

**A treatise on the etiology, pathology, and treatment of congenital dislocations of the head of the femur.**

**Contributors**

Carnochan, J. M. 1817-1887.  
Augustus Long Health Sciences Library

**Publication/Creation**

New York : Wood, 1850.

**Persistent URL**

<https://wellcomecollection.org/works/xgqf3epk>

**License and attribution**


This material has been provided by This material has been provided by the Augustus C. Long Health Sciences Library at Columbia University and Columbia University Libraries/Information Services, through the Medical Heritage Library. The original may be consulted at the the Augustus C. Long Health Sciences Library at Columbia University and Columbia University. where the originals may be consulted.

This work has been identified as being free of known restrictions under copyright law, including all related and neighbouring rights and is being made available under the Creative Commons, Public Domain Mark.

You can copy, modify, distribute and perform the work, even for commercial purposes, without asking permission.



Wellcome Collection  
183 Euston Road  
London NW1 2BE UK  
T +44 (0)20 7611 8722  
E [library@wellcomecollection.org](mailto:library@wellcomecollection.org)  
<https://wellcomecollection.org>







**Columbia University**  
**in the City of New York**


**College of Physicians and Surgeons**  
**Library**










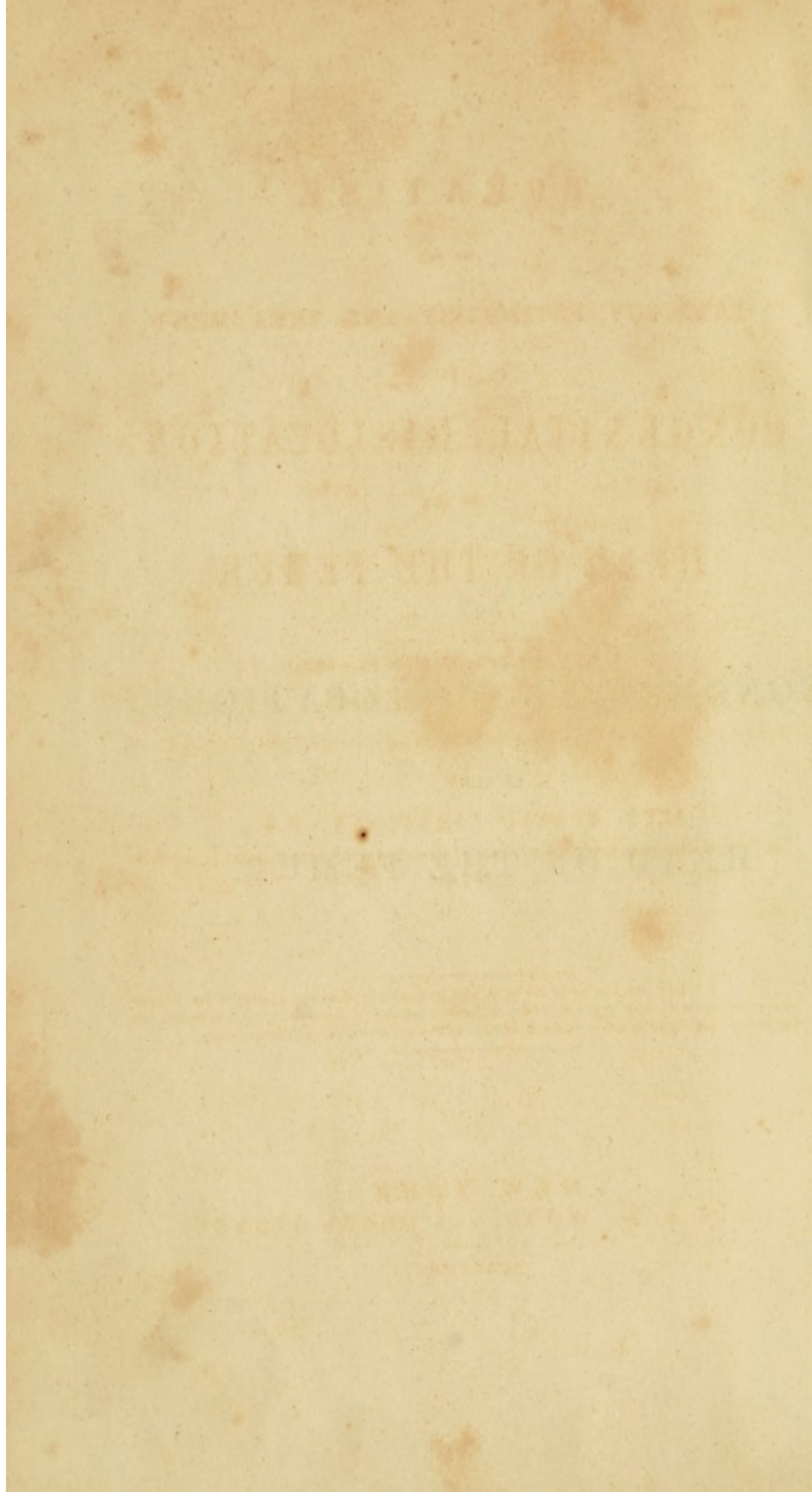


Digitized by the Internet Archive  
in 2010 with funding from  
Open Knowledge Commons



ON  
CONGENITAL DISLOCATIONS  
OF THE  
HEAD OF THE FEMUR.





A  
T R E A T I S E  
ON THE  
ETIOLOGY, PATHOLOGY, AND TREATMENT  
OF  
CONGENITAL DISLOCATIONS  
OF THE  
HEAD OF THE FEMUR.

---

ILLUSTRATED WITH PLATES.

---

BY  
JOHN MURRAY CARNOCHAN, M.D.,  
LECTURER ON OPERATIVE SURGERY WITH SURGICAL AND PATHOLOGICAL ANATOMY,  
&c., &c.

---

. . . . "mon but n'a point été de grossir le catalogue déjà trop nombreux des misères  
humaines, mais d'éviter aux praticiens de graves erreurs de jugement, et aux malades, des  
 traitemens aussi inutiles qu'ils sont dangereux."—DUPUYTREN—*Clinique Chirurgicale*.

---

NEW YORK:  
S. S. & W. WOOD, 261 PEARL STREET.

---

MDCCCL.

1850

Spec Coll  
Hist Coll  
RD  
101  
C21  
1850

ENTERED, according to Act of Congress, in the year 1850, by

JOHN MURRAY CARNOCHAN,


in the Clerk's Office of the District Court of the Southern District of New York.



# C O N T E N T S.



	PAGE
PREFACE . . . . .	vii
CHAP. I.—GENERAL OBSERVATIONS . . . . .	11
II.—ANATOMICAL REMARKS . . . . .	35
III.—ETIOLOGY . . . . .	46
IV.—SYMPTOMATOLOGY . . . . .	91
V.—DIAGNOSIS . . . . .	131
VI.—PROGNOSIS . . . . .	139
VII.—PATHOLOGY . . . . .	147
VIII.—TREATMENT . . . . .	215





## P R E F A C E .

---

SCIENCE is progressive, and it is necessary to keep pace with its rapid advancement.

The department of Surgery occupies an extensive domain ; its beneficial influence upon mankind is universally acknowledged, and its professors now hold a prominent rank in the great intellectual arena of the world.

The more correct and definite knowledge derived, in more modern times, from a better directed and closer study of Anatomy, Physiology, and Pathology, has led to vast improvements, and given, among others, a new impetus to what may be termed curative and conservative surgery.

The progress of this department of science, in its intimate connection with the great interests of the human race, demands of the surgeon of the present day, not only the ability of performing dexterously a complicated operation, but chiefly a profound knowledge of the various pathological conditions to which the human organism is liable. Without this knowledge, a correct discrimination among the various morbid affections of the body cannot be attained ; the diagnosis must be uncertain for want of reliable data for its basis, nor can remedial measures be adopted intelligently or judiciously.

From the increased light now shed upon Surgical Pathology,



it is to be hoped that the time has gone by for the recurrence of many grave errors in practice, heretofore committed, and that we shall not again hear, for instance, of opening an aneurism, under the supposition of merely giving exit to a collection of purulent matter, or of the application of the ligature upon a large arterial trunk, for the cure of aneurism, where no aneurism existed ;—the lamentable results of erroneous diagnosis.

Some few years since, while in Europe, and availing myself of the advantages at hand in the Hospitals and Surgical Schools of the great foreign capitals, I drew up the outline of a sketch, to be filled up on my return to the United States, which should embrace a general parallel between the state of British and French Surgery, and the actual condition of the science in our own country. Other matters, however, claimed my attention, and have prevented the immediate fulfilment of my design.

There is one point of Surgical Pathology, however, previously altogether unnoticed in this country, upon which, among other investigations, I bestowed considerable attention while abroad, and in relation to which I contributed at times brief articles to some of the Medical Journals :—I allude to the Congenital Dislocations of the Head of the Femur at the Iliofemoral articulation.

Contributions of that kind being, however, necessarily confined within narrow limits, and nothing having since appeared on the subject from other sources, in the English language, I have endeavored in the following pages, in some measure, to fill up the void existing in relation to this important point of surgery.

The arrangement I have adopted is a simple one ; beginning with the Etiology, and then passing on, successively, to the




Symptoms, the Diagnosis, the Pathology, and concluding with the Remedial Treatment.

The cause of this Displacement has given rise to much discussion, and the variety of opinions offered shows sufficiently the obscurity of the origin of this connate affection. I have ventured to propose my own opinions on this head, which, I trust, are justly founded upon Anatomy and Physiology.

The Symptoms and Pathology are illustrated by correct delineations, taken from cases, which came under my own observation, and from dissections, made by myself.

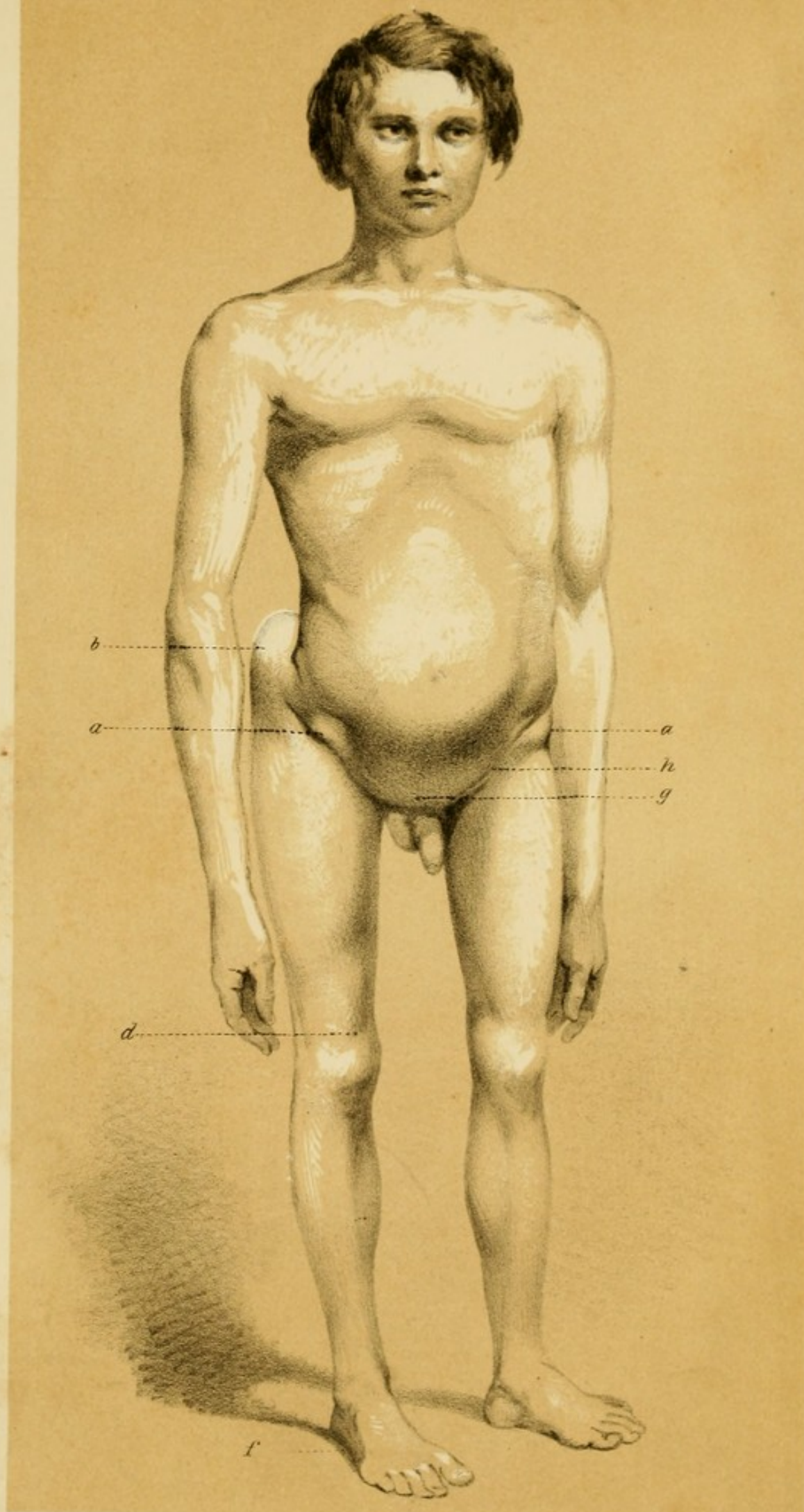
With regard to the Treatment, I have recorded that course which has been attended with success, and have also mentioned additional suggestions which have been advanced by eminent authority.

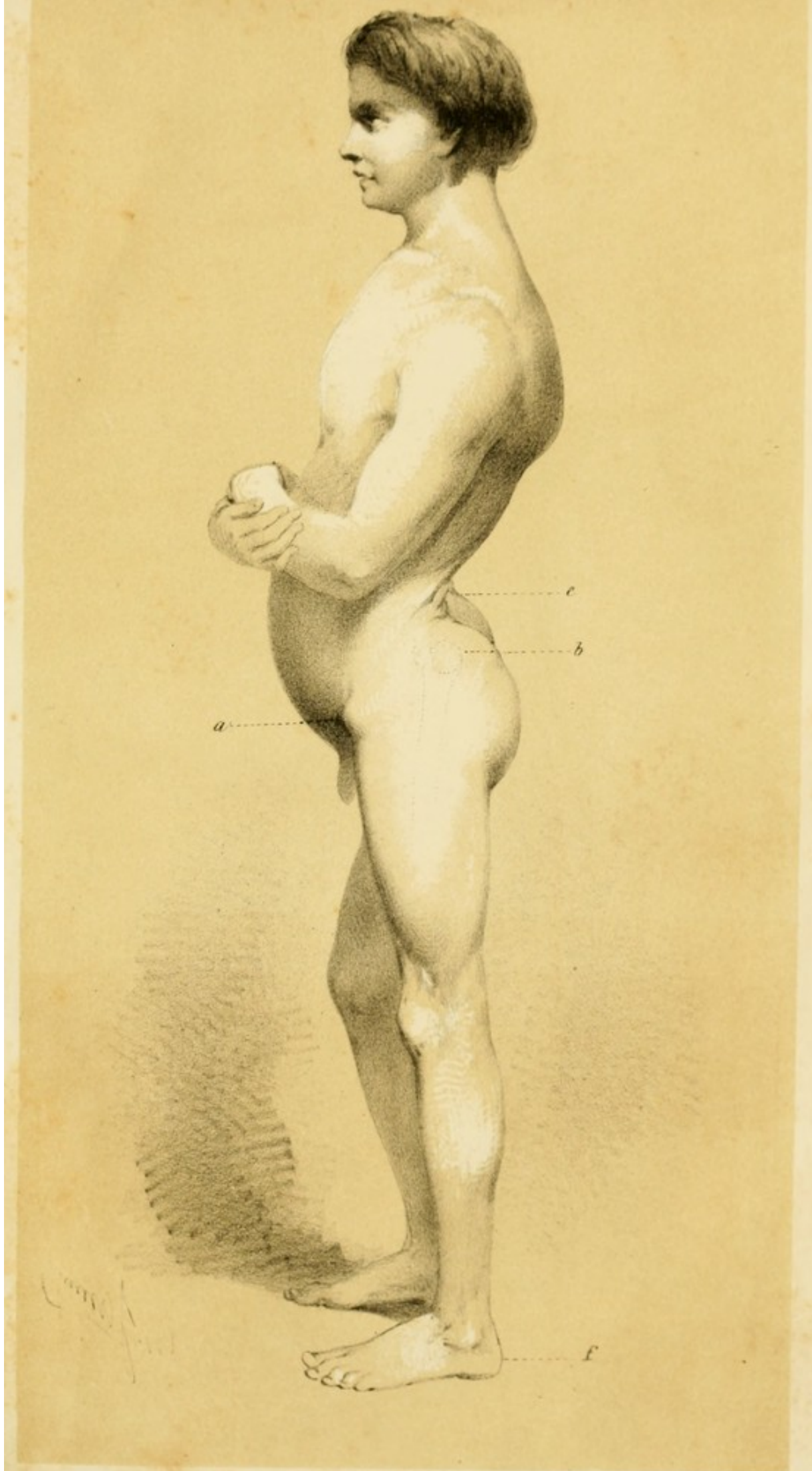The subject of the present monograph being a novel one, and, indeed, quite new upon the American continent, I may claim some indulgence for any imperfections which may be met with in its pages, on the ground of its being the first attempt to introduce to the Surgeons of this country a systematic account of this important affection of the human organism.


















## EXPLANATION OF PLATE No. I.

Antero-lateral view, as presented during life, in a case of Double Congenital Dislocation of the Head of the Femur upon the Dorsum of the Ilium.

- a* Anterior Inferior Spinous Process of the Ilium.
- b* Trochanter Major.
- d* Superior Margin of the Patella.
- h* Inguinal Fold.
- g* Region of the Pubes tilted downwards and backwards.
- f* The foot resting on the sole, the toes being directed forwards.



## EXPLANATION OF PLATE No. II.

Lateral view of the same case as the preceding, of Double Congenital Dislocation of the Head of the Femur upon the Dorsum of the Ilium.

- a* Anterior Inferior Spinous Process of the Ilium.
- b* Trochanter Major.
- e* The excurvation in the lumbar region.
- f* The foot resting on the ground, and directed forwards, without inversion or eversion of the toes.

*See Report of this Case, Chapter IV.*

THE HISTORY OF THE

PROGRESS OF THE

ROYAL SOCIETY OF LONDON

FROM ITS INSTITUTION

TO THE PRESENT TIME

BY

J. H. P. ...

OF THE ...

...

...

...

...

...

...

...



ON  
CONGENITAL DISLOCATIONS  
OF THE  
HEAD OF THE FEMUR.

---

CHAPTER I.

GENERAL OBSERVATIONS ON CONGENITAL DISLOCATIONS OF  
THE HEAD OF THE FEMUR.

THE diseases and accidents occurring at, or in proximity to, the coxo-femoral articulation, are numerous and complex. An intimate knowledge of the pathology of each of them is requisite, in order that, when circumstances render an opinion necessary, a correct differential diagnosis may be formed in relation to affections of this portion of the organism. The morbid conditions of the hip-joint are attended by peculiar and characteristic symptoms, frequently accompanied with displacement of the articulating surfaces, either gradual, from causes more or less prolonged, or immediate and simultaneous with external violence; and thus, the discrimination of one



pathologic state from another might be supposed to be free from difficulty or embarrassment. Yet errors in diagnosis do often occur in regard to the real nature of affections of this region, and, as an unavoidable sequent to error of judgment, an improper course of treatment is adopted, useless in itself, and dangerous in its results.

It is somewhat remarkable that those dislocations of the hip-joint which have been denominated *original* or *congenital*, and which are of equal importance in a scientific point of view with the traumatic displacements of the head of the femur, should have been so entirely overlooked by the surgical writers of England and of this country. The great authority on the subject of dislocations, Sir Astley Cooper, in his enumeration of the different varieties of articular displacement, has not referred to any other luxations of the head of the femur than those happening during the different epochs of extra-uterine existence, and resulting from external violence, from relaxation of the ligaments, from paralysis of the muscles, from excess of the synovial secretion, or from strumous ulceration at the joint,\* and even Brodie, whose researches into the pathology of the joints have been so extensive and erudite, has not made a cursory allusion to the re-

\* In the last London edition of Sir Astley Cooper's "Treatise on Dislocations," muscular spasm is mentioned as sometimes causing in certain individuals dislocation, for example, of the lower jaw; and an instance is alluded to where dislocation of the second phalanx of the little finger resulted from the shock of an electric machine, but in these cases he evidently has no reference to intra-uterine dislocations.



markable dislocation of the femur of which we are about to treat, and which has frequently been mistaken for other diseases of this part, and especially for *morbus coxarius*.

In examining the extensive collections in the museums attached to St. Thomas' and Guy's, and to the other hospitals of London and Great Britain, I was unable to find any specimens illustrative of congenital dislocation of the head of the femur; and I may make the same remark in regard to the pathological collections of this country.

From this fact, and from the silence of American surgical writers on the subject, I have thought that the following description of the causes, symptoms, and morbid appearances of this dislocation at the hip-joint, with the accompanying cases, and with drawings taken from dissections which I have had the opportunity of making, might be deemed worthy of perusal; or, at all events, that they might direct attention to a pathologic condition of this joint, not generally understood, and which, in the details of surgical practice, is not unlikely to be met with.

Luxations differing in their nature from those occurring as the result of traumatic lesion, are alluded to by Hippocrates, but in so vague a manner that no definite conclusion can be drawn from his remarks. In his Book "*De Articulis*"\* he says that children in the womb may have

\* Liber de Articulis, sect. 3. sent. 88 et 94; sect. 4, sent. 4 et 5.



their arms and legs dislocated by falls or blows, or by having been pressed upon, as is remarked in those who are born with club-foot.

This matter had fallen into oblivion when Ambroise Paré, and, at a later period, Verduc, again pointed out the existence of displacements occurring at the joints before birth, but still in language of much obscurity as regards their real nature.

Paré, in his Chapter on the Causes of Dislocations, thus expresses himself:—"Les causes des luxations sont trois en general, à sçavoir *internes*, et *externes*, et la troisième est *héréditaire*.

"Internes, comme quand il y a certaines humeurs et ventosités qui tombent aux iointures en si grande abondance, qu'elles lubrifient et relaschent les ligaments qui lient les os ensemble. *et les jettent hors de leur boëtte*: ou bien remplissent lesdits ligamens, de telle sorte qu'iceux engrossis, et par consequent accourcis, venans à se retirer ensemble, retirent ou les apophyses des os, dont ils ont leur origine, *ou bien les os mesmes hors leurs sinus et cavité*. . . La cause héréditaire est celle qui vient de père et mère aux enfans, comme quand les bossus engendrent des enfans bossus et contrefaits, *et les boiteux engendrent des boiteux*: dont l'experience fait foy, non pas tousiours, mais le plus souuent."\*

\* Le Quatorzième Livre Traitant des Luxations. Chapitre III (Edition by Malgaigne).



And again in his chapter "*De la luxation de la hanche*,"\* he says, "Mais és luxations faites de *cause interne*, elle peut estre incomplète, parce que les muscles et ligamens sont relaschés, et n'ont la force de ramener ledit os en sa iointe, ou cauité."

In these passages, and particularly where I have used italics, allusion to congenital luxations at the hip and elsewhere may be intended, but if Paré were conversant with the real nature of the displacement in question, he does not express himself in explicit language in relation to it; although it is probable that the hints thrown out by the great French surgeon of the sixteenth century have been made available by some modern writers. In fact, one recent writer, rejecting other opinions, has assumed the hypothesis that the cause of congenital luxation at the hip is nothing more than a superabundant secretion of fluid into the ilio-femoral articular cavity.

A distinct and definite statement of the existence of an intra-uterine dislocation, taking place before birth, at the ilio-femoral articulation, appears to have been made in 1812 by Chaussier, who is reported to have entered in the note-book of the *Hôpital de la Maternité* of Paris an account of the skeleton of a fœtus, in which many fractures were found, besides two congenital luxations, one situated at the humero-scapular articulation, the other at the hip joint; which luxations he designated by the name of spontaneous (*Luxations Spontanées*).

\* Le Quatorzième Livre, Chapitre XL. De la Luxation de la Hanche.



Palleta, an Italian surgeon, practising in Milan, at the commencement of the present century, is, as far as I can learn, entitled to the credit of having first given, in 1820, an intelligent description of the congenital dislocation of the head of the femur from the cotyloid cavity;\* but many years previously he had indicated with considerable precision this obscure morbid condition of the hip-joint in his work published in 1788, entitled "*Adversaria Chirurgica*." In the essay "*De Claudicatione Congenita*" he describes certain malformations at the hip-joint, which can only be referred to the class of dislocations at this articulation, which, under the name of congenital, have attracted the attention of some modern French surgeons. It is probable, however, that, at this early period of his labors, this author was not well acquainted with all the characteristics of the displacement. But from observations on the living, and dissections made of persons who had succumbed to various maladies, he had acquired more knowledge in regard to this morbid condition of the hip-joint than any of the surgical writers who had preceded him. The descriptions which he has left of the symptoms manifesting themselves during different stages of life, and of the results of the post-mortem examinations which he was enabled to make, conclusively show that the Italian surgeon was acquainted with the general pathological facts appertaining to this affection. In his first case,

\* *Exercitationes Pathologicæ.*



although unable to verify it further by autopsic examination, he thus proceeds: "Puerum octennem claudicantem consilii causa ad me adduxerunt 28 aprilis ann. 1780. . . . Erat crus sinistrum sesqui pollice brevius dextero; genu introrsum non nihil conversum, trochanter major ab læva parte eminentior. Resupinato puero dum manu altera trochanterem deprimebam, altera crus et genu extendere conabar, membrum affectum par sano reddebatur: sublata extensione idem membrum ad pristinam brevitatem reducebatur. Motus articuli in omnem partem erat facilis. Causa cui quidem ea contractio tribui poterat, nulla præcesserat manifesta. . . . . Quid eidem evenerit, ignoro, nunquam enim postea rediit."\*

Although there are symptoms in the above case that are common to other affections at, or about, the hip-joint, as well as to congenital luxation of the head of the femur, yet the age of the patient, the lameness—not being referred to external injury,—the easy extension of the limb, already shortened by half an inch, to the length of the sound member, the immediate return to its pristine shortness as soon as extension was removed, and the free motion of the joint, give, when taken collectively, a general character to the malady described, which precludes the supposition of its having been the result of strumous action, or of accidental lesion.

\* *Adversaria Chirurgica.*



Passing over another case similar to that just related, and of which also Palleta was prevented from making a post-mortem examination, we shall make an abstract of a case in which he had an opportunity of dissecting the various structures about the joint. “*Adolescens tenui habitus vigesimo ætatis anno moritur ex capitis vulnere, 8 maii 1783. Quum mensæ anatomicæ alium in finem imponeretur, crus dextri lateris contractum observavimus. Calcaneum tribus transversis digitis supra sinistrum erat, genu duos; trochanter tuberosior et eminentior; natis item rotundior et globosior, sulcus autem ejus vix mutatus erat excepto apice, qui paulo incurvus versus trochanterem tendebat. Cæterum nec triceps coxæ musculus distentius, nec pes in latus conversus observabatur; nec item alii musculi coxam ambientes quidquam à naturali diversum habebant, præter mutatam directionem. . . . . Capsa dein articulari incisa, . . . . . cotyle sanum erat, profundum, cartilagine sua obductum, figura duntaxat mutatum. Caput femoris in vertice valde depressum, atque inferius productum velut in obtusum rostrum terminabat. Tota ejus superficies cartilagine, colore, et crassitie naturali tegebatur, excepto exiguo tractu circa ligamenti teretis foveam, ubi sic attenuata cernebatur, ut diaphana redderetur. Ligamentum teres infra capitis centrum trochanteri minori propius inserebatur. Robustum tamen illud erat, crassum, et lata triangulari basi, ex coty-*



lis sulco prodibat. Femoris collum erat perbreve, si eo nomine distinguenda est ossea portio a capitis rostro in transversum ducta, atque in trochanteris basin inserta. Hæc porro una cum capite compressa ab lateribus, et circum eminentiis parvis obsita erat, circulari articuli ligamento inclusis.”\*

The author then proceeds by giving a detailed account of the dimensions and measurements of the articulating surfaces of the cotyloid cavity and head of the femur, &c., which it is unnecessary to repeat here. The extract just made is sufficient to point out some of the pathological conditions peculiar to the congenital dislocation of the hip-joint.

The next case, reported by the Italian surgeon, which presented an opportunity of inspecting the body after death, is also characteristic of this affection. It is detailed as follows.—“Femoris collum eo, quod descripsimus, modo vitari posse altera me docuit sectio in puella bimula. . . . . Hujus femur sinistrum transverso digito contractius erat; pes in neutram partem inclinabat; trochanter sublimior, et extrorsum crassior erat; sulcus qui natis terminum designat, paululum versus trochanterem inflectebatur. . . . . Ablatis musculis femur, de quo antea dubitabamus, cum cavitate cotyloïde *dearticulatum esse comperimus*. Capsam articulem à parte posteriori liberam, ut solet; à priore vero in vicinia foraminis ovalis cum interno ligamento accretam deprehendimus; cujus phænomeni ra-

\* Adversaria Chirurgica.



tio a singulari ipsiusmet ligamenti structura pendebat. Hoc enim neque in funiculum colligatum, neque in prismatis modum conformatum erat, sed expansum dijectumque in formam membranæ, atque sic totam acetabuli superficiem occupabat; dumque circulari et lato exoriebatur principio, mediam relinquebat cavitatem fere ad formam infundibuli, et deinde paulatim fibras contrahebat, quo capiti propius accessisset. *Utrumque cotylis labrum cartilagineum nempe et osseum valde depressum erat; orificium ipsum cotylis fere ovale, latius nempe a superiori parte, et ab ima magis coarctatum.* Ab acetabuli centro usque ad marginem segmenti inferioris surgebat tuber, aut colliculus osseus, lævi contactus cartilagine, atque convexus, qui ubi diligentius observabatur, ab ilii ossis, qui in acetabulum concurrit, processu præter modum crassescere videbatur productus, *Femur, pene dixerim, acephalum fuit; nam complanatam habebat faciem, qua sese aptabat tuberi ex cavitate articulari prominenti.*"\*

Here again, as in the following case, we have a description of pathological appearances found to exist at the ilio-femoral articulation, which have but little affinity with any other of the affections of this part, than those occurring as the result of the congenital form of displacement of the head of the femur. The same author thus proceeds with another observation of a case which afforded an opportunity for the autopsy;—"Eadem, ut significavi, die inter multa alia, ca-

\* Adversaria Chirurgica.



daver hominis robusti qui ex morbo inflammatorio decesserat se obtulit, *cujus dexterum crus decurtatum erat*. Artu diligenter examinato, collatoque cum sinistro *duobus transversis digitis deficere animadverti*; *natis sulcus paulo altior, et magis incurvatus erat*; nec præterea alterius morbi signum ullum extrinsecus notabatur. Dum capsula articularis incideretur, quæ justo densior apparuit; . . . . . *caput ovatum, a summo latius*, dein convergendo in obtusum rostrum abibat; . . . . . *ligamentum teres* . . . . . validissimum fuit ex duobus fasciculis compositum, primum quidem invicem decussatis, dein expansis in trianguli formam, cujus una radix anterior, posterior altera, tertia demum inferior ad pedis anserini similitudinem alte in sinum acetabuli defigebantur.\* Cotyle ossis depurati ad conoïdeam pariter figuram accedebat; . . . . . fundi autem cotyloïdis media pars superior cartilaginem suam habebat; altera cartilagine orbata peramplam pro triangulari ligamento arcam ostendebat. *Femoris collum erat breve*, novem linearum, transverse positum, cujus caput magis repandum pro ratione amplitudinis acetabuli, margines suos a parte inferiori, posteriorique multum ultra collum exporrectos habebat, atque ab ima parte in rostrum aduncum producebatur, interjecto profundo sinu inter femur, et rostri curvaturam; retrorsum vero idem excrescens margo sic dilata-

\* It is probable that this account of the ligamentum teres is drawn from the ligamentous agglomeration which sometimes occurs between the capsular ligament and the ligamentum teres, which become converted into a strong fibrous cord, as will be seen in a case described hereafter (vide plates viii. and ix.).



batur, ut tribus duntaxat lineis a minori trochantere distaret. Et quamquam antè ob colli brevitatem margo capitis naturalis et femori, et trochantere proximior esset, posterius tamen spatium illud, quod est inter caput, et utrumque trochanterem, pollicem unum, et tres lineas latum reperièbatur; atque id ex eo contigit, quod caput oblique positum in priorem partem, et simul in inferiorem declinaret; proptereaque trochanter, qui extrinsecus eminebat plurimum, totum etiam pollicem ipso capite eminentior erat. . . . . Capitis centrum occupabat area scabra, . . . . . ad cujus terminum longe infra capitis medium ligamenti teretis sinus erat conspiciendus."\*

The details of these cases, taken from Palleta, although not as complete or minute as those resulting from more modern investigations, are yet sufficiently distinct in their character to preclude the supposition of any of them being referable to a traumatic dislocation or fracture, or to any morbid or accidental lesion likely to occur at the hip-joint, other than the peculiar articular displacement which takes place at the ilio-femoral articulation during intra-uterine existence. They are interesting, as being the earliest attempts to illustrate anatomically this curious point of surgical pathology, and in giving an account of those cases which have come under my own observation, I shall have occasion to allude to them again.

Dupuytren, without taking any notice of the several

\* *Adversaria Chirurgica.*



observations of the learned Palleta, published in 1826 his Essay, entitled "*Mémoire sur le déplacement originel ou congénital de la tête du fémur.*"\* This production, clear in its descriptions, and practical in its tendency, attracted, when first issued, considerable attention among the scientific men of the French capital.

On the continent of Europe, where pathology is studied with so many advantages and with such assiduity, this point of surgical inquiry into the congenital dislocations of the hip-joint has been elucidated, in more modern times, by contributions from Breschet, Sedillot, Pravas, &c., and particularly from Jules Guérin, who has entered more philosophically than other writers into the etiology and treatment of this particular class of dislocations.

The obscurity of the nature of this diseased condition of the coxo-femoral articulation, and the circumstance of its being a lesion which occurs before birth, has deterred surgeons, until recently, from attempting any therapeutic means to bring about, and render permanent, the natural relation of the displaced articulation; and many enlightened practitioners have supposed permanent reduction to be beyond the reach of art. Of late years, cases have, however, been reported of successful attempts having been made to reduce fixedly the head of the femur to its natural position; and, to bring about this result, one French surgeon, referring this dislocation to the theory of active

\* Read before the Academy of Sciences, 1826.



muscular retraction (*retraction musculaire active*) as its cause, has advised, and, in accordance with notions founded on this supposition, put into operation, the sub-cutaneous section of the muscles supposed to be implicated, as well as of the new fibrous structure that may have been adventitiously thrown out as a consequence of the abnormal position of the articulating surfaces.

The varieties of the congenital dislocations of the femur, in regard to the position which the head of the bone may occupy relatively to the circumference of the acetabulum, have been enumerated as being four in number; the luxation, however, upwards and outwards upon the dorsum of the ilium being by far the most common. The other forms, occurring only in monstrosities, are not met with under circumstances where surgical relief is required, and therefore merit but a cursory allusion. They have been described as occurring, firstly, directly upwards; secondly, forwards and upwards; thirdly, a sub-luxation backwards and upwards.

Lastly, the term pseudo-luxation has been applied to certain permanent deviations in the direction of the femur, resulting from a morbid muscular retraction simulating dislocation at the joint, but without the exit of the head of the femur from the cotyloid cavity.

The causes of these pathological phenomena are not so free from obscurity as to be beyond controversy. Nearly every writer who has given attention to this subject, has



assumed a hypothesis to account for the origin of the displacement, and has found ingenious arguments to support his conjectures. Some authors construct their theory on ideas connected with the evolution of the embryo, and refer the incipency of the morbid condition of the joint to an *arrêt de développement*, to an aberration of the nutritive forces (*force formatrice*), or to a primitive alteration of the germ. Others, unable to comprehend that the head of the femur can be transported from its natural receptacle without the aid of a cause analogous in some way to that of traumatic luxations, attribute the displacement of the femur to improper traction exercised, by the *accoucheur*, upon the extremities of the infant, during its passage through the pelvis of the mother. Again, external violence acting upon the fœtus, while it is in utero, has been assigned as a cause. Also, the contractions of the uterus and of the abdominal muscles upon the extremities of the levers presented by the long bones of the inferior members of the child, the unnatural position occupied, perchance, by the fœtus in the cavity of the womb, the absence of the liquor amnii, permitting the walls of the uterus to act directly upon the fœtus during the contractions of this organ, have been regarded as mechanical antecedents, which, acting separately, or in combination, might displace the head of the femur from its natural situation. More recently, it has been attempted to trace an analogy between the congenital form, and that species of luxation which



occurs at different periods of life, as the result of relaxation of the muscular and ligamentous structures surrounding the joint. One recent author has gone so far as to take up again the theory of the ancients regarding certain articular displacements, and has attributed the abnormal position of the articular apparatus of the hip-joint, which takes place in the fœtus before birth, to the relaxation and elongation resulting from an effusion into the cavity of the articulation whilst the child is still in utero. On the other hand, it has lately been maintained that the articular apparatus, in the cases under consideration, is always primarily in a state of integrity, and that the derangement which takes place in utero at the articulations, destroying the normal relations of the component parts of the joints, without leaving any evidences or traces of inflammatory action, is dependent upon a morbid retraction of a portion of the muscular tissue, resulting from a defect in, or absence of, some portion of the nervous centres. My own opinion is, that the displacements of the hip-joint in question are the result of spasmodic muscular retraction, *not dependent, however, upon mere absence of the central nervous substance, but upon an irritation conveyed to, or originally existing in, the ganglionic centre of the medulla spinalis.* This irritation or altered action, which occasionally may result in structural lesion, is thence transmitted by the reflex-motor power of the excito-motor apparatus of the spinal system upon the muscles, *which conse-*



quently become affected, and by their continued retraction disarticulate the head of the femur. This last theory is based upon physiology, and, if assumed as a law, may be made available to explain the existence not only of the dislocations of the hip-joint occurring before birth, but also of many other congenital articular displacements found in the trunk and extremities.

Notwithstanding these conflicting hypotheses as regards the cause of this peculiar species of displacement at the ilio-femoral articulation, it is generally admitted that hereditary predisposition has a certain agency in the occurrence of the congenital dislocation of the hip-joint, as it has been acknowledged to have in the various kinds of club-foot or talipes.

Dupuytren relates a curious history, which was communicated to him of a family living at *Nantes*, in France, in which, as many individuals belonging to it were found affected with this displacement of the femur occurring before birth, this peculiar predisposition may be supposed to have been developed in an extraordinary degree; and as there is no instance recorded more illustrative of this point, I shall transcribe the description given by him in one of his "*Leçons Orales de Clinique Chirurgicale*," delivered at the Hotel Dieu of Paris. He proceeds as follows:—"We shall now relate a very curious one (fact) which appears to indicate that this vice of conformation



can be transmitted to many generations of individuals of the same descent.

“ There exists, in the town of *Nantes*, a family, many members of which have been, and are, affected with original luxation (*luxation originelle*) of the femurs. The oldest member of this family is a woman eighty years of age, named *Marguerite Gardas*, fruiterer, and here follow the particulars of her case, taken from her own lips, and corroborated by other persons of the same age.

“ Two of her aunts, on the maternal side, who died at seventy years of age, had been affected with a lameness from their earliest attempts at walking. These females, moreover, were in the habit of stating that they had always been lame. Their hips were elevated, protuberant, and abruptly salient. They walked with their elbows projecting backward, and hobbled like ducks. *Marguerite's* father had had a sister lame upon the right side from birth, who died at eighty years of age. Another sister, who was well formed, gave birth to a female child, which presented a shortening of the right inferior extremity.

“ *Marguerite Gardas*, who is the subject of this observation, is a large and robust woman, and appears to have possessed a remarkable degree of activity in her youth. With her the disease was not prominently marked until she was thirty years of age, and its symptoms are those of



a spontaneous luxation\* (*luxation spontanée*) of the femur. The affected member is one fourth less in diameter than the other, which is, besides, three or four lines longer. This woman has had, by her marriage with a healthy man, who had come from distant parts, a daughter named *Simone*, who has a congenital shortening of the right inferior member of about three inches. This girl is also married to a man of healthy conformation, but whose father had a congenital luxation of both femurs; she has had four children, two of whom present the hereditary infirmity. The one is a young woman aged twenty-three years; she has a luxation of the two femurs, the heads of which are situated in the *external iliac fossæ*; the other is a young man twenty-one years of age, who has a congenital luxation of the left thigh. The member affected is shorter by five inches than the other; the head of the femur has ascended upwards and backwards; the trochanter major projects forwards and outwards, and the toes are turned inwards; the two extremities are equally well developed."

After the recital of this instance, it would be difficult to doubt that hereditary predisposition exerts some influence over the recurrence of this disease in children whose parents or ancestors had previously been affected by it.

Another opinion is entertained, and generally agreed

\* The word *spontanée*, in the French text, is here used as synonymous with *originelle*.



upon to be correct, in relation to the more frequent occurrence of the congenital form of dislocation at the hip in the female than in the male sex; and, although I cannot coincide entirely with Dupuytren when he says that "*presque tous les individus affectés de cette luxation sont du sexe féminin*," I am satisfied from my own observation that the majority of persons in whom this disease is found to exist are females, and that the proportion of males affected should not be put down at more than one third. The cause of this greater proneness may possibly proceed from the susceptibility of the female organization to be more easily impressed by the existence of any morbid irritation of the nervous centres, which might be incited during the period of evolution of the embryo or foetus; and not improbably in connexion with this, or by itself alone, the anatomical configuration, such as the more forward position of the acetabulum in the female pelvis, might facilitate the action of the pelvi-trochanteric muscles when once thrown into a state of active morbid retraction, in producing the displacement of the head of the femur from its natural cavity.

The pathological appearances met with in cases of congenital dislocation vary with the period of life at which they are subjected to examination. The alterations observable in the articulations and the ligamentous structures concerned in the malady are greatly diversified. "In fact the primitive characters of this disease become more



extensively modified in proportion as they are more remote from its commencement. There arrives, indeed, a period when the alterations which are met with would not even indicate a primitive lesion, were it not that in some cases these very lesions had been previously found to exist. In relation to the congenital luxations, we are not permitted to see them produced. When we are able to examine them they have generally existed for some time; consequently the primitive lesions are modified by so much as the age of the patient is advanced. It is, then, in young subjects that the essential character of congenital displacements must be sought; for it is at this early age that the changes are least."

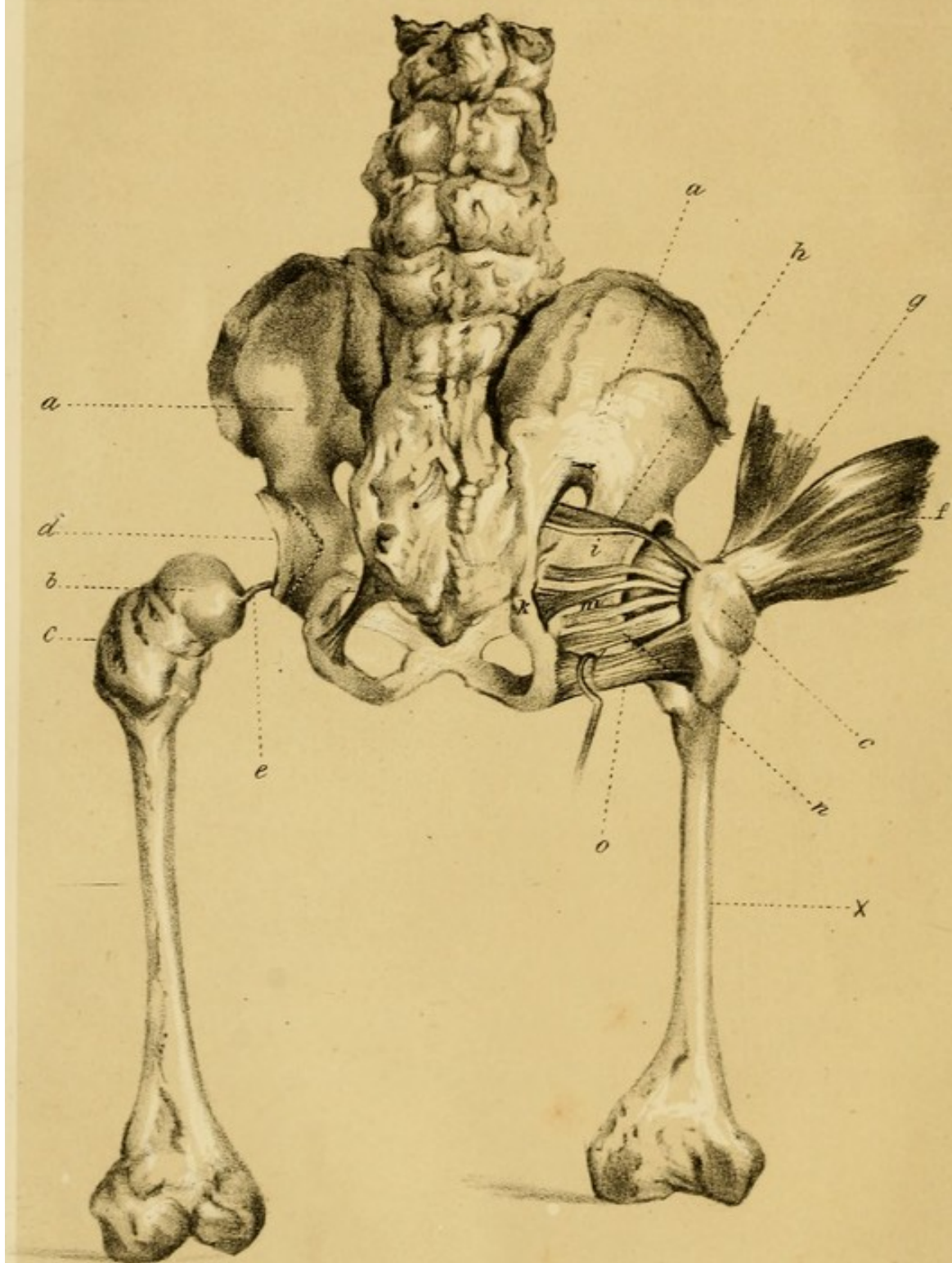
The extensive alterations met with in adult life are not to be seen in the congenital dislocations of the hip-joint in the new-born infant. In the latter, the signs of displacement are less marked than in the former. The soft tissues surrounding the articulation depart but little from the normal structure; the capsular ligament has as yet undergone but trivial change in its form or dimensions, and is found only lengthened and put upon the stretch by the partial ascent of the head of the femur; and the articulating surfaces of the acetabulum and of the head of the femur are found to be still in nearly a natural condition. But in the progress of advancing age, changes occur which completely modify the relations of the whole of the articular apparatus of the joint. The head of the femur becomes



softened, atrophied, or completely removed; the acetabulum becomes more or less contracted and altered in shape, and is sometimes filled up with a new semi-osseous material; and the fibrous capsule assumes an entirely novel appearance, presenting sometimes a cavity retaining the head of the femur, sometimes a perforation which allows of its transit, sometimes an agglomerated fibrous cord running between the remains of the ancient acetabulum and the atrophied remains of what was originally the head of the femur. Likewise, the head of the femur, escaping from its natural capsule, contracts new relations; a new fibrous capsule is formed for it, and either a depression is shaped out for the reception of the displaced head, or an acetabulum of new formation, less profound, but similar to the osseous effusion, which frequently takes place in cases of unreduced traumatic luxation at this part, springs up from the surface of the dorsum of the ilium, as an effort of nature to give support to the unfixed bone. The muscles, and other soft tissues, undergo corresponding perversion from their normal condition; and the bones appertaining to the dislocated limb participate in the general derangement, by showing a deterioration in their development and structure as regards their natural length, volume, and consistence.









### EXPLANATION OF PLATE No. III.

Posterior view of the Foetal Pelvis—about the end of the ninth month.

The drawing represents a dissection of the parts concerned in Congenital Dislocation of the Femur, and is intended to explain the manner in which the head of the femur may escape from the cotyloid cavity during foetal life; and also the mechanism by which the consecutive malformations are brought about, chiefly by means of muscular traction.

× The right Femur, slightly flexed.

*a* The Dorsum of the Ilium.

*b* Head of the Femur.

*c* Trochanter Major.

*d* Ligamentous Margin of the Acetabulum. The dotted line shows the portion of the acetabulum which is cartilaginous in this direction, at this period—the ilio-ischiatic depression is thus formed.

*e* Ligamentum Teres.

*f* Gluteus Medius.

*g* Gluteus Minimus.

*h* Pyramidalis.


*i* Superior Gemellus.

*k* Obturator Internus.

*m* Inferior Gemellus.

*n* Obturator Externus.

*o* Quadratus Femoris.





## CHAPTER II.

## ANATOMICAL OBSERVATIONS.

IN the adult, traumatic dislocations of the femur from the acetabulum are not of frequent occurrence. I am inclined to believe, from what I have seen, that the congenital form of luxation of the femur, more especially that variety where the femur ascends upon the dorsum of the ilium, is of as frequent occurrence, if not more so, as the corresponding dislocation caused by external violence during extra-uterine life.

During adult life, various causes are opposed to the displacement of the head of the femur from its proper receptacle. The depth of the acetabulum, the strength of the capsular ligament, aided by the auxiliary resistance of the ligamentum teres, the resisting influence of the pelvi-femoral muscles which surround the ilio-femoral articulation, the limited motion of the joint in certain directions, are obstacles which oppose the dislocation of the femur from its natural socket.

On the other hand, during foetal life, the anatomical disposition of the parts, and the flexed position main-



tained, generally, by the thighs upon the abdominal wall during this epoch, predispose the head of the femur to pass from its shallow acetabulum, and mount upwards and backwards, in the direction of the dorsum of the ilium.

It is probable that intra-uterine dislocations of the hip-joint may occur in the foetus from spasmodic muscular retraction as early as the third or fourth month of gestation.

If the doctrine be correct, as I suppose it to be, that a morbid condition of the medulla spinalis—as one of the important parts of the spinal excito-motor circuit—must be present, in the production of intra-uterine dislocations, the previous junction with the medulla spinalis of the nervous trunks, which are ultimately ramified in the muscles implicated, must also be essential. Now, according to M. Serres, the nerves have a separate evolution from the cerebro-spinal axis, and pass centripetally from the organs to the encephalon, and to the medulla spinalis. This junction takes place between the optic nerves and the tubercula quadrigemina, as remarked by this writer, at about the end of the second month ; and during the fourth month they become joined with the thalami and the corpora geniculata.

The Rachidean nerves, following the same law, join the medulla spinalis in a similar manner, and probably about the same time. The spinal excito-motor system



may reasonably be supposed to come into play then, and not previous to the nervous junction.\*

It would be superfluous to trace the modifications observable at the hip-joint during the different phases of embryotic and foetal life; I shall only therefore take a cursory glance at the anatomical relations of the ilio-femoral articulation, as it is seen about the middle period of intra-uterine existence.

In the adult, two bones enter into the formation of the osseous part of the ilio-femoral articulation—the os innominatum and the os femoris. In the foetus, however, a different arrangement results from the fact, that ossification is not yet completed either at the acetabulum or at the head of the femur. The articular part, corresponding to the osseous acetabulum in the adult, is here partly cartilaginous. The three portions, now called ilium, ischium, and pubes, and which ultimately join to form one bone, the os innominatum, are seen progressing towards development, by the deposition of osseous material in the cartilaginous matrix, or framework, by which, at this early period, the acetabulum is chiefly made up.

\* Several anatomists have recorded examples which go to prove the separate evolution of the nerves and of the nervous centres.—*Lallemand (de Montpellier). Thèse inaugurale.*—*Lonsdale.*—*Serres, Anatomie de Syst. nerv.*—I have myself seen an amyélencéphalous embryo of about the fourth month, in which the spinal nerves seemed to terminate in the vertebral canal, opposite the intervertebral foramina, like a range of minute dots.



These three osseous portions, in their centripetal progress towards final development, leave between them three spaces, occupied in the recent subject by cartilage; by means of which, and with the assistance of the ligamentous border, formed by the cotyloid ligament, the circular arrangement of the cotyloid cavity is completed in the foetus. This cotyloid cavity, at the fifth month, is found to measure about nine lines in circumference, and about two lines in depth. If the parts are now exposed to the air for a short time, the cartilaginous components of the acetabulum become dried and shrunken, and the extent to which the osseous portions contribute to form this cavity is exhibited; the three depressions already alluded to, and which were scarcely appreciable while the cartilage of the acetabulum was in its natural state, being now strongly marked around its perimeter. These marginal depressions of the acetabulum can be seen in the skeleton of the adult pelvis, but they are much more distinct in that of the foetus. One of these depressions is situated between the os ischium and the os pubis, and conducts, as it were, from the acetabulum to the foramen ovale; the other is between the os ilium and the os pubis, and is on a level with the horizontal branch of this bone; while the third occupies the posterior half of the margin of the acetabulum, corresponds to the space between the ilium and the ischium, and leads towards the ischiatic notch, or upwards to the dorsum of



the ilium. This last, or ilio-ischiatic depression, which in the skeleton of the fœtus is seen to be extensive, and which originally was filled up with yielding cartilaginous material, may permit, during fœtal life, the head of the femur to slip readily over the margin of the acetabulum, which, at this period, and in this direction, is so shallow—as observed in the dried state of the parts—that the margin, at its most depressed point, is almost on a level with the bottom of the cotyloid cavity. By this anatomical configuration, and the pressure of the head of the femur towards the lower and posterior part of the acetabulum during the flexed state of the thighs, the exarticulation of the head of the femur, upwards and backwards, towards the dorsum of the ilium, could, evidently, be easily accomplished by spasmodic muscular retraction prolonged and acting in the direction of the force which would be exerted by the two smaller glutei, and by some of the other pelvi-femoral muscles, if thus morbidly affected.

*Vide* PLATE III.

Above the acetabulum, the dorsum of the ilium is seen presenting upon its surface a slight elevation or ridge, which extends from the anterior third of the crest to the upper part of the acetabulum. This ridge, only slightly marked, divides the dorsum into two unequal parts. The more posterior presents a concave surface, which becomes continuous with the margin of the acetabulum, by an inclined plane, upon which the head of the femur, when



dislocated, will glide upwards towards the external iliac fossa upon the dorsum. Below the cotyloid cavity, and between its inferior margin and the tuberosity of the ischium, is the groove in which passes the tendon of the obturator externus; while, posteriorly, are seen the spine of the ischium, still cartilaginous, the groove for the passage of the obturator internus, and the several points which give origin to the small pelvi-trochanteric muscles. In front and below, is the obturator foramen filled by the membrane of the same name, which supports on its two surfaces the origin of the obturator muscles. Extending forward from the anterior portion of the acetabulum, is the horizontal branch of the pubes, terminating in its body. The horizontal ramus gives attachment to the pectineus, while the anterior surface of the body of the pubes and its descending ramus, and the ascending branch of the ischium,—the two last named portions being still cartilaginous,—give points of origin to the other adductors of the thigh. These anatomical details have a bearing upon the mechanism by which malformations, consequent upon the congenital dislocations at the hip-joint, are produced. *Vide* PLATE III.

THE ACETABULUM.—The acetabulum, composed as it is of the three osseous *facettes* which the ilium, ischium, and pubes present upon the inner aspect of its cavity, and the unossified, cartilaginous matrix which exists between



these osseous parts is, in its recent state, about the fifth month of gestation, a shallow cavity of about two lines in depth, and nine or ten lines in circumference. It is lined with synovial membrane for about four fifths of its extent superiorly, and presents a smooth surface—the portion uncovered by membrane being between the notch and the centre. One part of the inferior fifth is appropriated for the attachment of the round ligament; the other, by a fatty cellular mass, which tends, by its position, to diminish the depth of the cavity. The cotyloid ligament surmounts the margin of the semi-osseous and semi-cartilaginous acetabulum, and with the exception of this notch, through which the articular vessels and nerves pass, masks almost entirely the marginal depressions, already alluded to as existing so plainly upon the skeleton.

THE HEAD OF THE FEMUR.—The head of the femur, which, with the acetabulum, composes the ilio-femoral articulation, is entirely cartilaginous during foetal life. It is nearly globular, forming, as it does, a considerable segment of a sphere, which, in the recent state, is about three lines in diameter. The articular cartilaginous surface is covered by synovial membrane, and presents, at its inner and inferior part, a depression for the insertion of the ligamentum teres. It is supported by the *neck*, the pedicle of which is but little developed. The trochanter major is also cartilaginous; it gives attachment to the two

glutei muscles, which take their origin from the dorsum of the ilium, and is apparently continuous with the shaft of the femur; its summit being placed on a plane somewhat below the highest point of the head of the femur.

CAPSULAR LIGAMENT AND LIGAMENTUM TERES — The articulating surfaces of the semi-cartilaginous hip-joint are maintained in their natural relations by means of several ligaments. The capsular ligament, which in the adult is strong, is delicate in the articulation of the fœtus. It is attached on one side to the margin of the acetabulum and the contiguous surface around its circumference; on the other, to the neck of the femur. The accessory fibrous band, which has received the name of *ligamentum superius*, and which, in the adult, strengthens the capsule anteriorly, is scarcely perceptible in the fœtus. The capsule is lined upon its inner surface by a layer of synovial membrane, which passes also over the ligamentum teres and the other parts of the articulation. This capsule, when deprived of the tendinous expansions and muscular tissue, by which it is surrounded, permits the head of the femur to be separated considerably from the cotyloid cavity.

The other ligament, called the *round ligament*, slight and fragile in the fœtus, extends from the apex of the head of the femur, and becomes inserted at the marginal notch as well as at the depression found at the ante-



rior and inferior part of the bottom of the acetabulum.

The intra-articular vessels, which chiefly subserve the nutrition of the head of the bone, pass through this marginal notch, which becomes converted by the *transverse ligament* into a distinct foramen; and finally there is the *cotyloid ligament*, tipping the margin of the cavity with a delicate ligamentous border. *Vide* PLATE III.

In adult life many muscles are grouped around the ilio-femoral articulation, and protect the joint from external injury; but, in foetal life, if struck with the abnormal state of spasmodic retraction to which the muscular system is liable, they become, most probably, the active cause of the displacement of the head of the femur from its natural cavity. Some of these pelvi-femoral muscles, owing to the direction of their fibres, do not participate in producing this dislocation. After birth, however, and at a more advanced stage of the case, and in combination with other causes, such as the superincumbent weight of the trunk, and the ordinary physiological contraction which they then more vigorously exert, they tend to produce by their abnormal *traction* those consecutive malformations of the pelvis, and of the contiguous osseous tissue, that constitute one of the chief complications accompanying the congenital dislocation of the femur upon the ilium. *Vide* PLATE III.

The individual action of the muscles concerned in these results will be more fully stated, when the subject of the pathology comes to be considered.

A consideration of the anatomical disposition thus presented, of the component parts of the foetal ilio-femoral articulation, and of the influence which the strong muscles, inserted into the upper part of the femur, may be supposed to exert when once thrown into a state of morbid *retraction*, will aid materially in removing the difficulties in accounting for the displacement of the femur during intra-uterine life.

The os femoris of the foetus is generally flexed upon the anterior abdominal wall, and consequently the head of the bone is pressed against the posterior and inferior portion of the shallow acetabulum, and of the corresponding part of the capsular ligament. By this disposition of the parts, the head of the femur is supported in its place, as it were, in a sling, composed on one side of the pelvi-trochanteric muscles and of the two lesser glutei. While the femur is in this position, it may easily be supposed that an abnormal and continued spasmodic retraction of these muscles, especially of the glutei, will induce the head of the femur to slip from its cavity over the posterior part of the margin of the acetabulum, upon which is observed the depression, resulting from the unossified space, still existing between the rudimentary ilium and ischium. Having once passed the border of the cotyloid



cavity, the extension of the limb, after birth, will throw the head of the femur still more upon the ilium, and the retracted muscles, continuing to act, in combination with other causes which subsequently come into play, will in the progress of time induce the head of the femur to glide still further in the direction of the fossa, observed upon the dorsum of the ilium, and thus the displacement is effected to its ultimate limit.

## CHAPTER III.

ETIOLOGY OF CONGENITAL DISLOCATIONS OF THE HEAD  
OF THE FEMUR.

LIKE the ordinary traumatic dislocations of the hip-joint, the dislocation we now treat of, implies a removal of the articulating portion of the head of the femur from its natural receptacle, the acetabulum. Occurring during intra-uterine life, it differs materially from the form of dislocation caused by external violence, in its origin, progress, and symptoms; and therefore writers, who have paid attention to this point of surgery, have designated it by a distinctive name. Some have applied the term *spontaneous*; others the term *original*; and others again the term, *congenital*, to this form of dislocation. The term *spontaneous*, however, has also been used, in speaking of the displacement which occurs at the hip-joint as a result of *morbus coxarius*, and it is therefore objectionable. The word *congenital*, as indicating the existence of the disease when the child comes into the world, seems most applicable, and I shall therefore adopt it.

The congenital dislocations of the head of the femur occurring at the ilio-femoral articulation, are either *com-*



*plete* or *incomplete*; and they may exist upon one side only, or, as most frequently happens, the displacement may exist simultaneously on both sides, forming a double luxation.

The head of the femur may be completely dislocated before birth in three different directions:—

*Firstly*, upwards and outwards; this form of dislocation corresponds to that variety which is described by authors as being situated upon the dorsum of the ilium. It is the variety which is most common, and to it practical authors have chiefly directed their attention. The head of the femur is here situated, in the new-born child, above the margin of the acetabulum, and, in the progress of time, mounts upon the dorsum of the ilium, and rests in the *external iliac fossa*.\* Of this variety I have seen many examples, and the accompanying plates, taken from an adult during life,† and also from some dissections I have made, will illustrate the appearance and nature of the luxation in this direction. This form is generally a double luxation, but it is also met with upon one side only.

*Secondly*, the luxation directly upwards. This kind of dislocation has been seen only in those fœtal monstrosities which have been called *agénosome*, in which, with other anomalies, the abdominal walls are not completely developed. The head of the femur is here placed imme-

\* *Vide* PLATE vii.

† *Vide* PLATES i., ii., and iv.

diately external to the anterior and inferior spinous process of the ilium.

*Thirdly* the luxation forwards and upwards. Like the preceding, this displacement has been only met with in the foetal monstrosity. The head of the bone rests upon the *eminentia ilio-pectinea*, and forms a well marked tumor in the groin.

M. Guérin mentions, in addition to the forms already noticed, a sub-luxation upwards and backwards, which in reality appears to be but a modification or incomplete development of the dislocation upwards and outwards.\* He describes it as being characterized by the partial escape of the head of the femur, which does not pass beyond the margin of the acetabulum. This variety is met with in new-born children, and sometimes in cases where luxation from muscular *retraction* has occurred spontaneously soon after birth.

The same author has also indicated two varieties of what he terms *pseudo-luxations* of the hip; one, simulating a luxation backwards and outwards; the other, resembling a luxation downwards and forwards. "There exists," he says, "an order of congenital dislocations of the hip, to which I have given the name of *pseudo-luxations*, because they present the fallacious appearance of luxations, although the head of the femur has not escaped from the

\* Strictly speaking, the head of the femur, in the dislocation upon the dorsum of the ilium, passes upwards and backwards. I have retained, however, the designation adopted by Dupuytren, "*en haut et en dehors*."



cotyloid cavity ; the varieties of these pseudo-luxations are themselves the result of the muscular retraction, differently distributed among the pelvi-femoral muscles."

This pathologic condition of the pelvi-femoral muscles had already been noticed by Delpech,\* and the novelty presented by M. Guérin consists in the adoption of a designating term, which serves a useful purpose in individualizing a class of affections.

From this enumeration of the varieties of the congenital dislocations occurring at the hip-joint, it will be seen that several of them are only to be met with in the imperfectly developed fœtus, and consequently cannot come within the range of surgical practice : others, however, are met with in the living individual, and become the object of remedial attention. The former are interesting in a scientific point of view only ; the latter belong to the practical details of the profession.

To no other class of maladies is the phrase, "*felix qui potuit rerum cognoscere causas*," more applicable than to the congenital dislocations observed at the ilio-femoral articulation.

The researches into the origin and nature of the class of displacements which occur at the articulations of the fœtus, while still in the womb of the mother, have perhaps suggested more ingenious hypotheses than any other of the obscure parts of surgical pathology. Laying aside the predisposition engendered by hereditary transmission,

\* De l'Orthomorphie par rapport à l'espèce humaine.

and by sex, as being generally concurred in, the other causes mentioned by writers, as tending to bring about the dislocation in question, may be referred to different heads. First, external violence, acting upon the fœtus while in utero (*J. L. Petit*); second, a primitive alteration in the germ, or an aberration of the formative power (*force formatrice*) (*Dupuytren*); third, an arrest in the development of the osseous portions forming the cotyloid cavity (*Breschet*); fourth, certain articular maladies, occurring in the fœtus during intra-uterine life (*revived by M. Parise and others*); fifth, a primitive alteration in the nervous centres (*Chaussier*), revived by Delpech and Guérin; and lastly, to be more definite, I would add to the causes mentioned above, a pathological spasmodic retraction of the muscular tissue, *resulting from a perverted or disturbed condition of the excito-motor apparatus of the medulla spinalis; especially of that portion which is in direct relation with the nervous branches distributed among the pelvi-femoral muscles.*

1. EXTERNAL VIOLENCE.—Hippocrates,\* as before stated, says, that children yet contained in the organ of gestation, may have the arms or the inferior limbs dislocated by falls, blows, or by pressure exerted upon the abdominal walls of the mother.

The powerful contractions of the uterus acting upon the extremities of the levers presented by the femurs,

\* Liber de Articulis.



while the thighs are flexed upon the abdomen, and the effect of violent tractions exercised by the *accoucheur* upon the inferior extremities during a difficult parturition, as suggested by Paré, have also been regarded as sufficient to account for the displacement.\*

It is certain that dislocations at the hip-joint, from traumatic causes, are exceedingly rare in early life; and any force originating externally—and of a mechanical kind—of sufficient energy to act upon the fœtus in utero, might be supposed to produce fracture rather than dislocation. The tendency to hereditary transmission, and the frequent occurrence of congenital dislocation in the double form, and closely similar on both sides, would go to disprove the agency of any purely mechanical cause in the production of intra-uterine dislocation of the hip-joint.

The position of the inferior members of the fœtus, while it is contained in the uterus, has been brought forward to give probability to the effect said to be produced by causes of external origin. Before birth, as a general rule, the thighs of the child are flexed upon the abdomen; and the heads of the femurs consequently must make a continual pressure upon the posterior and inferior portion of the capsule of the joint. This circumstance is no doubt favorable to the displacement of the head of the

\* “Ce que aduient aussi souuentesfois aux enfentemens difficiles quand les sages-femmes tirans les bras des enfans, desloquent les iointures de l'espaule ou de la cuisse.”—*Paré, Chapitre 14me, Livre 14me. Edition by Malgaigne—(Old French).*

femur from its natural receptacle, but it is more in co-relation with the agency of morbid muscular retraction, to which further allusion will be presently made. Taking into consideration what has just been stated, and the probable action of more potent causes, originating primarily in the foetus itself, it does not appear that external injury, or mere mechanical agency, could have much influence in the production of intra-uterine dislocations of the head of the femur.

II. AN ORIGINAL DEFECT IN THE ORGANIZATION OF THE GERM, OR ABERRATION OF THE FORMATIVE POWER.—This hypothesis of Dupuytren is sufficiently vague and inexplicit. It refers the origin of the displacement to the first organization of the embryo, or, in other words, to an original vice of conformation, which depends upon a defect in the constitution of the germ. Adopting this theory, he says: "We may very well conceive the simultaneous displacement of both femurs, as is observed in most individuals affected, the perfect health which they enjoy at birth, and the complete absence of morbid action, or of symptoms of a previous or present malady, either around the head of the femur or in the cotyloid cavity."

This hypothesis of Dupuytren is unsatisfactory, and has no support from physiological facts, or the acknowledged doctrines regarding Embryogeny.



III. ARREST OF DEVELOPMENT AT THE COTYLOID CAVITY.—(*Arrêt de développement de la Cavité Cotyloïde.*)—M. Breschet refers the congenital luxations of the head of the femur to the laws, which, from his researches, he supposes, govern the evolution of the osseous system of the fœtus or of the embryo, and he considers these displacements as the result of an arrest of the development of the cotyloid cavity. He asserts that the osseous centres, from which development is last completed, are those from which the cavities and processes result, as is exemplified at the acetabulum, where several osseous pieces ultimately form a junction. It is known that the cotyloid cavity is composed originally of three pieces, and that the complete formation of this cavity takes place only at the late periods of osteogeny. The iliac bones are therefore liable, according to this author, to meet with obstacles in their development at the acetabulum, in which case the head of the femur—not having a proper receptacle—will be carried upwards, beyond the undeveloped cavity. Now, it so happens, that the cotyloid cavity and the head of the femur have both been found progressing to their normal development,\* or to have completed it, in cases of this dislocation which have come under observation; and although the cotyloid cavity in its osseous state is made up by the junction of the three original bones of the os innominatum, yet, according to M. Cruveilhier,† the carti-

\* *Vide* Cruveilhier, Anatomie Patholog.

† Cruveilhier, Anatomie Descript.

laginous matrix of the future bone is present, continuously at all its points, at the same time, and not at isolated points, as is the case with the osseous centres from which the bones are ultimately formed.

For myself, I am not aware of any case having been met with in the foetus, of a defect or perforation occurring at the union of the three bones which constitute the acetabulum, and which, according to the laws of centripetal development,—if the doctrine of *arrêt de développement* be true—would be the point where a deficiency should be found, if any existed. Even supposing that in some instances the head of the bone were deprived of its usual receptacle, by reason of its arrested development, those cases of dislocation, in which there were found to exist a correlative and normal development of the cotyloid cavity, as well as of the head of the femur, could not be explained by this theory. Besides, there frequently come under observation at the other articulations, instances of congenital dislocation, to explain or account for which, M. Breschet's theory would be wholly insufficient.

IV. CERTAIN ARTICULAR MALADIES OCCURRING IN THE FŒTUS DURING INTRA-UTERINE LIFE.—Pathological investigations have taught us that the foetus is liable to many affections while in utero, which may cause death, or terminate in resolution or health, before birth.\*

\* *Vide Cruveilhier's Anatomie Pathol.*



From this fact it was apparently a rational inference to suppose, that the same morbid cause which, in the adult, sometimes produces the *spontaneous* luxation at the hip, might also in the foetus determine the congenital luxation at this joint. This hypothesis is of old date, and has been revived by some recent writers with the parade of originality.\* We find that Paré, alluding to the fact "that a child while still in the womb, may have apostemes, which may open and cicatrize," proceeds to say, "it may happen also that the ligaments which retain the bones at their articulation are not firm, but slender and small in their conformation, or are humid in themselves, and very much lubricated, or moistened by a fluxion of pituitary and mucous humors, which relax, and render soft the ligaments that ought to bind the articulation; and hence the bones are easily displaced at their joints." Also, again alluding to this subject, he says elsewhere, that "the causes are internal, when there are certain humors and swellings, which fall upon the joints in such abundance that they lubricate and relax the ligaments which bind the bones together, and throw them from their socket."†

M. Parise, who is the most strenuous advocate of this theory, states, as his view, that the cause of the ligamen-

\* Gerdy ; Sedillot ; Malgaigne ; Parise.

† Paré, Le quatorzième livre. Edition by Malgaigne.

tous relaxation is an effusion of fluid into the ilio-femoral articulation, whence results the expulsion of the head of the femur from its natural cavity. This author asks: "Wherefore should it not be admitted that a few *decigrammes* of fluid can be secreted in the articulation of the hip-joint, when it is known that among the maladies to which the foetus is liable, articular dropsies are of the most frequent occurrence? . . . . Hereditary predisposition in either case can be as well conceived to exist in regard to a hydrarthrus, as to a vicious development; observations prove that different members of the same family have been attacked with dropsies, spontaneous luxations (*luxations spontanées*), &c. In this hypothesis it is necessary to admit that the luxation once produced, the dropsy disappears, and the dilated capsule returns to its proper dimensions; sometimes, in young subjects, it has been found more dilated, and containing more synovia than in the natural state; but that it should have returned to its nearly natural state at birth, ought not to astonish those who are acquainted with the energy of the assimilating force, and the rapidity of the nutritive revolutions appertaining to foetal existence. . . . . What renders so grave the *coxalgic* affections in the adult, is the extension of the inflammation to the neighboring osseous tissue, whence result caries, suppuration, fistulae. Now, it is not so with the foetus, the cotyloid cavity of which, as well as the head and neck of the femur, are cartilagi-



nous at birth. We do not even know any fact of coxalgia terminating by abscess in children under one or two years of age, although at this period ossification is already advanced." M. Parise, in the above remarks, seems to make no definite distinction between articular dropsy and coxalgia, and to overlook the different results which must follow from a simple effusion into the joint from a common inflammatory action, and that, consequent upon a scrofulous engorgement of the tissues of the articulation. In his hypothesis, on account of the absence, at the time of birth, of any marks of inflammatory disease in cases of luxation, he concedes, that as soon as the displacement is produced, the effusion must disappear, and the dilated capsule return to its natural dimensions. By those who are acquainted with the difficulty of procuring immediate or prompt resolution in strumous affections, this admission—if the effusion accompanying morbus coxarius be meant—could not be assented to; and we are inclined to view the objections urged by Dupuytren against the theory of effusion of fluid, being the cause of congenital luxations at the hip, as repugnant to the explanation given by M. Parise. "Many circumstances," says Dupuytren, "oppose the supposition that the origin of these congenital dislocations can be the same as that of coxalgia, and first, all the individuals in whom the displacement has been observed, had been in good health when they came into the world—a circumstance which would scarcely ad-



mit of the supposition that they had suffered from a malady so grave as that which induces the *spontaneous* luxation of the femur." Moreover, luxation of the ilio-femoral articulation has been met with in the foetus without the presence of any superabundant secretion in the joint.

V. A PRIMITIVE ALTERATION IN THE NERVOUS CENTRES.—The theory, which refers congenital luxations to this cause, will be best considered in connexion with the following :

VI. A PERVERTED CONDITION OF THE EXCITO-MOTOR APPARATUS OF THE MEDULLA SPINALIS.—The different parts of the body are not all developed at the same time. The nervous system begins its evolution primarily, and seems to take precedence and control over the other systems. The circulating organs soon appear, and successively are evolved the muscular, osseous, and other structures.

The muscular tissue is liable to be sensibly impressed by almost every incident which can take place during extra-uterine life, and its dynamic condition is constantly varying even in a state of health. "Comme on le sait, rien n'est plus variable que l'état dynamique des organes de ce système ; dans toute la durée de la vie le moindre événement y exerce une influence plus ou moins marquée. Une maladie aiguë, une lésion organique, une fièvre passagère, une perturbation temporaire dans les fonctions di-



gestives, la gestation, des travaux corporels, une contention d'esprit, le repos prolongé, le seul défaut des exercices habituels, l'abstinence, les excès, la simple frayeur, suffisent pour diminuer notablement, et quelquefois d'une manière grave, la contractilité musculaire."\*

It is reasonable to suppose that a set of organs, which have so extensive a sympathy in the animal economy, must, to a great extent, either in health or disease, be under the immediate influence of the nervous system.

The pathologic states manifested in the muscular system by means of which deformities, subluxations, and luxations at the joints are induced, are, a paralytic state of this tissue; and a morbid, tonic, spasmodic retraction. There is another cause, sometimes producing deformities at the joints through the muscles, which proceeds from direct irritation and the continuance of a vitiated position, such as is seen to result from the influence of rheumatic inflammation; but of this cause, being foreign to our present subject, it is unnecessary to speak farther.

The two causes first mentioned, viz. a *paralytic state of the muscles*, and a *morbid muscular retraction*, although conditions directly opposite to each other, sometimes produce a set of deformities, having, in many respects, a similar appearance. The modes, however, in which the various deformities are thus produced differ entirely.

In the one instance the disturbed relation of the parts

\* Delpéch, De l'Orthomorphie.



is the effect of the action of antagonistic muscles, although enfeebled themselves, overcoming the more defective action of the other set of paralysed muscles. This is well exemplified in those cases of club-foot, which occur from a paralytic state of one set of congener muscles, while their antagonists retain more or less of their activity.

When the paralysis is *entire*, this preponderance of greater apparent power in one set of muscles—almost always of the flexors—over another set, must be attributed to the inherent contractile tonicity, which is peculiar to the muscular system, and not to any influence derived from the nervous system.

In the other instance the deformity, which may be accompanied, or not, with luxation or subluxation, is brought about by a purely *abnormal retraction* of the muscular tissue, evinced by an immovable rigidity which pervades it, and which results from an unnatural tonic spasmodic condition of the muscles. Examples of deformity, proceeding from this latter cause, are also to be met with in cases of club-foot, where the disposition to morbid muscular retraction is localized in one set of muscles, while the other set act only within the range of their healthy contractile power. Some cases of lateral curvature of the spine, of torticollis, &c., may also be referred to this cause.\*

\* Delpech mentions a curious instance, where a complete talipes varus was formed



This abnormal muscular retraction, as has been already said, I believe to be the result of a morbid condition of the excito-motor apparatus of the medulla spinalis, either conveyed to its ganglionic portion, or primarily originating in it, and thence transmitted or reflected upon that portion of the muscular tissue in which the irritation becomes localized and manifested.

The muscular tissue is endowed with the healthy physiological property of alternate contraction and relaxation, which, whether it show itself as the result of volition, of involuntary motion,\* or as the sequent of the action of the excito-motor system, is subordinate to the influence of the nervous centres. Besides this healthy action, it is liable to pathological conditions, which are manifested by

in an adult, consecutively to the paralysis resulting from the division of the ischiatic nerve, by a bullet which traversed the thigh.

The same author mentions also a case where club-foot followed the continued use of an irritating injection in treating an abscess situated at the inferior and inner part of the thigh, and which was accompanied by necrosis. He thus describes the result : " Pendant cette longue maladie laquelle dura trois ans entiers, les muscles de la face postérieure de la jambe souffrant sympathiquement, ou plutôt, par les effets de la participation du nerf crural aux inflammations fréquentes et profondes de la région interne de la cuisse, tombèrent dans un état de contraction tel, que le pied en fut entraîné en bas, et en dedans, et déformé, comme dans l'état du pied-bot le plus complet et le plus avancé qu'il soit possible d'imaginer." Here the irritation must have been transmitted to the muscles producing the varus, or rather it may have been carried to the medulla spinalis, and thence reflected.

\* The functions of the Great Sympathetic Nerve are more or less under the influence of the Cerebro-Spinal System. " Tout ganglion sympathique communique ou bien avec les deux ordres de racines des nerfs spinaux, ou bien à la fois avec des nerfs crâniens moteurs et sensitifs."—*Longet, Système Nerveux.*



disturbance of its normal functions, limited and localized to a particular set of muscular fibres, or diffused more or less throughout this entire system. Farther, the investigations of science have also ascertained, that the morbid state of the muscular system, observed during certain of its diseased conditions, such as paralysis, tetanus, epilepsy, and some other affections accompanied by spasmodic muscular contraction, is likewise subordinate to a pathologic influence, located primarily in the cephalo-rachidian centres, or conveyed indirectly to them. It is therefore a fair deduction, that, as the healthy physiological contraction of the muscles is the result of healthy enervation, so the peculiar condition of the muscles which is manifested by the abnormal tonic retraction and spasmodic shortening of their fibres, is a sequent to the existence of an irritation, or of an altered condition of some kind in the central nervous system.

There is also another function exerted by the muscles, which is peculiar to them, and independent of any influence derived from the nervous system. This inherent property is manifested in certain cases where the influence of the nervous system has ceased to have any agency; the muscles themselves retaining the power of tonic contractility, as is exemplified in the rigid and contracted state of the ventricles of the heart, which occurs within an hour or two after death.\*

\* This inherent tonic muscular contractility is strikingly illustrated by a case



At the present day it is no longer a matter of doubt that the foetus, inclosed in its uterine envelopes, is liable to many of the diseases witnessed in extra-uterine existence.\*

Many years ago the French anatomist, *Chaussier*, from facts which came under his observation, and probably from suggestions derived from the learned *Palleta*, was induced to assert that convulsions might occur to the foetus while still in the uterus, and he was consequently led to refer the occurrence of certain congenital luxations, which came under his inspection, to a morbid alteration of the nervous centres.

The celebrated German physiologist, *Rudolphi*, entertained similar views; and *Delpech* has advanced opinions in corroboration of the dependence of congenital malformations and luxations of the articulations, such as the various forms of Talipes present, upon some morbid affection of the nervous apparatus.

In speaking of the analogy to be observed between club-foot and certain congenital deformities at the ilio-

published originally by Professor Herrmann of Bern, and recorded by Dr. Dewee, in which the contractile power of the uterus three days after death was strong enough to expel twins: "On the third day after the death of a young woman, who was in her sixth month of pregnancy, the nurse heard a loud noise proceeding from the corpse. A physician was immediately sent for, who on his arrival found that the deceased had brought forth twins, which were inclosed in a membrane quite entire, and not in the least putrid. The placenta only appeared to have suffered from the effects of putrefaction."—*Dewees' System of Midwifery*.

\* *Vide* Cruveilhier's Anatomie Pathol.

femoral articulation, owing to muscular retraction, the latter says: "Il nous semble difficile de séparer l'idée de ces déformités, surtout quand elles sont parallèle, répétées dans deux articulations, accompagnées, comme il n'est pas rare de l'observer, de quelques anomalies de plus, dans les articulations des genoux, dans la disposition des muscles de la fesse, de la cuisse, &c.; il nous semble, disons-nous, difficile de séparer l'idée d'une semblable aberration de l'acte nutritive, de celle d'un état anormale antérieure de l'un des grands foyers vitaux; la moëlle épinière, par exemple."

M. Guérin has reproduced this theory, and has extended it so far as to refer to an alteration, or rather to an absence of the whole, or of a part, of the nervous centres, the source of that morbid muscular retraction, which produces the class of deformities to which the foetus is subject, and which consequently have been called congenital. He has carried this theory, however, to the length of attempting to prove that there is always to be observed, a rigorous relation between the absence of the nervous centres, or a portion of them, and the extent, number, and locality of the dislocations which may be present. The labors of Guérin may have tended to give some additional light on this theory, but in his endeavors to simplify a point of science he has generalized too far, and in attempting to make facts square with his views, he has made assertions which have not been substantiated by correct observation.



Although not agreeing with M. Guérin in regard to the invariable antecedence of partial or total destruction, or absence, of the nervous centres, as the cause of morbid muscular retraction, it must be admitted that his remarks are ingenious. As the point in question is one of scientific interest, I have made the subjoined extract from a memoir read by him before the *Academy of Sciences* of Paris, which may serve as a summary of this writer's ideas upon the etiology of congenital displacements of the joints, and among them, of congenital luxation, at the head of the femur.

“ The observation of certain monstrosities presents to us in a striking manner the combination of these four orders of facts, namely, that in them may be observed, at the same time, a material lesion of the nervous centres, the retraction of the totality or of the greater portion of the muscular system, and of concomitant luxations; a rigorous relation between the seat, the extent, and the degree of the nervous lesion, and the seat, extent, and degree of the retraction; and finally, a relation of direction, of extent, and of degree, between this retraction and the dislocations which it produces.

“ I have already frequently shown you, in certain monstrosities, the coincidence of a partial or total destruction of the central nervous system, with a retraction, more or less general, of the muscular system, and the deformation of nearly all the parts of the skeleton, and particularly of



the articulations. Here is a series of anatomical specimens, and of drawings taken from specimens, which I have not been able to preserve, where this double fact appears in the most varied manifestations, from its most feeble and circumscribed expression, to its most energetic and extended. Thus you can see in these facts, cases where the alteration of the nervous centres has been superficial and transient; others, where they have been partially destroyed; and in each of these cases, the retraction of a greater or less number of muscles, and of luxations of the members, are met with simultaneously. And farther, you see represented monsters in which there is at the same time a complete disappearance of the nervous centres, and a retraction of the totality of the muscular system. I present to you in particular a foetus *anencéphale-symèle*, in which you observe, with this same retraction of the muscles, not only a turning of the head behind, and large curvatures of the vertebral column, but also dislocations, which are more or less complete, of the principal articulations, such as the hip-joint, the knees, the feet, the shoulders, the elbows, and the wrists.

“It is evident then that the congenital luxations form a part of a large group of deformities, springing from a common origin, and that they are only special manifestations of the same cause, which can be viewed in an isolated manner, only abstractly, and in relation to the different determinate portions of the skeleton which they occupy.



“ The anatomical circumstances which accompany the two facts, *the existence of which we have just established, viz. the absence, more or less complete, of the nervous centres on one part, and the shortening (raccourcissement) of the muscles on the other, fully demonstrate that the first is the result of a pathologic process, and not of an arrest in the development, as most modern authors have thought ; and that the second is not the result of a retraction, either passive or consecutive.*

“ In the first place one may be assured, by the comparative study of those monstrosities, where a greater or less portion of the brain or of the spinal marrow has disappeared, that the absent portion of the nervous pulp has really existed, but that it has been removed by means of gradual destruction. Without doubt, if we confine ourselves to determine this fact from a fœtus completely anencephalous, it would be difficult perhaps to demonstrate rigorously the anterior existence of this morbid process, of which the principal traces may have more or less disappeared for a long time. But if you consider that the specimens and the plates, now under view, show all the degrees of destruction of the nervous centres following in a decreasing series, which commences at the complete disappearance of the encephalon and the spinal marrow, and closes with a simple lesion of the membranes, you will easily understand by what chain of facts and of induc-



tions I have been enabled to establish rigorously, the reality of this destruction in those cases, where we no longer find the union of all the characters which appertain to it. In the second place, the retraction of the muscles maintaining the articulation displaced, has specific characters which enable it to be distinguished from the consecutive retraction. Thus the muscles are not, as in this last case, shortened merely within the limits of the physiological contraction, and simply between their two points of insertion. But on one part their shortening surpasses by far the range of this contraction; we see, for example, in the same *foetus* the muscles of the spine and the *gastrocnemii*, reduced to a third or a fourth of their natural length; on the other hand, they are in an extreme state of tension, and the osseous parts upon which they are inserted, or which they course along, are often the seat of alterations, of avulsions, and even of fractures, indicating that they have been subjected to considerable violence. Independent of this tension, these muscles present still, by reason of the more or less complete fibrous transformation which they have undergone, an extreme hardness, entirely in opposition to the soft consistence which their fatty transformation gives to muscles shortened consecutively. Finally, the generality of the retraction in a great number of cases, and this remarkable fact, that it takes place simultaneously and symmetri-



cally in the same articulations of both sides, fully show that it is not consecutive, and cannot be in any manner referred to external and local influences.

“ Here then are already established two orders of facts ; the existence of the lesion of the nervous system, and that of muscular retraction, considered in an isolated manner. Now, the relation which directly unites these two facts springs from the constant harmony which they present in their different degrees of manifestation, and in regard to the different portions of the nervous and of the muscular system which they occupy. . . . When besides there is harmony, harmony of seat, and harmony of degree, between the alterations of the cephalo-rachidian centre and the alteration of the muscles, it is impossible not to admit an immediate relation between them. This is constantly seen in cerebral pathology. Now, then, this harmony exists in the case which we are now considering. Examine the specimens which are before you, *and you will see in some of them, that the luxations confined to the inferior extremities coincide with the absence of the inferior portion of the spinal marrow ; the luxations of the superior extremities with absence of the superior portion ; and the luxation of the members upon one side only, coinciding with the absence of one half of the brain.* And here I can only give you rapid indications ; but I have established a decreasing series of cases of luxations, subluxations, and pseudo-luxations, produced by



muscular retraction in its different modes of combination—a series in which one may discover a very manifest relation between the seat and the degree of the destruction of the brain and of the spinal marrow, and the seat and the degree of the deformities of which we are treating. The specimens placed before you belong to this series, and suffice already to establish the existence of this relation.”\*

M. Guérin has here crowded together a number of generalities which it would be difficult for him to support by autopsic observations or physiological facts. In the first place he has in no manner, except by assertion, proved the anterior existence, and consequent disappearance, of the cerebral structure, or controverted the doctrine, now acknowledged, which admits the occurrence of *arrêt de développement*, or, in other words, of a hindrance in the progress of the complete evolution of the ovum, which evolution at the present day, as regards the nervous system, is admitted to extend in the progress of development from the periphery, as well as from the centre.

In the second place, the rigorous relation which he has attempted to determine, as existing between destruction, partial or total, of the encephalon and the medulla spinalis, and certain correlative deformities, is proved by numerous observations to be fallacious.† It is a paradox

\* Guérin, Memoir read before the Academy of Sciences.

† Vide Cruveilhier, Anatomie Pathol.



to say that morbid muscular retraction depends upon an altered condition of the nervous centres, and at the same time to assert that the nervous centres, upon the very existence of which the morbid muscular retraction depends, have ceased to be present. I have seen instances of the existence of general deformities at the joints similar to those mentioned by M. Guérin, and where the encephalon and the spinal marrow were not present; but I cannot understand how these deformities can be reasonably referred to an altered action of the nervous centres, which were found wanting, and which, to all appearance, had not previously existed. In those instances that I have seen, there was no reason to suppose that the nervous centres had existed and afterwards been destroyed. But supposing they had disappeared by means of a pathological process of destruction, their influence would cease with their disappearance, and the condition of things would then be the same as if no brain or spinal marrow had ever existed.

I see no way of accounting for those deformations which are met with at the articulations of the foetus, where no evidences or traces of the cerebro-spinal centres are present, but by referring them to the effect of the inherent contractile tonicity of the muscular system itself. There would certainly be an analogy between deformations thus caused during foetal life, and those instances of deformity arising from paralysis, having for their origin



extensive destruction of the medulla spinalis. In this latter case, the muscular tissue, deprived of the nervous influence derived from the medulla spinalis, acts independently of the nervous centres; and its inherent contractile tonicity predominating, as is the case in health, in the flexor muscles generally, determines the consecutive deformity, in the direction of the action of this set of muscles. It is so also with those monstrosities I have just mentioned, for the deformities present in them, were generally manifested in the direction of the action of the flexor muscles.

In regard to the other statement, that the absence of the inferior and superior portions of the medulla spinalis, and of specific portions of the brain, is followed by deformities, or by dislocations at specific articulations, I have merely to remark, that pathological observations do not corroborate the assertion. Besides the instances which have come under my own examination, the cases reported by Cruveilhier and others go directly to prove, that no such relation, as that upon which M. Guérin founds his theory, exists.

If the total or partial absence alone of the nervous centres were the invariable cause of congenital deformities, then they must occur as an invariable sequent, when this absence of the nervous centres takes place, and in proportion also to the greater or less disappearance of the nervous substance. In other words, there could be no



congenital displacements without absence of some portion of the central nervous system, nor could there be any foetal anencephalous monstrosities, without the existence of numerous luxations or subluxations.

As soon as the correlation of circumstances, reported by M. Guérin, is found to be at variance with facts, the generalization he has adopted, must be pronounced fallacious. Now, anencephalous foetal monsters are to be met with, in which no dislocations of the articulations are present, and it is no uncommon event to see congenital dislocations attributable to muscular retraction—not only of the hip-joints,—but also of many of the other articulations, without any palpable absence of the nervous centres.

Thus, in those cases I have to relate hereafter, and from which I have had the drawings taken, there was no absence of the nervous centres apparent, nor in the cases related by Palleta and Dupuytren, is the absence of any portion of the spinal marrow or of the encephalon alluded to.

The physiology of the nervous system, and its influence over muscular contraction, will nevertheless induce the inquirer to look to the centres of this system as the source, whence is radiated the pathologic influence, which manifests itself in the muscles, in the form of morbid muscular retraction, and upon which probably depend many congenital dislocations, and among them the dislo-



cation of the head of the femur from the cotyloid cavity. This doctrine is the most philosophical among the various theories which have been brought forward to account for the displacement, and seems to be corroborated by physiological induction.

The nervous centres of the cerebro-spinal axis are composed essentially of a grey or cineritious matter, which forms the ganglionic part, and the white fibrous or tubular structure, which is more or less intimately connected with the former. The physiology of the present day teaches us, that the grey material or ganglionic structure, is the source from which enervation emanates, and that the fibrous or white matter is the conducting medium, by means of which the various functions of sensation and motion, whether voluntary, involuntary, or consensual, are carried on. The cephalo-rachidian mass is formed by an aggregation of the fibres of the white tubular nervous substance, into a large nervous cord, composed of several columns or strands, which ascend, under the name of the medulla spinalis, through the osseous canal formed by the several vertebræ. Most of the fibres of these strands, emerging from the medulla oblongata, traverse successively, from behind forwards, the pons varolii, the tubercula quadrigemina, the optic thalami, and the corpora striata, and are then radiated in the cerebral lobes; while some pass to the cerebellum. Interspersed in different directions, and bear-



ing certain anatomical relations to the white fibrous structure, the vesicular grey matter is found, forming the several ganglionic centres, which, in conjunction with this white fibrous structure, are subservient to the performance of the several functions peculiar to the cerebro-spinal system. These various fundamental parts, besides the decussations which take place in certain directions, are more intimately connected by another set of white fibres, which are called commissures, and which run in such a direction as to form various communications between the different parts of the brain, but chiefly between the analogous organs of one side with those of the other.

Commencing above, we find the cerebral hemispheres covered by the hemispherical ganglia,\* holding a close relation with intelligence, and other psychological phenomena. These lie above the grey matter of the corpora striata and of the optic thalami, as well as above the ganglia which are in immediate connexion with the organs of special sense; the medulla oblongata furnishes ganglionic centres for the movements of respiration, mastication, and deglutition; from the upper portion of the medulla oblongata the cerebellum shoots off, supplied with its cineritious matter; and lastly, a continuous track of grey or cineritious matter, analogous to the chain of the locomotive ganglia in the articulata, is found extending the whole

\* *Hemispherical ganglion* is the term applied by Mr. Solly to the cineritious matter capping the cerebral hemispheres.



length of the medulla spinalis, invested by the white fibres of the tubular structure.

Besides contributing to the performance of certain other functions, most of these various cineritious deposits or ganglia are the centres of a class of exceedingly important phenomena in the animal economy, which in latter times have been denominated the excito-motory or reflex functions of the nervous system.\* Certain reflex movements are admitted by some modern physiologists to emanate from the ganglia contained in the cranium; but the medulla spinalis is undoubtedly the centre of the excito-motor functions manifested in the organs of locomotion.

The peculiarity of the healthy nervous action, termed reflex, consists in the occurrence of muscular movements or contractions, as the sequent to impressions, not involving sensation or consciousness, and taking place through the medium of a set of incident-excitor nervous fibres, and another set of reflex-motor nervous fibres, both of which are in connexion with the cineritious ganglionic mass, acting as the centre of the excito-motor circuit.

Examples of muscular movement, entirely independent of volition or of sensation, are presented in the experiment upon a frog which has been decapitated; the spinal marrow being left uninjured. In such a case, if the pat

\* This class of motor functions, independent of sensation, was known to Prochaska. The writings of Dr. Marshall Hall and of Müller have, however, greatly elucidated this subject in more recent times.



of the frog be touched with nitric acid, or any other sufficiently powerful irritant, the animal will evince muscular contraction of the limb, as if from volition.

The medulla spinalis, viewed as the centre of the spinal excito-motor system, offers other points for consideration in regard to its extensive connexions.

The thick cord which composes this portion of the cerebro-spinal axis, is distinctly a double tract, although united by numerous commissural bands, and is divided into two equal parts by an anterior median and a posterior median fissure. Each half is again subdivided into two columns—a posterior and an antero-lateral column—forming the strands for sensation, and for motion.

On each half of the spinal column three furrows are observed, one, called the posterior intermediate furrow, which commences on the outside of the small protuberance adjoining the nib of the *calamus scriptorius*, and terminates towards the middle of the dorsal portion of the medulla spinalis; another, situated a little outside of the preceding, called the postero-lateral furrow, extending the entire length of the spinal cord; and the third, extending the same length, called the antero-lateral furrow, situated a little external to the anterior median fissure. From these last two lateral furrows, on each side, spring the several spinal nerves, which are distributed to the organs of locomotion. All the spinal nerves\* emanate

\* The first spinal or sub-occipital nerves sometimes arise by a single set of roots, from the motor columns.



from the cord by two roots; an anterior, subservient to motion, which is seen to emerge from the antero-lateral furrow. and a posterior, subservient to sensation, which is implanted in the postero-lateral furrow. Upon the posterior root, at the intervertebral foramina, a ganglion is formed, immediately external to which, the two roots interlace, and unite into one cord, whence result the several branches which pass onwards to their ultimate distribution.

In tracing the roots of the spinal nerves into the substance of the medulla spinalis, we find that each root becomes connected by some of its fibres with the peaks which the cineritious matter of the cord forms, in approximating the antero-lateral and postero-lateral furrows on each side. The course and direction which the other nervous fibres take, after their junction with the cord, has not been clearly demonstrated in man, although from physiological analogy they no doubt become continuous with the white fibres of the spinal strands, and ascending with them, communicate with the encephalon.\*

\* *Vide* Grainger, Observations on the Structure and Functions of the Spinal Cord.

The anatomical connexion between the spinal cord and the roots of the rachidian nerves is a point of much interest, both in a medical and surgical point of view. From dissections made by Mr. Newport of some of the *Articulata*, it would appear "that of the fibres, constituting the roots, by which the nerves are implanted in the ganglia of the ventral cord, some pass into the vesicular matter of each ganglion, and after coming into relation with its vesicular substance, pass out again on the same side; while a second set, after traversing the vesicular matter, passes out by the trunks proceeding from the opposite side of the same



From this cursory statement it will be seen that the spinal column, besides the component parts necessary for the transmission of sensation and of voluntary motion, has in its composition the structural elements necessary for the performance of the excito-motor functions. Thus, there are the longitudinal white fibres ascending towards the encephalon; next, invested by these, is found the crescentic-shaped grey ganglionic mass; and in direct connexion with this cineritious nervous pulp, are the fibres appertaining to the double roots of the spinal nerves, some of which fibres join the ascending strands, and subserve volition; while others terminate more abruptly, and are subservient to the incident-excitor and reflex-motor action of the medulla spinalis.

It is a well ascertained fact that the posterior root of the spinal nerves is the structure, by means of which impressions are conveyed centripetally to the nervous centres, and also that the anterior root is subservient to the excentric or motor functions which take place in the

ganglion; and a third set runs along a portion of the cord which connects the ganglia of different segments, and enters the nervous trunks that issue from them, at a distance of one or more ganglia above or below. Thus it appears, that an impression conveyed by an afferent fibre to any ganglion, may excite a motion in the muscles of the same side of its own segment; or in those of the opposite side; or in those of segments at a greater or less distance, according to the point at which the efferent fibres leave the cord." This arrangement has not hitherto been discovered in man, but physiological facts would induce the belief of a similar arrangement, which would account anatomically for many of the complex phenomena of reflex action.—*Vide Carpenter's Physiology, and Newport, in Philosophical Transactions, for 1843.*



muscles, as the result of impressions. These facts are determined by what follows upon the section of the two roots of the spinal nerves. Thus, after the section of the posterior root, if an irritant be applied to the remote divided end, there is no manifestation of sensation ; while, if it be applied to the divided end near to the cord, the animal will show evident symptoms of pain. The contrary effect is observed when the anterior root is divided ; in that case muscular contractions follow the application of the irritant to the remote divided extremity of the nerve, while no manifestation is made when the stimulus is applied to the divided end next to the cord.

Here we have an *afferent* set of fibres which convey impressions to the central nervous system, and another set of *efferent* fibres, conveying thence the motor impulse to the muscles. There is no doubt that many of the sensations and manifestations of voluntary motion ascend to, and descend from, the encephalon, along the spinal strands ; but there is another set of muscular motions which are not attended by consciousness, and are wholly independent of the will. With the exception of those involuntary movements depending upon the influence of some of the inter-cranial cineritious masses,\* the class of

\* The reflex functions of the medulla oblongata, which is viewed merely as a prolongation of the medulla spinalis, are comprised in the spinal excito-motory system, as recognised by Dr. Marshall Hall. But Müller has gone further, and applied the principle of reflexion which takes place from the sensorial nerves upon the motor nerves, through the medium of the encephalic ganglionic masses, to the theory of all automatic movements consequent upon sensations.—*Vide Müller, Physiolog. Nerv. Syst.*



involuntary movements are dependent for their exercise upon the medulla spinalis. The grey cineritious mass of the spinal cord is the centre or source of enervation of these movements which are unconnected with volition ; and those fibres of the various nerves that are in direct connexion with it, are the incident-excitor and reflex-motor conductors, which, by their junction with the grey ganglionic mass of the medulla spinalis, form the true spinal excito-motory system.

The experiment of the decapitated frog, already alluded to, will serve to illustrate this principle. The head being removed, the influence of volition is at an end. But when the pat is irritated by the application of an ignited match, or any other efficient irritant, muscular contraction immediately takes place, and an apparently voluntary effort is made to escape from the effects of the irritant. If, however, the integrity of the spinal marrow be destroyed by passing a wire down the vertebral canal of the animal, no irritant, however powerful, applied to its foot or its cloaca, will excite any muscular movement.

Again, as is observed in the human subject, in cases of accidental fracture of the vertebræ, with serious lesion of the spinal marrow of the dorsal region, both voluntary motion and sensation are entirely destroyed in all the parts below the point of the solution of continuity. Notwithstanding the isolation of the inferior portions of the body from the encephalon, reflex movements can be

excited in the limbs by irritants applied to the feet, the anus, or any other part of the surface below the injured point. Here we have the manifestation of the normal reflex action of the spinal cord. The excito-motor circle is brought into play by the afferent conducting fibres, which convey the impression to the ganglionic centre. Thence, by means of the efferent set of fibres, the impression is again transmitted to the locomotor muscles, which consequently are thrown into a state of contraction.

The examples of the influence of the healthy excito-motory functions of the spinal cord over certain actions of the muscular system are numerous, but it is unnecessary at present to draw upon them for further illustration. Enough has been said to exhibit the principle upon which a large class of normal muscular phenomena depends.

Notwithstanding the assertion, already commented upon, of M. Guérin, that absence of the brain and spinal marrow are the essential antecedents to the production of congenital dislocations, I am inclined to believe that their origin must be accounted for in a different manner; and that derangement of the functions of the spinal excito-motor system must be regarded as the true cause of those congenital dislocations, which are the result of morbid muscular spasmodic contraction; and it is to that source I would attribute the dislocation of the hip-joint occurring to the child while still in utero.



The peculiar functions of the excito-motor apparatus, like the functions of the other portions of the nervous system, may become perverted or disturbed by pathological influences. It is probable that all spasmodic convulsive muscular movements, taking place in the different parts of the body, originate from the same principle, whether from reflex action of the spinal marrow, of the medulla oblongata, or of the nervous apparatus in connexion with the encephalic ganglia.

Examples of this perverted function of reflex action are met with in the symptomatic phenomena which are to be observed in tetanus, hydrophobia, epilepsy, &c.

It is to a morbid condition, then, of the reflex function of the spinal cord that the peculiar tonic spasmodic retraction of the muscles should be referred, which, either during intra-uterine or extra-uterine life, is sometimes seen to pervade the entire muscular system,\* or at others to show itself, by attacking in an isolated manner, a single set of muscles only, or within still narrower limits, by being confined to a few muscular fasciculi.

When the antagonistic muscles are equally affected, so

\* A case was shown me, while in London, by Mr. Tamplin, the eminent surgeon of the Orthopædic Institution, which exhibited in a remarkable degree this morbid tonic spasmodic muscular retraction. All the muscles of locomotion were affected, so that the trunk and limbs of the patient, a lad aged about fourteen, were in a state of absolute rigidity. The different sets of muscles, however, in this instance were equally affected, so that the flexors and the extensors antagonized each other, and consequently there was no deformity of the articulations.



that an equilibrium is still maintained, the relations of the articulating surfaces of the joints to each other are not disturbed; but in those instances where the retractive spasmodic influence appears to be particularly concentrated upon one set of congener muscles, luxations or subluxations are likely to occur.

Muscular spasmodic retraction, resulting from a perverted state of the excito-motor apparatus, may take place from irritation, whether localized at the periphery, or at some point along the course of the afferent or incident-excitor nervous fibres; or it may show itself, when the irritation is localized in the central ganglionic mass itself of the spinal cord; or it may result from this nervous centre being in a state abnormally susceptible to impressions. In this latter condition, a morbid train of reflex muscular movements is put into operation upon the occurrence of some trivial irritation of the afferent nervous fibres, which are proceeding towards the ganglionic centre of the cord. From the ganglionic centre, the morbid impression is ultimately transmitted to the muscles, through the agency of the reflex-motor nervous fibres.

Whether the irritation is primarily located in the central grey substance of the medulla spinalis, or is conveyed there by means of the incident-excitor fibres—whose function it is to convey impressions to it—I believe it is absolutely necessary that this ganglionic focus of enervation should be morbidly impressed, before the muscles



supplied by the reflex-motor nervous fibres can be thrown into convulsive spasm.

I should say, then, that the congenital displacements, occurring at the ilio-femoral articulation, result from active morbid muscular retraction ; that morbid muscular retraction itself is to be traced to a morbid condition of the central ganglionic mass of the cord ; and that this pathological condition is either located in the ganglionic mass, or conveyed thither by the incident-excitor nervous influence of the excito-motor apparatus of the medulla spinalis.

When the shallow condition of the acetabulum, and the flexed position of the thighs of the fœtus in utero—causing the head of the femur to press continually against the depressed lip of the acetabulum—are considered, it will not be difficult to comprehend the facility with which the head of the femur may escape from the cotyloid cavity, if the glutei muscles and the other pelvi-femoral muscles are thrown into a state of spasmodic muscular retraction.\*

It is probable, in congenital dislocation of the hip-joint, that the cineritious substance of that portion of the medulla spinalis, in direct relation with the reflex-motor nervous fibres which are distributed to the glutei and the other pelvi-femoral muscles, is the implicated point, from which the morbid impressions radiate, that ultimately affect the muscular tissue.

\* *Vide* PLATE III.



The numerous incident-excitor nervous fibres which are connected with the cord, the extensive communications existing between the various portions of the nervous system by means of the longitudinal fibres of the spinal strands and of the commissures, and the decussations which take place in certain directions, will serve to explain the facility with which impressions, arising from irritation located at a distance, may be conveyed towards certain points of the ganglionic portion of the nervous centres.

What this particular source of irritation or pathologic action—the necessary antecedent of morbid muscular retraction—may be, it is not easy to determine strictly. Whether it amounts to inflammation; or to *ramollissement*; or to vascular congestion of the cineritious matter, or of the white structure in contiguity with it; or simply to what is called nervous irritation, caused by pressure or otherwise; or whether it depends upon an abnormal accumulation of nervous fluid, which by some has been supposed to be as noxious in regard to the nervous substance, as the accumulation of blood in an inflamed tissue is to the several structures of the body; or whether from some poisonous condition of the blood—the nervous tissue bathed by this fluid as it circulates becoming morbidly impressed;—or whether an imperfect development of a portion of the medulla spinalis, or an atrophy of it, be essential, in producing this disturbance of



the excito-motor apparatus, are points which can only with great difficulty be decided in a rigorous manner.

Acute spasmodic muscular affections may have various *remote* or *ultimate* causes for their production,\* and it is not improbable that the sources of irritation above enumerated may at times act singly or conjointly, in arousing the more chronic form of spasmodic contraction, which shows itself in a tonic rigidity and retraction of the muscular tissue.

Pathological facts, then, will not sustain the theory, which supposes mere absence of the nervous centres to be the invariable cause of the spasmodic muscular retraction, upon which congenital displacements depend. Neither will facts derived from physiology induce this belief. Thus, if M. Guérin's assertion were true, that all anencephalous fœtal monsters present numerous luxations throughout the body, and that these are in proportion to the quantity, and in relation to the part of the brain, which is wanting, we should be led to believe that convulsions and spasmodic muscular movements would be produced by removal of the brain from an animal in the experiment of vivisection.

That this is not the case any one may determine by removing, for example, the cerebral lobes of a pigeon, leav-

\* Examples of this kind are the spasmodic muscular contractions which follow the exhibition of Strychnine,—occur in Traumatic Tetanus,—in Idiopathic Tetanus,—result from the virus of Hydrophobia, &c.

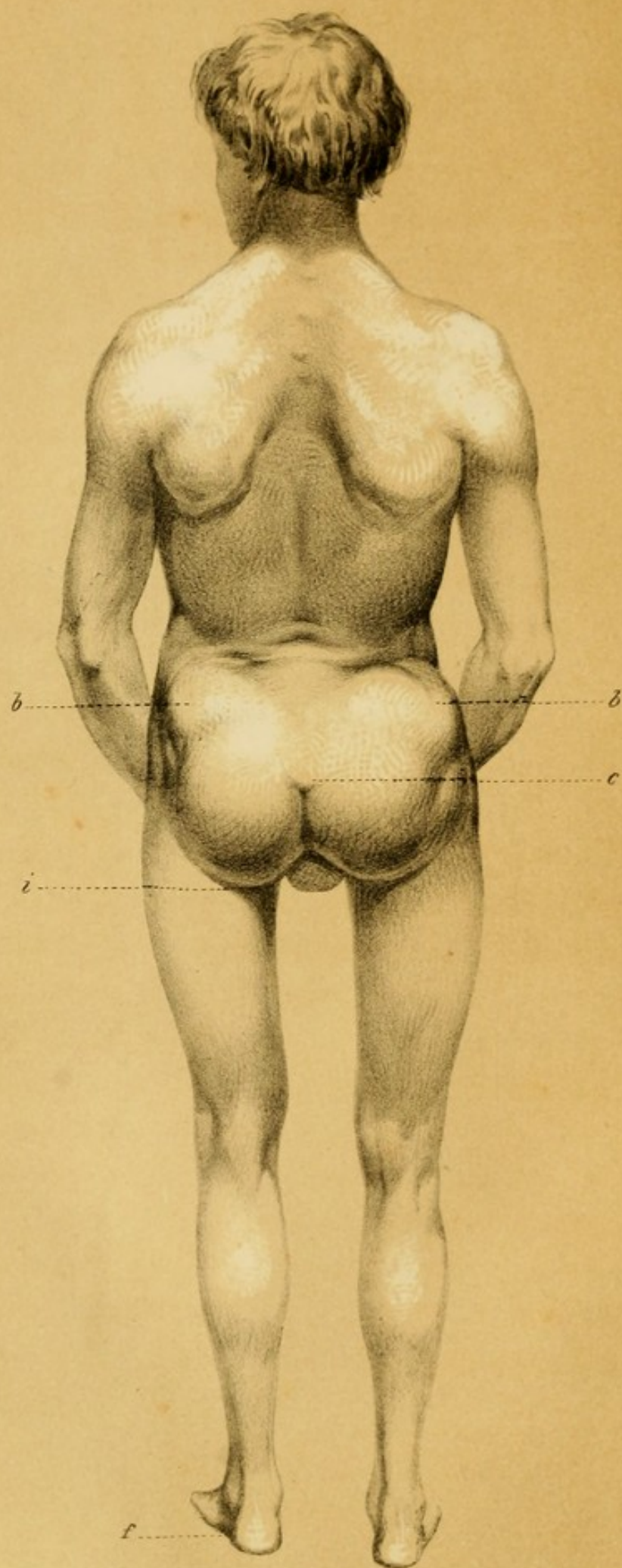


ing, however, the nervous apparatus of respiration, and of the other animal functions, intact. The animal thus treated, not only manifests no symptoms of convulsive muscular movements, but the muscles of respiration act normally for several days, and even the functions of walking and flying can be induced by pushing the animal onward, or by throwing it upward in the air; no evidences of spasm or of irregular muscular action being apparent.

After the examination of these various theories, I shall conclude these etiologic remarks by saying, that it appears most in accordance with science to refer the muscular spasmodic retraction, upon which congenital dislocation of the head of the femur from the cotyloid cavity depends, to a *perverted condition of the excito-motor apparatus of the medulla spinalis, and more especially of that portion of it which is in direct relation with the reflex-motor nervous fibres, distributed to the pelvi-femoral muscles surrounding, and in connexion with, the ilio-femoral articulation.*









#### EXPLANATION OF PLATE No. IV.

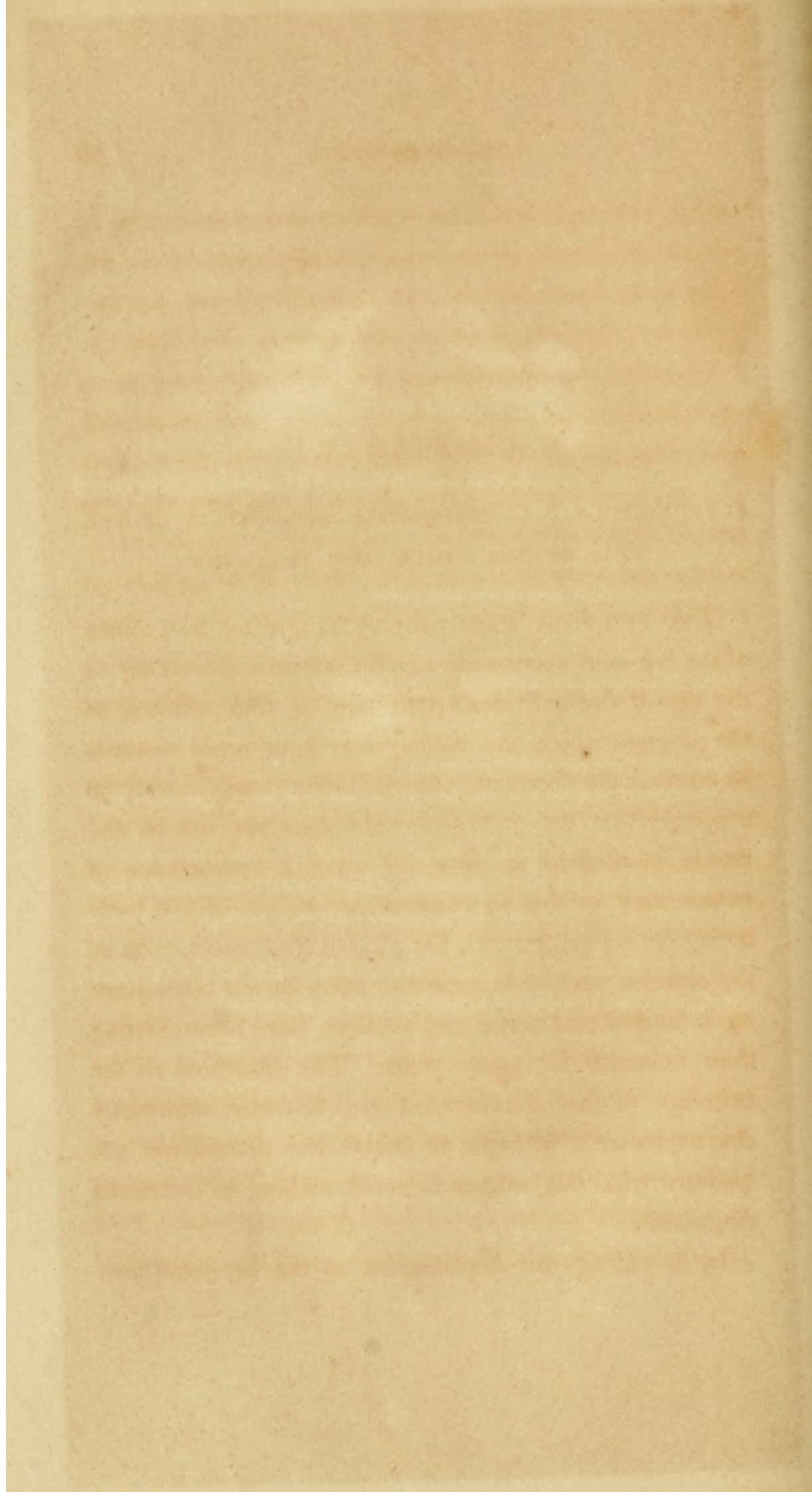
Posterior view of Double Congenital Dislocation of the Head of both Femurs upon the dorsum of the Ilium.

- b.* Trochanter Major.
- c.* Os Coccygis tilted upwards and backwards.
- d.* The Lumbar Region curved forwards by the traction of the Psoæ Muscles.
- i.* The fold between the buttock and thigh.
- f.* The Feet—directed forwards.

The case from which plates Nos. i., ii., and iv., were taken, came under my observation while I was temporarily in London.

The drawing was taken by Mr. Kearney, an excellent draughtsman, attached to St. Thomas' Hospital as Curator of the museum.

The surgeons of that hospital expressing a desire to see the case, as they were not acquainted with this form of dislocation of the hip-joint, I sent the lad for their examination. Mr. South, one of the eminent surgeons attached to St. Thomas', concurred with me in my diagnosis, and requested me to permit a full length cast to be taken of the case for the museum. I reported this case in the London Lancet, 1844, an abstract of which will be found in the following chapter.





## CHAPTER IV.

SYMPTOMATOLOGY OF CONGENITAL DISLOCATION OF THE  
HEAD OF THE FEMUR UPON THE ILIUM.

THE symptoms accompanying congenital dislocations of the hip-joint necessarily vary in intensity, according to the age of the individuals that may be thus affected, or the progress which the malady may have made towards its extreme development. In the infant it may readily be supposed that the pathognomonic signs are not so distinctly marked as in after life, when a combination of causes, such as the superincumbent weight of the body acting during progression, the physiological contraction of the muscles, and their imperfect development consequent upon their altered action and relations, have been exerting their influence for many years. The evidences of the existence of this displacement are, however, sufficiently characteristic, at all ages, to enable the practitioner acquainted with this subject to avoid making an erroneous diagnosis.

In describing the displacement at the hip-joint, now

under consideration, which, if not arrested or remedied in the early stages of life, is generally progressive in its course, I have preferred to delineate the symptoms as they are presented towards the period of puberty or adolescence, presuming that the general characters when once known, as they appear in a marked degree of development, could not easily be mistaken when met with in a form less distinctly defined.

As has previously been remarked, the head of the femur may be dislocated from the acetabulum in several directions. We shall pass over, however, those variations which occur in monstrosities only, and direct our attention to that form of displacement which is met with in practice, and in which the head of the femur is found upon the ilium, immediately above and behind the cotyloid cavity, or completely upon the dorsum of the ilium, according to the stage at which the examination of the luxation may be made.

The congenital dislocation upwards, and outwards upon the ilium, is found at times to be present simultaneously in the same individual, on both sides. In other instances the luxation exists on one side only.

The changes which have taken place in cases of this dislocation can be best studied by observing the malformations which are seen upon inspecting the patient when entirely stripped of clothing; by tracing the altered relations of the component parts of the ilio-femoral arti-



ulation, discoverable by manual examination; and by regarding the functional disturbance occurring at the joint itself, in reference to its various movements.

DOUBLE CONGENITAL DISLOCATION OF THE FEMUR UPON THE ILIUM.—When the dislocation is on *both sides*, as is most frequently the case, the deformity is often symmetrical. Both of the inferior extremities may have the same development and length, but the body being generally well formed, a marked disproportion is seen to exist between the relative height and size of the trunk, and the apparent shortness of the lower limbs.

Upon viewing an adult person while in the erect posture, affected with this kind of double luxation of the femur upon the ilium, the curvature forwards of the lumbar region, and the convexity which the anterior wall of the abdomen presents, are apt to be among the first characteristic features of the disease, which attract the attention of the surgeon. The pubic region appears to be tilted forwards and downwards, while the lower part of the trunk appears to have sunk down between the upper portion of the thighs; and this last circumstance, which actually takes place on account of the ascent of the ossa femorum, gives to the arms the semblance of being relatively too long, the extremities of the fingers ranging sometimes nearly on a level with the upper margin of the patellæ. *Vide* PLATES I. and II.



Both of the great trochanters project abnormally, and are seen to have mounted considerably higher, so as to be situated nearer than is natural to the crests of the ilia, forming with the retracted muscles which surround them, an unusual eminence, somewhat rounded on each side, at the superior and lateral part of the hip, while the lower and posterior portion of the nates is generally flatter than in the healthy condition of this region. The tuberosities of the ischia, carried outwards and more apart from each other, are denuded of muscular tissue, and covered only by the integuments.

The fold in the groins is deeper, its direction less transverse and more vertical, and the usual niche between the buttocks and the thighs is placed higher, and more curved outwardly than it ordinarily is.

The whole of the inferior extremities, probably owing to want of exercise, as well as to the imperfect development, which takes place from defective nutrition, and which manifests itself in the muscular and osseous tissues in this affection, appear more slender than is observed in a healthy individual.

The thighs sometimes retain their normal direction ; at other times they take an oblique direction from above downwards and inwards, forming with the leg, at the femoro-tibial junction, an angle obtuse outwardly, while the knee presents internally an unusually acute angular aspect.

Persons affected with this dislocation, when standing



erect in a passive state, can always, I believe, rest upon the entire sole of the foot. In this posture the muscles around the hip are more relaxed than when put into contraction, during the various exercises of progression or locomotion, and the femurs are thus allowed to ascend to their ultimate limit upon the iliac bones.

As a consequence of this ascent, the psoas magnus and iliacus internus muscles of either side are put upon the stretch, and draw forwards the lumbar and lower dorsal vertebræ, and thus in the most marked degree can be seen the unnatural excurvation of the loins with the corresponding exaggerated convexity of the anterior region of the abdominal parietes. Dupuytren says, "*ils ne touchent le sol que par la pointe des pieds.*" Observation, however, goes to contradict this assertion of the celebrated French surgeon. It would seem, in fact, that in the passive erect attitude, the patient can rest fully upon the soles of both feet; but, while the heel is descending to the ground, the lumbar region becomes still more incurvated, owing to the increased traction then exercised on both sides by the tendons of the psoas magnus and the iliacus internus.

The position of the patient remaining the same, the toes are frequently directed straight forward, as exhibited in the drawings,\* a reference to which will aid materially in following the verbal description given. Sometimes, however, the posture of the individual varying, the feet

\* Vide PLATES I., II., and IV.



may be turned outwards ; or inwards, as is the case in the corresponding dislocation of traumatic origin.

One of the most characteristic differential signs of congenital dislocation of the head of the femur upon the dorsum ilii, is the disappearance, as soon as the patient is placed horizontally on the back, of most of the symptoms observable to the eye, when he is standing in the erect posture. The superincumbent weight of the trunk is then removed, and the muscles around the articulation now permit the great trochanters to descend to a nearly natural position ; and as the small trochanters also approach their normal situation, the *psoæ* and internal iliac muscles become relaxed, and thus the curvature of the loins, and the corresponding convexity of the abdomen anteriorly, become diminished or effaced.

By the aid of manual examination, signs are discovered not less worthy of note than those which are observed by mere inspection. If traction upon the limb be exercised, so as to act from above downwards, the limb becomes elongated, the head of the femur descends, the great trochanter becomes more separated from the crest of the ilium, and the projection they previously formed, is found to have diminished ; while on the contrary, if force in an opposite direction is applied, that is, from below upwards, the head of the femur does not meet with resistance at the natural locality of the acetabulum, but mounts with facility to its abnormal position upon the dor-



sum ilii. The evidences of this symptom have been denied, and they have been attributed to a want of proper precaution in fixing the pelvis, while the traction was made upon one side; but in those cases where the dislocation exists on both sides, both limbs can be made to descend at the same time, and often to the same extent, when they are both simultaneously pulled upon. The only exception to this symptom occurring, is when the head of the femur has escaped from the natural capsule in which it was originally enclosed, and a new socket has been formed upon the dorsum of the ilium; after the manner of those new formations, which occur as the result of traumatic dislocations in this region. Under these circumstances, it will naturally follow that the head of the bone will be more or less confined in its new situation, and will be less influenced by motion imparted to it, than when it simply reposes on the surface of the ilium, unfettered by any adventitious osseous effusion in the shape of a new receptacle or acetabulum.

When the head of the femur exists, if a motion of flexion be given to the thigh upon the pelvis, the head of this bone, instead of turning upon its axis, will describe an arc of a circle, the centre of which will seem to be at the union of the neck with the trochanter major. This sign, under some circumstances, may be of service, but as the head and neck of the femur are often stunted and small, and sometimes even altogether removed during



the progress of the displacement, it must frequently be inapplicable and deceptive.

When the head of the femur is in its natural position, it can be felt by exploring the fold of the groin during rotation of the limb outwards. In seeking after this sign, the hand is made to grasp the upper and outer part of the thigh, so that the thumb may be placed transversely in the fold of the groin, a little external to the point where the pulsation of the femoral artery can be felt. If a movement of rotation be then given to the abdominal extremity, the head of the femur, if it be in its natural place, will be felt rolling under the thumb. The absence of this sensation of a rounded body moving under the finger, as M. Pravaz remarks, is a certain sign of displacement.

In obscure cases, as may occur particularly in young subjects, the diagnosis may be rendered more certain by tracing a line—having first flexed the thigh upon the pelvis, and given it a slight adduction—from the anterior superior spinous process of the ilium, to the most salient point of the tuberosity of the ischium. This line will, in the normal position of the head of the femur, nearly correspond with the summit of the trochanter major; while if the head be dislocated upwards and outwards, it will pass over the central part, or more towards the base of this process, according to the extent of the displacement. *Vide* PLATE V.

The functional derangements of the joint are made



manifest by the peculiarities observable during the different acts of locomotion, and by the confined or exaggerated movements which the joint can be made to perform.

An adult person laboring under the effects of dislocation of the heads of both femurs, presents peculiarities in his gait during the diversified efforts of using the inferior extremities, which are not to be met with in any variety of lameness resulting from the other maladies occurring at the hip-joint. In walking, owing to the want of fixedness of the heads of the femurs, and the displacement which they must undergo of alternate depression and elevation, according as the weight of the body is transferred from one inferior member to the other, and also owing to the strain which is put upon the psoas and the internal iliac muscles upon the side where, for the moment, the weight of the trunk is thrown, a kind of double lameness is produced, somewhat resembling the hobbling motion of the duck. "The subjects so affected, when about to commence walking, are seen to elevate themselves upon the point of the feet, to incline the superior part of the trunk towards the member which is about to support the weight of the body, and to lift the other with an effort, in order to bring it forward in advance. At this moment one of the great trochanters—that which corresponds to the column of sustentation—appears to become approximated to the crest of the ilium in a greater degree than while standing upon both feet. From this mobility in



the vertical direction, oscillations of the trunk take place, which render the walk as inconvenient as ungraceful. 'These oscillations are often accompanied by a crepitating sound loud enough to be heard at a distance of several paces.'

Contrary to what might have been anticipated, the effects, resulting from the abnormal condition of the heads of the femurs, after they have lost their natural support at the cotyloid cavity, and have mounted on the dorsa of the ilia, are less observable during the acts of running, leaping, dancing, &c., than during simple or slow progression. This can be accounted for, by the energetic contraction of the muscles surrounding the hip-joints retaining the heads of the femurs in a more fixed position during these quick movements, and by the rapid transfer of the weight of the trunk from one extremity to the other, which does not allow time enough for the heads of the femurs—thus somewhat solidly held by the muscles—to pass through their accustomed range along the external surface of the iliac bones. Protracted locomotion, however, of any kind is not borne well by individuals thus affected. The strain upon the muscles, consequent upon their change of direction and perverted action, the friction of the displaced heads of the femurs upon the ilia, the constant efforts kept up in balancing the body during the acts of progression, do not fail, if long continued, to produce the sensation of fatigue and pain.

As regards the isolated movements, which can be pro-



duced at the ilio-femoral articulation thus affected, by imparting motion to it through the inferior extremity, we find that rotation can be performed without much impediment. Extension and adduction are executed with facility; but the limb can undergo abduction only to a slight extent. Flexion can be produced with great ease, and some instances are related where the limb could be made to touch the anterior part of the shoulder.

It should be recollected, in reference to the diagnosis of this displacement of the hip-joint, that these various movements are not accompanied by pain, when moderation and not more than the requisite force is used in the examination of the functions of the joint.

The extent of these movements may be somewhat modified by the effusion of osseous matter upon the surface of the ilium, around or in contiguity with the head of the femur, as happens in those cases where nature has attempted to form a new acetabulum.

CONGENITAL DISLOCATION OF THE FEMUR UPON THE ILIUM, ON ONE SIDE ONLY.—When the dislocation of the head of the femur upon the ilium exists but on one side, the general characteristics in reference to the affected articulation, are the same as when the luxation is double.

During progression there is some deformity of the vertebral column, which, on account of the shortness of the displaced extremity, and in order to bring the centre of

gravity within the base of sustentation, is often inclined laterally. The side of the pelvis, corresponding to the affected articulation, is depressed.

The buttock inferiorly is more flat, while at the upper and external part of the hip there is seen a rounded protuberance corresponding to the unnatural portion occupied by the trochanter major.

The fold between the nates and the thigh of the abnormal side is situated higher, and is directed more outwardly than on the opposite side.

The inguinal fold is deeper and less transverse, and in the female, the border of the vulva corresponding to the luxated femur is slightly deflected, being carried upwards and outwards.

The trochanter major, now much more prominent than naturally, is seen to have mounted along the dorsum ilii, and to have approximated the crest of this bone. The limb is consequently shortened in proportion to the extent of the ascent of the femur, and this may vary from a few lines, to two or three inches, according to the age of the patient and the duration of the displacement.

The affected limb has the appearance of having suffered from defective nutrition, not being as large as the other; the flesh is also softer than that of the limb upon the sound side.

In cases not complicated with other deformity, the bones of the thigh and leg, measured together, offer but



little difference in length, in either extremity ; but in approaching the two members, the two anterior and superior spinous processes of the ilia being placed upon a level, the malleolus internus of the affected side is found to be situated higher than upon the sound side, and the extent of the shortening of the limb will be greater or less, according to the ascent of the head of the femur upon the ilium.

The thigh is more oblique from above, taking a direction downwards and inwards, with a tendency to cross the limb of the sound side, while the leg inclines in an opposite direction, from above downwards and outwards, presenting an angle more or less obtuse on the outer aspect of the knee-joint.

The foot, in a state of extension to counterbalance the defect resulting from the unnatural brevity of the limb, generally rests upon the toes, but when the body is inclined forwards, the sole of the foot may rest entirely upon the ground, the toes being neither remarkably inverted nor everted. When the sole of the foot rests upon the ground, and the weight of the trunk is thrown upon this side, the lumbar region of the vertebral column is inclined laterally and forwards.

Manual examination discovers the same characteristics appertaining to the dislocation on one side, as have already been noticed as accompanying the double luxation. If the hand is applied behind the trochanter major, and



movements of flexion and extension be imparted to the thigh, at the time of flexion, the head of the femur will be felt impressing itself upon the hand. In these movements, the head of the femur is felt describing the arc of a circle from above downwards, instead of pivoting upon itself as it does when situated in the acetabulum.

In searching by pressure, along the inguinal fold and to the outer side of the femoral artery, for the head of the femur while the thigh is rotated, instead of a rounded body rolling under the fingers, a vacuity is felt which indicates the absence of the head of the thigh from its natural situation.

If the patient be laid on the back, the lateral inflexion of the spine becomes less marked, or disappears, and the limb can be pushed upwards, so that the upper part of the femur can be felt within a short distance of the iliac crest, or it can be pulled downwards, so as to be about the same length as the sound limb.

After flexing the thigh upon the pelvis, and slightly adducting it, as has already been observed when speaking of the double dislocation, if a line be drawn from the anterior superior spinous process of the ilium to the most prominent part of the tuberosity of the ischium, and the summit of the trochanter major is found to surpass superiorly this line, the dislocation of the head of the femur, upwards, may be supposed with great certainty to have taken place. This sign is useful in detecting the presence



of the single congenital dislocation, the diagnosis of which is generally more difficult than in the double form of this displacement.

While in the erect posture, the patient, suffering from single congenital luxation of the femur, is apt to rest the toes of the affected limb upon the ground, in order to compensate for its defective length. When, however, the sole is entirely placed upon the ground, the sound limb, being then the longer, becomes flexed at the knee, and the psoas and the iliacus muscles in this position of the foot, pulling forwards the lumbar vertebræ towards the affected side, twist the trunk, which is also thrown backwards, and cause the region of the loins to be excurvated, and the abdomen anteriorly to become correspondingly convex in appearance.

As a consequence of the unfixedness of the head of the femur, and the tractions exercised by the psoas magnus and iliacus internus muscles of the affected side, the trunk of the patient, in the act of walking, is inclined at first towards the side where the luxation exists, the flank of the same side becomes curved forwards, and a movement of alternate depression and elevation of the hip takes place, producing a peculiar postero-lateral lameness.

When the patient, resting upon the displaced member alone, attempts to leap, he finds it almost impossible to do so owing to the absence of a *point d'appui* for



the head of the femur, and on account of the mutations which, during the effort, take place in the relative position of the component parts of the ilio-femoral articulation.

The different movements which take place at the abnormal articulation, in regard to their extent, direction, and freedom, are analogous to those which have been noticed while considering the symptoms of the double congenital dislocation of the hip-joint, and need not be again repeated.

In connexion with this account of the symptoms of congenital dislocation of the head of the femur upon the ilium, I have made an abstract of a case I published originally in the London Lancet in 1844, in which the characteristics of this affection, as presented in the double form, were exceedingly well marked, and which being free from the complications that often accompany this displacement, I insert here, as being well adapted to illustrate the symptomatology of this dislocation in the adult.

“ The affection of which I propose at present to speak, I consider to consist in a transposition of the head of the femur from the cotyloid cavity upon the external iliac fossa of the os innominatum, occurring during intra-uterine existence, generally not so fully manifested in the early period of childhood as it becomes in adult age, when some of the symptoms attendant upon it are peculiar, and the displacement greater and more marked



than in the usual luxation of this character resulting from external injury.

“Some weeks ago, a case came under my observation of a lad, who, from the curious and hobbling motion of his gait, and other symptoms, I judged to be laboring under that peculiar affection, which has been termed congenital dislocation of the head of the femur upon the dorsum of the ilium. With a view of ascertaining the nature of the affection, and of determining the diagnosis, I requested my friend Mr. Clark, of the British Navy, to see this case with me, and as upon examination, every appearance and account given, went to show that the displacement was owing to an unusual luxation of the heads of both femurs upon the iliac bones, I have deemed the case worthy of attention, and have drawn up the following statement of it, to which, as illustrative of the position of the parts presented externally, the annexed drawings are added. *Vide* PLATES I., II., and IV.

“Benjamin Gott, the subject of this article, is now nineteen years of age, a shoemaker by trade, of good temperament, and has always been in the enjoyment of perfect health, with the exception of slight indisposition at times. From his earliest recollection, as well as that of the persons who brought him up, he has labored under an impediment in his walking, but has never met with any accident which confined him to his bed, or to which his present condition could be attributed. There is no



abscess nor fistula around either hip-joint, nor is there any mark or cicatrix to be seen in the ilio-femoral region to induce the belief that those conditions which frequently attend or accompany the spontaneous luxation from morbus coxarius have ever existed.

“When looked at while he is standing in the erect position, a striking want of proportion and harmony between the upper and lower portions of the body is at once observed, the lower appearing relatively shorter than the upper, and the hands,—owing to the ascent of the heads of both femurs upon the iliac bones considerably above the usual situation of the cotyloid cavities, and the consequent falling down or sinking of the pelvis,—are seen to descend about five inches below their usual point, the ends of the fingers reaching beyond the superior margin of the patellæ, when the arms rest along the sides of the body.\* The head, neck, trunk, and superior extremities are well developed, but the trunk appears to be somewhat thrown forwards, and the lower or abdominal portion presents a remarkable and salient projection, while in the lumbar region there is a corresponding hollow or depression. The inferior extremities, which do not deviate much from the normal position, as regards the direction of the knees or toes, appear shorter, and are more attenuated than natural, and towards the junction of the pelvic extremities with the trunk, the thigh bones seem to be

\* *Vide* PLATES I. and II.



separated from each other farther than natural, so that, superiorly, a space between them is left, giving to the perineal region a resemblance in breadth to that of the female. With respect to the position of the knees and toes, this part of my description differs from that given by Dupuytren, who states that the toes were inverted in some of his patients, and that there was also a disposition of the knees to approximate. It is probable that this has been more or less the condition of things in the present instance, as the lad states that his foot had formerly an inward tendency, and that his limbs, within the last few years, have assumed a more natural direction. As regards the position of the sole of the foot, there is also a difference to be observed in this case, for in the erect position the sole rests entirely upon the ground, as will be seen by a reference to the drawings, nor is there any elevation of the heel, which forms a symptom of this kind of dislocation when it is the result of external injury. In tracing the femur of one side (both being similarly situated) downwards from its present resting-place, the upper margin of the great trochanter is felt to be nearly on a level with the crest of the ilium, and the shaft to incline slightly downwards and forwards to the femoro-tibial articulation, which, in every respect, is natural. The pelvis, instead of having the usual oblique position, approaches more to the vertical direction; the sacro-vertebral angle, and upper portion of the sacrum inclining downwards and forwards,



while the coccyx and lower pieces of the sacrum are forced upwards and backwards. By tracing the superior margins of the ossa ilia from the posterior superior spinous processes forwards, to the anterior superior spinous processes of these bones, the ossa innominata are found to be tilted much more forwards, than is observed in the normal inclination of the pelvis, and the anterior superior spinous processes are depressed downwards and forwards so far, that the convexity of the iliac crests presents almost an anterior aspect. The symphysis and arch of the pubes are thus thrown downwards, whilst the tuberosities of the ischia are made to ascend slightly upwards and backwards, so that these eminences are nearly on a level with the arch of the pubes, and the rami of the ischia and of the ossa pubis consequently almost horizontal. Although the position of the pelvis is thus out of its usual *inclination*, there is not apparent any relative alteration of the individual parts which compose this important part of the skeleton. Thus, the alæ of the iliac bones are not misshapen, and the tuberosities of the ischia are distant from each other about four inches, while at the anterior superior spines of the ilia there is a space of nine inches and a quarter. Between the anterior superior iliac spine and the tuberosity of the pubes the measurement is five inches and three-quarters, which is slightly more than in the generality of young adult males, and the pelvis so far generally well formed, as regards its relative dimensions, is



also apparently free from any of the results of rachitis, or any of the other forms of disease to which the osseous tissue is liable.\*

“The most prominent deviation from the normal state of parts, which the deformity in question presents, is caused by the unnatural position and remarkable projection of the great trochanters. The heads of the femurs, having escaped from the acetabula, have mounted upon the dorsa of the ilia so high as to carry the upper portions of the trochanters nearly on a level with the iliac crests. The heads of the femurs being thus so far removed from the proper situation of the cotyloid cavities, the nearly equilateral triangle which the anterior superior spine of the ilium, the tuberosity of the pubes, and the trochanter major, will form, when the coxo-femoral articulation is undisturbed, is entirely broken up, and a prominence is produced by the projecting trochanters on either side so

\* It is to be remarked that this subject was young, and that the changes which dissection proves take place in the osseous tissues at a more advanced period of the disease, had, as yet, in him become but slightly apparent outwardly.

Although in the case above described, as far as could be ascertained by measurements upon the living subject, the diameters of the pelvis remained nearly natural, I am perfectly satisfied from dissections I have made of several cases of this luxation, that the diameters of the pelvis, both at the superior and at the inferior straits, become materially altered.

This fact becomes of greater importance, from the ascertained evidence of this affection occurring more frequently in females than in males; and suggests to the accoucheur the necessity of being fully prepared to encounter much difficulty during parturition, where this luxation exists in the female, whether it be single or double.



marked, that even a casual observer could not fail to notice it. In the present case of congenital luxation, the heads of the femurs rest also higher up, and more posteriorly, than in the common dislocation from external injury, and the normal relative position of the head and trochanter, with the surface of the iliac bone, is maintained, that is, the head of the femur is not thrown backwards and the trochanter forwards, as generally takes place in this form of the traumatic luxation. The head and neck of the bone standing out, as it were, nearly at a right angle from the resting-place on the dorsum of the ilium, gives the trochanters the prominent appearance which they present, and this also will enable us to account for the non-inversion of the toes, and the almost natural direction of the limbs.

“ Besides the other symptoms, such as shortening of the limbs, the slipping up of the head of the bone on the external iliac fossa, and the unnatural relation of the great trochanter, which this luxation presents in common with the other dislocations in which the head of the femur is carried upwards and outwards, in a similar direction, the muscles in connexion with the joint offer some peculiarities worthy of remark. The spinal muscles, which form the sacro-spinal mass, taking their origin from the sacrum, umbar vertebræ, and posterior part of the ossa ilia, and running along the vertebral grooves on each side of the spinous processes of the vertebræ, are found to be hard,



tense, and prominent, particularly in the lumbar region ; the psoæ, and the internal iliac muscles,—coming from the lower dorsal and lumbar vertebræ and the internal iliac fossæ, to be inserted into the small trochanters,—being pulled upon by the ascent of the femur and stretched over the brim of the pelvis now acting like a pulley, are also found tense and cord-like, while nearly all the muscles of the superior part of the iliac region, the gluteus maximus, medius, and minimus, &c., are retracted towards the crest of the iliac bones,—‘où ils forment, autour de la tête du fémur une espèce de cône, dont la base est à l’os iliaque et le sommet au grand trochanter.’—(*Dupuytren.*)

“The particulars, so far stated, refer to the subject in the standing attitude ; but in the *recumbent* position, some of the causes of displacement, such as the physiological action of the muscles and the weight of the superior parts of the body ceasing to exist, the signs of this affection become evidently less marked, and in some respects almost effaced, which never is the case in the usual traumatic dislocation. The muscles, now, not being called into action, the hollow in the lumbar region disappears, the abdomen does not present the anomalous projection formerly alluded to, the pelvis seems to acquire a more natural inclination, the head and trochanter descend several inches more towards the usual situation of the cotyloid cavity, and present an elevation neither so prominent, nor so much removed from the normal position they



ought to occupy. The measurement from the tuberosity of the pubes to the summit of the great trochanter is seven inches and a quarter, when in the recumbent posture; while it is nine inches and a half when he is standing.

“ In *walking*, the heads of both femurs ascending and descending alternately, upon the dorsa of the iliac bones, and playing, as it were, through a space of nearly three inches, produce the hobbling motion which has been mentioned. Thus, while the body is supported upon the right limb in the act of stepping, the right femur ascends; while the left, being freed from the superincumbent weight of the trunk and superior extremities, descends, to ascend again as soon as the left foot rests upon the ground, and the weight of the body is transferred to it. Contrary to what, at first, might be anticipated, this unsteady gait is less observable in the act of running than in walking, the increased energy of the muscular contraction, and the more rapid movements of the limbs not permitting, nor allowing time for, the head of the bone to pass through its accustomed range of motion, during the slower mode of progression. Although, as has just now been said, the alternating movements of the body are not so marked in the quicker motion of running as in walking, yet owing to the friction, more or less, of the displaced head of the femur upon the external iliac fossæ, the altered and unfavorable position in which the muscles



have now to act, and the irregular and fatiguing swinging of the body from one side to the other, this individual is unable to take exercise in the erect posture, without soon evincing signs of discomfort, and complaining of considerable pain, more particularly in the groins and lumbar regions.

“By grasping the thigh, and moving the limb after the pelvis is fixed, a sensation of crepitus, resembling that given by joints which have suffered from rheumatic inflammation, or effusion into their cavities, is distinctly perceived. From the present abnormal position of the parts around, and in connexion with the ilio-femoral articulation, as a natural consequence, the various motions of the inferior extremities are considerably interfered with, and limited, but by no means are they so restricted as in the traumatic form of this dislocation. Adduction of the extremity is not much interfered with, and one thigh can be carried over the other with facility, but abduction is performed with difficulty, the thigh having but a few inches of latitude in this direction; and in the endeavor to sit, as in the attitude of riding on horseback, across a high chair of the common breadth in the seat, it is found that this position cannot be effected, owing to the limited extent of separation allowed to the ossa femorum. While the knee-joint is not bent, the movements anteriorly are considerably impeded, but when the thigh is flexed upon the

pelvis, as takes place in the act of stepping upon a footstool, or going up a stair-case, little effort is required. The motion of the thigh directly backwards is somewhat confined, but rotation inwards, and particularly outwards, is nearly natural.

“In the sitting posture, while the trunk is kept nearly erect, the lumbar vertebræ are not then dragged so much forward, and this appears to be the position least irksome while it can be maintained; but in the stooping attitude, as that of the cobbler at work, which in his trade this youth has to adopt, the lumbar and lower dorsal vertebræ assume a convexity backwards, and the psoæ being thus put upon the stretch, great uneasiness is experienced in the loins if this posture be prolonged for any considerable length of time.

“These, then, are some of the most marked pathognomonic characters observed in this congenital affection, which, I am inclined to believe, is of much more common occurrence than the slight notice, or rather entire silence observed regarding it by authors in Great Britain, or my own country, would induce me to suppose. Thus we are told by Dupuytren that he met with twenty-five cases of the “*luxation originelle de la tête du fémur*.” Jules Guérin records that he has seen over thirty cases, and within the last two years, since my attention has been attracted to the subject, although I have been prevented by circumstances from making as many observations on this subject



as I might otherwise have done, I have met with four well-marked cases.\*

“From a consideration of the serious evils which a continuation of this displacement will entail upon the sufferers, as regards the enjoyments of life, and the performance of its duties, it behoves the surgeon to be prepared to form a correct diagnosis in relation to this affection, to prevent erroneous and painful practice being resorted to, and in order that the proper therapeutic means, as far as yet known, or superior judgment might suggest, may be adopted to remedy the deformity before the approach of adult age would proscribe the utility of such an attempt. The subject of the case I have detailed has been sent down to Margate by his medical attendants, for six months at a time, for the benefit of his hip-joints, under the supposition of the affection being of a scrofulous nature; and we find Dupuytren writing as follows in regard to this point: ‘*Plusieurs individus, affectés de luxation originelle, ont été contraint, par suite de cette erreur de diagnostique, à garder le lit pendant plusieurs années. J’en ai vu d’autres, qu’on avait forcés à supporter des applications, sans nom-*

\* Since this paper was written, I have seen, at Paris, London, and New York, at least twenty more cases of this dislocation, which have still further confirmed the opinions I have advanced in relation to its greater frequency than is generally supposed. From these additional observations which I have had an opportunity of making, I am also inclined to corroborate the opinion of Dupuytren regarding its more common occurrence in the female sex.

bre, de sangsues, de vésicatoires, de cautères, et, surtout, de moxas. Je me rappelle, entre autres, une jeune fille qui souffrit l'application de vingt-et-un moxas autour des hanches, sans que ce traitement, inutile ou barbare, eût apporté aucun changement à la situation de cette infortunée.'

"The affections most likely to be confounded with or mistaken for, the congenital luxation of the head of the femur upwards and outwards upon the dorsum of the ilium, are the dislocation which takes place in the same direction at the ilio-femoral articulation, as the result of external injury; or that inflammation of the hip-joint whether accompanied, or not, by the spontaneous luxation, as it is called, of the femur upon the external iliac fossa, which results sometimes, as a consequence of the absorption and destruction of the head and neck of the bone, during the progress of that strumous disease of the hip-joint, known generally by the name of morbus coxarius. Upon examination, however, each of these affections will be found to possess characteristics sufficiently remarkable to enable us to arrive, with reasonable certainty, at the differential diagnosis. In the recent dislocation from external injury upon the dorsum ilii, the shortening of the limb, the inversion of the toes, the lessened mobility of the joint, and more flattened appearance of the affected hip, are not difficult of detection. The strumous diathesis of the patient, and the relation of his case by himself or friends,



the previous inflammatory condition of the hip-joint, with the accompanying symptoms of fever, pain, &c., the formation of abscess, the existence of fistulæ, and in the latter stage the ulceration and disappearance of the head and neck of the bone, the trochanter alone being left resting in the acetabulum, or upon the dorsum of the ilium, the frequent resulting ankylosis and flat aspect of the hip, are symptoms sufficiently pathognomonic to characterize the condition of things usually attendant upon the various phases of *hip-disease*. While, in regard to the congenital transposition of the head of the femur upon the external iliac fossa, the whole history of the patient, from the earliest period of infancy up to the time that relief or advice is applied for, the lameness shown upon the first attempts to walk, the general good health he has enjoyed, the total absence of primary inflammatory symptoms, the immunity from antecedent injury, the extraordinary hobbling (*clo-chant*) gait during the act of slow progression, the prominent aspect of the abdomen, and the corresponding hollow appearance of the lumbar region, the existence generally of a double and similar luxation on both sides, the partial or total disappearance of many of the above symptoms in the recumbent position, the unusual projection of the great trochanter, owing to the presence and direction of the head and neck of the femur, which are placed nearly at a right angle and not in a line with the surface of the iliac bone, as happens in the traumatic luxation; and above

all, the ascent and descent of the head of the femur upon the external iliac fossa, through a space of nearly three inches, the upper margin of the trochanter major becoming nearly horizontal with the crest of the ilium, or appearing several inches below the same point, and according as the limb is pushed upwards or pulled downwards ;—these data, taken collectively, and in connexion with the entire freedom from all pain during the attempts to move the parts about the seat of the displacement, will form an assemblage of peculiarities so evidently and palpably different from the circumstances accompanying either of the two forms of lesion already referred to, that we are obliged to look upon the morbid condition associated with the group of symptoms last enumerated as belonging to another species of disease, and to classify it as more properly belonging to that genus of affections which, in more modern times, have received the name of congenital luxations.

“ It would appear that the congenital luxation of the head of the femur is more or less of a hereditary character, and that females are more subject to it than males. I have not had the means of confirming the former observation, but should be inclined to give credence to it, as experience has corroborated the existence of this family predisposition in Talipes, which affection most probably belongs to the same class of maladies as the congenital dislocation of which we have been speak-



ing. In relation to its more frequent occurrence among females, Dupuytren states, that out of the twenty-five cases which he had seen, three only were males; of the cases which have come under my own observation, the greater proportion were females.

“The peculiarities and symptoms accompanying congenital luxation of the head of the femur upon the dorsum ilii, being found, upon comparison, to be so different from either of the other forms of the disease above alluded to, and with which, from a cursory examination, it might be confounded, we are naturally led from seeing a result or effect so different, to seek also for a difference of antecedence or *cause*. The celebrated surgeon, to whom we have last alluded, asks, in relation to the cause of displacement, ‘Can it be the product of a disease occurring to the foetus in the womb of the mother, and cured before birth? Can it be the result of an effort, or of violence, which might have caused the head of the femur to escape from the cotyloid cavity; and the cavity itself, might it not become obliterated without disease, and only because from want of action, it would become useless? Can nature have forgotten to mould a cavity for the head of the femurs,—or rather, can this cavity, which is the result of the concurrence and union of the three pieces of which the os innominatum is composed, have remained imperfect on account of some obstacle to the evolution of the bone, as M. Breschet has been induced to suppose?’



Each of the causes named in the foregoing interrogatories might, we can conceive, be supported by arguments more or less favorable, none of them, however, bearing a character so entirely conclusive as to carry implicit conviction, or sufficiently satisfactory to render farther investigation into the origin of these affections unnecessary. If disposed to attribute this transposition of the head of the bone to some violence exerted during the act of parturition, it would be difficult to imagine, even when we consider the different positions which the foetus may assume in the uterus, by what means the mechanical force could be applied so as to displace the head of the bone in an upward direction, or by what species of manipulation, either instrumental or manual, the accoucheur could so proceed, as to produce the transfer of the head of the femur upwards and outwards upon the dorsum ilii, in other words, in a direction exactly contrary to that of the force which may be supposed to be brought into play. Nor would it be more easy to follow the head of the bone, after it had been once dislocated downwards into the foramen ovale by traction,—as some have supposed, during a difficult labor with a breech or footling presentation,—taking again an upward course over the natural position it ought to occupy at the acetabulum, and refusing to remain quiescent until it had arrived at the external iliac fossa. Something may be said in support of the theory of the *arrêt de développement*, as con-



tributing to the primary displacement of the articulating surfaces, but, in the present case, if we can judge from the projecting trochanters, there is but little alteration as regards the head and neck of the femur, and autopsic examinations which have been made, go to prove the filling up and contraction of the acetabulum from its inutility and consequent inactivity, rather than any imperfection in the ossification of the cotyloid cavity at the junction of the three pieces which unite to form it, and which should be the place where the occurrence of any defect, if any existed in the evolution of the osseous tissue, would be observable, according to M. Breschet's theory. The hypothesis of M. Dupuytren, that a primary imperfection of the germ ('des vices de conformation originels, et qui tiennent à un défaut dans l'organisation des germes') must have some relation with the cause of the displacement—and which idea led him to give the name of *original* luxations to this class of affections—carries but little probability with it; nor does the position of the thighs, flexed as they are upon the abdomen of the child in utero, and the consequent pressure of the head of the femur against the lower and inferior portion of the ilio-femoral capsule, satisfactorily explain the reason of the ascent of the head of the bone upon the ilium. We can imagine that this position of the head of the femur, and the naturally shallow state of the acetabulum during foetal life, may predispose to the displacement; but we do not believe that mere position



without the action of some morbid auxiliary cause, could alone have the effect of bringing about the pathological condition of which we are treating. Although it is well known that the child, while yet in the womb, is liable to many diseases, yet children who have been born with this altered relation of parts at the ilio-coxal articulation have not shown any particular bad condition of health at birth, sufficient to attract the attention even of medical attendants, and this consideration and the absence of anything like inflammatory engorgement, abscess, fistula, or cicatrix, at the period of birth, must leave little doubt that the displacement cannot have for its origin that strumous affection which, in extra-uterine life, we sometimes remark to be the cause of *spontaneous luxation* of the head of the femur upon the dorsum of the ilium.

“The remote cause then, of the class of congenital deformities, and among them, that of congenital luxation of the head of the femur, we should be inclined to refer to a morbid condition of the nervous system or centres; and the proximate cause, or that which most obviously produces the displacement of the parts, to a pathological muscular contraction, which, acting as the unavoidable result of the primary disease, with more or less activity and diversified combination, ultimately effects the entire dislocation of the articulating surfaces. . . .

The existence of a state of disease which may have an influence so extensive over the whole muscular sys-



tem, or be limited to a particular portion only of it, may enable the pathologist to attribute to one common source, the origin of numerous maladies which formerly were referred to as many different causes, and from data now known we can thus, by generalization, simplify and reduce to a unity of origin the whole class of those deformities of the human shape which, as a result of morbid muscular action, take place at the articulations in the shape of club-foot, distortions of the spine, torticollis, congenital luxations, &c.

“ But congenital luxation of the head of the femur upon the ilium, although caused primarily, as we believe, by this dynamic or morbid retraction of a portion of the muscular apparatus, occurring during intra-uterine life, is also subjected to causes which begin to act only after birth, and which materially modify the appearance and extent of the displacement of the articulating surfaces in relation to the age of the individual affected. Thus, in this luxation, the head of the bone is generally, at first, placed near the confines of the acetabulum, resting upon its margin or a little above it, but as soon as progression begins to be performed, the superincumbent weight of the trunk carries the pelvis downwards, and the heads of the femurs being entirely freed from their natural cavities, and having now no point of resistance superiorly, ascend gradually upon the external iliac fossæ, until at last, as adult age approaches, as in the example before us, the pelvis is




wedged down between the upper portions of the ossa femorum, and the superior margins of the great trochanters are found almost on a level with the iliac crests. One of the primary effects of the pathological contraction of the muscles (as exemplified by the attenuated state of the muscles in the ordinary forms of talipes), is a diminished nutrition, which gives rise to a kind of '*arrêt de développement*' in the parts affected. The osseous structure of the pelvis increases as extra-uterine life advances, while those muscles originally affected, and which produced the displacement, suffering still from this impediment to their natural development, do not elongate in proportion to the increase of the other parts, and thus also when the head of the bone has once escaped beyond the limits of the cotyloid cavity, is its tendency to ascend on the external iliac fossa, promoted. It is not difficult to understand that the physiological action also of the muscles acting in the direction of the displacement, will have a tendency to induce a farther removal of the head of the bone upwards; and that the muscles, towards the internal part of the thighs, such as the long adductors, semi-membranosus, semi-tendinosus, &c., having changed their angle of insertion, will, during the progressive movements of the inferior extremities, act upon the ossa femorum so as to throw the head of each upwards and somewhat outwards. These auxiliary causes, viz. the weight of the body, the impeded growth of the muscles affected, and the physiological action of




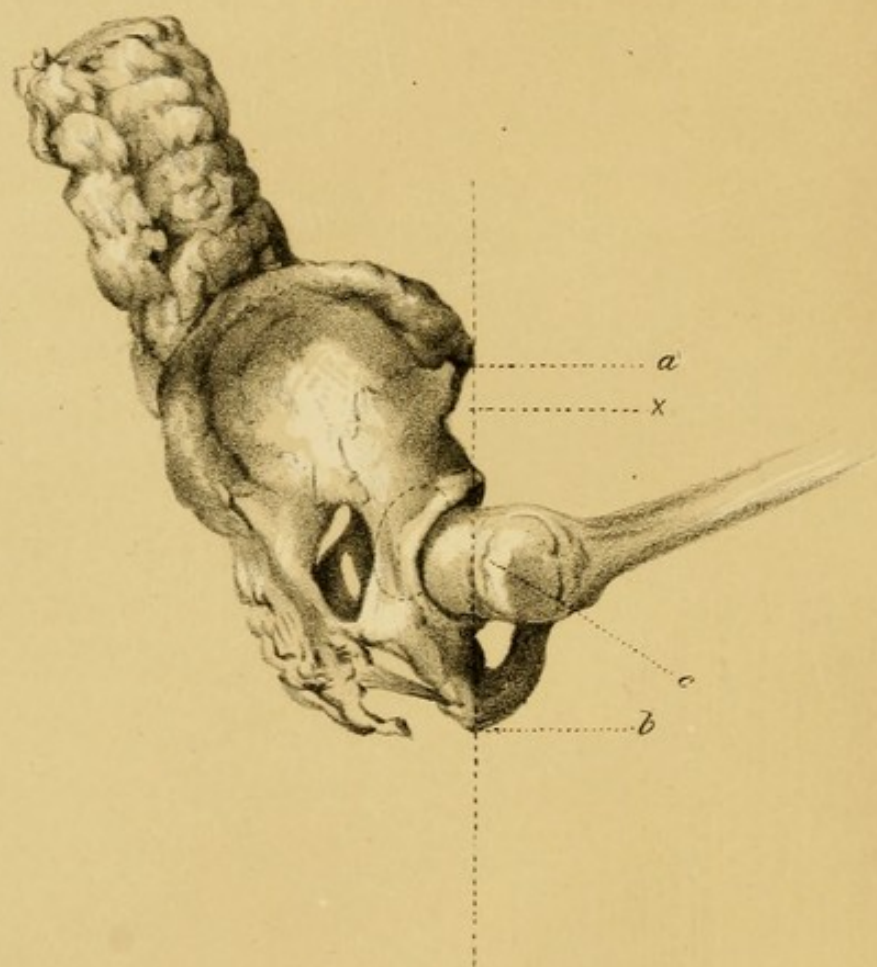
the muscles, taking effect only after extra-uterine life has begun, readily account for the transposition, in cases of congenital luxation of the hip-joint as well as in the other affections of this class, occurring in a gradual manner, and becoming in the course of time more marked, after these various causes of displacement have fully exerted their combined influences.

“Having said thus much at present in relation to the symptoms, diagnosis, and cause of the congenital luxation of the head of the femur upon the dorsum ilii, I shall recur at a future time to the pathological appearances observed upon post-mortem examination, and the therapeutic means which have been adopted to remedy the deformity or palliate its inconveniences.”—*London Lancet*, 1844, No. 27, vol. I.











### EXPLANATION OF PLATE No. V.

This figure represents a range of salient points, indicating the normal position of the head of the Femur. In cases of traumatic dislocation of the femur, or in congenital displacement of the head of this bone, where there is obscurity, this diagnostic sign may be made available.


The plate gives a side view of the foetal pelvis, about the end of the ninth month, with the femur flexed upon the pelvis, and slightly adducted.

*a.* Anterior Superior Spinous Process of the Ilium.

*b.* The prominent point of the tuberosity of the Ischium.

*c.* The upper margin of the Trochanter Major.

× A line along the range of these three points.





## CHAPTER V.

DIAGNOSIS OF CONGENITAL DISLOCATIONS OF THE HEAD  
OF THE FEMUR.

THE congenital dislocation of the head of the femur upwards and outwards upon the ilium, has probably been mistaken more frequently for morbus coxarius than for any of the other diseases which are met with at the ilio-femoral articulation. The hip-disease, as it is called, is essentially an inflammatory affection, and from its commencement to its termination,—whether in resolution, or in ulceration of the synovial membrane, cartilage, ligaments, and bones, and consequent dislocation,—symptoms of antecedent or present phlogosis can, on careful examination, generally be detected. While this inflammatory affection is in its dormant or incipient state, as a general rule, lameness does not occur, and it is not until lameness has manifested itself, in what is termed the second stage of the disease, that difficulty may arise in forming the correct diagnosis between the congenital dislocation

of the hip-joint and the affection known as *morbus coxarius*.

The history of the disease, and the consideration of the constitutional temperament of the individual, will serve as useful information to the surgeon, when about to analyse the real nature of a doubtful affection at the ilio-femoral articulation. It is unnecessary to recapitulate the several symptoms which have been enumerated in the preceding chapter as pathognomonic of the congenital dislocation of the femur upon the ilium; but there are certain characters, standing out in forcible contrast to the symptoms attendant upon the hip disease, which merit consideration. A knowledge of them ought to preclude the possibility of the congenital affection being mistaken for the other disease in question.

In the lameness resulting from congenital dislocation of the femur upwards and outwards, the shortening of the limb, which from the first can generally be detected, has not been preceded by pain or inflammatory symptoms of any kind; in the hip-disease, on the contrary, the lameness, which becomes apparent towards the latter part of the first stage of the complaint, is unaccompanied by any perceptible shortening of the limb, and considerable pain is felt when any motion is made which causes increased pressure of the head of the bone against the acetabulum, at the same time that great suffering is almost always experienced, which is generally referred to the region of the knee of



the affected side. In congenital dislocation, flexion of the joint is performed with great ease, while in the hip-disease, the same movement is attended with pain, and the patient shrinks from the touch.

In congenital luxation, when the patient is laid in the recumbent position, the deformity which is so evident in the erect attitude, disappears, and the head of the femur on the affected side, can be pushed upwards or drawn downwards, or rotated, without causing any uneasiness; whereas in hip-disease, any attempt to elongate by forcible traction the limb of the diseased side, is attended with great pain.

In hip-disease, during rotation of the thigh outwards, the head of the femur can generally be felt in the groin, occupying its natural place; in congenital luxation, the head and trochanter major can be felt above the acetabulum, on the surface of the ilium, while a palpable vacuity exists in the groin, opposite the acetabulum.

In hip-disease, the nates becomes flat, so that the usual niche between the buttock and the thigh is effaced; while in the congenital affection, this furrow is present, although situated higher up, and more curved outwards than natural.

Before the occurrence of *spontaneous* dislocation—which, as a result of ulceration of the border of the acetabulum, sometimes takes place, although rarely, in morbus coxarius—the thigh being flexed at right angles



with the pelvis, and slightly adducted, a line, drawn from the anterior superior spinous process of the ilium to the prominent point of the tuberosity of the ischium, will range nearly on a level with the upper margin of the trochanter major; while in congenital luxation, this line would pass over a part of the trochanter, approaching more or less to its base. *Vide PLATE v.*

Although there is much lameness in congenital luxation, the health of the patient does not directly suffer; he can walk, skip, or run for a short time with considerable facility, and without experiencing pain; whereas in hip-disease, the general health is always impaired, and the acts of locomotion are performed with much difficulty and pain.

In hip-disease, it is exceedingly rare for the malady to occur symmetrically and simultaneously on both sides—a circumstance which is of common occurrence in the congenital dislocation of the femur.

These differential signs, in connexion with the peculiarity of the gait and attitude, and the other symptoms mentioned in the previous chapter, as observable in individuals affected with congenital dislocation, exhibit the pathognomonic characters of the two affections in such a distinct manner, the one from the other, that if appreciated, the error of mistaking a congenital luxation of the coxo-femoral articulation for morbus coxarius will not be likely to occur.

In cases of incipient congenital luxation, or as it has been



termed, congenital subluxation of the femur, where the head of the bone rests on the margin of the acetabulum, a correct diagnosis will necessarily be more difficult of attainment, than when the femur has ascended higher on the dorsum ilii.

There are other affections which may be confounded with congenital displacement of the femur.

M. Guérin has described a class of congenital deformities at the hip, which he has named pseudo-luxations, because they offer the deceptive appearance of positive luxations. In these, however, the head of the femur is not transferred from the cotyloid cavity. Pseudo-luxations at the hip present two varieties, one simulating a dislocation of the femur backwards and outwards; the other, a dislocation of the bone downwards and forwards. This kind of deformity consists in a permanent abnormal direction of the members, referable, as its cause, to morbid muscular retraction, which, however, is exerted in a degree not sufficiently intense to produce the exarticulation of the head of the femur. Pseudo-luxations are allied only to congenital luxations, in having a common cause for their origin, and in presenting a kind of similarity in the external appearance of the deformity. The first variety of the pseudo-luxations mentioned above, may simulate somewhat the congenital luxation of the femur upon the ilium.\*

\* These pseudo-luxations, with other deformities from muscular retraction about the hip-joint, are alluded to by Delpech. *Vide* l'Orthomorphie.



There are certain alterations in the head and neck of the thigh bone, and of the acetabulum, which may also give rise to some doubt in forming the diagnosis of this congenital dislocation. We find that Palleta speaks of several malformations, which may resemble this affection; such as an unusual enlargement of the acetabulum, permitting a vacillating motion of the head of the femur; a malformation of the upper extremity of the femur, where the head and neck are in part atrophied, and, as it were, fused with the trochanter major which rises above them; an exostosis springing from the bottom of the acetabulum, and changing the natural relations of the femur; and an atrophy, manifesting itself upon one half of the pelvis and upon the inferior extremity of the same side.

Mr. Liston mentions a curious case of malady of the hip-joint,\* of a young infantry soldier, who died of pulmonary consumption after two years' confinement in the General Hospital at Chatham. In this case, the head of the bone was found approximated to the shaft, owing to absorption of the neck, without any ulceration of the articular cartilage. "Previously to his admission, he had regularly performed his duty, from which it is plain that his limbs were then of equal length, although when his body was examined, the affected femur was *upwards of*

\* Liston's Surgery—report of a case of Mr. Gulliver's.



*one inch and a half shorter than the other.* From a careful inquiry, after his death, it appeared that he had, five years previously, fallen on the trochanter, in consequence of which he often complained of pain in the hip, but continued to do his duty long after, never having been confined on account of the accident.\* The shortening of the limb in this case is attributed to the accident, and to the long confinement with the pulmonary malady, which ultimately proved fatal.

Sir Benjamin Brodie has noticed that the lower extremities are sometimes of unequal length, from original conformation; the femur, tibia and fibula of one side being shorter than these bones of the other side.

In aged persons, the neck of the femur becomes sometimes altered by interstitial absorption, causing an unnatural shortening of the inferior extremities; and this circumstance predisposes in a remarkable degree to fracture of the neck of the femur, accompanied by still farther shortening of the limb.

Delpech† has mentioned an osseous malformation causing lameness, most probably depending on a rachitic condition, where there is malposition of the acetabula either more forwards or more backwards than natural. The same surgeon also mentions an atrophied state of the halves of the sacrum and of the ilium, as causing

\* Liston's Surgery—report of a case of Mr. Gulliver's.

† Delpech, l'Orthomorphie.

lameness ; and M. Gerdy has described several anomalies of the upper extremity of the femur, from which a limping gait is produced, where the neck of this bone is inserted at a greater or less distance from the trochanter major, and in a direction, sometimes inclining obliquely forwards ; at others, obliquely backwards.

All these morbid affections may simulate, more or less, the congenital luxation of the head of the femur. A knowledge of, and familiarity with their existence, and the application to them of the signs which have been enumerated and described for determining the pathognomonic characteristics which accompany congenital dislocation of the femur upon the ilium, will enable the surgeon to arrive with great certainty at a just differential diagnosis.



## CHAPTER VI.

PROGNOSIS OF CONGENITAL DISLOCATIONS OF THE HEAD  
OF THE FEMUR.

IN congenital dislocations of the femur, much diversity of opinion has existed in regard to the possibility of effecting permanent reduction by the efforts of art. Dupuytren supposed that it was useless to attempt the permanent adjustment of the articulation, and confined his treatment simply to ameliorating measures.

Of late years science has advanced a step farther in this matter, and cases, successfully treated, of congenital dislocation of the femur, are recorded, which place beyond a doubt the possibility of reducing fixedly the head of the femur at the cotyloid cavity.

The difficulties, however, attendant upon the treatment of this affection are great, and the altered condition of the component parts of the articulation, which is apt to take place even in early life, as well as of the other tis-

sues surrounding the ilio-femoral articulation, render this displacement one of the most formidable maladies to which the articular apparatus of the body is liable; the surgeon then should be guarded in giving a prognosis which might be too favorable as regards the facility of reduction, or the certainty of a rapid and permanent cure.

It is certain that after middle life, the relative conformation of the acetabulum, and of the head of the femur, as well as of the articular capsule, are so entirely changed, that a reciprocal adjustment between these component parts of the joint is beyond the reach of surgery. A more favorable prognosis may be given, when the requisite treatment is adopted in early life.

The curability of congenital dislocations of the femur, and the principles upon which their treatment has been founded and attempted, will be spoken of in detail in a following chapter.

It has been stated that the single luxation of the head of the femur upon the ilium is more serious in its nature, from the fact, that in this form, the diameters of the pelvis are more deranged, than when the luxation is double. I do not believe there is much difference in this respect, in either case, as regards the impediment which will be presented during parturition, to the passage of the child, from defective space in some of the measurements of the pelvis.




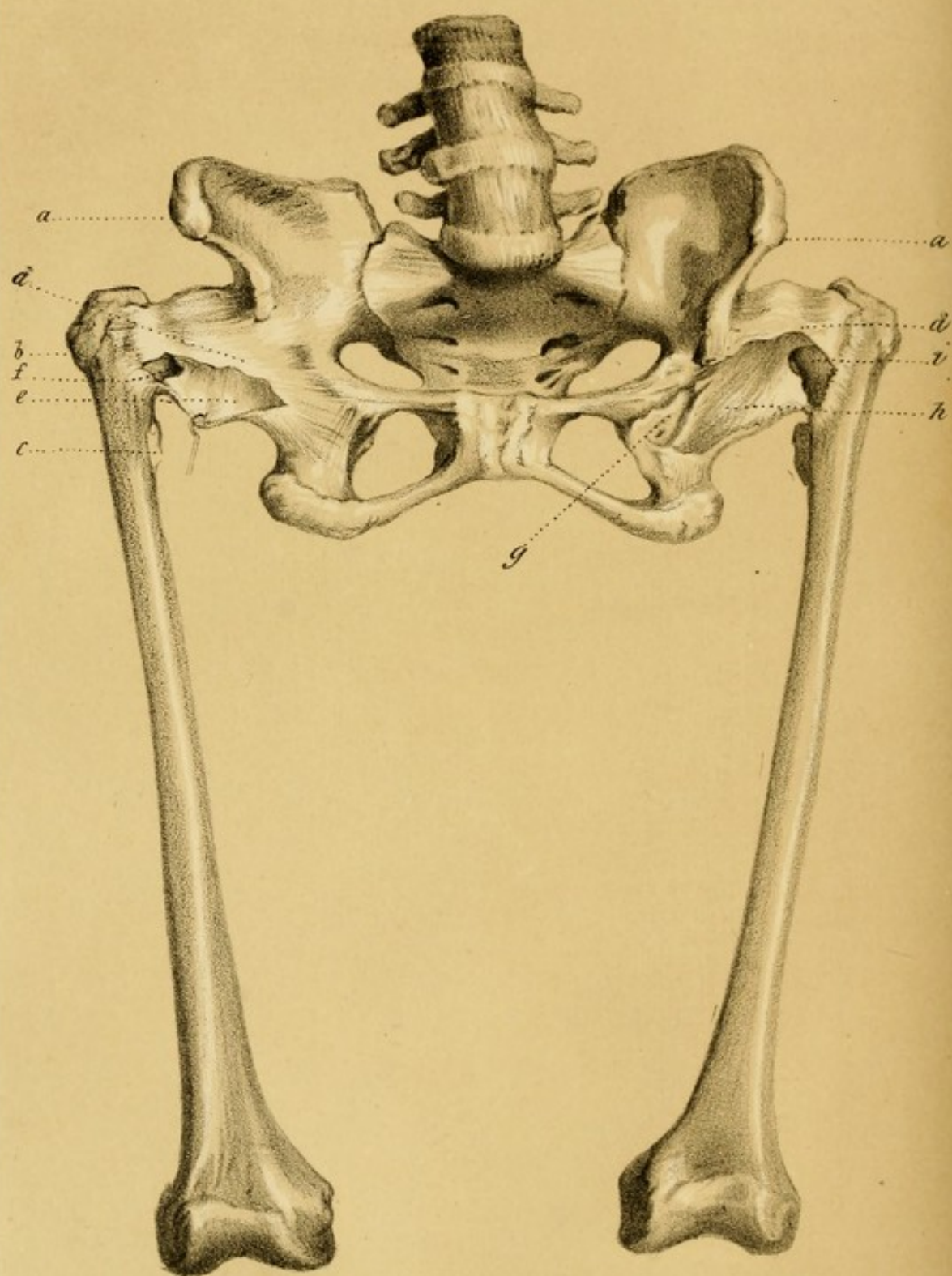
In cases where females, suffering from this displacement, have become pregnant, I think that pathological investigation will justify the expression of an unfavorable prognosis in regard to the probable facility or safety of the process of parturition. From the dissections I have made of persons who had been affected with congenital dislocation of the hip, I cannot doubt that the diameters and measurements of the pelvis, in cases either of the double or single form of this affection, are so modified and changed as to be most unfavorable for the passage of the head of the child through its two straits. Dupuytren, whose great authority always merits attention, has expressed himself in the following words, asserting that the pelvis retains its natural dimensions and conformation: "Il est à remarquer que les phénomènes qui ont lieu à l'exterieur du bassin n'influent en rien sur le développement de cette cavité, et qu'avant l'époque de la puberté, pendant cette époque, et après qu'elle est passée, le bassin acquiert les dimensions les plus favorables à l'exercice des fonctions des viscères qu'il renferme; et qu'il est aussi propre à recevoir, à conserver et à transmettre le produit de la fécondation que chez les personnes les mieux conformées."

The facts occurring from autopsic examinations go directly to refute the statement of Dupuytren. By a reference to PLATES Nos. VI., VII., VIII., and IX.,

and the description of the cases which they represent, it will be seen that in these specimens, the pelvic diameters are entirely altered from their natural standard.










## EXPLANATION OF PLATE No. VI.

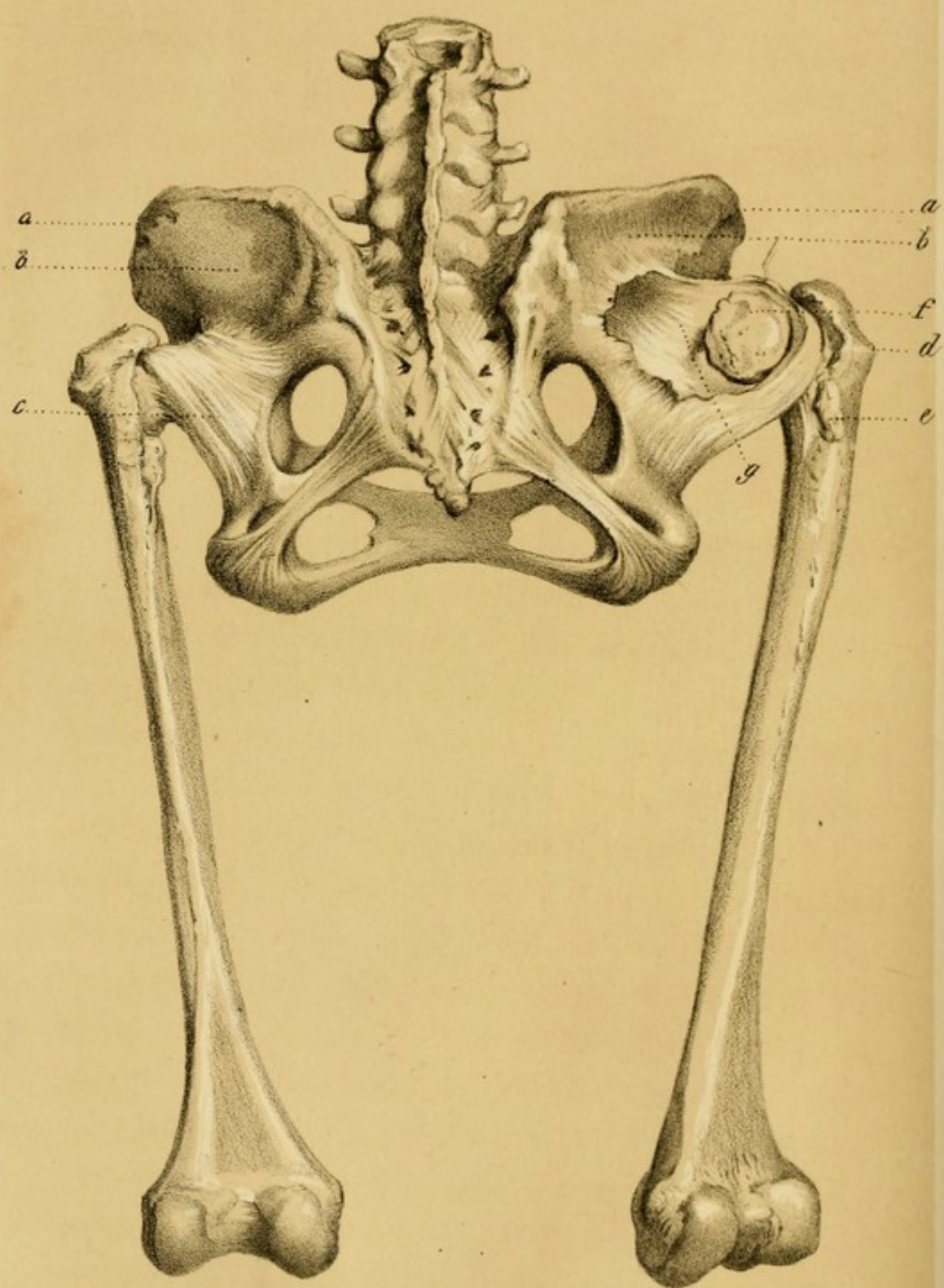
Front view of a dissection of a female pelvis, with Double Congenital Dislocation of the Femurs upon the Dorsa of the Iliia.

- a.* Anterior and Superior Spinous process of the Ilium.
- b.* Trochanter Major.
- c.* Trochanter Minor.
- d.* Anterior part of the Original Capsular Ligament.
- e.* The Original Capsule laid open.
- f.* The Annular Opening, by which the Head of the Femur escaped upon the Dorsum Ilii.
- g.* The Original Acetabulum, become now triangular.
- h.* The cavity of the Original Capsule laid open by removal of its Anterior Wall.
- i.* The Neck of the Femur grasped by the Annular Opening in the Capsule through which the Head passed.











#### EXPLANATION OF PLATE VII.

Posterior view of a dissection of the same pelvis, with Double Congenital Dislocation of the Femurs upon the Dorsa of the Ilia.

- a.* The Crest of the Ilium.
- b.* The Dorsum Ilii.
- c.* Posterior surface of the new Capsule entire.
- d.* Trochanter Major.
- e.* Trochanter Minor.
- f.* Head of the Femur lying in the new Capsule.
- g.* New Capsule laid open, showing its interior.





## CHAPTER VII.

PATHOLOGY OF CONGENITAL DISLOCATIONS OF THE HEAD  
OF THE FEMUR.

EXCEPT in cases of foetal monstrosities, instances of congenital dislocation at the ilio-femoral articulation, are not met with in any other form, than that in which the head of the femur is exarticulated from its socket, and passes upon the external surface of the ilium.

Another variety, under the name of a subluxation upwards and backwards, has been mentioned, where the head of the femur has not yet entirely cleared the margin of the acetabulum. This variety appears to be only the initiatory stage of the dislocation upon the dorsum of the ilium, and I shall only regard it as such. In fact, the head of the femur, to ascend on the ilium, must slip out of its socket, at the posterior portion of the acetabulum, where, in the foetus, there is a space unoccupied by bone. A depression thus exists on the *pourtour* of the acetabulum, between the ilium and ischium, occupied in

the recent subject by cartilage only ; the deepest part of which, in the skeleton, is almost on a level with the bottom of the acetabulum. It must be recollected also, that the thighs are generally flexed upon the abdomen before birth, and that after the head of the femur has once passed the posterior margin of the cotyloid cavity, the mere act of extension of the thigh after birth, will induce the head of the femur to describe a segment of a circle upwards in the direction of the *dorsum ilii*.

It has been supposed that in attempts to reduce the congenital dislocation of the femur upon the ilium, the head of the bone has been thrown into the ischiatic notch. This seems, however, to be only the result of the application of mechanical force, and the head of the femur does not appear to have been found primarily in this position.

The morbid appearances to be met with in this luxation, on autopsic examination, vary, according to the age of the individual, and to the extent of the alterations which may have occurred in the tissues at, or in contiguity to the ilio-femoral articulation ; but there are pathological characters which are common, amid the numerous changes which take place in the ligamentous and osseous structures of the joint, as well as in the soft parts by which it is surrounded.

If the examination of this displacement be made during the foetal period, or when extra-uterine life has been



of short duration, the cotyloid cavity is found to be but little altered in its normal shape and dimensions, and to retain the capacity of receiving the head of the femur. The period of life at which the cotyloid cavity begins to assume an alteration of shape and of dimensions is not the same in all cases ; it is probable, however, that beyond the twelfth or fourteenth year of age, the changes which this cavity has undergone, have so far destroyed the normal relations of the joint, that reciprocal adaptation would be impossible.

The acetabulum, surmounted by its fibrous border, at the earlier periods of this displacement, is generally found to present a depression on the superior and posterior part of its margin ; and a kind of adipose tissue, probably the degenerated and hypertrophied soft structure belonging to the cavity, is sometimes found to a greater or less extent, occupying the acetabulum, in place of the head of the femur.

The head of the femur now rests upon the margin of the acetabulum, or upon the ilium near its circumference, and presents but little deformity, retaining its hemispherical appearance, except upon its inner aspect, where it is sometimes flattened, from resting upon the ilium.

The capsular ligament is elongated, as also the ligamentum teres ; the structural integrity of both, however, is still maintained, and the capsule at this early period has been said to resemble an hour-glass, large at its pelvic



and femoral attachments, and small at its centre. The capsule is put upon the stretch by the ascent of the head of the femur, which is still kept from direct contact with the external surface of the os ilium by an intervening layer of the capsule.

The synovial secretion is found to exist sometimes in its natural condition.

This may be said to be the usual appearance in the early stage of this displacement; still exceptions may occur, as appears from a case already quoted from Palleta, on pages 19 and 20, of a child two years of age, where alteration had taken place at this early period of the affection, in nearly all the parts of the articular apparatus of the hip-joint; but in this instance there is reason to suppose that the head of the femur had become entirely detached, which would render the real nature of that case somewhat doubtful.

In proportion to the duration of the dislocation, and to the more or less advanced period of life, the nutrition of the parts, from various causes, being materially disturbed, the structural changes in the various tissues become also more marked.

The separation between the acetabulum and the head of the femur becomes gradually greater, owing to the progressive ascent of the latter upon the ilium.

THE COTYLOID CAVITY, in the progress of the affec-



tion, tends to become contracted, and to assume an oval or even a triangular shape, approximating, as it were, to the primitive form of the acetabulum during foetal life, before its three component parts have arrived at the period of osseous consolidation. The acetabulum remains sometimes, however, nearly circular, and presents upon its upper semicircumference a depression of a somewhat crescentic form, which allows the head of the femur to pass to and fro from the dorsum of the ilium into its original receptacle, now deprived of its cartilaginous lining. This was the condition in one of the cases of congenital luxation, of which I had an opportunity of making a *post-mortem* examination. This subject was a female, about fifty years of age. The head of the femur had passed through the upper part of the capsular ligament, and rested upon the external surface of the ilium, about an inch from the border of the acetabulum. A semicircle of new osseous material springing from the ilium, towards forming a new acetabulum, prevented the femur from ascending farther in this direction. The cotyloid cavity, although nearly circular, had become more shallow, but was sufficiently large to allow the head of the femur, which was not much under the natural size, to pass into it. Owing to the disappearance of a lunated portion of the upper circumference of the acetabulum, the head of the femur could readily pass from this cavity upon the ilium, and reduction could thus easily be effected, but in this condi-

tion of the parts, it could never have been rendered permanent.

Sometimes the cotyloid cavity is filled up with cellulo-osseous material, readily yielding to the pressure of a pointed instrument.

In one of the cases I have described farther on, it will be seen that the acetabula had assumed a contracted triangular shape, and were nearly filled up with softish adipo-osseous tissue. *Vide* PLATE VI.

In another case, the acetabula were found contracted to a cavity still smaller than in the previous instance, and were filled entirely with a semi-osseous tissue of a similar character to that before mentioned. *Vide* PLATE VII.

THE HEAD OF THE FEMUR becomes altered to as great an extent as the cotyloid cavity, and the neck also soon participates in the progressive alterations.

The head loses its spherical appearance, and becomes changed in its dimensions and texture. The articular cartilage, with which it is invested, having lost its relations with the articulating surface of the acetabulum, and not being naturally supplied with the synovial fluid, or with its usual amount of vascular nutrition, gradually undergoes mutations which lead to its ultimate disappearance, particularly where the head comes in direct contact with the osseous tissue of the ilium. The aspect of the head, where the round ligament ought to be inserted,



often presents a flattened surface, denuded of its articular cartilage, a thin brittle shell of bone only covering the deteriorated cancellated interior structure of the head. The neck of the femur is also small, short, and stunted, and assumes a more horizontal direction to the axis of the femur than is usual, the head being more on a level with the trochanter major, and losing its normal obliquity in relation to the shaft of the bone. *Vide* PLATES VI. and VII.

The consistence of the osseous tissue of the head is very considerably changed, being brittle and softer than natural, and presents the evidences of perverted or diminished nutrition.

In some instances, where the displacement has been of long standing, the head and neck are found to have entirely disappeared; the ligamentous connexions between the pelvis and the femur being attached, on the femoral side, to the trochanter major or to the upper portion of the shaft of the bone. This disposition of the parts is represented on PLATES VIII. and IX.

The head and neck of the femur may assume in this affection various shapes and degrees of deformity, from the simple changes which take place in early life, up to their complete atrophy and disappearance which occur sometimes in old age.

This will not seem extraordinary, when it is considered that the head of the femur is peculiarly situated in



regard to its vessels of nutrition, which chiefly pass to its structure by means of the round ligament, which is attached upon its inner aspect. The head of the femur is not ossified for some time after birth, and being isolated from the shaft by intervening cartilaginous tissue at the early periods of life, it receives no arterial supply from the vessels distributed through the other portions of the os femoris, and but little from those ramifying in the contiguous investing periosteum. From the nature of the displacement, the ligamentum teres must be unduly stretched in the very commencement of the luxation, and the arteries coursing along it, more or less compressed. When this circumstance, and even the total destruction of the round ligament, which frequently takes place, is taken into consideration, it can easily be understood how—particularly after the protracted existence of this affection during the course of many years—the nutrition of the head may become so perverted as to produce structural deteriorations, terminating sometimes in its total disappearance. In the case represented on PLATES VII. and VIII., it will be observed that the round ligament had entirely disappeared.

It is also possible, even in the early years of this displacement, for the head of the femur, before it is ossified, to become detached from the shaft, from the effects of violence or of friction, and its early disappearance may in this manner be accounted for. It is difficult to explain



the condition of the upper part of the femur, in the case described by Palleta, and already referred to, of a child two years of age, in which, he says, "*femur, pene dixerim, acephalum fuit*," except upon the supposition, that the cartilaginous head of the femur had thus become detached.

THE CAPSULAR LIGAMENT AND THE LIGAMENTUM TERES are found also to present various phases and alterations. As a natural consequence of the ascent of the head of the femur upon the dorsum ilii, the capsule must become elongated and stretched beyond its normal dimensions. The extent of the pelvic and femoral attachments will prevent the two extremities of the capsule from coalescing, but towards its middle portion, the walls approach, producing a contracted appearance at this part, so that the capsule in the primary stages of the malady, before it has given way in its continuity, has been compared, as already stated, to an hour-glass, large at each end and contracted in the middle. The round ligament also becomes stretched and more slender, and is embraced by the central contracted portion of the capsule through which it must extend while it remains unbroken.

The articular capsule may retain for many years its integrity, the head of the femur playing upon the dorsum ilii during progression, a layer of the capsule intervening between the head and the external surface of the



ilium. At length, from continued friction and pressure, absorption takes place, and a portion of the wall of the capsule gives way, so as to allow the head of the femur to escape from its cavity, and to come in direct contact with the osseous structure of the dorsum ilii. This state of things may exist for a longer or shorter period; the head of the femur passing to and fro between its original capsule and the external surface of the ilium. The acetabulum, however, having now lost its normal configuration, permanent reduction is scarcely attainable. When the capsule has been perforated, so as to allow the head to escape from it, the ligamentum teres, becoming elongated and slender, must give way, and soon disappears. This ligament, in the early stage of the displacement, is generally found to retain its continuity. *Vide* PLATES VI. and VII.

The capsule and ligamentum teres, as would appear from one of the dissections, hereafter more particularly described, may coalesce in proportion to the disappearance of the head, and form a strong ligamentous cord, running between the pelvis and the upper portion of the femur. *Vide* PLATES VIII. and IX.

NEW CAPSULE.—When the head of the femur has escaped from its natural capsule, and become placed in contact with the surface of the os ilium, a new set of phenomena takes place. Reparatory efforts are made to



restore the head of the bone to something like its former condition, and nature attempts to form a new capsular ligament, which on the one hand is attached to the dorsum and contiguous portion of the ilium, and on the other, to the outer and posterior surface of the old capsule, and to the margin of the perforation through which the head of the femur had made its escape. (*Vide* PLATES VI. and VII.) Or, the head may never have escaped upon the ilium, and in that case, in proportion as the head becomes atrophied and disappears, the sides of the old capsule become coalesced and glued together, as previously remarked. To the posterior part of the cord thus formed, a set of radiating fibres, springing from the dorsum of the ilium, become attached, and fortify it. These fibres probably represent, in another form, a recent capsule, which, under other circumstances, as when the head has pierced the old capsule and rests upon the dorsum ilii, would assume a regular capsular form. *Vide* PLATES VIII. and IX.

NEW ACETABULUM OR SOCKET.—By the formation of the new capsule, a false articulation is partly accomplished, which, to be complete, requires a new arrangement upon the dorsum of the ilium, to represent a new acetabulum. This end is attained in two different ways. In one, there is a simple glenoid depression scooped out, as it were, upon the dorsum of the ilium. (*Vide* PLATE



vii.) In the other, nature increases her efforts, and, as often happens after traumatic dislocations, new osseous matter is thrown out upon the ilium, which, at times, assumes to some extent the cup-like form of an acetabulum. In the first case, the new capsule attaches itself to the margin of the depression (*vide* PLATE vii.); in the second, to the osseous border of the new socket.

M. Guérin has stated that it was an invariable sequent, for a new osseous socket to be thrown out upon the dorsum ilii, as soon as the head of the femur, in congenital dislocations of this bone, has escaped from the articular capsule, and becomes placed in circumstances somewhat similar to those attendant upon the traumatic dislocation of the femur, and he has founded a theory of treatment upon this supposed fact. The formation of a new socket by osseous effusion, is not an invariable result of the perforation of the articular capsule and the escape of the head of the femur. The drawings of a pelvis, now in my possession, establish the presence of only a simple depression upon the dorsum of the ilium, notwithstanding that the head of the femur has on both sides passed through a large aperture at the upper part of the capsule, and has become placed in immediate contact with the osseous structure of the ilium. *Vide* PLATE vii.

The secondary depressions, or the sockets, intended to hold a certain relation with the displaced head, after it has passed from its original capsule, are generally lined



by a thin layer of tissue, depending probably upon the periosteum of the ilium; and this may at times present a smooth surface, somewhat analogous to the synovial membrane. At other times, from age and continued friction, an appearance of eburnation is present; at others again, a rough surface. The osseous tissues of the pelvis and of the femur, when thus deprived of the intervention of any soft tissue, come into immediate contact, and when moved upon each other, produce a harsh grating sound.

Another modification which the capsule is seen to assume, is represented in PLATES VIII. and IX. The head of the bone, in this case, has never escaped from the capsule, but has become absorbed, and the walls of the capsule coalescing, have finally become conglomerated into a firm, dense, ligamentous cord, running between the remains of the old acetabulum and the stunted upper extremity of the femur. Here, there is neither depression, nor new socket upon the ilium, and the numerous auxiliary ligamentous fibres, which seem to occupy the place of a new capsule, take their origin from the plain surface upon the ilium, and run forwards, converging, to become incorporated with the posterior aspect of the ligamentous remains of the ancient capsule. *Vide* PLATE IX.

THE SYNOVIAL MEMBRANE AND THE ARTICULAR CARTILAGE of the primitive cotyloid cavity, like the same



structures covering the head of the femur, gradually disappear, leaving, in some instances, the osseous tissue entirely denuded.

We see then, from this account of the articular apparatus of the hip-joint, as it appears in the different forms of congenital dislocation of the femur upon the ilium, pathological conditions, essentially distinct, which must exert an important bearing upon the prognosis, and probable efficacy of the therapeutic means that may be adopted in this affection. In one case, the capsule is found to retain its continuity of structure, and the head of the femur rests enclosed in it on the ilium, towards the margin of the acetabulum, or entirely upon the dorsum ilii. In another, the capsule is found converted into a conglomerated fibrous cord, which at one of its attachments grasps firmly the upper part of the femur, and is sufficiently extended to allow the head of this bone to play upon the dorsum ilii through a space of from one to three inches. (*Vide* PLATES VIII. and IX.) In this case the head of the femur has disappeared, but in neither of these two cases does nature attempt to produce a new osseous socket upon the external surface of the ilium, although a simple depression may sometimes be found.

In a third condition of the pelvis, the round ligament has most frequently disappeared, and the head of the femur is found in direct contact with the external surface of the ilium, having passed through a perforation in the upper portion of the articular capsule. (*Vide* PLATES VI.



and VII.) In cases of this kind, an effusion of new osseous matter, more or less profuse, in the shape of a socket, is often found upon the dorsum of the ilium. This effort of nature is similar to the process which occurs in those instances of traumatic dislocations that have been allowed to remain unreduced. At times, however, notwithstanding the assertion of M. Guérin to the contrary, a simple depression only exists upon the dorsum ilii, although the capsule has become perforated and the head of the femur lies in direct contact with the dorsum of the ilium. (*Vide* PLATE VII.) In the two first conditions of the parts, no new articulation is ever formed, but in the third, a new socket may be produced, as well as a new capsule, and a kind of pseudo-articulation thus result.

THE MUSCLES.—The pathological state of muscular retraction, by the instrumentality of which the dislocation of the head of the femur is primarily produced, has already been considered, under the head of etiology. The muscles surrounding the hip suffer a still farther shortening, owing to the contraction resulting from the unnatural position in which they are placed when the dislocation has actually occurred. The points of origin and of insertion of several of the muscles now become approximated, and this circumstance is another cause which tends still farther to produce a shortened state of



the muscles originally implicated in the production of the dislocation. The existence of the abnormal retraction of the muscles is necessarily one of the chief obstacles to the permanent success of the reduction of the head of the femur to its natural position.

At the same time that the points of origin and of insertion of the pelvi-femoral muscles are relatively changed, the course of their fibres assumes a different direction from that which is natural to them while the normal disposition of the component parts of the joint is maintained.

In progress of time, the muscular tissue itself becomes changed. It may present a fibrous appearance, or it may be pervaded by a fatty degeneration, and become atrophied; or in some cases it may even become hypertrophied. These conditions of the muscular tissue result from the perverted action of the pelvi-femoral muscles, some of them being so placed as seldom to be brought into a state of action, while additional exertion is required of others. The increased exercise which certain muscles have to undergo, induces a hypertrophic state, as often happens in some portions of the gluteus maximus, gracilis, &c., while, where the traction is still more energetic and continued, fibrous degeneration takes place, as is seen in the conjoined tendons of the psoas-magnus and iliacus internus, and frequently of the gluteus minimus; while



fatty degeneration and atrophy are the consequence of the relaxation and inertia which follow the approximation of the points of origin and insertion of some of the muscles, examples of which are met with in most of the pelvi-trochanteric muscles; such as the gluteus medius, &c.

From what has been said in relation to the morbid retraction of the muscles, and the fibrous transformation which pervades the tissue of some of them, it would seem that these conditions in themselves must sometimes form an insurmountable obstacle to the permanent reduction of the head of the femur. Upon this consideration, the principle of dividing the implicated muscles by subcutaneous section, as in the treatment of Talipes, and some other articular deformities, has been applied to the retracted muscles of the hip-joint, in cases of congenital dislocation of the head of the femur. This extension of myotomy was suggested by M. Guérin, and merits attention, as one of the resources that may be made available in cases of this displacement.

**ARTERIES AND VEINS.**—The arteries in persons affected with congenital dislocation of the femur do not take the direct course which is observed in their normal distribution. They are flexuous and serpentine, and exhibit a contracted state of their calibre, while the veins are direct in their course, and larger in diameter than in the natural



condition of the parts. The arteries of the ligamentum teres must, in the early period of the displacement, become compressed, and finally, when this ligament becomes ruptured, or has given way from pressure, and disappeared, the head of the femur must be deprived of the nutrition supplied to it through the medium of this structure.

NERVES.—The nerves, which are generally found to be smaller, are disposed in such a manner as to take a direct course to arrive at their distribution in the muscular tissue. Therefore they might, from the shortening resulting from this arrangement, be the source of considerable pain during the efforts made in attempting to accomplish the reduction of the luxation. The arteries in this respect are differently disposed; for being flexuous, the extension, by which the extremity can be elongated, would only efface their sinuosities without putting these vessels on the stretch.

CELLULAR TISSUE AND SKIN.—The cellular tissue is generally abundant, is studded with *pelotons* of adipose tissue, and pervades in considerable quantity the depressions resulting from the new disposition of the parts, as well as the inter-muscular spaces. The skin, in old subjects, is apt to be flaccid, but presents nothing unnatural, except the ordinary appearances which might be expected to result from enfeebled nutrition. The facility with



which the cutaneous and cellular structures will accommodate themselves by their elasticity to extension exerted upon the limb, would prevent their ever offering any obstacle in attempts to effect the reduction of the head of the femur to its natural position.

CHANGES WHICH TAKE PLACE IN THE OSSEOUS TISSUE.

—The alterations which occur in the parts of the skeleton in proximity to the morbid articulation, or even at a considerable distance from it, merit consideration. From the perverted and diminished nutrition to which the osseous tissue is subjected in this malady, alterations occur in the different portions of the pelvis, extending to the femur, and to the other component parts of the bony structure of the inferior members, producing ultimately formidable complications during the progress of this affection.

As far as my own observations extend, the diameters and the several measurements of the pelvis are invariably changed, and the tissue of the bones, not only of the ossa femora, but also of those more remote, undergo alterations in their texture, density, and volume. The thigh bones and the tibia and fibula, as is seen in the drawing of one of the cases I examined (*vide* PLATES VIII. and IX.), have participated very materially in the degeneration of structure.

This softened and fragile condition of the bones is dif-



ferent from that which has received the name of rachitis. In the osseous deterioration of the pelvis and femurs, in persons laboring under congenital dislocation of the hip-joint, there is no reparatory attempt made towards the restoration of the osseous structure while the displacement exists. In rachitis, however, the soft and yielding state of the bones is generally temporary, and in fact the rachitic bone, once cured, often presents a denser and more compact interior texture, than a bone which had never suffered from this disease, as may be observed on the concavity of the long bones which have suffered from rachitic derangement.

The osseous structure depends indirectly upon the vascular supply to the periosteum, and to the internal medullary membrane, for its healthy nutrition. As has already been observed, the arteries in the vicinity of the dislocation are not in their normal condition, besides being under their usual size. As a natural consequence of this, the medullary membrane is not supplied sufficiently for the interior nutrition of the bone, while from the same inadequate supply to the periosteum, the more superficial parts likewise suffer in this respect. When this is taken into consideration, it may reasonably be expected that the pelvis and femurs would become deteriorated in their texture.

In connexion with the increased muscular traction which, in congenital luxation, must take place during



locomotion, this deficiency of density and the fragile state of the bones predispose to the production of osseous malformations, and thus the curvatures, and fractures even, of the long bones, such as the femur, can be satisfactorily accounted for. *Vide* PLATES VIII. and IX.

CHANGES OBSERVED IN THE CONFIGURATION OF THE SKELETON OF THE PELVIS, &c.—The pelvic diameters and other measurements are materially changed in cases of long standing, the alterations being modified, according as the dislocation is present upon one side only, or simultaneously upon both. The assertion of Dupuytren, in regard to the natural conformation of the pelvis being maintained in cases of either single or double congenital dislocation of the femur on the ilium, is proved now by pathological investigations, to be incorrect. In the specimens which I have had the opportunity of examining and of dissecting, the diameters of the pelves were materially changed from the normal standard, and I have no doubt that similar irregularities will be observed to exist, as a general rule.

During life, and in the erect posture, where there is dislocation upon one side only, the hip posteriorly, of the side affected, is apparently more elevated, owing to the projection of the trochanter major; but the ilium is found to have descended lower than the corresponding part of the opposite side. In the skeleton, however, the half



of the pelvis, which corresponds to the dislocation, is dragged or twisted from before backwards, and from below upwards, so that the side of the pelvis upon which the dislocation has existed, is situated, in relation to the os innominatum of the sound side, upon a higher plane and more posterior, than on the side where the head of the femur has maintained its normal position.

At the superior strait, the antero-posterior diameter of the affected half is diminished, and the symphysis pubis is drawn beyond the mesial line, in the direction of the affected side. The semi-inferior strait corresponding to the affected side, on the contrary, appears more open and enlarged laterally, and is drawn, as it were, outwards and upwards. These malformations, occurring in the diameters of the straits, although confined chiefly to one side, necessarily interfere with the functions of parturition, and render it difficult and dangerous; and after reduction, where this is practicable, they would still be a source of lameness.

The individual parts of the pelvis on the affected side, present also deviations from the natural configuration. The ilium, besides being more thin and atrophied, is more vertical and less excavated. The anterior superior spinous process of the ilium is carried somewhat inwards; the inferior anterior iliac spine is more prominent than natural, and immediately below it, and between it and the eminentia ilio-pectinea,



is observed a deep groove, in which the conjoined tendon of the iliacus internus and psoas magnus has played. (*Vide* PLATE VIII.) The transverse or horizontal branch of the pubes is longer and more slender, and is directed more obliquely upwards and backwards, than the corresponding part of the sound side.

The ischium is drawn outwards by the pelvi-trochanteric muscles, so that the tuberosity is seen situated more externally than on the opposite side. As a consequence of the change of direction outwards of the ischium and of the descending ramus of the pubes, the long diameter of the obturator foramen is found to be disposed nearly transversely, instead of almost vertically.

When the head of the femur is dislocated upon the ilium *on both sides*, both halves of the osseous pelvis participate in the deformity, and frequently the alterations are so nearly alike on either side, that the resulting malformations are symmetrical.

The wings of the ossa innominata in this case, are found less dense, smaller, and more vertical; the anterior inferior spinous processes of the ilia are found prominent, and the depressions existing below them are seen to be deeply grooved by the continued traction of the tendons, which played in them during life. (*Vide* PLATES VI. and VIII.) The horizontal rami of the pubes are found also more slender and longer, extending considerably farther outwards, on each side from the symphysis, than in the



natural state ; while the body of the pubes, on each side of the symphysis, is less deep, and also more fragile in texture. The ischia are drawn outwards, and the long diameters of the foramina obturatoria run somewhat in a transverse direction, instead of being nearly vertical. The sacrum is generally more stunted, and narrower than natural. *Vide* PLATES VI. and VII.

The superior strait of the pelvis is contracted in the antero-posterior diameter, while laterally or transversely the measurement is proportionally increased, although, as the whole pelvis is generally on a smaller scale, this measurement is, in reality, less than is met with in a well formed pelvis.

The inferior strait presents a contraction in the measurement from the apex of the coccyx to the arch of the pubes, while the transverse diameter between the ischia, is considerably more ample than in the natural pelvis. *Vide* PLATES VI. and VII.

From this statement, it is evident that so great a departure from the normal relations of the different measurements and straits of the pelvis, must of themselves add to the lameness, as well as materially impede the progress of the head of the full grown foetus, in its passage through the pelvis, during parturition, and that a difficulty may be anticipated so formidable, as to render the intervention of instrumental aid necessary to preserve the life of the mother. From the extent of malformation which takes



place in the pelvis, whether the dislocation be single or double, there seems little reason to suppose that in either case the obstacles to parturition would be materially lessened.

ANALYSIS OF THE MALFORMATIONS OF THE PELVIS.—The extent of the deformity which pervades the pelvis of individuals who are affected with congenital dislocation upon the dorsum ilii, must in a great degree be subordinate to the extent of the displacement of the head of the femur, and also to the length of time the luxation may have existed. The characteristics, however, of these malformations are generally so similar and definitely marked, that they can be chiefly referred to a set of anatomical causes which must always exert their influence during the existence and progress of this affection.

The escape of the head of the femur from the confines of the acetabulum, and its ascent upon the dorsum ilii, will necessarily change the direction and relative action of all the muscles inserted into the upper portion of the femur. The *psoas magnus* and *iliacus internus*, on each side, when the luxation is double, will be put upon the stretch in proportion as their points of insertion at the trochanter minor are dragged upwards during the ascent of the head of the femur.

The *quadratus femoris*, the *gemelli*, the *obturatores*, the *pectineus*, and probably the upper portion of the *adductor magnus*, attached on the one side to the pelvis, and on



the other to the upper portion of the femur, are also put upon the stretch by the removal of their points of insertion at the femur to a greater distance from their points of origin. *Vide* PLATE III.

In connexion with the deteriorated organization of the bones of which the pelvis is constructed, the increased traction exercised by the muscles, and the perverted direction in which they must now act, during progression, will, to a certain extent, account for many of the changes which are observed in the form and dimensions of the pelvis. The vertical direction which the wings of the ilia acquire, may result from the suspended antagonism between the iliacus internus on the one hand, and the gluteus medius and gluteus minimus on the other. The ascent of the femur puts these two glutei into a state of relaxation and consequent inactivity, as regards their effect upon the dorsum ilii; while, on the contrary, the iliacus internus is in a state of tension, which tends to pull inwards the internal iliac fossa. The deep groove to be seen below the anterior and inferior spinous process of the ilium is evidently the result of the tractions exercised upon the conjoined tendons of the psoas magnus and iliacus internus muscles, which pass over this groove like the cord of a pulley, and play in it during progression. These tendons, by their continued traction on each side, will tend, besides, to elongate outwardly the horizontal ramus of the pubes. The ischia are pulled outwards by



the continued traction of the quadratus femoris, the superior and inferior gemelli, and the obturator internus, while the obturator externus impresses the mark of its passage over the anterior and external part of the body of the ischium ; the tractions of the upper fibres of the adductor magnus on each side may also aid in separating the descending rami of the pubes, and thus contribute to enlarge the angle below the symphysis pubis. *Vide* PLATES III., VI., and VII.

These abnormal results, in the configuration of the pelvis, brought about by the perverted action of the pelvi-femoral muscles, are materially augmented by the influence which the weight of the body exerts upon the muscles, during locomotion, after the heads of the ossa femorum have escaped from the limits of the acetabula. It may easily be understood that, as soon as the heads of the femurs have mounted on the ilia, and lost the fixed support which they naturally receive from the walls of the cotyloid cavity, the trunk must sink down, as it were, between the upper portions of the ossa femorum. An additional superincumbent weight being now thrown in a great degree upon the muscles surrounding the hip-joint, the traction exercised by those muscles which are attached to the framework of the pelvis, is necessarily increased, and the fragile osseous tissue becomes distorted in the direction of the action of their fibres.

It is also by the agency of the several causes above



mentioned, confined, however, to one side only, that the lateral parts of the pelvis corresponding to the side affected, become deformed and drawn upwards and backwards, in cases of single congenital luxation of the femur upon the ilium.

The occurrence of fracture of the femurs, as well as of the bending of these bones, and of the tibia and fibula, which is sometimes observed, must also be attributed to the deteriorated condition of the bones themselves, and to the increased action imposed upon the muscles, both by the superincumbent weight of the body, and by the ordinary muscular contractions which come into play during the different acts of locomotion.

These pathological remarks on the changes which take place in congenital dislocations of the femur, at the ilio-femoral articulation, in the osseous structure in proximity to it, and in the soft tissues by which this joint is surrounded, will be referred to, when the subject of treatment comes to be considered, as they have a direct bearing upon the curability of these affections.

I shall now proceed to the description of a case of double congenital luxation of the heads of the femurs upon the dorsa of the ilia, which I select from those I have had an opportunity of examining after death, as a pure and uncomplicated specimen of this affection, and as signally elucidating its pathological characters.\*

\* I take pleasure in acknowledging here the facilities afforded me in the prosecu-



It presented all the pathognomonic characters externally, appertaining to the case related at page 106 et seq., and which is delineated in PLATES Nos. I., II., and IV.

To aid the description of the parts, I refer to the admirably executed drawings of the pelvis and the ligaments of the coxo-femoral articulation, as seen immediately after the removal of the soft tissues, in PLATES VI. and VII.

The subject from which the following description is taken—a female, apparently between sixty and seventy years of age—as observed while lying on the table, is seen to be somewhat emaciated, but this condition is most evident as regards the inferior extremities. The soft parts about the basin are flabby; a considerable disproportion between the size of the trunk and the length of the inferior extremities is observable, owing to the ascent of the heads of the femurs upon the dorsa of the iliac bones. The head, thorax, and abdomen, present nothing abnormal while the body is in a recumbent position, but being placed in the erect attitude, the superior extremities appear too long for the trunk; the trunk itself appearing, as it were, wedged and sunk between the upper portion of the femurs. The thorax and abdomen are thrown forward with a salient anterior curve, while the region of the

tion of my inquiries on this subject, by M. De Lemarquay, at that time connected with the *Hôtel Dieu* and the *Ecole Pratique*, of Paris.



loins, and the lower part of the dorsal vertebræ, present a curvature forwards with a corresponding concavity. In this latter position, also, the anterior superior spinous processes of the ilia are thrown forwards, while the lower part of the sacrum and coccyx take a direction upwards and backwards; the base of the sacrum being consequently tilted forwards and downwards. The cristæ of the iliac bones are almost vertical, and the trochanters can be felt standing out at a right angle to the external surface of the dorsum, nearly on a level with the posterior portion of the crests, and forming the apex of a conoid eminence, the base of which is at the ilium itself. The heads of both femurs enjoy free motion upon the dorsa of the iliac bones, and, while the trochanters can be pushed upwards and outwards, so as to be within half an inch of the crests of the ilia, when traction in the opposite direction is exerted, they are felt to descend through a space of nearly two inches, and become nearly on a level with a direct line drawn transversely from the depressed anterior and superior spinous processes. The pelvis itself, with the exception of the unusual inclination of its axes, and the unnatural projection caused posteriorly by the abnormal position of the trochanters, appears to be, in other respects, tolerably well formed; the transverse diameter being, however, somewhat increased at the expense of the antero-posterior, but neither as regards the pelvis, nor the other osseous parts of the extremities or trunk, are there



to be seen any evidences of a rachitic disposition. Between the anterior and superior spinous processes, there is a distance of eight inches; between the anterior superior spinous process and the tuberosity of the pubes, four inches and a half; while between the tuberosities of the ischia there is a space of five inches and three quarters, showing a considerably exaggerated diameter in this direction. The nearly equilateral triangle observed in the natural position of the parts, between the upper margin of the trochanter, the tuberosity of the pubes, and the anterior superior spinous process of the ilium, is altogether changed, the measurements between these several points differing materially, according as the head of the femur is pushed upwards, or is drawn downwards upon the dorsum of the ilium. The play of motion which the head of the femur must have had in the act of progression during life, may be said to have been about two inches, as that extent of change of position of the head of the bone can be obtained, by an alternating force applied to its shaft, of traction downwards, or propulsion upwards. In the attempt to rotate or move in different directions, the inferior extremity, a sensation of crepitus is felt, analogous to that produced by effusion or thickening of the ligamentous structure about an articulation; and the various motions can be effected with less facility than is generally observed in a healthy joint. Adduction and the action of flexing the thigh upon the pelvis, is less impeded than the other



motions, but abduction and extension are permitted to a very limited extent.

As far as can be seen externally, the dislocation on both sides is exactly similar in every particular, and the two sides of the pelvis, in regard to the relations they bear with the displaced head and trochanter of the femur, offer no perceptible variety. It will be seen by reference to the case already inserted, at page 106 et seq., that the pathognomonic characters described, as belonging to the patient there alluded to, are perfectly analogous to those which claim our consideration in the present instance.

The external appearances then being, in both cases, the one a facsimile of the other, it may reasonably be supposed that the deeper tissues are also analogous. After these preliminary remarks, as regards the external characters or signs presented by the double congenital luxation of the head of the femur upon the dorsum ilii, we shall now describe the appearances met with upon dissection; first of the soft parts, and then in connexion with the articular surfaces appertaining to the skeleton.

The skin occupying the region of the haunch is soft and flaccid, but in other respects presents nothing remarkable. The subcutaneous adipo-cellular layer is dense and interspersed with pelotons of adipose tissue, which also are more condensed than usual. The aponeurosis covering the glutei is natural, but in attempting to remove this from the gluteus maximus, the fibres of this muscle



are found to be so friable, that it is impossible to remove the investing fascia, without carrying along with it some of the degenerated muscular tissue. The first layer of muscles being exposed, consisting of the gluteus maximus, the anterior portion of the gluteus medius, and the upper portion of the semi-membranosus, semi-tendinosus, and biceps, the general character of the muscular tissue is found to be much changed. These muscles are soft, flabby, and pale, and have undergone, in many points, a partial conversion from the muscular into a kind of yellowish, fatty tissue. This is particularly to be observed with regard to the gluteus maximus and the anterior portion of the gluteus medius, but the other muscles participate more or less in the degeneration. The muscular fibres, in regard to their length, seem to have accommodated themselves to their altered position, and are found to be shorter than they ought to be, when the normal relation of the parts exists, and this can easily be understood when it is considered that the points of origin and insertion are considerably approximated by the ascent of the head of the femur. The gluteus maximus being divided transversely through its middle, and the two portions reflected, an unusual quantity of adipo-cellular tissue is met with enveloping the large nerves, arteries, and veins situated beneath this muscle. By removing this loose tissue, the deep-seated muscles are exposed, and are found to have undergone the same fatty degeneration as



the more superficial layer, and the change or alteration in the direction of their fibres is particularly evident. Thus the quadratus femoris, obturator externus, gemelli, and obturator internus, instead of passing transversely outwards, as they generally do, assume a direction almost directly upwards, and but slightly outwards, to arrive at their point of insertion, at the root of the great trochanter. The pyriformis, which in the healthy subject is inclined downwards from its origin, has taken an inverse direction, and ascends upwards and outwards to reach its place of insertion at the digital fossa. In regarding the parts from above downwards, the gluteus medius, pyriformis, and obturator internus, instead of resting upon the posterior portion of the cotyloid cavity, lie upon the partially destroyed head of the femur and the posterior surface of the coxo-femoral capsule. The gluteus medius, the anterior fibres of which have become transverse, is pushed upwards towards the iliac crest, while the gluteus minimus is also shortened, and more fibrous than natural, particularly towards its insertion, where it becomes confounded with the capsular ligament.

Upon removing the tegumentary tissues from the anterior and upper part of the thigh, the femoro-pelvic muscles in that region are found to be shorter than natural, by the amount of the distance that the head of the femur has passed up beyond the cotyloid cavity. The same fatty degeneration and paleness of muscular tissue before



alluded to, is found to pervade, more or less, the rectus, tensor vaginæ femoris, and the belly of the iliacus internus. The sartorius and adductors present a more normal appearance of tissue, as does also the gracilis, which last is even somewhat hypertrophied. The psoas magnus, taking its usual origin from the bodies and transverse processes of the last dorsal and lumbar vertebræ, passes downwards, and becomes tendinous about its middle. Where it passes over the brim of the pelvis and becomes mixed with the iliacus internus, a strong cord-like tendon results from the junction of these two muscles, which, instead of passing downwards and outwards to the usual point of insertion, hooks, as it were, over the margin of the pelvis, below the anterior inferior spinous process of the ilium, where it forms a deep groove; it then takes a course upwards, outwards, and slightly backwards, to the extent of nearly three inches, to gain the trochanter minor. It is important to bear in mind the reflected course of the tendon of the psoas magnus, as it accounts anatomically for the curvature forwards of the lumbar region, and also operates in conjunction with the shortened state of the adductors in materially impeding the adduction of the limb. From the continued friction to which the parts must have been subjected during life in the act of locomotion, a large bursa, extending in various directions, exists beneath the conjoined tendons of the psoas and iliacus, and the finger, when inserted into it,



meets with an extensive cavity, which in the natural state would have been occupied by the margin of the acetabulum and a portion of the head and neck of the femur, covered with the anterior part of the capsular ligament.

The arteries are much smaller than natural, and present a remarkably tortuous disposition, not unlike the flexuosities of the vessels of the impregnated uterus. Thus the main arterial trunk of the pelvis and inferior extremity, from the bifurcation of the aorta into the primitive iliacs to the place where the femoral artery perforates the tendinous sheath of the adductor magnus, presents a series of sinuosities bending in various directions; and this disposition is observed in the smaller branches, as well as in those which spring from the internal iliacs to supply the parts on the gluteal region.

The veins corresponding to the arteries, if any difference exist, are larger than usual, and differ from the arteries in following a direct course, without presenting any irregular flexuosities.

The nervous centres in their structure present nothing abnormal in their individual parts, but they are somewhat under the average size. The remains of a small bloody effusion (*foyer sanguine*) exists in the substance of the corpus striatum of the left side, and also another in the cerebellum near the corpus dentatum. The spinal mar-



row, except the diminution in volume just alluded to, appears generally natural, and the nerves forming the cauda equina, as also the sacral plexus, and the branches which take their origin from them, viz. obturatrix, glutæals, less and greater sciatics, &c., are below the normal size.

The ligamentous structure of the coxo-femoral articulation presents peculiarities and changes even more remarkable than the other tissues already spoken of, and merits special attention as regards the possibility of effecting the reduction of this dislocation after a certain age, and the probability of maintaining the displaced articular surfaces in contact, should the attempt to reduce the dislocation be successful. The form and dimension of the capsular ligament have undergone a complete change, and in fact the disposition of the ancient capsule, and the parts it originally contained, have assumed altogether a new character, and abnormal relations with each other. The former ligamentous tissue itself has in some parts been replaced by a fatty structure, and has become thickened, or more attenuated in others.

It is not easy to describe by words the complex changes which the articular apparatus of the joint has undergone, but by a reference to the drawings on PLATES VI. and VII., the description of the parts, as disclosed by dissection, will be better understood. Upon each side, the coxo-femoral articulation has become, as it were, fur-



nished with two capsular ligaments; one, which is the remains of the ancient capsule, and the other, which is of more recent formation, and in which the head of the femur has been lodged since its escape from the original capsule. The old capsule, retaining its attachments at the margin of the acetabulum, has changed its usual direction, and is stretched upwards and outwards, in proportion as the head of the femur has mounted upon the dorsum ilii. The head of the bone becoming independent of the acetabulum, and placed during the erect posture of the subject at the upper portion of the interior of the natural capsule, would naturally ascend and descend, during the act of locomotion, and remain within the original capsule until, in the progress of time, farther changes occur. Owing to the weight of the body being now thrown chiefly on the capsular ligament, and the consequent pressure of the head of the femur against its upper portion, particularly during progression, it is reasonable to suppose that this part more especially of the capsular ligament, would be subjected to material changes. This apparently has been the case. The head of the femur acting from below upon the superior and inner portion of the old capsule, while the weight of the body afforded the counter resistance from above, this portion of the capsule, thus situated between the internal part of the head of the os femoris and the dorsum of the ilium, being continually subjected during the actions of



locomotion to the influences of powerful traction and pressure between two hard bodies, gives way, either by rupture, or more probably has become, as it were, worn through (*usé*) by a species of progressive absorption. The perforation of the capsule being now accomplished, and the weight of the body still continuing to be thrown upon the inferior extremities, the head of the os femoris, pressing in one direction and the superincumbent weight of the body in another, escapes at length through this perforation, and now becomes situated upon the dorsum of the ilium, in contact, superiorly and externally, with the deep surface of the gluteus minimus, and inferiorly with the upper surface of the old capsule, an annular portion of which passes around and thus encircles the cervix femoris. *Vide* PLATES VI. and VII.

As happens in traumatic dislocations, the formation of a new capsule has followed the escape of the head of the femur from the confines of its original receptacle. This new capsule, which entirely surrounds the head of the femur in its new position, is of a fibro-ligamentous character, mixed in some points with a considerable quantity of yellowish, dense, adipose structure. (*Vide* PLATE VII.) It is inelastic, but from the length of its fibres, free motion of the bone is allowed in every direction after the muscles have been removed. Internally, it is attached to the margin of an oval depression situated on the dorsum of the ilium in front of the ischiatic notch ;



externally, it has formed adhesions with the annular perforation in the ancient capsule, through which the head of the bone has passed. The external surface of the capsule is generally surrounded by a cellulo-adipose tissue, but above, it is confounded with the fibrous structure of the deep surface of the gluteus minimus, and below, with the outer and superior part of the original capsule. The internal surface of the new capsular ligament is smooth and shining, studded in various points with numerous pediculated granular bodies of a yellowish adipose appearance, and at the lower and external portion, may be observed the perforation already mentioned, and which is seen to allow a free communication between the ancient capsule and the one of more recent formation. Within the cavities of both capsules a considerable quantity of synovial liquid is found, which most probably has been secreted from the lining membrane of the original capsule.

The ligamentum teres, most likely after being ruptured or worn through, on account of the stretching it must have undergone by the displacement of the parts, has entirely disappeared, leaving no trace of its existence behind, either at its attachment to the head of the femur, or at the bottom of the cotyloid cavity.

The head of the femur has changed its character in regard to its size, shape, and consistence. Its dimensions are much smaller than natural, being at least one third



below the natural standard. (*Vide* PLATE VII.) The aspect upon which the round ligament is generally attached, is flattened, and seems either to have never been developed in this direction, or to have been absorbed, or, as it were, worn down by the friction to which it must have been subjected upon the dorsum of the ilium during progression. This flattened aspect presents superficially a thin lamina of bone, which is entirely denuded of articular cartilage, and on the surface of which are seen numerous irregular elevations and depressions perforated with small foramina, as if the subjacent cancellated tissue had been encroached upon. The osseous tissue of what remains of the head of the femur is entirely altered. Instead of the spherical form and resisting tissue of the adult normal bone, the head of the femur in the subject before us presents an unshapely, stunted appearance, covered externally by a thin, friable, osseous shell, which lies upon a spongy, cellular tissue of bone, so soft as to be easily crushed between the fingers, and incapable of resisting the pressure of a common writing quill. The articular cartilage exists, but to a very limited extent, and is seen to end abruptly in a greyish undulating line, leaving that portion of the head in contact with the dorsum of the ilium, as has already been mentioned, entirely bare. The neck of the femur is shorter and more slender than natural, and forms a right angle with the shaft of the bone, which arrangement, however, may in part



be accounted for by the advanced age of the patient. The ancient acetabula present changes no less remarkable than the corresponding heads of the femurs which have escaped from them. Instead of the round cup-like cavity, there is seen a triangular depression, not more than half an inch in depth, and two and three-quarter inches in perimeter. (*Vide* PLATE VI.) The upper and inferior borders of this triangle are nearly equal in length, but the inner is shorter, and presents an excurvation, which is probably the remains of the notch on the margin of the acetabulum, for the passage of the articular vessels into the joint. This notch is crossed by a transverse ligament, which completes the border of the cavity, but the cotyloid ligament, whose use in the natural state of the parts is to deepen the acetabulum, exists but in a rudimentary manner. To the margin of the acetabulum thus constituted, is attached the pelvic portion of the old capsular ligament. The capsular ligament, in its passage across the cotyloid cavity to be attached to the cervix femoris, becomes immediately connected with the celluloadipose tissue, which fills up that depression; still, by reason of its distinct fibrous structure, it can be distinctly traced to its attachments at the margin of the acetabulum. The bottom of the acetabulum is entirely ossified, showing no signs of an *arrêt de développement*. There is no remains of the ligamentum teres, and what fills up the cavity may be said to have a resemblance to the fatty



mass usually situated at the bottom of the acetabulum, and which has received the name of the glands of Havers.

There is no new cavity formed for the head of the femur in its new position, as might be supposed, but on the dorsum of the ilium, in front of the upper part of the sciatic notch, there exists an oval depression of about an eighth of an inch in depth at its centre, and which is excavated at the expense of the ilium. (*Vide* PLATE VII.) The head of the bone has played on this surface during life, and has probably determined this species of depression. The circumference of this depression receives the attachment of the new capsular ligament, the fibres of which extend in a radiating manner, and becoming confounded with the periosteum, have the appearance of lining its floor, except at the centre, where the friction of the two bones against each other must have been greatest; there the osseous tissue is entirely denuded, and at this point the ilium appears to be almost perforated. It will be seen that there has been no attempt at the formation of a new socket by ossific effusion from the surface of the ilia, as generally takes place in those instances of traumatic dislocation which have not been reduced. This is particularly worthy of remark, as M. Jules Guérin, of Paris, has stated that the deposition of new bony material, as an effort to form a new acetabu-



lum, was an *invariable* result in those cases of congenital luxation where the original capsular ligament had been ruptured or torn, so as to allow the head of the femur to escape, and it is from this supposition, erroneous, as proved by the case now under consideration, that he has deduced certain principles of treatment for these congenital affections of the hip-joint.

These are the principal alterations which are found to have taken place in the soft tissues, and at the ancient and recent articulations; but the changes of form and dimension which the bones of the pelvis, taken collectively, have undergone, merit also consideration, especially in a therapeutic point of view, and in relation to the passage of the head of the child during parturition. After the description which has been given of the muscles and of their abnormal direction, it is not difficult to suppose that the diseased retraction, as well as their physiological action, and the superincumbent weight of the body, acting conjointly, would modify, more or less, the natural shape of the bones under these influences during the early periods of infancy, while the osseous tissue was yet not completely consolidated. In analyzing the changes which the parts have undergone, most of the deviations in inclination, form, and dimension, can in a great degree be referred to the abnormal direction in which the muscles have been obliged to act after the displacement of the



head of the bone upon the dorsum of the ilium has taken place. It will be seen that the pelvis generally is more slender in its construction, the osseous texture at the same time being less compact, owing probably to an original and continued diminution of nervous and vascular supply.

*Vide* PLATES VI. and VII.

In comparing the denuded pelvis with that of the healthy female, the most prominent difference observed, in a practical point of view, is that between the upper and lower straits. In the present pathological specimen the upper strait is found to be generally below the usual measurements, both in the transverse and antero-posterior diameters; the latter, however, is proportionally much more contracted than the former. In a dried healthy female pelvis before me, the transverse diameter is five and a quarter inches, while in the morbid specimen it is four and seven-eighths inches; the antero-posterior diameter in the natural specimen is three and seven-eighths inches; in the other instance, it is only two and three-quarter inches.

The inferior strait in the morbid pelvis is still more anomalous. Between the apex of the coccyx, and the arch of the pubes, the measurement is one and seven-eighths inches, against four inches in the healthy pelvis; while the distance between the tuberosities of the ischia, making up, as it were, for the small antero-posterior diameter, is five and three-eighths inches; the healthy pelvis



in this direction being only four and a quarter inches.

*Vide* PLATE VII.

The wings of the ilia are smaller than natural, presenting angular prominences along the borders of the crests, and upon the dorsa are found the glenoid depressions already alluded to, where the heads of the femurs had played during life. Immediately below the anterior and inferior spinous process of the ilium on each side, the superficial groove in the healthy bone, over which the conjoined tendons of the psoas magnus and iliacus internus passed, is converted into a semicircular deep depression or gutter, giving a more than usually projecting appearance to the anterior inferior spine of the ilium. The descending rami of the pubes, and the ascending rami of the ossa ischia seem spread laterally, and pass almost transversely outwards, giving to the arch of the pubes more of a semicircular appearance than of an obtuse angle, which is observed in the natural condition of this part of the osseous structure. (*Vide* PLATES VI. and VII.) The long diameter of the foramina obturatoria, instead of running nearly parallel with the body, takes almost a transverse direction.

The sacrum is somewhat stunted, showing a greater curvature upon its anterior aspect than in the natural bone, and at its junction with the vertebral column, the sacro-vertebral angle is seen to be more prominent than usual. The spinal column in the lower part of the dor-



sal and lumbar regions, presents anteriorly a remarkable convexity, corresponding to the concavity seen in the loins during life.

Although the superincumbent weight of the body, and the original diseased retraction of the muscles have contributed materially to the production of the changes, just alluded to, in the direction of the bones, it is evident that the pelvi-trochanteric muscles, whose course and manner of action have become entirely altered from the relative change of position of their points of origin and insertion, after the heads of the femurs have been dislocated, and ascended on the dorsa of the ilia, must, in the ordinary performance of their functions, have aided somewhat in bringing about those deviations in direction and inclination, which the component parts of the pelvis have now assumed, so different from what is to be seen in one naturally constructed. The head of the femur having slipped upon the dorsum of the ilium, it is easy to suppose that in progression, the lower dorsal and lumbar vertebræ would be pulled forwards by the action of the *psoas magnus*, while the deep gutter observed on the brim of the pelvis below the anterior inferior spine of the ilium, is no doubt caused by the conjoined tendons of the *psoas magnus* and *iliacus internus* playing like a pulley in this depression; these muscles being almost continually in a state of tension, owing to the increased distance of the small trochanter, since the ascent of the femur upon the



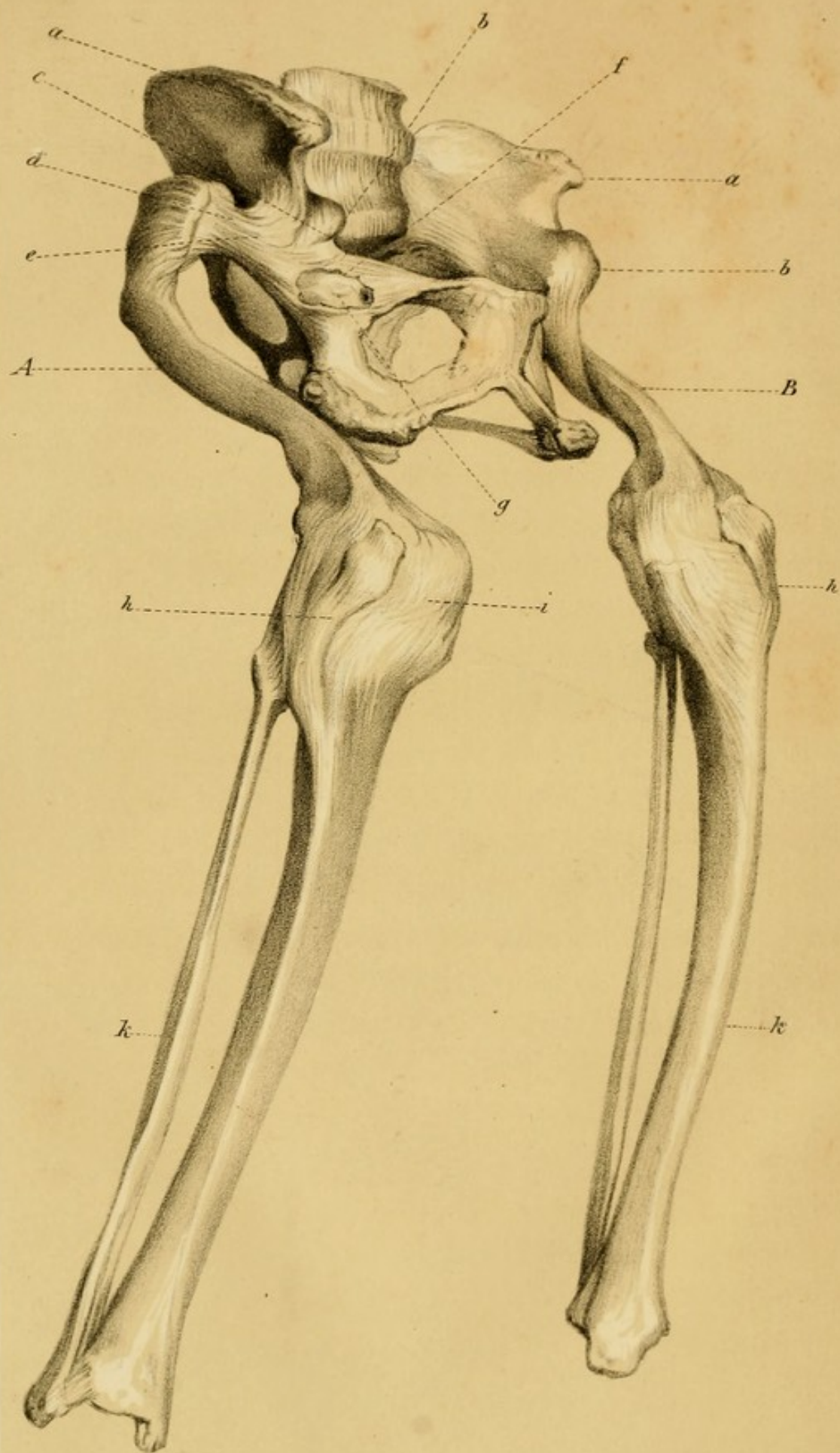
ilium. The same muscles will also, in acting on both sides, flatten or depress the brim of the pelvis, and thus the antero-posterior diameter is reduced; and in connexion with the relaxed state of the gluteus minimus and medius, the iliacus internus by its contractions will tend to render the wing of the ilium more vertical. The psoas magnus, through the medium of its connexion with the lumbar vertebræ, tilting forward the base of the sacrum, and the conjoined tendons, in their passage to their insertion, pushing downwards and backwards the brim of the pelvis, conduce to change the axes of the pelvis, and to render nearly vertical, in the erect posture, the crests of the ilia. The increased transverse diameter of the inferior strait and the almost horizontal direction of the rami of the pubes, and of the ischia, where they form the arch, as well as the outward direction and increased separation of the tuberosities of the ischia, can be accounted for by the perverted action of the quadratus femoris, the gemelli, the obturatores, and perhaps the upper fibres of the adductor magnus.\* *Vide* PLATES VI. and VII.

The case just related presents comparatively but little complication beyond the dislocation itself; in another, which I had an opportunity of examining, and which I now introduce, complications of various kinds will be

\* This case was originally furnished by me to the N. Y. Journal of Medicine, and published in the XXXI. No., for July, 1848.










### EXPLANATION OF PLATE No. VIII.

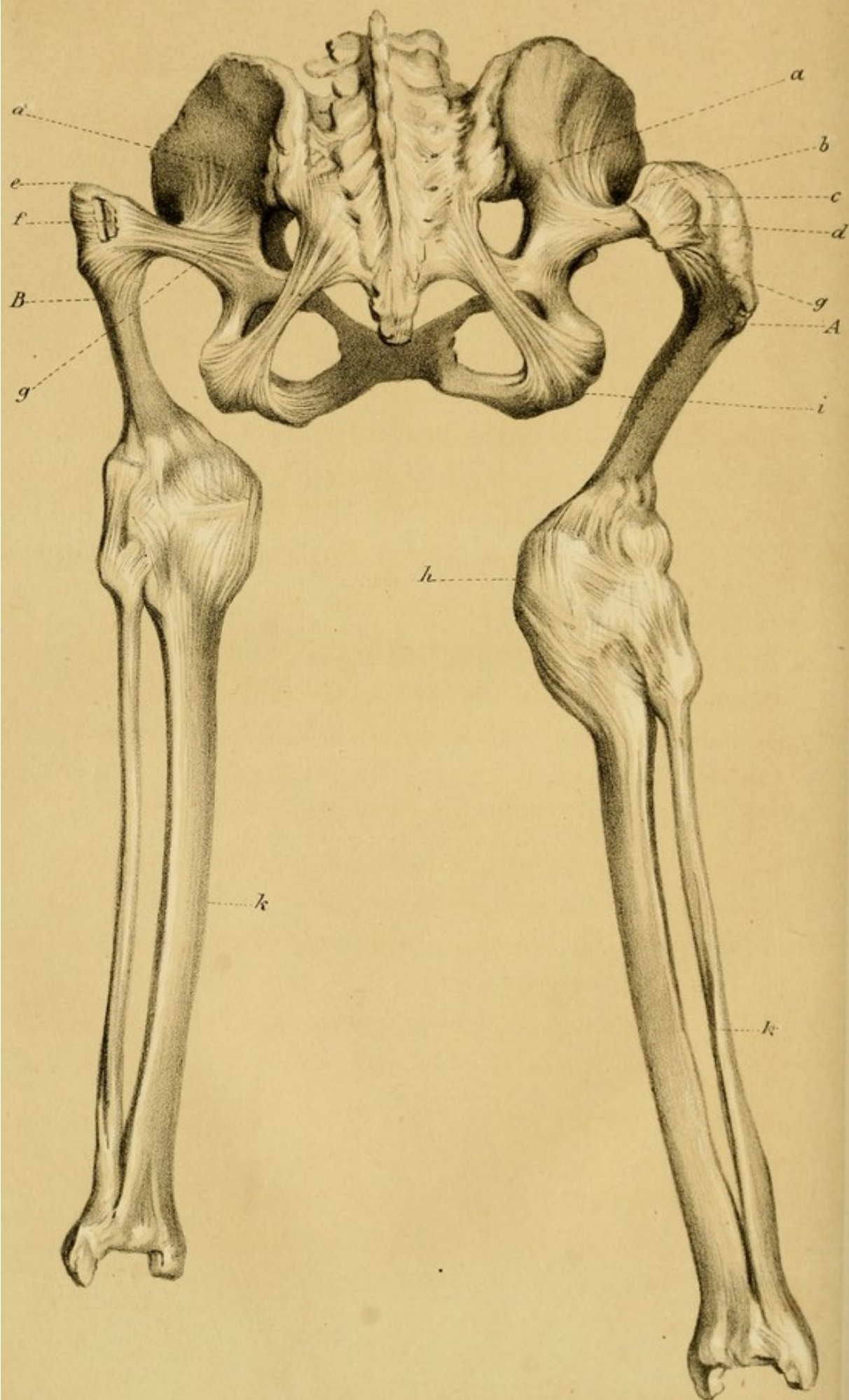
Antero-lateral view of a Male Pelvis, with Double Congenital Dislocation of the Femurs upon the Dorsa of the Iliæ, from a person aged about sixty.

- A. The right Femur deformed, bent, and stunted.
- B. The left Femur stunted and fractured towards its upper extremity.
- a. Anterior Superior Spinous process of the Ilium.
- b. Anterior Inferior Spinous process of the Ilium.
- c. Deep Groove under the Anterior Inferior Spinous process of the Ilium, in which has played the conjoined tendon of the Psoas Magnus and Iliacus Internus.
- d. The remains of the Head and Neck of the right Femur, now atrophied. The old Capsular Ligament, now converted into a cord-like structure, is firmly inserted into the upper extremity of the Femur.
- e. The Ancient Capsular Ligament agglomerated into a dense fibrous Ligamentous Cord. The Ligamentum Teres may have become incorporated with the fibrous Cord.
- f. The margin of a small oval-shaped cavity in the Original Capsule, which is laid open by removal of its Anterior Wall.
- g. The remains of the Ancient Acetabulum, which is contracted, and filled with a softish adipo-osseous material, penetrable by a probe for nearly an inch.
- h. Ligamentum Patellæ.
- i. Inferior extremity of the Femur partially luxated.
- k. Tibia and Fibula participating in the osseous degeneration.











## EXPLANATION OF PLATE No. IX.

Posterior view of the same pelvis, with Double Congenital Dislocation of the Femurs upon the Dorsa of the Ilii.

A. Right Femur degenerated in its tissue—Head and Neck atrophied.

B. Left Femur—its tissues also degenerated—the Head and Neck have entirely disappeared—the upper part of the Shaft has been fractured by muscular traction.

*a.* Dorsum Ilii.

*b.* Remains of the Head and Neck of the right Femur.

*c.* Trochanter Major.

*d.* Tendinous insertion of the Pelvi-Trochanteric Muscles.

*e.* Abrupt termination of the Shaft of the left Femur at the point of Fracture.

*f.* Pseudo-articulation, laid open, between the fractured portions of the Shaft of the Femur.

*g.* New Ligamentous Structure attached by radiating fibres to the Dorsum of the Ilium, and becoming incorporated with the posterior surface of the Original Capsule, so as to form in part the Ligamentous Cord upon which the superincumbent weight of the Trunk has been chiefly thrown during progression.

*h.* Inferior extremity of the Femur partially luxated from the Tibia.

*i.* Tuberosity of the Ischium.

*k.* Tibia and Fibula, smaller and less dense in structure than is natural.





met with, which have occurred as consequences of the primary exarticulation of the head of the femur.

The subject was a male, of about sixty years of age, and, as may be inferred from the annexed drawing of the pelvis, and the ossa femora appertaining to it, as presented in PLATES VIII. and IX., exhibited during life a deformity of a remarkable kind.

The trunk was tolerably well developed, but from the region of the pelvis downwards to the tibio-tarsal articulation, on both sides, the aberration from the usual formation was carried to an extraordinary extent. The peculiar appearance of the nates, the mobility, and other signs observable at the ilio-femoral articulation, indicated the existence of the congenital form of dislocation upwards and outwards of the femurs, at this joint. Besides the change in the relations of the component parts of the articulations, the appearance of the thighs showed the existence of complications which may sometimes occur in the later periods of this displacement.

The inferior members on each side could be pulled downwards or pushed upwards on the dorsum ilii, over a space of about three inches, and on account of the atrophied state of the upper portions of the ossa femora, the stunted superior portions only of these bones could be discovered during the rotation or flexion of the limb. The tuberosities of the ischia could be felt denuded of their muscles, and separated from each other much far-



ther than is seen in the normal pelvis. The thighs are of unequal length, that of the left side being the shorter, notwithstanding the curvature which exists on that of the opposite side. The femoro-tibial articulation is partially luxated, and the legs also present appearances of malformation, which is increased by the disposition of the parts at the tibio-tarsal articulation.

The skin, cellular tissue, muscles, arteries, veins, and nerves presented the same characteristics which were pointed out as existing in the dissection of the preceding case; it will therefore be unnecessary to reconsider these structures in the present instance. I shall therefore only describe the appearances and changes in the ligamentous and osseous structures of the joint itself, and of the skeleton in contiguity to it.

*Capsular Ligament.*—Instead of the natural and capacious capsule, a dense fibrous structure extends from the natural locality of the acetabulum to the upper portion of the femur, to which it is firmly attached, grasping, as it were, the superior part of this bone, on either side. This structure extends from the pelvis to the upper portion of the femur, and from the position it occupies, must be considered as the perverted remains of the original capsule which has become converted into a strong fibro-ligamentous cord, entirely solid, with the exception of a small oval cavity, situated opposite the old acetabulum. This



cavity is little more than half an inch in diameter, is lined by a smooth synovial surface, and from its situation and relations to the place where the remains of the ancient cotyloid cavity are seen, is evidently the representative of the large articular cavity which the capsular ligament presents under ordinary conditions. *Vide* PLATE VIII.

The weight of the trunk has been supported mainly by this strong ligament during progression; and the attachments it has formed to the ilium and to the femur are exceedingly firm and extensive. In front, it takes its origin from that portion of the ilium where the acetabulum would naturally exist, and from the osseous surface contiguous to the anterior inferior spinous process of the ilium, and becoming ligamentous at the outer part of the small cavity mentioned, it ascends upwards and outwards for the distance of about three inches, to become strongly attached to the upper extremity of the femur of both sides. On the right side, it grasps the atrophied remains of the head and neck of the femur, and on the left, the abrupt termination of the upper portion of the shaft of the femur, which on this side has been fractured by muscular traction. On the left side, where its attachments to the femur are formed, it encloses a small portion of bone, the remains of the upper fragment of the fractured shaft. This upper fragment rests horizontally among the fibres of the ligamentous cord, and presents a plane sur-

face, opposed to a corresponding smooth surface, which is met with on the inner aspect of the superior end of the lower fragment of the shaft. The fibres of this ligamentous cord, as they become attached to the *debris* of the upper portion of the femur, extend in a diverging manner over the place where the two fragments lie in contact. (*Vide* PLATE IX.) During progression these contiguous osseous surfaces must have been subjected to continued friction upon each other. There has been no attempt at union between them, but a moveable pseudo-articulation has resulted, invested by the fibres of the femoral attachments of the cord-like ligament, and lined internally by a smooth thin membrane.

Besides the attachments already spoken of as arising from the site of the old acetabulum, the cord-like ilio-femoral ligament receives a numerous accession of fibres, which take their origin in a radiating form from the *dorsum ilii*, and from the osseous surface adjacent to the anterior inferior spine of the ilium. These auxiliary fibres converge, and become incorporated with the other fibres of the ligament, whence results the strong fibrous cord running from the ilium to the femur. The *ligamentum teres* has most probably become agglomerated with the coalesced capsule, or it may have disappeared by absorption.

*The Acetabulum.*—The alterations which have taken



place at the acetabulum are so considerable as to have destroyed nearly every vestige of it. In examining the locality where the three primary bones unite to form the cotyloid cavity, at first view nothing is met with at all analogous to the large articular surface of the healthy acetabulum. Upon close inspection, however, a small depression is seen. Upon farther examination, this depression is found not to be the limit, but the entrance, as it were, to a contracted cavity, which is filled up by a soft semi-osseous deposit only. This semi-osseous material can be easily perforated to the depth of an inch, by a probe which, passing thus far, becomes impeded in its progress by an osseous tissue of a dense character. This kind of osseous canal, extending in the direction of the primary acetabulum, is all that remains to represent the ancient cotyloid cavity. The soft osseous material can be broken down with facility, and then the real bony limits of the depression are seen to approach somewhat to a triangular shape.

The disposition of the parts observed at the right acetabulum is the same at the left, with slight modifications. The soft osseous tissue filling up the cavity cannot be penetrated for more than half an inch, and the borders or limits of the altered acetabulum are, consequently, still more contracted than on the other side.

*The Head of the Femur.*—The superior extremities



of both femurs are entirely altered in shape and dimensions.

On the right side the head and neck have disappeared. The upper portion of the femur has become curved, so that the trochanter major takes an inward direction towards the ilium, and receives the attachments of the ligament which now takes the place of the capsular ligament. The corresponding portions of the left femur present appearances which are extremely abnormal. The upper portion of the remaining shaft terminates abruptly, and not the slightest trace of the head or neck remains. The upper portion of the shaft has been fractured from the muscular tractions exercised upon the bone, the structure of which had no doubt previously become softened and atrophied. The upper fragment, deprived of nutrition, has gradually disappeared, excepting a small portion only. This is pulled horizontally inwards, at right angles with the lower fragment, and it presents a smooth surface, which lies in apposition with the inner aspect of the superior end of the other portion. The ligamentous cord, attached on one side to the pelvis, on the other, grasps the upper extremity of the femur, in such a way as to maintain the surfaces of the fragments in contact, and thus a pseudo-articulation is formed between the upper and lower fragments of the broken shaft. *Vide* PLATE IX.

These extraordinary alterations, which the upper portions of the ossa femorum have undergone, are altogether



unaccountable, except by taking into consideration the pathological conditions which must supervene in the osseous structure of these bones, from the diminished nutrition with which they are supplied, soon after the head of the femur is exarticulated from its natural receptacle, and has ascended upon the ilium. If this circumstance be kept in mind, it will not appear strange that the heads of the femurs, deprived early, as they must have been, of nearly all vascular supply by the compression or destruction of the ligamentum teres, should become atrophied, and ultimately disappear.

The reduction of the calibre of the arterial tubes, which has been mentioned as obtaining in cases of congenital dislocation at the hip-joint, and the consequent impoverished supply of blood to the osseous tissue of the other portions of the femur, will explain the existence of that friable and atrophied condition of the osseous tissue, from which, owing chiefly to muscular tractions, has resulted the fracture of the shaft of the left femur. The almost total disappearance of the upper fragment must also be the result of its isolation from the sources of nutrition, after it has become detached from the other part of the femur. The right femur, suffering from the same causes, has not been fractured, but is curved in the direction of the muscular action, which has been aided probably by the influence of the superincumbent weight of the trunk.



*Dorsum Ilii. New Capsule. New Socket.*—In the description given of the post-mortem appearances of the previous case, the dorsum ilii was represented as being occupied by the attachments of the new capsule, by which the head of the femur had become enveloped after its escape from its original capsule. In the case which now claims our attention, the head on either side had never passed from the capsular ligament. The head of the femur appears to have become absorbed, and the cavity of the capsule contracting *pari passu*, as the head disappeared, has become agglutinated, and ultimately converted into a strong inelastic fibrous cord, upon which devolved the function of giving the chief support to the trunk during progression. The attempt to form a new capsule may have been simulated by the substitution of the additional ligamentous fibres, which are seen to spring from the dorsum ilii, and to converge towards the posterior surface of the old capsule—or rather, of the cord-like ligament, which now represents the capsule—with the fibres of which they become incorporated. (*Vide* PLATE IX.) The disposition of these converging fibres, which take their origin from the ilium, is somewhat analogous to the arrangement of the fibres which contribute to the formation of the new capsule in the previous case. *Vide* PLATE VII.

These ligamentous fibres, originating from the dorsum ilii, are the only substitute nature has adopted to fortify



the soft parts, which alone, in this case, have to support the weight of the trunk, in the absence of the normal arrangement at the ilio-femoral articulation. They are attached to the space of about an inch and a half in diameter upon the dorsum ilii; there is no depression, however, on the surface of the ilium, under these attachments. From the length of this ilio-femoral ligamentous cord, thus made up, the upper portions of the ossa femorum must have played, during progression, along the external surface of the ilium, over a space of about three inches in extent. There is no attempt whatever at the formation of a new socket, and with the exception of a slight groove, caused by the friction of the upper portion of the right femur upon the corresponding dorsum ilii, there is not even a depression present for the lodgement of the femur. As in the former case described, it is evident that in the present instance also, the upper parts of the ossa femorum could have had no fixed support upon the surface of the ilium, and consequently, during the acts of progression, the femurs must have ascended and descended, according as the weight of the trunk happened to be thrown upon one or the other inferior member.

The alterations which have taken place in the skeleton of the pelvis, as a consequence of the displacement of the head of the femur upon the ilium, are similar in their general characters to those observed in the case before



described, and it will be unnecessary to consider them as fully in the present instance.

The dislocation being double, and the causes of malformation acting with nearly equal intensity on each side, the two halves of the pelvis participate almost equally in the amount of deformity. The general configuration of the pelvis is below the average size, and the bones of the ossa innominata are thinner, softer, and lighter in texture, than the corresponding parts taken from a well formed skeleton.

The wings of the ilia are more vertical, thinner, and flatter; the sacrum is somewhat narrower, but is nearly of the natural size. The pelvis towards the pubic region is somewhat salient; and owing probably to the greater amount of muscular traction exerted on the side where the femur had suffered most, the corresponding horizontal branch of the pubes between the symphysis and the inferior spine of the ilium is longer by about three-eighths of an inch than on the opposite side.

The foramina obturatoria have their long diameters thrown into a direction almost transversal. The groove between the anterior inferior spinous process of the ilium, and the eminentia ilio pectinea, for the lodgement of the tendon of the psoas magnus and iliacus internus, is seen to be exceedingly deeply impressed.

The tuberosities of the ischia are retracted outwards,



and for a male pelvis present an unusually large measurement between them. *Vide* PLATE IX.

*Diameters of the Pelvis.*—Like the female pelvis, previously described, the diameters of the male pelvis in this case are perverted by the malformation which occurs consequent upon the dislocation of the femur upon the ilium. This circumstance in the male is of but little consequence, but it confirms the opinion, I have already expressed, that malformation of the pelvis is an invariable accompaniment of this form of congenital dislocation of the femur upon the ilium.

The statement simply of the measurements of the pelvis, from which this description is taken, will be sufficient at present, without again giving the comparative measurements of the well formed pelvis. They are as follows: From one anterior superior spinous process of the ilium to the other, seven and five-eighths inches; from the anterior superior spinous process of the ilium to the symphysis pubis, on the right side, five inches; on the left side, four and five-eighths inches; transverse diameter of the superior strait, four and a quarter inches; from the promontory of the sacrum to the symphysis pubis, three and one-eighth inches.

At the inferior strait, the transverse diameter between the inner side of one tuberosity of the ischium to that of the other, four and three-quarter inches; while the antero-



posterior diameter, from the point of the coccyx to the arch of the pubes, is two and three-quarter inches.

The depth of the pelvis anteriorly from the highest part of the ramus of the pubes to the corresponding tuberosity of the ischium, is three inches, and from the promontory of the sacrum to the point of the os coccygis, it is four inches.

These measurements show that the pelvis, taken as a whole, does not present the average dimensions, and that the contractions observable are proportionally greater in the antero-posterior, than in the transverse measurements.


The various influences, such as the shortening of the morbidly affected muscles, the influence of the superincumbent weight of the body during progression, and the ordinary muscular contractions which have contributed, either separately or conjointly, to increase the malformation of the pelvis and of the other adjacent bones, need not be recapitulated ; nor need the analysis of the deformities of the individual parts of the pelvis, and of the action of certain muscles in producing them, be repeated in this place, since the subject has been fully considered in the description of the preceding case of this dislocation.

It must be recollected, however, particularly in regard to cases like the present, where the malformation is so extensive, that these various causes owe much of their efficiency to the deteriorated condition of the osseous structure of the pelvis and of the other contiguous bones,




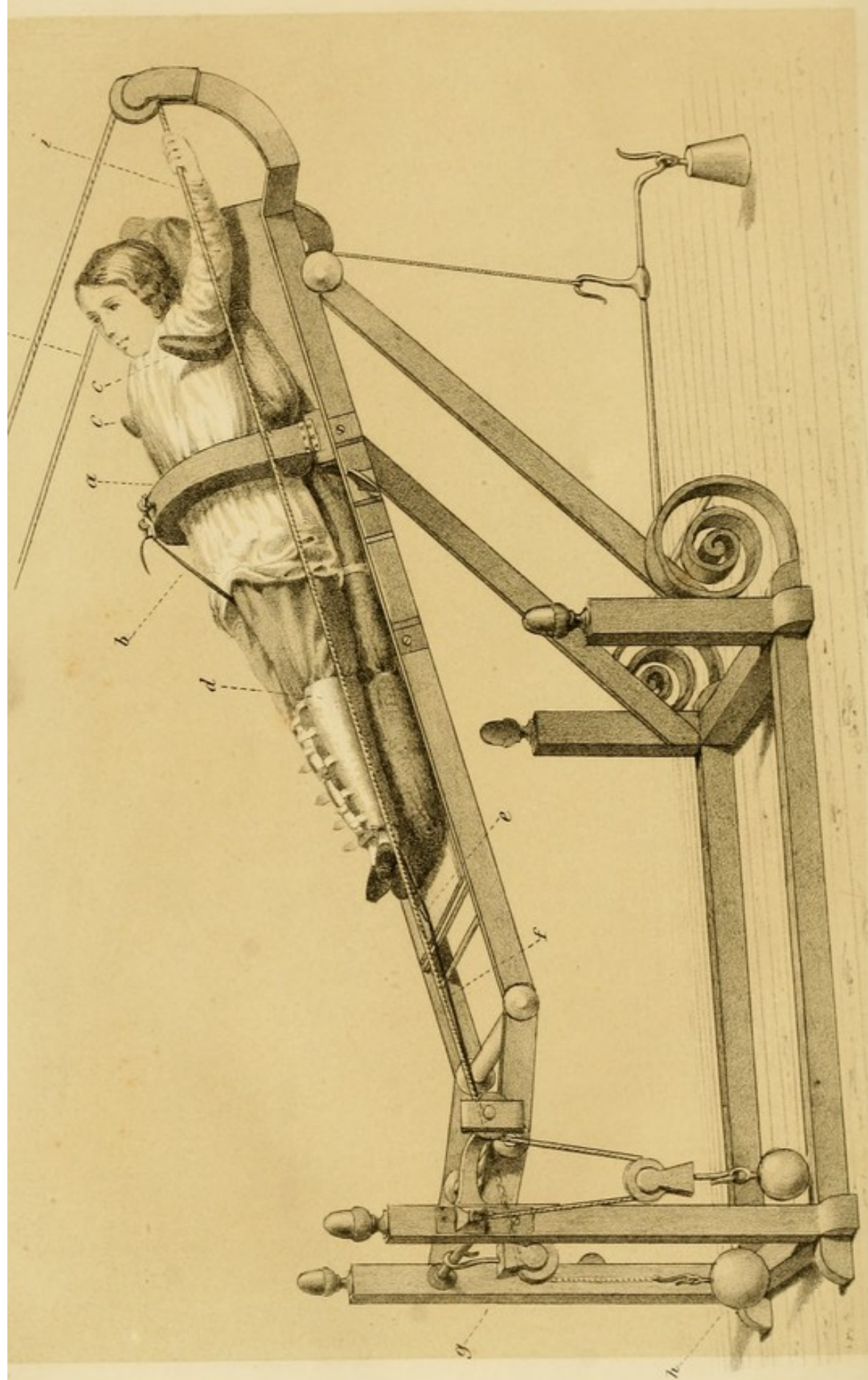
which either accompanies or results from the displacement of the head of the femur.

It is evident, as the result of these investigations, that there is a wide range in the morbid alterations which take place in the progress of congenital dislocations of the femur upon the ilium, from the simple changes in the initiatory stage, to the extreme complications presented in this last case, but the general pathological principles upon which they depend, I trust have been fully set forth.







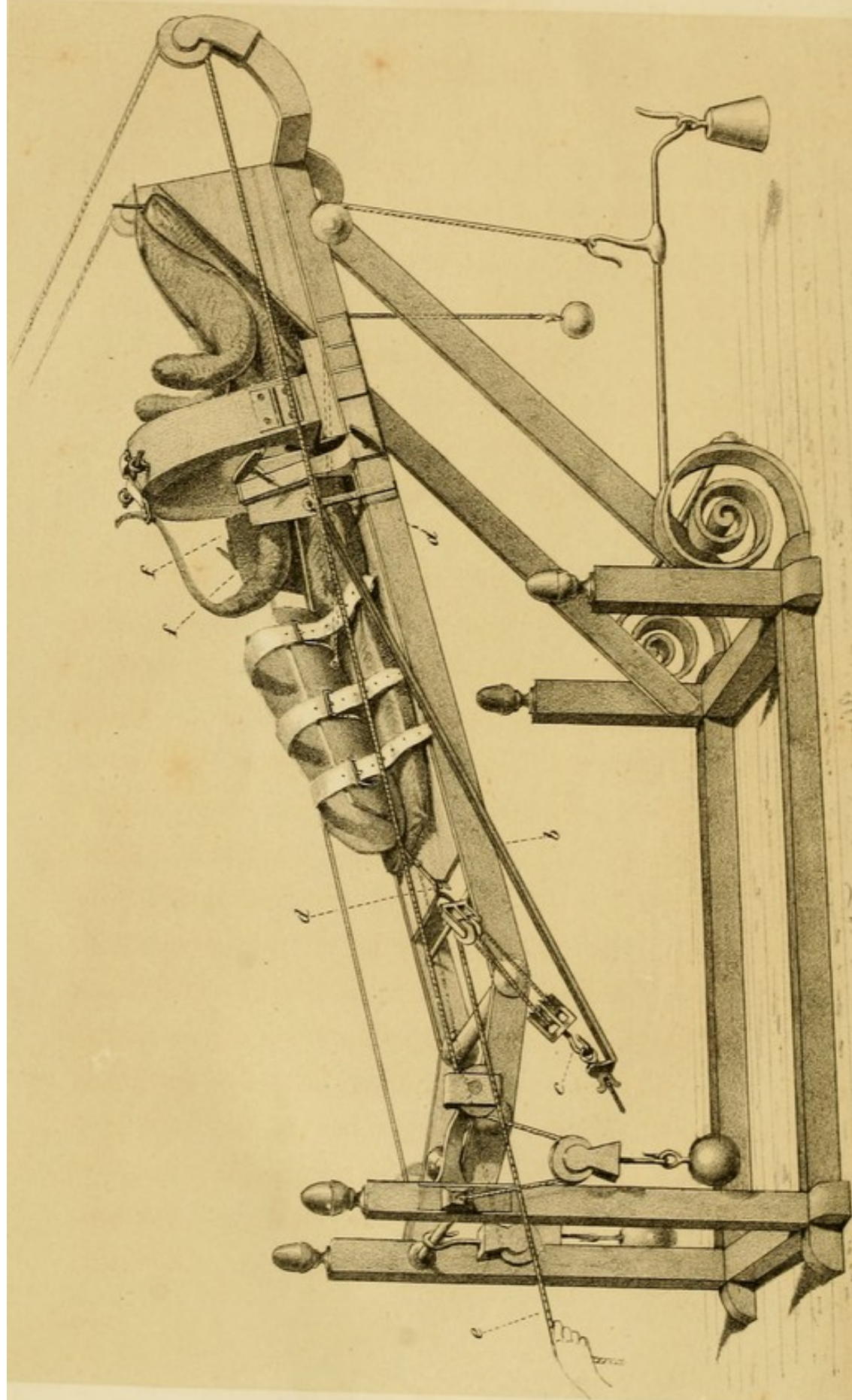




### EXPLANATION OF PLATE A.

This plate represents the Apparatus of Sustentation, upon which the patient reposes while the preparatory extension is being made to bring down the head of the femur opposite the acetabulum.

- a.* Arch opening at the centre, by means of a hinge on each side, passing over the patient, so as to give attachment to the strap of counter extension.
- b.* The strap for making the counter extension attached inferiorly to the plane of the bed, and passing from without inwards and upwards to its superior attachment at the centre of the arch.
- c.* Two crutch-like supports well padded, upon which the axillæ rest.
- d.* Encasement made of thick leather, padded, and furnished with straps and buckles, in which the limb is placed and retained.
- e.* Hook fixed to the leather encasement, for the attachment of the cord of extension.
- f.* Cord of extension passing over a pulley at the foot of the bed.
- g.* Pulley over which the cord passes.
- h.* Weight attached to the cord of extension, and by which the extension is kept up.
- i.* Cords, attached to a fixed point above the bed, and passing along its sides. The plane of the bed being movable, the patient by pulling these cords may take muscular exercise, without interfering with the extension.





## CHAPTER VIII.

TREATMENT OF CONGENITAL DISLOCATIONS OF THE HEAD  
OF THE FEMUR.

IN the natural condition of the ilio-femoral articulation a reciprocal harmony of configuration of a most perfect character exists between the head of the femur and the cotyloid cavity. Under ordinary circumstances these component parts of the joint are maintained in their normal relations by the pressure, from without, of the atmosphere, by the ligamentous connexions, by the action of the muscles, and by the depth of the cotyloid cavity.

From the pathological account heretofore given of the parts implicated in congenital dislocation of the femur upon the ilium, it is evident that the mutual adaptation of the various structures of the joint is early disturbed, and that ultimately the alterations become so extensive that the natural relations cannot be restored.

Dupuytren, reasoning from autopsic examinations, generally of individuals advanced in life, was of opinion



that permanent reduction of the head of the femur in cases of congenital dislocation was beyond the reach of art. "On se consoleraient aisément de ne pas connaître la cause de ces déplacements, si l'on connaissait les moyens de les faire cesser, ou du moins de pallier leur mauvais effets ; malheureusement il n'en est pas ainsi, et ces déplacements ne comportent ni remède curatif ni même de palliatif bien efficace." Notwithstanding the opinion of the celebrated surgeon of the Hôtel-Dieu, attempts have been made in more recent times to bring about permanent reduction of the head of the femur in these cases, and in some instances this object has been attained.

The first attempt to replace permanently the head of the femur at the acetabulum, appears to have been made by means of continued extension, by MM. Duval and Lafond, upon a child nine years of age, affected with double congenital luxation of the femur upon the ilium. The results, however, of this case do not appear to have been satisfactory, for although the limbs were observed to resume their proper length and direction, after the employment of extension for several weeks, yet there is no mention made of the permanency of the reduction.

In 1835, two other surgeons, MM. Humbert and Jacquier, who, like the preceding, confined themselves specially to the treatment of deformities, in a publication issued by them upon the mode of reducing congenital



dislocations, endeavored to prove that the component parts of the articulation, in these luxations at the hip-joint, were not always so entirely changed, as to preclude the possibility of reduction, and supported their opinion by cases, in which the treatment was said to have been successful and permanent. It is very certain that in some of those cases the head of the femur was forced to change its position, and that it assumed a new relation, which lessened or modified the lameness, and restored the limbs to a more natural length. Doubts, however, have been entertained regarding the positive success of the reduction, in the cases reported by these gentlemen, and the change of position of the head of the femur has been attributed to the conversion of the dislocation upon the ilium, into one, where the head of the femur was thrown into the ischiatic notch, consequent upon the extension and force made use of to effect reduction. However this may be, the report made of these cases excited attention, and led to farther attempts to treat congenital displacements of the femur, which in some instances, as verified by scientific authority, were attended with success.

Another surgeon of some eminence, M. Bouvier, of Paris, has also made attempts to reduce these dislocations, but failing to accomplish this object, he has denied the utility of therapeutic means in these affections.

The successful efforts, however, of M. Pravaz, of



Lyons, in the treatment of congenital dislocations at the ilio-femoral articulation, authenticated as they have been by positive testimony, place beyond a doubt the practicability of reducing, under favorable circumstances, the head of the femur to its natural receptacle, and the possibility of retaining it there permanently.

The utility of remedial means being doubted, and the curability of this dislocation being still denied by some men well instructed in the profession, the Royal Academy of Medicine of Paris, in 1838, appointed a commission to report upon a case presented by M. Pravaz, as establishing the possibility of reducing permanently the congenital dislocation of the head of the femur upon the ilium.

The subject of this critical examination was a male child, seven years of age, affected with congenital luxation of the right femur upon the external surface of the ilium. The diagnosis had been confirmed by an eminent surgeon, M. Richard, of Nancy—the treatment was commenced in March, 1836—and the commission of the Royal Academy of Medicine, composed of MM. Blandin, Gerdy, Sanson, and Naquart, reported on the case in 1838. They commenced their statement by admitting that the child had been affected with congenital dislocation on the ilium, and close their extended report—drawn up by M. Gerdy—as follows:—“D’après tout cela, Messieurs, est-il possible de contester le succès obtenu par M. Pravaz ? Nous ne le pensons pas, au moins quant au



jeune garçon dont nous venons de vous entretenir; et, pour n'assurer que ce que nous avons vu par nous-mêmes, nous affirmons que ce jeune malade n'est point affecté aujourd'hui de luxation congénitale."\*

Without mentioning other cases to the same effect, brought forward in addition by M. Pravaz, and confirmed by names eminent in science, I think the above case, reported upon by the commission of the Royal Academy of Medicine of Paris, and asserted subsequently as remaining cured, two years after the reduction, sufficient to establish the principle of the curability, under favorable circumstances, of congenital luxation of the femur upon the ilium.

Still more recently, additional resources have been used by M. Guérin, in the treatment of these displacements. In those instances where the head of the femur has been reduced, and where, from the continued muscular retraction, and the defective formation of the acetabulum, it has been found impossible to retain the head of the femur in its normal position, M. Guérin has advised the division of the retracted muscles, and has also practised subcutaneous scarifications in the vicinity of the cotyloid cavity, in order to provoke an effusion of organizing material, by which the defect in the acetabulum may be remedied, and the head of the femur thus be retained in its cavity, and supplied with a sufficient *point d'appui*.

\* Traité des Luxations Congénitales du Fémur, par le Docteur Pravaz, 1847.



In 1843, the Council General of the Civil Hospitals of Paris nominated a commission to inspect the treatment advocated and practised by M. Guérin, at the *Hôpital des Enfants*, in relation to congenital dislocations of the femur, and to other deformities. The commission was composed of MM. Rayer, Serres, Louis, Jobert, Blandin, and Orfila. In their report upon three cases of congenital dislocation of the femur upon the ilium, which they had observed, they thus conclude their report on the peculiar treatment adopted by M. Guérin :—"Quant à l'efficacité des méthodes de traitement, nul doute que les résultats obtenus, rapprochés surtout de ceux qui existaient déjà dans la science, ne témoignent de la manière la plus positive en faveur de ces méthodes. Il est à remarquer d'ailleurs que les améliorations d'un genre tout particulier, et consistant dans un ordre de faits entièrement nouveaux, obtenus dans les deux premiers cas, ouvrent à l'art des ressources sur lesquelles il n'avait pas compté jusqu'ici."\* Thus we see that congenital dislocations of the head of the femur, long considered beyond the reach of surgical aid—like other maladies of a kindred character, regarded at one time in the same light, such as Talipes, Strabismus, &c., though not equally complicated—have yielded to therapeutic resources, derived from the increased knowledge which pathology and physiology have afforded.

Let it not be supposed, however, that, in admitting the

\* "Rapport de la Commission," &c., 1848.



curability of these connate displacements of the hip-joint, I overlook the serious nature of this affection, and the difficulties to be encountered in effecting a permanent adjustment of the articulation.

As the treatment is not immediately effective, as in the traumatic dislocations of this joint, but necessarily prolonged and tedious, it may be a question, whether the advantages derived from a successful result would compensate for the delay and difficulty, by which only it could be obtained.

When the gravity of this affection and the evils it entails upon existence, and which go on increasing as long as the displacement remains, are considered, the importance of the re-adjustment of the articulation cannot admit of a doubt. The lameness alone, with its inconveniences, might be submitted to, but as a result of the displacement, nearly one half of the organism becomes perverted in its structure and functions, on account of the deterioration of the several tissues, extending even to the osseous. The pelvic diameters also, in the female, become so changed as to render parturition dangerous or impossible.

The treatment of congenital dislocations of the femur ought to commence as soon after the discovery of the displacement as the tractability of the patient may render practicable. Among the cases of success mentioned, the ages have been, from as early as three, to six, eight, and



twelve years; although an instance of successful reduction at the age of fifteen is recorded. The capsule at these early periods, although contracted at its centre, may yet be entire in its structure; the round ligament with its vessels, may be only elongated and stretched, but not yet ruptured or worn through; and the head of the femur and acetabulum, although somewhat modified in shape, from the disturbance of their normal relations, are still susceptible of being again brought into a state of reciprocal adjustment with comparative facility.

In connexion with these data afforded by the pathological conditions at the early period of this displacement—even where the acetabulum has become considerably changed in shape—the physiological principles, from which therapeutic means have been adopted, are expressed in the proposition, “that we may, by continued and progressive mechanical action, sometimes restore the head of the femur to the rudimentary cotyloid cavity, whence it had been dislodged before birth, and maintain it in this place of election, where, by the plastic effort of the organism,\* assisted by suitable movements, in imitation of those of ambulation, the head will, at last, form for itself a kind of artificial articulation.”†

\* This term, denoting the reparatory process, is synonymous with the *nisus formativus* of Blumenbach, and the *organic force* of Müller; for some interesting remarks on which see Paget's Lectures, in the London Medical Gazette.

† Pravaz.



If other favorable conditions, such as the general good health, besides the youth of the patient; the absence of a false articulation upon the dorsum ilii; the continuance, and free movement, of the head of the femur within the capsular ligament, accompany the case; the application of remedial measures may be commenced with a prospect of ultimate success.

The curative treatment of congenital dislocation of the head of the femur upon the ilium comprises three periods, viz., first, the preparatory extension; secondly, the reduction; thirdly, the normal consolidation of the articular structures, so that the head of the femur may be permanently retained in the acetabulum.

The different kinds of apparatus, which have been contrived to fulfil these indications, are complicated in structure, and cannot readily be understood from mere verbal description; I have therefore introduced drawings of them, from the designs in M. Pravaz' work, that the principles of treatment may be better comprehended.\*

The method of effecting the preparatory extension, and the apparatus used for the purpose, is represented on PLATE A, and the component parts of it are explained in the accompanying references. It will be seen, by turning

\* I have in this chapter only attempted to lay down the general principles of the treatment; for details of cases, the reader is referred to the Treatise of M. Pravaz, already named.



to the plate, that the patient is placed in the recumbent posture on a gently inclined plane. The limb is placed within a padded, thick leather encasement, in which it is secured by means of straps and buckles; and elastic extension is kept up by a weight, attached to the end of a cord, which passes over a pulley at the lower part of the apparatus, and the other end of which is attached to a hook, fastened upon the lower margin of the leg-case. The framework of the apparatus is movable, and the cords which the patient is seen to grasp, can impart various motions to it, by being pulled upon; and thus muscular exercise may be taken during the treatment, without interrupting the process of extension. The counter-extension is maintained by the thigh-strap, aided somewhat by the resistance which is afforded at the axillæ by the crutch-like supports. The patient is submitted to this kind of extension, which at first ought to be gentle, not exceeding at the outset a force of a few pounds, and should be progressively increased. The duration of this extension may vary from two to six months, in proportion to the resistance of the retracted muscles and ligaments.

As a part of the medical treatment, during the confinement necessarily accompanying the period of preparatory extension, the use of the condensed air-bath, at a pressure of from twelve to fifteen centimètres, has been recommended, especially for very young patients, in order to



equalize the circulation, and counteract the evil effects of the confinement.

When the preparatory extension has been maintained a sufficient length of time to effect the descent of the head of the femur a little below the anterior and inferior spinous process of the ilium, and the projection of the trochanter major has become less prominent, and the incurvation of the lumbar region diminished, reduction may then be attempted.

To effect reduction, gentle extension must be kept up, while at the same time the limb is abducted, and the head of the femur is pushed from above downwards, and from without inwards. One method of accomplishing this, will be understood by referring to PLATE B. The cord of extension is here removed from the crotchet attached to the inferior part of the leg-case, and, in its place, a set of pulleys is affixed. The other part of the same tackle is attached to the inferior extremity of an iron lever, which again is engaged upon a vertical pivot, at its upper extremity, so as to be movable in various directions. This vertical pivot, giving the *point d'appui* to the lever, is attached to the side of the apparatus of sustentation, a little below and to the outer side of the affected joint. After this arrangement is completed, the assistant is directed to exercise gentle traction upon the cord passing from the pulleys, while the operator himself, "pressing with one hand on the trochanter, from above downwards,



and from without inwards, directs, with the other, the lateral movement of the lever, which, turning upon its pivot, will carry outwards the member in powerful abduction."

According to the extent of the malformation which may exist at the acetabulum, the reduction is effected, either immediately, and is rendered evident by the improved conformation at the joint, sometimes attended by an audible sound, as happens in traumatic dislocations; or, the head of the femur can only be brought into its anatomical position and retained there, until the plastic power of the organism be aroused, and the elemental parts of the joint be gradually and mutually adapted to each other.

To prevent the re-escape of the head of the femur from the rudimental cotyloid cavity, a circumstance which is apt to occur, two large concave plates, padded and movable upon hinges, are fixed upon the side of the apparatus, as seen in PLATE B, and which, by means of screws, may be so adjusted as to embrace firmly the haunches, and thus retain the head of the femur in its new position.

When it is necessary to remove the patient from the bed, a girdle, with perineal straps, and confining the hips, is substituted, to prevent the femur from slipping from the acetabulum.

A short time after the reduction has been effected, pains, accompanied by heat and tumefaction, are manifested in









the inguinal region, attended by febrile symptoms, and sometimes by dysury and incontinence of urine. If these symptoms are excessive, they are to be calmed by a moderate extension of the affected limb, and by emollient applications; but as these phlogistic evidences are indicative of the occurrence of the organo-plastic effort, upon which the remodelling, as it were, of the acetabulum,—as well as the modifications of the adjacent parts, necessary for the maintenance of the head of the femur in its new position,—are dependant, they are to be regarded, when not excessive, as favorable signs; and where too feebly developed, they must be aroused by artificial means.

When the acetabulum and the head of the femur are considerably changed, the process of this plastic effort of reparation generally requires from five to six months, before the configuration of the head of the femur and the capacity of the acetabulum become reciprocally fitted for each other.

In cases where the head of the femur is at first placed upon the orifice, as it were, of the cotyloid cavity, during this process of reparatory co-aptation, the head of the femur is felt to pass progressively deeper into the acetabulum, until finally the more perfect adjustment is accomplished.

The muscles and other tissues, being now placed in more normal relations, commence to assume a



natural disposition, and a more healthy structural appearance.

When the articular apparatus of the joint has apparently become adjusted, and the head of the femur is felt to project but little below the horizontal branch of the pubes, and does not leave the articulation during the different movements of the limb, especially during that of adduction, the third period of treatment may be commenced.

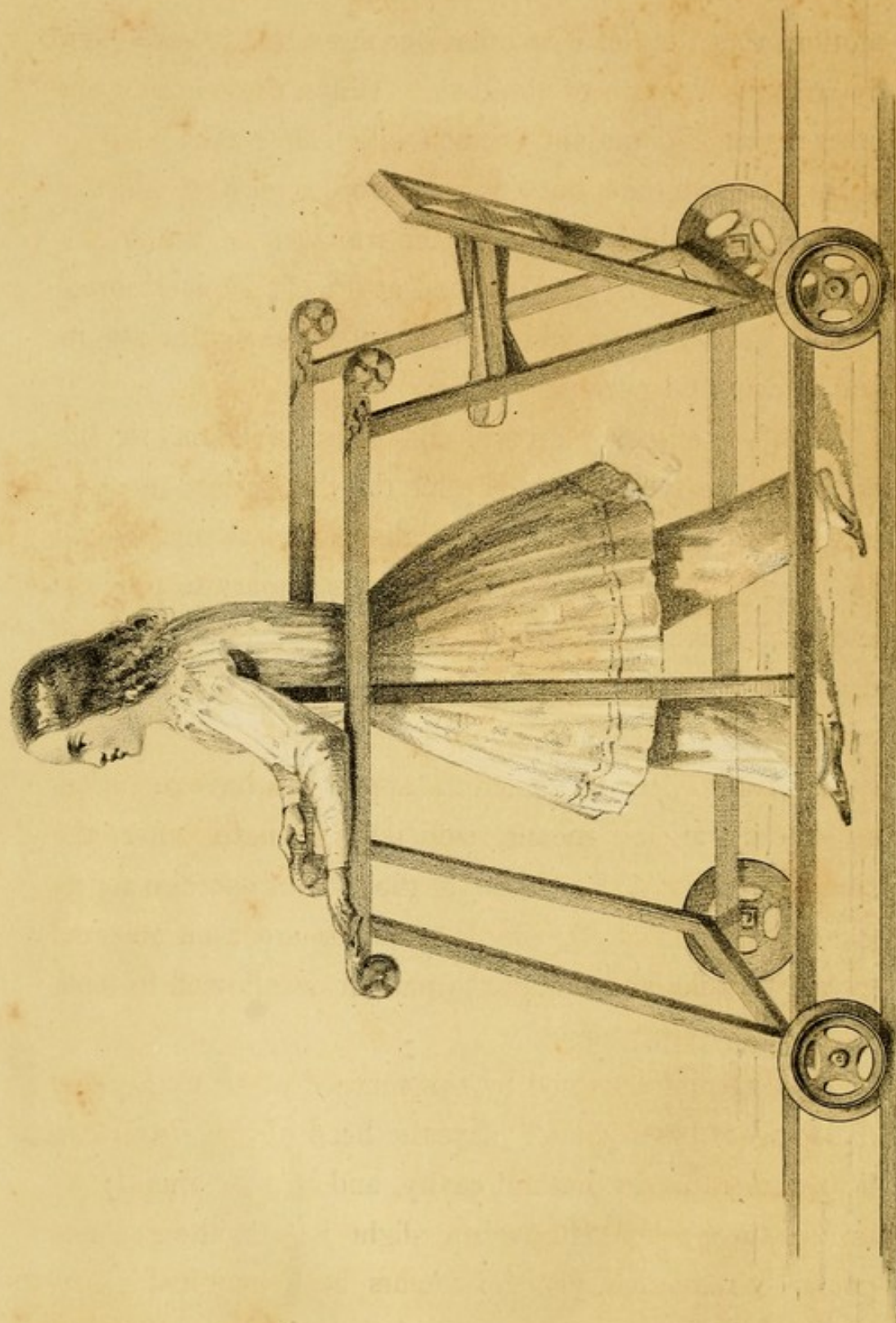
The articulation, being still feeble, is, as yet, generally unable to support the superincumbent weight of the trunk, without a recurrence of the exarticulation of the head of the femur.

To give time for the proper consolidation of the new relations of the different articular structures, at the same time that motion and exercise shall be imparted to the joint, while the weight of the body is removed; a kind of chair has been made use of, which is represented on PLATE C. Upon this apparatus, the drawing of which is sufficiently explanatory of its action, the patient can lie in the recumbent posture, and by means of its mechanism and facility of movement upon wheels, he can, by flexing and extending the limbs, simulate the process of ambulation, and throw the structures of the joints and surrounding parts into exercise.

This kind of exercise is persevered in daily, for four or five months, at the end of which time the articulation has generally acquired such solidity and freedom of









motion, that the head does not become exarticulated even by strong adduction of the limb. When these conditions are present, the patient is then allowed to take exercise in the erect attitude, but in order to lessen the effect of the superincumbent weight of the trunk upon the articulation, the apparatus, represented at PLATE D, is resorted to; a reference to which will sufficiently indicate its mechanism and purpose.

If, as sometimes happens, the exercise taken in the erect posture tends to reproduce the dislocation, recourse must again be had to the use of the apparatus represented on PLATE C; and it may even be necessary to provoke and maintain, by artificial pressure, a sufficient degree of irritation, to excite anew the plastic effusion in the region of the joint.

If, however, the articulation appears to have acquired, by these various means, sufficient strength, after the continuance, for a short time, of the kind of exercise represented on PLATE D, simple crutches are then resorted to, for a while, and finally the patient is allowed to walk unaided by any support.

The results obtained by this method of treating these dislocations have proved that the head of the femur can be returned to its natural cavity, and be permanently retained there: and although a slight halt in the gait has generally remained, yet the femurs have acquired a normal *point d'appui* at the articulation; and the inconve-



niences, as well as the unseemly deformity, resulting from the displacement, have been thus evaded.

The softer tissues around the articulation recover slowly, but the return to their natural condition may be aided by muscular exercise, the use of the different mineral baths, friction, electro-magnetism, and the adoption of a measured gait in walking.

In cases where the dislocation exists upon both sides, the difficulties of treatment are not materially increased, and the extension may be resorted to upon both limbs at the same time, and reduction attempted successively upon each, as soon as the position of the head of the femur and the elongation of the soft parts may warrant the proceeding.\*

In addition to the preparatory extension, and the other means mentioned above, which have been employed to effect, and render permanent, the reduction of the head of the femur in cases of congenital dislocation of this bone, M. Guérin has offered some novel suggestions in the treatment of this affection. One is, to practise the sub-

\* I have not alluded to the palliative treatment, such as that recommended by Dupuytren, of wearing a girdle around the haunches to embrace the pelvis, and which, by grasping the trochanters, is intended to prevent the motions of the exarticulated heads of the femurs along the dorsa of the ilia: since their use appears to be both inconvenient and inefficient. The choice of an occupation, however, for persons thus affected, and who from their age are beyond remedy, should be such as not to keep the deranged muscles, as the *psoas magnus* and *iliacus internus*, upon the stretch continually, during the exercise of their vocation.



cutaneous section of the retracted muscles, that produced the dislocation, generally of the glutei. This procedure is resorted to after the preparatory extension has been kept up for a time, and has been found unavailing in maintaining the head of the femur opposite the acetabulum.

In those cases where it has been found difficult to retain the head of the femur in the acetabulum, owing to its imperfect formation in certain points, after reduction had been effected, subcutaneous scarifications around the acetabulum have been recommended, in order to induce the effusion of new osseous material, to remedy the defective development existing upon its circumference.

The other suggestion is, to make a subcutaneous incision into the capsule, so as to permit the head of the femur to escape, and to become placed in direct contact with the dorsum of the ilium, in those cases where reduction cannot be accomplished on account of the altered state of the articulation, and where the head of the bone continues to play along the surface of the external iliac fossa. This proceeding is accompanied by additional scarifications at a place of election, in the vicinity of the acetabulum, in order to increase the irritation, and induce there the effusion of plastic material towards the formation of a new socket. The principle upon which this treatment is founded rests upon the supposition, that the



immediate contact of the two osseous surfaces of the head of the femur and of the ilium, will induce the formation of a new acetabulum upon the dorsum of the ilium, as takes place generally in cases of unreduced traumatic dislocation of the hip-joint in this direction. It is anticipated here that a new socket will be formed for the head of the femur, and that it will consequently become more fixed, and will be prevented from playing upon the external surface of the ilium, during progression.

The idea of tracing an analogy between the circumstances attendant upon an unreduced traumatic dislocation of the femur upon the ilium, and the congenital luxation of the femur in this direction, where the head has escaped from its capsular ligament, and has become placed upon the dorsum of the ilium, is plausible; but the supposition that the formation of a new socket always follows the escape of the head of the femur from the capsule, whether occurring spontaneously or artificially, is not correct, as is seen from the description of the pathological appearances in one of the cases of this displacement, previously given, and exhibited at PLATE VII.

The theory upon which this treatment is predicated is ingenious, but facts do not corroborate the notions upon which it is founded. Nevertheless, it is not improbable that the direct apposition of the osseous tissues of the femur and of the ilium, after the escape of the head of the femur from its capsule, may predispose to the forma-



tion of a vicarious socket. It is well known that the effusion of osseous material is invited sometimes by irritation, as is observed in Physick's method of treating disunited fractures by the insertion of the seton.

In practical surgery, every reasonable conjecture merits consideration; particularly in the treatment of an affection so formidable as congenital dislocation of the head of the femur upon the ilium.

The subcutaneous section of the retracted muscles may at times be advisable, as one of the resources of art, to facilitate reduction, as well as the peri-articular scarifications, to aid in maintaining reduction after it has been effected. The subcutaneous incisions of the capsular ligament, with scarifications practised at the same time, at a place of election, on the external surface of the ilium, may likewise be made available, in those cases where the head of the bone cannot otherwise be solidly fixed, nor prevented from playing along the dorsum of the ilium during progression.

Before closing these remarks, I shall offer a few observations on congenital sub-luxations and pseudo-luxations of the head of the femur.

Although, as heretofore stated, the partial removal of the head of the femur from the cotyloid cavity, termed CONGENITAL SUB-LUXATION OF THE HEAD OF THE FEMUR, may be regarded as the commencement of the absolute luxation of the femur upon the ilium, yet it may be proper to



observe that the head of the femur may remain for many years in this initiatory stage of displacement, thus in reality constituting a variety of the deformities of the hip-joint.

The head of the femur is here found resting upon the posterior and upper part of the margin of the acetabulum, and has only partially escaped from its cavity. This variety is found to exist at birth, and it also may take place soon after birth, from muscular retraction.

The diagnosis in instances of this kind must be carefully formed, by attentive examination, and from the facts heretofore laid down in the chapters on the Symptomatology and on the Diagnosis. The treatment must be regulated upon the general principles, already recommended, in relation to the complete congenital dislocations of the head of the femur.

With regard to the CONGENITAL PSEUDO-LUXATIONS of the hip-joint, as they are called, from the similarity they bear to perfect luxations of the head of the femur, two varieties have already been spoken of, viz., one, simulating a luxation of the head of the femur downwards and forwards; the other, simulating the luxation backwards and upwards.

The latter deformity only, can be mistaken for the congenital dislocation of the femur upon the ilium.

In these deceptive deformities, which are also caused by muscular retraction, the head of the femur still remains in



the acetabulum, and they must be distinguished from those cases where the head of the femur is exarticulated, by careful manual examination, and the application of the diagnostic symptoms, already pointed out, when this division of the subject was under consideration.

The head of the femur in these instances can generally be felt in the fold of the groin, a little to the outer side of the femoral artery, during rotation of the limb; and the restricted movements, and the permanent deviation of the members from their natural direction, can generally be traced to a retracted condition of the tensor vaginæ femoris and some of the other pelvi-femoral muscles in the vicinity of the joint.

The subcutaneous section of the retracted muscles, aided by the mechanical means applied on the principles usually observed in orthosomatic therapeutics, will often remedy these deformities, and restore the functions of the affected members to their natural condition.

## ERRATA.



*Page 24, line 18*, close the paragraph at "upwards." Then read as a new paragraph: "A sub-luxation backwards and upwards is also met with; and, lastly, the term pseudo-luxation." &c.


" 56, " 10, for "hydrarthus" read "hydrarthrus."

" 79, " 2, for "column" read "cord."


" 95, " 11, for "excurvation" read "incurvation."











## COLUMBIA UNIVERSITY LIBRARIES

This book is due on the date indicated below, or at the expiration of a definite period after the date of borrowing, as provided by the library rules or by special arrangement with the Librarian in charge.

<b>DATE BORROWED</b>	<b>DATE DUE</b>	<b>DATE BORROWED</b>	<b>DATE DUE</b>
C28 (747) M100			



RD101

Carnot

Condensation

OCT 8 19

C21

COLUMBIA UNIVERSITY LIBRARIES



0050087037

RD101

C21

1850

