

**Diseases of women : a manual for students and practitioners / by Charles Gardner Child, jr. Illustrated with 101 engravings.**

**Contributors**

Child, Charles Gardner, 1873-1941.  
Augustus Long Health Sciences Library

**Publication/Creation**

Philadelphia and New York : Lea & Febiger, 1909.

**Persistent URL**

<https://wellcomecollection.org/works/h96gdf2s>

**License and attribution**

This material has been provided by This material has been provided by the Augustus C. Long Health Sciences Library at Columbia University and Columbia University Libraries/Information Services, through the Medical Heritage Library. The original may be consulted at the the Augustus C. Long Health Sciences Library at Columbia University and Columbia University. where the originals may be consulted.

This work has been identified as being free of known restrictions under copyright law, including all related and neighbouring rights and is being made available under the Creative Commons, Public Domain Mark.

You can copy, modify, distribute and perform the work, even for commercial purposes, without asking permission.



Wellcome Collection  
183 Euston Road  
London NW1 2BE UK  
T +44 (0)20 7611 8722  
E [library@wellcomecollection.org](mailto:library@wellcomecollection.org)  
<https://wellcomecollection.org>

COLUMBIA LIBRARIES OFFSITE  
HEALTH SCIENCES STANDARD



HX00063886

Epitome Series

**RECAP**

# GYNECOLOGY

---

CHILD

---

PEDERSEN





RG111

C43

**Columbia University**  
**in the City of New York**

**College of Physicians and Surgeons**

**Library**




















The Medical Epitome Series

---

# DISEASES OF WOMEN

A MANUAL FOR STUDENTS AND PRACTITIONERS

BY

CHARLES GARDNER CHILD, JR., M.D. (YALE)


*Clinical Professor of Gynecology, New York Polyclinic Medical School and Hospital;  
Attending Gynecologist to the City Hospital; Junior Attending Surgeon  
to the Woman's Hospital*

SERIES EDITED BY

VICTOR COX PEDERSEN, A.M., M.D.

*Genitourinary Surgeon to the Outpatient Departments of the New York  
and Hudson Street Hospital*

ILLUSTRATED WITH 101 ENGRAVINGS



LEA & FEBIGER

PHILADELPHIA AND NEW YORK



---

Entered according to Act of Congress, in the year 1909, by  
LEA & FEBIGER,  
in the Office of the Librarian of Congress. All rights reserved.


---

RG-III

C43

TO  
HENRY McMAHON PAINTER, M.D.

WITH THE  
AUTHOR'S WARMEST ADMIRATION  
AND ESTEEM





## P R E F A C E.


---

IN writing this small work there has been no attempt made to enter the field so well and so exhaustively covered by the larger text-books on Diseases of Women, but to present to the student and practitioner as concise and authoritative a treatise on the subject as is consistent with brevity. Much valuable information has been obtained from the standard text-books, and from the works of Kelly, Allbutt, Playfair, Eden, Hart and Barbour, Findley, Roberts, Wertheim, Michalitsch, Döderlein and Krönig, Bovée, and Galabin.

A list of questions has been added at the end of the book for those who desire to use it as a quiz-compend.

C. G. C., JR.

NEW YORK CITY, 1909.





# CONTENTS.

---

## CHAPTER I.

DEVELOPMENT AND ANATOMY OF THE FEMALE GENITAL ORGANS	17
--	----

## CHAPTER II.

CAUSES OF DISEASES OF WOMAN . . . . .	27
---------------------------------------	----

## CHAPTER III.

HISTORY AND EXAMINATION OF THE PATIENT . . . . .	29
--	----

## CHAPTER IV.

THE EXTERNAL GENITALIA: Malformations. Diseases. Tumors.	
Herniæ . . . . .	36

## CHAPTER V.

THE VAGINA: Malformations. Diseases. Tumors . . . . .	49
---	----

## CHAPTER VI.

THE UTERUS: Malformations. Antelexion. Displacements . . . . .	60
--	----

## CHAPTER VII.

THE UTERUS (Continued): Malignant Diseases . . . . .	78
--	----



## CHAPTER VIII.

THE UTERUS (Continued): Benign Tumors . . . . .	84
---	----

## CHAPTER IX.

THE FALLOPIAN TUBES: Diseases. Tumors. Ectopic Gestation	92
--	----

## CHAPTER X.

THE OVARIES: Diseases. Displacements. Tumors . . . . .	97
--	----

## CHAPTER XI.

ECTOPIC GESTATION . . . . .	103
-----------------------------	-----

## CHAPTER XII.

DISEASES OF THE PARAMETRIUM . . . . .	107
---------------------------------------	-----

## CHAPTER XIII.

MENSTRUATION AND ITS DISORDERS . . . . .	111
--	-----

## CHAPTER XIV.

THE DYNAMICS OF THE FEMALE PELVIS . . . . .	116
---	-----

## CHAPTER XV.

DISPLACEMENTS OF THE UTERUS . . . . .	120
---------------------------------------	-----

## CHAPTER XVI.

GENERAL GYNECOLOGICAL OPERATIVE TECHNIQUE . . . . .	151
---	-----



# DISEASES OF WOMEN.

---

## CHAPTER I.

### DEVELOPMENT OF THE FEMALE GENITAL ORGANS.

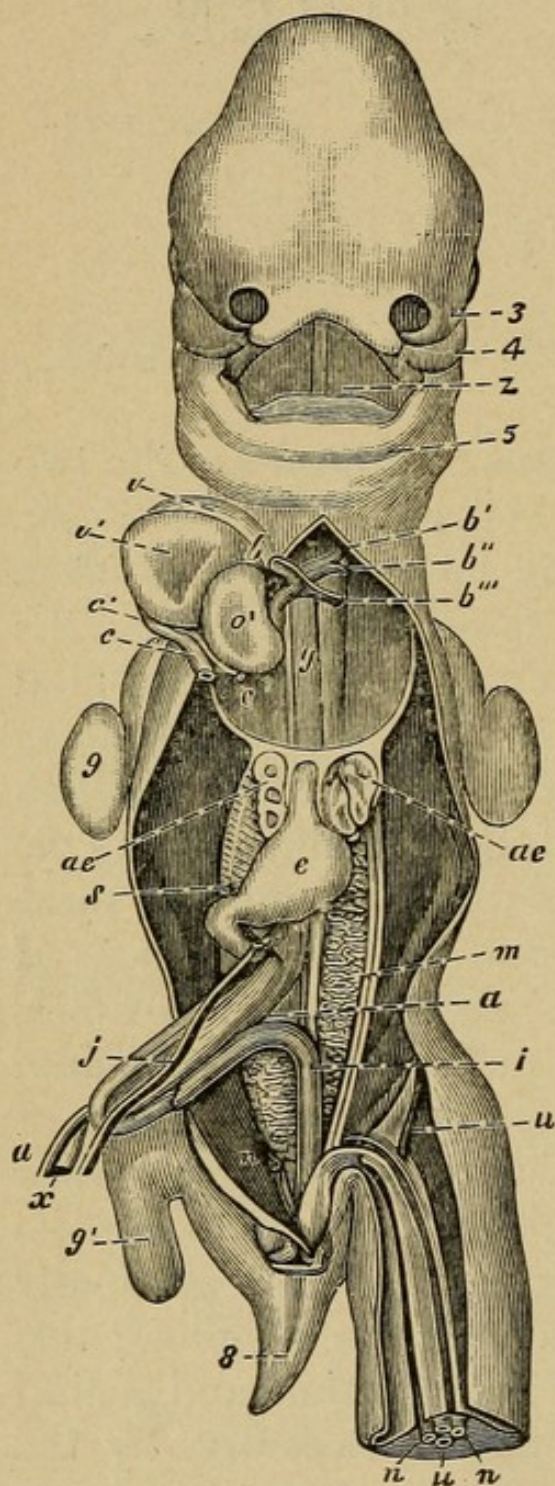
IN the **human embryo** the first organs to appear are the two **Wolffian ducts**, which are situated one on each side of the vertebral column, and which connect later with the **Wolffian bodies**. These are long and spindle-shaped, reaching from the diaphragm to the pelvis. The inner two develop the genital gland: ovary or testicle; the outer two develop the **Wolffian ducts** and later the **ducts of Müller**. Finally, the Wolffian ducts disappear, while the ducts of Müller remain, forming the genital tract. By the beginning of the sixth month these changes are complete; the upper portions of the ducts of Müller have remained separate, forming the Fallopian tubes, while the lower have coalesced to form the uterus and vagina.

The development of the external genitals from the ducts of Müller begins by an opening into the allantois, or the lower intestinal tract. In the genital tubercle, which makes its appearance at about the sixth week, a depression gradually develops which later communicates with the allantois; this is the cloaca, the common opening of the intestinal and genital tracts. Eventually this common opening becomes, by the formation of the perineum, divided into two, the genito-urinary and the anal. From the urachus is developed the bladder, its lower end becoming contracted to form the urethra. As the result of an imperfect fusion between these



ducts various errors in development, from a partial to a complete arrest, may occur, giving rise to numerous malformations, such as an entire absence of the uterus, a rudimentary uterus,

FIG. 1



Human embryo of thirty-five days (front view): 3, left external nasal process; 4, superior maxillary process; 5, lower maxillary process; z, tongue; b, aortic bulb; b', first permanent aortic arch; b'', second aortic arch; b''', third aortic arch, or ductus Botalli; y, the two filaments to the right and the left of this letter are the pulmonary arteries, which begin to be developed; c, the stem of the superior cava and right azygos vein; c', the common venous sinus of the heart; c'', the common stem of the left vena cava and left azygos; o', left auricle of the heart; v, right, v', left ventricle; ae, lungs; e, stomach; f, left omphalomesenteric vein; s, continuation of the same behind the pylorus, which becomes afterward the vena porta; x, vitello-intestinal duct; a, right omphalomesenteric artery; m, Wolffian body; i, gut; n, umbilical artery; u, umbilical vein; 8, tail; 9, anterior, 10, posterior limb. The liver has been removed. The white band at the inner side of the Wolffian body is the genital gland, and the two white bands at its outer side are the Müllerian and the Wolffian ducts. (Kölliker, after Coste.)

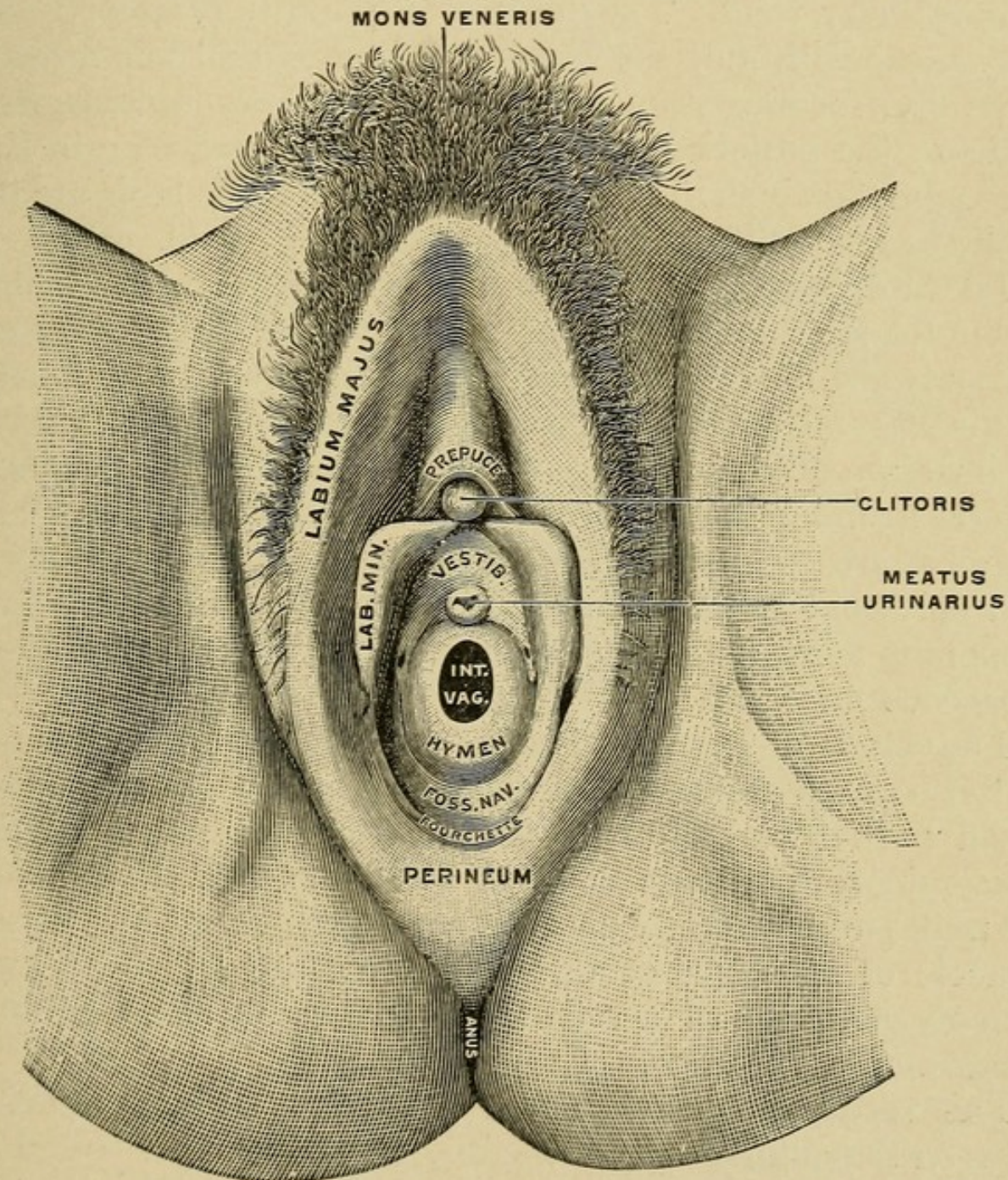
a one-horned uterus, a two-horned uterus, a double uterus, a double vagina, etc. These will be considered more fully under their respective headings.



## ANATOMY OF THE FEMALE GENITAL ORGANS.

The external genital organs, to which the term vulva is usually given, consist of the mons veneris, labia majora, labia

FIG. 2



Vulva of a virgin. The labia have been widely separated. (Testut.)

minora, clitoris, vestibule, meatus urinarius, hymen, fossa navicularis, fourchette, and perineum.



The **mons veneris** is a rounded eminence surmounting the pubes, composed of fatty tissue and covered by integument and hair.

The **labia majora** are two more or less prominent longitudinal folds of cutaneous tissue covered by hair and mucous membrane, continuous with the mucous membrane of the genitourinary tract. They enclose a quantity of areolar and fatty tissue with nutrient vessels and nerves, and join at each extremity, forming the **anterior** and **posterior commissures**. Between the posterior commissure and the anal margin is a space about an inch in extent, the **perineum**. The labia are the analogue anatomically of the scrotum in the male.

The **labia minora**, or **nymphæ**, are two smaller folds situated within the labia majora extending from the clitoris downward and outward for about one and one-half inches on each side of the vaginal orifice. At their convergence at the clitoris each labium divides into two folds. These surround the glans clitoris, forming its **prepuce** above and the **frenum** below. The nymphæ are composed of mucous membrane covered by a thin epithelial layer. They contain a plexus of vessels and numerous large mucous crypts, which secrete a quantity of sebaceous matter.

The **clitoris** is an erectile structure, the analogue anatomically of the corpora cavernosa of the penis, and is an elongated organ partially covered by the anterior extremities of the labia minora, and connected on each side with the rami of the pubes and ischia by a crus. It is surmounted by a small tubercle of spongy erectile tissue, the glans clitoris. Two corpora cavernosa of erectile tissue enclosed in dense fibrous tissue compose the body of the organ.

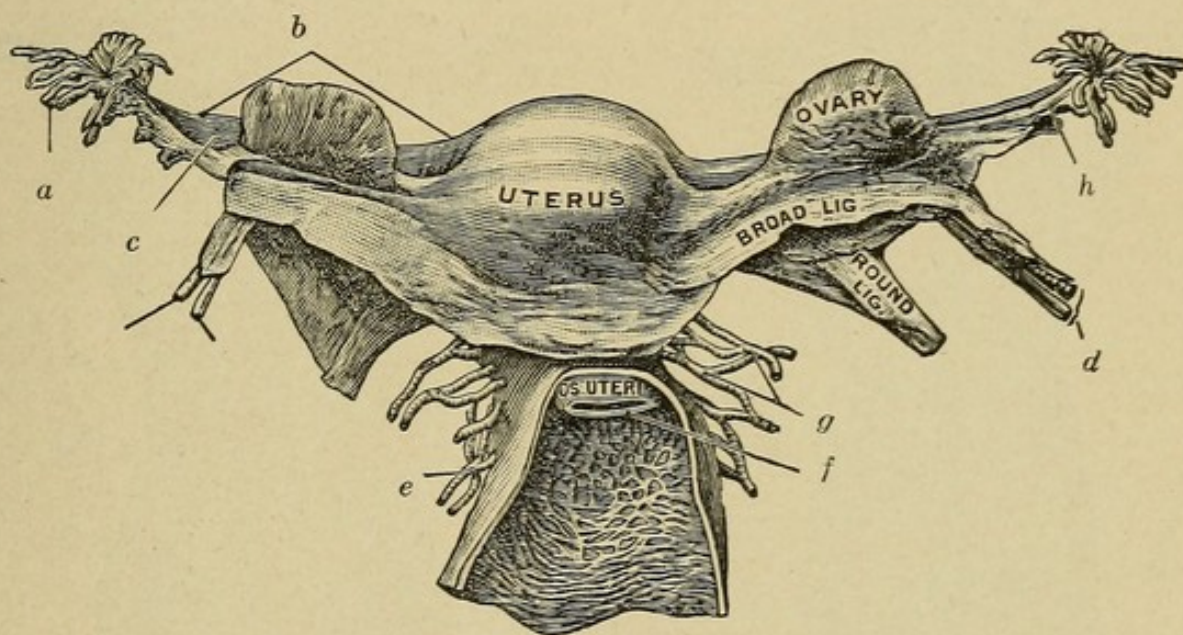
The **vestibule** is the smooth triangular surface situated between the clitoris and the vaginal entrance. It is bounded on either side by the labia minora, and contains the meatus urinarius.

The **hymen** is a thin semilunar fold of mucous membrane spread across the lower part of the vaginal orifice.



The glands of Bartholin are small oblong bodies, two in number, situated on each side of the commencement of the vagina above the deep perineal fascia, and are the analogues anatomically of the glands of Cowper in the male. Each gland, by means of a single duct, opens upon the inner surface of the nympha adjacent, just external to the hymen. They are compound mucous glands and secrete a colorless tenacious fluid which lubricates the vagina.

FIG 3



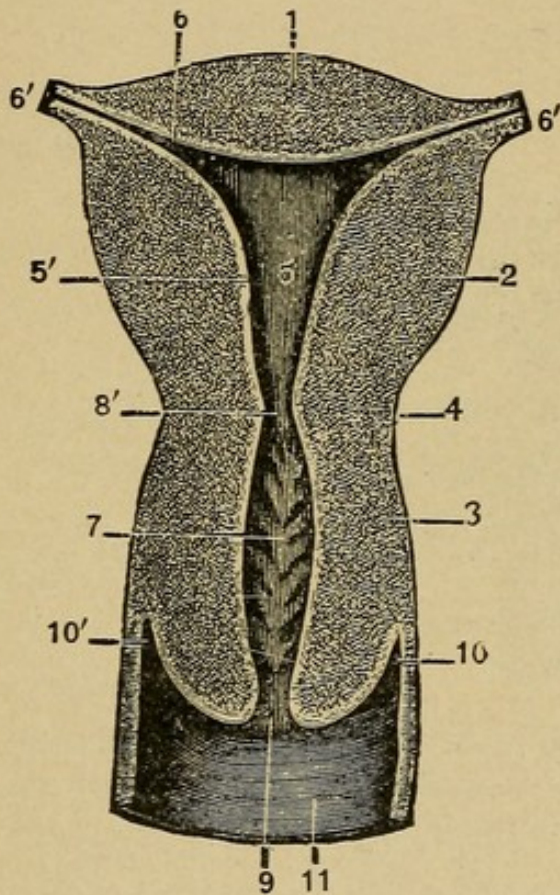
Internal organs of generation: *a*, fimbriated extremity of tube; *b*, Fallopian tube; *c*, broad ligament, upper part; *d*, ovarian vessels; *e*, vaginal artery; *f*, os externum; *g*, uterine artery; *h*, fimbria ovarica. (From a preparation in the Museum of the Royal College of Surgeons of England.)

The **vagina** is a membranous canal extending from the vulva to the uterus, connecting the external and internal organs of generation. In length it is between four and six inches, the anterior wall being from one to two inches shorter than the posterior. Lying in the cavity of the pelvis, in front of the rectum and behind the bladder, its direction is curved forward and downward, following first the line of axis of the cavity of the pelvis, and afterward that of the outlet. It consists of an internal mucous lining continuous above with the



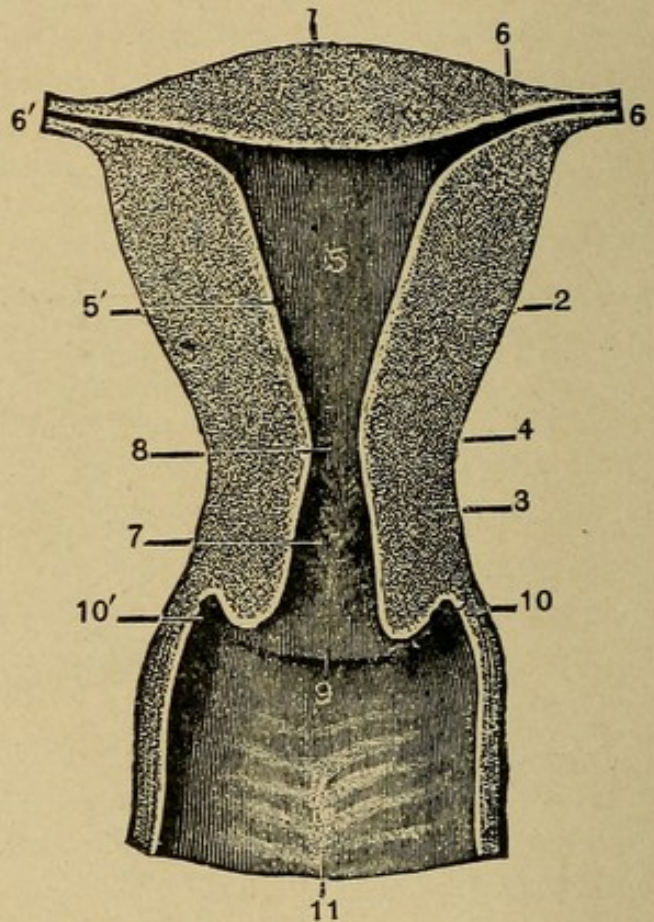
mucous membrane lining the uterus, and below with the integument covering the labia majora. Next is a muscular coat consisting of two layers—an external longitudinal and an internal circular. Between the mucous lining and the muscular coat is a layer of erectile tissue. The lower end of the vagina is surrounded by a band of striped muscular fibers comprising the sphincter vaginae.

FIG. 4



Coronal section of the uterus of a nulliparous woman.

FIG. 5



Coronal section of the uterus of a multiparous woman.

1, fundus; 2, lateral walls of the body; 3, cervix; 4, isthmus; 5, cavity of the body; 5', internal wall of the body; 6, cornu; 6', opening of the Fallopian tube; 7, arbor vitæ; 8, os internum; 9, os externum; 10, 10', lateral fornices; 11, posterior vaginal wall. (Testut.)

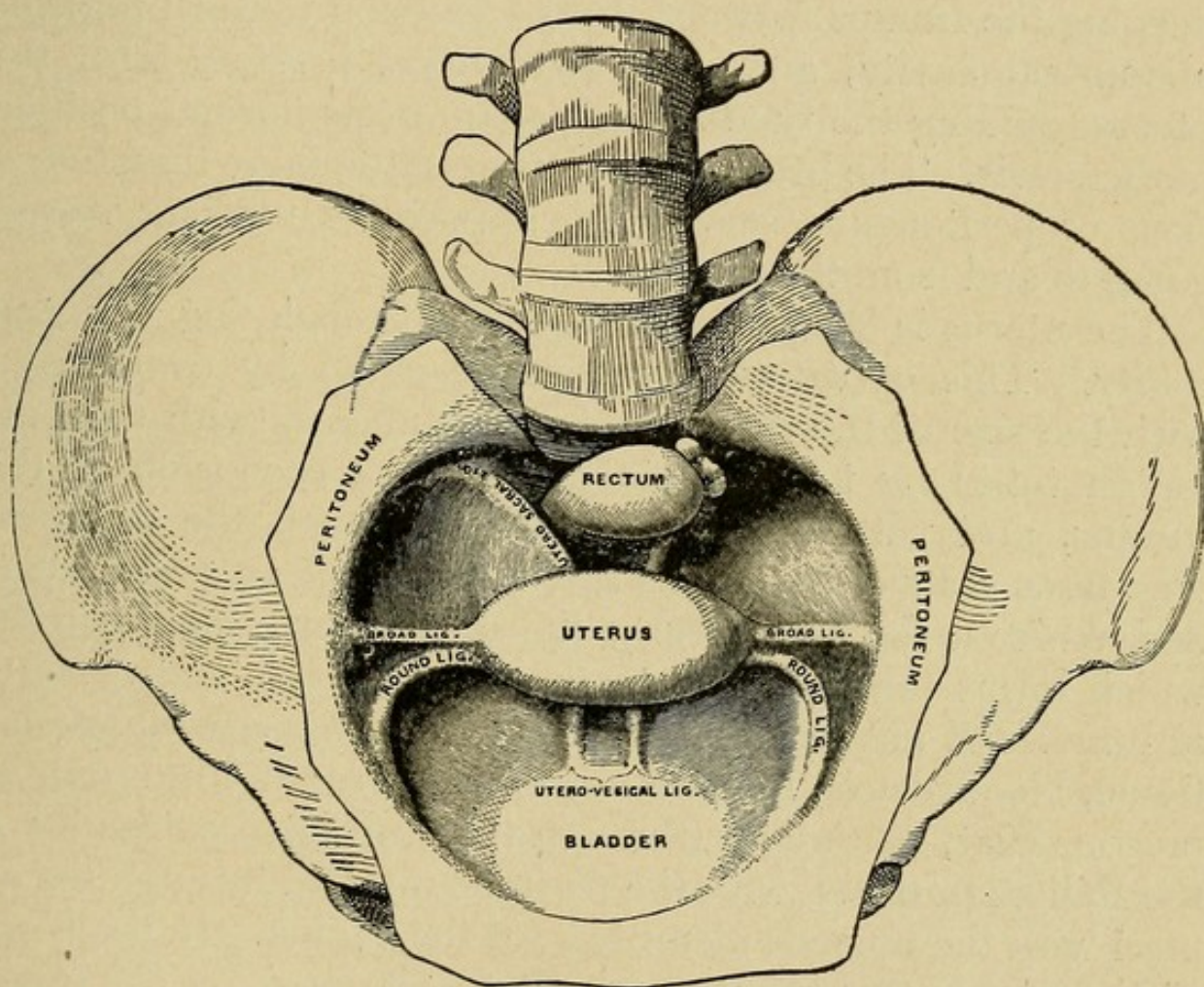
The **internal organs of generation**, or, as they are more commonly called, the **pelvic organs**, comprise the uterus, Fallopian tubes, and ovaries (Fig. 3).

The **uterus** is the organ of gestation, receiving the fecun-



dated ovum, supporting it during development, and expelling it at the time of parturition. It is a pear-shaped organ weighing from two to three ounces, situated in the cavity of the pelvis between the bladder and rectum, with its base directed upward and its apex downward. The upper broad extremity is called the fundus and the lower constricted por-

FIG. 6



Uterine ligaments.

tion the cervix. The body of the uterus gradually narrows from the fundus to the cervix, its anterior surface being covered for the upper three-fourths by peritoneum, while the lower fourth is connected with the bladder. The posterior surface is covered by peritoneum throughout.

The uterus is suspended in the pelvis by its **ligaments** (Fig. 6).



These are eight in number: Two anterior (utero-vesical), two posterior (utero-sacral), two lateral (broad ligaments), and two round ligaments. Of these, the utero-sacral, holding the cervix well up in the hollow of the sacrum, and the round ligaments, keeping the fundus well forward, enter most actively into the support of the uterus. The round ligaments are strong, muscular, fibrous cords, serving to hold the fundus forward. In pregnancy they increase in size with the uterus, keeping the fundus forward in its excursion upward into the abdominal cavity, and after parturition involute with the uterus, guiding the fundus back again to its normal position in the pelvis. The broad ligaments are little more than reflections of peritoneum, serving to support the nutrient vessels going to and from the uterus.

The uterus is composed of three coats, enclosing a central cavity. This **cavity of the uterus** is small by comparison with the size of the organ, and communicates with the Fallopian tubes by two minute openings at each side of the fundus, and with the vagina below through the os uteri. The **three coats of the uterus** are the external, or serous coat, derived from the peritoneum; the middle, or muscular coat, which forms the chief substance of the uterus, and consists of bundles of unstriped muscle fibers intermixed with areolar tissue, bloodvessels, lymphatics, and nerves; the internal, or mucous coat, continuous, through the fimbriated extremity of the Fallopian tubes, with the peritoneum, and through the os uteri with the mucous membrane of the vagina. In the body of the uterus this mucous membrane is lined by columnar ciliated epithelium, which loses its ciliated character during pregnancy. The epithelium in the lower half of the cervix is of the stratified variety.

The **blood supply of the uterus** is by the two uterine arteries from the internal iliac arteries. They run a remarkably tortuous course in the uterus and have many anastomoses. The veins are larger and correspond with the arteries. The lymphatics terminate in the pelvic and lumbar glands.



The **nerves of the uterus** are from the inferior hypogastric, ovarian plexuses, and third and fourth sacral nerves.

At different periods of life and under varying circumstances important **changes in the uterus** occur in form, size, and position. The *uterus of fetal life* is more an abdominal than a pelvic organ, the cervix is larger than the body, and between the two there exists a marked anterior angle of flexion. At puberty it has descended into the pelvis, the body is larger than the cervix, and the angle of flexion has disappeared. The *uterus of menstruation* enlarges, becomes more vascular; the superficial part of the mucous lining softens and is cast off. After menstruation rapid cell proliferation occurs, and a fresh mucous membrane is formed.

The *uterus of pregnancy* increases greatly in size, weighing from one to three pounds, and extends well above the pelvis into the abdominal cavity. After parturition it returns to nearly its former size, weighing about three ounces; the cavity, however, always remains larger than in the virgin state.

The *uterus of old age* atrophies, becoming much smaller, is pale and firm, and the cervical canal is often obliterated.

The **uterine appendages** are the Fallopian tubes, the ovaries and their ligaments, and the round ligaments.

The **Fallopian tubes**, or **oviducts**, convey the ova from the ovaries to the uterine cavity. Two in number, one on each side and situated in the free border of the broad ligaments, they extend from each horn of the uterus outward to the sides of the pelvis. Each tube is about four inches in length and has a small canal beginning at the uterus in a minute opening, the *ostium internum*, and gradually widening to its termination, the *ostium abdominale*, by which it communicates with the peritoneal cavity. The *fimbriæ*, a series of fringe-like processes, surround the ostium abdominale, and this distal end is known as the fimbriated extremity. There are three coats to the tube: an external or serous, derived from the peritoneum; a middle or muscular, continuous with that of the uterus; and an internal or mucous, continuous with the lining of the uterus



and peritoneum, and covered with ciliated columnar epithelial cells.

The **ovaries**, analogues anatomically of the testes in the male, are two ovoid bodies situated one on each side of the uterus on the posterior aspect of the broad ligament, below and behind the Fallopian tubes. Each is connected by its anterior margin to the broad ligament; internally to the uterus by the ovarian ligament; externally to the fimbriated extremity of the Fallopian tube by a short ligamentous cord. The ovaries are white in color, about one and one-half inches in length, three-quarters of an inch in width, and one-third of an inch thick, and weigh about 2 drams each.

The **structure of the ovary** consists of numerous Graafian vesicles embedded in a network of stroma and invested by a serous covering derived from the peritoneum. This differs widely, however, from the peritoneum in both appearance and structure, and is known as the **germinal epithelium of Waldeyer**.

Each ovary contains many **Graafian vesicles** of varying size, according to their degree of maturity. These contain the ova. As the Graafian vesicle matures it enlarges in size, gradually approaching the surface of the ovary, and at the time of ovulation ruptures, liberating the ovum that it may pass into the Fallopian tube. In this it is assisted by the finger-like processes of the fimbriæ at the extremity of the tube.

Immediately following rupture the Graafian vesicle undergoes certain changes, formerly thought to result in the formation of a corpus luteum. In view of recent investigations, however, this is open to doubt, and it would seem that the corpus luteum plays a more important role than was formerly supposed. According to Fraenkel, it is a gland "which is renewed every four weeks in women during reproductive life, and controls the nutrition of the uterus in a cyclic fashion, preventing it from relapsing into its infantile or passing into its senile condition, and prepares as well the endometrium for the reception of the ovum. If the ovum be fertilized, the



corpus luteum continues to exist and to maintain the raised nutrition of the uterus during pregnancy, but if fertilization does not take place the hyperemia of menstruation merely is produced and the corpus luteum then degenerates."

Lying above the ovary in the broad ligament between it and the Fallopian tube is the **organ of Rosenmüller**, or **parovarium**. This is the remnant of a fetal structure, and in the adult consists of a few closed convoluted tubes lined with epithelium, the whole connected at its uterine extremity with the remains of the Wolffian duct—the **duct of Gärtner**.

The **ovarian ligament** extends from the inner extremity of the ovary to the superior angle of the uterus. The round ligaments, two in number, are about five inches in length and are situated between the layers of the broad ligament, one on each side of the uterus in front, and below the Fallopian tube. They pass forward and outward from the uterus, through the internal abdominal ring, along the inguinal canal, and out at the external abdominal ring.

The **arteries of the ovaries** and **Fallopian tubes** are the ovarians from the aorta anastomosing with the termination of the uterine arteries as they enter the attached bodies of the ovary. The **veins** follow the course of the arteries, forming a plexus near the ovary, the pampiniform plexus.

---

## CHAPTER II.

### CAUSES OF DISEASES OF WOMAN.

As woman possesses certain organs, and plays a part in life peculiarly her own, one should naturally expect to find her subject to certain diseased conditions more or less dependent on her anatomy, physiology, and mode of life.



The most frequent causes of the diseases of woman may be summed up under the following headings:

**Civilization.**—Among primitive people, woman is notoriously free from many of the diseases to which her sister in our present-day civilization is especially prone. As we ascend the scale of civilization, departing from a natural and adopting an artificial mode of life, we find that Nature enacts due penalties for the transgression of her laws. The female among savage tribes has every advantage and opportunity to develop physical perfection, and her endurance suffers little, if any, by comparison with the male. How different is our modern system when the young girls are sent early to school and subjected daily to long hours of study, often in badly ventilated classrooms, for nine months in the year, and this at the time of puberty, one of the most important periods of their life when they need plenty of outdoor exercise. Surely, as Goodell says: "If woman is to be thus stunted and deformed to meet the ambitious intellectual demands of the day, if her health must be sacrificed upon the altar of her education, the time may come when to renew the wornout stock of this Republic it will be necessary for our young men to make matrimonial excursions into lands where educational theories are unknown."

**Menstruation.**—Carelessness and neglect of this function is directly responsible for many of its disorders. Physical and mental rest at this time, and especially at puberty, are seldom practised, but the daily routine is gone through regardless of consequences.

**Dress.**—There can be little doubt but that abdominal constriction, such a prominent feature in woman's present mode of dress, is an important predisposing element. The contraction of the normal size of the abdominal cavity, with the subsequent compression and displacement of its viscera, must of necessity produce dynamic changes in the pelvis that cannot be otherwise than injurious to the pelvic organs. Tight lacing, or any lacing, aside from the remote effects so unnatural



a practice must produce, causes marked atrophy of the abdominal muscles. These are often so weakened that during labor they cannot properly assist the uterus in effecting delivery, and as a result instrumental interference, with its attendant dangers, becomes necessary.

**Prevention of Conception.**—This practice is very common among civilized women, and has a most deleterious effect upon the pelvic organs, as well as upon the general system. Insulted and disappointed nature exacts penalties far-reaching in their effects and little dreamed of by the offender.

**Criminal Abortion.**—The chief danger from the criminal interruption of gestation is sepsis. This may be acute in character and fatal in its termination, or chronic in nature, leading to permanent injury of the uterus and tubes, sterility, and chronic invalidism.

**Childbirth.**—Injuries sustained during parturition are a frequent cause of pelvic disease.

**Venereal Diseases.**—Syphilis exerts its usual baneful influences, but gonorrhea is responsible for more pathological lesions in the female pelvis than any other one factor. Its attack, if not resulting in ultimate loss of life, always leaves the tissues in an impaired condition, from which resolution is rare. It is doubtful if a woman once infected with gonorrhea ever recovers from its ravages. As a cause of sterility its power is beyond estimation.

---

## CHAPTER III.

### HISTORY OF THE PATIENT.

A general medical history, as well as a special gynecological history, should be taken of each case, and careful inquiry into the woman's mode and habits of life should always be made.



In taking the **gynecological history** it is well to confine all questions to certain fixed headings designed to elicit the information desired (Fig. 7). Constant study should be given to the personal equation, and every effort made to discover, and to place at their proper valuation the chief symptoms complained of by the patient.

In order to systematize the history-taking it is necessary to have a regular routine, so that omissions may not occur. At the first interview it is well to give the patient an opportunity to tell her story first before proceeding with interrogation, as it relieves her mind, inspires confidence, and affords the physician a valuable opportunity to study the personal equation. The history should comprise the following data in all cases:

**Age.**

**Social Condition.**—Whether single, married, or widowed. If married, the length of time spent in the marital state.

**Menstruation.**—Age and state of health at onset, regularity, duration, amount, symptoms. Date and character of last menses. Any change in character of the menstruation since its establishment should be noted.

**Abortions or Miscarriages.**—Number, date, period of gestation, cause, and subsequent convalescence.

**Children.**—Number, date, and nature of delivery, whether easy, difficult, or instrumental.

**Puerperia.**—Whether normal or protracted.

**Diseases of Childhood** (especially the exanthemata).—**Function of the bladder and bowels, occupation,** and all details ascertainable of a previous **operation or serious illness** since reaching puberty.

Having obtained as clear a history as possible, the **physical examination** of the patient should follow. On the degree of thoroughness with which this is possible depends the success of the diagnosis, and every effort should be made to gain the confidence and coöperation of the patient, otherwise failure in many cases will result.



Fig. 7

Date	Pt. of Dr.		Diagnosis	
Name	Address		Operation	
Age	S. W. M.	Occupation	Nativity	Time in U. S.
Diseases			Urination	Max. Weight Present
Menst. History: 1st	reg	Duration	Days	Amount
				Pain
				Last
Para	1st			
	Labors			
	Last			
Miscarriages	Last			Puerperia
Symptoms				
Abdomen				Cervix
				Uterus
Vag. outlet				R. Appendages
Vagina				L. Appendages
Remarks				

History card.



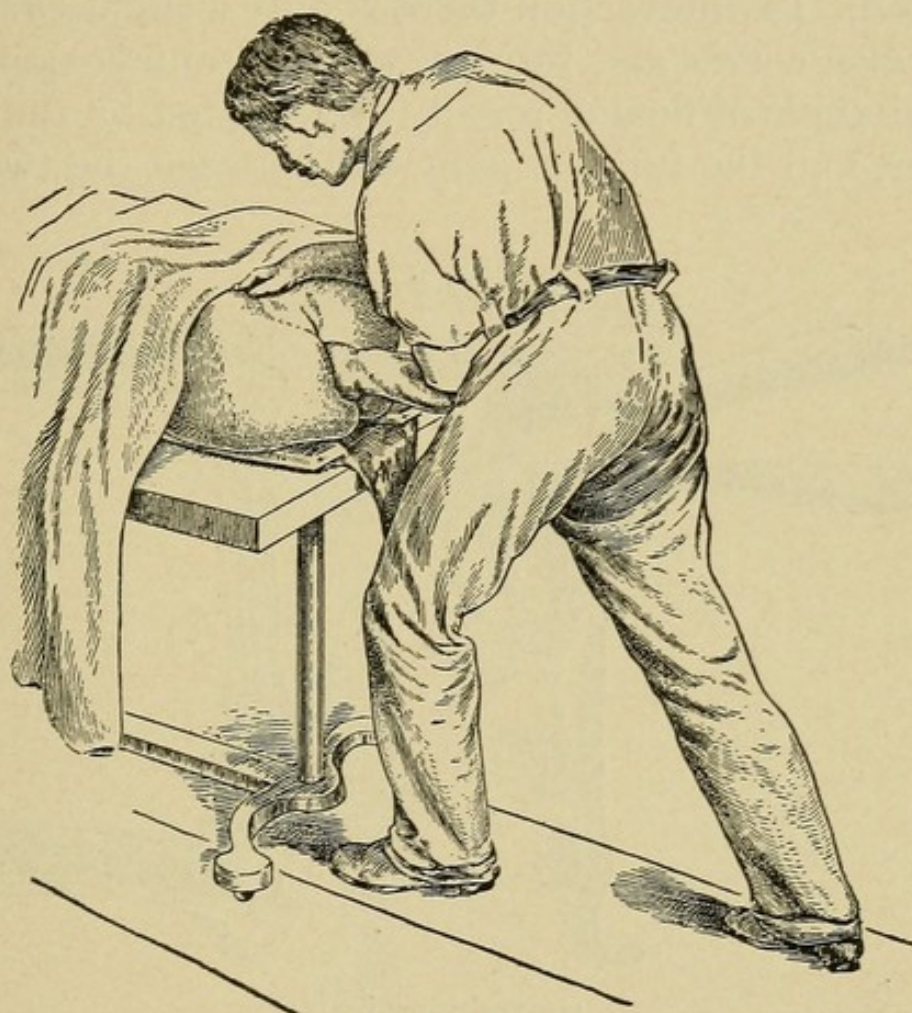
**Abdominal Examination.**—*Inspection* should disclose any marked deviation from the normal contour, such as is produced by the presence of large tumors and cysts. When these spring from the pelvis, the prominence usually begins abruptly at the symphysis pubis where the growth leaves the pelvis. A uniform enlargement is more usually associated with ovarian cysts and general uterine fibrosis. Tumors of the appendages and pedunculated uterine fibroid, generally give an irregular enlargement more marked on one side than the other. *Palpation* should decide the character and probable source of any tumor present, and locate any points of tenderness in the region of the appendix vermiformis or in the inguinal regions. The inguinal and femoral rings should be examined for the presence of hernia.

**Vaginal Examination.**—Though usually avoided during menstruation, this should never be neglected for this reason when conditions warrant it. The bowels and bladder should have been previously thoroughly emptied. The position of the patient is important, and a suitable examining table is desirable. If in bed, the patient should be placed on her back, crosswise of the bed, with her hips well over the edge, legs flexed and supported on chairs or held by an assistant. The external genitals are inspected and any abnormality noted. The ductal orifices of the vulvovaginal and periurethral glands are examined for evidences of past or present inflammation, of which gonorrhea is the most frequent cause. Inserting the index finger into the vagina, downward pressure is made upon the perineum for its resistance. The anterior and posterior vaginal walls are examined for cystocele or rectocele. The finger is then passed along the anterior vaginal wall and parallel to it until the cervix is reached, when its size, consistency, and position are determined. The position of the cervix, with its relation to the axis of the vagina, is an important guide to the position of the uterus, for the cervix and fundus cannot materially change in position independently of one another. With the cervix in normal position—that is, per-



pendicular to the axis of the vagina—the fundus must be anterior, in normal position as well. When the cervix is in the abnormal position—that is, parallel to the axis of the

FIG. 8



Correct position in making a gynecological examination. (Goffe.)

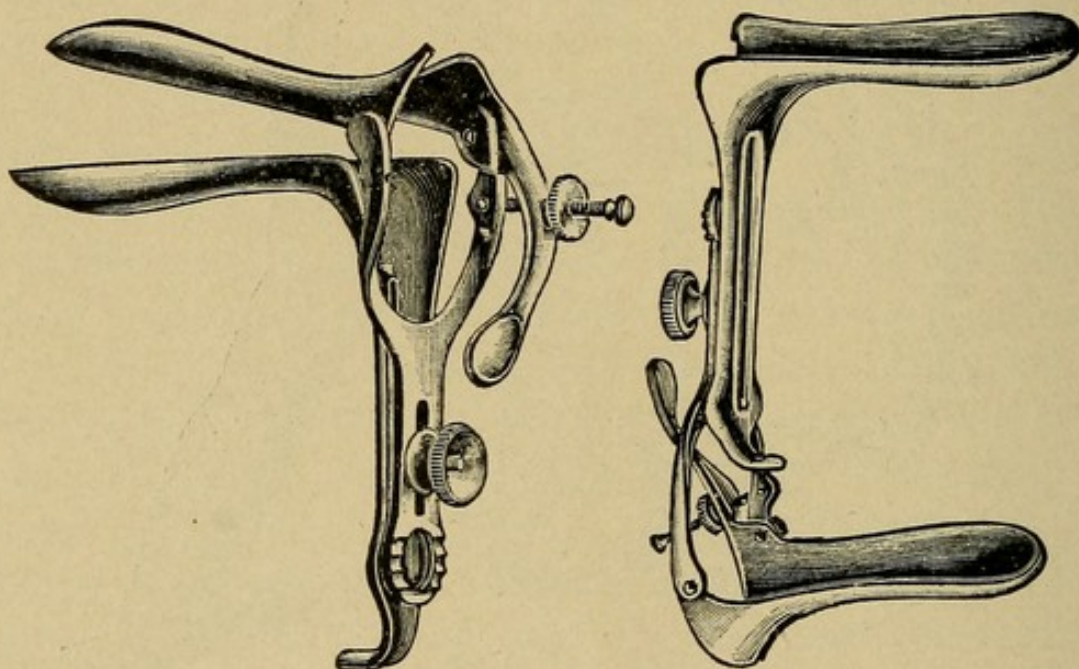
vagina—the fundus will be found to be abnormally located as well, and will always be in one of three positions, viz., anteflexion, retroversion, or retroflexion.

**Bimanual Examination.**—The free hand is placed upon the abdomen just above the brim of the pelvis and firm, steady pressure made toward the uterus, gradually pressing the abdominal wall inward toward the pelvis. If the abdominal muscles are very tense, relaxation may be obtained by elevating the shoulders and flexing the thighs upon the abdomen.



The index finger in the vagina now seeks the posterior fornix and gently taps the cervix toward the abdominal hand. If the fundus is anterior its impact will be felt by the abdominal hand, and the vaginal finger, palpating the anterior fornix, distinguishes between normal anteversion of the uterus and anteflexion. In anteversion there is only a slight curve in the line between cervix and fundus, while in anteflexion there is a marked angle of flexion readily appreciated by the examining finger, and the fundus, palpated between the two hands,

FIG. 9



Graves' speculum.

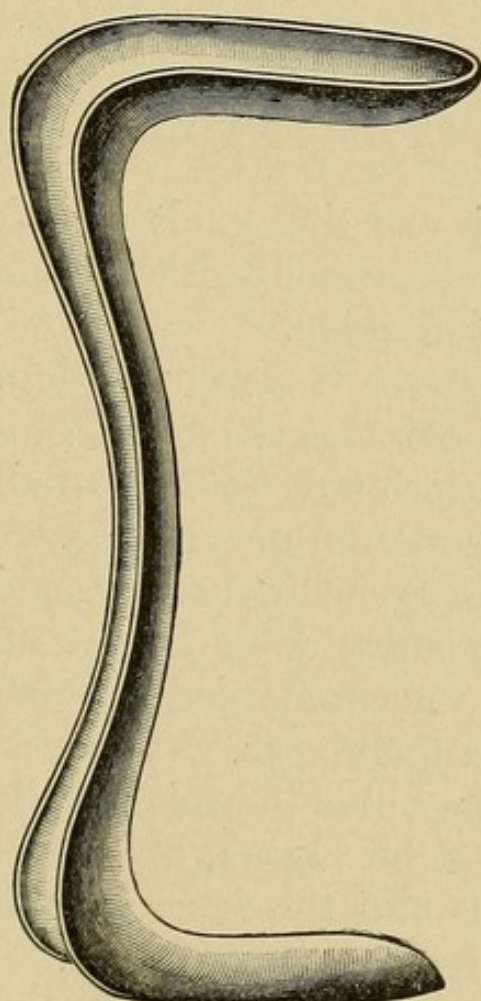
is small and lies under the symphysis. If the fundus is not located anteriorly the vaginal finger in the posterior fornix follows up the cervix, and in retroflexion feels the rounded fundus lying back in the hollow of the sacrum, with a marked angle of flexion between fundus and cervix. Retroversion, if not actually palpated, may be inferred by exclusion. Enlargements of the uterus and tumors of the uterus are most certainly recognized by the bimanual examination. When the location of the uterus has been determined its size and mobility should be noted, and the pelvis examined for adhesion bands,



exudates, tumors, involvements of the appendages, etc. (For complete diagnosis, see special chapters.) The normal appendages are difficult and at times impossible to palpate, as both the tube and ovary easily elude the fingers, and differ very little in resistance from the surrounding structures.

**Rectal Examination.**—The internal examination made *per rectum* is often of great value, especially in retroflexion and small tumors in the pouch of Douglas. In virgins it should always be the method of election.

FIG. 10



Sims' speculum.

**Examination with the Speculum.**—Following the bimanual examination, the vagina and cervix should be carefully inspected. This is only possible by retracting the vaginal walls with a proper speculum. These are of three kinds: the tubular, the grooved or Sims, and the valvular. The first of



these is now seldom used. In introducing the speculum the labia are separated, the index finger introduced into the vagina retracts the posterior vaginal wall, and the speculum is then introduced up to the cervix. The separation of the blades of the speculum should be so manipulated as to expose the cervix to full view when any pathological lesion may readily be seen.

---

## CHAPTER IV.

### THE EXTERNAL GENITALIA.

#### **MALFORMATIONS OF THE EXTERNAL GENITALIA.**

**Malformations** arise as the result of defective development in either the genital eminence, the genital folds, the genital furrow, or the genital ridge.

**Absence of the vulva** is a rare condition, usually associated with absence of the internal organs of generation as well. Partial absence associated with normally formed internal organs is of more common occurrence.

**Double vulva** is an exceedingly rare condition.

**Infantile type of vulva** may persist after puberty. This anomaly is usually accompanied by defective development of the uterus and appendages.

With **atresia of the vulva** there is usually found also a communication between the vagina, bladder, and rectum. Complete atresia is rare and the fetus is seldom viable. Partial atresia is of more frequent occurrence.

**Hypospadias** is a persistence of the urogenital sinus, both urine and menstrual fluid escaping through a common opening in the base of the clitoris, which is usually hypertrophied. In this condition doubt often arises as to the sex of the fetus.

**Epispadias** is a defect in development of the upper wall of the urethra whereby the urethra appears as a groove passing upward under the symphysis to the bladder.



The **clitoris** may be entirely wanting, bifid, or hypertrophied; the latter is the most usual anomaly. It is frequently found entirely covered by a redundant or adherent prepuce.

The **hymen** may be double, absent, or imperforate. Many anomalies in form and structure exist, but are of little practical importance. The imperforate hymen causes retention of the menstrual fluid, and the abnormally rigid hymen causes dyspareunia.

**Hermaphroditism.**—This term, used by the older writers to designate cases which they considered as possessing the organs of both sexes, is now used to indicate those in which the sex is doubtful. In ancient Rome these individuals were destroyed, while in the East they were deified. In the human embryo there is a stage in development when it is impossible to foretell the sex. Whether the sexual gland will become testicle or ovary; whether the Müllerian ducts or the Wolfian ducts atrophy; whether the genital tubercle become a penis or a clitoris, are points all in doubt, and the embryo at this period awaits a dominant force to determine its sex.

The cases of **true hermaphroditism** are divided into: bilateral, with an ovary and testicle on both sides; unilateral, in which there is an ovary and testicle on one side with either an ovary or testicle on the other; and lateral, where an ovary is present on one side and a testicle on the other.

**Pseudohermaphroditism** is caused by anomalies in development of the female external genitalia already described, or by malformations of the penis and scrotum in the male, whence doubt as to sex arises.

## DISEASES OF THE EXTERNAL GENITALIA.

### VULVITIS.

**Definition.**—An acute or chronic inflammation of the external genitalia, either specific or non-specific in character.



**Pathology.**—In the *acute stage* the mucous membrane around the vaginal orifice is red, swollen, and painful. The glands of Bartholin and the periurethral glands often become infected and suppurate. The sebaceous glands of the labia majora are also at times affected—**follicular vulvitis**. In the *chronic stage* secretion is abundant, and papillomata often form around the vaginal opening. **Erysipelatous, gangrenous, and diphtheritic vulvitis** occur.

**Etiology.**—Seventy-five per cent. of the cases are caused by gonorrhea (Veit). Other causes are the accumulation and subsequent decomposition of discharges from the uterus and vagina in endometritis and vaginitis. Putrid discharges from neglected pessaries and vaginal tampons, sloughings from cancers and myomata may act as exciting causes, and contact with ammoniacal and saccharine urines has a similar effect. In infants the condition is usually due to want of cleanliness in failing to remove decomposing urine and feces.

**Objective Symptoms.**—In acute vulvitis the external genitalia are swollen and edematous, and bathed in pus. The inguinal glands and glands of Bartholin are usually somewhat enlarged and tender when the disease has existed for any length of time. In the gonorrheal form the specific microorganisms are found in the pus during the early stages of the disease.

**Subjective symptoms** are a feeling of heat accompanied by more or less burning and itching. Walking causes an aggravation of the symptoms, due to friction of the inflamed parts, and micturition further increases the distress.

In gonorrheal cases the disease is more extensive, involving the vagina, urethra, periurethral glands, and glands of Bartholin. The gland-infection frequently results in abscess formation.

**Diagnosis.**—**Vulvar furunculosis** is characterized by multiple small abscesses of the sebaceous and sweat glands.

**Puerperal vulvitis** is the result of uncleanness during the puerperium, the lochial discharge being allowed to accumulate and decompose on the vulva. The diffuse erythema



arising may be followed by ulceration, which is generally superficial. The organism most commonly present is the streptococcus.

**Syphilitic vulvitis** may occur in any stage of the syphilis. When accompanying the chancre in the primary stage the vulvitis is slight, but in the secondary stage, where the vulva is often covered with moist patches and condylomata, an extensive vulvitis exists. In the tertiary stage vulvitis is rarely present.

**Erysipelatous vulvitis** may result from a primary infection of the vulva, and is occasionally seen in the newborn.

**Tuberculous vulvitis** is of rare occurrence. It is characterized by irregular ulcerations on the external genitals.

**Diphtheritic vulvitis** is occasionally seen, the ulcerated surfaces being covered by a pathogenic false membrane.

**Actinomycosis** involving the labia majora has been observed; two cases are recorded.

**Treatment.**—In the *acute form* the patient should be put to bed, a wet antiseptic dressing applied to the vulva and kept constantly moist. If there is much pain the solution should be sedative.

R<sub>y</sub>—Plumbi acetatis . . . . . ℥j  
 Tincturæ opii . . . . . ℥ss  
 Aquæ . . . . . q. s. ad ℥vj.—M.  
 Sig.—External use.

In the *chronic form* the vulva should be shaved, thoroughly cleansed, and a mild ointment applied daily thereafter, such as

R<sub>y</sub>—Acidi salicylici . . . . . gr. xx  
 Zinci oxidi . . . . . ℥ij  
 Petrolati . . . . . q. s. ad ℥j.  
 M. et ft. ungt.  
 Sig.—External use.

When the vulvitis is due to the irritation of discharges which cannot be checked, such as from inoperable carcinoma and urinary fistula, much may be accomplished in a pallia-



tive way by thorough cleansing of the surfaces and the application of zinc ointment as a protective.

Condylomata, when an exciting cause, should be removed before any attempt is made to treat the vulvitis. This is best accomplished by the scissors under a general anesthetic, and the resulting raw surfaces brushed with the actual cautery, or pure carbolic acid.

### PRURITUS VULVÆ.

**Definition.**—Pruritus vulvæ should be perhaps more properly considered as a symptom than as a pathological condition. It is characterized by an intense itching of the vulva, with more or less swelling of the parts and extreme nervous irritability.

**Etiology.**—Doubtful, believed to be due to local inflammatory changes in the vulvar corium and considered by some as a pure neurosis.

**Pathology.**—The changes in the skin producing pruritus vulvæ have not been as yet accurately determined. The region of irritability is usually the upper angle of the labia majora and mons veneris. The skin is inflamed, thickened, and excoriated from continual scratching.

**Subjective Symptoms.**—An intense and at times almost unbearable burning and itching about the vulva, beginning most often around the clitoris, paroxysmal in character, and aggravated by warmth and motion.

**Objective Symptoms.**—The skin is somewhat thickened in the more or less chronic cases, and appears dull and dry, and is covered with small fissures and scratches, the result of mechanical irritation by the patient in her endeavors to relieve her suffering.

**Diagnosis.**—Inspect carefully the vulva for any irritating skin eruption, and make microscopic examinations of the scrapings for parasites. The urine should be examined for



sugar, and the vagina and cervix for the presence of irritating leucorrhea.

**Systemic Treatment.**—General tonic treatment should be given in all cases. Diabetes, gout, rheumatism, masturbation, irritating discharges from the vagina or rectum, and in children worms and highly acid urine should receive appropriate treatment. Internally the bromides and arsenic are often of value.

The **local treatment** is usually that of chronic vulvitis. Strong solutions of bichloride of mercury, nitrate of silver or tincture of iodine often relieve the itching, and cocaine ointment gives temporary relief. When the condition persists after the removal of a definite cause, and in spite of continuous careful treatment, the division and resection of a portion of the nerve or nerves supplying the affected areas, as recommended by Hirst, is often of value.

### KRAUROSIS VULVÆ.

**Definition.**—Progressive atrophy and shrinking of the tissues of the vulva.

**Etiology.**—Obscure. Probably a trophic disturbance.

**Pathology.**—A rare condition first described by Breisky in 1885, and characterized by an atrophic shrinking of the skin of the vulva and perineum. The surface of the skin is dry, shining, and whitish in appearance. It is so exceedingly brittle that extensive fissuring often follows the slightest manipulations. The sebaceous and sweat glands are diminished in number, and painful vascular patches develop early around the vaginal orifice.

**Symptoms.**—Burning and itching of the vulva, with extreme tenderness in the early stages. The contact of urine on micturition causes pain and smarting. Coitus becomes difficult or impossible on account of the pain and injury it causes.



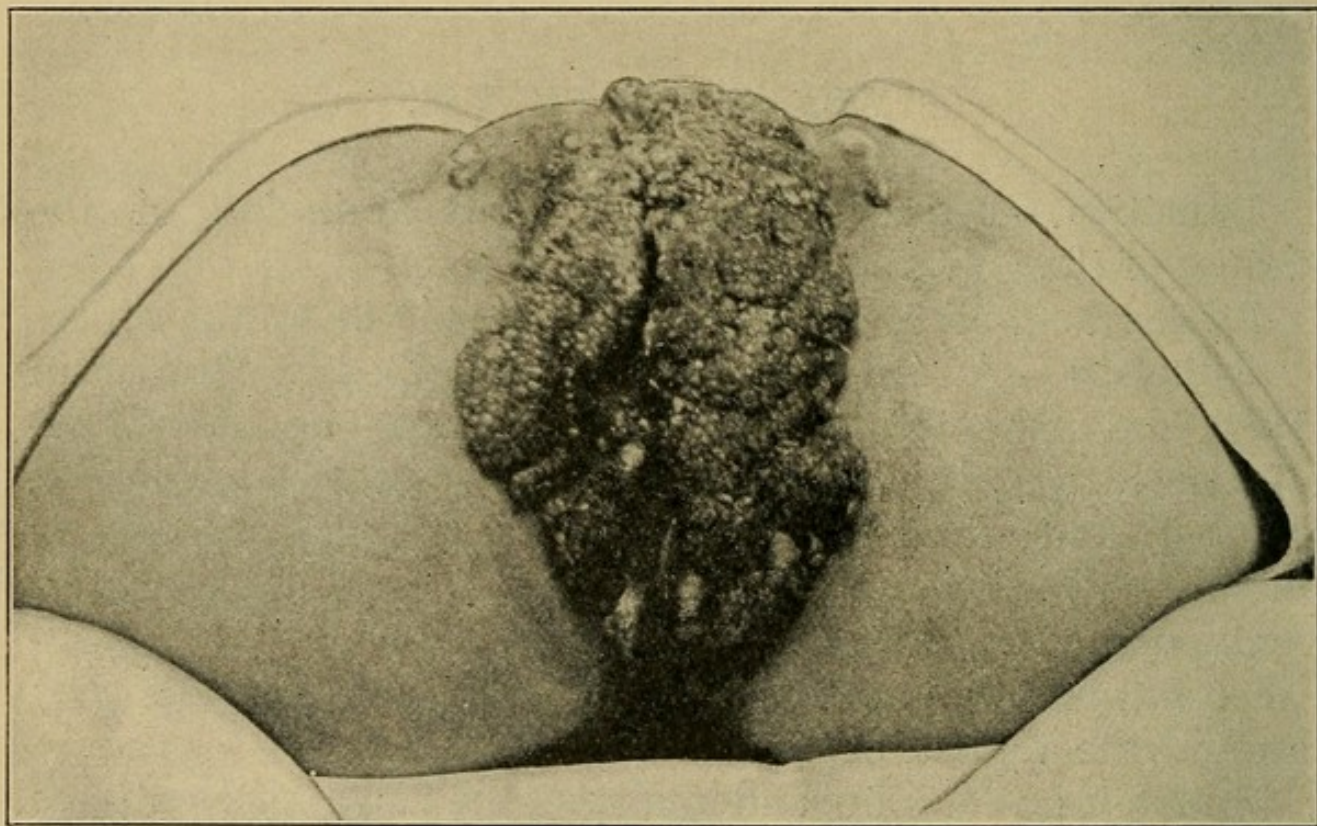
**Diagnosis.**—Usually easy in advanced cases. In the early stages the symptoms may be slight or entirely absent. Kraurosis should not be confused with pruritus vulvæ.

**Treatment.**—Palliative measures are unsatisfactory. The symptoms may be at times relieved by the application of pure carbolic acid, and the fissures touched with silver nitrate stick. Cocaine is of little service. In order to effect a cure complete operative removal of the diseased tissues must be practised.

### VENEREAL ULCERS AND DISEASES.

The venereal ulcers and the venereal diseases are not peculiar to women and do not call for special consideration in a work

FIG. 11



Papilloma of the vulva.

on gynecology. Of the so-called venereal warts, however, the condylomata acuminata deserve special mention (Fig. 11).



**Condylomata Acuminata.**

**Definition.**—A hypertrophic inflammatory papillomatous lesion.

**Etiology.**—Almost invariably of gonorrheal origin.

**Pathology.**—Numerous warty outgrowths, becoming confluent, are distributed over the vulva, perineum, and buttocks, often reaching up into the vagina. The lesion is essentially an overgrowth of the papillæ.

**Symptoms.**—Besides the presence of the growth, which often reaches large size, the symptoms are those of the accompanying vulvitis to which the irritating discharge from the condylomata generally gives rise.

**Diagnosis.**—These warts are easily recognized. Beginning as pale, red growths, their color later turns to gray. Rapid growth during pregnancy is the rule.

The **treatment** should consist in operative removal. Small condylomata may be burned off with the actual cautery. Large ones should be removed with the scissors or knife under a general or local anesthetic.

**HEMATOMA OF THE VULVA.**

**Definition.**—An accumulation of blood in the loose cellular tissue of the vulva.

**Etiology.**—Spontaneous rupture of an overdistended vein in pregnancy or during labor is the most frequent cause. At times the rupture may be of traumatic origin, the result of a blow or fall.

**Pathology.**—The hemorrhage is always venous and comes most often from the rupture of a dilated vein. Copious bleeding occurs, readily favored by the loose cellular tissue of the vulva, so that the tumor is of rapid growth and often reaches considerable size. Gradual absorption is the rule in small hematomata. The larger ones frequently suppurate.



**Symptoms.**—A hard, elastic tumor develops suddenly in the labium, accompanied by tension and by extreme tenderness on pressure when of traumatic origin. There is often a feeling of faintness and a desire to urinate.

**Diagnosis.**—The tumor is easily recognized as an elastic swelling showing its characteristic deep purple color through the skin. The history is always one of sudden onset. It is important to distinguish hematoma from vulvar hernia.

**Treatment.**—Rest in bed and cold applications to the part, preferably ice. Absorption usually takes place in a few days, but should this not occur and suppuration intervene, free incision with subsequent drainage should be carried out. Early aspiration before the blood has clotted, with subsequent firm pressure for several days is good treatment for the large hematomata where absorption seems improbable.

### VARICOCELE OF THE VULVA.

**Definition.**—Enlarged, distended veins in the vulva.

**Etiology.**—Venous obstruction in pregnancy and pressure from abdominal and pelvic tumors.

**Pathology.**—The enlarged veins may be symmetrical and involve both labia, or be present in isolated patches only. Occasionally the condition reaches to the rectum and vagina.

**Symptoms.**—A feeling of weight and distention in the labia, often attended with burning and itching.

**Diagnosis.**—The enlarged veins are easily seen.

**Treatment.**—Only the worst cases are benefited much by treatment. This should consist of rest in bed, the free administration of a saline cathartic, and when rupture seems imminent, compression of the dilated veins by means of a T-bandage. When rupture of the vein occurs, the hemorrhage is usually into the cellular tissue of the vulva, forming a hematoma. In superficial veins that rupture externally, the bleeding is often severe and should be controlled by firm pressure, or if necessary by clamp and ligature.



## CYSTS OF THE VULVA.

**Type.**—The most common form of cyst met with in the region of the vulva is that of the duct of Bartholin's gland, situated in the labia majora. Cysts of the labia minora are very seldom seen.

**Definition.**—A localized swelling in the lower third of the labia majora.

**Etiology.**—The obliteration of the orifice of the duct which causes the retention is nearly always the result of previous gonorrhea. Accidental ligation of the duct during operations on the perineum is an occasional cause.

**Pathology.**—Generally a retention cyst of the duct, the gland being rarely affected. The cyst wall is quite thin and contains a thin, viscid mucus. When the cyst arises in the gland the swelling is more deeply situated. These cysts are liable to attacks of acute inflammation, and often suppurate, forming an exceedingly painful abscess.

**Symptoms.**—None other than from the size of the swelling, unless inflammation occurs. There is then acute localized pain, marked tenderness on pressure, and often high fever, reaching its maximum as suppuration begins.

**Diagnosis.**—A hard, tense, localized enlargement in the labium majus. Tender to pressure when acute inflammation is present. When an abscess forms, considerable induration and thickening occur and the pain becomes intense.

**Treatment.**—When sufficient size is attained to cause constant annoyance, or to interfere with coitus, the cyst should be removed. This is best accomplished by a thorough dissection, for if any part of the cyst wall remains, recurrence is apt to result. For inflammation of the cyst, rest in bed and cold applications are indicated. When an abscess forms, free incision and drainage should be resorted to. When complete removal of the cyst wall by dissection is difficult, on account



of adhesions, it is best to thoroughly destroy its secreting surface by the application of pure carbolic acid with subsequent gauze drainage.

### ELEPHANTIASIS OF THE VULVA.

**Definition.**—A hyperplasia of the skin and subcutaneous cellular tissue rarely seen in western countries.

**Etiology.**—Uncertain; an endemic form in certain countries points to infection.

**Pathology.**—Three forms exist (Cornil and Ranvier). In the first the entire derma is hypertrophied; in the second the engorgement of the tissues extends over a circumscribed area only; and in the third the thickening of the skin is enormous and involves all its structure. In all three the characteristic lesion is a dilatation of the lymphatics.

**Symptoms.**—Discomfort and inconvenience caused by the increase in the size of the labia. Edema and friction ulcers often develop.

**Diagnosis.**—The labia majora enormously hypertrophied, and frequently hanging down as far as the knees, are the chief diagnostic feature.

**Treatment.**—Total removal of the diseased structures by operation. Special care should be taken to guard against excessive hemorrhage at the time.

### BENIGN TUMORS OF THE VULVA.

**Type.**—Newgrowths of the vulva are of extreme rarity; the *fibromata* are the variety most often seen.

**Etiology.**—Uncertain; the *fibromata* probably originate from the round ligament in the canal of Nuck.

**Pathology.**—The *fibromata* spring from the connective tissue of the labia. They are of slow growth, hard, rounded,



and circumscribed, and composed of connective tissue intermixed with muscle fiber. The lipomata arise from the subcutaneous fat on the mons veneris. Sebaceous cysts are occasionally seen on the labia.

**Symptoms.**—These are mechanical from the presence of the tumor.

**Diagnosis.**—The fibromata are recognized by their hard, firm consistency; the lipomata are soft. Both appear as circumscribed globular swellings covered by non-adherent integument and are not painful to pressure, nor is there any impulse on coughing. The sebaceous cysts are small semi-transparent elevations filled with sebaceous material.

**Treatment.**—The liability of the fibromata to undergo sarcomatous changes calls for operative removal. The lipomata need special treatment only from their size. The sebaceous cysts frequently become inflamed and suppurate, necessitating removal.

## MALIGNANT TUMORS OF THE VULVA.

**Varieties.**—Sarcomata and carcinomata.

**Etiology.**—The same as in cancer elsewhere.

**Pathology.**—The vulva, of all regions of the female genital tract, is the one least often attacked by carcinoma. Schuury found it only thirty times in 1147 cases. The disease begins most frequently in the clitoris or in the groove between the labia, first appearing as a small nodule, which rapidly goes on to ulceration. Quick growth with infiltration of the surrounding tissues and early involvement of the inguinal and femoral glands is characteristic.

**Symptoms.**—Pain appears early in the disease and is a constant symptom. Rapid growth with superficial or diffuse infiltration of the neighboring tissues and a constant foul discharge from the ulcerating surface completes the clinical picture. In the later stages the emaciation is marked.



**Diagnosis.**—Age is of importance, as is also the effect on the genital system. The growth ulcerates early and involvement of the vaginal glands is usually found. The microscope is necessary for a positive diagnosis.

**Treatment.**—Early removal of the growth, together with the inguinal and femoral glands of the same side, should be practised. In the later stages operation is contra-indicated and palliative measures only should be employed.

**Prognosis.**—The prognosis, except in very early cases, is unfavorable.

**Sarcomata** of the vulva are of rare occurrence, the melanotic variety being relatively frequent. Recurrence is almost certain, though early operation is advisable.

## VULVAR HERNIA.

**Definition.**—A protrusion of the intestines, omentum, or both, into the labia majora.

**Etiology.**—The same as hernia in general.

**Pathology.**—The escaped viscera descend by the side of, or in, the processus vaginalis of Nuck and enter the labium by the inguinal canal. A variety known as *perineal* may occur when the viscera pass down by the side of the vagina into the labium.

**Symptoms.**—More or less constant pain in the region of the swelling, especially on exertion. Acute pain with gastrointestinal symptoms if strangulation occurs.

**Diagnosis.**—A painful swelling of varying size situated in the labium majus is found. Important to make a differential diagnosis from tumor of the labium, or cyst of Bartholin's gland.

### *Hernia.*

Soft or elastic.

Size increases on coughing.

Tends to disappear on pressure.

### *Cyst or Tumor.*

Firm or hard.

Unchanged on coughing.

Unchanged by pressure.



**Treatment.**—Reduction by gentle taxis when possible and retention by truss. When irreducible or strangulated, operation becomes necessary.

---

## CHAPTER V.

### THE VAGINA.

#### MALFORMATIONS OF THE VAGINA.

As the vagina has its **development** in part from the ducts of Müller, various errors in formation are found analogous to those occurring in the uterus and tubes. A complete absence or imperfect development may exist, and where the Müllerian ducts fail to coalesce, a double vagina results. If coalescence without absorption takes place, a septum, partial or complete, dividing the vagina into two passages, is left.

**Absence of the vagina** results from a failure in the development on the part of the Müllerian ducts. When the entire Müllerian tract fails to develop there is a corresponding absence of vagina, uterus, and tubes.

**Atresia of the vagina** is usually incomplete, the lower segment being closed. Behind the obstruction there is an accumulation of blood from successive menstruations, which when in the vagina alone is known as **hematocolpos**, when in the uterus, **hematemetra**, and when in the tubes, **hematosalpinx**. The retained blood seldom coagulates.

**Double vagina** is due to imperfect fusion of the ducts of Müller, and the two canals lie side by side.

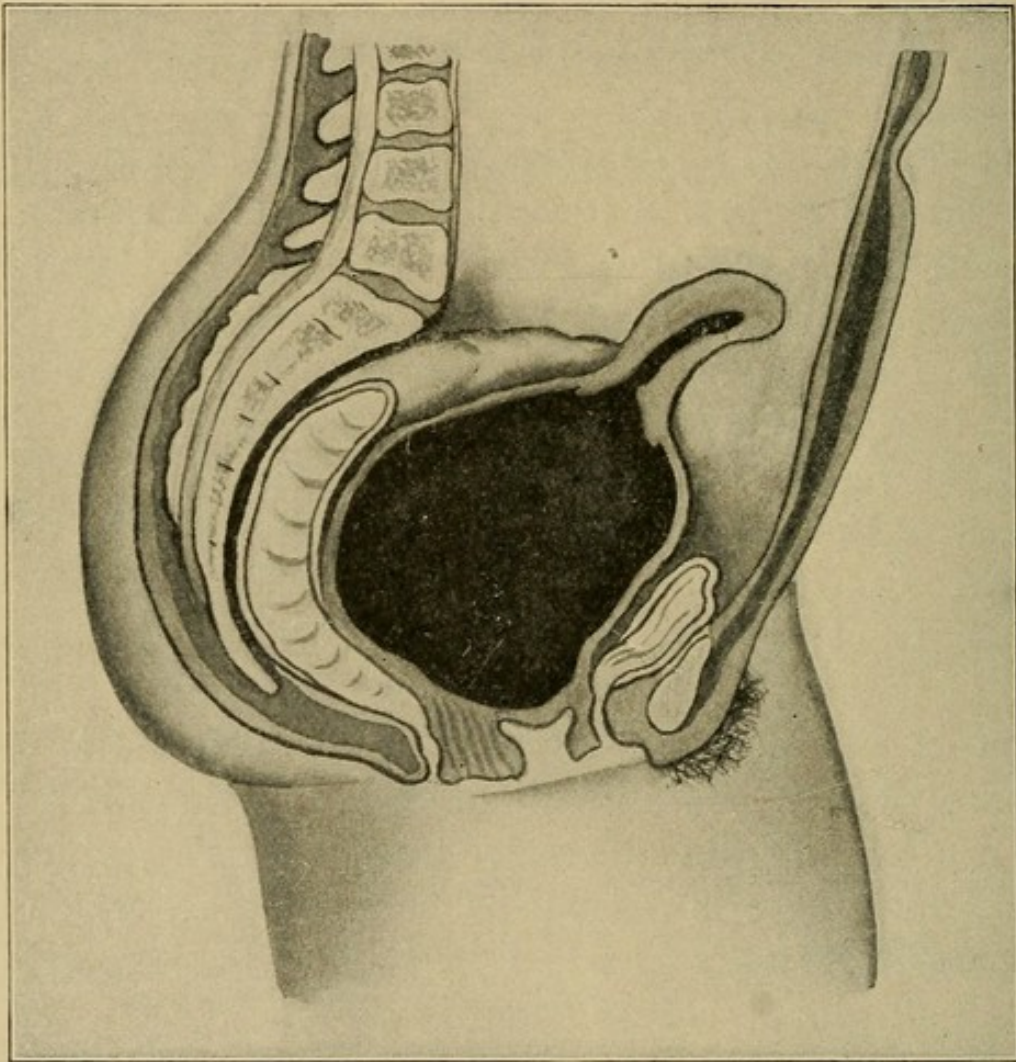
**Hour-glass contraction of the vagina** results from an improper fusion of the upper and middle third of the vagina, and is frequently seen in cases of anteflexion of the uterus. The constriction may be so marked that the cervix cannot be seen or examined through it.



### ATRESIA OF THE GENITAL CANAL.

**Definition.**—Atresia of the genital canal is an occlusion of the genital tract usually accompanied by accumulation of the menstrual blood. The obstruction may be at one of three places—the hymen, the vagina, or the cervix.

FIG. 12



Atresia of the vaginal outlet; hematocolpos.

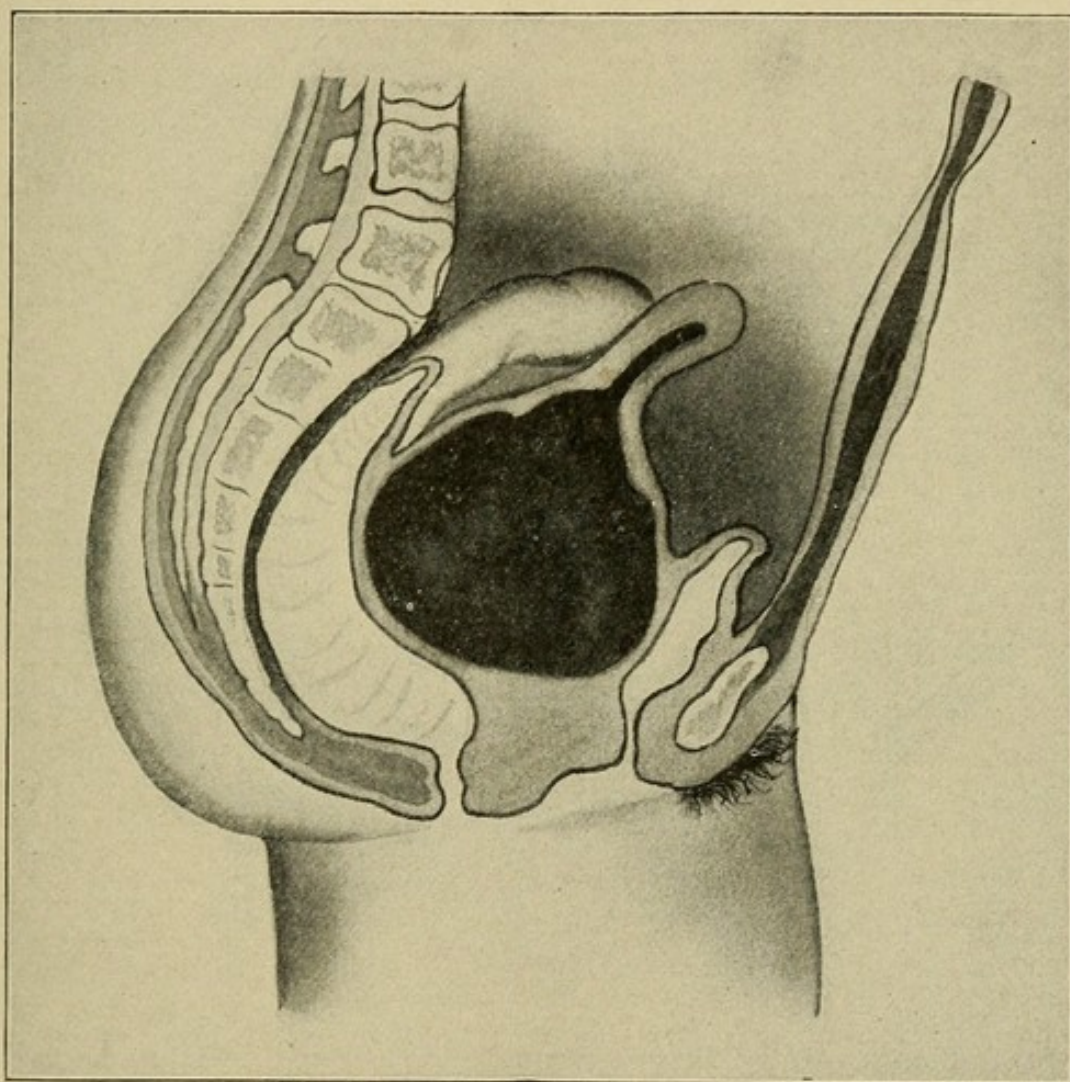
**Etiology.**—Atresia may be either congenital or acquired. The former is due to non-development or closure during fetal life. The acquired form may be produced by inflammation of the mucous membranes and subsequent adhesions of



the opposed surfaces, or cicatrization following injuries received in childhood, or during labor. Atresia may follow sloughing after the caustic effect of very strong douches.

The most usual form of atresia met with is congenital, due to imperforate hymen.

FIG. 13



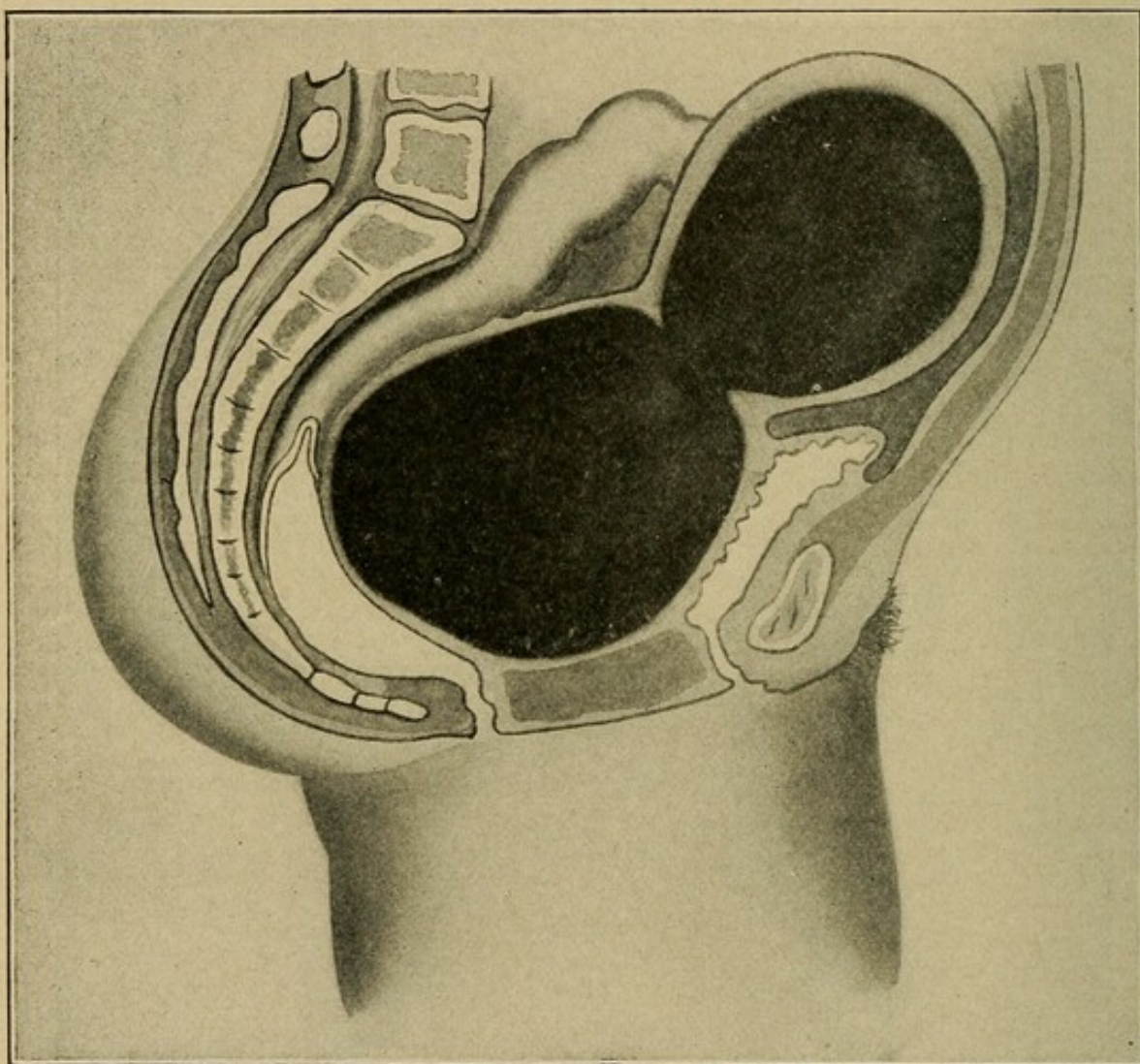
Atresia of the lower third of the vagina.

**Pathology.—Atresia Hymenalis.**—The hymen exists as a continuous membrane, tougher than normal and quite thick. The accumulation of menstrual blood distends the vagina, forming a tense fluctuating mass that at times fills the whole pelvis, even reaching well up into the abdominal cavity. The uterus either lies on top of the mass, or after the cervix dilates becomes itself distended with blood. In **atresia vaginalis** the



seat of the obstruction is most often in the lower third of the vagina, though the atresia may exist at more than one point. In **atresia cervicalis** the obstruction, usually slight, exists most often at the internal os.

FIG. 14



Atresia of the vaginal outlet: hematocolpos and hematometra.

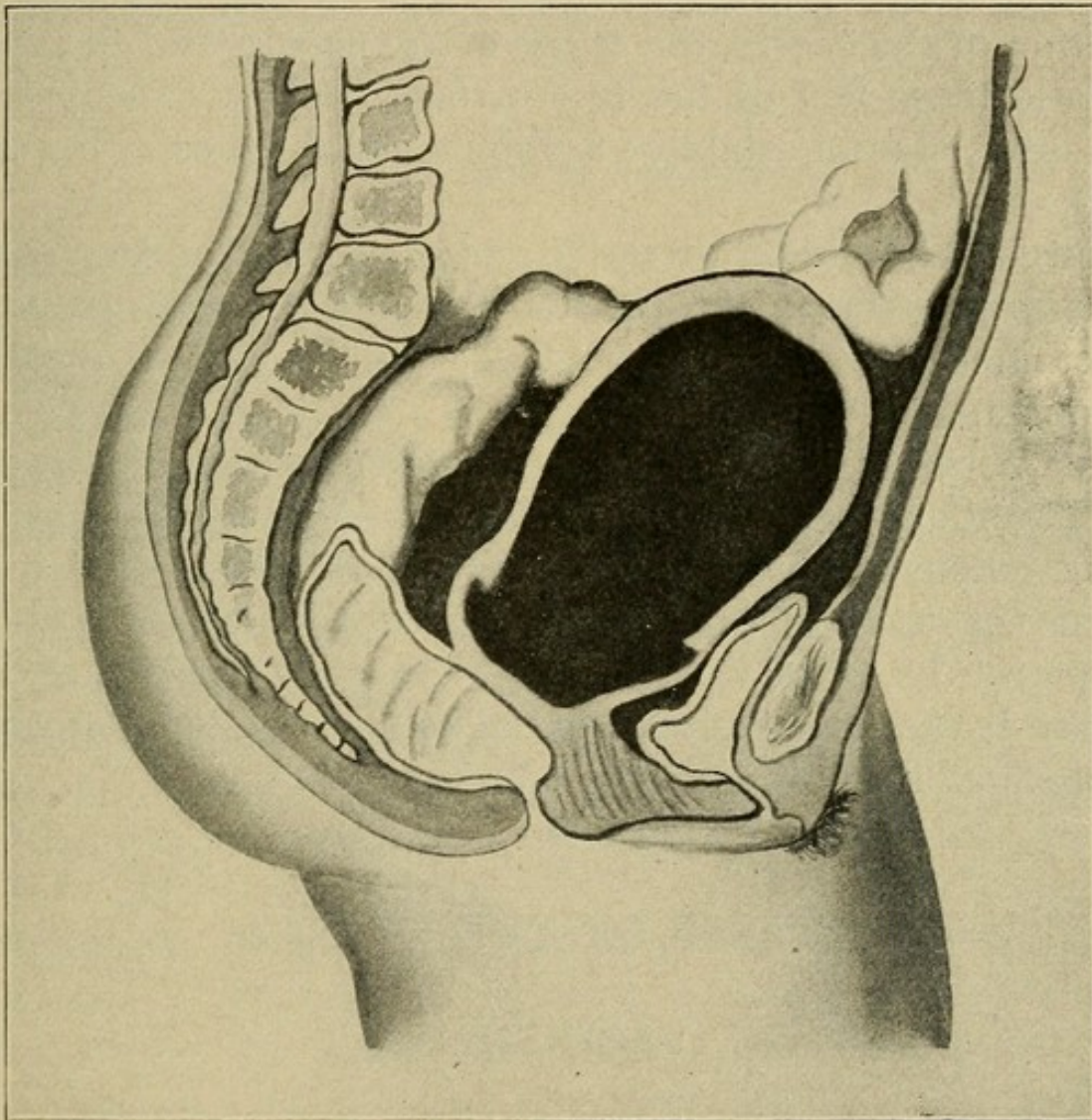
The retained blood is of a dark chocolate color, thick in consistence, and is free from coagula. It contains shrunken red blood cells, flat epithelial cells, blood pigment, and debris.

**Symptoms** do not arise until puberty, and consist of menstrual molimina unaccompanied by the appearance of the menstrual discharge. As the distention increases transitory pain develops, later becoming continuous. The abdomen



enlarges and pregnancy may be suspected on account of the existing amenorrhea. Unless relieved by operation the condition usually terminates fatally through rupture of the uterus or cervix, or through peritonitis arising independent of rupture.

FIG. 15



Atresia of the lower two-thirds of the vagina: hematocolpos and hematometra above atresia.

**Diagnosis.**—In general by **vulvovaginal examination** little difficulty will be experienced in arriving at a correct diagnosis.

In **obstruction at the hymen** its imperforate condition is readily detected and rectal examination shows a tense, elastic tumor filling the vagina. By **abdominal examination**



this may be felt at the pelvic brim, or even up as high as the umbilicus. The uterus may be mapped out as a small, hard tumor on the summit of the mass.

In **atresia of the vagina** the hymen does not bulge; the other conditions will be found practically the same.

In **atresia of the cervix** difficulty in distinguishing from early pregnancy may arise. On careful examination, however, the condition of the cervix, the shape of the uterus, and the characteristic tense feel of the tumor, together with the history of the case, should establish a differential diagnosis (Figs. 12 to 15).

**Treatment** should be operative and carried out as soon as the diagnosis is certain. An incision through the obstruction to the retained fluid should be made, and gradual evacuation accomplished.

The operation is not free from danger, and should be performed under a general anesthetic in a hospital or at the patient's house—*never in the physician's office*. Too rapid collapse of the sac may cause the rupture of a distended Fallopian tube, or of vascular adhesions in the pelvis, and be followed by a fatal hemorrhage unless immediate laparotomy is performed and the bleeding vessels tied.

## DISEASES OF THE VAGINA.

### VAGINITIS.

**Definition.**—Vaginitis is an inflammation of the mucous membrane lining the vagina.

**Pathology.**—There are increased vascularity and redness of the mucosa, the epithelium is swollen, the rugæ are exaggerated, red, and easily bleed. The deeper vaginal and cellular tissues are involved only in the severest types. Exfoliation may take place, leaving raw patches, which ultimately cohere and give rise to atresia.



The microörganisms most commonly the cause are the gonococcus, Loeffler's bacillus, the streptococcus of erysipelas, the staphylococcus, and fungi. A small number of cases are caused by mechanical and thermic irritation from irritating pessaries and too hot or too concentrated douches.

**Etiology.**—Vaginitis may be due either to direct invasion by bacteria, or to secondary irritation by discharges from the uterus.

### Varieties of Vaginitis.

**Catarrhal, or simple, vaginitis** is the most usual form. It is characterized by a uniform redness of the mucosa, with swelling and an increase in the vaginal secretions.

**Granular vaginitis**, an advanced stage of the catarrhal type, is due to long-continued or repeated attacks.

**Diphtheritic vaginitis**, due to the bacillus of diphtheria, occurs either in localized patches, or involves the whole vagina. The mucous membrane is thickened and covered with a diphtheritic membrane.

**Senile vaginitis** comes only after the menopause, and produces a cicatricial contraction of the vagina. Patches of the epithelium are shed, thus producing raw surfaces that frequently adhere together.

**Gonorrheal vaginitis** is due to infection by the gonococcus of Neisser. This form is the most intractable save the senile form, and may persist for years or life. Extension of the infection to the uterus, Fallopian tubes, and peritoneal cavity, producing endometritis, pyosalpinx, and localized peritonitis is more common than many physicians realize.

**Symptoms.**—Pelvic pain; frequent micturition, with more or less smarting and burning; a sensation of heat and burning in the vagina; and a copious mucopurulent discharge.

These symptoms may be present in both simple and gonorrheal vaginitis, but in the latter the urinary disturbances are more marked. The symptoms, particularly in gonorrhea of



the vagina, date from a distinct onset, are of longer duration, yielding less readily to treatment, and complications, such as enlargement of the inguinal and vulvovaginal glands, endometritis, salpingitis or cystitis, often make their appearance early.

**Diagnosis.**—Inspection shows a mucopurulent discharge contained in or escaping from a much reddened and inflamed vagina. The mucous membrane is swollen, eroded in patches, and extremely tender and bathed in pus. In the gonorrheal type the orifices of the ducts to the vulvovaginal and periurethral glands will be seen to be red and inflamed. A **differential diagnosis** between simple and gonorrheal vaginitis may only be made with certainty when the gonococcus is found in the discharge. In every case of purulent vaginitis repeated microscopic examinations of the pus should always be made.

**Treatment.**—In **acute cases** rest in bed and prolonged vaginal irrigation three times a day with a 1 to 1000 bichloride solution. Where the gonococcus is present in the pus the vaginal walls, cervix, and cervical canal should be dried and a thorough application of a 20 per cent. silver nitrate or 50 per cent. argyrol solution made every other day. This is best done with the patient in the knee-chest position, as the air distention of the vagina obliterates the rugæ, giving a smooth surface for the local application.

In the **chronic cases** the *gonococci* are most frequently found in the *posterior fornix*, in the natural pocket just behind the posterior cervical lip. It is here that the application of silver nitrate should be particularly thorough.

As serious complications in the uterus and Fallopian tubes result from direct invasion of the gonococci every effort should be made early in the disease to destroy the germs, while they are still limited to the vagina and cervix. Cessation of sexual intercourse is imperative.



### VAGINISMUS.

**Definition.**—Vaginismus is a painful reflex muscular contraction of the vaginal orifice.

**Etiology.**—Most often observed in patients of nervous and sensitive temperament, and is the result of an inflamed, partially ruptured hymen, or small ulcers or fissures about the fourchette, fossa navicularis, or anus. Urethral caruncle is sometimes a cause.

**Symptoms.**—Painful or difficult sexual intercourse (**dyspareunia**). The suffering is at times so great as to drive the patient to seek medical advice, though this is often prevented by a sense of delicacy. A very common cause of dyspareunia, however, is some pathological lesion in the pelvis, as a prolapsed, adherent, and inflamed ovary or pus tube. Relative sterility is often a symptom.

**Diagnosis.**—In some cases the patient wears an anxious, careworn expression, and in others is markedly hysterical. Vaginal examination is usually painful and should be preceded by a careful inspection of the external genitals for any ulcers, fissures, or atresia. Cocainization may aid extreme cases.

**Treatment.**—Any cause of local irritation, such as urethral caruncle, should be removed. A thick inflamed hymen should be incised, and any ulcer or fissure about the vagina or rectum properly treated. When no local lesion may be discovered, forcible dilatation of the vaginal orifice under an anesthetic is often of benefit. Complete rest from sexual intercourse should be enjoined during treatment. Tonics, exercise, and a complete change of scene are beneficial.

### TUMORS OF THE VAGINA.

The more common varieties of tumor of the vagina are, in the order named, cysts, fibromata, carcinomata, sarcomata, and tuberculosis.



**Cysts of the Vagina.—Occurrence and Pathology.**—Cysts are the commonest of the vaginal tumors. They are most frequently found in the lower third of the anterior vaginal wall. Generally single and lined with a single layer of cylindrical epithelium. Of small size, rarely larger than a hen's egg.

The **etiology** of cysts of the vagina is uncertain.

**Symptoms** are seldom present except in cysts large enough to cause dyspareunia.

**Diagnosis** rests on the recognition of smooth, elastic tumors situated inside the vagina. Cysts of the vagina should not be confounded with the cysts of the vulvovaginal glands, which are outside the vagina in the labia.

**Treatment.**—Small cysts do not call for treatment. Larger ones, when causing symptoms, should be removed by careful dissection.

**Fibroid Tumors.**—The **etiology** is the same as of fibromata in general.

**Pathology.**—Fibroma of the vagina composed chiefly of fibrous tissue interlaced with unstriped muscular fibres. They rarely originate in the vagina, but when present usually grow from the anterior vaginal wall by a well-developed pedicle.

**Symptoms** arise only when the tumor is of large enough size to interfere with micturition, menstruation, or coitus.

The **diagnosis** offers little difficulty when the pedicle may be found and traced to its origin. The tumor is hard, firm, and usually rounded in form, and not particularly tender.

**Treatment.**—Ligature and division of the pedicle, or, when the tumor is sessile, enucleation.

**Carcinoma of the Vagina.—Definition.**—Carcinoma of the vagina is a primary malignant involvement of the vaginal wall.

**Pathology.**—Primary carcinoma of the vagina is of rare occurrence. Two forms are recognized, a **diffuse infiltration** and a **localized papillary infiltration**. Extension into the para-



vaginal tissues is rapid, and enlargement of the vaginal glands, due to carcinomatous invasion, generally appears sooner or later.

**Etiology.**—Most common between the ages of fifty and sixty. Prolonged irritation from a foreign body, such as a pessary, may play an important role.

**Symptoms.**—Hemorrhage and a fetid discharge from the vagina. In the early stages pain is slight or entirely absent.

**Diagnosis.**—Often doubtful on account of the difficulty in securing a satisfactory examination of the cervix, the most common seat of carcinoma in the genital tract.

The growth rarely reaches large size, but remains as an ulcer having an uneven base, bleeding freely when touched, and covered with a putrid secretion. Secondary nodules are often seen on the vagina at a distance from the principal lesion.

**Treatment.**—Success depends on an early diagnosis and complete operative removal of the diseased tissue. Total extirpation of the vagina may be called for. In cases beyond the operative stage the use of the actual cautery is recommended as a relief for the sloughing and fetor.

**Sarcoma of the Vagina.—Occurrence.**—Sarcoma of the vagina is a rare condition. It may occur quite early in life, one case where it was apparently congenital being recorded.

The **symptoms** do not differ materially from those of sarcoma of the uterus, and the treatment consists in early removal. Recurrence is very likely to take place.

**Tuberculosis of the Vagina.—Occurrence.**—Primary tuberculosis of the vagina is of extreme rarity, and the secondary form only of importance. This, as a part of the general affection, calls for constitutional rather than special treatment.



## CHAPTER VI.

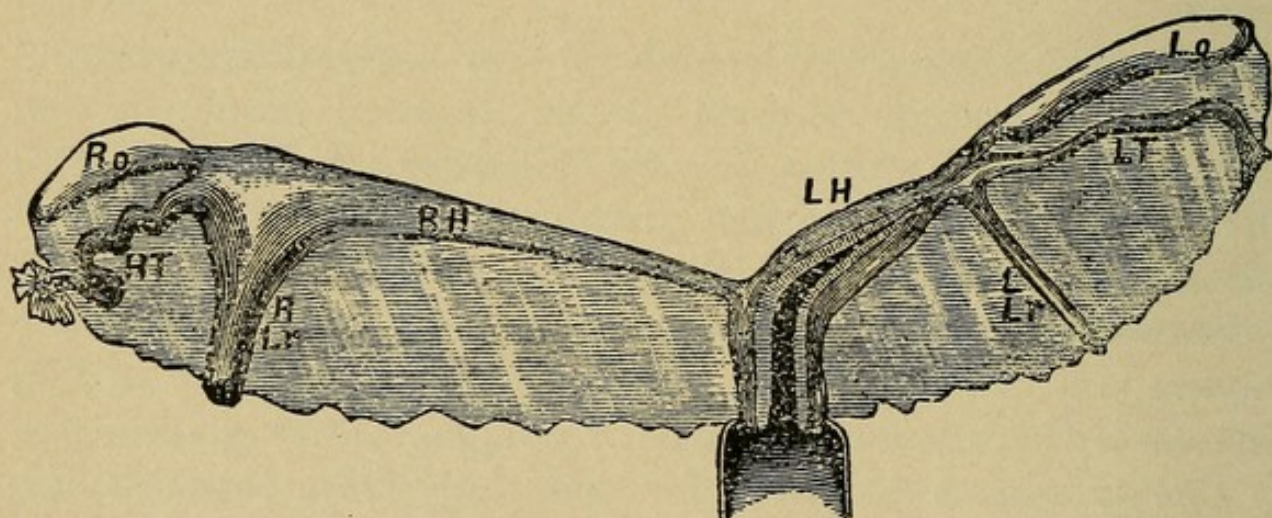
### THE UTERUS.

#### MALFORMATIONS OF THE UTERUS.

THE varieties of uterine malformation most commonly encountered are: Uterus bipartitus, unicornis, didelphys, bicornis, septus and infantilis.

These various conditions known as malformations are not such in a real sense, but arise as a result of arrested develop-

FIG. 16



Uterus unicornis: *LH*, left horn; *LT*, left tube; *Lo*, left ovary; *LLr*, left round ligament; *RH*, right horn; *RT*, right tube; *Ro*, right ovary; *RLr*, right round ligament. (From Schroeder.)

ment. The term, as generally used, means an incomplete result rather than a defective process. In other words, a lack of development and not a maldevelopment. In general terms, therefore, two causes operating together—arrested development and arrested growth—are responsible for these results.

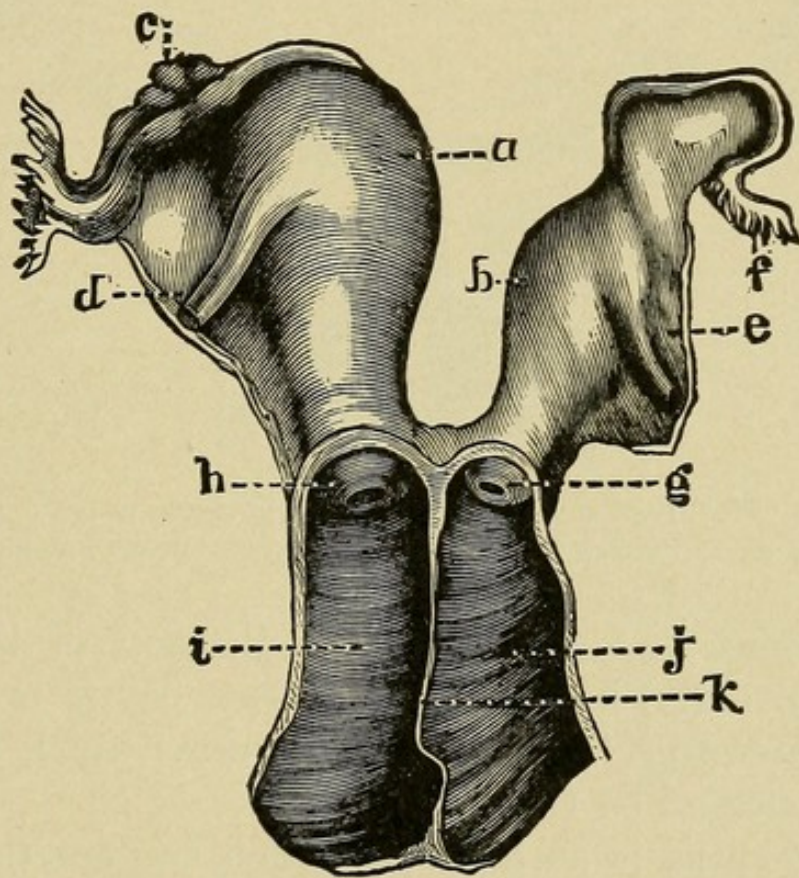
**Pathology.**—Complete absence of the uterus is of rare occurrence, but a rudimentary uterus consisting of a few fibers with some connective tissue is occasionally met with.



**Uterus bipartitus** presents rudimentary horns which may, or may not, be patent. The ovaries at times may be well developed. The external genitals and the breasts may be perfectly formed.

**Uterus unicornis** may sometimes have an accompanying rudimentary second horn. The vaginal portion of the cervix is small, the body of the uterus is of disproportionate length, the fundus small and tapering, with a single Fallopian tube and ovary (Fig. 16).

FIG. 17



Uterus didelphys: *a*, right cavity; *b*, left cavity; *c*, right ovary; *d*, right round ligament; *e*, left round ligament; *f*, left tube; *g*, left vaginal portion; *h*, right vaginal portion; *i*, right vagina; *j*, left vagina; *k*, partition between the two vaginae. (From De Sinéty, after Ollivier.)

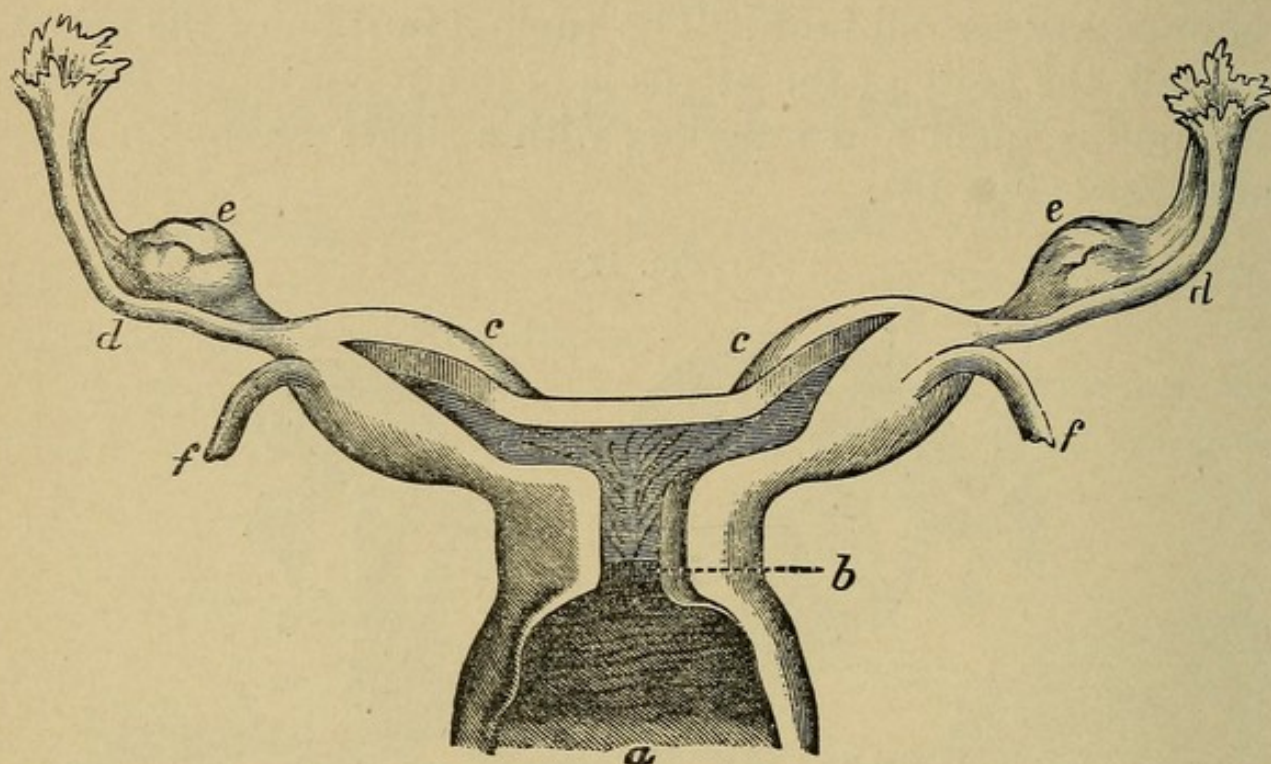
**Uterus didelphys** shows two uterine halves separate throughout their course. The vagina may be double, single, or entirely absent (Fig. 17).

**Uterus bicornis** consists in the separation into two horns, more or less appreciable externally, according to the degree of



bifurcation present. This may be only a mere depression at the middle of the fundus, or a well-marked separation extending down as low as the internal os (Fig. 18).

FIG. 18



Uterus bicornis unicollis of a virgin: *a*, vagina; *b*, single neck; *c*, *c*, horns; *d*, *d*, tubes; *e*, *e*, ovaries; *f*, *f*, round ligaments. (From Kussmaul.)

**Uterus septus** has no external indication of the division existing; internally, however, the uterine cavity is divided by a septum extending from the fundus downward, at times as far as the external os (Fig. 19).

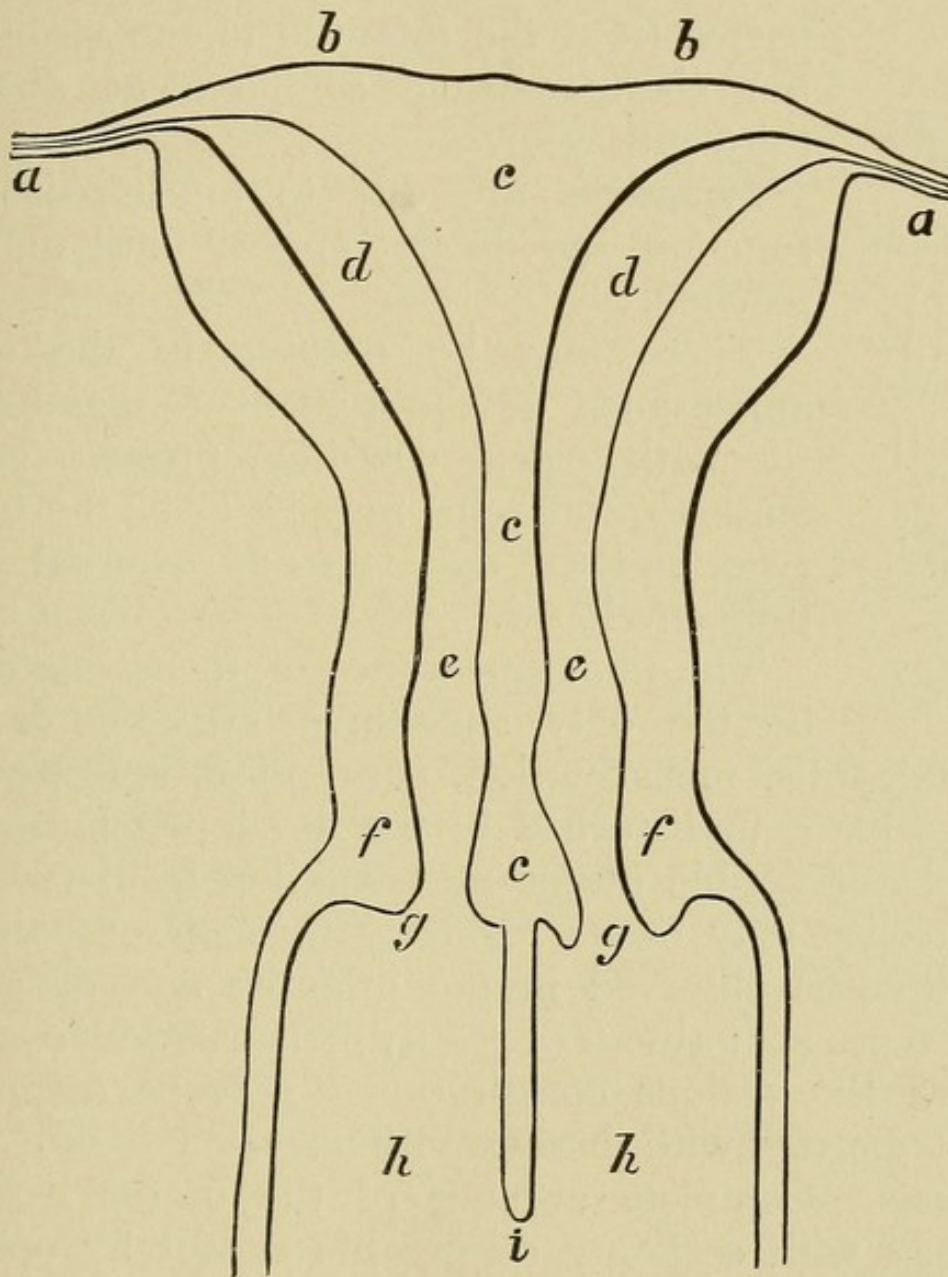
**Uterus infantilis** is as a uterus much smaller than normal and there is a persistence of the relative proportion between body and cervix normal up to the time of puberty. The body is small and short and the cervix disproportionately long, and a marked angle of flexion exists between the two (Fig. 20.)

**Etiology.**—The malformations vary according to the period at which the arrest in development and growth occurs. From the first to the third month the septum between the ducts of Müller is undivided. By the end of the third month this septum has entirely disappeared, and the upper portions of



the ducts remain separate, forming the uterine cornua and the Fallopian tubes. During the fourth and fifth months the

FIG. 19



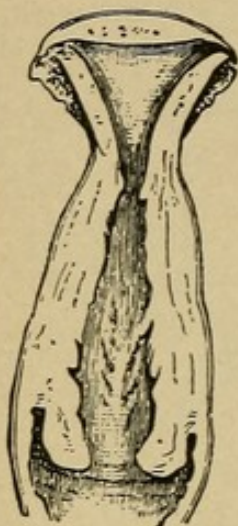
Uterus septus duplex (natural size), completely double uterus, and incompletely double vagina of a girl aged twenty-two years: *a, a*, tubes; *b, b*, fundus of the double uterus; *c, c, c*, partition of uterus; *d, d*, cavities of the uterine bodies; *e, e*, internal orifices; *f, f*, external walls of the two necks; *g, g*, external orifices; *h, h*, vaginal canals; *i*, partition which divided the upper third of the vagina into two halves. (From Kussmaul.)

angle between the cornua disappears, and in the last five months that portion of the fundus between the Fallopian



tubes becomes arched. From birth to puberty no important change takes place, but at puberty further development occurs, the fundus enlarges, the angle of flexion between the cervix and fundus disappears, and the uterus passes from the infantile to the virgin form, the change being complete at about the thirteenth year.

FIG. 20



Infantile uterus.  
(Schroeder.)

**Symptoms** are due to an impairment of function and do not appear until puberty is reached.

There may be nothing in the external appearance of the patient to point toward the pathological condition present. Figure, features, and voice may be all of the feminine type, and the mammæ and external genitals fully developed.

The non-appearance of menstruation may be the only suggestive symptom. In the uterus unicornis, menstruation, conception, and pregnancy may take place undisturbed in the developed horn.

In cases of double uterus menstruation from the second uterine cavity may occur regularly throughout pregnancy. The symptoms observed in the infantile and congenitally atrophic types are: absent or scanty menstruation, dysmenorrhea, and the various constitutional nervous disturbances usually associated with these conditions.

**Diagnosis.**—Complete absence of the uterus cannot be determined with certainty during life except by operation. A rudimentary condition may remain undiagnosed even after careful examination. The uterus unicornis and uterus didelphys are rare and seldom diagnosed. The uterus bicornis is more frequently met with, and when well marked is easily recognized. The uterus septus is easily detected if the septum extends downward as far as the external os.

When doubt exists, and it is of importance to determine the exact condition present, a thorough instrumental and



digital examination under a general anesthetic should be made.

**Treatment.**—The malformations of the uterus, as a rule, do not call for operative treatment, except in the presence of marked interference with the normal functions of that organ.

In the infantile and congenitally atrophic types much may be done toward stimulating further growth and development, if the case is taken in time. A thorough divulsion of the cervix and firm packing of the uterine cavity with gauze, repeated at three-month intervals, will often produce very beneficial results and should always be given a fair trial. Plenty of outdoor exercise and good nutritious food are of great importance in the treatment.

### MALFORMATIONS OF THE CERVIX UTERI.

**Small External Os.**—In this condition, undoubtedly of congenital origin, the external os is much smaller than normal, at times having hardly more than the so-called pin-hole opening. The cervix is long and conical in shape and of firm consistency, due to increase of its connective tissue. Rigidity of the cervix is commonly associated with this condition, as well as stenosis of the internal os.

**Atresia of the Cervix.**—Occlusion of the canal is rare as a congenital condition, but is more frequently seen in patients well past the menopause. It is at times acquired after amputation of the cervix and after long-continued application of caustics to the cervical canal. (See chapter on Atresia.)

### ATROPHY OF THE CERVIX AND UTERUS.

**Occurrence.**—Atrophy of the cervix and uterus are met with under varying conditions. It may be either congenital or acquired. It is seen associated with certain constitutional



affections, such as phthisis and chlorosis, and in acute general affections, such as scarlet and typhus fever. It may result from superinvolution in the puerperium, and is normal in the senile uterus after the menopause.

**Symptoms and Diagnosis.**—There will be found by **vaginal examination** a small, flat cervix projecting only slightly into the vagina, and upon making the **bimanual examination** the uterus, much smaller than normal, is recognized with difficulty. To determine the causes responsible for the condition found necessitate a careful consideration of the patient's history. Amenorrhea, or scanty menstruation, and delayed puberty point to a congenital condition of imperfect development. The constitutional condition is revealed by the state of the blood and lungs. A history of childbirth or abortion, followed by the non-appearance of menstruation, would indicate superinvolution. Advanced life would point toward a senile cause. One must bear in mind the possibility of this change coming on early, at times before the age of thirty-five years.

### **HYPERTROPHY OF THE CERVIX.**

**Varieties.**—Hypertrophy of the cervix may be divided into **hypertrophy of the vaginal portion**, and **hypertrophy of the supravaginal portion**. The latter is usually accompanied by more or less elongation.

**Pathology.**—The vaginal portion is much enlarged and thickened by hyperplastic changes.

**Etiology.**—Unknown. The condition is a true hypertrophic growth, very uncommon, and should not be confused with simple thickening occurring as a result of chronic inflammation following laceration at childbirth.

**Symptoms.**—Hypertrophy of the vaginal portion is characterized by a general increase in size, which may be so extensive as to cause its protrusion through the vaginal orifice. The patient has in general bearing-down pains in the pelvis,



leucorrhea, discomfort in walking, and ulceration and excoriation of the cervix when it protrudes at the vulva.

**Diagnosis.**—The vagina is found filled to a more or less extent by the enlargement of the cervix. The fornices are of normal depth, and the fundus uteri is found at its normal height in the pelvis.

**Treatment.**—Amputation of the cervix.

### HYPERELONGATION OF THE CERVIX.

**Definition.**—A lengthening of the supravaginal portion of the cervix.

**Pathology.**—This condition is most commonly met with in prolapse of the uterus, but may exist unaccompanied by descent of the fundus. The cervix is drawn out and narrow, at times hardly thicker than a whip cord.

**Etiology.**—The elongation is tensile in origin, due to downward traction on the cervix exerted by a rectocele or cystocele working against the uterine supports. If the patient is put to bed and the bowels kept loose, thereby excluding this mechanical factor, the elongation shows a marked tendency to subside, and we often see a greatly lengthened cervix reduced one-half or more in a few weeks with no other treatment. In complete laceration of the perineum, where a rectocele cannot develop, hyperelongation of the cervix is unknown.

The **symptoms** are those of the accompanying cystocele or rectocele. When the cervix is so elongated as to appear at the vulva troublesome friction ulcers arise.

**Diagnosis.**—The vaginal outlet is relaxed, and there is a marked rectocele, bulging at the introitus with every expulsive effort. A cystocele is also commonly present, so that the vaginal fornices are shallow or entirely obliterated. **Bimanual examination** may or may not show the fundus at its normal level in the pelvis, and the thin stretched-out cervix may be easily palpated between the index finger and thumb in the



vagina. Introduction of the uterine sound demonstrates a marked increase in the distance from external os to fundus.

**Treatment.**—Amputation of the cervix, and repair of the rectocele and perineum. Several weeks rest in bed with daily vaginal douches should precede the operation.

### LACERATION OF THE CERVIX.

**Definition.**—A solution of continuity in the lower segment of the uterus.

**Varieties and Pathology.**—The most usual form encountered is a **left unilateral tear**. Next in frequency come the **bilateral** and **stellate tears**. **Anteroposterior lacerations** are of rare occurrence. Lacerations of the cervix are found in about 30 per cent. of all parous women, and a well-marked tear is one of the most reliable signs of previous parturition. The immediate effect of laceration of the cervix is hemorrhage, dependent in severity on the extent of the lesion. The remote effect is interference with involution; the cervix is congested and inflamed, and its tissues become hypertrophied, hard, and indurated. Erosion of the mucous membrane and cystic degeneration of the cervical glands result.

**Etiology.**—The majority of lacerations of the cervix occur during parturition as the result of delivery through an imperfectly dilated cervix. In cases of spontaneous delivery, especially if precipitate, we often find well-marked lacerations, but it is during the performance of the various obstetrical operations through a partially dilated cervix that the greatest injuries are sustained. A small percentage of lacerations result from rapid miscarriages, and some few are caused by careless instrumental dilatation.

The **symptoms** may be divided into immediate and remote. The **immediate signs**, when the laceration is severe, are hemorrhage and, later, subinvolution. The **remote symptoms** are many and oftentimes obscure. Leucorrhea, thick and



mucoid in character, profuse menstruation and sterility are the common symptoms. When the tear has extended through the internal os, resulting in an "open-door" uterine cavity above, habitual abortion is a prominent symptom.

**Diagnosis.**—The examining finger in **palpation** outlines the fissuring of the cervix; the presence of hardened areas caused by the formation of cicatricial tissue, and a patulous os often admitting the finger tip. **With the speculum** the cleft in the cervix is easily seen, and the anterior or posterior lip, or both, will be found covered with red irregular patches, which bleed readily upon manipulation. These are caused by erosion of the epithelium from the cervical canal, which the ectropion of the lips resultant on the laceration has turned out into the vagina. When a good view of the cervix cannot be obtained by the use of the speculum alone it should be grasped by a traction forceps and drawn into the field of vision.

**Treatment.**—Proper tampon treatment will do much toward improving the condition in mild cases. Tampons of ichthyol, 10 per cent., in glycerin introduced twice a week against the cervix and allowed to remain in place forty-eight hours will often relieve many of the symptoms.

After childbirth, immediate suture of the laceration should be practised when possible. Secondary repair is indicated when the tear extends through the internal os, and in cases of extensive erosion.

## CATARRH OF THE CERVIX.

**Varieties.**—Cervical catarrh may be either acute or chronic. The **acute variety** is seen most often as part of a general infection involving both body and cervix, and will be described later under acute endometritis. The **chronic variety** is a most common condition, and difficult to treat successfully.

**Definition.**—Catarrh is an inflammatory condition involving the mucous membrane of the cervical canal, otherwise known as **endocervicitis**.



**Pathology.**—The surface of the mucous membrane is covered with a single layer of epithelial cells forming a new glandular secreting surface containing many recesses and papillæ. This addition to the extent of the secreting surface causes an increase in the leucorrhœal discharge. The whole substance of the cervix is likewise affected by the inflammatory process. The origin of the new epithelial structure is in dispute. Veit holds it is produced by proliferation of the cells of the deep layer of the rete Malpighii; Hart and Barbour, that it is occasioned by proliferation of the epithelium lining the cervical glands. There is an increase in connective tissue, retention cysts form in the glands of Nabothi, and single large cysts sometimes develop in the cervix, due to obstruction of the mucous glands.

**Etiology.**—The most important cause is injury and lacerations of the cervix. Gonorrhea is a relatively frequent cause. Retrodisplacements of the uterus producing passive congestion in the cervix may be a factor.

**Symptoms.**—Leucorrhœa, profuse and frequent menstruation, pain in the back and loins, and sterility.

**Diagnosis.**—On introducing the speculum and examining the cervix a string of thick mucus is seen presenting at the external os, and in parous women usually signs of laceration and erosion of the cervix are present. A thin watery discharge from the cervix usually accompanies endometritis, while a thick purulent discharge is indicative of gonorrhea.

**Treatment.**—A complete cure is difficult to effect. Hot vaginal douches containing sulphate of zinc (℥j to Oj) should be given for ten minutes every night. Local application of tincture of iodine twice a week for several months. Displacements of the uterus should be corrected, and lacerations of the cervix repaired. When subinvolution of the uterus exists, ichthyol (10 per cent.) and glycerin tampons should be inserted into the vagina behind the cervix twice a week. In nulliparæ congenital erosions of the cervix call for operative repair. Local depletion of the cervix by scarification is of value.



**ENDOMETRITIS.**

**Definition.**—Endometritis is an inflammation of the uterine mucosa, more or less transitory in character, with a tendency to extend to the Fallopian tubes and peritoneum. Its varieties are acute or chronic.

**Acute Endometritis.—Pathology.**—The whole mucosa is inflamed; the glandular elements are increased; there is an infiltration of the connective tissue with leukocytes; cell proliferation occurs, and subsequent degeneration of the epithelium with early destruction of its ciliated cells. In severe cases the whole endometrium is destroyed and the deeper muscular tissues of the uterus invaded; the veins and lymphatics are involved and the disease spreads to the surrounding peritoneum and cellular tissues, and may even reach the pelvic veins and lymphatics.

**Etiology.**—Endometritis may occur during the course of any acute exanthem, and occasionally upon exposure to cold during the monthly period of pelvic congestion. The most frequent exciting causes are microorganisms: the gonococcus, streptococcus, staphylococcus, and sapremic bacteria being the most important.

**Gonorrheal Endometritis.—Symptoms.**—General pelvic pain, intermittent at first and then constant, with rapid elevation of temperature and pulse. A purulent discharge from the cervix appears early, usually on the second day, and dysuria and ardor urinæ are early symptoms. In 15 per cent. of the cases there is an accompanying vaginitis, while salpingitis, pyosalpinx, and local peritonitis are common sequelæ.

**Diagnosis.**—Absolute when gonococci are found in the discharge. On **examination** the uterus is found extremely sensitive to pressure, and the vagina and urethra reddened, edematous, and bathed in pus.

**Treatment.**—The cervix is dilated and the interior of the uterus, cervical canal, and vagina swabbed out with a 10 per cent. silver nitrate solution. Subsequent daily vaginal douches



of bichloride solution (1 to 5000) followed by normal saline solution should be given for at least one week. The bowels should be kept well open, and opiates may be necessary to relieve the pain.

**Septic Puerperal Endometritis.**—Puerperal sepsis may occur during the first few weeks after delivery, usually within the first few days, and is an infection due to the streptococcus or the staphylococcus.

**Symptoms.**—The attack is usually ushered in by a chill, preceded by a steady rise of temperature and pulse. The face is flushed at first, but becomes pale and the expression anxious as the disease advances. Pain is slight or absent. The lochia becomes diminished or ceases entirely, and is without odor. The mortality is from 5 to 25 per cent.

**Diagnosis.**—It is of the utmost importance that an early diagnosis be made and the disease distinguished from putrid endometritis. For this purpose the secretion should be taken directly from the uterine cavity and examined for streptococci and staphylococci. The interior of the uterus, under careful **exploration by the finger**, will prove to be smooth and contain no debris. In putrid endometritis the surface is rough, retained placenta or blood clots will be found, and the discharge will have an offensive odor.

**Treatment.**—Never use the curette. Having explored the uterus and found it empty, irrigate with normal salt solution and pack with 10 per cent. iodoform gauze. Frequent saline enemata, liquid diet, stimulation with brandy and strychnine in full doses, and free catharsis should be employed. Intravenous infusion of normal saline solution is indicated in desperate cases, also a posterior cul-de-sac incision and thorough packing of the pelvic cavity with 10 per cent. iodoform gauze (Pryor). The gauze in both the uterus and pelvis should be gradually withdrawn, beginning on the third and ending on the ninth day.

**Putrid Endometritis.**—**Etiology and Pathology.**—Putrid endometritis is caused by the presence of dead material, such



as retained secundines, sloughing polypi, or fibroids infected by the saprophytic bacteria from the vagina.

**Symptoms.**—An initial chill is occasionally present. There are high fever, tense, bounding pulse, flushed face, and little or no pain. A foul, putrid discharge is present except when a large blood clot blocks the cervical canal. In postpartum cases the lochia is scant but rarely suppressed. Upon **examination** there is little or no tenderness in the uterus or appendages.

The **diagnosis** is, as a rule, easy, from the history and clinical symptoms; but great care should be taken to distinguish putrid endometritis from puerperal septicemia.

#### DIFFERENTIAL DIAGNOSIS.

Symptoms compared.	Forms of endometritis compared.	
	Septic puerperal endometritis.	Putrid endometritis.
Onset . . . . .	Sudden with chill	Gradual, with or without chill
Temperature . . . . .	High and continuous	Maximum early, with subsequent fluctuations
Pulse . . . . .	Rapid, thin, and later thready, 130 and over	Full and regular, rarely over 120
Discharge . . . . .	Scant and odorless, thin at first, and purulent later	Free and putrid
Microscope . . . . .	Streptocci or staphylococci pyogenes	Saprophytic bacteria
Interior of uterus . . . . .	Smooth, no debris present	Ragged, debris present

**Treatment.**—The cervix should be dilated and the cavity of the uterus thoroughly explored with the finger. All debris should be removed, rough surfaces curetted, a copious saline irrigation given, and the uterus firmly packed with 10 per cent. iodoform gauze, which should not be removed too early, about the third to ninth day. Stimulation when indicated.



Free catharsis and a liquid diet until the temperature becomes normal.

**Chronic Endometritis.—Definition.**—A chronic inflammation of the uterine mucosa characterized by marked hypertrophy of the mucous membrane.

**Pathology.**—The endometrium is much thickened and vascular. The glandular elements are increased, and the intercellular substance is thickened by exudation. Several **different varieties** are recognized: a glandular, interstitial, mixed, and the fungoid variety of Olshausen. Ultimately the mucosa becomes atrophied, the ciliated and cylindrical epithelium are lost, and finally, the mucous membrane disappears entirely, to be replaced by a layer of connective tissue.

**Etiology.**—Chronic endometritis is occasionally the result of the acute form, but most frequently arises independently. Subinvolution of the uterus following parturition, and displacements of the uterus, are the most frequent causative factors. Foreign bodies in the uterus and direct injuries, or infections, may give rise to chronic endometritis. A senile form exists coming on after the menopause.

**Symptoms.**—Menorrhagia, dysmenorrhea, leucorrhea, pain in the back, pelvis, and loins, with sterility, or habitual abortion.

**Diagnosis.**—Generally to be made from the clinical symptoms, of which increased duration of the menstrual flow, with a prolongation over the intermenstrual period, is the most constant. To **differentiate endometritis** and **malignant disease** in its early stages is of paramount importance, and for this purpose the curette is invaluable. The scrapings removed and examined under the microscope will often show the lesion present, and determine the diagnosis.

**Local Treatment.**—A thorough vaginal, and in virgins rectal, examination should be made, and any displacement of the uterus corrected and foreign bodies, such as polypi and fibroids, removed. Subinvolution calls for prolonged hot douches daily and tampons of boroglyceride, or, where there



is much pain, ichthyol, 10 per cent. in glycerin. These should be inserted high into the vagina, behind the cervix, three times a week, and allowed to remain twenty-four hours. Where hemorrhage is a prominent symptom, curettage affords the best hope of effecting a cure; but where the discharge is mucopurulent in character, intra-uterine medication is necessary. This may be given independently of, or follow the curettage. The interior of the uterus and cervical canal are thoroughly and carefully swabbed with caustic solution, such as pure carbolic acid, or, better, Churchill's tincture of iodine. Subsequent applications may be required. The preliminary use of the curette is desirable. Cauterization of the mucosa by steam is useful in severe hemorrhagic cases.

**Constitutional treatment** must be carried out as well, and proper attention should be given to the bowels and daily hygiene.

## METRITIS.

**Definition and Varieties.**—Metritis is an inflammation of the muscular walls of the uterus, and is either acute or chronic.

**Acute Metritis.**—**Pathology.**—There is marked enlargement of the uterus, its walls are thickened and soft, with enlarged veins, and an infiltration of the muscular tissue with pus corpuscles. The endometrium is thickened and vascular, while the outer peritoneal surface is covered with plastic exudate.

**Etiology.**—Metritis is caused by extension of the inflammation in acute endometritis. It is most commonly seen in puerperal sepsis and acute gonorrhea.

**Symptoms.**—Fever and elevation of the pulse in direct proportion to the severity of the infection are present. Menstruation is usually diminished and may be suppressed. Pelvic pain is constant and aggravated by motion and on emptying the bladder and rectum. Many of the symptoms are those of the primary disease (see Acute Endometritis).



**Diagnosis.**—Metritis is usually accompanied by acute endometritis and pelvic peritonitis. It rarely exists alone. Abscess formation is the most serious complication and its possibility should always be borne in mind. Vaginal examination shows a large tender uterus, with more or less restriction of mobility.

**Treatment.**—Much that has been said under the treatment of acute endometritis applies here. The cause should be sought and removed. Curettage and irrigation of the uterine cavity, where it contains infecting material, is indicated. Where the metritis is a complication of pelvic peritonitis the treatment must be largely medical. Absolute rest in bed, hot turpentine stupes over the lower part of the abdomen, enemata—not purgatives—for the bowels, and opium suppositories when indicated. Prolonged hot (115°) vaginal douches of twenty minutes' duration are of great service, and should always be given when well borne by the patient.

**Chronic Metritis.**—**Pathology.**—There is an increase of connective tissue developed in the walls of the uterus, the muscular tissue remaining little if any changed. In the **first stage** the uterus is enlarged, soft, and hyperemic; in the **later stage** it becomes hard, indurated, and anemic. With the increase in thickness of the uterine walls there is an accompanying increase in the size of the uterine cavity.

**Etiology.**—Most of the cases of chronic metritis develop as the result of some interference with the normal postpartum involution of the uterus. The most potent factors are: retained placental tissues, blood clots, lacerations of the cervix non-lactation, too early rising after delivery, and frequent miscarriages. Prolonged venous stasis, the result of displacements, is an active etiological factor.

The **symptoms** usually date from a previous confinement or abortion. Weakness and pain in the back, irregular and increased menstruation, and leucorrhea. Repeated abortions may occur in the early stages, and sterility is the rule when the disease is well established.



**Diagnosis.**—On examination the uterus is found slightly enlarged, its cavity increased in depth, and the whole organ often fixed by adhesions in a retroverted or retroflexed position. To differentiate metritis from general fibrosis of the uterus, or small fibroid tumors, is often impossible, except by operation. Great care is at times necessary, however, to distinguish metritis from early pregnancy, the possibility of which should always be borne in mind and the sound never used except directly after menstruation. In pregnancy the uterus is soft, elastic, and shows progressive enlargement; menstruation is absent. In chronic metritis the uterus may be soft or hard, but is usually firm and non-elastic, constant in size, with the exception of a slight increase preceding menstruation, and which subsides as the pelvic congestion wanes.

**Treatment.**—Displacements must always be corrected when possible, and pelvic circulation stimulated by prolonged hot vaginal douches, a daily laxative for the bowels, and tampons of boroglyceride every other day. For the menorrhagia, fluidextract of ergot,  $\text{mxx}$ , every three hours, is indicated. In many cases styptol (neutral cotarnine phthalate), in  $\frac{3}{4}$ -grain doses given every three hours, is of value. Tincture of iodine to the cervix and vaginal vault during the intermenstrual period is of service. Lacerations of the cervix may call for repair.

## SUPERINVOLUTION OF THE UTERUS.

**Definition.**—An acquired atrophic condition of the uterus following childbirth or miscarriage.

**Pathology.**—The uterus is much smaller than normal. Its walls are thin and of dense fibrous consistency and its mucous membrane scanty, or absent entirely. There is usually an accompanying atrophy of the ovaries. The cervix is small, hard, and nearly or quite flush with the vaginal vault. The os is contracted.



**Etiology.**—The frequency of this condition has been estimated at from 1 to 2 per cent. Prolonged lactation, anemia, tuberculosis, and puerperal sepsis are supposed causes. It may be produced by too frequent and too energetic curettage.

**Symptoms.**—Sterility, amenorrhea, and neurasthenia.

**Diagnosis.**—A small, flat, pale cervix is at once suggestive. The fundus is proportionately small and only located with difficulty. It may be necessary to pass a sound in order to demonstrate its presence.

**Treatment.**—Unsatisfactory. Iron and constitutional treatment should be employed.

The **prognosis** is most favorable in those cases due to protracted lactation. Atrophy resulting from puerperal sepsis is incurable.

---

## CHAPTER VII.

### MALIGNANT DISEASE OF THE UTERUS.

THERE are two **principal types** of malignant disease of the uterus, viz., epithelial and connective tissue: carcinoma is an example of the former, and sarcoma of the latter. Two **rare forms** exist—adenoma malignum and deciduoma malignum.

As we find the cervix differing anatomically from the body of the uterus, so we expect to find distinct pathological differences as well. While fibroid tumors are common in the body of the uterus, they are rare in the cervix. In carcinoma the cervix is the seat of the disease in 95 per cent. of all cases, while the fundus is rarely involved.

### CARCINOMA OF THE CERVIX.

**Definition.**—Carcinoma is a malignant disease of the neck of the uterus.

**Pathology.**—There are two types of carcinoma of the cervix, according to whether the disease develops on the external,



or internal aspect of the cervix. The **external form** originates in the deeper layer of squamous cells covering the vaginal aspect, and the resulting proliferation of the epithelium forms a mushroom-like tumor projecting into the vagina—the so-called epithelioma. The **internal or glandular cancer** originates from the cervical glands or epithelium lining, the cervical canal, and the proliferating epithelium extends into the gland, or the connective tissue, as the case may be. Thus, a tubular structure is found having a lumen covered by several layers of epithelial cells. The type of cell arrangement follows in general that of a gland, only the arrangement is in layers without definite order.

The disease may begin in one of **three clinical forms**: (1) As hard nodules lying under the mucous membrane. These increase in size, work their way to the surface, and ulcerate. (2) Beginning inside the cervical canal, the disease works along the mucous membrane excavating the canal. (3) As an ulcerating surface on the vaginal aspect of the cervix, or as an irregular tumor of papillary growth projecting into the vagina. Only in the early stages can these three clinical forms be differentiated; later they become indistinguishable. The growth spreads either downward into the vagina, up into the uterus, or laterally into the connective tissue of the pelvis. The first two are the more favorable for operative treatment; the latter offers the greatest difficulties. Dissemination of the growth takes place through the lymphatics into the lumbar, iliopelvic, and inguinal glands. The latter are rarely affected, but the iliopelvic are frequently involved, and may be readily palpated *per rectum* when much enlarged. In the late stages involvement of the neighboring organs is common, so that vesicovaginal and rectovaginal fistulæ often result.

**Etiology.**—The immediate etiology is as yet unknown. Heredity, age, and lowered vital powers are general predisposing causes, while erosions and lacerations of the cervix are supposed to act as local exciting causes.

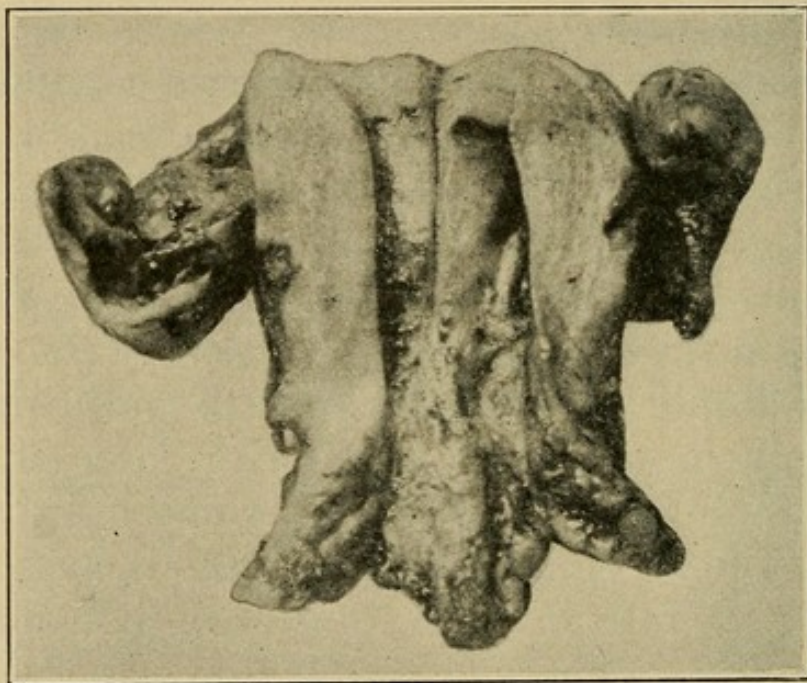


**Symptoms.**—Hemorrhage is the early and all-important symptom. Its significance should never be underestimated. After the menopause it is almost always pathognomonic of cancer. Later, an offensive serosanguinous discharge develops, with loss of weight and general debility.

Pain is not an early symptom, appearing only after the disease has spread to the surrounding tissues.

**Diagnosis.**—**Vaginal examination** shows an enlarged thickened cervix and on one or both lips an ulcerated surface or a

FIG. 21



Carcinoma of the cervix.

distinct tumor, bleeding readily upon manipulation. A section of this tissue examined under the microscope will generally determine the diagnosis.

In advanced cases induration in the broad ligaments and restriction of the normal mobility of the uterus, with enlargement of the iliopelvic glands, may be made out.

**Treatment.**—In recent cases early operation, as soon as the diagnosis is made, offers the only hope of cure. The operation should be of radical character, and calls for the removal of the uterus, appendages, and as much of the broad ligaments and



upper third of the vagina as possible. It is advisable often to remove the iliopelvic and lumbar glands as well.

In old cases advanced beyond the stage of radical operation, where there is profuse hemorrhage, ligation of the internal iliac, round ligament, and obdurator arteries will control this distressing feature, and by shrinking the growth relieve much of the pelvic pain. Ergot and adrenalin internally, with an intra-uterine tampon of adrenalin gauze, are valuable palliative measures in hemorrhagic cases. When the discharge is very offensive, daily vaginal douches should be given—bichloride (1 to 2000) or Condy's fluid.

R <sub>y</sub> —Potassium permanganate . . . . .	53 parts.
Alum sulphate crystals . . . . .	333 “
Hot water . . . . .	777 “

The pain may only be controlled by the free administration of opium, which should be deferred as long as possible.

## CARCINOMA OF THE FUNDUS OF THE UTERUS.

**Definition.**—A malignant disease of the body of the uterus.

**Pathology.**—A rare disease, found in only about 2 per cent. of all cases of uterine cancer; starting either in the epithelium of the mucosa or the glands. It develops as a diffuse or nodular growth.

**Etiology.**—Unknown. Is more frequent in non-parous women than in those who have borne children.

**Symptoms.**—Pain, hemorrhage, and fetid discharge. The first two are usually present early in the disease.

**Diagnosis.**—The uterus is enlarged and more often found freely movable than in carcinoma of the cervix. Vaginal examination shows a normal cervix, with a slight dilatation of the canal. Certainty of diagnosis should be established, if possible, and the condition differentiated from deciduoma malignum, sloughing fibroid, or retained placental tissue.



For this purpose the cervix must be dilated, the uterine cavity explored with the finger, and curettings removed for microscopic examination.

**Treatment.**—Complete early extirpation of the uterus. When this is done the chances of obtaining a cure are better than in carcinoma of the cervix.

### SARCOMA OF THE UTERUS.

**Definition.**—A malignant, connective-tissue tumor of embryonic type.

**Pathology.**—Sarcoma, differing from carcinoma, rarely develops in the cervix. Two forms are recognized, viz., a diffuse and circumscribed. The **diffuse form** is a growth of the mucosa arising in the subepithelial connective tissue, and characterized by an infiltration of round cells, rarely of spindle cells. The mucous membrane is swollen, becomes soft and friable, and often breaks down. The **circumscribed form** originates in the muscular walls of the uterus, and may be submucous, interstitial, or subperitoneal. The tumor much resembles a fibroid in feel and appearance. Secondary nodules occur in the vagina and peritoneum.

**Etiology.**—Little is known as to the etiology. Most frequent between the ages of forty and fifty. Sterility seems to be a factor.

**Symptoms.**—Hemorrhage is an early symptom, with a thin, watery discharge having little or no odor. Pain is infrequent.

**Diagnosis.**—When the tumor presents at the external os as a soft, friable mass, diagnosis is easy. If limited to the uterine cavity the cervix must be dilated, the uterus explored, and curettings taken for microscopic examination.

The uterus is enlarged, forming a distinct tumor, and though movable at first, early becomes fixed. Differential diagnosis from carcinoma, deciduoma malignum, and intra-uterine fibroid is often difficult.



**Treatment.**—As in carcinoma, the treatment must be radical, and complete removal of the uterus and appendages practised. Curetting is of avail only as an aid to diagnosis.

### DECIDUOMA MALIGNUM.

**Definition.**—A malignant disease of the uterus developing in the puerperium.

**Pathology.**—The uterus is enlarged, its cavity gangrenous when the tumor breaks down, and secondary growths occur in the cervix and lungs. The tumor consists of islands of multinucleated large cells, surrounded by loose tissue containing individual cells, and penetrates the muscular wall of the uterus. Metastases in distant organs are a common feature.

**Etiology.**—Develops shortly after delivery, abortion, or hydatid mole. The clinical resemblance to sarcoma suggests that it may be an ordinary sarcoma modified by pregnancy, or developed from the products of conception.

**Symptoms.**—Hemorrhage is usually the first symptom, and is followed later by a foul discharge and fever. The course of the disease is rapid, and secondary growths in the vagina and labia may be the first symptoms to attract attention.

**Diagnosis.**—Absolute, from the examination of tissue removed by the curette. The uterus is found enlarged and oftentimes increases rapidly in size. Metastases in the lungs, vagina, liver, and spleen are frequent. The disease is one of short duration, death occurring in from two to six months.

**Treatment.**—Success can only be obtained by complete removal of the uterus and appendages before metastases have developed. The mortality is over 50 per cent.



## CHAPTER VIII.

### BENIGN TUMORS OF THE UTERUS.

#### FIBROMYOMATA.

**Definition.**—Non-malignant newgrowths of the uterus.

**Frequency.**—Of all the newgrowth formations of the uterus, the fibromyomata are most often encountered. Various observers estimate their frequency at from 20 to 40 per cent. in all women over thirty-five years of age. Contrasted with cancer, they show marked differences, not without interest. Appearing early in life, they attack the well-to-do; are more common in sterile women, and rarely endanger life except by complications.

**Pathology.**—Occur more often in the body than in the cervix of the uterus. When located in the body, the posterior wall is the common site. They are composed of non-stripped muscular fiber and fibrous tissue, are of firm consistency, and a cut section presents a pale, glistening, uneven surface. A capsule of loose fibrous tissue generally surrounds the growth. Few bloodvessels penetrate the tumor, nutrition being derived from the surrounding tissues, which are extremely vascular.

Slow growth, in direct proportion to the predominance of the fibrous over the muscular tissue, is the rule, but during pregnancy a rapid increase in size is often observed. In the puerperium they become smaller as the uterus involutes. An arrest in development, and often marked decrease in size, may take place after the menopause, but this is variable and may not be counted on.

**Varieties.**—All fibromyomata begin as interstitial or intramural growths, but with increase in size project either into the walls of the uterus, or toward the mucous or peritoneal surface. Three varieties are, therefore, recognized—interstitial, submucous, and subperitoneal.



**Interstitial fibromata** remain in the substance of the uterine wall, are usually multiple, varying in size.

FIG. 22

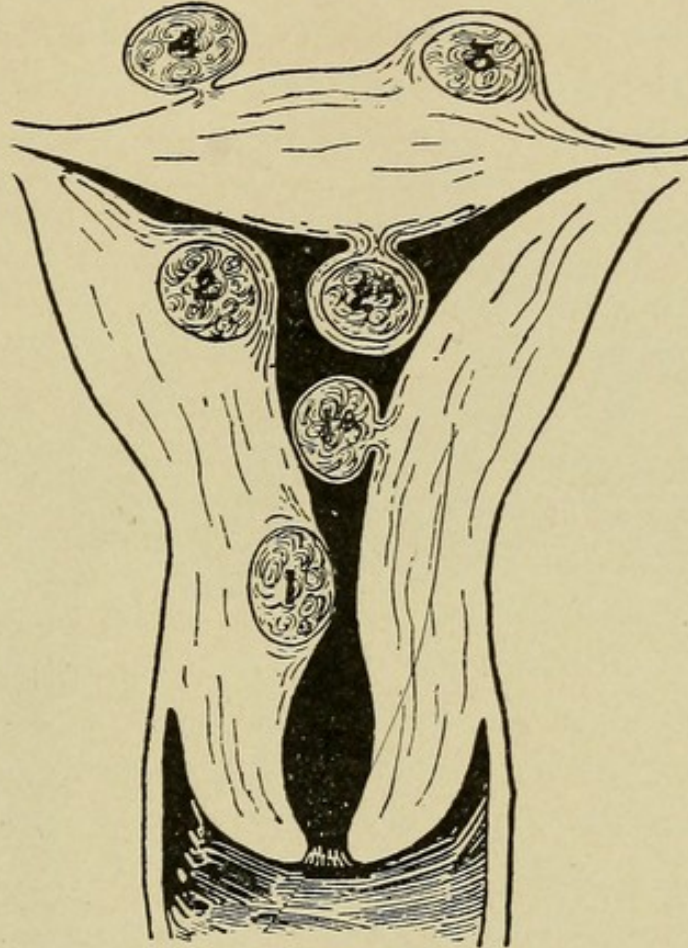
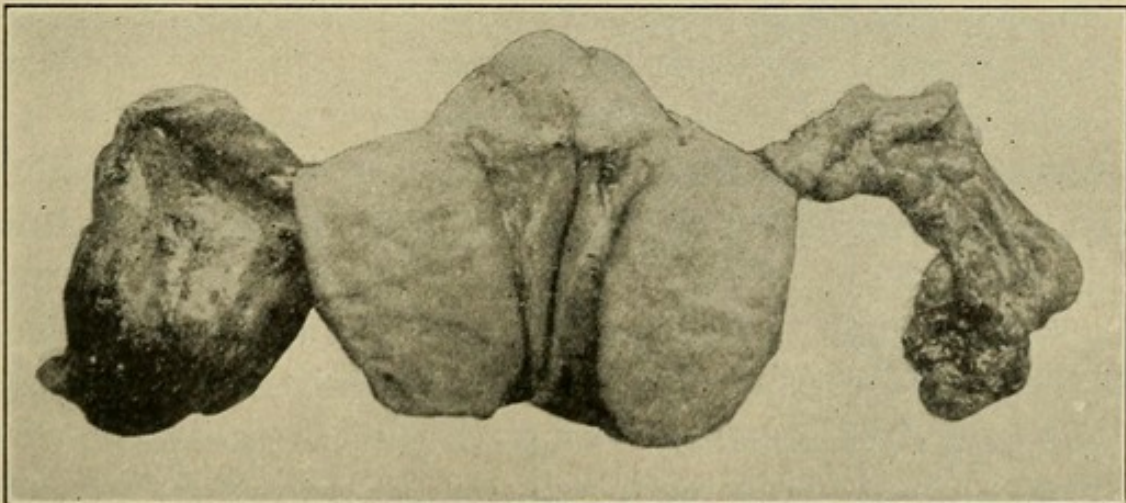


Diagram of growth of uterine fibroids: 1, 1*a*, free submucous; 2, 2*a*, encapsulated submucous; 3, encapsulated subserous; 4, free subserous. (Allbutt.)

FIG. 23

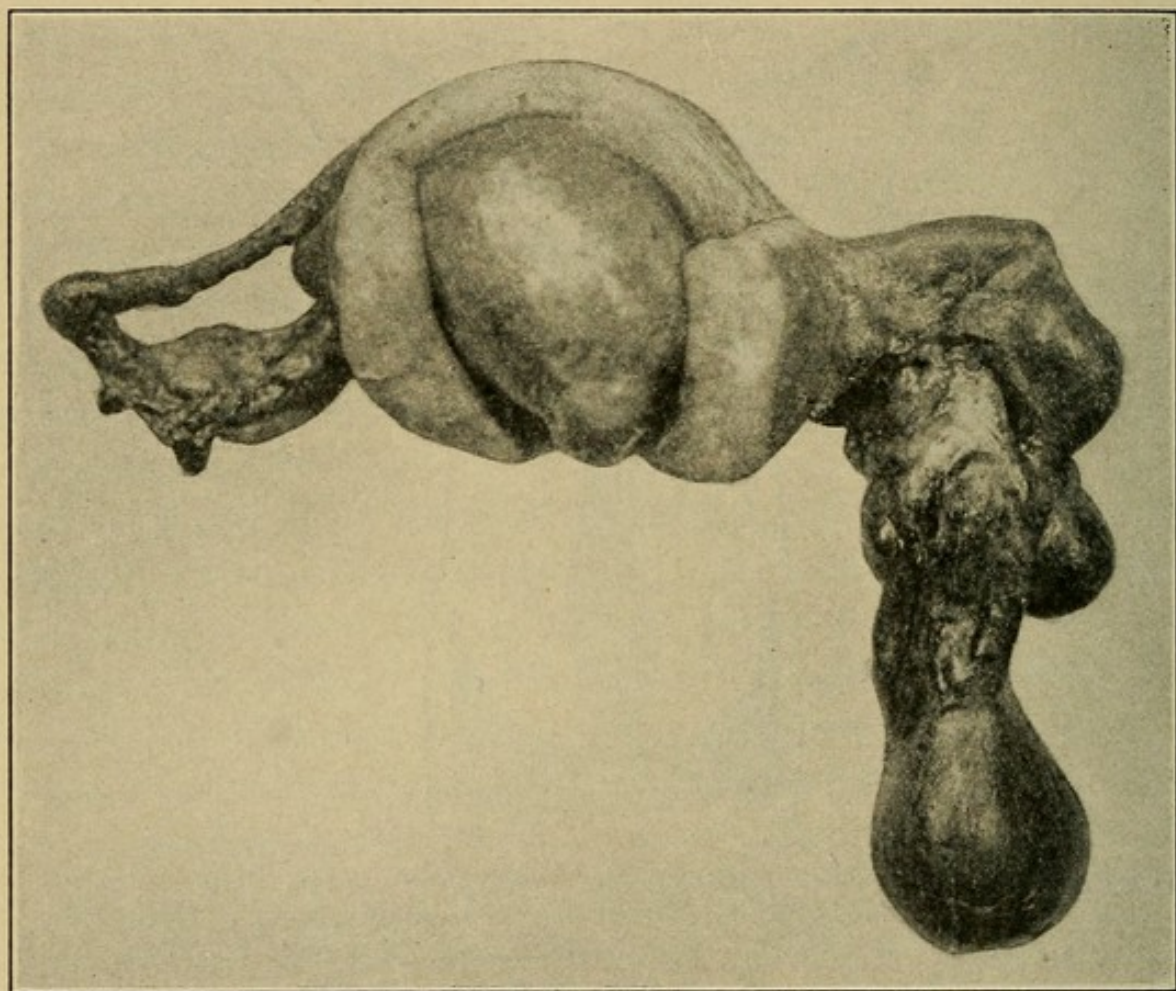


General uterine fibrosis, showing great thickening of the uterine walls.



**Submucous fibromata** project into the cavity of the uterus, being covered by the mucosa, are attached to the uterus by a broad base, or pedicle and sometimes undergo spontaneous amputation and expulsion from the uterus.

FIG. 24



Intra-uterine fibroid, small pyosalpinx. Large cyst of Morgagni and general uterine fibrosis.

**Subperitoneal fibromata** project outward into the peritoneal cavity, are covered by peritoneum, and generally pedunculated.

Marked changes in the size and position of the uterus occur with these different varieties. In the interstitial and submucous types the muscular hypertrophy in the walls of the uterus is marked, while with pedunculated fibroids the uterus often remains normal in size, but is frequently displaced.



The fibromyomata during their lifetime are often the seat of many changes. Although steady growth in the original pathological direction is the rule, necrosis, fatty or myxomatous degeneration may intervene, producing a marked softening, while calcification may change the tumor to a hard, stone-like mass—the womestone of the ancients. Suppuration is an occasional complication. Whether malignant degeneration ever develops is still a disputed point. Twist of the pedicle with resulting necrosis of the tumor may occur.

**Etiology.**—Of the causes of fibromyomata we know very little. A generous vascular supply seems to be necessary to their growth and continued development, and they seldom arise before puberty, or after the menopause. Between the ages of thirty and forty is the time of greatest activity.

**Symptoms.**—These are in direct proportion to the size and location of the tumor. Large subperitoneal tumors with plenty of room in which to grow may not cause any symptoms for a long time, while small submucous tumors, and those low down in the cervix, produce early disturbance. The more usual symptoms are dysmenorrhea, menorrhagia, sterility, and abortion. Pain is caused by the size and weight of the tumor, and by pressure on the bladder, rectum, and nerves. Hemorrhoids, varicose veins of the legs and edema appear as the result of interference with the venous circulation. Elevation of temperature and pulse is seen where necrosis and suppuration develop. Death rarely results from the tumor *per se* except when complications arise. Intestinal obstruction, resulting from the pressure of a fibroid in the pelvis, is a rather rare though easily recognized complication.

**Diagnosis.**—Is easy or difficult, depending on the size of the tumor. The small fibroids, unless submucous or subperitoneal, are difficult of recognition. When projecting into the uterine cavity, **digital exploration** will locate a tumor of hard consistency springing from the wall of the uterus. The subperitoneal type, even when quite small, may be readily



palpated through a thin abdominal wall. The interstitial variety produces a condition resembling general uterine enlargement, and must not be confused with early pregnancy; when, however, the soft character of the tumor, with other accompanying signs of pregnancy should clear the diagnosis. The large fibromyomata extending above the pelvic brim are easy of recognition. Inspection shows an enlargement of the abdomen differing in contour from either pregnancy or ovarian cyst; while palpation gives a firm, solid tumor springing from the pelvis in the median line. Intermittent contractions are absent, except in the very soft variety, and auscultation fails to reveal a fetal heart. On **vaginal examination** the cervix is hard and high up, while in pregnancy it is soft, and in ovarian cyst normal in consistency and usually low down. If the fibroid is pedunculated, **bimanual examination** may distinguish the uterus distinct from the tumor. Where it is impossible to rule out pregnancy, a waiting policy should always be adopted. It is very rare to have cessation of menstruation with fibromyoma, but the possibility of pregnancy in a fibroid uterus must always be borne in mind. The most common error in diagnosis is to mistake a normal pregnant uterus for a soft fibromyoma, and the following summary may aid in making a differential diagnosis:

*Fibromyoma.*

Consistency constant, though intermittent contractions may occur, giving slight variations.  
Cervix never soft, generally hard.  
Fetal heart sounds absent.  
Fetal movements absent.  
Menstruation increased in quantity or unaffected.

*Pregnancy.*

Consistency varies, and intermittent contractions are always present.  
Cervix always soft.  
Fetal heart sounds present.  
Fetal movements present.  
Menstruation absent.

When fetal death has occurred it may be impossible to make a correct diagnosis, but when doubt exists, wait.

**Treatment.**—Many fibromyomata live a symptomless existence calling for little in the way of treatment, either



palliative or radical. Operative removal should, as a rule, be resorted to, however, when the symptoms are pressing, for palliative measures have little or no effect in checking the growth of the tumor. The menorrhagia may be controlled for awhile by the administration of ergot in increasing doses, and suprarenal extract often proves of value. The indications for operative removal may appear early in cases of submucous fibroids, whereas the subperitoneal form often reaches enormous size before the patient applies for treatment. Curetting may improve the menorrhagia for a time by removing the diseased endometrium usually present, but is of only temporary benefit. Removal of the ovaries, producing an artificial menopause, with the idea of checking the bleeding and stopping the growth of the tumor, has been practised with favorable results in small fibroids, but removal of the tumor itself would probably have been the simpler operation. Ligation of the uterine arteries is of service in cases of severe bleeding, where removal of the tumor, on account of the age or condition of the patient, is impracticable, but should not be performed when there is reason to suppose that the tumor is undergoing necrosis.

**Indications for Operation.**—Actual size of the tumor, pressure symptoms, necrosis, suppuration, and persistent hemorrhage. Location has much to do with determining operation, as in intra-uterine, pedunculated growths, and those low down in the cervix obstructing the pelvic outlet.

Removal may be carried out by either the **abdominal** or **vaginal route**. The submucous pedunculated fibroids are easily removed, after dilating the cervix, by ligating or twisting the pedicle. On opening the peritoneal cavity the condition present should be carefully studied and every effort made to preserve the uterus where possible. Myomectomy should be the rule and the uterus never sacrificed, except when advanced general fibrosis of its walls exist.



### ADENOMYOMA.

**Definition.**—A tumor composed of glandular and muscular tissues.

**Pathology.**—Adenomyomata are probably the result of infiltration of a fibromyoma by glands from the endometrium, and are of uncommon occurrence. The glands are normal uterine glands confined entirely to the newgrowth and showing no tendency to invade the normal muscular tissue. The adenomyomata are, as a rule, intramural growths, have no capsule, and are situated most often at the tubal angles, and in the posterior wall of the uterus. Three varieties are recognized—diffuse, subperitoneal, and interligamentary.

**Etiology.**—Unknown.

**Symptoms.**—Depend on the size and situation of the tumor. When diffuse, it is common to find a history of lengthened menstrual periods, accompanied by dull, grinding pain in the back and pelvis, often extending down the legs. As the condition advances severe hemorrhages occur, becoming more and more frequent, and at times continuous bleeding is present. In the nodular form symptoms are often absent.

**Diagnosis.**—Difficult to distinguish from fibromata. Where frequent and increasing hemorrhages are associated with a hard and enlarged uterus, adenomyoma may be suspected. In the subperitoneal and ligamentous variety accurate diagnosis is impossible except at operation. **Vaginal examination** shows a cervix nearly, if not quite, normal and a hard enlarged uterus generally fixed by adhesions as the disease advances.

**Treatment.**—Hysterectomy is indicated. Myomectomy is not practical on account of the diffuse nature of the growth.

### UTERINE POLYP.

**Definition.**—A pedunculated tumor attached to the uterine mucous membrane.



**Pathology.**—Distinction should be made from the pedunculated submucous fibroids which grow from the muscular wall of the body of the uterus. The mucous polypi are developed from the mucous membrane, are of soft, pulpy consistency, extremely vascular, and have the same microscopic structure as the mucous membrane from which they are derived.

**Etiology.**—Unknown.

**Symptoms.**—These are hemorrhage, dysmenorrhea, leucorrhea, endometritis, and sterility.

**Diagnosis.**—When the polypus presents at the external os it may be readily recognized as a small, highly vascular growth, bright red in color, and soft in consistency. When not seen at the os the cervical canal must be dilated and explored. From pedunculated fibroids the diagnosis is made by the small size, soft consistency and extreme vascularity.

**Treatment.**—Operative removal. Dilate the cervix if necessary, grasp the polyp with a heavy pair of forceps, twisting the pedicle until the tumor comes away. Ligation and division of the pedicle may be practised when the tumor is within easy reach. After the removal of the polyp the uterus should be curetted and packed with gauze.

## TUBERCULOSIS OF THE UTERUS.

**Primary tuberculosis of the uterus** is rarely encountered. The cervix may be involved independently of the body, but origin at the fundus with extension downward is more common. Ulceration begins in the endometrium, all tissues of the uterus being eventually involved. **Secondary tuberculosis of the uterus** is not uncommon in general tuberculous infection.

**Symptoms.**—None that are pathognomonic. There is usually a profuse and purulent leucorrhea, with occasional hemorrhage. Tubercle bacilli may be found in the granulation tissue discharged, or removed by the curette.



**Diagnosis.**—Difficult to make from cancer except when the *tubercle bacilli* are found.

**Treatment.**—High amputation of the cervix or complete removal of the uterus, dependent on the extent of the disease.

### SUBINVOLUTION OF THE UTERUS.

**Definition.**—Incomplete involution of the uterus following miscarriage or labor.

**Pathology.**—The endometrium is thickened by glandular hypertrophy, the muscle cells are enlarged, the lymphatics distended, and the bloodvessels engorged.

**Symptoms.**—Premature return of menstruation or menorrhagia, dull, heavy feeling in the pelvis, backaches, and leucorrhea.

**Diagnosis.**—On examination the uterus is found to be large, soft, low down in the pelvis and often retroposed.

**Treatment.**—Displacements should be reduced and a proper pessary inserted. Recent cases yield readily to the depleting action of boroglyceride or ichthyol tampons three times a week, with prolonged hot vaginal douches at bedtime. Ergot, though generally recommended in subinvolution, should not be given to nursing mothers because of its tendency to diminish or stop the flow of milk. Curettage is indicated in cases of long standing.

---

## CHAPTER IX.

### DISEASES OF THE FALLOPIAN TUBES.

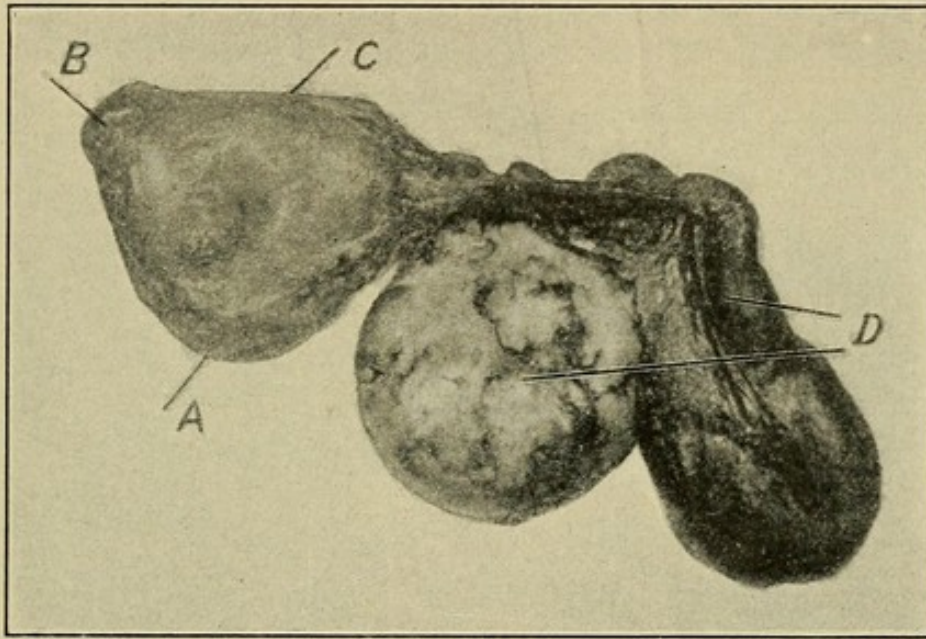
**Abnormalities** are of infrequent occurrence, and seldom call for treatment. Congenital absence of one or both tubes, defective development, accessory fimbriated end, and hernia



of the tube, either inguinal, femoral, or obturator, have been observed.

The most important **pathological conditions** met with are the inflammations which are usually due to microorganisms, of which the gonococcus is the most common. The acute exanthemata (scarlet fever, diphtheria, measles, etc.) are responsible for some cases.

FIG. 25



Congenital absence of the right tube and ovary: A, uterine canal divided at internal os; B, right horn of uterus; C, fundus; D, left cystic ovary and pyosalpinx.

## SALPINGITIS.

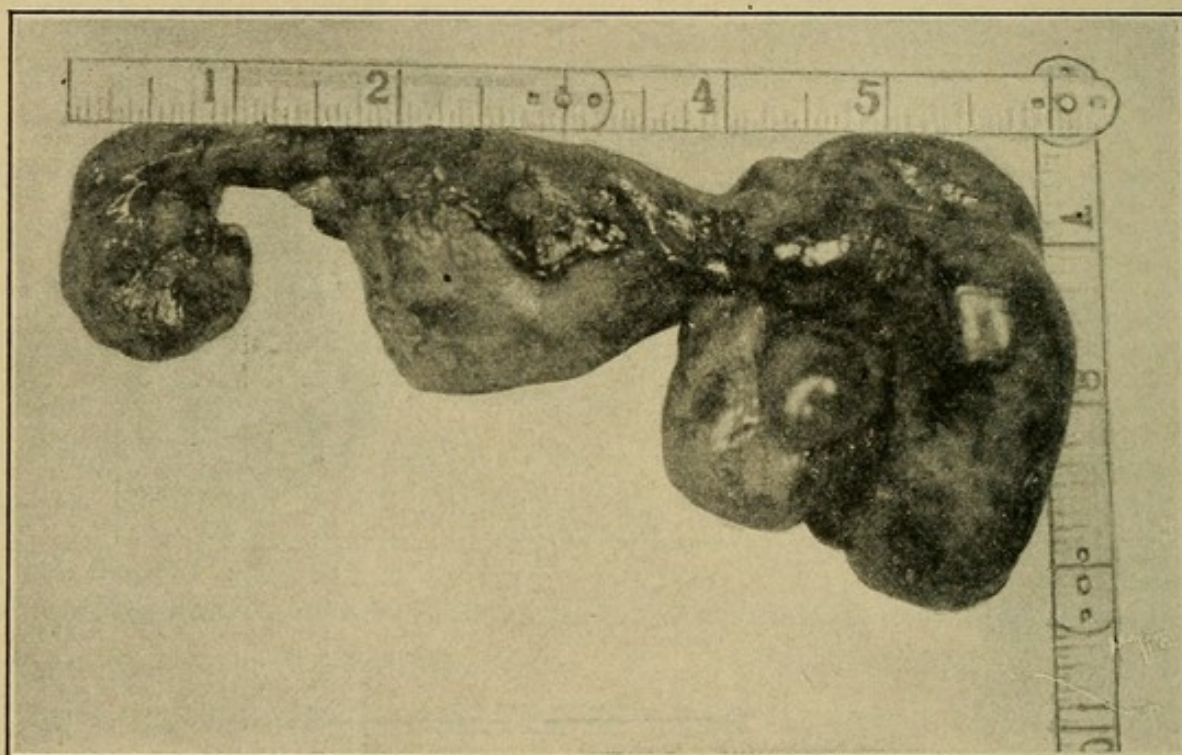
**Definition.**—An inflammation of the tube, either acute or chronic.

**Pathology.**—The tubal tissues become swollen, the result of small-cell infiltration; the tube, as a whole, thickens with exaggeration of its normal “kinks.” The distal end may become closed, forming a club-shaped tube. When the inflammation runs into the purulent stage the fimbriated end is usually closed by adhesions, the pus accumulates in the tube and a **pyosalpinx** is produced. In cases of long standing the pus is absorbed or degenerates into a thin, watery fluid, forming a **hydrosalpinx**. **Adhesions** may or may not form



between the tube and neighboring viscera. If a pyosalpinx adhering to a cystic ovary perforates at the point of adhesion, pus may escape into one of the cysts and a **tubo-ovarian abscess** result. **Perforation** and **evacuation** may take place into the bladder or intestines. Occasionally a pus tube drains spontaneously by way of the uterine cavity and vagina. Pus infection in the tube usually leads to complete destruction of its normal epithelium, and the mucosa and muscular coat are eventually represented by fibrous tissue.

FIG. 26



Pyosalpinx.

Complete regeneration and restoration of function often occurs in mild infections, the abdominal end of the tube remaining patent.

**Etiology.**—Salpingitis is usually caused by invading micro-organisms from the uterus. Wertheim gives the following percentages, drawn from 376 cases:

	Per cent.
Gonococci . . . . .	20.2
Streptococci or staphylococci . . . . .	13.2
Pneumococci . . . . .	1.8
Bacillus coli . . . . .	0.7



**Symptoms.**—Following a septic or gonorrheal infection in the uterus or vagina the patient complains of pain in the region of the tube, aggravated by exercise or long standing. Where the condition is acute, elevation of temperature and pulse are observed, with occasionally nausea and vomiting. The symptoms of chronic salpingitis are those referable to adhesions and congestion, the most prominent being continuous pain in the region of the tube. Menorrhagia and dysmenorrhea are fairly constant symptoms.

**Diagnosis.**—From the history is elicited the fact of a recent septic or gonorrheal infection. Vaginal examination discloses marked tenderness and resistance in the lateral or posterior fornix, according to the acuteness of the disease. In chronic salpingitis the thickening of the tube may be felt. Where a pyosalpinx or tubo-ovarian abscess has formed it is possible to map out a distinct tumor by the side of or posterior to the uterus. In right-sided salpingitis it is important to distinguish from appendicitis, and the following summary of respective symptoms may be of service:

*Acute Salpingitis.*

Previous gonorrheal or puerperal infection.  
Gradual onset of pain, dull, continuous, and radiating in character.  
Elevation of temperature and pulse slight and variable.  
Muscular rigidity absent unless peritonitis exists.  
Vaginal examination always painful.  
Nausea and vomiting unusual.

*Acute Appendicitis.*

No previous local disturbances.  
Sudden onset, pain acute and localizing in right iliac region.  
Elevation of temperature and pulse marked and constant.  
Muscular rigidity pronounced on right side of abdomen.  
Vaginal examination seldom painful.  
Nausea and vomiting usual.

The appendix is involved secondarily in about 20 per cent. of purulent infections of the right appendages, but the inflammation is seldom acute.

**Treatment.**—Varies materially according to the stage of the disease.

**Acute Salpingitis.**—Absolute rest in bed, prolonged hot vaginal douches, and hot-water bag to the affected side.



Morphine internally or opium suppositories when the pain is severe. The bowels should be kept well opened, and frequent vaginal examination is to be avoided.

**Pyosalpinx.**—Same as for acute salpingitis while in the acute stage. If the abscess shows a tendency to constant enlargement, an incision in the posterior vaginal fornix should be made and the tube opened and drained. After subsidence of the acute symptoms, operative removal of the tube will often be necessary.

**Tubo-ovarian Abscess.**—Here resolution seldom takes place and operative measures are the best treatment. Evacuation and drainage by the vaginal route offers reasonable hope of cure, and is always advisable where interference during the acute stage becomes necessary, or when there is a large accumulation of pus. Ablation of the diseased appendages is the accepted radical treatment, and may be performed by either the vaginal or abdominal route.

**Chronic Salpingitis.**—Where the symptoms are alone due to the inflammation in the tube, ichthyol (10 per cent.) and glycerin tampons to the posterior fornix three times a week do much to improve the condition. Extensive disease of the tube with adhesions usually calls for radical treatment by operation, necessitating removal of the tube or the separation of adhesions with resection of the diseased portion. Every effort should be made to conserve the function of the tube and resection, rather than complete removal, practised wherever it offers reasonable hope of leaving a patent canal.

### INFECTIOUS GRANULOMA.

**Definition.**—An infection of the tube, either syphilitic, actinomycotic or tuberculous, of which only the last is of practical importance.

**Pathology.**—The Fallopian tube is the most common seat of tuberculosis of the genital tract. It may be either primary or secondary to peritoneal tuberculosis. The changes pro-



duced are quite marked; the mucosa shows a round-cell infiltration with giant cells and bacilli, the whole tube is thickened, beaded, and in the late stages contains pus and caseous debris.

**Etiology.**—Infection by the tubercle bacilli. The source of invasion is not clear, probably through the blood by metastasis.

**Symptoms.**—Early cases show few symptoms. Menstruation is usually more frequent and profuse. Pain is not constant, and may be elicited only on examination. As the disease becomes advanced, local symptoms, the result of enlargement of the tube, appear.

**Diagnosis.**—Vaginal examination may show a thickened, nodular tube, or, where there is much distention with pus, a distinct tumor. Constant elevation of temperature and pulse are present in advanced cases. The presence of tuberculosis elsewhere in the body may aid in the diagnosis.

**Treatment.**—**Operation:** Removal by abdominal section where practical, but in advanced cases, with extensive adhesions and secondary pockets of pus, the operation will give the best results if not carried beyond the exploratory stage as in general tuberculous peritonitis.

**Neoplasms of the Fallopian tubes** are of rare occurrence. Papilloma, fibromyoma, lipoma, cystoma, carcinoma, and sarcoma have been met with. They are seldom diagnosed before operation, and the treatment is removal.

**Tubal Gestation.**—See Ectopic Gestation, p. 103.

---

## CHAPTER X.

### DISEASES OF THE OVARY.

As the result of **maldevelopment** one or both ovaries may be absent, or show only a **rudimentary development**. Occasionally a third ovary is present: **supernumerary ovary**.



### OVARITIS.

**Definition.**—An inflammation of the ovary, **acute** or **chronic**.

**Pathology.**—In the **acute form** the ovary is slightly enlarged, there is a proliferation in its connective-tissue elements and the peripheral follicles are distended with a turbid fluid or pus.

In the **chronic variety** the ovary may be small and cystic, there is destruction of the follicles, and a cirrhotic condition develops, giving rise to marked impairment of function. In **passive congestion of the ovary** slight enlargement is present.

**Etiology.**—Gonorrhea, septic infection from adjacent tissues, acute febrile diseases, mumps, and pelvic peritonitis. Prolapse of the ovary frequently gives rise to a condition of chronic inflammation.

**Symptoms.**—Pelvic pain, dysmenorrhea, menorrhagia, and dyspareunia.

**Diagnosis.**—On vaginal examination a large, tender ovary is found often prolapsed and lying in the posterior fornix. It glides under the finger and gives acute pain when pressed. Accompanying disease of the tube often makes a differential diagnosis difficult. It is well to remember that a certain degree of congestion and enlargement in the ovary is normal at the time of ovulation.

**Treatment.**—Ichthyol (10 per cent.) and glycerin tampons three times a week, with appropriate treatment of the bowels. In long-standing cases operative removal may be the only means of giving relief.

### DISPLACEMENTS OF THE OVARY.

**Varieties.**—The ovary may be found lying in the inguinal or femoral canal. Prolapse is the most frequent displacement.

**Prolapse of the Ovary.**—**Pathology.**—The ovary occupies a much lower level in the pelvis than normal, due to relaxation of the ovarian and infundibulopelvic ligaments. These may be



abnormally lax, or become stretched by increased weight of the ovary. Adhesions often form, fixing the ovary in its abnormal position.

**Etiology.**—Congenitally long and lax ligaments, or their subinvolution after parturition. Gravity acting on an enlarged heavy ovary, and posterior displacements of the uterus, in which the ovary follows the fundus backward.

**Symptoms.**—Radiating pains in the pelvis, pain on defecation and coitus, reflex nervous symptoms.

**Diagnosis.**—Bimanual examination fails to locate the ovary in its normal position, and a small, firm, tender body low down on the broad ligament or in the posterior fornix is found. Rectal examination will often give a clearer picture, and help in differentiating from fecal concretions, a frequent source of error.

**Treatment.**—Displacements of the uterus, when corrected, often bring the ovary into normal position. Boroglyceride tampons will aid in the involution of the ligaments, relieve the ovarian congestion, and often give marked relief. When the ovary is fixed by adhesions operation must be resorted to, the ovary restored to its normal position, and the relaxed ovarian ligament shortened.

## TUMORS OF THE OVARY.

The most common tumors of the ovary are the cystomata. Sarcomata and carcinomata are less frequently encountered. Stander estimates their relative frequency as follows:

	Per cent.
Cystadenoma . . . . .	69.49
Carcinoma . . . . .	13.56
Sarcoma . . . . .	6.78

The subject of ovarian tumor is exceedingly complex, and very difficult to treat in the abbreviated form necessary to a work of this character.



**Pathology.**—Probably the best classification is that of Pfannenstiel:

Class A. Tumors arising from the parenchyma of the ovary.

Class B. Tumors arising from the stroma.

Class C. Mixed tumors.

**Class A** consists of: 1. The **simple serous cysts**—usually monolocular, containing a sero-albuminous fluid and lined with a single layer of columnar epithelial cells.

2. **Adenomata**, the most common form of cystic tumor of the ovary, are composed of cyst and pedicle. The pedicle is formed by a drawing out of the broad ligament during the growth of the tumor. The cyst may eventually attain enormous size, is multilocular, and the contained fluid, thick and tenacious, is secreted by the lining epithelium.

3. **Papillomata**, which are characterized by papillary projections of connective tissue covered with columnar epithelium, may be situated either on the surface of the tumor or inside the cyst. The fluid contents are thin and serous.

4. **Dermoids and Teratomata**.—Dermoids arise from the germ layers, and are usually cystic in character. They contain relics of ectodermic origin (skin, hair, teeth, bones, etc.). The teratomata are solid dermoids, usually malignant in nature.

**Class B** consists of: 1. **Non-malignant solid tumors**—myoma, fibroma. They may involve the whole ovary, or only spring from it by a pedicle, and are usually of small size.

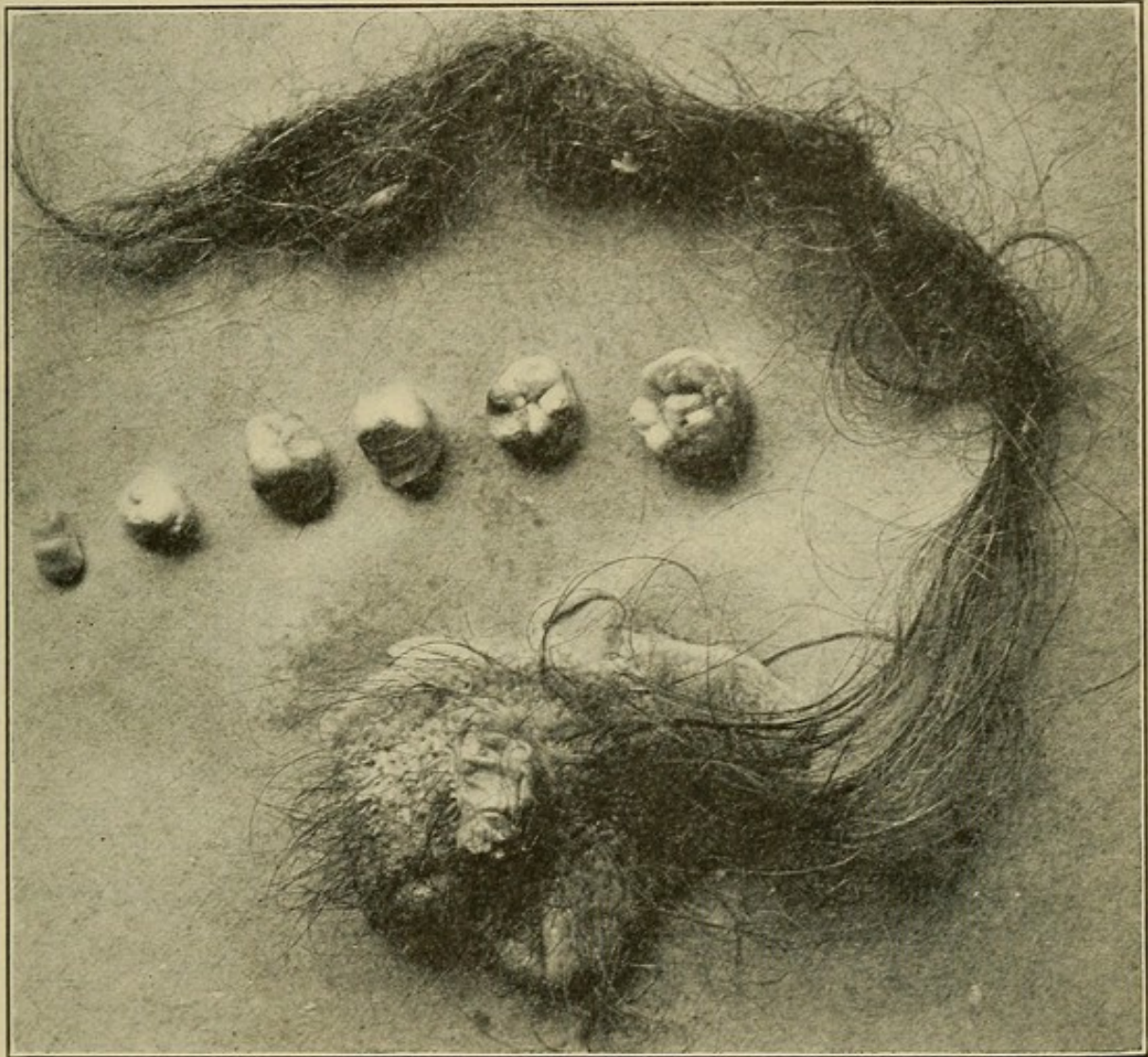
2. **Malignant tumors** frequently complicate cystic degeneration and also arise independently as primary sarcoma or carcinoma. The angiomata, enchondromata, and myxomata are rare. Tuberculosis is occasionally seen.

3. **Parovarian cysts** are unilocular tumors developed from the parovarium, are thin-walled, and contain a thin, watery fluid. They are commonly small, but may attain large size, cubical or squamous cells usually compose the lining membrane; ciliated cells are sometimes found.



**Class C** consists of: The association of dermoids, sarcomata, or carcinomata, with the multilocular adenomatous forms.

FIG. 27



Hair and teeth removed from a dermoid cyst of the ovary.

**Symptoms.**—These are in direct proportion to the size of the tumor, and rarely become acute, except in ovarian cysts, when torsion of the pedicle, suppuration, and septic or gonorrheal infection occurs. There is then pain with elevation of temperature and pulse due to local peritonitis.

**Diagnosis.**—The larger the tumor the more certain become the diagnosis. The small and medium-sized tumors are best made out by **bimanual examination**, which discloses a tense, rounded, hard, or fluctuating mass in the ovarian region.



The uterus, displaced downward and to one side, may usually be mapped out distinct from the tumor.

The large tumors are generally cystic and easily recognized. **Vaginal examination** shows the cervix depressed and the whole pelvis filled by a tense fluctuating mass. On abdominal examination the abdomen is seen more or less distended by a lateral or uniform swelling; palpation gives marked fluctuation, while on percussion there is dulness over the entire tumor unaffected by changes in position on the part of the patient. Confusion in diagnosis between ovarian cysts and free fluid in the peritoneal cavity (ascites) may arise, and the following tabulation by Findley will aid in distinguishing between the two:

ASCITES.	LARGE OVARIAN CYST.
DEVELOPMENT RAPID.	DEVELOPMENT SLOW.
<i>Inspection of abdomen, dorsal position.</i>	<i>Inspection of abdomen.</i>
Flattened anteriorly with bulging in the flanks.	Rounded anteriorly, flat in the flanks.
Umbilicus prominent.	Umbilicus not prominent.
<i>Percussion.</i>	<i>Percussion.</i>
Dulness in flanks.	Dulness over abdominal prominence.
Tympany in median area.	Tympany in flanks.
Change in area of dulness with change in position of patient.	Such change absent.
<i>Palpation.</i>	<i>Palpation.</i>
No tumor outline can be distinguished.	Tumor can be outlined.

**Treatment.**—The treatment of all ovarian tumors should be removal by operation, where no contra-indications exist. The presence of the tumor *per se* may not be incompatible with perfect health, but there is no tendency to spontaneous cure and serious complications often arise when least expected.



## CHAPTER XI.

### ECTOPIC GESTATION.

**Definition.**—Pregnancy outside the uterine cavity.

**Pathology.**—Impregnation of the ovum may normally occur at any point in its passage from the ovary to the uterine cavity, but arrest of the fertilized ovum before reaching the uterine cavity is pathological, and constitutes the condition known as extra-uterine gestation.

When permanent arrest occurs it is designated as primary, and when change of the position accompanies further development it is known as secondary.

Kelly gives the following table to show the changes which the primary form may undergo:

<i>Primary Forms.</i>		<i>Secondary Forms.</i>	
Interstitial . . . . .	may become	{	Intra-uterine.
		{	Abdominal (fetus dies).
		{	Intraligamentary (fetus dies).
		{	Mole (fetus dies).
		{	Abortion (fetus dies).
Tubal . . . . .	may become	{	Tubo-abdominal.
		{	Tubo-ovarian.
		{	Abdominal.
		{	Intraligamentary (fetus dies).
Ovarian . . . . .	may become	{	Abdominal (fetus dies).

Interstitial and ovarian implantations are rare; tubal is common.

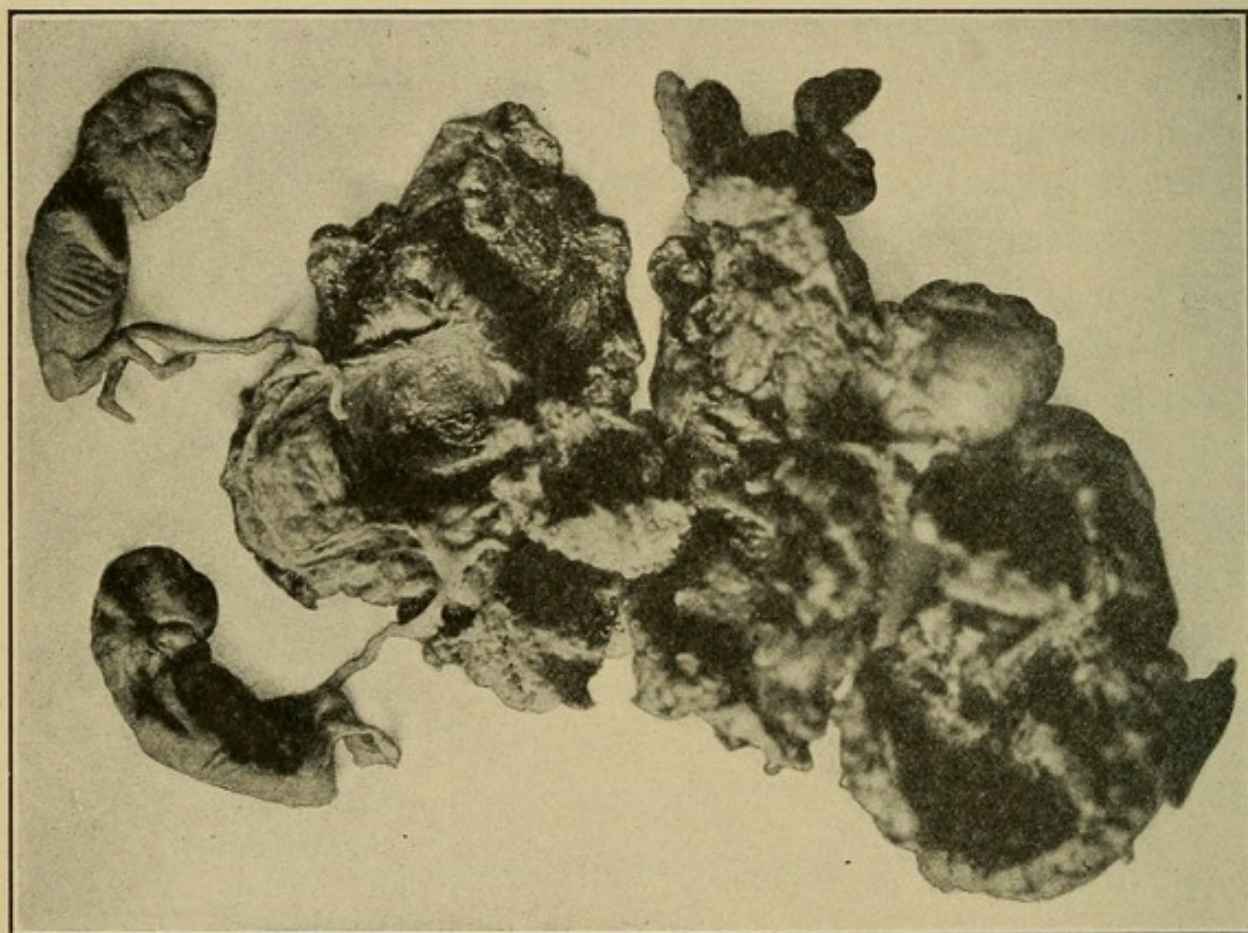
In all the primary forms death of the fetus, or early rupture, is the rule, while of the secondary forms the intra-uterine, tubo-abdominal, tubo-ovarian, and abdominal frequently go on to term.

When the death of the fetus takes place, termination in absorption, suppuration, or its retention in a mummified condition result. When rupture occurs the fetus usually dies and



a pelvic hematocoele develops. Rarely the extra-uterine gestation may be associated with intra-uterine gestation, and cases of multiple tubal pregnancy have been reported, where each tube contained an ovum (twin tubal gestation) and where one tube contained two ova (tubal twin pregnancy) (Fig. 28).

FIG. 28



Tubal twin pregnancy. Ruptured.

**Etiology.**—The causes of extra-uterine pregnancy are still surrounded with obscurity. The predisposing causes, interfering with the passage of the fructified ovum to the uterine cavity, may be want of development, abnormal length or permanent contraction of the tube, or disease of its mucosa.

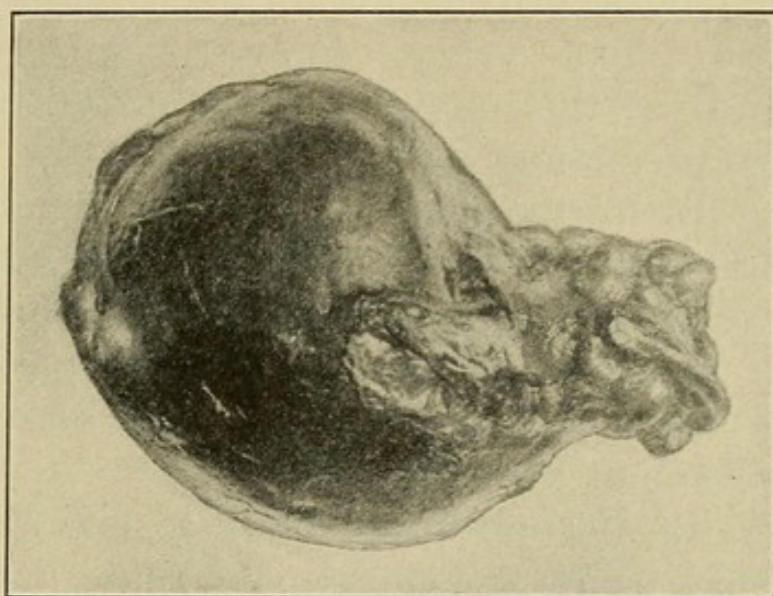
**Symptoms.**—Cessation of menstruation accompanied by other signs of pregnancy are the early symptoms. Later pelvic pain develops, there is irregular hemorrhage, more or less profuse, from the uterus, and occasionally the discharge of



a decidual cast is observed. With rupture there is sudden severe pain in the region of the tube, and symptoms of internal hemorrhage appear, varying with the severity of the bleeding,

**Diagnosis in General.**—The two most important factors in establishing a diagnosis are the history of the case and the physical examination. The signs vary with the period of gestation, ruptured or unruptured condition of the sac, and with a dead or living fetus

FIG. 29



Tubal pregnancy removed before rupture.

**Diagnosis before Rupture.**—Cessation of menstruation, one or more periods having been missed, or the patient may be only a few days overdue. Nausea and other early signs of pregnancy may be present.

On **vaginal examination** a soft, elastic ovoid tumor is found to one side of the uterus. This increases progressively in size unless death of the fetus takes place. The uterus is slightly enlarged, and may throw off a decidual cast.

**Diagnosis after rupture** depends on the sudden onset of acute symptoms. Severe pain in the pelvis, elevation of pulse, subnormal temperature, blanched anxious expression,



and collapse. Vaginal examination fails to reveal a tumor lying by the side of the uterus, which may have been previously diagnosed. If the internal hemorrhage is profuse, bulging in the posterior vaginal fornix and dulness in both flanks, denoting free fluid in the peritoneal cavity, can be made out. A posterior vaginal incision into the peritoneal cavity often gives confirmatory evidence by liberating free blood, although it is rarely necessary to establish a diagnosis. The patient may die, never rallying from the collapse, or slowly recover. A succession of hemorrhages at varying intervals and increasing in severity is not an uncommon occurrence. The possibility of hemorrhage into an ovarian cyst should be borne in mind, as this condition may occasionally closely resemble tubal pregnancy.

**Treatment.**—In unruptured cases the treatment is operative removal as soon as the diagnosis is established.

Ruptured cases with severe symptoms call for immediate operation. If the symptoms are slight and the patient recovering from the initial shock, operation may be deferred and further improvement awaited.

When operation is performed early to check the hemorrhage, it should be by the abdominal route and consist in rapid ligation of bleeding vessels with removal of the products of gestation, blood, and blood clots. The tube may or may not call for removal.

Late operation for the removal of the debris where active hemorrhage has ceased may be performed by the vaginal route, and will be considered under pelvic hematocele. Stimulation is always indicated: Strychnine sulphate,  $\frac{1}{30}$  grain, given hypodermically, and repeated every two hours as long as necessary, and intravenous infusion of normal saline solution, where the shock is severe.



## CHAPTER XII.

### DISEASES OF THE PARAMETRIUM.

#### PELVIC PERITONITIS.

**Definition.**—Inflammation of the pelvic peritoneum, either acute or chronic.

**Pathology.**—Following the primary injection of the peritoneum, serous effusion and the formation of plastic exudate soon develop, causing adhesions between the uterus, intestines, omentum, and appendages. These may be slight and transitory in character, or dense and permanent, according to the nature of the infection.

**Etiology.**—Generally caused by microörganisms. Frequently secondary to diseases of the appendages, especially gonorrheal salpingitis.

The **symptoms of acute pelvic peritonitis** manifest themselves by elevation of temperature and pulse, and sharp, shooting pains in the pelvis. Constipation is usually present. The dorsal position is the one of choice, the patient lying with both legs drawn up to relieve the pain.

The **symptoms of chronic pelvic peritonitis** are dull, continuous pain in the pelvis, aggravated by exercise, coitus, and vaginal examination. Menorrhagia, dysmenorrhea, and backache are special symptoms.

**Diagnosis.**—A careful **vaginal examination** should be made to decide if possible the condition of the appendages. In the acute cases, on account of the extreme pain it causes, this reveals nothing usually beyond a hot, tender vagina with pulsating vessels at the fornices. After exudation has occurred a more or less distinct bulging may be felt in the posterior fornix, and if absorption does not take place and the case goes on to abscess formation, this bulging assumes the form of a hard, tense tumor obliterating the fornix and producing marked



bulging of the posterior vaginal wall. The mobility of the uterus is greatly restricted.

In chronic cases an obscure thickening is felt at the fornices and adhesion bands may be made out in the cul-de-sac. The uterus is often found in a retroposed position, and its mobility is generally more or less restricted.

**Treatment of acute pelvic peritonitis** should be by absolute rest in bed, saline laxatives, prolonged hot vaginal douches, and opiates, when indicated, for the pain. If the case proceeds to suppuration, a posterior vaginal incision to liberate the pus should be made (see under Pelvic Abscess). In the **chronic form** ichthyol (10 per cent.) and glycerin tampons, three times a week, will give marked relief. When the adhesions are extensive, and displacement of the uterus with diseased appendages exist, operative treatment must be considered (see Salpingitis, page 93).

### PELVIC HEMATOCELE.

**Definition.**—Pelvic hematocele is more properly a symptom of some previous pathological condition existing in the pelvic organs, generally the tubes. A collection of blood in the pelvic peritoneum or connective tissues.

**Pathology.**—The hemorrhage is most often intraperitoneal, the result of some disturbance in the development of an ectopic gestation. An extraperitoneal form is recognized, but is of infrequent occurrence.

**Etiology.**—The chief cause is extra-uterine gestation.

**Symptoms.**—When developing suddenly there is severe pain with symptoms of internal hemorrhage (see Ectopic Gestation, page 103).

**Diagnosis.**—Previous signs of internal hemorrhage, with, on vaginal examination, a bulging tumefaction in the pelvis posterior or lateral to the uterus. This is soft and fluctuating in character and only slightly tender on pressure.



**Treatment.**—When seen early, as a symptom of ectopic gestation, abdominal section for the primary condition may be indicated. In late cases, when the initial shock is past, the patient recovering, and no further hemorrhages have occurred, absorption is the favorable termination to be hoped for, the treatment being rest in bed, prolonged, hot vaginal douches, and stimulants when indicated. If suppuration occurs, the treatment becomes that of pelvic abscess.

### PELVIC ABSCESS.

**Definition.**—An intrapelvic suppuration in the region of the uterus.

**Pathology.**—The infection begins usually as a localized peritonitis resulting from an invasion by any of the pus producing microorganisms. These may gain entrance to the pelvic peritoneum through the Fallopian tube as in gonorrheal infection, or through the uterine wall and parametrium by the lymphatics, as in streptococcus infection. Adhesions form in advance of the suppuration; plastic exudate is thrown out, forming a thick abscess wall. As suppuration advances extension takes place in all directions, but gravity favors the posterior vaginal fornix—the most frequent seat of spontaneous rupture.

**Recovery** may take place in one of two ways. Small accumulations of pus may undergo absorption, while in large abscesses evacuation and subsequent drainage are established by spontaneous rupture into the vagina, rectum, or an adjacent coil of intestines. Rupture into the free peritoneal cavity rarely occurs except as the result of traumatism.

**Etiology.**—Of the microorganisms causing pelvic suppuration, the gonococcus, streptococcus, and colon bacillus are most frequently encountered. The gonococcus travels along the mucous membrane of the tube, gaining access to the pelvic peritoneum through the fimbriated opening; the staphylococcus passes through the uterine wall and parametrium by



the lymphatics; the colon bacillus by direct migration through the intestinal walls. Gonorrheal infection is most frequently secondary to gonorrhea of the tubes, while streptococcus infection most often follows in the wake of a carelessly conducted puerperium or a criminally induced abortion.

**Symptoms.**—These are acute during the actual formation of pus, and more severe in the streptococcus and colon bacillus infections than in the gonorrheal. There are elevation of the temperature and pulse, intense pelvic pain, local tenderness, and some abdominal distention. The effect of pus absorption is soon felt, and symptoms of sepsis arise early. A gradual subsidence of the acute symptoms may leave the patient in a weak, exhausted condition, running a low temperature, with continuous pelvic pain, painful defecation and micturition, and a purulent vaginal discharge. Subsequent acute exacerbations may occur, extending over a period of years, if a pus focus remains.

**Diagnosis.**—From the **history of the case** the source of the infection may usually be traced to a previous attack of gonorrhea, or a septic labor, or a criminal or ordinary abortion. The temperature and pulse run a characteristic septic course. **Vaginal examination** shows the uterus elevated toward the symphysis pubis and fixed, while posterior to the cervix, often obliterating the fornix and bulging the posterior vaginal wall, lies a hard, dense, at times fluctuating, shapeless mass, extremely tender on pressure. In the **chronic stage** a differential diagnosis from impacted fibroid is often possible only by operation.

**Treatment** during the **acute stages** should be expectant as long as the patient's condition warrants it. Absolute rest in bed, prolonged hot vaginal douches, hot or cold applications to the abdomen, free catharsis, and morphine when indicated. When the abscess steadily increases in size and the symptoms show no improvement, operative interference is imperative. The simplest method is evacuation by direct incision into the abscess, posterior to the cervix, with subsequent drainage by gauze or rubber tubing.



## CHAPTER XIII.

### MENSTRUATION AND ITS DISORDERS.

#### **NORMAL MENSTRUATION.**

**NORMAL** menstruation is a cyclical change occurring monthly in the female. It is **characterized** by a flow of blood from the uterine cavity, accompanying which is an exfoliation of the superficial layers of its mucosa. Its period of onset varies in different countries, being earlier in warm climates (ten to twelve years) and later in cold ones (fifteen to seventeen years); the **average onset** is at the age of fourteen years. **Suspension of menstruation** occurs during pregnancy and lactation. **Continuation of the menses** is seen in robust, healthy women up to the time of the menopause (forty to fifty years). Once established, menstruation recurs monthly at intervals of twenty-eight to thirty days, the duration of the flow being two to eight days, and the quantity about one ounce per day. **Constitutional symptoms in normal menstruation** should be absent, except a slight sense of weight and fullness in the pelvis and the amount of blood lost should not be sufficient to cause any degree of weakness or debility. The various **deviations from normal menstruation** are oftentimes but symptoms, and will be considered as they arise.

#### **PREMATURE MENSTRUATION.**

Menstruation may occur **before puberty**, and is then precocious. Cases are recorded where the function has developed as early as the first year. In most of these cases there is likewise a premature general and sexual development; hair appears on the pubes and in the axillæ, the breasts enlarge, and the generative organs undergo marked development.



Premature menstruation is in a measure **hereditary**, but early direction of attention to the sexual organs by the association with older and vicious children would appear to be an important predisposing element.

The **treatment** should be directed as far as possible toward removing the cause. Local irritation tending to masturbation should be corrected, nervous excitement avoided, and general rest and tonics prescribed.

### **DELAYED MENSTRUATION.**

Delayed menstruation is often **caused** by tardy development of the generative organs, the flow not being established until the seventeenth to nineteenth year of life. Heredity, lack of nutrition and proper exercise are the more important causative factors. In the **management** of these cases change of occupation and suitable hygienic measures will generally suffice.

### **VICARIOUS MENSTRUATION.**

When the menstruation is absent or suppressed, **periodic vicarious bleeding** sometimes occurs from the mucosa of the alimentary or respiratory tracts, ear, and nose, or from an existing raw surface, such as a leg ulcer.

### **AMENORRHEA.**

**Definition.**—Absence of menstruation.

**Pathology.**—Amenorrhea exists **normally** during pregnancy and lactation; **pathologically** it may be the result of lack of development of the generative organs. The uterus and ovaries may be absent or in a rudimentary condition, or maldevelopment, such as atresia of the cervix, vagina, or hymen, may exist.



**Etiology.**—Delayed puberty, anemia, chlorosis, diabetes, malaria, tuberculosis, and acute illnesses may be a cause. The nervous system is a potent factor, and may suppress the menstruation or cause amenorrhea by autosuggestion. Change of climate and prolonged lactation are accountable for numerous cases.

**Symptoms.**—These arise at or after the time of puberty, and the chief symptom is absence of the periodic flow. In amenorrhea associated with atresia no external signs of bleeding occur, but there are periodical monthly attacks of colicky, cramp-like pains in the pelvis, increasing in severity as the retained menstrual blood distends the uterus or vagina.

**Diagnosis.**—When the symptoms point to atresia as the cause, a careful examination under anesthesia should be made. Where obstruction exists, an imperforate hymen, vagina, or cervix will usually be found. The pelvis is occupied by a soft fluctuating elastic tumor often rising above the brim of the pelvis. If no atresia exists, and the pelvic organs are well developed, some constitutional cause, such as anemia, chlorosis, or phthisis must be sought.

**Treatment.**—Where atresia of the hymen, vagina, or cervix exists the treatment is operative (see page 54).

In cases due to anemia or chlorosis Bland's pills are indicated, and every endeavor should be made to improve the patient's general physical condition.

## MENORRHAGIA.

**Definition.**—Excessive bleeding at the menstrual periods. Intermenstrual hemorrhage is known as **metrorrhagia**.

**Pathology.**—Is that of the condition which produces it.

**Etiology.**—The causes are either constitutional or local, the latter being the more important. These are endometritis, metritis, displacements and malignant diseases of the uterus, fibroids, polypi, and diseases of the ovaries. Chronic alco-



holism is frequently a cause. The possibility of pregnancy with impending abortion should be borne in mind.

**Symptoms.**—Sudden or gradual increase in the amount of blood lost during the periods, secondary anemia, weakness, and debility.

**Diagnosis.**—Dependent on the history and symptoms of the case. Important to distinguish between menorrhagia and metrorrhagia, as the latter is often the first sign of cancer of the uterus.

**Treatment.**—In young girls and unmarried women ergot is valuable, thirty drops of the fluidextract, three times a day, or styptol, gr.  $\frac{3}{4}$ , every three hours. In married women prolonged hot douches (120° F.) may be given. A **local examination** in urgent cases should always be made. Severe hemorrhage may require vaginal packing and the hypodermic injection of ergotin (10 to 20 minims).

### DYSMENORRHEA.

**Definition.**—Pain before, during, or directly after the period of menstruation, and directly referable to the menstrual function.

**Pathology.**—That of the condition producing it. Various theories have been advanced in explanation of the pain, and of these, the obstruction and congestion theories are most frequently referred to.

**Obstruction Theory.**—That an angle of flexion in, or a narrowing of, the cervical canal offers an obstacle to the outflow of the products of menstruation. This retention stimulates contractions in the uterus in order to effect expulsion, and the attempt to overcome the mechanical resistance causes the pain.

**Congestion Theory.**—That the pain arises from the resistance which the muscular tissue of the uterus offers to the hyperemia. This undue vascular tension causes compression of the nerve endings, and pain is the result.



It is probable that in all cases of dysmenorrhea some pelvic abnormality exists and that the pain is due to the increased determination of blood to tissues already in a state of **chronic inflammation** or **congestion**.

**Etiology.**—A small, undeveloped condition of the pelvic organs (**infantile type**) is often found. Subinvolution and malpositions of the uterus, endometritis, and diseased adnexa are frequent causes. A membranous type of dysmenorrhea is recognized where the endometrium is discharged in shreds, or as a complete cast of the uterine cavity.

**Symptoms.**—The menstruation may be either scanty, moderate, or profuse. The pain varies, being in the form of slight, intermittent attacks of colic preceding or occurring on the first day or two of the flow, or severe, continuous, and agonizing in character, producing in some cases marked maniacal symptoms.

**Diagnosis.**—An accurate diagnosis should be made, as upon this depends successful treatment. A careful **vaginal examination**, and in virgins **rectal examination**, should be made, under anesthesia if necessary, and the condition of the uterus and appendages determined.

**Treatment.**—Any marked pelvic lesion will usually necessitate operative treatment. Posterior displacements of the uterus should be corrected, and when of long standing the accompanying endometritis calls for curettage. The free use of salines before and laxatives during the periods to diminish the pelvic congestion is of great service, and rest in bed and the hot-water bag are valuable adjuncts. For the actual pain, pulsatilla in 5 minim doses every hour, or styptol in  $\frac{3}{4}$  grain tablets every three hours, will be found of service. *Avoid opium and alcohol in every form.* In cases due to defective development of the pelvic organs in young girls only palliative treatment is justifiable; general tonics should be given and plenty of healthy outdoor exercise ordered.



## CHAPTER XIV.

### THE DYNAMICS OF THE FEMALE PELVIS.

There has existed in the past, and still exists at present, considerable difference of opinion regarding the normal position of the uterus and the means by which this position is maintained.

The uterus, more so than any other organ in the body, rests in a state of unstable equilibrium, and undergoes frequent changes in position consequent upon a shifting centre of gravity and physiological changes in the adjacent viscera.

Being of small bulk, in weight less than three ounces, and suspended by highly elastic structures in a cavity large enough to admit of considerable latitude of movement, it can be readily understood how very slight a cause may often be sufficient to produce a permanent displacement.

To understand how the normal balance is maintained, it will be necessary to turn for a moment to the anatomy of these parts. With the woman standing upon her feet the pelvis occupies an oblique position with regard to the trunk of the body, and is placed at an angle of 60 to 65 degrees with the ground upon which she stands. Within the pelvis lies the uterus, parallel or nearly so to the horizon, its fundus directed forward and resting by its anterior face on the posterior aspect of the bladder, to which it is united by a reflection of peritoneum. The cervix is directed backward toward the hollow of the sacrum, perpendicular to the axis of the vagina, and nearly so to that of the pelvis. This relative position between uterus and pelvis remains pretty constant, though considerable variation within physiological limits may occur. For example, as the bladder fills with urine it rises in the pelvis, carrying the fundus upward and backward and the cervix forward until the fundus approximates the promontory of the sacrum and the uterine axis is nearly



parallel to that of the pelvis; then, as the bladder is emptied the uterus sinks again to its former position. An overdistended rectum crowds the uterus well forward, even flexing the cervix upon the fundus, and at times raising the fundus well out of the pelvis. As the body is bent forward the uterus changes somewhat its position in the pelvis, which it tends to leave, approaching the abdominal cavity. In the dorsal posture the uterus sinks somewhat back toward the hollow of the sacrum, although normally this occurs only to a slight degree.

Now, the means by which this support, allowing as it does of such extensive change in position, is accomplished are the same as in all other organs of the body, namely, suspension by ligaments, for Nature makes no exceptions to her rules and takes no chances, and here on the cradle in which she nurtures to fruition her greatest and most marvellous achievement, she has been particularly lavish, as no other organ in the body compared in size has so many and so strong ligaments as the uterus.

The principal suspensory ligaments of the uterus are the uterosacral, two in number, passing from their origin at the third and fourth bones of the sacrum downward and forward to their insertion at the waist of the uterus. Composed largely of connective tissue, they are not as elastic as the other ligaments, and with the uterovesical ligaments running forward to the bladder form a firm sling of tissue which holds the cervix in place. So long as they remain intact the cervix stays high up in the hollow of the sacrum, and retrodisplacement, the first step of which is descent of the cervix, cannot occur. The uterovesical ligaments together form a thick fibrous band, connecting the neck of the uterus to the posterior surface of the bladder, and control the anteroposterior motions of the uterus.

The broad ligaments are reflections of the peritoneum, passing from the lateral walls of the pelvis to the sides of the uterus. Their role is largely a passive one in relation to the uterus; their chief function seems to be the support of the uterine appendages and bloodvessels going to the uterus.



The part played by the round ligaments is largely an accessory one, and only at times are they called upon to actively enter into the support of the uterus. Attached to the fundus, they serve to guide and limit its excursions upward, and, pulling always forward by virtue of their attachment at the external ring, it is easily seen how a tendency to retroversion is prevented so long as they maintain their normal tone. Largely muscular in structure, they possess, in common with other muscles, the power of undergoing hypertrophy, which is well illustrated in pregnancy. Here they enlarge with the uterus, their chief function being to hold the fundus well forward as it rises in the abdominal cavity, thus keeping it in contact with the anterior abdominal wall and preventing injury to the intestines that might occur should they become anterior to the uterus and compressed between it and the abdominal wall.

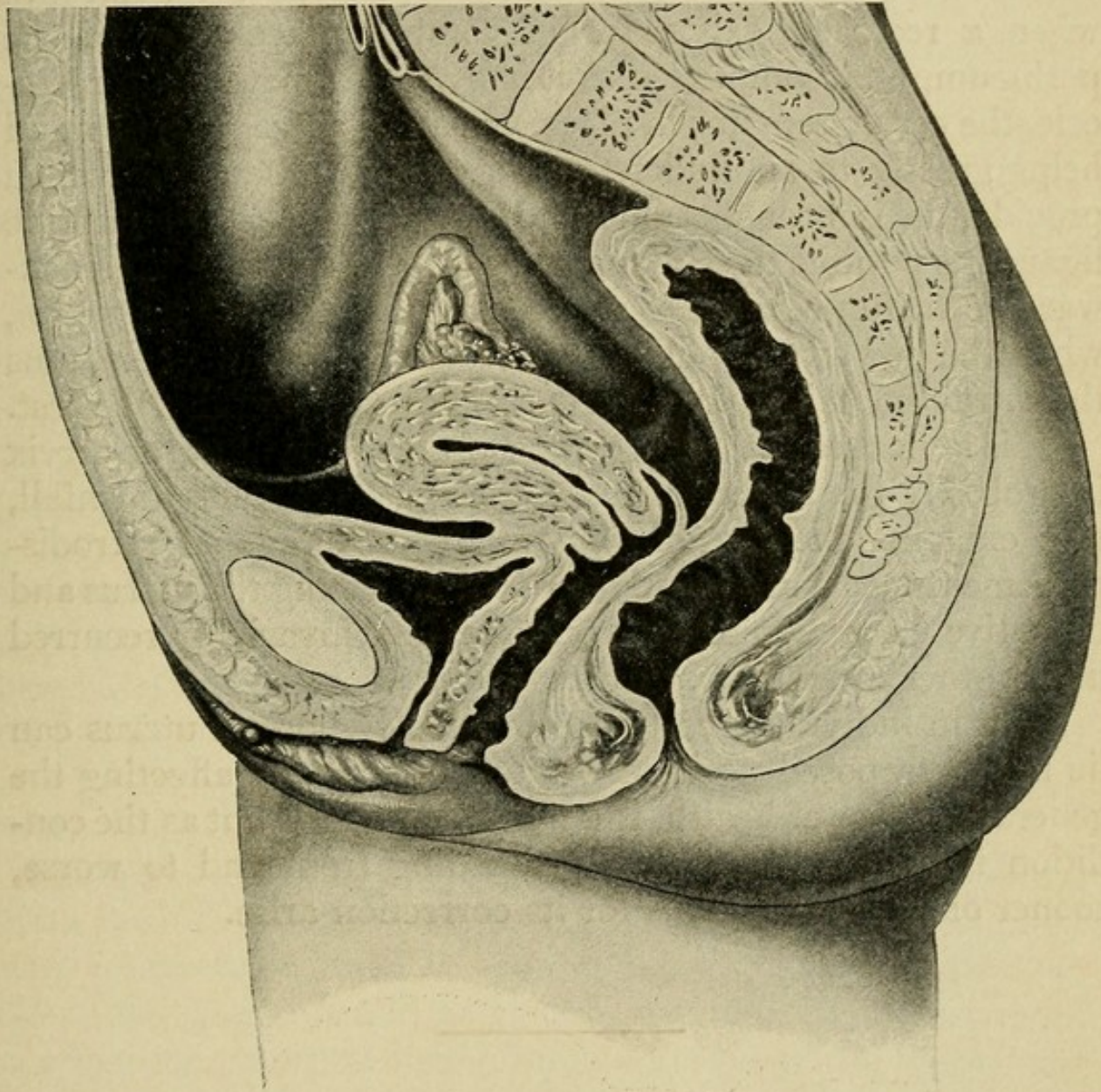
After delivery involution takes place in the ligaments as well as in the uterus, and the subsiding fundus is held forward until it again reaches the pelvis in safety.

The malpositions most commonly met with are the retro-deviations and procidentia. The former admit of two divisions, the versions and flexions, the difference between them being simply one of degree. We have seen how normally the uterus lies in the pelvis, supported by the broad ligaments on either side, and the firm sling of tissue composed of the uterosacral and uterovesical ligaments holding the cervix well up in the hollow of the sacrum, the fundus being held forward, guided and limited in its excursions by the round ligaments. In this position the intra-abdominal pressure directed against its posterior surface helps also to keep the fundus forward. The first step in all retrodisplacements and procidentia is the sinking of the cervix, which results when the support of the uterosacral ligaments is lost. This brings the axis of the uterus more in line with the axis of the pelvis, changing its horizontal position, and admitting of a posterior recession of the fundus to the limits of control exerted by the round ligaments. This position is an extremely hazardous one for



the uterus and one that cannot be maintained for any great length of time. Sooner or later the round ligaments, unable to stand the continuous strain put upon them, yield, either slowly, or suddenly, as in the traumatic displacements, thereby

FIG. 30



Normal position of the uterus. The uterus lies anteposed, anteverted, and slightly anteflexed when the bladder and rectum are empty and the patient is in the upright position. (Findley.)

allowing the fundus to recede and the intra-abdominal pressure to act on its anterior face, forcing it back into the hollow of the sacrum. So long, then, as the cervix remains in place it is impossible for the retrodeviations and procidentia to



develop, for the fundus and cervix cannot change their positions to any extent independently of each other. How, then, is this relaxation of the uterosacral ligaments, whereby the support of the cervix is lost, brought about? Probably the all-important mechanical factor in its causation is the constant traction downward exerted on the cervix by the posterior vaginal wall when a rectocele exists, for in complete laceration of the perineum, unaccompanied as it is by the formation of a rectocele, the cervix remains in place. Bearing these facts in mind helps greatly to an understanding of the process by which procidentia is brought about. Relaxation of all the uterine ligaments permits the sinking of the cervix, the swinging backward of the fundus, and the descent of the uterus in the pelvis, when the downward pull of the rectocele and cystocele, plus the intra-abdominal pressure from above, accomplish the rest.

This almost continuous tugging of the rectocele at the cervix is probably the all-important factor in causing its downfall, and explains the reason why many uncompleted retrodisplacements are permanently cured by replacing the uterus and operative correction of the rectocele, that invariably recurred under other forms of treatment.

That in individual cases the previously normal uterus can lie in a retroposed position without in any way affecting the general balance of health, is a well-known fact, but as the condition is a progressive one, proceeding from bad to worse, sooner or later indications for its correction arise.

---

## CHAPTER XV.

### DISPLACEMENTS OF THE UTERUS.

UTERINE displacement, for our purpose, may be **classified** into the **minor displacements**, consisting of retroversion, retro-



flexion, and the lateral deviations; and the **major displacements**, procidentia, inversion, and hernia.

As the difference between retroversion and retroflexion is largely one of degree, they will be considered together under the head of retrodisplacements.

Anteflexion, though for many years so considered, is not properly a displacement, but rather a lack of development, and is considered elsewhere.

### RETRODISPLACEMENTS.

**Definition.**—Retroversion of the uterus may be said to exist when the axis of the uterine body forms an obtuse angle with the axis of the pelvic inlet, and retroflexion when the posterior uterine wall is bent upon itself.

**Pathology.**—The cervix is directed downward and forward, lying in the axis of the vagina, and the fundus lies posterior to the plane of the pelvic inlet. There is passive congestion with its accompanying dilatation of the bloodvessels and increase in connective tissue. The tubes and usually the ovaries follow the displaced fundus. Relaxation and loss of tone in the ligaments, the supporting structure of the uterus, exist.

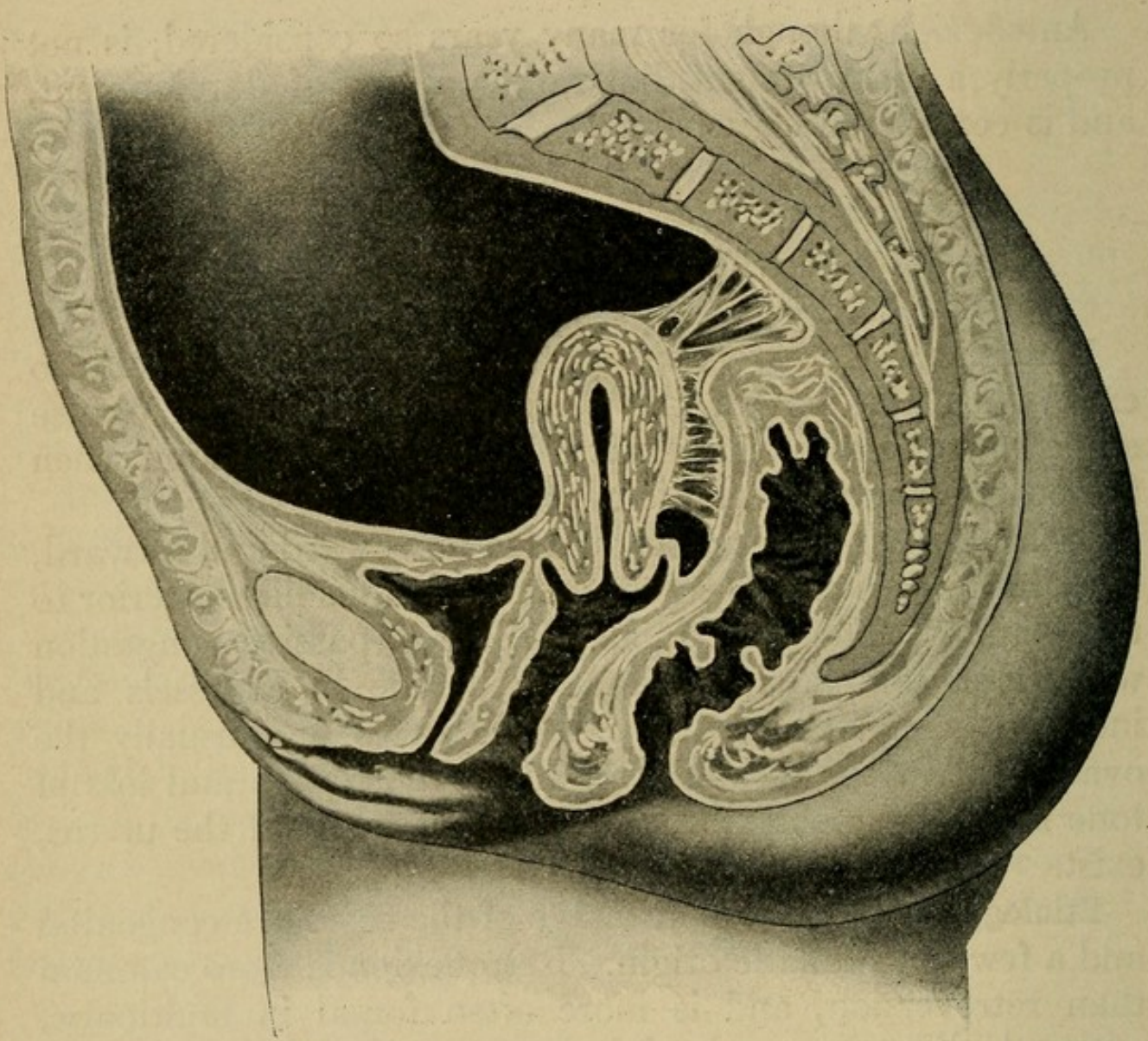
**Etiology.**—A certain percentage of the cases are congenital and a few of traumatic origin. Retroflexion is more common than retroversion, and is more often found in multiparæ, where the ligaments and pelvic floor are relaxed and have not regained their normal tone. Subinvolution of the uterus and its ligaments after confinement is the most important etiological factor. Adhesions resulting from diseased appendages may draw the uterus into a position of retroversion.

**Symptoms.**—Backache, a sense of weight in the pelvis, constipation, dysmenorrhea, menorrhagia, leucorrhea, and sterility or repeated abortion. In cases of long standing general constitutional symptoms develop.



**Diagnosis.**—On vaginal examination the cervix is found lying in the axis of the vagina and usually low down in the pelvis (Fig. 31).

FIG. 31



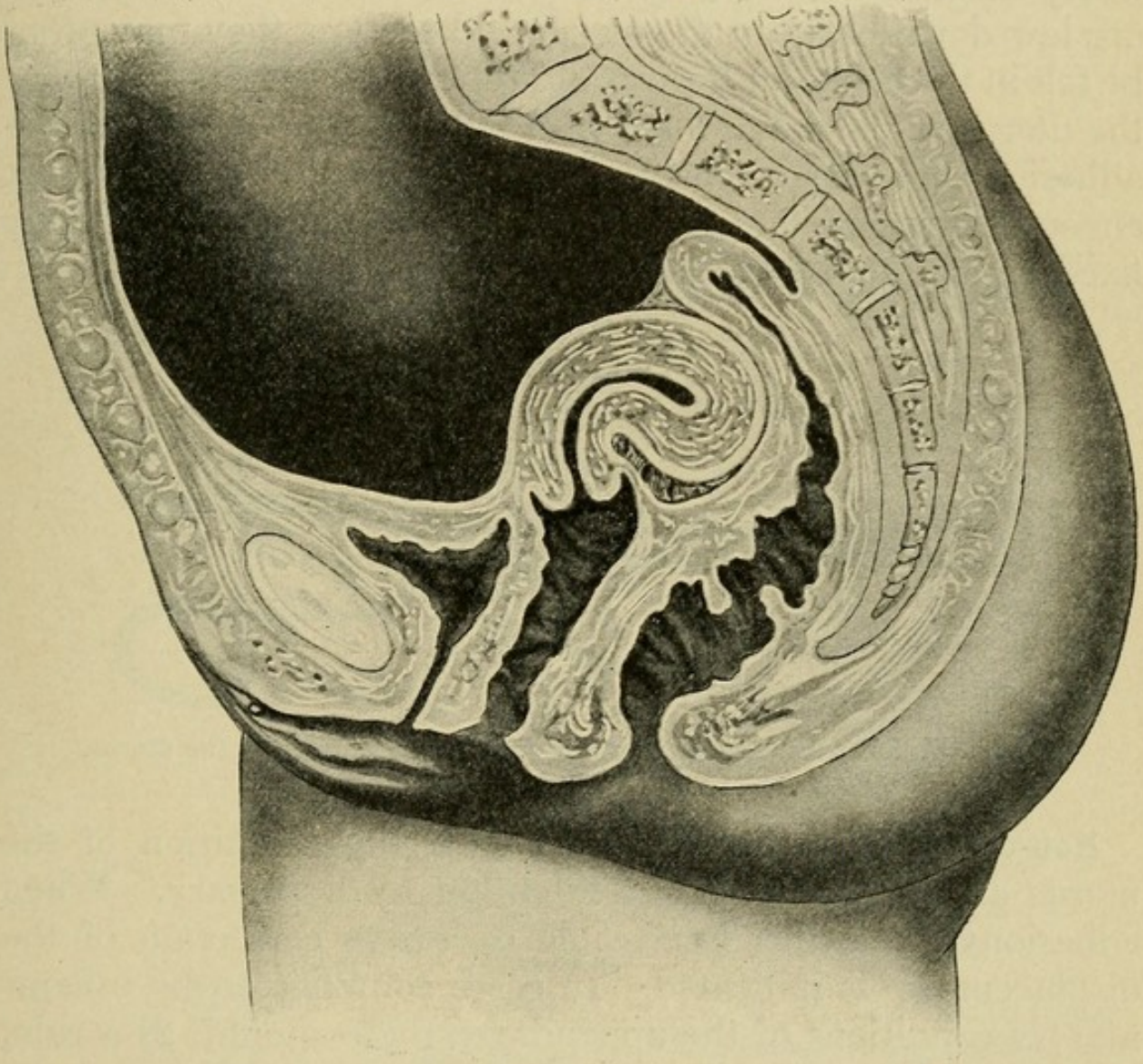
Retroposition and retroversion of the uterus, with fixation. Peritoneal adhesions bind the posterior surfaces of the uterus to the sacrum and rectum, holding the uterus firmly in retroversion and retroposition. (Findley.)

**Bimanual examination** shows absence of the fundus anteriorly, and reveals a firm, rounded body in the posterior fornix, continuous with the cervix. In retroflexion a groove, more or less distinct according to the degree of flexion present, is felt between the cervix and fundus, and little difficulty is



experienced in locating the fundus low down in the pelvis—at times on a level with the cervix. **Differential diagnosis** between retroflexion, a fibroid in the posterior uterine wall, or a small

FIG. 32



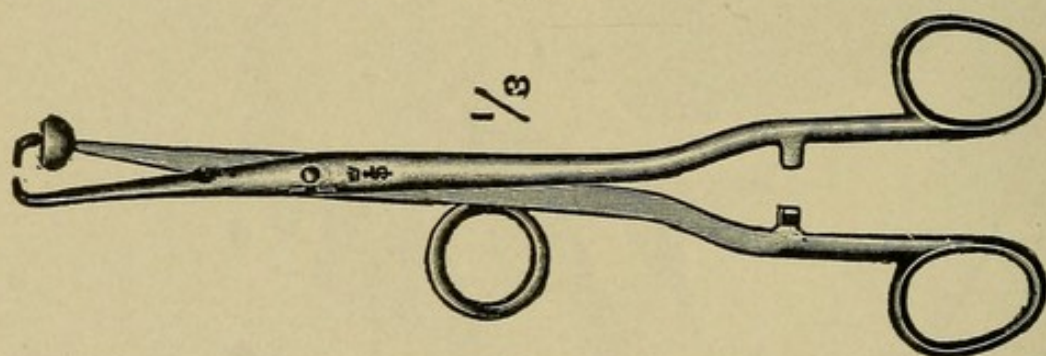
Retroversioflexion of the uterus, with adhesions. The body is adherent in the cul-de-sac. The long axis of the uterus is bent backward and the cervix is directed downward. (Findley.)

prolapsed adherent ovarian tumor, is often difficult, but can usually be made by careful and repeated bimanual examinations, eventually locating the fundus in front. If necessary, the uterine sound may be brought into acquisition, and is a



valuable diagnostic aid, showing at once, by the direction it takes, whether the fundus is anterior or posterior. It should only be used under rigid aseptic precautions, and never when doubt as to pregnancy exists. Having located the fundus, the next step is to decide as to the mobility of the uterus, whether freely movable or fixed by adhesions. When the adhesions are low down between the uterus and rectum, they may often be felt in the posterior fornix, and repeated attempts to elevate the uterus in the pelvis meet with failure. In cases where the adhesions are very extensive downward traction on the cervix encounters immediate resistance, the uterus lying absolutely fixed in its pathological position (Fig. 32).

FIG. 33



Author's forceps for correcting posterior displacements of the uterus.

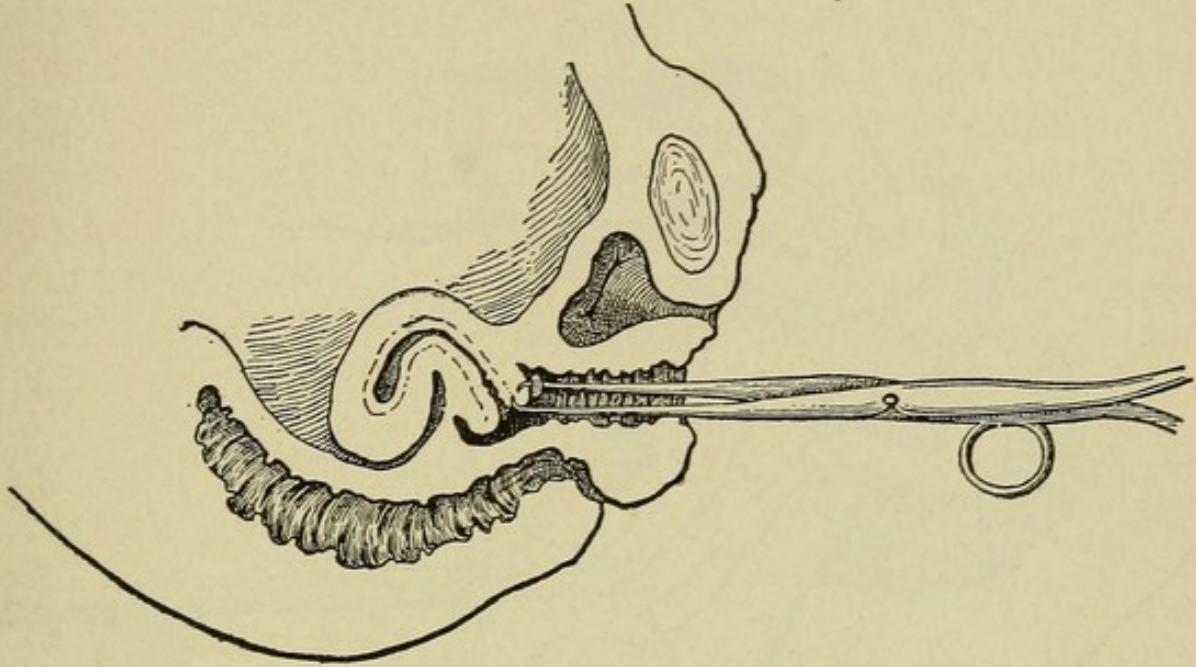
**Non-operative treatment** consists in the reposition of the uterus and, where possible, retention by a pessary. When adhesions make this impossible operative correction of the displacements is indicated. In cases complicated by inflammatory conditions of the appendages these should, as a rule, receive appropriate treatment before any effort is made to correct the displacement of the uterus; otherwise much harm may be done.

**Reposition (Vaginal Method).**—With the patient in the dorsal position and her thighs well flexed on the abdomen, the vagina is retracted, the anterior cervical lip firmly grasped with a traction forceps (Fig. 34), and steady downward traction made for a few moments to gradually overcome the



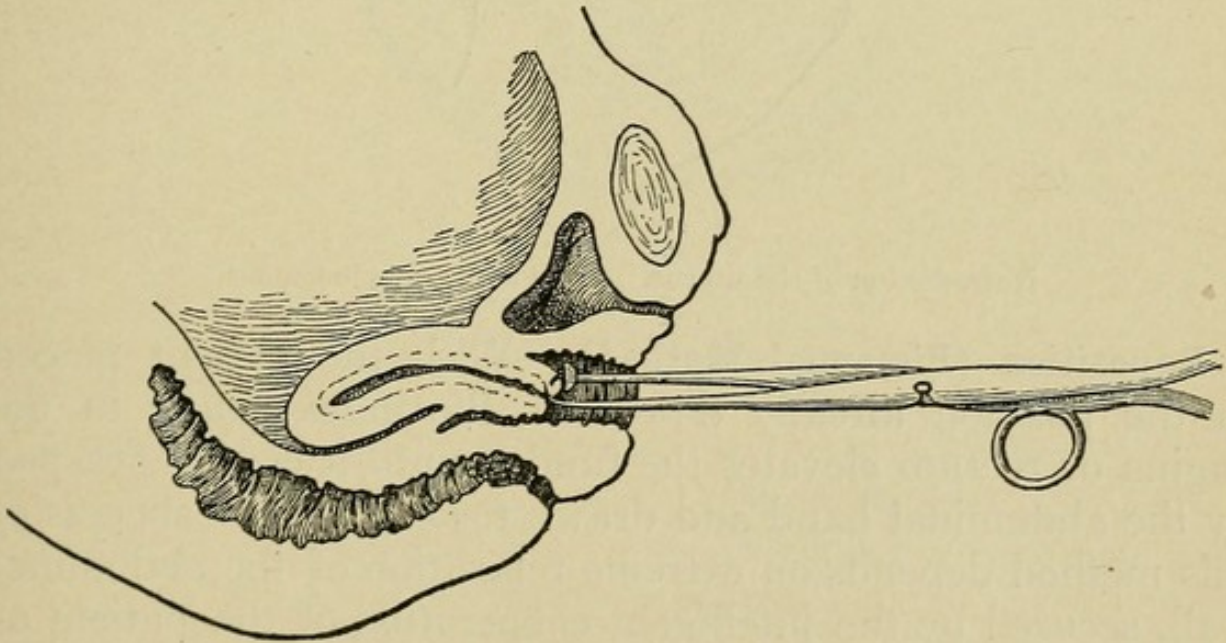
resistance of the tissues (Fig. 35). The index finger of the disengaged hand is then passed as high up against the pos-

FIG. 34



Retroflexion of the uterus. First step in replacement.

FIG. 35



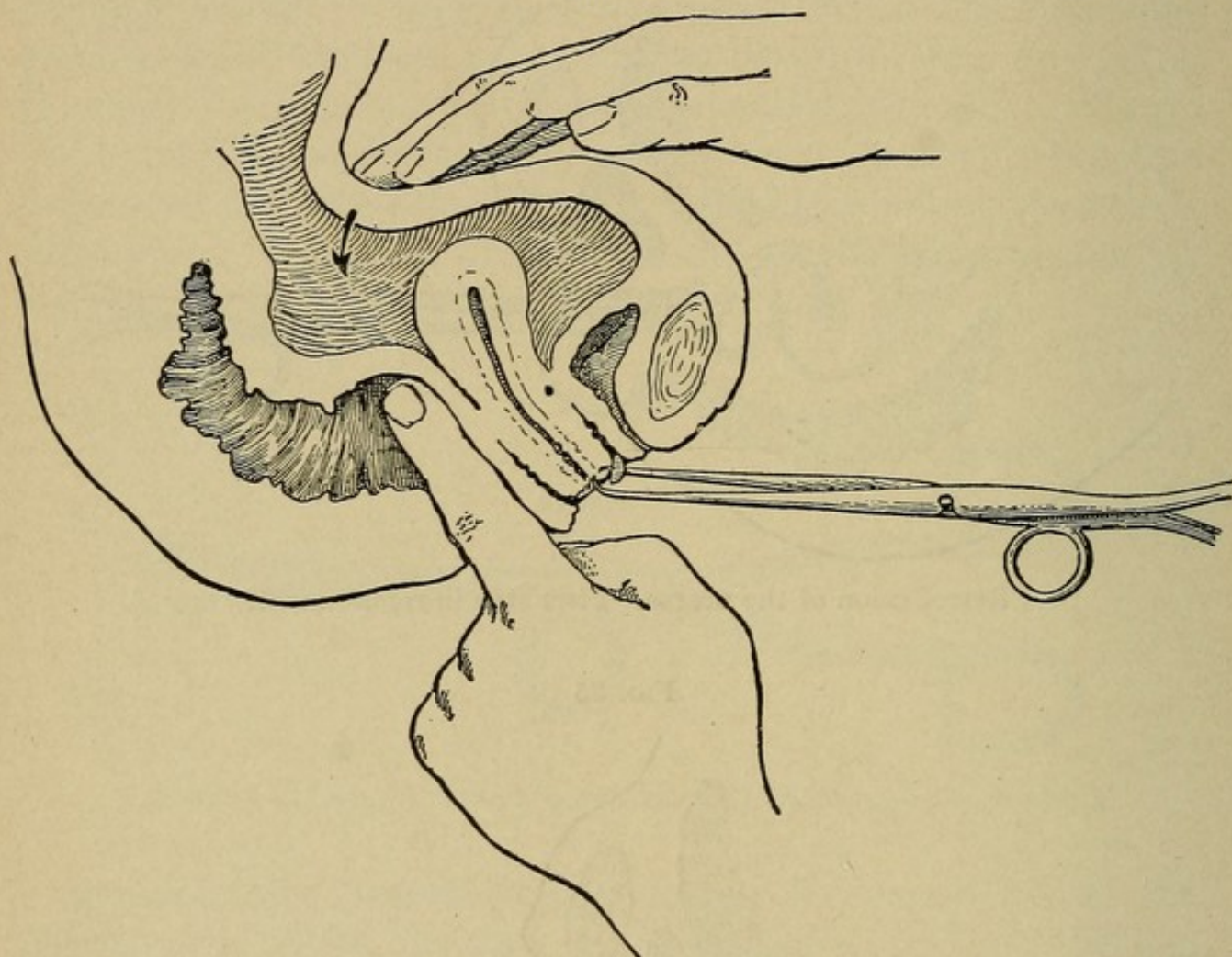
Retroflexion of the uterus. Second step in replacement.

terior wall of the uterus as possible, in either the vagina or rectum, and with this point as a fulcrum the cervix is pushed



back into the hollow of the sacrum, when the fundus will swing forward into position. Occasionally it may be necessary to assist the fundus forward by counterpressure over the abdomen (Fig. 36).

FIG. 36



Retroflexion of the uterus. Third step in replacement.

**Reposition (Bimanual Method).**—With the patient placed in the position already described, the index finger in the vagina or rectum elevates the fundus until it can be grasped by the abdominal hand and drawn forward. The success of this method depends on extreme relaxation of the abdominal wall, secured by the intelligent coöperation of the patient or the administration of an anesthetic.

**Reposition (Gravity Method).**—In many simple cases, if the patient is put in the knee-chest position, gravity will correct the displacement, but the pessary must be inserted before



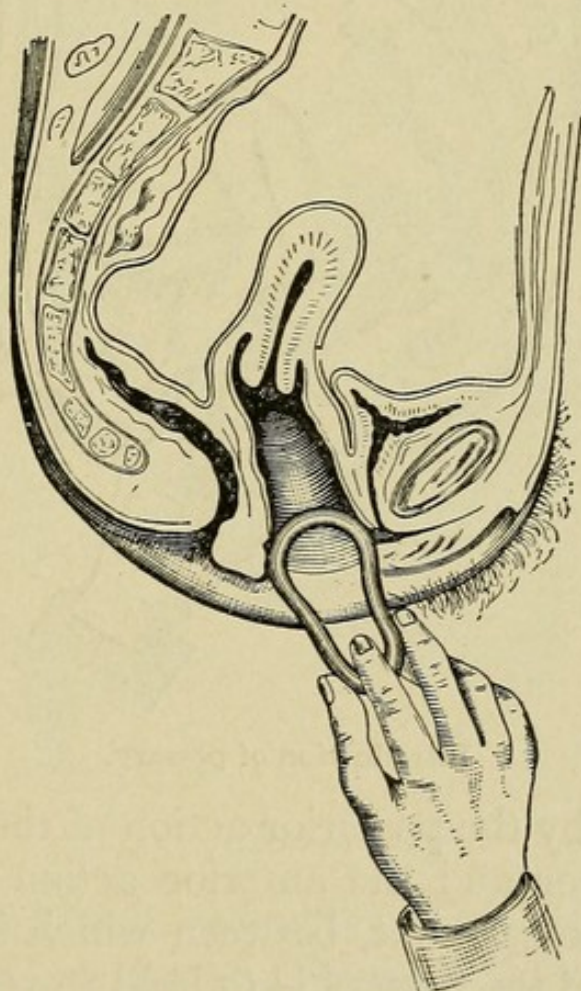
the patient changes her position, otherwise the fundus will return to its posterior position. In difficult cases anesthesia may be required, and is always advisable in young unmarried women.

FIG. 37



Albert Smith pessary for retroversion.

FIG. 38



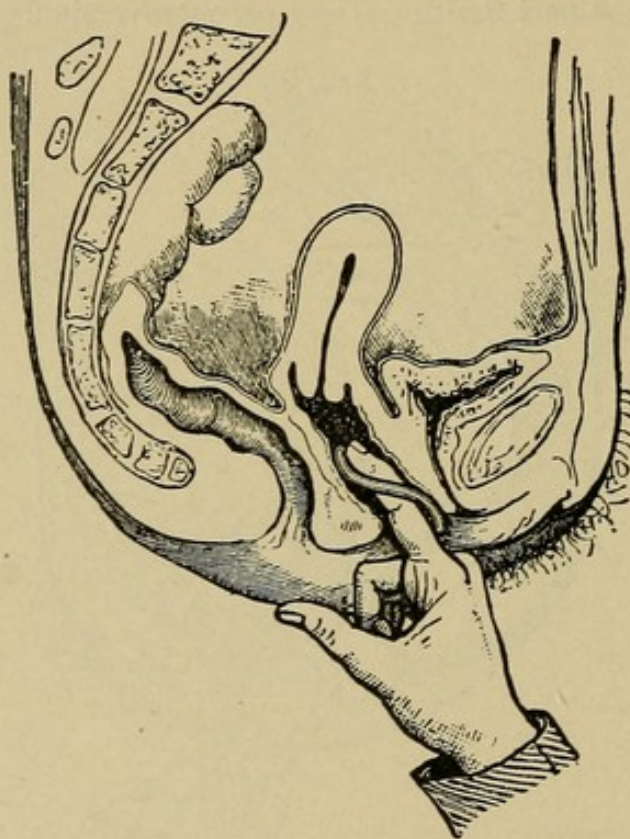
Introduction of pessary.

**Introduction of the Pessary.**—In selecting a pessary, the size and shape depend much on the requirements of each individual case. An Albert Smith, 3-inch, hard rubber retroversion pessary (Fig. 37) is a good one to begin with. Having



replaced the uterus, the perineum is retracted by the index finger, and as the vulvar orifice is anteroposterior and the cavity of the vagina transverse, the pessary must be introduced with its plane surface vertical and afterward rotated into the same plane with the vagina (Figs. 38, 39, 40), the concavity of its large curve being in contact with the anterior vaginal wall. The index finger pushing against the upper bar guides it into position behind the cervix. The pessary is

FIG. 39



Introduction of pessary.

held in position by the posterior action of the sacral segment of the pelvic floor and the anterior action of the posterior face of the pubic segment, between which it is compressed.

The **function of the pessary** is to hold the cervix up in position, thus relieving the tension on the overstretched uterosacral and round ligaments, giving them a chance to regain their normal tone and supporting power.

**Operative treatment** is called for when the pessary fails to cure and where adhesions or complicating diseases of the

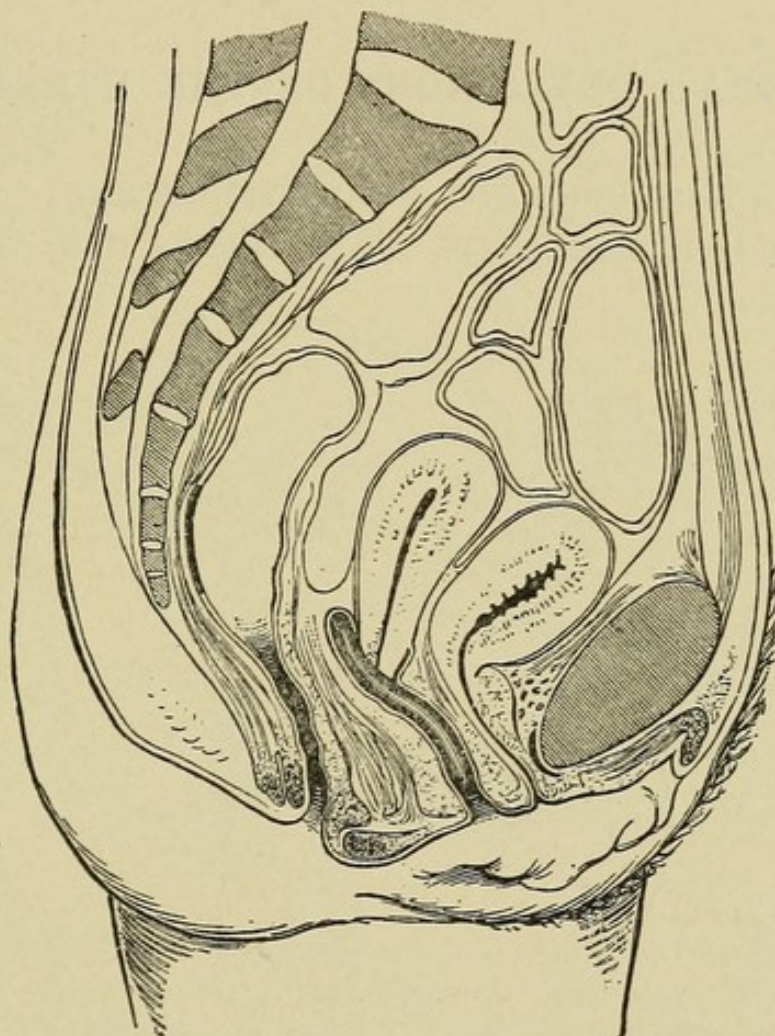


adnexa exist. It may be either extraperitoneal or intraperitoneal.

**Extraperitoneal Methods** (where adhesions or diseased appendages are absent):

(a) **Vaginal Fixation:** The fundus is brought forward and sutured to the anterior vaginal wall.

FIG. 40



The pessary in position.

(b) **Alexander-Adams Operation:** The fundus is brought forward and held in place by shortening the round ligaments at the external abdominal rings.

**Intraperitoneal Methods** (where adhesions or diseased appendages are present):

(a) **Vaginal Celiotomy:** Adhesions are separated, any disease of the appendages treated, the fundus is brought forward



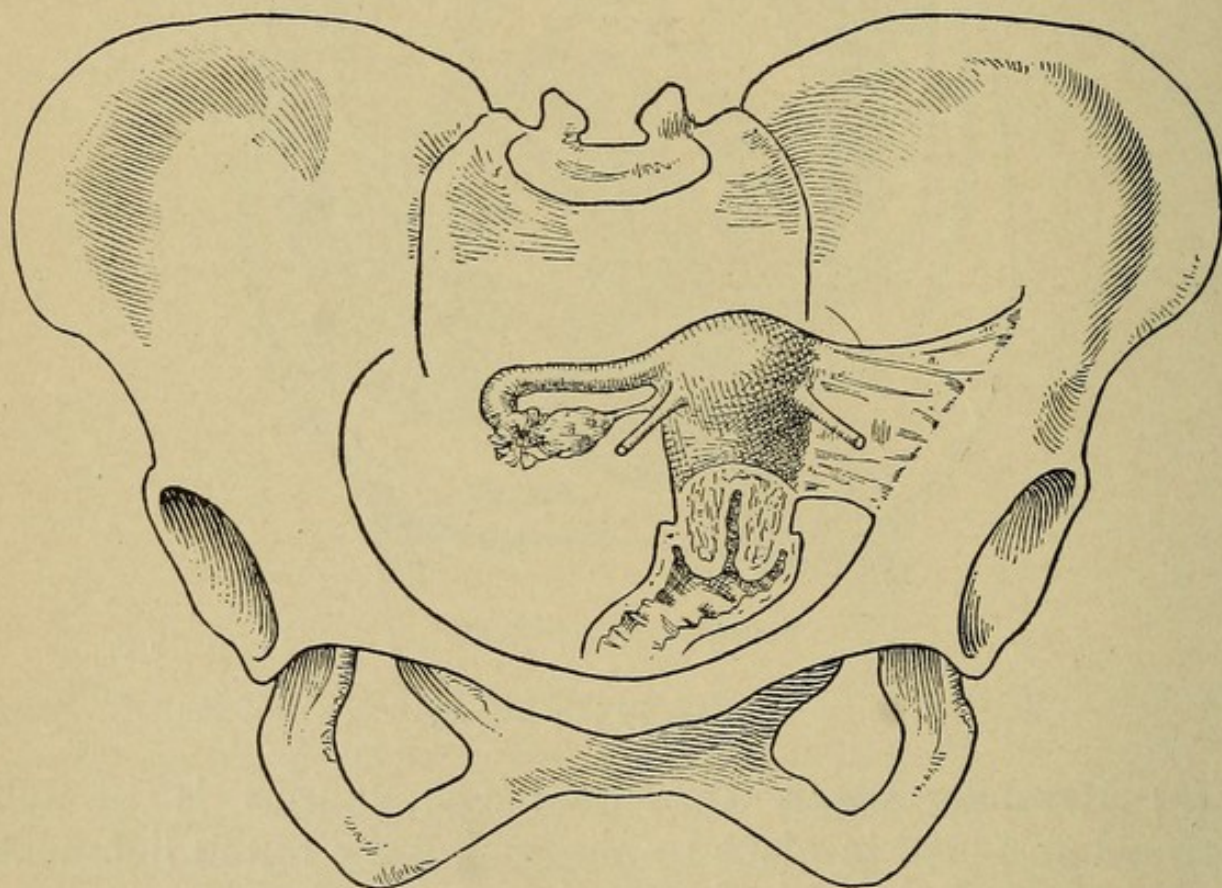
and vaginal fixation performed, or the round ligaments shortened.

(b) **Abdominal Celiotomy:** Adhesions are separated, any disease of the appendages treated, the fundus brought forward and sutured to the abdominal wall, or the round ligaments, uterosacral ligaments, or both, may be shortened to hold the uterus in position

### LATERAL DEVIATIONS OF THE UTERUS.

Lateral displacements are of little **importance**, rarely giving rise to distinctive symptoms. The uterus may be found in

FIG. 41



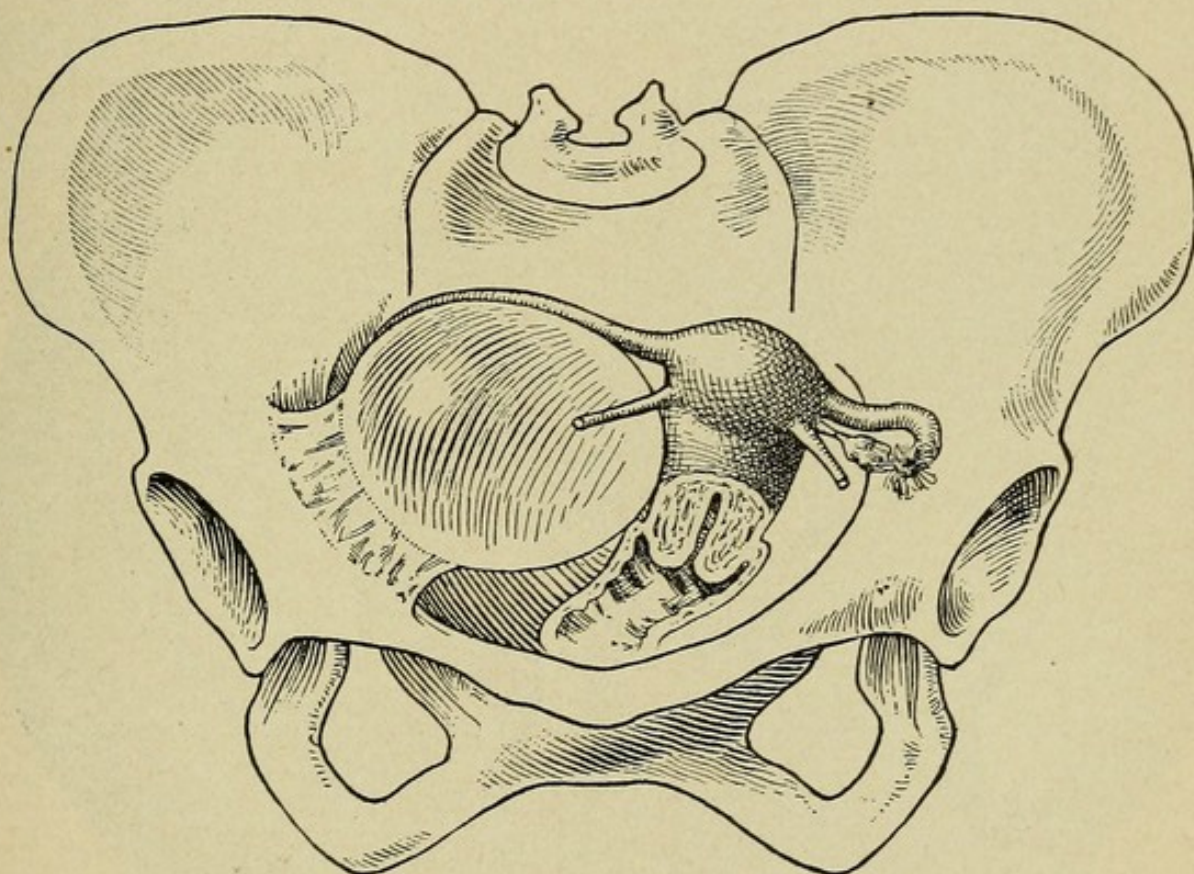
Left laterodisplacement of the uterus. The left broad ligament is thickened and contracted and has drawn the uterus to the left. (Findley.)

**displacement to the right or left**, lying only slightly to one side of the median line, or well over to the pelvic wall. The **cause of**



the displacement will usually be found to lie in the appendages, or broad ligaments. A large tumor of the tube or ovary may crowd the uterus to the opposite side of the pelvis, or it may be drawn to one side by contraction in the broad ligament, the result of previous inflammation of the appendages on that side.

FIG. 42



Left lateroversion of the uterus. The uterus is crowded to the left side of the pelvis, the long axis of the uterus inclines to the left. The cause of the displacement is a broad ligament cyst of the right side adherent to the wall of the pelvis. (Findley.)

The **treatment** is that of the pathological condition producing the displacement.

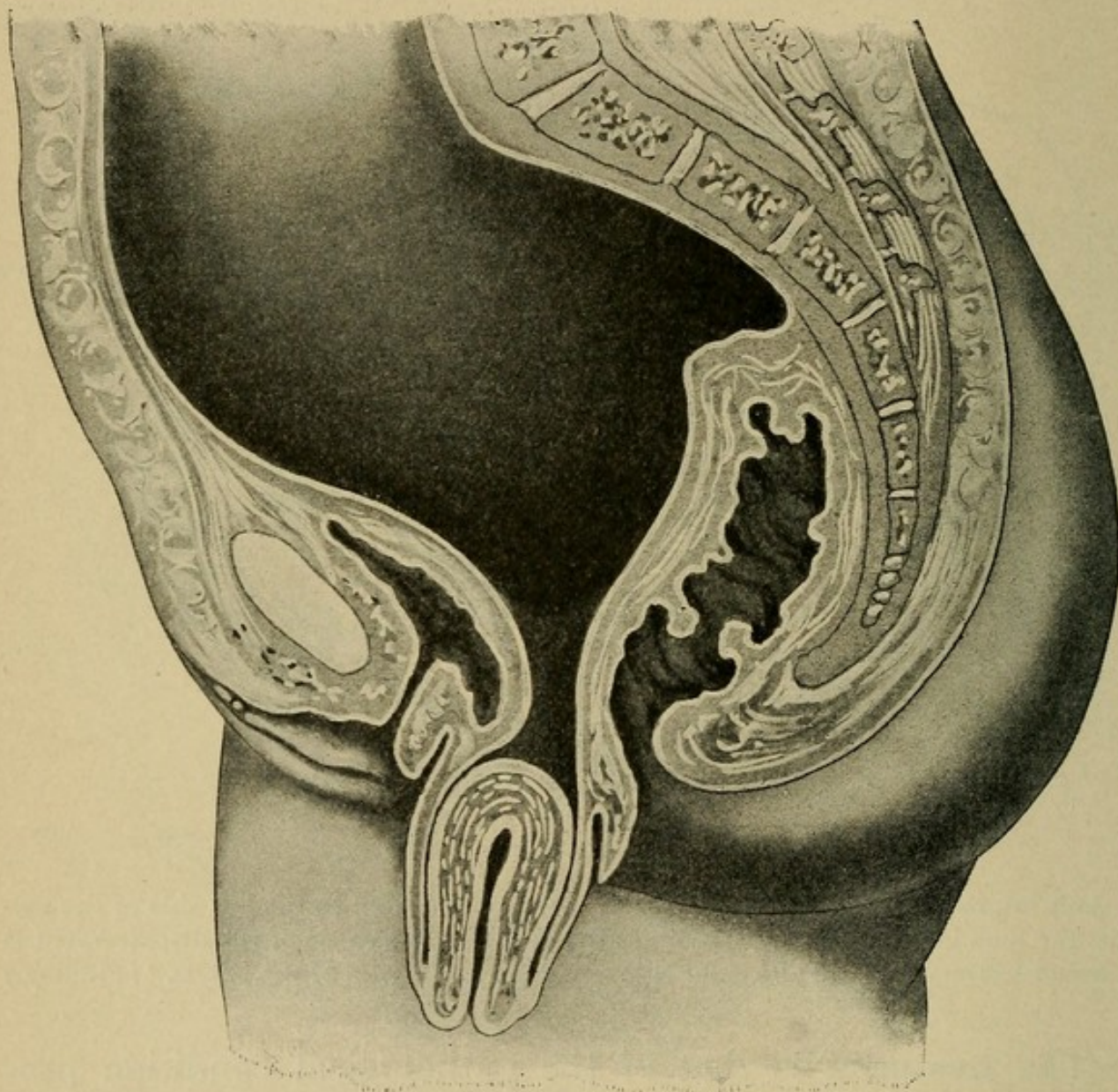
### DOWNWARD DISPLACEMENT OF THE UTERUS.

**Definition.**—A descent of the uterus below its normal level in the pelvis.



**Varieties.**—When the uterus remains in the vagina the condition is called **incomplete prolapse**, or **descensus uteri**, and when the organ escapes at the vulva, **complete prolapse**, or **procidentia** (Figs. 43, 44).

FIG. 43



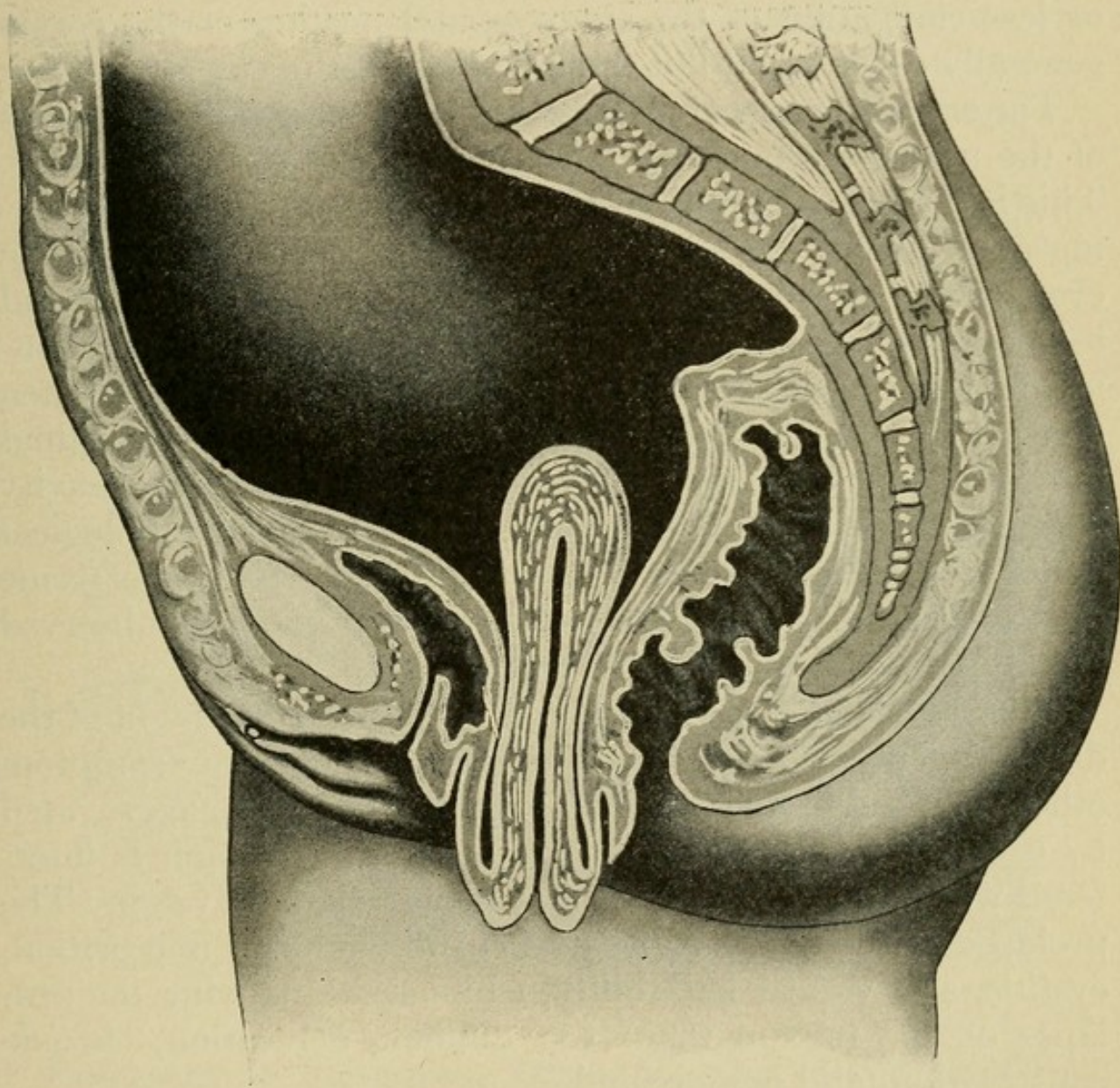
Primary prolapse of the uterus. The uterus lies wholly outside the vulva. The vaginal walls are completely inverted; the cervix is not elongated.

**Pathology.**—Descent of the uterus is essentially a hernia through the pelvic floor. The **first step** in the descent of the uterus is retroversion, the fundus swings back into the hollow of the sacrum, and the cervix forward into the axis of the



vagina. The **second step** is the sinking of the uterus in the pelvis until the cervix appears at the vaginal outlet, and the **final step** is the complete protrusion (procidentia) of the entire

FIG. 44



Secondary prolapsus uteri with elongation of the cervix. Both vaginal walls are completely inverted. The cervix protrudes from the vulva. Neither the bladder nor the rectum are found in the protruding structures.

organ at the vulval orifice, with inversion of the vagina. The appendages usually accompany the uterus, and are often found lying in the vaginal sac.

The anterior vaginal wall, distended by the bladder, may



come down first, to be followed later by the posterior vaginal wall, drawing with it the rectum, or the reverse may be the case.

The epithelium of the vagina and vaginal portion of the cervix, exposed to the air, becomes dry, thickened, and hard, and friction of the clothing may produce ulceration. More or less elongation of the supravaginal portion of the cervix generally exists in all but the acute traumatic cases.

The **essential cause of prolapse** is a weakening of the supports of the uterus, accompanied by a yielding of the pelvic floor. This is favored by multiparity, with its attendant overstretching or injury of the levator ani and the pelvic fasciæ. The ever-present downward traction exerted by the cystocele and rectocele on the cervix is probably the most important mechanical factor. Occasionally the fundus remains in place, when the cervix alone descends by elongation of its supravaginal portion. In prolapse occurring shortly after delivery, gravity acting on the large subinvolved uterus is an etiological factor. Sudden traumatic prolapse may follow extreme muscular effort or a fall from a height, and has been observed in nulliparous women.

The **symptoms of prolapsus uteri** depend on the extent of the displacement. Slight prolapse may produce no symptom other than a dull ache in the lumbosacral region, aggravated by exercise. As further descent occurs, circulation is interfered with, and endometritis and menorrhagia develop. The prolapse of the bladder gives rise to difficulty in micturition, cystitis, and vesical irritability, while accompanying the prolapse of the rectum there are difficult defecation, chronic constipation, and hemorrhoids.

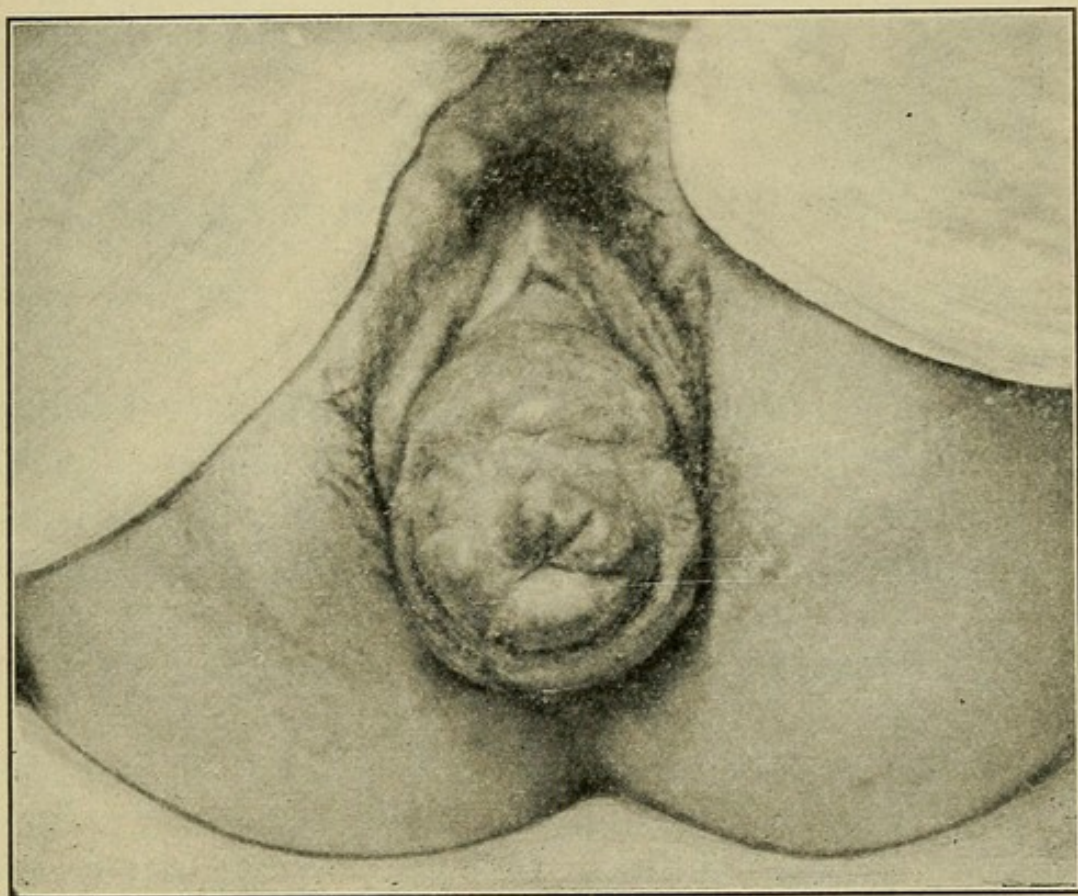
In cases of sudden prolapse, shock is present, with the sensation of something having given way in the pelvis, and marked edema of the uterus and vagina appears.

**Diagnosis of Incomplete Prolapse.**—The vaginal finger encounters the cervix low down in the axis of the vagina; the fundus is found retroverted, lying in the hollow of the sacrum. When the patient bears down the uterus descends toward the vaginal outlet.



**Diagnosis of Complete Prolapse.**—The cervix and inverted vagina are seen protruding at the vulva, and on palpation the fundus and appendages may be felt lying within this sac entirely outside of the introitus as shown in Fig. 45. Hyperelongation of the cervix simulates prolapse, but the thinned-out portion of the cervix running up through the sac can usually be made out, and bimanual examination shows the fundus in place.

FIG. 45



Procidentia.

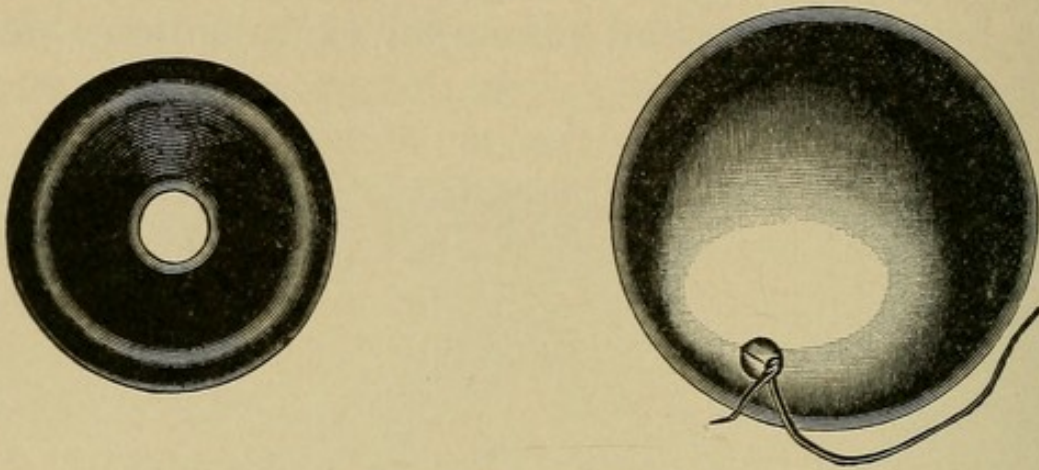
**Treatment of Incomplete Descent.**—The uterus should be replaced and a retroversion pessary worn for six months. Extreme relaxation of the vaginal outlet with marked cystocele and rectocele should be corrected by operative measures.

**Treatment of Procidentia.**—The uterus should be replaced and a cup or ball pessary introduced (Fig. 46). This accompanied by rest in bed, with daily prolonged hot vaginal douches, for a few weeks will accomplish marked benefit, even in advanced cases, and is, as a rule, all that is indicated in very



old and feeble patients. In younger women, as very little permanent benefit is to be hoped for from such measures, operation is indicated. This consists in amputation of the cervix when much elongated, repair of the cystocele, rectocele, and

FIG. 46



Pessaries for procidentia.

perineum, with shortening of the round, uterosacral and broad ligaments, and in some cases, ventral suspension as well. In cases that are not cured by these measures vaginal hysterectomy will offer the best chances of a permanent cure.

### INVERSION OF THE UTERUS.

**Definition.**—A rare condition, where the uterus is turned inside out. May be either acute or chronic.

**Pathology.**—The condition has its onset as a cup-shaped depression of the uterine wall, usually at the fundus, and as the inversion becomes more and more complete the fundus passes through the cavity of the uterus, past the cervix, into the vagina, and out at the vulva. The appendages follow the fundus. In acute cases the inverted organ forms a large pear-shaped tumor, soft and vascular. In chronic cases the mass is smaller, hard, and resembles a polypus. Pathological changes occur in the exposed endometrium, and friction ulcers are common. The inversion usually stops at the cervix, which forms a broad, strong ring surrounding the neck of the tumor. A certain amount of prolapse accompanies most of these cases.



**Etiology.**—The **acute form** may arise in the puerperium as the result of traction on the cord of an adherent placenta, and was formerly of more frequent occurrence before the proper management of the third stage of labor was well understood. The **chronic form** is found secondary to uterine tumors, occurring frequently in sarcoma, and as a rare complication of pedunculated, submucous fibroids.

**Symptoms.**—In the **acute cases** there are severe pain, hemorrhage, and even collapse, with subsequent swelling and edema. In the **chronic cases** there is constant pain, with a sensation of weight in the pelvis. Severe menstrual and intermenstrual hemorrhages occur, and the patient becomes weak and anemic. A profuse, and at times offensive, leucorrhea is usually present.

**Diagnosis.**—In **acute cases** **abdominal palpation** shows the rounded fundus replaced by a cup-like depression, and on **vaginal examination** a large, soft body is found to fill the vagina, presenting at its outlet. If the placenta has not been removed, its soft friable consistency is easily recognized, and care should be taken in removing it not to further increase the inversion (Fig. 47).

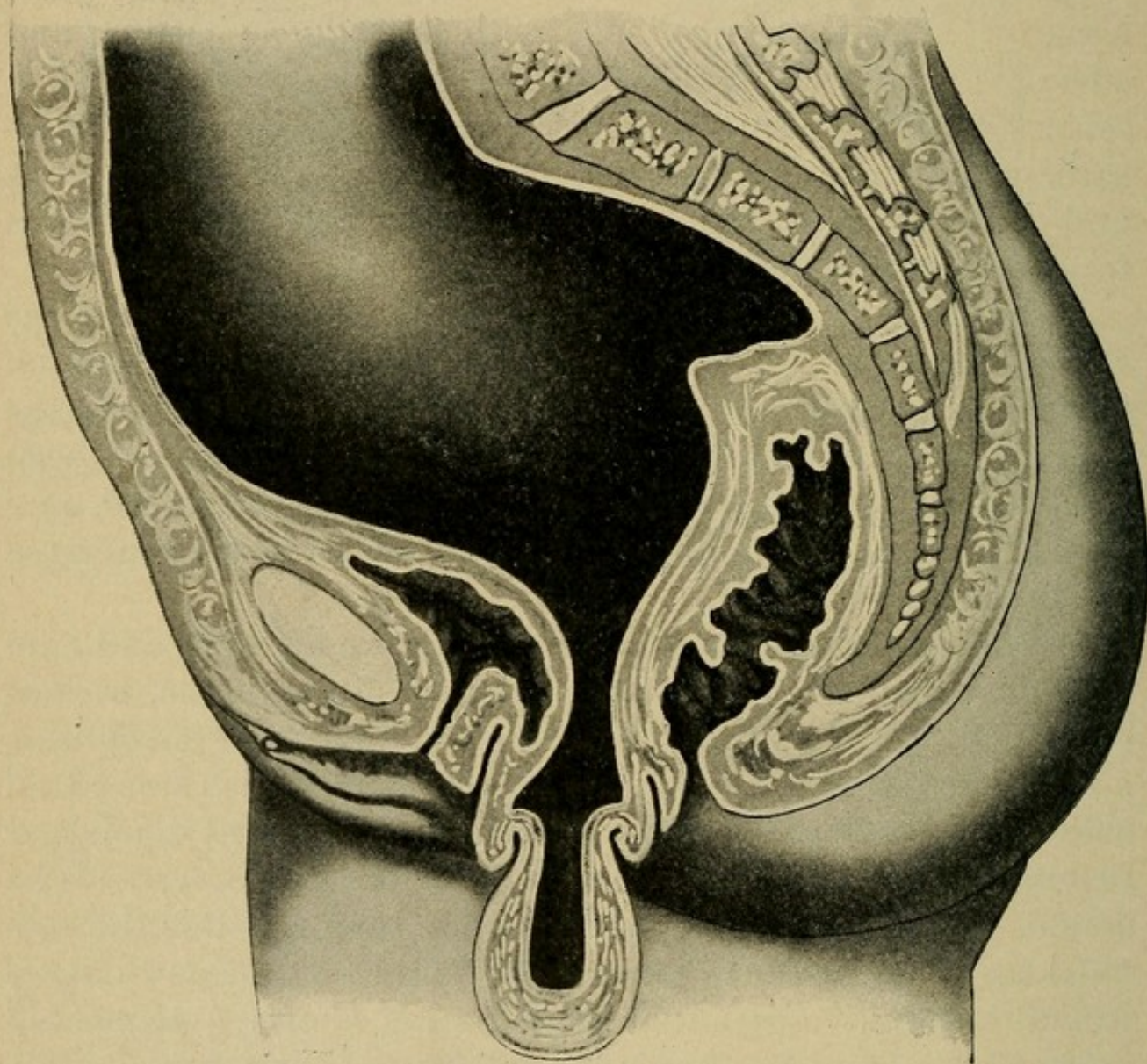
In **chronic inversion** the diagnosis is more difficult, and care is required to distinguish from intra-uterine polypus, pedunculated fibroid, and prolapse. The vaginal finger encounters a rounded vascular tumor that bleeds easily, and is free on all sides, as the finger sweeps around it, except at its upper extremity, which is encircled by the dilated cervix. The sound, passed up along the side of the tumor, enters the cervical canal for a short distance only, and no uterine cavity is found beyond. Bimanual examination shows a truncated body with a cup-like depression in place of the fundus.

**Treatment.**—In **acute cases** immediate manual reposition should be practised, and offers little difficulty if the case is seen early; if much swelling and edema are present prolonged hot douches should be first given. In **chronic cases** reposition offers many difficulties, operation being generally required.



This consists of anterior vaginal section, with incision of the cervix up to a point on the anterior uterine wall that will give space enough to push the fundus through into its proper place; the incision is then closed with catgut sutures. In cases of long standing this may prove impossible and vaginal hysterectomy be required.

FIG. 47



Complete inversion of the uterus. (Findley.)

**Hernia of the Uterus.**—A rare condition, where the uterus is found in the sac of a crural or inguinal hernia, or an enlarged pregnant uterus may escape forward into the sac of a ventral hernia.



### ANTEFLEXION.

**Definition.**—A persistence of the fetal type of uterus, where the angle of flexion between the cervix and fundus persists.

**Pathology.**—Anteflexion is found most commonly in nulliparæ. The angle of flexion is at the upper portion of the cervix, the fundus lying well forward under the symphysis pubis, and the cervix is bent sharply forward, lying in the axis of the vagina. The cervix is small and long, and usually has a small external os. The internal os is often constricted.

**Etiology.**—A congenital condition. An acquired form is recognized by some writers.

**Symptoms.**—Dysmenorrhea and sterility are the most prominent. Leucorrhea is a late symptom, and dyspareunia—pain on sexual intercourse—may be present.

**Diagnosis.**—On **vaginal examination** the cervix is found long and conical, and lying in the axis of the vagina. There is often a tender spot behind the cervix. The examining finger in the anterior fornix feels the angle of flexion between the cervix and the fundus. **Bimanual examination** confirms the anterior position of the fundus, which is usually small in proportion to the size of the cervix.

**Treatment.**—When anteflexion is associated with an infantile uterus, the most successful treatment is that directed toward further developing the uterus. (See Infantile Uterus.) Various intra-uterine stem pessaries and plastic operations on the cervix have been devised for the treatment of anteflexion. Pregnancy to full term usually effects a symptomatic as well as an anatomical cure, although the flexion sometimes persists after delivery.

### THE MENOPAUSE.

**Definition.**—The end of menstrual life. Also called the climacteric, and change of life.



**Pathology.**—The active period of menstrual life lasts, on an average, for thirty years, and lapses into abeyance at between the fortieth and fiftieth years. With the establishment of the menopause fertility ceases—fifty-three years being the age limit recognized by the courts. The onset may be sudden or gradual. Atrophic changes occur in the pelvic organs: the uterus shrinks, its muscular tissue partly disappears, and its walls become thin, soft, and relaxed. The ovaries become small and cirrhotic, and the Graafian follicles disappear. The vagina is shortened and narrowed and loses its elasticity. Various morbid conditions are very apt to develop at this time. Premature cessation of menstruation may occur as the result of mental shock, wasting diseases, or change of climate. Artificial menopause follows radical operations on the pelvic organs when the ovaries have been removed. Too radical a curettage may have the same effect.

**Symptoms.**—Many cases are unaccompanied by any unpleasant symptoms, though nervous disturbances, such as cardiac palpitation, sensations of heat and cold, with marked flushings of the face, are the rule. Depression of spirits, melancholia, and even mania at times develop. Irregular hemorrhages, when a symptom, should always be carefully investigated with reference to possible cancer.

**Diagnosis.**—Usually offers little difficulty, except when the menopause occurs prematurely. Careful observation with the history of the case should settle the question.

**Treatment.**—Exercise and fresh air, with freedom from anxiety, worry, and alcohol, are essential. The nervous symptoms should receive appropriate treatment as they arise. In cases of artificial menopause thyroid extract, 20 to 30 grains a day, is of service.

Premature menopause may be at times averted by dilating the cervix and firmly packing the uterine cavity with gauze. This stimulates contractions in the uterine muscle, which has a tendency to check the beginning atrophy.



## RELAXATION OF THE VAGINAL OUTLET.

**Definition.**—A loose, gaping introitus.

**Pathology.**—The supporting structure of the vaginal outlet, the anterior portion of the levator ani muscle, has sustained a break in its continuity, or has been stretched to a point where its muscular fibers are unable to contract sufficiently to close the introitus.

**Etiology.**—Frequent childbirth, the bearing of large children, unduly prolonged perineal stage of labor, and the performance of obstetrical operations.

**Symptoms** are those arising from the lack of proper perineal support; a feeling of weight and pressure in the pelvis.

**Diagnosis.**—Upon **inspection**, with the patient in the gynecological position, the vaginal opening is seen large and gaping. The anterior and posterior vaginal walls are no longer closely approximated but lie apart, and often more or less everted, constituting cystocele and rectocele. When the patient coughs, or bears down, a marked pouting of the vagina results, its walls tend to roll out, exposing a portion of the anterior and posterior walls.

The **examining finger in the vagina**, pressing down toward the anus, fails to encounter the firm resistance of the strong levator ani fibers.

**Treatment.**—Slight relaxation requires none. When the symptoms are progressive, and cystocele or rectocele begins to develop, operative repair of the perineum should be performed.

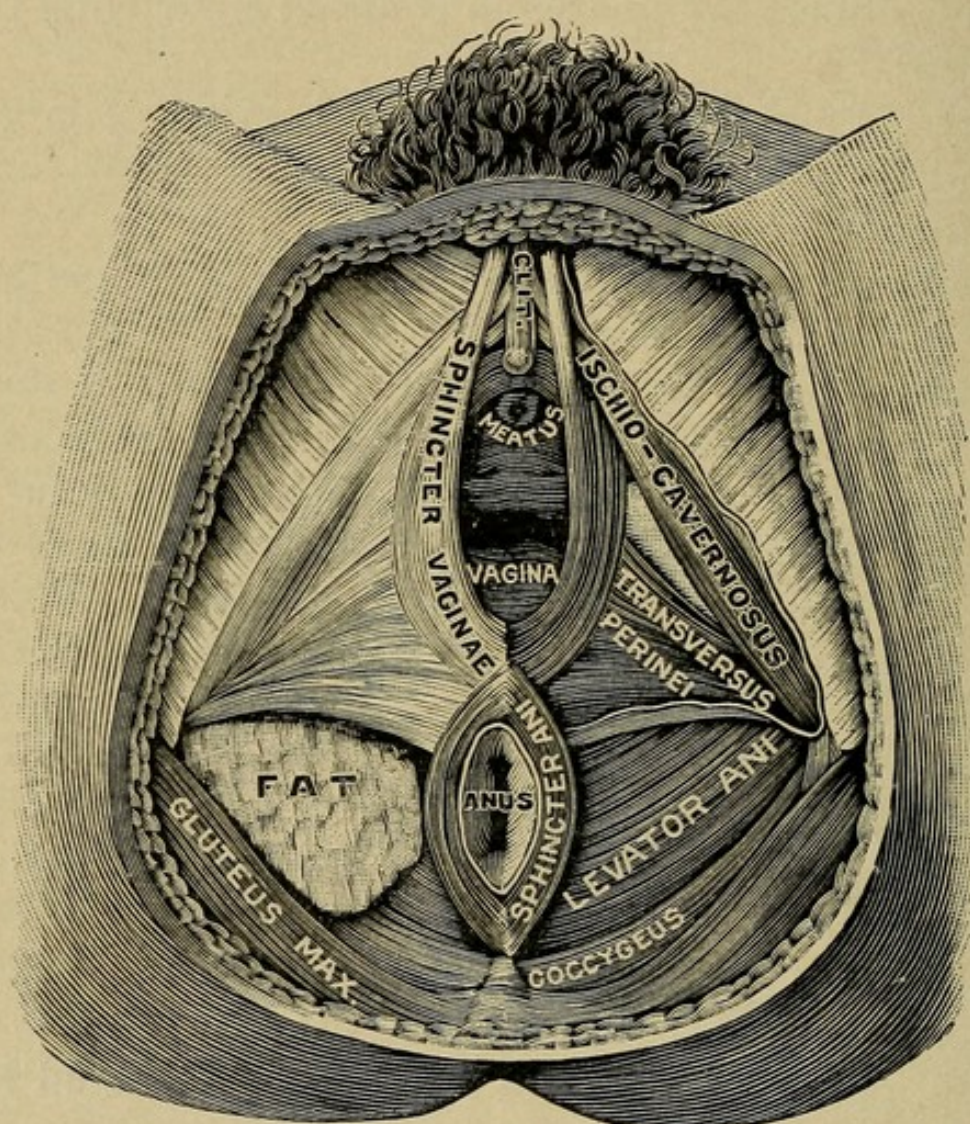
## LACERATIONS OF THE PERINEUM.

**Definition.**—A tear of the rectovaginal septum. May be either incomplete, where the rectum is not opened, or complete, where the rectal and vaginal openings are converted into one,



**Pathology.**—In childbirth, when the elasticity of the perineal tissues does not allow of sufficient dilatation for the birth of the presenting part, rupture occurs in the line of least resistance—usually the median raphe, though laceration to one side or the other is of not uncommon occurrence. The

FIG. 48



Muscles of the female perineum. (Testut.)

tear may be only through the fourchette (first degree), down to the sphincter ani (second degree), through the sphincter ani (third degree), or into the rectum (complete laceration, or fourth degree).

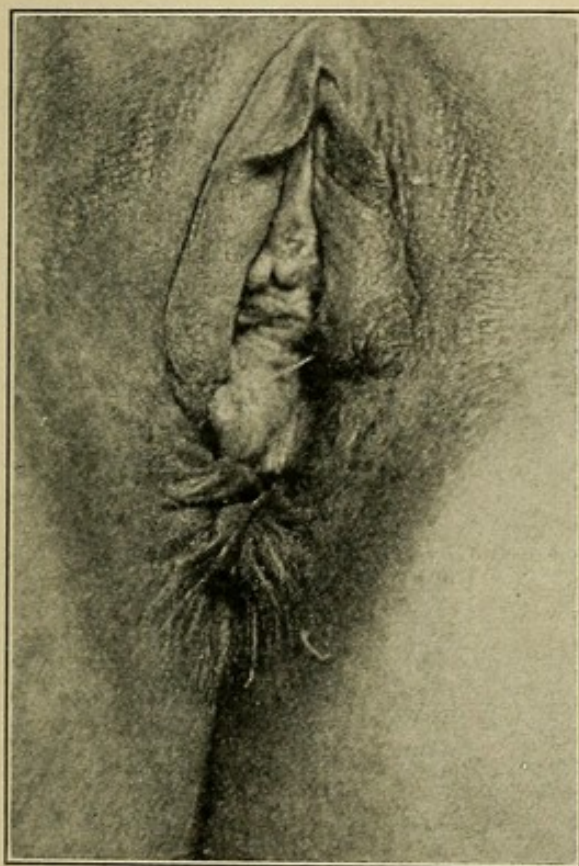
**Etiology.**—Important predisposing factors are rigidity of the soft parts, especially in elderly primipara, and precipitate



labor. A large head, broad shoulders, persistent occipito-posterior positions, and the various obstetrical operations are also common causes.

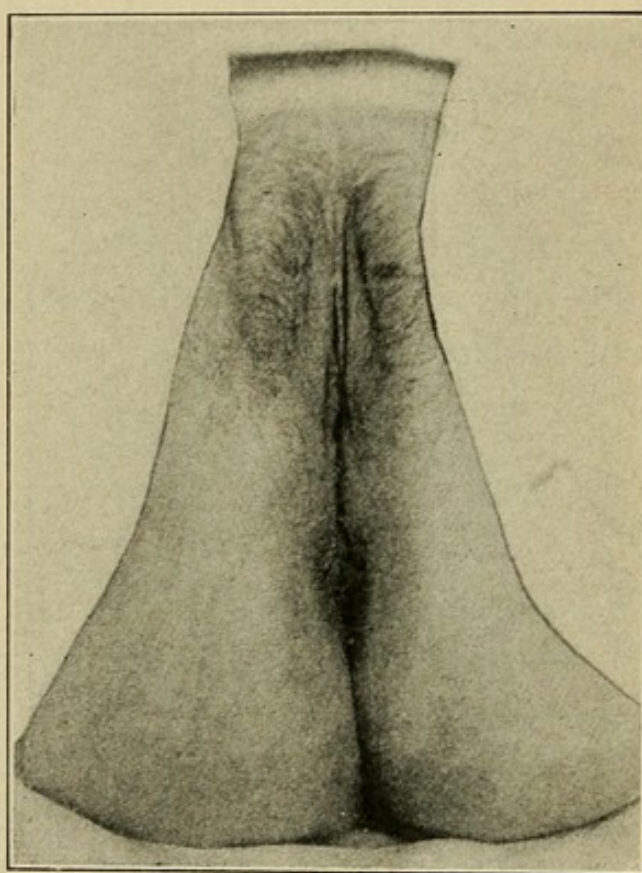
The **symptoms** are usually dependent on the extent of the laceration and the length of time it has existed. A feeling of weight and fulness in the pelvis are generally complained of. Bladder and rectal symptoms are present if the laceration has

FIG. 49



Complete perineal laceration.  
Before operation.

FIG. 50



After operation (by Ristine's  
method).

been extensive enough to cause the development of a cystocele and rectocele. In complete laceration of the perineum the patient loses control of gas and feces in the rectum.

**Diagnosis.**—Much that has been said under the diagnosis of relaxation of the vaginal outlet applies as well to cases of laceration. The normal height of the perineum is destroyed, the vaginal opening approximates the anal, until, in complete



cases, they become one. The vulval opening gaps and the anterior and posterior vaginal wall, either one or both, are exposed to view and roll outward when the patient strains. One or both lateral sulci are deeper than normal, and depression with the examining finger fails to encounter the resistance of the transversus perinei fibers. When the tear has gone through the sphincter, the normal puckering of the anus will be found to have disappeared anteriorly, and little dimples form on either side denoting the retracted ends of the sphincter muscle. The anal and rectal mucous membrane may be exposed and the examining finger introduced into the rectum meets with little or no resistance at the anus.

**Treatment.**—The proper prophylaxis for saving the perineum belongs to obstetrics. **Immediate repair** should always be performed. **Secondary repair** is called for in the presence of marked symptoms.

### CYSTOCELE.

**Definition.**—A hernia of the bladder into the vagina.

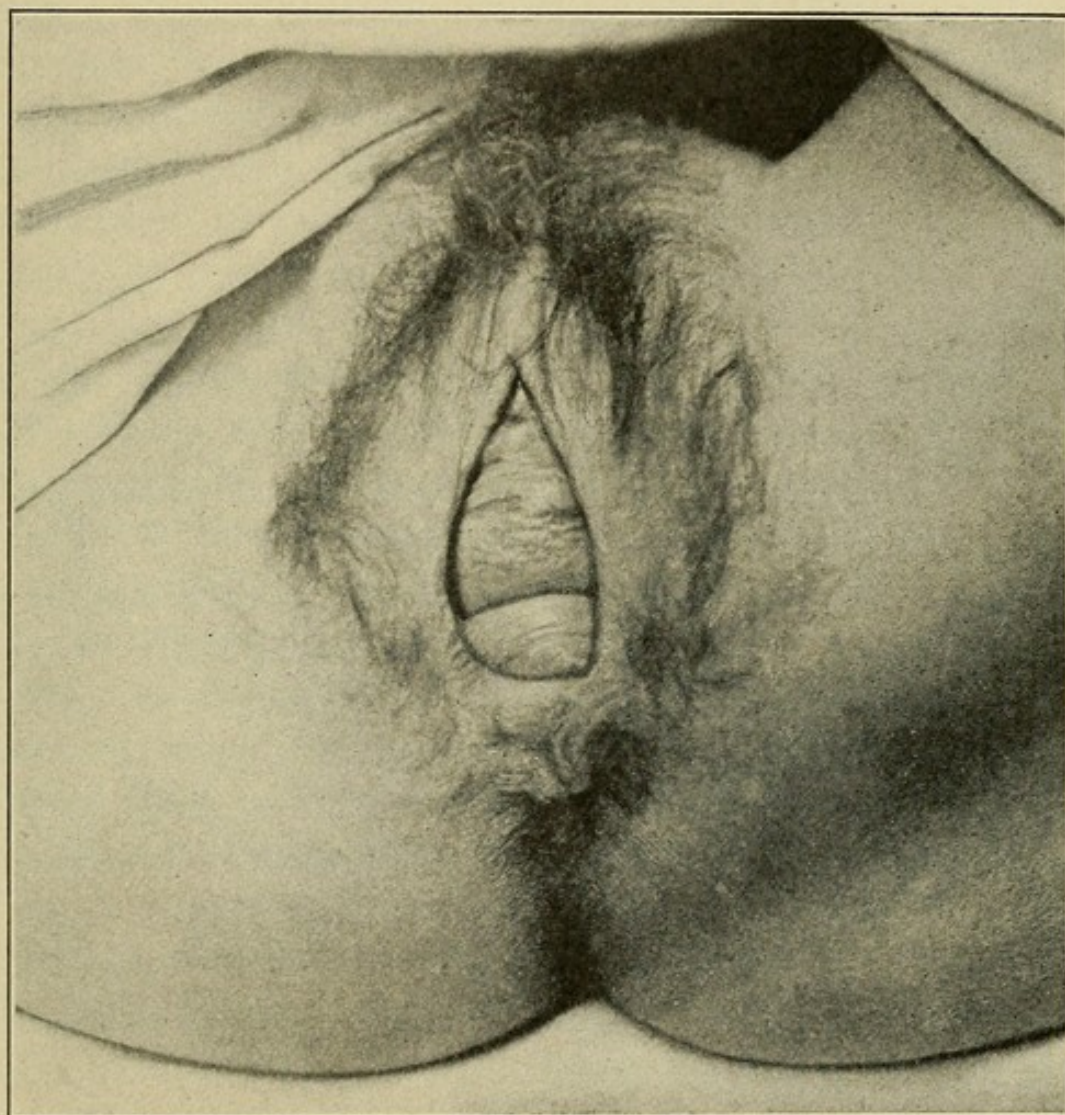
**Pathology.**—As a result of relaxation, or destruction, of its normal supports the bladder descends into the pelvis, pushing before it the anterior vaginal wall. The anterior vaginal wall yields, its fascia thins out and disappears, or becomes so stretched that the bladder approaches and may even partially escape at the vaginal opening. As the bladder sinks into the pelvis, increasing difficulty in micturition is experienced, the patient is no longer able to thoroughly empty her bladder, and the residual urine eventually causes a cystitis, accompanied by more or less dilatation of the bladder.

**Etiology.**—Laceration of the perineum with its resulting relaxation of the pelvic floor is an important etiological factor. Traumatic cases in nulliparæ are occasionally seen. A prolapsing uterus may drag the bladder with it in its descent, though it is possible in some cases, that the cystocele causes



the prolapse. Undue relaxation of the vesical ligaments and pelvic floor, with habitual overdistention of the bladder, are responsible for the majority of cases (Fig. 51).

FIG. 51



Laceration of the perineum showing cystocele and rectocele.

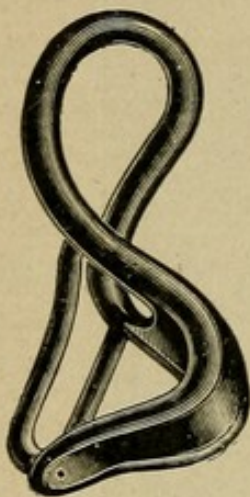**Symptoms.**—A sensation of weight and dragging in the pelvis, accompanied, when the bladder is full, by a feeling of distention at the vaginal outlet. Vesical irritability and cystitis are later symptoms.

**Diagnosis.**—In the dorsal position, on examination, the anterior vaginal wall is seen presenting at the vulva, forming in marked cases a distinct tumor, which increases in size on



straining. This tumor may be replaced, and its size increased or decreased by filling or emptying the bladder. Retraction of the posterior vaginal wall shows that the anterior wall no longer forms a straight line from the introitus to the cervix,

FIG. 52



Skene's pessary.

but bulges down into the vagina. The normal folds, or rugæ, are obliterated, and the surface is smooth, pale and has a stretched appearance. In extreme cases, when the bladder comes outside the introitus, its vaginal covering, from exposure to the air and friction of the clothing, is dry and hard.

**Treatment.**—Palliative treatment by pessaries is suitable in certain cases. If the cystocele is slight, and the relaxation of the vaginal outlet moderate, good results may be obtained with Skene's pessary (Fig. 52).

In more extreme cases the cup pessary may be tried. Complete cure, however, is only accomplished by operative measures. Anterior vaginal section should be performed, the bladder freed from the anterior vaginal wall and from the uterus up to the peritoneal reflection, and replaced. The thinned-out portion of the vaginal wall is removed and the incision closed by suturing the vaginal wall to the uterus from the cervix to the peritoneal reflection. Relaxation of the vaginal outlet should be corrected at the same time.

### RECTOCELE.

**Definition.**—A hernia of the anterior rectal wall into the vagina.

**Pathology.**—Relaxation or laceration of the levator ani muscle deprives the lower end of the rectum of its proper support, so that during the expulsion of feces, forward distention of the anterior wall into the vagina results. The posterior



vaginal wall is carried before the advancing anterior rectal wall, and appears at the introitus as a bulging tumor, increased in size with every expulsive effort. This dragging on the posterior vaginal wall causes downward traction on the cervix, which may eventually produce hyperelongation of the cervix, retroversion, or prolapse of the uterus. Feces are forced into this pouch and difficulty in emptying the rectum is often experienced.

**Etiology.**—Difficult labor and prolongation of the perineal stage, resulting in an overstretching, or laceration, of the levator ani muscle, are the exciting causes.

**Symptoms.**—The chief symptoms are difficulty in defecation and inability to entirely empty the rectum. There is, in addition, a feeling of weight and depression in the pelvis.

**Diagnosis.**—Easily made with the patient in the dorsal position. Through the gaping introitus the posterior vaginal wall presents as a soft, rounded tumor increasing in size on expulsive effort, and disappearing on pressure. The index finger introduced into the rectum readily demonstrates the distended anterior rectal wall, which may be pushed forward into the vagina and out through the vaginal orifice.

**Treatment.**—**Palliative management** is directed toward preventing the rectocele from increasing in size by regulating the bowels and thus avoiding the injurious effects of chronic constipation with its violent expulsive efforts. **Radical treatment** consists in the operative repair of the perineum and pelvic floor.

## GENITAL FISTULA.

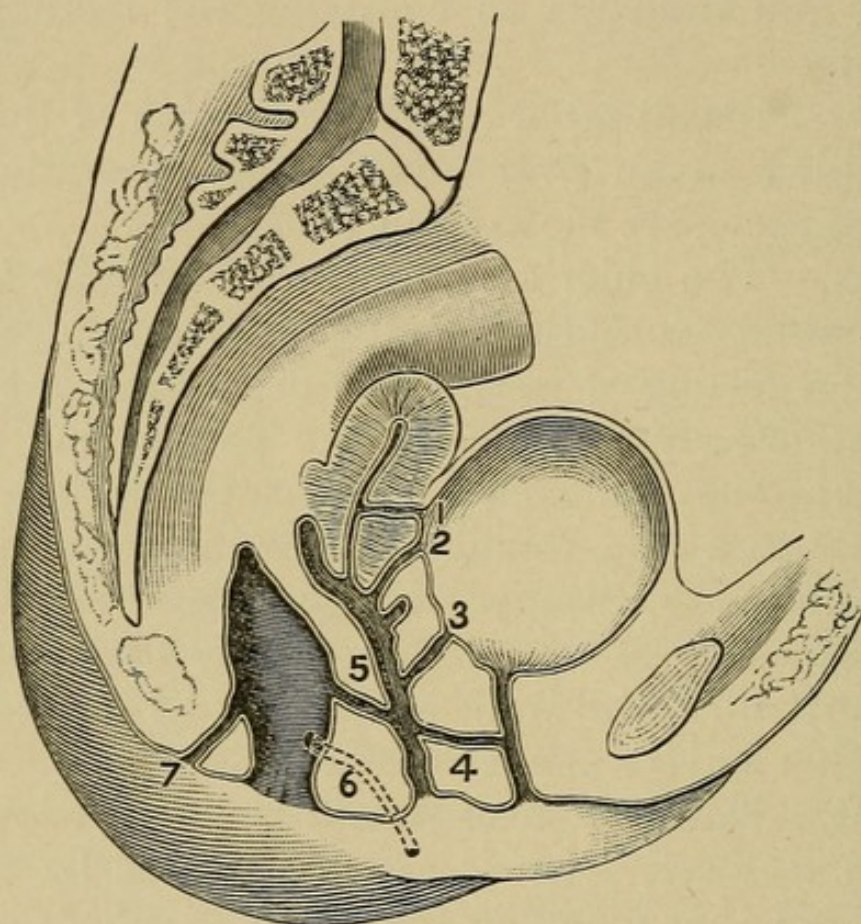
**Definition.**—A genital fistula is an abnormal opening between the uterus or vagina and the urinary tract or intestines (Fig. 53).

**Pathology.**—The fistulæ most often met with are vesicovaginal, where the communication is between the bladder and vagina. Of less frequent occurrence are rectovaginal, between



the rectum and vagina; urethrovaginal, between the urethra and vagina; ureterovaginal, between the ureter and vagina; vesico-uterine, between the bladder and uterus. Rare forms sometimes encountered are utero-uterine, rectoperineal, and enterovaginal.

FIG. 53



Location of various forms of fistula: 1, vesico-uterine fistula; 2, vesico-utero-vaginal fistula; 3, vesicovaginal fistula; 4, urethrovaginal fistula; 5, rectovaginal fistula; 6, rectolabial fistula; 7, fistula in ano.

**Etiology.**—Vesicovaginal, rectovaginal, urethrovaginal, and vesico-uterine fistulæ are generally seen as the result of tissue necrosis following prolonged pressure of the fetal head in labor, and were formerly much more common than at present, due to delay in the use of forceps. Any of the fistulæ may result from the sloughing of malignant, growths or from injury inflicted at operation.

**Symptoms.**—The characteristic symptom is the involuntary discharge of urine or feces through the abnormal opening.



**Diagnosis.**—The greatest difficulty is at times encountered in locating the fistula. If large, it may usually be seen and probed by proper retraction of the tissues, but when small and high up, other means are often necessary. For the vesical fistulæ the bladder should be emptied by catheter and injected with a colored solution, sterilized milk, or methylene blue, so that its point of escape may be more easily seen. The small fecal fistulæ are more readily located by blackening the stools with bismuth subnitrate or charcoal.

**Treatment.**—Spontaneous closure sometimes occurs during the first year, but rarely later. In all chronic cases radical operative measures give the best results.

## STERILITY.

**Definition.**—Incapability of reproduction.

**Varieties.**—The reproductive function is the most complex and probably least understood of all the functions of life. Sterility, in the usual acceptance of the term, implies that condition in which the woman does not conceive, or if conception occurs she is unable to bear a viable and living child. When conception has never occurred the term applied is **absolute sterility**, and when conception takes place, but early death of the embryo or fetus habitually occurs, resulting in abortion or the birth of a non-viable child, the condition is said to be one of **relative sterility**.

In many cases of absolute sterility the fault is with the male, and the female is only too often unjustly blamed. But the question of male sterility does not concern us here, save to emphasize the fact that his fertility should never be taken for granted. No woman should be accused of sterility and her life endangered by a serious surgical operation aimed at its correction, without first examining her husband's spermatozoa and deciding his fertilizing powers.

**Etiology.**—The causes of sterility may be considered under age, structural defects, either congenital or acquired, and



functional. The age of the woman has a strong bearing on the question. Matthew Duncan investigating this subject in England, found "that about 7 per cent. of all the marriages between fifteen and nineteen years of age, inclusive, were without offspring; that those married at ages from twenty to twenty-four, inclusive, were almost all fertile; and that after that age sterility gradually increases according to the greater age at the time of marriage." Among the congenital defects should be mentioned imperforate hymen; absence or malformation of the vagina, uterus, ovaries, or tubes. Of the acquired structural defects, many are the result of a previous inflammation which has occluded the tubes or so thickened the cortex of the ovaries that the ova cannot escape. Endometritis, whether primary or secondary to displacements of the uterus, affords an unfavorable soil for the lodgement and growth of the fecundated ovum. Cervical lacerations and syphilis are responsible for many cases of habitual abortion. The functional causes are complex. Good health, plenty of outdoor exercise, and the avoidance of alcohol are favorable to fecundity, while luxury and great wealth with their attendant evils appear to go hand-in-hand with sterility.

**Treatment.**—The average interval between marriage and the birth of the first child is twenty months. If after several years of married life conception has not occurred, or a viable child not been born, the cause should be sought for. Congenital and acquired defects should receive their appropriate treatment.

When no bar to conception has been found, but where the sterility is of long standing and conditions warrant it, exploratory celiotomy may be performed, and many times the fimbriated ends of the tubes will be found closed by thin cobweb-like adhesions, the cause of the sterility. When these are separated and the tube opened, conception frequently occurs within the first six months after operation.

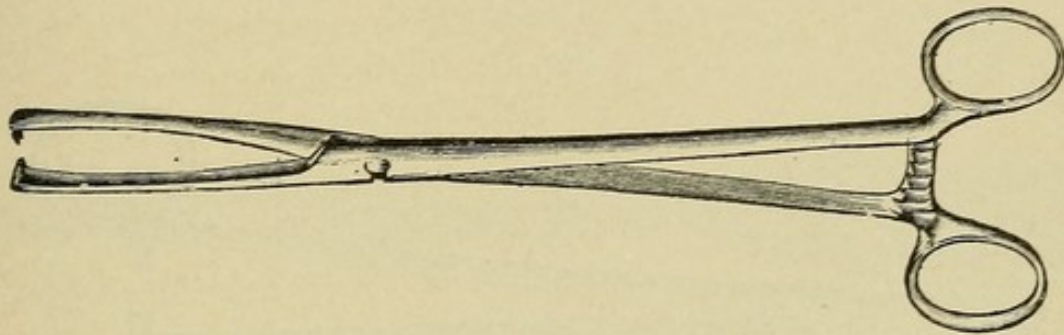


## CHAPTER XVI.

### GENERAL GYNECOLOGICAL OPERATIVE TECHNIQUE.

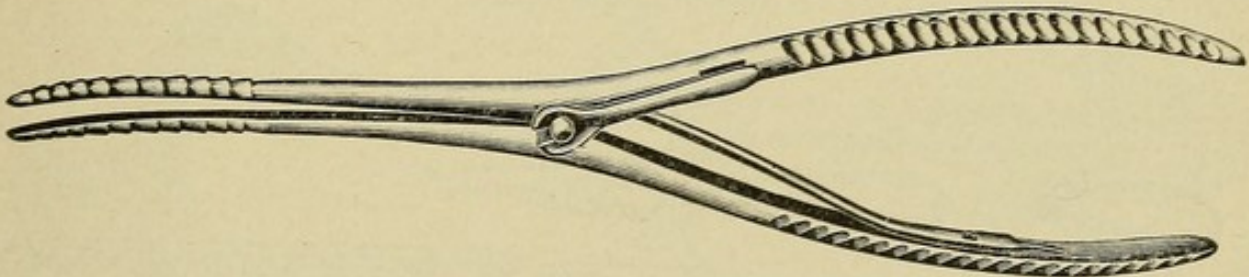
The classes of surgical operations on women required for the treatment of diseases peculiar to them are two, minor and major.

FIG. 54



Doyen's traction forceps.

FIG. 55



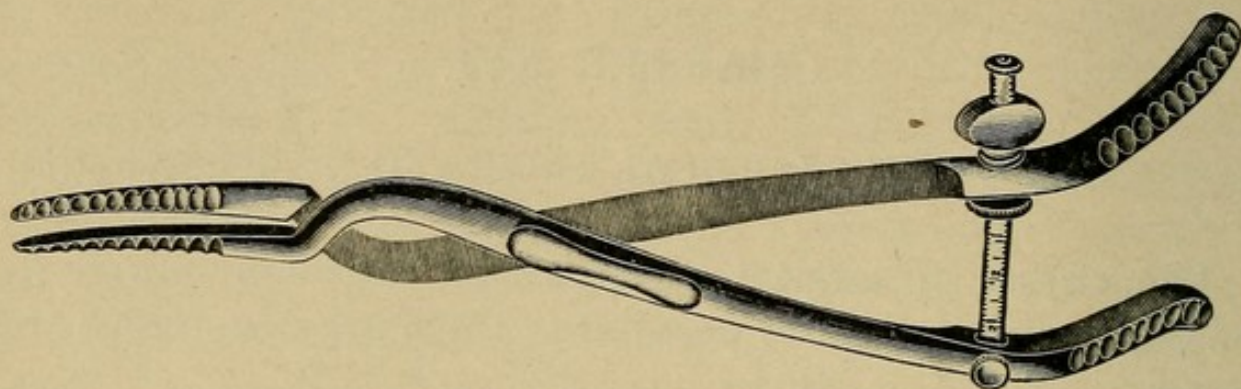
Pryor's dilator (small).

The **minor operations** comprise dilatations of the cervix, curettage, repair of the cervix, repair of the perineum, the various minor surgical operations on the vulva and vagina, and the extraperitoneal operations for the correction of retrodisplacements of the uterus.

The **major operations** include all procedures where the peritoneal cavity is opened. Two methods of approach are available, the abdominal and the vaginal. Occasionally both may be used with advantage in the same case.

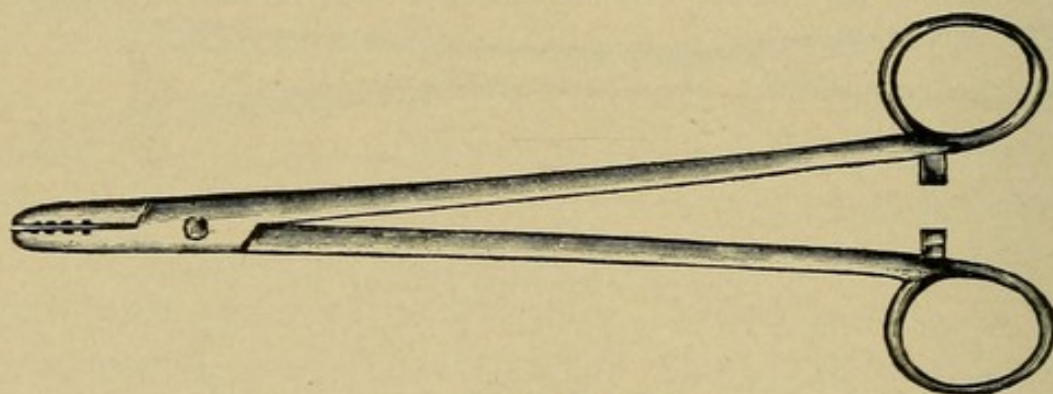


FIG. 56



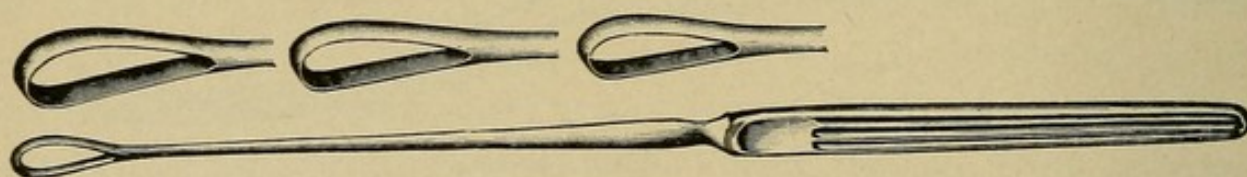
Wathen's dilator (large).

FIG. 57



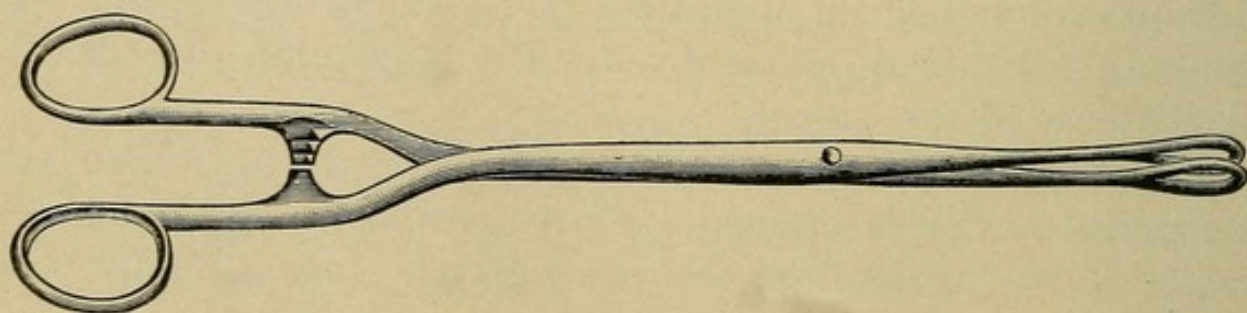
Abbey needle-holder.

FIG. 58



Sims' curette.


FIG. 59



Foerster's sponge-holder.




FIG. 60



Martin's uterine sound.

FIG. 61



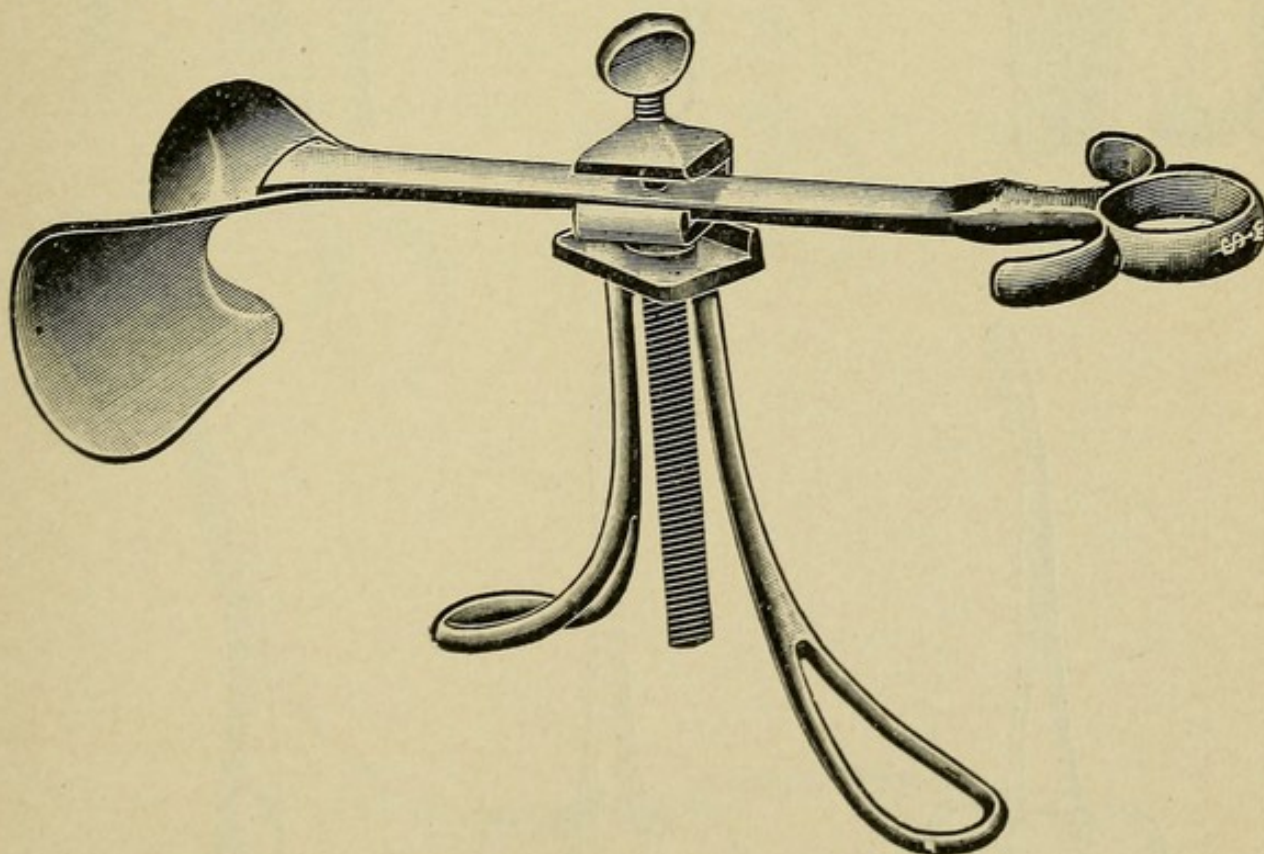
Sims' tampon screw.

FIG. 62



Scalpel.

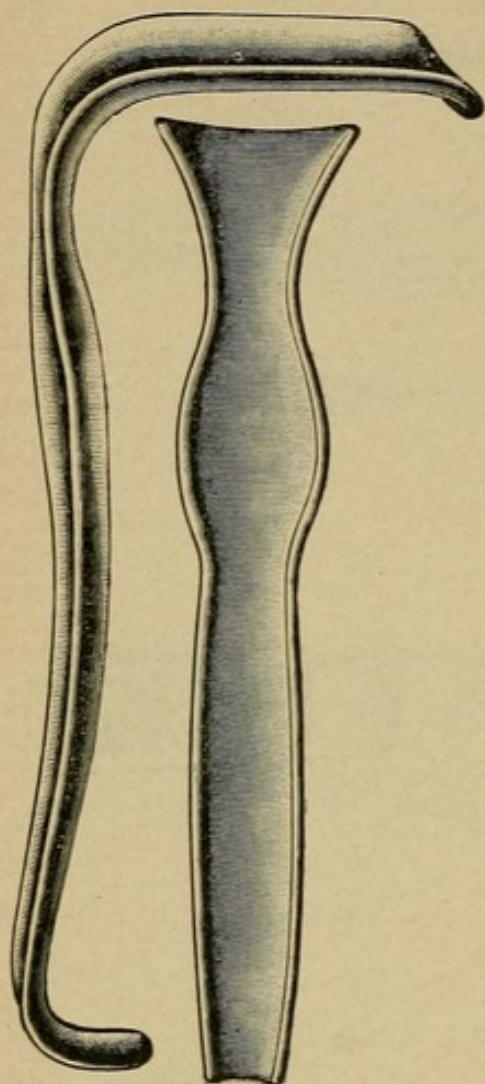
FIG. 63



Author's modification of Doyen's abdominal retractor.



FIG. 64



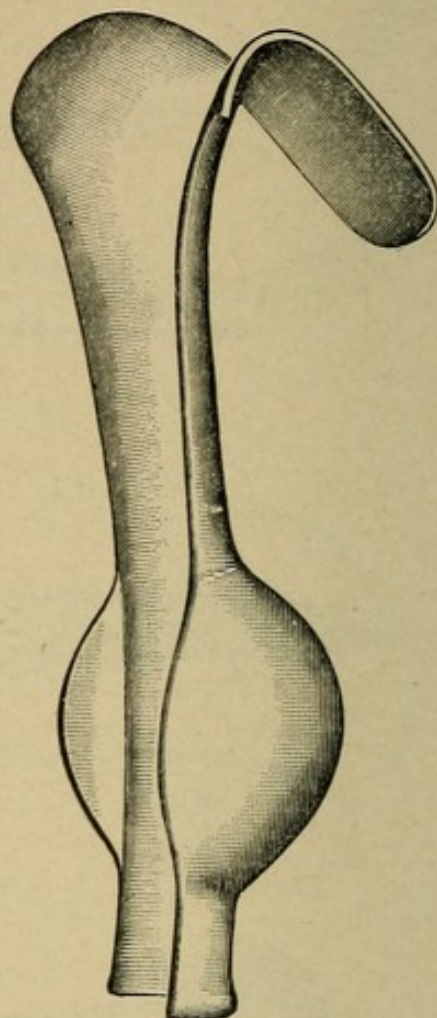
Eastman's retractor.

FIG. 65



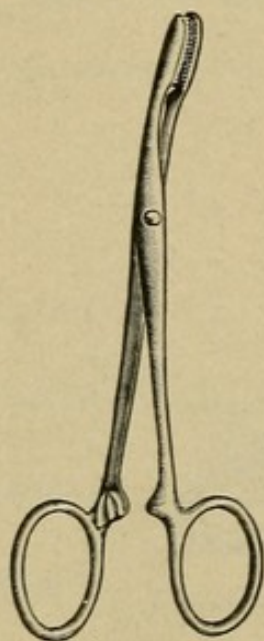
Tissue forceps.

FIG. 66



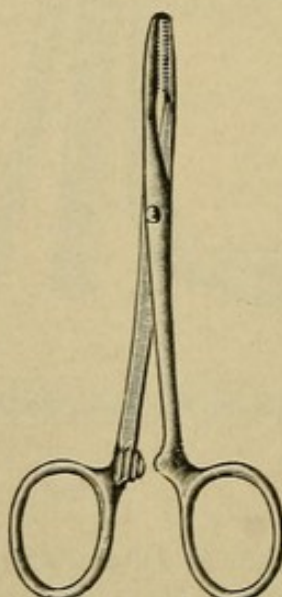
Garrigues' speculum.

FIG. 67



Pean's 3 inch artery clamps.

FIG. 68



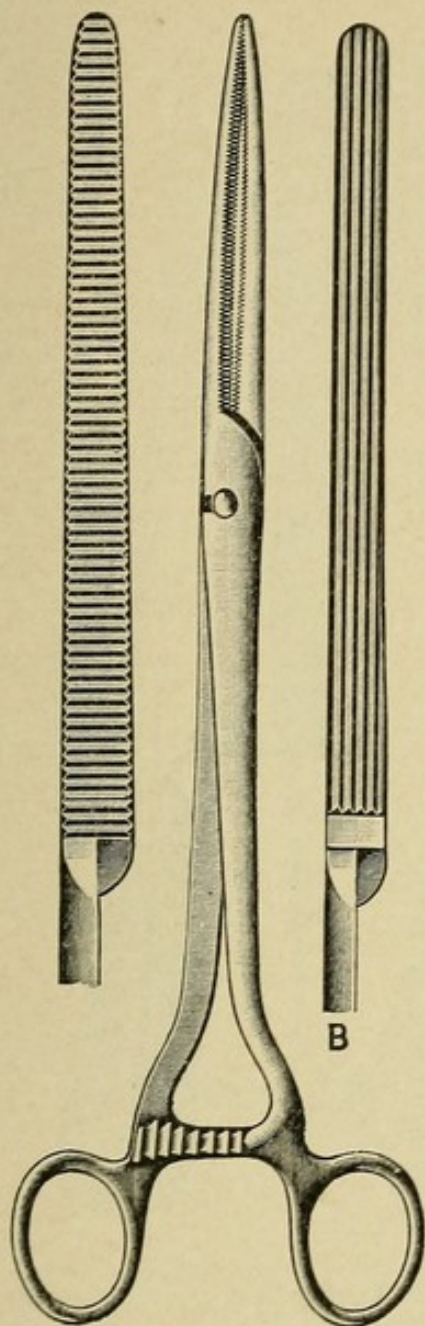
Pean's 8 inch artery clamp.

FIG. 69



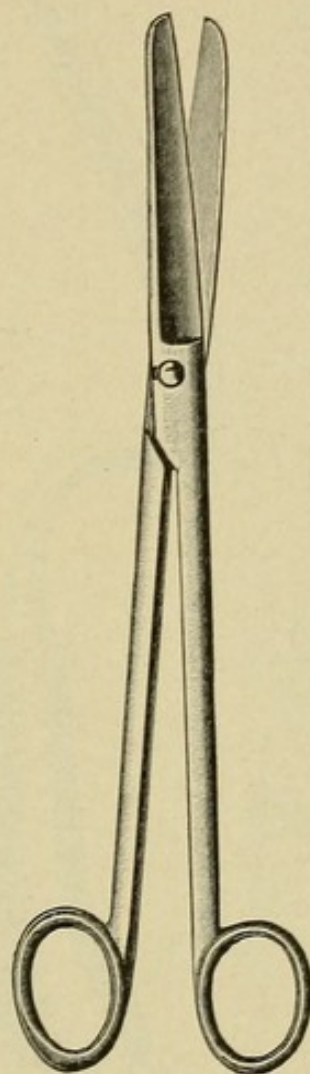


FIG. 70



Pean's hysterectomy clamp.

FIG. 71



Scissors.

FIG. 72

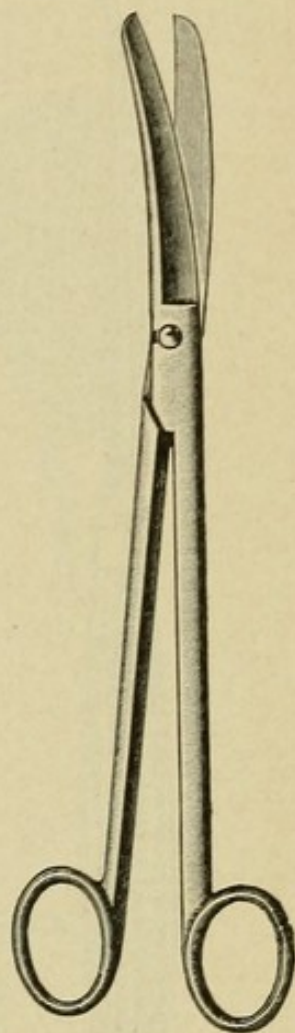
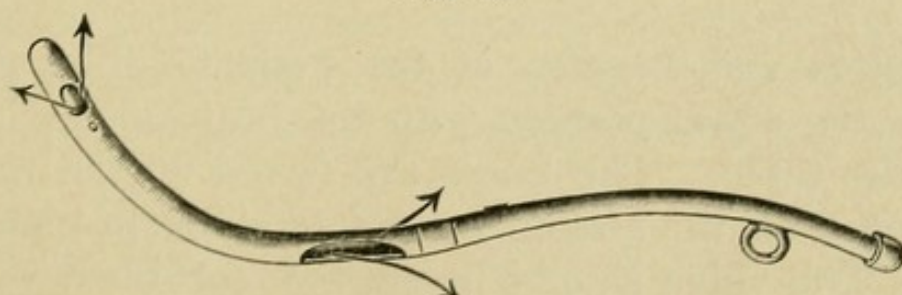


FIG. 73



Fritsch-Bozeman uterine irrigator.



FIG. 74

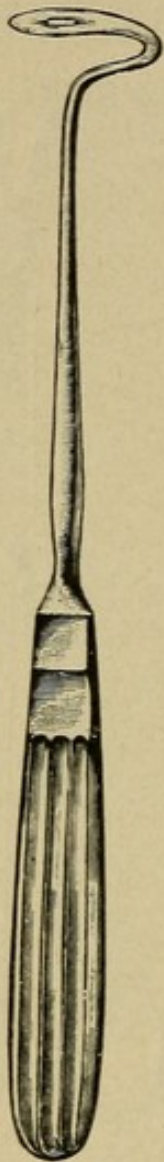

FIG. 75

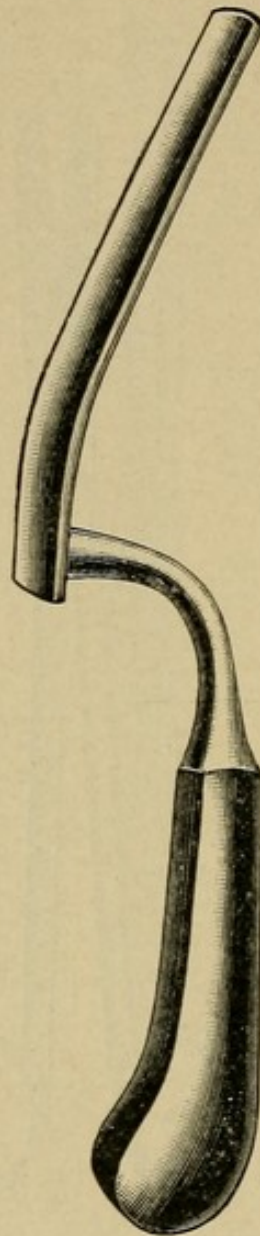
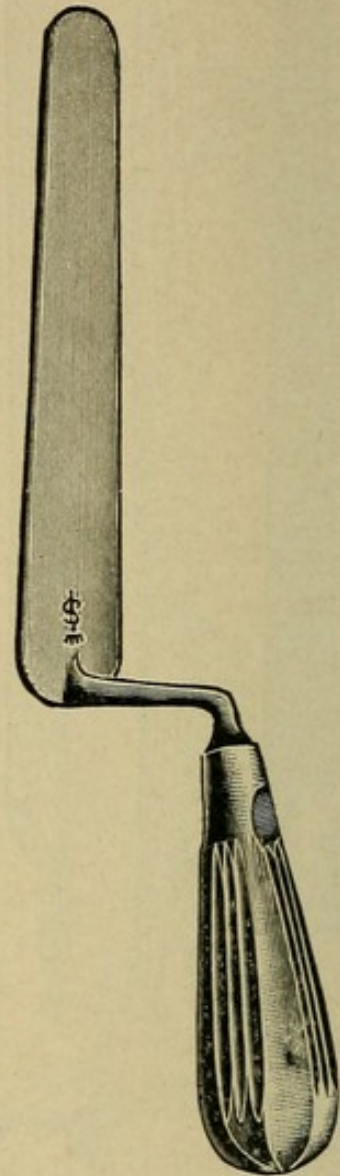


FIG. 76



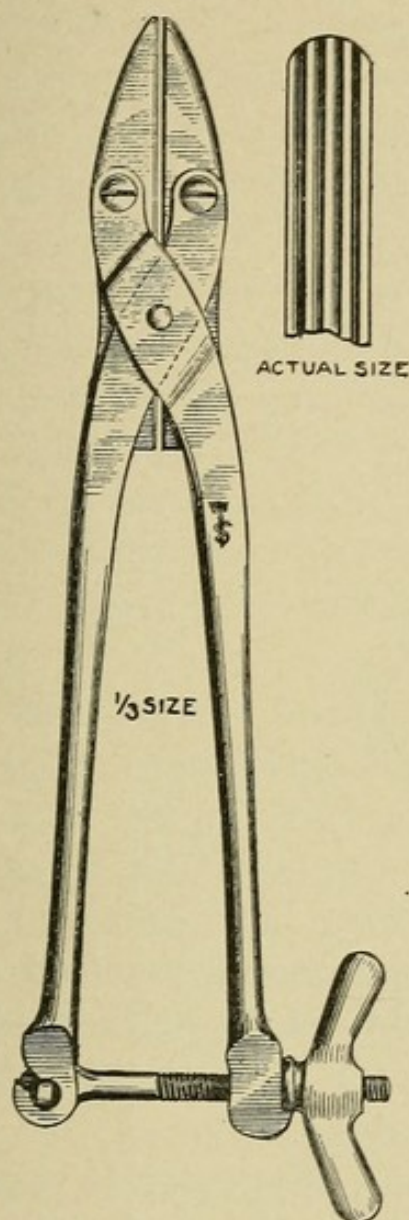
Deschamps' ligature carrier. Pryor's trowel retractor. Author's trowel retractor.

### THE MINOR OPERATIONS.

**Preparation and Position of the Patient.**—The patient is placed in the dorsal position with the buttocks well over the edge of the table. The knees are flexed on the thighs, the thighs flexed on the abdomen, and retained in place by leg-holders. The vulva should be shaved, scrubbed with gauze wet with tincture of green soap, and washed with sterile water.

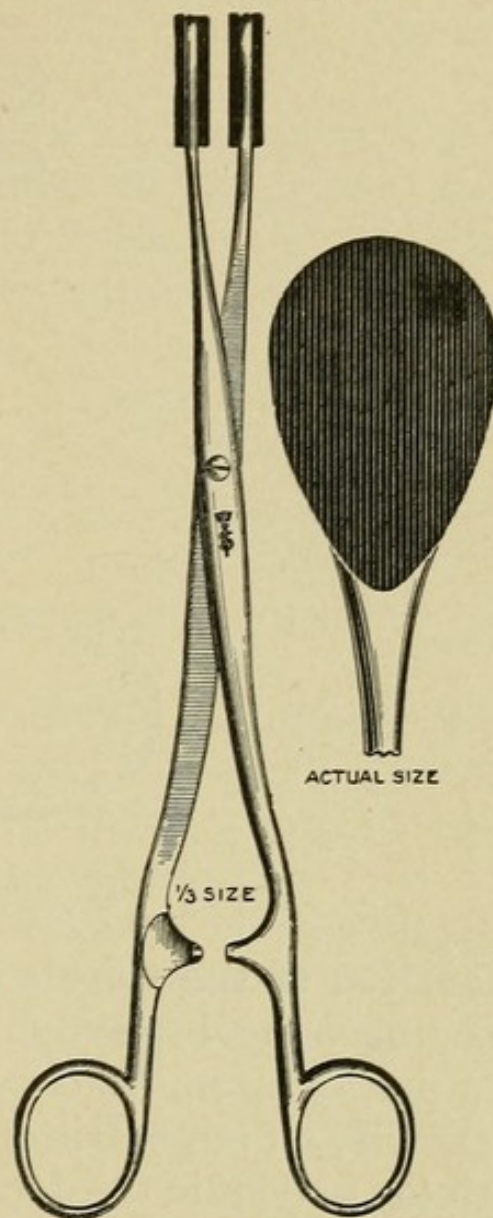


FIG. 77



Author's angiotribe.

FIG. 78



Author's intestinal forceps with rubber jaws.

The vagina should be thoroughly cleansed with the tincture of green soap, preferably with the patient in the knee-chest position, and a final prolonged douche of sterile water given.

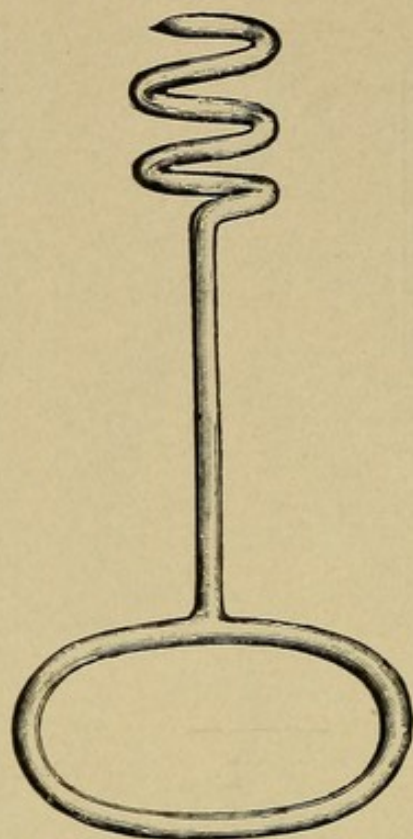
**Preparation of the Surgeon's Hands.**—Scrub for five minutes the hands and forearms with the tincture of green soap, wash in sterile water, scrub for two minutes in Stewart's solution:

Sulphate of aluminum	. . . . .	3j
Chloride of lime	. . . . .	3ij
Water	. . . . .	Oij

And give a final rinsing in sterile water.



FIG. 79



Doyen's tumor screw.

**Dilatation of the Cervix.**—The instruments required are, a retracting vaginal speculum, preferably of the self-retaining type, a pair of strong traction forceps for holding the cervix, and a small and large pair of cervical dilators.

With the patient in the dorsal position, the posterior vaginal wall well retracted, the anterior cervical lip is firmly grasped with the heavy traction forceps and drawn down as near the vaginal outlet as possible. The dilator is then introduced into the cervical canal up to its shoulder, the traction on the cervix relieved, and before dilatation is begun, the cervix, with the dilator in place, is pushed up into the vagina until the vaginal walls are put well on the stretch. By this procedure, recommended by Goffe, the cervix is firmly held on the dilator during dilatation, and there is no danger of its jumping off and the blades of the dilator accidentally tearing the cervix. If the cervix is held down in view during dilatation, it is possible for the traction forceps to tear out, releasing the cervix,



which, as it slides off the dilator, may be badly lacerated by the points of the dilator blades. This accident unfortunately is of only too common occurrence.

Having observed this precaution, dilatation is now begun by gradually separating the blades of the dilator, and continued until the desired degree of dilatation is reached. The pressure of the dilator should be constant rather than intermittent, and gradually increased, so as to dilate and not tear the muscular fibers in the cervix. The time required depends on the rigidity of the cervical tissues, but should not, as a rule, be less than ten minutes, as this is about the length of time required to thoroughly dilate, and so paralyze the muscular fibers that immediate contraction of the cervix will not occur.

**Curettage.—Instruments Required.**—In addition to those necessary for dilatation of the cervix, a uterine sound, two curettes (small and medium), a sponge holder, a uterine irrigator, and a tampon screw are necessary.

Following the **preliminary dilatation** of the cervix, the operator should make a thorough **exploration of the uterine cavity with the sound** to determine its size and any irregularities in shape.

1. If the patient presents a **case of retained secundines**, they should be removed as thoroughly as possible with the sponge holder or placental forceps and the rough surface of the uterine wall denoting the placental site lightly, but thoroughly, gone over with the curette.

2. When the operation is performed for a **case of chronic endometritis**, the curette is carried up to the fundus, firm pressure made against the uterine wall, and a strip of endometrium removed by a steady downward stroke of the curette as far as the internal os. At the end of the stroke, all pressure on the curette is stopped and the instrument again gently carried up to the fundus, repeating the process until the whole interior of the uterus has been covered, removing all the diseased endometrium. Strong and steady downward traction on



the cervix during the operation straightens out the uterine canal, so that in anteflexion and retroflexion the surface at the fundus is more easily reached with the curette. The cervix during a curettage should never be held by an assistant, but always by the operator himself. Following the curettage the uterus should be irrigated for three minutes with a normal saline solution at a temperature of 110° F. If packing of the uterus is indicated, a tape of sterile bichloride or iodoform gauze is carried up to the fundus with the tampon screw, and the whole uterine cavity firmly packed down to the internal os. The end of the uterine gauze in the vagina is tied to a wide strip of gauze, with which the vagina is packed, and a vulvar pad worn to absorb the drainage. On the third day all the gauze is removed and a hot vaginal saline douche given three times a day for a week.

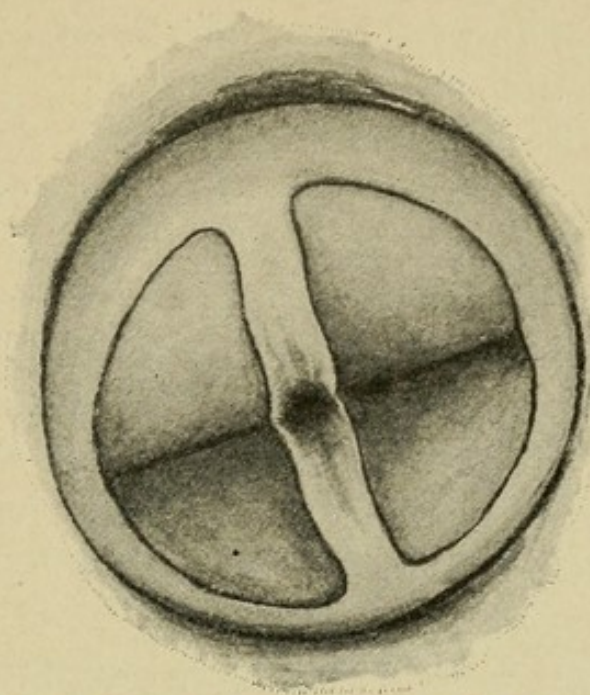
In curetting, my preference is for the sharp curette, which surely removes the endometrium more thoroughly and with less traumatism than does the dull instrument, and if due care be used is just as safe.

**Imperforate Hymen.—Technique.**—A small incision is made through the hymen, and any retained blood or mucus in the vagina slowly evacuated. The incision is then enlarged to the full width of the hymen and crossed at right angles by another of the same length. A thorough vaginal douche is given and the vagina lightly packed with gauze. The hymen is frequently quite thick, though rarely very vascular, so that the gauze packing generally controls any undue bleeding. The gauze is removed on the third day and another douche given. The patient should be subsequently examined at monthly intervals, and the opening kept patent with dilators if necessary until all chance of closure from cicatricial contraction is past.

**Trachelorrhaphy.**—**Preliminary dilatation** and curettage usually precede the operation, and the additional **instruments required** are two retractors for the vagina, six artery clamps, a pair of scissors, a heavy pair of tissue forceps, two traction

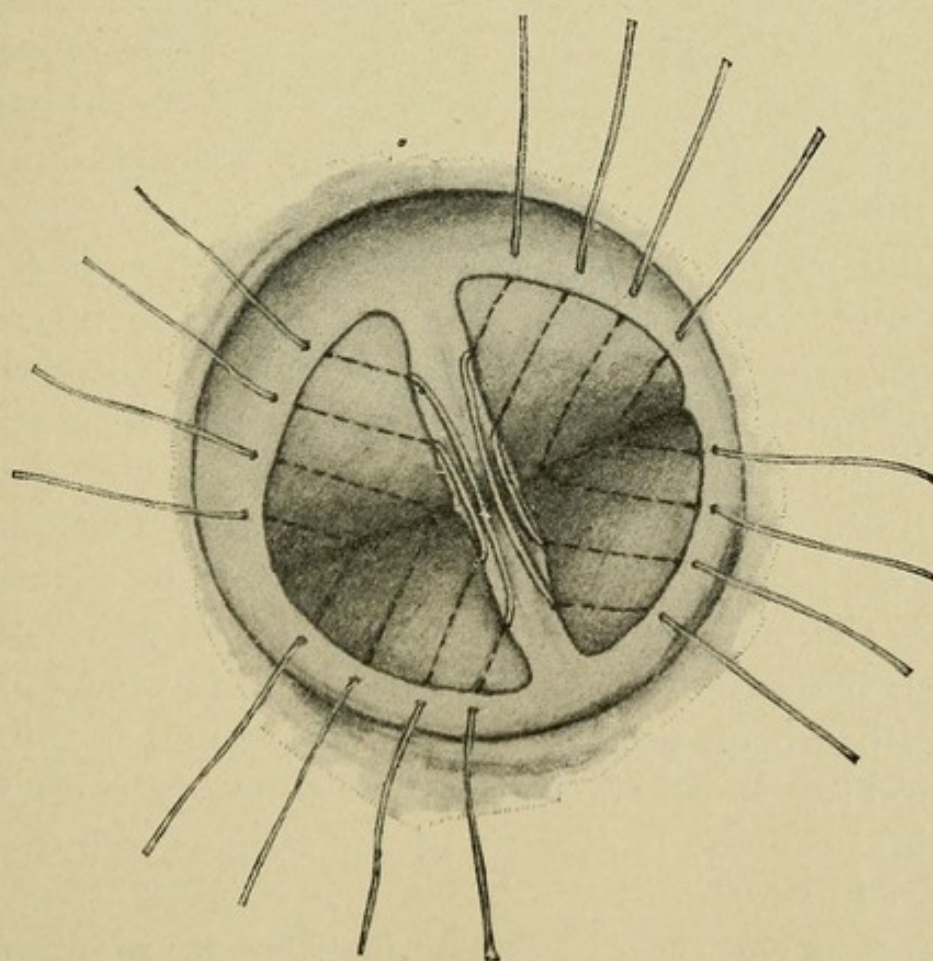


FIG. 80



Trachelorrhaphy, both sides denuded. (Davenport.)

FIG. 81



Trachelorrhaphy, sutures in position on both sides. (Davenport.)



forceps, a knife, a needle-holder, two full curve  $1\frac{1}{4}$  inch Hagedorn needles, and for suture material, either No. 3 silk-worm gut or chromicized catgut.

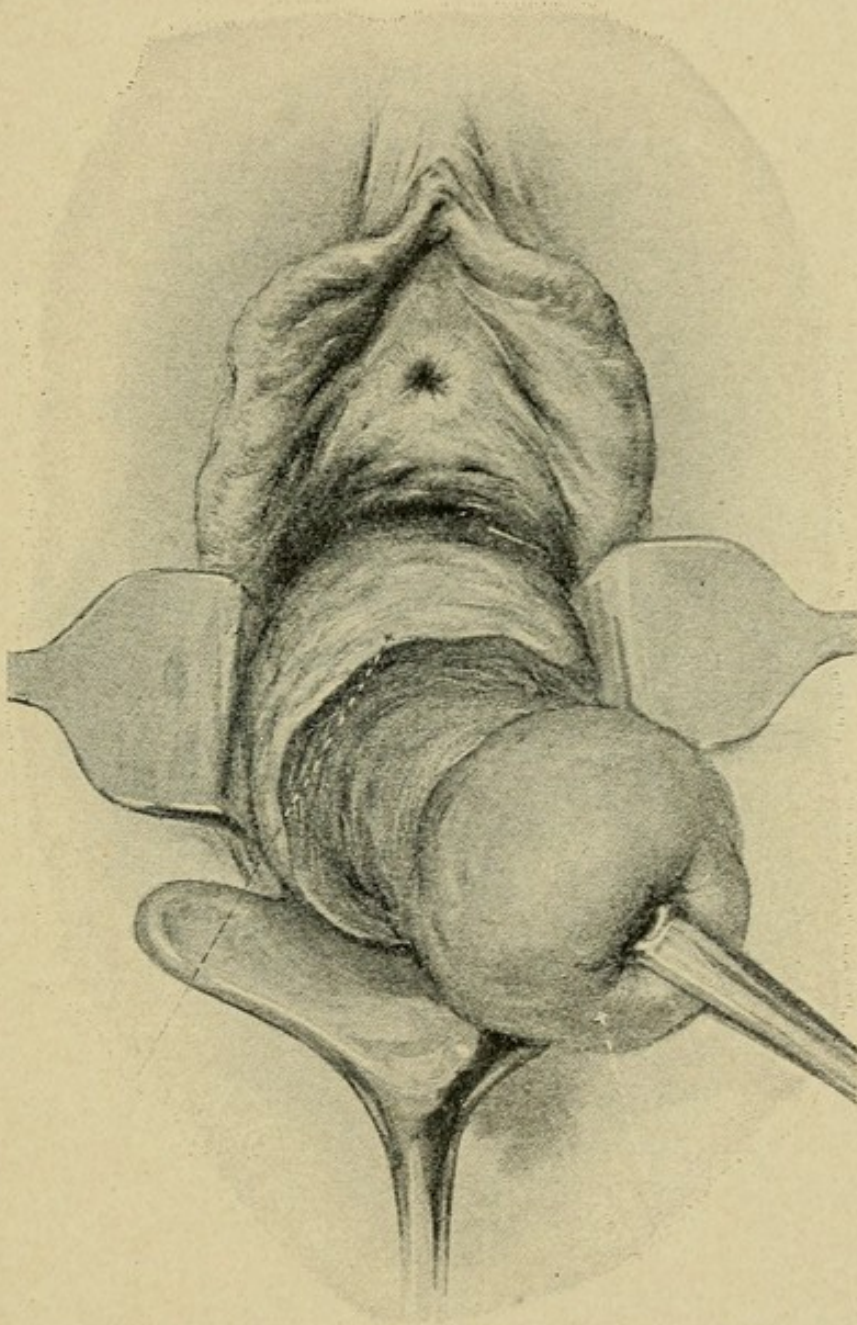
The vaginal walls are retracted, exposing the cervix to view, the anterior and posterior cervical lips grasped with the small traction forceps and drawn firmly down and to one side. In cases of unilateral tear it is usually only necessary to repair the one side, whereas in the bilateral and stellate types both sides should be operated upon. Passing the knife into the cervical canal, slight incisions are made on the anterior and posterior walls from the internal to the external os, so outlining the internal limits of denudation as to leave a strip of mucous membrane  $\frac{1}{4}$  inch wide on both lips to line the new cervical canal. With the point of the knife, the cervix is then transfixed on its vaginal aspect at the angle of the tear, and the external limits of denudation outlined on both lips (Figs. 80 and 81). Care should be taken to include all diseased tissue within these limits. The outlined areas are then removed with either the knife or scissors, cutting well down to healthy tissue. The sutures, usually three to four on each side, are introduced through one lip at a time, and should be entered on the vaginal aspect  $\frac{1}{8}$  inch from the raw edge, pass well under the denuded area, and emerge at the edge of the central strip of mucous membrane. The needle is then entered at a corresponding point on the opposite lip, passed in a similar manner, and brought out on the vaginal aspect at a point opposite its first point of entrance. The sutures should not be tied until all are passed. The cervical lips are now separated, all blood clots removed, and the stitches tied, just tight enough to snugly approximate the tissues without undue tension. If silkworm gut has been used, the ends should be left 2 inches long, or all tied together to facilitate their subsequent removal. A daily vaginal douche is given and the stitches removed at any time after fourteen days.

**Amputation of the Cervix.**—The instruments required are the same as for trachelorrhaphy.



**Technique.**—With a small traction forceps on either lip the cervix is drawn strongly down and held firmly in position. A

FIG. 82



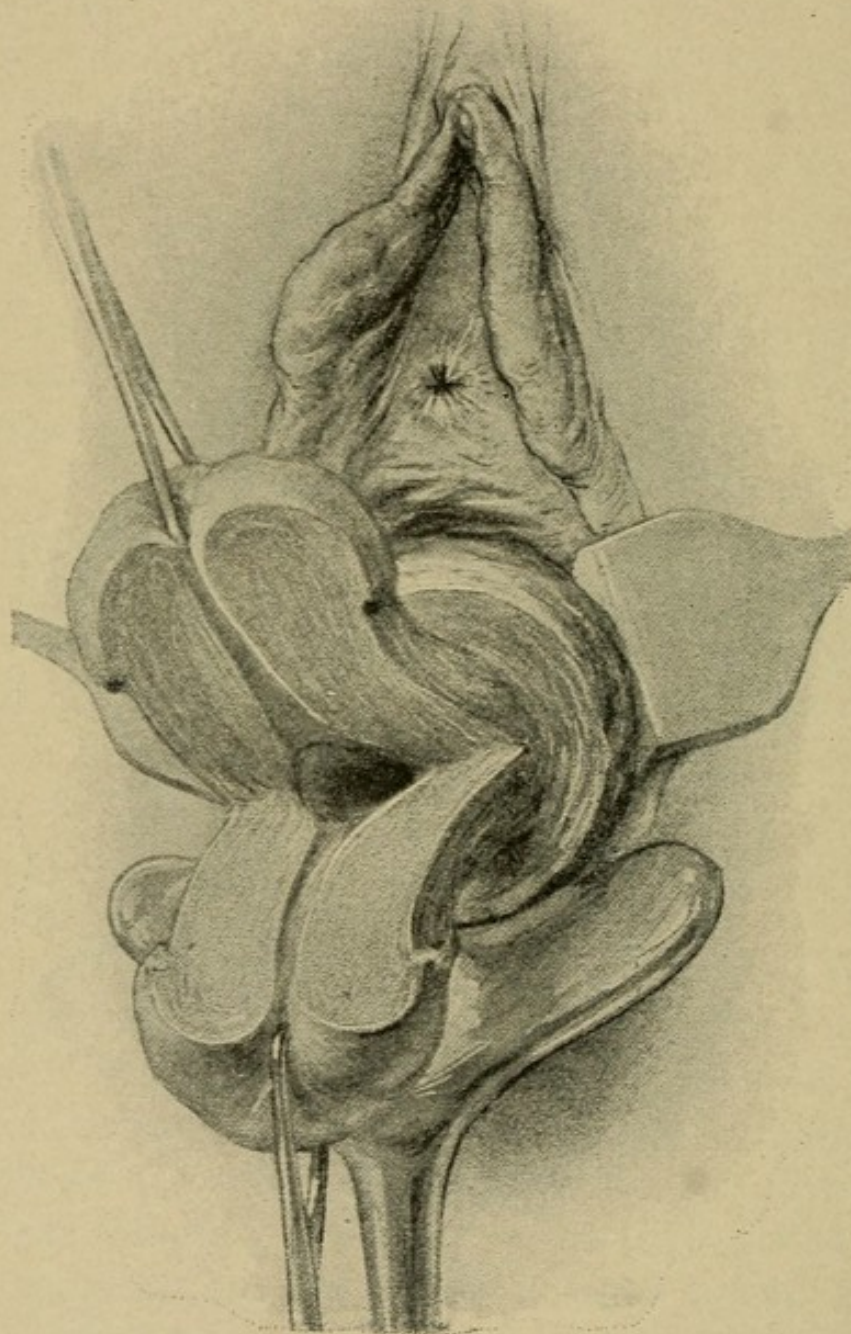
Amputation of the cervix. Cervix drawn down and circular incision made, separating the vagina at its point of contact.

circular incision with the knife separates the vagina from the cervix at its point of attachment, and by blunt dissection the cervix is freed from the surrounding tissues. During this



dissection pressure should always be directed against the cervix to avoid injury to the bladder in front or the rectum

FIG. 83



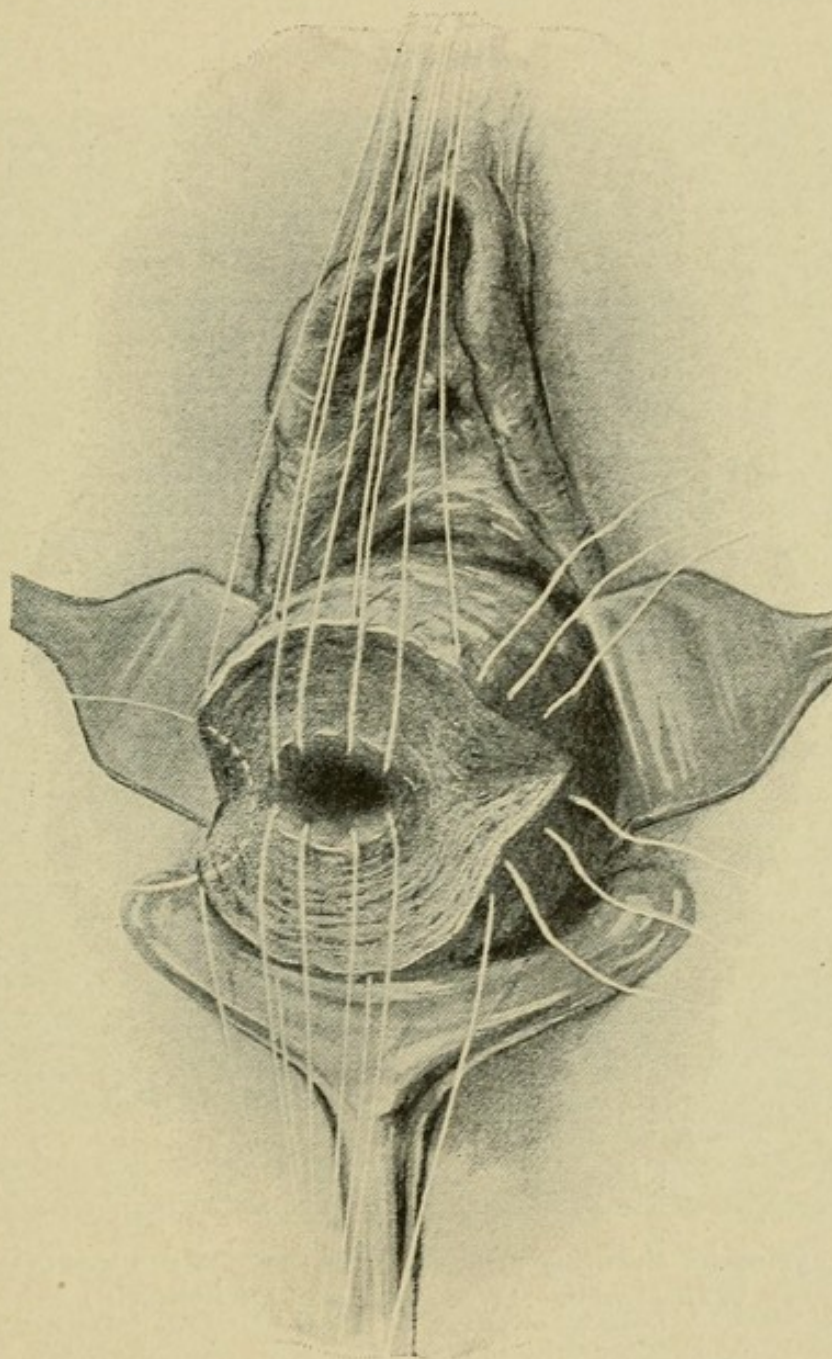
Amputation of the cervix, bilateral division of the cervix.

behind. At either side, where the vessels enter the cervix, the tissues should be ligated with catgut close to the cervix and cut. When the desired length of cervix has been bared,



amputation by transverse incision is performed. The anterior and posterior vaginal flaps are now sewed to the cervical stump in such a manner as to cover its raw surface, leaving

FIG. 84



Amputation of the cervix, sutures in position.

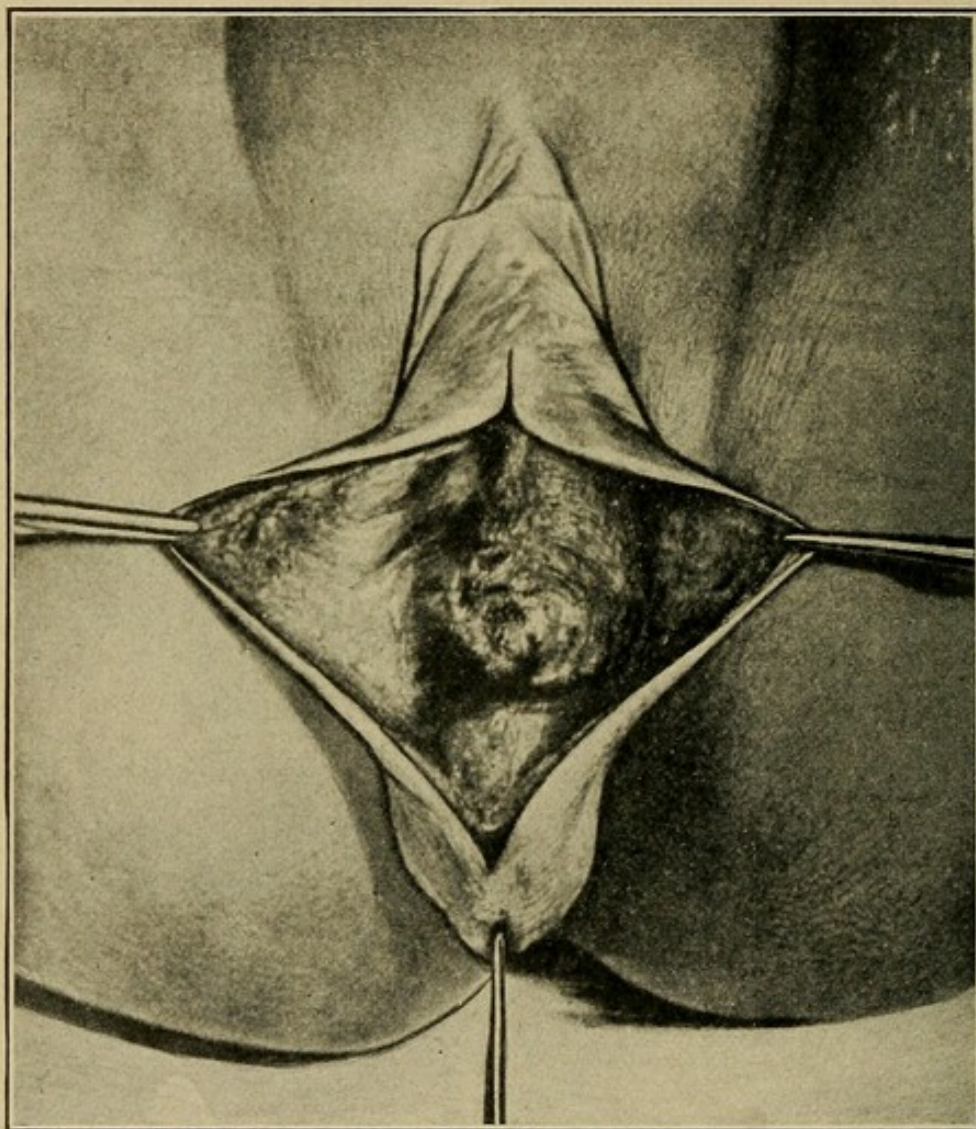
the cervical canal patent, and approximating vaginal and cervical mucosa at the new external os. Deep sutures of silkworm gut, or chromic gut, should be used for attaching



the vagina to the cervix, and plain catgut for accurate superficial approximation. The stitches should not be removed before the end of the second week.

**Cystocele.**—The instruments required and the patient's position are the same as for trachelorrhaphy.

FIG. 85



Operation for cystocele, showing separation of bladder from cervix and anterior vaginal wall. (Wertheim and Micholitsch.)

**Technique.**—The cervix, grasped with a pair of traction forceps, is drawn strongly down to the vaginal outlet and lateral retractors introduced. A longitudinal incision is made through the anterior vaginal wall from the cervix to the anterior limit of the cystocele, usually about one inch from



the opening of the urethra. The bladder is now dissected free from the vagina, well into the lateral fornices, and from the uterus up to the peritoneal reflection. A self-retaining catheter is introduced into the bladder and the urine withdrawn. Curved incisions in the vagina on either side of the longitudinal one extending well out into normal the vaginal tissue, and uniting above and below, remove the thinned-out portion of the anterior vaginal wall. Interrupted sutures of silkworm gut approximate the raw edges of the vagina. These begin at the cervical end of the wound, and each includes a portion of the anterior uterine wall up to the peritoneal reflection. Beyond this point they pass through the vaginal flaps only. The self-retaining catheter is kept open for forty-eight hours to prevent distention of the bladder, and is then removed. The sutures are removed at the end of the third week.

In cases of very large cystocele, Goffe's operation may be performed as follows: When the peritoneal reflection of the bladder on the uterus is reached, "the vesico-uterine pouch is entered and the peritoneum torn across the face of the uterus and well out on to the face of the broad ligaments. The bladder is stitched by an interrupted suture of chromic gut at three points only, the middle of the anterior face of the uterus and two points on the broad ligaments sufficiently wide apart to spread out the bladder wall. The sutures are all passed and left sufficiently long to protrude from the vulva before any one is tied. When all three are in place the middle one is tied first, then the others."

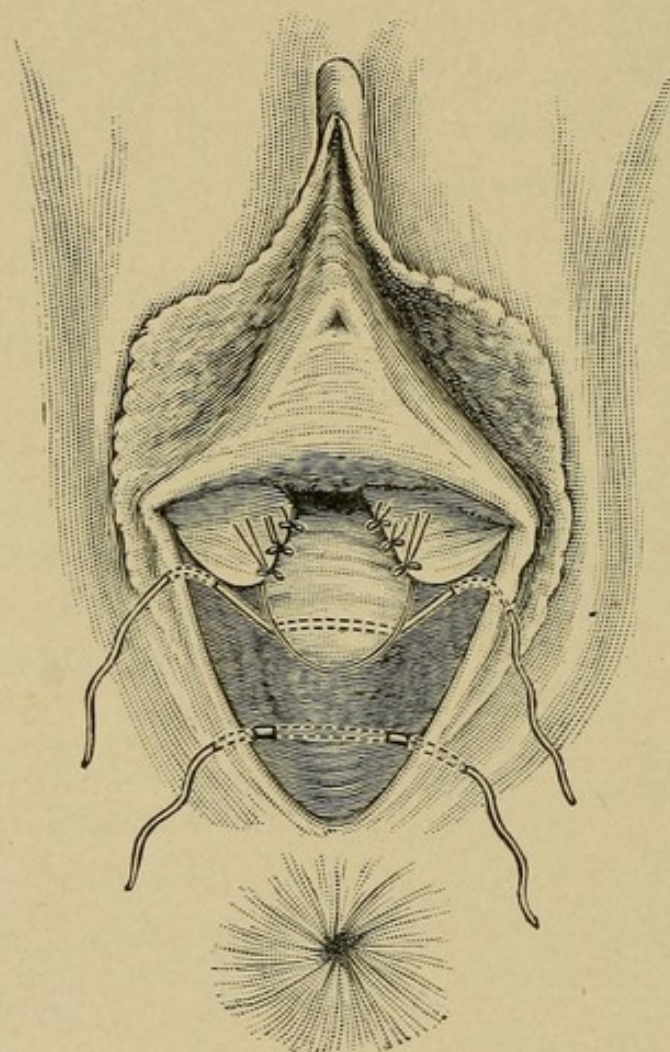
**Perineorrhaphy.**—The choice of operative procedure depends on the degree of relaxation of the vaginal outlet present, and the extent of the vaginal tear. For simple cases almost any of the methods devised will give good results. Where extreme relaxation exists the operations of Emmet and Goffe are particularly applicable. For secondary repair of complete perineal laceration, Ristine's operation is ideal.



The instruments required are the same as for trachelorrhaphy.

**Emmet's Perineorrhaphy.**—The accompanying illustrations are so graphic that but little explanatory text is required. In making the denudation, as Kelly says: "No one pattern will fit all cases; as an excessive relaxation requires a more

FIG. 86



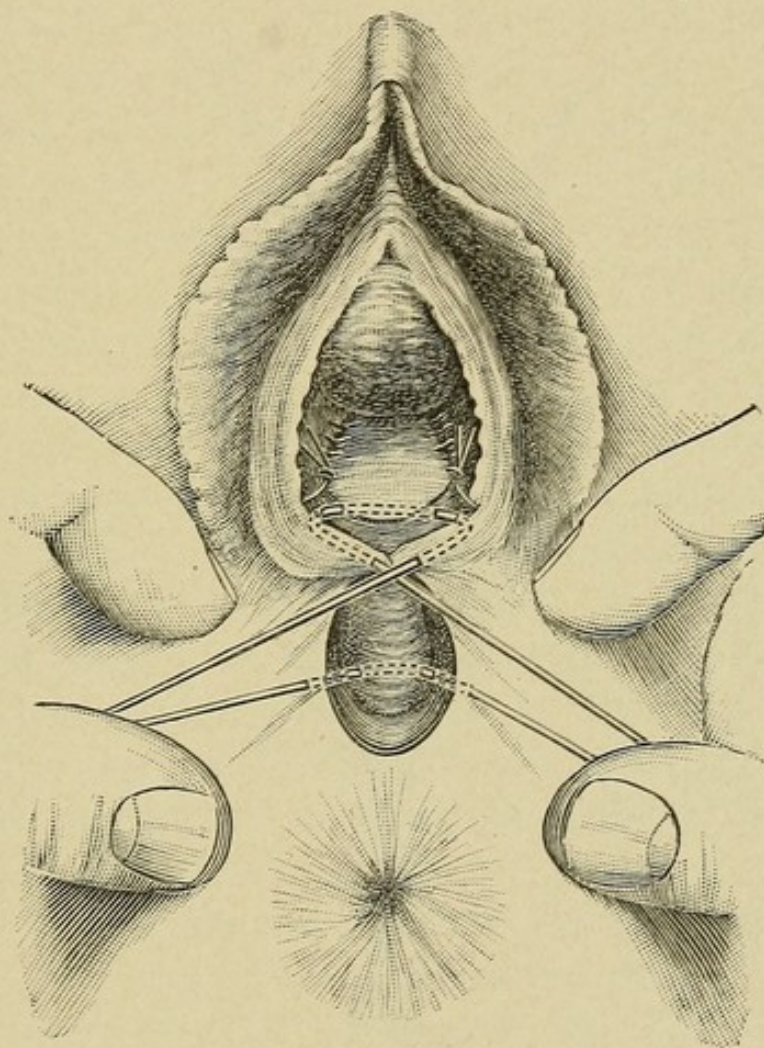
Emmet's perineorrhaphy.

extensive resection than one of moderate degree. The correct pattern to have in mind in resecting is the nulliparous outlet." The limits of the area of denudation being decided upon, the tissue to be removed should first be outlined with the knife. The incisions in the vaginal sulci should be one to two inches long, depending on the amount of relaxation



present. The flap of tissue removed should include the whole thickness of the vaginal wall. Hemorrhage is often profuse, but is easily controlled. For the deep sutures silk-worm gut is the preferable material.

FIG. 87



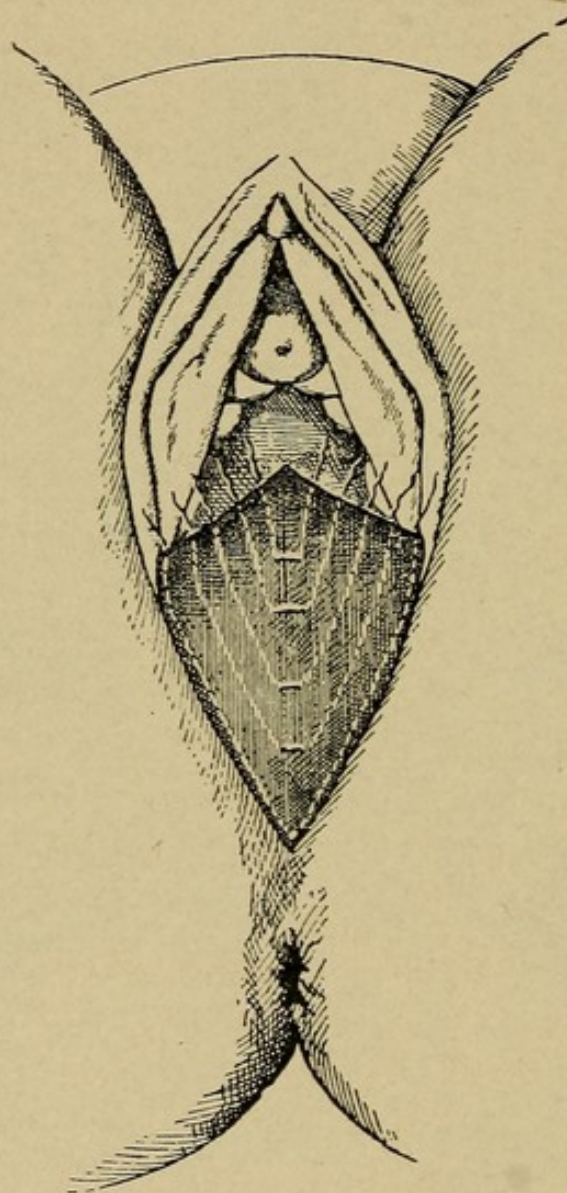
Emmet's perineorrhaphy.

**Goffe's Perineorrhaphy.**—The lines of **incision** extend from the highest point on the rectocele, outward, to the lowest caruncle on either side, and are connected by following the curve of the mucocutaneous juncture below. This triangular flap of tissue, composed of the vaginal mucous membrane, is stripped off in one piece from the underlying tissue by blunt dissection. The method of passing the sutures is



very well shown in the illustration (Fig. 88). "Catching the tissue at the upper part of the rectocele with an artery clamp, which is elevated by the hand of an assistant and with the index finger of the left hand in the rectum, the needle is

FIG. 88



Perineorrhaphy. Goffe's method of denuding and inserting sutures.

inserted about one-quarter inch from the angle of the denudation. Passing through the mucous membrane, the needle is swept out toward the side of the pelvis and gradually curved toward the median line until it emerges near it, and about one inch and one-half down the rectocele. It is then



withdrawn, and again inserted about one-eighth inch on the opposite side of the median line, and swept back through the tissues in a reverse direction until it emerges upon the mucous membrane at a point equally distant from the angle of denudation and corresponding with the point of insertion. A second stitch is inserted about one-quarter inch farther down the edge of the mucous membrane, and made to pursue a course corresponding to the first suture. "In inserting, these sutures should be passed sufficiently far down the rectocele to carry it entirely up into the vagina when the sutures are tightened. The two or three succeeding sutures which are similarly passed bring together the separated edges of the muscle and fascia in front of the rectocele. The last suture is inserted just above the position of the caruncle, which was removed on one side, swept down around the entire circumference of the denuded surface, and made to emerge above the site of the corresponding caruncle on the opposite side. It will be noticed that the sutures, instead of being passed through the skin, as in Emmet's operation, are inserted in the mucous membrane of the vagina, and take their points of support from the fascia, thus lifting the rectocele and anus, instead of dragging them down, as is true of the operation mentioned."

**Ristine's Perineorrhaphy.**—"The basic principle of this operation is inserting into the rectum a frill of mucous and cicatricial tissue which is dissected from the vagina. The advantages of the operation over all others is obvious. The rectum is shut off completely from the denuded area by the inverted frill, with its mucous surface forming the anterior wall of this organ, giving an unbroken rectal mucous lining. There are no stitches in the rectum to carry infection or require removal."

The technique as described by Ristine is as follows: "Outlining with the eye the extent of the lateral denudation requisite to construct a perfect perineum, and noting the extent of the rectal rent, I begin high up in the vagina, and



dissect off an apron or frill of mucous and cicatricial tissue, corresponding to the extent of the vaginal tear, and proportioned to the length of the rectal laceration, down to the apex of this rent, making sure to have enough of tissue when released from above to fold over the rectal rent and extend somewhat beyond the sphincter ani when that shall have been closed. Extending my dissection laterally to the points I have selected for the lower border of the future vagina and upper of the perineum, I continue down the torn edge of the perineum (at the juncture of the mucous membrane and skin) to a point well below the pits representing the retracted ends of the sphincter ani muscle. Just here is where failure overtakes many operators; not only should the integumentocicatricial tissue surrounding this pit be freshened, but most essential, stretch the sphincter ani muscle, draw out the retracted ends with tenacula, and scarify them thoroughly. Dissect the lateral flaps down as close to the rectal tear as it can be carried without interfering with its integrity at this point. During all the dissection avoid buttonholing the apron or frill. Now, having freed the apron from all attachments, save that to the margin of the rectal rent—which must not be disturbed—I insert the apron into the rectum, thereby converting the smooth vaginal tissue into a lining for the anterior rectal wall, and leaving a raw perineovaginal surface to be dealt with as would a simple Hegar perineorrhaphy, except the union or adjusting of the sphincter muscle, which is accomplished by passing a chromicized catgut suture through the drawn-out ends of the muscle, gentle traction is made upon this suture, causing the ends of the muscle to approximate; now pass a silkworm-gut suture through skin and muscle, taking a more secure hold, so as to reinforce and release the strain on a catgut anastomosis suture, and place the sphincter ends in comfortable apposition when this suture is tightened. Observe, now, that we have only a simple incomplete laceration to deal with, the rectum securely shut off, and no stitch in it to carry infection or require removal. Place



the vaginal and perineal sutures just the same as is done in any simple perineorrhaphy—vaginal, of chromicized catgut, and perineal, of silkworm gut.”

The **after treatment of perineorrhaphy** is simple. The wound area should be kept clean and protected. The patient may be allowed to void, the urine being diluted as passed by a saline irrigation played over the surface of the wound. It is desirable that the first few stools after operation be semiliquid. This may be accomplished by teaspoonful doses of compound licorice powder given at frequent intervals, beginning as soon as the stomach will tolerate it. Daily vaginal douches may be given if indicated. The non-absorbable sutures should be removed on the fifteenth day, when the patient may with safety leave her bed.

Failure to secure primary union in secondary repair of the perineum is of rare occurrence, and is usually due to the introduction of too many sutures. Just as few as possible should be used, and tied only tight enough to snugly approximate the tissues, avoiding all unnecessary constriction, that so often interferes with the proper nutrition of the tissues.

## FISTULÆ.

**Definition.**—The genital fistulæ are abnormal openings connecting the perineum, vagina, or uterus with the urinary tract or intestines.

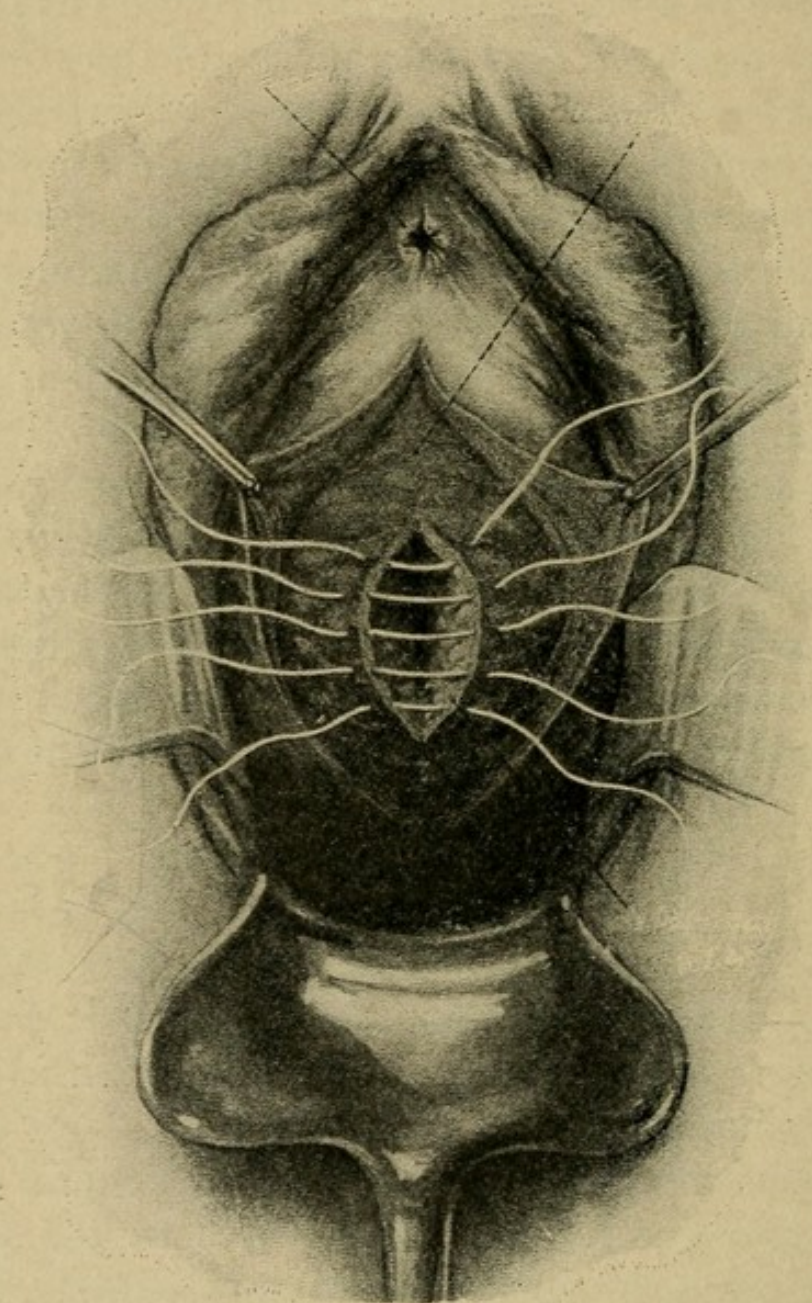
**Operative treatment of genital fistulæ** in general consists of freeing the two communicating cavities at the site of the fistula, and closing the opening in each separately.

**Vesicovaginal.—Technique.**—The vaginal wall is freely incised, through the fistula, down to the bladder. The bladder is then separated from the vagina by blunt dissection for one-half inch surrounding the fistula. The edges of the bladder opening are then freshened and united by interrupted sutures of chromic catgut passed through the outer coats of



the bladder down to but not including the mucous lining. The vaginal incision is closed by interrupted sutures of silk-worm gut (Fig. 89). The bladder sutures are introduced

FIG. 89



Repair of vesicovaginal fistulæ. (Döderlein and Krönig.)

close together, not more than one-eighth of an inch apart. The bladder should be continuously drained by means of a self-retaining catheter for from four to six days after the operation, and the week following its removal the patient



should be required to void her urine every two hours, day and night.

**Vesico-uterine.**—Through an anterior vaginal section the bladder is freed from the uterus up to the fistula. The opening in the bladder, after freshening its edges, is then closed with interrupted chromic gut sutures reinforced with a continuous Lembert suture of the same material. The opening in the uterus, unless large, does not require suturing, and may be left to close spontaneously. The incision in the anterior vaginal wall is closed and the bladder drained as previously described.

**Urethrovaginal.**—The opening in the urethra is disclosed by incising the vagina over the fistula, the edges of the urethral opening are freshened and brought together by interrupted sutures of chromic gut, and the vaginal incision closed in the same manner. Subsequent bladder drainage is unnecessary.

**Ureterovaginal.**—These fistulæ are usually the result of injury inflicted during vaginal operations. When of small size they will often close spontaneously if the ureter is catheterized and the catheter left in place for three days. The operative repair is difficult, and usually has to be done through an abdominal incision. The posterior peritoneum is opened, disclosing the ureter, as close to the fistula as possible. A ureteral catheter should be introduced before the operation is begun and left in place for several days afterward. The edges of the fistula are freshened and sutured together with interrupted sutures of fine linen thread. When this cannot be satisfactorily accomplished, the ureter should be divided, the distal end ligated, and the proximal end implanted into the bladder at such a point as to leave the ureter free from tension.

**Rectovaginal.**—An incision is made through the fistulous opening in the vagina. By blunt dissection the vagina is separated from the rectum for one-half inch in all directions. The edges of the openings in both vagina and rectum are now freshened and separately sutured. When possible the lines



of sutures should cross each other at right angles. A rectal tube is kept in the rectum for forty-eight hours after operation, to avoid gas distention. In some cases the fistula will be found too high up in the vagina to repair by this route, when the abdominal must be selected, the operation then being performed the same as for enterovaginal fistula.

**Rectoperineal.**—These fistulæ must first be treated by incising the overlying tissue down to the fistulous tract. This severs the sphincter ani muscle, allowing the proper denudation of the sinus tract. The wound is then sutured in a manner similar to that employed in dealing with perineal lacerations involving the sphincter ani muscle.

**Rectolabial.**—By free incision the sinus tract is laid bare, converting it into a simple fistula in ano.

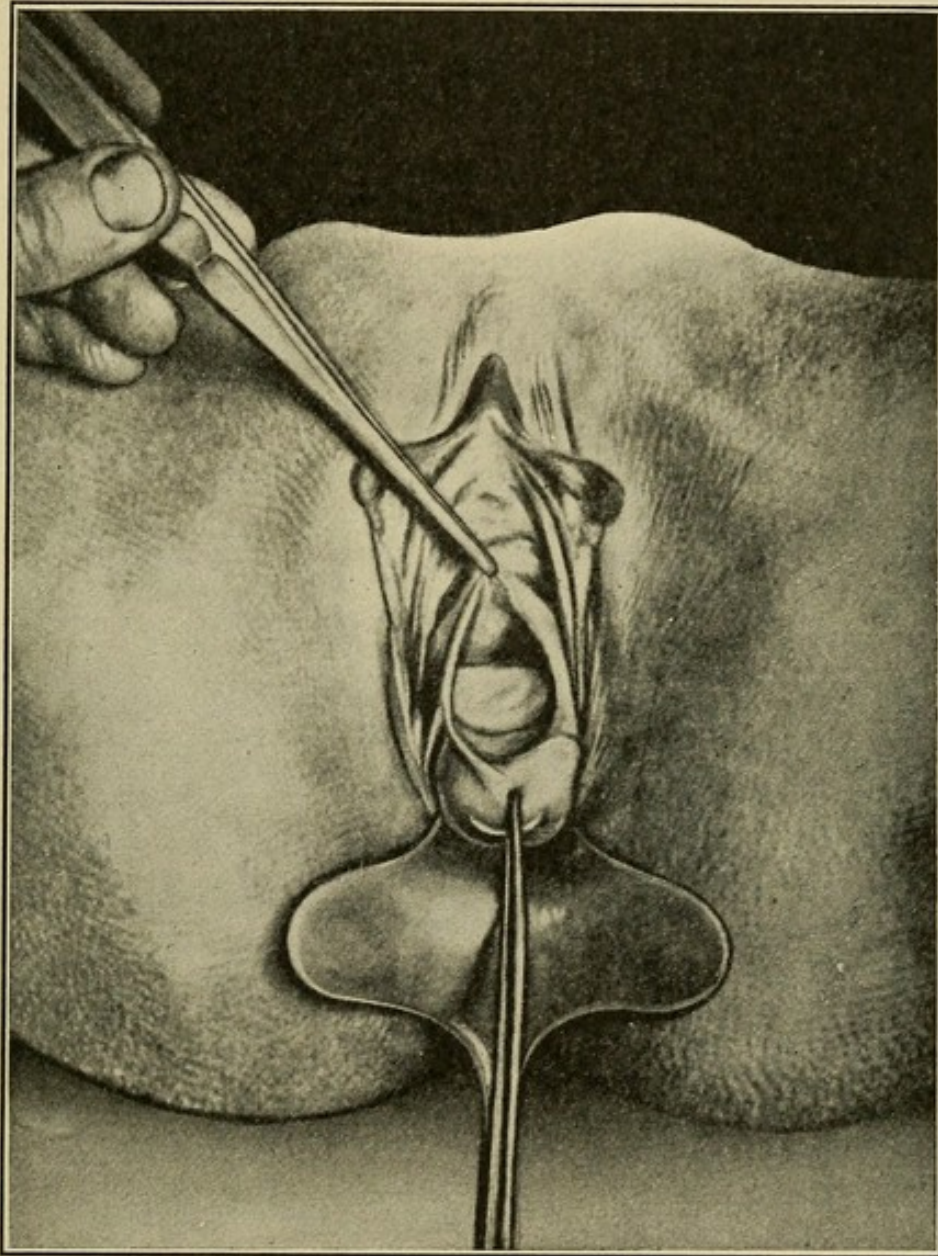
**Enterovaginal.**—Success seldom attends the operative repair of these fistulæ when performed through the vagina, though it may be attempted if the vagina is sufficiently large to allow plenty of working room. As a rule, the abdomen must be opened, the intestine freed at the point of communication with the vagina, and the fistulous opening repaired separately. This is easily accomplished now that the liberated intestine can be drawn up within reach. After freshening the edges, the opening is closed by a purse-string suture of fine linen thread, reinforced with a Lembert suture of the same material. The vaginal opening can be left to close spontaneously or drained with gauze.

**Anterior Vaginal Celiotomy.**—The special instruments required are a weighted speculum, two retractors, trowel retractors, large traction forceps, two small traction forceps, small and large artery clamps, curved and straight long-handled scissors, sponge holders, ligature carrier, needle holder, small, medium, and large needles, ligature material, two scalpels, and heavy tissue forceps. The patient is placed in the **dorsal position**, the speculum introduced, the cervix grasped with the large traction forceps, and strong downward traction made. An anterior transverse **incision** (Fig. 90)



one inch long separates the vagina from its attachment to the anterior cervical lip. The uterovesical ligament is picked up with the forceps and severed, and by blunt dis-

FIG. 90



Anterior vaginal celiotomy. (Wertheim and Micholitsch.)

section the bladder is freed from the uterus up to the peritoneal junction. An additional longitudinal incision is made through the anterior vaginal wall to within one inch of the urinary meatus, and the bladder freed from the anterior



vaginal wall on both sides. Introducing the trowel retractor between the bladder and uterus, the peritoneum is exposed and incised transversely at its uterine reflection, thus opening directly into the peritoneal cavity.

The trowel then elevates the bladder, the omentum and intestines are packed away with small celiotomy pads, and adhesions separated with the index finger passed over the fundus. The following operative procedures may then be carried out.

### **Anterior Vaginal Celiotomy for Retrodisplacements.—**

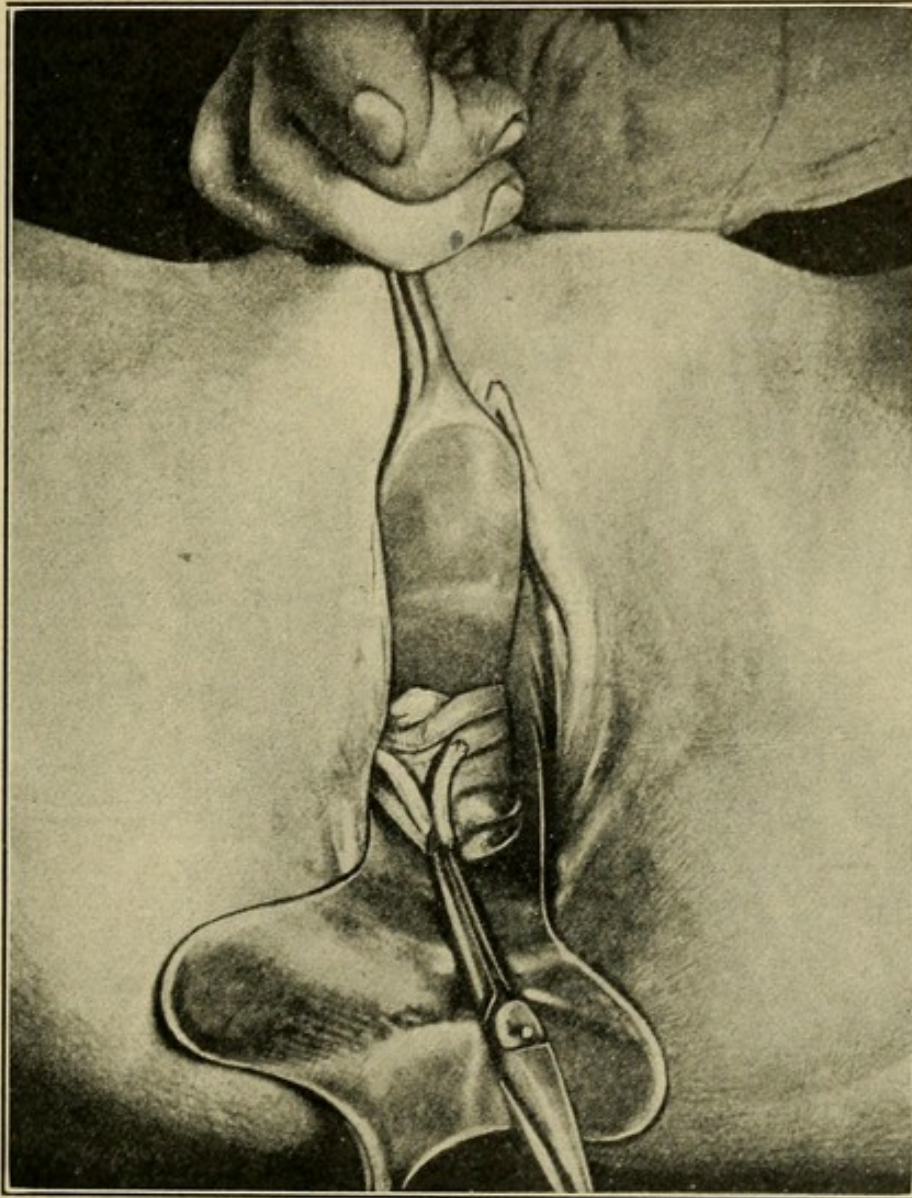
**Vaginal Fixation.**—The fundus is drawn forward into contact with the anterior vaginal wall, and held in place by a silkworm-gut suture. This passes through the vaginal flaps at about the middle point of the longitudinal incision, taking a bite in the anterior uterine wall at a point high enough up on the fundus to hold it well forward in position. It is tied just tight enough to approximate the fundus and the vaginal wall; the longitudinal incision is closed with interrupted sutures, the transverse left open for drainage. Where there are no adhesions, or complicating disease of the appendages, it is not necessary to make the longitudinal incision or to open the peritoneal cavity. The transverse incision suffices. Through it the bladder is separated from the uterus up to the peritoneal reflection, and from the anterior vaginal wall up to a point midway between the cervix and urinary meatus. The fundus is brought forward by traction at the peritoneal reflection, or by introducing the uterine sound, and the silkworm-gut suture passed. This suture can be removed at any time after the third week.

**Shortening the Round Ligaments.**—Each ligament is grasped at a point 1 to 2 inches from the uterus, depending on the degree of relaxation present, and drawn forward to develop a loop. The folds of the loop are transfixed and brought together by interrupted sutures of medium-sized silk or linen thread; the free end of the loop is sutured to the fundus just in front of the tube (Fig. 91).



**Shortening the Ovarian Ligament.**—The ligament is grasped with the forceps at its middle point and looped. One or two fine silk or linen thread sutures unite the folds.

FIG. 91



Shortening the round ligaments through the anterior vaginal incision for retrodisplacement. (Wertheim and Micholitsch.)

**Salpingectomy.**—The tube is freed from adhesions, delivered into the vagina, ligated, and removed.

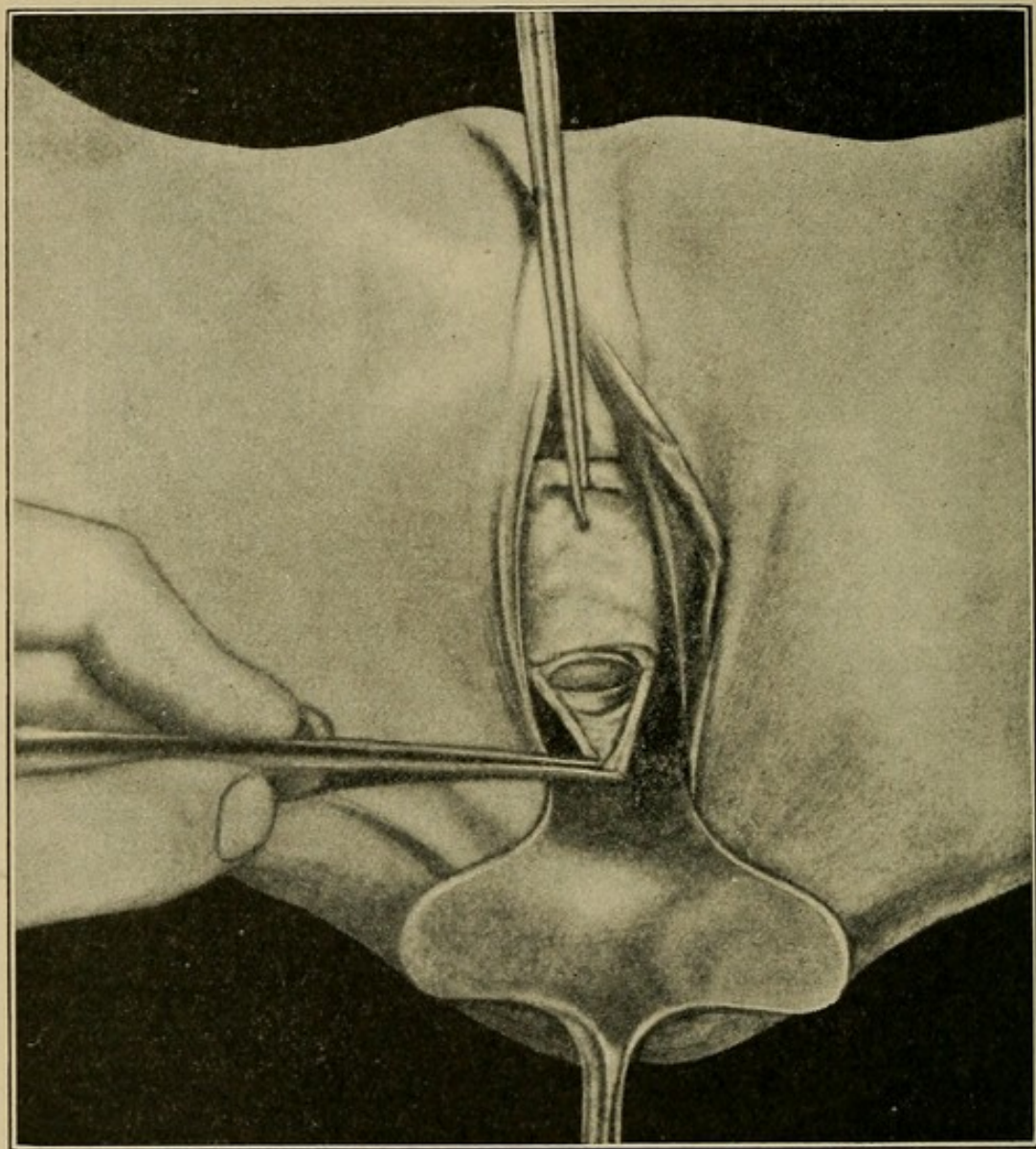
**Oöphorectomy.**—The ovary is freed from adhesions, delivered into the vagina, its pedicle ligated and cut, and the organ



removed. Resection of the tube or ovary instead of removal may be practised if indicated.

**Posterior Vaginal Celiotomy.**—Posterior vaginal celiotomy has a limited field of usefulness, and is performed prin-

FIG. 92



Posterior vaginal celiotomy. (Wertheim and Micholitsch.)

cipally for diagnostic purposes in doubtful cases of ectopic gestation, and for pelvic drainage.

**Technique.**—The posterior cervical lip is grasped with the heavy traction forceps and drawn strongly down to the vaginal outlet. A transverse **incision** one and one-half inches



long at the junction of the posterior vaginal wall with the cervix separates the two, and by blunt dissection with the index finger (Fig. 92), exerting pressure against the uterus, the rectum is freed up to its peritoneal reflection. The peritoneum is then caught and incised transversely, affording direct entrance to the peritoneal cavity. At the conclusion of the operation the peritoneum may be closed by sutures and the vaginal wound left open, or a gauze drain left in place without suturing.

**Vaginal Hysterectomy.—Technique.**—The weighted speculum is introduced, both lips of the cervix grasped with the heavy traction forceps, and strong downward traction made to steady the uterus. A circular **incision** around the cervix at the vaginal junction separates the vagina from the cervix. The peritoneum is opened posteriorly, care being taken to keep close to the uterus so as not to injure the rectum, and the index finger in the cul-de-sac of Douglas frees the uterus and appendages from any posterior adhesions. The anterior fornix is now opened the same as in vaginal celiotomy. Although the longitudinal incision in the anterior vaginal wall is not always necessary, it affords more working room and is generally advisable. The broad ligaments are now quilted off with a long continuous ligature passed close to the cervix to avoid including the ureters. The amount of tissue included in each bite of the ligature should not exceed one-half of an inch, and should be cut each time before another knot is tied. When the uterine artery is reached, its pulsation may be readily felt between the thumb and index finger. Beyond this point the ligature can be gradually carried far enough out into the broad ligament to surround the appendages without danger to the ureter. As the free edge of the broad ligament is reached the round ligament should be caught up and tied with a separate ligature. The continuous ligature then surrounds the free border of the broad ligament, between the infundibulopelvic ligament and the appendages, is finally tied, and the included tissue cut. For the broad ligament ligature,



heavy chromic catgut, kangaroo tendon, silk or linen thread cut in one foot strands is generally used, and may be passed on either a large full curved needle or a ligature carrier. The knots should be tied as tight as possible without breaking, and the tissue cut far enough away to avoid all danger of subsequent slipping. In most cases the quilting of the broad ligaments should be done part way on one side, and then on the other, so that the uterus and appendages may be further delivered into the vagina with each succeeding step. If the uterus is large it may be safely hemisected, after both uterine arteries have been tied, and each half removed separately, or by morcellation. When contraction of the broad ligaments makes ligation beyond the uterine arteries difficult or impossible, the angiotribe may be used instead. It should remain on the tissues two minutes before they are divided. At the end of the hysterectomy the broad and round ligament stumps should be drawn down and sutured to the raw edges of the vaginal vault and the longitudinal incision in the anterior vaginal wall closed. Enough gauze (10 per cent. iodoform) should be introduced into the peritoneal cavity to keep the intestines and omentum away from the wound, and the vagina tightly packed. The vaginal gauze is removed on the third day and a vaginal douche of boric acid solution (3j to Oj) given twice a day thereafter. The withdrawal of the peritoneal gauze is begun on the fourth day, a few inches being removed at each dressing until it is all away, usually by the eighth day. Any granulation tissue in the vaginal wound should be cauterized every other day with silver nitrate.

**Abdominal Celiotomy.**—The preparation of the patient is begun twenty-four hours before operation. The bowels are thoroughly opened and all hair removed from the vulva. The abdomen from the umbilicus to the pubes is scrubbed for five minutes with tincture of green soap, rinsed off with sterile water, and rescrubbed for two minutes with Stewart's solution, followed by a cleansing with water. A protective dressing of sterile gauze is applied. The same preparation of the field



of operation is repeated shortly before the anesthesia is begun, and the protective dressing left in place until the patient is ready for operation. There is no final scrubbing while the patient is under the anesthetic.

The **hands of the operator, assistants, and nurses are prepared** as on page 157 and sterile rubber gloves worn. The patient should be in the **Trendelenburg position** during the operation.

The **instruments required** are 2 scalpels, curved and straight scissors, 2 pairs of tissue forceps, large and small; 6 pairs of small artery clamps, 3 pairs of large artery clamps, 2 hysterectomy clamps, a ligature carrier, needle-holder, 2 wound retractors, 12 self-retaining abdominal retractors, a trowel retractor, small and large needles, and suture and ligature material.

The **incision** may be made either longitudinal in the median line, transverse either between the anterior superior iliac spines (Pfannenstiel) or at the pubic hair line. The first and second are preferable for large tumors, and the latter when the field of operation lies mostly in the pelvis.

**Longitudinal abdominal celiotomy** through skin, subcuticular tissue, and fat down to the fascia covering the recti muscles. The sheath of one rectus muscle, generally the right, is opened, the muscle separated from the linea alba and retracted to the outer side. This discloses the peritoneum, which is picked up with two pairs of artery clamps, care being taken not to include underlying intestines or omentum. The peritoneum is then incised between the clamps and entrance to the abdominal cavity accomplished.

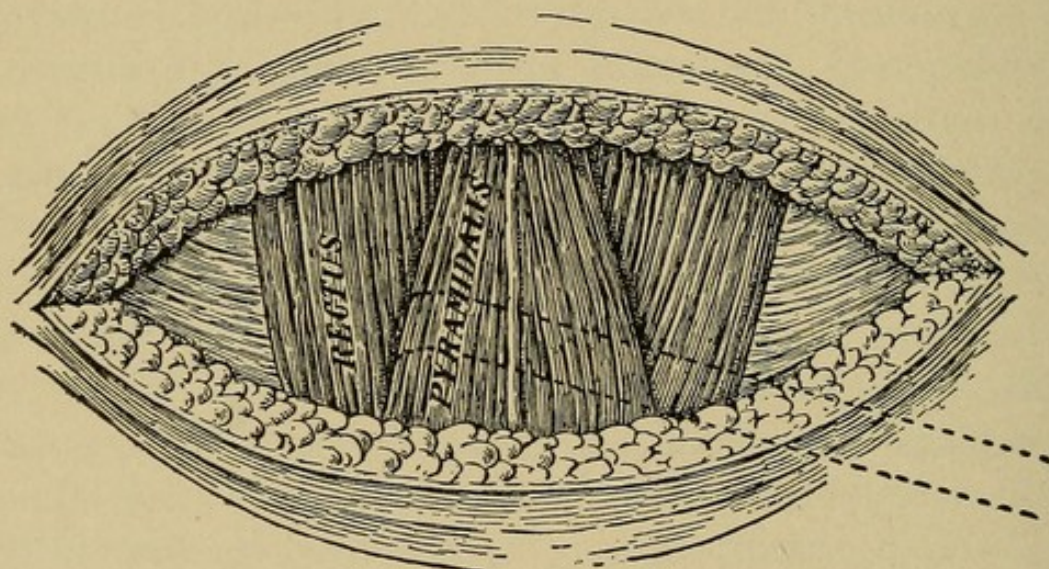
**Transverse Abdominal Incision** (Pfannenstiel).—A straight incision five to six inches in length is made between the anterior superior iliac spines. This extends through the skin, fat, and fascia, exposing, the recti muscles. The upper and lower fascial flaps are dissected free from the linea alba and the recti retracted, disclosing the peritoneum, which is opened in a vertical direction.



**Transverse Suprapubic Incision (Author's).**—A straight incision two to three inches in length parallel to the symphysis pubis is made just in the pubic hair, or slightly above it in the transverse fold. The skin, subcuticular tissues, and fascia are incised, exposing both recti and pyramidalis muscles (Fig. 93).

The fascia is dissected free from the linea alba and muscle for two inches above and below, care being taken not to injure the pyramidalis muscles. The right rectus muscle is separated

FIG. 93



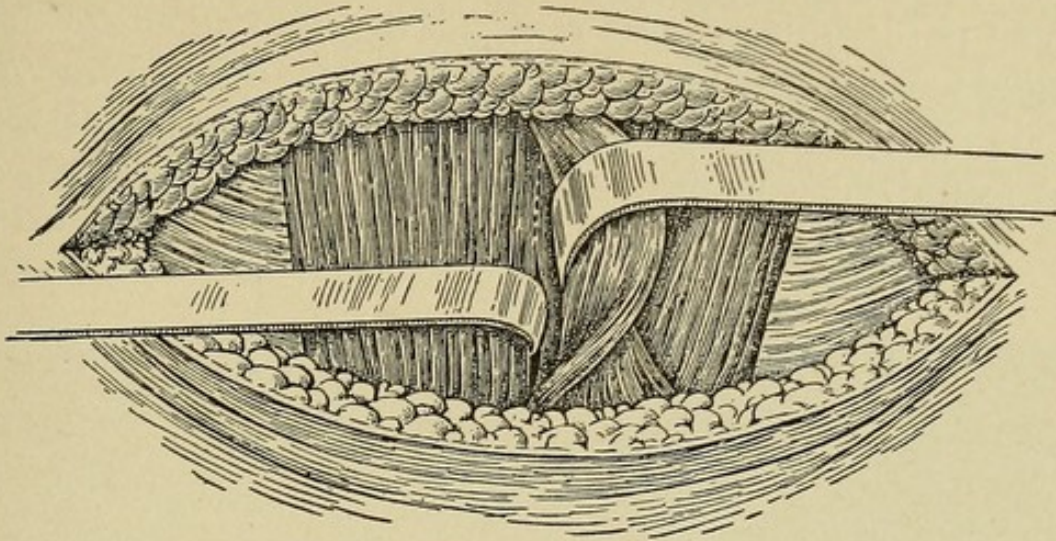
Transverse suprapubic incision.

from its pyramidalis and from the linea alba, retracted outward, the pyramidalis is retracted toward the middle line, and the peritoneum opened (Fig. 94).

This incision is an ideal one for pelvic surgery, as, being directly over and parallel to the pelvic organs, it gives a better exposure of the field of operation than a median longitudinal incision of twice its length (Fig. 95). As it is made intermuscular, the danger of subsequent hernia is minimized and the resulting scar, on account of its location, leaves little to be desired from a cosmetic standpoint (Fig. 96).

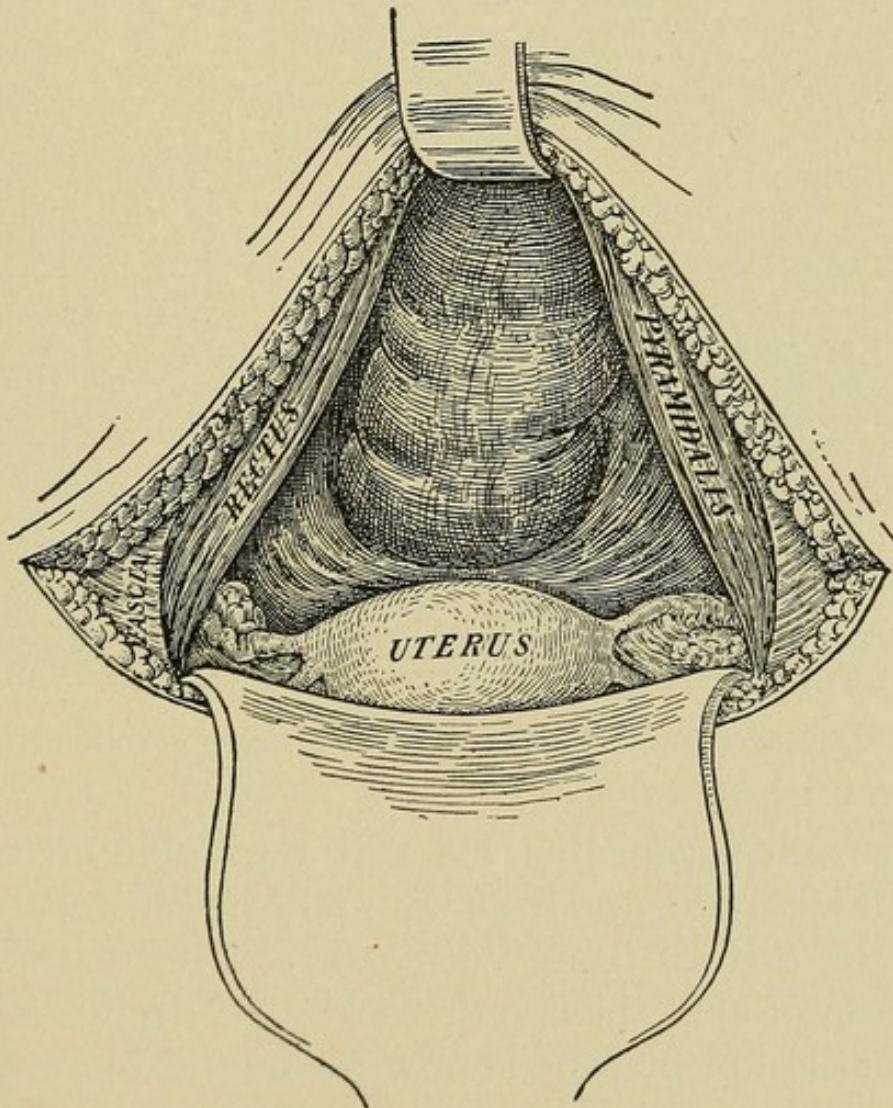


FIG. 94



Transverse suprapubic incision.

FIG. 95

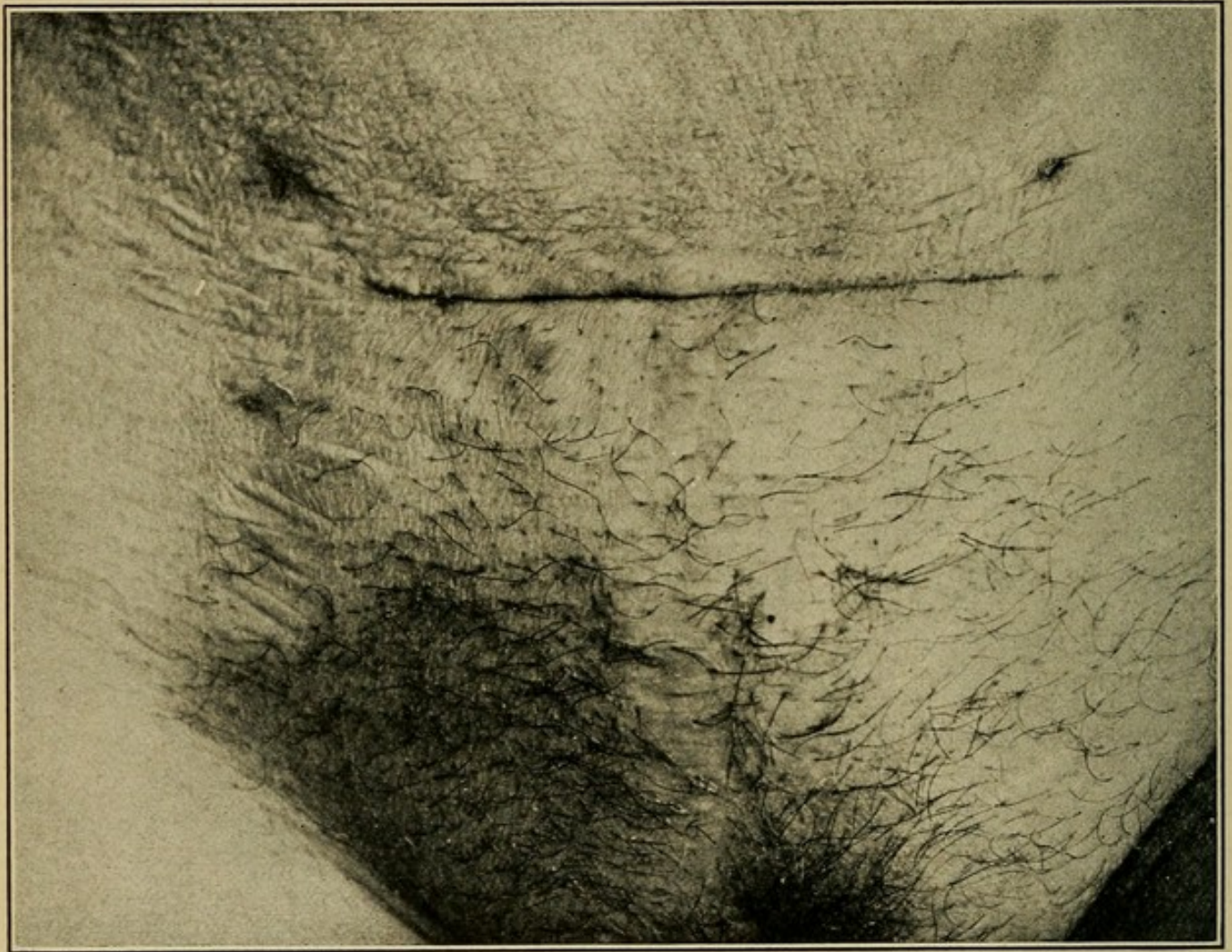


Transverse suprapubic incision.



After opening the peritoneum, the self-retaining retractor of Doyen is introduced and remains in place until the intra-peritoneal work is finished. Thorough inspection of the pelvic organs is now made, and for this purpose trowel retractors will be found very useful. They may be passed deep into

FIG. 96



Transverse suprapubic incision (ten days after operation).

the pelvic cavity, affording efficient retraction in otherwise inaccessible localities, and from their polished surfaces reflected light may be thrown in any direction, giving extremely valuable illumination of the operative field. Careful study of the pathological lesion present is now made and the appropriate operative treatment decided upon.



**Abdominal Celiotomy for Retrodisplacements.**—After freeing the uterus from adhesions, the round ligaments may be shortened by any one of several methods. The ligaments lie directly in front of the tube and are easily recognized.

**Mann's Method.**—The ligament is picked up with a large artery clamp, looped twice on itself, and the three folds sewed together.

**Goffe's Method.**—Each ligament is folded once on itself a short distance from the uterus, the folds sewed together and the free end of the loop sutured to the fundus just in front of the tube.

The normal origin of the round ligament is from the fundus just in front of the tube. Occasionally the point of origin will be found farther down on the uterus toward the internal os. In these cases the shortening is accomplished by suturing the ligament to its proper height on the fundus.

The uterosacral ligaments may be shortened, as advocated by Byford, to correct the retrodisplacements by drawing the cervix upward and backward. This is always desirable when there is much descent of the cervix. The fundus is held forward against the symphysis pubis by the trowel retractor passed deep into the cul-de-sac of Douglas. This develops the ligaments, which are then picked up, folded on themselves, and shortened sufficiently to bring the cervix to its normal height in the pelvis. For these operations on the ligaments medium-sized silk or linen thread as suture material is used.

In cases where it is desirable to correct the retrodisplacement by ventral fixation, suspension, or round ligament suspension, one of the following methods may be chosen:

**Kelly's Operation.**—The fundus is brought forward and two sutures of chromic gut are carried transversely through one-half inch of uterine tissue at the level of the Fallopian tubes. These sutures lie one-half inch apart and the free ends pass through the peritoneum one inch above the symphysis pubis. They are then tied separately.



**Gilliam's Operation.**—"An abdominal incision three or four inches in length is made in the median line at the usual site between the umbilicus and pubes. The adhesions are broken up and the fundus brought forward. With a finger, thumb, or a pair of bullet forceps, the broad ligament of one side is seized and brought to the opening. By lifting up the anterior surface of the broad ligament on the tip of a finger applied to its posterior surface, the round ligament is brought into view and is picked up either between the thumb and finger or with a bullet forceps. Selecting a point one inch and one-half from the uterus, a thread is passed under the ligament and the ends of the thread are brought out of the opening and secured in the bite of a clamp forceps, which is laid upon the surface of the abdomen. The other ligament is sought for and secured in the same manner.

"At a point about one and one-half inches above the pubes, the peritoneum, muscle, and fascia at one edge of the wound are caught up by a volsella and pinned together, being careful that the edges of these layers are in line. Traction is now made, and, with a small retractor, the skin and superficial fat are drawn in the opposite direction, uncovering the fascia. With a narrow-bladed knife, or, better, with the perforating forceps devised for the purpose, a stab wound is made from the surface of the fascia into the peritoneal cavity, the instrument entering about one-half inch from the edge of the abdominal incision, and passing obliquely downward and outward, emerging on the peritoneum one inch from the edge of the abdominal incision.

"If the perforating forceps is used, the jaws are separated, and, by an outward movement of the handle, brought into plain view at the large opening. The thread which loops the round ligament is now placed in the jaws, the clamp forceps removed, and the perforating forceps withdrawn, bringing with it the thread and the ligament. If a knife has been used to make the perforation, it is withdrawn and a slender forceps introduced, with which the thread is caught up and



the ligament drawn into place. Now, while the ligament is held taut, with its loop and one-fourth or one-third of an inch above the surface of the fascia, a catgut suture is passed through it, including the tissues on either side, and back again, where it is tied. This is cut close to the knot, the suspending thread cut on one side close to the ligament and withdrawn, and the volsella and retractor removed. The other side is dealt with in like manner and the abdominal incision closed."

**General Indications of Abdominal Celiotomy.**—**For Procidentia.**—The uterosacral ligaments are shortened to bring the cervix up to its normal level in the pelvis, and round ligament ventrosuspension of the uterus performed by Gilliam's technique to hold the fundus forward.

**Oöphorrhaphy.**—The ovarian ligament is picked up at a point midway between the uterus and ovary and the loop thus formed sewed together with two or three sutures of medium-sized silk or linen thread.

**Oöphorectomy.**—In severing the ovary entire it is pulled strongly upward, developing a pedicle, which contains the ovarian artery. This pedicle is then transfixed and ligated before the ovary is removed. In many cases it is found unnecessary to sacrifice the entire ovary, and the diseased portion only should be cut away, the incision being closed with a continuous suture of fine catgut or silk.

**Salpingostomy.**—Occluded tubes are often encountered, and in many cases do not call for complete removal. If the tube can be easily separated from adhesions, its distal end may be opened, the inverted fimbria freed, and the entire tube saved. Where this is not practical a new opening may be made as near the fimbriated end as possible. When the disease does not involve the entire tube, it is only necessary to remove the affected portion. The remaining stump, even though it be only a fraction of an inch in length, may functionate if left patulous. To accomplish this end a small-grooved director is passed into its lumen and the tube incised for one-half



inch along its dorsum. With a small needle and fine suture material the mucous and serous coats of the tube are united around the new opening.

**Salpingectomy.**—The tube, separated from adhesions, is drawn strongly up, and the pedicle thus developed in the broad ligament quilted off with one continuous ligature from distal to proximal end. When the uterine cornu is reached the ligature surrounds the tube close to the uterus and the final knot is tied before cutting away the tube. In some cases the uterine portion of the tube should be removed as well. This is accomplished by free dissection into the horn of the uterus, removing the tube entire, and the uterine wound is then closed by interrupted sutures.

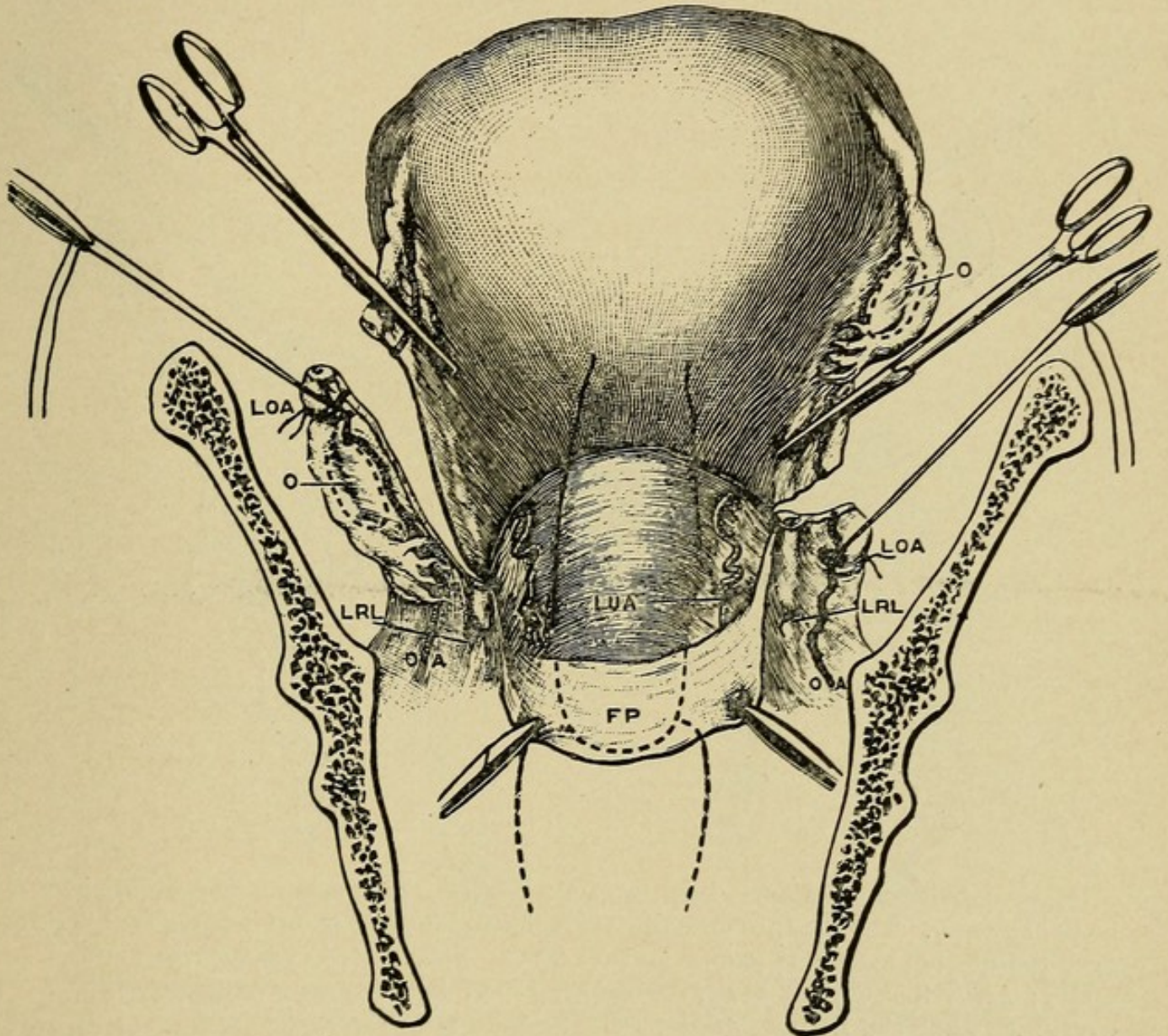
**Abdominal Hysterectomy.**—Either complete removal of the uterus, or removal just above the vaginal portion of the cervix, may be performed, according to the requirements of the case. The latter operation is with many the one of choice in all but malignant cases (Fig. 97).

**Supravaginal Removal.**—The fundus is grasped with the heavy traction forceps and drawn strongly up out of the pelvis. The peritoneal reflection from the bladder to the uterus is divided transversely, from broad ligament to broad ligament, and the bladder freed from the uterus, by blunt dissection. The broad ligaments are now clamped with the heavy hysterectomy clamps, from the infundibulopelvic ligament to the cervix, at the desired level of amputation, and uterus and appendages cut away. The cervical stump is caught with the small traction forceps, and two or three sutures bring together its raw edges. First one broad ligament clamp and then the other is removed, each ovarian and uterine artery being ligated separately. The round ligament stumps are drawn down and sutured to the cervix, and the anterior and posterior folds of the broad ligament are sutured together, covering in all raw surfaces from the infundibulopelvic ligaments to the cervix. The stump of the cervix is covered by suturing the peritoneal reflection from the bladder to the peritoneum on the posterior



aspect of the cervix. This covering in of the raw surfaces by uniting peritoneum over them may be done with a continuous

FIG. 97



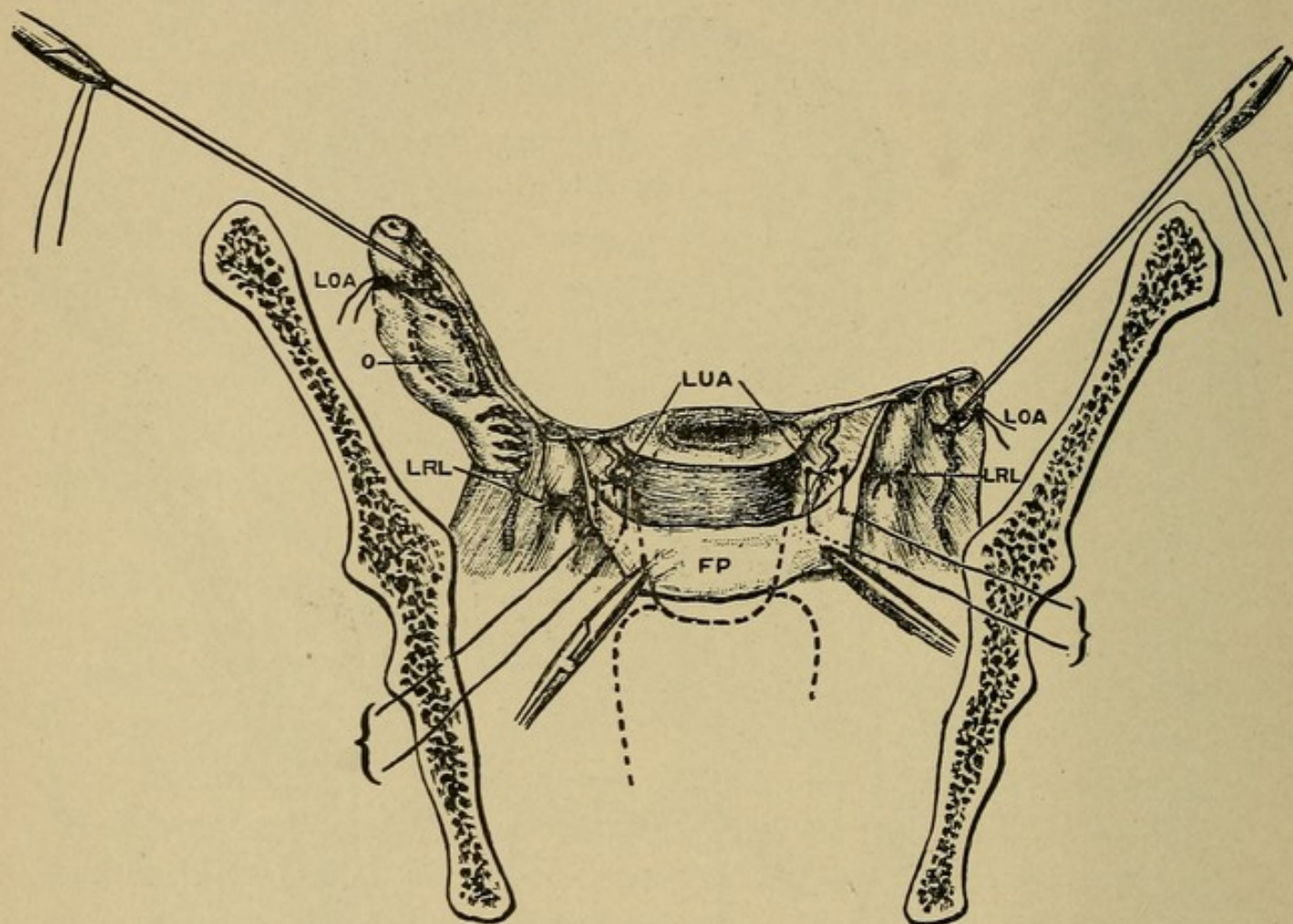
Operation of supravaginal hysterectomy, seen from the front. Second stage. The outer part of the broad ligament is divided on each side. The anterior peritoneal flap is stripped down and held by two pressure forceps. One ligature is placed on each uterine artery. A second ligature is passed through the broad ligament, just within it, ready for subsequent use. *LOA*, ligature on ovarian artery; *LRL*, ligature on round ligament; *LUA*, ligature on uterine artery; *O*, ovary; *OA*, ovarian artery; *FP*, anterior flap of peritoneum. (Galabin.)

suture, running from one infundibulopelvic ligament to the other. As the cervical stump is reached the suture passes



through it several times, thus holding it in contact with the peritoneal covering and obliterating the dead space (Fig. 99).

FIG. 98



Supravaginal hysterectomy, seen from the front. Third stage. The uterus has been cut away. The ligature on each side, for stitching the anterior peritoneal flap over the uterine artery, is passed and ready for tying. *LOA*, ligature on ovarian artery; *LRL*, ligature on round ligament; *LUA*, ligature on uterine artery; *O*, ovary; *FP*, anterior flap of peritoneum. (Galabin).

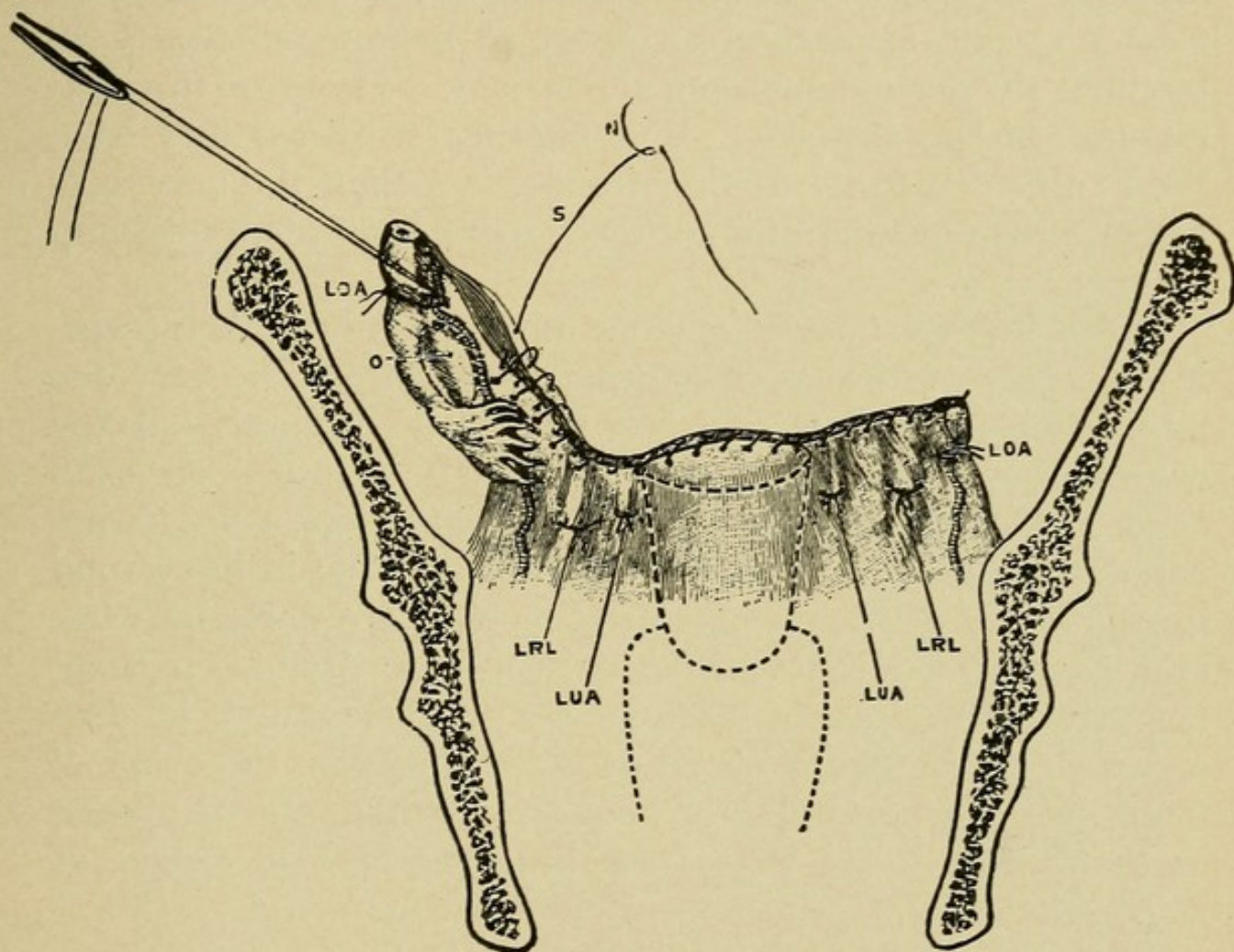
**Complete Removal.**—The steps of this operation are the same as for supravaginal removal, with the following exception:

When the uterus is cut away, instead of leaving the cervical stump behind, the cervix is freed from its vaginal attachment and removed entire with the uterus. In some cases it is easier to perform a supravaginal removal first, taking out the



cervix afterward. Some operators prefer to quilt off the broad ligaments with a continuous ligature, as in vaginal hysterectomy, instead of using clamps

FIG. 99



Supravaginal hysterectomy, seen from the front. Fourth stage. The continuous suture, uniting the peritoneum, is nearly completed. All the main ligatures are cut short, except that on the right ovarian artery. *LOA*, ligature on ovarian artery; *LRL*, ligature on round ligament; *LUA*, ligature (second) on uterine artery; *O*, ovary; *S*, continuous suture; *N*, needle. (Galabin).

**Removal of Pedunculated Tumors.**—The tumor is separated from adhesions, the pedicle transfixed, ligated, and cut. In fibroids too large to be delivered through the abdominal wound the pedicle may be clamped, the tumor removed by morcellation, and the pedicle then ligated.



**Myomectomy.**—Is performed for subperitoneal and interstitial fibroids. The uterine tissue over the fibroid is incised, the tumor enucleated and the incision in the uterus united with interrupted sutures.

**Closure of the Abdominal Incision.**—In closing the incision through the abdominal wall after operation three structures need accurate apposition in order to restore, as nearly as possible, the normal anatomical relations. These are the peritoneum, fascia, and skin. The muscles, provided they have been subjected to no further traumatism than the necessary displacement or separation of their fibers, require no retaining sutures.

In holding the tissues together until union has taken place, it is desirable to use as few sutures as possible, for every one introduced into the wound is a foreign body, increasing the chance of infection. The sutures should be so introduced as to accomplish their purpose without strangulation of the tissues which they unite, for where the sutures are tied in the wound the nutrition of the tissues they include is interfered with, and atrophy, if not actual necrosis, results. This is particularly true of the fascia, more poorly nourished, as it is, than either the peritoneum or the skin. Moreover, the tying of knots in the wound greatly increases the amount of foreign material introduced that later must become absorbed or encysted.

A careful consideration of the above facts and theories has led the author to adopt the following method of closing the abdominal wound in the majority of celiotomies, with most excellent results (Fig. 100).

**Technique.**—The peritoneum is brought together by a continuous suture of fine silk or kangaroo tendon. The fascia is united by a running quilted stitch of large-sized silk-worm gut, drawing the raw edges together without undue tension, and instead of being tied, the ends are brought out through the skin and left long near the angles of the wound.

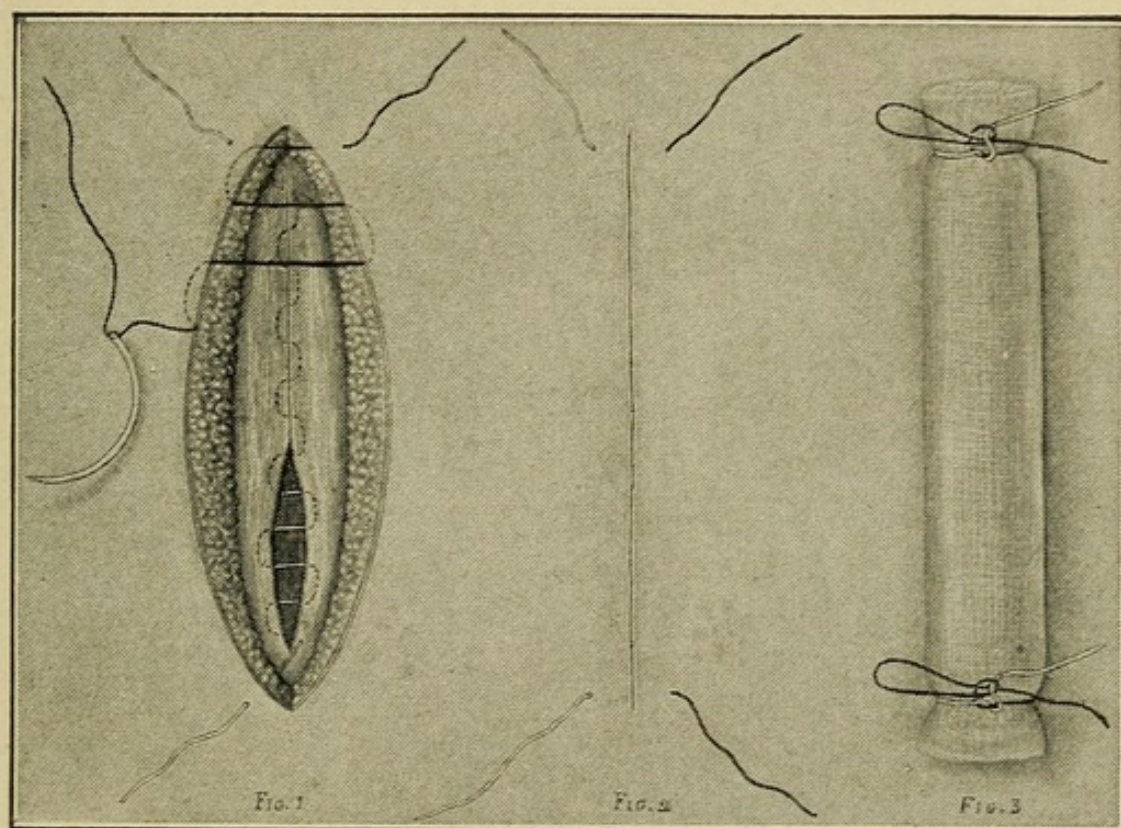
The incision in the skin is closed by a continuous subcutic-



ular stitch of silkworm gut, and the ends are also brought out long through the skin near the angles of the wound, but on the opposite sides from the fascial stitch.

A firm roll of gauze, one inch thick and slightly longer than the wound, is now laid over it, and over this, at each end, the skin and fascial stitches are tied together in a single bowknot, just tight enough to take up any slipping that may have

FIG. 100



Author's method of closing the abdominal wound.

occurred in the fascial stitch since its introduction. At the first dressing on the second day the gauze between these knots is cut out so as to allow subsequent daily inspection of the wound.

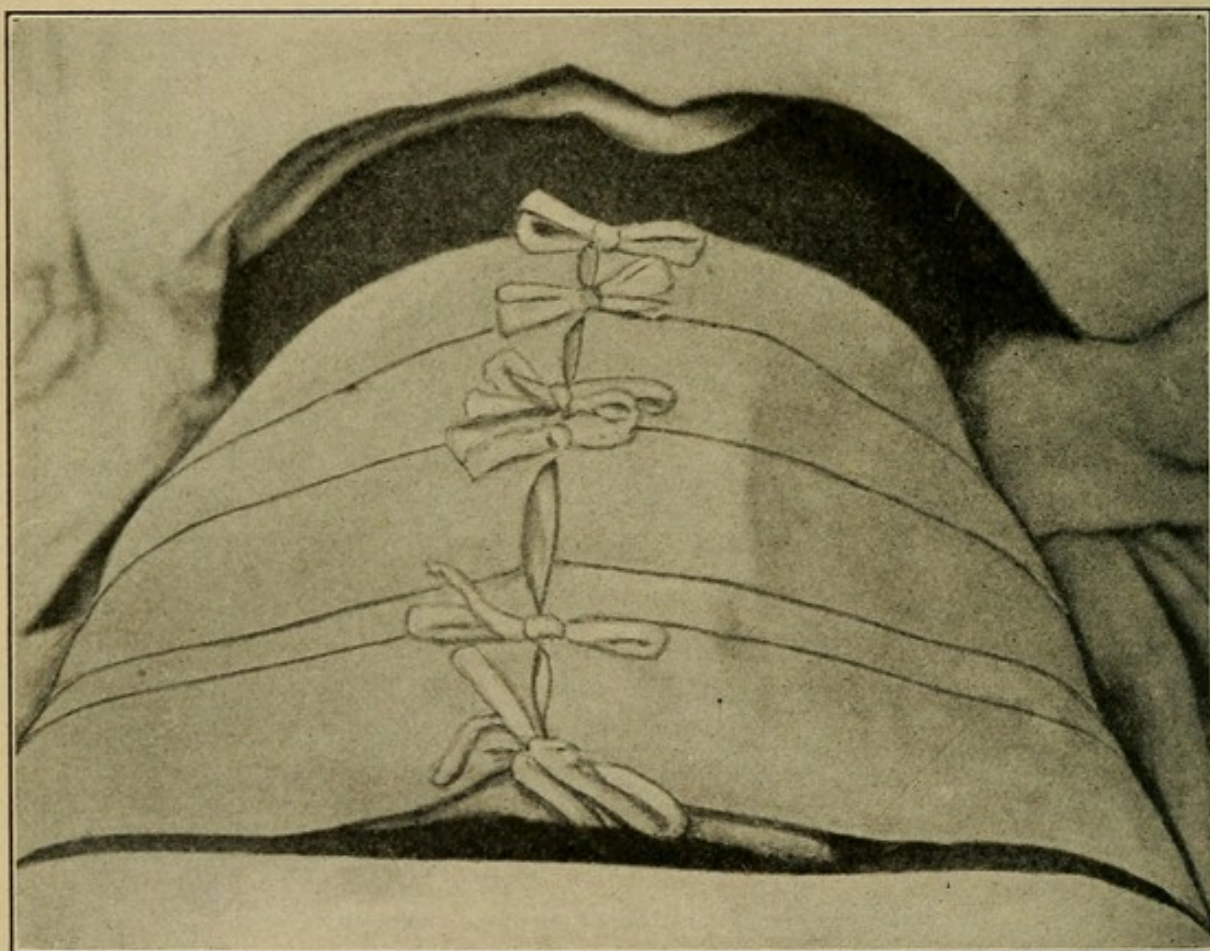
At the end of the first week the knots are untied, releasing the remaining ends of the gauze roller, and the skin stitch is cut off at one end and drawn out. One week later the fascial stitch is removed in a similar manner, thus leaving no suture



material behind in the wound between the peritoneum and skin.

In case there is failure on the part of the wound to heal by primary union, the skin stitch should be withdrawn and the fascial incision inspected. If this shows infection, or if the infection is under the fascia, its edges can be readily separated by loosening the suture without removing it, and proper

FIG. 101



Abdominal dressing for laparotomy cases.

drainage secured. Later, when the infection has subsided and union begun, the edges of the fascia can again be drawn together and good approximation obtained. Thus, the introduction of secondary sutures to close the separation in the fascia so often observed following suppurating wounds, and such a frequent cause of postoperative hernia, is avoided, saving much annoyance to both patient and surgeon.



**Dressing of the Abdominal Wound.**—The skin surface around the wound is dusted with a dry aseptic powder, and a firm gauze pad covers the wound area. Over this is placed a covering of thin rubber tissue, and the whole dressing is held in place with overlapping strips of adhesive plaster two inches in width. At the lower end of the dressing the last strip of plaster is applied to the skin over the symphysis and out on to the groins, sealing the dressing below to prevent possible contamination by urine or feces (Fig. 101).

**Subsequent Care of the Abdominal Wound.**—On the second day after operation the dressing is opened by cutting the adhesive plaster and rubber tissue in the middle line. The two flaps are turned to either side, the rubber tissue preventing them from sticking to the gauze. The gauze is removed and the wound inspected. Fresh gauze is then applied, the adhesive plaster covering brought together, and either laced or held by short strips of plaster. The wound is inspected each day until the dressing is finally removed.



## QUESTIONS.

---

- Describe the development of the genital tract.  
Mention the more common errors of development.  
Name the external organs of generation.  
Describe the labia majora.  
Describe the labia minora.  
Describe the vestibule.  
Describe the glands of Bartholin.  
Describe the clitoris.  
Describe the hymen.  
Describe the vagina.  
What are the internal organs of generation?  
Describe the uterus.  
Describe its peritoneal covering.  
What is the chief function of the broad ligaments?  
What are the supports of the uterus?  
Describe the uterovesical ligaments.  
Describe the uterosacral ligaments.  
Describe the round ligaments.  
What important changes take place in the uterus at puberty?  
What changes occur in the uterus at menstruation?  
Describe the changes occurring at the menopause.  
Describe the Fallopian tubes.  
With what variety of epithelium are they lined?  
Describe the ovaries.  
Describe the ovarian ligaments.  
What is a Graafian follicle, and how does it mature?  
Define corpus luteum.  
How are the ovaries held in place?  
Discuss the relations of the pelvic organs with the neighboring viscera.  
What are the more common causes of diseases among women?  
What precautions should be observed during menstruation?  
Give the leading questions necessary in taking a gynecological history.  
How would you make an abdominal examination?  
Describe the technique of a vaginal examination.  
Describe the bimanual examination.  
State the importance of making a rectal examination.  
How would you use the vaginal speculum?  
What are the principal malformations of the external genitalia, and how do they arise?



- Describe the different forms of hymen.
- To what is hermaphroditism due?
- Give the pathology of vulvitis.
- What glands are liable to become infected?
- Give the etiology of vulvitis.
- What are the common causes of infantile vulvitis?
- Give the objective symptoms of vulvitis.
- Give the subjective symptoms.
- Describe the different varieties of vulvitis.
- How would you diagnosticate a case?
- Give the treatment of acute vulvitis.
- Give the treatment of chronic vulvitis.
- What is the treatment of condylomata of the vulva?
- What is pruritus vulvæ?
- Give the symptoms of pruritus vulvæ.
- What is the treatment?
- Define kraurosis vulvæ.
- Give the treatment.
- What is the etiology of hematoma of the vulva?
- What is the pathology?
- Distinguish from hernia of the vulva.
- Give the symptoms.
- What is the treatment of hematoma of the vulva?
- What is the pathology of varicocele of the vulva?
- What is the treatment?
- What is the most common form of cyst of the vulva?
- Describe the pathology.
- Give the etiology of cyst of the vulva.
- What are the symptoms?
- Describe the treatment of cyst of the vulva.
- When should complete removal of the cyst wall be practised?
- What is elephantiasis of the vulva?
- What three forms are recognized?
- Give the pathology of elephantiasis of the vulva.
- What is the most common benign growth of the vulva?
- Give the diagnosis.
- What is the treatment?
- What forms of malignant tumor develop on the vulva?
- What is their pathology?
- Describe the symptoms.
- Give the treatment for carcinoma of the vulva.
- What is the prognosis of sarcoma of the vulva?
- How would you distinguish between hernia and a newgrowth formation of the vulvæ?
- What is the treatment of vulval hernia?
- What are the malformations of the vagina?
- What varieties of atresia are met with?
- Describe atresia hymenalis.
- Describe atresia vaginalis. Atresia cervicalis.
- Describe hour-glass contraction of the vagina.



- What are the more common diseases of the vagina?  
What is the pathology of vaginitis?  
Give the etiology of vaginitis.  
Describe the different varieties of vaginitis.  
Give the symptoms of acute vaginitis.  
Describe the diagnosis.  
Outline the treatment of acute vaginitis.  
What is vaginismus?  
Give its etiology.  
Describe the symptoms.  
What is the treatment?  
Give the causes of dyspareunia.  
What are the more common tumors of the vagina?  
Describe carcinoma of the vagina.  
Discuss the diagnosis.  
What are the malformations of the uterus?  
Describe uterus bicornis.  
Describe the infantile type of uterus.  
What is the etiology?  
Give the treatment.  
What is the significance of the non-appearance of menstruation?  
Describe atrophy of the cervix.  
Describe hypertrophy of the vaginal portion of the cervix.  
Distinguish between hypertrophy and hyperelongation of the cervix.  
What is the pathology of cervical laceration?  
Etiology of laceration of the cervix?  
What are the immediate symptoms of laceration?  
What are the late symptoms of laceration?  
Describe the treatment of the different forms of cervical laceration.  
Define cervical catarrh.  
What is its pathology?  
Discuss the diagnosis.  
What is the treatment?  
Define endometritis.  
What is the pathology of acute endometritis?  
What is the etiology of acute endometritis?  
Give the symptoms of gonorrheal endometritis.  
How would you determine the diagnosis?  
What are the symptoms?  
Describe the treatment.  
What is septic puerperal endometritis?  
Give the symptoms.  
Give the diagnostic signs.  
What is putrid endometritis?  
Give the symptoms.  
Outline the treatment.  
How would you differentiate between septic puerperal endometritis and putrid endometritis?  
What is the pathology of chronic endometritis?  
Give its etiology.



- What are the symptoms?
- Discuss the use of the curette in the various forms of endometritis.
- What are the contra-indications to its use?
- What is metritis?
- Distinguish between the acute and chronic variety.
- Give the pathology of chronic metritis.
- Give the etiology of chronic metritis.
- Describe the precautions to be taken to avoid its occurrence.
- What are the symptoms of chronic metritis?
- What are the effects of chronic metritis on conception?
- Describe the diagnosis of chronic metritis.
- Distinguish from early pregnancy.
- Give the treatment in a case of chronic metritis.
- Is tuberculosis of the uterus of frequent occurrence?
- What part of the uterus is most commonly involved?
- Give the symptoms.
- Define subinvolution of the uterus.
- What is its pathology?
- Give the symptoms.
- Distinguish between subinvolution and superinvolution.
- What is the most common cause of superinvolution?
- What is the treatment of subinvolution?
- Discuss the value of ergot, and give a contra-indication to its use.
- Define atresia of the genital canal.
- What are the different points at which obstruction may occur?
- What is the most common variety?
- Give the symptoms of atresia hymenalis.
- What is its treatment?
- What are the two principal types of malignant disease of the uterus?
- Give an example of each.
- What are the symptoms of carcinoma of the cervix?
- Give its pathology.
- In what three ways may it begin?
- Discuss the treatment of an inoperable case.
- Is carcinoma of the fundus of frequent occurrence?
- What is its pathology?
- Give the principal diagnostic features.
- With what conditions is it most often confused?
- What is the principal point of difference between carcinoma and sarcoma?
- Describe the treatment of sarcoma of the fundus.
- Does the growth ever occur in the cervix?
- Define deciduoma malignum.
- What is its pathology?
- Give its etiology.
- When is it most liable to develop?
- State the symptoms.
- How may an absolute diagnosis be made?
- What is the duration of the disease?
- What is the prognosis?



Give the treatment.

What is the most frequent form of benign tumor met with in the uterus?

At what age are they most often seen?

Contrast with cancer so-called.

How do all fibromyomata begin?

Describe their growth.

How are they influenced by the puerperium?

Does arrest ever occur at the menopause?

What are the three recognized varieties?

Which variety is most liable to change the size of the uterus, and which its position?

What are some of the changes that may take place in a fibroid during its growth?

Does suppuration ever occur, and what is its cause?

On what do the symptoms of fibromyomata depend?

Give the more common symptoms.

What influence do they have on conception?

What effect do the fibromyomata have on menstruation?

Is amenorrhea common with the fibroids?

Mention the more common complications they may cause during pregnancy.

What is the most common error in diagnosis?

Give the differential diagnosis between fibromyoma and pregnancy.

Discuss the value of myomectomy.

What are the indications that call for the operative removal of the tumor?

Of what benefit is curettage in these cases?

Give the pathology of adenomyoma.

Define adenomyoma uteri.

What are the symptoms?

How should these tumors be treated?

Define uterine polyp.

Give the pathology of these growths.

Give the symptoms of uterine polyp.

What is the treatment?

What is the most important pathological condition met with in the Fallopian tubes?

Give the pathology of acute salpingitis.

Describe the formation of a tuboövarian abscess.

Does spontaneous rupture of a pyosalpinx ever occur?

In what manner may perforation and evisceration occur?

How does salpingitis cause sterility?

Give the etiology of salpingitis.

What is the most common infecting medium?

What are the symptoms of acute salpingitis?

Give the diagnosis.

How would you diagnosticate from acute appendicitis?

Discuss the treatment of acute salpingitis.

Of pyosalpinx.



- Of tuboövarian abscess.
- Of chronic salpingitis.
- Discuss the indications for the resection of a diseased tube rather than its complete removal.
- What are the infectious granulomata that affect the tubes?
- Give their pathology.
- Is pain a constant symptom?
- Give the neoplasms which may develop in the tubes.
- Define ectopic gestation.
- Give its pathology.
- What are the different varieties?
- Describe the most common one.
- What is the rule in regard to the life of the fetus?
- State the different ways in which termination may take place.
- Describe tubal twin pregnancy.
- What is the etiology?
- Give the symptoms of tubal pregnancy before rupture.
- Give the symptoms of tubal pregnancy after rupture.
- Describe the diagnosis before rupture.
- After rupture.
- Discuss the treatment before rupture.
- Discuss the treatment after rupture.
- Define ovaritis.
- What is its importance?
- Describe the chronic variety.
- What are the symptoms of chronic ovaritis?
- Name the more common tumors of the ovary.
- In what three ways do these tumors arise?
- Give the diagnosis of chronic ovaritis.
- What is the treatment of acute ovaritis?
- What is the treatment of chronic ovaritis?
- What are the displacements of the ovary?
- Which one is most commonly met with?
- Give the pathology of prolapse of the ovary.
- Mention some of the more important etiological factors.
- What are the symptoms?
- How would you make a diagnosis in a case of adherent prolapse?
- Describe the treatment.
- Give the pathology of the simple cysts.
- Of the adenomata.
- Of the papillomata.
- Which variety attain the largest size?
- To what complications are they liable?
- Describe the dermoid variety.
- What is an ovarian teratoma?
- What are the non-malignant tumors of the ovary?
- What are the malignant involvements?
- Describe the parovarian cysts.
- What are the symptoms?
- Distinguish parovarian from simple cyst.



How would you diagnosticate an ovarian cyst?  
Give the differential diagnosis between ascites and ovarian cyst.  
What is the treatment of the ovarian tumors?  
Define pelvic peritonitis.  
What are the two varieties?  
Give the pathology.  
Describe the symptoms of acute pelvic peritonitis.  
What is the etiology?  
What are the two principal avenues of infection?  
State the chief diagnostic features of the disease.  
What is the ordinary cause of a case of pelvic peritonitis?  
Describe the treatment.  
What are the indications for operative treatment?  
Define pelvic hematocele.  
What is its pathology?  
What is its most frequent cause?  
What are the symptoms?  
Discuss the diagnosis.  
Give the treatment.  
Define pelvic abscess.  
What is its pathology?  
Give its etiology.  
What are the symptoms?  
Discuss the diagnosis.  
Give the treatment for this condition.  
Describe normal menstruation.  
At what two periods in life is it suspended?  
What is the average age of onset?  
How does this vary in different climates?  
Describe premature menstruation.  
Delayed menstruation.  
What is vicarious menstruation?  
Define amenorrhea.  
Give the pathology of amenorrhea.  
Give the etiology of amenorrhea.  
Of what is it often a symptom?  
Give the treatment.  
Define menorrhagia.  
What is its etiology?  
Give the treatment.  
Define metrorrhagia.  
Of what condition is metrorrhagia often the first sign?  
Define dysmenorrhea.  
What is the pathology of dysmenorrhea?  
What is its etiology?  
Discuss the two recognized theories of dysmenorrhea.  
What are the symptoms of dysmenorrhea?  
Give the treatment.  
What is the normal position of the uterus?  
How is this position maintained?



Mention some of the causes of variations in position within physiological limits.

Name the most important supporting ligaments of the uterus.

Describe their action.

What is the first step in all displacements?

What is the most important factor in causing retrodisplacements of the uterus?

Describe the position of the cervix in retroflexion.

Describe the position of the fundus in retroflexion.

What are the minor displacements of the uterus?

What are the major displacements?

What is the pathology of the retrodisplacements?

Give the etiology of the retrodeviations.

What are the symptoms of retroflexion?

Give the diagnosis.

Describe the bimanual method of examination.

How would you distinguish between retroflexion and a small fibroid in the posterior uterine wall?

What is the treatment of uncomplicated retroflexion?

Describe the vaginal method of replacement.

Describe the bimanual method.

What is the action of the retroversion pessary?

How is it held in place?

How would you introduce it?

Give the treatment for a case of adherent retroflexion.

What are the most used operations for the treatment of retroflexion?

Give the operative indication.

Discuss the relative merits of the various operations.

What is the importance of the lateral deviations of the uterus?

What are the downward displacements?

Distinguish between them.

Give the pathology of prolapsus uteri.

Is prolapse common in cases of complete perineal laceration?

Give the pathology of procidentia.

Give the diagnosis.

Give the etiology.

What is the first step in the descent of the uterus?

What are the symptoms?

What are the symptoms of traumatic prolapse?

Describe the non-operative treatment.

Give the operative treatment.

Define inversion of the uterus.

What is its pathology?

What is its etiology?

What are the symptoms?

Give the diagnosis.

Discuss the treatment?

Distinguish between inversion and uterine polypus.

What is hernia of the uterus?

Define antelexion.



Give its pathology.

What is the etiology?

Give the symptoms.

How would you diagnosticate a case?

Discuss the treatment.

Distinguish between ante flexion and infantile uterus.

What is the effect of pregnancy on ante flexion?

What is the effect of pregnancy on the infantile uterus?

Give the operative treatment for a case of ante flexion.

What is the menopause?

What is the average period of active menstrual life?

At what age does it commonly stop?

Describe the most common manner of cessation.

What are the causes of premature cessation?

What morbid conditions are apt to develop at this time?

Give the well-recognized symptoms of the climacteric.

What is the importance of irregular hemorrhages at this time?

Give the differential diagnosis between premature menopause and pregnancy.

What is the treatment?

What do you understand by relaxation of the vaginal outlet?

Give its pathology.

What is the etiology?

Describe the symptoms.

How would you diagnosticate this condition?

What are the factors that should determine operative repair?

Describe the different varieties of perineal laceration.

Give the pathology.

Discuss the etiology.

Give the symptoms.

Describe the condition existing in complete laceration of the perineum.

What is the treatment?

Define cystocele.

Give its pathology.

How does the presence of a cystocele affect micturition?

What are the remote effects on the kidneys?

Discuss the etiology of cystocele.

What are the symptoms?

Give the diagnosis.

What is the palliative treatment?

Describe the pessary treatment.

When should operative treatment be carried out?

Define rectocele.

What is its pathology?

Give its etiology.

What are the symptoms?

Discuss its bearing on prolapse of the uterus.

What is the treatment of rectocele?

Define genital fistula.



- Mention the different varieties.
- What is the pathology?
- What is the etiology of vesicovaginal fistula?
- Give the symptoms.
- Does spontaneous cure ever result?
- What are the indications for operative treatment?
- Define sterility.
- State the difference between absolute and relative sterility.
- What is the etiology of sterility?
- What is the most fertile period of a woman's life?
- What congenital defects are often present in sterility?
- Describe the treatment.
- What are the minor gynecological operations?
- What are the major gynecological operations?
- Describe the preparation of a patient for a vaginal operation.
- What are the indications for curettage?
- What instruments are required?
- Describe dilatation of the cervix.
- Describe the operation of curettage.
- What precautions should be taken to prevent laceration of the cervix during divulsion?
- What is the effect of too rapid dilatation?
- What are the indications for packing the uterus after curettage?
- What material would you use?
- How should it be introduced into the uterus?
- When should it be removed?
- Describe the operation for imperforate hymen.
- What is the after-treatment?
- Define trachelorrhaphy.
- What are the indications for repair of the cervix?
- Describe the operation of trachelorrhaphy.
- What are the indications for amputation of the cervix?
- Describe the operation.
- Describe an operation for cystocele.
- Give the indications for perineorrhaphy.
- Describe one of the more common operations.
- Describe an operation for the secondary repair of complete tear of the perineum.
- What is the after-treatment of a case where perineorrhaphy has been performed?
- Describe an operation for vesicovaginal fistula.
- Should the bladder be subsequently drained, and, if so, for how long a period?
- Describe an operation for vesico-uterine fistula.
- Describe an operation for ureterovaginal fistula.
- Discuss the relative advantages of the vaginal and abdominal methods of approach.
- Describe the repair of a rectovaginal fistula.
- Give the after-treatment.
- Describe the operation of anterior vaginal celiotomy.



What treatment of the pelvic organs may be carried out through this incision?

Describe a method of correcting retrodisplacements through this incision.

Describe the operation of posterior vaginal celiotomy.

Contrast its field of usefulness as compared with that of anterior vaginal celiotomy.

Mention some of the indications for vaginal hysterectomy.

Describe the operation.

What precautions should be taken to avoid injury to the ureters?

Describe the preparation of a patient for abdominal celiotomy.

Give the technique of the median line abdominal incision.

Give the technique of the transverse abdominal incision.

Discuss the relative merits of the transverse and median line incisions.

What are the advantages of the Trendelenburg position?

Describe a method of shortening the round ligaments for retroflexion.

Give the origin and insertion of the round ligaments.

What variations in origin are met with?

Discuss their bearing on the normal position of the uterus.

Describe the technique of shortening the uterosacral ligaments.

What are the indications for the operation?

Describe the operation of ventral suspension.

Discuss its merits.

What operative procedures should be carried out in a case of pro-cidentia?

How would you correct the condition of ovarian prolapse?

What are the indications for salpingostomy?

Describe the operation.

Describe the operation of salpingectomy.

What precautions should be taken in removing a pyosalpinx?

In what cases is supravaginal hysterectomy preferable to complete removal?

Describe the removal of a pedunculated fibroid.

Discuss the indications for myomectomy in a case of multiple fibroids of the uterus.

Describe the technique of closure of the abdominal incision after operation.

Discuss the after-treatment of a case of abdominal celiotomy.



# INDEX.

## A

- ABBEY, needle-holder, 152  
 Abdominal celiotomy, 182  
     for retrodisplacements of uterus, 130  
     examination, 32  
     hysterectomy in abdominal celiotomy, 190  
     retractor, Child's, 153  
     Eastman's, 154  
 Abnormalities of Fallopian tubes, 92  
 Abortion, criminal, diseases of women and, 29  
 Abscess, pelvic, 109  
     tuboövarian, 94  
 Actinomycosis of Fallopian tubes, 96  
     of labia majora, 39  
 Adenoma of ovary, 100  
 Adenomyoma of uterus, 90  
 Alexander-Adams operation for retrodisplacements of uterus, 129  
 Amenorrhea, 112  
     definition of, 112  
     diagnosis of, 113  
     etiology of, 113  
     pathology of, 112  
     symptoms of, 113  
     treatment of, 113  
 Amputation of cervix, 162  
 Angiotribe, Child's, 157  
 Anteflexion of uterus, 139  
 Atresia of cervix, 65  
     of vagina, 49, 50  
     of vulva, 36  
 Atrophy of cervix, 65  
     of uterus, 65

## B

- BARTHOLIN, glands of, anatomy of, 21  
 Bimanual examination, 33  
 Blood supply of uterus, 24

## C

- CARCINOMA of cervix, 78  
     of uterus, 81  
     of vagina, 58  
     of vulva, 47  
 Catarrh of cervix, 69  
     of vagina, 55  
 Celiotomy, abdominal, 182  
     hysterectomy in, 190  
     care of wound in, 197  
     closure of wound in, 194  
         Child's method, 194  
     complete removal in, 192  
     dressing of wound in, 197  
     indications for, 189  
     longitudinal, 183  
     myomectomy in, 194  
     oöphorectomy in, 189  
     oöphorrhaphy in, 189  
     removal of pedunculated tumors in, 193  
     for retrodisplacements, 187  
         Gilliam's operation, 188  
         Goffe's method, 187  
         Kelly's method, 187  
         Mann's method, 187  
     of uterus, 130  
     salpingectomy in, 190  
     salpingostomy in, 189  
     supravaginal removal in, 190



- Celiotomy, abdominal, transverse, 183  
     suprapubic, 184  
     vaginal, anterior, 176  
         for retrodisplacements, 178  
         oöphorectomy, 179  
         salpingectomy, 179  
         shortening of ovarian ligaments, 179  
         of round ligaments in, 178  
         vaginal fixation in, 178  
     posterior, 180
- Cervix uteri, amputation of, 162  
     technique of, 163  
     atresia of, 65  
     atrophy of, 65  
         diagnosis of, 66  
         occurrence of, 65  
         symptoms of, 66  
     carcinoma of, 78  
         definition of, 78  
         diagnosis of, 80  
         etiology of, 79  
         pathology of, 78  
         symptoms of, 80  
         treatment of, 80  
     catarrh of, 69  
         acute, 69  
         chronic, 69  
         definition of, 69  
         diagnosis of, 70  
         etiology of, 70  
         pathology of, 70  
         symptoms of, 70  
         treatment of, 70  
     dilatation of, 158  
     hyperelongation of, 67  
         definition of, 67  
         diagnosis of, 67  
         etiology of, 67  
         pathology of, 67  
         symptoms of, 67  
         treatment of, 68  
     hypertrophy of, 66  
         diagnosis of, 67  
         etiology of, 66  
         pathology of, 66  
         symptoms of, 66  
         treatment of, 67
- Cervix uteri, laceration of, 68  
     anteroposterior, 68  
     bilateral, 68  
     definition of, 68  
     diagnosis of, 69  
     etiology of, 68  
     left unilateral, 68  
     pathology of, 68  
     stellate, 68  
     symptoms of, 68  
     treatment of, 69  
     varieties of, 68  
         malformations of, 65
- Childbirth, diseases of women and, 29
- Child's abdominal retractor, 153  
     angiotribe, 157  
     intestinal forceps with rubber jaws, 157  
     method of closure of wound in abdominal celiotomy, 194  
     trowel retractor, 156
- Civilization, diseases of women and, 28
- Clamp, Pean's hysterectomy, 155
- Clitoris, absence of, 37  
     anatomy of, 20  
     bifid, 37
- Conception, prevention of, diseases of women and, 29
- Condylomata acuminata, 43  
     definition of, 43  
     diagnosis of, 43  
     etiology of, 43  
     pathology of, 43  
     symptoms of, 43  
     treatment of, 43
- Curettage, 159
- Curette, Sims', 152
- Cystocele, 144  
     definition of, 144  
     diagnosis of, 145  
     etiology of, 144  
     operation for, 166  
     pathology of, 144  
     symptoms of, 145  
     treatment of, 146
- Cysts of ovary, 100  
     of vagina, 58  
     of vulva, 45



**D**

- DECIDUOMA malignum, 83  
 definition of, 83  
 diagnosis of, 83  
 etiology of, 83  
 pathology of, 83  
 symptoms of, 83  
 treatment of, 83  
 Delayed menstruation, 112  
 Dermoid cyst of ovary, 100  
 Descensus uteri, 132  
 Deschamp's ligature carrier, 156  
 Dilatation of cervix, 158  
 Dilator, Pryor's, 151  
 Wathen's, 152  
 Diphtheria of vagina, 55  
 of vulva, 38, 39  
 Displacements of uterus, 120  
 downward, 131  
 lateral, 130  
 Doyen's traction forceps, 151  
 tumor screw, 158  
 Dress, diseases of women and, 28  
 Dynamics of female pelvis, 116  
 Dysmenorrhea, 114  
 definition of, 114  
 diagnosis of, 115  
 etiology of, 115  
 pathology of, 114  
 symptoms of, 115  
 theories of, 114  
 treatment of, 115  
 Dyspareunia, 57

**E**

- EASTMAN'S retractor, 154  
 Ectopic gestation, 103  
 definition of, 103  
 diagnosis of, after rupture, 105  
 before rupture, 105  
 etiology of, 104  
 pathology of, 103  
 symptoms of, 104  
 treatment of, 106  
 Elephantiasis of vulva, 46  
 Emmet's perineorrhaphy, 168  
 Endocervicitis, 69

## Endometritis, 71

- acute, 71  
 etiology of, 71  
 pathology of, 71  
 chronic, 74  
 definition of, 74  
 diagnosis of, 74  
 etiology of, 74  
 pathology of, 74  
 symptoms of, 74  
 treatment of, 74, 75  
 definition of, 71  
 gonorrheal, 71  
 diagnosis of, 71  
 symptoms of, 71  
 treatment of, 71  
 putrid, 72  
 diagnosis of, 73  
 etiology of, 72  
 pathology of, 72  
 symptoms of, 73  
 treatment of, 73  
 septic puerperal, 72  
 diagnosis of, 72  
 symptoms of, 72  
 treatment of, 72  
 Enterovaginal fistula, operation for, 176  
 Epispadias, 36  
 Erysipelas of vulva, 38, 39  
 Extraperitoneal operations for retrodisplacements of uterus, 129

**F**

- FALLOPIAN tubes, abnormalities of, 92  
 actinomycosis of, 96  
 anatomy of, 25  
 arteries of, 27  
 infectious granuloma of, 96  
 definition of, 96  
 diagnosis of, 97  
 etiology of, 97  
 pathology of, 96  
 symptoms of, 97  
 treatment of, 97  
 inflammations of, 93  
 neoplasms of, 97



Fallopian tubes, syphilis of, 96  
 tuberculosis of, 96  
 Female pelvis, dynamics of, 116  
 Fetal life, uterus of, 25  
 Fibroid tumors of vagina, 58  
 Fibroma of vulva, 46  
 Fibromyoma of uterus, 84  
   interstitial, 85  
   submucous, 86  
   subperitoneal, 86  
 Fistula, enterovaginal operation  
   for, 176  
   genital, 147  
   rectolabial, operation for, 176  
   rectoperineal, operation for, 176  
   rectovaginal, operation for, 175  
   ureterovaginal, operation for,  
     175  
   urethrovaginal, operation for,  
     175  
   vesico-uterine, operation for, 175  
   vesicovaginal, operation for, 173  
 Foerster's sponge-holder, 152  
 Follicular vulvitis, 38  
 Forceps, intestinal, Child's, 157  
   tissue, 154  
   traction, Doyen's, 151  
 Frenum, 20  
 Fritsch-Bozeman uterine irrigator,  
   155  
 Furunculosis of vulva, 38

## G

GANGRENE of vulva, 38  
 Garrigues' speculum, 154  
 Genital fistula, 147  
   definition of, 147  
   diagnosis of, 149  
   etiology of, 148  
   operations for, 173  
   pathology of, 147  
   symptoms of, 148  
   treatment of, 149  
   organs, anatomy of, 19  
   development of, 17  
 Gilliam's abdominal celiotomy, 188  
 Glands of Bartholin, anatomy of,  
   21

Goffe's abdominal celiotomy, 187  
   perineorrhaphy, 169  
 Gonorrhea of vagina, 55  
 Gonorrheal endometritis, 71  
 Graafian vesicles, 26  
 Granular vaginitis, 55  
 Graves' speculum, 34  
 Gynecological history, 29  
   operations, major, 151  
   minor, 151, 156  
   position of patient in, 156  
   preparation of surgeon's  
     hands for, 157

## H

HEMATEMETRA, 49  
 Hematocele, pelvic, 108  
 Hematocolpos, 49, 713  
 Hematoma of vulva, 43  
 Hematosalpinx, 49  
 Hemorrhage, intermenstrual, 113  
 Hermaphroditism, 37  
 Hernia of uterus, 138  
   of vulva, 48  
 Hydrosalpinx, 93  
 Hymen, absence of, 37  
   anatomy of, 20  
   double, 37  
   imperforate, 37  
     operation for, 160  
 Hyperelongation of cervix, 67  
 Hypertrophy of cervix, 66  
 Hypospadias, 36  
 Hysterectomy, abdominal, in ab-  
   dominal celiotomy, 190  
   clamp, Pean's, 155  
   vaginal, 181

## I

IMPERFORATE hymen, operation  
   for, 160  
 Inflammation of Fallopian tubes,  
   93  
   of ovaries, 98  
   of vagina, 54  
   of vulva, 37



Intermenstrual hemorrhage, 113  
 Interstitial fibromyoma of uterus, 85  
 Intestinal forceps, Child's, 157  
 Intraperitoneal operation for retro-displacements of uterus, 129  
 Inversion of uterus, 136

**K**

KELLY's abdominal celiotomy, 187  
 Kraurosis vulvæ, 41  
   definition of, 41  
   diagnosis of, 42  
   etiology of, 41  
   pathology of, 41  
   symptoms of, 41  
   treatment of, 42

**L**

LABIA majora, actinomycosis of, 39  
   anatomy of, 20  
   minora, anatomy of, 20  
 Lacerations of cervix, 68  
   of perineum, 141  
 Ligaments, ovarian, 27  
   of uterus, 23

**M**

MALFORMATIONS of cervix uteri, 65  
   of uterus, 60  
   of vagina, 49  
   of vulva, 36  
 Mann's abdominal celiotomy, 187  
 Martin's uterine sound, 153  
 Menopause, 139  
   definition of, 139  
   diagnosis of, 140  
   pathology of, 140  
   symptoms of, 140  
   treatment of, 140  
 Menorrhagia, 113  
   definition of, 113  
   diagnosis of, 114  
   etiology of, 113

Menorrhagia, pathology of, 113  
   symptoms of, 114  
   treatment of, 114  
 Menstruation, delayed, 112  
   diseases of women and, 28  
   disorders of, 111  
   normal, 111  
   premature, 111  
     treatment of, 112  
   uterus of, 25  
   vicarious, 112

Metritis, 75  
   acute, 75  
     diagnosis of, 76  
     etiology of, 75  
     pathology of, 75  
     symptoms of, 75  
     treatment of, 76  
   chronic, 76  
     diagnosis, 77  
     etiology of, 76  
     pathology of, 76  
     symptoms of, 76  
     treatment of, 77  
   definition of, 75  
 Metrorrhagia, 113  
 Mons veneris, 20  
 Müller, ducts of, 17  
 Myomectomy in abdominal celiotomy, 194

**N**

NEOPLASMS of Fallopian tubes, 97  
 Nerves of uterus, 25  
 Nymphæ, 20

**O**

OÖPHORECTOMY in abdominal celiotomy, 189  
   in vaginal celiotomy, 179  
 Oöphorrhaphy in abdominal celiotomy, 189  
 Ovarian ligament, 27  
   shortening of, in anterior vaginal celiotomy, 179  
 Ovaries, adenoma of, 100



- Ovaries, anatomy of, 26  
 arteries of, 27  
 cysts of dermoid, 100  
   parovarian, 100  
   simple serous, 100  
 displacement of, 98  
 inflammation of, 98  
 maldevelopment of, 97  
 papilloma of, 100  
 passive congestion of, 98  
 prolapse of, 98  
   diagnosis of, 99  
   etiology of, 99  
   pathology of, 98  
   symptoms of, 99  
   treatment of, 99  
 rudimentary, 97  
 structure of, 26  
 supernumerary, 97  
 teratoma of, 100  
 tumors of, 99  
   diagnosis of, 101  
   malignant, 100  
   pathology of, 100  
   symptoms of, 101  
   treatment of, 102
- Ovaritis, 98  
 acute, 98  
 chronic, 98  
 definition of, 98  
 diagnosis of, 98  
 etiology of, 98  
 pathology of, 98  
 symptoms of, 98  
 treatment of, 98
- Oviducts, 25
- P**
- PAPILLOMA of ovary, 100  
 of vulva, 42
- Parametrium, diseases of, 107
- Parovarian cysts, 100
- Pean's hysterectomy clamp, 155
- Pelvic abscess, 109  
 definition of, 109  
 diagnosis of, 110  
 etiology of, 109  
 pathology of, 109
- Pelvic abscess, symptoms of, 110  
 treatment of, 110
- hematocele, 108  
 definition of, 108  
 diagnosis of, 108  
 etiology of, 108  
 pathology of, 108  
 symptoms of, 108  
 treatment of, 109
- peritonitis, 107  
 acute, 107, 108  
 chronic, 107, 108  
 definition of, 107  
 diagnosis of, 107  
 etiology of, 107  
 pathology of, 107  
 symptoms of, 107  
 treatment of, 108
- Pelvis, female, dynamics of, 116
- Perineorrhaphy, 167  
 after-treatment of, 173  
 Emmet's, 168  
 Goffe's, 169  
 Ristine's, 171
- Perineum, anatomy of, 20  
 lacerations of, 141  
 definitions of, 141  
 diagnosis of, 143  
 etiology of, 142  
 pathology of, 142  
 symptoms of, 143  
 treatment of, 144
- Peritonitis, pelvic, 107
- Pessary, Skene's, 146
- Polyps of uterus, 90
- Pregnancy, uterus of, 25
- Premature menstruation, 111
- Prepuce, 20
- Procidentia, 132
- Prolapse of ovary, 98  
 of uterus, 132
- Pruritus vulvæ, 40  
 definition of, 40  
 diagnosis of, 40  
 etiology of, 40  
 pathology of, 40  
 symptoms of, 40  
 treatment of, 41
- Pryor's dilator, 151
- Pseudohermaphroditism, 37



Puerperal vulvitis, 38  
 Putrid endometritis, 72  
 Pyosalpinx, 93  
   treatment of, 96

**R**

RECTAL examination, 35  
 Rectocele, 146  
   definition of, 146  
   diagnosis of, 147  
   etiology of, 147  
   pathology of, 146  
   symptoms of, 147  
   treatment of, 147  
 Rectolabial fistula, operation for, 176  
 Rectovaginal fistula, operation for, 175  
 Relaxation of vaginal outlet, 141  
 Retrodisplacements of uterus, 121  
 Ristine's perineorrhaphy, 171  
 Round ligaments, shortening of, in anterior vaginal celiotomy, 178

**S**

SALPINGECTOMY in vaginal celiotomy, 179  
 Salpingitis, 93  
   acute, treatment of, 95  
   chronic, treatment of, 96  
   diagnosis of, 95  
   etiology of, 94  
   pathology of, 93  
   symptoms of, 95  
   treatment of, 95  
 Salpingostomy in abdominal celiotomy, 189, 190  
 Sarcoma of uterus, 82  
   of vagina, 59  
   of vulva, 48  
 Senile vaginitis, 55  
 Septic puerperal endometritis, 72  
 Sims' curette, 152  
   speculum, 35  
   tampon screw, 153  
 Skene's pessary, 146

Speculum, examination with, 35  
   Garrigues', 154  
   Graves', 34  
   Sims', 35  
 Sterility, 149  
   absolute, 149  
   definition of, 149  
   etiology of, 149  
   relative, 149  
   treatment of, 150  
 Subinvolution of uterus, 92  
 Submucous fibromyoma of uterus, 86  
 Subperitoneal fibromyoma of uterus, 86  
 Superinvolution of uterus, 77  
 Syphilis, diseases of women and, 29  
   of Fallopian tubes, 96  
   of vulva, 39

**T**

TERATOMA of ovary, 100  
 Tissue forceps, 154  
 Trachelorrhaphy, 160  
 Traction forceps, Doyen's, 151  
 Trowel retractor, 156  
   Child's, 156  
 Tubal gestation, 97  
 Tuberculosis of Fallopian tubes, 96  
   of uterus, 91  
   of vagina, 59  
   of vulva, 39  
 Tuboövarian abscess, 94  
   treatment of, 96  
 Tumors of ovary, 99  
   of uterus, benign, 84  
   malignant, 78  
   of vagina, 57  
   fibroid, 58  
   of vulva, benign, 46  
   malignant, 47  
 Tumor screw, Doyen's, 158

**U**

ULCERS, venereal, of vulva, 42  
 Ureterovaginal fistula, operation for, 175



- Urethrovaginal fistula, operation for, 175  
 Uterine irrigator, Fritsch-Boze-  
   man, 155  
   sound, Martin's, 153  
 Uterus, absence of, 60  
   adenomyoma of, 90  
     definition of, 90  
     diagnosis of, 90  
     etiology of, 90  
     pathology of, 90  
     symptoms of, 90  
     treatment of, 90  
   anatomy of, 22  
   anteflexion of, 139  
     definition of, 139  
     diagnosis of, 139  
     etiology of, 139  
     pathology of, 139  
     symptoms of, 139  
     treatment of, 139  
   appendages of, 25  
   atrophy of, 65  
     diagnosis of, 66  
     occurrence of, 65  
     symptoms of, 66  
   bicornis, 61  
   bipartitus, 61  
   blood supply of, 24  
   carcinoma of, 81  
     definition of, 81  
     diagnosis of, 81  
     etiology of, 81  
     pathology of, 81  
     symptoms of, 81  
     treatment of, 82  
   cavity of, 24  
   coats of, 24  
   didelphys, 61  
   displacements of, 120  
     major, 121  
     minor, 120  
   downward displacements of, 131  
     definition of, 131  
     diagnosis of, 134, 135  
     etiology of, 134  
     pathology of, 132  
     symptoms of, 134  
     treatment of, 135  
     varieties of, 132  
   of fetal life, 25  
     fibromyoma of, 84  
       definition of, 84  
       diagnosis of, 87  
       etiology of, 87  
       frequency of, 84  
       interstitial, 85  
       pathology of, 84  
       submucous, 86  
       subperitoneal, 86  
       symptoms of, 87  
       treatment of, 88  
       varieties of, 84  
   hernia of, 138  
   infantilism, 62  
   inversion of, 136  
     acute, 136  
     chronic, 136  
     definition of, 136  
     diagnosis of, 137  
     etiology of, 137  
     pathology of, 136  
     symptoms of, 137  
     treatment of, 137  
   lateral deviations of, 130  
     treatment of, 131  
   ligaments of, 23  
   malformations of, 60  
     diagnosis of, 64  
     etiology of, 62  
     pathology of, 60  
     symptoms of, 64  
     treatment of, 65  
   of menstruation, 25  
   nerves of, 25  
   of old age, 25  
   polyps of, 90  
     diagnosis of, 91  
     etiology of, 91  
     pathology of, 91  
     symptoms of, 91  
     treatment of, 91  
   of pregnancy, 25  
   prolapse of, 132  
     complete, 132  
       diagnosis of, 135  
       treatment of, 136  
     incomplete, 132  
       diagnosis of, 134  
       treatment of, 135



- Uterus, retrodisplacements of, 121  
 definition of, 121  
 diagnosis of, 122  
 etiology of, 121  
 pathology of, 121  
 symptoms of, 121  
 treatment of, 124  
   abdominal celiotomy in, 187  
   extraperitoneal methods, 129  
     Alexander-Adams operation, 129  
     vaginal fixation, 129  
   intraperitoneal methods, 129  
     abdominal celiotomy, 130  
     vaginal celiotomy, 129  
 introduction of pesary in, 127  
 operative, 128  
 reposition, bimanual method, 126  
   gravity method, 126  
   vaginal method, 124  
 vaginal celiotomy, anterior, in, 178  
 rudimentary, 60  
 sarcoma of, 82  
   definition of, 82  
   diagnosis of, 82  
   etiology of, 82  
   pathology of, 82  
   symptoms of, 82  
   treatment of, 83  
 septus, 62  
 subinvolution of, 92  
   definition of, 92  
   diagnosis of, 92  
   pathology of, 92  
   symptoms of, 92  
   treatment of, 92  
 superinvolution of, 77  
   definition of, 77  
   diagnosis of, 78  
   etiology of, 78  
   pathology of, 77  
   prognosis of, 78  
   symptoms of, 78
- Uterus, superinvolution of, treatment of, 78  
 tuberculosis of, 91  
   diagnosis of, 92  
   symptoms of, 91  
   treatment of, 92  
 tumors of, benign, 84  
   malignant, 78  
 unicornis, 61
- V**
- VAGINA, absence of, 49  
 anatomy of, 21  
 atresia of, 49, 50, 51  
   definition of, 50  
   diagnosis of, 53  
   etiology of, 50  
   hymenalis, 51  
   pathology of, 51  
   symptoms of, 52  
   treatment of, 54  
 carcinoma of, 58  
   definition of, 58  
   diagnosis of, 59  
   etiology of, 58  
   pathology of, 59  
   symptoms of, 59  
   treatment of, 59  
 cysts of, 58  
   diagnosis of, 58  
   etiology of, 58  
   occurrence of, 58  
   pathology of, 58  
   symptoms of, 58  
   treatment of, 58  
 double, 49  
 hour-glass contraction of, 49  
 inflammation of, 54  
 malformations of, 49  
 sarcoma of, 59  
   occurrence of, 59  
   symptoms of, 59  
 tuberculosis of, 59  
   occurrence of, 59  
 tumors of, 57  
   fibroid, 58  
     diagnosis of, 58




- Vagina, tumors of, fibroid, etiology of, 58  
 pathology of, 58  
 symptoms of, 58  
 treatment of, 58
- Vaginal celiotomy, anterior, 176  
 posterior, 180  
 for retrodisplacements, anterior, 178  
 of uterus, 129  
 examination, 32  
 fixation in anterior vaginal celiotomy, 178  
 in retrodisplacements of uterus, 129  
 hysterectomy, 181  
 outlet, relaxation of, 141  
 definition of, 141  
 diagnosis of, 141  
 etiology of, 141  
 pathology of, 141  
 symptoms of, 141  
 treatment of, 141
- Vaginismus, 57  
 definition of, 57  
 diagnosis of, 57  
 etiology of, 57  
 symptoms of, 57  
 treatment of, 57
- Vaginitis, 54  
 catarrhal, 55  
 definition of, 54  
 diagnosis of, 56  
 diphtheritic, 55  
 etiology of, 54  
 gonorrheal, 55  
 granular, 55  
 pathology of, 54  
 senile, 55  
 symptoms of, 55  
 treatment of, 56  
 varieties of, 55
- Varicocele of vulva, 44
- Venereal ulcers of vulva, 42
- Vesico-uterine fistula, operation for, 175
- Vesicovaginal fistula, operation for, 173
- Vestibule, anatomy of, 20
- Vulva, absence of, 36
- Vulva, atresia of, 36  
 carcinoma of, 47  
 cysts of, 45  
 definition of, 45  
 diagnosis of, 45  
 etiology of, 45  
 pathology of, 45  
 symptoms of, 45  
 treatment of, 45  
 types of, 45  
 double, 36  
 elephantiasis of, 46  
 definition of, 46  
 diagnosis of, 46  
 etiology of, 46  
 pathology of, 46  
 symptoms of, 46  
 treatment of, 46  
 fibroma of, 46  
 hematoma of, 43  
 definition of, 43  
 diagnosis of, 44  
 etiology of, 43  
 pathology of, 43  
 symptoms of, 44  
 treatment of, 44  
 hernia of, 48  
 definition of, 48  
 diagnosis of, 48  
 etiology of, 48  
 pathology of, 48  
 symptoms of, 48  
 treatment of, 49  
 infantile, 36  
 inflammation of, 37  
 malformations of, 36  
 papilloma of, 42  
 sarcoma of, 48  
 tumors of, benign, 46  
 diagnosis of, 47  
 etiology of, 46  
 pathology of, 46  
 symptoms of, 47  
 treatment of, 47  
 type of, 46  
 malignant, 47  
 diagnosis of, 48  
 etiology of, 47  
 pathology of, 47  
 prognosis of, 48



- Vulva, tumors of, malignant, symptoms of, 47  
treatment of, 48  
varieties of, 47  
varicocele of, 44  
definition of, 44  
diagnosis of, 44  
etiology of, 44  
pathology of, 44  
symptoms of, 44  
treatment of, 44  
venereal ulcers of, 42  
Vulvitis, 37  
definition of, 37  
diagnosis of, 38  
diphtheritic, 38, 39  
erysipelatous, 38, 39  
Vulvitis, etiology of, 38  
follicular, 38  
furuncular, 38  
gangrenous, 38  
pathology of, 38  
puerperal, 38  
symptoms of, 38  
syphilitic, 39  
treatment of, 39  
tuberculous, 39
- W**
- WATHEN's dilator, 152  
Wolffian bodies, 17  
ducts, 17











## COLUMBIA UNIVERSITY

This book is due on the date indicated below, or at the expiration of a definite period after the date of borrowing, as provided by the rules of the Library or by special arrangement with the Librarian in charge.

[illegible]



RG111

C43

Child



