

Face and foot deformities / by Frederick Churchill.

Contributors

Churchill, Frederick, 1843-1918.
Augustus Long Health Sciences Library

Publication/Creation

London : J. & A. Churchill, 1885.

Persistent URL

<https://wellcomecollection.org/works/fd4weawv>

License and attribution

This material has been provided by This material has been provided by the Augustus C. Long Health Sciences Library at Columbia University and Columbia University Libraries/Information Services, through the Medical Heritage Library. The original may be consulted at the the Augustus C. Long Health Sciences Library at Columbia University and Columbia University. where the originals may be consulted.

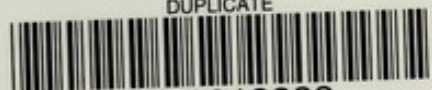This work has been identified as being free of known restrictions under copyright law, including all related and neighbouring rights and is being made available under the Creative Commons, Public Domain Mark.

You can copy, modify, distribute and perform the work, even for commercial purposes, without asking permission.



Wellcome Collection
183 Euston Road
London NW1 2BE UK
T +44 (0)20 7611 8722
E library@wellcomecollection.org
<https://wellcomecollection.org>

DUPLICATE



HX00018988


FACE
AND
FOOT
DEFORMITIES

8/6

With the Author's kind regards

May 1885,

FACE AND FOOT
DEFORMITIES.



Digitized by the Internet Archive
in 2010 with funding from
Open Knowledge Commons

FACE AND FOOT DEFORMITIES.

BY

FREDERICK CHURCHILL, C.M.,
SURGEON TO THE VICTORIA HOSPITAL FOR CHILDREN.

*With Illustrations of New Appliances for the Cure of
Birth-Mark, Club-Foot, etc.*



LONDON
J. & A. CHURCHILL
11, NEW BURLINGTON STREET.
1885

~~Webster Library~~

RD523

C47

PREFACE.

IT is needful at the outset that I should explain, and if possible justify the selection of a title which to some minds may appear rather indefinite.

There can be, of course, no hard and fast line between that which is deep, and that which is superficial.

I use the term deformities in its broadly generic sense, as applicable to all surface lesions and symmetrical defects.

It is important to make this explanation because, no doubt, we, as surgeons, have become too much accustomed to such a restricted definition of deformities as may be found in some text-books of orthopædic surgery, the authors having limited themselves to a description of alterations in the normal outlines of the body from changes in the osseous and ligamentous structures.

By deformities I understand any recognised alteration in structure, whether temporary or permanent, whether produced by disease, by congenital deficiencies or outgrowths, by want of symmetry in the general configuration of the body, or by structural

and surface changes the result of injury or disease. A deformity in fact, is anything that is manifestly ugly or crooked.

As regards the foot, there can be no difficulty in understanding what is meant by deformity of that member of the body.

Limiting myself to surface deformities and modern methods of treatment thereof, I do not undertake the general surgery of the deep structures of the foot or face. It would not only very much enlarge the scope of my work to do so, but it would lead me to embark upon a path which has been so ably and well trodden by writers upon systematic surgery. For the same reason, I do not enter upon a full consideration of the etiology and pathology of skin diseases, but I give a brief outline of skin eruptions as they appear on the face. Moreover, in dealing only with those deformities which appear on the surface, I believe I am more accurately discharging my duty when defining my position in regard to the title of this work.

To introduce such subjects as cleft palate and disease of the antrum into any work which is limited to the surgery of the face, is, I think, to overstep the natural limitations of the subject under consideration. I have therefore omitted all reference to diseases of the jaws, mouth, etc.

It may be asked,—why I should associate the face with the foot, as these are the two extreme parts of the body? Chiefly because deformities of these members of the body being more manifest than

deformities elsewhere, they constitute a greater hindrance to success in life. They not only deform but deface, by reason of their great disfigurement, the artistic proportions of those parts of the body upon which the eye of the observer or critic most loves to rest.

I may add that as Surgeon to the Victoria Hospital for Children, these deformities of the body have occupied much of my thought and attention, with an earnest desire to erase from the chapter of accidents as many as possible of such unsightly disfigurements, so that in the inevitable struggle for supremacy, in after life, these poor children may stand a better chance of competing for the prizes, and not be so heavily handicapped in the race by their more fortunate competitors.

The litho illustrations are taken from cases that were under my care while this book was passing through the press.

The chromographs and monotonies are taken from photographs enlarged by the camera lucida process, and are accurate representations of the before and after effects. Mr. Burgess, the well-known anatomical and pathological artist, has faithfully carried out my instructions in every detail. I shall be happy to show the photographs to any surgeons who may desire to see them.

I am indebted to the publishers of Erichsen's, Fergusson's, Pirrie's, and Bryant's Manuals of Surgery for permission to copy some of their woodcuts

Mr. Brodhurst has also kindly lent me two woodcuts to copy.

I have made some selected quotations from Mr. Adams' prize essay on Club-foot, because few, if any, surgeons can have had such good opportunities as he had of studying by dissection the osseous and ligamentous changes as they appear in the several varieties of club-foot.

I regret that I have only been able to give a limited space to the consideration of deformities upon collateral subjects, such as skin eruptions, and surface lesions of the eye.

There are an endless variety of congenital deficiencies, and our museums are full of strange examples of developmental defects. Most of these being irremediable, I have not allotted a section to such malformations.

I have omitted some of the rarer forms of deformity of the face, as, for example, elephantiasis, anasarca, and atrophies dependent upon neurovascular degeneration. But these are local manifestations of general diseases, and are therefore passed over. Still I am conscious of having failed to exhaust the repertory of deformities within the range of my definitions, and may consider the subject open for more elaborate treatment hereafter.

FREDERICK CHURCHILL.

4, CRANLEY GARDENS, S.W.

April 1885.

GENERAL CONTENTS.

PART I.

THE FACE.

SECTION	PAGE
I.—STRUCTURAL DEFORMITIES — BIRTH-MARKS, CONGENITAL GROWTHS, NÆVI, ETC.	I
II.—FACE ERUPTIONS—ABSCESSES, ULCERATIONS, PARASITIC DISEASES, SURFACE TUMOURS, DENTAL ABSCESS, ETC.	19
III.—INJURIES OF THE FACE—INCISED WOUNDS, FRACTURES AND DISLOCATIONS, BURNS AND SCALDS	64
IV.—PLASTIC SURGERY—NOSE, HARE-LIP, ETC. ..	72
V.—OTHER DEFORMITIES OF THE LIPS	90
VI.—DEFORMITIES OF THE EYELID AND EYEBALL —DISEASES OF CORNEA, ETC.	95
VII.—DEFORMITIES OF NEUROTIC ORIGIN	114

PART II.

THE FOOT.

VIII.—DEFORMITIES INDUCED BY INJURY OR DISEASE —DISLOCATIONS OF THE ANKLE, AMPUTA- TION STUMPS, ETC.; INGROWING TOE-NAIL; SIMPLE ONYCHIA, ONYCHIA MALIGNA, ETC. ..	117
---	-----

SECTION	PAGE
IX.—DEFORMITIES INDUCED BY BAD HABITS—FAULTY BOOTS, BUNIONS, CORNS, DISTORTED TOES, ETC.	127
X.—CONGENITAL AND PARALYTIC DEFORMITIES— CONTRACTION OF PLANTAR FASCIA; CON- TRACTION OF ONE TOE; WEAK ANKLES; CLUB-FOOT; VARIETIES OF TALIPES—THEIR CAUSES, CLASSIFICATION, AND TREATMENT; FLAT-FOOT; CHOREIC, HYSTERIC, AND SPAS- TIC CONTRACTION OF GROUPS OF MUSCLES; WEBBED TOES, SUPERNUMERARY TOES, ETC.	138
APPENDIX OF CASES	185

CONTENTS OF SECTIONS.

THE FACE.

	PAGE		PAGE
SECTION I.		E. nodosum	22
STRUCTURAL DEFORMITIES.		Erysipelas	22
Introduction	1	Traumatic erysipelas	23
"Liver marks"	4	Urticaria	24
"Port-wine stains"	4	Eczema	25
Birth-marks	5	Impetigo	27
—— treatment of, by		Lichen	27
the stippling process, etc.	7	L. strophulus	28
Aneurism by anastomosis ..	8	Herpes	28
Mother's marks and nævi ..	9	Miliaria	28
Nævus araneus	12	Ecthyma	29
Erectile tumours	11	Pemphigus	29
Warts	13	Rupia	30
Scars of burns	14	Pityriasis	30
Wens	15	Psoriasis	30
Pigmentary changes	16	Facial Carbuncle	31
Moles	16	Anthrax	31
Bronzing of skin	17	Malignant pustule	32
Leucoderma	18	Keloid	33
Freckles	18	Xanthelasma	33
Horny growths	18	Abscesses, simple	34
Horns	19	Fistulous tracks	35
SECTION II.		Strumous abscesses	35
ERUPTIONS, ETC.		Furuncles	35
Erythema	20	Hordeolum	35
E. simplex	21	Ulcers, simple	36
E. marginatum	21	—— syphilitic	36
		Acne	36
		Stearrhœa	38
		Acne indurata	38

	PAGE		PAGE
Acne rosacea	40	SECTION IV.	
Molluscum	42	PLASTIC SURGERY.	
Lupus	43	Primary union	72
— exedens	44	Deformities of the nose ..	74
— devorans	45	Dislocation „ „ ..	75
— non-exedens	46	Atrophy „ „ ..	75
— erythematosus	47	Taliacotian operation ..	76
Cancrum oris	48	Plastic surgery of the eyelid	78
Congenital syphilitic eruptions	49	Harelip	79
PARASITIC DISEASES.		— plastic operation for	82
Scabies	50	— Hainsby's truss ..	85
Pediculi	50	Double harelip	86
Tinea tonsurans	51	Plastic operations on lower	
— circinata	51	lip	90
— sycosis	52	SECTION V.	
— favosa	53	OTHER DEFORMITIES OF THE	
Chloasma	54	LIPS.	
Pityriasis versicolor	54	Excessive growth of hair ..	90
SURFACE GROWTHS.		Simple cracked lip	91
Lipoma	54	Cracks at angle of mouth ..	92
Fatty tumours	55	Small nævoid growths ..	92
Primary cancer	56	Hypertrophy	93
Rodent cancer	56	Chancre	93
Epithelioma	57	Cysts	94
Sebaceous cysts	59	Congenital cystic growths ..	94
Dental abscess	60	Sub-mucous ulceration ..	95
Salivary fistula	63	SECTION VI.	
SECTION III.		THE EYE.	
INJURIES.		Ecchymosis	95
Incised wounds	64	Emphysema	96
Fractures of bones	67	Wounds	96
Dislocation of jaw	67	Injuries from corrosion ..	96
Fracture of nasal bones ..	68	Sub-conjunctival ecchymosis	96
Burns and scalds	69	Penetrating wounds of cornea	97
Cicatrices, removal of ..	71	Excavation of cornea ..	97

	PAGE		PAGE
Ptosis	97	Pinguecula	110
Spasmodic irritation	98	Keratitis	111
Epicanthus	99	Opacity of cornea	111
Entropion	99	Ulcers	111
Trichiasis	99	Staphyloma	111
Ectropion	100	Conical cornea	112
Encysted steatomas	101	Arcus senilis	112
Chalazion	101	Syphilitic keratitis	113
Strabismus	102	Suppurative keratitis	113
Abscesses and cellulitis ..	103		
Ophthalmia tarsi	103		
Blepharitis	104		
Symblepharon	104		
Obstructed lachrymal ducts	105		
————— sac .	105		
Acute inflammation of sac .	105		
Fistula lachrymalis	106		
Catarrhal ophthalmia	106		
Purulent ophthalmia	107		
Gonorrhœal ophthalmia	109		
Phlyctenular ophthalmia ..	109		
Pterygium	110		

SECTION VII.

DEFORMITIES OF NEUROTIC
ORIGIN.

Choreic spasms	113
Hysteria	114
Nerve irritation	114
Hemiplegia	114
Paralysis of the insane ..	115
Tetanus	115
Facial paralysis	116

THE FOOT.

SECTION VIII.

INJURIES AND SURFACE
DISEASES.

Contusion	117
Partial displacement of astragalus	117
Separation of the tarsus ..	118
Dislocation of ankle, varieties of	118
Compound dislocation ..	120

Dislocation of other tarsal bones	121
Hypertrophy of foot	121
Cellulitis	121
Amputation stumps	122
Excisions	122
Chilblains	122
Diseased toe-nails	124
Ingrowing toe-nail	124
Simple onychia	125
Onychia maligna	126
Horny growths	126

	PAGE		PAGE
Exostoses	126	Tenotomy	157
Perforating ulcers	126	Scarpa's shoe	158
Tumours, etc.	127	Moulding of bones	158
		Reunion of divided tendon	159
SECTION IX.		Resistance of ligaments ..	160
DEFORMITIES FROM BADLY		Talipes varus, congenital	
FITTING BOOTS.		and acquired	161
Partial dislocation of meta-		Uselessness of irons	163
tarsal bone	130	Fixation apparatus	165
Bunions	133	Method of applying it ..	166
Inflamed bunions	134	Talipes equino-varus	168
Hard corns	135	Talipes valgus, congenital	
Soft corns	136	and acquired	168
Distorted toes	137	Tenotomy in talipes valgus	169
		Causation of talipes valgus	170
		As in disease of hip or knee	170
SECTION X.		Flat-foot	171
CONGENITAL AND PARALYTIC		Causation	171
DEFORMITIES.		Treatment	172
Infantile paralysis	139	Talipes equinus, congenital	
Congenital deficiencies ..	139	and acquired	173
Contraction of plantar fascia	139	Relative frequency of talipes	174
————— of one toe ..	140	Cause of talipes equinus ..	175
Weak ankles	140	Treatment of talipes equinus	175
Club-foot	140	Talipes calcaneus	176
Varieties of talipes	140	Causation	176
Causes of talipes	142	Treatment	176
Pathology of talipes	143	Spastic contractions of	
Relative positions of the		muscles	178
bones and ligaments ..	144	Choreic spasms	178
Intra-uterine compression ..	151	Partial paralysis	180
Spinal irritation	151	Congenital displacement of	
Treatment	154	toes	182
Little's shoe	154	Webbed toes	182
Deformity of bones	155	Supernumerary toes	183
Osteotomy for talipes ..	155		
		APPENDIX	185

ILLUSTRATIONS.

CHROMOS.

	PAGE
NÆVUS OF NOSE	<i>to face</i> 10
EXTENSIVE NÆVOID GROWTH	
("PORT-WINE MARK") ..	} .. <i>between</i> 184 & 185
DITTO, AFTER OPERATION ..	

MONOTONES.

PAPILLOMATA OF CHIN, NECK, AND BUCCAL	
MUCOUS MEMBRANE	<i>to face</i> 14
NECROSIS OF SUPERIOR MAXILLA; EVERSION	
OF EYELID: PLASTIC OPERATION	„ 62
TALIPES VARUS	„ 162
ACQUIRED TALIPES VALGUS AND PULPY DIS-	
EASE OF KNEE-JOINT	„ 170
TWO CASES OF FLAT-FOOT: (a) AFTER EX-	
CISION OF HIP-JOINT, WITH A SHORTENED	
LIMB; (b) AFTER EXCISION OF (c) THE OS	
CALCIS	„ 194

NOTE.—All these plates show the condition of the patient before and after operation, except the last plate, which gives the after effect in two cases.

WOODCUTS.

THE FACE.

	PAGE
CANCERUM ORIS	48
REMOVAL OF CICATRICES	71
PLASTIC SURGERY OF THE NOSE	77
INCISIONS FOR HARELIP	82
HAINSBY'S TRUSS	85

THE FOOT.

LITTLE'S SHOE	<i>To face</i> 154
DEFORMITY OF BONES IN TALIPES	156
THREE GRADES OF TALIPES VARUS	<i>To face</i> 162
TALIPES EQUINO-VARUS	<i>To face</i> 162
MOULDING PROCESS IN TALIPES	165
FIXATION APPARATUS	166
TALIPES VALGUS	<i>To face</i> 168
TALIPES EQUINUS (FOUR VARIETIES)	<i>To face</i> 174
TALIPES CALCANEUS	<i>To face</i> 176

FACE AND FOOT DEFORMITIES.

PART I. THE FACE.

SECTION I.

STRUCTURAL DEFORMITIES — BIRTH-MARKS, CONGENITAL GROWTHS, NÆVI, ETC.

IT is impossible to drive or walk through the streets of London without meeting almost daily with cases presenting hideous deformities and blotches about the face. These unfortunate people, many of them in the upper ranks of society, have probably come under the observation of many critics, and a host of sympathetic friends will not fail to give them more or less valuable advice. The result has been that these face-blotches—tumours, morbid growths, port-wine stains, birth-marks, moles, etc.—being pronounced incurable, continue to harass the mind of the unfortunate victim. He is an outlaw from society by reason of this affliction, and he has to pass his long weary days with the finger of reproach secretly pointed at him wherever he goes, “a proverb and by-word among the people.”

Those who stare so unmercifully at every eccentricity that comes under their notice, forget, or they would not be so unkind, that the man or the child who is the victim of this social ban has had to run the gauntlet of a hundred critics already during each day of his customary pilgrimage through the streets.

Fortunately the rapid advances in the knowledge of electricity and galvanism during recent years as applied to modern surgery, permit us to attack some of these disfigurements with every probability of successful eradication. Nevertheless, it appears that such progress in surgical manipulation has outstepped the popular creed on the subject. Diseases and blotches which were once considered incurable may now be safely and effectually removed by one of the many beautifully constructed instruments which are being gradually introduced to public notice, and that without leaving any appreciable deformity. Of course the new skin or scar tissue will not have in all cases the same velvety structure as that of the sound skin, but this is a trifle compared with the marked beneficial results of obliterating the deformity. Some people have very erroneous ideas about these growths. They think the roots are so deep that it would be dangerous to remove them, or that being in the neighbourhood of some important structure, as for example the eye, the sight would be destroyed.

Then again, if it is a wart or hairy mole, whether small or large, they resolve to consider this a trifle "not worth troubling about." It is all very well to joke about these birth-marks being "beauty spots," but young ladies in their teens would certainly prefer to

have their features unspotted by such disfigurements. A blemish which is very obvious to strangers, people become so habituated to, that they take little notice of it themselves. Visitors cannot help, much against their will, fixing their eye upon the blemish, evidently to the discomfiture of both parties. Sometimes it is the scar of a burn that has contracted the skin into a number of rugosities. These rugosities may be removed with the greatest ease in some cases, although the bulk of the scar tissue must continue to distort the features and render them unsightly. The rigidly contracted scars may destroy the natural outlines of the face by drawing the skin into a very distorted shape. The scars will often drag down the eyelid so as to expose the lower part of the eyeball together with the conjunctiva. Under these circumstances the deformity is very great. The lower eyelid is for all practical purposes destroyed. It no longer lubricates the delicate membrane covering the eyeball. Sand, dust, and grit will find their way into the eye not only at the lower part, but also under the upper lid. The result of this will be that the conjunctival membrane both ocular and tarsal will become permanently thickened, and not unlikely the cornea will also become opaque and the power of sight obscured. As a still further development of mischief consequent upon such chronic irritation will be choroidal changes and atrophy of optic disc, which I need only mention by way of warning, so that an attempt may be made to rectify this deformity without delay.

The ramus of the lower jaw is often obscured by a firm cicatricial band extending from the face to the

clavicle, thus obliterating the outline of the neck in this situation.

These strong bands of scar tissue may be very lumpy and unsightly, but we may well hesitate before dividing them, as the resulting cicatrix may be worse than that caused by the original burn. We may as a rule safely, and with considerable advantage, smooth down the rugosities by the cautious use of Paquelin's cautery.

The large red sluggish veins and venous capillaries which spread over the surface may be destroyed by caustics, as for example nitric acid, ethylate of sodium, etc. Subcutaneous division of the fibrous bands which glue down the skin and integument to the deep fascia may often liberate the neck, and remove the distortion to some extent. All such operations must be undertaken with care, remembering that it is impossible to recreate that which has been destroyed, viz. the velvety elastic sound skin. The surgeon will therefore have his plans well matured before cutting boldly through a rigid band of scar tissue.

Besides the unsightly "liver marks," "port-wine" stains, tumours, and growths so frequently displayed on the face, there are others that grow on the body. Because they are out of sight patients resolve to leave them out of mind, but they may degenerate after years of inert growth into a rapidly fungating and destructive disease, such as cancer. Sometimes the superficial veins of the face become dilated, tortuous, and hypertrophied, giving a peculiar "mapping out" character to the vessels of the cheek and also of the nose. This is very common in cases of hyper-

trophy of the right side of the heart, or from valvular incompetence. If such turgescence of the capillaries is general, and evenly distributed over the face, no local treatment is desirable, but in some cases only a few of the venous trunks are prominently marked out as causing an unsightly "spray" of purple streaks, and these may be obliterated, by the use of the needle cautery, without leaving any scar or mark.

"*Port-wine mark*" or "liver stain" is one of the most unsightly disfigurements to the face of any of these congenital growths. It is very diffuse, often involving the whole of one side of the face like a splash of some purple dye, and the colour is so persistent and so purple, that these blotches may be seen at almost any distance. The sight of them is naturally very repellent at close quarters. Consequently, the victims of this unaccountable freak of nature have to submit to many uncharitable remarks, however much they may try to pass unnoticed through the world. Fortunately for treatment, this growth is all on the surface like the display in a shop window, and may therefore be destroyed without doing permanent damage to the proper structures of the face. These purple vessels ramify in the skin, which though unusually thin and transparent is of normal texture. It is not necessary to destroy the skin in our attempts to destroy the vessels. No large effort has at present been made to deal effectually with these deformities, because, as I have already said, they are generally pronounced incurable, and the unfortunate victims are condemned to a life of perpetual worry because surgeons do not care,

as a rule, to meddle with them. Some dermatologists, having made the skin their special study, have treated this deformity by making numerous transverse incisions in all directions across the face ; the incisions being like the furrows left in a field by a plough which has turned up all the weeds together with the soil which clings to their roots. The result of such treatment is undoubtedly beneficial to some extent, in that it breaks up and destroys these tortuous purple vein capillaries, but it also of necessity destroys the surface skin which covers the vessels and imparts beauty and character to the features. These capillary vessels are situated in what is called the true skin, the result of such destruction must be the formation generally of scar tissue which is parchmenty, and, as we see often in the case of a burn, this is very unsightly.

The plan of treatment which I have adopted with some success is to attack only the vascular trunks. Instead of scarifying these together with the surrounding skin, I transfix the vessels with the needle cautery, and thus seal them up at the distal and proximal ends, causing absolute arrest of the blood current, and the formation of hundreds of microscopic equidistant scars which are vertical to the surface. These scars resemble the sebaceous puncta, or the sweat-pores, in the natural skin. The scars being vertical through the thickness of the skin, they are practically invisible, and being designed so as to destroy that which is subjacent to the surface with as little of the cuticle or superficial layer of the skin as possible, the result has been found very satisfactory. Each puncture is surrounded by a ring of sound skin

which has small capillaries ramifying through it to keep up the nutrition. These numerous small islets of sound skin contribute to preserve the normal variations of vascular supply which are dependent upon the inhibitory action of the vaso-motor nerves, as displayed in the two extreme conditions of blushing from nervousness, and pallor from fright.

Before commencing the operation I prepare the skin by hardening it, and I then spread a coating of collodion over the portion of growth which I propose to destroy. A thin metal plate perforated with holes about one-eighth or one-sixteenth of an inch apart is firmly pressed over the portion of skin to be operated on. With a series of rapid punctures all equidistant, and all through the substance of the skin, I obtain the desired effect. I prefer to do about a square inch at one sitting, and then cover the whole with carbolic oil dressing, to favour the separation of the minute eschars. (*Vide* the chromo drawings giving the exact appearance of the patient before and after the treatment by thermo-puncture.) The result of these operations is given in the Appendix.

The skin of the face is so transparent and delicate, and blemishes are so conspicuous, that any growths such as moles, scars, warts, or nævous structures, however minute they may be, are sure to attract attention.

It is very desirable for parents to recognise the importance of early removal of these blemishes, and to understand that successful and total extirpation of the growth may be accomplished without much disfigurement, especially in favourable cases. The amount of "splash" varies so much, as also the

character of the abnormal growth, that it is impossible to determine beforehand the actual benefit to be derived. Often the tissue of the face is gathered up in parts by numerous elevations distributed over the growth, causing additional anxiety to the possessor of this abnormality. Or there may be mingled with it some nævoid growth, so that the outline of the face is lumpy and very much covered with shot-like masses which are highly vascular.

Aneurism by anastomosis may occur in the tissue of the face. It appears as a prominent swelling usually of one cheek, of a blueish colour, and filled with tortuous vessels which ramify through it. Sometimes a vibratory thrill may be felt, or a pulsation synchronous with the heart's action. When compressed the vessels will empty, and then expand after the pressure is taken away. They may be met with at all periods of life. Although it is probable that this condition of dilated, tortuous and sacculated vessels existed in an embryo condition from infancy, some local cause may have aroused the activities of growth, so that at a later period of life the dormant character is changed into an actively developing tumour. We may generally succeed in tracing tortuous vessels leading to it both above and below the growth. This form of tumour is very vascular, and it would be risky to cut into it, as the bleeding is generally very free. It may be ligatured at the base of the growth, or the blood supply can be cut off by ligaturing the trunk vessels of supply.

Mother's marks and nævoid growths are very common. They grow with considerable rapidity,

spreading from the centre outwards. There are two or three distinct varieties of this form of growth. Some are entirely subcutaneous, involving chiefly the veins and venous sinuses in the cellular tissue covering the muscles and other structures under the skin; others are mottled and not elevated above the level of the surrounding skin. It is sometimes difficult in these cases to determine the precise character of the growth. Nævus growths are the result, as it may be called, of a "freak of nature." The smaller veins and capillaries ramify in the normal and healthy skin like the ultimate twigs of a tree. Just as, in a forest, the small branches of neighbouring trees intermingle without amalgamating, so should it be with the vascular trunks and their terminals. The vessels interdigitate as it is technically called; but where a nævus growth appears the ultimate radicals have become fused, so that there is a permanent collision of blood-currents, causing venous and vascular dilatation, distension and sacculation, with hypertrophy of vessels in the surrounding connective tissue. Having had the charge of one of the largest surgical clinics in London for children during a period of fifteen years, I have had an unusually large number of such cases under my care. During the past five years I have operated upon over two hundred cases of nævus, many of them being multiple, and some of them very large and in very critical situations. (Vide chromo drawing of child with a nævoid growth involving the whole of the soft tissues of the nose. The precise method of destroying this growth is given in the Appendix.)

Nævi, mother's marks, and erectile tumours are

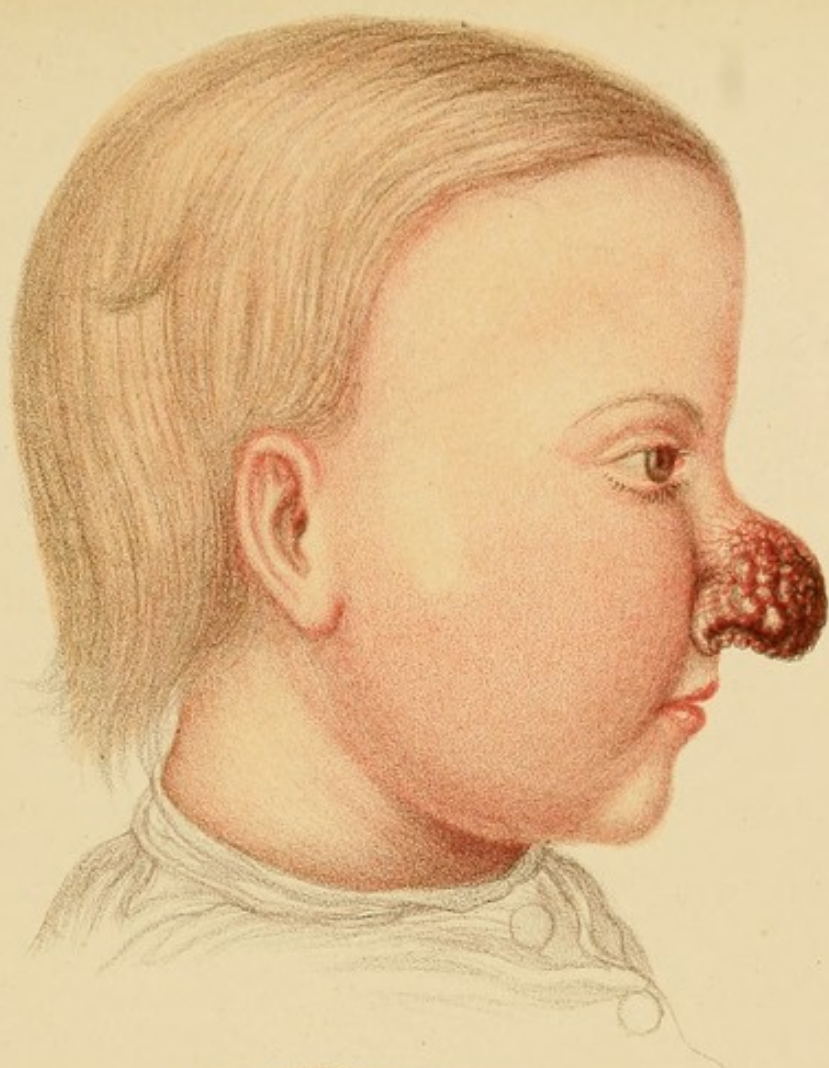synonymous names for describing a variety of vascular growths which occur frequently in children on the face. The structure varies considerably, being in simple cases flat and level with the surrounding skin, in others protruding like a button or cherry from the surrounding healthy skin, and very defined in its outline, or it may be wholly or almost wholly subcutaneous.

These latter are called venous *nævi*, because they involve the subcutaneous veins especially. They become considerably distended when the child screams or cries. The subcutaneous *nævus* may be mistaken for a fatty tumour, being elastic and compressible, but as a rule they are characterised by a small spray of purplish and dilated veins on the surface, indicating the character of the growth beneath.

The subcutaneous variety is sometimes encapsuled with a firm fibrous membrane. These growths are as a rule stationary, though they will occasionally spread with great rapidity. More often the *nævus* flattens out with the growth of the integument, having a pearl-like tissue in the centre, and an undulating *nævoid* structure all round. So that it would appear to grow more by a natural process of development, than by any intrinsic tendency to proliferation.

I have also found a doughy character about them quite distinct from that of lipomatous tumours. By firm compression we may succeed in driving out the blood from the sacculi as we should empty a sponge, and then we can feel the sinuses gradually filling again when the pressure is taken off.

Where the *nævus* has been rubbed by the friction of the clothes it may ulcerate, especially in delicate





feeble children, and thus a natural cure may be the result. But this only happens occasionally.

Mr. Erichsen, in the 'Science and Art of Surgery,' vol. ii. p. 76, says under the heading of *nævi* of the cheek, that "mother's mark admits of no satisfactory treatment in most cases; the subject of it must submit to continue through life to exhibit the characteristic discolouration." It is partly for the purpose of showing that, by the use of modern instruments of precision, we may successfully remove such marks, and without any serious or ugly scarring of the face, that I have written this small monograph. *Nævus* of the lip may require to be treated as a hare-lip, the growth being excised by a V-shaped incision, and the edges approximated with the short harelip pins which I have had made for my use. The method of removal by setons, vaccination, and caustics, I do not approve of, as they seldom destroy the growth effectually.

Sometimes pressure properly applied will obliterate a *nævus*; as for example those on the vertex of the head over the longitudinal sinus, or over the parietal eminences. It will be necessary to secure a firm base upon which to exert the pressure, and the subjacent bone must be well ossified. A small coin, as for example a halfpenny, may be placed firmly over the swelling and secured by strapping. Then a capiline bandage brought under the chin and twisted upon itself over the tumour, so as to carry the ends round the forehead and again over the compress, may suffice if properly applied. Small *nævi* may be destroyed by nitric acid. I have sometimes removed prominent or pendulous *nævi* by excision, but I generally repent of

using this method, on account of the bleeding and the difficulty of obtaining union of the wound. It generally gapes, and is a long time closing by granulation, or the pus may burrow subcutaneously, setting up cellulitis all around.

I need not describe the various methods of applying the ligature for the purpose of strangulating the base of the growth, as the different plans are well described, with accompanying woodcuts, in the text-books of surgery.

A very common variety of *nævus* on the face is called *nævus araneus* because it resembles a small spider. There is a globular prominence in the centre, with tortuous radiating vessels all round the central growth, spreading like the legs of a spider. They are commonly situated on the cheek, the nose, and the eyelid. By destroying the central prominence with the needle cautery, the tortuous vessels which derive their blood from it will become reduced in time to their natural dimensions.

I think it very important to remove unsightly vascular growths as early as possible. I do not agree with those who advocate delay to see whether the *nævus* will disperse. Though, as I have already described, it may spread out and leave a parchmenty structure surrounded by distended veins, I do not think this is at all a satisfactory termination. The method of removal by operation is so simple and so easily effected with scarcely any resulting scar, that I think parents are to blame if they allow their infants to grow up without resorting to operative measures. The galvanic puncture of subcutaneous *nævi* is, I

think, a very unsatisfactory method of dealing with these growths. We never know how far the sloughing may extend subcutaneously and destroy that which is not structurally at fault. The irritation caused by electrolysis to the patent vein-sinuses has occasionally set up phlebitis and extensive cellulitis. I rely almost entirely upon the ligature passed underneath a firm steel pin which has previously transfixed the base of the growth. In this way all the large tortuous vessels are strangulated, the spongy texture is forcibly compressed, and the resulting scar is almost nil.

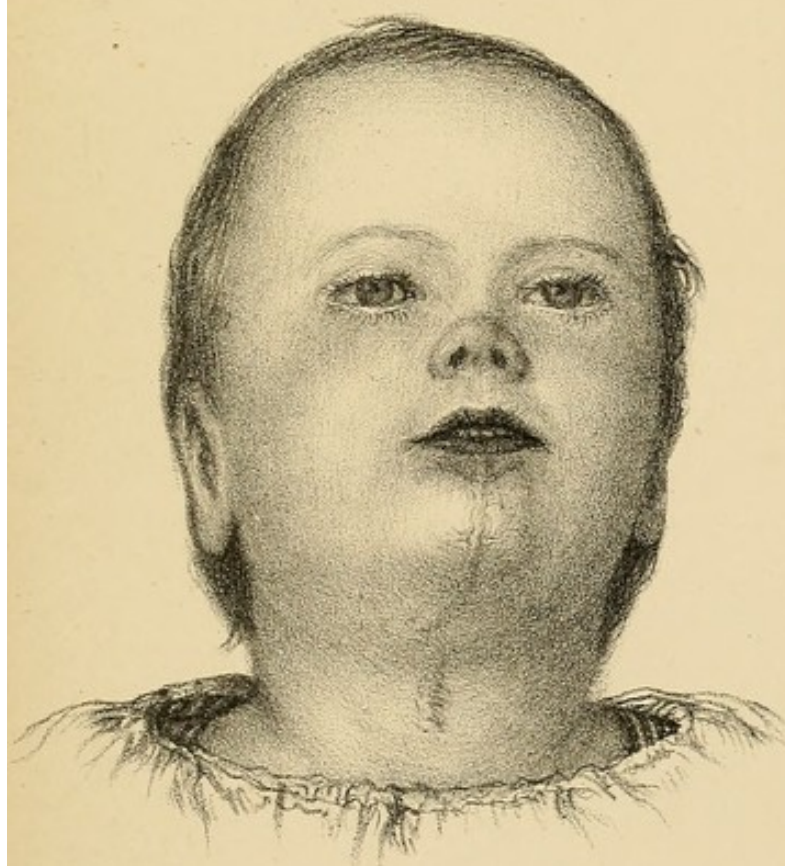
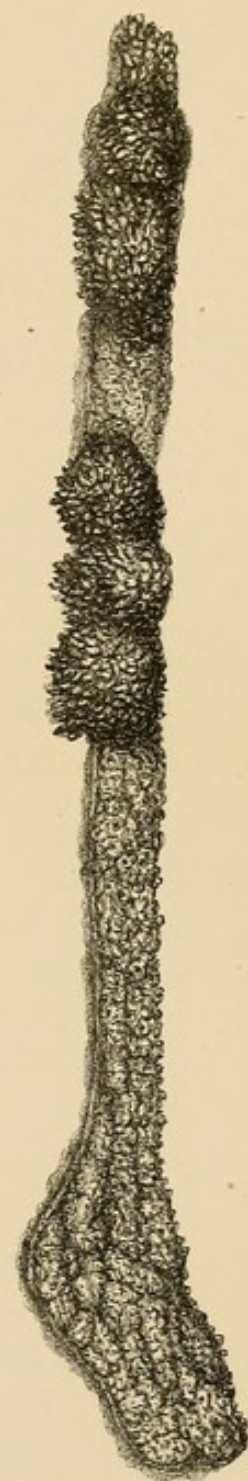
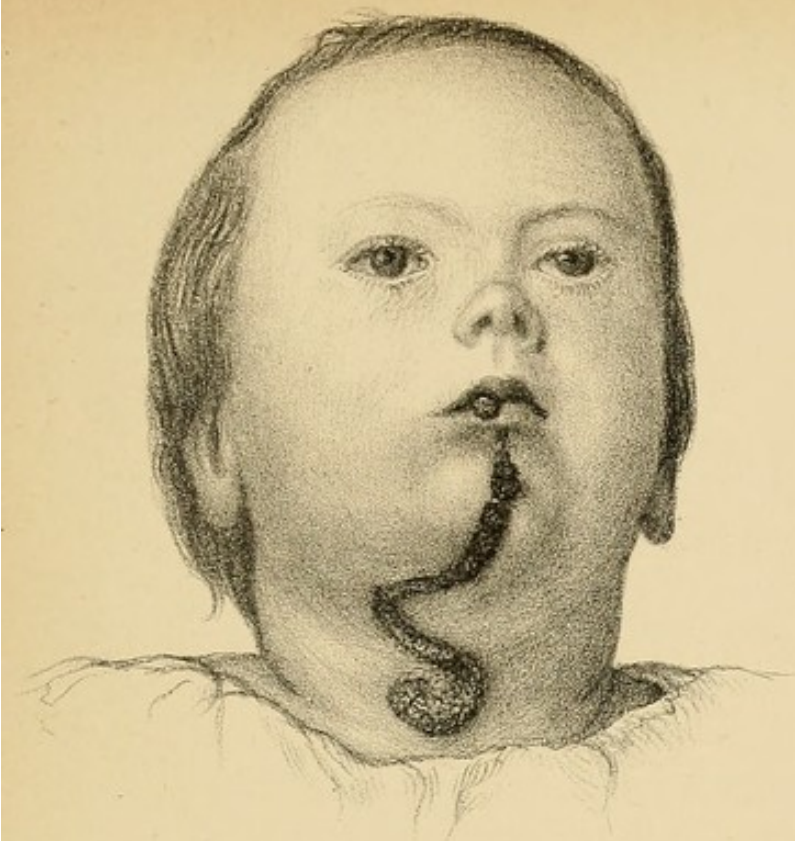Growths about the size of a small pin-head may be effectually destroyed by cutting a piece of porous wood, as for example the end of a "match," to a very fine point and dipping it in acid, either acetic or nitric, and then cautiously planting the point in the centre of the growth, so that it destroys the vessels which are feeding it, and carbonises the surrounding integument to a slight extent, so as to obliterate the main trunks. Care is of course necessary to limit the destructive process to the adventitious growth constituting the deformity. It is hardly worth while to "rig up" the needle cautery for such small growths when the nitric acid may be applied so expeditiously, and with such decidedly good effect.


Warts are hypertrophic growths of the papillæ of the skin, caused often by some local irritation, as a scar or a small surface wound, which failing to close properly, the epithelial covering of the papilla takes on excessive growth, resulting in hypertrophy and elongation of this group of papillæ. Some skins are very susceptible to the formation of these warty

growths, and they appear to spread in some cases by inoculation. They may ulcerate at the base and thus a spontaneous cure is effected. Warts may be sessile, i.e. growing from a broad base, or conical and pedunculated, having a small attachment to the skin. Pedunculated warts sometimes form where a cutaneous vein has been pricked. As the wound does not quite close, the encircling epithelium develops concentrically in excess. If irritated by rubbing, etc., or if caustics are imperfectly applied, they will grow more rapidly. The surgeon can destroy them with great ease by tying a thread round the base, or by first transfixing with a needle so as to get the thread well below the root. Conical warts which rise above the surface may be transfixed at the base, and a thread tied firmly below, so as to cause mortification of the growth. Unless the root is thoroughly destroyed it will grow again. Hence it would be useless to attempt to remove them without consulting a surgeon, although it may seem a very simple thing to do. (*Vide* lithograph to illustrate a very unusual development of papillomata in the mouth, on the chin, and on the front part of the neck.)

Small warts may be effectually destroyed by the careful application of strong caustics. It is foolish to delay the treatment because it may appear a trivial matter, for these papillomata are very disfiguring, and if neglected they may develop into some active form of growth, as often happens where the wart has been repeatedly irritated by washing the face, etc., or, as with chimney-sweepers, they may become cancerous.

Burns of the face and severe injuries may cause, by





their subsequent contraction, great disfigurement. Such contractions may be cured by plastic surgery, portions of integument being selected from available places to cover in the deformity or gap. Methods of effecting such transpositions of skin are described elsewhere.

Parents must not forget that boys at school may get very much bullied and laughed at if they have blemishes or marks on their body. These surface growths can be so easily removed or destroyed without any pain by placing the child under chloroform that those who, for sentimental reasons, recoil from a simple operation that would confer marked and permanent benefit upon a child, are very much to blame.

I constantly come across adults with squint eye, which might have been cured in infancy, but unfortunately the harrowing details which some ignorant persons have falsely told about the operation, have deterred the parents from submitting to the ordeal.

No doubt many cases of modified squint are remediable by the use of properly adjusted glasses, and these should be given to the child early, before the muscles of the eye have become rigidly contracted.

Wens on the scalp or in the neighbourhood of the eye are usually caused by the blocking up and subsequent dilatation of the sebaceous glands which are part of the normal structure of the skin. They project on the surface, having a smooth oval or conical shape. The contents are cheese-like, and they are inclosed in a firm parchment-like bag, the counterpart of the dilated and overgrown follicle. I have seen cases of great disfigurement from such tumours being dotted over the scalp and being allowed to increase to the size

of a small orange. In some cases these tumours lie in the deeper structures underlying the muscles of expression and do not appear to have originated from a blocked sebaceous follicle. These can also be enucleated without any difficulty, and it is important to do so, because as they continue to grow they press upon important structures, and may cause absorption of the subjacent bone. It is not necessary to give chloroform in all cases. If preferred the tumour may be frozen and the sac of matter drawn out of its encasement through a small incision of the skin. Some highly nervous patients have come to me repeatedly for the removal of these sacculated growths, and have sat quite composedly while the incision was made across the frozen tumour.

Pigmentary Changes occur in the deeper layers of the epidermis or scarf-skin. These changes may be manifested either in excess or deficiency of pigment, and they may occur in patches or spots, or in a large area of the skin. Heat and light have the effect of producing yellowish-brown spots, generally round, sometimes irregular in shape, on exposed parts of the body, especially the face, of children and adults with fair complexions. These are called freckles.

Moles are congenital spots of varying size and shape, and there is a decided excess of pigment in them, sometimes presenting quite a black appearance. They are occasionally very prominent, and may vary from the size of a pin's head to two or three inches in diameter. There are often several of them on the body. I recommend the removal of those that are unsightly, because this may be effected without any

difficulty, and because they have occasionally turned to cancer in after life.

Large moles are usually circular but sometimes oval or irregular in shape, upon the surface of the skin. They may be raised above the surface of the surrounding skin, and be slightly nodular like aggregated warts and covered with down or hair. They are sometimes very large, even three or four inches in diameter. Most people are troubled with one or two on the surface of the body. If not on exposed parts of the body and small, they may be left alone, but when appearing on the face, neck etc., they should be removed early because they are so disfiguring. Moles are as a rule congenital, but they may appear later in life. We may also have a mole projected forward by the growth of a *nævus* at the base. These are sometimes called pigmentary *nævi*. Such growths sometimes degenerate into a form of cancer, especially what is called the melanotic variety. I recommend excision or ligature of prominent moles according to size.

It is a great mistake for parents to conclude, as they often do in these congenital cases, that it is right, to accept this condition without attempting to remove it. Such fatalism, if it should enter into the calculations of daily life, would be found a serious barrier to general improvement, such as we are effecting little by little in the houses and lives of our poorer populations more particularly.

Sometimes the whole of the cutaneous surface becomes involved in a deep bronze colouration. This is seen in Addison's disease of the suprarenal cap-

sules. I have succeeded in blanching portions of the skin in these cases by freezing it with ether, which causes the pigmented cuticle to exfoliate, leaving flesh-coloured skin beneath. When such ugly blotches are limited to one part of the face, and so cause annoyance by their unsightliness, they may be easily removed by rubbing with acids, which destroy the epidermis without blistering or scarring the true skin.

Leucoderma is a condition of localised absence of pigment, as seen in the case of the white elephant that was shown in this country. The skin and the hair growing on the skin are quite white, because the rete Malpighii is destitute of pigment. Albinism is a condition of universal absence of pigment throughout the body.

Freckles are flat spots of pigment, generally small, very numerous, and appearing mostly on the face, forehead, etc. Fair children with transparent skins are especially liable to them, if they visit the sea-side or are much exposed to the direct rays of the sun without proper sun-hats to shade the face. These spots may in some cases be removed when they cause disfigurement by carefully applied lotions of acetic acid, ether, etc.; but as a rule, it is best to leave them alone.

Horny growths appear on different parts of the face. The structure is generally epithelial and due to an aggregation of stratified epithelium, growing upon an inflamed or irritated follicle which has in process of time developed into an unsightly excrescence. These may be effectually removed with safety and without the fear of recurrence.

Horns consist of an accumulation of condensed epithelium, and are marked on the outside by lines which show the mode of growth and development. They usually grow from a matrix which is more or less vascular. They are sometimes connected with cancerous warts. The only treatment to be efficacious is excision. If they are found to grow from the interior of a cyst they require to be dissected out.

SECTION II.

FACE ERUPTIONS — ABSCESSSES, ULCERATIONS, PARASITIC DISEASES, SURFACE TUMOURS, ETC.

Face Eruptions come under the care both of the physician and the surgeon, though they are often claimed for treatment by specialists in dermatology. It is very important to remember that the outward manifestation of an eruption is but, in too many cases, the index of a constitutional taint, which will need very careful and scrutinising treatment before we arrive at the primary cause of this outburst of disease on the surface. Hence the necessity of caution and latitude of observation before we commence to treat the disease.

The skin of the face being so much exposed to atmospheric influences, it is very frequently the seat of chronic eruptions that are difficult to cure. The blistering effects of exposure to the direct rays of the sun, and the drying effects of exposure to blasts of cold east wind, will be followed in many cases by

scaly furfuraceous eruptions, especially about the angles of the mouth, where the saliva keeps up the irritation caused by any cracks or fissures. Children often have patches of chronic eczema on the cheek and round the mouth. Adults with very tender thin skins often suffer from unsightly blotches mapped out on different parts of the face. The application of irritants, as toilet vinegar or rose-water, will only increase the mischief. Even preparations containing glycerine, so often vaunted before the public eye, will increase the irritation. Besides careful attention to the general health, it may be necessary to place some emollient application to act as a protective to the denuded skin. A lotion which has been used with considerable success in these cases consists of 30 grains of calamine, 10 of oxide of zinc, and 10 minims of glycerine to lime-water an ounce. The small quantity of glycerine is enough to fix the protective without causing any local irritation.

It may be well that I should define briefly the more frequent and transitory eruptions of the face.

Erythema may be described as a persistent inflammatory blush on the surface of the skin, generally in patches and slightly elevated. It is attended with heat and tingling. It may terminate in deeper seated dermatitis, or in resolution with a furfuraceous desquamation. It is accompanied by slight fever and is ushered in with some general malaise, shivering, headache, pains in the limbs, etc. The characteristic blush is recognised by its immediate disappearance under pressure, and quick return when the pressure is taken away. It may be produced by some irritant

to the skin, or by exposure of the face to harsh dry winds, or to the direct rays of the sun.

A diffused patch of redness often occurs with the dyspeptic, the *bon vivant*, or the habitual drunkard. It may also occur in a chronic form in delicate constitutions, from what is called "poverty of blood," languid circulation, and a tendency to local congestion of the surface capillaries. Females at the period of the menstrual climacteric, or when suffering from irregular menstruation, may have large distributed patches over the face. What is often called scurvy of the face, in which large, well-defined patches of livid redness occur, often with some excoriation or peeling, is of an erythematous character. It is sometimes mistaken for simple cutaneous erysipelas. When associated with some irregularity of bowels the eruption may disappear very suddenly. There may be slight desquamation of skin when the eruption subsides.

E. simplex may be associated with derangements of the digestive organs. Erythema is very liable to attack symmetrical parts of the body. The face may become considerably puffed up by the inflammation spreading into the subcutaneous cellular tissue. In these cases the disease must be designated as erysipelas if associated with febrile symptoms.

E. marginatum is a patchy eruption, more elevated at the edges than in the centre. *E. papulatum* consists of numerous small rounded elevations about the size of a pea and of a deep red hue, with a radiating blush all round each papule. This form of eruption tends to become chronic or intermittent. There may be, in addition to the symptoms enumerated above,

some nausea, vomiting, pains in the back and head, loss of appetite and general malaise. It may appear as an epidemic in hospitals and buildings where many people are housed together, and where the sanitary arrangements are defective.

E. nodosum may occur on the face and arms as a sequel to vaccination. Brawny circumscribed patches of redness about the size of a florin surround a central vesicle or ulcer, having an irregular or punched-out appearance.

The treatment of this disease is very simple. The inflamed patches should be protected from exposure. Warm lotions of lead and opium may be applied to relieve the heat and tingling, or warm water dressing. In the chronic forms a stimulating lotion may be required, as sulphate of copper in elder-flower water, or sulphate of zinc in rose-water. The primæ viæ must be attended to, especially in spare and delicate subjects; warm baths, gentle aperients, and light and nutritious diet. Anæmic patients with menstrual irregularities may require saline aperients with aloes and iron, followed by tincture of calumba, extract of cinchona, nourishing food, and some light wine.

Erysipelas of the face is a disease which usually commences with marked febrile symptoms, shivering, pains in the back and limbs, loss of appetite, quick pulse, dry hot skin, and much thirst. There may be swelling of tonsils and some cynanche. The skin swells and the redness becomes very diffused, spreading rapidly with no well-defined margin. There is a burning or tingling heat of the skin, and considerable tumefaction of the eyelids, so that they often

become quite closed up. Vesications appear on the surface and exude an acrid, clear, transparent serum, which may blister the adjacent sound skin wherever it spreads.

The patient has decided constitutional disturbance, with nausea and vomiting, headache, high fever, and occasional delirium, with recurrence of chills and rigors. The pulse is quick and the temperature very high. The disease terminates in desquamation of the cuticle on the tenth or twelfth day. Suppuration may occur in the cellular tissue under the skin, with sloughing or mortification. Well-planned incisions may be necessary to evacuate the pus.

Traumatic erysipelas originates in some local injury which may or may not have caused a wound of the surface. Brewers' draymen, cabmen, and those who indulge to excess in alcoholic drinks, and are much exposed to the inclemency of the weather, are very liable to erysipelas following upon some slight abrasion of the skin, especially of the head. Death may result from inflammation attacking some internal organ, as the brain. There may be some asthenic fever of a typhoid character, quickly prostrating the patient, or there may be phlebitis, with purulent deposits in lungs, liver, etc.

The disease must be promptly treated with bark and ammonia or tonics and antiphlogistic measures if the fever is very pronounced. Calomel and Dover's powder may be required to allay the fever and procure sleep. The tincture of iron and chlorate of potash are relied upon generally as useful in these cases, preceded or not by a saline draught as haustus

sennæ co., or the pulv. jalapæ co. Nourishing food, such as beef tea, egg and milk, etc., must be given, and wine if necessary. Large linseed-meal poultices sprinkled with carbolic lotion must be applied to the surface where the erysipelas is inclined to spread.

Urticaria, or nettlerash, is a localised ephemeral congestion of the skin. It appears on the cheek often of highly sensitive females and those of a rheumatic tendency, especially after some error of diet or exposure to east wind, etc., causing gastric disturbance. The characteristic wheals vary considerably in size and elevation above the surface. They usually give rise to much stinging and tingling sensations, increasing at night or when seated before the fire. We know how the eating of shell-fish, and sudden changes of temperature, may be followed by the appearance of this eruption. In the acute variety the eruption quickly fades, but in chronic urticaria it will be necessary to regulate the diet and prescribe change of air and other methods for improving the general health.

Occasionally I have had under my care cases of nettlerash caused by the habit of unlimited use of prescriptions that were only intended to serve the particular emergency for which they were given. Now that economical principles, and co-operative stores are considered interchangeable terms, such mistakes are more often made, and patients have to suffer in consequence. The transitory eruption may become very chronic. The slightest excitement in persons of an irritable delicate skin may bring out a copious eruption. Some alterative medicine, the mineral acids or bark, and ammonia with hydro-

cyanic acid, and careful dieting, will usually suffice for the cure of this eruption. If the disease should recur frequently, a combination of quinine and arsenic may be required for the cure.

Eczema is the most common skin disorder. It is a dermatitis or inflammation of the skin, and appears as a diffused eruption, more or less covering the face. There may be a discharge of clear fluid from the surface of the vesicles, which concretes and forms a scab or crust, having a deeply inflamed substratum of skin. There are many varieties of *eczema*. It may be associated with *impetigo*, in which case the eruption is more defined, and the vesicles more circumscribed, and the contents purulent. These pustules may coalesce, and the scales which form a crust on the surface like a shield, may cause considerable irritation. The cuticle is sometimes raised into papules or vesicles.

Eczema faciei consists of an eruption of minute transparent vesicles closely aggregated together, very prominent, having an inflamed areola. The contents of the vesicles sometimes become purulent. It is generally attended with burning pain, itching, some swelling, and considerable irritation. The vesicles burst, coalesce, and a scab forms, with a yellow crust, which, when removed, exposes an ulcerated surface below. The vesicles often appear in crops. The epidermis desquamates as the disease subsides. There may be some slight feverishness, with pain and itching of the eruption. The exudation from the inflamed base is thin and watery. The eruption, if neglected, may assume a chronic and indolent character, lasting in some cases for months, or even years. Infants during

the teething period are very liable to this disease, especially on the forehead and head, associated with impetigo. The chronic form is usually characterised by the formation of fissures in the skin, which pour out a clear ichorous fluid that quickly dries and forms scabs.

Sedentary occupations in close, ill-ventilated rooms are a frequent cause of this disease. Shop-girls, who are badly fed and badly housed, and are otherwise much neglected as regards the sanitary arrangements of workrooms and dormitories, frequently suffer from this disease, as also from acne, etc. Infants with delicate skins may develop this disease in consequence of hand-feeding, over-feeding, and bad management.

It may be necessary to give grey powder and jalap as an aperient, and the local application of lead ointment, or of caps of lint and oiled silk fitted to the head and moistened with lead and glycerine lotion. The lint must not be made too wet, as this may favour the spread of the eruption. The itching can be relieved by the application of elder-flower water, cherry-laurel water, etc. In chronic eczema the benzoated zinc ointment, well rubbed into the raw surface after removing the crusts, will prove very useful. In some cases vaseline, and in other cases the ordinary petroleum ointment will be required. Weak carbonate of soda lotion (ten grains to the pint) to bathe the parts with when red and inflamed, is often used with advantage. Internal remedies must not be neglected, generally aperients to commence with, and there must also be a careful regulation of diet. The syrup of the iodide of iron with iodide of potassium in cases of strumous origin or of suspected syphilitic taint. Cod-liver oil and the

hypophosphite of iron in chronic strumous cases. Arsenic may be cautiously administered when the disease is of an indolent character. Adults may require a course of aperient medicine, the use of mineral waters, or a few weeks at one of the Continental spas, such as Aix-les-Bains, Heilbrunn, or other health resorts established for this purpose.

Impetigo is an eruption of the skin closely allied to eczema. It is a pustular disease followed by the formation of thick crusts from the exudation of the purulent contents. The pustules may be flat and aggregated together in groups, or they may be acuminated and more or less scattered. The pustules generally have an inflamed base, and the neighbouring lymphatic glands are frequently enlarged and may suppurate, especially with strumous children. The eruption frequently seen under the chin of young children, and followed by an elevated transparent crust with oozing of fluid beneath, is called "achores." There is not much constitutional disturbance with this disease, and the eruption seldom leaves any scar on the face unless the child has picked at it much. There are many varieties of impetigo, and it would seem that some varieties are contagious.

For the treatment of this disease the crusts must be carefully removed with bathing and poulticing. The sore places underneath should be constantly dressed with zinc or lead lotion, or painted with nitrate of silver, and the zinc ointment applied during the later stages. Salines, stomachics, and quinine and iron may be required to improve the general health.

Lichen is an eruption of small, hard, red pimples

which do not disappear on pressure. They are uniform in size, are slightly raised above the surface, and have a distinct outline. It is a non-contagious disease, and it may terminate in desquamation.

The papules of lichen may itch or tingle, and the irritation of the patient in consequence may increase the local inflammation. There is usually some derangement of the alimentary canal requiring proper treatment and management, including sulphur baths and cooling lotions.

L. strophulus, or red-gum, appears in infants about the period of the first dentition. The child requires some regulation of diet, and a little rhubarb and soda or fluid magnesia. When the disease resists the ordinary treatment it may be necessary to give arsenic in small doses, and to lance the gums if required.

Herpes comes out in crops about the angles of the mouth and forehead, in children and adults suffering from febrile disorder, pneumonia, etc. The clusters of vesicles are aggregated together in pearl-like masses usually about the size of a shilling. Each vesicle is raised above the surface, uniformly convex in shape and larger than in eczema. The eruption may have a distinct "mapping-out" character, as it follows the course of the facial nerve. There may be considerable pain when the eruption is developed in the course of a nerve-trunk, as in shingles. Herpetic eruptions may fade quickly, or the vesicles may coalesce and leave a scab on the surface. Herpes should be treated with some cooling ointment, as vaseline or the oxide of zinc, and attention given to the general health.

Miliaria is an eruption of very minute, millet-seed-

like, closely packed vesicles, the contents at first transparent and then consolidated. It appears on the face in children with delicate skins, especially in summer. The margins of the vesicles, though often surrounded with a faint blush, are not inflamed, and there are no constitutional symptoms. The contents of the vesicles are sometimes purulent. Tepid bathing and tonics will be required to cure the disease.

Ecthyma is a distributed sparse eruption of a few large well-defined pustules, each having a callous inflamed base like a furuncle, with a deep zone of inflammation. In each case the scabs should be removed by bathing and poulticing, and the ulcerating surface below healed by the application of zinc or lead ointment, or lotion, or the ung. hydr. nitratis. The nitrate of silver lotion is very useful when the ulcerating surface is indolent. The patient should have general tonic treatment and careful dieting. The eruption may be acute or chronic. The acute form may be associated with febrile symptoms and loss of appetite. Large ecthymatous pustules often occur with scabies in young children.

Pemphigus is an eruption which occurs on all parts of the body, including the face. It is ushered in usually by some febrile symptoms such as lassitude, sickness, etc. It is a somewhat unusual form of eruption, occurring in delicate and ill-nourished infants and young children, the result often of gastric irritation from improper feeding, etc. It generally remains dormant for a few weeks and may become chronic. The raised blister-like character of the eruption is very typical, surrounded by a deep zone of irritation.

The vesicles or blisters should be slit up, and the ulcerating surface of skin beneath treated with some stimulating lotion, and if the child is in a weak cachectic state he will require careful dieting, and quinine, or the ammonia and bark mixture.

Rupia is also a disease of the skin with large bullæ filled with serum or pus. *Rupia prominens* is a more chronic variety with superimposed scabs resembling a limpet shell. The subjacent derma is ulcerated. It requires the same treatment as pemphigus.

Pityriasis is a superficial irritation of the skin, followed by bran-like desquamation. There is often undue redness of the skin, but less inflammation than with psoriasis. The diluted nitrate of mercury or the precipitate ointment may be used in these cases, as also the borax and camphor lotion. *Pityriasis versicolor* is described under the head of Chloasma.

Psoriasis is a somewhat rare disease when it attacks the skin of the face only. It usually occurs in well-defined patches over the body. It presents a very characteristic appearance, consisting of scale-like masses of epithelium, slightly elevated, and resting upon a more or less inflamed base. It is so far distinct from any of the moist eruptions on the face. It requires local and general treatment. Dilute chrysophanic acid or pitch ointment may be advantageously applied to the surface, and arsenic may be given internally, together with the perchloride of iron. Careful washing will be necessary to soften the crusts, and the inflamed base may be washed with carbolic soap or the juniper tar soap. Psoriasis is not contagious but it is often hereditary, especially in those of

a gouty or syphilitic tendency. We must therefore never neglect the due attention to any gastric disturbance that may be present. Where we have a syphilitic history it will be desirable to give iodide of potassium or perchloride of mercury internally.

Facial carbuncle is a painful and persistent disease of the aggregated follicles of the face. Commencing usually as a small pustule near or on one of the lips, and surrounded with firm œdematous infiltration, it spreads rapidly into the surrounding cellular tissue. The inflammation does not generally pass on to supuration. The surface of the sore has an excavated appearance dotted over with small sloughs of cellular tissue. The edges are usually of a red colour with an even contour. The general health of the patient quickly participates, and there is often great depression of the nervous system. There is some feverishness, the pulse is small and frequent, skin hot and dry, tongue coated, appetite failing, and general malaise. The blood becomes infected, and the disease may terminate rapidly in pneumonia or pyæmia, in consequence of phlebitis of the neighbouring vein-trunks and the absorption of purulent matter.

Carbuncles are very disfiguring, besides being very intractable. Generally the health of the patient previously has been much undermined by some constitutional disorder. They appear as an aggregation of numerous furuncles or boils, with a deeply inflamed base and sloughing surface. They may require crucial incisions through the sloughing cellular tissue, and stimulating lotions or poultices to favour separation of the inflammatory products. The patient must

be treated with liberal diet, some light wine, and a mixture of bark and ammonia or quinine.

Anthrax or Malignant Pustule.—Several cases of this disease have been recorded by the surgeons at Guy's Hospital, as occurring among the workmen employed at the wharves and warehouses of Bermondsey. Bovine anthrax has been recognised for many years as a prevalent malady among cattle, especially those of foreign importation ; but it seems only of late years to have been traced as directly communicable to man. The skin-dressers, who have to handle and prepare the hides which are imported in large quantities from abroad, have been the principal sufferers. The face being the exposed part of the body, is occasionally rubbed or scratched by the hand, and so a process of auto-inoculation takes place. Within a few hours a red swelling appears, and this is quickly followed by severe constitutional symptoms, great depression of spirits, rigors, sleeplessness, delirium, vomiting, and high fever. The growth has a very similar appearance to that of the benign carbuncle. There is a spreading flat surface of red inflammatory swelling, slightly depressed in the centre, and covered with a dark scab or a smooth pellucid membrane. The skin surrounding the growth is puffy and œdematous, and the submaxillary glands are large. The margin of the eschar is usually covered with some distinct vesicles. Numerous bacilli characteristic of this disease were found in the blood and sputum. Cases that have been treated promptly by excision have recovered ; others have died from the disease spreading to the mucous mem-

brane of the intestine and the pulmonary tissue. All the nodules were found to contain large numbers of the *Bacillus anthracis*. There were also serous effusions into the pleural and pericardial cavities. To successfully combat this disease, the patient must be treated with diffusible stimulants, as bark and ammonia or quinine, and plenty of nutritious food, if the appetite does not fail.

Keloid may appear in a scar of the face after the removal of any tumour or growth, or after a burn. It has been known to follow a scraping for lupus. In this disease the remnants of the scar-tissue become invaded by a growth which spreads and infiltrates with claw-like prolongations in the imperfectly developed fibrous tissue. Scars may remain for years in a quiescent state, and then from some unexplained cause they may develop keloid. The growth presents a raised elastic surface, traversed with distended veins, giving it a marbled appearance. There may be some pain as the growth expands. The only remedy for this condition is excision, or destruction by the actual cautery, but the disease is very liable to return.

Xanthelasma or vitiligoidea are names for a very rare disease occurring occasionally on the face, and especially the eyelids, in the form of tuberos nodules. An eruption appears on the skin at first of a lichenous character, sometimes covering the body. These small spots become raised into papules, forming solid masses of sessile or pedunculated growths. The tubercles enlarge, and the apices are often of a pale-yellow colour, hence the name *Xanthelasma*. Associated with this disease, the patient generally suffers from

symptoms of congestion of liver or of diabetes. It is a very unusual and apparently incurable disease, unless we proceed to remove the tumours by excision or cauterisation, and they are, as a rule, too numerous for such a radical method of treatment.

Abscesses frequently cause great disfigurement of the face. They may depend upon some deeper-seated mischief, as, for example, the blocking up of the canaliculi and ductus ad nasum of the lachrymal apparatus, which is designed for the conduit of the tears in a stream across the surface of the eye, to the nose. Or they may be connected with chronic caseation of cervical glands. Probably the most frequent cause of face abscesses is caries of the teeth and cellulitis of soft structures surrounding an alveolar abscess. The patient has been unwilling to have the decayed teeth extracted, and so the suppuration which occurred in the tooth-socket has invaded the cheek. Let us warn such that a permanent deformity of the face will inevitably occur from the puckering of the scar which follows the evacuation of the abscess, and from the adhesions of the skin to the subjacent bone.

No doubt in these, as in other cases of depressed cicatrices, it is possible, by a subcutaneous operation, partly to remove the deformity by dividing the fibrous bands which result from the healing of the abscess.

When the surgeon has the opportunity of treating these abscesses in the first instance, he should endeavour to evacuate them through the buccal mucous membrane. In doing so he must make provision for the removal of the pus so that the patient does not swallow it, as so frequently happens when he or she

fails to come under prompt medical and surgical treatment.

Fistulous tracks leading down to decayed bone may exist for many years as the residuum of facial abscesses.

Strumous abscesses may occur on the face and cause considerable anxiety to young people. They are very chronic and indolent in their development and formation. They at first appear as indurated swellings, with an inflamed base. The skin on the surface thins, and a sinus forms, which discharges unhealthy pus of a curdy or caseous character, and the skin becomes undermined with indolent pale granulations. The modern method of wearing a "Princess" ruffle may successfully screen the ugly scars and gatherings of strumous ulcerations and chronic sinuses round the neck, but it is not so easy to cover up the face. It is therefore important to treat these cases promptly, and endeavour to promote a speedy resolution of the local disease. Scraping away the callous granulations and the application of caustics may stimulate the subjacent tissues to healthy action.

Furuncles may appear singly or in crops. They have a conical shape, hard to the touch, and are sometimes very painful. They have an inflamed base. A *core* or slough of cellular tissue forms in the centre, and a sac of pus develops around it. As the boil comes to a head the pus finds an exit at the prominent part.

Boils may be protected from the chafing of the collar by a piece of thick lead plaster spread on wash-leather, and cut in the centre like a corn-plaster.

Hordeolum or sty is a small boil on the edge of the

eyelid in connection with limited obstruction of the follicles of the Meibomian glands. These boils may recur, and they may be tedious in their formation. They should be bathed well with warm water and poulticed.

Ulcers of different kinds occur on the face. We may have simple ulcers of an indolent character in people who are subject to ecthymatous ulcerations on the body. Or we may have syphilitic ulcers, especially that well-known form of extensive chronic ulceration associated with caries of the frontal bone, due either to syphilis or phosphorus poisoning. True infecting syphilitic sores may appear on the lips, and these require to be destroyed by caustic, and with antisyphilitic treatment internally, so as to avoid secondary symptoms, if possible. Mercurial fumigation and inunction are the best means of dealing with syphilitic sores. The remedy in this way quickly permeates the system and neutralises the poison, or mitigates the constitutional effects of the disease.

In all these cases it is desirable to remember how quickly the whole constitution becomes invaded and the blood poisoned. Consequently, how desirable to attend to the general health, to brace up the system by change of air, a sea voyage, if possible, and careful dieting, and to give iodide of potassium internally. Syphilitic cases often go from bad to worse in consequence of the injudicious administration of anti-syphilitic remedies without proper attention to the *primæ viæ*.

Acne is one of those troublesome complaints incidental to young people at the period of adolescence, just at the time when they should be "coming out."

This disfiguring eruption often appears on the face. A number of black points are observed dotted over the surface, which, if squeezed, will exude a worm-like coil of cheesy matter. Though popularly thought to be a worm, on account of its round contour and apparent wriggling motion, as it escapes from the follicle, it is really only a concretion of sebaceous matter in the skin, where it has gradually accumulated. The black head is nothing more than a collection of dirt which has been gradually rubbed into the follicle and has acted as a cork to prevent the exit of this secretion. However carefully the face may have been cleansed daily, these black spots will collect in the follicles of some skins. It is difficult to persuade patients that they have been deceived by the wormlike appearance. Occasionally the *acarus folliculorum* may be found at the bottom of the follicle when searched for by the microscope. If neglected the follicles will inflame, an effort being made, as it were, to evacuate the cheesy matter which is blocking them up. In such cases the skin will be dotted with numerous pustules, more or less transparent and raised above the surface. These pustules do not coalesce, but appear as small red acuminate elevations, with a yellowish point at the apex. Many of the pustules do not mature, but remain as an indolent eruption, the contents becoming consolidated, and having a hard base. Some dermatologists limit the definition of acne to this inflammatory condition, and place the disease above described, of blocked follicles, under the heading of hypertrophy of sebaceous follicles. But as I generally find the inflammatory condition associated

with blocked follicles, I prefer to class the diseases together and consider the latter as a further development of the more chronic disease of the skin.

Stearrhœa is by some authorities described as a distinct disease, characterised by the oozing out of a greasy, sometimes offensive, secretion from the follicles of plethoric people, and from skins that may be described as "unctuous."

The surface of the skin in acne will be more or less raised and lumpy by the accumulation of the sebaceous matter in the follicles. The irritation caused by the blocking of these follicles may tend to the formation of furuncles or boils, which are very unsightly.

Acne indurata is a chronic variety of the above disease. In these cases the elevated tubercles on the surface, caused by the long obstruction of the tubes, become very prominent, rising like numerous mole-hills on the surface, each about the size of a small pea. This disease occurs at a later period of life, when the skin of the face itself has become more indurated, and the venous capillaries slightly distended or varicose. The causes of acne may be generally found to be associated with sedentary habits, a deranged condition of the digestive organs, or with excessive indulgence in the use of indigestible food, or the too free use of alcoholic liquors. Some of the worst cases of this disease are found associated with masturbation and in connection with uterine irregularities. Or the disease may be hereditary.

It must not be supposed that any one of these is the primary cause of the disease. It is necessary to bear this in mind while directing the main part of the

attack to the *primæ viæ*, with a view to regulate the digestive system, and to see that the important functions of secretion and assimilation are in working order, to prescribe plenty of outdoor exercise, and to remember, above all, that young people who are rapidly expanding into manhood and womanhood require very careful watching and superintendence to avoid excesses of all kinds.

The eruption crops out on the surface as a number of closely aggregated spots or pimples, mostly limited to the face and upper part of the body. The prominent surface of the spots may be distended with a little serum or pus, and the subjacent follicle may inflame, leaving a hardened base. The apertures of the distended sebaceous follicles are blocked up with black points or specks.

In restricting the diet, be careful to provide ample food of a nutritious and easily digested kind, avoiding such things as raw fruits (except in July*), salads, shell-fish, savoury dishes, beer, &c.

A very inveterate case of *acne indurata* occurred in a young girl, aged nineteen, with extensive scrofulous disease of the submaxillary glands on both sides of the neck. The acne was cured in a few weeks by the use of the ung. sulph. hypochlor. co. and the administration of arsenic internally, but the large chronic abscesses in the neck were opened, and a quantity of cheesy material was evacuated. The resulting ulceration was very difficult to cure in consequence of the chain of glands

* This may be thought rather a strange exception, but I desire to draw a marked distinction between fresh-gathered soft fruits and those which ripen later in the year.

which pass deeply into the neck being consolidated by the same tubercular infiltration and caseation. As the patient's health improved, however, the caverns in the neck closed up, under the daily application of stimulating lotions of sulphate of zinc or nitrate of silver.

Acne rosacea is a somewhat frequent complaint of adult life. It is a slowly developing disease of the cellular tissue and follicles of the skin. At first there is noticed a swelling and distension of the superficial capillaries, followed by congestion of the surrounding tissue and blockage of the sebaceous follicles, with consequent engorgement and swelling. It is doubtful whether the follicles are the primary cause of the disorder. The superficial skin becomes distended, shiny, and generally coated with moist effusion from the follicles. The patient may complain of some itching or irritability, with a sense of heat, especially towards evening, and there may be some dyspeptic symptoms which increase the capillary engorgement. The tip of the nose becomes unusually purplish on exposure to cold. The same tendency to engorgement may be noticed in the capillaries of the cheek, presenting a marbled appearance. In the female it is generally associated with menstrual irregularities. So that we may be tolerably certain that in all these cases there is superadded to the local complaint a general engorgement of the venous capillaries, and along with this probably some dilated and flabby condition of the right side of the heart. It will therefore be necessary, in the treatment of these cases, to attend to the *primæ viæ*, to see that the liver, the largest organ of the body and the centre of the portal system,

is not engorged. There must be regulation of diet, abstinence from alcoholic drinks as far as possible, except of the lighter kind, as claret and Burgundy. The patient should take plenty of active exercise in the open air to circulate the arterial blood and to increase the vitality of the tissues. He should see that the waste products are rapidly carried off, not forgetting to regulate the bowels, and thus to remove another frequent cause of congestion of the portal system. If the patient has the means and ability to undertake the journey, he should be strongly urged to visit some of the foreign watering places, such as Carlsbad and Vichy, or he may go to Cheltenham, Leamington, &c. The mountain air, change of diet, and a salubrious climate will greatly assist the mild aperient waters in effecting a radical change in the constitution of the patient.

One variety of this disease is observed frequently among cabmen and omnibus drivers who are addicted to intemperate habits. The sebaceous follicles are enlarged and inflamed. The surrounding cellular tissue becomes infiltrated with spongy material. As the disease progresses it assumes a nodulated or tuberculated appearance, and the blocked follicles may inflame, forming minute pustules with "mattery heads." The cutaneous veins get more distended, slightly varicose, and the heat and activity of growth increase the deformity and discomfort to the patient. The treatment of this disease is both local and constitutional. The digestive system must be attended to, alteratives and stomachics may be required. We must not be misled by the somewhat bloated appearance

of the face to assume that the patient is in robust health. The character of the pulse and the condition of the body generally will show that he is in rather a feeble state of health. He must be encouraged to observe moderation in the use of alcoholic drinks, and in some cases total abstinence will be required. The local treatment must not be neglected. If persevered in, it will usually effect considerable relief, and if taken in time it may suffice for a cure. The patient should bathe the nose frequently with warm water or the carbonate of soda lotion. A little mercurial ointment may be rubbed into the follicles to favour the softening and absorption of the concreted blocks which are distending the tubes. When the congestion is allayed, the hypochloride of sulphur ointment may be rubbed in. Brecknell and Turner's skin soap is recommended for the face. When the disease has progressed for some months it may be necessary to resort to removal of the diseased integuments, retaining that part of the nose which is not involved in the disease. Some very successful results have been obtained, and the ingenuity of the surgeon is often displayed in providing sufficiently healthy skin from the neighbouring integument to take the place of that which was diseased.

The iodide of sulphur ointment, ten grains to the ounce, is very useful in chronic acne, as also the liquor hydrarg. perchlor. lotion.

Molluscum is a disease of a more chronic character, with enlargement of the sebaceous follicles and retained secretion. The eruption appears generally on the face and very rarely on the body, as indolent

tumours, which are sessile or pedunculated, and containing a cheesy kind of matter. Each tumour appears semi-transparent, from the skin being distended over it. It is a contagious disease, and it may crop out on the surface in distinct groups or colonies. It is characterised by the appearance on the skin of round soft tumours, slightly umbilicated, varying in size, though averaging that of a small currant. There is no pain or local irritation, but simple hypertrophy of the sebaceous follicles. These tumours are distinguished from warts by their softness and uniform character, their colour, and the central depression at the apex ; and from fatty tumours by their elasticity and slow growth. As to treatment, the more solid growths require to be carefully dissected off or excised, and the base destroyed with caustic.

Lupus may be described as a strumous degeneration of the skin, followed by rapid ulceration, which may and often does destroy the subjacent bone, causing very great disfigurement. There are four varieties of lupus, viz. *L. exedens*, *L. non-exedens*, *L. devorans*, and *L. erythematosus*. They may all occur in children and young people with delicate or strumous constitutions. The breath is offensive, and the tongue is coated with a cream-coloured fur. There are symptoms of flatulence and gastric disturbance, and generally a feeble action of the organs of nutrition and assimilation. There is usually some anæmia and a flabby condition of the skin and muscles. It is eminently a disease of youth, being rare before the age of ten and during adult life. It is associated with the strumous diathesis, and is more frequent with girls than boys.

In *L. exedens* the ulcerative process attacks the deeper-seated tissues, and appears generally on the face, first as one or two small brownish specks, which may become confluent as the disease spreads. The surrounding skin inflames and the epidermis swells, becomes raised above the surface, and a crust forms with spreading ulceration of the skin beneath. It is often difficult to distinguish this disease from syphilitic ulceration. This variety is sometimes called *L. serpiginosus*, on account of the ulceration extending unnoticed under the thick crust of epidermis. Fresh crops of papules and tubercles appear in the neighbourhood of the nose, and the disease will spread subcutaneously. The ulceration may extend very deep into the tissue of the skin, destroying areolar tissue, muscles, cartilage, periosteum, and ending in destruction of bone. The eyelids may be dragged down and the features much distorted.

Lupus exedens often occurs on the alæ of the nose of children and young people of a strumous temperament, and is very destructive and rapid in its spread. It is a simple local growth, and if attacked boldly may be quickly destroyed with powerful caustics or cauterisation; the surgeon being careful to remove all remnants of the disease.

In some cases the disease will creep on, and heal in the part first attacked, leaving a serpiginous ulceration and a scar resembling that from a burn, the rugæ of which radiate towards the spreading sore. The contraction of the cicatrix may cause considerable deformity by dragging down the nose to one side, or by obliterating the alæ of the nose.

L. devorans or Noli-me-tangere commences with destructive ulceration of the various structures beneath the skin. Muscles, tendons, cellular tissue, cartilage, &c., being quickly involved in the spreading ulceration. It often begins at the tip of the nose, and spreads into the septum nasi, or roof of the mouth. This variety does not spread so rapidly as *L. serpinginosus*.

Lupus may be distinguished from ordinary strumous ulceration by the absence of a tendency to spread from the centre outwards, also by the absence of tubercles or papules around the sore. The lymphatic glands may be involved in scrofulous ulceration, but this rarely occurs in lupus.

In the Section of Dermatology at the International Medical Congress of 1884, Professor Dutrelepont opened a discussion on the ætiology of lupus. He stated his belief that lupus is really a tuberculosis of the skin. Not only are the histological characters of the lupus nodules and the miliary tubercle very similar, but the specific bacillus of tuberculosis is found in both. The clinical course of the two diseases also presents, as he thought, some very marked points of resemblance, the slow course, for example, of some forms of phthisis, accompanied with many relapses. But the most important and most direct proof has been found in the inoculation of small pieces of lupus tissue into the cornea of rabbits, and the growth of distinct tubercle at the point of inoculation. He was followed by several speakers, who considered that the slow course and frequent recurrences in lupus were very like the course and relapses of tuberculosis.

As regards the treatment of lupus, experience seems to show that any treatment short of eradicating the disease only stimulates it to spread. Powerful caustics have been applied, which only tend to enlarge the area of ulceration, unless they are applied so effectually that they burn out the disease. The constitutional treatment should be pushed also with vigour. Careful attention to hygienic measures must not be neglected. The patient must have plenty of pure air, good food, and exercise in the open air. The ordinary tonics may be given, such as quinine and iron, or the mineral acids, also cod-liver oil, and the liquor arsenicalis, iodide of potassium, and the iodide of iron. To eradicate the disease I should recommend that the patient be placed under chloroform, and the whole of the ulcerating surface exposed by the removal of the crusts. With a sharp spoon or curette the morbid growth may be scraped away, so as to leave a raw surface to heal by granulation, after applying strong carbolic acid to the denuded derma. A solution of jequirety or chloride of zinc paste, or a stick of chloride of zinc may be passed firmly over the growth, or the fumes of nitric acid may be used, so that the base of the growth can be destroyed, and a poultice may then be applied to liberate the charred crusts which remain. Since the introduction of Paquelin's cautery we have a quick and very effectual method of dealing with these surface growths.

Lupus non-exedens is a variety of the disease characterised by less vigorous development, and it is less destructive in its tendencies. It commences as a small tubercle of a reddish-yellow colour. There is

little if any ulceration, but the tubercle seems to grow subcutaneously, and it may spread all over the face. The treatment is much the same as for lupus exedens, but the cauterisation need not be quite so deep. Caustic potash may be painted on the surface with much effect. The syrup of the iodide of iron and cod-liver oil may be given internally.

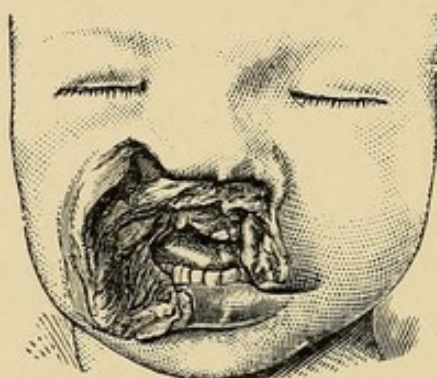
Lupus erythematosus generally manifests itself on the nose, cheek, or eyelids. It does not destroy the soft tissues or the cartilages so rapidly as the other forms of lupus. The scabs are of a pearly whiteness, and are very difficult to remove. It is a non-tubercular growth, not raised above the surface, and it appears in the otherwise robust, and less seldom in the scrofulous or consumptive. It begins in patches of a purple red colour, and these may be covered with scabs or crusts, underneath which a scar tissue is formed, as with the other forms of lupus. It generally progresses very slowly, commencing as a small, punched-out, callous ulcer, with a red, irritable base. This growth may be destroyed by the actual cautery, or by Paquelin's thermo-cautère, or by the application of caustic potash in solution. The usual tonic treatment in these cases is necessary.

The milder forms of lupus are best destroyed by using a weak solution of nitric acid. The disease may be aggravated by exposure to cold winds or furnace heat, or by mental anxiety and poverty.

It may be distinguished from syphilitic ulceration, because this occurs, as a rule, only in adults, and may spread from the throat outwards to the surface. There may be papules around, but they will be of a

coppery colour, and a history of syphilis may be traced in such cases. The edges of the ulcer in syphilis are foul and sloughy. The margins are sharply cut and not indurated.

Cancrum oris commences with swelling and redness of the cheek near the angle of the mouth, with some sloughing of the mucous membrane and offensive breath. A mouth-wash may be used of chlorinate of soda, and chlorate of potash should be given as a medicine. The ulceration of the mouth extends rapidly, and the child's health suffers in consequence



Cancrum oris. Model 26⁵, Guy's Hospital Museum.

of swallowing the foul discharges. If not promptly cauterised the cheek soon becomes perforated, and the glands of the neck enlarge. The treatment must be heroic, the whole of the sloughing surface must be destroyed with the actual cautery or with solid chloride of zinc, or fuming nitric acid. The child must have plenty of nourishing food, beef tea, eggs, milk, and wine, etc. Quinine and iron should be administered internally. The child is generally very feeble from insufficient food, and from living in the

midst of foul odours, and other evil effects of overcrowding, so that it is needful also to remove it from such pernicious insanitary conditions. The drawing which I append is from a model in the museum of Guy's Hospital.

Congenital Syphilitic Eruptions may give rise to various deformities about the face, either by the production of scars or from the outbreak of disfiguring skin lesions. The characters of such eruptions are various. They may crop out as disseminated squamous eruptions like chronic eczema, or as mucous tubercles about the mouth and nostril, or as red indurated nodules or papules with an inflamed areola, generally leaving a coppery stain as the eruption fades. The complexion of the face in these cases is characteristic ; it is more or less "muddy," presenting the so-called *café au lait* tinting of the cheeks and forehead. The lips may be thick and excoriated. Radiating fissures all round the mouth will often be seen in these cases. There are also constitutional symptoms, such as snuffling at the nose, distended alæ, and flattened bridge of the nose. The child may be rickety, emaciated, suffering from tabes and general marasmus. There may be syphilitic nodes and cranio-tabes ; also some chronic intertrigo of pudenda, and condylomata, or mucous tubercles around the anus. Such children may lose flesh rapidly, and they often die from inanition. The treatment of these cases must be prompt and decisive, by a course of antisyphilitic remedies as follows :—Hydrarg. c. creta, iodide of potassium, with the syrup of the iodide of iron, and the inunction in some cases of mercurial ointment.

Parasitic Diseases.—Scabies may occasionally appear on the face, but very rarely. This is a vesicular or pustular disease, caused by the presence of an animal parasite, the *acarus scabiei*, or *sarcoptes*, which burrows under the skin and deposits its eggs there. Very quickly the disease spreads, from the active habits of the male itch insect, travelling over the surface of the skin. The disease is thus favoured by the dirty habits of the poorer classes. Children that are badly fed and poverty-stricken suffer most severely from the spread of parasitic diseases. A vesicle or pustule appears where the female insect has burrowed and deposited the eggs.

The child should have a good lather of carbolic soap and water before the fire, and then the sulphur ointment can be rubbed well into the softened skin. It may be necessary to give sulphur baths. The pustules of itch are disseminated, generally on parts which are protected from friction, as the folds of the skin.

A thickened inflammatory condition of the eyelids and eyelashes may be caused, in the first instance, by pediculi. This occasions considerable local irritation, and swelling of the Meibomian glands and follicles. A glutinous secretion blocks them up, and so the eyelid swells and becomes very unsightly. This disease is called blepharitis, and it will need careful attention to reduce the swelling, and to sponge away the crusts which form at the roots of the eyelashes. Strumous children often suffer from blepharitis, not caused by any animal parasite. In each case cleanliness, and the regular use of the dilute citrine ointment, will effect a cure if persisted in daily for some time.

Very careful bathing with warm water will soften down the glutinous exudation which clings to the lids, and distends the follicles under the skin.

Of vegetable parasites, we have, for example, ringworm, i. e. *Tinea tonsurans*, occurring often on the forehead. These parasitic diseases are of course very contagious. Ringworm appears first in patches about the size of a shilling or sixpence, with a raised red margin. The surface is covered with loose laminated scales which are opaque and peel off. The hairs which are involved in the disease become brittle and break off near the skin, so that the scalp presents the characteristic "stubble-field" appearance. The spores of the fungus infiltrate into the tissues of the bulb and hair follicles. The mycelium and sporules of the disease spread in all directions among the roots of the hair. When the spores are thus deeply imbedded in the follicles of the skin, it is difficult to eradicate the disease. We have a variety of local applications suitable for the treatment of this disease. It is important to see that the parasiticide penetrates to the base of the follicles, and not to neglect general treatment.

If the disease is in well-defined patches, I sometimes brush the surface firmly with iodine or rub in the ung. hydr. amm. or the ointment of sulphur and acetic acid or the oleate of mercury. Disseminated ringworm is best treated with a lotion of equal parts of sulphurous acid, glycerine, and liquor hydrarg. perchlor., constantly applied, or strong carbolic acid.

Tinea circinata may occur on the cheek. It is a disease of a furfuraceous character and without much constitutional derangement. It often occurs in

strumous or delicate children. Some dermatologists consider that this is not a parasitic disease of itself, but an herpetic eruption with the grafting upon it of *tinea tonsurans*. It may be painted with acetic acid or iodine, and some tonic treatment administered.

Tinea sycosis may attack the skin which is covered by whiskers or the beard. Sycosis is a pustular disease of the hair follicles of the face, especially of the chin and upper lip. It is developed first by inflammation of the roots of the hair, and is increased by any attempt to keep the part shaved. Conical pustules form on the surface, and a dry scab concretes over the eruption and mats the hair. The disease appears to originate in a vegetable parasite, which attacks the epithelial lining of the follicles. There is considerable local itching, pain, and swelling of the parts. The irritated skin bleeds very freely. The deeper tissues of the skin swell and harden, and there may be small abscesses form in the subcutaneous cellular tissue. If the disease continues unarrested the hair follicles will be destroyed, the beard falls out, and baldness is the result. The disease is propagated by the mycelium or spawn of the vegetable parasite which is found blocking up the follicles and destroying the hair-bulbs. It is, of course, most needful to beware of "easy shaving shops" where cleanliness is not rigidly attended to. Those who require to go to the barber must select the man that uses every precaution to prevent the spread of parasitic disease.

It is important to remember that every disease that attacks the chin is not sycosis. We often have

impetigo limited to the chin or upper lip, but this is not sycosis. A microscopic examination of the root of the hair will determine the precise character of the disease. Sycosis is a very difficult disease to eradicate. It may last for years. It is important to attend to the general health, especially of the digestive organs. Mild aperients and alteratives may be required, followed by vegetable tonics. The beard, instead of being shaved with a razor, should be kept close cut with a sharp pair of scissors. The iodide of lead or the iodide of sulphur ointment may be rubbed into the eruption with care and diligence. Merely to smear the surface will not suffice. The follicles being shaped like the finger of a glove, an attempt must be made to press the healing ointment down into the open ends of the follicles. Careful attention to diet and regimen, and the avoidance of spirits and highly seasoned food must be attended to. The eruption may be bathed with a sulphate of copper or sulphate of zinc lotion, about five grains to the ounce, or carbolic lotion, and the face washed with the juniper tar soap.

Tinea favosa occasionally attacks the chin and eyebrows. The mycelium and sporules of the *Achorion Schönleini* cause the spread of this disease. It consists of cup-shaped yellow crusts resembling a honeycomb. These crusts are often very extensive, and they emit an offensive odour. The hair-follicle in the centre of the crust is quickly destroyed by the fungus. It may be associated with pediculi of the face. Lotions or ointment containing sulphur and mercury will be required in these cases to destroy the fungus.

Chloasma, or liver-spot, otherwise called Pityriasis versicolor, appears sometimes on the forehead, of a dull brownish-yellow colour. I think it is doubtful whether we should not consider the two diseases chloasma and pityriasis versicolor as quite distinct one from the other. Some dermatologists favour a parasitic origin for these diseases. The *microsporon furfur* has been discovered in pityriasis versicolor, but I think the patches of chloasma indicate more a deposit of pigment in the rete mucosum, in consequence of retarded circulation from nerve prostration and general debility. It is often the result of want of cleanliness, but generally from some enfeebling debilitating cause, specially of a neurotic character, as in myxœdema and degenerative changes in the structure of the heart. The lotion of perchloride of mercury is useful in these cases. The patient must be treated on general principles. The digestive and assimilative organs must be carefully attended to. Preparations of quinine, iron, and arsenic are generally required to follow gentle aperients.

Surface Tumours of the Face which involve the skin only, do not often come under treatment. There are, of course, an endless variety of tumours connected with the deeper structures, but these I do not propose to describe, as the deformity in such cases is the result of the forward growth of the tumour towards the surface, rather than being in itself a direct cause of deformity and disfigurement.

Lipoma is a disease of the integumentary coverings of the nose, it does not involve the bones or the cartilages. This growth must of course be distinguished

from the ordinary lipomatous or fatty tumour which may be found on different parts of the body. The structure is quite different, and appears to partake of the character of a general hypertrophy of the adipose tissue and sebaceous follicles with infiltration into the surrounding cellular tissue, and is also followed by engorgement of the neighbouring vessels. It is a disease situated generally at the apex, and spreading laterally along the alæ of the nose. Sometimes it is more pendulous than others, so that as the patient walks his nose swings about like the pendulum of a clock. Sometimes it is nodular and very vascular, and the surface capillaries are distended and blocked with sluggish blood, giving the growth the strawberry colour which is so characteristic and so unsightly. This is a simple painless growth, and develops slowly. Fortunately the removal of it may be effected with great ease, and without the danger of a recurrence. The growth should be carefully dissected off the cartilage without removing the mucous lining of the nostril. Possibly a little plastic surgery may be desirable to provide a fresh covering of adjacent sound skin for the denuded cartilages.

Fatty tumours appear sometimes on the face in the substance of the cheek or lip. They may be pendulous or sessile. When the patient has a number of these growths scattered over the body, some will be found occasionally on the face, and require to be removed on account of their unsightliness. When acting as Surgeon to the Westminster General Dispensary I removed a large fatty tumour from between the genio-hyoglossi muscles in the exact situation of ranula.

The patient came under my care with a swelling which showed very prominently when the mouth was open, tilting up the tongue and also projecting downwards, giving a double chin appearance and interfering with his power of speech. The mucous membrane of the floor of the mouth was distended over it, and it projected above the teeth. The tumour had apparently a uniform outline. It was quite elastic. I proceeded to remove it by an incision as for ranula. Instead of the usual glairy fluid escaping, I found the opening in the mucous membrane blocked up by a white smooth surface tumour, which I seized with vulsellum forceps and found that it was of a fatty nature, the size and shape of a Geneva watch. I succeeded in freeing it from the cellular tissue covering the muscles which embraced the lower edge of the tumour. The case progressed favourably, and the man's power of vocalisation returned to its normal condition. The specimen is, I believe, unique. It is now in the museum of the Royal College of Surgeons.

Primary cancer of the face, as distinguished from cancerous tumours which involve the face subsequently by spreading from the deeper structures, may be formed in two or three distinct varieties, viz. rodent cancer, epithelioma, and melanotic sarcoma.

Simple warts or cracks of the lip if irritated by smoking, &c., may develop into a form of cancer or rodent ulcer which requires prompt excision.

Rodent cancer occurs in old people, and ulcerates very slowly, but it may invade the deeper structures, and it shows no tendency to heal. There is often severe pain in this disease as contrasted with lupus,

which is almost always painless, except when irritated by caustics, etc.

Rodent cancer commences frequently over the malar bone, beneath the lower eye-lid, extending by a slow growth towards the nose. It is essentially a disease of old age, rarely occurring under fifty years of age. It is sometimes described as a local cancerous growth with the peculiar character of spreading by contiguity of structure, rather than through the neighbouring lymphatics and glands. It first appears as a permanent tubercle on the skin, and two or three may form afterwards close by, which coalesce with the primary tubercle. This little prominence ulcerates and forms a fungating mass with a deeply excavated ulcer. The surrounding tissues become callous and eroded by the spread of the disease. It infiltrates the neighbouring glands and subsequently involves the osseous tissues. As it spreads it invades the nerve-trunks, and then the patient suffers a great deal of pain. The treatment must be very decisive, no half-measures will suffice. Powerful escharotics must be used for its destruction, or the galvanic cautery. The results of early destruction of these growths are very satisfactory, for the glandular tissues do not as a rule become permanently involved in the disease at first. Scraping the surface of the ulcers will sometimes suffice to destroy the heterogeneous growth of the epithelial elements. Upon the denuded surface we may sometimes do some skin-grafting with evident benefit to the patient for the obliteration of the deformity, taking care to destroy the growth first in all cases.

Epithelioma commences as a small dry wart which cracks and ulcerates. It frequently appears at the junction of the skin and mucous membrane, and so is distinguished from rodent cancer, which it greatly resembles in the early stages of development. The outline of growth in epithelioma is more rugged and uneven, and the surface is raised and papillated. The lymphatic glands become involved very early. There are distinct microscopic characters which distinguish the one from the other, showing the epithelial cells undergoing rapid proliferation, with large granular contents, the nuclear elements expanded, and the growth itself extending along the course of the lymphatics into the neighbouring structures without any line of demarcation. Epithelioma in consequence of its infiltrating character has a tendency to recur in the part from whence it has been removed. So that this growth requires to be treated promptly and expeditiously to effect a satisfactory cure. It may remain dormant for many years, causing very little pain or inconvenience. Suddenly without any very clear cause it may expand, fissures appear on the surface, and then the disease quickly involves all the neighbouring structures. It may be excised or burnt out by escharotics, such as chloride of zinc, the actual cautery, &c. It sometimes appears on the end of the nose, and frequently at the lower lip near the angle of the mouth. If the teeth be examined it will generally be found that those which are adjacent to this fungating ulcer are worn down by the constant friction of a pipe without a mouthpiece. The long clay pipe used to be considered a frequent cause of this disease in old

men, who being past work are seldom able to exist without the soothing effect of a little tobacco. For the removal of these growths it will be necessary to make a V-shaped incision on either side through sound tissue, piercing through the mucous lining to the mouth, so as to avoid any infiltrated or swollen gland tissue. The lines of incision should approximate just above the depression which exists midway between the lip and the chin. The hæmorrhage should be controlled by compression, first of all with dressing forceps, or the forceps specially designed for the purpose, and then with strong harelip pins we may place the raw edges in accurate coaptation. Torsion may be required to arrest the hæmorrhage from large bleeding vessels.

Large sarcomata, myeloid tumours, adenoid growths, &c., develop in the tissues of the face, including the parotid gland and adjacent cervical glands. These I merely allude to *en passant* as surface deformities.

Sebaceous cysts may appear on any part of the face. They consist of a concretion of epithelial débris caused by the prolonged closure of some one or more cutaneous and subcutaneous follicles. The contents are putty-like and are generally enclosed in a distinct sac of a pellucid membrane, which must be carefully shelled out at the operation, otherwise the tumour will grow again. Sometimes the sac will be adherent at the base, and as they generally lie underneath the superficial muscles, the attempt to remove them must be undertaken with considerable care. They increase slowly, but they have been known to excavate the subjacent tablet of bone by the pressure of the ever-increasing contents. They are usually

round or oval in shape, and move under the examining finger with an elastic feel. Before commencing the operation for their removal, it is occasionally desirable to pass a pin below the tumour and then to tie a silk thread underneath so as to bring the tumour prominently to the surface, and also to fix it, so that when the usual incision is made across the tumour, the contents may be promptly evacuated together with the sac. Many congenital tumours on the face consist of a combination of solid and cystic growth, presenting a honeycombed appearance, and having contents which vary much in character. We have also blood-cysts, dentigerous cysts, mucous cysts, dermoid cysts, hydatids, congenital hygromas, and other varieties of cystic growth forming in the substance of the cheek, etc. All these require to be excised, unless the attachments are too deep.

Warts and wens I have placed in the introductory section, under the head of "Structural Deformities."

We may have congenital absence of one or more of the bones of the face, causing considerable deformity. Such cases scarcely come within the range of thought for rectifying the deformity, as they are not capable of much if any improvement, as a rule.

Dental Abscess.—Amongst the poor particularly, who are exposed to rough weather, and are very loth to go to the dentist, it occasionally happens that an abscess around the fang of a tooth may spread to the jaw and the glands of the neck, requiring an incision at the dependent parts to evacuate the pus. If great care is not taken, the resulting scar will pucker, become adherent to the jaw, and form a permanent pit

or depression in this situation, and it may terminate in necrosis of the subjacent bone.

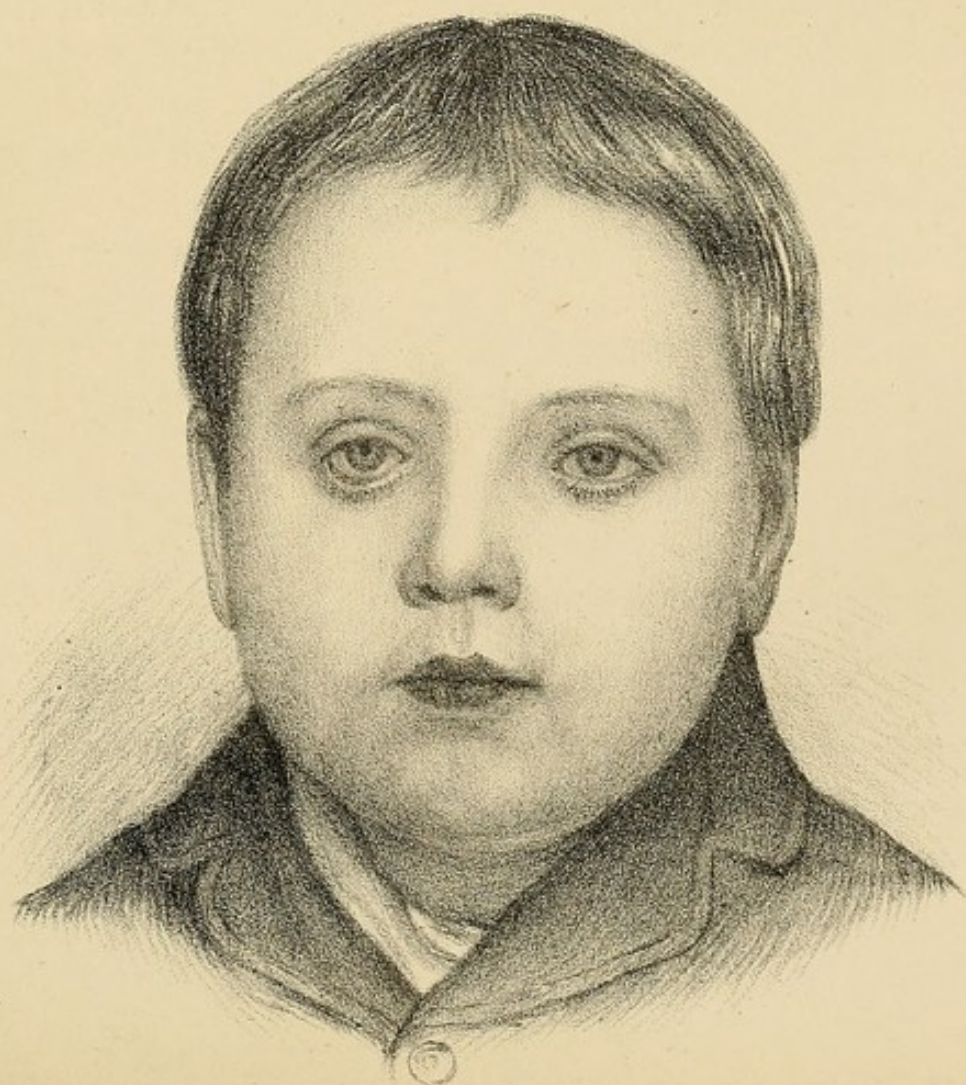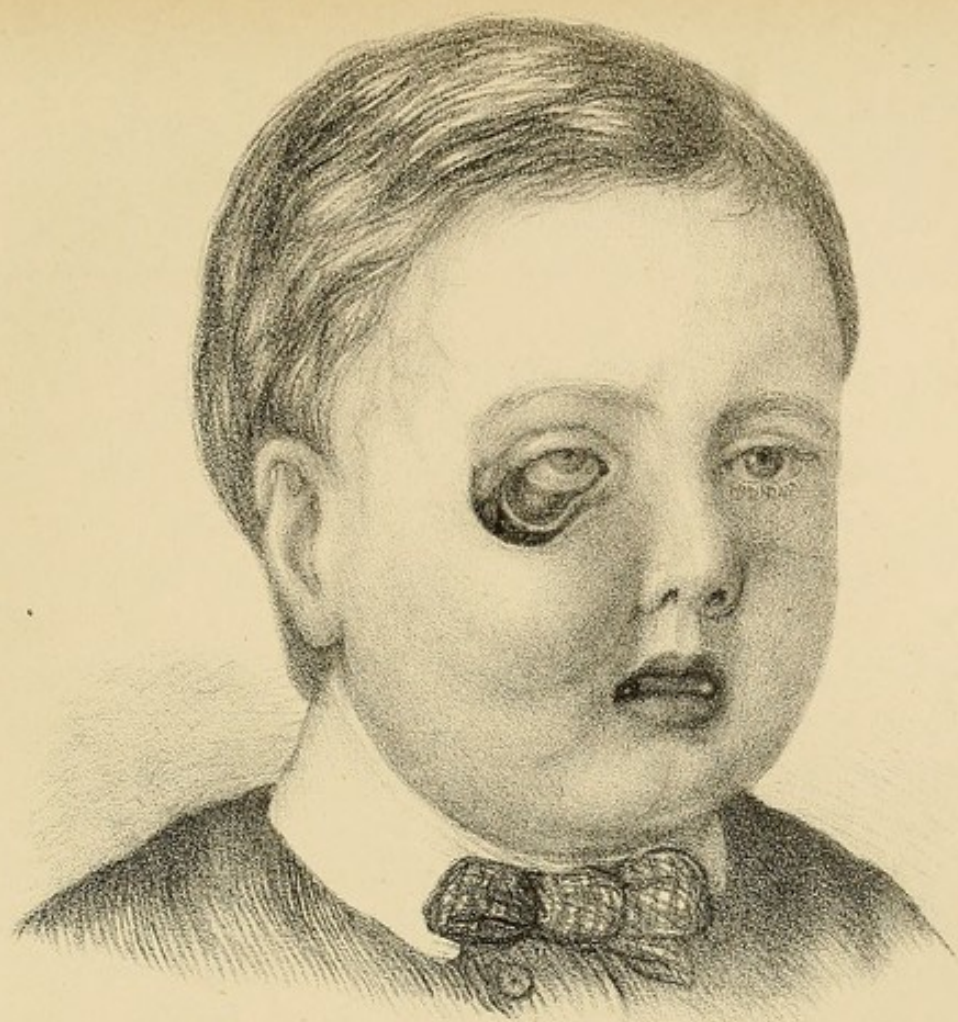Decayed teeth may give rise to many deformities of the face more or less permanent. They may set up a chronic osteitis of the jaw, with diffuse swelling of the soft tissues covering it, and probably abscess. If neglected, there may be necrosis of the alveolar border of the jaw, which may invade the antrum, destroy the incubating permanent teeth, or spread into the substance of the lower jaw, causing abscess in the neck just below the chin. The seventh nerve occasionally becomes involved in these abscesses of the face, and then we may have facial paralysis with a loss of expression on that side. The face muscles being flaccid and inert, the features become distorted in consequence of the unbalanced action of the muscles on the opposite side of the face.

Salter relates in his book several cases of loss of sight following abscess in the antrum. When the antrum is much distended by the accumulation of pus there will be much distortion of the face.

A case of extensive superficial necrosis of the upper jaw and malar bone came under my care lately at the Victoria Hospital. I removed the necrosed portions with cutting pliers and gouge, and found that the disease extended up to the orbital border of the malar bone. I then passed the gouge through a fistulous track situated just below the lower eyelid which led to the carious cavity, and removed the exfoliating surface. The wound was plugged with oiled lint, and the extensive surface of bone which had necrosed gradually rounded off, and became

covered with mucous membrane. The large prominence on the cheek caused by the superficial cellulitis and inflammatory exudation subsided, but the operation rather tended to increase the deformity which had already appeared on the eyelid. By the extreme eversion of the lower eyelid and conjunctiva caused by the binding down of the above-mentioned fistulous track to the external surface of the malar bone, the under surface of the eyeball was completely exposed to the atmosphere, and to sand and grit. (*Vide* annexed Plate.) The antrum was not involved.

At a subsequent operation, having a firm base of solid bone covered with mucous membrane to depend upon, I proceeded to make a horizontal incision just below the eyelid, and over the prominence of the malar bone. I then dissected up the lower eyelid, which, instead of being convex, was concave and depressed into a deep pit by the large swelling over the malar bone. The conjunctiva was completely everted, and the upper eyelid was dragged downwards and outwards by the contracting cicatrix, causing a very marked deformity in this situation. I dissected up the lower eyelid from its deep attachment, and by making two short vertical incisions at each end of the horizontal incision, I displaced the flap inwards towards the nose, and raised it up to the normal situation covering the eyeball. The conjunctiva was retained in its position of accurate apposition to the eyeball by a coarse silk suture which perforated this membrane in two places, and was then passed down over the malar prominence and into the mouth by transfixing





the buccal mucous membrane close to the cavity of the canine tooth.

The drawings will show how completely the prominent swelling of the face has subsided, how the unsightly pouch over the malar bone was obliterated, and also how the new lower eyelid was formed by transposing the integument and conjunctiva from this situation.

I need not now refer to the many causes of face deformity induced by paralysis of the opponent muscles, to wry-neck, fixity of jaw, epileptic spasm, hemiplegia or chorea. These require special management, besides local treatment, and I am only describing the surface deformities of the face. I desire to confine myself almost exclusively to the more usual types of face deformity.

Salivary fistula may result from the formation of an abscess or tumour in the neighbourhood of Steno's duct, or from destruction of the cheek by lupus or cancrum oris, or from sabre wounds. Calculi imbedded in the duct may cause an abscess to form, which being incised will be found to communicate direct with the parotid gland. The fistula which forms in consequence of the continued flow of saliva along the duct must be diverted so as to empty the contents through the buccal mucous membrane. This may be done by tracking the direction of the tube with silk and perforating the cheek, leaving the silk *in situ* until the new channel is complete, and then paring and closing up the external opening with sutures.

SECTION III.

INJURIES OF THE FACE—INCISED WOUNDS, FRACTURES AND DISLOCATIONS, BURNS AND SCALDS, ETC.

Injuries of the Face may be said to occur very frequently among those engaged in dangerous occupations, as the manufacture of explosives, or in building operations, &c. Children often come under the surgeon's care suffering from incised or lacerated wounds of the cheek or forehead, or from bruises or sub-fascial extravasations, as occasionally happens when the vessels under the occipito-frontalis muscle are damaged. In such cases there will be a circumscribed swelling fluctuating on pressure, communicating a sensation as though the frontal bone was depressed. There may, or may not, be symptoms of concussion. The child should be kept away from school, and have an evaporating lotion applied if there is pain. Or he may have a bandage and compress to promote absorption of the effused blood. He may have fallen down on a sharp stone, or some mischievous playmate may have thrust a knife or pointed instrument into the face, either purposely or accidentally, or the wound may be self-inflicted by playing with swords, guns, &c. The eye, being well protected by the eyelids and orbital prominences, seldom gets injured; but considerable deformity results from wounds of the face when they are not properly closed at the time. The skin, too, of the face is so very delicate in texture, that it requires very careful manage-

ment to approximate the divided edges. Often the surgeon will strap together the edges of the wound quite accurately, but the movement of the muscles of expression, as in laughing, or of the deeper muscles of mastication may cause it to gape. I never trust to anything but very fine needles for face wounds of all sizes. I have had some specially made for me corresponding to the smallest needle that is manufactured, and this being furnished with a glass head, may easily be transfixed across the wound. I do not care to cut off the point, because this is unnecessary. I simply press the point into a piece of cork to protect the surrounding skin, after I have fixed the needle with fine silk in the usual way. Whenever the skin is divided, an attempt must be made to have the resulting scar which is inevitable, as linear as possible, so that it may scarcely be seen when the child grows up. Parents must not be disappointed if they find the scar increase in size, for, like all other tissues, it grows with the growth of the body. When we have primary or immediate union by agglutination of the clean cut edges, the wound should heal at once, and the line of cicatrix be scarcely visible. Besides careful adjustment of the edges, it is important to keep the deep parts of the wound in contact with the fascia beneath. I often find this rule neglected by dressers and house surgeons. However well adjusted the surface wound may be, the inner edges are often allowed to bleed subcutaneously, inflammation will then occur, and the wound will not unite. I always put a firm pad and strapping over the suture needle, and a bandage round the head to keep up constant and equally distributed

pressure. It often happens that a child from falling out of bed, or tumbling off a wall and alighting on some sharp or rough stones may have a severe gash in the forehead, with a depressed fracture of the outer table of the skull, or the inner, more brittle table, may be fissured and the dura mater torn, in which case there will probably be escape of cerebro-spinal fluid.

It is astonishing the slight amount of cerebral disturbance resulting from extensive fractures of the skull in young children. I had a case of this sort under my care recently at the Victoria Hospital in a boy aged six years. The probe passed in for about an inch through a vertical fissure into the interior of the skull, penetrating through the right frontal eminence, and there was a quantity of bony callus and fibrous thickening around. The pus which formed subcutaneously, gravitated downwards, and I had to make a counter opening. The inner side of the integument had a granulating surface, and the periosteum was very vascular, bleeding freely at each dressing. I had a strip of lint charged with a solution of nitrate of silver passed subcutaneously across the fissure, and a pad of lint placed externally so that the thick œdematous condition of the skin and the distension of the veins soon subsided. The fissure in the skull closed up very well. The child was kept at rest in bed, and a capiline bandage applied over all. There were no cerebral symptoms from first to last during the child's stay in hospital. As far as I can remember, there was very little evidence of concussion symptoms at the time of the injury. The child was not admitted for some days after the accident. It

was the prominent swelling of forehead that prompted the mother to bring the child to the Hospital.

Children playing with edged tools may suddenly inflict serious and irreparable damage in a moment of irritation. There are many lesions and deformities of the face caused by bullet wounds, sword thrusts, and numerous other sharp instruments, which require careful management so as to make the resulting scar as linear as possible. It is unnecessary to refer to these in detail.

Fractures and Dislocations of the lower jaw I might almost omit, only the risus sardonicus, so characteristic of the latter deformity, seems to compel a passing allusion to it. The fixity of the jaw, with gaping mouth, pain at the temples from spasm of masseter and pterygoid muscles, and the alarm and discomfort occasioned by this condition, are well known to most surgeons. Any attempt to forcibly close the jaw will be sure to end in failure. Some people are habituated to partial dislocation, when gaping or laughing somewhat immoderately. The articulating surface slips momentarily out of the glenoid cavity from relaxation of the surrounding ligaments, but the temporal and masseter muscles, firmly contracting when the jaw is depressed, facilitate the operation of reduction so that it can generally be replaced without much difficulty. Sometimes an attempt to crack a nut may cause this dislocation. No time should be lost in effecting replacement of the dislocated jaw. The patient should be placed in an arm-chair, and the head fixed against the chest of a person standing behind him. The surgeon, after protecting his

thumbs with a bandage or roll of lint, plants them as far back as possible upon the alveolar margin of the jaw, and presses firmly down to bring the glenoid head of the bone into relation with the margin of the glenoid cavity. The muscles will then quickly draw it up into its place. The patient should be fed upon slops for a few days, so as to keep the jaw at rest and favour the contraction and consolidation of the capsular ligament. He should also have a bandage or leather strap round the chin and head to keep the lower jaw steady while the ligaments are becoming consolidated.

Fractures of the lower jaw seldom occur. The signs are very obvious. There is drooping of the jaw, unusual mobility, crepitus of the fragments, loosening of teeth, and hæmorrhage in the mouth. The fracture may be about the middle or near the neck and coronoid process. They require to be treated with moulded leather or gutta-percha splint, and the mouth kept closed as much as possible with a bandage tied over the head for four or five weeks. The adjacent teeth may be tied together with wire. The upper jaw may also be crushed by severe external violence. The bone being rather brittle and hollow it breaks without much force. There is flattening of the face on this side, hæmorrhage in the mouth, and the crepitation may be felt on examination within the mouth. The fragments should be removed if possible, and loose teeth tied together.

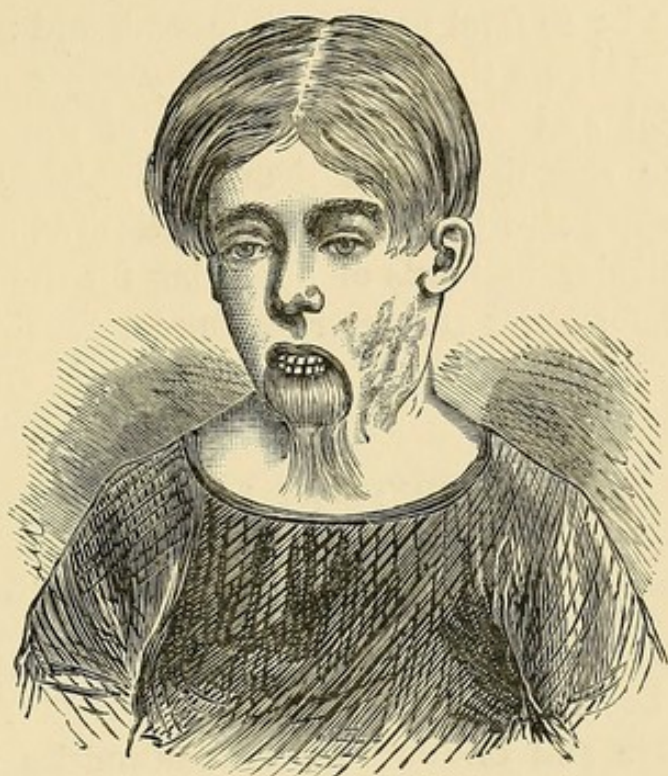
Fractures of the nasal bones will cause considerable deformity to the face, especially where the nose is very prominent. Unfortunately, this injury occurs rather frequently in over-crowded streets and thoroughfares

from people being knocked down and run over ; also in consequence of railway collisions, &c. The fracture may be simple, or it may be compound and comminuted. The fragments being crushed into the nasal cavity may block it up, and the turbinated bones may also be damaged. There is usually very free hæmorrhage from the nose in these cases. The surgeon must replace the fragments as skilfully as he can with dressing forceps and retain them in position with pads, strapping, and bandages, and plug the nostrils so as to arrest the hæmorrhage.

Very extensive deformities result from burns and scalds of the face in consequence of the contraction of the cicatrix. The sound skin being dragged from all parts, causes a serious distortion of the features, and obliteration of the normal outlines of the face. The surgeon must bear in mind the importance of promoting a surface healing of the skin, which is in part destroyed by the burn, so as to leave as little contraction as possible. It may be necessary to fix the head by some apparatus. Though the healing may be slow in such cases, it may be better in the end, by leaving less deformity from the contraction of the scars. Each case requires to be carefully studied on its own merits, so as to fit in by a plastic operation some sound integument to the deformed part, after dividing the prominent constricting bands of callous skin. The surgeon must be quite sure before commencing his operation that he has sufficient integument for transposition, otherwise he may find that division of these bands will cause a gap which cannot be filled in, and the last state of the patient will be worse than the first.

Removal of Cicatrices.—It is well known how much mischief and deformity is occasioned by the contracted cicatrices of burns about the face and neck dragging down the elastic integument concentrically, till all the features are distorted. When the eyelids are drawn down, the red conjunctival membrane is exposed. The delicate membrane covering the eyeball becomes thickened, and the sight blurred by the irritation of dust, which gets access to the eye because the eyelids, being designed to keep foreign bodies out, cannot close. (*Vide* adjoining woodcuts, showing results before and after operation, from Fergusson's 'Surgery'.)

Patients must not be too sanguine of success in regard to the removal of such cicatrices. We may divide the rigid contracting bands but we cannot create new tissue. The body is covered by skin which if destroyed we cannot replace. Still I have reason to say that many of these deformities may by a well-planned operation be considerably mitigated, if not altogether removed. Though the skin covers the body without redundancy or folding, yet we can often borrow a little from the neighbourhood without endangering the sound skin, and this we must endeavour to do. The surgeon must take accurate measurements of the tissue available for the purpose before dividing the scar, and it may be desirable to plan the operation to be done in stages, so as to avoid making a huge gap which we afterwards find it impossible to close with sufficient breadth of sound skin. The new cicatrix which forms after the division of an old band will contract the tissues just as before. Our aim should be to arrange for the contraction in a direction which



would not be so fatal to free movement, and not be so likely to disfigure the face. We may effect much by the careful and constant inunction of warm oil to soften the scar-tissue, and then by applying an extending apparatus to stretch it in the desired direction. The particular methods of operating for the removal of such deformities are described under Section IV.

SECTION IV.

PLASTIC SURGERY—NOSE, HARELIP, ETC.

Plastic Surgery.—On no part of the body has the surgeon been able to show more abundant success in the cure and obliteration of deformities than on the face. Opportunities abound for the exercise of his ingenuity and skill in adopting measures for transplanting sound skin where it happens to be loose or free, and moving it to a situation where it can cover over an ugly scar or deformity, constituting one of the greatest triumphs of modern surgery. There have been numerous cases of cure effected by this method of plastic surgery. As, for example, in the provision of a flap of skin from the forehead to cover the unsightly openings to the nostrils, when these are exposed to view by a falling-in of the arch, either as the result of disease of the nasal bones, or from severe injury. The provision of a new eyelid to take the place of that which has been destroyed is an operation of this kind, and is usually very successful. The public appear to be still very ignorant of the real

powers possessed by surgeons at the present day for obliterating deformities, or we should not see so constantly as we do, exposing themselves to public gaze, frightful specimens of humanity doomed to perpetual banishment from society, because they do not know what effectual means the surgeon is able to use in order to rectify this deformity.

There is one apparent disadvantage of our modern civilisation as regards plastic surgery, and it is that we are debarred from *experimenta in corpore vili*, as would be done among barbarous tribes where slavery prevails. A person of exalted rank suffering from such deformity would have no difficulty in obtaining from a slave the substitution of a faulty member, and the unfortunate slave would be condemned to a life of ignominy and reproach in consequence.

Far from advocating a return to such relics of barbarity, I would merely remark here that cases have been known where volunteers have willingly surrendered the skin of their arm, if it could not be obtained from the patient, to cover over a face deformity. Failing such help the surgeon must do the best he can with the patient himself. He must endeavour to get a transposition of integument to obliterate the deformity and rectify the unsightliness from the most available source, always remembering to have a connecting link of sound skin so as to keep up the nutrition through the vessels which convey the blood to the flap. The effusion of plastic lymph will agglutinate the raw edges so as to close the wound. The surgeon must be careful to plan his incisions so that there may be good primary union of the approximated

freshly incised edges with as little delay as possible. He must also see that by proper padding and support the flap is kept well in its place and the circulation gradually re-established through the connecting link of skin.

Deformities of the Nose may be congenital or caused by some severe blow or fall upon the ground or from ulceration of the septum. Such a crooked condition of the prominent feature of the face is very disfiguring.

Infants are sometimes born with imperforate nostrils, or absence of the nose, but this is a very rare condition. If the tube is merely closed by a membranous fold of mucous membrane, this may be removed by a crucial incision, the flaps being reflected inwards to unite with the lining membrane.

Considerable deformity of the nose may result from severe blows or from disease of the nasal bones. These cases require special treatment for rectifying the deformity, and in children who have small and undeveloped noses every effort should be made to rectify the deformity while the cartilages are easily manipulated, and when even the bones may be carefully divided and set in the mesial line erect. Subcutaneous osteotomy may often suffice to remove severe deformities of the nasal bones.

Polypus nasi may cause some deformity of the nose by lateral distension of the ala as it presses upon the mucous membrane. These growths may be removed, as a rule, without much difficulty by evulsion with dressing forceps.

The bridge of the nose may be absent, either from congenital deficiency, syphilitic or strumous ulcera-

tions, or from damage. The deformity is, of course, very great. Such cases require some skill to obliterate or mitigate the deformity. The nose being the most conspicuous feature of the face, it is a very difficult thing to rectify deformities thereof.

Dislocation of the bones of the nose may be rectified by forcible manipulation and leverage of the septum nasi into its proper position. Long standing cases are seldom able to be cured.

There may be congenital deficiency of the vault of the nose from syphilitic disease, or there may have been necrosis of the many delicate and spongy textured bones of the nose or of the septum, the result of strumous or lupus disease tending to atrophy.

Some very successful attempts have been made to remedy this very serious deformity by transplanting flaps of integument from the cheeks, the forehead, or the arm, to cover over the nose, and to serve as a screen to hide the unsightly caverns which show so prominently in these cases. Where the nostril is blocked by deformity, as from the alæ being collapsed and lying against the septum, the voice is much altered and becomes nasal in character. It is desirable, if possible, by careful packing of the nostril and distention to make this nostril patent.

Before commencing to operate for the provision of an artificial nose, the surgeon must take accurate dimensions of the locality where the nose is to be placed with a piece of thin cardboard. This may be placed on the forehead or arm, whichever is to supply the flap for covering in the gap, and the sound flap of skin should be traced out with ink the required size.

Some little allowance must be made for the contraction of the skin during the healing process. If taken from the forehead as usual, the connecting link of skin, just close to the bridge of the nose, at the lower part of the forehead, must be twisted upon itself to allow of the flap coming down and covering the nose. If it be desired to provide a long septum for the nose this may be obtained from the upper lip. The margin of the collapsed nose must be deeply incised, following the outline of the *alæ nasi*, so as to get a firm bed of support for the new flap of integument, and then with a very sharp knife and with brisk rapid incision the traced outline of integument may be incised and the flap rapidly turned down and stitched with wire sutures in the new situation.

The flap should be lightly sponged so as to arrest the bleeding and remove all clots before approximating the cut edges. Great care will be necessary to see that the vivified edges are not glazed over, but are perfectly "fresh," and are brought together very accurately with the sutures. There must be no tension of the sutures, otherwise the flap may slough. The *columna nasi* may then be dissected up from the lip and united to the edge of the flap with fine sutures. The nostrils should be dilated, kept open, and fixed *in situ* by the insertion of plugs of cotton-wool and cork, or by the use of quills to prop up the new nose.

The wound in the forehead or the arm left by the removal of the flap must be partly closed with sutures and the upper part allowed to granulate, so that it may close up by degrees without leaving a very unsightly scar. (*Vide* case of Mr. Wood's reported in

the *Medical Times and Gazette*, June 22nd, 1867, and the subjoined woodcuts.) Pads of lint rolled



into a convenient shape may be applied outside so as to bolster up the new flap and support it

during the first few anxious days when the healing process is proceeding, the slightest disturbance of which may be fatal to the success of the operation. The surgeon must not be too sanguine of success in these cases, for notwithstanding the success of some plastic operations, failure from some unaccountable cause must not be omitted from our calculations.

Plastic surgery of the eyelids is sometimes required for eversion of lid or loss of substance, as the result of burns, wounds, &c. Such an operation, if done carefully, will very materially improve the patient's appearance. Sometimes what is called the gliding operation will suffice, viz. the subcutaneous dissection of the skin and the transposition of it by means of sutures to the required position. Sometimes the eyelid will become adherent to the ball of the eye, together with the formation of a hard and knotty cicatrix. A flap may be made from the loose integument below the eyelid, and then lifted into its new situation after removing the unsightly scar. There it may be fixed with several fine sutures and carefully padded with lint and strapping, so as to make the union as complete and absolute as possible throughout the whole of the inner surface of the transposed flap.

As regards the several attempts which have been made, more or less successfully, by plastic operations, to cover the gap occasioned by the destruction of parts of the face by disease, by the contracting cicatrix of burns, by cancerous disease, &c., the mode of designing the respective flaps must depend largely upon the amount of available skin in the neighbourhood, as also upon the size of the gap to

be covered in. The Taliacotian operation consists in the transplantation of a piece of skin from the inner and upper aspect of the forearm, and shaping it to fit over what remains of the nasal bones and cartilages. After paring and reviving the edges, the surgeon incorporates and agglutinates it to the corresponding edge of the cheek and lip at the base of the nose, in the situation where the nose would normally find its junction with the cheek.

In making plastic operations it is important to divide the soft parts freely from the subjacent bone. The integument of the face being elastic and mobile, it may be skilfully adjusted to fill in the gap occasioned by the malformation or the disease. The drawings which describe the accustomed methods of performing these plastic operations may be found in most manuals of surgery.

Harelip is a deformity so obvious and so disfiguring that it requires very little description and still less argument in support of the very simple and effective operation for the obliteration of this deformity. Plastic surgery has its peculiar triumph in an operation of this kind. The double surface for accurate coaptation secures that primary union, so essential for success, shall be obtained if possible in all cases.

Harelip is caused by a congenital deficiency in the commissure or pillars of the upper lip. Very rarely indeed has the under lip been subject to the same kind of deformity. The dimensions of the gap vary considerably. In some cases the fissure extends up into the nostrils and is connected with a fissure in the hard palate. In other cases there is a V-shaped

gap exposing the gums and only partially involving the upper lip. The smaller the deformity the easier, of course, it will be to effect a radical cure. When associated with cleft palate, the deformity is very great and the disfigurement very serious. There may be a double fissure of the lip with a central portion of lip between, attached to the intermaxillary bone.

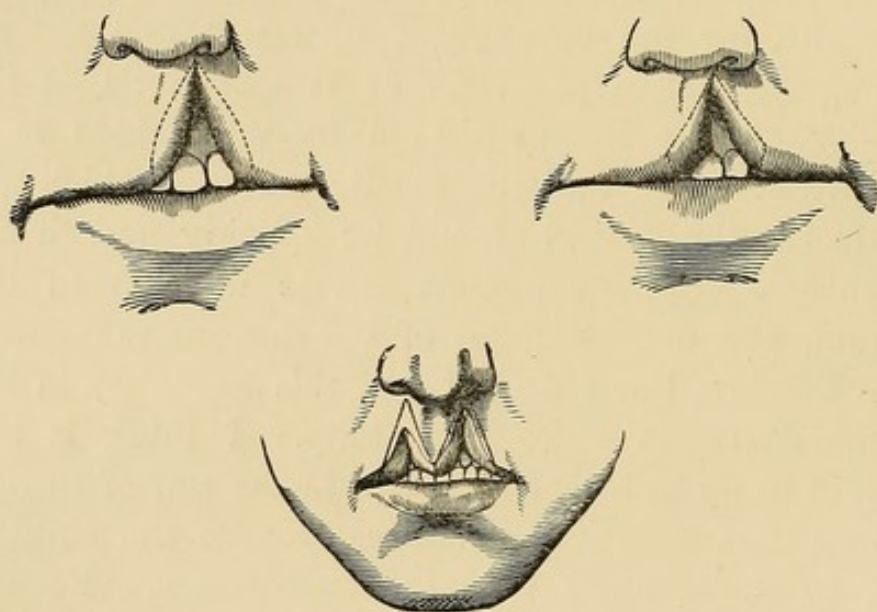
Embryologists will understand the particular reasons for the remarkable deficiency in this commissure. Speaking generally, the development and closure of the blastoderm in the embryo proceeds from the circumference towards the centre or mesial line, closing over the visceral and branchial arches, so that all the surface tissues in the central line of the body are formed by this final act of closure. It is easy, therefore, to suppose that some accidental circumstance disturbing the developmental processes at this early period of embryonic life will prevent the closure of this labial cleft. It would seem to be associated with a congenital proclivity, as the deformity often happens with successive children of the same parents. Though somewhat resembling the normal fissure or gap seen in the hare, it of course differs materially in being an abnormality, and in being situated at the side, the mesial column being entire both in single and double hare-lip. The cleft is usually found connected with the left nostril. The adjacent edges are covered with mucous membrane continuous with the free margin of the lips. It is a mistake if parents allow their children to grow up without the simple operation necessary for the closing of the cleft. When the teeth form,

the harelip is still more marked, as they show up the gap much more distinctly.

To remedy this deformity, the infant should be put under chloroform, say at three months old, and placed on an operating table, with the head raised towards the light. When the child is very flabby and feeble it may be desirable to postpone the operation, and meanwhile so to regulate the diet that after being properly nourished, it may be in a fit state of health for the subsequent operation and the resulting reparative process. It is essential that the vitality of the tissues should be maintained in a healthy state, so that the plastic material which agglutinates the wound should be quickly and firmly organised. Some surgeons advise division of the frenum, and dissecting up of the mucous membrane from the jaw, but I do not find this necessary in the ordinary simple cases of harelip. I think it important to do as little as possible in the way of cutting to any part except the fissure, because the child is sure to suffer more pain in consequence. Feeling with the tongue the cut edge of the mucous membrane, the parts become disturbed. This causes it to cry much more. By operating early we can adjust the flaps as required. The jaws not being fully developed, there is usually plenty of freedom and redundancy of tissue about the upper lip. As the child grows, the lip will be sure to develop according to the natural requirements for accurate adaptation to the under lip.

The dotted lines on the drawings show different methods of paring the edges before bringing them together.

It is important to commence the incision by transfixion from above with a narrow-bladed knife, and to cut downwards and outwards, curving the incision slightly towards the labial border so as to prolong the raw edges which require to be approximated. (*Vide* drawings.) To prevent hæmorrhage from the coronary arteries, the lip should be compressed with broad-bladed forceps with nearly parallel blades



like dressing forceps, so as to distribute the compression. The lowest pin should be passed first, with the double object of securing the coronary arteries and of accurately adjusting the labial borders so that they may unite with as little deformity as possible. The pins must be passed, like a skewer in meat, through the thickness of the lip, and then buried in it towards the buccal edge, but never to transfix or pierce the lip so as to appear on the buccal surface. Care must be taken not to stretch or strain

the tissues unduly, and so to pass the pins that they will not cut out. I have had some harelip pins specially made of all sizes, so that it will not be necessary to cut off the free ends. I cover the point with a piece of cork, and protect the skin subjacent to the point and glass head, with small pieces of strapping. The silk used to draw the edges together should be well waxed. Before fixing the edges, ascertain that the lower margin is level with the rest of the lip. If it should be V-shaped, the surgeon has not removed enough of the labial margin, and should do so before he approximates the edges.

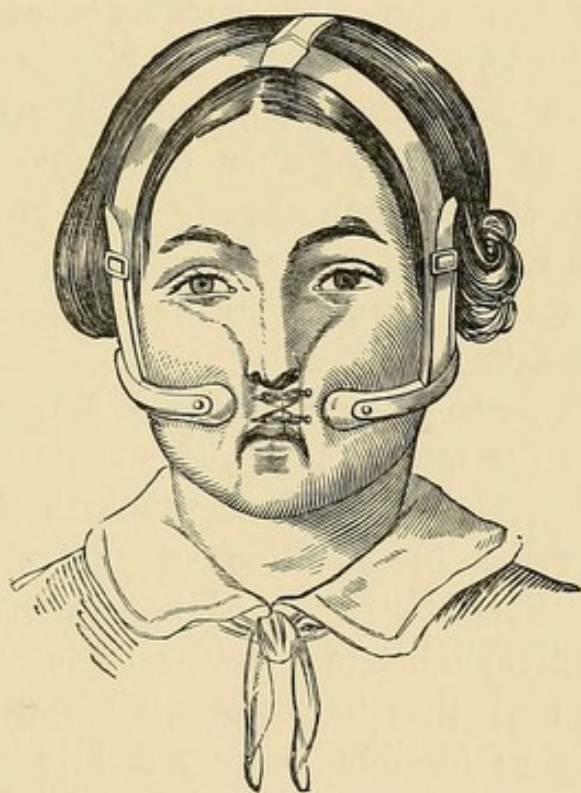As regards the different modes of operating for harelip, I think it important to allude to some of the leading features of the operation as performed by myself. As I have already said, I do not agree with some surgeons that division of the frenum labiæ, or dissection of the labial mucous membrane off the maxillary bone is necessary in all cases. I seldom require to resort to this. I have operated in very extreme cases with complete fissure and entire absence of both hard and soft palate, except as a rudimentary remnant, and I have found coaptation of the pared edges effected without any difficulty. Moreover, by retaining the connection to the frenum and alveolar mucous membrane, I find that I am better able to secure fixation of the flaps and less disturbance of the healing process by the movements of the patient and the spasmodic irritation of the facial muscles. When we have to depend so much upon the good behaviour of the baby and the avoidance of crying, I think it is undesirable to have a source of irri-

tation within the mouth occasioned by the divided frenum. I also adhere to the short harelip pin, as securing a firm leverage, and a solid bar of distributed compression over all the tissues of the lip. By this means the hæmorrhage is best controlled and the movements also. I generally unite the labial border of the gap with a silver wire suture. It is desirable to give some specific instructions to parents about the dieting and general management of the child, as these cases are generally left to the care of the mother. I have little confidence in the use of mechanical appliances after operation, to relieve tension of the lip, for the muscles which lie under the skin cannot be effectually controlled by any retentive apparatus.

Some slight modification of the usual operation will be necessary in cases where the cleft is irregular or not quite through the thickness of the lip.

The after-treatment of these cases must be carefully attended to. The mother must endeavour to pacify the infant as soon as possible. There will be no objection to giving it the breast or the feeding-bottle with a good nipple. The child should suck without effort, and so the boat-shaped feeding-bottle should be used. Let the baby sit up when taking its food, to avoid choking or anything that might cause a sense of irritability to the larynx, as this might provoke a cough or a sneeze, and thus strain the sutures. If the child should gape or cry, the mother or nurse should approximate the cheeks with the finger and thumb. Be careful to keep it out of draughts to avoid a cold or influenza. Any discharge from the nose might collect around the sutures and set up cellulitis which would interfere with primary union. The sur-

geon need not be in a hurry to remove the sutures, though he must carefully watch that they do not cut out. In some cases of vigorous children the wound will consolidate quickly, others will be longer. Strapping should be applied after the removal of the pins. I do not believe in the use of Hainsby's truss for controlling the tendency of the facial muscles to strain open the wound. It may be a cause of irritation



to the child. The adjoining woodcut, taken from Fergusson's 'Surgery,' will show the effect of this retentive apparatus.

I prefer to dress the wound, after removing the sutures, with Leslie's strapping, dumbbell-shaped, extending across the entire surface of the cheeks and round the angles of the lower jaw. I sometimes fix two firm pads on the cheek with strapping, and over

all I pass a strip of muslin a yard long and an inch wide, having first obtained some fixation for it at the occipital protuberance. The free ends are then brought round under the ears and crossed over the mesial line of the lip, so as to compress any irregularity and to keep the lip firmly supported against the alveolar process of the jaw. After crossing the muslin, the free ends are taken back to the occipital protuberance and firmly tied there, another layer of strapping covering it all in.

A simpler method of approximating the cheek muscles is to stitch together with coarse silk the broad pieces of strapping already fixed to the cheeks, crossing the ends over the upper lip and tying them together, another piece of strapping being used to cover in the silk.

In *double harelip* there are two fissures, one on each side of the middle line with a central protrusion of the isolated portion connected with the septum nasi, and some modification of the operation is necessary. This protrusion of bone corresponds to the premaxillary bone in the vertebrate animals. It is a question whether to remove it before the plastic operation or to forcibly depress it into the proper position between the maxillary bones. Sometimes this bone appears twisted upon itself, causing much deformity of the jaw. With a strong pair of forceps the surgeon may place it in position between the superior maxillæ and retain it there. The operation should be performed before dentition has commenced. The closing of this gap in the mouth facilitates the action of sucking by providing a proper vacuum

between the tongue and the palate. A healthy child may be operated on during the first month or six weeks with success under chloroform, as infants take the anæsthetic very well, and are really much quieter than those that are a little more knowing. The younger the infant, provided it is in robust health, the more satisfactory the union, and the scar is of course relatively smaller and less perceptible in after life. I rarely find it necessary to do more than divide the free border of the gap from the nose downwards. I then carefully approximate the raw edges with as little delay as possible. There is so much mobility of the lip upon the fold of the cheek that if the edges can be drawn together without undue straining, I prefer to leave the buccal mucous membrane intact. In some children we may apply a spring truss for approximating the cheeks and relieving tension upon the sutures, but careful strapping will suffice in most cases to keep the parts at rest. I think there is less risk of hæmorrhage after the operation, and the child will be less likely to disturb the parts by thrusting its tongue to the front, if the buccal side of the wound is carefully approximated. Having secured the coronary arteries between the finger and thumb of an assistant or with dressing forceps, the free edge of the gap must be carefully and uniformly pared and the arc of the fissure also carefully denuded of mucous membrane. Strong harelip pins should be used, with spear-shaped points, varying in size from half-an-inch upwards, so that there is no necessity to use the cutting pliers to remove the ends, with the consequent

delay and disturbance of the flaps. The harelip pins must be passed deeply into the substance of the lip, care being taken not to transfix it, but to bring the points through the incised margin and towards the buccal side so as to compress the coronary arteries. Having then transfixed the corresponding part of the right side of the fissure the edges may be drawn together with a strong silk thread passed several times over the projecting extremities of the pin and crossed underneath. The same method of fixation may be used with a second and sometimes a third pin. The red margin of lip and that of the nose may sometimes require special approximation with a silk or wire suture. Care must be taken to shape the flaps so that there shall not be a pendulous portion rather than a gap at the margin of the lip. I place a piece of cork on the sharp end of the pins and protect the skin from pressure by small pieces of strapping. After the sutures have been applied so as accurately to adjust the edges of the wound both front and back, the whole may be covered with a strip of strapping from ear to ear, the cheeks being approximated at the same time. Fortunately the child's cries do not seem to have much effect upon the healing process. The action of the orbicularis oris muscle, it might be thought, would disturb the healing process, but in consequence of the wound having a double free edge the adhesion is generally primary and immediate. If in double harelip the proboscis-like bone protrudes so as to interfere with the coaptation of parts, it may be removed with pliers, prior to the operation, after dissecting it away

from the nose portion of integument, or it may be dislocated forcibly backwards to bring it level with the superior maxillæ.

Ordinary cases of *double harelip* may be treated in the same way as for simple harelip, viz. by carefully adjusting the two fissures after paring the edges. If the nose is flattened and the central tongue of skin small in bulk, it may be necessary to dissect this up so as to tilt forward the nose and bring down the median commissure. In order to form a new columna for the nose this process may be affixed to the apex and by approximating the two extreme borders of each fissure, the line of suture will be single instead of double; but I prefer to make use of this central portion of the lip to act as a stay to the outer edges of the incision by transfixing it with one of the harelip pins. The intermaxillary bone is often very prominent, and projects in a very unsightly fashion beyond the nose. Some surgeons advise the removal of this bone, but I generally retain it if possible as a support to the flaps, so as to prevent the child having an underhung appearance in after life, as would happen if the child were without incisor teeth in the upper jaw. It is so necessary in the surgery of children, not only to rectify the existing deformity, but to make careful calculations so as to anticipate as far as possible the result of such surgical operations in adult life, and by attention to small matters of detail, adapting skin to skin with accuracy, we may secure for the patient immunity from unsightly scars, and thus greatly add to his comfort and welfare in after life.

Plastic operations on the lower lip may be required after removal of cancerous and other tumours if in this situation. The ingenuity of the surgeon will be necessary to construct two flaps from the cheek to fill up the deficiency.

Generally the V-shaped gap may be closed in by prolonging the angles of the mouth outwards through the orbicularis muscle, and by displacing the cheek inwards to cover over the incisor teeth. Or by an incision downwards and outwards along the ramus of the jaw, the mucous membrane being carefully dissected off the bone, the raw edges may be tilted up and united in the mesial line.

To restore the upper lip destroyed by disease or injury, an incision may be made, passing upwards along the sulcus of each ala nasi. The mucous membrane should be dissected off, and the flaps displaced mesially under the nose to cover the teeth. Large gaps are often occasioned by the destructive effect of lupus of the cheek. This requires a well-planned operation for paring the retracted callous edges, and dissecting off the mucous membrane so as to approximate the edges accurately.

SECTION V.

OTHER DEFORMITIES OF THE LIPS.

Excessive growth of hair on the face of females, forming an embryo beard or moustache, is a lifelong annoyance to the victims, and especially to young people. It is a great eyesore and vexation. Many would gladly suffer much to have the growth of hair

stopped. Efforts have been made by extraction to destroy the growth, but this does not touch the hair-bulb, and so the hair grows stronger next time. With great patience and determination on the part of both patient and operator it is possible to depilate each hair separately, and with caustic or actual cautery to destroy the bulb, so that the hair may not grow again. A fine needle with a point of iridium has been made by Mr. Ladd, the optician, to be connected with a Grove's battery. The point being heated, was passed into the vacant hair-follicle, so as to destroy the hair-bulb. Mr. Milton, Surgeon to St. John's Hospital, tells me he has used this needle with success in these cases. Hairy moles of large and small size appear awkwardly upon the face and attract the attention of passers-by. These may be removed in the same way as for nævoid growths.

There are several varieties of disease which involve the mucous membrane and deep structures of the lip, requiring careful consideration and treatment.

The *simple cracked lip* may be caused by the continuance of cold frosty weather. It appears usually at the middle line. When the child laughs or cries it will split again, and be very painful. Generally these cracks, especially those at the angles of the mouth, are caused by a feverish condition of the patient, the digestive system being out of order. Strumous children with flesh that heals badly are very frequently subject to these painful fissures. A gentle aperient may suffice to cool the blood, and a little vaseline may be rubbed deeply into the fissure. When the edges become callous and indurated from the

crack remaining open for some time, the surrounding lip becomes infiltrated, swollen, prominent, and unusually red. It should be treated by the application of the solid nitrate of silver, carefully passed with a fine point into the deepest part of the furrow. If the upper lip is involved, evert the mucous membrane, and it will be seen to spread up almost as high as the gum. In long standing cases it may be necessary to incise gently the base of the crack, or even to pare the edges and bring them together with fine sutures.

Some of the most characteristic symptoms of constitutional syphilis are radiating fissures and excoriations around the mouth which are difficult to heal.

Cracks at the angles of the mouth are sometimes very indolent, because the constant movement of the lips and mouth keeps them from healing. The food also gets into the crack and irritates it, as also the saliva. These fissures often occur in strumous children and those that have a syphilitic history.

Small nævoid growths frequently occur on the lips. They vary much in character, sometimes being prominent and button-like, at others involving the deep structure of the lip and showing little on the surface. Transfixion with a needle, and the silk tied under a small pin passed beneath the growth, will effectually obliterate it.

I have operated on several cases of nævoid growth in the substance of the lips, both upper and under. I generally destroy the nævus by the application of the actual cautery to the buccal mucous membrane, taking care not to pierce the skin or do damage to the integument of the face.

Sometimes the whole thickness of the lip is involved in an ugly mass of infiltrated and hypertrophied cellular tissue, causing the lip to pout considerably. We may require either to cauterise, or what is probably better, to excise the growth, and to pare the edges that they may be brought together with pins, as in harelip, and the resulting deformity will be almost nil. When nævus occurs on the cheek and shows little on the surface, I prefer to destroy it by passing the Paquelin point quickly into the centre of the growth, so as to destroy it deeply and circumferentially. The external wound will then be small and the deep part cavernous. The cavern will close by granulation after the destruction of the growth at the fountain head.

We have a simple method of removing subcutaneous nævi by the application of a ligature, which, burrowing under the sound skin, will destroy the growth without interfering with the healthy skin which covers the nævus. This subcutaneous method is described in the text-books, and I have had some successful cases of obliteration of large diffuse nævoid growths by the application of such a ligature. Vaccination is seldom successful in the case of nævi, because it does not destroy the roots of the disease.

Chancre of the Lip may occur at any period of life, and young people who have contracted the disease may suffer considerably in consequence of their folly. The true Hunterian chancre is raised above the surface, is button-like, with a central depression and indurated edges. The neighbouring glands soon become tender and swollen. This disease must be

treated very promptly with caustics or excision, as the patient may suffer all the usual and distressing symptoms of secondary syphilis.

Prompt measures for excising the disease are also required in the case of epithelial cancer of the lip.

The differential diagnosis of these two diseases is a question of importance, though not usually of any difficulty. Cancer of the lip is a disease of old age ; it does not involve the lymphatic glands so early as with chancre. Cancer destroys all the surrounding structures by its irregular eroding development. Cancer of the lip occurs mostly in males, and chancre in women.

Cysts of the Lip occur generally in the mucous membrane of the lower lip. The skin is usually free on the front towards the buccal surface. These growths are raised above the surface, and are covered by thin membrane of a semi-transparent character, and they contain a viscid glairy mucus. They may be multiple like a bunch of grapes, though generally they appear singly. The character of the growth is simple and non-malignant. They are painless and grow slowly unless irritated by a projecting tooth. Such cysts are probably developed from some obstructed follicular gland. They should be evacuated and the floor and wall of the cyst cauterised with nitric acid or some other escharotic, otherwise the fluid will tend to recur and the cyst to reform.

Congenital cystic growths may form in the cellular tissue of the lip, especially of the lower lip, and towards the buccal surface, causing hypertrophy of the mucous glands. These must be excised or ligatured, and the subjacent membrane should be cauterised.

Adults sometimes suffer from a serpiginous ulceration creeping into the submucous tissue of the lip, and showing itself on the surface by small blisters and fissures. A little vaseline rubbed in and covered with goldbeater's-skin or collodion will allay the irritation.

Myxomatous tumours occasionally appear in the substance of the lips, as also gliomata. These should be removed as soon as their character has been detected.

Several cases of malformation of the ears and of complete absence of the meatus have been reported, and the method of relieving the deformity described, but this hardly comes within the scope of my treatise, and I have had little personal experience of beneficial operations upon the auricular appendages for such deformities, so that I pass this by. I have had to remove several nævoid and polypoid growths from the auricle.

Considerable deformity of the face often results from paralysis or spastic irritation of the portio dura nerve, also from alveolar abscess in connection with decayed teeth. These require general as well as local treatment.

SECTION VI.

DEFORMITIES OF EYELID AND EYEBALL— DISEASES OF CORNEA, ETC.

Injuries of the Lids.—*Ecchymosis* into the areolar tissue of the eyelid may be caused by a blow upon the eye, presenting a very unsightly appearance, the blood from the damaged venous capillaries having escaped into the subcutaneous cellular tissue. Eva-

porating lotions or soothing poultices may promote absorption of the effused blood.

Emphysema of the eyelids may also be caused by a severe blow upon the cheek fracturing the lachrymal or ethmoid bones. A little gentle pressure may be required to disperse the emphysema.

Wounds of the eyelid should be carefully closed with fine sutures. A deformity called coloboma may result from the imperfect closing of a wound in the upper lid. This may be rectified by excision of the ugly scar.

Caustic alkalies and mineral acids may be spurted into the eye accidentally or out of mischief, and they may produce very destructive effects. The surgeon should neutralise the poison and then apply some castor oil to the damaged conjunctiva and endeavour to avoid the formation of adhesive bands between the eyeball and the lid.

Lime, sand, or splinters of metal imbedding themselves in the eye should be promptly taken out with a scoop or needle.

Subconjunctival ecchymosis may take place as the result of violent exertion, as from coughing or retching, or from a wound. The appearance of the blood under the semi-transparent membrane is very distinct, and it may alarm the patient. A little gentle pressure and a cooling lotion will favour the absorption of the effused blood.

Penetrating wounds of the cornea or conjunctiva may cause considerable damage to the delicate structures of the eye. There may follow chemosis of conjunctiva, escape of aqueous humour, or even the lens

and vitreous, and prolapse of the iris. The eye should be closed and kept at perfect rest with cotton-wool compress, and bandage over all. The resulting scar may be linear or it may form a large leucoma or opaque spot, which prevents the access of light to the fundus. Atrophy of disc and blindness may result from this severe damage to the eye.

Wounds and Excavations of the cornea and conjunctiva may be caused by sharp instruments, or from a spiculum of stone, glass, or metal being thrust into the eye, or from contusion of the eyeball. If the wound penetrates the cornea there will probably be prolapse of the iris. This should be returned by gentle pressure, and the sphere of the cornea searched in case any foreign body is lodged in the tissue or in the anterior chamber. It will require some dexterity on the part of the surgeon to extract these minute bodies, which if left may set up serious mischief in the eye. After removal the eye must be kept at rest and the light shut out. The patient should have a sedative draught, and atropine should be instilled into the eye daily, until the inflammation has subsided.

Ptosis signifies a drooping of the upper eyelid, generally from a paralytic condition of the third nerve, which controls the levator palpebræ muscle. It may be accompanied by headache, giddiness, and cerebral congestion. If so, some active derivative medicines will be required. It may be associated with cerebral tumour or ramolissement, and then it is attended with dimness of vision and a sluggish dilated pupil. If the ptosis has come on gradually without any assignable cause it may be desirable to

ascertain whether there is any occult cause for it, such as intestinal irritation, ascarides, morbid cravings, masturbation, or general feebleness from loss of appetite, or a tendency to mental depression.

The drooping of the upper eyelid may be so marked that it covers the eyeball unnaturally, and even falls over the pupil. Such cases may be effectually rectified by the removal of an elliptical piece of skin from the upper eyelid midway between the edge of the lid and the eyebrow, and by the approximation of the divided edges.

The same kind of operation, though to a less extent, may be required for inversion of the eyelid, with turning in of the eyelashes, so that the conjunctiva becomes irritated. This is a very needful operation, because the protracted irritation caused by the inverted eyelashes produces thickening of the membrane and opacity of the cornea. The kind of operation which it may be desirable to make depends much upon the character of the inversion, and the condition of the tarsal cartilage. In some cases a vertical incision near the angle of the eyelid will suffice to evert the tarsal border, and in others that are more troublesome, it may be necessary to cut away the whole of the free border, so as to destroy the roots of the eyelashes.

Spasmodic twitching of the eyelid, which produces a visible quivering of the skin around the orbit, is an intermittent deformity which occurs in people of an irritable or nervous temperament. Like most spasmodic affections, it is decidedly increased under severe mental anxiety or strain, and it is often caused by

intestinal irritation. Careful dieting, aperient medicines, and tonics may suffice for its cure.

Epicanthus is a deformity of the eyelid caused by a folding in of redundant skin at the inner corner of each eye, partially concealing the caruncle. It is often observed in children that have a depression in the vault of the nose. By excising a vertical fold of integument just below the eyebrow and approximating the edges we may remove this redundant tissue.

Entropion being caused by the contraction of the ciliary margin of the eyelid, the upper border of the lid is inverted as well as the follicular apparatus. Some surgeons have considered this deformity to be caused by a contraction of the tarsal conjunctiva. A perverted action of the orbicularis muscle is supposed by others to cause this inversion, and Mr. Haynes Walton has proposed to divide the muscle by a vertical incision, and thus to check the spasm which causes the inversion. Another method of curing this deformity is to remove a narrow slip of the muscle with the superjacent skin, parallel with and close to the tarsal margin. By dissecting the muscle away from the cartilage and approximating the cut edges, we may succeed in everting the lid.

Trichiasis is a deformity characterised by a growing in of the eyelashes, so that they rub against the sensitive membrane covering the ball of the eye, which is called the conjunctiva. It is caused either by congenital inversion of the ciliary margin of the tarsal cartilage, or it is due to chronic inflammation and consequent thickening of the margin of the eyelid, so that it contracts upon itself and inverts the follicles of the

ciliary processes. Various operations have been proposed for the removal of this cause of irritation. If the eyelashes are plucked out they will grow again. An elliptical piece of the eyelid may be excised, and the gaping edges approximated, by which means the tarsal border may be everted. Another and a neater method, though more difficult in execution, is to transpose the margin of the ciliary follicles by four parallel incisions, so that a narrow strip of skin about one-sixteenth of an inch in width is interposed by plastic transposition between the ciliary follicles and the conjunctiva. A connecting link of skin is of course retained at the outer and inner canthus to keep up the vitality of the transposed strips. Another method of effecting the same object is to dissect off the hair bulbs from the cartilage, after reflecting a flap of integument, so as to expose the deep attachments of the hair follicles.

Ectropion, or excessive eversion of the lid, may be caused in a variety of ways. Chronic inflammation of the conjunctiva which has been neglected or improperly treated, ulcerations about the margins of the lids and in the follicles, abscesses in the lachrymal duct, burns and other destructive ulcerations of the skin of the face, may cause a dragging down of the eyelid.

In extreme cases we not only have eversion of the lid, but exposure of the conjunctiva, causing considerable irritation to the sensitive membrane covering the eyeball, which should be always kept moist by the constant washing of the locomotive lids.

In these cases a satisfactory operation is not always

possible, because the amount of destruction or wasting of the lower eyelid is often very great, and it is difficult to restore the remnant of lid to its proper position as a cover to the eyeball. A V-shaped piece of tarsal cartilage, and integument covering it, may be removed in simple cases. In more severe cases it may be necessary to cut down horizontally through the eyelid upon the conjunctiva, and drawing that membrane through the wound to raise and invert the tarsal border of the lid upwards towards the globe. The redundant membrane may then be cut off and the edges of the wound approximated in the usual way.—*Vide* lithograph of plastic operation upon the lower eyelid.

I have devoted a sub-section to the consideration and treatment of surface deformities of the eyeball. This will be found at the end of this section.

Encysted steatomas, called chalazion, are often found as pearl-like swellings under the skin of the eyelid, easily shifting under the pressure of the finger, and circumscribed so that the removal may be effected without difficulty. The contents may be putty-like or fluid, according to the length of time allowed for growth, and the amount of inflammation, if any, that may have occurred in the primary formation. They sometimes show more prominently on the outer surface, but at others they press inward upon the eyeball, and may be best enucleated by dividing the tarsal conjunctiva. If the growth is distinctly more prominent towards the surface, and there is thinning of skin over, doubtless it would be simpler and better to remove the cyst by an external incision.

Strabismus or squint is a deformity of the face either congenital or acquired, and characterised by the absence of parallelism between the optic axes of the two eyes. Such parallelism is more apparent than real, for there is generally some slight divergence of the optic tracks to give wider scope of vision. When using the eyes for near vision, we often unconsciously try to relieve the tension of the ciliary muscle by making use of the internal recti muscles to concentrate the optic axes upon the object which we are scrutinising with some care. The action of the ciliary muscle is to compress the lens and render it more convex for the inspection and examination of near objects. When the strabismus is but slight or of recent development it may be corrected by the use of convex glasses to cure the hypermetropia which is blurring the sight for near vision.

Strabismus is frequently the result of brain disturbance, as from the deposit of tubercles in the membranes of the brain.

Very pronounced cases of convergent strabismus cannot be cured without the division of the internal recti muscles. The operation is very simple and quite painless under chloroform, and the marked beneficial effect which follows is very gratifying. In unilateral squint it will suffice to divide the rectus muscle on that side. If parents desire to delay the operation they will endanger the sight of the eye, as the nerve atrophies in consequence of not being used. There must therefore be no hesitation as to the advantage of submitting to the operation when the surgeon has decided upon it. I prefer the valvular

incision through the conjunctiva and then through the capsule of tendon, so as to leave a dependant incision.

It is necessary that the child should be supplied with suitable glasses to correct what remains of hypermetropia and to keep up the balanced action of the two eyes.

When the eyeball is everted, it is seldom desirable to divide the external rectus muscles, as this deformity often recurs.

Disease of the antrum, malar bone, or alveolar abscess, may cause a glueing down of the eyelid, so that the lid becomes everted.

Abscesses in the neighbourhood of the orbit may cause the lid to be involved in the puckered cicatrix, so that not only is it drawn down and the conjunctiva everted, but the upper lid also has to yield to the contracting force of the scar, and the result is an acquired ptosis, even to the extent of overlapping the pupillary aperture.

Ophthalmia tarsi is an inflammation of the palpebral conjunctiva and the free edge of the lids. It is attended with disordered secretion from the Meibomian glands, so that the lids become glued together, especially at night. There may be considerable pain and soreness. It is usually chronic and difficult to cure. The roots of the eyelashes may be destroyed. There may also be some gastric disturbance. The health must be attended to. There must be frequent bathing of the eyelids with warm milk and water, and the edges should be smeared with dilute citrine ointment at night. Astringent collyria may be required if the conjunctiva is inflamed.

Blepharitis signifies an inflammation, either acute or chronic, of the deep tissues of the lid, especially the follicles and glands. If the disease is allowed to go on unchecked the eyelids become thickened and lumpy. There is an accumulation of hardened secretion around the eyelashes at the margin of the lid. This must be carefully sponged away every morning, or else the follicles will become obstructed and the disease increase. By carefully everting the lid so as to expose the outlet of these follicles, and by warm bathing to soften down the secretion and open up the follicles, we may succeed in allaying the irritation. Some dilute citrine ointment should be rubbed into the follicles, not merely smeared on, but with the definite purpose of pressing it into the follicles, so as to act as an absorbent to the products of inflammation.

Symblepharon is an adhesion between the lids, or if one lid, usually the upper, to the eyeball, the result of acute ophthalmia. The patient requires a plastic operation to remove the deformity. Division of these cicatricial bands may be advantageous, and then the application of some fine sutures to approximate the edges, but we must not expect any very good results.

One of the most unsightly deformities about the eyelid is that of destruction of the hair bulbs from chronic inflammation, and consequent atrophy of the tarsal cartilage, with eversion of the lid and exposure of the red margin of the conjunctiva. This deformity occurs in delicate strumous children, many of these having been neglected in infancy. The patients continue through life to suffer from chronic inflammation of the conjunctiva, caused by the access of dust and

irritating particles to the eye ; there is also usually some photophobia and blepharospasm. The eye should be bathed with soothing lotions to allay the spasm and chronic inflammation. Glasses should be worn to protect the eyes from dust, &c.

Obstructed lachrymal ducts may cause temporary or permanent disfigurement.

Inflammation of the lining membrane of the ducts may produce swelling, and consequent inability to pass the tears through the ductus ad nasum, so that they fall over the cheek. Warm bathing or poulticing will subdue the inflammation and remove the obstruction in some cases.

When the canaliculi are closed as the result of chronic inflammation, they should be slit up on a fine probe or grooved director.

Obstruction of the lachrymal sac from chronic thickening of the mucous membrane is not uncommon in delicate or strumous children. The tears escape on to the cheek instead of flowing down through the canaliculi to the nose. The lachrymal sac becomes distended with mucus and muco-pus. The skin over the sac will then inflame, and a fistulous track will form, if the abscess is allowed to open on to the surface of the face. Unless this is operated on so as to re-establish the aqueduct for the tears, an unsightly swelling with puckered edges will be seen just below the tendo oculi on that side.

Simple acute inflammation of the sac may be relieved by leeches, fomentations, and aperient medicine. When the sac first becomes distended the patient should endeavour to evacuate the contents by gentle

pressure upon the outside, so as to open up the duct.

To restore the ducts to their normal condition, and to close up the fistulous track, it will be necessary after the inflammation has abated to slit up the canaliculi, and to pass some silver probes down through the lachrymal duct to the nose. This probing should be repeated daily till the ducts remain patent.

Catarrhal ophthalmia often causes distinct deformity of the face from swelling and tumefaction of the eyelids. There is considerable smarting, heat, and pain in the eye, with a sensation of grittiness, as though dust had got into it. It often, in fact, develops in consequence of sand or grit becoming lodged in the meshes of the conjunctiva. Sparks from a furnace or splinters from iron, &c., may penetrate this membrane and lodge in the cornea, setting up inflammation all round. Those of a rheumatic constitution, exposed to draughts of cold east wind, and living in an unhealthy atmosphere, such as dark and ill-ventilated dwellings or crowded offices, frequently suffer during the winter months from catarrhal ophthalmia. The pain may be very severe or it may be slight. Want of exercise, excessive use of stimulants and tobacco, nervous prostration, inducing sleeplessness, imperfect digestion, &c., may all be important factors in the causation of this disease, and require consideration when treating these cases. The sight becomes blurred when the inflammation has spread to the ocular conjunctiva. There is some intolerance of light, and considerable lachrymation. The disease

may be slight and transient, or it may involve the whole membrane, both tarsal and ocular. As the disease progresses the conjunctiva becomes very red, and a thick purulent discharge may occur. The semilunar fold and caruncle are also red and swollen. There may be some ulceration, especially where the conjunctiva is reflected on to the eyeball. If the sclerotic is involved the patient will suffer from photophobia and lachrymation. There is almost sure to be considerable debility and nervous prostration, requiring general treatment. This disease may become chronic. There is generally a sense of fulness and discomfort in the eye, and the lids glue together at night. It is desirable to use the lotio arg. nitras, 2 grains to the ounce, or the lead lotion or rose-water, and to bathe the eye with lotio papaveris. The surgeon must not fail to search for a foreign body which may be lodged in the eye. For this purpose he must evert the lid, and with a probe, carefully used, he may succeed in extracting the splinter from the conjunctiva.

Purulent ophthalmia or ophthalmia neonatorum is a disease *per se*, occurring in delicate infants, generally the offspring of mothers that are subject to vaginitis. In such cases the edges of the lids become glued together and the discharge is very abundant so that pus collects under the eyelids which distend and become suffused. It also presses upon the orbit. Prompt measures must be taken to cure this disease, as the cornea very quickly becomes destroyed by the spreading inflammation, and the eyeball collapses in consequence. The surgeon should evert the eyelid and carefully syringe out all the pus and flakes of lymph.

He should then with a stick of modified caustic, i.e. equal parts of argenti nitras and potassæ nitras, touch the exposed surface of the conjunctiva. Care must be taken, in everting the lids, not to press upon the globe of the eye, because if the cornea is very soft and ulcerating, it may burst open and thus lead to the destruction of the eyeball. Some astringent collyria may be necessary, as alum or acetate of lead, to favour the subsidence of the inflammation.

Purulent ophthalmia in adults begins with the same symptoms. The conjunctival membrane is very red and inflamed. It may become distended by sub-conjunctival infiltration overlapping the edge of the cornea. The patient suffers considerable pain in the temples, with headache, and prostration. He is generally very feeble, with a pallid face and irritable or depressed temperament. It may be caused by the introduction of lime, sand, &c., or by an unhealthy or miasmatic atmosphere, as in the Egyptian variety, which is contagious. We know how rapidly this disease will spread in crowded barracks, schools, and hospitals, unless rigid measures are adopted for checking its progress.

In the milder cases the purulent secretion becomes arrested by the astringent lotions, but in the severe cases the conjunctiva will ulcerate and the cornea may slough, leading to prolapse of iris, chemosed conjunctiva, and destruction of the sight.

Very careful treatment will be required to combat successfully this disease. The patient should have a soothing treatment at first, with a sedative at night to relieve the pain. He may then have nutritious food

and careful dieting, with a mixture of quinine and iron or some useful tonic and stomachic, and plenty of fresh air.

Gonorrhœal ophthalmia is produced by the application of gonorrhœal matter to the eye. It has a very rapid development. There is considerable local irritation and the pus is thick and abundant. There is generally some chemosis of the ocular conjunctiva, and the disease may spread to both eyes, probably by inoculation. To save the eye it will be necessary to resort to active measures of treatment as the cornea may slough within a few hours unless the inflammation is subdued. The membrane must be touched all over with the modified caustic. The patient may have some poppy fomentation to relieve the pain and a Dover's powder at night. He usually requires tonic supporting treatment, as bark and ammonia, also nourishing food. Leeches to the temples may be required, and the lids may be smeared at night with the citrine ointment.

Phlyctenular or strumous ophthalmia is characterised usually at the commencement by extreme photophobia; the eyelids being kept spasmodically closed and the head turned away from the light, and the tears flow in abundance. At the junction of the cornea with the sclerotic there are one or more red specks or circumscribed ulcers, and the sclerotic zone of vessels around the margin of the cornea may be also inflamed, forming a closely meshed network of vessels. We may succeed in apparently curing the disease, but it will return again in the course of a few months. The children attacked are usually of a strumous

temperament, and may have fissured lips, ulcerations behind the ear, swollen glands in neck, &c. A gentle aperient, as rhubarb and soda, may be required at the commencement of treatment, followed by iron tonics, cod-liver oil, &c. It will be desirable to place the child in a healthy home, with plenty of fresh air and nourishing food. The photophobia may be relieved by bathing the eye with poppy fomentation and by the instillation of atropine drops, two grains to the ounce, or the ung. flav. dil. may be found useful. Iron and quinine may be given internally. The eyes should be protected from the light by the use of shades. If an astringent lotion is required we may use the solution of acetate of lead.

Pterygium is a triangular deformity of the conjunctiva, consisting of enlarged and distended vessels radiating from the cornea outwards over the hemisphere of the sclerotic. It seems to develop gradually and is not associated with conjunctivitis.

Surface Deformities of the Eyeball.—Tumours of a fibroplastic, fatty, papillary, or cancerous nature may form on the conjunctiva. These should be ligatured or excised.

Pinguecula is a small fibrous tumour which appears on the eyeball close to the corneal margin, of a triangular form with the base towards the cornea. It may be surrounded by a spray of dilated vessels. These are harmless growths, which may or may not be removed by excision or ligature, according to the amount of annoyance to the patient.

Diseases of the cornea are various and usually cause much disfigurement. In simple inflammation

the cornea becomes opaque, red, and swollen, like steamy glass. A zone of pink vessels surrounds the margin of the cornea.

Keratitis is generally associated with much photophobia and lachrymation. Children who suffer from keratitis are usually of a strumous or anæmic constitution. There is usually some opacity of the cornea. There may be some constitutional disturbance, feverishness, etc. Fomentations, atropine, and blisters to the temples may be required, as also tonic treatment.

Opacity of the cornea may be interstitial or on the surface, and it may occur in one large patch usually at the centre, or the cornea may be stippled, i.e. numerous small opacities are dotted over the cornea, and these are interstitial. Sometimes the patch is a mere haziness, at others it is quite opaque and pearl-like. These opacities are more or less permanent, especially when the deposit of lymph is very abundant. Large opacities are called leucomata. These cannot be cured by excision, but we may remove the unsightly character of this deformity by tattooing the leucoma with Indian ink. When, as generally happens, the pupil is blocked up by such opacity it will be necessary to make an artificial pupil by excising a portion of the iris corresponding to a transparent part of the cornea by the operation called iridectomy. By making such a window through the curtain of the iris the rays of light can pass unhindered to the retina through the transparent media.

Ulcers of the cornea appear frequently in strumous and delicate children, especially those who have suffered from privation. Ulceration may also follow a

severe attack of the exanthemata, measles and small-pox. The ulcer may have an excavated appearance, with well-defined edges, or there may be a spray of dilated vessels from the conjunctiva extending to it, with some localised opacity, showing some active efforts at repair. Or the ulcer may give rise to considerable keratitis, photophobia, and constitutional disturbance. The disease must be treated promptly with mydriatics and tonics, nourishing food, and fresh air. The child should wear a shade and avoid anything that might press upon the eyeball. Let the atropine be dropped in daily. It acts as a direct sedative to soothe the inflammation. It also, by dilating the pupil, relieves the tension upon the cornea, and favours the healing process. The ung. flav. dil. is useful in these cases. A five per cent. solution of cocaine has also proved useful as a sedative in these cases.

Staphyloma is a conical protrusion of the cornea, generally the result of undue distension of the anterior chamber with aqueous fluid and the consequent thinning of the cornea. It may lead to perforation and hernia iris. In acute cases the eyelids must be kept closed to support the cornea, and atropine drops must be instilled daily, to dilate the pupil and remove the iris from contact with the cornea. It may be necessary to tap the anterior chamber.

Conical cornea consists of a general protrusion of all the tissues of the cornea, the membrane retaining its transparency. It gradually increases in extent, and causes considerable disturbance of all the visual apparatus, amounting in severe cases to total deprivation of sight. The deformity is caused by excessive

secretion of the aqueous humour, and distension of the anterior elastic lamina of the cornea. It is capable of being reduced by tapping the anterior chamber, and removing a portion of the iris by iridectomy.

Arcus senilis is an annular deformity of the cornea caused by the deposit of fatty material in the outer zone of the cornea, close to its attachment to the sclerotic. There is no cure for it.

Syphilitic keratitis commences usually at the centre of the cornea. The substance of the cornea becomes hazy and covered with white specks of opacity between the laminæ. There will probably be some increased vascularity of the corneal vessels. In a few weeks' time the other cornea becomes similarly invaded, unless active measures are taken to arrest the disease. There are usually the evidences of constitutional syphilis,—the pegged defective teeth, broad and flat nose, thick upper lip, fissured margins of the lips, peculiar muddy complexion, etc., all indicative of the disease,—the child should be treated with nourishing food, iron tonics, as the iodide of iron or the perchloride, and some iodide of potassium.

Suppurative keratitis is a still more serious disease, the laminæ of the cornea may be destroyed and the pus will collect in the lower part of the anterior chamber, and this is called hypopion. Atropine should be dropped into the eye daily in these cases.

SECTION VII.

DEFORMITIES OF NEUROTIC ORIGIN.

Choreic Spasm.—I have had boys under my care who have acquired a habit, as it would appear, of making grimaces. When talking or in company, the muscles of one side of the face will spasmodically contract, drawing up the angle of the mouth and the cheek into all kinds of contortions. No amount of scolding or punishment will remedy this awkward and irregular co-ordination of muscles. The surgeon would do well to inquire into the habits of the boy, and prescribe some constitutional treatment with a view of strengthening the nervous system during the period of growth and adolescence, and check any bad debasing habit that he may have acquired. The teeth should be examined to ascertain that there is no source of irritation to the dental nerves, setting up a reflex action in the contiguous branches of the portio dura nerve.

Parents should particularly see that the mental powers of their children are not being over-wrought. The prevalent idea of educating boys in large schools, and forcing them all up to the required standard, notwithstanding the varying amount of brain power and general capacity, is most pernicious in its consequences. I will not say more on this subject, as I have written elsewhere on the prevalent evils of "high-pressure education."

More often these choreic spasms are due to ex-

treme nervous sensibility, hysteria, and want of proper control over the complex and highly sensitive nerve organisations. We must not, however, blind our eyes to the possible existence of some minute bony exostosis pressing upon a nerve or thickening the nerve-trunk so as to cause this local spastic contraction. It is astonishing what change of air will effect in such cases, especially if accompanied with change of scene and occupation. It might be advantageous to send a boy suffering in this way to school on the Continent. If he has been living in a malarious or relaxing climate, arrangements should be made to send him to a dry bracing place. Sometimes galvanism to the opposite muscles may suffice. Soothing remedies are as a rule preferable, as liniments, rubbed in where there is much muscular spasm. Also the subcutaneous injections of morphia or other hypodermic sedatives where the excessive activity is localised.

Paralytic deformities from hemiplegia of the face muscles, the result of brain lesion and apopleptic seizures, may be alluded to here as a not uncommon cause of face deformities. Such paralysis is not amenable to surgical treatment, and therefore as a rule it comes under the care of the physician, the treatment being directed to improvement in the general health. I shall therefore make no further allusion to the subject. Possibly the aid of the surgeon may be invoked in cases of *stillicidium lachrymarum*, the consequence of paralysis of the orbicularis muscle, and also in cases of constant dribbling of saliva from the mouth in these paralytic cases; but there is very little local

treatment that can be depended on for the cure of these cases.

The general paralysis of the insane causes drooping and relaxation of the facial muscles so that there is the customary vacant stare of imbeciles from loss of power in the muscles of expression. This of course is irremediable. The face muscles, in connection with the muscular system generally, may undergo fatty degeneration in imbeciles, so that there is a decided loss of feature. The emotional expression under animation which gives force and character to the individual is lost in such cases. Spasmodic action of the portio dura nerve may give rise to a kind of tetanic spasm of the orbicularis, and other face muscles, in patients with much mental anxiety or torpidity of liver. Such cases may be relieved or cured by the careful regulation of diet, and by directing treatment to the liver and alimentary canal.

Facial paralysis may occur in cases of abscess in the petrous portion of the temporal bone pressing upon or destroying the portio dura nerve. It depends, of course, upon the amount of damage to the facial nerve, whether the child will recover the power in the muscles of the face. The deformity is most marked on the opposite side to the paralysis, especially when the child cries or laughs. Sometimes the petrous portion will come away as a mass of necrosed bone in cases that have been much neglected.

PART II.

THE FOOT.

SECTION VIII.

DEFORMITIES INDUCED BY INJURY OR DISEASE—
DISLOCATIONS OF THE ANKLE, AMPUTATION
STUMPS, ETC.; INGROWING TOE-NAIL; SIMPLE
ONYCHIA, ONYCHIA MALIGNA, ETC.

CONSIDERABLE deformity of the foot results from severe sprain or *contusion of the ankle*. Not only do we have in these cases effusion into the synovial membranes and bursæ, but the soft tissues become infiltrated from damage to the vessels. The surgeon must be careful to diagnose this injury from fracture of the bones. If neglected the foot will swell up considerably. The astragalus may be slightly displaced and also the fibula. The effusion around the joint may cause chronic swelling about the ankle, requiring active treatment and firm bandaging to promote absorption.

Absolute rest in bed is the only effectual way of treating these injuries. A rectangular splint may be fixed to the inside of the leg and foot, and an evaporating lotion or ice-bag applied to the dorsum of the foot. The bed-clothes must be supported by a cradle, so as to keep the foot as cool as possible.

If there is any wound or serious damage to the soft parts, this may be treated with carbolic lotion or fomentations.

Separation of the tarsus from the metatarsus.—A case of this kind came under my care at the Victoria Hospital, in a child eight years of age. She had caught her foot, when running, between the bars of a grating, and gave it a severe wrench. She had been treated for contusion of the foot, but the parents finding after six weeks of treatment that she had lost all power with the limb, and was obliged to walk with crutches, they brought her to the Hospital.

Finding the forward part of the foot quite loose and moving freely upon the tarsus, I placed it in a firm encasement of plaster of Paris, including the toes and the ankle-joint. The limb was kept at perfect rest for three weeks, and the general swelling of the foot subsided. Consolidation of the ligaments took place, so that in the course of another month she was able to get about without any lameness and to put the weight of her body upon the damaged foot.

Dislocation of the Ankle-joint may occur outwards, as in severe cases of Pott's fracture, also inwards, backwards, and forwards.

In the outward displacement, the fibula is generally broken just above the ankle, the foot becomes loose and everted, and the outer edge raised, and a vacancy occurs at the inner ankle where the lateral ligaments have been torn away. The upper fragment of the fibula is turned inwards, giving the appearance of a hollow in the leg above the outer ankle. The strong ligaments which bind the astragalus to the os calcis

are also torn away in some cases. The astragalus being displaced from its normal relation to the articulating surface of the tibia, may in all these dislocations be felt as a prominent swelling, away from the tibia. The foot is more or less rigidly fixed by the spasmodic contraction of the muscles of the leg.

With the laceration of the internal lateral ligament, there may be a small fragment of the tibia broken off.

For the inward dislocation of the foot, much greater force is required, and it is therefore a much rarer form of dislocation. In these cases the foot is inverted, the outer ankle shows very prominently, and the sole of the foot being inclined upwards and inwards, the end of the fibula is nearly level with the ground.

These dislocations are caused by some severe strain and twist, as in falling off a roof or jumping from any great height. To correct this deformity the foot should be taken in hand without delay, and promptly restored to its normal position. The leg should be flexed on the thigh so as to relax the muscles, and the limb may then be put up on side splints with foot-pieces. When the swelling has subsided plaster of Paris encasement, or gum and chalk bandage may suffice to keep the ankle fixed.

Dislocation backwards may occur from the foot being gripped or checked during a fall forwards, with a heavy momentum upon the body. The capsular ligament will be torn, and the fibula may be broken. In this case the heel will be very prominent at the back, and the foot foreshortened with the tibia protruding upon the dorsum of the foot. The foot must be

extended with the leg flexed and brought forward, and then placed in a retentive apparatus. There is not generally so much damage to the bones and soft parts in this dislocation as in the other varieties of dislocation of the ankle. The astragalus itself may be displaced either forwards or backwards, and embedded among the tendons, so that reduction may be impossible. In such cases it will be necessary to consider the propriety of excising this bone, so as to restore the foot as far as possible to its normal position under the tibia.

Compound dislocations may occur in the same way, and they probably happen more frequently from severe railway accidents, the crush of brewers' drays, etc., than from ordinary accidental falls. When acting as Resident Assistant Surgeon at St. Thomas's Hospital, I had several of these cases admitted from the Nine Elms Goods Station, and from the coal depôts. Coal-heavers are generally a very clumsy and boosy class of men, and they often come in for these serious injuries. Unfortunately there is usually so much damage to the vessels and soft parts that erysipelas is very likely to supervene, or the patient may have delirium tremens, and so there is a large per-centage of deaths from compound dislocations of the foot. The question of amputation will of course have to be carefully considered in such cases.

For the treatment of these injuries it will be necessary to examine the amount of damage to the soft parts, and to act promptly in accordance with past experience of the merits or demerits of conservative treatment. The surgeon will not fail to inquire into

the habits of the patient, and give him the chance of preserving the limb if possible. Since the introduction of antiseptic treatment we have been able to hold out better hopes of retaining the limb, though it may require long and tedious treatment. The soft parts must be cleansed and approximated as far as possible, and the limb put up on a McIntyre splint or other fixation apparatus, to keep the joint steady. The wound to be dressed antiseptically.

Dislocation of the other tarsal bones is extremely rare, so I shall make no further reference to these.

Hypertrophy of the foot is occasionally met with from excessive growth of all the soft parts, or it may be limited to one or more toes. In such cases it will be necessary to consider carefully the question of amputation, though in consequence of the absence of any malignant disease developing in the foot, it may suffice to treat the case by elastic compression and suspension, so as to promote absorption of the effused or hypertrophied cellular and adipose tissue.

There are many diseases of tropical climates found among the natives, such as those caused by their habits of walking barefoot through marshy ground and rice plantations that are full of animal life. Prominent among these are the fungus disease or Madura foot, elephantiasis, cellulitis of foot from poisonous plants, snake bites, penetration of earthworms, as the Guinea worm, etc. I have no experience of tropical disease, and must therefore refer my readers to such writers as Norman Chevers, Fayrer, Macnamara, etc., who have spent most of their lives in India, and have made good use of their opportunities for studying such

diseases. I must also refer my readers to the section on the Face for a description of the diseases which correspond to those that are to be found on the foot.

Among the most frequent deformities of the foot are stumps, the result of gangrene or partial amputation of the foot or toes, and various abnormal contractions of the foot after excision of bones and the removal of tumours.

I have had some very satisfactory and good permanent results from excisions of bones of the tarsus and metatarsus. I have given in the Appendix particulars of a typical case of deformity after excision of the largest bone of the foot—the os calcis—showing what may be done by conservative surgery of the foot. The illustration shows the limited amount of deformity resulting from this operation.

It will be observed that I am not discussing the general surgery of the foot and face, my object being to limit myself to surface deformities as far as possible. Concerning questions of excision or amputation, there is very little of novelty to write on this subject. I must refer my readers to the current textbooks on Surgery for information on the deep surgery of the foot.

Chilblains are caused by local congestion of the skin at the extremities, where the circulation of blood is always very feeble. In the case of weak or delicate young people with deficient vital energy, there is a tendency to stasis of blood in the capillaries, and this particular form of congestion is the consequence. Young people must be warned against the lazy habits of toasting their toes on the fender, and

of keeping at home, instead of taking a brisk constitutional every day, however much it may grate against their inclinations. The three volume novels have much to answer for, in the production of chilblains. Young women are especially liable to this complaint, and it may last on and off for years. Sudden changes of temperature, as a thaw after a long frost, are very likely to produce this disease. The symptoms at first are tingling and itching of the affected extremities, then tenderness, and finally vesication, if unchecked, tending in some cases to indolent ulceration of the integument. Some suffer in the hands, and others in the feet only. The exact time of commencement of the swelling, redness, and irritation is generally about the same, daily, for each individual attacked. There is a predisposition to this complaint in families, from an asthenic condition of the blood causing feeble circulation in the extremities.

Sufferers from this painful malady must be enjoined not to wear tight garters, tight shoes or gloves, or elastic bracelets on the arms. Gentle friction to the extremities daily will help the sluggish circulation. The patient may take a little port wine daily for lunch, or some warm milk night and morning in bed. Additional underclothing should be worn to keep the limbs warm, and a good supply of blankets at night. Stimulating liniments may be used to accelerate the circulation. The affected toes may be painted with collodion and castor oil, or the amyl colloid. If the itching is intolerable, bathe the feet with poppy fomentations, or apply ung. belladonnæ externally.

When vesication or ulceration appears, dress each

toe separately with carbolic oil or zinc ointment. There may be deep sloughing ulcers form around the toes and dorsum of the foot, which are very indolent and difficult to heal. If the ulcers are indolent they may be dressed with lead or zinc lotion.

I have not given a separate section for skin eruptions on the foot, because these can scarcely be called deformities or disfigurements, and because the several varieties of skin disease are, for the most part, described under the heading of Face Eruptions.

Diseased Toe-nails may require treatment in various ways. They may peel off in laminated shreds, a form of psoriasis, or they may grow in a very nodulated fashion, from some disease or defect of the matrix. Toe-nails sometimes grow very rapidly, and being neglected, may become hypertrophied, forming a horny mass, which projects beyond the toe, constituting an impediment to the patient in walking. It may be necessary to destroy or remove the nail under these circumstances.

In-growing Toe-nail is a painful and often troublesome, though frequent complaint, involving the toes, especially the big toe. It is caused in part by the pressure of a badly fitting narrow boot, and also from the habit of paring the nail at the side, so that the sharp incisive edge of the toe-nail presses deep into the sulcus of soft integument which overlaps the nail at this part. So long as the ulceration commonly called "proud flesh" continues, the efforts of nature to heal the sore are unavailing. There is considerable pain and discomfort. The treatment must be directed to liberating the soft tissues from the incisive

pressure of the toe-nail. By pushing a thin strip of lint or soap plaster, or sheet lead under the lateral edge of the nail, the ulcer may then heal in the usual way. The toe should be dressed with stimulating lotions, as the zinc and lavender, or if the granulations are exuberant, the base of the sore may be touched with the solid nitrate of silver.

In long-standing cases, when the nail is deeply embedded in the granulations, it is useless to attempt these milder methods of treatment. A sharp pair of pointed scissors must be pressed under the nail on this side, and without much difficulty the faulty section can be quickly slit up and removed. Patients need not have the dread of this operation which they sometimes display, in ignorance of the real benefit to be derived from the removal of this cause of irritation. The ulcerating process which has been going on for some time has separated the matrix of the nail at this part from the nail proper. If the surgeon is expeditious, he will succeed in removing the portion of loosened nail before the patient has much time to complain. Directly this is done, the ulcer being freed from "the thorn in the flesh," as represented by the in-growing nail, will quickly heal under the application of warm water dressing, or lead lotion.

Simple Onychia is a disease of the matrix of the nail, with suppuration, limited usually to one side of the nail. It may have been caused by some slight injury, as a bruise, or by the entrance of a thorn under the nail. Warm water dressing will usually suffice to subdue the inflammation. A new nail will probably form in due course.

Onychia maligna is a disease of the matrix at the root of the nail, with sloughing of the cellular tissue around the nail. It commences by inflammatory swelling of the terminal phalanx, followed by suppuration underneath the nail, which is often of a very foetid character, and there is usually a dusky red inflammation all round the root of the nail. The surgeon discovers that the nail is quite loose, being separated from its natural attachments to the phalanx, and embedded in soft sloughy material, surrounded by swollen and congested skin of a livid red colour. The infiltration of the soft parts all round gives rise to a very unsightly deformity of the toe. It occurs in feeble, delicate children. The dead nail must be raised from the ulcerating surface beneath, and cut away so as to expose the sloughing matrix, which should be destroyed with caustics, and then poulticed or dressed with a soothing lotion, or the liquor potassæ arsenitis, strength 1 part to 10. The child should have some tonic treatment, such as chlorate of potash and perchloride of iron, or the bark and ammonia mixture. The matrix is often entirely destroyed.

Horny growths and exostoses occasionally develop from the matrix of the nail at the end of the phalanx, tilting up the nail so as to become an impediment in walking. These growths may be excised without any difficulty, and they are not likely to return.

Deformity from Perforating Ulcers.—Mr. Dent showed at the Pathological Society last year a case of symmetrical deformity of the feet following perforating ulcers. In this case the phalanges and greater part of the metatarsal bones in both feet

were destroyed by a gradual process of quiet necrosis. The integuments of the toes retracted so as to cover the stumps of the metatarsal bones. The skin of the soles of the feet became unusually thick and horny, although the patient was not able to walk any distance. His maternal grandmother had feet similarly affected, showing the hereditary nature of the disease. Two of the brothers had the same condition of ulceration of the feet.

There are also many deformities from the growth of tumours, abscesses, ulcers, cellulitis, necroses, exostoses, ossifying enchondromata, malignant disease, etc., which I merely enumerate as indirect causes of deformity of the foot. Also gouty, syphilitic, tubercular, and rheumatic diseases of the bones and articulations of the foot, which require to be treated as local and constitutional affections rather than as deformities.

SECTION IX.

DEFORMITIES INDUCED BY BAD HABITS—FAULTY BOOTS, BUNIONS, CORNS, DISTORTED TOES, ETC.

Deformities induced by Bad Habits.—Some children acquire bad habits of limping or scuffling along awkwardly when walking, unless properly checked. Or they may acquire an awkward posture when standing, such as stooping, waddling in their gait, shrugging the shoulders, making ugly grimaces, habits which they cannot apparently control. Some children will fall down suddenly and hurt themselves without

any accountable cause, except it be from clumsy habits of walking and running, rather than from tripping against any obstacle.

These habits and many others, such as wetting the bed, are often pronounced incurable, whereas most of them may be rectified by judicious management and proper treatment.

As regards deformities of the foot and other bad habits which children contract, and which if neglected may develop into some permanent disability, I have had some encouraging experiences in the treatment of such cases. Recognising the fact that the child is budding out into life with an unknown future before it, possibly with great expectations, I do not despair, when I remember that a young and green twig may be gradually trained or twisted in almost any direction, whereas a hard woody stem will break in the attempt to alter its configuration.

Under this heading I include those numerous cases of distorted toes and feet, the result of badly fitting boots. When we examine the normal foot of a newly-born babe, or the ideal foot of some Phidian sculpture, we see at once how terribly nature has been made to model herself according to the prevailing fancies and customs of the time.

Judged from the light of Oriental and English history, it would seem to be the peculiar mark of good breeding to travesty nature to the utmost extent by the eccentric fashions which have prevailed at different epochs. We owe it much to the teaching of modern sanitarians of both sexes that many of these bad habits are now being overcome, so that the slaves

of fashion are permitted to mix in genteel society with liberated limbs and untortured bodies.

An exception, however, must be made as regards shoes and boots. The Chinese fashion of cramping the feet so as to reduce them to the smallest dimensions seems to have got a firmer hold upon the *jeunes dames*, the consequence being that feet, which would otherwise appear in due relative proportion to the rest of the body, are cramped into boots and shoes of about half the required size. With the view of throwing the body forward and raising the heels from the ground, high conical blocks are fixed to the centre of the sole, and the wearer has to learn the clever feat of balancing herself upon two or three square inches, instead of upon the full extent of the plantar surface provided by nature for her to walk on.

The evil consequences of such folly are immediate and prospective. Modern young ladies are compelled to sedentary occupations, because of the trouble and difficulty of perambulation. Brisk walking becomes "a bore," and is therefore seldom indulged in. Failing healthful exercise and occupation, young people get discontented and querulous. Constipation is the rule rather than the exception, and, in short, the vigorous healthy growth of the body, so necessary at the period when our young maidens are expanding into womanhood, is checked, and they must sooner or later reap the bitter fruit of pandering to such baneful fashions and customs.

I am constantly being consulted by young ladies for deformities of the feet occasioned by such bad habits. The whole weight of the body is thrown on

to the ball of the big toe, so that instead of the phalangeal bone of the toes being continuous with, and in a line with, the long bones of the dorsum of the feet, they are turned up at right angles to these bones, and the ball of the big toe becomes decidedly enlarged and prominent.

Partial dislocation of the metatarsal bone of the great toe is occasioned by this cramped posture. An unduly arched condition of the foot is caused by the high French heels and pointed toes of modern shoes for ladies. The length of the shoe is not more than three-fourths that of the foot. To accommodate the foot to this cramped position it is necessary that the toes should be tilted perpendicularly up, and the metatarsal bones made to lie in an axis oblique to the plane of the foot, forming with the toes a V-shaped curve. Consequently, the metatarsal bone gets displaced upwards on to the cuneiform bone; and there is no remedy for it but to wear larger and flatter, if less elegant, boots and shoes. Nature has provided that the weight of the body should be impinged upon the keystone of a strong double arch, viz. the astragalus. These young ladies, by extreme pointing of toes, throw the centre of gravity forwards on to the ball of the great toe, and so the heel serves more to balance the body, than to act as a main prop for the superimposed weight of bone and muscle.

In other cases there is an overlapping of the smaller toes, the bones of the feet get displaced, so that there is an awkward rise in the centre of the instep which is often tender and painful. In such cases prevention is of course better than cure, and a return

to the use of boots and shoes which not only do not cramp the foot is essential, but also such as allow a broad planting of the sole of the foot upon the ground, so as to poise in an elegant way the superincumbent weight of the body. Let surgeons ask such votaries of fashion whether it would not be thought very inelegant and improper to place a statue upon a narrow tottering pedestal, so small and diminutive as to require a stick to prop it up?

Arguing then from analogy, may we not succeed in convincing at least some of our patients, that the abandonment of the walking stick, and of the China-woman's shoe, by no means necessarily involves the adoption of a charwoman's ponderous sandal, but a useful and well-fitting encasement to the foot, which shall allow of the expansion and distribution of pressure equally to all parts, and the consequent elastic spring of the double pedal arch of the foot that was once the pride and delight of our British maidens.

We must warn our patients against depending too much upon the advice of the shoemaker. Purveyors of fashion must keep true to the prevailing tastes of their customers and recommend "what is worn." We cannot expect a wholesale conversion from the ranks of park habitués, but let us urge compliance with well proved hygienic principles of dress upon the more thoughtful and educated of our patients, for their comfort and health, and the claims of future womanhood.

Instead of the transverse measurement of the foot level with the toes being, as bootmakers appear to consider, the narrowest part of the foot, the fact is

the foot tapers gradually towards the heel, the toes being the broadest part, in order to give an extended surface for planting the foot and balancing the body when walking. Nature has made the inner line of the foot straight, as seen in young infants, but how few are permitted to grow up with this proper symmetry of the foot! The same causes may give rise to inversion of the little toe with consequent bursitis of the pad overlying the joint. The removal of the cause constitutes the chief indication for treatment. The sufferer should be furnished with properly fitting boots. It is essential for the ultimate cure of the inflammation. The distortion of the toe may be in part rectified by the application of a splint and strapping, after the subsidence of the inflammation. Moist applications of a soothing character may be required to allay the irritation, as poppy fomentations, warm water dressing, &c. In chronic inflammation the skin may be painted with iodine and protected by soap plaster. Avoid boots with high heels. See that a vertical line passing from the toe of the boot to the heel traverses the middle of the boot. Select a boot that is not curved inwards by arching it up too much on the inner side, as is too often the case with cheap boots. The effect of such incurvation is to foreshorten the foot, and to throw undue pressure upon the joint of the little toe.

The rapidly increasing desire of young ladies to obtain distinction at the competitive examinations in science, mathematics, &c., will convince them far more than argument, of the *raison d'être* of that which I have been pleading for—the beautifully perfect

structure of the foot, with its double arch, the bones being wedge-shaped, resembling the upper stones of an archway. The os calcis or heel-bone being by far the largest and most solid bone of the foot, shows that nature designed it to take the chief weight of the body in walking. The front of the foot should be used mainly in promoting that elasticity and elegance, which I trust will soon again become the rule rather than the exception with the fair sex.

What can be more inspiring and encouraging than to watch the elastic spring of a regiment of soldiers as they march past at quick time in review order? I should much like to see the *jeunes dames* exchange their woodeny scuffle for the comfortable spring of a well-shod foot.

Bunions are usually situated over the joint of the great toe, at its junction with the metatarsal bone of the foot. They are caused by inflammation of a bursa or pad which nature has provided to protect the joint from undue pressure. This bursa becomes inflamed by the inversion of the foot under the constant irritation of a narrow boot. The joint being exposed to injury, and to undue pressure on the inner side, may also inflame.

We have here a still further development of mischief from badly fitting boots. The big toe and the little toe are very frequently involved in these ugly protuberances. Omnibus drivers, butlers, and cabmen often suffer in this way. Their sedentary occupations and their drinking propensities seem to favour this deformity. I suppose the constant irritation caused by the exposed condition of this displaced and

swollen joint accounts for the frequency with which gout attacks the ball of the great toe.

If neglected these bunions will suppurate and form an abscess, which discharges very freely, and may invade the joint structures; or if inflamed, erysipelas is very likely to appear in the foot. In such cases the patient must be encouraged to give absolute rest to the part, to apply poultices and warm water bathing when painful, and to dress the foot with a warm Goulard lotion so as to favour absorption of inflammatory products, and healing of the wound. If the skin is unbroken, and the swelling large, it may be painted with iodine. In young people an attempt should be made to restore the foot to its proper shape by strapping and bandaging.

Inflamed bunions may give rise to a great deal of pain and discomfort, from their great enlargement.

When erysipelas appears on the dorsum of the foot, the patient should be enjoined to give the leg complete rest for a day or two. Warm lotions may be applied, as the lead and opium, and the foot may be encased in lint and guttapercha cloth. It will also be needful to administer some antiphlogistic treatment, followed by aperients and iron tonics. Sometimes after suppurating, these bunions leave a callous indolent tissue or ulcer, with uneven or hardened edges. It may be some weeks before these ulcers heal. The biniodide of mercury ointment, 5 grains to the ounce, may perhaps be useful, or the simple warm water dressing.

With the packing together of the toes one upon another in consequence of wearing badly fitting boots we sometimes get ulcerations between the toes, painful

and suppurating corns upon the prominent toe joints, elevation or depression of one toe so as to project on the dorsum. Such distorted toes appear sometimes as an awkward prominence at the sole of the foot.

Palliative measures must be employed in these cases to cure the corns or ulcers. If the displaced toe causes much inconvenience it will be necessary to remove it by amputation. This would be a very simple operation, and could be done without much inconvenience, and certainly with permanent and considerable relief to the patient. The necessity of having perfect comfort in walking must obviously determine the sufferer in resolving to submit to a temporary inconvenience, for the sake of a permanent beneficial result. Some people acquire a habit of walking upon the heel or the front of the toes, in consequence of some chronic ulcer on the sole of the foot which has existed for some months or years, and which they seem to think incurable. Such cases require prompt and decisive treatment to restore the patients to a condition in which they may walk without lameness or awkwardness.

Corns are simply caused by local excess of the epidermis, arranged in a concentric form, and produced by intermittent pressure from badly fitting boots. The modern fashion of narrow pointed toes, causing the whole weight of the body to be thrown perpendicularly on to the instep by the high heel which ladies generally wear, must inevitably produce corns, because the part where all the pressure comes, thus intermittently, is very tender and sensitive. Anything which prevents the even spread of the foot, and the

regular planting of the sole of the foot flat down on the ground, so that the pressure may be distributed, will produce corns. There is probably an hereditary tendency to the transmission of these horny outgrowths on the toes.

Corns are either hard or soft, flat, conical, or laminated, consisting of accumulated nodules of epithelium, which are dry, hard, and scaly. When conical they may be shelled out with comparative ease, and certainly do not need the high sounding title of chiropodist to signify the person who is willing to remove them for a consideration. Occasionally corns will suppurate, and if neglected, the formation of an abscess beneath the corn may lead to decay of the subjacent bone. Suppuration beneath a corn may be recognised by severe pain and throbbing in the part, with swelling and tenderness. The foot must be poulticed, and as soon as fluctuation is felt, the pus should be evacuated by incision. Some corns are peculiarly painful and tender to the touch, crippling the patient, and preventing him from walking with comfort. They are usually circumscribed and consist of tufts of elongated and swollen papillæ.

Soft corns are generally found in situations where the moisture of adjacent parts keeps them infiltrated with perspiration, as for example between the toes, and these being vascular are very sensitive and painful. Children with these infirmities will often acquire a habit of limping in their walk or inclining to one side of the body, so that a corn may be the precursor of permanent mischief to the spine. Consequently in curvatures of the spine we must be sure

that they are not induced by a constant attempt to avoid throwing the weight of the body on a painful corn.

The treatment of corns is very simple, and the public are certainly not likely to gain any advantage by consulting those who are unacquainted with even the rudiments of anatomy. The hardened cuticle must be softened by the application of compresses and warm bathing or poultices. The part must be protected from pressure by soap plaster. Strong acetic acid may be painted on the corn to soften it. When the corn is sufficiently soft it may be extracted without pain. Nitrate of silver caustic may be applied in some cases, especially to the soft varieties.

People do not as a rule persevere sufficiently long with a hard corn. It may be that a protracted illness in bed will suffice to cure all the corns from which the patient has been suffering for so many years. Those who pay regular visits to the chiropodist may certainly obtain a few weeks of ease, but it is at the cost, generally, of many more weeks of suffering. Those who are thus afflicted must arrange to have special boots made for them, and never purchase ready made articles. They should avoid the use of patent leather, and have a material called "pannuscorium" or a soft substitute for the upper leather.

Distorted Toes.—I need not particularise the various congenital distortions of the toes, nor those caused by the habit of wearing badly-fitting boots. There are, unfortunately, few adults in this country who do not "know where the shoe pinches." The dusky races, such as our soldiers are now fighting in the Soudan, can furnish plenty of illustrations of the

normal growth of the foot when not encased in shoe-leather. Habitual pressure of the toes will be certain to compress them into almost any shape, and so they frequently become square instead of round. Callosities form on the dorsum of the toes. The ungual phalanges are turned under and the joints become raised, and therefore compressed by the upper shoe-leather. By the friction of the foot, and the necessary movement of the toes in walking, considerable irritability may be caused to the skin and to the joint-structures. The flexor tendons contract, and so add to the mischief. It may be necessary to divide these tendons subcutaneously, and to extend the faulty toes upon splints.

SECTION X.

CONGENITAL AND PARALYTIC DEFORMITIES —
CONTRACTION OF PLANTAR FASCIA ; CONTRAC-
TION OF ONE TOE ; WEAK ANKLES ; CLUB-FOOT ;
VARIETIES OF TALIPES, THEIR CAUSES, CLAS-
SIFICATION, AND TREATMENT ; FLAT-FOOT ;
CHOREIC, HYSTERIC, AND SPASTIC CONTRACTION
OF GROUPS OF MUSCLES ; WEBBED TOES ; SUPER-
NUMERARY TOES.

Congenital and Paralytic Deformities.—There are many deformities of the foot which require careful consideration with a view to surgical treatment, but talipes deformities constitute the bulk of the cases which come under this definition. When we remember how much depends upon the correct balancing of the body upon the complicated mechanism of the ankle-joint, it becomes important to see that the feet

are properly developed from infancy upwards, that the joint movements are quite normal, and that nothing shall interfere with the free and unfettered movement of all the component parts of the foot.

Infantile paralysis, the result of teething troubles, &c., may develop some deformity of the foot from the atrophy of muscles supplied by the paralysed nerves. In these cases the foot lies in a cold torpid condition, with the toes pointed and the limb cold. The joints are very lax, and there may be some puffiness on the dorsum of the foot. We may also have a condition of pseudo-hypertrophic paralysis. Such cases will require both local and constitutional treatment. Plenty of nourishing food, and tonics, such as Easton's syrup and steel wine, to improve the condition of the blood and nervous system; plenty of friction and galvanism, to stir up the slumbering muscles and press them into action by massage.

Congenital deficiencies, such as those produced by sporadic cretinism, and unsymmetrical hypertrophies, do not come under surgical treatment as a rule, because they are seldom capable of any improvement by operation. I shall therefore make no further allusion to these deformities of the foot.

Contraction of the plantar fascia may cause considerable arching of the instep, and curving downwards of the metatarsal bones of the foot, such as is seen in Chinese women, from their self-induced deformity. This is effected by bandaging and compressing the foot from infancy upwards, so as to prevent it growing large. In these cases, where the tendons are not much at fault, it may suffice to divide the plantar fascia, and

to extend the leg and foot upon a grooved back splint with a flat foot-piece, or to use a McIntyre splint.

Contraction of one toe may cause some inconvenience by the formation of a corn on the prominent point of the faulty toe, which may subsequently inflame. By the irritation of the boot in walking, an abscess may develop on the dorsum of the deformed toe. This deformity is caused by contraction of the digital prolongation of plantar fascia and the digital tendon, or the toe may be displaced on to the dorsum of the foot. It generally affects the second toe, and may give rise to permanent lameness. These bands of fascia and faulty tendons should be divided subcutaneously, and the toe forcibly extended, and then fixed on a splint for about eight or ten days.

Weak ankles may be congenital or they may be associated with an acquired habit of unduly everting the foot. A consequent fall of the arch may occur in delicate and rickety children from relaxation of ligaments. The general health must be carefully attended to, with a view of consolidating the bony framework. Tidman's sea-salt baths, friction, and bilateral splints to support the ankles must be used in these cases for some months, until the bones have become firm and the joints more solid.

Club-foot may be described as having four distinct varieties, viz. :—

Talipes varus, in which the foot is inverted and drawn up mainly by the action of the tibialis posticus, and in part by the tendo Achillis.

Talipes valgus, which is generally associated with some depression of the pedal arch, and eversion of the

foot. It is more or less dependent upon contraction of the peronei muscles.

Talipes calcaneus, in which the foot is drawn up towards the tibia by the action of the extensor muscles, and the heel is depressed.

Talipes equinus is the deformity characterised by pointing of the toes and elevation of the heel, somewhat resembling the foot of a horse.

As sub-varieties, or combinations, of these, we have T. equino-varus, T. equino-valgus, T. calcaneo-varus, and T. calcaneo-valgus.

A further classification is made by some authors dividing the prime varieties into those which are congenital, and those which are acquired. Varus may be considered as the type of congenital club-foot, and valgus that of acquired distortion.

There are also several degrees of severity in the cases which come under treatment. Scarcely two cases exactly correspond in the amount of muscular rigidity and contraction. In some cases there is only a slight elevation of the heel, and the consequent lameness is scarcely perceptible. The general outline of the foot in such cases is fairly normal. In other cases the deformity is very marked.

About nine-tenths of non-congenital deformities depend either upon spasm or paralysis of certain muscles or groups of muscles. In paralytic cases the muscles rapidly waste and atrophy. Some of the most severe kinds of deformity of the foot occur in cases of spastic contraction from convulsive affections in children. Nearly all the muscles of the body may be involved in this rigidity, induced by some cerebral

disease that is probably of a tubercular character. Such cases must be pronounced incurable.

Long persistent deformity of a limb under spasmodic contraction will lead to permanent rigidity, and the limbs are then, as a rule, drawn inwards by the flexors, and the joints become stiff. Such deformities are seen in the cases of patients recovering from hemiplegic attacks.

Although the tendency in infantile paralytic affections is towards recovery, such recovery may not be complete, though it may enable the patient to walk with or without assistance.

It is important to remember that club-foot deformities may be congenital, the child being born with such deformity of the foot, or they may be acquired. The accompanying drawings will show the varying shapes and contortions of the foot when subject to this deformity, as also the difference between congenital club-foot and that which is acquired. In all these cases there is evidently some amount of paralysis of the opponent muscles, chiefly the extensors of the foot as they take their origin from the front of the leg. I do not find that the paralysis in congenital cases is as a rule absolute. I am careful to advise gentle friction of the leg over these muscles to stimulate them to action after the foot has been liberated, as also galvanism in some cases. It has been attempted to account for the existence of congenital club-foot by some trophic disease of the ganglia and nerve-centres for directing the co-ordinate action of the opponent muscles; but I have my doubts as to the cause and effect of the alleged degeneration of nerve-cells. I

consider that the distortion is produced in the first place by a cramping and awkward posture of the foetus in utero, the foot being kept in this constrained position sometimes by deficiency in the liquor amnii, or by the contiguous pressure of the uterine walls, and superimposed viscera. The growth of a limb and of its muscles through the period of intra-uterine development must inevitably lead to permanent distortion thereof, in whatever direction the surrounding viscera may force it. Doubtless our pathologists may be able to trace some central degeneration of the nerve-centres, exactly corresponding to the nerves supplying the faulty muscles, though this may be by some considered a consequence, rather than a cause of the deformity. The muscles being rendered powerless by the cramped position in which they have been held during the months of intra-uterine life, degenerate in structure, and so also the ganglia of the brain from which the volitional acts proceed for the customary movements of the corresponding muscles. Together with the defective development of the muscles, there is a deformed and contracted condition of the small bones which form the double arch of the foot. These bones, being similar to the ordinary stones of an arch, are wedge-shaped and about the size, in infants, of dice.

The longer the foot is allowed to grow in this wrong direction, the more firmly consolidated will the bones, ligaments, and tendons become in the altered position in which they are placed. It will therefore be much more difficult to rectify the deformity. We must carefully distinguish between the cases of congenital deformity, and those which are acquired in after life

from irregular or spasmodic contraction of certain muscles or groups of muscles. In the latter case there is probably some special irritation centrally, or in the medulla spinalis, and we must treat this condition before hoping to effect much with the deformity, for the bones in acquired club-foot are of course not as a rule developed in a wrong direction.

Each of the varieties of club-foot as depicted in the drawings may be considered to have varying degrees of intensity. In some cases the deformity is only seen under emotion, or when walking carelessly. If the child is paraded before the surgeon, it may be clever enough to screen from observation the deformity which otherwise would be very manifest.

In the treatment which I am endeavouring to enforce, as alone efficacious for the final and satisfactory removal of congenital talipes, it will be seen that I lay very particular stress upon the importance of rectifying the osseous deformities, by long-continued treatment of the distorted bones and ligaments, besides the customary division of the contracted tendons. Such treatment to commence at the earliest possible period of infantile life.

Mr. Adams, one of the acknowledged authorities on club-foot, in his Jacksonian Prize Essay on the subject of deformities, has made some very careful dissections to illustrate the morbid anatomy of club-foot. I quite agree with him that the osseous deformities are most marked in Talipes varus, and that in the commonest form of congenital talipes, it is useless to attempt to cure the deformity without bearing this in mind in our course of treatment.

The fabric, as it were, of the foot must be entirely reorganised, for it has acquired a wrong direction of growth, and being fortunately made up of a number of small wedge-shaped bones, jointed together by connecting bands of ligamentous tissue, it is quite possible so to manipulate the foot, and so to divide the constricting bands, that by a series of consecutive operations, mouldings, and manipulations, the different stones (i. e. bones) of the double pedal arch shall be moulded into something like a correct "plumb," in accurate adaptation to the articulating extremities of the tibia and fibula, from which they have been congenitally displaced.

If the deformity is not corrected in infancy, the bones, by reason of the weight of the body impinging upon them in a wrong direction, become still more twisted and moulded out of their true shape, and so the obstacles to rectification are increased.

Mr. Adams describes the faulty condition of the larger bones of the foot in talipes varus as follows :—
"The os calcis is altered in position to an extreme degree, but its deviation in form is slight; in severe cases it occupies a very oblique, almost a vertical position, from its tuberosity being drawn upwards by the gastrocnemius and soleus muscles. Its direction is also somewhat changed laterally, the anterior extremity of the bone being directed obliquely forwards and inwards, and its tuberosity inclined towards the fibular aspect of the leg, and in severe cases it is found in actual contact with the fibula. In form the os calcis is also somewhat altered, being regularly arched in the direction of its length, with the con-

vexity directed outwards, in adaptation to the curved position of the foot, but this deviation is not very obvious, except in severe cases" (p. 151).

"The astragalus is found, at the period of birth, to present several important deviations, both in position and form. In position it is tilted obliquely forwards and downwards, and to a certain extent displaced from its socket, in consequence of the altered direction of the os calcis and elevation of its tuberosity, so that the anterior third, or more, of the superior articular facet, or cochlea, of the astragalus is thrust on to the dorsum of the foot, where it is covered only by the elongated anterior portion of the capsular ligaments of the ankle-joint and the skin. The body of the bone, or that portion of it which normally enters into the composition of the ankle-joint, is to a greater or less extent rotated outwards, so that the external lateral articular facet is firmly in contact with the fibula, and appears to be somewhat increased in size, in consequence of its anterior portion being extruded from the joint. The internal lateral articular facet of the astragalus is scarcely to be traced, and in severe cases is not at any part in contact with the articular surface of the inner malleolus" (p. 151).

"Moreover, the line of the ankle-joint, instead of being horizontal—when viewed from the front, after the joint has been laid open—presents an oblique direction upwards and outwards towards the fibula, corresponding to the rotation outwards of the astragalus" (p. 152).

"The astragalus presents several important deviations from its natural form, and these are observable

in its head and neck, its articular surfaces, and its posterior border. The articular head of the astragalus does not present a regularly convex surface looking directly forwards, as in the healthy bone, but has an antero-lateral aspect. In a severe case, the articular surface of the head of the astragalus is divided into two articular facets, at nearly right angles to each other, and separated by a distinctly angular ridge and surface, the larger looking directly inwards and articulating with the displaced navicular bone. The other looks directly forwards and downwards, and is left exposed on the dorsum of the foot by the altered position of the navicular bone, and is covered only by the elongated portion of the ligament normally passing from the neck of the astragalus to the edge of the navicular bone."

"The lateral articular facets of the astragalus present some important abnormal conditions in respect both of position and form. They are both partially extruded from the ankle-joint, and appear in front of the malleoli, in consequence of the altered position of the astragalus" (p. 153).

"In consequence of the oblique or nearly vertical position of the astragalus, only the posterior two-thirds, or less, of its superior articular surface enters into the composition of the ankle-joint."

"The navicular bone in its displaced position articulates with the lateral articular facet of the head of the astragalus, and therefore holds a lateral instead of anterior position with respect to the astragalus. In fact, the long axes of these bones are parallel instead of being at right angles to each other. The

long axis of the navicular bone is therefore parallel with the long axis of the leg instead of being at right angles to it" (p. 156).

In extreme cases the navicular bone leaves the astragalus, being forced upwards towards the inner malleolus by the contraction of the tibial tendon.

The deviations in the conformation of the other tarsal bones are also carefully described and delineated by Mr. Adams.

Mr. Parker and Mr. Shattock* advocate a mechanical causation for this deformity. Their opinions rest on a careful dissection of five cases (three of varus and two of calcaneus), and on a study of specimens in various London museums. They contend that there is nothing special in club-foot, nothing which may not be found in other joints. In one of the dissected cases there was histological integrity of the nerve-centres, of the nerve-trunks, and of the muscles of the affected limb, but there was also some extra obliquity in the neck of the astragalus. In another case, however, there was no such malformation in the astragalus. Hence, they argue, the insufficiency of the usually accepted nerve-theory of causation, and of the theory that the deformity depended on the conformation of the astragalus. It was further shown that the conformation of the astragalus which was met with in most cases of talipes was the normal condition in the Simiidæ, although these animals were not talipedic. Thus it appeared that some other cause must be invoked, and they sought it in the environments of

* "Pathology of Congenital Club-foot," Pathological Society's Trans., 1884.

the foetus during intra-uterine life. As additional proofs of pressure (besides the talipes), they related instances of torsion of the bones of the leg and of the astragalus, and also a case in which depressed patches of atrophied skin, with bursæ beneath, were found on the external malleolus and on the head of the astragalus, comparable with what was found in persons who had walked on the unreduced talipedic foot. The varieties of varus and calcaneus were thought to depend on the date of onset, and in both cases were exaggerations of positions normal at some time or other of foetal life.

Mr. Parker said that they did not wish to make out that all forms were produced in identically the same way. The physiological calcaneus only lasted a few days after birth.

Dissection teaches us, says Mr. Adams, that "the ligaments contribute materially to the permanence of the deformity at all ages, and experience proves that the success of the treatment is considerably impeded by the resistance they offer to the restoration of the foot to its natural form. Ligamentous adaptation and contraction maintain the bones so firmly in the deformed position, that the foot cannot be restored to its natural form and position, even after division of all the contracted tendons. This process of adapted shortening or defective growth of some of the ligaments must be taking place during the period of intra-uterine development" (pp. 162, 163). So also are the opposing ligaments found to be elongated. The deltoid and other strong ligaments of the sole of the foot often constitute very strong obstacles to the

surgeon, when endeavouring to rectify the deformity. It may be necessary to divide these before commencing the moulding process. In some cases of less severity there is no ligamentous rigidity, the deformity has probably taken place at a much later period of uterogestation. Appreciable changes in the muscular structures are not essential to the production of talipes varus. As a general rule, there is an absence of any distinct abnormal condition of the muscles.

Mr. Adams then describes the result of some dissections he had made to show the alteration of structure which occurs in some cases.

Arrest of muscular development may depend upon some abnormal condition of the nervous centres. The degeneration may be traced partly to the influence of long continued inaction. The legs are usually thin in proportion to the thighs, as if showing a deficiency of muscular development and nutrition generally below the knee.

Mr. Adams sums up his arguments by saying that, "On the whole, I am disposed to agree with the dynamic or spasmodic rather than the mechanical theory as applied to congenital talipes varus. The arguments in support of malposition and pressure in utero are exceedingly weak. But it is probable that malposition and pressure in utero may be the cause of some deformities." The malformation of the astragalus existing at the period of birth depends, Mr. Adams thinks, "upon the malposition of the os calcis and navicular bones caused by contraction of the muscles of the calf and the anterior and posterior tibial muscles."

I prefer to associate both these conditions, viz. intra-uterine compression and spinal irritation, as proximate causes of the deformity. I connect these with a distinct and probably subsequent distortion of the bones and articulating surface; such want of symmetry in the normal outlines of the bones being directly traceable to their growth and development in a posture of constraint. Placing the causation, then, of such deformities in what would appear to be the direct order of sequence, I should say we have mechanical constraint, which may have been due to a primary reflex spasm of the developing uterine muscle. Then we have the dynamic agency of the foetal spinal cord, as contributing to the distortion by reason of the incarceration of the foot in such a confined space. And lastly we have the growth and development of the bones in the direction which is least affected by these two causes. The deformed bones always contribute largely to the obliquity of the limb in its crippled condition as it appears after birth. Whether the partial paralysis of the opponent muscles is due to the prolonged inactivity during incarceration, or that the paralysis was the primal cause of the distortion, and so of the incarceration, I cannot attempt to decide.

Certainly there seem to me very strong arguments against the mechanical theory advocated by Mr. Parker and Mr. Shattock. For example, do we find that deficiency of liquor amnii, so obviously associated with a cramped posture of the foetus in utero, can be traced as discoverable in such cases? Then again, as with many other troubles, do we not find an unusually

large per-centage of club-foot in the children of the poor as contrasted with the children of the rich? If we are to accept the allegation that a mechanical causation will account for this deformity in most cases, we should naturally expect to find a large and increasing per-centage of club-foot among the offspring of the rich, seeing that the prevailing fashion of the day, to which so many young married ladies succumb, viz. that of tight lacing, must make its direct impress upon the foetus in utero.

I suppose there is not a doubt that uterine displacements have largely increased in numbers during recent years, not only because young married ladies go more into society than formerly, but because with tight lacing and other efforts to keep their figures in, they succeed in compressing the uterus, and so interfering with pregnancy.

In the event of a fashionable lady becoming pregnant the claims of society have a prominent place in her thoughts. During the season she resolves to keep her engagements as long as possible, and the maid must give the stays an extra squeeze to make her presentable at Court. Am I presenting an exaggerated picture? I can only say that my experience leads me to affirm that such cases are by no means rare. What becomes then of the theory of compression in these cases?

Messrs. Parker and Shattock say that "the supposed nerve-lesions have never been demonstrated." In the one case which they had dissected "the nerve-centres and the nerve-trunks were perfectly normal." Because no nerve-lesion was detected in this case it

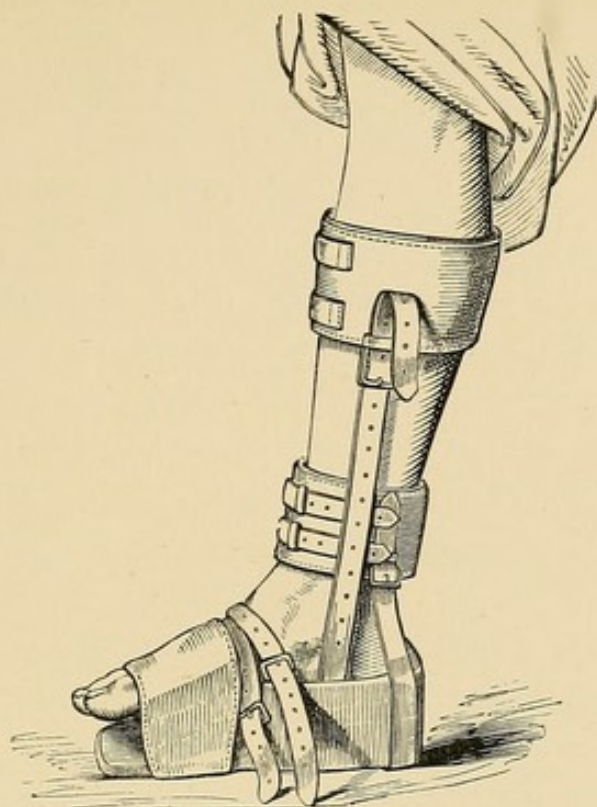
does not follow that none existed, nor does it prove that other cases would fail to show any morbid changes in the spinal cord. Functional disturbance of the cerebro-spinal system may be due to the most trifling cause, such as vascular engorgement or slight effusion into the neurilemma. A few of the multipolar cells or conducting fibres may have become disorganised, and yet the highest powers of the microscope, and a laborious sectionalising of every inch of the spinal cord would fail to unravel the mystery of such a trifling disturbance. The effect, however, upon the distal fibres of the implicated nerve may be very pronounced, and the observer cannot be blamed for his failure to discover any pathological lesion.

The argument that the feet of infants naturally fall into the equino-varus condition would support the idea of a multiple causation, such as I am advocating.

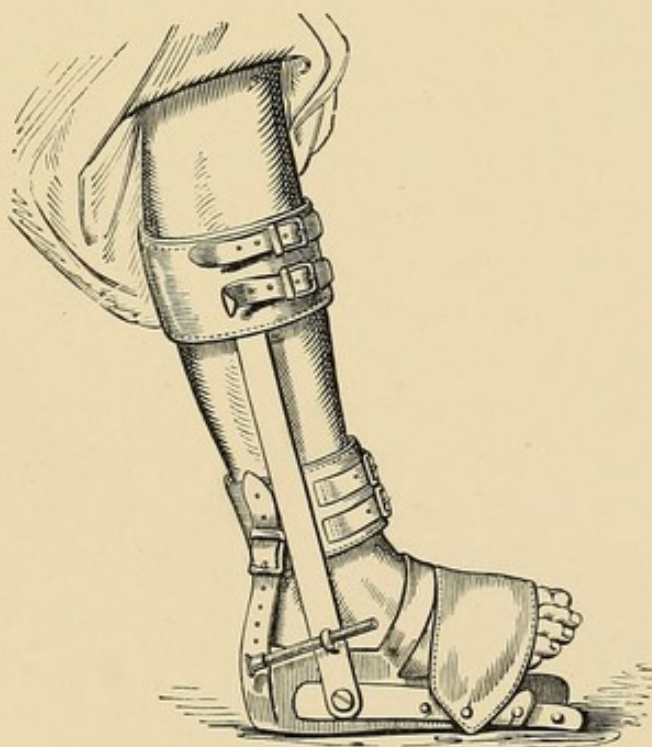
Flexion of the foot upon the leg by the action of the gastrocnemius is as natural as flexion of the forearm upon the arm by the action of the biceps. I think it very important to lay considerable emphasis upon the direct action of the tendo Achillis to oppose in great measure the peroneal tendons, and so to invert the foot. We must never forget what a powerful double muscle we have in connection with this tendon, and how relatively small the opponent muscles are.

Finding the deformity to be due in most cases not only to some abnormal contraction of tendons or muscles, but to a corresponding malposition and imperfect development of bones and ligaments, I look upon the customary division of the constricting bands as but the first stage of a long process of forcible

manipulation of the distorted limb. It is to these latter stages that I attach prime importance. The temptation is great, from the pressure of private practice, to leave the after treatment to some qualified assistant or house surgeon. Or in other cases to put up the limb or the body in some complicated apparatus with numerous joints, pivots, straps, buckles, screws, &c., all designed to exert some specific control upon the distorted and crippled framework of the body. I must confess that I am a great enemy of the surgical appliance maker in the treatment of these cases—a business which, under the high-sounding title of orthopædic mechanic, is, I believe, very remunerative. Passive extension is simply absurd when you consider the strong counter forces which you have to contend with (*vide* the drawings giving two views of Little's shoe, as applied to the talipedic foot after division of tendons). I very seldom use a Scarpa's shoe or its modifications by Little, Adams, &c., for club-foot, or an expensive spinal apparatus for curvature of the spine. I recognise the fact that in each case the bony frame-work of the body is distorted, and nothing short of trained muscular force skilfully and repeatedly applied on the part of the surgeon will rectify these deformities; such rectification of the normal curves of the body to be permanently secured by the immediate application of a closely enveloping case of plaster of Paris with certain mechanical additions which I shall describe hereafter. The plaster of Paris case fitting like a mould into all the sinuosities and configurations of the body, forms a solid accurately fitting "external skeleton," accomplishing that which the bony frame-



Little's shoe applied. One view.



Little's shoe applied. Opposite view.



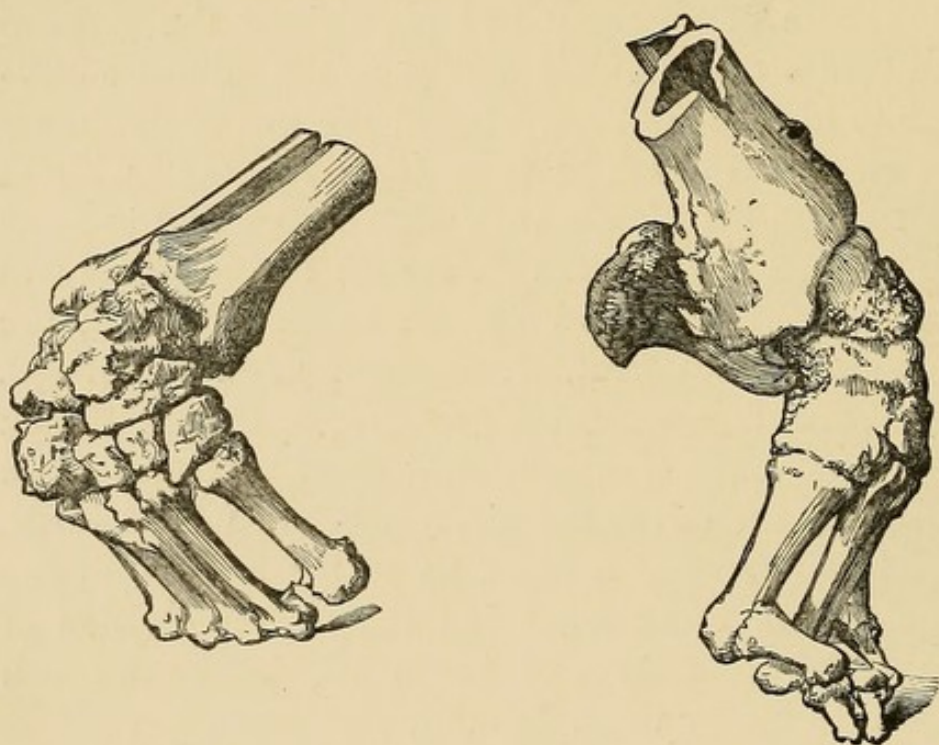
work was designed to do, but at present cannot. It also serves as a solid retentive apparatus, to conserve and support the soft tissues of the body during the period of growth and development of muscles and ligaments in their newly acquired positions as they are brought into serviceable action by the constant and careful tutelage of the surgeon. With an accurate knowledge of anatomy and physiology the surgeon can turn his mechanical genius to the utmost advantage to his little patient, without the risk of damaging the structures which he is manipulating, and without buoying up the friends with false hopes that in some unexplained fashion, the deformity of the bones and sinews will be rectified by the magic power of the orthopædic instrument, with its many screws and straps.

The drawings which I append (see next page), taken from Erichsen's '*Surgery*,' will show what extensive deformity there is of the tarsal bones in talipes varus, and how necessary it must be to persevere with the moulding of these bones in infancy after division of the faulty tendons and ligaments, before we can expect to rectify the deformity.

At the International Medical Congress held last year at Copenhagen, some of the foreign surgeons advocated the excision of the astragalus and cuboid bones to rectify the deformity. I have never seen cases requiring such severe measures, and I cannot think it at all necessary to make a permanent deformity of the limb and a stiff ankle, in order to restore the foot to its normal position in relation to the tibia.

Some well-known Scotch surgeons, who are great advocates of osteotomy for every deformity, spoke in

favour of this method of treating talipes, but their objections to tenotomy fell to the ground when they expressed approval of dividing the tendo Achillis in some cases. Still less can I approve of Davies Colley's operation for the removal of a wedge-shaped section of the tarsus in severe cases of club-foot, in-



cluding portions of the os calcis, cuboid, and cuneiform bones, except in the case of adults with ankylosis.

It is not necessary to repeat the directions which may be found in all systematic works on surgery, for the subcutaneous division of tendons in club-foot. The precautions necessary to avoid wounding important vessels and nerves, and to guard against making the skin wound too large, are also carefully defined in such treatises.

I would only add, as a precautionary measure, the desirability of so carefully padding the retracted tendon and fixing the foot in a splint, that movement for the first few days will be impossible. I do not find this sufficiently emphasised by authors. By doing this we prevent the subcutaneous oozing of blood, and gain all that we desire by a well-planned valvular incision.

I look upon the division of the faulty tendon as a condition precedent to rectification of the deformity. I therefore dissent from the opinions of many surgeons who have advocated as a first stage of the mechanical treatment, the eversion of the foot by the Scarpa's shoe, and then the division of the tendo Achillis. The shortening of the fibres of this tendon in many cases of talipes varus makes it impossible to evert the foot in a satisfactory manner, until after the division of the faulty tendon.

Mr. Adams, when advocating the eversion of the foot before the division of the tendo Achillis, says that "it must be accomplished gently and very gradually, the apparatus (Scarpa's shoe modified by Adams) being removed every other day, that undue pressure may be avoided." To intermit mechanical appliances "every other day" must not only be a great inconvenience, needless expense, and cause of delay, but it suggests a fault in Scarpa's apparatus, which Mr. Adams seems to admit, for he says:—"It cannot be matter of surprise that with great attention, and in competent hands, good results should follow the application of an ill adapted instrument" (p. 266). I am afraid I cannot endorse such a sanguine view

of an imperfect instrument. He then points out the relative advantages which he claims for his modification of this retentive apparatus.

I must not omit to add that Mr. Adams enumerates some objections to the Scarpa's shoe as an instrument for talipes varus. He says that "it is very apt to cause sloughs from undue pressure," and that "it exerts no influence over the rotation of the anterior portion of the foot" (p. 268).

Experiments on the lower animals have shown how unnecessary it is to keep the foot inclined towards the deformity after tenotomy, and our clinical observations have also confirmed this evidence by showing that we can rely upon a satisfactory renewal of attachments of the cut tendon in almost all cases.

In the treatment of these cases we must not only divide the rigid tendons and ligaments, but we must mould the bones into shape, and not forget to strengthen by friction and galvanism the elongated muscles on the opposite side, so that, by contracting, they may help to retain the foot in its proper position.

I do not attach much importance to the effort to obviate the retraction of the divided tendon, because it is certain to retract very forcibly within the sheath so soon as the tension is relieved by the division of the tendon. I think there must be in all such cases a well-defined space of at least half-an-inch between the cut surfaces of the tendon. However wide the gap may be, I always find in infants and young children a very satisfactory adhesion set up, and the formation of a new fibrous cord in place of the tendinous attachment to the bone.

This, I think, is mainly secured by the vascularity of the lining membrane of the sheath, which, being undivided and remaining in continuity with the bone, acts in the same way as the periosteum to restore the natural bond of union between the tendon and the bone.

Numerous dissections have been made to show how perfectly the tendons reunite, or rather become re-attached, after tenotomy. After placing the foot in its normal position, we are enabled to bring all the groups of muscles into active exercise, so that the balance of muscular power may be restored. From dissections and experiments which I made as a student for my graduation thesis upon the lower animals, for the purpose of determining the exact process of repair of wounds through arterial trunks, and their final closure or obliteration after ligature, I have no doubt that a somewhat similar process of repair takes place in divided tendons. I found that the terminal portion of artery below the ligature does not, as was supposed, necessarily slough and die, and so form a focus for the development of inflammatory mischief, as alleged by the advocates of acupressure; but that in many cases the strangulated end of artery becomes reorganised by becoming incorporated into the surrounding tissues. I find also that a fibrous blastema forms in that part of the sheath from which the divided tendon has retracted, and this bridges over the gap between the cut surfaces of the tendon. This blastema becoming consolidated, then organised from the surrounding vascular membrane, a new material is formed, which gradually assimilates itself to the

tendinous structure, and in this way the tendon is elongated and repaired.

Any admixture of inflammatory lymph and exudation cells must be regarded as a complication of the reparative process. The nuclei of the cells coalesce or become elongated, and form a fibrillar arrangement, the new material afterwards becoming organised and consolidated. The new tendinous material is thus firmly grafted on to the texture of the old tendon.

I quite agree with the generally received opinion as to the desirability of early operations in cases of congenital talipes. The more so, because of the necessity of ample and frequently repeated manipulation and moulding of the bones of the tarsus, so as to adjust them to the altered axis of the foot. With infants of a few weeks old, the operation being so simple and subcutaneous, may be done promptly and without chloroform if thought desirable. The interosseous ligaments will yield to the moulding process. Whereas if the operation is delayed, the surgeon finds that his efforts to rectify the deformity will be seriously limited by his power of manipulation. We must also remember that the bones of the tarsus, especially the large ones, will become ossified in the acquired position of deformity unless attempts are made to rectify it. In some extreme cases of talipes it may be necessary to divide the ligaments which bind the astragalus to the os calcis and to the navicular bone on the inner side of the foot. In making use of the various mechanical appliances which have been constructed at various times, with evident ingenuity, and introduced to public notice, it is necessary

to bear in mind that we have to treat the deformity as a whole, and to seek by the adjustment of a well-fitting apparatus to rectify the deformity which is manifest in every tissue of the foot. Consequently the cleverly designed straps, buckles, elastic bands, ball-and-socket joints, which have entered into the construction of most of these appliances, would cause undue pressure to impinge on one or more portions of the foot. The result of such adjustments is that the skin is very liable to slough just where the pressure is required. This condemnation would seem to apply to almost all the instruments that have been brought before our notice.

Talipes varus is by far the most frequent form of congenital deformity of the foot, and this is generally modified by elevation of the heel from the ground.

In *T. varus* the front of the foot is turned inwards and upwards. The sole of the foot looks backwards. Thus the inner border of the foot is turned upwards, and in children that are allowed to walk corns or callosities will form on the part where the pressure occurs. The foot being bent upon itself becomes foreshortened, and there is also some defective development of the bones of the tarsus. The navicular bone is displaced inwards, and the plantar fascia is firmly contracted upon itself. The anterior portion of the foot has some independent movement at the transverse tarsal joint, and so the unnatural curve and high arching of the foot may be in part rectified more effectually, by the use of the fixation apparatus elsewhere described, than by the use of a complicated apparatus requiring daily adjustment.

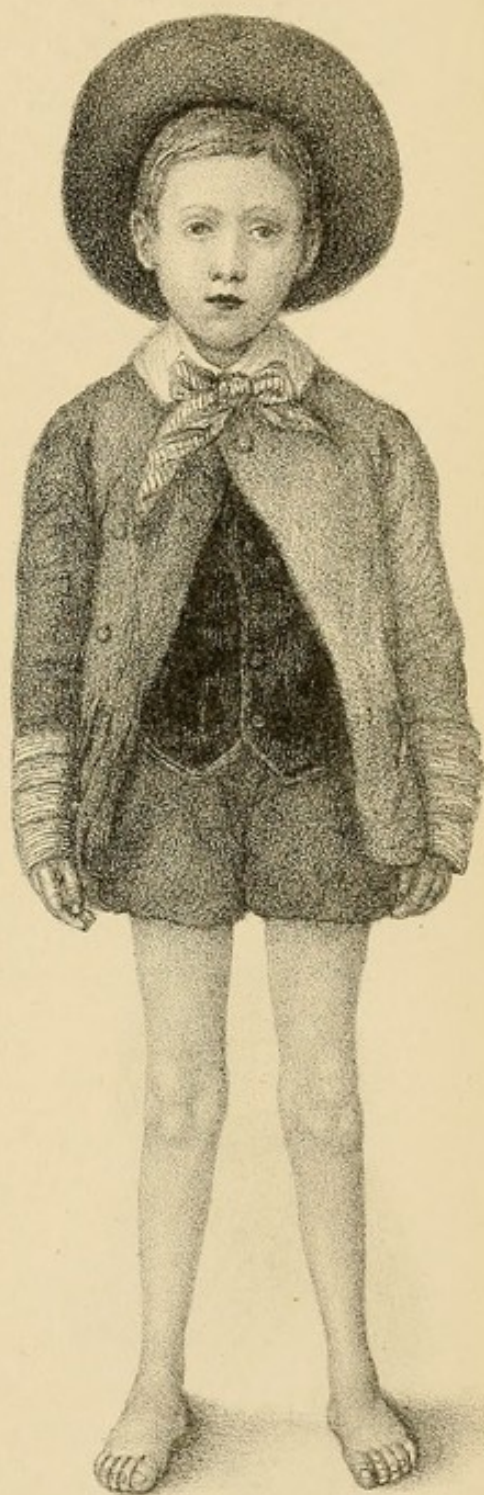
When we have what is called *T. equino-varus*, the *tendo Achillis* being the combined tendon of the great calf muscles, is that which is most at fault. This is a large solid tendon, inserted into the back part of the *os calcis* by a broad attachment of fibres which are compacted together from the calf. Fortunately the tendon may be brought out prominently in relief by extending the foot, when it will be felt as a tense band subcutaneously above the heel. In the treatment of this deformity it will be necessary to divide the tendon, and thus to bring down the heel. The patient should be laid flat on the bed and the heel raised. The surgeon grasps the foot and extends it forcibly. He then inserts the tenotomy knife with its thin narrow blade underneath the tense prominent tendon, close to and parallel with its inner edge, taking care to avoid the posterior tibial artery which passes behind the inner ankle. Turning the sharp edge towards the tendon, with a gentle sawing motion he divides the tense fibres, without opening up the sheath or the investing membrane which covers the tendon.

The after treatment of these cases is what we find so important in order to secure beneficial results.


The surgeon must persevere for months with the moulding of bones and friction of muscles and also the renewal at regular intervals of the fixation apparatus. The reason why cases so often relapse is because parents have not been sufficiently careful to continue the treatment until all the deformity has been rectified, and the several tendons brought into action in the newly acquired position of the foot,



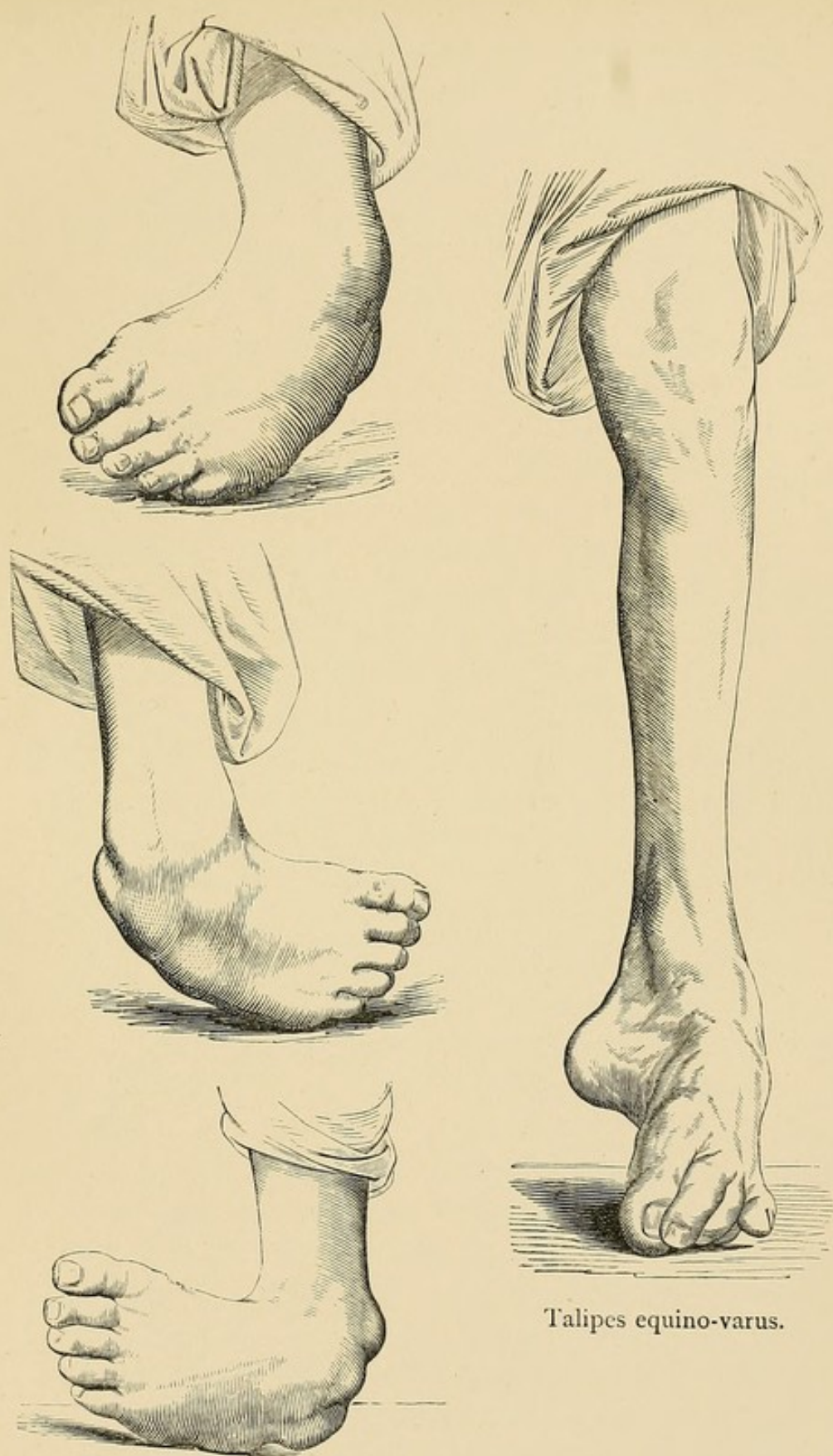
E. Burgess lith.



West, Newman & Co. imp.




TALIPES VARUS.



Talipes equino-varus.

Three grades of Talipes varus.



especially when, as usual, there is a partially paralysed condition on the opposite side to the deformity.

I think it is very seldom that we require to divide the tibial tendons in infants, because these will stretch considerably by the use of the retentive fixation apparatus. In extreme cases, not only must the tibial tendons be divided, but the long flexor tendons, and also the fascia which prevents expansion of the foot to its proper dimensions. Orthopedic surgeons are, I think, too inclined to classify the respective deformities, and to associate contraction of the tendo Achillis with equinus deformity only.

We must not fail to remember the peculiar formation of the foot. There is a partial absence of relative symmetry between the respective parts of the foot, and particularly is this seen in the attachment of the tendo Achillis. Though, of course, the primary action of this tendon is to raise the heel, yet so soon as this is done the strong inner fibres, which are attached by a broad base to the head of the os calcis, draw the foot inwards, so that the varus deformity is almost entirely produced or maintained by the inner fibres of this tendon.

I do not believe in "irons" for children suffering from these or any other deformities. They are much too cumbersome, and to be of any use they must cripple the child more than when he is without such appendages. It is absurd to see children going about with irons and crutches at the same time. Some few cases of weak ankles I have seen benefited by the careful application of jointed irons well made to fit the child. When parents suggest to me, as they

often do, the use of "irons," I generally tell them to spend the money more profitably upon putting "iron" inside the body rather than outside.

In talipes varus Mr. Adams describes the morbid anatomy of the bones as follows:—"The os calcis is altered in position, being drawn up by the action of the calf muscles. It is also slightly arched inwards in severe cases. The astragalus is partly displaced from the socket. The upper articular facet is pressed up so as to appear on the dorsum of the foot. The lateral facets are partially protruded from the joint. The bone appears in extreme cases twisted upon itself, with an oblique inclination of the body of the bone. The back of the astragalus is narrow and wedge-shaped, the navicular bone being drawn upwards."

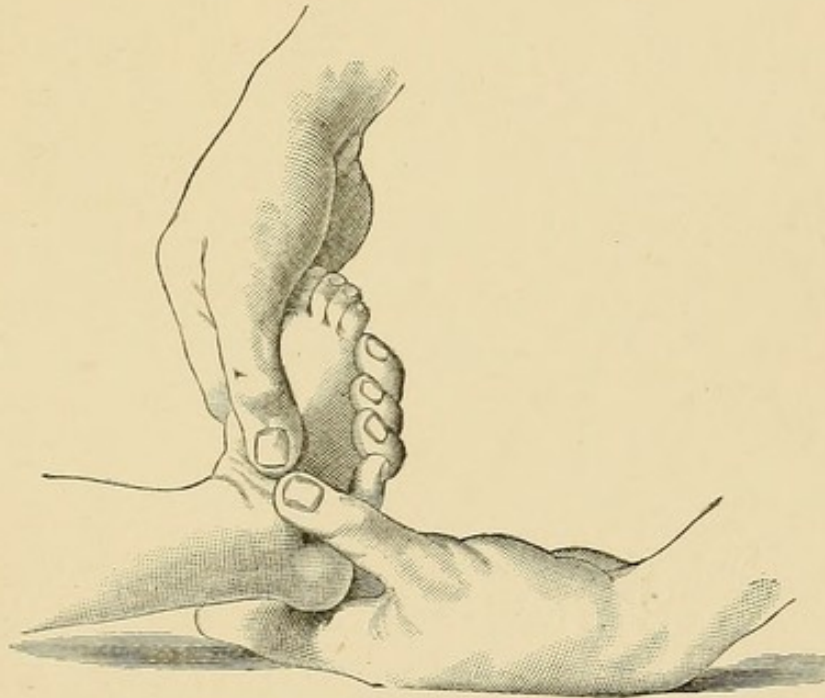
I do not at all agree with many writers on orthopedic surgery who say that we must rectify the varus deformity before dividing the tendo Achillis. We must not forget that though the muscles corresponding to the faulty tendons should atrophy and the attachments of the tendon be imperfect, we have the deeper muscles to rely upon for effecting most of the movements required, and although the results may not appear equally promising in all cases, we generally have a useful limb ultimately. No doubt much depends upon early operations. I have observed considerable wasting of the calf muscles, from division of the tendo Achillis for club-foot, of children that are advanced in years.

The method of applying my fixation apparatus for club-foot is as follows:—

The foot is first carefully and powerfully manipu-

lated, the ligaments stretched, and the bones moulded as much as possible to the correct position.

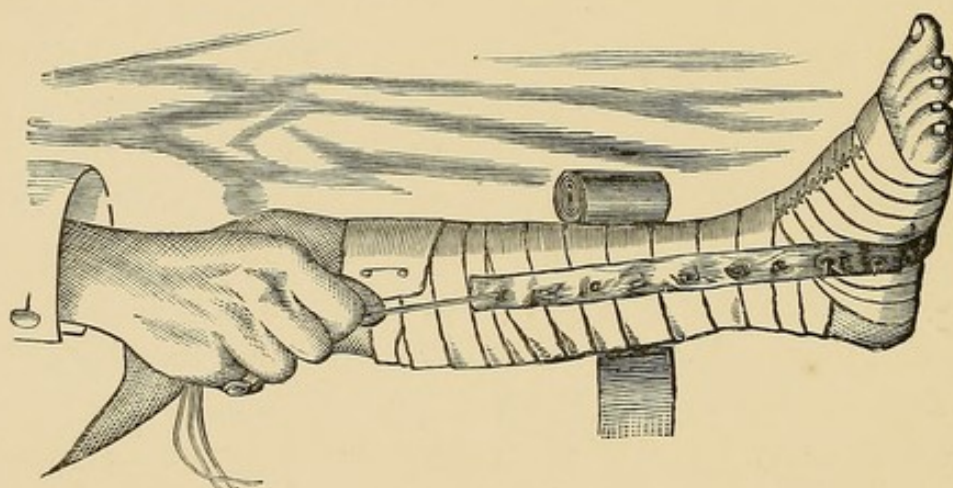
A circle of webbing is fixed with letter clips round the foot, a strip of thick tin about one inch wide is perforated so as to have jagged edges on both sides. It is then bent at right angles, the short arm of which goes across the sole of the foot,



level with the joint of the great toe, and is clipped to the webbing previously applied over the flannel bandage. The long arm goes more than half-way up the leg, and to the end of this arm a piece of string is attached. By pulling the string the foot is levered into a proper position, and is easily kept so by a plaster of Paris bandage applied while the extension

is being kept up. The muslin clings to the jagged edges and perforations in the tin, and holds the foot with a firm grip. The flannel bandage must of course be previously applied to the foot, ankle, and leg, and the jagged perforations of the tin will then cling to the flannel so as to prevent rotation of the limb within the case.

The child may be allowed to walk about with this



encasement, after it is properly set. In this way the astragalus and os calcis will be further moulded into the proper position by the weight of the body. Should the plaster of Paris break away, a new case must be applied after carefully moulding the tarsal bones as before.

One of the direct and most serviceable advantages of this retentive apparatus over that of Scarpa's shoe is that the tendency to flat-foot so often observed after prolonged use of the shoe does not follow in these cases, because the short arm of the tin is constantly pressing up the arch of the foot.

In valgus cases the fixation apparatus is the same, but the tin must be applied to the inner side of the foot and leg, so as to invert the foot and stretch the peronei and extensor muscles of the leg. The arch of the foot is generally so much collapsed that the child walks upon the inner side, and in addition to the tin, I generally recommend a sausage-shaped pad, made so firm that the weight of the body will not materially compress it in walking, and this is placed across the sole of the foot, so that the tarsal and metatarsal bones shall be raised gradually into their normal position, and the arch of the foot be restored by centre compression and corresponding depression of the distal ends of the metatarsal bones.

In modified cases, where there is simply relaxation of the internal lateral ligament and flat-foot, the sausage pad with a spica bandage of plaster of Paris around the ankle will suffice.

Non-congenital talipes varus occurs much less frequently as a deformity than the congenital variety. It is generally caused by some paralysis of the opponent muscles in infancy during the teething period. In these cases the foot is usually cold and flabby from feeble circulation of the blood. The aspect of the limb is different from that of the congenital variety, because the condition of the bones is normal. The foot, instead of being forcibly drawn upon itself in a radiating manner, is inverted *en masse* at a rectangular plane with the leg, and the distortion increases with the superimposed weight of the body in walking. In consequence of the deformity being positional and not structural, the rectification of the foot to its

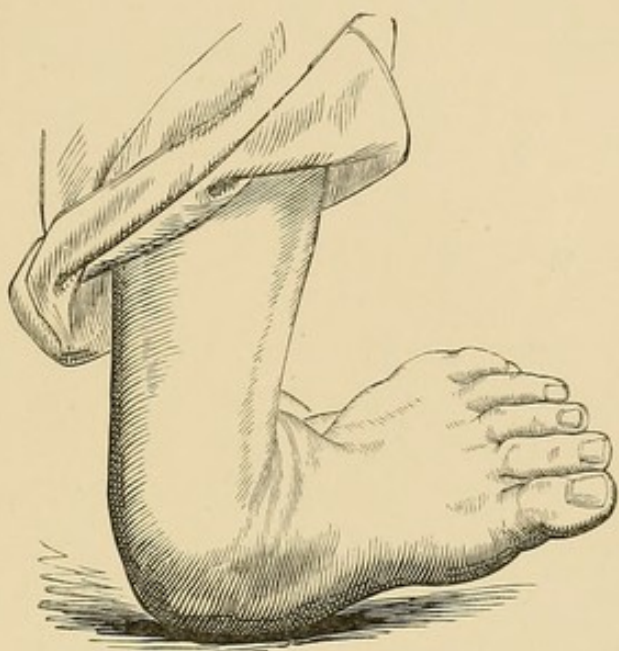
proper position after division of the tendons is a much simpler affair. The after-treatment will require probably more care, on account of the paralytic condition of the muscles, which sometimes undergo fatty degeneration, and also because the soft tissues and the ankle-joint are much more lax, and the foot easily returns to the position of deformity.

The extensor muscles may be paralysed, and then the toes are flattened out and sprayed. In spasmodic cases the toes are drawn back, and curled upon the sole of the foot. The patient in walking often damages the toes, and causes excoriations or corns upon the points of acquired pressure.

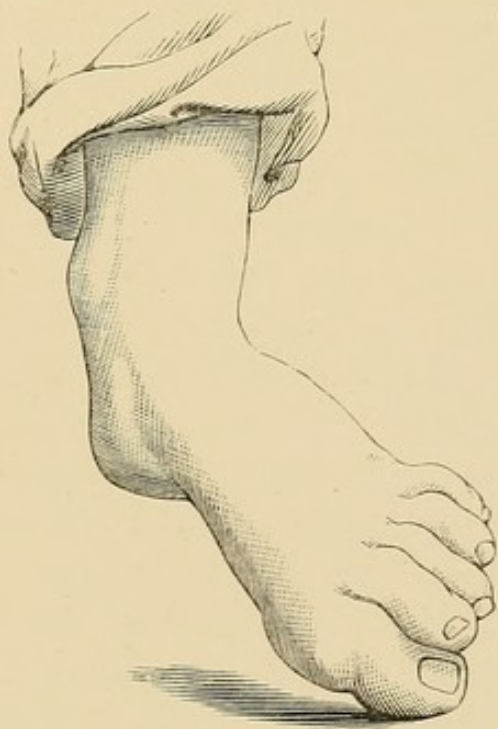In talipes equino-varus we have a very similar condition, only it is associated with some inversion of the foot caused by a firm contraction of the tibial tendons, so that the navicular and cuboid bones become displaced inwards. It may be necessary to divide the tibial tendons in this deformity, but no rule can be laid down as the cases vary so much. The calcaneo-cuboid ligament is often firmly contracted, and requires to be divided in order to liberate the anterior portion of the foot, which is bent upon itself at the transverse tarsal joint.

Talipes valgus occurs less frequently in children than that of varus, being seldom found as a congenital deformity. With it we have not only eversion of the foot and relaxation of the internal lateral ligament, but generally a collapse of the arch of the foot, so that the patient walks flat upon the ground, without any spring—his gait resembling the “clod-hopper” style of the rough country boy who follows the plough.

TALIPES VALGUS.



Congenital.



Acquired.



The patient scuffles along without properly lifting his feet, the toes are unduly everted, the foot is abducted and rotated outwards, and there is not the flexibility of the ankle in walking, that betokens the elegant pedestrian, although the foot itself is abnormally weak and supple. The inner margin of the foot is markedly depressed towards the ground by the partial or total obliteration of the longitudinal and transverse arches of the foot. Porters at the docks accustomed to carry very heavy weights frequently suffer from this deformity. The pain caused by pressure upon the nerves incapacitates them for work, and walking is very irksome. Hence the importance of prompt treatment. In extreme cases of talipes valgus it will be necessary to divide the faulty peronei tendons. The tendo Achillis is not generally involved. It may be contracted with elevation of the os calcis or not. If the heel is decidedly raised from the ground with considerable deformity, we may term this variety equino-valgus, and then will arise the question as to the necessity of dividing the tendo Achillis. There is very little deformity of the bones in this form of talipes, though the ligaments are decidedly elongated and lax, and defective in their structural character.

In extreme cases it may be necessary to divide the peroneal tendons, and also the extensor longus tendons. The majority of cases will yield to the mechanical treatment when it is carefully and continuously applied for some months.

The perforated tin or iron splint, and the plaster of Paris bandage exercise a very strong controlling influence over this form of club-foot. Sometimes one

or two straight wooden splints fixed to the leg and foot, with or without a foot-piece, may best provide for the inversion of the foot.

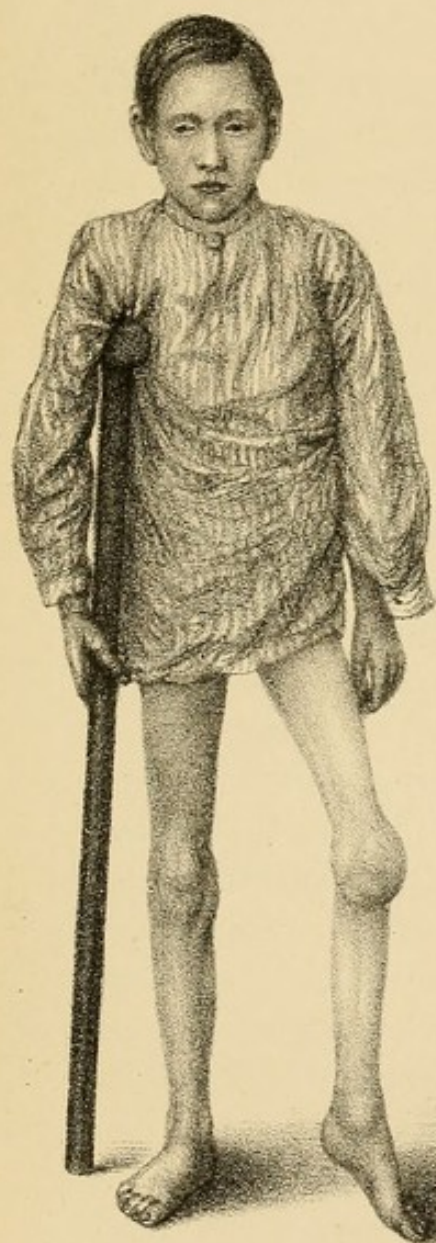T. valgus often follows upon deformity of some other joint of the leg, as, for example, knock-knee, the effect of which is to throw the foot out and incline the tibia away from the proper axis of the limb. The relaxation of the internal lateral ligament of the knee, and the enlargement of the inner condyle of femur in consequence of the weight of the body falling upon the external condyle chiefly, will cause the leg to incline obliquely outwards, and so force the foot into a valgus position.

This also may happen when there is strumous degeneration of the knee-joint with backward displacement of the tibia, because the inner condyle is often more infiltrated with pulpy degenerative material than the outer. (See lithograph.)

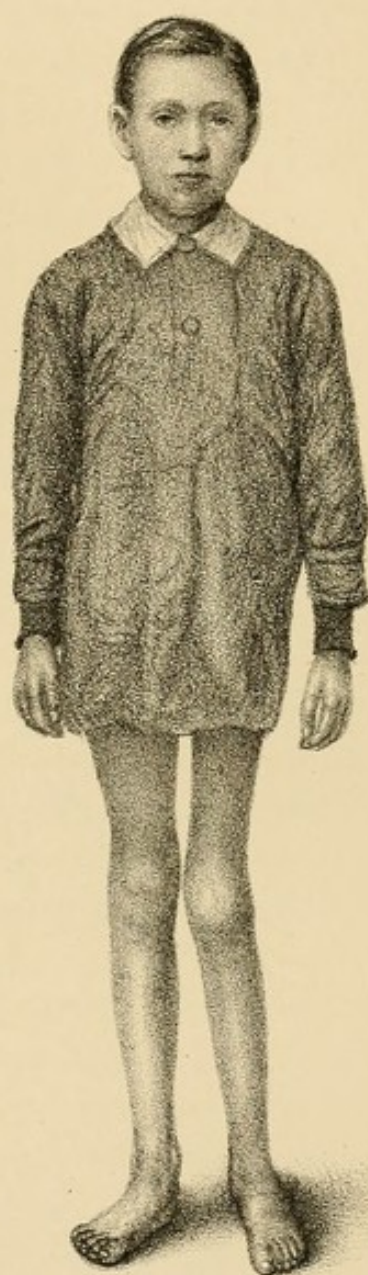
It is often also a concomitant of hip-joint disease. The patient swings the leg so as to put the chief weight of the body upon the sound leg, and then the foot becomes everted and depressed.

Rickety deformity of the tibia is frequently associated with laxity of joint structures, and so the superimposed weight of the body determines a valgus deformity.


Flat-foot with little or no contraction of the tendo Achillis, is a very frequent deformity among young girls growing apace, without consequent correlative consolidation of bones and ligaments to support the increased weight of the body. Such children have perhaps been brought up with unhealthy surround-



E. Burgess lith.



West, Newman & Co. imp.



ings, a deficiency of light, air, and nourishing food. They are compelled to assist in the house work, to carry heavy weights, as for example pails of water or coals, and no wonder that in these non-congenital varieties the foot sprays out, and the arch yields to the superincumbent weight. The child, that is growing out of its clothes so rapidly, is also growing into all manner of awkwardnesses in posture and deportment.

In consequence of the depression of the inner ankle, which now becomes very prominent and almost touches the ground, the parents sometimes assume that their child is double-jointed.

In the valgus deformity as distinguished from varus there is often considerable pain in walking, so that the child in time finds it impossible to walk on the flattened foot. Non-congenital valgus usually affects both feet.

There is always considerable muscular weakness in these cases. The child is pale, delicate looking, and what is called "overgrown," like a plant that is grown away from the light.

In children, the subject of rickets, we usually find very lax ankle joints and flat-foot. If the case is treated early, and the bones fairly consolidated before the child attempts to walk, the flat-foot may be overcome. But in all such cases it will be necessary to persevere with the treatment for some months, to prevent this troublesome deformity becoming persistent. The same remarks apply to the treatment of valgus when it is dependent upon early infantile paralysis. By galvanising the muscles and applying friction to the joints, with tonic treatment internally, we may rectify

the deformity before it becomes too late. Valgus may result from commencing disease of the ankle-joint, the child walking on the outer side of the foot to avoid pressure upon the tibial articulation.

Flat-foot is found of frequent occurrence in delicate children of rapid growth. The ligaments which bind the bones together on all sides become lax, and the double arch which gives an elegant spring in walking collapses, and so the child walks upon a broadened-out flat sole, and as the nerves and vessels are distributed through this normal arch of the foot, and become unduly pressed upon in walking, the child complains often of pain and tenderness. The loss of spring in the foot makes him soon tired, and he walks in a slovenly slip-shod way. I find it necessary to treat these cases both locally and constitutionally. I place across the sole a firm pad, that will not yield much to the pressure from above. I strap this on with several "figure-of-8" turns round the instep, and also approximate the metatarsal bones to the os calcis by the use of firm strapping, or plaster of Paris bandage. The child is allowed to walk under a regulated system of daily exercise, so that the arch is forced up by the pressure of the pad, and the tarsal bones come into their proper relation to the heel. With careful dieting and tonic treatment the ligaments become consolidated and considerable improvement is the result. But the parents must consent to several months of persistent treatment. It is easier to destroy an arch provided by nature than to restore it. The surgeon has to struggle against an effort to perpetuate the collapse of the

arch, by the continuous weight of the body favouring a condition of flat-foot. When the deformity is of an extreme character we generally have some valgus associated with it. That is to say, when the longitudinal arch of the foot, which is almost entirely on the inner side of the foot, collapses, the outer part of the foot everts, and the external lateral ligament which binds the astragalus and os calcis to the tibia becomes stretched, and we have the child walking sometimes, so that the tibia very nearly reaches the ground. In these cases it is necessary to apply splints to the ankle and leg, and to fix them with plaster of Paris bandage, and to press on the tonic treatment. We seldom require to divide the peroneal tendons.

Talipes equinus, so called because it resembles somewhat the foot of a horse, the heel being raised and the body resting upon the toes and metatarsal bones. The foot itself becomes distorted, and the plantar arch increased. The articulating surface of the astragalus is felt subcutaneously, and very prominent on the dorsum of the foot.

T. equinus is, as a rule, a non-congenital deformity. Very slight contraction or rigidity of the tendo Achillis, accompanied by lameness, may first direct the attention of friends to this deformity, which, if neglected, may become more marked, the heel being raised from the ground.

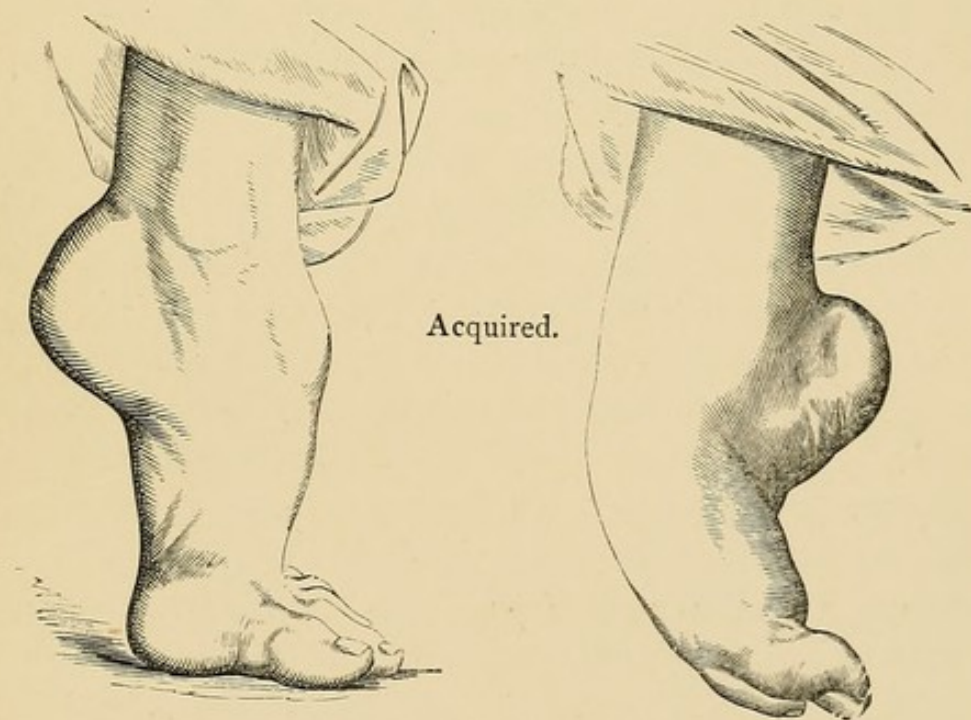
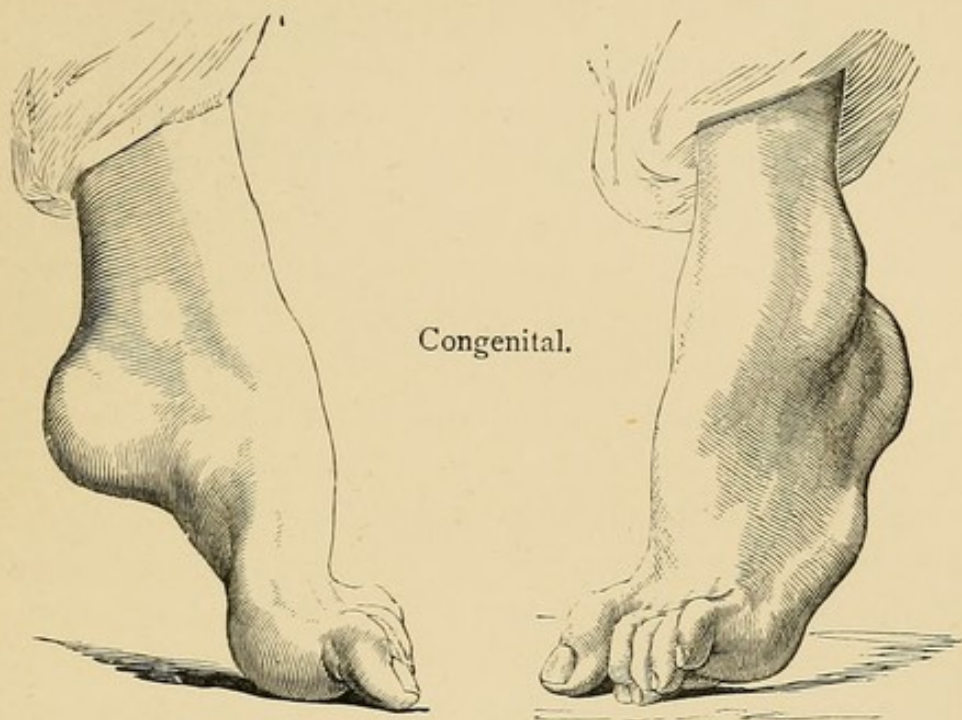
To test the amount of flexion of the ankle-joint, place the child in a bed or on a couch and move the foot up and down. Also notice the range of movement possessed by the patient. We must always

remember that infants, in consequence of the undeveloped state of the gastrocnemius muscle, have a wide range of movement at the ankle-joint, so that in many cases the toes may be made to touch the tibia. When the muscles are well developed the foot can seldom be raised beyond a right angle with the leg. Not only do corns form on the prominent parts of the foot subject to pressure, but the child may acquire a distorted condition of the spine in consequence of walking awkwardly. No doubt in many of these cases the distortion is due, in great measure, to the firm contraction of all the flexor muscles upon the metatarsal bones, causing a bending downwards of the anterior portion of the foot, and a relaxation of the transverse tarsal articulation, so that besides a partial raising of the os calcis by the contraction of the tendo Achillis, the equinus condition is produced to a great extent by the sloping of the metatarsal bones. The ligaments which bind the astragalus to the scaphoid and cuboid bones are considerably elongated.

Mr. Adams gives a table of 1780 cases of deformities of the foot, of congenital and non-congenital origin. Of these, 1016 were tabulated as of non-congenital origin. T. equinus took the lead, with 401 cases; then T. valgus, with 181 cases; next, T. equino-varus, 162; T. calcaneus, 110; T. equino-valgus, 80; T. varus, 60 cases.

The causes of this deformity are various, but chiefly unbalanced spasm of groups of muscles from paresis of the extensors of the leg. There are also traumatic causes, as, for example, wounds of the calf muscles,

TALIPES EQUINUS.



Talipes equinus without paralysis.

Talipes equinus with paralysis.



abscesses of strumous origin of the leg, ankylosis of joint-structures, the result of inflammation in or around the joint. When, as often happens, the plantar fascia is contracted, as well as the tendo Achillis, it will be desirable to delay the division of this until after the healing of the divided tendon. In other cases it will suffice to divide the plantar fascia, and not the Achilles tendon.

When the toes are doubled round upon the sole of the foot, or reflected back by tendinous contraction on to the dorsum of the foot, it may be necessary to divide the implicated tendons, so as to rectify their position. It may be that careful bandaging, and extension with the perforated tin arrangement will suffice.

It is desirable to divide the tendo Achillis in all cases of *T. equinus* where the contraction cannot be overcome by a suitable appliance. When the anterior muscles are paralysed or weak, it will still be well to divide the tendon, so as to rectify the malposition of the foot. By so doing, we raise the foot and place it in a position for the anterior muscles to contract.

In *talipes equinus*, Mr. Adams agrees in considering that it is useless to try mechanical treatment alone, except in cases of very slight and recent contraction. It is necessary to combine with these active and passive exercises.

Talipes calcaneus is a much rarer form of deformity, especially in the non-congenital variety. In these cases, the toes are raised from the ground, the heel depressed, so that the child walks upon the heel, the foot being flexed upon the leg by the constricting action of the anterior muscles. Congenital cases are found where

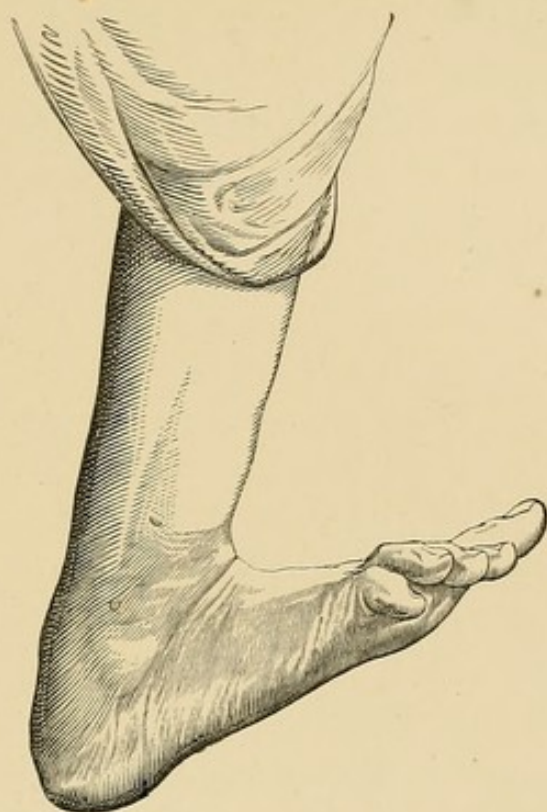the legs have been cramped, and doubled up in utero, as in breech presentations. The muscles which cause the deformity are the long extensors and the tibialis anticus.

These cases sometimes undergo spontaneous cure by the pressure of the superincumbent weight of the body, and the natural inclination to point the toes. As the calf muscles, which are usually very strong, develop with the growth of the body, the heel becomes raised and the foot depressed. Much may be done in these cases by resorting to gentle friction of the muscles of the calf. There is not usually much rigidity, so that with perseverance we may often succeed in rectifying the deformity without operative interference. The paralysed muscles may be stimulated to proper action by friction and galvanism. The fixation apparatus may be applied to the back of the leg and sole of the foot, so as to point the toes and depress the anterior part of the foot. In extreme cases, a grooved splint with a foot-piece made of tin, may be applied to the anterior part of the foot, so as to extend the foot at the ankle. If the tendons are at fault and rigidly contracted, we must of course resort to tenotomy before applying the splint.

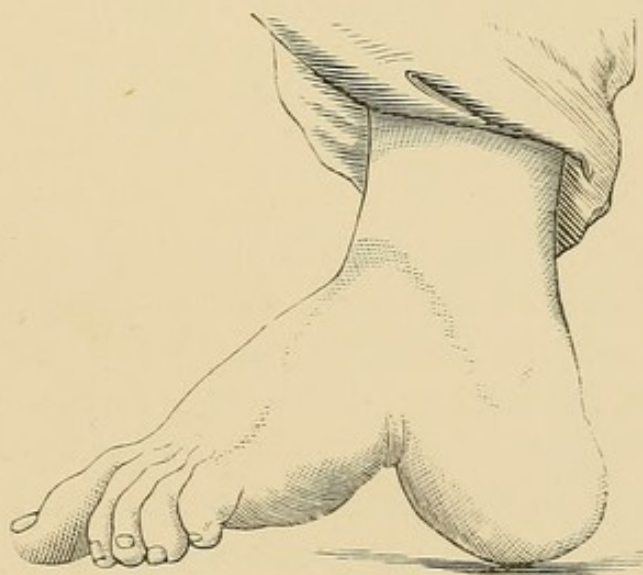Non-congenital cases being the result usually of confirmed paralysis of the sural muscles, the treatment of this condition is not so simple. The plantar fascia is usually much contracted transversely, so that the tuberosity of the os calcis and metatarsal bones are approximated.

In the treatment of these cases we must remember that wasting and palsy of the calf muscles is a condi-

TALIPES CALCANEUS.



Congenital.



Acquired.



tion which we can only hope to remedy by a course of tonic treatment and galvanism to the paralysed muscles. I have had no experience of the method lately introduced of excising an oblique segment of the elongated tendo Achillis and then splicing the two ends with kangaroo tendon. It would appear to me, judging from the descriptions given of the details of the operation and its results, that "*le jeu ne vaut pas la chandelle*," especially in a muscle that is deficient in vital energy. When we have undue length of a tendon, that does not, I think, justify excision of a segment. We know how nature will accommodate herself to the altered posture of a limb. Wherever there is redundancy of muscular or tendinous tissue the fibres will gradually contract, and the wavy tendon will retract within its sheath. I have seen attempts to cure varus deformity by excising a portion of the redundant skin over the outer ankle. This I consider a most unscientific method of getting rid of redundant tissue. I prefer rectification of posture, then compression and stimulation, which must lead to ultimate absorption of the excess of tissue.

It may happen that the calcanean deformity is the consequence of mismanagement of a case of tenotomy or talipes equinus, so that the tendo Achillis fails to obtain a fresh link of attachment to the os calcis after division. Or there may be a constitutional debility, rendering the reparative process ineffectual. It often follows upon infantile paralysis at the teething period.

Non-congenital deformities of the foot may arise

from some definite derangement of the nervous system, causing partial or complete paralysis of certain groups of muscles, so that the antagonistic muscles acquire undue power, and so draw up the foot in the direction of their contractile power. In other cases we have central irritation of the nervous system, as in sclerosis of the spinal cord, which gives rise to various spastic distortions of a more or less sudden character, such spastic contractions being especially manifested during any attempt to excite motor action in the unbalanced muscles, as for example in the usual clinical methods of testing reflex action. In all these cases the deformity is not so pronounced as in congenital cases, and as soon as the spasm relaxes the foot returns, to some extent, to its normal position. Except in long-standing cases where the adductors, for example, have acquired a very firm unyielding contraction so that the thighs become fixed and the joints rigid.

I am constantly having cases of a modified condition of club-foot, or spasm of groups of muscles brought to me, and the parents are much discomfited because the child will not display the deformity when told to parade for observation.

It is much the same with cases of local choreic *spasms of groups of muscles*. It is well known that chorea or St. Vitus's dance is a very prevalent complaint with young girls between the ages of six and fifteen, and is rarely seen in boys. This disease is generally much exaggerated under the influence of emotion.

A case of this sort came under my care recently presenting some very interesting points for diagnosis.

A pale, fair-complexioned child, with bright auburn hair and very transparent skin, of seven years of age, was sent to me by my friend Dr. Pearson of Kensington. The child had aroused considerable interest in her case, in consequence of her plaintive helpless condition when these spasmodic attacks occurred. When unrestrained she always managed to draw her legs up with her knees to the chin, and any attempt to rectify this position was followed by extreme excitement, and expression of intense pain referable to the knees and ankles. The child walked very cautiously on her toes, and seemed very feeble; she had very pronounced lordosis under excitement, almost amounting to opisthotonos. Sometimes she complained of pain in one leg, and sometimes in the other. By a little moral and firm persuasion she would allow the surgeon to move the joints slightly without resistance. There was no real rigidity of any of the joints, or contraction of tendons. There was, however, evidently some amount of enlargement of the great trochanter on the left side, which aroused my suspicions and prevented me from determining the case as that of a malingerer.

The child was put under chloroform, and the legs then became quite straight without any forcing. She was put up with a Bryant's splint, and after a few days' rest in bed she was set to walk, and could get along fairly well with assistance, though very tremblingly.

The child was dirty in her habits, and had probably been brought up with very bad home influences.

I had the patient put up with double spica flannel bandages from ankles to axillæ. I then applied my

perforated tin splints on both sides, encasing them in plaster of Paris bandages from the axillæ downwards, so arranged that she would have free use of the feet, and could get about fairly well, notwithstanding the solid investment of both knees and hips.

She was sent down to Margate to restore her general health, and she came back looking very much better.

I removed the apparatus and found that she could walk and run about without any pain or discomfort. I can only account for the enlargement of the great trochanter as traceable to some fall that she may have had in infancy, and being a strumous child the contusion of the bone, which would have vanished in a healthy child, set up a dormant osteitis, and remained as a kind of nest-egg for future trouble.

When we have non-congenital cases of talipes in children associated with some spasmodic or paralytic affection of muscles or groups of muscles, the foot is distorted from unbalanced action of the flexors, the extensor muscles being partially or wholly paralysed. In many of these cases the child is subject to fits, or has some mental aberration, imbecility, &c. The condition of spastic contraction of the calf muscles varies, but the feet are usually raised at the heel, and the child scuffles along on its toes with stiffened and flexed knees, and is very prone to tumble about. The muscles may atrophy, but so long as the child gets about, the nutrition of the muscle keeps up. In some cases, however, in consequence of the constitutional delicacy, the muscles not only waste, but undergo fatty degeneration. Sometimes we have a condition

of valgus and extreme wasting of the limb from some early damage to the hip joint and the sciatic nerve. Infantile convulsions may set up varying conditions of foot deformity and paralysis.

In all such cases it becomes important to decide upon the value of operative interference. No doubt these deformities are not so simply managed as the uncomplicated congenital talipes, for in such we have simply to treat a local deformity induced apparently, for the most part, by a local cause. Where, however, we have to treat a limb which is deformed in consequence of paralysis or irregular spastic action of groups of muscles, we must carefully consider the benefit to be derived from a division of the faulty tendons. I think that in extreme cases the foot is placed in such an awkward position and the deformity is so unsightly that it is expedient to divide the tense bands of fascia and tendons, so that the foot may be brought down to a position corresponding to that of the other leg, if only for the sake of symmetry. Generally, however, the liberation of the foot by tenotomy will give freedom to the opponent muscles to contract, and if stimulated by galvanism, friction, etc., we may in time get some movement of these muscles and power developed in them so as to counteract the drawing up of the foot again into a distorted position. In imbecile cases where there is much distributed spasm and tension of muscular action, and in epileptic cases, it is necessary to treat the case also on constitutional principles. The result of freeing the ankle may reveal a loose and imperfect condition of the joint, so that there is no power for putting any weight

upon it. In all these cases it is well to try the effect of inunction of warm oil and opiate liniment with an attempt to strengthen the nervous system by providing change of air to the seaside, and only in extreme cases of distortion to resort to operative measures. I have had some very successful cases of spastic action of the calf muscles where the heel was slightly raised from the ground, by bandaging the foot upon a stirrup splint and forcibly stretching the tendons so as to bring the heel down to its proper position, and keeping up the extension by the use of carefully adjusted appliances.

Congenital displacement of toe on to the dorsum of the foot sometimes requires treatment. In such cases it will be necessary to examine the deformity with a view to the removal of so much as is likely to be an impediment in walking.


Occasionally we have deformities of the foot coming under treatment for congenital deficiency or excess, as, for example, when we have supernumerary toes, or only three or four toes.

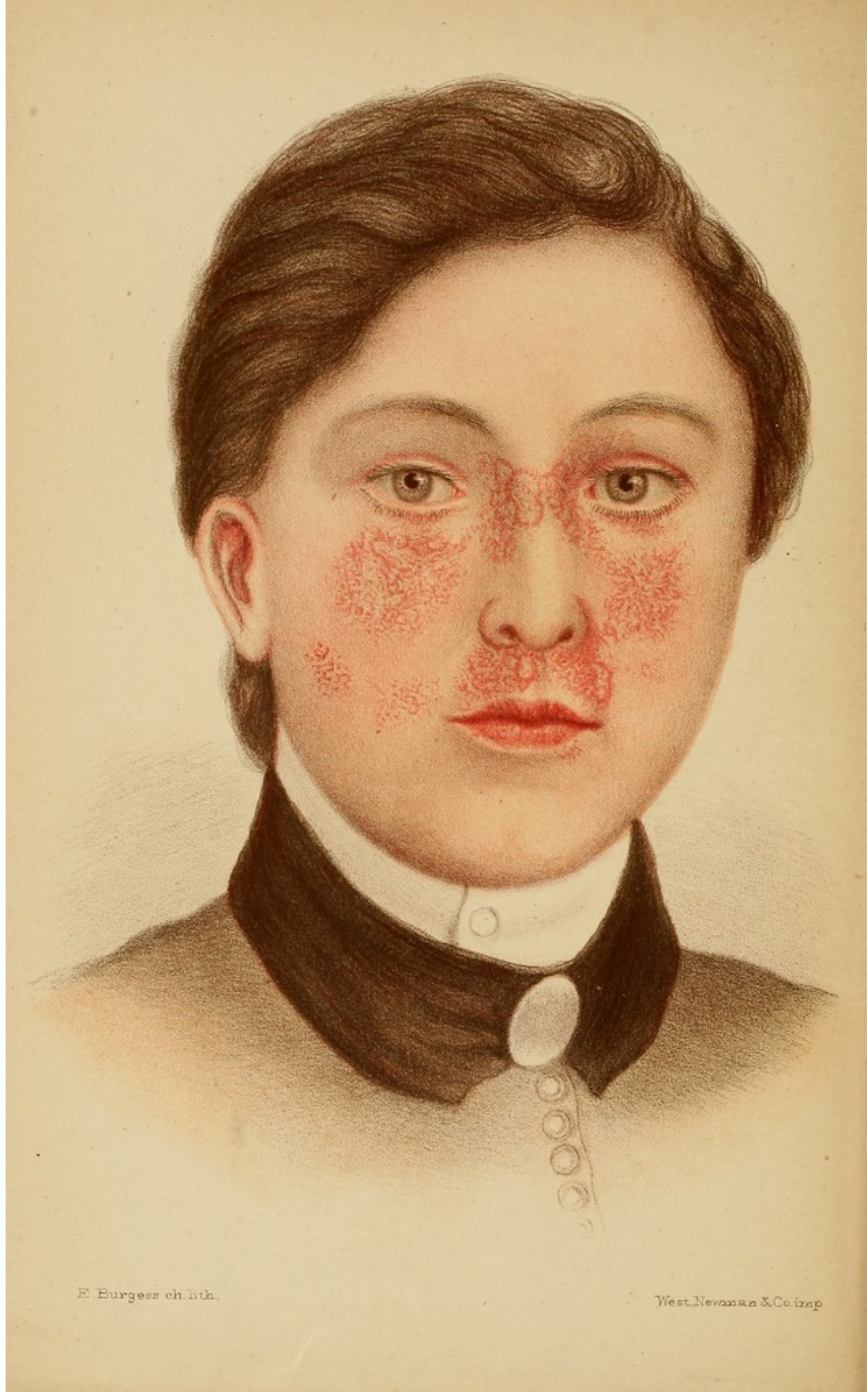
Webbed toes, like webbed fingers, sometimes come to the Hospital for treatment. It is of much less importance to the comfort and freedom of motion of the foot to divide the web between adjacent toes, than in the case of the membranous union of fingers. The division may, however, be accomplished with comparative ease, and it suffices to satisfy the parents if we divide the toes, and remove that which may be considered an unsightly deformity. The union is generally very close, so that the adjacent nails almost touch one another, and this makes it somewhat awk-

ward to separate the toes, because there is a deficiency of skin to cover in the spaces between them, and so the healing process is sometimes retarded by the slow formation of cicatricial tissue. I do not care for the method of dissecting the skin from the dorsum of one toe and applying it to the lateral aspect of the adjacent toe after division of the septum.

Supernumerary toes may be amputated if the surgeon is convinced that the impediment to the child is sufficient to interfere with his powers of walking, or if they should necessitate the use of specially made boots.

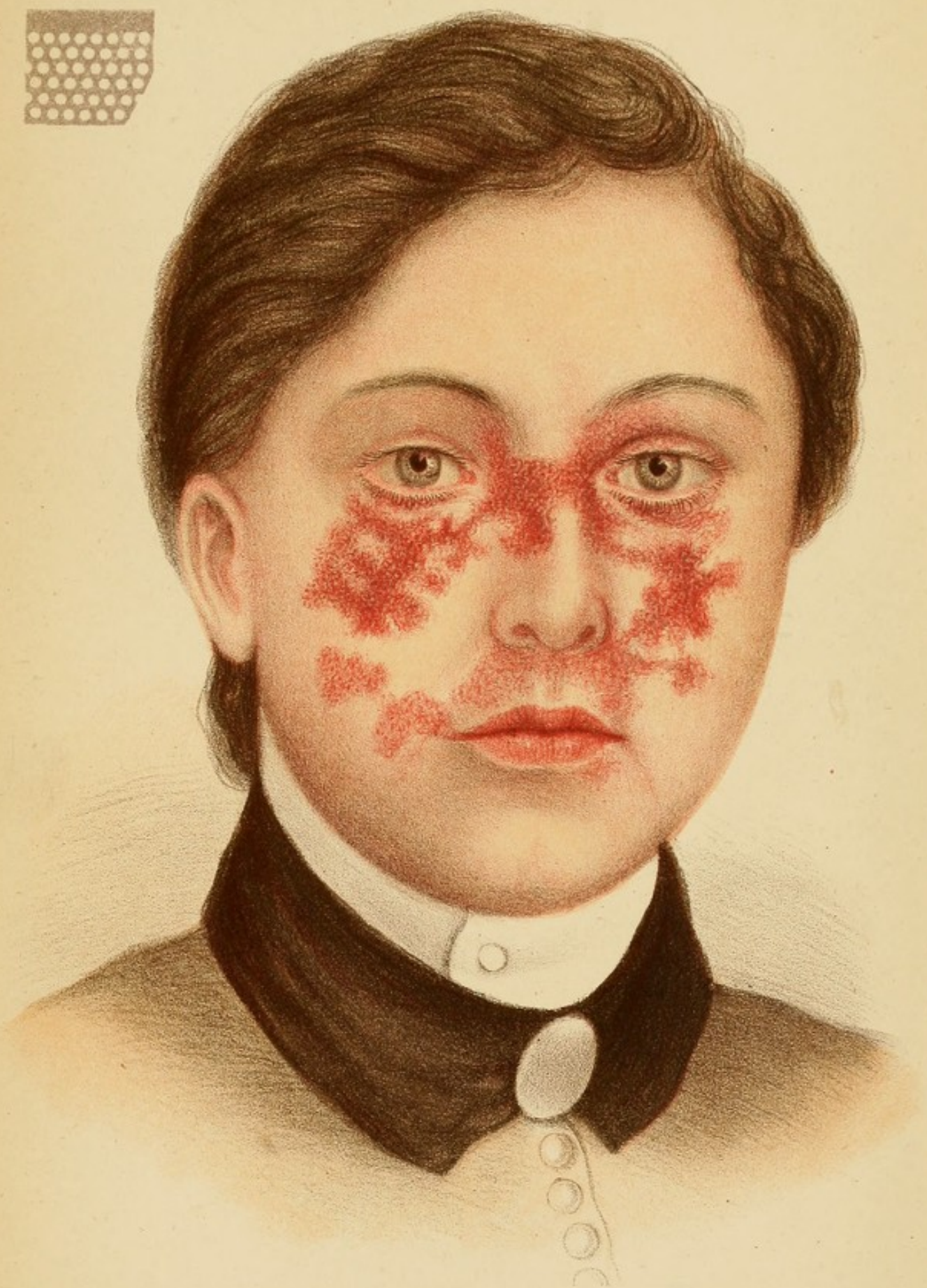






E. Burgess ch. lith.

West Newman & Co. imp.





APPENDIX

GIVING DETAILS OF THE EIGHT TYPICAL CASES SELECTED FOR
ILLUSTRATION IN CHROMO- AND MONOTONE LITHOGRAPHY.

CASE I. *Extensive Nævoid Growth (Port-wine Mark) on Face.*—H. P., æt. 19, showing the distributed capillary vascularity of the face which is so graphically depicted in the Plate, was admitted as an In-patient to St. John's Hospital, and by the courtesy of Mr. Startin I was enabled to take charge of the case with him. The growth was not only deep-seated in the tissues of the face, but it was raised above the surface in parts. Whenever the patient flushed up, the growth was highly congested and purple in colour. There are some similar patches of capillary engorgement on different parts of the body. She was placed under the influence of anæsthetics, and I then proceeded to operate with the fine Paquelin cautery by the stippling process, which I have already described in the text. I proceeded very cautiously, only destroying small areas at a time, so as to avoid any sloughing of the skin or deep destruction of the derma. I operated about once a week, and after about ten or twelve operations I succeeded in destroying about two-thirds of this vascular growth. The gauge of the zinc diaphragm used for the thermopuncture is shown at the left-hand corner.

The next Plate shows the after effect in progress of these operations upon the face. As the growth was so deeply

seated in the tissue of the face, and the surface hardened by the frequent application of strong caustics during several previous attempts to destroy the growth, it was found difficult to treat the case successfully. The centres of each patch were blanched by the stippling process, as shown in the second chromo. I hope to bring the result of this and other cases before the Societies as soon as they are cured.

Remarks by Mr. Startin.—Having carefully watched this case during the months that the patient was under treatment, I can see no reason why it should not ultimately prove quite successful.—J. S.

CASE 2. *Nævus of the Nose.*—Rose —, æt. $1\frac{1}{2}$, was kindly transferred to my care as an In-patient by my colleague Mr. Pye. The drawing represents very accurately the amount of distortion of the features by this vascular growth. Several attempts had been made at this and another hospital to destroy the nævus by electrolysis, but without any appreciable effect. (*Vide p. 10.*)

The child being put under chloroform, I made a vertical incision through the apex of the nose and anterior half of septum. This was of course followed by copious hæmorrhage. With a fine needle-point of the Paquelin cautery I succeeded in arresting the hæmorrhage and also in destroying the main trunks of the nævoid growth, by passing the red-hot point well up under the skin of both alæ of the nose. It was some weeks before the sloughs separated, so as to leave a healthy granulating surface. I was careful to preserve the septum, and also the healthy skin of the nose, from destruction by the cautery.

At a subsequent operation I proceeded to pare the edges of the cavernous openings which overlapped the cartilages of each nostril, and then to approximate, as for harelip, the vivified edges of the bifid septum and alæ nasi. This lozenge-shaped gap was closed in very carefully with my miniature steel pins, and the wound healed very well, leaving only a linear cicatrix in the mesial line of the nose.

The result of this operation is well shown at the lower part of the Plate.

CASE 3. *Papillomata of Chin, Neck, Buccal Mucous Membrane, etc.*—Ernest M., æt. 3, was admitted under my care at the Victoria Hospital, on June 24th, 1884, on account of an ugly chain of warty growth, extending from the gums in the median line of the face down to the thyroid cartilage. The median line of the lower lip was thus involved, both on the buccal and cutaneous surfaces, with this papillomatous growth. Some of the warts were sessile, others pedunculated. They were all growing from a raised base of hardened and dark epithelial tissue. The continuous chain of warts deviated from the middle line as it passed from the chin to the thyroid cartilage. Some of the warts were filiform or brush-like, and very prominent. The others were about the size of a split pea, and all those on the skin were deeply pigmented. Those on the gum and mucous lining of the lip were flat, having the red velvety structure of mucous membrane. When damaged in mastication, they bled very freely. (*Vide* p. 14.)

On July 26th the cutaneous growth was removed by two linear vertical incisions, designed so as just to include the mass of papillomata in a wedge-shaped section, without invading the mouth. The edges of the gaping wound were then approximated with strong harelip pins and wire sutures, some deep and others superficial, and in this way the hæmorrhage was arrested.

On July 31st the sutures were removed and also the pins, the wound having healed throughout by primary union.

On October 17th I proceeded to remove the corresponding growth from the buccal mucous membrane. That on the gums was destroyed with the Paquelin cautery, and that on the lip by a double ligature transfixed upon a harelip pin. Mr. Shaw, the Registrar, reports "original scar hardly apparent."

The resulting photograph and lithograph show that the linear scar is scarcely traceable (p. 14).

CASE 4. *Superficial Necrosis of Superior Maxilla with Depression and partial Absorption of Lower Eyelid and complete Ectropion.*—Edmund E., æt. 3½, was admitted under my care at the Victoria Hospital on the 21st of March, 1884, presenting a very unsightly deformity of face as the result of cellulitis of cheek, superficial necrosis of subjacent malar and maxillary bones, and the formation of a sinus over the malar bone which communicated with the superficial necrosis. Towards this sinus the loose tissue of the lower eyelid had been drawn down, so that the skin puckered around the edges of the sinus. The elevation of the cheek by this inflammatory thickening caused a pit or pouch to form level with the orbital plate of the malar bone. In the plastic operation which I subsequently performed it was necessary to dissect up the atrophied lid from the inner wall of this crater-like pouch. (*Vide* p. 62.)

A probe, when passed into the sinus, impinged upon soft bare bone, but it did not penetrate to the antrum. All the teeth on the right upper jaw had decayed away, leaving only the stumps. There was direct communication between the alveolar sockets, and the germinal membrane surrounding the embryo teeth of the second dentition. It was in the bone that encased these teeth that the necrosis was detected.

On March 29th my colleague Mr. Fox, Dental Surgeon, removed two of the stumps and one embryo tooth lying loose in the cystic cavity.

On April 19th I dissected up the buccal mucous membrane over the superior maxilla, and gouged away the superficial necrosis of the malar and superior maxillary bones. With a tenotomy knife I liberated the puckered cicatrix and sinus from its deep bony attachments. Suppuration continued for a few weeks, necessitating careful removal of the pus by pledgets of lint packed in the mouth, so that it should not be swallowed.

At a subsequent operation I made a semilunar horizontal incision around the outer margin of this crater-like pouch, and carefully dissected up the remnant of lower eyelid. This flap was then displaced upwards and inwards, so as to cover the exposed ball of the eye. The thickened everted conjunctiva was thus turned inwards, and by passing a silk suture twice vertically through the conjunctiva, and out at the mouth, I was enabled to use some traction upon the membrane to keep it in position against the eyeball, and so to restore it as a lining membrane in juxtaposition with the newly formed lid by a plastic operation. (*Vide* the Plate, p. 62, for the result of these operations.)

CASE 5. *Congenital Talipes Varus of both Feet—Treatment delayed by parents for four years—Subsequent rectification of the Deformity.*—A. S., æt. $4\frac{1}{2}$, was admitted under my care at the Victoria Hospital with double congenital talipes varus, the amount of deformity being the most extreme that I have ever seen. Both feet were drawn inwards at an acute angle with the leg, and the boy walked upon the outer edges of the feet. He walked in a gyrating fashion, lifting one foot over the other. He could not walk alone, and besides the deformity there was considerable weakness about the muscles of the legs. I kept the boy under my care for nine months, during which time I performed several operations upon the feet, dividing the Achilles tendons, the tibialis posticus and anticus muscles of both legs, many of the deep flexor tendons in the sole of the foot, the plantar fascia, etc. I also manipulated all the bones of the feet, and divided some of the interosseous ligaments. The feet were encased in the plaster of Paris arrangement with the extension apparatus, as described in the text. (*Vide* p. 162.)

The photograph showing the after effect was taken two years after he first came under treatment, and it shows how completely the boy has gained the power of walking and running alone. So firmly can he stand now, that the photographer did not attempt to steady him with the usual prop

behind. He goes regularly to school, and there is not the slightest sign of deformity.

The photograph shows how completely the astragalus in each case has been forced back by the digital compression, into the correct relation to the tibial articulation (p. 162).

CASE 6. *Acquired Valgus from shortening of Leg, the result of Hip Excision.*—J. S., æt. 6, son of a bricklayer's labourer, came under my care at the Victoria Hospital with extensive disease of the hip-joint of many months' duration. It was evident that the disease was in the third stage of progress. He was quite unable to bear any weight on this leg. There was also evidence of active mischief progressing within the joint. Sinuses had formed which could be traced leading direct to the acetabulum, and there was distinct grating, and severe pain when the head of the femur was rotated in the acetabulum. (*Vide* p. 194.)

The boy's health had also become seriously undermined from the long-continued purulent discharge, and from the rapid decay of the joint-structures. There was no question that excision of the joint would afford the only chance of preserving his life. Having explained the circumstances to the parents, I obtained their consent to the operation, and proceeded to excise the joint by the usual semilunar incision over the great trochanter. Before enucleating the head of the femur, I evacuated a large quantity of pus from the joint. I then discovered that the acetabular cavity was completely destroyed, and I could pass my index finger freely into the pelvic cavity. The head, neck, and upper third of the great trochanter were then sawn across, and the necrosed portion of acetabulum gouged away. The limb was fixed to a Bryant splint.

The patient continued to progress favourably, with the exception that coincident with the partial closure of the external wound a rectal abscess terminating in a fistula formed in the buttock, and the pus burrowed under the gluteal muscles. It was evident that there had been

established a direct communication between the rectum and the acetabulum by the gravitation of pus within the pelvis, the perforation of the levator ani muscle, and the separation of the pelvic fascia at the ileo-pectineal line.

I treated the abscess and fistula in the usual way, by making some free incisions into the buttock, and by dividing the sphincter ani upon a grooved director.

The boy made a good though slow recovery. A new joint was established close to the old acetabulum. The tissues became firmly consolidated. The acetabular cavity closed in entirely, and the drawing (*a*) which I append shows the satisfactory cure of this protracted case two years after the excision, together with the *acquired valgus* which was undergoing treatment, and was nearly cured when the photograph was taken. There was only about $1\frac{1}{2}$ inch of shortening.

Remarks.—I have cited this case as a typical one of compensatory valgus caused by unrestricted walking upon a shortened limb with tilted pelvis; and also on account of the rarity of *fistula in ano* associated with hip disease, serving as another proof of the generally satisfactory results which may be obtained from hip excision in the later stages of the disease. (In fact, I think my experience would go to prove that excisions in the early stages of the disease are not justified, on account of the greater mortality at this stage from excision than when the joint-structures are seriously involved and the encrusting cartilages destroyed.) I merely append this remark in parenthesis because I am not now at liberty to discuss the important question of hip excision and its consequences.

CASE 7. *Acquired Valgus from Pulpy Degeneration of Knee-joint, associated with extreme backward and outward displacement of the Tibia.*—W. L., æt. 10, came under my care as an out-patient at the Victoria Hospital, in the condition represented by the first drawing on the Plate. The limb was completely atrophied and useless. He had valgus deformity of both feet, but especially of the left foot. The

joint-structures were quite disorganised, so that the leg hung loose like a flail, and he was unable to bear any weight on the leg. (*Vide* p. 170.)

There was considerable backward displacement of the tibia, together with pulpy degeneration of the knee-joint and a very prominent swelling of the inner condyle of the femur, causing the eversion of the leg which was so marked.

The case seemed in a hopeless condition for conservative treatment. The boy suffered a good deal of pain in the knee, and there was also some pain elicited when I approximated the articular surfaces, although there was apparently no erosion of cartilage. There was almost complete fibrous ankylosis of the joint-structures. I admitted him as an in-patient, intending to excise the joint, and so to bring the outwardly distorted tibia into its proper relation to the femur, and also for the purpose of removing the disease in the joint.

A more complete examination of the condition of the joint, and the subsidence of the acuter symptoms during his stay in the Hospital, determined me to try the rectification of the deformity of the foot, and the cure of the disease in the knee, by complete rest and absolute fixation of the joint. I placed the leg on a long outside splint, and afterwards on a straight back splint slightly grooved. Having encased the limb in a flannel bandage, I then applied a plaster of Paris bandage from the ankle to the groin, so as to keep the joint at perfect rest. He was kept in bed for some weeks, when the swelling of the joint becoming decidedly less, I resolved upon the continuation of this method of treatment, and proceeded to tilt forward the tibia by placing a pad below the popliteal space, so as to bring the head of the bone again into proper relation with the condyle by the regular application of a firm calico bandage over the knee. I succeeded in so everting the joint by a moulding process as to bring it well on to the straight splint, and then to retain it there with a strap and buckle. I also broke down the

adhesions under chloroform. The valgic condition of the foot was cured by the application of the perforated tin apparatus, and also by the use occasionally of a rectangular outside wooden splint to invert the foot. The boy was soon enabled to get about with scarcely any lameness, and go to school.

The second drawing shows how the muscles of the limb are developing, and how almost entirely the deformity, both of knee and ankle, has subsided. He has also some limited power of flexion of the knee-joint.

Remarks upon Osteotomy for Knock-knee.—As soon as the white swelling had become reduced by the constant application of pressure bandages, the question arose whether osteotomy would be the best method of rectifying this very pronounced angularity of the knee-joint. Certainly the amount of distortion was quite up to the average of cases usually submitted to the osteotomy operation. Considering, too, his age, and the length of time that the distortion had existed, it seemed very desirable to take some decisive steps to rectify the deformity. For reasons which I will not here detail, I have very grave doubts as to the beneficial effects of osteotomy, considering the wholesale way that it is now being performed in some of our British hospitals. I have carefully weighed the *pros* and *cons* of this operation in my own practice, and have come to the conclusion that, with perseverance we can, as a rule, in young children, secure a more useful limb by patient extension on a straight back splint with plaster of Paris bandages, though, of course, there are many cases in which we require to resort to subcutaneous osteotomy for extreme distortions.

CASE 8. *Deformity of Foot from Excision of Os Calcis.*—B. J., æt. 3, the daughter of a draper, was enjoying a swing with her little brothers on a rocking-horse at Christmas time, when the left foot being caught between the

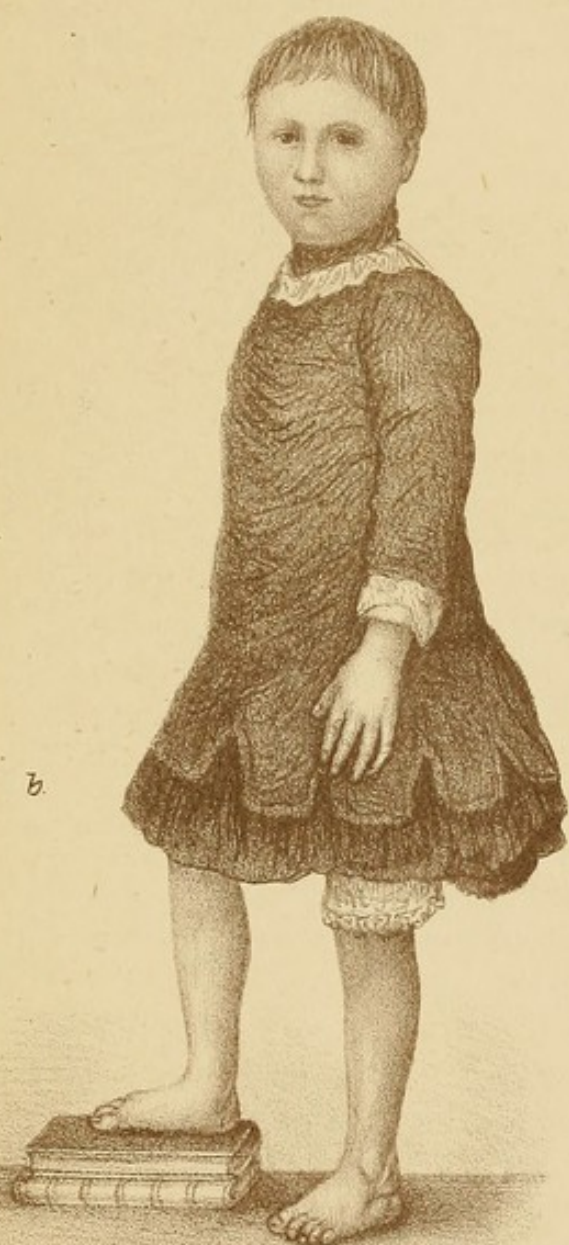framework and the floor it was severely bruised. Some persistent swelling followed, so that the child had to be kept off her foot, and a chronic abscess formed over the os calcis. After taking her to three or four surgeons, she was brought to the Victoria Hospital. By this time the swelling had in part subsided. There was no heat about the foot and no redness, but the skin had certainly thinned over the os calcis, and there was distinct fluctuation. I therefore evacuated the abscess by a small incision, and finding that the sinus did not close, I passed a probe and detected carious bone, apparently loose within a shell of investing bone and articular cartilage. The surface of this decayed bone I gouged away, but finding that the child's health was failing in consequence of the confinement and the prolonged discharge, I resolved to excise the os calcis *en masse*. After the operation, there was some decided swelling of the synovial membrane at the ankle-joint, with pain on pressure of the foot upwards, and it was thought by some of my surgical friends that the foot must be amputated.

I resolved to watch the effect of the minor operation first of all.

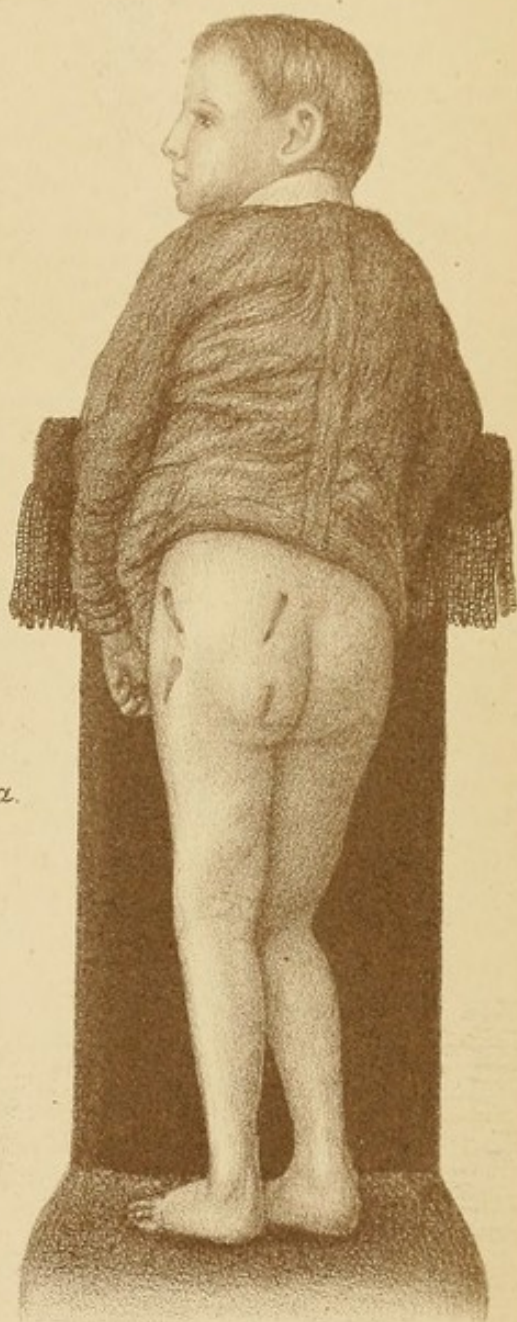
The lithograph well shows the satisfactory result of the operation and the puckered scar indicating the line of incision. It also shows well the re-formation of a new os calcis from the portion of periosteum which I left behind, the re-attachment of the tendo Achillis to the new bone, the subsequent development of the calf muscles, and the very limited amount of deformity which resulted from the removal of this, the largest bone of the foot.

I need not detail the steps of the operation nor the progress of the patient. It will suffice to say that the child made an excellent recovery, that she gained complete control over all muscular movements of the foot and ankle, that she can flex and point the toes equally well with both feet. She even runs races with her brothers and sisters,

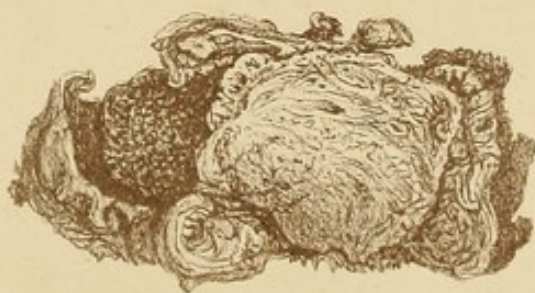b.




a.



c.





and beats them in running. The joint-structures are completely restored to their normal condition, and there is not the slightest lameness or awkward posture of the foot.


Remarks.—The above case I have selected for illustration from among my cases of deformity after partial excision of the tarsus, because it well represents the generally uniform success which follows the conservative treatment of strumous disease of individual bones of the foot.


I may say here, what I could not very well embody in the text—that local disease of joint structures in the foot, as, for example, of the metatarso-phalangeal joint of the big toe, may be successfully treated by excision of the faulty joint or bone, without having recourse to amputation of the foot, whether partial or complete. A very useful foot will result from such treatment in most cases.

As in the case of the os calcis, we can generally trace some traumatic cause as the starting-point for the strumous decay of the bones of the foot. I therefore feel it to be incumbent upon surgeons to retain, if possible, the adjacent bones which are found not to be involved in the disease.

The recuperative powers of children, even of delicate constitutions, are so great that under careful and judicious nursing, such as they may secure at a hospital for children, we may generally anticipate in these cases a satisfactory termination to the disease, and a useful limb.







COLUMBIA UNIVERSITY LIBRARIES (hsl, stx)

RD 523 C47 C.1

Face and foot deformities /



2002097117

