

Manual of dental surgery and pathology / Thoroughly rev. and adapted to the use of American students and practitioners, by Thomas C. Stellwagen.

Contributors

Coleman, Alfred.
Stellwagen, Thomas C.
Augustus Long Health Sciences Library

Publication/Creation

Philadelphia : Lea, 1882.

Persistent URL

<https://wellcomecollection.org/works/h4jebbkf>

License and attribution

This material has been provided by This material has been provided by the Augustus C. Long Health Sciences Library at Columbia University and Columbia University Libraries/Information Services, through the Medical Heritage Library. The original may be consulted at the the Augustus C. Long Health Sciences Library at Columbia University and Columbia University. where the originals may be consulted.

This work has been identified as being free of known restrictions under copyright law, including all related and neighbouring rights and is being made available under the Creative Commons, Public Domain Mark.

You can copy, modify, distribute and perform the work, even for commercial purposes, without asking permission.



Wellcome Collection
183 Euston Road
London NW1 2BE UK
T +44 (0)20 7611 8722
E library@wellcomecollection.org
<https://wellcomecollection.org>

COLUMBIA LIBRARIES OFFSITE
HEALTH SCIENCES STANDARD



HX64072584

RK522 C67 1882 Manual of dental sur

RECAP

62/2
PRESENTED TO THE COLLEGE OF
DENTAL AND ORAL SURGERY
NEW YORK BY THE DEAN
WILLIAM CARR, M.D. D.D.S.


RK522 C67


Columbia University 1882
in the City of New York


School of Dental and Oral Surgery
Copy 1




Reference Library









Digitized by the Internet Archive
in 2010 with funding from
Open Knowledge Commons


MANUAL
OF
DENTAL SURGERY AND PATHOLOGY.

BY
ALFRED COLEMAN, L.R.C.P.,
F.R.C.S. EXAM. L.D.S., ETC.,

SENIOR DENTAL SURGEON AND LECTURER ON DENTAL SURGERY TO ST. BARTHOLOMEW'S
HOSPITAL; SENIOR DENTAL SURGEON AND LECTURER ON DENTAL SURGERY TO
THE DENTAL HOSPITAL OF LONDON; MEMBER OF BOARD OF EXAMINERS
IN DENTAL SURGERY, ROYAL COLLEGE OF SURGEONS; FORMERLY
PRESIDENT ODONTOLOGICAL SOCIETY OF GREAT BRITAIN.

*THOROUGHLY REVISED AND ADAPTED TO THE USE OF AMERICAN
STUDENTS AND PRACTITIONERS.*

BY
THOMAS C. STELLWAGEN, M.A., M.D., D.D.S.,
PROFESSOR OF PHYSIOLOGY AT THE PHILADELPHIA DENTAL COLLEGE.



PHILADELPHIA:
HENRY C. LEA'S SON & CO.
1882.

RK522

C67

1882

Cop. 1

Entered according to Act of Congress, in the year 1882, by
HENRY C. LEA'S SON & CO.,
in the Office of the Librarian of Congress. All rights reserved.

COLLINS, PRINTER.

PREFACE TO THE AMERICAN EDITION.

IN introducing Mr. Coleman's *Manual of Dental Surgery and Pathology* to the American profession the preface furnished by the author renders it unnecessary for the editor to say more than will suffice to indicate very briefly his own share in its preparation for publication. The care which Mr. Coleman has bestowed upon his work has left but comparatively few additions to be supplied.

In no direction, perhaps, has the ingenuity of the American mind been more actively exercised than in the production of an immense variety of instruments for the use of the dental surgeon. The difficulty experienced by the student in making proper selections from these has seemed to justify the insertion of a special chapter devoted to their choice.

A chapter on the present greatly improved methods of crowning teeth, has been added in view of this being generally performed by the operative dentist, and because of its bearing upon the efforts now made for the preservation of the natural teeth and roots. Throughout the work have been inserted many notes descriptive of certain modes of treatment demanded by the peculiarities of our climate, or indicative of the latest and most approved systems of operating adopted on this Continent.

To accommodate the one hundred and twelve added illustrations, delineating some three hundred and twenty instruments and appliances, an increase in the size of the page has been

rendered necessary. The original text has been preserved with but few alterations, and all additions, amounting to about one hundred pages, have been distinguished by inclusion in brackets [].

In conclusion, the editor desires to acknowledge his indebtedness to Drs. James W. White and Wilbur F. Litch for their assistance in preparing this work for publication.

NO. 1627 CHESTNUT STREET, PHILADELPHIA,

February, 1882.

P R E F A C E.

IF illustration were wanted to show that immense advances have been made in the science and practice of Dental Surgery during the last thirty or forty years, no better one could be furnished than the circumstance that most of the leading works on the subject at the commencement of that period comprehended, and within very modest limits, all its branches, viz.: Dental Anatomy, Physiology, Surgery, Pathology, Therapeutics, Materia Medica, and often even Mechanics.

The establishment, in this and several other countries, of a defined and systematic course for the student of Dental Science, including distinct courses of lectures upon Dental Anatomy and Physiology, Dental Surgery and Pathology, and Dental Mechanics, has, perhaps more than anything else, led to a demand for separate and more complete treatises on these several departments.

In some of these subjects this want has been completely supplied, and the Dental Student can have nothing more to desire than the recent admirable treatise on Dental Anatomy, Human and Comparative, which has appeared from the hands of my talented colleague, Mr. C. S. TOMES.

Another subject, viz., Dental Mechanics, has been separately and successfully treated upon in the manual of Mr. OAKLEY COLES, and the English student desirous of fuller information can obtain the same in his own language, in "A Practical Treatise on Mechanical Dentistry," by Dr. JOSEPH RICHARDSON, of Ohio, U. S.

On the subject of Dental Surgery—and to my lot has fallen the privilege of lecturing thereon at the largest Medical School in London consecutively for fifteen years—it can hardly be said that any work perfectly suitable as a text-book has yet been produced. The excellent works of Mr. JOHN TOMES, and of that gentleman in conjunction with Mr. C. S. TOMES, which have been so much employed and valued for that purpose, include also Human Dental Anatomy and Physiology, which by many, and especially the general medical student, whose requirements I have endeavored to bear in mind, may not be needed. On the other hand, Mr. SALTER's much appreciated work, though chiefly confined to Dental Pathology and Surgery, is, as the author states, "a digested collection of all my previous essays and papers, arranged in the form of chapters; and several more chapters have been added to previously published matter," rather than a systematic treatise upon the subject.

It is therefore hoped that the present work may supply a want which I believe to exist, although I cannot venture to presume that it will satisfy the requirements of the student as fully as the work of Mr. C. S. TOMES accomplishes its object; nevertheless, I trust that the large amount of experience which has fallen to my lot, as a consequence of holding hospital appointments for nearly a quarter of a century, may not have been lost upon me, and that the results may in these pages be rendered profitable to others.

One of my chief desires has been to make the work as systematic as possible, associating under the same head a variety of subjects which bear upon one another, rather than isolating them under distinct chapters, and to avoid as much as possible the recording of cases, even though rare and interesting, which could not be considered appropriately under any proper classification.

In attempting to make the work a practical treatise, I have laid myself under heavy obligation to those who have so kindly

assisted me. To Mr. C. S. ROGERS, the demonstrator at the Dental Hospital of London, my best thanks are due for the chief contents of the pages devoted to the description of filling with cohesive gold. To Messrs. C. ASH & SONS, of London, my warmest thanks are due for the valuable loan of some 250 illustrations of instruments, appliances, etc.; as they are also to the eminent practitioners by whom many of the latter were invented, and whose names I have endeavored always to insert in the foot-notes referring to them. To the Council of the Odontological Society I am indebted for permission to copy the illustrations which have appeared in my papers published in their "Transactions." To Mr. NOBLE SMITH I owe much for the pains and skill that he has bestowed upon the original woodcuts which illustrate the work. To very many authors I am largely indebted for material collected from their works, which, I fear, I have on some occasions, omitted to acknowledge. Finally, I am under heavy obligations to Mr. E. HARRISON, barrister-at-law, for his kindness in undertaking the tedious and uninteresting work of revising my pages.

A. C.

CONTENTS.

CHAPTER I.

	PAGE
The First Dentition. Order and Periods of Eruption. Normal and Abnormal Conditions occurring during Teething	17

CHAPTER II.

Irregularities in the Temporary Teeth. Diseases of the Temporary Teeth.	
The Second Dentition	38

CHAPTER III.

Irregularities in the Permanent Teeth, in Size, in Form (Odontomes), in Number, in Position—Class I. Accidental and Avoidable (Fractures of the Jaws)	54
---	----

CHAPTER IV.

Irregularities in the Permanent Teeth in Position, continued—Class II. Congenital and Unavoidable	88
---	----

CHAPTER V.

Injuries to the teeth. Concussion, Dislocation, Fracture	108
--	-----

CHAPTER VI.

Dental Caries. Description of the Disease, Microscopical Appearances.	
Theories of Dental Caries	114

[CHAPTER VII.]

Selection of Instruments	134]
------------------------------------	------

CHAPTER VIII.

Treatment of Dental Caries (Anticipation and Prevention), by Excision, by Stopping, Filling, or Plugging. Preparation of the tooth for Filling, Materials Employed, and the Processes of their Manipulation	161
---	-----

CHAPTER IX.

	PAGE
Treatment of Dental Caries, continued. Difficulties and Complications met with in the Operation of Filling Teeth	216

CHAPTER X.

Periodontitis. Symptoms, Pathology, and Treatment	235
---	-----

CHAPTER XI.

Necrosis. Absorption of Permanent Teeth. Exostosis	250
--	-----

[CHAPTER XII.

Fitting Artificial Crowns to Roots of Natural Teeth	257]
---	------

CHAPTER XIII.

Extraction of Teeth, General Directions. Extraction of Individual Teeth	264
---	-----

CHAPTER XIV.

Extraction of Roots of Teeth, with the Forceps, with the Elevator, etc.	
Extraction of Temporary Teeth	290

CHAPTER XV.

Difficulties and Complications occurring in Extraction, due to Malformed Teeth, Contraction of the Jaws, Impacted Teeth, Alveolar Hemorrhage, etc.	302
--	-----

CHAPTER XVI.

Anæsthesia, History of, by Nitrous Oxide Gas, by Ether, by Chloroform . .	319
---	-----

CHAPTER XVII.

The Replantation and Transplantation of Teeth	345
---	-----

CHAPTER XVIII.

Congestion of the Gums. Salivary Calculus. Ulcerations of the Gum.	
Necrosis of the Jaws	353

CHAPTER XIX.

Cicatrices closing the Jaws	370
---------------------------------------	-----

CHAPTER XX.

	PAGE
Tumors of the Gums and upon the Jaws	372

CHAPTER XXI.

Dentigerous Cysts	379
-----------------------------	-----


CHAPTER XXII.

Diseases of the Antrum	386
----------------------------------	-----

CHAPTER XXIII.

Nervous and Muscular Affections dependent upon Dental Irritation . . .	391
--	-----

INDEX	399
-----------------	-----



LIST OF ILLUSTRATIONS.

FIG.	PAGE
1. The temporary teeth of the right side in the upper and lower jaws	19
2. Dental pocket lancet	26
3. Upper secondary temporary molar with four fangs	39
4. Lower second temporary molar with three fangs	39
5. Geminatio of a temporary lateral incisor and cuspidatus of the lower jaw	39
6. Upper jaw of a child in which the lateral incisors are absent	40
7. Lower jaw of a child in which all the incisors are absent	40
8. Upper jaw containing a supernumerary lateral incisor on the right side	40
[9. Protrusion of the superior incisors (Dental Cosmos)	40]
10. Chin retractor as applied	41
[11. Another form of chin retractor	41]
12. Upper jaw with portions of the roots of temporary central incisors exposed	42
13. Lower jaw with one root fully and one partially exposed	42
14. Upper maxilla with portions cut away to exhibit the developing permanent teeth	45
15. Upper permanent teeth of the left side	49
16. Lower permanent teeth of the right side	50
17. Permanent teeth of unusually large dimensions	54
18. Permanent teeth of unusually small dimensions	54
19. Honeycombed teeth of the upper jaw	56
20. Syphilitic teeth in upper and lower jaws as they appear when recently erupted	57
21. Syphilitic teeth in upper and lower jaws which have been erupted some time	57
22. Supernumerary permanent tooth of the most common type	58
23. Supernumerary tooth not unfrequently met with in the region of the upper central incisors	58
24. Three specimens of gemination	58
25. Supernumerary teeth in the upper jaw of a youth	61
26. Supernumerary bicuspid of the upper jaw, right side	61
27. Upper jaw in which the lateral incisors have not been erupted	62
[28. The positions of the developing permanent teeth and the fangs of the temporary teeth (White)	64]
29. Side view of the jaw of a child with permanent teeth forming	65
30. Lower jaw in which the permanent central incisors have been erupted behind the temporary central incisors	67

FIG.	PAGE
31. The condition termed partially underhung	67
[32. Impression cup for wax, upper jaw	68]
[33. Impression cup for wax, lower jaw	68]
[34. Impression cup for plaster, lower jaw	69]
[35. Impression cup for plaster, upper jaw	69]
36. Plate adapted for pressing out the central incisors	70
37. Plate adapted for drawing inwards the front teeth of the upper jaw	73
38. Right central incisor of the upper jaw erupted at an angle to the dental arch from want of space	73
[39. The half hitch	75]
[40. The square knot	75]
[41. The surgeon's knot	75]
[42. The clove hitch	75]
[43. Drawing a tooth forward into the arch by an elastic ligature	75]
[44. Rings cut from rubber tubing	75]
[45. McQuillen's cap to prevent occlusion of the teeth (Dental Cosmos)	76]
[46. McQuillen's bar for drawing teeth forward (Dental Cosmos)	76]
[47. A method of drawing a tooth into position by an elastic ligature (Dental Cosmos)	77]
[48. Flagg's method of tying ligature for torsion	77]
[49. A case of torsion and retraction of central incisors by a plate with pins and elastic ligatures (Dental Cosmos)	78]
[50. Guilford's torsion apparatus	79]
[51. Mode of applying the above	79]
[52. Represents position of teeth before treatment by Guilford's apparatus	80]
[53. Represents position of teeth after treatment by the same	81]
[54. Represents peculiar formation of teeth in which the same treatment can be followed	81]
55. Fracture of the lower jaw treated by means of a metallic cap	83
56. Vertical fracture of the lower jaw between the left cuspidatus and first bicuspid	84
57. Adaptation of the fractured parts by a plaster cut	84
58. Gunning's interdental splint for fractures of either jaw	85
59. Hammond's splint <i>in situ</i>	86
60. Well-developed upper jaw in a youth aged about twelve years	89
61. Imperfectly-developed upper jaw with irregular dental arch. The lateral incisors are bitten over by the lower cuspidati	90
62. Imperfectly-developed upper jaw, and where the dental arch assumes the V-shaped form	91
63. Imperfectly and ill-developed upper jaw, a case suitable for treatment by expansion of the dental arch	92
64. Coffin's method for expanding the contracted dental arch by means of a divided plate and spring formed of pianoforte wire, the back teeth being capped	94
65. Contracted dental arch	94
66. The expansion of a V-shaped arch by means of Coffin's plate	94

FIG.	PAGE
67. The jack-screw, three sizes	94
68. Appearance after treatment by expansion	95
69. Result of an early removal of all of the bicuspid in the upper jaw .	97
70. Result of an early removal of three bicuspid in the lower jaw .	97
[71. Deformity from too early extraction of sixth year molar (Dental Cosmos)	98]
[72. Deformity from extraction of sixth year molar after the eruption of the twelfth year molar (Dental Cosmos)	98]
73, 74. Cases in which the removal of the first molars from each jaw would be beneficial	100
75, 76. Cases in which the removal of the first bicuspid of the upper jaw only is advisable	100
77, 78. Before and after removal of the upper first bicuspid only .	101
79, 80. Cases in which the removal of the two second bicuspid from the upper and the right lateral incisor from the lower jaw is to be recommended	101
81. Results of an early removal of the temporary molars in an ill-developed lower jaw	103
82, 83. Comparative advance of the first permanent molars after the shedding of the temporary molars	105
84. Ill-result of removing the temporary incisors and cuspidati to give room for the permanent incisors	106
85. Treatment by removing from the lower jaw the temporary teeth only as their successors appear	106
[85A. Bands for protecting teeth, to be moved by jack-screws	107]
86. Impacted fracture in an upper incisor tooth	112
87. Microscopic section of tooth affected with caries	115
88. The tobacco-pipe-stem appearance of the chalky decay (Tomes) .	117
[89. Translucent zone in a tooth that had been filled with gold	117]
[90. Cross-section of carious dentine magnified 1000 diameters (Abbott) .	118]
91. Fracture of dentine covered with leptothrix and micrococci	119
92. Cuspidatus of the lower jaw worn on its lingual surface by the friction of a plate	130
[93. New socket handles	135]
[94. Student's instrument case	136]
[95. Scalers—Forbes' gouge	137]
[96. Scaler, to be sharpened on both edges for gum lancet	138]
[97. Combined-foil carrier and plugger	138]
[98. Curved scissors	138]
[99, 100. Magnifying mouth-mirrors	139]
[101. Glass syringe	139]
[102. Jack's enamel chisels	140]
[103. Dental files	140]
[104. D. D. Smith's plug finisher	140]
[105. Kæber saw frame	141]
[106. Scoops	142]
[107. Hatchets	143]

FIG.	PAGE
[108. Hoes	143]
[109. Diamond-shaped points	143]
[110. Auger drill.—Round burs.—Odd or acorn burs	144]
[111. Wheel burs	145]
[112. Oval burs	145]
[113. Palmer's nerve-canal instruments	145]
[114, 115. Retaining-point drills, spade, and spear-points	146]
[116. Stump files and corundum wheels, for pivoting	146]
[117. Round burs	147]
[118. Wheel burs	147]
[119. Inverted-cone burs	147]
[120. Fissure burs	147]
[121. Pointed fissure drills	147]
[122. Spear-pointed drills	148]
[123. Five-sided drills	148]
[124. Fine-cut round burs	148]
[125. Fine-cut pear-shaped burs	148]
[126. Sugar-loaf drills	148]
[127. Dr. Holmes' engine-bit oiler	149]
[128. Screw-head mandrels with and without shoulder	149]
[129. Northrop's corundum points	149]
[130. Arkansas-stone polishing points.—Diamond-disk wheel	149]
[131. Flexible rubber disk for polishing proximate surfaces	150]
[132. Diamond disk for separating teeth	150]
[133. Ellis' pluggers.—New York set of pluggers.—Lord's pluggers and burnishers	153]
[134. Jack's matrix.—Set of Jack's matrices.—Matrix plugger, magnified.—Set of matrix pluggers.—Pliers for adjusting matrices.—Sectional views of cavities on proximate surfaces	155]
[135. Hand or mallet pluggers.—S. S. W. burnishers.—Darby's burnishers.—Engine burnishers	156]
[136. Flagg's condensing forceps.—Weston's amalgam pluggers	157]
[137. Palmer's metal tube with lead filling, for mallet-head	158]
[138. Cutting pliers	159]
[139. Wedge pliers, Palmer's pattern	159]
[140. Forms of enamel chisels or cutters	164]
[141. Paraboloid and gouge chisels of Jack and Forbes	165]
[142. The S. S. White dental engine	165]
[143. The S. S. White water motor applied to the dental engine	167]
[144. Corundum points used with the dental engine	167]
145. Typical form of a cavity when prepared for receiving a filling	168]
146, 147, 148, 149. Various forms of mandrel or handpiece for the dental engine	170]
150. Flexible India-rubber syringe	171]
151. Rogers' saliva-ejector	173]
152. Sectional view of Fisk's ejector	173]
[153. Punch for making holes in the rubber-dam	174]

FIG.	PAGE
154. Silvered glass mouth-mirror, with ball-and-socket joint	174
155. Instrument for applying the coffer-dam	176
[156. Clamp forceps (Bowman Allen)	176]
[157. Tees' rubber-dam clamps	176]
158. Method of applying the rubber-dam (Elliott)	177
159. The rubber-dam and clamp <i>in situ</i>	178
[160. Cogswell's rubber-dam holders	178]
[161. Shape for rubber-dam to admit of easy respiration	178]
162. Owen's dental table	179
[163. The Morrison bracket	180]
[164. Allan's pattern of table for the bracket	181]
[165. Houghton's steel spatula for finishing off gutta-percha and amalgam fillings	181]
[166. Flagg's lamp and water-bath	182]
167. McAdams' combined spatula and stopper	184
168. Rowney's agate burnisher	184
169. Polished steel burnishers of various forms	187
170. Useful forms of amalgam stoppers	187
171. Iron spoon or ladle with wooden handle	189
172. Pestle and mortar for breaking up the copper amalgam when heated	189
173. The mercury drop-bottle	190
174. Balance for weighing out Fletcher's filings and mercury in proper proportions	190
175. Fletcher's mixing-tube for shaking together filings and mercury	191
176. Fletcher's mortar and plunger for compressing platinum amalgam into disks	191
177. Pinney's thin metal clamp for forming a temporary sustaining wall	192
178. Arrangement for giving support to an amalgam filling upon an almost flat surface	192
179. The Wilkerson operating chair	194
180. Lyon's adjustable stool	195
181. Scissors for dividing the sheets of gold and other foil	195
182. Knife for folding gold or other foil	196
183. Tweezers of suitable form to be employed in plugging teeth	196
184. Hand mallet of hard wood filled with lead	197
185. Automatic mallet (Snow and Lewis)	197
[186. Flagg's condensing forceps	198]
187. File-carrier for filling teeth at the back of the mouth	199
188. Steel holder for Arkansas or corundum points	199
189. Harding's tape-carrier with steel-spring ratchet for tightening the tape	200
190. Method of taking up gold foil for insertion into a cavity on the plan of stars or strips	200
191. Tomes' foil roller for making cylinders in foil	201
192. Form of gold foil prepared in cylinders	201
193. Form of gold foil prepared in blocks with parallel layers	201
194. Spade drills	205

FIG.	PAGE
195. Shallow and spoon-shaped cavity in a cuspidatus tooth . . .	205
196. Spirit-lamp and tray for heating (annealing) gold foil . . .	206
197. Spirit-lamp suitable for heating (annealing) gold foil . . .	206
198. Rich's tweezers for carrying cohesive foil to the retaining points or grooves	207
199. Three forms of plugger for condensing cohesive foil . . .	207
200. Kirby's pneumatic mallet	207
201. Power's mallet	207
202. Three forms of bit for Power's engine mallet	208
203. Electro-magnetic mallet	209
204. Corundum wheel to fit the mandrel of a dental engine . . .	209
205. Corundum wheel with Ives' tongue and cheek protector . . .	210
206. Moffat's hot-air syringe	210
207. Cavity in a bicuspid tooth prepared for filling by the combined process	213
[208. Fissure burs	213]
[209. Oval burs	213]
[210. Adjustment of Jack's matrices	214]
211. Jarvis' screw separators	217
212. Barbed nerve-extractor made of soft steel for removal of dental pulps . . .	225
213. The galvanic cautery	225
214. A lancet of convenient form for excising a polypus	225
215. Instruments for removing the disorganized contents of a pulp-cavity . . .	228
216. Pluggers of delicate form for filling the fang-cavities with foil . . .	228
217. Pulp-cavity drills to be employed with the dental engine . . .	231
[218. Cast of mouth showing a cystic tumor	237]
[219. The same after treatment	237]
220. Passage of the white blood-corpuscles through the walls of a blood-vessel	239
221. Farrar's alveolar-abscess syringe	247
[222. Hot-air syringe	252]
223. Unerupted wisdom tooth, causing absorption of the approximal surface of a second molar	253
224. Absorption of the roots of three permanent incisor teeth . . .	253
225. Cases of hyperostosis and exostosis in the fangs of teeth . . .	254
[226. Pivot files and wheels	258]
[227. Gates-Bonwill crowns	262]
[228. The teeth of the left side of the mouth	266]
229. Key instrument for extracting teeth	268
230. Forceps for extracting upper incisor and cuspidati teeth . . .	269
[231. Superior incisor forceps	271]
[232. Inferior incisor, canine and bicuspid forceps	271]
[233. Upper molar forceps for either side	271]
[234. Lower molar forceps for either side	272]
[235. Root forceps	272]
[236. Upper molar and wisdom teeth forceps	272]
[237. Forceps for cutting out the roots	273]

FIG.	PAGE
[238. Right and left upper molar forceps	274]
[239. Root forceps	274]
[240. Right and left upper molar forceps	275]
[241. Lower molar forceps, either side	275]
[242. Cutting forceps	276]
[243. Lateral incisor forceps	276]
[244. Lower incisor and root forceps	276]
245. Transverse sections of the teeth of the upper jaw made at their necks	278
246. Transverse sections of the teeth of the lower jaw made at their necks	278
247. Central incisor of upper jaw, front and side views	279
248. Lateral incisor of upper jaw, front and side views	279
249. Cuspidatus of upper jaw, front and side views	279
250. Upper first bicuspid, front and side views	281
251. Upper second bicuspid, front and side views	281
252. First molar of the upper jaw	282
253. Second molar of the upper jaw	282
254. Third molar or wisdom tooth of the upper jaw	283
255. Central incisor of the lower jaw, front and side views	285
256. Lateral incisor of the lower jaw, front and side views	285
257. Cuspidatus of the lower jaw, front and side views	285
258. First bicuspid of the lower jaw, front and side views	285
259. Second bicuspid of the lower jaw, front and side views	285
260. First molar of the lower jaw	287
261. Second molar of the lower jaw	287
262. Third molar of the lower jaw right side	288
263. Coleman's forceps for the removal of upper first and second molar roots	292
264. The above applied to a molar root	292
265. Forceps for separating the fangs of upper molar teeth	293
266. Stevens' forceps for extracting the roots of upper molars	293
267. Baly's forceps for extracting the roots of upper molars	293
268. Coleman's forceps for extracting the roots of upper third molars	294
269. Forceps for extracting the roots of lower molar teeth when attached to the crowns	295
270. George's elevator, front and side view	295
271. Tomes' elevator, with a spoon-shaped blade	296
272. Scissors with the blades at an angle to the handles	298
273. Elevator with the blades at an angle to the handles	299
274. Elevator, the blade of which can be set at any angle	299
275. Thompson's elevator	299
276. Two forms of screw instruments for extracting roots of teeth	300
277. Teeth which would present a considerable resistance in their removal	304
278. A trephine for removing the alveolar process in front of a tooth	304
279. Malformed upper third molar, to which the ordinary forceps could not be properly adjusted	304
280. Forceps for extracting lower incisors and cuspidati when crowded	305
281. Forceps for extracting upper incisors and cuspidati when crowded	305

FIG.	PAGE
282. Cattlin's alveolar forceps with saw-edged blades	306
283. Coleman's mouth-opener or gag.—The instrument as applied	307
284. Steel probes of various curves for detecting unerupted teeth	308
285. Upper first molar tooth with a portion of the external alveolar plate attached	310
286. Upper third molar with the tuberosity of the superior maxilla attached	310
287. Forceps for cutting away projecting portions of alveolar process, etc.	311
[288. Wedge cutter	312]
289. Diagrammatic representation of the arteries of the right side of the neck	317
290. Richardson's ether-spray apparatus	321
291. Complete apparatus for generating nitrous oxide gas	325
292. Gasometer for collecting and storing nitrous oxide gas	326
293. Simple form of apparatus for administering nitrous oxide	326
294. Nitrous oxide apparatus	327
295. Clover's face-piece and two-way stopcock	328
296. Simple form of mouth-prop or gag	331
297. McAdam's mouth-prop	331
298. Electro-magnetic apparatus for stimulating the heart's action	335
299. Diagram illustrating Lauder Brunton's views of the cause of arrest of the heart's action under chloroform administration	337
300. Coleman's chloroform apparatus	341
301. Apparatus represented in Fig. 300 with a nose piece for maintaining anæsthesia with the mouth open	341
302. Coleman's apparatus for administering chloroform through the nose	342
303. Chair-couch for operations upon the mouth under chloroform	342
[304. The S. S. White pedal lever chair	343]
305. A form of scaler for removing tartar	358
306. Two forms of polishing brushes to be used with the dental engine	359
307. Necrosis of nearly the whole of the right superior maxilla following ulcerative stomatitis	364
308. Hypertrophy of gum which disappeared after removing some loose teeth	374
309. Case of considerable exostosis of the lower jaw	378
310. Cystic tumor of the upper jaw caused by a diseased bicuspid root	380
311. A cyst removed with a bicuspid of the upper jaw	382
312. Small cyst in connection with a bicuspid root	385
313. Instrument for making an opening into the antrum	388
314. Diagrammatic representation of the fifth pair of cerebral nerves	393

MANUAL

OF

DENTAL SURGERY AND PATHOLOGY.

CHAPTER I.

THE FIRST DENTITION.

THAT the Teeth are important agents in the animal economy, evidence is afforded in their early development; for, at the seventh week of intra-uterine existence may be seen the commencement of these organs, which enable the possessor to become independent of the maternal parent. In order that this independence should be possible at an early period of existence, most animals are provided with two sets of teeth, one temporary and comparatively rapidly developed, which appears generally at or soon after birth, and supplies the individual with the means of securing and comminuting its food during the period while the second and more permanent organs are undergoing their slower and more perfect development. [This is especially true of the higher mammalians. According to Owen, replacement occurs in them but once.¹ The phenomenon of a third dentition in man yet requires verification. Occasionally, cases of eruption of one or more third teeth may take place, but that an entire dentition should be replaced a second time seems to be very rare if not entirely unauthenticated.]

Man, of all animals the most dependent upon his own species, is not, as a rule, furnished with any teeth until nearer the end than the commencement of the first year of his existence, and

[¹ "Owen's Odontography, or a Treatise on the Comparative Anatomy of the Teeth, etc.," vol. i. p. 307. Hippolyte Baillière, London, 1840-45.]

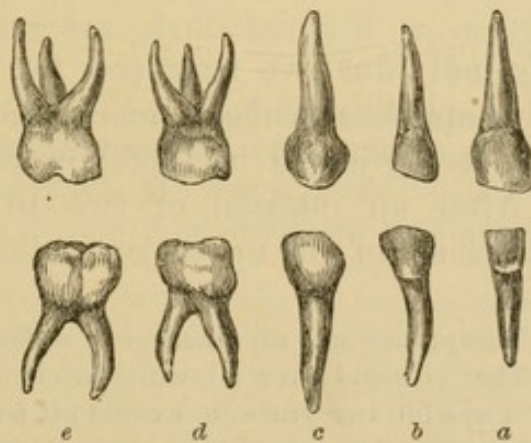
the process has seldom terminated much before manhood is attained. During the period between birth and the possession of a sufficient number of teeth to render the individual independent of the mother, it is supplied with a food in form and composition the most suitable to its requirements, viz., a bland, palatable fluid, holding in solution all the constituents out of which its various tissues can be nourished and developed. The young animal merely drinks its food, which it can readily digest in its more simply developed alimentary canal. Contemporaneously with the development of the teeth, other organs are also becoming developed, whose function will be necessary when the former are so far advanced as to enable the individual to obtain its food from other sources, and which, being of a less simple form and character, will require more complicated processes to bring it into a condition in which it can be assimilated and turned to the same account.

If we examine the mouth of an infant shortly after birth, we shall see, more or less distinctly, the outlines of the forms of the temporary teeth—especially the front ones—situated apparently a very little distance beneath the surface of the gums on the external aspect of the jaws. As the infant grows older, they become, owing to the increased development of the alveolar processes and mucous membrane, less and less apparent, until the outline is almost lost. A little ridge, on the summit of each jaw, and closely resembling a cicatrix, scarcely if ever perceptible at birth, becomes more apparent as the period of dentition approaches: it is probably the developed remains of the “primitive Dental Groove” of Goodsir, the dipping down of the fold of “epithelium,” from which the enamel is developed. During the period prior to dentition, it will be remarked that the mouth of the infant is less moist than is that of the adult; whilst, as dentition approaches, the reverse is apparent, the saliva generally flowing in considerable quantity from the infant’s mouth. Whilst supplied with fluid food, the office of the saliva, in liquefying and lubricating it at the commencement of the alimentary canal, is not called for; but, as the time approaches for a harder, drier, and more complicated food being sought for, the salivary glands become more perfectly developed. Unduly stimulated, no doubt, by the irritation of dentition, their secretion becomes abnormal in quantity, and thus, draining the blood at this region

of certain of its constituents, reduces, as some have supposed, the tendency to inflammatory action; a view supported by the fact, that, in certain inflammatory conditions of the gums, relief is often secured by producing this condition artificially, by the agency of what are termed sialagogues. [In which, at least, the practitioner follows the apparent action of nature, for many who have cut the sensitive dentine of teeth have noticed the immediate augmentation of the flow of saliva. So constantly is this witnessed that it may be accepted as an indication of the intensity of the pain and irritation inflicted.]

As the period of dentition approaches, it will be noticed that the now greatly increased alveolar processes present on their summits uneven elevations, like mounds or hillocks. They vary much in different individuals: if they be watched from day to day, we notice, as they become more distinct, that they become lighter in color, until they so nearly resemble that of the teeth themselves, that it is only by the assistance of touch that we can positively determine that the teeth have been erupted; where the mucous membrane has been much elevated, its subsidence, after the eruption of a tooth, leaves the latter projecting some distance above the level of the surface, as if the tooth were erupted more rapidly at this than at other periods in the process.

Fig. 1.



The temporary teeth of the right side in the upper and lower jaws. *a*, central incisors; *b*, lateral incisors; *c*, cuspidati; *d*, first molars; *e*, second molars.

The temporary teeth in man are twenty in number: ten in the upper and ten in the lower jaw, placed symmetrically on each side of the mesial line, their formula (representing each side of the mouth) is: incisors $\frac{2}{2}$, cuspidati $\frac{1}{1}$, molars $\frac{2}{2}$.

They receive their names from either their form or their office, thus: incisors — cutters; cuspidati — pointed; molars — grinders.

The order and periods in which the temporary teeth are erupted—the first dentition, as the process is called, or more popularly, “teething”—are subject to great variation. Teeth may be erupted at or even prior to birth, or they may not appear until the second year has been almost completed: extremes which that master-observer of human nature, Shakspeare,¹ has not overlooked. The writer has met with several instances of well-formed teeth occurring in the mouths of children at birth, and a few cases where “teething” did not commence till after the twentieth month. Formerly, it was the practice to remove the teeth erupted at or soon after birth, it being almost impossible for such children to be nursed at the breast; but, since the introduction of india-rubber nipple-shields, this harsh treatment has been abandoned. These cases are, however, different from those in which, at or near birth, small sharp teeth, loosely attached to the mucous membrane, and having no fangs, are discovered in the mouths of infants. These should be at once removed, as they will prove only a source of distress to the possessor. They are the exfoliated calcified caps of dentine of necrosed temporary teeth, and their existence would lead us to a strong suspicion that the child is the subject of inherited syphilis.²

In the healthy individual we may look for a lower central incisor making its appearance about the commencement of the eighth month, and being joined by its fellow within a week or so afterwards. After an interval of two to three months, appears a central incisor of the upper jaw, followed soon after-

¹ *York.* Marry, they say, my uncle grew so fast,
That he could gnaw a crust at two hours old;
'Twas full two years ere I could get a tooth.
Grandam, this would have been a biting jest.

Richard III., act ii., sc. iv.

² The writer had the opportunity of seeing the following curious case in the practice of his friend, G. R. Ord, of Streatham. A child had at birth a sac-like projection of the mucous membrane about the symphysis of the lower jaw, in which could be felt the two central incisors quite loose; as it impeded the child in sucking, Mr. Ord opened it, and removed two imperfectly developed but living teeth. In this case there was no suspicion of syphilis.—[A. C.]

wards by its comrade, and, within a month to six weeks, by the lateral incisors of the same jaw. Some authorities, erroneously we consider, name the lateral incisors of the lower jaw as next in succession to the central incisors of the upper jaw; but these do not generally appear until after the corresponding teeth of the upper jaw have been erupted some two months,¹ bringing the period to twelve months or thereabouts; and within another period of two months, and at some little distance from the lateral incisors, and posterior in the dental arch, will appear the four first molars. A pause of four to five months ensues before the "cuspidati," the next in order, appear, which will be when the individual is about eighteen months old; and they take their position in the spaces left between the lateral incisors and first molars, and many authorities consider that in their eruption more trouble is experienced than with any of the other teeth; if so, it is not attributable to their size and form, as of all the teeth we should, judging from these, expect the cuspidati to be the easiest to erupt.²

The cuspidati occupy about two to three months in their eruption, and, after an interval in the process of three to five months, appear the second molars—the fifth and last group—about the beginning of the second year. They take a position in the dental arch posterior to the first molars, and are all usually erupted within a period of three to five months, when the process of the first dentition will be completed,³ which is

¹ Trousseau and C. S. Tomes adopt this arrangement, and West probably, but there is evidently some error in the text of his work, "Diseases of Infancy and Childhood," 5th edit. p. 553, line 9, *et seq.* Ashburner adopts the other, viz., that the lateral incisors of the lower jaw are erupted before those of the upper.

² West regards the first molars as being the teeth to cause generally the most trouble; Trousseau and some others the cuspidati, and account for it "from their having long roots," "their sockets being very narrow, and their being erupted between teeth already cut," "the distance they are developed from the surface;" reasons which we consider in themselves insufficient as explanations, the condition of the nervous system at the period having probably more influence in the matter than any local conditions.

³ The arrangements and dates which we have given are mainly those of Trousseau, whose calculations are based upon the observations of his pupil Duclos; he, however, gives the period of eruption of the first tooth at six months and a half, which we consider earlier than the average, and we therefore prefer adopting the commencement of the eighth month as such period.

said, and we believe correctly, to commence earlier, and terminate sooner, in girls than in boys. Certain diseases, especially rickets, are stated to delay the period of eruption.

To assist the memory, the following table, which is a fair approximation to the truth, may be found useful:—

Group	Months
1. Lower central incisors	7
duration of eruption 1 to 10 days	
pause 2 to 3 months.	
2. Upper central and lateral incisors	9
duration of eruption 4 to 6 weeks	
pause 2 months.	
3. Lower lateral incisors	12
First molars	14
duration of eruption 1 to 2 months	
pause 4 to 5 months.	
4. Cuspidati	18
duration of eruption 2 to 3 months	
pause 3 to 5 months.	
5. Second molars	26
duration of eruption 3 to 5 months. ¹	

The period of the first dentition is one watched with more or less anxiety, as it is well known to be a critical one, for good or evil, in the history of the individual. An infant, healthy up to the time of teething, may then show symptoms of future delicacy or disease; it is evidently a time of trial, as is, we well know, the period when the young of the feathered tribe are changing their down for feathers. Infants weak and delicate from their birth often go through the process of dentition under most comfortable conditions, whilst fine and apparently strong ones may suffer severely, and are left with lesions which impair their future well-being.

[¹ The children of this country (U. S.) frequently erupt their teeth from one-half to one-seventh earlier than these dates. Whether this apparent precocity is due to the very general encouragement of children to eat of adult's food, or to the difference of climate, is as yet undetermined. The inconveniences attending suckling, generally here submitted to by the mother, may result in earlier weaning than where it is to the interest of the wet-nurse to prolong her season of pecuniary profit. On the other hand, the earlier maturation here of many of the cereals, owing to the higher average temperature, may be an argument favoring the idea of earlier development. It is, however, unsafe to rely implicitly upon tables which are only compiled to express averages. The symptoms showing a disturbance of the general system in teething are, of course, in individual cases the most correct guides.]

Under the most favorable circumstances, the teeth may appear one after another at the usual time, and in the groups named, with so little apparent disturbance to the individual, that their presence may be only accidentally discovered; more commonly, however, the child, for some little time previous to the eruption of each group, becomes restless, has an increased flow of saliva, and more or less often presses its knuckles against the gums.¹ The mouth, if examined at such period, will exhibit the gums somewhat swollen, and of a rather higher temperature than usual, and more than normally injected with blood. As the process advances, the more elevated portions of the gum become of a paler color, until, as before stated, they so resemble that of the coming teeth that it is almost impossible to say when they have actually penetrated it. When the group of which they are members are all erupted, the symptoms for the time usually disappear. In many cases, however, the condition of matters is not so favorable; for some time previous to the eruption of each tooth or group, the child becomes fretful and irritable, and the gums appear hot, swollen, and tender; the rubbing, evidently grateful in the former cases, now causes pain and resistance, and infants, from this cause, are seen to relinquish the breast, suddenly crying and struggling. If the symptoms are more severe, they are not confined to the local ones; the little sufferer is feverish and thirsty, evidenced, as

¹ To the natural irritation experienced in dentition, which in the lower animals probably never exceeds more than a slight amount of discomfort, a useful purpose may be assigned. The sensation of thirst, arising from deficiency of fluid in the blood, is referred to the region of the mouth and fauces, and we can readily comprehend the young animal grasping in consequence the teat of the mother by the mouth. The sense of hunger, arising from deficiency of solid nutritive material in the blood, is less definite in its location, and is felt in regions which are not accessible to applications.

At the period of teething, the young animal is continually applying to its mouth various solid substances, as our mats and carpets often testify, and, no doubt finding some of the substances palatable and agreeable, swallows them. Soon the sense of smell recalls to the creature the recollection of that with which previously an agreeable taste was connected. Sight also assists, and these two senses soon enable the individual to select its own food, and become wholly independent of the maternal supply.

[N. B.—The above condition in the lower animals is much modified by the practice of artificial rearing of the domestic animals, now so generally being followed in various selections of breed, etc., producing conditions approaching more nearly the artificial life of man.]

West points out, by its sucking greedily at the breast and then vomiting a portion from the more than satisfied stomach. [This must not be confounded with the mere regurgitation of food, the milk coming up comparatively pure and sweet immediately after feeding, in consequence of the child's movements causing pressure of the abdominal walls upon the over-distended stomach.] Diarrhœa, the result of extended or reflex irritation to the intestinal mucous membrane, is not uncommon, the motions being often offensive, and having the so-called chopped-spinach appearance, as when mercury has been administered. A troublesome cough, likewise the result of irritation conveyed to the respiratory mucous tract, often sets in with the eruption of each tooth, and, like the diarrhœa, ceases when the tooth or group has become erupted. But the symptoms most to be dreaded are those which show the nervous system to be influenced; for, although West has taught us, and no doubt correctly, to regard convulsions in the infant as comparable to delirium in the adult, they yet appear, even when arising only from the cause in question, to be capable of leaving lesions more serious than are generally seen to follow the delirium of prostrating illnesses.

Thus, in cases where the convulsions have been very severe, the brain occasionally appears to have been permanently affected thereby, and this where there may be no reason to suspect tubercular or other constitutional taint; nor are such results confined to the brain alone: the most distant parts may suffer, as seen in the cases of talipes equinus resulting from this cause.

During the eruption of the temporary teeth, cutaneous affections are by no means uncommon, the most frequent and troublesome, after the fugitive and unimportant erythematous and papulous rashes, being eczema, impetigo, and herpes.

Teething is a natural process, and not a disease, yet it does occasionally happen that a child may be said to die directly from it, and independently of any of its complications. A weak child may be so exhausted by the process as to sink under it. A marked case came under the notice of the writer:—a male infant, which had the misfortune to lose its mother at the birth, and, with her, that means of nourishment most adapted for a weakly child, did fairly well up to the usual period of teething, when tooth after tooth, irrespective of group, rapidly made its

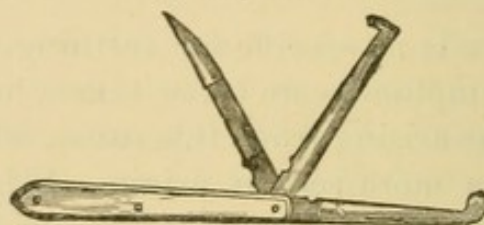
appearance; the appetite fell off, yet the food taken, though small in quantity, was fairly digested; the little sufferer's rest was broken, and it gradually lost strength from day to day, and week to week, until it finally sank, exhausted. Now, had this weakly child erupted its teeth in groups, with the proper periods of repose between each, instead of *en masse*, so to speak, there is fair reason to believe that it might have gained sufficient strength in the intervals to enable it to pass through the trials as they arrived. In this case there was no disease, and therefore there could be no actual treatment, and this may be said of teething in general. [Sometimes lancing freely seems to restore the normal conditions, and delay teeth that are prematurely erupting.]

But, whilst there is no specific for teething, much may often be done to allay symptoms, care being taken, however, that they are not mistaken as arising from this cause, when they have in fact another and a more serious origin. When the process is naturally conducted, the less nature is interfered with the better; but we may inculcate on those having charge of infants the importance of their being especially guarded, particularly during the eruption of a group, from things in respect of which there is less necessity for care when the process is completed. Thus, at such periods, the following matters should be especially avoided; weaning, or other important changes in diet, exposure to changes of temperature by alteration in clothing or situation, the chance of infection of zymotic diseases, etc., and vaccination.

If called to children whose symptoms are confined to local ones, we may, if we find the gums somewhat swollen and congested, though not tender, afford some relief by lightly scarifying them with a sharp lancet;—we lay much stress on sharp, as it then causes very little pain, and, by cleanly dividing the superficial vessels, affords greater relief through freer bleeding;—but, should the gums be very tender, as evidenced by the cry or altered cry of the infant when it is commenced, it should at once be discontinued, for an inflamed surface is mostly acutely sensitive, and the less cruel method of applying a leech at the angle of the jaw should be adopted. We doubt whether much relief, or relief of any duration, is attained by the operation of scarifying the gums; yet that it does afford relief, and cause but

little pain, is evidenced by the fact that we have occasionally been asked by children, old enough to do so, to perform it, from their recollection of the relief which they had experienced on former occasions. [One of the writer's children, before she was nineteen months old, insisted upon the lancing of her gums, and persevered until eight incisions were made over the four erupting molars, when, with an embrace and a kiss as recompense for the relief afforded, she immediately fell into a tranquil sleep.] In case, however, of other conditions than the merely local ones prevailing, should we find the gums elevated at certain points, and, on inquiry, ascertain that certain teeth of a group have

Fig. 2.



Three forms of lancet useful in dental surgery ; the blade in a line with the handle is that best suited for lancing the gums.

been erupted, and should the gum, moreover, appear stretched over such spots as correspond to other members of such group, we may then with advantage freely divide the gum until the tooth is reached, which should be but a short distance from the surface. In performing this simple operation, especially in the front of the mouth, care should be taken to incise upon the anterior rather than upon the posterior aspect of the gum ; as it might be possible, in the latter case, for the lancet to slide down the posterior surface of the tooth and injure the germ of its permanent successor. The operation, however, should be quite exceptional ; its general employment, as was the case some half-century ago, was undoubtedly cruel and uncalled for ; yet there is a danger, in the present day, of a really valuable and simple means of allaying serious symptoms being for fashion's sake discarded.

[By many, with whom my own experience has universally agreed, it is still deemed best to completely sever all the bands of overlying tissue, thus entirely freeing the underlying formative pulp and nervous tissue from the irritation of pressure. The bleeding relieves even deep-seated congestion, and the

cicatrix that may form over the tooth is much more readily penetrated than the original tissue.¹ There is also less liability to other symptoms of a general and serious nature such as are enumerated in the next paragraph.]

In respect of the diarrhœa accompanying teething, and regarded by some as an effort of nature to relieve or prevent local inflammations, and therefore not to be actively dealt with, the greatest circumspection on the part of the practitioner is requisite; processes natural in themselves at the outset may yet become habitual, and continue after the cause of their existence has disappeared; and diarrhœa, simply the result of the reflex action of a cutting tooth, may soon result in symptoms alarming, and conditions difficult of control. It is not always easy, in cases of diarrhœa occurring at the period of teething, to diagnose its true cause, and therefore it will be the more prudent, at all events, to try and restrain it within moderate bounds, even though our suspicions strongly point to a dental origin. Our conclusions upon the subject may, however, be much assisted by our learning whether, in case of teeth having been previously erupted, such conditions then prevailed, and passed off when the process was accomplished. Our attention should also be directed to ascertaining, whether other portions of the mucous membrane are likewise affected, as shown by catarrhal symptoms generally; and the condition of the alvine ejections, and the circumstance of a group of teeth being, or about to be erupted, should also be ascertained. Above all, we must inquire into the conditions under which the child is receiving its nutriment: if from the breast, then whether circumstances have occurred which could alter the character of the milk, or whether the child be allowed the breast too frequently or at irregular intervals; if by hand, then whether any changes have been made in the character of the food, or in its consistency. The milk, if that has been employed, may have been obtained from another source or supplied in too large quantity, or not sufficiently diluted—both very common errors in the nurture of infants. A child may often do well by hand, on milk and water

[¹ See "Paget's Surgical Pathology," Lindsay and Blakiston, Phila., 1865, pp. 88, 158, 159, 194. For example, a lip once split by chapping, will after healing open again upon the slightest stretching.]

(the best food for ninety-nine out of a hundred children for the first year) until the period of teething, when the digestive organs appear less capable of digesting the casein of cow's milk, especially when too little diluted with water. As in the milk of cows casein exists in larger quantity than in that of the human species, a certain dilution, especially in the case of delicate children at this period, is essential; but there is no doubt also that it exists in the former in a less digestible form; "the casein of cow's milk coagulates in large clots, whilst woman's milk produces only small flocculent coagula." Should the casein be not digested, we usually at first find symptoms of constipation; the motions are voided with difficulty and pain, and are much of the consistency and appearance of dry putty; the action of the liver appears almost suspended, and the napkins are scarcely soiled. If this condition of things be allowed to continue, diarrhœa, often culminating in so-called infantile cholera, especially in hot seasons, may soon occur; but this is not the diarrhœa of teething, though it may be greatly incited and aggravated thereby.

[It has been the writer's practice always to examine personally the condition of the feeding-bottle and appliances. Of these the simplest and most easily cleaned are the best—an ordinary smooth, strong, wide-mouthed bottle, free from thin scales of glass and sharp edges or corners, either within or without, and a thin, black, elastic, vulcanized rubber nipple. The former should be scrupulously scalded, and both washed with soda and water immediately after using, and after thorough rinsing be kept in clean, cold water that is unclouded by any residue of milk, until the time to feed arrives, which is probably shown by the disquiet of the child. Then, tasting and being assured by critical examination that the milk is sweet and good, fresh from an ice chest or cold spring-house, it may, if cow's milk, be slightly warmed by the addition of one-third part of boiling water. To this mixture (or less advantageously to the milk immediately upon its being received from the dairyman), add of lime water one or two teaspoonfuls for each pint of milk. Sweeten with a small quantity of sugar of milk, say two teaspoonfuls to the pint. As the child advances in age the amount of water may be decreased until about the beginning of the period of dentition, when the milk may be used pure from the cow, except

where feverish conditions point to the desirability of diluting it with water. The rules for proper nourishment for young infants and animals have probably been more the result of empirical domination than those for any other age in life; this is the natural sequence of the timidity of the young mother, the dictation and ignorant confidence of the so-called experienced nurse, together with the utter helplessness of the little sufferer and the impossibility of its making known its wants. To form arbitrary and invariable rules with regard to the time of feeding and amount or kind of nourishment to be given to babes, is as unreasonable as it would be to dress them in clothes made according to one pattern and of one uniform material. Disquiet and a peculiar *rooting* movement of the nose and head are generally the signs of an infant's hunger, and invite attention to its need. Many of man's morbid appetites come of eating and chewing various articles to temporarily relieve the discomfort of hunger. There is but little danger of the young of any animal being overfed, so long as the food furnished is perfectly healthy and free from condiments and unnatural constituents. Carbonaceous food, such as candy, sugar, molasses, cake, and sweets, is too often resorted to as placebos until a pernicious appetite is formed by the child, which destroys the value of the craving or desire for aliment as a guide to its administration. Sydenham is credited with the proposition that the more nearly a medicine approaches a food the better, but the modern developments of knowledge in the direction of physiology and pathology seem to warrant the broader assertion that probably in the modification of the diet is to be found the greatest power to control or modify the entire animal economy, and the mind is often in such sympathy with the body as to be likewise affected by the regimen. The importance of proper food is such that no parent can be said to have performed his or her duty, in the cultivation of the highest capabilities of the bodies or the minds of their children, if the strictest attention is not paid to their diet.

For most infantile troubles, as already intimated, proper air, food, and clothing, and thorough lancing when indicated, are all-sufficient when the child has no marked inherited disease. The diarrhœa of our warm summer weather often, however, requires, where the babe is artificially nourished, some special modification of the milk. A good plan is to boil flour in a bag

for four hours; then, removing the outside crust when required for use, the interior may be grated to powder and added to the preparation above mentioned to form pap.]

Here our attention must be directed to diet almost exclusively; goat's milk may be substituted for cow's, and should this not prove effective, ass's milk, which more nearly approaches the human than any other available, will often be digested;¹ or, where these are not accessible, the valuable suggestion of forming a compound analogous to human milk may be adopted.²

[Where so situated as to be unable to get or keep cow's milk pure and sweet, children thrive for a time upon condensed milk; this in the absence of goat's or ass's milk (both kinds very rare in this country) has done great service in furnishing a healthy

¹ Butter-milk has been much commended in some parts of the Continent.

² To a friend and former teacher—Dr. Frankland, of the Department of Science and Art,—we are indebted for the following plan, slightly altered at our suggestion with his concurrence, for preparing a food for infants, closely resembling in its composition human milk.

Take the cream furnished by a pint of milk and add it to $\frac{2}{3}$ pint of new milk. Into the skimmed milk from which the cream is taken, put a piece of rennet about one inch square, and set the vessel containing it in warm water, until the milk is fully curdled, which should occupy about 5 to 15 minutes. The rennet, being removed, washed, and then kept in salt and water, will be serviceable for a month. Next break up the curd, and carefully strain it from the whey, which latter should be heated to the boiling point, and then again strained from the casein formed during the boiling "feetings." Add to the hot whey 110 grains of milk-sugar, and when dissolved mix the whole with the $\frac{2}{3}$ pint of new milk and added cream. The artificial milk thus prepared should be used within twelve hours of its preparation, and all vessels employed should be scrupulously clean.

Analyses of milk, from "Frankland's Experimental Researches:—"

	Woman.	Ass.	Cow.	Artificial.
Casein	2.7	1.7	4.2	2.8
Butter	3.5	1.3	3.8	3.8
Milk-sugar . . .	5.0	4.5	3.8	5.0
Salts2	.5	.7	.7

It is not impossible also, that a portion of the milk having been acted on with pepsine, the casein of the fresh milk added may undergo some beneficial change: at all events, the food has in most cases appeared to answer quite as well as human milk. The trouble, however, of preparing it is by no means inconsiderable, and would lead most to seek the more simple yet morally doubtful expedient of a wet nurse.

In large institutions, such as foundling hospitals, etc., this process might no doubt be adopted, and with great advantage.

and nourishing temporary substitute. But persons who desire to raise healthy children, and who are compelled to make use of artificial food, must be prepared to seek such localities as afford pure fresh cow's milk. Who would expect to become a successful grazer and raiser of cattle where the food had to be imported? Yet parents give less thought on this matter with reference to their children than to their stock.

In this country most physicians have, from English authorities and training, been more or less forgetful of our extremes of temperature and the modifications of dress demanded by them. In winter the child should live in rooms only moderately warmed (during the day) by direct radiation of heat from a stove, or better by an open fire, and be clad in heavy woollen material. The sleeping apartments should offer free admission of the outside air through large open windows, and during the arctic waves fur covering at night is advisable. The summer, however, often requires the tropical dress of simple, flowing, loose night shirts of cotton stuff for even a week or more at a time during the prevalence of our hot waves. Many weak children have been and will continue to be sacrificed—the unreasoning prejudice of their should-be protectors tormenting them to a sure but painful death during the heated terms by flannel clothing, or inviting the horrors of croup in winter by the sudden changes from a tropical atmosphere in the nursery to a polar one without.]

In our treatment of these cases, it will make little difference whether the cause be teething or otherwise; though, as before stated, we shall of course treat it, the diarrhœa, in the former less actively; next to a correction of any errors which we may have discovered, as regards diet or exposure to cold, a common factor in the diarrhœa of infants, we may with much advantage administer, for three or four successive days, a small teaspoonful of an emulsion, composed of equal parts of castor-oil and gum-syrup, which may in some cases be repeated more than once in the day, but should be discontinued on the cessation or moderation of the diarrhœa; in severe cases, a small quantity, one to three drops at most, of *vinum opii* may be added, and this opiated form should be especially employed in cases of relapse.

[While, as a rule, opium is a most pernicious drug for infants,

it may be occasionally of use in extreme cases of diarrhœa, under the familiar form of camphorated tincture of opium, of which ten to thirty drops may be administered after the *prima via* has been cleared of its contents by a purgative dose, say one to two teaspoonfuls, of aromatic syrup of rhubarb.

Without attempting to pass into a discussion of the physiological action, it may here be stated that some of the obstinate cases of this complaint in both adults and children have been cured apparently by a teaspoonful or tablespoonful of pure cider vinegar, the former amount, diluted with water, for children.]

When the child is found to be much exhausted and emaciated, great benefit often ensues from adding to its food a little brandy, \mathfrak{m}_{ij} or \mathfrak{m}_{iij} at each of its meals, but not in the whole exceeding 8 to 10 drops in the day. If there be much vomiting, the same quantity of *sal volatile* may be substituted. The food must be greatly diminished in such cases, and perhaps only a teaspoonful should be given at a time, but at more frequent intervals. Great benefit is also often experienced from the application of a large but light linseed-meal poultice, applied warm over the abdomen, and covered over with oil silk, a very small proportion of mustard only being added, the surface being previously slightly oiled. Enemata of starch and laudanum, about \mathfrak{m}_{j} to \mathfrak{m}_{v} of the latter according as they are retained, may at times be usefully employed.

[This raw starch injection, with from a half drop to three drops of liquid extract of opium, cannot be too highly recommended in cases of dysentery, where the irritated surface of the rectum causes intense pain and keeps up the disease at a point so remote from the mouth that drugs administered by that orifice cannot reach their destination without undergoing change and causing deleterious action, both constitutionally and upon surfaces traversed in their course.]

When called to an infant in whom the symptoms, however slight, indicate that the nervous system is affected, we must never omit a careful inspection of the mouth; and, should there be the smallest evidence for believing that the symptoms may depend upon the cause now before us, the gum-lancet should be freely used; for little harm can be done by incising, though unnecessarily, a healthy gum, compared with the mischief which may result from overlooking this cause of infantile convulsions.

The symptoms may be slight, such as mere restlessness, light and uneasy sleep, with the thumbs slightly contracted on the palms; or there may be more restlessness accompanied by muscular twitchings, the child sleeping with the eyelids but partially closed, moaning in its sleep, and waking with a start, and crying violently; or the symptoms may be the still more severe ones of active convulsive movements, succeeded after a time by complete unconsciousness. Should the movements be unilateral, they would of course most probably point to another cause than dental irritation. Even in the severest cases, the simple operation of lancing the gums has, under our hands, often allayed in a marvellously short time the symptoms which have continued more or less for twenty-four and even thirty-six hours. But it would never be right to depend upon this alone: the warm bath, to which a handful of mustard is a valuable adjunct, should be likewise employed. To the head if hot, cold should be applied, whilst the feet on removal from the bath should be wrapped in hot flannel. Should the face be flushed, the pulse full and incompressible, and the fontanelles prominent, a few leeches applied at the occiput and removed directly an effect is produced, will often prove of great service: when these cannot be obtained, an ounce or two of blood according to age may be taken from the external or anterior jugular veins, and, when required, an aperient must never be omitted. But it is most necessary, in treating cases of infantile convulsions from teething, not to mistake for these symptoms somewhat similar ones arising from a wholly different cause, viz., the convulsions of anæmia; as the above-mentioned treatment would most probably be attended with a fatal result. They arise from the same cause as do the convulsions witnessed in those who have suffered from severe hemorrhage in parturition, and we well know what would be the likely result of a depleting course in such condition. The following symptoms—a pale though occasionally flushing face, a dry skin with hair of head somewhat erect, conspicuous veins and sunken orbits but prominent eyeballs, fontanelles depressed, and pulse rapid and almost imperceptible, and quick respiration, with occasionally a loud, shrill, and distressing cry, often the precursor of a fatal termination,—call for stimulants, warmth, and nourishment, rather than depletion or depressants, to arrest the convulsions, of which the cause is not in any such instance

the teeth, but is probably an exhaustive diarrhœa, or imperfect nutrition.

[The thorough use of the lancet has, according to my own experience, been an almost invariable relief and ever valuable remedy in reducing the nervous symptoms of teething children, that add so seriously and often fatally to the complications of the conditions of many of the diseases of that age. It is a sheet anchor of hope in moderately healthy constitutions, and it is urged upon the profession as an instrument whose strokes, if properly made, equal the reputed power of the passes of the magician's wand in fairyland.

The difficulties that obstruct its use are overcome without much trouble by those who are determined to succeed, and are really less than those attending the forcing of a medicine down the little patient's throat. Let the child be held firmly and immovably from the waist up by a seated attendant, who holds the infant in his lap, facing the operator and the light, with its back against the assistant's breast, and the right arm of the latter over the child's arms, grasping them above the elbows, while the left hand over the forehead and eyes holds the child's occiput under the attendant's chin.

The surgeon, with a sharp curved bistoury, guarded by a strip of cloth wound around the blade, allowing only an eighth to a quarter of an inch of the latter to be exposed, will make a single cut for incisor teeth in the line of the arch, and two cuts, forming the St. Andrew's cross, for the other teeth—in these cases the cuts crossing the tooth diagonally. To do this, the lancet should be inserted perpendicularly through the gum, until the distal corner of the tooth is distinctly felt, and then, taking care to hold it down upon the tooth, draw it forward from the disto-lingual or palatal to the mesio-buccal or labial angle, and from the disto-buccal to the mesio-palatal or lingual angle, completely severing all the tissues above the teeth.

Another and simple method of holding the child, is to seat both the operator and the attendant face to face. Lay the child upon the latter's lap upon its back, with its head firmly grasped between the knees of the operator, the wrists of the child being held by the hands of the attendant.

Without nerve, firm conviction, and confidence in the immense value of the lancing, sufficient to impress those attend-

ing, and enable the surgeon to operate deliberately, the results have so often been vexatious as to have caused many to condemn the operation, when in reality the failure was due to their own inefficiency.]

With regard to the cutaneous eruptions often seen during the period of teething, which anxious parents so urgently solicit the practitioner to cure, a palliative treatment only is the best course to pursue, as active interference is often attended by severe and permanent injury to other organs, especially the respiratory. The removal of the crusts, when large, by poultice, and scrupulous attention to cleanliness, with perhaps the employment of some mild astringent and cooling lotion, form the best treatment.

[Starch mixed with cold water to a creamy consistency as for enemata, but without the opium, unless there is great pain, will prove a marvellous remedy to apply to these surfaces of irritation. When on the head, anointing with castor oil, and washing with dilute solution of borate of sodium in water, is a very safe and cleanly treatment.]

A disease has been described under the appellation, "odontitis infantum," in which the gum over an erupting temporary tooth becomes swollen, congested, and finally ulcerated, when the tooth has penetrated it. The examples we have met with, *i. e.*, if they be the disease in question, were certainly, in our opinion, no other than cases of ulcerative stomatitis, modified to some extent by the condition of the parts during the process of dentition, which readily yielded to the specific for that disease, viz. chlorate of potash.

[Sage tea and honey are very highly recommended also in these cases, but for children or adults a simple touching of the ulcers with a crystal of alum, the mucous membrane surrounding the parts immediately affected having been previously dried, will generally produce the most speedy and effective cure.¹ In stubborn cases, where the white ulcerated surfaces indicate the presence of the *oidium albicans* (a parasitic vegetable growth giving the appearance of a dead and soaked piece of skin, or curd, or layer of starch covering the bottom of the ulcer), a saturated

[¹ Nitrate of silver has been recommended by Dr. J. Wm. White, "Holmes's System of Surgery," vol. ii. p. 517. 1881.]

tincture of iodine is invaluable, and may be applied by dipping the end of a piece of wood, like a match stick, in the solution, and then applying to the ulcer, previously dried to prevent spreading of the medicament to the surrounding surface.]

In very delicate children, especially those who may have suffered from whooping-cough, measles, etc., the mucous membrane covering an erupting tooth may completely slough; for this we have found no remedy so efficient as strong carbolic acid. Another condition that may be witnessed at this period is the formation of a small sac containing serous fluid above the summit of a coming tooth, which is doubtless, as suggested by J. Tomes, an abnormal secretion of serum into the space between the enamel of the tooth and the remains of the enamel organ.

In describing some of the untoward conditions which occur during teething, and how they may best be met, the limits and objects of this work enable us only to give but a brief and consequently imperfect outline, and the student desirous of more information will do well to consult the writings of West, Trousseau, and Dickinson, also an excellent article in the "*Journal de Thérapeutique*" for July 25, 1877, on the *Diarrhœa of Infants*, by M. Blache, translated in the '*Lancet*' of September 15, 1877, from which works we have occasionally quoted verbatim.

[In our extreme warm weather I cannot too highly recommend the laying of the child in grass or open network hammocks, instead of the arms of the nurse or upon the bed, to admit of the freest circulation of air about it, together with frequent ablutions in water of a temperature of 85° to 90° Fah., to keep down the accumulation of caloric and the subsequent danger of heat fever, or, as it is commonly called, sunstroke or insolation. Wrapping the child in a sheet and then sprinkling it with water of the above temperature will rapidly cool and reduce feverish conditions where there are dryness of the skin and heat exhaustion. A little brandy diluted with water may be administered internally in anæmia. In all febrile conditions, to sip a teaspoonful of cool water, say 50 to 60° Fah. every quarter or half hour, is most grateful, and, by keeping the mucous surfaces moist and replacing the loss of water by evaporation from the body, it will do more to relieve suffering, reduce the temperature,

and effect a cure than any drug ever known. With young babes cotton bird-eye diaper is always preferable to linen, it being less likely to chill, and it is equally useful as an absorbent, while only about one-fourth the price. The diapers should always be changed the moment they are soiled, then washed and dried in the sun upon the grass, or hung out to be aired until they have the freshness of smell that is characteristic of clean washed material. Under all circumstances the abominable contrivances of water-proof stuffs to protect the child's dress while feeding, and the nurse's lap, should be regarded as the enemy of health, inasmuch as they retain the heat and the imperceptible perspiration and poisonous effluvia arising from the body.^{1]}

[¹ See p. 520 to 526, Prin. of Human Physiology, by Wm. B. Carpenter, with notes and additions by Prof. Francis G. Smith, M.D. Philadelphia, Henry C. Lea, 1876.]

CHAPTER II.

IRREGULARITIES IN THE TEMPORARY TEETH. DISEASES OF THE TEMPORARY TEETH. THE SECOND DENTITION.

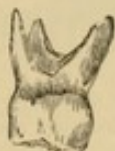THE temporary teeth have but few abnormal conditions, and probably no diseases peculiar to themselves, which are not also common to them and the permanent teeth; so that, whilst we now point out some of the former, we shall reserve a description of the latter till we treat of the diseases of the permanent teeth.

In the temporary, as in the permanent series, we may meet with irregularities in size, form, number, and position. In regard to abnormality in size, the temporary teeth differ less than the permanent, but occasionally cuspidati, and second molars, are met with so developed that they might readily be mistaken for those of the second series. As it is important, especially in the treatment of irregularities in position, that such an error should be avoided, we may point out that, independently of size, the teeth of the first series may be generally recognized by their more delicate and translucent color, by the enamel at their necks terminating in an extended and abrupt manner (see Fig. 1, p. 19), and, at a time when they could be so mistaken, by their masticating surfaces exhibiting more or less evidences of wear: in the case of the cuspidati, they would probably be slightly loose to the touch at a time when they could be mistaken for their successors, and in that of the second temporary molars their position in the dental series ought generally to determine their true class.

In form, likewise, the temporary teeth are more constant than are the permanent ones. With regard to the number of their roots they do not often vary, but observation on this point cannot be so certainly determined, as in the natural course of events they are lost by absorption, at the period of eruption of the permanent teeth. We have in our possession four upper cuspidati, each bifurcated at the radical extremity, and a lower

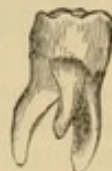molar with three and an upper molar with four fangs. A more common departure is where two teeth are united (geminated) together; the union may occur in the cementum only, or in the

Fig. 3.



Upper second temporary molar with four fangs.

Fig. 4.



Lower second temporary molar with three fangs.

dentine and enamel. In the latter case a pulp cavity may be common to both: union of teeth by cementum only may take place after the teeth are developed as a pathological process.

In number also, the temporary series are more constant than the permanent. Absence from the series is rare, although the writer has under observation a family in which one member is deficient in the four laterals, another in all the incisors excepting the upper centrals, and a third in whom again the lateral incisors are absent. In these three cases, all females, it could be almost certainly prognosticated, from the want of development of the jaw at birth, that such teeth would be absent. In this family there is the history of the maternal grandmother and a great-uncle having had a deficiency in the second series.¹ [A case similar to Fig. 5 occurred in the mouth of one of the writer's children, involving only the right lower cuspid and lateral incisor.]

Fig. 5.



Gemination of a temporary lateral incisor and cuspidatus of the lower jaw, left side.

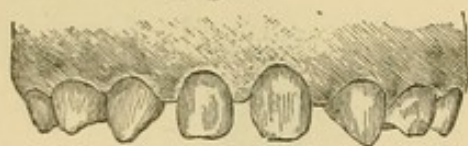Excess in number is, though rare, probably more common; the writer has met with eight or nine cases of an additional lateral incisor of the upper jaw, and almost always well formed, like teeth of the same class.

As the temporary teeth are erupted in the line of the position

¹ The writer has recently met with a case of a little girl, in whom was wanting one of the temporary incisors of the lower jaw, but who now has not only the full number of permanent teeth, but also a well-formed supernumerary lower lateral incisor.

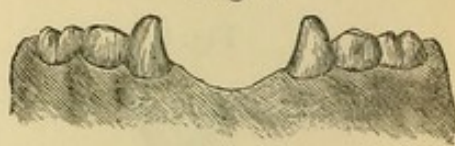
of their development, which is not so in the case of the permanent teeth, they are, as we should naturally expect, much less

Fig. 6.



Upper jaw of a child in which the lateral incisors are absent.

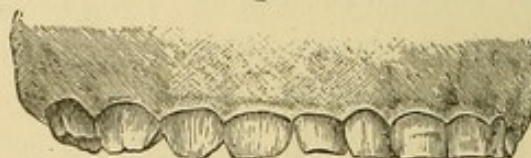
Fig. 7.



Lower jaw of a child in which all the incisors are absent.

liable to deviation from the normal arrangement. Irregularities in position of the temporary teeth are comparatively rare, the most common being a slight overlapping of the upper central

Fig. 8.

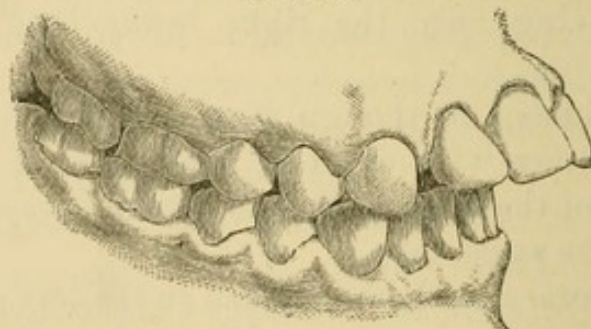


Upper jaw containing a supernumerary lateral on the right side.

incisors at their mesial extremities; occasionally an edge to edge bite, that is, when the cutting extremities of the front teeth of each jaw meet each other, instead of the upper slightly overlapping the lower teeth, as is natural; and more rarely this is extended to what is termed underhung, *i. e.*, when the lower teeth overlap the upper when the mouth is closed.

We have noticed this latter taking place some years after the teeth have been erupted, their original position having been normal. Tumors, by their pressure, will of course also produce

[Fig. 9.]



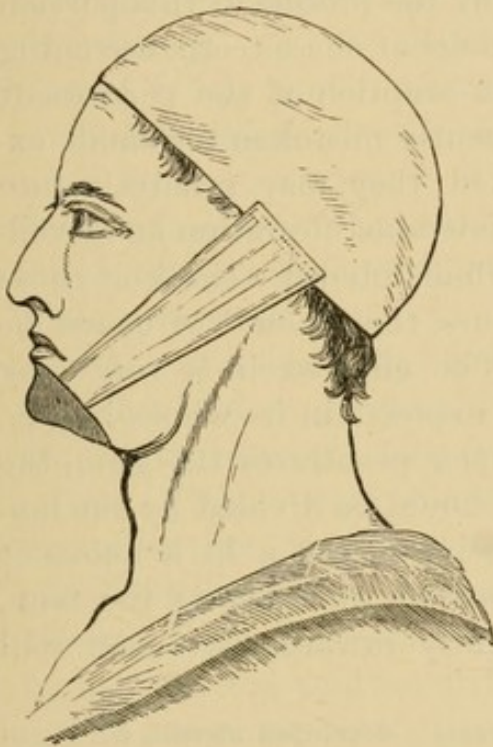
Protrusion of the superior incisors, a frequent result of thumb or finger sucking. (From the Dental Cosmos.)

this class of irregularity. Thumb-sucking, likewise, may occasion a deformity. We have a case now under observation

where the teeth and alveolar process of the right side of the upper jaw are considerably pressed outwards by this habit always practised on that side. [It is not uncommon for this habit, unless cured, to be the cause of a deformity in the permanent teeth, producing a disfigurement giving an almost idiotic expression by the protrusion of the upper incisors far beyond the lower. (See Fig. 9.)]

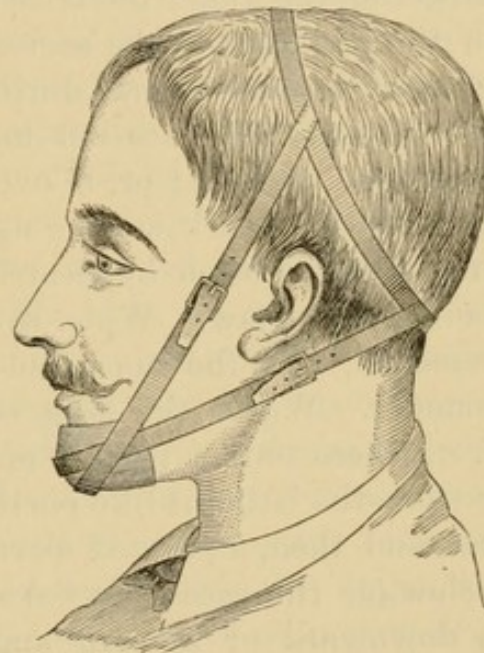
With regard to treatment, we have never seen occasion to interfere in the case of supernumerary temporary teeth, which are sometimes followed, and sometimes not, by permanent suc-

Fig. 10.



Chin retractor as applied.

[Fig. 11.]



Another form of chin retractor which by the lower bandage draws the chin directly backwards, and by the buckles the tension may be altered at pleasure. Both bandages may be made of elastic webbing, and pads may be put under the buckles.]

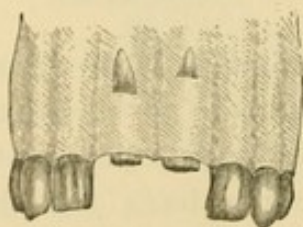
cessors. In the cases, however, where there is an increasing tendency to become underhung, due doubtless to some excess of development in the lower jaw, or imperfect development in its ascending ramus, an appliance for drawing back the chin, by means of an elastic band attached to a cap for the head, may quite prevent, at an early age, the occurrence of this unsightly irregularity.

The temporary teeth cannot be said to be liable to any diseases special to themselves which are not common to both series.

Caries, the most common of all, appears to arise from the same causes, and run much the same course; still, there are slight differences which may be briefly noticed. It often appears in a very superficial form, attacking all the front teeth at once, and giving them an appearance of having been eaten away by an acid solvent. In its more ordinary form, its progress appears somewhat more rapid, and attended by necrosis at an earlier period, which may perhaps arise from the temporary teeth containing a larger proportion of organic constituents than do the permanent ones.¹ The result of this loss of vitality is usually alveolar abscess, or gum-boil, appearing generally on the labial aspect of the gum: the bone lost by the process at this portion of the jaw leads to the necrosed fangs of these teeth becoming exposed at such points during the eruption of the permanent teeth, where they are not unfrequently mistaken for small exfoliations of bone; or, if overlooked, they may penetrate into the adjacent cheek, setting up considerable ulceration and swelling, followed often by cicatrices which bind the cheek at those points to the jaw. When this occurs, they should of course be removed, and the operation may be effected in a very easy manner. Where the fang is not exposed in its whole length, *i. e.*, where only a portion of its apex penetrates the gum, the latter—the isthmus-like portion—should be divided by the lancet, and then, a pointed elevator being placed a little above or below (as the case may be) and behind the apex of the fang, a downward or upward and slightly inward movement will

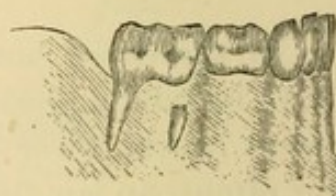
¹ The temporary teeth also being more rapidly developed should, we might naturally expect, show less power of resistance than their more slowly developed

Fig. 12.



Upper jaw with portions of the roots of temporary central incisors exposed.

Fig. 13.



Lower jaw with lower second temporary molar having one root fully and one root partially exposed.

successors, whilst a proportionately larger pulp cavity would result in an earlier exposure of its contents, and an earlier death of the tooth.

speedily detach the tooth; with the removal of the tooth the ulceration and swelling soon disappear, although the small cicatrix above mentioned may result. [Excision of the exposed ends of the roots, and their subsequent smoothing by a file, have resulted in very happy healing and restoration of the utility of such teeth in the writer's practice.]

The treatment of caries of the first teeth will be conducted upon much the same principles as will be detailed when we treat of that disease in the permanent set: we cannot, however, too strongly inculcate an early employment of the tooth-brush, especially at night: parents are commonly disposed to imagine that practice unnecessary with children, and the latter suffer accordingly. In the case of superficial caries, where the operation of filling cannot be resorted to, the cleansing process becomes imperative: it should be performed after each meal, and a few drops of a mixture of sal volatile and alcohol¹ applied at the conclusion. When this is persevered in, the progress of the caries seems to be generally arrested, and the teeth affected are often preserved until the ordinary time for shedding them arrives. Moreover, the teeth, which, when affected with the superficial decay, are usually very sensitive to bite upon, become with this treatment free from tenderness and useful in mastication. [Lime-water diluted with three or four parts of water makes an excellent local application or mouth-wash; and prepared chalk, rubbed around these teeth with the finger, and allowed to remain during the night, will afford relief, and often by neutralizing acid conditions effect a cure.]

The temporary teeth, having fulfilled their office, retire from active service in favor of their more durable successors. Whether the act of their departure pertains more to themselves or to their successors has been for some years a moot point. An ancient view was that the permanent teeth in their advance absorbed and assimilated for their own benefit their temporary predecessors, and in this cannibal view perhaps a modicum of truth existed. A more recent view regards the temporary

¹ R. Spiritus ammoniæ aromat. ʒj ;

Spiritus vinæ, ʒiij ;

M. ft. applicatio.

About 10 drops of the above to a teaspoonful of water to be applied on the tooth-brush after cleansing the teeth.

teeth as subject to that condition which appertains to all tissues of the body—cells, fibres, and their combinations, even to the whole body itself, viz., in having a fixed period of existence, which includes the stages of development and growth, of maintenance and maturity, and of degeneration and decay, in which last they undergo changes which involve their being cast off from the surface like hair, epithelia, etc., or breaking up and being carried away in the circulatory system, as are all subcutaneous tissues in the body; and to this rule the fangs of the temporary teeth form no exception: they also undergo, at fixed periods of their existence, ramollissement, and are removed amongst the products of metamorphosed tissues. Whilst we are fully prepared to admit the truth of this doctrine, in so far as that a change in the condition of a temporary tooth precedes its absorption, it is yet evident that the process is closely in relation with that which effects the eruption of its successor; for, should the latter be absent, the process often does not take place for many years later; indeed, it is not uncommon to see temporary teeth in the mouth and firm after maturity has been attained. The writer once filled a lower second temporary molar with gold, in the person of a gentleman above sixty.

As this process of absorption is so closely connected with the eruption of the permanent teeth, we may here give our views upon the latter process, which were first expressed in a course of lectures delivered at St. Bartholomew's Hospital in 1867, and published subsequently, but certainly not until after almost similar views had been expressed in an admirable paper in the "*Vierteljahrsschrift*," by the pen of Herr Robert Baume.¹ To account for the eruption of the teeth, two views have until recently been advanced: one, in which the process is attributed to the growth of the fangs of the teeth causing their crowns to be raised out of their alveoli; and the other, in which that process is attributed to a growth of bone at the lower portions of the alveoli, squeezing, as it were, the teeth out of their sockets. The first is still the view entertained by some,² but its inaccu-

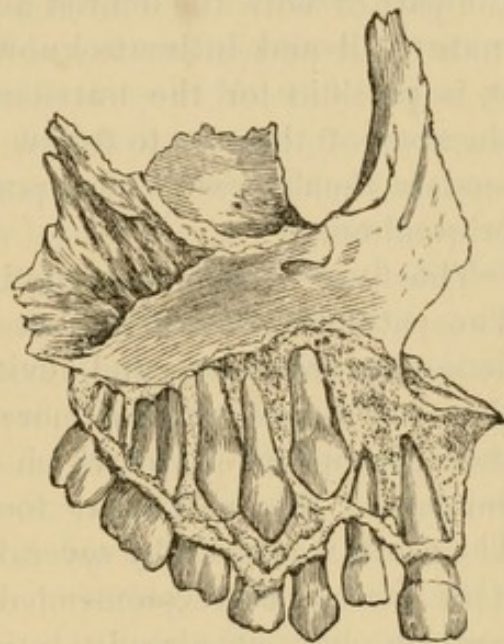
¹ Translated in the *Monthly Review of Dental Surgery*, vol. i.

² "The eruption of the teeth is a process of gradual elongation of the teeth on the one hand, and of simultaneous absorption of the superimposed tissues on the other. The absorption commences, first in the overhanging margins and front walls of the alveoli, which gradually disappear until room is afforded

racy is readily verified upon the examination of preparations at various periods in the second dentition. In the woodcut below, taken from a normal preparation in the Museum of the Odontological Society, will be seen a bicuspid tooth, with the fang fully formed, yet not erupted, and other teeth, the fangs of which are nearly completed, also not erupted, but which undoubtedly would have been so in due course had the individual survived. For the second and later assigned cause there is actually no ground, as it cannot be shown that there is greater development of bone taking place during the eruption of the teeth at the apices of the alveoli than at other parts of that district of the maxillæ.

[A remarkable case was exhibited by Dr. George W. Neidich, before a meeting of the Pennsylvania State Dental Society, of a young gentleman with a central incisor presenting a corner of its cutting edge under the mucous membrane of the gum near the frænum of the lip, and its root at the length of the tooth back in the palate. It was treated by him, and the tooth brought down to a normal position, save that it was considerably twisted upon its longitudinal axis and presented the mesial face to the front. A change of residence, by removal of the family, caused him subsequently to come under the writer's care, and the tooth gave every evidence of being sound and

Fig. 14.



Upper maxilla of the right side, with portions cut away to exhibit the developing permanent teeth. It will be observed that the fang of the first bicuspid is fully developed, and the fangs of the cuspidatus and second bicuspid are nearly so, while no portion of the crown of these teeth has been erupted. The platform of bone spoken of in the text is seen supporting the first temporary molar.

for the free passage of the advancing tooth. The growth of the tooth keeps pace with this absorption, and the crown at length pressing against the membranous coverings, these undergo atrophy, and, becoming by degrees thinner and at last transparent, give way and disclose the advancing crown."—The Student's Guide to Dental Anatomy and Surgery, by Henry Sewell, M.R.C.S., 1876, p. 27.

healthy, although the apex had traversed one-half to three-quarters of an inch through the bone. This remarkable operation, aside from the wonderful perseverance and endurance on the part of both the dentist and the patient, with the consummate skill and intimate knowledge of the former, shows that it is possible for the nutrient vessels and nerve filaments of the apex of the root to follow it through the bone and accommodate themselves to new positions widely distant from their original ones.

The final history was confirmative of the above diagnosis. The patient preferred to take the risk, of immediate torsion detaching the vessels and devitalizing the pulp, rather than the slow and almost sure but more painful methods; indeed it was the only operation to which he would submit, although the danger to this particular tooth was fully explained to him. The tooth was then, by several operations of immediate torsion with forceps, as recommended by Tomes, brought into proper position, but, as already intimated, the pulp died and was treated accordingly. With but slight change of brilliancy it remained at his last visit to me perfectly serviceable, although several years had elapsed since devitalization of the pulp. I may add that this is the only case of death of pulp following that operation in my practice, although I have repeatedly performed it.]

The only probable explanation which it appears to us can be offered, is in the general growth and advance of the bone towards the surface, carrying with it the contained teeth.

This assertion consequently implies a continual growth of bone (as is the case with epithelia, cartilage, etc. etc.) from its nutrient centres towards its circumference, and also that at the latter absorption must be frequently taking place, as we have evidence of its occasionally doing during the process of absorption of the temporary, and advance of the permanent, teeth, where portions of bone—platforms, as they might be called, supporting the former—are often seen extending much beyond the general level, as represented in the woodcut; which platforms become absorbed as soon as the sustained teeth fall out. To which tissue or structure this power of absorption pertains, we will not venture to decide; though we are inclined to the conclusion that it is effected by the osteo-blastic layer of the

periosteum assuming an osteo-elastic function. But that such power exists, none we think can deny from the foregoing considerations, as also when we take into account those conditions of loss at certain parts and gain at others which take place in the inferior maxilla between childhood and manhood; moreover, it affords a more rational explanation of the exfoliation of teeth and roots, when unopposed by pressure, also of sequestra of bone, than the assertion that nature casts such off because useless. In the treatment of irregularity in position by mechanical appliance, we often see certain teeth, which have been relieved from opposing pressure by such means, become unduly elongated; whilst in cases where a tooth, from loss of its comrades, becomes subjected to undue pressure, it will be found often more deeply imbedded in the jaw than is natural. According then to the views advanced, a tooth developed in the maxilla is carried with the growth of that bone towards the surface. Arriving at the surface, the bony covering becomes absorbed, and the more so as the tooth advances, until the crown, projecting above the surface, meets with some opposition to its further advancement, and is retained in position,¹ when the bone immediately surrounding it—its alveolus—becomes more dense in character, and less rapid in growth, than the surrounding cancellous interalveolar portions. These harder portions of bone being more stationary, we have, doubtless, so to speak, bone currents continually existing in the maxillæ, but more especially during the periods of the first and second dentitions, when these bones are in a condition of more than ordinary active development.² If we now apply these views to the question before us, viz., the absorption of the temporary teeth, we shall understand that the bone, carrying with it the permanent teeth, advances to the surface, where it becomes absorbed; and, as this process of absorption must at these times be very active and extensive,

¹ Besides the operation of opposing teeth in effecting such retention, we may take into consideration the retaining power exercised by the mucous membrane firmly attached to the necks of the teeth, which attachment, when lost by disease, is almost invariably followed by their exfoliation.

² These views have been more fully expressed in a contribution to the *St. Bartholomew's Hospital Reports*, p. 91. They have met with the approval of Professor Owen, who has kindly pointed out to the writer a similarity of idea in his description of the development of teeth in the elephant, *Odontography*, p. 639; but C. S. Tomes still regards the process as obscure and unexplained.

as indeed we know it to be, it seems probable that the periosteal covering to the temporary teeth meets the same fate, or becomes so altered in character that its osteo-blastic elements may become active and osteo-clastic agents. In either way, it so happens that the fangs of the teeth come into contact with these elements, which are found in collections about their roots, and constitute the "absorption-organs of Tomes." In confirmation of the position taken above, we have the fact that there is no appearance of periosteum where the process of absorption is taking place. These cells, the elements of absorption, are in no wise different from those of actively-growing bone; indeed, J. Tomes shows that the process of absorption is often alternating with that of formation, but, the balance being in favor of the former, the greater part of the dentine, and generally some portion of the enamel, eventually disappears. It is not uncommon to see a temporary tooth, especially a molar, at the period of its being shed, appearing of a pink color, owing to its transparency, showing through it the vascular and proliferating bone-elements beneath it. The condition termed necrosis, in which a tooth or bone has undergone changes other than a mere loss of vitality—which is not the case with simply dried teeth or bone removed from living or recently-killed animals, where chemical change or decomposition has not ensued—is a barrier, and fortunately so, to the process of absorption, such tooth or sequestrum being got rid of by the general advance of bone to the surface; but, where, through resistance by obstacles, etc., necrosed temporary teeth or roots are retained *in situ*, they form a common cause of irregularity in their permanent successors. [Sometimes, however, a process of erosion of these dead roots takes place, and they are removed or exuviated with but little irregularity as to time or manner.]

But, whatever be the means, the absorption of the temporary teeth is so far effected that they lose their hold upon the mucous membrane, and fall, or are rubbed off, from it: the order of their disappearance is usually that of the appearance of their successors. The process is happily a gradual one, otherwise animals would be left for a time in an unpleasant predicament, and it usually occupies about ten to twelve years or even longer. [Generally, in this country, the eleventh or twelfth year finds the process completed so far as the replacement of the

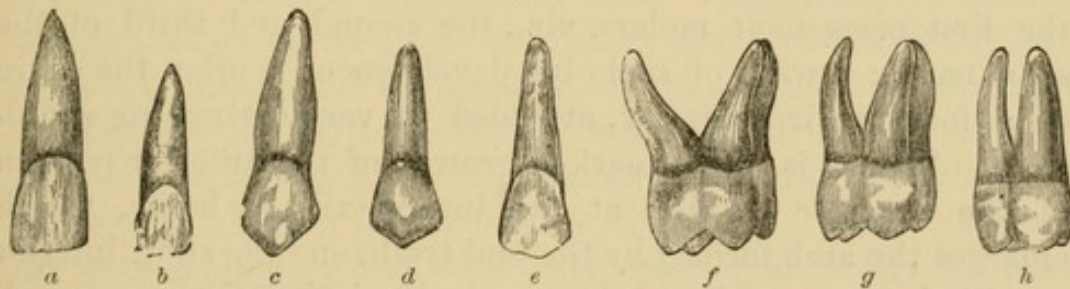
deciduous teeth is concerned.] In most cases, the falling out of a tooth is followed by the appearance of its successor within a few days; in some, the successor appears before the predecessor has departed, and then in an abnormal position; and in some it does not appear for months or even years after.

The teeth of the permanent set are thirty-two in number: they therefore contain in their series twelve more than the temporary set. They are arranged in the same manner, viz., an equal number in each jaw, and symmetrically on each side of the mesial line of the mouth.

Their formula is incisors $\frac{2}{2}$, cuspidati $\frac{1}{1}$, bicuspid $\frac{2}{2}$, molars $\frac{3}{3}$; the cuspidati are also called canine and eye teeth, and the bicuspid premolars. [The cuspid of the lower jaw are frequently called "stomach teeth," in contradistinction to those of the upper.]

The first permanent tooth that makes its appearance is the first molar,¹ and it is generally the largest in size of all. When

Fig. 15.



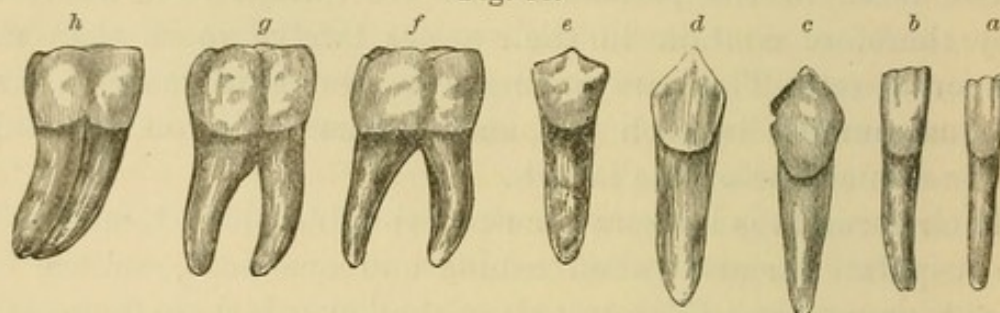
Upper permanent teeth of the left side. *a*, central incisor; *b*, lateral incisor; *c*, cuspidatus; *d*, first bicuspid; *e*, second bicuspid; *f*, first molar; *g*, second molar; *h*, third molar.

the second temporary molar has been erupted, it almost wholly occupies the space between the first molar and the coronoid process of the lower and the tuberosity of the upper jaw; but, as the period of the second dentition approaches, considerable

¹ This tooth holds a somewhat singular position in the dental series. In regard to its development, it is closely allied to the temporary series, in having its formation from a special duplication of the mucous membrane, and in not being any offshoot from a temporary tooth, and also in its furnishing the offshoots for the second and third molars. From the age at which it is erupted, and from its not undergoing absorption, and its not having a successor in its place, also from its position, etc., in the series, it is classed amongst the second or permanent teeth; its claim, however, to permanency in another sense, especially in the present day, is a very doubtful one.

space will be found to exist posterior to those teeth, which is produced in the lower jaw by an absorption or loss of bone at the anterior and inferior portions of the coronoid processes, with corresponding increase at the posterior and inferior por-

Fig. 16.



Lower permanent teeth of the right side. *a*, central incisor; *b*, lateral incisor; *c*, cuspidatus; *d*, first bicuspid; *e*, second bicuspid; *f*, first molar; *g*, second molar; *h*, third molar.

tions of the ascending rami; and is produced in the upper jaw by additions to the tuberosities; and this process, mainly dependent upon the presence of developing teeth, is continued until room sufficient is afforded for two more large teeth behind the first permanent molars, viz., the second and third of the same name: a want of such due development is often the cause of a form of irregularity, attended by very distressing conditions. [There is also a marked growth of the anterior portion of the superior maxilla at the intermaxillary bones, which enlarges the arch formed by the oral teeth, and the adult inferior maxilla is increased in size less markedly, but at the corresponding portion.] The first permanent molars generally make their appearance between the years of six and seven, and the next in order are the central incisors of the lower jaw; but the following table will convey fairly the periods of eruption for all, and will probably be easier for recollection:—

	YEARS
1. First molars	6
2. Central incisors, lower jaw	7
3. Central incisors, upper jaw	8
4. Lateral incisors, both jaws (lower preceding upper)	9
5. First bicuspid	10
6. Second bicuspid	11
7. Cuspidati	12
8. Second molars	13
9. Third molars	17 to 20

[These ages are likewise too advanced for this country. The permanent teeth are in their eruption, like the deciduous teeth, subject to great variation. An allowance of about one-sixth may be made for the first molars, they being often erupted at five years of age.]

That the second dentition should be accomplished under much more favorable conditions than are usual with the first, has, when we consider the size of the permanent teeth and their irregular positions during development, been a matter of surprise, and has led to various explanations to account for it. That which appears to us the most satisfactory attributes it to the peculiar condition of the nervous system at the period of the first dentition, and when the nervous apparatus is undergoing a condition of development incomparably greater than occurs at any other period of life.¹

Although the second dentition may be regarded with different feelings from those with which we estimate the first, yet it occasionally happens that conditions present themselves which we must be careful not to overlook. Thus, independently of any special symptoms, a child during the second dentition, and especially during the eruption of the molars, may appear wanting in its usual spirits, sometimes suffering, though not severely, with headache, or slight neuralgic pains, and the appetite is not unfrequently either diminished or capricious. Such symptoms are most commonly met with when the second molars are being erupted, and they are, though no doubt much influenced by, often attributed wholly to, the period of puberty having arrived. [The faculty of speech is now well established, and we not infrequently find the child complaining of the discomforts of teething. After one experience of the trifling pain of lancing and the great relief from it, a repetition of the operation, over the remaining second molars, is not uncommonly demanded by the patient.] Other conditions, more especially pertaining to the nervous system, may frequently be manifested at this period, and dental influence may be witnessed by the symptoms lessening when the teeth become erupted, and of these chorea, quite independent of rheumatic origin or influence, is not an uncom-

¹ West, op. cit.

mon one; also those tricks of nervous movements, which often become habitual when the cause that produced them no longer exists. With history of or tendency to epilepsy the period of the second dentition is one of importance and anxiety, especially during that of the eruption of the third molars. Several such cases have come under our notice, and in more than one of them marked benefit has followed their removal, as soon as it was possible to accomplish it.

The local conditions, though generally less marked than in the first dentition, may at times demand attention. It is not uncommon to find children complaining of pain when they eat, and, on inspecting the mouth, to find the gums so swollen over the coming first molars that the mucous membranes of each jaw meet and are pressed upon when the mouth is closed. Soothing applications will generally reduce the swelling, and with it the cause of discomfort; more rarely the gum may appear white in color, and evidently stretched over the cusps of a molar tooth; here the gum-lancet will speedily relieve. It is in the eruption of the third molars, however, that most pain and discomfort are usually experienced, and even at times when ample room for them exists, and where there is no undue distension of the gum, as is manifested by a small probe being easily passed between it and the tooth; the surrounding gum, too, becomes often acutely inflamed, swollen, and even ulcerated; the pain is not confined to the spot, but is felt in the ear, running up to the vertex, and down at times as far as the clavicle; not unfrequently the inflammation extends to the tonsil of the affected side. For this condition we have found a solution of chlorate of potash in poppy fomentation an excellent and most effectual remedy;¹ it seems more certain than any we know of, for reducing the trismus often so severe and trying in these cases.

Matter occasionally forms at or near the roots of third molars, but we shall refer to these conditions when speaking of irregularities in position of the permanent teeth.

[Extraction of the third molar may be demanded to relieve

¹ R. Potassæ chloratis ℥iss.

ft. pulv. xij.

To one ounce of warm poppy fomentation add one of the powders and foment the inside of the mouth.

these cases. Sometimes the second molar is the tooth whose removal gives the most immediate relief; but where the first molars are very defective, and the second comparatively intact, the removal of the former is generally preferred, as nature will usually move the twelve-year molar forward unless it be locked in its place by occlusion with its antagonist of the other jaw; a condition which seems to make its extraction instead of the first molar preferable.]

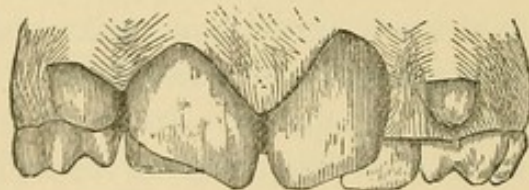
CHAPTER III.

IRREGULARITIES IN THE PERMANENT TEETH.

IRREGULARITIES in the permanent teeth constitute a very important department in dental surgery. We shall consider them under the same heads as we arranged them in the temporary series.

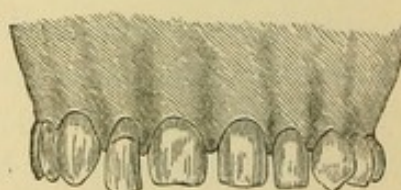1. In size: here we have great variation independent of any pathological imperfection. In the following cuts are shown the central incisors of the upper jaw, actual size from a cast in the possession of S. Cartwright; also, for comparison, the same teeth abnormally small but free from any pathological defects.

Fig. 17.



Permanent teeth of unusually large dimensions, copied from a cast in the possession of S. Cartwright, actual size.

Fig. 18.



Permanent teeth of unusually small dimensions, copied from a male patient of the writer's.

Malformed supernumerary teeth are often met with, of very small size; probably the smallest on record are those in the museum of the Odontological Society, attached to which is a very interesting history.¹ A not unusual condition of things is, to

¹ They occurred in the mouth of a nurse in one of the wards for syphilitic patients at St. Bartholomew's Hospital, who frequently had to perform mercurial inunction, and who had been often in consequence salivated, and had lost all her permanent teeth. Some years after she had lost her second, there appeared at times on the mucous membrane of the mouth very minute malformed teeth not larger than a No. 6 shot, which were regarded as teeth belonging to a third set. We can hardly doubt but that they were teeth developed in a dentigerous cyst, such as have been described by Carl Tellander, of Stockholm, and Mathias, of India. [The writer remembers having seen in the prac-

see one of the upper lateral incisors, or sometimes both, small and conical in the crown, resembling the commonest type of supernumerary tooth, and especially is this the case when one of these teeth may be wanting. It indicates that the tooth has appeared in its most rudimentary form, a stage just beyond not appearing at all. The teeth which vary most in size are probably the third molars; they sometimes present themselves on the lower jaw, quite one-third larger than the second molars, appearing almost as if they were a combination of themselves with a smaller tooth, whilst in the upper jaw especially they may appear quite rudimentary in form, like the small upper incisors alluded to.

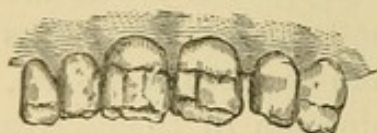In the treatment of these cases we do not interfere unless the deformity caused is very unsightly. In a case where the upper central incisors were out of all proportion in excess of size over the other teeth, and projected over the lower lip, giving to the individual a strongly rodent expression, we removed them and succeeded in bringing the laterals together, so as to quite close up the gap. [Sometimes such teeth may be cut down to a more slightly size by means of files or revolving discs and points upon the burring engine, in which case after they are polished, they may last for a long service. In extreme cases pivoting will be preferable to extraction, but both this and the cutting down are only serviceable where the roots are firm in their alveoli, and tolerably healthy, which is not always found to be the case, especially where the trouble is from hypertrophy of the cementum or surrounding tissues.] We have often also in young persons removed with advantage one or both of the unsightly diminutive laterals spoken of.

2. In form: the variations to which the permanent teeth are subject may be said to be almost endless, and it would much exceed the limits of this work, as well as not fulfil its objects, were we to attempt to enumerate them. Amongst the most common departures from the normal type are the so-called honey-combed teeth, the enamel of which has been so imperfectly developed that it is wanting, or almost wanting, at many parts: it

tice of his preceptor, Dr. N. L. Dickey, of New Orleans, in 1859, a dentigerous cyst, in the mouth of a negress, which was opened by the extraction of a molar. The contained teeth were about the size and appearance of grains of rice.]

most commonly takes an arrangement of parallel horizontal lines on the teeth, which, however, are not equidistant from the cutting surface on the crown on each, and therefore probably correspond to certain periods in the development when those

Fig. 19.



Honeycombed teeth of the upper jaw (from a cast in our possession).

conditions prevailed which prevented the perfect arrangement of the enamel fibres or the deposition of the lime-salts. The teeth most affected are the central incisors, cuspids, and first molars. The lateral incisors occasionally escape, as do more frequently the bicuspid; the second and third molars enjoy the greatest immunity. Jonathan Hutchinson attributes this condition of the teeth to being largely dependent on the effects of mercury administered in infancy. The facts which he brings forward are well supported, but it cannot be denied that typical cases occur where that drug has never been taken, and we have overwhelming proof that it is inherited from parents. It is an unsightly and disfiguring condition, and our gratitude should be accorded to any who may endeavor to seek out its cause and means of prevention or mitigation. [It may be seen that the markings upon the teeth will afford a pretty correct idea of the time at which the trouble took place, and inasmuch as the teeth are dermal appendages, they will almost invariably be found to have occurred at a time when the skin or mucous membrane was affected by some disease. The major exanthemata almost invariably leave traces in the way of pittings or markings on the teeth at points corresponding to the parts undergoing dentinification at the time the disease was experienced.¹ Prof. C. A. Harris long ago called attention to the cause of odontatroph.]

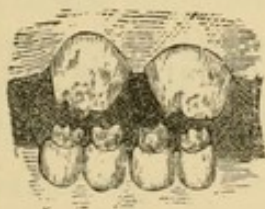
We are indebted to Hutchinson also for having first called our attention to another very important form of this class of irregularity, viz. the teeth of the subjects of inherited syphilis, which first attracted his attention whilst working at ophthalmic diseases. In recognizing a syphilitic form of keratitis which had previously been regarded as strumous, and had been confounded

[¹ Prof. Chapin A. Harris, M.D., D.D.S., in his "Dental Surgery," p. 394. Lindsay & Blakiston, Philadelphia, 1866.]

with the latter, Hutchinson's attention was directed to a peculiarity in the permanent teeth of the syphilitic. We had the good fortune at that time to be a colleague of his, and were able to confirm his conclusions, by which he has supplied another and valuable means of diagnosis in this most important branch of pathology. The teeth chiefly affected are the central incisors, cuspidati, and first molars of each jaw; but the most marked are the central incisors of the upper jaw; these when erupted are deficient in enamel at the central portion, especially of their cutting edges,—that portion which corresponds to the middle of the three centres of development in these teeth. This thin portion soon becomes worn away, and then the teeth have a notched appearance. A general deficiency of substance at the cutting edge of all syphilitic teeth gives to them a peculiar conical or peg-shaped form, which contrasts strongly with that of normal-shaped teeth.

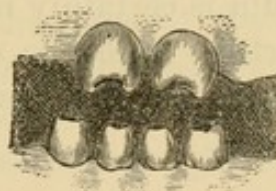
Whilst giving our fullest adhesion to the correctness of Hutchinson's views in general, we may yet remark that we have in

Fig. 20.



Syphilitic teeth in upper and lower jaws as they appear when recently erupted.

Fig. 21.



Syphilitic teeth in upper and lower jaws which have been erupted some time, and from which the slighter portions at the cutting edges have been worn away.

one or two instances, and among the members of a healthy family, met with a case of an individual in whom the above-mentioned type of teeth existed, and where we should have supposed it almost impossible that the cause could be syphilis; yet, the possibility existing, we are unable to deny the fact, though on the other hand it would be shocking to suspect unfaithfulness which did not exist.

The teeth termed supernumerary are more frequently of abnormal form than otherwise: the variations are too numerous to be here described in detail, their most common type being of conical form and small, more nearly approaching that of temporary cuspidati. In front of the central incisors they are often,

though less frequently, large, with four or more cusps on the crown, like a small molar, but having one root. In rare instances they have the appearance of being broad and flat and folded upon themselves, and of thus having a central hollow lined with enamel; but these, independently of being supernumerary, as we have met with them in three cases, appear rather to belong to the class odontomes. Union or gemination

Fig. 22.



Supernumerary permanent tooth of the most common type.

Fig. 23.

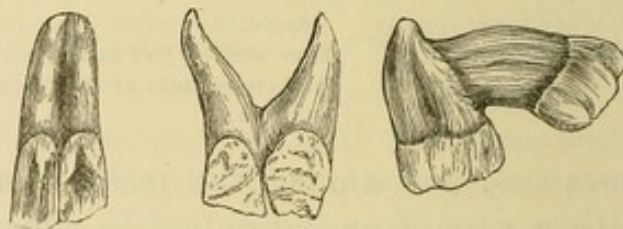


Supernumerary tooth of the form not unfrequently met with in the region of the upper central incisors.

of teeth also exists in the permanent as in the temporary series, but is probably less common, though the union of fangs through cementum is certainly more so.

Departure from the ordinary number of fangs is not infrequent, the most common being excess of number in upper third

Fig. 24.



Three specimens of gemination. That on the right, from a specimen in our possession, is an upper second and third molar, in which the union is by cementum only (probably). That in the centre is an upper lateral incisor and cuspidatus of the left side; and that on the left hand is an upper lateral and cuspidatus of the right side, as seen from behind, copied from preparations in the museum of the Odontological Society.

molars, these often having from four to six slender roots; lower molars, the first especially, having three fangs, upper bicuspid the same number, and lower cuspidati two.

[Some years since the writer found in the mouth of an adult lady the right inferior second and third molars so perfectly united as to show only a slight fissure at the point of union.

Several bicuspid with trifurcation of the upper third of the root are in the museum of the Philadelphia Dental College.]

The greatest departures in form from the normal types appear in those irregular masses of dentinal tissue termed odontomes. They are doubtless the result of some hypertrophic conditions affecting the tooth-germ; and M. Broca, who has somewhat deeply investigated the matter, has divided them into four classes, according to the periods at which the hypertrophy has occurred during the development of the tooth. Thus, should it occur during the earliest periods of development, and before any of the true structures, out of which enamel or dentine are formed, have made their appearance, the mass will resemble a capsulated, or almost capsulated, fibro-plastic tumor, which may be shelled out, as in the case of a similar tumor in other parts, the uterus for example. Whether it is correct to assume that all such tumors occurring in the jaws are of dental origin, is certainly open to discussion. The foregoing constitute Broca's first class, viz.,—*odontomes embryoplastiques*.

The second class, *odontomes odontoplastiques*, are presumed to be due to the same condition of hypertrophy occurring after the development of the special formative elements of the dentine and enamel—the odontoblastic layer or *membrana eboris*, and the columnar cells, otherwise termed the internal epithelium of the enamel organ. In the course of the abnormal development these structures become more or less distended over the irregular surface of the growth, and, when calcification has taken place, a large, hard mass of tooth structures, most confusedly mixed up together, results, bearing little resemblance to a human tooth. The chief bulk of the growth will be found, as would be presumed, to consist of secondary dentine. In the classes which we have described, the tumors appear at times to be representatives of one, and at others of more than one tooth; in the two following classes they apparently are always the representative of one tooth; but in all, we believe, they originate in the teeth of the permanent series.

The third class, *odontomes coronaires*,¹ are presumed to be due to hypertrophy arising after some calcification of the enamel and dentine, and when such portions are incapable of distension,

¹ "Warty teeth," Salter.

which distension consequently takes place at parts as yet not calcified. In these, certain portions of the tooth, especially its coronal ones, bear their normal appearance, or nearly so. This class is by far the most frequently met with of any, especially if we include, as some have done, those malformed teeth, usually supernumerary, which appear as if a flattened tooth-pulp had been folded upon itself, and often, previously to a section being made, appearing like a tooth developed within a tooth. We think, that if these should be classed at all as odontomes, they belong rather to Broca's second class than to the third.

In the fourth class, *odontomes radicularies*,¹ are comprised those rare cases where hypertrophy has arisen after the calcification of the crown of the tooth. Here the components will be dentine and cementum, or the latter only: the mass may be of very considerable size, and be readily mistaken for an immense exostosis.

Teeth may also occasionally be found with small nodules of enamel on the portions of their surfaces otherwise covered with cementum, or there may be distinct cusps covered with enamel, which project above the gum and may readily be mistaken for distinct and supernumerary teeth, the error only being discovered when their removal is attempted; the main portion of the tooth from which they spring being seen to move with them. With our more accurate knowledge of the development of teeth, the occurrence of these nodules and offshoots is more readily explained.

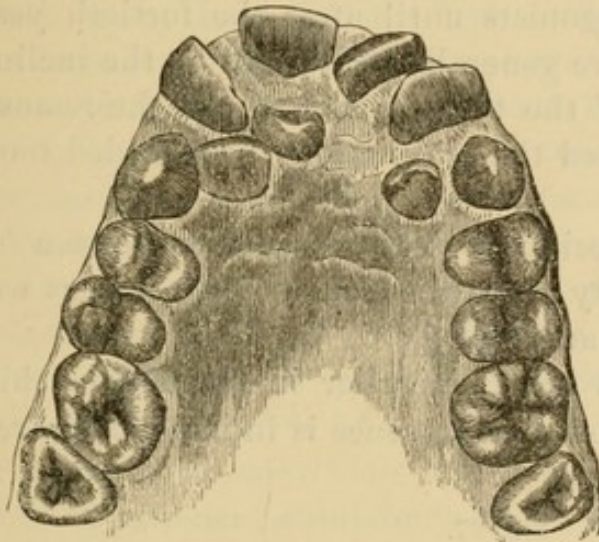
[There would seem to be a tendency to proliferation (but yet not a fully completed formation of distinct sacs and teeth in these cases) somewhat similar to the development of the three molars.]

3. Irregularity as regards number. We have spoken of supernumerary teeth in the last section; they may be found in considerable number, even to four or five in the same mouth, and upon almost all portions of the alveolar and palatal processes of the maxillæ; we recently saw one, discovered lying horizontally between the articulations of the latter processes, the crown pointing backwards. They are more common in the upper than in the lower jaw, and, when in the latter, are generally met

¹ "Hernia of the fang," Salter.

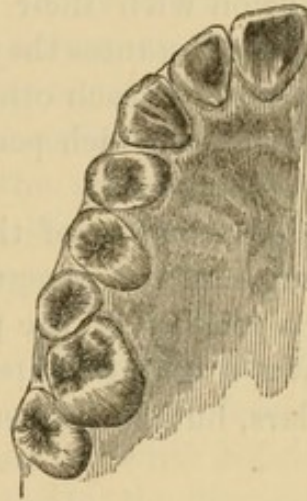
with in the neighborhood of the third molars. Whilst all excess above the ordinary number must be regarded as supernumerary, we may also class as such, irrespective of the proper number present, additional teeth occurring in positions where they

Fig. 25.



Supernumerary teeth in the upper jaw of a youth.
Copied from a cast in our possession.

Fig. 26.



Supernumerary bicuspid of the
upper jaw, right side.

partake of the same type as their neighbors; thus, we should regard as supernumerary a third well-formed bicuspid, or a fourth molar, though its presence might cause no actual excess in the proper number.

[There are, however, puzzling exceptions to this rule. Among the writer's patients is a young gentleman, now a student of medicine, who had six superior incisors so well formed as to defy attempts to indicate which were supernumerary. There are now remaining five of these teeth well formed, and so regularly arranged as to escape notice except when attention is particularly called to them.]

Deficiency in number is by no means unusual, and we may venture to express the opinion that it is more common now than formerly. The teeth most commonly absent are the lateral incisors of the upper jaw, and when one of these is wanting, that present often assumes, as before noticed, the small pointed form characteristic of a supernumerary tooth. Next in order of deficiency we would reckon the lateral incisors of the lower jaw, and following these the second bicuspid of the same. The

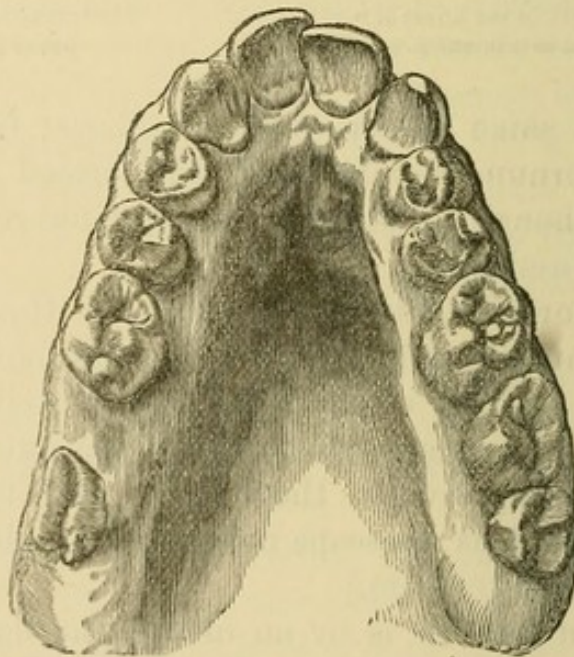
second bicuspid of the lower jaw are often impacted between the first bicuspid and first molars, and therefore may be present without showing themselves at all, or until later in life, when they present an appearance usually internal to the dental arch.

[Cases of retention of the bicuspid have been presented in the writer's practice where they did not come up to the line of occlusion with their antagonists until after the fortieth year. In these instances they were generally held down by the inclination towards each other of the two adjacent teeth, the removal of either of which permitted the eruption of the retarded tooth to be completed.

The retention of the deciduous teeth may likewise be a frequent cause of irregularity as to the time of eruption as well as to position of the permanent set.]

We might perhaps have placed earlier in the list the third molars, but the evidence of their absence is in many cases ren-

Fig. 27.



Upper jaw in which the lateral incisors have not been erupted.

dered difficult by the fact that the first permanent molar is often regarded as a temporary tooth when it is removed at an early age, and the space so afforded being quite occupied by the second molar, the third is not uncommonly regarded as the second.

Still they are sometimes erupted at so late a period in life that they may be present when not suspected.¹

[The writer has recently seen two of the wisdom teeth but partially erupted through the gum in the mouth of a patient fifty years of age.]

Another form of excess in number is where a third set of teeth is supposed to have been erupted. Although every case we have investigated, and they have been numerous, has turned out to be the eruption of retarded or missing teeth, of true supernumerary teeth, or of portions of fractured roots of teeth which become in time carried to the surface in the manner described at page 46, yet cases have been narrated by authorities whose accuracy and candor must compel us to accept the fact that a third set of teeth is a possibility.

4. Irregularity in position. To the dental surgeon this division of the subject is by far the most important and interesting. It is moreover one which often largely taxes both his ingenuity and his patience; sometimes to be attended by the disappointment of failure; but, when successful, bringing the reward of almost unspeakable satisfaction, for to restore to symmetry and beauty so important a feature as the mouth, when out of harmony with the rest, is certain to insure for the practitioner the lasting gratitude of the patient and the patient's friends.

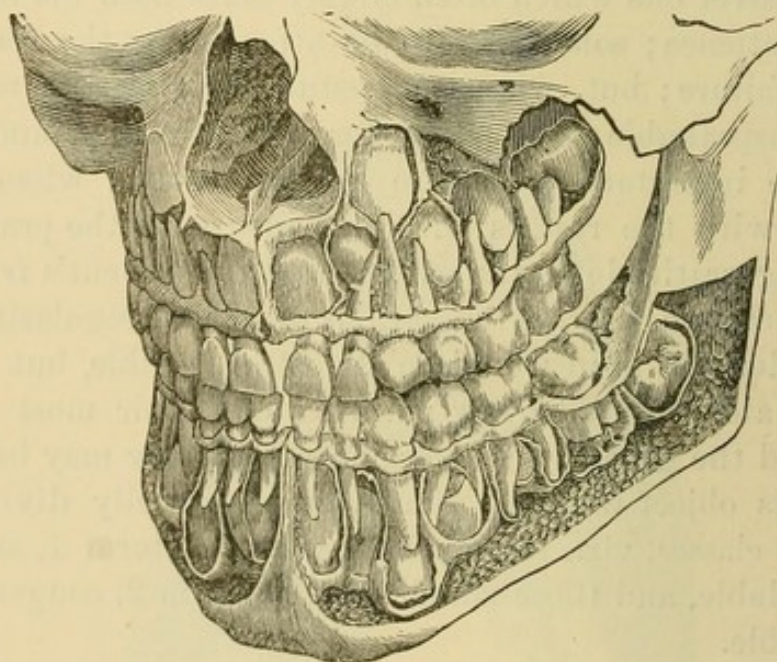
To attempt to describe the various forms of irregularity which occur under this head would be almost impossible, but we may, we trust, aid the student by pointing out their most common causes and the general principles on which they may be treated. With this object we shall somewhat arbitrarily divide them into two classes, viz., those which we shall term 1, accidental and avoidable, and those which we shall term 2, congenital and unavoidable.

1. Accidental and avoidable. This form most commonly arises from the persistence of temporary teeth which from some cause have not undergone absorption of their roots commensurate with the advance of the permanent teeth, or from the retention of necrosed roots which do not undergo absorption. The

¹ In a communication recently made by Professor Flower to the Odontological Society, *vide* vol. xii. p. 32, that high authority classes the third molars as the teeth that are most frequently absent in man.

tooth in consequence assumes an abnormal position sometimes anterior or external to the proper dental arch, but more commonly internal to it. To clearly comprehend this portion of our subject, it is necessary that we should understand the relative positions of the permanent and the temporary teeth, about the age when the second dentition commences. If we take the skull of an individual who died at the age of, say, six years, and before any of the temporary teeth have been shed, and pare away the anterior surfaces of the alveolar processes, we shall find the following arrangement and condition of the teeth to prevail. Commencing with the upper jaw, we shall find the crowns of the permanent central incisors situated on a higher plane than the temporary teeth, with an inclination directed more outwards, forming with the latter an angle of fifteen degrees or thereabouts, and, when they are erupted, placing them

Fig. 28.



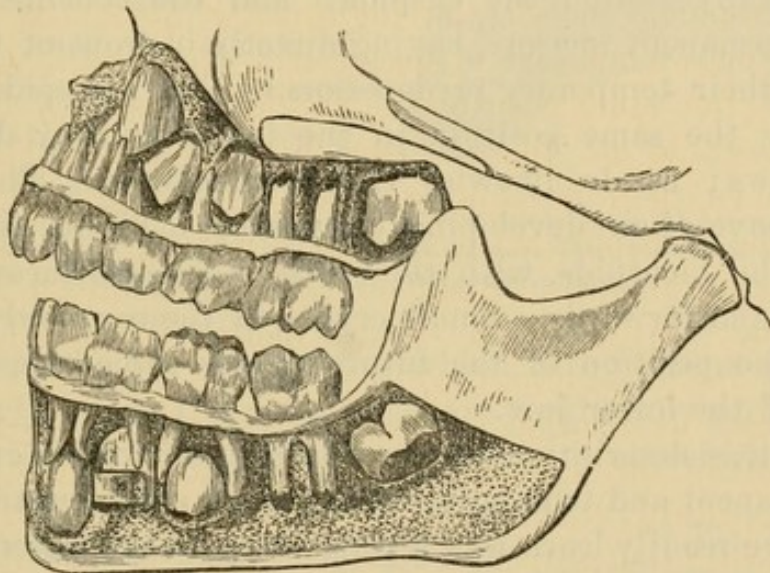
View of the upper and lower jaws of a child aged about $6\frac{1}{2}$ years. The external portions of the bones have been removed to show the positions of the developing permanent teeth and the fangs of the temporary teeth. The bifurcation in the fangs of the upper cuspidati is abnormal. [From "The Mouth and the Teeth," by J. W. White, M.D., D.D.S.]

in a more prominent and consequently a wider dental arch commensurate with their larger dimensions; they are also situated behind the roots of the temporary central and lateral teeth, which show some slight indication of absorption at this period, and the imperfectly developed extremities of their fangs abut closely upon the thin osseous floor of the nares, whilst their

cutting edges reach to about the middle of the roots of the temporary incisors.

The cuspidati, the crowns of which are but barely developed, are situated on a much higher level than the last-named, viz., about $\frac{1}{3}$ of an inch below the floors of the orbits (hence probably their designation eye-teeth), and at the sides of the outer walls of the nares, the floor of which is level with the centre of their crowns. The infra-orbital canals are about $\frac{1}{4}$ in. above and external to their undeveloped extremities. Posterior to these latter in the dental arch, but situated on a lower level and more external, are the first bicuspid, and between these and the central incisors, and on nearly the same plane, are the lateral incisors, placed however internal in the dental arch to the cuspidati and central incisors. The crowns of the first and

Fig. 29.



Side view of the jaw of a child with permanent teeth forming.

second bicuspid, not fully developed, are seen placed directly above and embraced by the fangs of the first and second temporary molars respectively. The first permanent molars, the crowns of which nearly meet their comrades of the lower jaw, and which must have been erupted some weeks, have their fangs about one-half developed, whilst the second molars, or rather the small developed portions of their crowns, hold a position above, and posterior to, the first molars, with their masticating surfaces looking downwards and backwards towards the lower portions of the external pterygoid processes; little crypts on a still

higher level in the tuberosities of the bone show the position of the future *dentes sapientiæ* of the upper jaw.

In the lower jaw, the central permanent incisors, the fangs of which are about one-fourth developed, occupy a more vertical position, in a narrower circle, than do the corresponding teeth of the upper jaw; and this holds good generally with all the teeth of the lower jaw, but especially the six front ones. They are situated directly behind the partially absorbed roots of the temporary centrals, and partially behind the temporary laterals, their cutting edges having but a very thin layer of bone interposed between them and the surface. The *cuspidati* occupy a lower plane in the same arch, their developing roots resting upon the thin dense portion of bone which forms the inferior surface of the body of the lower maxilla, the roots of their temporary predecessors being directly in front of them. Between and partially behind the *cuspidati* and the centrals are the lateral permanent incisors, having directly in front of them the roots of their temporary predecessors.¹ The *bicuspidi*² occupy relatively the same position in the lower as they do in the upper jaws; as do likewise the first molars. The second molars have their developing crowns on a higher level than that of the *bicuspidi*, with their masticating surfaces looking upwards and forwards. Small crypts in the coronoid processes denote the position of the future *dentes sapientiæ*, or third molars of the lower jaw.

From this description of the relative positions occupied by the permanent and temporary teeth prior to the eruption of the former, we readily learn how a persistency in the latter through an unabsorbed root will effect deviation, and the direction which it will cause a permanent tooth to take, when in the process of eruption; thus, persistence in the lower temporary incisors will of necessity, under the above-mentioned conditions, cause these teeth in the permanent series to occupy a position within the

¹ In a preparation before us, small round holes in the jaws, immediately above the summits of the lateral incisors, show absorption of the roofs of their bony crypts to have taken place in advance of any other of the six front teeth.

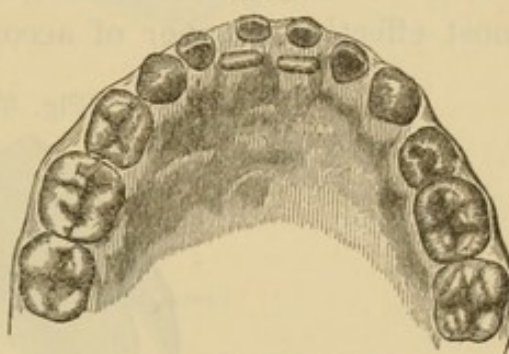
² The first *bicuspidi* lie immediately internal to the mental foramina, which, remaining but little changed in position during life, constitute, as shown by J. Tomes, valuable fixed points for estimating the various alterations which the inferior maxilla undergoes.

dental arch. If it be a temporary lateral tooth or root, the permanent successor must appear behind the permanent central and the temporary cuspidatus, the temporary cuspidati will have the same effect upon the permanent ones, whilst persistence of the roots of the temporary molars will cause the bicuspidi to deviate to positions either internal or external to the dental arch.

The treatment of these cases will be evident, viz., removal of the obstructing teeth or roots. In the lower jaw we frequently meet with cases where the permanent incisors are erupted behind the temporary ones; and, by the removal of the latter, the former are soon brought by the pressure of the tongue into proper position; and, in considering the treatment of irregularities in position, we must ever bear in mind the continual beneficial action of this member, as well as that of the lips, in causing the teeth to assume their normal positions. The former is constantly pressing the lower teeth outwards, until they become arrested by the upper teeth which bite in front of them; whilst the latter, by their elasticity, are continually acting upon the upper teeth in the opposite direction; it therefore happens that by these means great irregularity is reduced to symmetry when simply opposing obstacles are removed.

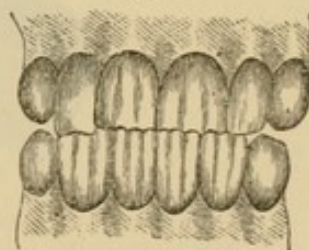
But it may chance to happen, in the case of the upper jaw, that we are not consulted until the misplaced tooth or teeth have been so far erupted that they are bitten over by the lower teeth whenever the mouth is shut, resulting, in the case of one or two teeth, in the subjects being partially, and in the case of the six front ones, in their being wholly underhung. It will here be apparent that removal alone of the temporary obstructives will be unavailing: a new and more serious impediment

Fig. 30.



Lower jaw in which the permanent central incisors have been erupted behind the temporary central incisors.

Fig. 31.

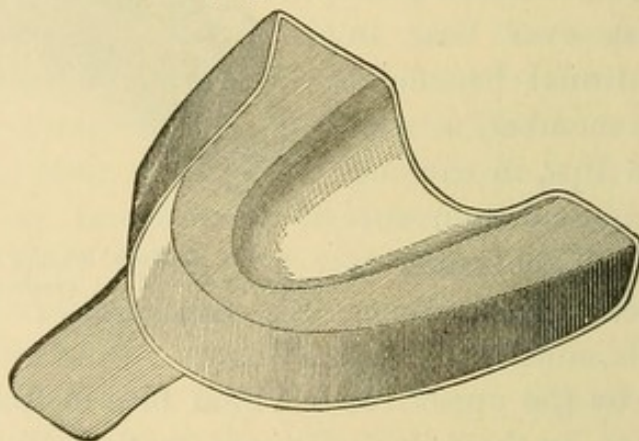


The condition termed partially underhung: it will be observed that the four incisors of the lower jaw bite in front of the central incisors of the upper jaw.

exists, and the case, if left to itself, can only become worse and more disfiguring as time advances. The lower jaw becomes gradually drawn forwards, the angles at the union of the body and rami forming more obtuse angles than the natural ones, and the features characteristic of that species of dog in the company of which it was at one time considered disgraceful to be seen. Besides removing the temporary teeth, we must employ means which will obviate the closing of the lower in front of the upper every time that the mouth is shut, and at the same time we may greatly accelerate the process by applying pressure behind the misplaced teeth.

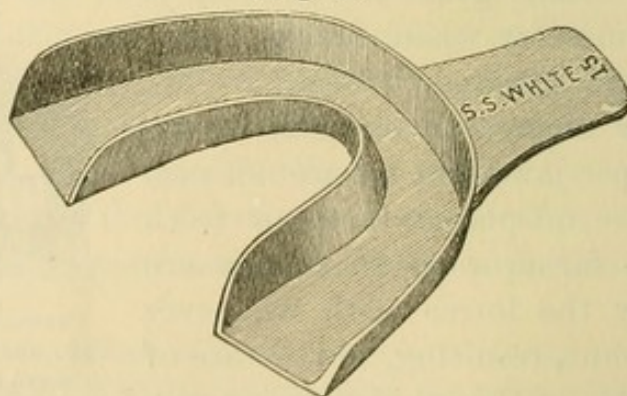
The following, we believe, will be found the simplest and most effective manner of accomplishing our object. We first

[Fig. 32.]



Upper jaw. Impression cup for wax.]

[Fig. 33.]

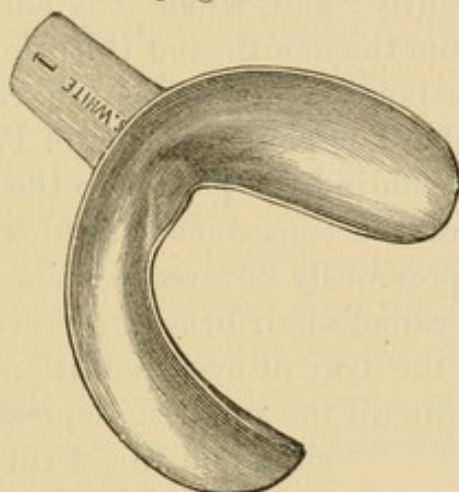


Lower jaw. Impression cup for wax.]

obtain an accurate model of the mouth, by means of an impression or mould taken in wax, plaster of Paris, gutta-percha, or the compounds known as Stent's and Hind's compositions—

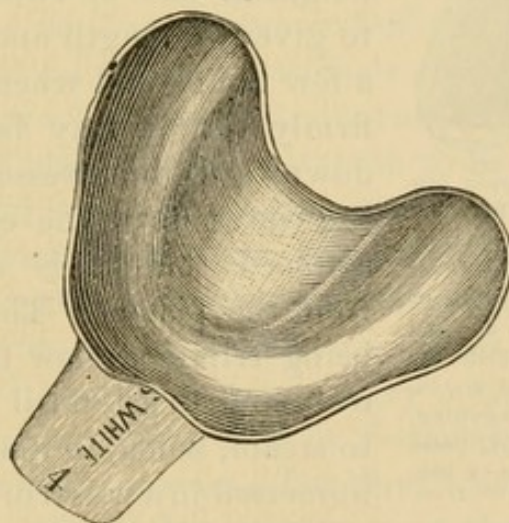
we recommend the two latter—and from this a casting is made in plaster of Paris. To describe this more fully, we obtain a metal tray of the size that will roughly adapt itself to that of the upper dental arch of the patient, and be inserted without much stretching of the mouth. Into this tray we put a sufficiency of the Stent's or Hind's composition, which has been

[Fig. 34.]



Lower jaw. Impression cup for plaster.]

[Fig. 35.]



Upper jaw. Impression cup for plaster.]

thoroughly softened in almost boiling water, then dried and kneaded in the hands to render it quite consistent; a spirit lamp aiding the latter process, and causing it to attach itself to the tray, which should be filled evenly to the level of its sides. The surface being just rubbed over with a little olive oil, we insert the tray, which we are careful to see is not hot enough to hurt the lips, into the mouth, one side before the other being

attended with the least stretching, and then press it with its contents steadily upwards in an almost vertical direction, and high enough to obtain an impression of the surfaces of the teeth above the gum and also of the whole of the hard palate. We allow it to remain in its position for from two to four minutes, as the patient can submit, then bring it vertically downwards, feeling for and following the direction in which it comes the most readily; and, when it is below the level of the teeth, remove it from the mouth, and thus we obtain an accurate impression of the portion of the mouth required. Into this impression, when hard, is poured plaster of Paris of fine quality, mixed by carefully adding the plaster to the water, until, when, well stirred, it is of the consistence of thick cream. [The impression may be previously covered with a thin coat of olive oil, by means of a camel's-hair brush, to prevent adhesion of the model.] We tap the tray at every addition, in order to allow the plaster to go into all the smallest depressions in the impres-

Fig. 36.

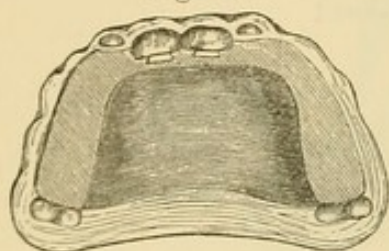


Plate adapted to the upper jaw suitable for raising the bite and pressing out the central incisors when bitten over by the teeth of the lower jaw. Behind each central incisor is shown the dovetail cut into the plate in which the pieces of compressed deal are inserted, and which by swelling, when they become moist, press forward the teeth they are in contact with.

sion, and to get rid of the air-bubbles, and, as the plaster becomes thick enough, we build up the model to the height of one or two inches in order to give it strength and solidity. After a few hours, and when the plaster has firmly set, it may be held tray-side downwards in a vessel of nearly boiling water until the composition is so softened that it is readily removed from the plaster. The model is, after being trimmed, now transferred to an oven and dried until it almost ceases to steam, when, to render it hard, it is immersed in a vessel of melted stearine, and boiled in it about half a minute, and then removed to dry. We have dwelt upon this process of taking impressions of the mouth because it is not merely applicable in dental cases, but may also be of use in many ordinary surgical ones. We have found it very useful, when watching the progress of certain tumors, or obtaining representations of them before removal, or estimating the extent of cleft-palate, *i. e.*, whether the case be more suitable for surgical

or for mechanical treatment, and in cases where a second opinion at a distance may be sought for without a journey.

The model is now placed in the hands of the mechanical dentist, who constructs a plate of metal—gold, platina, silver, or dental alloy—or vulcanite, which last we prefer in ordinary cases. The plate should cap over the bicuspid and such molars as are erupted, and may be made to keep up securely, by our having scraped away the model slightly round, a very little below the necks of the teeth capped, and on their outer surfaces, where consequently the plate grasps them; the thickness of the plate over these teeth should just prevent the front ones from meeting. Behind each tooth to be pressed out should be sawn a space, of dove-tail form, to be filled up by a piece of soft deal firewood which has been greatly reduced in size by pressure for some hours in a strong vice, the compressed surface of the wood being opposed to the tooth. The plate is introduced into the mouth, to which it should attach itself firmly, and then the compressed wood by absorbing moisture swells, and the upper teeth, having now no obstruction from the lower biting in front of them, are pushed rapidly outwards, often in the space of a week, though generally longer, and are carried beyond the lower, so that on removal of the plate they bite in front of them and cannot return to their abnormal position. In the place of the wood a loop of India-rubber, drawn through a small hole in the plate behind the tooth to be pressed out, may be employed; and is perhaps better where patients are unable to pay frequent visits, but under ordinary conditions we prefer the wood. The patient should be instructed to eat with the plate in the mouth, and to remove it only for cleansing, which should be done thoroughly after every meal. In no case do we recommend plates being tied or fastened in, as injury may be done to the teeth in even a few days when they cannot be removed for cleansing. In cases amongst the poor, and where the above-mentioned treatment cannot be resorted to, success is occasionally attained by continually holding a paper knife or thin piece of wood so that it rests in front of a lower tooth, and behind an upper that is bitten over; this method requires great perseverance, and probably succeeds only where the patient sleeps with the mouth open. In a few hospital cases we have, by the aid of a thin elastic rubber band, extended

round the head and across the face, where it is padded with wool to prevent uneven pressure, and then carried behind the misplaced tooth, succeeded in drawing it forwards as desired; in this and the last-mentioned treatment thin India-rubber, drawn between some of the posterior teeth on each side, will, by keeping the mouth from closing, much aid the process; but the irritation thus occasioned cannot be long tolerated. The same retention of the teeth or roots may, when the permanent upper incisors, for instance, are erupted anterior to them, which occasionally occurs, cause the latter to project. When the projection is slight, the pressure of the upper lip will generally, after the removal of the obstruction, bring matters right; but, when it is more prominent, they come to rest upon the lower lip, and thus meet with a continual agency, in the form of an elastic cushion, to further projection. For such cases we may employ a somewhat similar plate to the last, and, by attaching to its palatal surface a small India-rubber ring, draw the prominent teeth backwards into position: the plate must of course be cut away at the backs of such teeth to enable it to do so. It must be borne in mind that teeth so moved have not, as in the underhung cases, a barrier to prevent their return to the abnormal positions—there will be nothing but the elasticity of the lip; the plate must therefore be worn much longer, namely, until the vacancy in the anterior portions of the alveoli caused by the movements of the teeth have become filled up with bony material. In the movement of teeth by mechanical means, it is important to bear in mind the fact that the earlier it is attempted after their eruption the more easily it will be effected, as at that time the teeth are not closely surrounded by bone as they become afterwards.

A detained root or tooth may also have the effect of causing an erupting permanent tooth to become twisted on its long axis, so that its inner and outer edges become placed in the antero-posterior direction, and its cutting or masticating edge at right angles to the opposing tooth of the opposite jaw. When this condition has occurred in an upper central or lateral incisor or cuspidatus, it has been recommended that where there is a sufficiency of room the case should be treated by what may be termed immediate torsion, *i. e.*, by grasping the tooth near its neck with a pair of forceps, guarded with thin leather or other substance

to prevent injury and give firmness, and then steadily but forcibly rotating it into position. Against such practice when first advocated we urged a protest, on the ground of injury likely to occur to vessels and nerves upon which the vitality of a tooth

Fig. 37.

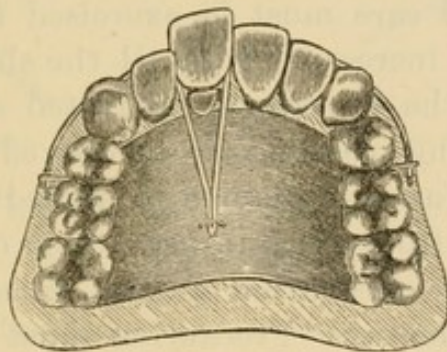
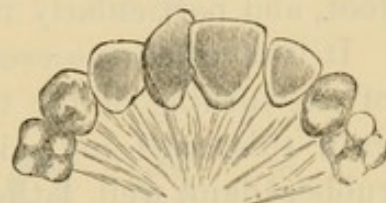


Plate adapted for drawing inwards front teeth of the upper jaw. The right central incisor has been erupted anterior to its temporary predecessor, the root of which is figured, and which should of course be extracted prior to treatment, which will consist either in drawing the central incisor back by an elastic India-rubber band or by a band of platinum, which passes in front of the tooth and which by means of nuts and screws at the side of the plate can be gradually tightened by turning the nuts. The latter arrangement is best suited in the case of having to act on several teeth at once.

depends, and the results of that operation which have come under our notice have verified our predictions. We recently had to remove a necrosed upper right lateral tooth which had been thus rotated; yet the eminence of the operator was a guarantee that the operation had been most carefully performed. The tooth had never come down to the proper length, and was very dark in color; when it was removed, it was found that the fang was, more than half of it, absorbed. Such cases, then, we should recommend to be treated by means of a plate, so constructed that pressure may be applied at each edge of the offender, and in this way it will be mediately rotated in its sockets with perfect safety. We have thus rotated a central incisor tooth nearly two-thirds of a complete circle.

[As elsewhere remarked, immediate torsion is frequently preferred, indeed, is often the only thing that the patient will submit to, so great is the soreness resulting from the slower method,

Fig. 38.



Right central incisor of the upper jaw erupted at an angle to the dental arch from want of space.

so long kept up. Generally the performance of the operation, as well as most attempts at correction of position by force, should be delayed until the formation and dentinification of the end of the root has been fully completed, which may usually be considered to be within a few months after the tooth has been in antagonism with those of the other jaw. The tooth should be firmly grasped, and care must be exercised to apply the force moderately, slowly increasing it until the slight movement of the tooth affords the operator's cultivated and delicate sense of touch the warning necessary to be obeyed if the root is not straight, and therefore not adapted to immediate torsion. This knowledge derived from touch in extraction of teeth, in the use of probes, and in the excavation of teeth, is naturally constantly cultivated in the dentist. Precaution must be observed that the tooth is not pushed upward in its socket, and the apex of the root in that way brought to bear upon the bone; or, on the other hand, not to allow a downward movement, as in extraction, on account of the danger of injuring the apical nerve filaments or bloodvessels. The subsequent treatment is generally simple enough,—in the majority of cases the tooth is best held in its new position by its fellows. Ligatures are dangerous because liable to slip up around the neck and cause additional inflammation of the pericemental tissues.

The failures reported thus far indicate the signal importance of precautions against injuries to the tissues at the apex of the root, and particularly if the apices are not completely formed.

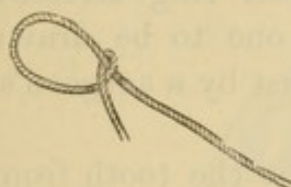
It is of course necessary that there should be room to admit of the turning of the tooth crown between its fellows, and to gain this, wedging will sometimes be necessary. Very thin rubber dam, well lathered with soap, will act as a guard if passed between the impinging points of the adjacent teeth and the one to be moved; but care must be taken to interpose nothing that will interfere with the observation of the movement, which must be slow and deliberate.

After-treatment is rarely required, but may be antiphlogistic. To keep down inflammation, a small pledget of cotton, saturated with lead-water and laudanum, may be laid between the lip and gum over the root, and in extreme cases systemic treatment, as a saline cathartic, might be indicated.

It has been with many in this country the practice to correct

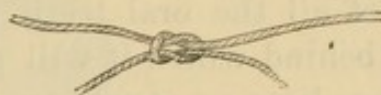by ligatures most cases of irregularity, as recommended by Prof. J. F. Flagg. For this purpose the art of tying several knots

Fig. 39.



The half hitch.

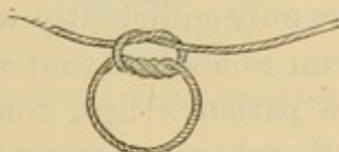
Fig. 40.



The square knot.

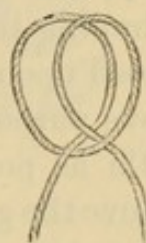
must be learned: 1st, the half hitch; 2d, the square knot; 3d, the surgeon's knot; 4th, the clove hitch.

Fig. 41.



The surgeon's knot.

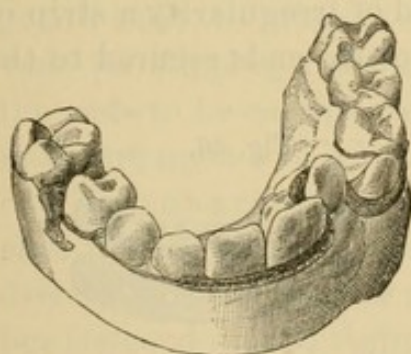
Fig. 42.



The clove hitch.


Suppose it be desired to draw a single tooth out to a position in the arch corresponding to its fellows, as the left lateral in Fig. 43: Take a piece of highly elastic rubber, conveniently a

Fig. 43.



Drawing a tooth forward into the arch by an elastic ligature. (After a plaster cast.)

Fig. 44.



Rings cut from rubber tubing.

ring cut from a French rubber tubing such as is used for separating teeth, Fig. 44, say from $\frac{1}{8}$ th to $\frac{1}{4}$ th inch in diameter, tie to this by a square knot a piece of strong sewing-machine shoe-

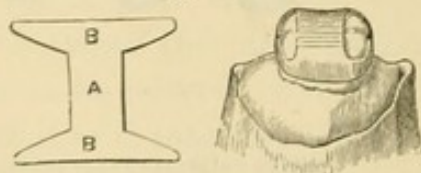
thread, leaving the end six or eight inches long from the ring; by these ends tie the rubber tightly against the first bicuspid or molar on that side. Tie a similar piece of thread and rubber to a bicuspid or molar of the other side, and pass one end of another thread through the rubber ring stretching in front of all the oral teeth, except the one to be drawn into place, behind which it will pass. Tie fast by a surgeon's knot, and thus keep up steady tension.

If the teeth antagonize so as to prevent the tooth from passing front to its position, one or more of the lower teeth in the vicinity may be capped with gutta percha, silver, or gold, to prevent the occlusion and interference.

To make the caps, take a small piece of gutta-percha (the pink trial plate will do well), warming it slightly and pressing over and shaping it on the teeth designed to be capped; let the jaws be closed upon it until they are only sufficiently wide apart for the above purpose, and then trim to a shape that will interfere as little as possible with the patient's lips, tongue, and cheek; remove the gutta-percha while yet warm; squeeze slightly together the edges that grasp the necks of the teeth, and chill it quickly in cold water. The cap will then require to be sprung over the teeth to which it is adapted, and will retain itself in position. This method was taught by Prof. J. F. Flagg.

The late Prof. McQuillen recommended a thin piece of plate (silver or gold) to be cut and folded as in the diagrams, after the manner in which paper boxes are made. Prof. McQuillen also recommended for correction of this kind of irregularity a strip of gold clasp plate, as in the diagram, the two ends secured to the

Fig. 45.



Prof. McQuillen's cap to prevent occlusion of the teeth. (From the Dental Cosmos.)

Fig. 46.



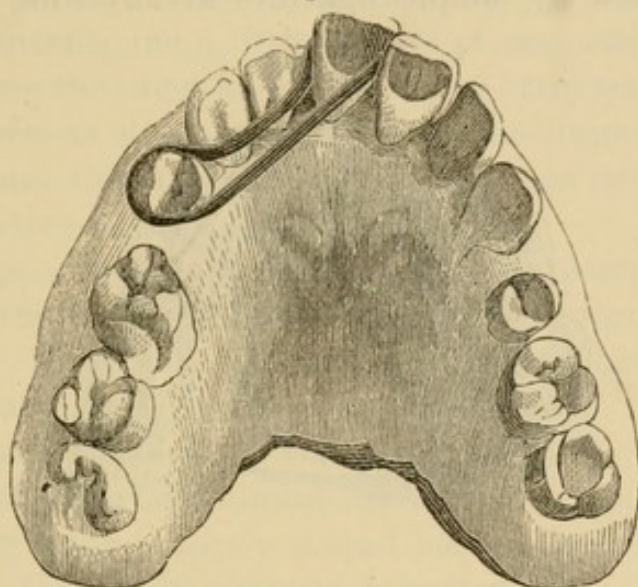
Prof. McQuillen's bar for drawing teeth forward. (From the Dental Cosmos.)

bicuspid or molar on either side, and rubber ligatures or rings thrown over the dovetail-shaped parts and the tooth or teeth that it is desired to draw forward.

In most cases it is best to attempt the moving of but one or

at most two at a time, both on account of the greater soreness and the danger of displacing the teeth used as fulcrums.

Fig. 47.

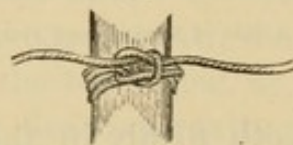


A method of drawing a tooth into position by an elastic ligature. (From the Dental Cosmos.)

If the same tooth were placed outside of the arch, a rubber ring might be tied to the palatal face of each of the first bicuspid or molars, and a strand of the ligature stuff carried through both rings and in front of the tooth, which upon tying would stretch the rubber and cause it to draw the tooth inward.

If a tooth were to be twisted upon its axis, Prof. Flagg recommended the clove hitch, over which the ends of the ligature are passed and then tied tightly with a surgeon's knot, to grasp it so firmly as to prevent its slipping on the tooth, and enable the ends to be carried to a rubber ring tied as before upon a neighbor, and by its elasticity keep up a constant torsion pull. Or both ends may be wound around the tooth in the direction that it is to be turned, and one of these carried to a rubber fastened on the right side, and the other to a similar rubber on the left side, of the mouth, thus doubling the power. Sometimes plates are used with advantage, as in the accompanying cuts.

Fig. 48.

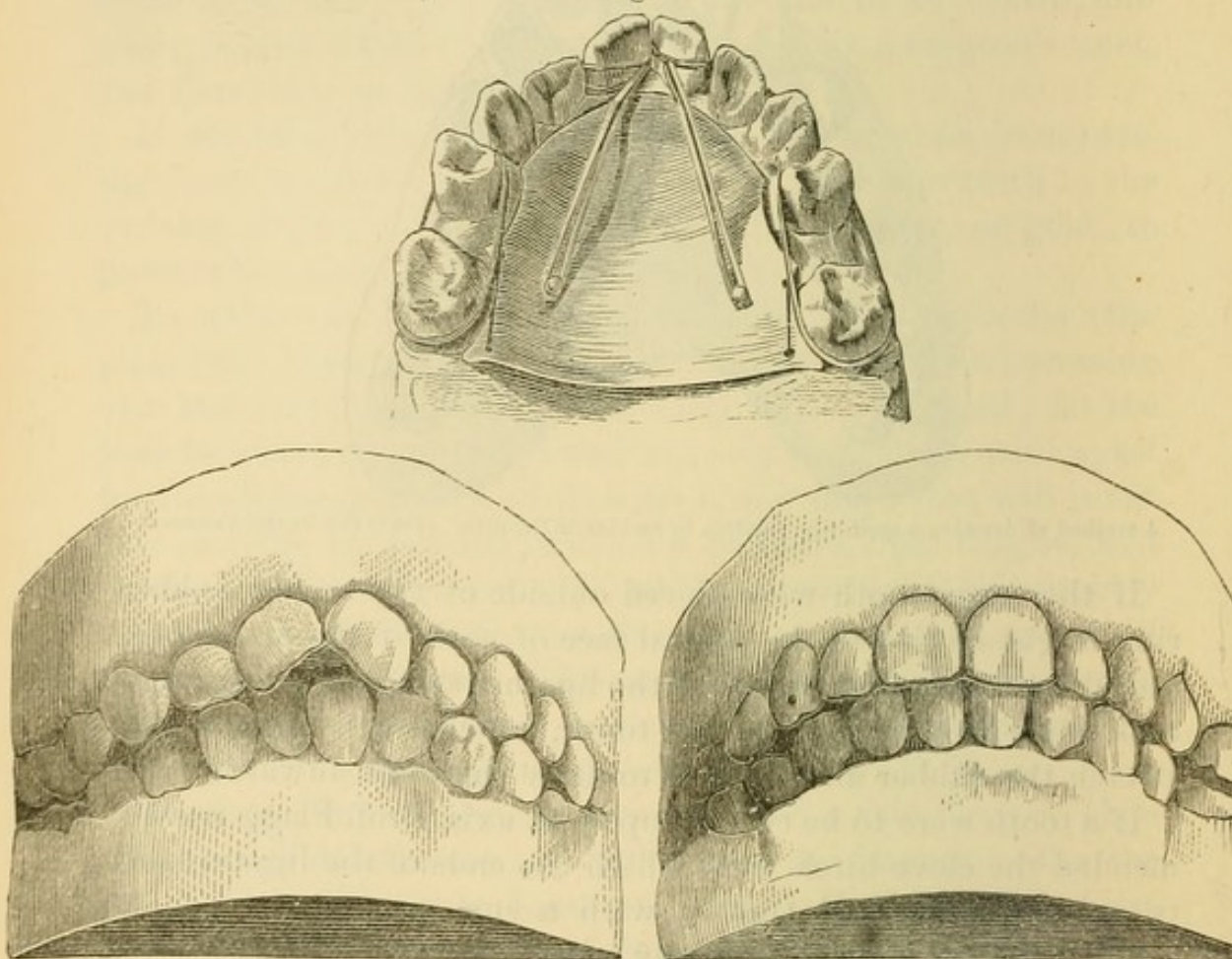


Prof. Flagg's method of tying ligature for torsion.

Should it be desired to draw the lower oral teeth so as to close behind the upper, the elastic rings should be attached to the inside of the bicuspid or molars, and by a ligature as

shown in Fig. 49, concentrate their pressure upon one tooth at a time until they are brought in about one-sixteenth to one-eighth of an inch behind the point desired. The rubber rings may be replaced by simple ligatures at any time to hold the

Fig. 49.



A case of torsion and retraction of central incisors by a plate with pins and elastic ligatures.
(From the Dental Cosmos.)

teeth firmly in the position gained, or to give a respite from the pressure which it sometimes becomes advisable to relieve.

Prof. Guilford, to avoid the pain caused by the slipping up of the ligatures and wounding of the gums, has devised the attachment of thin gold clasps to the teeth, which may be held in position by a cement, as the oxy-phosphate, and the tying of the ligatures to these.

The same operator has also devised a simple appliance for producing torsion, which I give in his own words:¹—

¹ From the Dental Office and Laboratory, Oct. 1878.

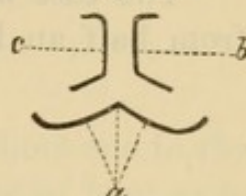
"It is made entirely of gold, and is constructed as follows: A model of the teeth being secured in plaster, a piece of gold backing was cut, an eighth of an inch wide, and long enough to extend along the palatine surfaces of the two centrals, and a little beyond at each end. After rounding the edges and corners, this strip was bent to conform as closely as possible to the lingual surfaces of these teeth, and the ends turned forward so as to slightly clasp the disto-palatine angles as shown in Fig. 51.

Fig. 50.



"Two strips were then cut from upper-plate scrap, a little narrower than the first piece, and bent in the form of *b* and *c* respectively. These were made long enough to be bent slightly over the labial surface of the teeth, extending along the mesial surface to the palatine, and then along this surface almost to the distal angle. After being properly shaped according to the model, they were clamped together and soldered along their contiguous surfaces. This part was then placed in position on the model, and the long ends bent to conform to the inner surface of *a*, held temporarily in position. The parts were then removed, and the part *b-c* was clamped and soldered to *a* in its proper position. The only thing then to be done to complete the piece was to reduce the thickness of the part *b-c*, by filing, where it passed between the teeth, and polish the appliance. Before applying, a piece of thin rubber was placed between the natural teeth for a day, to separate them slightly and admit of the introduction of the appliance. When properly constructed, the labial part of the apparatus will rest against the teeth just at, or slightly above, the most prominent part of their convexity; while the lingual portion will be near the gum, but not quite touching it, and the slightly-curved ends of this part will catch just above the little nodule usually found on the disto-palatine angle near the gum. When thus made and placed, the piece cannot become displaced by the action of the lip or tongue.

Fig. 51.



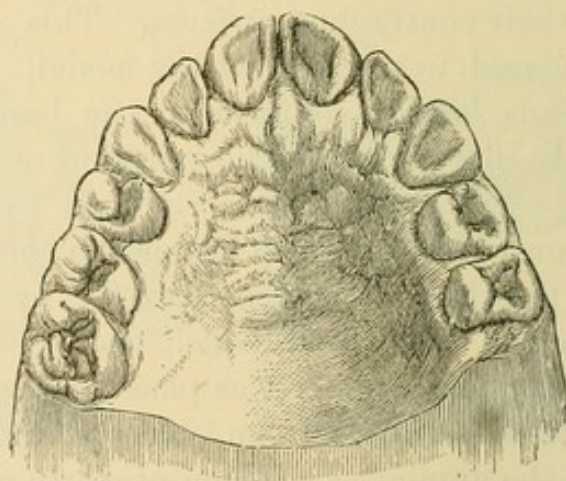
"The whole process of effecting the double-rotation of these teeth with this appliance, is to see the patient every day, each time bend the long palatine arms slightly toward the short labial ones, and spring it back into position on the teeth. The elasticity of the gold, increased by the stiffness the solder has

given to it, will do the work. This daily bending should be continued until the teeth are rotated into their proper position. This can usually be effected in about ten days.

"By this method the use of all rubber or silk ligatures, so irritating to the gum, and so painful in their application, is dispensed with. There is nothing unsightly about it, as the only part exposed to view is the very small portion on the labial surface; nor is there enough of the whole appliance to irritate either the lip or tongue, or in the least annoy the patient. It dispenses, also, with the wearing of a plate on the roof of the mouth, a very great desideratum in the matter of distinct enunciation, for our patients at the time of these operations are always in their school-days.

"The ease with which it can be constructed, requiring only from half an hour to an hour, and the rapidity with which it

Fig. 52.



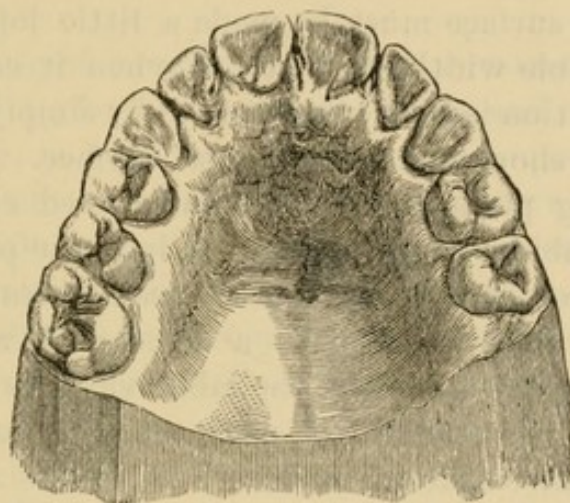
can be removed, bent and replaced each day, are also among its great recommendations. To guard against its accidental loosening and loss, especially at night, it has been my custom to tie a thread around one of the centrals and under the front bar.

"One of three cases treated in this way during the summer of 1874, the patient being seen every day, was easily corrected in ten days' time. Fig. 52 is a representation of her teeth before treatment, and Fig. 53 afterward.

"The same appliance can be used with equal effectiveness in cases (not so frequently met with) just the opposite of those I have been describing—that is, where the distal surfaces are in-

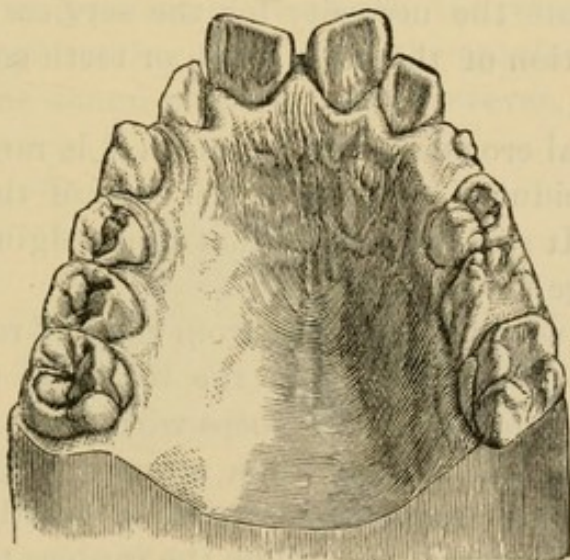
clined outward, and the mesial inward. In these cases the whole operation has, of course, to be reversed. The long arm

Fig. 53.



or band goes on to the labial surface, and the short one to the palatine, and the ends of the long arm have to be so bent as to throw the distal angles inward. I have just finished a case of this kind, shown in Fig. 54, with perfect satisfaction, using no other appliance than the one above described.

Fig. 54.



“The same appliance, slightly modified, I have also used for rotating but one of the teeth, where the other is already in position. In this case the half of the appliance touching the

tooth not to be moved is made to fit it nicely, both on the palatine surface and on the labial; but the other half must be made long enough at the part that goes between the teeth to grasp the protruding tooth around its mesial surface, and the long arm on the palatine surface must be made a little longer, to accommodate the whole width of the tooth when it comes into position. The rotation is then usually done by simply bending from day to day the short arm on the labial surface.

"A retaining plate for the first mentioned class of cases is best made of rubber, having imbedded in it the palatine portion of the appliance—while one for the class illustrated by Fig. 54, consists of a rubber plate with a light gold wire imbedded, extending along the middle of the labial surfaces of the centrals and laterals, and so constructed as to certainly touch the angles of the teeth that before protruded.

"As this simple appliance has proved so efficient and satisfactory in my hands, and in the hands of some friends who have tried it, I have been induced to give it to the profession in this public way, hoping that it may serve to lighten the labors of fellow-dentists, and lessen the discomforts of their patients."

The permanent superior oral teeth, as a rule, should erupt on the labial side of the deciduous teeth, and those of the inferior jaw should present upon the lingual side. Any deviation from this will indicate the necessity for the services of the dentist and the extraction of the milk tooth or teeth corresponding to those erupting.

Where lateral crowding is threatened, it is rarely desirable to remove the deciduous teeth on either side of the erupting permanent one. It seems probable that the wedging into position tends to enlarge the arch.

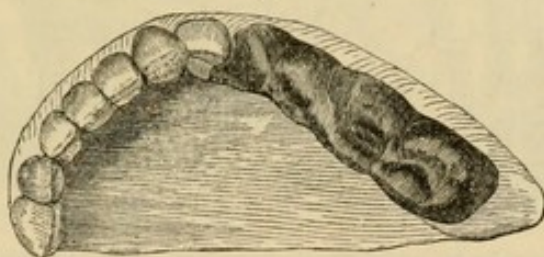
It not infrequently occurs that from want of room the canines erupt outside of the arch, and the bicuspid are so far into position as to interlock their cusps with those of the opposite jaw when occluded. Rather than attempt to jump the bicuspid cusps over their antagonists, it will generally be best to extract the first bicuspid and allow the canines to fall back into the spaces vacated by the extraction. This avoids the irritation of the tissues and the initiation of abnormal blood currents, which might ultimately induce hypertrophy, or other trouble, about the roots.

It has long been a rule with dentists to preserve the deciduous canines, for their position in the arch is important; they act somewhat like keystones, tending to preserve the regularity and beauty of the curve described by the teeth of the permanent denture.]

Another cause of irregularity of the permanent teeth in position, is stated to be the habit of thumb and tongue sucking. It is probably, in such cases, due to some peculiarity in the manner in which the habit is practised; for we may have, as in the family of the writer, a member who was subject to a considerable projection of both temporary and permanent upper incisors, yet who never had the habit: whilst the next in age, a most inveterate thumb-sucker, has the most perfectly formed arch of a large family. On the other hand, we have under observation a child about five years of age, who invariably sucks the right thumb, and in whom not only the front teeth, but the alveolar process of that side, are abnormally prominent. The treatment, of course, will be the prevention of the habit, and the wearing of a coarse worsted glove will generally effect the object: if not, the continual application of aloes to the favorite thumb will probably do so. The treatment of irregularities which are the result of tumors will of course consist in attention to the latter.

Irregularity in position of the teeth, the result of fracture of the jaw, although coming more under the province of the general than that of the dental surgeon, may, however, in the majority

Fig. 55.

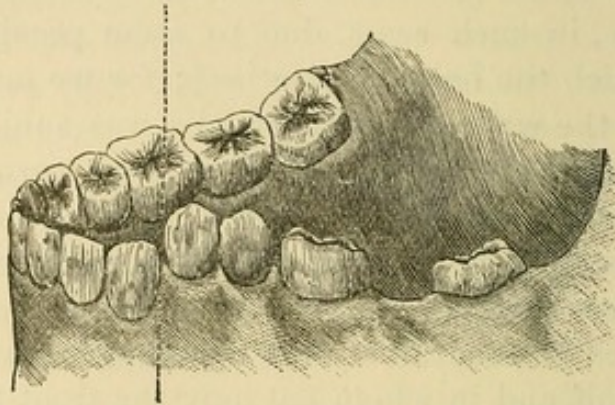


Case of fracture of the lower jaw, transversely through the body, treated by means of a metallic cap, which fits tightly over teeth on each side of the fracture, and thus holds the fragments in firm apposition.

of cases be treated most successfully by the means and appliances which are best known to the latter, and especially in cases where many of the teeth are not wanting. To put up a fracture of the lower jaw, where much distortion exists, with a well-adapted

gutta-percha splint, moulded to the chin, and retained by a four-tailed bandage, appears to us about as good a means for perpetuating a deformity as would be the application of a plaster-of-Paris bandage to an unreduced fracture in a limb. A simple form of treatment of a fracture in either jaw will

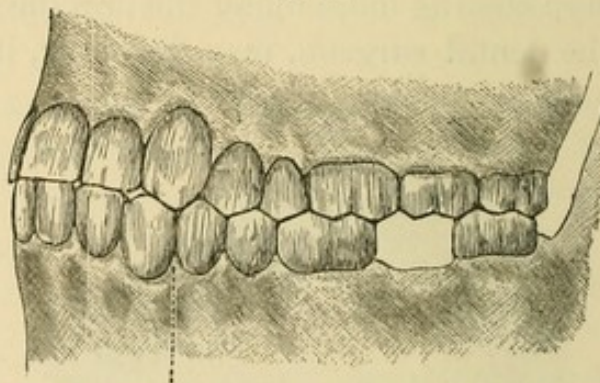
Fig. 56.



Model taken from a vertical fracture of the lower jaw between the left cuspidatus and first bicuspid. The dotted line, which indicates the fracture, is the line to be sawn through in order to bring the model into the normal position of the jaw.

consist in constructing a plate of metal that will cap and securely hold several of the teeth on both sides of the injury. To effect this, wax or plaster impressions are taken of both jaws, the fractured one in its abnormal position; from these plaster

Fig. 57.

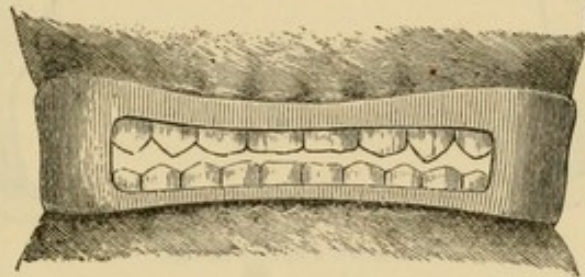


The engraving shows how, by means of a cast of the upper jaw, the two fragments of Fig. 56 can be placed in precisely the normal position of the lower jaw before the fracture occurred.

models are obtained, and that representing the injured jaw sawn through in the line of the fracture. The two divided portions are now fitted by the crowns of the teeth to their corresponding places with the crowns of the teeth in the model of the uninjured jaw, and the relative positions of both—the

bite or articulation—as they existed before the injury are thus obtained, and the divided portions are again united by plaster. To the model representing the fractured jaw a metal or vulcanite plate is constructed, capping three, four, or more teeth on both sides of the injury as the case may admit. To obtain a good hold, the plate may be lined with gutta-percha, which, at the time of its application, is made warm and retained until cold; or small screws may, as adopted by Barrett, pass through the sides of the plate and between the teeth at their necks. If, however, a little care be taken in the construction of a metal plate, so that it fits accurately and firmly at the necks of the teeth, the gutta-percha or screws may be dispensed with. Small holes are sometimes drilled in the plates, to admit of syringing and the egress of discharge, but in a plate that merely caps the teeth these will not be required. A double interdental

Fig. 58.



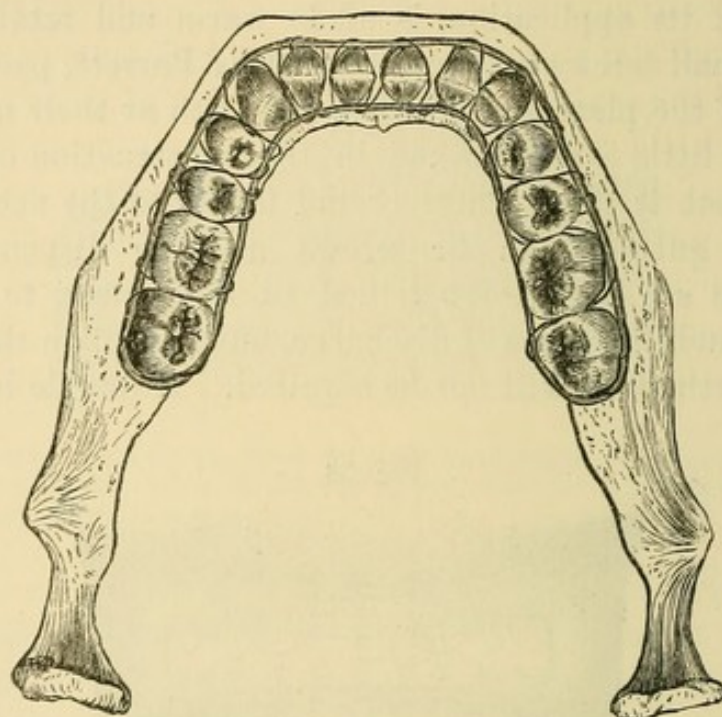
Gunning's interdental splint for fractures of either jaw, and in which the sound jaw assists in retaining in position the fragments of the fractured one.

splint has been devised by Gunning, and is especially adapted to cases in which more than one vertical fracture through the body of the bone exists. It is best constructed of vulcanite, and consists of an interdental splint for each jaw, constructed in one piece. By it, the two jaws act upon each other, the sound one assisting in holding the injured one in position. The jaws are kept a short distance apart, and an opening between the two splints in front of the mouth admits of the introduction of fluid food without movement of the jaws. The plates may be retained by the screws, but with adults this is not as a rule necessary, as a bandage round the head will keep the two jaws together.

But of all appliances devised to this end, and especially for fractures of the lower jaw, the splint of Hammond certainly, in

our opinion, appears the most efficacious. It consists of a stout piece of iron wire, bent so as to include the whole dental arch on both sides of it, and soldered at its terminations. When applied to the dental arch, it should just rest upon the gum on

Fig. 59.

Hammond's splint *in situ*.

either side at the level of the necks of the teeth. When so placed, it is firmly secured to the jaw by passing fine silver or iron binding wire between the teeth at their necks, and attaching it to, and twisting it tightly upon, its inner and outer portions. It is a somewhat tedious and unpleasant process, but such labor is well repaid when, as in a case recently treated at St. Bartholomew's Hospital by our esteemed colleague, I. Lyons, the patient within half an hour of its application had eaten a mutton-chop and smoked a pipe with much satisfaction. In the case of edentulous jaws, vulcanite splints may be adapted, but even if lined with soft rubber, a material about as hard as leather, their pressure on the soft mucous membrane can be but ill tolerated, and especially when in the lower jaw they are secured to the chin, by connecting the splint with a gutta-percha cap fitted over the latter.

[As a temporary splint for fractures of the jaws, two or three

sizes of silver, or gold, plates struck up like lower impression cups, without handles, might be kept on hand. Cut these open at the incisors to afford feeding space, and drill holes to pass wire for binding them together; fill with gutta-percha rendered plastic by heat. They should then be pressed upon the teeth, after the fractures are reduced, and wired together to hold the jaws and the parts in position, until more elaborate splints are made, if necessary. This splint, suggested and used by the writer, has been found sufficient, and actual practice on fractured jaws has demonstrated that often no other was required.]

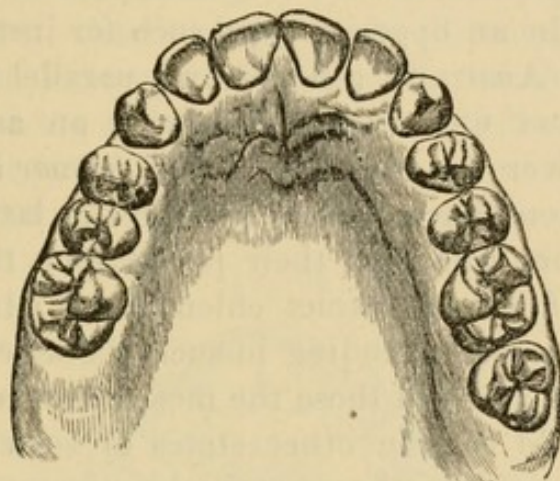
CHAPTER IV.

IRREGULARITIES IN THE PERMANENT TEETH (*continued*).

II. CONGENITAL AND UNAVOIDABLE.—The irregularities which we have classed under this head are the result of an undue relationship between the teeth and the maxillæ, *i. e.*, where the latter are developed in excess as regards the former, and *vice versa*. The former alternative, by far the less common in the present day, may result in the teeth having abnormal interspaces, and most commonly between the two central incisors of the upper jaw; or, as is not unfrequently the case, a bicuspid may have been erupted so that its lateral surfaces become placed in the reverse position, *viz.*, externally and internally. That, however, which is certainly more common in the present day is where the reverse of the above prevails, and the maxillæ, especially their alveolar portions, are not developed commensurately with the teeth. That such condition prevails to a greater extent now than some generations since, and is apparently on the increase, is, we believe, the unvarying opinion of practitioners who have had the opportunity of having under observation the mouths of three and often four generations of the same families; and such opinions are confirmed by the comparison of old skulls with those of persons of the present age. The examination of some 200 skulls in the crypt of the church at Hythe, when measured from the anterior fang of one first upper molar near its neck to the same portion of the corresponding tooth upon the opposite side of the jaw, gave—greatest width, $2\frac{5}{8}$ inches; least width, $2\frac{1}{8}$ inches; average width, $2\frac{1}{2}$ inches: which, compared with the average in recent skulls, gives an excess in favor of the former, whilst the teeth appeared to be about the same average size formerly as now: “In no single instance was there anything seen approaching to that which under the term ‘contracted arch’ so commonly exists in the present day; they all presented an architecture characteristic of

the church that contained them; the Gothic architecture of a more refined period in them also had not as yet made its appearance."¹ But what was still more conspicuous in these old skulls was the inclination outwards of the teeth and alveolar

Fig. 60.



Well-developed upper jaw in a youth aged about twelve years.

processes, of especially the upper jaw, which gave a more prominent and consequently more capacious dental arch; so much so that in many the third molars occupied the position which we now see occupied by the first molars.

There can be no doubt but that the chief cause for this departure is that assigned by Darwin² and Wallace, viz., those altered conditions in the food of man, with the less necessity for exercising his teeth and jaws, in an age of advanced civilization. Together with this explanation must also be considered the effect of a sexual selection or breeding-in,³ which tends perpetually to continue, and further develop an approved type.

[Tonsillitis⁴ has likewise been pointed out as a cause of the contraction of the arches at the bicuspid. The labored breathing, from the filling up of the fauces by these swollen glands,

¹ "Remarks upon the Collection of Skulls in the Crypt of Hythe Church, Kent," by Samuel Cartwright and A. Coleman, *Trans. Odont. Soc.*, vol. iv. p. 221, old series.

² The Descent of Man, by C. Darwin.

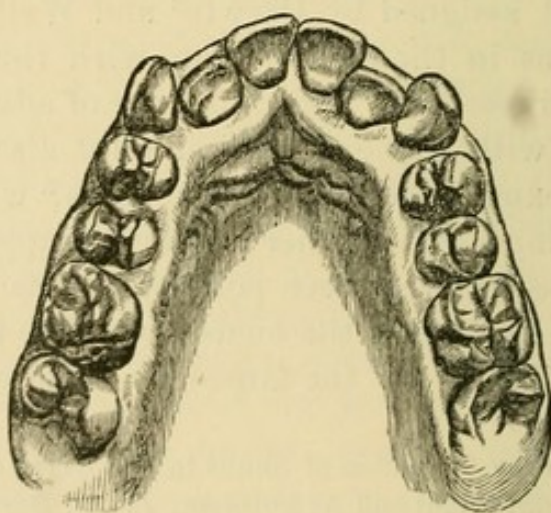
³ "Reflections on the Cause and Treatment of some forms of Irregularity," by S. Cartwright, *Trans. Odont. Soc.*, vol. iv. p. 114, old series.

⁴ See p. 11, "Oral Deformities," by Norman W. Kingley, M.D.S., D.D.S., D. Appleton & Co., New York, 1880.]

causes the cheeks to be compressed over the lateral parts of the mouth.]

One of the characteristics of this type will be a more vertical development of the teeth and alveolar processes, as well as a greater prominence of forehead and chin, so that a straight line would fall nearly parallel with forehead, base of nose, lips, and chin; whereas in an opposite type, such for instance as is seen in the native of Australia, a line drawn parallel with forehead, base of nose, and upper lip would form an angle with one parallel with lower lip and chin: in the former arrangement a much smaller dental arch exists than in the latter. As mankind become more refined in their perceptions, the forms most indicative of refinement attract chiefly their admiration; and thus those the most abounding in such characteristics are the most likely to marry, and those the most deficient in them the least likely to do so. In other states of society we see the reverse of this picture: the savage who possesses the greatest physical strength (which is usually met with in a form most wanting in those characteristics of which we have just spoken), becomes usually a chief among his people, and receives the greatest marks of favor from the females of his tribe; and, where polygamy exists, numbers more wives than does he whose

Fig. 61.



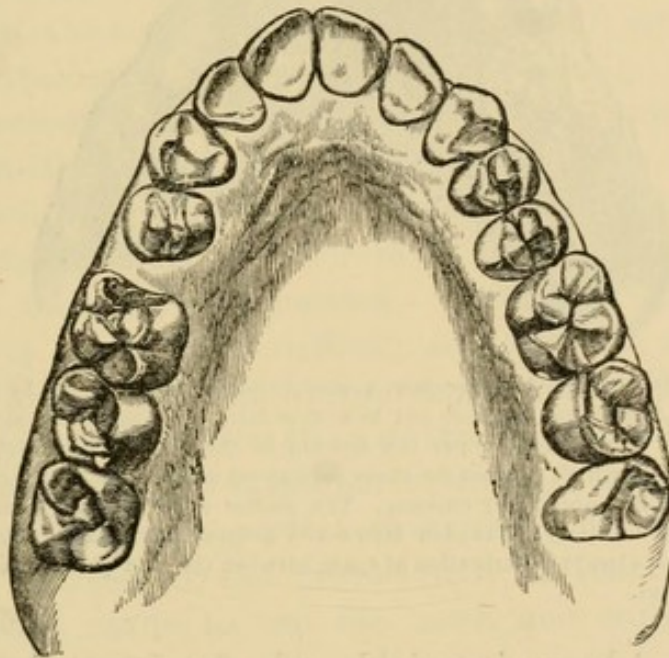
Imperfectly developed upper jaw with irregular dental arch. The lateral incisors are bitten over by the lower cuspidati.

tendencies to refinement render him an object of contempt, and doubtless exclude him from female association. Thus the savage races preserve for ages the characteristics of their class with far

less deviation from them than do those in civilized communities; there being some limits to physical strength and barbarism, there being none to intellectual and moral progress, save in perfection.

Whatever may be the causes of a less perfect development of the maxillæ, and especially of a more vertical position in the teeth and alveoli, the result must be obvious, supposing the teeth to be normal in regard to size; viz., the dental arch must be irregular, and the most common form which such irregularity will assume will be what our acquaintance with the positions of the permanent teeth just prior to eruption would indicate;

Fig. 62.



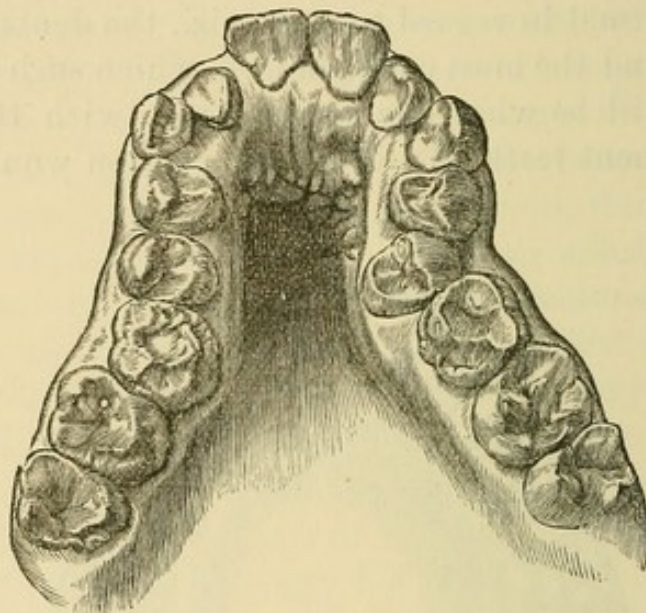
Imperfectly developed upper jaw, and where the dental arch assumes the V-shaped form.

thus, the central incisors and cuspidati will be unduly prominent in the dental arch, whilst the lateral incisors will be within the dental arch, and, in the upper jaw, most probably bitten over by the inferior cuspidati. In another variety of this form of irregularity we have the teeth fairly in line, but the incisors, especially of the upper jaw, are forced out, often overlapping at the mesial line, and giving to the arch a V-like form.¹ We

¹ A praiseworthy attempt has recently been made to classify the various forms of normal and abnormal maxillæ that are met with in the present day, by J. Okley Coles, *Trans. Odont. Soc.*, vol. xii. p. 103. The subject, however, requires much careful consideration before any classification of so intricate a subject can be adopted.

have regarded this type as caused by the eruption of the cuspidati before the bicuspid, so that they assume earlier a position in the arch at the expense of the incisors, which are driven forwards, although it may of course result as a consequence of the position in which the front teeth are originally developed.

Fig. 63.



Imperfectly and ill-developed upper jaw, a case suitable for treatment by expansion of the dental arch. C. S. Tomes has pointed out how this form of irregularity may be explained. Thus, if the cornua of the foetal upper jaw are not in the first instance divergent, the subsequently added portions which support the three permanent molar teeth will form an angle in the bicuspid region with that previously existing. The matter is interesting from another point of view, viz., in regard to idiocy. Langden Down has pointed out that, in regard to congenital idiots, there is almost always a diminution of space between the bicuspid, with abnormally high vaulting of the palate.

[This cannot be an invariable rule, for repeated examination by Drs. J. W. White and N. W. Kingsley,¹ of the mouths of the inmates of two large institutions in this country, for the treatment and care of the feeble-minded, has demonstrated that generally the entire digestive apparatus is almost abnormally developed. The jaws and teeth show a perfection of adaptation that corresponds with the well-known capacity and the alimentary capability of these unfortunates.]

[¹ See Dental Cosmos, April, 1872. "The Relation between the Development of the Mouth and Teeth to Systemic and Mental Development." By Dr. J. W. White.

See Kingsley's Oral Deformities, pp. 36-37, where Drs. White, Peirce, and the writer are quoted as concurring in the above view.]

To such form of irregularity two methods of treatment present themselves by which the teeth and maxillæ may be brought into harmonious relationship, viz., an expansion of the alveolar and dental arches, or a diminution in the number of teeth. The first naturally commends itself as rational and conservative, especially where the teeth appear sound, and should be attempted where there is not excessive crowding, and particularly where one dental arch may be perfectly developed whilst the other is narrow and contracted, and the more so should the ill-developed arch be the upper. The process of treatment will consist, in the upper jaw, of constructing a plate adapted to the palate and internal surfaces of the teeth; a removal of a small quantity of the plaster from the model at the necks of the teeth, and between each, will generally insure the firm attachment of the plate, and then, by means of the wedges previously described, the dental arch may be in a few weeks expanded. As the tendency to return to the abnormal condition will be considerable, a plate should be made, adapted to the perfected arch, in order to retain the teeth for several months in their altered position. The same process in the lower jaw is much more difficult to carry out, and generally not nearly so successful in its results; fortunately the teeth in the lower jaw are less seen than in the upper, and therefore its treatment by expansion is seldom attempted, unless to improve mastication by a more perfect antagonism of the two dental arches. If attempted, the process will be best effected by a metallic plate, made to cap the teeth and capable of being expanded by a spring.

A more elegant but less rapid process for expanding the upper dental arch than that suggested above consists in constructing a plate as described—although it will generally be found necessary to cap the teeth in this case—dividing it into two halves in the line of articulation of the palate, and then vulcanizing into each a portion of a spring constructed of piano-forte wire, of the form shown in Fig. 64.¹ The objection to the constant breakage of the spring from rusting may be greatly

¹ For this ingenious device, we believe, we are indebted to Coffin, of London, and the latter suggestion, we are informed, to Kingsley, of New York. J. S. Turner tins his steel springs.

overcome by inserting in the vulcanite a very small piece of zinc in contact with the wire. The dilatation of the dental arch by this apparatus, though less rapid than by wedging, is one requiring far less constant attention on the part of the

Fig. 64.

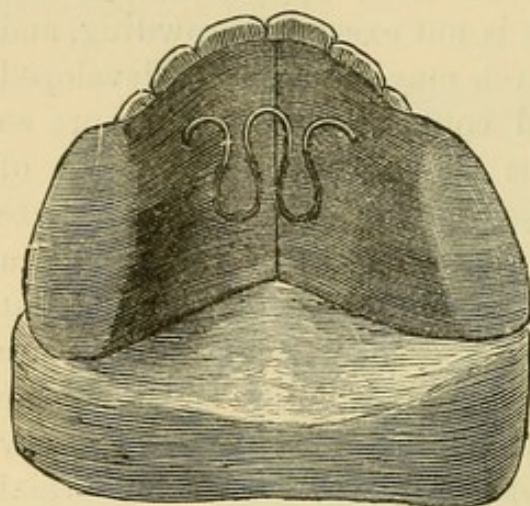
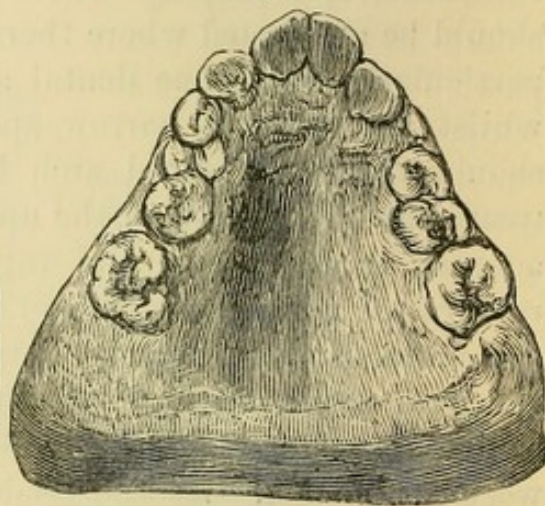


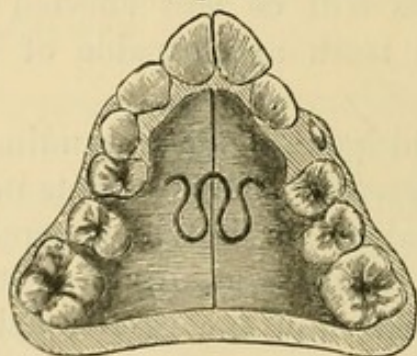
Fig. 65.



Contracted dental arch. Coffin's method for expanding the same by means of a divided plate and spring formed of pianoforte wire, the back teeth being capped.

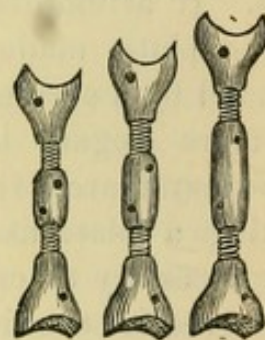
practitioner, and the most suitable for patients who reside at a distance from him. In the place of the wire spring the jack-screw may be employed. It is vulcanized into a plate of similar construction to that just described, or it may be used

Fig. 66.



The expansion of a V-shaped arch by means of Coffin's plate. The back teeth not capped.

Fig. 67.

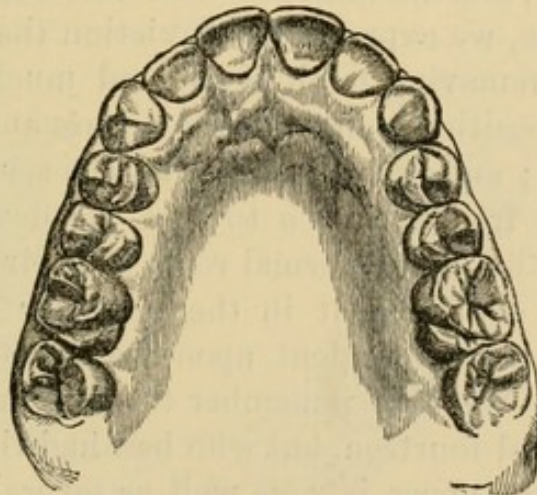


The jack-screw, three sizes.

without any plate at all, viz., by attaching its extremities against the palatal surfaces of two opposite teeth. By inserting a small pin into the central portion and turning it in one direction the jack becomes elongated, and thus the teeth are pressed outwards

in the dental arch. There is probably no appliance to equal it in the rapidity with which it effects its object, and it is readily under control of the patient or the patient's guardians. But in the treatment of these cases our attention must not be exclusively restricted to the condition of the dental arches; these may be brought into the most perfect symmetry, and yet the result may be anything but gratifying; and this is a matter which, we think, has not received its due share of attention at the hands of the dental practitioner. Our views on the subject can perhaps be best explained by narrating the history of a very instructive case. About the period when the writer entered upon practice, a great deal was written and said on the unjustifiable procedure of removing sound teeth for the purpose of regulating the dental arch, and expansion of the arch to effect that purpose was stated to be, under almost every condition, the correct and legitimate treatment. Adopting the views of his seniors, the writer had the opportunity of putting them into practice in the case of a young lady of prepossessing appearance, much marred, however, by the irregularity of her teeth, which presented the type first described; thus, as shown in Fig. 61, the upper centrals and cuspidati were unduly prominent, whilst the lateral incisors were bitten over by the cuspidati of the lower jaw. In consequence of this arrangement,

Fig. 68.



The same case as Fig. 61 after treatment by expansion.

the chin appeared elongated and unduly prominent, partially underhung. The result of the treatment was an undoubted improvement, the upper front teeth were brought into perfect

regularity, the face shortened, and the chin no longer prominent. In a dental point of view the result might have been considered perfect, but not so in a facial point of view, as the mouth had been rendered unduly large in proportion to the other features, giving it somewhat of a plebeian aspect. After a year or two, the lower first molars became carious and were removed, as were also the two upper first bicuspid: the effect was, that the dental arches became reduced in size, and the mouth assumed harmony with respect to the other features. Such, then, will be found, in a large number of cases of irregularity by crowding, to be the proper treatment, viz., lessening the number of teeth, which, it has already been stated, are in the present day so often found in excess of development in relation to the maxillæ, even when the latter are not out of proportion to the other bones of the cranium. In other points of view, this latter has great advantage over the former plan, inasmuch as the teeth are less pressed upon by their neighbors, whereby a very fruitful cause of decay is removed; and also from the consideration that plates are less frequently needed, or, if required, are seldom necessary for so long a period.

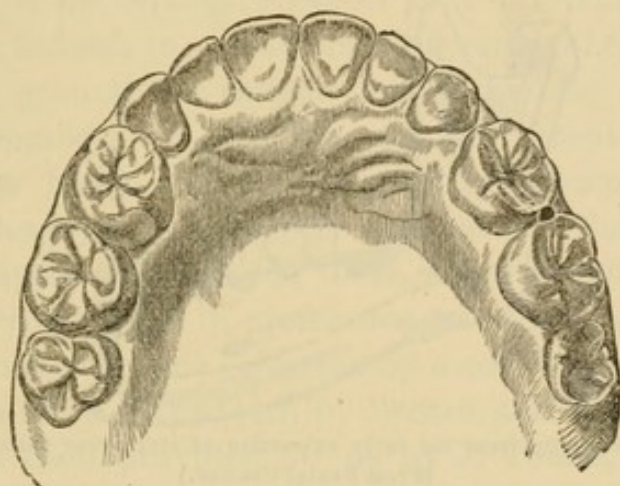
But, if we decide to treat a case of irregularity in position by the removal of teeth, the important questions arise, At what age is it best attempted? and what teeth shall be selected?

With regard to the age, much must be left to the discretion of the practitioner, and no hard and fast rule can be laid down; at the same time, we express our conviction that in many cases the practice of removing teeth is adopted much too soon, probably from a disposition to lean to the wishes and persuasions of anxious parents; and the result is, that the spaces thus created fill up too soon from the *vis a tergo* of the developing molars, which latter, in finding abnormal room in their eruption, fail to effect that full development in the posterior portions of the maxillæ which is so dependent upon their presence in the normal situations. We well remember the case of a youth whose age did not exceed fourteen, but who had had the four bicuspid removed from the upper jaw, as well as several teeth from the lower, to afford space. In the upper jaw the first molars were pressing against the cuspidati which were still unduly prominent, and the general expression of the individual was quite ruined by the absence of proper development in the region of

the mouth. In another case, of which we give an illustration (Fig. 70), in the lower jaw on the left side one, and on the right both, of the bicuspid had been removed at an early age, and the spaces had quite closed up, but a defective development of the angle between the ramus and the ascending portion of the jaw had resulted, so that the front teeth did not meet when the mouth was closed.

Other things concurring, we believe the best period for les-

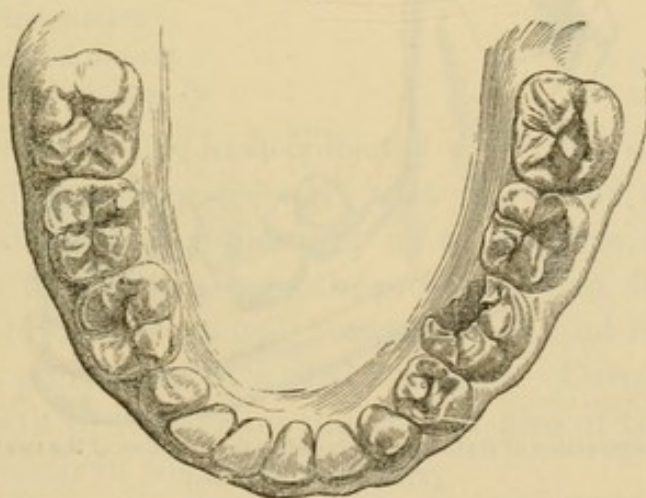
Fig. 69.



Result of an early removal of all of the bicuspid in the upper jaw.

sening the occupants of the dental arch will be when the individual has just erupted the second molars; and later still if it

Fig. 70.



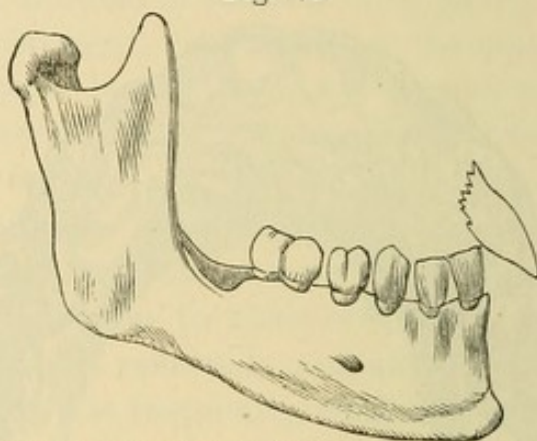
Result of an early removal of three bicuspid in the lower jaw.

be decided to remove the first molars, and apply mechanical means for devoting the space which they occupy to the benefit

of the anterior of the arch, as the second molars will be necessary as points of traction.

[Dr. Louis Jack has shown that deformities of the mouth from the injudicious extraction of the first molars are twofold. First, when removed before the second molars are presenting through the gum, the necessity for chewing, and the loss of the grinding faces of these teeth, cause undue use of the anterior teeth; with unnatural development of the alveolar processes of

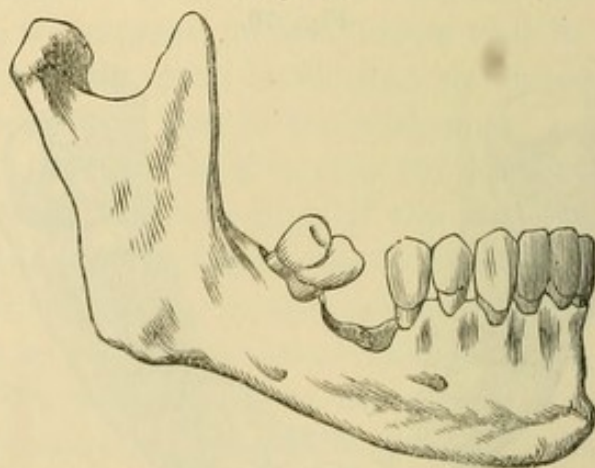
Fig. 71.



Deformity from too early extraction of sixth year molar.
(From Dental Cosmos.)

this region, the curving of the lower jaw, by the contraction of the cicatrix, and tension of the anterior portion of the masseter

Fig. 72.



Deformity from extraction of sixth year molar after the eruption of the twelfth year molar.
(From Dental Cosmos.)

muscles, and projection outwards of the superior incisors. Secondly, if the extraction be delayed until the second molars have fully erupted, these latter teeth may lean towards the

bicuspid, and in many cases the edges of the grinding surfaces of their crowns meet, impairing their use for mastication and favoring the retention of food in the triangular space between the proximal surfaces of these teeth and the gum, until decay may add complication to the trouble already existing.^{1]}

With regard to the teeth which ought to be removed, it is even more difficult to lay down any fixed rules, except, of course, that we should, if it can possibly effect our object, take by preference teeth of abnormal form, or teeth so affected by disease that there is no certain prospect of their being permanently saved; and, indeed, in not attempting removal too soon, we may often have ground for satisfaction in finding that disease has set in, in members which it was not our intention to sacrifice. On the other hand, a very early manifestation of disease would no doubt lead us to prompter treatment. Supposing that all the teeth appear sound, and there is no urgent reason for our selecting certain teeth in preference to others, we may be satisfactorily guided to our selection by a consideration of the comparative liability of the teeth to disease, and information on this subject has been provided for us by J. Tomes, whose valuable table we copy.²

Central incisors	25
Lateral "	62
Canines	36
First bicuspid	227
Second bicuspid	393
First molars	1090
Second molars	575
Third molars	230

Other practitioners have collected somewhat similar statistics, which in the main agree with that given, and the information gathered therefrom would lead us to sacrifice a first molar in preference to any other tooth, provided that in so doing our object could be equally well accomplished, and in like manner a second in preference to a first bicuspid. Cuspidati we should be very loath to remove on the ground also of their being characteristic teeth in the dental arch.

[¹ See proceedings of Odontographic Society of Pennsylvania, in Dental Cosmos for May 1874, pp. 252 and 253.]

² "Analysis of 2638 cases of extraction on account of caries," by J. Tomes, F.R.S., Lectures on Dental Surgery and Anatomy.

The only way in which we can pretend to aid the student in this matter is, by taking a few typical cases, and the manner in which we should treat them. In case 1 (Figs. 73, 74), where both jaws are generally over-crowded, our best course would no

Fig. 73.

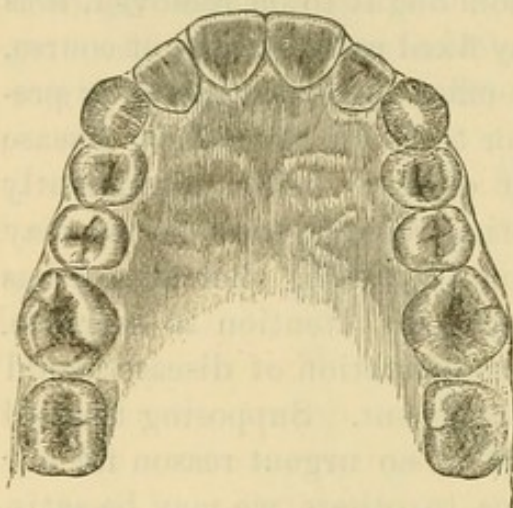
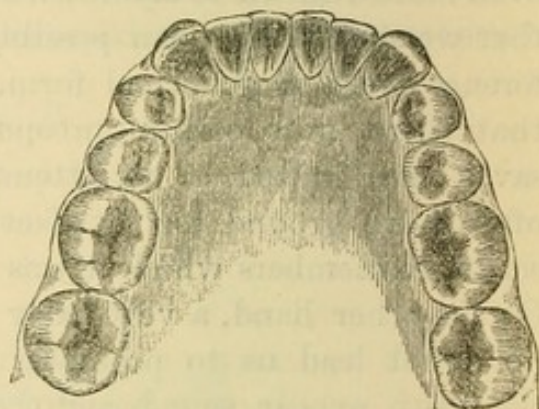


Fig. 74.



Figs. 73 and 74 represent case 1, in which the removal of the first molars from each jaw would be beneficial.

doubt be to remove the four first molars. In case 2 (Figs. 75, 76), where the lower arch, though rather imperfectly developed, contains the teeth in a fairly even position, but the upper arch is V-shaped, and the front teeth are unduly prominent, but not resting on the lower lip when the mouth is closed, we should

Fig. 75.

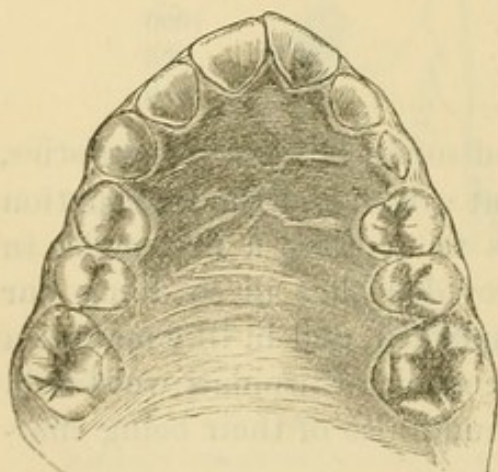
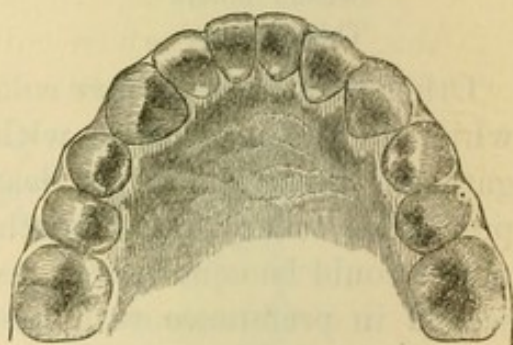


Fig. 76.



Figs. 75 and 76 represent case 2, in which the removal of the first bicuspid of the upper jaw only is advisable.

remove the upper first bicuspid only, and the action of the lips would probably bring the projecting teeth into good position.

Should the incisors rest upon the lower lip, we must in addition make use of the plate shown in Fig. 37, p. 73, for drawing them

Fig. 77.

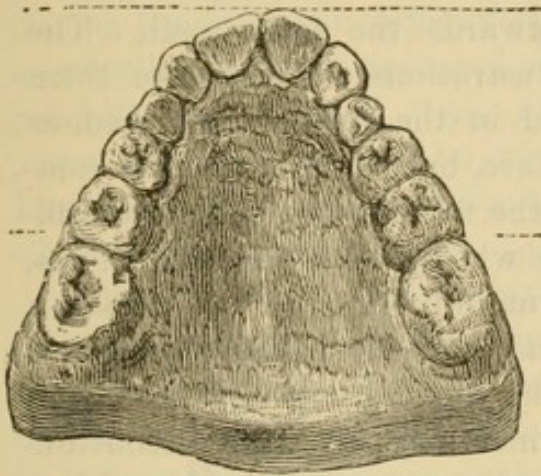
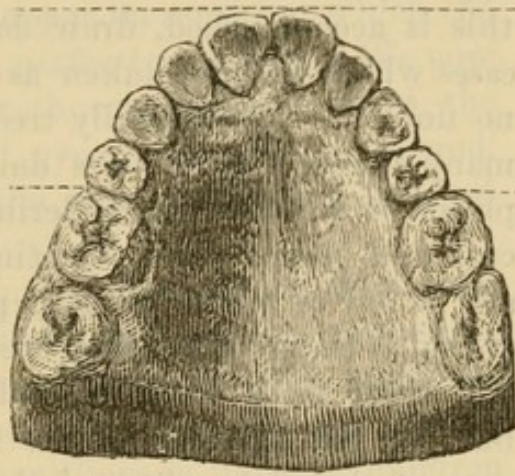


Fig. 78.



Figs. 77 and 78 represent case 2, before and after treatment. The dotted lines show the distance the front teeth have been drawn backwards. In 79 the second permanent molars have been erupted.

backwards. In case 3 (Figs. 79, 80,) we should in the upper jaw remove the second bicuspid, which we should always select in preference to the first, when any suspicion may exist that the space made may not wholly fill up, as well as from their greater

Fig. 79.

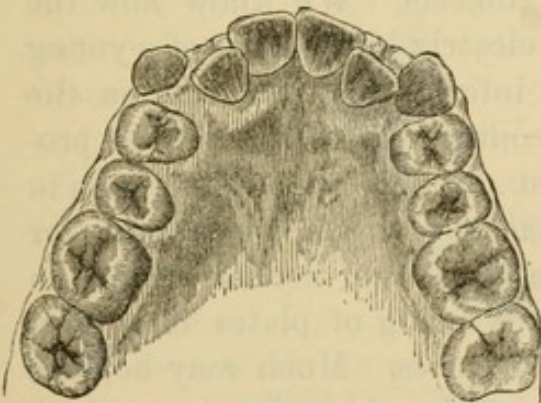
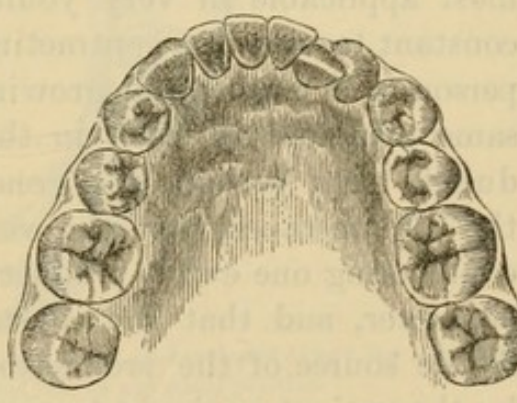


Fig. 80.



Figs. 79 and 80 represent case 3, in which the removal of the two second bicuspid from the upper and the right lateral incisor from the lower jaw is to be recommended. [The principal difficulty attending this treatment has been alluded to on page 82.]

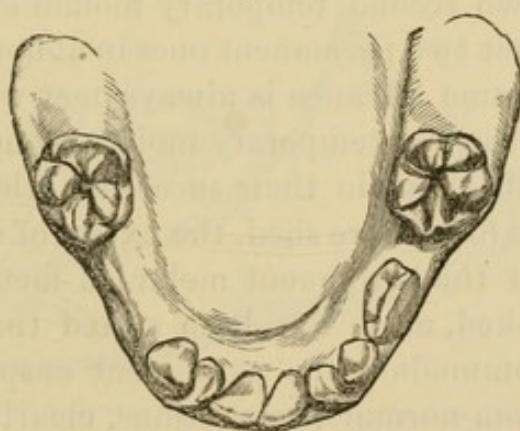
liability to caries; we should also adapt a plate to press out the lateral incisors bitten over by the lower cuspidati, and probably also to draw back the upper cuspidati; in the lower jaw we should remove the right lateral incisor. In case 4 (Fig. 66, p. 94), where we have not only prominent incisors resting upon the lip when the mouth is closed, but also a considerable nar-

rowing of the dental arch at its sides, causing the bicuspid and first molars to close more or less within the lower dental arch, we should, the lower arch being well-developed, expand the upper by pressing out the bicuspid and first molars, and, when this is accomplished, draw backwards the front teeth. The cases which we have taken as illustrations could each of them no doubt be satisfactorily treated in the manner suggested, as many almost similar ones daily are, but there are many complications which arise, rendering the treatment much more difficult and tedious, and sometimes wholly defeating our efforts, and a few of which we may point out; thus, in the case of a patient's being underhung, we may without difficulty press out the upper front teeth beyond the cutting edges of the lower, but yet the shortness of the former may, after the discontinuance of the plate, allow of their return to their old position, and the same thing may occur from the back teeth meeting too soon. In the first case little can be done beyond wearing a plate adapted to the palate only for a long time in order to try and retain the teeth in proper position, and trust that they may drop somewhat after a time when not bitten upon; in the second case we have often found the chin-retractor (Figs. 10 and 11 p. 41), which elevates it as well, of great service, it being of course most applicable in very young subjects. We know how the constant tension of a contracting cicatrix in the neck of a young person will distort the growing inferior maxilla, and on the same principle an effect in the contrary direction may be produced. But perhaps the greatest obstacle to success exists in the circumstance, that the very means which we employ for overcoming one evil is productive of another not less serious in character, and that the constant wearing of plates is a most fertile source of the production of caries. Much may be done by the patient no doubt to prevent this; thus, the plate, which should never be so attached but that the patient can remove it, should be scrupulously cleansed with soap and precipitated chalk after every meal, as well as the teeth themselves, and the plate and mouth finally rinsed in a weak solution of spirit and water. In one very obstinate case we were tempted to secure in the mouth a plate, having the soft deal wedges before spoken of, by ligatures for about ten days, when it was seen that the enamel had become defective on all the teeth in contact with

the wedges; an immediate discontinuance of the plate, and the application of salvolatile to the spots six times in the day, happily arrested all further mischief, at least so far as it was possible to determine. The same thing has occurred where a platina band went in front of the upper incisors, but which the salvolatile treatment appeared also perfectly to arrest. We now generally recommend, that, after thorough cleansing of the plate, all bands should be wiped over with that compound. The mischief is no doubt due to the decomposition of the food which lodges in such places.

A question of no little importance is whether, by the timely removal of temporary teeth in contracted arches, more space may be afforded for their successors. It is a subject to which we have long both given and called attention,¹ having had reason to believe that thousands, perhaps millions of unhappy children have submitted to operations about as necessary as we now regard those of bleeding and gum-lancing as practised some half century ago. To take very common cases, in the lower jaw for instance: when that bone is well developed, we shall observe

Fig. 81.



Results of an early removal of the temporary molars in an ill-developed lower jaw; the first permanent molars having advanced into an abnormal position.

that, as the period of the second dentition approaches, the temporary teeth, especially the six front ones, become more prominent in the dental arch, and also separated, laterally, from each other, so that, as each drops out, room is afforded for its successor (see Fig. 30, p. 67). In imperfectly developed maxillæ such prominence and separation do not occur, so that when the first incisor is erupted, it will appear behind its predecessor and par-

¹ Vide Trans. Odont. Soc., old series, vol. iv. p. 227.

tially behind the lateral incisor of that side: in like manner the permanent lateral incisor will appear behind the temporary and cuspidatus teeth.

[To aid in the expansion and normal development of the jaws, the late Prof. McQuillen always urged the importance of preserving the deciduous teeth, by filling and treating them so that their use would be unattended by pain, and he further recommended that food requiring considerable force for mastication be given to children—such aliment being seemingly demanded from the well-known tendency of children to gnaw or chew wood, roots, gum, etc.]

The treatment was, and is unhappily still, very commonly adopted of removing all interfering temporary teeth, *to afford the permanent ones room in the dental arch*. It did not occur, we think, to those who thus acted, that the limits of the dental arch are almost entirely determined before such treatment commences; that there are fixed points to its limits in the two already erupted permanent molars, which, especially in crowded arches, are ever ready to usurp any room afforded to them in an anterior direction, as shown in Fig. 81 (p. 103), where an early removal of the two second temporary molars is followed by an eruption of the first two permanent ones in abnormally advanced positions. The same advance is always met with in normally developed jaws: the two temporary molars occupy a larger space in the dental arch than do their successors, the two bicuspidi, but, as soon as the former are shed, the excess of space is usurped by the advance of the permanent molar; a fact which has been generally overlooked, as it has been stated that such space is accorded to accommodate the permanent cuspidati. Figs. 82 and 83, drawn from normal preparations, clearly illustrate this point.

In well-developed maxillæ the early removal of the temporary teeth will have little effect upon the permanent dental arch. Cases, where all have been removed before the eruption of one permanent tooth, are taken to illustrate this point, but it is certainly very different in the case of a defective maxilla. Thus, as in the cut (Fig. 84) of a case which we treated unfortunately in this way very many years ago, where the incisors and cuspidati of the first series were removed to accommodate the four incisors of the second series, and where everything

looked very satisfactory up to the eruption of the cuspidati, when two bicuspidis had to be removed, and a plate worn to

Fig. 82.

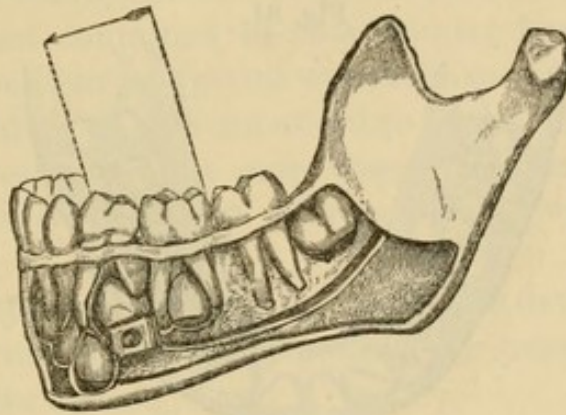
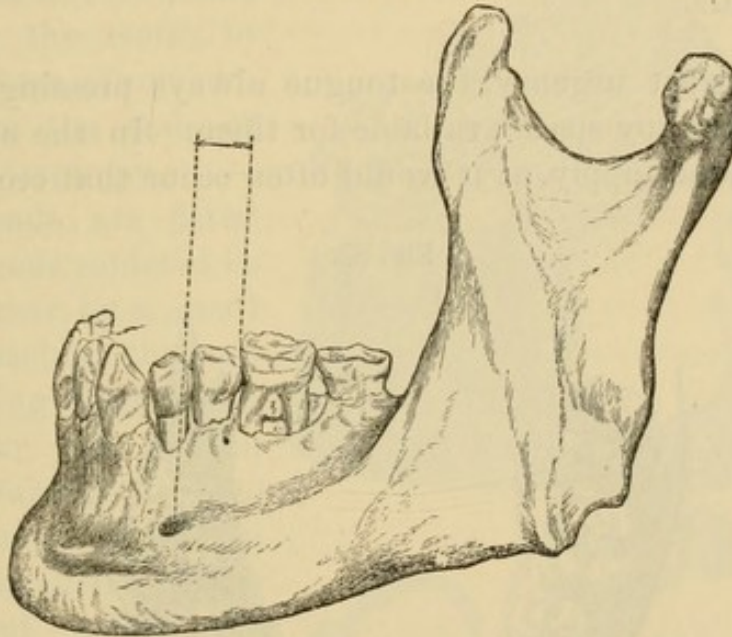


Fig. 83.

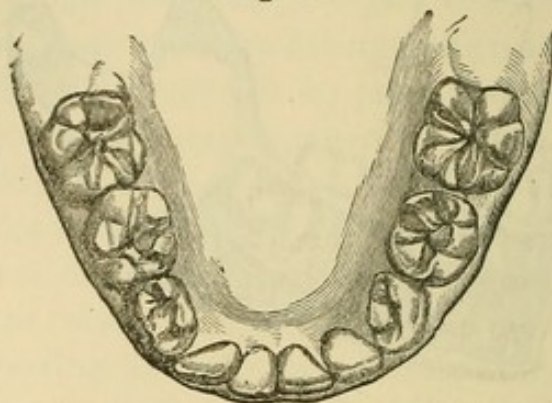


Figs. 82 and 83 show when compared the usual advance of the first permanent molars after the shedding of the temporary molars; and that no room is afforded to the teeth anterior to the first molars by the difference in size between the temporary molars and the bicuspidis.

accommodate the cuspidati; it would have been far better for the case, and much more agreeable to the patient, had we done nothing further than remove, if necessary, any temporary teeth whose successors had appeared, when, as in the illustration (Fig. 85), one incisor would eventually have assumed a position anterior or posterior to the dental arch, and its removal alone would have effected all that could be desired. It must be distinctly borne in mind that these remarks apply solely to the treatment of the lower jaw, and to the rule that we would lay down—if it

be safe to lay down any rule at all in the treatment of irregularities in position—viz., simply to remove each temporary tooth as its permanent successor appears: and this indeed not as a

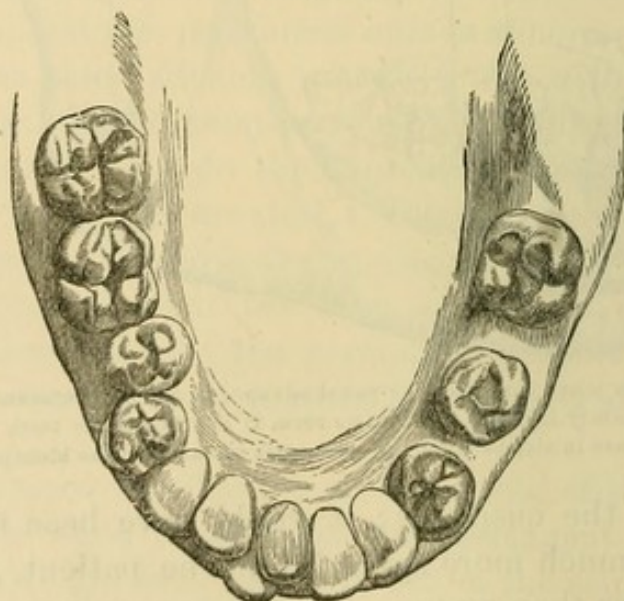
Fig. 84.



Result of the common treatment of removing the temporary incisors and cuspidati to give room for the permanent incisors. The incisors appear to be in good position, but no room is left for the permanent cuspidati.

matter of great urgency, the tongue always pressing forward the teeth into any space available for them. In the upper jaw this rule cannot apply, as it would often occur that teeth would

Fig. 85.



Method of treatment by removing from the lower jaw the temporary teeth only as their successors appear. Here the removal of the right lower central incisor will be the only treatment necessary.

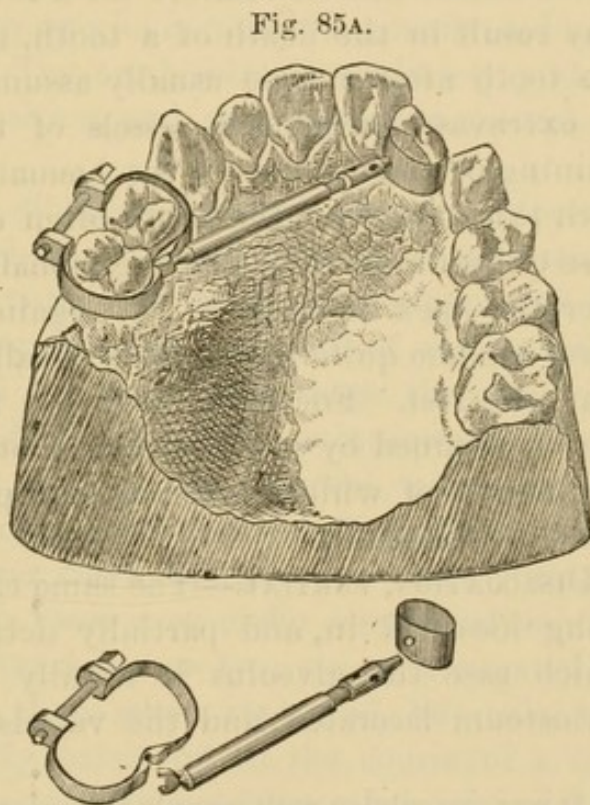
be kept within the arch, and bitten over by those of the lower jaw. The temporary teeth must be removed which prevent the permanent ones from assuming their right position; also the

difference in size of the upper incisor teeth with regard to each other would, as a rule, forbid our removing one of these to afford space, and we therefore generally select bicuspids or molars.

We willingly confess to the imperfect manner in which the important subject contained in this chapter has been treated; but to have done it more justice would have involved a larger space in the volume than we can afford to allot to it. The student desirous of investigating it more deeply may with advantage consult the excellent work of Norman Kingsley on Oral Deformities.¹

[Dr. M. H. Cryer has exhibited an ingenious device for protecting the teeth from injury when undergoing pressure, by means of the jack-screws figured on page 94. It consists of thin platinum bands, encircling the teeth, to protect them from injury where the ends of the screw impinge.

The bands are fitted and the ends soldered or held together by a small screw passing through and binding them somewhat after the fashion of Dr. Farrar's device. Then by burnishing down to the inequalities of the teeth, and filling the spaces between the band and the tooth with a quick setting amalgam, it is made immovable.



Bands for protecting teeth, to be moved by jack-screws, after model by Dr. M. H. Cryer.

Into one of these bands a hole is drilled to receive the point of the jack-screw, and upon the other small lugs may be soldered, between which the crotch ends of the jack-screw may fit tightly, and thus be prevented from slipping.]

¹ A Treatise on Oral Deformities as a branch of Mechanical Surgery, by Norman W. Kingsley, M.D.S., D.D.S., etc. D. Appleton & Co., New York, 1880.

CHAPTER V.

INJURIES TO THE TEETH.

CONCUSSION.—From violence caused by a blow or fall, or where the lower jaw has been driven forcibly against the upper, one or more of the teeth may suffer. If slight, it may merely result in tenderness and discomfort for a few days; if more severe, it may result in the death of a tooth, under which circumstance the tooth after a time usually assumes a pale fawn color, due to extravasation of the vessels of the pulp, and consequent staining of the dentine by the hæmato-globuline of the blood: with this exception, the tooth often continues for years¹ otherwise quite unimpaired, but occasionally a small gum-boil forms over the apex of its root. Or, again, a tooth so injured may never become quite firm, and is usually lost at an earlier period than the rest. For such cases, rest for the organ, so far as it can be obtained by soft food, and soothing fomentations within the mouth, of which camomile and poppy are the best, will be the only treatment.

DISLOCATION, PARTIAL.—The same cause may result in a tooth being loosened in, and partially detached from, its socket, in which case the alveolus is usually more or less injured, the periosteum lacerated, and the vessels and nerves, which enter

¹ It was our opinion until recently that recovery of its proper color in a tooth that had once lost it, in consequence of a blow, was impossible; but a case came under our observation in which there was undoubted evidence to the contrary, the brown tint was gradually disappearing from the cutting edge of an upper central incisor towards its neck. In such case we apprehend that extravasation of blood had occurred, but not death of the pulp, and that the blood was being absorbed.

[The writer had a patient who, in the lowered vitality from a dangerous attack of typhoid fever, had a lower incisor lose its translucency and present the appearance of a dead tooth, which, as she regained her strength and general tonic, regained its color until no visible difference existed between it and its healthy fellows.]

at the radical extremity of the tooth, generally severed. In such cases the mouth should be washed with tepid water until bleeding has ceased, and the tooth or teeth pressed carefully between the finger and thumb, and steadily but forcibly back into their proper positions, whilst the same members of the other hand should simultaneously reduce any displaced portions of alveolus. The above-mentioned applications for concussion may be employed, but great tenderness may be often relieved by the application of one or two leeches to the neighboring part.

[Dr. C., a graduate of both dentistry and medicine, several years since had his lower incisors and the anterior plate of the alveolar process pulled over the lower lip by a horse stumbling while the rider was putting on gloves, and temporarily holding the reins in his mouth. The teeth were immediately pushed back into their proper position, and now appear as natural as the adjacent ones.]

DISLOCATION, COMPLETE.—Should this result of violence occur, the mouth should be washed until bleeding has ceased, when the alveolus is cleared of coagula by cotton, and afterwards by the syringe and tepid water, to insure removal of any particles of cotton, tartar, etc.; and the tooth or teeth, as the case may be, which should be freed from all foreign substances and kept immersed in tepid water during the interval, carefully but firmly replaced in their sockets, and the alveoli, probably more injured than in the former cases, moulded to their sides as before. In almost all the cases now under consideration, the teeth thus treated will, after a day or two, appear elongated in their sockets, and looser than when replanted, but this, the result of effusion, generally passes off in the course of a few days. If the alveolar process has not been much injured, the operation is generally successful, and we should not despair of success even where a tooth has been out of the mouth for several hours. We shall again refer to this subject in the chapter on Replantation and Transplantation.

[Dr. H. E. Pflüger reports having known teeth with extirpated pulps to again have the cavities filled with sensitive vascular tissue resembling the original. Prof. McQuillen exhibited before the Odontographic Society and Academy of Natural Sciences, in Philadelphia, a pigeon whose cerebrum he had

four-fifths extirpated, and which regained the lost functions. The cranial cavity was refilled with tissue that, on microscopic examination, presented the appearance of typical nerve cells.^{1]}

As the result of violence, an accident almost the reverse of dislocation may occur, viz., where a tooth is driven into and beyond its alveolus. It is more likely to occur to the teeth of the upper than to those of the lower jaw, and in some cases has even effected a perforation of the floor of the nares. The treatment here will be to bring the tooth down to its proper level by the aid of forceps; and in this case a ligature attached to an adjoining tooth or adjoining teeth, to retain it *in situ*, may be essential; and there can be no objection to the employment of a ligature, as plenty of space in the alveolus will exist for any exudation to occupy. In the case of ordinary dislocation, as we have described it, we do consider the ligature of the replaced tooth to its neighbors, as generally recommended, objectionable, as it prevents the effusion of lymph into the alveolus, which forms the medium of union between the severed portions of the alveolo-dental membrane.

[The writer has a child, who fell and drove the crowns of both superior deciduous central incisors up into the gum, one almost out of sight. They were at once drawn down by forceps to their original position. A few weeks after, the one most displaced by the first accident, was again driven up by a similar fall. This tooth was a second time drawn down, but never recovered completely, as it soon showed unmistakable signs of death of the pulp and was shed a year or so afterwards, in advance of its fellow and the presentation of the permanent teeth—which latter, however, came properly into position, and now, as when erupted, are to every test normal.]

Fracture of the teeth may be another consequence of violence, and may vary in amount from slight chipping of the enamel to complete division at the neck or elsewhere. Where very slight, it may be attended with no further result than its unsightliness. Should, however, a portion of the dentine be involved, it will be generally very sensitive when touched, and also to heat and cold for some time; but, if fractured so as to expose the

[¹ Proceedings of Odontographic Society of Pennsylvania and Proceedings of Academy of Natural Sciences of Philadelphia, Feb. 4, 1878, p. 342.]

pulp, there will be considerable pain on the slightest contact of even soft substances. Fracture may, of course, be complicated with partial or complete dislocation.

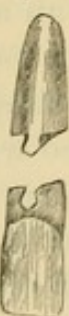
TREATMENT.—In the first simple cases we may, by a judicious employment of the file, often lessen the unsightliness; thus, if the chip be at the cutting edge of an incisor, we may, by rounding it off, and slightly shortening the tooth, render it scarcely conspicuous. When the dentine has been exposed, especially in a young subject, we must wait until the sensitiveness has passed off (which may be accelerated by the application of salvolatile or solution of zinc chloride) before the file can be employed, and we may often with advantage sacrifice a little of the enamel of the contiguous teeth. When, however, the tooth has been much fractured, and especially if the pulp has been exposed, one of two alternatives must be adopted,—either the destruction of the pulp, or the removal of the tooth,—our decisions as to which, will depend upon the nature of the fracture, the age at which it occurs, the crowding or otherwise of the teeth, and their relative sizes. Should the fracture include more than a small portion below the neck of the tooth, or be accompanied with much injury to the alveolus, we should without hesitation at once extract. Should it occur in a patient over fifteen years of age whose teeth are not crowded, and should the fracture not extend obliquely below, or much below, the surface of the gum, we should adopt the former plan, the process for which we shall hereafter describe, and supply the patient with an artificial tooth to be attached to the root of the fractured tooth. Should, however, the patient be under fifteen, when the fang of an incisor or cuspidatus is not fully developed, and also when there exists no very marked difference in size between the various front teeth, with especially a tendency to crowding, or, at all events, to the teeth not being separated from each other, we shall then do best to extract, as we may feel pretty sure that without, but almost certain that with, mechanical aid, the space will in time be quite filled up. We removed, about two years ago, a large upper central incisor from the mouth of a little girl aged ten, and a year afterwards its fellow: the lateral incisors now meet closely together, and the mouth looks far better than it did at first, as the teeth in question were abnormally developed. They were removed on account of caries.

[This recalls, of two cases bearing upon the subject, one of a young lady who had lost the left central incisor at fifteen, which space was completely obliterated, and the mouth and teeth were comely and shapely; the other of a lad of eleven years, whose central incisor was broken by a stone thrown against the tooth, splitting the root longitudinally, and completely destroying the crown. Acting upon the experience of the first case, which was originally under the care of another dentist, this was similarly treated and the remains of the root were at once removed. Within four years the space has almost closed.]

The uniting of the portions of a fractured fang is so very rare an event that we can hardly ever look for its occurrence; nevertheless, as cases have been recorded, we should at all events be in no great hurry to extract where such event has occurred. The favorable cases would no doubt be in young persons, where, of course, the vitality of the pulp has not been destroyed or the periosteum much injured. The medium of union in such cases appears to be cementum, but the pulp in the region of the fracture had in one case recorded become calcified. Teeth fractured by violence in their fangs may be retained with moderate firmness by the periosteum for some time, but they sooner or later become a source of inconvenience, and the crown portion either has to be removed, or becomes loose and drops out; still we have seen them so retained for

several years. Two cases are recorded where a tooth had been fractured by violence, and the crown portion removed, but the pulp left had been converted into secondary dentine of more than normal dimensions; also another, where the same accident occurred, but where the surface of the retained portion became coated with cementum.¹ The only recorded case of impacted fracture of a tooth is, we believe, one we communicated to the Odontological Society.² The case was interesting, inasmuch as the existence of the fracture was not discovered until after the tooth was extracted; it was an upper central

Fig. 86.



Case of impacted fracture in an upper incisor tooth. The two fragments dove-tail into each other.

¹ A System of Dental Surgery, by John Tomes, F.R.S.

² Trans. Odont. Soc., vol. xi. p. 140.

incisor, and one practitioner of eminence had even drilled through the crown, and partially removed the contents of and filled the pulp-cavity to relieve periostitis, without perceiving the mischief. It occurred in the person of a youth of fourteen, and was certainly a most favorable case for re-union, as the two fragments were immovable and kept in accurate position for three years, but the violence of the shock had caused death of the pulp.

Under the term "dilaceration" J. Tomes has described a condition supposed to be due to violence, in which the crown of a tooth is found bent at a considerable angle to its fang; a section in such a case will exhibit the dentinal tubules abruptly bent or deviated at such angle. We have ever been inclined to regard such deviation as more dependent upon the ordinary lines of development having become abruptly altered; and this view has been entertained by others:¹ at the same time, a blow or other violence might readily determine an altered course of development, which we can readily comprehend if we adopt the views already given with regard to the growth of bone resulting in the eruption of the teeth; thus, in a tooth, the crown of which is just or nearly developed, any condition that would cause the surrounding growing bone to advance to the surface in an altered direction would naturally alter the relationship of that portion of the tooth to the rest. In a very well marked case of this deformity, a central incisor of the upper jaw, which we handed to J. Tomes, and which, we believe, he has figured in one of his works, there was a distinct history of violence at the period when the crown of such tooth would have been nearly calcified, but the character of the violence rendered it difficult to imagine that its results could have affected one tooth only, or have affected it so as to cause its being so much bent upon its fang.

¹ The Pathology of the Teeth, by Carl Wedl.

CHAPTER VI.

DENTAL CARIES.

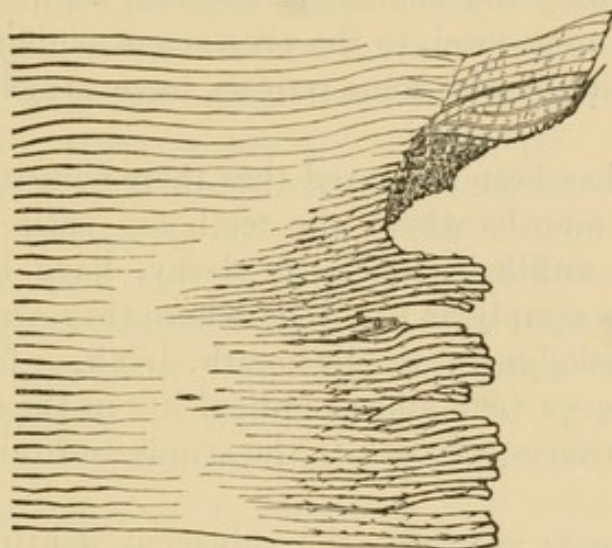
To the dental practitioner there can be no subject more important or interesting than the disease which bears the above-mentioned designation, for of the cases which come before him some ninety per cent. will most probably be more or less dependent upon its presence or its results. Its interest, too, is enhanced by the fact that it is a disease much more common to civilized than to uncivilized communities, and is undoubtedly, but less happily, like civilization, greatly on the increase. That such is the case, we accept again the experience of those who have had under observation the mouths of several generations in the same families, as well as avail ourselves of the results of our own practical examination of the skulls of past generations as compared with those of individuals now living.¹ There is, probably, no disease so common to the civilized portion of the human race in the present day as dental caries; so much so, that it is rare to find a mouth in which some manifestation of its ravages is not present, or an individual so fortunate as to have never experienced the pain which commonly accompanies it. Nevertheless, it is remarkable that no one amongst its numerous and talented investigators has yet offered for a disease so common and apparently so favorable for observation an explanation of its causes or nature that has been at all generally accepted by dental practitioners. The most diversified and opposite views have been put forward, and to the speculative here are theories to the heart's content. It will be our duty to notice the most important of these, but we shall first attempt to describe what actually takes place if we watch the disease from its commencement to its termination.

According to our own observations, made when it has com-

¹ Trans. Odont. Soc., vol. iv. p. 227, old series.

menced in positions favorable for observation, the first manifestation of its existence has been a small whitish opaque spot on the enamel as contrasted with the yellowish and somewhat

Fig. 87.



A section of tooth affected with caries. On the upper part at the right side will be seen a small portion of enamel involved; the rods appear more distinct than when normal, and also exhibit the transverse markings. In the affected dentine the tubuli appear more distinct, with tendency to separate from each other; the diseased portions are seen dipping down amongst the healthy structure in the direction of the pulp cavity. That portion situated between the diseased and healthy tissue, and where the markings of the tubuli are less distinct, is the translucent zone of Tomes. (From a section in possession of the author.)

opalescent appearance of that structure. In its progress it generally assumes a somewhat darker, light brown, or fawn color, though this much depends upon the rate of its progress, for where this is very rapid, a light color is maintained throughout. Microscopical examination at the earliest stages, which it is difficult to conduct owing to the friable nature of the enamel,¹ shows this structure to possess an orange-brown hue in the parts affected, especially in the basis-substance of the enamel rods, which latter have their outlines more distinct than when normal: they also present transverse markings which are seldom seen, or seen distinctly, in the perfect tissue. In the interstices

¹ Dr. Frank Abbott, *Dental Cosmos*, vol. xxi. p. 59, recommends the following method as employed by Dr. Bödecker, viz. :—

A section sawn from a carious tooth perfectly fresh should be ground by a corundum wheel under the surface of water, and, when sufficiently thin, immersed in a dilute solution of chromic acid, viz., $\frac{1}{2}$ per cent., for twenty-four hours: it should be then stained in carmine solution and mounted in a mixture of glycerine and water, two parts of the former to one of the latter.

between the enamel rods some investigators¹ have discovered delicate beaded fibres, which may be stained by carmine, whilst on the outer surface appear flat epithelial-like bodies, supposed to be the remnants of Nasmyth's membrane. At the earliest stages, when only the enamel is affected, we find no traces of leptothrix or micrococci, to the presence of which in causing or promoting dental caries some writers have attached much importance.

[A theory has been advanced that these parasites, which may be found in mouths where the teeth are perfectly sound and without any unfilled cavities of decay, have lodged in the carious places simply as locations where they are partially protected from dislodgment by the breath, drink, or food, as fissured rocks will support vegetable or animal life in the crevices, while the smooth surfaces, exposed to the winds and rains, are bare of vegetation.]

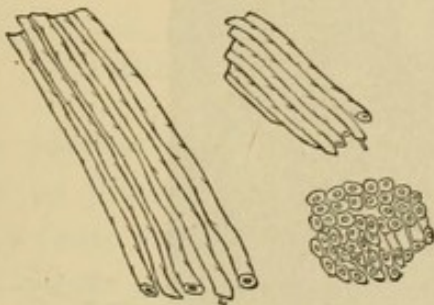
As the disease advances, the subjacent dentine becomes involved, and, it being a much less dense and less homogeneous structure than the enamel, the disorganization takes place in it more rapidly, the lime-salts disappear, leaving the gelatinous basis-substance much in the same condition as it was when its calcification took place. In some cases, those of so-called chalky decay, it would appear as if the calcified structure broke down at once. In both the enamel and dentine the greatest destruction appears at the outer surfaces, *i. e.*, the part first attacked, for dental caries arises from without, not from within, a tooth, and this will give to the parts affected cone-like forms; in the enamel one having its base at the surface whilst its truncated apex is in apposition to the base of that of the dentine, which is a larger and more perfect representation of this figure. In the dentine it pursues its course in the direction of the dentinal tubuli, *i. e.*, towards the pulp-cavity into which they open. Microscopical examination at this period² shows the enamel more broken up

¹ Dr. Frank Abbott, *Dental Cosmos*, vol. xxi. p. 62.

² Dr. Frank Abbott, *op. cit.*, recommends the following process: The carious tooth, or a suitable portion of it, should be immersed for two months in a 1 per cent. solution of chromic acid, to which a few drops of dilute hydrochloric acid should be added every other day, the mixture being changed weekly; at the end of the two months the tooth should be embedded in warm paraffine, to which a little beeswax has been added, and, when it is cold, sections should be cut off with a razor, stained with carmine, and mounted in the glycerine solution.

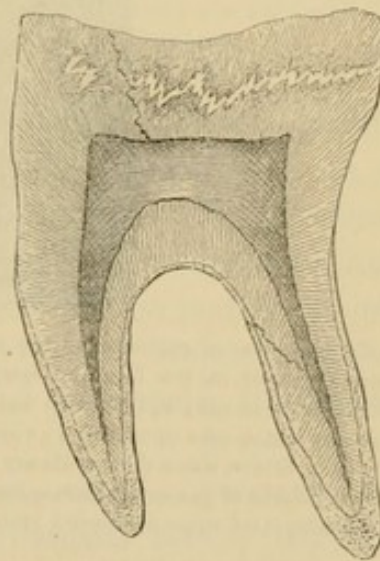
and disorganized than in the former case, and the subjacent dentine of a yellowish color, having festoon-shaped boundaries separating it from the healthy structure; whilst, especially in acute cases, portions having the yellow color are seen dipping down at some distance from the principal centre of the disease towards the pulp-cavity. At the margin of the diseased structure the dentinal tubuli appear less distinct than they do in the perfectly healthy tissue nearer the pulp-cavity; viewed with a low power this portion has a zone-like form, the zone of Tomes, who regarded it as a consolidation of the contents of the tubuli, an effort of nature, in fact, to put a barrier between the healthy and diseased structures; other and later observers have, however, regarded it as a result of diseased action producing an absolute exclusion of air from the tubuli, thus rendering them invisible when viewed by transmitted light, but amongst several living authorities the views of J. Tomes are still adopted. [Fig. 89

Fig. 88.



The tobacco-pipe-stem appearance (Tomes); the drawing is made from a specimen of the chalky decay.

[Fig. 89.

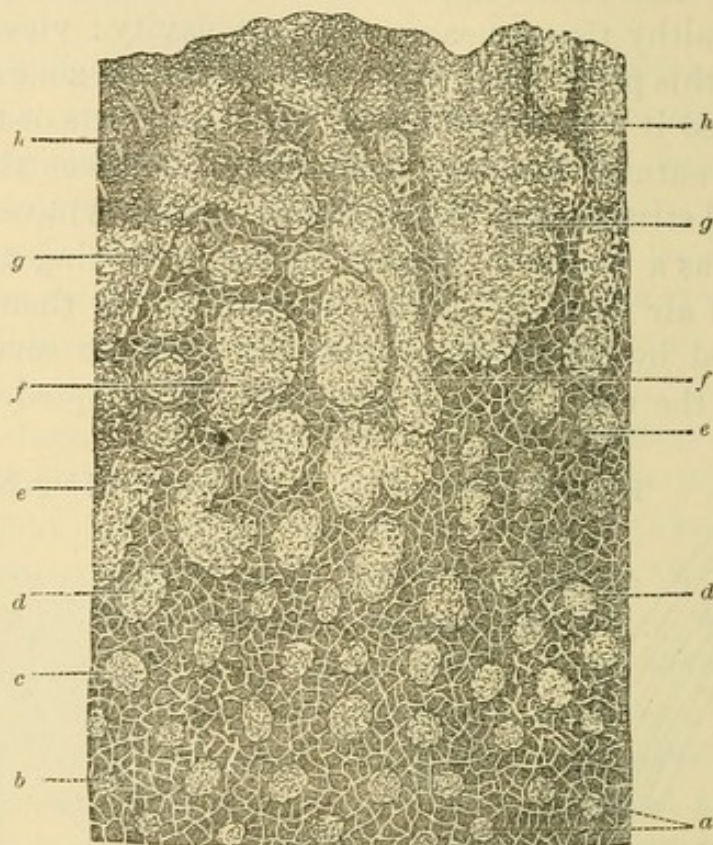


Translucent zone in a tooth that had been filled with gold.]

was drawn from a microscopical section made from a tooth where the translucent zone was found beneath a gold filling. Prof. McQuillen had a section where this zone was shown to have formed under a retaining pit in a tooth that had been successfully filled with gold.] At the more affected portions, *i. e.*, nearer to the surface, we observe the tubular structure of the dentine to be more apparent than in the healthy tissue, and for the reason, doubtless, that the intertubular substance is the first to be attacked, the walls or external portions of the tubuli appearing to possess a greater power of resistance. When the diseased portion is seen in

transverse, or in partially transverse, section, its appearance reminds us of a bundle of tobacco-pipes when broken short off in their stems, as described and figured by J. Tomes.¹ But a section, cut so as to exhibit the results of the disease at various distances from the surface and viewed by a very high power,²

Fig. 90.



Cross-section of carious dentine magnified 1000 diameters, copied from Dr. Frank Abbott's excellent paper in the Dental Cosmos (vol. xxi. p. 117); *a*, canaliculi, with radiated offshoots, in the healthy tissue; *b*, the same enlarged by extension of disease and exhibiting granules and threads which take up carmine; *c* and *d*, the same more affected by disease; *e*, canaliculi enlarged to ten or fifteen times their ordinary diameters, and filled with partly-nucleated protoplasm; *f* and *g*, confluence of two or more canaliculi; *h*, basis substance entirely disappeared, and beyond this a disintegrated mass composed probably in great part of micrococci.

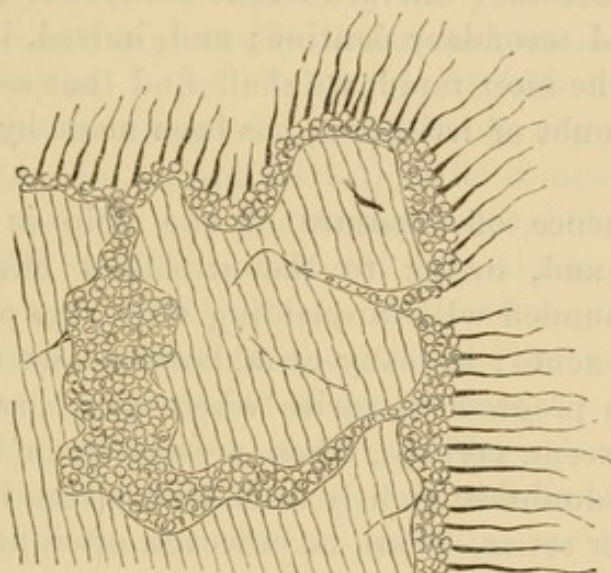
shows, at its neighborhood to the healthy tissue, the canaliculi unaffected; but as the decayed surface is approached, these are enlarged, and filled apparently with granules and threads, which receive the staining of carmine; still nearer to the surface they are enlarged to two or three times their normal diameters, exhibiting within them a network of living matter, and occasionally, where more enlarged, nuclei also. Further outwards

¹ System of Dental Surgery, 2d edit. p. 296.

² Dr. Frank Abbott, Dental Cosmos, vol. xxi. p. 116.

they are so extended that several become confluent; as this increases, the basis substance disappears, the outermost layer consisting of a disintegrated mass of tissue mixed up with micrococci and leptothrix.

Fig. 91.



Fragment of dentine covered on its surface, and interstices with leptothrix and micrococci.

The drawing must be regarded as diagrammatic rather than accurate.

If a portion of carious dentine be tested with litmus-paper, it will be found to possess a strong acid reaction, whilst in a healthy tooth the dentine—probably the contents of the canaliculi—yields a decidedly alkaline reaction. The acid reaction of carious dentine we have accounted for by the neutral phosphates of lime which are incorporated with the basis substance becoming converted into the soluble acid phosphate, the hypophosphate of lime.

To revert to our general observation of the process, we next, probably, get the effects of mechanical strain on the enamel, which is imperfectly supported by the subjacent softened dentine, and breaks down, leaving a more or less exposed cavity. Where the disease has been very rapid and interstitial, *i. e.*, occurring between teeth, the breaking of the enamel is often the first intimation to the patient of what has existed, he not unfrequently attributing the fracture to an accident in mastication, and the decay as sequence to and result of the accident: where it has been less rapid, the enamel disintegrates in minute particles. In both cases the progress of the disease

becomes more rapid when an actual cavity exists, one at least that can readily retain portions of food, and ere long in the natural order of events the pulp-cavity becomes invaded. Such, however, is not always the case, for it may happen, and this is more likely where the disease advances very slowly, that the pulp becomes calcified—converted, that is, into what has been termed secondary dentine; and, indeed, in almost all cases, even in the most rapid, we shall find that some attempt, the result no doubt of irritation, has been made by the pulp in this direction.

The consequence of exposure of the pulp is usually its inflammation, and, owing to the attendant effusion into a structure surrounded with unyielding walls, the pain set up is generally most acute; in many cases, however, we find the pulp exposed in the progress of caries where pain has never been experienced, except, perhaps, when pressed upon by food, and where we may doubtless rightly infer that severe inflammatory action has never set in. Pain is, however, often felt before the pulp is actually exposed; sometimes in the very earliest stages, and, indeed, in a few cases, before any actual manifestation of the disease is discernible, but where, at the spot referred to, the disease after a time makes its appearance. Exposure of the pulp is usually attended with ulceration of its surface, and with such ulceration more or less exudation of serous or sanguiniferous fluid. This has generally been spoken of as suppuration of the pulp; but, although actual pus may occasionally be formed by the pulp, it is very different from the first-named fluid, and contains only a small proportion of the *débris* of the white corpuscles. The crimson surface of an exposed pulp is most comparable to that of the “irritable ulcer,” and the fluid exuded not dissimilar, except that it decomposes more rapidly, emitting a most offensive cadaverous smell. The reaction of this fluid is alkaline, and it certainly tends to neutralize the acid condition of the dentine at least at the surface, for we have found it acid a short distance below, and thus probably, as has been pointed out, to some extent retards the progress of the disease, whilst the pulp gradually sloughs away more or less rapidly. The pulp being lost, the dentine softens rapidly, the enamel breaking away as its support is withdrawn from it, until the carious surface becomes level, or nearly so, with the

surrounding gum, where, from protection of surface by the latter, aided probably by that other protection against decomposition which living substances exert towards organic bodies in their immediate vicinity, the softening of the dentine of the fang or fangs advances much more slowly. Still the residue, gradually carried to the surface by the process which we have described, becomes continually diminished until its hold on the mucous membrane is so slight that it falls away under the friction of the tongue or in mastication. Such, then, is the ordinary career of a carious tooth from its commencement to its end. Many variations in the process occur, but the conditions above described may be considered typical; and now the far more difficult task devolves upon us of attempting to describe briefly, and with justice to the authors, the various theories which have been propounded to account for it.

Hunter, who, amongst modern pathologists, was one of the first to investigate dental diseases, and give to them the prominence which they deserved, denominated this as "the decay of the teeth arising from rottenness;" but that he implied something different from what we now generally comprehend by slow chemical decomposition of animal or vegetable substances is evident from his statement "that such decay would appear to deserve the name of mortification;" and still something more, for "the simple death of the part would produce but little effect," and he suspects that during life there is some operation going on which produces a change in the diseased part. When it attacks the bony part of a tooth, it appears first to destroy the earth, as the bony part becomes softer and softer. It begins sometimes in the inside of a tooth, although but rarely: if it always so commenced, it might have been supposed to arise from a deficiency of nourishment from some fault in the vascular system, but, as it most commonly begins externally, where the teeth in their most sound state receive little or no nourishment, it cannot be referred to that cause. It does not arise from external injury or from menstrea, which have a power of dissolving part of a tooth, for such could not act so partially; and it is reasonable to suppose that it is a disease arising originally in the tooth itself, because, when once the shell of the tooth has given way to the cavity, the cavity itself soon becomes

diseased in the same way: in a sound tooth broken by accident no such quick decay ensues.

From a perusal of Hunter's work,¹ it can scarcely be gathered that that great man held any very distinct theory or definite views upon the causes and nature of dental caries; although with regard to it, and what is observed during its progress, he writes with a clearness which is a characteristic of all his works.

Fox,² who wrote about a quarter of a century later than Hunter, alludes to the disease as "caries, or, as it is most commonly called, decay," showing that it had received the former designation,—though by whom we have not been able to ascertain,—since the period in which Hunter's work was published. He states, in opposition to Hunter, that the disease originates from within the tooth, *i. e.*, "the bony part of the crown of the tooth," and "that when it has made some progress internally, a small opaque spot appears on the enamel," etc. "The proximate cause of caries appears to be an inflammation in the bone of the crown of the tooth, which, on account of its peculiar structure, terminates in mortification." Again, the cause of the mortification in the bone of the tooth is inflammation occurring to the dental pulp, "occasioned by any excitement that produces irregular action," and which, "when inflamed, separates from the bone, and the death of the tooth is the consequence," in the like manner "that a caries of other bones is caused by a separation of those membranes which cover them and which are attached to them."

It is evident, from what is stated above, that Fox attempted to show the similarity of dental caries to that disease in bone, adopting the theories respecting the latter prevalent in his day.

The next writer of eminence is Thomas Bell,³ whose work appeared about thirty years after the last-named, and whose views do not so very materially differ from his. During the period just mentioned more correct views had come to be entertained in regard to diseases in bone generally, the structure of

¹ The Natural History of the Human Teeth, by John Hunter.

² The Natural History and Diseases of the Human Teeth, by Joseph Fox.

³ The Anatomy, Physiology, and Diseases of the Teeth, by Thomas Bell, F.R.C.S., etc.

that tissue being better understood. Bell commences by severe strictures on the name "caries," which he considers "is totally misapplied," and desires to substitute for it "gangrene of the teeth," "as the disease has not the slightest analogy to true caries in bone." "Its proximate cause is inflammation in the bony structure of the tooth, set up by cold or any other cause, and the part which suffers the most severely is unable, from its possessing comparatively but a small degree of vital power, to recover from the effects of the inflammation, and mortification of that part is the consequence." Roots that have lost their vitality, owing to the destruction of the pulp, "are no longer the subject of disease, and often continue for years in nearly the same apparent state."

Robertson, of Birmingham, in a work almost exclusively devoted to this subject, and published in 1835,¹ adopts a wholly different view from either of the foregoing, believing the disease to be essentially the result of a chemical action upon the teeth. "The only cause capable of explaining the partial operation and the particular situations of decay is the corrosive or chemical action of the solid particles of food which have been retained and have undergone a process of putrefaction, or fermentation, in the several parts of the teeth best adapted for their reception."

At the time when Robertson wrote, the true structure of dentine was but little understood; he held that the sole object of the pulp was to supply additional bone to the tooth when worn by mastication; but, if so, why a pulp-cavity at all? Even when the researches of J. Tomes with regard to the contents of the dentinal tubuli had been made known, this writer still held that the office of the pulp or bloodvessels was not to supply nutriment to the bone of the tooth, but for the object above mentioned;² but then he avows himself a disbeliever in the value of microscopic research in throwing light upon either the cause or the nature of dental caries.

John Tomes,³ whose opinions have generally received the appellation of the Chemico-Vital Theory of Dental Caries, and

¹ A Practical Treatise on the Diseases of the Teeth, in which the Origin and Nature of Decay are Explained, etc., by William Robertson.

² Trans. Odont. Soc., vol. i. p. 101.

³ A Course of Lectures on Dental Physiology and Surgery, by John Tomes, 1848.

are a happy combination of the two very opposite views which had been advanced, believes that it "may be defined as the death and subsequent progressive decomposition of a part or a whole of the tooth;" that with the loss of its vitality the dentine loses also its power of resisting chemical action, and that consequently the dead part is, under favoring circumstances, decomposed by the fluids of the mouth; "that there must be a concurrence of dead dental tissue and of a condition of the oral fluids capable of decomposing the dead part before the phenomena of caries can be developed;" that in the course of its progress there are distinct evidences of vital action, to wit, the transparent zone, the formation of secondary dentine in the pulp, and the occurrence of pain in a tooth often long before the disease has encroached upon the pulp-cavity. The manner in which the decomposition of the dead dentine is brought about is by the chemical solution of its earthy ingredients, the solvents being probably furnished by the saliva in abnormal condition, especially when containing excess of acid mucus. It is also suggested in a note that the decomposition of the gelatine may furnish an acid of sufficient strength to rob the contiguous dentine of its lime. The predisposing causes of dental caries have for the most part a structural origin, they are faults in the development of the dental tissues, and especially of the enamel: such are the pits in honey-combed teeth, abnormal depth in the fissures on the masticating surfaces of teeth, imperfections in the enamel fibres themselves, and imperfections in their union with each other, and in the dentine an imperfect calcification of that structure. Fevers, a scrofulous diathesis, salivation, indigestion, a low damp situation, are amongst the general predisposing causes. "Circumstances which favor the chemical decomposition of the dental tissues may lead also to the loss of vitality which renders them susceptible of decomposition. Thus caries may, no doubt, be excited by the local application of numerous substances, such as the mineral acids, either when incautiously taken in medicine or in sweetmeats, and also by the presence of the gastric acids eructated during a fit of indigestion."

In a later work¹ than that from which we have quoted, the same views are maintained, though more stress is laid upon the

¹ A System of Dental Surgery, by John Tomes, F.R.S., 1859.

influence of acid mucus in the process; but the saliva or even the stomach may supply the necessary acid by which the vitality of the part is destroyed and decomposition succeeds the loss of life.

In the latest work of this author, edited also by his son, C. S. Tomes,¹ the leaning is evidently towards the views of Robertson, which have recently received some confirmation at the hands of Magitot, Leber and Rottenstein, and Wedl, all of whom more or less avow that the conditions observed in carious teeth are to be met with in human teeth and hippopotamus ivory which have been employed as artificial substitutes in the mouth. Thus, according to this author, "there is an overwhelming body of evidence to show that caries—in so far as it is a process of disintegration—has no relation whatever to the connection of the teeth with the living body." The translucent zone of the earlier works is in this no longer an evidence of a vital action occurring in the progress of the disease, but a result of chemical decomposition of the dentine, as adduced by Wedl and Leber and Rottenstein, but in opposition to Magitot and Salter. Finally, the conclusion is, "that, inasmuch as no characteristic appearances can be found to distinguish caries as occurring in living from that attacking dead teeth, it seems that the hypothesis of vital action in any way modifying the disease must be abandoned *in toto*, and dental caries cannot, strictly speaking, be said to have any 'pathology.'"

Bridgman, who was the successful candidate for a prize essay on dental caries,² attributes the phenomena witnessed in that disease to purely electrical conditions. He compares the mouth to an electrolytic apparatus, in which the crowns of the teeth represent under ordinary conditions the positive electrodes, whilst their roots, with the cutis, etc., represent the negative electrodes, the saliva of course being the electrolyte. When certain abnormal conditions in the saliva or vascular system exist, then electrical action is set up with such intensity that the positive pole, the crown of a tooth, yields up its lime salts, which pass to the negative pole represented by the root, where

¹ A System of Dental Surgery, by John Tomes, F.R.S., etc., and C. S. Tomes, M.A. 1873.

² Trans. Odont. Soc., vol. iii. p. 369.

they are at times deposited as tartar. It is impossible in a short statement to do justice to a theory which, although at variance with certain facts as we now know them to exist, is nevertheless maintained by much ingenious argument.

Spence Bate, of Plymouth, attributes dental caries¹ chiefly to the presence of carbonic acid in abnormal positions and in abnormal quantities. A death and decomposition of the membrane covering the enamel will furnish this acid in a nascent state, in which condition it will act readily upon the lime-salts of the subjacent structure, especially if that structure be imperfectly developed. When the disease has reached the dentine, the dentinal tubuli become opened, and empty their contents into the carious cavity, which likewise decomposing furnish further supplies of nascent carbonic acid to continue and augment the process.

Finally, Leber and Rottenstein² advocate the view that the disease in question is mainly due to the presence of the leptothrix. As this cryptogamic growth is not met with in the earlier stages of caries, when confined to the enamel only, they apprehend that portion of the process to be due to the solvent action of an acid; but, when the subjacent dentine becomes exposed, then the leptothrix, finding its way into the dentinal canals, effects a rapid disintegration of the dentine.

Of the various opinions advanced, that which most accords with our own views is the so-called chemico-vital theory of J. Tomes, notwithstanding that, as stated in the last edition of his work, the editors have followed the opinions of certain Continental writers, who, judging from the comparison of microscopical preparations obtained from carious teeth, and teeth softened and acted upon by food and oral fluids when attached to artificial dentures, have adopted apparently the purely chemical theory of Robertson. That the conditions prevailing in the progress of dental caries are dissimilar to those which take place in the inflammation of most soft structures, which are hyperæmia, effusion, cell-migration, softening, fatty degeneration, etc. etc., we can readily admit, without denying to the process a pathological character.

¹ The Pathology of Dental Caries, by C. Spence Bate, F.R.S., Trans. Odont. Soc., vol. iv. p. 40.

² Recherches sur la Carie Dentaire, par Leber et Rottenstein, Paris, 1868.

The teeth of every person must in the mouth, like every other portion of the body—the hair, nails, and skin included—be continually exposed to conditions, which, but for a prevailing something, would ere long subject them to those changes which all highly complex nitrogenous bodies undergo when removed from its sphere or influence. It is this prevailing something, ceasing or changing with the loss of life in an individual, that immediately permits the existence of those affinities, or no longer opposes their action, which tend to break up into simpler forms the more complex chemical compounds of which an animal or vegetable body consists, and to which consequently we apply the vague term “vital force,” which, if actually a force, is probably not more distinct from the chemical than the latter is from the electrical, or any of the so-called forces; indeed, it may be only one manifestation of the chemical force. Whilst this exists or remains unchanged, the teeth are, so to speak, protected from conditions, viz., moisture, warmth, action of acids, and bodies themselves undergoing change and decomposition, which would otherwise certainly allow the exercise which those affinities are ever exerting to break up complex organic compounds.

We are prepared to grant that such affinities may when strong overcome that resistance, as well as have their full action when it is weakened, changed, or withdrawn, but this would in our eyes constitute it a pathological process.¹ If we follow its course as we have described it, we shall find, as a rule, that the disease continues to be more circumscribed and limited

¹ That the microscopical appearances as exhibited in the decay that occurs in teeth employed as artificial substitutes should closely resemble the same in teeth naturally attached in the mouth is rather what we should look for, and, to our mind, is no evidence that the process is not a pathological one, both having been brought into the same or nearly similar condition by pathological processes; the former by probably the death of the whole individual of whom the tooth formed a part, the latter by the death of the portion of the tooth attacked, the conditions of the subsequent decomposition being almost precisely the same. If we are bound to assert that the loss of vitality in the dentine of a living tooth is a result of inflammatory action, then we must admit that our evidences of its existence are very small; recent research would rather tend to show that it might be so, and, in the case of affected cementum, there is every ground for believing it to be so; but the loss of vitality in a part may occur independently of inflammatory action, and yet, we presume, deserve the appellation of pathological.

so long as the pulp retains its vitality; with the loss of vitality a much more general softening of the surrounding dentine ensues, which is more comparable to that of natural teeth attached to artificial dentures. Our views, which on the whole differ but little from those of J. Tomes, are that the disease arises from the action of particles of food, or mucus, or the combination of both, undergoing decomposition in contact with the teeth at parts where, owing to certain conditions, that influence which protects living structures is weakened or absent. The favoring conditions will be imperfection in development, either in the structure itself, or in the form of the teeth, whereby a greater opportunity for the lodgment and retention of food and mucus is afforded. This latter alone, we are prepared to admit, may in time be able to overcome the resisting force where otherwise the development may not be imperfect. To the acids formed in such decomposition of food and mucus has been generally assigned the entire agency in the work; but, whilst admitting the great importance of the part they play, we cannot but believe that another condition is largely concerned in it, viz., that arising from the contact of bodies undergoing molecular change upon bodies in a stable condition. This, though no longer allowed to be the potential agency in fermentation, is still admitted to exist in the case of bodies in a state of putrefaction. Fermentation, in which the leptothrix may play no unimportant part, probably does take place to some extent in the food collected in a carious cavity, and may produce the acids which certainly assist in the process. Experiments which we made some years ago,¹ where carious teeth, from which all softened dentine had been removed, were exposed to the action of different kinds of food contained in loosely covered vessels, and mixed some with water and some with water and saliva, and kept at about 100° F. for twenty days, showed that the greatest amount of change was not always in proportion to the greatest amount of acid generated, or even to the character of the acid. Ordinary baker's bread in a solution of water and saliva was the most active, although the solution was far less rich in those acids which are known to decompose most readily the phosphates of lime than was the case in a similar experi-

¹ "On the Nature of Dental Caries," Trans. Odont. Soc., vol. iii. p. 80.

ment with cane-sugar, water, and saliva. The appearance, too, of the softened dentine in the bread and saliva experiment certainly more closely resembled that obtained from a carious tooth than in any other. In the case of teeth exposed under the same conditions in vessels including meat and water, and meat, water, and saliva, no softening whatever took place, but it must be admitted that the liquids at the end of the experiment were strongly alkaline.

[This starchy deposit of the remainder of bread or biscuit or cracker, which hangs like a sour pulp or paste around or at the necks of the teeth, is apparently the active cause in many mouths of labial or buccal surface decay; for teeth that are freed from this, by their shape or the movements of the soft tissues over them, will escape, while those where lodgment is allowed, in the same mouths, afford notable examples of the ravages of the disease.]

In considering the question before us, we have laid no stress upon the existence of the zone of Tomes as evidencing a vital action in the process, its nature having been disputed by high authorities; but, putting aside this phenomenon, we may certainly see in those cases where very superficial caries has existed and become arrested, as frequently witnessed upon the coronal surfaces of first molars, a hardening, which, as compared with the subjacent structure, can, we think, hardly be explained as wholly the result of friction and polishing. Here we must leave the subject, and with the same remark as when we entered upon it, viz., that no explanation of the causes or nature of dental caries has yet been offered which has been generally acceptable to dental practitioners.

The question may now be considered—is the disease which we have been describing, and which presents at times different features, one disease, or may we be comprehending in our description more than one? Some authorities incline to the latter view, and divide dental caries into soft and white decay, and hard and dark decay, in which latter condition the structures affected are at times almost black. Most authorities, however, are agreed that the disease is precisely the same, the conditions being varied by the former being rapidly, the latter slowly, progressive. A variety of caries termed chalky, and met with most frequently in the third molars especially of the upper

jaw, would, from the appearance which the affected portion presents, give the idea that its disintegration had not been preceded by a solution and removal of the lime-salts, but that the calcified structure had itself broken down. If we take some of the chalky powder, which upon the finger-nail appears to resemble whitening, and examine it under the microscope, we shall find it to consist of fragments of dentinal tubuli and inter-tubular substance (see Fig. 88), in which the tobacco-pipe appearance noticed by J. Tomes is very conspicuous: a little hydrochloric acid added to the specimen liberates abundant bubbles of gas.

Another condition is where a loss of substance occurs generally at the necks of the teeth, giving the appearance of a portion of the tooth having been removed by a file, and the place highly polished. This form has been termed "decay by denudation," or "erosion." It is most commonly seen upon the labial aspects of the teeth, especially the bicuspid, but it also does occur, though less frequently, upon their lingual surfaces, and in other spots inaccessible to the tooth-brush, which proves that it does not arise from the friction of that appliance, as some have supposed: it is also stated to be met with in some of the lower animals. [It has, however, frequently been noticed that the canines where prominent seem to suffer most, and the left

Fig. 92.



A cuspidatus of the lower jaw worn on its lingual surface by the friction of a plate.

one in right-handed people is generally more deeply grooved, which would look as if the tooth-brush may play an important, if only an auxiliary and secondary, part in removing the partially softened enamel and dentine, while it may also add to the irritation that may be the prime cause of the acid secretion from the gum.] It appears, however, almost perfectly identical in appearance with the wearing away of a tooth at its neck by the friction of a clasp to support a denture; such

clasps invariably retain small portions of food, bread-substance especially, so that the rapid loss of substance they occasion is probably something more than friction. It is stated to be more common to the upper than to the lower teeth, and we believe this to be correct. Although most frequently met with at or below the termination of the enamel at the neck of the tooth,

it occasionally, *i. e.*, on the assumption that it is the same affection, attacks the enamel itself. We have cases on record where the two upper central incisors have so suffered, and in persons of undoubtedly good constitutions. In one case, which we had under observation for more than twelve years, the disease had appeared on the labial surface of the enamel, midway between the cutting surface of the tooth and the gum. As it progressed, there was no discoloration, and the surface presented was highly polished, and intensely hard and sensitive. [In a number of cases of this kind, treated by cutting retaining grooves and filling with gold, there seemed relief sufficient to warrant its recommendation in almost every case that has progressed to a depth much below the enamel.] Eventually one of the teeth broke off, the pulp having become dentinified in the progress of the disease; the other has remained in much the same condition for a number of years, the patient, a lady, aged now about thirty-five, having most assiduously kept the cavity sealed with white wax, which almost completely hides the deformity. We feel inclined to attribute the condition which we have described to the solvent action of an acid secreted by certain labial and other mucous glands. It is by no means uncommon for dental caries in its ordinary form to appear upon the eroded portions of the necks of teeth, when the difference in the two conditions is very manifest. Cases are recorded where the teeth generally, but especially the six upper front ones, have undergone a general loss of substance above the gum; such loss has been too general to be accounted for in any other way than that they have been attacked by some solvent which has acted upon them generally. [Pressure, if continued, upon the soft tissues will produce absorption, and even the bony structure will after a time yield to the same cause.]

Allusion has been made to the greater frequency of dental caries in the present day than formerly, and we may probably investigate this question more profitably, and with more hope of a satisfactory solution, than the former one, *viz.*, its pathology. One of the chief causes of this degeneracy we believe to be the change, both in character and mode of preparation, which the food of man has undergone during the last few centuries. Take, for instance, his bread; this, as compared with that of the present day, was imperfectly ground and contained a larger

proportion of husk of the grain, and, in consequence, a larger proportion of phosphates. Baked into a hard mass, it required no small amount of force to bite and reduce it to a pulp with the saliva; yet this was readily accomplished by the well-developed jaws and strong teeth of bygone ages. His meat, cooked soon after the death of the animal that provided it, was presented to him in a condition which would sorely tax both teeth and jaws of the present generation: it was not then the custom to hang meat until upon the eve of putrefaction, or render it so soft by culinary art that it can be almost sucked into division, rather than brought to that state by laceration and pounding. But further than this condition of his food, let us remark his manner of devouring it. The meat was torn from the bone by the grasp of the incisors and cuspidati, whilst in the present day by appliances indispensable in civilized life, the knife and fork,¹ the office of those teeth has become almost a sinecure. Organs or structures not properly exercised undergo, after, it may be, many generations, some form of degeneration, and it is only reasonable to conclude that the teeth and jaws follow that same law; the former unprotected, losing their power of resisting external agencies; the latter protected, appearing in diminished size and incapable of affording capacious dental arches, and hence also results a crowding of the teeth with pressure, which is an acknowledged predisposer to caries. The evidence of the injurious effects of soft food upon the teeth of dogs is strong support of the foregoing conclusion.

Another result arising from too soft a food is the unhealthy condition of the gums. From loss of a natural stimulus they become hyperæmic, soft, and spongy, not only causing, by absorption of the alveoli, premature shedding of the teeth, but secreting an abnormal quantity of acid-forming mucus. To the above must be added all conditions unfavorable to the perfect development and health of the body; the preservation of the weak and feeble, such as in a less civilized state would never attain to manhood, and consequent matrimony with progeny; the depressing effects due to over-exertion of mental and nerv-

¹ Perhaps there was less absurdity in a bishop in the reign of Queen Elizabeth preaching a sermon against the use of the fork, than has been commonly attributed to him in our time.

ous energies; and the far too great indulgence in the luxuries of the table, especially stimulants,¹ which weaken the digestive organs and vitiate the saliva. The mixing of blood also appears to have an unfavorable influence generally upon the physique of a nation, and especially upon their teeth. The effects of administering medicines, especially acid ones, have by some been considered important factors in producing dental caries. We believe that it has been overrated; at the same time, the long continuance of acid medicines renders such secretions as the saliva abnormally acid; and the direct contact of such acids as phosphoric, hydrochloric, and nitric may no doubt in time affect the teeth, as they certainly do certain kinds of metallic fillings in them. As sulphuric acid has but a very slight action upon the dental tissues, from the circumstance that an insoluble sulphate of lime is formed as soon as it touches them, it may well be, where possible, substituted for any of the former. The common practice of employing a tube when taking acid medicines is of but small advantage compared with a thorough rinsing of the mouth with a solution of bicarbonate of potash or soda afterwards.

¹ Amongst the various classes of mankind whose teeth we have had the opportunity of inspecting, few have surpassed in beauty those of the *Bedouin* of the Arabian desert; and their much greater freedom from caries, as compared with the Arab of the town, is, by Waller Bey, of Cairo, who is able to speak from large experience, attributed to the former being total abstainers from alcoholic beverages. Their purity of breed, and the very perfect sanitary conditions of their surroundings, must not, however, be left out of the account. [The less the conditions of natural selection and survival of the fittest are disturbed, the greater the likelihood of a healthy race. The writer's observation of the *Bedouin* confirms the universally received rule, that under adversities of life the bold and hardy survive, and beget children who inherit the physical endurance of their parents, or else, if delicacy of constitution be their lot, death soon weeds them out. The law may be laid down that the teeth are equally valuable guides as to savage man's chances of life as they are to an animal's. It must, however, be recognized sooner or later that children, who are reared in the free open air of a healthy climate, are better qualified for the battle of life than those raised under the enervating influences of house or institute training. Children with decay running riot in their systems have been so frequently saved by a change to open-air life, as to make the fact no longer disputable. Dental caries has so frequently yielded to a change from an in-door to an out-door life, that it must be admitted that the Greeks with their open-air gymnasia understood and reaped the benefits of pure air. The tendency now is to a better ventilation of school-rooms, and even to open-air sessions during the summer season.]

[CHAPTER VII.]

THE SELECTION OF INSTRUMENTS.¹

THE selection of instruments is one of the most important duties of the dental preceptor or teacher, and the varieties of sets recommended by different operators seem to be limited only by the number of the recommenders. For some years the set selected by the writer, and about to be mentioned, has been the source of much satisfaction in its adaptability to the various demands made upon it, and is the standard upon which or from which sets have been selected and used by many students. The only objection has been as to its expense, which at first sight may seem considerable, but, after some years of study of the peculiarities of dental students, it may be safely said that they rarely enter practice with less than the amount here spoken of, and often more, much of which is after trial discarded as unhandy and useless.

In the first place, true economy will be practised by the purchase of a case, in order that each instrument may have a separate and appropriate place; for misplacement and loss will try the temper of the patient, the operator, and the instrument. If thrown loosely together, the edges are impaired or destroyed on each other, and this, although not always understood by the young operator, makes a wonderful difference in time and remuneration in practice.


Beyond all else the points of the instruments are to be considered. As to the handles, it is more a question of taste; yet the balance and shape have much to do with the dexterity of the operator.

The new models of milled socket handles, made by the S. S. White Dental Manufacturing Company, seem to answer much that is desired in this direction, while they offer a ready and

¹ [Acknowledgment is due to The S. S. White Dental Manufacturing Co., for the courtesy in permitting the use of illustrations of a number of the instruments in this chapter.]

expeditious means for renewing the points that may be broken, to say nothing of the cleanliness and sightliness of the set when

Fig. 93.

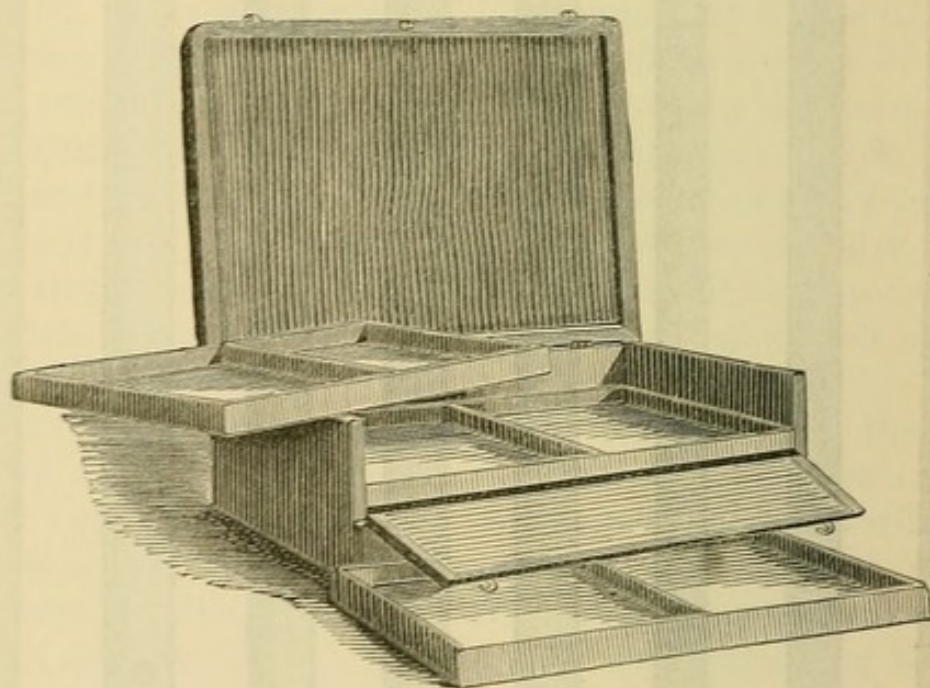


New socket handles.

spread upon a snow-white linen napkin ready for use. If cleanliness is considered next to godliness by our patients, they certainly appreciate it in anything designed for use in their mouths. There are always enough disagreeable and painful associations connected with dental offices to make it highly

desirable that they should be, as far as possible, relieved of every unpleasant feature. The recent demonstrations of Pasteur before the world's medical congress show, that many diseases are liable to propagation as ferments and infusoria, which from minute particles will propagate, grow, and increase to immense numbers under conditions favoring their development, as in the inoculation or vaccination from an infected animal's fluids. This would seem to make an additional reminder necessary that anything short of the most exacting and scrupulous care on the part of the dentist or surgeon is an offence against the health of the community, that will be classed as criminal, and before many years—if not already—it may be punished as such.

Fig. 94.



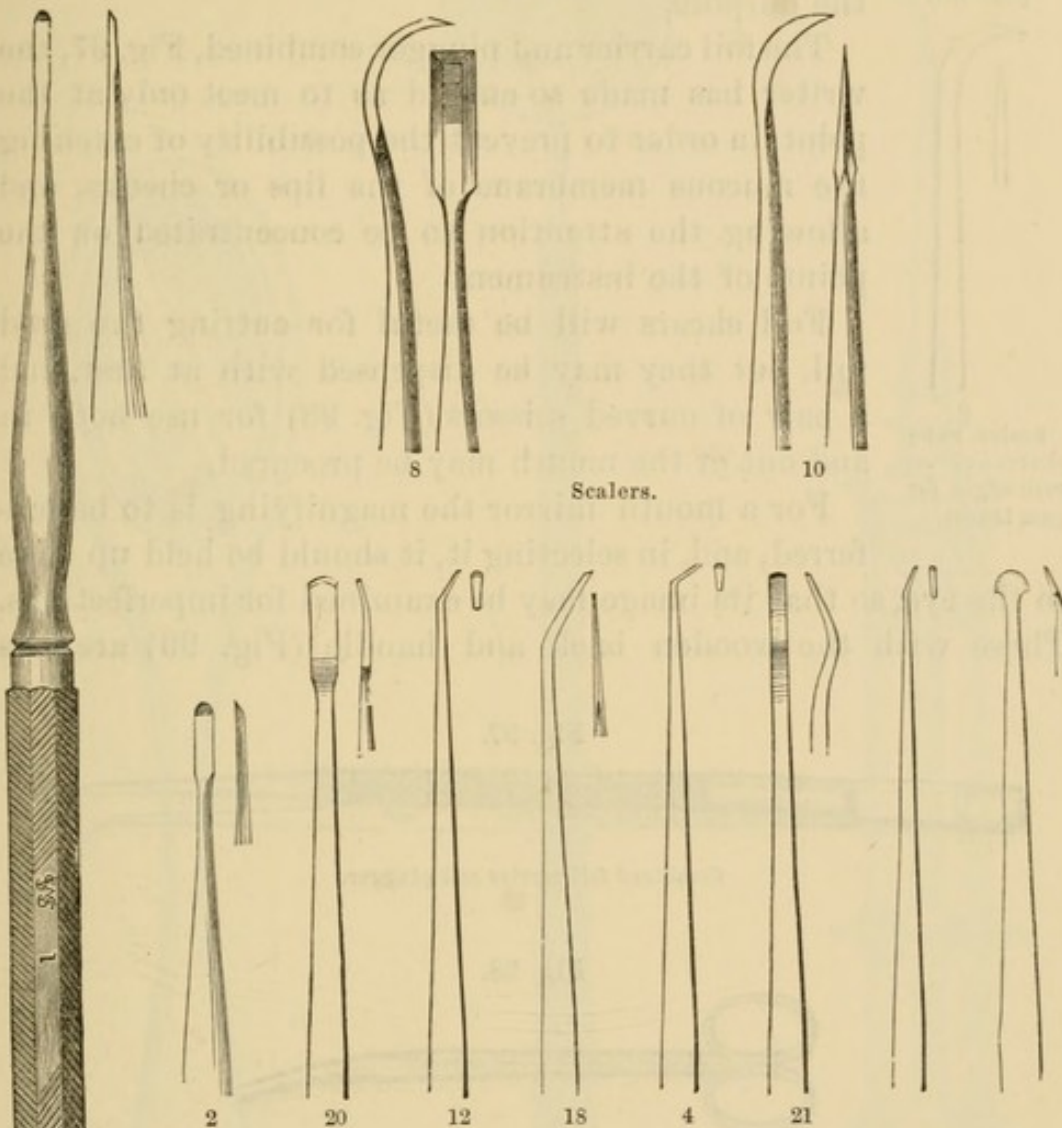
Student's instrument case.

The student will do well to provide himself with a case like that shown (Fig. 94), which may have four trays for the instruments, or, what is perhaps better, have the separate smaller cases such as are made for the socket handles.

For the tray for instruments for examination of the mouth, removing salivary calculus, and finishing fillings: first, obtain two fine probes for examination of cavities. These should be soft and capable of being bent into convenient shapes for passing around or between the teeth, and a little thicker than heavy bristles.

For scalers, use the S. S. W. Nos. 10 and 8 (Fig. 95), which may be supplemented with a pair of the right and left. In the

Fig. 95.



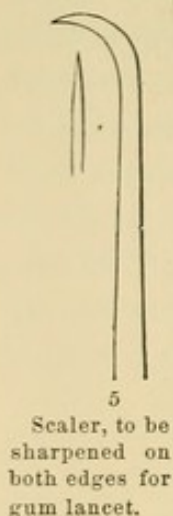
operation of scaling we can also be greatly assisted by a selection from the ordinary excavators; the scoops presently to be spoken of being invaluable and almost universal in their application (Fig. 106).

For opening cavities and removing overhanging walls, Dr. Forbes' Nos. 1 and 2, and Dr. Head's Nos. 20, 12, 4, are desirable, and later on may be added as required Nos. 18 and 21 of the latter set.

Next a curved sickle-shaped lancet will be desirable for opening abscesses, lancing the gums of children, or around the wisdom or such other teeth as have the

gums attached—generally only those that have stood alone in the mouth for some time. Fig. 96 represents a scaler that may be sharpened on both edges, and made to answer the purpose.

Fig. 96.



The foil carrier and plugger combined, Fig. 97, the writer has made so curved as to meet only at the point, in order to prevent the possibility of catching the mucous membrane of the lips or cheeks, and allowing the attention to be concentrated on the points of the instrument.

Foil shears will be useful for cutting the gold foil, but they may be dispensed with at first, and a pair of curved scissors (Fig. 98) for use both in and out of the mouth may be procured.

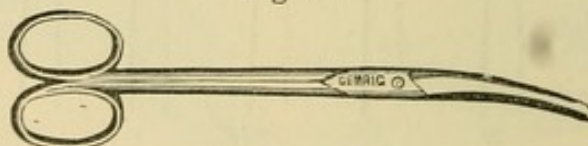
For a mouth mirror the magnifying is to be preferred, and, in selecting it, it should be held up close to the eye, so that its image may be examined for imperfections. Those with the wooden back and handle (Fig. 99) are less

Fig. 97.



Combined foil carrier and plugger.

Fig 98.



Curved scissors.

expensive and very serviceable, but the nickel-plated back and carefully-fitted water-tight mirrors (Fig. 100) are the best, and probably the most economical, all things considered.

The syringe may be of glass (Fig. 101) or hard rubber; lately a pattern of nickel-plated brass has given much satisfaction.

Hickory pivot wood, cotton and box-wood strips, are useful for cleansing, wedging, cauterizing, and pivoting teeth. Provide also a strip of Scotch or Hindostan stone, celluloid polishing strips, a box of pulverized pumice, and one of peroxide of tin.

Fig. 99.

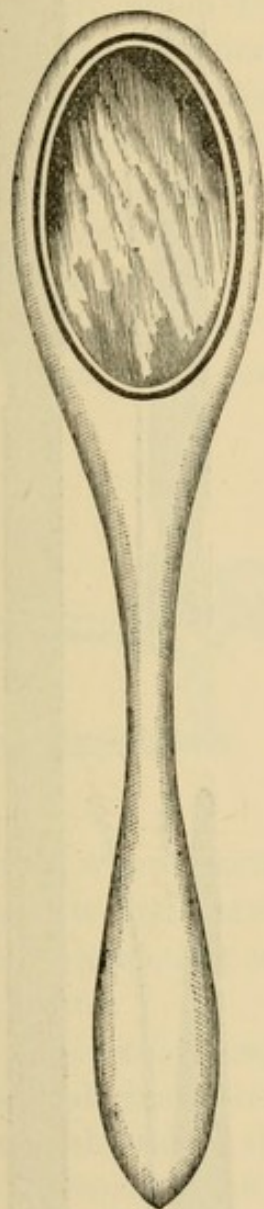


Fig. 100.

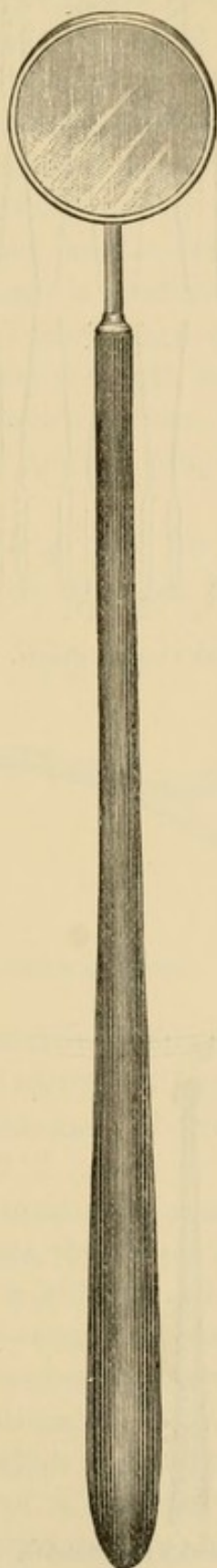
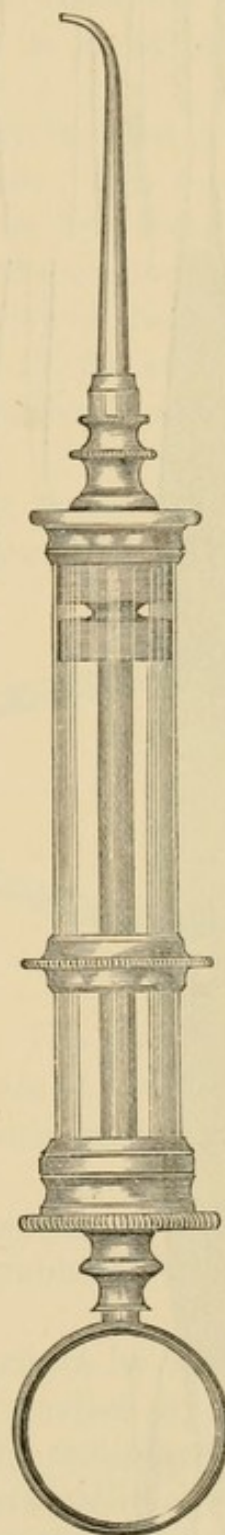


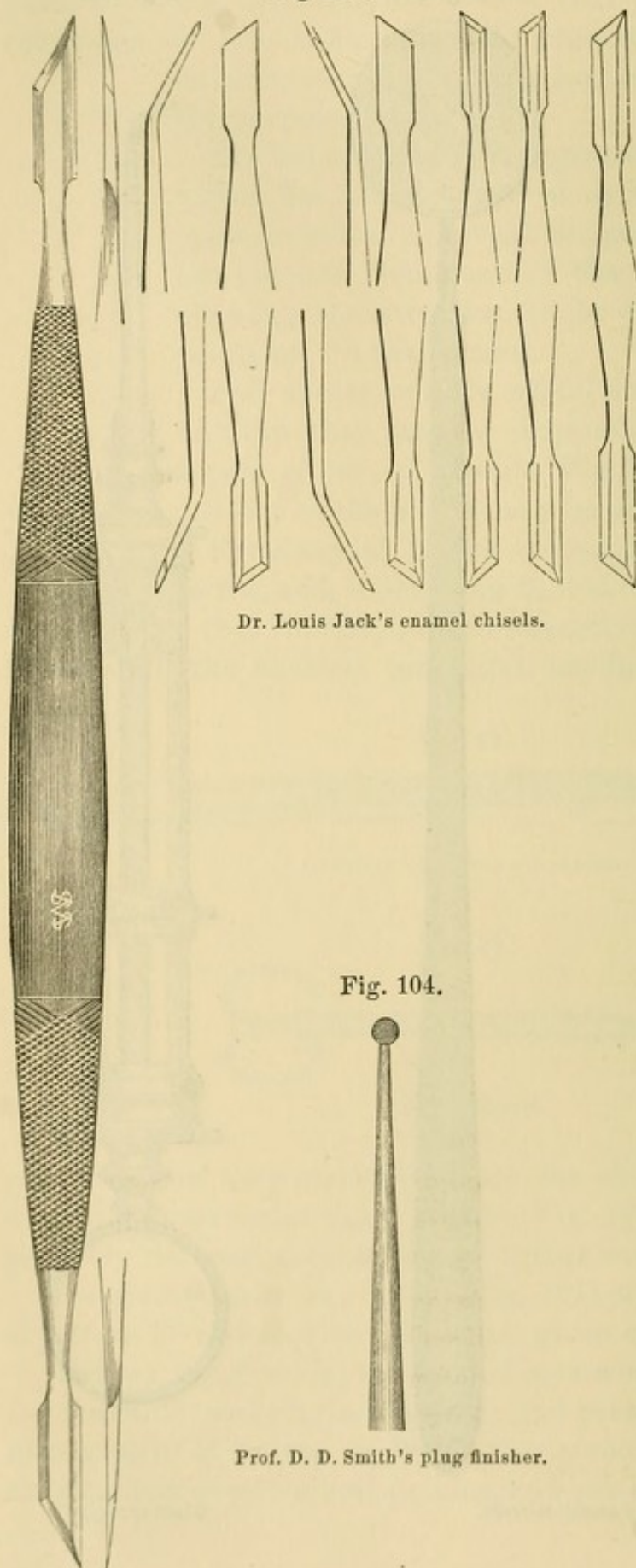
Fig. 101.



Magnifying mouth mirrors.

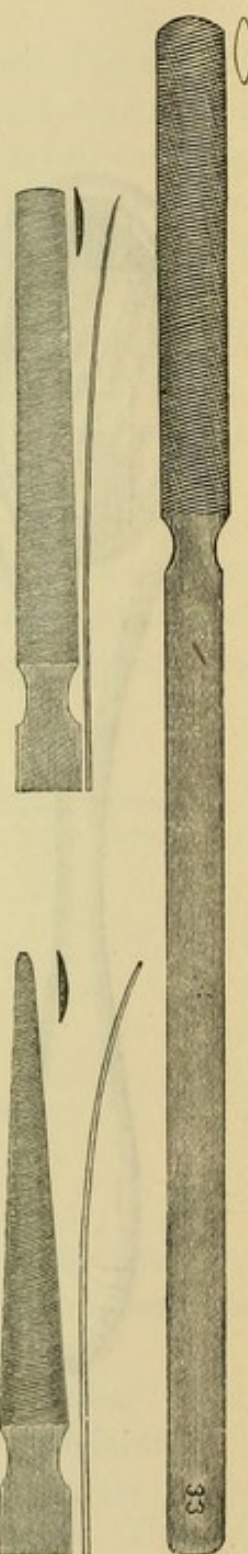
Glass syringe.

Fig. 102.



Dr. Louis Jack's enamel chisels.

Fig. 103.



Dental files.

Fig. 104.



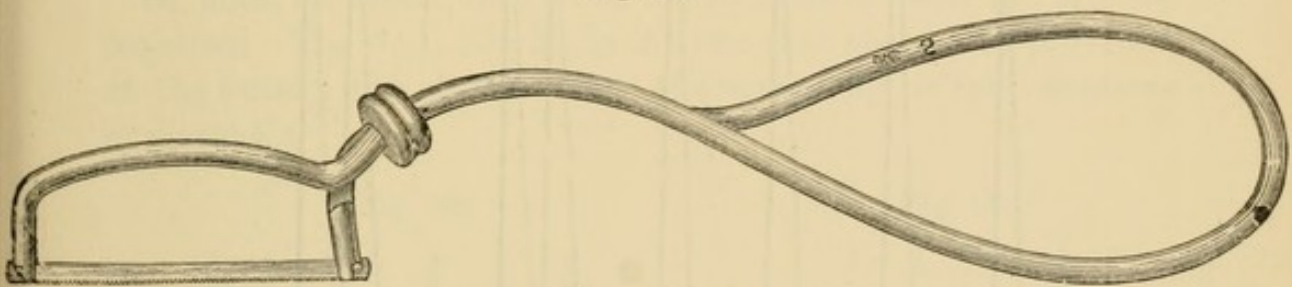
Prof. D. D. Smith's plug finisher.

Dr. Jack's chisels (Fig. 102) are often put into this tray as convenient for opening cavities and for cutting separations between the proximal surfaces of the teeth. The writer has his made with a heavier handle and single point, as he believes they are less liable to be injured by a fall.

For plug finishing, the various bur drills may be used, particularly when the student has a dental engine. By some, however, the hand cutting is preferred; or, as is generally recommended, the student may learn without the engine, and after acquiring the necessary strength and dexterity of the hand the engine may be employed. Files, Nos. 14, 19, 20, and 33, together with Prof. D. D. Smith's plug finishers, Nos. 4 and 5, will be of value.

A Kæber saw frame, Fig. 105, for carrying watchmakers' fine saws, will be handy in starting an opening between the

Fig. 105.



Kæber saw frame.

teeth, where permanent separation is desired. The passage of the saw first between the teeth, will make the use of the file or disk much less unpleasant and laborious to both patient and operator.

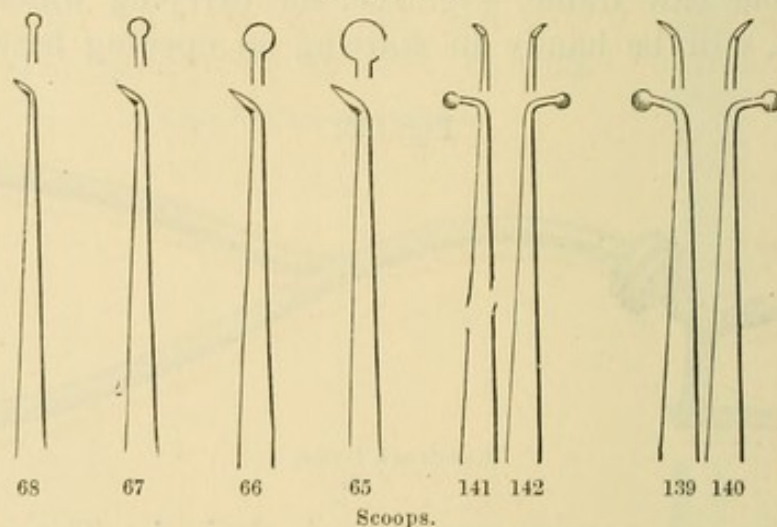
The second tray may contain the excavators proper; and here, as in all dental instruments, the shapes that resemble the human hand should be the most highly prized.

Foremost in the rank—the very poetry of points in steel—stands a set of six finger-shaped instruments, devised by Dr. Corydon Palmer. Unfortunately they cannot be recommended to every tyro, any more than a genuine Cremona violin should be placed in the hands of a sawyer. But for the light and skilled hand of the maestro, to have once made their acquaintance is to be ever thankful with and unhappy without them. To a child who knows the principles of digging sand holes

these instruments will show their adaptation. All that is necessary is to remember that the cutting edge is the finger nail and the instrument the finger. A wood-cut will not convey the idea, and, therefore, attempts to illustrate them have not been made.

Next will follow the regular scoops, which resemble the open hand, and are nearly as universal in their application. They should be made with the palmar side flat instead of hollowed, as the latter shape weakens the edges for cutting the more solid portions of the teeth, and particularly for cutting down overhanging walls of enamel—a use for which they are well calculated. Fig. 106, Nos. 67 and 68, are the most useful, but larger

Fig. 106.

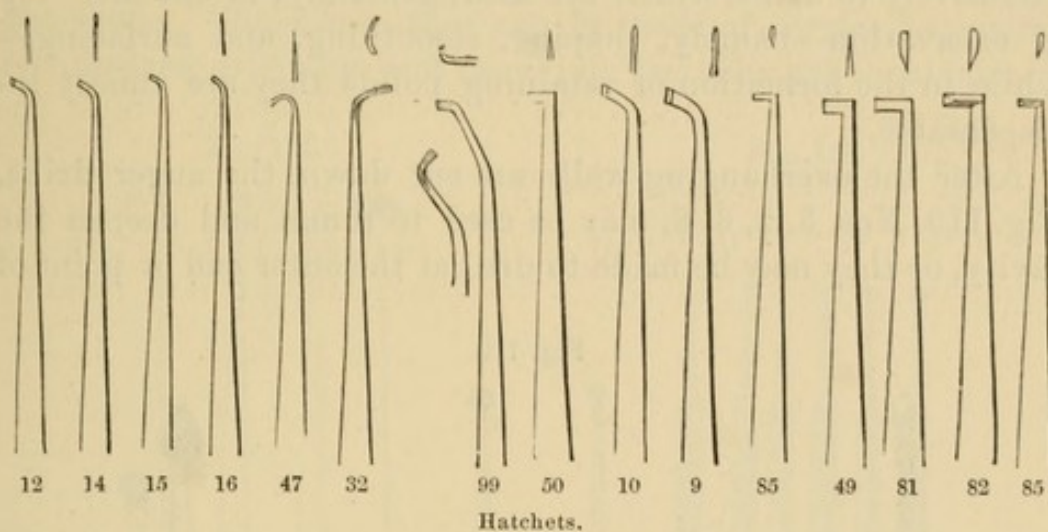


sizes may be required, and as they are worn down in sharpening they will approach these favorite numbers. Some curved, as the last four, for rights and lefts, may be likened to the hand, arm, and elbow; they are useful to reach down between teeth upon the floors of the approximal surface cavities, cutting that portion near the necks of the teeth, the sides may best be finished by the plain scoops or hoes. They may be used also upon the mesial walls of molar crown cavities.

For hatchets, there may likewise be no explanation of their use required, beyond the reminder that there is great temptation to cut with them in lines parallel to the dentinal tubuli; a thing to be avoided, except where the tooth-substance is dead or its connection with the pulp cavity severed. The first two,

Nos. 14 and 16, may be well recommended, of the others it may be said that they are offered as guides to select from.

Fig. 107.



Of hoes, no description as to the method of their use will be required. The first, No. 27, is the one that should be provided at the outset, and of the others the same may be said as above of hatchets.

Fig. 108.

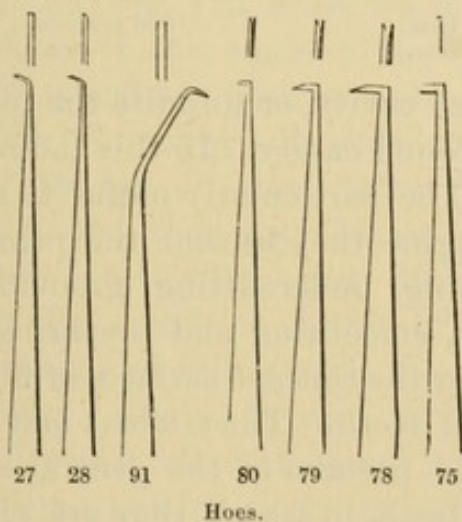
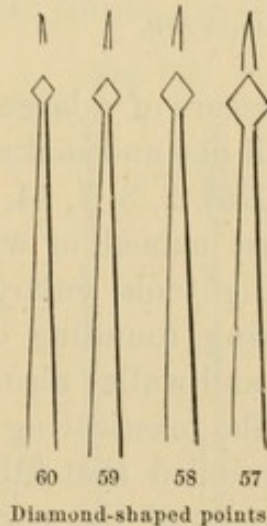


Fig. 109.



The diamond-shaped points, Fig. 109, Nos. 58, 60, 59, 57, are gradually going out of use since the introduction of the engine points. They are, however, very useful in opening cavities, particularly upon the deeply-fissured crowns of molars.

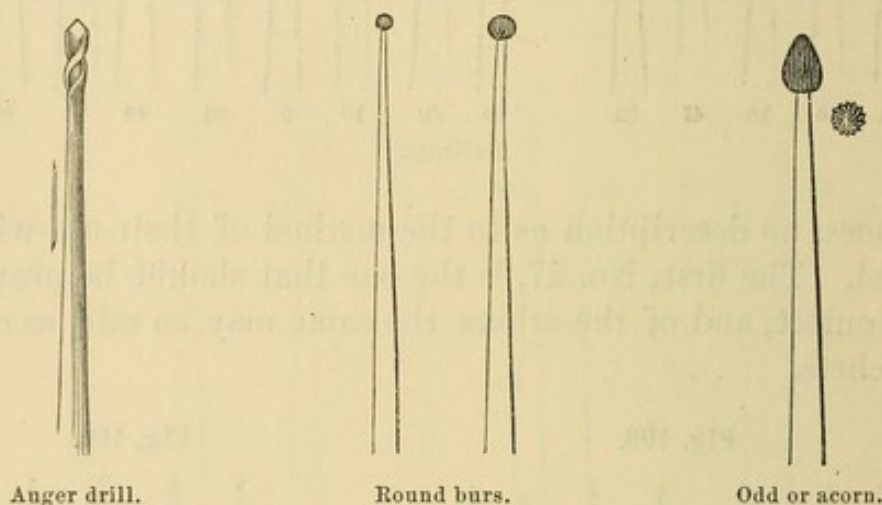
With the above we may fill another tray, or, by selection and

combining with the next, they, with part of the following, may be put into one tray.

In the full set of instruments the third tray is devoted almost exclusively to drills, which are used, generally, in the last step of excavation—namely, shaping, smoothing, and surfacing—while in the formation of retaining points they are almost indispensable.

After the overhanging walls are cut down, the auger drills, Fig. 110, Nos. 3, 2, 6, 8, may be used to round and deepen the cavity, or they may be made to drill at the outer end or point of

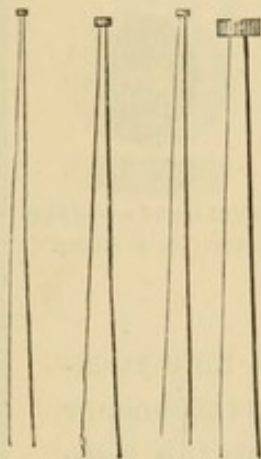
Fig. 110.



each fissure of a large star-shaped cavity, or to unite the rays of a small one and make a plain, round cavity. In this the round burs, Nos. 2, 3, 7, 14, 9, 12, will be particularly useful to assist the first named, or with the engine they become the principal working tools, enlarging, shaping, undercutting, grooving or guttering, rounding or curving, smoothing and preparing the floors and walls; also in finishing the concave surfaces of fillings upon the masticating surfaces of teeth. The student may here be reminded that fillings should partake of the general shape externally of the parts of the teeth in which they are placed. Being designed to replace, to a certain extent, the lost tissue and protect the remainder of the tooth-substance, the fillings should rarely project as full as the original material, and overhanging edges, except where the cavities are countersunk expressly for the purpose, are not to be recommended, as the thin edges may turn up, break off, or become defective.

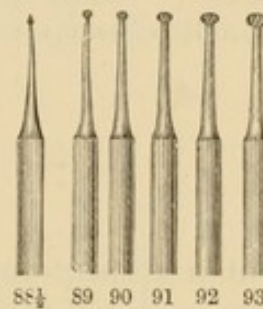
Wheel burs, Nos. 1, 3, 5, 7, 12, 15, and 18, are auxiliary to the above, and are excellent for flattening floors and enlarging the interior of cavities, serving to make them slightly larger within than at their openings, giving them a shallow-jar or pomatum-pot shape. Sometimes they can be made of service in cutting out fissures, grooving, and rounding, but they are invaluable in

Fig. 111.



Wheel burs.

Fig. 112.



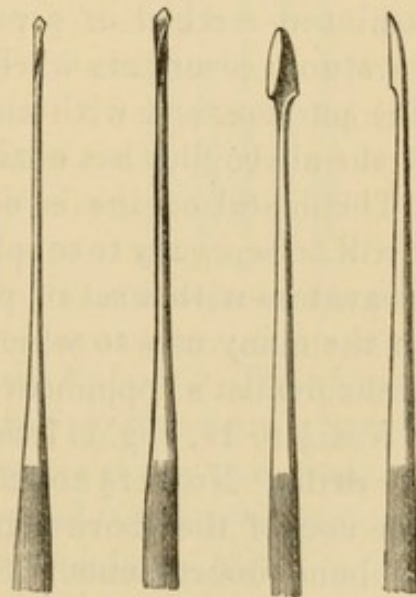
Oval burs.

shallow places upon labial or buccal surfaces to undercut grooves for the retaining of the filling. For the latter purpose, Nos. 88½ to 93, Fig. 112, as shown for the engine points, are slightly ovoid, as if the edges of the tire of the wheel had been worn by use.

Palmer's root or pulp canal drills, Fig. 113, are of great value, Nos. 2, 3, 5, 15; they may be made to enlarge, straighten, and open or ream the canals to admit of the treatment and filling with the least difficulty; and with care in their use they will follow the canal rather than cut a hole through the side of the root—an accident to be strictly guarded against.

The best form of retaining-point drill is the spade, Fig. 114, Nos. 121 to 124, in the cuts for the engine-

Fig. 113.

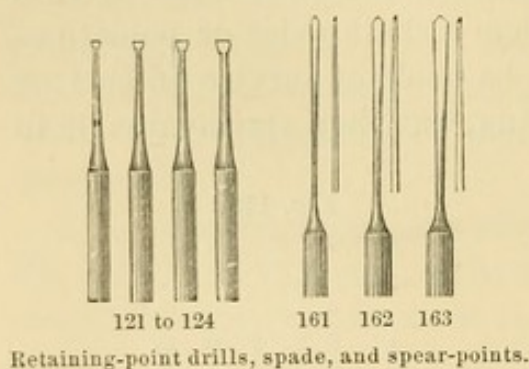


2 3 5 15
Palmer's nerve, canal instruments.

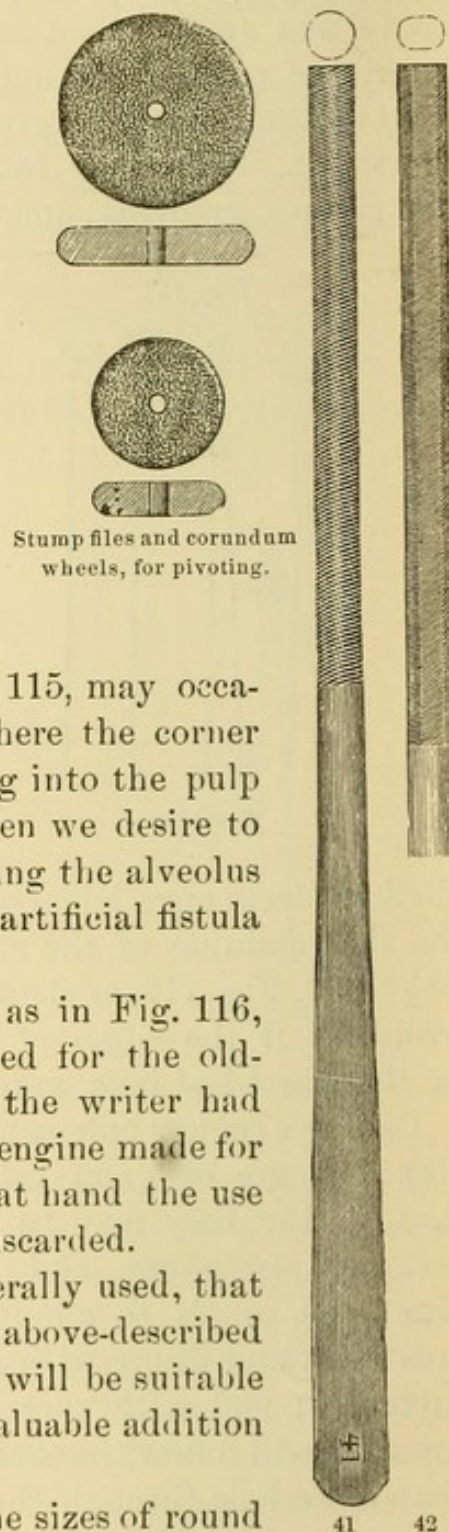
Fig. 114.

Fig. 115.

Fig. 116.



Retaining-point drills, spade, and spear-points.



Stump files and corundum wheels, for pivoting.

points, but a spear-point drill, Fig. 115, may occasionally be used for this purpose where the corner of the spade would endanger opening into the pulp chamber. These are also useful when we desire to cut to considerable depths, on entering the alveolus at the apex of the root, to form an artificial fistula for the relief of an abscess.

For pivoting, a nearly round file, as in Fig. 116, Nos. 41, 42, and 40, will be required for the old-fashioned method of pivoting, but the writer had the stump corundum wheels for the engine made for this purpose, and with these latter at hand the use of the above files has almost been discarded.

The dental engine is now so generally used, that it will be necessary to supplement the above-described excavators with a set of points that will be suitable for the many uses to which this invaluable addition to the dentist's appliances is put.

Nos. $\frac{1}{2}$ to 11, Fig. 117, represent the sizes of round bur drills. Nos. $11\frac{1}{2}$ to 22, Fig. 118, are wheel burs. The uses of the above points have already been described with the hand instruments. The inverted cones, Fig. 119, Nos. $33\frac{1}{2}$ to 37, enable the operation of enlarging the floor, or base of the cavity, to be performed readily and expeditiously. Fig. 120, Nos. $55\frac{1}{2}$ to 59, is a set of fissure drills that enable the operator

to cut down the walls and round out the points, or ends, of the stellate cavities, avoiding the jar and danger of slipping, which

Fig. 117.

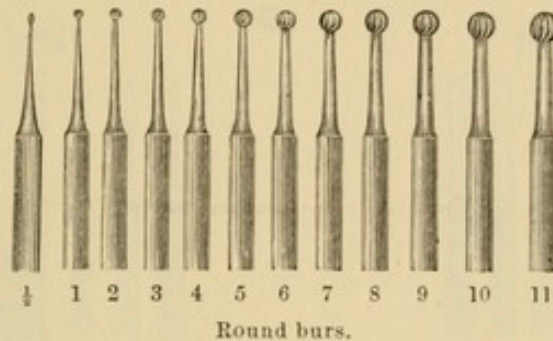


Fig. 118.

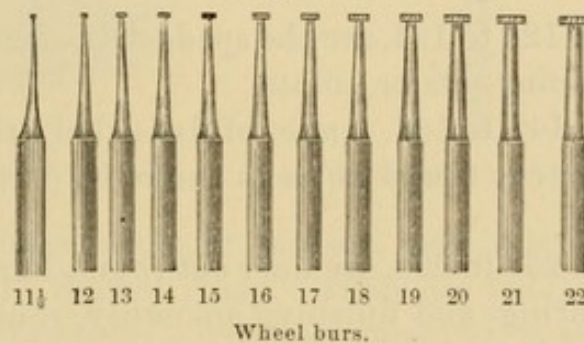


Fig. 119.

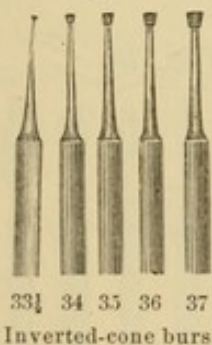


Fig. 120.

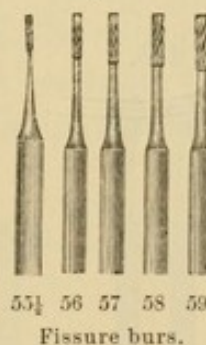
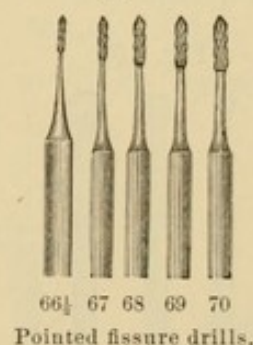


Fig. 121.

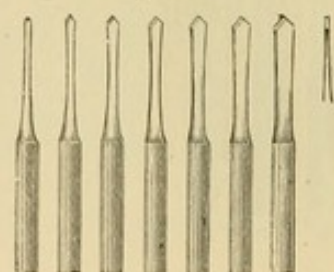


are such drawbacks to the cutting of these by hand. The square ends will make a finish of the same kind on the floor. Sometimes it is desired to enter and enlarge a somewhat smaller fissure, and after cutting away the enamel, as should be done with the chisels and points already referred to, p. 137, Fig. 95, the pointed fissure drills 66½ to 70, Fig. 121, may be of service.

The oval burs Fig. 112 are also employed in the finishing of the surfaces of the fillings.

Fig. 122, Nos. 100 to 106, shows a set of spear-point drills which enable the operator to open into the pulp cavities of dead teeth, remove old fillings, or enlarge or deepen the cavities to be filled.

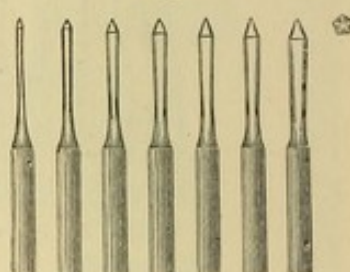
Fig. 122.



100 101 102 103 104 105 106

Spear-point drills.

Fig. 123.



142 143 144 145 146 147 148

Five-sided drills.


Fig. 114, Nos. 121 to 124, are the spade drills before mentioned for cutting retaining-pits or points.

Fig. 123, Nos. 142 to 148, is a set of five-sided drills for enlarging and making true round holes in the roots of teeth designed to be pivoted.

Fig. 124, Nos. 200 to 204, are finer cut round burs for finishing fillings, or preparing, and finishing smoothly, round cavities.

Fig. 125, Nos. 230 to 234, are the useful pear-shaped burs for the same purpose as Nos. 200 to 204.

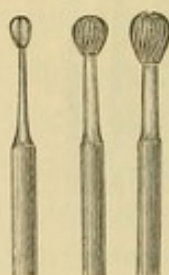
Fig. 124.



200 202 204

Fine cut round burs.

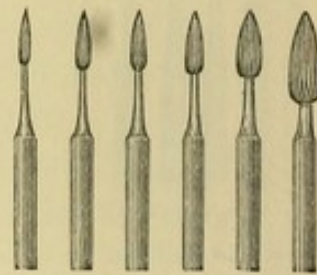
Fig. 125.



230 232 234

Fine cut pear-shaped burs.

Fig. 126.



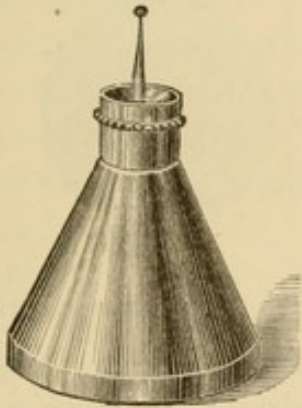
242 243 244 245 246 247

Sugar-loaf drills.

Fig. 126, Nos. 242 to 247, called the sugar-loaf drills, were first shown to the writer by Dr. Louis Jack, whose idea they embody. These points have a variety of uses between the teeth for making the now well-known V-shaped openings with curved faces; to remove proximate surface superficial decay, and finish fillings in the same situations.

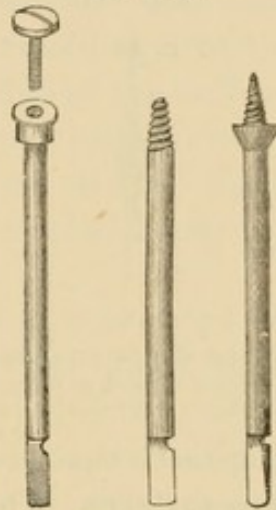
Fig. 127, Dr. A. W. Holmes's engine-bit oiler, is a neat contrivance for keeping the sockets and bits clean and oiled to prevent rusting, and obviate annoyance in making the necessary changes expeditiously.

Fig. 127.



Dr. Holmes's engine-bit oiler.

Fig. 128.



Screw-head mandrels with and without shoulder.

Fig. 128 represents the screw-head mandrels; the first one was invented by Dr. Robert Huey. Their use for carrying disks for cutting, or the various points for polishing, is so well suggested by their form that further description is unnecessary.

Fig. 129 is a portion of a very complete set of corundum points, recommended by Dr. A. L. Northrop, of New York. They may be fashioned from broken corundum wheels, or disks, by warming slightly and revolving against a piece of wood.

Fig. 129.

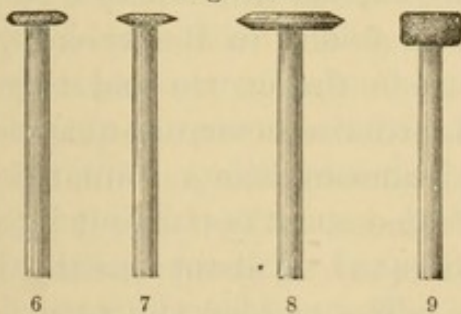
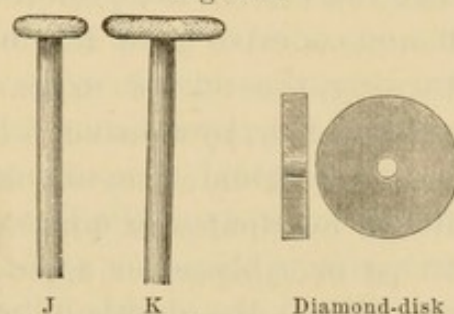


Fig. 130.



Arkansas-stone wheels.

Diamond-disk wheel.

Fig. 130, Hindoostan or Arkansas stone points, for polishing fillings and surfaces of teeth. J and K are figured as the most serviceable, but there are many other shapes made and figured in the catalogues.

Soft rubber disks (Fig. 131), of somewhat similar forms, for carrying the polishing tutty, from their pliability may be brought into contact with many forms of curved surfaces.

The diamond disk, Fig. 132, is of great value for slightly

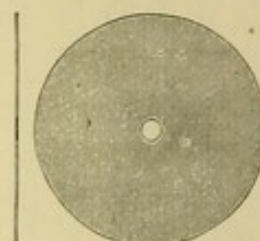
Fig. 131.



E

Flexible rubber disk for polishing proximate surfaces of teeth or fillings.

Fig. 132.



Diamond disk for separating teeth.

separating teeth that are unduly crowded and defective on their proximate surfaces. These are manufactured of very thin plates of nickel with the diamond powder imbedded on their surfaces. Somewhat similar wheels of celluloid and corundum are likewise very useful, and from their flexibility can be conformed somewhat to the surfaces of the teeth.

Non-cohesive gold should be packed as a lewis is put into a stone for hoisting it, or much as damp cigars may be packed into a tumbler, pressing a wedge into the middle, and forcing the cigars against the sides and putting fresh ones in the centre until full. For fillings of this description the gold may be prepared in cylinders by rolling upon a watchmaker's fine broach. The three-sided are preferred. To accomplish this Abbey's No. 6 non-cohesive gold foil may be twice folded in the book by turning the outside edge of the leaf to the centre and then making this, by a second folding in the same manner, one-quarter of the original size, and of four thicknesses, like a miniature folded newspaper or quarto. This folded sheet is then cut into strips or ribbons or tapes, in width equal to about one-third more than the depth of the cavity. The end of the tape is laid upon the index finger of the left hand, the broach put across the extreme end, and the thumb of the same hand then laid on this. By drawing the thumb over the broach and ribbon toward the free end of the latter, the gold is wound tightly on the steel broach, and then, by guiding the ribbon straight

with these fingers, the handle of the broach may be twirled between the thumb and index finger of the right hand, making the gold into a tightly rolled cylinder, the ends of which are formed by the edges of the ribbon, and appearing something like a diminutive block of the kind used by milliners, a true cylinder, not bulging like a barrel in the centre. The back of the thumb-nail of the left hand may be pressed against the end of the cylinder as it is finished, and the edge of the nail held upon the broach while the latter and the cylinder are revolved. After this the cylinder may be carefully pushed off the broach by the thumb-nail of the right hand or a pair of pliers, taking care not to unwind the gold.

Ropes are made by folding the same foil into strips or ribbons one-fourth or one-sixth the width of the sheet, taking care that the edges are inwards, and then twisting the ribbon tightly between the forefingers and thumbs, making it uniform in density. To finish a rope neatly it may be rolled between two pieces of plate glass until a degree of density is obtained that is uniform and the rope smooth surfaced. The rope, as first recommended, may be made of half or quarter sheets for very small cavities, and it is generally best cut into short pieces from one-sixteenth to one-fourth of an inch in length. These may be used much like the cigars above mentioned, or as cylinders, being stood upon their ends upon the floor of the cavity and allowed to project in tight cylinders equal to one-third of the depth, or in loose ropes rather more than the depth of the hole. They should be shaped to the walls by pressure at a right angle to the latter, or in the direction of the spokes of a wheel toward the rim. The last cylinder or piece of rope, will be the key piece to the whole, acting like the hub of a wheel to press outwards toward the walls. The softest cylinders are used against the walls, and the hardest for the centre or key pieces.

In such operations, the last stage of filling consists of condensing upon the ends of the cylinders or ropes, pressing the projecting gold into the cavity, and finishing up by filing or burring and burnishing alternately, until the whole surface is flush with that of the tooth, and uniformly hard, and capable of a high polish, which latter is desirable as preventing the lodgment of food or any deleterious matter about the edges or surface.

Tapes may be made of the same gold by folding or cutting into strips as before described, and these may be packed in alternate foldings and refoldings, so that the layers when finished will run perpendicularly to the floor of the cavity. Long tapes and ropes are in danger of being moistened and ruined by the saliva of the mouth. They are best cut into pieces as described, one-sixteenth to one-fourth of an inch long.

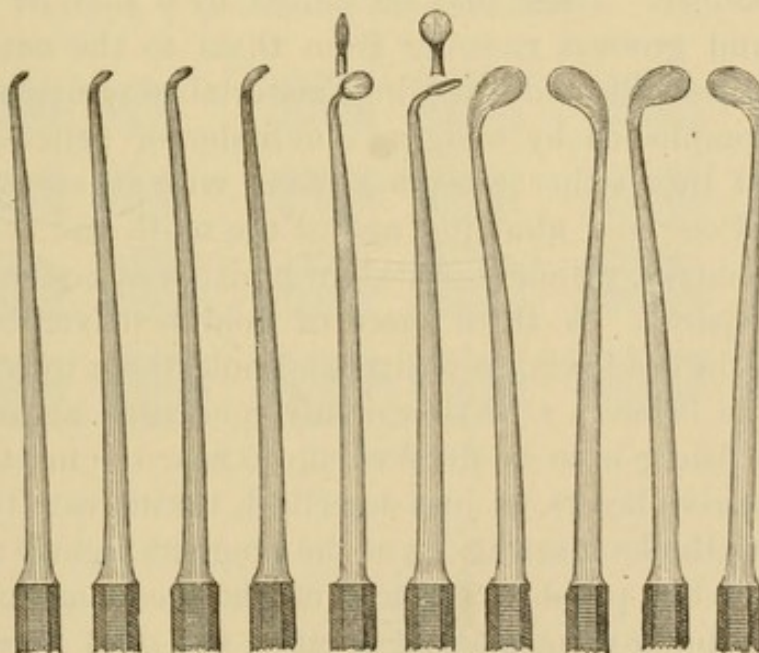
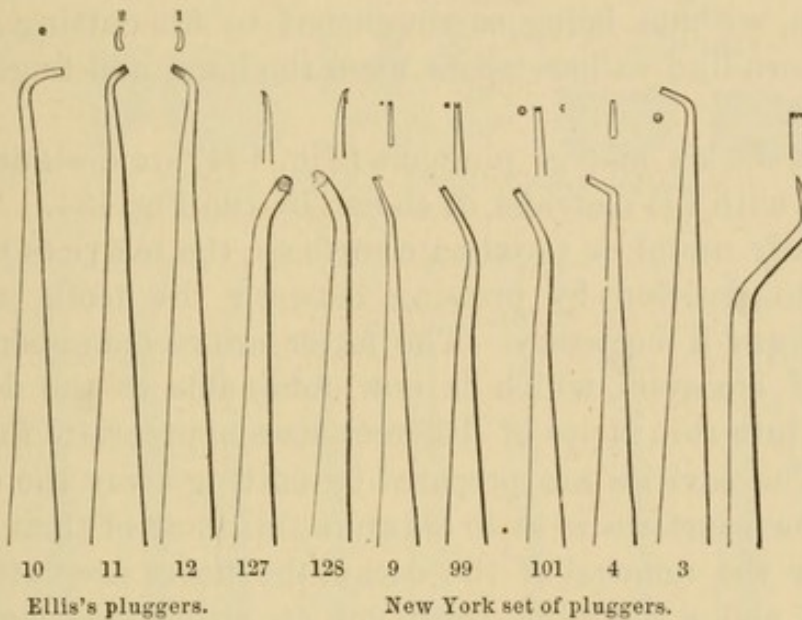
The condensation of the filling should be commenced with coarse and heavy points and finished with smaller ones, testing the density by boring with a slight brad-awl-like movement of the instrument's point, and if found to penetrate, enlarging the opening to its utmost and filling the hole made by another pellet or cylinder.

Cohesive gold should be prepared by folding as above, using Abbey's No. 4 foil, and cutting or tearing with instrument points into pieces having from four to eight thicknesses, and about one-thirty-second to one-fourth of an inch square. The greatest pains must be taken to preserve it free from moisture, from breath condensation, or any cause; also from all other foreign substances, as grease, saliva, dust, etc., as they will impair its working property, which depends upon the cohesion. Unlike the former gold, which was recommended to be worked like piling to fill a cavity, this operation should be commenced by anchoring the gold in retaining points, except in very small cavities, on the floor, and building up like masonry, laying the pieces so as to break joints with each other, carrying each layer parallel to the floor, or horizontally with the general direction of the floor, or at right angles to the axis of the cavity. The general principles of architecture and engineering, the arch and buttresses, trussing, bolting, screw piles, etc., must be followed upon a very minute scale. Sometimes, in moderately small cavities, say one-eighth to one-fourth of an inch in diameter, with smooth rounded walls, cohesive gold may be packed against them, a little higher than in the centre, by using Dr. Benj. Lord's pluggers presently to be described. But in larger cavities there is always danger of the gold bridging over, causing defects and hollow spaces, which impair the value of the filling.

From the difference in the manner of using non-cohesive and cohesive gold, it may be inferred that a set of instruments specially designed for each will be required. The first being

wedged into the cavity, will require slightly tapering points, and often deep serrations, to prick the gold pellets one into the other. (See Fig. 133.) Nos. 9, 99, 101, 1, 4, 127, and 128 of the

Fig. 133.



Dr. Lord's pluggers and burnishers.

New York set are selected, together with (Fig. 133) No. 3 of Prof. E. T. Darby's set; also a bayonet packer and condenser. Dr. G. W. Ellis's, Nos. 11, 12, and 10, Fig. 133, may be used for either kind of gold, as also may Dr. Benj. Lord's (Fig. 133.)




The latter are remarkable from their general resemblance to the finger or hand of man, and render packing almost so easy of accomplishment with them as to need no further description. The two on the right of the cut are for burnishing. These points are on unpolished handles and shafts, which afford a better grasp, without being so roughened by file cutting as to make the corn-like callous spots upon the hand and fingers of the operator.

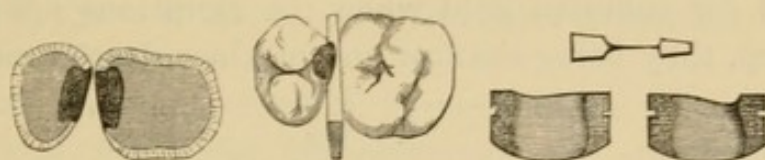
Dr. Louis Jack's matrix pluggers (Fig. 134) are designed by him for use with his matrices, as shown by the Fig. 134. They are principally useful on proximate surfaces, the matrices being wedged into position by pressing between the teeth, using wooden wedges if necessary. The latter are recommended to be made of boxwood, which is now obtainable at the dental depots, cut into thin strips of different sizes appropriate for the purpose. The cavities are prepared by cutting away the overhanging crown-surfaces so as to obtain a full view of their interior. After the removal of the decay, the floors are flattened or rounded, and a retaining point cut on either side, clear of the pulp-chamber. These may be united by a shallow groove if desired, and grooves running from them to the cutting or masticating face will hold the filling material in position. The filling is accomplished by wedging a cylinder or pellet of non-cohesive gold into either retaining point, with its side against the floor, and one end abutting against the tooth and the other against the matrix, which is placed in position after the cavity has been prepared. A third piece of gold is driven between these two, as in the lewis, to wedge and hold them in position, and the whole layer is now thoroughly condensed against the walls. The filling is to be finished up to near the masticating face by successive layers, as just described, taking care to drive the gold with the long serrations of the pluggers tightly against the walls and the polished surfaces of the steel matrices, and over each retaining-point making a pit in the gold by driving a plugger in each layer to leave a corresponding pit for anchorage of the next. The filling may be finished with cohesive foil at the top, where the wear of mastication is greatest.

If properly made, when the matrix is removed, but little work will be required to finish the filling, as the smooth steel

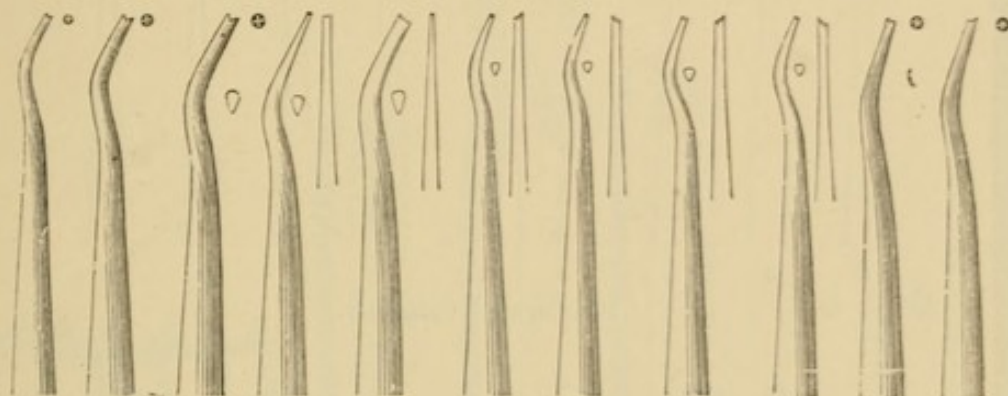
Fig. 134.



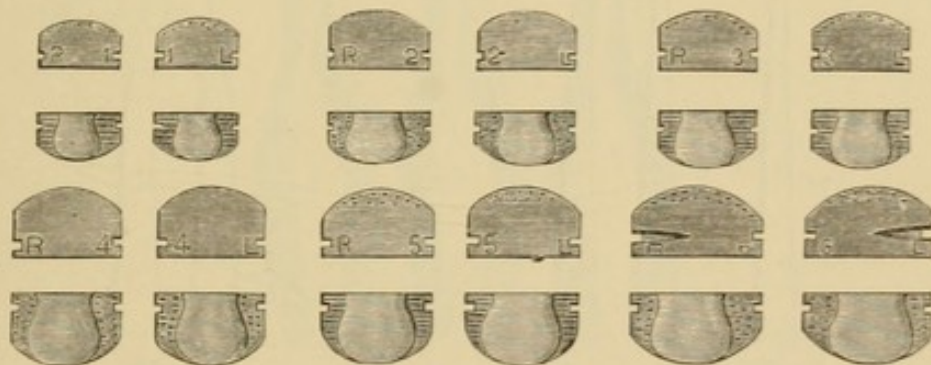
Dr. Jack's matrix.



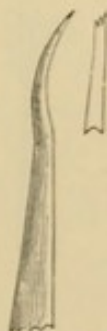Sectional views of cavities on proximate surfaces.




Dr. Jack's matrix pluggers.



Dr. Jack's matrices.



Dr. L. Jack's matrix plugger, magnified.



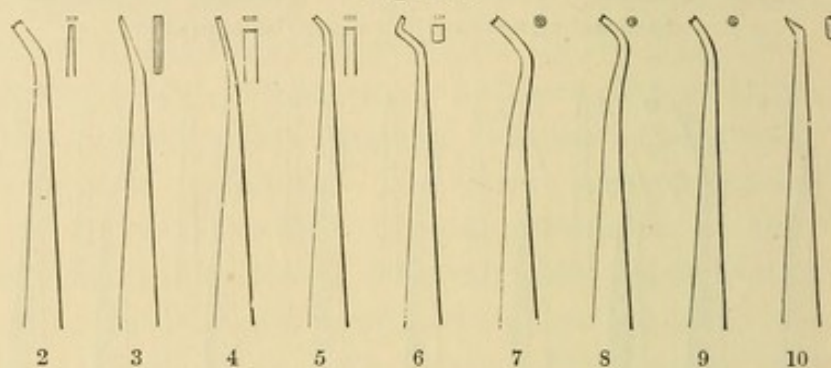
Pliers for adjusting Dr. Jack's matrices.



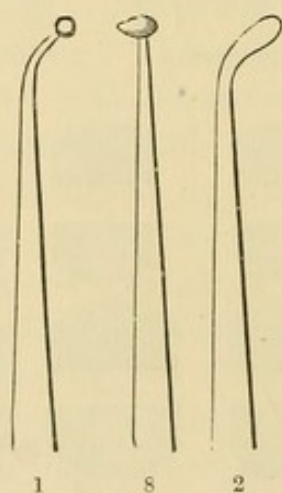
surface of the matrix leaves the gold almost ready for the burnisher.

A set (Fig. 135), called in the catalogues after the writer, but really only selected and arranged by him, has been designed for hand or mallet pressure, and may be used for cohesive gold when the serrations are new and sharp, they being shallow and of the patterns most gene-

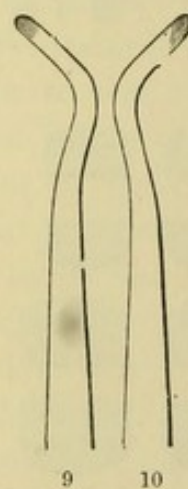
Fig. 135.



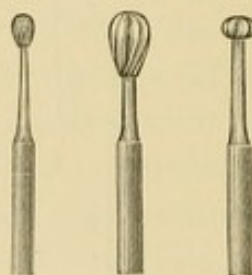
Hand or mallet pluggers.



S. S. W. burnishers.



Prof. E. T. Darby's burnishers.

E H J
Engine burnishers.

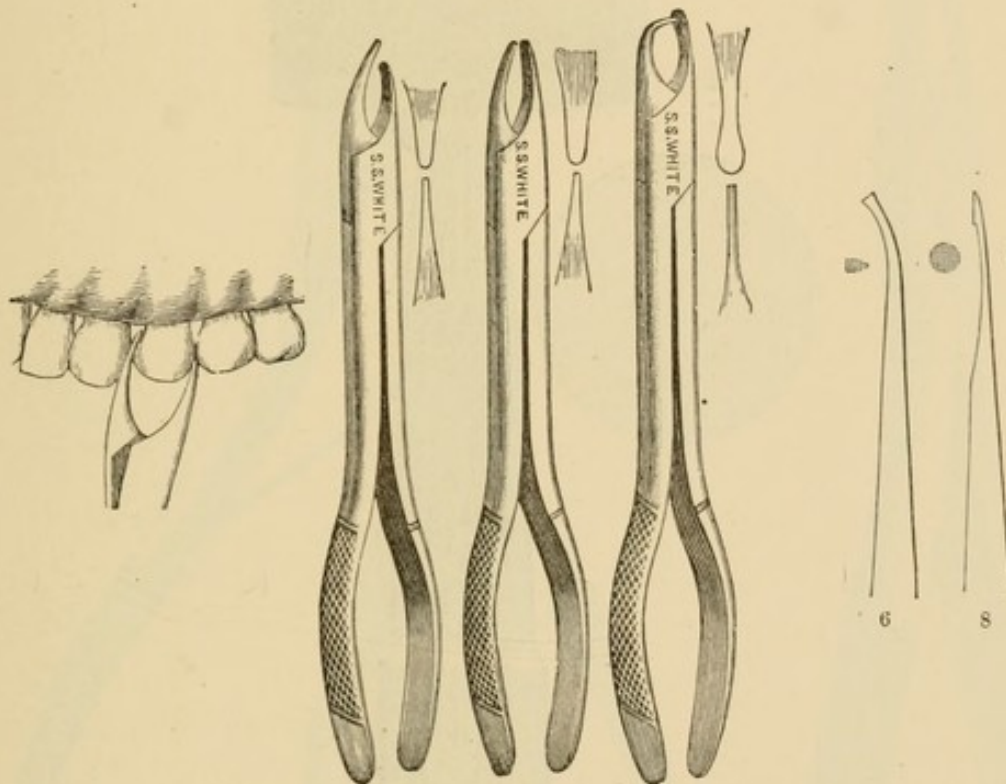
rally used. As the instruments become worn by use, they will serve nicely to condense the surfaces of fillings.

Fig. 135 gives patterns of the most useful shapes of burnishers—Nos. 1, 8, and 2, of the S. S. W. set, for general use, and Prof. Darby's, Nos. 31 and 32, for proximate surfaces and fissures.

Fig. 135, Nos. E, H, J, give the smooth-pointed burnishers for the dental engine.

Fig. 136 represents Prof. J. Foster Flagg's patterns of plugging forceps, which, for non-cohesive gold, afford a very easy

Fig. 136.



Prof. J. F. Flagg's condensing forceps.

Weston's amalgam pluggers.

but powerful means of getting desirable density and finish. The plain beak is put upon the side of the tooth, which may be protected by some intervening substance if desired, and, using this as a fulcrum, the other beak is pressed upon the gold.

Fig. 136, Nos. 6 and 8, Dr. Weston's patterns of amalgam pluggers, may be added.

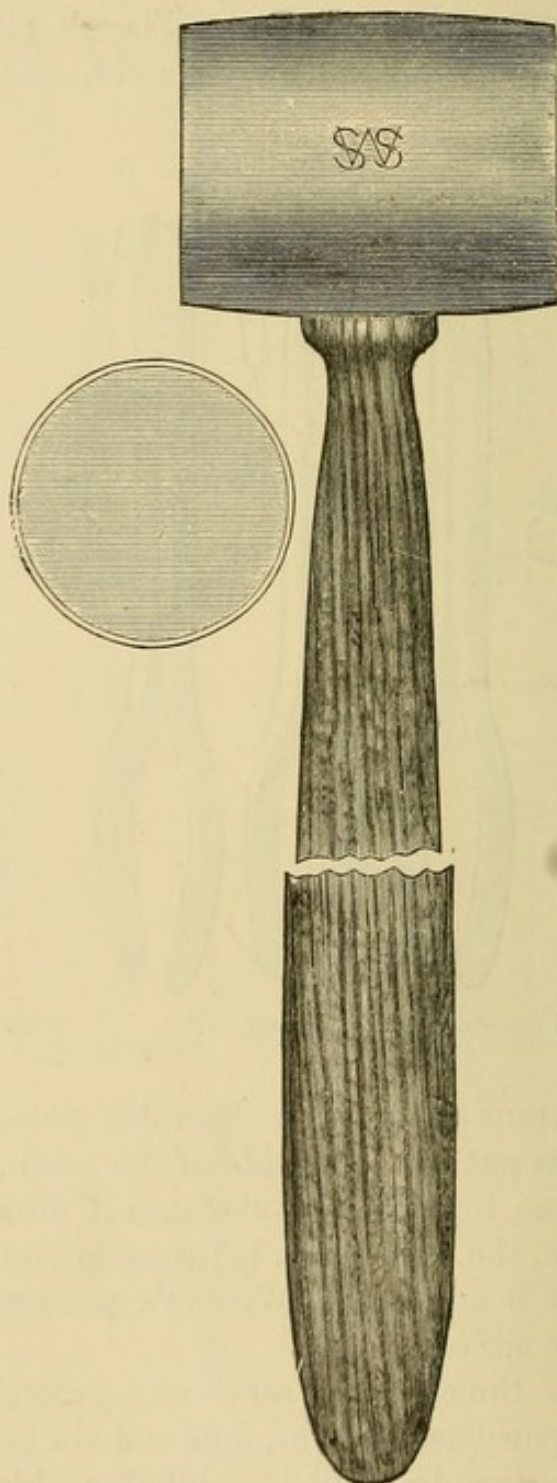
The bottom of the case will serve as a general receptacle for gold, polishing powders, napkins, four and six inches square, for keeping the cavities dry, amadou, bibulous, blotting, and test

papers. Rubber dam and punches, clamps, holders, and wedge-cutters for use with the same, may here be kept.

A hand magnifying-glass is useful to examine *débris* in excavating, surfaces of fillings, etc.

An ivory paper-folder will be of service for folding the gold, and may be kept here.

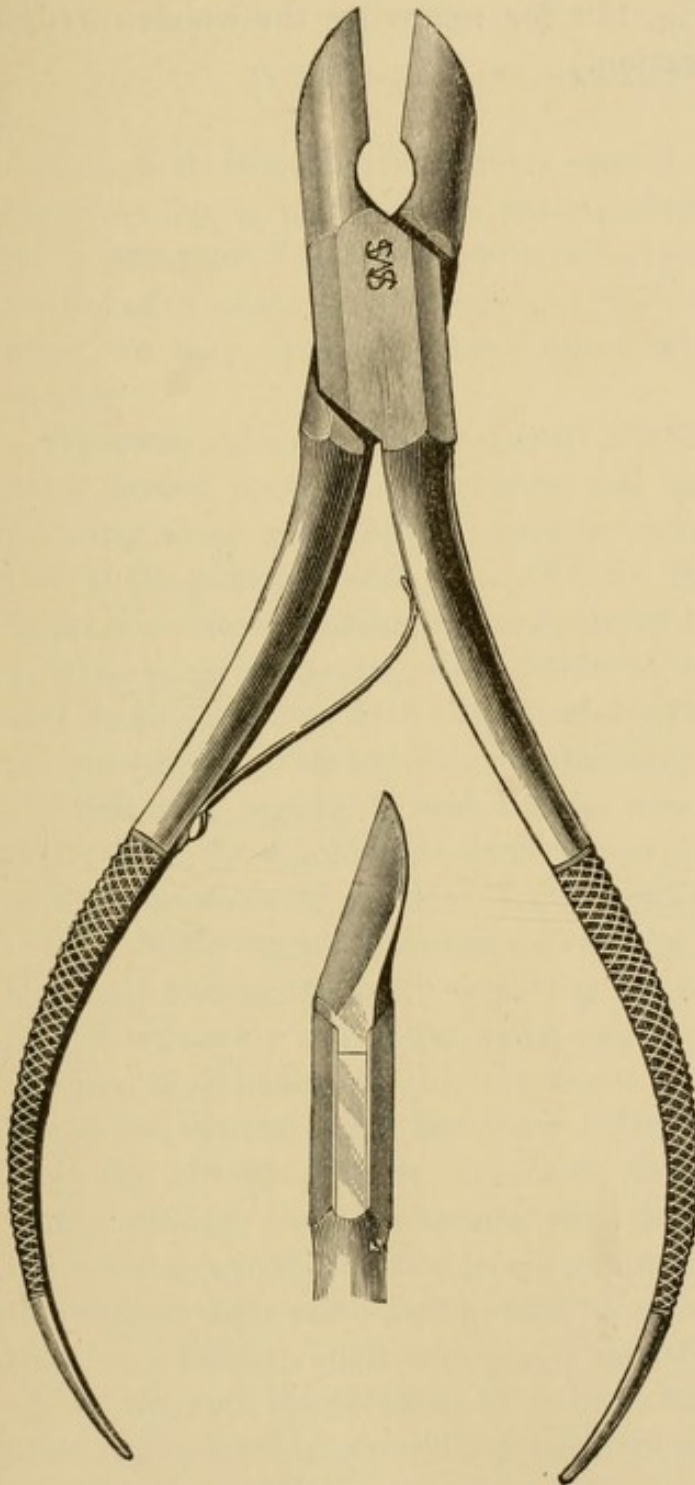
Fig. 137.



Dr. Corydon Palmer's metal tube with lead filling for mallet-head.

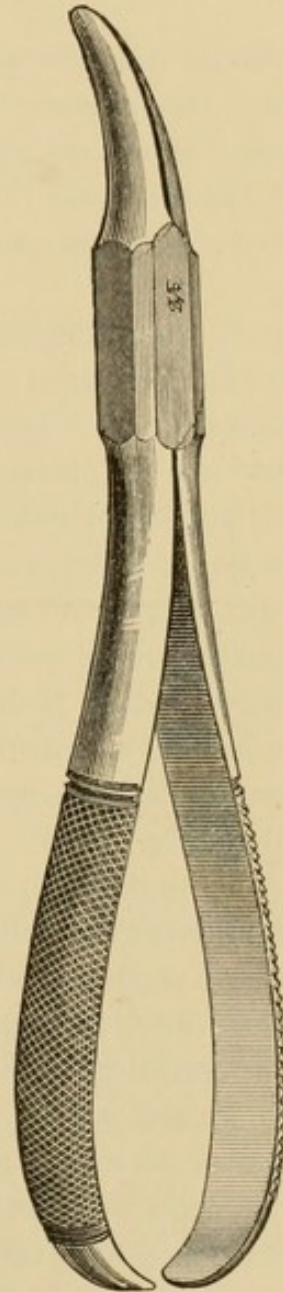
The mallet (Fig. 137), as designed by Dr. Corydon Palmer, is best kept in the tray with the plugging instruments. This pattern of mallet has the lead run into a piece of metal pipe to

Fig. 138.



Cutting pliers.

Fig. 139.



Wedge pliers. Dr. Corydon Palmer's pattern.

prevent its spreading at the ends or faces by use. This mallet may weigh half a pound, and is best used with a dead or pushing blow.

A cutting plier, Fig. 138, will also be of service for cutting off wooden wedges in separating teeth, or projecting spiculæ of the septum of bone between the alveoli after extraction of the teeth ; also a pair of pliers, Fig. 139, for removing the wooden wedge after finishing the operation.]

CHAPTER VIII.

TREATMENT OF DENTAL CARIES.

THE first consideration with regard to any disease should certainly be, if possible, its anticipation and prevention; and if, in Chapter VI., we have at all rightly comprehended the nature of dental caries, or the conditions which favor its existence, we may approach the subject with some confidence of success.

[Exercise, of an earnest and even laborious character, has long been looked upon as a safe, sure, and sensible tonic treatment to bring about a normal appetite for normal food. The Greeks had their palæstra and gymnasia, in the open air, or for bad weather under colonnades; the moderns have substituted the ill-ventilated gymnasium. But a ride on horseback, or a game of ball, or any exercise with the stimulus of an object to be attained, far outweighs in benefit derived the mere labor for labor's sake.]

First, with regard to food, we can now generally obtain bread made from the whole-meal flour, which, if not quite so palatable at first, becomes to children brought up on it preferable to any other. With regard to meat we can say little. Some attribute the early loss of the teeth to eating too large a proportion of it; but, if so, surely the Esquimaux ought to suffer considerably, whereas they have probably the finest teeth of any nation under the skies; on the other hand are tribes having excellent teeth who are almost entirely vegetable feeders. For children we would request the indulgence, viz., that during the period of their nurseryhood they be freely supplied with bones on which to exercise their teeth and gums. A child's invariable predilection for a bone to suck and gnaw must be some strong dictate of nature, and the freedom of a bone from all else than bone, after it has been in a child's possession, proves that nature most successfully fulfils her own demands.

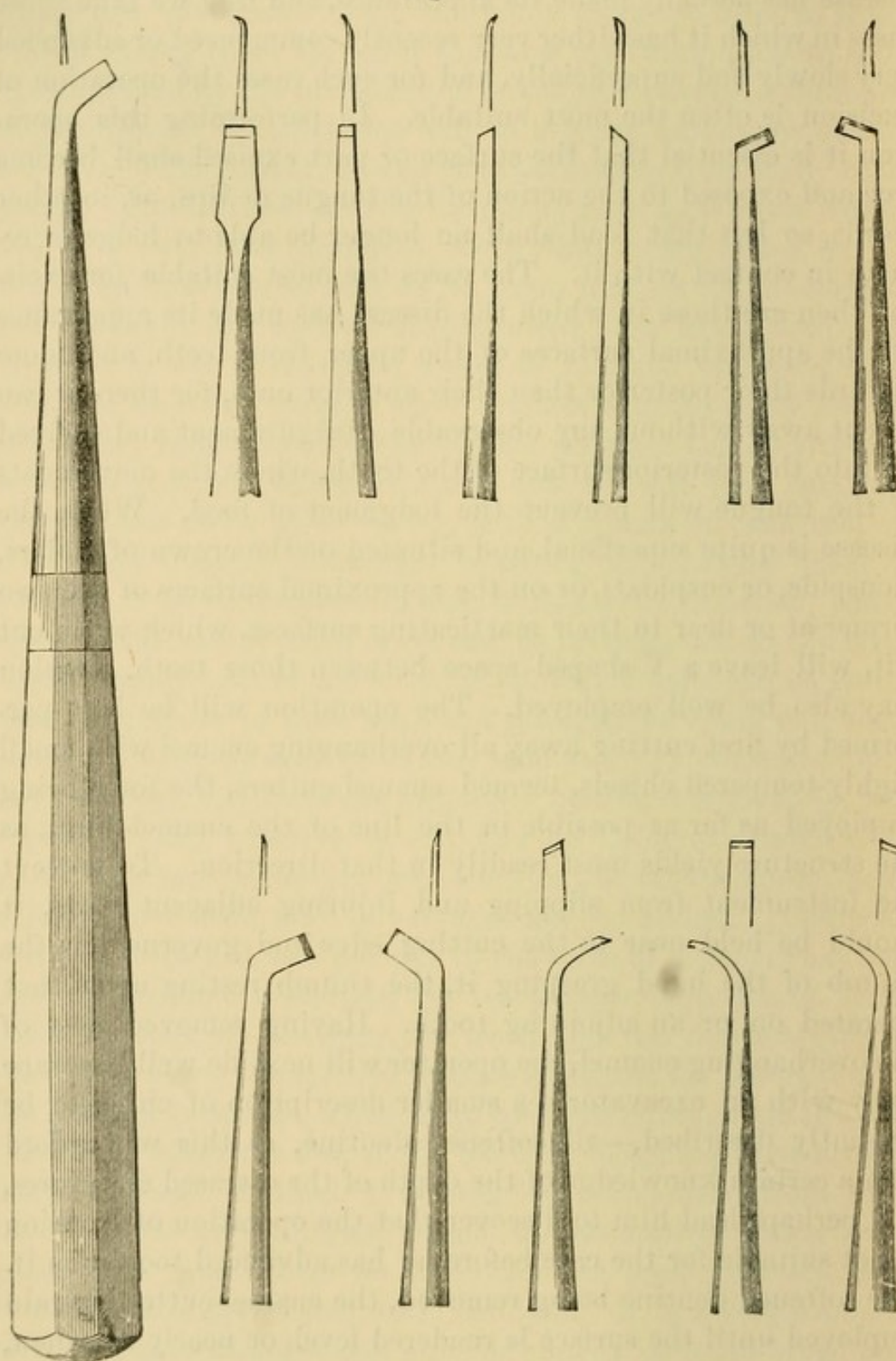
We have spoken of the knife and fork, which we believe

have much to answer for; or, perhaps, rather the civilization which has introduced them, and holds them too dear to think of ever giving them up. But the same civilization has to some extent atoned by the introduction of the tooth-brush, a thorough employment of which latter will to a great extent counteract the evils of the former, as well as those arising from many other causes. The Chinese are and have long been a civilized nation, and as a rule have excellent teeth; but every house has its family tooth-brush, as well as its comb and its tongue-scraper, and the teeth are scrupulously cleansed after every meal. At the head of his boat, where would in England be seen a short pipe, the Canton boatman fixes his tooth-brush, ready for use after every meal; and in like manner do most Indian tribes of both the new and old worlds who live on soft food carefully cleanse their teeth after eating, with a species of cane root or even hard wood. Thorough brushing after every meal is strongly to be recommended, and, if this were practised, water alone would suffice; still there can be no objection to the occasional employment of a dentifrice, of which none can be better than a mixture of pure soap and precipitated chalk; in some cases an antiseptic may be added, such as finely powdered purified charcoal, but these are generally best used separately, and a pleasant and effective one is Eau de Cologne diluted with water, to which, when the secretions of the mouth appear acid, a little salvolatile may advantageously be added. [Charcoal, while unsurpassed as a purifier in the form of a dentifrice, has, like all insoluble materials, the insuperable objection of being liable to work up between the teeth and the free margins of the gums, where the spiculæ initiate a disease, the absorption of the alveolar processes, which may continue throughout life and eventually effect the loss of the teeth by loosening their attachments.] Cases in which the foregoing recommendations have been scrupulously followed speak for themselves when compared with those where no such care has been exercised, and this especially is the case with children. It is a very common error to argue, that, because animals employ no tooth-brush and yet have excellent teeth, that appliance cannot be necessary. An animal's tooth-brush is its proper food, which, if changed for an improper one, will often result in injury to the teeth.

But we must now direct our attention to cases in which the

disease has actually made its appearance, and first we take those cases in which it has either very recently commenced or advanced very slowly and superficially, and for such cases the operation of excision is often the most suitable. In performing this operation it is essential that the surface or part excised shall become free and exposed to the action of the tongue or lips, or, in other words, so left that food shall no longer be able to lodge or remain in contact with it. The cases the most suitable for excision then are those in which the disease has made its appearance on the approximal surfaces of the upper front teeth, and more towards their posterior than their anterior ones, for there it can be cut away without any observable disfigurement and shelved off into the posterior surface of the tooth, where the movements of the tongue will prevent the lodgment of food. When the disease is quite superficial, and situated on the crown of molars, bicuspid, or cuspidati, or on the approximal surfaces of the two former at or near to their masticating surfaces, which when cut out, will leave a V-shaped space between those teeth, excision may also be well employed. The operation will be best performed by first cutting away all overhanging enamel with small highly-tempered chisels, termed enamel-cutters, the force being employed as far as possible in the line of the enamel-fibres, as the structure yields most readily in that direction. To prevent the instrument from slipping and injuring adjacent parts, it should be held near to the cutting edge and governed by the thumb of the hand grasping it, the thumb resting upon that operated on, or an adjoining tooth. Having removed most of the overhanging enamel, the operator will next do well to scrape away with an excavator,—a smaller description of chisel to be presently described,—all softened dentine, as this will afford him a certain knowledge of the depth of the diseased structures, and perhaps lead him to discover that the operation of excision is not suitable for the case before he has advanced too far in it. The softened dentine being removed, the enamel-cutter is again employed until the surface is rendered level, or nearly so, when, with files curved and bent so as to reach otherwise inaccessible places, a perfectly smooth surface is obtained, and may be finally polished by rubbing it with finely powdered pumice and water applied on a pointed piece of wood. [To obtain a more highly polished surface, many operators then use polishing-putty or

Fig. 140.



A variety of forms of enamel chisels or cutters. The forms given will, we believe, be found the most useful in practice.

tutty (the peroxide of tin), which is applied in a similar manner. For approximal surfaces it may be placed upon tape, or probably better, the old-fashioned oil lamp-wick, that has been

Fig. 141.

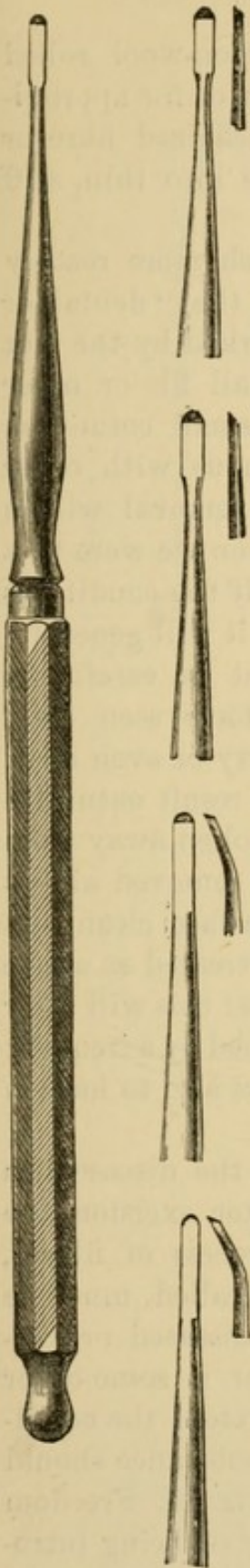


Fig. 142.

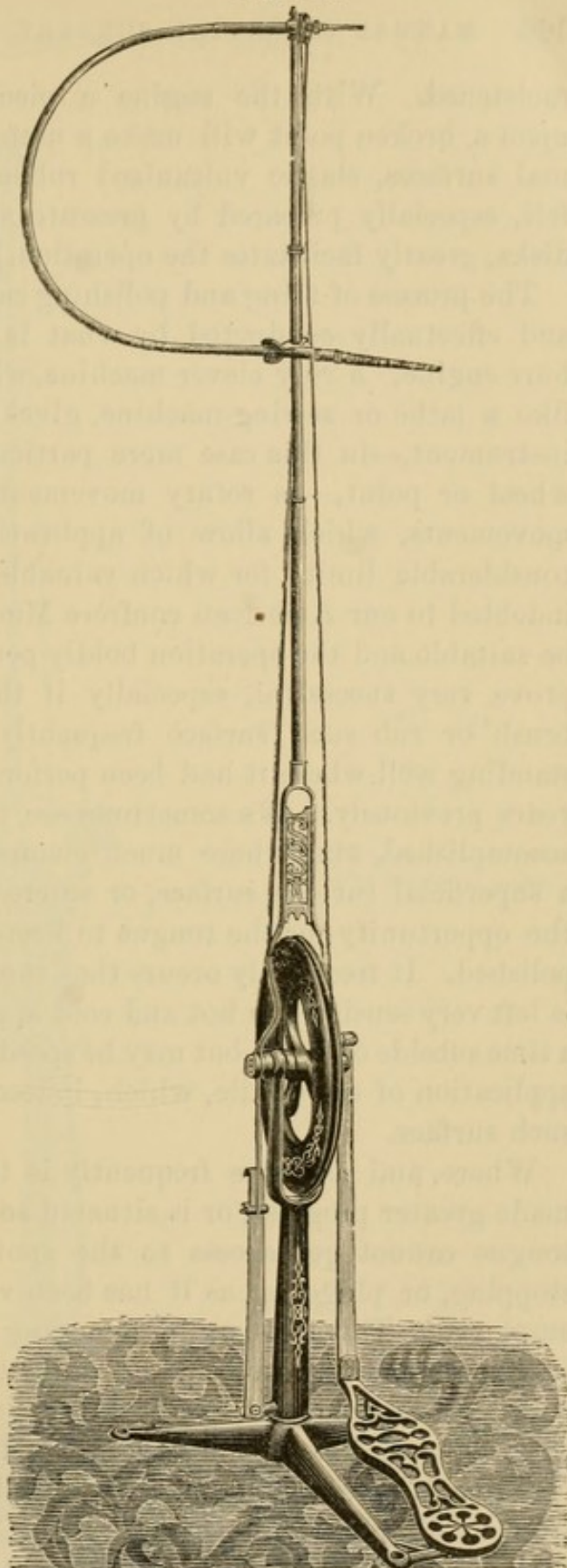


Fig 141. Very serviceable paraboloid and gouge chisels of Drs. Jack and Forbes. Fig. 142 shows the S. S. White dental engine. The fly-wheel rotated by a treadle, gives movement to the band which turns the small wheel at the top of the instrument with multiplied velocity. The small wheel is attached to a wire cord which passes in the centre of the flexible stem connected with the mandrel, and terminates in an arrangement in the latter which securely holds a burr or other instrument. To the instrument a very rapid rotatory motion is given, whilst the flexibility of the stem and wire cord permit at the same time its movement in almost any direction.

moistened. With the engine a piece of cotton-wool rolled upon a broken point will make a useful carrier, or for approximal surfaces, elastic vulcanized rubber or vulcanized fibre or felt, especially prepared by pressure and made into thin, stiff disks, greatly facilitates the operation.]

The process of filing and polishing can be much more readily and effectually conducted by what is termed the "dental or burr engine," a very clever machine, which, worked by the foot like a lathe or sewing-machine, gives to a small file or other instrument,—in this case more particularly a small corundum wheel or point,—a rotary movement continuous with other movements, which allow of application and removal within considerable limits, for which valuable invention we were first indebted to our American confrère Morrison. If the conditions be suitable and the operation boldly performed, it will generally prove very successful, especially if the patient be careful to brush or rub such surface frequently. We have seen cases standing well where it had been performed thirty or even forty years previously. We sometimes see the same result naturally accomplished, viz., where much enamel has broken away from a superficial carious surface, or where a tooth removed allows the opportunity for the tongue to keep such surface clean and polished. It frequently occurs that the surface treated as above is left very sensitive to hot and cold applications: this will after a time subside of itself, but may be speedily lessened by a frequent application of salvolatile, which, indeed, appears also to harden such surface.

Where, and as more frequently is the case, the disease has made greater progress, or is situated so that, after excision, the tongue cannot get access to the spot, the process of filling, stopping, or plugging, as it has been variously called, must be employed. This consists in removing all the diseased or softened portion of the tooth, and substituting for it some other substance capable of fulfilling to the greatest extent the conditions and qualities of the structure lost. Such substance should combine, if possible, the following conditions, viz.: 1. Freedom from liability to cause irritation; 2. Capability of being introduced in a soft state, and then, without change of bulk, becoming hard enough to resist the friction and wear of mastication; 3. Power of resisting to a considerable degree the action of chemical reagents, or the effects of any such temperature as

[Fig. 143.

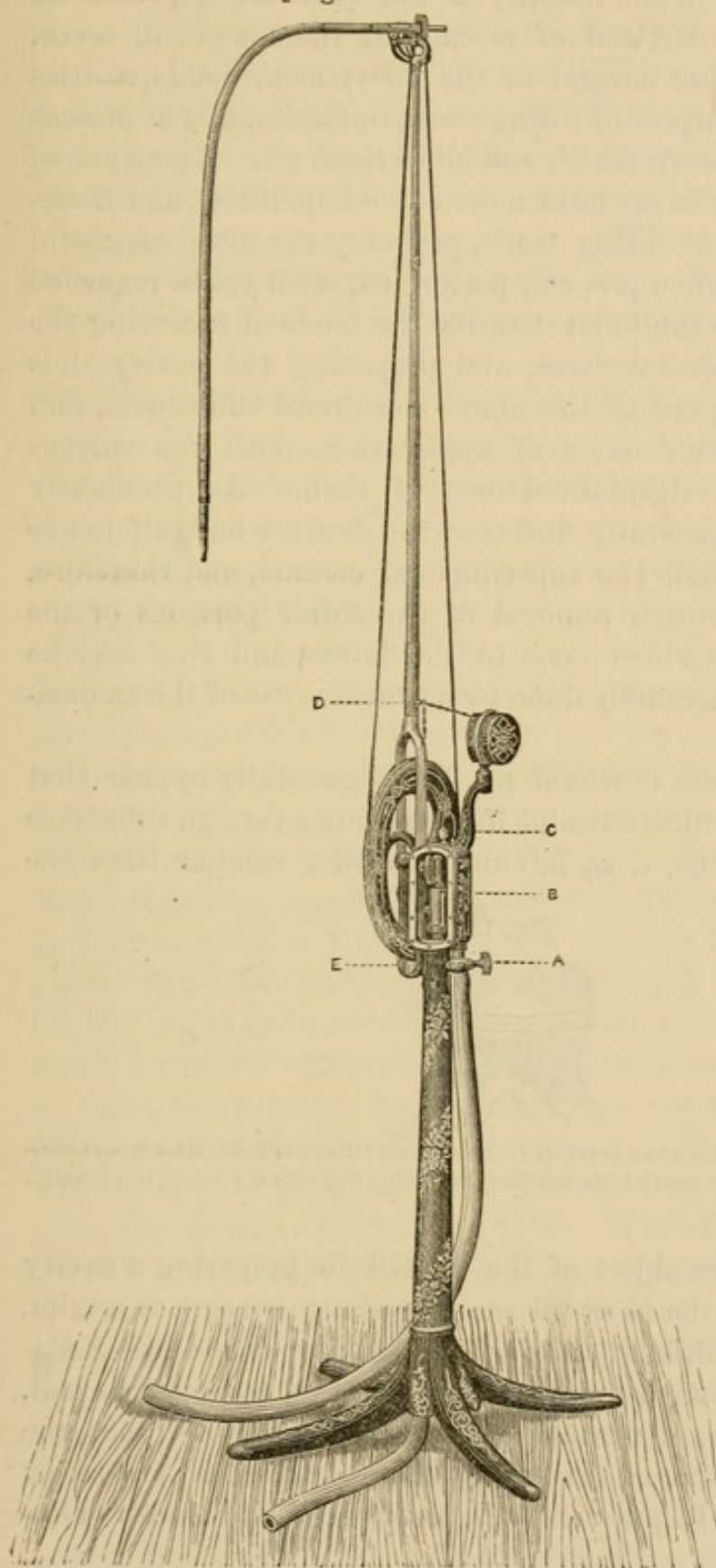
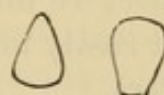


Fig. 144.

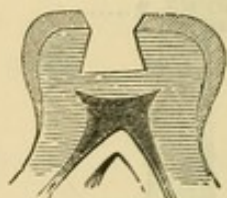
Corundum points used
with the dental engine.

The S. S. White water motor, dental engine.]

could be tolerated in the mouth; 4. The qualities of possessing an unchangeable color, and of resembling the enamel of teeth. Substances possessing several of the above-mentioned qualities are in use for the purpose of filling teeth, but unhappily at present there is not one known which combines them all. Every one of these substances fails in one or more of such qualities, and therefore the operation of filling teeth, probably the most successful of any in surgery when properly performed, must yet be regarded as imperfect. We shall first describe the mode of removing the softened disorganized dentine, and preparing the cavity thus made for receiving one of the above-mentioned substances, and then point out their mode of application, with the various qualifications and disqualifications of each. As previously noticed, we shall generally find that the dentine has suffered to a greater extent than the superimposed enamel, and therefore, to insure the thorough removal of the softer portions of the former, we must sacrifice some of the latter, and this may be most easily and effectually done by a cautious use of the enamel-cutters.

At the first aspect it would no doubt generally appear that the form of cavity most suitable for retaining a foreign substance would be cavernous, *i. e.*, having an orifice smaller than the

Fig. 145.



The typical form of a cavity when prepared for receiving a filling: in the dentine it represents a truncated cone, the base of which is the bottom of the cavity, whilst in the enamel it is bevelled off in the opposite direction.

cavity itself. [The object of the dentist in preparing a cavity for filling, should be to avoid making sharp corners or angles, as they are more difficult to adapt the gold or other filling material to. Indeed with amalgam, owing to its tendency to ball, or form spheroids, our latest authorities recommend that the cavities should be shaped to correspond with the forms most likely to be assumed.]¹ In practice it is, however, found that a cylin-

[¹ "Plastics and Plastic Filling," by Prof. J. Foster Flagg, D.D.S., p. 81. Presley Blakiston, Phila., 1881.]

drical, or nearly cylindrical, form will be the best; the most perfect being slightly conical in the dentine, the base being the bottom of the cavity, and the same in the enamel, but reversed; in fact, two cones meeting towards their truncated apices. It will, of course, be impossible in many cases to obtain a cavity of such form, but taking it for a type we may always endeavor to obtain some approximation to it. Where the orifice to the softened dentine is small or narrow, we shall best enlarge it by the broach or burr drill, the former a kind of five-cornered drill, the latter a file to be rotated. Sufficient enamel having been removed to allow the use of excavators, if necessary—for small cavities may be entirely cleared out by the broach or burr drill—the softened dentine is scooped out until a clear and ringing sound, and sensation of density to the fingers, announce that this portion of the process is completed. The excavators before mentioned are small chisels, or scoops, and may be obtained of suitable sizes, and almost every form conceivable, to reach cavities in obscure places. They should be made of the best steel, tempered high at their points, but low just beyond where the instrument becomes thin, and frequently bent at an angle. Great difference of opinion in regard to their form may be exercised without prejudice; but in our experience those having the cutting extremity resembling a spoon do the work most rapidly and thoroughly, and with less risk of penetrating to dangerous places than those having the ordinary chisel points. It is well for the beginner to endeavor to ascertain at the outset the most useful forms, and those especially adapted for the greatest variety of cases, there being much loss of time and fatigue in having continually to change the instruments. The defective dentine will be soft in proportion to the rapidity of the disease, and generally sensitive in the same ratio. Whilst it is most desirable that all the softened and diseased dentine should be removed, it is yet all-important that the vascular and nervous portions which occupy the central cavity in the tooth should not be injured or exposed; and the student will do well to avail himself of opportunities of splitting into sections extracted teeth, in order to gain a lively recollection of the relative positions of the so-called pulp. After removal of the softened dentine it will often be found that the resulting cavity is too shallow and too saucer-shaped to retain a filling; under these circumstances some of the healthy

structure must be sacrificed. Here excavators of the chisel form will be most effective: they should be made very sharp and applied with a firm and unvibrating stroke to a dried surface, which reduces the amount of pain experienced.

Fig. 146.

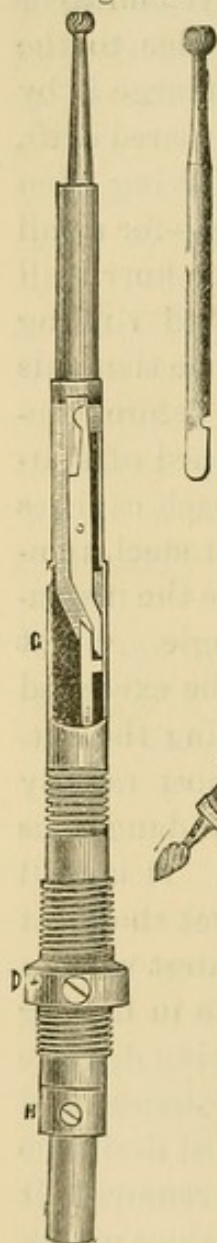


Fig. 147.

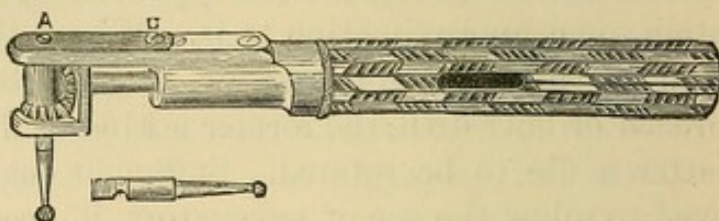


Fig. 148.

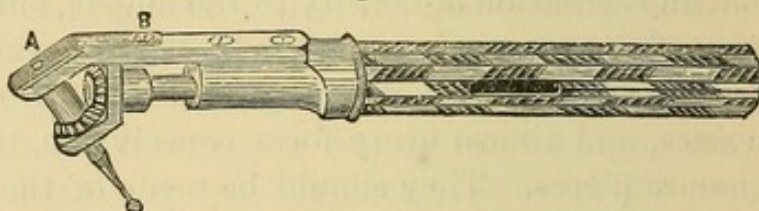



Fig. 149.



Figs. 146, 147, 148, and 149, various forms of mandrel or handpiece for the dental engine, 146 straight, 147 right angle, 148 acute angle, 149 obtuse angle. In Fig. 146 is shown the method for securing the instrument or bit.

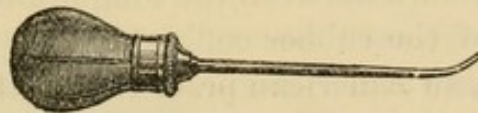
[Recently the writer has been using a universal handpiece, of pattern devised by Dr. H. C. Register, having a device for grasping and centering any ordinary drill. The construction seems to be very simple and effective, resembling the universal lathe-chuck. In addition to the ease with which points may be changed in it, the grip of the tool is equally firm whether revolved to the right or left. The latter is of great advantage when running the disk between teeth, as the cutting is less unpleasant, and the wheel less likely to jam when it cuts in the direction from the necks towards the edges or masticating faces of the teeth.

For painless excavation, the scoops are rapidly gaining friends, because they enable the operator, by passing down to the floor of the cavity, with a few sweeping rotary cuts, to sever the connection with the pulp of the dentine to be removed; then, by drawing the instrument outwards toward the enamel, the *débris* is drawn out almost without sensation. In this way, with a little care and skill from practice, it frequently happens that the pulp of the tooth may be uncovered of its overlying softened carious dentine without a single complaint from the patient.

It may also be added that the scoop is of almost universal use. Upon turning the edge downward, the overhanging enamel and perpendicular walls may be cut. Fissures may be followed up by the same movement, which can be assisted by a slight or partial rotation of the instrument upon its axis. For many cases one or two sizes of scoops, say Nos. 68 and 67, will be all that are required to prepare a tooth for filling.]

When it can be tolerated, the healthy dentine is most readily removed with burrs rotated by the engine, and which can be applied at almost any angle. It is desirable, after removal of the dentine, to render smooth the enamel where cut by enamel-cutters, either by the file or by the corundum point with the engine, and give to it a slightly countersunk form. All particles of tooth or *débris* should now be carefully removed from the cavity by the syringe, either with tepid water or with air; the latter only where the tooth has been kept quite dry during the process of excavation. The small India-rubber syringes (Fig. 150) employed for this are very convenient, as they necessitate

Fig. 150.



Flexible India-rubber syringe.

the use of but one hand, and when empty refill themselves if the nozzle is placed below the surface of water before relaxation of the pressure which emptied them.

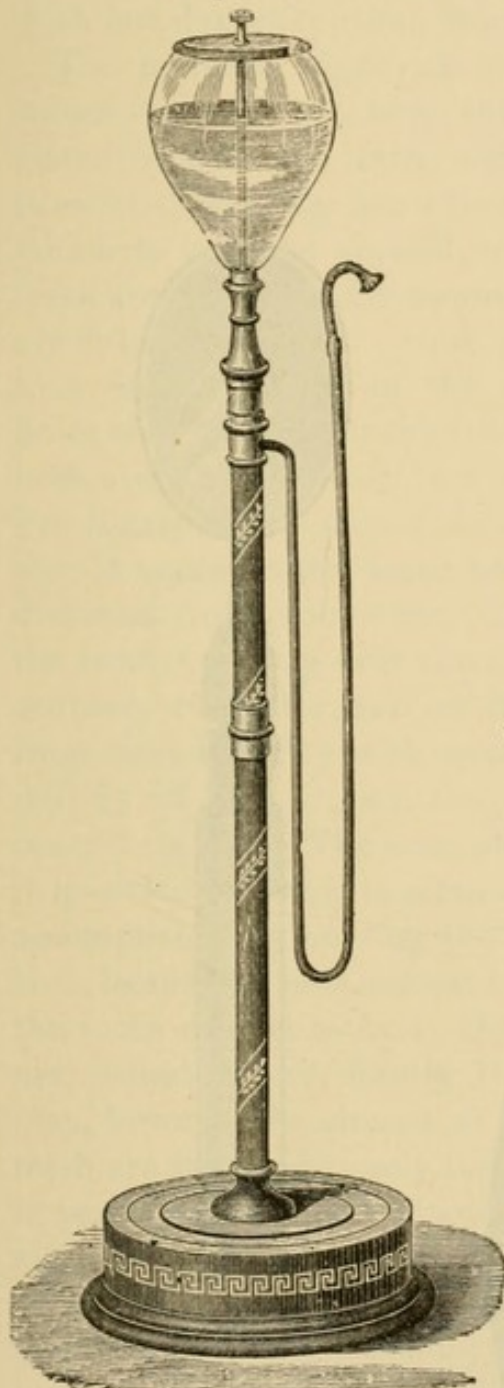
[Some of these, however, have the great objection that, when they stand a short time during the operation about half filled with warm water, the air within them becomes saturated

with a sulphurous odor that makes it inexpressibly disagreeable when it is forced into the mouth. Glass, celluloid, and metal syringes are not yet surpassed for cleanliness, and the trifling inconvenience of refilling may be submitted to, as it may be performed while the patient is expectorating.]

The next consideration, and a very important one, if this has not already been done, will be the protection of the cavity from access of moisture during the insertion of the filling. It may be effected by placing folds of blotting-paper or linen cloth, or the folded extremities of a long narrow piece of diaper, the older and softer the better, on the one side between the tooth and the tongue, and on the other between the tooth and the cheek, and retaining the same by the finger and thumb of the left hand; or, if the patient be more than ordinarily intelligent and tractable, by his fore and middle fingers of either hand. A variety of ingenious instruments termed napkin-holders have been devised, but those long accustomed to this method of protection will mostly prefer the cloth or paper under the control of their own hands. If the operation prove a long one, and especially upon teeth of the lower jaw, the saliva will be almost certain to saturate the paper or cloth and find its way to the cavity. To obviate this, valuable instruments, termed saliva-ejectors, have been introduced, that devised by Claude S. Rogers (Fig. 151) being probably the simplest, if not quite so effective as Fisk's (Fig. 152). Its action consists in creating a vacuum in a tube by the pressure of water flowing down the same, entering through an orifice in the tube. To the upper open extremity of the latter an elastic tube, terminating in a suitably curved nozzle, is attached, which the patient holds in the sulcus in his mouth between the tongue and lower jaw. The ingenious device of the rubber coffer-dam, for which we are indebted to Barnum, an American practitioner, if less agreeable to the patient, certainly achieves in a most perfect manner the object contemplated. Its advantages are the following, viz.: It being placed in position before excavation is commenced, the cavity does not become continually filled with saliva, nor the view of the same obscured, nor consequently frequent drying required, the *débris* being blown out with the air syringe. It also permits the patient from time to time to close the mouth and to swallow the saliva, also better to intimate if he suffer

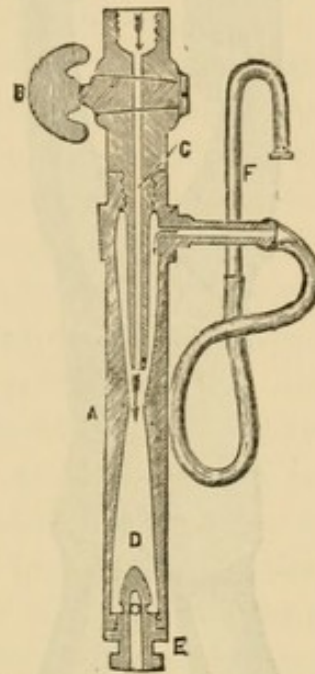
pain, etc., unduly. By its use both hands of the operator are set at liberty. The operator will find this of immense advantage to him when filling teeth in positions the cavities of which

Fig. 151.



C. S. Rogers's saliva ejector.

Fig. 152.



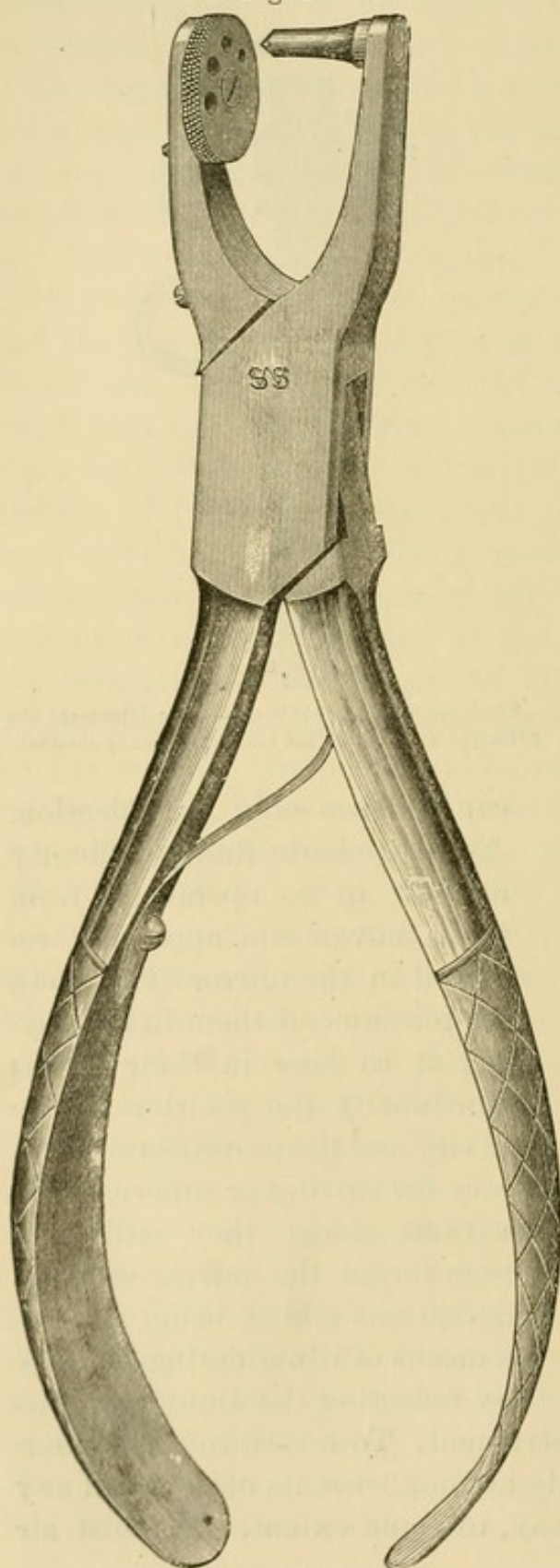
Sectional view of Fisk's ejector, to illustrate the principle upon which the sucking action is obtained.

can be seen only by reflection. As all students find a difficulty at first in so operating, from their movements appearing reversed in the mirror (Fig. 154), we recommend them in employing it to bear in their minds continually the position of the cavity and the movements necessary for cutting or otherwise its various sides: they will thus soon forget the mirror with its deceptions whilst using it. As a means of illuminating a cavity by reflecting the light, the mir-

ror is also a very valuable instrument. To return to the rubber-dam, it much more thoroughly accomplishes its object than any other plan, even keeping away, to some extent, the moist air

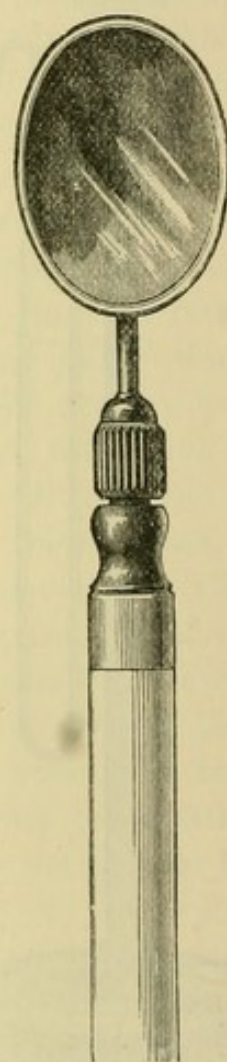
exhaled from the lungs. By the aid of clamps it can be applied in almost any situation, and can be used, and to the comfort of

Fig. 153.



[Punch for making holes in the rubber dam.]

Fig. 154.



Silvered glass mouth-mirror, with ball-and-socket joint for placing it at various angles.

the patient, in conjunction with the saliva-pump. As this appliance has become so important a feature in the present day, we shall describe its mode of application, admitting at the same time that in common with many of the older practitioners we have used it much less, and therefore probably can apply it with less dexterity, than many of our juniors.

The material employed is thin sheet India-rubber: in substance it should not be so thick as to occupy much space when placed between the teeth, nor so thin as to tear. Of this a size is selected, varying according to the position of the tooth to which it is to be applied, being necessarily larger when back teeth are included. By means of a punch (Fig. 153) circular holes are cut in the rubber: thus, if we were about to apply it, say, to a central incisor of the upper jaw, we should make three holes so as to include the tooth in question and its two neighbors, and about $\frac{1}{32}$ inch in diameter, and $\frac{1}{8}$ inch from each other. For bicuspsids we should do much the same, but for molars we should make rather larger holes, $\frac{1}{16}$ inch, and at rather greater distances from each other. In place of the punch we may draw the rubber tightly over the extremity of the steel handle of an ordinary excavator, and on its being touched a short distance from the extremity with a penknife, a small quite round disk will fly off from it; a little practice will enable an operator to control its size. The next proceeding will be, to place the dam in position, and this is often anything but easy to do. It is best accomplished by holding the dam by the thumbs and fingers of both hands, the hole nearest to the operator being stretched over the tooth nearest to him; then the next in order is in like manner included, and, finally, the third tooth: this arrangement may, however, be altered as convenience dictates. Where the teeth are arranged closely together, difficulty will be experienced in passing the rubber between them: to facilitate this an instrument (Fig. 155) carrying a tensely stretched piece of silk or thread will be found very convenient, and the thread or silk may be detached and employed for tying round the teeth adjoining the one to be filled. Floss silk rubbed with beeswax will be found the most suitable material for tying with, from its smaller liability to slip.

In cases where teeth stand alone, or where, even when the dam can be tied on to adjoining ones, it cannot be carried so far

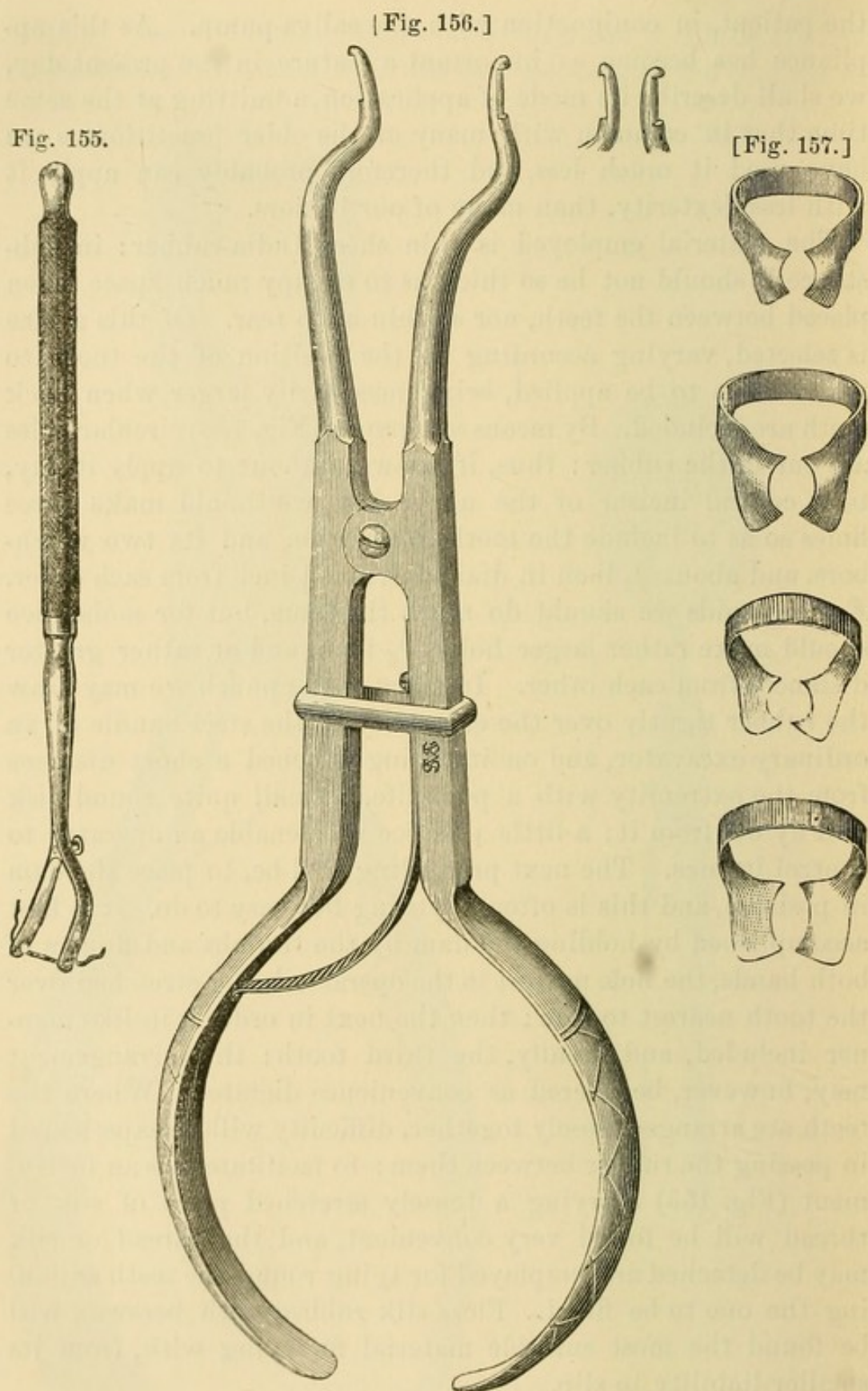


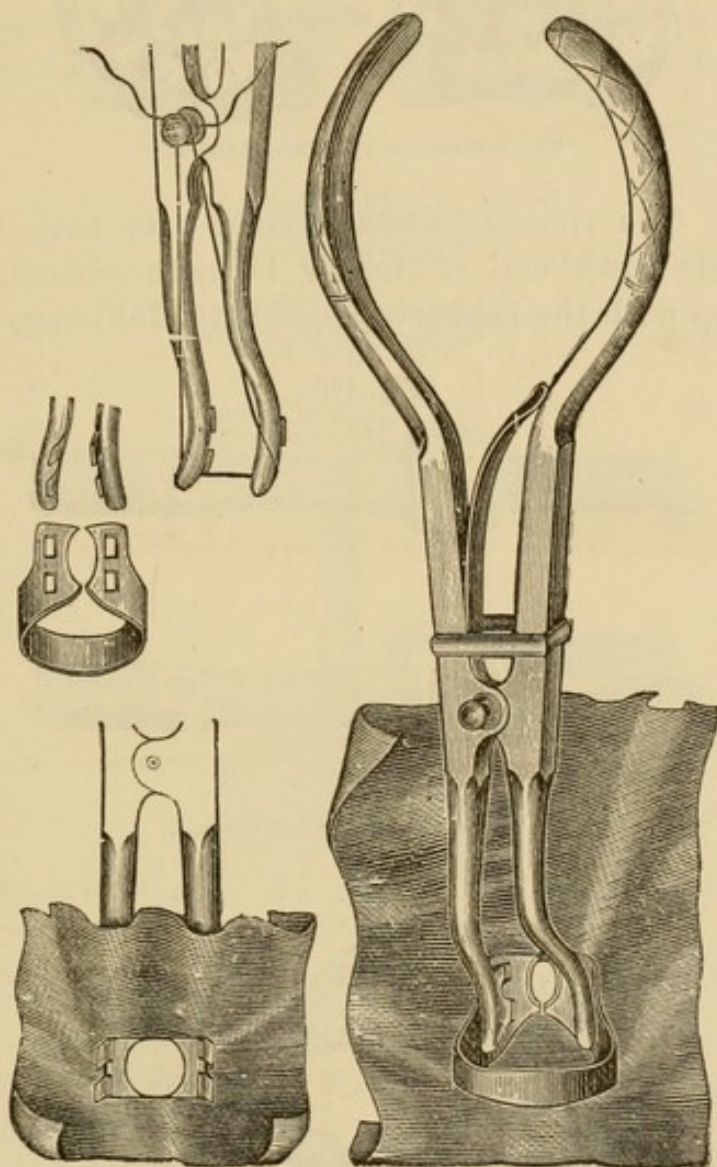
Fig. 155. Instrument for applying the coffer-dam. Silk or thread is passed into the grooves of the fork end, and tightened by winding it round the steel button. By means of the tense thread the dam can be pressed between the teeth.

[Fig. 156. Clamp forceps. Bowman Allen.]

[Fig. 157. Dr. Tees' rubber-dam clamps.]

upon the neck of a tooth as to bring it beyond the radical extremity of the cavity, the clamp may be employed; thus, if we

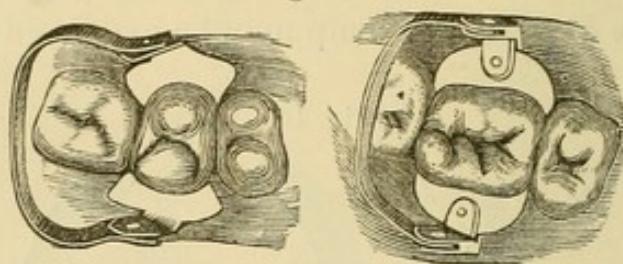
Fig. 158.



Method of applying the rubber-dam as secured by means of the clamp. In this arrangement (Elliott's) the clamp forceps may also be employed in the place of Fig. 156.

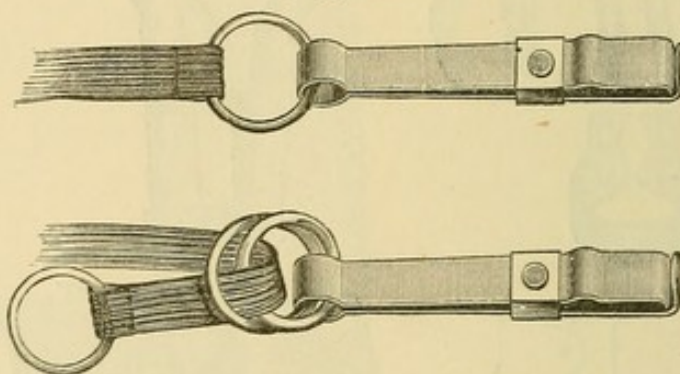
were desirous of placing the dam upon an upper or lower third molar standing alone, we should carry the clamp to the tooth by the clamp forceps. This ingenious appliance (Fig. 156), when its blades are inserted into the clamp, and its handles pressed upon, not only obtains a secure hold upon the clamp, but also distends its elastic sides, permitting them to go over the crown of a tooth and be adjusted to its neck, when, by relaxation of the pressure, the blades of the forceps are set free, and the clamp

Fig. 159.

The rubber-dam and clamp *in situ*.

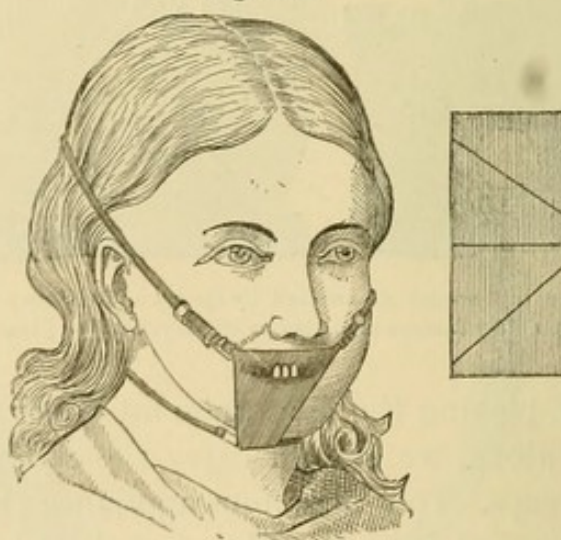
left *in situ*. The rubber is now applied over both clamp and tooth, a little additional stretching being necessary (Fig. 159), or the clamp with the rubber upon it (Fig. 158) may be applied

[Fig. 160.



Dr. Cogswell's rubber-dam holders.

Fig. 161.



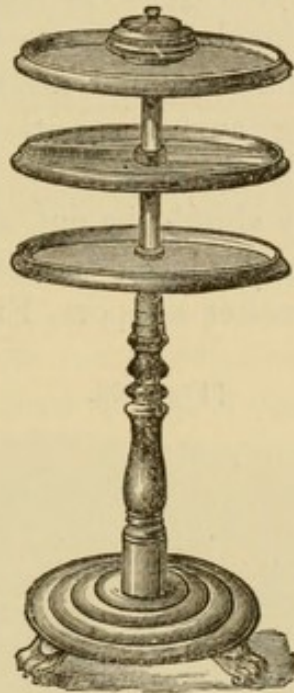Shape for rubber-dam to admit of easy respiration and to make two triangular pieces of one square.]

at the same time. The rubber-dam being adjusted, its projecting sides are drawn to the cheek of the patient by the dam-holder,

an elastic band which passes round the head, and terminates at either end in clips which grasp the rubber-dam (Figs. 160 and 161).

The cavity being protected from access of moisture, and carefully dried, if necessary, by amadou, thin bibulous paper, or cotton prepared purposely, the operator proceeds to insert the filling which he has selected. Let us first presume this to be a

Fig. 162.



Owen's dental table with three trays to hold instruments, and suitable box on top tray for holding gold.

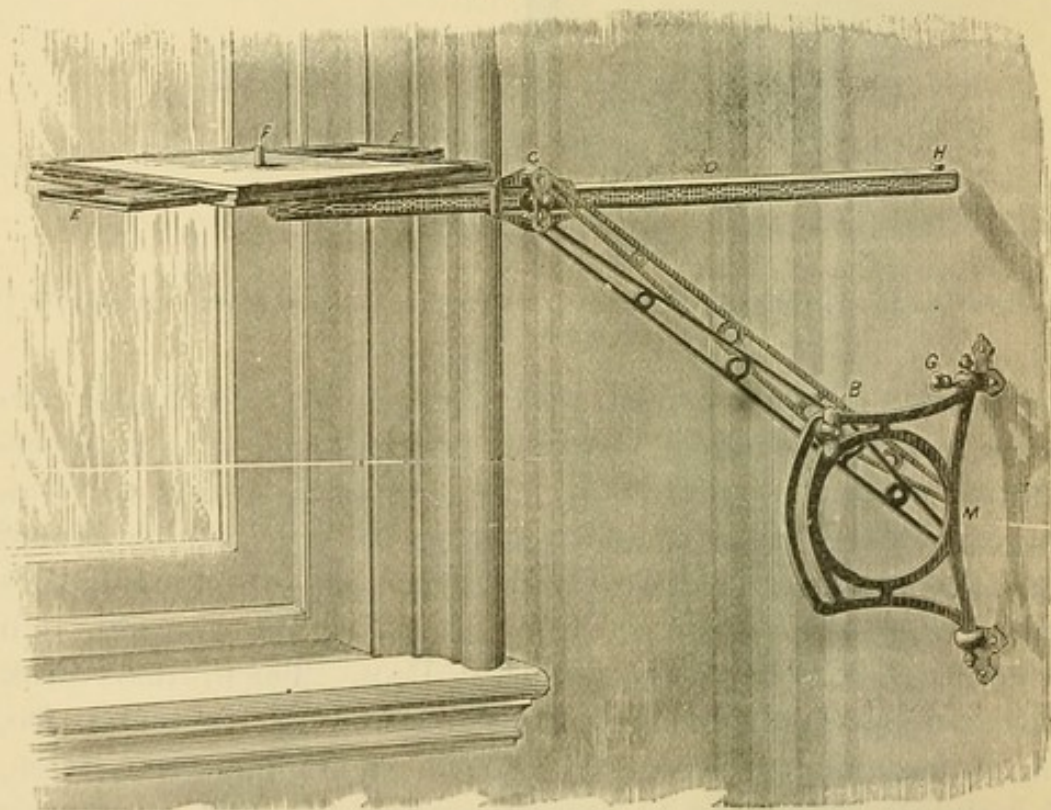
preparation of gutta-percha, which, as employed for dental purposes, is a compound of the gum purified, and with it incorporated some fine siliceous or hard material, giving to it an increased hardness without impairing its color, which should be nearly white. The two varieties most employed are Jacob's and Hill's,—the names of their respective introducers. [In America, S. S. White's and Johnston Bros. The ordinary pink gutta-percha as prepared for impressions, and for trial plates also, has its use and its friends.] The first, an English preparation, is certainly, according to our experience, the best as regards both color and durability; but the latter, an American compound, is more easily employed, because rendered softer and more adhesive at a lower temperature. [Great stress is now laid by some practitioners upon the different grades of plasticity of different preparations of gutta-percha. They commence in the

deeper portions of cavities with the material that softens at the lowest temperature, in order to avoid irritation of the teeth pulps, finishing by overlaying this with a harder grade that requires more heat to render it plastic.

This material is now highly recommended for the filling of cavities on approximal surfaces of teeth, and particularly when they run to the cementum, in which position it very effectually resists the action of the acid from the irritated gum, which will attack and cause oxychloride fillings to be washed out at these points. The fillings, when deemed desirable, may be finished toward the masticating surfaces with oxychloride, to give strength to weak walls.]

Some of either variety should be cut into pieces smaller than the cavity to be filled, and placed on a small, but steady table, Fig. 162, or movable bracket support, Fig. 163, placed near to,

[Fig. 163.

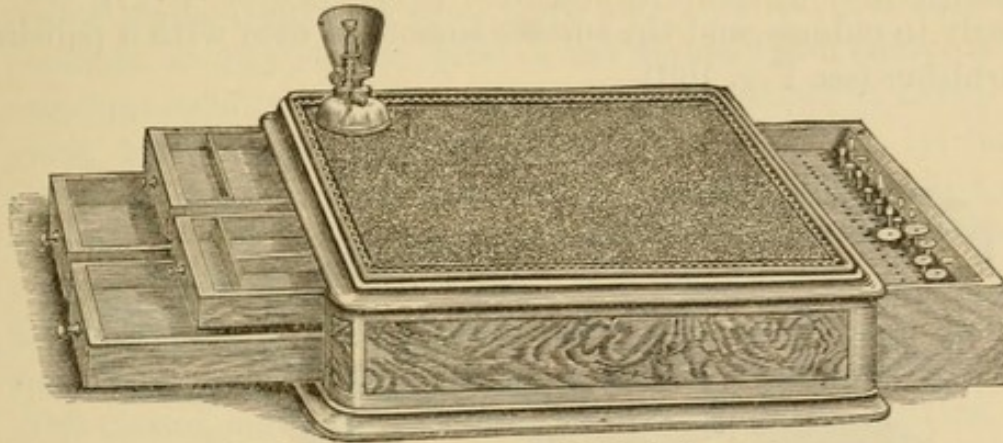


The Morrison bracket.]

and about the same level as, the patient's mouth, on which should be arranged all the instruments and appliances that the operator will, or will be likely to, require during the operation. Amongst these a spirit lamp will be requisite; and, all being

ready, he should warm the point of a small steel instrument bent at a suitable angle, and covered at a short distance from

[Fig. 164.



Dr. C. F. Allan's pattern of table for the bracket.]

the extremity with some non-conducting substance, to prevent the lips from being burned should it chance to touch them, and thus attach it to a piece of the gutta-percha. These instruments are conveniently formed out of broken excavators, of which the operator has generally but too large a stock, and with these the gutta-percha is carried to the flame of the spirit-lamp and passed just over or through it, backwards and forwards, long enough to soften it, but before any smoke is seen to ascend from it. At a less degree of heating it is not sufficiently soft or adhesive: at a greater, it will burn, and its surface be injured and powdery. A more suitable appliance than the spirit-lamp for heating the gutta-percha is a tray or dish surrounded with hot water, Fig. 166, as the material is more evenly heated and

Fig. 165.

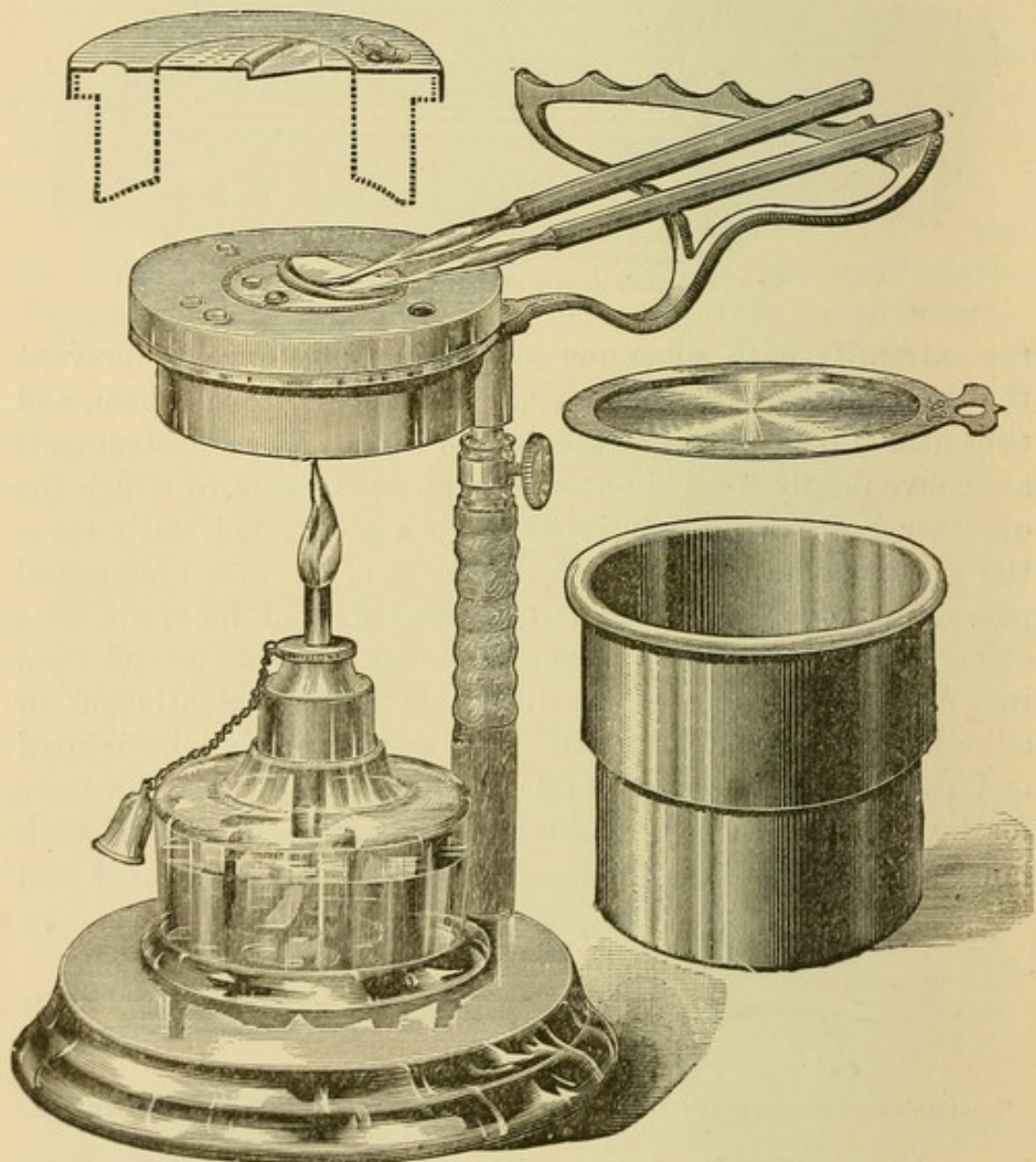


Houghton's steel spatula of suitable form for finishing off gutta-percha and amalgam fillings.

in no danger of being burnt. When thus heated to the right degree it is carried to the cavity and attached to that side or part of it which is the least accessible, and this is often accelerated by employment of a second instrument not heated. The heat on contact may cause some pain, but seldom of long duration, and the second and succeeding portions, when attached to

the first, which should adhere firmly, cause generally much less pain. In this way the cavity is filled, or a little over-filled, when the superfluous portion may be cut off with a thin spatula of steel, or, better still, of platina, see Figs. 165, 167, heated nearly to redness, and the surface smoothed over with a polished burnisher (see Fig. 169).

[Fig. 166.]



Prof. J. F. Flagg's lamp and water-bath.]

Gutta-percha filling possesses the following recommendations. It is applied without much difficulty, becoming readily softened by heat, and very soon hard again; it adheres to a tooth with some force, and may therefore be employed when a cavity is

shallow and badly adapted for retention; it requires but little pressure, a qualification where the walls of a tooth are slender; it is, probably owing to its vegetable nature, the least likely to cause irritation of all the substances that we so employ; it resists moderately well such acids and alkalies, also such temperature, as may be met with in the mouth; and, lastly, it is of excellent color, very fairly resembling the enamel of teeth. Its great disadvantage is, however, a serious one, viz., its insufficient hardness to resist the force of mastication; and it soon wears away, and is also pressed away from surfaces exposed to friction. In time also it appears to break up and become somewhat permeable to fluids, and therefore to emit an offensive smell; still we have in favorable cases seen it preserving a tooth after eleven, and even twelve, years without reapplication. Its employment will be found most valuable in cavities situated at the necks of teeth, especially when extending under the gum. [The pain from the heat may be almost entirely avoided by using at first thin layers or disks of easily softened gutta-percha upon the floor of the cavity. The finishing with a warmed instrument must be cautiously done, lest the gum or the filling be burned. It is better to pass the warmed instrument but once after wiping, and always toward the edges of the filling. Chloroform used upon a pellet of cotton or a piece of common lamp wick, makes a nice-looking finish, but it seems to soften the surface and dissolve off the gutta-percha, rendering it less likely to retain its proper contour. The greatest difficulty in these fillings is the danger of moisture, blood, etc., working in before the filling is completed, as they will prevent the adhesion of the gutta-percha to the teeth or the cohesion of one portion of layer to another.]

Zinc oxychloride, vended under the absurd names of osteoplastic, os-artificial, artificial enamel, etc., are supplied by various makers in the form of zinc oxide in powder, and the zinc chloride in fluid: in many the former is mixed with some finely powdered siliceous material, to increase the hardness, whilst, the latter containing some water, a combination is formed resulting in a cement, which, like others of a similar class, takes up some of the water as a base, and thus forms hydrated oxychlorides of the metal.

In employing this filling, a little of the powder is placed on

a glass or porcelain slab with a drop or two of the liquid, and the two mixed into a thick paste with the platina or an ivory spatula, and conveyed by the same to the cavity, previously dried, and is carefully worked against its sides, to ensure per-


Fig. 167.



McAdams's combined spatula and stopper, constructed of hard platina and mounted in ivory, suitable for oxychloride and pyrophosphate of zinc fillings.

fect adaptation and the exclusion of air-spaces; the later portions added may with advantage be of thicker consistency. The filling, if fresh, sets in a few minutes, but it may be well to coat it with varnish, or gutta-percha dissolved in chloroform, before permitting the moisture of the mouth to have access to it. After it has properly set, rubbing its surface with some highly polished substance, such as agate, for instance (Fig. 168),

Fig. 168.



Rowney's agate burnisher for polishing and hardening the surface of fillings.

will, by lessening its porosity, increase its resisting powers in the mouth.

[The burnisher may be warmed, and thus hasten the setting of the oxychloride, with seeming gain of hardness. A patent has been taken out for the use of instruments made of talc, by which the warming may be accomplished and the surface of the filling polished, and thus rendered somewhat less likely to permit water to soak into the mass.]

The advantages possessed by the zinc oxychloride are: Ease in application, rapidity in setting, a considerable degree of hardness when set, attachment to surfaces when dry with considerable force, and therefore great suitability for shallow cavities and cavities with very fragile walls, and a color, though not equal in this respect to gutta-percha, still nearer to that of the teeth than many other substances employed. Its disqualification, and that a most important one, is, that it is acted on by weak acid

and alkaline solutions, and even, to a minute extent, by pure water, hence it cannot be relied on as a permanent filling, yielding, in contrast to gutta-percha, the most unfavorable results when applied at or near to the margin of the gum. It also produces considerable pain when applied to very sensitive dentine; but this disadvantage is more than counterbalanced by its power of destroying such sensibility, as we shall presently show. It would be difficult and unsafe to make any statement as to the varieties which are most to be depended upon, further than that in our hands the compounds of Franzelius and Ash have, on the whole, yielded the best results. No doubt, in time, these compounds will be rendered more perfect.

Closely resembling the oxychloride in character is the pyrophosphate of zinc, vended like the former, but having the pyrophosphoric acid in crystals. Therefore, when it is employed, the crystals must be melted, which is best done in a platina or porcelain spoon held over a spirit-lamp, ebullition being avoided; and, when fluid, or reduced to about the consistency of glycerine, it is dropped on the slab mentioned, which, in cold weather at least, should be previously warmed. It mixes less readily than does the oxychloride, and, if it be mixed too thickly, a crumbling mass results, or, if too thinly, a sticky, unworkable one: the proper combination will be, when it can be rolled between the finger and thumb without sticking to them or breaking to pieces. As it sets very rapidly, no time must be lost in conveying it to the cavity, and its introduction into the cavity is facilitated by the pressure of a highly polished steel burnisher: a platina one would no doubt be preferable. Its qualifications and disqualifications are so similar to the oxychloride above mentioned, that we need only say that it differs from it in proving far more durable, especially when applied at the necks of the teeth. With both these compounds it is essential that they should be employed when recently made; exposure to air, especially in the case of the pyrophosphates, causing considerable deterioration. It is unfortunate, therefore, that they are not vended in smaller quantities and in hermetically sealed vessels. The pyrophosphate, to which our remarks are referable, is that sold as Pulson's: other varieties may require somewhat modified manipulation.

[Flagg's, Guillois', Weston's, acme and agate cement, and cement plombe have their friends in this country, and it seems that, although some may be better capable of resisting solution in certain mouths than others, doubtless one of the principal causes of difference of success, resides in the variation of manner of mixing and inserting. Although at first sight these plastics would seem to be readily managed, it is now conceded that great expedition and expertness are demanded for thorough mixing and use before setting has progressed so far as to impair their value.¹]

Of the alloys of mercury with other metals, termed amalgams, those which become hard after mixture have long enjoyed a reputation amongst the substances employed in filling teeth. As they possess no direct property of adhesion to the walls of a tooth, it is necessary, in preparing a cavity for their reception, that there be some undercutting, or dove-tailing, to retain them. [Sharp angles, grooves, undercuts, and pits, are contraindicated from the well-known tendency of the amalgam to assume the spheroidal shape.²] Two classes of these compounds apparently exist, viz., where the combination is a binary one, and appears something more than a mere mixture or solution of one metal in the other, heat being evolved in the union; and the result is, probably, a definite chemical compound, dissolved in either metal which may be in excess of atomic quantity—analogue, probably, to the mixtures of sulphuric acid in water—at all events, the resulting alloys, as in the cases of mercury and palladium, or silver, or copper, are admitted to undergo less change in bulk after their mixture and application than do any of the other compounds consisting of more than two metals and which comprise the second class. Unfortunately, the first class possesses one great drawback, viz., unsuitable color; and the silver and copper compounds the additional one of staining the teeth, the silver a bluish-black color, and the copper a greenish; of the second class, some are now prepared which, when properly manipulated, keep their white silvery color for many years.

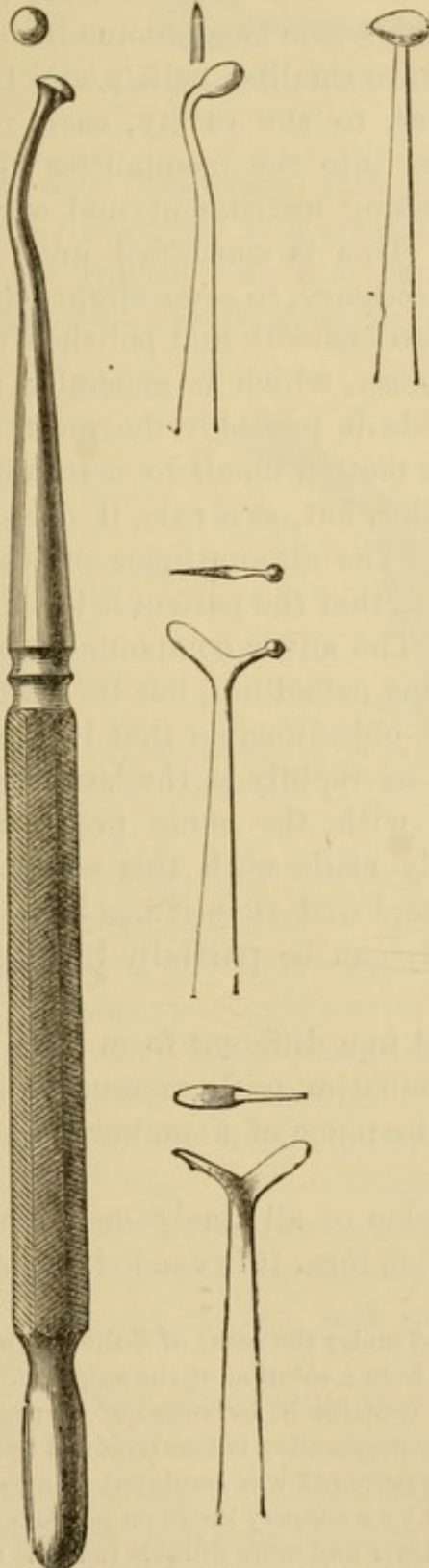
In applying the amalgams, certain precautions are necessary, according to the description employed; thus, with palladium, its compound sets very rapidly, so much so that we have found

[¹ See Flagg's "Plastics and Plastic Filling."]

[² See page 191.]

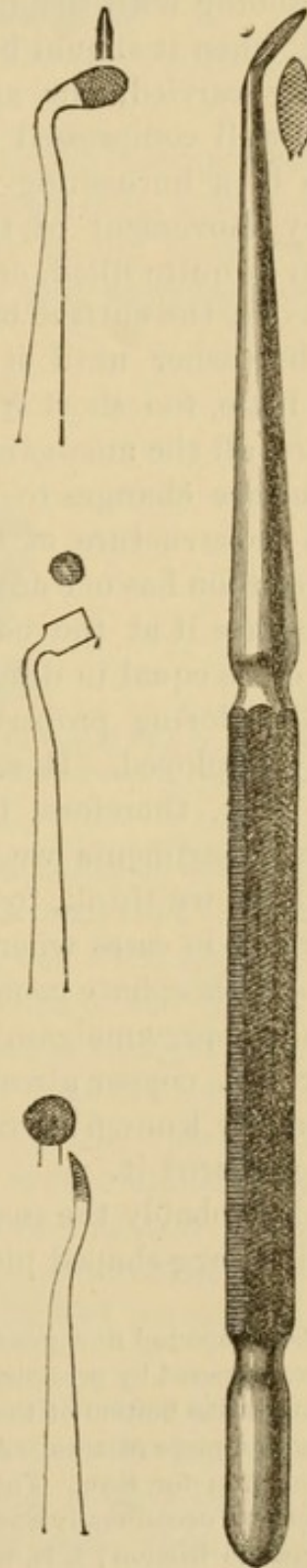
some specimens, and probably the purest, almost useless; also, when mixed in largish quantities at a time, say enough for a

Fig. 169.



Polished steel burnishers of various forms.

Fig. 170.



Four useful forms of amalgam stoppers.

good-sized cavity, it evolves so much heat as to explode with emission of light. About as much mercury as would fill the cavity to be treated is placed in the palm of the hand, and the palladium powder very gradually added. It requires some careful rubbing with the forefinger before the two become incorporated, when it should be divided into smallish pellets, and these rapidly carried, one after another, to the cavity, each piece being well compressed and rubbed into the inequalities of its walls by a burnishing or compressing instrument, and with a rotary movement of the hand. This is continued until the cavity is quite filled, or even, if necessary, to some slight extent built out, the surface being rendered smooth and polished with the burnisher until it has quite set, which is generally in a very little, too short a time. This is probably the most durable of all the amalgams, but the most difficult to manipulate. Its surface changes to a black color, but, as a rule, it does not stain the structure of the tooth. The circumstance of its setting so soon has one advantage, viz., that the patient is less liable to displace it at the next meal. The silver compound is probably quite equal in durability to the palladium, but its staining and discoloring properties are so objectionable that it is very rarely employed. It sets almost as rapidly as the last named, and must, therefore, be worked with the same precautions. Some experiments we have lately made with this compound entitle it, we think, to be more employed than it has been, and especially in cases where the cavity can be partially lined with the pyrophosphate cement.


The copper amalgam¹ is supplied in a different form from any other, viz., copper already in combination with mercury, and is commonly known as Sullivan's, the name of a maker who has long prepared it.

It is probably the easiest to employ of all amalgams. One of the little egg-shaped pieces, in which form it is vended, is placed

¹ The compound now generally supplied under the name of Sullivan's is, we believe, prepared by precipitating copper from a solution of the sulphate, with mercury at the bottom of the vessel that contains it, by means of stirring the fluid with a piece of zinc. A much better preparation is that obtained by substituting iron for zinc. The latter as so prepared was employed many years ago, and we occasionally now recognize it by a coppery lustre on portions most subjected to friction; it is, we believe, harder and more durable than the zinc-prepared material.

in a small iron spoon or ladle (Fig. 171), and gently heated over the flame of a spirit-lamp, until minute globules of mercury

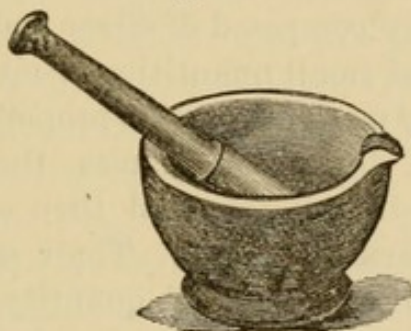Fig. 171.



Iron spoon or ladle with wooden handle for heating, over a spirit-lamp, the copper (Sullivan's) amalgam.

exude upon its surface, with generally a slight hissing noise; it is then transferred to a glass or agate mortar (Fig. 172), broken up, and rubbed into a smooth paste; it should then be well washed with a weak solution of sulphuric acid; some recommend

Fig. 172.



Pestle and mortar for breaking up the copper amalgam when heated. For this purpose they should be constructed of either agate or glass, as the compound adheres to Wedgwood's composition.

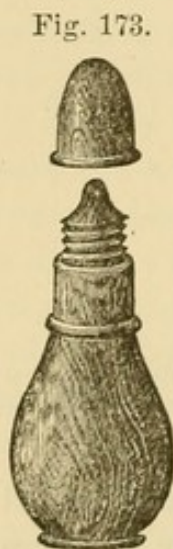soap and water, until no longer any black fluid can be obtained from it, when the acid or soap should be removed with clean water, and if the latter quite dissolved out with alcohol, and the amalgam thoroughly dried between folds of soft linen.

[It has been some years since well-known amalgam workers have objected to washing as likely to make a less perfect filling, from the impossibility of removing the water or fluid in time to employ the amalgam. It is even claimed that the discoloration under an amalgam filling, is in a measure preservative, tending to fill up the dentinal tubuli; particularly is stress laid upon this in very soft teeth with marked porosity of the dentine.]

A quantity of mercury may generally, after the amalgam is dried, be squeezed out through wash-leather, leaving it in an almost powdery condition, which, on being rubbed in the palm of the hand, will soon become coherent and soft, when still more mercury may be squeezed out. The drier it can be employed

the better, provided it will cohere in the cavity of the tooth, which cohesion will be favored by the warmth of the mouth, and this also admits of drier portions being added to those first employed. The patient should be strictly enjoined to avoid eating upon it for several hours, or be restricted to a soup diet for that day. Under the above-mentioned conditions a moderately hard and durable stopping can generally be effected; but its black color, together with staining of the tooth, are objections to its employment; doubtless it will always be useful for certain cases, such as the almost inaccessible cavities near to the gum between back teeth.

Those varieties in which the compounds are apparently more of the nature of mixtures than the foregoing, are generally composed of silver and tin, to which may be added small quantities of either gold or platina, or both,¹ mixed in certain proportions by the various makers, by whose names they are designated, melted into ingots, and then cut into the convenient form of filings. Their mode of application is as follows: a small quantity of mercury should be shaken from the drop bottle into the palm of the left hand, and to this is added by degrees the filings, which are thus dissolved in the former until the mass is scarcely coherent; it should then be transferred to the mortar and thoroughly mixed and incorporated; it may then be again rubbed in the palm of the hand until it exhibits a slight consistency.²




The mercury drop bottle from which the metal can be shaken in fine globules.

¹ One formula is, gold one part, silver three parts, tin two parts.

² T. Fletcher, of Warrington, has introduced a very perfect and efficient

Fig. 174.




Balance for weighing out Fletcher's filings and mercury in proper proportions. The arrangement admits of two varieties being weighed: thus mercury is put into the most distant of the two cups and counterbalanced by filings at the opposite extremity for his platinum amalgam, but put into the other cup and in like manner counterbalanced for his extra plastic amalgam.

method of manipulating his amalgam (platina and gold alloy). By a simple form of balance, the right proportions of filings and mercury are obtained, and

This mixture is carried in small portions to the cavity of the tooth, where it must be patiently rubbed and pressed, and any

Fig. 175.

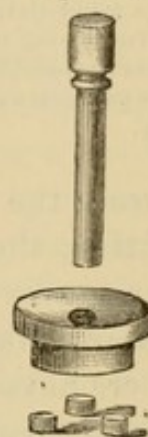


Fletcher's mixing-tube for shaking together the filings and the mercury.

appearance of free mercury be met by the addition of portions containing smaller and smaller quantities of that metal, keeping up the pressing and rubbing until indications of setting are becoming evident; and this process may be necessary for a considerable time, its object being to avoid that condition which fluid and semifluid bodies have a tendency, by attraction of their particles, to assume, viz., the spheroidal form, which we believe we were the first to point out in regard to amalgams, as one cause of their separation from the margins of a cavity. To ensure a more perfect result in regard to both durability and appearance, all amalgam fillings after a few days should have their surfaces carefully polished. It often happens that in smoothing over their summits some of the compound is spread over the surrounding tooth, and this thin layer breaks away, leaving slight irregularity and imperfection; if filing be not feasible, such superfluous portions may be wiped off, when the filling is completed, with a piece of soft amadou.

As it is very difficult to carry out an amalgam filling in a powdery condition, with a cavity in which one of the sides is wanting, considerable assistance is afforded by the employment

Fig. 176.



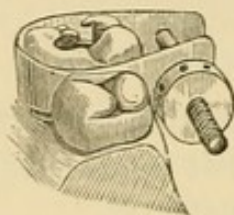
Fletcher's mortar and plunger for compressing his platinum amalgam into disks prior to insertion in the tooth.

these are incorporated by agitation in a test-tube until thoroughly mixed, when the powdery mass is transferred to an ivory compressor, which reduces it into small cakes of cheese-like form: these are divided into smaller fragments and introduced into the cavity of a tooth, and worked into a consistent mass by a broad plugger pressed upon by the hand or the action of a mallet. Of both the preparation and the mode of its manipulation we can speak most highly.

of a thin metal clamp applied round the tooth so as to supply during the process a temporary wall, and which is removed when the filling is completed.

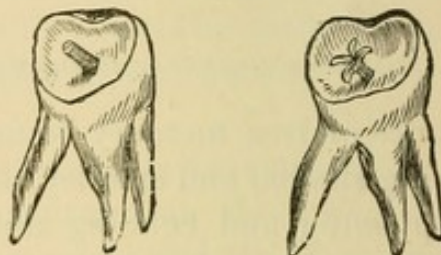
In cases where it is desired to build up the lost crown of a tooth upon a surface almost level with the gum, and which will afford a very uncertain hold for the amalgam, we may greatly

Fig. 177.



Thin metal clamp (Pinney's) suitable for passing round a tooth and forming a temporary wall for sustaining an amalgam during the process of filling.

Fig. 178.



An arrangement for giving support to an amalgam filling upon an almost flat surface by screwing pieces of gold wire into the substance of the tooth or its fangs. The free extremity of the wire is sawn, and the sections can be bent outwards after the insertion of the wire.

increase the latter by screwing pieces of gold wire into the root-cavities; the projecting portions of the wire being previously sawn across with a hair saw, they may be opened and pressed outwards like the petals of a flower (Fig. 178). As some practitioners have believed that they have suffered from mixing these mercurial compounds in the hand, the mortar may be employed throughout.

Some few general precautions in regard to amalgam fillings may here be insisted on; thus, they should never be placed in cavities where pulps are almost exposed, without some intervening body of less heat-conducting properties. They are less suited for the teeth of young people, such, for instance, as have large cavities in the first permanent molars at the ages, say, of seven to fourteen; in this, as in the former case, there is great liability to death of the pulp. They are never to be inserted, without special precautions, upon surfaces of sensitive teeth, where they may come into contact with the gold clasps of artificial dentures, as severe pain will be experienced by an electrical action set up by the two metals coming in contact. Near the front of the mouth they must be used, if at all, very sparingly; but we cannot lay down the law that the whitest varieties shall never be inserted into the front teeth. We have even seen palla-

dium inserted in the back portions of front teeth, the presence of which we should never have detected but for the mouth-mirror; but here the thickness of tooth-substance between the cavity and the surface was considerable. We have met with some varieties of palladium which have stained the teeth quite as badly as the copper compound.¹

The next and last of the materials which we shall describe as used for filling teeth are the metals in their unalloyed state; they are employed either in the form of thin sheets, or in a finely precipitated condition, but much more commonly in the former. Those thus used are gold, platina, and tin, of which gold only has been as yet supplied in the precipitated form.²

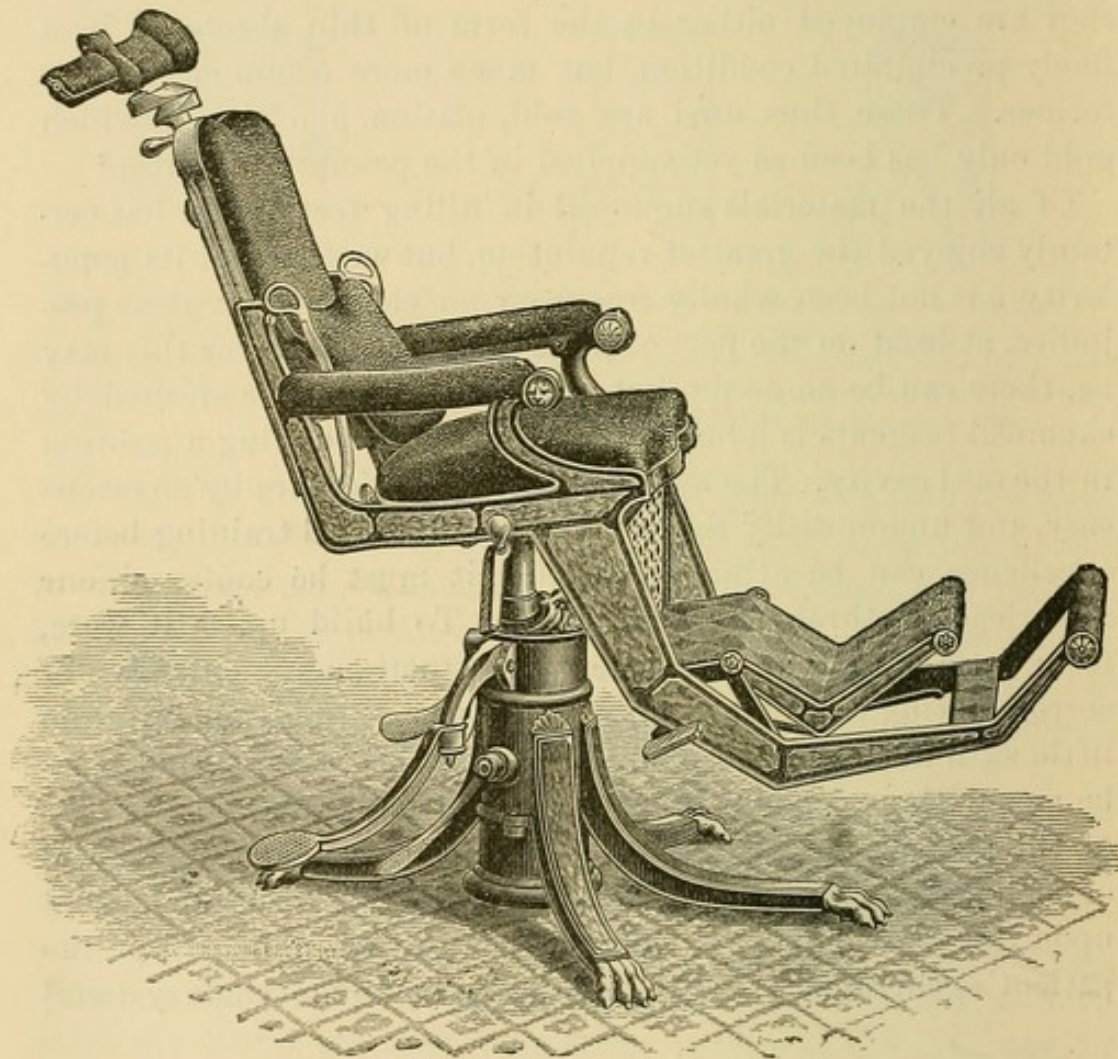
Of all the materials employed in filling teeth, gold has certainly enjoyed the greatest reputation, but we fear that its popularity has not been wholly free from an element of vulgar prejudice, at least on the part of some patients. However this may be, there can be no doubt but that a metal so little affected by chemical reagents is admirably adapted for occupying a position in the oral cavity. The modes of its application are by no means easy, and undoubtedly require a long and careful training before excellence can be attained, such as, it must be confessed, our American brethren have exhibited. To build up, as it were, from little more than a fragment of a tooth, a golden crown of corresponding anatomical form to the structure lost, requires no little skill and experience on the part of the operator, and must be met with an amount of patience and endurance on the part of the patient not always to be obtained, even at the prospect of such a reward. [Many cases of so-called building up of gold upon the teeth have been conducted with such disregard of the patient's general health as to produce injury to the whole system.]

¹ Some years ago a readily fusible metallic compound was occasionally employed for filling purposes; it appeared to make a durable stopping of good color, but the heat necessary to soften it was more than could be generally borne, even in dead teeth.

² Within the last two years a preparation has been introduced, termed Sladen's compound, which consists of an amalgam in a very finely divided condition, and which is consolidated by pressure in much the same way as precipitated gold, to be spoken of presently. It seems to be capable of making a stopping of good color, with little liability to change its dimensions, but sufficient time has not yet elapsed to enable us to speak with any confidence in regard to its true value.

As the operations of filling teeth with gold, especially when employed in the cohesive form, are lengthy and fatiguing ones, we counsel the beginner to make early attempts to conduct them in the sitting posture, and to this end we believe he will find no appliances so valuable as a Wilkerson's operating chair and a Lyon's stool. The numerous movements of the former, so easily

Fig. 179.



The Wilkerson operating chair. The various movements of the seat, back, head-piece, foot-board, and of the whole chair itself upon its pedestal, are as perfect as it is possible to imagine, and are carried out with a patient seated, rapidly and with a very small amount of force.

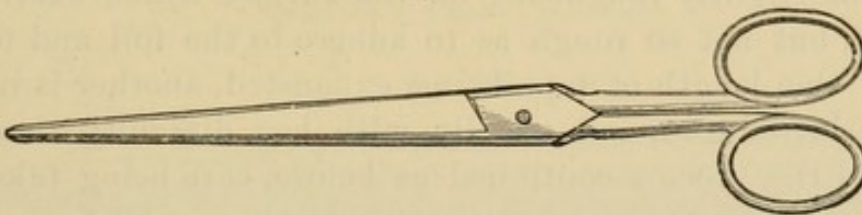
effected with the patient in the chair, and the suitable angles at which the latter can be placed, are only fully appreciated by those who have learned to operate in a sitting posture.

The gold, prepared in sheets or leaves, is technically termed foil, each sheet being usually about four inches square, and varying in weight from 2 up to 240 grains; of late years the makers

have conveniently attached the number to each represented by their weight in grains. In the employment of different numbers there is much variety of opinion, some preferring the lower and some the higher; if there be any rule, it would be the obvious one of the former being selected for small and the latter for large cavities. Which-ever be selected, one rule does prevail, and that is, to endeavor to insert the foil in folds parallel to the side walls of the cavity, *i. e.*, vertically to the base and orifice of the cavity, as there will then be less liability in the metal to flake off than if some of its layers were arranged parallel to the bottom and orifice of the cavity: the following methods to this end are adopted:—

1. By tape or ribbon.—A sheet, say, of No. 5 foil is divided by a long clean pair of scissors (Fig. 181) into three or four even strips, and each of these folded upon itself until the reduced width is about the diameter of the cavity to be filled.

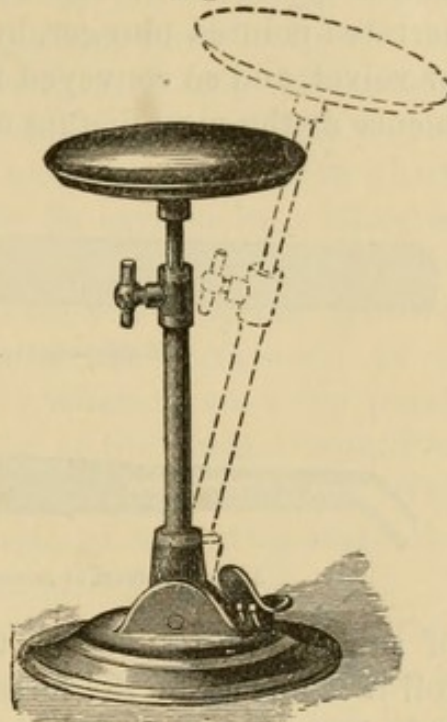
Fig. 181.



Scissors suitable for dividing the sheets of gold and other foil.

The folding may be best accomplished with a gilder's knife (Fig. 182), as the ribbon or tape so formed will be more uniform in size, and less fingered, than if folded by the hand. If the cavity be protected from moisture by a napkin kept in position by the forefinger and thumb of the left hand, one end of the tape is

Fig. 180.



Lyons' adjustable stool; the seat can be raised to any necessary height and also placed at various angles.


seized by the foil forceps (Fig. 183) or attached to the end of a serrated-pointed plugger, by pressing on the foil laid upon cloth or velvet, and so conveyed to the cavity, where it is best to commence at the most distant or most inaccessible part. In the case

Fig. 182.



Knife suitable for folding gold or other foil.

Fig. 183.



A suitable form of tweezers to be employed in plugging teeth.


of rubber-dam protection, where both hands are at liberty, the foil is taken up by the forceps in the left hand, whilst by a suitable instrument held in the right it is pressed down into folds parallel with the sides of the cavity, each fold being made a little longer than the cavity is deep, thus projecting slightly above its orifice. After a few folds are thus arranged, the forceps are gently removed and the folds pressed against one side of the cavity, where, with a little management, they will be held with sufficient force to support the remainder of the tape. The instrument for forming the folds in the cavity should be flat, thin, and serrated, but not so sharp as to cut the gold (Fig. 133); that for compressing them, called from its shape a foot-plugger (Fig. 135), should be slightly roughened on the surface which exerts the pressure, but not so rough as to adhere to the foil and tear it away.¹ One length of tape being exhausted, another is in like manner introduced, and usually with less difficulty than the first, and the process continued as before, care being taken to compress each thoroughly with the foot-plugger with as much force as the walls of the tooth can safely withstand. Having thus introduced as many lengths of tape as possible, a sharp wedge-shaped instrument should be forced into the centre of the filling, parallel with the folds, and moved backwards and forwards, but with much caution, as the leverage thus exercised

¹ Many other forms of plugger will be found necessary; those shown in Fig. 133 are amongst the most useful.

on the walls of the cavity is considerable. Into the space thus made more tape is inserted, and this process continued until the wedge is with moderate force unable to penetrate the surface. The last added portions not being easily accomplished by the tape arrangement, it may be effected according to the plan which we shall next detail. If the above be carried into effect as described, we shall then have a cavity filled with gold foil, in layers parallel with each other, and held firmly by mutual compression, so that any dragging action on the surface will be resisted by the whole depth of the foil; whereas, were the parallelism of the folds reversed, the layer at the surface would be sustained only by the narrow portion forming its first fold. The process, however, has yet to be completed, as at this stage the gold should project slightly above the orifice of the cavity.

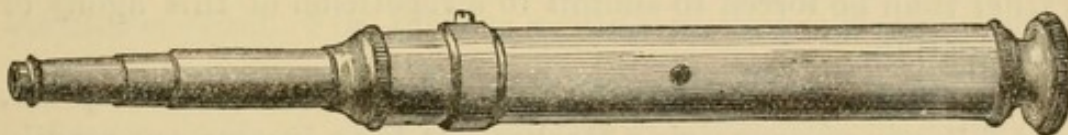
With instruments terminating in somewhat broad extremities, and file-cut, to prevent their slipping (Fig. 133), the surface is condensed by considerable pressure, greatly augmented by a slight rolling movement being given to them at the same time.

Fig. 184.



Hand mallet, the head of which is constructed of hard wood filled with lead, which lessens the amount of vibration when used.

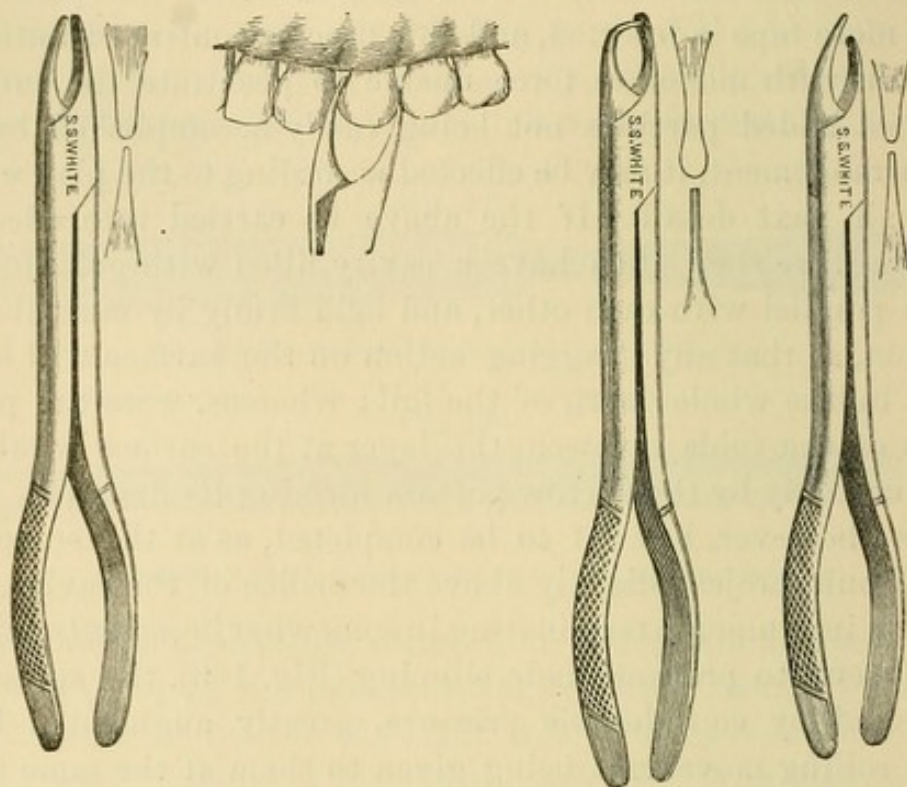
Fig. 185.



Automatic mallet (Snow and Lewis). The bit or plugger is inserted at the small end of the instrument, and when pressed upon raises a mallet against the resistance of a spring, and which at a given height is liberated by a trigger and strikes the bit. The amount of force can be regulated by the screw at the head of the instrument.

[Such movement being very like the carpenter's use of the bradawl]. In the place of hand pressure, force may be conveyed to plugging instruments by a mallet (Fig. 184), the substance forming the head being a soft metal, which occasions less vibration

Fig. 186.



Prof. Flagg's condensing forceps.

than does hard wood. The mallet may be an automatic one and then its employment necessitates only the use of one hand. The first of such instruments was devised by J. Tomes, but the American contrivances of Salmon and Snow, in which the force is regulated by a screw, are certainly preferable.

[With these mallets the short period of time, between the pressure of the point upon the filling and the blow from the automatic hammer, is with nervous people a seemingly much prolonged stage of dread, and many will change their dentist rather than be forced to submit to a repetition of this agony of anticipation.

The pneumatic mallet of Williams gives most excellent, quick, and following or squeezing strokes. It is an instrument readily kept in order, being simple and neat in its construction. The use of the electric mallet has been abandoned of late by many who formerly advocated its employment, and some of the forms of engine mallet have been substituted for it.]

When the cavity is situated between teeth—approximal, as it has been termed—the condensing pressure may be often advantageously applied by means of compressing forceps, one

blade of which is applied to the surface of the filling and the other to the opposite side of the tooth. The instrument is especially indicated for teeth somewhat loose in their sockets, as great pressure can be employed without moving them in the same. The degree of condensation will inform the operator of the extent of perfection to which the first portion of the process has been carried; for should he be able to condense to more than a slight extent, he may rest assured that he has not introduced the tapes as closely together or wedged them as tightly as they ought to have been. Such a filling may have a hard surface and may last for a time, but not so long as one that is more dense throughout in its entirety. If the process be successful, the surface after compression should be still slightly above the level of the cavity, and it may now be reduced with suitably shaped files (Fig. 103), directed by the hand, or burs


Fig. 187.



File-carrier for filling teeth at the back of the mouth.

rotated by the engine. If at the side of a tooth, endeavor should be made to leave the filling contour, *i. e.*, of the form which that portion of the tooth originally presented; but, if on a masticating surface, experience shows that it is best not to attempt to imitate the cusps, a flat and perfectly level surface being found to stand the longest; indeed, some operators even reduce to the same level the adjacent cusps of the enamel. After the file a more perfect finish can be given by polishing the gold with an Arkansas point (Fig. 188), or a little finely powdered pumice

Fig. 188.

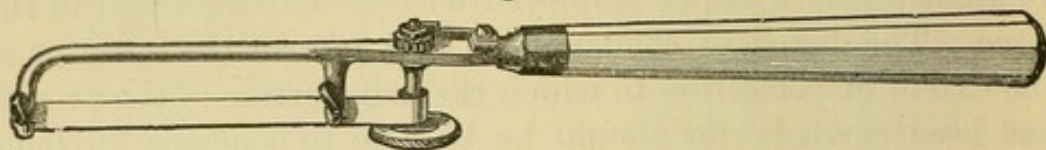


Steel holder for carrying Arkansas or corundum points for polishing stoppings.

and water applied on a piece of wood or tape (Fig. 189), and as a final application, whiting or crocus in the same manner. Such a surface will, in a solid plug, be left and remain highly polished,

with far less tendency for food to accumulate about it than if it were rough or uneven. With some operators it is customary to

Fig. 189.

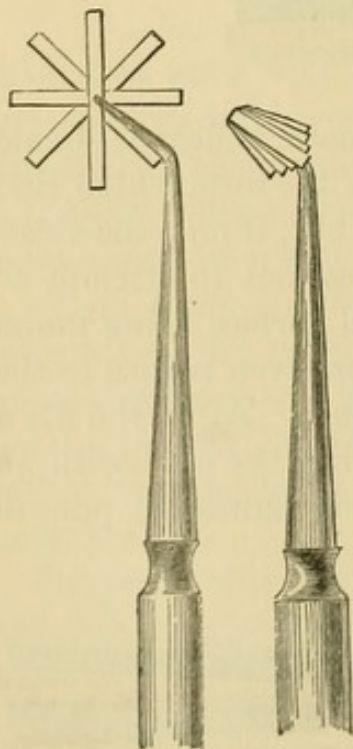


Harding's tape-carrier with steel spring ratchet for tightening the tape. The instrument is employed for polishing the surfaces of gold fillings situated between teeth.

carry out much of the finishing and polishing process by forcibly rubbing the gold surface with highly polished steel instruments—burnishers (Fig. 169, p. 187). By their aid a very highly polished surface may be attained, but it is a somewhat deceptive one, especially where the filling is none too dense, and it seldom remains any length of time.

2. By ropes.—This is simply a modification of the last method, the gold foil being rolled into a form resembling rope and applied in precisely the same manner. In this form it is rather more easy to manipulate, but a less perfect parallelism of the foil is attained; it is best suited to the more irregularly shaped cavities, into the inequalities of which it can be more readily compressed.

Fig. 190.




Method of taking up gold foil for insertion into a cavity on the plan of stars or strips. The cut to the left represents the mode of taking up the foil with tweezers; that on the right of doing so on the point of a plugger.

3. By stars of strips.—This process consists in folding the foil into a broad tape, about half or three-quarters of an inch in breadth, and then cutting it at right angles to its length into narrow strips. Of these three or four, arranged over each other in form of a star (Fig. 190), are taken up at their centres by the foil-forceps, or the pointed extremity of a plugger, and inserted, the central portions downwards, into the cavity, after which the projecting ends are folded downwards and inwards, and pressed into the space left by the forceps or plugger: further portions are in like manner added, the foot-pluggers being

constantly employed to condense laterally, and the wedges used in the latter stages, until the cavity is densely filled, when the finishing process, as before, is employed. This method is best adapted for narrow and deep cavities, where a perfect parallelism is less important, as the surface is small in comparison with the depth of the cavity: it is also very usefully combined with other methods, especially in applying the last portions of gold: a heavy gold, twenty grains to the leaf, is in such cases very readily pressed down to the bottom of a small deep orifice, when a lighter foil would stick on the way, or be perforated by the narrow instrument.

4. By cylinders.—By this elegant method the most perfect parallelism of folds is attained.

Fig. 191.



Tomes's foil roller
for making cylinders
in foil.


Fig. 192.



The form in which gold foil prepared in cylinders is now sold.

It is accomplished by dividing, say, a leaf of No. 5 foil into two, three, or four strips, and folding them into tapes, a little broader than the cavity to be filled is deep. These are rolled

Fig. 193.



The form in which gold foil prepared in blocks with parallel
layers is now sold.

round a fine broach or pair of delicate forceps (Fig. 191), constructed for the purpose, into little rolls (Fig. 192), like those in which ribbon is sold. Cylinders of various thicknesses and sizes, also blocks with the foil parallel, are now prepared expressly, and are superior to those made as described, which are of necessity

thicker and more dense at each end where folded than in the centre, which is not the case with those sold. The cylinders are conveyed to the cavity in the tooth by the foil-forceps, and inserted with the folds parallel to the walls of the same; their disposition, when so placed, being best understood by the happy illustration of J. Tomes, "packed into the tooth as you would proceed to pack cigars into a tumbler."

Each cylinder, as introduced, should be well compressed to one side of the cavity before the next is introduced, and so on until no more can be added; but, as it is difficult to complete the operation with cylinders, it will be best to accomplish it by filling up the interstices made by the wedge with foil in the form of strips. In treating interstitial cavities, viz., those existing between teeth, we shall find it most convenient to commence at the least accessible position, *i. e.*, where the cavity impinges on the gum, and to complete towards the crown.

The foregoing descriptions of the methods of employing gold foil are equally applicable to platina and tin. The former is not much used on account of its harshness and the difficulty experienced in thoroughly adapting it, without intervening spaces, to the irregular walls of some cavities; otherwise, in color, it surpasses gold, which also it equals as regards freedom from chemical action.

Tin, whilst sufficiently pure and unalterable by reagents, does not yield a plug sufficiently hard to resist, in exposed situations, the wear of mastication for many years: when applied in situations not so exposed, it appears to last in some cases even better than gold, and, being an inferior conductor of heat, is well suited to very sensitive teeth, especially the temporary ones, and also the permanent ones in young persons. Cavities situated on the buccal surfaces, and shallow cavities, retain this metal as well as, and often better than, any other material, and it might probably be employed with advantage much more frequently than it is at present.

[Tin has likewise been used to line cavities, from its lower conductibility, its softness, and comparatively easy adaptation, where gold was to be the main substance of the filling; lead in like manner has been used on the floors of cavities for the last quarter of a century at least, and varnishes, gutta-percha, oxy-chloride, oxyphosphate, and amalgam have each had their advo-

cates for this purpose. This practice, as a universal rule, has two objections—one the prejudice felt against plated ware and shams generally; the other the fact that every compound filling has the additional point of weakness at the junction of the two materials, this being an objection even to the use of two kinds of gold, as cohesive on non-cohesive.]

Gold, however, possesses a special qualification under certain conditions, viz., that of being cohesive either in the precipitated form spoken of, or rendered so by exposure to heat: more correctly, perhaps, it should be stated that gold is naturally cohesive, but that from exposure to air or other gases it loses this property, probably from weak chemical affinities which attach to its surface gases or vapors, and which prevent its particles from actually coming into perfect contact when two pieces of the metal are brought together. If a portion of non-adhesive gold foil be passed through the flame of a spirit-lamp, at a heat short of redness, a vapor will be seen to issue from its surface, after which such piece of gold will, when pressed upon a similar one, become united to it so intimately, that, if an attempt be made to separate them, the gold will yield first in many places rather than at the attached surfaces. This property is not peculiar to gold or certain metals: it only requires the actual molecules of a body to be brought sufficiently close to those of another portion of a similar body, or in many cases a different body, for attraction of cohesion to take place, a condition most readily brought about by the process of liquefaction.¹

[Probably very few to-day understand that non-cohesive gold means a foil that is not capable of being made cohesive by annealing. Most cohesive foils, if left exposed to the air, lose that property temporarily, and are capable of being used somewhat like non-cohesive gold, with the great objection that they are more harsh or stiff, and liable to break or fold in sharp angles. The non-cohesive, such as has been made by Messrs. Chas. Abbey & Son for the last sixty-five years, has the kid-like softness which makes it perfectly passive under the instrument, lying just where it is put. The force necessary to work it is

¹ Whilst making the foregoing statement, with regard to gold being rendered cohesive, we must admit that a certain eminent English chemist regards the union as simply a mechanical adhesion.

about that which is required to work lead, and gold has the advantage of toughness which allows it to be pushed before the instrument's point without being penetrated by it.]

Gold possessed of the property of cohesion can, it will be clearly perceived, be employed with much advantage in a variety of cases, especially in filling shallow cavities, building up lost portions of the teeth, etc.

In considering the subject of filling teeth with cohesive gold¹ it will be advisable, first, to give some attention to the shaping of cavities with relation to their means of retaining the filling.

The primary point to determine is, whether the filling shall be held in entirely by the general form of the cavity, or by retaining points or pits; the former being the more to be desired and the most generally applicable; the latter, however, must be relied on in certain shallow cavities, when the filling must be entirely cohesive.

Let us take as an example a saucer-shaped cavity on an approximal surface of a cuspidatus tooth, where we will suppose the decay to have penetrated but little further than the enamel. On all the disorganized enamel being chipped away, together with any diseased dentine that there may be, and the edges of the enamel being smoothed off with an Arkansas wheel on the dental engine, a shallow saucer-shaped cavity will be left, perfectly incapable of retaining any filling that will not adhere to its walls.

If into such cavity half a dozen retaining pits be now drilled near to the margin of the dentine, in directions divergent from one another, and so as to avoid all proximity to the pulp-chamber, sufficient hold will be attained to securely retain the gold.

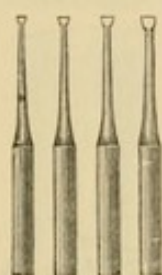
[The number of pits may vary from three to six, according to the strength of the walls; if these are weak the pits must be shallow, but gaining by number for lack of individual strength. The principle of putting in retaining pits, may be likened to a three-legged stool, in which the direction of the legs is in a line with the forces to be resisted, and so inclined that they would meet if brought to a common point of resistance. If the force the filling has to withstand is greater toward one point than

¹ In the following description we have availed ourselves of the kind assistance of Claude S. Rogers, the demonstrator at the school of the Dental Hospital of London.

another, that one may be strengthened by extra size of the pit, or if the wall be weak by an extra number.]

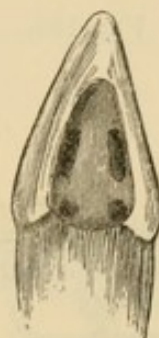For making these retaining pits, a small square-pointed drill (Fig. 194) should be used, and the pits cut no deeper into the

Fig. 194.



Spade drills.

Fig. 195.



A shallow and spoon-shaped cavity in a cuspidatus tooth with two retaining points at its gingival margin and two retaining grooves, one at each side, cut into it.

dentine than about the diameter of the drill itself; or a small wheel-bur (Figs. 111 and 118) used in the engine will do equally well. If the cavity be somewhat deeper than has been supposed in the foregoing, it may be well to join two or three of these pits together on two opposite sides of the cavity, thus forming two opposing grooves (Fig. 195).

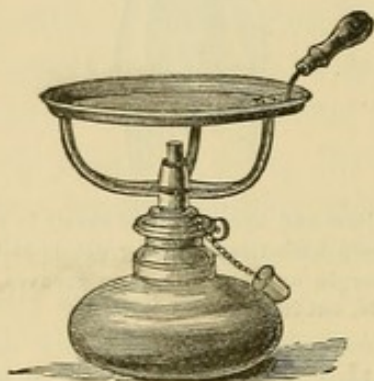In these, as in all other forms of cavity, the enamel edges should be smoothed off either with an Arkansas wheel, as before mentioned, or with small chisels; in fact, a somewhat counter-sunk form should be given to the edges, so that the plug when completed shall fit like a screw-head (see Fig. 145, p. 168).

The cavity having been prepared and the rubber-dam applied, if that has not been previously done, the cavity is now ready for the filling.

The gold should be employed in loosely rolled pellets; small sizes of Williams's A cylinders answer exceedingly well. [For cohesive gold the sheet of No. 4 Abbey's may be folded twice by turning the outer edge of the leaf as it lies in the book in toward the sewed part or back of the book; then closing the book and pressing lightly with the fingers to flatten the sheet. Repeat this folding and we will have a ribbon one-fourth the width of the original sheet, which may be cut off into eight or more pieces, according to the size of the cavity in the tooth.]

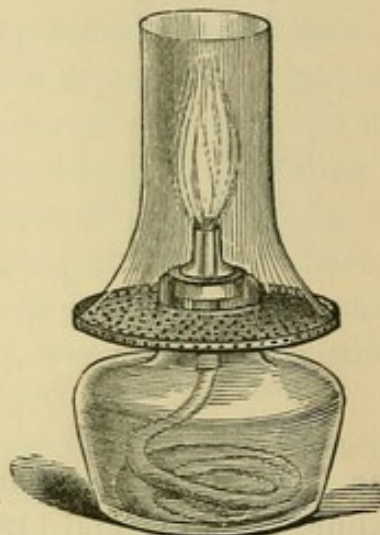
If foil be preferred, No. 4 is the best, whole sheets being made into a rope and cut up into small pellets. As this should be done before the foil is annealed, it is best to use non-cohesive foil, to be made cohesive by heating slightly in a tray over the spirit-lamp (Fig. 196), or by passing each pellet over the flame

Fig. 196.



Spirit-lamp and tray for heating
(annealing) gold foil.

Fig. 197.




Spirit-lamp suitable for heating
(annealing) gold foil.

before placing it *in situ*. In annealing the gold, care should be taken not to over-heat it, as in that case the gold becomes harsh and brittle, losing all the beautiful softness that it possesses: if this be avoided, a degree of heat considerably below redness is all that is necessary; indeed, for very small pellets a single wave over the spirit-flame will be found sufficient.

The gold having been thus prepared, we proceed to fill each retaining pit with the pellets, conveying them by means of the foil-carriers and thoroughly condensing each pellet as it is put in its place. This is best done with pluggers having fine serrated points (Fig. 199), which may receive their force from the hand, from the ordinary mallet (Fig. 184, p. 197), from the automatic mallet (Fig. 185, p. 197), from the pneumatic mallet (Fig. 200), which is worked by the foot, from a very ingenious mallet which can be attached to the dental engine (Fig. 201), or from the electro-magnetic mallet (Fig. 203). [A following or dead blow, as from the pneumatic or the lead mallet, is desirable; the effort being to imitate the squeeze of a vice as much as possible, so that the gold is laid in its place gently but firmly and held

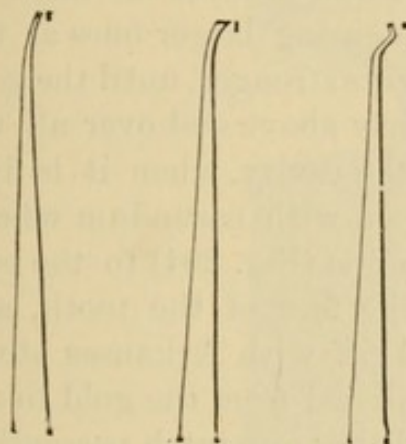
there by a momentary persistence of the pressure.] The retaining pits being filled, the gold is carried over from one to the

Fig. 198.



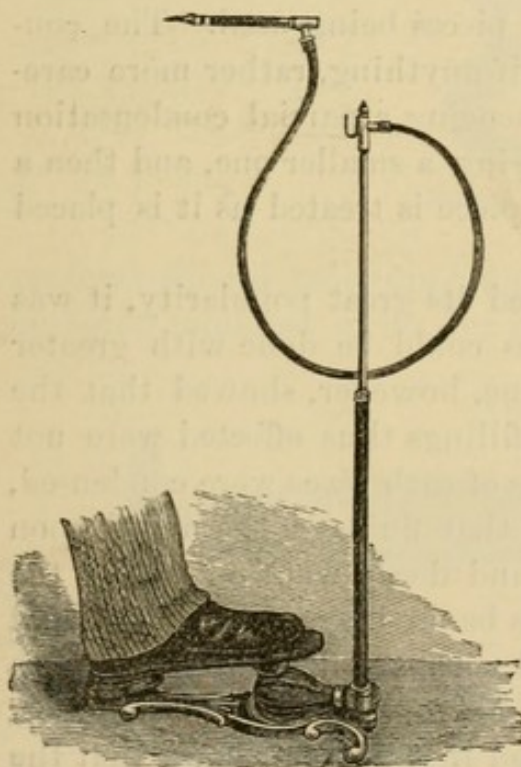
Rich's tweezers suitable for carrying cohesive foil to the retaining points or grooves.

Fig. 199.




Three forms of plugger suitable for condensing cohesive foil.

Fig. 200.



Kirby's pneumatic mallet.

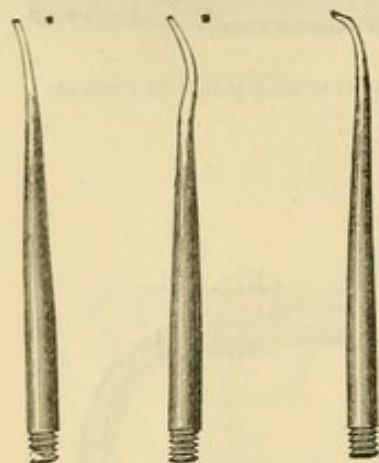
Fig. 201.



Power's mallet, which is attached to and worked by the dental engine.

other, across and back again, gradually covering the surface of the cavity, the centre first and the margins afterwards. This should not be done too quickly, as there is a tendency in the

Fig. 202.



Three forms of bit to be employed with Power's engine mallet.

gold to curl away from the surface if the mass be too thin: a careful guard should therefore be kept, that the plug in its early stages is sufficiently strong in its centre to prevent this. We now proceed to mass on the pellets, using larger ones as the plug becomes stronger, until the gold stands fairly above and over all the edges of the cavity, when it is filed or cut down with corundum wheels in the engine (Fig. 204) to the contour of the face of the tooth, and smoothed off with Arkansas stone,

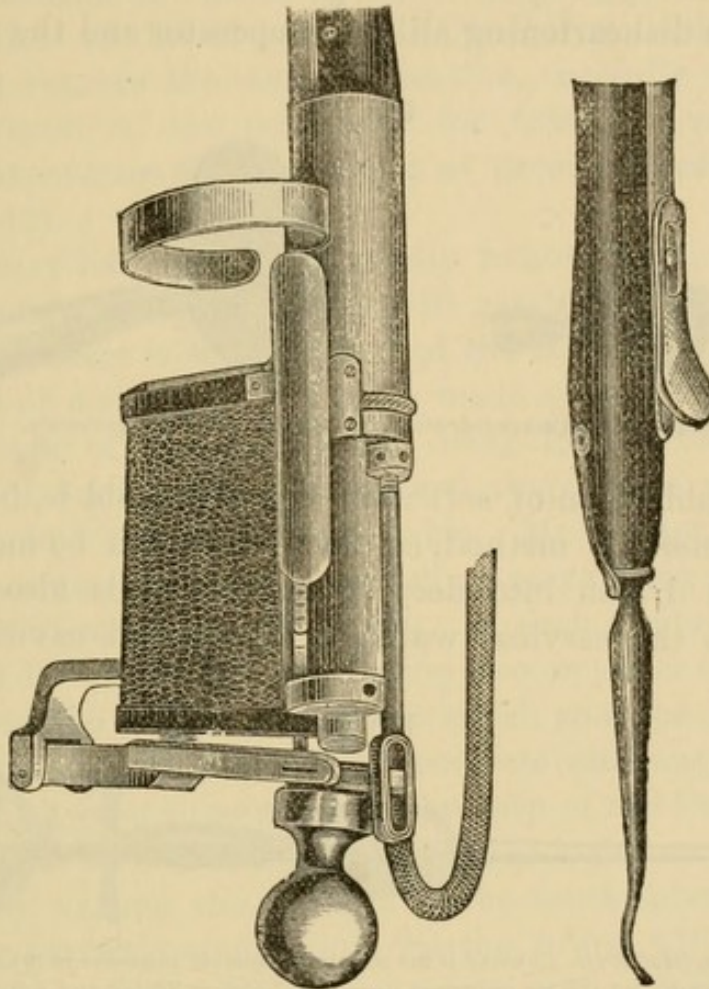
so that a pointed instrument can be passed from the gold to the enamel, and *vice versa*, without there being any catch perceptible to the touch. The finishing process is polishing with crocus powder on a soft rubber point.

If sponge gold be employed, the process is conducted in the same manner, somewhat smaller pieces being used. The condensing force also requires to be, if anything, rather more carefully and thoroughly done, commencing a partial condensation with a large plugger, then employing a smaller one, and then a still smaller one; and thus each piece is treated as it is placed *in situ*.

When sponge gold first attained its great popularity, it was estimated that with it operations could be done with greater rapidity than with the foil. Time, however, showed that the apparently sound and beautiful fillings thus effected were not solid; in fact, only the outer fibres of each piece were condensed, the centres remaining porous, so that fluids of the mouth soon worked into the weak portions, and decay went on around the filling. If, however, small pieces be used, as before stated, and each piece thoroughly condensed with small points, as good a filling can be made of sponge gold as with foil; it requires, however, more time and labor, and it is in this respect that the

chief objection to it lies. In employing any form of adhesive gold it is all-important that it be kept perfectly dry during the

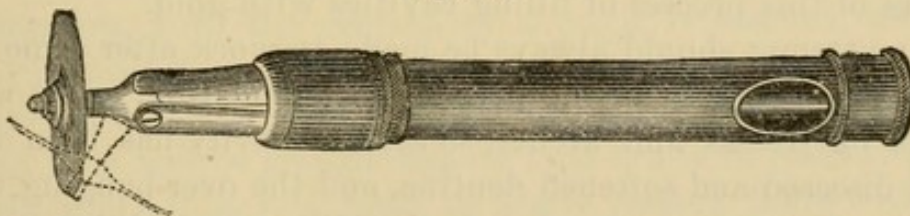
Fig. 203.



Electro-magnetic mallet.

process; should moisture happen to get to it, the surface must be again rendered quite dry by wiping it with amadou, after

Fig. 204.

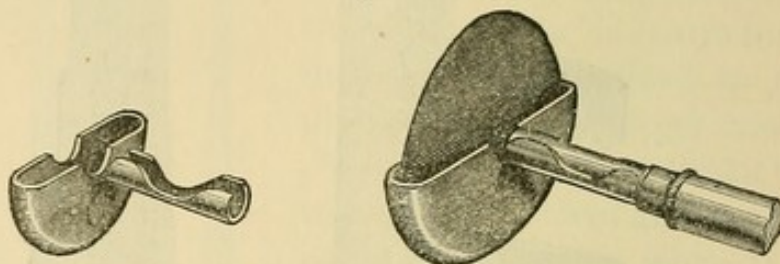


Corundum wheel attached to the mandrel of a dental engine, which is capable of being fixed at various angles.

washing it with pure water or spirit, and finally by blasts of heated air from the air-syringe (Fig. 206).

[It will generally be found more expeditious and satisfactory to remove at once all the gold and renew the operation. In attempts to work over a surface, the cohesive property of which has been destroyed by moisture, precious time is lost, the resulting fatigue disheartening alike the operator and the patient.]

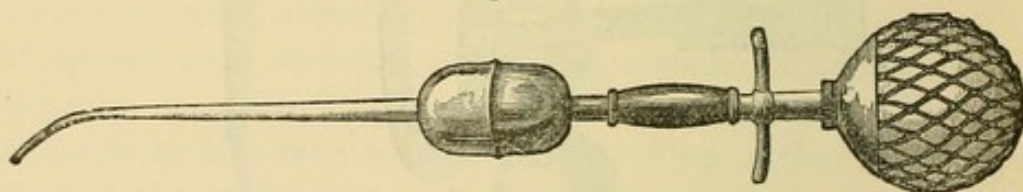
Fig. 205.



Corundum wheel mounted with Ives' tongue and cheek protector.

The combination of soft with cohesive gold is, however, by far the preferable method, as the former can be more readily placed and driven into deep undercuts: it is also far better adapted to the cervical walls in approximal cavities. Since

Fig. 206.



Hot-air syringe (Moffat's). In using it the metal air-chamber is heated in the flame of a spirit-lamp, and the air propelled through it becomes heated and dried.

annealed gold will cohere readily to the unannealed form, or retaining pits in the latter are readily obtained, a good starting point for the cohesive pellets can be thus made. A description of one or two of the more difficult cases may serve as good examples of this process of filling cavities with gold.

[An attempt should always be made to work after some definite plan. Just as an engineer lays a foundation, raises walls, builds buttresses and arches, so after a cavity has been freed of all diseased and softened dentine, and the over-hanging walls of enamel cut down, a plan for its filling should be decided upon, and proper excavations for foundations made.]

We will take a carious cavity of decay extending over the whole mesial wall of an upper incisor tooth, encroaching upon

its labial and lingual surfaces, and up to but not beneath the gum. We first cut away all frail edges of enamel with fine chisels, which permits the cavity to be freely viewed in all parts for the removal of the decay and for filling, and at the same time renders the labial and lingual walls less liable to fracture. We next remove the decayed dentine, carefully avoiding the neighborhood of the pulp, and for this purpose the spoon-shaped excavators will be found of excellent service (see Fig. 106, p. 142).

All decay having been carefully removed, the next step is to shape the cavity so that it will retain the filling securely. Sometimes there is sufficient left of the labial and lingual walls to admit of a slight groove being made all round, except at the cervical wall of the cavity, that being kept as flat as possible, for fear of leaving the thin enamel there to be split off with pressure, to which it is very liable. More often, however, it will be necessary to partly or wholly remove these walls, leaving a somewhat spoon-shaped cavity: in such a case anchorage is obtained for the filling by cutting two opposite angles, one of which may be termed the cervico-labial, and the other the cervico-lingual, angle, and a third good retaining angle or pit may be made between these towards the cusp of the tooth. If these three angles be cut sufficiently deep, though not so deep as to materially weaken the strength of the tooth-substance at such points, a perfectly secure hold for the filling will be obtained. To proceed with the filling: we take a soft cylinder of medium density, and place it, transverse to the long axis of the tooth, at the cervico-lingual angle, and with a fine foot-plugger press it against the lingual wall. If it will not lodge there alone, we hold it in its place with another instrument held in the other hand, and insert a second cylinder, or a third, and a fourth if necessary, until the cervico-labial angle is reached, when, taking a large foot-plugger, we press the whole mass towards the cervical wall. If the angles have been sufficiently and properly cut, they will be all-sufficient to hold firmly in place this bed of soft gold: if not, it must be firmly pressed there with an instrument in the left hand, until sufficient of the non-cohesive gold has been built on to allow of its being removed without any fear of the mass shifting its position. On this bed of soft gold cohesive pellets can be packed, each one being condensed

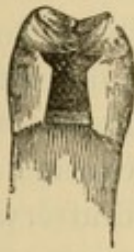with the mallet well up to, but not on to, the walls of the cavity, care being taken to see that the lingual edge is well perfected during the process, since this part is the most difficult to rectify afterwards; if it be not so, we keep the gold well out in the required contour, so as to do as much of the malleting in the long axis of the tooth as possible, as in this direction it will tolerate force better than in any other. If the angle at the junction of the lingual and labial walls, *i. e.*, near the cusp of the tooth, be a deep one, then one or two small soft non-cohesive cylinders may be placed there on which the cohesive foil is to be built, and at this point it will be necessary to change the direction of the force to the transverse. The remainder of the operation is the piling on of cohesive pellets up to the contour of the tooth, letting it come well up to and over its edges: we then trim down with various forms of corundum wheels and files applicable, and polish with tape and polish powders.

For our second example we will take the case of approximal decay on the anterior surface of an upper second bicuspid, extending from the crown to the gingival margin, the pulp not being invaded. In all these cases, whether the decay extends quite to the grinding surface or only nearly to it, it is best to cut right down from the crown with the enamel chisel, clearing away the undercut angles beneath the cusps, since by this means a much more effectual stopping can be made, as we get rid of corners where it is most likely to fail from imperfect packing; also the whole of the cavity is well open to view.

We next remove all frail portions of the enamel as before, and shape the cavity either by so sloping the walls that the filling shall be retained like a carpenter's dovetail, or by making two lateral grooves which shall diverge as they proceed upwards. If it be decided to proceed on the former plan, small obtuse-angle chisels should be used, so cutting the lingual and labial walls that they shall converge in the direction of the neighboring tooth and diverge in the upward direction, leaving the cervical wall quite flat, the enamel edge being slightly bevelled off. [For this purpose the fissure bur (No. 55½ to 59, Fig. 208) and small oval bur (No. 88½ to 93, Fig. 209) are useful, being moved up and down where the groove is to be made. Care must be taken that the bur be not large enough to weaken the wall outside the groove or to expose the pulp.] The cutting should be carried

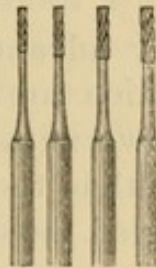
far enough upwards to form cervico-lingual and cervico-labial angles, that rounded form of cervical wall being thus removed which is so frequently a cause of rocking of the filling when partially completed.

Fig. 207.



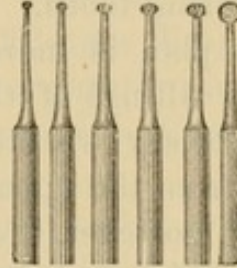
A cavity in a bicuspid tooth prepared for filling by the combined process, *i. e.*, with soft and cohesive gold foil.

[Fig. 208.]



Fissure burs.]

[Fig. 209.]



Oval burs.]

Should any fissure of decay, however slight, exhibit itself on the grinding surface, it must be cut out, as this will also add materially to the retention of the filling.

In inserting the gold much the same process is pursued as in the last-mentioned case; large, soft, non-cohesive cylinders are placed at the cervical wall, with their cut ends projecting towards the neighboring tooth, commencing at one angle and progressing to the other, when they are condensed towards the cervical wall: if the angles and walls have the proper form, this mass of gold will be held firmly in its place. Another row of soft cylinders may be placed on this if it be a deep cavity, and then condensed upwards in the same manner, about one-half the cavity being thus filled with non-cohesive gold.

On this cohesive pellets are packed in the usual manner, care being taken always to carry the condensing force well up to the tooth substance. If a crown fissure exist, this should be also filled with cohesive gold, and united to that in the main cavity: we then file down and finish in the usual way.

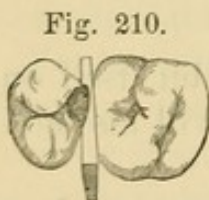
Tin cylinders may be used instead of gold at the cervical wall, and especially in those cases where the decay extends below the gum;¹ tin having the advantage of remaining per-

¹ We desire to make this statement with some reservation, as we have seen cases in which there has been an appearance of the filling, so performed, hav-

fectly soft and adaptable after any amount of condensation, it can be better condensed and burnished on to the edge of a cervical wall than gold. It is sometimes well to partially finish the surface of the filling at the cervical wall when the filling is only half completed, as then it is more easily reached than when the whole plug has been finished and built out against the neighboring tooth.

This plan is more especially advantageous when two contiguous fillings of this description are effected at one sitting; that is to say, we file or cut down with a chisel the superfluous filling from the upper half of both of them to the required level, leaving, however, the polishing of these parts until afterwards, and finishing as before.

[Dr. Jack's matrices, when properly adjusted, make the finishing of approximal surfaces comparatively an easy matter, and enable the operator to gain a density and adaptation of the gold to the tooth, that are invaluable.]



Jack's matrices.

In cases where the decay is small, and situated too high up on the proximal surface of a tooth to justify the cutting down from the crown, an opening may be made by cutting in from the labial or buccal wall, and shaping the cavity as before directed,—merely transposing its relative positions.

In attempting to draw any comparison between the two kinds of gold filling, it may be stated, that, whilst the cohesive is probably the more dense and solid, and less liable to wear or chip away, it is certainly less elastic, and more likely, as in the case of amalgams, to become, by changes of temperature, slightly detached from the walls of a cavity. The slight elasticity which a non-cohesive filling possesses compensates for any change of temperature.

ing failed from electro-chemical action at the point where the two metals came in contact.

[It seems unlikely that the joining of the two metals would make a very serious difference, indeed, when the sensation of galvanic action in the tooth is persistent, it is recommended to relieve it by joining the metals by an increase in the size or an intermediate filling.]

When an ordinary amalgam filling is not kept bright and polished, its surface soon becomes covered with oxide and grease sufficient to reduce the galvanic action to an almost imperceptible amount, if not altogether.]

We may venture, however, to lay down the rule, that, whilst the non-cohesive method is the best for small and fairly deep cavities, the cohesive method is decidedly the best for very large and shallow ones. The majority of very large cavities filled with non-cohesive gold are seen to fail after a few years.

[The condensation of thin plates of cohesive gold against the walls not infrequently causes crumbling of them or sufficient destruction of their integrity to make the filling a disappointment, both for the operator who respects his reputation and for the patient who has placed his faith in the salvation of the tooth by the filling.]

Gold, it must be admitted, when solid and highly polished, is in the front of the mouth very conspicuous. To obviate this, the following ingenious method has been adopted by some. Thin leaves of platina are gilded, and made adhesive, and then are worked in parallel layers, and, when filed and polished, the color of the combined metals resembles, to a very considerable degree, that of the teeth. The process must be conducted with considerable care; first in the annealing of the foil, as, if not heated sufficiently, it will not be adhesive, and, if a little overheated, the gold readily melts off from the platina. A perfect parallelism of the layers must also be maintained, otherwise there will appear on the surface patches of gold. [Combination, for the sake of color, of perpendicular layers of tin and gold have in like manner been used.]

CHAPTER IX.

TREATMENT OF DENTAL CARIES.—*Continued.*


WE must now describe some of the difficulties and complications not unfrequently met with in the operation of filling teeth.

First, with regard to the position of the cavity; it may be so placed that no justifiable employment of the chisel or file can obtain room for the insertion of the stopping, or, indeed, for the proper excavation of the cavity. To effect our object, then, the teeth must be separated, and this separation may be either immediate or mediate. The immediate method consists in taking a thinly-pointed wedge of wood, inserting its point between the teeth where lies the cavity, near to or even a little below the gum, and then giving to the wedge a smart blow or blows with a mallet until sufficient space is attained; a portion of each projecting end is then cut off with cutting pliers. The sensation to the patient is by no means agreeable, and the operation, if performed without due caution, may endanger the vitality of the teeth, or even liberate one of them from its alveolus, to the vexation of patient and operator. We do not recommend the plan as so pursued, but we may often, especially where no very great or increased amount of room is required, obtain it by simply pressing steadily with the fingers a similar wedge of wood cut from a piece of soft deal, which has been firmly compressed in a strong vice for some hours: such a wedge will expand when moistened, but the force is gradual and even, not sudden and violent.

[Dr. Corydon Palmer has described a method of rapid wedging which is not open to all the objections of this plan. A wedge cut from a thin tape of wood or quill is first placed between the teeth to protect the gum. Next to that a square-tapered wedge of orange or box wood is put at the gum, so as not to interfere with the view of the wall of the cavity. This

is to remain during the operation, and is driven to hold the space gained by the third,—a broad wedge which is pressed by hand or mallet between the cutting edges of the teeth with its point toward the gum. The operation is performed little by little,

Fig. 211.



Dr. Jarvis's screw separators.

allowing some intermissions between the different steps for the tissues to accommodate themselves to the increasing pressure. Sometimes the screw separators of Dr. Jarvis's pattern are substituted for this third wedge, and it has been recommended that the teeth may be protected by thin slips of wood, but a little care in their use is generally sufficient. Rapid wedging should be limited to cases where the space desired is not very great, and the structures supporting the teeth are comparatively soft and spongy.]

If the room so afforded be not sufficient, the wedge may be cut close to the teeth and gum, and left *in situ* for a day or two, then changed for a larger one, and so on, till sufficient space is attained, which space is soon lost after discontinuance of the wedge. Where the rubber-dam is not employed, the wedge, from its position, serves the useful purpose of preventing moisture from the gum having access to the cavity, and, by forming an artificial ledge, often assists in retaining the gold first inserted at the cervical edge of the cavity. Instead of the wedge, strips of India-rubber may be employed, but in our experience these cause more irritation and discomfort than the wood. Cotton pressed between the teeth and changed daily will in a little time effect a considerable separation in the teeth, and gutta-percha likewise will so act upon them when packed closely between the two teeth. The last mentioned is a convenient plan when a second visit is not obtainable for some three to six months.

[It is, however, dangerous to leave teeth with a wedge between them for so long a time, since the irritated gum seems to

secrete a mucus highly injurious to the teeth, and cavities may thus be seriously enlarged. Generally the rubber may be left one day, and after that a piece of cotton-wool saturated with sandarach varnish, or dry cylinders of letter paper, may be packed in to maintain the space for another day and relieve the soreness. In this way the teeth will be generally well enough to fill on the third day. Dry cotton-wool or several thicknesses of tape, gradually increasing the number, may be used for gaining the space required with comparative ease to the patient. Provided the occlusion of the teeth does not add to their soreness by bringing the cusps against each other, instead of the normal occlusion—cusps into depressions—slow wedging is generally preferable.]

A cavity in a tooth thus situated may be excavated as far as possible, and gutta-percha introduced and left projecting against the adjoining tooth. We have never seen injury arise from the gutta-percha in contact with the sound tooth, but if cotton be used, it should be moistened with alcohol or Eau de Cologne before being applied.

From the manner in which we have spoken of the operation of excision, and the excavation of cavities in carious teeth for receiving fillings, it might almost be imagined that we had to deal with structures as free from sensation as hair, nails, etc. Unfortunately it is mostly otherwise; dentine is often acutely sensitive, and its excision so unbearable that no other than a very enduring patient can tolerate the process; and this perhaps constitutes one of the greatest, if not the greatest, difficulty which the dental surgeon has to encounter in his conservative efforts. The cause of this æsthesia, though perhaps not a finally settled point, is generally admitted to depend upon the contents of those minute canals,—the dentinal tubuli,—which ramify from the pulp chamber to, and often beyond, the peripheral surface of the dentine. At first regarded as solid fibres, then as tubes conveying nutritive fluid, they were shown by J. Tomes to be tubes, containing soft semi-solid contents, and, like nerve-filaments, capable of conducting sensory impressions. Later research has shown them to be prolongations of those cell-like bodies, the odontoblasts, which are arranged in a layer on the outer surface of the pulp, and appear so intimately concerned in the formation of dentine. Their union with the nerves

which ramify throughout the pulp has not yet been clearly established; they may, as Boll¹ conjectures, but has not been able to verify, be so united within the dentinal tubuli; and this, we believe, we have made out in the pulp of a calf; or it may be through the stellate cells of the pulp itself.

With respect to the odontoblasts, we are inclined to accord to them another function besides the important one of assisting in the development of dentine, viz., a special sensory property like that of touch-corpuscles, Pacinian bodies, rods and cones of the retina, the olfactory cells, and various similar bodies in the auditory apparatus, all connected with nerves, and which in the teeth renders them capable of judging, and somewhat accurately, of the nature of bodies which come under their action,—the difference between a crisp rusk and a fragment of cinder being directly distinguished, and thus enabling them to act as guardians to the delicate structures of the alimentary canal. To determine the exact position of the food during mastication, it seems essential that the teeth should be sensory organs conveying nervous influence by branches to the same centre that receives impressions from all structures and parts concerned in the process, viz., lips, tongue, cheeks, and floor and roof of mouth, etc., whilst the muscles which are concerned in the movements should be controlled and harmonized by a common centre. That the process is almost purely a reflex one, and can be conducted without the aid of the cerebrum, is evidenced by the manner in which the act is performed by anacephalous monsters.² Whatever the physiological explanation may be, and we doubt not that the foregoing is an approximation to the truth, the practical, unpleasant fact exists that dentine is generally a highly sensitive structure, and in many cases is probably pathologically hyperæsthetic. It often appears intensely sensitive when first touched by an instrument, but becomes less so after a little time, which may arise from the nerves becoming exhausted by frequent irritation. Often when it is cut in one direction, say from right to left, the pain is un-

¹ Arch. 1, Mikrosk. Anat. iv. 1868.

² It is an undoubted fact, that persons who have artificial teeth supplied to them find at first considerable difficulty in ascertaining when their food has been sufficiently comminuted.

endurable: when the movement is reversed from left to right it becomes endurable.

[It should always be the endeavor of the operator to prevent, as early as possible, all painful impressions by severing all connection with the pulp cavity, using keen instruments to cut at right angles to the dentinal tubuli, at the points nearest to the pulp itself. He should, above all, avoid the crushing of the tubuli longitudinally, either toward or from the pulp, as it is an unbearable and unnecessary torture.]

Many applications have from time to time been advocated as capable of reducing this sensitiveness; chloroform, carbolic acid, creosote, and aconite, at times mitigate it¹ so much as to bring it within bearable limits, but generally they have little effect other than that of encouraging the patient to more endurance. Where, however, the sensitiveness compels us to desist, we may induce our patients themselves to apply a solution of tannin in ether;² or we may dress the tooth with creosote and morphia, covered over with cotton steeped in mastich-varnish, which should be changed every four or five days; the spirit of the varnish leaves it, on account of its greater affinity for the fluids of the mouth than for the mastich, which latter is left incorporated in the meshes of the cotton, and makes a useful temporary stopping for some days. The application of very small quantities of arsenious acid has been recommended, but there is some danger of the pulp being compromised in the process, its object being the destruction only of the contents of the dentinal tubuli. [Arsenious acid used for this purpose has, however, destroyed so many pulps that its employment is not now practised.] To obviate the trouble and unpleasantness of such applications as those above mentioned, we may resort to temporary fillings. Those varieties of gutta-percha compounds which are most readily softened by heat are very serviceable, and their efficacy may be increased by placing them over small disks of card moistened with creosote or carbolic acid. They may be

¹ The last we have found the best. All are applied on very small dossils of cotton to the sensitive surface only.

² R. Acidi tannici, ʒiij.

Ætheris, ʒj.

M. ft. applicatio.

To be applied on cotton, and changed two or three times daily.

left in from one month to three months, when the tooth will probably be found much less sensitive. No application that we know of attains the end in view so certainly as the oxychloride of zinc, but its application may be attended with severe pain; still it can be borne in most cases, and for this the preparation vended as Fletcher's is the best; for, not containing any hardening foreign material, it is much the easiest to remove, which should be done after one to three months.

[The actual cautery by a coal of fire on the end of a piece of pivot wood, touching only for an instant at a time, but often repeated, first using only the ash, and gradually increasing the heat to an incandescent coal by rapidly moving the stick through the air,—will burn out all superficial sensitiveness.¹ Pure nitric acid on a match stick is occasionally of service in posterior teeth, but great care must be exercised to use very minute quantities, and as soon as the work is done to neutralize the acid with chalk, ammonia water, or other alkali. If these means fail or are impracticable, resort may be had to general anæsthesia.]

However careful we may be in removing the softened dentine, we at times cannot avoid exposing the dental pulp, especially when it is abnormally situated, as is occasionally the case in upper incisor teeth. The pain inflicted generally, but not always, indicates to us what has happened, and the cavity of the tooth becomes filled with blood. The blood being staunched with a little carbolic acid or solution of tannin, and the cavity having been completed, a small cap of metal of concavo-convex form may be laid, the concave surface over the exposed spot, and the filling completed as if no such occurrence had happened. Instead of metal (gold, tin, lead) quill or card caps may be used, or we may touch the exposed spot with strong nitric acid, and, without capping, fill over with foil, taking care so to place a large and firm cylinder over the exposed spot, that it may be condensed without touching the pulp.²

[The editor would suggest the use of chips or powder from the healthy dentine of the tooth itself, made by scraping the

[¹ See American Journal of the Medical Sciences, p. 561, April, 1877; or Johnston's Dental Miscellany, p. 155, April, 1877.]

² The practice, we believe, of Bogue, of New York.

walls of the cavity upwards towards the point of exposure, and covering it with the powdered dentine, then covering with a gutta percha cap. It is claimed that much of the success in pulp-capping may be owing to this process having been followed inadvertently. The theory is based upon the general principle of grafting, recently so highly recommended in healing ulcerated surfaces of the skin. This dentine certainly does make the most natural non-conducting cover. In all cases of closing wounds, it is well to await the glazing over of the surface by the lymph undergoing coagulation, and when this takes place, the chips or powder will readily adhere to the surface. So-called medication with carbolic acid, tannin, and other articles has, at least, to be defended against the charge of introducing foreign bodies into the wound, a practice which savors of an age in surgery happily long passed. We should avoid an imposition upon nature, which would require her to throw off foreign matter, in addition to healing the wound. It may be added that even if the scraped dentine be dead, it is at least the nearest in condition to the natural pulp-capping of any material that can be used, and is likewise most convenient and ready for application.]

The process of capping is likewise employed with advantage wherever the disease has so far encroached upon the pulp that we have reason to suspect that only a thin layer of dentine intervenes, and where the irritation of a metallic filling, through such close proximity or changes of temperature, might lead to irritation, if not destruction, of that organ: this protection is especially desirable in the treatment of the teeth of young persons.

But the pulp may have become exposed in the progress of the disease, and, when this is the case, its surface is almost invariably found to present an ulcerated condition, most difficult to be made to heal over, and excreting a thin sanious and offensive fluid, most resembling perhaps the puriform fluids exuded from gangrenous parts. As before noticed (see p. 120), this fluid is commonly spoken of as pus; but, although pus may sometimes be found in the pulp-cavity, it differs greatly from that bland, cell-formed excretion. Whilst the ulcerated surface of the pulp continues to excrete this or any other fluid, no attempt to hermetically close up the cavity must be attempted; for the fluid, continuing to form, and having no outlet, would press back upon the pulp, and those painful condi-

tions, generally culminating in severe alveolar abscess, would ensue, which are but too well known to patients as well as to practitioners. A few years ago it was the general custom to treat by destruction almost all cases of exposure of the pulp by disease, and not a few even of those of exposure by the excavator. The process is a convenient one to the practitioner, as it leaves a tooth which may be afterwards excavated without sensation into any requisite convenient shape for filling. Experience, however, having proved that a large percentage of such cases do, after a time, become liable to periodontal irritation and inflammation with its results, more conservative plans have been adopted, and, when those have failed, there is generally the *dernier ressort* left, of destruction of the pulp. Since the introduction of carbolic acid and the zinc oxychlorides, a larger number of pulps have no doubt been preserved, and with considerable comfort to the patient. The proceeding consists in removing all the softened dentine, and then well dosing the exposed pulp with carbolic acid;¹ over the pulp is then placed a cap of thin address-card or stiff paper, also moistened with carbolic acid, and this is covered by a larger cap, coated on one side with mastich-varnish to cause it to adhere, and also to prevent any of the oxychloride from reaching the pulp, with which compound the filling is completed. If such a filling be removed after some months, the pulp may be found exposed, living, and free from discharge; or it may be found still exposed and discharging, in which case the discharge has relieved itself into, and even through, the porous oxychloride, which will be found saturated with it; or it may be found to have lost its vitality. Under the first conditions it may now be capped over and filled permanently; under the second, the process must be repeated or the pulp destroyed; under the third, the dead pulp must be removed, and the fangs, as well as the pulp-cavity, filled in the method to be shortly described. For some years we have adopted a plan which has yielded excellent results, and by means of which the pulp, and consequently the vitality of the tooth, is preserved, whilst the tooth is perma-

¹ A good form is the pure crystallized acid, rendered fluid by a few drops of chloroform. [It may be introduced as a crystal, and the heat of the tooth will melt it, but the pellicle of carbolized pulp is not as likely to form a normal covering as the natural lymph.]

nently filled at the same time; and it is more especially suited to cases in which the exposed pulp, say, of a molar tooth, is found of a crimson color, freely exposed, and even granulating into the carious cavity beyond the pulp-cavity,—an early stage of polypus of the pulp, and a condition in which the attempt at preservation by carbolic acid is seldom successful, and destruction by arsenious acid often tedious and uncertain. The softened dentine having been cleared away, and the cavity otherwise prepared, the sensitiveness of the exposed pulp is lessened by a free application of carbolic acid, and then a small disk of card, but little larger than the exposed surface, and well saturated with the strongest nitric acid, is laid gently upon it, and so retained for about half a minute: at times a sensation like tooth-ache, but never severe, is felt for a few minutes afterwards. After removal of the nitric acid, a cap of thick paper, moistened with carbolic acid, is placed over the pulp, and, if the tooth is to be filled with foil, over the paper cap one of metal, concave on the pulp surface, to guard the pulp from all pressure: the filling is then completed as if no exposure of the pulp had existed. The same process may be adopted in the case of an amalgam filling, but it will be found a good plan to give a coating of oxychloride over the first paper cap in the place of the metal one; and this is best done by keeping such caps in readiness, as there is then no danger of moist oxychloride getting access to the pulp. The oxychloride being an inferior conductor of heat to metal, there will be less chance of irritation due to changes of temperature. In almost all cases where we have had the opportunity of seeing the result of this treatment, we have found the pulp alive and apparently healthy, but never calcified.

In the place of nitric acid the actual cautery may be employed (Fig. 213), the best form being the galvanic, in which a bent platina wire is maintained at a white heat. After destroying a portion of the surface of the pulp by the heated wire, we proceed as in the treatment after the application of nitric acid.

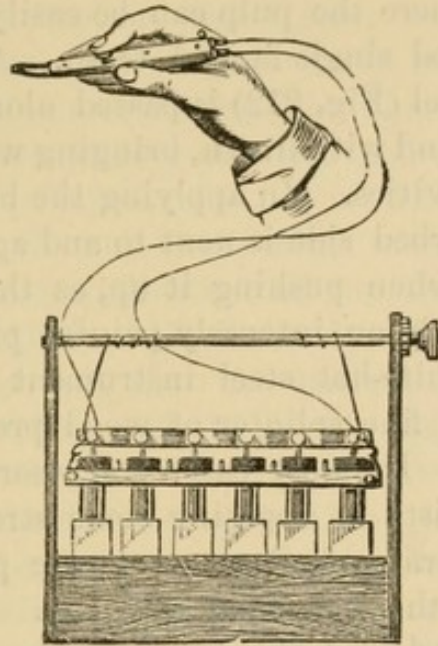
We have spoken of hypertrophy of the pulp when exposed by disease. In many cases, especially those of extensive caries on masticating surfaces, the pulp becomes enlarged to several times its own normal dimensions, extending to the level of the

Fig. 212.



Barbed nerve-extractors made of soft steel for removal of dental pulps.

Fig. 213.



The galvanic cantery. The portion held in the hand is constructed of ivory, and insulates the wires from the battery, which terminate in a loop of fine platina wire: the latter becomes white hot when the battery is in action.

Fig. 214.



A lancet of convenient form for excising a polypus either of the dental pulp or of the gum.

crowns of adjoining teeth. It presents a pale rose color, and is tender when pressed upon, but not nearly as much so as an ordinarily exposed pulp; it bleeds freely when touched, and excretes a fluid of most offensive odor, often tainting the breath considerably. A section shows its surface to be covered with very regularly arranged papillæ, but we have not been able to make out any special secreting glands. In most cases the teeth thus affected are too far destroyed to induce us to attempt their preservation, but, in cases where it has been considered worth while, we have generally by the following plan succeeded. We first dose the growth with carbolic acid to deaden its sensitiveness, and then, with a scythe-shaped lancet, cut away as much of it as possible. After the

bleeding has ceased, we carry out precisely the nitric acid process above described.

When it is deemed expedient to destroy the pulp, this may

be effected immediately or mediately. The former is only suitable in cases where the pulp can be easily reached, notably in cases of fractured single-fanged teeth. A thin barbed instrument of soft steel (Fig. 212) is passed along the pulp to its extremity, rotated and withdrawn, bringing with it the contents of pulp and fang cavities. [In applying the broach, care should be used that the barbed side is next to and against the walls of the pulp-chamber when pushing it up, as thus less pain is inflicted.] It is mostly an intensely painful process without an anæsthetic. A white-hot steel instrument causes much less pain, as does also a fine splinter of wood previously dipped in strong nitric acid. In most cases we resort to the mediate process, which consists in applying some strong escharotic, as chloride of zinc, nitrate of silver, or caustic potash, or irritant, such as arsenic, to the surface of the pulp. The latter is the agent most employed, and the process is best accomplished as follows: The softened dentine being removed, it is essential to have the pulp freely exposed, and, although the process is painful, it is little to the agony experienced when, from insufficient exposure, the inflamed and swelling pulp becomes compressed in the unyielding pulp-cavity; the frequent application of carbolic acid generally renders it tolerable, whilst it at the same time staunches the bleeding. Upon the pulp, now freely exposed, is gently laid a small disk of card, saturated with carbolic acid, and having attached to its pulp-surface about $\frac{1}{20}$ to $\frac{1}{16}$ of a grain of pure arsenious acid. The moistened card readily takes up the acid when laid upon it.

[While it is most certainly preferable to cut away the overlying dentine, the operation must not infrequently be dispensed with, until after the devitalization of the pulp, on account of the pain inflicted.

Arsenic may be combined with morphia and carbolic acid to form a convenient paste, for which there are various formulas. Prof. J. Foster Flagg's is very generally used:—


R—Arsenic, grains	j.
Acetate of morphia, grains	ij.
Carbolic acid, drops	iiij.]

The cavity is now lightly but carefully filled up with a little beeswax softened by heat. The patient should be seen the

next day, and, on removal of the wax and card, the pulp will be generally found free, or almost free, from sensitiveness, although it not unfrequently bleeds freely when the fine-barbed nerve-extractors are inserted into the fang-cavities, gently rotated, and withdrawn, having attached to them, it may be hoped, the contents of the fang-cavities, all of which should be thoroughly removed. Should the patient not be seen again for some days after the application of the arsenic, the pulp will probably be found softened, devitalized, and not vascular. Some deem it very important that the patient should be seen the next day, having a fear that the arsenic may in time get access to the system, a view the absurdity of which is manifest when we recollect that the amount applied, and locally to a structure destitute of absorbents, is seldom more than the full dose administered to a patient internally in the course of a day, and bears no comparison to the quantities applied externally in the destruction of a malignant growth. Nevertheless due care should be exercised that none of the agent finds its way directly to the mouth. In cases when the patient cannot be seen for some weeks after the application of the arsenic, it will be best, after placing it upon the pulp, to cover it with a concave metal cap, and then fill over with Hill's gutta-percha stopping; cases thus treated often remain well for years. Arsenious acid has probably two kinds of action when applied to soft living tissues; one, escharotic, in which it destroys vitality by forming compounds with their albuminous constituents; and the other, as a powerful irritant, exciting severe inflammation; and it is generally believed that it is chiefly the latter action, which, terminating in sphacelus, causes destruction of vitality in the dental pulp. Arsenious acid has also, as is well known, a powerful antiseptic action, and is unequalled in preventing for lengthened periods the decomposition of animal substances; hence the pulp, though destroyed, is seldom found putrid after its action, and this property may, as we shall see, be turned to good account in certain troublesome cases. To resume: the fang-cavities being cleared out,—no easy matter in the case of lower molars,—they should be filled up, and, though gold may be employed in certain easy cases, it is better to use the oxy-chloride of zinc, mixed rather fluid, and incorporated with finely-chopped cotton-wool; this must be worked into the fangs by a

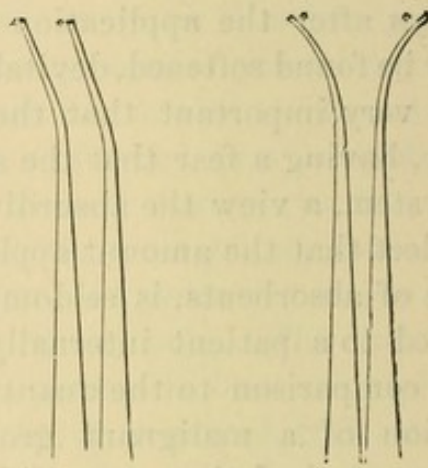
sort of pumping action, by which means the air is pressed out and the stopping pressed in; the oxychloride being powerfully antiseptic, little hurt is likely to accrue if any small particles of soft tissue be left in the fang-cavities. If gold be used, it is well to wash out the fang-cavities with carbolic acid or creasote

Fig. 215.



Form of instruments for removing the disorganized contents of a pulp-cavity.

Fig. 216.



Pluggers of a delicate form for filling the fang-cavities with foil.

before attempting to insert it. [At this stage of the operation there seems to be no question that the use of pure carbolic acid in crystals is the best means of disposing of the fine filaments and the vessels within the apex of the root.]

Occasionally, though rarely, and more especially in single-fang teeth, we may find that the pulp has undergone a species of dry gangrene, and on removal appears free from unpleasantness, and of a pithy consistency; the tooth has not changed color, and the periodontal membrane appears perfectly healthy, showing that the tooth, though possessing no vitality except probably at its cementum, is no cause of irritation to surrounding tissues. In other cases we may find that the whole of the dental pulp has sloughed away, leaving the surrounding dentine softened, but not putrid, both of which classes of cases we should treat precisely as if we had removed the pulp. It may, however, happen that, whilst the pulp has sloughed away, the canal-cavities are filled with puriform fluids, the dentine itself being moist and very offensive; and it is rare to find, in such cases, freedom from periodontal irritation, caused no doubt by the presence of septic substance. Such cases have been usually treated by the

frequent application of strong antiseptics, carbolic acid and creasote, alone, or mixed with iodine, being the favorites; but for some years we have employed arsenious acid, as with one application we have obtained more certain results than with ten or twenty applications of those above mentioned: we simply clear out the pulp-cavity, wash out with carbolic acid, and apply the arsenic precisely as if for destruction of a pulp, laying the application over the orifice or orifices of the fang-cavities, and then filling over with oxychloride of zinc. If the latter be removed after two or three months, the pulp and fang-cavities will generally be found dry and perfectly sweet; indeed, we believe that there is really no necessity for fang-filling in these cases, as the arsenic effectually renders their contents incapable of further decomposition; but upon this point we would speak with reserve.

[Prof. Flagg has recommended that the arsenical paste (p. 226) be pricked into the canals by slow movements of a fine broach toward the apex, and even at one sitting the contents may be removed with little more pain than an occasional pin-scratch would give.

To impress upon the reader the difference of action of the two classes of antiseptics, the following extracts from a paper on the subject by Prof. Wilbur F. Litch are here offered.¹

"All antiseptics, when applied in sufficient strength, have the power of destroying minute organisms, and of thus arresting fermentative and putrefactive changes; but a careful discrimination must be made between the powers respectively of such antiseptics as carbolic acid, creasote, oil of cloves, etc., and such other antiseptics as chlorine, bromine, iodine, etc., which, in addition to their antizymotic power, are true chemical antagonists of those sulphuretted hydrogen compounds of which putrefactive gases are constituted, such gases being immediately decomposed by them, their hydrogen element going either to the chlorine, bromine, or iodine, to form respectively hydrochloric, hydrobromic, or hydriodic acid, the sulphur being in each case precipitated."

"In the antiseptic treatment of putrescent pulp-canals, great advantage is to be derived from a dressing composed of car-

[¹ See Pennsylvania State Dental Society Transactions, 1881.]

bolic acid or creasote and iodine. By the use of this combination, not only is putrefaction arrested, but its products are decomposed, each molecule of the putrefactive gas being, as it is formed, seized by the iodine, and its elements forced into such other combinations as shall render them incapable of exercising pressure under the conditions ordinarily present in the pulp-chamber of a devitalized tooth."

The following formula is recommended:—

R—Iodinii (crystals),
Acidi carbolici (crystals), āā 3j.
Alcoholis, f3ij. M.

Sig. Saturate with this mixture a pledget of cotton of suitable size, and place in the pulp-canal (previously cleansed) of the tooth to be treated.]

We have thus treated many cases permanently at the first sitting, and, so far as time has permitted, we may speak most favorably of the results. In such cases only part of the cavity has been filled with the oxychloride, the remainder with foil or amalgam. In very many of the cases slight periodontal irritation, which previously existed, has disappeared, the teeth becoming again fully serviceable for mastication. In treating upon the subject of discharging pulps, the student cannot be too forcibly impressed with the importance of always ascertaining whether such condition exists previous to inserting a filling into a tooth: the cavity may deceive, from being shallow and at a distance from the pulp, and may yet communicate with it by a very fine channel. During the progress of excavation, clean cotton-wool should be more than once introduced into the cavity, and, when it has been removed, the sense of smell will seldom fail to detect any existence of discharge. Liability to the opposite error may, however, arise in cavities close to, or below, the gum, where the latter has bled and its serum become decomposed in the cavity, when the same stench is afforded. In such doubtful cases the cavity may be purified by permanganate of potash, and then after a little time fresh cotton applied, which will be sweet or otherwise, according as discharge exists or not. A ready but less perfect means of treating cases where discharge exists in the fang-cavities, consists in capping over the pulp-cavity, and at once filling the tooth, after which a fine hole is drilled either through the side


of the tooth just below and through the margin of the gum, or through the filling itself into the pulp-cavity: the process of decay, though not wholly arrested, is thus very much retarded, whilst the discharge obtains a free outlet, and generally after a few years ceases to be secreted. [This is probably only justifiable in teeth of aged persons who may not have the prospect of very long need of them, and yet who are not likely to be under the inconvenience of learning to use artificial ones.]

The same process may be adopted when pain comes on after a tooth has been filled, especially if it be conjectured that the pulp has perished, when the gases and fluids generated will obtain an outlet.¹ Hullihen has recommended our doing so in cases where we may believe the pulp to be still living: we have drilled into the living pulp on a few occasions, and on the whole with benefit to the patients, thereby no doubt relieving the tension of the organ.

In most cases, however, where pain is set up in a tooth that has been filled, especially if it be constant and increasing, we shall do best to remove the stopping, and ascertain, if possible, its cause. We may find that exposure of the pulp at a certain spot existed, and has been overlooked, for it is quite possible for a pulp to be exposed and yet excrete no unpleasant discharge, as we have occasionally found to be the case. It may prove, as in the case of amalgams especially, that changes of temperature readily conducted through them have led to irritation of the not far distant pulp; or even, in the case of an amalgam which expands slightly in setting, the adjoining dentine may have thus suffered from pressure. In the two latter cases, the substitution of a gutta-percha filling, for a time, in the place of the metallic one, will be the safest course to pursue.

Pain, of a moderate amount, may come on at intervals in a tooth in which we may have good reason to believe that none of the above-mentioned causes exist. Coming into a warm room, suddenly moving the head, as in stooping or going down stairs;

Fig. 217.



Drills to be employed with the dental engine,—suitable for drilling into the pulp-cavity of a tooth.

¹ An operation more than a century old, and now most readily accomplished by the bur-engine.

and also being exhausted or fatigued, especially during fasting, may seem to excite it. Under such conditions we may surmise that the pulp is subject to occasional congestions, the explanation, we presume, of what is termed an irritable pulp. For the relief of these cases we have found no class of remedies so serviceable as counter-irritants, and that which we most employ is a saturated solution of chloride of ammonium in water, rubbed upon the surrounding gum. Experiment has shown that for a considerable distance below the spot at which a blister has been applied the various structures, and not essentially all of those which receive their blood from the same source, are more anæmic than normal, which explains the action of counter-irritants in relieving congestion. [Saturated tincture of iodine will blister nicely. The gum should be dried, and a pellet of cotton saturated with the tincture applied on the part overlying the root of the tooth.]

Many other conditions not enumerated will at times crop up, to interfere with or even defeat the best and most patient efforts of the operator. Cramp in the jaws, from wide distension, is a trouble from which some patients suffer much, at times relieved by their having a prop to bite upon, which is often a comfort also to those whose mouths are kept long open. Very small mouths, or rather mouths with very small openings, considerably obstruct an operator; but that which is perhaps worse than any of the above-mentioned peculiarities, is the tendency of some patients to faint as soon as an operation is attempted: we have best succeeded with these at an early period of the day, *i. e.*, soon after breakfast and the night's rest.

The teeth of very young people, however carefully filled, have a strong tendency to an extension of the mischief around the fillings. We have seen some of the most excellent fillings fail thus, though made by operators of the highest reputation. We believe that it will be found good practice to fill the teeth of these first with either the zinc-chlorides or zinc-phosphates, which, probably from their making perfectly water-tight fillings, have a tendency to harden the tooth in the neighborhood of the filling. In strong teeth, though it be very desirable, it is not absolutely imperative that a filling should be perfectly water-tight. If we select from amongst the teeth which we have removed some which have been filled with gold or amalgam

for a number of years, and in which the fillings still appear quite perfect, and immerse them for some time in a colored fluid which is a chemical compound, *i. e.* not merely a colored body held in suspension,—Draper's ink answers the purpose very well,—we shall, on removing the teeth, and splitting them across the filled spots, almost invariably find that the color has penetrated between the stopping and the cavity. It would seem, therefore, that the presence of more solid substance is essential, in strong teeth at least, to the progress of caries, which favors the opinion we have expressed with regard to it (see p. 128). [There must be some allowance made in this experiment for the shrinkage of the tooth from drying, and of the filling from difference of temperature.]

In those whose teeth have on the whole stood well, changes in the constitution may have a great effect for the worse, and amongst these pregnancy is undoubtedly the most common. Women who have had excellent teeth up to the period of a first pregnancy, often lose them one after another, and usually with considerable suffering, especially if a family come very fast. Various explanations have been offered, none of which appear to us so satisfactory as that the secretions of the mouth are altered in character, and the teeth have their power of resistance lessened. Again, we have seen teeth in young persons, which we have pronounced excellent, become completely altered in character after an attack of one of the exanthemata, especially scarlatina. Great mental strain is another cause of teeth taking on sudden and rapid decay, and this is well illustrated in the case of those who have been working for some time for severe competitive examinations. A visit abroad, notwithstanding the general good done to the system, often has a deleterious influence upon the teeth, and a short residence in Switzerland is so marked in this respect, that we cannot but believe it to be due to certain local conditions, probably the water. On the other hand, a residence in some countries has the opposite effect, and we believe we may say without contradiction, that residence for a time in India or China, the former especially, proves beneficial to these organs. In treating teeth which have suffered from the above-mentioned causes, we shall find the ordinary metallic fillings most unsatisfactory, and we shall employ to most advantage the zinc-phosphate or gutta-percha, until

we can conclude that the abnormal conditions have to a great extent passed off. A most careful employment of the tooth-brush after every meal must be inculcated, and the ammonia and spirit-mixture spoken of (see p. 43) may be used with advantage.

[Chalk may be freely applied by the finger around the teeth on retiring, and lime-water used to wash it away in the morning. This will at least modify the local conditions, but the general health and appetite should never be lost sight of. Fresh air, exercise, regular meals of healthy, substantial food, such as bread made from unbolted flour, fresh meat, particularly that of small birds, the bones of which should be eaten; lobsters, crabs, oysters, and every form of food containing lime, together with milk and lime-water, will bring about an improvement in the tooth-structure.]

In the present chapter we have incidentally spoken of almost all the abnormal conditions which may occur to the dental pulp. Some writers have considered it desirable to attempt to classify them, and to define each at some length. We believe such attempt to be more likely to confuse the dental student than to aid him, at least in his practical work; his treatment of a tooth will probably never be influenced by his considering the question,—is the pulp in this case in a congested condition only, or may it be in a state of chronic inflammation? He can obtain but at most a very imperfect knowledge of its condition, enclosed as it is in its bony surroundings, unless it be at some spot exposed to view, and he will then act, in nine out of ten instances, according to the appearance that it presents, whether for its preservation or for its destruction. If for the purposes of an examination such knowledge be deemed requisite, we would simply remind the student that the dental pulp is very liable to all those conditions and stages that are to be met with in delicate structures largely supplied with nerves and bloodvessels, comprehended under the general designation of inflammation, which we shall dwell upon in connection with the subject of the following chapter.

[There has come to my knowledge at least one case of threatened apoplexy, which was aggravated if not induced by pulp capping and which was averted by extraction of the tooth. Operations performed without due regard to the general health of the patient, are not infrequently the cause of serious disease.]

CHAPTER X.

PERIODONTITIS.

INFLAMMATION of the periosteum of the tooth—the periodontal or alveolo-dental¹ membrane—is, as has been already pointed out, a very common sequence to caries, and therefore a description of its symptoms, pathology, and treatment naturally follows that of the latter disease. It occurs in both the acute and chronic forms, sometimes commencing in the former and terminating in the latter, and *vice versâ*. Although by far most frequently the result of dental caries, it at times appears with apparently perfectly sound teeth; it is also a concomitant of stomatitis, whether of idiopathic, rheumatic, syphilitic, or mercurial or other medicinal origin. As a concomitant of dental caries its origin is probably due to the presence of septic matter generated by a decomposing pulp, which may come into direct contact with the membrane itself, or may, through the dentine and cementum, so influence it; or may, as some have supposed, affect it through the vessels which supply both the pulp and the alveolo-dental membrane. It is possible, when occurring to a perfectly sound tooth without any conditions which may account for it, that it may arise from embolism of the nutrient vessels of the pulp; when due to rheumatism or syphilis, it no doubt arises from depositions, the result of those affections which have a predilection or affinity for such fibrous structures. Cold or violence may in this, as in any other structure, be the proximate cause of inflammation. The symptoms of acute periodontitis are generally of the following character, as we have ourselves experienced it, which agrees in the main with the description given by other writers.

In the first place, a tooth becomes the subject of attention on

¹ The Latin term has been adopted by C. S. Tomes, as it explains more correctly the true nature of this structure.

account of peculiar and uncomfortable, rather than of painful, sensations. It soon appears to be slightly elongated, *i. e.*, extruded from its socket, and also slightly loosened, which is the case, for, on closing the mouth, it can be felt to be pressed into its socket, and on opening the mouth it seems to part from its antagonist with a sensation of stickiness. Biting on the tooth at this stage appears to offer comfort, although it probably by no means improves the condition of matters. It may happen that recovery takes place at this, the first stage, although the disease more frequently runs on to another, in which the result of pressure is anything but agreeable; and this tenderness increases until even the slightest attempt to close the mouth, and even contact with the tongue, becomes intolerable. Independently of that caused by pressure, pain of a constant character, varied only by an aggravation at each pulsation, is experienced, which generally continues, it may be for some days, until a swelling appears in the neighborhood of the tooth, or some adjacent part, when, as a rule, there is considerably mitigation. Subsequently the swelling becomes more defined and prominent at one part,—the pointing of an abscess,—which bursts and evacuates the matter it contains, when a still greater mitigation of all the unpleasant symptoms is experienced. It is generally some little time before the swelling entirely disappears, or the discharge ceases to be secreted: often for years afterwards a small fistulous opening remains, through which small quantities of pus, increased through cold, gastric disturbance, etc., find their way to the surface.

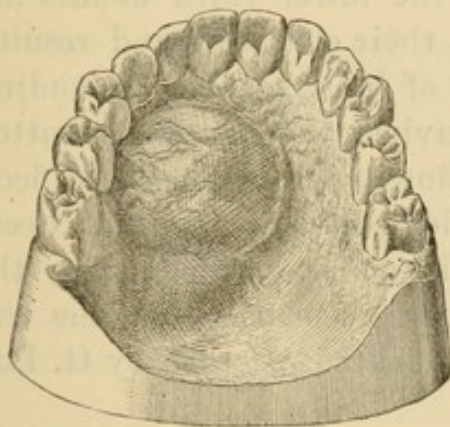
Of all the teeth, the lateral incisors of the upper jaw appear the most liable to attacks of acute periodontitis. The fact has been pointed out, but the reason not explained. When it attacks these, the upper lip usually becomes considerably swollen, as does also the facial depression formed by the myrtiform fossa, and the tissues to the outer side of the nasal process of the superior maxilla; the swelling often extending up to the lower eyelid, with considerable ecchymosis at this part. There may, on the other hand, be little or no swelling on the anterior portions of the jaw, but there may be considerable in the palate, extending quite as far as the limits of the hard palate. No teeth are, we believe, so likely to cause the palatal swellings as the upper lateral incisors, which swellings often exist for a considerable

time, when the cause of their existence has apparently been removed. Swellings in the same positions may arise from any of the upper six front teeth, and pus may evacuate itself anteriorly over the apices of their roots, or in the palate, or into the nares, and more rarely upon the surface of the face. In the case of the bicuspid and molars, the matter generally points over the roots on the external alveolar wall, where the bone is thinnest; occasionally it appears on the inner surface of the cheek opposite to the tooth, and not far from Stenon's duct; it probably takes this course when the matter is formed above the inner fibrous covering to the buccinator muscle. From these teeth also pus may evacuate in the palate, especially when the mischief pertains chiefly to the palatine fangs of the molars.

[Prof. Garretson had an unusually interesting case of this character, where perforation of the salivary duct occurred, causing a persistent opening upon the external face of the cheek, a diagnosis being thereby very much obscured.

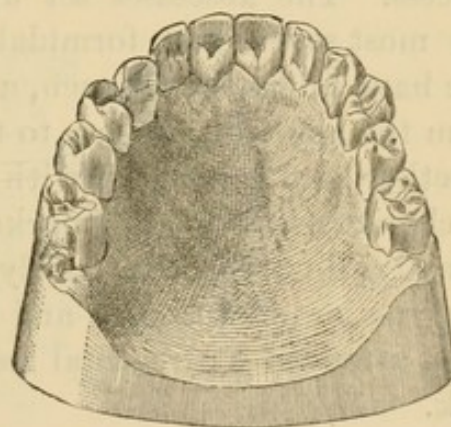
Somewhat like the above was the case of Mr. R., in whom a diseased lateral incisor excited inflammation and abscess opening into the antrum, and thence into the nares, resulting in

Fig. 218.



From cast of mouth showing a cystic tumor.

Fig. 219.



The same after treatment.

a huge sack, dependent from the roof of the mouth. This was treated by making an opening from the mouth through the external alveolar plate into the tumor, and introducing stimuli, principally tincture of iodine. The bony palate was absorbed at one point, admitting the finger to press up the mucous tissues through the palatal process of the superior maxilla. In time the opening in the bone was filled by a cartilaginous ma-

terial, which when last seen had probably been ossified, as it was hard and resistant.

It may be added that the first figure (Fig. 218) is taken from an impression made after the size of the cyst had been much reduced by emptying it through the opening in the alveolar plate, and the tissues were no longer distended by their fluid contents.

Attention is called to the dropping inward of the right cuspid, from the loss of the bone and the contraction of the cicatrix of the palatine process of the superior maxilla.]

In the lower jaw, such abscesses, occurring from incisors and cuspidati whilst generally opening near the apices of their fangs on the external alveolar surface opposite to the lower lip, occasionally point on the outer surface under the chin; more rarely they do so on the inner surface of the alveolus about the root of the tongue. Abscesses from the bicuspids and molars most commonly open on the external alveolar surface, about the apices of the roots, but also very frequently on the external surface, not far from the angle of the jaw; and these, if permitted to continue, give rise to an unsightly puckered scar, not unfrequently resembling and mistaken for the result of a strumous abscess. The abscesses set up by the lower third molars are the most severe and formidable in their character and results. We have witnessed, as such, a mass of brawny tissue extending from the angle of the jaw to the clavicle, the structures matted together, and infiltrated with pus flowing from several orifices, all characteristic of well-marked phlegmonous erysipelas. Occasionally, but happily rarely, such abscesses open into the pharynx or œsophagus; and a case of evacuation into the trachea, attended with a fatal result, has been recorded by G. Pollock.

The pathology of periodontitis has been variously described, but we believe that the following account of its nature and progress, which may differ in some respects from the views of others, will be found, upon the whole, in accordance with the conditions as they present themselves. Owing to the causes already alluded to, viz., cold, violence, the extension of previous inflammation in adjacent parts, the presence of obnoxious material in the form of rheumatic or syphilitic deposits, but more especially of septic material, the alveolo-dental membrane suf-

fers irritation at certain spots. This irritation results in those changes which have been so industriously studied in the web of the frog's foot, wing of the bat, mesentery of the frog, tail of the fish, etc. The vessels at the irritated spot, whether primarily contracted or not, become dilated, whilst the blood which they contain becomes retarded in its flow, with complete stagnation at certain points: without the limits of the area of irritation the vessels are dilated, and the circulation more than normally active. This probably constitutes the stage of congestion of the alveolo-dental membrane, which becomes enlarged in consequence, and this enlargement can only be effected by an elevation of the tooth in its socket: hence also the apparent looseness of the tooth. Pressure on the tooth at this period forces the blood from the dilated vessels of the membrane, and hence no doubt the comfort experienced by this act. In the next stage, at the stagnant parts, the vessels become crowded and finally blocked up with the red corpuscles which adhere to their walls, whilst the white corpuscles, in like manner adherent, are seen in increased quantity: these latter put forth processes which penetrate the walls of the vessels, and, enlarging

Fig. 220.

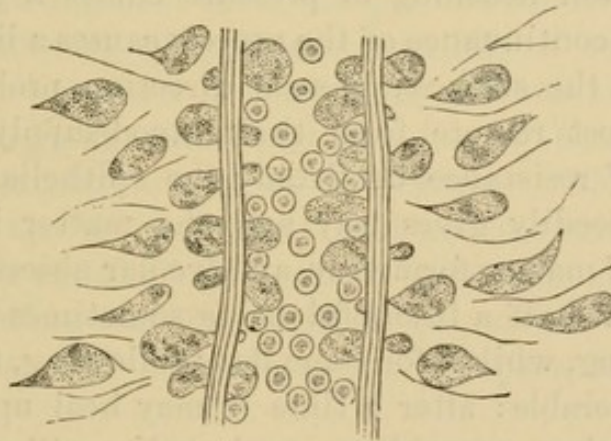


Diagram to illustrate the passage of the white blood-corpuscles through the walls of a blood-vessel, and their subsequent migration between the fibres of the surrounding connective tissue. The red and white blood-cells are not represented in their due proportions, as this would obscure the chief point we desire to illustrate.

on the outer sides of the vessels, and diminishing on the inner, thus transport their contents or substance through them (Fig. 220): when free, the cells travel towards the irritated spots by aid of their amœboid contractility, the changes in the surrounding connective tissue, by the softening and fusion of its fibres,

rendering their passage more easy. Besides the passage of the white blood-cells, serum, more or less considerable in quantity, has passed out of the vessels into the surrounding tissue, and probably by its presence and pressure gives rise to the pain experienced at this stage, when biting on the tooth can no longer simply empty the vessels of their surplus quantity of blood, but causes abnormal pressure on the hyperæsthetic nerves.

In the next stage, we get a rapid cell-proliferation at the spots of chief irritation, accompanied also no doubt by a similar proliferation of the cells of the adjacent connective tissue, and these formations, taking place within hard and unyielding surroundings, account for the constant pain, increased by the further pressure of each pulsation before alluded to. But the ever-present connective tissue of the body, not excluding bone itself, shares in the process of suppuration, until finally the external surroundings become involved: we discard the idea of a pyogenic membrane, which on the one side possesses a property of secreting pus, and on the other a property of absorbing adjacent tissues. When the bone is lost, the pressure of the mass of cells with the products of their fatty degeneration—pus—readily distends the softer tissues of the mucous membrane, and with this swelling and lessening of pressure comes a general relief from pain. A continuance of the process causes a like breaking-down towards the surface; in such direction probably because the tissues most remote from their blood-supply possess the least power of resistance until only the epithelial covering is left, which speedily gives way and the matter is evacuated. The amount of matter formed in an alveolar abscess varies considerably, about half a teacupful being sometimes evacuated at the first opening, whilst, for some days following, the discharge may be considerable: after a time it may heal up by granulation, but its doing so rapidly, or otherwise, will much depend upon the nature of its first cause: thus, if it has been due to the presence of septic matter, the result of a necrosed tooth, so long as this remains so long will pus in smaller or greater quantities be secreted. When such abscesses open externally, as in the case of the lower molars especially, an opportunity is afforded for seeing for how long a time after the opening of the abscess pus continues to exude, drop by drop, from the fistulous orifice, which consists of a mass of granulations of nipple form,

whilst the surrounding structures are glued to the bone by adhesions which have undergone contraction, presenting a most unsightly spectacle.¹

The general symptoms are those which are included under the term pyrexia; such as an elevation of the temperature, a quickened, full, and incompressible pulse, a dry tongue, thickly coated with brown fur, thirst, head-ache, absence of appetite, urine scanty and high-colored, and bowels usually constipated.

The treatment will of course be local and general. In the early or first stage, when the act of biting upon the tooth gives a sense of comfort, the application of continued warmth, which is best accomplished by means of poppy or chamomile decoctions, a little warmer than the temperature of the mouth, and held within it, will often afford relief and occasionally arrest further progress. Cold, no doubt, might effect the same result, and probably more expeditiously, but it is almost impossible to apply cold continuously to the mouth, and a frequent alternation of temperature is worse than useless. Cold, most probably, by causing a contraction of the vessels at the part congested, as well as a lessening of the active vital changes, restricts the process; warmth, on the other hand, has the opposite tendency, viz., to promote and augment those changes and conditions which are a part of inflammatory processes, especially of cell-activity and proliferation; but then it encourages a more healthy circulation in the stagnant vessels, and thus lessens the congestion and tendency to exudation and cell-migration. Cold, to be effective, must be applied very early, and continuously maintained, until a cure is effected. In a small burn, such as the dropping of ignited sealing-wax upon the finger, which ordinarily produces a blister and painful sore, if the part be immediately

¹ A rare consequence of a dental fistula may be a salivary fistula. A case of this kind came under our notice many years ago, in the person of a male adult, and when we were attached to the Metropolitan Free Hospital. The dental fistula which arose from the root of a lower tooth had been in existence for some time, and, when the root was removed, the opening remained patent and the saliva continually flowed through it. A probe introduced through the opening in the cheek passed readily into the open alveolus of the tooth. By freeing the surroundings of the opening from the bone to which they were adherent, and paring its edges, the opening was readily closed by a silver wire suture, and healed up without trouble.

plunged into cold water, intense relief is experienced; and, if it be kept there long enough, no blister will appear, or other usual consequences of such an injury. [The cold may be applied by the ether spray apparatus, care being taken not to carry it to the point of producing a frost-bite.]

In the second stage, where we have reason to believe that exudation is taking place, the application of one or two leeches to the gum over the external alveolus, corresponding to the apex of the fang of the tooth, is often productive of great relief, the tooth generally appearing to recede again into its socket; indeed, the same remedy may be employed with benefit, if it be considered worth the trouble, in the first stage. [Holding hot water in the mouth, although it produces an exacerbation of pain at first, will almost invariably be followed by relief after persevering in its use for half an hour or more, the result of the reaction from continued hot applications.] The bleeding should be encouraged, after the leech has ceased sucking, with warm water, within moderate limits, and when it has quite ceased, the poppy or chamomile fomentation may be continuously used. It is never well to apply the fomentation or poultices to the external surface, for, although they undoubtedly afford relief, they render the tendency greater for an abscess to open on such surface. In the second stage, if it has not been seen to in the first, the bowels should be well opened; the whole trouble having probably arisen as much from a systemic as from a local cause. We often remove teeth in which there has never been other than the inflammation which would have been caused by the simplest irritants, yet not only the pulp-cavity and dentine are in a highly offensive condition, but also the alveolo-dental membrane; the latter a mass of apparently noxious septic material, exuding fluids of the same character. We can therefore only account for those severer forms of erysipelatous character as being due to a peculiar state of the system, or to an altered condition in the surrounding vessels. [Extraction is now only resorted to in rare cases, and should not be performed during a high state of inflammation, as it is likely to add greatly to the irritation already existing.] The former is probably the more correct view, and for the reason that we find these attacks generally associated with some debilitating condition, such as probably conduces, as Simon points out, to an

accumulation of those products of disintegrated tissues in the blood which in health are eliminated from it by important excreting organs of the body. A sudden chill appears a very common forerunner of these attacks, and nothing is more likely to affect the excreting organs; great mental strain and overwork is another, and probably also by their indirect effects on the same organs. [A chill is a very valuable diagnostic sign of the formation of pus in any part of the body, and it is not exceptional when pus forms at the root of a tooth. It may be indefinite, as a mere crawl or creeping of a cool sensation, generally down the back, or it may be so pronounced as to be quite evident to others than the patient.] Aperients and diuretics are therefore certainly indicated in the early stages of acute periodontitis. When these have exhibited their desired effects, we may with much advantage prescribe tonics, the best of which, in our experience, are bark and sulphuric acid.¹ Nothing appears so readily to remove the fur from the tongue as this does; and, though it may be said to favor suppuration on the one hand, it undoubtedly strengthens the system to bear it on the other, and may even enable the system to dispose of the products of cell-formation without permitting them to degenerate into pus. We witness this in certain rare cases where the disease is arrested in the second stage, the products of inflammation becoming organized and remaining as a swelling, which after some time entirely disappears. [These cases are frequently annoying from the persistence of the swelling; they are at times benefited by deep lancing and treating the interior with iodine. Constant pressure, by a pad of cotton wool or carbolized flax or oakum laid between the gum and cheek, will reduce them generally with the least trouble and pain.] In the later stages, when suppuration is inevitable, the patient should be well supported with soft nutritious diet, and, if necessary, a liberal amount of stimulant. During the period of the acutest pain, when it is more than probable that matter has formed, it is a question whether much relief might not be afforded by treating

¹ R.—Acidi sulphurici dil. ℥ij.

Decoct. cinchonæ, ℥viij.

M. ft. haust.

An eighth part twice or thrice in the day

as for abscess in bone, *i. e.*, by trephining; an anæsthetic might be employed during the process. Could we always insure hitting upon the exact spot, it might be safely recommended; but, as these abscesses often form at no inconsiderable distance from the tooth, failure would probably add much to the patient's sufferings; the lower jaw would probably be safer so to operate on than the upper. [An ordinary spear point drill (No. 163, Fig. 115) in the engine will penetrate in a moment and give relief in a large percentage of cases within half an hour.]

Bell, in treating upon alveolar abscess, makes a distinction between those which occur in the immediate neighborhood of a tooth and those which occur at some distance; believing, however, the cause of both to be one and the same we see no object in drawing such distinction.

Should the disease occur in teeth apparently sound, and without any previous debilitating or otherwise predisposing conditions, we may suspect, in those who are the subjects of rheumatism, that it is of such origin, and we have found it yield readily to an alkaline treatment. In those who are the subjects of syphilis, iodide of potassium is doubtless the best remedy; and, should it occur as the result of mercurial treatment, chlorate of potash, both internally and as a lotion, appears to give the most speedy relief.

In describing the treatment of periodontitis we have presumed that the tooth or teeth affected have been sound, or at all events serviceable ones; should it be otherwise, and not the result of extended inflammation, or occurring from the causes enumerated in the foregoing paragraph, we may cut the matter short by extraction. [Since the introduction of Dr. Richmond's gold and the Gates-Bonwill porcelain crowns, the facility with which roots are used for supporting their share of masticatory pressure, adds to the duty of persistent efforts to save the roots and delay extraction.] In former days it was not the custom to remove teeth the surroundings of which were greatly inflamed; we know of no objection to so doing other than the pain occurring at the time, and generally for some hours after. A surgeon would surely never refuse to withdraw a splinter from the flesh, however severely inflamed, provided he could readily grasp the same; in each case the removal of the foreign body, the cause of the mischief, would, if practicable, be the right course; at the same

time no positive rule on the subject can be laid down; there are, for instance, those forms of inflammation having the tendency to ulceration of surface, in which an open wound would be a most undesirable condition. With regard to opening the abscess by the knife, or allowing it to open spontaneously, much will depend upon its position and condition; if it appear to be pointing in a suitable position and without hindrance, it may be left alone, but we may by a somewhat bold incision prevent its opening on the external surface; where it appears bagging, and discharging at one or more small openings, we may with advantage make a free incision at the most dependent part. [When the tissue overlying the pus is over one-eighth of an inch thick lancing may be delayed without much prolongation of the pain until the pus finds its way nearer the surface; otherwise a tent, saturated with carbolic acid or iodine to keep open the fistula, may be necessary, but when used it often adds to the smarting pain.]

Chronic periodontitis is not unfrequently the condition left after the acute form has passed off, whilst, on the other hand, as before noticed, the chronic may suddenly take on the acute form. It may and generally does occur to a greater or lesser extent with teeth the vitality of which has been lost through violence, or destroyed by the employment of escharotics in the process of filling, especially where the fang-cavities have not been carefully cleansed and filled, as before described; also with teeth that are much injured by caries with discharging pulps. It is, we believe, a fact that such teeth become much freer from chronic periodontitis after the whole of their pulps have sloughed away, and the place of their former occupation is found sweet and inoffensive. A tooth that has been long affected with chronic periodontitis is generally much discolored, which gives it the appearance of having been filled with a dark amalgam; it is usually more or less coated with salivary calculus, as are also, not only its immediate neighbors, but the corresponding teeth of the opposing jaw. If pressed upon laterally it is seen to move slightly in its socket, and when tapped gives more or less pain, and yields a duller and less clear sound than in the case of a healthy tooth. The mucous membrane covering that portion of the alveolar process, on the external surface especially, which corresponds to the situation of the apices of its root or roots, will be seen to be

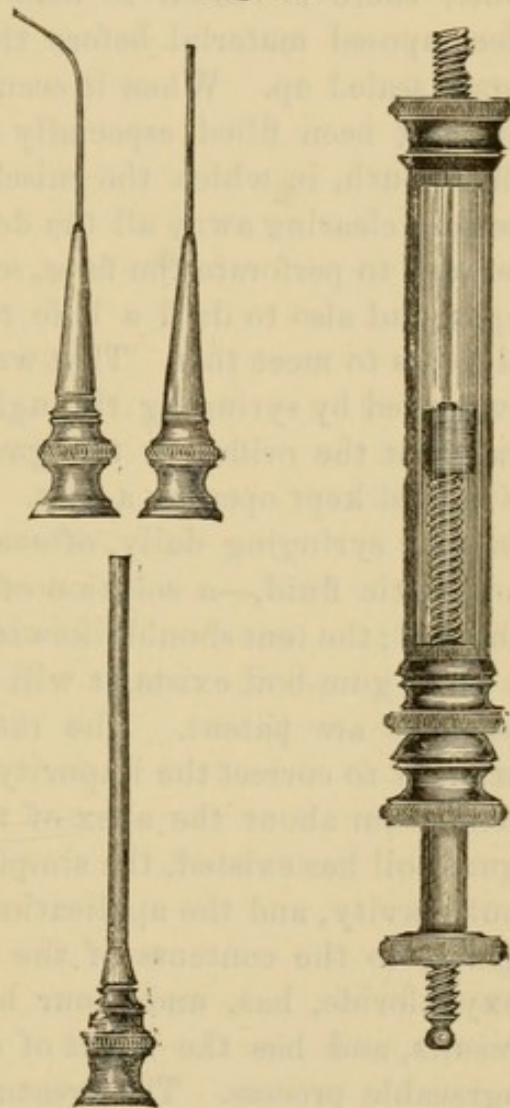
congested and of a deep purple color, whilst in the same region will occasionally be seen a small pustule, which at times enlarges and discharges itself: in the latter case the tooth is generally less sensitive to pressure, and will often bear biting on. [The line of demarcation between the deep color of the gum under the lip and the light pink color of that around the teeth has been called the health line. In proportion as it is distinct and clear it is a sign of health of the teeth-roots and of freedom from inflammation; as this line falls toward the free margin of the gum, or becomes indistinct, the condition of disease is more pronounced.] The discharge has been considered by some to be the fluid generated by the pulp, which, especially in the case of filled teeth, thus makes its way to the surface; an error palpable from the fact that the two fluids have hardly any similarity, the former being ordinary inoffensive pus, but which, however, may arise in consequence of the presence of the latter.

If we remove a tooth, the subject of long-existing chronic periodontitis, we shall generally find that it will require less force than a healthy one. It mostly brings with it a considerable portion of its alveolo-dental membrane, which we find considerably hypertrophied, of a dark-red color, and emitting a most offensive odor. The apices of the fangs are generally bared of membrane. In some cases the tooth comes away free from any of the membrane, moist, and glistening with purulent fluid; this is generally in the severer cases. If we examine the hypertrophied alveolo-dental membrane, we find that it separates much more readily from the root, especially near the apex, than when healthy, being firmer as we approach the neck of the tooth, where it is less affected. We have accounted for the separation of the membrane at the apex of the fang as due to the large amount of cementum there, which, no doubt, is in these cases necrosed. The membrane is found highly congested and infiltrated with lymph and serum, and at the portion attached to the apex of the fang there is often a small amount of pus, and, as its form when folded together somewhat resembles a sac, it has often been regarded as the sac of an abscess. Small abscesses situated in the thickened alveolo-dental membrane, as well as small cysts, do occasionally come away entire with the tooth. Under the microscope the fibrous tissue of the membrane appears less compact and discernible than in health; we perceive amongst its meshes

abundant cells and nuclei; many of the cells are nucleated and oat-shaped, elongated at their extremities to form fibres; and some of the cells appear in an active state of proliferation, whilst others appear to be undergoing fatty degeneration.

The treatment of chronic periodontitis will much depend upon the condition of the tooth affected; if its origin be that of violence, and in a sound tooth, a leech may be applied, followed by fomentation; or, when the disease is very slight, and has occurred from time to time, a small piece of toasted fig, or a little warm bread and milk, may be placed in the sulcus formed by the gum and cheek before the patient retires to rest. [There has been so much objection to the effect of the fig or raisin upon the adjoining teeth that they may be said to be almost if not entirely substituted by hot water, cotton, or tow as recommended (pp. 242, 243.)] In like manner we may treat a tooth which has been filled, and which at times gives evidence of periodontal irritation; but in such cases counter-irritants appear more effectual, and we would recommend what we have suggested and found very serviceable, viz., a saturated solution of chloride of ammonium,¹ which is especially applicable in cases where pain comes on in a tooth after entering a hot room, or when the in-

Fig. 221.



An alveolar-abscess syringe (Farrar's), for injecting stimulating and antiseptic fluids through the fangs of teeth, for the treatment of alveolar-abscess and chronic periodontitis.

¹ R.—Ammoniae hydrochl. ʒiij.

Aquæ, ʒj.—M.

To be applied to the gum with the finger when pain comes on.

dividual is over-fatigued. If in either condition we have reason to suppose that it depends upon the presence of a diseased or devitalized pulp, or any portion of it, in the one case, viz., that of a sound tooth, an opening should be drilled through the crown into the pulp-cavity; in the other, the stopping should be removed, and all the diseased substance carefully cleared out. The pulp-cavity should be dressed with antiseptic substances until there is reason to believe that the dentine is free from decomposed material before the fangs are filled and the cavity again sealed up. When it occurs in a tooth that is carious and has not been filled, especially one situated near to the front of the mouth, in which the mischief has existed for some time, besides clearing away all the decomposed pulp-substance, it may be well to perforate the fang, so as to enlarge the foramen at its apex, and also to drill a hole through the external wall of the alveolus to meet this. That we have accomplished this, will be evidenced by syringing through the fang and seeing the fluid exude at the orifice in the gum, which should be of moderate size, and kept open by a tent. The treatment will then consist in thus syringing daily, oftener if possible, with some strong antiseptic fluid,—a solution of iodine and creasote is probably the best; the tent should likewise be dipped in the same. Where a small gum-boil exists, it will be only necessary to see that the passages are patent. The rationale of this treatment is the attempt to correct the impurity of the necrosed dentine and the cementum about the apex of the root of the tooth. When no gum-boil has existed, the simple removal of the contents of the pulp-cavity, and the application of arsenious acid, about $\frac{1}{15}$ of a grain, to the contents of the fang-cavity, covering with zinc oxychloride, has, under our hands, afforded very satisfactory results, and has the merit of saving a long, tedious, and disagreeable process. The treatment is on the same principle as that described above, viz., a correction of an existing septic condition. As a final resort, extraction and replantation, to be described hereafter, may be employed. If the tooth attacked be so imperfect that it would be of little or no value if retained, we may then speedily effect the cure by its removal; and how this operation should be best performed will shortly occupy our attention in a subsequent chapter.

[Arsenic cannot safely be applied if there be inflammation and pain already existing, as it is a searching, powerful, and dangerous irritant, which may so increase the pain as to make it excruciating. It is better to apply first for a day the simple morphia paste, so as to relieve the pain and quiet the inflammatory action.]

CHAPTER XI.

NECROSIS. ABSORPTION OF PERMANENT TEETH.
EXOSTOSIS.

NECROSIS.—Of this we have already spoken on several occasions, but more particularly in the chapter treating upon injuries to the teeth. Though it is, no doubt, in sound teeth by far most frequently the result of an accident, yet we sometimes find teeth losing their vitality without any apparent cause, those most liable being the front teeth, and in the upper jaw, the lateral incisors especially. When arising spontaneously, it not improbably results from embolism of the nutrient artery supplying the pulp, which structure undergoing change allows the coloring matter of the blood to stain the dentine or the contents of the dentinal tubuli, giving to the tooth a fawn color, which as time progresses changes to a darker hue. The vitality of the dentine is lost, but that of the cementum may be retained, and the tooth then remains serviceable though unsightly. It is rare, however, for the cementum not to suffer to some extent, and, in consequence, the alveolo-dental membrane. As we have before pointed out, we may have a living pulp with more or less necrosis of the cementum; this latter most frequently occurs in cases of absorption of the alveoli. We have met with a case in which the irritation, caused by a patch of necrosed cementum on the anterior surface of a third lower molar, gave rise to so much pain that the tooth had to be removed; when split open, the pulp appeared perfectly healthy.

With regard to treatment we may, in the first class of cases, drill into the pulp cavity,—if a front tooth, through the posterior surface of its crown,—and clear out the whole of its contents: this will lessen the chances of the cementum suffering, and, if done early, also probably lessen the discoloration; indeed, we may attempt to bleach the tooth, oxalic acid having been found the most effective agent, and finally fill up the pulp-

cavity and hole in the crown. In the second class of cases, where the cementum only is affected, little, likely to be of benefit, can be suggested. Could we accurately diagnose that only a small portion of cementum had suffered, and at a given spot, we might open down upon it, and excise it, or subject it for a time to the action of creasote and iodine.

[*Bleaching teeth.*—To be successful in bleaching teeth it is important to remember that the stain may be due to various chemical agents, and that each group will require a different bleaching material. Thus the stain from fruits and vegetable matter generally has hydrogen for its base, and therefore chlorine, from the affinity between them, is the proper application to make. For this purpose nothing will answer better than fresh chloride of lime, which may be purchased in small air-tight packages, and applied as a putty or like a temporary filling. Labarraque's solution is also very good, but a trifle more expensive. In the use of this and other chemicals for bleaching, the rubber dam should first be applied to save the unaffected teeth and the mucous membrane of the mouth and lungs from irritation by the fluids or gases.

For the liquidation of blood clots, ammonia water is valuable. Where a tooth is discolored from this cause it should first be washed out thoroughly; then a crystal of oxalic acid dissolved by a drop of water in the tooth, to remove the iron or ink stain, carefully washing again, and as a precaution neutralizing any remaining acid by alkalies, as ammonia, etc.

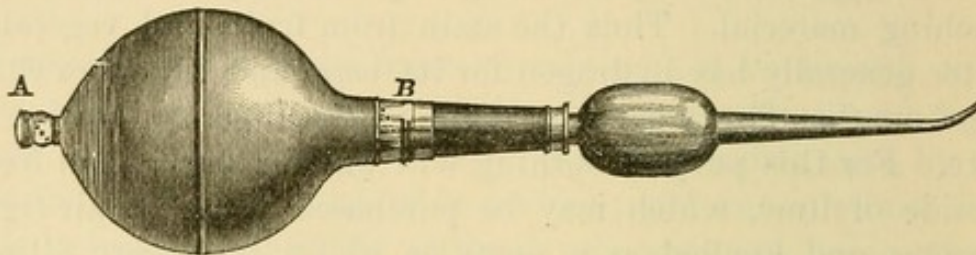
Nitric acid will dissolve out amalgam residue, but it must be used with caution, by dipping in it the extreme tip of a small pointed stick and touching it for a few moments to the discoloration; then plentiful syringing with water, taking care to finish by applying ammonia water to neutralize any remaining acid.

The deadly poison, cyanide of potassium, may be used as a solvent for the metallic dyes, applied like oxalic acid only with exceeding caution.

All bleaching to be permanent will, however, depend upon a thorough removal of the discoloration, even if considerable tooth substance has to be taken with it, and if leakage is liable to occur again through the apex of the root or pulp canal, the latter is best filled solidly with gold—indeed, it is generally the first step in the treatment after the recovery of the apical tis-

sues, and essential to prevent irritation of the apical pericemental tissue, by the bleaching material; even the fumes are ordinarily sufficient to cause trouble. This preparatory canal filling should not come down quite to the point at which the dentinal tubuli leave the canal for the neck of the tooth, as it is through these that the bleaching is accomplished in the dentine under the enamel.

Fig. 222.



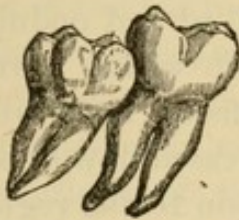
Hot air-syringe. *A*, Entrance valve; *B*, Valve to prevent the heated air from passing back into the rubber bulb.

Finally, complete drying by the hot air syringe will be followed in most cases by the greatest improvement. The filling may be made to subserve a good purpose in those cases where the tooth still remains slightly darker, as by inserting oxychloride of zinc we may obtain the advantage gained from a white reflecting surface under the dentine.]

Absorption of permanent teeth.—This condition, which we regard as normal and necessary in the case of the temporary teeth, is a pathological one when occurring in the case of the permanent teeth, although at times the two processes are not very dissimilar: thus it is not very uncommon to find the fang of a lateral incisor more or less absorbed where an unerupted or partially erupted cuspidatus has approximated abnormally to it; or, again, a second molar of the lower jaw may in like manner be found to have undergone absorption at the point impinged upon by the crown of an erupting wisdom tooth (Fig. 223). [This is a not infrequent predisposing cause of decay, and mouths will be found otherwise almost free from the disease, except at the points where lodgment of food has caused almost irreparable injury.] Teeth which have suffered from violence often undergo more or less absorption at their fangs; a tooth subjected to immediate torsion, as we have narrated, was found to have lost nearly the whole of its fang. Transplanted dried

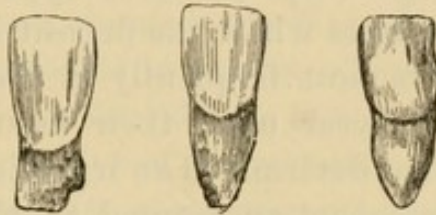teeth almost invariably suffer in the same manner. But the condition of absorption in the permanent teeth is most commonly witnessed where for a long time a more or less congested or inflamed periosteum has existed. In attempting to account for the various phenomena met with in absorption of the teeth, the difficulties have, we think, been augmented by our looking for special organs capable of effecting the process. Altered con-

Fig. 223.



Unerupted wisdom tooth, which by pressure has caused absorption of the approximal surface of a second molar.

Fig. 224.



Absorption of the roots of three permanent incisor teeth.
(Copied from specimens in the author's possession).

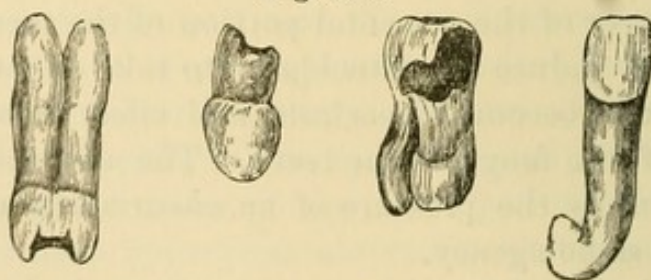
ditions in their surroundings have no doubt the greatest influence in effecting either their hypertrophy or their atrophy; an undue determination of blood may stimulate the osteoblastic layer of the cemental portion of the alveolo-dental membrane, and so produce hypertrophy of the cementum. On the other hand, stimulation of the osteoblastic layer of the alveolar portion of the same membrane may induce growth of the alveolus inwards. The result of this latter may be pressure upon the osteoblastic layer of the cemental portion of the membrane, and in consequence induce the osteoblasts to take on an absorptive action, in fact to become osteoclasts, and effect more or less the destruction of the fangs of the teeth. The absorption of bone brought about by the pressure of an aneurism is no doubt effected by the same agency.

The condition of absorption may attack teeth singly, or several at a time, and we have seen a case where the whole of the upper six front teeth were thus lost, one after another. In the way of treatment we fear we can suggest but little that will prove of benefit. To endeavor to preserve the mucous membrane of the gums as free from hyperæmia as possible, is of course indicated, but when the teeth become loose and troublesome, we can only suggest their removal and substitution by

artificial ones. In cases in which it results from the pressure of an unerupted tooth, and is usually accompanied by considerable pain, the same treatment is the only one which presents itself.

Exostosis.—This is the reverse of the condition which we have last described, and consists in an augmentation to the cemental layer covering the fangs. When it is pretty evenly distributed over the surface of the fang or fangs we may with advantage adopt the term *hyperostosis*, and confine the former term to cases where the deposit is circumscribed and nodulated. It occurs most frequently in the case of teeth which have suffered by wear upon their masticating surfaces, and this, no doubt, has determined an irritation, with increased flow of blood, and consequent augmented supply of nutrition to the region of their roots. By this means an abnormal energy is given to the odontoblastic layer of the cementum, causing an increase in the latter, sometimes to a very considerable extent. Such structure, when examined, will be found to approach ordinary bone in its character; thus we often have Haversian canals, and irregularly formed Haversian systems, which are rare but not impossible to meet with in ordinary cementum. The conditions of dental hyperostosis have been examined and ably described by Hubert Shelley, but we think that his descriptions apply rather to cases where more inflammatory action accompanies

Fig. 225.



Cases of hyperostosis and exostosis in the fangs of teeth. (Copied from specimens in the author's possession.)

the process than to the more gradual and more characteristic ones. In most cases, but not in all,—nor even in marked ones,—there is more or less of pain attendant on the process, attributable, no doubt, to a want of due correspondence between the enlargement of the cementum and a complementary enlargement of the alveolus, with consequent pressure upon the

nerves of the intermediate tissue. If this be the right explanation, it is not difficult to account for the process occurring at times without pain, at other times with moderate pain of even and persistent character, and again at times with pain of an excruciating character. The pain also is not unfrequently referred to other parts than the ones affected, occurring in the head and face, about the ear, indeed, at any of the terminal branches of the fifth pair. Many supposed cases of neuralgia have their origin in this cause, which is often, before the removal of the teeth so affected, very obscure. Such teeth may be free from tenderness when percussed or bitten on. The margin of the gum around teeth which are the subjects of hyperostosis may present, but not invariably, a line of congestion said to be characteristic of this condition. In such cases the electric mouth-illuminator of Hart might prove valuable, as the roots of teeth are distinctly seen when the apparatus is placed within the mouth.

As may well be expected, the removal of such teeth is often attended with much difficulty, especially where the deposition has been greatest towards the extremity of the root or roots. We shall infer this to be the condition, when, after separating a tooth from its membranous attachments, we find it loose, yet having a strong impediment to its removal: a curved fang would likewise offer the same resistance. We must here very cautiously and patiently continue the loosening movements, until we have so dilated the upper portion of the alveolus as to permit the enlarged or twisted root to come out. From this cause, lower bicuspid teeth or roots are not uncommonly very difficult to remove, even when not so considerably enlarged at their radical apices. Our museums show to what an extent the cementum may increase in rare cases, at times even uniting together the roots of contiguous teeth, but cases of a moderate amount of increase are extremely common.

With regard to treatment, we again fear that little more can be offered than the radical one of extraction; but, before we resort to this extremity, iodide of potassium, in somewhat large doses, should have a trial.

[It is always of service to place such teeth in a normal condition, by having them meet their antagonists properly; this may require modification of their shape by filing, or grinding

with corundum wheels on the dental engine; sometimes capping the adjoining ones to relieve undue pressure, and at others, where no antagonizing tooth is present, inserting an artificial one. Counter-irritation, as a blister over the root, by painting the gum with the saturated tincture of iodine, is also serviceable. These remedies may be quite effective if applied early; but after the disease has progressed to the extremity described, benefit might be derived from cutting away the hypertrophied portion with a point in a burring engine.]

It is not a very uncommon occurrence to meet with the two conditions just spoken of existing together, and to find the fang of a tooth in one portion hyperostosed and in another more or less absorbed.

[CHAPTER XII.]

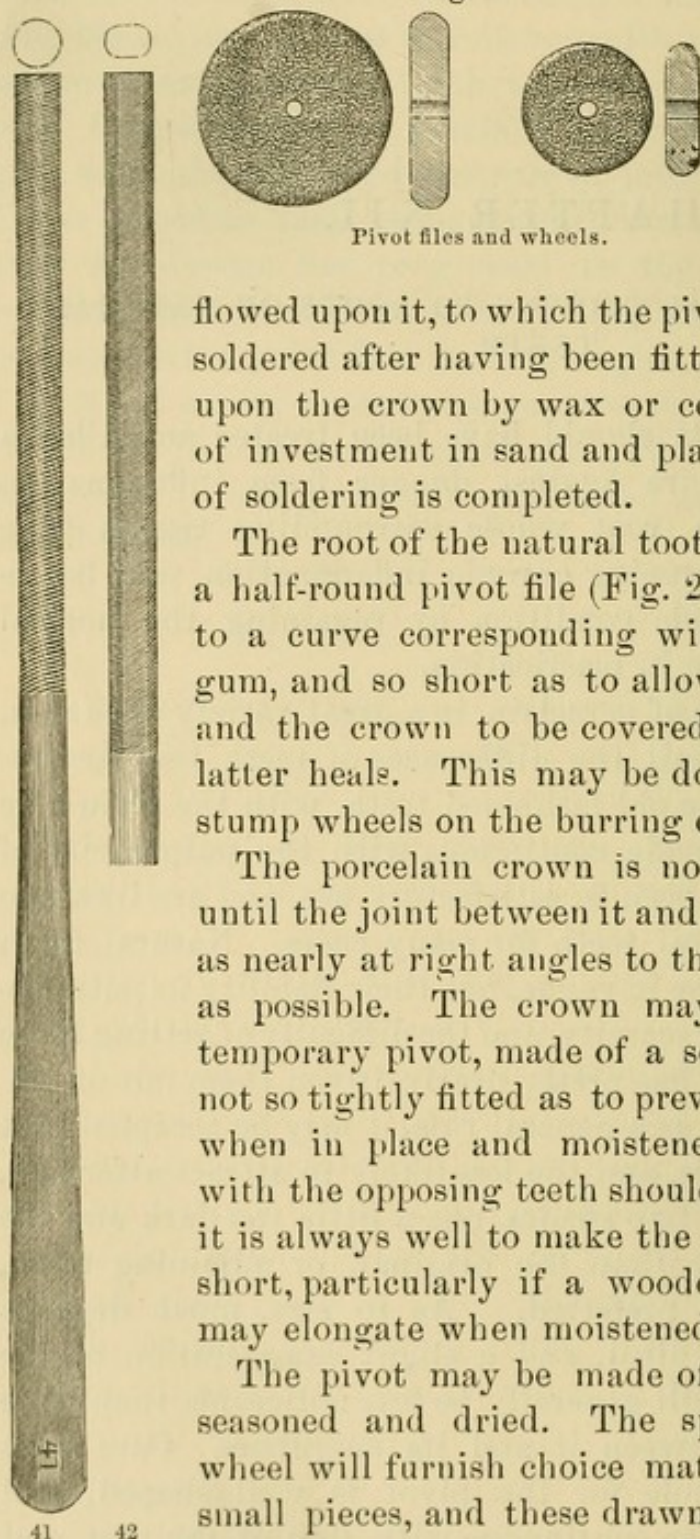
FITTING ARTIFICIAL CROWNS TO ROOTS OF NATURAL
TEETH.

IN all cases the roots should have been treated and filled a sufficient time to insure against danger from inflammation or abscess. Often, a root whose surrounding tissues have been tender, and threatening chronic inflammation, will be restored to a comfortable condition by regaining the normal stimulation of pressure in mastication.

Pivot teeth are made of porcelain, in a great variety of shapes, sizes, and shades, to suit the differences of teeth they are required to replace. The old fashioned teeth, with the plain hole in the centre, to be made continuous with the pulp cavity of the natural root, have been in satisfactory use, and are likely to continue so for the oral teeth for many years. Natural teeth crowns were at one time in vogue, but their liability to putrefaction in the mouth, their scarcity, and the difficulty of getting those that were satisfactory, has pretty nearly driven them out of use.

In selecting a tooth, as a general rule, it may be accepted that the less prominent it is, and the less likely to attract attention, the better. Hence, of two shades, one a little too dark and the other as much lighter than the original, or adjoining teeth, the former is to be preferred. As to size, much depends upon the space to be filled, and a slight exaggeration of the breadth of the tooth will generally be less noticeable than wide spaces intervening between it and its neighbors. Care must be taken, that the hole for the pivot is well shaped, and in such position as to be continuous with that of the root, and while sufficiently large to admit a pivot strong enough to support the pressure it will be required to bear, yet it should not be so large as to seriously weaken the crown or root, and thereby defeat its object. In such case it may be necessary to fit a plate tooth and back it with gold, or thin platinum with gold

Fig. 226.



Pivot files and wheels.

flowed upon it, to which the pivot of gold wire may be soldered after having been fitted and secured *in situ* upon the crown by wax or cement, so as to admit of investment in sand and plaster while the process of soldering is completed.

The root of the natural tooth should be filed with a half-round pivot file (Fig. 226, Nos. 40, 41, or 42) to a curve corresponding with the festoon of the gum, and so short as to allow the joint between it and the crown to be covered by the gum after the latter heals. This may be done very nicely by the stump wheels on the burring engine.

The porcelain crown is now fitted by grinding until the joint between it and the root is perfect, and as nearly at right angles to the force of mastication as possible. The crown may then be tried with a temporary pivot, made of a soft piece of wood, but not so tightly fitted as to prevent its ready removal when in place and moistened. The articulation with the opposing teeth should then be studied, and it is always well to make the artificial tooth a trifle short, particularly if a wooden pivot is used, as it may elongate when moistened.

The pivot may be made of hickory wood, well seasoned and dried. The spoke of a sound old wheel will furnish choice material. It is split into small pieces, and these drawn repeatedly through a wire draw-plate to the sizes desired, and about three inches in length. The size of the hole in the root and in the crown is then measured with a steel wire or a wooden matchstick, drawn in the same manner, only that it may be slightly moistened. After fitting it as to the length and diameter, it will serve as a pattern for the permanent hickory pivot.

The latter must be inserted into the carefully dried porcelain crown, and then pressed into the hole made by previously reaming out the pulp canal.

The moisture of the mouth, or, if desired, a few syringefuls of water thrown around the neck of the tooth, will cause the wood to swell and hold the crown firmly and at the same time with an elasticity rarely equalled by more modern methods.

There has been much said against the wooden pivots, but the writer has seen them, when cut off in the root and exposed for years, serve as a filling, and protect the cavity quite successfully. If properly made, they cannot be very porous, and will not be such receptacles for putrefaction as those who oppose their use would have us believe, while their elasticity and softness prevent injury to the dentine of the root from chafing or wearing.

When it is desired, a gold or platinum wire may be fitted into the crown and held there by packing a few pieces of gold foil around it and then flowing solder into the joint. Tapering the wire slightly, warming and covering it with gutta percha, it may be pressed up into the root. Sometimes the wire pivot will be better if barbed.

Several roots may thus be pivoted at once by a plate with teeth crowns soldered to it; or one root, with the assistance of gold clasps around adjoining teeth, or wire projections into them, may be made to sustain two or three crowns. The cavities in which the projections are fitted should be filled, the spaces being completely obliterated by gold or gutta-percha.

The Richmond Crowns.—Dr. C. M. Richmond some years since devised the means of rendering roots serviceable by fitting gold crowns upon them, by the use of a band which encircles the necks or parts of the roots above the alveolar processes like ferrules. These seeming slight attachments have proven sufficient under severe use in a great number of cases. Holes may be made by enlarging the pulp canals, and gold or platinum screws or bolts may be passed through the crowns down to the roots to serve as additional stays.

The process of making these crowns may be briefly described as follows:—

The gold should be of the fineness of coin—for convenience and economy the five dollar gold piece is the best—and should be

of the dark rich color of the recent U. S. coinage, the alloy of which is mostly copper. The coin is passed through the rolling mill until reduced to about No. 27 gauge, which makes it of an elliptic shape, about $3\frac{1}{2}$ inches long, and perhaps a trifle wider than the original coin. The ends and sides are now pared off to bring the plate to a rectangular shape, and, after weighing, the parings are melted upon a piece of jeweler's charcoal, and one-fifth of their weight of fine brass wire, cut into pieces about half an inch in length, is added. Care must be taken that the melted gold is well covered with flux (borax) to prevent the burning of the brass, which latter may be added piece by piece at a time, so as not to chill the button too rapidly, one end of each being pushed into the molten button. This forms the solder, which is rolled down to about the thickness of the plate, and cut into small pieces as wanted for use.

The root is prepared by filing or grinding with the stump corundum wheels or files to flatten the exposed end. A strip of the plate is cut, wide enough to reach from the alveolar process to a little above this end of the root, and long enough to encircle the same; for this a pattern of soft lead or tin foil may be tried and made as a guide. This strip of gold plate is now bent and filed so as to make a close fitting ferrule; indeed, it may be made a trifle smaller, say two or three times the thickness of the plate, as it is liable to stretch, the ends abutting edge to edge, and these soldered together. A piece of plate large enough to cover the upper or crown end of the ferrule is now cut, and a small piece of the solder flowed over one side of it, when it is laid, with the soldered side down, upon the end of the ferrule, properly covered with borax ground in water to the consistence of cream, and by heating to the melting point of the solder, the blowpipe flame being thrown down upon it, this lid or end is united with the ferrule proper. With the file the edges of the lid are dressed down level with the ferrule, the outside is smoothed, and the end next the bone has the proximate surfaces cut away with a round file to correspond with the festoons of the gums and septa of bone between the teeth, where they hang lower. The edge next the gum is then slightly beveled from the outside, making a chisel or gouge-like edge to pass up around the root and in the closest contact with it. The ferrule is now placed upon the root and pushed or driven home, and the points for putting on the

cusps of the crown are marked. Buttons, made by melting scraps of the coin, are first slightly flattened by the blows of a hammer, while they are lying upon a smooth steel surface, then tried as to size and shape, allowing a very slight thickness for grinding off, to perfect the occlusion or biting against the antagonizing teeth, after the crown is finally placed. The part of the ferrule that is to be next the lip or cheek may have a slight mark scratched upon it for the sake of convenience in replacing the crown, and the ferrule may then be drawn off from the root by working it down with a dull hoe excavator, being careful not to nick the edge of the gold or scratch the tooth.

The ferrule should now be solidly filled with moistened sand, to which a little plaster has been added, as for investing plates and artificial teeth for soldering, and the whole, excepting the top or lid, should be embedded in a slightly conical mass of the same. The buttons to form the cusps should be placed in position on the lid of the ferrule as soon as the plaster has dried, the solder piled up around the buttons, and the whole covered with the borax flux. To attach the mass it must now be heated by the blowpipe until the solder is melted and flows freely, forming a perfect crown in shape; but care must be exercised not to flake off the plaster investment and expose to the flame the soldered portion of the work already finished, lest the ferrule come out from this heating defective, or with a hole burned through it. The crown is now shaped, smoothed, and afterwards polished upon a felt wheel, it being held in contact with the latter by a stick fitted into the open end of the ferrule. Care must be taken that we may be able to recognize readily the buccal or labial side either by the cusps or by allowing the scratched mark to remain. In cases where the appearance of the gold is objectionable a plain porcelain tooth of proper shade may be fitted, backed, and soldered on in the place of the outside cusp or cusps, and in such teeth it is best that the ferrule should not come below the free margin of the gum upon the labial face.

A small hole may now be drilled into the hollow portion at a convenient point of entrance from the outside, affording escape for the cement when the crown is being pressed into position. The root and surrounding gum being well wiped and kept thoroughly dry by means of a folded napkin, the interior of the ferrule is filled with some plastic filling materials, oxy-chloride

or oxyphosphate of zinc, mixed rather thinner than usual for insertion into cavities. The crown is then to be pushed upon the root and a bite taken by the patient to force it to its place before the cement filling has set, where it should be held immovable until the plastic filling has hardened. The overflow opening may then be filled with gold. The crowns may then be ground with the corundum points on the dental engine until the articulation is perfect.

The writer has worn with great satisfaction for nearly three years two teeth made as described, and with them he breaks up the hardest substances ordinarily used as food, preferring to risk the gold crowns rather than frail natural ones.

Drs. Gates and Bonwill's crowns are made of porcelain. After being ground to fit the previously smoothed stump, and articulate properly with the antagonizing teeth, they are held in position by three-cornered barbed platinum wires, which have been secured in the roots by driving them in, and filling around them. The spaces left between the platinum, the crowns, and the roots are filled with a quick-setting amalgam or gutta-percha.

Fig. 227.



Gates-Bonwill crowns.

The Flagg pivot is explained in the following terse description in his own words:¹—

“Select plate-tooth, fit it to root, and bevel it from near the pin—cervical—or pins, if cross-pins, to the labio-cervical edge. Solder a platinum pin to it as a backstay and pivot combined, leaving it rough or grooved on both sides of the pin for a retaining hold to the finishing palatal amalgam.

“Fill the root, which is treated, prepared for strong maintenance of filling, and ‘bell-muzzled,’ or ‘open-mouthed,’ with a good *usual* or *contour* alloy, quick setter, non-shrinker, good edge strength. I prefer to give this a day to harden thoroughly,

[¹ See p. 129, *Plastics and Plastic Filling*.]

but in case of need it may, with care, be worked in an hour or two.

"Into the root filling drill a hole rather larger than the platinum pin, as near to the *palatal* portion of the filling as possible, and directed slantwise to the apical centre of root-filling; then fissure-drill the hole towards the labial portion of the filling, trying the tooth until it sets just right, with the pivot-pin pressing hard against the labial side of the now *oval* pivot hole. *By this method the tooth is accurately placed in position and easily held firmly in place while the pin is secured by filling the pivot hole with amalgam.*

"Let this harden for half an hour, and then add amalgam in contour to the root filling and palatal face of the porcelain tooth. It is at this point of the operation that the need for 'bevelling' the cervical portion of the tooth is demonstrated, for, by this bevel, one is enabled to make, by filling, a perfectly tight joint at the labio-cervical junction of tooth with root, and also to secure a strength of amalgam equal to the entire surface of root-filling."

There yet remains for notice an ingenious practice described by Dr. Bing, of Paris, for filling or restoring large portions of crowns. A thin plate of pure gold is struck up to the shape desired to be placed upon the tooth, and upon the under side is soldered by the ends two pieces of wire shaped like staples. After fitting this gold cap or cover, the tooth is filled with gutta-percha, and while it is yet soft, the cap is warmed and pressed into place, and burnished down to fit tightly and protect the edges of the tooth and the whole filling. The cavity in the tooth may be rounded in contour, the edges smoothed and polished, so as to enable the operator to burnish the gold, to form a tight and close-fitting joint.]

CHAPTER XIII.

EXTRACTION OF TEETH.

THE operation of extraction bears an analogy to that of amputation, inasmuch as it is the removal of a useless or obnoxious member for the welfare of the rest. As no conscientious surgeon would ever think of resorting to the latter so long as any well-grounded hope existed of a limb or member being again restored to a state of usefulness, so no intelligent dentist will ever think of extracting a tooth as long as there remains a fair prospect of its also being restored to a state of usefulness. On the other hand, the surgeon knows that an artificial limb, however limited its capabilities, is yet infinitely better than a painful and useless one; and the dentist likewise knows that an artificial tooth is infinitely better than a useless and painful one. In another point of view, however, the two operations widely differ, viz.:—in their effects upon the individual, the one being comparatively safe and almost momentary in point of duration, the other being severe in character, and highly dangerous in its results; at the same time, this ought in no way to lessen a due consideration before sacrificing so useful though humble a member as a tooth, and this consideration becomes of still more importance when the tooth or teeth to be removed happen to be sound ones.

The teeth, about the removal of which we hesitate the least, are those which have become so loose from absorption of their alveoli as to be quite useless, indeed impediments to mastication; those long affected with chronic periodontitis, whose tartar-crusted crowns are evidence of their long season of uselessness, as well as that of their immediate neighbors; teeth erupted in abnormal positions, incapable of being brought into position, and interfering with movements of the tongue or lips; also the roots of teeth causing unhealthy gums or secreting offensive fluids. [The method of fitting artificial crowns has, however,

rendered the preservation of roots a matter of much importance, and to-day many such are in constant and highly satisfactory use.]

Having convinced ourselves of the expediency of resorting to extraction, we must in its performance carefully observe three conditions: first, to carry it out completely, in other words, to remove the tooth in its entirety; secondly, to accomplish it with the least possible injury to surrounding parts; and thirdly, to inflict as little pain as possible. Usually carefully pursuing the second condition, we fulfil the third. The form of articulation of the teeth to the jaws has been classically termed gomphosis, but this gives an erroneous idea of the exact attachment; the teeth are not retained in their sockets as are nails in wood, by their elastic surroundings. In a dried skull the teeth will be felt loose in their alveoli; some will, indeed, drop out by their own weight; the rest are retained by the dovetailing of their fangs in their sockets. It is a strong periosteum, the alveolo-dental membrane, which is the true medium of attachment of the teeth and maxillæ, and it is the sundering of this which, in normal cases, necessitates the amount of force that must be employed, and which should occupy our chief attention, the thin alveolar walls in the moist condition yielding more readily.

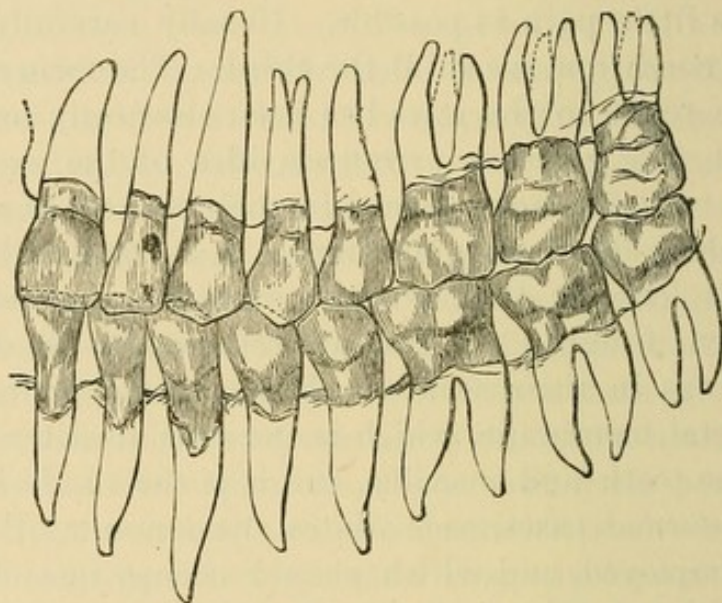
[*Extraction.*—The peculiar nervous condition into which most patients find themselves brought by the suffering which precedes and often compels the operation of extraction, entitles them to the most sympathetic consideration of the dentist and to his most gentle efforts for their relief. Weak children, delicate women, and sturdy men alike succumb, and lose all self-control in the face of the expected torture, and no amount of ordinary faith or courage will suffice to keep down their agitation and quiet their expressions of dread.

To deal with such conditions requires peculiar gifts on the part of the dentist, which are so rare as to make their possessor both well known and successful. He must have confidence, which can only be well founded by a thorough knowledge of his subject; his movements must be rapid but easy; his manner firm but patient; above all his sympathy must be genuine.

The anatomy of the teeth and surrounding parts.—In this study we first note the insertion of their roots (for description of which

see pages 49 and 50) into a more or less spongy bone, with an exceedingly tough membrane uniting the two, and which may be slightly thickened about the necks of the teeth, forming the so-called *ligamentum dentis*, which, however, is of so slight importance from an operative standpoint that we may remind the student that its existence is doubted by some.

Fig. 228.

The teeth of the left side of the mouth.¹

A little below the bottom of the cavity in which the tooth fits, which is called the *alveolus*, we find in the living bone an artery which gives off minute filamentary branches to enter the apex of each root, and with this passes also a nerve and vein of like proportions. At the back part of the upper jaw-bone, immediately behind and above the last tooth, is a tuberosity which is richly supplied with blood from several branching vessels of the alveolar artery, entering by small holes or foramina, the largest is the superior dental artery. Traversing the body of the bone almost perpendicularly is a branch of the infra-orbital artery, which it leaves in the canal under the orbit and descending sends small twigs to the upper incisors and antrum, a cavity in the bone connecting with the nose and formed immediately above the molars, whose roots, covered with a thin layer of bone and mucous membrane, often project into it. This cavity may be

¹ From "The Mouth and the Teeth." By Dr. Jas. W. White, Philadelphia.

opened into by the extraction of one of these teeth, or it may be diseased and involve them, but lined with mucous membrane like that of the nose, its being opened by accident in extraction is not of necessity a serious matter.

In disease such opening serves as an avenue for treatment, and is often purposely made.

Two bloodvessels, one on either side, are to be found running forward from the posterior part of the palate, nourishing that portion between the teeth which is commonly called the roof of the mouth; they pass upward to the nose through the anterior palatine canal which is in the anterior portion of the upper jaw immediately behind the central incisors.

In the lower jaw the inferior dental artery, a branch of the internal maxillary, enters the bone on the inside of the ramus by the inferior dental foramen, the opening of a canal in the bone through which it passes forward to the neighborhood of the root of the second bicuspid where it divides. One branch, the inferior incisor, passes forward to nourish the anterior part of the bone and oral teeth; the main stem, diminished in size, and now called the mental artery, finds an exit on the labial side of the bone to nourish the lower lip and gums.

The tongue is a highly vascular organ, having two arteries, the ranine, running parallel from its base on the underside toward its tip, and two above, the dorsali linguæ. The arteries above named anastomose toward their terminations.]

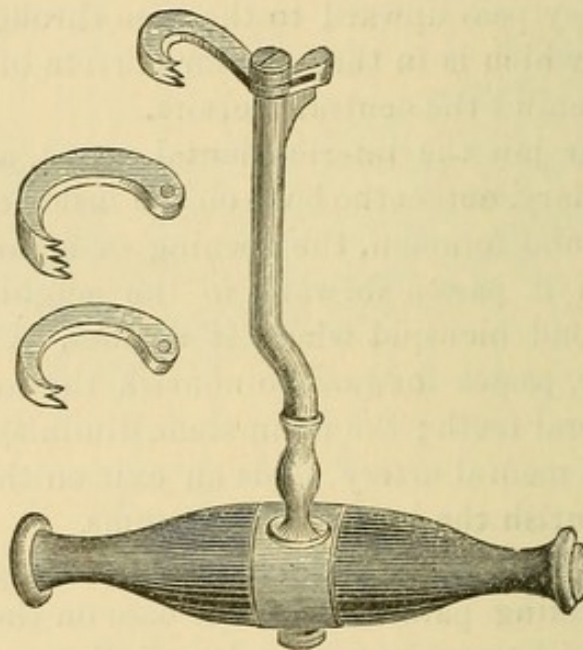
In proceeding to consider the operation of extraction, it is desirable that we should first describe the instruments employed, and in thus doing we shall merely allude to one, which, though serviceable in its day, should now possess only historical interest. The key (Fig. 229), so largely employed for many years, is now, or at least should be, entirely superseded by other and more efficient instruments.

It formed, when in action, a most powerful lever of the first order, and therefore became, especially in inexperienced hands, a dangerous instrument; moreover, when it was once applied to a tooth, the force exerted could be in only one given direction, and this might happen to be that in which the greatest resistance was offered; and lastly, as the fulcrum of the instrument was applied upon a soft tissue—the gum; this, although it might be relieved by padding, had to bear the force necessary

for removing the tooth, mostly bruising it, sometimes lacerating it. [Some operators were, however, quite expert in its use, by placing the fulcrum upon the tooth, and thus avoiding the injury to the gum.]

To the great improvements in the forceps is due the retirement of the key, which was not an improper instrument so long as the forceps employed was not adapted to be accurately

Fig. 229.




Key instrument for extracting teeth. The upper portion represents, on the right hand, the bolster or fulcrum, and on the left hand a claw which revolves upon a screw shown at quite the extremity. The steel bar, which connects this portion with the handle, is bent, so as to permit it to clear the front teeth. The detached claws represent different widths for application to larger or smaller teeth.

applied to each tooth, and, therefore, touching only at a few points, acted mostly like a cutting instrument, either slipping off from, or fracturing, the crown. The point is well illustrated in the case of the fitters of gas and water pipes, whose pincers or tongs, being segments of circles at their grasping points, securely hold the circular pipes, which ordinary pincers would only slide upon or crush. Changes in appliances, as in ideas, are mostly gradual; many practitioners, knowing the disadvantages of the key, endeavored to remedy the evil by adapting the existing forceps, as far as possible, to certain teeth, but the key received its death-blow when J. Tomes took in hand not only the construction of forceps adaptable to every tooth,

but conferred the greater benefit of enabling practitioners to obtain the same, a privilege of which every dentist of the present day should not be unmindful; and the public may also rejoice that from the time he did so the excruciating "key note" has gradually faded from the surgeries of dentists.

The forceps is a modified pair of pincers (Fig. 230), and consists essentially of the same parts, viz., a pair of blades or jaws

Fig. 230.



Forceps for extracting upper incisor and cuspidati teeth. The blades at the upper portion of the instrument are connected with the handles at the lower portion by the round hinge.

with handles which meet and cross each other at the hinge: each half becomes a lever of the first order, having its common fulcrum at the hinge, and this fact should always be remembered in grasping a tooth, which is a tube, and often a very fragile one.

The instrument, it need hardly be mentioned, should be of excellent steel, and the blades, or grasping portion, so tempered as to slightly bend rather than break if any very unusual force be encountered. Besides being made to fit accurately to the neck of the tooth, for which the instrument is constructed, they should be thin and sharp at their edges, so as to detach the gum from the neck of the tooth, and even, if desired, enter between the root of the tooth and its alveolus. When closed upon a tooth, the blades should rest parallel with its neck for some short distance, and not merely touch it with their edges, and be quite free from impinging upon the crown, a fault sometimes overlooked at the present day; and, giving sufficient room for the crown, they should be no longer than is absolutely necessary, as power is thereby lost, the long blades often bending upon the neck of a very firm tooth instead of moving it. In the construction of the hinge, care should be exercised, not only that it is strong, but that it is not liable when closed to include portions of the lips, tongue, or cheek. The round form devised by D. George, now generally seen, has the latter advantage to perfection, but it fails, we think, in not affording a little lateral

movement. In constructing the adapted forceps, it is usual, after forging and filing the blades as nearly to the required shape as possible, to fit them still more perfectly by applying them to the neck of a normally formed tooth, colored with pigment; the spots marked by the pigment are cut away, and the process continued until an almost perfect adaptation is attained, after which the blades are tempered. Thus constructed, the blades should accurately fit upon the external and internal surfaces about the neck of the tooth; but, as these do not always bear the same relative position to each other, it is well to have a little play at the hinge, which will allow of the blades accommodating themselves to this departure. The handles should be strong, broad, and roughened, long enough to afford a firm grasp, but no more, for although length in the handles gives greater leverage, they make the instrument cumbrous, and interfere with delicacy of movement.

[Forceps for the operation of tooth extraction should be generally straight, or so nearly so as to make the force applied to be in a direct line with the axis of the tooth. Manufacturers are still compelled to satisfy a demand for various twisted and curved implements which remain in favor with many. Hooked handles on forceps is an example of the power of conservatism; except the hooks be upon both handles, the tendency is to cause the force exerted to press to one side, changing the direction to an oblique one with the axis of the tooth. Forceps cannot be selected ready made without these cumbersome contrivances, and therefore the student must pardon their appearance in the illustrations.]

The beaks of the forceps as now sold are generally good as regards their shape, but in selecting it may not be amiss to test them upon typical teeth of the kind for which the forceps are designed.

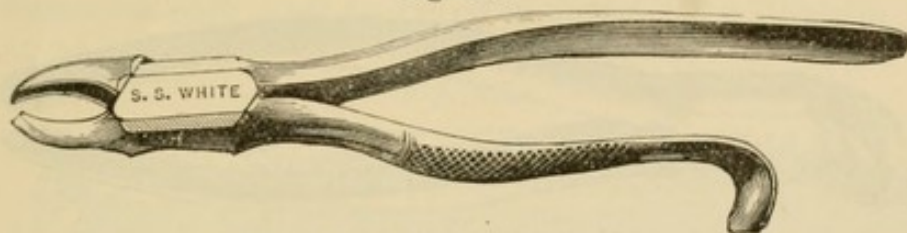
By many the joints are preferred of an oval form, being stronger and likewise less liable to wound the lips or cheeks, if the patient struggles.

In indicating what may be called a set of forceps it has been the endeavor to name them in the order of their relative value.

Fig. 231 is an incisor forceps, which has the qualities described, being straight in its axis, and although not shown in the cut, can be purchased with oval joints and straight han-

dles. This instrument is of use often as far back as the bicuspid, and although intended for incisors only, it is used by many even

Fig. 231.

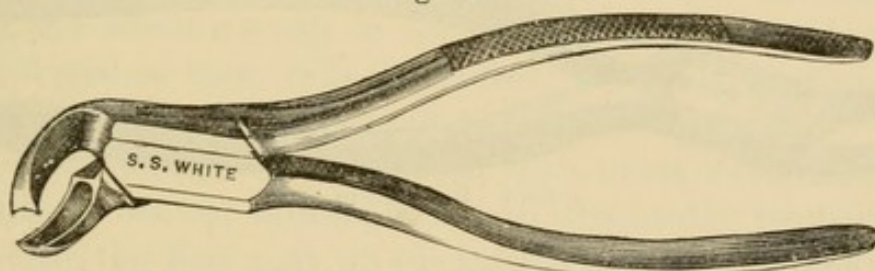


No. 13. Superior incisor forceps.

for molars, but in all cases except for the teeth for which it is designed, the danger of fracturing the crowns must not be overlooked.

Fig. 232 is designed for lower bicuspid teeth, but may serve well for incisors by grasping the tooth upon the lip and tongue sides and making the motion forward and backward, instead of from right to left as in the bicuspid. Molars may in like

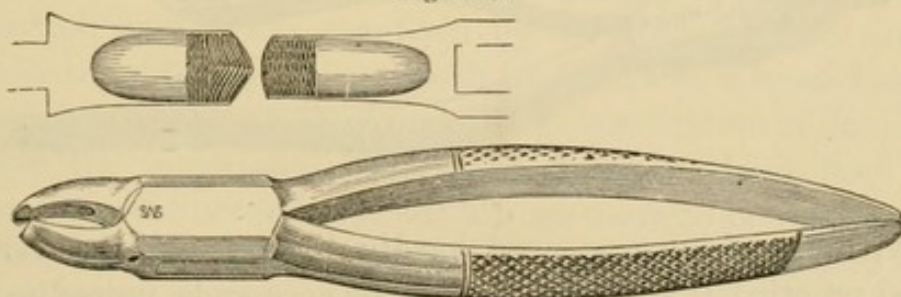
Fig. 232.



No. 21. Inferior incisor, canine and bicuspid forceps.

manner be extracted with it if not too firm in their sockets and by turning the beaks up the superior molars and wisdom teeth may be grasped with it.

Fig. 233.

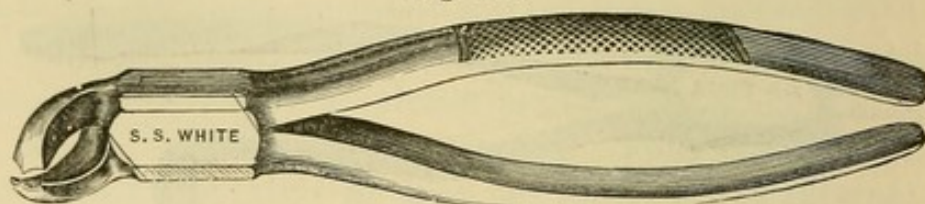


No. 68. Upper molar forceps for either side.

Fig. 233 and Fig. 234 are, better adapted to all upper and lower molars, except perhaps the wisdom teeth. The

former (Fig. 233), having one beak with a point for passing between the buccal roots, and, being perfectly straight, may be used

Fig. 234.

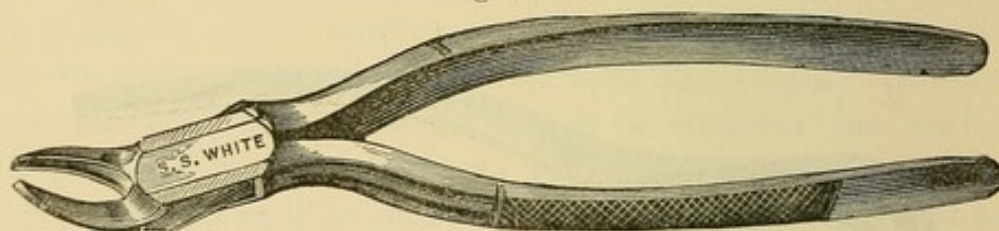


No. 17. Lower molar forceps for either side.

upon either side by placing the pointed beak outward or next the cheek. The latter (Fig. 234) can be seen at a glance to be adapted to pass its pointed beaks between the two roots of a lower molar on either side.

Fig. 235 is well designed for upper roots, being often serviceable all around, occasionally even in the lower jaw.

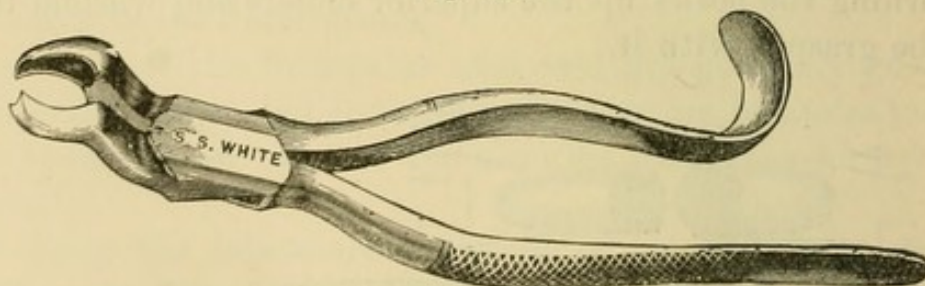
Fig. 235.



No. 7. Root forceps.

Fig. 236, in cases of upper second molars and wisdom teeth, will complete the set of six that are most useful and essential,

Fig. 236.



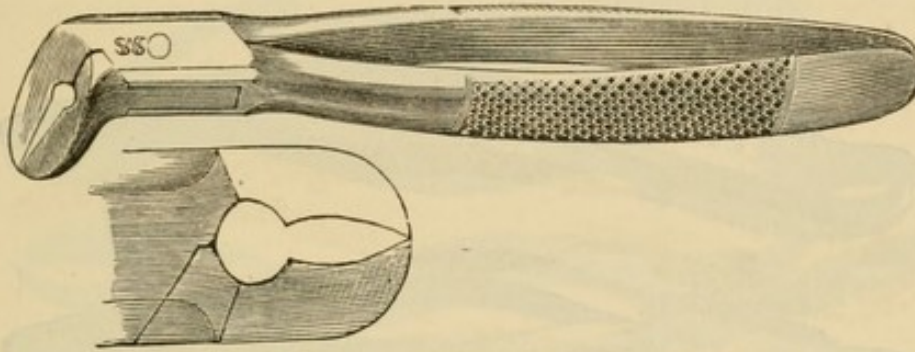
No. 10. Upper molar and wisdom teeth.

and without which one need hardly hope to gain a very extended practice, if any other dentist be accessible, unless he too is poorly provided.

To the above set might well be added Fig. 237, a forceps designed by the writer for cutting out the roots without remov-

ing a portion of the bone; for separating hooked roots, so that they may be extracted separately; also to use as elevators for wedging between wisdom teeth and second molars. In the latter use care must be taken to support the fulcrum tooth,

Fig. 237.



No. 66. Forceps for cutting out the roots.

if there be no tooth immediately in front, by placing a small piece of wood to impinge on it and the next one to the front. A little caution will likewise be necessary to prevent the turning of the wisdom tooth so completely out of its socket as to have it pushed back into the fauces; particularly should this be observed if the patient be under an anæsthetic.

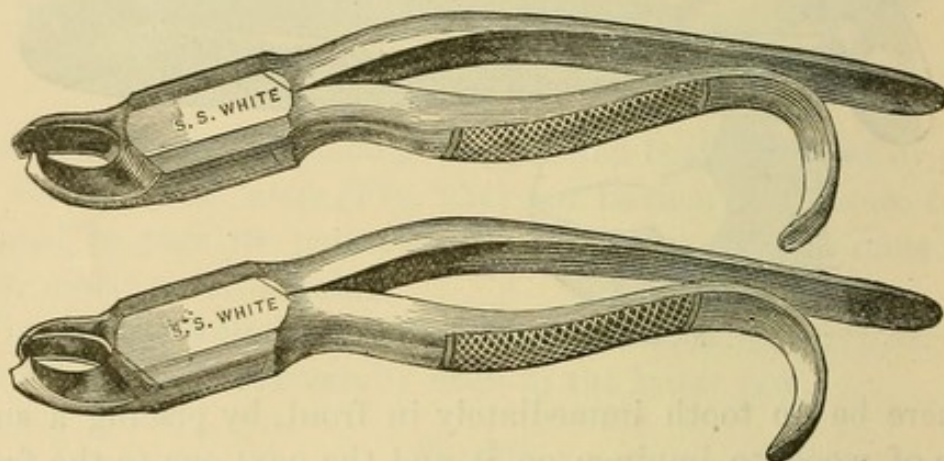
To these forceps may be added with great advantage some few others, which, although not so frequently required, will well repay the first cost by the satisfaction of having them at hand when wanted. Extraction is an operation that must be performed with confidence on the part of the operator, and no better rule has been given for it than that of Tomes. "The whole of the tooth should be removed with as little injury as possible to the surrounding structures and the least pain necessary to the case." Digging out a tooth piece-meal, or other barbarities, such as are practised by the African, who relieves his companion of an aching tooth by means of a spear-head for an instrument,¹ cannot come under the classification of dentistry. Blacksmiths' tongs, cold chisels, and hammers have been used for the purpose successfully, but are no more to be reprehended than some of the methods the writer has seen and heard of as adopted by dentists.

[¹ It was related to the writer by Dr. Visick, of England, that one of his relatives had actually witnessed such an operation.]

Therefore, as auxiliary to the above list of seven instruments, every practising dentist will do well to furnish himself with the following:—

Fig. 238, upper molar forceps, right and left. In these are found a deviation from the straight line so urgently recommended,

Fig. 238.

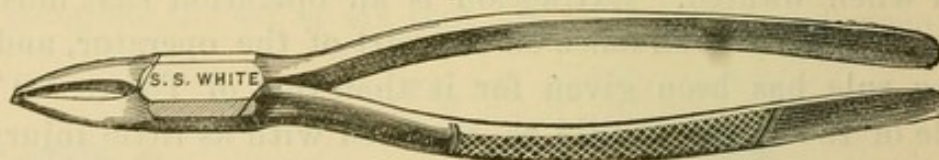


No. 18. R. & L. upper molar forceps.

but to enable the operator to reach well back in mouths with a small opening, they will very frequently be found desirable, if not absolutely necessary.

Fig. 239, root forceps. The cut represents a pair, rather heavy for the purpose designed. For the operator who is content to

Fig. 239.



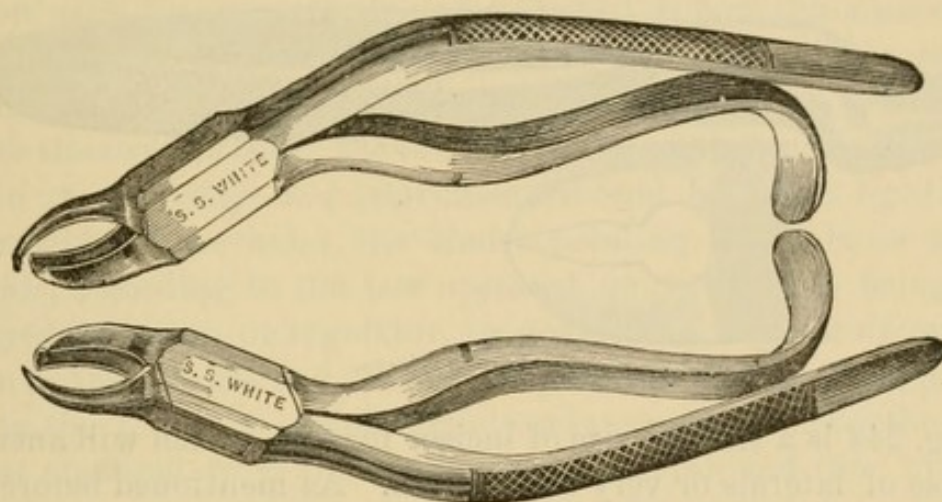
No. 1. Root forceps.

consider the possible fracture of an instrument as of more importance than the pain inflicted by forcing up the beaks between the root and gum, it may do. There are, however, more delicate instruments made than the one figured, and if specially ordered, they can be made so light as to be capable of passing between the root and bone with a surety of success in the removal of the root.

Fig. 240, right and left, is the cut of a pair of instruments that, although rarely used, are very valuable in extreme cases where the crowns are so far crumbled away or weakened as to

be incapable of resisting a force sufficient to remove the teeth. The horn-like beak passes between the buccal roots, and should

Fig. 240.

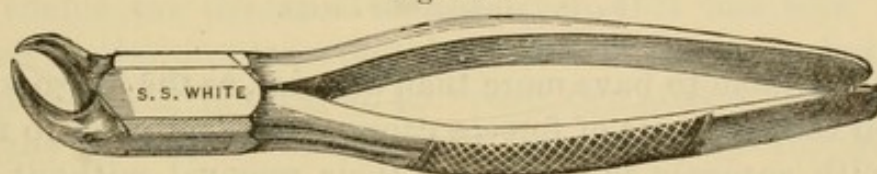


No. 20. R. & L. upper molar forceps.

either bring them away or divide them so that with the curved or universal root forceps, Fig. 235, they may be susceptible of removal.

Fig. 241 is the lower forceps designed for the same purpose in the lower jaw. It is not an unfrequent experience that the

Fig. 241.



No. 23. Lower molar forceps, either side.

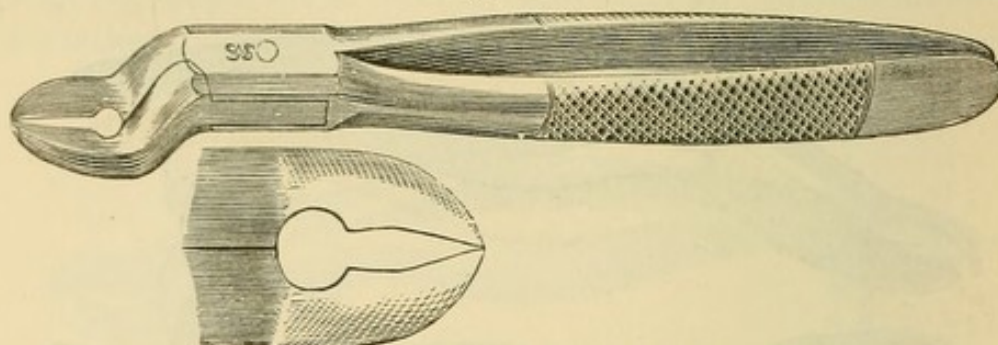
mere closure of the beaks between the roots will wedge the whole tooth out of its socket, and to complete the operation it is only necessary to lift it out of the mouth.

Fig. 242 is a cutting forceps for the upper jaw, corresponding in its use to that of Fig. 237, adapted, however, by the curve, to reach back to the upper molars, and, by cutting through the bone, seizing and removing their roots. The gum may be divided first by the lancet upon either side of the root; an unnecessary operation if the patient is anæsthetized.

The advantage of these instruments over those that have double cutting edges on each beak is, that the healing is much more promptly effected than when a mass of bone is removed,

and at the same time the alveolar process is not lost—a great desideratum when the patient is to wear an artificial substitute.

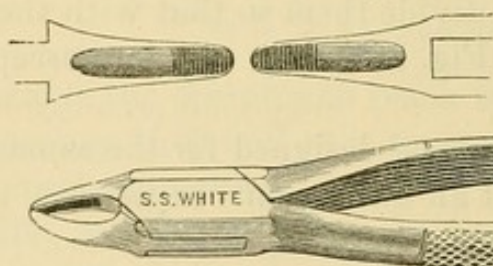
Fig. 242.



No. 67. Cutting forceps.

Fig. 243 is a smaller size of incisor forceps, which will answer in case of laterals or very small teeth. As mentioned before, it

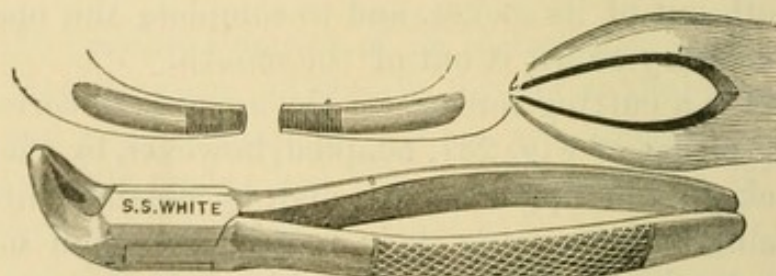
Fig. 243.



No. 48. Lateral incisor forceps.

is often desirable to have more than one size, as the incisors vary so much that one pair of forceps cannot be relied upon to fit all cases with accuracy sufficient for their removal without accident or fracture.

Fig. 244.



No. 49. Lower incisor and root forceps.

Fig. 244 represents a lower forceps, which may be used alike for incisors or canines; of this the same may be said as of the pair previously described.]

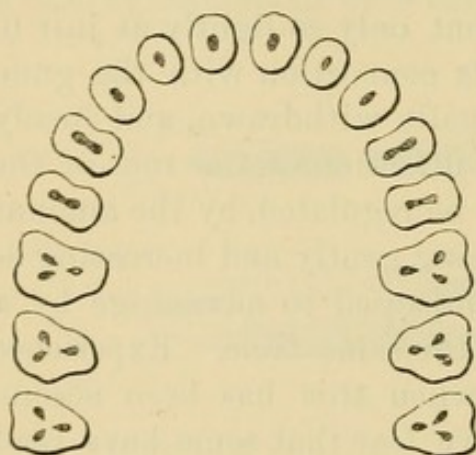
In employing the forceps, the student cannot do better than follow the excellent directions laid down by J. Tomes,¹ who divides the process into three stages, insisting most properly upon each being perfectly accomplished before the succeeding one is attempted. The stages are—"first, the seizure of the tooth; second, the destruction of its membranous connection with the socket; third, the removal of the tooth from the socket."

In *the first stage* the instrument should be taken lightly in the palm of the hand, the blades pointing upwards or downwards, according to the jaw operated on, the thumb being employed as a stop or regulator, to govern the amount of separation of the handles and consequently of the blades. In applying it to the tooth, it is well first to adapt one blade to the side most obscured from the view of the operator, and then to close the other upon the opposite side, but only so lightly as just to touch the tooth at the point of its connection with the gum. This done, the thumb is now gradually withdrawn, and steady but forcible pressure made in the direction of the root of the tooth. The force employed should be regulated by the amount of resistance experienced, commencing gently and increasing as the case demands, and often accompanied to advantage by a very slight rotatory movement at the same time. Experience will enable the operator to tell when this has been accomplished to the proper extent, but we fear that some have read too literally the injunction, to "push the jaws of your forceps into the socket, as though you intended they should come out at the top of the head or under the chin," as we have seen it fulfilled on teeth which needed no such roughness, causing unnecessary pain. The operator must judge, as he progresses, how much force is required, commencing gently, but continuing to increase the force until the object in view, viz., a firm grasp of the tooth at or above its neck, as the state or diseased condition may indicate, is obtained. Perhaps more judgment is required in this portion of the operation than in any other; and it must be admitted that, if it be unskilful to use unnecessary force in it, it will prove more unfortunate to err on the other side, and cause the fracture of a tooth by employing too little. The tooth being grasped at the right spot,

¹ Lectures, etc., p. 326.

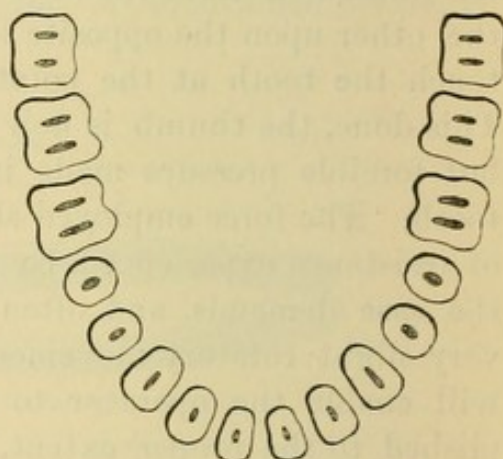
it must be retained by a force sufficient to prevent the instrument from slipping, but not so great as to endanger the somewhat fragile object; and then *the second stage* of the operation, the severing of it more or less from its membranous attachment, is commenced. This will consist in either a slightly rotatory movement in the long axis of the tooth, as in the case of one having a conical fang, or an inward and outward one, *i. e.*, between the adjoining teeth to and from the mesial line of the dental arch, when the fang is not conical, or there are more fangs than one. In making these movements, we should follow certain general directions to be presently mentioned; but, if we fail with moderate force to cause the tooth to yield, we may

Fig. 245.



Transverse sections of the teeth of the upper jaw made at their necks.

Fig. 246.



Transverse sections of the teeth of the lower jaw made at their necks.

These figures will be frequently referred to in the present chapter.

employ it in others, gradually increasing it as we find our efforts availing. The yielding of the alveolo-dental membrane gives a sensation which we can readily perceive, and, when it is sufficiently severed, we may connect with our movements of detachment those more truly extractive, *the third stage* of the operation. Judgment must be exercised here too; for, if the extractive force be put on too soon, fracture, or too great a resistance, will be experienced; if put on too late, much unnecessary pain is inflicted: error in the former alternative is likely to be attended with the unwelcome exhibition of portions of alveolar process. The extractive force should, as a rule, be exerted chiefly in the direction of the long axis of the tooth; but it is a rule with many exceptions. The skilful operator will

judge in which direction the loosened tooth is coming most readily, and in the *direction of least resistance* he should exert the traction. It is in this respect that the forceps is so superior to the key or other instruments, viz., in its enabling the operator to vary the direction of the force that he employs.

Having described the mode of applying the forceps in general, we now proceed to explain its application in the case of individual teeth, and must, in so doing, take it for granted that the reader is conversant with dental anatomy, and fully acquainted with the forms which the teeth in man present. He must know that horizontal sections of upper incisors and cuspidati (Fig. 245), made at or a little below their necks, present at the divided surfaces an almost circular form, the anterior and posterior aspects of which will be arcs of a circle—the anterior a rather larger one than the posterior. The blades of the forceps must be constructed to correspond to such forms, and to cover, when applied, rather more than a third of the surface of the tooth grasped. In the perfect instrument the inner blade should represent a less obtuse angle with the inner handle than the outer blade does with the outer handle, in accordance with the form presented by the roots of these teeth (Figs. 247, 248, 249). Whilst the

Fig. 247.

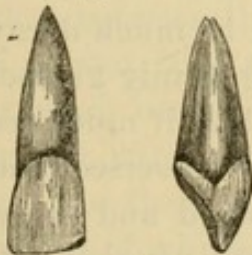
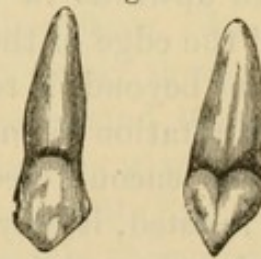
Central incisor of upper jaw,
front and side views.

Fig. 248.

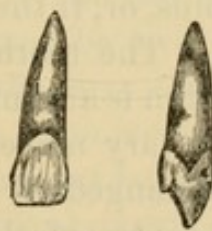Lateral incisor of upper jaw,
front and side views.

Fig. 249.

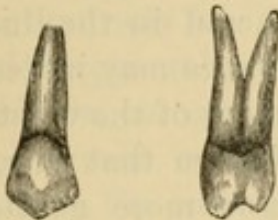
Cuspidatus of upper jaw,
front and side views.

same instrument may be employed for all the above-mentioned teeth, a pair with narrower blades (Fig. 243) may be desirable when very small lateral incisors have to be dealt with. The operation of extracting these teeth is thus performed: the patient should be seated and facing a good light, and, if a proper dental chair be not at hand, an old-fashioned easy one, provided with a cushion, to raise the body so that the head may recline steadily on the top of it, will answer sufficiently well. If such a chair be not procurable—for these operations have often to be per-

formed at patients' houses—the following may be adopted: The patient is seated upon an ordinary chair, whilst a second chair is placed at the back; on this latter the operator firmly places his left foot, and covering his knee with a towel, makes it a soft but firm support for the patient's head. The foregoing suggestions are, of course, available also with all the teeth of the upper jaw. In applying the forceps to the teeth in question—upper incisors or cuspidati—the operator should stand rather in front, and on the patient's right side; with the thumb of the left hand the lip should be raised, whilst the fingers of the same resting upon the patient's forehead afford steadiness to both patient and operator: if preferred, the operator may apply the finger and thumb of the left hand to each side of the alveolar process adjoining the tooth; this latter has the advantage of affording some knowledge of the yielding of the tooth to the force applied. [The concave portion of the palm of the left hand will be over the cheek and the prominence made by the zygomatic arch. The prominence near the wrist or the fingers may rest lightly upon the orbital process or temporal region of the head.] The forceps, held as before directed, should be applied to the neck of the tooth, to its posterior surface first, and then closed gently upon it by the thumb being withdrawn: the instrument is now forced upwards in the direction of the long axis of the tooth, until the edge of the alveolus, or, if the tooth be much decayed, a point beyond, is reached. The tooth being firmly grasped, a slight rotation in one direction is attempted; but, if much resistance be encountered, the rotary movement is reversed, and, if still resisted, it may be exchanged for an inward and outward one, *i. e.*, to and from the centre of the palate, coupled with a return to the rotary. [Generally the rotary movement should be very slight for all teeth save the superior central incisors.] As the tooth begins to yield from its attachments, the force may be gradually changed to a downward one in the direction of the long axis of the tooth, but it should be steady and guarded, inclining to the direction in which the tooth seems the most willing to yield. It is not elegant or agreeable to witness the tooth parting from its socket with a sudden jerk, although it not unfrequently shoots from it, owing to its sliding along the double inclined plane formed by the blades of the forceps; an occurrence not always possible to avoid, but one which we should do our

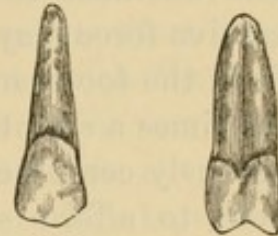utmost to prevent, as the tooth may disappear into the throat or even larynx under such circumstances. More force will be necessary in the removal of the cuspidati than in that of the central incisors, and more in the case of the latter than in that

Fig. 250.



Upper first bicuspid, front and side views.

Fig. 251.



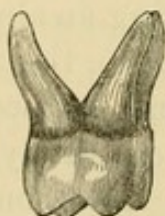
Upper second bicuspid, front and side views.

of the lateral incisors. [The apices of the roots of the latter teeth very often have a sharp turn or crook, which will be broken by a hasty movement in the wrong direction. These crooked portions of all teeth roots that curve have a general inclination away from the mesial line toward the distal face, requiring the motion to be backward, or such as to unhook it.] We now pass on to the bicuspid of the upper jaw, sections of which at their necks (Fig. 245) are of a less circular form than is that of the teeth just considered, which, instead of having an almost conical root, have a somewhat flattened one (Fig. 250), the teeth being broadest between their external and internal surfaces. In the place of one fang there may be two or very rarely three, this being more common in the first than in the second bicuspid (Figs. 250, 251), although some works on anatomy give the reverse. For these teeth we must have an instrument (Fig. 243), the blades of which must be segments of the circle presented by the external and internal surfaces of these teeth at their necks, and for all practical purposes segments of the same circle will suffice; otherwise we should require a pair for each side of the mouth, as the handles are bent at an angle with the blades, to prevent the former from pressing against the lower lip during the operation. The breadth of the blades should be about the same as in the instrument for the central incisors and cuspidati. The operator assuming much the same position as that just described, which is generally best suited to the removal of all the upper teeth, the instrument is applied and forced upwards, as before directed. The severing movements must be accom-

plished by force exerted to and from the palate—we prefer it in that order *i. e.*, first inwards towards the palate, followed by a more forcible one in the opposite direction, rotation in the case of the bicuspsids being out of the question; their flattened fangs, and the circumstance of their having often two fangs, would offer great resistance to such movement. As the tooth yields the extractive force may be commenced, and in the line of the long axis of the tooth, or varied, as resistance may indicate; and with it at times a slight shaking movement of the wrist may be advantageously combined. We may observe that in removing these teeth to afford space a slower and more gentle action should, if possible, be adopted; for, while a small fractured portion of a healthy fang, when left, is seldom attended with unpleasant consequences, it would in these cases much retard, if not prevent, adjacent teeth from moving into the space thus made.

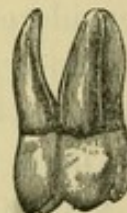The molars of the upper jaw (Figs. 252, 253) present, on section at their necks (see Fig. 245) a more varied figure than the foregoing, viz., in the external surface being segments of two circles united at one extremity, of which the anterior is

Fig. 252.



First molar of the upper jaw.

Fig. 253.



Second molar of the upper jaw.

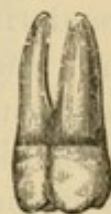rather the larger, whilst the internal surface represents the segment of a circle much larger than either. In conformity with these circles must be the blades of the instrument (Fig. 238), which must be broader and somewhat stronger than those already considered, as should be the instrument generally; it will also be desirable to have the blades at a greater angle with the handles than in that last described. In addition to this angle, some prefer also a curve in the handles, as shown in the figure, the bend being towards the roof of the mouth when the instrument is employed. It is a matter of little importance, but in our opinion rather a defect than otherwise, as in practice the straight handles afford a better grasp, and are quite as convenient as the curved.

In removing a tooth of such dimensions and resisting form as an upper molar, we must be prepared to exert a larger amount of force than upon smaller teeth, and this especially in grasping them, and when a very slight lateral movement accompanying the forcing upwards of the instrument will often prove advantageous. From the directions of the fangs we at once see that only an inward and outward movement is feasible, and the rule generally given to commence with the inward one is, we believe, correct: it is not, however, to be persisted in until some movement is effected, for, should this not come pretty readily, then the outward movement is to be adopted, and with this a moderate amount of force, exerted also in the downward direction, often effects the complete removal of the tooth. [The inner plate of the alveolar process is, as a rule, the heavier, and does not yield as readily as the outer one.] Generally, however, the lateral movements may have to be repeated before the truly extractive ones can be attempted. It must here be remembered that we have, besides the strong membranous attachments, to overcome the dovetailing of the roots and alveolus; consequently the latter must be dilated in most cases; fortunately they are, in the recent state, soft and moderately yielding.

[The loosening movement should be continued until the tooth seems almost enough detached to be taken out by the fingers. In the temple of Apollo, at Delphi, it is said, a leaden extractor was exhibited, to teach the student that no tooth should be extracted until it was loose enough to be easily removed.¹]

The second molar may be removed precisely in the same manner, and with the same instrument as the first; generally more readily, as the tooth is not so large, nor its fangs so divergent. The third molar (Fig. 254) of the same jaw has the two external circles at its neck so feebly pronounced (Fig. 245), that an instrument (Fig. 236), both blades of which are segments of one large circle, will be found better adapted than the form suitable for the first and second molars; consequently such an instru-

Fig. 254.



Third molar or wisdom tooth of the upper jaw.

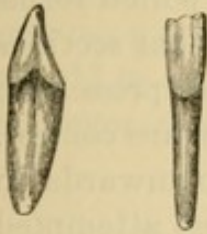
[¹ See pp. 4 and 13, "A Practical Guide to Operations on the Teeth," by James Snell, Dentist; Carey & Lea, Phila., 1832.]

ment may be employed for either side, whereas for the latter instruments for the right and left side are necessary. The handles ought to form a considerable angle with the blades, otherwise it will be impossible to adjust them accurately, and in the direction of the vertical axis of the tooth. Except from the inaccessibility due to their position, the third upper molars are not, as a rule, very difficult to remove; their roots, if not agglutinated, are generally but slightly divergent; and the bone in which they are placed is soft and spongy. From the direction of their long axes, the movements of detachment and removal may be combined in an outward and downward one from first to last, it often being necessary to make the latter considerable; indeed, a circle passing from the crown of the tooth, downwards, outwards, and upwards in the direction of the zygomatic process; an exaggerated curve corresponding to that which the fang of the tooth often assumes in its alveolus.

When we operate upon the teeth of the lower jaw, the patient may conveniently be seated in an ordinary easy chair, the head being in a line with the body, *i. e.*, in the usual sitting posture, or nearly so. As horizontal sections of incisor teeth of the lower jaw at their necks represent an ovoid figure, flattened laterally (see Fig. 246), the anterior and posterior surfaces of which are segments of a circle much smaller than that presented by the upper incisor teeth, the blades of the instrument to be employed for their removal must be narrower and arcs of a smaller circle, than in the case of the upper incisors, and in relation to the handles, curved as in Fig. 244. In employing the instrument, the operator may stand on the right of the patient, steadying the lower jaw with the fingers of the left hand, whilst the thumb depresses [the tongue, and the index finger] the lower lip, rendering clear to view the teeth upon which he is looking down. The instrument being well pressed down, the severing or detaching movements, which can only be inward and outward in direction, must be very cautiously performed, as the fangs of these teeth are very slight (Figs. 255, 256, 257), and consequently easily fractured; they will be found to yield most readily in the outward direction, in which, combined with an upward direction also, the final extractive force should be exerted.

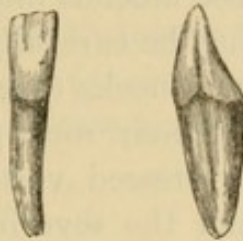
For the lower cuspidati not only should the blades of the instrument be somewhat broader, but they should represent segments of a larger circle; still in practice the same as that suitable for the incisors is found to answer very well. The

Fig. 255.



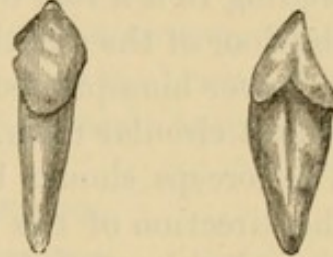
Central incisor of the lower jaw, front and side views.

Fig. 256.



Lateral incisor of the lower jaw, front and side views.

Fig. 257.

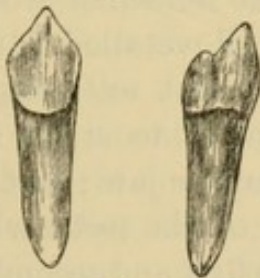


Cuspidatus of the lower jaw, front and side views.

severing movements, as suggested from a lateral view of their roots (Fig. 257), must be in the same directions, viz., to and from the centre of the dental arch, but they will require more force in their removal than the incisors usually do. [This motion should be generally toward a point representing the centre of the arc in which the teeth are arranged, or, in other words, in and out on a line corresponding to the radius of the curve which is formed by the teeth.] In removing the tooth of the left side, the operator should stand almost in front of the patient, or the patient's head should be turned towards the operator.

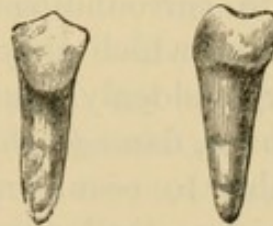For the bicuspid of the lower jaw (Figs. 258, 259) we shall

Fig. 258.



First bicuspid of the lower jaw, front and side views.

Fig. 259.



Second bicuspid of the lower jaw, front and side views.

best employ an instrument differing little from that last described, except that [it may be slightly heavier]; these must be employed more from the front of the mouth.

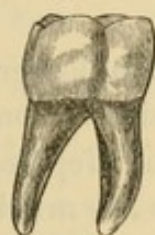
In operating with the straight forceps on the right side of the mouth, the best position is, to stand almost in front of the patient

whilst for the left side we should recommend a position at the back of the patient, bending over towards his head, but in both cases employing the finger and thumb of the left hand for separating the lips and tongue from the gums, in order to enable him to see clearly where to apply the instrument, and avoid including in it a fold of the loose mucous membrane which forms the floor of the mouth. It may be carefully noted, that sections of lower bicuspid teeth at their necks (see Fig. 246) present an almost circular form, and that their roots generally are conical. The forceps should be firmly pressed vertically downwards in the direction of the tooth, and the severing process attempted by a slight rotatory movement, first in one direction and then in the opposite; but it often happens that detachment is felt at the first movement, and then force applied in a direction upwards and a little outwards will remove the tooth. The lower bicuspid are, however, very uncertain teeth to deal with; occasionally parting from their surroundings with but little persuasion, yet at times presenting very great resistance; we must, therefore, apply our rotatory force with discretion, changing it for an inward and outward one, or even combining the two, rather than risk a force greater than that which holds the particles of a tooth to each other, viz., its cohesive attraction. The roots of these teeth, normally conical in form, and eminently suitable for the rotatory movement,¹ are very liable to be curved or twisted, or to have enlargements at their extremities, thus opposing obstacles to such and other movements for their detachment; and very often also, when they are detached from their immediate surroundings, they are yet dovetailed into their alveoli, from which they may, if care be not exercised, come away very suddenly, causing the instrument to strike against, and, perhaps, damage the teeth of the upper jaw; but this is more liable to occur in the extraction of the teeth which we next consider—the lower molars. For the first and second molars (Figs. 260 and 261) the position of the operator in regard to the patient will be much the same as in the case of the teeth last mentioned.

¹ It should be distinctly borne in mind, that the bicuspid are the only teeth of the lower jaw to which a rotator movement in extraction is admissible.

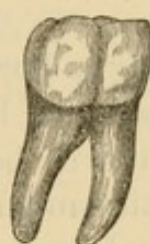A horizontal section of a lower molar tooth at the neck (Fig. 246) shows both its external and internal surfaces, of much the same form as the external surface of the first upper molar, viz., two segments of circles touching each other at one extremity, of which the anterior segment is the larger. The blades of the instruments must, therefore, be made to correspond in like manner; and, in order to insure the greatest accuracy, there should be an instrument for each side of the mouth; practically, however, the difference between the sides of the tooth is so small

Fig. 260.



First molar of the lower jaw.

Fig. 261.



Second molar of the lower jaw.

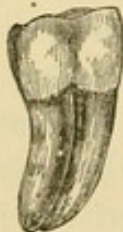that one instrument may suffice (except in the case of the additional curve spoken of), provided the hinge possesses a little play. It is essential, too, that the angle between the blades and handles should be nearly a right angle. In using these forceps, the operator should stand in the same positions as those recommended in the case of the bicuspid, and employing the left hand in the same manner; but he may with advantage, in employing the instruments applied at the front of the mouth, after separating the lips and tongue from the gum, and placing the forceps on the tooth, place the fingers under the chin to support the jaw, and employ the thumb to press the forceps well down. Slight inward movement may first be attempted, but the tooth will generally yield most readily in the outward direction, where the alveolus is less thick; and, in raising the tooth, it will also be found to come most readily in the same direction. The two large and dense fangs (Fig. 260), anterior and posterior, especially of first lower molars, often occupy more space than does the tooth at its crown, where it is in contact with its neighbors. To raise it vertically, without injury to the latter, would be impossible: and, where the fangs spread to any extent, the tooth becomes locked, and then it is necessary to continue for some time

the lateral movements in order to dilate the alveolus, varying them with extractive force in a direction considerably outwards, but taking every care that the instrument in coming upwards does not strike and injure the upper teeth: the left thumb, in such cases, may be well retained on the upper part of the forceps. A pinch of the thumb may result, but the operator will smart less from this than if he fractured his patient's sound tooth.

For a tooth which happens to be locked in the manner above mentioned, the lateral movements are no doubt best performed by the instruments which are applied from the front of the mouth.

On comparing a horizontal section of a lower third molar, made at the neck (see Fig. 246), with a similar one in a first or second molar, it will be observed that the depressions on each side marking the union of the two fangs are much less distinct. In making the lateral severing movements, we shall generally experience great resistance, the cause of which will be evident if we examine such a tooth *in situ*, by removing the external alveolar plate of the maxilla. When it is thus exposed, it will be noticed that the fangs incline backwards (Fig. 262), *i. e.*,

Fig. 262.



Third molar of the lower jaw right side. It will be observed how much the fangs incline in the direction of the coronoid process of the jaw.

towards the angle of the jaw, a curving which is seen to increase from the first to the third molar tooth; the greater such curve is, the greater obviously will be the resistance to lateral movement, as a larger surface is impinged upon. The form of the curve also indicates the direction in which such a tooth will most readily yield to force, *viz.*, upwards and backwards, towards the coronoid processes. Such a movement it is almost impossible to effect with the forceps, but it is the precise one which an instrument, virtually one-half of a pair of forceps—the elevator—can readily effect; and this in-

strument, which we shall presently describe, we recommend for removing third molars, especially when the second molars remain *in situ*.

[The cutting forceps (Fig. 237) may be used to divide the roots so that they may be separately removed, especially if they should

curve toward each other, embracing as they often do a portion of the bone, which otherwise would require to be broken off in the removal of the tooth.

The same forceps may be used as elevators as described before.]

We have endeavored to tabulate the foregoing instructions, as we hope by so doing to make them more available to the student.

Teeth of Upper Jaw.

Patient seated raised and with head resting backwards [and turned to the left for extraction of teeth from the right side of the mouth].

Teeth.	Fangs.	Forceps.	Detaching movements.	Operator.
Inc. and cusp.	1 conical	Figs. 231 and 243	Slight rotation	On right side and rather in front of P.
Bicuspid	1 or 2 flattened laterally	Figs. 231 and 235	Inwards and outwards	Do.
Molars, 1st and 2d	3, 2 external and 1 internal	Figs. 233 and 240	Do.	Do.
Molars, 3d	Do. often agglutinated	Figs. 236 and 242	Do.	Do.

Teeth of Lower Jaw.

Patient seated at ordinary height, head in vertical position [and turned to the left for extraction of teeth from the right side of the mouth].

Teeth.	Fangs.	Forceps.	Detaching movements.	Operator.
Inc. and cusp.	1 flattened laterally	Figs. 232 and 244	Inwards and outwards	To the right of P.
Bicuspid	1 conical	Do.	Slight rotation	Do. for right side, for left side in front to right of P.
Molars, 1st and 2d	2, 1 ant. and 1 post.	Figs. 234 and 241	Inwards and outwards	In front of and to the right of P.
Molars, 3d	Do. often agglutinated.	Figs. 234 and 237	Do.	Do.

CHAPTER XIV.

EXTRACTION OF ROOTS OF TEETH.

THUS far we have taken it for granted that the teeth on which we have been operating are fairly strong ones, not diseased or injured much below the level of the gums. When teeth in the latter condition present themselves, our instruments, as well as our line of operation, must be somewhat modified. The instruments must for such conditions have their blades sligher, also more pointed and sharper at their extremities, to enable them to obtain a secure hold, and to readily divide much of the membranous attachments, and penetrate into the alveoli, often to a considerable distance. As regards the remainder of the instruments, handles, hinges, etc., they may be of much the same construction as those for sound teeth, and the directions already given in regard to position of patient, operator, etc., are also applicable to them; but in making the severing movements we shall do well to exert the force more gently and more cautiously, preferring to lessen the danger of fracture by occupying a longer time: in the extractive movements also the same considerations should influence us.

For the roots of upper incisors and cuspidati, instruments like those described for those teeth, but having thinner, sharper, and more pointed blades, are used (Figs. 235, 239). In pressing them up care must be exercised that they are neither too widely open nor too closely shut: the latter is the error generally made by a beginner, especially when there is no portion of the tooth visible above the gum, or only a portion of one side of it left to guide him, when the instrument becomes forced upon the root itself. The right direction being ascertained or allowed for—and, if a knowledge of dental anatomy be essential to insure a good extractor of teeth, it becomes of imperative necessity when hidden roots are operated upon—the instrument is forced upwards in the direction of the long axis of the root, this being often much


assisted by a slight rotatory movement of the wrist as well ; the amount of pressure necessary will be determined by the resistance to it, and the extent to which the disease has advanced. At times we find the roots of these teeth so hollowed out, that but little more than their cemental covering remains ; and, as such fragile tubes must of necessity collapse upon the slightest pressure, we shall do well to fill them previously with gutta-percha, or the oxychloride compound, which soon sets, and will render them somewhat solid ; or we may employ the instrument (Fig. 276), which consists of a conical screw. This is inserted into the hollow cavity in the fang until firmly held in position. Having secured a good hold, with very cautious grasp, we must proceed gently to make the same rotatory, or other severing movements [taking care that they are made to the right always with this instrument to tighten the screw], followed by extractive ones.

The roots of upper bicuspid require blades possessing the same characters as for those of incisors and cuspidati (Fig. 235), and the operation of their removal will be performed with the same precautions. It must be borne in mind that these teeth have often two slender roots, especially the first bicuspid, and their divergence affords a less perfect grasp than in the case of a single and more conical one ; also that, when the tooth is grasped, the two roots often become detached, and, moving one upon the other, cause the instrument to slide off them. A fine, long-pointed pair of forceps (Fig. 239) may here successfully remove each root separately.

Our greatest difficulties will perhaps be encountered in attempting the removal of upper molar roots, when the teeth are broken to the neck, but have the fangs still firmly united to the remains of the crown. Such a root roughly represents an inverted truncated cone, and the root-forceps which we have as yet described represents, when applied, another truncated cone, but not inverted. These can never be adapted to each other, they will only touch at points, and the forceps will be found incapable of moving the tooth. With the exception of instruments which cut bodily through the external alveolar wall and thus admitted a grasp of the tooth above its neck, those similar to Fig. 235 (page 272) were the only forceps employed for the removal of such roots at or near the period when we entered

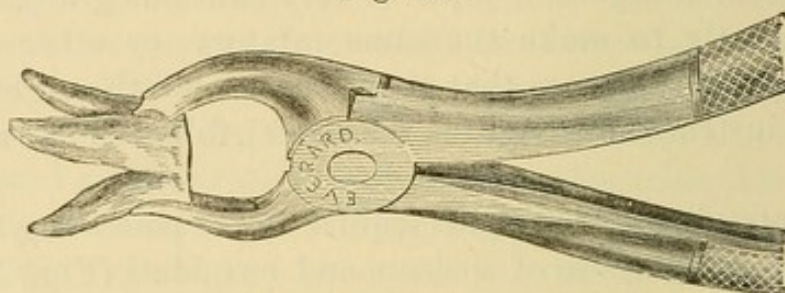
upon practice; and, to supply this want, we constructed some specially adapted to the conditions in question. The outer blade (Figs. 263, 264) is made like that for an ordinary molar tooth,

Fig. 263.



Prof. Coleman's forceps, designed for the removal of upper first and second molar roots when not separated from the crown.

Fig. 264.

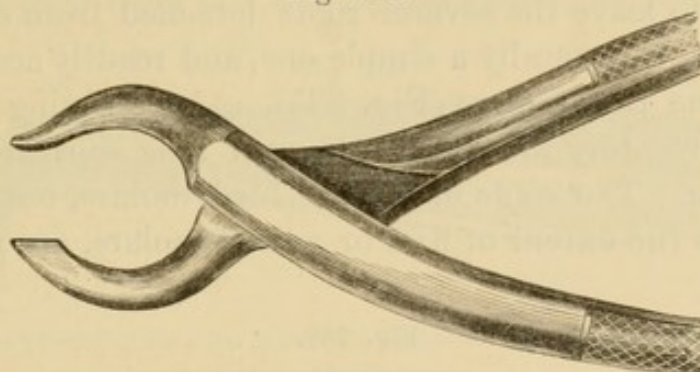


Represents the forceps described in Fig. 263 applied to a molar root.

but narrower, rather longer, and with the inter-circle point more pronounced and sharper: the inner blade is also narrower, thinner, longer, and sharper, and, near its extremity, bent outward in the direction which the palatine fang takes. Such an instrument can be pressed up parallel with such a root, and, when closed upon it will insure a firm grasp at or between the two external fangs, as well as upon the palatine fang. In operating, the force should be perhaps most inclined inwards, as there is some liability of the instrument slipping off the tooth when it is moved in the opposite direction. If the fangs be not firmly united to the crown, the instrument will then divide them, generally bringing away one or more of them, and doing the work of cutting-forceps designed especially for the separation of such roots. These latter forceps have their inner or palatine blade of much the same form as in those last described, whilst the outer or buccal blade terminates in a vertical cutting edge (Fig. 265), which, when closed, approaches within a short distance of the former. In the application of them, the palatine blade is first adjusted and then the outer closed upon it; generally, but not always, in such application dividing a portion of the

mucous membrane and the thin outer edge of the alveolar process. Increased pressure cuts through the two external roots,

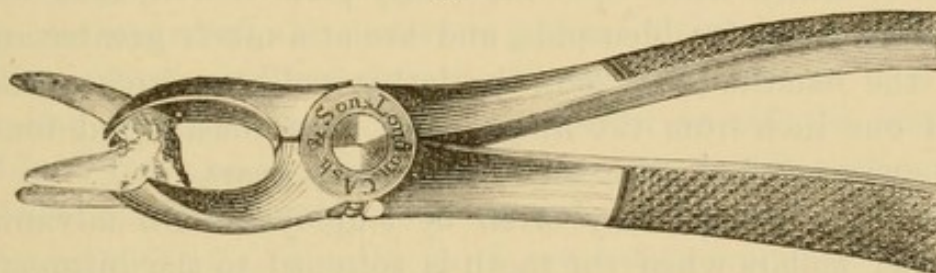
Fig. 265.



Forceps for separating the fangs of upper molar teeth. The cutting-edge blade is applied between the two external fangs, the opposite blade to the palatine fangs.

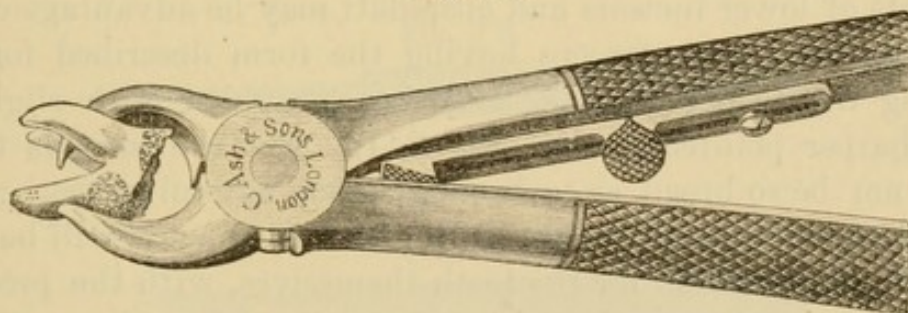
the sharp blade penetrating into the palatine root, which is generally brought away in the forceps, and the operation con-

Fig. 266.



Forceps (Stevens) for extracting the roots of upper molars. The palatine blade is divided into two points which grasp the palatine root on either side and prevent the instrument from slipping off the tooth.

Fig. 267.




Forceps (Baly's) for extracting the roots of upper molars. This is very similar in construction to the dividing forceps, but by means of the stop can be employed for removing the fang *en masse*.

cluded by removing the separated external roots with fine fang-forceps.

That such roots have proved a difficulty to practitioners is

evidenced by the variety of instruments that have been devised for their removal (Figs. 266, 267). When, however, the disease has advanced so far as to have destroyed the whole of the crown, and to leave the several roots detached from each other, the operation is generally a simple one, and readily accomplished with the fine root-forceps (Fig. 235), and by giving to the instrument a rotatory movement, as each fang separately is of a conical form. The roots of upper third molars, not generally divergent to the extent of first or second molars, are not, except

Fig. 268.



Coleman's forceps for extracting the roots of upper third molars.

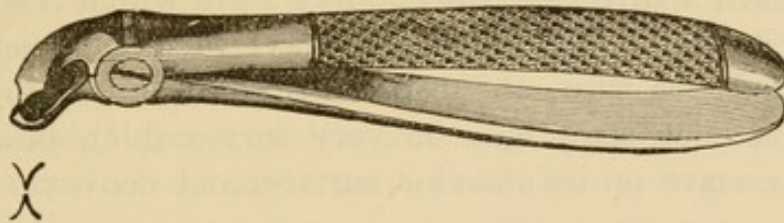
from their position, very difficult to remove. Root-forceps, the blades of which when open are nearly parallel with each other, and wider than for bicuspid, and are at a much greater angle with the handles (Fig. 268), the latter inclining backwards at about one inch from the hinge, have been constructed for us, and have proved of great service for many years.

The same forceps may often be employed with advantage for other molars when the tooth is softened to the bifurcation of its fangs: for, when firmly thrust up the alveolus, it seldom fails to bring away one, two, or sometimes all, the roots at once.

Roots of lower incisors and cuspidati may be advantageously operated upon with forceps having the form described for removing the bicuspid (Fig. 232), but provided with slighter and sharper pointed blades (Fig. 244). For the incisors they must not be so broad as to impinge upon adjoining teeth; for the bicuspid we may use the same; the movements will be the same for the roots as for the teeth themselves, with the precautions given with regard to roots generally. For either of the foregoing we may also employ the instrument figured (Fig. 237). Roots of lower may, like those of upper molars, be found detached or united to their crowns; and forceps have been constructed for dividing them, or specially acting upon them (Figs. 237, 241, and 269) in this condition. These we have found un-

necessary, because, according to our experience, those just described accomplished the object more perfectly. If we take the case where the roots are connected with the crown; we prefer root-forceps used from the side of the mouth, as just described,

Fig. 269.

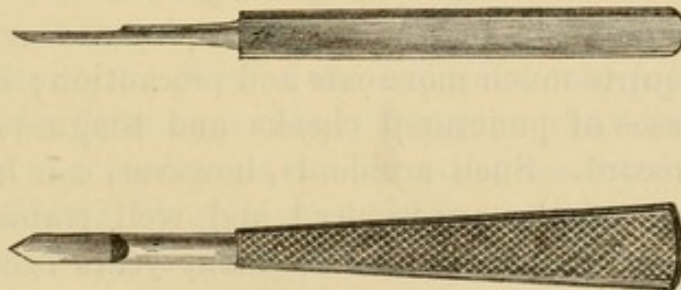


Forceps for extracting the roots of lower molar teeth when attached to the crowns.

and apply them in the direction of one of the fangs, the most visible being by preference selected. The ordinary movements for these teeth will generally bring away the two fangs, but it may be one only, and then the other is in like manner removed. Care, however, must be taken to apply the instrument directly to the fang and not to the space between the two fangs. When these are separated, the matter is generally simple enough.

The elevator we have already compared to one-half of a forceps, but perhaps it would be more correct to call the latter a double elevator, as the obstetric forceps is a double vectis; and no doubt many practitioners employed one blade of the forceps in the manner of an elevator, and some even employed the single blade detached, previously to the introduction of the instrument described and figured by Bell in his work, to whom must be accredited its parentage.

Fig. 270.




George's elevator, front and side view, the best for general purposes.

The elevator, for the term punch can in no way be considered as applicable to it, consists essentially of two portions (Fig. 270), viz., the blade and the handle, yet in all forms of it a portion

exists which is intermediate between the two, and may be either straight or curved. The blade is that portion which, as in the case of the forceps, is applied to the tooth, and some forms are constructed as if with the intention of fitting a root in its long diameter (Fig. 271); but, as the elevator is rarely, if ever, applied in such a direction, the cup-like form which it sometimes presents is only a barrier to its effective employment. The blade should be thin, about one-fifth of an inch in breadth (though smaller sizes will be very serviceable), flat, or but slightly concave on its anterior surface, and convexly rounded

Fig. 271.



Tomes's elevator, with a spoon-shaped blade.

on its posterior surface, and from the latter to the former beveled off, and sharpened to a V-shaped point: the anterior surface may with advantage be finely grooved in its long axis,¹ the posterior quite smooth, and the extremity kept quite sharp.

The handle should be fully four inches in length, roughened, and of sufficient width to afford a very firm grasp. It may be either of metal, wood, or ivory; the latter two are preferable, as being lighter.

In explaining its action we shall, not to mince matters, call a "spade a spade," and, as roots of plants are dug out of the ground by that instrument, so precisely are teeth raised from their sockets by the elevator, notwithstanding that the process in the latter has been dignified by a higher title.

It is not so easy an instrument to employ as the forceps, and certainly requires much more care and precaution; it may easily slip, and cases of punctured cheeks and tongues are unfortunately on record. Such accidents, however, can hardly occur in the hands of the experienced and well trained. Certain members of the profession have for many years been celebrated for their skill in the use of the elevator, and amongst these the name of Cartwright has in the mouths of practitioners been a household word. It was our privilege to be associated for many

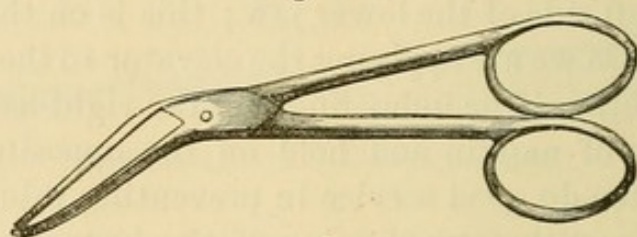
¹ We believe that this was first suggested by Salter.

years with a member of that family, and we cannot feel too grateful for having so often witnessed this most valuable instrument employed with consummate skill.

When the elevator is applied, it should be firmly grasped at the handle, and held much like the knife at dinner, the forefinger of the right hand resting upon it about half an inch from the extremity of the blade; this not only gives steadiness, but also acts as a stop or guard should the instrument happen to slip. The forefinger should as a rule be applied to the back of the elevator in an operation on teeth of the upper jaw and right side of the lower jaw, but to the front of it in an operation on teeth of the left side of the lower jaw; this is on the assumption that in each case we are applying the elevator to the anterior surface of the tooth. [The index finger of the right hand, protected by a few folds of napkin and held on the opposite side of the tooth, will often do good service in preventing injury to the soft tissues of the mouth from slipping of the instrument or sudden movement of the tooth. This finger in like manner serves to prevent the tooth from being dropped into the throat, a particularly dangerous accident when the patient is unconscious from an anæsthetic.] For illustration, let us suppose that we are about to operate on a third molar of the right side of the lower jaw, extensively decayed upon its buccal surface. The elevator being held as before described, the operator, standing somewhat behind and leaning over the patient's head, and separating, with the finger and thumb of the left hand, the tongue and cheek from the jaw, should introduce the point of the instrument at the margin of the gum and at the interstice between the necks of the second and third molars; and the point should incline towards the root of the latter rather than the former, and in relation to its alveolus the handle should point upwards, forwards, and a little outwards. The gum must be penetrated in inserting the blade, and its introduction into the alveolus will be facilitated by giving to the instrument a very slight rotatory movement, an increased amount of which will doubtless have the effect to some extent of loosening the tooth; this movement combined with an upward one, effected by depressing the handle, will generally raise the tooth from its socket, and in the curve before mentioned, viz., that of which its crown and fangs form a segment. In the final stage of the operation the

force must be exerted almost directly upwards, and here every care must be taken to prevent the instrument from darting backwards, when resistance is no longer offered. In the case of lower third molars, it not unfrequently happens, that, when elevated from their sockets, they remain attached to the mucous membrane which is firmly adherent to their necks at their posterior surfaces, from which they must afterwards be detached by a sickle or hoe-shaped lancet, or scissors having curved blades (Fig. 272). The elevator is employed in much the same manner

Fig. 272.



A pair of scissors with the blades at an angle to the handles, suitable for separating a lower wisdom tooth from mucous attachments after extraction.

for the other teeth, except that in the upper jaw, and especially for the roots of single fang teeth, it must be introduced in a more vertical direction.

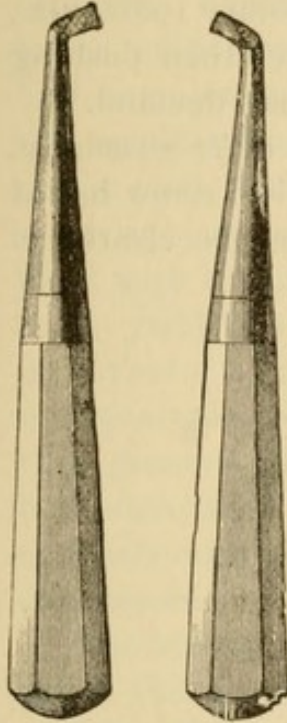
[Lancing before commencing the operation is only desirable in teeth that stand alone, to avoid tearing the soft tissues. The latter are often attached to the wisdom teeth. But when an anæsthetic is used, it may be as well to leave the attachment to act as a safeguard against the tooth being swallowed or drawn into the glottis. It may then be severed as above.]

For detached roots of both jaws, elevators having the blades at an angle to the handles may often be employed with great advantage (Figs. 273, 274). The form devised by Thompson (Fig. 275) has a very suitable angle, but possesses the objectionable spoon-shaped blade. This latter, reduced to about half its thickness, as we have altered it, forms a very serviceable instrument; it must, however, be borne in mind, that with a curved instrument there is a sacrifice of power.

For upper wisdom-teeth, or their roots, the use of the elevator may be attended with such disastrous consequences, that it is well, as a rule, to forbid its employment. The force being exerted in the direction of the tuberosity of the upper jaw, this portion

of the bone may be readily detached, and with it, perhaps, which is more important, the hamular process of the internal pterygoid

Fig. 273.



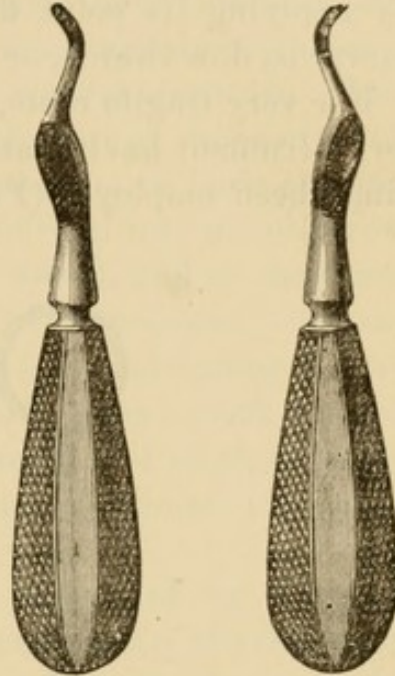
Shows elevator with its blades at an angle to the handles, right and left instruments.

Fig. 274.



An elevator the blade of which can be set at any angle.

Fig. 275.



Shows the elevator of Thompson, right and left instruments.

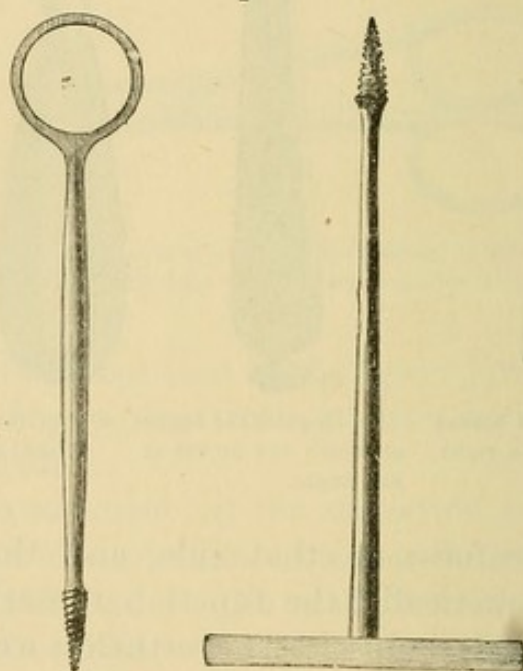
plate, causing deafness on that side, and thus unpleasantly demonstrating, practically, the function recently attributed to the circumflexus-palati muscles: nevertheless we have witnessed recently the same complication occurring in the employment of the forceps, and in the hands of one who could only be characterized as a most careful and successful operator. This process of bone is at times so slightly attached to its surroundings, as in the case just noticed, that interference with the latter must almost of necessity cause its separation. An instrument even more likely to produce this result than the elevator, is one designed for the removal of wisdom-teeth, and resembling a pair of bone-cutting forceps, with the blades bent at rather more than a right angle to the handles: when closed, the blades form a smooth inclined plane along which the tooth glides. In its employment, say for an upper wisdom-tooth, the open blades are closed forcibly between that tooth and the second molar—very much in the manner that one would adopt if it were desired to

cut away the wisdom-tooth with the tuberosity—with the intention of causing the tooth to slide along the smooth inclined plane formed by the blades when thus closed.

The elevator may be used in a manner different from the foregoing, especially in the case of loose and temporary roots, viz., by applying its point firmly against them, and then pushing upwards, downwards, or laterally, as the case may demand.

For very fragile roots, of single-fanged teeth more especially, an instrument having at one termination a conical screw has at times been employed (Fig. 276). The root must be cleared of

Fig. 276.



Shows two forms of screw instruments for extracting roots of teeth.

softened dentine, and the screw is then inserted into its interior. We are amongst the very few who, in this country at least, have experienced its application upon ourselves. The process was somewhat tedious but the results quite satisfactory. Other instruments for the removal of roots of teeth have been devised and employed, but, as they are seldom used, we think a description of them will only tend to complicate the subject.

[The temporary teeth should rarely be extracted when more force is required than the fingers, protected by a napkin or a scoop excavator, are capable of exerting. When, however, a forceps is required, selection from the smaller ones figured and described will accomplish the object.]

The roots of the temporary molars are more divergent in proportion to their crowns than those of the permanent ones, and are consequently more liable to fracture in their removal; they are generally, however, very readily removed with a small elevator. Cases do, though rarely, occur, in which the roots of a lower temporary molar so envelop its permanent successor, that both come away together; but a more than casual occurrence of this would reflect the reverse of credit on the operator. Temporary teeth during the stage of absorption are at times in actual union at spots with the surrounding bone, and in their removal yield with a snap, strongly suggestive of fracture; membranous union yielding may also give the same sound, and so characteristic, that a bystander often exclaims, "It is broken!" To one unacquainted with the appearances a tooth undergoing absorption presents, the conviction is that a portion is left; and, as both sight and touch often reveal the presence of tooth-substance the instrument is again applied, and an undeveloped bicuspid is disinterred.

[The surest and probably the best safeguard by which to avoid the above accidents is to fill and retain the deciduous teeth until absorption renders their removal a very simple and easy operation.]

To the medical student who may have patiently followed us thus far through the present chapter, we can well imagine the feelings of dismay with which, after our condemnation of the key as an instrument unjustifiable in the present day, he has had instrument after instrument heaped upon him to supply its place; and he will probably exclaim, "This is a methodical way of shutting me out from ever undertaking an extraction through the costliness of the instruments necessary." To such an one we would reply, that we have only been attempting to describe the very best manner in which the operation of extraction can be performed, and we may now for his satisfaction inform him, that a set consisting of seven forceps and an elevator will, with a moderate amount of experience, and the faculty for adaptation, serve him well for all but quite extraordinary cases.

CHAPTER XV.

DIFFICULTIES AND COMPLICATIONS OCCURRING IN
EXTRACTION.

WE must now consider some of the difficulties and complications that may be expected in the operation of extraction. A very common difficulty is great resistance to our efforts on the part of the tooth, and our judgment as well as our skill will be taxed in deciding how much force we may lawfully employ. We may expect to find teeth of a yellowish shade, and somewhat worn on their crowns, especially about middle age and in persons of wiry constitution, more difficult to remove than large light-colored ones in younger persons. The size of the crowns will be no criterion, as the fangs or their firmness may be out of all proportion to them.

[Indeed large crowns are not seldom found upon quite ordinary or even small roots and *vice versa*. The distinct and well defined cusps are likewise a common accompaniment of comparatively well pronounced and spreading roots, and teeth whose crowns have the cusps presenting the appearance of being fused together will often have their roots nearly parallel and somewhat joined. In fact it would seem to be profitable to study these organs as made up of germs that have undergone more or less distinct segmentation. The central incisor presents a very faint trace of the cingulus upon the palatine face, and an almost conical root. As we pass backward the development of the tubercle resembles still more a cusp in the canine tooth, and finally in the bicuspid it is not uncommon to find the pulp canals, roots, and crowns almost divided. The molars present a still further tendency in the above direction.]

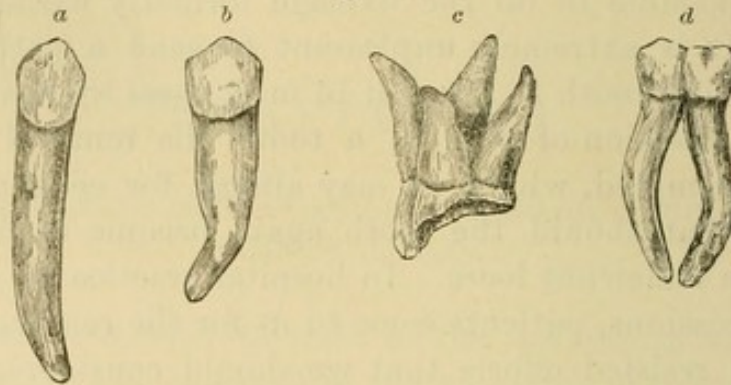
A tooth, especially a first or second molar standing alone, will often prove unusually hard to remove. Our judgment will often be sorely taxed in such cases, but we may well lay down as a rule, that the practitioner, especially if a strong man, should

never expend the whole of the strength he can summon on any tooth; the amount necessary to be exerted may be great, but must be restricted within limits; happily with the forceps it is hardly possible to do the damage formerly witnessed with the key. It is extremely unpleasant to send a patient away with an aching tooth *in situ*, but in most cases we have found a temporary cessation of pain in a tooth the removal of which has been attempted, whilst we may almost for certain give the assurance, that, should the tooth again become tender, it will also become somewhat loose. In hospital practice we have had, on many occasions, patients come to us for the removal of teeth which had resisted efforts that we should consider dangerous and unwarrantable, but in whom, in most cases, the teeth yielded to a moderate amount of force. Some days, however, had elapsed since those efforts, the result of which was inflammation, with softening about the alveolus and the alveolo-dental membrane. Young practitioners are apt to attribute success in such cases to their superior skill; time and experience will, however, set them right in such matters. A tooth may be fractured when only a moderate amount of force is employed, and that skilfully; and we are convinced that some teeth are more liable to this than others. We have had patients whose statement has been that they have never had a tooth removed in its entirety. A tooth, the attachments of which are of greater strength than its own cohesive force, must of necessity yield by fracture, as will a rotten carrot when attempted to be pulled from the ground. In such cases, should the remaining portion prove very firm, we may have to employ judgment as to the length of time for which we are to persevere in our efforts to remove it; it might turn out that we are attempting an impossibility, as evidenced at times by the abnormal form of its roots or growths upon them. Should a living pulp be left attached to the remaining portion, our efforts should be more persistent than if it had come away from it; but in the latter cases repeated applications of carbolic acid will be of much service.

The form and direction of the fangs are a common source of difficulty; the single-fanged teeth may have the roots spirally twisted or bent at almost any angle. The molars may have their fangs so divergent or convergent (Fig. 277 *c, d*) that their removal, except singly, would be almost an impossibility; and

here the dividing forceps will prove of good service (see Figs. 237, 242). In the case of enlarged or twisted single roots they may,


Fig. 277.



Teeth which from the form and direction of their fangs would present a considerable resistance in their removal; *a*, lower canine with excessively long fang; *b*, lower bicuspid, fang curved; *c*, upper molar with four very divergent fangs; *d*, lower molar with long and convergent fangs. Copied from specimens in our possession and drawn actual size.

as a last resource, have their alveoli trephined over, and thus be got out (Fig. 278), but this should be done only in case of great pain being set up by them.

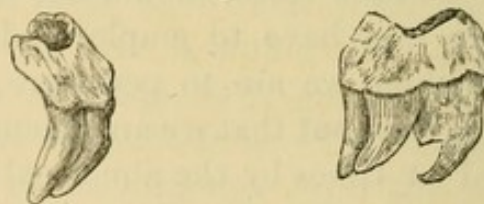
Fig. 278.



A trephine for removing the alveolar process in front of a tooth.

Teeth may, owing to abnormal forms in their crowns (Fig. 279), be rendered more difficult of removal, no ordinary instru-

Fig. 279.

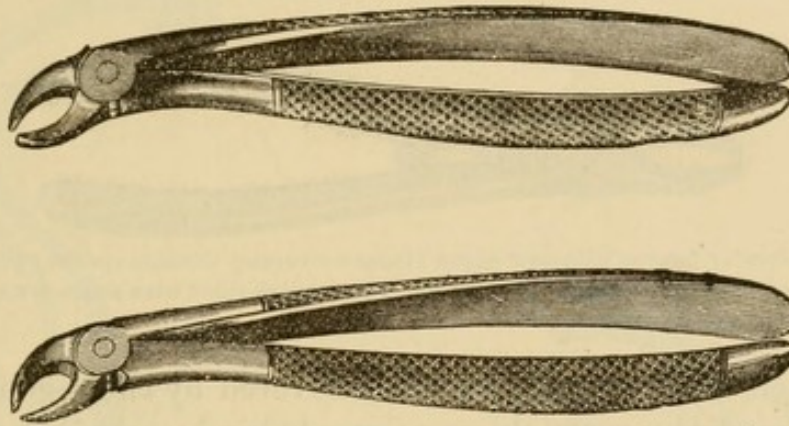


A front and lateral view of a malformed upper third molar, to which the forceps of ordinary construction could not be properly adjusted; *a*, front or buccal aspect; *b*, side or approximal aspect.

ment being capable of adaptation to them; and the positions assumed by teeth in regard to their neighbors may wholly prevent the employment of the ordinary instruments, or at all events in the usual directions. This condition, the result of crowding, is not unfrequently met with in the lower incisors; an incisor may be placed so directly before or behind other teeth

that there will be no space in the former for the posterior blade, or in the latter for the anterior blade, to be applied. To meet such cases, forceps having a very narrow posterior or a very narrow anterior blade are constructed (Fig. 280); but, as these


Fig. 280.



Forceps for extracting lower incisors and cuspidati when crowded internally or externally. In one instrument the inner, and in the other instrument the outer, blade is made very narrow.

narrow blades are very apt to nip off the crown, we, as a rule, prefer employing one of the ordinary forms of root-forceps, grasping the tooth laterally, and pressing the blades towards the alveolus at an angle to the crown. For the teeth of the upper jaw similar forceps to those before mentioned are constructed (Fig. 281), but to these we apply the same remarks as in the case of the teeth of the lower jaw.

Fig. 281.



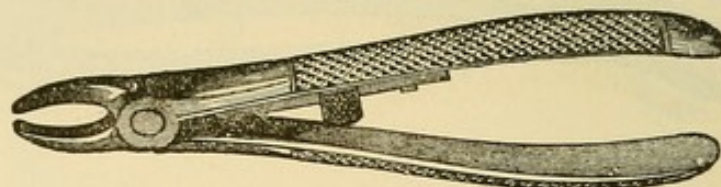
Forceps for extracting upper incisors and cuspidati when crowded internally or externally.

The dental surgeon may be called upon to remove teeth which are only partially erupted, or even not erupted. Misplaced or supernumerary teeth appearing in the palate are at times almost impossible to remove without cutting away some of the overhanging alveolus:¹ it is best in such cases to wait until these

¹ This object can be most effectually attained by Cattlin's forceps (Fig. 282), which are provided with serrated blades and a stop which keeps them open at a given distance.

are more fully erupted. The lower third molars are often a source of considerable trouble before they are fully erupted, setting up abscesses of considerable extent in their immediate neighborhood, or at some distance from them. From their position when much crowded it is almost impossible to remove

Fig. 282.



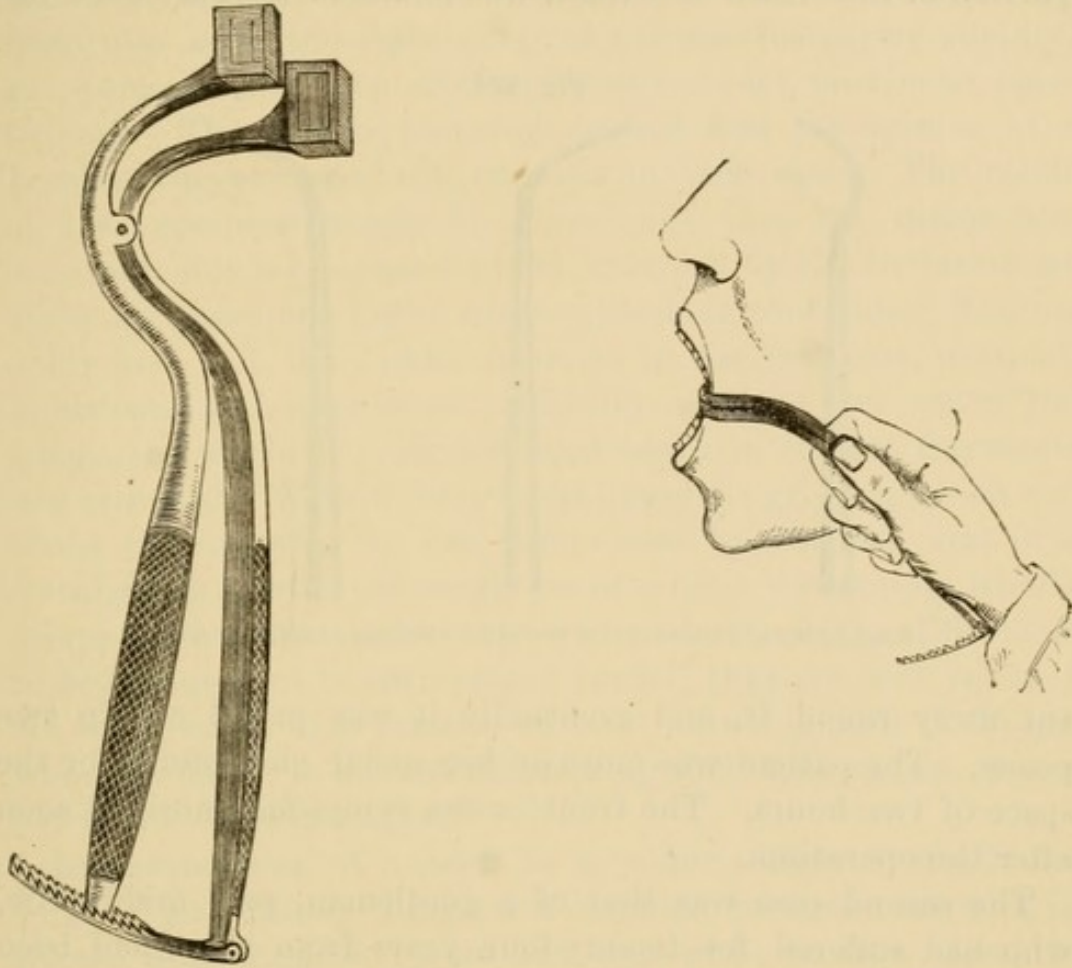
Cattlin's alveolar forceps with saw-edged blades for cutting through alveolar process, to give a firm grasp on teeth, otherwise not obtainable. They are provided with a stop to keep the blades at a fixed distance apart.

them, their crowns being partially covered by the second molars in front, and the coronoid processes behind; and it is therefore necessary at times in such cases to sacrifice the second molar. We should have naturally expected that under these conditions the third molar would have lost its vitality; and have still continued to be some source of trouble; but cases have occurred, in which all trouble and discharge disappeared soon after the removal of the second molar. In many of these cases, a further complication exists, from the contraction of the muscles which close the mouth: this, however, may be generally overcome by very gradually introducing between the teeth wedges of soft deal of increasing size, until sufficient room is obtained, which for the elevator will only be that sufficient to raise the tooth out of its socket. Under an anæsthetic the mouth may be forcibly opened either by the screw-dilator, or by an instrument that we devised several years ago for such cases (Fig. 283), constructed somewhat like a pair of forceps, but reversed at the hinge, so that by compressing the handles we can open the blades: the latter, protected by some soft substance, are, when closed, pressed between the teeth or, if there be none, the gums; and, the handles being forcibly pressed towards each other, the muscular resistance is overcome and the mouth opened.¹

¹ Much more recently an instrument on precisely the same principle was devised by our friend F. Mason, who was unaware of the existence of ours. We are bound to say that his form is in most respects superior to ours, and has

Teeth which are impacted, or from other causes unerupted, often become a source of serious trouble, and in attempting to

Fig. 283.



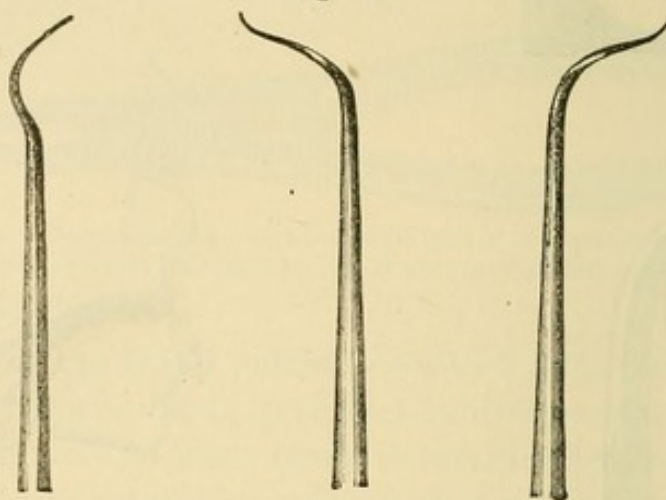
The author's mouth-opener (or gag) described in the text. The cut on the right side shows the instrument as applied.

treat such cases we may overlook the actual condition. Of three such instances we will give a brief account. The first was that of a lady, rather past middle age, who had suffered for a considerable time from abscesses in the right side of the neck: in looking for a cause we discovered a small opening in the gum over the spot at which a wisdom-tooth would be developed. A steel probe (Fig. 284), introduced fully half an inch below the surface, struck against a hard substance, and conveyed a strong

been strongly recommended by the late Sir W. Fergusson for employment in the operation of staphyloraphy. In one particular, however, it is less serviceable, viz., in the greater space occupied by the blades when closed, making it difficult to introduce them between the teeth with the mouth closed or nearly closed.

impression that that substance was enamel. Chloroform was administered, a free incision made, and after a time, for the bleeding was very copious and much interfered throughout, a portion of the crown of a tooth was rendered visible; bone was

Fig. 284.



Steel probes of various curves useful for detecting unerupted teeth.

cut away round it, and eventually it was prised out in two pieces. The patient was more or less under chloroform for the space of two hours. The troublesome symptoms subsided soon after the operation.

The second case was that of a gentleman, past middle-life, who had suffered for twenty-four years from what had been regarded as disease of the inferior maxilla on the right side; as in the former case, a hard substance presented itself, which was detected at some distance, about two-thirds of an inch, from the surface. When struck by a probe it likewise gave the impression of being tooth-substance. To avoid the trouble from hemorrhage as in the former case, the patient was first subjected to nitrous oxide, when a free incision was made into the swollen tissues, and the opening well dilated with the finger. He was then allowed to recover consciousness, and the position of the tooth, which could not be seen, was ascertained as nearly as possible. When bleeding had ceased, chloroform was administered, and the tooth, first loosened with an elevator, was without much difficulty removed by a pair of long-bladed root-forceps. This case was rendered interesting by the length of time during which its true cause had remained overlooked; especially as the

jaw had on one occasion been trephined in the hope of opening up an abscess.

The third case was that of a gentleman aged seventy-two, who had suffered for some few months from a tumor in the neck, also upon the right side. As it was increasing rapidly, an operation had been advised by an eminent provincial practitioner. The friends, however, desired first the opinion of a London surgeon specially eminent in such cases. The result of his examination was the conclusion that the tumor was most probably a lymphatic gland, enlarged by the irritation set up by an unerupted lower wisdom tooth of that side. Nitrous oxide first, and then chloroform, as in the last case, were administered, and, after much difficulty, and the free use of the gouge, the whole of a three-fanged tooth in several fragments was removed. Within forty-eight hours the growth, which was about the size of a fig, had diminished by one-half, and in a fortnight had, with the exception of a little thickening, wholly disappeared. The reader may well understand the difficulties to be encountered in such cases; happily they are rare, yet they all occurred in the practice of one individual, Sir J. Paget, whose accumen, in at once discovering their true causes, cannot but excite our admiration.

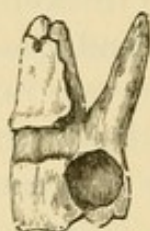In the removal of a tooth in a young subject, it would not be at all an unlikely thing for a neighbor to come out with it, if care and precaution were not exercised; in such cases, the adjoining tooth will be seen generally to move with the one operated on. We believe that in such cases no bony septum exists between the two teeth, and the periosteum is common to both. When this occurs, the operator should firmly press with the left thumb upon the crown of the tooth so seen to move, and should, in using the forceps or elevator, not apply more force than can be controlled by the thumb; until a severance is felt, when the removal may be safely accomplished. Should an adjoining tooth be partially or wholly removed from its socket, it should be immediately reinstated, and firmly pressed into its place, when it will most probably again become united to its membranes, and as serviceable as if nothing had occurred. In removing teeth of young persons with the elevator, especially where an adjoining tooth has not been erupted, great care must be exercised, or the unerupted tooth may be disinterred

also; it is best, therefore, if possible, always to employ the forceps in such cases.

Teeth, as previously stated, are sometimes found united to each other at their roots; the resistance to removal which such will offer can well be imagined. It is almost impossible to diagnose such condition or the existence of extensive exostosis beforehand; yet, as before noticed, an application of the electric light such as we once witnessed at the Odontological Society might materially aid us in such matters. The appliance was the invention of Hart, electrician of Edinburgh, and so perfectly illuminated the mouth that the fangs of the teeth could be seen through the structures which enveloped them.

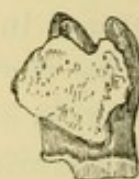Whilst exercising every care, we find it at times impossible to avoid removing with the tooth small portions of the alveolar

Fig. 285.



Upper first molar tooth with a portion of the external alveolar plate attached to it. From the form that the portion of bone presents and its absence at the extremity of the fangs, it would have been almost impossible to remove the tooth without removing it as well.

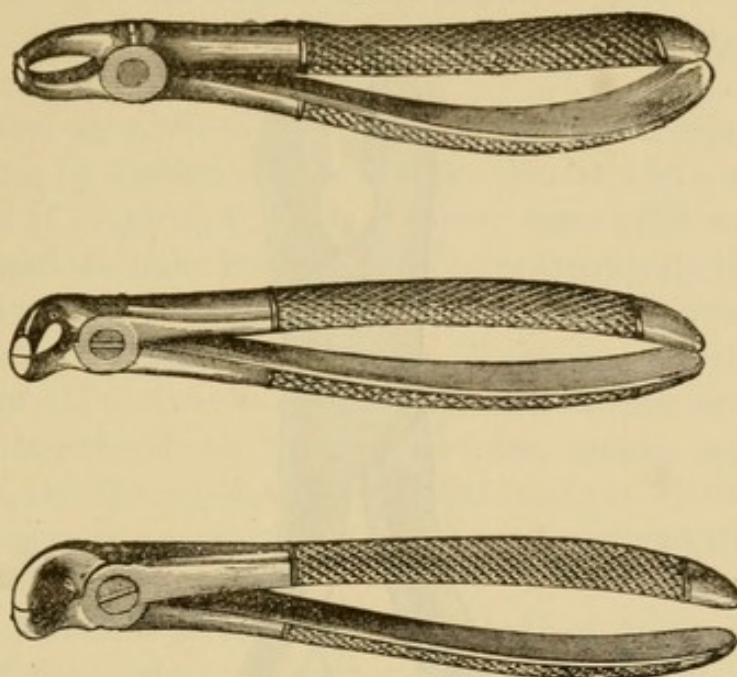
Fig. 286.



Upper third molar with the tuberosity of the superior maxilla attached to it. In this case also the form of the bone rendered its removal with the tooth a matter of necessity. This case is alluded to at pp. 298 and 299.

process attached to it. Thus, especially with the upper first molars, the outer alveolar wall is often extremely thin and slight, and these thin portions yield more readily than does the alveolo-dental membranes to which they are united. We need not distress our patients by an exposition of the same, or lead them to imagine that something untoward has occurred, but mentally congratulate them, as these sharp portions, if left, are often a source of worry and inconvenience until they either separate or are absorbed. Where the alveolar process is abnormally high, and becomes, as it frequently does, conspicuous above the surface when several contiguous teeth have been removed, we may with advantage pare off the prominent portions with suitable bone-cutting forceps (Fig. 287); the process

Fig. 287.



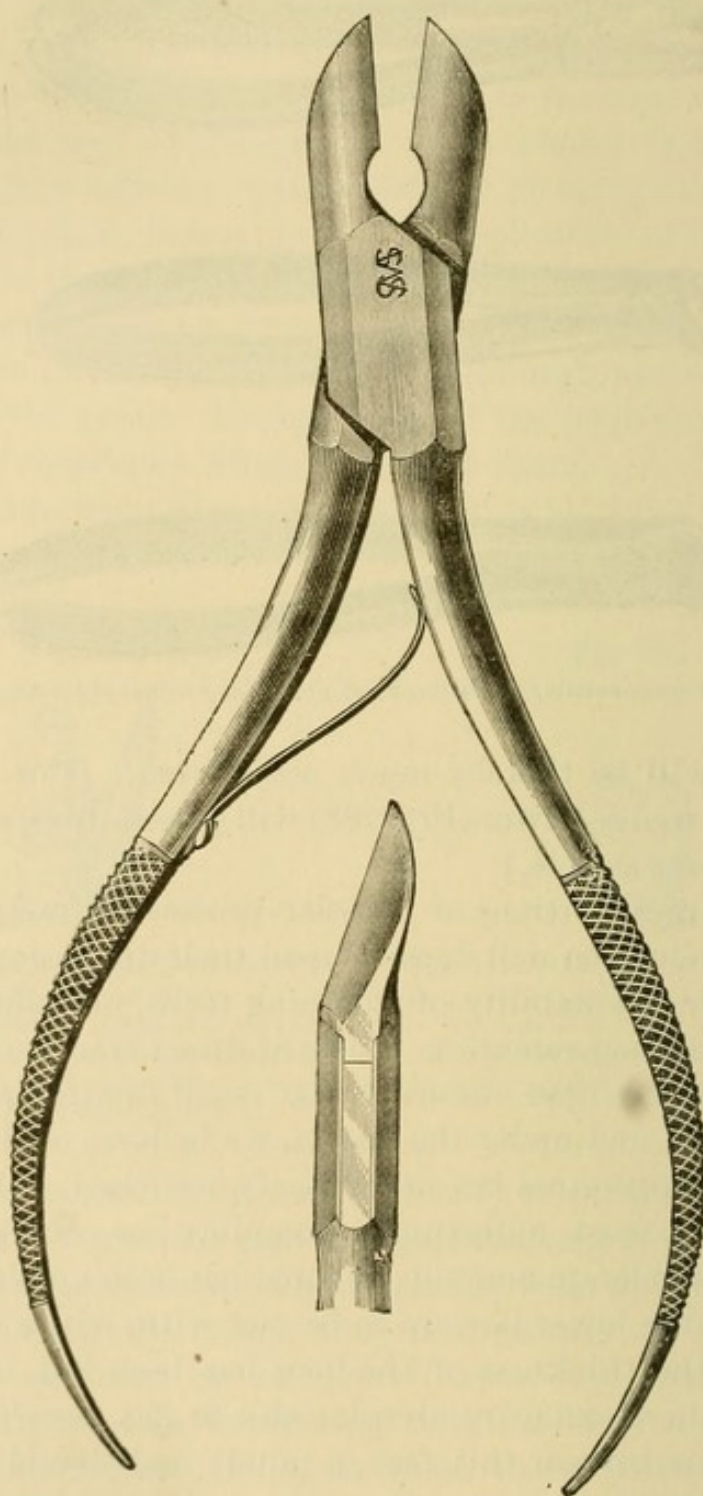
Three forms of forceps suitable for cutting away projecting portions of alveolar process, etc.

of healing will be thereby much accelerated. [For the above purpose the wedge-cutter (Fig. 288) will generally be sufficiently strong and serviceable.]

Should larger portions of alveolar process be fractured, their removal or retention will depend upon their dimensions: if they at all involve the stability of adjoining teeth, our efforts should be directed to their retention. Cases of direct transverse fracture of the lower jaw have occurred, the result of attempting to remove a tooth; and under the hands, we believe, of those whose skilfulness as operators has never been questioned. We can understand this most unfortunate complication occurring when only a very moderate amount of force has been employed: preparations of the lower jaw are to be met with, where more than one-half of the thickness of the bone has been lost by alveolar abscess. Where extensive alveolar abscess has occurred, it will be well for us to bear this fact in mind; and should such accident occur, the dental surgeon ought to be the best person to rectify it.

A more common accident attendant upon extraction of teeth than the foregoing will be dislocation, partial or complete, of the inferior maxilla; it most frequently occurs during the administration of an anæsthetic, doubtless in consequence of the relaxed

Fig. 288.



Wedge cutter.

condition of the muscles. To reduce it, the two thumbs of the operator, well protected by a napkin or folds of lint, should be placed upon the back-teeth, and, whilst the jaw is thus depressed at its posterior portions, its anterior portion should be elevated

by the pressure of the fingers under the chin. In adopting this, the ordinary process, we have never met with any difficulty in accomplishing our object.

Cases have occurred in which the lower teeth, especially the third molars, by embracing the inferior dental nerve with their fangs, have of necessity in their removal caused the severance of the latter, and we have known a case where paralysis of the same nerve followed the extraction of a third molar, which could only be accounted for as the result of shock. To the patient the result of this injury is distressing, as from loss of sensation the saliva trickles from that side of the mouth without his knowledge, and the consequent effort to retain it within the lips. The nerve usually more or less unites, and resumes its function after a time.

It will often be difficult to determine which tooth is actually the seat of pain when several contiguous ones are much diseased: percussion, or the application of cold to each, will generally reveal the true offender, but it will occasionally happen that the seat of pain is at some distance from the spot referred to by the patient—actually in the opposing jaw. [A single drop of cold water may be put upon any smooth, cold surface, and by means of a syringe, previously chilled and emptied, the drop of water may be carefully drawn into the end of the nozzle, from which it can be blown into a suspected cavity. Should the pulp be exposed and living, a sharp pain, generally of very short duration, is experienced. Pain upon pressure or from slight tapping on the tooth with a light excavator handle, will indicate periosteal trouble.] If we only followed patients' impressions, we should often remove teeth, which though undoubtedly bad, are not at the time of their visit the cause of their sufferings. We must bear in mind that pain, set up by a diseased tooth, does not always cease with its removal; and this is especially the case where inflammation has set up in, or extended to, its periosteum. The pain after the laceration of membranes in such a condition is, we can well comprehend, usually very acute, and may last for several hours, according to the stage of inflammation at which the tooth was removed. We have found the most serviceable application at the time to be a mixture of pure carbolic acid with a small quantity of chloroform, applied on cotton to the alveolus. If the pain continue for several days, soothing

fomentations, especially poppy with chlorate of potash (see p. 52), will be found the most efficacious. [It is well always to relieve the pain before extracting the tooth. For this purpose, in the case of exposed pulps, use morphia paste or toothache-drops, or chloral and camphor, or camphor dissolved in chloroform. The toothache-drops are made by adding to a saturated solution of morphia in sweet spirits of nitre an equal measure of oil of cloves, and to every drachm of this mixture should be added ten drops of fluid extract of gelseminum.] A cold taken after extraction is often the explanation given, but we think that in many cases we see on the mucous membrane precisely what we should on an external surface describe as an erythematous inflammation, but of which cold may undoubtedly be the originator. The healing of a vacated alveolus, is chiefly, no doubt, effected by granulation; still in many cases the overhanging mucous membrane so nearly meets, that it may be regarded as partially by first intention; but all wounds on healthy mucous membranes heal more readily than on outer surfaces, as from their positions they partake more of the character of subcutaneous ones. In the above-mentioned cases, we find the mucous membrane surrounding the alveolus swollen, congested and everted, and the alveolus commonly occupied by a slough. [Compressing the alveolar walls between the index finger and thumb will often be sufficient to arrest the bleeding, and assist in healing by replacing them to such a distance as will make the smallest amount of cicatricial tissue necessary for the healing.]

A not uncommon complication occurring after extraction is abnormal hæmorrhage: this may be primary or secondary. There is always more or less bleeding immediately after the removal of a tooth, greater and prolonged if there has been long standing inflammation, the vessels under such conditions having less tendency to contract. Should it continue to any unusual extent, we may employ cold by iced water, exposure to the air, tannic acid, or even perchloride of iron, or plugging; but the last is seldom necessary with the primary hæmorrhage. The secondary hæmorrhage is much more difficult of control, and generally occurs under the following or similar circumstances. The patient who has undergone removal of a tooth in the day, and with no specially untoward circumstances, wakes up in the night with his mouth full of blood, and finds

that a considerable quantity has been running from it during sleep. He probably feels somewhat faint from the loss, and, if he do not seek advice and assistance, it may go on until fatal syncope supervenes. Death from this cause, especially in remote country places, is not very rare, and even does occur at times in large towns. The cause of the secondary hæmorrhage is of a constitutional rather than a local character, and is stated to be more dependent upon a diseased condition of the muscular coats of the bloodvessels, than upon a want, in the blood, of the property of forming a firm coagulum or clot. Both, no doubt, may produce this condition, the former probably in those who are ever liable to it, *i. e.*, persons suffering from hæmophilia or the hæmorrhagic diathesis, the latter in those who may have only been subject to it at particular times. Where such tendency is known to exist, we must exert all resources before extracting a tooth; and, if compelled to do so, must plug the alveolus in the manner which we shall now describe, and which, we are happy to say, has never failed in our hands, although we have been called to cases where other means proved of no avail, and where the patients appeared fast sinking. A piece of matico leaf, which has been immersed in water for a few minutes, should be rolled up, the under-surface of the leaf outwards, into as many little pellets, about the size of a pea, as the roots of the tooth removed: a narrow tent of lint, about one-third of an inch wide, and about four or five inches in length, should be prepared, as also a pad of the same about the size of a chestnut. The mouth should be cleansed from blood, and the socket carefully cleared of coagula with cotton, and immediately after the removal of the cotton a pellet of matico introduced into each alveolus and pressed firmly down with the broad compressing plugger; upon the matico the tent of lint is with the same instrument to be firmly packed layer upon layer, until the alveolus is filled a little above the surface of the gum, and upon this is placed the pad, which should extend above the crowns of the adjoining teeth, and be pressed upon when the mouth is closed. The mouth should be kept closed by a bandage passing round the head and under the chin.¹ The horizontal position, with the head and shoulders

¹ We have known several cases where the application of B. W. Richardson's styptic colloid has proved most successful.

slightly raised, should be maintained, and the apartment kept cool, and hot and spirituous drinks avoided; but, should the patient appear sinking, some stimulant must be administered, and the patient kept warm; as a very little lowering of temperature, after great loss of blood, may suffice to extinguish the spark of life; the occurrence of convulsions will indicate for certain the latter treatment, if not, in addition to it, transfusion of blood. Strong beef jelly should also be given in small quantities, but at frequent intervals, the finger of a bystander being kept pressed upon the pad whilst the mouth of the patient is opened. Gallic acid, gr. v-x; tinct. ferri perchlor. ℥ xv-xxx; or acetate of lead, gr. j-iv, may be administered. Care should be taken to allow the plug to remain until it is pressed out of the alveolus by plastic formation beneath it; but in very severe cases we must be prepared for a return of the hæmorrhage when this takes place.

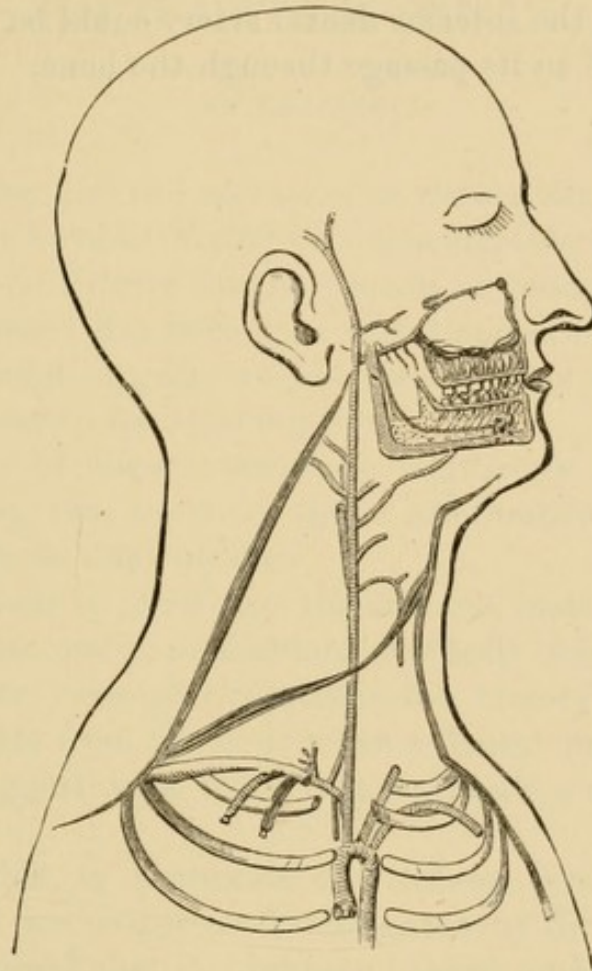
[The extracted tooth will serve as a very perfect fitting compress; likewise cotton-wool with gallic or tannic acid worked through it while dry, and then packed in quickly, so that the absorption of moisture and consequent swelling will assist in producing pressure upon every part of the bleeding surface. The tincture of the perchloride of iron is not so well thought of by some, on account of the danger of sloughing and secondary hæmorrhage after its application.¹]

Should, however, our efforts at controlling the bleeding, by pressure or other means, prove unavailing, even after we have substituted a gutta-percha or vulcanite plate for the lint pad, and this has been attended with success, we must, as a last resource, be prepared to cut off the supply of blood from the part, although this would probably be worse than useless where the hæmorrhagic diathesis is well marked. In other cases it may prove successful. Should this step be imperative, we are disposed not to recommend the course which is generally adopted, viz., diligation of the common carotid artery, but rather to ad-

[¹ "Touching a bleeding gum with Monsel's solution, or with nitrate of silver, is dangerous practice. The only alarming cases of hæmorrhage ever seen by the author have been the results of these applications." A System of Oral Surgery, by Jas. E. Garretson, M.D., D.D.S. Philadelphia: J. B. Lippincott & Co., 1881.]

vise diligation of the external carotid (Fig. 289), and for the reason that most disastrous consequences are very likely to result from shutting off one of the four principal supplies of blood

Fig. 289.



A diagrammatic representation of the arteries of the right side of the neck.

to the brain. Anatomical considerations would also lead us to fear secondary hæmorrhage when a collateral circulation has been established through the free inosculation of vessels at the base of the brain—Willis's circle—but experience points to the fact that this is not the case. The operation of tying the external carotid in the living subject is not as simple as the same operation on the common trunk,¹ but this is a minor consideration when compared with the greater danger to life from the

¹ If the case be one in which the hæmorrhagic diathesis exists, there may be less danger, on the whole, in tying the common carotid artery, as fewer vessels will be interfered with than in the operation of tying the external carotid.

latter. Before proceeding to this extreme resort, we should naturally try the effects of pressure on the vessels, and this might be kept up for a moderate time, but, owing to the nature of the structures pressed upon, could not be tolerated for any lengthened period. In the case of hæmorrhage from a tooth of the lower jaw, the inferior dental artery could be readily got at, and obliterated in its passage through the bone.

CHAPTER XVI.

ANÆSTHESIA.

WHEN performing the operation of extraction under an anæsthetic, we may have to modify to a considerable extent the rules that we have laid down for the process in general; and, as this has in the present day become a very important branch of the practice of dental surgery, we feel that we may with advantage devote a chapter to its consideration.

The history of anæsthetics is so intimately connected with Dental Surgery, that we think that a brief outline of it may not be out of place in this volume.

While we bear in mind that the ancients had made attempts, more or less successful, to alleviate or wholly obliterate the pain attendant upon surgical operations, the history of anæsthetics must really date from the hour when a dental practitioner had, at his own suggestion, a tooth removed with a total absence of sensation.

Nitrous oxide, or protoxide of nitrogen, was discovered by Priestley, and its properties investigated by Sir H. Davy, who actually suggested that it might be used as an anæsthetic; but this suggestion probably never met the eye or reached the ear of Horace Wells, and, so far as we are cognizant, was not, as such ever acted upon. Wells's inspiration came from witnessing a slight accident occur without pain being felt, at a popular lecture by one Colton, who was illustrating upon one of his audience the exhilarating properties and ludicrous effects of nitrous oxide gas—a very common practice some years ago. The failure of Wells when attempting to employ the agent for long surgical operations, owing no doubt to defective apparatus, led him to discontinue his investigations, and to embark in unsuccessful speculation resulting in a sad premature death. Fortunately for humanity, a former associate of Wells took up the matter and with more successful results. With Morton, to

whom we are alluding, must be associated the name of Jackson: the latter supplied, while the former administered, ether, and for the extraction of a tooth. The result was a perfect success, and ether, being more easy of administration than nitrous oxide, soon proved available also in extensive surgical operations.

[In August, 1840, Dr. Horace Wells¹ is claimed to have remarked, "*That he believed that a man might be made so drunk by this gas (nitrous oxide) or some similar agent, that dental or other operations might be performed upon him without any sensation of pain on the part of the patient.*"

On the 11th of September, 1844, Dr. Horace Wells proved upon himself the correctness of his views by having Dr. J. M. Riggs, of Hartford, Conn., extract a tooth for him while he was under the influence of the gas administered by Mr. Colton.

Dr. P. A. Wilhite, of Anderson, S. C., claims, according to Dr. J. Marion Sims,² of New York, that in the "fall of 1839," when he was seventeen, he etherized a negro boy for fun at a quilting party and ether frolic near Athens, Ga. Subsequently, when a medical student of Crawford W. Long, M.D., at Jefferson, Jackson Co., Georgia, he mentioned the matter, and with his preceptor and three fellow students they all tried its intoxicating power at various times, and Dr. Long etherized Mr. James M. Venable, and extirpated painlessly a tumor from the back part of the patient's neck. The report in the Southern Medical and Surgical Journal, Dec. 1849, says, "He gave no evidence of suffering during the operation, and assured me after it was over, that he did not experience the slightest degree of pain from its performance."

"This operation was performed on the 30th of March, 1842; a second one upon the same person was performed on June 6th, 1842."

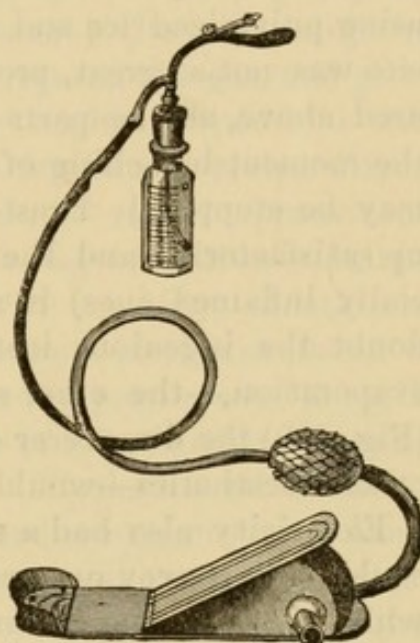
The same operator followed these by other successful administrations, as on July 3d, 1842, for amputation of a toe; Sept. 9th, 1843, for exsection of three small cystic tumors from the head: on the 8th of Jan. 1845, for amputation of two fingers.]

[¹ See pp. 4 and 5 of a pamphlet entitled "Dr. Wells, the Discoverer of Anæsthesia" Published by Robert Larter, 44 Ann St., New York, 1864.]

[² Virginia Medical Monthly for May, 1877. Richmond, Landon B. Edwards, M.D.]

The news of the great discovery soon crossed the Atlantic, and Robinson, a dentist, had the honor of first administering ether in this country. The pungency of ether, together with a degree of difficulty in its administration, led to the investigation of the properties of bodies of the same class, and amongst these chloric ether was administered by Jacob Bell. As often happens in such experiments, the cases selected proved unfortunate ones; the after-affects were unsatisfactory, and this discouragement led to the abandonment of that which under other circumstances would no doubt have anticipated the brilliant discovery of Sir J. Simpson. Chloric ether we now know to be a mixture of chloroform and alcohol, but its composition was not at that time understood, because chloroform, as such, had not been isolated. It was not long, however, before Waddy, of Liverpool, obtained this fluid pure, and sent some of it to Sir James Simpson, who established the value of its anæsthetic properties; and in a little time chloroform, owing to its more agreeable flavor and easier administration than ether, almost entirely superseded the latter, at least in this country. The agent soon became employed almost whenever requested, and administered with probably even less precaution than is nitrous oxide in the present day; when lo! a patient died suddenly under its influence: "because they do not know how to give it," remarked one whose great experience had led him to a rash confidence in himself; but a few days had scarcely passed when the like sad event occurred under his own hands. A reaction now set in, and, as might be expected, stronger than was warranted; some medical authorities refusing almost entirely to sanction its use in any case. Other compounds were carefully investigated, mixtures of chloroform and ether,

Fig. 290.



B. W. Richardson's ether-spray apparatus. By means of a hand or foot bellows air is forced into a graduated jar containing very highly rectified ether, which is projected from a fine jet in the form of a spray, and this evaporating rapidly produces intense cold. In the drawing above is shown Welsh's tongue or cheek holder attached to the jet-piece.

chloroform and alcohol, or the three together, were tried, but with little better results, while some few reverted to ether, which had never been wholly discarded. The idea of producing local anæsthesia naturally occupied the minds of many. A frozen part is painless, and Arnott froze small tumors with a mixture of ice and salt. Teeth were frozen in their sockets, by an ingenious apparatus devised by W. Blundell, a dentist, and removed without painful sensation. [Dr. Branch, of Chicago, is mentioned by some as the inventor of a similar apparatus for using pulverized ice and salt. The danger of producing frost-bite was not so great, probably, with the neat instrument figured above, as the parts can be continually kept in view, and the moment blanching of the tissues commences the application may be stopped.] Frost-bitten wounds do not generally heal up satisfactorily, and the sensation of freezing structures (especially inflamed ones) is not the most agreeable, otherwise no doubt the ingenious instrument for producing cold through evaporation,—the ether-spray devised by B. W. Richardson, (Fig. 290) the discoverer of bichloride of methylene and many other anæsthetics—would be very generally employed.

Electricity also had a trial, on the supposition that a nerve could only convey one species of sensation at a time, and that whilst it was occupied in conducting that of electric shock, it would fail to convey that of pain. The more recent discovery of Brown-Séquard—that for various sensations special channels of conduction are essential—did not enter into the calculation. Patients who parted with teeth whilst under the influence of electric shock were puzzled to realize how much of what they felt was shock, and how much was pain: but their general conclusions were, that it was as pleasant without the electricity as with it. Nineteen years had elapsed since the short-lived triumph of Horace Wells, and little had been done in the mean time to further investigate the anæsthetic properties of nitrous oxide; still from time to time we in this country heard of our brethren in the New World speaking cautiously, yet on the whole favorably, of it for dental purposes.

Colton had not forgotten how well people took the gas, and, in comparison with other anæsthetics, how much better they recovered from it, and was led to introduce its employment upon a large scale in New York. Armed with such credentials as

the record of some 20,000 successful administrations, Colton visited Paris in the Exhibition year of 1878, and there exhibited this agent. The faculty in France did not appear to espouse it warmly, but it was otherwise with some American practitioners resident there, especially T. W. Evans, a dentist, and Marion Sims, a surgeon-accoucheur. In the spring of the following year, the former visited London, and administered the gas before the staff of the Dental Hospital. The value of an agent evidently so safe, and so well suited for dental purposes, was only too apparent, and within a week of witnessing Evans's administration we had arranged an apparatus, prepared the gas, and given it successfully to four patients. Our readers, acquainted with the present modes of and appliances for administering nitrous oxide, would smile at the cumbrous and rough apparatus at first employed. A large India-rubber bag or balloon contained the gas, connected by a long tube with a wooden mouth-piece with inlet and outlet valves. The mouth-piece was placed between the patient's teeth, and the lips compressed over it by the fingers, whilst the finger and thumb of a bystander unceremoniously closed the patient's nostrils. To the liberal donations of Evans, who contributed a fund for investigating the merits of nitrous oxide, must be attributed in a great degree the rapidity with which our knowledge of the properties of the gas, and the improved modes of its administration, have come about.¹

The greatest of these improvements has been the vending of the gas, first in a compressed and finally in a liquid form; otherwise its bulk, or the inconvenience of the practitioner having to prepare it on his own premises, would ever have been a serious drawback to its general use.

Of the anæsthetics generally employed in Dental Surgery we will first speak of that last mentioned, the earliest introduced, as we have shown, and, under our present state of knowledge, the most suitable by far for the majority of such short operations as the extraction of teeth. A very safe and rapidly acting anæsthetic is the desideratum for such cases, and this we have in nitrous oxide. That it is the safest anæsthetic of any that we

¹ *Vide* report of a committee to inquire into the Value, etc., of Protoxide of Nitrogen as an Anæsthetic, etc. Trans. Odont. Soc., vol. i. (new series) p. 31, and vol. v. (do.) p. 11.

possess, there can be little doubt; but this may arise rather from the method of employing it than from anything peculiar to its composition. To fairly compare it with other anæsthetics, it would be necessary to administer it for the same periods of time. Still it must not be regarded as perfectly safe, for, although out of several hundreds of thousands of administrations in this country only two deaths have been recorded, and it is very doubtful whether one of these, that which occurred at Exeter,¹ was attributable directly to the gas, it is yet by no means a difficult matter to destroy life with it; only let the administration be pressed a little too far, and death must result as a consequence: therefore we would insist that it should be administered only by competent and experienced persons, and, as a rule, never single-handed; departure from this rule is the assumption of an unwarrantable responsibility.

It cannot be stated for certain how nitrous oxide produces its anæsthetic effects; there can, however, be little doubt but that it is not owing to its decomposition in the lungs: the experiments of Hermann, Frankland,² the writer,³ and others have set that question at rest; and the probability is, that its action is due rather to the absence of oxygen in the blood. Nitrogen, it might then be supposed, would answer the purpose as well; but nitrogen, although it may be for a short time readily respired, is not like nitrous oxide, soluble in the blood, and therefore is not capable of replacing its oxygen. In addition to the results of chemical determination, the following facts are, as we have elsewhere pointed out,⁴ conclusive ones to negative the notion that nitrous oxide is decomposed in the blood. Nitrous oxide consists of two volumes of nitrogen and one volume of oxygen, occupying the space of two volumes; if a quart of the gas be respired to and from a bladder, after the lungs have been emptied of air as far as possible, the contents of the bag will nearly disappear. What has become of it? it has not been decomposed in the lungs, as the same bulk, *i. e.*, two volumes, would have been returned to the bag; it must, therefore, have

¹ Report on a Death from Nitrous Oxide. Trans. Odon. Soc., vol. v. (new series) p. 83.

² Report on Nitrous Oxide. Trans. Odont. Soc., vol. v. (new series) p. 13.

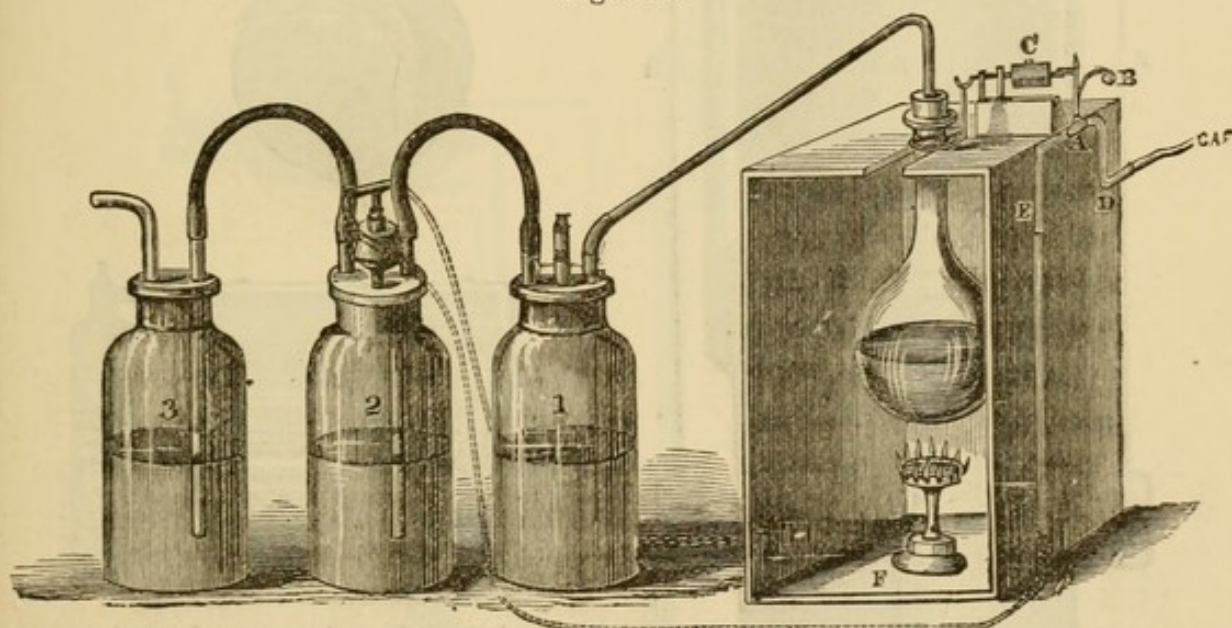
³ *Ibid.*, p. 21.

⁴ St. Bartholomew's Hospital Reports, vol. v. p. 153.

entered the blood, and, if decomposed in the latter, what becomes of the nitrogen, set free, as every chemist must admit it would be, and which would at once prove fatal to life? We suspect that those constituents of the blood which have an affinity for oxygen have the like for nitrous oxide, and thus travel with it in the circuit, but without its being decomposed. The appearances of the patient inhaling it are those which are manifested when the blood in the arteries and capillaries assumes a venous character.

Nitrogen when respired, if it can enter the circulation at all, can do so only in infinitesimal quantities, and hence the oxygen in the blood, following a general law, is yielded up to the tissues the more slowly as its quantity is diminished; in other

Fig. 291.

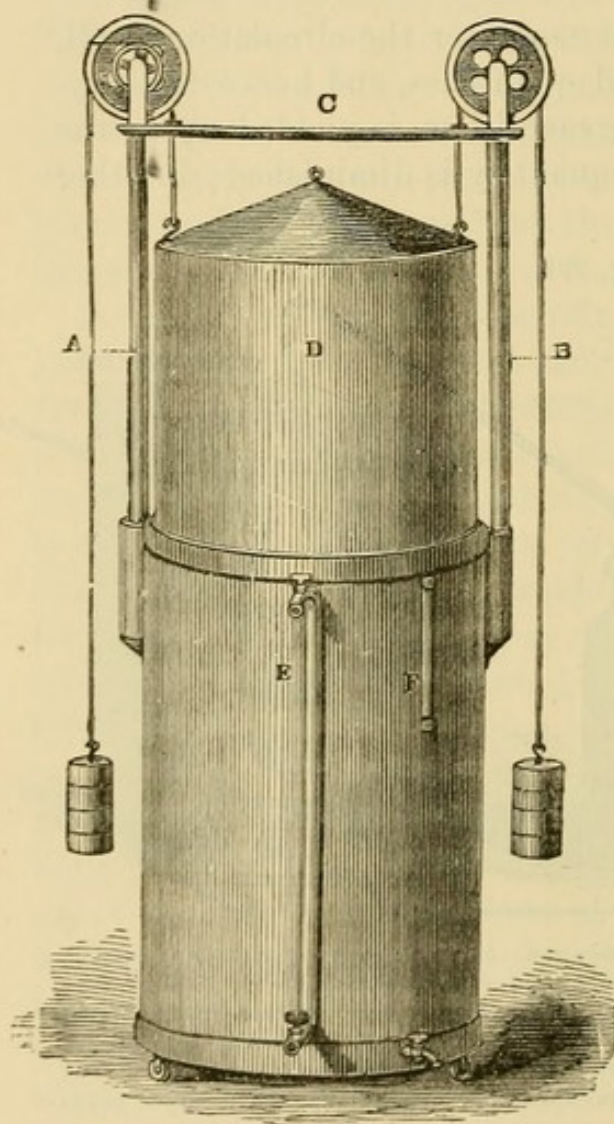


Complete apparatus for generating nitrous oxide gas. A, box for supporting the flask containing one, two, or more lbs. of nitrate of ammonia, and also for protecting the gas flame, F, from currents of air. The gas when generated first passes through water in bottle No. 1, it next passes through a solution of proto-sulphate of iron (3 oz. to $1\frac{1}{2}$ pt.) contained in bottle No. 2, and finally through a solution of caustic potash (1 oz. to $1\frac{1}{2}$ pt.) contained in bottle No. 3. The other letters apply to Ash's and Kirby's ingenious apparatus for regulating the supply of gas to the burner, and extinguishing the flame at the proper period.

words, it is retained in the circulation much longer than when it is replaced at the lungs by another gas; hence the anæsthesia produced by nitrogen is slow and imperfect as compared with that produced by nitrous oxide, which, by replacing the oxygen, more readily abstracts it from the blood.

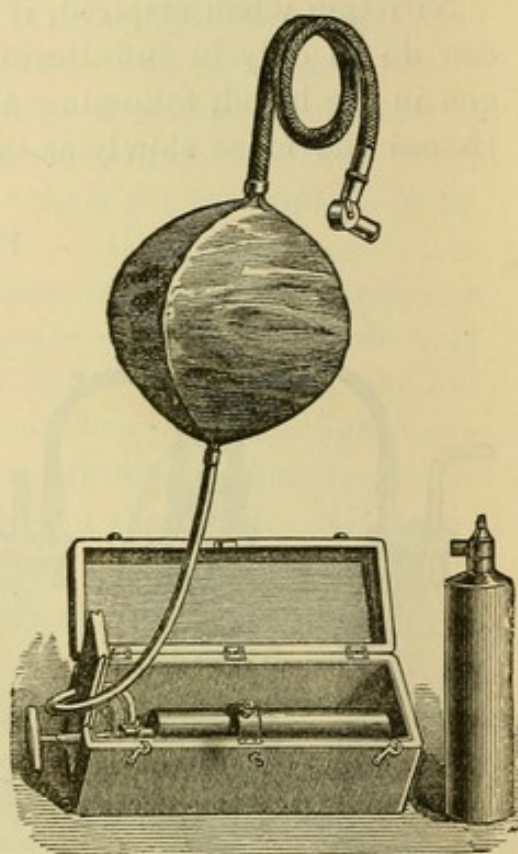
Nitrous oxide gas may be readily prepared by heating nitrate of ammonia in a glass flask (Fig. 291) and collecting the products over water, which may be stored in a gasometer (Fig. 292), or by pressure in wrought-iron vessels (see Fig. 293). The salt undergoes a double decomposition, resulting in nitrous oxide and water. As thus prepared the gas will contain impurities, viz., some of the higher combinations of nitrogen with oxygen,

Fig. 292.



Gasometer for collecting and storing nitrous oxide gas.

Fig. 293.



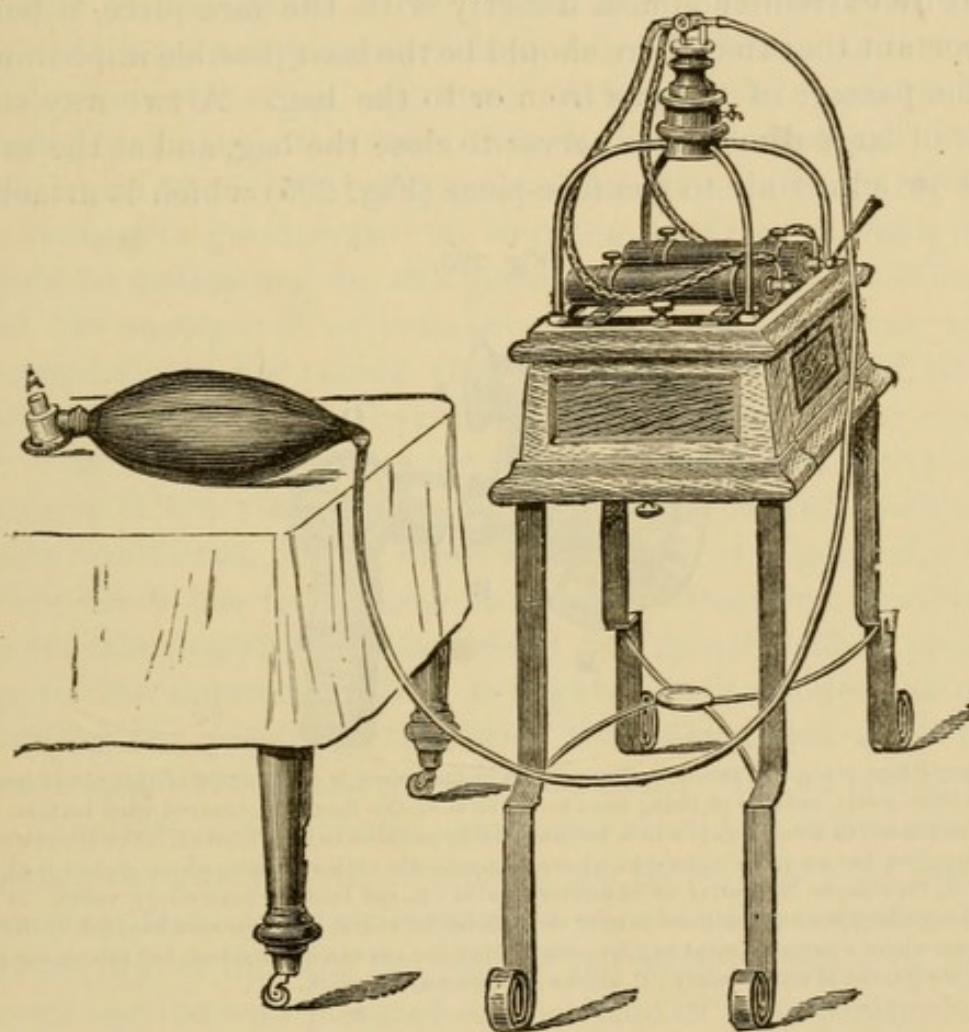
A simple form of apparatus for administering nitrous oxide. It consists of a box to hold the apparatus, in which a clamp securely fixes a bottle of liquid gas: this latter is connected with an India-rubber bag by a flexible tube: a flexible tube of larger dimensions connects the bag with a Clover's two-way stopcock which is attached to the face piece.

and often carbonic acid from the presence of carbonate of ammonia in the nitrate. It should, therefore, before being collected in a gasometer, pass through a series of Woulffe's bottles, containing respectively: 1, water; 2, solution of protosulphate

of iron; and 3, solution of caustic potash. The chief precaution necessary is, to see that the heat is gradually applied and evenly maintained.

Fortunately, however, practitioners are saved the trouble of preparing their gas, it being supplied to them in the liquid form by several firms, who guarantee—a most important matter—the safety of the wrought-iron vessels which contain it.

Fig. 294.

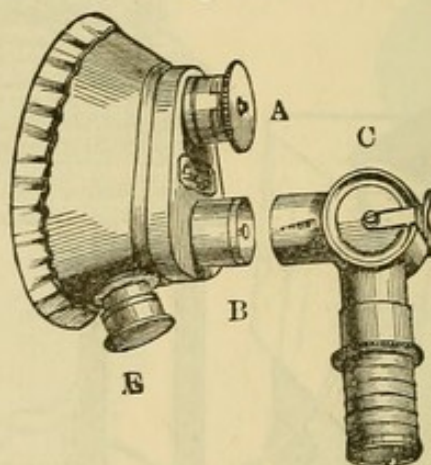


Nitrous oxide apparatus consisting of an iron stand with drawer to hold necessary appliances. The stand supports two bottles of gas so arranged that in case of one failing the other can be employed (Barth's plan, we believe). The gas passes from either bottle to a sausage-shaped bag, and directly from this to the face-piece, a two-way stopcock only intervening. This arrangement (Clover's) possesses great advantages, as the gas comes to the patient more readily than when its progress is impeded by the friction of a tube. Above the gas-bottles is shown an arrangement for administering ether with the gas. It consists of a vessel to receive the ether, under the surface of which a tube dips: by turning a two-way stopcock the current of gas is made to pass through the ether. An outer vessel for holding hot water is also shown, but we have not found it necessary even in the coldest weather.

With regard to the mode of administration, etc., we may first describe the apparatus, which, in a simple form, may consist of

a wrought-iron bottle of liquid gas supported in a box or strong firm frame, so that it can readily be opened by the hand or foot of the administrator (Fig. 293). A more perfect arrangement is when two bottles (Fig. 294) are so connected that, on one failing, the other may be brought into use. By a small flexible tube communication is made between the bottle or bottles and a bag constructed of sheet India-rubber, of oval or sausage form, and capable of containing about one gallon, connected at its opposite extremity almost directly with the face-piece, it being important that there should be the least possible impediment to the passage of the gas from or to the bag. A two-way stopcock of large dimensions serves to close the bag, and at the same time to admit air to the face-piece (Fig. 295) which is attached

Fig. 295.



Clover's face-piece and two-way stopcock. The face-piece is constructed of thin sheet lead or composition metal, capable of being bent to the form of the face, and covered with leather. As the metal is apt to break away, a thin but unyielding metal is to be preferred. The face-piece as now supplied has an air or water-pad where it meets the patient's face, which makes it fit airtight: A, represents the outlet or expiratory valve; B, the inlet or inspiratory valve. In the apparatus which we employ there is only the expiratory valve, the plan now adopted by Clover. E, shows where a supplemental bag for economizing the gas can be attached, but this on the plan which we pursue is unnecessary; C, shows the two-way stopcock.

to it: the latter we prefer constructed of thin but unyielding metal, provided with an outlet-valve only, capable of being closed whilst the edges which approximate to the face are surrounded with an India-rubber water-pad. The object of having an outlet-valve only capable of being closed, is to enable the administrator, at a certain stage of the proceeding, when the product of respiration is almost entirely pure nitrous oxide, to permit the gas to be breathed over again, and thus greatly economize it, without in any way impairing the results, a condi-

tion entirely dependent upon the fact that the gas is not decomposed in the system. [It is doubtful if this economical use of the gas is justified, as more or less of excreta from the lungs and respiratory track, as epithelium, mucus, etc., must find their way into the bag.]

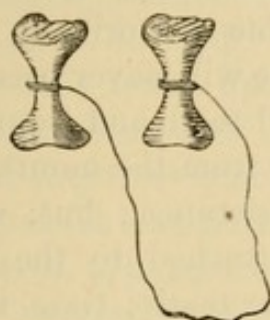
Before applying the anæsthetic, the operator should most thoroughly decide in his own mind what he intends to effect, and should also take into consideration the fact that he may not be able to accomplish all he desires, and therefore what under the conditions had best be attempted first. Thus a patient may be desirous of having, say, three teeth removed; one has been causing pain, the other two, though diseased, perhaps not; in such a case the one giving pain should, even though the least convenient to the operator for so doing, be first removed, for it would be distressing for the patient on becoming conscious to find his enemy still in permanence, and circumstances might contra-indicate his taking the gas a second time. If no one tooth has been especially painful, we should as a rule remove lower teeth or roots before upper ones, to avoid the blood interfering with our view; roots before whole teeth, and back teeth before front ones, for the same reason; and it is generally best, where much has to be done and on more than one occasion, to confine the operation to one side of the mouth before proceeding to the opposite. [This is highly recommended, as often enabling the patient to eat with the unwounded side of the mouth until the opposite one has healed.] In the preliminary examination of the mouth, every care should be taken to avoid making the gums bleed, or causing the patient pain or any unnecessary fear; yet the inspection should be conducted most thoroughly, so that the position of the teeth or roots to be removed may be well pictured on the mind of the operator when the face is obscured from view. He should next quietly select his instruments, taking care to have not only those most handy which he is sure to use, but also any which he may chance to require, and these should be arranged in the order for use on a small table or bracket close at hand. [It is well even to try all the instruments laid out to be used upon the teeth, after explaining to the patient that the object is merely for observation as to their fitness and adaptability.] We strongly recommend, in operations with anæsthetics, the employment of as few instruments

as possible. Time is a very important element, especially in the case of nitrous oxide, and a few seconds wasted often render further administration necessary; but this does not mean that we are to attempt at any time to use an unsuitable instrument. Those which we most frequently employ in such operations are the upper root-forceps suitable for wisdom teeth (Fig. 268), and the lower root-forceps (Fig. 269). The curved elevators are also very serviceable; with one of these we can often, proceeding from the back of the mouth forwards, remove in an incredibly short space of time ten or more roots from the lower jaw. In addition to ordinary instruments there should always be ready at hand a few small sponges attached to handles, a Clover's spoon for depressing the tongue and preventing roots from falling into the throat, a pair of œsophagus forceps, a tracheotomy-tube, etc. Care should be exercised to prevent the patient's garments from being soiled.

These preliminaries being arranged, it is well, after calmly telling the patient that you are ready, to assure him that he has nothing to do, it will all be done for him, he need not even try to breathe or to think about breathing, that "all will be completed in a minute or two if he will only try and remain quite passive." We are convinced that the complicated instructions often given to patients about breathing are a mistake, tending only to make them nervous and confused. There is almost invariably some sensation of suffocation in inhaling nitrous oxide, and this, we are sure, is increased by commencing with very deep respirations. In the next proceeding, that of inserting the prop or gag (Fig. 296) to keep the mouth open, the patient being informed of its object, care should be taken to stretch the mouth as little as possible—but yet sufficiently to afford ample room for the instruments being applied—and to see that the prop is secure from slipping. Spring-props (Fig. 297) are in this respect most to be depended on, but all complications render the fracture of an appliance more likely to occur, and this has been attended with a fatal result in one, if not two instances. Props made of hard wood or vulcanite, roughened to meet the cusps of antagonizing teeth, and secured by strong cord from entering the throat, are probably the most useful and simple. We recommend the operator, especially the less experienced, after inserting the prop, to take a view of the mouth, in order

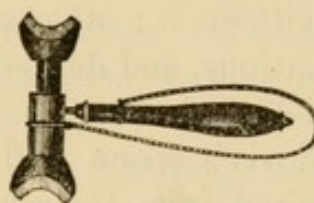
to enable him to see the exact relationship of the teeth to the tongue, etc., from the position in which he will have to operate. The patient should then be requested to close the lips as much as possible, which, not only by likewise closing the jaws, renders

Fig. 296.



Simple form of mouth-prop or gag, constructed of hard wood or vulcanite, for keeping the mouth open in nitrous oxide administration. When coupled in pairs as shown above, the one not in use prevents the possibility of the other falling into the throat.

Fig. 297.



McAdam's mouth-prop. Between the upper and lower portions is a spring, so that the gag will rise if the patient opens his mouth. The extremities touching the teeth are covered with soft vulcanite. The pin shown in the cut is for securing the spring when compressed, and also for placing the prop *in situ*.

the position of the prop more secure, but also permits the face-piece, now to be applied, to more perfectly include the mouth and nares. Upon applying the face-piece it is desirable to allow the patient for a few seconds to breathe air through the two-way stopcock before turning on the gas; it is also well not to commence with the bag fully distended with gas, as the sudden pressure is startling and unpleasant. A nervous patient may soon commence movements of the extremities, or resist breathing; a kind but firm appeal will often have the best effect, even when the patient is nearly unconscious, which may occur from within ten seconds to two minutes of the inhalation; should it be longer than the latter period, we may infer that some air is inhaled with the gas. Time then affords us little criterion as to the anæsthetic condition having arrived, and this knowledge can only be attained by experience. The state of the conjunctiva, or the more sensitive palpebræ, is also no sure test; a patient may be unconscious of pain, but still capable of such reflex action; or be conscious of pain, and yet have lost it. Respiration will best guide us in the matter, and an experienced anæsthetist could, from the vibrations conveyed to the inhaler, tell in the dark when he ought to discontinue the administration. He

should warn the operator as the moment approaches, and when the face-piece is removed the latter should at once commence. Such operations are probably more roughly, because more rapidly, performed under nitrous oxide, but still it will be best to do little, and that thoroughly, than to attempt too much and fail. It is never well for the student to attempt extractions under gas until he has acquired considerable dexterity in operating without it; otherwise, we predict, he will never become a safe, cautious, and dexterous operator. All teeth and fragments when detached should be at once removed from the mouth, and here Clover's spoon will be of much assistance; but, where teeth raised from the alveoli are firmly attached to the gum, the operator may at once pass on to other teeth; time would be uselessly expended in removing them, or the gum would be unduly lacerated. They can be best separated after recovery, and this is especially the case with lower wisdom teeth when detached by the elevator. In removing teeth from the lower jaw, the finger that protects the tongue from injury may perchance press back that organ, and so close the glottis.

The operation being completed, the patient's head should be pressed gently forwards, especially if there be much hæmorrhage, and a suitable basin held under the chin. This position it is well to continue for some half-minute or so, without rousing the patient or attempting forcibly the removal of the prop, the latter often leading the half-conscious patient to imagine that the operation is still in progress. It is a good proceeding to remove the patient after a few minutes from the chair to a sofa or couch, and let him assume the semi-recumbent posture for at least a quarter of an hour, or much longer if desirable; the patient should also be counselled to keep quiet if possible, *i. e.*, without exciting or fatiguing occupation, for the remainder of the day. We have frequently found, where unpleasant after-effects have been complained of, that an opposite course has been followed. Administrations of nitrous oxide may in most cases be repeated at least once, but should, if possible, be avoided on the following grounds. Bleeding of the mouth may be a cause of inconvenience, if not of danger, and the patient usually suffers much more from prostration after a second than after one administration; and it will probably be better to employ nitrous

oxide with ether in lengthy cases than to repeat nitrous oxide administrations.

In describing the symptoms or appearances indicative of danger, we must bear in mind that happily fatal cases have been so rare that no one can speak from large experience. The ordinary appearance of a patient inhaling nitrous oxide is in most cases decidedly alarming; we well remember the first impressions made upon us and upon bystanders. We have become accustomed to such appearances, but yet we may, if careless of them, overlook the real indications of danger which they to some extent mask. In some cases not only is the asphyxiated appearance strongly marked, but convulsive movements suggestive of an epileptic attack are also present, and for the reason, no doubt, that we have in these cases some of the conditions which exist in epileptic seizure. Provided that the patient be breathing freely, we have only in such cases to supply fresh air, gently slap the face with a wet towel, and protect the patient from self-injury. The symptom which should most impress itself upon us, as indicating danger, is a cessation of respiration during the administration, and still more so if the inhalation be completed. Sometimes the breathing is shallow, rapid, and puffing, very commonly so with nervous females, and commencing soon after the inhalation is commenced; in such cases the air in the lungs is but slowly exchanged, the patient is longer in becoming unconscious, and more exhausted subsequently. It is here that a firm request to breathe more slowly will generally be of avail. A little later in the administration we often find the patient forcibly resisting respiration, in which case the breath may be held for eight or ten seconds without cause for alarm, but if for a longer period the face-piece should be withdrawn, and, if that produce no effect, the thorax should be firmly pressed upon, and after a respiration or two of pure air the process may be continued.


The truly dangerous condition is when respiration has ceased, the lungs being nearly empty, the face perfectly immovable, as in death, or as when a patient is breathing through a tracheotomy-tube, and the countenance being livid, the eyeballs congested and turned upwards, and the temperature of the body reduced. Under such conditions, which on one or two occasions we have witnessed, the tongue should be immediately drawn

forward and the thorax firmly pressed upon ; and, if this course should not, after one or two efforts, be followed by natural respiration, resort should be had at once to artificial respiration. In carrying this out we believe no plan can be more effective, at least to commence with, than mouth to mouth inflation of the lungs. [This has been very highly objected to in this country as unnecessary and extremely unclean, it being claimed that bellows for the purpose should always be at hand.] It is a most disagreeable process, but in such emergencies a good deal may be sacrificed. The mere pulling forward of the tongue may, by opening the larynx, often suffice, as the nitrous oxide in the lungs would soon be exchanged for air by the law of diffusion of gases ; but the respiratory movement also no doubt conduces to the continuance of the heart's movements. The experiments made by the committee appointed to investigate the merits of nitrous oxide,¹ showed that in the case of healthy animals death took place in the following order of symptoms:—the inhalation having been continued about two minutes after complete unconsciousness was attained, the respirations became slower and slower, with an increased interval between every succeeding one, until they entirely ceased ; during the same time the pulse became gradually weaker, but the heart's action could be felt for some time, generally about 30'' or rather longer, after respiration had terminated. In these experiments the committee invariably found that, if they discontinued the administration before respiration had ended, the animal recovered without assistance ; when respiration had ceased, but the heart's action had not done so, artificial respiration resuscitated the animal, but not otherwise ; whilst after cessation of the heart's action no means that are known to us could restore animation. It should be borne in mind that the animals operated upon in these experiments were, or most probably were, healthy ones, otherwise such experiments would teach us without hesitation that, so long as the patient is breathing, he is safe, and, so long as the heart continues its action, artificial respiration may, we should almost feel confident, resuscitate him. Unfortunately our dangers will probably not occur with the healthy but with the unhealthy, and, if we have to deal with one suffer-

¹ Op. cit.

ing from a weak and fatty heart, how can we expect the action of such an organ to continue any time after respiration has ended? Whilst the pulse must not be neglected, there can be no doubt that the respiration should occupy our chief attention,

Fig. 298.



Electro-magnetic apparatus which may be employed for stimulating the heart's action when arrested during the administration of an anæsthetic.

and this failing, we rush immediately to our sheet anchor, artificial respiration; other restoratives, if at hand,—galvanism applied at the phrenic nerve and diaphragm, ammonia to the nostrils, slapping the chest with a wet towel,—also may be employed, but these should be used as auxiliaries to, not as substitutes for, the efforts of those who are engaged in the aërating process.

The question which may next occupy our attention is, whether there are any known conditions of the system in which nitrous oxide is contra-indicated.

Pregnancy, our experience informs us, is no barrier to its employment; it appears in no way prejudicial to either mother or fœtus. [It cannot be said that any surgical operation is justifiable during pregnancy except under the most pressing urgency, when delay may be fraught with more danger than the infliction of the pain.

In this connection, attention is called to the statement in the following paragraph, which the writer's experience confirms—¹

[¹ Anæsthetics Medico-legally Considered, by J. G. Johnson, M.D., of Brooklyn, N. Y. See Bulletin of the Medico-Legal Society of New York, vol. iv. Nos. 7 and 8, May-December, 1881.]

"1. Anæsthetics do stimulate the sexual functions; the anogenital region is the last to give up its sensitiveness. Charges made by females under the influence of an anæsthetic should be received as the testimony of an insane person is. It cannot be rejected, but the *corpus delicti aliundi* rule should be insisted on. Dentists or surgeons who do not protect themselves by having a third person present, do not merit much sympathy."

"6. Gross violations of the well-known rules of administering anæsthetics, life being lost thereby, will subject the violator to a trial on the charge of manslaughter."

"8. The physician who administers an anæsthetic should attend to that part of the work and nothing else. He should have carefully examined the heart and lungs beforehand. He should have the patient in the reclining position with his clothes loose, so as not to interfere with respiration; should have his rat-tooth forceps, nitrite of amyl, and ammonia, and know their uses and when to use them and artificial respiration."]

Phthisical patients take nitrous oxide fairly well, becoming anæsthetized with less gas than ordinary patients, as we should have anticipated: anæmic patients do the same.

Patients who have suffered from acute rheumatism, resulting in damaged valves of the heart, etc., appear to take nitrous oxide as well as ordinary patients, but the appearance of a lady affected with cyanosis was such that we should in future decline to administer it in similar cases. Those with weak and fatty hearts must ever be unsafe subjects for the gas or other anæsthetics, though probably they have been given to many thousands of such unknowingly. Should we have a knowledge or suspicion that we have to deal with a patient so circumstanced, not from the patient's assertion, for nearly half of the patients to whom we administer nitrous oxide tell us that they believe there is something the matter with their hearts, we should, besides redoubling our precautions with regard to careful observation of all symptoms, pay especial attention to the conditions of the pulse. We also strongly recommend operating only whilst the patient is fully anæsthetized, for the reason that there will be less chance of arresting the heart's action through shock. In the case of the death which occurred at Exeter, closely following the administration of nitrous oxide, an upper molar tooth had been split into fragments by a powerful instru-

ment forced into its pulp-cavity. We do not say that this was the cause of death, yet we may well bear in mind the views of Brunton with regard to shock occurring under chloroform administration.¹

¹ Through the kindness of our colleague, L. Brunton, we are enabled to present the reader with the views of that gentleman, illustrated by a diagram that he has prepared for us (Fig. 299).

Fig. 299.

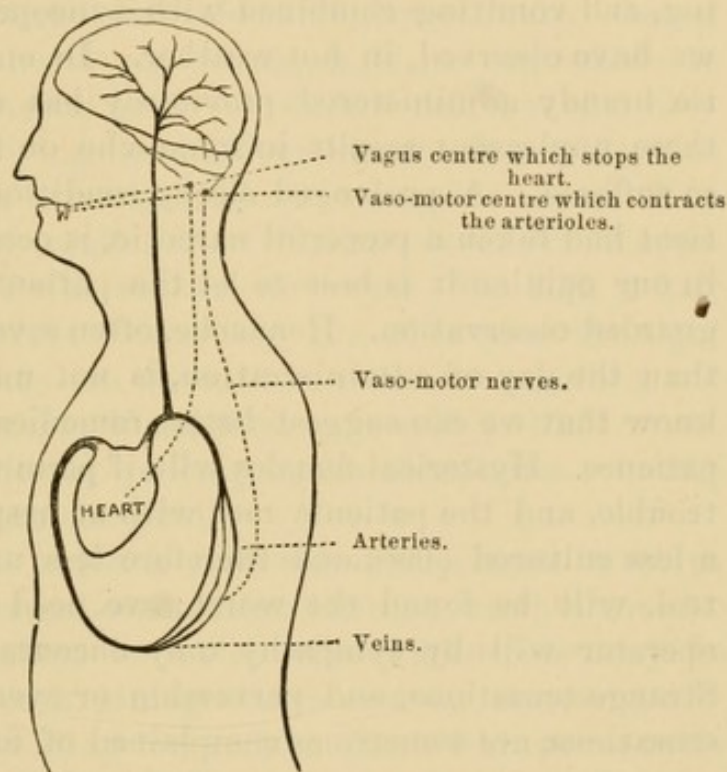


Diagram illustrating Lauder Brunton's views of the cause of arrest of the heart's action under chloroform administration.

"The blood, when it reaches the veins, is useless for the nutrition of the tissues, as we see in a corpse, when the whole of the blood in the body is contained in the veins, the arteries being empty: only so long as it is in the arteries can it maintain the vitality of the tissues. The blood is kept in the arteries, 1, by fresh supplies being pumped out of the venous system into the arterial by the heart; 2, by the contraction of the arterioles, which prevent it from running back too quickly into the veins.

"When a tooth is drawn without chloroform, the irritation is carried by the fifth nerve to the nerve-centres: it irritates the vagus roots, and also the vaso-motor centre. The irritation of the vagus may depress or arrest the heart's action so that no blood is sent into the arterial system for several seconds; but this is counterbalanced by the irritation of the vaso-motor centre, which causes contraction of the arterioles, and thus correspondingly diminishes the outflow. In a person thoroughly under chloroform, *both* nerve-centres have

Of all the conditions in which, according to our opinion, nitrous oxide may be hurtful, there are none more likely to prove so than where a patient is affected with atheromatous disease of the cerebral vessels, upon which any additional strain, such as most probably occurs during its inhalation, would be dangerous; and we think that as a rule it would be well to refuse it in such conditions.

Independently of danger, nitrous oxide may be attended with very disagreeable after-conditions; of these we may have vomiting, and vomiting combined with syncope, more commonly, as we have observed, in hot weather. In one or two cases, a little brandy administered previously has apparently prevented these unpleasant results in some who on former occasions had so suffered. A prolonged sleepy condition, much as if the patient had taken a powerful narcotic, is occasionally manifested; in our opinion it is best to let the patient sleep this off, under guarded observation. Headache, often severe and lasting longer than the day of administration, is not uncommon: we do not know that we can suggest better remedies than rest, quiet, and patience. Hysterical females will, if permitted, often give much trouble, and the patients met with at hospitals being as a rule a less cultured class, and therefore less under intellectual control, will be found the worst; we need hardly say that the operator will by sympathy only encourage such exhibitions. Strange sensations, and perversion or even absence of ordinary sensations, are sometimes complained of for days succeeding an administration, the result, no doubt, of changes from which the nervous centres have suffered owing to the abnormal condition of the blood during the inhalation. One patient has informed

their reflex sensibility abolished, and so the irritation has no effect on either; but with partial anæsthesia the vaso-motor centre may be rendered insensible before the vagus centre, and consequently, when the irritation is applied to the fifth nerve, the vagus centre only is excited, the heart is depressed or stopped, and the inflow of blood into the arterial system is diminished or arrested, while there is no contraction of the arterioles, and therefore no corresponding diminution of the outflow. The arterial system therefore becomes more or less empty, *i. e.*, it approaches more or less to the condition of death, and fatal syncope may result."

With nitrous oxide, however, by which the blood in the arteries is brought into a venous condition, and thus acts as a stimulus to the vaso-motor centre, the danger from syncope is reduced to a minimum.

us that he has detected sugar in his urine after each inhalation of nitrous oxide,—an interesting fact, if it be at all general, and pointing, of course, to cerebral irritation.

Before we quit the subject of nitrous oxide, we would give a warning with respect to patients inhaling it, especially those pregnant, with other than moderately empty bladders; otherwise there is risk of a catastrophe distressing to the patient and detrimental to an elegantly covered chair.

Ether, although no doubt a much safer anæsthetic than chloroform, is yet probably less safe than nitrous oxide. Owing to its pungent and irritating nature, it is less agreeable to inhale than either nitrous oxide or chloroform; but this may be overcome by employing it, as Clover was the first to do, viz., in combination with nitrous oxide. It requires some little practice and dexterity to administer it with his admirable apparatus, but with that which we have described (Fig. 294, p. 327) it only needs a little care in turning the ether on at the right period; if this be done too soon, there will be struggling, and suspension of respiration; if too late, there will be little or no benefit from the ether in prolonging the anæsthesia. In this matter experience alone can guide.

Ether with nitrous oxide is most suitable for cases in which several teeth are to be removed at one sitting; we think it also well calculated for those in which severe after-pain may be anticipated, as in a tooth giving rise to alveolar abscess in any of its stages, recovery being less sudden than with nitrous oxide alone.

With regard to symptoms indicating danger, these will be much the same as with nitrous oxide alone, though perhaps less apparent, and consequently requiring greater watchfulness, as with ether there is usually less lividity. Whilst the respiration is carefully watched, the pulse should be more regarded than with nitrous oxide. In employing the ether combination we must look for more tendency to vomiting. This is a most unpleasant drawback to the use of anæsthetics, and therefore one of the greatest merits of nitrous oxide is that it is the most free from it. With regard to ether *versus* chloroform, the latter has been reckoned by Jonathan Hutchinson as the safer for very old people, there being less violent struggling, and consequently less exhaustion; but this must apply to ether adminis-

tered alone, as, with the nitrous oxide combination, when carefully administered, there is probably less struggling than under any other method. Chloroform is preferable to ether in the case of patients suffering from bronchitis.

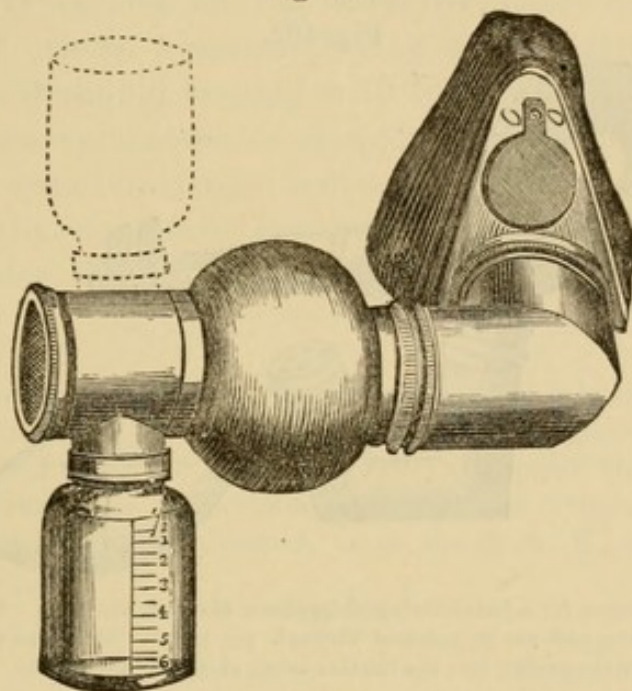
The administration of chloroform in dental operations has now, and most properly, become so exceptional a matter that we need devote but a short space to its consideration; there are, however, a few rare cases in which it is preferable to other anæsthetics. Thus we find instances of patients who recover so rapidly from nitrous oxide, or its combination with ether, that it is hardly possible to remove one tooth or root without pain being felt, and such patients may require the removal of a large number of either.

In cases when great muscular contraction has to be overcome, as with impacted wisdom teeth, chloroform will be generally preferred; although our colleague, J. Mills, of St. Bartholomew's, informs us that in the reduction of dislocations he has found ether almost, if not quite, as efficacious as chloroform. In the cases bordering on the limits between dental and general surgery, such as the removal of epulis and kindred tumors, the dissecting out of cicatrices, and other operations which must occupy some time in their performance, and where the anæsthesia has to be kept up during the period, chloroform will no doubt be generally preferred.

As to the modes of administration, we doubt whether there is any one vastly superior to another. The Scotch school have, as a rule, performed it in the simplest manner and without apparatus, and with, we believe, as much, if not more, success than in England, where apparatus has been more generally employed. Our conclusion has long been, that safety depends far more upon the experience and judgment of the administrator than upon the mode of administration; and we need here hardly remark, that, if it be an unwarrantable assumption of responsibility to administer single-handed nitrous oxide for a dental operation, it is absolutely criminal to do so with chloroform. Practitioners are often pressed by patients to give it to them, with such assurances as "I take chloroform so well, my maid often gives it to me," etc. A wise practitioner, some little time since, saved himself from an awful responsibility, as the patient who so requested him subsequently died under the hands of an

experienced anæsthetist. With regard to chloroform-inhalers, and their name is legion, we must undoubtedly pronounce the most perfect to be that devised so ingeniously by Clover, on the suggestion of Snow, in which definite proportions of the

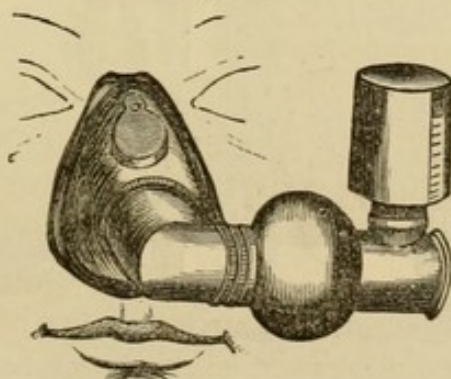
Fig. 300.



The author's chloroform apparatus, consisting of a graduated drop-bottle which contains the chloroform, and which can be, by turning it, inverted so that the fluid drops on to a piece of sponge. The expanded portion has in front of it a piece of fine wire gauze, which has the object of thoroughly mixing the chloroform-vapor and air together, rendering the vapor less pungent.

vapor and air are previously mixed together; its only objection is its somewhat formidable appearance, which may terrify some

Fig. 301.

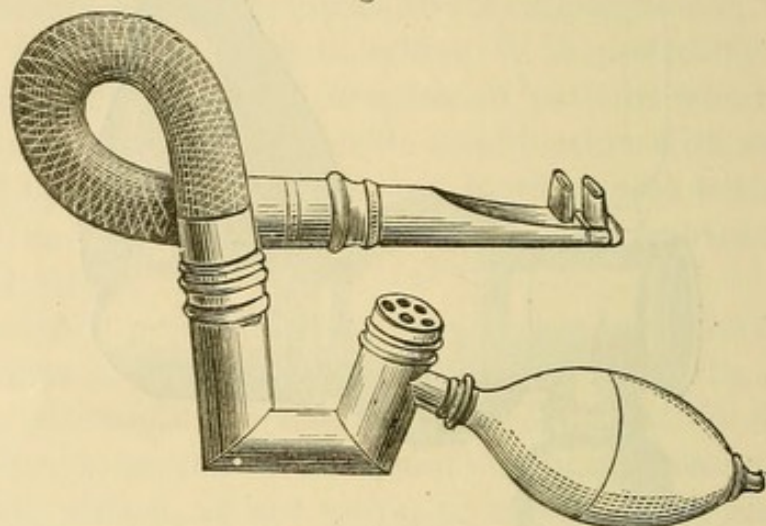


Apparatus figured in 300 with a nose piece for keeping up the anæsthesia whilst the mouth is open.

very nervous persons or children, a condition always to be avoided, as adding another element of danger, viz., the depres-

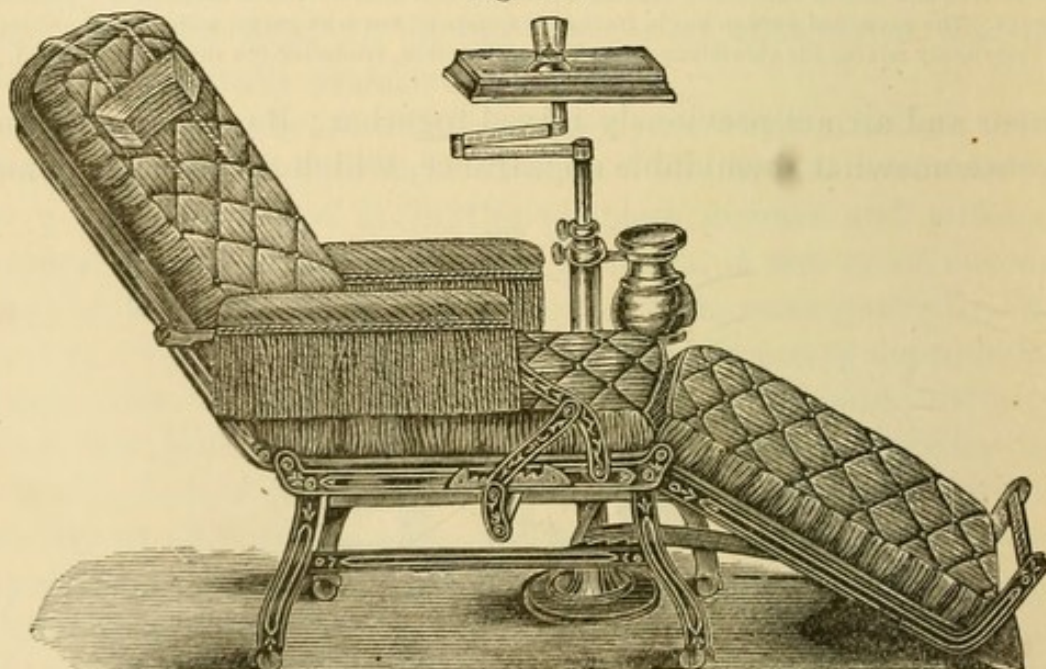
sion consequent on fear; but it must be remembered that the process can always be commenced with the lint and the drop-bottle, and maintained afterwards by the apparatus. An inhaler which we devised some years ago (Figs. 300, 301) combines the drop-bottle with a very simple apparatus, like the

Fig. 302.



The author's apparatus for administering chloroform through the nose. The small tubes are inserted into the nares, and air is pumped through the inhaler by means of the India-rubber syringe, the small holes opening into the inhaler being closed by the thumb.

Fig. 303.



A form of chair-couch very convenient for operations upon the mouth under chloroform.

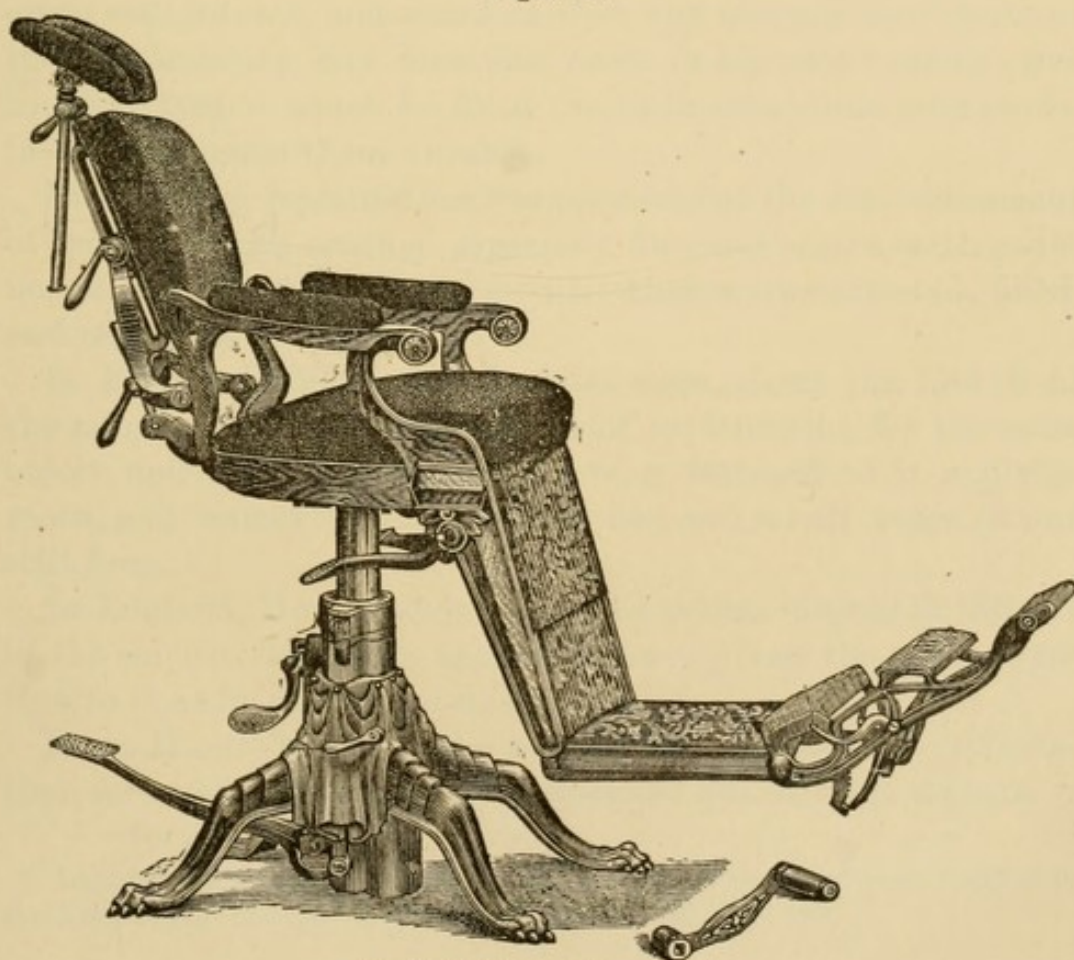
smaller one of Snow, but having an arrangement for more thoroughly mixing the vapor with air, which renders a deep

inspiration free from the otherwise disagreeable irritating sensation so conspicuously absent in the Clover apparatus. For keeping up the anæsthesia we have employed an India-rubber air-propeller (Fig. 302) attached to an apparatus, by which means air impregnated with chloroform is forced into the nares; but, unpleasant symptoms having occurred under our own hands, and those of others, when employing similar arrangements, we suggest that it should be used with the greatest caution. With regard to the symptoms of danger and the best methods of averting or counteracting them—the latter of which are, unfortunately, by no means generally decided upon at present—we must refer the reader to works specially devoted to the subject.¹

¹ In operating upon patients under the influence of chloroform it is very desirable that they should be, as far as possible, placed in the recumbent posture, and, were it much employed in dental surgery, the chair above figured (Fig. 303), which permits this, would be found of much service.

[The ordinary dental chair should, as in the S. S. W. chair, Fig. 304, be

Fig. 304.



The S. S. White pedal lever chair.

We have refrained from alluding to other and less generally employed anæsthetics than those mentioned above, such as bichloride of mythelene, bromide of ethyl, ethidene-dichloride, etc., on the ground of their not having been employed extensively, or often enough to enable us to speak of their comparative safety. The last-mentioned agent appears, from the experiments performed by a committee of the British Medical Association, to hold a position as regards safety between chloroform and ether. In flavor it is much more pleasant than the latter; and our experience in it leads us to think that it may become a favorite and useful anæsthetic in dental surgery.

capable of letting the patient down to a reclining position, and in extreme anæmia the feet may with advantage be raised higher than the head, to promote gravitation of blood to the brain.]

CHAPTER XVII.

THE REPLANTATION AND TRANSPLANTATION OF TEETH.

REPLANTATION.—The operation, either of restoring dislocated teeth to their sockets, or of extracting them on account of pain and then replacing them, appears to have been practised several centuries ago.

We find, in an excellent paper on this subject and that of transplantation, by A. Mitscherlich,¹ that Dupont, in 1633, extracted and replanted a tooth on account of violent pain, and that it became firmly attached; subsequently Dion Pomaret states that he had witnessed a successful result of the same process; and about a century later Fauchard speaks of it as a fact quite well known, and wonders that any one can still doubt of its practicability, and mentions cases in his own practice, five in all, in two of which he filled the teeth some time afterwards, in order to make them durable.

In Germany, replantation was practised at the commencement of the eighteenth century, especially for cases where teeth could not be properly filled in the mouth; they were extracted, filled, and replaced.

In France, L'Ecluse and Bourdet were, about the middle of the same century, great promoters of replantation for the same object, and the latter extracted a fang, fastened to it a pivot-tooth, and reinserted it, and after five and a half years it was still firm.

In England, Hunter about the same period interested himself in the subject, but never appears to have given the same attention to it as he did to transplantation.

From Hunter's time to the present, the operation of replantation, for teeth which have been knocked out of their sockets, or

¹ Langenbeck's *Archiv für Chirurgie*, vol. iv. Translated into English in the *Archives of Dentistry*, by Edwin Truman, vol. i. p. 169.

extracted by mistake, has been continuously performed; and, exceptionally, in cases where intense pain has existed, and also where a filling could not without great difficulty be performed in the mouth.

In speaking of the operation, almost all, if not all, who have written upon the subject lay down the rule that it is never to be attempted with teeth the roots of which are diseased. Hunter, while strongly enforcing this opinion, yet admits, "to extract the tooth and then to file off any diseased part of it, and immediately to replace it, has been practised, but often without the desired success; for it has often happened that a tooth has been introduced into a diseased jaw. This practice, however, has now and then succeeded."

Hunter certainly does not advocate it; and Mitscherlich, evidently summing up the opinions of those who have gone before him, as well as expressing his own, says, "Teeth whose roots are diseased are always to be removed, and must not be inserted, as they cannot, from grounds to be given later, again become united."¹

It can scarcely, we think, be stated that replantation, as a systematic treatment for chronic periodontitis, was ever advocated until the appearance of two papers which we read before the Odontological Society in 1869 and 1870. In speaking therein of that most intractable of diseases, and its almost universal treatment by extraction, we pointed out, that by the removal of a tooth so affected, the careful scraping from its fangs of diseased membranes, the clearing out, purifying, and then filling of its pulp and fang cavities, and then, after washing it as well as its alveolus with an antiseptic fluid, returning it to its socket, we might hope to preserve it as a useful member, and we gave a statement of fourteen cases in which this treatment had been adopted, but upon its ultimate success it was at that period too early to offer any opinion.

¹ In *A System of Dental Surgery*, by John Tomes, F.R.S., and C. S. Tomes, M.A., p. 658, the following is stated: "It should have been mentioned in the section relating to alveolar abscess that experiments have lately been performed by Mr. Coleman, *following in the steps of Mitscherlich and others*, in which carious teeth were extracted and replaced, after scraping off the thickened and diseased periosteum." We think that the words which we have put in italics should more properly have been rendered "in opposition to the views of Mitscherlich and others."

Since the publication of our papers, the subject has excited much interest and attention both on the Continent and in America. Magitot has brought it under the attention of the Academy of Sciences of Paris, and his papers upon it have been published in the "*Comptes Rendus*," and the "*Bulletins et Mémoires de la Société de Chirurgie*." In the latter the treatment of sixty-three cases is recorded, out of which only five, at the time when the paper was written, had turned out failures. Magitot's success, so much greater than our own in a more limited number of cases, may be due to his method of procedure, which consists in simply excising the denuded portion of the fang,—filling the tooth, of course, if necessary,—and returning it without application of antiseptic to either the root or the alveolus. As in our own recommendations, he has seldom found it necessary to retain the tooth in its socket either by ligature to adjacent teeth or by mechanical appliance. He also deems it most important to maintain a free drainage from the alveolus, especially in the severer cases. The success of the operation he considers to be entirely dependent upon the existence of a complete ring of healthy periodontium on the tooth to be replanted.

We have preferred alluding, though in general terms, to the methods adopted by Magitot rather than to our own, as both his experience and success have been greater; also because we must go over much the same ground in treating upon our second head, viz., Transplantation.

TRANSPLANTATION.—This operation appears to have been performed at an earlier period than that which we have just considered. Some have attributed its origin to Abulcasis (died 1122), but the passage quoted in favor of this supposition refers more probably to the fixing of an artificial tooth. Ambrose Paré, however, records a case where a young princess had a sound tooth of her waiting-maid inserted in the place of a carious one extracted, and with a successful result. Nothing, however, appears to have been done in this direction for some 150 years, until the operation was resuscitated by Fauchard, and with much greater zeal by Bourdet, who appears to have obtained his teeth for transplanting from Savoyard boys, whose great poverty induces them to be thus victimized.

The operation of transplantation found considerable favor in the eyes of Hunter, Pffaf, Graebner, Richter, Jourdain, and some

others; but it had many strong opponents, even more so than in the case of replantation. The chief arguments employed against the operation were, as we pointed out some years ago,¹ the three following, viz., 1. Liability to failure; 2. Chance of inoculation of disease; 3. The moral objection.

1. *Liability to failure.*—This is considerable, and may arise from the so-called scion-tooth not being, from its size, form of fang, or injury occurring to it in its removal, etc., adaptable to the socket of the tooth which it is intended to supplant. Also, when the above-mentioned conditions are not unfavorable, it often happens that the scion-tooth is implanted in an alveolus more or less diseased from the long existence of a necrosed tooth. Pain and tenderness are for some days a common sequence to the operation, and even under favorable circumstances are often severe; and, the tooth being very loose, the patient is tempted to obtain relief by removing it. The method also commonly employed of attempting to secure the transplanted tooth to adjacent ones by means of ligature was, as we think we shall be able to show, another very probable cause of failure.

2. *Chance of inoculation of disease.*—This we believe to have been much more imaginary than real, although it cannot be denied that there might be a chance of transferring, with a tooth removed from a person at a certain stage of the disease, such affections as syphilis, smallpox, scarlatina, measles, etc.; and the same objection would apply in an equal degree to skin-grafting from one person to another, as well as to several other surgical proceedings. We are inclined, however, to believe that this argument was employed rather to deter and dissuade persons from undergoing an operation so properly discontinued on the ground of—

3. *The moral objection.*—That the poor and generally degraded should have been induced by a pecuniary temptation to part with organs as essential, or probably even more essential, to their well-being than the wealthy coveters who could purchase them, became, and rightly so, to be regarded as an injustice and a wrong. A much greater skill and success in saving defective teeth, and in supplying artificially their place when lost, no

¹ On the Transplantation of Teeth, by Alfred Coleman. St. Bartholomew's Hospital Reports, vol. xiv. p. 101.

doubt also, to a very great extent, diverted attention from the operation of transplantation.

The success that attended our experiments in replantation, though not very encouraging, determined us nevertheless to attempt that of transplantation, but under conditions wholly free from the moral objection above stated.

It has been pointed out in previous pages (see Chapter IV.) that amongst civilized nations the maxillæ of the present generation are of smaller size than they were in people who lived some centuries ago; whilst the teeth, if they have diminished in size, have not done so in the same proportion, and thus occur crowding and irregularity in position of the latter. The dental surgeon is often called upon to correct this by the removal of sound teeth, and that these young and healthy teeth should be cast away as useless, whilst there were so many for whom the operation of transplantation, if successfully performed, would be the greatest boon, appeared to us a sad misfortune.

We have, therefore, from time to time during the last six years performed the operation of transplanting teeth from the mouths of those who had to part with them through overcrowding to the mouths of those from whom they were removed on account of disease, and with a much greater proportionate success than in the operation of replantation for the cure of periodontitis. We have performed it on at least twelve occasions, and we believe with only two failures, both resulting from the tooth not being adaptable to its new habitation. Besides these cases, it has been performed by others under our observation some fifteen times, not, we believe, with quite the same success, as the cases were probably not so carefully selected. Our first case, that of a medical student, in 1875, for whom a right lateral incisor was thus supplied, was, when last heard of, about a year ago, perfectly satisfactory. In two of the cases we transplanted misplaced laterals to alveoli on the opposite side in the same patients, and were successful. In another case, that of a youth aged sixteen, two upper laterals were transplanted from another subject with perfect success.

The operation, which we always conducted under an anæsthetic, was thus performed. The individual to receive was operated upon first, every care being taken in the removal of the tooth or root to injure the alveolus as little as possible; the mouth was

washed out with tepid water until bleeding had nearly ceased. The patient to contribute was then operated on, and, his tooth being also carefully extracted, it was carried directly to the former, and firmly pressed into the vacant alveolus, after clearing out the same, first with cotton-wool and then with the syringe, the finger and thumb only being employed. In no instance was any ligature employed, this being in our opinion more likely to prove mischievous than beneficial, and for the following reason. The tooth, however firmly pressed into the socket, soon becomes slightly raised from it by effusion into the latter, which causes it also to be more or less loose. Now this effusion has no doubt much to do with the future union of the tooth and alveolus, through the medium of the alveolo-dental membrane; and to prevent this effusion, as must be the case to a great extent when the tooth is firmly tied into the socket, is to interfere with the process of attachment. Moreover, we are strongly inclined to attribute to this procedure those untoward results, viz., severe inflammation, abscess, necrosis of alveoli, etc., which have been spoken of by former writers as not unfrequently following this operation, but which we have never met with. After having implanted the tooth, we have simply directed the patient to carefully avoid masticating upon, or touching it with, the opposing ones for some days, and to employ soothing fomentation to relieve any tenderness. There could be no objection to construct, previously to the operation, a plate that would protect the tooth from any violence or pressure.

In some cases a week only has sufficed to allow the tooth to become moderately firm, free from tenderness, and even capable of bearing a certain amount of pressure; but a fortnight has more commonly been required. A point of no small importance is, to select for transplantation, if possible, teeth the fangs of which are rather less in dimensions than those for which they are to be substituted. When transplanted they may not appear so firm as larger ones, but in the end they become so. In our practice, lateral incisors inserted into the alveoli of centrals and cuspidati have turned out very successful. In speaking of the transplantation of teeth, which, under the conditions spoken of, may, we consider, from our experience of it, be recommended as a useful and perfectly legitimate operation, we may

repeat what we have elsewhere written.¹ "I am in hopes that having called attention to the operation and its merits, it may be the means of conferring much benefit, especially upon a class whose pecuniary circumstances prevent them from attaining comforts which their more affluent neighbors can well afford. I cannot but believe that with our dental departments and dental hospitals, at which so many thousands of young and healthy teeth are annually sacrificed, these might be turned to profitable account, and by selection of suitable cases out of large numbers, the operation of transplantation might be again regarded as legitimate and useful."

Before concluding this chapter, we must say a few words upon the transplantation of dead, or rather dried, teeth, such as have usually been obtained from the corpse. This operation has, like the same process with living teeth, had its advocates and its opponents. The former evidently, as shown by the contradictory nature of their statements, have been prejudiced and partial with regard to it. Hunter, who describes the process at some length, says: "The insertion of a dead tooth has been recommended, and I have known them to continue many years;" whereas in another place he says: "A tooth which has been extracted for some time, so as to lose the whole of its life, will never become firm or fixed." Hirsch, another advocate, in like manner contradicts himself.

That such an operation should, as a rule, prove unsuccessful, is what we could but anticipate. A tooth long removed from the mouth, and dried, would not only be entirely devoid of vitality in all its structures, but would have lost all medium for uniting those devitalized tissues to adjacent living ones. The fact that some of the dental structures, for instance the dentine, pulp, and enamel—*i. e.*, if it possess any—had lost their vitality, would not, as we have elsewhere shown, if they be free from putridity and septicity, be a barrier to a tooth being transplanted, provided that the cementum and remains of the alveolo-dental membrane retained theirs, as they frequently do under such conditions. Where all the structures are devoid of vitality, we should expect such teeth, if at all retained, to be so simply mechanically, and never to become firm, or more probably to

¹ Op. cit.

share the same fate as do ivory pegs when inserted into bone, viz., to be absorbed. But that such teeth when inserted have in rare instances undoubtedly become perfectly firm, indeed so much so as to present the greatest resistance to their removal, needs some further explanation, and this is satisfactorily furnished in the experiments of Mitscherlich, recorded in the excellent paper before referred to.

He took an upper incisor from a dog's skull, and inserted it into the corresponding alveolus of a living dog, which he killed after six weeks, and then he immediately injected the carotids. A longitudinal section, made through the tooth and jaw, showed the periosteum to be discoverable in only a few places: where this was absent, the tooth was eaten away. In some of the cavities thus formed, osseous tissue directly connected with the "alveolar processes existed, and so held the tooth with such extraordinary firmness;" and into this the injection had readily passed. He says, "It was so fully developed, that the process had to be looked upon as fully accomplished, and therefore a later exfoliation of the tooth was not to be expected." We think the latter sentence expressed in too confident terms. The researches of J. Tomes, already referred to, with regard to the absorption of temporary teeth, show a very similar condition prevailing at times, viz., where the dentine in such teeth is directly connected at certain parts with osseous tissue which again becomes absorbed. On the other hand, we may point out that in our examination of the teeth found in ovarian tumors some have been met with directly united to surrounding bone without any intermediate tissue.

Finally, attempts have been made to insert porcelain teeth, and even teeth having fangs composed of gold, into alveoli, and with the success that we should naturally have expected; and we may conclude our remarks upon the process of transplantation by observing, that to insure a fair amount of success the operation must be conducted with living teeth, obtained from individuals under middle age, and inserted into the mouths of those not past middle age, which must be fairly healthy, and free from the existence, to any extent, of alveolar mischief. [The writer has suggested the use of living teeth from the lower animals, as justifiable and probably practicable for transplantation.]

CHAPTER XVIII.

CONGESTION OF THE GUMS—SALIVARY CALCULUS—ULCERATIONS OF THE GUM—NECROSIS OF THE JAWS.

CONGESTION OF THE GUMS.—The mucous membrane covering, and included in the structures called the gums, should in the healthy subject be of a pale rose-color, marbled by minute vessels of a rather darker tint, presenting around the teeth a festooned edge as thin as ordinary writing-paper, and appearing to be firmly attached to the necks of the teeth, but in reality attached a little distance off, being folded down to the cementum, where it becomes intimately blended with the alveolo-dental membrane. The interstices between the teeth, at and near to their necks, should also in the healthy subject be fully occupied by the same structures, rendering it scarcely possible for food to become lodged there. In highly civilized communities, and especially amongst the denizens of large cities, we not uncommonly find the structures in question, without actually exhibiting disease, of a darker color, thicker texture, and not fully occupying the spaces between the necks of the teeth. Amongst dyspeptic persons such conditions are generally seen in an exaggerated form, whilst many of the worst cases are those met with in the subjects of glandular struma: from the constant tendency of the gums to bleed, this has been termed false scurvy, or scurvy of the gums. Under the latter conditions the mucous membrane, especially that adjacent to the teeth, appears deeply congested with venous blood, tumid and thickened, but not filling up the interstices at their necks, and detached, for some distance from the surface, from the fangs. A thick fetid discharge may often be pressed up between the teeth and mucous membrane, which gives to the breath a very repulsive odor. This condition of things continuing, the alveoli become absorbed and at times more or less denuded, whilst the fangs of the teeth become coated with a layer of thin hard greenish-brown tartar. Ultimately, the disease progressing, the teeth one after

another drop out. The loss of the teeth by alveolar absorption, if not a natural order of things, is, at least in very old age, an event generally looked for, as much so as is the loss of hair from the head. When occurring prematurely, and in connection with the condition of mucous membrane above described, it certainly constitutes a disease, and a very refractory one to deal with. Authorities differ much as to both its cause and its nature: some attribute it wholly to local causes, notably to neglect in cleansing the teeth and permitting tartar to accumulate about their necks; others believe that it has its origin in the alveolo-dental membrane; and some, C. S. Tomes in particular, that the structure first affected is the alveolar process at its free edges. Our own views accord most with those who maintain that it arises from an unhealthy condition in the mucous membrane in the neighborhood of the necks of the teeth. This may be the result of constitutional conditions before alluded to, or it may and probably does arise from the want of a due stimulus to the mucous membrane supplied in the form of harder food than that which civilized nations as a rule consume. The presence of tartar may no doubt increase and aggravate it, but we see cases where this deposit has existed for many years without producing such results. The very conditions of its existence tend to increase and perpetuate it; friction by brushing, rubbing, etc., being avoided on account of the pain experienced. The congestion and separation of the gum at the necks of the teeth permit the access of the fluids of the mouth, and the formation of tartar, modified in character probably by the acid mucus furnished by the gum, and adhering most firmly to the roots of the teeth. As the separation extends, the free edges of the alveoli become denuded, and consequently suffer a slight necrosis, perhaps most comparable to caries, but on a very small scale.

In this, which may be deemed its acute form, it is most common about the middle period of life, yet we have met with it in individuals under twenty. It must not be confounded with a premature loss of the teeth, as occasionally witnessed in individuals who have suffered severely from debilitating illnesses; when they thus come out, they are free, or almost wholly free from deposition of tartar; and here, no doubt, the cause is absorption of the alveolar process without any exposure.

The treatment of this disease is very uncertain and some-

what severe; indeed, it is only during the last few years that any real treatment has been attempted. Riggs, to whom we owe the introduction of the only known methods at all likely to be of service, and who, by calling our attention so prominently to the affection, has led many to associate his name with it, recommends in the first place a most careful removal of all salivary deposition from the exposed fangs of the teeth. This can only be effected by very narrow sharp scalers, and, as it causes both pain and bleeding, will generally necessitate many sittings. Considerable mitigation is, however, obtained by a frequent employment of carbolic acid conveyed to the space between the gum and the necks of the teeth, on a pointed piece of soft wood. Together with the removal of the tartar, must be that of the exposed edge of the alveoli, and this must be done until it is concluded that all diseased portions are removed. To insure the removal of both, it is advisable, after the scraping process, to apply to the parts a strong or diluted solution of aromatic sulphuric acid. Not having been able to procure the original account of Riggs's treatment, we may perhaps not have done him full justice; but we believe that the statement given above accords in the main with what he has recommended. After the operation has been performed, the patient must be instructed to pay particular attention to the gums, brushing them frequently with a soft brush, and counteracting any tendency to congestion by the application of tinct. iodinii comp., tannin, or alum or borax solution. We can hardly venture to hope that teeth so treated will ever at the parts scraped become united to the surrounding mucous membrane, but this, if healthy, may come into such close contact with them as to prevent the access of fluids and the consequent deposition of tartar. With regard to tartar or salivary calculus, which is deposited upon the teeth in much the same manner as are the lime-salts upon the sides of a steam-boiler, we may say a few words. Analyses have shown it to be chiefly composed of earthy phosphates and animal matter.¹ It is the latter doubtless that gives to

¹ Analysis of tartar (Berzelius).

Earthy phosphates	79.0
Mucus	12.5
Ptyaline	1.0
Animal matter sol. in hydrochloric acid	7.5
	<hr/>
	100.0

most varieties its repulsive odor. The organic matter is of course furnished by the mucus and epithelia, also by the leptothrix and micrococci found in abundance in many mouths, and doubtless occasionally by minute portions of food: the lime-salts from the saliva in which they are held in solution. Some observers have described the existence of minute crustacea in salivary calculus; but this is probably an error arising from the appearance presented by the precipitation of lime-salts in a colloid fluid.

Tartar varies in character, owing, no doubt, to the conditions under which it is deposited; thus, where very rapid and in large quantities, it is of a whitish-yellow color, and comparatively soft. It is surprising to what an extent it can accumulate in a little time: we have under observation a young lady who has for some years visited us annually, and on every occasion we have removed quite as much tartar as represents in bulk the crowns of the teeth on which it has collected. Most of her teeth have become very loose, but are, for their condition, remarkably free from tenderness, and in no respect resemble the condition to which Riggs has called our attention. There is in her case almost as much deposit on the upper as on the lower teeth, which is unusual, especially with this variety; the part where it is most commonly met with being the depression formed by the inner surface of the body of the lower jaw in front, and the root of the tongue behind: it is here that the saliva collects in largest quantity, and by evaporation, and probably chemical changes, doubtless increased alkalinity, the lime-salts are precipitated, carrying down with them more or less of the insoluble and semi-soluble organic matter. A second variety is much harder in consistency than that last mentioned, and of almost a black color; it is usually deposited in patches, or in the form of a ring around the teeth at their necks, and often just below the free margin of the gum; and it appears quite as common to the upper as to the lower teeth, to which it adheres with considerable tenacity. The third variety may be that which we have already described as in connection with Riggs's disease, so called. A fourth variety is that which appears most frequently upon the upper front teeth of young persons just above the margin of the gum, and is of a greenish-black color; it is very thinly deposited, and so difficult to remove, that some have

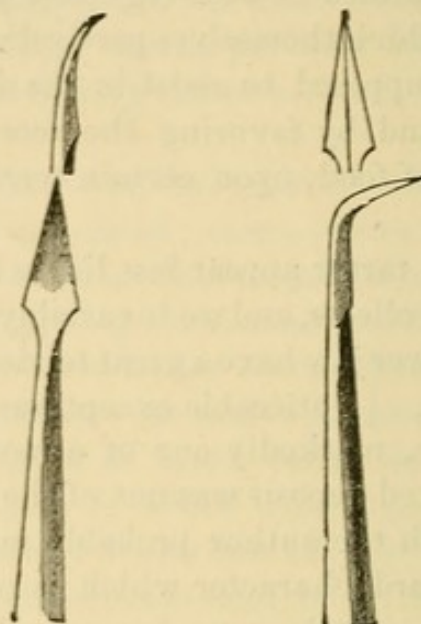
regarded it rather as a changed condition of the cemental covering to the enamel (Nasmyth's membrane) than as any deposition. It certainly, when removed, leaves the enamel roughened and minutely pitted; it is said never to return after removal, but of this we speak doubtfully.

[This has been claimed to be a vegetable growth that throws down attachments which themselves partly disintegrate the tooth substance, and are supposed to assist in the destruction both by this direct action and by favoring the retention, and thereby the decomposition of food, upon certain territories of the tooth surface.]

Teeth coated with tartar appear less liable to caries than teeth upon which it never collects, and we invariably find that, when the front teeth of the lower jaw have a great tendency to decay, tartar is absent from them. [Noticeable exceptions have been met in the writer's practice, markedly one of a mother and daughter where the accumulated deposit was not of the ordinary yellowish chalky nature, which the author probably means, but rather of the brownish and hard character which is most frequently met with in mouths where little or no decay can be found.] If then it were not for the indirect injury that tartar occasions, as also for the discomfort and unpleasantness that its presence creates, we might consider its removal more than superfluous, especially as we occasionally meet with a carious cavity in which its deposition has made a fair filling. A small amount of yellow or brownish tartar at the backs of the lower front teeth is more a matter of general existence than not, and appears productive of little harm. Very different is the presence of an equal quantity on the anterior aspect of a lower incisor, at the margin of the gum, which, by continual increase in the direction of the fang, causes its anterior surface to become exposed, occasionally almost up to its apex. When, therefore, we meet with it in such positions, and indeed in all, except perhaps the very slight deposits at the backs of the lower front teeth, it certainly ought to be removed; and this is best accomplished by pressing upon it chiefly in the direction of the fangs of the teeth with suitable sharp-pointed steel instruments. The form which we have found most useful is that figured below (Fig. 305); but it is not to be employed in the manner that we have experienced upon ourselves, viz., hooked under the lower edge of the deposit and

then pulled upwards, which lacerates the gum, jars the teeth considerably, and most imperfectly removes the mass. [Here, although not a very important matter, the writer would decidedly prefer the method condemned, as more expeditious, less

Fig. 305.

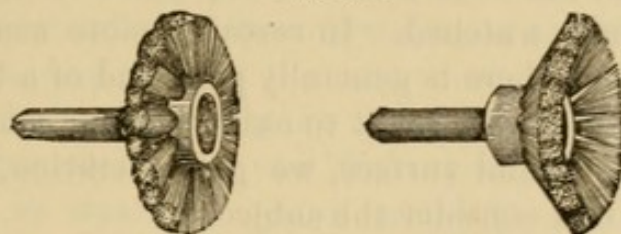


A form of scaler which is very serviceable in removing tartar.

likely to cause pain or injury to the tooth, and not calculated to push the detached particles of calculus under the gum and thereby cause irritation.] The thumb of the hand holding the instrument should rest upon the cutting edge or masticating surface of the tooth operated on, in order to steady it, and then, by the point of the instrument being pressed into the tartar and in the direction of the root, or perhaps somewhat towards either side of it, the mass flakes off in fragments of considerable size. In the process of scaling, great care should be exercised to remove all fragmentary portions from between the teeth, where they not unfrequently extend to some distance below the surface and are often overlooked. After removal of all visible portions of the concretion, for which a variety of shapes in the scalers may be necessary, the more minute remnants may be removed by brushing with moistened pumice-powder, applied on cane-roots, or by the little circular brushes (Fig. 306) which are rotated by the burr-engine and are so serviceable for the general cleansing of the teeth. [A piece of cotton-wool or string or lamp wick, wound upon an old or broken engine point,

will make an excellent porte polisher for this purpose and for finishing fillings or filed surfaces. It is quickly made, and there is no temptation to use it for a second patient.] All tartar having been removed, and the surfaces of the teeth left smooth and

Fig. 306.



Two forms of brush to be used with the dental engine for polishing the teeth after the removal of tartar.

comfortable, the patient will find much benefit from an astringent lotion,¹ both to allay irritation caused to the gum by the process, and also to render the now more exposed necks of the teeth less sensitive to changes of temperature. A careful and frequent use of the tooth-brush must be insisted on, a soft one in preference to a very hard one, at least for a time; and a dentifrice composed of prepared chalk and pure soap, flavored with a little orris-root, and scented with a minute quantity of oil of roses, may be employed with much advantage, and to this can be added, if necessary, a small quantity of tannin, borax, or alum.

[The latter has, however, been much objected to, as liable to injure the enamel, and, since the desired astringency can be better and more pleasantly supplied by pulverized galls or gallic acid, it will be safer to discard it.]

By removal of the tartar we shall have got rid of a very common local cause of congestion of the gum, to which subject we now return. With regard to treatment, we may in the milder cases recommend some simple astringent lotion, of which we have found the tincture of tannin already mentioned to be the most serviceable; in the more severe cases, and those which are more of the character of chronic inflammation, we shall have to

¹ R. Acidi tannici, ζ ss.
(Eau de Cologne) ζ iv.

M. ft. applicatio.

About 10 or 12 drops of the above to a teaspoonful of tepid water, to be held in the mouth two or three times daily.

pay greater attention to the general health. In persons thus suffering we shall generally find the whole alimentary mucous tract to be affected, and remedies acting directly on that membrane will be indicated; thus ipecacuanha in one to two grain doses often does much to relieve, but that which we have found most successful has been *nux vomica*,¹ but it is a remedy that must be carefully watched. In cases of more acute inflammation of the gums, there is generally pain, and of a burning character; and, as it is rare for it to exist without some abrasion of the delicate epithelial surface, we get ulceration, under which head we may best consider the subject.

ULCERATIONS OF THE GUM.—Aphthous ulcerations of the mucous membrane covering the gums are by no means uncommon, especially in those who have long suffered from prostrating illness, and are frequently witnessed towards the termination of phthisical disease. Less common, but yet often met with in the comparatively healthy, they appear in connection with dyspeptic conditions, and usually present themselves, in the first place, as small detached vesicles, not unlike those in herpes, which soon burst, leaving a denuded surface. On the tongue, such ulcers, for they are most probably the same, although we cannot so often here witness their vesical stage, are very sensitive, giving a sharp pricking or stinging sensation when touched, and appearing like a small circle of lighter color than the surrounding tissues, with a central dark spot as if drawn by a pair of compasses.

With the thrush of children some have associated ordinary aphthous ulceration, but the former has certainly a different origin and character. It is due to the presence of a cryptogamic growth, the *oïdium albicans*, which finds suitable conditions for growth and development in the mucous membrane of children fed under unfavorable conditions. [This form of vegetable parasite is often the cause of considerable suffering in older persons. The writer calls to mind the case of a patient who had been for years under the care of numbers of practitioners,

¹ R. Extr. nucis vom. gr. vj.
Mist. acaciæ,
Tinct. cardam. co., aa fʒj.
Aquæ dest. ad fʒvj.

One-sixth part for a dose.

or R. Tinct. nucis vom. ℥xv.
Ex aquâ
bis terve die.

both general and special, who she said had in vain attempted to cure her. Patches of the size of 25 to 50 cent silver pieces were on the tongue, cheeks, and soft palate. The growth was immediately checked by the application of the tincture of iodine, followed by an astringent and stimulating mouth-wash frequently used. A reapplication of the iodine was made every few days if the *oidium albicans* made its appearance, and in less than two weeks' time the mouth was perfectly healthy. The trouble, however, recurs at times, generally in the spring season, but always yields to the above treatment.] Thrush appears at first in small patches, of white flocculent matter, not unfrequently mistaken for small portions of milk-curd; but its true nature is seen when wiped off, as it then leaves a surface devoid of epithelium, studded with minute bloody spots.

In the treatment of ordinary aphthous ulceration we may with advantage apply locally mel-boracis on a camel-hair brush. If it occur in the moderately healthy, a course of alterative treatment, combined with mild purgation, may be desirable. When it affects the subjects of exhausting diseases, the local treatment above suggested is alone applicable. The painful ulcers of the tongue may generally be cured by touching them with a crystal of sulphate of copper, or with a mixture of strong carbolic acid and glycerine.

In the thrush of infants, attention must be directed first to the diet, which is most frequently at fault. In the next place, the mouth should be carefully wiped out after each meal with a soft piece of rag dipped in cold water, the rag not being used a second time; the denuded surfaces should be dabbed with a small piece of rag attached securely to a piece of wood, and moistened with a solution of alum or borax, about eight grains to the ounce of water; in intractable cases, a dilute solution of carbolic acid and glycerine may be used. The appearance of thrush about the anus will indicate a more general extension of the disease in the alimentary mucous track, and indicate a more serious condition.

Another variety of ulceration has received the somewhat indefinite appellation of ulcerative stomatitis: it is chiefly met with in children residing in the unhealthy districts of large cities, but we have met with it in cases where sanitary conditions could not be found fault with, except that green vegetable

diet was almost wholly excluded from their bill of fare. The latter cases were those of children at a large public institution, who invariably suffered towards the end of a term. The least local irritation determined the ulceration, even regulation plates had to be abandoned on this account; yet on their return from vacation their mouths had resumed a perfectly healthy aspect. The disease usually presents itself during early childhood, from two to five or seven years of age being the commonest period. It is more common in the lower than in the upper jaw, and is generally seen upon the outer margin of the gum at the necks of the first and second temporary molars or the incisors, and most frequently but not always confined to one side of the mouth. Seen in the early stages the mucous membrane at the necks of the teeth will be found deeply congested with venous blood, swollen, and, from tension, somewhat shining, the conditions being much aggravated by the presence of necrosed teeth, denuded fangs, or tartar. As the disease progresses, ulceration of a gray ashy color makes its appearance at the free margin of the gum, and is accompanied by a thin sanious discharge, of offensive odor.

This condition of things continuing, more of the mucous membrane becomes involved, while the opposing cheek, where it rests against the gum, suffers in like manner. At this stage there is some swelling observable on the outer surface of the cheek. Further extension leads to exposure and exfoliation of the alveoli, with loss of the temporary teeth, and occasionally also of the bone containing the crypts of the permanent ones. Whether the disease if left to itself would go on until life was involved, or undergo a spontaneous cure at an advanced age, it is difficult to say: its having a constitutional cause would favor the former conclusion; but, no doubt, even the most neglected cases meet with treatment before such results could be likely to happen.

The disorder is happily so thoroughly under control, that, were we asked to mention a disease for which there was a certain specific, we should unhesitatingly pronounce ulcerative stomatitis to be the disease, and chlorate of potash the specific. The effect of the drug is visible in a few days, and all but the worst cases appear cured in ten days to a fortnight, and this without any local application whatever. The quantity of the

salt that we employ is, in infants up to three years old, three to five grains; to four or five years old, ten grains; and to seven or nine years old, fifteen grains; in all three times daily, and diluted in water, varying in quantity from a teaspoonful to an ounce, to which a little sugar may be added if desired. In the very debilitated, quinine may be combined with advantage, and fresh vegetable diet should certainly be recommended.

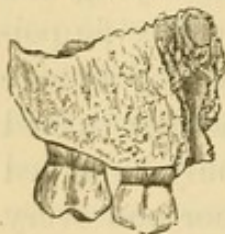[But in all these diseases, as well as in health, too much stress cannot be laid upon the importance of pure air.

The writer's consideration of the value of wood smoke as a disinfectant for the teeth, was suggested by some experiments with it in cases of scarlet fever. Believing that the nascent creasote would prove an active and more penetrating antiseptic than any ordinarily used, and further reasoning upon the advisability of some ready and convenient means of destroying the septic effluvia, and preventing the retention of the specific poison in the apartments, he had the sick-room warmed by a stove burning wood, and at regular intervals had the damper turned so as to drive the smoke into the room. It need only be added that blankets, bureau-drawers, the seams of the floor and every part of the bedding, the body and even the hair of the patients were kept constantly saturated with the odor. The disease not only did not spread, but was apparently mitigated very markedly. The writer is persuaded that measles, scarlet fever, diphtheria, and many of the diseases which of late years seem to have grown to be of a more virulent type, are very much indebted for this deadly power to the modern system of heating with hot-air and its mixture with coal gas.]

Besides the loss of some of the permanent teeth, troublesome cicatrices, binding the cheek to the gums, may result; but, unless they interfere to any extent with the opening of the mouth, they will not be of much consequence. The above-mentioned conditions appear in the most severe form when following the exanthemata, especially scarlatina, measles, and small-pox, and less frequently after continued fever; it is a question whether they are not then identical with the cases to which Salter was the first to draw attention, and for which he offers an ingenious explanation. He points out that the extensive necrosis of the maxillary bones, occurring after the above-mentioned diseases, and in the order of frequency in which we

have placed them, occurs usually at an age when the most active tooth-development and rapid nutritional changes are going on in the jaws, viz., between three and eight years, five years being the most common age. He believes that, as in the case of maxillary necrosis due to phosphorus fumes, so in that following the eruptive fevers, the cause is the application of a specific poison to the vascular parts of the teeth; but that in the latter the poison is generated within the individual. As the poison of the exanthemata,—scarlatina in particular,—affects especially the dermal tissues, the teeth, as a part of the dermal system, suffer with the rest, and in like manner affect their surroundings. The exfoliation here figured (Fig. 307) was the result of a neglected case of undoubted ulcerative stomatitis occurring

Fig. 307.



Necrosis of nearly the whole of the right superior maxilla of a child, the result of ulcerative stomatitis, occurring soon after measles.

within a few weeks after measles. It yielded readily to chlorate of potash; that is, the ulcerative condition entirely disappeared; but the necrosis which comprises the greater portion of the right superior maxilla did not become evident until some two months afterwards. Salter, however, says,¹ "it has seldom been preceded by swelling or pain, or accompanied by periosteal abscess," and, moreover, "its tendency is to be symmetrical." The above-mentioned case is then probably one of ordinary ulcerative stomatitis intensified by the effects of measles. With ulcerative stomatitis has

often been confounded another form of ulceration, happily rare in its occurrence, because of a much more serious character, very often fatal in its results.

[The respiratory track is much soothed by the smoke from bituminous coal or by the odor of tar, and the writer doubts not that these ulcerated surfaces would be less likely to occur if occasionally a piece of the former, the size of a walnut, were burned in the apartment, or if some oakum or freshly tarred rope, were kept to impregnate the air in the living room or nursery. He has frequently cut short threatened attacks of croup by the smoke of the former, and to-day one of the most successful means

¹ Dental Pathology and Surgery, by S. James A. Salter, M.B., F.R.S., p. 310.

of relieving the consumptive's painful cough is by exposing large surfaces coated with tar for the air of the room to absorb.]

Cancrum oris, or gangrenous stomatitis, as it has been variously termed, is a disease most common in children aged from two to twelve years. It does not always appear to attack the most emaciated or unhealthy, although more frequently those residing with unhealthy surroundings, and especially those who have suffered from exhausting fevers and other diseases. It commonly appears upon the inner surface of the cheek, soon causing it to swell, and giving it on the outer surface a prominence, tense, red, and glistening like an apple. To the touch it appears dense and unyielding. With the swelling of the cheek the neighboring glands will be found more or less enlarged, and the salivary secretion increased, being of a thick ropy consistency. As the disease advances, there will, on inspection of the mouth, be seen—not without difficulty, owing to the tenseness of the cheek, unless the practitioner employs a small mouth-mirror—a ragged-edged brownish ulcer, whilst the gums opposite appear to share the same condition. As the disease progresses, the saliva becomes highly offensive, tinged with blood, and colored by the disintegrated tissues separated from the ulcerated surface. The ulceration, which extends from the cheek to the adjacent mucous membrane, soon involves the alveolar process and the body of the bone itself. On the cheek the prominent red spot becomes black, and this is soon followed by sloughing, which exposes the interior of the mouth and reveals the frightful mischief which has occurred, and which is generally out of all proportion to the apparent spirits and the pain suffered by the patient, who, after this, soon sinks exhausted. This is but a very imperfect sketch of this frightful disease;¹ it is hardly likely to come under the attention of the dental surgeon in his ordinary vocation, yet it is well that he should be able to recognize it, as it is only in the earliest stages that the disease can be grappled with successfully.

The treatment will be first and chiefly directed to the local conditions. The patient being placed under chloroform, strong nitric acid should be applied to the ulcerated surface on the

¹ For an excellent account in the English language of Gangrenous Stomatitis, see West on Diseases of Infancy and Childhood, p. 652 *et seq.*

interior of the cheek, which may be best accomplished by conveying it upon a piece of amadou held by dressing-forceps: the amadou takes up a considerable quantity, and the acid is less likely to drop from it than from lint or cotton. The opposing surface of the gum must, if possible, be protected by a spoon or cheek-retractor, unless the ulceration has extended to it also; but the risk of touching healthy mucous membrane must not override the certainty of bringing the acid well into contact with the gangrenous parts. In severe cases the thermal cautery might, we suggest, be advantageously employed as well as the nitric acid. Soothing applications, combined with unirritating antiseptics, should follow the cauterization, whilst the patient must be well supported by nourishing diet, especially strong extract of meat, stimulants, and tonics. Port wine, bark, and iron are strongly indicated; chlorate of potash, which in some hands has proved of great service, may also be tried in doses of 10-20 grains every four hours. From time to time the mouth must be examined, and the nitric acid reapplied to any spot showing extension of the disease. In some cases much milder treatment has proved successful, but for typical ones bold and severe measures can alone be relied on.

Ulcerations of the gum may arise from other causes and conditions than those mentioned; thus in syphilis, salivation, and strumous and malignant affections, they appear in connection with, sometimes as the forerunners of, necrosis of the maxillæ. Broken teeth, or even worn-down teeth, presenting sharp and irregular surfaces, are a very frequent cause of ulceration of the mucous membrane of the mouth. Those formed on the tongue are often considerable in size, intensely painful, and at times of very suspicious appearance; the filing smooth or removal of such teeth will, if the cause be purely local, soon effect a cure. We cannot, however, too strongly impress upon our patients the importance of having such sources of irritation removed as soon as possible; for, should any tendency to malignant disease exist, they would be most likely to determine its appearance.

We frequently find ulceration arising in the neighborhood of the outer and posterior aspects of a lower third molar which is carious at this spot, and irritates the mucous membrane moved over it when the mouth is opened or shut. Filling, filing, or extraction will remedy the evil, but at the same time we may

employ with great advantage the combination of chlorate of potash with decoction of poppies spoken of at page 31.

We have already alluded to cases where the roots of temporary teeth became denuded of gum, and, owing to the advance of the permanent teeth, project, and often severely ulcerate the cheek. This occurs, though less commonly, in connection with permanent teeth, as their fangs when exposed are not pressed outwards in the same manner.

We have on more than one occasion, whilst considering the subject of ulcerations of the gum, alluded to necrosis of the jaws, upon which matter it is necessary to add a few words. Besides a death of portions of the maxillæ, the result of the ulcerative processes which we have described, necrosis may occur in what we term an idiopathic form, which term is little better than a disguise for our not being able to trace it to its true cause. When it thus appears, it is very desirable that the dental surgeon should not overlook the real trouble of his patient, who will very likely apply to him on account of pain which he refers to certain teeth. These may be found free from caries, but, perhaps, slightly loose and tender when percussed. The surrounding gum will often indicate by its puffy condition, and apparently loose attachment to the subjacent bone, what has occurred; and a fistulous opening in it, if such exist, will of course reveal the true state of matters. [The student may be reminded that the fistulæ from diseased bone have their openings through small, teat-like projections, and although the same general appearance may be met when the teeth produce the abscesses, the protrusion is generally very much smaller, ordinarily about the size of one-half a grain of rice.] It is not that he will do much harm in removing teeth which most probably will be lost in the progress of the disease, but that he may get, as many most unjustly have done, the unmerited credit of having caused it. When the mischief has been correctly diagnosed, we shall do well to warn our patient to prepare for what will be tedious and most disgusting to him; as, if we attempt to remove the diseased bone before nature has set the limit to its boundaries, and separated it from its healthy surroundings, we shall probably do more harm than good; at the same time we have found that, by cutting away, without violence, exposed and projecting portions, we have lessened the discharge and rendered the

mouth more comfortable. [Prof. Garretson¹ objects to the unnecessary meddling with or cutting of the dead bone.] Support by good nourishment, a moderate amount of stimulant and tonics, with, if possible, a change of air, will be the best means of assisting nature to do her work; whilst frequent washing, or, if possible, syringing with Condyl's fluid, weak solution of carbolic acid, or the *lotio sodæ chlorinatæ*, will reduce to a minimum the offensiveness of the discharges, which too often causes a susceptible patient to be constantly sick and to loathe his food. [Permanganate of potassa, a few crystals of which may be dissolved in a sufficient quantity of water, makes a disinfectant mouth wash of a pleasing color, and not exceedingly unpleasant taste.]

As soon as the sequestrum is found to be detached from the neighboring bone it should be removed, to effect which it will often be found necessary to free it more or less by the knife from the surrounding mucous membrane. The portions of the maxillæ most liable to necrosis are undoubtedly the alveolar portions, which it is not difficult to account for when we consider their immediate relationship to organs so prone to disease as are the teeth. [Carelessness in allowing arsenic used for destroying pulps to escape from the cavities and get upon the gum or the jaw-bone, has likewise been a cause of necrosis. In one case, in the mouth of a lady who had been under the care of a dentist of note, the septum of bone between two lower molars was devitalized; after being a source of annoyance for some months, the patient came under the writer's care, and was quickly relieved by the removal of the sequestrum.] When we consider how much this portion of the bone suffers during alveolar abscess and chronic periodontitis, it is surprising that necrosis of more or less of it does not follow as a rule rather than an exception; indeed, we may to some extent overlook this cause of necrosis. Whilst we are now writing, this matter is undergoing investigation by our colleague, I. Lyons, who has already collected several cases of necrosis in which the history points to considerable pain and inflammation having existed long previously in teeth which have apparently recovered, but their injurious effects on the surrounding bone have become subsequently evident. Should this be proved to be other than excep-

¹ [Garretson, *Oral Surgery*, pp. 712-717-723.]

tional, it may lead us to adopt a somewhat less conservative treatment with regard to teeth which are the subjects of severe periodontitis. The teeth which appear most frequently to cause necrosis in their neighborhood are the incisors of the upper jaw: whether this be due to any peculiarity in the structure or condition of the bone at such parts, or to the circumstance that we are more loath to remove these than any other teeth, even when much diseased, is a question that we will not venture to decide. The exfoliations are often not considerable, involving only a portion of the external alveolar plate.

[It may likewise be remembered that this portion of the bone is liable to injuries from blows, being less covered by muscular tissue, and is moreover at the periphery of the hæmal system, and the blood may often fail to circulate in these parts during depression and weakness.]

The necroses which occur in connection with syphilis, mercurial salivation, phosphorus-poison, etc., form a portion of general surgery which the dental surgeon will have to study from works devoted to that subject: their consequences will more directly affect him as he will be called upon to supply the vacuities which those diseases have effected.

As regards the removal of teeth in cases where necrosis is going on, much judgment must be exercised. If they are unsound, and evidently a cause of irritation, they should be extracted; but, if sound and not apparently exciting irritation, they may be left, in the hope that new bone may, after the separation of the old, be developed around them, as has been recorded in a few rare instances. The new bone formed in the lower maxilla especially has been shown to have a strong tendency to become atrophied or absorbed: some have attributed this to a want of proper use or exercise, and it has been suggested—even attempted, we believe—to effect this object by supplying artificial dentures to rest and exert pressure upon it, but with what result we have never learned.

[The writer saw a most remarkable case of reproduction of the bone of the lower jaw, in one of Prof. Garretson's patients, where the floor of the mouth seemed to have a bony basis reaching from one side of the inferior maxilla to the other.¹]

¹ ["Garretson's Oral Surgery," p. 724.]

CHAPTER XIX.

CICATRICES CLOSING THE JAWS.

THESE may occur as the result of most of the forms of ulceration which we have considered. Those resulting from ulceration of the cheek, by irritation of the fang of a temporary tooth, or a mild attack of ulcerative stomatitis, although very common, are seldom of sufficient inconvenience to call for interference. Those following severe cases of ulcerative stomatitis, or the ulcerations which are the result of mercurial salivation, or following the exanthemata or gangrenous stomatitis, are much more serious and difficult to deal with. In these latter cases there is often not merely a loss of mucous structure, but likewise of muscular and bony tissue. This hiatus becomes in the first place supplied by connective tissue, but, as time advances, it contracts and becomes condensed, and in some cases even ossified;¹ thus holding, on that side of the mouth, the two jaws in firm apposition, nay, even drawing them unnaturally together, as seen in the displacement of the bicuspid and molar teeth. It is a question whether something might not be done to prevent these results by treatment at an early stage, *i. e.*, after the ulceration has terminated and the healing process commenced, and the treatment which we are about to suggest would, no doubt, be more effectual were it generally applied earlier. To those only who have undertaken the separation of webbed fingers or toes is known the difficulty of preventing the reunion of the severed tissues, and it is much the same with the mouth. The mere dissecting-out of the cicatrices is utterly useless, the same tissue appearing in its place soon afterwards, perhaps less elastic even than its predecessor. Dentists are familiar with deep sulci covered with healthy mucous membrane that are met with in

¹ Perhaps we should rather say makes way for osseous tissue developed at the spots where the bone has been lost.

the mouths of patient individuals who have worn gold plates, the outer edges of which were too deep, and formed ulcers, these healing over when the furrows thus formed were sufficiently deep. It occurred to one of that body, J. C. Clendon, to treat,—and we believe with the greatest success yet attained,—cases where the cicatrices had been freely divided at their attachments to the maxillæ, by means of metallic plates, the edges of which prevented reunion between the cheek and the opposing maxillæ. The proceeding is best accomplished by placing the patient under chloroform, freely dividing the attachments of the cicatrix from both maxillæ, and then forcing open the jaws and obtaining an impression of the defective side with Stent's material, taking care that some of it passes between the divided surfaces. Plates are then struck up adapted to the jaws of that side, and firmly attached to the teeth, if there be any; if not, they should be kept in place by a strong spiral spring, the outer side of such plates passing well between the divided surfaces. The plates should be introduced whilst the patient is again under an anæsthetic, when the knife may be further employed, if necessary. The plates must be worn continually for weeks or even months after their insertion, and, in addition to this, it may be necessary to retain between them some elastic material. In the more severe and complicated cases, where irregular masses of bone fuse together the two maxillæ, the only measure at all calculated to afford relief is the operation of Esmarch, which consists in removing a wedge-shaped section of the lower jaw anterior to the obstruction, and obtaining at that point a false joint. In a most interesting communication made to the Odontological Society by Claude Rodgers,¹ a case was narrated in which a lower gold plate bearing artificial teeth, and connected with an upper one by springs, had completely divided the jaw-bone on the right side, and had partially done so on the left side. "The patient said he suffered little or no pain." Surely, we are here offered a valuable suggestion for a perfect and efficient means of effecting the division of the jaw, with the certainty of preserving its mobility; indeed, the hint might prove valuable in many other surgical cases.

¹ Trans. Odont. Soc., vol. xii. p. 53.

CHAPTER XX.

TUMORS OF THE GUM AND UPON THE JAWS.

THESE can be most conveniently described in relation to the structures which form their essential part. Small mucous tumors of the gum are very common; the cause of their origin is, usually, the uneven edge of a carious tooth. The teeth move slightly in their sockets during mastication, as witnessed by the polished facets which they present where they touch each other laterally. This movement, under the above-mentioned conditions, no doubt greatly irritates the gum, producing a hypertrophy of the mucous membrane at the spot, and the growth, especially if there be an adjoining tooth, assumes a polypoid form. These mucous polypi are of a darker color than the surrounding gum, and soft, but not very sensitive to the touch, and they bleed very readily when irritated; they seldom grow as far as, and hardly ever beyond, the level of the crowns of the adjacent teeth. When they occur in parts of the gum not occupied by teeth their origin is still, doubtless, due to some irritation. Their treatment will consist in removal: this will be readily effected by cutting them off close to, or a little below, the level of the gum with a scythe-shaped lancet (see Fig. 214), and touching with caustic the spots from which they have sprung. Those which have their origin in the irritation of the ragged edge of a carious tooth will, if that be not removed, soon appear again; hence, after their excision, the carious cavity must be filled. In such cases the wooden wedge placed between the teeth will be of much service, as it will not only press away the gum and arrest its bleeding, but also enable the operator to have the stopping perfectly smooth at the cervical edge of the cavity. When these growths occur in connection with roots, the latter, as a rule, should be removed, and the polypi will soon disappear of themselves.

PAPILLARY TUMOR OF THE GUM.—This growth, which was, we believe, first described by Salter,¹ and which consists almost entirely of hypertrophied epithelial tissue, is a rare form of tumor which occasionally invades the region of the jaws. We have met with but one instance of it, about the size of a bean, and situated at the junction of the alveolar process of the superior maxilla with the body of that bone, and resembling a bunch of spring onions in miniature. It had existed several years, and, as its presence was not the object of our patient's visit to us, we neither suggested interfering with it nor were desired to do so, but we inculcated the importance of carefully watching it, and of having attention paid to it, should it appear to increase in size, as, in a second case, occurring in Salter's practice, which was operated on by Cock, of Guy's, it recurred and proved fatal.

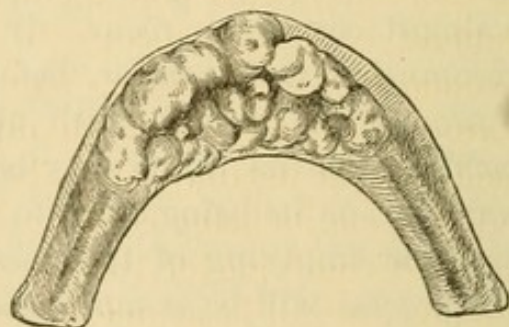
VASCULAR TUMORS OF THE GUM.—In this form of growth, it is the vascular element that chiefly predominates. They do not in general extend to any great distance above the level of the surrounding gum, but may occupy no inconsiderable area upon it. Their color is of a deep purple, and their origin is congenital, in fact, they are doubtless venous *nævi* upon the gums. In their removal,—the only treatment that presents itself,—care must be taken to thoroughly extirpate them, as, if any portion be left, they are almost certain to recur. In order to do this effectually, we recommend the operator, before employing the knife, to mark around the growth with nitrate of silver or strong carbolic acid, so that its limits may be seen during the process of removal; for, on its being cut into, it almost entirely disappears through the emptying of the vessels which give it distinctness. The process will be as much one of scraping as of cutting, and upon the surface of the bone, which, when laid bare, should be washed over with strong nitric acid, or, better still, be rubbed over with the extremity of a thermal cautery, which will destroy such portions of the growth as have their origin in the vessels of the periosteum. Tumors having their origin in the periosteum of the jaw, or the alveolo-dental membrane, are by no means unfrequent. They may be general or

¹ Guy's Hospital Reports (1866).

circumscribed; in the former they constitute what has been termed *hypertrophy of the gums*.

HYPERTROPHY OF THE GUMS.—This may be congenital, or appear long after birth. It seldom attracts much attention until after the first teeth are erupted, when the growth becomes more active. On examining such a case, we shall find the gums greatly enlarged, and nodulated like the surface of a mulberry; in color a little darker than normal, but still not unhealthy-looking in this respect. The teeth erupted appear moved by the growth to abnormal positions, and are enveloped by it up to, and at times beyond, the summits of their crowns. In the upper jaw the projections from the alveolar borders may meet and completely fill up the arch of the palate, as in a case which we met with at the London Dental Hospital, and which we referred to the consulting surgeon, C. Heath, who has published an account of the same.¹ The non-congenital cases, which never, or hardly ever, appear to increase to the dimensions assumed by the congenital ones, seem to have their origin in the irritation caused by teeth; for, when these, which have been generally loose for some time, are removed, the hypertrophy, as a rule, disappears (Fig. 308). It may, however, be, that in removal of

Fig. 308.



Hypertrophy of the gum—not congenital—which disappeared after the removal of some loose teeth.

the teeth, the alveolar processes, from which they appear chiefly to spring,—as shown by C. S. Tomes in an examination of the case just referred to,—become absorbed, and thus the growth becomes atrophied. Complete removal is the treatment indicated in the congenital cases. It is an operation by no means

¹ Trans. Odont. Soc., vol. xi. p. 18.

easy to perform, especially in the case of young children, and must be done piecemeal. The knife must be employed as much as possible for incising at the margins of the growth, but the bulk of the process will have to be performed with bone-cutting forceps, which should include a considerable portion of the alveolar margins as well as the growth. In arresting the hæmorrhage and destroying small portions of the growth not included by the cutting-forceps, we shall find the thermal cautery of much service. [The burr upon the dental engine has been much used by Prof. Garretson, who likewise urges the importance of leaving a goodly portion of the body or lower rim of the bone, even if it may be at the risk of having to repeat the operation, rather than cutting entirely through and destroying the continuity of the bone.¹] In the non-congenital cases, removal of the teeth is the treatment; for, if an attempt were made to remove the growth and save the teeth, portions would be almost sure to be left to incite further growth; still, if the teeth appear sound, firm, and useful, such an attempt may be made.

EPULIS.—The more circumscribed tumors, the chief constituents of which are fibrous tissue, and which usually come under the denomination of fibrous epulis, appear closely connected with those last mentioned, as regards both their structure and their seat of origin. Their being so frequently found in connection with diseased teeth, or roots of teeth, would lead us to conclude that they resulted from irritation of the periosteum of the jaw, or alveoli of the teeth; they occasionally arise, however, in the proximity of perfectly sound ones. In color their surfaces resemble that of healthy mucous membrane, except where they are from their size bitten upon by opposing teeth, or otherwise irritated, when they appear indented and superficially ulcerated. Upon pressure they feel either smooth or nodulated, firm, and slightly elastic; moderate pressure is not attended with pain; and it is probable, from their altogether painless nature, that prior to the days of anæsthetics, patients allowed them to grow to enormous dimensions before resorting to medical advice; now they seek sooner to be relieved of their inconveniences, and we seldom see them of anything like the size described in the works of older surgical writers. The

¹ [See "Garretson's Oral Surgery," pp. 703-754.]

largest that we ever removed was about the size of a mandarin orange. As it arose from the outer border of the upper alveolus, and occupied a place between the cheek and the gums, it gave comparatively little inconvenience, which up to that time had been endured by the patient in preference to its removal; this latter we accomplished without much difficulty, as it was pedunculated. The most common period for their appearance is towards and about middle life. In structure they present chiefly a fibrous character intermingled with fibro-plastic cells. The fibres are collected in bundles arranged in a wavy form, springing up and radiating from the periosteum of the alveolar process, or from the alveolo-dental membrane, and containing the cells in their interstices. Spiculæ of bone, or small nuclei of bone-development, are frequently found in the more central and basal portions of the growth. They are moderately vascular, but more so than the ordinary type of fibrous tumor. The treatment will consist in their removal by excision; nevertheless we have met with some of small dimensions which have been more than kept in check by a continual application of tannin. We had these under observation for several years, and they certainly decreased in size; but of the ultimate results we have no history. In their removal by operation, the structure from which they have their origin must be borne in remembrance; for, to merely excise them to the surrounding level will be but to leave the foundation for a future growth of a more active character, and harder to deal with than its predecessor. The growth, including a small portion of surrounding healthy tissue, and quite to the surface of the bone, should be removed with the scalpel; the bare bone should then be scraped or superficially cut away with a gouge or bone-forceps; and finally we recommend the application of strong nitric acid, which will affect those portions of periosteum which superficially enter the bone, and which the gouge cannot reach. Instead of scraping the bone, and applying the nitric acid, we may employ the actual cautery; the latter is best suited to cases where the exposed bone presents an even surface, the former to those where it presents an uneven and irregular one. It is better to be over-severe in our treatment than to err on the opposite side, and subject our patient to the chance of a recurrence of the growth, causing

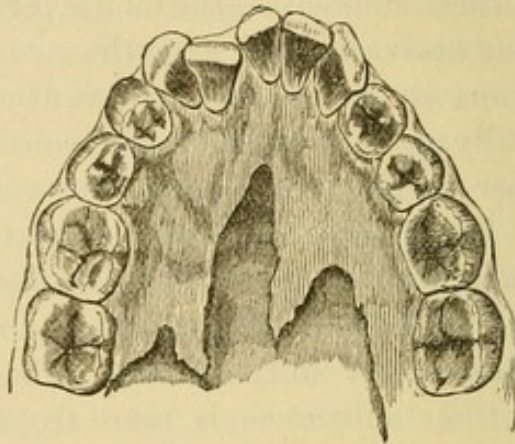
him not only inconvenience, but probably a wretched anxiety with regard to its true nature

MYELOID EPULIS.—This is considered by Heath as only a variety of that last mentioned, differing in being more vascular and containing in much larger quantity the polynucleated cells or myelo-plaxies which led Paget to give them this descriptive name. Whether these elements—the characteristic ones of marrow and bone in an active state of growth—are to be found invariably in all fibrous epules, we will not venture to express an opinion, but we fully agree with those who consider these tumors as having a deeper origin than the fibrous variety, viz., below the periosteum. They occur, as a rule, at an earlier age, are of more rapid growth, and more readily become ulcerated than the former; while in appearance they are of a darker and more purple color, and are softer to the touch. The presence of portions of bone in their substance is more frequent than in the fibrous variety. They appear upon the alveolar processes of both jaws, but are, we believe, more common to the lower than to the upper jaw. The treatment will consist in their removal; and, as they have a deeper origin than those last described, we must sacrifice with them more of the subjacent bone. In a case where we removed a myeloid growth of considerable size from the right alveolus of the lower jaw, in a boy aged nine years, we contented ourselves with removing the bone only that covered the unerupted cuspidati and bicuspidi, hoping thereby to be able to preserve those teeth; and, so far as we were able to follow the case, our object was attained, and no return of the growth ensued, but the actual cautery was freely applied to the surface of the bone where it had been excised.

OSSEOUS GROWTHS.—Those upon the alveolar surface are far from uncommon. Their most usual seat is upon the lower jaw, on its inner surface: here they somewhat interfere with the comfortable adjustment of an artificial denture, and are thus brought conspicuously under the notice of the practitioner, the patient being in many cases quite unaware of their existence. Our belief is that they correspond to splints as seen in the legs of horses—an effort of Nature to strengthen a part somewhat unduly taxed. The teeth of these subjects are generally strong, and show evidences of having been well employed. The most marked cases that have come under our notice have been in indi-

viduals who lived largely on oatmeal. The illustration given (Fig. 309) was taken from a cast of the mouth of an eminent physician; and, although the prominent portions of bone projected considerably under the tongue, they never gave rise to

Fig. 309.



A case of considerable exostosis of the lower jaw.

inconvenience. From their density of structure they would be difficult to remove, as much so perhaps as the so-called ivory exostoses of the cranium.

Malignant growths occur in the regions that fall under the province of the dental surgeon, as well as in other parts of the body. Their presence is no doubt sometimes determined by the irritation of diseased and broken teeth; but, even when we bear in mind the amount of irritation which may be thus set up, it is very rare indeed to be able to assign this as a direct cause of cancerous growth. It is only right that every dental surgeon should be able to diagnose such tumors in the earliest stages of their existence, and in this he will hardly fail if he has paid due attention to that surgical portion of his course of study which rightly forms an important part of a dental curriculum.

CHAPTER XXI.

DENTIGEROUS CYSTS.

UNDER this designation are included two if not three varieties of cystic disease; first, the occurrence of cysts in the alveolo-dental membrane, or at some little distance from it; secondly, cysts which form in connection with teeth which have suffered impaction or otherwise delayed eruption; and perhaps thirdly cysts found where a tooth or teeth should exist, and containing a number of very imperfect, irregularly formed, teeth attached to their walls. The first are much more frequent in occurrence than has been generally supposed, and, though not absolutely confined to the permanent teeth, much more common in connection with them than with the temporary teeth. Our attention was turned to the subject of their existence many years ago, and our interest awakened in it from watching the progress of two cases operated on by the late Sir W. Lawrence, whilst we were acting in the capacity of dresser to that gentleman.

The tumors were then called and treated as "hydrops antri," but we perceived in their structure, and more especially in their contents, clear evidence that they were cystic growths, and we shortly afterwards published our views to the effect that "hydrops antri" as a disease had no real existence,¹ a view which had already, unknown to us, been advanced by Giraldes.

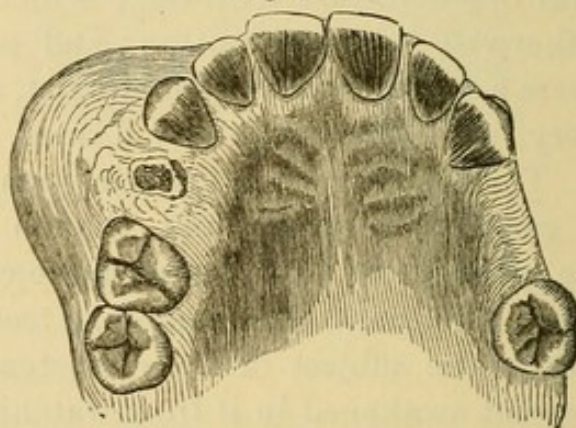
The situation in which this disease most frequently presents itself is directly above the apices of the fangs of upper first or second bicuspid; we have seen it, but more rarely, over upper cuspidati, and, on one or two occasions only, in connection with upper lateral incisors and upper molars. In the lower jaw, on the contrary, a molar has been most frequently associated with it. It generally appears at first as a small painless swelling over a tooth on the outer alveolar wall, and is very frequently

¹ Trans. Odont. Soc., February, 1862.

mistaken for an abscess. As it increases in size, it produces more or less discomfort and inconvenience, from food lodging between it and the cheek, and we have generally been told by patients that the swelling has increased and been somewhat tender when they have suffered from catarrh. [A case where a cyst or abscess had involved the antrum is spoken of on page 237.]

To the touch the swelling will yield a semi-elastic feeling, with no distinct sensation of fluctuation; but that which is most characteristic is the crackling parchment-like sensation,—“craquement,”—felt on pressing it, and due to the yielding of the thin outer layer of bone distended by its growth (Fig. 310).

Fig. 310.



The appearance of a cystic tumor of the upper jaw caused by a diseased bicuspid root.

This, however, is not always present; the bone may be too dense to permit movement, as is generally the case in the lower jaw. At times a distinct bony ridge is felt upon the surface of the swelling.

The cause of these growths is obscure. We may perhaps attribute their frequent occurrence in connection with teeth to the liability of the latter to conditions producing irritation and hyperæmia about their roots. It may be observed that two classes of organs in the body especially liable to the occurrence of cysts in their surroundings, viz., the teeth and the testicles, are both of them developed in positions from which they afterwards migrate; but the liability of the ovary and its surroundings to the same conditions would preclude our laying much stress on this analogy. In most cases, we believe, it will be found that these dental cysts have their origin in the cellular tissue which forms the sheath to the nerves and bloodvessels in their course to the teeth; as, in the case of the bicuspid espe-

cially, these pass through the bone, forming the base and outer wall of the antrum; the development of a cyst distends the bone on the one side externally, and on the other internally into the antrum.

On the subject of the treatment of this class of cysts, extracts from a paper which we contributed to the "St. Bartholomew's Hospital Reports"¹ will, we trust, as they include cases actually treated, prove acceptable to the reader.

"I have remarked that the treatment often adopted for this disease is not always so simple as is actually called for.

"The plans I have for several years carried out have in all cases in a very short time effectually cured the complaint, and have been, I imagine, far more acceptable to the patient than those directed by, at least, our older authorities upon the subject, such as removal of a considerable portion of the outer wall of the antrum; removal of a molar tooth and perforation of the floor of the antrum through its alveolus with a trocar; or even the slitting through of the cheek to facilitate the first operation, which process I have myself witnessed in the person of a female some years ago.

"The process of treatment I would recommend can, I think, be best illustrated by selecting three cases out of those I have met with during the present year.

"CASE I.

"M. T., male, æt. 27, out-patient at St. Bartholomew's Hospital. Bony prominence above left upper cuspidatus unyielding to pressure. Tooth carious, but too good to be sacrificed. Free incision through bony wall of tumor with strong scalpel, escape of serous fluid, introduction of tent of lint, about one inch of which moistened with carbolic acid to irritate and provoke suppuration of cyst—lint to be removed by patient at the end of twenty-four hours. Pain and swelling ensuing, the lint was removed after about eight hours, but suppuration set in and ceased in about ten days.

"CASE II.

"A female, æt. 19, in Lawrence Ward, under the care of Sir James Paget. Swelling on left side of mouth above upper bicu-

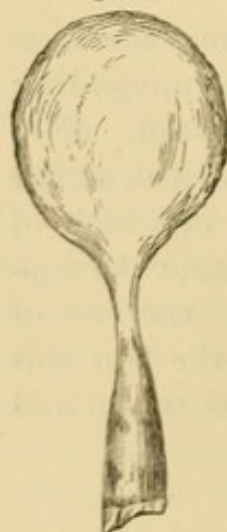
¹ St. Bartholomew's Hospital Reports, vol. vii.

pid teeth, or rather their roots. These, with those of the first molar, were removed under the influence of nitrous oxide. On removal of the second bicuspid root, there was a gush of serous fluid. Through the alveolus of this tooth the lint, as in the former case, was introduced into the cyst, suppuration set in in the course of a few hours, and the patient was discharged in the course of a few days.

“CASE III.

“Mr. W., æt. 24, a private patient, sent to me by my friend Mr Pocklington, of Wimbledon. This patient applied on account of what he believed to be a gum-boil, situated on the right side of the face, above the roots of the first and second upper bicuspid teeth. He informed me that he had never suffered pain from it, but he applied on account of the swelling, which was beginning to present deformity. The second bicuspid was carious to the level of the gum; the first bicuspid carious, but capable of being preserved by filling. Under the influence of nitrous oxide, the second bicuspid fang was forcibly grasped with a sharp pair of root-forceps, which were well pressed up. A large quantity of serous fluid immediately escaped; and as the tooth was removed a membranous substance was likewise removed attached to it. This proved to be a cyst

Fig. 311.



A cyst removed with a bicuspid of the upper jaw.

of almost the exact form and size, when distended, of a pigeon's egg (Fig. 311), which had been ruptured in the process of removal. The patient was congratulated upon having escaped a painful and troublesome portion of the treatment, previously explained to him—viz., that of having to endure the tent of lint and the subsequent suppuration, in consequence of the cyst having been removed—but too hastily, for secondary hæmorrhage set in the same evening, and Mr. Pocklington had to plug the cavity the tumor had left. Within about two months I operated upon the same patient for similar disease upon the left side of the mouth. This time it was connected with the first upper bicuspid, also a root. When this was removed, the cyst did not come away, so the tent was introduced, and somewhat forcibly,

to prevent if possible the unpleasant complication which occurred in his former case. But of no avail. Hæmorrhage, to which this gentleman and several members of his family are liable, again took place; and Mr. Pocklington's services were again required to forcibly plug the cyst, through the aperture of the alveolus of the first bicuspid.

"I need not comment further upon the treatment of these three typical cases than to observe that the following rules may be adopted. If the disease be traced to a tooth, and that tooth, though diseased, be capable of being saved, we should open the tumor above it, and by suitable means promote suppuration of the cyst, which will end in a cure. If the disease be connected with a useless tooth or root, we should remove either, and cause the tumor to suppurate through the alveolus. Should the cyst come away with the tooth, we may congratulate ourselves and the patient that the best thing for the credit of the former, and the best thing for the comfort of the latter, has happened.

"I have laid much stress upon making the cyst, when left, suppurate, and upon this ground. I have seen cystic tumors, in which the cyst has been tapped several times, and in which stimulating injections have been employed, close up again, and continue to secrete the characteristic fluid; but when once suppuration has occurred, healing up and gradual disappearance of the swelling has been the result."

In the second variety an unerupted tooth is the cause. There can be little doubt but that the serous fluid is secreted within the dental capsule, which thereby becomes distended. On cutting open such a cyst and evacuating its contents—a light straw-colored or brownish fluid, which on settling becomes coated over with shining crystals of cholesterine, the product of fatty degeneration and common to cystic growths—the crown of a tooth is found projecting into it, the fang being more or less attached to the surrounding bone; or it may happen that the cyst has so far encroached upon the bone which sustained the tooth—its alveolus—that the tooth has lost its hold and is found lying at its most dependent part.

The symptoms of this form of dentigerous cyst will be on the whole very similar to that first described, viz., a painless and unaccountable swelling in the maxilla at or near to the alveolar process, except that where it is situated a tooth will be

wanting, unless, of course, its origin should have been from a supernumerary one.

Considerable difficulty exists in explaining the cause of these cysts. Thus, unerupted or impacted teeth often exist without any such condition manifesting itself. The most probable explanation to our mind is one that we have given in connection with the views which we have already expressed with regard to the eruption of teeth.¹ Teeth developed in abnormal positions become, when carried to the surface in the process of eruption, impacted amongst the dense and more stationary layers of bone which form the alveoli of other teeth; thus their progress is interrupted whilst the surrounding bone still pursues its course.

We must also bear in mind that these tumors most commonly manifest themselves at a period succeeding that when the alveolar portions of the maxillæ have been in a state of active development, in which they can readily furnish such an amount of bone as will perfectly envelop such teeth. By and by, as this activity lessens, such will not be the case, and there will be a tendency to the existence of a "hiatus" at that portion of the tooth most distant from the nutrient or medullary portion of the bone. The capsule of the tooth, the remains of the so-called enamel-organ, has been shown by J. Tomes to be, after the calcification of the enamel, quite free and detached from that structure, but, being attached to its surroundings, it will be carried with these away from the crown of the tooth; a space will thus be left, into which, as a matter of course, serous fluid must, under atmospheric pressure, be effused, and thus a cyst be formed. The further progress of the disease will be the approach of the cyst to the surface, where, if not interfered with, it will eventually evacuate itself. Before this takes place it not uncommonly happens that it has so exposed the fang-portion of the tooth, that the tooth loses its hold, and falls into the cyst.

The third variety has probably more analogy to the dentigerous cysts found in ovarian tumors than to those above described: here we have evidently a cyst developing teeth on its

¹ On the Pathology of One Form of Dentigerous Cyst, St. Bartholomew's Hospital Reports, vol. xii. p. 91.

internal mucous membrane. The teeth also in their irregular form and structure, such as appeared in Tellander's and Mathias's cases, before alluded to, resemble those often met with in ovarian cysts. In both we have found teeth destitute of any pulp-cavity.¹ This class, as representing a tooth, might also be regarded as odontomes.

In the treatment of the latter two classes we shall adopt much the same plan as in the first, except that in addition to opening the cyst we shall remove any tooth or teeth that it may contain. The third class have generally evacuated themselves spontaneously, as will be the case with each variety if not interfered with. After serous fluid has been discharged for some time, the secretion becomes changed in character, until finally it appears as pus. In this condition the case is not unfrequently mistaken for alveolar or antral abscess.

It has been said that alveolar abscesses are sometimes converted into cystic tumors, and a case of this kind is reported by Salter;² without denying the possibility of such conversion we cannot say that any case has come before us to support us in entertaining that view. We have met with two cases where abscesses arose in connection with roots of teeth with which cysts were connected (Fig. 312): the cysts had evidently from their condition, the results of inflammation, been the cause of the abscesses. Had these cysts been left, and had they increased to ordinary dimensions, the inference would have been that they had originated out of the abscesses. We doubt much whether a surface, even though a true serous membrane, which has once secreted pus, and which remains more or less damaged in consequence, can again secrete a serous fluid. Indeed, in attempting to destroy the serous secretions of these cysts, we do so by exciting that of pus.

Fig. 312.



A small cyst in connection with a bicuspid root. The cyst had lost its vitality, and had given rise to an abscess in its immediate neighborhood; otherwise the cyst had no connection with the abscess.

¹ Trans. Odont. Soc., Nov. 2, 1863.

² Dental Pathology and Surgery, p. 241.

CHAPTER XXII.

DISEASES OF THE ANTRUM.

THE cavity which exists in the superior maxillary bone, and has for many centuries been known as the antrum of Highmore, is lined with a thin covering of mucous membrane, continuous with that of the respiratory tract, through its small opening into the middle meatus nasi, which is liable to disease, as are also its bony surroundings. We have recently treated of cysts in connection with teeth which frequently occupy much or the whole of the antrum, and which were mistaken for a disease, "hydrops antri," presumed to have its origin in the occlusion of the meatus antri, which prevented the secretion of mucus from finding an outlet. The normal secretion from the lining membrane of the antrum probably never accumulates in sufficient quantity to flow out of the cavity, or, indeed, to do more than slightly moisten its surface. When congested or slightly inflamed, as in catarrh, it probably, like the frontal and sphenoidal cavities, contributes its abnormal share of mucus or muco-purulent fluids; but even on this point we have no direct evidence. When, however, it is the subject of chronic inflammation, the membrane secretes, and in abnormal quantity, a thin purulent fluid of very offensive smell, which is continually flowing into the nostril of that side. The origin of this condition is obscure, for, though in many cases it may be traced to the irritation of diseased teeth, the roots of which are in some instances in absolute contact with it, in many it cannot in any way be so connected. The symptoms too are not clearly marked: a dull continuous pain about the region of the maxilla affected, as also the orbit of that side, and an offensive discharge from the same nostril, increased in quantity when the head is laid upon the opposite side, are the most reliable; but these may occur when one of the turbinated bones, or its covering, is affected, and the


antrum of that side is perfectly healthy. With regard to treatment, there can be no difference of opinion upon one point, viz., that, when the distressing symptoms mentioned above are present, we should remove all roots or very faulty teeth from the superior maxilla of the affected side. Much may be learned as well as gained by this step, for, by examining with a silver probe the vacant alveoli, we may find that with but slight pressure it will pass into the antrum, when an odor from the probe, or the reverse, will at once settle the question.

For abscess of the antrum, or suppuration in the antrum, as it is variously termed, may be mistaken cases where alveolar abscesses have opened into that cavity. The symptoms here are, probably, more severe pain at the outset, referred especially to an upper tooth; then more or less relief followed by a copious discharge of well-formed pus from the nostril of that side. The removal of such a tooth may be followed by a flow of pus from its alveolus, either immediately, or after the introduction of a probe through it into the antrum.

The treatment of true chronic inflammation of the membrane lining the antrum, although generally successful in the end, is very tedious, much depending upon the age and general health of the patient. Our first object will be, to secure a free communication between the cavity of the antrum and the mouth. If, on the removal of a tooth, a probe will pass through the alveolus into the antrum, the opening should be enlarged to fully $\frac{1}{3}$ inch. Should no communication be effected with the probe, or no tooth be removed the roots of which run to the floor of the antrum, then an opening should be made just above the first molar tooth on the outer surface of its walls: we do not recommend the removal of a sound tooth for perforation through its socket. The instrument best suited for the operation is that figured (Fig. 313), which we constructed out of a round file sharpened to a four-sided point: a vulcanite button about $\frac{3}{4}$ an inch from the point prevents the instrument from entering further into the antrum, and endangering the orbit, and with it the operation can be performed in a few seconds. The next, and a most important point will be, keeping the opening patent, as it will have a strong tendency to close up, and this will best be effected in the following manner. A piece of gold or platina

tube, about $\frac{1}{10}$ inch in diameter, is constructed, and also a metallic plate to fit over that portion of the jaw in which the

Fig. 313.



Instrument for making an opening into the antrum.

opening exists, and this may be made available for artificial teeth if required. The tube is soldered to the plate in such a position that when the plate is fitted to the mouth the tube passes through the opening into the antrum, projecting into it about $\frac{1}{8}$ inch from its floor. As it is important to preserve correctly the relative positions of the tube and the plate to the jaw and the orifice, we may describe how this can readily be effected. The plate and tube being constructed, the former has a hole made in it corresponding to that leading into the antrum: through this, when the plate is in the mouth, the tube is passed into the antrum to the required depth, and then its inferior portion, which projects below the plate, is attached to the latter by some plaster of Paris. When the plaster has set, the plate and tube are removed from the mouth and soldered in the correct positions, and the superfluous portion of tube is filed off level with the plate.

The height of the tube in the antrum prevents the purulent fluid from running into the mouth, whilst the open tube enables the patient to wash out the antrum in the simplest manner possible: he has only to take fluid into his mouth, close the nostril of the opposite side with his finger, and then, by compressing his cheeks, force it through the tube into the antrum and out at the open nostril. As constant washing out of the antrum constitutes a most important element in the treatment, and as the process effected by the syringe is awkward and painful to conduct, we feel sure that no practitioner who adopts our plan will ever again resort to the latter.

With regard to the lotions recommended for washing out the antrum, Condyl's fluid, weak carbolic acid, chlorinated soda, are amongst those most employed; but the agent which in our hands has proved the most efficient in controlling the discharge and promoting a healthy condition of the cavity, is a dilute solution of phosphoric acid: the patient should commence with

a very weak one, say, one part of the dilute acid to twenty of water, and increase the strength until it cannot be borne without discomfort. [Tincture of iodine diluted with water has given most excellent results, both as a stimulant and disinfectant. Aromatic sulphuric acid diluted has likewise been growing in favor of late years with many practitioners for the treatment of difficulties where the bone is involved.] The washing-out process may have to be continued, and generally, in true cases of antral disease, for several years; yet by the plan recommended the discomfort and annoyance are reduced to a minimum. The cases reported, which recover soon after the removal of a carious tooth and with a few injections of the antrum, are, we believe, in most instances, those in which an abscess connected with a tooth has burst into the antrum, and which are thus readily treated. When the discharge has quite disappeared, the plate and tube may be discontinued; or, if the former carry teeth, the latter may be cut off, and the hole into the antrum will then close up. We have never met with an instance where it has not speedily done so, but, should there be any such difficulty, we apprehend that a little strong nitric acid applied to its edges, as proposed by F. Mason for small openings in the palate, would no doubt lead to their granulating together. Much larger openings, the result of necrosis, we have closed by paring the edges and drawing them together by silver wire sutures. The subject of closure of large openings in the palate, either congenital or arising from disease, by operation,—staphyloraphy,—belongs to the domain of general surgery, that of closure of the same by mechanical appliances to dental mechanics; and here the reader desirous of information cannot do better than consult the excellent work of Norman Kingsley.¹

Cases of irritation set up in the antrum by the lodgment of a root of a tooth, pressed into it in attempting to extract the latter, are on record. One so described by Cattlin led him to furnish us with the best account extant of the form and variations in form of that cavity. Another case occurred recently at the Dental Hospital of London. In both the above-mentioned cases the portion of root was removed through an opening made into that cavity, but we do not recommend this being done unless

¹ Op. cit.

irritation has been set up: we know a gentleman who has had the root of a second bicuspid in his antrum for at least twenty years, and without the least discomfort therefrom.

The antrum may be the seat of morbid growths which are common to other parts. Of these cystic tumors appear amongst the most frequent: they may occur as a single growth,—unilocular,—or exist as a large collection of smaller cysts,—multilocular. Mucous, fibrous, fibroid, and osseous tumors are also met with: we remember diagnosing an interesting case of the latter whilst acting as dresser for the late Sir W. Lawrence. Of the above-mentioned the cystic and mucous may be generally extirpated by moderate-sized openings made into the antrum, but the last-mentioned three usually necessitate removal of the whole of that maxilla. [For an operation devised to avoid a scar upon the exterior of the face, the student is referred to Garretson's Oral Surgery, p. 755.]

CHAPTER XXIII.

NERVOUS AND MUSCULAR AFFECTIONS DEPENDENT UPON
DENTAL IRRITATION.

PAIN, the result of diseased teeth, may be felt in, and referred to, parts remote from the source of mischief; the most common is, perhaps, otalgia, having its origin in a defective molar, especially a third, of the lower jaw. When a patient presents himself complaining of pain about the region of the ear, side of the face and head, and running down the neck of the clavicle, an inspection of the teeth should never be omitted, as it will be frequently found to have its origin in the tooth specified. On the other hand, it must be borne in mind that any irritation to a portion of a sensory nerve, in its passage to the brain, will cause pain, which is referred to the peripheral extremities of the fibres irritated; hence there may apparently be pain in teeth which are in no way the cause of it. The most common instance of the transference of impressions with regard to dental irritation is where pain in a carious tooth is referred to a sound one, often in the opposite jaw. In rare cases, the dental irritation may excite pain in the nervous centres of parts most remote from them; thus we have recently had a case under observation where pain in a tooth was invariably accompanied with that in one of the testes. Brunton has pointed out, that in many such cases it may be accounted for by the irritation, conveyed to the centres of the sensory branches of the fifth pair, being transmitted to those of the vaso-motor centres, from which they are not far distant, and thus the bloodvessels in distant parts become affected.

[Instances of most curious reflex pain from tooth trouble are reported, a few of which may be mentioned as showing how far from the ordinary and beaten track they may wander. Dr. Hyde Salter relates a case where an affection of a lower molar tooth caused neuralgia of the arm; Dr. Benjamin Rush, a case of

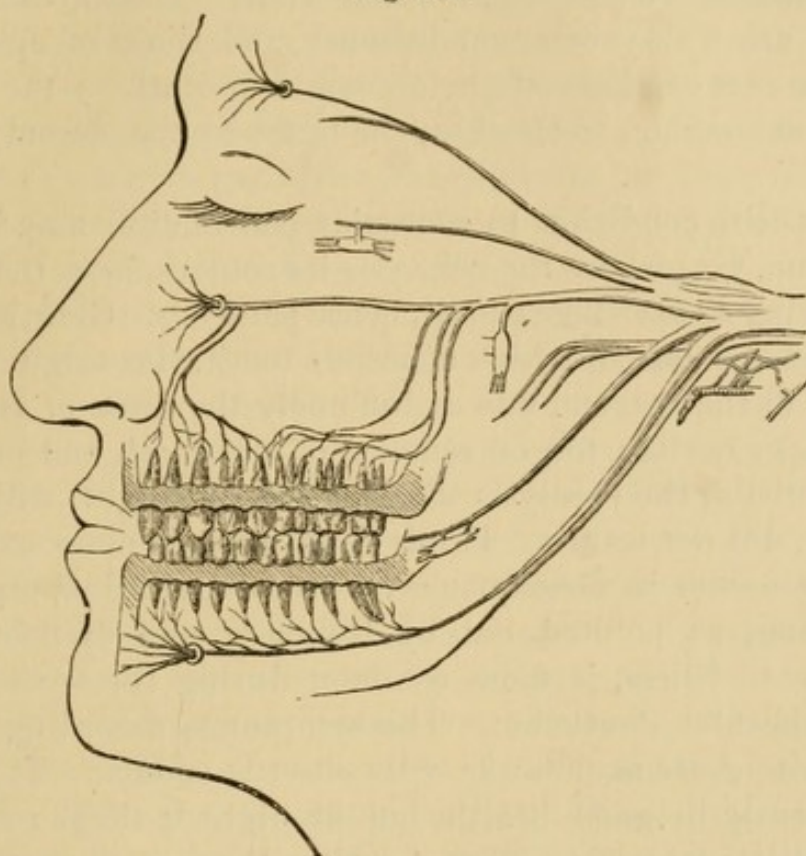
neuralgia of the nates cured by extraction of a tooth. M. Petot cured megrims by extraction of crowded and supernumerary teeth, and likewise cases of difficult and vicarious menstruation. The writer had a case of intense neuralgia and threatened apoplexy in a member of his family, the exciting cause apparently being a capped pulp. Trismus often threatens during the eruption of the wisdom teeth; tetanus and death are reported as following the pivoting of teeth. The late Prof. Geo. T. Barker had a case of tetanus following upon replantation of a tooth. Wry-neck and epilepsy are recorded as accompaniments of tooth trouble; strabismus and amaurosis are associated sometimes with crowded teeth. The tongue persistently furred upon one side and the turning of the hair gray have been caused by toothache. Insanity is often aggravated if not induced by toothache. Dr. Mainwaring, in the *Lancet* (Apr. 11, 1863), reported a case of ulceration of the cervix uteri as causing neuralgia of the fifth pair of nerves. Friedberg reports a case where, after the removal of several aching teeth, one not complained of was extracted and double neuralgia of the fifth pair cured.^{1]}

But, besides sensory impressions, the result of dental irritation, being thus transferred, the same irritation may produce motor-movements. The most common illustration of this reflex action is that of which we have already treated, viz., where a diseased tooth is accompanied by contraction of the muscles which close the mouth, and which speedily relax after the tooth has been removed. Another familiar instance is the occurrence of strabismus due to teething. In rarer cases distant parts are also affected, as in the instances where the irritation of teething causes a permanent contraction of the muscles of the calf of the leg—*talipes equinus*.² Sercombe has related a case, where, through irritation of the exposed pulp of a tooth, contractions of the uterus were immediately brought on: if such cases were common, it would certainly be dangerous to remove teeth from those who are pregnant.

¹ [The student may be referred to "A System of Dental Surgery," by John Tomes, F.R.S., G. & A. Churchill, London, 1873, or Presley Blakiston, Phila. Also to "Diseases of the Teeth," by Benjamin Ward Richardson, H. Baillière, London, 1860.]

² It must be borne in mind that the conditions referred to here and on page 393 may arise from paralysis of opposing muscles.

Fig. 314.



Diagrammatic representation of the fifth pair of cerebral nerves.

[Indeed, the extreme susceptibility of the uterus to morbid action, which in pregnant women is often most unexpectedly developed, makes it desirable to avoid all operations unless the delay will entail greater danger to the mother and foetus than the pain, or even the mental impressions, are liable to cause. This applies equally to filling and extracting teeth. The writer is reminded of a case where the mother of five healthy full-term children, after the excitement produced by some young villains, who made use of coarse and beastly language in the hearing of her children, was thrown into labor, and delivered of a premature child. Cases of this kind are so numerous that it is unnecessary to cite them. The Mosaic law gave the solemnity of its protection to enceinte women, and even prescribed death as a punishment for such offences as produced this trouble.]

Intermittent, or clonic, spasm is likewise occasionally a consequence of the like irritation; and we now and then witness cases where an attack of odontalgia, or the removal of a tooth,

causes spasmodic twitchings for some time. The convulsions of children are a very common instance, and those of epilepsy a more rare one, of these effects of dental irritation; the former being most common to the first, the latter to the second, dentition.¹

An opposite condition to muscular contraction may be likewise set up, viz., where the nerve, or its centres, loses the power of conveying or exciting stimuli, hence paralysis. Gain, of Bath, has recorded a case in which a carious tooth, the origin of suppuration in the antrum, was undoubtedly the cause of paralysis of the upper eyelid; for, on removal of the tooth and puncture of the antrum, the paralysis disappeared, but sight, which had been lost, did not return. Paralysis of a much more extensive character occurs in consequence of dental irritation, especially in teething, as pointed out by Romberg and Henock, and, according to Fliess, is more common during the second than during the first dentition. The symptoms, according to the latter writer,² are as follows: "Its onset is sudden. The child is apparently in good health, but at night it sleeps restlessly, and is a little feverish. Next morning the arm, or more rarely the leg, is paralyzed. The arm drops; it is warm but swollen, and of a reddish-blue color. It is quite immovable, but the child suffers little or no pain. Not unfrequently paralysis is preceded by choreic movements. Sometimes recovery is rapid, but at other times the limb atrophies, and the paralysis may become associated with symptoms indicating more extensive disturbance of the spinal cord and brain, such as difficulty of breathing, asthma, palpitation, distortion of the face, and squint, ending in coma and death." The pathological anatomy in these cases is difficult of explanation; the most probable hypothesis is, that they have their origin in disturbance of the vaso-motor system.

The organs of special sense are likewise not exempt from the influences of dental irritation; the eye appears unfortunately to

¹ True cases of epilepsy do, however, occur, the result of irritation set up by diseased temporary teeth. Some of these have come under the notice of the writer, in which there could be no doubt as to cause and effect. Odontalgia from carious teeth was followed by true epileptic seizures, which latter ceased on the removal of the painful teeth.

² Quoted by Brunton in Trans. Odont. Soc., vol. xii. p. 163.

be the most liable. Hutchinson regards the blindness to be reflex, and analogous in its causation to essential paralysis of children. The blindness is generally preceded for a long time by facial neuralgia, associated with toothache. In other cases, as we have met with them, the loss of vision has occurred without any attendant pain; such was the condition in a patient at the Dental Hospital, who became affected with total blindness in one eye, following upon the pivoting of an upper incisor tooth, but who quite recovered the sight upon the removal of the tooth. Cases of deafness from the like cause have been recorded; and we know a gentleman, the subject of facial neuralgia, whose last attack was followed by a total loss of the sense of smell. Finally, the cerebral faculties may suffer from a similar cause, and cases are on record where insanity followed severe toothache, and disappeared upon the tooth being removed. In contrast to this may be related the case of an insane lady, who continually troubled us and other practitioners to remove her sound teeth on account of the uncomfortable sensations which she referred to them. [The writer once gave great offence to a retired military officer by refusing a peremptory written order of the latter to extract his sound teeth. Softening of the brain was soon after pronounced to be the affliction of this unfortunate sufferer.]

The diagnosis of the cause of neuralgia of the fifth pair is extremely difficult. Should a patient so suffering apply to us, our first care should be a thorough inspection of the teeth. We must not simply content ourselves with a visual examination, but must percuss all, especially those connected with the divisions of the nerve most affected. The application of heat and cold, by a jet of water, may also aid in detecting the origin of the pain. In neuralgia of the fifth pair, pressure on the terminal branches, at or about their emergence from the bony channels that they occupy, will usually give pain, more severe in the case of the division most affected; it has also been pointed out by Trousseau, that in the same condition great tenderness is felt when pressure is made upon the spinous processes of the first two cervical vertebræ. These two symptoms would be admirable for diagnosis between odontalgia and true neuralgia but for the fact that the same conditions are set up by carious teeth, at least in the more advanced stages. Our position will not be an easy one when a patient complains of severe pain referred to a

sound tooth, and one in which neither percussion nor changes of temperature reveal abnormal tenderness. We must not, however, conclude that the tooth is in no way the cause of the pain; whilst, on the other hand, it may occur in true neuralgia that a tooth becomes tender after every attack and yet is not the cause of the mischief. In the first case, a formation of secondary dentine, involving in some way the nerves of the pulp by pressure, may be the cause; we and others have removed apparently sound teeth at the urgent request of our patients, and have found such condition to exist. We should, however, now, in these days of anæsthetics, prefer opening up the pulp-cavity, and destroying its contents, to extracting the tooth.

Periodicity in the attacks may be some guide to the true nature of the pain, but it is almost as common to neuralgia arising from dental irritation, as it is when due to chlorosis, anæmia, rheumatism, etc.

From the foregoing remarks it will appear that we can offer but little that will assist the student to distinguish odontalgia from neuralgia, having another origin; and, indeed, our laying down any clear line for the diagnosis would only lead to his disappointment. The treatment must consequently be somewhat empirical. After a thorough inspection of the mouth, and setting of the same in order by the removal or rectification of all likely sources of irritation, attention must be directed to the system in general. Thus, should it be inferred that the patient is chlorotic, iron will be indicated, and the best form for it is probably the ammonio-citrate; if anæmic, we should prefer the ferro-citrate of quinine, especially if the conditions be marked by much periodicity in the attacks; in the cases where we may expect a rheumatic origin, we may commence with alkalies, and, if necessary, follow up with iodide of potassium. A fair trial may be given to the medicines regarded as directly specific for neuralgia, viz.—quinine, arsenic, bromide of potassium, chloride of ammonium in large and frequently repeated doses, and gelsemium administered in like manner; but the last two should be discontinued after twelve hours if no effect be produced, or if continued, be applied only in much smaller doses. That form, and a not uncommon one, in which the attacks come on after the patient has been asleep for an hour

or two, and which has usually a dental origin, may be accounted for by local congestion, either at the painful spots or at the nervous centres. It is relieved by sitting up in bed, or by walking about, and a glass of port wine acts almost like magic in affording relief; all of these, and notably the last, stimulate the heart's action, which overcomes the congestion induced by the weaker action of the organ during sleep. [A toothache recurring at regular intervals, without any local cause, has yielded to quinine used as an anti-periodic; in one instance in a patient who disclaimed all exposure to malarial influence, yet who during the following spring was attacked by, and for weeks suffered from a pronounced case of malarial fever.] When all remedies appear to fail, the question of an operation is open for consideration; which will consist in exposing the nerve in a portion of its course, and either stretching or dividing it. In the former, we should, when able to do so, expose the nerve between the brain and the spot to which the pain is especially referred, and, having done so, draw it chiefly towards the brain. In the case of the fifth nerve, it is clear that we could only so treat the inferior dental branch; in other cases, we must expose it where it emerges from its bony surroundings, and draw it forwards. In thus treating the nerve we probably alter the condition of its vascular supply. To a somewhat similar action, *e. g.* that of nerve-stretching, we are inclined to attribute the temporary relief often afforded by the removal of sound teeth in cases of true facial neuralgia, the branches which give off the dental filaments being stretched or influenced thereby.

When nerve-stretching has failed, division of a branch may be performed; this, in the case of the fifth pair, is again only, to any extent, practicable in the inferior dental, in its course through the substance of the lower jaw. The nerve should be not merely divided, but a section actually removed from it. In other cases, the nerve may be divided at its emergence from any of the three foramina which give exit to the terminal branches of its three principal divisions. The objections to nerve-division are the subsequent existence of anæsthesia in the parts supplied by the distal portion of the divided nerve, and the chance of the divided proximal extremity becoming bulbous. Severe neuralgic pain may be referred to a spot where a tooth has been

previously removed ; we long ago formed the opinion that its occurrence was most probably due either to compression of a nerve-filament by bone in the alveolus or in a cicatrix, or to bulbous enlargement of the extremity of a severed dental nerve-branch. Our treatment consisted in cutting down upon the sensitive spot, freeing the mucous membrane from the surface of the bone, and removing a portion of the latter, which operation we performed many years before it was advocated by Gross in his excellent work.

INDEX.

- A**BBOTT, Prof. F., on dental caries (*note*), 115
- Abscess, threatening, treated by pressure, 242, 243, 247
- Absorption may be caused by pressure, 131
- of alveoli, 353
- of organized lymph, how to effect, 243
- of permanent teeth, 252
- of temporary teeth, 44
- Acids, their effects upon teeth, 133
- Actual cautery, 221
- Air, importance of fresh, for children, 29, 31, 161
- Alkalies for treatment of caries, 234
- local application to teeth, 43
- Alum objected to for use on the teeth, 359
- Alveolar abscess, 236
- artificial fistula, to form, 144
- causing salivary fistula, 237
- opening into antrum, 237
- process, fractures of, 310
- of incisors, liability to disease of, 369
- the inner plate the heavier, 283
- Alveolo-dental membrane, inflammation of, 235
- Amalgam, copper, 188
- for fillings in soft teeth, 189
- how to prepare, 189
- mixed metals, 190
- palladium, 186
- silver, 188
- Amalgams for filling teeth, 185
- two classes, 186
- Anæmia, convulsions due to, 33
- Anæsthesia by chloroform, 339
- by cold, 322
- by electricity, 322
- by nitrous oxide, 322
- and ether, 339
- how produced, 324
- discovery of, 319, 320
- Anæsthesia—
- history of, 320
- medico-legal rules for, 336
- the reclining position in, preferred, 338, 344
- Anæsthetics, chair for administration of, 343
- effect upon the genitals, 338
- Anatomy of teeth and surrounding parts, 265
- Animals, teeth of, artificially bred, approach more nearly the human conditions, 23
- Antiseptics, Prof. W. F. Litch on, 229
- Antral trouble, use of iodine and sulphuric acid, 389
- Antrum, diseases of, 386
- opened into by alveolar abscess, 237
- suppuration in, 386
- Apthous ulcers of the mouth, 35
- Apoplexy in pulp capping, 234
- Arabs, Bedouin, good teeth of, 133
- Arsenic a cause of necrosis, 368
- as an antiseptic, 228
- destruction of dental pulp by, 226
- not to be applied during inflammation of pulp, 249
- Arsenical paste, Prof. J. F. Flagg's, 226, 229
- Arsenious acid not to be used for sensitive dentine, 220
- Atheromatous cerebral vessels with regard to nitrous oxide, 338
- Atmosphere, attention to changes of, 31
- importance of fresh and pure air, 133, 161
- of room, to impregnate with creosote, 363
- B**ANDAGE for retraction of chin, 41, 102
- Barbed brooch, how to use, 226
- Bate, C. Spence, on dental caries, 126
- Baume, on eruption of teeth, 44
- Bedouins, teeth of, 133

- Bellows for resuscitation in apparent death, 334
- Bell, T., on dental caries, 122
- Bicuspid with trifurcated roots, 59
- Bleaching teeth, 251
- Bleeding in teething, 34
- Blindness due to dental irritation, 395
- Blistering for counter-irritation, 232
- Bone, appearance of fistulæ in diseased, 367
- dead, to be allowed to separate, 368
- exfoliation of, 47, 364, 368
- liable to disease over incisor teeth, 369
- reproduction of, 369
- septa, to remove, 311
- Branch's, Dr., method of applying cold, 322
- Breathing made easy by odor of tar, 364
- Breeding-in, influence upon the jaws, 89
- Bridgman on dental caries, 125
- Broca, odontomes, 59
- Burnishers, agate, 184
- steel, 187
- Burr-drills, 169
- CANCERUM ORIS**, or gangrenous stomatitis, 365
- Capping pulps, 221, 223
- Carbolic acid for exposed pulps, 223
- Caries, acid reaction in, 119
- chalky, 129
- conditions favoring, 132, 233
- effect of vegetable parasites on, 357
- from decomposition in starchy deposits on teeth, 129
- general course of, 115
- in temporary teeth, 42
- treatment of, 43
- on the increase, 114
- prevention of, 161
- soft and hard, 129
- theory of Bate, C. Spence, 126
- of Bell, T., 122
- of Bridgman, 125
- of Fox, 122
- of Hunter, 121
- of Leber and Rottenstein, 126
- of Robertson, 123
- of Tomes, J., 123, 126
- treatment of, by excision, 162
- by filling or stopping, 166
- use of alkalies locally in, 234
- of dental engine in operation for, 369
- Cartwright, S., on irregularities in teeth (*note*), 89
- Cattlin on the antrum of Highmore, 389
- Cautery, galvanic, uses of, 225
- simple, by burning point and stick, 221
- thermal, uses of, 366
- Cavities for filling, preparation of, 168
- spheroidal shape of, 168
- Cement fillings, how to hasten the setting of, 184
- how to use, 186
- Chair, operating, 194
- Chalk as a local application to teeth, 43
- Charcoal, objections to its use as a dentifrice, 162
- Chill an indication of pus formation, 243
- Chin retractor, 41, 102
- Chinese, teeth of, 162
- Chloroform, anæsthesia by, 340
- apparatus for, 341
- Clover's, 341
- cause of death from (*note*), 337
- Cicatrices closing the jaws, 370
- following lancing of gums more easily penetrated than original tissue, 27
- Clamps for amalgam fillings, 192
- for rubber-dam, 176
- Cleanliness, importance of, for children, 37
- Clendon, on treatment of cicatrices, 371
- Closing of spaces resulting from extraction of incisor teeth, 112
- Clover's apparatus for chloroform, 341
- for nitrous oxide and ether, 339
- Coffin, expansion plates of, 93
- Cold for periodontitis, 242
- for producing anæsthesia, 322
- Coles, Oakley, on abnormal maxillæ (*note*), 91
- Combinations for color in fillings, 215
- Compound fillings, objections to, 203
- Concussion of teeth, 108
- Congestion of the gums, 353
- Contracted dental arch, C. S. Tomes on, 92
- Convulsions, bleeding in, etc., 25, 34
- due to anæmia, 33
- in teething, 23
- lancing the gums for, 25, 32
- Creasote, nascent, for teeth, 363
- Crowning teeth roots, 244, 257, 264
- Drs. Gates and Bonwill's method, 262
- Dr. Richmond's method, 259
- Prof. Flagg's method, 262
- Cryer's, Dr. M. H., device for bands to protect teeth from injury when undergoing pressure by jack-screws, 107

Cusps and roots of teeth, 302
 Cutaneous eruptions in teething, 24, 35
 Cyanosis with regard to nitrous oxide, 338
 Cysts, bony, use of iodine and sulphuric acid for, 389
 dentigerous, 379

DARWIN on ill-developed maxillæ, 89

Deafness due to dental irritation, 395
 Decay by denudation, 130
 Deciduous teeth, gemination of, 39
 restored to position after being driven into the bone, 110
 to be retained, 301
 to extract, 300
 Deficiency in permanent teeth, 61
 in temporary teeth, 39
 Dental arch, expansion of, 92
 Dental engine, 167
 to polish with, 358
 Dental pulp, abnormal conditions of, 234
 Dentifrice, 359
 Dentifrices, objections to insoluble matters in, 162
 Dentigerous cysts, 55 (*note*), 379
 Dentine, cutting sensitive, causes increased flow of saliva, 19
 for capping exposed pulps, 221
 secondary, 120
 Dentition, eruption of children's teeth earlier in the United States than in Europe, 22
 exceptional cases of third teeth may occur, 17
 lancing for too rapid presentation of teeth, 25
 relief of pain following lancing, 26
 replacement occurs but once in the higher mammals, according to Owen, 17
 second, time of completion, 48
 See Teething.
 Development of teeth, 17, 47
 Diagnosis of exposed pulps, 313
 of periostitis, 313
 of pus formation by a chill, 243
 Diarrhœa in teething, 24
 treatment of, 27
 of infants, lancing the gums in, 29
 treatment of, in children, 32
 Dickey, Dr. N. L., case of dentigerous cyst, 55 (*note*)
 Dickinson on teething, 36
 Difficulties in extraction, 302
 due to forms of teeth, 303

Difficulties in extraction—
 from closure of jaws, 306
 from impaction of teeth, 307
 in filling teeth, 216
 Dilaceration, 113
 Discovery of anæsthesia, 320
 Diseases of infants, lancing the gums, 29
 Disinfectant mouth wash, 368
 Dislocation of jaw, 311
 of teeth, 108
 Dress for children, 31, 37
 Drilling openings into pulp cavities for putrescent pulps, 231

ELECTRICITY as an anæsthetic, 322

Elevator, application of, 297
 forms of, 295, 296
 how to use, 297
 principles of, 295
 Enamel-cutters or chisels, 163
 Enamel-nodules, 60
 Enema for dysentery, 32
 Engine, dental, 167, 170
 points, to prepare, for cleaning teeth, 358
 Epilepsy during second dentition, 52
 due to dental irritation, 293
 Epulis, fibrous, 375
 myeloid, 377
 Erosion of teeth, 48, 130
 Eruption of permanent teeth, 49
 earlier in the United States, 51
 of teeth, how effected, 39
 of temporary teeth, earlier in females, 22
 order and periods of, 20
 prior to birth, 20
 of third molars late in life, 63
 Eruptions, cutaneous, in teething, 24
 treatment of, 35
 Esmarch, operation of, 371
 Esquimaux, teeth of, 161
 Ether as an anæsthetic, 339
 Ether-spray, 322
 Ethidene-dichloride, 344
 Exanthemata marking teeth, 56
 Excavators, forms of, etc., 169
 Excision in caries, 162
 of exposed roots of teeth, 43
 Exercise in the open air with an object, 161
 Exfoliation of bone, 46, 364
 Exostosis of teeth, 254
 causes of, 254

Exostosis of teeth—
 consequences of, 255
 of the jaws, 377
 Expansion and development of jaws by
 mastication of hard food, 104
 of dental arch, 92
 Experiments with regard to caries, 128
 Extraction for relief of crowding third
 molars, 52
 hæmorrhage after, 314, 316
 objected to during pregnancy, 335,
 393
 of deciduous teeth, 82
 of roots by the elevator, 295
 by the forceps, 290
 by the screw, 291, 300
 rules for, 290
 of sixth year molars may cause
 irregularity, 98
 of teeth, 96, 267
 anatomy of teeth and sur-
 rounding parts, 265
 caution with lateral incisors,
 281
 consideration of patient, 265
 difficulties in, 302
 for irregularity, 96
 forms of forceps, 270
 movement for, 280, 285
 position of the operator's
 hands, 280
 rules for, 264
 tables to guide in, 289
 with the forceps, 268
 with the key, 267, 268
 with the screw, 291
 of temporary teeth, 300, 301
 painless, by cold, 322
 under an anæsthetic, 329
 when to lance, 298

F AINTING, to send the blood to the
 brain, 344
 Fang-filling, operations for, 227
 Fangs, excess of, in number, 39, 58
 exposure of, through the gums, 42,
 367
 forceps for extracting, 290
 Feeding, artificial, for infants, 28
 Fig-poultice, objection to, 247
 Filling fangs of teeth, 228
 teeth, difficulties in, 216
 materials for, 166
 operations for, 166
 plan for, 210
 to prevent progress of erosion,
 131
 with amalgams, 185

Filling teeth—
 with gold, 193
 Filling materials, combinations for color,
 215
 Filling, renew if moistened, 210
 Fillings, how to make of gold, 150
 of gutta-percha, 179
 watertight, 232
 Finger, to protect, when using the
 elevator, 297
 Fistula, artificial, to form, 244
 Fistulæ from diseased bone, 367
 from diseased teeth, 367
 Flagg, Prof. J. Foster, arsenical paste,
 220, 229
 caps to prevent occlusion, 76
 condensing forceps, 157
 correction of irregularity, 75
 pivoting teeth, 262
 water-bath, 182
 Flexible rubber syringes, objection to,
 172
 Flour for diarrhœa of infants, 29
 Flower, on absence of teeth (*note*), 63
 Food, artificial, for infants, 27
 how to prepare, 28, 30
 Forceps, compressing or plugging, 198
 dividing, 293
 excising, 310
 extracting, for roots of teeth, 290
 general, 268
 for condensing, Prof. Flagg's, 157
 for teeth, forms of, 270, 288
 for temporary teeth, 300
 the leaden, 283
 Formula of permanent teeth, 49
 of temporary teeth, 19
 Fracture of jaws, in extraction, 311
 treatment of, 84
 by Gunning's splint, 85
 by Hammond's splint, 86
 temporary splints for, 87
 of teeth, 110
 Fractured teeth, union of, 112
 tooth, impacted, 112
 Frankland, on action of nitrous oxide, 324
 on artificial milk (*note*), 30
 Freezing before extraction, 322

G ALVANIC action between fillings,
 212
 Gangrene of dental pulp, 121
 dry, 228
 Gangrenous stomatitis, 365
 Garretson, Prof. J. E., allowing dead
 bone to separate, 368
 case of reproduction of jaw-
 bone, 369

- Garretson, Prof. J. E.—
 salivary fistula, 237
 use of burring instrument for
 operation on bone, 369
- Gemination of permanent teeth, 58
 of temporary or deciduous teeth, 39
- Genitals last affected by anæsthetics,
 338
- Gold, filling with, may be too tedious for
 patient, 193
 for filling teeth, 193
 cohesive, 203
 objection to, 215
 non-cohesive, 194
 precipitated, 208
 how to prepare and fill with, 150
- Goodsir, primitive dental groove of, 18
- Grooves for retaining filling, 212
- Groups, teeth erupted in, 20
- Gumboil, consequences of, 42
- Gums, congestion of, 353
 hypertrophy of, 374
 irritation of, by tooth-brush, a cause
 of caries, 130
 lancing of, in teething, 25, 32
 the health line of, 246
- Gunning, interdental splint of, 85
- Gutta-percha and cement fillings, 180
 fillings, how to finish, 183
 for fillings, 179
 how to avoid pain from heat, 183
- HÆMORRHAGE**, alveolar, 314
 primary, 314
 secondary, 314
 to arrest, 314, 316
- Hæmorrhagic diathesis, 315
- Hammond's splint, 86
- Hand-piece for dental engine, Dr. H.
 C. Register's, 170
- Health line of the gums, 246
 of patient impaired by tedious ope-
 rations, 193
- Heat, 242
- Heath, C., on hypertrophy of gums,
 374
 on myeloid epulis, 377
- Heat-stroke, to prevent, 35
- Hermann, on nitrous oxide, 324
- Honeycombed teeth, 55
- Horseback exercise in the open air, 161
- Hot-air syringe, 252
- Hullihen, operation of, 231
- Hunter, on decay of teeth, 121
- Hutchinson, J., on blindness due to den-
 tal irritation, 395
 on honeycombed teeth, 56
 on syphilitic teeth, 57
- Hyperostosis of fangs, 253
 causes of, 254
 consequences of, 255
- Hypertrophy of gums, 374
- Hysteria with regard to nitrous oxide,
 338
- ILLUMINATOR**, mouth, Hart's, 255,
 310
- Impacted teeth, 307
 consequences of, 384
- Impressions, method of taking, 68
- Indians' mode of cleansing the teeth, 162
- Inflammation of dental periosteum, 235
 of dental pulp, 120
 of the gums, 359
- Injuries to teeth, 108
- Insolation, treatment to prevent, 35
- Instruments, selection of, 134
- Insufflation by bellows, 334
- Intermaxillary bones, growth of, 50
- Iodine for blistering, 232
 for treatment of *oidium albicans*,
 360
- Irregularities in permanent teeth, in
 form, 55
 in number, 60
 in position, 63, 88
 in size, 54
 in temporary teeth, 38
- Irregularity of teeth, bands for teeth
 undergoing pressure by jack-
 screws, 107
 caps to prevent occlusion of
 teeth, 76
 caused by extraction of sixth-
 year molars, 98
 by tonsillitis, 89
 correction of, not to be at-
 tempted until dentinification
 of the ends of the roots is
 completed, 74
- Dr. L. Jack's observation of
 extraction of sixth-year mo-
 lars, 98
- Dr. G. W. Neidich's case, 45
- Drs. J. W. White and N.
 Kingley's observation of
 mouths of idiots, 92
- importance of retaining decid-
 uous teeth for prevention of,
 82, 104
- ligatures and knots for treat-
 ment of, 75
 not common in idiots, 92
- Prof. J. F. Flagg's caps to pre-
 vent occlusion, 76
 method of correction, 75

Irregularity of teeth—

Prof. J. H. McQuillen's bar
for correction of, 76
caps to prevent occlusion,
76

Prof. S. H. Guilford's clasps
for correction of, 79
rubber plate for retaining teeth
in position, 82
springs for correction of,
75

torsion by forceps, 73
by ligatures, 77

Irritation in dentition, object of (*note*), 23

JACK-SCREW, for expanding dental arch, 94

Jack's, Dr. L., matrices and pluggers, 155

Jarvis', Dr., separators, 217

Johnson's, Dr. J. G., views on the use of anæsthetics, 336

KEY instrument for extraction, 267

Kingsley, Dr. Norman W., on oral deformities, 107, 389

Knife and fork, influence of, on the teeth, 132

LAMP for working gutta percha for filling, 182

Lancing the gums as a remedy for complications in diseases of infants, 29

how to perform the operation, 34

in teething, 25, 32

of older children, 51

relief afforded by, in dentition, 26

seems to assist abnormal eruption of teeth, 25

should be thorough, 26

to reduce nervous symptoms, 34

when to perform it, 245

for extraction, 298

Leaden extractor, 283

Leber and Rottenstein, on caries, 125, 126

Leptothrix in caries, 119, 126

Lime-water for mouth-wash, 43

Lining cavities, 202

Litch, Prof. W. F., on antiseptics, 229

Lord's, Dr. Benj., pluggers, 153

Loss of teeth, premature, 354

Luxation of teeth and successful replacement, 109

Lyons, L., on fracture of jaws, 86
on necrosis of jaws, 368

MAGITOT, on caries, 125

on replantation, 347

Malarial toothache, 397

Mallet for filling teeth, 197

automatic, 197

objection to, 198

dental engine, 207

electro-magnetic, 209

Palmer's, Dr. C., lead, 158

pneumatic, 198, 207

Mason, F., on small openings in palate, 389

Matrices and pluggers, Dr. L. Jack's, 155
for approximal fillings, Dr. L. Jack's, 214

Maxillæ, development of, 88

Darwin on, 89

McQuillen, Prof. J. H., caps to prevent occlusion, 76

reproduction of nerve-cells, 109

restoration of function in ablated cerebrum, 109

Medico-legal aspect of anæsthetics, 336

Micrococci, in caries, 119

Milk, ass's, 30

cow's, casein of, as compared with human milk, 28

preparation for infants, 28, 31

goat's, 30

imitation of human, Frankland (*note*), 30

of woman, ass, cow, etc., analysis of (*note*), 30

substitutes for human, 30

Mitscherlich, on replantation, 345

on transplantation, 352

Moisture while filling, 210

Morrison's dental engine, 166

Mouth mirror, 139

Muscular contraction dependent upon dental irritation, 306, 392

NECROSIS caused by arsenic, 368

of cementum, 246, 250

of maxillæ, 367

following fevers, 364

of permanent teeth, 108, 250

of temporary teeth, 42

Neidich's, Dr. G. H., case of irregularity, 45

Nerve, rupture of, in extraction, 313

- Nerve-stretching for neuralgia, 397
 Nervous affections dependent upon dental irritation, 391
 disturbance, lancing for, 34
 Neuralgia of the fifth pair, 395
 Nitrogen as an anaesthetic, 324
 Nitrous oxide, apparatus for administering, 327
 as an anaesthetic, 323
 deaths from, 324
 mode of administering, 329
 of preparing, 325
 of storing, 326
 physiology of effects of, 324
 safety of, 323
 symptoms of danger with, 333
 Nodules of enamel on teeth, 60
 Non-cohesive gold, difference from cohesive, 203
 for filling, 215
 Non-conductors, for lining cavities, 202
- O**CCCLUSION of teeth in periodontal irritation, 255
 Odontitis infantum, 35
 Odontoblasts, function of, 218, 253
 Odontomes, 59
 Oidium albicans, treatment, 35
 by iodine, 360
 Opium in diarrhœa, 31, 32
 in dysentery, 32
 Order of eruption of permanent teeth, 49
 of temporary teeth, 20
 Organized lymph, how to cause absorption of, 243
 Osseous union of the jaws, 370
 Owen, Prof. R., on dentition of elephant (*note*), 47
 replacement of teeth occurs but once in the higher mammals, 17
 Oxychloride of zinc for filling teeth, 183
- P**AGET, Sir J., diagnosis of impacted teeth, 309
 Pain after extraction, 313
 in stopped teeth, 231
 Painless excavation, 171, 220, 221
 Palmer's, Dr. C., method of wedging, 216
 Papillary tumor of the gum, 373
 Paralysis due to teething, 394
 following extraction, 313
 Parasites, in cavities of carious teeth an accidental accompaniment, 116
- Periodontal irritation, occlusion in, 255
 Periodontitis, chronic, 245
 treatment of, 247
 ether spray for, 242
 extraction, objection to, 242
 hot water for, 242
 pathology of, 238
 symptoms of, 235
 treatment of, 241
 Periostitis, to diagnose, 313
 Permanganate of potassa for mouth-wash, 368
 Peroxide of tin, for polishing teeth, 163
 Perspiration, imperceptible, danger of retention, 37
 Pflüger's, Dr. H. E., restoration of pulp tissue in teeth, 109
 Phthisis in regard to nitrous oxide, 336
 Pitted teeth, 56
 Pivoting teeth, 257
 Plates, regulation, 70, 73
 treatment of fractures of jaw by, 84
 Pluggers, Dr. L. Jack's, 155
 Dr. Benj. Lord's, 153
 Polishing teeth with peroxide of tin, 163
 Polypus of dental-pulp, 225
 of gum, 372
 Pregnancy, a cause of abortion in, 131
 effects of, on the teeth, 233
 unfavorable time for operations, 335, 393
 with regard to nitrous oxide, 335
 Pressure in threatening abscess, 242, 243, 247
 Primitive dental groove, Goodsir, 18
 Pulp capping, apoplexy from, 234
 destruction of, 225
 exposure of, by disease, 120, 222
 traumatic, 110, 221
 general abnormal conditions of, 234
 inflammation of, 120
 removal of, 227
 treatment of, when exposed, 222
 ulceration of, 120
 Pulp, exposed, to diagnose, 313
 Purgative for infants in diarrhœa, 32
 Pus formation accompanied by a chill, 243
 Pyrophosphate of zinc, for filling teeth, 185
- R**EFLEX pain from teeth, 391
 Relative liability of teeth to caries, 99
 Removal of temporary teeth for crowding, 67, 103, 104

Replantation of teeth, 345
 Reproduction of nerve-cells of cerebrum of pigeon, Prof. J. H. McQuillen's case, 109
 of pulp-tissue of teeth, Dr. H. E. Pfluger's case, 109
 Respiration, soothing effect of tar, 364
 Respiratory organs, affected by teething, 24
 Retaining grooves, 212
 points for fillings, 204
 Rickets, with respect to delayed dentition, 22
 Riggs' disease, 355
 Robertson, W., on dental caries, 123
 Rogers, Claude, case of division of jaw by a plate, 371
 saliva-ejector, 172
 Roots of teeth, extraction of, 290
 Rotary movement for extraction of teeth, 280
 Rotation or torsion of teeth, 46, 73, 77
 Rottenstein and Leber, on caries, 125, 126
 Rubber-dam, Barnum's, 172
 appliances for, etc., 174
 clamps, Dr. Ambler Tees', 178
 how to cut and apply, 178

SALIVA, abnormal increase of in teething, 18
 offices of, 18
 pain from cutting sensitive dentine augments the flow of, 19
 Saliva-ejectors, 172
 Salivary calculus or tartar, 355
 vegetable parasites, 357
 fistula, Prof. Garretson's case, 237
 Salivation, results of, 366, 369
 Salter, on necrosis after fever, 363
 on papillary tumor, 373
 on "warty teeth," 59
 Savages, teeth of, a guide to their chances of life, 133
 Scalers for removing tartar, 358
 Scoops for excavation, 171
 Screw, how to use, 291
 Screws for extraction, 291, 300
 Scurvy of the gums, 353
 Secondary dentine, 120
 Sensation in teeth, object of, 219
 Sensitive dentine, how to excavate, 171
 Sensitiveness of dentine, 218
 Separation of teeth, processes for, 216
 Separators, Dr. Jarvis', 217
 Septa of bone, to remove, 311
 Sequestra not to be removed before detached, 368

Sexual selection, influence of, on the jaws, 90
 Shelley, Hubert, on exostosis, 254
 Shrinkage of tooth in drying, 233
 Skulls, collection of, at Hythe, 88
 Sloughing of gum over an erupting tooth, 35
 Smell, case of loss of, with neuralgia, 395
 Smoke of bituminous coal for allaying irritation of respiratory track, 364
 Softening of the brain, trouble with the teeth from, 395
 Space between teeth, how to gain, 216, 217
 Spatulas, 181, 184
 Spheroidal form with regard to amalgams, 191
 shape for cavities for filling, 168
 Splints, temporary, for fracture of jaws, 87
 Starch enema, 32
 fermentation of, a cause of caries of teeth, 129
 raw, for abraded surfaces, 35
 for chafing, 35
 Stomach teeth, 49
 Stopped teeth, pain in, 231
 Stopping teeth, *see* Filling teeth.
 Stuffing teeth, *see* Filling teeth.
 Supernumerary teeth, 40, 58, 60, 61
 Syphilitic teeth, 20, 57
 Syringe, glass, metal, celluloid, 172
 hot air, 252
 objections to flexible rubber, 172

TABLE of eruption of permanent teeth, 50
 of temporary teeth, 22
 of operations in extraction, 289
 of relative liability to caries, 99
 Tale for coating cement fillings, 184
 Talipes equinus, due to teething, 24, 392
 Tartar, or salivary calculus, 355
 Teeth aching from softening of the brain, 395
 alum not to be used on the, 359
 appearance of fistulæ over diseased, 367
 bleaching of, 251
 commencement of development of, 17
 erosion of roots, 48
 exposed pulps, to diagnose, 313
 extraction of, 264
 for crowding, 53
 of temporary, 300, 301

Teeth—

- forceps, forms of, 270, 288
 - the leaden, 283
 - gemination of deciduous, 39
 - of permanent, 58
 - markings of, from exanthemata, 56
 - occlusion of, in abnormal conditions, 255
 - of artificially bred animals approach more nearly the conditions found in man, 23
 - of savages a guide to their chances of life, 133
 - permanent, eruption of, 49
 - honeycombed, 55
 - irregularities in, 54
 - number, formula, etc., of, 49
 - period of eruption in United States, 51
 - syphilitic, 56
 - pivoting, 257
 - reflex pain from, 391
 - relative proportions of roots and crowns, 302
 - retention of bicusps, 62
 - of third molars, 63
 - roots, importance of, for crowning, 244
 - supernumerary, 61
 - temporary, absence of, 39
 - absorption of, 43
 - classification of, 20
 - diseases of, 40
 - erupted earlier in girls, 22
 - prior to birth, 20
 - excess of, 39
 - extraction of, 300
 - geminated, 39, 58
 - necrosed, not absorbed, 48
 - number, arrangement, etc., of, 19
 - order, periods of eruption, etc., of, 20
 - retarded eruption of, 20
 - the cingulus of, 302
 - the stomach, 49
 - third sets of, 63
 - to clean with the engine, 358
 - treatment of unusually large incisors, 55
 - two sets of, object of, 17
 - vegetable parasites, effect of, on the, 357
 - wedging, 216, 217
- Teething, conditions in, abnormal, 23
- normal, 22
 - convulsions in, 33
 - cutaneous eruptions in, 35
 - deaths directly from, 24

Teething—

- management of children during, 25
- sloughing of gum in, 35
- Temperature for nursery, 31
- Theories of dental caries, 121
- Thrush in infants, 360
- Thumb-sucking, a cause of irregularity, 40, 83
 - result of, 40
- Tomes, C. S., on contracted dental arch, 92
 - on dental caries, 125
- J., on absorption of teeth, 48
 - on dental caries, 123
 - on relative liability of the teeth to caries, 99
 - "zone of," 117, 129
- Tonic treatment by out-door work, 161
- Tonsillitis as a cause of contraction of dental arch, 89
- Toothache drops, 314
 - malarial, 397
- Tooth, aching, not to be extracted, 314
- Tooth-brush, as employed by Chinese, 162
 - effects of a stiff brush on necks of teeth, 130
 - value of, 43, 162
- Tooth-extractor, the leaden, 283
- Tooth-pulp, arsenic objected to when inflamed, 249
- Tooth, the extracted, the best compress, 316
- Torsion, immediate, by forceps, 46
 - for irregularity, 73, 77
 - of teeth, 73
- Translucent zone under gold fillings, 117
- Transplantation of teeth, 347
- Treatment of caries by excision, 163
 - by filling, 166
- Trousseau, on neuralgia, 395
 - works of, recommended, 36
- Tumors, a cause of irregularity, 40, 83
 - of the gum, 372
 - upon the jaws, 375
- Typhoid fever, lowered vitality of teeth in, 108

ULCKERATION of dental pulp, 120

- of the gum, 360
- aphthous, 360
- strumous, mercurial, syphilitic, 366

Ulcerative stomatitis, 361

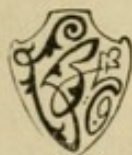
Ulcers, aphthous, of mouth, treatment, 35

- V**ASCULAR tumors of the gum, 373
Ventilation, importance of, in children's apartments, 31
Vinegar for diarrhœa, 32
Vomiting of infants not to be confounded with mere regurgitation of food, 24
V-shaped dental arch, 100
- W**ALLS of cavities may crumble under pressure, 215
Warmth for children, 31
Water-bath for gutta-percha fillings, Prof. Flagg's, 182
- Wedging, rapid, 216
teeth, how to perform, 217
Wedl, C., on dental caries, 125
on dilaceration, 113
Wells, Dr. H., use of nitrous oxide, 320
West on convulsions, 24
works of, recommended, 36
Wilhite's, Dr. J. P., use of ether, 320
Wood-smoke for teeth, 363
- Z**INC oxychlorides for filling teeth, 183
pyrophosphate, 185
Zone of Tomes, 117, 129

Catalogue of Books

PUBLISHED BY

Lea Brothers & Company,



706, 708 & 710 Sansom St., Philadelphia.
111 Fifth Ave. (Cor. 18th St.), New York.

The books in the annexed list will be sent by mail, post-paid, to any Post-Office in the United States, on receipt of the printed prices. No risks of the mail, however, are assumed either on money or books. Gentlemen will therefore in most cases find it more convenient to deal with the nearest bookseller.

STANDARD MEDICAL PERIODICALS.

The Medical News,

THE LEADING MEDICAL WEEKLY OF AMERICA,

Combines most advantageously for the practitioner the features of the newspaper and the weekly magazine. Its frequent issues keep the reader posted on all matters of current interest and in touch with the incessant progress in all lines of medical knowledge. Close adaptation to the needs of the active practitioner is shown by a list of subscribers large enough to justify the reduction in price to **\$4.00 per annum**, so that it is now the cheapest as well as the best large medical weekly of America. It contains from twenty-eight to thirty-two quarto pages of reading matter in each issue.

The American Journal of the Medical Sciences.

Containing 128 octavo pages each month, THE AMERICAN JOURNAL accommodates elaborate Original Articles from the leading minds of the profession, careful Reviews and classified Summaries of Medical Progress. According to the highest literary authority in medicine, "from this file alone, were all other publications of the press for the last fifty years destroyed, it would be possible to reproduce the great majority of the real contributions of the world to medical science during that period."

Price, \$4.00 Per Annum.

COMBINATIONS AT REDUCED RATES.

THE AMERICAN JOURNAL OF THE MEDICAL SCIENCES,	} Together	} In all
\$4.00		
THE MEDICAL NEWS, \$4.00	\$7.50	
THE MEDICAL NEWS VISITING LIST for 1897 (see below and on page 16),		
\$1.25 With either or both above periodicals, 75 cents.		
THE YEAR-BOOK OF TREATMENT for 1897 (see page 16), \$1.50.		\$10.75
With either or both above periodicals, 75 cents.		
		\$8.50.

The Medical News Visiting List.

This LIST, which is by far the most handsome and convenient now attainable, has been thoroughly revised for 1897. A full description will be found on page 16. It is issued in four styles. Price, each, \$1.25. Thumb-letter Index for quick use 25 cents extra. For Special Combination Rates with periodicals and the Year-Book of Treatment see above.

ABBOTT (A. C.). *PRINCIPLES OF BACTERIOLOGY*: a Practical Manual for Students and Physicians. New (3d) edition thoroughly revised and greatly enlarged. In one handsome 12mo. volume of 492 pages, with 98 engravings, of which 17 are colored. Cloth, \$2.50. *Just ready.*

ALLEN (HARRISON). *A SYSTEM OF HUMAN ANATOMY; WITH AN INTRODUCTORY SECTION ON HISTOLOGY*, by E. O. SHAKESPEARE, M.D. Comprising 813 double-columned quarto pages, with 380 engravings on stone on 109 full-page plates, and 241 woodcuts in the text. Bound in one volume, cloth, \$23. *Sold by subscription only.*

A TREATISE ON SURGERY BY AMERICAN AUTHORS. FOR STUDENTS AND PRACTITIONERS OF SURGERY AND MEDICINE. Edited by Roswell Park, M.D. In two magnificent octavo volumes. Vol. I., *General Surgery*, 799 pages, with 356 engravings and 21 full-page plates in colors and monochrome. Vol. II., *Special Surgery*, 796 pages, with 451 engravings and 17 full-page plates in colors and monochrome. *Complete work just ready.* Price per volume, cloth, \$4.50; leather, \$5.50. *Net.*

AMERICAN SYSTEM OF PRACTICAL MEDICINE. A SYSTEM OF PRACTICAL MEDICINE. In Contributions by Various American Authors. Edited by ALFRED L. LOOMIS, M.D., LL.D., and W. GILMAN THOMPSON, M.D. In four very handsome octavo volumes of about 900 pages each, fully illustrated. Vol. I., *just ready.* Vol. II., *in press.* Vols. III. and IV., *in active preparation.* Per volume, cloth, \$5; leather, \$6; half Morocco, \$7. *For sale by subscription only.* Prospectus free on application to the Publishers.

AMERICAN SYSTEM OF DENTISTRY. IN TREATISES BY VARIOUS AUTHORS. Edited by WILBUR F. LITCH, M.D., D.D.S. In four very handsome super-royal octavo volumes, containing about 4000 pages, with about 2200 illustrations and many full-page plates. Volume IV., *preparing.* Per volume, cloth, \$6; leather, \$7; half Morocco, \$8. *For sale by subscription only.* Prospectus free on application to the Publishers.

AMERICAN TEXT-BOOKS OF DENTISTRY. IN CONTRIBUTIONS BY VARIOUS AUTHORS. In two octavo volumes of 600–800 pages each, richly illustrated:

—— *PROSTHETIC DENTISTRY.* Edited by CHARLES J. ESSIG, M.D., D.D.S. 760 pages, 983 engravings. Cloth, \$6; leather, \$7. *Net. Just ready.*

—— *OPERATIVE DENTISTRY.* Edited by EDWARD C. KIRK, D.D.S. *In press.*

AMERICAN SYSTEMS OF GYNECOLOGY AND OBSTETRICS. In treatises by the most eminent American specialists. Gynecology edited by MATTHEW D. MANN, A.M., M.D., and Obstetrics edited by BARTON C. HIRST, M.D. In four large octavo volumes comprising 3612 pages, with 1092 engravings, and 8 colored plates. Per volume, cloth, \$5; leather, \$6; half Russia, \$7. *For sale by subscription only.* Prospectus free on application to the Publishers.

ASHHURST (JOHN, JR.). *THE PRINCIPLES AND PRACTICE OF SURGERY.* For the use of Students and Practitioners. Sixth and revised edition. In one large and handsome 8vo. volume of 1161 pages, with 656 engravings. Cloth, \$6; leather, \$7.

ASHWELL (SAMUEL). *A PRACTICAL TREATISE ON THE DISEASES OF WOMEN.* Third edition. 520 pages. Cloth, \$3.50.

A SYSTEM OF PRACTICAL MEDICINE BY AMERICAN AUTHORS. Edited by WILLIAM PEPPER, M.D., LL.D. In five large octavo volumes, containing 5573 pages and 198 illustrations. Price per volume, cloth, \$5; leather, \$6; half Russia, \$7. *Sold by subscription only.* Prospectus free on application to the Publishers.

ATTFIELD (JOHN). *CHEMISTRY; GENERAL, MEDICAL AND PHARMACEUTICAL.* Fourteenth edition, specially revised by the Author for America. In one handsome 12mo. volume of 794 pages, with 88 illustrations. Cloth, \$2.75; leather, \$3.25.

BALL (CHARLES B.). *THE RECTUM AND ANUS, THEIR DISEASES AND TREATMENT.* New (2d) edition. In one 12mo. volume of 453 pages, with 60 engravings and 4 colored plates. Cloth, \$2.25. *Just ready.* See *Series of Clinical Manuals*, page 13.

BARNES (ROBERT AND FANCOURT). *A SYSTEM OF OBSTETRIC MEDICINE AND SURGERY, THEORETICAL AND CLINICAL.* The Section on Embryology by PROF. MILNES MARSHALL. In one large octavo volume of 872 pages, with 231 illustrations. Cloth, \$5; leather, \$6.

BARTHOLOW (ROBERTS). *CHOLERA; ITS CAUSATION, PREVENTION AND TREATMENT.* In one 12mo. volume of 127 pages, with 9 illustrations. Cloth, \$1.25.

BARTHOLOW (ROBERTS). *MEDICAL ELECTRICITY. A PRACTICAL TREATISE ON THE APPLICATIONS OF ELECTRICITY TO MEDICINE AND SURGERY.* Third edition. In one octavo volume of 308 pages, with 110 illustrations.

BELL (F. JEFFREY). *COMPARATIVE ANATOMY AND PHYSIOLOGY.* In one 12mo. volume of 561 pages, with 229 engravings. Cloth, \$2. See *Students' Series of Manuals*, p. 14.

BELLAMY (EDWARD). *A MANUAL OF SURGICAL ANATOMY.* In one 12mo. volume of 300 pages, with 50 illustrations. Cloth, \$2.25.

BERRY (GEORGE A.). *DISEASES OF THE EYE; A PRACTICAL TREATISE FOR STUDENTS OF OPHTHALMOLOGY.* Second edition. Very handsome octavo volume of 745 pages, with 197 original illustrations in the text, of which 87 are exquisitely colored. Cloth, \$8.

BILLINGS (JOHN S.). *THE NATIONAL MEDICAL DICTIONARY.* Including in one alphabet English, French, German, Italian and Latin Technical Terms used in Medicine and the Collateral Sciences. In two very handsome imperial octavo volumes, containing 1574 pages and two colored plates. Per volume, cloth, \$6; leather, \$7; half Morocco, \$8.50. *For sale by subscription only.* Specimen pages on application to the Publishers.

BLACK (D. CAMPBELL). *THE URINE IN HEALTH AND DISEASE, AND URINARY ANALYSIS, PHYSIOLOGICALLY AND PATHOLOGICALLY CONSIDERED.* In one 12mo. volume of 256 pages, with 73 engravings. Cloth, \$2.75.

BLOXAM (C. L.). *CHEMISTRY, INORGANIC AND ORGANIC.* With Experiments. New American from the fifth London edition. In one handsome octavo volume of 727 pages, with 292 illustrations. Cloth, \$2; leather, \$3.

BROADBENT (W. H.). *THE PULSE.* In one 12mo. volume of 317 pages, with 59 engravings. Cloth, \$1.75. See *Series of Clinical Manuals*, page 13.

BROWNE (LENNOX). *THE THROAT AND NOSE AND THEIR DISEASES.* New (4th) and enlarged edition. In one imperial octavo volume of 751 pages, with 235 engravings and 120 illustrations in color. Cloth, \$6.50.

— *KOCH'S REMEDY IN RELATION ESPECIALLY TO THROAT CONSUMPTION.* In one octavo volume of 121 pages, with 45 illustrations, 4 of which are colored, and 17 charts. Cloth, \$1.50.

BRUCE (J. MITCHELL). *MATERIA MEDICA AND THERAPEUTICS.* Fifth edition. In one 12mo. volume of 591 pages. Cloth, \$1.50. See *Students' Series of Manuals*, page 14.

BRUNTON (T. LAUDER). *A MANUAL OF PHARMACOLOGY, THERAPEUTICS AND MATERIA MEDICA;* including the Pharmacy, the Physiological Action and the Therapeutical Uses of Drugs. In one octavo volume.

BRYANT (THOMAS). *THE PRACTICE OF SURGERY.* Fourth American from the fourth English edition. In one imperial octavo volume of 1040 pages, with 727 illustrations. Cloth, \$6.50; leather, \$7.50.

BUMSTEAD (F. J.) AND TAYLOR (R. W.). *THE PATHOLOGY AND TREATMENT OF VENEREAL DISEASES.* See *Taylor on Venereal Diseases*, page 15. *Just ready.*

BURNETT (CHARLES H.). *THE EAR: ITS ANATOMY, PHYSIOLOGY AND DISEASES.* A Practical Treatise for the Use of Students and Practitioners. Second edition. In one 8vo. volume of 580 pages, with 107 illustrations. Cloth, \$4; leather, \$5.

BUTLIN (HENRY T.). *DISEASES OF THE TONGUE.* In one pocket-size 12mo. volume of 456 pages, with 8 colored plates and 3 engravings. Limp cloth, \$3.50. See *Series of Clinical Manuals*, page 13.

CARPENTER (W. B.). *PRIZE ESSAY ON THE USE OF ALCOHOLIC LIQUORS IN HEALTH AND DISEASE.* New edition, with a Preface by D. F. CONDIE, M.D. One 12mo. volume of 178 pages. Cloth, 60 cents.

— *PRINCIPLES OF HUMAN PHYSIOLOGY.* In one large octavo volume.

CARTER (R. BRUDENELL) AND FROST (W. ADAMS). *OPHTHALMIC SURGERY.* In one pocket-size 12mo. volume of 559 pages, with 91 engravings and one plate. Cloth, \$2.25. See *Series of Clinical Manuals*, page 13.

CASPARI (CHARLES, JR.). *A TREATISE ON PHARMACY.* For Students and Pharmacists. In one handsome octavo volume of 680 pages, with 288 illustrations. Cloth, \$4.50.

CHAMBERS (T. K.). *A MANUAL OF DIET IN HEALTH AND DISEASE.* In one handsome 8vo. volume of 302 pages. Cloth, \$2.75.

CHAPMAN (HENRY C.). *A TREATISE ON HUMAN PHYSIOLOGY.* In one octavo volume of 925 pages, with 605 illustrations. Cloth, \$5.50; leather, \$6.50.

CHARLES (T. CRANSTOUN). *THE ELEMENTS OF PHYSIOLOGICAL AND PATHOLOGICAL CHEMISTRY.* In one handsome octavo volume of 451 pages, with 38 engravings and 1 colored plate. Cloth, \$3.50.

CHEYNE (W. WATSON). *THE TREATMENT OF WOUNDS, ULCERS AND ABSCESES.* In one 12mo. volume of 207 pages. Cloth, \$1.25.

CHURCHILL (FLEETWOOD). *ESSAYS ON THE PUERPERAL FEVER.* In one octavo volume of 464 pages. Cloth, \$2.50.

CLARKE (W. B.) AND LOCKWOOD (C. B.). *THE DISSECTOR'S MANUAL.* In one 12mo. volume of 396 pages, with 49 engravings. Cloth, \$1.50. See *Students' Series of Manuals*, page 14.

CLELAND (JOHN). *A DIRECTORY FOR THE DISSECTION OF THE HUMAN BODY.* In one 12mo. volume of 178 pages. Cloth, \$1.25.

CLINICAL MANUALS. See *Series of Clinical Manuals*, page 13.

CLOUSTON (THOMAS S.). *CLINICAL LECTURES ON MENTAL DISEASES.* New (4th) edition. In one octavo volume of 740 pages, with 15 plates. *Shortly.* See also FOLSOM's *Abstract of Laws of U. S. on Custody of Insane.* In one octavo volume of 108 pages. Cloth, \$1.50.

CLOWES (FRANK). *AN ELEMENTARY TREATISE ON PRACTICAL CHEMISTRY AND QUALITATIVE INORGANIC ANALYSIS.* From the fourth English edition. In one handsome 12mo. volume of 387 pages, with 55 engravings. Cloth, \$2.50.

COATS (JOSEPH). *A TREATISE ON PATHOLOGY.* In one volume of 829 pages, with 339 engravings. Cloth, \$5.50; leather, \$6.50.

COLEMAN (ALFRED). *A MANUAL OF DENTAL SURGERY AND PATHOLOGY.* With Notes and Additions to adapt it to American Practice. By THOS. C. STELLWAGEN, M.A., M.D., D.D.S. In one handsome octavo volume of 412 pages, with 331 engravings. Cloth, \$3.25.

CONDIE (D. FRANCIS). *A PRACTICAL TREATISE ON THE DISEASES OF CHILDREN.* Sixth edition, revised and enlarged. In one large 8vo. volume of 719 pages. Cloth, \$5.25; leather, \$6.25.

CORNIL (V.). *SYPHILIS: ITS MORBID ANATOMY, DIAGNOSIS AND TREATMENT.* Translated, with Notes and Additions, by J. HENRY C. SIMES, M.D., and J. WILLIAM WHITE, M.D. In one 8vo. volume of 461 pages, with 84 illustrations. Cloth, \$3.75.

CULBRETH (DAVID M. R.). *MATERIA MEDICA AND PHARMACOLOGY.* In one handsome octavo volume of 812 pages, with 445 engravings. Cloth, \$4.75. *Just ready.*

CULVER (E. M.) AND HAYDEN (J. R.). *MANUAL OF VENEREAL DISEASES.* In one 12mo. volume of 289 pages, with 33 engravings. Cloth, \$1.75.

DALTON (JOHN C.). *A TREATISE ON HUMAN PHYSIOLOGY.* Seventh edition, thoroughly revised and greatly improved. In one very handsome octavo volume of 722 pages, with 252 engravings. Cloth, \$5; leather, \$6.

— *DOCTRINES OF THE CIRCULATION OF THE BLOOD.* In one handsome 12mo. volume of 293 pages. Cloth, \$2.

- DAVENPORT (F. H.).** *DISEASES OF WOMEN.* A Manual of Non-Surgical Gynecology. For the use of Students and General Practitioners. Second edition. In one handsome 12mo. volume of 314 pages, with 107 engravings. Cloth, \$1.75.
- DAVIS (F. H.).** *LECTURES ON CLINICAL MEDICINE.* Second edition. In one 12mo. volume of 287 pages. Cloth, \$1.75.
- DAVIS (EDWARD P.).** *A TREATISE ON OBSTETRICS.* For Students and Practitioners. In one very handsome octavo volume of 546 pages, with 217 engravings, and 30 full-page plates in colors and monochrome. Cloth, \$5; leather, \$6. *Just ready.*
- DE LA BECHE'S GEOLOGICAL OBSERVER.** In one large octavo volume of 700 pages, with 300 engravings. Cloth, \$4.
- DENNIS (FREDERIC S.) AND BILLINGS (JOHN S.).** *A SYSTEM OF SURGERY.* In Contributions by American Authors. In four very handsome octavo volumes, containing 3652 pages, with 1585 engravings, and 45 full-page plates in colors and monochrome. *Complete work just ready.* Per volume, cloth, \$6; leather, \$7; half Morocco, gilt back and top, \$8.50. *For sale by subscription only.* Full prospectus free on application to the Publishers.
- DERCUM (FRANCIS X.), Editor.** *A TEXT-BOOK ON NERVOUS DISEASES.* By American Authors. In one handsome octavo volume of 1054 pages, with 341 engravings and 7 colored plates. Cloth, \$6; leather, \$7. (*Net.*)
- DE SCHWEINITZ (GEORGE E.).** *THE TOXIC AMBLYOPIAS; THEIR CLASSIFICATION, HISTORY, SYMPTOMS, PATHOLOGY AND TREATMENT.* Very handsome octavo, 240 pages, 46 engravings, and 9 full-page plates in colors. Limited edition, de luxe binding, \$4. (*Net.*)
- DRAPER (JOHN C.).** *MEDICAL PHYSICS.* A Text-book for Students and Practitioners of Medicine. In one handsome octavo volume of 734 pages, with 376 engravings. Cloth, \$4.
- DRUITT (ROBERT).** *THE PRINCIPLES AND PRACTICE OF MODERN SURGERY.* A new American, from the twelfth London edition, edited by STANLEY BOYD, F.R.C.S. In one large octavo volume of 965 pages, with 373 engravings. Cloth, \$4; leather, \$5.
- DUANE (ALEXANDER).** *THE STUDENT'S DICTIONARY OF MEDICINE AND THE ALLIED SCIENCES.* Comprising the Pronunciation, Derivation and Full Explanation of Medical Terms. Together with much Collateral Descriptive Matter, Numerous Tables, etc. New edition. With Appendix. In one square octavo volume of 690 pages. Cloth, \$3; half leather, \$3.25; full sheep, \$3.75. Thumb-letter Index for quick use, 50 cents extra. *Just ready.*
- DUNCAN (J. MATTHEWS).** *CLINICAL LECTURES ON THE DISEASES OF WOMEN.* Delivered in St. Bartholomew's Hospital. In one octavo volume of 175 pages. Cloth, \$1.50.
- DUNGLISON (ROBLEY).** *A DICTIONARY OF MEDICAL SCIENCE.* Containing a full Explanation of the Various Subjects and Terms of Anatomy, Physiology, Medical Chemistry, Pharmacy, Pharmacology, Therapeutics, Medicine, Hygiene, Dietetics, Pathology, Surgery, Ophthalmology, Otology, Laryngology, Dermatology, Gynecology, Obstetrics, Pediatrics, Medical Jurisprudence, Dentistry, etc., etc. By ROBLEY DUNGLISON, M.D., LL.D., late Professor of Institutes of Medicine in the Jefferson Medical College of Philadelphia. Edited by RICHARD J. DUNGLISON, A.M., M.D. Twenty-first edition, thoroughly revised and greatly enlarged and improved, with the Pronunciation, Accentuation and Derivation of the Terms. With Appendix. In one magnificent imperial octavo volume of 1225 pages. Cloth, \$7; leather, \$8. Thumb-letter Index for quick use, 75 cents extra. *Just ready.*
- EDES (ROBERT T.).** *TEXT-BOOK OF THERAPEUTICS AND MATERIA MEDICA.* In one 8vo. volume of 544 pages. Cloth, \$3.50; leather, \$4.50.
- EDIS (ARTHUR W.).** *DISEASES OF WOMEN.* A Manual for Students and Practitioners. In one handsome 8vo. volume of 576 pages, with 148 engravings. Cloth, \$3; leather, \$4.
- ELLIS (GEORGE VINER).** *DEMONSTRATIONS IN ANATOMY.* Being a Guide to the Knowledge of the Human Body by Dissection. From the eighth and revised English edition. In one octavo volume of 716 pages, with 249 engravings. Cloth, \$4.25; leather, \$5.25.

EMMET (THOMAS ADDIS). *THE PRINCIPLES AND PRACTICE OF GYNÆCOLOGY.* For the use of Students and Practitioners. Third edition, enlarged and revised. In one large 8vo. volume of 880 pages, with 150 original engravings. Cloth, \$5; leather, \$6.

ERICHSEN (JOHN E.). *THE SCIENCE AND ART OF SURGERY.* A new American from the eighth enlarged and revised London edition. In two large octavo volumes containing 2316 pages, with 984 engravings. Cloth, \$9; leather, \$11.

ESSIG (CHARLES J.). *PROSTHETIC DENTISTRY.* See *American Text-books of Dentistry*, page 2.

FARQUHARSON (ROBERT). *A GUIDE TO THERAPEUTICS.* Fourth American from fourth English edition, revised by FRANK WOODBURY, M.D. In one 12mo. volume of 581 pages. Cloth, \$2.50.

FIELD (GEORGE P.). *A MANUAL OF DISEASES OF THE EAR.* Fourth edition. In one octavo volume of 391 pages, with 73 engravings and 21 colored plates. Cloth, \$3.75.

FLINT (AUSTIN). *A TREATISE ON THE PRINCIPLES AND PRACTICE OF MEDICINE.* New (7th) edition, thoroughly revised by FREDERICK P. HENRY, M.D. In one large 8vo. volume of 1143 pages, with engravings. Cloth, \$5; leather, \$6.

— *A MANUAL OF AUSCULTATION AND PERCUSSION;* of the Physical Diagnosis of Diseases of the Lungs and Heart, and of Thoracic Aneurism. Fifth edition, revised by JAMES C. WILSON, M.D. In one handsome 12mo. volume of 274 pages, with 12 engravings.

— *A PRACTICAL TREATISE ON THE DIAGNOSIS AND TREATMENT OF DISEASES OF THE HEART.* Second edition, enlarged. In one octavo volume of 550 pages. Cloth, \$4.

— *A PRACTICAL TREATISE ON THE PHYSICAL EXPLORATION OF THE CHEST, AND THE DIAGNOSIS OF DISEASES AFFECTING THE RESPIRATORY ORGANS.* Second and revised edition. In one octavo volume of 591 pages. Cloth, \$4.50.

— *MEDICAL ESSAYS.* In one 12mo. volume of 210 pages. Cloth, \$1.38.

— *ON PHTHISIS: ITS MORBID ANATOMY, ETIOLOGY, ETC.* A Series of Clinical Lectures. In one 8vo. volume of 442 pages. Cloth, \$3.50.

FOLSOM (C. F.). *AN ABSTRACT OF STATUTES OF U. S. ON CUSTODY OF THE INSANE.* In one 8vo. volume of 108 pages. Cloth, \$1.50.

FORMULARY, THE NATIONAL. See *Stillé, Maisch & Caspari's National Dispensatory*, page 14.

FOSTER (MICHAEL). *A TEXT-BOOK OF PHYSIOLOGY.* New (6th) and revised American from the sixth English edition. In one large octavo volume of 923 pages, with 257 illustrations. Cloth, \$4.50; leather, \$5.50.

FOTHERGILL (J. MILNER). *THE PRACTITIONER'S HAND-BOOK OF TREATMENT.* Third edition. In one handsome octavo volume of 664 pages. Cloth, \$3.75; leather, \$4.75.

FOWNES (GEORGE). *A MANUAL OF ELEMENTARY CHEMISTRY (INORGANIC AND ORGANIC).* Twelfth edition. Embodying WATTS' *Physical and Inorganic Chemistry*. In one royal 12mo. volume of 1061 pages, with 163 engravings, and 1 colored plate. Cloth, \$2.75; leather, \$3.25.

FRANKLAND (E.) AND JAPP (F. R.). *INORGANIC CHEMISTRY.* In one handsome octavo volume of 677 pages, with 51 engravings and 2 plates. Cloth, \$3.75; leather, \$4.75.

FULLER (EUGENE). *DISORDERS OF THE SEXUAL ORGANS IN THE MALE.* In one very handsome octavo volume of 238 pages, with 25 engravings and 8 full-page plates. Cloth, \$2. *Just ready.*

FULLER (HENRY). *ON DISEASES OF THE LUNGS AND AIR-PASSAGES.* Their Pathology, Physical Diagnosis, Symptoms and Treatment. From second English edition. In one 8vo. volume of 475 pages. Cloth, \$3.50.

- GANT (FREDERICK JAMES).** *THE STUDENT'S SURGERY.* A Multum in Parvo. In one square octavo volume of 845 pages, with 159 engravings. Cloth, \$3.75.
- GIBBES (HENEAGE).** *PRACTICAL PATHOLOGY AND MORBID HISTOLOGY.* In one very handsome octavo volume of 314 pages, with 60 illustrations, mostly photographic. Cloth, \$2.75.
- GIBNEY (V. P.).** *ORTHOPEDIC SURGERY.* For the use of Practitioners and Students. In one 8vo. volume profusely illustrated. *Preparing.*
- GOULD (A. PEARCE).** *SURGICAL DIAGNOSIS.* In one 12mo. volume of 589 pages. Cloth, \$2. See *Students' Series of Manuals*, page 14.
- GRAY (HENRY).** *ANATOMY, DESCRIPTIVE AND SURGICAL.* A new American edition, thoroughly revised. In one imperial octavo volume of 1239 pages, with 772 large and elaborate engravings. Price with illustrations in colors, cloth, \$7; leather, \$8. Price, with illustrations in black, cloth, \$6; leather, \$7. *Just ready.*
- GRAY (LANDON CARTER).** *A TREATISE ON NERVOUS AND MENTAL DISEASES.* For Students and Practitioners of Medicine. New (2d) edition. In one handsome octavo volume of 728 pages, with 172 engravings and 3 colored plates. Cloth, \$4.75; leather, \$5.75. *Just ready.*
- GREEN (T. HENRY).** *AN INTRODUCTION TO PATHOLOGY AND MORBID ANATOMY.* New (7th) American from the eighth London edition. In one handsome octavo volume of 595 pages, with 224 engravings and a colored plate. Cloth, \$2.75.
- GREENE (WILLIAM H.).** *A MANUAL OF MEDICAL CHEMISTRY.* For the Use of Students. Based upon *BOWMAN'S Medical Chemistry*. In one 12mo. volume of 310 pages, with 74 illustrations. Cloth, \$1.75.
- GROSS (SAMUEL D.).** *A PRACTICAL TREATISE ON THE DISEASES, INJURIES AND MALFORMATIONS OF THE URINARY BLADDER, THE PROSTATE GLAND AND THE URETHRA.* Third edition, thoroughly revised and edited by SAMUEL W. GROSS, M.D. In one octavo volume of 574 pages, with 170 illustrations. Cloth, \$4.50.
- HABERSHON (S. O.).** *ON THE DISEASES OF THE ABDOMEN*, comprising those of the Stomach, Œsophagus, Cæcum, Intestines and Peritoneum. Second American from the third English edition. In one octavo volume of 554 pages, with 11 engravings. Cloth, \$3.50.
- HAMILTON (ALLAN McLANE).** *NERVOUS DISEASES, THEIR DESCRIPTION AND TREATMENT.* Second and revised edition. In one octavo volume of 598 pages, with 72 engravings. Cloth, \$4.
- HAMILTON (FRANK H.).** *A PRACTICAL TREATISE ON FRACTURES AND DISLOCATIONS.* Eighth edition, revised and edited by STEPHEN SMITH, A.M., M.D. In one handsome octavo volume of 832 pages, with 507 engravings. Cloth, \$5.50; leather, \$6.50.
- HARDAWAY (W. A.).** *MANUAL OF SKIN DISEASES.* In one 12mo. volume of 440 pages. Cloth, \$3.
- HARE (HOBART AMORY).** *A TEXT-BOOK OF PRACTICAL THERAPEUTICS*, with Special Reference to the Application of Remedial Measures to Disease and their Employment upon a Rational Basis. With articles on various subjects by well-known specialists. New (5th) and revised edition. In one octavo volume of 740 pages. Cloth, \$3.75; leather, \$4.75. *Just ready.*
- *PRACTICAL DIAGNOSIS.* The Use of Symptoms in the Diagnosis of Disease. In one octavo volume of 566 pages, with 191 engravings, and 13 full-page plates in colors and monochrome. Cloth, \$4.75. *Just ready.*
- HARE (HOBART AMORY), Editor.** *A SYSTEM OF PRACTICAL THERAPEUTICS.* By American and Foreign Authors. In a series of contributions by eminent practitioners. In four large octavo volumes comprising about 4500 pages, with about 550 engravings. Vol. IV., *in press*. Price per volume, cloth, \$5; leather, \$6; half Russia, \$7. *For sale by subscription only.* Full prospectus free on application to the Publishers.

HARTSHORNE (HENRY). *ESSENTIALS OF THE PRINCIPLES AND PRACTICE OF MEDICINE.* Fifth edition. In one 12mo. volume, 669 pages, with 144 engravings. Cloth, \$2.75; half bound, \$3.

— *A HANDBOOK OF ANATOMY AND PHYSIOLOGY.* In one 12mo. volume of 310 pages, with 220 engravings. Cloth, \$1.75.

— *A CONSPECTUS OF THE MEDICAL SCIENCES.* Comprising Manuals of Anatomy, Physiology, Chemistry, Materia Medica, Practice of Medicine, Surgery and Obstetrics. Second edition. In one royal 12mo. volume of 1028 pages, with 477 illustrations. Cloth, \$4.25; leather, \$5.

HAYDEN (JAMES R.). *A MANUAL OF VENEREAL DISEASES.* In one 12mo. volume of 263 pages, with 47 engravings. Cloth, \$1.50. *Just ready.*

HAYEM (GEORGES) AND HARE (H. A.). *PHYSICAL AND NATURAL THERAPEUTICS.* The Remedial Use of Heat, Electricity, Modifications of Atmospheric Pressure, Climates and Mineral Waters. Edited by Prof. H. A. HARE, M.D. In one octavo volume of 414 pages, with 113 engravings. Cloth, \$3.

HERMAN (G. ERNEST). *FIRST LINES IN MIDWIFERY.* In one 12mo. volume of 198 pages, with 80 engravings. Cloth, \$1.25. See *Students' Series of Manuals*, page 14.

HERMANN (L.). *EXPERIMENTAL PHARMACOLOGY.* A Handbook of the Methods for Determining the Physiological Actions of Drugs. Translated by ROBERT MEADE SMITH, M.D. In one 12mo. vol. of 199 pages, with 32 engravings. Cloth, \$1.50.

HERRICK (JAMES B.). *A HANDBOOK OF DIAGNOSIS.* In one handsome 12mo. volume of 429 pages, with 80 engravings and 2 colored plates. Cloth, \$2.50.

HILL (BERKELEY). *SYPHILIS AND LOCAL CONTAGIOUS DISORDERS.* In one 8vo. volume of 479 pages. Cloth, \$3.25.

HILLIER (THOMAS). *A HANDBOOK OF SKIN DISEASES.* Second edition. In one royal 12mo. volume of 353 pages, with two plates. Cloth, \$2.25.

HIRST (BARTON C.) AND PIERSOL (GEORGE A.). *HUMAN MONSTROSITIES.* Magnificent folio, containing 220 pages of text and illustrated with 123 engravings and 39 large photographic plates from nature. In four parts, price each, \$5. *Limited edition. For sale by subscription only.*

HOBLYN (RICHARD D.). *A DICTIONARY OF THE TERMS USED IN MEDICINE AND THE COLLATERAL SCIENCES.* In one 12mo. volume of 520 double-columned pages. Cloth, \$1.50; leather, \$2.

HODGE (HUGH L.). *ON DISEASES PECULIAR TO WOMEN, INCLUDING DISPLACEMENTS OF THE UTERUS.* Second and revised edition. In one 8vo. volume of 519 pages, with illustrations. Cloth, \$4.50.

HOFFMANN (FREDERICK) AND POWER (FREDERICK B.). *A MANUAL OF CHEMICAL ANALYSIS,* as Applied to the Examination of Medicinal Chemicals and their Preparations. Third edition, entirely rewritten and much enlarged. In one handsome octavo volume of 621 pages, with 179 engravings. Cloth, \$4.25.

HOLDEN (LUTHER). *LANDMARKS, MEDICAL AND SURGICAL.* From the third English edition. With additions by W. W. KEEN, M.D. In one royal 12mo. volume of 148 pages. Cloth, \$1.

HOLMES (TIMOTHY). *A TREATISE ON SURGERY.* Its Principles and Practice. A new American from the fifth English edition. Edited by T. PICKERING PICK, F.R.C.S. In one handsome octavo volume of 1008 pages, with 428 engravings. Cloth, \$6; leather, \$7.

— *A SYSTEM OF SURGERY.* With notes and additions by various American authors. Edited by JOHN H. PACKARD, M.D. In three very handsome 8vo. volumes containing 3137 double-columned pages, with 979 engravings and 13 lithographic plates. Per volume, cloth, \$6; leather, \$7; half Russia, \$7.50. *For sale by subscription only.*

HORNER (WILLIAM E.). *SPECIAL ANATOMY AND HISTOLOGY.* Eighth edition, revised and modified. In two large 8vo. volumes of 1007 pages, containing 320 engravings. Cloth, \$6.

- HUDSON (A.).** *LECTURES ON THE STUDY OF FEVER.* In one octavo volume of 308 pages. Cloth, \$2.50.
- HUTCHINSON (JONATHAN).** *SYPHILIS.* In one pocket-size 12mo. volume of 542 pages, with 8 chromo-lithographic plates. Cloth, \$2.25. See *Series of Clinical Manuals*, page 13.
- HYDE (JAMES NEVINS).** *A PRACTICAL TREATISE ON DISEASES OF THE SKIN.* New (4th) edition, thoroughly revised. In one octavo volume of 808 pages, with 110 engravings and 12 full-page plates, 4 of which are colored. *Shortly.*
- JACKSON (GEORGE THOMAS).** *THE READY-REFERENCE HANDBOOK OF DISEASES OF THE SKIN.* New (2d) edition. In one 12mo. volume of 589 pages, with 69 engravings, and one colored plate. Cloth, \$2.75. *Just ready.*
- JAMIESON (W. ALLAN).** *DISEASES OF THE SKIN.* Third edition. In one octavo volume of 656 pages, with 1 engraving and 9 double-page chromo-lithographic plates. Cloth, \$6.
- JONES (C. HANDFIELD).** *CLINICAL OBSERVATIONS ON FUNCTIONAL NERVOUS DISORDERS.* Second American edition. In one octavo volume of 340 pages. Cloth, \$3.25.
- JULER (HENRY).** *A HANDBOOK OF OPHTHALMIC SCIENCE AND PRACTICE.* Second edition. In one octavo volume of 549 pages, with 201 engravings, 17 chromo-lithographic plates, test-types of Jaeger and Snellen, and Holmgren's Color-Blindness Test. Cloth, \$5.50; leather, \$6.50.
- KIRK (EDWARD C.).** *OPERATIVE DENTISTRY.* See *American Text-books of Dentistry*, page 2.
- KING (A. F. A.).** *A MANUAL OF OBSTETRICS.* Sixth edition. In one 12mo. volume of 532 pages, with 221 illustrations. Cloth, \$2.50.
- KLEIN (E.).** *ELEMENTS OF HISTOLOGY.* Fourth edition. In one pocket-size 12mo. volume of 376 pages, with 194 engravings. Cloth, \$1.75. See *Students' Series of Manuals*, page 14.
- LANDIS (HENRY G.).** *THE MANAGEMENT OF LABOR.* In one handsome 12mo. volume of 329 pages, with 28 illustrations. Cloth, \$1.75.
- LA ROCHE (R.).** *YELLOW FEVER.* In two 8vo. volumes of 1468 pages. Cloth, \$7.
- *PNEUMONIA.* In one 8vo. volume of 490 pages. Cloth, \$3.
- LAURENCE (J. Z.) AND MOON (ROBERT C.).** *A HANDY-BOOK OF OPHTHALMIC SURGERY.* Second edition. In one octavo volume of 227 pages, with 66 engravings. Cloth, \$2.75.
- LAWSON (GEORGE).** *INJURIES OF THE EYE, ORBIT AND EYELIDS.* From the last English edition. In one handsome octavo volume of 404 pages, with 92 engravings. Cloth, \$3.50.
- LEA (HENRY C.).** *CHAPTERS FROM THE RELIGIOUS HISTORY OF SPAIN; CENSORSHIP OF THE PRESS; MYSTICS AND ILLUMINATI; THE ENDEMONIADAS; EL SANTO NINO DE LA GUARDIA; BRIANDA DE BARDAXI.* In one 12mo. volume of 522 pages. Cloth, \$2.50.
- *A HISTORY OF AURICULAR CONFESSION AND INDULGENCES IN THE LATIN CHURCH.* In three octavo volumes of about 500 pages each. Per volume, cloth, \$3. *Complete work just ready.*
- *FORMULARY OF THE PAPAL PENITENTIARY.* In one octavo volume of 221 pages, with frontispiece. Cloth, \$2.50.
- *SUPERSTITION AND FORCE; ESSAYS ON THE WAGER OF LAW, THE WAGER OF BATTLE, THE ORDEAL AND TORTURE.* Fourth edition, thoroughly revised. In one handsome royal 12mo. volume of 629 pages. Cloth, \$2.75.

LEA (HENRY C.). *STUDIES IN CHURCH HISTORY.* The Rise of the Temporal Power—Benefit of Clergy—Excommunication. New edition. In one handsome 12mo. volume of 605 pages. Cloth, \$2.50.

— *AN HISTORICAL SKETCH OF SACERDOTAL CELIBACY IN THE CHRISTIAN CHURCH.* Second edition. In one handsome octavo volume of 685 pages. Cloth, \$4.50.

LEE (HENRY) *ON SYPHILIS.* In one 8vo. volume of 246 pages. Cloth, \$2.25.

LEHMANN (C. G.). *A MANUAL OF CHEMICAL PHYSIOLOGY.* In one 8vo. volume of 327 pages, with 41 engravings. Cloth, \$2.25.

LEISHMAN (WILLIAM). *A SYSTEM OF MIDWIFERY.* Including the Diseases of Pregnancy and the Puerperal State. Fourth edition. In one octavo volume.

LOOMIS (ALFRED L.) AND THOMPSON (W. GILMAN), Editors. *A SYSTEM OF PRACTICAL MEDICINE.* In Contributions by Various American Authors. In four very handsome octavo volumes of about 900 pages each, fully illustrated in black and colors. Volume I., *just ready.* Volume II., *in press.* Vols. III. and IV., *in active preparation.* Per volume, cloth, \$5; leather, \$6; half Morocco, \$7. *For sale by subscription only.* Full prospectus free on application to the Publishers.

LUDLOW (J. L.). *A MANUAL OF EXAMINATIONS UPON ANATOMY, PHYSIOLOGY, SURGERY, PRACTICE OF MEDICINE, OBSTETRICS, MATERIA MEDICA, CHEMISTRY, PHARMACY AND THERAPEUTICS.* To which is added a Medical Formulary. Third edition. In one royal 12mo. volume of 816 pages, with 370 engravings. Cloth, \$3.25; leather, \$3.75.

LUFF (ARTHUR P.). *MANUAL OF CHEMISTRY,* for the use of Students of Medicine. In one 12mo. volume of 522 pages, with 36 engravings. Cloth, \$2. See *Students' Series of Manuals*, page 14.

LYMAN (HENRY M.). *THE PRACTICE OF MEDICINE.* In one very handsome octavo volume of 925 pages with 170 engravings. Cloth, \$4.75; leather, \$5.75.

LYONS (ROBERT D.). *A TREATISE ON FEVER.* In one octavo volume of 362 pages. Cloth, \$2.25.

MACKENZIE (JOHN NOLAND). *THE DISEASES OF THE NOSE AND THROAT.* In one handsome octavo volume of about 600 pages, richly illustrated. *Preparing.*

MAISCH (JOHN M.). *A MANUAL OF ORGANIC MATERIA MEDICA.* New (6th) edition, thoroughly revised by H. C. C. MAISCH, Ph.G., Ph.D. In one very handsome 12mo. volume of 509 pages, with 285 engravings. Cloth, \$3.

MANUALS. See *Students' Quiz Series*, page 14, *Students' Series of Manuals*, page 14, and *Series of Clinical Manuals*, page 13.

MARSH (HOWARD). *DISEASES OF THE JOINTS.* In one 12mo. volume of 468 pages, with 64 engravings and a colored plate. Cloth, \$2. See *Series of Clinical Manuals*, page 13.

MAY (C. H.). *MANUAL OF THE DISEASES OF WOMEN.* For the use of Students and Practitioners. Second edition, revised by L. S. RAU, M.D. In one 12mo. volume of 360 pages, with 31 engravings. Cloth, \$1.75.

MITCHELL (JOHN K.). *REMOTE CONSEQUENCES OF INJURIES OF NERVES AND THEIR TREATMENT.* In one handsome 12mo. volume of 239 pages, with 12 illustrations. Cloth \$1.75. *Just ready.*

MORRIS (HENRY). *SURGICAL DISEASES OF THE KIDNEY.* In one 12mo. volume of 554 pages, with 40 engravings and 6 colored plates. Cloth, \$2.25. See *Series of Clinical Manuals*, page 13.

- MORRIS (MALCOLM).** *DISEASES OF THE SKIN.* In one square 8vo. volume of 572 pages, with 19 chromo-lithographic figures and 17 engravings. Cloth, \$3.50.
- MULLER (J.).** *PRINCIPLES OF PHYSICS AND METEOROLOGY.* In one large 8vo. volume of 623 pages, with 538 engravings. Cloth, \$4.50.
- MUSSER (JOHN H.).** *A PRACTICAL TREATISE ON MEDICAL DIAGNOSIS,* for Students and Physicians. New (2d) edition. In one octavo volume of 931 pages, illustrated with 177 engravings and 11 full-page colored plates. Cloth, \$5; leather, \$6. *Just ready.*
- NATIONAL DISPENSATORY.** See *Stillé, Maisch & Caspari*, page 14.
- NATIONAL FORMULARY.** See *Stillé, Maisch & Caspari's National Dispensatory*, page 14.
- NATIONAL MEDICAL DICTIONARY.** See *Billings*, page 3.
- NETTLESHIP (E.).** *DISEASES OF THE EYE.* Fourth American from fifth English edition. In one 12mo. volume of 504 pages, with 164 engravings, test-types and formulæ and color-blindness test. Cloth, \$2.
- NORRIS (WM. F.) AND OLIVER (CHAS. A.).** *TEXT-BOOK OF OPHTHALMOLOGY.* In one octavo volume of 641 pages, with 357 engravings and 5 colored plates. Cloth, \$5; leather, \$6.
- OWEN (EDMUND).** *SURGICAL DISEASES OF CHILDREN.* In one 12mo. volume of 525 pages, with 85 engravings and 4 colored plates. Cloth, \$2. See *Series of Clinical Manuals*, page 13.
- PARK (ROSWELL), Editor.** *A TREATISE ON SURGERY,* by American Authors. For Students and Practitioners of Surgery and Medicine. In two magnificent octavo volumes. Vol. I., *General Surgery*, 799 pages, with 356 engravings and 21 full-page plates in colors and monochrome. Vol. II., *Special Surgery*, 796 pages, with 451 engravings and 17 full-page plates in colors and monochrome. *Complete work just ready.* Price per volume, cloth, \$4.50; leather, \$5.50. *Net.*
- PARRY (JOHN S.).** *EXTRA-UTERINE PREGNANCY, ITS CLINICAL HISTORY, DIAGNOSIS, PROGNOSIS AND TREATMENT.* In one octavo volume of 272 pages. Cloth, \$2.50.
- PARVIN (THEOPHILUS).** *THE SCIENCE AND ART OF OBSTETRICS.* Third edition. In one handsome octavo volume of 677 pages, with 267 engravings and 2 colored plates. Cloth, \$4.25; leather, \$5 25.
- PAVY (F. W.).** *A TREATISE ON THE FUNCTION OF DIGESTION, ITS DISORDERS AND THEIR TREATMENT.* From the second London edition. In one 8vo. volume of 238 pages. Cloth, \$2.
- PAYNE (JOSEPH FRANK).** *A MANUAL OF GENERAL PATHOLOGY.* Designed as an Introduction to the Practice of Medicine. In one octavo volume of 524 pages, with 153 engravings and 1 colored plate. Cloth, \$3.50.
- PEPPER'S SYSTEM OF MEDICINE.** See page 2.
- PEPPER (A. J.).** *SURGICAL PATHOLOGY.* In one 12mo volume of 511 pages, with 81 engravings. Cloth, \$2. See *Students' Series of Manuals*, page 14.
- PICK (T. PICKERING).** *FRACTURES AND DISLOCATIONS.* In one 12mo. volume of 530 pages, with 93 engravings. Cloth, \$2. See *Series of Clinical Manuals*, p. 13.
- PIRRIE (WILLIAM).** *THE PRINCIPLES AND PRACTICE OF SURGERY.* In one octavo volume of 780 pages, with 316 engravings. Cloth, \$3.75.
- PLAYFAIR (W. S.).** *A TREATISE ON THE SCIENCE AND PRACTICE OF MIDWIFERY.* Sixth American from the eighth English edition. Edited, with additions, by R. P. HARRIS, M.D. In one octavo volume of 697 pages, with 217 engravings and 5 plates. Cloth, \$4; leather, \$5.
- *THE SYSTEMATIC TREATMENT OF NERVE PROSTRATION AND HYSTERIA.* In one 12mo. volume of 97 pages. Cloth, \$1.

POLITZER (ADAM). *A TEXT-BOOK OF THE DISEASES OF THE EAR AND ADJACENT ORGANS.* Second American from the third German edition. Translated by OSCAR DODD, M.D., and edited by SIR WILLIAM DALBY, F.R.C.S. In one octavo volume of 748 pages, with 330 original engravings. Cloth, \$5.50.

POWER (HENRY). *HUMAN PHYSIOLOGY.* Second edition. In one 12mo. volume of 396 pages, with 47 engravings. Cloth, \$1.50. See *Students' Series of Manuals*, page 14.

PURDY (CHARLES W.). *BRIGHT'S DISEASE AND ALLIED AFFECTIONS OF THE KIDNEY.* In one octavo volume of 288 pages, with 18 engravings. Cloth, \$2.

PYE-SMITH (PHILIP H.). *DISEASES OF THE SKIN.* In one 12mo. volume of 407 pages, with 28 illustrations, 18 of which are colored. Cloth, \$2.

QUIZ SERIES. See *Students' Quiz Series*, page 14.

RALFE (CHARLES H.). *CLINICAL CHEMISTRY.* In one 12mo. volume of 314 pages, with 16 engravings. Cloth, \$1.50. See *Students' Series of Manuals*, page 14.

RAMSBOTHAM (FRANCIS H.). *THE PRINCIPLES AND PRACTICE OF OBSTETRIC MEDICINE AND SURGERY.* In one imperial octavo volume of 640 pages, with 64 plates and numerous engravings in the text. Strongly bound in leather, \$7.

REICHERT (EDWARD T.). *A TEXT-BOOK ON PHYSIOLOGY.* In one handsome octavo volume of about 800 pages, richly illustrated. *Preparing.*

REMSSEN (IRA). *THE PRINCIPLES OF THEORETICAL CHEMISTRY.* New (5th) edition, thoroughly revised. In one 12mo. volume of 326 pages. Cloth, \$2. *Just ready.*

REYNOLDS (J. RUSSELL). *A SYSTEM OF MEDICINE.* Edited, with notes and additions, by HENRY HARTSHORNE, M.D. In three large 8vo. volumes, containing 3056 closely printed double-columned pages, with 317 engravings. Per volume, cloth, \$5; leather, \$6. For sale by subscription only.

RICHARDSON (BENJAMIN WARD). *PREVENTIVE MEDICINE.* In one octavo volume of 729 pages. Cloth, \$4; leather, \$5.

ROBERTS (JOHN B.). *THE PRINCIPLES AND PRACTICE OF MODERN SURGERY.* In one octavo volume of 780 pages, with 501 engravings. Cloth, \$4.50; leather, \$5.50.

— *THE COMPEND OF ANATOMY.* For use in the Dissecting Room and in preparing for Examinations. In one 16mo. volume of 196 pages. Limp cloth, 75 cents.

ROBERTS (SIR WILLIAM). *A PRACTICAL TREATISE ON URINARY AND RENAL DISEASES, INCLUDING URINARY DEPOSITS.* Fourth American from the fourth London edition. In one very handsome 8vo. volume of 609 pages, with 81 illustrations. Cloth, \$3.50.

ROBERTSON (J. MCGREGOR). *PHYSIOLOGICAL PHYSICS.* In one 12mo. volume of 537 pages, with 219 engravings. Cloth, \$2. See *Students' Series of Manuals*, page 14.

ROSS (JAMES). *A HANDBOOK OF THE DISEASES OF THE NERVOUS SYSTEM.* In one handsome octavo volume of 726 pages, with 184 engravings. Cloth, \$4.50; leather, \$5.50.

SAVAGE (GEORGE H.). *INSANITY AND ALLIED NEUROSES, PRACTICAL AND CLINICAL.* In one 12mo. volume of 551 pages, with 18 typical engravings. Cloth, \$2. See *Series of Clinical Manuals*, page 13.

SCHAFER (EDWARD A.). *THE ESSENTIALS OF HISTOLOGY, DESCRIPTIVE AND PRACTICAL.* For the use of Students. New (4th) edition. In one handsome octavo volume of 311 pages, with 288 illustrations. Cloth, \$3.

SCHMITZ AND ZUMPT'S CLASSICAL SERIES.*ADVANCED LATIN EXERCISES* Cloth, 60 cents; half bound, 70 cents.*SCHMITZ'S ELEMENTARY LATIN EXERCISES.* Cloth, 50 cents.*SALLUST.* Cloth, 60 cents; half bound, 70 cents.*NEPOS.* Cloth, 60 cents; half bound, 70 cents.*VIRGIL.* Cloth, 85 cents; half bound, \$1.*CURTIUS.* Cloth, 80 cents; half bound, 90 cents.**SCHOFIELD (ALFRED T.).** *ELEMENTARY PHYSIOLOGY FOR STUDENTS.* In one 12mo. volume of 380 pages, with 227 engravings and 2 colored plates. Cloth, \$2.**SCHREIBER (JOSEPH).** *A MANUAL OF TREATMENT BY MASSAGE AND METHODICAL MUSCLE EXERCISE.* Translated by WALTER MENDELSON, M.D., of New York. In one handsome octavo volume of 274 pages, with 117 fine engravings.**SEILER (CARL).** *A HANDBOOK OF DIAGNOSIS AND TREATMENT OF DISEASES OF THE THROAT AND NASAL CAVITIES.* New (5th) edition. In one 12mo. vol. of about 425 pages, with about 120 engravings and 2 colored plates. *In press.***SENN (NICHOLAS).** *SURGICAL BACTERIOLOGY.* Second edition. In one octavo volume of 268 pages, with 13 plates, 10 of which are colored, and 9 engravings. Cloth, \$2.**SERIES OF CLINICAL MANUALS.** A Series of Authoritative Monographs on Important Clinical Subjects, in 12mo. volumes of about 550 pages, well illustrated. The following volumes are now ready: *BROADBENT on the Pulse*, \$1.75; *YEO on Food in Health and Disease*, new (2d) edition, \$2.50; *CARTER and FROST's Ophthalmic Surgery*, \$2.25; *HUTCHINSON on Syphilis*, \$2.25; *MARSH on Diseases of the Joints*, \$2; *MORRIS on Surgical Diseases of the Kidney*, \$2.25; *OWEN on Surgical Diseases of Children*, \$2; *PICK on Fractures and Dislocations*, \$2; *BUTLIN on the Tongue*, \$3.50; *SAVAGE on Insanity and Allied Neuroses*, \$2; and *TREVES on Intestinal Obstruction*, \$2.

For separate notices, see under various authors' names.

SERIES OF STUDENTS' MANUALS. See next page.**SIMON (CHARLES E.).** *CLINICAL DIAGNOSIS, BY MICROSCOPICAL AND CHEMICAL METHODS.* In one handsome octavo volume of 504 pages, with 132 engravings and 10 full-page plates in colors and monochrome. Cloth, \$3.50. *Just ready.***SIMON (W.).** *MANUAL OF CHEMISTRY.* A Guide to Lectures and Laboratory Work for Beginners in Chemistry. A Text-book specially adapted for Students of Pharmacy and Medicine. Fifth edition. In one 8vo. volume of 501 pages, with 44 engravings and 8 plates showing colors of 64 tests. Cloth, \$3.25.**SLADE (D. D.).** *DIPHTHERIA; ITS NATURE AND TREATMENT.* Second edition. In one royal 12mo. volume, 158 pages. Cloth, \$1.25.**SMITH (EDWARD).** *CONSUMPTION; ITS EARLY AND REMEDIABLE STAGES.* In one 8vo. volume of 253 pages. Cloth, \$2.25.**SMITH (J. LEWIS).** *A TREATISE ON THE DISEASES OF INFANCY AND CHILDHOOD.* New (8th) edition, thoroughly revised and rewritten and greatly enlarged. In one large 8vo. volume of 983 pages, with 273 illustrations and 4 full-page plates. Cloth, \$4.50; leather, \$5.50. *Just ready.***SMITH (STEPHEN).** *OPERATIVE SURGERY.* Second and thoroughly revised edition. In one octavo vol. of 892 pages, with 1005 engravings. Cloth, \$4; leather, \$5.**SOLLY (S. EDWIN).** *A HANDBOOK OF MEDICAL CLIMATOLOGY.* In one handsome octavo volume of about 450 pages. *Shortly.***STILLE (ALFRED).** *CHOLERA; ITS ORIGIN, HISTORY, CAUSATION, SYMPTOMS, LESIONS, PREVENTION AND TREATMENT.* In one 12mo. volume of 163 pages, with a chart showing routes of previous epidemics. Cloth, \$1.25.— *THERAPEUTICS AND MATERIA MEDICA.* Fourth and revised edition. In two octavo volumes, containing 1936 pages. Cloth, \$10; leather, \$12.

STILLE (ALFRED), MAISCH (JOHN M.) AND CASPARI (CHAS. JR.). *THE NATIONAL DISPENSATORY*: Containing the Natural History, Chemistry, Pharmacy, Actions and Uses of Medicines, including those recognized in the latest Pharmacopœias of the United States, Great Britain and Germany, with numerous references to the French Codex. Fifth edition, revised and enlarged in accordance with and embracing the new *U. S. Pharmacopœia*, Seventh Decennial Revision. With Supplement containing the new edition of the *National Formulary*. In one magnificent imperial octavo volume of 2025 pages, with 320 engravings. Cloth, \$7.25; leather, \$8. With ready reference Thumb-letter Index. Cloth, \$7.75; leather, \$8.50.

STIMSON (LEWIS A.). *A MANUAL OF OPERATIVE SURGERY*. New (3d) edition. In one royal 12mo. volume of 614 pages, with 306 engravings. *Just ready*. Cloth, \$3.75.

— *A TREATISE ON FRACTURES AND DISLOCATIONS*. In two handsome octavo volumes. Vol. I., *FRACTURES*, 582 pages, 360 engravings. Vol. II., *DISLOCATIONS*, 540 pages, 163 engravings. Complete work, cloth, \$5.50; leather, \$7.50. Either volume separately, cloth, \$3; leather, \$4.

STUDENTS' QUIZ SERIES. A New Series of Manuals in question and answer for Students and Practitioners, covering the essentials of medical science. Thirteen volumes, pocket size, convenient, authoritative, well illustrated, handsomely bound in limp cloth, and issued at a low price. 1. *Anatomy* (double number); 2. *Physiology*; 3. *Chemistry and Physics*; 4. *Histology, Pathology and Bacteriology*; 5. *Materia Medica and Therapeutics*; 6. *Practice of Medicine*; 7. *Surgery* (double number); 8. *Genito-Urinary and Venereal Diseases*; 9. *Diseases of the Skin*; 10. *Diseases of the Eye, Ear, Throat and Nose*; 11. *Obstetrics*; 12. *Gynecology*; 13. *Diseases of Children*. Price, \$1 each, except Nos. 1 and 7, *Anatomy and Surgery*, which being double numbers are priced at \$1.75 each. Full specimen circular on application to publishers.

STUDENTS' SERIES OF MANUALS. A Series of Fifteen Manuals by Eminent Teachers or Examiners. The volumes are pocket-size 12mos. of from 300–540 pages, profusely illustrated, and bound in red limp cloth. The following volumes may now be announced: *HERMAN'S First Lines in Midwifery*, \$1.25; *LUFF'S Manual of Chemistry*, \$2; *BRUCE'S Materia Medica and Therapeutics* (fifth edition), \$1.50; *TREVES' Manual of Surgery* (monographs by 33 leading surgeons), 3 volumes, per set, \$6; *BELL'S Comparative Anatomy and Physiology*, \$2; *ROBERTSON'S Physiological Physics*, \$2; *GOULD'S Surgical Diagnosis*, \$2; *KLEIN'S Elements of Histology* (4th edition), \$1.75; *PEPPER'S Surgical Pathology*, \$2; *TREVES' Surgical Applied Anatomy*, \$2; *POWER'S Human Physiology* (2d edition), \$1.50; *RALFE'S Clinical Chemistry*, \$1.50; and *CLARKE and LOCKWOOD'S Dissector's Manual*, \$1.50.

For separate notices, see under various authors' names.

STURGES (OCTAVIUS). *AN INTRODUCTION TO THE STUDY OF CLINICAL MEDICINE*. In one 12mo. volume. Cloth, \$1.25.

SUTTON (JOHN BLAND). *SURGICAL DISEASES OF THE OVARIES AND FALLOPIAN TUBES*. Including Abdominal Pregnancy. In one 12mo. volume of 513 pages, with 119 engravings and 5 colored plates. Cloth, \$3.

— *TUMORS, INNOCENT AND MALIGNANT*. Their Clinical Features and Appropriate Treatment. In one 8vo. volume of 526 pages, with 250 engravings and 9 full-page plates. Cloth, \$4.50.

TAIT (LAWSON). *DISEASES OF WOMEN AND ABDOMINAL SURGERY*. In two handsome octavo volumes. Vol. I. contains 554 pages, 62 engravings, and 3 plates. Cloth, \$3. Vol. II., *preparing*.

TANNER (THOMAS HAWKES). *ON THE SIGNS AND DISEASES OF PREGNANCY*. From the second English edition. In one octavo volume of 490 pages, with 4 colored plates and 16 engravings. Cloth, \$4.25.

TAYLOR (ALFRED S.). *MEDICAL JURISPRUDENCE*. Eleventh American from the twelfth English edition, specially revised by CLARK BELL, Esq., of the N. Y. Bar. In one octavo vol. of 787 pages, with 56 engravings. Cloth, \$4.50; leather, \$5.50.

TAYLOR (ALFRED S.). *ON POISONS IN RELATION TO MEDICINE AND MEDICAL JURISPRUDENCE.* Third American from the third London edition. In one 8vo. volume of 788 pages, with 104 illustrations. Cloth, \$5.50; leather, \$6.50.

TAYLOR (ROBERT W.). *THE PATHOLOGY AND TREATMENT OF VENEREAL DISEASES.* In one very handsome octavo volume of 1002 pages, with 230 engravings and 7 colored plates. Cloth, \$5; leather, \$6. *Net.*

— *A CLINICAL ATLAS OF VENEREAL AND SKIN DISEASES.* Including Diagnosis, Prognosis and Treatment. In eight large folio parts, measuring 14 x 18 inches, and comprising 213 beautiful figures on 58 full-page chromo-lithographic plates, 85 fine engravings, and 425 pages of text. Complete work now ready. Price per part, sewed in heavy embossed paper, \$2.50. Bound in one volume, half Russia, \$27; half Turkey Morocco, \$28. *For sale by subscription only.* Address the publishers. Specimen plates by mail on receipt of 10 cents.

— *SEXUAL DISORDERS IN THE MALE AND FEMALE.* In one octavo volume. *In active preparation.*

TAYLOR (SEYMOUR). *INDEX OF MEDICINE.* A Manual for the use of Senior Students and others. In one large 12mo. volume of 802 pages. Cloth, \$3 75.

THOMAS (T. GAILLARD) AND MUNDE (PAUL F.). *A PRACTICAL TREATISE ON THE DISEASES OF WOMEN.* Sixth edition, thoroughly revised by PAUL F. MUNDE, M.D. In one large and handsome octavo volume of 824 pages, with 347 engravings. Cloth, \$5; leather, \$6.

THOMPSON (SIR HENRY). *CLINICAL LECTURES ON DISEASES OF THE URINARY ORGANS.* Second and revised edition. In one octavo volume of 203 pages, with 25 engravings. Cloth, \$2.25.

— *THE PATHOLOGY AND TREATMENT OF STRICTURE OF THE URETHRA AND URINARY FISTULÆ.* From the third English edition. In one octavo volume of 359 pages, with 47 engravings and 3 lithographic plates. Cloth, \$3.50.

TODD (ROBERT BENTLEY). *CLINICAL LECTURES ON CERTAIN ACUTE DISEASES.* In one 8vo. volume of 320 pages. Cloth, \$2.50.

TREVES (FREDERICK). *OPERATIVE SURGERY.* In two 8vo. volumes containing 1550 pages, with 422 illustrations. Cloth, \$9; leather, \$11.

— *A SYSTEM OF SURGERY.* In Contributions by Twenty-five English Surgeons. In two large octavo volumes, containing 2298 pages, with 950 engravings and 4 full-page plates. Per volume, cloth, \$8. *Just ready.*

— *A MANUAL OF SURGERY.* In Treatises by 33 leading surgeons. Three 12mo. volumes, containing 1866 pages, with 213 engravings. Price per set, \$6. See *Students' Series of Manuals*, page 14.


— *THE STUDENTS' HANDBOOK OF SURGICAL OPERATIONS.* In one 12mo. volume of 508 pages, with 94 illustrations. Cloth, \$2.50.


— *SURGICAL APPLIED ANATOMY.* In one 12mo. volume of 540 pages with 61 engravings. Cloth, \$2. See *Students' Series of Manuals*, page 14.


— *INTESTINAL OBSTRUCTION.* In one 12mo. volume of 522 pages, with 60 illustrations. Cloth, \$2. See *Series of Clinical Manuals*, page 13.

TUKE (DANIEL HACK). *THE INFLUENCE OF THE MIND UPON THE BODY IN HEALTH AND DISEASE.* Second edition. In one 8vo. volume of 467 pages, with 2 colored plates. Cloth, \$3.

VAUGHAN (VICTOR C.) AND NOVY (FREDERICK G.). *PTOMAINS, LEUCOMAINS, TOXINS AND ANTITOXINS*, or the Chemical Factors in the Causation of Disease. New (3d) edition. In one 12mo. volume of 603 pages. Cloth, \$3. *Just ready.*







RK522

C67

1882

Coleman

Copy 1


Manual of dental surgery.

10-57-36

COLUMBIA UNIVERSITY LIBRARIES (hsl, stx)

RK 522 C67 1882 C.1

Manual of dental surgery and pathology.



2002449625

