

Essentials of physical diagnosis of the thorax / by Arthur M. Corwin.

Contributors

Corwin, A. M. 1864-1933.
Augustus Long Health Sciences Library

Publication/Creation

Philadelphia : Saunders, 1896.

Persistent URL

<https://wellcomecollection.org/works/qrhks2qv>

License and attribution

This material has been provided by This material has been provided by the Augustus C. Long Health Sciences Library at Columbia University and Columbia University Libraries/Information Services, through the Medical Heritage Library. The original may be consulted at the the Augustus C. Long Health Sciences Library at Columbia University and Columbia University. where the originals may be consulted.

This work has been identified as being free of known restrictions under copyright law, including all related and neighbouring rights and is being made available under the Creative Commons, Public Domain Mark.

You can copy, modify, distribute and perform the work, even for commercial purposes, without asking permission.

**wellcome
collection**

Wellcome Collection
183 Euston Road
London NW1 2BE UK
T +44 (0)20 7611 8722
E library@wellcomecollection.org
<https://wellcomecollection.org>

COLUMBIA LIBRARIES OFFSITE
HEALTH SCIENCES STANDARD



HX64116816

RC76 .C81 1896 Essentials of physic

RECAP

ESSENTIALS
OF
PHYSICAL DIAGNOSIS
OF THE
THORAX.
—
CORWIN.

RC76-C81
1896

RC 76

C 81

Columbia University 1896
in the City of New York


COLLEGE OF PHYSICIANS
AND SURGEONS




Reference Library


Given by

Dr. Beverley Robinson.









ESSENTIALS
OF
PHYSICAL DIAGNOSIS
OF THE
THORAX.

BY

ARTHUR M. CORWIN, A. M., M. D.,

DEMONSTRATOR OF PHYSICAL DIAGNOSIS IN RUSH MEDICAL COLLEGE;
ATTENDING PHYSICIAN TO THE CENTRAL FREE DISPENSARY,
DEPARTMENT OF RHINOLOGY, LARYNGOLOGY,
AND DISEASES OF THE CHEST.

SECOND EDITION, REVISED AND ENLARGED.

PHILADELPHIA:
W. B. SAUNDERS,
925 WALNUT STREET.
1896.

1886

PHYSICAL DIAGNOSIS

THORAX

COPYRIGHT, 1896,

By W. B. SAUNDERS.

ARTHUR W. LITTLE, M.D.

LECTURE COURSE IN PHYSICAL DIAGNOSIS
DELIVERED AT THE HARVARD MEDICAL SCHOOL
IN THE YEAR 1890-1891
BY ARTHUR W. LITTLE, M.D.
AND PUBLISHED BY THE AUTHOR.

PHILADELPHIA: W. B. SAUNDERS, 1896.

ELECTROTYPED BY
WESTCOTT & THOMSON, PHILADA.

PRESS OF
W. B. SAUNDERS, PHILADA.

PREFACE TO THE SECOND EDITION.

THE first edition of this book, published under the title "Outline of Physical Diagnosis of the Thorax," was chiefly intended to meet the immediate wants of my classes. From its rapid distribution it has seemed to have reached a wider field. The present edition under the new title, as published by Mr. Saunders, is a revision of the original text, with an added section setting forth the signs found in each disease of the chest.

In the preparation of this synopsis I have availed myself of the works of the best writers upon Diagnosis, General Medicine, Physiology, and Anatomy, from which I have endeavored to cull the essentials of the subject in hand.

To Drs. Wm. R. Parkes and John Edwin Rhodes I desire to express my thanks for their valued services rendered in the reading of the proof.

A. M. C.

FOREWORD TO THE SECOND EDITION

The first edition of this book published under the title "A History of Physical Diagnosis of the Thorax," was widely distributed and the immediate success of my class. It has now reached a second edition. It has seemed to have reached a second edition. The present edition under the new title, as published by the publishers, is a revision of the original text with no essential changes being made. The signs found in each disease are the same.

In the preparation of this revision I have revised several of the chapters of the book written upon Physical Diagnosis of the Thorax, Physiology, and Anatomy, from which I have endeavored to get the essentials of the subject in hand. To Dr. Wm. H. Jones and John Edwin Jones I desire to express my thanks for their valued services rendered in the revision of the book.

A. M. A.

PREFACE TO THE FIRST EDITION.

THE following outline aims to present in systematic form the gist of the science of physical diagnosis as applied to the thorax.

In this form it is hoped that the salient points of the subject may be the more readily grasped by those who are all too busy, while in medical college, to seek them out of extensive treatises and to arrange them for proper assimilation.

It is designed to meet the immediate demands of the student, and to be a further guide to a more elaborate study of the theme as set forth in existing literature, and as furnished in the clinical material of public and private practice.

While the intention has been to confine the subject to the thorax, reference has been made to some of the abdominal organs, and to various phenomena of the circulatory system outside of the chest, where these have seemed to be specially related to the chest cavity and its organs.

I am indebted to Drs. John M. Dodson, James B. Herrick, John Edwin Rhodes, and George H. Weaver for suggestions in the correction of proof.

A. M. C.

PREFACE TO THE FIRST EDITION

The following volume is the result of a project which has been carried out in the Department of Psychology at the University of Cambridge. It is the first of a series of books which are being published in the series of the Cambridge University Press. The books are intended to provide a comprehensive and up-to-date account of the current state of research in the field of psychology. The first book in the series is on the topic of 'The Psychology of Learning'. This book is intended to provide a comprehensive and up-to-date account of the current state of research in the field of learning. The second book in the series is on the topic of 'The Psychology of Memory'. This book is intended to provide a comprehensive and up-to-date account of the current state of research in the field of memory. The third book in the series is on the topic of 'The Psychology of Perception'. This book is intended to provide a comprehensive and up-to-date account of the current state of research in the field of perception. The fourth book in the series is on the topic of 'The Psychology of Cognition'. This book is intended to provide a comprehensive and up-to-date account of the current state of research in the field of cognition. The fifth book in the series is on the topic of 'The Psychology of Development'. This book is intended to provide a comprehensive and up-to-date account of the current state of research in the field of development. The sixth book in the series is on the topic of 'The Psychology of Personality'. This book is intended to provide a comprehensive and up-to-date account of the current state of research in the field of personality. The seventh book in the series is on the topic of 'The Psychology of Social Interaction'. This book is intended to provide a comprehensive and up-to-date account of the current state of research in the field of social interaction. The eighth book in the series is on the topic of 'The Psychology of Health and Illness'. This book is intended to provide a comprehensive and up-to-date account of the current state of research in the field of health and illness. The ninth book in the series is on the topic of 'The Psychology of Education'. This book is intended to provide a comprehensive and up-to-date account of the current state of research in the field of education. The tenth book in the series is on the topic of 'The Psychology of Aging'. This book is intended to provide a comprehensive and up-to-date account of the current state of research in the field of aging. The eleventh book in the series is on the topic of 'The Psychology of the Environment'. This book is intended to provide a comprehensive and up-to-date account of the current state of research in the field of the environment. The twelfth book in the series is on the topic of 'The Psychology of the Individual'. This book is intended to provide a comprehensive and up-to-date account of the current state of research in the field of the individual. The thirteenth book in the series is on the topic of 'The Psychology of the Group'. This book is intended to provide a comprehensive and up-to-date account of the current state of research in the field of the group. The fourteenth book in the series is on the topic of 'The Psychology of the Society'. This book is intended to provide a comprehensive and up-to-date account of the current state of research in the field of the society. The fifteenth book in the series is on the topic of 'The Psychology of the Culture'. This book is intended to provide a comprehensive and up-to-date account of the current state of research in the field of the culture. The sixteenth book in the series is on the topic of 'The Psychology of the World'. This book is intended to provide a comprehensive and up-to-date account of the current state of research in the field of the world.

A. M. C.

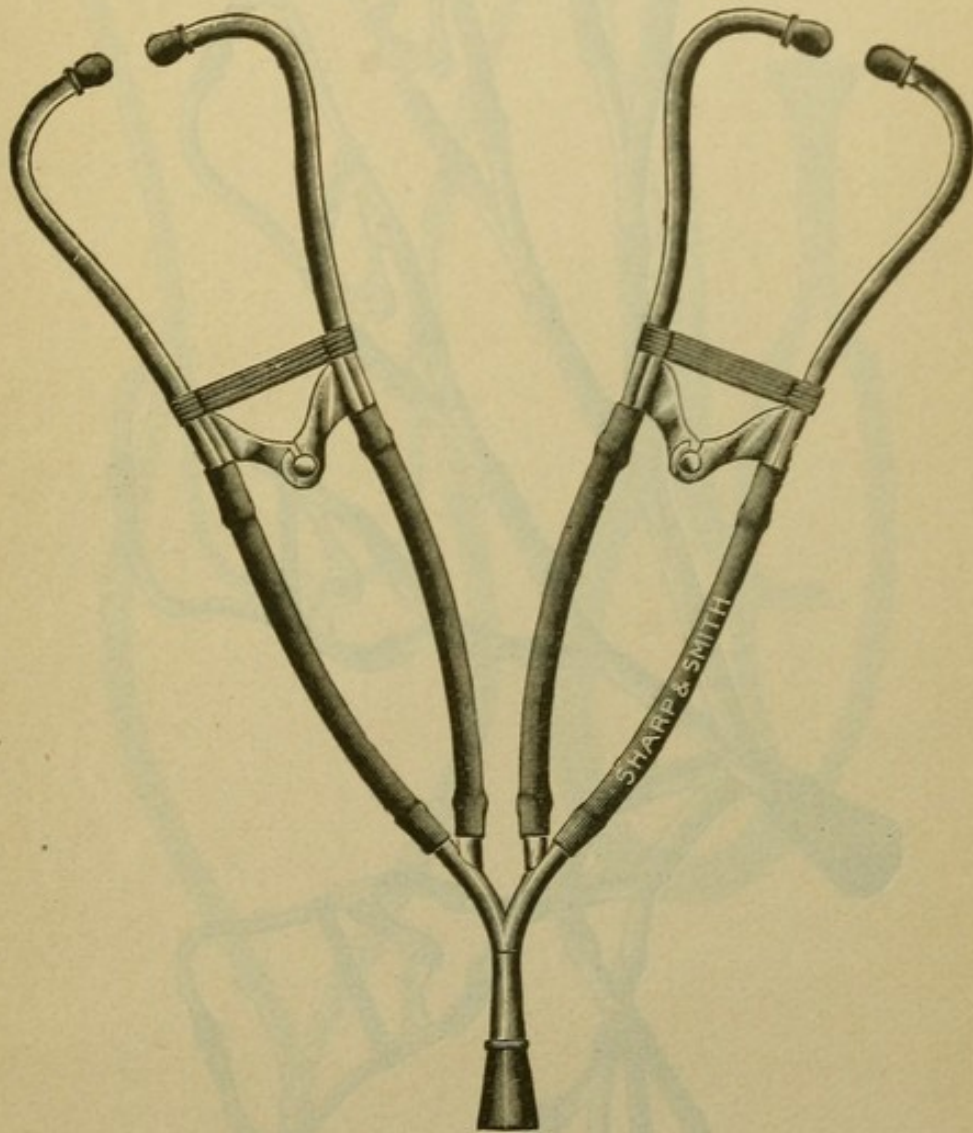


FIG. 1.—Corwin's Double Binaural Stethoscope.

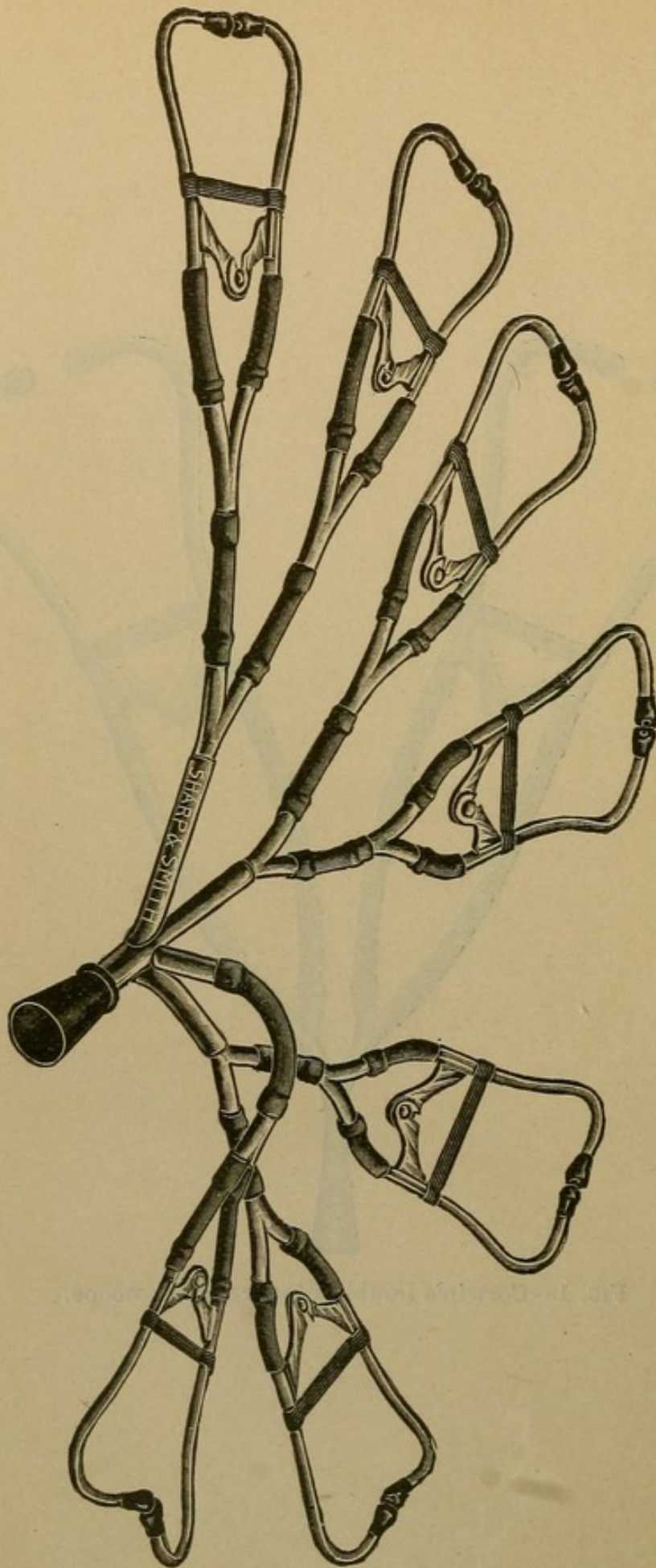


FIG. 2.—Corwin's Multiplex Stethoscope.

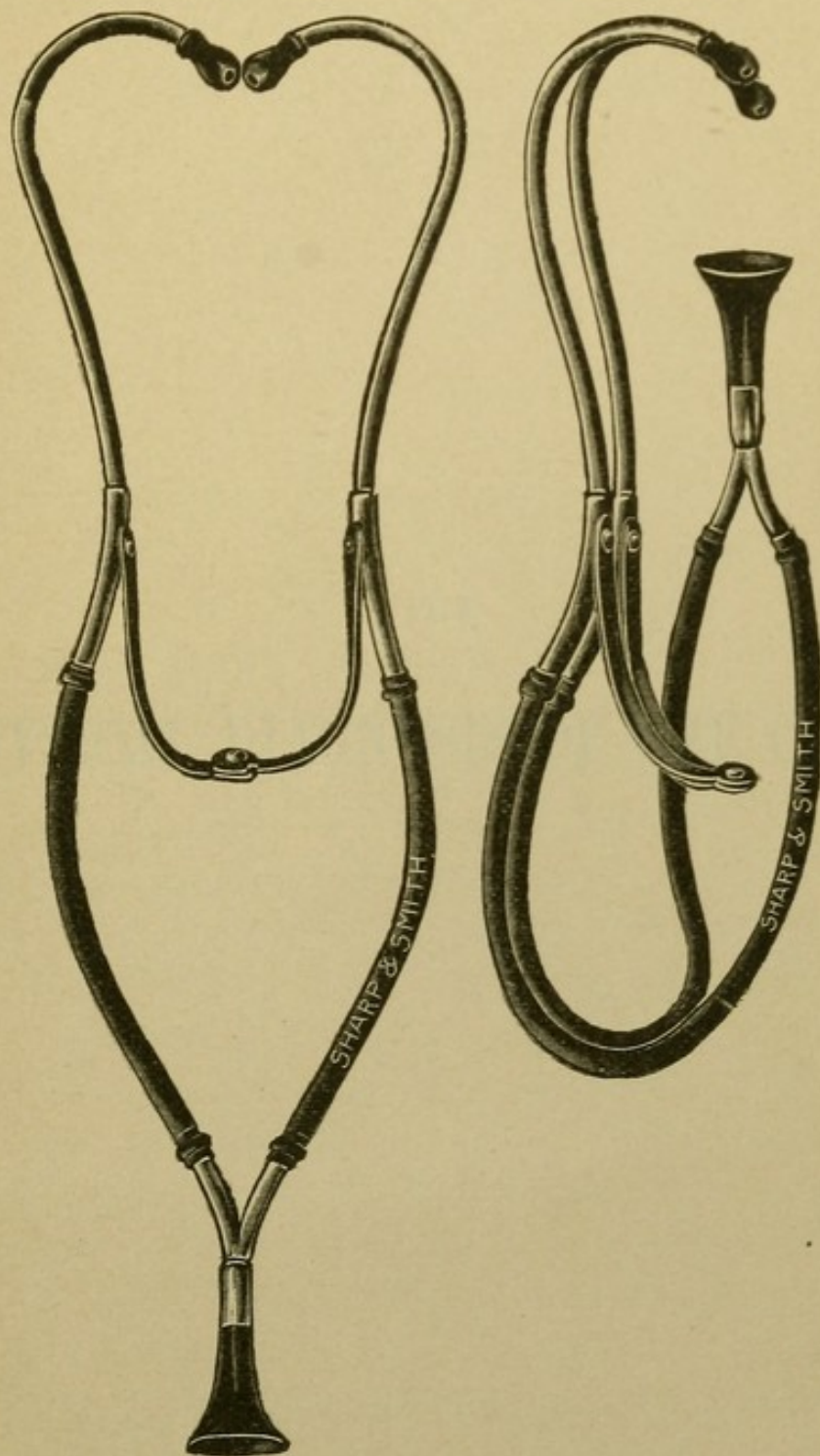



FIG. 3.—Folded Single Stethoscope.



Faint, illegible text or a signature, possibly a name or date, located at the bottom center of the page.

THE
PHYSICAL DIAGNOSIS OF THE CHEST.

PHYSICAL DIAGNOSIS OF THE CHEST

THE
PHYSICAL DIAGNOSIS OF THE CHEST.

Definition.—Physical Diagnosis is the science and art of objective examination of the body as practised upon its surface.

The *science* of physical diagnosis deals with the character, causes, and significance of physical signs, and the methods of eliciting them. *Signs* are objective features, as distinguished from *symptoms*, which are purely subjective.

The *art* of physical diagnosis is the practical application of the science. Its aim is, therefore, to distinguish objectively between health and disease, and between various diseases.

Introductory Note.—Objective examination, though dealing in a broad way with the entire body, finds its most profitable application to the thorax, which is therefore the field of its operation as considered in the following synopsis. The four divisions of the subject are (1) Topography of the Chest; (2) Landmarks of the Chest; (3) Methods of Physical Diagnosis; (4) Physical Signs common in and peculiar to each Disease of the Chest.

TOPOGRAPHY OF THE CHEST.

THE topography of the chest deals with the regions, their boundaries and their contents.

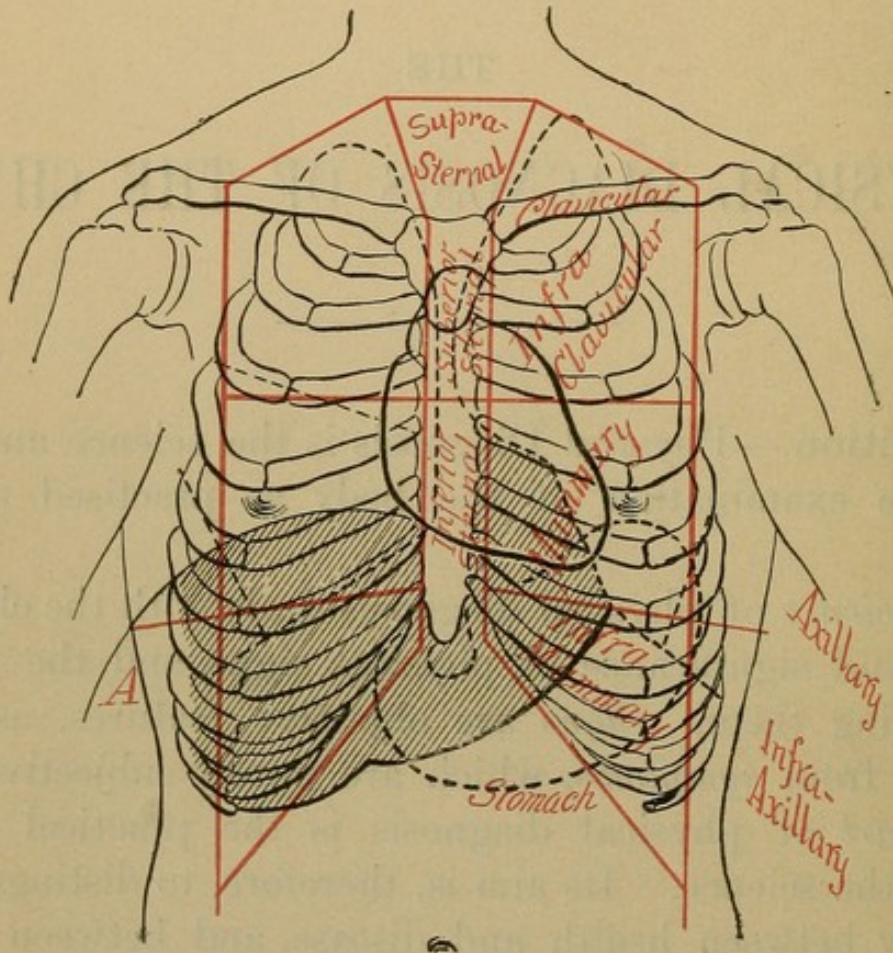


FIG. 4.—Anterior surface of the chest.

ANTERIOR REGIONS.

SUPRA-CLAVICULAR regions.

Boundaries :

ABOVE, the line drawn from the junction of the external with the middle third of the clavicle to a point at the inner margin of the sterno-mastoid muscle, on a level with the upper ring of the trachea.

BELOW, the superior border of the inner two-thirds of the clavicle.

INTERNALLY, the anterior border of the sterno-cleido-mastoid muscle.

Contents: the apices of the lungs; parts of the sub-

clavian and carotid arteries; and the subclavian and jugular veins, on either side.

CLAVICULAR regions.

Boundaries: the margins of the inner two-thirds of the clavicle.

Contents:

RIGHT SIDE, the apex of the lung.

EXTERNALLY, the subclavian artery.

INTERNALLY, the innominate artery and recurrent laryngeal nerve.

LEFT SIDE, the apex of the lung.

EXTERNALLY, parts of the subclavian vessels.

INTERNALLY, parts of the subclavian and carotid vessels.

INFRA-CLAVICULAR regions.

Boundaries:

ABOVE, the lower border of the clavicle.

BELOW, the lower border of the third rib.

INTERNALLY, the border of the sternum.

EXTERNALLY, a line let fall from the junction of the middle with the outer third of the clavicle, and passing down an inch to the outer side of the nipple (some authorities give the mammillary line).

Contents:

EITHER SIDE, lung tissue.

RIGHT SIDE, a part of the aorta, descending vena cava, and right bronchus.

LEFT SIDE, the pulmonary artery and left bronchus, the base of the heart and great vessels.

MAMMARY regions.

Boundaries:

ABOVE, the lower border of the third rib.

BELOW, the lower border of the sixth rib.

INTERNALLY, the margin of the sternum.

EXTERNALLY, a line let fall from the junction of

the middle with the outer third of the clavicle, passing an inch to the outer side of the nipple.

Contents :

RIGHT SIDE, the lung, right lobe of the liver, right auricle, right ventricle, and diaphragm.

LEFT SIDE, the lung and heart.

INFRA-MAMMARY regions.

Boundaries :

ABOVE, the lower border of the sixth rib.

BELOW, the lower border of the false ribs and cartilages (the costal arch).

INTERNALLY, the costal arch.

EXTERNALLY, a line let fall from the junction of the middle with the outer third of the clavicle.

Contents :

RIGHT SIDE, the lung on deep inspiration, the right lobe of the liver.

LEFT SIDE, the lung and the left lobe of the liver.

SUPRA-STERNAL region.

Boundaries :

ABOVE, a line on a level with the first ring of the trachea.

BELOW, the inter-clavicular notch.

LATERALLY, the anterior borders of the sternocleido-mastoid muscles.

Contents : the trachea, thyroid gland, vessels, and œsophagus.

SUPERIOR STERNAL region.

Boundaries :

ABOVE, the inter-clavicular notch.

BELOW, a line on a level with the third costal cartilages.

LATERALLY, the margins of the sternum.

Contents : the lung below the level of the second costal

cartilage, the descending vena cava, aorta, pulmonary artery, and bifurcation of the trachea.

INFERIOR-STERNAL region includes the sternum below the level of the third costal cartilages.

Contents : a part of the right auricle and the origins of the pulmonary artery and aorta ; a small part of the left lung ; a part of the right ventricle, right lung and liver, and a part of the attachment of the pericardium to the diaphragm.

LATERAL REGIONS.

AXILLARY regions.

Boundaries :

ABOVE, the axilla.

BELOW, a line on a level with the lower border of the mammary region.

ANTERIORLY, a vertical line let fall from the junction of the middle with the outer third of the clavicle.

POSTERIORLY, the anterior or axillary border of the scapula.

Contents : lung-tissue, and the main bronchi deeply placed.

INFRA-AXILLARY regions.

Boundaries :

ABOVE, the axillary region.

BELOW, the margins of the false ribs.

ANTERIORLY, the external boundary of the inframammary region.

POSTERIORLY, a line let fall from the inferior angle of the scapula (scapular line).

Contents :

EITHER SIDE, lung-tissue.

RIGHT SIDE, the right lobe of the liver.

LEFT SIDE, the spleen and part of the stomach.

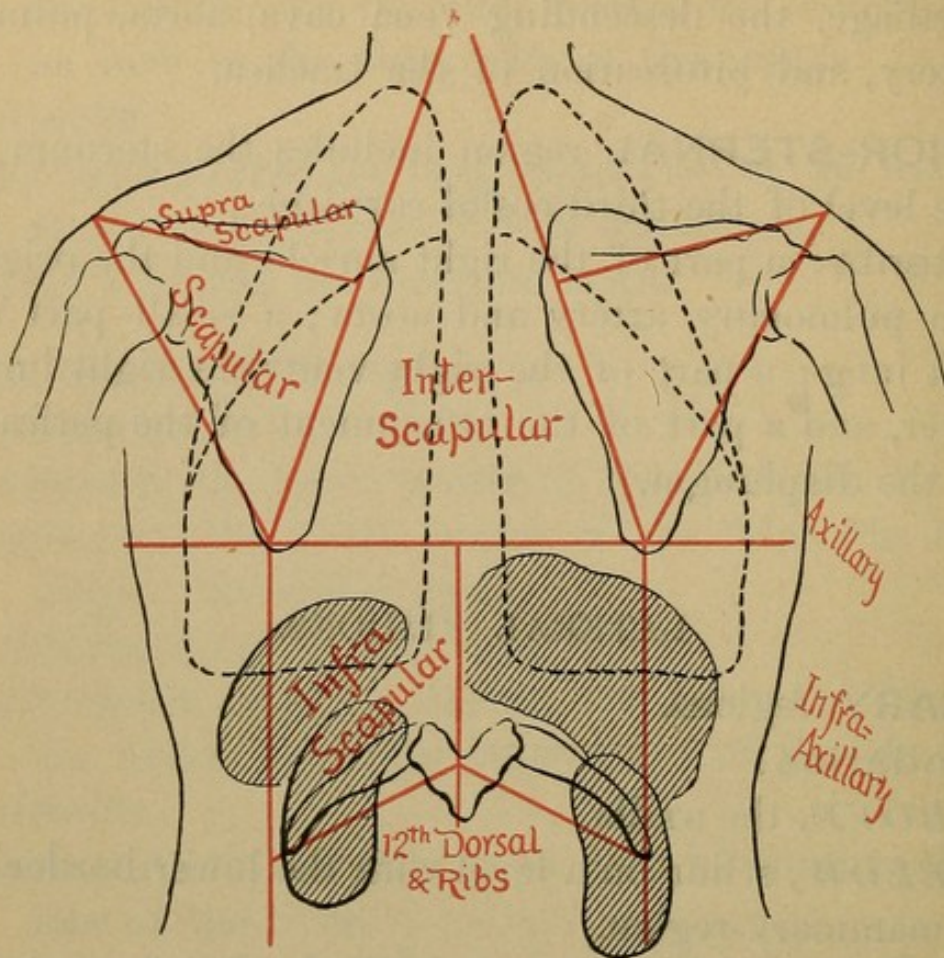


FIG. 5.—Posterior surface of the chest.

POSTERIOR REGIONS.

SUPRA-SCAPULAR regions.

Boundaries, those of the supra-spinous fossæ.

Contents: the apices of the lungs.

SCAPULAR regions.

Boundaries, those of the infra-spinous fossæ.

Contents: lung-tissue.

INTER-SCAPULAR region.

Boundaries:

EXTERNALLY, the posterior borders of the scapulæ.

The region extends from the level of the second to that of the seventh dorsal vertebra.

Contents:

RIGHT SIDE, the lung, bronchial glands, and main bronchus.

LEFT SIDE, the lung, glands, main bronchus, aorta, thoracic duct, and œsophagus.

INFRA-SCAPULAR regions.

Boundaries :

ABOVE, inter-scapular and scapular regions.

BELOW, the margins of the false ribs.

POSTERIORLY, the spines of the dorsal vertebræ, below the seventh.

ANTERIORLY, the scapular line.

Contents :

RIGHT SIDE, the liver, lung, and upper end of the kidney.

LEFT SIDE, the lung and a part of the spleen, kidney, and intestines.

LANDMARKS OF THE CHEST.

The landmarks include the various points, lines, and measurements to which reference may be made in showing the relation of the deep organs to the surface.

LINES OF REFERENCE.

VERTICAL lines of reference.

Meso-sternal line, the mid-line of the sternum.

Sternal lines, right and left, corresponding to the lateral margins of the sternum.

Mammillary (not mammary) lines, right and left, passing vertically through the nipples.

Para-sternal lines, right and left, passing vertically midway between the mammillary and sternal lines on the respective sides.

Anterior Axillary lines, right and left, passing vertically through the points at which the pectorales majores leave the chest, the arms being at right angles to the body.

Posterior Axillary lines, right and left, passing vertically

through the points at which the latissimus dorsi leave the chest, the arms being at right angles to the body.

Mid-axillary lines, right and left, midway between the anterior and posterior axillary lines.

Scapular lines, right and left, passing vertically through the inferior angles of the scapulæ.

Vertebral line, passing through the spines of the vertebræ.

HORIZONTAL line of reference.

Horizontal Nipple Line.

OBLIQUE line of reference.

Linea-costo-articularis, drawn from the left sternoclavicular articulation to the free end of the left eleventh rib.

LANDMARKS OF THE LUNGS.

OUTLINE of the lungs.

Outline of the Right Lung.

THE APEX extends an inch and a half above the first rib, and is apt to be a little lower than the apex of the left lung.

THE ANTERIOR BORDER lies in the meso-sternal line from the level of the second to the level of the sixth costal cartilage.

THE INFERIOR BORDER in adults lies as follows, in the average position; on deep inspiration it is depressed an inch and a half lower; in children it is from a half to a full interspace higher; in the aged it is often as much lower:

IN THE MAMMILLARY LINE at the sixth rib.

IN THE MID-AXILLARY LINE at the eighth rib.

IN THE SCAPULAR LINE at the tenth rib.

Outline of the Left Lung.

THE APEX extends one inch and a half to two inches above the first rib.

THE ANTERIOR BORDER lies in the meso-sternal line from the level of the second to the level of the fourth costal cartilage.

THE INFERIOR BORDER lies (in the average position),

IN THE MESO-STERNAL LINE, at the fourth costal cartilage.

IN THE PARA-STERNAL LINE, at the fifth rib.

IN THE MAMMILLARY LINE, at the sixth rib.

IN THE MID-AXILLARY LINE, at the eighth rib.

IN THE SCAPULAR LINE, at the tenth rib.

The inferior border of the left lung reaches half to three-quarters of an inch lower than the right in the mid-axillary and scapular lines.

FISSURES of the lungs.

Fissures of the Right Lung.

THE LONG FISSURE.

ITS POSITION : it separates the lower from the middle and upper lobes.

ITS DIRECTION is from above and behind, obliquely downward and forward.

ITS RELATION to the chest is about as follows :

Near the Vertebral Column it is three inches below the apex of the lung (near the inner end of the spine of the scapula).

In the Mid-axillary Line it is about the level of the fourth rib.

Just within the Mammillary Line it cuts the lower margin of the lung at the sixth rib.

THE SHORT OR LESSER FISSURE.

ITS POSITION : it separates the upper from the middle lobe.

ITS DIRECTION is obliquely downward and forward from a point near the anterior border of the scapula, where it joins the long fissure.

ITS RELATION to the chest-wall is about as follows :
It lies at first nearly under the third rib, but crosses the third intercostal space about the mammillary line, and cuts the anterior border of the lung about the junction of the fourth costal cartilage with the sternum.

Fissure of the Left Lung.

THE LONG FISSURE (the left lung has but one fissure).

ITS POSITION : it separates the upper from the lower lobe.

ITS DIRECTION is from above and behind, obliquely downward and forward.

ITS RELATION to the chest-wall is as follows (in the average position) :

Near the Vertebral Column it is about three inches below the apex of the lung.

In the Mid-axillary Line it is about the level of the fourth rib.

In the Mammillary Line it cuts the lower margin of the lung at the sixth rib.

LOBES of the lungs.

Anteriorly :

ON THE RIGHT SIDE,

THE UPPER LOBE lies above the third intercostal space.

THE MIDDLE LOBE lies below the third interspace, reaching to the lower margin of the lung.

THE LOWER LOBE is practically absent anteriorly.

ON THE LEFT SIDE,

THE UPPER LOBE reaches from the apex to the lower margin of the lung.

THE LOWER LOBE is practically absent anteriorly.

Laterally :

ON THE RIGHT SIDE,

THE MIDDLE LOBE is present above the fourth rib.

THE LOWER LOBE reaches from the fourth rib to the lower margin of the lung.

ON THE LEFT SIDE,

THE UPPER LOBE lies above the fourth rib.

THE LOWER LOBE reaches from the fourth rib to the lower margin of the lung.

Posteriorly :

ON BOTH SIDES,

THE UPPER LOBE practically lies above the spine of the scapula.

THE LOWER LOBE reaches from the spine of the scapula to the lower margin of the lung.

THE TRACHEA.

Dimensions.

LENGTH, four and one-half inches.

CALIBRE, three-fourths to one inch.

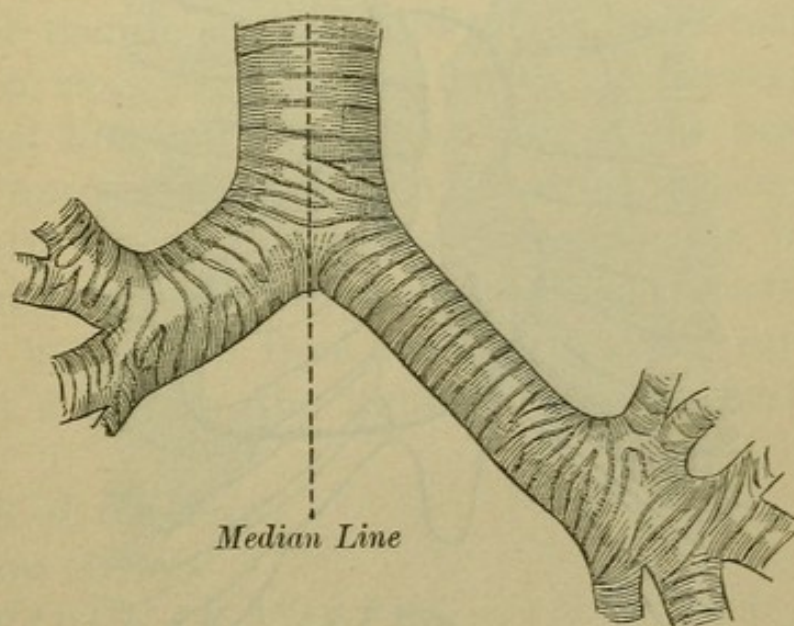


FIG. 6.—Showing divergence of main bronchi.

Bifurcation, under the middle of the sternum about the level of the second costal cartilage, at the level of the third dorsal vertebra. The septum or line of divergence between the two bronchi is to the left of the median line, thus influencing the direction of foreign bodies which enter the trachea.

THE PRIMARY BRONCHI.

Direction.

THE RIGHT bronchus is nearly horizontal.

THE LEFT bronchus is oblique.

Position.

THE RIGHT lies under the second rib.

THE LEFT lies under the second intercostal space.

Length.

THE RIGHT is about one inch long.

THE LEFT is nearly two inches long.

Calibre.

THE RIGHT bronchus is larger than the left.

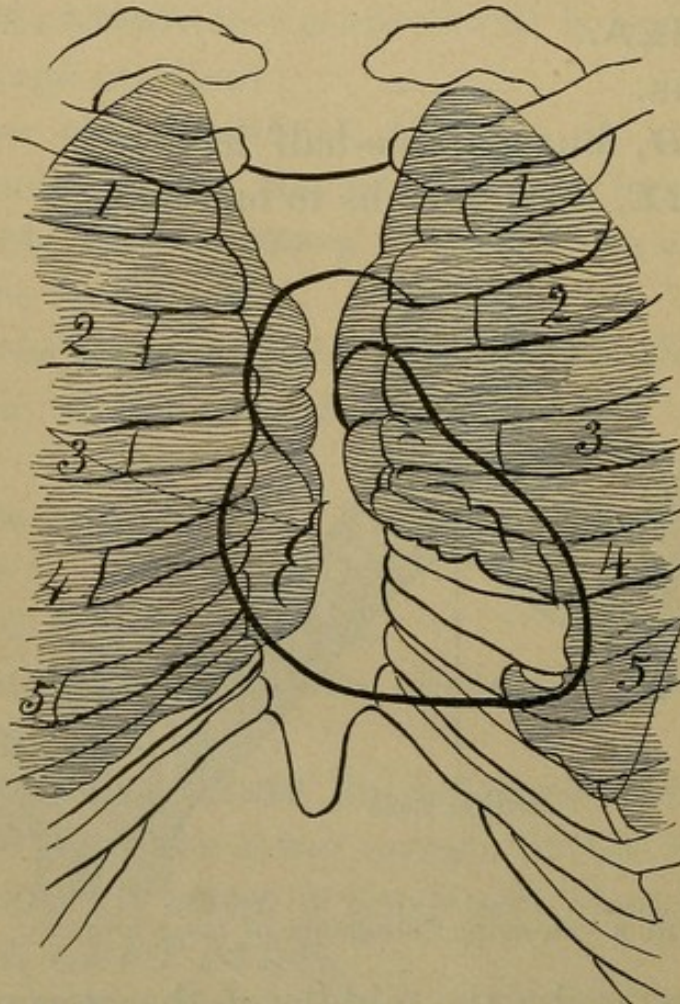


FIG. 7.—Relations of the heart (Holden).

LANDMARKS OF THE HEART.

OUTLINE of the heart.

The **Base** nearly corresponds in level with the superior margin of the third rib.

The **Apex** lies under the fifth intercostal space,
TWO INCHES BELOW the nipple (in the male) and
HALF AN INCH TO THE RIGHT of the left mam-
 millary line.

The **Right Margin** corresponds with a line beginning on
 the third costal cartilage half an inch to the right of
 the right sternal line, curving slightly to the right and
 downward to the end of the sternum.

The **Left Margin** corresponds with a line beginning on
 the third costal cartilage an inch to the left of the left
 sternal line, curving to the left and downward to the
 apex beat, but not including the nipple.

The **Lower Margin** corresponds nearly with a line join-
 ing the apex and the end of the sternum.

RELATION of the heart to the lung in front.

It is **Covered** by the lung (*cardiac dulness*) from the
 upper margin of the third to the lower margin of the
 fourth rib, and below the fourth rib between the para-
 sternal line and the left margin of the heart.

It is **Uncovered** by the lung (*cardiac flatness*) in the tri-
 angular or irregularly quadrilateral area bounded on
 the right by the meso-sternal line, on the left and above
 by a line drawn from the fourth costal cartilage to a
 point a little to the right of the apex beat.

VALVES of the heart.

Position (Gray).

SEMILUNAR VALVES.

THE PULMONIC valve lies behind the left sternal
 line at the level of the third costal cartilage.

THE AORTIC valve lies close to the left sternal line,
 behind the third intercostal space.

AURICULO-VENTRICULAR VALVES.

THE TRICUSPID valve lies behind the meso-sternal
 line about the level of the fourth costal cartilage.

THE BICUSPID or mitral valve lies about one inch to the left of the sternum behind the third intercostal space.

LANDMARKS OF THE AORTA.

The aorta is most superficial in the right second intercostal space at the edge of the sternum. The arch of the aorta lies an inch below the inter-clavicular notch.

LANDMARKS OF THE INNOMINATE ARTERY.

Its course may be traced by an oblique line drawn from the mid-sternal line at the level of the second costal cartilage to the right sterno-clavicular articulation.

LANDMARKS OF THE LIVER.

RIGHT LOBE of the liver.

Its Upper Margin lies,

IN THE MAMMILLARY LINE, at the fourth intercostal space.

IN THE MID-AXILLARY LINE, at the sixth rib.

IN THE SCAPULAR LINE, at the eighth rib.

Its Lower Margin lies half an inch below the costal arch, in the average healthy adult male.

Relation of the liver to the lung.

IT IS COVERED by lung (*hepatic dulness*),

IN THE MAMMILLARY LINE, from the fourth interspace to the sixth rib.

IN THE MID-AXILLARY LINE, from the sixth to the eighth rib.

IN THE SCAPULAR LINE, from the eighth to the tenth rib (the lower margin of the lung may be depressed an inch and a half on deep inspiration).

IT IS UNCOVERED by lung (*hepatic flatness*) from these points (sixth, eighth, and tenth ribs) downward.

LEFT LOBE of the liver.

Its **Upper Margin** lies under and against the diaphragm, adjoining the heart.

Its **Lower Margin** (in the median line) lies about midway between the end of the appendix sterni and the umbilicus.

Its **Left Margin** reaches nearly to the left mammillary line.

LANDMARKS OF THE SPLEEN.

THE SPLEEN IS COMPLETELY SHELTERED beneath the ribs, and cannot be felt in health except in rare cases.

THE OUTLINE of the spleen.

Its **Upper Margin** lies under the ninth rib.

Its **Lower Margin** lies under the eleventh rib.

Its **Anterior Extremity** nearly reaches the linea cost-articularis, drawn from the free end of the eleventh rib to the left sterno-clavicular articulation.

Its **Posterior Extremity** approaches within two-thirds of an inch of the body of the tenth dorsal vertebra.

THE DIRECTION is obliquely backward and upward, the long axis corresponding nearly with the direction of the tenth rib.

THE RELATION of the spleen to the lung.

It is **Covered** by lung in its posterior and upper third, which lies in the infra-scapular region.

It is **Uncovered** by lung in its anterior and lower two-thirds, which lie chiefly in the infra-axillary region.

LANDMARKS OF THE VERTEBRÆ.

THE SEVENTH CERVICAL VERTEBRA, vertebra prominens, is readily made out.

THE TWELFTH DORSAL VERTEBRA may be located by reference to the twelfth rib, which may be felt when the lumbar muscles are relaxed; in muscular subjects it

may be located by following the lower margin of the trapezius muscle.

ALL THE SPINES are located by slight friction with the finger, reddening the skin over their tips.

SLIGHT CURVATURE of the vertebral column to the right or left exists in right- or left-handed persons.

LANDMARKS OF THE RIBS.

THE SECOND RIB is on a level with the prominence (*angle of Lewis*), more or less marked in all persons, at the junction of the first and second pieces of the sternum.

THE SEVENTH RIB lies at the inferior angle of the scapula when the arms hang at the sides.

THE FIFTH RIB is just covered by the convex lower border of the pectoralis major.

THE THIRD COSTO-STERNAL JUNCTION is on a level with the body of the sixth dorsal vertebra.

THE HORIZONTAL NIPPLE LINE cuts the sixth intercostal spaces in the mid-axillary lines.

THE ELEVENTH AND TWELFTH RIBS can always be felt when the abdominal wall is relaxed.

THE INFERIOR END OF THE STERNUM is on a level with the tenth dorsal vertebra.

LANDMARKS OF THE SCAPULA.

The scapula lies over the ribs from the second to the seventh. The inner end of the spine of the scapula is nearly on a level with the third dorsal vertebra, main bronchus, and beginning of the pulmonary fissures behind.

METHODS OF PHYSICAL DIAGNOSIS.

THE methods of physical examination are inspection, palpation, mensuration, percussion, auscultation, and succussion.

INSPECTION.

Inspection reveals color, nutrition, size, form, posture, and movements.

COLOR may be due to pigmentation, or vascularization, or both.

Color dependent upon *pigmentation* may be

NORMAL.

LOCAL, as in the areolæ about the nipples, color of the eyes and hair.

GENERAL, as in the Negro, Malayan, Indian, brunette, and blonde.

ABNORMAL.

LOCAL, moles, lentigo, chloasma, the seat of scars, leucoderma.

GENERAL, icterus, argyria, Addison's disease.

Color dependent upon *vascularization*.

NORMAL, erythema, ruddy complexion or the opposite.

ABNORMAL.**LOCAL.**

Arterial, congestion, eruptions, etc.

Venous, ecchymosis, enlarged superficial veins and capillaries.

GENERAL.

Arterial, congestion, or its opposite, pallor, chlorosis, anæmia.

Venous, cyanosis, morbus cæruleus.

Color dependent upon both vascularization and pigmentation is observed in various cachexiæ, malignant disease, disease of the liver, etc.

NUTRITION is manifested by the degree of fatty deposits or muscular development, as well as by the color.

SIZE of the chest.

Normal size of the chest.

CIRCUMFERENCE of the chest at the level of the nipples in man, just above the mammæ in women.

AVERAGE circumference thirty-four inches in men, thirty-two in women.

USUAL EXTREMES, twenty-eight to forty-four inches.

CHEST-MEASUREMENT AS RELATED TO HEIGHT AND WEIGHT.

Height.	Chest.	Standard Weight.	20 per cent. under weight.	45 per cent. over weight.
5 feet	33½	115	92	167
5 " 1 in.	34	120	96	174
5 " 2 "	35	125	100	181½
5 " 3 "	36	130	104	188½
5 " 4 "	36½	135	108	195
5 " 5 "	37	140	112	203
5 " 6 "	37½	143	114	207
5 " 7 "	38	145	116	210
5 " 8 "	38½	148	119½	215
5 " 9 "	39	155	124	224½
5 " 10 "	39½	160	128	232
5 " 11 "	40½	165	132	239
6 "	41	170	136	246

RESPIRATORY EXPANSION, two to seven inches.

Average of the chest, two inches and a half.

Usual Extremes, two to four inches.

SEMI-CIRCUMFERENCE laterally.

THE RIGHT SIDE is usually half an inch larger than the left in right-handed persons.

Abnormal size in

CIRCUMFERENCE; this may be disproportionately **SMALL** compared with the vertical diameter of the chest, when it is generally associated with flatness or hollowness of the upper anterior part of the chest, wing-like projection of the scapulæ, an acute costal angle, and deficient respiratory expansion. The circumference is apt to be disproportionately

LARGE in marked emphysema.

SEMI-CIRCUMFERENCE; either side of the chest may be

SMALL compared with the other, as a result of fibroid contractions of the lung on that side, following pleurisy, pneumonia or collapse. It may be

LARGE as compared with the other, in case of extensive pleuritic effusion or pneumothorax.

FORM of the chest.

Normally the chest is a nearly symmetrical, truncated, conical pyramid, flattened slightly in its antero-posterior diameter.

Abnormal forms of the chest.

ASYMMETRICAL forms.

LOCAL BULGINGS may be due to irregularities of the *Chest-wall*; tumors or swellings such as sarcoma, abscess, periostitis, or deformities of the bony framework.

Pressure from within, due to the
Thoracic Organs.

CIRCULATORY organs.

Enlargement of the heart in children.

Hydro- or pneumo-pericardium, aneurysm.

LUNGS AND MEDIASTINUM.

Tumors or swellings.

Pleuritic accumulation of gas, fluid, or solids,
e. g. pneumothorax, serothorax, tumors.

Abdominal Organs.

Enlargement of abdominal organs.

Abnormal accumulation of gas, fluid, or solids,
encroaching upon the thorax.

LOCAL DEPRESSIONS, as the retraction of the supra- and infra-clavicular regions from contraction of the apex of the lungs in phthisis; or the retraction of the chest in any region following fibroid induration of the lung.

RELATIVELY SYMMETRICAL forms of the abnormal chest.

THE PIGEON BREAST deformity of the chest occurs chiefly in childhood, and is characterized by lateral constriction of the thorax, with straightening of the true ribs and prominence of the lower end of the sternum ; this is a result of rhachitis.

THE RHACHITIC CHEST is developed in early life ; it is characterized by lateral retraction of the thoracic walls, the anterior surface being broader than in the pigeon breast, and the sternum less prominent ; the costo-chondral junctions are thickened, presenting a series of bead-like eminences known as the *rhachitic rosary*.

THE ALAR CHEST is characterized by *wing-like* projections of the scapulæ, usually associated with a narrow chest, sloping shoulders, and an acute costal angle. It is commonly significant of constitutional weakness, which favors the development of pulmonary phthisis.

THE EMPHYSEMATOUS OR BARREL-SHAPED CHEST is characterized by roundness of contour, the antero-posterior diameter being lengthened, the transverse diameter shortened, and the upper end of the sternum prominent ; the intercostal spaces are wide and full, the shoulders are thrown forward, the scapulæ separated, and the whole posture stooping.

FUNNEL BREAST, characterized by sinking in of the lower end of the sternum, is a congenital deformity sometimes observed in several branches of the same family ; it may be so marked as to interfere seriously with respiration. *Shoemakers' breast* is an acquired deformity of similar form, and is caused by the pressure of tools against the lower part of the sternum.

HARRISON'S GROOVE is a horizontal line of depression along the false ribs, corresponding to the insertion of the diaphragm; it is sometimes observed in conditions of chronic inspiratory dyspnoea necessitating powerful action of the diaphragm, especially in rachitic children.

SPINAL CURVATURES; the chest may be asymmetrical or symmetrical, deviations being either antero-posterior or lateral, or both. These may be due either to defective development of the bodies of the vertebræ or to caries.

POSTURE. The position of the body as a whole or in its parts is significant as an aid to diagnosis.

Voluntary posture, as ordered by the examiner.

NATURAL postures.

FIXED position, upright, standing, sitting, recumbent.

CHANGE from the upright posture to recumbency may reveal movable organs, fluids or gases, or evidence of pain.

UNNATURAL or specially-arranged postures to facilitate examinations—genu-pectoral, left lateral semi-prone, etc.

Involuntary posture, as assumed by the patient as a result of disease.

POSTURE OF THE BODY AS A WHOLE.

DROOPING, relaxed, or reclining posture as indicating lassitude, debility, helplessness.

FORWARD, BACKWARD, OR LATERAL inclination more or less fixed, as a result of *Prolonged Habit*, or from occupation.

Partial Destruction of the Bony Support (Pott's disease, etc.).

Muscular Contraction from

INFLAMMATION of the soft parts, and

ABNORMAL PRESSURES from tumors or enlarged

organs—viz. forward inclination to relieve the backward pressure of an aneurysm or other tumor against the trachea, marked flexion of the body in peritonitis, colic, etc.

Lesions of the Central or Peripheral Nervous System may produce *opisthotonos* or over-extension of the vertebral column from tonic contraction of the posterior, cervical, dorsal, and lumbar muscles, with associated extension of the thighs and extension of the legs in tetanus, spinal meningitis, hysteroid convulsions.

RECUMBENCY UPON OR INCLINATION TOWARD THE AFFECTED SIDE is common in the first stage of pleurisy.

INABILITY TO LIE ON THE AFFECTED SIDE in many cases of pleurisy with effusion, and in case of superficial inflammations, or in some cases of cardiac disease.

INABILITY TO LIE DOWN AT ALL in certain cardiac and pulmonary diseases interfering with respiration—viz. asthma.

POSTURE OF THE BODY IN ITS PARTS.

FIXED POSITION of the limbs in any position in catalepsy.

LIMBS RELAXED or parts of the body drawn to the opposite side in unilateral paralysis.

LIMBS OR HEAD DRAWN INTO DISTORTED POSITIONS by muscular or fibroid contractions.

POSITION OF A LIMB involuntarily corresponds to that giving least pain in disease of the joints.

FACIAL EXPRESSION is closely related to posture, and depends largely upon the influence of the intellect, feeling, and will.

Intellectual, expression of intelligence or imbecility, etc.

Emotional, expression of pain, anxiety, fear, grief, anger, joy, etc.

Volitional.

Voluntary control in the change of expression.

Involuntary distortion of features as seen in paralysis and contraction.

MOVEMENTS.

General muscular movements are of interest as being normally or abnormally present or absent, as in paralysis and chorea, or as eliciting pain.

GAIT is peculiar in various diseases of the central or peripheral organs.

CONVULSIONS OR TREMORS may be present.

COUGHING, SNEEZING, SNORING, SIGHING, YAWNING, AND HICCOUGH, while visible signs as well as symptoms often of disease, are better classed with subjective features. Cough as a sign is referred to under Auscultation.

Respiratory movements.

NORMAL breathing is termed *eupnœa*. The two sides of the chest should expand equally, and the upper part of the chest should be well filled with each inspiration. There is a slight falling in of the intercostal spaces during inspiration, and a corresponding shallowness of these during expiration.

THE RHYTHM or ratio of the inspiratory to the expiratory *act* is as six to seven (Gibson), there being no pause between them.

THE TYPES of respiration include costal or *superior costal* breathing as observed in women, *inferior costal* breathing as usually observed in men, abdominal or *diaphragmatic* breathing as seen in children.

THE RAPIDITY of normal respiration varies according to

Intrinsic Conditions.**Age.**

Under one year,		44	per	minute.
One to five	years	26	“	“
Five to twenty	“	20	“	“
Twenty to twenty-five	“	18	“	“
Twenty-five to thirty	“	16	“	“
Thirty to fifty	“	18	“	“

Physical

STATE, posture.

ACTIVITY, general muscular, digestion, etc.

Mental

STATE, temperament.

ACTIVITY, emotional, volitional.

Extrinsic Conditions.

Rarity of the Atmosphere, elevation, etc.

Excessive Heat acting on body-temperature.

ABNORMAL breathing regards the**FORM** of the chest during respiration.***Expansion*** of the chest in abnormal breathing.Diminished expansion may be unilateral or bilateral (*vide* the conditions and causes of feeble respiration).

Bulging of the intercostal spaces during expiration is observed in emphysema.

Retraction of the soft parts of the chest, xiphoid process, and false ribs in inspiration occurs in croup, paralysis of the vocal cords, and other conditions involving obstruction of the upper air-passages.**RAPIDITY OF ABNORMAL RESPIRATION.*****Abnormally Rapid*** respiration is termed *hyperpnœa*. This is observed in most conditions causing dyspnœa (*vide*), notably in the following : In Fever, especially in nervous persons, and in children.

In all Conditions Causing Painful Breathing, such as diseases of the pleura, diaphragm, and peritoneum, fracture of the ribs, pleurodynia.

In Diseases Narrowing the Bronchial Tubes : asthma, bronchitis.

In Conditions Lessening the Aerating and Circulatory Areas of the Lungs.

PULMONARY DISEASE : emphysema, œdema, pneumonia, etc.

PLEURITIC AFFECTIONS : air, fluids, or solid tumors in the pleural cavity pressing on the lungs.

ABDOMINAL AFFECTIONS : tumors, swellings, or effusion, or gas.

In Disease of the Heart affecting the pulmonary circuit.

In some Diseases of the Nervous System.

Abnormally Slow Respiration might well be termed *hypopnœa*. This is observed in the course of Cheyne-Stokes respiration, and sometimes in diseases of the brain and meninges ; in acute infectious diseases with marked mental dulness ; in stenosis of the upper air-passages, due to intra-tracheal tumors, foreign bodies, inflammation, compressions from without, and paralysis of the abductors of the vocal cords.

Suspended Respiration is termed *apnœa*, which is due to want of a proper stimulus to respiration, owing to saturation of the blood with oxygen and the presence of a deficient amount of carbonic-acid gas ; it is observed in the course of Cheyne-Stokes respiration. It seems to be the condition of the fœtus in utero.

Asphyxia literally means absence of the pulse—*i. e.* the almost pulseless condition of suspended vitality resulting from lack of oxygen in the

blood or its saturation with CO_2 . The stages of asphyxia (Landois) are

Hyperpnœa, lasting about one minute.

Convulsions, lasting about one minute.

Exhaustion, lasting about three minutes, during which the heart continues to beat, but feebly. When the heart ceases to beat recovery is impossible.

VARIATION IN THE RHYTHM OF RESPIRATION.

An increase in the number or depth of respirations, or both, is the chief characteristic of *dyspnœa* or difficult breathing.

Dyspnœa.

Varieties of *Dyspnœa.*

INSPIRATORY *dyspnœa*: *dyspnœa* may be purely inspiratory, or it may be associated with difficult expiration in varying degree; it is the result of obstruction to the ingress of air into the lung, and is observed in croup, compression of the trachea, and paralysis of the diaphragm, etc.

EXPIRATORY *dyspnœa*, pure, or associated with difficult inspiration, is due to obstruction to the exit of air from the lung, as is typically observed in asthma and emphysema.

MIXED expiratory and inspiratory *dyspnœa* is most frequent; it is observed in many diseases of the lungs and heart, and in fever.

EXAGGERATED *dyspnœa*, or *orthopnœa*, requiring the sitting or standing posture and the use of the extra muscles of respiration, is observed in acute asthma and in advanced cardiac disease, etc.

CHEYNE-STOKES RESPIRATION is characterized by a number of shallow respirations

which become deeper and more dyspnœic to a given point at which there may be a groan, and then grow more superficial till they apparently cease; after a pause (apnœa) the series is repeated, the whole cycle occupying from thirty-five seconds to a minute, the number of respirations usually being about thirty. During the pause the pupils are contracted and immobile to light, and consciousness is usually lost. In some cases consciousness returns with deep breathing, and the pupils dilate and react to light. This is *normal* in animals during hibernation; *abnormal* in man, due to cerebral or medullary disease (meningitis, hemorrhage, tumors), uræmia, certain affections of the heart, and to opium-poisoning.

Causes of Dyspnœa.

RESPIRATORY CAUSES OF DYSPNŒA may depend upon

Insufficient quantity of air supplied to the lungs, owing to—

1. Imperfect respiratory movements, due to—

(a) Paralysis, lesions of the central or peripheral nervous system.

(b) Pain, as in inflammation of the pleura and peritoneum, pleurodynia, intercostal neuralgia, trichinosis of the diaphragm, etc.

(c) Muscular weakness.

(d) Yielding walls of the chest due to rickets and fractures.

(e) Loss of elasticity of the chest-wall: myositis ossificans, scleroderma.

2. Loss of elasticity of the lungs from

- emphysema, pleuritic adhesion, prolonged compression.
3. Lessened capacity of the chest, due to—
 - (a) Bony malformations.
 - (b) Pressure from thoracic or abdominal effusion or tumors.
 4. Lessened lumen of the air-passages :
 - (a) Extra-mural causes : cicatricial contractions, pressure of tumors, etc.
 - (b) Intra-mural causes : thickening of the walls of the air-passages, muscular spasm, as in bronchitis, asthma, and laryngismus stridulus.
 - (c) Inter-mural : foreign bodies, secretions, and false membranes within the air-passages.
 5. Diminished surface for circulation and interchange of gases in the lung, owing to—
 - (a) Inflammation of the lungs : pneumonia, fibrosis, tuberculosis.
 - (b) Collapse or compression of the lung from pressure of air, fluid, or solids : tumors, pleuritic effusion, pneumothorax.
 - (c) Destruction of the alveolar capillary network, as in emphysema.

Modified quality of the air which is inhaled.

1. Insufficient density due to heat, high altitude, decreased atmospheric pressure.
2. Deleterious adulterations : noxious gases, etc.
3. Insufficient oxygen.

CIRCULATORY CAUSES OF DYSPNŒA include

Diminished quantity of blood aërated, owing to—

1. Oligæmia, after acute hemorrhage.
2. Pulmonary ischæmia, from
 - (a) *Vis a fronte*, due to
 - Pulmonary disease: emphysema, fibrosis, compression, etc.
 - Arterial disease.
 - Extra-mural: compression, ligation.
 - Intra-mural: inflammation of the arterial coats.
 - Inter-mural: embolism.
 - (b) *Vis a tergo* may be diminished owing to
 - Cardiac inefficiency from
 - Valvular disease.
 - Compression of the heart by pericardiac or pleuritic effusion.
 - Muscular weakness of the heart from atrophy, myocarditis, degeneration, etc.

Modified quality of the blood.

1. Super-heated blood acts on the respiratory centre, *heat-dyspnœa*.
2. Deteriorated blood: pernicious anæmia, fevers, poisons.

Circulatory Movements.

VASCULAR MOVEMENTS.

VENOUS movements (pulsations).

Normal Venous Movements.

Jugular Presystolic pulsation (slight) is rarely visible in health (Vierordt).

Abnormal Venous Movements.

Jugular Systolic pulsation occurs in tricuspid regurgitation.

Hepatic venous systolic pulsation is sometimes visible in marked tricuspid regurgitation.

ARTERIAL movements (pulsation).

Normal Arterial Movements.

Carotid pulsation is frequently visible under the angle of the jaw, varying with the degree of adiposity and the force and excitation of the heart.

Aortic pulsation is exceptionally visible in the supra-sternal region (high position of the arch).

Abnormal Arterial Pulsation.

Carotid pulsation, when marked, may signify hypertrophy of the left ventricle, insufficiency of the aortic valve, arterial sclerosis (aortic), or aneurysm.

Aortic pulsation

IN THE NECK is sometimes due to insufficiency of the aortic valve, to aneurysm, or to hypertrophy of the left ventricle.

IN THE RIGHT SECOND INTERCOSTAL SPACE pulsation is always abnormal, and is usually significant of one of the conditions just mentioned.

Pulmonary arterial pulsation appears to the left of the sternum in aneurysm of this artery. Pulsation of this artery may sometimes be seen in fibrosis of the lung.

Capillary pulsation (Quincke) may be seen in

MARKED HYPERTROPHY OF THE LEFT VENTRICLE, but more often in marked AORTIC INSUFFICIENCY. The pulsation is observed in the bed of the finger-nails, at the fundus of the eye, in the mucous membrane of the lip under pressure of a glass slide, and also in the line of erythema caused by drawing

the finger-nail with some force over the patient's surface.

CARDIAC MOVEMENT (pulsation).

APEX BEAT of the heart.

Cause of the apex beat: The heart changes in form, shortening and thickening, in systole, and at the same time changes in position, revolving on its axis, the apex being projected forward.

Visibility of the apex beat.

Normally the visibility varies with the

SHAPE of the chest and the width of the intercostal spaces ;

THICKNESS OF THE CHEST-WALL from the presence of fat, muscle, and mammary gland ;

POSTURE OF THE BODY, the apex being less visible in recumbency ;

FORCE OF THE HEART'S ACTION, as dependent upon its innate power and its excitation.

Abnormally the visibility of the apex beat varies greatly.

VERY MARKED pulsation is usually observed in hypertrophy ;

SLIGHT OR ABSENT pulsation is observed in *Conditions of cardiac weakness* from

1. General debility, or
2. Local weakness of the heart's muscle, dependent upon cardiac atrophy ; cardiac degeneration, fatty, fibroid, or amyloid ; or cardiac dilatation.

Interposition of air between the heart and chest-wall: emphysema, pneumothorax, pneumo-pericardium ; *fluid*: pleuritic or pericardiac effusion ; *solids*: tumors, fibrinous deposit.

Thickening of the chest-wall: excessive fat,

scleroderma, œdema, emphysema of the chest-wall.

Displacement of the heart, as by traction from behind by fibroid contraction.

Location of the apex beat.

Normal Location of the Apex Beat.

IN THE ADULT MALE it is in the fifth intercostal space, two inches below and one inch inside the nipple line.

VARIATIONS from the position in the healthy adult male accord with

Age: in children under ten years the apex beat is usually in the fourth intercostal space inside or outside the left mammillary line; in old age it is apt to be lower down, sometimes in the sixth intercostal space.

Respiration. Deep inspiration may carry it down to the sixth interspace.

Posture on the

1. Left side, may carry it to the left of the nipple line.
2. Right side, to the right of the usual position.

Physical exertion or emotion. The apex beat may become stronger or broader, or may be carried to the left when the individual is greatly excited.

Abnormal Location of the Apex Beat; it may be displaced,

UPWARD.

Pushed up by deformity of the chest-wall; pericardiac effusion (here it is apparently so); abdominal tympanitis, tumors, and ascites; paralysis of the diaphragm.

*Pulled up*ward by fibroid contraction of the upper lobe of the left lung.

UPWARD AND TO THE LEFT.

Pushed upward and to the left by hypertrophy of the left lobe of the liver or by abdominal tumors.

Pulled by fibroid contractions of the left lung.

DOWNWARD AND TO THE LEFT.

Pushed downward and to the left by deformity of the chest-wall ; large aneurysm of the arch of the aorta ; mediastinal tumors ; right pleuritic effusion or pneumothorax ; hypertrophy of the left ventricle (strong apex beat) ; dilatation of the left ventricle (weak apex beat).

Pulled downward and to the left by fibroid contractions of the pleura and lung.

TO THE RIGHT.

Pushed to the right by deformity of the chest-wall, emphysema of the lungs, left pleuritic effusion, or pneumothorax.

Pulled to the right by fibroid contractions of the right lung, or held by pleuritic adhesion.

Located on the right side in transposition of the thoracic organs (a rare condition).

PRECORDIAL PULSATION is observed together with the apex beat,

In Valvular Disease frequently ; in cardiac irritability, especially in thin or young persons ; in adhesive pleurisy with mediastinal pericarditis, here there is usually a systolic drawing in of several intercostal spaces.

In Infiltration of the Lung lying in front of the heart.

In Empyema Pulsans, which may occur when pus in the pleural cavity lies in front of the

heart, the cardiac movements being communicated to the fluid. It is probably favored by paresis of the intercostal muscles, high tension in the fluid and a powerful heart.

EPIGASTRIC PULSATION.

Hypertrophy of the Right Ventricle, especially if accompanied by pulmonary emphysema, frequently causes a systolic pulsation or trembling of the epigastrium.

Pulsation of the Normal Heart may be transmitted to the epigastrium through an hypertrophied left lobe of the liver.

Pulsation of the Normal Aorta may be seen in the epigastrium in thin persons, especially when the stomach is empty.

Pulsation of an Abdominal Aneurysm of the aorta may be visible in the epigastrium.

Venous Hepatic Pulsation, observed in the epigastrium, may occur in marked tricuspid insufficiency (rare).

PALPATION.

Palpation is the method of physical examination by the sense of touch, and it confirms much of what has been obtained by inspection; it reveals

SIZE, SHAPE, contour, roughness, etc.

CONSISTENCE, fluctuation,

MOISTURE AND HEAT; and elicits

PAIN.

Area.

LOCALIZED, as in intercostal neuralgia (Valleix's three tender points).

GENERAL sensitiveness, hyperæsthesia.

Depth.

SUPERFICIAL.

SKIN, inflammation.

MUSCLE, pleurodynia.

FRACTURE OF RIBS (crepitus, tenderness, dislocation).

DEEP-SEATED.

PLEURA.

MOVEMENTS.

Muscular.

Respiratory.

Circulatory.

CARDIAC MOVEMENTS, apex beat, precordial pulsation, etc. (*vide* under inspection).

EXTENT.

Localized.

Diffused.

CHARACTER.

Intensity.

Rhythm.

VENOUS MOVEMENTS.

ARTERIAL MOVEMENTS upon palpation.

AORTIC dilating pulsation of aneurysm, etc.

CAROTID pulse.

RADIAL pulse.

Factors in the Production of the Pulse.

Force of the Heart's Beat.

Elasticity of the Large Vessels.

Resistance at the Valvular Orifices of the heart.

Resistance in the Arterioles and capillaries.

Volume of the Blood.

Characteristics of the Pulse, as regards

Quality of the pulse.

DEGREE OF TENSION of the pulse.

Increased or high tension makes the incompressible or hard pulse. Tension is increased during inspiration, being highest :

1. At the beginning of expiration, except in pulsus paradoxicus.
2. By accelerated action of the heart.
3. By stimulation of the vaso constrictors, as by the action of cold, electricity, and certain drugs.
4. By diminished outflow of blood at the periphery.
5. By disease of the vessel walls : atheroma, sclerosis, old age ; drugs—*e. g.* lead-poisoning.
6. By compression of the large arterial trunks, ligation, or pressure.
7. By impeded venous flow, as in pregnancy, constipation, chronic bronchitis, emphysema, nephritis, etc.

Decreased or low tension makes the compressible or soft pulse ; tension is decreased during expiration, being lowest :

1. At the beginning of inspiration, except in pulsus paradoxicus.
2. After a hemorrhage.
3. By stoppage of the heart.
4. In elevated parts of the body.
5. By stimulation of the vaso dilators, action of drugs.

DEGREE OF FULNESS of the artery or volume of the pulse.

Increased volume of the pulse makes the large or full pulse. This is seen in cardiac hypertrophy, plethora, early stage of chronic nephritis.

Decreased volume of the pulse makes the small empty pulse as seen in general weakness from wasting disease, cardiac weakness, cardiac valvular lesions, aortic stenosis, mitral stenosis, or marked insufficiency without compensation.

Alternate increase and decrease of the volume of the pulse is observed in aortic insufficiency, giving the collapsing or *water-hammer pulse* of Corrigan.

Force of each pulse-wave depends chiefly upon the energy of the cardiac systole, and also upon the amount of vascular tone.

INCREASED FORCE of each pulse-wave, making the strong pulse, occurs with increased cardiac energy and vascular tone.

DECREASED FORCE of each pulse-wave, making the weak pulse, is the result of cardiac debility.

Duration of each pulse-wave depends upon the dilatation of the artery by the blood-current, and its contraction during the passage of the blood into the capillaries.

PROLONGED DURATION of each pulse-wave, giving the slow or sluggish pulse, occurs in all diseases producing contraction of the smaller arteries, as nephritis, artero-sclerosis, angina pectoris.

SHORTENED DURATION of each pulse-wave, giving the active, quick pulse, is present in all diseases and conditions giving relaxed arteries, as in febrile affections and in aortic regurgitation.

Rhythm of the Pulse.

VARIETIES OF RHYTHM.

Irregular pulse, as respects time, rate, and volume.

1. Irregular in time : varying length of successive intervals between beats, either rhythmical or arrhythmical. Irregularity in rate may be manifested by change in rapidity from fast to slow or *vice versá*.
2. Irregular in volume : varying strength or fullness of successive beats.
 - (a) Pulsus bigeminus : beats occurring in pairs, with intervals between each pair, the second beat of each pair being weaker than the first.
 - (b) Dicrotic pulse : characterized by a double beat—*i. e.*, a large beat followed by a small after-beat, occurring with each cardiac systole ; it is a weak pulse of low tension. It is obtained in fever patients and in some conditions of great exhaustion.
 - (c) Pulsus trigeminus : groups of three beats, the groups being separated by intervals.
 - (d) Intermittent pulse : here a beat is dropped out or is abortive, cardiac systole not being strong enough to send through the arteries a wave of sufficient size to be felt at the wrist.
 - (e) Pulsus paradoxicus : normally the tension of the pulse is increased during inspiration, but in pulsus paradoxicus it is decreased during inspiration, the pulse being very small or even absent at that time. It depends upon diminished lumen of the aorta, and notably occurs in mediastinal pericarditis, concretii

pericardii, and with large pleuritic effusion.

- (f) Irregularity or incoördination of the two radial pulses is sometimes observed in aortic aneurysm or aneurysm of the pulmonary artery.

CAUSES OF BROKEN RHYTHM of the pulse.

General causes of broken rhythm.

- | | |
|----------------|-------------------------------|
| 1. Nervous | } action of drugs or disease. |
| 2. Circulatory | |

Local causes of broken rhythm.

1. Reflex, dyspepsia, etc.
2. Circulatory, diminished blood pressure in the arteries, as in anæmia.
3. Cardiac weakness from
 - (a) Degeneration, atrophy, etc.
 - (b) Mechanical interference with its action ;

Acting within the cardiac apparatus, due to valvular disease, pericardiac effusion.

Acting from outside the heart : pleuritic effusion, distended stomach, hepatic enlargement, tumors, deformities of the chest.

Frequency of the Pulse, rate or number of beats.

THE AVERAGE PULSE RATE in healthy adult males is seventy-one beats ; in females, eighty per minute ; the pulse is relatively more rapid also in infancy, in small persons, in the upright position, in high altitudes, in late periods of the day, after meals, during emotional excitement, intellectual exercise, or muscular exertion.

THE SLOW PULSE, *bradycardia*, is character-

ized by a rate of sixty beats or less per minute; it has been observed as low as fifteen beats. It is

Normal in

1. Certain persons, habitually, apparently inherited.
2. Women immediately after child-birth.
3. Old age.

Abnormal.

1. Symptomatic in

(a) General diseases and conditions attended by great exhaustion, *e. g.* convalescence from acute fevers, typhoid, diphtheria, pneumonia, and in diabetes and anæmia.

(b) Digestive tract: aggravated dyspepsia, gastric ulcer, cancer of the œsophagus.

(c) Urinary tract: uræmia.

(d) Cardiac coronary sclerosis, myocardial degeneration, fatty, fibroid, etc., aortic stenosis.

(e) Nervous system.

Central diseases with gross lesions, as in early stage of meningitis, apoplexy, tumors of the cerebrum, injuries to the cervical cord.

Peripheral, pressure upon the vagus by tumors, etc.

Neuroses, so-called idiopathic disease of the nervous system—epilepsy, hysteria in certain cases, mania, general paresis, following fright.

Toxic: tea, coffee, lead, uric acid (uræmia), bile (jaundice).

THE RAPID PULSE, *tachycardia*, is character-

ized by a rate of eighty-five beats or more per minute; it has been observed as high as two hundred and fifty beats in adults.

Normally, the pulse is rapid in certain healthy adults habitually, and in certain individuals who are able *voluntarily* to increase the rate of the heart; in women at gestation: and in children as follows:

Infants, 130 to 150.

One year old, 120 to 130.

Two years old, 105.

Three years old, 100.

Five years old, 90 to 94.

Variations from emotions and physical exercise, etc., *vide* the average pulse.

Abnormally rapid pulse may be

1. Symptomatic, arising from

(a) Undue irritation of the nervous system, as related to

Age: young rapidly-growing weak persons.

Sex: women usually at establishment of menstruation and the menopause, especially when anæmic and chlorotic.

Habits: venereal excess, masturbation.

Toxic: tobacco, alcohol, tea, coffee.

Fatigue: physical or mental.

Fever.

(b) Lesions of the cardiac nervous mechanism.

Central: bulbar disease impairing the function of the vagus, tumors

or swellings, softening in the medulla or cord, hemorrhage.

Peripheral: tumors or swellings pressing upon the vagus, neuritis.

Neuroses.

Exophthalmic goitre.

Epilepsy, hysteria, irritable heart of soldiers.

Neurasthenia.

2. Reflex.

(a) Circulatory: lesions of the heart or vessels.

(b) Respiratory: nasal growths and hypertrophies, pharyngeal and laryngeal disorders.

(c) Gastro-intestinal: dyspepsia, intestinal worms in children.

(d) Genito-urinary: ovarian and uterine disease, nephritis, phimosis.

Fremitus is a trembling felt by the hand on examination. It has been termed *frémissement cataire* from its likeness to the vibration felt upon the back of a purring cat.

CIRCULATORY FREMITUS or thrill is due to vibrations originating within the heart or great vessels, and it includes:

ANEURYSMAL or **VASCULAR FREMITUS**, sometimes felt over large superficial aneurysms, and occasionally over the carotids in valvular disease of the heart, and over the jugular veins in tricuspid insufficiency; also,

ENDOCARDIAL or **CARDIAC FREMITUS**, not infrequently obtained, upon palpation of the præcordia, in certain valvular lesions.

Causes of Cardiac Fremitus: like certain cardiac murmurs it may be due to the whirling of the

blood-stream against a roughened surface or past a constriction.

Frequency of Cardiac Fremitus.

It generally occurs with loud cardiac murmurs, but comparatively few murmurs are accompanied by a thrill.

It is most common with mitral obstruction (presystolic) and aortic obstruction (systolic).

It is more rare with aortic regurgitation (diastolic), mitral regurgitation (systolic).

It is very rare with lesions of the right heart.

Location of Cardiac Fremitus.

It is generally felt best when the murmur is heard loudest—*e. g.*, just above the apex in mitral obstruction; in the aortic area in aortic obstruction and atheroma; over the jugulars in case of constriction of these vessels from pressure, as in enlargement of the thyroid gland; over the carotids (systolic) in aortic regurgitation from the sudden filling of the relatively empty vessels.

Intensity of Cardiac Fremitus.

It is apt to be, like Murmurs, increased by exertion.

It may disappear in cardiac weakness, and return with reviving strength or upon excitement.

FRICITION FREMITUS is a rubbing or grating sensation felt by the hand in palpation over a part where two roughened, inflamed, serous surfaces are moving upon each other, as in the first stage of pleurisy, occasionally in pericarditis, and rarely in peritonitis.

RHONCHAL, BRONCHIAL, or râle **FREMITUS** is caused by the passage of air through fluid in the trachea and larger bronchi during respiration; the vibrations produced are sometimes so marked as to be felt by the hand upon palpation.

CAVERNOUS FREMITUS: this may sometimes be felt over superficial cavities in the lung, owing to the vibration of fluid within them.

VOCAL FREMITUS, variously termed voice fremitus, vocal vibration or pectoral fremitus, is a trembling felt by the hand when placed upon the chest of a person who is speaking *aloud* (tussive or cough fremitus is of the same nature).

INTENSITY OF VOCAL FREMITUS.

Increased or marked vocal fremitus.

Normal, is found with

LOW PITCHED VOICES,

STRONG VOICES ; near to the

LARYNX ; over the

TRACHEA and

GREAT BRONCHI ; it is more marked over the

RIGHT APEX of the lung than over the left,

owing to the size and direction of the right bronchus ; it is more marked over

THIN CHESTS from the absence of muscle or fat.

Abnormal, increased vocal fremitus is found :

OVER CONSOLIDATION of the parenchyma of the lung, when the bronchial tubes, of large and medium size, are patulous, as obtains in phthisis and pneumonia ;

OVER COMPRESSED or collapsed lung above the level of the effusion ;

OVER A CAVITY near the surface, with dense walls and a free opening into a large bronchus.

Diminished or Suppressed vocal fremitus.

Normal, vocal fremitus is weak or absent with

HIGH PITCHED VOICES ;

WEAK VOICES ;

WOMEN, over lower half of chest ;

CHILDREN, over the whole chest ; and at a
DISTANCE FROM THE LARYNX and large
bronchi ; over

THICK CHEST-WALLS from excess of fat, mus-
cle, or mammary gland.

Abnormal, diminished vocal fremitus is due to
INTERPOSITION OF

Fluid, as in hydrothorax, pleurisy with effu-
sion, etc. ;

Air, as in emphysema, pneumothorax ;

Solids, as in adherent and markedly thick-
ened pleura, large solid tumor.

OBSTRUCTION OF THE LARGE BRONCHIAL
TUBES from the presence of a foreign body,
or compression by a tumor or stricture.

MENSURATION.

Measurement determines size and the symmetry or asym-
metry of the chest ; in the latter case it is instituted from the
middle point behind to the middle point in front.

PERCUSSION.

Percussion is the art of eliciting sounds by striking the
body.

METHODS of percussion.

Immediate, striking directly upon the part ; this method
is of comparatively little use.

Mediate, striking upon an intermediate object held against
the part.

INSTRUMENTS, in mediate percussion (varieties).

Hammer, plexor or plessor.

Pleximeter, or plessimeter, the medium upon which the
hammer strikes.

THE NATURAL and most useful instruments are the middle or index fingers of one hand, serving as plexor, and one or more fingers of the other hand, as pleximeter. **ARTIFICIALLY**, they may be made of hard rubber, wood, etc.

RULES FOR PERCUSSION.

The Patient.

THE SURFACE should be bare of clothing.

THE LIMBS symmetrical, the same position being maintained in the examination of the two sides.

TO EXAMINE THE FRONT of the chest the arms should be at the sides.

TO EXAMINE THE BACK the arms should be folded in front.

TO EXAMINE THE SIDES the arms should be folded above the head.

POSITION OF THE BODY.

EASE OF POSITION, to avoid discomfort and to insure like muscular tension on the two sides.

POSTURE: the erect, recumbent, or sitting posture, or all these may be required, as in determining change of position of solid organs or of the level of fluids; recumbency must be maintained if there is danger of heart failure.

The Examiner should maintain a position symmetrical with regard to the patient, the ear being at the same relative distance from the points percussed.

The Instruments (their use).

THE PLEXIMETER should be applied

WITH FIRMNESS, to avoid a cushion of air beneath it; the firmness of pressure should be uniform at all points of percussion.

PARALLEL TO THE RIBS, upon or between them.

OVER SYMMETRICAL POSITIONS on the two sides of the chest for comparison.

THE PLEXOR and its use :

THE STROKE should be made **WITH THE ENDS OF THE FINGERS** rather than with their pulps.

THE STROKE SHOULD BE MADE PERPENDICULARLY to the surface.

THE STROKE should be **REBOUNDED**, in using the hand the motion should be from the wrist.

THE STROKES should be **MODERATELY RAPID** in succession.

THE STROKE should be made with **MODERATE FORCE**, never causing pain, but more forcible for sounding deep-seated organs than for superficial.

THE TWO SIDES SHOULD BE PERCUSSED IN LIKE STAGES OF RESPIRATION, preferably at the end of expiration.

PERCUSSION SOUNDS.

The Elements of Sound in percussion.

QUALITY, the characteristic property or chief attribute which distinguishes one sound from another—*e. g.* full, empty, shallow, clear, soft, hard, toneless, dead, “thigh sound.”

INTENSITY, the quantity or loudness, largely governing the distance at which a sound can be heard; varying with

THE FORCE OF THE BLOW.

THE VOLUME OF AIR under the part.

THE THINNESS AND ELASTICITY OF THE CHEST-WALL.

DURATION, the length of time a sound can be heard.

PITCH, the degree of elevation in the musical scale.

ITS RELATION to duration and intensity, the lower the pitch the longer the duration, and the greater the intensity, and per contra.

THE FACTORS IN ITS PRODUCTION.

The Larger the Cavities (containing gas) in the part, the lower the pitch, and per contra.

The Greater the Tension of the Inclosing Wall, the higher the pitch, and per contra.

Proximity of Solid Bodies elevates the pitch.

The Larger the Opening in a cavity, the higher the pitch.

The Varieties of Percussion Sounds.

NORMAL PULMONARY OR VESICULAR RESONANCE or lung sound.

LOCATION, over those parts of the healthy lung which do not overlap the heart, liver, or spleen, and which are not covered by the scapulæ (*vide* the landmarks). The resonance obtained over the lung which overlaps these organs, while normal vesicular, is relatively less resonant, and hence properly termed dulness. Resonance is less intense and higher in pitch over the right apex than over the left.

CAUSE of the normal vesicular resonance; it is probably due to the combined vibration of the walls of the chest, alveoli, and bronchi and the air contained within them, the resonance of the deeper parts being modified by the thickness of the fleshy parts and by the elasticity of the bony elements.

CHARACTER of normal vesicular resonance.

Quality, soft, clear, full, resonant, vesicular.

Pitch, low.

Intensity, great.

Duration, long.

VARIATIONS IN CHARACTER.

In the Same Individual.

In a Given Location vesicular resonance varies with the degree of respiratory expansion.

In Different Locations it varies according to the size or amount of lung under the part and the thickness of the chest-wall.

In Different Individuals it varies according to the same factors.

EXAGGERATED PULMONARY RESONANCE.

LOCATION.

Normal, over both lungs in children.

Abnormal.

Over both Lungs in marked anæmia, in emphysema (the resonance present in this disease has also been termed by Flint vesiculo-tympanic).

Over One Lung when the other is partially or wholly crippled by consolidation, compression, etc.

Over Sound Parts of a crippled lung.

CAUSE, the lung is over-distended with air, either functionally, or from organic trouble as in emphysema.

CHARACTER: this is like that of vesicular resonance, except for increase of intensity and duration and slightly lower pitch.

VARIATIONS IN CHARACTER accord with the amount of air in the part, within reasonable limits.

BONE RESONANCE.

LOCATION, over the sternum and clavicle, and to a slight extent over the ribs.

CHARACTER.

Quality, non-tympanic, resonant, ringing.

Pitch, higher than that of vesicular resonance.

Intensity, less than that of vesicular resonance.

Duration, shorter than that of vesicular resonance.

DULNESS, diminished resonance. It includes vesicular and tympanic dulness.

LOCATION.

Normal Vesicular Dulness is obtained where the lung overlaps the heart, liver, and spleen and underlies the scapulæ. Normal tympanic dul-

ness is found over the lower part of the liver, heart, and spleen when the stomach and colon are distended with gas.

Abnormal Vesicular Dulness is obtained over

Thickening of the Chest-wall from œdema, tumor, or inflammatory swelling.

Interposition, between the lung and chest-wall, of solids or fluids; a moderately thick layer of inflammatory lymph on the pleural surface; a moderate amount of pleuritic effusion, inflammatory or non-inflammatory; extra-pulmonary tumors of small size.

Consolidation of the Lung, moderate in amount: pneumonia, tuberculosis, syphilis, new growths, œdema, pulmonary hemorrhage, collapse of lung.

CAUSE, less air or relatively more solids beneath the part than in normal lung.

CHARACTER.

Quality, harder, emptier, less clear, less vesicular than normal pulmonary vesicular resonance.

Pitch, higher.

Intensity, less.

Duration, shorter.

VARIATIONS, in character in different individuals and in different localities, accord with the relative amount of air or solids, approaching the character of pure pulmonary resonance on the one hand and flatness upon the other.

FLATNESS.

LOCATION.

Normal, over those organs or parts containing no air, hence over that portion of the heart, liver, spleen, and kidneys uncovered by lung.

Abnormal, over the chest when there is an exaggeration of any of those morbid conditions which

in a slight degree produce dulness : pleurisy with effusion, emphysema, hydro-thorax, etc.

CAUSE, entire absence of air or gas in and for some distance beneath the organ under the part percussed.

CHARACTER.

Quality, hard, empty, muffled, non-resonant, the "thigh sound."

Pitch, very high, highest of all percussion notes.

Duration, very short.

NO VARIATIONS OF ITS CHARACTER, as such, occur ; it may be modified by tympanitic resonance, where hollow gas-containing organs like the stomach or colon underlie a solid organ like the liver ; it is then termed tympanitic dulness, really a modification of tympany.

TYMPANITIC RESONANCE or tympany.

LOCATION.

Normal, where the stomach or colon, distended with gas, underlies the infra-mammary, infra-axillary, and infra-scapular regions, and sometimes over the lower part of the mammary and inferior sternal regions ; also over the trachea.

Abnormal.

Over a part of the chest when Gas is present in the Pleural Sac, pneumo-thorax.

Over a Pulmonary Air-containing Cavity of large size, phthisis, abscess.

Complete Solidification of a Part of the upper lobe of the lung, tympany being obtained from the trachea beneath ("tracheal tone" of Williams), second stage of pneumonia, phthisis.

Bronchiectasis with surrounding solidification, interstitial pneumonia.

Conduction of Stomach Resonance high up on the left side, when the lower lobe of the left lung is solidified.

CAUSE, percussion over a hollow gas-containing organ or cavity, the walls of which are more or less thin and tense.

CHARACTER.

Quality, non-vesicular, resonant, ringing, but harder than vesicular resonance.

Pitch, higher than vesicular resonance, variable.

Intensity and duration variable.

VARIETIES OF TYMPANY.

Closed Tympany is the sound obtained by percussion over a cavity filled with gas, and not communicating freely by an opening with the external air—*e. g.*, the stomach and colon. It is obtained also in some cases of pneumothorax.

Open Tympany includes amphoric and cracked-metal resonance.

Amphoric Resonance is obtained over a cavity with a large opening, as in percussion of the cheeks with the mouth open.

LOCATION.

Normal over the trachea, and sometimes over the upper part of the chest in children.

Abnormal, abscess or tubercular cavity communicating with a large bronchus.

CAUSE, percussion over a moderate sized gas-containing cavity with rigid, non-collapsing walls and free communication by a large opening; the examiner's ear or the mouth of the stethoscope should be near the patient's open mouth.

CHARACTER, its *quality* is tympanitic but peculiarly ringing and hollow like the sound produced by blowing across the mouth of a bottle; its *pitch* is higher than vesicular resonance, but varies with the size of the cavity

and of the opening, and the condition of the adjacent lung. Its *intensity* and *duration* are variable.

CHANGE IN THE CHARACTER of amphoric resonance.

Wintrich's change of sound only occurs over a cavity which freely communicates with a bronchus ; a louder, more amphoric, and higher-pitched note is produced over a cavity when the mouth is open, especially with the tongue protruding. The note with the mouth closed may be dull but slightly tympanitic.

Williams' tracheal tone, or change of sound, so called, is the tympanitic note obtained by percussion over the trachea, its change in character being similar to that in *Wintrich's change of sound*.

Interrupted Wintrich's change of sound (*Gerhardt, Moritz*). This differs from the former in that the change is marked in some positions of the body, in others indistinct or absent owing to the closure of the opening by the secretions within the cavity.

Gerhardt's change of sound. A tympanitic sound, whether open or closed, may change in pitch with change in posture. This may be due to the change in the tension of the chest-wall and that of the cavity, and to the change in location of fluids within the cavity.

Friedreich's, or the respiratory change of sound. A tympanitic note over the lung, or over a cavity within it, is higher in pitch at the end of deep inspiration than

in expiration, due probably to the higher tension.

Cracked-metal Resonance is a form of open tympany, and may be imitated by striking upon the knee with the hands loosely clasped palm to palm.

LOCATION AND CAUSE.

Normal.

1. If the chest be covered with much hair, under percussion.
2. If the pleximeter be loosely applied.
3. Sometimes it is obtained over the upper part of the chest of children, especially when crying.
4. Sometimes in adults when singing a prolonged note.

Abnormal.

1. Over some air-containing pulmonary cavities communicating with a bronchus by a small opening; percussion should be firm, and during expiration, the patient's mouth being open.
2. Occasionally in pleurisy, over the lung above the effusion; sometimes in the engorgement stage of pneumonia.
3. When an opening exists through the chest-wall into the pleural sac.

AUSCULTATION.

METHODS of auscultation.

Immediate or direct.

Mediate or indirect.

INSTRUMENTS of mediate auscultation, the stethoscope.

Varieties.

UNIAURAL, hollow and solid.

BINAURAL, Knight's, Camman's, Dennison's, Allison's differential, Corwin's multiplex.

Objections to the stethoscope.

IT HAS A SPECIAL RING or roaring sound like a shell.

OFTEN POORLY MADE.

FRIGHTENS CHILDREN.

NOT ALWAYS AT HAND.

Advantages of the stethoscope.

SHUTS OUT OUTSIDE SOUNDS.

CONCENTRATES and circumscribes sounds.

INTENSIFIES sounds.

CERTAIN PARTS OF THE CHEST ARE INACCESSIBLE to the unaided ear.

IT IS SOMETIMES INDELICATE to apply the ear directly to the chest.

IT IS SOMETIMES UNPLEASANT and may be *DANGEROUS* to apply the ear to the chest.

RULES for auscultation.

The Patient should have regard to

SYMMETRY, immobility, and ease of position.

THE CHEST SHOULD BE BARE for mediate auscultation, and should have a single layer of thin soft covering for immediate auscultation.

The Examiner should have

THE HEAD on a plane higher than the body to prevent congestion of the auditory apparatus ;

THE ATTENTION concentrated upon one sound or set of sounds at a time.

The Instruments.

THE EAR-PIECE should fit the external meatus accurately and point in the same direction as the canal, downward and forward.

THE TUBES should be, in lumen, the size of the external auditory canal ; it is of no advantage to have them larger.

THE LARGER CHEST-PIECE should not exceed one and one-fourth inch in diameter at the distal end. It is designed for the lung sounds.

THE SMALLER CHEST-PIECE is especially designed for the sounds of the heart and vessels. But it answers very well for auscultation of the lungs.

THE ENTIRE LENGTH of the instrument from ear-piece to chest-piece should not exceed about twenty-two inches (*vide* cut of simple compact stethoscope which the author has found a most satisfactory combination).

The Act of auscultation.

THE ROOM should be quiet.

THE EAR OF THE STETHOSCOPE should be firmly applied to the chest.

THERE SHOULD BE NO FRICTION between parts of the instrument; between the chest and the instrument; between the hand and the instrument; between the hand and the chest; between the hand and the clothing; between the chest and the clothing.

CORRESPONDING PARTS OF THE CHEST should be compared, and in like stages of respiration.

THE ENTIRE CHEST should be examined.

SOUNDS HEARD upon auscultation.

The Elements of sound.

QUALITY,	} <i>vide</i> percussion sounds.
PITCH,	
DURATION,	
INTENSITY,	

RHYTHM is the relation of sounds to each other, as that of inspiration to expiration, or the relation of the first and second sounds of the heart.

Varieties of Sounds upon auscultation.

PULMONARY sounds.

RESPIRATORY sounds vary in kind, intensity, and rhythm.

Kinds or Varieties of Respiratory Sound.

Normal Vesicular Breathing (persons should breathe more forcibly than usual, but with the same rhythm).

LOCALITY: it is heard over the parenchyma of the lung away from the main bronchi; best in the infra-scapular regions.

CAUSE of the vesicular sound (opinion varies).

It may be produced at the glottis, and modified by conduction through the spongy tissue of the lung.

It may be due to the entrance of air into the alveoli during dilatation.

It may be due to the vibration of the lung substance from increased tension in inspiration and the reverse in expiration.

CHARACTER.

Inspiratory sound.

Quality, breezy, rustling, soft, vesicular.

Pitch, low compared with that of laryngeal breathing.

Intensity, variable.

Duration, coincident with the inspiratory act.

Expiratory sound.

Quality, like the inspiratory but less vesicular.

Pitch, lower than that of the inspiratory sound.

Intensity, variable; the sound may not be appreciable but is generally so.

Duration, much shorter than the expiratory act.

Rhythm: the ratio of the inspiratory to the expiratory sound is about three

to one, there being a slight interval between them.

Variation in character largely depends upon the nearness of the point of auscultation to the large bronchi.

Bronchial Breathing.

LOCALITY and CAUSE.

Normal, heard over the trachea.

Abnormal (as a sign of disease), heard over consolidated lung, the main bronchi leading to which are patulous, consolidated lung being a better medium of conduction of the sound from the larynx. It is heard in pneumonia and phthisis.

CHARACTER, it is substantially like that of tracheal breathing, though slightly less intense.

Laryngeal and Tracheal Breathing differ from each other but little.

LOCALITY, heard over the larynx and trachea.

CHARACTER.

Inspiratory sound.

Quality, tubular, blowing, but changing in harshness with the force of the act.

Pitch, higher than that of the inspiratory sound of normal vesicular breathing, and varying in pitch with the force of the act.

Intensity, great but variable.

Duration, a little shorter than the inspiratory act.

Expiratory sound.

Quality, very similar to that of inspiration.

Pitch, higher than that of inspiration.

Intensity, greater than that of vesicular breathing.

Duration, longer than that of the expiratory sound of vesicular breathing.

Rhythm : the expiratory sound is as long as the inspiratory, and a short interval exists between them.

Cavernous Breathing.

LOCALITY (it is an abnormal sound) heard over some pulmonary cavities.

CAUSE, empty pulmonary cavity with easily collapsing and expanding walls in expiration and inspiration.

CHARACTER.

Inspiratory sound.

Quality, soft, blowing, or puffing, but neither vesicular nor tubular.

Pitch, low.

Intensity, variable, but usually slight.

Duration, variable.

Expiratory sound.

Quality, like that of the inspiratory sound.

Pitch, lower than that of the inspiratory sound.

Intensity, variable, but usually slight.

Rhythm : the expiratory sound is about the same length as the inspiratory.

Broncho-cavernous Breathing.

LOCALITY and CAUSE, cavity surrounded by solidified lung, as is found sometimes in the late stage of tuberculosis, abscess, or gangrene.

CHARACTER, both cavernous and bronchial elements are heard together.

VARIETIES, metamorphosing breathing ; here the inspiratory sound is bronchial at first, but suddenly becomes cavernous.

Vesiculo-cavernous.

LOCALITY and CAUSE, cavity covered by more or less healthy lung.

CHARACTER, as indicated by its name.

Amphoric Breathing.

LOCALITY, over a large cavity with relatively rigid walls and with a large opening, as may be obtained in tuberculosis and occasionally in pneumothorax.

CAUSE, the peculiar vibration of air in its passage in and out of, or across the mouth of a flask-like cavity.

CHARACTER.

Inspiratory sound most distinct.

Quality, musical, hollow, metallic, harder than that of cavernous breathing.

Pitch of expiratory sound lower than that of bronchial breathing.

Intensity, usually greater than that of cavernous breathing.

Rhythm : amphoric breathing is usually heard best in inspiration.

Intensity of Respiratory Sounds.

Exaggerated, Supplementary, or Puerile Breathing.

LOCALITY.

Normal in childhood, the chest-walls being thin and elastic.

Abnormal, over one lung when the other is crippled by consolidation, obstruction, etc. ; over healthy parts of a crippled lung.

CAUSE, the lung is performing more than its usual function.

CHARACTER, like that of normal vesicular breathing, except of greater intensity ; both inspiratory and expiratory sounds are louder and longer than usual.

Feeble Respiration.**LOCALITY.***Normal.*

Over thick chest-walls, as in muscular or fat persons; over the female mammæ and over the scapulæ.

At a distance from the large bronchi, over the lower part of the chest, especially in women.

In superficial breathing.

The vesicular murmur is normally less intense on the right than on the left side.

Abnormal from

Imperfect transmission, due to œdema or swelling of the chest-walls; air, fluid, or inflammatory lymph in the pleural sac.

Loss of elasticity of the lung, emphysema. Partial blocking of the air-cells with blood or serum, as in pulmonary œdema.

Consolidation of lung with filling up of the bronchi.

Obstruction of the larynx, trachea, or bronchi from a collection of pus, mucus, blood, or fibrin; foreign body; thickening of the mucous membrane; pressure of tumors.

Constriction of the tubes from muscular contraction, asthma, bronchiolitis.

Deficient action of the respiratory muscles.

Mechanical obstruction, as in tympany, ascites, abdominal tumors.

Pain, as in pleurisy, peritonitis, pleurodynia, neuralgia.

Paralysis of the diaphragm.

Suppressed Respiratory Sound ; entire absence of respiratory sounds.

LOCALITY and CAUSE, an exaggeration of the conditions which produce feeble respiration : pneumo-thorax, hydro-thorax, occlusion of the larger air-passages.

Rhythm of Respiratory Sounds.

Interrupted, Jerking, Wavy or Cog-Wheel Respiration.

LOCALITY.

Normal, in nervous persons, agitated by examination ; here it is apt to be heard more or less over the whole chest, but it may be localized ; sometimes it is heard in healthy persons from no apparent cause.

Abnormal, it may accompany :

Pain, as in pleurisy, pleurodynia, intercostal neuralgia ; it is generally heard over the whole chest.

Phthisis, here it may be an early sign, localized over the affected apex.

CAUSE of cog-wheel breathing : in some cases (pain and nervousness) it may be due to the irregular and undecided manner of respiration, in others (phthisis) it is probably caused by the break or delays in the passage of air through the affected bronchioles.

CHARACTER : either the inspiratory or expiratory sound, or both, may be broken into several parts, or may be characterized by successive variations in intensity ; usually it is most marked in inspiration.

Interval between Inspiration and Expiration may be more or less prolonged.

IN EMPHYSEMA, owing to a deferred expiratory sound.

IN CONSOLIDATION of the lung owing to shortening of the inspiratory sound.

Shortened Inspiratory Sound.

LOCALITY (where and when heard) and CAUSE.

In emphysema it is due to the beginning of the respiratory act before the beginning of the sound.

In consolidation (bronchial breathing) it is due to the ending of the inspiratory sound before the ending of the inspiratory act.

CHARACTER.

When due to emphysema.

Quality, vesicular.

Pitch, comparatively low.

When due to consolidation.

Quality, tubular.

Pitch, high.

Prolonged Expiratory Sound.

LOCALITY.

Normal, over the right apex; sometimes prolonged expiratory sound over the left apex in slightly less degree; over the larynx, trachea, and bronchi (*vide* the landmarks).

Abnormal, over consolidated lung; over a cavity; over emphysematous lung; in asthma; in case of certain valve-like obstacles in the air-passages.

CAUSE: difficult and prolonged exit of air from the lungs—*e. g.*, in emphysema, owing to loss of elasticity of the lung; in asthma, owing to spasm of the bronchial muscles.

CHARACTER.

When due to solidification of the lung.

Quality, tubular.

Pitch, high.

When due to a cavity.

Quality, blowing, cavernous or amphoric.

Pitch, low.

When due to emphysema.

Quality, vesicular.

Pitch, low.

When due to asthma.

Both quality and pitch are obscured by dry râles.

VOCAL SOUNDS.

Elements of Sound: these are like those considered in respiration and percussion, though not all of them are so significant in the consideration of vocal sound.

Varieties of Vocal Sound.

Normal (Vesicular) Vocal Resonance.

LOCALITY, it is heard

Over the lung at a distance from the trachea and bronchi while the person is speaking.

In adult males it is generally heard over the entire lung.

In women and children it is heard over the upper part of the chest, and but indistinctly over the lower part.

CAUSE: it is due to the transmission of the voice through the parenchyma of the lung and the chest-wall.

CHARACTER.

Quality, diffused, muffled, buzzing, seeming to come from the deep parts of the lung (articulation not transmitted).

Pitch, varies with the pitch of the voice.

Intensity, greater over the right apex than over the left, especially in the infra-clavicular region.

VARIATIONS from the normal are chiefly in intensity.

Diminished vocal resonance.

Locality and cause : it is the result largely of those conditions which cause feeble respiratory sounds.

Exaggerated vocal resonance.

Locality : it is heard over moderately consolidated lung ; pneumonia, phthisis, etc.

Cause, consolidated lung is a better medium for transmitting sound from the larynx than is ordinary lung tissue.

Character : it differs from normal vocal resonance simply in being more intense, seeming to come from a point not far distant from the surface. It is usually associated with broncho-vesicular respiration.

Bronchophony or Bronchial Voice.**LOCALITY.**

Normal, heard over the main bronchi.

Abnormal, heard.

Over consolidated lung as in the second stage of pneumonia, phthisis ; above the level of the fluid in pleuritic effusion.

Over a vomica with firm walls (sometimes), surrounded by consolidation.

CAUSE, consolidated lung a better medium of transmission.

CHARACTER. It is more concentrated than normal vocal resonance and exaggerated vocal resonance, seeming to come from a point near the ear, immediately under the stethoscope (no distinct articulation). It is usually associated with bronchial breathing, though not necessarily. Its *pitch* varies, and its *intensity* also, though usually increased above that of normal resonance.

VARIETIES OF BRONCHOPHONY.

Egophony (goat voice).

Locality, over consolidated lung, covered by a thin layer of fluid in the pleural cavity, as in pleuro-pneumonia with slight pleuritic effusion.

Character, it is like that of bronchophony, except that it is of less intensity and has a tremulous sound, seeming to come from a considerable depth.

Pectoriloquy (speaking through the chest).

Locality and cause. It is heard

1. Over consolidated lung, phthisis, pneumonia.

(a) Quality, clanging, metallic.

(b) Pitch, high.

2. Over a cavity with smooth walls and a large opening, abscess, bronchiectasis, etc.

(a) Quality, soft.

(b) Pitch, low.

Character, it is like that of bronchophony with the addition of distinct articulation in the transmitted voice.

Amphoric Voice.

LOCALITY, over pneumo-thorax or pulmonary cavity with a free opening.

CHARACTER.

Quality, hollow, musical.

Pitch and *Intensity*, variable. It is frequently associated with amphoric respiration and resonance.

WHISPERING SOUNDS.

Normal Whispering Resonance.

Exaggerated Whispering Resonance.

Whispering Bronchophony.

Cavernous Whisper.

Whispering Pectoriloquy.

Amphoric Whisper.

These whispering sounds correspond largely in locality, cause and character to the vocal sounds, the sound of phonation being substituted by that of aspiration.

TUSSIVE OR COUGH SOUNDS. Cough though a symptom is a sign of importance.

Definition. A deep inspiration is followed by closure of the glottis, contraction of the muscles of expiration, rise of tension within the pulmonary air-passages, and sudden opening of the glottis with violent explosive escape of the compressed air and vibration of the vocal cords.

Relation to Auscultation. Much the same laws govern the sounds produced by coughing as apply to vocal sounds in auscultation of the chest.

Cough may Remove Temporary Obstacles from the air-passages, thereby changing or destroying sounds.

It Necessitates Subsequent Deep Inspiration with consequent distention of the air-vesicles.

Varieties of Cough. It is dry or moist according to the amount and character of the accompanying secretion.

Laryngeal Cough, hacking, often spasmodic, and due to laryngitis, local irritation, or to reflex nervous trouble.

Bronchial Cough, dry or tight, quick, harsh, and brassy. Loose, more or less rattling, owing to secretion within the tubes. It is frequently accompanied by pain along the attachments of the diaphragm, and more or less soreness under the sternum. **Bronchitis.**

Cavernous Cough has a hollow quality, and is usually intense and accompanied by gurgling sounds.

Amphoric Cough is ringing, with the peculiar resonance heard in blowing across the neck of a bottle.

The terms cavernous and amphoric cough refer to sounds heard upon auscultation in certain cases where cavities open into large bronchi.

Causes of Cough. It may be

Voluntary, or may be

Involuntary, due to stimulation of the

NERVE CENTRE in the floor of the fourth ventricle.

REFLEX.

Nerve-trunks.

Vagus or superior laryngeal nerves.

Peripheral.

Direct stimulation of the mucous membrane of the air-passages by irritating particles, cold air, etc. Especially the surface of the

Soft palate and pharynx. The

Larynx is the most sensitive part of the air-passages.

Trachea and bronchi: the most sensitive part is at the bifurcation of the trachea.

Indirect stimulation.

Irritation of the *pleura* (the costal layer) as in pleurisy.

Irritation of the *auditory meatus*.

Decayed *teeth*.

Irritation of the *post nares*.

Irritation of the *skin* by cold draughts.

Derangement of the *stomach* possibly a cause of cough.

ADVENTITIOUS SOUNDS.

Râles.

Moist Râles.

LARGE, COARSE, or mucous râles.

Locality, where produced : large and middle-sized tubes ; "death rattle" heard in the trachea.

Cause, air bubbling through fluid, whether mucus, blood, or pus.

Character.

Quality, bubbling, moist.

Pitch, usually low but variable.

Intensity, variable.

Duration, they may be removed by coughing or deep inspiration.

Rhythm, they may accompany inspiration, expiration, or both.

Condition, acute and chronic bronchitis, profuse pulmonary hemorrhage, etc.

SMALL, FINE, mucous, or subcrepitant râles.

Locality, small tubes.

Cause, air bubbling through fluid.

Character.

Quality, moist, fine, bubbling, or crackling or sticky (mixed in size).

Pitch, varying with size of tube and condition of surrounding lung.

Intensity, variable.

Duration, they may be removed by deep inspiration or cough.

Rhythm, they may accompany either or both acts of respiration.

Condition, capillary bronchitis, third stage of tuberculosis, lobular pneumonia, pul-

monary congestion and œdema, severe hemorrhage, chronic bronchitis, etc.

Dry Râles.

SONOROUS RÂLES.

Locality, large tubes.

Cause, narrowing of the lumen of the bronchi, from viscid mucus adhering to their wall; swelling of the mucous membrane; spasm of the annular bronchial muscles; fibroid contractions; pressure upon the bronchi by an aneurysm or other tumors or swellings.

Character.

Quality, snoring.

Pitch, low.

Intensity, variable, usually very loud.

Duration, they are usually not removable by cough or deep inspiration, except when due to viscid mucus.

Rhythm, they may accompany either or both acts of respiration.

Conditions, asthma, bronchitis, and other more rare conditions causing narrowing of the tubes.

SIBILANT RÂLES.

Locality, small tubes.

Cause, same as that of sonorous râles.

Character.

Quality, whistling, hissing, creaking.

Pitch, high.

Intensity, less than sonorous, but variable.

Duration, they may be removed by cough or deep inspiration.

Rhythm, they may accompany either or both acts of respiration.

Conditions, asthma and bronchitis.

CREPITANT RÂLES.

Locality, they are produced in the ultimate air-vesicles.

Cause (probably), sudden separation of the walls of collapsed air-vesicles, adhering more or less, from the presence of fibrinous exudate upon their surfaces.

Character.

Quality, like the crackling of salt thrown upon the fire, dry, very fine, numerous, and uniform in size, as compared with subcrepitant râles, which are coarser, bubbling, moist, fewer in number, and of different sizes.

Pitch, high.

Intensity, variable.

Duration, they are not disturbed by cough.

Rhythm, they are never heard in expiration, always in inspiration, usually at its end.

Condition, typically in the first stage of lobar pneumonia, sometimes in incipient tuberculosis at the apex of a lung; rarely in pulmonary hemorrhage and œdema. They may frequently be found at the lower part of the posterior aspect of the chest for a few deep inspirations in feeble persons who have been in the recumbent posture for some time.

INDETERMINATE RÂLES.

Crumpling sounds.

Locality.

Normal, sometimes heard at the end of a forced inspiration, usually bilateral.

Abnormal, they are sometimes heard in emphysema.

Cause, none known definitely.

Character, something like the sound of parchment when wrinkled, and occurring at the end of forced inspiration.

Condition, emphysema.

Friction Sounds.

Locality, over inflamed pleura or pericardium, rarely over the peritoneum.

Cause, rubbing together of two serous surfaces, roughened by exudate, or dry from diminished secretion.

Character.

QUALITY, rasping, grating, grazing, creaking, simulated by rubbing the hand upon the chest during auscultation. They are few in number compared with râles, and are irregular in occurrence.

DURATION, they are not removable by cough or deep inspiration.

RHYTHM, usually they are most prominent at the end of inspiration or beginning of expiration.

Condition, pleurisy and pericarditis in the first stage; rarely in peritonitis over the spleen or liver.

Unclassified Adventitious Sounds.

Metallic Tinkling.

LOCALITY.

Normally, it may be heard at times over the stomach.

Abnormally, over the pleural cavity containing air and fluid, especially when communicating with a bronchus above the level of the fluid.

CAUSE: the dropping of fluid in a cavity containing fluid and air.

CHARACTER.

Quality, silvery, tinkling, or splashing.

Pitch, high.

Intensity, slight, but variable.

Rhythm, either in inspiration or expiration, or during cough, or occasionally independent of them.

CONDITION, pneumo-hydrothorax, pulmonary abscess, etc.

Splashing or Succussion Sound.

LOCALITY, same as that of metallic tinkling.

CAUSE, splashing of fluid within an air-containing cavity, heard when the body is shaken, with the ear of the examiner against the surface, over the part.

CHARACTER, splashing.

CONDITION, pneumo-hydrothorax or pneumopyothorax.

Bell Sound.

LOCALITY, it is heard over a large air-containing cavity.

CAUSE: with the ear against the cavity, percussion is made upon the chest at the opposite side of the cavity, two coins being used as plexor and pleximeter; the sound heard is due to the vibration of the air within the cavity.

CHARACTER, ringing, hollow, metallic.

CONDITION, pneumothorax.

SOUNDS PRODUCED BY THE CIRCULATORY MECHANISM.

CARDIAC SOUNDS.

Normal Cardiac Sounds.

First Sound of the Heart.

CAUSE of the first sound: it is chiefly due to the closure of the auriculo-ventricular valves

(mitral and tricuspid). To a slight extent this sound may also be due to contraction of the walls of the ventricle in systole, the impulse of the apex against the chest-wall, and the rush of blood through the ventricles.

ELEMENTS of the first sound.

Mitral element, heard best at the apex, and behind at the angle of the scapula. It is slightly louder than the tricuspid.

Tricuspid element, heard best at the lower end, a little to the left, of the sternum.

CHARACTER of the first sound.

Quality, "lubb," dull, soft, booming.

Pitch, lower than that of the second sound.

Intensity, greatest at the apex beat, varying with the strength of the heart, the condition of the valves and cavities, and the amount of tissue interposed between the heart and the listening ear.

Duration, long as compared with the second sound.

Rhythm, systolic, synchronous with the systole of the ventricles, the apex beat, and carotid pulse; preceded immediately by the long pause, succeeded immediately by the short pause.

Second Sound of the Heart.

CAUSE of the second sound: it is chiefly due to the closure of the semilunar valves, augmented by the vibration of the neighboring parts.

ELEMENTS of the second sound.

Aortic element, heard best in the second intercostal space, close to the right of the sternum.

Pulmonic element, heard best in the second intercostal space to the left of the sternum ; not so loud as the aortic.

CHARACTER of the second sound.

Quality, "dupp," sharp.

Pitch, higher than that of the first sound.

Intensity, greatest at the base of the heart ; variable like the first sound.

Duration, shorter than the first sound.

Rhythm, it is preceded immediately by the short pause, and succeeded immediately by the long pause. The relation of the first and second sounds with the intervening pauses may be represented thus :
 "lubb," — "dubb," ———.

Modifications of the Normal Heart Sounds.

Modification of the First Sound, in

INTENSITY AND DURATION.

Diminished intensity of the first sound, from Weakness of the heart as a result of—

1. General diseases, fevers, chronic wasting disorders, aneurysm, etc.
2. Local diseases of the heart : fatty degeneration or infiltration ; atrophy, amyloid, or fibroid degeneration ; valvular disease ; pericardiac effusion, etc.

Interposition of tissues, as in emphysema, pleuritic effusion, thick chest-walls from fat or muscle.

Increased intensity and duration of the first sound ; it may be

Longer in duration, loud and booming, as in hypertrophy of the left ventricle from cirrhotic kidney ; aortic stenosis and sometimes in aortic aneurysm, or

Shorter in duration and sharper, as in case of thin chest-walls, emotional excitement, physical exertion, onset of febrile disease.

QUALITY : the first sound may be impure ; it may be sharper or duller than usual, more flapping or clacking.

RHYTHM.

Reduplication.

Cause : non-synchronous action of the mitral and tricuspid valves, or possibly non-synchronous action of the cusps of either valve.

Character, as related to the second sound ; it may be represented thus : "lubb," "lubb," — "dupp," ———.

Frequency : it is not uncommon, but the second or diastolic sound is more frequently reduplicated than the first or systolic sound of the heart.

Significance : it is usually temporary, but may be permanent ; it is either physiological or pathological, and it is not peculiar to any particular lesion or condition.

Irregularity may involve time or intensity, or both.

Intermittency or dropping of the first sound.

Modification of the Second Sound.

INTENSITY.

Diminished intensity of the second sound from

Diminished power of the right or left ventricle, by which less blood is thrown into the aorta and pulmonary artery, producing less tension in them, and

hence, less forcible recoil of their elastic walls, and less sudden and forcible closure of the semilunar valves.

1. General debilitating diseases, or
2. Local diseases impairing the strength of the heart or elasticity of the main arteries.

Stenosis of the mitral or tricuspid orifices or of the orifices of the aortic or pulmonary artery, reducing the tension in those vessels.

Lesion of the pulmonary or aortic valves impairing their closure.

Increased intensity or accentuation of the second sound.

Pulmonic second sound may be accentuated as a result of increased tension in the pulmonary artery from hypertrophy of the right ventricle; obstructed pulmonary circulation dependent upon pulmonary disease or valvular disorder of the left heart.

Aortic second sound may be accentuated as a result of increased tension in the aorta from hypertrophy of the left ventricle or obstruction in the aortic or general circulation: chronic renal disease and some cases of aortic aneurysm.

QUALITY: the second sound of the heart may be sharper or duller, or flopping or more booming in character.

RHYTHM.

Reduplication of the second sound.

Cause: non-synchronous action of the aortic and pulmonic valves, or possibly

non-synchronous action of the cusps of either of these valves.

Character, as related to the first sound it may be represented thus: "lubb," — "dupp," "dupp," ———.

Frequency and significance (*vide* reduplication of the first sound).

Irregularity and

Intermittency of the second sound (*vide* first sound of the heart).

Abnormal Cardiac Sounds or Murmurs.

Exocardial Murmurs.

PERICARDIAC FRICTION SOUNDS.

Locality, over the præcordia, usually best heard over the base of the heart, or over the junction of the left fourth costal cartilage with the sternum.

Cause, inflammation of the pericardium causing roughness and dryness of the membrane in the first and at the end of the third stage.

Character.

Quality, rubbing, grating, rasping, creaking.

Intensity, variable, increased by forced expiration, by pressure of the stethoscope, and by forward inclination of the patient. They seem to be more superficial than endocardial murmurs.

Rhythm, independent of respiration and synchronous with systole or diastole, or both.

PERICARDIAC SPLASHING AND CHURNING sounds have been heard occasionally in cases of sero- or pyo-pneumo-pericardium.

PLEURO-PERICARDIAC friction sounds similar

in character to pleuritic friction sounds, but produced by the motion of the heart in systole, causing to-and-fro rubbing of the inflamed pleura. The pleura alone, or both the pleura and pericardium, may be involved in the inflammation.

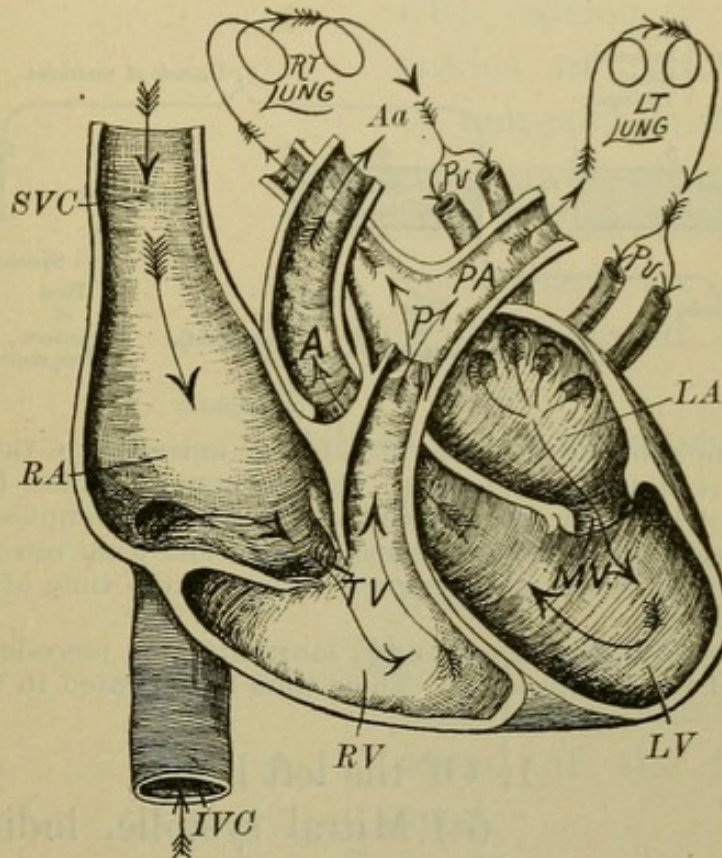


FIG. 8.—Normal blood-currents in the heart and relative position of the ventricles, auricles, and great vessels. *IVC*, inferior vena cava; *SVC*, superior vena cava; *RA*, right auricle; *TV*, tricuspid valves; *RV*, right ventricle; *P*, pulmonary valves; *PA*, pulmonary artery; *Pv*, pulmonary veins; *LA*, left auricle; *MV*, mitral valves; *LV*, left ventricle; *A*, aortic valves; *Aa*, arch of aorta. (From Page.)

PNEUMO-PERICARDIAC or cardio-pulmonary sounds are soft blowing murmurs of rare occurrence, produced by the motion of the heart in forcing air from an adjacent pulmonary cavity, the air supposedly being expelled from the cavity in systole and returning during diastole.

Endocardial Murmurs include organic and inorganic.

ORGANIC endocardial murmurs include valvular and non-valvular.

Valvular, organic, endocardial murmurs include systolic and diastolic.

Systolic, organic, valvular murmurs include those of the right and those of the left heart.

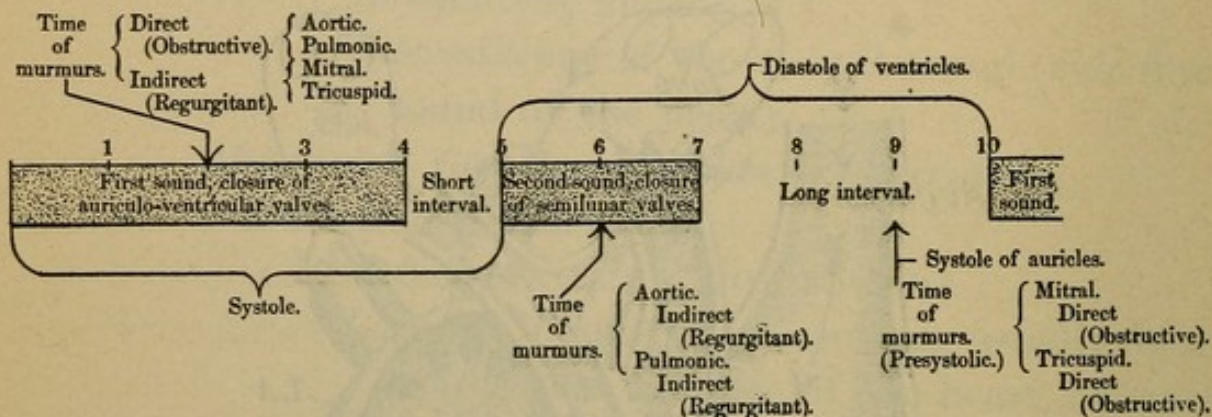


FIG. 9.—Diagram showing the time of valvular murmurs in the cardiac cycle. The *cardiac cycle* is divided into tenths. The *first sound* occupies four-tenths; the *short interval*, or silence between first and second sounds, occupies one-tenth; the *second sound* occupies two-tenths; the *long interval* following second sound occupies three-tenths; the *systole of the ventricles* occupies the time of the first sound and the short interval.

Relation of murmurs to the heart-sounds: murmurs may precede, occur with, or take the place of the heart-sounds. Their time is indicated in the diagram by arrows.

1. Of the left heart.

(a) Mitral systolic, indirect, or regurgitant murmurs.

Cause: insufficiency of the mitral valve from

Tearing or perforation of a cusp.
Inflammatory retraction of the cusps.

Rigidity of the cusps.

Vegetations, preventing closure.

Rupture or shortening of the chordæ tendineæ.

Dilatation of the left ventricle without compensatory lengthening of the chordæ.

Spasm of the columnæ carneæ.

Usual accompanying symptoms and signs :

Pulse, compressible and more or less irregular.

Indications of pulmonary, hepatic, and renal congestion with œdema of the feet and ankles are common in cases of non-compensation.

Enlargement of the left heart, with especial increase in transverse diameter.

Pulmonic second sound accentuated.

Character of the murmur of mitral regurgitation :

Quality, apt to be blowing and soft.

Rhythm, systolic, accompanying, or replacing, the first sound of the heart at the apex.

Intensity, varies in different cases, but the loudness of a murmur is not proportionate to, and does not indicate the severity of the lesions causing it. This is equally true of all organic murmurs.

Area of maximum intensity is at the apex.

Propagation of the murmur is frequently to the left of the apex ; it is often heard at the lower angle of the scapula, but is not

usually heard at the base of the heart, and is never transmitted into the carotids. The transmission of murmurs to the left of the apex depends upon the following factors :

Time : whether or not it occurs when the apex of the heart strikes the chest-wall (systole).

Enlargement of the heart.

Position of the heart relative to the transverse diameter of the chest-cavity.

Condition of the left lung.

Thickness of the chest-wall.

Intensity of the murmur.

Frequency of the murmur of mitral regurgitation, it is the most frequent of all valvular murmurs.

(b) Aortic systolic, direct murmur.

Cause :

Obstruction at the orifice, guarded by the aortic semi-lunar valve due to thickening and rigidity of the cusps from fibroid, calcareous, or atheromatous change ; vegetations ; adhesion of the cusps ; induration and contraction of the fibrous ring or margin of the aortic opening ; congenital malformation (rare).

Simple roughening of the cusps.

Marked dilatation of the aorta immediately beyond the valvular opening, the latter re-

maintaining relatively normal in size.

Usual accompanying symptoms and signs in cases of marked obstruction :

Pulse : hard, wiry, small, but regular unless the heart be greatly embarrassed.

Thrill or fremitus often felt over the base of the heart, especially over the aortic area.

Evidence of cerebral anæmia not uncommon ;

Enlargement of the left heart ;

Pulmonic second sound, feeble ;
and

Aortic second sound, feeble or inaudible.

Character of the aortic direct murmur :

Quality, usually harsh when due to stenosis or marked obstruction, otherwise it is apt to be soft.

Rhythm, systolic, with the first sound.

Area of maximum intensity : the right, second intercostal space close to the sternum, sometimes over the left interspace or over the upper part of the sternum at the same level.

Propagation, into the arteries of the neck and down the sternum, and toward the apex, but with diminished intensity. It is also

frequently heard when loud, behind to the left of the fourth dorsal vertebra, but is not usually transmitted to the left of the apex.

2. Of the right heart (systolic, organic, valvular murmurs).

(a) Tricuspid systolic, indirect or regurgitant murmur.

Causes may be similar to those of mitral regurgitant murmur, but usually it results from relative incompetency of the valve in dilatation of the right ventricle, secondary to diseases of the lungs or serious lesions of the left heart.

Usual accompanying symptoms and signs: Commonly pulmonary diseases or lesions of the left precede those of the right heart; the associated manifestations are often those of

Congestion of the brain and abdominal organs; pulsation of the

Jugular and sometimes of the Hepatic veins.

Enlargement of the right heart and usually of the left.

Pulmonic second sound, feeble.

Character of the murmur of tricuspid regurgitation:

Quality, blowing.

Rhythm, systolic, with or re-

placing the first sound of the heart.

Area of maximum intensity, the tricuspid area at the end of and along the left side of the sternum:

Propagation very limited; if anywhere, it is transmitted to the right, sometimes even to the axilla. It is not heard at the apex or behind or over the carotids, and is seldom audible above the third rib.

Frequency: it is comparatively rare, and very uncommon, from primary lesion of the tricuspid valve.

(b) Pulmonic, systolic, direct murmur.

Cause: usually obstruction from conditions somewhat similar to those affecting the aortic orifice; rarely are lesions of this valve the result of rheumatism. They are generally congenital.

Usual accompanying symptoms and signs:

Enlargement of the right heart;
Evidence of venous engorgement;

Bruit de diable occasionally heard over the jugulars.

Pulmonic second sound weak.

Character of the murmur of pulmonic obstruction:

Quality, variable, apt to be harsh.

Rhythm, systolic, accompanying the first sound.

Area of maximum intensity: in the left second intercostal space close to the sternum.

Propagation occasionally toward the left shoulder, never toward the apex nor along the aorta. It is not heard over the lower part of the sternum, nor behind.

Frequency: very rare.

Diastolic, organic, valvular murmurs.

1. Of the left heart.

(a) Mitral diastolic (presystolic), direct murmur.

Cause: obstruction of the mitral opening. This murmur may possibly occur, according to Flint, without mitral lesion, where there is aortic regurgitation with marked dilatation of the left ventricle.

Usual accompanying symptoms and signs:

Pulse, in marked cases, small.

Purring thrill or fremitus, presystolic and most distinct at the apex, not uncommon.

Evidence of pulmonary engorgement.

Enlargement of the left auricle.

Pulmonic second sound accentuated.

Character of the murmur of mitral stenosis:

Quality, harsh, churning, grinding, blubbering.

Duration, it is apt to be longer than other murmurs.

Rhythm, diastolic (presystolic), probably occurring in auricular systole.

Area of maximum intensity : at the apex beat or half an inch above it. Usually louder when the patient is erect.

Propagation limited : not transmitted to the left of the apex, nor into the arteries of the neck, nor is it heard behind.

Frequency : common.

(b) Aortic, diastolic, indirect, regurgitant murmur.

Cause : insufficiency of the valve from much the same causes as those producing mitral insufficiency, except those referring to the chordæ tendineæ.

Usual accompanying symptoms and signs :

Pulse full, strong, and collapsing in diastole ; forcible beating of the

Carotids.

Capillary pulsation in marked cases.

Enlargement of the left heart, with perhaps secondary enlargement of the right.

Character of the murmur of aortic regurgitation :

Quality, soft, blowing, rushing, and occasionally musical.

Rhythm, diastolic, accompanying, or replacing, or immediately following the second sound of the heart.

Area of maximum intensity : in the right second interspace, or over the sternum at the level of the second costal cartilage, frequently in the left, second interspace, and sometimes at the xiphoid cartilage.

Propagation : down the sternum to the epigastrium ; to the apex, where it is sometimes very loud and conveyed to the left ; to the arch of the aorta and into the carotids ; and behind, along the right side of the spinal column. It may be heard occasionally even in the radial and femoral arteries. The area of diffusion is greater than that of any other murmur.

Frequency : it stands third in order of frequency.

2. Of the right heart.

(a) Tricuspid, diastolic (presystolic), direct murmur.

Cause : obstruction at the tricuspid opening (*vide* aortic and mitral stenosis).

Usual accompanying symptoms and signs : those of systemic venous engorgement. Some-

times there is a fremitus to be felt over the right heart.

Character of the murmur of tricuspid obstruction :

Quality, harsh.

Rhythm, presystolic.

Area of maximum intensity : over the lower two-thirds of the sternum.

Propagation : may be toward the base faintly, but never toward the apex ; it is not heard above the base.

Frequency : extremely rare.

(b) Pulmonic, diastolic, indirect, regurgitant murmur.

Cause : insufficiency of the pulmonic valve, usually following pulmonary diseases or serious lesions of the left heart.

Usual accompanying symptoms and signs are those of the antecedent lesion ; evidence of venous engorgement ; enlargement of the right heart.

Character of the murmur of pulmonic regurgitation :

Quality, soft, blowing.

Rhythm, diastolic, accompanying or replacing the second sound.

Area of maximum intensity : over the left, second intercostal space.

Propagation : downward toward the xiphoid cartilage.

Frequency : rare.

Non-valvular, organic murmur.

Intra-ventricular or intra-auricular murmurs.

Cause: roughening of the endocardial lining in acute endocarditis; rarely it may be due to a tendinous cord stretched across the ventricle (congenital); or cardiac aneurysm; or an abnormal congenital opening between the two cavities, patulous foramen ovale.

Usual accompanying symptoms and signs: none constant, though they may be those of acute endocarditis.

Character of the organic, intra-ventricular murmur:

Quality, variable, usually soft.

Rhythm, systolic.

Area of maximum intensity at or near the apex.

Propagation: limited.

Frequency: quite common in acute endocarditis.

INORGANIC, OR FUNCTIONAL, ENDOCARDIAL MURMURS.

Inorganic valvular murmurs.

Systolic, inorganic, valvular murmurs.

1. Of the left heart.

(a) Mitral, systolic, inorganic, regurgitant murmur.

May occur purely from functional incompetence without actual lesion of the valve. Its character does not differ from the organic murmur. Such a murmur may appear and disappear with-

out previous, accompanying, or subsequent evidence of endocarditis.

Frequency: it is comparatively rare.

(b) Aortic, systolic, inorganic murmurs.

Cause: anæmia.

Accompanying symptoms and signs, those of

Anæmia: pallor, lassitude, weak pulse,

Venous hum over the jugulars, and frequently an

Arterial, systolic murmur, produced in the carotids which is usually of different quality and pitch from the cardiac murmur.

No cardiac enlargement is present or other sign of valvular lesion.

Character:

Quality, soft.

Rhythm, systolic.

Area of maximum intensity: over the base of the heart, above the third rib, frequently in the aortic area.

Propagation occurs into the arch of the aorta and the carotids; frequently a louder murmur produced in, and heard over the carotids, may accompany it.

Frequency: the inorganic, aortic, systolic murmur is more common than the organic.

2. Of the right heart.

(a) Tricuspid, inorganic, regurgitant murmur.

Cause: functional incompetence of the tricuspid valve, similar to that of the mitral valve.

(b) Pulmonic, systolic, inorganic murmur.

Cause: anæmia.

Character: similar to that of the aortic, systolic, inorganic murmur.

Area of maximum intensity is over the pulmonary area.

Propagation is limited: it is not transmitted above the base of the heart, but may be accompanied by an anæmic murmur produced in the carotids, which is frequently of different quality and pitch.

Diastolic, inorganic murmur of both left and right heart are very rare and practically unimportant.

Inorganic, non-valvular murmurs are indefinite and unimportant.

VASCULAR SOUNDS, sounds heard over the vessels.

Arterial Sounds.

Normal Arterial Sounds.

DIASTOLIC SECOND SOUND OF THE HEART may be transmitted into the aorta and carotids. (It may be impure or entirely wanting.)

OVER THE AORTA and commonly over the carotid and subclavian arteries is to be heard a systolic, indistinct, rushing sound

produced by the blood pulsating through the arteries.

OVER THE SUBCLAVIAN ARTERIES at the end of inspiration a systolic, blowing murmur may be frequently heard in health.

OVER THE ABDOMINAL AORTA and CRURAL arteries is sometimes to be heard a pulsating sound, corresponding in rhythm to the pulse in those arteries.

OVER THE SMALL VESSELS nothing is to be heard.

PRESSURE OF THE STETHOSCOPE over any of the large arteries may produce a murmur occurring with the local pulsation.

OVER THE ANTERIOR FONTANELLE and sometimes over the carotids of children, between the ages of three months and six years, a blowing, systolic murmur, of variable intensity, is frequently heard, "cerebral blowing."

OVER THE UTERUS in the latter months of pregnancy, uterine souffle, from entrance of blood into the dilated arteries of the uterus.

Abnormal Arterial Sounds.

OVER THE AORTA, CAROTID, and SUBCLAVIAN ARTERIES may be heard systolic and diastolic murmurs produced at the aortic orifice of the heart; in aneurysm of these vessels a systolic whizzing or blowing murmur may be heard over them, rarely a diastolic murmur in aortic aneurysm.

OVER THE CRURAL, BRACHIAL, RADIAL, and ULNAR ARTERIES, and even the peroneal and dorsalis pedis, a murmur may be heard with the pulse in the respective vessels in some cases of aortic insufficiency.

OVER THE CRURAL ARTERIES a systolic murmur may sometimes be heard in anæmia and chlorosis and in high fever (as well as occasionally in health).

OVER THE CRURAL ARTERIES a double murmur, diastolic and systolic, may be heard in some cases of aortic insufficiency (Traube); exceptionally in mitral stenosis (Weil); in lead-poisoning (Matterstock); and in pregnancy (Gerhardt).

OVER THE CRURAL ARTERIES, also, in many cases of aortic insufficiency, a double murmur may be produced by the pressure of the stethoscope over the artery, "Duroziez's double murmur." This can only occur with a large, quick pulse.

OVER THE SUBCLAVIAN ARTERY a systolic murmur (sometimes normal, as when due to pressure of the stethoscope) may be produced by pressure of tumors on the vessel; traction by lung in fibroid disease of the apex.

Venous Sounds, bruit de diable.

Normal Venous Sounds.

OVER THE JUGULAR VEIN, most frequently the right, a venous hum, whistling, or rushing sound is exceptionally heard in health, either continuous or rhythmically synchronous with diastole or inspiration. It may be produced sometimes by pressure of the stethoscope, or by turning the person's head to the opposite side.

OVER THE CRURAL VEIN, occasionally in health, especially in thin persons, a sound may be heard, produced by sudden straining efforts or coughing (Friedreich).

Abnormal Venous Sounds.**OVER THE JUGULAR VEIN.**

In tricuspid insufficiency a systolic murmur may sometimes be heard.

In anæmia and chlorosis a venous hum more or less continuous is often present over this vessel, associated with a systolic, blowing murmur in the carotids. Venous murmurs arising in the cervical veins and in the intrathoracic venous trunks may exceptionally be conducted to the heart, simulating valvular murmurs.

Cause uncertain.

Character.

Quality: whizzing, rushing, or humming (like a singing top).

Duration: intermittent or constant, but disappearing with the anæmia.

Intensity: loudest over the right jugular, with the patient erect and the head turned to the left. The intensity is increased during ventricular diastole, during inspiration, by moderate pressure of the stethoscope, and by quickening of the circulation.

OVER THE CRURAL VEINS, exceptionally, in tricuspid insufficiency may be heard a double sound, indicating first auricular then ventricular contraction (Friedreich); this is not easily distinguished from like murmurs produced in the crural artery.

SUCCUSSION.

The succussion or splashing sound is produced in a cavity which contains both fluid and gas, by shaking the patient. Normally, it may sometimes be heard over the stomach;

pathologically, it is a sign of pneumo-hydrothorax. The character of the sound is like that produced when a small keg, partly filled with liquid, is shaken (*vide* p. 89).

PHONOMETRY.

The tuning-fork may aid in the detection of changes which have affected intrathoracic organs. If it be vibrated and placed over normal lung its sound is accentuated; if over airless parts its sound is attenuated.

PHYSICAL SIGNS IN THE DISEASES OF THE CHEST.

Note.—A clear understanding of the morbid anatomy of a disease is essential to an appreciation of its physical signs. In the following synopsis, therefore, each disease, with a few exceptions, is introduced by a definition epitomizing its gross pathology. In the enumeration of the signs discovered by the several methods of objective examination the order will be followed, as far as practicable, as indicated in the preceding pages—viz. under inspection, color, nutrition, size, form, posture and movements, etc.

DISEASES OF THE CHEST-WALL.

PLEURODYNIA AND INTERCOSTAL NEURALGIA.

Definition.

PLEURODYNIA is a thoracic, rheumatic myalgia.

INTERCOSTAL NEURALGIA is a functional or organic affection of the intercostal nerves, chiefly manifested by pain and localized points of tenderness, and usually affecting women.

Signs.

INSPECTION shows

ANÆMIA commonly present.

RESPIRATION in severe cases shallow and more or less rapid as evidence of pain.

MOVEMENTS OF THE BODY restricted to avoid pain, especially in pleurodynia.

PALPATION may reveal

IN PLEURODYNIA—

Tenderness on pressure, more or less **DIFFUSE** when superficial muscles are involved.

IN INTERCOSTAL NEURALGIA—

Tenderness in from one to three *isolated points* (Valleix's).

Behind, near the dorsal vertebræ.

Laterally, in one or more intercostal spaces along the axillary line.

Anteriorly, in one or more intercostal spaces near the sternum or over the epigastrium.

PERCUSSION shows—

ABSENCE OF DULNESS, unless there be complicating or causative disease of the lungs, pleuræ, or circulatory organs.

AUSCULTATION yields—

NORMAL VESICULAR RESPIRATION, except slightly diminished in intensity or interrupted owing to restricted movements.

ABSENCE OF PLEURITIC SOUNDS and of crepitant râles.

SWELLINGS AND TUMORS OF THE CHEST-WALL.

Definition: these include inflammatory and granulomatous affections and tumors.

Signs: the varying color, size, shape, location, tenderness, consistence, and movability of each affection, whether originating from or involving bone, cartilage, or soft

parts, are properly considered in works on general surgery. Suffice it to say here, that the usual respiratory and vocal sounds are to a degree obscured over them and vocal fremitus correspondingly enfeebled. The absence of positive signs of intrathoracic disease is suggestive of one or the other of these affections.

EMPHYSEMA OF THE CHEST-WALL.

Definition: a rare affection characterized by inflation of the subcutaneous areolar tissue with air or other gas. It is usually associated, when marked, with a like involvement of the cervical and abdominal region, and it may extend over the entire body.

Signs.

INSPECTION may reveal—

PALENESS of the surface.

PUFFINESS, tending to obliterate the usual depressions and prominences.

APEX BEAT absent.

PALPATION reveals—

PECULIAR SENSE OF YIELDING or softness, with crepitation fremitus felt by the finger tips pressed upon the surface.

AUSCULTATION.

CREPITANT SOUNDS, myriad, fine, and somewhat similar to the râles in pneumonia, heard when the ear or stethoscope is pressed upon the surface.

DISEASES OF THE BRONCHI, PLEURÆ, LUNGS, AND MEDIASTINUM.

ACUTE AND SUBACUTE BRONCHITIS.

Definition: inflammation of the mucous membrane lining the larger and medium-sized tubes of both lungs. The early dryness and swelling is followed by more or less profuse secretion.

Signs.

INSPECTION reveals little abnormal except—

RESPIRATORY MOVEMENTS slightly accelerated.

COUGH at first dry, harsh, with scanty secretion, later moist (loose), rattling.

DYSPNŒA rarely, except from retained secretion in the tubes, as in infants, the aged, or the enfeebled.

PALPATION reveals—

SURFACE TEMPERATURE and pulse slightly modified.

VOCAL FREMITUS normal.

RHONCHAL FREMITUS in case of considerable secretion, especially in children, or in adults with thin chest-walls.

PERCUSSION.

RESONANCE normal.

SLIGHT DULNESS rarely, over lower part of the chest, due to accumulation of bronchial secretion, though this may be removed by expectoration.

AUSCULTATION.

RESPIRATORY SOUNDS apt to be somewhat harsh over the larger tubes.

VESICULAR MURMUR may be more or less suppressed over parts of the lungs supplied by bronchi partially or wholly occluded by mucus.

VOCAL RESONANCE normal.

ADVENTITIOUS SOUNDS.

Dry Râles common in the first stage, slightly obscuring the vesicular murmur.

Moist Râles (large and small) may be heard bilaterally in varying numbers after the first day or so, with the occurrence of hypersecretion. These are variable in intensity, location, and time, and are apt to disappear upon cough, and upon deep inspiration or forced expiration. A few dry râles may occur with them.

CAPILLARY BRONCHITIS.

Definition: inflammation extending from the larger to the smaller tubes (bronchiolitis).

Signs.

INSPECTION, in addition to the usual visible signs of acute bronchitis, reveals the age.

AGE, young children or the aged.

EXPRESSION of anxiety or distress common.

CONGESTION and a more or less bloated appearance of the face sometimes seen.

LIVIDITY of the face becomes more or less evident, both from want of proper oxygenation of the blood and its undue accumulation in the right heart, leading to a fatal termination.

ALÆ NASI dilated in the struggle for air.

THE CHEST in a young child may be notably distended at the anterior upper and middle part from acute compensatory emphysema, which disappears if recovery occurs.

GENERAL RESTLESSNESS.

DYSPNŒA, amounting sometimes to orthopnœa, and

HYPERPNŒA, amounting to 60 or 70 respirations per minute in children.

PALPATION.

THE SURFACE IS HOT, and later may be covered with clammy perspiration.

THE PULSE rapid, weak.

PERCUSSION may obtain

NORMAL RESONANCE, or

EXAGGERATED RESONANCE over the upper lobes owing to emphysema, which compensates for occlusion of the many small bronchi with collapse of their terminal air-vesicles.

AUSCULTATION, usually the signs of

GENERAL BRONCHITIS of the larger tubes, and in addition

SIBILANT RÂLES, very abundant early in the disease,
replaced later by
SUBCREPITANT RÂLES, both bilateral.

CHRONIC BRONCHITIS.

Definition: prolonged inflammation of the bronchial mucous membrane. This means derangement of secretion, thickening and irregularity of the surface, hypertrophy of the muscular and fibrous coats, with final atrophy and fibrosis, eventuating in bronchiectasis, asthma, or emphysema.

Signs: largely those of acute and subacute bronchitis.

THE CHIEF CONTRAST is in the greater number of moist râles and the relatively few dry râles in the chronic affection. As the disease may tend to *EMPHYSEMA*, and frequently to more or less *ASTHMA*, the signs are correspondingly modified.

THE ABSENCE of emaciation, pallor, tachycardia, hyperpnœa, and other evidences of phthisis is especially important.

PLASTIC BRONCHITIS.

Definition: an acute or chronic inflammation of the bronchi, chiefly characterized by the exudation of fibrinous matter, with the formation of plastic casts in the smaller, sometimes involving the larger tubes.

Signs: those of ordinary bronchitis, with the evidence of partial or complete obstruction of some of the bronchi, detected by the absence or diminution of the respiratory sounds over the affected parts and dulness over collapsed lung.

BRONCHIECTASIS.

Definition: dilatation of the bronchial tubes with more or less associated bronchitis, fibrosis, and emphysema.

Signs.

INSPECTION.

DEPRESSION OF INTERCOSTAL SPACES and **RIGIDITY OF THE CHEST-WALL**, more or less marked, commonly unilateral.

RESPIRATORY MOVEMENTS somewhat limited.

COUGH with

EXPECTORATION, usually very profuse, purulent, and offensive. At times more profuse in certain postures.

PALPATION gives

SIGNS VARYING greatly from time to time with the amount of secretion retained in the bronchiectatic cavities.

Rhonchal Fremitus may be present.

Vocal Fremitus may be abnormally *increased* over a cavity if large, and freely communicating with the upper air-passages; *diminished* when the communication is closed.

PERCUSSION.

DULNESS usual over the affected lung; most commonly over the right, middle and lower lobes. It is sometimes removed or diminished by free expectoration, or replaced by vesiculo-tympanitic, cracked-pot, or amphoric resonance.

AUSCULTATION.

RESPIRATORY MURMURS sometimes

Suppressed over Cavities, while respiratory sounds are apt to be harsh and exaggerated.

Broncho-vesicular or *Broncho-cavernous* respiration may be obtained over a part after free expectoration, where before no sounds were present.

VOCAL AND WHISPER SOUNDS may suffer like changes.

ADVENTITIOUS SOUNDS are usually present in the form of

Râles, moist and dry, and
Gurgles, both of which are variable in character
 and time.

ASTHMA.

Definition : a neurosis of the respiratory mechanism, characterized chiefly by paroxysms of dyspnœa probably due to spasm of the annular bronchial muscles.

Signs during a paroxysm.

INSPECTION.

POSTURE, standing or sitting with elbows on the knees or resting upon some support.

EXPRESSION OF ANXIETY and distress.

NOSTRILS dilated, **MOUTH** open.

PERSPIRATION profuse, commonly.

STERNO-CLEIDO-MASTOID MUSCLES rigid and prominent.

CYANOSIS of the face and neck may become very marked, conjunctivæ congested.

CHEST approaches the barrel-shape or inflated type in cases of long standing or great frequency.

CHANGES OF POSTURE usually very deliberate.

RESPIRATORY MOVEMENTS restricted.

Dyspnœa (orthopnœa) chiefly expiratory, and respiration not necessarily increased in rate, but may be decreased.

Inspiratory Movements short and quick.

Expiratory Movements prolonged.

PALPATION, MENSURATION, and PERCUSSION signs not specially significant except when emphysema has developed.

PULSE small, feeble, and rapid in proportion to the deficient aëration of the blood and overdistention of the right heart.

SURFACE OF THE BODY cold and moist (clammy).

AUSCULTATION gives

COG-WHEEL RESPIRATION, harsh.

RÂLES.

Dry (sonorous and sibilant).

Chiefly in Expiration.

Over Whole Chest.

Obscuring Vesicular Murmur.

Loud enough, usually, to be heard at a distance from the patient (wheezing).

Moist (large and small, subcrepitant),

In the Later Stage in proportion to the bronchitis with accompanying secretion.

EMPHYSEMA OF THE LUNGS.

Definition: an abnormal inflation of the lung from loss of elasticity, overdistention of the air-vesicles, and in pronounced cases more or less destruction of the alveolar walls by rupture, with accumulation of air in the interlobular connective tissue.

Signs: in senile emphysema, where atrophy of the lungs is the chief feature, and in moderate emphysema, there is little change in the shape of the chest.

INSPECTION in well-marked cases.

FACE apt to be dusky and frequently more or less swollen.

Eyes prominent and watery, conjunctivæ injected.

Lips, end of Nose, and Tongue bluish.

Nostrils dilated.

ALONG ATTACHMENT OF DIAPHRAGM there is frequently a zone of dilated venous capillaries, though this is not peculiar to emphysema.

POSTURE, stooping.

STERNO-CLEIDO-MASTOIDS tense and prominent.

NECK apparently shortened and thick, owing to the elevation of the sternum and shoulders.

SHOULDERS elevated and drawn forward.

FORM of the chest barrel-shaped.

General Contour rounding out.

Upper Part of Sternum,

Infra-clavicular and *Mammary Regions* prominent.

Antero-posterior Curvature of the spine increased, and therefore

Antero-posterior Diameter of the chest increased.

May be even greater than the transverse.

Vertical Diameter apt to be decreased.

Lower Part of Chest usually contracted, but it may be dilated, with a wide obtuse costal angle.

Intercostal Spaces wide, especially at the upper part of the chest.

Supra-clavicular fossæ may be deepened or shallow, or bulging, especially during cough.

Scapulæ separated widely.

Deep Transverse Depression sometimes present across the abdomen at the level of the twelfth rib, especially during expiration.

General Emaciation.

RESPIRATORY EXPANSION diminished.

Breathing Chiefly Diaphragmatic.

Ribs and Sternum move upward and forward as if made of one piece.

Intercostal Spaces and supra-clavicular fossæ fall in markedly during forced inspiration, and bulge out during expiration and cough.

False Ribs and neighboring interspaces retract during inspiration.

Dyspnœa more or less persistent and exaggerated by attacks of bronchitis, asthma, and on exertion.

Inspiratory Act short and quick.

Expiratory Act distinctly prolonged.

APEX BEAT of heart not usually visible, except in the area of cardiac flatness; the pulsation of the

enlarged right ventricle is communicated to the epigastrium through the left lobe of the liver.

JUGULARS prominent, and sometimes pulsate.

PALPATION.

SKIN dry and harsh.

VOCAL FREMITUS frequently enfeebled, but it may be normal or exaggerated.

APEX BEAT rarely palpable; frequently there is a systolic impulse in the lower sternal and epigastric regions.

MENSURATION shows the barrel

SHAPE of the chest and

DIMINISHED RESPIRATORY EXPANSION.

PERCUSSION yields

HYPER-RESONANCE, bilateral; in exaggerated cases the note is high-pitched, vesiculo-tympanitic.

AREA of pulmonary resonance reaches lower than normal, and may extend to the costal margin, lessening the dulness over the heart, liver, and spleen, and encroaching upon or obliterating the areas of flatness.

AUSCULTATION.

RESPIRATORY SOUNDS.

Length.

Inspiratory Sound delayed and shortened.

Expiratory Sound prolonged, and may be two or three times as long as the inspiratory.

Quality, Pitch, and Intensity.

In typical cases both sounds are *low* in pitch, *soft*, breezy in quality, and *diminished in intensity*, but frequently they are harsh and blowing.

ADVENTITIOUS SOUNDS.

Dry Crackling or crumpling at the end of inspiration and beginning of expiration, supposed to be produced in the wall of the vesicles.

VOCAL RESONANCE is increased, diminished, or normal.

HEART SOUNDS usually feeble, those at the apex displaced downward and to the right, sometimes distinct in the epigastrium.

Pulmonary (second) sound usually distinct, and may be accentuated.

Murmurs of relative tricuspid insufficiency may be heard when there is great dilatation of the right ventricle.

ATELECTASIS.

Definition: congenital (apneumatoxis) or acquired collapse of the lung.

Signs.

INSPECTION usually discovers the subject a

WEAK SICKLY INFANT.

PALLOR or **DUSKINESS** of the surface.

EMACIATION and evident great *prostration*.

RESPIRATORY MOVEMENTS feeble.

Hyperpnœa, in children 60 to 80 per minute, common.

Rhythm of Respiration altered, the pause following instead of preceding inspiration.

Dyspnœa marked without relatively proportionate lividity.

Retraction of the Intercostal Spaces and Lower Ribs marked during inspiration.

In the Newly-born apneumatoxis is denoted by shallow, rapid respiration, feebleness of the cry, dyspnœa, especially evident in inability to nurse properly, and absence of cough.

PALPATION.

EXTREMITIES cold.

PULSE feeble and rapid.

VOCAL FREMITUS normal or slightly exaggerated over the base of both lungs.

PERCUSSION is less satisfactory in children than in adults.

NORMAL RESONANCE, if the collapsed vesicles are so few or small and scattered as to be marked by the resonance of adjacent over distended lung.

DULNESS more or less marked over the affected parts where of considerable area.

AUSCULTATION.

VESICULAR MURMUR frequently normal where the percussion note remains normal. It is diminished, and the breathing harsh and broncho-vesicular over large patches of collapsed lung.

RÂLES are usually numerous except in apneumatosiis.

LOBAR PNEUMONIA.

Definition: an acute infectious disease, characterized locally by inflammation of the lung, clinically manifested in three stages.

FIRST STAGE, ENGORGEMENT.

SECOND STAGE, CONSOLIDATION (red and gray hepatization).

THIRD STAGE, PROGRESSIVE RESOLUTION.

Signs: for convenience the signs of the three stages will be considered under each of the methods of physical examination. The signs of the first stage are usually present within the first twenty-four hours unless the pneumonia is central.

INSPECTION.

POSTURE is often on the affected side.

CIRCUMSCRIBED FLUSH, mahogany colored, over one or both cheeks.

GENERAL PALLOR, occasionally at the onset the face has a dusky hue; later sallow.

LIPS, deep red at first, they become cyanosed with

greatly disturbed circulation and pale at the crisis.

HERPES labialis very frequent (50 per cent. of cases, Osler) ; at times herpes on cheeks, nose, and eyelids.

SUDAMINA accompany profuse sweating.

JAUNDICE, more or less marked, is common and an early sign, not apparently related to hepatic engorgement, but probably due to duodenitis.

EXPRESSION anxious, eyes bright at first, later dull or expressionless.

INTERCOSTAL SPACES not filled out as in pneumo- or hydrothorax.

RAPID LOSS OF FLESH apparent in a few days.

DELIRIUM active, violent, or low and muttering.

SUBSULTUS TENDINUM attends the great prostration of the "typhoid state."

CONVULSIONS may usher in the attack in children.

RESPIRATORY MOVEMENTS of the affected side restricted, markedly so in extensive consolidation of the lower lobe ; exaggerated movements of the healthy side. In double pneumonia respiratory movements largely diaphragmatic and inferior costal.

Hyperpnœa always present, 30 to 80 per minute. Ratio between respiration and pulse, 1 to 2 or even 1 to 1.5.

Dyspnœa frequent, panting in character.

Inspiratory Act short and superficial.

Expiratory Act often associated with a grunt, especially in children. *Dyspnœa* depends upon various *factors* :

AMOUNT OF LUNG INVOLVED,

RAPIDITY OF INVOLVEMENT,

FEVER,

PAIN, and

DERANGEMENT OF THE NERVOUS SYSTEM.

Cough frequent, short, hacking, dry in the first stage, loose during resolution.

MENSURATION may show, in the second stage, a very slight increase in the volume of the affected side during expiration.

PALPATION discovers the

SKIN usually hot and dry till the crisis, but it may be moist from the onset (a favorable sign).

PRESSURE may elicit deep-seated tenderness.

VOCAL FREMITUS in the

First Stage is not affected ; in the

Second Stage, greatly increased over the consolidation, unless this be central or pleuritic effusion covers it, or the large and medium-sized bronchi become blocked (massive pneumonia), or if there is complicating bronchitis with free secretion.

Third Stage, progressive return to the normal type.

FRICTION FREMITUS may be obtained in some cases owing to accompanying pleuritis.

LOCATION OF APEX BEAT may show the heart slightly displaced away from the affected side.

PULSE,

Rapidity.

In Mild Cases, from 90 to 120.

In Severe Cases, from 120 to 160.

In Children, 100 to 200.

Volume and Tension.

At Onset it is full, bounding.

After the Third or fourth day it becomes compressible, small, weak, and may be dicrotic and intermittent in unfavorable cases.

In Old Age the radial pulse is not reliable, and the pulse should be taken at the apex beat.

PERCUSSION.

FIRST STAGE.

Dulness increasing at the end of the first stage except in central pneumonia. The note may sometimes be *vesiculo-tympanitic*.

SECOND STAGE.

Marked Dulness over the consolidation with a sense of resistance to the pleximeter finger, less than in pleurisy with effusion.

Hyper-resonance over the healthy parts.

Tympanitic Note occasionally,

Over Healthy Lung adjacent to consolidation.

Over a Consolidated Upper Lobe due to conduction of resonance from the trachea and main bronchi.

Cracked-pot Note occasionally over relaxed lung adjacent to the consolidation.

THIRD STAGE.

Dulness slowly diminishing with progressive resolution; normal resonance established only after weeks.

AUSCULTATION.**RESPIRATORY SOUNDS** are—

Early in the First Stage feeble, and apt to be dry and somewhat harsh over the affected part.

Later it becomes broncho-vesicular. In the *Second Stage*.

Bronchial Breathing, provided the large bronchi are patulous.

Exaggerated Breathing over the healthy lung.

Third Stage.

Breathing becomes broncho-vesicular, approaching the normal.

VOCAL SOUNDS.

First Stage normal.

Second Stage.

Bronchophony and frequently

Pectoriloquy are characteristic of complete consolidation.

Ægophony not uncommon about the upper level of the fluid if little pleuritic effusion accompany the consolidation, voice sounds being absent or indistinct below.

Third Stage.

Bronchophony and Pectoriloquy give place to exaggerated vocal resonance approaching the normal sounds.

ADVENTITIOUS SOUNDS.

First Stage.

Crepitant Râles, lasting usually from 12 to 24 hours. These may be

ABSENT.

- (1) If stages follow each other rapidly.
- (2) In pneumonia complicating rheumatism.
- (3) In lobes secondarily attacked.
- (4) They are absent oftener in pneumonia of children than in adults.

Second Stage.

Subcrepitant Râles may or may not be present.

Third Stage.

Crepitant Râles return, "crepitant r le redux," but are largely obscured by the coarser

Subcrepitant R les, which are frequently accompanied by a few dry r les and more or less large mucous r les.

LOBULAR OR BRONCHO-PNEUMONIA.

Definition : this is essentially an inflammation of terminal bronchi, with their branches and surrounding air-vesicles, which make up the pulmonary lobules. It occurs in the course of bronchitis, extending to the finer tubes, and is manifested in isolated or in groups of lobules. These show interstitial inflammation of both

tubes and air-cells, both being filled with a mucopurulent secretion.

Signs: these are not distinctive unless there is considerable consolidation, and even then rarely sufficient for diagnosis without the aid of history and symptoms.

INSPECTION shows the patient usually

AN INFANT or in **ADVANCED AGE**.

FACE PALE and **ANXIOUS**, becoming **CYANOTIC** in severe cases.

EMACIATION very rapid. Chest bilaterally retracted at the lower part, where there is extreme pulmonary collapse in children.

DYSPPNŒA marked.

Inspiration often shortened and

Expiration lengthened.

HYPERPPNŒA constant.

RESPIRATORY MOVEMENTS DEFICIENT.

Slight expansion of the ribs.

Elevation of the chest-wall at the upper part, and retraction of the soft parts and lower ribs on inspiration.

COUGH dry, hacking, non-paroxysmal, painful.

RESTLESSNESS and jactitation in children gives place to *lethargy* with advancing consolidation and obstruction of the bronchi.

PALPATION may elicit

VOCAL FREMITUS, slightly increased over small areas, where neighboring lobules are consolidated.

PULSE often reaches 140 to 150 per minute; small, compressible, feeble after the first twenty-four hours.

PERCUSSION.

DULNESS more or less marked, but in *patches* usually, bilateral and limited to the posterior and lower regions of the chest; sometimes unilateral.

HYPER-RESONANCE over upper and anterior part

of chest where functional emphysema occurs in the corresponding part of the lungs.

AUSCULTATION.

VESICULAR MURMUR feeble.

BRONCHO-VESICULAR and bronchial respiration.

VOCAL FREMITUS exaggerated.

RÂLES, moist and high-pitched over the lower part of the chest, irregular in time and place.

UNDEFINED MUCOUS CLICKS, on forced respiration. Signs of emphysema are frequently found over the anterior and upper part of the chest.

PULMONARY TUBERCULOSIS.

Definition: this affection is extremely varied in its primary location and manner of development, and therefore needs a few words of introduction.

It is characterized **ETIOLOGICALLY** by the entrance of tubercle bacilli into the lungs with the respired air or through the lymphatic or blood-vessels.

PATHOLOGICALLY, therefore, the initial tubercle may result early in (1) *bronchial ulceration*, or the initial lesion may be in the small tubes of one or more lobules, giving the usual early catarrhal signs of (2) *tubercular bronchiolitis*, as so often manifested at one or the other apex, and followed *pari passu* by the signs of consolidation as the neighboring vesicles become involved. Again, sudden rupture of a bronchial lymphatic gland or other tuberculous focus, with aspiration of its infectious contents into the bronchi of many lobules, may result in rapidly developing (3) *caseous pneumonia*, involving more or less of one lobe. Finally, the entrance of a large number of tubercle bacilli into the circulation, from a primary systemic focus, and their wide dissemination in the lung (as well as in many

other organs), results in (4) *acute miliary tuberculosis*, the pulmonary signs of which are insignificant.

The morbid conditions which may appear in the course of pulmonary tuberculosis, more or less slow in its progress, are tubercular bronchitis, lobular and lobar consolidation, the formation of cavities, compensatory emphysema, fibrosis and calcification, bronchiectasis, œdema, collapse, and pleuritis, with or without effusion or pneumothorax.

Signs of pulmonary tuberculosis, beginning as a bronchopneumonia.

INITIAL OR CATARRHAL STAGE before the advent of consolidation.

INSPECTION.

Color and Nutrition may not be much affected.

Flat or "Alar Chest" more or less marked in many cases.

No Abnormal Local Retraction of the chest as yet.

Respiratory Expansion of one or the other apex may be slightly deficient or apparently lagging as compared to the other.

No Hyperpnœa as yet.

PALPATION and mensuration *negative*, or

Pulse rate slightly increased, and

Respiratory Expansion deficient at one apex.

PERCUSSION negative.

AUSCULTATION.

Respiratory Murmur frequently feeble, having *interrupted* or cog-wheel rhythm, and accompanied by

Subcrepitant Râles, which may be feeble, few, and distant at an early stage, but become more distinct. Later and sometimes early the respiratory murmur may be harsh, occasionally there are

A Few Sibilant Râles.

A Mucous Click or friction or indistinct crumpling sound may be heard.

STAGE OF CONSOLIDATION (tuberculosis).

INSPECTION yields, in addition to the signs of the first stage,

Pallor and *Emaciation*.

Hectic Flush, and frequently very red lips.

Tenia Versicolor, common on the surface of the thorax and other parts.

Retraction of the supra-clavicular and infra-clavicular region at the affected apex.

Hyperpnœa, superficial breathing and a tendency to *cough* on deep inspiration.

Apex Beat enlarged in area and abnormally rapid.

PALPATION.

Skin hot and dry, or apt to be bathed in perspiration.

Respiratory Movements diminished.

Vocal Fremitus increased over consolidation. It is normally greater at the right apex than the left. Vocal fremitus may be diminished if the pleura is greatly thickened over the consolidated lung.

Pulse rate usually above a hundred.

PERCUSSION.

Dulness above and over the clavicle, or in the supra-scapular region, early; proportionately more extensive with the advance of consolidation. The two apices should be percussed while the patient holds his breath after full inspiration, especially to elicit the presence of but slight dulness.

Dulness corresponds to the consolidation in any part of the lung.

Deep-seated consolidation with overlying normal lung may not be detected.

A small portion of superficial consolidation, with underlying and surrounding overdistended lung, may not be easily detected.

Dulness in any case may be in part due to the simple acute pneumonia surrounding tubercular consolidation, which may clean up, leaving only the smaller area of dulness due to the tubercular part.

Tympanitic Resonance at times may be obtained over consolidation adjacent to the trachea.

AUSCULTATION.

Respiratory Sounds are apt to be harsh and broncho-vesicular or purely bronchial, according to the amount of consolidation.

Whisper and Vocal Resonance are apt to be exaggerated and bronchial. The latter amounts to pectoriloquy when the consolidation surrounds a large bronchus.

Heart Sounds are apt to be exaggerated over neighboring consolidation, and the second pulmonic sound is frequently accentuated.

Adventitious Sounds are more or less numerous.

Râles large and small, dry and moist, often peculiarly sticky in character.

Friction Sounds are often present, due to circumscribed pleuritis.

STAGE OF THE FORMATION OF CAVITIES.

INSPECTION shows usually—

Pronounced Anæmia and *Emaciation*, and in exaggerated cases signs of poor circulation, such as local cyanosis of lips, nose, and extremities.

Clubbing of the Fingers.

Face is apt to bear the impress of prolonged wasting illness, drawn haggard expression (exceptionally cavities may be formed in cases apparently healthy).

Marked Depression of the chest from retraction of the affected lung.

Respiratory Movements limited, on the affected side and abnormally rapid.

Apex Beat rapid, weak, and frequently displaced toward the affected side.

PALPATION.

Vocal Fremitus increased over a cavity if empty and freely communicating with a bronchus.

Rhonchal and *Friction Fremitus* commonly present.

Pulse small, compressible, feeble, and rapid.

PERCUSSION in the stage of cavities (see also pages 68 and 69).

Dulness of consolidation is modified by the resonance of a cavity.

Amphoric or Cracked-pot Resonance when a cavity communicates more or less freely with a bronchus. The resonance disappears with the filling of a cavity with fluid. Sometimes even a large cavity communicating freely with a bronchus gives dulness or cracked-pot resonance when the patient's mouth is closed, but marked amphoric resonance with the mouth open (see Wintrich's change of sound, p. 69).

Small cavities deeply located are not easy and are often impossible to locate by percussion.

Numerous Isolated Cavities at the apex without much fibrosis or pleuritic thickening may give resonance not far from the normal vesicular resonance, in contrast to the auscultatory signs.

AUSCULTATION in the stage of cavities when the cavity is empty and freely communicates with a bronchus.

Respiratory Sounds.

Cavernous Respiration, soft blowing or puffing

in character, the expiratory sound prolonged and low-pitched.

Broncho-cavernous Respiration, when the cavity is not large and is surrounded by consolidation.

Amphoric Respiration, which is more metallic and resonant than cavernous respiration, is heard in exceptional cases.

Vocal and Whispering Sounds correspond in change to the respiratory sounds. Vocal resonance amounts to pectoriloquy. If the cavity is filled with fluid or its opening closed none of these sounds may be heard.

Adventitious Sounds.

Râles, dry and moist and gurgling.

Metallic Tinkling, occasionally.

In most cases of advanced phthisis the pulmonary signs of all three stages may be present, depending upon the pathological condition of the part.

FIBROID PHTHISIS.

Definition : a chronic inflammatory affection of the lung characterized pathologically by more or less hyperplasia of the peribronchial, inter-alveolar, and inter-lobular connective tissue and pleura, which in contracting encroaches upon the lumen of vessels and air-passages. The fibrosis is accompanied by degenerative processes and often by tuberculosis. The signs in a typical case are, therefore, out of proportion to the relatively mild symptoms, which are those of chronic bronchitis.

Signs.

INSPECTION may reveal—

NUTRITION and **COLOR** but little changed.

FLATTENING OR RETRACTION of the chest-wall over the affected side.

DEPRESSION OF THE CORRESPONDING SHOULDER, influencing posture.

DYSPNŒA may or may not be apparent.

COUGH frequent and variable.

RESPIRATORY MOVEMENTS limited on the affected side; increased on the opposite side except late in the case, after the unaffected lung has become emphysematous.

HEART dislocated toward the contracted lung, as evidenced by the apex beat.

PALPATION frequently elicits—

EXAGGERATED VOCAL FREMITUS over the contracted lung, though the greatly thickened pleura and contracted bronchi may diminish vocal fremitus in some cases.

PULSE more or less rapid according to the interference with respiration or the amount of infection or fever present.

PERCUSSION gives—

DULNESS over the affected part.

EXAGGERATED RESONANCE on the sound side, frequently extending across the mid-sternal line and to the limits of the pleural cavity (to the costal arch) below.

AUSCULTATION gives—

BRONCHIAL BREATHING and **BRONCHOPHONY**, and frequently feeble respiration on the affected side. Vesicular murmur absent.

EXAGGERATED OR NORMAL breathing on the sound side.

VOCAL RESONANCE more or less bronchial over the affected side.

ADVENTITIOUS SOUNDS variable.

RÂLES dry or moist are common.

PULMONARY HYPERÆMIA.

Definition: excess of blood in the pulmonary vessels (active or passive).

Signs not distinct, apart from sudden dyspnœa and other signs of pulmonary œdema.

PULMONARY ŒDEMA.

Definition: a serous transudate into the vesicular and interstitial tissues of the lung. It usually affects the most dependent parts of the lungs.

Signs.

INSPECTION and PALPATION.

CYANOSIS.

HYPERPNŒA.

DYSPNŒA (sudden in occurrence).

COUGH with frothy sputum.

SIGNS OF GENERAL DROPSY and its causative disease, such as anæmia, cardiac disease, or scorbutus, may be present.

PERCUSSION.

DULNESS over the lower portion of one or both lungs.

AUSCULTATION.

RESPIRATORY MURMUR vesicular or slightly broncho-vesicular, but feeble.

RÂLES abundant, fine, *subcrepitant*, usually heard both in expiration and inspiration.

VOCAL RESONANCE normal, or it may be slightly increased.

PULMONIC SECOND SOUND is apt to be accentuated.

PULMONARY HEMORRHAGE.

Bronchial Hemorrhage.

DEFINITION: hemorrhage from the wall of a bronchial tube or the trachea.

SIGNS: often none at all, except cough and hæmoptysis. During hemorrhage and for hours following it, may be found

RÂLES large and small, moist in character, over the same part of the chest, and

FEEBLE RESPIRATION and perhaps slight dulness.

Pulmonary Apoplexy.

DEFINITION: extravasation of blood from a ruptured vessel into the lung tissue. It is rare, and usually occurs in the lower lobes.

SIGNS.

INSPECTION usually reveals if the hemorrhage is large.

Dyspnœa with *cough* and *hæmoptysis*.

PALPATION practically negative.

PERCUSSION.

Dulness more or less extensive unless the patches of hemorrhagic infarcts are few and small or deeply seated.

AUSCULTATION reveals—

Early,

Râles, moist, large and small, and possibly crepitant in the region of the hemorrhage, previous to coagulation.

Later, after coagulation, the

Respiratory Murmur is apt to be feeble or suppressed, especially with the blocking of a bronchus of large size.

Bronchial Breathing and Voice may be more or less marked in some cases.

PULMONARY THROMBOSIS AND EMBOLISM.

Definition.

PULMONARY THROMBOSIS is a gradual obstruction of a pulmonary artery (venous radical) or one of its branches by a clot formed *in situ*.

PULMONARY EMBOLISM is a sudden blocking of a pulmonary vein or bronchial artery by a foreign body, usually a fragment of a vegetation from a cardiac valve or a fragment of a thrombus from some of the systemic veins.

Signs.

INSPECTION and **PALPATION** may reveal dyspnoea, cyanosis, and rapid heart, and possibly pulsation of the jugulars.

PERCUSSION may elicit exaggerated resonance over the depleted area resulting from increase of air in the cells corresponding to the decrease of the blood in their walls.

AUSCULTATION.

RESPIRATORY MURMUR feeble or suppressed in the same area.

PULMONARY ABSCESS.

Definition: a circumscribed collection of pus within the lung.

Signs.

INSPECTION may reveal—

PALLOR, EMACIATION, and evidences of pyrexia and prostration.

DEPRESSION OF THE CHEST-WALL may be present, with atrophy of the intercostal muscles over a cavity where this is large and superficial.

DYSPNŒA, COUGH, and sometimes marked bulging of the intercostal spaces over the cavity during cough.

PALPATION.

VOCAL FREMITUS.

Decreased at first, and

Increased over the cavity when large, superficial, and freely communicating with a bronchus.

PERCUSSION.

DULNESS circumscribed or general in case of pneumonia, giving place to tympany over the cavity if of sufficient size (see p. 68).

AUSCULTATION.

RESPIRATORY MURMUR feeble or absent, or sometimes bronchial over the abscess.

INDISTINCT RÂLES, and after escape of the pus the **SIGNS OF A CAVITY**.

PULMONARY GANGRENE.

Definition: necrosis of lung-tissue, accompanied by decomposition. It may occur in one or more sharply defined foci, varying from the size of a pea to that of a hen's egg, usually in the periphery of the lower lobe. More rarely it is diffuse, involving more or less of one lobe or the whole of one lung.

Signs are not distinctive, as the same may be present in other forms of phthisis.

THE ODOR OF THE BREATH is well-nigh pathognomonic.

INSPECTION.**COUGH.**

Temporary in circumscribed gangrene.

Persistent in the diffuse form.

HYPERPNŒA largely in proportion to the amount of lung involved.

CIRCUMSCRIBED DEPRESSION of the chest-wall toward recovery.

PALPATION.

VOCAL FREMITUS normal, absent, or increased.

PERCUSSION.

DULNESS or flatness over the gangrenous foci, and surrounding consolidation if sufficiently extensive.

AMPHORIC OR CRACKED-POT resonance with the formation of cavities in case the patient survive.

AUSCULTATION.

RESPIRATORY MURMUR absent, or feeble bronchial breathing over the foci, largely dependent upon the openness of the corresponding larger tubes.

AMPHORIC or **CAVERNOUS RESPIRATION**, with the formation of cavities, if freely communicating with a large bronchus.

ADVENTITIOUS SOUNDS.

Râles moist in character are apt to be present.

Gurgling Sounds with the formation of cavities.

PULMONARY CANCER.

Definition: sarcoma or carcinoma of the lung rarely primary, and when secondary either involving the part by *contiguity* from primary affection of neighboring organs, as the œsophagus and liver, or *metastasis*, as emboli from a distant focus.

Signs: these vary with the character, extent, and location of the tumor. The signs may be those of bronchitis, pneumonia, or tuberculosis in any of its stages. Nodular cancer may give few or all of the following:

INSPECTION.

CACHEXIA evident.

LOCAL enlargement of superficial veins.

RETRACTION of the chest-wall, depending upon collapse of the lung.

BULGING or fulness when the tumor is large or accompanied by pleuritic effusion.

PALPATION.

VOCAL FREMITUS feeble or absent.

PERCUSSION.

DULNESS or flatness over the lung, or possibly normal resonance surrounded by dulness.

AUSCULTATION.

RESPIRATORY SOUNDS feeble or possibly bronchial.

VOCAL SOUNDS feeble, sometimes bronchophony.

ADVENTITIOUS SOUNDS, râles, etc., variable.

ENLARGED BRONCHIAL GLANDS.

Definition: enlargement of the lymphatic glands which lie at the bifurcation of the trachea and about the main bronchi is rare as an independent disorder, and is chiefly of interest as a local manifestation of tuberculosis or malignant growths or syphilis.

Signs.**INSPECTION.**

EMACIATION and hectic flush and other visible evidences of *tuberculosis* may be present.

CERVICAL VEINS may be distended.

CYANOSIS present when there is marked pressure upon large venous radicles.

RESPIRATORY MOVEMENT deficient on one side as a result of pressure upon a main bronchus.

COUGH dry, ringing, paroxysmal, a common sign.

DYSPNŒA common.

PALPATION.

TENDERNESS in the inter-scapular region near the fourth or fifth rib is occasionally present.

PERCUSSION.

DULNESS over the glands when they are greatly enlarged. Dulness uniform over one side may result from pulmonary collapse from occlusion of the main bronchus.

AUSCULTATION usually discovers—

MURMURS, arterial and venous, from pressure upon corresponding vessels.

RESPIRATORY SOUNDS feeble or absent on one side, owing to pressure on the main bronchus. Deep respiration may develop sounds not present in ordinary respiration.

VOCAL SOUNDS also diminished for the same reason.

ADVENTITIOUS SOUNDS, râles are apt to be present owing to the secretion within the tubes as a result of bronchitis.

HYDATID CYSTS OF THE LUNG.

Rare, usually secondary to hydatids of the liver. Signs fairly distinct when the cysts are large.

Signs.**INSPECTION.**

DECUBITUS upon the sound side.

SLIGHT BULGING of the intercostal spaces over the cyst, and possibly slight

ENLARGEMENT of the affected side.

RESPIRATORY MOVEMENT limited on the affected side and increased on the sound side.

PALPATION.

VOCAL FREMITUS absent over the cyst.

FLUCTUATION may sometimes be detected when the cyst is large and superficial.

PERCUSSION.

DULNESS or flatness circumscribed over the cyst, surrounded by resonance. Dulness unchanging with posture of patient.

AUSCULTATION.

RESPIRATORY MURMUR absent over areas of flatness, normal or slightly broncho-vesicular immediately around it.

PLEURISY, acute, subacute, and chronic.

Definition: an inflammation of the pleura, characterized locally by early dryness of the pleuritic surfaces, followed by the exudation of fibrinous lymph and more or less fluid. The latter is attended by proportionate compression of the lung, displacement of the organs, and interference with normal functions. There may be more or less complete resolution or crippling of the lung by thickening of the pleura and adhesions, with permanent disarrangement of normal organic relations.

Signs.

AT THE ONSET of an attack.

INSPECTION.

Posture usually on the sound side to relieve pressure from the inflamed pleura.

Hyperpnœa due to

Fever, or in

Compensation for shallow respiration.

Limited Movement (slight) on the affected side to avoid pain.

Increased Movement on the sound side.

PALPATION may elicit—

Friction Fremitus on the affected side.

Surface Temperature possibly higher on affected side.

Tenderness or pain upon deep pressure on affected side. In diaphragmatic pleurisy pain may be elicited at the tenth rib at the insertion of the diaphragm.

PERCUSSION negative except for the production of pain.

AUSCULTATION.

Vesicular Murmur on the affected side.

Diminished in intensity and duration owing to the restrained respiratory movements.

Rhythm Disturbed, jerky, cog-wheel.

Friction Sounds.

Pleuritic.

AREA circumscribed or diffused.

TIME, with inspiration and expiration, but most marked in the former and broken and jerky in rhythm.

CHARACTER, superficial and fine, grazing or coarse, creaking; or grating, rasping, or sawing in sound.

Pleuro-pericardiac Friction Sounds.

AREA usually most distinct at the apex or along the right or left border of the

heart, where the pleurisy is adjacent to the heart.

TIME, synchronous with the heart's motion, and accompanied by others (coarser) during respiration.

CHARACTER, usually fine, grazing.

Bronchial Râles from coexisting bronchitis (incidental).

WHEN THERE IS MODERATE EFFUSION—

e. g., at the level of the fifth rib in front, not sufficient to markedly displace organs or change contour of the thorax.

INSPECTION.

Posture on either side or back.

Respiratory Movement limited on the affected side, now due in part to compression of the lung.

Hyperpnœa and perhaps *dyspnœa*.

PALPATION.

Restricted Respiratory Movements.

Vocal Fremitus enfeebled over the effusion.

MENSURATION.

Slight loss of respiratory expansion.

PERCUSSION.

Beginning Dulness over the fluid, first noticeable in the infra-scapular and infra-axillary regions.

Dulness just below the level of the fluid merging into flatness below.

Elasticity wanting as felt by the pleximeter finger.

Upper Line of Dulness not horizontal in the erect posture, but highest in the axillary region, descending in front and behind, forming the letter S curve posteriorly.

Slight Change in level takes place slowly in change from the erect posture to recumbency, and *vice versa*, where no limiting adhesion exists above the effusion.

AUSCULTATION.

Respiratory Sounds feeble and distant or absent over the fluid, except in children, where they may be distinctly broncho-vesicular.

Immediately Above the level of the fluid respiratory sounds are exaggerated or broncho-vesicular and harsh.

Over the Sound Lung exaggerated respiratory sounds corresponding to increased function.

Vocal Resonance.

Over the Fluid, diminished or absent.

At the Upper Border of the fluid occasionally ægophony may be heard.

Elsewhere normal.

WHEN THE EFFUSION IS LARGE IN AMOUNT.**INSPECTION.**

Posture, usually on or toward the affected side to give the unobstructed lung free play.

Pallor, from anæmia, and

Emaciation usually present, not necessarily marked.

Cyanosis of the lips, chin, end of nose, and tips of extremities not infrequent.

Unilateral Enlargement of the chest on the affected side, especially the lower half.

Nipple and *Scapula* farther from the median line.

Shoulder elevated.

Lower Intercostal Spaces widened and filled out, rarely bulging.

Hypochondrium prominent on the affected side, especially if this be the right.

Hyperpnœa, and usually dyspnœa, very marked on slight exertion.

Respiratory Movements markedly restricted on the affected side, increased on the sound side.

Apex Beat displaced to the right or left away from the effusion.

PALPATION in large pleuritic effusion.

Restricted Movement and *Enlargement* of the affected side.

Intercostal Spaces widened and filled out.

A Sense of Fluctuation sometimes obtained by applying the finger to the intercostal spaces and making percussion on the opposite aspect of the affected side.

Vocal Fremitus absent over the fluid, except in children, where it may be present over effusions of considerable size. It may be conducted through the effusion along the line of an extensive adhesion or band. Posteriorly it may sometimes be conducted for some distance over the effusion from the sound side by the chest-wall as a medium.

Apex Beat displaced.

Pulse accelerated, small in volume, low in tension, especially in large effusions of the left side. It is apt to be irregular in both time and force.

Tender Points of intercostal neuralgia not infrequently present.

MENSURATION.

Enlargement and loss of movement on the affected side.

PERCUSSION in large pleuritic effusion.

Flatness over a large part of the affected side.

In the Largest Effusions all resonance disappears except over a limited area (dulness) in the upper inter-scapular region, over the compressed lung. Flatness may extend across the sternum, encroaching on the opposite lung.

In Right-sided Effusions the liver dulness is depressed, sometimes depressed even to the navel.

In Left-sided Effusions flatness extends to the margin of the ribs, masking the spleen or depressing it in the abdomen, and obliterating stomach tympany in the so-called semilunar space of Traube.

Vesiculo-tympanitic note may be present in the supra-scapular and supra-clavicular region (Skoda). This is owing to a loss of pulmonary tension, or to vesicular emphysema, or possibly to the formation of vapor in the pleuritic space.

Cracked-pot resonance sometimes in infra-clavicular region.

Cardiac Dulness may be found to the right of the sternum.

AUSCULTATION in large pleuritic effusion.

Respiratory and vocal sounds wholly absent over the affected side, except feeble bronchial sounds in the inter-scapular region over the compressed lung. These are absent in extreme cases.

Whisper Resonance sometimes distinct over sero-fibrinous effusions, but absent over pus (Baccelli).

Position of Heart can frequently be made out by the relative distinctness of its sounds, when its impulse is invisible and cardiac dulness uncertain.

Systolic Murmurs may be heard over the heart, which disappear after aspiration or absorption of the effusion.

AFTER RESORPTION OF THE EFFUSION

when the effusion has been long present.

INSPECTION.

Affected Side shows—

Circumscribed Depressions or more general retraction.

Displacement of the Intra-thoracic organs by retraction of the lung and fibrous pleuritic adhesions.

Shoulder lowered on the affected side.

Intercostal Spaces narrow.

Scapulæ may project in a wing-like manner.

Spinal Column, scoliosis toward the sound side.

Sound Side shows exaggerated normal condition.

PALPATION.

Apex Beat displaced.

Vocal Fremitus exaggerated, or diminished when the main bronchi are contracted or the pleura is greatly thickened.

Pulse, normal in rate and force where the contracted lung has not become tubercular.

PERCUSSION.

Dulness over the contracted lung.

Hyper-resonance over the sound lung, which may extend across the mid-sternal line even to the parasternal line.

AUSCULTATION.

Respiratory Sounds diminished on the affected side and more or less bronchial. On the sound side respiratory sounds exaggerated, or diminished and vesicular when emphysema has developed.

PNEUMOTHORAX and PNEUMO-HYDROTHORAX.

Definition: an accumulation of air or other gases outside the lung in the pleural cavity. The lung, unless bound by adhesions, retracts and finally exists as a collapsed, nearly airless, fleshy mass at the upper and back part of the chest-cavity. There comes to be more or less fluid, serous or purulent, at the lower part of the cavity (pneumo-hydrothorax or pneumo-pyothorax).

Signs.

INSPECTION.

PALLOR and **EMACIATION** characteristic of advanced phthisis.

CYANOSIS may be marked when perforation occurs.

ENLARGEMENT of the affected side.

INTERCOSTAL SPACES wide and full, or bulging, and do not recede on inspiration.

HYPERPNŒA and **DYSPNŒA** amounting to orthopnœa, especially at the line of perforation. These may subside except on exertion.

RESPIRATORY MOVEMENT lost on the affected side, increased on the sound side.

APEX BEAT displaced usually to the opposite side of the chest.

PALPATION.

VOCAL FREMITUS, feeble or absent over the affected side.

SUCCUSSION FREMITUS when present, characteristic of pneumo-hydrothorax.

PULSE feeble and rapid.

MENSURATION.

ENLARGEMENT OF THE AFFECTED SIDE.

PERCUSSION.

OVER THE AIR more or less *tympany*, varying in pitch according to the amount of air present and the degree of tension. *Amphoric* resonance when a large opening communicates with a bronchus. When the air is under great tension, as in cases where the opening has a valve-like action, the percussion note may be positively dull.

OVER THE FLUID flatness at the lower part of the chest according to the amount present. The upper line is horizontal and straight, and changes with the posture of the patient.

OVER THE SOUND SIDE hyper-vesicular resonance.

AUSCULTATION.

RESPIRATORY and **VOCAL SOUNDS.**

Over the Air vesicular murmur absent.

Respiratory, Vocal and Whisper Sounds when present are amphoric, but may be feeble. All respiratory and vocal sounds are absent if the opening into a bronchus is closed.

Over the Fluid they are absent.

Over the Compressed Lung, at the upper interscapular region. Respiratory and vocal sounds are feeble, but bronchial when present at all.

Over the Sound Side puerile respiration.

ADVENTITIOUS SOUNDS.

Râles when present over the affected side are metallic in character.

Metallic Tinkling when fluid drops from the upper part of a cavity into the fluid ; it may also be due to the bubbling of air through the fluid when it rises above the mouth of the opening into a bronchus.

Succussion splashing sounds, upon agitation of the fluid by shaking the body, have a metallic quality.

Bell or Coin Sound is produced as the ear is applied to one aspect of the affected side while percussion is made by two coins used as plexor and pleximeter (see page 89).

FALSE PNEUMOTHORAX.

Definition : the term has been applied to subdiaphragmatic air-containing abscess cavities, usually on the right side, between the liver and diaphragm, occasionally on the left. They originate from perforating ulcers in the wall of the stomach or duodenum.

Signs of a limited pneumothorax are sometimes present.

DIAPHRAGMATIC HERNIA gives signs similar to those of pneumothorax, such as

Evidence of Displaced Heart and compressed lung.

Tympanitic Resonance.

Respiratory Sounds absent.

Metallic Tinkling may be absent.

Sudden Disappearance or advent of signs due to return of the bowel to the abdominal cavity or to the abnormal position.

Borborygmi characteristic.

HYDROTHORAX.

Definition : a serous transudate (non-inflammatory) into the pleural cavity. It is usually a part of general dropsy, but may occur with but slight œdema of the lower extremities.

IN RENAL DISEASE and anæmia it is usually bilateral.

IN HEART DISEASE it is commonly unilateral, but if bilateral is apt to be unequal on the two sides.

IN VENOUS OBSTRUCTION it may be either unilateral or bilateral.

Signs.

INSPECTION frequently reveals

CYANOSIS, profuse perspiration.

EXPRESSION of anxiety.

DYSPNŒA, orthopnœa, even without exertion ; respiratory movements limited.

ABSENCE OF INFLAMMATORY SIGNS.

PALPATION reveals

NO TENDERNESS or rise of temperature.

PERCUSSION and **AUSCULTATION** demonstrate signs of unilateral or bilateral effusion, similar to those in pleurisy, without the presence anywhere of friction sounds or other evidences of inflammation.

HÆMOTHORAX.

Definition : an effusion of blood into the pleural cavity as distinguished from hemorrhagic pleurisy.

Signs largely those of hydrothorax, with evidence in the pallor and effect on the circulation of considerable loss of blood.

DISEASES OF THE PERICARDIUM, HEART,
AND GREAT VESSELS.

RARE AFFECTIONS OF THE PERICARDIUM, essentially undemonstrable during life, even with the help of history and symptomatology. These include

ABSENCE OR DEFECTS of the PERICARDIUM.

TUMORS, HYDATIDS, and SYPHILIS of the pericardium.

PERICARDITIS.

Definition: inflammation of the pericardium.

Signs.

INSPECTION.

EXPRESSION of anxiety common; expression of pain upon change of posture or deep pressure over the heart.

POSTURE, usually in dorsal semi-recumbency.

VENOUS distention (ectasia) in the neck in rare cases where effusion makes pressure upon the superior vena cava.

PRECORDIAL REGION prominent.

In Children, owing to the pliancy of the chest-wall.

In Adults, rare, though it may be present with effusion of 12 to 15 ounces. Potain saw it with much less.

INTERCOSTAL DEPRESSIONS, may be obliterated, or bulging of intercostal spaces may be present over a large pericardiac effusion (paresis of the intercostal muscles).

BULGING OF EPIGASTRIUM occasionally present with a large effusion, though it does not occur early, owing to the ready displacement of the lungs before much lowering of the diaphragm is effected.

STUPOR, DELIRIUM, CONVULSIONS, and COMA

may occur in the late stage, with cardiac failure and venous stagnation.

DYSPNŒA is usually present both early and late.

APEX BEAT.

Forcible and rapid, and increased in area in the first stage.

Weak or absent in recumbency, but may, in the presence of effusion, become both visible and palpable in forward inclination of the body, as in the knee-elbow posture. Weakness of the apex beat may also be due to simple weakening of the cardiac muscle, usually late.

PALPATION.

PULSE not necessarily affected, except in rate, even when the heart is under considerable pressure from effusion.

APEX BEAT elevated apparently, and changed with posture.

FRICTION FREMITUS common in the early stage.

PERCUSSION.

IN THE FIRST STAGE negative.

IN THE SECOND STAGE,

Dulness corresponds largely to the amount of effusion.

Early, it is usually first to be detected at the base of the heart in the second interspace, and to the right of the sternum in the fifth interspace (this is a very important sign). A quantity of fluid less than four ounces may not be recognizable.

Later, dulness extends to the left of the apex beat.

IN LARGE EFFUSIONS flatness and dulness occur in a triangular area, with its apex extending above the base of the heart, the base below, and extending far to the right of the sternum and to the left of the mammillary line.

Dulness in recumbency becomes much increased in area in the upright posture, and may cause bulging of intercostal spaces which before were sunken.

AUSCULTATION.

FRICITION SOUNDS.

Time synchronous with cardiac movements "too and fro," systolic and diastolic. They may at times disappear for a few beats and return. They occur independent of respiration, but may be somewhat influenced by respiration. They may be present for the first few hours, or may last during the greater part of the disease, and reappear after resorption of the effusion.

Seat, over the precordia, usually first heard *over the base*, but may be loudest at the apex or over the right ventricle.

Character.

Quality, grazing, rough, harsh, or soft, and at times squeaking.

Intensity variable, may be heard at a distance from the chest, may be increased by pressure of the stethoscope or by exercise, and may be influenced by respiration.

Duration: they disappear with the occurrence of effusion or adhesion.

Propagation: they are feebly transmitted, and are usually confined to the precordia.

HEART SOUNDS.

Early, normal but rapid.

Later, weakened, with the occurrence of a large effusion, which at first muffles them and later weakens them by weakening the heart muscle. Arrhythmia may occur with weakening of the heart muscle by pressure or adhesions.

RESPIRATORY SOUNDS.

Bronchial breathing may be developed over lung adjacent to and compressed by the effusion. It may disappear with change of posture to reappear over other parts.

MEDIASTINO-PERICARDITIS.

Definition: inflammation leading to adhesion between the parietal layer of the pericardium at the base and the wall of the chest or mediastinal tissue. In such cases the two layers of the pericardium are apt to be adherent. Fibrous bands or adhesions may implicate the great vessels at the base, and also the pleura and diaphragm.

Signs.

INSPECTION may show—

INTERCOSTAL SPACES retracted with each systole. **DYSPNŒA, ARRHYTHMIA**, and weakening of the apex beat, and other signs of pericarditis may be present.

INSPIRATORY SWELLING OF THE JUGULARS has been noticed, probably from compression of the innominate vein or superior vena cava.

PALPATION.

PULSUS PARADOXUS has been noticed in some cases (see page 54). Pulse may be irregular.

PERCUSSION.

AREA OF CARDIAC FLATNESS may be increased, since adhesion of the pericardium to the chest-wall prevents expansion of the lung in front of the heart.

AREA OF CARDIAC DULNESS may be increased as an indication of cardiac enlargement following degeneration.

AUSCULTATION.

MURMURS, systolic aortic, or pulmonic, most marked on inspiration, may be heard in some cases.

HYDRO-PERICARDIUM.

Definition: Serous transudate (non-inflammatory) into the pericardium, usually as a part of a general dropsy.

Signs similar to those of pericarditis with effusion, minus the features dependent upon inflammation and pyrexia.

HÆMO-PERICARDIUM.

Definition: effusion of blood into the pericardium, usually sudden onset, with local

Signs similar to those of hydro-pericardium.

PYO-PERICARDIUM.

Definition: purulent effusion into the pericardium.

Signs, those of inflammatory effusion.

PNEUMO-PERICARDIUM.

Definition: gas in the pericardium. Usually it is accompanied by fluid (pneumo-pyo-pericardium). Onset usually sudden.

Signs.

INSPECTION.

EXPRESSION anxious or pained.

CYANOSIS, sudden collapse. This may be due to pressure upon the great vessels at the base of the heart.

PRECORDIAL PROTRUSION of the chest-wall and bulging of the intercostal spaces.

DYSPNŒA.

PALPATION.

PULSE rapid, weak, small, and may be irregular.

APEX BEAT absent, or may become visible and palpable upon forward inclination of the body.

PERCUSSION.

TYMPANITIC RESONANCE over the air in the upper part of the cavity.

FLATNESS over the fluid. The relative position of these changes with the change of posture.

AUSCULTATION.

FRICITION SOUNDS, metallic in quality, sometimes audible.

METALLIC TINKLING, or gurgling, splashing, churning sounds, metallic in quality, sometimes heard, even by the patient or others.

HEART SOUNDS, metallic in timbre.

CONGENITAL ANOMALIES OF THE HEART AND GREAT VESSELS.

Definition: the heart may be

TOO SMALL or

TOO LARGE, or may occupy various

ABNORMAL POSITIONS.

ITS CAVITIES may be too small or too large, or may be crossed by abnormal bands; also

THE SEPTA between them may be deficient, or foetal openings may remain patulous.

THE AORTA and **PULMONARY ARTERY** may be abnormally small.

Signs: many of these abnormalities have existed during a part or the whole life without discoverable symptoms and signs. Usually they show at some time physical evidences, of which the following are the chief:

INSPECTION.

CYANOSIS, early in occurrence, is the most marked sign of congenital cardiac deformity, though its presence is not diagnostic, and its absence does not always exclude a defect. It is not infrequently entirely absent, slight in amount, or late in development. Some cases of congenital cyanosis may be due to abnormality of the pulmonary capillaries.

FAULTY DEVELOPMENT OF THE BODY is a natural effect of a defective heart.

PRECORDIAL PROTRUSION is common.

ABNORMAL CARDIAC ACTION, arrhythmia and the signs of cardiac enlargement.

DYSPNŒA.

PALPATION.

PRECORDIAL THRILL not uncommon.

AUSCULTATION.

MURMURS may indicate

Patulous Ductus Arteriosus.

Seat.

POSTERIORLY in the left interscapular region at the level of the third and fourth dorsal vertebræ.

Time, systolic.

Character.

INTENSITY.

Increased on inspiration.

Diminished on expiration.

Uniform on holding the breath.

Patulous Foramen Ovale (according to Sansom).

Seat.

ANTERIORLY at the level of the third and fourth costal cartilages, to the left of the sternum.

Time, systolic and presystolic murmurs present.

Perforation of the Inter-ventricular Septum (according to Roger).

Seat.

Upper third of the precordial space about the third interspace.

Character.

Limited area, not propagated, unaffected by respiration or posture.

CARDIAC ATROPHY.

Definition: a degenerative loss of muscular volume, generally as a result of arterio-sclerosis, which, however,

usually causes cardiac enlargement, exceptionally atrophy. It accompanies general marasmus from disease or age, and results in diminution in the actual size of the heart, unless dilatation occurs.

Signs.

INSPECTION.

GENERAL signs of marasmus and poor blood-supply.

LOCAL.

Apex Beat faint or absent, even under emotional excitement, which tends to render it more visible and palpable.

PALPATION.

APEX BEAT and **PULSE** weak.

PERCUSSION.

CARDIAC DULNESS diminished in both deep and superficial areas. Allowance must be made for the lung in all cases.

An Enlarged Heart overlapped by lung may show but little dulness.

Marked Emphysema may obliterate all dulness of the heart whether of normal size or enlarged.

Retraction of the Lung with displacement of the heart may increase relative flatness and dulness.

AUSCULTATION.

HEART SOUNDS will depend upon the strength of the heart muscle.

First Sound, especially weak or absent at the apex.

Second Sound, pulmonic distinct, aortic apt to be weak.

CARDIAC HYPERTROPHY.

Definition: muscular thickening of the walls of one or more cavities of the heart. It rarely occurs without some degree of enlargement (dilatation of the cavities).

Signs.

INSPECTION.**PROMINENCE OF THE PRECORDIA** in children.**APEX BEAT.***Force* increased.*Area* increased ; sometimes movement of the whole precordia. It extends to the left of normal.*Epigastric Pulsation* strong in hypertrophy of the right ventricle.**CAROTIDS** beat forcibly.**PALPATION** confirms inspection.**PULSE** regular, full, and forcible.**PERCUSSION.****CARDIAC DULNESS** increased to the right of the sternum in hypertrophy of the right ventricle, and markedly to the left of normal if the left or both ventricles are enlarged.**CARDIAC FLATNESS** increased in area from displacement of the lung.**AUSCULTATION.**

In the absence of valvular lesions the heart sounds are apt to be sharp, loud, and often peculiarly ringing.

HYPERTROPHY WITH DILATATION gives more pronounced evidences of enlargement, but the signs otherwise are similar as long as hypertrophy compensates.**CARDIAC DILATATION.****Definition :** abnormal increase in the size of one or more of the cavities of the heart, whether the walls are attenuated or normal.

Signs.

INSPECTION reveals—**EVIDENCES OF POOR CIRCULATION.**

JUGULAR VEIN varicosed, and pulsating with marked dilatation of the right heart.

APEX BEAT absent or very weak and undulatory in character, with no definite point of maximum intensity.

PALPATION.

PULSE and **APEX BEAT** weak and rapid and frequently irregular.

PERCUSSION shows—

DULNESS and flatness increased.

AUSCULTATION.

HEART SOUNDS soft, feeble, apt to be abrupt, and frequently of equal length.

Second Sound may be inaudible at the apex and the

First Sound reduplicated.

Arrhythmia frequently present.

MURMURS if present are apt to be of slight intensity.

MYOCARDITIS.

Definition: diffuse or circumscribed inflammation of the wall of the heart.

ACUTE, ending in suppuration, resolution, or fibrosis.

CHRONIC, commonly considered as including various degenerations which are prone to accompany and follow inflammation. It may result from atheroma, calcification, thrombosis, or embolism of the coronary artery, with resulting infarction, which may be hemorrhagic, anæmic, or infected. The chronic form is apt to accompany pericarditis or endocarditis. The effect in some cases depends upon direct local work of micro-organisms, in others upon toxins or toxalbumins.

Signs.

SIGNS OF ACUTE MYOCARDITIS: this form is present typically in typhoid fever, and also may be present in diphtheria, scarlet fever, cerebro-spinal

meningitis, variola, erysipelas, and in acute endocarditis and pericarditis.

In addition to the signs of these diseases a few or many of the following may be present :

INSPECTION.

Pallor.

Dyspnœa and Sighing Respiration.

Apex Beat absent.

PALPATION.

Coldness of the extremities.

Pulse feeble, often extremely irregular (arrhythmia).

PERCUSSION.

Cardiac Dulness normal unless dilatation or pericardial effusion is present.

AUSCULTATION.

Arrhythmia.

Tachycardia.

Heart Sounds muffled. They are apt to assume the foetal type.

SIGNS OF CHRONIC MYOCARDITIS.

INSPECTION and PERCUSSION.

The signs of weak heart as in the acute form ; also *Cyanosis* and *Œdema of the Extremities*. The signs of acute febrile disease absent.

PALPATION.

Pulse shows—

Marked Arrhythmia present early and frequently persistent, but little influenced by drugs.

Irritability of the Heart upon slight excitement or exertion.

AUSCULTATION.

Heart Sounds muffled, indistinct, irregular.

First Sound reduplicated not infrequently.

CARDIAC LIPOMATOSIS, or fatty infiltration of the heart.

Definition : an accumulation of fat upon the heart. This is usually a part of general obesity, although it may occur occasionally in lean persons.

IN MODERATE AMOUNT it has little or no effect upon the heart's function, though the amount consistent with health varies with age, habits, constitution, etc.

WHEN EXCESSIVE, and deposits take place not only on the surface, but infiltration occurs between the muscle fibres, the result is hampering of the heart's action, and finally pressure-atrophy with true fatty degeneration, to which the resulting symptoms and signs are due.

CARDIAC FATTY DEGENERATION.

Definition : a more or less localized or disseminated retrogressive change of the muscular fibres of the heart into fat, almost without exception associated with hyaline and fibroid degeneration.

Signs : these become evident only when degeneration has become sufficient to cause dilatation from weakening of the muscular wall.

INSPECTION may reveal

ARCUS SENILIS and other signs of age.

VENOUS STASIS and evidence of insufficient blood-supply to the organs.

ŒDEMA of the extremities is present in the late stage.

DYSPNŒA may be pronounced on slight exertion.

PALPATION.

PULSE feeble, especially when the arm is held high.

It is frequently irregular in both time and force, and may be slow. In a late stage it is always rapid.

PERCUSSION.

CARDIAC DULNESS, superficial and deep, *increased*.

AUSCULTATION.

HEART SOUNDS weak, and are apt to be modified

and obscured by relative murmurs (dependent upon dilatation).

ARRHYTHMIA and, late, delirium cordis.

RUPTURE OF THE HEART, traumatic or non-traumatic.

Non-traumatic or spontaneous rupture of the heart occurs suddenly in case of degenerative changes, the weakened heart-wall being subjected to some sudden strain whether from mental or physical cause. It may occur in such a heart during perfect tranquillity of mind and body.

The Signs obtainable are but few, owing to the suddenness of the accident. The person may, with or without an outcry, fall at once into collapse, or, as occurs not infrequently, live several hours, manifesting

CYANOSIS, COLD SWEATS, DYSPNŒA, with, perhaps, convulsions and coma. In other cases, where the rupture is at first small, there may be attacks of nausea, vomiting, anxiety, vertigo, syncope, with or without evidence of anginal pain.

SYPHILIS OF THE HEART may show no signs, and when present they do not differ from those of myocarditis and degeneration from other causes.

ANEURYSM OF THE HEART.

Definition : though cardiac dilatation is in so far a species of aneurysm, the term is limited to *localized* attenuation of the wall, acute or chronic, with circumscribed dilatation which may be distinctly saccular.

Signs : usually neither the subjective nor objective features are distinctive, and the disease may be latent, revealed only by autopsy after sudden death, otherwise the signs are apt to be those of myocarditis. More or less

CYANOSIS,

DYSPNŒA,

ARRHYTHMIA,

TACHYCARDIA and other signs of weak heart. Exceptionally there is evidence of pulsating tumor and increase of cardiac dulness.

DIASTOLIC MURMURS have been heard, probably due to the regurgitation of blood from the aneurysmal sac.

THROMBOSIS OF THE HEART (ante-mortem).

Definition : formation of a clot within the cavities of the heart. This is usually adherent to its walls, and somewhat firmly enmeshed among its tendinous and muscular bands, but it may form polypoid structures or non-adherent floating masses.

TWO FACTORS usually combine to its occurrence :

A retarded circulation.

A toxic condition of the blood or local diseased foci upon the wall of the heart.

Signs : the process may not be apparent during life. When the coagula interfere with the valves, or detached masses form emboli, the symptoms and signs may vary widely. The diagnosis is usually impossible.

TUMORS OF THE HEART.

Carcinoma usually secondary, by extension from neighboring structures.

Sarcoma more rare.

Myomata and **Fibromata** occasional.

SIGNS very uncertain.

PARASITES, such as **CYSTICERCUS** and **ECHINOCOCCUS**, are relatively rare, and their diagnosis usually impossible, except from their recognition in other organs and the presence of cardiac disturbance of more or less gravity.

NEUROSES OF THE HEART. The so-called cardiac neuroses do not properly claim notice here.

ANGINA PECTORIS and PALPITATION are subjective.
BRADYCARDIA and TACHYCARDIA and ARRHYTHMIA
are considered under the pulse.

ACUTE ENDOCARDITIS.

Definition : inflammation of the endocardium largely confined to the valves. It may be

SIMPLE, characterized by the growth upon the valves of vegetations of granulation tissue, capped with fibrin and accompanied by subendothelial, small-celled infiltration. The tendency of this is to resolution by absorption of the vegetation with nodular thickening and contraction.

MALIGNANT or ulcerative endocarditis is marked by connective tissue vegetative proliferation, accompanied by necrosis with ulceration or suppuration. In either case the vegetations may be carried away as emboli, to form corresponding simple or infective infarcts.

Signs.

SIGN OF SIMPLE ENDOCARDITIS : these, apart from the symptoms and history, are not characteristic. Many cases are latent, with but little or no evidence of cardiac trouble. When the disease is confined to the wall of the heart (not involving the valves) signs are usually absent.

In addition to the evidences of the primary disease

INSPECTION may reveal—

Facial anxiety.

Apex Beat is apt to be increased in force and area in the beginning.

PALPATION elicits—

Pulse full, bounding, and perhaps irregular.

PERCUSSION negative in uncomplicated cases.

AUSCULTATION may be negative, even with marked lesions ; but a soft

Systolic Murmur, usually at the apex, is common. *Reduplication of the Second Sound* may be present.

SIGNS IN ULCERATIVE ENDOCARDITIS.

NOT DISTINCT apart from the septic or typhoid manifestations which are usually present as a part of the causative affection. In such cases the presence of endocardial murmurs with other signs of valvular disease, and the evidences of embolic processes, point strongly to the diseases in question.

CHRONIC ENDOCARDITIS.

Definition: it is essentially a sclerosis of the valves which produces deformity with more or less consequent obstruction or incompetence.

Signs: when the disease is confined to the wall of the heart (rare) it may show no signs. Even valvular disease may not be recognizable by signs during life.

INSPECTION may disclose more or less of the following:

ANXIETY.

CYANOSIS of the prolabia and of the nose, chin, cheeks, and tips of the ears is common in mitral regurgitation; marked when incompetence occurs.

PALLOR of the face, especially in aortic and mitral obstruction.

ICTERUS common, and may be extreme, in case of secondary duodenal catarrh.

ŒDEMA of the extremities, progressing upward in case of cardiac weakness.

PRECARDIAL PROMINENCE sometimes present in children with cardiac enlargement.

APEX BEAT.

Position: displaced to the left and downward.

Strength: *weak* and invisible in dilatation; *immoderately strong* in hypertrophy.

CAROTIDS show excessive beating in hypertrophy and in aortic regurgitation.

JUGULAR PULSE is present in marked tricuspid regurgitation.

DYSPNŒA on exertion amounting to orthopnœa in advanced cases.

PALPATION.

APEX BEAT displaced with enlargement of the ventricles.

PULSE.

Compressible, weak and small in cardiac incompetence and frequently irregular.

Full, bounding, powerful in hypertrophy.

Diastolic Collapsing, in aortic regurgitation.

Small, Wiry in aortic obstruction.

FREMITUS, or thrills, correspond to the seat of the murmur. Most frequent in mitral obstruction, pre-systolic, at the apex; less frequently in aortic obstruction, at the base; rarely with regurgitant murmurs; common over the subclavians and carotids (systolic) in aortic regurgitation. (See *Fremitus*, p. 59.)

PERCUSSION.

OUTLINE OF THE HEART is extended to the left and right in enlargement of the organ, according to the cavities affected. Often it is difficult, sometimes impossible, to make out by percussion the actual size. Evidence of enlargement is an important sign in differentiating from functional murmurs.

AUSCULTATION.

THE HEART SOUNDS may be

Replaced by murmurs,

Modified in character, muffled, accentuated, or

Reduplicated, or otherwise more or less

Changed in Rhythm.

MURMURS usually accompany lesions. (See the various *Valvular Lesions*.)

Quality.

Obstructive murmurs usually harsh and high-pitched.

Regurgitant murmurs apt to be blowing and soft. Either of them may be musical or soft, like whispered "who," or creaking or grating.

Intensity and Duration.

Sometimes Very Faint even with serious lesions.

All murmurs are apt to become weak with weak heart action, grave lesions being in such cases not infrequently unaccompanied by murmurs. Sometimes indistinct murmurs become loud or of changed quality and pitch after exercise or the administration of cardiac tonics. In tumultuous action of the heart, especially with arrhythmia, all sounds may be confused, and murmurs only become audible after cardiac stimulation.

Sometimes Murmurs are so Loud as to be heard at a distance from the patient.

Certain Postures may intensify or bring out a murmur. Asoulay recommends dorsal posture, head flexed, chin in contact with the chest, arms elevated, thighs and legs flexed on the abdomen. SITTING or STANDING posture may intensify murmurs.

According to Gerhardt, in beginning aortic insufficiency a murmur which may be absent in recumbency may be heard in the upright posture, while the reverse is true in beginning mitral insufficiency.

Pitch varies with the lesion, and the tension and rapidity of circulation. It is of value in differentiating between two murmurs occurring at the same time.

Time refers to the relation in the cardiac cycle.

Systolic refers to the contraction of the ventricles (the auricles being ignored), and hence concomitant with or destroying the first sound, and with the apex beat and carotid pulse.

INDIRECT OR REGURGITANT.

Mitral and Tricuspid.

DIRECT OR OBSTRUCTIVE.

Aortic and Pulmonic.

Diastolic refers to the dilatation of the ventricle, hence not with first sound, apex beat, and carotid pulse.

DIRECT, OBSTRUCTIVE.

Mitral and Tricuspid, occurring in the latter part of diastole just before systole (hence presystolic).

INDIRECT OR REGURGITANT.

Aortic and Pulmonic, occurring in the first part of diastole, taking the place of the respective aortic and pulmonic second sound.

Transmission or Diffusion.

Extent: the murmur of aortic regurgitation may be heard very widely from its seat, even as low as the femoral vessels, though rarely. A murmur may be very limited in diffusion, as in mitral obstruction (heard only about the apex). A murmur must necessarily be loud to be well transmitted.

Medium of transmission.

THE VESSELS.

The Aorta and its branches transmit the murmurs of both aortic obstruction and regurgitation, which are therefore frequently heard above the base of the heart and posteriorly along the left side of the vertebral column, especially above the fifth dorsal vertebra.

The Pulmonary Artery carries the pulmonic obstructive murmur up under the second left interspace, hence it is not widely diffused.

THE STERNUM and RIBS.

Loud Aortic Murmurs are frequently transmitted down the sternum owing to the comparative proximity of the vessel to the bone over it.

Mitral Systolic Murmurs are transmitted to the left along the ribs from the apex, which strikes the chest-wall at the time they are produced.

THE DIAPHRAGM doubtless transmits the murmur of aortic regurgitation. The murmur is produced during diastole while the left ventricle is in most intimate contact with the diaphragm, the blood being directed downward toward it. The murmur is therefore transmitted along the diaphragm to its attachment at the end of the sternum, and along the costal arch close to the left of the sternum. Here it is frequently heard with greatest intensity.

THE BLOOD CURRENT within the heart. In general, murmurs are transmitted best in the direction in which the blood is flowing at the time the murmur occurs.

In Mitral Obstruction the murmur is carried into the ventricle toward the apex with the blood-current. It is not usually transmitted to the left, because the apex is not in contact with the chest-wall at the time.

In Mitral Regurgitation the murmur is undoubtedly carried into the auricles with the blood, as may be verified in some

cases where this lesion is complicated by CONSOLIDATION OF THE LUNG at the base of the heart, which transmits the murmur to the surface at that point, or where there is retraction of the lung uncovering the auricle anteriorly. The normal lung, owing to the oblique position of the heart, is relatively thick over the base, and does not transmit the murmur.

Seat of a murmur: the place of its greatest intensity.

Valvular Lesions.

AORTIC INSUFFICIENCY.

DEFINITION: a defect of the aortic valve, allowing regurgitation into the left ventricle during diastole.

SIGNS.

Inspection.

Face usually pale.

Precordial Region is apt to be prominent in children, in cases of long standing.

Apex Beat.

AREA enlarged, reaching to the left, it may be even to the mid-axillary line.

FORCE of impact, increased where compensation is good, sometimes shaking the chest markedly or agitating the entire trunk.

SYSTOLIC RETRACTION of an intercostal space over the apex, occasionally present. It may be due to retraction of the lung and action of the heart in systole.

Carotids and other arteries pulsate violently and distinctly collapse in diastole.

Capillary Pulse (Quincke) may be seen in a line of artificial hyperæmia drawn upon the surface, and in the bed of the finger-nails, fundus

of the eye, and in the mucous membrane when slightly pressed beneath a glass slide.

Rhythmical Swelling of the Uvula (Müller) may sometimes be seen.

Faint Venous pulse has been seen in the hand and arm (Quincke)—rare.

Palpation reveals also

Apex Beat displaced, area enlarged, and force usually increased.

Fremitus.

DIASTOLIC THRILL is rarely felt over the base of the heart in the aortic area.

SYSTOLIC THRILL commonly felt over the carotids and subclavian arteries.

Pulse: "water hammer," "pistol," "collapsing" in diastole. When the wall of the left ventricle is strong the pulse is full, bounding, and sudden in systole, but falls away from the finger, leaving an apparently empty artery, in diastole. This is especially marked when the arm is held high, owing to the effect of gravity on the fall of blood directly toward the ventricle. Examine the arm in both the high and low positions and note the difference.

Percussion.

Cardiac Dulness over an increased area, defining the border of the heart far to the left of the nipple line.

Cardiac Flatness much increased in area from enlargement of the heart and crowding back of the lung (see p. 160).

Dulness may be marked in the left second interspace in case of relative aortic insufficiency from dilatation of the aorta at its beginning.

Auscultation.

Murmur.

TIME : diastolic, with or obscuring the second sound.

SEAT : in the aortic area, second right interspace, sometimes over the sternum at this level, occasionally over the lower end of the sternum and costal arch close to the left, over the attachment of the diaphragm. In the latter case, I believe the murmur is transmitted along the diaphragm (see p. 172).

CHARACTER.

Quality usually somewhat soft, gushing, or swishing. Occasionally rough where deposits have occurred upon the valves. It may be musical, and especially is it apt to be so in relative insufficiency (Groedel).

Intensity and pitch variable. It is usually loudest with large openings ; sometimes loudest with the arms elevated. Cases have been reported where the murmur was intermittent.

Duration long.

PROPAGATION.

Down the Sternum, owing to the proximity of the aorta to this bone over it.

Toward the Apex, down the left ventricle.

Along the Diaphragm to the lower part of the sternum and the costal arch close to the left.

Above the Base of the heart, along the vessels. When the murmur is loud it may be very widely disseminated, even to the main arteries of the extremities (rare).

ASSOCIATED MURMURS.

Aortic Systolic murmur may often be heard, though insufficiency more frequently exists alone than stenosis.

Mitral Systolic murmur frequent on account of relative mitral insufficiency from dilatation of the left ventricle. The murmur of aortic insufficiency may be absent where there is a marked insufficiency of the mitral valve (Timofejew and Bolkin).

Presystolic Murmur sometimes heard at the base, and may be accompanied by a fremitus.

The cause is uncertain, but probably it is due to vibration by the current from the auricle of the larger segment of the mitral valve, previously floated out by the reflux blood from the aorta.

Systolic Murmurs are usually heard over the carotids and subclavians accompanied by a fremitus, both probably due to the sudden systolic filling of these vessels, which were previously emptied in diastole. Both murmur and thrill over a subclavian may disappear when the arm is raised above the head.

Double Murmurs (systolic and diastolic) are sometimes heard over the larger arteries, such as the femoral.

HEART SOUNDS.

Mitral and Tricuspid first sounds intact if the corresponding valves are competent.

Aortic Second sound destroyed.

Pulmonic Second sound normal or obscured by the loud aortic murmur. It is only accentuated with disturbed compensation, resulting in relative mitral insufficiency and pulmonary engorgement. This accentuation disappears with failing compensation of the right ventricle.

AORTIC OBSTRUCTION.

DEFINITION : a defect of the aortic valve interfering with the current from the left ventricle into the aorta.

SIGNS.

Inspection.

Face is apt to be pale.

Precordial Region may be prominent where cardiac enlargement occurs in childhood.

Apex Beat displaced downward, sometimes to the sixth interspace and somewhat to the left.

Area and force variable.

Carotids and other arteries show but little pulsation.

Palpation.

Apex Beat, when hypertrophy is good, is marked as contrasted with the small pulse.

Fremitus, systolic thrill sometimes felt in the aortic area in pure aortic stenosis, which is rare.

Pulse tardy, slow, small, and sometimes very hard and wiry.

Percussion.

Cardiac Dulness increased downward and to the left.

Auscultation.

Murmur.

TIME, systolic, with the first sound.

SEAT, aortic area.

CHARACTER.

Quality apt to be harsh, strident, sometimes whistling or hissing.

Intensity and pitch vary in different cases.

Duration long, owing to the relatively slow discharge of the ventricle.

PROPAGATION.

Above the Base, into the carotids.
Toward the Apex, and when loud
Down the Sternum.

Associated Murmurs.

AORTIC DIASTOLIC murmur is usually present, as pure stenosis without regurgitation is rare.

HEART SOUNDS.

Mitral and *Tricuspid* sounds normal, the former often peculiarly loud, unless relative mitral insufficiency exists as a result of dilatation of the ventricle.

Aortic Second sound feeble.

Pulmonic Second, normal or accentuated.

MITRAL INSUFFICIENCY.

DEFINITION : a defect of the mitral valve allowing regurgitation into the left auricle during systole.

SIGNS.

Inspection reveals but little abnormal, while compensation is efficient, except the signs of hypertrophy in greater or less degree. When compensation fails, the visible signs are cyanosis, œdema, dyspnœa, cough, etc.

Palpation during loss of compensation may reveal
 Pulse weak, small, rapid, and more or less irregular.

Apex Beat usually to the left, owing to enlargement of the right heart and slight hypertrophy of the left ventricle.

Percussion usually shows cardiac enlargement both to the right and left. Dulness may be found as high as the second rib, to the left of the sternum, owing to enlargement of the left auricle.

Auscultation.

Murmur.

TIME, systolic, destroying the mitral first sound.

SEAT at the apex.

Rarely it is heard with great, if not with equal intensity at the base, about two inches to the left of the sternum. This is thought (Naunyn) to be due to the propagation of the sound with the blood as it rushed into the point of the appendix of the left auricle, which in some cases, when enlarged, curves around and lies in front of the pulmonary artery.

CHARACTER.

Quality usually soft, blowing, like the whispered "who," occasionally rough, musical, hissing, or rasping, etc.

Pitch and Intensity variable.

Duration: it may last up to the second sound.

PROPAGATION commonly to the left of the apex, and when loud may be heard posteriorly at the lower angle of the scapula; it is not usually heard at the base, and not above the base nor over the sternum.

Heart Sounds.

SECOND PULMONIC sound accentuated, owing to increased tension in the pulmonary artery, but the accentuation disappears when the compensatory hypertrophy of the right ventricle fails.

MITRAL STENOSIS.

DEFINITION: a defect of the mitral valve, interfering with the current from the left auricle into the ventricle.

SIGNS.

Inspection.

Pallor of face and

Cyanosis, more or less marked as compensation fails.

Epigastric Pulsation from enlargement of the right heart.

Palpation.

Fremitus, or thrill, presystolic, not infrequent at the apex.

Pulse apt to be small and weak. When compensation fails it becomes rapid and extremely arrhythmic in both time and force.

Percussion.

Dulness often in the second interspace to the left of the sternum over the dilated auricle, and dulness also evident to the right of the sternum and to the left of the normal line when enlargement of the right ventricle is marked. The left ventricle enlarges if at all by atrophy and dilatation from poor nutrition, but no hypertrophy occurs in it.

Auscultation.**Murmur.**

TIME, presystolic, in the latter part of diastole, ending in the first sound or in a systolic regurgitant murmur, which frequently is associated with it.

SEAT at the apex, sometimes just above and slightly to the left, because the left ventricle is displaced, backward to a degree and to the left, by the greatly enlarged right ventricle, which in this case gives the apex beat.

CHARACTER.

Quality, rough, rumbling.

Pitch, Duration, and Intensity variable. It is a relatively prolonged murmur.

PROPAGATION very limited. It is usually confined to a small area at the apex, and is not heard far to the right or left or at the base.

Associated Murmurs.

MITRAL SYSTOLIC regurgitant murmur is

usually present, as obstruction rarely occurs without producing some incompetence of the valve.

PULMONIC DIASTOLIC murmur from relative insufficiency of the pulmonary valve, due to continuous high pressure in the pulmonary artery. This is heard only when the right ventricle is powerful, and may be absent when there is relative tricuspid insufficiency.

TRICUSPID SYSTOLIC murmur from relative insufficiency of that valve. When compensation of the right ventricle fails the heart becomes extremely rapid and irregular, and the sounds and murmurs faint, a condition termed *delirium cordis*.

Heart Sounds.

MITRAL first sound, when not destroyed by an accompanying murmur of regurgitation, is intact and seemingly terminates the murmur.

TRICUSPID first sound is often peculiarly loud.

PULMONIC second sound is accentuated in case the right ventricle is hypertrophied. Accentuation disappears with failing compensation of the right ventricle.

AORTIC second sound is apt to be faint.

REDUPLICATION of the second sound is frequent, probably from the difference in tension in the pulmonary artery and aorta.

PULMONARY INSUFFICIENCY.

DEFINITION : a defect of the pulmonary valve allowing regurgitation into the right ventricle during diastole. It is usually congenital, but may be a part of a general endocarditis, or relative from dilatation of the pulmonary artery at its beginning.

SIGNS.*Inspection.*

Apex Beat displaced to the left.

Pulsation frequently visible in the

SECOND LEFT INTERSPACE. Pulsation of the RIGHT VENTRICLE between the ensiform cartilage and costal arch.

Palpation.

Fremitus, diastolic thrill over the second left interspace, occasional.

Pulse, generally regular but not large. May be variously affected, owing to the lesions of other valves usually present.

Percussion.

Dulness of the enlarged right ventricle to the right and left of the sternum.

*Auscultation.***Murmur.**

TIME diastolic, replacing the second pulmonic sound.

SEAT at the base in the second interspace.

CHARACTER not peculiar, except that it is increased in intensity during expiration (Gerhardt).

PROPAGATION limited; not transmitted into the cervical vessels. Being usually loud, it may be heard over the whole heart, distinct over the right ventricle.

Associated Murmurs.

TRICUSPID SYSTOLIC murmur from relative insufficiency is apt to occur.

At a distance from the heart may occasionally be heard on inspiration an interrupted vesicular respiration, possibly due to pulmonary capillary pulse, analogous to the collapsing capillary pulse of aortic regurgitation (Gerhardt).

Heart Sounds.

MITRAL and AORTIC sounds apt to be weak.

PULMONIC SECOND destroyed by the murmur.

TRICUSPID accentuated, if hypertrophy of the right ventricle be adequate and no relative insufficiency of the tricuspid valve occurs.

PULMONARY STENOSIS.

DEFINITION: a defect of the pulmonary valve interfering with the systolic current from the right ventricle. It is among the very rarest of acquired lesions, but most frequent of the congenital valve lesions, and usually associated with other anomalies.

SIGNS.

Inspection reveals deranged circulation and malformation and general arrest of development.

Eyes prominent; Lips thick, red.

Superficial Veins enlarged.

Cyanosis often extreme.

Thorax narrow and precordia prominent.

Abdominal Protrusion.

Finger Ends clubbed, blue; nails curved, thick.

Cardiac Impulse displaced and often increased so as to agitate the chest.

Dyspnoea common.

Palpation.

Fremitus in the second left interspace.

Apex Beat displaced.

Pulse weak.

Surface, and especially the extremities, cold.

Percussion.

Enlarged Right Ventricle, giving dulness to the right of the sternum.

Auscultation.

Murmur.

TIME, systolic, with the first sound.

SEAT, second left interspace.

TRICUSPID INSUFFICIENCY.

DEFINITION : a defect of the tricuspid valve allowing regurgitation into the right auricle during systole. Except in foetal life, it is usually relative, consecutive to valve lesions which have caused dilatation of the right ventricle.

SIGNS.*Inspection.*

Face is apt to show more or less cyanosis. In marked insufficiency of long standing with failure of compensation there is marked cyanosis with

Œdema of the extremities.

Ectasia of the superficial vessels.

Prominence of the epigastric and right hypochondriac regions occurs from enlargement of the liver.

Dyspnœa.

Pulsation of the right ventricle evident at the ensiform cartilage and epigastrium.

Jugular Pulsation present in well-marked cases.

The venæ cavæ and innominate vein have no valve, but for the production of jugular pulsation this vein must be sufficiently dilated to overcome the valve at its root, which otherwise long resists the backward pressure.

TIME, systolic.

SEAT, most marked on the right side. The bulb of the jugular first pulsates. Sometimes it may be seen just above the clavicle outside the sterno-cleido-mastoid. When the internal jugular pulsates the external does also.

INTENSITY : it only occurs with a relatively powerful right ventricle.

Pressure easily obliterates all pulsation above the point of its application.

It is greatest during inspiration.

Hepatic Venous Pulsation is better felt than seen.

Femoral Vein may pulsate if its valve (Eustachian) has been overcome by the dilatation of the vessel.

Palpation.

Apex Beat weak.

Pulse weak, rapid, unless compensation is good.

Hepatic Venous Pulsation may occur, since these veins have no valves.

TIME, systolic.

SEAT, chiefly in the left lobe, as it is most easily expanded.

INTENSITY and character like that of an erectile tumor.

Percussion.

Cardiac Dulness increased, and may be obtained well to the right of the sternum.

Hepatic Dulness increased.

Auscultation.

Murmur.

TIME, systolic, taking the place of the tricuspid first sound.

SEAT at the ensiform cartilage or the lower half of the sternum.

CHARACTER.

Quality usually soft, blowing.

Intensity and pitch not peculiar. The murmur may be absent, and is often difficult to make out in the presence of several associated murmurs. It is commonly overlooked.

PROPAGATION distinct to the

Right of the Sternum, sometimes even as far as the axillary line.

Into the Jugular Vein, where the mur-

mur is loud and the venous pulse well marked.

Associated Murmurs of the aortic and mitral valves are usually present.

Heart Sounds.

MITRAL sound usually destroyed by incompetence of the valve.

TRICUSPID sound absent.

AORTIC sound may be present, but is weak.

PULMONIC sound weak from the low tension in the pulmonary artery.

TRICUSPID STENOSIS.

DEFINITION : a defect of the tricuspid valve interfering with the presystolic current (auricular systole) into the right ventricle. It is exceedingly rare, and is usually of foetal origin.

SIGNS : it is generally accompanied by other congenital lesions which mask it.

Inspection.

The signs are those of extreme systemic venous stasis.

Palpation, percussion, and auscultation signs not distinctive. So rare is this affection that the characteristics of the accompanying murmur, if present, are not definitely settled. Hypothetically it has been described as

Time, presystolic.

Seat, tricuspid area.

Propagation limited to the right side of the heart.

FUNCTIONAL ENDOCARDIAL MURMURS.

These are due chiefly to anæmia and transient causes, such as fever, excitement, etc.

Time, systolic ; diastolic murmurs are usually organic.

Seat, usually the base of the heart in the pulmonary area ; sometimes the aortic area ; occasionally at the apex.

Character, usually soft, blowing in quality.

Propagation very limited.

Associated Signs those of

ANÆMIA, nervous excitement.

HEART normal in size, its sounds all present, though they may be slightly modified.

ANEURYSM OF THE AORTA (THORACIC).

Definition : a fusiform or saccular dilatation of the aorta in any part of its course, above the diaphragm. Its enlargement causes pressure, disturbing and destructive to neighboring organs.

Signs.

INSPECTION may reveal

AN INFLAMED AREA of reddened, thin, glazed skin covering the site of the aneurysm, if this has by pressure come sufficiently near the surface.

LIVIDITY of the face, neck, and upper extremities from pressure upon venous trunks. Lividity and œdema, when sudden in occurrence, may be due to rupture into one of the great venous trunks.

TURGESCENT and **VARICOSITY** of the superficial veins points to deep-seated interference with venous trunks.

EXPRESSION : the eyeballs may become prominent ; expression of distress may indicate the more or less continuous boring pain commonly present.

LOCALIZED ŒDEMA results from pressure upon the superior vena cava or innominate vein. It may be absent from establishment of collateral circulation.

Capillary turgescence may produce

A THICK FLESHY COLLAR at the base of the neck, which may be unilateral.

These pressure signs may of course be produced by other conditions, such as tumors, swellings, inflammatory contraction, thrombosis, etc.

INEQUALITY OF THE PUPILS, or persistent bilateral myosis, may result from pressure upon the sympathetic nerve trunks or branches. Pupil may be contracted on the affected side.

EMACIATION and **ENFEEBLEMENT** progressive.

ENLARGEMENT or **BULGING** common at the site of the aneurysm ; variable in size.

Site.

None Present when the Aneurysm is located at the Valves of Valsalva. The signs in this case are apt to be obscure.

Bulging to the Right of the Sternum in the second interspace, sometimes extending far into the infra-clavicular and mammary region, is apt to occur from aneurysm of the ascending portion, if large. More rarely it appears to the left of the sternum at a corresponding level. The sternum may be perforated.

Bulging at the Upper Part of the Sternum and adjacent infra-clavicular region results from aneurysm of the transverse portion.

Bulging Posteriorly, below the level of the fourth rib, to the left of the vertebral column, may result from aneurysm of the thoracic aorta. Very rarely it appears to the right of the vertebral column. Frequently there is an absence of a tumor.

PULSATION, if visible, at the site of an aneurysm.

Time, systolic (with apex beat).

Character, expansile in all directions, not simply lifting as from a tumor lying upon a large artery.

Intensity: to detect slight pulsation the light must be good. It may sometimes be detected by looking across the surface.

Divergence of two projecting objects with each pulsation may reveal an otherwise slight expansion—*e. g.* stick upon

the surface over the suspected part two small strips of paper, so that they may project several inches at right angles from the surface.

DEFICIENT MOVEMENT in the arteries of the left side may be seen, especially in aneurysm of the transverse part.

PULSATION OF THE CAROTIDS may be exaggerated. **APEX BEAT** is apt to be displaced downward and somewhat to the left with corresponding dislocation of the heart.

EPIGASTRIC PULSATION may be marked with enlargement of the right heart as a result of disturbed pulmonary circuit.

RESPIRATORY MOVEMENT may be deficient or absent on one side, usually the left, from pressure on the main bronchus.

DYSPNŒA and **HYPERPNŒA**, amounting to orthopnœa, may be present, either due to laryngeal paresis or to interference with the lungs, trachea, or bronchi (especially in aneurysm of the transverse portion).

COUGH a frequent sign with or without profuse secretion, variable.

PALPATION.

AREA OF TENDERNESS over the aneurysm not infrequent, and there may be tender points characteristic of intercostal neuralgia.

CONSISTENCE of the tissue over an aneurysm may be soft, yielding, and even fluctuating when cartilage and bone have been destroyed.

THRILL systolic over the tumor a frequent sign, sometimes very early obtained by pressure of the fingers in the supra-sternal notch.

IMPULSE obtained over the tumor usually

Systolic.

Diastolic Shock (usually slight) may also be present, due to the falling back of an unusual volume

of blood against the aortic valve, which must be competent to give it. (Diastolic shock absent in insufficiency of the aortic valve.)

RADIAL and **CAROTID** pulse, or both, may be unequal in volume on the two sides owing to pressure on the innominate artery or one of its branches, or to obstruction by coagulum.

THE SUPERFICIAL ARTERIES, temporals, radials frequently show rigidity, inelasticity, unevenness, or tortuosity as a part of general atheroma.

PULSATION OF THE ABDOMINAL ARTERY and its branches may be very weak in a large aneurysm of the descending part of the thoracic aorta.

TRACHEAL TUGGING is sometimes an early sign. Dr. Wm. Ewarts's method of examination :

Patient seated, head thrown back against examiner as he stands behind. Trachea gently stretched by pressure made with tips of both index fingers placed under the lower edge of the cricoid cartilage. Sensation of traction or tugging downward is felt with each heart-beat.

VOCAL FREMITUS may be diminished over the aneurysm or over the lung, the main bronchus of which is obstructed.

PERCUSSION must be made gently in case of suspected aneurysm for fear of causing embolism.

DULNESS is present over the aneurysm.

SENSATION OF RESISTANCE to the pleximeter may be less than over consolidated lung unless the aneurysm is filled with fibrin.

DULNESS OVER THE LUNG may be present also when the main bronchus is compressed and the corresponding lung congested or collapsed. Dulness over a part of the lung in which consolidation is due to pressure or to tuberculosis, which is apt to set in where the pulmonary artery is compressed.

THE HEART is not usually enlarged when the aortic valve is unaffected, but it may be displaced.

AUSCULTATION.

MURMUR is present in about half the cases. Frequently absent in saccular aneurysm (Douglas Powell).

Systolic Bruit most common. In some cases a murmur may only be detected by placing the chest-piece of the stethoscope in the patient's mouth, his lips being closed about it (Sansom). The murmur is then conveyed by the trachea.

Drummond, of New Castle, has noted a systolic murmur over the trachea, possibly due to expulsion of air at each distention of the aneurysmal sac against the trachea.

Diastolic Murmur may sometimes be heard over a saccular aneurysm independent of aortic regurgitation, the second aortic sound of the heart being clear and loud. This murmur may be due to the elastic recoil of the wall of the sac forcing the blood back into the aorta, as represented in the following diagram :

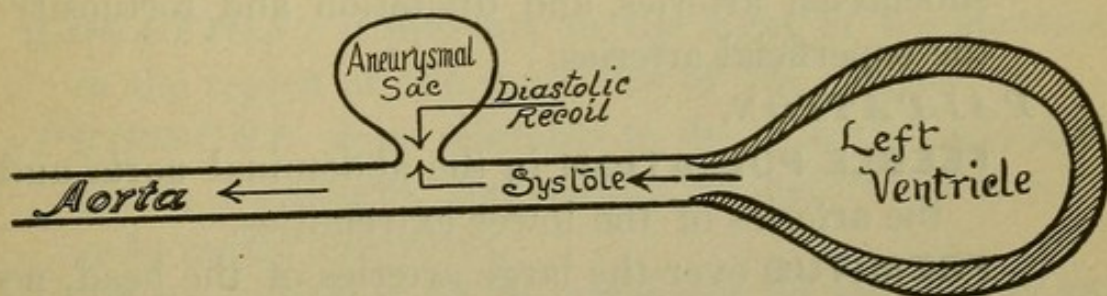


FIG. 10.—Illustrating the elastic recoil of an aneurysmal sac, producing a diastolic murmur.

Diastolic Murmur of Aortic Insufficiency, taking the place of the second aortic sound, is frequently present in aneurysm involving the valves of Valsalva.

VENOUS HUM in the neighborhood of the aneurysm may be produced by pressure against a large vein or perforation into the vein. It is continuous, and apt to be accentuated with each systole.

SECOND AORTIC SOUND is frequently accentuated and of a ringing, drumming, or clanging character, unless replaced by the murmur of insufficiency.

RESPIRATORY AND WHISPER AND VOCAL sounds may be

Bronchial over a compressed lung or over the aneurysm when resting upon the trachea.

Diminished or Absent over a whole lung when the main bronchus is compressed.

Forced Inspiration may in such cases give distinct respiratory sounds, absent on ordinary respiration.

COARCTATION OF THE AORTA.

Definition: a contraction or partial stenosis of the aorta (rare).

Signs.

INSPECTION reveals evidence of cardiac hypertrophy, dilatation of the arch of the aorta and carotid and subclavian arteries, and dilatation and tortuosity of the superficial arteries.

PALPATION.

FEEBLE PULSATION in the abdominal aorta and in the arteries of the lower extremities.

FREMITUS over the large arteries of the head, neck, and upper extremities.

PERCUSSION negative.

AUSCULTATION.

MURMUR.

Quality harsh.

Pitch high.

Intensity usually loud.

Time, systolic or diastolic (post-systolic).

Propagation into the subclavian and carotid arteries, and it may be heard posteriorly,

ANEURYSM OF THE PULMONARY ARTERY.

Very rare, and difficult of diagnosis, even with the aid of subjective manifestations.

Signs which have been obtained.

INSPECTION.

CYANOSIS marked.

DROPSY.

DYSPNŒA pronounced.

PULSATING swelling limited to the second interspace to the left of the sternum, where aneurysms of the ascending aorta are not as likely to present as those of the descending aorta, which commonly present posteriorly.

PALPATION, systolic thrill.

AUSCULTATION.

MURMUR, systolic or diastolic, and not propagated above the clavicle.

ANEURYSM OF THE INNOMINATE ARTERY.

Signs differ from those of aortic aneurysm in

LOCATION: it presents to the right of the sternum, in the region of the inner end of the clavicle.

PRESSURE signs referable to the recurrent laryngeal nerve, œsophagus, and trachea are *not so apt to occur* as in aortic aneurysm.

COMPRESSION, by the examiner, of the carotid and subclavian arteries diminishes the pulsation of aneurysm of the innominate artery, but does not affect aortic aneurysm appreciably.

ANEURYSM OF THE FURCIFORM ARTERY

This is a rare form of aneurysm, and is situated at the junction of the

artery with the aorta.

It is characterized by a pulsating tumor, which is situated

at the junction of the artery with the aorta.

The tumor is situated at the junction of the artery with the aorta.

It is characterized by a pulsating tumor, which is situated

at the junction of the artery with the aorta.

The tumor is situated at the junction of the artery with the aorta.

It is characterized by a pulsating tumor, which is situated

at the junction of the artery with the aorta.

The tumor is situated at the junction of the artery with the aorta.

It is characterized by a pulsating tumor, which is situated

at the junction of the artery with the aorta.

ANEURYSM OF THE INNOMINATE ARTERY

This is a rare form of aneurysm, and is situated at the junction of the

artery with the aorta.

It is characterized by a pulsating tumor, which is situated

at the junction of the artery with the aorta.

The tumor is situated at the junction of the artery with the aorta.

It is characterized by a pulsating tumor, which is situated

at the junction of the artery with the aorta.

The tumor is situated at the junction of the artery with the aorta.

It is characterized by a pulsating tumor, which is situated

at the junction of the artery with the aorta.

The tumor is situated at the junction of the artery with the aorta.

It is characterized by a pulsating tumor, which is situated

at the junction of the artery with the aorta.

INDEX.

- ADVENTITIOUS SOUNDS, 85
Ægophony, 82
Alar chest, 36
Amphoric breathing, 75
 cough, 84
 resonance, 68
 whisper, 83
Aneurysm of the innominate artery, 193
 pulmonary artery, 193
Angle of Lewis, 32
Aorta, aneurysm of the, 187
 coarctation of the, 192
 landmarks of the, 30
 sounds over the, 108, 109
Aortic insufficiency, 173
 obstruction, 117
 pulsation, 46
 in the epigastrium, 50
 valves, 29
Apex beat, 28, 47
 in emphysema, 121
Apneumotosis, 123
Apnoea, 41
Arterial movements, 45
 sounds, 108, 109
Asphyxia, 41
Asthma, signs of, 119
Atelectasis, 123
Atrophy, cardiac, 159
Auscultation, 70, 72
Axillary lines, 23
BARREL-SHAPED CHEST, 36, 121
Bell sound, 89
Blood currents and murmurs, 172
Bone resonance, 65
Bradycardia, 55
Breathing, abnormal, 40
 amphoric, 76
 bronchial, 74
 broncho-cavernous, 75
 cavernous, 75
 cog-wheel, 78
 exaggerated, puerile, 76
 feeble, 77
 interrupted, 78
 laryngeal, 74
 metamorphosing, 75
 normal, 59
 vesicular, 75
 rapidity of, 40
 suppressed, 77
 vesiculo-cavernous, 75
Bronchial hemorrhage, 137
Bronchiectasis, 117
Bronchi, diseases of, 114
 primary, 28
Bronchitis, 114-117
Bronchophony, 81
Broncho-pneumonia, 128
Bruit de diable, 110
CAPILLARY BRONCHITIS, 116
 pulse, 46, 173

- Cardiac atrophy, 159
 dilatation, 161
 diseases, 153
 dulness, 29, 160
 fatty degeneration, 164
 flatness, 29
 fremitus, 58
 hypertrophy, 160
 lipomatosis, 163
 movements, 47
 rupture, 165
 sounds, 89
 modified, 91
 Carotids, pulsation of, 46
 Cavernous breathing, 75
 cough, 84
 whisper, 83
 Cavity, cracked-metal resonance
 in, 70
 in pulmonary tuberculosis, 131,
 134
 Cerebral blowing, 108
 Chest, form of, 35
 size of, 34
 Chest-wall, diseases of, 112
 Cheyne-Stokes respiration, 42
 Cog-wheel respiration, 78
 Collapsing pulse, 174
 Color, 38
 Costal arch, 20
 breathing, 39
 Cough, varieties of, 83, 84
 Cracked-metal resonance, 70
 Crepitant râles, 84
 in pneumonia, 128
 Crumpling sounds, 87

 DIAPHRAGM and murmurs, 172
 Diaphragmatic breathing, 39
 hernia, 151
 pleurisy, 144

 Diastolic murmurs, 102
 shock in aneurysm, 189
 Diseases of the chest, 112
 heart, 153
 lungs, 143
 pericardium, 153
 Ductus arteriosus, patulous, 159
 Dulness, cardiac, 29, 160
 hepatic, 30
 splenic, 31
 in pulmonary tuberculosis, 132
 pleurisy, 145
 pericarditis, 154
 Dyspnœa, 40
 in atelectasis, 123
 asthma, 119
 pneumonia, 125

 EMPHYSEMA, pulmonary, 120
 of the chest-wall, 114
 Emphysematous chest, 36, 121
 Empyema pulsans, 49
 Endocardial murmurs, 95
 Endocarditis, 167
 Enlarged bronchial glands, 142
 Epigastric pulsation, 50
 Eupnœa, 39
 Exocardial murmurs, 94
 Expiratory sound prolonged, 79

 FATTY HEART, 163
 Fibroid phthisis, 135
 Fissures of the lungs, 25
 Flatness, 51
 cardiac, 29
 hepatic, 30
 in pleurisy, 147
 splenic, 31
 Fontanelle, sounds over the, 108
 Foramen ovale, patulous, 159
 Form of the chest, 36

- Fremitus, 58-60, 169
 Friction sounds, 88
 pericardiac, 94, 155
 pleuritic, 144
 pleuro-pericardiac, 94
 Friedreich's change of sound, 69
 Functional murmurs, 186
 Funnel breast, 36

 GERHARDT'S change of sound, 69

 HÆMO-PERICARDIUM, 157
 Hæmothorax, 152
 Harrison's groove, 37
 Heart, aneurysm of the, 165
 congenital anomalies of the, 158
 diseases of the, 153
 fatty, 163
 landmarks of the, 28
 neuroses of the, 166
 parasites of the, 166
 relation to the lungs, 29
 rupture of the, 165
 sounds (see Cardiac), 89
 in pulmonary tuberculosis, 133
 syphilis of the, 165
 thrombosis of the, 166
 tumors of the, 166
 valves of the, 29
 Hepatic dulness, 30
 flatness, 30
 venous pulsation, 46
 Herpes in pneumonia, 125
 Hydatid cysts of the lung, 143
 Hydro-pericardium, 157
 Hydrothorax, 152
 Hyperpnœa, 40
 Hypopnœa, 41

 INNOMINATE ARTERY, aneurysm
 of the, 193
 landmarks of the, 30

 Inspection, 33
 Inspiratory sound, 79
 Intercostal neuralgia, 112
 Interrupted Wintrich's change of
 sound, 69
 Interval in respiration, 78

 JUGULAR MURMUR, 111
 Jugulars, inspiratory swelling of
 the, 156
 presystolic pulsation of the, 45

 LANDMARKS of the chest, 23
 Lines of reference, 23
 Liver, landmarks of the, 30
 relation to the lungs, 30
 Lobar pneumonia, 124, 128
 Lungs, diseases of the, 114
 fissures of the, 25
 landmarks of the, 24
 lobes of the, 26
 outline of the, 24
 relation to the liver, 30

 MAMMILLARY LINES, 23
 Mediastinum, diseases of the, 114
 Mediastinal pericarditis, 156
 Mensuration, 61
 Metallic tinkling, 88
 Metamorphosing breathing, 75
 Mitral insufficiency, 178
 stenosis, 179
 valve, 30
 Movements, 39, 51
 cardiac, 47
 circulatory, 45
 respiratory, 39
 Murmurs, aneurysmal, 191
 aortic diastolic, 103
 systolic, 103
 cardiac, 94
 diastolic, 102

- Murmurs, endocardial, 95
 exocardial, 94
 functional endocardial, 186
 inorganic, 106
 mitral diastolic, 103
 systolic, 96, 172
 non-valvular, organic, 106
 pulmonic, 101
 transmission of, 171
 tricuspid diastolic, 104
 systolic, 100
- Myocarditis, 162
- NEUROSES of the heart, 166
- Normal vesicular breathing, 73
 dulness, 56
- Nutrition, 83
- ORGANIC MURMURS, 96
- Orthopnoea, 42
- PALPATION, 50
- Para-sternal lines, 23
- Pectoriloquy, whispering, 83
- Percussion, 61-63
- Pericardiac friction sounds, 94
 splashing sounds, 94
- Pericarditis, 153
- Phonometry, 112
- Pigeon-breast deformity, 36
- Pleuræ, diseases of the, 143
- Pleurisy, cracked-metal resonance
 in, 70
- Pleurodynia, 112
- Pleuro-pericardiac friction sounds,
 94, 144
- Plexor and pleximeter, 61
- Pneumo-hydrothorax, 149
- Pneumo-pericardiac sounds, 95
- Pneumo-pericardium, 157
- Pneumothorax, false, 151
- Posture, 37
- Posture in asthma, 119
 in lobar pneumonia, 124
 in pleurisy, 116, 144, 145
- Precordial bulging in pericarditis,
 153
 pulsation, 49
- Pulmonary abscess, 139
 apoplexy, 138
 arterial pulsation, 46
 artery, aneurysm of the, 193
 cancer, 141
 capillary pulse, 182
 hemorrhage, 137
 hyperæmia, 137
 gangrene, 140
 insufficiency, 181
 oedema, 137
 resonance exaggerated, 65
 sounds in auscultation, 72
 stenosis, 183
 thrombosis, 138
 tuberculosis, 130
- Pulsation of the epigastrium, 50
- Pulse, capillary, 46
 collapsing, 174
 characteristics, 51-55
 dicrotic, 54
 in asthma, 119
 broncho-pneumonia, 129
 lobar pneumonia, 126
 radial, 51
 "water hammer," 174
- Pulsus bigeminus, 54
 paradoxicus, 54
 trigeminus, 54
- Pyo-pericardium, 157
- QUINCKE'S pulse, 46
- RÂLES, varieties of 85
 in asthma, 120

- Râles in broncho-pneumonia, 130
 in lobar pneumonia, 128
 Regions of the chest, 1-8
 Resonance, amphoric, 68
 cracked-pot, 70
 exaggerated vesicular, 65
 tympanitic, 67
 vesicular, 64
 vocal, 80
 Respiration (see Breathing), 39
 Respiratory change of sound, 69
 expansion in emphysema, 121
 sounds, 72-78
 Rhachitic chest, 36
 rosary, 36
 Rhonchal fremitus, 59
 Ribs, landmarks of the, 32
- SCAPULA, landmarks of the, 32
 Shoemaker's breast, 36
 Sibilant râles, 86
 Size of the chest, 34
 Sonorous râles, 86
 Sound, bell, 89
 elements of, 63
 Sounds, auscultatory, 72
 cardiac, 89
 cough, 83
 friction, 88
 percussion, 63
 pleuritic, 144
 pulmonary, 72
 succussion, 89, 111
 tussive, 83
 vascular, 108
 venous, 110, 111
 whispering, 83
 Spinal curvatures, 37
 Spleen, landmarks of the, 31
 Sternal lines, 23
- Stethoscopes, 70, 71
 Subclavian artery, sounds over
 the, 100, 109
 Swellings of the chest-wall, 113
- TACHYCARDIA, 56
 Thrombosis of the heart, 166
 Trachea, 27
 "Tracheal tone," 67
 "tugging," 190
 Tricuspid insufficiency, 184
 stenosis, 186
 valve, position of, 29
 Tuberculosis, acute miliary, 131
 Tumors of the chest-wall, 113
 heart, 166
 Tussive or cough sounds, 83
 Tympany, 67
- VALLEIX'S points of tenderness,
 113
 Valves, cardiac, 29
 Valvular lesions, 173
 murmurs, 96
 Vascular sounds, 108
 Venous hum, 111
 in aneurysm, 191
 pulsation, 45, 174
 sounds, 110
 Vertebrae, landmarks of the, 31
 Vesicular resonance, 64
 respiration, 73
 interrupted, 182
 Vesiculo-tympany in pleurisy, 108
 Vocal fremitus, 60
 sounds, 80
- WHISPER, amphoric, 83
 cavernous, 83
 William's tracheal tone, 67, 69
 Wintrich's change of sound, 69

The first part of the book is devoted to a general
 introduction to the subject of the history of the
 world. The author begins by pointing out that the
 history of the world is not a mere chronicle of
 events, but a study of the human mind in action.
 He then proceeds to discuss the various stages of
 human civilization, from the earliest times to the
 present day. He shows how the human mind has
 developed from a state of ignorance and
 superstition to a state of knowledge and
 reason. He also discusses the various forms of
 government and the progress of the human race.
 The second part of the book is devoted to a
 detailed account of the history of the world, from
 the beginning of time to the present day. The
 author discusses the various events and
 movements of the world, and shows how they
 have shaped the human race. He also discusses
 the various forms of government and the progress
 of the human race. The third part of the book
 is devoted to a discussion of the future of the
 world. The author discusses the various
 theories of the future of the world, and shows
 how they have shaped the human race. He also
 discusses the various forms of government and the
 progress of the human race.

The first part of the book is devoted to a general
 introduction to the subject of the history of the
 world. The author begins by pointing out that the
 history of the world is not a mere chronicle of
 events, but a study of the human mind in action.
 He then proceeds to discuss the various stages of
 human civilization, from the earliest times to the
 present day. He shows how the human mind has
 developed from a state of ignorance and
 superstition to a state of knowledge and
 reason. He also discusses the various forms of
 government and the progress of the human race.
 The second part of the book is devoted to a
 detailed account of the history of the world, from
 the beginning of time to the present day. The
 author discusses the various events and
 movements of the world, and shows how they
 have shaped the human race. He also discusses
 the various forms of government and the progress
 of the human race. The third part of the book
 is devoted to a discussion of the future of the
 world. The author discusses the various
 theories of the future of the world, and shows
 how they have shaped the human race. He also
 discusses the various forms of government and the
 progress of the human race.

A TEXT-BOOK
OF
Materia Medica, Therapeutics,
AND
Pharmacology.

BY

GEORGE F. BUTLER, Ph. G., M. D.,

*Professor of Materia Medica and of Clinical Medicine in the
College of Physicians and Surgeons, Chicago; Professor of
Materia Medica and Therapeutics, Northwestern Uni-
versity, Woman's Medical School, etc.*

**A HANDSOME OCTAVO VOLUME OF 858 PAGES.
ILLUSTRATED.**

**Prices: Cloth, \$4.00 net; Sheep or Half-
Morocco, \$5.00 net.**

A clear, concise, and practical text-book, adapted for permanent reference no less than for the requirements of the class-room. The arrangement is believed to be at once the most philosophical and rational, as well as that best calculated to engage the interest of those to whom the academic study of the subject is wont to offer no little perplexity.

Special attention has been given to the Pharmaceutical section, which is exceptionally lucid and complete.

Sent post-paid on receipt of price.

W. B. SAUNDERS, Publisher,
925 Walnut St., Philadelphia, Pa.

Saunders' New Aid Series of Manuals.

A MANUAL
OF
SYPHILIS
AND THE
VENEREAL DISEASES.

BY
JAMES NEVINS HYDE, M. D.,
PROFESSOR OF SKIN AND VENEREAL DISEASES, RUSH MEDICAL COLLEGE,
CHICAGO,

AND
FRANK H. MONTGOMERY, M. D.,
LECTURER ON DERMATOLOGY AND GENITO-URINARY DISEASES, RUSH MEDICAL COLLEGE, CHICAGO.

PROFUSELY ILLUSTRATED.

DOUBLE NUMBER. PRICE, \$2.50 NET.

This Manual is intended as a thoroughly practical guide, and represents the latest knowledge of the Venereal Diseases which are included under the heads of Syphilis, and Gonorrhœa and its complications, with very complete instructions for their diagnosis and carefully prepared instructions for their treatment, cure, and alleviation.

The illustrations (some of which are colored) have been selected with the greatest possible care, and with the view of elucidating the text.

Sent post-paid on receipt of price.

W. B. SAUNDERS, Publisher,
925 Walnut Street, Philadelphia, Pa.

Saunders' New Aid Series of Manuals.

A MANUAL
OF
THE MODERN THEORY AND TECHNIQUE
OF
SURGICAL
ASEPSIS.

BY

CARL BECK, M. D.,

Visiting Surgeon to St. Mark's Hospital and to the German Poliklinik, New York City, etc.

A Handsome Post-Octavo Volume of over 300 Pages, containing 65 Illustrations in the Text and 12 Plates.

PRICE, \$1.25, NET.

“While the leading idea in this Manual has been to write a *practical* book that would in a measure meet the deficiency of the larger works on the subject, yet *theory* could not be entirely omitted, inasmuch as most of the technique of modern wound treatment is founded upon experiments conducted in the laboratory. An important feature of the book is that a stricter line of demarcation than usual is drawn between wounds aseptically performed by surgeons and those otherwise inflicted. In the latter category *antisepsis* asserts its prerogatives, but only as subordinate to *asepsis*.”—*Excerpt from Preface.*

Sent post-paid on receipt of price.

W. B. SAUNDERS, Publisher,
925 Walnut Street, Philadelphia, Pa.

NOW READY, VOLUME FOR 1896.

SAUNDERS'
AMERICAN YEAR-BOOK OF MEDICINE and SURGERY.

Edited by GEORGE M. GOULD, A. M., M. D.

Assisted by Eminent American Specialists and Teachers.

NOTWITHSTANDING the rapid multiplication of medical and surgical works, still these publications fail to meet fully the requirements of the *general physician*, inasmuch as he feels the need of something more than mere text-books of well-known principles of medical science. Mr. Saunders has long been impressed with this fact, which is confirmed by the unanimity of expression from the profession at large, as indicated by advices from his large corps of canvassers.

This deficiency would best be met by current journalistic literature, but most practitioners have scant access to this almost unlimited source of information, and the busy practiser has but little time to search out in periodicals the many interesting cases whose study would doubtless be of inestimable value in his practice. Therefore, a work which places before the physician in convenient form *an epitomization of this literature by persons competent to pronounce upon*

The Value of a Discovery or of a Method of Treatment

cannot but command his highest appreciation. It is this critical and judicial function that will be assumed by the Editorial staff of the "American Year-Book of Medicine and Surgery."

It is the special purpose of the Editor, whose experience peculiarly qualifies him for the preparation of this work, not only to review the contributions to American journals, but also the methods and discoveries reported in the leading medical journals of Europe, thus enlarging the survey and making the work characteristically **international**. These reviews will not simply be a series of undigested abstracts indiscriminately run together, nor will they be retrospective of "news" *one or two years old*, but the treatment presented will be *synthetic* and *dogmatic*, and will include **only what is new**. Moreover, through expert condensation by experienced writers these discussions will be

Comprised in a Single Volume of about 1200 Pages.

The work will be replete with **original** and **selected** illustrations skilfully reproduced, for the most part in Mr. Saunders' own studios established for the purpose, thus ensuring accuracy in delineation, affording efficient aids to a right comprehension of the text, and adding to the attractiveness of the volume. Prices: Cloth, \$6.50 net; Half Morocco, \$7.50 net.

W. B. SAUNDERS, Publisher,
925 Walnut Street, Philadelphia.

The knowledge gained is equal to a post-graduate course.

Uniform with the "American Text-Book" Series.

