

Essentials of gynaecology : Arranged in the form of questions and answers prepared especially for students of medicine / by Edwin B. Cragin.

Contributors

Cragin, Edwin B. 1859-1918.
Augustus Long Health Sciences Library

Publication/Creation

Philadelphia : W.B. Saunders; London : Henry Renshaw; Melbourne : George Robertson, 1890.

Persistent URL

<https://wellcomecollection.org/works/wxuyfu9s>

License and attribution

This material has been provided by This material has been provided by the Augustus C. Long Health Sciences Library at Columbia University and Columbia University Libraries/Information Services, through the Medical Heritage Library. The original may be consulted at the the Augustus C. Long Health Sciences Library at Columbia University and Columbia University. where the originals may be consulted.

This work has been identified as being free of known restrictions under copyright law, including all related and neighbouring rights and is being made available under the Creative Commons, Public Domain Mark.

You can copy, modify, distribute and perform the work, even for commercial purposes, without asking permission.



Wellcome Collection
183 Euston Road
London NW1 2BE UK
T +44 (0)20 7611 8722
E library@wellcomecollection.org
<https://wellcomecollection.org>

COLUMBIA LIBRARIES OFFSITE
HEALTH SCIENCES STANDARD



HX64115461

RG111 G84

Essentials of gynaec

Question Compend

RECAP

ESSENTIALS OF
GYNÆCOLOGY
EDWIN B. CRAGIN, M.D.

Preparing—Ready about March 1st, 1891.

MEDICAL DIAGNOSIS.

RG111

C84

Columbia University
in the City of New York

College of Physicians and Surgeons

Library



In this work, as in no other hitherto published upon the subject, are given full and accurate explanations of the phenomena observed at the bedside. *It is distinctly a clinical work* by a master teacher, characterized by thoroughness, fulness, and accuracy. It is a mine of information upon the points that are so often passed over without explanation. The student who is familiar with its contents will have a sound foundation for the practice of his profession.

The author gives a complete, though brief, presentation of the micro-organisms whose recognition and discrimination are made possible by cultivation and inoculation, and which, through the labors of those eminent bacteriologists—Pasteur, Koch, and others—have already made such a marked change in the application of remedial agents in the cure of disease.

Saunders' Question-Compendes,

Arranged in the Form of Questions and Answers.

THE LATEST, CHEAPEST, AND BEST ILLUSTRATED
SERIES OF COMPENDS.

Price, Cloth, \$1.00; Interleaved for Taking Notes, \$1.25.

For sale by all Booksellers or sent, post-paid on receipt of price, by

W. B. SAUNDERS, Medical Publisher,
913 Walnut Street, Philadelphia, Pa.

THE ADVANTAGES OF QUESTIONS AND ANSWERS.—The usefulness of arranging the subjects in the form of **QUESTIONS** and **ANSWERS** will be apparent, since the student, in reading the standard works, often is at a loss to discover the important points to be remembered, and is equally puzzled when he attempts to formulate ideas as to the manner in which the **QUESTIONS COULD BE PUT IN THE EXAMINATION ROOM.**

New York Medical Record:—

"This series of students' manuals are concise, without the omission of any essential facts."

University Medical Magazine:—

"Best of their class that have yet appeared."

Southern California Practitioner:—

"Mr. Saunderson's series of Compendes are the best ever published in this country."

Manuals of this kind are in no way intended to supplant any of the text-books, but to contain as their titles declare, the essence of those facts with which the average student must be familiar.

No. 1.—Essentials of Physiology. SECOND EDITION. ILLUSTRATED, REVISED AND GREATLY ENLARGED. By H. A. HARE, M.D., Clinical Professor of Diseases of Children, University of Pennsylvania, Demonstrator of Therapeutics and Instructor in Physical Diagnosis in the Medical Department, and Instructor in Physiology in the Biological Department, of the University of Pennsylvania, etc., etc.

No. 2.—Essentials of Surgery. Containing also, *Surgical Landmarks, Minor and Operative Surgery, and a Complete Description, together with full Illustration of the Handkerchief and Roller Bandage.* SECOND EDITION, WITH NINETY ILLUSTRATIONS. By EDWARD MARTIN, M. D., Instructor in Operative Surgery and Lecturer on Minor Surgery, University of Pennsylvania; Surgeon to the Out-Patients' Department of the Children's Hospital, and Surgical Register of the Philadelphia Hospital, etc., etc.

No. 3.—Essentials of Anatomy. Including, *Visceral Anatomy,* BASED UPON THE LAST EDITION OF GRAY. SECOND EDITION. Over three hundred and fifty pages, with one hundred and seventeen illustrations. By CHAS. B. NANCREDE, M. D., Professor of Surgery and Clinical Surgery in the University of Michigan, Ann Arbor; Corresponding Member of the Royal Academy of Medicine, Rome, Italy; Late Surgeon Jefferson Medical College, etc., etc.

No. 4.—Essentials of Medical Chemistry. Organic and Inorganic, containing also Questions on Medical Physics, Chemical Physiology, Analytical Processes, Urinalysis and Toxicology. FOURTH THOUSAND. By LAWRENCE WOLFF, M.D., Demonstrator of Chemistry, Jefferson Medical College; Visiting Physician to German Hospital of Philadelphia; Member of Philadelphia College of Pharmacy, etc., etc.

No. 5.—Essentials of Obstetrics. ILLUSTRATED. FOURTH THOUSAND. By W. EASTERLY ASHTON, M. D., Demonstrator of Clinical Obstetrics in the Jefferson Medical College, and Chief of Clinics for Diseases of Women in the Jefferson Medical Hospital, etc., etc.

No. 6.—Essentials of Pathology and Morbid Anatomy. Illustrated. By C. E. ARMAND SEMPLE, B.A., M.B. Cantab., L.S.A., M.R.C.P., Lond., Physician to the Northeastern Hospital for Children, Hackney; Professor of Vocal and Aural Physiology and Examiner in Acoustics at Trinity College, London, etc., etc.

LIST OF COMPENDS.—Continued.

No. 7.—Essentials of Materia Medica, Therapeutics and Prescription Writing. By HENRY MORRIS, M.D., late Demonstrator, Jefferson Medical College; Fellow College of Physicians, Philadelphia; Co-Editor Biddle's *Materia Medica*; Visiting Physician to St. Joseph's Hospital, etc., etc.

Nos. 8 and 9.—Essentials of Practice of Medicine. (Double number, over five hundred pages.) By HENRY MORRIS, M.D., Author of *Essentials of Materia Medica and Therapeutics*, etc., etc.

No. 10.—Essentials of Gynæcology. With numerous Illustrations. By EDWIN B. CRAIGIN, M.D., Attending Gynæcologist, Roosevelt Hospital, Out-patients' Department; Assistant Surgeon, New York Cancer Hospital, etc., etc.

No. 11.—Essentials of Diseases of the Skin. 75 Illustrations. By HENRY W. STELWAGON, M.D., Clinical Lecturer on Dermatology in the Jefferson Medical College, Philadelphia; Physician to Philadelphia Dispensary for Skin Diseases; Chief of the Skin Dispensary in the Hospital of University of Pennsylvania; Physician to Skin Department of the Howard Hospital; Lecturer on Dermatology in the Women's Medical College, Philadelphia, etc., etc.

No. 12.—Essentials of Minor Surgery and Bandaging. With an Appendix on VENEREAL DISEASES. Illustrated. By EDWARD MARTIN, M.D., author of the "Essentials of Surgery," etc., etc.

No. 13.—Essentials of Legal Medicine, Toxicology and Hygiene. One hundred and thirty five Illustrations. By C. E. ARMAND SEMPLE, M.D., Author of "Essentials of Pathology and Morbid Anatomy," etc., etc.

No. 14.—Essentials of the Refraction and Diseases of the Eye. Illustrated. By EDWARD JACKSON, A.M., M.D., Professor of Diseases of the Eye in the Philadelphia Polyclinic and College for Graduates in Medicine; Member of the American Ophthalmological Society; Fellow of the College of Physicians of Philadelphia; Fellow of the American Academy of Medicine, etc., etc.; and

Essentials of Diseases of the Nose and Throat. Illustrated. By E. BALDWIN GLEASON, M.D., Assistant in the Nose and Throat Dispensary of the Hospital of the University of Pennsylvania; Assistant in the Nose and Throat Department of the Union Dispensary; Member of the German Medical Society, Philadelphia, Polyclinic Medical Society, etc., etc.

No. 15.—Essentials of Diseases of Children. Illustrated. By WILLIAM M. POWELL, M.D., Physician to the Clinic for the Diseases of Children in the Hospital of the University of Pennsylvania; Examining Physician to the Children's Seashore House for Invalid Children at Atlantic City, N. J.; formerly Instructor in Physical Diagnosis in the Medical Department of the University of Pennsylvania, and Chief of the Medical Clinic of the Philadelphia Polyclinic.

No. 16.—Essentials of Examination of Urine, COLORED "VOGEL SCALE," and numerous Illustrations. By LAWRENCE WOLFF, M.D., Author of "Essentials of Chemistry," etc., etc.; price, 75 cents.

No. 17. Essentials of Diagnosis. By DAVID D. STEWART, M.D., Lecturer on Diseases of the Nervous System at the Jefferson Medical College; Late Chief of the Medical Clinic Jefferson Medical College Hospital; Physician to St. Mary's and St. Christopher's Hospitals; Fellow of the College of Physicians of Philadelphia, etc., etc. (in press).

At the present time, when the student is forced by the rapid progress of medical science to imbibe an account of knowledge which is far too great to permit of any attempt on his part to master it, a book which contains the "essentials" of a science in a concise yet readable form must of necessity be of value.

Intended to assist Students to put together the knowledge they have already acquired by attending lectures.

Specially prepared for the use of Students of any Medical College.

NOW READY.

NANCREDE'S ESSENTIALS OF ANATOMY

—AND—

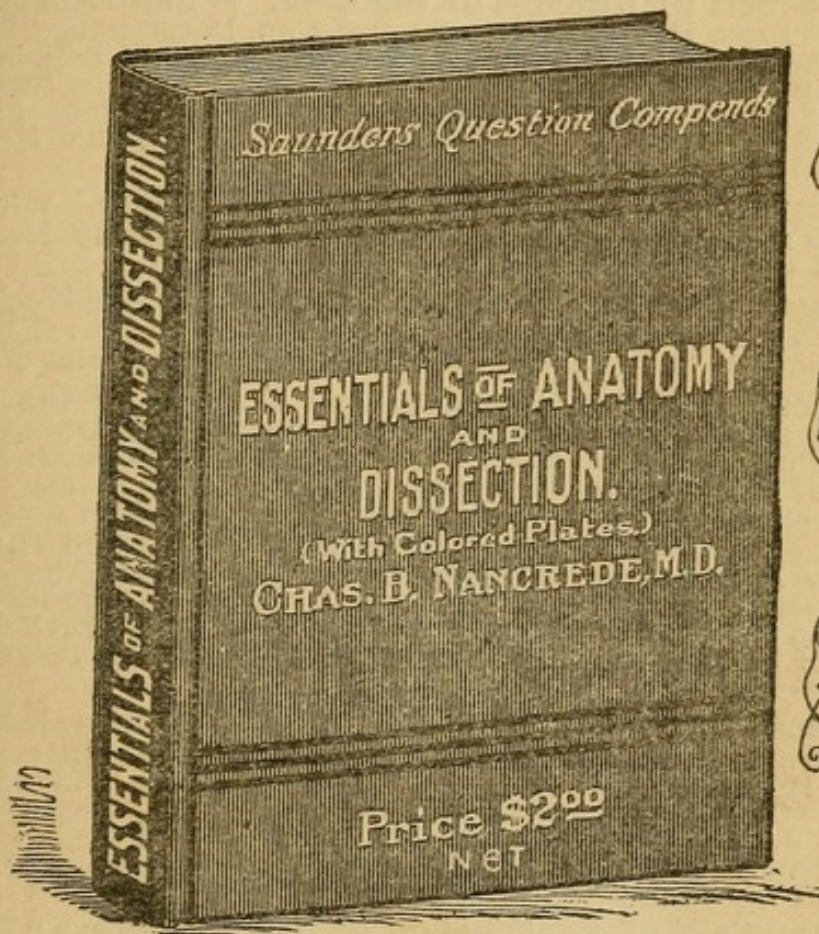
MANUAL OF PRACTICAL DISSECTION,

WITH HANDSOME FULL-PAGE LITHOGRAPHIC PLATES IN COLORS,
OVER 200 ILLUSTRATIONS.

W
I
T
H

C
O
L
O
R
E
D

P
L
A
T
E
S



Price, Extra Cloth or Oilcloth for the Dissec-
tion Room, \$2.00 Net,
Medical Sheep, 2.50 Net.

For sale by all booksellers, or sent, postpaid, on receipt of price by

W. B. SAUNDERS, MEDICAL PUBLISHER,
913 WALNUT STREET, PHILADELPHIA, PA.

NOW READY.

ADDITIONS TO THE SERIES OF
SAUNDERS' QUESTION-COMPENDS,
SINCE LAST SEASON (1889-90.)

Nos. 8 and 9.—Essentials of Practice of Medicine. (Double number, over five hundred pages.) By HENRY MORRIS, M.D., Author of Essentials of Materia Medica and Therapeutics, etc., etc.

No. 10.—Essentials of Gynæcology. With numerous illustrations. By EDWIN B. CRAIGIN, M.D., Attending Gynæcologist, Roosevelt Hospital, Outpatients Department; Assistant Surgeon New York Cancer Hospital, etc., etc.

No. 11.—Essentials of Diseases of the Skin. 75 illustrations. By HENRY W. STELWAGON, M. D., Clinical Lecturer on Dermatology in the Jefferson Medical College, Philadelphia; Physician to Philadelphia Dispensary for Skin Diseases; Chief of the Skin Dispensary in the Hospital of University of Pennsylvania; Physician to Skin Department of the Howard Hospital; Lecturer on Dermatology in the Women's Medical College, Philadelphia, etc., etc.

No. 12.—Essentials of Minor Surgery and Bandaging. With an Appendix on VENEREAL DISEASES. Illustrated. By EDWARD MARTIN, M. D., author of the "Essentials of Surgery," etc., etc.

No. 13.—Essentials of Legal Medicine, Toxicology and Hygiene. One hundred and thirty fine Illustrations. By C. E. ARMAND SEMPLE, M. D., Author of "Essentials of Pathology and Morbid Anatomy," etc., etc.

No. 14.—Essentials of the Refraction and Diseases of the Eye. Illustrated. By EDWARD JACKSON, A.M., M.D., Professor of Diseases of the Eye in the Philadelphia Polyclinic and College for Graduates in Medicine; Member of the American Ophthalmological Society; Fellow of the College of Physicians of Philadelphia; Fellow of the American Academy of Medicine, etc., etc., and **Essentials of Diseases of the Nose and Throat.** Illustrated. By E. BALDWIN GLEASON, M. D., Assistant in the Nose and Throat Dispensary of the Hospital of the University of Pennsylvania; Assistant in the Nose and Throat Department of the Union Dispensary; Member of the German Medical Society, Philadelphia, Polyclinic Society, etc., etc.

No. 15.—Essentials of Diseases of Children. Illustrated. By WILLIAM M. POWELL, M. D., Physician to the Clinic for the Diseases of Children in the Hospital of the University of Pennsylvania; Examining Physician to the Children's Seashore House for Invalid Children, at Atlantic City, N. J.; formerly Instructor in Physical Diagnosis in the Medical Department of the University of Pennsylvania, and Chief of the Medical Clinic of the Philadelphia Polyclinic.

No. 16.—Essentials of Examination of Urine. COLORED "VOGEL SCALE," and numerous Illustrations. By LAWRENCE WOLFF, M.D., author of "Essentials of Chemistry," etc., etc.; price, 75 cents.

No. 17.—Essentials of Diagnosis. By DAVID D. STEWART, M. D., Lecturer on Diseases of the Nervous System at the Jefferson Medical College; Late Chief of the Medical Clinic Jefferson Medical College Hospital; Physician to St. Mary's and St. Christopher's Hospitals; Fellow of the College of Physicians of Philadelphia, etc., etc.

No. 18.—Essentials of the Practice of Pharmacy. By L. E. SAYRE, Professor of Pharmacy and Materia Medica in the University of Kansas.

For Sale by all booksellers.

PRICE: CLOTH, \$1.00; INTERLEAVED FOR TAKING NOTES, \$1.25.

SAUNDERS' QUESTION-COMPENDS, No. 10.

ESSENTIALS OF GYNÆCOLOGY.

ARRANGED IN THE FORM OF

QUESTIONS AND ANSWERS

PREPARED ESPECIALLY FOR

STUDENTS OF MEDICINE.

BY

EDWIN B. CRAGIN, M.D.,

ATTENDING GYNÆCOLOGIST TO THE ROOSEVELT HOSPITAL, OUT-PATIENT DEPARTMENT;
ASSISTANT SURGEON TO THE NEW YORK CANCER HOSPITAL, ETC.

WITH 58 ILLUSTRATIONS.

PHILADELPHIA:
W. B. SAUNDERS,
913 WALNUT STREET.

LONDON: HENRY RENSHAW. MELBOURNE: GEORGE ROBERTSON & Co.

1890.

RG III
C84

Entered according to Act of Congress, in the year 1890, by
W. B. SAUNDERS,
In the Office of the Librarian of Congress, at Washington, D. C.

PRINTED AT
COLLINS PRINTING HOUSE,
PHILADELPHIA, U. S. A.

PREFACE.

No one appreciates more fully than the Author the inadequacy of this little work for a thorough study of Gynæcology. This has not been the aim. He only hopes that as a means of review and as a summary of the results of more extensive reading, the student may find the work of some value. The Author wishes also to state that in its compilation he has freely consulted, and made use of, the standard works of Hart and Barbour, Thomas, Schroeder, The American System of Gynæcology, notes on the lectures of Prof. Geo. M. Tuttle at the College of Physicians and Surgeons, New York, and numerous journals.

New York, February 1st, 1890.

INDEX

The following is a list of the names of the persons who have been named in the foregoing chapters, and the pages on which they are mentioned. The names are arranged in alphabetical order, and the pages are given in Roman numerals.

A. B. C. D. E. F. G. H. I. J. K. L. M. N. O. P. Q. R. S. T. U. V. W. X. Y. Z.

CONTENTS.

	PAGE
Mons Veneris,	17
Labia Majora,	17
Labia Minora,	18
Clitoris,	18
Vestibule,	20
Fourchette,	20
Fossa Navicularis,	20
Bulbs of the Vagina,	20
Vulvo-vaginal Glands,	21
Hymen,	21
Vagina,	21
Uterus,	23
Mucous Membrane of Uterus,	25
Fallopian Tubes,	30
Ovaries,	31
Parovarium,	34
Urinary Tract,	34
Bladder,	35
Rectum,	37
Pelvic Floor,	39
Perineal Body,	40
Muscles of the Perineum,	41
Ischio-rectal Fossa,	41
Development of Pelvic Organs,	42
Physical Examination of Pelvic Organs,	42
Vaginal Examination,	43
Bimanual Examination,	45
Rectal Examination,	46
Instruments,	48
Specula,	48
The Sims Speculum,	48

	PAGE
Instruments, the Fergusson Speculum,	50
The Brewer Speculum,	51
Volsella,	52
Uterine Sound,	53
Uterine Probe,	57
Dilators,	57
Tents,	57
Graduated Hard Dilators,	59
Elastic Dilators,	61
The Curette,	61
Vulvitis,	62
Acute Simple Catarrhal,	63
Chronic Catarrhal,	63
Gonorrhœal,	64
Phlegmonous,	65
Diphtheritic,	66
Gangrenous,	66
Follicular,	67
Cyst and Abscess of Vulvo-vaginal Gland,	68
Pudental Hernia,	69
Pudental Hæmatocele,	70
Hemorrhage from Vulva,	71
Skin Diseases of the Vulva,	72
Erythema of the Vulva,	72
Eczema of the Vulva,	72
New Growths of the Vulva,	74
Simple Papillomata,	74
Pointed Condylomata,	74
Syphilitic Condylomata,	75
Pruritus Vulvæ,	75
Hyperæsthesia of the Vulva,	77
Vaginismus,	77
Coccygodynia,	78
Irritable Urethral Caruncle,	79
Prolapse of Urethral Mucous Membrane,	80
Malformations of the Vulva,	80
Diseases of the Vagina,	81
Simple Catarrhal Vaginitis,	81
Gonorrhœal Vaginitis,	82

	PAGE
Diseases of the Vagina, Ulcerative Vaginitis,	83
Diphtheritic Vaginitis,	84
Pelvic Peritoneum,	84
Pelvic Peritonitis,	85
Pelvic Cellulitis,	87
Pelvic Hæmatocele and Hæmatoma,	91
Menstruation,	96
Disorders of Menstruation,	96
Amenorrhœa,	96
Vicarious Menstruation,	98
Menorrhagia and Metrorrhagia,	98
Dysmenorrhœa,	99
Obstructive,	100
Congestive,	100
Neuralgic,	101
Ovarian,	102
Membranous,	102
Malformations of the Vagina,	104
Atresia of the Vagina,	104
Malformations of the Uterus,	106
Displacements of the Uterus,	110
Anteversion,	111
Anteflexion,	112
Retroversion and Retroflexion,	115
Pessaries,	119
Alexander's Operation,	123
Hysterorrhaphy,	124
Prolapsus Uteri,	124
Laceration of Perineum and Relaxation of Vaginal Outlet,	127
Saenger-Tait Operation,	128
Emmet's Operation,	132
Hypertrophy of the Cervix,	134
Stenosis of the Cervix,	135
Laceration of the Cervix,	136
Trachelorrhaphy,	139
Endometritis,	140
Acute Endometritis,	141
Chronic Endometritis,	142
Metritis,	146

	PAGE
Metritis, Acute Metritis,	147
Chronic Metritis,	148
Atrophy of the Uterus,	151
Fibroid Tumors of the Uterus,	151
Inversion of the Uterus,	158
Polypi,	163
Carcinoma Uteri,	167
Vaginal Hysterectomy,	169
High Amputation of the Cervix,	170
Sarcoma of the Uterus,	171
Salpingitis,	172
Affections of the Ovaries,	174
Hemorrhage into the Ovaries,	174
Ovaritis,	175
Prolapse of the Ovary,	178
Tumors of the Ovary,	179
Parovarian Cysts,	184
Extra-uterine Gestation,	186
Fistulæ,	188
Recto-vaginal Fistula,	190

ESSENTIALS OF GYNÆCOLOGY.

What is included in the term external genitals?

That portion of the genital tract which is visible when the patient is in the dorsal position, with knees elevated and the labia separated with the fingers, viz. : Mons Veneris, Labia Majora, Labia Minora, Clitoris, Vestibule, Fourchette and Fossa Navicularis.

What other terms are in common use for the external genitals?

Pudendum and Vulva.

The term vulva is inexact, as it originally applied to the labia, nevertheless it is in common use.

What comprise the internal organs of generation?

The Uterus, Fallopian tubes and Ovaries.

The Vagina connects the external with the internal generative organs.

Budin regards the Hymen as anatomically a folding in of the vaginal walls.

Mons Veneris.

Describe.

The Mons Veneris is a triangular projection, or cushion of adipose tissue, situated over the symphysis pubis. Anatomically, in addition to adipose tissue, it contains fibrous and elastic tissue. After puberty it is covered with hair, which has a tendency to curl, and is usually somewhat darker than the hair of the head. Numerous sebaceous and sweat glands are present.

Labia Majora.

Describe them.

The labia majora are two folds of skin which extend from the mons veneris in front to meet in the fourchette posteriorly; they

are covered externally with coarse hair, and richly supplied with sebaceous and sweat glands; they also contain adipose, fibrous and elastic tissue. Above, the round ligament can be traced into them on either side; also the remains of the canal of Nuck, which sometimes continues pervious and admits of hernia. The inner surface of the labia is smooth, and somewhat resembles mucous membrane, a few fine hairs, however, are visible on close inspection.

The labia majora in the virgin lie in contact; in old women they become atrophied and allow the labia minora to protrude.

The arterial supply is the superficial perineal branch of the internal pudic. The veins communicate with the bulbs of the vagina and take the course of the arteries. The lymphatics empty into the inguinal glands. The nerve supply is from the superficial perineal branches of the internal pudic.

Labia Minora.

Describe.

The labia minora, or nymphæ, are two folds of muco-cutaneous tissue which arise about the middle of the labia majora on their inner surfaces, and extending upward divide into two portions; the two lower uniting just below the clitoris to form the frænum, the two upper just above the clitoris to form the prepuce. The venous supply is rich; it communicates with the bulbs of the vagina and with the pudic and perineal veins. The arterial supply, nerves and lymphatics are the same as for the labia majora. The sebaceous glands are very abundant.

Clitoris.

Describe.

The clitoris, the analogue of the penis in the male, is situated at the apex of the vestibule; it consists of a glans, a body and two crura.

The glans, the only part visible, is a mass of erectile tissue, about the size of a small pea, very abundantly supplied with nerves and partially covered by its prepuce.

The body also consists of erectile tissue; it is about an inch long, surrounded by a firm fibrous covering, and shown, on section, to

consist of two halves, corpora cavernosa, separated by an imperfect septum.

The crura are two prolongations of erectile tissue with a dense fibrous sheath; they arise from the anterior borders and inner surfaces of the pubic and ischiatic rami, and extend forward to unite in the body just beneath the pubic arch.

Give the vascular supply of the clitoris.

The arterial supply is from the two terminal branches of the internal pudic. The blood is returned by the dorsal vein which empties into the vesical plexus.

Describe the lymphatics of the clitoris.

The clitoris is surrounded by a plexus of lymphatics which terminate in the inguinal glands.

Describe the nerve supply of the clitoris.

The clitoris receives numerous filaments both from the sympathetic system and from the pudic nerve.

According to Savage, "small as this organ is compared with the penis, it has in proportion four or five times the nervous supply of the latter."

What are the differences between the clitoris and the penis?

The clitoris has neither corpus spongiosum nor urethra, both of which are present in the penis.

What are the points of resemblance between the clitoris and the penis?

They are both erectile.

They each consist of a glans, a body and two crura.

They each have two corpora cavernosa separated by an incomplete septum. The glans in each is partly covered by a prepuce, with its frænum attached below.

What do we find in the female as the analogue of the corpus spongiosum in the male?

The bulbs of the vagina and the labia minora, which, in the female, lie at the side of the urethra, correspond to the corpus spongiosum in the male.

What in the male is the analogue of the labia majora in the female?

The scrotum.

Vestibule.

Describe.

The vestibule is a triangular area covered with mucous membrane, in the base of which is situated the meatus urinarius; the apex lies just below the clitoris; the sides are formed by the inner edges of the labia minora, the base by the upper margin of the vaginal orifice. Beneath the mucous membrane lies a venous plexus called the pars intermedia. The vestibule differs from the labia and mons veneris in having no sebaceous glands.

Fourchette.

Describe.

The fourchette, or posterior commissure, is a mere fold of skin formed by the junction of the labia majora at the anterior edge of the perineum.

Fossa Navicularis.

Describe.

The fossa navicularis is a boat-shaped cavity which is formed between the lower portion of the hymen and the inner aspect of the fourchette, when the latter is pulled down with the finger, or the labia are separated.

When the parts are at rest, no such hollow exists.

Bulbs of the Vagina.

Describe them.

The bulbs of the vagina are two oval masses of erectile tissue situated on either side of the ostium vaginæ and base of the vestibule; posteriorly, they lie in contact with the anterior layer of the triangular ligament; they are partially covered in front by the bulbo-cavernosi muscles; they extend as high as the meatus urinarius, and are connected by the pars intermedia with the cavernous tissue of the clitoris. Their size varies greatly from that of a bean, as given by Hart and Barbour, to a mass an inch and a half long.

Vulvo-Vaginal Glands.

Describe.

The vulvo-vaginal, or Bartholinian glands are small oval bodies about the size of an almond, lying just behind the lower extremities of the bulbs; they lie behind the anterior layer of the triangular ligament, and each gland has a duct about half an inch in length which opens just in front of the hymen on each side.

They secrete a glairy mucus which lubricates the parts.

Hymen.

Describe.

The hymen is a fold of mucous membrane which surrounds the ostium vaginæ; it has a connective tissue framework, and contains blood vessels and nerves. *mus. c. trans.*

According to Budin, it is an infolding of the entire vaginal wall.

The hymen may be of several forms; the most common being the crescentic. Other forms are the annular, making a ring about the ostium; the cribriform, perforated by numerous small holes; and the fimbriated, with a fringed edge. It is sometimes imperforate, a pathological condition.

What value has the hymen as a criterion of chastity?

Very slight, as neither is its absence proof that intercourse has taken place, nor is its presence an absolute proof to the contrary.

What are the *carunculæ myrtiformes*?

They were formerly regarded as the remains of the hymen, but are now considered the tags resulting from the laceration, sloughing and cicatrization incident to childbirth.

Vagina.

Describe.

The vagina is spoken of by Hart and Barbour as "a mucous slit in the pelvic floor;" it is the canal connecting the uterus and the vulva, lying between the bladder and urethra in front and the rectum behind; its walls, which are anterior and posterior, are normally in contact.

The anterior wall measures 2-2³/₂ inches in length, the posterior 3-3¹/₂ inches. The anterior wall is shorter than the posterior, from the fact that the uterus is set into the anterior wall.

The vagina is very dilatable, and when distended is conical in shape, being much more roomy above than below.

The vaginal walls on section are seen to consist of three layers : 1, mucous ; 2, muscular ; 3, connective tissue.

The mucous membrane on both anterior and posterior walls presents at the lower portion of the canal numerous ridges or rugæ, extending transversely from a central column ; the anterior being the more distinct. The epithelium covering the mucous membrane is of the squamous variety.

The muscular coat consists of two layers of unstriped muscle, the inner being longitudinal (Henle) and the outer circular.

The outer coat is of connective tissue, and contains the external plexus of veins.

The roof, or fornix of the vagina, that portion of the canal surrounding the cervix, is, for convenience, divided into four portions : the anterior fornix, the posterior fornix, and the lateral fornices ; of these the posterior is the deeper. A very few mucous glands are found in the vagina. The secretion is an acid mucus.

What is the arterial supply of the vagina ?

The arterial supply is from the vaginal arteries, which supply the lateral walls ; branches of the uterine arteries supplying the upper extremity, and branches of the pudendal arteries supplying the lower extremity. These anastomose with each other and with the vesical and rectal arteries.

Describe the veins of the vagina.

The vaginal veins form plexuses which surround the canal-like sheaths ; one being external to the muscular layer, the other just beneath the mucous membrane.

“These communicate freely with the pudendal, vesical and hemorrhoidal plexuses below, and with the plexuses of the broad ligament above.” These veins contain no valves.

Describe the lymphatics of the vagina.

The lymphatics of the lower fourth of the vagina, together with those from the external genitals enter the inguinal glands.

The lymphatics from the upper three-fourths of the vagina join with those from the cervix and bladder, and enter the iliac glands.

According to Le Bec, they enter the obturator glands.

Describe the nerve supply of the vagina.

The vagina is supplied by branches of the inferior hypogastric plexuses of the sympathetic system. These plexuses lie on either side of the vagina.

Give the relations of the vagina.

The anterior vaginal wall is connected in its lower half with the urethra, in its upper half with the neck and fundus of the bladder; the former connection is much more intimate than the latter. The posterior vaginal wall in its lower fourth lies in connection with the perineal body, in its middle two-fourths with the rectum, in its upper fourth with the cul-de-sac of Douglas. The anterior fornix is distant $1\frac{1}{2}$ inches from the utero-vesical pouch, and through this fornix can normally be felt the body of the uterus and the angle it makes with the cervix.

The posterior fornix is in contact with the cul-de-sac of Douglas. The lateral fornices are in relation with the bases of the broad ligaments, and through these fornices can normally be felt the vessels of the broad ligament, and occasionally the ovary and tube of that side.

The vagina makes an angle of 60° with the horizon when the woman is erect.

Uterus.

Give the gross anatomy.

The uterus, the organ of gestation, is a hollow, pear-shaped organ, flattened antero-posteriorly, situated in the pelvis between the bladder and rectum. It measures in the virgin about 3 inches in length, 2 inches in breadth, at the level of the Fallopian tubes, and one inch in thickness. The weight of the virgin uterus varies from 1 to $1\frac{1}{2}$ oz.

It consists of three portions: the cervix, body and fundus.

As viewed externally, the uterus, on its anterior surface, is nearly flat, its posterior surface convex; a little below the centre is a slight constriction called the isthmus.

The cervix is that portion of the uterus below the isthmus, and which projects in part into the vagina.

The body is that portion between the isthmus and the line joining the entrance of the Fallopian tubes.

The fundus is the portion above this line.

Describe the uterine canal.

The uterine canal measures normally $2\frac{1}{2}$ inches, and holds about 12 drops; the cervical portion of the canal is spindle-shaped; the remainder is triangular, with anterior and posterior walls in contact.

What are the openings into the uterine cavity?

There are three: the os externum, which communicates with the vagina; and the orifices of the Fallopian tubes at the upper angles,

FIG. 1.

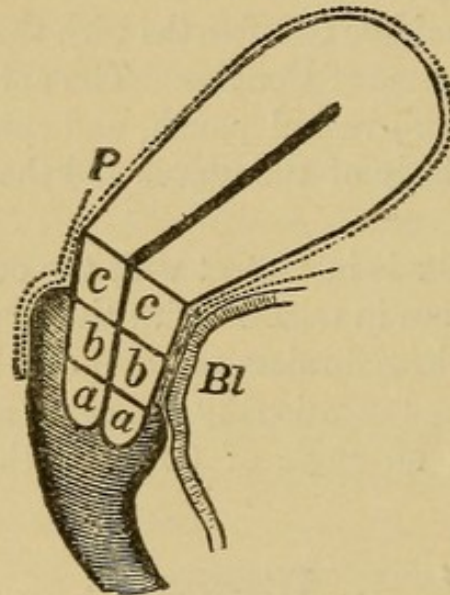


Diagram of Uterus, to show divisions of Cervix. (Schroeder.)

a, Infra-vaginal portion; *b*, Intermediate portion; *c*, Supra-vaginal portion; *Bl*, Bladder; *P*, Peritoneum. The dotted line shows peritoneum.

which connect the uterine with the peritoneal cavity. The os internum connects the cavity of the cervix with that of the body.

What divisions of the cervix are made?

Schroeder divides the cervix into three portions, as seen from the accompanying figure, (Fig. 1, *a*, *b*, *c*).

- a*. The infra-vaginal portion.
- b*. The intermediate portion.
- c*. The supra-vaginal portion.

The infra-vaginal portion of the cervix (*a*) is that below the level of the attachment of the anterior vaginal wall.

The supra-vaginal portion (*c*) is that above the level of the attachment of the posterior vaginal wall.

The intermediate portion (*b*) is that between the infra- and supra-vaginal portions.

What portions of the cervix project into the vagina ?

The infra-vaginal portion of the anterior lip, and the infra-vaginal and intermediate portions of the posterior lip.

For practical purposes, it is sufficient to divide the cervix into the supra-vaginal portion, that above the attachment of the vagina ; and the infra-vaginal, that within the vagina.

What are the three elements in the structure of the uterus ?

1. The mucous membrane.
2. The muscular coat.
3. The peritoneal coat.

Mucous Membrane of the Uterus.

Describe that of the cervix.

The mucous lining of the cervix differs from that of the body of the uterus. In the cervix it is thrown into folds presenting the arbor vitæ appearance, there being a central ridge on both anterior and posterior walls, and from these ridges secondary ridges extending obliquely.

The anterior and posterior ridges are not directly opposite, but fit past one another. The epithelium is ciliated on the ridges, non-ciliated in the depressions (de Sinéty).

The mucous membrane covering the vaginal portion of the cervix closely resembles that of the vagina, consisting of vascular papillæ covered by squamous epithelium.

Describe the mucous membrane of the body of the uterus.

The mucous lining of the body of the uterus is smooth, velvety and of a grayish red color ; it is directly connected with the muscular coat, with no submucous layer. It averages about $\frac{1}{25}$ of an inch in thickness, and consists of columnar, ciliated epithelium, on a base of connective tissue between whose fibres numerous lymph spaces

are found. The mucous membrane is thickly studded with glands, the utricular glands, which penetrate the whole thickness of the mucous layer. These glands are of the tubular variety, and are frequently bifurcated at their blind extremities. They are lined with prismatic ciliated epithelium, resting on a thin membrana propria. Their direction is not at right angles to the surface, but, according to Turner, more or less oblique.

Describe the muscular structure of the uterus.

The muscular structure of the uterus is most marked after impregnation ; it can then be separated into three layers :—

1. The external, superficial or longitudinal.
2. The middle or oblique.
3. The internal or circular.

The external layer is most distinct on the anterior and posterior surfaces, where it is seen to consist of fibres running up longitudinally over the fundus ; it sends fibres into the broad, round, ovarian and utero-sacral ligaments and also into the Fallopian tubes.

The middle, or oblique layer has no regular arrangement ; some of the fibres run longitudinally, some transversely and some obliquely ; they surround the blood vessels, and on this account this layer is of great importance ; it constitutes the chief portion of the uterine wall.

The internal or circular layer shows fibres arranged in a circular manner, most distinct around the orifices of the Fallopian tubes and at the os internum.

Describe the peritoneal coat of the uterus.

The peritoneum covers the anterior surface of the uterus above the level of the internal os ; it extends over the fundus, covers its posterior surface as low as the attachment of the posterior vaginal wall, and extends down the latter for about an inch.

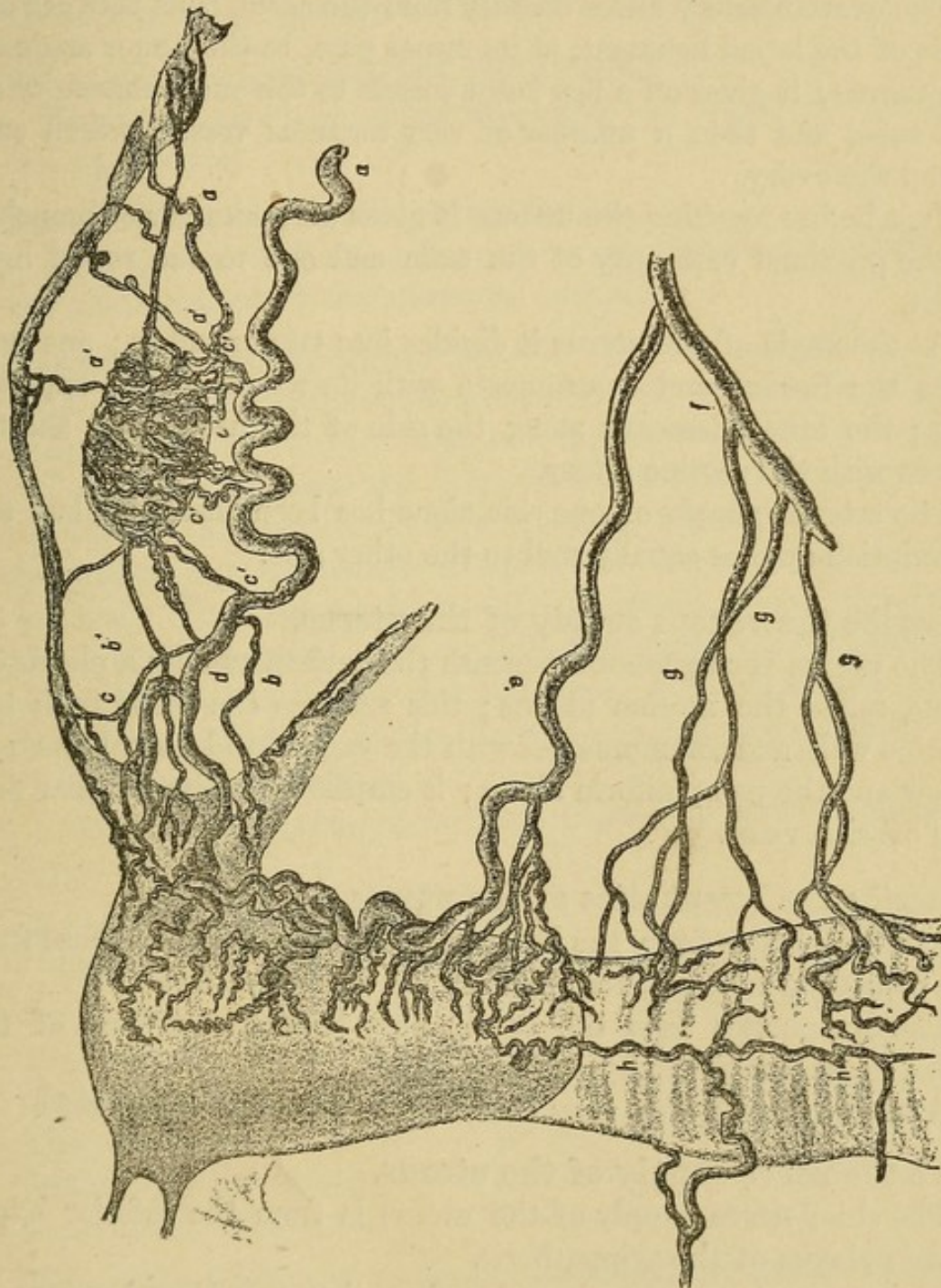
Describe the arterial supply of the uterus.

The uterus is supplied by the uterine and ovarian arteries, as seen by the accompanying figure. (Fig. 2.)

The uterine artery arises from the anterior division of the internal iliac, runs between the folds of the broad ligament to about the level of the os externum, and then turns upward along the side of the uterus to unite with the descending branch of the ovarian artery ;

it gives off numerous lateral branches to the uterus, anastomosing with those of the opposite side; these are very tortuous and are called the "curling arteries of the uterus."

FIG. 2.



Distribution of ovarian, uterine and vaginal arteries (*Hyrll*).
a, ovarian artery; *a'* and *b'*, branches to tube; *c'*, branches to ovary; *b*, branch to round ligament; *c*, branch to fundus; *d*, branch to join uterine artery; *e*, uterine artery; *f*, anterior branch of internal iliac; *g*, vaginal arteries; *h*, azygos artery of vagina.

Sometimes the vaginal artery springs directly from the uterine.

Opposite the internal os, the uterine artery gives off a branch which, uniting with its fellow of the opposite side, surrounds the cervix and is called "the circular artery."

The ovarian artery arises directly from the aorta, runs between the folds of the broad ligament, at its upper part, to the upper angle of the uterus; it gives off a few large vessels to the outer extremity of the tube, and then a number of very tortuous vessels which surround the ovary.

Just before reaching the uterus, it gives off a number of branches to the proximal extremity of the tube and one to the round ligament.

At the angle of the uterus it divides into two branches; one supplies the fundus and anastomoses with its fellow of the opposite side; the other descends along the side of the uterus and anastomoses with the uterine artery.

The arterial supply of one side alone has been described, but the description applies equally well to the other side.

Describe the venous supply of the uterus.

The uterus is surrounded beneath the peritoneum by a plexus of veins, called the uterine plexus; this receives the blood from the uterine walls and communicates with the vaginal and vesical plexuses below and the pampiniform above; it empties into the internal iliac and ovarian veins.

Describe the lymphatics of the uterus.

The lymphatics from the body of the uterus join with those from the ovary and tube and terminate in the lumbar glands.

The lymphatics from the cervix pass beneath the base of the broad ligaments to the hypogastric glands.

According to Le Bec, they terminate in the obturator glands.

Give the nerve supply of the uterus.

The chief nerve supply of the uterus is from the inferior hypogastric plexus of the sympathetic.

The cervix also receives branches from the upper sacral nerves.

What is the normal position of the uterus?

This question has been frequently discussed and at great length.

It is now sufficient for practical purposes to say that the uterus, when the pelvic organs are normal and when bladder and rectum are empty, lies slightly anteflexed and slightly anteverted; but the position is constantly changing with the degree of distention of the bladder and rectum, especially the former.

What are the ligaments of the uterus?

There are two utero-vesical ligaments, two round, two broad and two utero-sacral.

Describe the utero-vesical ligaments.

They are two folds of peritoneum passing between the bladder and the lower portion of the uterus on each side.

Describe the round ligaments.

They are two musculo-fibrous cords, 4-5 inches in length, which extend from the superior angles of the uterus, in the anterior folds of the broad ligaments and below the Fallopian tubes, forward and outward to the inguinal canal; thence through this canal where they terminate in three points of insertion: the external, middle and internal. The external blends with the outer pillar of the ring near Gimbernat's ligament. The middle terminates in the upper portion of the external ring. The internal unites with the conjoined tendon. Besides muscular and fibrous tissue, these ligaments contain areolar tissue, vessels and nerves.

They are of importance as being those shortened in Alexander's operation.

Describe the broad ligaments.

They are two folds of peritoneum which extend from the sides of the uterus to the wall of the pelvis, "along a line which is situated between the great sacro-sciatic notch and the margin of the obturator foramen as far down as the level of the ischial spine." The inner and greater part of its superior border, on each side, is occupied by the Fallopian tube; the part of the superior border not so occupied is called the infundibulo-pelvic ligament.

What two folds are made in the broad ligament in addition to that occupied by the Fallopian tube?

An anterior fold caused by the round ligament and a posterior fold caused by the ovarian ligament.

Describe the ovarian ligament.

It is a fibro-muscular cord about an inch in length, which connects the ovary with the side of the uterus, just below the entrance of the Fallopian tube. It lies in, and is surrounded by, the posterior fold of the broad ligament.

What are contained between the folds of the broad ligament on either side?

The round ligament, Fallopian tube, ovarian ligament, the paro-varium, cellular tissue, uterine and ovarian arteries, the pampiniform plexus and other veins, numerous lymphatics and nerves.

The ovary is attached to the anterior fold of the broad ligament and projects through the posterior fold.

Describe the utero-sacral ligaments.

They are folds of peritoneum containing muscular and cellular tissue, which extend from the lower part of the sides of the uterus, backward and outward to the second sacral vertebra.

What is the meaning of the term "uterine appendages," as usually employed?

The Fallopian tubes and ovaries.

Fallopian Tubes.**Describe them.**

They are two tubes 3-5 inches in length, which extend laterally from the superior angles of the uterus; they lie within the folds of the broad ligaments, and their direction is first outward, then forward, backward and inward toward the ovary.

They are divided for consideration into three portions: the isthmus, the ampulla and the fimbriated extremity.

The isthmus is the narrowest portion; it measures about an inch in length, and extends from the angle of the uterus directly outward, joining the ampulla; its lumen is only large enough to admit a fine bristle.

The ampulla is the curved, dilated portion of the tube; its lumen admitting an ordinary uterine sound.

The fimbriated extremity (infundibulum) is the expanded, funnel-shaped outer end, which is surrounded by fringe-like processes (fim-

briæ), both primary and secondary, the latter arising from the former, which are 4-5 in number. The longest of the primary fimbriæ lies to the inner side, is grooved, and is attached to the ovary; this is called the fimbria ovarica.

The tubes, on section, are seen to consist of four layers or coats; the peritoneal coat; two muscular coats, the outer being longitudinal, the inner circular; and a mucous coat.

There is no submucous layer.

The mucous membrane is thrown into longitudinal folds; the epithelium is columnar and ciliated.

Give the arterial supply of the Fallopian tubes.

The Fallopian tubes are supplied by the ovarian arteries, which send branches directly to the outer and inner portions of the tube and supply the middle third through branches from the plexus about the ovary.

Describe the veins, lymphatics and nerve supply of the Fallopian tubes.

The veins of the tubes enter the pampiniform plexus on either side.

The lymphatics join with those from the upper part of the uterus and from the ovary, and terminate in the lumbar glands.

The nerve supply is from the inferior hypogastric plexuses.

What is the supposed direction of the current in the motion of the ciliæ of the epithelium in the uterus and tubes?

In both cases toward the fundus; in the uterus, from below upward; in the tubes, from the fimbriated extremity toward the uterus.

Ovaries.

Give their gross anatomy.

The ovaries are two "flattened ovoid" bodies lying in the plane of the brim of the pelvis, on either side of the uterus. According to Coe, they are attached to the anterior folds of the broad ligaments, and project through the posterior. They are situated below the outer extremities of the tubes.

They present for consideration two borders, an anterior and pos-

terior; two surfaces, a superior and an inferior; and two extremities, an outer and an inner.

The anterior border is nearly straight; the posterior is convex.

The anterior border is called the hilum, and serves for the entrance of blood vessels and nerves.

The superior surface is nearly flat; the inferior is convex.

The outer extremity is broad and convex; the inner is narrow and tapers into the ovarian ligament.

An ovary averages about $1\frac{1}{2}$ inches in length, $\frac{3}{4}$ of an inch in breadth and $\frac{1}{2}$ an inch in thickness; it weighs about 87 grains.

Give the minute anatomy of the ovary.

The ovary, on section, is seen to consist of a medullary and cortical portion; the former being more vascular and of a softer consistency than the latter. The microscope shows connective tissue with numerous Graafian follicles scattered through it, blood vessels, lymphatics, nerves and unstriped muscular fibres.

The ovary is usually regarded as covered by a layer of short columnar epithelium, "germinal epithelium," from which the primitive ova are supposed to spring. (Tait, on the other hand, regards the ovary as entirely covered by peritoneum.)

The layer of "germinal epithelium" rests on a thin, dense musculo-fibrous layer, called the tunica albuginea.

The Graafian follicles are small vesicular bodies, more numerous and smaller in the cortex than in the medulla, with the exception of a few which have matured and have approached the surface of the ovary from the medulla.

Foulis estimates that at birth each human ovary contains not less than 30,000 Graafian follicles (Playfair).

Give the structure of a Graafian follicle.

On examining a Graafian follicle from without inward, we find the following structures see (Fig. 3):—

The *tunica fibrosa*, which is highly vascular; within this the *tunica propria*, of more condensed connective tissue; within this is the *membrana granulosa*, a layer of columnar epithelium which encloses the *liquor folliculi*; at one side there is a cellular eminence called the *discus proligerus*, which encloses the ovum. The outer covering of the ovum is the *vitelline membrane*, or *zona pellucida*,

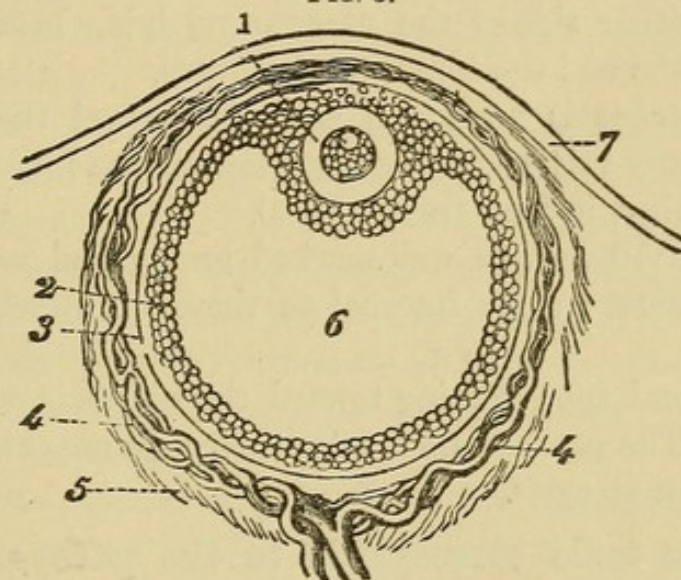
surrounding the *vitellus* or *yellc.* At one point of the latter is seen the *germinal vesicle*, and within this the *germinal spot*. A Graafian follicle measures from $\frac{1}{100}$ to $\frac{1}{20}$ inch in diameter ; a germinal spot not over $\frac{1}{3000}$ inch.

Give the arterial and venous supply of the ovaries.

The ovaries are supplied by the ovarian arteries, which arise directly from the aorta.

The veins of the ovary emerge at the hilum and enter the collection of veins called the "bulb of the ovary." This communicates with the veins from the Fallopian tube and upper portion of the

FIG. 3.



Diagrammatic Section of Graafian Follicle.

- 1. Ovum. 2. Membrana granulosa. 3. External membrane of Graafian follicle.
- 4. Its vessels. 5. Ovarian stroma. 6. Cavity of Graafian follicle. 7. External covering of ovary.

uterus, forming a collection called the pampiniform or ovarian plexus ; from this springs the ovarian vein, which, on the right side, terminates in the inferior vena cava, on the left side, in the left renal vein. The left ovarian vein has no valve at its termination. Some apply the term pampiniform plexus to all the veins in the broad ligament.

Give the lymphatics and nerve supply of the ovary.

The lymphatics join with those from the tube and upper portion of the uterus and terminate in the lumbar glands. The nerve supply is from the inferior hypogastric plexus.

What is the position of the long axis of the ovary?

This question has been much discussed. The long axis of the ovary may be regarded as lying a little obliquely to the transverse axis of the pelvis, and with a direction slightly backward. His describes the long axis as vertical, but this does not coincide with the results of autopsies where the pelvic contents have been normal.

Parovarium.**Describe it.**

The parovarium, which is the remains of the Wolffian body, consists of a series of tubes situated between the folds of the broad ligament, on either side of the uterus, and lying between the ampulla of the tube and the hilum of the ovary.

One of the tubes is horizontal and runs toward the uterus; the others are nearly vertical, converging toward the hilum; they vary greatly in number, in fact, from 6 to 30.

The outer 6-10 have a well-marked lumen and are lined with ciliated epithelium; those internal to these are merely fine fibrous cords.

The horizontal tube running toward the uterus is called the duct of Gärtner. The parovarium is of pathological importance, as occasionally the seat of cysts.

What in the male corresponds to the parovarium in the female?

The epididymis.

Urinary Tract.**Describe the urethra.**

The female urethra is a musculo-membranous canal about $1\frac{3}{8}$ inches in length, imbedded in the anterior vaginal wall, and extending from the vestibule to the neck of the bladder; it runs upward and backward, "parallel with the plane of the pelvic brim."

It consists of three coats; the outer two being muscular, the inner, mucous membrane.

Of the muscular coats, the outer is circular, the inner longitudinal. The mucous membrane in the lower portion of the canal is covered with squamous epithelium, while higher up the epithelium is transitional, like that of the bladder.

The meatus urinarius, the outer extremity of the urethra, is situated in the median line at the base of the vestibule.

Describe Skene's tubules.

Just within the meatus, on each side, are the openings of Skene's tubules, which he describes as lying near the floor of the urethra, just beneath the mucous membrane, and extending parallel to the canal about three-fourths of an inch. Their function is unknown.

Bladder.

Describe it.

The bladder is a hollow musculo-membranous organ, situated in the pelvis "between the symphysis pubis in front and the vagina and uterus behind."

The bladder presents for consideration a body, a base or fundus, and a neck. The body is all that portion above the lines joining the ureteric openings and the centre of the symphysis pubis.

All below these lines is the base or fundus. The portion of the fundus between the urethral and ureteric orifices is the trigone.

The constricted portion continuous with the urethra is the neck.

The wall of the bladder consists of three coats: a peritoneal, a muscular and a mucous.

The peritoneal coat is found only on the summit of the bladder and on the upper part of the posterior surface. The muscular coat consists of two layers: an outer longitudinal and an inner circular; the latter being most marked around the urethral orifice.

The mucous membrane consists of several layers of transitional epithelium resting on a membrana propria; the superficial cells are squamous.

The mucous membrane is thrown into numerous folds, except at the trigone, where it is more closely connected with the underlying tissue.

The mucous membrane is supported by a submucous layer of fibrous and elastic tissue, containing blood vessels, lymphatics and nerves.

What is the arterial supply of the bladder and urethra?

The bladder receives its arterial supply from the superior, middle and inferior vesical, and from branches of the uterine and vaginal arteries.

They are all derived from the anterior division of the internal iliac.

The urethra is supplied by branches from the vaginal arteries.

What is the venous supply of the bladder and urethra ?

“The veins form a complicated plexus round the neck, sides and base of the bladder.” (Gray.)

This is called the vesical plexus ; it lies external to the muscular coat and terminates in the internal iliac vein.

The urethra is surrounded by a venous plexus which communicates with the vaginal plexus.

Give the lymphatic and nerve supply of the bladder and urethra.

The lymphatics of the bladder and urethra empty into the hypogastric glands. Their nerve supply is derived from the inferior hypogastric plexuses of the sympathetic system, and from the 3d and 4th sacral nerves of the cerebro-spinal system.

What are the principal venous plexuses of the pelvis ?

The vaginal plexuses.

The vesical plexus.

The hemorrhoidal plexus.

The uterine plexus.

The pampiniform, or ovarian plexus.

The bulb of the ovary.

Describe the course of the ureters in the pelvis.

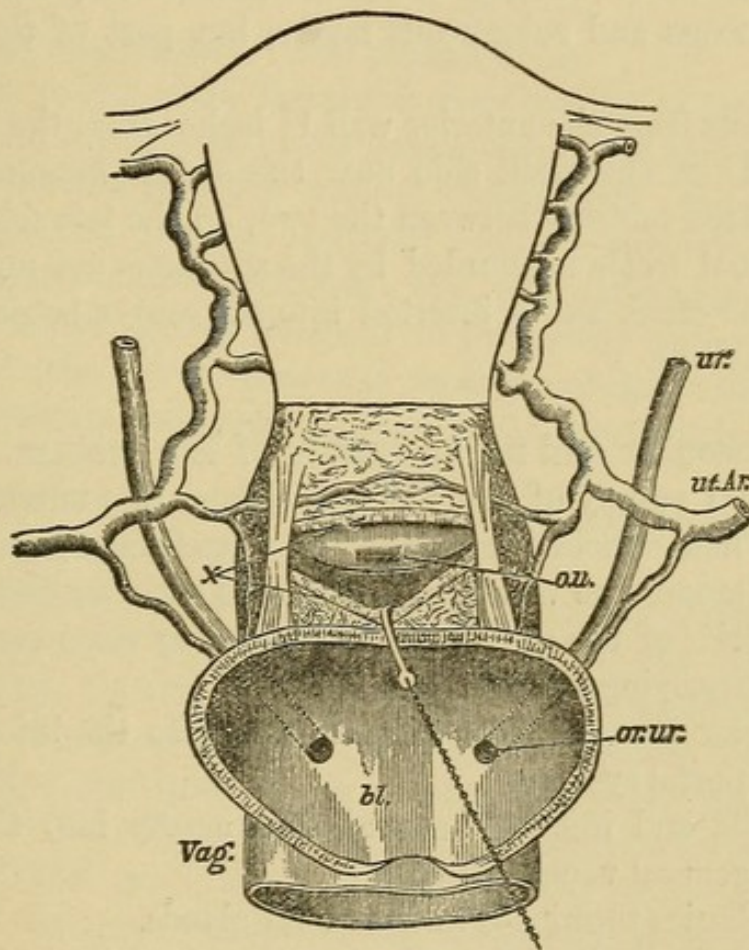
The ureters cross the external iliacs just beyond the bifurcation of the common iliacs ; they then pass downward and outward along the lateral walls of the pelvis, enter the broad ligaments and run forward and inward. At the level of the internal os they are crossed by the uterine arteries (see Fig. 4), and are there situated about half an inch from the uterus. They pass alongside of the vagina a little way, converge still more, enter the vesico-vaginal septum and pierce the bladder a little above the middle of the anterior vaginal wall ; they are here separated two inches from each other and one-half to three-fourths of an inch from the cervix.

Rectum.

Describe.

The rectum is the lower extremity of the large intestine, about 8 inches in length, extending from near the left sacro-iliac synchondrosis to terminate in the anus between the coccyx and perineum.

FIG. 4.



Drawing from a dissection made to show relations of ureters, uterine arteries, bladder, etc. (J. Greig Smith.)

ur., ureter; *ut.Ar.*, uterine artery; *ou.*, os uteri exposed by an incision, *x*, made through the top of the vagina; *bl.*, bladder, the walls of which are cut down to the insertion of the ureters into its base, *Vag.*, vagina.

It presents three curves :—

1. Downward, backward and inward to the 3d sacral vertebra.
2. Forward to the apex of the perineum.
3. Backward to the anus.

The rectum is invested by peritoneum at its upper part.

It consists of a mucous and a submucous layer and two muscular layers—a longitudinal and a circular, the former being external.

The mucous membrane is covered with columnar epithelium and contains numerous follicles of Lieberkühn.

At its lower portion the mucous membrane is thrown into perpendicular folds called columns of Morgagni; the depressions between them being called the sinuses of Morgagni.

There are three oblique folds of importance, including not only the mucous and submucous layers, but part of the muscular coat.

One projects from the anterior wall $1\frac{1}{2}$ inches from the anus.

Another is on the right side near the sacral promontory, and a third is situated midway between the two, on the left side.

The external orifice is guarded by the sphincter ani muscle which surrounds the canal, and is inserted into the coccyx behind and the perineum in front.

Give the vascular and nerve supply of the rectum.

The arterial supply of the rectum is from the superior, middle and inferior hemorrhoidal arteries. The veins form a plexus beneath the mucous membrane which communicates with another surrounding the exterior of the canal; from this spring veins corresponding to and accompanying the arteries.

The superior hemorrhoidal vein empties into the inferior mesenteric of the portal system.

The middle and inferior hemorrhoidal empty into the internal iliac of the general venous system.

The lymphatics terminate in the sacral glands.

The nerves are derived from the hypogastric and sacral plexuses.

Give the relations of the rectum.

At its upper portion the rectum is surrounded by peritoneum and lies in direct relation anteriorly with the cul-de-sac of Douglas.

At about 3 inches from the anus the peritoneum leaves the rectum, which then lies loosely attached to the posterior wall of the vagina for $1\frac{1}{2}$ inches.

The remainder is separated from the vagina by the perineal body.

Posteriorly, the rectum is connected at its upper part by the meso-

rectum to the sacrum ; at its lower part by fibrous tissue to the sacrum and coccyx.

On each side it receives the insertion of the levatores ani and is surrounded below by the sphincter ani.

Pelvic Floor.

Describe the segments of the pelvic floor.

According to Dr. Hart, the pelvic floor consists of two segments : the pubic and sacral ; the *pubic* consisting of the bladder, urethra, bladder peritoneum and the anterior vaginal wall ; the *sacral* comprising the rectum, perineal body and posterior vaginal wall.

According to the same authority, also, the pubic segment is made up of loose tissue, loosely attached to the pubes, and is drawn up during labor ; the sacral segment is made up of dense tissue, closely attached to sacrum and coccyx, and is driven down during labor.

Describe the muscles and fascia of the pelvic floor, as dissected from above.

On examining the pelvic floor from above, we find the pelvic fascia attached laterally to the brim of the pelvis, to the spine of the ischium behind, to the lower portion of the symphysis pubis in front, and to a tendinous band—"white line"—joining the two latter points. Behind the spine of the ischium the pelvic fascia is continuous with a thin layer covering the pyriformis muscle. At the "white line" the pelvic fascia divides into the recto-vesical fascia, which covers the upper surface of the levator ani muscles, and the obturator fascia, covering the obturator muscles. The recto-vesical fascia arising from the "white line" extends downward and inward, and unites in the median line with its fellow of the opposite side. This forms a fascial diaphragm which is perforated by the rectum and vagina, to each of which it is firmly attached and furnishes a sheath from that point downward. The bladder and rectum also receive ligaments from this fascia.

On removing this fascial diaphragm, we meet with a muscular diaphragm formed by the levator ani and coccygeus muscle of each side meeting in the median line.

The coccygei arise from the ischial spines, and are attached to the sides of the lower segment of the sacrum and to the sides and anterior surface of the coccyx.

The levatores ani arise from the posterior aspect of the pubes, from the spine of the ischium and from the "white line" of the pelvic fascia connecting these points. They extend downward and inward and are attached to the vagina, the rectum, to each other and to the tip of the coccyx. This muscular diaphragm surrounds both vagina and rectum.

The under surface of this muscular diaphragm is covered by a thin layer of fascia which is attached on each side to the obturator fascia. On removing the muscular diaphragm with its upper and lower fascia, there remains, filling the pelvic outlet, the perineal body, the muscles of the perineum and the ischio-rectal fossa.

Perineal Body.

Describe.

The perineal body is a mass of muscular, fibrous and adipose tissue, somewhat pyramidal in shape, lying between the lower ends of the vagina and rectum; it measures $1\frac{1}{2}$ inches in height, $1\frac{1}{2}$ inches in breadth and $\frac{3}{4}$ inch antero-posteriorly. Its base is covered by skin which is sometimes wrongly spoken of as "the perineum," which should always refer to the perineal body.

The muscles which are attached to the perineal body are the bulbo-cavernosi, transversi perinei, sphincter and levatores ani.

Give the vascular and nerve supply of the perineal body.

The arterial supply of the perineal body is from the internal pudics.

The veins terminate in the pudic veins.

The lymphatics end in the inguinal glands.

The nerve supply is from the pudic nerve.

What are the functions of the perineal body?

1. To prevent vaginal rectocele.
2. To help form a compact pelvic floor.
3. To serve as a fixed point for muscular attachment.

Muscles of the Perineum.

Name and describe them.

On each side of the vaginal orifice we find three muscles : bulbo-cavernosus, ischio-cavernosus or erector clitoridis, and the transversus perinei.

The bulbo-cavernosus arises from the perineal body on each side of the vagina, with its fellow encircles the vaginal bulbs and vestibule, and divides into three slips ; one going to the posterior surface of the bulb, another to the under surface of the corpus cavernosum of the clitoris, and the third to the mucous membrane of the vestibule.

The bulbo-cavernosi compress the bulbs of the vagina.

The transversus perinei arises from the ramus of the ischium and is lost in the perineal body.

The ischio-cavernosus or erector clitoridis, arises from the front of the tuberosity of the ischium and is inserted into the crus clitoridis.

These muscles are supplied by the internal pudic artery and by branches of the pudic nerve.

The veins enter the pudic veins.

The lymphatics terminate in the inguinal glands.

Ischio-rectal Fossa.

Give its gross anatomy.

It is a pyramidal-shaped area, largely filled with fat, situated on either side of the rectum ; the sides are formed by the obturator internus without and the levator ani within ; the base by the transversus perinei and the lower edge of the gluteus maximus.

Describe the fascia covering the pelvic floor below.

From without inward we find the superficial fascia in two layers, the external being continuous with the general superficial fascia of the body. The deep layer is attached to the border of the pubic arch in front and laterally ; posteriorly, it passes around the transversus perinei muscles and is attached to the base of the anterior layer of the triangular ligament.

Beneath the perineal muscles we find the triangular ligament, consisting of two layers of fascia, the anterior and posterior, filling in the pubic arch.

Development of the Pelvic Organs.

Describe briefly.

In the latter part of the first month there appear in the foetus, on either side of the primitive vertebræ, the Wolffian bodies, which play the part of temporary kidneys. They soon wither, and by the end of the 3d month have largely disappeared, but their remains persist, in the female, in the parovarium and Gaertner's duct. At the inner side of the Wolffian bodies there appears an invagination of the germ epithelium; this develops into the duct of Mueller, one for each Wolffian body. These coalesce below to form the uterus and vagina.

The ovary first appears as a white ridge on the inner side of the Wolffian body; this ridge being formed of connective tissue covered with germ epithelium; from the former is developed the stroma of the ovary, and from the latter are formed the Graafian follicles and ova.

Until the latter part of the second month of foetal life the urinary, genital and intestinal canals open into a common vault—the cloaca. At about the 6th–7th week this common opening is divided into the anal opening posteriorly and the uro-genital anteriorly. This separation is completed by the formation of the perineal body at about the tenth week.

The uro-genital canal is later divided into the urethra anteriorly and the vagina posteriorly.

Physical Examination of the Female Pelvic Organs.

What are the methods of examination?

I. Non-instrumental. II. Instrumental.

I. Non-instrumental.

- a.* Inspection of external genitals; only when especially indicated.
- b.* External abdominal examination.
- c.* Vaginal examination.
- d.* Bimanual examination, with its modifications.
- e.* Rectal examination.

What should you notice on inspection of the external genitals?

1. Notice whether or not the vulva is the seat of venereal sores warts, abscesses, pediculi, etc.

2. Separate labia and notice condition of hymen and perineum, whether intact or lacerated; the shape of hymen if intact. If perineum lacerated, notice whether through the sphincter ani or not; notice, also, condition of urethra.

3. Tell patient to strain, and with labia still separated, notice whether anterior or posterior vaginal walls prolapse or not, thus forming cystocele or rectocele.

What are the principal elements in a complete external abdominal examination?

1. Position and Preparation of patient.—Patient should be on back with knees drawn up; the abdomen should be uncovered as low down as the pubes; the latter not being exposed; bladder and rectum should be empty.

2. Inspection.—Observe the form and color; notice whether irregularities in form are present or not.

3. Palpation.—Use both hands; they should be warm; use the palms and palmar surface of fingers rather than their tips; employ very little force. If a tumor is present, notice whether it is solid or fluctuating, whether fixed or mobile; if possible, determine whether or not it is attached to one of the pelvic organs. *or abdominal*

Notice whether it pulsates or is the seat of intermittent contractions. *(preg. or fibroid)*

Palpate inguinal regions for enlarged glands or herniæ. *thrombosis*

4. Percussion.—Patient should be first percussed in usual manner while lying on back and then when turned on either side.

5. *Auscultation*

Vaginal Examination.

Describe the method of performing it.

Have the patient on back; knees drawn up; if a married woman, employ two fingers, if unmarried, use one.

Have the examining finger or fingers well lubricated and folded into the palm until you approach the vulva; then let them sweep over the perineum and fourchette between the labia till they enter

the vaginal orifice. Do not pass from above downward over the clitoris. After entering the vagina pass the finger or fingers backward toward the hollow of the sacrum.

What are the contraindications to a vaginal examination?

A vaginal examination should not be made in an unmarried woman unless there are strong reasons for suspecting trouble with the pelvic organs, and then only in the presence of a relative or female friend.

It should not be made during a normal menstruation.

What is the value of a vaginal examination per se?

The value of a vaginal examination by itself is comparatively small; and it is rarely employed save as a part of a bimanual examination.

One can, however, determine the following points by a vaginal examination, and they should be carefully noted:—

The condition of perineum and vaginal orifice.

Presence or absence of Painful Spots;

Spasm;

Enlargement of vulvo-vaginal glands; etc.

Condition of vaginal walls:—

Heat;

Moisture;

Presence or absence of

Rugæ;

New growths;

Fistulæ; etc.

Projections of vaginal walls from

Fæces in rectum;

Inflammatory deposits;

Tumors in the peritoneal pouches.

Condition of cervix:—

Position;

Shape;

Size;

Density;

Mobility;

Lacerated or not.

Condition of os :—

Size ;
Shape ;
Projections through it.

Bimanual Examination.

What is the method of performing it?

The position of the patient and the method of introducing fingers are the same as for the vaginal examination just described. As regards which hand shall be used internally, the right is usually employed first ; but to make a complete bimanual, it is best to employ internally the right hand for the right side of the pelvis, and the left hand for the left ; in this way the palmar surfaces of the internal and external fingers are approximated, and any departure from the normal, on either side, is better mapped out than when the right hand alone is used for the internal examination.

Describe the use of the external hand in the bimanual.

The ulnar surface of the external hand should be used rather than the palm ; it should be applied to the abdomen a little above the pubes and steadily depressed toward the opposing fingers within the vagina, while the patient relaxes her abdominal muscles and breathes quietly, with mouth open.

Describe the use of the internal examining fingers in the bimanual.

While the ring and little fingers are strongly flexed into the palm and the thumb lies on the pubes or between the thighs, place the middle examining finger on the cervix and the index in the anterior fornix and raise the uterus toward the external hand. The first step for the student in acquiring skill in the bimanual is to feel, through the abdominal wall, a body which transmits motion from the external hand to the finger on the cervix. This, in a normal case, is the fundus of the uterus ; future examinations will enable one to map out more and more the shape of the fundus.

What is a good order to follow in making a bimanual examination?

1. Determine the position of the uterus by attempting to approxi-

mate external and internal fingers ; the internal being placed first on cervix, then in anterior fornix and then in posterior ; the external hand exerting counter pressure.

2. Determine condition of tubes, ovaries and parametria ; using right hand internally for right side of the pelvis and left for left.

Should you normally feel a hard body in any of the four fornices of the vagina ? If so, which one, and what is it ?

Yes, in the anterior fornix ; the body of the uterus.

Should you normally feel a hard body in the posterior or either of the lateral fornices ?

No.

What mass might you feel in the anterior fornix ?

1. A fibroid on anterior wall of the uterus.
2. Inflammatory or blood effusions, rarely.

What mass might you feel in either of the lateral fornices ?

Inflammatory deposit from cellulitis or peritonitis.

Blood effusion.

Enlarged tube or ovary.

Body of uterus latero-flexed.

Lateral fibroid.

What mass might you feel in posterior fornix ?

Displaced fundus.

Fæces in rectum.

Fibroid on wall of uterus.

Peritonic or cellulitic deposit.

Hæmatocele.

Displaced ovary.

Tumor.

Rectal Examination.

What are the methods ?

1. Simple rectal.
2. Abdomino-rectal.
3. Simon's method.

What are the preliminaries to any rectal examination ?

Have bowels empty.

Tell patient what you are to do.

Have soap under finger-nail.

Lubricate finger.

How would you perform the simple rectal examination?

Having observed the preceding preliminaries, pass the finger forward, noting the presence or absence of hemorrhoids, fissures, polypi, stricture, etc., till the cervix is felt, then pass along posterior wall of the uterus.

How would you perform the abdomino-rectal examination?

Passing the right index finger into the rectum as just described, use the left hand externally, placed on the abdomen as in the ordinary bimanual.

What is Simon's method?

This consists in passing the whole hand, shaped like a cone, gradually through the anus into the rectum.

What is the value of the different methods of rectal examination?

Both the simple rectal and abdomino-rectal are of especial value in virgins, where the ordinary bimanual is painful or objected to.

By means of a volsella forceps you may draw down the cervix, and then, with finger in the rectum, palpate the posterior surface of uterus, tubes and ovaries.

The above methods of rectal examination are of value in any case where you wish to reach higher than is possible with the ordinary bimanual.

Advantage is sometimes gained by making the rectal examination with patient in Sims' position.

Simon's method is dangerous and seldom justifiable.

INSTRUMENTS.

Specula.

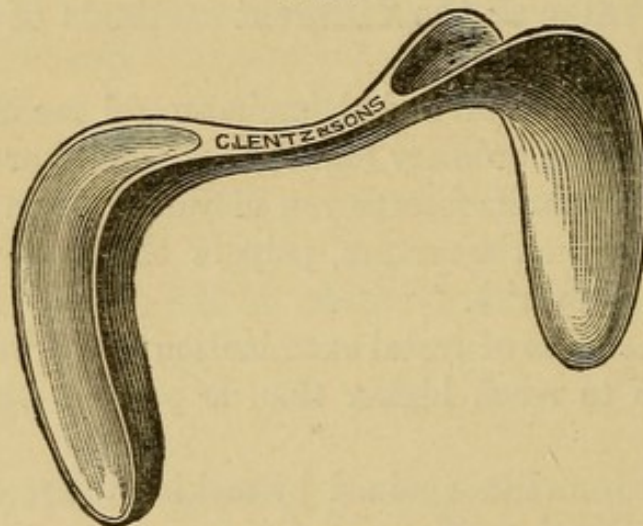
What are the three classes of specula in most common use?

1. The Spatular. *Sims*
2. The Cylindrical. *Tubular - Ferguson*
3. The Bivalve. -

Give one of the best examples of the spatular variety; describe it.

The Sims speculum (see Fig. 5) is the best example of this class; it consists of two blades united by a handle at right angles to them,

FIG. 5.



Sims' Speculum.

the blades being convex on the sides facing each other, concave on the opposite. Many modifications are made by which the length of blade, angle at which it joins the shaft, and weight of the whole instrument are altered. One blade of the Sims speculum is usually made shorter and smaller than the other.

What are the advantages of Sims' speculum?

It does not distort cervix.

It gives a good view of all but the posterior vaginal wall, and is the best suited for operations on cervix and anterior vaginal wall.

What are the disadvantages of Sims' speculum ?

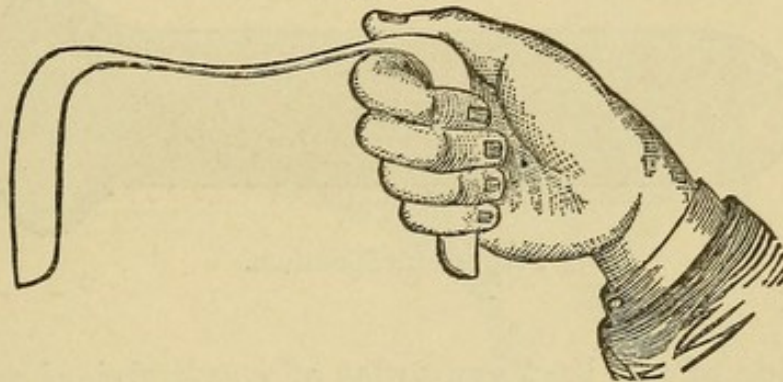
It requires an assistant with some training to hold it.

It requires, in most cases, the use of a vaginal depressor, thus employing one hand.

What is the proper position of the patient for the use of Sims' speculum ?

A patient in the so-called "Sims position" should lie on her left side, with left buttock on the left corner of the table, as you face it; the head being at the right corner of the head of the table, the left arm behind the patient; the right arm should lie over the right edge of the table, the right shoulder being kept as near the table as

FIG. 6.



possible. The knees should be drawn up, the right a little above the left.

How would you introduce a Sims speculum ?

Having placed the patient in the correct Sims position, select the blade you are to use; warm and lubricate the convex side of it; take the speculum in the right hand with the index finger lying in the concavity of the blade, and introduce finger and blade together. The breadth of the blade should be in line with the labia until it has entered the vaginal orifice; it should then be rotated till the convexity lies in apposition with the posterior vaginal wall, which it should hug closely till the posterior fornix is reached and the index finger detects the cervix in front of it; the speculum is then given to an assistant to hold. Some introduce the finger first and pass the blade along it.

How would you hold a Sims speculum ?

There are two methods in common use :—

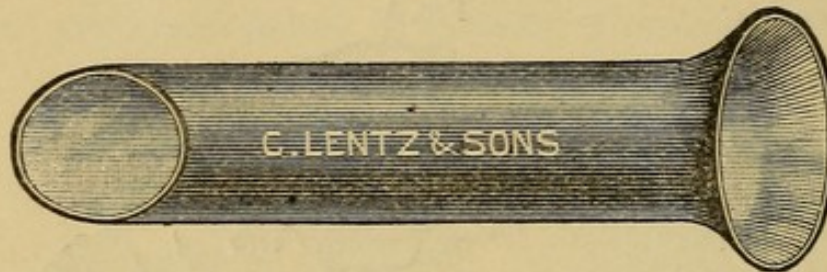(a) One is to grasp the outside blade with the right hand, the angle between blade and handle fitting over index finger, as seen in Fig. 6 ; the thumb lying in the concavity of the blade over the angle.

The right buttock should be raised with the left hand.

(b) The other method is to grasp the handle of the speculum with the right hand, having the convexity of the outside blade rest in the hollow between the thumb and index finger.

The right buttock being raised as in the other method.

FIG. 7.



Fergusson's Speculum.

**What is one of the best examples of a cylindrical speculum ?
Describe it.**

The cylindrical speculum of Fergusson (see Fig. 7) is probably the best of its class ; it is a cylinder of glass or hard rubber, with one extremity beveled and the other trumpet-shaped.

The glass ones usually present a mirrored surface from within.

The beveled extremity is the one first introduced.

What are the merits of the Fergusson speculum ?

It is of very limited use ; it may be employed for inspecting the cervix or making applications to it. It is useless for operations on the cervix ; it is only partially self-retaining, and its introduction in nulliparæ is painful.

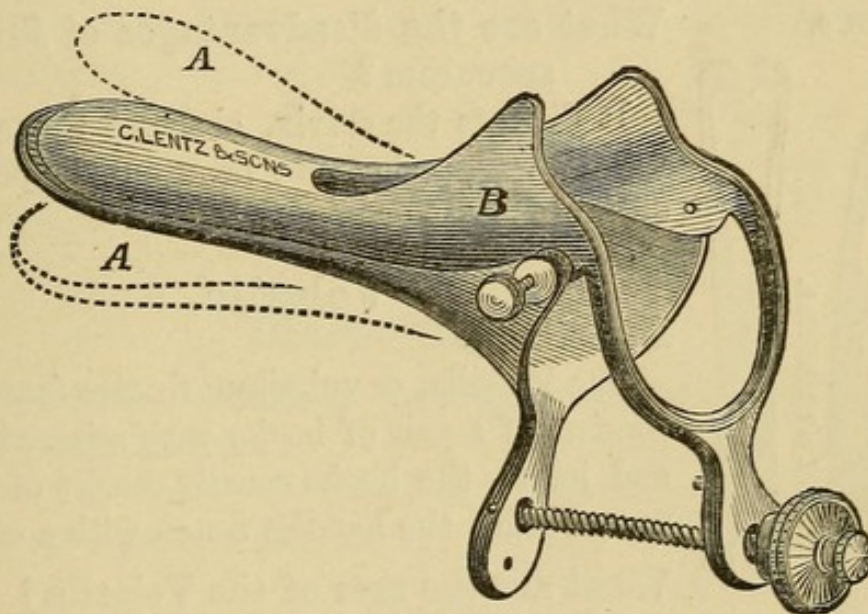
How would you introduce a Fergusson speculum ?

In this country the Fergusson speculum is usually employed with the patient in the dorsal position.

Separate the labia with the fingers of the left hand ; holding the trumpet-shaped extremity with the right hand, introduce the beveled extremity into the vaginal orifice having the shorter side anterior ; depress well the perineum, directing the speculum toward the hollow of the sacrum ; by slight vertical, horizontal or rotatory motion of the speculum while looking into it, the cervix is now usually brought into view without difficulty. It is occasionally convenient to draw the cervix more fully into view by means of a tenaculum.

Some gynæcologists use the Fergusson speculum with the patient in Sims' position.

FIG. 8.



Brewer's Speculum.

**What is one of the best examples of a bivalve speculum?
Describe it.**

The Brewer bivalve (see Fig. 8) is probably the best speculum of its class ; it consists of two blades, the outer extremities being trumpet-shaped where they are jointed ; the anterior blade is shorter than the posterior, and has a slot in its outer half, to avoid pressure on the urethra ; this also facilitates the introduction of the sound or probe. The speculum is opened by approximating the handles of the blades and held there by a thumb-screw. There are two sizes of Brewer's speculum, the long and short.

How would you introduce a Brewer speculum ?

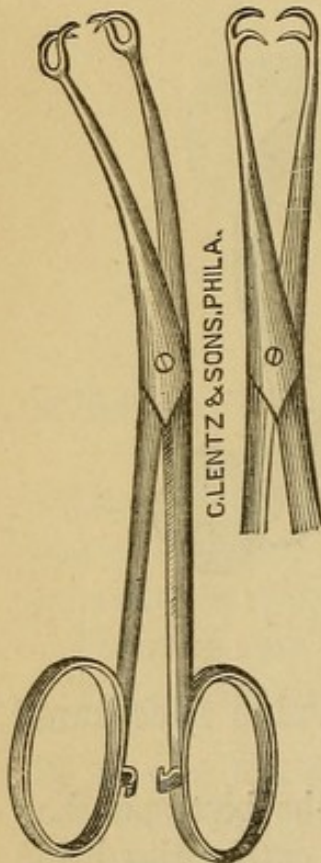
Place patient in dorsal position ; pass speculum into vaginal orifice with the blades lateral, then rotate till they are antero-posterior ; begin to open blades just before they reach the cervix ; when completely open, hold with thumb-screw.

What are the merits of Brewer's speculum ?

For inspection of, and applications to, the cervix, it is very valuable ; it is self-retaining, thus obviating the necessity of an assistant.

The long instrument is better than the short, as with it the vaginal walls are not as likely to obstruct the view by falling in beyond the blades, and at the same time it accomplishes all that the short instrument does.

FIG. 9.



The Volsella.

What are the disadvantages of Brewer's speculum ?

It distorts the cervix, obscures the anterior vaginal wall, and cannot be used for operations on the cervix or vagina.

Volsella.**Describe it.**

The Volsella, or vulsellum forceps (see Fig. 9) consists of a pair of hooks with scissor handles and joint ; the hooks usually consist of two or more teeth ; the handles fasten with a catch.

What are the uses of the Volsella ?

In all operations on the cervix, trachelorrhaphy, dilatation, etc., the volsella, or one of its substitutes, is almost indispensable, to draw down and hold the cervix.

For applications to, or operations on, the interior of the body of the uterus, the volsella is also of great value.

The use of the volsella to draw down the cervix, in connection with the finger in the rectum, in the combined rectal examination, is of great importance. *Uterus lies behind pubis.*

How would you introduce and apply the Volsella ?

The position for most operations on the cervix is the Sims position,

Contra-indicated - acute peritonitis - cellulitis - distended Fal. tubes, haematocoele, advanced cancer - Should cause no pain

consequently the volsella is most often used in this position. It may be introduced either without or with the use of the speculum; if without the speculum, the first two fingers of the right hand are introduced till the anterior lip of the cervix is felt; the volsella is then passed along them and applied to the anterior lip, which is then drawn down.

The better way is usually to employ Sims' speculum and apply the volsella directly to the anterior lip by sight.

The volsella is occasionally employed with patient in the dorsal position, the instrument being introduced either by touch, or sight aided by a speculum.

What could you substitute for a Volsella?

The U. S. bullet forceps, having only one pair of teeth, may often be substituted for a volsella.


A tenaculum, such as Sims', which is a sharp hook on a long slender shank, is often of great use in holding the cervix and drawing it in any direction, and can sometimes be substituted for a volsella.

Uterine Sound.

What are the two sounds in most general use? their description and merits?

The Sir J. Y. Simpson's sound and that of A. R. Simpson are the two in most general use.

FIG. 10.



Sir J. Y. Simpson's Sound.

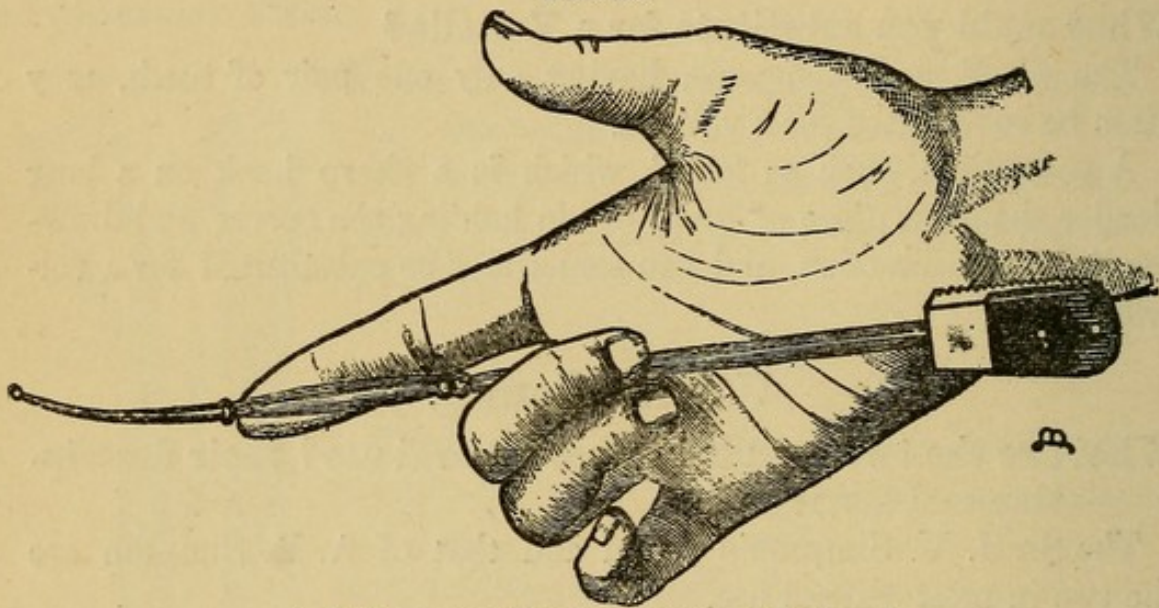
They are both rods of copper, nickel-plated, and so pliable that they can easily be bent with the fingers.

The sound of Sir J. Y. Simpson (see Fig. 10) is 12 inches long, with a notched knob $2\frac{1}{2}$ inches from the end, and notches at $3\frac{1}{2}$, $4\frac{1}{2}$, etc., up to $8\frac{1}{2}$ inches, *$2\frac{1}{2}$ " normal length of uterus -*

The handle is roughened on the side of the concavity of the curve.

The sound of A. R. Simpson (see Fig. 11) is only 9 inches long; it has a prominent ring at $2\frac{1}{2}$ inches and two rings at $4\frac{1}{2}$ inches; there are also markings at $3\frac{1}{2}$ and $5\frac{1}{2}$ inches. This sound has an advantage over the preceding in that, being only 9 inches long, the handle, which is broad, can rest firmly on the ball of the little finger even when the tip of the index finger is on the $2\frac{1}{2}$ inch ring, thus giving one a complete control of the instrument when the finger is in the vagina with the sound. This is impossible with the sound of

FIG. 11.



A. R. Simpson's Sound. (Hart and Barbour.)

Sir J. Y. Simpson, as in similar circumstances the handle is far above the hand, and one can only grasp the shank, which readily rotates. The presence of the double ring is also an advantage in an enlarged uterus.

What are the contraindications to the use of the sound?

Patient has skipped a menstrual period.

Menstruation present.

Acute inflammation present in uterus or neighborhood.

Malignant disease of uterus.

What are the preliminaries to the use of the sound?

1. Be sure that the patient has not skipped a menstrual period.
2. Determine position of uterus by a careful examination.

Bimanual - if in doubt rectal

3. Curve sound to the curve of the uterus.

4. Cleanse the vagina with an antiseptic solution. This is of importance to avoid carrying septic material from vagina to uterus by the sound. For this reason it is often wiser to introduce the sound with the aid of a speculum which separates the vaginal walls and enables you to reach the os directly.

5. Position of the patient :—

This is largely a matter of choice, but in this country the dorsal position is usually selected, and it has the advantage that in this position the bimanual may be easily combined with the use of the sound.

How would you introduce the sound with patient in the dorsal position ?

Having observed the preliminaries just mentioned, introduce the index finger of the left hand until it reaches the anterior lip of the cervix, then along the finger as a guide, pass the sound with the concavity backward until it thoroughly engages in the cervix ; then, if the fundus lies forward, turn the sound, not by rotating the shank, but by making the handle describe a semicircle from behind, to the left and forward ; the point of the instrument remaining nearly stationary. By depressing the handle toward the perineum, the sound will then usually pass without trouble. If the point catches in the crypts of the cervix, slight motion will usually disengage it.

What variation in this procedure would you make if the fundus lay posteriorly ?

Having introduced the sound into the cervix as before, with concavity backward, continue the introduction without the semicircular motion of the handle.

When the fundus lies forward, the sound is often introduced by placing the left index-finger on the posterior lip of the cervix and then passing the sound along this with concavity forward, continuing the introduction into the uterus without reversing the curve.

If the fundus lies backward, this method necessitates the semicircular motion of the handle in the opposite direction—from before, to the left, backward.

**How would you pass the sound in a marked case of ante-
flexion?**

If the uterus is anteflexed, the introduction of the sound is facilitated by curving the sound sharply, drawing down the cervix with a volsella and pushing up the fundus with the finger in the anterior fornix.

How would you introduce the sound with patient in Sims' position?

Having observed the preliminaries, introduce right index-finger till it touches anterior lip of the cervix; pass sound, held in left hand, along it with concavity backward till it engages well in the cervical canal, then make handle describe a semicircle from the perineum upward past the right buttock, down toward pubes, then continue the introduction.

If the uterus lies posterior, the semicircular motion of the handle is unnecessary.

When uterus lies to the front, the sound is sometimes introduced by passing the first two fingers of left hand till they touch the posterior lip of the cervix, and then introducing sound directly with the concavity forward.

What are the uses of the uterine sound?

- (a) To determine—
1. The length of uterine canal.
 2. Its permeability. *mobility.*
 3. Its direction.
 4. Condition of endometrium.
 5. Growths in uterus.
 6. Relation of uterus to tumors.

(b) To replace a displaced uterus. *application of sounds to endomet.*
The mobility of the uterus and the relation of cervix and body should be determined by the bimanual, not by the sound.

What are the dangers in the use of the sound?

1. Pelvic peritonitis or cellulitis, from introduction of sepsis.
2. Abortion.
3. Hemorrhage, especially in malignant disease.
4. Perforation of uterine walls.

Uterine Probe.

Give its description and uses.

The uterine probe is usually a slimmer instrument than the sound, made of silver, hard rubber or whalebone, with end slightly bulbous. Except in cases of stenosis, it is harder to introduce than the sound, and of less general value. It should be introduced by sight, while cervix is steadied with a tenaculum.

Dilators.

What are the methods of dilating the cervical canal?

1. By tents.
2. By graduated hard dilators.
3. By dilators of the glove-stretcher variety.
4. By elastic dilators—Barnes' bag or Allen's pump.

Tents.

What do you mean by a tent as employed in gynæcology?

Give the varieties in use.

A tent is a cone of some expansile material, which, by absorption of moisture, expands after introduction into the cervix sufficiently, both in extent and force, to dilate the canal.

There are several varieties of tents in use, named according to their material.

1. Sponge. *impregnated with some antiseptic. covered with grease.*
2. Sea-tangle (*Laminaria digitata*).
3. Tupelo (*Nyssa aquatilis*).
4. Cornstalk.

What are the merits of each?

The sponge tent expands easily, but it is the most dangerous of all, from the fact that it absorbs so readily material which easily becomes septic. *Remove grease before inserting.*

The sea-tangle tent is less dangerous than the preceding, and dilates well, but it expands unevenly, and its edges are rough after expansion.

If blood follows use of tents, postpone for 48 hrs. & apply pure Carb. ac. to endometrium.

The tupelo tent is the best of all. It expands evenly and smoothly, and is the least liable to cause sepsis.

The cornstalk is feeble in action and seldom used.

What are the indications for the use of tents ?

1. To dilate the cervical canal for purposes of diagnosis or operation.
2. To check hemorrhage.

What are the merits of tents for these uses ?

The employment of tents has greatly, and very wisely, diminished of late. For diagnostic purposes they are still occasionally employed to dilate the cervical canal, so that the finger can be introduced, but they are dangerous, slow and painful, and we have, in most cases, better means, in dilators of the glove-stretcher variety or Allen's pump, for accomplishing the same result.

The use of tents to check hemorrhage was chiefly in abortion ; the dilatation of the canal being sought for at the same time. We now have better means in the elastic dilators.

What are the preliminaries to the use of tents ?

All antiseptic precautions should be observed. Patient should have an antiseptic vaginal douche.

You should determine accurately the position of the uterus.

Tents should be curved to the direction of the canal.

A string should be passed through the tent, for ease in withdrawal.

Patient should be in Sims' position. *should be passed at home*

How would you introduce a tent ?

1. Introduce Sims' speculum ; draw down cervix with volsella, then taking the tent in a pair of dressing forceps or on a tent carrier, pass it into cervical canal by sight ; insert a tampon and give an opium suppository.

What should be the future treatment of the case ?

Tents should not be left in over 6-12 hours ; sponge tents not over 6 hours. In removing a tent, do not rotate it.

Patient must remain in bed for 24 hours, and not leave the house for 3-4 days.

Graduated Hard Dilators.

Describe them.

There are several varieties in common use, among which are Peaslee's, Kammerer's, Hank's, etc. *Huggins are best (H.B.)*

The first two resemble male sounds, except that the curve is less acute, and at $2\frac{1}{2}$ inches there is a bulb.

Hank's dilator has a more olive-shaped extremity of various sizes.

Ordinary male sounds, Nos. 15 to 18, French, may often be substituted for the dilators just mentioned.

What are indications for the use of graduated hard dilators?

1. By themselves to dilate a stenosis of the cervix causing dysmenorrhœa or sterility. Under stenosis here is included that caused by flexions.

2. To maintain a dilatation produced by one of the more powerful dilators.

Describe the mode of employment of these graduated hard dilators.

Give patient ^{*chloroform*} an antiseptic douche; place her in Sims' position; introduce Sims' speculum; draw down and hold cervix with a tenaculum or volsella; introduce dilator by sight, as you would the uterine sound, beginning with the smallest size and increasing to the largest. Cleanse the vagina with an antiseptic solution (bichloride 1-5000), insufflate iodoform against the cervix and insert an iodoform gauze tampon; keep patient in bed 12-24 hours.

Occasionally, the curve of the uterus is such that it is easier to introduce the dilators with patient in the dorsal position and with the aid of the bivalve speculum.

In employing these graduated dilators for stenosis of cervix causing obstructive dysmenorrhœa, how often should they be introduced?

It is usually necessary to introduce them once a week during the first month, and once or twice a month for a few months afterward; exercising each time the same antiseptic precautions.

Describe the dilators of the glove-stretcher variety.

The two chief styles of these are the Sims and Ellinger's; in the

latter of which the blades are caused to move parallel, and on the handle there is a graduated scale. There are numerous modifications of these dilators, among which may be mentioned Wylie's and Goodell's.

What are the indications for the employment of these dilators ?

The same indications obtain as for the preceding, and in addition where a more complete dilatation of the cervix is desired.

The first and more complete dilatation is often performed with a dilator of this class, and then the dilatation maintained by the graduated hard dilators.

What are the preliminaries to the use of the glove-stretcher dilators ?

The patient should have an antiseptic douche, and for complete dilatation, anæsthesia.

Describe the method of employing these dilators.

The patient is usually placed in Sims' position ; insert Sims' speculum ; draw down cervix and introduce dilator to the shoulder ; separate blades gradually to the desired extent, being careful that the instrument does not slip suddenly and lacerate the cervix. The dilatation is sometimes also performed with patient in the dorsal position.

To what extent should you carry the dilatation ?

Usually from $\frac{1}{2}$ to 1 inch.

ELASTIC DILATORS.

Barnes' Bags, Allen's Pump.

Describe them and the method of using them.

They consist of India-rubber bags, of different sizes, the former being fiddle-shaped, the latter more elongated. They are introduced under strict antiseptic precautions, in a collapsed condition, and are then slowly distended with air or water, usually the former; the Barnes' bags by means of a Davidson's syringe, Allen's by the pump.

What are the advantages of these elastic dilators?

Their method more closely resembles the physiological method of dilating the cervix; the dilatation can be made extensive; the danger of laceration of the cervix is slight.

With Allen's pump the dilatation can be made comparatively rapid.

What are the dangers of mechanical dilatation?

Laceration of the cervix.

Endometritis.

Salpingitis.

Peritonitis.

The Curette.

Describe it.

The curette consists usually of a loop of wire, either blunt or sharp, on a rather long shank, used for scraping irregularities or new growths from the endometrium.

Occasionally, it is made like a small cup, with a sharp edge, attached to a long shank. Simon's spoon is of this description.

What are the varieties in common use?

✓ Thomas' wire loop, dull and flexible.

✓ Sims' curette.

✓ Recamier curette.

✓ Simon's spoon.

Martin's - best (H + B)

What is the value of the curette?

It is a very valuable instrument, both for diagnosis and treatment.

a. For diagnosis, to scrape away some of the contents of the uterus, for examination, to determine the cause of hemorrhage.

b. For treatment, to scrape away villous growths, which, by their vascularity, easily cause hemorrhage.

In malignant disease of the uterus, the curette is also of value to remove sloughing masses.

What are the preliminaries to the use of the curette?

The patient should have an antiseptic douche, and all antiseptic precautions should be observed in regard to instruments, hands, etc.

She should be placed in Sims' position; Sims' speculum introduced; cervix drawn down and steadied by a tenaculum; the cervix, if necessary, should be dilated.

If the sharp curette is to be used, it is better to use anæsthesia; if only the blunt curette is to be employed, anæsthesia is unnecessary.

Describe briefly the method of curetting.

If the operation is to be curative, scrape the interior of the uterus carefully till the walls feel smooth; then wash out uterus with an antiseptic solution, with the aid of a double current catheter; dry the vagina, then touch the interior of the uterus with carbolic acid or the so-called iodized phenol, consisting of iodine, gr. xl, carbolic acid ʒj. Confine patient to bed 12-24 hours.

What are the dangers of the curette?

Inflammation of the uterus or its adnexa.

Peritonitis.

Hemorrhage.

Septicæmia.

Vulvitis.**What are the varieties?**

- | | | |
|---|---|---|
| <i>a.</i> Occurring in both children and adults : | { | <ol style="list-style-type: none"> 1. Simple catarrhal, acute or chronic; 2. Gonorrhœal; 3. Phlegmonous; 4. Diphtheritic; 5. Gangrenous; |
| <i>b.</i> Occurring in adults : | | Follicular. |

I. ACUTE SIMPLE CATARRHAL VULVITIS.

What are the causes ?

Lack of cleanliness ;
 Strumous diathesis ;
 Discharges from cervix, or vagina ;
 Injuries or friction from exercise ;
 Masturbation ;
 Awkward, or excessive coitus ;
 Pregnancy ;
 Foreign bodies ;
 Parasites ;
 Acute exanthemata.

What are the symptoms ?

General malaise ; some local pain and burning ; parts are œdematous, congested, covered with a glairy, mucous, excoriating discharge, which may extend to the urethra.

What is the treatment ?

Rest in bed ; warm sitz-baths ; lead and opium wash frequently applied to the vulva ; lint soaked in it kept between the labia. Bismuth, starch, or borax may with advantage be dusted on the vulva in the intervals between the applications of the lead and opium wash. If the vulvitis is from ascarides, employ enemata of infusion of quassia, ℥ ij-Oj.

CHRONIC CATARRHAL VULVITIS.

Describe its occurrence and course.

Catarrhal vulvitis in children is most apt to be chronic ; it is seen most frequently in strumous children, often with no history of the acute stage.

What are the symptoms ?

1. Discomfort in walking and in micturition ;
2. Pruritus ;
3. Stains on linen.

What is the treatment ?

Build up the constitution by tonics and fresh air ; observe cleanliness ; if much discomfort, use lead and opium wash, followed later

by nitrate of silver (gr. x- $\bar{3}$ j) applied to the vulva ; bismuth or borax being dusted on between the lotions.

II. GONORRHŒAL VULVITIS.

What is the etiology ?

It is produced either directly by intercourse with one who has contracted gonorrhœa, or indirectly by soiled linen, instruments, etc.

What is the diagnostic value of Neisser's gonococcus, found in the discharge ?

Dr. W. J. Sinclair, in his work on "Gonorrhœal Infection in Women," arrives at the following conclusions :—

1. "If gonococci are present in the discharge from an inflamed mucous membrane, the discharge is of gonorrhœal origin."

2. "A secretion containing gonococci, when brought into contact with a mucous membrane capable of infection, gives rise with certainty to a gonorrhœal inflammation ; and conversely, a secretion, whatever its origin may be, which does not contain gonococci, is incapable of giving rise to a gonorrhœal inflammation."

What is the differential diagnosis between gonorrhœal vulvitis and acute simple catarrhal vulvitis ?

In gonorrhœal vulvitis, the onset is more violent ; more fever, pain and œdema ; the inflammation extends up the vagina and urethra ; pus can often be pressed out of urethra ; gonococci can be found in the discharge ; often warts or buboes are present, and sometimes gonorrhœal rheumatism.

What is the treatment of gonorrhœal vulvitis ?

Keep patient quiet ; give light diet ; keep bowels open ; irrigate parts with bichloride 1-1000 or 2000, or creolin 1-100 or 200 ; then dust with calomel, bismuth, or borax. If discomfort is very great, lead and opium wash may be frequently applied to the vulva, and patient may take warm sitz-baths. The labia should be kept separated with lint or gauze smeared with some simple antiseptic ointment.

If the vulvitis tends to become chronic, apply nitrate of silver, gr. x- $\bar{3}$ j.

III. PHLEGMONOUS VULVITIS.

What is the etiology?

It may arise from the following :—

- Traumatism ;
- Irritating discharges ;
- Acute exanthemata ;
- Furunculosis.

What are the symptoms?

- a.* Subjective : Heat and pain, increased by standing or walking.
- b.* Objective : Congestion, swelling, induration ; later, suppuration.

From what must you differentiate phlegmonous vulvitis?

- a.* Pudendal hernia ;
- b.* Dislocated ovary ;
- c.* Hydrocele of round ligament ;
- d.* Hæmatoma of vulva.

How would you differentiate phlegmonous vulvitis from pudendal hernia?

<i>Phlegmonous Vulvitis</i>	vs.	<i>Pudendal Hernia.</i>
Signs of acute inflammation.		None unless strangulated, or injured.
Dullness on percussion.		Tympanitic on percussion.
No impulse on coughing.		Impulse on coughing.
Not reducible.		Usually reducible.
History of traumatism, etc.		History of strain.

How would you differentiate phlegmonous vulvitis from a dislocated ovary?

<i>Phlegmonous Vulvitis</i>	vs.	<i>Dislocated Ovary.</i>
Signs of acute inflammation.		Usually absent.
Gradual development.		Sudden development.
No especial exacerbation during menstruation.		Larger and more sensitive during menstruation.
No sense of ovarian compression when pressed upon.		Peculiar sensation when pressed.
Not the shape of an ovary.		Has the shape of an ovary.

How would you differentiate phlegmonous vulvitis from hydrocele of the round ligament?

<i>Phlegmonous Vulvitis</i>	vs.	<i>Hydrocele of Round Ligament.</i>
Signs of acute inflammation.		No signs of acute inflammation.
Opaque.		Translucent.
Never communicates with abdominal cavity.		Sometimes communicates with abdominal cavity.

How would you differentiate phlegmonous vulvitis from hæmatoma of vulva?

<i>Phlegmonous Vulvitis</i>	vs.	<i>Hæmatoma of Vulva.</i>
Gradual formation.		Sudden onset.
Less frequent during parturition.		More frequent during parturition.
First hard, then soft.		First soft, then hard,
Less often preceded by varicosities.		More often preceded by varicosities.

What is the treatment of phlegmonous vulvitis?

Tonics : Arsenic, quinine, etc.

Sedatives : Hot lead and opium.

When pus formed, open, drain and dress antiseptically.

IV. DIPHTHERITIC VULVITIS.

Give the etiology, symptoms and treatment.

Diphtheritic vulvitis is an expression of constitutional diphtheria ; the membrane sometimes appears first on vulva ; it resembles that usually found in the throat. The constitutional symptoms are those of diphtheria, and should be treated as such ; the local condition demands antiseptics.

V. GANGRENOUS VULVITIS.

Give the etiology and treatment.

Gangrenous vulvitis is most frequently found complicating pregnancy, severe types of acute exanthemata, and very violent cases of vulvitis of other varieties. The treatment consists of constitutional tonics and local antiseptics.

VI. FOLLICULAR VULVITIS.

Give the pathology.

Follicular vulvitis is an inflammation of the mucous and sebaceous glands and hair follicles of the vulva ; all may be simultaneously affected, or one set alone involved.

What is the etiology ?

It occurs only in adults ; any of the causes of simple acute catarrhal vulvitis may produce it ; among the most common are the following :—

- a.* Lack of cleanliness ;
- b.* Discharges from above, especially senile leucorrhœa ;
- c.* Pregnancy ;
- d.* Acute exanthemata.

What are the symptoms ?*a.* Subjective :—

Local heat and pain ;

Pruritus ;

Increased secretion ;

Hyperæsthesia ;

Vaginismus occasionally present ;

Vulvar extremity of urethra is sometimes affected, then ardor urinæ results.

b. Objective :—

The mucous membrane appears very red in spots, resembling the papillæ of the tongue. When the sebaceous glands and hair follicles are chiefly affected, they will be found as little round red papillæ, scattered over labia and base of prepuce and clitoris, not on vestibule ; later, a drop of pus appears in the apex of these papillæ ; they then disappear.

How would you treat a case of follicular vulvitis ?

Pay strict attention to cleanliness ; during the acute stage use sedative lotions, as lead and opium wash ; later, apply nitrate of silver (gr. x-℥j). Bismuth or calomel may be used as a dusting powder ; keep labia separated.

Cyst and Abscess of Vulvo-vaginal Gland.

CYST OF VULVO-VAGINAL GLAND.

Give the etiology and pathology.

A cyst of the Bartholinian or vulvo-vaginal gland is formed by a distention of the duct, or gland itself, caused by any occlusion of the duct, especially from inflammation, either simple catarrhal or gonorrhœal. A cyst of the duct is more elongated than of the gland itself; a cyst of the gland is occasionally multiple.

ABSCESS OF THE VULVO-VAGINAL GLAND.

What is the etiology?

The causes of a vulvitis may produce abscess of the vulvo-vaginal gland; gonorrhœa is the most common cause.

What are the symptoms?

Pain; heat; swelling and redness, especially near orifice of duct; it is tender on pressure; at first hard, later fluctuating.

How could you differentiate a cyst from an abscess of the vulvo-vaginal gland?

<i>Cyst</i>	<i>vs.</i>	<i>Abscess.</i>
Gives no signs of inflammation.		Shows inflammation.
Insensitive to pressure.		Sensitive to pressure.
Duration long.		Duration shorter.

What is the treatment of a cyst of the vulvo-vaginal gland?

The usual treatment is to excise an elliptical area of mucous membrane over the sac on its inner surface; this exposes the sac; now cut out a large ellipse from it; empty the sac, pack it with iodoform gauze, and apply an antiseptic outside dressing.

A better plan is usually to dissect out the whole sac, if possible, and bring together the edges of the wound with catgut; then apply an antiseptic dressing as before.

From what may you get considerable hemorrhage in extirpating the sac?

From the transversus perinei artery, and from the bulbs of the vagina.

How would you treat an abscess of the vulvo-vaginal gland?

Before the presence of pus is detected, keep the patient quiet in bed; apply soothing lotions like hot lead and opium wash. As soon as pus is detected, proceed as with the cyst till sac is opened, then with a sharp curette scrape the interior of sac wall; irrigate with bichloride (1-1000); pack with iodoform gauze, and apply an anti-septic outside dressing of iodoform gauze, bichloride gauze, absorbent cotton and a T-bandage.

From what must you differentiate vulvo-vaginal cyst or abscess?

From hernia and phlegmonous vulvitis.

How would you differentiate vulvo-vaginal cyst or abscess from hernia?

<i>Cyst or Abscess</i>	<i>vs.</i>	<i>Hernia.</i>
No impulse on coughing.		Impulse on coughing.
Irreducible.		Usually reducible.
Dull on percussion.		Tympanitic on percussion.
Abscess shows signs of inflammation.		None, unless strangulated, or injured.
More circumscribed.		Less circumscribed.

How would you differentiate abscess of vulvo-vaginal gland from phlegmonous vulvitis?

The vulvo-vaginal abscess is more distinctly circumscribed and globular; the phlegmonous vulvitis is more diffuse.

Pudental Hernia.**Describe.**

The process of peritoneum which follows the round ligament through the inguinal canal to its termination in the labium majus is usually obliterated at birth; occasionally this obliteration does not occur, and this channel, called the canal of Nuck, furnishes a path for hernia. The hernia may consist of intestine, omentum, ovary or bladder. The uterus has even been said to follow this canal.

What are the causes?

Blows, falls, coughing or violent muscular exertion.

What are the symptoms ?

The patient experiences a feeling of discomfort, especially on walking, and finds a swelling, which, if intestine, presents the following features: It gives an impulse on coughing; is tympanitic on percussion; can usually be reduced, and, unless strangulated, or injured, presents no signs of inflammation.

If the hernia consists of an ovary, it gives the ovarian sensation on pressure, and its size and tenderness are both increased during menstruation.

What is the treatment ?

Place patient on her back, with knees elevated; reduce by gentle taxis, if possible, and apply a suitable truss. If strangulation has occurred, a surgical operation is necessary. If the hernia consists of an ovary which has become adherent, protect it from pressure by a hollow pad, or if it occasions great distress, remove it.

Pudental Hæmatocele.**What are the synonyms ?**

Hæmatoma or thrombus of vulva.

Define.

Pudental hæmatocele consists of an effusion of blood into the tissue of the vulvo-vaginal region, usually into one labium, or into the areolar tissue surrounding the vaginal walls.

What is the etiology ?

Pudental hæmatocele is predisposed to by any condition causing, or accompanied by, a dilatation of the vessels of the vulva:—

Pregnancy ;
Tumors ;
Varicocele ;
Labor.

The exciting causes are blows, falls, muscular efforts, etc.

Describe the symptoms and course.

The patient experiences pain of a tearing character, which, if the

effusion is large, may be accompanied by faintness. Sometimes the effusion presses on the urethra and causes difficulty in micturition. The swelling is at first soft; later, hard.

If small, it is usually absorbed; it sometimes remains for a long time; sometimes suppurates.

How would you differentiate pudental hæmatocele from hernia?

<i>Pudental Hæmatocele</i>	<i>vs.</i>	<i>Hernia.</i>
History.		History.
No impulse on coughing.		Impulse on coughing.
Dull on percussion.		Tympanitic.
Irreducible.		Usually reducible.
First soft, then hard.		More uniform.

How would you treat a case of pudental hæmatocele?

While effusion is in progress, apply ice and pressure. If the effusion is large, occurs during labor and obstructs the passage of the head, incise, turn out the clots and pack with iodoform gauze. If the effusion is small, apply soothing lotions like lead and opium wash; if suppuration occurs, or if absorption is long delayed, incise, irrigate with bichloride 1-1000, and pack with iodoform gauze.

Hemorrhage from Vulva.

What is the etiology?

The predisposing causes are the same as for pudental hæmatocele and hæmatocele itself. The existing causes are the following:—

- Violent muscular efforts;
- Blows;
- Punctures or lacerations.

What is the treatment?

If it is a ruptured hæmatocele, incise, turn out the clots and pack; otherwise, catch bleeding points and ligature, or apply pressure, assisted by a tampon in the vagina.

Skin Diseases Affecting the Vulva.

What are the most common?

Erythema and eczema are most frequently seen; the latter may be acute or chronic.

Erythema of the Vulva.

Give the etiology, symptoms and treatment.

Etiology.—Erythema is most apt to occur in fleshy people, especially in hot weather. The exciting causes are :—

- Lack of cleanliness ;
- Irritating discharges ;
- Exercise.

Symptoms.—The parts become red, sensitive, often excoriated and painful, especially in walking.

Treatment.—Cleanliness ;

- Attention to bladder and urine ;
- Desiccating powders, such as bismuth, borax or oxide of zinc.

Eczema of the Vulva.

Give the etiology.

Eczema is predisposed to by functional disturbance of the gastrointestinal tract, gout or rheumatism; it is especially apt to occur in women near the menopause. The most frequent exciting cause is an irritating discharge from the cervix or vagina.

What are the symptoms?

The disease may be acute or chronic. In the acute form, the parts become reddened and œdematous; vesicles appear, break and discharge a thick, tenacious fluid, which forms crusts. The subjective symptoms are severe burning and itching.

In the chronic form, the parts become thickened and scaly; the subjective symptoms resemble those of the acute, but are a little less marked.

What is the treatment?

In the acute form, observe strict cleanliness; if the burning is very severe, use lead and opium wash; later, or at first, if burning and itching are not intense, an ointment like the following is very good:—

R. Acidi salicylici, gr. xv,
 Zinci oxidi, ℥ ij ss,
 Pulv. amyli, ℥ ij ss,
 Petrolati, ℥ j.

M. Sig.—Apply locally.

In the chronic form, use the same treatment during the exacerbations as for the acute; later, an ointment containing oil of cade will be found of value.

What are the most common parasites found on the vulva?

The pediculus pubis, or crab louse, is the parasite most often found infecting the vulva.

The acarus scabiei, or itch mite, is occasionally, but rarely, found on the vulva as part of a general infection.

Give the etiology, symptoms and treatment of infection with pediculi pubis.

Etiology.—The pediculus pubis is almost always conveyed directly from person to person, usually in sexual intercourse.

Symptoms.—There is burning and itching; often an eruption resembling eczema. The diagnosis is made by finding the pediculus closely adherent to the roots of the hair.

Treatment.—Any one of the following:—

Oleate of mercury, 10 per cent.;
 Corrosive sublimate, 1-1000;
 Tincture of delphinium;
 Carbolic 5 per cent. solution.

It is often best to shave the pubes before applying the lotion or ointment.

Give the etiology, symptoms and treatment of scabies of the vulva.

Etiology.—The acarus scabiei is rarely found on the vulva, but this occasionally occurs as part of a general infection.

Symptoms.—There is an intense pruritus, worse when the body is warm. The diagnosis is made by finding the burrows on other parts of the body, especially between the fingers.

Treatment.—A warm soap and water bath, followed by an ointment composed of sulphur alone, or combined with balsam of Peru.

New Growths of the Vulva.

Mention the principal new growths occurring on the vulva?

a. Papillomata—

1. Simple ;
2. Pointed condylomata ;
3. Syphilitic condylomata.

b. Cyst of vulvo-vaginal gland.

c. Carcinoma.

d. Sarcoma.

e. Elephantiasis.

f. Fibromata.

g. Lipomata.

h. Neuromata.

i. Lupus.

Simple Papillomata.

What is the etiology and treatment?

Etiology.—A simple papilloma, or wart, occurs rarely on the vulva ; it is usually congenital and of little importance.

Treatment.—It may be destroyed with nitric acid, or it may be excised under cocaine, and the wound closed with fine sutures.

Pointed Condylomata.

What is the etiology and appearance?

Pointed condylomata, or gonorrhœal warts, are caused by the gonorrhœal poison ; they are always multiple, and occur most frequently on the inner surfaces of the labia majora, on the vestibule and perineum ; they are of a grayish color and often pediculated ;

their summit is divided into pointed lobules. When on the skin, they are sometimes dry and hard; on a mucous surface they are soft. In some cases pointed condylomata appear to arise from an irritating discharge, the gonorrhœal character of which cannot be proved.

What is the treatment of pointed condylomata?

The best treatment is to cut them off with scissors or knife and touch the base with nitric acid; under the use of cocaine this may be made practically painless.

Syphilitic Condylomata.

What is the etiology, appearance and treatment?

Syphilitic condylomata, or mucous patches, are the result of the syphilitic poison. They are broad and flat, situated most frequently on the inner surface of the labia majora, and usually covered with a grayish, mucus-like secretion. According to Duhring, they sometimes take on a more warty growth.

Treatment.—Cleanliness;
Calomel locally;
Constitutional treatment for syphilis.

Pruritus Vulvæ.

Define.

Pruritus vulvæ, a symptom rather than a disease *per se*, consists of an irritation of the nerves of the vulva, accompanied by intense itching, at first localized, later extending, from the mechanical irritation of scratching.

What is the etiology?

The predisposing causes are:—

- a. Poor health.
- b. Disorders of the digestive tract.
- c. Anything producing congestion of the vulva, such as—
 - Pregnancy;
 - Tumors in neighborhood;
 - Diseases of uterus or appendages;
 - Menopause.

d. Lack of cleanliness.

The exciting causes are chiefly the following :—

1. Irritating discharges from cervix, vagina, urethra or vulva.
2. Diabetic urine.
3. Eruptions.
4. Parasites.
5. Masturbation.
6. Vegetations on vulva.

What are the symptoms ?

An intense itching, at first only at intervals after active exercise, over-indulgence at the table, lying in a warm bed, or sexual intercourse. Later, the itching becomes constant ; the desire to scratch becomes irresistible, causing the patient to avoid society ; it sometimes leads to nervous depression and melancholia.

What is the treatment ?

First ascertain the cause, if possible.

Build up the general health.

Regulate the diet.

Observe strict cleanliness.

Destroy parasites if present.

If sugar present in the urine, give salicylate of soda.

Treat eruptions.

If there is an acid discharge from above, tampon vagina.

Let patient use frequent warm sitz-baths.

Apply any one of the following :—

Hot lead and opium wash ;

Carbolic solution, 2-3 per cent. ;

Bismuth or borax dusted on vulva ;

Nitrate of silver (gr. x- \bar{z} j) ;

Cocaine, 4 per cent. solution.

Hyperæsthesia of the Vulva.

Describe.

This consists of an excessive sensibility of the nerves supplying the mucous membrane of some portion of the vulva.

What is the etiology?

The menopause seems to predispose to it; also the hysterical and melancholic state. An irritable urethral caruncle sometimes acts as an exciting cause. Often no cause can be assigned.

What are the symptoms?

Hyperæsthesia, especially about the vestibule and labia minora; there is no pruritus, and signs of inflammation are absent except occasional erythematous spots; dyspareunia is very marked; the slightest friction causes pain.

What is the treatment?

Build up the constitution with tonics, change of air, etc.

Interdict sexual intercourse.

Administer the bromides internally.

Externally apply one of the following:—

Carbolic lotion, 2-3 per cent;

Lead and opium wash;

Four per cent. solution of cocaine.

Vaginismus.

Define.

Sims defined vaginismus as "an excessive hyperæsthesia of the hymen and vulvar outlet, associated with such involuntary spasmodic contraction of the sphincter vaginæ muscle as to prevent coitus."

What is the pathology?

There are usually found sensitive papillæ about the base of the hymen; an hypertrophy of the papillæ and connective tissue of the hymen; occasionally the lesion seems to be at a distance, as in the uterus or appendages; sometimes no lesion is visible.

What is the etiology?

The predisposing causes are—

1. A narrow vagina.
2. A dense, thick hymen.
3. Malposition of the vulva.

The exciting causes are—

1. Disturbances of the sexual function.
2. Masturbation.
3. Inability of the male to complete the sexual act.

What is the treatment?

Palliative.—Forcibly dilate the hymen, under anæsthesia, by inserting and separating the thumbs; then insert one of Sims' glass vaginal plugs.

Radical.—Excise the hymen and insert one of Sims' plugs.

Coccygodynia.**Define and give the etiology.**

Coccygodynia, or coccyodynia, is a "painful affection of the muscles, tendons, and nerves of the coccyx, with or without disease of the bone itself." (Mann).

It occurs most frequently after childbirth, but is also produced by mechanical causes, such as blows, falls, kicks, etc. Among other causes are disease of the pelvic organs, rheumatism and gout. Hysteria largely predisposes to it; in some cases no cause can be assigned.

What are the symptoms?

Pain in the coccygeal region, increased by motion bringing into play the muscles attached to the coccyx; especially rising after sitting, defecation, coitus, sometimes even walking.

Pressure on the coccyx elicits the characteristic pain.

The condition must be differentiated from disease of the rectum or anus, and from pure hysteria.

What is the treatment?

First attend to the general condition, rheumatism, hysteria, etc.; if this fails, we have two operations:—

1. Cutting the attachments of the muscles to the coccyx.
2. Extirpation of the coccyx.

Irritable Urethral Caruncle.

Define.

An irritable urethral caruncle is a deep red mass, very vascular and sensitive, situated at the mouth of the urethra, or just within the canal ; it consists, according to Hart and Barbour, of dilated capillaries in connective tissue, the whole being covered with squamous epithelium.

What is the etiology ?

But little is known of its etiology ; it occurs at all ages, and in both married and single women.

What are the symptoms ?

The patient complains of frequent and painful micturition ; later, this dysuria increases, and pain is caused by walking, pressure or friction of any kind. Intercourse causes both pain and hemorrhage. The nervous symptoms are well-marked ; hysteria, melancholia, etc.

On examination, one finds a raspberry-looking mass at the meatus ; it is very sensitive and bleeds easily ; it may be single or multiple.

From what must you differentiate an irritable urethral caruncle, and how ?

From polypi, venereal warts and prolapse of the urethral mucous membrane.

Polypi are usually higher in the urethra, are less vascular and less sensitive.

Venereal warts are less vascular, insensitive, and usually accompanied by others. The history may aid.

Prolapse of the urethral mucous membrane may resemble a caruncle in appearance, but it usually surrounds the meatus more, is less vascular and less sensitive, is continuous with the urethral mucous membrane, and can usually be reduced.

What is the treatment ?

Employ anæsthesia ; cut off the caruncle and touch the base with nitric acid or the actual cautery. You may ligate before cutting.

What is the prognosis ?

If the growth is single and near the meatus, the prognosis is good ; if multiple and extending up the urethra, they may recur.

Prolapse of the Urethral Mucous Membrane.

Describe.

Prolapse of the urethral mucous membrane may involve the whole circumference of the meatus, or only a portion; if the latter, it is the lower portion which is usually affected; a slight redundancy at the meatus is common; a prolapse sufficient to form a tumor is rare. At first the exposed mucous membrane is of its normal pink color; later it assumes an angry red color, often becomes excoriated and sensitive; urethritis and cystitis may result.

What is the etiology?

Frequent child-bearing, dilatation of the urethra and a lax condition of the tissue, from whatever cause, undoubtedly predispose to prolapse of the urethral mucous membrane. The exciting causes are usually vesical and rectal irritation, accompanied by straining.

What are the symptoms?

Frequent micturition, which soon becomes painful, tenesmus, and if vesical tenesmus previously existed, it becomes much aggravated.

What is the treatment?

If the prolapse is recent, an attempt at cure may be made by reducing the mucous membrane, keeping the patient quiet in bed, making astringent applications to the urethra and removing the cause of previous vesical or rectal tenesmus, if present.

If these procedures fail, remove the prolapsed portion by one of the following methods:—

1. Ligate and excise.
2. Remove with a galvano-caustic wire, and keep catheter in the bladder for a few days.
3. Emmet's "button-hole" operation.

Malformations of the Vulva.

What are the principal malformations of the vulva?

1. Absence of the vulva.
2. Hypospadias, in which the posterior wall of the urethra is defective.

3. Epispadias, in which the anterior urethral wall is defective, usually combined with a defect in the anterior wall of the bladder.
4. The clitoris may be absent, rudimentary, or hypertrophied.
5. The labia majora may be absent, rudimentary, or greatly hypertrophied, as in the "Hottentot apron."
6. Less often the labia majora may be hypertrophied.
7. True hermaphroditism, where both an ovary and a testicle exist in the same person, although very rare, is said to occur in a few cases.
8. Pseudo-hermaphroditism, where the external genitals alone resemble those of both sexes, is more common.

Diseases of the Vagina.

What are the varieties of inflammation of the vagina ?

1. Simple catarrhal vaginitis, or colpitis.
2. Gonorrhœal.
3. Ulcerative, senile or adhesive.
4. Diphtheritic.

Simple Catarrhal Vaginitis.

What is the etiology ?

The predisposing causes are—

- a.* General bad health.
- b.* Anything causing local congestion, as—
 - Disease of heart or lungs ;
 - Disease of the pelvic organs ;
 - Pregnancy.

The exciting causes are :—

- a.* Irritating discharges from the cervix.
- b.* The use of too hot, too cold or irritating douches.
- c.* Awkward or excessive coitus.
- d.* Foreign bodies, as pessaries, tampons, etc.

What are the symptoms ?

Simple catarrhal vaginitis may be acute or chronic.

The subjective symptoms of the acute are a feeling of heat in the vagina, pain in the pelvis, and sometimes vesical and rectal irritability.

The objective symptoms are a muco-purulent vaginal discharge which may irritate the vulva; the vagina appears red, perhaps granular or cystic in places.

The chronic form resembles the acute except in degree; in it the subjective symptoms, save itching caused by the leucorrhœa, are usually absent.

What is the treatment of simple catarrhal vaginitis?

In the early stages, keep the patient quiet; keep the bowels open, and give light diet; if there is much pain, allow an opium suppository; keep the urine bland by alkaline diluents. If the itching is severe, let the patient take frequent warm alkaline sitz-baths; in addition, irrigation of the vagina with warm water containing either of the following will be found of value: *Liquor plumbi subacet*, ℥j-Oj; borax ℥j-Oj.

After irrigation it is well to dust some desiccating powder, like borax, upon the vulva.

When the vaginitis becomes subacute or chronic, make application to the vagina of nitrate of silver gr. x-xxx-℥j, or pyroligneous acid.

Let the patient use daily vaginal douches of hot water containing borax, ℥j-Oj; or sulphate of zinc, ℥ss-℥j-Oj; or alum, ℥j-Oj.

The douches should be taken while the patient is in the dorsal position, not sitting.

Gonorrhœal Vaginitis.

How does gonorrhœal vaginitis differ from the simple catarrhal?

- a. The onset is usually more acute.
- b. The discharge is more purulent, viscid and offensive than in the simple catarrhal.
- c. Urethritis is more common.
- d. Sometimes a history of exposure to infection can be obtained.
- e. Often gonorrhœal warts or buboes are present.
- f. The most certain diagnostic point is the presence of gonococci.

What are the frequent complications and results of gonorrhœal vaginitis?

Vulvitis, urethritis, endometritis, salpingitis, ovaritis and peritonitis.

The dangers of gonorrhœal vaginitis have been greatly underestimated.

What is the treatment of gonorrhœal vaginitis?

Keep patient as quiet as possible ; attend to diet, bowels and urine as in the simple catarrhal ; if there is much pain give an opium suppository ; irrigate vagina with warm bichloride sol., 1-1000-5000, then insufflate iodoform, and insert, to keep vaginal walls separated, iodoform gauze soaked in the following solution :—

Iodoform, 1 part.
 Chloral, 1 “
 Glycerine, 4 “

This gauze may be left in 6-12 hours. The complicating vulvitis may require the regular treatment for gonorrhœal vulvitis.

It is well to repeat the bichloride vaginal irrigation every day or two during the acute stage ; later, applications to the vagina of nitrate of silver, gr. x-xxx-℥j, are of value.

Ulcerative Vaginitis.

Describe.

Ulcerative, senile or adhesive vaginitis is present to a greater or less extent in nearly every woman over 60.

There is a desquamation of the squamous epithelium in spots, and where these raw areas lie in apposition, adhesion is apt to occur. There is usually a thin leucorrhœa, which irritates the vulva and causes pruritis.

What is the treatment?

The treatment consists in the application to the vagina of such solutions as nitrate of silver, gr. x-xx-℥j, or pyroligneous acid, and the use by the patient of astringent vaginal douches, such as sulphate of zinc ℥ss-Oj, alum ℥j-Oj, or borax ℥j-Oj.

Diphtheritic Vaginitis.

What is the etiology and treatment?

Diphtheritic vaginitis is an expression of constitutional diphtheria, with its regular etiology and symptoms.

The treatment should consist of local antiseptics and the constitutional treatment for diphtheria.

Pelvic Peritoneum.

Describe.

The pelvic peritoneum is a continuation of that lining the inner surface of the walls of the abdomen; it covers, more or less completely, the pelvic organs (the ovary is regarded as not covered by peritoneum), lines the pelvic walls and also the floor of the pelvis. Traced from before backward, in the median line, it leaves the anterior abdominal wall about $1\frac{1}{2}$ inches above the symphysis, is reflected over the fundus of the bladder and down its posterior surface to about the level of the internal os; it then passes over to the uterus, covers its anterior surface above that point, passes over the fundus and down its posterior surface to the vaginal junction, thence down the vaginal wall for about an inch; it then passes to the rectum, covers the anterior surface of the middle portion, and surrounds the upper portion completely. The pelvic peritoneum is thrown into several folds and forms several pouches.

Describe the folds and pouches of the pelvic peritoneum.

The principal folds are the broad, utero-vesical and utero-sacral ligaments (so-called). The broad ligaments, extending from the sides of the uterus to the sides of the pelvis, in front of the sacro-iliac synchondrosis, divide it into two fossæ, the anterior and posterior; these are also subdivided, the anterior by the utero-vesical ligaments, the posterior by the utero-sacral. The pouch between the utero-vesical ligaments is called the utero-vesical pouch; that between the utero-sacral, the pouch of Douglas, which is the deepest part of the peritoneal cavity.

The pouches between the utero-vesical and broad ligaments are called the para-vesical pouches; those between the utero-sacral and broad ligaments are called by Polk the "retro-ovarian shelves."

Two other pouches are mentioned, which depend on the condition of the bladder : the vesico-abdominal, when the bladder is distended ; and the utero-abdominal, when the bladder is empty and contracted.

What are the boundaries of the utero-vesical pouch ?

It is bounded in front by the posterior surface of the bladder, behind by the anterior surface of the uterus, and laterally by the utero-vesical ligaments.

What are the boundaries of the pouch of Douglas ?

It is bounded in front by the posterior surface of the uterus and the upper portion of the posterior vaginal wall, behind by the rectum, and laterally by the utero-sacral ligaments.

What are the boundaries of the retro-ovarian shelves ?

They are triangular in shape, bounded in front by the base of the broad ligament, internally by the utero-sacral ligament, and externally by the wall of the pelvis.

Pelvic Peritonitis.

What is the pathology ?

The peritoneum first becomes hyperæmic ; it loses its lustre, and exudation materials are poured out.

1. There may be scarcely any serum exuded ; the inflamed area is coated with fibrin, and adhesions form, binding together the pelvic organs and intestines.

2. The exudation may consist largely of serum, either free in the peritoneal cavity, or encapsulated by adhesions.

3. The exudation in severe, especially septic cases is often purulent.

Hence the varieties :—

- a.* Adhesive.
- b.* Serous.
- d.* Purulent.

What is the etiology ?

In a general way, the etiology of pelvic peritonitis may be stated as an extension to the peritoneum of inflammation of the uterus,

ovaries or tubes ; in a large majority of the cases, inflammation of the tubes.

There is, usually, first an endometritis, then a salpingitis, and then a peritonitis.

Individual causes are as follows :—

- a.* Catching cold during menstruation.
- b.* Introduction into the uterus of septic instruments.
- c.* Gonorrhœa.
- d.* Injection of fluids through uterus and tubes into the peritoneal cavity.
- e.* Introduction of sepsis during parturition, abortion or operations.
- f.* Tubercular or cancerous disease of the pelvic organs.
- g.* Pelvic cellulitis and peritonitis are often associated as being produced by the same causes.

What are the symptoms ?

Pelvic peritonitis may be either acute or chronic.

Acute pelvic peritonitis is usually ushered in by a rigor ; this, however, is not always present. There is pain and tenderness in the lower part of the abdomen ; patient lies on the back, with knees elevated ; the pulse is small, wiry and rapid ; the temperature is elevated, sometimes $104^{\circ}-5^{\circ}$, usually lower ; nausea and vomiting are common ; more or less tympanites is present ; the bowels are constipated ; there is frequently irritability of the bladder ; often menorrhagia.

Chronic peritonitis may exist and present scarcely any symptoms save a dull pain in the pelvis ; usually, there is vesical and rectal irritability, dyspareunia, leucorrhœa, and a disturbance of menstruation, especially menorrhagia.

Chronic peritonitis may follow the acute, or may begin as chronic.

Pelvic peritonitis is often characterized by exacerbations.

What are the physical signs of acute pelvic peritonitis ?

The vagina is hot and dry ; pressure in either fornix, or on the abdomen, is intensely painful ; the bimanual is impracticable ; the uterus, tubes and ovaries are usually bound fast ; the slightest attempt to move them causes intense pain. The fornices may seem to be covered by a hard, flat roof, formed by a matting together of

the pelvic contents, often compared to plaster-of-Paris poured into the pelvis and hardened ; you may feel a tumor close to the uterus, consisting of serum or pus, roofed in by adhesions ; the most common situation of this tumor is in the pouch of Douglas.

What are the common results of pelvic peritonitis ?

Displacement of uterus, ovaries and tubes, the tubes being often distorted and stenosed by the traction of adhesions ; as a result of these conditions we get disturbances of menstruation, sterility and extra-uterine pregnancy.

What is the prognosis of pelvic peritonitis ?

Simple adhesive peritonitis often ends in complete recovery ; displacement of the pelvic organs may remain, however, and give rise to symptoms. The prognosis of purulent peritonitis is grave.

What is the treatment of pelvic peritonitis ?

In the acute form, keep the patient quiet in bed, give fluid diet, apply hot poultices or turpentine stupes to the lower part of the abdomen ; if the temperature is very high, use the cold-water coil instead of the hot applications ; if there is great pain, give a little morphine ; after a few days, move the bowels gently, as by calomel gr. j every hour for 3-4 doses, assisted, if necessary, by an enema. After the acute stage has passed, and in chronic cases, use iodine externally and per vaginam, blisters and glycerine vaginal tampons. A wet towel, covered by a dry one or a protective, worn about the pelvis at night, is sometimes of value in chronic peritonitis. Look after the general health by attention to fresh air, administering tonics, and regulating the bowels.

Pelvic Cellulitis.

What are the principal situations of the cellular tissue in the pelvis ?

1. Between the abdominal wall and peritoneum, behind the pubes.
2. In front of and behind the cervix.
3. In the broad ligaments.
4. In the utero-sacral ligaments.

What is the etiology of pelvic cellulitis ?

The etiology of pelvic cellulitis may almost invariably be summed up in two words—traumatism and sepsis ; the traumatism being, usually, labor, abortion, or operations on the cervix.

Pelvic cellulitis was formerly considered very common, but in the light of recent experience, gained by laparotomies, the “masses,” “thickenings,” etc., are most often found to be salpingitis and peritonitis.

In other words, pelvic cellulitis, although it does exist, is comparatively infrequent.

What is the pathology ?

There is an exudation of serum, fibrin and white cells ; this may resolve, it may form new connective tissue, cicatricial tissue, or it may, and often does, suppurate. If suppuration occurs, the pus may point above the pubes ; this is especially common in puerperal cases. It frequently ruptures into the vagina, bladder or rectum, sometimes into the uterus ; it occasionally makes its way through the sciatic or obturator foramen ; rarely, it ruptures into the peritoneal cavity.

What are the symptoms of pelvic cellulitis ?

The disease is usually ushered in by a rigor, which is often marked ; the temperature rises, 103° – 105° ; the pulse is full and rapid ; the pain is not very acute ; nausea is occasionally present ; vomiting is usually absent, unless peritonitis is a complication. If pus forms, septic symptoms become pronounced. There is often irritability of bladder and rectum.

Chronic cases may present few symptoms save a feeling of weight in the pelvis, irritability of bladder and rectum, and menorrhagia.

What are the physical signs ?

Usually, there is a tense, elastic tumor bulging into the vagina, most commonly on the left side, pushing uterus over to the right ; it is sensitive, but not acutely so. Sometimes the inflammatory process involves nearly all the connective tissue of the pelvis, and the exudation can be felt in the iliac fossæ and above the pubes. When pus forms you have the physical signs of an abscess—tenderness, fluctuation, etc.

From what should you differentiate pelvic cellulitis?

- From—
- a. Pelvic peritonitis.
 - b. Pelvic hæmatocele.
 - c. Fibroid tumor of uterus.
 - d. Impaction of fæces.
 - e. Ovarian tumor.
 - f. Salpingitis.

How would you differentiate pelvic cellulitis from pelvic peritonitis?

In many cases it is almost impossible to differentiate the two; they frequently complicate each other. The chief points of difference are these: Pelvic cellulitis almost never occurs except after labor, abortion, or operation on the cervix; pelvic peritonitis may arise from any cause of inflammation of the uterus or its adnexa, which may extend to the peritoneum. Pain and tenderness, as a rule, are less marked in cellulitis than in peritonitis. Cellulitis is more apt to bulge into the vagina than is peritonitis. Cellulitic deposits are more apt to suppurate than are peritonic. Vomiting is less frequent in cellulitis than in peritonitis.

How would you differentiate pelvic cellulitis from pelvic hæmatocele?

Chiefly by the history of an hæmatocele, *i. e.*, sudden sharp pain, pallor, faintness, and the physical signs of a collection of fluid which afterward coagulates and hardens. The above symptoms of shock and hemorrhage are wanting in cellulitis.

How would you differentiate cellulitic or peritonic deposits from fibroids of the uterus?

<i>Cellulitic or peritonic deposits</i>	<i>vs.</i>	<i>Fibroid tumors.</i>
History of acute inflammation.		Slow growth.
Pain and tenderness.		Insensitive.
Less plainly outlined.		Outlines more distinct.
Less intimately connected with the uterus.		Closely connected with the uterus.
Perhaps menorrhagia during the acute stage, then irregular menstruation.		Usually menorrhagia, gradually increasing till the menopause.

How would you differentiate impaction of fæces from pelvic peritonitis or cellulitis ?

In impaction of fæces, the mass is sausage-shaped, has a doughy feel, and is less closely connected with the uterus than an exudation of peritonitis or cellulitis ; it is not as tender on pressure, and gives no history of acute inflammation. The diagnosis is made certain by clearing out the rectum.

How would you differentiate a small ovarian tumor from pelvic peritonitis or cellulitis ?

There are no signs of acute inflammation as in cellulitis or peritonitis ; the ovarian cyst is usually fluctuating ; its multilocular character can sometimes be felt. The menstrual disturbances common in peritonitis and cellulitis are usually absent in cases of ovarian cysts ; an ovarian cyst gradually increases in size.

How would you differentiate pelvic cellulitis from salpingitis ?

By a careful bimanual, in a case of salpingitis, you can generally map out an enlarged, tortuous tube, usually distended, extending from the side of the uterus to the region of the ovary ; if distended with fluid, you may detect fluctuation. It does not bulge into the vagina as does cellulitis.

The history of the case is of value in the diagnosis.

What is the treatment of pelvic cellulitis ?

1. Prophylactic :—

Strict cleanliness and antiseptic precautions during labor, abortion, operations, etc.

2. Abortive :—

Put patient to bed, give a diaphoretic, as Dover's powder, and administer prolonged hot-water vaginal douches.

3. When exudation has occurred :—

Apply hot poultices to the abdomen, administer hot-water vaginal douches, move bowels, and attend to the general health.

4. When the cellulitis has become chronic :—

Apply counter-irritation externally by means of iodine or blisters ; per vaginam, employ hot-water douches, applications of iodine to the fornices, also glycerine tampons.

5. When the exudation suppurates :—

If the abscess points, incise under antiseptic precautions and drain. If it does not point, it is better to do an exploratory laparotomy in order to remove the abscess sac en masse, or, if this is not practicable, to determine the best place for opening into it from the vagina.

Pelvic Hæmatocele and Hæmatoma.

Define, and give the pathology.

Pelvic hæmatocele is an effusion of blood into the cavity of the pelvic peritoneum, enclosed by anatomical structures or inflammatory adhesions. (Hart and Barbour.)

Pelvic hæmatoma is an effusion of blood into the connective tissue of the pelvis beneath the peritoneum, usually between the folds of the broad ligaments.

In a pelvic hæmatocele, the effusion is usually into the pouch of Douglas ; if this is closed by adhesions, or if the effusion is very large, the blood may flow over into the utero-vesical pouch. The former condition gives rise to the name retro-uterine, the latter to ante-uterine hæmatocele. The blood is at first fluid ; it then coagulates. It may remain unchanged for a long time ; if small, it is usually absorbed. It may suppurate and break through into the rectum or vagina, rarely into the bladder or peritoneum.

What is the etiology ?

A. Predisposing causes :—

Active menstrual life, 25-35.

Extra-uterine gestation.

Frequent child-bearing.

Varicose condition of veins of broad ligament.

Disease of tubes or ovaries.

Previous pelvic peritonitis, with adhesions.

Atresia of genital tract.

Hæmophilia.

Poor surroundings.

Low state of the system.

Anything causing congestion of the pelvic viscera.

B. Exciting causes :—

Traumatism, blows, falls, etc.

Violent coitus during menstruation.

Sudden arrest of menstruation by exposure to cold.

Labor.

Some authorities now think that most of the cases of pelvic hæmatocele are due to extra-uterine pregnancy.

What are the symptoms of pelvic hæmatocele ?

A sudden sharp pain, and symptoms of shock and hemorrhage. The face becomes pallid, the expression anxious ; the pulse is rapid and feeble ; surface covered with a cold perspiration ; perhaps nausea and vomiting. Later, if the patient survive, we have symptoms of peritonitis and of pressure, either from the effusion or the displaced uterus. The pain and tenderness continue for several days ; there is usually painful defecation and dysuria ; sometimes menorrhagia is present. In a few days, if suppuration does not occur, the effusion diminishes in size and the symptoms abate. If suppuration occurs, septic symptoms appear.

The above are the symptoms of a well-marked case ; where the effusion is small the symptoms may be much less severe.

How do the symptoms of pelvic hæmatoma compare with those of pelvic hæmatocele ?

In pelvic hæmatoma there is, as a rule, less pain and less shock. If the effusion is large, however, there may be the symptoms of shock and hemorrhage.

What are the physical signs of pelvic hæmatocele ?

A tumor, usually behind the uterus, pushing the latter forward ; it is tense, elastic, tender ; at first soft, later smaller and harder. If suppuration occurs, it again becomes soft and fluctuating. If the abscess is to break into the rectum, this event is usually preceded by a mucous discharge from the latter.

What are the physical signs of pelvic hæmatoma ?

A small, tense, elastic tumor at the side of the uterus, not as tender as an hæmatocele.

What is the prognosis of pelvic hæmatocele ?

The prognosis is grave ; they may die at once from shock and

hemorrhage, or later from peritonitis or sepsis. If the effusion is small and well encapsulated, recovery often occurs. If the hæmatocele results from the rupture of an extra-uterine fruit sac of any considerable size, the case, without operation, is usually fatal.

What is the prognosis of pelvic hæmatoma?

Usually good. If the effusion suppurates, the prognosis is less favorable.

How would you differentiate pelvic hæmatocele from acute pelvic peritonitis?

Pelvic hæmatocele vs. *Acute pelvic peritonitis.*

History of sudden, sharp pain, with symptoms of shock and hemorrhage.	Less sudden in onset; symptoms of shock and hemorrhage wanting.
Absence of acute inflammation at first.	Symptoms of acute inflammation at first.
Uterus usually displaced forward.	Uterus fixed, not markedly displaced.

How would you differentiate pelvic hæmatocele from a fibroid tumor of the uterus?

Pelvic hæmatocele vs. *Fibroid tumor.*

History of sudden, sharp pain and symptoms of shock and hemorrhage.	Of slow growth; symptoms gradually developed.
Soon followed by signs of inflammation.	Absence of signs of inflammation.
Less intimately connected with the uterus.	More intimately connected with the uterus; moves with it.
Sensitive to pressure.	Insensitive to pressure.
Density less.	Density greater.

How would you differentiate pelvic hæmatocele from a retroflexed or retroverted uterus?

<i>Pelvic hæmatocele</i>	<i>vs.</i>	<i>Retroflexed or retroverted uterus.</i>
Acute history of pain, shock and hemorrhage.		Usually a long history.
Fundus of uterus usually lies forward.		Fundus backward; absent in front.
Sensitive to pressure.		Less sensitive, unless surrounded by peritonitis.

How would you differentiate pelvic hæmatocele from an ovarian cyst?

<i>Pelvic hæmatocele</i>	<i>vs.</i>	<i>Ovarian cyst.</i>
Acute history of pain, shock and hemorrhage.		History of slow growth, with few general symptoms.
More sensitive to pressure.		Less sensitive to pressure.
First elastic and soft, then hard.		Usually fluctuating throughout.

How would you differentiate pelvic hæmatocele from impacted fæces?

By the history, rectal examination, and thorough emptying of the rectum.

How would you differentiate pelvic hæmatocele from retro-uterine carcinoma?

<i>Pelvic hæmatocele</i>	<i>vs.</i>	<i>Retro-uterine carcinoma.</i>
Acute history of pain, shock and hemorrhage.		History of a chronic disease.
Uterus usually pushed forward.		Uterus but little displaced.

How would you differentiate pelvic hæmatoma from pelvic cellulitis?

<i>Pelvic hæmatoma</i>	<i>vs.</i>	<i>Pelvic cellulitis.</i>
History of sudden, sharp pain, perhaps symptoms of shock and hemorrhage.		History of labor, abortion, or operation on the cervix.
Signs of acute inflammation absent at first.		Signs of acute inflammation from the first.
Less sensitive.		More sensitive.

What is the treatment of pelvic hæmatocele?

The indications are :—

1. To arrest hemorrhage and relieve the shock.
2. To treat inflammatory complications and cause absorption of the exudation.
3. To avoid sepsis.

Keep the patient perfectly quiet; it is well to give a small hypodermic of morphine to quiet alarm and mitigate the shock. Some recommend the application of ice to the vagina and abdomen. Give light diet.

Later, apply heat externally and internally, by hot poultices to the abdomen and hot-water douches to the vagina; blisters may be of value.

If the hæmatocele is the result of the rupture of an extra-uterine fruit sac, open the abdomen, check hemorrhage (by clamping, and later, ligaturing broad ligament), cleanse the abdominal cavity and drain it.

If the effusion of blood suppurates, free drainage is desired. This is usually best accomplished by opening the abdomen, and if the pus sac cannot be removed, drain through the vagina, with the aid of sight and touch given by the abdominal opening. By this means one can puncture where sac is adherent to vagina without going through healthy peritoneum or intestine.

What is the treatment of pelvic hæmatoma?

The indications for treatment are the same as for pelvic hæmatocele: Quiet, cold, followed later by heat externally and internally; blisters. If suppuration occurs, drain through the vagina. It is often advisable to open the abdomen to determine the best situation to establish drainage through the vagina.

MENSTRUATION.

Define.

Menstruation is a periodical series of phenomena, the most marked of which is a discharge of blood from the uterine mucous membrane, with a shedding of its superficial layers, beginning, on an average, in this country, at fourteen, and recurring monthly till forty-four. The relation of menstruation to ovulation is still unsettled; Lawson Tait claiming that the Fallopian tubes have more influence on menstruation than have the ovaries.

Describe the factors which influence the onset of menstruation; what is the average frequency and duration of each period?

In temperate climates, menstruation usually appears at 13-15 years; it is earlier in warmer climates, later in cooler; it appears in girls who live an indoor, city life, earlier than in the country. The periods normally appear every 28 days, but in this there are great variations; some women in perfect health menstruate every 3 weeks, some only every 5 weeks.

The average duration of each period is 3-4 days, but this varies between 2 and 8. The discharge of blood is usually slight at first, reaches maximum on the second or third day, then gradually diminishes.

Disorders of Menstruation.

Amenorrhœa.

Define.

Amenorrhœa is the absence of menstruation between puberty and the menopause. It is the normal condition during pregnancy and lactation. It may be divided into:—

a. *Emansio mensium*—

Where menstruation has never appeared.

b. *Suppresio mensium*—

Where menstruation has appeared, but fails to reappear.

What is the etiology of amenorrhœa ?

The most frequent cause is anæmia, especially that form called chlorosis. Other causes are phthisis, or other debilitating diseases; acute diseases at puberty; non-development of the generative organs; atrophy of the generative organs; increasing obesity; removal of ovaries and tubes by operation.

What are the symptoms ?

Amenorrhœa is itself more a symptom than a disease, and the symptoms which usually accompany amenorrhœa are those of the disease which causes it—most frequently anæmia or phthisis. Thus, from anæmia we have :—

Pallor.

Dyspnœa and palpitation of the heart on exertion.

Depraved appetite.

Constipation.

Headache.

Œdema.

Murmur at the base of the heart.

Neuralgic pains.

Hysteria.

From phthisis we get the regular symptoms of cough, emaciation and night sweats.

What is the prognosis ?

When associated with simple anæmia the prognosis is good. When due to non-development of the generative organs the amenorrhœa usually continues. When associated with phthisis or other wasting disease, the prognosis is that of the disease.

What is the treatment of amenorrhœa ?

a. When due to anæmia :—

Some form of iron, as Blaud's pills; oxygen; nourishing food; fresh air; regulation of the bowels, and attention to the mode of life. Permanganate of potash and the black oxide of manganese are recommended, but their usefulness is doubted by many.

b. When due to imperfect, or non-development of the generative organs :—

Determine, under anæsthesia, whether ovaries are present or not; if absent, do not attempt to induce menstruation. If the ovaries are

present, besides attention to the general health, the following methods may be employed :—

- Hot water vaginal douches ;
- Boro-glyceride tampons ;
- Electricity to uterus and over ovaries.

c. When associated with phthisis, or other wasting disease, the treatment is that of the associated disease.

In cases of acute suppressio-mensium, due to exposure to cold, etc., hot mustard foot baths, hot applications to the pelvic region and diaphoretics internally, may be used with safety and advantage.

Vicarious Menstruation.

Describe.

Vicarious menstruation is a periodical discharge of blood from some part of the body other than the interior of the uterus. It may occur with either amenorrhœa or scanty menstruation ; it usually appears at about the time of the regular flow. It may come from almost any mucous membrane : from the nose, mouth, breast, etc. ; it may also come from an open sore ; it is usually due to a watery condition of the blood and a poor condition of the blood vessels. Direct treatment is usually not required.

Menorrhagia and Metrorrhagia.

Define.

Menorrhagia is a prolonged or excessive menstrual flow.

Metrorrhagia is “uterine hæmorrhage occurring independently of the menses.”

What is the etiology?

Menorrhagia and metrorrhagia may be produced by causes acting at a distance, or local, in or about the uterus itself. Acting at a distance are :—

1. Obstructed general circulation from disease of heart, lungs or liver.
2. Low condition of blood and vessels in certain wasting diseases.

Acting about the uterus are :—

1. Inflammation of the pelvic peritoneum ;
2. Disease of tubes or ovaries ;
3. Tumors.

The most common causes are situated in the uterus itself, and among them are the following :—

1. Subinvolution of the uterus ;
2. Retained secundines ;
3. Submucous, or interstitial fibroids ;
4. Polypi ;
5. Carcinoma ;
6. Fungous granulations of the endometrium.

The last is the most common cause of all.

What is the treatment of menorrhagia and metrorrhagia ?

When due to causes acting outside of the uterus, the treatment is that of these causes ; at the same time, there will often be found fungous granulations of the endometrium which magnify the influence of the distant causes ; these fungosities need to be removed by the curette, under antiseptic precautions, and iodine, or carbolic acid, or a mixture of the two, applied to the endometrium ; it is then advisable to administer the fluid extracts of *hydrastis canadensis* and *ergot*. Disease of the pelvic peritoneum, tubes or ovaries requires its own treatment. Fibroids may demand removal of ovaries and tubes. Polypi require removal. Carcinoma needs its own treatment. Fungous granulations demand curetting as above.

Dysmenorrhœa.

Define.

“Dysmenorrhœa may be defined as the occurrence of pain just before, during or after the menstrual period” (Hart and Barbour).

What are the varieties of dysmenorrhœa ?

The following varieties are mentioned, but seldom distinctly differentiated :—

1. Obstructive ;
2. Congestive ;
3. Neuralgic ;
4. Ovarian ;
5. Membranous.

OBSTRUCTIVE DYSMENORRHŒA.

What is the etiology?

Both the etiology and pathology of the different varieties of dysmenorrhœa are still far from settled, but the conditions usually associated with obstructive dysmenorrhœa are :—

- a.* Flexions of the uterus ;
- b.* Stenosis of os externum, os internum, or the whole cervical canal ;
- c.* Polypi ;
- d.* Fibroids distorting uterine canal ;
- e.* Long, conical cervix ;
- f.* Spasmodic contraction of os internum.

What are the symptoms?

Intermittent, cramp-like pains, accompanying the expulsion of blood clots which have formed above the obstruction ; this expulsion is followed by relief. A sound passed between the periods usually shows hyperæsthesia of the internal os.

What is the treatment?

Mechanical dilatation of the cervical canal by one of the dilators of the glove-stretcher variety, and the maintenance of the patency by the occasional passage of graduated sounds for a few weeks, or, as some recommend, by the introduction of an intra-uterine stem so arranged as to drain ; this may be of hard rubber, or of wire, as that of Outerbridge.

It is often wise to touch the internal os after dilatation with carbolic acid, or iodized phenol.

The intra-uterine stem should only be used while the patient is in bed.

CONGESTIVE DYSMENORRHŒA.

What is the etiology?

“Congestive dysmenorrhœa depends upon an advance of the menstrual congestion beyond the physiological limits” (Reeve).

The conditions associated with congestive dysmenorrhœa are the following :—

- a.* Exposure to cold ;
- b.* Defective general circulation ;

- c.* Metritis ;
- d.* Endometritis ;
- e.* Displacements of the uterus ;
- f.* Pelvic tumors ;
- g.* Pelvic peritonitis.

What are the symptoms ?

Between the periods there are usually symptoms of pelvic trouble, or defective general circulation.

Just before the flow begins, there appear feelings of weight and heat in back and pelvis, headache, flushing of the face, and some rise of temperature ; the pulse is rapid. The symptoms are usually relieved by a free flow.

What is the treatment ?

a. During the attack—

1. Hot mustard foot-baths ;
2. Hot sitz-baths ;
3. Diaphoretics ;
4. Hot pelvic applications.

b. During the intermenstrual periods—

1. Seek to remove the cause ;
2. Scarify cervix occasionally ;
3. Employ glycerine tampons ;
4. Avoid excessive coitus and exertion.

Just before the flow begins, use hot-water vaginal douches.

NEURALGIC DYSMENORRHEA.

What is the etiology ?

This frequently occurs in combination with some of the other forms of dysmenorrhœa, especially the congestive ; it is most often associated with an indolent, indoor life, anæmia, malnutrition, chronic malarial disease or hysteria. Sometimes no cause can be assigned.

What are the symptoms ?

Pain, sometimes referred to uterus, sometimes to ovaries, sometimes elsewhere ; it changes its situation ; is often shooting in character ; usually begins a little before the flow ; is sometimes relieved

by a free flow. Between the periods, no pathological changes can be detected in the pelvic organs, but patient suffers from neuralgia elsewhere—facial, intercostal, etc.

What is the treatment?

Attention to the mode of life; fresh air; exercise; tonics, especially iron, arsenic and quinine; at the onset of the pelvic pains employ hot sitz-baths and hot-water vaginal douches.

OVARIAN DYSMENORRHŒA.

What is the etiology?

This is applied to a class of cases associated with disease of the ovaries, but the etiology is far from settled, and the class not distinct.

What are the symptoms?

Between the periods there is pain and tenderness over the region of the ovary, increased by exercise, defecation and coitus; these symptoms are increased at the menstrual periods.

MEMBRANOUS DYSMENORRHŒA.

Describe.

“Membranous dysmenorrhœa is characterized by the expulsion at the menstrual periods of organized membranes either as a whole or in pieces.” (Reeve.)

What is the etiology and pathology?

These are both matters of dispute, but we usually find in these cases chronic endometritis and poor general health. The inner surface of the membrane is smooth and shows the openings of the utricular glands; its external surface is rough and shaggy (see Fig. 12).

According to Hart and Barbour, “It is of the greatest importance to remember that it is not a product of conception, and should not be mistaken for an early abortion.” It is composed of the superficial layer of the endometrium, with increased connective tissue; blood accumulates under it and dissects it off.

What are the symptoms?

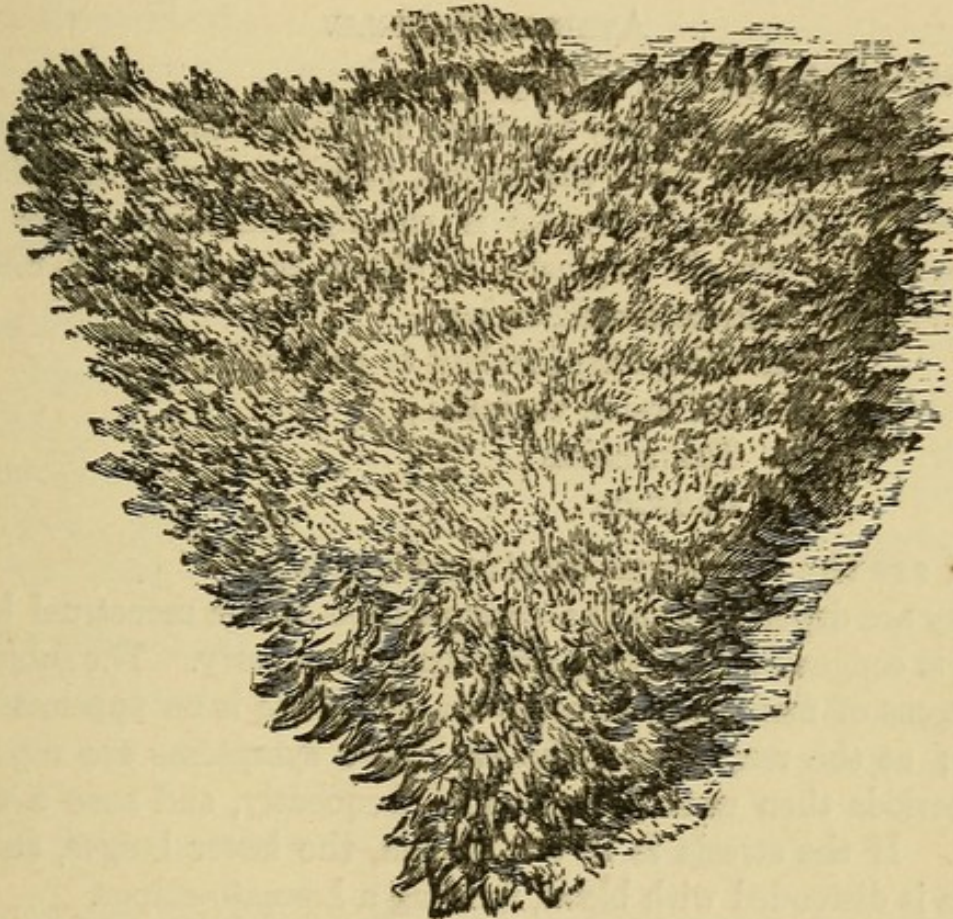
Severe colicky pain, usually recurring at each period; the flow is

often intermittent ; thus the symptoms resemble those of obstructive dysmenorrhœa. The course is usually protracted.

How would you differentiate membranous dysmenorrhœa from an early abortion ?

By the absence of chorionic villi and by the repeated occurrence.

FIG. 12.



Sketch of a Dysmenorrhœal Membrane as seen under Water (Sir J. Y. Simpson).

What is the treatment ?

a. Between the periods—

Dilate the cervix, curette the uterine canal, and apply to the endometrium iodized phenol, pure carbolic, or tincture of iodine.

b. During the menstrual period—

Use hot baths, hot applications to the pelvis, and diaphoretics.

Malformations of the Vagina.

What are the important varieties ?

- a. Atresia vaginæ ;
- b. Double vagina ;
- c. Absence of vagina.

ATRESIA VAGINÆ.

Give the varieties and etiology.

Atresia of the vagina may be either at the hymen, forming atresia hymenalis, or higher up in the vagina, forming atresia vaginalis.

Etiology.—Atresia hymenalis is usually congenital, from mal-development. Atresia vaginalis is either congenital, or may be acquired from cicatrization following—

- a. Sloughing incident to parturition ;
- b. Adhesive vaginitis ;
- c. Traumatism ;
- d. Caustics.

What are the symptoms of atresia vaginæ ?

They are dependent on the accumulation of the menstrual blood, hence in congenital cases they are absent till puberty. The subjective symptoms of menstruation come on, but there is no appearance of blood ; at the next period the subjective symptoms are repeated. The periods then usually come more frequently, and soon a tumor forms. If the atresia is at the hymen, the latter bulges, and the vagina is distended with blood, forming a hæmato-colpos.

In atresia hymenalis the cervix is usually not dilated ; in atresia vaginalis the dilatation may extend to the uterus and tubes.

If the atresia is acquired, of course there will be no symptoms till the menstrual blood is retained.

What are the results of atresia hymenalis if unrelieved by operation ?

If the hymen is thin, it may rupture ; if thick, the vagina may rupture ; after rupture, septicæmia may occur.

What are the results of atresia vaginalis ?

The vagina may rupture.

The uterus and tubes may become distended, forming hæmato-metra or hæmato-salpinx, and may rupture.

The atresia may rupture.

After rupture, septicæmia may occur.

Where else in the genital tract than in the vagina may atresia occur? Give the etiology and symptoms.

Atresia may occur at the cervix.

Atresia of the cervix may be congenital, or acquired from cicatrization following parturition, the use of caustics, or from a too close trachelorrhaphy. Symptoms appear when the menstrual blood accumulates behind the atresia, and resemble those of atresia vaginæ. The amenorrhœa and enlargement of the uterus may make one suspect pregnancy.

What are the results of atresia of the cervix if unrelieved by operation?

If it is present during menstrual life, the uterus and tubes become distended, and are liable to rupture, with the danger of peritonitis and death. If it occurs for the first time after the menopause, it may cause little trouble, or the atresia may rupture.

What is the character of the retained fluid?

During menstrual life the blood is of a brownish, chocolate color; it is grumous and treacle-like in consistency, kept from clotting by the mucus.

After the menopause, the retained fluid is honey-like.

What is the treatment of atresia of the genital tract with retention of the menstrual blood?

Aspirate slowly; under strict antiseptics, incise the obstruction, and maintain the opening by a glass plug.

What are the dangers of rapid evacuation of a hæmato-metra?

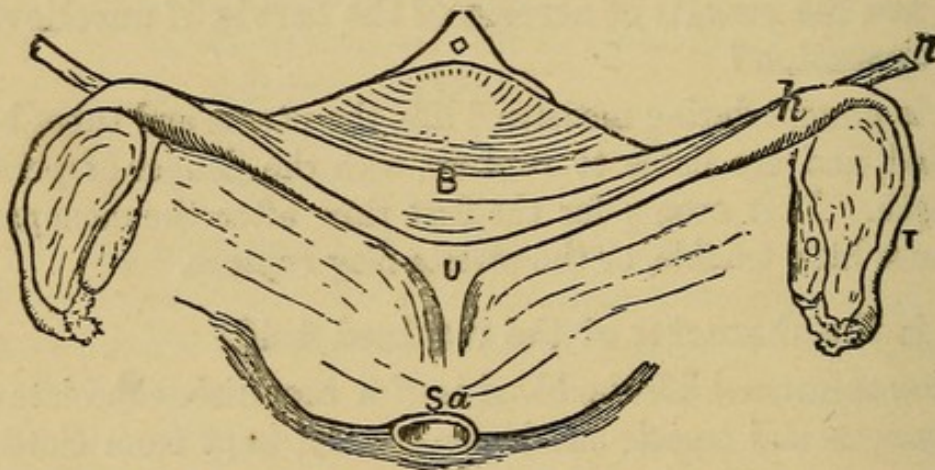
The tubes are probably distended, and have formed adhesions; the rapid collapse of the uterus would tend to tear the tubes from their adhesions, with the danger of rupture of the tubes, and peritonitis.

Malformations of the Uterus.

What are the principal varieties?

1. Rudimentary uterus ;
2. Uterus bipartitus ;
3. Uterus unicornis ;
4. Uterus bicornis ;
5. Uterus didelphys ;
6. Uterus septus ;
7. Infantile uterus ;
8. Congenital atrophy of the uterus ;
9. Complete absence of the uterus, very rare.

FIG. 13.



Rudimentary Uterus (Veit). *Sa*, sacrum; *U*, solid rudiment of uterus; *h*, rudimentary horn; *B*, bladder; *O*, ovary; *T*, Fallopian tube; *r* round ligament.

Describe the rudimentary uterus.

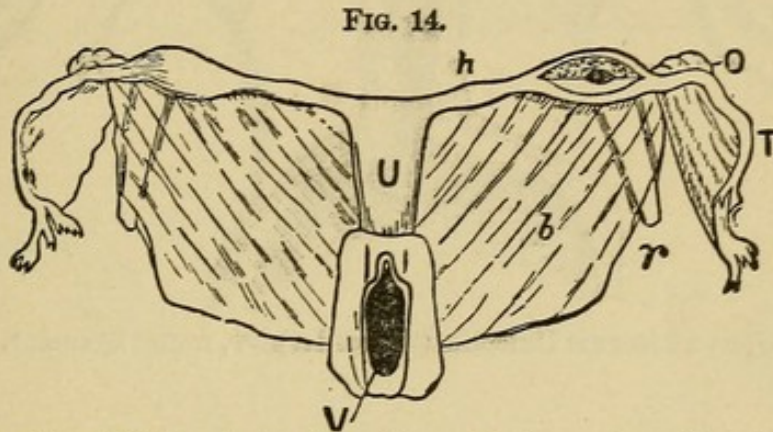
In this case (see Fig. 13) "the uterus is represented by a band of muscular fibre and connective tissue on the posterior wall of the bladder." (Hart and Barbour.)

Describe the uterus bipartitus.

In the uterus bipartitus (see Fig. 14) the rudimentary horns are present, and are either hollow or solid and cord-like; they are connected to each other and to the vagina by the cervix, which is represented by a fibrous band. The ovaries, breasts and external genitals may be well developed.

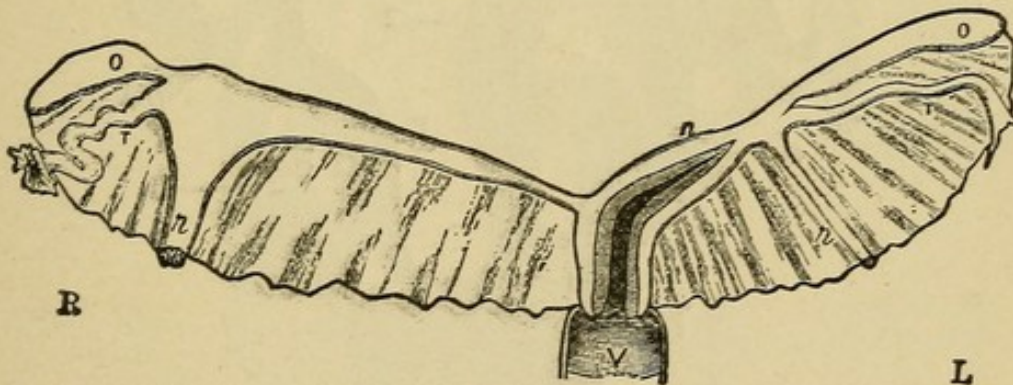
Describe the uterus unicornis.

The body of the uterus in this variety (see Fig. 15) is long and narrow, and is directed to one side; its fundus has attached to it one Fallopian tube and ovary; on the opposite side of the body is seen the representative of the other horn, which is either solid or hollow;



Uterus Bipartitus (Rokitansky). *V*, vagina; *U*, uterus; *h*, rudimentary horn; *O*, ovary; *T*, tube; *r*, round ligament; *b*, broad ligament.

FIG. 15.



Uterus Unicornis (Schroeder). *R*, right side; *L*, left side. The left horn (*h*) is well developed and communicates with the uterine cavity. The right horn is in the form of an elongated band; its point of connection with the Fallopian tube is indicated by the insertion of the round ligament, which is hypertrophied. Other letters as in preceding diagrams.

connected with this, and separated from it by the attachment of the round ligament, are the tube and ovary of that side.

Describe the uterus bicornis.

In this form (see Fig. 16) the division into two horns is distinctly visible externally; the division is usually seen also in the interior of the uterus on section.

FIG. 16.

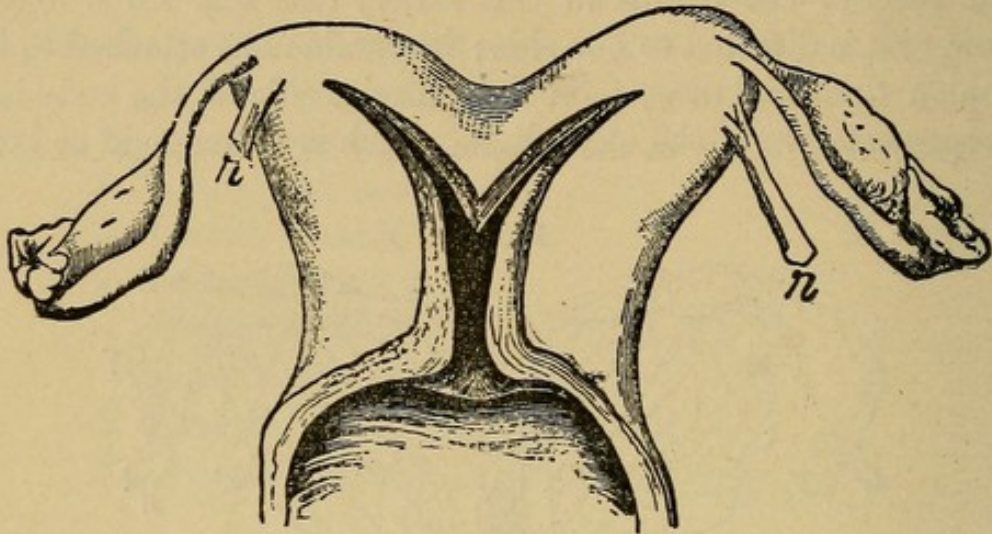
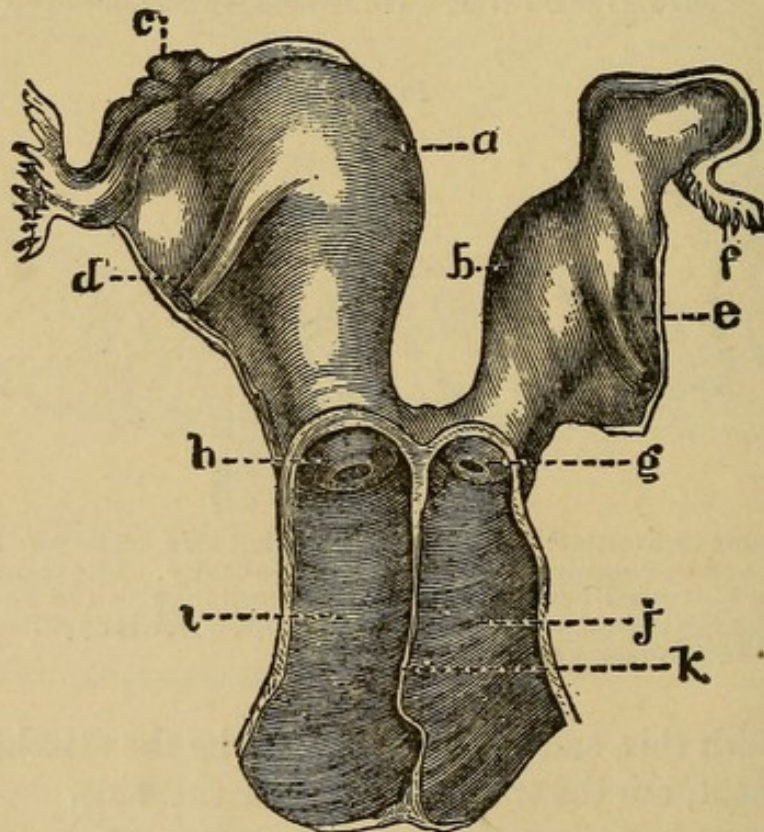
Uterus Bicornis Unicollis (Schroeder). *r*, round ligament.

FIG. 17.



Uterus Didelphys. *a*, right cavity; *b*, left cavity; *c*, right ovary; *d*, right round ligament; *e*, left round ligament; *f*, left tube; *g*, left vaginal portion; *h*, right vaginal portion; *i*, right vagina; *j*, left vagina; *k*, partition between the two vaginæ. (From De Sinety, after Ollivier.)

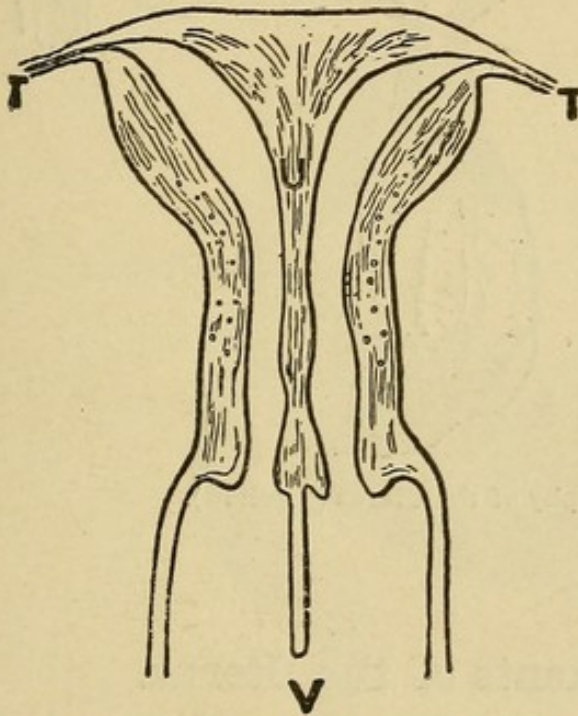
What is the uterus didelphys?

Here the two halves of the uterus are separated throughout (see Fig. 17). This condition is very rare.

Describe the uterus septus.

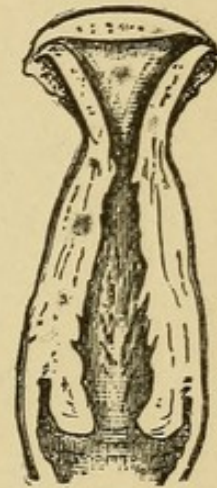
Here the division is entirely internal (see Fig. 18); beginning at the fundus, it extends a variable distance toward the os externum, sometimes reaching it. There is no indication of the division from the outside.

FIG. 18.



Uterus Septus in Vertical Transverse Section (Kussmaul). *U*(uterus), placed on septum which divides cavity into two lateral portions; *T*, Fallopian tubes; *V*, vagina divided into lateral cavities by prolongation of septum downward.

FIG. 19.



Infantile Uterus (Schroeder).

What is an infantile uterus?

In this condition (see Fig. 19) the cervix is 2-3 times longer than the body, the relation of cervix to body remaining as at birth. The uterus as a whole is smaller than normal.

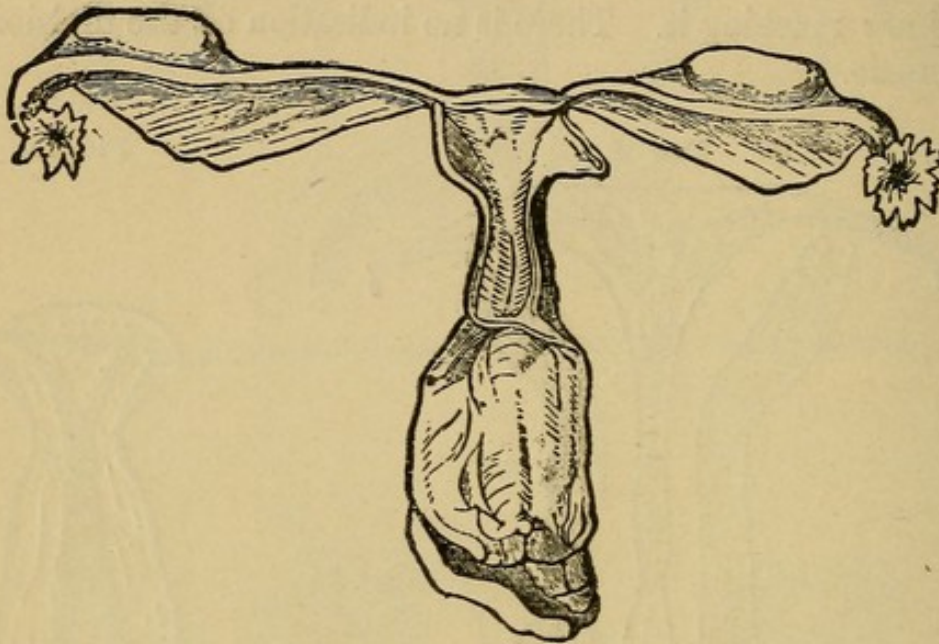
What is meant by congenital atrophy of the uterus?

The relative lengths of cervix and body (see Fig. 20) conform to those of a virgin uterus, but the whole uterus is atrophied.

What is the occurrence of complete absence of the uterus?

It is very rare indeed, and can only be ascertained by a post-mortem examination. Many cases of supposed absence of the uterus are proved, on autopsy, to be cases of rudimentary uterus.

FIG. 20.



Primary Atrophy of the Uterus (Virchow).

Displacements of the Uterus.

What do we mean by a displacement of the uterus in a clinical sense?

“Changes in the position of the uterus only become displacements, in the clinical sense, when they are more or less stable. Limitation or hindrance of the normal movements of the uterus is a main characteristic of its displacements.” (Schultze.)

What are the principal displacements of the uterus?

- a.* Anteversion ;
- b.* Anteflexion ;
- c.* Retroversion ;
- d.* Retroflexion ;
- e.* Prolapse.

What is the difference between a "version" and a "flexion?"

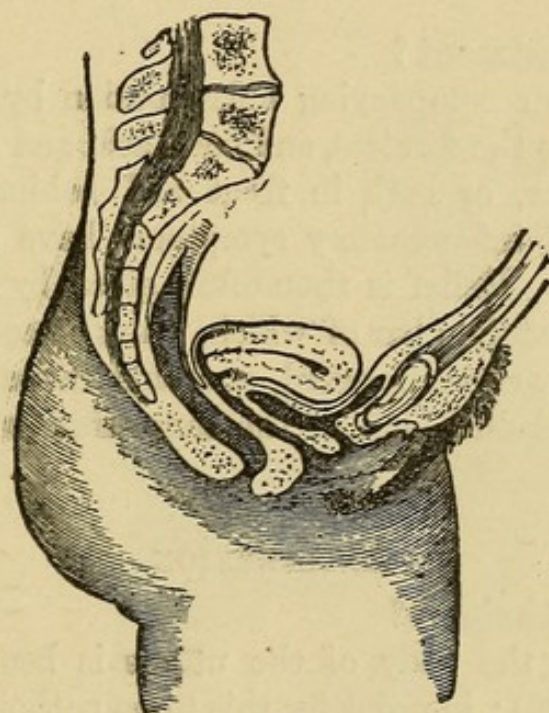
In a "version" the canals of the cervix and body are in the same straight line; in a "flexion" they make an angle with each other.

ANTEVERSION.

What is the pathology?

The uterine axis is straightened (see Fig. 21), so that the fundus lies forward, and the cervix is directed backward toward the hollow

FIG. 21.



Anteversion of the Uterus (Schroöder).

of the sacrum; the uterus is usually enlarged and more rigid, especially about the internal os. The anteverted uterus may be fixed or movable.

What is the etiology?

The chief causes are those of a metritis, and pelvic peritonitis or cellulitis, thus: Subinvolution, laceration of the cervix, with sepsis, and other causes of pelvic inflammation.

What are the symptoms?

They are the symptoms of the accompanying metritis, peritonitis or cellulitis. One of the most marked symptoms is frequent mictu-

rition, due to the pressure of the uterus on the bladder, the uterus being fixed forward and not allowing the bladder to expand normally.

Schroeder describes a discomfort arising from the motion of the enlarged, sensitive, anteverted uterus, occurring with the movements of the patient. Menorrhagia sometimes occurs.

What are the physical signs?

The cervix is far back, pointing toward the hollow of the sacrum ; the body of the uterus lies just above the anterior vaginal wall, the fundus just behind the pubis. The normal angle between cervix and body is obliterated ; the mobility or fixity is easily detected.

What is the treatment?

First treat the accompanying inflammation by hot-water vaginal douches, iodine to the fornices, and boric acid and glycerine tampons behind the cervix, or both in front and behind. Continue this treatment till all inflammatory symptoms have subsided and the uterus is mobile. Relief is then often given by such a pessary as Emmet's, the posterior bar of which, when placed in the posterior fornix, pushes the cervix forward, and thus raises the fundus somewhat from the bladder, and at the same time raises the uterus a little as a whole.

ANTEFLEXION.

What is the pathology?

In anteflexion the body of the uterus is bent forward on the cervix (see Fig. 22) ; in order for this to be pathological, there must be rigidity at the point of flexion.

What is the etiology?

It may be congenital (puerile, Schultze) or acquired.

The most common causes of the latter are a metritis occurring in a flexible uterus, or an inflammatory process occurring in the utero-sacral ligaments, drawing the upper portion of the cervix upward and backward. This latter is the most usual cause. Bandl thinks cervical catarrh the first cause, extending to the cervical tissue, and then to the cellular tissue in the utero-sacral ligament.

It is sometimes caused by the adhesions of peritonitis drawing the upper portion of the cervix backward.

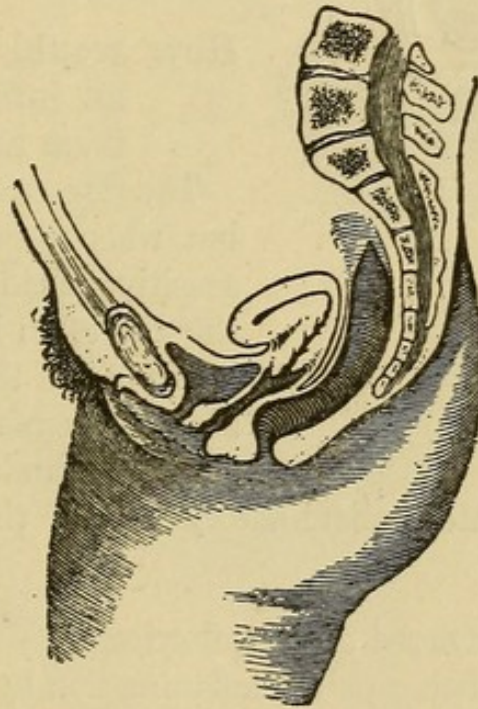
What are the symptoms ?

- a.* Dysmenorrhœa ;
- b.* Sterility ;
- c.* Disturbance of bladder functions—frequent micturition ;
- d.* Leucorrhœa ;
- e.* Other symptoms are those of the accompanying inflammation.

What are the physical signs ?

The cervix lies rather high ; the os is directed downward and forward ; as you pass the finger up along the anterior wall of the

FIG. 22.



Anteflexion of the Uterus (Schroeder).

cervix, it runs into a marked angle between cervix and body. The body can be felt lying in front of the cervix, just above the anterior vaginal wall. The cervix is often long and the os small. The uterus is sometimes both anteflexed and retroverted.

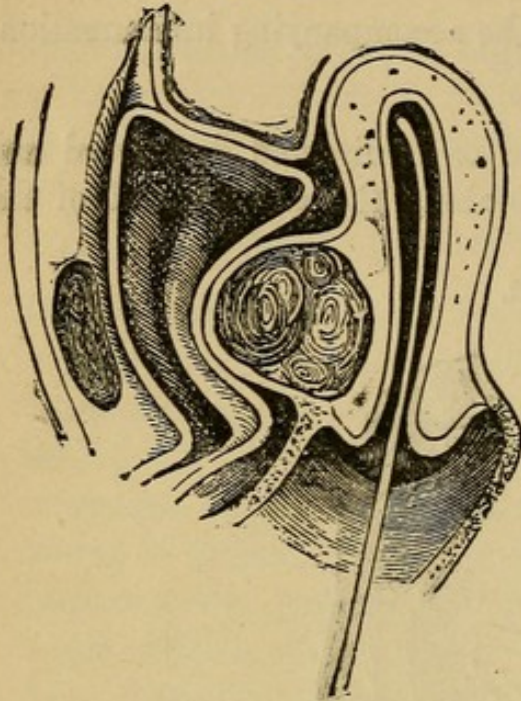
From what must you differentiate an anteflexion ?

- From—1. A fibroid tumor in the anterior wall of the uterus ;
 2. An inflammatory deposit in front of the cervix.

How would you differentiate an anteflexed uterus from a fibroid tumor in the anterior wall?

In an anteflexion you cannot feel the fundus elsewhere, and a sound passes when sharply curved into the body felt in front of the cervix.

FIG. 23.



Sound passed to show that a Fibroid of the Anterior Wall is not an Anteflexion (Leblond).

In a fibroid in the anterior wall (see Fig. 23) the sound does not pass into the body felt in front of the cervix, but behind it, and the fundus can be felt above and behind the fibroid.

How would you differentiate an inflammatory deposit from an anteflexion?

The former is comparatively rare, but when present is usually more sensitive than an anteflexion; in the case of an inflammatory deposit in front of the cervix, a careful bimanual examination will usually show the fundus elsewhere.

During the acute, inflammatory period the sound is contra-indicated.

What is the treatment of anteflexion?

First treat all existing pelvic inflammation, by means of hot-water douches, counter-irritation and glycerine tampons. When all inflammatory symptoms have subsided, dilate the cervix, under antiseptic precautions, with one of the glove-stretcher dilators, and apply carbolic acid or iodized phenol to the region of the internal os. Maintain the dilatation by the introduction of the graduated hard dilators, or sounds, once or twice a month for two to three months.

Some employ the intra-uterine stem for maintenance of the dilatation, but this is accompanied by danger.

Outerbridge's wire tubes are also employed for this purpose.

RETROVERSION AND RETROFLEXION.

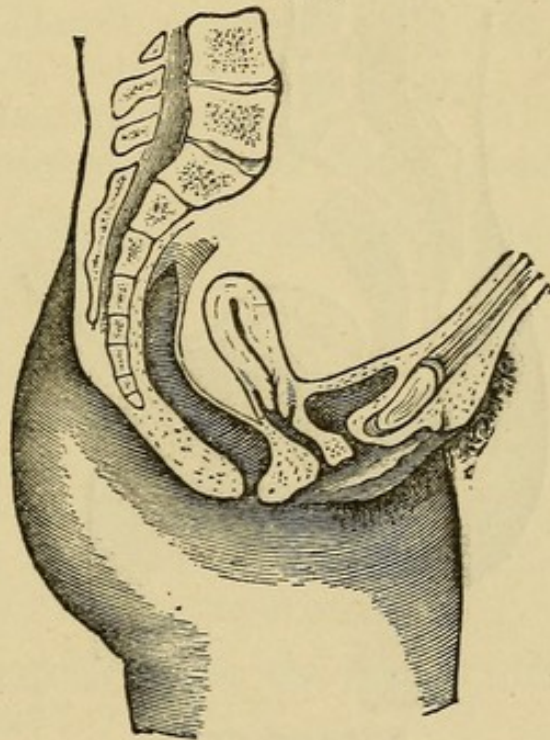
Define.

“Retroversion may be defined as the permanent dislocation backward of the fundus uteri, when the form of the uterus is such that axis of body and axis of cervix are identical. Retroflexion denotes the permanent backward dislocation of the fundus uteri, with simultaneous flexion of the uterus over the posterior surface.” (Harrison.)

What is the etiology and pathology?

Retroversion (see Fig. 24) may exist by itself, but with retroflexion there is always more or less retroversion. Usually the uterus is first

FIG. 24.



Retroversion of the Uterus (Schroeder.)

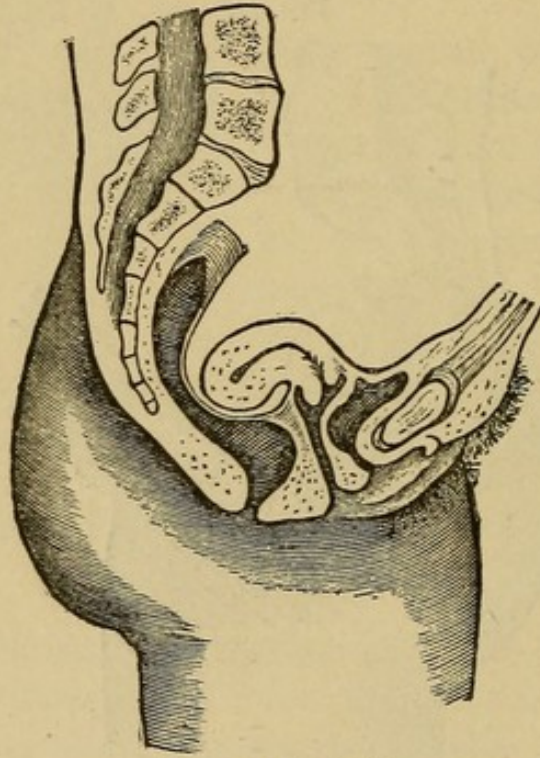
retroverted, and then intra-abdominal pressure continuing, if the uterus is flexible, the fundus is pushed backward and downward. The combination of the two is thus most common, and is described as retroversio-flexio (see Fig. 25). Retroversio-flexio is most frequent in multiparæ following parturition, where the ligaments are lax and patient lies on the back, and especially if the patient rises before involution has occurred. It may occur, however, in nulliparæ

or virgins, from severe blows, falls, lifting, straining, etc.; also from inflammatory adhesions, drawing the uterus backward.

The most common agent in pushing a movable uterus behind the perpendicular is distention of the bladder; intra-abdominal pressure may then act on the anterior surface of the uterus. Relaxation of the utero-sacral ligaments, and thickening and shortening of the utero-vesical, favor retroversio-flexio.

Pathologically, we usually find the body of the uterus congested and enlarged, and more or less rigidity at the junction of cervix and body, from development of fibrous tissue.

FIG. 25.



Retroversio-flexio.

What are the symptoms?

1. More or less constant pain in the back;
2. Symptoms of pelvic inflammation;
3. Constipation;
4. Irritability of the bladder;
5. Leucorrhœa;
6. Menorrhagia;
7. Dysmenorrhœa, especially when flexion is marked;

8. Abortion ;
9. Sterility ;
10. Reflex neuroses.

What are the physical signs ?

On making the bimanual examination, you find the cervix nearer the vulva than normal, the fundus absent in front, and the os pointing more or less forward ; on running the vaginal fingers along the posterior wall of the cervix, you find a body which, in a retroversion, continues the line of this wall, in a retroflexion makes an angle with it. This body moves as a part of the uterus ; the sound passes into it.

From what must you differentiate retroversio-flexio ?

1. Fibroid tumor on posterior wall of the uterus ;
2. Fæces in the rectum ;
3. Inflammatory deposits ;
4. Prolapsed ovary or small ovarian tumor.

How would you differentiate retroversio-flexio from a fibroid on the posterior wall ?

Make a careful bimanual examination. In case of a backward displacement of the uterus, we find an absence of the fundus in front, the cervix points more or less forward, and the sound, when introduced, goes backward.

In case of a fibroid on the posterior wall, the fundus may be felt in front of it, and the sound passes forward. The tumor may feel more irregular and harder than the uterus.

How would you differentiate the fundus uteri from fæces in the rectum ?

On bimanual examination, the fundus can often be felt forward, and the sound passes forward ; the fæces have a more doughy feel than the uterus ; if doubt exists, always empty the rectum before making a diagnosis.

How would you differentiate the fundus uteri from inflammatory deposits in the pouch of Douglas ?

During the stage of acute inflammation this may be very difficult, as the sound is then contraindicated. Finding the fundus in front is the chief element in the diagnosis.

When acute inflammation has subsided, introduction of the sound will give great assistance.

How would you differentiate the fundus uteri from a prolapsed ovary or small ovarian tumor?

By making a careful bimanual examination, the uterus is found lying in front of the prolapsed ovary or tumor. Assistance may be given by the use of the sound, or drawing down the cervix with a volsella.

What are the indications in the treatment of retroversio-flexio?

1. To treat the pelvic peritonitis or cellulitis, if present, according to the regular methods;
2. To replace the uterus;
3. To retain it in place.

What are the methods of replacing a retroverted or retroflexed uterus when movable?

1. Place the patient in Sims' position; introduce index and middle fingers of the right hand into the posterior fornix vaginæ; have patient breathe deeply and slowly; during an expiration, raise the body of the uterus with the backs of the vaginal fingers till it passes the promontory of the sacrum, then transfer one or both fingers to the front of the cervix, and push that backward; this throws the fundus forward.

2. Another method is to replace the uterus while patient is in the dorsal position, by means of the bimanual, either vagino-abdominal or recto-abdominal. In this method the body of the uterus is raised by the fingers in the vagina or rectum until it can be grasped by the external hand, when it is then brought forward.

3. When the body of the uterus is very sensitive, so that pressure by the fingers is very painful, the uterus may be replaced by means of the sound, as follows: Introduce the sound with the concavity backward; then make the handle describe an arc of a circle from behind forward; then slowly depress the handle toward the perineum; this throws the uterus forward.

4. To replace the gravid uterus, the following method is sometimes employed: Place patient in the genu-pectoral position; draw down

cervix with the volsella, and press fundus uteri toward the bladder, with the finger in the rectum.

When the uterus in a retroversio-flexio is rigid at the angle of flexion, we do not expect to remove the flexion, but only to correct the version.

What are the methods of replacing a retroverted or retroflexed uterus when fixed by adhesions?

If signs of pelvic inflammation are present, treat the inflammation by hot douches, sitz-baths, wet pelvic packs, attention to the bowels, etc. When the inflammation has subsided, the uterus may gradually be replaced by cautious manipulation and stretching of the adhesions, and gentle attempts at raising the uterus, a few moments at a sitting, with the fingers in the posterior fornix vaginae; after the manipulation insert a tampon, to be worn for twenty-four hours. The manipulations may be assisted by hot-water vaginal douches between the sittings.

Schultze's method of forcible reposition consists in placing the patient under anæsthesia, in the lithotomy position, inserting index and middle fingers of left hand high up into the rectum, and with these fingers forcibly, but gradually, elevating the fundus uteri and breaking up the adhesions; the right hand is placed on the abdomen, and as the uterus is elevated, it is grasped by this external hand and brought forward.

This method is rarely advisable.

What are the means for retaining the uterus in place after reposition?

1. Pessaries;
2. Operative procedures.

Pessaries.

What are the varieties in most common use?

1. The Albert Smith;
2. The Emmet;
3. The Thomas.

Describe them.

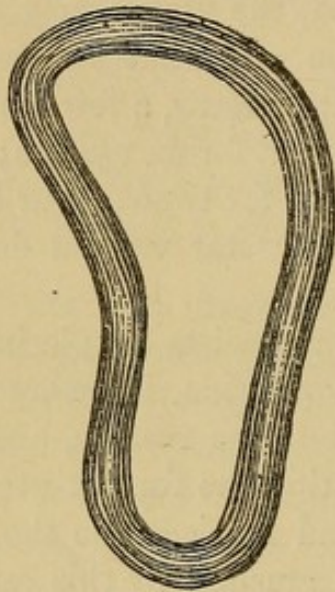
They are all usually made of hard rubber.

The Albert Smith (see Fig. 26) is a modification of the Hodge pessary; its anterior extremity is narrow, the posterior broad; the posterior extremity curves upward behind the cervix, the anterior downward away from the urethra.

The Emmet pessary is usually made of a larger bar than the Albert Smith, and the curve is much flattened.

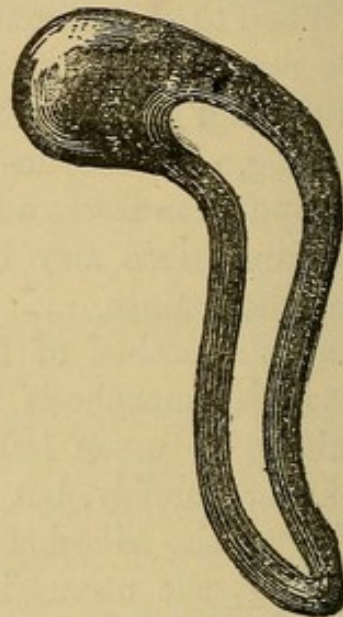
The Thomas (see Fig. 27) is long, narrow, and has its posterior bar much enlarged.

FIG. 26.



Albert Smith Pessary.

FIG. 27.



Thomas Pessary.

How does a retroversion pessary act?

Not by pushing up the body or fundus, but by making the posterior vaginal wall tense, thus drawing the cervix backward, and in this way throwing the fundus forward.

What are the contraindications to the use of a pessary?

A pessary should not be introduced till all pelvic inflammation has subsided, and, as a rule, not until the uterus can be well brought forward; "but occasionally, when the uterus is elevated to about the promontory, the pessary may be applied."

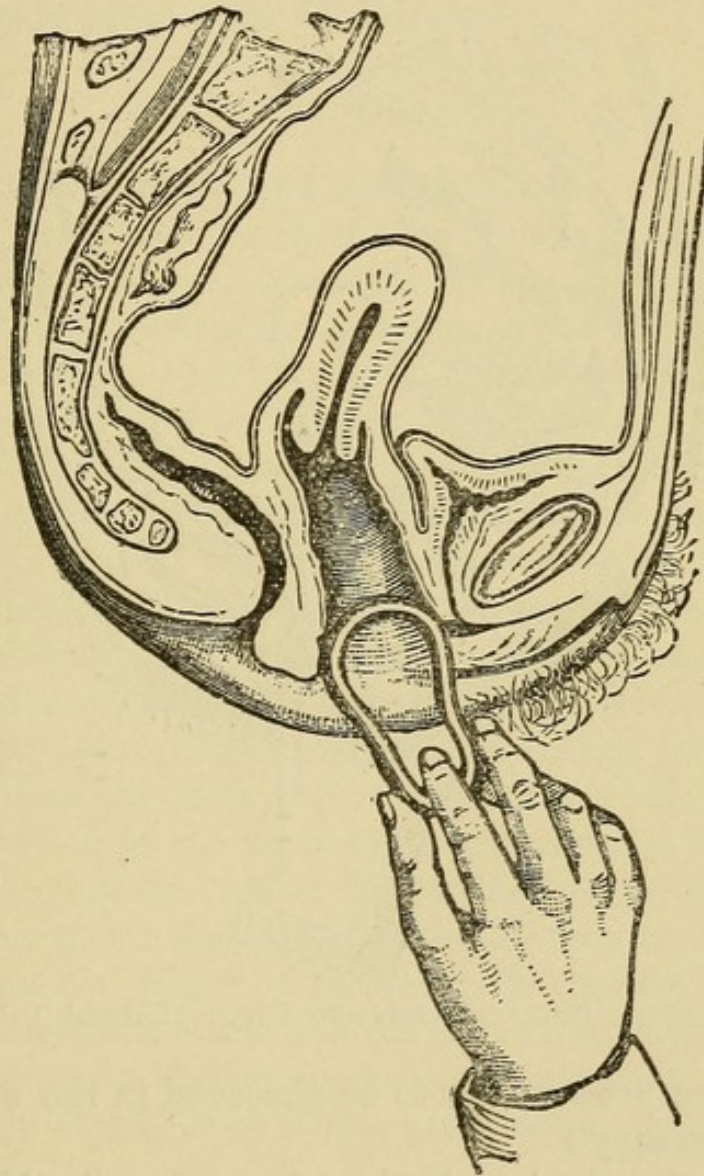
What is the proper position of a retroversion pessary after introduction?

The broader extremity should lie behind the cervix and curve upward; the narrow in front and curve downward.

How would you introduce one of these retroversion pessaries?

They may be introduced with patient either in the dorsal or in Sims' position, preferably in the latter, and in the following manner: Standing at the side of the table, near the buttocks of the patient, separate the labia a little with the fingers of the left hand; taking

FIG. 28.

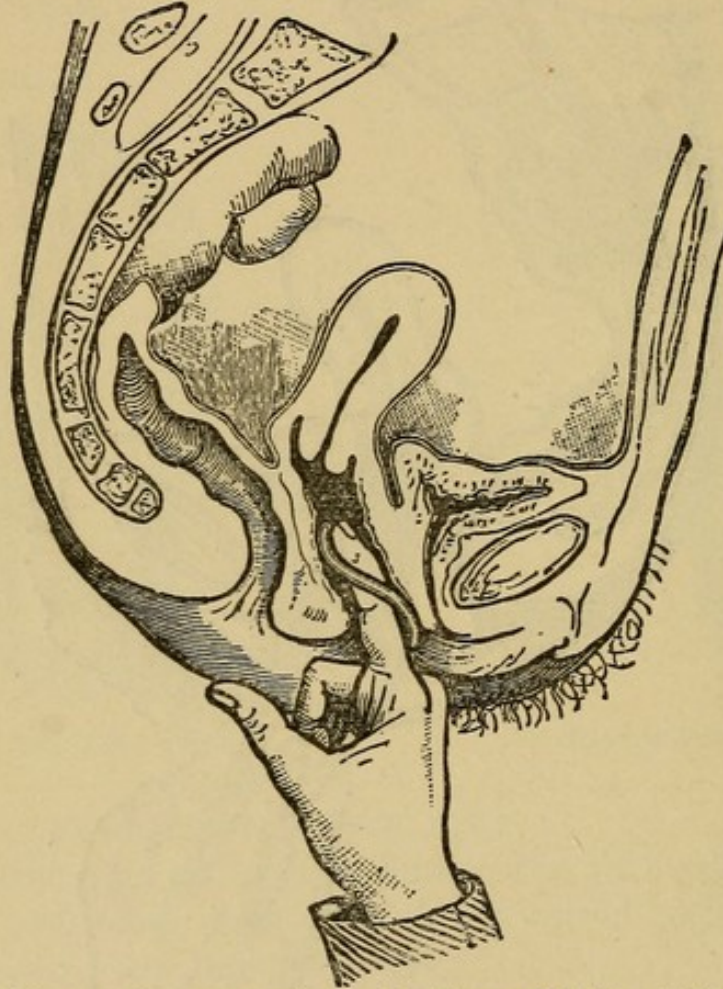


Introduction of Pessary, First Stage (Hart and Barbour).

the pessary by the smaller end with the thumb and index and middle fingers of the right hand, introduce it between the labia, with the breadth of the pessary in the line of the labia (see Fig. 28); depress the perineum with the pessary as you introduce it about half way,

then rotate, so that the breadth of the pessary lies at right angles to the labia; now grasp the external portion of the pessary with the left hand; pass the index finger or index and middle fingers of the right hand in front of the posterior bar (see Fig. 29) and carry the pessary along the posterior vaginal wall, being careful that it does not slip up in front of the cervix.

FIG. 29.



Second Stage: Pessary carried on by Finger (Hart and Barbour).

What are the precautions to be observed in the employment of a pessary?

A patient after the introduction of a pessary should be made to walk a little about the room, then to sit on a chair and cross one knee over the other, to ascertain if the pessary causes pain; if it does, it should not be kept in. A patient should always be told, on leaving, that if the pessary causes her pain, she must introduce her finger and remove it. She should be seen in a few days after its

introduction, to ascertain if the pessary is in position and is holding the uterus in place. The pessary should be removed and cleaned as often as once a month; in the meantime the patient should be instructed to use a vaginal douche for cleanliness, two to three times a week.

What are the operative procedures for holding a retroverted uterus in place after reposition?

- a. Alexander's operation;
- b. Hysterorrhaphy.

Describe briefly Alexander's operation.

Alexander's operation for shortening the round ligaments is performed as follows: The skin about the pubes is shaved and prepared antiseptically; the pubic spine is taken as the first landmark; an incision is then made, $1\frac{1}{2}$ -3 inches long, from that point upward and outward, in the direction of the inguinal canal; the incision is deepened until the tendon of the external oblique is seen; the external abdominal ring is now visible; the intercolumnar fascia is cut through in the long diameter of the ring; the round ligament can usually now be seen, with the genital branch of the genito-crural nerve along its anterior surface. The ligament is then separated from neighboring structures and gently drawn out a little to show it is free. Alexander then leaves this side covered with a clean sponge and operates on the other side in the same way. The uterus is then thrown forward by the sound in the hands of an assistant and the ligaments drawn out till they are felt to control the uterus; the ligaments are then given to an assistant to hold, and they are each sutured with catgut to the pillars of the ring; the bruised ends are cut off and the remainder stitched in the external wound; a fine drainage tube is inserted and an antiseptic dressing applied. The patient is kept in bed two to three weeks, and wears a pessary for several months.

What are the objections raised to Alexander's operation?

It is not applicable unless the uterus is freely movable.

The ligaments are sometimes difficult to find.

Unless a firm perineal support is built up, the uterus is very apt to resume its former malposition.

Risk of Inguinal Hernia

Describe briefly the operation of hysterorrhaphy for retro-versio-flexio.

The abdomen is opened in the median line as for an ovariectomy; the adhesions binding the uterus backward are broken up, the fundus brought forward and the uterus stitched with hardened catgut to the anterior abdominal wall, the sutures being passed into the uterus at the insertion of the round ligaments. The abdominal wound is closed in the usual manner and an antiseptic dressing applied. A vaginal pessary is usually inserted for a time.

PROLAPSUS UTERI.

What is meant by the expression?

Hart and Barbour define prolapsus uteri as a downward displacement of entire displaceable portion of pelvic floor, uterus and appendages past entire fixed portion, with coincident descent of small intestine.

What is meant by the "entire displaceable portion of pelvic floor"?

"The entire displaceable portion comprises bladder, urethra and vaginal walls. It has resting upon it the uterus, broad ligament, Fallopian tubes and ovaries."

What is the "entire fixed portion of pelvic floor"?

That outside of the entire displaceable portion, *i. e.*, tissue attached to the posterior surface of the symphysis; all outside the inner aspect of the levatores ani; the rectum and tissue attached to the sacrum.

What are the degrees of prolapsus uteri?

According to Thomas there are three:—

1. When the organ has sunk in the pelvis.
2. When the cervix is at the ostium vaginæ.
3. When a part or the whole of the uterus lies between the thighs.

What is the etiology?

The three elements in the etiology of prolapse are—

1. Relaxation of the ligaments of the uterus, combined with lack of tone in the entire displaceable portion of the pelvic floor and "slackening of loose tissue around it."

2. Lack of support in the entire fixed portion of the pelvic floor, especially laceration of the perineum.

3. Intra-abdominal pressure.

The chief predisposing causes are parturition, laborious occupations, anything increasing weight of the uterus, advanced age. Prolapse is sometimes produced acutely by blows, falls, heavy lifting, etc., but is usually the gradual result of the three elements mentioned above.

What are the symptoms ?

Those of the acute prolapse are sudden, severe pain, vomiting, retention of urine and signs of peritonitis. The symptoms of the gradual prolapse are a dragging sensation in lower abdomen and back, and the discomfort from the protrusion and excoriation of the parts ; difficulty in urination is sometimes present.

What are the physical signs ?

These depend on the degree of the prolapse. If the prolapse is partial, the anterior vaginal wall bulges at the ostium vaginæ, the cervix is lower than normal, and if there is marked laceration of the perineum the posterior vaginal wall also bulges. The uterus becomes more and more retroverted as it sinks in the pelvis. When the prolapse is complete, the cervix and more or less of the body of the uterus lies outside of the vulva; the anterior vaginal wall and part of the lower bladder wall have prolapsed with the cervix; the posterior vaginal wall with or without part of the anterior rectal wall is also everted. The uterus is usually enlarged and the cervix elongated.

From what must you differentiate prolapsus uteri ?

1. Hypertrophy of the cervix :—

- (a) Vaginal portion.
- (b) Supra-vaginal portion.
- (c) Intermediate portion.

2. Cystocele.

3. Rectocele.

4. Inversion and polypi.

How would you differentiate prolapsus uteri from a cystocele ?

In prolapse the uterus is sunken in the pelvis ; in cystocele the

uterus lies in its normal position, and the protruding mass is found, by the introduction of the sound into the bladder, to consist of the anterior vaginal and posterior vesical wall.

How would you differentiate prolapsus uteri from a rectocele?

In prolapse the uterus is sunken in the pelvis; in rectocele, pure and simple, the uterus lies in its normal position, and the protruding mass is found, by the introduction of the finger into the rectum, to consist of the posterior vaginal and anterior rectal wall.

Both cystocele and rectocele are common complications of prolapsus uteri.

What is the treatment of prolapsus uteri?

1. By pessaries.
2. By operation.

If the prolapse is slight in amount, the perineum preserved, and the anterior vaginal wall protrudes but a little, a pessary, like that of Albert Smith, may suffice to hold up the uterus. If this fails, a cradle pessary will sometimes answer.

If the perineum is badly lacerated, or there is much cystocele, an operation is imperative.

The operative procedures are:—

1. That which restores the perineal support and unites the lower portion of the labia majora—episioperineorrhaphy.
2. That which combines with the latter a “reefing” of the anterior vaginal wall—anterior colporrhaphy, with or without amputation of the cervix.
3. That which combines episioperineorrhaphy with Alexander’s operation, or hysterorrhaphy.
4. Vaginal hysterectomy.

What are the indications for these different operations?

Where the prolapse is slight, of the first or second degree (Thomas), with little or no cystocele, episioperineorrhaphy will usually suffice; it may be supplemented by the use of a pessary. When the prolapse is more marked and associated with cystocele, the second procedure is indicated, with amputation of the cervix, if this is greatly hypertrophied. Some operators, in cases of marked prolapse, prefer the combination of episioperineorrhaphy with hysterorrhaphy

or Alexander's operation, to the method just described. Vaginal hysterectomy for prolapse is only indicated where the prolapse is complete, and other methods seem impracticable.

Laceration of Perineum and Relaxation of Vaginal Outlet.

What is the etiology?

The most common cause of laceration of the perineum is childbirth, either natural or instrumental; rarely, however, it may arise from external violence, as falling astride of some sharp object. Relaxation of the vaginal outlet, aside from being produced by these visible lacerations, is also caused by submucous and subcutaneous rupture or overstretching of the fibres of the levator ani muscle, or perineal fascia; this, too, occurs most often during parturition.

What are the varieties of perineal laceration?

The laceration may be slight, involving the fourchette, and extending a short distance on the skin surface of the perineum.

It may be extensive, beginning with the fourchette and extending through the sphincter ani and some distance up the rectum.

It may be chiefly internal, the skin perineum being preserved; these internal lacerations are usually lateral, extending into the vaginal sulci on either side of the columna, and either side of the rectum; they are often bilateral.

What is the importance of laceration of the perineum?

It consists in the fact that in cases of marked laceration, the fibres of the levatores ani, the chief support of the vaginal outlet, are torn; especially those fibres which are attached to the rectum; at the same time there is laceration of the fibres of the perineal fascia. These conditions cause relaxation of the vaginal outlet, with a tendency to rectocele, cystocele and prolapsus uteri.

If the laceration is through the sphincter ani, incontinence of fæces usually results.

What are the subjective symptoms of laceration of the perineum with relaxation of the vaginal outlet?

The patient usually feels incapacitated for any great exertion,

complains of a dragging pain in the back and the feeling of weight in the pelvis.

How would you determine relaxation of the vaginal outlet?

Insert the thumbs or index fingers into the vaginal orifice; separate the labia by carrying the thumbs or fingers backward and outward, at the same time telling the patient to strain; the lax condition of the outlet will then be readily felt, and anterior and posterior vaginal walls will be seen to protrude.

What are the principal operative procedures for repair of lacerated perineum or relaxation of the vaginal outlet?

The two chief operations are—

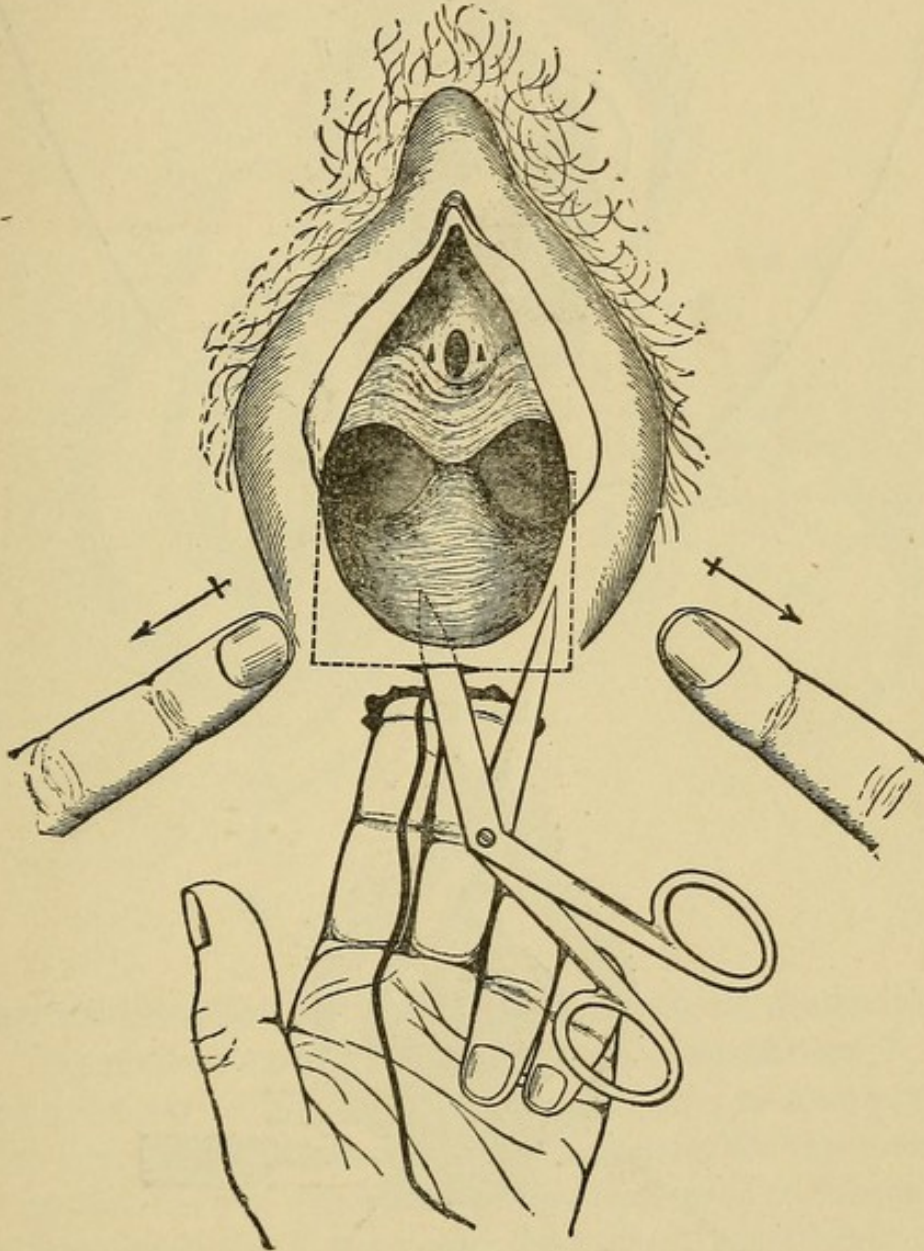
1. Saenger's modification of Tait's operation.
2. Emmet's operation.

Describe the Saenger-Tait operation.

The patient is prepared for operation by having the bowels freely moved, the vulva shaved, and an antiseptic vaginal douche given. She is then anæsthetized and placed in the lithotomy position, with knees supported by Kelly's "leg holder" and hips resting on Kelly's perineal pad. The vagina and vulva are now irrigated with an antiseptic solution, and an assistant so stationed that he can allow a mild antiseptic solution or boiled water to trickle on the wound during the operation. A tampon is inserted into the rectum, the string left projecting. The index and middle fingers of the left hand are now inserted into the rectum, as seen in Fig. 30; the labia are separated by an assistant, the blades of the scissors (Tait uses angular scissors and inserts only one blade; scissors curved slightly on the flat, with points rather sharp, and both blades inserted, may be used with advantage) inserted into the recto-vaginal septum just in front of the anus, and the vaginal and rectal mucous membranes separated for some distance around the point of insertion. A horizontal incision is now made through the point of insertion, extending on either side to a perpendicular through the lower extremity of the nymphæ; an incision is made with the scissors up along this perpendicular to the lower extremity of the nymphæ. The flap so marked out is then dissected up to the crest of the bulging posterior vaginal wall. See Fig. 31.

The parts are now freshly irrigated, and the sutures of silver wire introduced as follows : Either a Peaslee's needle or a long, straight needle with a thread loop may be used ; the sutures, 3-4 in number,

FIG. 30.



are inserted just within the denuded area on one side, and brought out just within the denuded area on the other. See Fig. 32. The tampon is removed from the rectum, the sutures twisted up and either left long or shotted and cut short. The skin is now brought

FIG. 31.

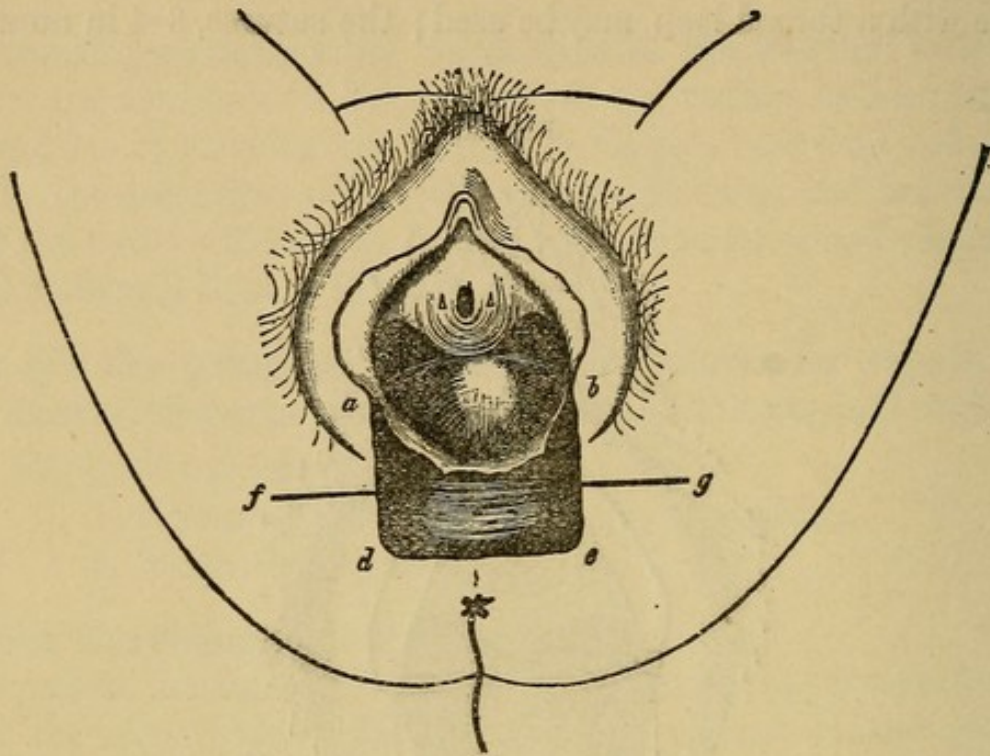
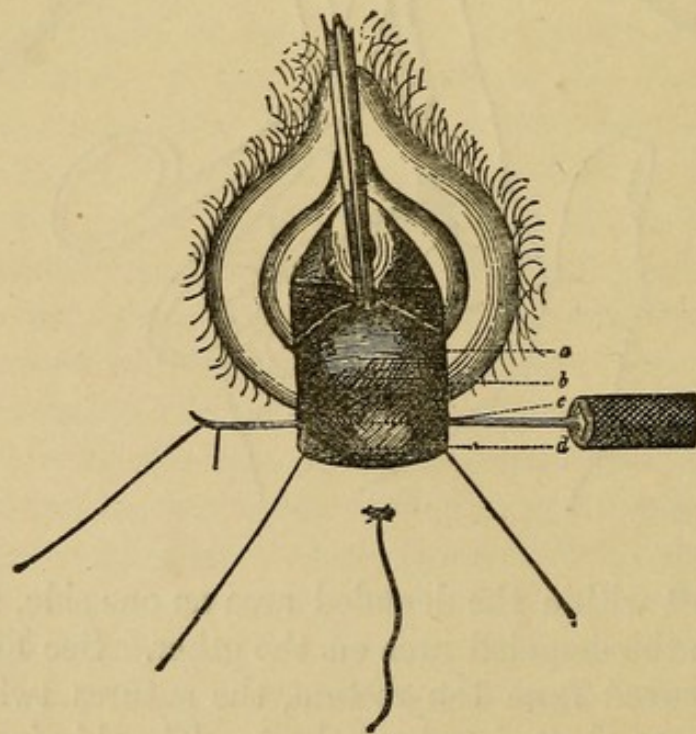


FIG. 32.



into apposition by superficial silkworm-gut sutures introduced between the wires, giving the result seen in Fig. 33. An antiseptic dressing and a T-bandage are applied, and the patient is put to bed.

The bowels are moved about the third day, and the sutures removed on the eighth.

FIG. 33.

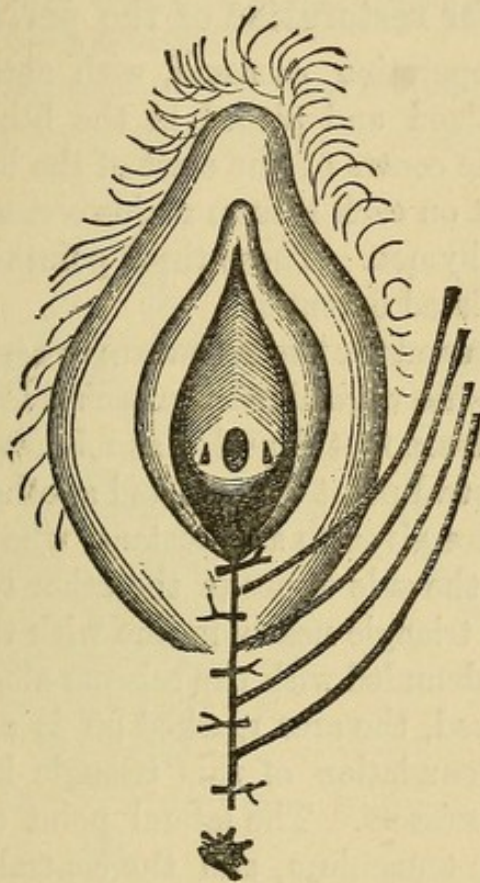
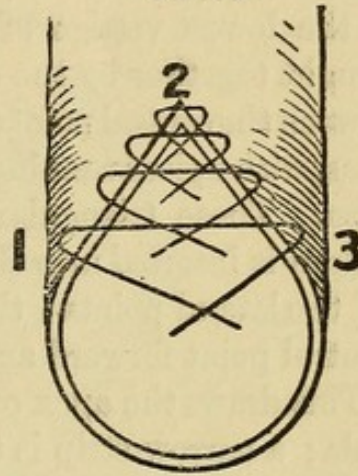


FIG. 34.



What modification of this operation can be made when the laceration extends through the sphincter ani?

Begin the vaginal flap as before (see Fig. 30); as soon as the lower portion has been separated, denude a narrow V-shaped area, with apex up the rectum, representing the torn wall of the latter, and with the arms of the V resting on the ends of the divided sphincter muscle; the denuded surface may be a little larger at these latter points. Sutures of chromicized catgut or silkworm gut are now introduced, as seen in Fig. 34, with ends in the rectum. A wire tension suture is inserted around this V, entering the skin at 3, passing through the end of the sphincter muscle, then up around

the apex 2, and down through sphincter muscle and skin at 1. The gut sutures are now tied in the rectum, beginning above; the wire is not twisted until later. The vaginal flap is now dissected up and wire sutures introduced as before. (See Fig. 32.) The wires are now all twisted up, the skin brought into apposition with silkworm gut, and an antiseptic dressing applied.

Describe Emmet's operation for restoration of the perineum.

The patient is prepared for operation as usual, with antiseptic douches, etc. She is anæsthetized and placed in the lithotomy position; a point is selected in the centre of the crest of the bulging posterior vaginal wall, and a point on each labium majus corresponding to the lowest vestige of the hymen. These three points are to be brought together by the completed operation.

Between the central point chosen and the two lateral are two triangular areas, with apices running into the vaginal sulci on each side of the columna. These triangular areas are first denuded as follows: One tenaculum is inserted into the central point chosen, and another into one of the lateral points; these are given to an assistant, who draws the central point forward and to the side opposite the other tenaculum. This draws the apex of the triangle nearly in line with the two tenacula; a narrow strip is then denuded with the scissors along this line. When the tension is relieved, the area marked off is seen to be triangular, as before. The denudation of this triangle is then completed by long snips of the scissors. The lateral point on the other side is now seized with the tenaculum, and the central point drawn toward the denuded side; this triangle is denuded as before, also, as much of the skin surface of the perineum as is necessary. The parts are now thoroughly irrigated and the sutures introduced as follows: The two triangular areas are to be in the vagina, and are sutured with either silkworm gut, chromicized catgut or silk. The apex of one triangle is first closed, the suture entering and emerging from the vaginal mucous membrane near the denuded surface; the succeeding sutures of this triangle are made to enter the vaginal mucous membrane on one side, slant toward the operator, emerge at the centre of the denuded surface, reënter, slant away from the operator and emerge from the mucous membrane of the other side a little in front of the preceding suture. This method is repeated in

the other triangle. There then remains but a small external denuded area to be closed ; this is best done with silver wire. The upper or crown suture, entering the skin on one side, passes through the anterior extremity of the column of the posterior vaginal wall, and emerges from the skin on the other side. The bowels are moved about the third day and the sutures removed on the eighth.

What modification does episio-perineorrhaphy make in these operations ?

The denudation is carried higher on the labia majora (see Fig. 35), and the lower portions of the latter are united as seen in Fig. 36.

FIG. 35.

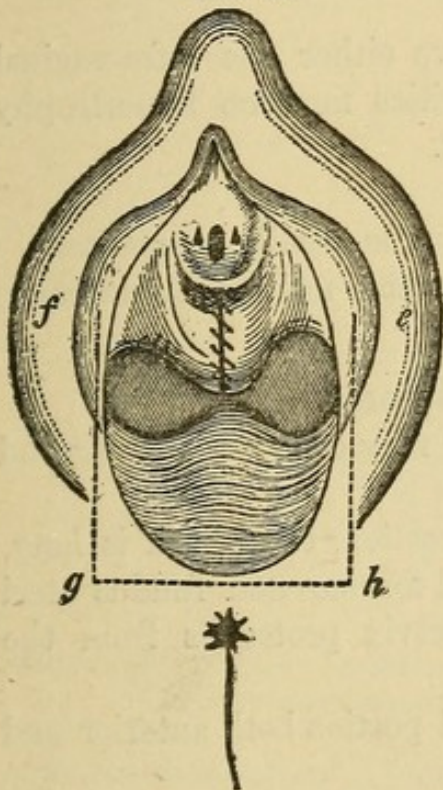
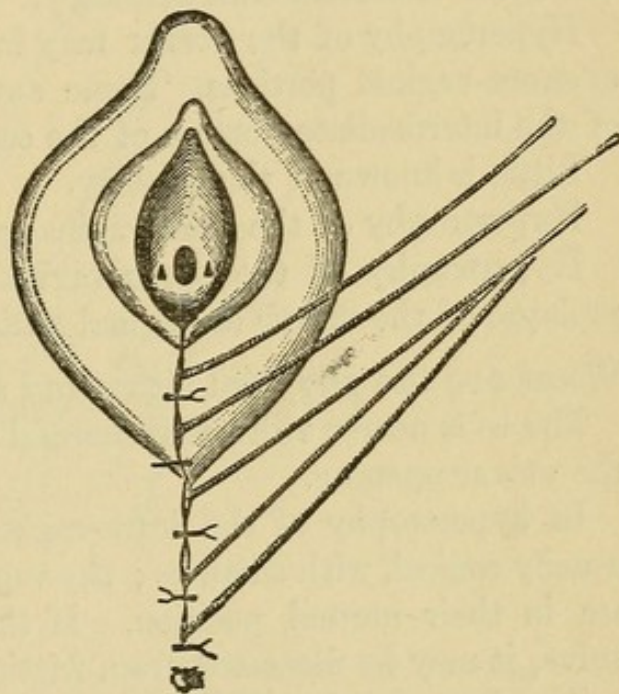


FIG. 36.



Describe the operation anterior colporrhaphy.

This consists in the excision of an elliptical piece of mucous membrane from the anterior wall of the vagina, and suturing together the edges of the mucous membrane. The ellipse should extend from the urethral prominence to a point a little in front of the cervix. The incision which defines the ellipse should penetrate the entire thickness of the mucous membrane ; the flap is then dissected off. The suturing is best done, according to Martin's method, by a continuous suture of chromicized catgut, as follows : A line of suture

is first made longitudinally along the centre of the denuded ellipse ; this reduces its size slightly ; another tier of sutures is then inserted back over the first, uniting tissue more superficial ; thus the sutures are introduced tier upon tier, each narrowing the denuded area and causing the edges of the mucous membrane to approach each other, till finally in the last tier these edges are included.

This operation may be combined with either the Saenger-Tait or the Emmet on the perineum and posterior vaginal wall.

Hypertrophy of the Cervix.

Give the varieties and etiology.

Hypertrophy of the cervix may involve either the infra-vaginal or supra-vaginal portions. Some authorities mention hypertrophy of the intermediate portion of the cervix.

Little is known of the etiology.

Hypertrophy of the infra-vaginal portion is usually congenital.

Hypertrophy of the supra-vaginal portion usually accompanies prolapse of the uterus or vaginal walls.

What are the physical signs and symptoms ?

The os is nearer vulva than normal ; it may even project beyond the vulvar opening.

In hypertrophy of the infra-vaginal portion, the cervix is long, usually conical, with small os ; the vaginal fornices and fundus uteri are in their normal position. If the cervix protrudes from the vulva, it may be ulcerated, from friction.

“In hypertrophy of the supra-vaginal portion both anterior and posterior fornices are obliterated.”

“In hypertrophy of the intermediate portion the posterior fornix remains, while the anterior fornix is obliterated.” (Hart and Barbour.)

What are the symptoms ?

The symptoms of hypertrophy of the infra-vaginal portion are chiefly mechanical :—

- Leucorrhœa, from vaginal irritation.
- Discomfort in exercise.
- Sense of weight in the pelvis.
- Sterility.

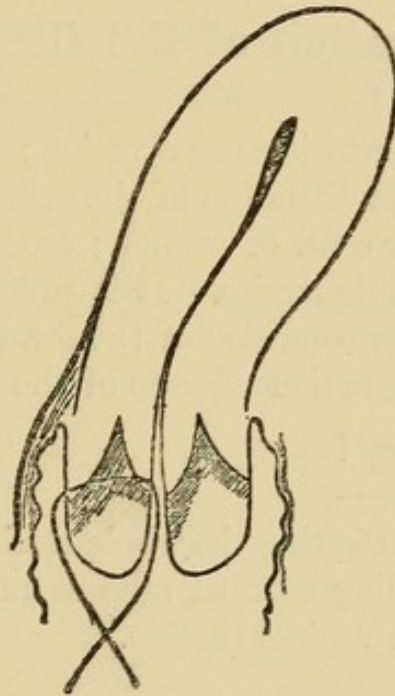
The symptoms of hypertrophy of the supra-vaginal portion are those of the prolapse of the uterus or vaginal walls, which it usually accompanies.

What is the treatment ?

Amputation of the cervix.

There are several methods of operation, the best being that of Simon and Marckwald, in which the cervix is first divided by a transverse incision into an anterior and posterior lip ; a wedge-shaped

FIG. 37.



Marckwald's method of splitting the cervix into an anterior and posterior lip and then uniting cervical to vaginal mucous membrane (*Schroeder*).

piece is then removed from each (see Fig. 37), and the flaps of each lip are brought together with silver-wire sutures.

Stenosis of the Cervix.

What is the etiology ?

It may be either congenital or acquired. When congenital, it is usually associated with a small uterus. Stenosis of the external os is more frequent than of the whole canal.

Acquired stenosis results from cicatrization following the use of

too strong caustics, endocervicitis, or a too complete closure of the cervical canal in a trachelorrhaphy.

What are the symptoms ?

Dysmenorrhœa and sterility.

What is the treatment ?

Dilate the cervix with one of the glove-stretcher dilators and maintain the dilatation by the occasional introduction of graduated sounds. Outerbridge's tubes may be used to maintain the dilatation.

Laceration of the Cervix.

What is the etiology ?

The usual cause is parturition or abortion ; it occasionally occurs as a result of mechanical dilatation of the cervix. It occurs in parturition in about 32 per cent. of women ; especially in tedious, precipitate or instrumental deliveries. It is predisposed to by a rigid os, faulty presentation or condition of the fœtus, premature rupture of the membranes and previous disease of the cervix.

What is the pathology ?

The laceration may be—

1. Complete. Penetrating the whole thickness of the cervix.
2. Partial. Including cervical mucous membrane, but not appearing on the vaginal surface.

It may be—

- (a) Unilateral (see Fig. 38).
- (b) Bilateral.
- (c) Stellate (see Fig. 39).

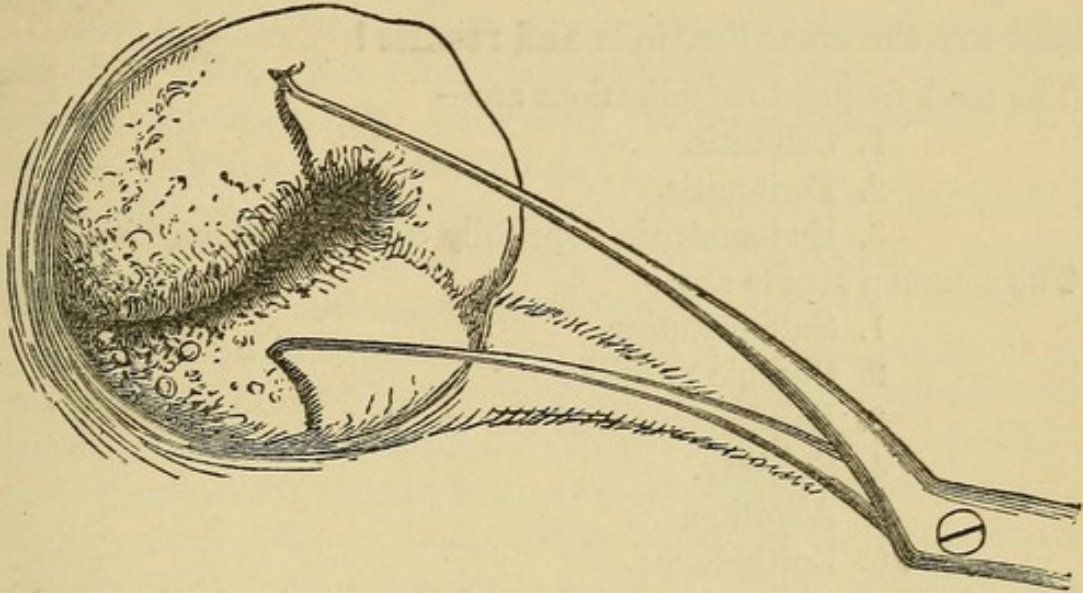
The unilateral laceration is most apt to occur in the line of the right oblique diameter of the pelvis, *i. e.*, either anteriorly and to the left or posteriorly and to the right, especially the former. This is supposed to arise from the greater frequency of the first position of the vertex.

Bilateral lacerations are usually more dangerous than those of the anterior or posterior lip, because opening up the cellular tissue of the broad ligaments.

Stellate lacerations are more apt to be superficial.

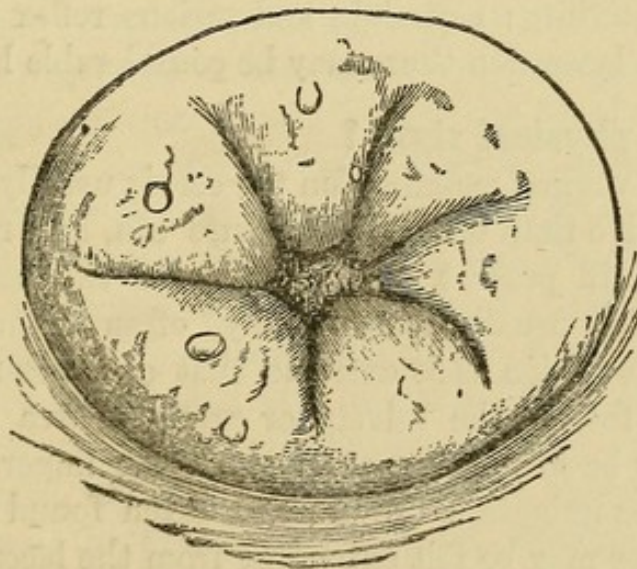
If the surfaces of laceration are kept clean, more or less union

FIG. 38.



Single Laceration. The flaps are held apart with a double tenaculum (*Emmet*).

FIG. 39.



Multiple or Stellate Laceration (*Emmet*).

will occur. Usually there is partial union, with eversion and proliferation of the cervical mucous membrane, hyperplasia of the connective tissue and proliferation of the glandular structure.

What are the complications and results ?

The most frequent complications are—

1. Cellulitis.
2. Peritonitis.
3. Endometritis, especially cervical endometritis.

The common results are—

1. Subinvolution.
2. Chronic metritis.
3. Displacements of the uterus.
4. Sterility.
5. Abortion.
6. Epithelioma.

If the laceration has extended through the anterior fornix, a vesico-vaginal or vesico-uterine fistula may remain.

What are the symptoms ?

They are chiefly those of the complications ; especially cellulitis and peritonitis. The patient usually complains of a feeling of weight in the pelvis ; leucorrhœa, disturbances of menstruation, especially menorrhagia ; sterility ; neuralgia and various reflex neuroses. At the time of the laceration there may be considerable hemorrhage.

What are the physical signs ?

On making a vaginal examination the cervix usually feels enlarged and more sensitive than usual ; the fissure can, as a rule, be readily detected ; also, if present, the eversion of the cervical mucous membrane, which usually feels velvety, often granular or cystic. Sometimes the eversion is so extreme that one does not notice the fissure, simply feeling the velvety or granular area about the os. The latter may be so patulous as to admit the finger. On making the bimanual examination the uterus is often found enlarged as a whole ; cicatrices may be felt extending from the laceration into one of the vaginal fornices. With the aid of the speculum one sees the erosion on one side of or surrounding the os, and by drawing the edges of the laceration together with tenacula the extent of the tear

is visible. Without this latter procedure, one is greatly deceived, in some cases, as to the degree of the injury.

What is the treatment?

Unless there is hemorrhage, immediate treatment is seldom resorted to. If the hemorrhage is severe, a silver-wire suture may be inserted and twisted up. Hot-water vaginal injections will usually obviate the necessity of the suture.

The treatment after the puerperium is as follows: The complications, if present, are first treated, especially peritonitis or cellulitis, by counter-irritation, hot-water vaginal douches, glycerine tampons, etc.

The cervical endometritis is treated by pricking the cysts, if present, and applying to the cervical mucous membrane carbolic acid or iodized phenol. The corporeal endometritis is treated by the curette, if necessary, and applications as in cervical endometritis.

The growth of the squamous epithelium over the erosions is stimulated by astringent applications, especially pyroligneous acid. Under the above procedures the uterus often returns to its normal size, and the symptoms associated with the laceration disappear.

If the symptoms continue after the foregoing treatment, and neither peritonitis nor cellulitis are present, Emmet's operation of trachelorrhaphy is indicated.

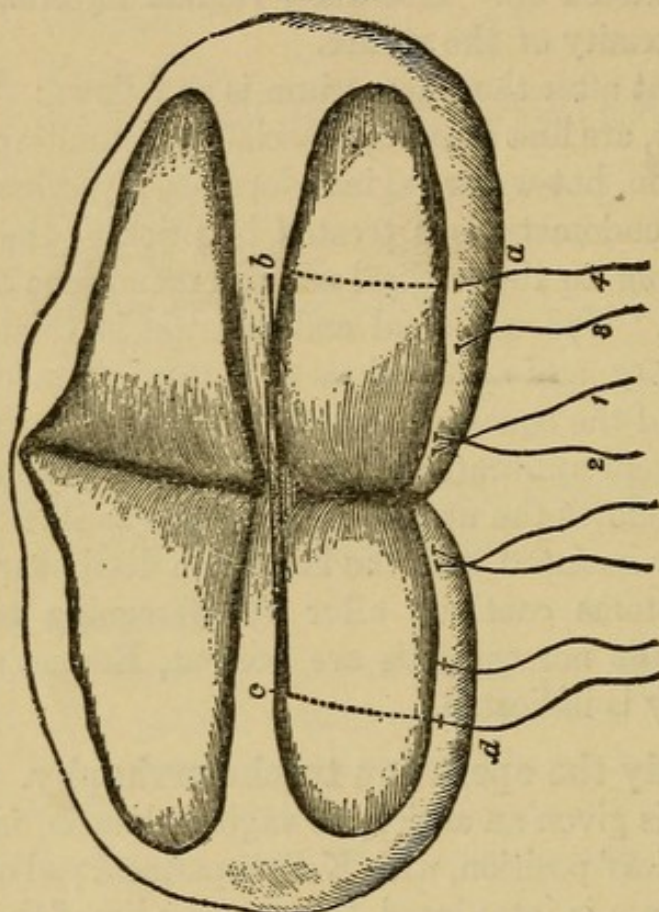
Describe briefly the operation trachelorrhaphy.

The patient is given an antiseptic vaginal douche, is anæsthetized and placed in Sims' position, with Kelly's perineal pad under the hips. A Sims' speculum is introduced, the anterior lip of the cervix seized with a volsella and the uterus drawn down and held by an assistant.

The edges of the laceration are now pared with scissors or knife, giving the denuded area seen in Fig. 40, and leaving enough mucous membrane in the centre for the cervical canal. Care should be taken to excise the plug of cicatricial tissue at the angle of the laceration. The parts are now irrigated with an antiseptic solution, and the sutures of silver wire introduced, usually 3-4 on a side, beginning at the upper angle. Each is passed from the surface of the vaginal portion, through the thickness of one lip, emerging in the edge of the undenuded mucous membrane; thence is passed into the edge of the undenuded mucous membrane of the other lip, through the lip's substance, and emerges on the surface of the vaginal portion.

The other sutures of the same side are introduced in a similar manner, care being taken to bring the parts into close apposition and leave no pockets. If the laceration is bilateral, the suturing of the other side is conducted in the same manner. The parts are again irrigated; the sutures twisted up, left $\frac{1}{2}$ – $\frac{3}{4}$ inch long and bent down

FIG. 40.



Extent of Denuded Surface and Course of Sutures according to Emmet (*Emmet*). The sutures are passed in order 1, 2, 3, 4; the course of suture 4 alone is indicated by letters a, b, c, d.

on the cervix. Iodoform is insufflated against the cervix, and a tampon of iodoform gauze introduced. The sutures are left 8–10 days; they may be left longer if the perineum is repaired at the time of the trachelorrhaphy.

Endometritis.

Define and give the varieties.

Endometritis is an inflammation of the lining membrane of the uterus; it may be either acute or chronic. Acute endometritis usually involves both cervix and body.

The chronic is often confined to either cervix or body, and called in the former case cervical endometritis, endocervicitis, or chronic cervical catarrh; in the latter case, corporeal endometritis.

Occasionally, chronic endometritis affects the whole uterus.

ACUTE ENDOMETRITIS.

What is the etiology?

Before puberty it is rare. The most common causes are the following:—

1. Traumatism and sepsis, especially from dirty instruments.
2. Gonorrhœa.
3. Catching cold during menstruation.
4. Excessive coitus near menstruation.
5. Severe types of the exanthemata.
6. It is one of the lesions in puerperal septicæmia.

What is the pathology?

Usually the endometrium of both body and cervix is involved, but the former more than the latter. The mucous membrane is swollen and softened; extravasations of blood into it occur; the epithelium is destroyed and desquamated. The secretion is first serous, later purulent, perhaps bloody.

What are the complications?

The most common are—

- Vaginitis.
- Urethritis.
- Salpingitis.
- Peritonitis.

What are the physical signs?

The cervix is enlarged, soft and slightly sensitive; the endometrium is very sensitive to the sound or probe, and these should be avoided. There is often an erosion about the os, which is usually filled with a ropy secretion. The cervix sometimes looks and feels like that of early pregnancy.

What are the symptoms?

The characteristic symptom is the discharge, which is first watery, then creamy. There is usually a slight rise of temperature and a dull pain in back and pelvis.

If gonorrhœa was a factor in the etiology the symptoms are usually more marked. Sometimes vesical and rectal irritability are present.

What is the treatment?

Put the patient to bed; give light diet; keep the bowels open; give a little opium if the pain requires it; apply hot fomentations over the hypogastrium. When the secretion becomes purulent, administer warm-water douches; it is well to add borax to the latter, ʒj-Oj.

CHRONIC ENDOMETRITIS.

What are the varieties?

- (a) Chronic cervical endometritis.
- (b) Chronic corporeal endometritis.

A. Chronic Cervical Endometritis.

What are the synonyms?

Chronic cervical catarrh and endocervicitis.

What is the etiology?

Chronic cervical endometritis is predisposed to by any low state of the system, from whatever cause produced.

The most common exciting causes are—

- (a) Laceration of the cervix.
- (b) Extension upward of a vaginitis.
- (c) Extension downward of a corporeal endometritis.
- (d) Displacements of the uterus, especially flexions.
- (e) Stenosis of the cervix.
- (f) Traumatism, especially septic.
- (g) Excessive coitus.
- (h) Catching cold during menstruation.

What is the pathology?

In mild cases the mucous membrane alone may be involved, but often more or less of the substance of the cervix is affected. In a well-marked case the epithelium, glands and interstitial tissue are all involved in the change.

The cylindrical epithelium of the canal proliferates and replaces the squamous epithelium on the vaginal portion of the cervix. This

is especially true where the cervix is lacerated, and the cervical mucous membrane is everted.

The glands of the cervix are hypertrophied and proliferated, and in addition to this, according to Ruge and Veit, the surface of the mucous membrane is thrown into numerous folds, producing glandular recesses and processes.

The connective tissue of the cervix is also increased.

The reddened areas about the os, where cylindrical epithelium has replaced the squamous, and the glandular structure has increased, are called erosions, sometimes wrongly spoken of as "ulcerations."

What are the varieties of erosion?

According to the depth of the recesses in the folds of the mucous membrane covered with cylindrical epithelium, Ruge and Veit distinguish three varieties:—

1. The simple erosion.
2. The papillary.
3. The follicular.

When the mouths of these recesses become occluded, it forms the cystic erosion. These cysts may enlarge and extend toward the surface of the cervix where it is covered with squamous epithelium.

What are the physical signs of chronic cervical endometritis?

In nulliparæ the cervix may feel normal, save a little swollen and sensitive; sometimes the neighborhood of the os has a granular or velvety feel.

In multiparæ, especially where the cervix is lacerated, the granular area about the os is larger, and small cysts in greater or less numbers can usually be felt.

What are the symptoms?

The characteristic symptom is the leucorrhœa; this may irritate the vulva, causing pruritus.

Pain in the back and loins, especially on exertion, is usually present, but may be slight.

Other symptoms are disturbances of menstruation, especially menorrhagia, sterility and reflex neuroses.

What is the treatment?

Attend to the general health and remove, as far as possible, the causes of the endometritis.

In mild cases, especially in nulliparæ, use hot-water vaginal douches containing an astringent, as sulphate of zinc ʒj-Oj.

If more severe, remove the ropy mucus from the canal with a large-mouthed syringe and apply iodized phenol.

When the cervix is cystic or much congested, prick the cysts or scarify the cervix.

FIG. 41.

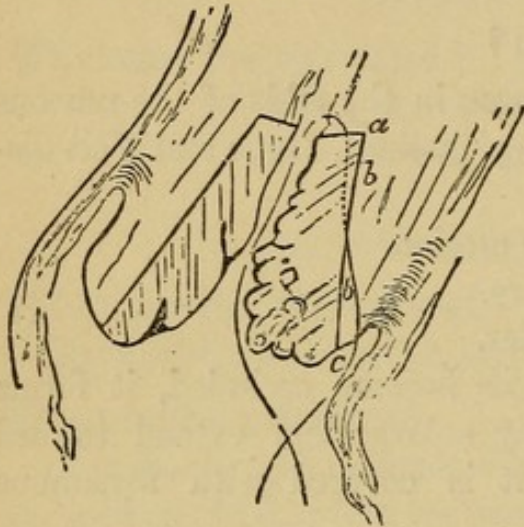
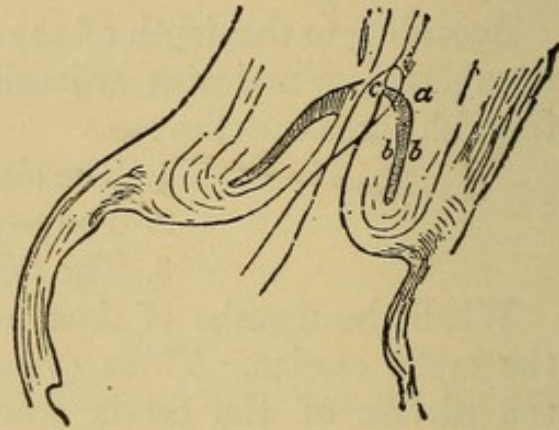


FIG. 42.



Schroeder's excision of the cervical mucous membrane in cervical catarrh.

Fig. 41. Line of incision in mucous membrane. Fig. 42. Mucous membrane excised and flap *bc* turned in on *ab* (Schroeder).

If the above treatment fails, thoroughly curette the cervix, dilating if necessary, and apply iodized phenol.

Schroeder's operation consists in dividing the cervix into an anterior and posterior lip, excising the mucous membrane by a V-shaped incision (see Fig. 41), and turning in and uniting the lips as seen in Fig. 42.

When the cervix is badly lacerated trachelorrhaphy is indicated.

B. Chronic Corporeal Endometritis.

What is the etiology?

It sometimes follows the acute, more often begins as chronic.

The most common causes are—

1. Parturition, especially when the secundines are not thoroughly removed.

2. Displacements.
3. Traumatism, especially septic.
4. Tumors, especially fibroids and polypi.
5. Excessive coitus.
6. Extension of inflammation from the cervix.
7. Chronic metritis.

What is the pathology ?

The mucous membrane is diseased in one or all of its elements.

1. The glands may be chiefly affected, being hypertrophied, and new glandular tissue may be developed by infoldings of the mucous membrane. The glands may become cystic or may atrophy.

2. The cells and intercellular substance may be increased, and constitute the characteristic change.

3. The blood vessels may be dilated and increased.

4. All the elements may be involved : the glands, interstitial tissue and blood vessels may all be increased.

The hypertrophied mucous membrane may assume polypoid or fungous shapes, giving rise to the names "uterine fungosities" and "villous endometritis." This is a result of the preceding forms, usually the mixed, where all parts are involved ; it is especially apt to arise from the inflammation started by retained secundines ; it causes more hemorrhage than the other forms.

Chronic cervical endometritis and chronic corporeal endometritis are often associated.

What are the symptoms of chronic corporeal endometritis ?

- (a) Leucorrhœa.
- (b) Menstrual disturbances, especially menorrhagia.
- (c) Dysmenorrhœa.
- (d) Pain in back and pelvic region.
- (e) Sterility.
- (f) Abortion.
- (g) Reflex neuroses.

What are the physical signs ?

On bimanual examination the uterus is usually found more or less enlarged ; perhaps a little tender.

The sound, on introduction, shows the cavity enlarged, and usually detects irregularities in its mucous membrane ; it frequently causes slight bleeding.

What are common complications ?

Metritis.
Salpingitis.
Peritonitis.
Displacements.
Vaginitis.

What is the treatment ?

1. *Prophylactic.*—Be careful that the uterus is thoroughly emptied after labor or abortion. Avoid exposure during menstruation. Observe strict cleanliness and antisepsis in the use of uterine instruments.

2. *When no Irregularities of the Endometrium are Detected.*—Make occasional applications of iodized phenol to the endometrium. Administer internally, three or four times a day, fifteen drops each of the fluid extracts of ergot and hydrastis canadensis.

3. *When Irregularities of the Endometrium are Detected.*—If no acute inflammation is present in the neighborhood, curette the uterus under antiseptic precautions, dilating the cervix previously if necessary ; wash out the uterus with an antiseptic solution, making use of a double-current catheter ; then apply to the endometrium iodized phenol, and administer internally ergot and hydrastis, as before. The curetting, if thorough, is best done under anæsthesia. It is well to confine the patient to bed for a few days, and occasional applications of iodized phenol to the endometrium may be necessary.

Metritis.

Describe and give the varieties.

Metritis is an inflammation of the parenchyma of the uterus, as distinguished from that of its mucous lining or serous covering. The two varieties are the acute and chronic.

ACUTE METRITIS.

What is the etiology?

Acute metritis rarely if ever exists as an independent condition; it is almost always associated with an endometritis or peritonitis; especially the former.

The chief causes are—

1. Acute endometritis.
2. Septic absorption during labor, abortion or operation.
3. Acute peritonitis.

Acute metritis occasionally arises from exposure to cold during menstruation, gonorrhœa or sexual excess, but these usually first produce endometritis, secondarily metritis.

What is the pathology?

The uterus is enlarged, especially antero-posteriorly, infiltrated with serum, soft and tender. The endometrium is also thickened and congested. The peritoneal investment is often covered with lymph. "Microscopically the muscular bundles are infiltrated with pus corpuscles" (Hart and Barbour). Circumscribed abscesses occasionally, though rarely, occur in the uterine walls; they are sometimes absorbed, sometimes become encapsulated and cheesy, and sometimes empty into the uterus, bladder, rectum, vagina, intestines, peritoneum or through the abdominal walls.

Acute metritis may resolve at the end of a week, but often passes into the chronic form.

What are the symptoms?

They usually resemble those of acute endometritis, but are more severe. The disease is often ushered in with a rigor; temperature and pulse rise; there is pain in the hypogastrium and in pelvis. The uterus is very tender on pressure; there is nausea, usually vesical and rectal tenesmus, and menstruation, as a rule, is disturbed, sometimes suppressed; more often menorrhagia is present.

What is the treatment?

If due to sepsis, try to remove the cause; giving, if necessary, intrauterine injections of carbolic (1-100) or bichloride (1-5000). Keep the patient quiet in bed, apply poultices or turpentine stupes to the hypogastrium; if temperature very high, use the ice coil.

Keep the bowels regular by enemata; if pain very severe, allow opium by suppository. Later, employ long, hot-water douches and glycerine tampons.

CHRONIC METRITIS.

What are common synonyms?

Areolar hyperplasia (Thomas). Chronic parenchymatous inflammation of the womb (Scanzoni). Diffuse interstitial metritis (Noeggerath).

What is the etiology?

According to Hart and Barbour, the causes may be divided as follows:—

(a) Causes which operate through interference with the normal involution of the puerperal uterus.

(b) Causes which operate through the production of repeated or protracted congestion of the uterus.

(A) Frequent causes of subinvolution are—

1. Retained secundines.
2. Laceration of the cervix.
3. Pelvic inflammation following parturition.
4. Rising too soon after parturition.
5. Non-lactation.
6. Repeated miscarriages.

(B) Causing repeated or protracted congestion are the following—

1. Chronic endometritis.
2. Displacement of the uterus.
3. Tumors near the uterus.
4. Chronic pulmonary, cardiac, hepatic or nephritic disease.
5. Excessive coitus.

Chronic metritis sometimes follows the acute but usually begins as chronic.

What is the pathology?

The pathological changes may be divided into three stages—

1. Hyperæmic.
2. Hyperplastic.
3. Sclerotic.

In the first or hyperæmic stage, the uterus is enlarged, soft, tender, and contains more blood than normal.

In the second or hyperplastic stage, there is an increase of the intermuscular connective tissue, with or without a slight increase of the muscular tissue. The vascularity is decreased by the growth of connective tissue around and compressing the blood vessels.

The third, or sclerotic stage is a result of the former, the uterus becoming more dense, less and less vascular and finally atrophied.

What are the symptoms?

Most of the symptoms are either due to the increased size of the uterus or to the complicating endometritis. The symptoms usually date from parturition or abortion. The following are common—

A feeling of weight in the pelvis.

Pains radiating to the back, limbs and different parts of the body.

Irritability of bladder and rectum.

Leucorrhœa.

Menstrual disturbances, especially menorrhagia, due to the endometritis.

Abortion in the early stages.

Sterility, later.

Reflex neuroses.

What are the physical signs?

The uterus in the early stages is uniformly enlarged, soft and tender; later harder, and in the late stages irregularities of shape may be detected. The canal is enlarged in all its dimensions and the sound passes easily. The os is usually patulous; the cervix may be large and nodular.

From what must you differentiate chronic metritis?

From early pregnancy, small fibroid tumors and malignant disease.

How would you differentiate chronic metritis from early pregnancy.

In early pregnancy the enlargement of the uterus is more in the antero-posterior diameter; in metritis the enlargement is more uniform.

The uterus is tender in metritis, usually not in pregnancy.

In pregnancy, also, the cessation of menstruation and softening of the cervix usually aid us in the diagnosis.

How would you differentiate chronic metritis from fibroid tumors ?

In small fibroid tumors of the uterus, the irregular shape is contrasted with the more uniform enlargement in metritis. The uterine cavity is usually more spacious in chronic metritis than when fibroids are present.

The sound will often aid in the diagnosis. In some cases it is justifiable to dilate the cervix and introduce the finger to determine the presence or absence of a submucous fibroid tumor.

How would you differentiate chronic metritis from malignant disease of the uterus ?

Malignant disease of the uterus is more apt to occur late in life; metritis earlier.

Cachexia and menorrhagia are more marked in the former than in the latter.

What are common complications of chronic metritis ?

- (a) Chronic endometritis.
- (b) Salpingitis.
- (c) Peritonitis.
- (d) Ovaritis.
- (e) Vaginitis.
- (f) Displacements.

What is the treatment of chronic metritis ?

1. Prophylactic.—Care during and after confinement.
2. Curative.—

First treat the complications, if present, especially endometritis and displacements, in the usual manner. Attend to the general health, bowels, exercise, etc. Let the patient rest a part of each day, especially at menstruation; limit coitus. Weir Mitchell's treatment of rest, over-feeding and massage is sometimes of value.

Local treatment.—Prolonged hot-water vaginal douches; glycerine or boroglyceride tampons; tincture of iodine to cervix and fornices of the vagina; scarification of the cervix with Buttle's spear.

Emmet's operation of trachelorrhaphy, or amputation of the cervix by the Simon and Marckwald method is sometimes indicated.

Apostoli strongly recommends the use of galvanism.

Atrophy of the Uterus.

What is the etiology?

It is the natural condition after the menopause, and is produced artificially by the removal of ovaries and tubes. It is sometimes associated with phthisis and other exhausting diseases. It occurs as a superinvolution after childbirth, especially as a result of metritis, peritonitis, ovaritis or salpingitis. This superinvolution is the variety of most importance.

What are the symptoms?

Amenorrhœa.
Sterility.
Reflex neuroses.

What are the physical signs?

The uterus is small, both in body and cervix, and the canal is shortened.

What is the treatment?

Attend to the general health.

Before the menopause, galvanism of the uterus and ovaries may be tried.

The treatment is generally unsatisfactory.

Fibroid Tumors of the Uterus.

What are common synonyms?

Fibro-myomata and myomata. Strictly speaking, fibro-myomata is the more correct designation, as the tumors are composed of both fibrous and muscular tissue.

What is the etiology?

Little is known of the cause of fibroids. They are much more common in the African than in the white race; are most frequently found between the ages 30-45, and are said to be more common in married than in unmarried women. They rarely, if ever, begin before puberty, and never after the menopause.

What is their structure?

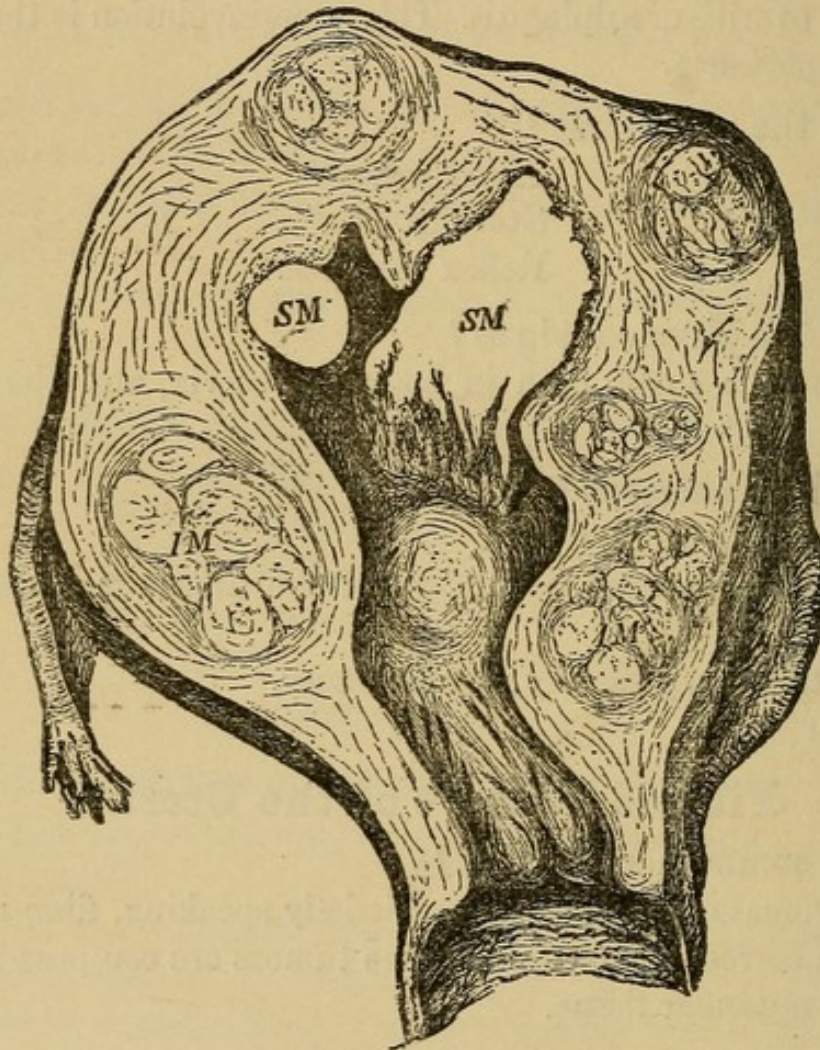
Fibroids, or fibro-myomata of the uterus, are tumors composed of

both fibrous and muscular tissue, either of which may predominate over the other. The fibrous tissue is usually in excess.

Those composed chiefly of fibrous tissue are usually more or less encapsulated and of slow growth.

Those composed chiefly of muscular tissue are rare, not encapsulated, and are of rapid growth.

FIG. 43.



IM. Interstitial fibroids.
SM. Submucous. (Schroeder.)

What are their situations ?

They are much more frequent in the body of the uterus than in the cervix. They are most often found on the posterior wall, next in frequency on the anterior wall, rarely on the lateral walls. The soft, rapidly-growing fibroids are more frequent in the fundus.

The tumors always begin in the substance of the uterine walls ;

they may continue their growth there ; may extend into the uterine cavity, lifting up the mucous membrane, or outward, lifting up the peritoneum. Hence the three varieties :—

1. Interstitial.
2. Submucous.
3. Subperitoneal.

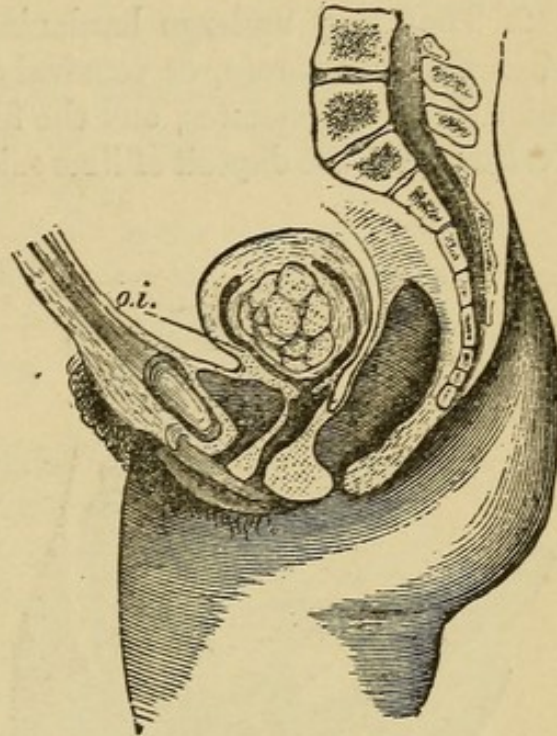
Describe the three varieties.

The interstitial or intramural fibroids (see Fig. 43), are usually multiple and are situated in the substance of the uterine wall. The submucous fibroid (see Fig. 44), may be either sessile or attached by a long pedicle. In the latter case it is called a fibrous polypus.

The subperitoneal or subserous fibroids (see Figs. 45 and 46), are often multiple ; may be sessile or pedunculated ; may grow upward into the abdominal cavity

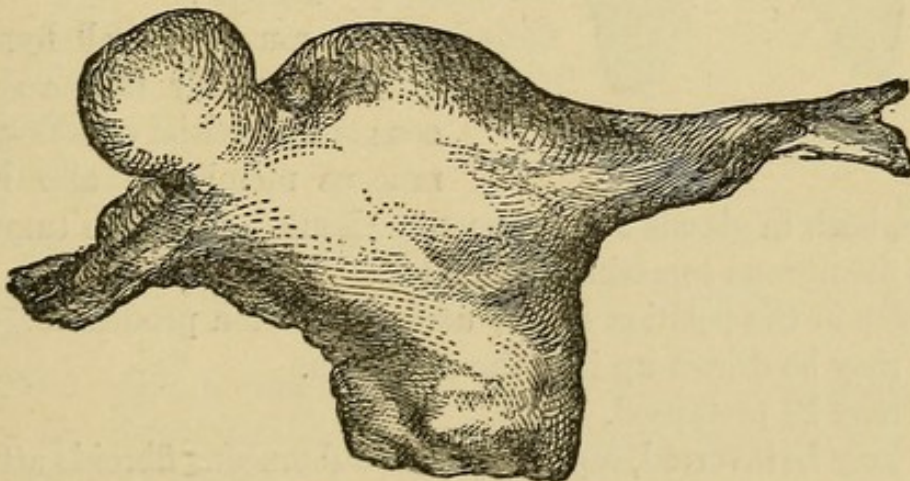
and draw uterus up, or grow downward into the pelvis, and perhaps

FIG. 44.



Submucous fibroid. (Schroeder.)

FIG. 45.



Subperitoneal Fibroid.

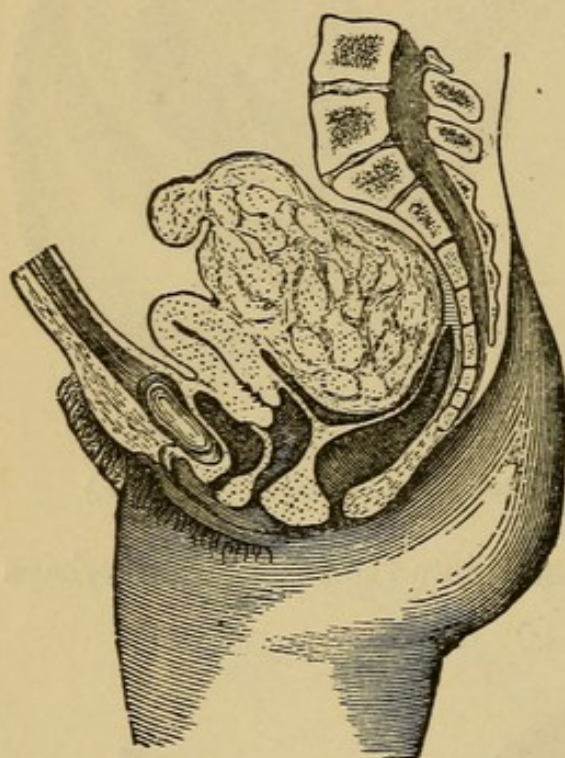
become incarcerated. They may form adhesions with other organs, get their nutrition through the adhesions and become detached from the uterus.

What changes may occur in fibroids ?

1. They may undergo softening due to œdema or myxomatous degeneration, rarely fatty degeneration. By this softening fibrocysts may be formed.

2. They may undergo hardening, due to (a) atrophy, especially after the menopause, or removal of ovaries and tubes. The muscular tissue degenerates, and the fibrous tissue contracts. (b) Calcification, with the deposit of lime salts, beginning usually in the centre, sometimes at the periphery.

FIG. 46.



Subperitoneal Fibroid.

3. They may suppurate. This occurs most often in submucous fibroids, especially after instrumental traumatism ; rarely in the subperitoneal variety after torsion of the pedicle.

4. Submucous fibroids may become more and more pedunculated, forming polypi. They are sometimes extruded from the uterus. Sometimes the capsule ruptures, and spontaneous enucleation occurs.

What changes occur in the uterus ?

The muscular wall hypertrophies, especially in the submucous or interstitial varieties. The mucous membrane also hypertrophies, both in glands and connective tissue. Over the tumor the mucous membrane sometimes ulcerates.

Changes in the position of the uterus are often produced :—

1. It may be drawn up into the abdomen.
2. It may be prolapsed.
3. It may be inverted, especially from submucous fibroids attached to the fundus.

Describe briefly fibroids of the cervix.

They, too, may be either interstitial, submucous or subperitoneal ; they are usually hard and single.

The subperitoneal often grow out between the folds of the broad ligament.

The submucous and interstitial are apt to become pedunculated and form polypi. The interstitial fibroid of the cervix is sometimes mistaken for inversion of the uterus.

What are the symptoms of fibroid tumors of the uterus?

1. Hemorrhage.—First, menorrhagia, later metrorrhagia; this occurs especially in the submucous variety.

2. Pain.—(a) Dysmenorrhœa, chiefly in the submucous variety.

(b) Pain due to pressure on the pelvic nerves or to peritonitis around the tumor.

3. Symptoms due to pressure :—

On bladder, causing :—

Irritability.

Retention.

Cystitis.

On urethra, causing :—Difficulty in micturition.

Perhaps retention.

On ureter, causing :—Hydronephrosis.

On rectum, causing :—Constipation.

Sometimes tenesmus.

Rarely complete obstruction.

On pelvic nerves, causing :—

Neuralgia.

Numbness.

On veins, causing :— Varicosities.

4. Sterility.

5. Abortion.

What are the physical signs?

Except in the case of some subperitoneal fibroids, the uterus is enlarged.

If within reach, a tumor is felt, harder than the muscular substance of the uterus, and movable with the uterus unless it is attached with a very long pedicle.

If it is a small fibroid in the cervix it may bulge into the vagina and resemble inversion of the uterus.

If it is a submucous fibroid, high up in the uterus, the sound may

detect it, but often it is necessary to dilate the cervix and introduce the finger.

If it is subperitoneal and on the anterior wall, a hard mass is felt in the anterior fornix moving with the uterus; the fundus may be felt above and behind it, and the sound on introduction does not pass into it.

If on the posterior wall, a hard mass is felt in the posterior fornix; the bimanual shows fundus in front of it, and the sound passes in front of it.

If it is a large fibroid extending into the abdomen, it is flat on percussion unless intestine overlies it; auscultation may detect the uterine souffle, especially at the sides, and the mass seems to belong to the uterus.

From what must you differentiate a fibroid tumor of the uterus?

Chronic metritis.
Flexions of the uterus.
Pregnancy.
Ovarian cyst.
Extra-uterine gestation.
Pelvic hæmatocele.
Inflammatory deposits.
Inversion of the uterus.

How would you differentiate a small fibroid tumor from chronic metritis?

<i>Small Fibroid</i>	<i>vs.</i>	<i>Chronic Metritis.</i>
Enlargement not uniform, usually hard irregularities.		Enlargement uniform.
Less sensitive.		More sensitive.
Os usually unaffected.		Os usually everted.

Both conditions may co-exist.

The differential diagnoses between fibroids and flexions of the uterus have already been given (see page 114, Fig. 23).

How would you differentiate a fibroid tumor from pregnancy?

<i>Fibroid Tumor</i>	<i>vs.</i>	<i>Pregnancy.</i>
Menstruation continues; usually increased.		Amenorrhœa is the rule.
Cervix not softened.		Cervix softened.

Later.

Absence of positive signs of pregnancy. Positive signs present.

How would you differentiate a fibroid tumor from an ovarian cyst?

<i>Fibroid Tumor</i>	<i>vs.</i>	<i>Ovarian Cyst.</i>
Hard and firm.		Soft and elastic.
More intimately connected with uterus.		Less intimately connected with uterus.
More central.		More lateral.
Menorrhagia common.		Menstruation normal or irregular; menorrhagia rare.

How would you differentiate a fibroid tumor from an extra-uterine gestation?

<i>Fibroid Tumor</i>	<i>vs.</i>	<i>Extra-uterine Gestation.</i>
No menstrual period skipped.		Menstrual period or periods usually skipped.
Grows less rapidly.		Grows more rapidly.
More central.		More lateral.
More intimately connected with uterus.		Less intimately connected with uterus.
No decidual membrane cast off.		Decidual membrane cast off.
Absence of attacks of very severe sharp pain, with symptoms of collapse.		Such attacks occur.

How would you differentiate a fibroid tumor from a pelvic hæmatocele?

<i>Fibroid Tumor</i>	<i>vs.</i>	<i>Pelvic Hæmatocele.</i>
Gradual development.		Rapid development.
Absence of acute symptoms.		Symptoms of sudden sharp pain, shock and hemorrhage.
Insensitive to pressure.		Sensitive to pressure.
Hard and firm.		First soft, later harder.
Moves with uterus.		Does not move with uterus.

How would you differentiate a fibroid tumor from a pelvic inflammatory deposit?

<i>Fibroid Tumor</i>	vs.	<i>Inflammatory Deposit.</i>
Slow growth ; no history of acute inflammation.		History of rapid development, and acute inflammation.
Moves with uterus, and seems a part of it.		Usually does not move with uterus, and seems less a part of it.
Insensitive to pressure.		Sensitive to pressure.

What is the treatment?

Palliative.—The administration of ergot in some cases will keep the symptoms under control until after the menopause, when the symptoms, as a rule, gradually disappear ; the menopause, however, is usually considerably delayed.

If endometritis is associated with the fibroid, curetting the uterus is often of value.

Curative.—Tait's operation of removal of the ovaries and tubes, artificially producing the menopause, is perhaps the best general plan of treatment. In some cases hysterectomy is indicated.

Apostoli's treatment by means of galvanism with currents of high intensity is still *sub judice*.

When the tumor is subperitoneal and pedunculated, myomotomy may be indicated.

Inversion of the Uterus.

What is the pathology?

In inversion, the uterus is turned more or less completely inside out (see Fig. 47).

It may be either—

1. Partial—where the depressed uterine wall does not extend beyond the os externum ; or
2. Complete—where the inverted body, covered with mucous membrane, lies outside of the os externum, either in the vagina or between the labia.

The mechanism of production of the inversion is as follows :—

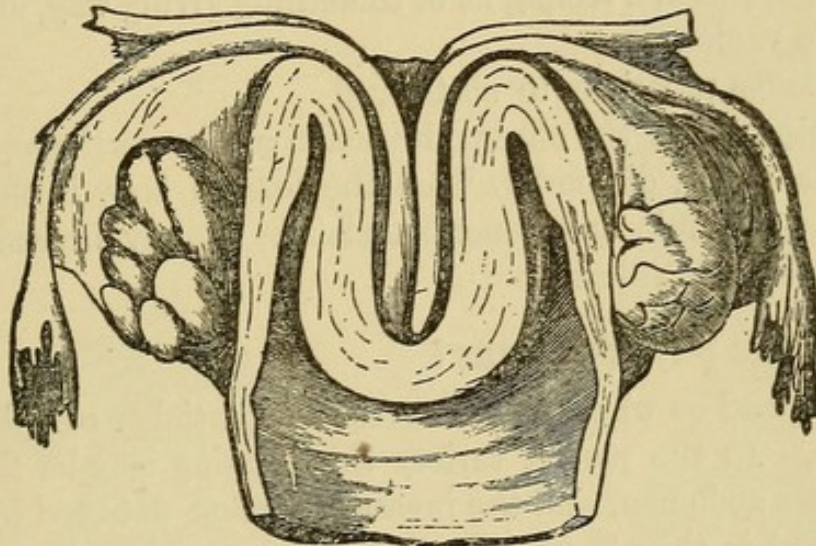
A portion of the uterine wall loses its tone, is depressed into the

uterine cavity, usually by traction from below or abdominal pressure from above; the depressed portion is then grasped by the undepressed portion and forced toward or through the cervix.

The peritoneum follows the depression of the uterine wall, and lines the cup thus formed. The appendages may or may not lie within the cup.

The inversion occurring during the puerperium* usually begins at the placental site; when produced by intra-uterine tumors, it usually begins at the attachment of the tumor. The uterine mucous membrane is usually congested; it may ulcerate; sometimes it becomes gangrenous. Occasionally it becomes covered with squamous epithelium, and resembles skin.

FIG. 47.



Inversion of Uterus (half-size, *Barnes* from *Crosse's* essay). The fundus lies in the vagina; the cervix is not inverted; the lips are flattened out to a swelling seen below the angle of inversion. The ovaries (seen from behind) are not in the peritoneal cup.

What is the etiology?

Inversion is predisposed to by—

- (a.) Parturition.
- (b.) Distention of the uterus from any cause.
- (c.) Intra-uterine tumors.
- (d.) Degeneration of uterine walls.

According to the time and cause of production, two varieties are recognized:—

1. Puerperal.—Produced during the puerperium, either by ab-

dominal pressure or mismanagement in the delivery of the placenta, especially the latter, traction on the cord being the most frequent cause.

2. Non-puerperal.—Secondary to intra-uterine tumors; especially pedunculated fibroids growing from the fundus.

The puerperal variety is much more common than the non-puerperal. The former is usually rapid in development; the latter gradual.

When the inversion is developed and reduced during the puerperium, it is called acute; otherwise, chronic inversion.

What are the symptoms?

At the time of the occurrence of acute inversion, there is pain, hemorrhage, shock, a feeling as of something giving way, and of fullness in the vagina.

This belongs especially to obstetrics.

The symptoms of the chronic inversion are hemorrhage, dragging pain in the pelvis, discomfort from the foreign body in the vagina, leucorrhœa, anæmia and general malaise. Rarely inversion exists with very few symptoms.

What are the physical signs?

These depend on whether the inversion is partial or complete, acute or chronic. In the partial variety the cupping may be felt by the hand on the abdomen, and the inverted portion detected by the use of the sound in the uterus. In the acute, complete inversion, one feels a soft, bulging tumor in the vagina or between the labia; it bleeds easily, is sensitive and smaller above where it is encircled by the cervix; it may or may not have the placenta attached to it. The sound passes around the tumor, but only a short distance into the cervix. The hand on the abdomen detects the absence of the fundus and the presence of the cervical ring. The physical signs of the chronic inversion are similar, save that the mass in the vagina is smaller, harder, and in the non-puerperal variety perhaps has attached to it the tumor which was its cause.

From what must you differentiate inversion of the uterus?

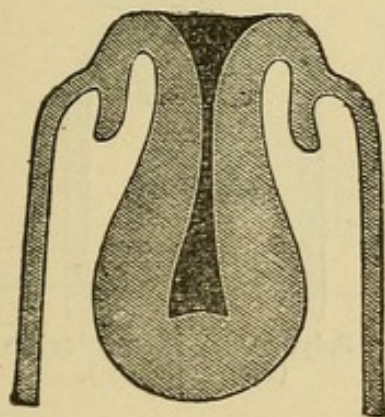
From polypi and prolapsus uteri.

How would you differentiate inversion of the uterus from a polypus?

The diagnosis of a complete inversion (see Fig. 48) from a polypus lying in the vagina (see Fig. 49) would be made as follows:—

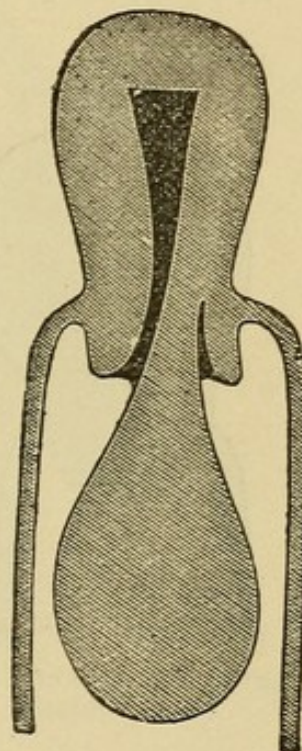
<i>Inversion</i>	<i>vs.</i>	<i>Polypus.</i>
Fundus not felt in the abdomen; cervical ring felt.		Fundus felt in the abdomen.
Sound passes all around tumor, but only a short distance into the cervix.		Sound passes into the uterus, at the side of the tumor, more than 2½ inches.

FIG. 48.



Inversion of Uterus (after Thomas). A cup-shaped depression is in the place of the uterus. Sound arrested at angle of flexion.

FIG. 49.



Uterine Polypus (after Thomas). The uterus in its normal position. Sound passes into uterine cavity.

The differential diagnosis between a partial inversion and an intra-uterine polypus (see Figs. 50 and 51) is often quite difficult. Careful examination by the ordinary bimanual and by the abdomino-rectal method may detect the cup-shaped depression of the partial inver-

sion. Enlargement of the uterus rather favors the diagnosis of polypus.

Both of these conditions may rarely coexist.

How would you differentiate inversion of the uterus from complete prolapse?

This rarely causes difficulty. It is made by finding in the latter the external os, the obliteration of the fornices, and by passing the sound into the uterine canal.

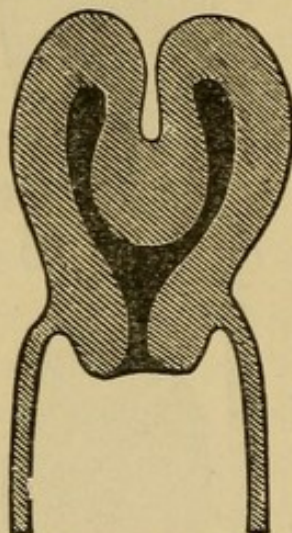
What are the results of an untreated inversion?

Very rarely it reduces itself. Rarely the patient suffers little inconvenience from it.

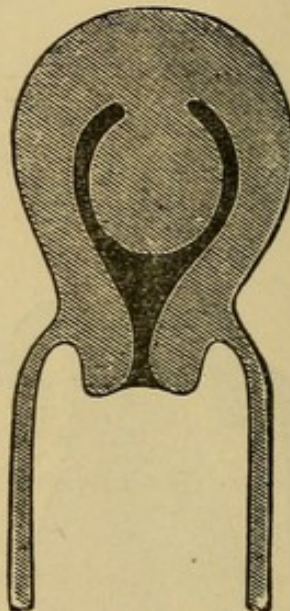
Usually the patient dies from hemorrhage or sepsis.

FIG. 51.

FIG. 50.



Partial Inversion of Uterus
(after Thomas).



Polypus still Intra-uterine
(after Thomas).

What is the treatment?

The object sought is the reposition of the fundus uteri.

Emmet's method (see Fig. 52) consists in inserting the right hand into the vagina, grasping the fundus in the palm, inserting the fingers into the cervix and pushing upward; at the same time separating the fingers as much as possible. The left hand meanwhile exercises through the abdomen counter-pressure on the cervical ring.

Noeggerath begins the reposition by dimpling in one horn of the uterus, and then uses this as a wedge to dilate the cervix.

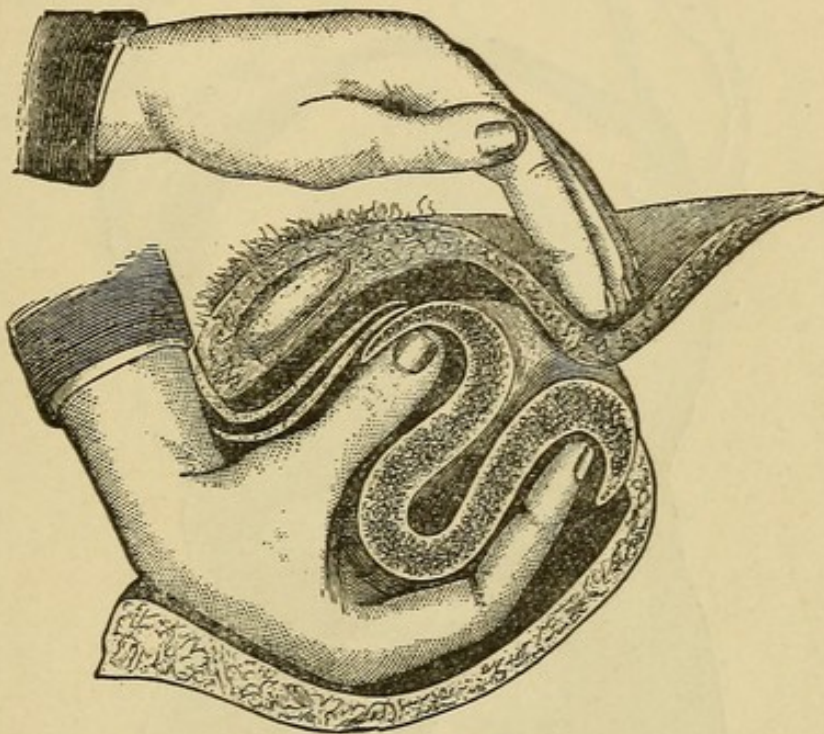
Instead of the hand alone, cup-shaped repositors are often made use of.

In all these methods the patient is usually best prepared for the manipulation by the administration of prolonged hot-water douches, and the introduction of a vaginal elastic bag, to be distended with air or water, and worn twelve to twenty-four hours.

The manipulations are best performed under anæsthesia.

When the above methods fail, hysterectomy probably offers the best result.

FIG. 52.



Reposition of the Inverted Uterus with the Hand alone (after Emmet).

Polypi.

What is meant by the term "uterine polypus," and what are the varieties?

A polypus is a pedunculated tumor attached to the uterine mucous membrane. The following varieties are recognized:—

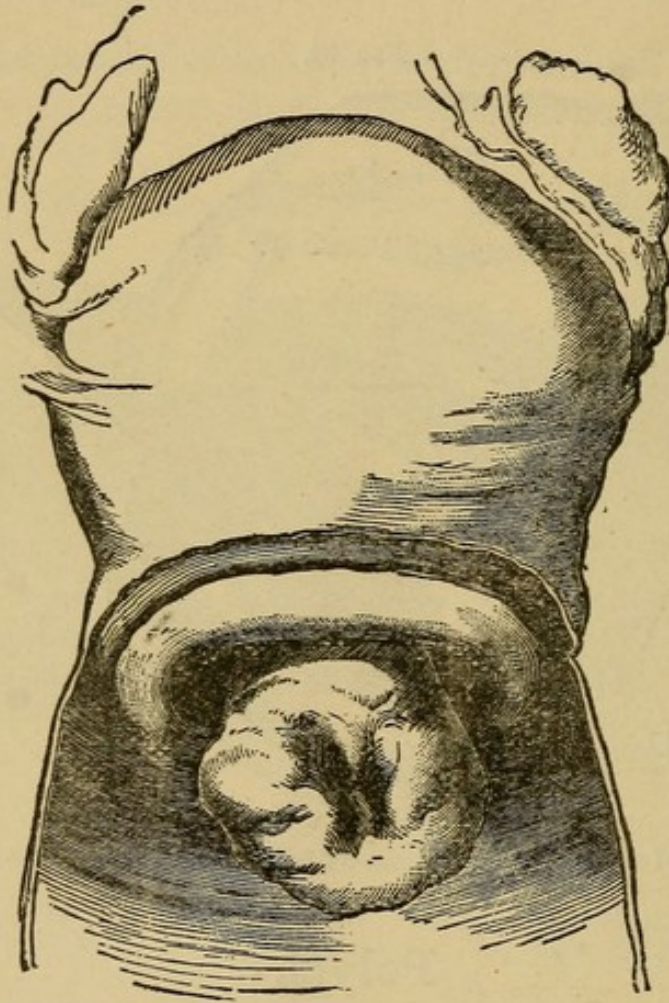
1. Fibrous polypi.
2. Mucous polypi.
3. Pedunculated Nabothian follicles.
4. Placental polypi.
5. Papillomata of the cervix.

Describe briefly the fibrous polypi.

Fibrous polypi are submucous fibroids which have become pedunculated; at first lying within the uterus; later, dilating the cervix and becoming vaginal (see Fig. 53), sometimes even projecting beyond the vulva.

They spring from the muscular wall of the uterus, more often

FIG. 53.



Intra-uterine Submucous Fibroid which is becoming Vaginal (*Sir J. Y. Simpson*).

from the body than cervix; they are composed chiefly of fibrous tissue with few blood vessels. Their presence sets up uterine contractions, which gradually expel them. Their shape is usually pyriform or ovoid.

Describe the mucous polypi.

These spring from the uterine mucous membrane, chiefly that of the cervix. There are usually more than one (see Fig. 54); they are

small, soft, vascular, and on section present the structure of mucous membrane.

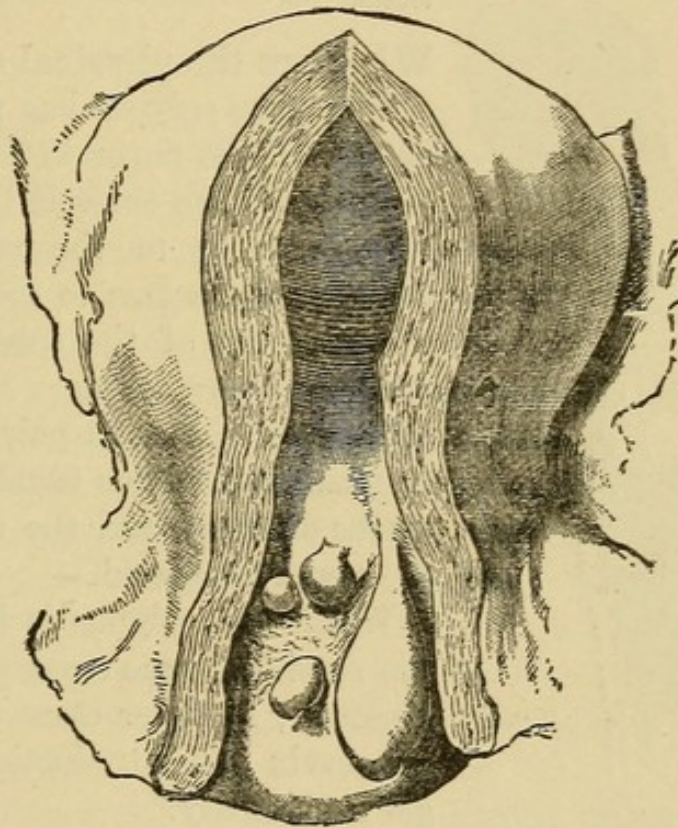
What are the pedunculated Nabothian follicles?

They are the glands of the cervical mucous membrane which have become obstructed, formed retention cysts and assumed the polypoid shape.

What are placental polypi?

They are portions of undetached placenta which have received nutri-

FIG. 54.



Group of Mucous Polypi growing in the Cervix Uteri (*Str J. Y. Simpson*).

ment from their attachment to the uterus, have become coated with fibrin and so increased in size. By the uterine contractions they are made more pedunculated, and may be extruded from the cervix.

Describe the papillomatous variety of polypus.

Papilloma of the cervix is almost always either a malignant new growth or tends soon to become so. It is often called a "cauliflower excrescence" (Clarke), (see Fig. 55), is usually soft, friable, and bleeds easily.

What are the symptoms of polypi?

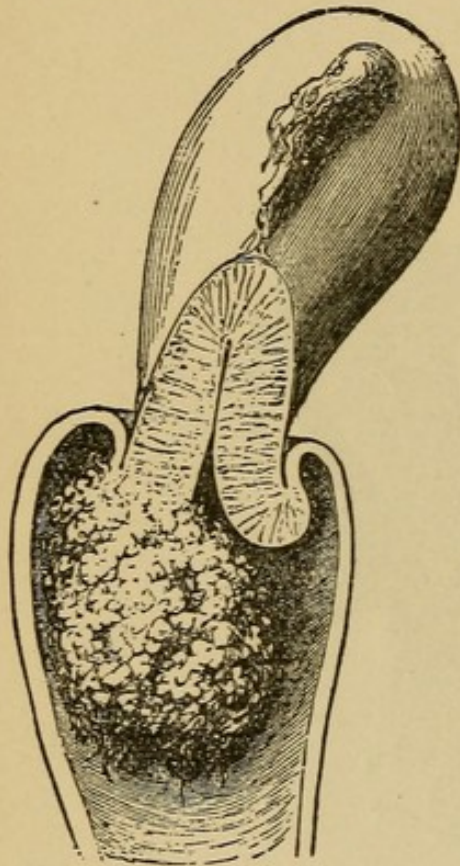
1. Hemorrhage.—First menorrhagia, then metrorrhagia, the source of the blood being the mucous membrane, which covers, or in the mucous variety forms, the substance of the polypus.

2. Leucorrhœa.—Due to the accompanying endometritis.

3. Pain.—Due to the efforts of the uterus to expel the tumor.

4. Sterility.—Due to the mechanical obstruction and to the endometritis.

FIG. 55.



Cauliflower Excrescence growing from the Cervix Uteri (*Sir J. Y. Simpson*).

5. Anæmia and general malaise.—Resulting from the foregoing conditions.

What are the physical signs?

When the polypus has passed the os externum, the finger in the vagina detects a pyriform or ovoid body, hard or soft according to the variety; it is movable and seems to come from the os. The use of the speculum determines its appearance.

If it is a fibrous polypus, the bimanual examination usually shows the uterus enlarged, and the sound proves the cavity elongated.

When the polypus is intra-uterine, the sound in some cases will detect its presence; in other cases dilatation of the cervix and introduction of the finger is necessary.

The fibrous polypus, according to Hart and Barbour, is larger than a walnut and of firm consistency.

The mucous polypus is about the size of an almond and of a pulpy consistency.

For differential diagnosis between inversion of the uterus and polypi see inversion.

What is the treatment?

When the polypus is of considerable size and lies within or

external to the os, the best treatment is removal by the wire *écraseur*, putting the wire loop as near the uterine attachment of the pedicle as possible.

Small polypoid projections may be scraped away with the curette; mucous polypi may usually be twisted off with the forceps.

When the polypus lies within the uterus, dilate the cervix with Allen's pump or a tupelo tent and apply the *écraseur*.

If the pedicle is small, blunt, dull scissors may be substituted for the *écraseur*. If the pedicle is large or dilatation of the cervix is necessary, anæsthesia is to be employed.

All antiseptic precautions are to be used.

Carcinoma Uteri.

What is the pathology?

Carcinoma, with its usual microscopical characteristics, may involve either the body of the uterus or the cervix; it is very much more frequent in the latter, and the usual form is epithelioma. It may begin on the vaginal portion of the cervix, in the substance of the cervix, or in the mucous membrane of the canal.

When situated on the vaginal portion it often begins as an induration of the superficial layers, which then ulcerate with irregular and indurated edges. It may take the form of cauliflower excrescences.

When beginning as nodules in the substance of the cervix, these nodules enlarge, come to the surface of the mucous membrane and ulceration follows.

When beginning in the mucous membrane of the canal, it may excavate the whole canal and extend to the parametrium.

Carcinoma of the body of the uterus usually begins in the endometrium. Whether it ever begins in the substance of the uterine wall is a disputed point. It may be circumscribed or diffuse. It often assumes a polypoid shape.

What is the etiology?

The etiology of cancer of the uterus is still unsettled. The factors which favor its development are age, heredity, parturition, laceration of the cervix, with erosion and depreciation of the vital powers.

1. *Age*.—It occurs most frequently between the ages of 40–50.
2. *Heredity*.—Although regarded as of less importance than formerly, its influence seems to be exemplified in some cases.
3. *Parturition*.—Frequent child-bearing apparently creates a marked predisposition.
4. *Laceration of the Cervix*.—Cancer of the cervix seems often to arise from a laceration, with erosion and cervical endometritis.
5. *Depreciation of the Vital Powers*.—Poor surroundings, poor food and air and hardships of any kind seem to predispose to cancer.

What are the symptoms?

1. *Hemorrhage*.—This is usually the first symptom. If hemorrhage occurs after the menopause, always suspect cancer.
2. *Offensive Discharge*.—Does not occur until ulceration begins.
3. *Pain*.—When the cervix is alone involved, pain is usually absent. When the disease has extended to the cellular tissue or peritoneum, or involves the body, pain is common.
4. *Cachexia*.—This is always present to a greater or less extent in the later stages.

What are the physical signs?

If the disease affects the vaginal portion of the cervix, the examining finger detects a rough, ulcerated and indurated area, or perhaps a fungoid mass. On withdrawal, the finger is usually stained with blood and emits a foul odor. The speculum gives us the appearance of the growth.

When the uterine canal is involved, the sound usually detects the abnormal condition, which may be diagnosed by microscopical examination of fragments removed by curetting. In cancer of the body, the uterus is usually enlarged.

What is the treatment of carcinoma of the uterus?

1. *Radical*.—

- (a) Vaginal hysterectomy.
- (b) High amputation of the cervix.

When the disease is confined to the body of the uterus and the latter is movable, hysterectomy is indicated.

When the disease involves the cervix, and operation is not contra-indicated by extension of the disease to the parametria or vagi-

nal walls, either hysterectomy or high amputation of the cervix may be performed. Authorities differ in their choice of the two operations, the preference at the present time being most often given to hysterectomy.

2. *Palliative*.—When a radical operation is contraindicated, the following methods of treatment are of value :—

If hemorrhage is a marked symptom, and sloughing masses are present at the seat of ulceration, thoroughly curette the surface and apply carbolic acid, iodized phenol, or a solution of chloride of zinc. Frequent insertions of iodoform gauze soaked in a 4 per cent. solution of chloral will be found to act as an antiseptic and anæsthetic to the ulcerated surface.

For the foul discharges, vaginal douches of a weak solution of creolin are valuable.

The pain and distress in the later stages demand opium.

Attention to the general health is of course indicated.

Describe briefly the operation of vaginal hysterectomy.

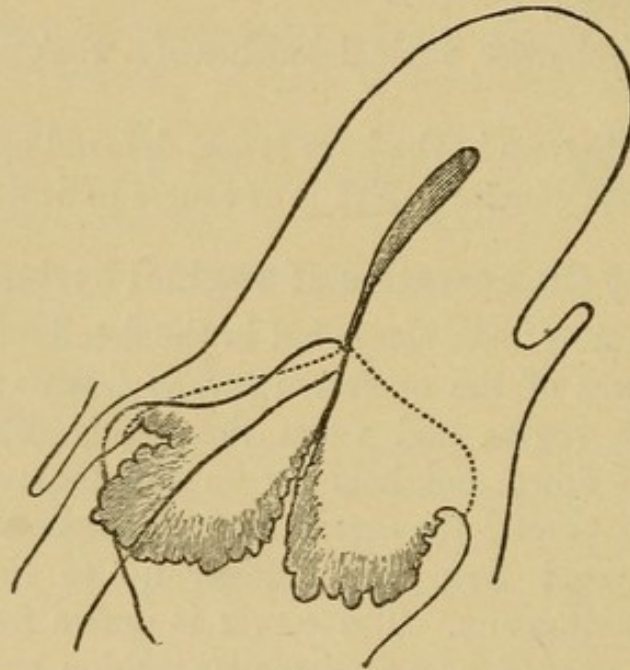
Different operators differ somewhat in the details of the operation. The main features of the operation are as follows: The vulva is shaved, and the vagina and vulva thoroughly disinfected. The uterus is drawn down and held by an assistant; a semicircular incision is made around the cervix in the anterior fornix, and the cervix is separated from the bladder up to the utero-vesical pouch of the peritoneum. The cervix is drawn forward and the posterior fornix opened by a semicircular incision about the cervix, which is then freed up to the pouch of Douglas. The pouch of Douglas may now be opened, and a clean sponge, with a silver wire attached, introduced to keep back the intestines. The uterus is freed from the lower portion of the broad ligaments by clamping or ligaturing in section, and then cutting with scissors close to the uterus. The latter may now be retroverted through the opening in the pouch of Douglas, and freed from the upper portion of the broad ligaments by clamping or ligaturing, and cutting close to the uterus. It is well to draw the ovaries into the clamp or ligature, so that they will be removed with the uterus. The anterior reflection of peritoneum may now be divided, or, as practiced by many operators, this may be done before retroverting the uterus. All hemor-

rhage is checked and the parts irrigated; the peritoneum is sometimes stitched to the vaginal wall, but this is unnecessary. The parts are dusted with iodoform, and an iodoform gauze vaginal dressing applied. If the broad ligaments have been clamped, the clamps should be left on about forty-eight hours.

Describe the operation for high amputation of the cervix.

The cervix is drawn down with a volsella and held by an assistant; an incision is made through the anterior fornix around the cervix, and the latter is separated from the bladder nearly to the

FIG. 56.



Line of Incision and Position of Sutures in the Supra-vaginal Amputation of the Cervix (*Schroeder*).

peritoneum. The cervix is now drawn forward, the posterior fornix opened, and the cervix freed behind as in front. The knife is carried through the anterior lip to the cervical canal at the desired height (see Fig. 56). The posterior lip is then amputated in a similar manner. The anterior lip and anterior vaginal wall are united by sutures; also the posterior lip and post-vaginal wall (see Fig. 56). It is usually necessary to suture the ends of the wound in the lateral fornices.

Sarcoma of the Uterus.

What is the pathology?

Sarcoma, a new growth developing from the connective tissue and presenting the microscopical characteristics of sarcoma elsewhere, occurs in the uterus, either in the form of a diffuse infiltration or as a circumscribed tumor. It usually affects the body of the uterus, being rare in the cervix. The masses are usually grayish in color, soft and brain-like; occasionally the circumscribed masses are firm and resemble fibroids, but have no capsule. They usually do not ulcerate as rapidly or deeply as carcinoma, and metastases are less common.

What is the etiology?

Little is known concerning it. It is most frequent between the ages forty to fifty, but, unlike carcinoma, often occurs in nulliparous women.

What are the symptoms?

1. Hemorrhage.
2. Watery discharge.
3. Pain.
4. Cachexia.

Thus the symptoms are similar to those of carcinoma. Some authors claim, however, that the discharge is less offensive than in carcinoma, because there is less tissue necrosis.

What are the physical signs?

The uterus is usually enlarged; the sound, when introduced, detects great irregularity of the endometrium, and usually causes bleeding. If the curette is used, a grayish, brain-like material is removed.

With what are sarcoma and carcinoma of the body of the uterus most likely to be confused, and how is the diagnosis made?

They are chiefly to be confused with villous endometritis, sloughing polypi or retained secundines. The diagnosis is made by removing fragments with the curette, knife or scissors, and subjecting them to

microscopical examination. Marked anæmia and emaciation would lead one to suspect malignant disease, yet severe endometritis or a vascular polypus may cause similar symptoms.

What is the treatment?

Hysterectomy gives us the only prospect of cure.

The palliative treatment consists in curetting and applying caustics to the interior of the uterus, keeping the vagina clean with anti-septic douches, as weak creolin, and relieving pain with opium.

Salpingitis.

What is the pathology?

In salpingitis there is usually first a catarrhal inflammation of the mucous membrane of the tube; this extending to the peritoneum sets up a localized peritonitis which usually closes the fimbriated extremity, and often by adhesions distorts the tube. From the closure of the outer extremity and the narrowing of the lumen in different places by the traction of peritonic adhesions, the secretions are retained and distend the tube. This distention is favored by the softening arising from the catarrhal inflammation. Other portions of the tube may be thickened, partly from inflammation of the tube itself and partly from the neighboring peritonitis. In some cases the obstruction at the uterine end of the tube is overcome by the pressure of the tubal contents, which may then be expelled into the uterus and vagina, constituting the condition called "salpingitis profluens."

The varieties of salpingitis, named according to the tubal contents are—

1. Hydrosalpinx.
2. Hæmatosalpinx.
3. Pyosalpinx.

Tubercular salpingitis is now thought to occur either as a primary or secondary affection.

What is the etiology of salpingitis?

It usually arises from an extension to the tube of an inflammation

of the endometrium, and its etiology is that of the endometritis, especially—

1. Sepsis during parturition or abortion.
2. The use of septic instruments.
3. Gonorrhœa.

What are the characteristics of a hydrosalpinx ?

In a hydrosalpinx the tube is distended with serum, the result of a catarrhal inflammation. The softening of the walls easily allows the distention, which varies in position according to the traction of peritonitic adhesions.

What are the characteristics of a hæmatosalpinx ?

Here the tube is distended with blood, which may have one of three sources :—

1. It may be exuded from the tubal mucous membrane as a result of the catarrhal inflammation.
2. It may occur as an extension of a hæmatometra due to atresia of vagina or cervix.
3. It may occur as a result of a tubal pregnancy.

The tube is usually first hypertrophied, later thinned, and it may rupture ; this accident is usually delayed by peritonitic thickening about the tube. The blood is generally thick and tarry.

What are the characteristics of a pyosalpinx ?

The tube is usually more thickened and surrounded by more peritonitic adhesions than is hydrosalpinx.

The pus may be slight in amount, or the tube may be immensely distended with very fetid pus.

Adhesions are apt to form between tube and neighboring viscera, and the pus sometimes ruptures into them, especially into rectum or bladder.

What are the symptoms of salpingitis ?

The patient usually suffers from a burning and dragging pain in the region of the affected tube, especially on standing and walking. Dysmenorrhœa is common ; repeated attacks of peritonitis are not infrequent. In the case of pyosalpinx septic symptoms may be present. There is tenderness on pressure in the lateral vaginal fornix,

and on making a bimanual examination an elongated cystic mass can usually be detected at the side of the uterus.

What are the results of salpingitis?

A hydrosalpinx or hæmatosalpinx occasionally subsides so as to cause few symptoms; they may become purulent and form pyosalpinx.

A hæmatosalpinx may rupture into the peritoneum or into the broad ligament, forming an hæmatocele in the former case, and a hæmatoma in the latter.

A pyosalpinx if unrelieved by operation may continue for years, producing chronic invalidism, or may rupture and cause septicæmia or peritonitis.

What is the treatment of salpingitis?

1. *Prophylactic*.—Cleanliness and antisepsis during the puerperium and in the use of all instruments.

2. *Palliative*.—During the acute stage of invasion, rest in bed, poultices, and, if much pain is present, allow opium.

When the case becomes subacute, apply counter irritation to vaginal fornix over the affected tube or tubes, and employ tampons of boric acid and glycerine and hot water vaginal douches.

3. *Radical*.—If the distention and thickening of the tube fails to subside under the foregoing treatment, perform laparotomy and remove the tube and ovary of the side affected. Usually both sides are involved and require removal.

In a pyosalpinx, if complete removal is impossible or it has ruptured into the broad ligament, it may be best to drain through the vagina.

Affections of the Ovaries.

HEMORRHAGE INTO THE OVARIES.

What is the etiology and pathology?

Hemorrhage into the ovary is caused by anything producing a congestion of the organ, such as obstruction to the circulation, pelvic diseases, tumors, disorganization of the blood, disease of heart or lungs, catching cold during menstruation, and excessive or violent sexual intercourse. The hemorrhage may be either follicular, occur-

ring into the Graafian follicles, or interstitial. The former being comparatively frequent, the latter rare. The ovary is usually enlarged and irregular in shape and more sensitive to pressure; the follicles may rupture and form pelvic hæmatocele or set up peritonitis.

What are the symptoms?

Although the hyperæmia of the ovary may be suspected from menorrhagia, throbbing pains over the ovaries and their acute enlargement, no positive symptoms are produced until rupture occurs, when, according to the amount of blood poured out, they may vary from symptoms of slight pain and shock to those of fatal hemorrhage and collapse.

What is the treatment?

While hyperæmia of the ovary is suspected, regulate the mode of life and enjoin rest just before and during the early part of menstruation. Apply counter-irritation to the ovarian region; attempt to elevate the ovaries by soft packing if they are prolapsed, and administer hot-water vaginal douches. If rupture occurs, the treatment is that of pelvic peritonitis or hæmatocele.

OVARITIS.

What is the pathology?

Ovaritis or inflammation of the ovary may be acute or chronic.

Tubercular ovaritis is usually described separately.

Acute ovaritis may be follicular or interstitial; the two are often combined. In the follicular form, the epithelium of the follicles degenerates, the liquor folliculi becomes purulent, and the ovum is destroyed.

In the interstitial form, the stroma is infiltrated with serum and leucocytes and the connective tissue cells are increased; abscesses often form between the bundles of fibers; sometimes gangrene occurs.

Chronic ovaritis, often the result of the acute, may exhibit 3 forms—

1. The atrophic.
2. The hyperplastic.
3. The cystic.

In the atrophic form the ovary is small, hard, and nodular; the tunica albuginea is much thickened.

In the hyperplastic form, the ovary is enlarged, hard, and comparatively smooth; it usually prolapses from the increased weight.

In the cystic variety, the change is not confined to the follicles, but the stroma is involved as well.

The atrophic form may be present in one part of the ovary and the hyperplastic in another; the tunica albuginea is thickened and prevents rupture of the cysts. Ovaries the seat of ovaritis are usually more or less surrounded by peritonitis.

What is the etiology of ovaritis?

It occasionally occurs in severe cases of the infectious diseases or metallic poisoning, but is most often secondary to disease of the tubes or peritoneum. It is predisposed to by anything causing congestion of the ovary, such as displacement of the uterus or ovary or excessive venery. A salpingitis with its own etiology is the most frequent cause of ovaritis. Among individual causes, the following are especially to be mentioned:—

Sepsis during labor, abortion or operations.

Gonorrhœa.

Catching cold during menstruation.

What are the symptoms?

The symptoms of acute ovaritis are usually mingled with those of the accompanying salpingitis or peritonitis. There is generally sharp pain in the ovarian region or regions, radiating to the back; often pain in micturition and defecation, and various reflex neuroses. If an abscess forms, septic symptoms may be present.

In the chronic form the symptoms are usually less marked; there is dull pain in the ovarian region, increased by walking. There is dyspareunia and, especially if the ovary is prolapsed, painful defecation.

What are the physical signs?

These may be obscure, from the fact that the ovary and tube are bound together by peritonitic adhesions into one indistinct mass.

When definable, we feel, on making a bimanual examination, a round body at the side of the uterus, but separated from it by a

slight interval; it is sensitive to pressure, producing pain of a sickening character; it may or may not be movable. When the ovary is prolapsed, this round, tender mass may be felt in the pouch of Douglas.

From what must you differentiate an inflamed ovary?

- From—
- Salpingitis.
 - Peritonic deposit.
 - Exudation into the broad ligament.
 - Fibroid tumor.
 - Fæces in the rectum.

How would you differentiate ovaritis from salpingitis?

This is often very difficult, from the fact that the two conditions frequently coexist. The chief features in the differential diagnosis are found in the physical signs, as follows:—

<i>Ovaritis</i>	vs.	<i>Salpingitis.</i>
Lies farther from the uterus; more globular in shape.		Lies nearer the uterus; more elongated.
Less fluctuating unless abscess present.		More fluctuating.
The ovary cannot be felt elsewhere.		The ovary can often be felt separate from the mass.

How would you differentiate an ovaritis from an exudation in the broad ligament?

<i>Ovaritis</i>	vs.	<i>Exudation in Broad Ligament.</i>
More circumscribed.		Less circumscribed.
Less closely related to vaginal vault.		More closely related to vaginal vault.
Less fixity of the uterus.		More fixity of the uterus.

How would you differentiate ovaritis from a lateral uterine fibroid?

<i>Ovaritis</i>	vs.	<i>Lateral Fibroid.</i>
Sensitive to pressure.		Insensitive to pressure.
Less intimately connected with the uterus.		More intimately connected with the uterus; moves with it.
Density less.		Density greater.
Menorrhagia less common.		Menorrhagia more common.

How would you differentiate ovaritis from fæces in the rectum?

<i>Ovaritis</i>	<i>vs.</i>	<i>Fæces.</i>
More sensitive.		Less sensitive.
Globular.		Elongated in shape.
Does not indent on pressure.		Indents on pressure.
Found after emptying rectum.		Disappears on emptying rectum.

What is the treatment of ovaritis?

During the acute stage keep patient quiet in bed; apply hot poultices to the lower abdomen; keep bowels open and fæces soft; give an anodyne, if necessary. Later, apply counter-irritation by means of iodine to the vaginal fornix over the affected organ, and support the ovary with a tampon. An excellent method is to soak a roll of gauze in a solution of iodoform 1 part, chloral 1 part, and glycerine 4 parts, and place this about the cervix, especially on the affected side. After the withdrawal of this support, which may be left in twelve to twenty-four hours, a hot-water vaginal douche may be used with advantage.

As a last resort, after a faithful trial of the above palliative measures for months without avail, and if the patient is a great sufferer, removal of the offending organ by laparotomy is indicated.

If abscess of the ovary is present, early laparotomy is indicated.

PROLAPSE OF THE OVARY.

What is the etiology and pathology?

Prolapse of the ovary may occur either as a result or cause of disease. From the increase in size, due to congestion or inflammation, the ovary is apt to prolapse.

In a retroversion or retroflexion of the uterus, the ovaries also are usually drawn backward, and from their disturbed circulation become congested and diseased. In their descent they usually first lie on the retro-ovarian shelves, and may then further descend, especially the left, into the pouch of Douglas.

What are the symptoms?

They are those of ovaritis and of ovarian compression; the latter being most marked, viz.: painful defecation and dyspareunia. (The differential diagnosis has been given under ovaritis.)

What is the treatment?

(a) *Palliative*.—If due to a displacement of the uterus and both uterus and ovaries are movable, replace the uterus and maintain it in position by means of a pessary.

When the ovary alone is displaced, if movable, support it at first with a tampon; later a pessary may perhaps be worn.

When the ovary is fixed by adhesions, an attempt should be made to cause resolution of the adhesions by counter-irritation, glycerine or boroglyceride tampons, hot-water douches and gentle massage.

(b) *Radical*.—If the palliative measures fail and the symptoms are severe, a laparotomy is indicated, either to remove the prolapsed ovary, or, if the uterus is displaced backward, to break up the adhesions and fasten the uterus forward by hysterorrhaphy or by shortening the round ligaments.

TUMORS OF THE OVARY.**What are the chief varieties?**

- (a) Cysts.
- (b) Carcinomata.
- (c) Sarcomata.
- (d) Fibromata.

Tuberculosis of the ovary is sometimes described under tumors of the ovary.

What are the varieties of ovarian cyst? Describe them.

The varieties of ovarian cyst are—

- The simple follicular.
- The proliferating glandular.
- The proliferating papillary.
- The dermoid.

The simple follicular cyst is formed by distention and coalescence of Graafian follicles. This variety of cyst is usually small, often unilocular.

The proliferating glandular cyst is developed from the "glandular or germinal epithelium, either before or subsequent to the formation of the Graafian follicles" (Howell). This is the ordinary multilocular cyst which may attain a large size. Within one main cyst there

may be several secondary or daughter cysts. The fluid is viscid, usually greenish, often gelatinous.

The proliferating papillary cyst is developed from the remains of the Wolffian body at the hilum of the ovary. On the interior of the cyst, and often on the exterior, are papillæ or villi in simple or compound form. These papillary cysts are often accompanied by ascites, often infect the peritoneum, and often become malignant.

The dermoid cyst on its interior seems lined with skin. It may contain hair, sebaceous matter, teeth or irregular fragments of bone, etc.

The present accepted idea as to the origin of dermoid cysts is that they are caused by an abnormal inclusion of the epiblast; *i. e.*, that certain misplaced embryonic cells grow within the ovary and produce the tissue to which they were destined.

What is the etiology of ovarian cysts?

Concerning this little is known. They occur most frequently between the ages of 20-50, but are found both in the young and old.

Simple ovaritis or injury of the ovary are said by some to predispose to the formation of a cyst.

What changes may occur in an ovarian cyst?

The principal changes are the following:—

It may rupture, usually from traumatism.

Hemorrhage may occur into it.

It may become gangrenous or may suppurate.

The hemorrhage, gangrene and suppuration are usually the result of torsion of the pedicle.

Suppuration may also arise from the introduction of sepsis if the tumor is tapped, as formerly practiced.

What are the symptoms of an ovarian cyst?

They are chiefly those of pressure. There may be difficulty in urination and defecation; in the later stages the patient is greatly exhausted by the great weight, and often suffers with dyspnoea.

What are the physical signs of an ovarian cyst?

These vary with the location. When small and in the pelvis we get a tense elastic mass, usually fluctuating and insensitive to pressure. The multilocular variety may seem hard. The uterus is displaced by the tumor.

When the cyst has extended to the abdomen, we get distention of the abdomen and dullness on percussion over the tumor. Fluctuation can usually be detected.

From what must you differentiate an ovarian cyst when small and situated in the pelvis?

- From (a) Distended tube.
 (b) Peritonic exudation.
 (c) Inflammatory exudation into broad ligament.
 (d) Extra-uterine gestation.

How would you differentiate a small ovarian cyst from a distended tube?

<i>Ovarian Cyst</i>	<i>vs.</i>	<i>Distended Tube.</i>
No inflammatory history; gradual development; little if any pain.		History of acute inflammation; pain usually prominent.
More globular.		More elongated.
Less intimately connected with the uterus.		More intimately connected with the uterus.
Insensitive to pressure.		Sensitive to pressure.
Usually lower in pelvis.		Usually higher.
Less fixity.		More fixity.

How would you differentiate a small ovarian cyst from a peritonic exudation?

<i>Ovarian Cyst</i>	<i>vs.</i>	<i>Peritonic Exudation.</i>
No history of acute inflammation.		History of acute inflammation.
Insensitive.		Sensitive to pressure.
More mobile.		Fixed.
More lateral.		Usually in pouch of Douglas.

How would you differentiate a small ovarian cyst from an inflammatory exudation into the broad ligament?

<i>Ovarian Cyst</i>	<i>vs.</i>	<i>Inflammatory Exudation.</i>
Absence of history of inflammation.		History of inflammation following labor, abortion, or operation. If a hæmatoma, history of sharp pain, shock, perhaps symptoms of hemorrhage.

More mobile.	Fixed.
Induration of parametrium wanting.	Induration present.
Insensitive.	Sensitive to pressure.
Bulges less into vagina.	Bulges more into vagina.

How would you differentiate an ovarian cyst from an extra-uterine pregnancy?

<i>Ovarian Cyst</i>	vs.	<i>Extra-uterine Pregnancy.</i>
Slow growth.		Growth more rapid.
No symptoms of pregnancy.		Constitutional symptoms of pregnancy.
Menstruation usually not far from normal.		Amenorrhœa usually followed by menorrhagia.
More mobile.		More fixed.
Uterus usually not enlarged.		Uterus enlarged.
Pain only from pressure; no acute attacks.		Attacks of pain; finally a severe attack, symptoms of shock and hemorrhage.

From what must you differentiate a large ovarian cyst occupying the abdomen?

- From (a) Pregnancy.
 (b) Ascites.
 (c) Fibroid tumor of the uterus.
 (d) Distended bladder.
 (e) Hæmatometra.

How would you differentiate a large ovarian cyst from a pregnant uterus?

<i>Ovarian Cyst</i>	vs.	<i>Pregnant Uterus.</i>
More lateral.		More central.
Menstruation continues.		Amenorrhœa the rule.
Positive symptoms of pregnancy absent.		Positive symptoms of pregnancy present.
Uterus small, separate from tumor; cervix softened.		Uterus forms the tumor; cervix softened.
Fluctuating.		Less fluctuating; foetal parts felt.

Intermittent contractions absent.	Intermittent contractions present.
Growth less rapid.	Growth more rapid.

How would you differentiate a large ovarian cyst from ascites?

<i>Ovarian Cyst</i>	<i>vs.</i>	<i>Ascites.</i>
Patient on back :—		Patient on back :—
Swelling central or unilateral.		Swelling bilateral.
Dullness in front.		Tympanitic in front.
Tympanitic on the sides.		Dullness on the sides.
Percussion note varies little on turning patient from side to side.		Percussion note varies greatly in turning from side to side.
Circumscribed.		Diffuse.

How would you differentiate a large ovarian cyst from a large fibroid tumor of the uterus?

<i>Ovarian Cyst</i>	<i>vs.</i>	<i>Fibroid.</i>
Fluctuating.		Firm, non-fluctuating.
Less intimately connected with the uterus.		More intimately connected with the uterus; moves with it.
Menorrhagia uncommon.		Ménorrhagia common.
Uterus usually not enlarged.		Uterus usually enlarged.

How would you differentiate a large ovarian cyst from a distended bladder?

<i>Ovarian Cyst</i>	<i>vs.</i>	<i>Distended Bladder.</i>
More lateral.		Central.
Rarely in front of the uterus.		Lies in front of the uterus.
Remains after patient is catheterized.		Disappears when patient is catheterized.

How would you differentiate a large ovarian cyst from a hæmatometra?

<i>Ovarian Cyst</i>	<i>vs.</i>	<i>Hæmatometra.</i>
Menstrual flow appears.		Menstrual blood retained.
More lateral; separate from the uterus.		Central; tumor formed by the distended uterus.

Pain only from pressure.	Periodical attacks of pain, due to increase of contents.
Atresia absent.	Atresia of vagina or cervix present.

What is the treatment of an ovarian cyst?

The only treatment is removal by laparotomy.

PAROVARIAN CYSTS.

Describe briefly.

They are cysts developed in the broad ligament from the parovarium, the remains of the Wolffian body. These cysts are usually, though not always, unilocular; the contents colorless, thin and watery. The cyst wall is usually thin, and fluctuation very distinct. As the cyst grows, it opens up the folds of the broad ligament.

What is the treatment?

Removal by laparotomy is probably the best treatment. One fold of the broad ligament is incised and the tumor enucleated.

They were formerly treated by tapping, but there is danger of sepsis and peritonitis, and they often refill.

What are the chief points in the technique of a laparotomy for the removal of the uterine appendages or a cyst?

Have the bowels of the patient thoroughly emptied, and allow only fluid diet for twenty-four to forty-eight hours preceding the operation. On the evening before the operation, it is well to thoroughly wash the abdomen, especially about the umbilicus. On the day of the operation, the abdomen and pubes are shaved, scrubbed with soap and water, washed with alcohol, and then with bichloride 1-1000.

All antiseptic precautions must be observed in regard to instruments, hands, sponges, etc.

The patient having been anæsthetized, a final cleansing of the abdomen with alcohol and bichloride is performed. An incision, about three inches long, is made in the median line, beginning just below the umbilicus; this incision is deepened to the peritoneum; bleeding points are clamped, and the wound irrigated with bichloride 1-1000. The peritoneum is raised with thumb forceps, one held by the operator, the other by an assistant, and the peritoneum cut between the forceps; the incision is lengthened with the scissors,

cutting on the finger to the length of the abdominal wound. The latter may be lengthened, if necessary.

If the operation is for the removal of the appendages, the fundus of the uterus is felt for as a landmark; the ovary and tube of the affected side are brought into the abdominal wound and surrounded by warm sponges or pads. A Staffordshire knot (see Fig. 57), is tied about the pedicle; the parts outside the ligature are cut away, the stump is dusted with iodoform, the ligature cut short and the stump dropped back into the abdominal cavity. The other side is treated, if necessary, in the same way.

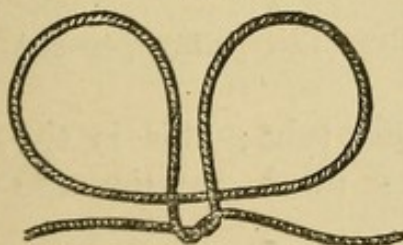
If the operation is for an ovarian cyst, after opening the abdomen the cyst is punctured with a trocar, the emptied sac drawn out of the abdominal wound, the adhesions separated, if necessary, the pedicle tied with silk in a Staffordshire knot, and the stump treated as before.

If any pus has gotten into the abdominal cavity, the latter is freely irrigated with hot boiled water, and a glass drainage tube inserted. If no irrigation is practiced, the tube is usually omitted.

The abdominal wound is closed by one of several methods. A very good one is to use silver wire, passing through skin, muscle, fascia and peritoneum, and then bring the skin into apposition by sutures of silkworm gut introduced between the silver wires. Some suture the peritoneum separately, but this is unnecessary. The wound is irrigated with bichloride, 1-1000; iodoform is dusted on and then a dressing of iodoform gauze, bichloride gauze and borated cotton applied and held in place by plaster strips and an abdominal binder. The patient is then put to bed and surrounded with hot-water bottles.

How is the Staffordshire knot tied?

FIG. 57.



STAFFORDSHIRE KNOT (*Tait*).
This shows knot after loop has been brought over, one end brought above it, and the first turn of the artery knot made.

The suture is passed from you through the centre of the pedicle by means of an aneurism needle, and the needle withdrawn; the loop is then brought forward over the tumor, one end of the suture brought above and the other left below it (see Fig. 57). The two ends are now tied in a double knot, then passed around the pedicle in the crease formed by the loop and tied in a double knot on the other side.

What is the after treatment of the case?

The patient receives no food by the mouth for 12-24 hours, nutrient enemata being used in the meantime. The urine is drawn with a catheter. As little opium as possible is used. The bowels are moved on the third day by a turpentine enema, calomel gr. iv (gr. j every half hour) or salines. If tympanites occurs at any time, the bowels are moved.

The stitches are removed on the 7-8th day, and the patient is allowed up on the 14th.

How would you prepare catgut for ordinary ligature and suture?

1. Soak the gut in ether for 1 hour.
2. Wipe with a bichloride towel.
3. Soak in bichloride 1 : 1000 for 8 hours.
4. Wipe with a bichloride towel.
5. Store it in absolute alcohol.

How would you prepare the chromicized (McEwen's) catgut?

Soak the gut for 48 hours in the following solution :—

℞.	Acidi chromici,	3 iij-	3 vss
	Aquæ,	q. s. ad	Oj
M. et adde			
	Glycerini,		Ov.

Then store the gut in carbolized glycerine 1-5.

Wipe with a bichloride towel before using.

Extra-Uterine Gestation.**What are the varieties?**

Extra-uterine gestation, or ectopic gestation (Tait), may present the following varieties :—

(a) *Tubal*.—Growing within the Fallopian tube; this is the most common variety. Three varieties of tubal gestation are noticed :—

1. Interstitial.—In that portion of the tube within the uterine wall.
2. In the tube proper.
3. Tubo-ovarian.—Between the tube and ovary.

(b) *Abdominal*.—This was probably originally tubal.

(c) *Ovarian*.—That gestation ever occurs within the ovary is very doubtful. Tait says that he never saw such a case.

What is the etiology?

Disease of the tube, or obstruction of its lumen by tumors, pressure, or traction are regarded as the chief causes.

What are the symptoms?

There is usually a history of previous sterility; then symptoms of early pregnancy; usually amenorrhœa at first, later irregular menstruation or menorrhagia. Attacks of pain with symptoms of shock may be present; then when the sac ruptures, symptoms of hemorrhage, severe shock and collapse.

What are the physical signs?

The uterus is found somewhat enlarged. At the side or posterior a tumor is felt, tender on pressure, and containing abundant blood vessels. Ballottement is sometimes detected.

What is the course and result?

Extra-uterine pregnancy is usually, if not always, primarily tubal. At about the third month the tube usually ruptures either into the peritoneal cavity or into the broad ligament. The foetus may die at this time. If small, it, with the effused blood, may be absorbed; if large, it may become encysted and retained for years, or suppuration may occur and the bones be extruded through the rectum, vagina, abdominal wall, or bladder.

The foetus, on the other hand, may live, the placenta being attached, in the abdominal variety, to the abdominal wall, intestines or any of the viscera. Tait regards the extra-uterine children reaching full term as in the broad ligament.

From what must you differentiate extra-uterine pregnancy?

Suppurative cellulitis.

Fibroid tumor.

Ovarian cyst.

Dermoid cyst.

Parovarian cyst.

Salpingitis.

Retroversio-flexio.

What is the treatment?

(A) Before the viability of the child, two views are held at the present day:—

1. Perform laparotomy as soon as the diagnosis is made, and remove, if possible, the fœtus, or its remains, and the sac.

2. Destroy the life of the fœtus by electricity, and only perform laparotomy after the failure of nature to remove the products of gestation.

Thomas gives as a rule in ectopic gestation prior to the viability of the child: "A diagnosis of extra-uterine pregnancy being arrived at, destroy fœtal life as promptly as possible." Of several methods of accomplishing this, he decidedly prefers electricity without acupuncture.

When rupture of the sac into the peritoneal cavity occurs, the usual indication is to perform laparotomy and cleanse the abdominal cavity.

(B) After the viability of the fœtus, the best rule is probably to wait till full term and perform laparotomy, with the hope of saving both mother and child.

Fistulæ.**What are the chief varieties met with in gynæcology?**

They may be either urinary or fecal.

Urinary fistulæ present the following varieties (see Fig. 58):—

1. Urethro-vaginal.
2. Vesico-vaginal.
3. Vesico-uterine.
4. Uretero-vaginal.
5. Uretero-uterine.

The most common is the vesico-vaginal.

The fecal fistula which especially concerns us is the recto-vaginal.

What is the etiology of a vesico-vaginal fistula?

The most common cause is sloughing following long-continued pressure, usually in parturition, but occasionally from a pessary. It may be produced by direct laceration through the septum. It is predisposed to by the causes of a tedious labor.

What are the symptoms ?

The involuntary escape of urine.

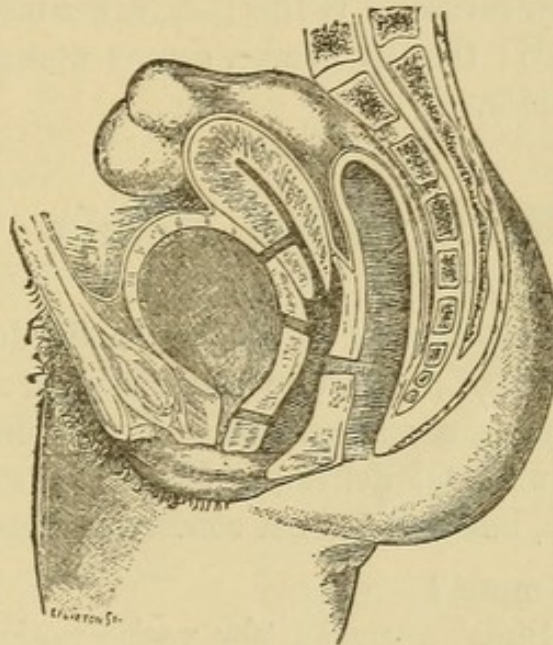
A urinous odor about the person.

Irritation and excoriation of the vulva and parts around.

How is the diagnosis made ?

If the fistula is not evident on exposing the parts with a Sims' speculum, the patient being in Sims' position, the bladder may be distended with some colored antiseptic fluid, like creolin solution, and by the exit of the latter the fistula may be detected, and then verified by a probe.

FIG. 58.



TO REPRESENT THE CHIEF VARIETIES OF URINARY FISTULA—URETHRO-VAGINAL, VESICO-VAGINAL AND VESICO-UTERINE.—Those with the ureters are not seen. The seat of a recto-vaginal fistula is indicated (*De Sinéty*).

What is the treatment ?

The treatment usually pursued in this country is the operation of Sims, which is performed as follows: The patient is anæsthetized, an antiseptic vaginal douche given, and all antiseptic precautions observed during the operation. She is placed in Sims' position and Sims' speculum introduced. The edges of the fistula are pared with the knife or scissors, the mucous membrane not being included in the incision. Silver-wire sutures are then introduced, about one-fifth to one-fourth inch apart, not penetrating the mucous mem-

brane. The parts are brought into apposition by twisting the sutures, and then a self-retaining catheter is introduced. The sutures are left for eight days. The operation for a urethro-vaginal fistula is similar to the above.

What are the chief steps in the operation for the cure of a vesico-uterine fistula?

Emmet regards the condition as due to a laceration of the cervix extending into the bladder, the laceration healing only below. The operation is based on this idea, viz.: The cervix is split up to the fistula; the edges of the latter are denuded, and the whole brought together in a manner similar to a trachelorrhaphy, especial care being taken with the upper sutures. If this fails, it has been recommended to close the os uteri; this, of course, causes uterine discharges to empty into the bladder.

Recto-vaginal Fistula.

What is the etiology?

This, like the vesico-vaginal fistula, is usually due to sloughing caused by long-continued pressure in parturition, or may be produced by laceration through the septum, either by the unaided efforts of nature or by instrumental delivery. Cancer or syphilis may, of course, cause fistula, but this will not concern us here.

What is the treatment?

It is similar to Sims' operation for vesico-vaginal fistula. The edges are denuded and brought together by silver wire, the rectal mucous membrane being uninjured. If the fistula is near the vulva, it is usually best to divide the sphincter ani and perineum up to the fistula, to dissect this out, and then close the parts as in a laceration of the perineum through the sphincter ani.

INDEX.

ALEXANDER'S operation, 123
Amenorrhœa, 96
Atrophy of the uterus, 151

BIMANUAL examination, 45
Bladder, 35
Bulbs of the vagina, 20

CARCINOMA uteri, 167
Cellulitis, pelvic, 87
Clitoris, 18
Coccygodynia, 78
Condylomata, pointed, 74
 syphilitic, 75
Curette, 61

DEVELOPMENT of the pelvic organs, 42
Dilators, 57
 elastic, 61
 graduated, hard, 59
Displacements of the uterus, 110
 anteflexion, 112
 anteversion, 111
 retroversion and retroflexion, 115
Dysmenorrhœa, 99

ECZEMA of the vulva, 72
Emmet's operation, 132
Endometritis, 140
 acute, 141
 chronic, 142
Erythema of the vulva, 72
Extra-uterine gestation, 186

FALLOPIAN tubes, 30
Fibroid tumors of the uterus, 151
Fistula, recto-vaginal, 190
Fistulæ, 188
Fossa navicularis, 20
Fourchette, 20

HÆMATOCELE and hæmatoma, pelvic, 91
Hæmatocele, pudendal, 70
Hemorrhage from vulva, 71
Hernia, pudendal, 69
High amputation of the cervix, 170
Hymen, 21
Hyperæsthesia of the vulva, 77
Hypertrophy of the cervix, 134
Hysterectomy, vaginal, 169
Hysterorrhaphy, 124

INSTRUMENTS, 48
Inversion of the uterus, 158
Irritable urethral caruncle, 79
Ischio-rectal fossa, 41

LABIA majora, 17
 minora, 18
Laceration of the perineum, 127
 of the cervix, 136

MALFORMATIONS of the uterus, 106
Malformations of the vagina, 104
 atresia of the vagina, 104
 of the vulva, 80
Menstruation, 96
 disorders of, 96
 amenorrhœa, 96
 dysmenorrhœa, 99
 obstructive, 100
 congestive, 100
 neuralgic, 101
 ovarian, 102
 membranous, 102
 menorrhagia and metrorrhagia, 98
 vicarious menstruation, 98
Metritis, 146
 acute, 147
 chronic, 148
Mons veneris, 17

NEW growths of the vulva, 74

OVARIES, 31
 affections of, 174
 hemorrhage into, 174
 prolapse of, 178
 tumors of, 179
 Ovaritis, 175

PAPILLOMATA, simple, 74
 Parovarian cysts, 184
 Parovarium, 34
 Pelvic floor, 39
 Perineal body, 40
 Perineum, muscles of, 41
 Peritoneum, pelvic, 84
 Peritonitis, pelvic, 85
 Pessaries, 119
 Physical examination of pelvic organs,
 42
 Polypi, 163
 Probe, uterine, 57
 Prolapse of urethral mucous mem-
 brane, 80
 Prolapsus uteri, 124
 Pruritus, vulval, 75
 Pudental hæmatocele, 70
 hernia, 69

RECTAL examination, 46
 Rectum, 37

SAENGER-TAIT operation, 128
 Salpingitis, 172
 Sarcoma of the uterus, 171
 Skin diseases of vulva, 72

Sound, uterine, 53
 Specula, 48
 Sims' speculum, 48
 Fergusson's speculum, 50
 Brewer's speculum, 51
 Stenosis of the cervix, 135

TENTS, 57
 Trachelorrhaphy, 139

URINARY tract, 34
 Uterus, 23
 Uterus, mucous membrane of, 25

VAGINA, 21
 diseases of, 81
 Vaginal examination, 43
 Vaginismus, 77
 Vaginitis,
 simple catarrhal, 81
 gonorrhœal, 82
 ulcerative, 83
 diphtheritic, 84
 Vestibule, 20
 Vicarious menstruation, 98
 Volsella, 52
 Vulva, malformations of, 80
 Vulvitis, 62
 acute simple catarrhal, 63
 chronic catarrhal, 63
 gonorrhœal, 64
 phlegmonous, 65
 diphtheritic, 66
 gangrenous, 66
 follicular, 67
 Vulvo-vaginal glands, 21
 cyst and abscess of, 68

IN PREPARATION.

A NEW
UNABRIDGED DICTIONARY OF
MEDICINE
AND ACCESSORY SCIENCE,

— BY —

JOHN M. KEATING, M. D., (Univ. of Pa.),

FELLOW COLLEGE OF PHYSICIANS OF PHILADELPHIA; VISITING OBSTETRICIAN TO THE PHILADELPHIA HOSPITAL, AND LECTURER ON DISEASES OF WOMEN AND CHILDREN; GYNÆCOLOGIST TO ST. JOSEPH'S HOSPITAL; SURGEON TO THE MATERNITY HOSPITAL, ETC.; EDITOR "CYCLOPÆDIA OF DISEASES OF CHILDREN"; AUTHOR OF "MATERNITY—INFANCY — CHILDHOOD," ETC.

AND

HENRY HAMILTON,

AUTHOR OF "A NEW TRANSLATION OF VIRGIL'S ÆNEID INTO ENGLISH RHYME"; CO-AUTHOR OF "SAUNDERS' MEDICAL LEXICON," ETC.

A voluminous and exhaustive hand-book of Medical, Surgical and Scientific Terminology, containing concise explanations of the various terms used in medicine and the allied sciences, with Accentuation, Etymology, etc. The work, when completed, will form a handsome Royal 8vo. volume of some 1000 pages, beautifully printed from new type on paper especially manufactured for this purpose; it will contain the most recent additions to scientific nomenclature, important tables, etc., under the most convenient system of arrangement—the whole forming the most complete, reliable and valuable dictionary in the market. Indispensable alike to the Student and Practitioner, not only for occasional reference, but for daily use.

SAUNDERS' SERIES OF MANUALS
FOR
STUDENTS & PRACTITIONERS.
WITH COLORED PLATES.

The great popularity shown by the large and increasing sale of the Question-Compends, together with a demand from Students and others for somewhat larger reference works, has induced the publisher to issue the present series of manuals.

Anatomy and Practical Dissector.

BY

CHAS. B. NANCREDE, A. M., M. D.

Professor of Surgery and Clinical Surgery in the University of Michigan, Ann Arbor; Corresponding Member of the Royal Academy of Medicine, Rome, Italy; Late Surgeon Jefferson Medical College, etc.

Thirty fine Lithographic plates in colors and 175 Wood cuts in the text. Post 8vo, over four hundred pages, cloth or oilcloth for the dissecting-room, \$2.00. Medical sheep, \$2.50.

IN PREPARATION.

DISEASES OF WOMEN,

BY

HENRY J. GARRIGUES., A.M., M.D.

Professor of Obstetrics in the New York Post-Graduate Medical School and Hospital; Gynecologist to St. Mark's Hospital in New York City; Gynecologist to the German Dispensary in the City of New York; Consulting Obstetrician to the New York Infant Asylum; Obstetric Surgeon to the New York Maternity Hospital; Fellow of the American Gynecological Society; Fellow of the New York Academy of Medicine; President of the German Medical Society of the City of New York, etc., etc.

READY SHORTLY.

DISEASES OF THE EYE.

BY

GEO. E. De SCHWEINITZ, M. D.

Ophthalmic Surgeon to Children's Hospital and to the Philadelphia Hospital; Ophthalmologist to the Orthopædic Hospital and Infirmary for Nervous Diseases, etc.

OTHERS PREPARING.

NOW READY.

SYLLABUS OF OBSTETRICAL LECTURES

IN THE MEDICAL DEPARTMENT,
UNIVERSITY OF PENNSYLVANIA.

BY

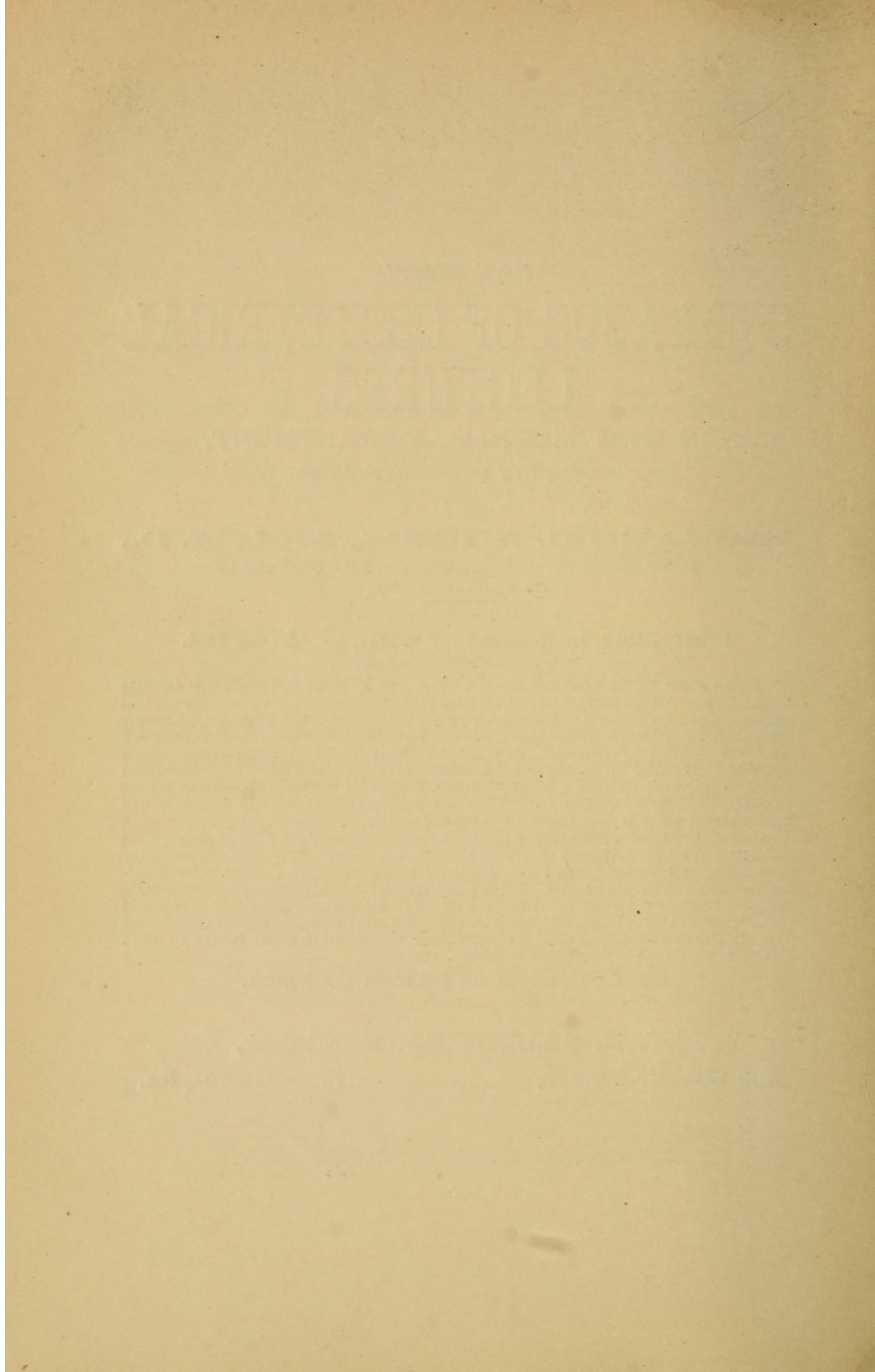
RICHARD C. NORRIS, A. M., M. D.,
DEMONSTRATOR OF OBSTETRICS IN THE UNIVERSITY
OF PENNSYLVANIA.


Price, Cloth, Interleaved for Notes, - \$2.00 Net.


*The New York *Medical Record* of April 19th, 1890, referring to this book says: "The modest little work is so far superior to others on the same subject, that we take pleasure in calling attention briefly to its excellent features. Small as it is it covers the subject thoroughly and will prove invaluable to both student and the practitioner as a means of fixing in a clear and concise form the knowledge derived from a perusal of the larger textbooks. The author deserves great credit for the manner in which he has performed his work. He has introduced a number of valuable hints which would only occur to one who was himself an experienced teacher of obstetrics. The subject matter is clear, forcible and modern. We are especially pleased with the portion devoted to the practical duties of the accoucher, care of child, etc. The paragraphs on Antiseptics are admirable, there is no doubtful tone in the directions given. No details are regarded as unimportant. No minor matters omitted. We venture to say that even the old practitioner will find useful hints in this direction which he cannot afford to despise."

SENT POSTPAID ON RECEIPT OF PRICE.

W. B. SAUNDERS, Publisher,
913 WALNUT STREET, PHILADELPHIA, PA.







SAUNDERS' QUESTION-COMPENDS.

OPINIONS OF THE PRESS.

Extract from Medical Brief, St. Louis, May, 1890.

Semple's Legal Medicine Toxicology and Hygiene. "A fair sample of Saunders' valuable compends for the student and practitioner. It is handsomely printed and illustrated, and concise and clear in its teachings."

Extract from Southern Practitioner, April, 1890.

Stelwagon's Disease of the Skin. "The subject is as tersely and briefly considered as is compatible with learners, and as a means of refreshing the memory or permanently fixing therein the most important facts of Dermatology, it will fill an important place with students of medicine."

Extract from Medical and Surgical Reporter, April, 1890.

Craigin's Essentials of Gynæcology. "This is a most excellent addition to this series of question compends, and properly used will be of great assistance to the student in preparing for examination. Dr. Craigin is to be congratulated upon having produced in compact form the Essentials of Gynæcology. The style is concise, and, at the same time the sentences are well rounded. This renders the book far more easy to read than most compends and adds distinctly to its value."

Extract from the New York Medical Journal, May, 1890.

Stelwagon's Diseases of the Skin. "We are indebted to Philadelphia for another excellent book on Dermatology. The little book now before us is well entitled "Essentials of Dermatology," and admirably answers the purpose for which it is written. The experience of the reviewer has taught him that just such a book is needed. We are pleased with the handsome appearance of the book, with its clear type and good paper, and would specially commend the woodcuts that illustrate the text."

Extract from Journal of Cutaneous and Genito-Urinary Diseases, May 1890.

"An examination of the manuals before us cannot fail to convince one that the authors have done their work in a satisfactory manner.

"Dr. Stelwagon's Essentials of Diseases of the Skin is an admirable compend of our knowledge of Dermatology. The author's experience as a teacher has enabled him to formulate questions covering all essential points, while the answers are comprehensive with sufficient accuracy of detail to be thoroughly intelligible. Of especial value and completeness is the therapeutical part of the work.

"Dr. Wolf in the Examination of the Urine, has given an account of the normal and pathological constituents of the urine and a *resumé* of the recent and most improved methods for its chemical and microscopical examination. The importance of a knowledge of urinology and urinalysis to the student of dermatology and genito-urinary diseases cannot too strongly be insisted on."

"Dr. Craigin in his Essentials of Gynæcology embraces many morbid conditions of much interest to the specialist in cutaneous and genito-urinary diseases, as the skin diseases affecting the vulva, new growths of the vulva, the various forms of vulvitis, vaginitis urethritis, endometritis, salpingitis, ovaritis, etc., which occur as sequelæ of gonorrhœal inflammation."

Extract from Boston Medical and Surgical Journal, May 1, 1890.

"Craigin's Gynæcology, a little book that *does* contain the essentials of gynæcology and may be recommended to the student as a safe and useful guide to him in his studies."

COLUMBIA UNIVERSITY LIBRARIES

This book is due on the date indicated below, or at the expiration of a definite period after the date of borrowing, as provided by the rules of the Library or by special arrangement with the Librarian in charge.

	DATE BORROWED	DATE DUE	DATE BORROWED	
the				that
selv				em-
wh				and
arr				its
and				logy
of t				sion
the				All
Uri				s to
in				lled
ren				are
elab				more
like				book
inst				and
can				and
art.				book
our				der
com				and
rec				g to
esc				ntly
	C28(1141)M100			

Extract from Southern Clinio, January, 1890.

MORRIS' MATERIA MEDICA.—“The arrangement and subject-matter of this book leaves nothing to be asked for, either for the student or medical practitioner. It is a valuable substitute for larger and more expensive works.”

NOW READY.

Nancy's Anatomy and Dictionary,

RG111

C84

Cragin

NANCY
executed
TION O
graphic

No pa
yet conci
this cour

The
Arteries
drawn a
senting
11th Ed
over 400

Price,

Price 75 Cents, Cloth.

Price 1.00 Leather, Buckram

This new and comprehensive work of reference is the outcome of a demand for a more modern handbook of its class than those at present on the market, which, dating as they do from 1855 to 1884, are of but trifling use to the student by their not containing the hundreds of new words contained in current literature, especially those relating to Electricity and Bacteriology.

