

**Applied anatomy : the construction of the human body considered in relation to its functions, diseases and injuries / by Gwilym G. Davis. With six hundred and thirty illustrations, mostly from original dissections and many in color ; by Erwin F. Faber.**

### **Contributors**

Davis, Gwilym G. 1857-1918.  
Augustus Long Health Sciences Library

### **Publication/Creation**

Philadelphia : Lippincott, [1910], ©1910.

### **Persistent URL**

<https://wellcomecollection.org/works/jhmqg88h>

### **License and attribution**

This material has been provided by This material has been provided by the Augustus C. Long Health Sciences Library at Columbia University and Columbia University Libraries/Information Services, through the Medical Heritage Library. The original may be consulted at the the Augustus C. Long Health Sciences Library at Columbia University and Columbia University. where the originals may be consulted.

This work has been identified as being free of known restrictions under copyright law, including all related and neighbouring rights and is being made available under the Creative Commons, Public Domain Mark.

You can copy, modify, distribute and perform the work, even for commercial purposes, without asking permission.



Wellcome Collection  
183 Euston Road  
London NW1 2BE UK  
T +44 (0)20 7611 8722  
E [library@wellcomecollection.org](mailto:library@wellcomecollection.org)  
<https://wellcomecollection.org>



COLUMBIA LIBRARIES OFFSITE  
HEALTH SCIENCES STANDARD



HX00018546



**Columbia University  
in the City of New York**


THE LIBRARIES




**Medical Library**

MEMORIAL LIBRARY  
NEUROLOGICAL INSTITUTE  
COLUMBIA-PRESBYTERIAN  
MEDICAL CENTER











# APPLIED ANATOMY

THE CONSTRUCTION OF THE HUMAN BODY

CONSIDERED IN

RELATION TO ITS FUNCTIONS,  
DISEASES, AND INJURIES

BY

GWILYM G. DAVIS

ASSOCIATE PROFESSOR OF APPLIED ANATOMY, UNIVERSITY OF PENNSYLVANIA;

M.D., UNIVERSITIES OF PENNSYLVANIA AND GOETTINGEN; MEMBER OF THE ROYAL COLLEGE OF SURGEONS, OF ENGLAND; SURGEON TO THE EPISCOPAL, ST. JOSEPH'S, AND ORTHOPÆDIC HOSPITALS; ORTHOPÆDIC SURGEON TO THE PHILADELPHIA GENERAL HOSPITAL; FELLOW OF THE AMERICAN SURGICAL ASSOCIATION; MEMBER OF THE SOCIETY OF CLINICAL SURGERY; MEMBER OF THE AMERICAN ORTHOPÆDIC ASSOCIATION; FELLOW OF THE PHILADELPHIA ACADEMY OF SURGERY, THE PHILADELPHIA COLLEGE OF PHYSICIANS, AND THE AMERICAN ACADEMY OF MEDICINE, ETC.

WITH SIX HUNDRED AND THIRTY ILLUSTRATIONS, MOSTLY  
FROM ORIGINAL DISSECTIONS AND MANY IN COLOR

BY

ERWIN F. FABER



PHILADELPHIA & LONDON

J. B. LIPPINCOTT COMPANY



QM531

D29

1910

COPYRIGHT, 1910  
By J. B. LIPPINCOTT COMPANY

*Transfer from Neuro*

*Printed by J. B. Lippincott Company  
The Washington Square Press, Philadelphia, U. S. A.*




JUN 29 1956

To

GEORGE A. PIERSOL, M.D., Sc.D.

PROFESSOR OF ANATOMY IN THE UNIVERSITY OF PENNSYLVANIA,  
AN IDEAL SCIENTIST, TEACHER, AND FRIEND

Gift of Mrs. L. W. 5/10/56



Digitized by the Internet Archive  
in 2010 with funding from  
Open Knowledge Commons



## PREFACE.

---

It is not the object of this work to teach plain anatomical facts ; its aim is to show the relation of structure to function, whether it is normal function or function disturbed or impaired by injury or disease. It is explanatory and utilitarian in character, and not encyclopedic. The bare facts of anatomy can be obtained from the systematic treatises, and they are here only briefly given in order to refresh the memory of the reader, who is supposed to be familiar to a certain extent with systematic anatomy. A person who has studied the subject only from a systematic standpoint cannot utilize and apply the knowledge so acquired unless he considers its relation to the various affections encountered in practice. He can study anatomy, but he will not see its application until it is pointed out to him. He may have studied the palmar fascia, but, unless he is shown how its construction influences the course of pus originating beneath it, his anatomical knowledge is of little value. The inability to make any practical use of the facts or to see their application is the reason why anatomy is so frequently regarded as a dry, uninteresting study and too often designedly neglected.

In considering the subject, after a few general remarks on the part involved, the skeleton and muscles are briefly described, and thereby one is enabled to understand the surface anatomy, which immediately follows. Then comes a consideration of the various affections of the part, with such allusion to the nerves and vessels as is desirable to elucidate the subject. As the book is not intended to be a systematic treatise on anatomy, such anatomical facts as cannot be shown to be useful in practice are not mentioned. To give them here would make the volume too large, obscure its main object, and defeat its purpose.

As regards the anatomical nomenclature used, there is no system so generally accepted as to justify its exclusive adoption. In the desire, however, to aid in furthering the adoption of better anatomical terms, as much of the BNA terminology has been used, or included in parentheses, as a consideration of the subject from the standpoint of a general practitioner would allow.

Most of the illustrations are from original drawings of preparations made by the author and his assistants. Those derived from other sources are duly credited ; if there has been any failure in this respect, it is unintentional.

The clinical material, except where otherwise stated, is from the author's own experience.

To the artist in charge, Mr. Erwin F. Faber, and to Mr. Herman Faber, who made a large number of the original sketches, my best thanks are due for their great skill, untiring energy, and most intelligent aid ; their work speaks for itself.



I am under great obligations to many friends who have kindly rendered me their aid. Professor George A. Piersol has given me much valuable information and allowed me the unstinted use of his anatomical material ; Dr. Astley P. C. Ashhurst made many of the dissections and aided in correcting and preparing the manuscript for the press ; Dr. Frank D. Dickson did most of the proof-reading and prepared the index ; Dr. T. Turner Thomas made many of the earlier preparations ; and Dr. Henry Beates aided in the revision of the first portion of the manuscript. To these and others who have contributed to the formation of the book I desire to express my thanks.

To the hearty coöperation and unfailing generosity of my publishers is due the presentation of such an attractive volume. I asked them for nearly everything I could think of, and they gave me nearly everything I asked for.

In conclusion : this work is recognized as being far from complete, but it is intended to be suggestive rather than absolute. It is not designed so much to present facts as to furnish reasons, and it is hoped that it will appeal to the practising physician and surgeon as well as to the student.

GWILYM G. DAVIS.

PHILADELPHIA, August, 1910.







	PAGE		PAGE
Ligation of Arteries.....	141	Surface Anatomy.....	287
The Cervical Fascias.....	150	Veins of the Elbow.....	288
Lymphatics of the Neck.....	156	Brachial Artery.....	290
Operations on the Air Passages.....	161	Dislocations of the Elbow.....	291
Operations on the Thyroid Gland.....	163	Fractures in the Region of the Elbow.....	295
The Parathyroid Bodies.....	165	Diseases of the Olecranon Bursa; Diseases	
Œsophagus—Cervical Portion.....	166	of the Elbow-Joint.....	300
Cut-throat.....	168	Resection of the Elbow.....	301
Affections of the Neck.....	169	Amputation at the Elbow.....	302
THE THORAX.		THE FOREARM.	
Sternum, Ribs, and Costal Cartilages ..	174	Bones.....	303
Thoracic Vertebrae.....	176	Movements of Pronation and Supination.....	304
Soft Parts of Chest.....	176	Muscles.....	305
Muscles of Chest.....	177	Surface Anatomy.....	312
Surface Anatomy of Thorax.....	180	Arteries.....	314
Breast or Mamma.....	182	Nerves.....	317
Lymphatics of Breast.....	184	Fractures.....	321
Abscess of Breast; Tumors.....	185	Amputation.....	326
Excision of Breast.....	187	Operations.....	328
The Mediastinum.....	187	REGION OF THE WRIST.	
Pleural Effusions.....	191	Bones of the Wrist.....	330
The Chest Contents.....	192	Inferior Radio-ulnar Articulation.....	332
Longitudinal lines; Regions.....	192	Wrist-Joint.....	333
The Pleurae.....	194	Anterior Annular Ligament.....	335
The Lungs.....	196	Posterior Annular Ligament.....	336
Pericardium.....	201	Surface Anatomy of the Wrist.....	338
The Heart.....	204	Compound Ganglion.....	342
The Aorta.....	208	Fractures of the lower end of the Radius	
The Œsophagus.....	211	and Ulna.....	342
The Thoracic Duct.....	214	Dislocations at the Wrist.....	345
THE UPPER EXTREMITY.		Excision of the Wrist.....	347
The Shoulder-Girdle.....	217	Amputation at the Wrist.....	347
Bones of the Shoulder.....	219	THE HAND.	
Shoulder-Joint.....	222	Bones of the Hand.....	349
Muscles of the Shoulder.....	226	The Phalanges.....	351
Surface Anatomy.....	227	Joints.....	352
Axilla.....	229	Muscles.....	353
Dislocations of the Clavicle.....	230	Surface Anatomy.....	354
Dislocations of the Shoulder.....	232	Palmar Fascia.....	357
Fractures of the Clavicle.....	241	Arteries.....	358
Fractures of the Scapula.....	243	Nerves.....	360
Fractures of the Upper end of the Hu-		Dislocations.....	362
merus.....	244	Fractures.....	364
Epiphyseal Separations.....	247	Wounds.....	364
Amputation at the Shoulder-Joint.....	247	Abscesses.....	365
Interscapulothoracic Amputation.....	250	Lymphatics.....	368
Excision of the Clavicle.....	250	Amputations.....	368
Excision of the Scapula.....	251	THE ABDOMEN.	
Excision of the Head of the Humerus.....	251	Surface Anatomy.....	370
Diseases of the Shoulder-Joint and Bursæ		Abdominal Viscera.....	372
axillary Vessels.....	253	Abdominal Walls.....	374
Axillary Lymphatics.....	263	Muscles of the Abdomen.....	375
Abscesses of Axilla.....	264	Vessels of the Abdominal Walls.....	378
THE ARM.		Abdominal Incisions.....	381
The Humerus.....	267	Herniæ.....	382
Muscles of the Arm.....	267	Umbilical.....	383
Intermuscular Septa.....	271	Inguinal Congenital.....	383
Surface Anatomy.....	271	Acquired Inguinal Hernia.....	385
Brachial Artery.....	272	Radical Cure.....	387
Amputation of the Arm.....	275	Femoral Hernia.....	390
Fractures of the Humerus.....	276	The Lumbar Region.....	392
Operations on the Arm.....	279	Lumbar Fascia.....	393
REGION OF THE ELBOW.		Lumbar Abscess.....	394
Bones of the Elbow.....	280	Lumbar Incisions.....	395
Elbow-Joint.....	282	The Interior of the Abdomen.....	396
Muscles of the Elbow.....	284	Peritoneum.....	396



	PAGE		PAGE
Abdominal Viscera.....	399	Male External Genitals.....	465
Stomach.....	401	Penis.....	465
Affections of the Stomach....	403	Scrotum.....	467
Operations on the Stomach....	405	Testicles.....	468
The Small Intestine.....	406	Epididymis.....	468
Duodenum.....	408	Spermatic Cord.....	469
Jejunum and Ileum; Operations ..	409	Urethra.....	470
The Mesentery.....	410	Muscles.....	471
The Large Intestine.....	411	Passage of Sounds and Cathe-	
Cæcum and Appendix.....	414	ters.....	471
Appendicitis.....	414	The Male Perineum.....	472
The Colon.....	414	The Perineal Fascias.....	472
The Liver.....	416	The Perineal Spaces.....	475
Wounds and Injuries.....	417	Practical Application.....	475
Abscess.....	420	Rupture of the Urethra.....	475
Gall-Bladder and Biliary Passages..	420	Median Lithotomy.....	475
Gall-Stones.....	422	Lateral Lithotomy.....	476
The Pancreas.....	422	Anal Triangle and Ischiorectal	
Cysts and Abscesses.....	423	Region.....	476
The Spleen.....	424		
Splenic Enlargement.....	424	THE BACK AND SPINE.	
Wounds.....	424	Surface Anatomy.....	477
The Kidneys.....	424	The Vertebral Column.....	478
Displacement of the Kidneys...	427	Curves.....	478
Tumors of the Kidney.....	427	Movements.....	478
Abscess of the Kidney.....	428	Deformities of the Spinal Column..	478
Operations on the Kidney.....	428	Kyphosis.....	479
The Suprarenal Gland.....	438	Lordosis.....	479
The Ureter and Renal Pelvis.....	439	Scoliosis.....	479
Operations on the Ureter.....	431	Affections of the Spinal Column...	481
THE PELVIS.		Injuries of the Spinal Column....	482
Pelvic Walls.....	434	Spinal Cord and its Membranes ...	483
Pelvic Floor.....	435	Transverse Spinal Lesions.....	484
Pelvic Fascia.....	436	Spinal Meninges.....	484
Iliac Vessels.....	438	Spinal Hemorrhage.....	486
Pelvic Viscera.....	438	Functions of the Cord and Spinal	
Rectum and Anal Canal.....	440	Localization.....	487
Blood-Vessels.....	442	Lesions of the Cord.....	487
Affections of Rectum and Anus ..	442	Operations on the Spine.....	488
Imperforate Anus.....	442		
Hemorrhoids.....	443	THE LOWER EXTREMITY.	
Fistula.....	443	General Considerations.....	489
Fissure.....	443	The Bony Pelvis.....	489
Excision of Rectum.....	444	Mechanism of the Pelvis.....	490
Bladder.....	447	Fractures of the Pelvis.....	491
Bladder in the Female.....	448	Attachment of the Lower Extremities to	
Cystoscopic Examination.....	448	the Trunk.....	491
Operations on the Bladder.....	448	Anteroposterior Equilibrium.....	492
Prostate.....	450	Lateral Equilibrium.....	493
Hypertrophy.....	450	Deviations of the Spine above the	
Prostatectomy.....	451	Sacrum.....	495
Abscess.....	452	Distortions Accompanying Affections of	
Seminal Vesicles.....	453	the Lower Extremities.....	496
Vas Deferens.....	454	Measurement of the Lower Limbs....	497
Development of the Urogenital System.	454	Walking.....	498
Female Generative Organs.....	454		
Uterus.....	456	THE REGION OF THE HIP.	
Ovary.....	456	Bones of the Hip.....	499
Fallopian Tubes.....	457	Muscles of the Hip.....	503
Vagina.....	457	Surface Anatomy.....	504
Ureter in the Female.....	458	Ligation of the Gluteal, Sciatic, and	
Blood-Vessels.....	458	Internal Pudic Arteries.....	505
Lymphatics.....	459	The Hip-Joint.....	506
Pelvic Examinations.....	459	Dislocations of the Hip.....	508
Operations on the Female Pelvic Organs	460	Mechanism of the Production of...	509
Hysterectomy.....	461	Reduction of.....	512
Oophorectomy.....	461	Congenital Luxations of Hip.....	514
Vaginal Hysterectomy.....	462	Coxalgia.....	515
The Female External Genitals.....	462	Hip Abscess.....	516
Clinical Considerations.....	463	Coxa Vara.....	517
Female Perineum.....	464		



	PAGE		PAGE
Coxa Valga.....	517	REGION OF THE ANKLE.....	
Operations on the Hip-Joint.....	517	Surface Anatomy.....	553
Lateral Operations.....	517	Ankle-Joint.....	554
Anterior Operations.....	519	Ligaments.....	554
Inferior Operations.....	519	Movements.....	554
		Tuberculosis of the Ankle.....	555
THE THIGH.		Excision of the Ankle.....	555
Muscles.....	520	Sprain of the Ankle.....	556
Surface Anatomy.....	522	Dislocations of the Ankle.....	556
Scarpa's Triangle.....	522	Fractures of the Ankle.....	557
Femoral Artery.....	523	Fracture by Eversion or Pott's	
Hunter's Canal.....	524	Fracture.....	557
Long Saphenous Vein.....	525	Fracture by Inversion.....	558
Lymphatics.....	527	Amputations at the Ankle.....	559
Sciatic Nerve.....	527	Syme's.....	559
Fractures of the Femur.....	529	Pirogoff's.....	560
Fracture of Neck.....	529		
Fracture through the Trochan-		REGION OF THE FOOT.	
ters.....	531	The Construction of the Foot.....	561
Fracture of the Shaft.....	531	Diseases and Injuries of the Foot.....	561
Amputation at the Hip-Joint.....	532	Treatment of Affections of the Feet.....	562
Amputation of the Thigh.....	532	Bones of the Foot.....	562
		Arch of the Foot.....	563
REGION OF THE KNEE.		Joints and Ligaments of the Foot.....	564
Surface Anatomy.....	533	The Ligamentous Support of the Arch	
The Knee-Joint.....	534	of the Foot.....	566
Movements.....	534	Muscles of the Foot.....	568
Bones.....	534	Action of the Muscles in Supporting	
Ligaments.....	535	the Arch.....	568
Bursæ of the Knee.....	538	Action of the Muscles as Flexors	
Fracture of the Patella.....	539	and Extensors.....	569
Dislocation of the Patella.....	540	Action of the Muscles as Abductors	
Dislocation of the Knee.....	541	and Adductors.....	570
Dislocation of the Semilunar Carti-		Surface Anatomy of the Foot.....	570
lages.....	541	Tendons of the Foot.....	571
Epiphyseal Separations.....	541	Joints of the Foot.....	572
Resection of the Knee.....	542	Arteries of the Foot.....	572
Tuberculous Disease of the Knee-		Amputations.....	574
Joint.....	543	Chopart's.....	575
Knock-Knee and Bow-Legs.....	543	Lisfranc's.....	575
Osteotomy.....	544	Plantar Abscess.....	575
Ligation of the Popliteal Artery.....	544	Deformities of the Feet.....	576
Amputation through the Knee-Joint.....	544	Talipes Varus.....	576
		Talipes Valgus.....	577
THE LEG.		Flat Foot.....	577
Surface Anatomy.....	546	Talipes Equinus.....	578
Muscles of the Leg.....	546	Talipes Calcaneus.....	578
Fascia of the Leg.....	548	Talipes Cavus.....	578
Arteries of the Leg.....	548	Hallux Valgus.....	579
Veins of the Leg.....	550	The Toes.....	579
Varicosities of.....	550	Ingrown Nail.....	579
Lymphatics of the Leg.....	551	Hammer Toe.....	579
Fractures of the Leg.....	551	Luxation of the Toes.....	580
Amputation of the Leg.....	552	Metatarsalgia.....	580
		Resection of the Metatarsophalan-	
		geal Joint.....	580
		Amputation of the Toes.....	581



# APPLIED ANATOMY.

## THE SCALP.

THE scalp is formed by the movable soft tissues which cover the skull. It is composed of three layers: *skin*, *superficial fascia*, and *occipitofrontalis muscle* with its *aponeurosis*. It is attached to the underlying pericranium by loose connective tissue called the *subaponeurotic layer*. The *pericranium*, or *periosteum* of the skull, is loosely attached to the bones by a small quantity of connective-tissue fibres called

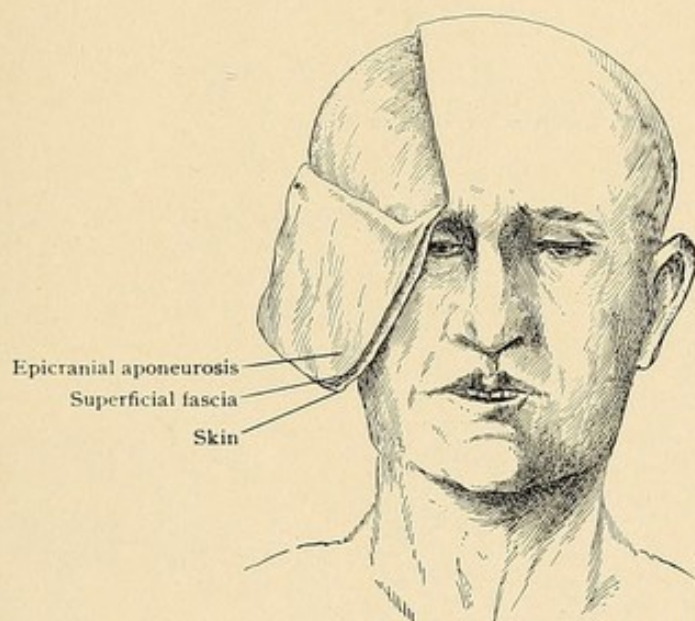


FIG 1.—The scalp.

by some anatomists the *subpericranial connective tissue*. At the sutures, however, it is very firmly attached.

The principal affections of the scalp are wounds, inflammation, affections of the blood-vessels, tumors, and neuralgia. The peculiarities of these affections are determined by the anatomical structure of the parts.

The **skin** of the scalp is probably the thickest in the body, although not so dense as that of the heel. Besides the hair, it contains abundant sweat and sebaceous glands. These latter are connected with the hair-follicles and are near the surface. The skin increases in thickness from the frontal to the occipital region.

The **superficial fascia** consists of a net-work of connective-tissue fibres which run from the skin above to the aponeurosis of the occipitofrontalis below. In its meshes are fat, blood-vessels, nerves, and lymphatics. The hair-bulbs often pierce the skin and extend into this layer.

The fibres of the superficial fascia bind the skin so firmly to the aponeurosis beneath that when the skin is moved the aponeurotic layer is carried with it. The



arrangement of the fibres is shown in Fig. 3. Fibres starting from the point *A* not only pass directly down to *B*, but also to each side to the points *C* and *D*. In the same way, fibres starting from *B* not only pass upward to *A*, but also forward to *E* and backward to *F*. Now, if the skin is moved in the direction of the forward arrow, the fibres *EB* and *AD* are tightened and drag the aponeurosis forward. If the skin is moved in the direction of the backward arrow, the fibres *AC* and *FB* are tightened and so drag the aponeurosis backward. Thus it is seen that the aponeurosis must follow the movements of the skin.

The **occipitofrontalis muscle with its aponeurosis** arises from the superior curved line of the occiput and is inserted into the skin of the frontal region.

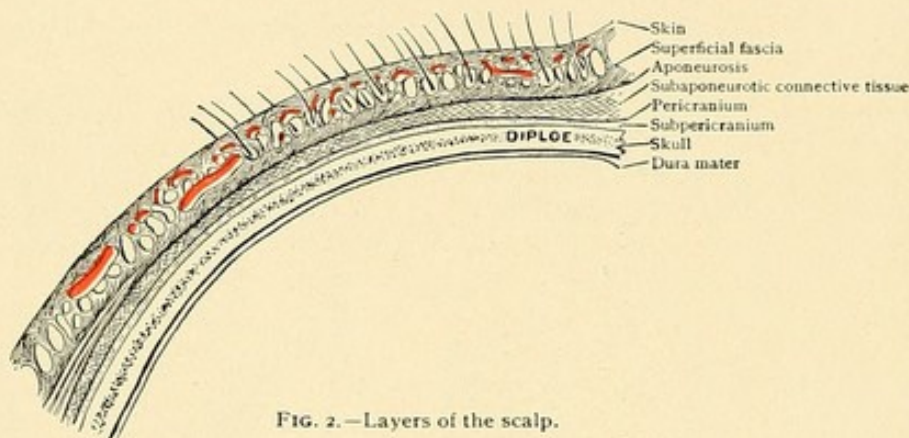


FIG. 2.—Layers of the scalp.

Merkel describes the epicranial aponeurosis as dividing into two layers, one inserting into the skin and the other into the rim of the orbit (*Hand. der top. Anat.* Bd. 1, p. 17). The bellies of the muscle are comparatively short, about 5 cm. in length, the remaining tissue extending between them constituting the aponeurosis. As it comes downward from the temporal ridge, over the sides of the head, the aponeurosis becomes thinner and gives attachment by its superficial surface to the *anterior* and *superior auricular* muscles. It then proceeds downward to be attached to the upper edge of the *zygoma*.

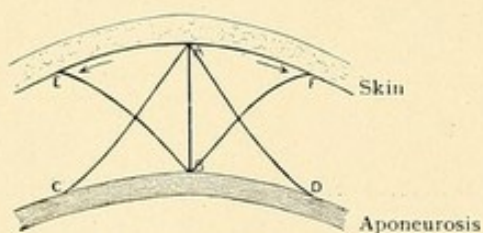


FIG. 3.—Diagram illustrating the method of attachment of the skin to the aponeurosis of the occipitofrontalis muscle.

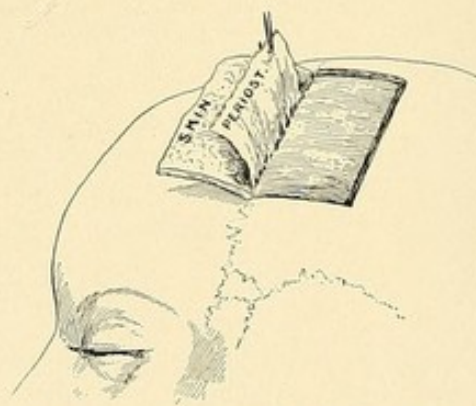

FIG. 4.—Showing now the periosteum in childhood dips between the bones in the line of the sutures.

Contraction of the occipitofrontalis muscle causes the skin of the forehead to wrinkle transversely. It is a muscle of expression, and blends with the *pyramidalis nasi* and *corrugator supercilii*. It is supplied by branches of the facial nerve.

The **subaponeurotic tissue** is very loose and abundant, so that it does not tend to confine the movements of the scalp, but favors them. Hence the scalp is readily torn loose from the skull in scalping, machinery accidents, etc. This tissue is so loose that effusions accumulate here and spread extensively. It contains only a few blood-vessels.

The **pericranium** in its normal condition is a thin, tough membrane containing few blood-vessels. Except at the sutures, where it is firmly attached and dips down between the bones, it is comparatively easily stripped from the skull and



does not convey much nourishment to it. It is deficient in osteogenetic or bone-forming properties, so that when it is raised off the skull in operations, and the bone removed from beneath, as occurs in trephining, fractures, etc., new bone is not produced.

The **subpericranial tissue** is so scanty and loose, particularly in infancy, that it readily allows the pericranium to be raised and effusions to occur beneath.

### THE ARTERIES OF THE SCALP.

The scalp is supplied by the *frontal*, *supra-orbital*, and sometimes a small branch from the *lacrimal arteries*, from the *ophthalmic*; by the *temporal*, through

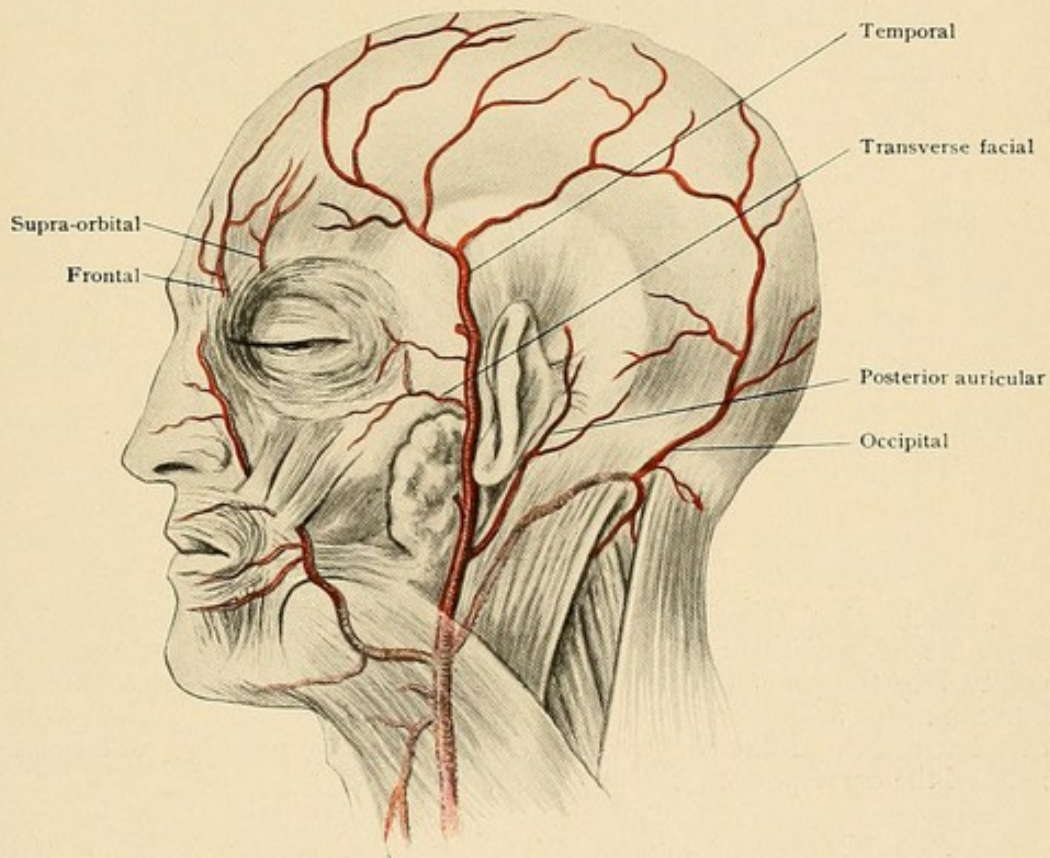


FIG. 5.—Arteries of the scalp.

its anterior and posterior branches; and by the *posterior auricular* and the *occipital arteries* from the *external carotid*. These arteries communicate freely with each other, not only laterally, but also across the top of the scalp. It is not unusual to see a large branch of the temporal communicating directly with the occipital.

The **temporal artery** begins in the substance of the *parotid gland*, just below the condyle of the jaw, and mounts over the zygoma, a centimetre (or less) in front of the ear. It lies on the temporal fascia and its pulsations can be felt at this point, if desired, during the administration of an anæsthetic. About four centimetres ( $1\frac{1}{2}$  in.) above the zygoma, it divides into the anterior and posterior branches. The *auriculotemporal branch* of the *fifth nerve* lies just in front of the ear and between it and the temporal artery.

The **occipital artery** mounts to the scalp in the interval between the posterior border of the *sternomastoid muscle* and the anterior border of the *trapezius*. It is about midway between the posterior border of the *mastoid process* and the *occipital protuberance*. If it is desired to expose it from this point forward, the



sternomastoid, splenius capitis, and trachelomastoid muscles will have to be cut, because it passes beneath them. The *occipitalis major nerve* lies to the inner side of the artery.

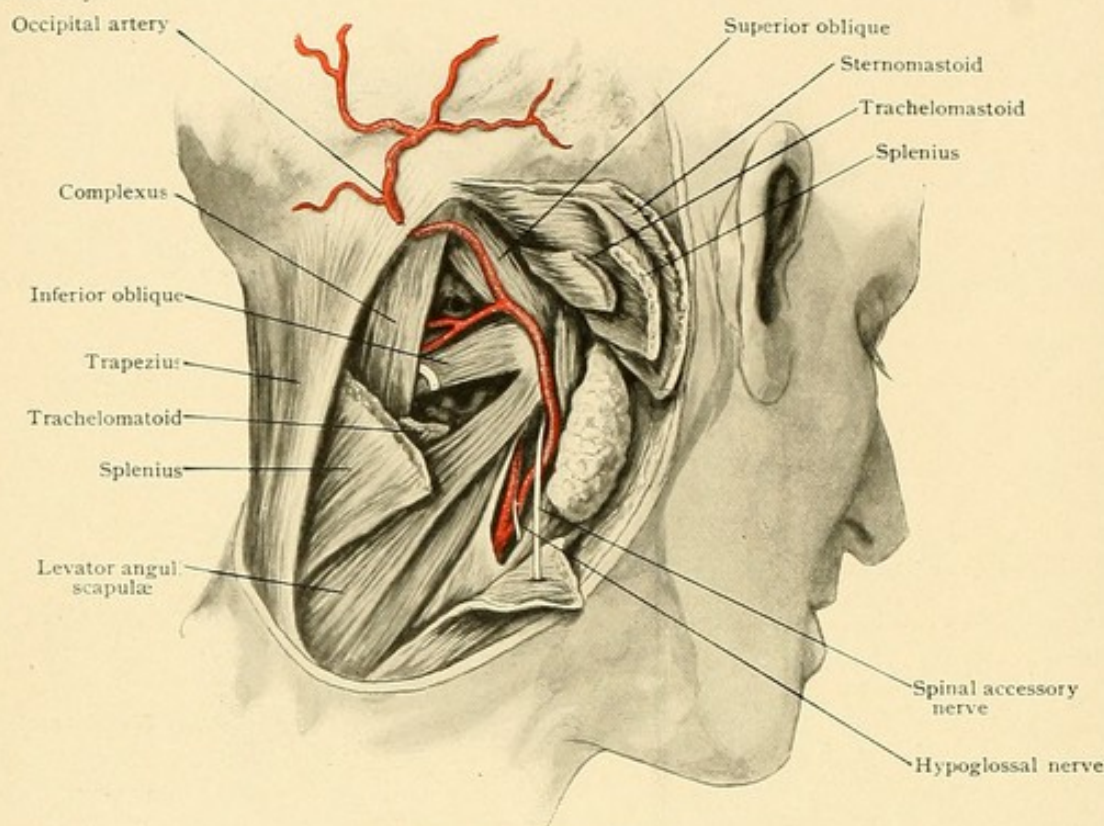


FIG. 6.—Occipital artery.

### LYMPHATICS OF THE SCALP.

The lymphatics anteriorly near the median line pass down between the orbits to reach the submaxillary nodes. Those of the anterior parietal and temporal regions empty into the pre-auricular nodes; those of the posterior parietal and temporal, into the nodes behind and below the ear; and those of the occipital region into the occipital nodes. Infectious troubles of these regions, therefore, will cause enlargement of the corresponding nodes.

### AFFECTIONS INVOLVING THE LAYERS OF THE SCALP.

*Wounds of the scalp* are common. Incised wounds bleed more freely and the hemorrhage is more difficult to control than in wounds elsewhere on the surface. This is due to the exceedingly free blood supply and to the peculiar arrangement of the blood-vessels in the tissues.

Small wounds of the scalp do not gape, particularly if they are longitudinal in direction and not very deep. The skin is so intimately bound to the aponeurosis beneath that displacement is impossible. If the cut is deep enough to divide the aponeurosis extensively, especially if the wound is transverse, gaping is marked. This is produced by contraction of the two bellies of the occipitofrontalis muscle, which pulls the edges apart.

Bleeding is apt to be persistent and hard to control because the arteries running in the deep layers of the skin and fibrous trabeculae are firmly attached and, therefore, when cut, their lumen cannot contract nor their ends retract. When large flaps are torn in the scalp, they rarely die because of their free blood supply, and sloughing is limited to the parts which are actually contused. As the subaponeurotic space is often opened, if the wound is sewed too tightly shut, subsequent bleeding instead of escaping externally may extend widely under the aponeurosis. Inasmuch as hair and dirt are often crushed into these wounds, great care should be taken to



disinfect them. A cut will open the hair bulbs and sebaceous glands, and, as the hairs project into the subcutaneous tissue, they may serve as a starting point for infection.

Contraction of the occipitofrontalis muscle may prevent healing in extensive wounds. To avoid this the scalp is covered by a recurrent bandage or otherwise fixed.

Lacerated wounds do not bleed so freely as do incised wounds, but they are accompanied by a more extensive loosening of the scalp. Large flaps of tissue are frequently raised and turned to one side. The most severe of these injuries have been produced by the hair being caught by a revolving shaft, tearing nearly the whole scalp off. Its loose attachment to the pericranium and bone beneath by the loose subaponeurotic tissue, readily explains the reason of these extensive detachments.

*Contusions* cause only a moderate amount of swelling, which is usually circumscribed. While the skin is not broken, the blood-vessels and other tissues beneath are often ruptured, and, therefore, extravasation of blood occurs. When this is confined to the superficial fascia, it is small in amount and limited in area. It does not tend to work its way for any great distance beneath the skin. If the extravasation extends below the aponeurosis, it may cover a considerable area of the skull. When it occurs beneath the pericranium it is called *cephal hæmatoma*, or in the new-born *caput succedaneum*. *Caput succedaneum* is found almost always on the right side, involving the parietal eminence. It is limited by the attachment of the pericranium at the sutures.

*Hæmatomas* of the scalp possess the peculiarity of being soft in the centre and surrounded by a hard oedematous ring of tissue. In *cephal hæmatoma* of long standing this ring may ossify, and the new bone may even extend and form a more or less perfect bony cyst. This, however, is very rare.

*Hæmatomas* produced by blows on the head are often mistaken for fractures. The raised edge is so hard as sometimes to be thought to be the edge of broken bone. The tissues beneath the skin at the site of impact seem to be pulpified and remain perfectly soft to the touch; the smooth unbroken skull can usually be felt over an area equal to the site of impact. Surrounding this soft area is the hardened ring, composed of tissues between the skin and the bone, into which serum and blood have been effused.

*Inflammation* and *abscess* are caused by infected wounds, furuncles, erysipelas, caries of the skull and suppurating sebaceous cysts.

The scalp is a favorite location for erysipelas; if not started primarily by an infected wound, the scalp may be involved secondarily by extension from the face.

Caries of the skull is often of syphilitic origin.

Abscesses may occur in three places:

1. Subcutaneous.
2. Subaponeurotic.
3. Subpericranial.

1. Subcutaneous abscesses are usually small and do not tend to spread but rather to discharge through the skin. This is because the firm fibrous trabeculae prevent lateral extension. Furuncles are quite common in childhood; they are, of course, superficial to the aponeurosis. Sebaceous cysts are especially common in the scalp and they sometimes suppurate. The orifice of the obstructed duct is not usually visible. Sometimes in a small cyst a black spot on its surface indicates the opening of the duct. By means of a needle or pin this opening can be dilated and some of the contents expressed. Of course, if nothing further is done it will reaccumulate. When these cysts become inflamed they become united to the skin above so that it has to be dissected off. If pus forms, it either remains localized to the cyst or bursts through the skin and discharges externally. It does not tend to burrow under the skin laterally on account of the fibrous trabeculae uniting the

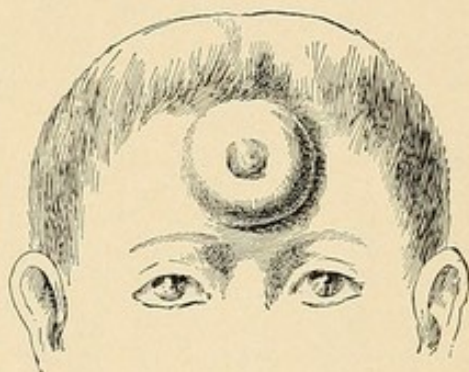


FIG 7.—Hæmatoma on the forehead of a child.



skin and aponeurosis. The aponeurosis beneath is intact, therefore the pus does not get below it. The cyst, with the lining membrane entire, should be removed, otherwise it will recur.

2. Subaponeurotic abscesses come from infected wounds, erysipelas, or caries of the bones. It is not desirable to close deep wounds of the scalp too tightly. Some suppuration is liable to occur which, not finding an easy escape externally, may spread under the aponeurosis if the wound has been deep enough to divide it. Infection of wounds is the most frequent source of these abscesses, hence the desirability of providing for drainage for at least a short period. In erysipelas, serous



FIG. 8.—Arterial angioma or cirroid aneurism.

effusion, which may become purulent, occurs in the subaponeurotic tissue, as well as in the layers above. It may sink downward and point in the temporal, occipital, or frontal region. In the temporal region the descent of the pus may be limited by the attachment of the lateral expansion of the aponeurosis to the zygoma. The attachment of the occipitalis muscle posteriorly to the superior curved line of the occiput prevents the effusion from coming to the surface at that point. The liquid accumulates low down on the forehead over the orbits, being prevented from entering by the attachment of the *orbitotarsal ligament*, and tends to point close to the median line. The frontal muscles of the two sides are apt to be slightly separated, leaving a weak spot just above the root of the nose, and this is where fluctuation can most easily be felt. These accumulations in the frontal, temporal, and occipital regions may require incisions for their evacuation and drainage. Suppuration arising from carious bone readily perforates the pericranium and then infiltrates the loose

subaponeurotic tissue. The bones of the vault of the skull are not infrequently affected by syphilitic disease, producing caries and suppuration, which invade the subaponeurotic space.

3. Subpericranial abscesses are comparatively rare. They usually start from diseased bone and spread laterally beneath the pericranial tissue. The pus may be limited to a single bone on account of the firmer attachment of the pericranium at the site of the sutures. To avoid breaking into the subaponeurotic space, a free opening should be made into the abscess so as to allow the pus to drain externally.

### AFFECTIONS OF THE BLOOD-VESSELS.

The arteries or veins alone may be affected, or both may be involved.

*Arterial varix* is the name given to an enlargement of a single artery. It forms a swollen, tortuous, pulsating mass in the course of the artery. The temporal artery is liable to be so affected, particularly its anterior branch.

*Cirroid aneurism*, or aneurism by a *ramosities*, is formed by numerous enlarged arteries. It is sometimes called an *arterial angioma* or *plexiform angioma*. The veins are also somewhat involved. Pulsation is marked.

*Venous angioma* is a tumor formation in which the venous blood is contained in large spaces, which are lined with endothelium, instead of in normal veins.

*Telangiectasis* or *nævus* is formed of enlarged capillaries. It is often called port wine mark, mother's mark, etc.

*Aneurismal varix*, or *arteriovenous aneurism*, is where an adjacent artery and vein being wounded,—as the temporal artery and vein,—the blood passes directly from the artery into the vein.



*Varicose aneurism* is where a sac intervenes between the artery and vein, so that the blood passes first from the artery into the sac and then into the vein. The temporal artery with its companion vein has been so affected.

**Treatment of Vascular Affections of the Scalp.**—Vascular tumors are usually ligated and excised. Acupressure pins may be passed under the larger arterial trunks, but the exceedingly free anastomosis renders thorough excision preferable; even this is not seldom unsuccessful.

### TUMORS OF THE SCALP.

*Sebaceous cysts* arise from obstructed sebaceous glands; the contents consists of epithelial cells, fat, and cholesterin. They sometimes calcify. They spread in the subcutaneous tissue, stretching and raising the skin above and causing atrophy of



FIG. 9.—Sebaceous cyst of scalp.

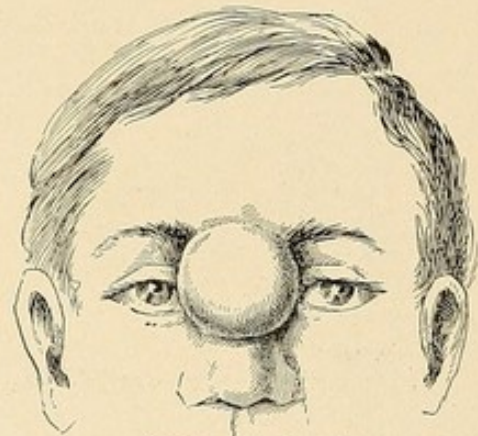


FIG. 10.—Meningocele.

the hair bulbs, but do not involve the epicranial aponeurosis below. In removing them, if they have never been inflamed, they can readily be turned out through a slit in the skin. The subaponeurotic space will not be opened, therefore their removal is not often followed by bad results.

*Encephalocele* is a tumor formed by a protrusion, through the skull, of the membranes of the brain, containing brain matter and cerebrospinal fluid.

*Meningocele*, or a tumor containing the meninges of the brain and cerebrospinal fluid, is more rare in the skull than is the case when the spine is affected. It protrudes through an unossified part of the skull, and, according to Sutton, two-thirds of the cases occur in the occipital region, between the foramen magnum and torcular Herophili. He characterizes it as a hydrocele of the fourth ventricle, and says that nine out of ten cases die if operated on. The next most frequent seat for meningocele is at the root of the nose (Fig. 10).

*Cephalhydrocele* is the name given to a pulsating tumor communicating with the interior of the skull through a traumatic opening. It contains cerebrospinal fluid.

*Dermoid tumors* occur in the median line and, according to Sutton, are most common over the anterior fontanelle and external occipital protuberance. They often have a thin pedicle attaching them to the dura mater and may grow either inside or outside the skull. They are formed by an inclusion of some of the tissue of the ectoderm by the bones as they approach from each side to ossify and unite in the median line.

A congenital tumor located at the root of the nose is probably an encephalocele; one located at the anterior fontanelle is probably a dermoid; a tumor in the occipital region may be either, but a dermoid is apt to be higher up than an encephalocele.



## THE SKULL.

The skull is the bony framework of the head. It is divided into the bones of the cranium and those of the face. The hyoid bone is usually classified with the bones of the head.

The **cranium** consists of the bones forming the brain case. They are the *occipital*, two *parietals*, the *frontal*, two *temporals*, the *sphenoid*, and the *ethmoid*.

The **bones of the face** are fourteen in number, there being two single bones and six pairs. The single bones are the *mandible*, or *inferior maxilla*, and *vomer*; the pairs are the *superior maxilla*, *malar*, *nasal*, *palate*, *lachrymal*, and *inferior turbinated bones*.

### THE SKULL IN CHILDHOOD.

The skull of the infant is markedly different from that of the adult. At birth the face is quite small and undeveloped, while the cranium is relatively large. The frontal and parietal eminences are very marked. The vault of the skull is not entirely ossified and the sutures are not completed.

The bones of the base of the skull originate in cartilage, while those of the vault originate in membrane. This membrane has one or more centres of ossification appearing in it for each bone. These centres increase in size and finally meet at the edges of the bone, thus forming the sutures. At the time of birth the sutures are represented by membrane, which joins the adjacent bony edges.

The frontal bone has two centres of ossification; one for each side. These form a suture in the median line of the forehead which becomes obliterated in the course of the first or second year. Traces of it in the shape of a groove or ridge can sometimes be seen or felt in the adult skull. The *frontal eminences* are far more marked in childhood than later in life and give to children the prominent forehead which is so characteristic.

A similar peculiarity is seen in the parietal bones, the parietal eminences

being quite prominent. On this account, they are often injured in childbirth, sometimes being compressed by the obstetrical forceps, and are frequently the seat of *hæmatoma neonatorum*. The cranial bones not being firmly united allow of a certain amount of play or even overlapping, thus facilitating the delivery of the head at birth.

**Fontanelles.**—At the juncture of the various bones are six spaces called fontanelles. Two, the anterior and posterior, are in the median line of the cranium, and four, the two anterolateral and two posterolateral, are at the sides. The fontanelles are situated at the four corners of the parietal bones.

The *anterior fontanelle* is the largest. It is diamond-shaped and formed by the frontal suture in front, the interparietal behind, and the coronal at each side. It is usually closed by the end of the second year, but may be delayed until the fourth. In rickets and malnutrition the fontanelles remain open longer than would otherwise be the case.

The *posterior fontanelle* is formed by the juncture of the parietal (sagittal) suture with the lambdoidal suture. It is triangular in shape with the apex forward between the two parietal bones, the sides passing down, one to the right and the other to the left of the top of the occipital bone.

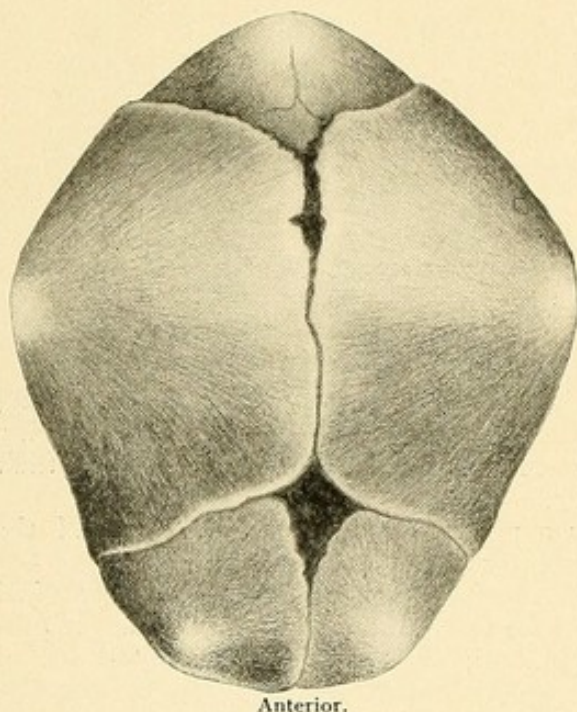


FIG. 11.—Infant's skull, showing posterior and anterior fontanelles.



These fontanelles are of the greatest importance in diagnosing the position of the head during labor. If the examining finger encounters first a large diamond-shaped or four-cornered depression with its anterior angle more acute than the posterior, the accoucheur will know that it is the anterior fontanelle which is presenting. By following one of the sutures backward he will come to a triangular or Y-shaped ridge which will be recognized from its shape as being the posterior fontanelle. He will then know that the position of the head is occipitoposterior. If the position is the more usual occipito-anterior one, the finger will first encounter the posterior fontanelle with its three sutures, which are distinctly recognizable. On following the suture which leads backward, the four-cornered anterior fontanelle will be felt. The various sutures constituting the fontanelles can usually be distinctly felt, and, as the presentations are nearly always occipito-anterior, the fontanelle that will usually be first felt will be the posterior, and the sutures forming it can readily be counted.

The *antero-* and *posterolateral fontanelles*, located at the anterior and posterior angles of the parietal bones, are of no service in diagnosing the position of the head. They are indistinct, nearly closed, and thickly covered by tissue. In injuries to the skull in young children and infants, we should not mistake the fontanelles and lines of the sutures for fractures. Fissures extending into the occipital bone from the posterolateral fontanelles are normal at birth and not due to injury.

**Dura Mater.**—The dura mater in children is more firmly attached to the interior of the skull than in adults. If, therefore, a true fracture does occur, laceration of the dura is more liable to be produced. This firm attachment also prevents the formation of epidural hemorrhages, because the force of the blow is not sufficient to loosen the dura from the bone, and when the middle meningeal artery is torn, as Marchant has pointed out, the bleeding is more apt to be external than internal.

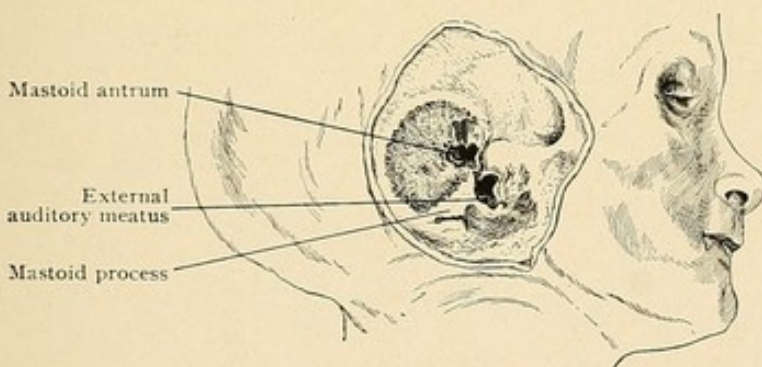


FIG. 13.—The surface of the temporal bone has been chiselled off, showing the relative size and position of the mastoid antrum and external auditory meatus.

of the face so slightly developed that there is no room for the cavities which afterward develop in them. The ridges of the bones also become more marked as age advances. The young child has no superciliary ridges.

The *maxillary sinus*, or *antrum of Highmore*, and the *mastoid antrum* are the only cavities that exist at birth. They are both much smaller than they ultimately become.

The mastoid antrum in relation to the size and age of the child is comparatively large, being about five millimetres in diameter. As the bone in the child is undeveloped, and the tympanum lies nearer to the surface, the antrum likewise is somewhat higher and nearer to the surface than is the case in adults. This should be borne in mind when operating on the bone in this region (Fig. 13).

The *frontal*, *ethmoidal*, and *sphenoidal sinuses* appear about the seventh year, but it is not until puberty is reached that they really begin to develop. The mastoid

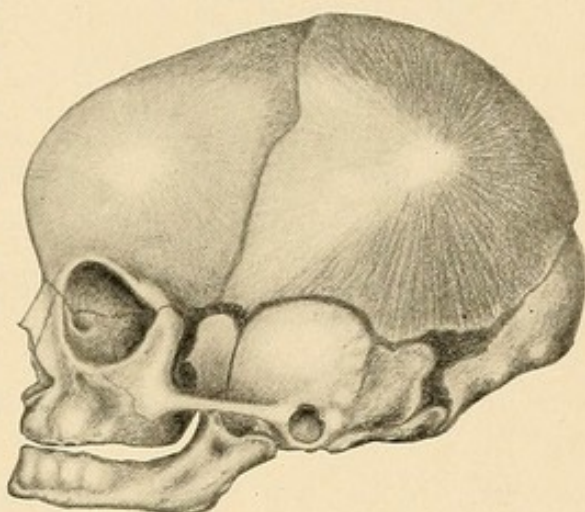


FIG. 12.—Infant's skull, showing anterolateral and posterolateral fontanelles.

#### Cells and Air-sinuses.

—The infant has the bones



cells likewise appear at puberty and increase with age. At birth, they are represented by simple cancellous bone.

### THE SKULL IN ADULTS.

As the child grows, the bones of the face increase more rapidly than do those of the vault. The bony prominences become marked, due to the action of the various muscles of mastication, expression, etc., inserted into them. The face is much larger in size in proportion to the calvarium than was the case in infancy. While in infancy bone is practically homogeneous, in late childhood and early adult life cavities begin to develop in it.

Outer and inner tables of compact tissue are formed, separated by diploic structure. The frontal, ethmoidal, and other air-sinuses are an exaggeration of these diploic spaces. They are lined with mucous membrane and communicate with the nasopharynx. The diploë first begins to appear about the age of

ten years, but is not well formed until early adult life. It contains large veins, called the diploic veins, which communicate with the veins both of the inside and outside of the skull. In injuries to the skull bleeding from these veins is rarely troublesome and usually stops spontaneously.

The skull is thinner in the white than in the negro race. It is thickest over the occipital protuberance and mastoid processes. The bone is thinnest in the temporal and lower occipital regions. The two tables are separated widely from one another in the region of the frontal sinuses.

**Tables.**—The inner table is thinner and more brittle than the outer one, and in fractures it is almost always more extensively splintered than the outer. In rare cases the outer table may be temporarily depressed by a glancing blow and spring back into place without showing any depression, while the inner table may be fractured.

The two tables are not exactly parallel. Where the skull is thin, as in the temporal and occipital regions, they are close together; where it is thick, they are farther apart. The outer surface of the skull is comparatively even and smooth. The inner surface is quite uneven, being depressed in places to receive the convolutions of the brain. For this reason it is necessary to use the trephine with great care, as it may cut through on one side of the circle and injure the dura mater before it cuts through the other part.

The **sutures** of the skull begin to ossify at about the age of forty years and continue to fuse until about the eightieth year.

**Frontal Sinuses.**—The frontal sinuses begin to develop at the age of seven years, but do not increase rapidly in size until puberty. When adult age is reached

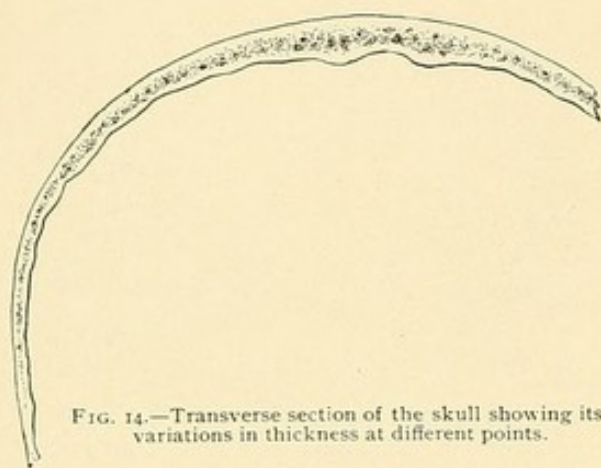


FIG. 14.—Transverse section of the skull showing its variations in thickness at different points.

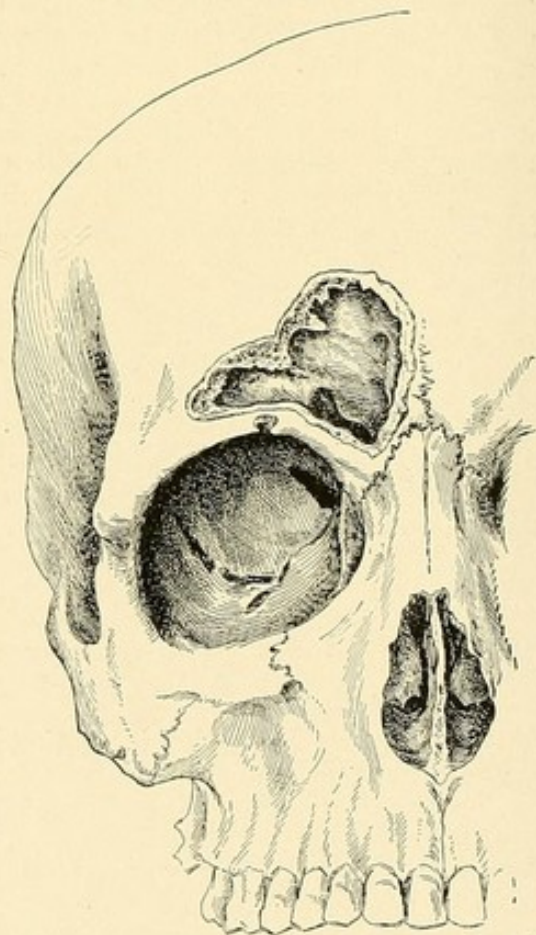


FIG. 15.—Frontal sinus of one side; the anterior wall has been cut away, exposing its interior.



they are well developed. They may extend well out over the orbits, reaching to within a short distance of the temporal ridge, while in other instances they do not go beyond the supra-orbital notches. In height they may reach the lower portion of the frontal eminences or may cease at the level of the superciliary ridges. The size of the sinus cannot be judged from the size of the bony prominences. Neither is the

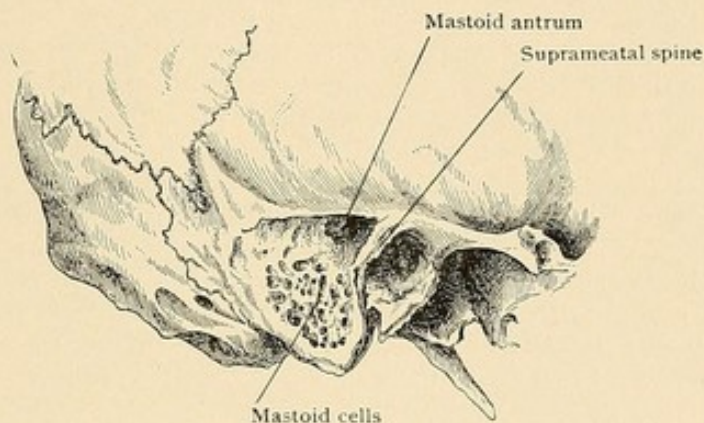


FIG. 16.—Surface chipped away to show the mastoid antrum and cells, the latter unusually well developed.

size nor sex of the individual any criterion. In a small female we have seen them of considerable size. When diseased sufficiently to give rise to symptoms, they will be found to be quite large. They are separated from each other by a septum, and if extensive are divided into several pockets or recesses. They open into the infundib-

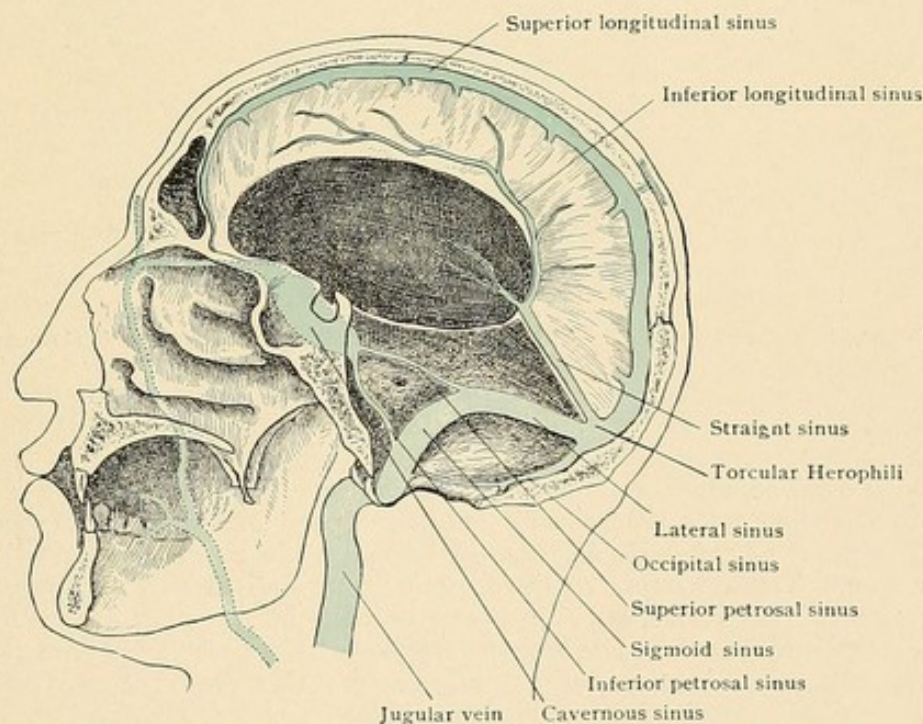


FIG. 17.—The cerebral blood sinuses.

ulum, at the anterior extremity of the middle turbinated bone in the middle meatus of the nose. Fracture of the outer wall of the sinus not infrequently occurs without involving the inner table.

**Mastoid Process.**—The mastoid process is continuous with the superior curved line of the occiput. It increases in size from the time of birth, but is composed of cancellous tissue until after the age of puberty, when the mastoid cells develop. The mastoid antrum, a cavity five millimetres in size at birth, which opens into the upper posterior portion of the tympanum, is relatively larger at birth than in the adult.



It is of importance in operating for infection arising from middle-ear disease. Minute veins run from the antrum into the lateral sinus.

**Suprameatal Triangle.**—This triangle, so named by Macewen, is formed above by the posterior root of the zygoma, anteriorly by the bony posterior wall of the external auditory meatus and posteriorly by a line from the floor of the meatus passing upward and backward to meet the first line. The mastoid antrum is reached by operating through this triangle (see section on Ear).

**Cerebral Venous Sinuses.**—The fibrous membrane which lines the interior of the skull is composed of two layers which are in most places intimately united, forming one single membrane known as the *dura mater*. The outer layer is applied to the bone, while the inner layer covers the brain. In certain places these two layers separate to form channels in which venous blood flows; these channels are called sinuses. In certain other places these layers separate and enclose some special structure, as the *Gasserian ganglion*.

The cerebral sinuses of most importance are the *superior longitudinal*, the *lateral* or *transverse*, and the *cavernous*.

The *superior longitudinal sinus* runs in the median line from the foramen cæcum in the ethmoid bone in front, to the torcular Herophili behind. As it passes back-

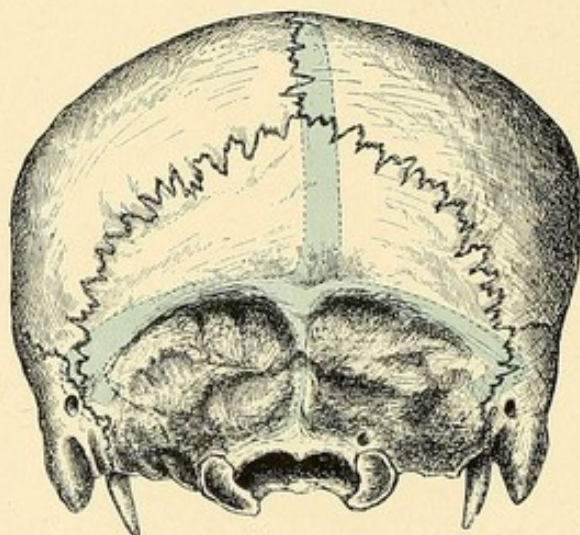


FIG. 18.—Posterior view of the skull, showing the relation of the superior longitudinal sinus and torcular Herophili to the median line and external occipital protuberance.

ward it inclines more to the right side, so that at the torcular Herophili the left side of the sinus is about in the median line. This sinus receives the veins from the cortex of the brain and also some from the diploë of the bones above it. A vein pierces the upper posterior angle of each parietal bone and forms a communication between the superficial veins of the scalp outside and the superior longitudinal sinus within. The deviation of the superior longitudinal sinus toward the right, as it proceeds posteriorly, is to be borne in mind in operating in this region, as one can approach the median line nearer on the left side posteriorly than the right, without wounding it. In the parietal region the *Pacchionian bodies* are surrounded by extensions from the longitudinal sinus and free hemorrhage will ensue if the bone is removed too close to the median line.

The *torcular Herophili*, or confluence of the sinuses, does not correspond exactly to the external occipital protuberance or *inion* on the exterior of the skull. It is a little above and to the right of it. This torcular Herophili is formed by the meeting of the longitudinal sinus from above, the lateral, or transverse sinuses from the sides, the straight sinus from in front and the occipital sinus from below.

The *lateral* or *transverse sinuses*, of which there are two, pass from the torcular Herophili toward each side in the tentorium between the cerebrum and cerebellum, following the superior curved line of the occiput until just above the upper posterior portion of the mastoid process. They then bend downward to within a centimetre of



the tip of the process and again curve forward to end in the jugular foramen and be continued as the internal jugular vein. The S-shaped curve which they make in this part of their course has given rise to the name *sigmoid sinus*. In its course along the superior curved line the sinus rises above the level of a line drawn from theinion to the centre of the external auditory meatus.

In operating for cerebellar abscess, care should be taken to place the trephine opening sufficiently low down to avoid wounding this sinus. It is in great danger of being wounded in operating for septic conditions involving the mastoid antrum and cells. Its distance from the surface of the skull varies in different individuals, and it gets farther from it as it descends to the level of the tip of the mastoid process. It

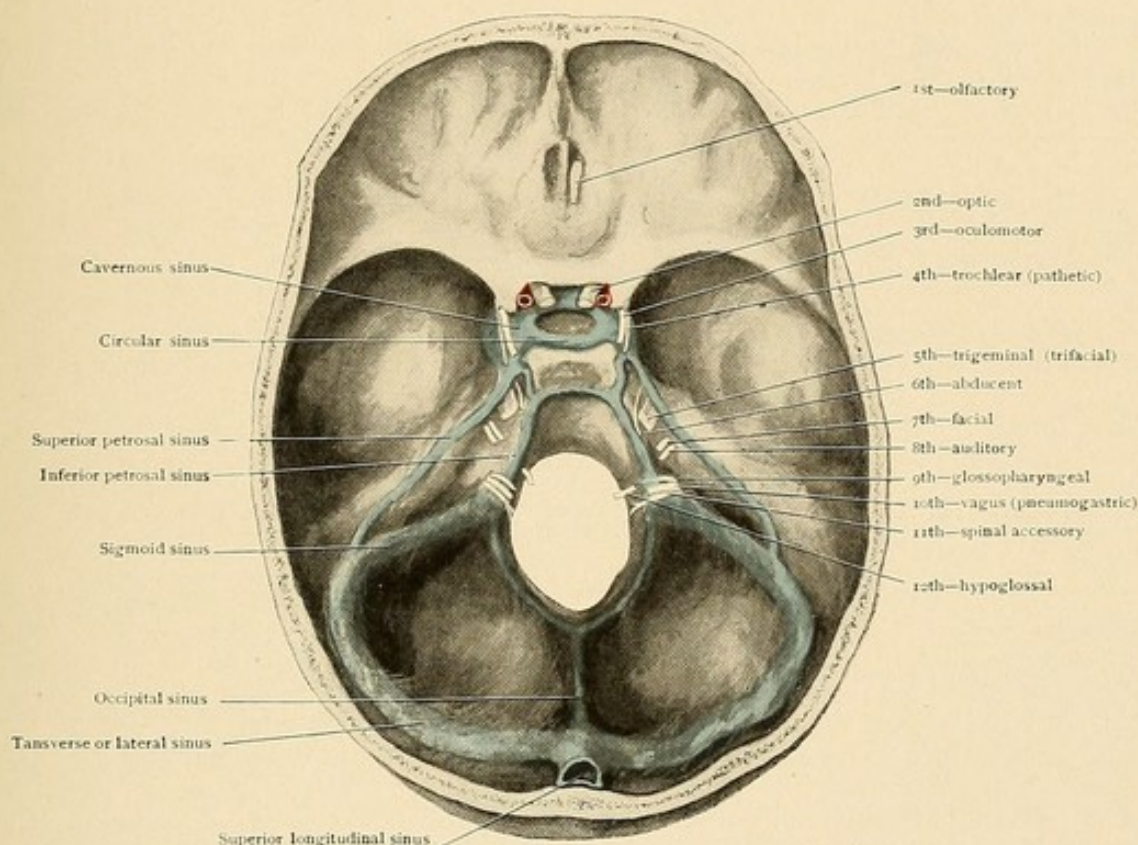


FIG. 19.—Exit of cranial nerves and venous sinuses at the base of the skull.

receives the blood from the posterior lower portion of the cerebrum and upper portion of the cerebellum, and communicates with the veins outside the skull through the mastoid and posterior condyloid foramina.

Running along the upper posterior edge of the petrous portion of the temporal bone, in the attachment of the tentorium, is the *superior petrosal sinus*. It connects the lateral or transverse sinus about its middle with the *cavernous sinus*. More deeply situated, and running from the cavernous sinus to the lateral sinus, just as it enters the jugular foramen, is the *inferior petrosal sinus*.

The petrosal and lateral sinuses are frequently torn in fractures of the skull. A fracture passing through the petrous portion of the temporal bone may tear the petrosal sinuses, and hemorrhage from the ear might come from this source. A fracture through the posterior cerebral fossa may tear the lateral sinus. Leeches are sometimes applied behind the ear in inflammation of the brain, with the idea of drawing blood from the lateral sinus through the mastoid vein.

The *occipital sinus* is usually small and brings the blood up from the region of the foramen magnum to the torcular Herophili.

The *straight sinus* runs along the line of juncture of the tentorium and falx cerebri. It receives the blood from the ventricles of the brain which are drained by



the veins of Galen, and the blood from the falx through the *inferior longitudinal sinus*. This latter is usually very small and sometimes almost lacking, the blood in that case passing upward to empty into the superior longitudinal sinus.

The *cavernous sinus*,—one on each side,—is a large, irregular space on the side of the body of the sphenoid bone. It runs from the sphenoidal fissure in front to the apex of the petrous portion of the temporal bone behind. In front it is continuous with the ophthalmic vein, and receives the *sphenoparietal sinus* which brings the blood from the diploë; behind it communicates with the superior and inferior petrosal sinuses. The two sinuses communicate across the median line around the pituitary body, forming the *circular sinus*, and across the basilar process, forming what is sometimes called the *transverse sinus*, but which is more correctly described as a plexus of veins.

The cavernous sinus has embedded in its outer wall the third and fourth nerves and the ophthalmic branch of the fifth. Farther below and to the outer side of the sinus are the superior and inferior maxillary or mandibular branches of the fifth

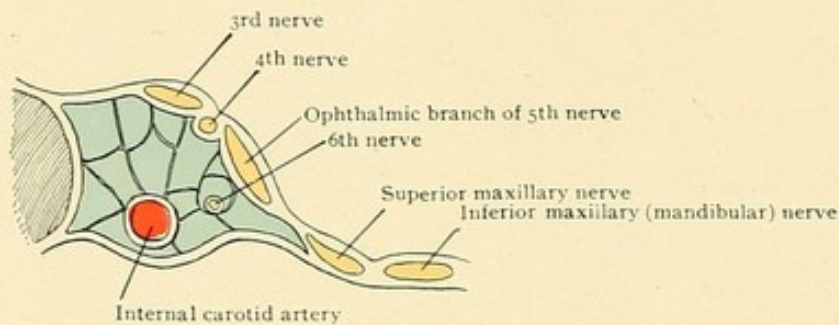


FIG. 20.—Transverse section of the right cavernous sinus, showing the position of the nerves and internal carotid artery (from a dissection).

nerve. Within the sinus and toward its lower and inner portion, is the *internal carotid artery*. It is surrounded by the blood-current. Between the carotid artery and outer wall of the sinus runs the sixth nerve, held in place by fine, trabecular, fibrous bands which pass from side to side in the cavity of the sinus.

The cavernous sinuses are sometimes torn in fractures of the base of the skull, resulting in a traumatic communication between the carotid artery and the sinus. The cavernous sinus is not infrequently torn in attempting the removal of the Gasserian ganglion, particularly if its ophthalmic branch is attacked. Its interior is not one large cavity, but is subdivided by fibrous septa, which pass from side to side. It is sometimes the seat of thrombosis and infection, which may reach it through the ophthalmic vein in front.

## FRACTURES OF THE SKULL.

Fractures of the skull are almost always produced by violent contact of the skull with some solid body. In some cases the fracture is produced by a blow from a moving body, as when a person is struck by a club. In others, the skull is moving and strikes a body at rest, as when a person falls and strikes the head on a pavement. It is not necessary to discuss in detail the mechanism of fractures of the skull; it is sufficient to state that nearly all fractures start from the point of impact and radiate to distant regions. The effect of fracturing blows on the skull of a child is different from their effect on the skull of an adult.

**Fractures of the Skull in Children.**—A child's skull is thin and weak, and while, to a certain extent, fragile is more flexible than that of an adult. It is on this account that blows are more liable to expend their force locally, at the point of impact, and not produce fractures at a distance. Therefore, it follows that fractures of the base are rare in children in comparison with fractures of the vault. Extensive fissured fractures are also rare. A blow will crush the skull of a child at the point of impact, much as an egg-shell is broken at one spot by hitting it with a knife handle. A marked example of this was seen in the case of a small boy who,



while playing, was struck by a baseball on the left frontal eminence. A distinct circular depression or cup was produced exactly corresponding to the shape of the ball. There were no symptoms of cerebral concussion, because the force of the blow was expended on the bone and not transmitted to the brain within. As pointed out by Mr. Rickman Godlee, the sutures in very young children being soft, the transmission of the force from one bone to another is prevented.

The diploic structure of the skull is not well developed until adult age, therefore the bone is homogeneous. It is also elastic, and, particularly in infants, it may be dented without being seriously fractured; these dents are apt to disappear and become level with the surrounding bone as the child grows older. The dura mater is more adherent in children and fractures are, on that account, more liable to tear it and even lacerate the brain beneath.

**Fractures of the Skull in Adults.**—As adult life is reached the inner and outer tables of the bones become separated, leaving the space between to be filled by the diploic tissue. The diploë consists of cancellous bone in the meshes of which run the diploic veins and capillaries. Both the inner and outer tables are brittle, but the inner especially so. It is also harder and more compact than the outer table. On account of this difference we find in cases of fracture that the inner table is more comminuted than the outer, so that, while the outer may show a single line of fracture, the inner table immediately beneath may be broken into several fragments. This is one reason why trephining is so frequently resorted to.

In rare cases there may be depression of the inner table with none of the outer. A case of this kind occurred during our Civil War. A soldier, while looking over a rampart, was struck a glancing blow by a bullet, on the upper anterior portion of the skull. The outer table at the site of injury was not at all depressed, but the inner table had a large piece broken off, which injured the membranes.

The elasticity of the skull is shown in cases of fracture in which hairs are found imbedded in the line of fracture. Figure 21 is from such a case. A negro was struck on the head by a falling rock and an extensive longitudinal fracture was produced in which many hairs were fastened. About a centimetre from the main fracture was a small fissure, not over a centimetre long, and sprouting up out of it, like bushes from the bare ground, were a number of hairs. In such cases the hairs are carried into the line of fracture by the force of the blow; the elastic bone then springs back into place and pinches the hairs, thus holding them in place.

The bones of the adult skull are very strong and firmly fixed. The sutures begin to unite at the age of forty years and are likely to have disappeared at the age of seventy. Even in young adults the fibrous tissue between the bones has so nearly disappeared that they practically act in transmitting force as one continuous bone. For these reasons slight blows do not cause fractures. It takes a very heavy blow usually to cause a fracture and the force is so great that shock or concussion of the brain with disturbance of its functions is a common symptom.

The force of the blow is expended first at the point of impact, and if a fracture occurs it usually starts there. From that point it radiates to other portions of the skull, so that fractures of the vault frequently extend to the base. The course pursued by the fracture has been formulated into a law by Aran; that they take a straight line from the point of impact on the vault to the base of the skull, and are not deflected by the sutures.

Charles Phelps ("Traumatic Injuries of the Brain") found that in 127 cases of fracture of the base of the skull, 12 implicated the base only. So that, if we are able to say that there is a fracture of the base of the skull, there are over 10 chances to one of its extending up into the vault. In only two were the fractures more than a slight fissure; so that in a marked fracture of the base there would be 63 chances to one of its extending into the vault. Also, from Aran's law, we see that, if we diagnose a fracture through the middle ear, we may be pretty sure that the force was applied directly above, and be led to trephine accordingly.

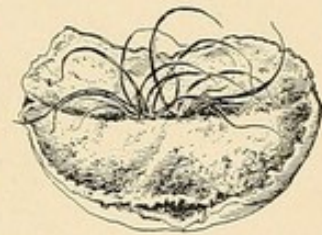

FIG. 21.—Small piece of the skull showing hairs imprisoned in a linear fracture—actual size.



A man fell from an electric light pole and was brought to the hospital with bleeding from the ear and other symptoms of fracture of the skull. He became wildly delirious, and, feeling sure that the fracture of the base was an extension from the vault, although no depression could be felt, he was trephined above the external auditory meatus and a large epidural effusion of blood evacuated. He recovered and resumed his work. In this case, as soon as the bone was exposed, a thin line of fracture was seen running down to the base in the region of the external ear.

**Fractures by Contrecoup or Counter Stroke.**—Fractures by counter stroke are now regarded as of much less frequent occurrence than formerly. Charles Phelps found in 147 cases of fracture of the base of the skull 12 which had not extended from the vault. In these, the force had been applied to the parietal region in six, and in five to the occiput; most of the resulting fractures were in the region

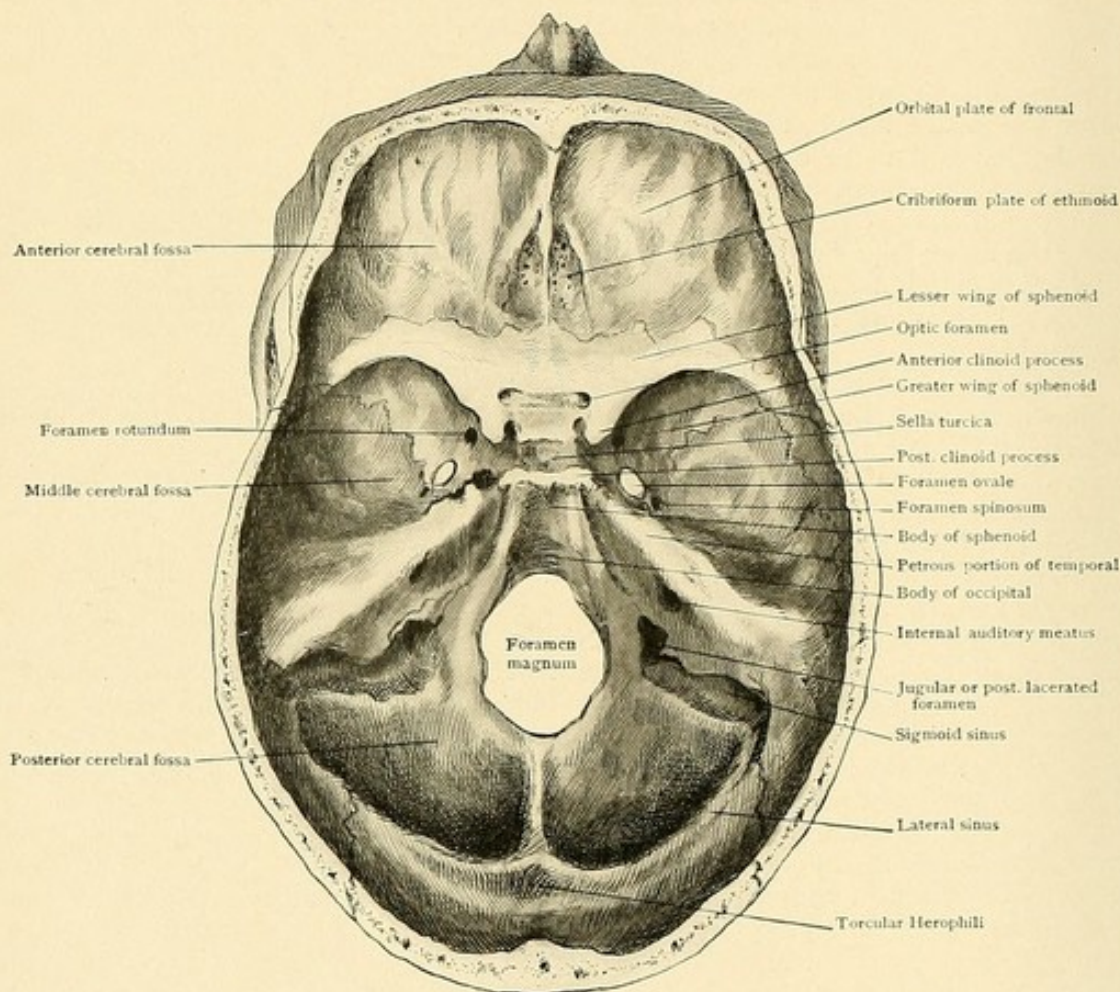


FIG. 22.—Interior view of the base of the skull, showing the parts most liable to be involved in fractures.

of the orbit. Only two of the twelve cases were serious fractures, the remaining ten being slight fissures, which produced no symptoms.

**Hemorrhage in Fractures of the Skull.**—Hemorrhage is a frequent and most valuable symptom in diagnosing the existence of fracture and in determining its location.

Fracture through the anterior cerebral fossa may open the frontal, ethmoidal, or sphenoidal cells and cause bleeding from the nose and mouth.

A fracture through the roof of the orbit causes bleeding into the orbital cavity; the blood works its way forward and makes its appearance under the conjunctiva of the ball of the eye. Its progress forward toward the lids is blocked by the orbitotarsal ligaments, and it therefore works its way downward to the bulbar conjunctiva, under which it advances to the edge of the cornea. The ordinary ecchymosis of the lids and cellular tissue around the eye is usually due to a rupture of the vessels of the subcutaneous tissue by a blow from the outside, and not to a fracture of the base of the skull.



Fracture through the middle cerebral fossa may pass through the body of the sphenoid or basilar process of the occipital bone and cause bleeding into the mouth. It may also cause an accumulation of blood behind the posterior wall of the pharynx, pushing it forward. When it passes through the petrous portion of the temporal

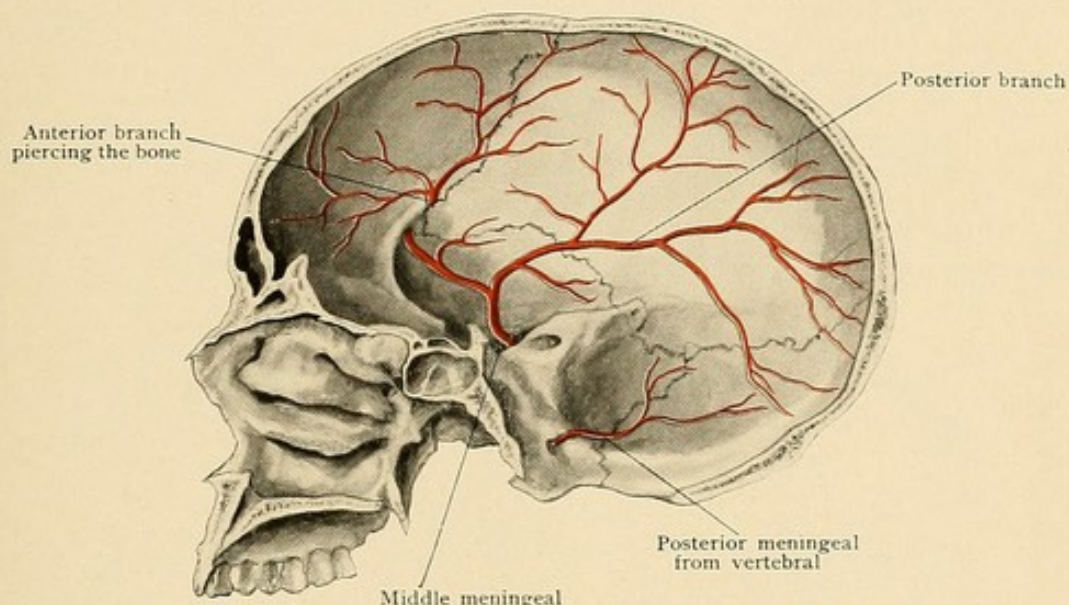


FIG. 23.—Middle and posterior meningeal arteries supplying the interior of the skull.

bone, as is frequently the case, it may involve the external auditory meatus and bleeding from the ear will result.

Fractures through the posterior cerebral fossa may cause bleeding into the structures of the back of the neck. This is not common.

*Middle Meningeal Hemorrhage.*—Bleeding from the middle meningeal artery, epi- or extradural hemorrhage, occurs in those fractures which pass through the region

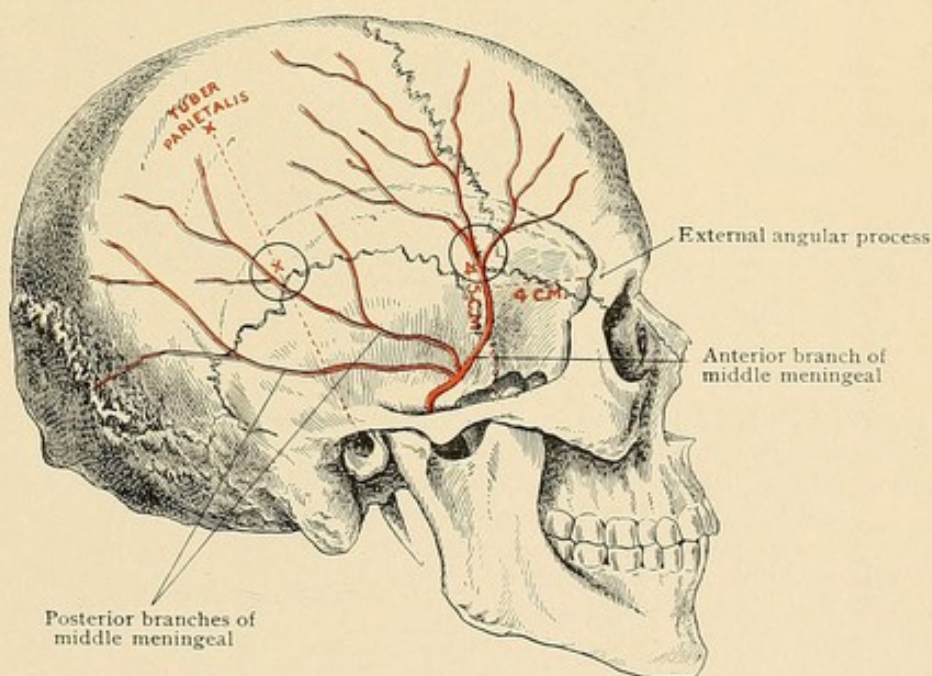


FIG. 24.—Points of trephining for hemorrhage from the middle meningeal artery. The course of the artery has been marked on the outer surface of the skull.

of the pterion. This point is the junction of the coronal and sphenoparietal sutures, about 4 cm. (1½ in.) behind and slightly above the external angular process of the frontal bone. The middle meningeal artery comes up through the foramen spinosum and then goes forward, upward, and outward to the lower anterior angle of the



parietal bone. It sends branches forward to the frontal region and backward to the parietal and temporal regions. During two to three centimetres of its course, at the pterion, it passes entirely through bone, and therefore if a fracture occurs at this point it must of necessity tear the artery. The posterior branches are not regular in their course, one passing backward, low down, parallel to the zygoma, and another higher up in the direction of the parietal eminence. The branches of the meningeal artery nourish the bone as well as the dura, therefore if the dura is loosened from the bone hemorrhage from these branches occurs. The most frequent site of middle meningeal hemorrhage is in the region of the pterion or temple.

In trephining for it, the centre of the trephine is to be placed on an average of 4 cm. ( $1\frac{1}{2}$  in.) behind the external angular process of the frontal bone, and on a level with the upper edge of the orbit or 4.5 cm. ( $1\frac{3}{4}$  in.) above the zygoma. If the artery is not sufficiently exposed more bone is to be removed by the rongeur

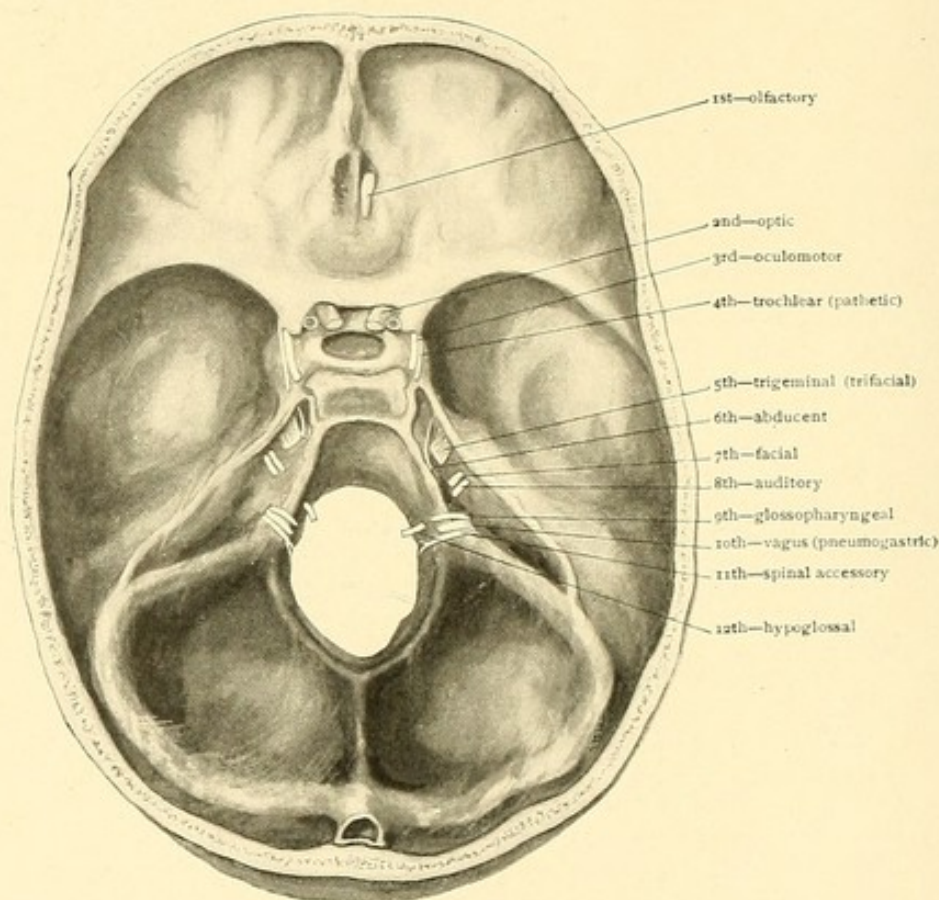


FIG. 25.—Exit of cranial nerves at the base of the skull.

forceps. It is in this region that epidural hemorrhages are apt to be extensive, because the vessels torn are the largest; but epidural hemorrhage can also occur in the frontal region from the anterior branches and in the parietal from the posterior.

Trephining for bleeding from the posterior branch of the middle meningeal artery is somewhat uncertain. In some cases the artery runs low down, about 2 cm. ( $\frac{4}{5}$  in.) above the zygoma and parallel to it. In other cases it runs upward and backward toward the parietal eminence. The trephine may be placed as high up as for the anterior branch of the middle meningeal artery, 4.5 cm. ( $1\frac{3}{4}$  in.), and 5 cm. (2 in.) farther back. This will be below and anterior to the parietal eminence and about midway on a line joining the parietal eminence and external auditory meatus. After the button of bone has been removed, additional bone may be cut away with the rongeur forceps until access can be had to the bleeding point (see page 23 for a case of rupture without fracture).

Rupture of the large venous sinuses and of the small vessels passing between the bone and dura also contribute to the formation of the clot. Owing to the firmer



attachment of the dura mater in children, the meningeal arteries are more liable to be torn and cause hemorrhage than is the case in adults. For the same reason the blood pressure is not sufficient to dissect the dura from the skull, therefore epidural clots are rare. If there is a fracture, blood may collect beneath the scalp, and if an external wound exists, the blood will find an exit through it.

*Bleeding from the Venous Sinuses.*—Bleeding may occur from the sinuses of the base as well as from those of the vault. In severe injuries of the vault detached fragments frequently penetrate the superior longitudinal and lateral sinuses. In these cases profuse bleeding occurs as soon as attempts are made to remove the loose pieces of bone, and it is necessary to use a packing of gauze to control it. Fractures passing through the petrous portion of the temporal bone wound the petrosal sinus and this no doubt contributes to the blood which flows from the ear.

Emphysema is most likely to occur if the frontal air sinuses are involved, particularly if the patient blows his nose in the attempt to relieve it of blood clots. Emphysema is not so liable to occur in cases of fracture involving the mastoid cells.

Cerebrospinal fluid may escape whenever the meninges are torn and the subarachnoid space is opened. It is most frequently seen in the fractures involving the middle fossa and passing through the internal auditory meatus. The meninges are prolonged into the internal meatus, and the clear fluid is not infrequently seen coming from the ear of the injured side. Although the normal amount of cerebrospinal fluid is only about two ounces, much greater quantities can escape. A serous discharge, perhaps of several ounces, is indicative of a rupture into the subarachnoid space.

**Injuries to Nerves in Fracture of the Skull.**—The nerves most often disturbed in injuries of the skull are the first, second, third, seventh, and eighth.

The *first* or *olfactory nerve* may be injured directly in the line of fracture, or by concussion.

I have had under my care two such cases in women who struck the occiput on an asphalt pavement in getting off backward from a moving trolley car. These patients left the hospital after several weeks with the sense of smell still lacking.

Injuries to the *second* or *optic nerve* are apt to be accompanied by such severe injuries to other parts as to cause the death of the patient before the loss of sight is discovered. If the optic nerve is injured at the optic foramen, there may be impairment of sight without any intra-ocular changes to be seen with the ophthalmoscope. Inside of two weeks, however, the pinkish color of the disk gives way to the gray-white color of atrophy, and this progresses until complete. The nerve never resumes its functions and the patient remains blind.

Injury of the *third* or *oculomotor nerve* has also come under my notice. In this the pupil of the affected eye is moderately dilated and does not respond to light. The ciliary muscle is supplied by the third nerve, as well as the circular fibres of the iris, so that the accommodation is paralyzed and, if the eye has been normal in its refraction, the patient will be unable to read or see objects clearly at close distances. The extrinsic muscles of the eye, with the exception of the superior oblique and external rectus, are also supplied by this nerve and the eye is therefore pulled outward and slightly downward, and diplopia, or double vision, may be produced. The patient is unable to move the eye either upward, inward, or downward. The levator palpebræ muscle is also paralyzed and there is ptosis or drooping of the upper lid. The orbicularis palpebrarum muscle, being supplied by the seventh nerve, has its functions unimpaired, and the eyelids can be closed.

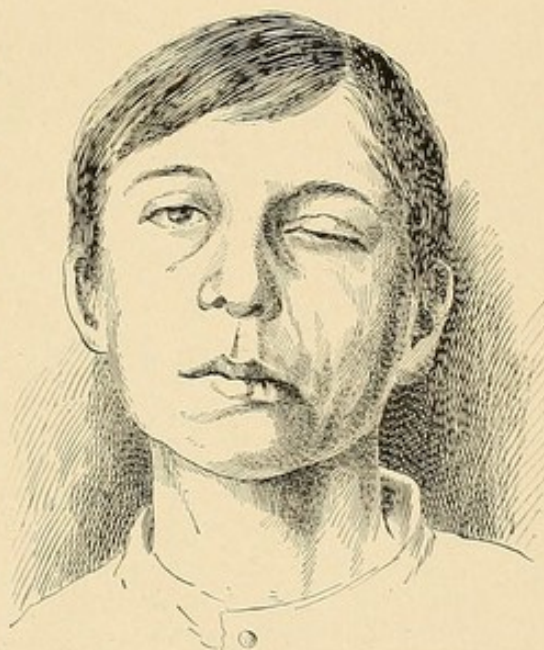

FIG. 26.—Paralysis of the facial nerve from fracture of base of skull (author's case).



The *fourth* or *pathetic nerve* is almost never injured. It supplies the superior oblique muscle, which turns the eyeball down and slightly outward. Paralysis of it causes diplopia, with the image of the injured eye below that of the sound eye and tilted to the right, if the right eye is affected, and to the left, if the left is affected.

The *fifth* or *trifacial nerve* is very rarely injured. If it is completely paralyzed there will be loss of motion in the muscles of mastication and loss of sensation over the side of the face, of one-half of the interior of the mouth, of the side and front of the tongue, and of the eye.

The *sixth* or *abducent nerve* supplies the external rectus muscle of the eye, and if paralyzed causes internal strabismus, the eye looking inward. While more often paralyzed than the fourth and fifth, it is not so frequently paralyzed as are the two following nerves.

The *seventh* or *facial nerve* is the one most frequently injured in fractures of the skull. It enters the internal auditory meatus with the auditory nerve, being above it. Reaching the end of the meatus internus, it enters the canal of Fallopius and emerges from the temporal bone at the stylomastoid foramen. When paralyzed, the face on that side remains motionless, the eye cannot be closed, and food accumulates between the teeth and cheek. The corner of the mouth is drawn to the opposite side when the muscles of the face are contracted.

The internal auditory meatus contains a prolongation of the dura mater and arachnoid, so that a fracture through it would open the subarachnoid space and allow the cerebrospinal fluid to escape. In these cases there is also usually bleeding from the ear. Escape of cerebrospinal fluid is to be distinguished from a flow of serum by its greater quantity, sometimes many ounces escaping.

The *eighth* or *auditory nerve* is injured with moderate frequency, but perhaps hardly so often as supposed, for the deafness which sometimes follows injuries to the head may not be caused by an injury to the auditory nerve itself, but is rather due to the injury done by concussion of the brain in the region of the first temporal convolution, or possibly to the tympanum. The eighth nerve is embraced in the same extension of the meninges into the internal meatus as is the seventh, and injuries to it may also be accompanied with loss of cerebrospinal fluid. The seventh and eighth are said to be more often paralyzed than any of the other nerves.

Injuries to the remaining four nerves—the *glossopharyngeal*, *vagus*, *spinal accessory*, and *hypoglossal*—have been observed too rarely to require any extensive attention here.

## THE MENINGES.

The meninges of the brain consist of three separate coverings: the outer being the *dura mater*, the middle the *arachnoid*, and the inner the *pia mater*.

The *dura mater* or fibrous covering of the brain is tough and strong and intended to protect it. Injuries of the skull without a laceration of this membrane are much less serious than when it is involved. When it is torn, not only is the brain beneath likely to be injured, but an opportunity is given for infection to enter and affect the brain itself and even produce a hernia cerebri or hernial protrusion of brain matter through the rent.

The dura mater is composed of two layers, the outer one acting as a periosteum to the bones. The two layers are in most places closely united, but at others they separate and form sinuses or canals, connected with the veins and carrying venous blood. The *falx cerebri* (Fig. 27) which is the fibrous partition separating the hemispheres of the brain from one another, as well as the *tentorium*, which separates the cerebrum from the cerebellum, is formed by the inner layer of the dura mater projecting inward and forming a partition. On the floor of the skull, the dura mater accompanies the nerves and gives them a sheath. The Gasserian ganglion of the fifth nerve is held in a pocket formed by the separation of the two layers of the dura mater.

The cerebral blood sinuses have already been considered. The dura is nourished by the meningeal arteries; bleeding from these has already been alluded to (page 17). Thin fibres of the dura pass to the bone, also branches of the meningeal arteries and veins pass to the inner table and diploë: these all serve to fasten the



dura to the skull. This attachment is firmest on the base of the skull. On the vault, after an opening has been made through the skull by a trephine, the dura can be readily separated from the bone by means of a thin, flat, steel spatula. On account of the small size of the vessels passing from the dura to the bone, this procedure is not usually accompanied by much hemorrhage. In separating the dura from the base of the skull, as is done in operations on the Gasserian ganglion, the bleeding from this source is often quite free. The dura is liable to be torn in lifting it from the bone if the greatest care is not exercised.

The middle meningeal artery, at a distance of 4 cm. ( $1\frac{1}{2}$  in.) posterior to the angular process of the frontal bone and about the same above the zygoma, usually passes within the bone for a distance of 1 or 2 cm. Therefore, in operating in the temporal region, if the dura is detached the vessel will be torn and free bleeding will

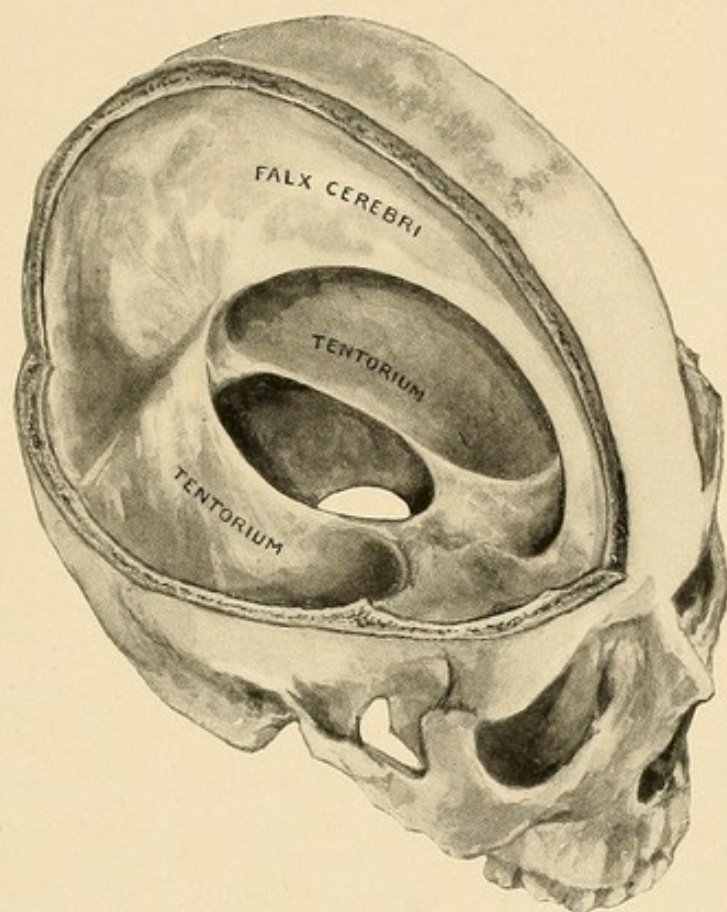


FIG. 27.—Vault of the skull opened and brain removed, showing the falx cerebri and tentorium.

follow. The vessel is liable to be torn in endeavoring to remove bony fragments in fractures of this region. The dura is also more firmly attached in the median line; and on each side of the median line are the depressions in the parietal bone which lodge the *Pacchionian bodies*. The largest are usually located at a distance of from 2 to 5 cm. posterior to a line drawn across the skull from one external auditory meatus to the other. They are prolongations from the arachnoid and are surrounded by blood from the longitudinal sinus.

**The Arachnoid—also called Arachnopia or Parietal Layer of the Pia.**

—The arachnoid is a thin fibrous membrane, which passes over the convolutions of the brain and does not dip into the sulci between. It is more marked on the base than on the convexity of the brain. It is not attached to the dura above, and this subdural space, while moist, contains little or no free fluid. Hemorrhages do not occur into this space unless the membranes are torn, because the bleeding from the vessels of the dura is always epidural and the arachnoid derives its nourishment from the pia mater below, so that hemorrhages start beneath the arachnoid, but may rupture through the arachnoid into the subdural space. From its under surface, fibrils of loose



tissue pass to the pia mater; the space between the fibrous layer of the arachnoid above and the pia mater and convolutions of the brain below is called the *subarachnoid space*. This is a lymph space and contains the cerebrospinal fluid. This fluid is normally about 60 c.c. (2 ounces) in quantity, but in injuries to the brain in which the subarachnoid space is opened, the fluid is secreted and discharged very rapidly.

As has already been mentioned, the arachnoid sends a prolongation into the internal auditory meatus, hence a fracture through it would open the subarachnoid space. This space communicates with the ventricles of the brain through three openings in the pia mater at the lower back portion of the roof of the fourth ventricle; these are called the *foramina* of *Magendie*, *Key*, and *Retzius*. The cerebrospinal fluid extends down the spinal canal and can be removed by tapping with a trochar, as is practised in the lumbar region.

**The Pia Mater.**—The net-work of vessels, with their supporting membrane, which covers the convolutions of the brain, forms the pia mater. The fibrils of connective tissue supporting the vessels are attached to the fibrous layer of the arachnoid above, so that the pia and arachnoid are in reality continuous structures. The spaces between these fibrils are often quite large and communicate with each other, forming the subarachnoid space. The lower portions of these fibrils are united and form a basement membrane which lies directly on the convolutions of the brain and dips into the sulci. The blood-vessels are intimately connected with this lower pial membrane and not with the arachnoid above. These vessels penetrate into the substance of the brain, carrying with them a covering or sheath of pia mater. This is called the *perivascular lymph sheath* and, of course, communicates with the subarachnoid space above. These vessels nourish the brain. The perivascular lymph sheaths are also said to form capsules around the great pyramidal and large glial cells of the cortex.

#### AFFECTIONS OF THE MEMBRANES OF THE BRAIN.

Both the dura mater and the pia mater are subject to inflammation and hemorrhages. The arachnoid being practically a part of the pia mater is involved in its diseases, so that no mention is made of it as being separately affected.

**Inflammation of the Dura Mater; Pachymeningitis.**—The outer surface or inner surface of the dura may be involved, constituting pachymeningitis externa or interna.

*Pachymeningitis Externa.*—The external surface is most often affected by injuries from without, or by extension of diseases from the adjoining bone. In cases of fracture the inflammation which accompanies healing frequently causes the dura to become densely adherent to the overlying skull. This is noticed particularly when trephining operations are performed for the relief of focal or Jacksonian epilepsy. Should the fracture be compound or open, the occurrence of sepsis will tend to involve the adjacent dura mater. The same occurs in cases of necrosis. Syphilitic disease of the bones is most apt to affect the vault of the skull, while the dura towards the sides and base is most often involved by suppurative ear disease. The dura also becomes involved in tumors and gummata.

Inflammation of the dura is not apt to be a marked disease. It is a very dense membrane with few blood-vessels, therefore it is quite resistant to inflammatory processes. It acts as a barrier to the farther extension of an inflammation rather than as a carrier. Therefore we see epidural collections of pus existing for a considerable time without brain symptoms supervening.

The dura mater contains the large cerebral venous sinuses, and when the inflammatory process occurs in those regions, the sinuses become inflamed and thrombosis or clotting occurs. The clot becoming infected breaks down, the pus and debris pour into the general circulation, and general septicæmia, and even death, is caused. This is most liable to occur in the region of the ear, where the infection is apt to reach and involve the lateral (transverse) sinus. Infection of the longitudinal sinus is much more rare.

*Pachymeningitis interna* is an inflammation of the inner surface of the dura. It occurs, to a certain extent, in cases of gumma or other new growths involving the inner surface of the dura or extending from the pia mater below. The name pachymeningitis interna, also called hæmorrhagica, is usually restricted to a chronic inflammation of



the inner surface of the dura, with the formation of one or more hemorrhagic membranous layers. Adhesions to the pia do not occur. The disease has been seen in purpuric and infectious diseases, as well as in alcoholic and demented individuals.

**Dural Hemorrhage.**—Hemorrhage arising from injury to the dura through fracture of the skull has already been discussed (see page 18). Epidural hemorrhage may, however, occur from an injury to the skull and detach the membrane from the bone without a fracture being present. The possibility of this occurring is proved by the remarkable case reported by Dr. J. S. Horsley (*New York Med. Jour.*, Feb. 9, 1901). A man was struck on the head with a wooden club. He was momentarily stunned, but soon recovered and felt perfectly well. An hour and a half later he became drowsy, and in a few hours was in a state of stupor. The right side of the body and face was paralyzed, and the left arm and leg were in constant jerking convulsions. He was trephined over the left parietal eminence and four to six ounces of blood clot removed. There was no evidence of fracture or wound of the dura. Recovery was prompt. There have also been other recorded cases.

In operations involving the separation of the dura from the bone, bleeding may be quite free. This comes from rupture of the veins passing from the bone to the dura, and sometimes from the rupture of a vein passing over or in the dura itself.

Subdural hemorrhages always originate from the pia mater.

**Inflammation of the Pia Mater; Meningitis.**—This, when not of a tuberculous character is called *leptomeningitis*. It is commonly known as inflammation of the brain, or meningitis. The pia mater of the brain being directly continuous with that of the spinal cord, inflammations of the former extend to and involve the latter in about one-third of the cases. The disease is then called *cerebrospinal meningitis*.

Infection is the usual cause of *leptomeningitis*. Direct injury to the membranes and their bony envelopes may cause it, but it occurs usually through some secondary avenue of infection. Thus, it may follow fractures opening into the mouth, nose, the various accessory bony sinuses, ear, etc. The infection may, however, not be traumatic, but occur through the blood, following or accompanying the various infectious diseases. Owing to the fact of the pia lying on the brain substance, and its vessels with their perivascular sheaths penetrating it, the disease naturally tends to involve the brain, if it is very severe or long standing. If such is the case, the affection is called *cerebritis* or *encephalitis*.

The inflammation may be serous, plastic, or even purulent. The pia mater being continuous with the choroid plexuses, the ventricles may be dilated by the increased fluid. The infection may follow the vessels into the brain and produce brain abscess. The effusion being often localized at the base of the brain interferes with the functions of the cerebral nerves. The first, or olfactory, is comparatively rarely affected. The optic, or second, is more often so, producing intolerance of light. There may be choked disk, and I have even seen a case in which there was total blindness without any change being visible in the nerve by means of ophthalmoscopy. In this case atrophy of the disk soon followed. The third, or motor oculi, according to Church and Peterson, is almost always affected. This would be shown by strabismus, diplopia, and changes in the pupil. Facial paralysis, from implication of the seventh nerve, is sometimes seen, and the auditory, or eighth, may also be affected. Involvement of the hypoglossal or twelfth nerve, will be shown by deviation of the tongue. The origin of the cranial nerves from the base of the brain is shown in Fig. 28.

**Tuberculous Meningitis.**—In this form of meningitis the infection comes through the blood, and the tuberculous lesions follow the vessels. They are most marked on the base of the brain, involving the circle of Willis and the Sylvian fissure. The infection follows the vessels of the pia mater through the transverse fissure into the ventricles. The effusion accumulating in the ventricles has given rise to the name *acute hydrocephalus*. It also follows the perivascular sheaths of the smaller vessels into the brain substance, producing a *cerebritis*; thus it is seen how a knowledge of the circulation of the brain explains the location of the lesions.

The exudate involving the nerves of the base of the brain produces corresponding symptoms by interfering with their function.

**Pial Hemorrhage.**—Meningeal hemorrhage may be either subarachnoid or subdural. If the hemorrhage has not been violent, it spreads out under the arach-



noid in the subarachnoid space. If, however, the blood has escaped with considerable force, it tears its way through the arachnoid and spreads in the subdural, as well as through the subarachnoid space. The origin of this form of hemorrhage is the vessels of the pia mater. The arachnoid does not give rise to hemorrhages, neither does the inner surface of the dura, unless it has previously been the seat of pachymeningitis interna.

The hemorrhage is the result either of injury or disease. In children it is usually due to injury; in adults to either injury or disease. These hemorrhages are most common in infancy and occur in childbirth. They are due apparently to hard, protracted labor or injury done to the child in effecting delivery by forceps, etc., especially in infants born before full term. They are a cause of idiocy and the cerebral palsies of childhood. These hemorrhages in the new-born have been

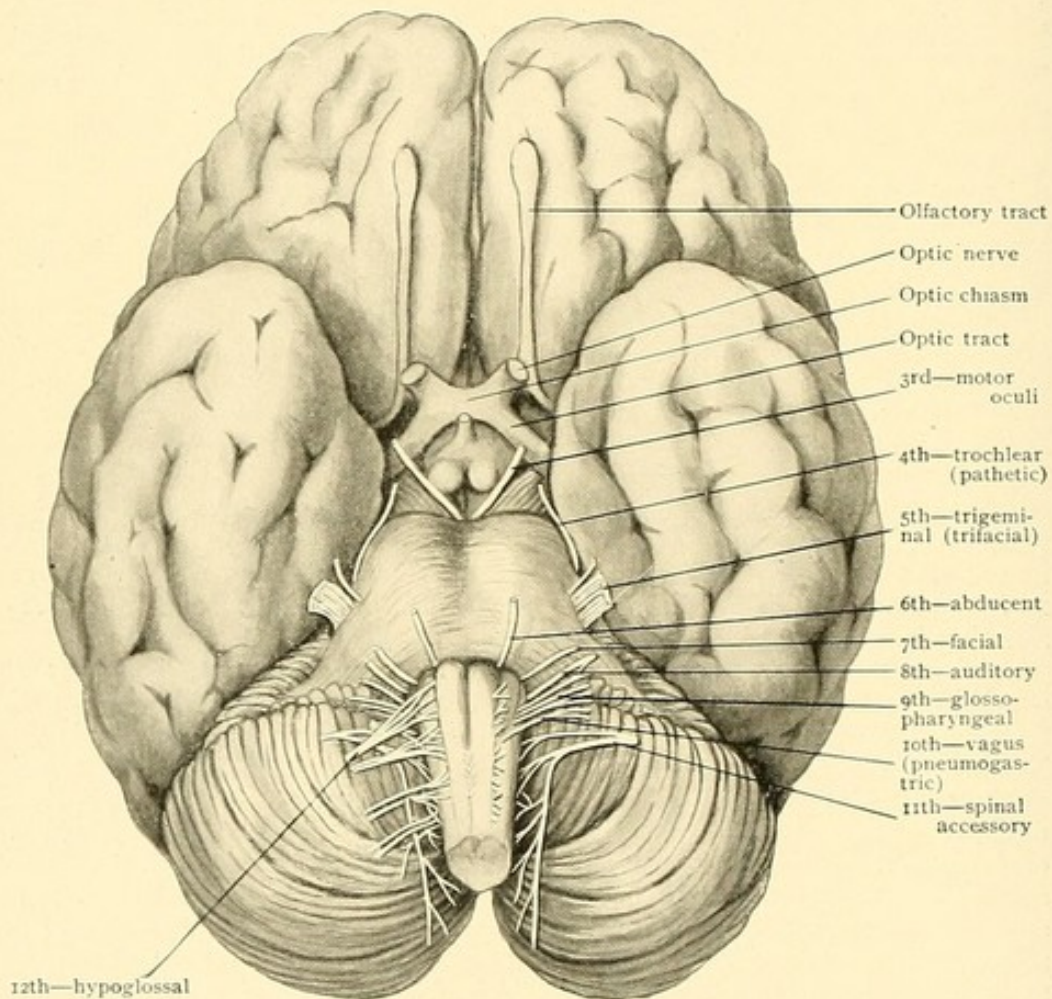


FIG. 28.—Base of brain, showing exit of cranial nerves.

recognized by the convulsions they produce, and successful operations have been performed for their relief (see Harvey Cushing—"Surgical Intervention for the Intracranial Hemorrhages of the New-born"—*Am. Jour. Med. Sci.*, October, 1905).

Injuries received later in life from blows on the head often produce subdural or pial hemorrhages, without breaking the overlying bone. They are found either at the site of impact or on the side opposite that on which the blow was received, the latter being produced by contre-coup. When pial hemorrhage occurs from disease, it is usually from rupture of an aneurism of one of the vessels of the pia mater. If it does not break through the arachnoid into the subdural space, it may spread over a considerable portion of the cerebral cortex, especially filling the sulci. Unless the quantity is quite large, so that it interferes with the motor area, hemiplegia will not occur. Convulsions may occasionally occur from irritation of the cortex. Blood in the subdural space may travel along the base of the brain and into the sheath of the optic nerve.



## THE BRAIN.

The affections of the brain of most anatomical interest are those involving its circulation, the motor areas, and the motor paths. Paralyzes may arise from (*a*) interference with the motor areas in the cortex by hemorrhages, injuries, or tumors; (*b*) destruction of the motor paths from the cortex to their point of exit from the brain; (*c*) injury of the nerves at their exit from the brain.

Disturbances of the circulation may be either of the nature of anæmia or ischæmia, causing softening, or of congestion, causing apoplexy.

Tumors of the brain interfere with the functions of the part in which they are located, as do also wounds. In all of these a knowledge of brain localization is essential.

## THE CIRCULATION OF THE BRAIN.

The blood reaches the brain by means of the two internal carotid and the two vertebral arteries. The vertebrals enter through the foramen magnum and unite to

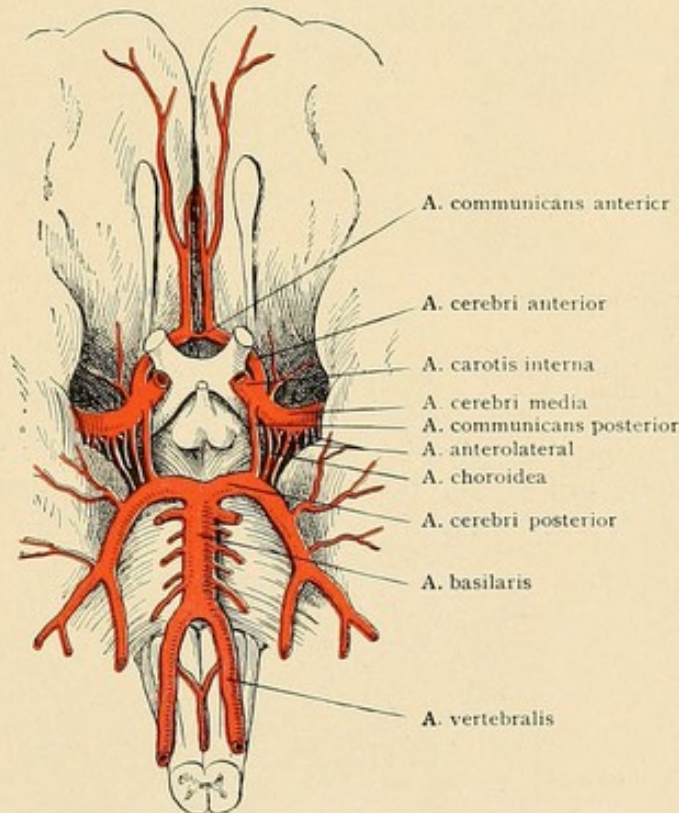


FIG. 29.—Circulus arteriosus or circle of Willis.

form the basilar, which at the upper border of the pons divides into the two posterior cerebrals. These give off two small branches which go to the internal carotids; they are the posterior communicating arteries. The carotids divide into the anterior and middle cerebral arteries, the anterior communicating with one another by means of the anterior communicating artery. Thus we have the *circle of Willis* (*circulus arteriosus*), formed by the *posterior cerebral*, *posterior communicating*, *internal carotid*, *anterior cerebral*, and *anterior communicating* arteries on each side.

The blood supply of the brain is divided into an anterior division, furnished by the carotids, and a posterior division, supplied through the basilar and posterior cerebrals. The communication branch running between these two sets of vessels is so small that if either is occluded the supply of blood is practically cut off from that point and ischæmia results, at least in most cases.

The anterior division is subdivided into a right and a left half by the two carotid



arteries. These communicate across the median line through the anterior cerebral and anterior communicating. Here again the anterior communicating branch is so small that it is sometimes unable to furnish blood to the opposite side of the brain

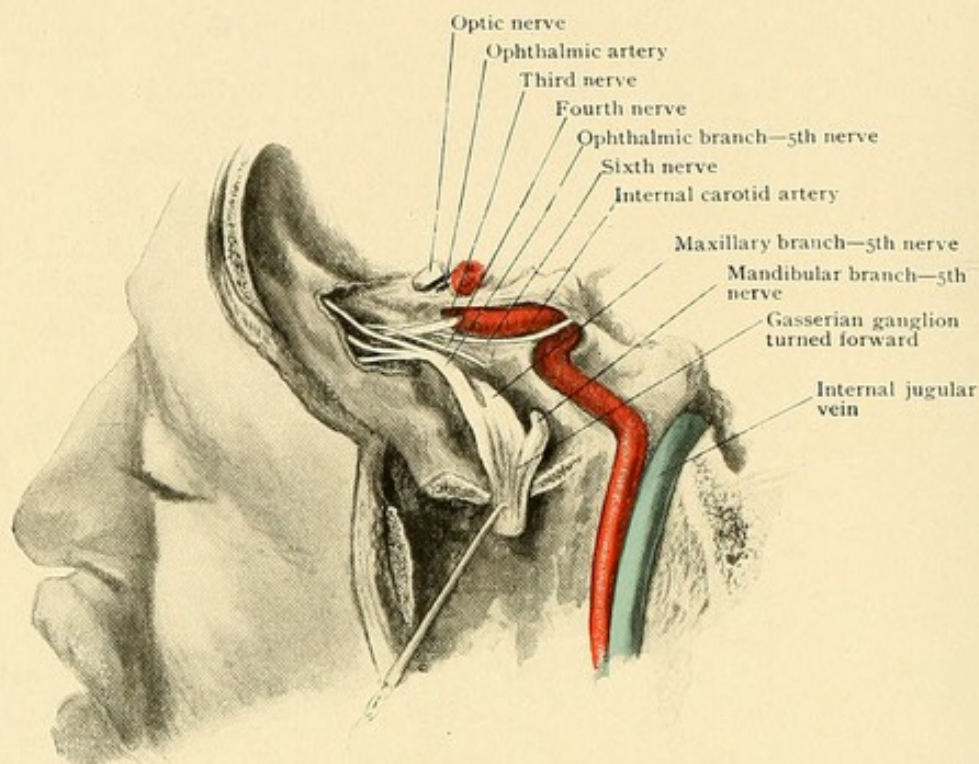


FIG. 30.—The internal carotid artery in its course through the skull, showing its relations to the jugular vein and cranial nerves. The Gasserian ganglion has been raised from its bed and turned forward.

when the carotid supply of one side is shut off. This may cause syncope, stupor or delirium, hemiplegia, and often softening and death. These results have not

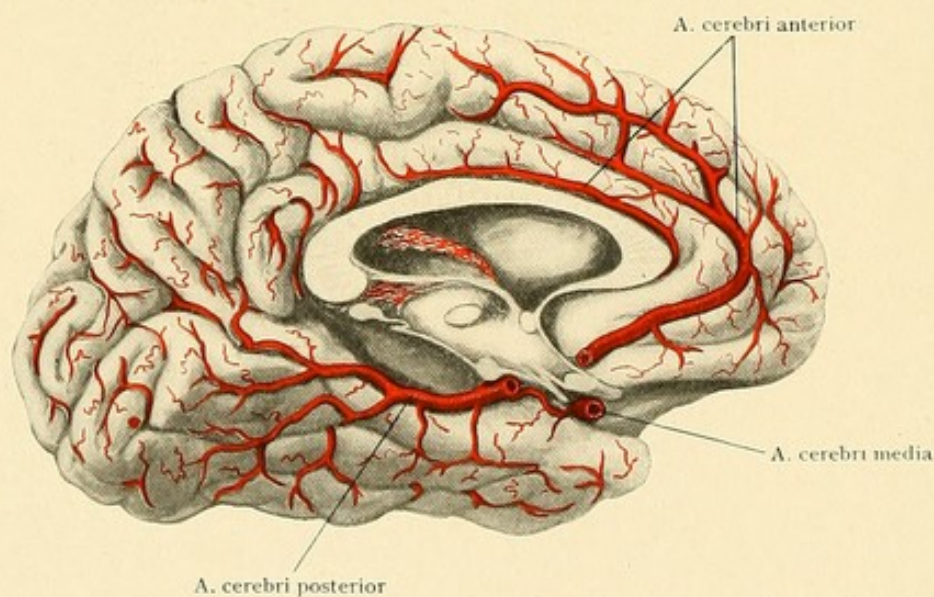


FIG. 31.—Distribution of the A. cerebri anterior and A. cerebri posterior on the medial surface of the brain.

infrequently followed ligation of the carotid artery in cases of aneurism. Obstruction of one vertebral artery would produce no effect because circulation would be restored by the other vertebral through the basilar.



**Internal Carotid Artery.**—The internal carotid artery (Fig. 30) enters the petrous portion of the temporal bone, then turns inward and upward through the foramen lacerum medium, then forward through the cavernous sinus and finally turning

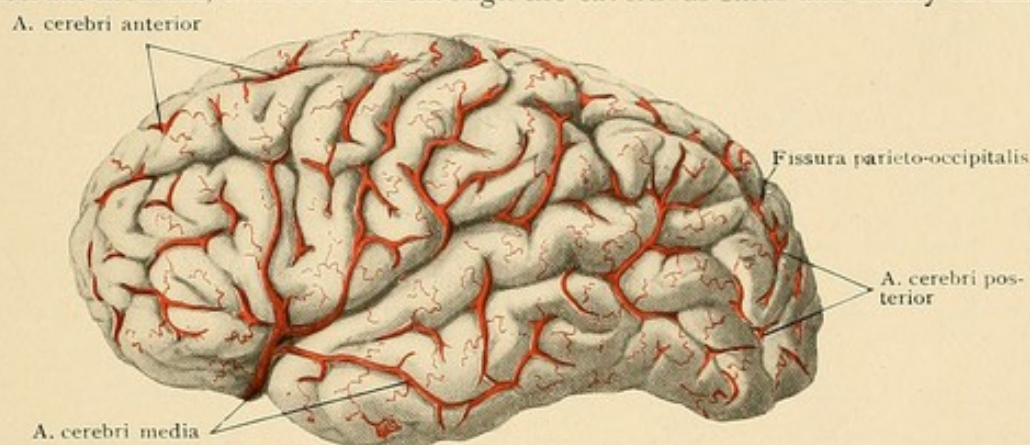


FIG. 32.—Distribution of the A. cerebri anterior, A. cerebri posterior, and A. cerebri media on the lateral surface of the brain.

upward gives off the ophthalmic artery; it then pierces the dura mater just behind the anterior clinoid process, where, after giving off the posterior communicating and anterior choroid, it divides into the anterior and middle cerebral arteries.

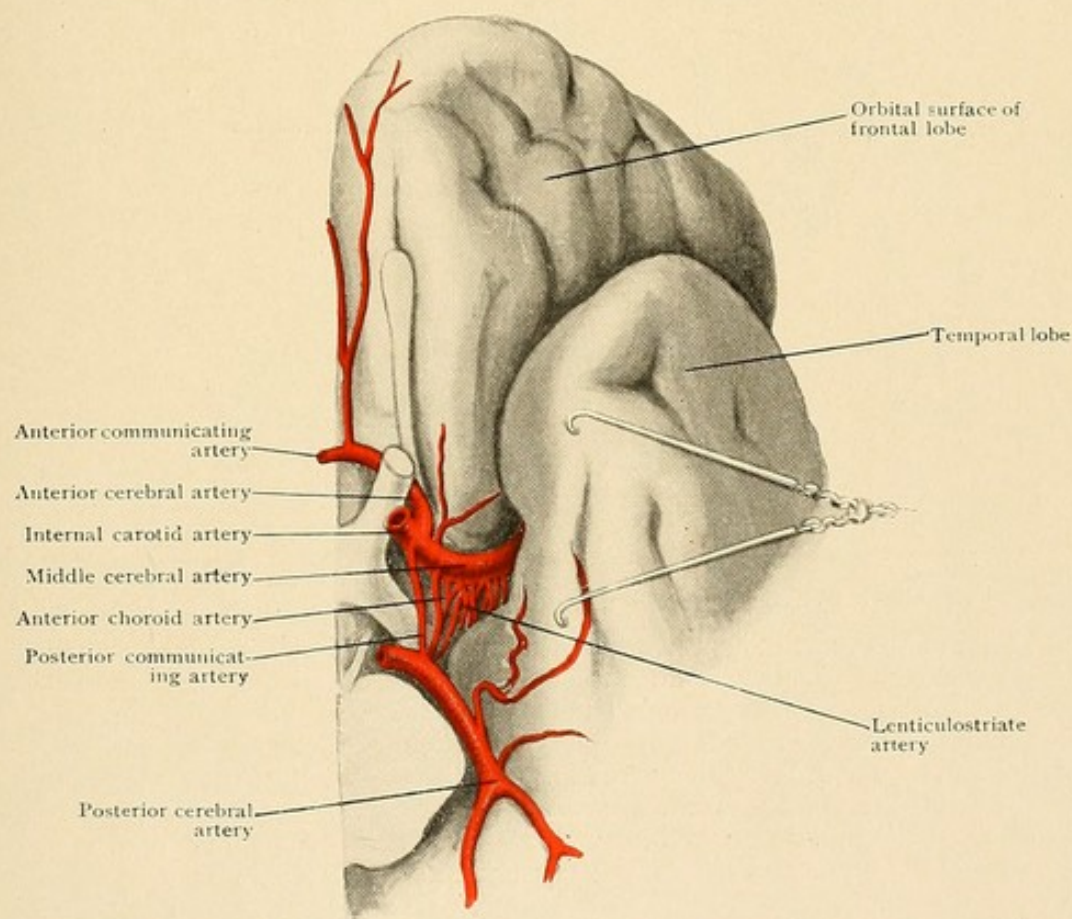


FIG. 33.—Arteries of the base of the brain, especially the branches of the middle cerebral giving rise to apoplexy.

**Anterior Cerebral Artery.**—The anterior cerebral (Fig. 31) passes forward and inward over the anterior perforated space, between the olfactory and optic nerves, to the median fissure. It gives off the anterior communicating artery at this point, which joins the anterior cerebral of the opposite side. The main trunk then runs upward



in the longitudinal fissure on the corpus callosum, giving branches to the frontal and parietal lobes, and finally anastomoses at the posterior end of the corpus callosum with the posterior cerebral. This shows the wide extent of brain tissue on the medial surface of the brain which would be affected by the blocking of this vessel by an embolus.

The terminal branches of the anterior cerebral spread laterally over the surface of the brain (Fig. 32) outward from the longitudinal fissure for a short distance, about 2 cm. As it crosses the anterior perforated space, it gives off the antero-median perforating (ganglionic) arteries which pierce the lamina cinerea to supply the anterior portion of the caudate nucleus above.

**Middle Cerebral Artery.**—The middle cerebral artery passes upward and outward in the fissure of Sylvius, dividing, when opposite the island of Reil, into the branches which supply the cortex of the brain (see Fig. 32). On its way toward

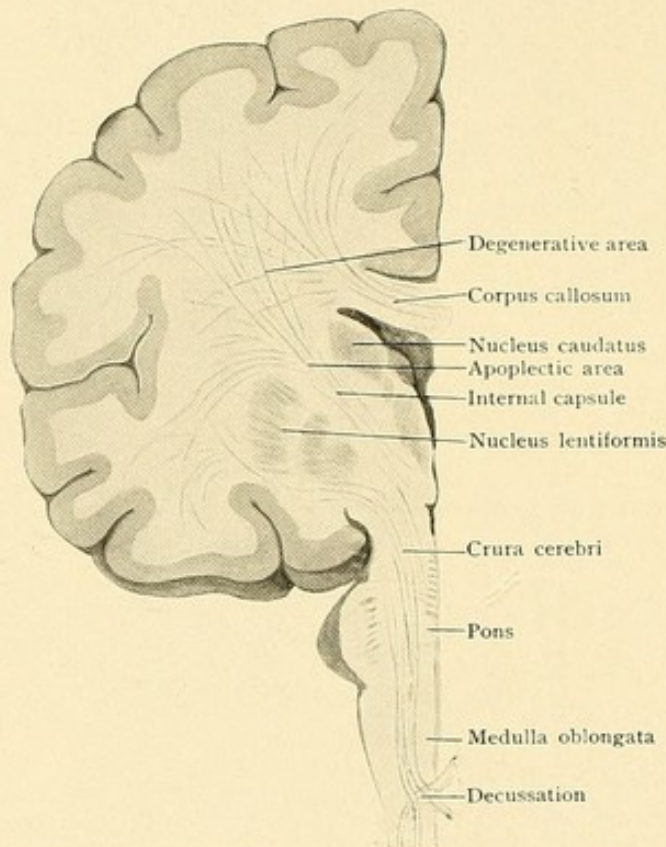


FIG. 34.—Showing the degenerative and apoplectic areas of the brain and the course pursued by the motor fibres from the cortex, through the internal capsule, crura, pons, and medulla to the decussation, where they cross the median line to supply the opposite side of the body.

the island of Reil, at the commencement of the fissure of Sylvius, many small straight branches enter the brain substance to supply the basal ganglia. Two or three supply the caudate nucleus, others, called the anterolateral perforating (ganglionic), enter the anterior perforated space to supply the lenticulostriate ganglion and the anterior portion of the thalamus. One of the largest of these arteries, the *lenticulostriate*, has been called the *artery of cerebral hemorrhage*, by Charcot, on account of the frequency with which it is found ruptured in cases of apoplexy (Fig. 33).

**Anterior Choroid.**—The anterior choroid artery comes sometimes from the internal carotid and sometimes from the middle cerebral. It passes backward and outward on the optic tract and crus cerebri and enters the transverse fissure at the descending horn of the lateral ventricle. It ends in the choroid plexus (see Fig. 33).

**Posterior Cerebral Artery.**—The posterior cerebral artery passes outward over the crus cerebri, just above the pons, to the under surface of the posterior portion of the cerebral hemisphere. Before it receives the posterior communicating artery it gives off the posteromedian perforating (ganglionic) arteries, which enter the posterior perforated space to supply the thalamus and third ventricle. Just beyond the poste-



rior communicating artery it gives off the posterolateral perforating (ganglionic) arteries, which supply the posterior portion of the optic thalamus, crus cerebri, and

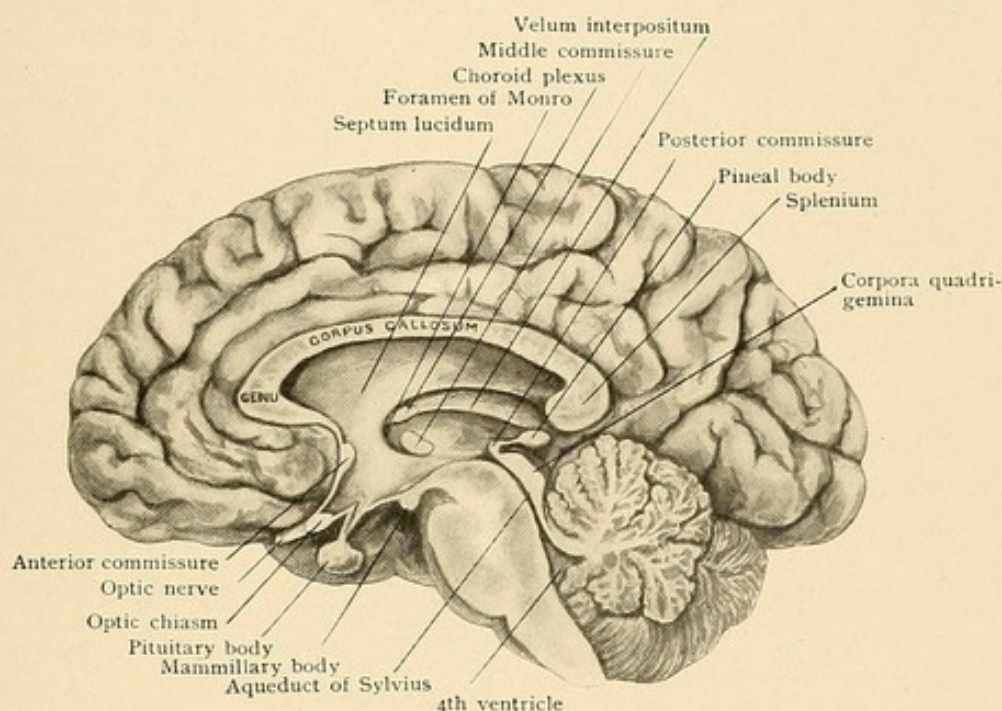


FIG. 35. - Medial section of the brain.

corpora quadrigemina. The branches to the cortex supply a small portion of the inferior surface of the temporosphenoidal lobe and the occipital lobe as seen in Figs. 31 and 32.

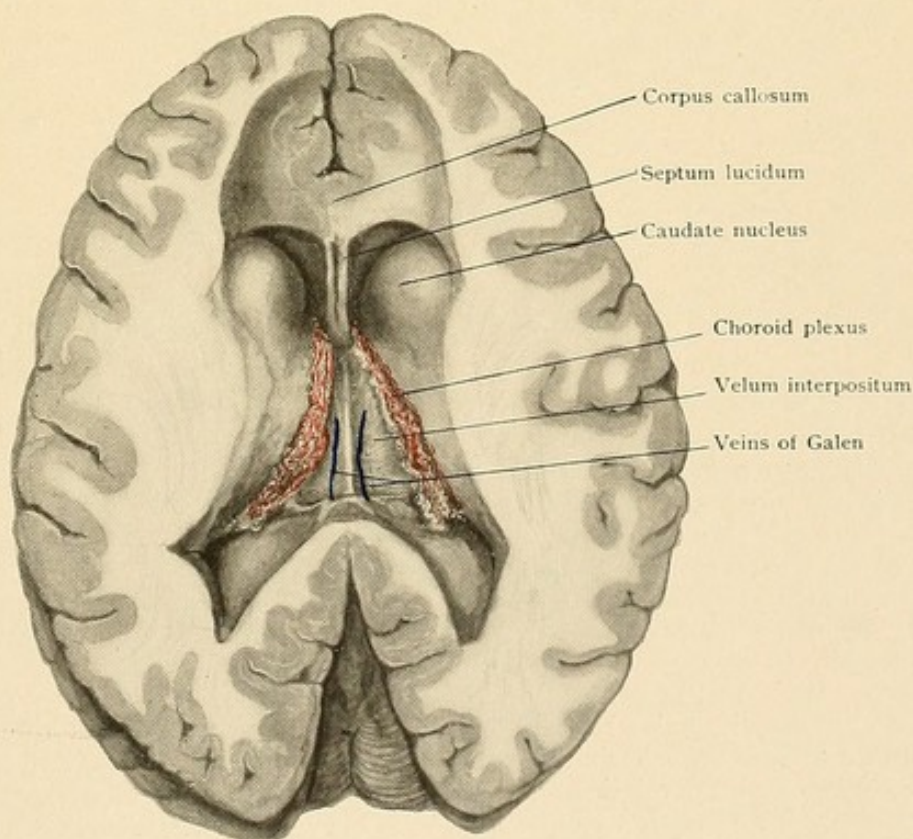


FIG. 36. - Horizontal section of brain; the corpus callosum and fornix have been removed, exposing the lateral ventricles, with the caudate nuclei projecting into them anteriorly and the velum interpositum farther back, with the choroid plexus at the sides and the veins of Galen nearer the middle line. The lateral ventricles in this brain are somewhat larger than usual.



**Cerebral Softening.**—This occurs in the young from embolism; it then affects the cortex, but the more common variety is caused by thrombosis in arteries which are diseased, usually in the aged. The part farthest from the source of blood supply is the most apt to suffer, therefore we find it occurring most frequently in the anterior capsuloganglionic region, just above the usual site of apoplexy (Fig. 34). The affected area will be seen to be most remote from both the cortical and basal blood supply. The perforating arteries supplying this region are in the nature of terminal branches and do not anastomose to any extent either with each other or with the branches coming from the cortex, hence their occlusion inflicts irreparable damage.

**Apoplexy.**—By apoplexy is meant the rupture of a blood-vessel with consequent extravasation of blood, either in or on the brain. It may occur in any portion of the brain, and either from the arteries of the *base*, or from the smaller arteries of

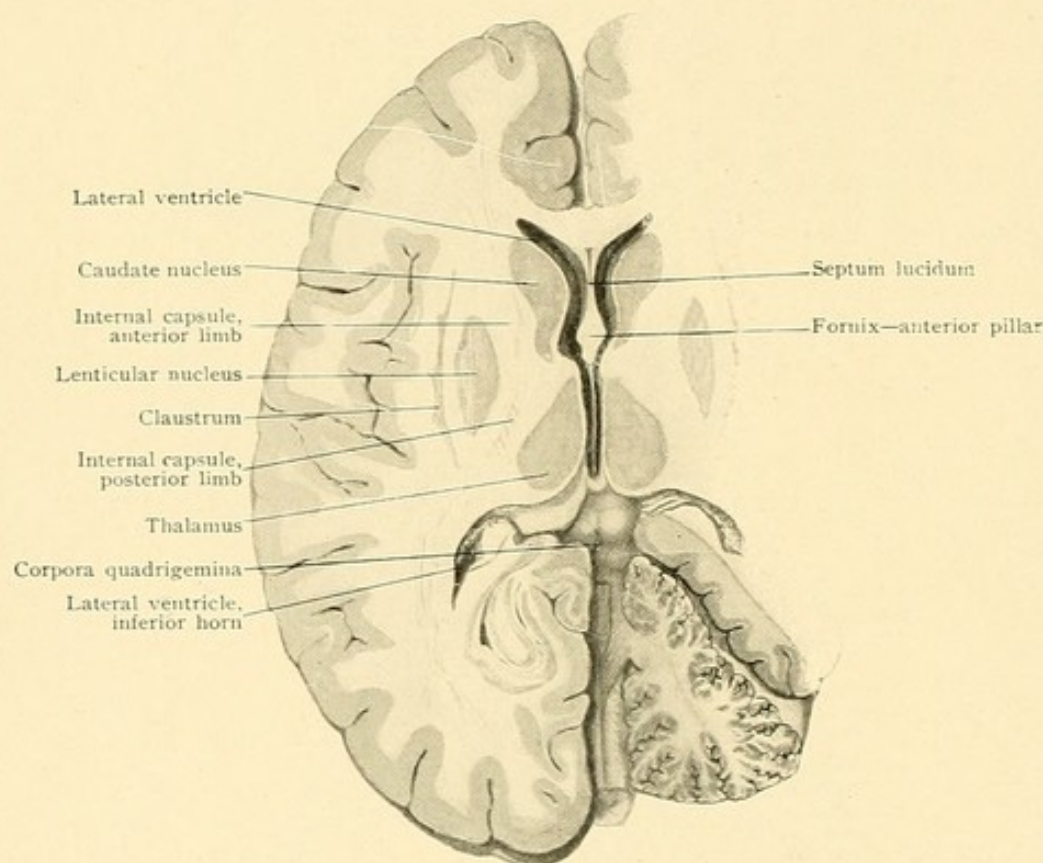


FIG. 37.—Horizontal section of the brain, showing the internal capsule and its relation to the lateral ventricles.

the *cortex*. The former is the more frequent. The arteries that most often rupture are the branches of the middle cerebral which enter the anterior perforated space, especially its outer portion. One of the largest of these anterolateral arteries, as has already been mentioned, known as the lenticulostriate, has been called by Charcot the artery of cerebral hemorrhage.

The portions of the brain usually affected are the posterior portion of the lenticular nucleus, internal capsule, and surrounding parts.

Figure 35 is a medial section of the brain, giving a lateral view of the ventricles.

Figure 36 is a horizontal transverse section of the brain, opening up the ventricles. In front are seen the two *lateral ventricles*, separated by the *septum lucidum*. The cavity shown in the septum lucidum is the so-called *fifth ventricle*. The round body bulging into the lateral ventricle and forming its floor is the *caudate nucleus* portion of the corpus striatum. The *third ventricle* is posterior and below the lateral ventricles, and extends from the septum lucidum in front to the posterior pillars of the fornix behind. It extends from side to side as one large cavity with no median partition. Bulging into the third ventricle on each side are the (*optic*) *thalami*. They are separated from the corpora striata by some white fibres, the *tænia semicircularis*. To the inner side of the *tænia semicircularis* is seen the *choroid plexus*, which



runs down anteriorly over the thalamus to the *foramen of Monro*, through which it enters the lateral ventricle. Two large veins, the *veins of Galen*, pass down near the middle line of the third ventricle to empty into the *straight sinus*. Posteriorly, the choroid plexus follows the descending horn of the lateral ventricle. The choroid plexus hangs from the under surface of the *velum interpositum*, which is a fold of the pia mater entering through the transverse fissure. The veins of Galen run between the two layers of the velum interpositum.

Turning now to Fig. 37, showing a somewhat deeper transverse horizontal section, running through the *corpus striatum* and *thalamus*, it will be seen that to the outer side of the corpus striatum and thalamus is a white layer constituting the *internal capsule*. It divides the corpus striatum into two parts, one to its inner side, which projects into the lateral ventricle, called the *caudate nucleus*, and

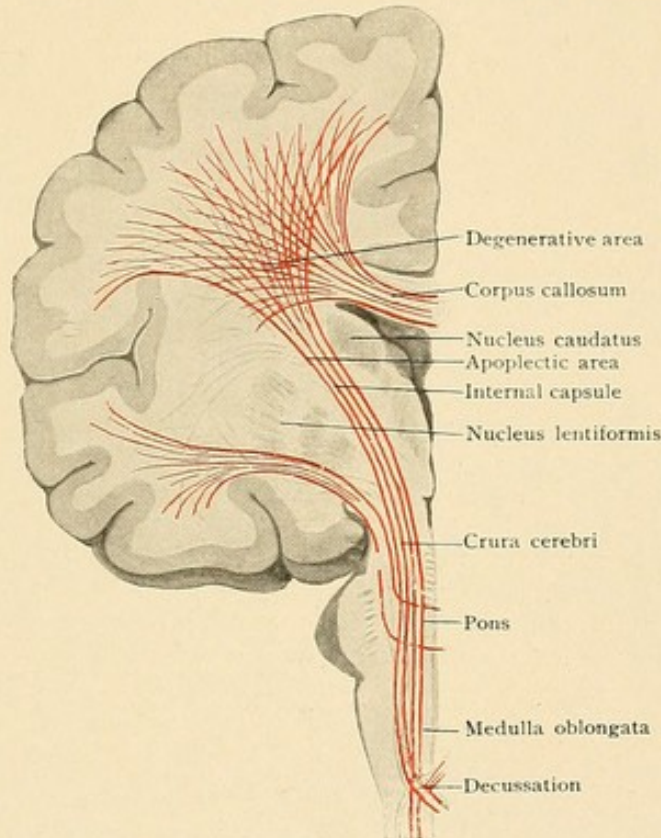


FIG. 38.—Showing the degenerative and apoplectic areas of the brain and the course pursued by the motor fibres from the cortex, through the internal capsule, crus cerebri, pons, and medulla to the decussation, where they cross the median line to supply the opposite side of the body.

the other to its outer side, called the *lenticular nucleus*. To the inner side of the posterior portion of the lenticular nucleus and internal capsule is seen the thalamus. To the outer side of the lenticular nucleus one sees other white fibres called the *external capsule*. An apoplectic hemorrhage occurring in the lenticular nucleus or internal capsule may push forward and rupture into the lateral ventricle. It may go backward and involve the anterior portion of the thalamus and burst into the third ventricle, and if it extends outward it involves the external capsule. Sometimes, if the hemorrhage is low down, it ruptures downward through the base of the brain, showing itself, of course, at the anterior perforated space. Fig. 38 shows these structures as seen in a medial section of the brain.

In Fig. 38 there is a coronal transverse section of the brain, showing the course of fibres of the internal capsule from the cortex of the brain through the corpus striatum, between the lenticular and caudate nuclei: then, forming the *crus cerebri*, the fibres pass through the pons and medulla to enter the spine, decussate, and pass to the extremities. This constitutes the motor pathway from the cortex to the extremities, and when it is injured in apoplexy, the extremities of the opposite side are paralyzed.



**Hemorrhage into the Pons—Crossed Paralysis.**—Apoplexy may also occur in other portions of the brain. It may occur in the pons (see Fig. 39). This produces

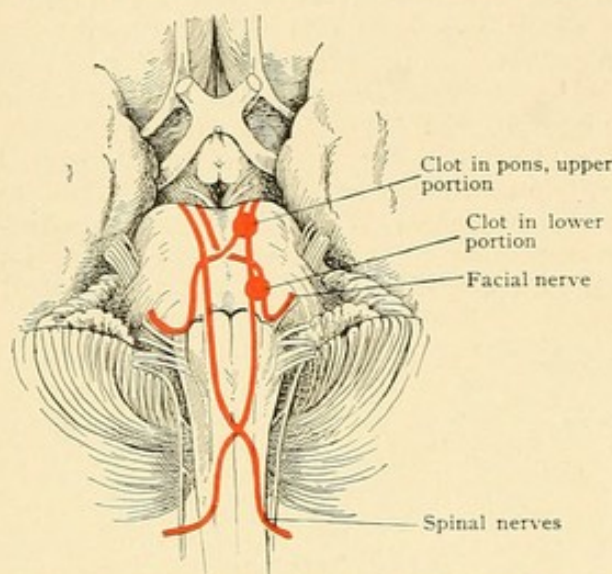


FIG. 39.—Diagram illustrative of crossed paralysis. A clot in the upper portion of the pons causes paralysis of the muscles of the face and extremities of the same side of the body. A clot in the lower portion of the pons causes paralysis of one side of the face and the extremities of the opposite side of the body.

two different sets of symptoms, according to its location, which is due to the fact that the fibres of the seventh or facial nerve, in their passage from the cortex to the face, decussate in the pons. If a small hemorrhage occurs into the upper portion of the pons, it will destroy the motor fibres to the face and the extremities of the opposite side. If, however, the hemorrhage is below the point of decussation, the side of the face on the side of the lesion will be paralyzed and the extremities of the opposite side, thus producing what is known as crossed paralysis, that is, a paralysis of the face on one side and of the extremities on the other.

**Cortical Apoplexy.**—Hemorrhages of the cortex are apt to be less in extent and more localized on account of the smaller size of the vessels affected. They either destroy or

irritate the brain at the site of injury, and produce, if they involve certain areas of the brain, definite peripheral symptoms which serve to indicate the seat of lesion.

### THE CEREBRAL LOBES.

Each cerebral hemisphere is composed of five lobes, called the *frontal*, *parietal*, *occipital*, *temporosphenoidal*, and *central*, or *island of Reil*.

The **frontal lobe** comprises the anterior portion of the brain, as far back as the fissure of Rolando or central sulcus, and as far toward the base as the fissure of Sylvius.

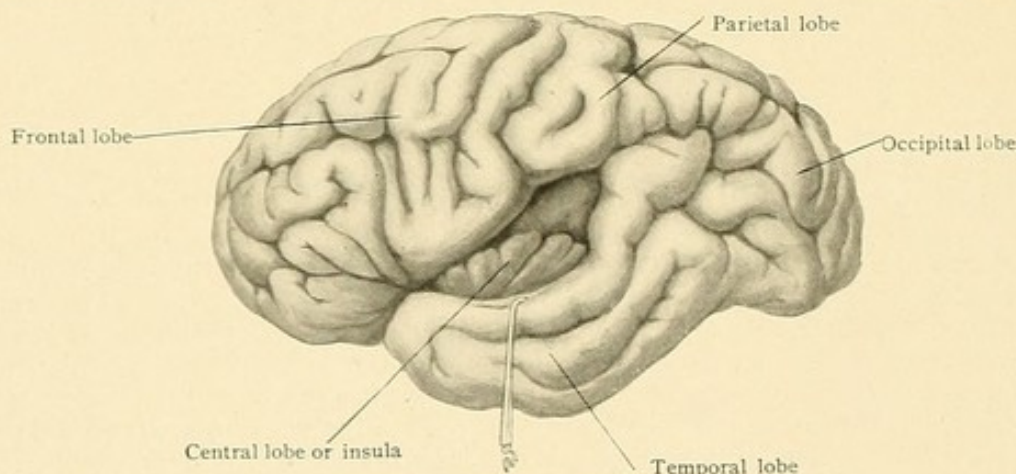


FIG. 40.—Lobes of the brain.

The **parietal lobe** extends from the fissure of Rolando (central sulcus) in front to the parieto-occipital fissure behind. Below, it is limited anteriorly by the fissure of Sylvius, while its posterior portion merges into the temporosphenoidal lobe.

The **occipital lobe** extends posteriorly from a line joining the occipitoparietal fissure above to the pre-occipital notch below.

The **temporosphenoidal lobe** consists of that portion of the brain below the fissure of Sylvius, as far back as the pre-occipital notch. It occupies the middle fossa of the skull.



The **central lobe** or **island of Reil**, also called the **insula**, consists of five to seven convolutions which radiate upward; it can be seen by separating the two sides of the anterior portion of the fissure of Sylvius.

### THE FISSURES AND CONVOLUTIONS OF THE BRAIN.

The surface of the brain is wrinkled or thrown into folds, producing elevations and depressions. The elevations are called convolutions or *gyri*, and the depressions, fissures or *sulci*.

The fissures are called main or subsidiary fissures, according to their importance. The five main fissures are the *longitudinal fissure*, which separates the hemispheres; the *transverse fissure*, which separates the cerebrum and cerebellum and communicates with the third ventricle; the *fissure of Sylvius*; the *fissure of Rolando*, or central fissure, and the *parieto-occipital fissure*.

### THE LATERAL SURFACE OF THE HEMISPHERES.

The frontal lobe has a superior, an inferior, and a precentral sulcus. The first two divide the anterior portion into the *superior*, *middle*, and *inferior frontal convolutions*.

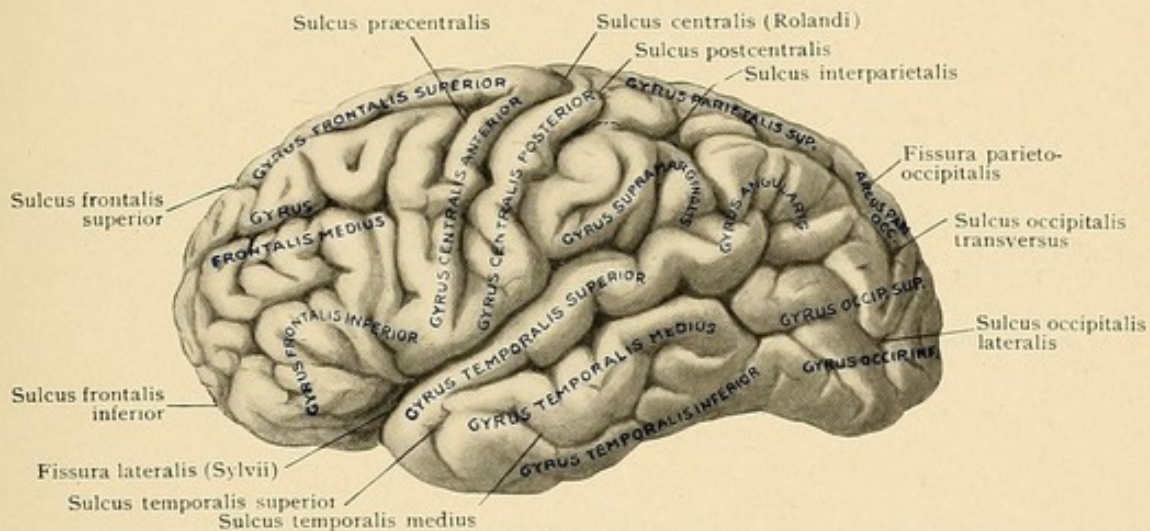


FIG. 41.—Fissures, sulci, and gyri (convolutions) of the lateral surface of the cerebral hemisphere.

*lutions*. That portion of the inferior or third left frontal convolution which surrounds the ascending limb of the fissure of Sylvius is called *Broca's convolution*, and is the *centre for speech*. Posterior to these and running upward and backward, forming the anterior wall of the central fissure, is the *precentral* or *ascending frontal convolution*.

The convolution forming the anterior extremity of the parietal lobe and the posterior wall of the central sulcus or fissure of Rolando is called the *postcentral* or *ascending parietal convolution*. Immediately behind it is the postcentral or interparietal sulcus. The upper portion of this sulcus divides, one branch going upward and one backward. Immediately above the posterior branch is the *superior parietal gyrus* or lobule, and below it and surrounding the posterior extremity of the fissure of Sylvius is the *supramarginal gyrus*. Posterior to the supramarginal gyrus and surrounding the posterior extremity of the superior temporal, or temporosphenoidal sulcus is the convolution known as the *angular gyrus*.

The occipital lobe on its convex surface is divided into *superior* and *inferior occipital convolutions* by the lateral occipital sulcus.

The temporal or temporosphenoidal lobe is also divided into *superior*, *middle*, and *inferior*, or *first*, *second*, and *third temporal convolutions* by the superior, or parallel, and middle fissures. On the under surface is a *fourth temporal convolution*, separated from the third by the inferior temporal fissure. These fissures may not be distinct.



## THE MEDIAL SURFACE OF THE HEMISPHERES.

If now the medial surface of the hemisphere, which forms one side of the longitudinal fissure, be examined, there is seen a large convolution running just above and parallel with the corpus callosum. It is called the *gyrus cinguli* (*fornicatus*). Below and separating it from the corpus callosum is the callosal fissure; above it is the callosomarginal fissure. The convolution above the latter, forming the margin of the hemisphere, is the *marginal convolution*. The callosomarginal fissure at its posterior portion turns upward and ends on the margin of the hemisphere, just posterior to the fissure of Rolando, or central fissure, and serves to identify it. This marks the posterior limit of the frontal lobe. The posterior end of the frontal lobe surrounds the upper end of the central fissure and on that account is called the *paracentral lobule*. Its anterior boundary is marked by the paracentral fissure, or sulcus. Between the callosomarginal fissure in front and the parieto-occipital fissure behind is the parietal lobe, called, from its square shape on the medial surface, the *quadrate lobule*, or from being anterior to the cuneus lobule, the *precuneus*. Running downward and back-

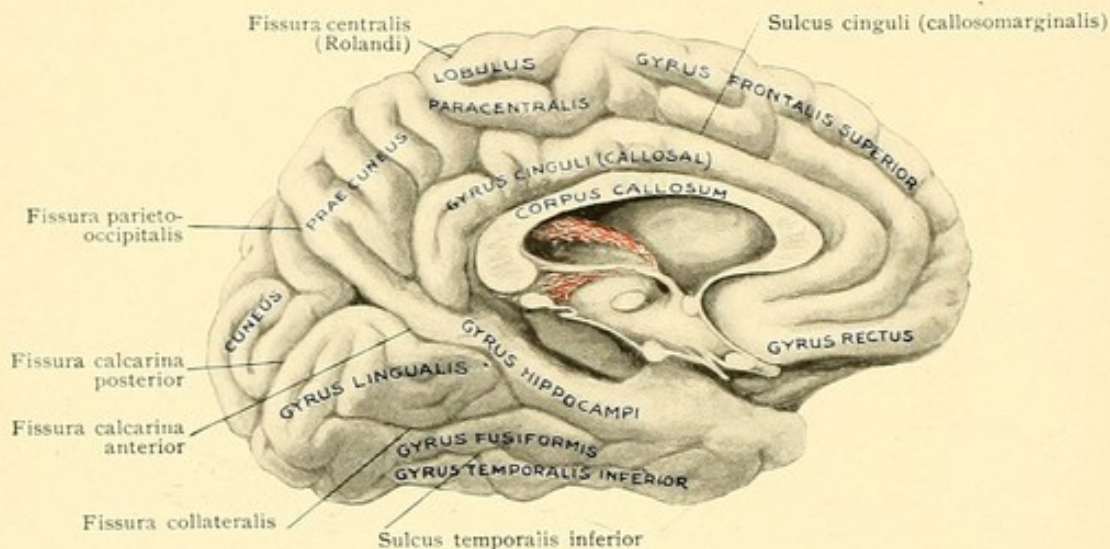


FIG. 42.—Gyri, sulci, and fissures of the medial surface of the cerebral hemisphere.

ward from the deeper portion of the parieto-occipital fissure is a very distinct depression called the *calcarine fissure*. These two fissures include a wedge-shaped piece of the occipital lobe called, from its shape, the *cuneus lobule*. It is of interest in reference to the sense of sight.

## FUNCTIONS OF THE CORTEX OF THE BRAIN: CEREBRAL LOCALIZATION.

A knowledge of the functions of the various portions of the brain is necessary in order to localize a diseased area. The diseases and injuries to which the brain is exposed oftentimes do not involve the whole brain, but only certain distinct and isolated parts. The brain is not a single, homogeneous organ that acts only as a whole; it is complex. It is composed of a number of separate parts or areas, which may act either singly or in conjunction with other areas. These separate areas have different functions, so that if the disease or injury is limited to one of them, we have its functions abolished, and the symptoms produced indicate the area affected.

These areas are situated on the surface or cortex of the brain in the gray matter. They receive impressions from, and transmit impulses to, all parts of the body through the white matter or fibres of the brain. An injury to the cortex or gray matter destroys the originating and receptive centres. An injury to the white matter destroys the paths to and from these centres and therefore prevents them from receiving impressions or sending out impulses. Thus, we may have a paralysis of the leg and arm caused by an injury to the leg and arm centres in the cortex of the brain, as by a hemorrhage from a fracture, or we can have the same paralysis



produced by an injury to the path leading from those centres, the motor tract as it is called, by a hemorrhage, as from apoplexy, involving the corresponding white matter fibres.

The exact localization of the functions of all parts of the brain has not been accomplished, but the functions of many areas have been definitely proven. In cases of brain tumor, abscess, hemorrhage, injury, etc., a knowledge of these areas enables one to localize the seat of the lesion.

#### FUNCTIONS OF THE CONVOLUTIONS ON THE SURFACE OF THE CEREBRUM.

The frontal lobe may be conveniently divided into three areas; prefrontal, midfrontal, and postfrontal. The **prefrontal area** embraces all the superior, middle, and inferior frontal convolutions, with the exception of their posterior ends. On the medial side it reaches to the callosomarginal fissure. The function of the prefrontal area is said to be that of higher cerebration, as attention, judgment, and comparison. This region, particularly the lower portion, is liable to injury, owing to its anterior position and to the fact that it overlies the orbit. The roof of the orbit is quite thin and liable to fracture by penetrating bodies, as umbrellas, canes, etc. Sometimes a portion of this part of the brain may be destroyed without marked interference with the mental qualities of the patient. This occurred in the case of a

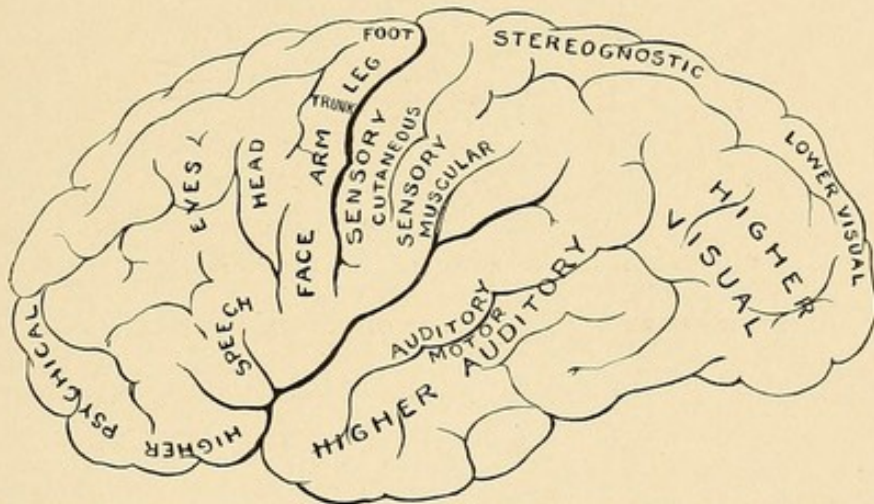


Fig. 43.—Diagram illustrating the probable functions of the lateral surface of the brain.

boy who was struck in the eye by a carriage pole (personal observation). The eye was burst, necessitating its removal. Several pieces of the fractured bone of the roof of the orbit were removed and brain tissue came away for several days. The boy recovered and for sixteen years apparently had no resulting mental deficiency.

The **midfrontal area** embraces the posterior portion of the superior and middle convolutions, with the upper posterior portion of the inferior. It is concerned in certain movements of the eyes and lids, and also in turning the head toward the opposite side. This midfrontal division is the most anterior portion of what is called the *motor area*.

**Speech Centre, or Broca's Convolution.**—The centre of speech is located in right-handed people in the posterior portion of the third left frontal convolution, where it arches around the ascending limb of the fissure of Sylvius. It is called Broca's convolution. The faculty of writing or written speech is attributed to the graphic centre in the posterior extremity of the second frontal convolution just above and behind Broca's convolution.

The **postfrontal area** embraces the ascending frontal convolution in front of the fissure of Rolando or central fissure. It is concerned in the various movements of the trunk and extremities, and forms the anterior portion of the Rolandic area; it will be considered under that head.

**The Rolandic Area.**—This is the area which gives rise to most of the voluntary movements of the body. When affected, it causes positive symptoms of paralysis



or contraction of the muscles connected with it, and is the region most frequently affected by injuries. This is partly due to the fact of its proximity to the middle meningeal artery, as a hemorrhage from that vessel produces a clot which covers and involves this area.

The Rolandic area embraces the ascending frontal, or precentral, and posterior portion of the three frontal convolutions, the former being in front of the fissure

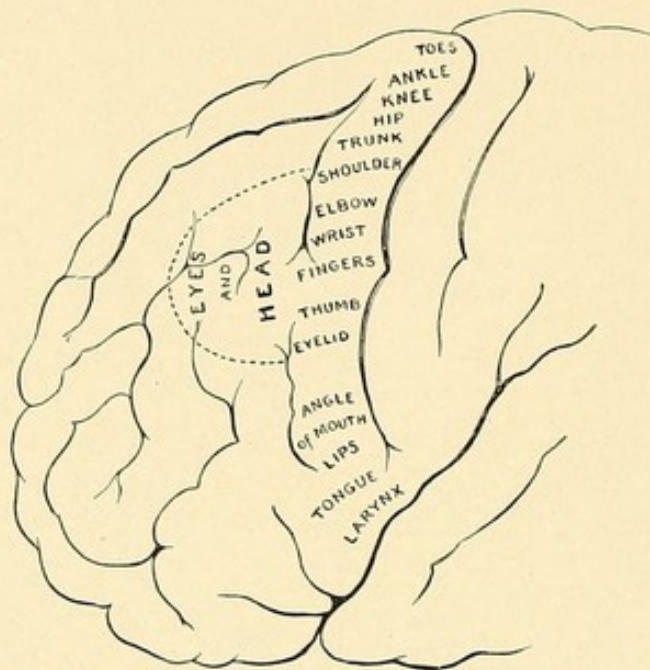


FIG. 44.—Diagram illustrating the motor areas of the lateral surface of the brain.

of Rolando, or central fissure. The fissure of Rolando passes downward and forward from the longitudinal fissure, at an angle of about  $70^\circ$ , nearly to the fissure of Sylvius, being separated from it by the joining of the ascending parietal and ascend-

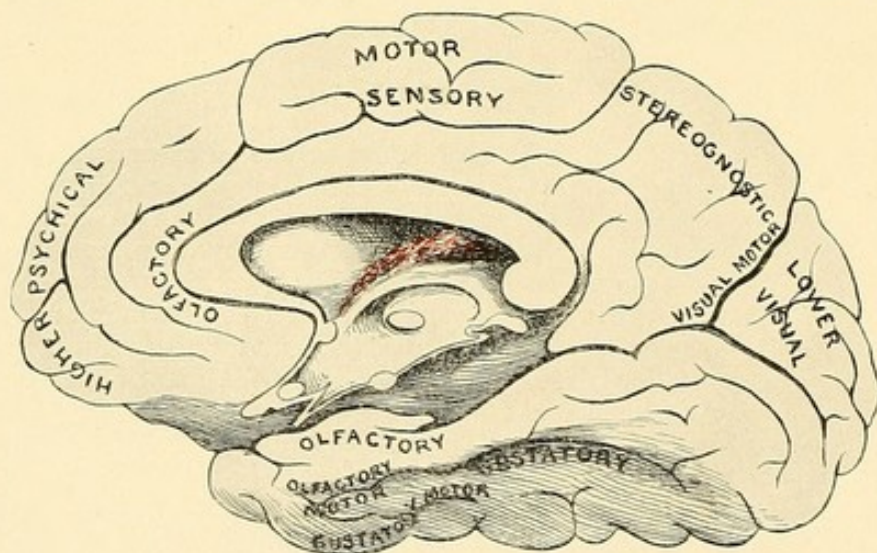


FIG. 45.—Diagram illustrating the probable functions of the gyri (convolutions) of the medial surface of the brain.

ing frontal convolutions. Sherrington and Grünbaum have shown that the motor area is almost exclusively anterior to the central fissure.

The upper portion of the motor area, near the longitudinal fissure, is concerned with the movements of the toes and lower extremity. The leg centres are toward the upper end of the central fissure; next are those of the abdomen and chest. The arm centres are toward the middle, and the face centres, including the larynx,



tongue, and platysma myoid muscle, around its lower extremity. The leg, arm, and face centres are, respectively, opposite the posterior extremities of the superior, middle, and inferior frontal convolutions.

The upper portion of the motor area passes over the upper margin of the hemisphere and down on its medial side almost as far as the callosomarginal fissure and paracentral lobule.

**The Sensory Area.**—The portions of the cerebrum involved in cutaneous and muscular sensibility embrace the posterior portion of the parietal convolutions, the precuneus or quadrate lobule, and gyrus fornicatus as far forward as the motor area on the medial aspect.

The **visual area** embraces the occipital lobe, particularly its cuneus lobule, and region of the calcarine fissure on the medial surface of the hemisphere. The anterior portion of the occipital lobe and the region of the angular gyrus are con-

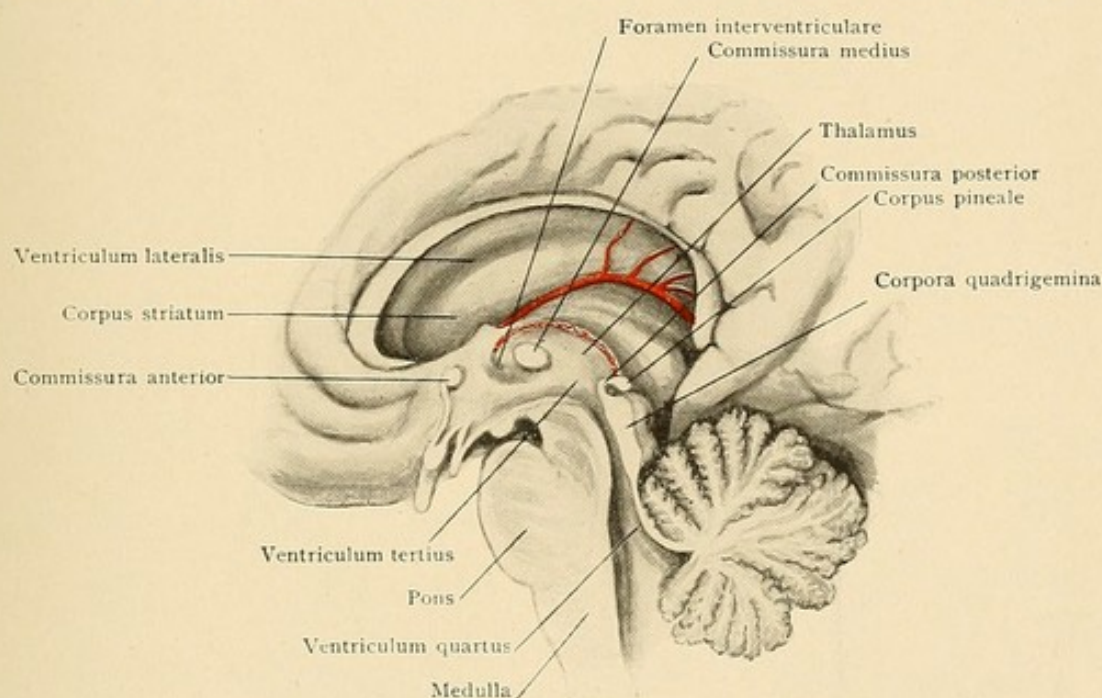


FIG. 46.—Foreshortened view showing corpus striatum, thalamus, corpora quadrigemina, lateral, third, and fourth ventricles, etc.

cerned in the more complex phenomena of sight, and their destruction produces word-blindness. Destruction of the centres on both sides produces what has been called mind-blindness, because objects can no longer be recognized.

**The Auditory Area.**—The centre for hearing is located in the superior and middle temporosphenoidal convolutions. It requires destruction of these convolutions on both sides of the brain to produce total cerebral deafness. The memory or recognition of spoken words (word hearing) is apparently performed by the posterior ends of the superior and middle (1st and 2d) temporosphenoidal convolutions.

**Gustatory Area.**—The sense of taste is supposed to be located on the under and inner surfaces of the temporosphenoidal lobe or fourth temporal convolution.

**Olfactory Area.**—The sense of smell is supposed to involve the anterior portion of the gyrus fornicatus and the upper medial portion of the temporosphenoidal lobe.

The cerebral areas for both smell and taste have not been as yet accurately determined.

#### FUNCTIONS OF THE BASAL GANGLIA.

**Corpus Striatum and Thalamus.**—The exact functions of the corpus striatum, embracing the caudate and lenticular nuclei, and of the thalamus are not known. They are most often affected in apoplexies; lesions of the corpus striatum are accompanied by disturbances of motion, and those of the thalamus by disturbances of sensation.



**Corpora Quadrigemina.**—The anterior corpora quadrigemina are associated with sight, the posterior possibly with hearing and equilibrium. Note their proximity to the cerebellum.

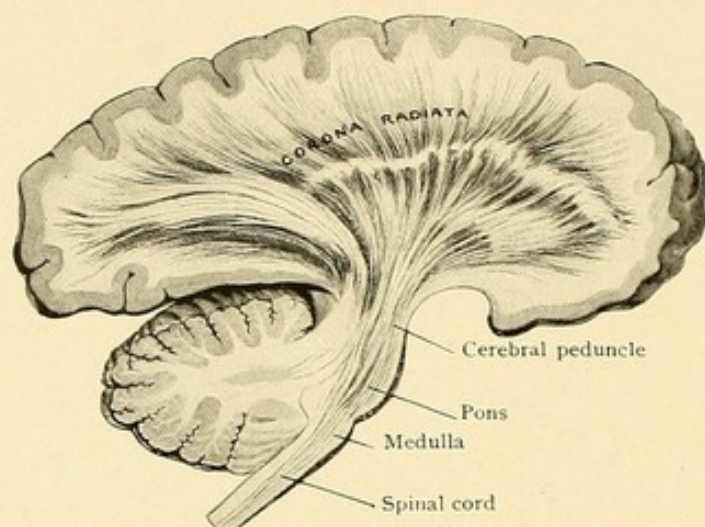


FIG. 47.—The corona radiata or projection fibres which connect the cortex above with the thalamus, corpus striatum, tegmental region, pons, medulla, and spinal cord below. These fibres go to form the internal capsule.

**Crura Cerebri.**—The crura cerebri transmit both sensory and motor impulses. Note their proximity to the third nerve, as they are apt to be involved by the same lesions, thus accounting for paralyses or sensory disturbances of the trunk or extremities accompanied by ocular paralysis.

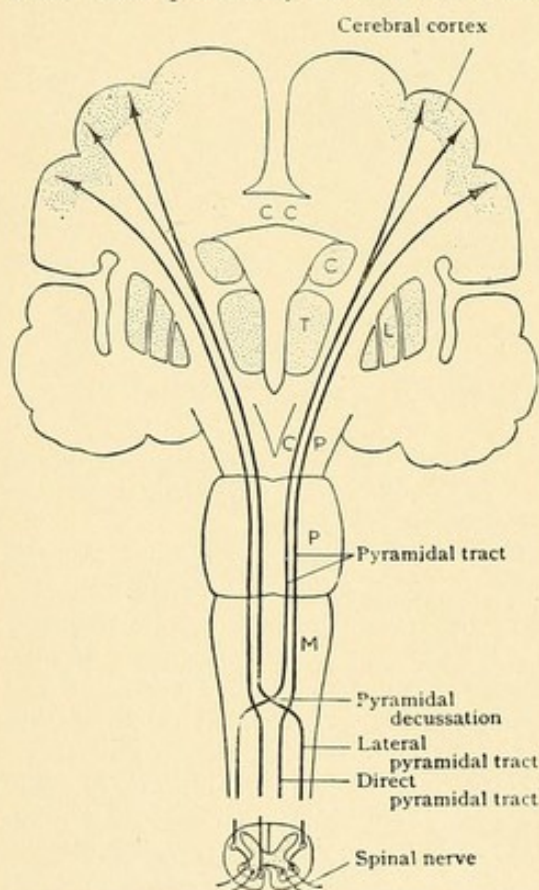


FIG. 48.—Diagram showing course and decussation of corticospinal (pyramidal) tract; M, medulla; P, pons; CP, cerebral peduncle; T, thalamus; C, L, caudate and lenticular nuclei; CC, corpus callosum. (Piersol.)

The functions of the external capsule, which lies to the outer side of the lenticular nucleus, are not known.

**Pons Varolii.**—The pons transmits the motor or pyramidal tract, and also the fifth, sixth, and seventh nerves. Implication of the seventh or facial nerve, together with the motor tract, has already been alluded to (page 32). If the sixth or abducent nerve is involved, the external rectus muscle on that side will be paralyzed. If the fifth, or trifacial nerve is affected, irritation of its motor root may produce trismus or clenching of the jaws, and interference with its sensory root may cause anæsthesia of one side of the face.

#### THE CORONA RADIATA, INTERNAL CAPSULE, AND MOTOR TRACT.

The *corona radiata* is the bundle of white fibres which spreads out like a fan and connects the cortex of the brain with the basal ganglia and spinal cord. Proceeding downward from the cortex, the corona radiata becomes smaller and passes, in the form of a band, between the lenticular nucleus on the outside and the caudate nucleus and thalamus on the inside. This band is known as the *internal capsule*. It transmits in its anterior portion fibres from the prefrontal or higher psychical area; then come the motor



The *motor fibres of the internal capsule* pass downward through the anterior portion of the crus cerebri and pons into the medulla, at the lower part of which the majority decussate and pass into the anterior columns of the cord as the *pyramidal tracts*. Thus, it is seen that destruction of any portion of the motor tract, from the point of *pyramidal decussation* below, through the internal capsule to the cortex above, will cause a paralysis on the opposite side of the body.

## CRANIOCEREBRAL TOPOGRAPHY.

For the purpose of operating on the brain it is essential to know the bony landmarks of the skull, the lower level of the brain, and the relation which the various fissures and convolutions bear to the surface.

The most important fissures are the *longitudinal*, *Sylvian*, *Rolandic*, and *parieto-occipital*. If these can be properly located, the convolutions and subsidiary fissures can be readily filled in.

### BONY LANDMARKS.

**Nasion.**—The nasofrontal suture in the median line.

**Glabella.**—The smooth spot in the median line on the frontal bone between the superciliary ridges. It is about on a level with the upper edge of the orbit.

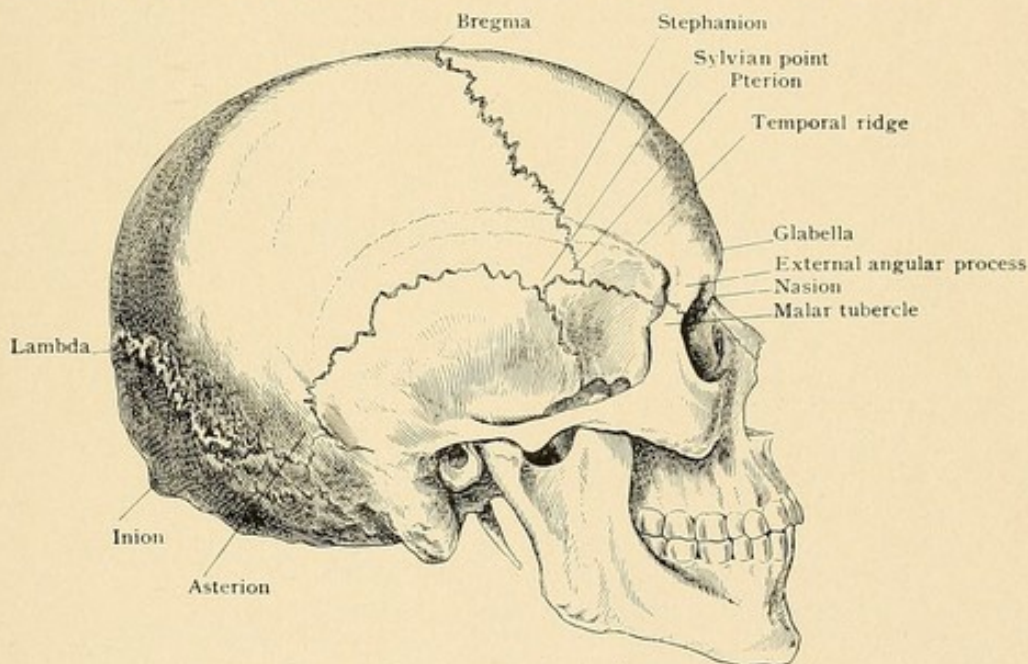


FIG. 49.—Landmarks of the skull.

**Bregma.**—The point in the midline where the sagittal and coronal sutures cross. It corresponds with the anterior fontanelle in the infant.

**Lambda.**—The point of meeting of the sagittal and lambdoid sutures. It is about 6 cm. ( $2\frac{1}{4}$  in.) above the occipital protuberance.

**Inion.**—The external occipital protuberance.

**Pterion.**—This name was given by P. Broca to the point where the frontal, parietal, and sphenoid bones meet in the region of the temple. It is about 2.5 cm. (1 in.) behind the angular process and should not be confounded with the Sylvian point, which is 1.5 cm. ( $\frac{5}{8}$  in.) farther posterior, where the temporal, parietal, and sphenoid bones meet. Horsley called this latter point the pterion. The region of the pterion is the seat of the anterolateral fontanelle in the foetus.

**Asterion.**—This lies 2 cm. ( $\frac{1}{2}$  in.) behind the base of the mastoid process, where the parietal, occipital, and temporal bones meet. It is on the superior curved line and in fetal life forms the posterolateral fontanelle.

**Temporal Ridge.**—This marks the upper attachment of the temporal fascia and muscle. It begins at the external angular process of the frontal bone and ends



at the asterion. Its anterior third is well marked, but as it crosses the coronal suture it fades away and gradually broadens out, its upper margin being called the superior and its lower the inferior temporal ridge. The superior ridge marks the attachment of the superficial layer of the temporal fascia, the inferior, the deep layer.

**External Angular Process.**—This is the outer extremity of the frontal bone, where it articulates with the malar. The line of the suture can be distinctly felt in the living.

**Malar Tubercle.**—This is the small bony projection on the posterior edge of the malar bone, 1.25 to 2 cm. ( $\frac{1}{2}$  to  $\frac{3}{4}$  in.) below the frontomalar suture.

**Stephanion.**—The point where the temporal ridge crosses the coronal suture.

### TOPOGRAPHICAL POINTS.

**Pre-auricular Point.**—The depression in front of the ear and just behind the condyle of the lower jaw.

**Sylvian Point.**—Where the anterior ascending and anterior horizontal limbs come off from the posterior horizontal limb of the fissure of Sylvius. It lies 4 cm. ( $1\frac{5}{8}$  in.) posterior and a little above the external angular process, at the junction of the parietal, sphenoid, and temporal bones.

**Superior Rolandic Point.**—Where the upper end of the line marking the Rolandic fissure crosses the median line.

**Inferior Rolandic Point.**—Where the lower end of the line marking the Rolandic fissure crosses the line of the Sylvian fissure.

### THE LOWER LEVEL OF THE BRAIN.

The lower level of the brain is marked by a line beginning in the median line 1 cm. ( $\frac{2}{3}$  in.) above the nasion, thence above the orbit 1 cm. from its edge to the external angular process; from here it goes to the middle of the zygoma, thence backward along its upper border, above the auditory meatus and along the superior curved line to the inion (occipital protuberance).

### FISSURES AND CONVOLUTIONS.

The conformation of the various fissures and convolutions varies so much within normal limits that it is not possible to outline them on the surface of the scalp or skull with absolute exactness. The various lines which are laid out to indicate their course are, therefore, only approximate, but they are sufficiently accurate for operative purposes. To allow for variations, the openings made are usually large, and the motor areas are sometimes identified by the application of an electrode.

**Fissure of Sylvius (*fissura cerebri lateralis*).**—To indicate the course of the Sylvian fissure, a line is drawn from the external angular process of the frontal bone through a point 2 cm. ( $\frac{3}{4}$  in.) below the most prominent part of the parietal eminence and ending 1.5 cm. ( $\frac{5}{8}$  in.) above the lambda. The main portion of the Sylvian fissure begins 2 cm. ( $\frac{3}{4}$  in.) behind the angular process; 2 cm. farther back or 42 mm. ( $1\frac{5}{8}$  in.) behind the angular process is the Sylvian point, where the anterior horizontal and anterior ascending limbs are given off. From this point the posterior horizontal limb passes backward to 2 cm. ( $\frac{3}{4}$  in.) below the highest point of the parietal eminence and then curves upward and backward for a distance of 1.25 cm. to 2 cm. ( $\frac{1}{2}$  to  $\frac{3}{4}$  in.).

**Central Fissure, or Fissure of Rolando (*sulcus centralis*).**—The line of the central fissure begins at the upper Rolandic point, 1.5 cm. ( $\frac{5}{8}$  in.) behind the middle of a sagittal line passing from the glabella to the inion. It then passes down and forward at an angle of approximately  $70^\circ$  ( $67\frac{1}{2}$ , Chiene) toward the middle of the zygoma (Le Fort) to end at the lower Rolandic point, where it intersects the Sylvian line. It is about 9 cm. ( $3\frac{1}{2}$  in.) long. The central fissure stops 1 cm. above the Sylvian line or fissure.

**Parieto-occipital Fissure (*fissura parieto-occipitalis*).**—The position of this fissure is quite variable, an average being 1.5 cm. ( $\frac{5}{8}$  in.) above the lambda, and extending 1.25 cm. ( $\frac{1}{2}$  in.) out from the median line. It is about 6 cm. ( $2\frac{1}{4}$  in.) above the inion and on or below the line of the Sylvian fissure.



## SUBSIDIARY FISSURES AND CONVOLUTIONS.

The **precentral and postcentral sulci** are about 15 mm. ( $\frac{3}{8}$  in.) anterior and posterior to the fissure of Rolando.

The **inferior frontal convolution** lies between the line of the fissure of Sylvius below and a line just below the temporal ridge above.

The **middle frontal convolution** lies under the frontal eminence, and occu-

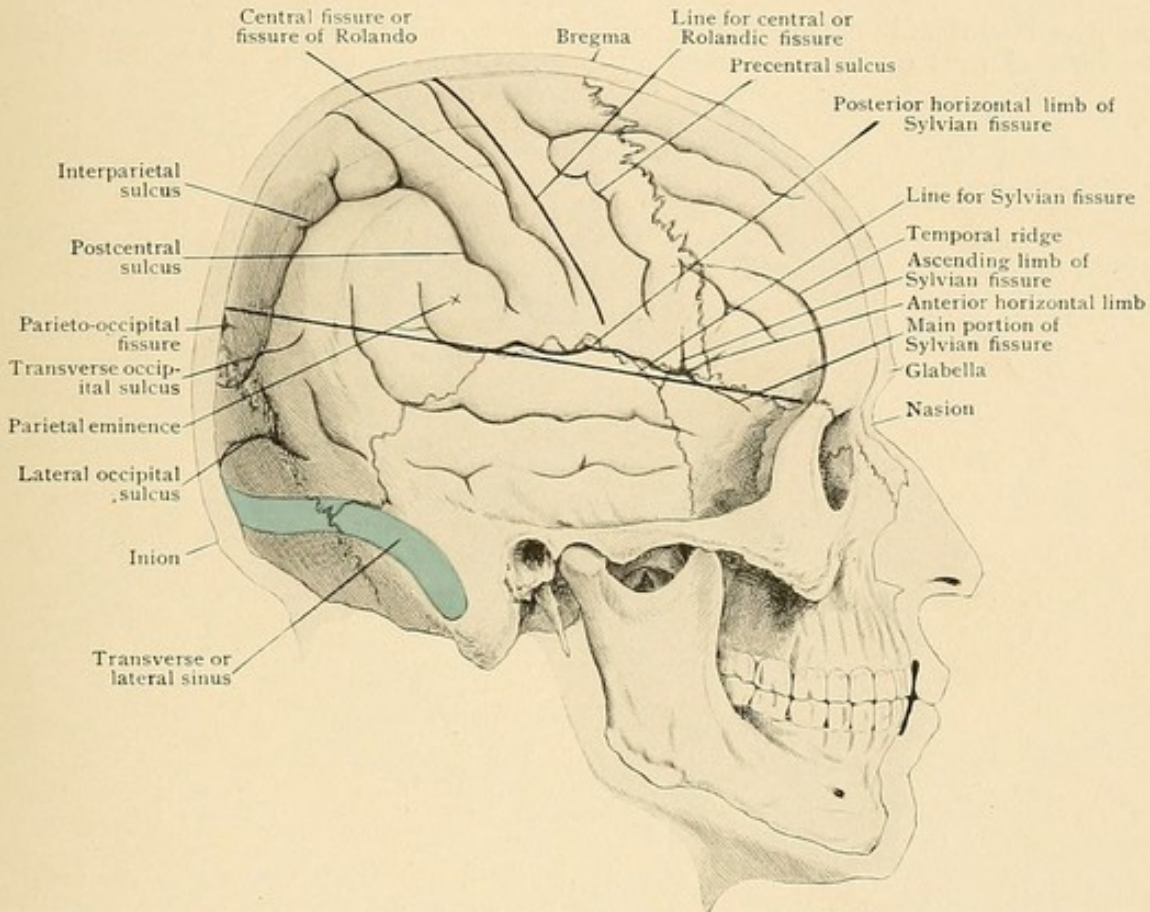


FIG. 50.—Semidiagrammatic view of head, showing relation of Rolandic and Sylvian fissures and lines.

pies about the lower two-thirds of the distance between the temporal ridge below and the midline above.

The **superior frontal convolution** covers about the upper one-third of the distance from the median line above to the temporal ridge below.

The **superior frontal sulcus** passes upward from the supra-orbital notch.

The **inferior frontal sulcus** runs just below the temporal ridge.

The **first or superior temporal convolution** runs along the lower side of the fissure of Sylvius. It is about 15 mm. ( $\frac{3}{8}$  in.) wide.

The **first or superior temporal sulcus** or **parallel fissure** runs parallel to the Sylvian fissure and 15 mm. below.

The **second or middle temporal convolution** is wider than the first and lies a short distance above the level of the base of the skull.

The **middle temporal sulcus** runs close above the zygoma.

The **third or inferior** and the **fourth temporal convolutions** lie on the base of the brain, separated by the inferior temporal sulcus. The fourth temporal convolution has on its inner side the collateral fissure (see Fig. 42).

The **interparietal sulcus** (**pars horizontalis**) leaves the postcentral sulcus near its middle and passes upward and backward to a point opposite the lambda.

The **supramarginal convolution** surrounds the termination of the fissure of Sylvius and is, therefore, under the parietal eminence.



The **angular gyrus** surrounds the posterior end of the first temporal sulcus (parallel fissure) and is, therefore, 3 or 4 cm. ( $1\frac{1}{4}$  to  $1\frac{1}{2}$  in.) posterior to the parietal eminence.

The **transverse occipital sulcus** is a continuation of the interparietal sulcus to just beyond the parieto-occipital fissure.

The **lateral occipital sulcus** lies close to the tentorium; it divides the occipital lobe into superior and inferior convolutions. (Sometimes these two sulci divide the lobe into three convolutions, superior, middle, and inferior.)

**The Fissures in Children.**—In childhood the fissure of Rolando is somewhat more vertical than in adults; the fissure of Sylvius has its point of division a little higher and runs up to and usually above and in front of the parietal eminence (Dana, *Med. Record*, Jan. 1889, p. 29). After the age of three years, the relative position of the fissure to the parietal eminence begins to approach that of the adult. (For variations due to age see Cunningham: "Contributions to the Surface Anatomy of the Cerebral Hemispheres," 1892.)

The objects of cerebral topography are mainly to ascertain in case of injury or disease of the superficial structures what parts of the brain beneath are liable to be involved, and for operative

procedures, in order to expose the affected areas. The convolutions and sulci are so variable that all guides are only approximate. In order to overcome this defect and provide for unusual conditions, the openings in the skull are usually made quite large. The flaps of scalp and bone may even embrace the entire parietal bone or a quarter of one hemisphere. As regards the various points—the upper Rolandic point is generally conceded to be 15 mm. ( $\frac{1}{2}$  to  $\frac{5}{8}$  in.) posterior to the midpoint between the glabella andinion. The angle which the fissure forms with the median line varies from  $64^\circ$  to  $75^\circ$ . Cunningham gives it as  $70^\circ$  and Arthur W. Hare as  $67^\circ$ . Chiene's method of finding the desired angle is usually accepted as reliable. He takes a square piece of paper and folds it obliquely from corner to corner making  $45^\circ$ , and then folds it a second time making  $22\frac{1}{2}^\circ$ . The two being added together give  $67\frac{1}{2}^\circ$  as the angle made by the fissure of Rolando with the anterior portion of the longitudinal fissure.

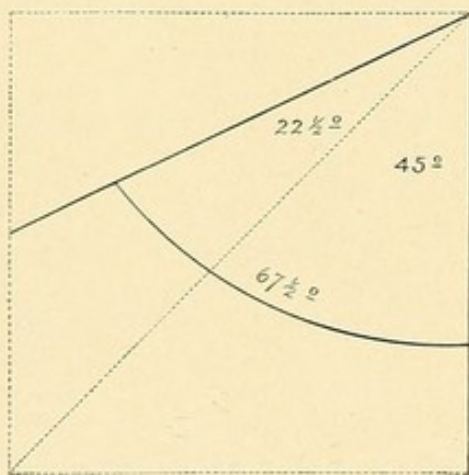


FIG. 51.—Chiene's method of folding a square piece of paper in order to obtain an angle of  $67\frac{1}{2}$  degrees.

The pterion was placed by Broca at the coronal suture. This is 15 mm. ( $\frac{3}{8}$  in.) in front of the Sylvian point. In several formalin hardened brains, we found this latter to be at the posterior angle of the pterygoid wing, and in twenty measured skulls the Sylvian point averaged 42 mm. ( $1\frac{5}{8}$  in.) behind the angular process. Reid placed it at 50 mm. (2 in.), which we think too much. Anderson and Makin placed it at  $1\frac{1}{2}$  to 2 in. Thane and Godlee placed it 35 mm. back and 12 mm. up, which is just a trifle farther forward than we have located it. Landzert and Heffler gave it as at the summit of union of the great wing of the sphenoid with the temporoparietal suture, as we have given it.

When prolonged, the Sylvian fissure sometimes crosses the median line 1.5 cm. ( $\frac{3}{8}$  in.) above the parieto-occipital fissure, but more usually we have found it to be close to the fissure, which agrees with Reid. The parieto-occipital fissure has been located by some authors near the lambda, but we would place it 1.5 cm. ( $\frac{3}{8}$  in.) above. We believe the parietal eminence to be a fairly reliable guide to the posterior extremity of the fissure of Sylvius.

**Method of Anderson and Makin for Locating the Fissures of the Brain.**—For the sake of comparison the following method of

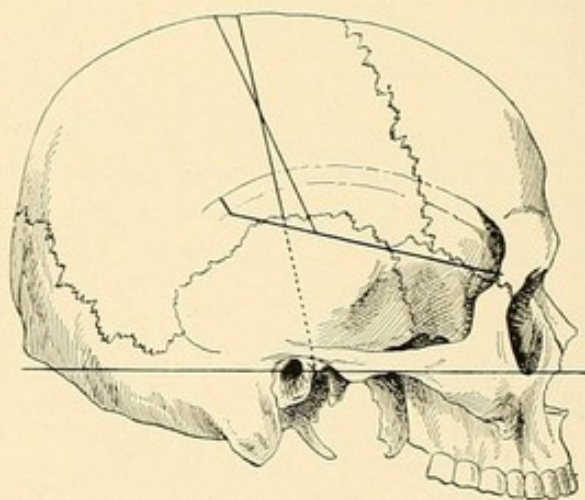


FIG. 52.—Method of Anderson and Makin for locating the fissures of the brain.

Wm. Anderson and George Henry Makin (*Jour. Anat. and Phys.*, vol. xxiii, 1888-89, p. 455) is



given. Draw a mid- or sagittal line from opposite the highest point of the supra-orbital arches to the external occipital protuberance. From the midpoint on this line draw another to the pre-auricular point at the level of the upper border of the meatus. This is the frontal line. From the most prominent point of the external angular process draw a line to the junction of the middle and lower thirds of the frontal line and prolong it  $1\frac{1}{2}$  in. beyond.

The Sylvian fissure begins between  $1\frac{1}{8}$  and  $1\frac{1}{2}$  in. behind the angular process or  $\frac{5}{12}$  of the distance between that point and the frontal line. The bifurcation is  $1\frac{1}{2}$  to 2 in. behind the angular process or  $\frac{7}{12}$  of the distance between it and the frontal line, the fissure then runs to an equal distance behind the frontal line, and up for  $\frac{1}{2}$  in. parallel to the frontal line. The fissure of Rolando runs from a point  $\frac{3}{8}$  in. behind the midsagittal point to one  $\frac{3}{8}$  of an inch in front of the intersection of the frontal line and line of the Sylvian fissure. The parieto-occipital fissure is  $\frac{7}{12}$  of the distance from the midsagittal point to the inion. It lies near the apex of the lambdoid suture.

**The Lateral Ventricles.**—The lateral ventricles sometimes become distended by serous or purulent effusions or, as in apoplexy, by blood. In order to tap them Keen ("Reference Hand-

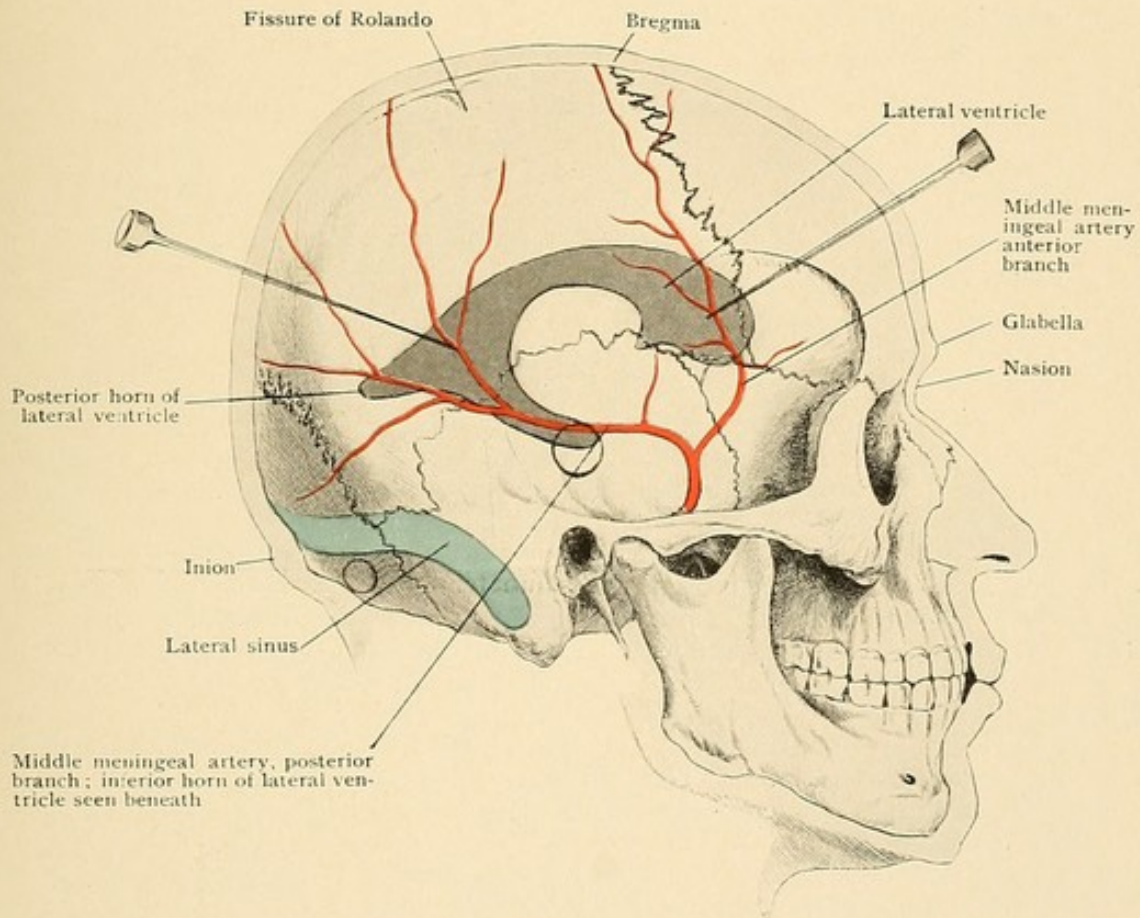


FIG. 53.—Tapping the lateral ventricles and trephining for cerebral abscess. Semidiagrammatic view of head, showing relation of Rolandic and Sylvian fissures and lines.

book of the Medical Sciences," vol. viii., p. 229) has given three points, as follows: (1) One-half to three-fourths of an inch (1.25 to 2 cm.) on either side of the median line and one-third of the distance from the glabella to the upper end of the central (Rolandic) fissure. This is high enough to avoid the frontal air-sinuses and is in advance of the motor area. A grooved director is to be thrust in the direction of the inion. The ventricle is reached at a depth of 5 to 6.5 cm. (2 to  $2\frac{1}{2}$  in.) through the first frontal convolution. (2) Midway between the inion and upper end of the central (Rolandic) fissure 1.25 to 2 cm. ( $\frac{1}{2}$  to  $\frac{3}{4}$  in.) from the median line. The director is to be thrust toward the inner end of the supra-orbital ridge of the same side. The ventricle will be reached at a depth of 5.5 to 7 cm. ( $2\frac{1}{4}$  to  $2\frac{3}{4}$  in.) from the surface. (3) Three centimetres ( $1\frac{1}{4}$  in.) behind the external auditory meatus and the same above Reid's base line (from the lower border of the orbit through the centre of the external auditory meatus). The director is to be thrust toward a point 6.25 to 7.5 cm. ( $2\frac{1}{2}$  to 3 in.) directly above the opposite external meatus. The ventricle will be reached 5 to 5.75 cm. (2 to  $2\frac{1}{4}$  in.) from the surface. The director passes through the second temporal convolution; this is the preferred method.



Spitzka (*New York Med. Jour.*, Feb. 2, 1901, p. 177) has pointed out how these ventricles vary in shape, and has given the surface relations in two brains. T. T. Wilson (*Jour. Anat. and Phys.*, vol. xxviii, 1894, pp. 228-235) has described and figured them in three drawings. Spitzka states that the ventricles will hold about 60 c.c. of liquid.

**Cerebral Abscess.**—About one-half of the abscesses of the brain occur from disease of the middle ear, and they are located in the temporosphenoidal lobe, in the cerebellum, or between the dura and petrous portion of the temporal bone. The remainder are caused either by blows or infection carried to the part in infectious diseases. They may, therefore, occur anywhere in the brain.

When the motor areas around the fissure of Rolando are involved, the location of the trouble will be shown by spasm or paralysis of the corresponding muscles. If the occipital lobe is affected there may be disturbance of sight, as hemiopia. Involvement of the frontal lobes produces mental dulness, and if of the third left frontal gyrus, or Broca's convolution there may be impairment of speech. Disease of the middle lobe of the cerebellum may be accompanied by a staggering gait. In many cases localization symptoms are rare, particularly when the abscess is small and located in the temporosphenoidal, parietal, or frontal lobes (see chapter on cerebral localization).

**Trephining.**—If the abscess arises from middle-ear disease, it is customary to first open the mastoid antrum (see chapter on ear) and then by removing the bone above to explore the surface of the petrous portion of the temporal bone. To explore the temporal lobe an opening may be made 2.5 cm. (1 in.) above the external auditory meatus and a needle passed inward, forward, and a little downward.

To reach the cerebellum, the trephine should be applied 5 to 7 cm. (2 to 2¾ in.) behind the external meatus and well below the superior curved line. The bone at this point is apt to be thin and care is to be exercised not to wound the membranes. The place of trephining in abscesses from other causes is to be decided by the localizing symptoms.

## THE FACE.

The face may be divided into the regions of the *forehead, temples, ears, eyes, nose, mouth, cheek*, and *upper and lower jaws*. The regions of the eyes, ears, nose, and mouth will be considered separately. Owing to the face being that part of the body most open to scrutiny and most difficult of concealment, deformities and disfigurements of it, resulting from injury or disease,—to both of which it is prone,—assume a greater importance than the same troubles elsewhere. Therefore, the anatomy of the part should be studied with regard to the treatment of its various affections from a cosmetic as well as from a curative point of view. What is usually regarded as constituting the face embraces the anterior half of the head as viewed from the front.

**The Bones.**—The bones of the head have been divided into those of the cranium and those of the face. The bones of the cranium are eight in number, viz.: the frontal, occipital, two temporals, two parietals, the sphenoid, and ethmoid. The bones of the face are fourteen in number, of which twelve are in pairs, viz.: superior maxillary, malar, nasal, palate, lachrymal, and inferior turbinated bones—the vomer and inferior maxilla or mandible are the two single bones.

From this it will be seen that the bony framework of the face embraces some of the bones of the skull, as well as those of the face proper; thus, the region of the forehead is formed by the frontal bone, the temporal region is formed by the frontal, parietal, sphenoid, and temporal bones, all belonging to the cranium, and so on. The palate bones are called face bones, yet they are placed deep in the region of the mouth and nose.

**The Soft Parts.**—The soft parts are likewise of importance. The skin, thin in some parts, thick in others, is in many places loosely attached and has inserted in it the muscles of expression. It is frequently the seat of disease, particularly of cancer.

On each side of the face are the parotid glands, often the site of inflammations.

The **blood-vessels**, both arteries and veins, particularly the former, are very numerous and give special characters to wounds and diseases of the face.

The **nerves** are abundant and complex. They are, with the exception of the *auricularis magnus*, which comes from the second and third cervical, and to a slight extent the *occipitalis minor* from the second cervical, all derived from the cranial nerves and are both motor and sensory. The paralyzes and neuralgias which



affect them are among the most distressing and disfiguring of any in the body, wounds of the face producing paralysis of the muscles of expression.

The relatively small size of the face in relation to the cranium in the child as compared to that of the adult has already been alluded to (see page 8). The reasons for this are evident: dentition must be complete to insure the proper development of the jaws; the use of the special senses and the expression of the emotions cause the facial muscles to develop, and this in turn causes the bones to which they are attached to become more rugged in outline and larger in size. In old age, as the teeth are lost, the jaws are diminished in size by absorption of their alveolar processes.

### THE FRONTAL REGION.

The frontal region embraces that part of the face above the eyes and nose in front and anterior to the temples at the sides.

**The Frontal Suture.**—The frontal bone develops from two centres of ossification, one on each side. These unite in the median line to form the frontal suture which joins the anterior fontanelle and is closed about the same time, within the age of two years. The suture occasionally persists through life and sometimes the line of junction can be felt in the living; it should not be mistaken for fracture.

The **frontal eminences** in the child are particularly prominent, the forehead projecting beyond the edge of the orbit. This makes it difficult to apply a bandage securely to the head in children unless it is twisted to draw in its sides.

The **superciliary ridges** are about a centimetre above the edge of the orbit over its inner half. Aided by the hair of the eyebrows they serve to divert the sweat to the sides, as pointed out by Humphry. They are best developed in the adult male. Directly between them in the median

line on a level with the upper edge of the orbit is a depression called the *glabella*. It is the anterior point from which measurements are taken in cerebral topography.

**Frontal Sinuses.**—Beneath the superciliary ridges are the frontal air-sinuses, but the size of the sinuses is not necessarily proportional to that of the ridges; they may extend quite far back over the orbit. Fractures of the outer wall of these sinuses not infrequently occur without the inner table being injured. A septum separates one sinus from the other, not always in the median line. The lining membrane of these sinuses is often inflamed and suppurates, discharging pus into the nose. Tumors also grow in them.

**Margins of the Orbit.**—At the upper and outer margin of the orbit is the *external angular process* of the frontal bone. The line of junction or suture between it and the malar bone can be distinctly felt in the living both on the side of the orbit and on the side toward the temple. This is an important landmark in cerebral topography, as it is used to locate the fissure of Sylvius and also the middle meningeal artery. On the upper margin of the orbit at about the junction of its middle and inner thirds is the *supra-orbital notch*. This can usually be readily felt through the skin. Sometimes it is a complete foramen instead of simply a notch. It is then to be located by feeling on the orbital surface just behind the edge. It transmits the supra-orbital nerve and artery.

The **supra-orbital nerve**, a branch of the ophthalmic division of the fifth nerve, is sometimes the seat of neuralgia, for which resection of the nerve is performed.

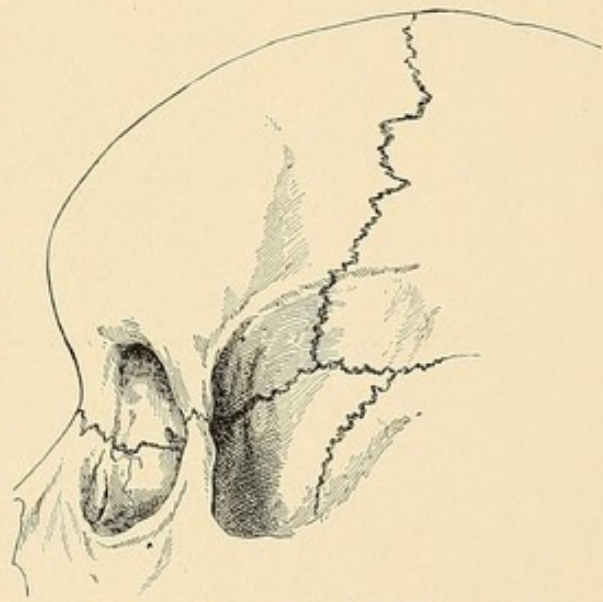


FIG. 54.—Frontal region of a child's skull.



The pain is felt above the orbit radiating from the supra-orbital notch, sometimes as far up as the vertex. Pain is also felt on pressure over the supra-orbital notch. If the entire ophthalmic branch of the fifth nerve is affected, pain is felt in the eyeball and down the side of the nose. The incision in operating may be made at the lower border of the eyebrow, its centre being over the notch. If the notch is not readily felt on the edge of the bony orbit at the junction of the inner and middle thirds, it can be detected by feeling with the tip of the finger on the orbital surface. The incision is made through the fibres of the orbicularis palpebrarum, corrugator supercilii, and frontalis muscles, then through the palpebral ligament immediately below the bony edge of the orbit, and the orbital fat separated with forceps; the nerve is then caught with a hook before it enters the notch, and brought up and removed. Considerable ecchymosis may follow this operation if the accom-

Branches of the supra-orbital nerve

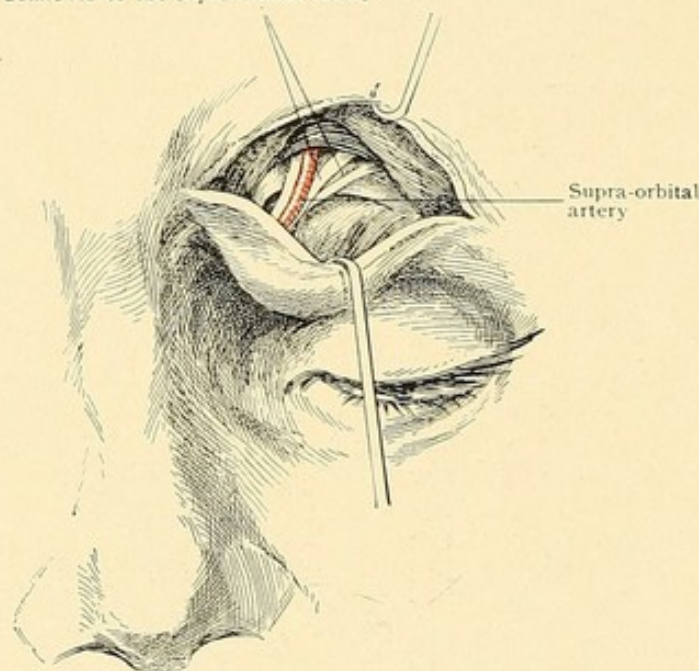


FIG. 55.—Supra-orbital nerve and artery.

panying artery is divided. Operations on the ophthalmic division of the fifth nerve have usually been done in connection with removal of the Gasserian ganglion, the other branches being also involved.

**Nasion.**—About a centimetre below the glabella, in the adult skull, is the nasion, or line of junction of the frontal and nasal bones. It is along this frontonasal suture, to one side of the median line, that an anterior meningocele is apt to show itself.

The **internal angular process** of the frontal bone articulates with the nasal process of the superior maxilla and the lachrymal bones. The line of suture is continuous with the nasion in front and the upper edge of the ethmoid behind. Pus originating in the ethmoidal cells, frontal sinuses, and lachrymal apparatus is apt to point at this locality. The frontal bone is a favorite seat of exostoses.

### THE TEMPORAL REGION.

The region of the temple is on the side of the head as far forward as the eye and as low as the zygoma and infratemporal crest. The floor of the temporal fossa is formed by the posterior portion of the frontal and anterior portion of the parietal bones as high as the temporal ridge, the outer surface of the greater wing of the sphenoid, and the squamous portion of the temporal bone. These four bones meet to form the region of the pterion (see p. 39 and 42). The anterior edge of the temporal bone overlaps and is superficial to the posterior edge of the sphenoid. The



anterior edge of the parietal overlies the posterior edge of the frontal. The upper edges of the temporal and sphenoid overlap the lower edges of the frontal and parietal bones. That the temporal region of the skull is distinctly weaker than other regions is due to the thinness of the bones, and the reason that fractures here are exceptionally dangerous is on account of the middle meningeal artery running through a canal in the bone in this region; so that in cases of fracture the artery is torn and hemorrhage occurs above the dura, which causes compression of the brain (Fig. 56).

The **infratemporal crest** (*crista infratemporalis*) or pterygoid ridge separates the temporal region above from the pterygoid region below. It is an important landmark in operating on the Gasserian ganglion.

A spot two centimetres behind the external angular process and slightly above its level marks the anterior extremity of the fissure of Sylvius. In trephining in the

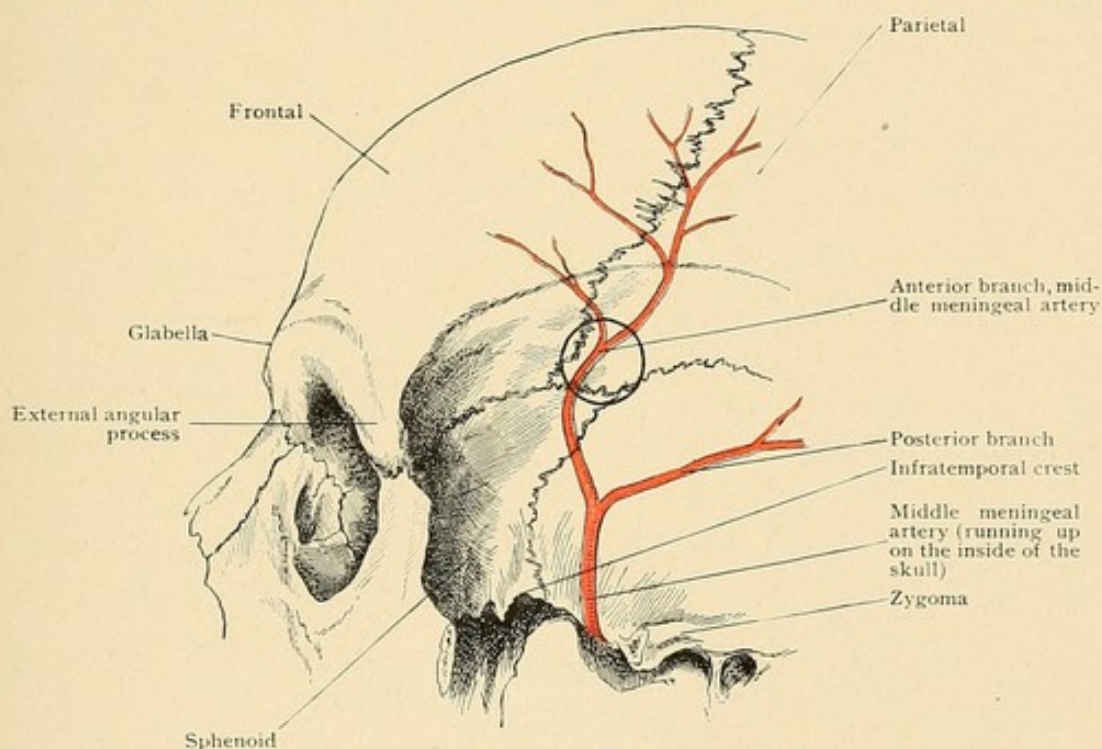


FIG. 56.—Frontal and temporal regions of an adult skull.

temporal region no diploë is found in the bones, so that extreme care is necessary to avoid wounding the dura mater. The trephine may be placed 4 cm. ( $1\frac{1}{2}$  in.) behind the external angular process and 4.5 cm. ( $1\frac{3}{4}$  in.) above the zygoma to strike the middle meningeal artery. This will be level with or a little above the highest part of the edge of the orbit.

**Temporal Fascia.**—This is the dense fascia covering the temporal muscle; it is formed as follows: The pericranium as it comes down from the vault of the skull and reaches the temporal ridge passes under and gives attachment to the temporal muscle. The temporal fascia consists of two distinct sheets of fascia, the superficial one from the superior temporal ridge being attached to the zygoma below and to the malar bone in front; the deeper layer from the inferior temporal ridge covers the temporal muscle, and a short distance above the zygoma divides into two layers, one of which is attached to the outer edge, and the other to its inner edge. The upper or superficial layer of the temporal fascia leaves the bone at the superior temporal ridge and is attached below to the top of the zygoma, blending near the bone with the layer beneath. This is a distinct layer though not always readily demonstrable in dissections. Between the layers above the zygoma is some fat and the orbital branch of the middle temporal artery. Anteriorly the temporal fascia is attached to the posterior border of the malar bone and the temporal ridge of the frontal. The temporal fascia is tough and dense and gives attachment by its under



surface to the temporal muscle. Abscess occurring under the temporal fascia, therefore, does not tend to come to the surface, but sinks downward. It is prevented from making its exit on the face below the zygoma by the parotid gland and masseter muscle, so it passes inward to the pterygoid region and may point in the throat or go down into the neck.

The occipitofrontal aponeurosis, or *galea aponeurotica* as it approaches the side of the head becomes thinner and passes down to insert into the top of the

zygoma so that in the temporal region the layers are as follows: Skin, superficial fascia, *galea aponeurotica*, two layers of the temporal fascia, temporal muscle, an indistinct periosteum, and bone. Immediately above the zygoma we have the deep layer of the temporal fascia dividing instead of a single layer as is the case higher up. The temporal fossa contains considerable fat which disappears in serious illnesses. Disfiguring depressions are also left in this region after operations involving the temporal muscle.

The **temporal artery** begins opposite the neck of the lower jaw, then passes over the temporomaxillary articulation, lying on its capsule, thence over the zygoma about a centimetre in front of the ear. It lies on the temporal fascia and about 4 cm. above the zygoma divides into an anterior and posterior branch. The course of the temporal artery and its anterior branch is usually quite conspicuous in old people and affords a ready means of ascertaining whether or not the arteries possess the calcareous deposits characteristic of atheroma. The location of the artery in front of the ear should be remembered, as the pulse is readily felt there in the administration of anæsthetics. In certain angiomas of the scalp the blood supply may be diminished by ligating the vessel at that point.

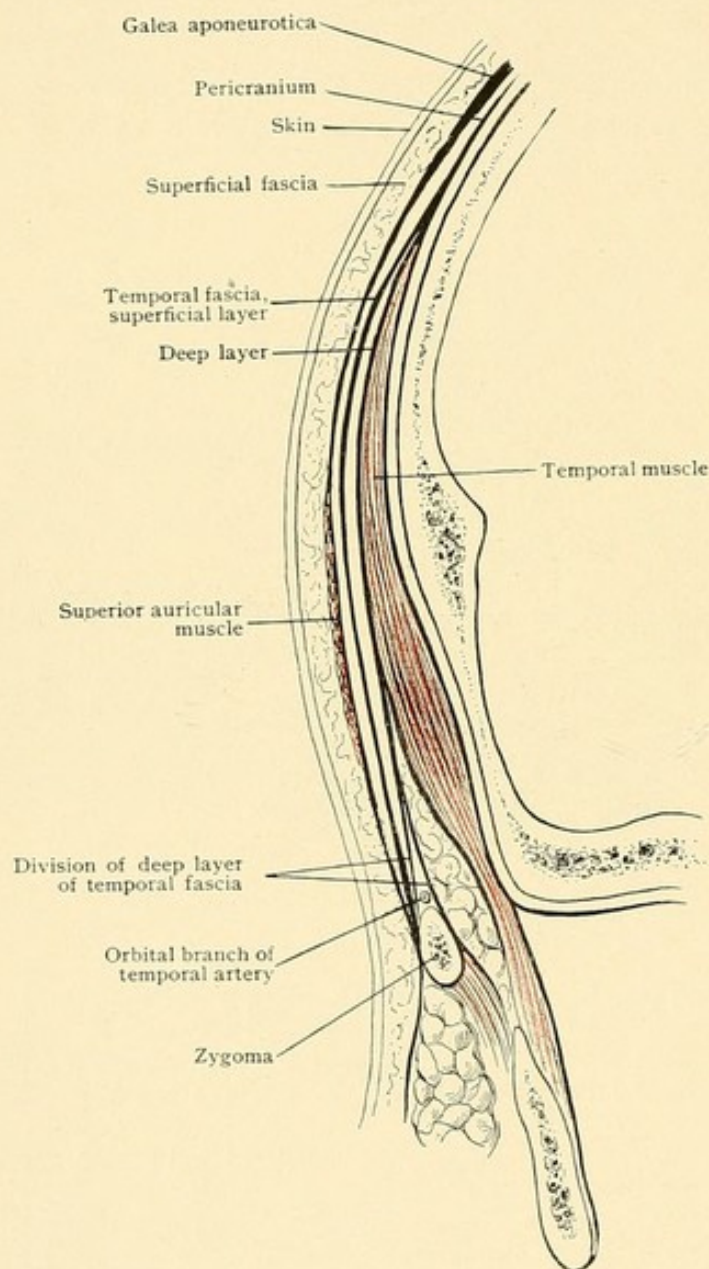


FIG. 57.—Transverse coronal section in the region of the temple, showing the various layers.

The *temporal muscle* receives blood from the middle temporal artery which comes from the temporal and perforates the temporal fascia just above the zygoma, and from the anterior and posterior temporal branches of the internal maxillary. The temporal fossa is frequently the seat of operations to expose the Gasserian ganglion and the bleeding from these various temporal arteries contributes to their gravity. The auriculotemporal nerve lies slightly posterior to the artery and the vein in front of it. They are not important.



## THE REGION OF THE CHEEK.

In this region we may include the parts limited above by the zygoma, in front by the eye, nose, and mouth, below by the lower edge of the lower jaw, and behind by the ear. The soft parts of the cheek are supported by the malar and superior and inferior maxillary bones. Between the skin and the buccinator muscle, the hollow beneath and in front of the malar bone and masseter muscle is filled with fat, sometimes called the sucking pad or cushion. In disease this fat disappears, hence the hollow cheek of invalids. The muscles of expression are superficial to this fat and have their insertion in the skin. Swelling occurs readily from contusions and inflammations because the tissues of the cheek are lax. Inflammations may either start in the skin, which is quite prone to disease, or may be the result of inflammation of some surrounding structure, as the parotid gland, the roots of the teeth, the lachrymal sac, eyelids, etc.

The **skin** of the cheek contains numerous sebaceous and sweat glands. It is a favorite site for the pustular eruptions of infancy and childhood, the acne of youth,

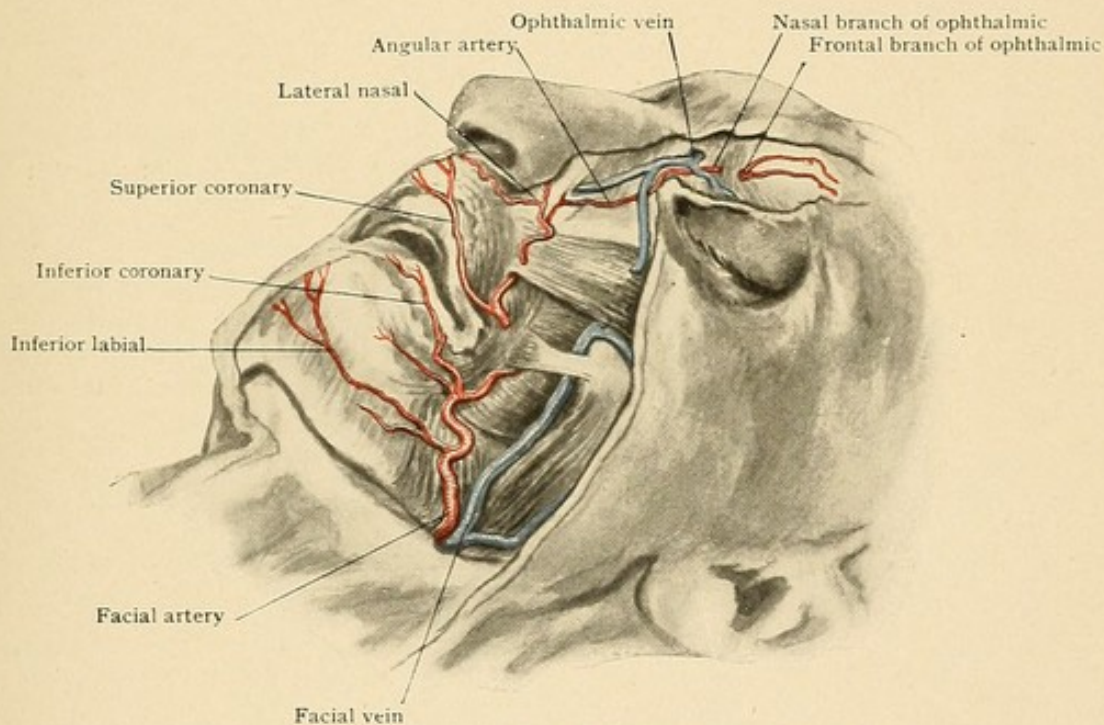


FIG. 58.—The facial artery and its branches.

and the non-malignant as well as the cancerous ulcers of the aged. It is also the seat of *noma* or *cancrum oris*. This starts on the mouth surface as a gangrenous stomatitis and implicates the cheek, causing death or great disfigurement owing to the loss of cheek substance. Facial carbuncle or malignant pustule occurs on the cheek, or sometimes on the lips. It is very fatal.

*Wounds* and *contusions* of the cheeks are common, and, as the blood supply is abundant, bleeding is free and healing prompt. On account of the insertion of the muscles into the skin, gaping is quite marked.

The **malar bone** is the most prominent bone of the cheek. It is such a strong bone and so strongly supported that fracture of it, as well as that of the zygoma, is rare. It may be broken by direct violence, as being hit with a stone, etc. It is extremely difficult and often impossible to restore the fractured parts to their original level, therefore deformity following fracture is of frequent occurrence. The fracture may involve the margin of the orbit and cause an effusion of blood into the orbit, pushing the eye forward. A fracture of the zygoma, if very much depressed, may interfere with the use of the temporal muscle below, necessitating operation. This occurrence is, however, rare.



The **facial artery** runs upward and inward, from a couple of centimetres in front of the angle of the jaw, along the anterior border of the masseter muscle to the angle of the mouth, and thence to the inner canthus of the eye. The anterior edge of the masseter muscle can usually be distinctly felt beneath the skin. At this point the vessel can be ligated or temporarily compressed by passing a pin beneath it and winding a silk ligature above it, around the ends of the pin. This procedure is desirable in some operations on the cheek, as angiomas frequently affect this region. If the facial artery is ligated, the blood supply comes from the superior and inferior coronary arteries of the opposite side; the nasal branch of the ophthalmic, anastomosing with the angular; the transverse facial below the zygoma, from the temporal; the infra-orbital, a branch of the internal maxillary; and to a slight extent from the inferior labial and others still less important (Fig. 58).

The **internal maxillary artery**, one of the terminal branches of the external carotid, arises in the parotid gland opposite the neck of the lower jaw. This is just below and behind the articulation, which can be readily felt through the skin. It

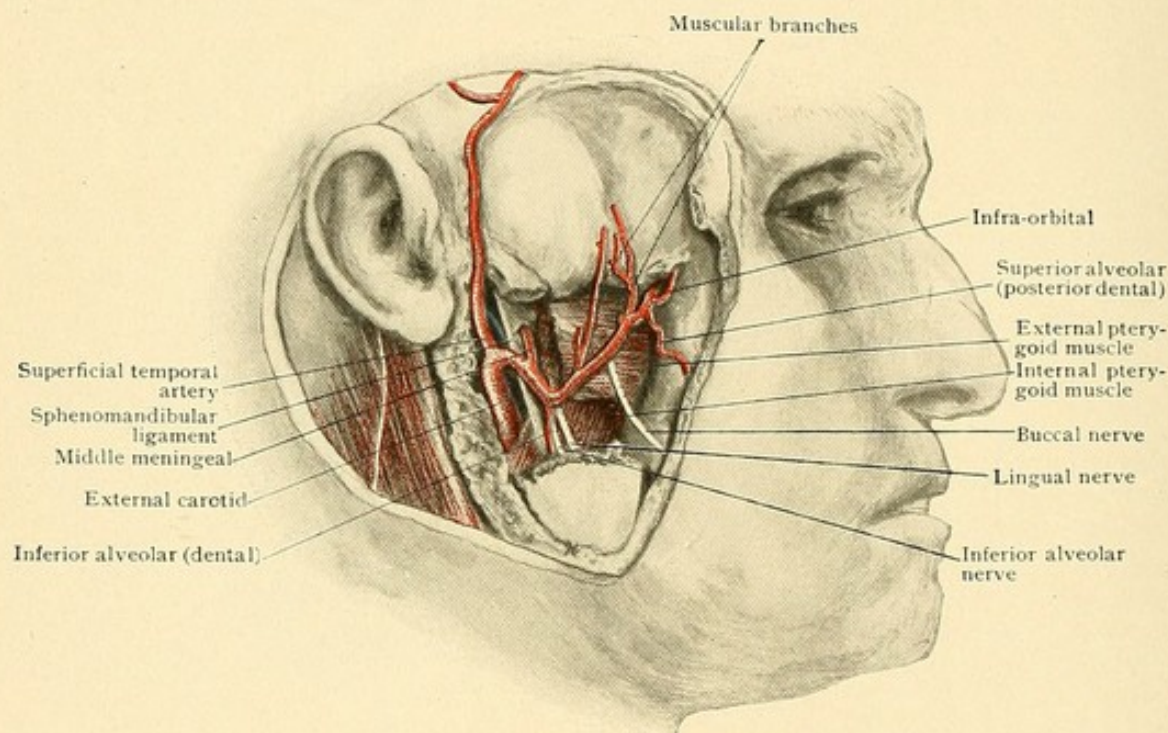


FIG. 59.—The internal maxillary artery.

passes between the bone and the sphenomandibular (long internal lateral) ligament, then between the two pterygoid muscles or between the two heads of the external pterygoid muscle to the posterior surface of the superior maxillary bone in the sphenomaxillary fossa. The branches of its first part, where it is behind the neck of the jaw, are the *deep auricular*, *tympenic*, *middle* and *small meningeal*, and *inferior alveolar (dental)*. The branches of its second part, as it passes between the pterygoid muscles, are all muscular: they are the *masseteric*, *pterygoid*, *anterior* and *posterior deep temporal*, and the *buccal*. The branches of the third portion of the artery, in the sphenomaxillary fossa, are the *posterior dental*, *infra-orbital*, *descending palatine*, *Vidian*, *pterygopalatine*, and *spheno- or nasopalatine*.

The main trunk of the internal maxillary artery is not often involved either by injury or operations. The various branches are, however, of considerable importance, as they supply parts which are often the site of operative measures. The importance of the middle meningeal artery in reference to fractures of the skull has already been pointed out. The inferior alveolar gives rise to troublesome hemorrhage when the lower jaw is operated on. The deep temporal branches bleed freely when the temporal muscle is incised in operating on the Gasserian ganglion. The infra-orbital is involved in operating on the infra-orbital nerve. The posterior or descending palatine branch descends in the posterior palatine canal, in company with a branch



from Meckel's ganglion, to emerge on the roof of the mouth at the posterior palatine foramen. It causes free hemorrhage in operating on cleft palate.

The Vidian and pterygopalatine branches supply mostly the roof of the pharynx; they bleed when adenoids are removed. The descending and sphenopalatine supply the upper part of the tonsil with blood and may give rise to serious hemorrhage in the removal of the tonsils. In operating on Meckel's ganglion, bleeding from these vessels is free. The nasopalatine runs forward in the nose in the groove on the vomer. It is often the cause of serious nasal hemorrhages in operations on the septum. In removal of the upper jaw, bleeding occurs from many of the branches of the internal maxillary, but it is hardly so free as might be expected, especially if the external carotid has been previously ligated.

#### PAROTID GLAND.

The parotid gland lies on the cheek, behind the jaw and below the ear. The limits (Fig. 60) of the gland are important because suppuration may occur in any portion of its structure. Its extent is as follows: above to the zygoma, lying below its

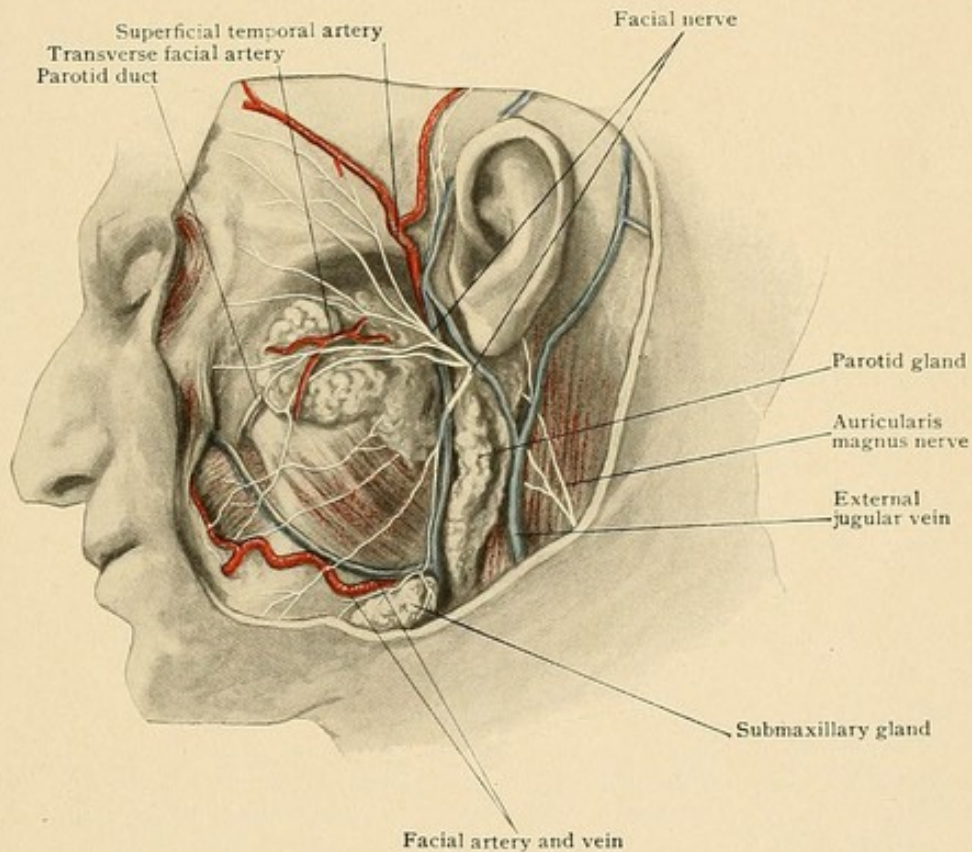


FIG. 60.—Parotid gland and structures of the side of the face.

posterior two-thirds; posteriorly, to the external auditory canal, the mastoid process, and digastric and sternomastoid muscles; below to a line joining the angle of the jaw and mastoid process; and in front about half the width of the masseter muscle. This latter is, however, quite variable.

The **parotid duct**, also called *Stenson's duct*, leaves the upper anterior portion of the gland about a centimetre below the zygoma and runs on a line joining the lower edge of the cartilaginous portion of the ear with the middle of the upper lip. It opens on a papilla on the inside of the cheek opposite the second upper molar tooth. This papilla can readily be seen and a fine probe can be inserted from the mouth into the duct; thus the presence of a calculus may be detected. In operating on the cheek the line of this duct must be borne in mind, as wounding it may cause a salivary fistula. Wounds of the lobules of the gland are not nearly so liable to result in fistula as those of the duct itself.



**Parotid Fascia.**—The gland is covered by the parotid fascia. This fascia is moderately dense and is continuous with the fascia separating the lobules of the gland. Above it is attached to the zygoma; in front it is continuous with the masseteric fascia over the masseter muscle; and below and posteriorly it is continuous with the deep fascia of the neck. It stretches from the angle of the jaw to the sternomastoid muscle and somewhat deeper to the styloid process; the band running from the styloid process to the lower jaw is called the stylomandibular ligament. From thence it is continued over the internal carotid artery and the upper surface of the internal pterygoid muscle.

**Lobes of the Parotid Gland.**—The gland has extensions in various directions (Fig. 61). A prolongation behind the articulation of the lower jaw, into the posterior portion of the glenoid cavity immediately in front of the external auditory canal, is called the *glenoid lobe*. Another extension winds around the posterior edge of the lower jaw on the lower surface of the internal pterygoid muscle and is called the *ptery-*

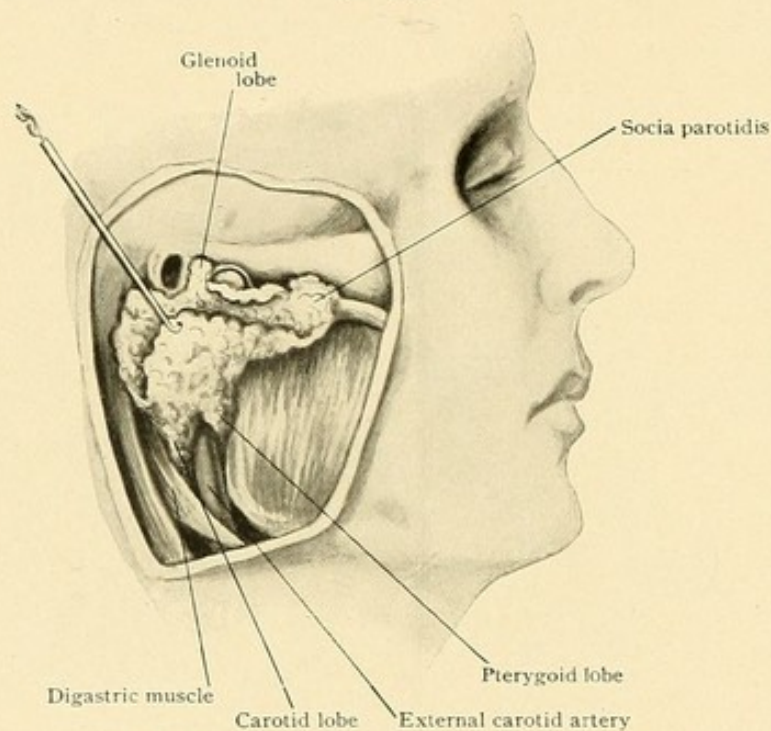


FIG. 61.—The lobes of the parotid gland.

*goid lobe*. A prolongation inward, passing between the external carotid on the outside and the styloid process and the internal carotid artery on the inside, is called the *carotid lobe*. A separate portion of the gland, sometimes quite detached, lies at its upper anterior portion between the zygoma and the duct of Stenson; it is called the *socia parotidis*.

**Vessels and Nerves Traversing the Gland.**—The external carotid artery enters the gland to divide opposite the neck of the lower jaw into the temporal and internal maxillary. The temporal, before it leaves the gland, gives off the transverse facial artery which runs forward on the face between the zygoma and parotid duct. It is usually small but at times may be quite large and even go over to the angle of the mouth and form the two coronary arteries (as shown in M'Clellan's "Regional Anatomy"). The temporal vein, as it descends into the gland, is joined by the internal maxillary vein to form the temporomaxillary vein, which, after it receives the posterior auricular vein, goes to form the external jugular.

The facial nerve emerges from behind the jaw just below the lobe of the ear and divides into its various branches while still in the gland. There is usually a large branch passing parallel to the duct of Stenson and below it. The auriculotemporal nerve follows the temporal artery, emerging from the gland a little posterior to the artery. It is not of much surgical moment. The auricularis magnus from the second and third cervical supplies the skin over the gland.



Lymphatic nodes are found both on the gland and in its substance. These may be involved in general disease of the cervical lymphatics.

**Affections of the Parotid Gland.**—The duct may be affected with calculus, as already mentioned. As the opening of the duct at the papilla is smaller than the lumen of the canal farther back, calculi are apt to lodge close to the anterior extremity. They are, therefore, readily felt and removed by incision on the inside of the mouth. The gland proper is subject to inflammations and tumors.

Simple *parotiditis* or *mumps* really is an infectious inflammation, nevertheless, it rarely suppurates. *Suppurative parotiditis* may occur from infected wounds or arise in the course of the eruptive fevers, etc. In inflammation of the gland, pain and swelling are important symptoms. The pain, which is considerable, is not due so much to the so-called dense parotid fascia covering the gland, for this is only moderately thick, as it is to the fact that the gland is of a racemose type and the

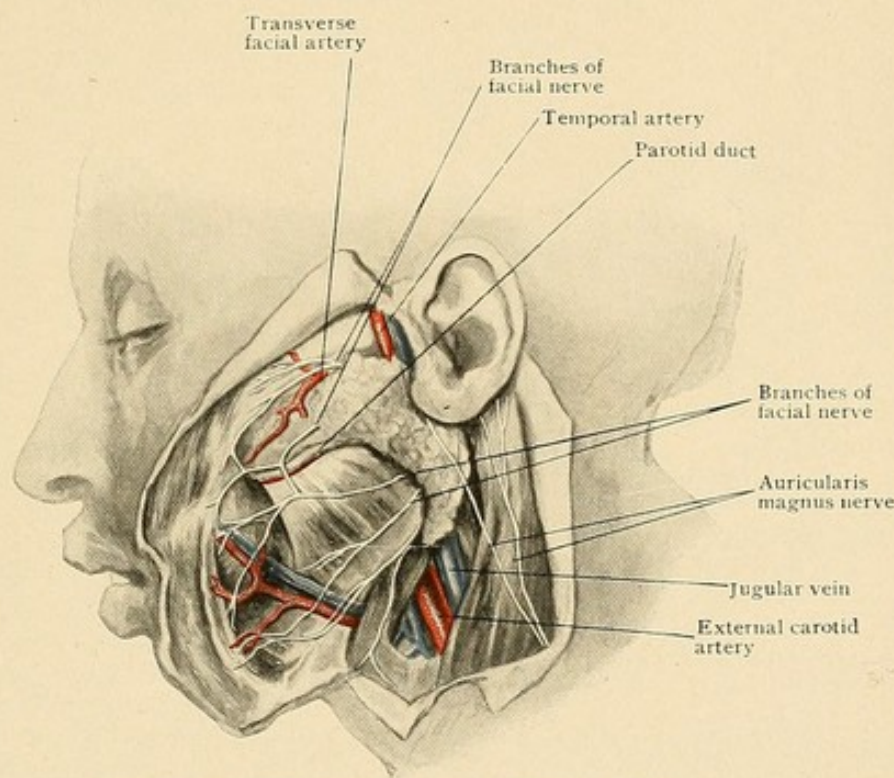


FIG. 62.—Structures in relation with the parotid gland.

fibrous septa between the lobules are abundant and prevent free expansion of the contained lobules. Expansion is also hindered by the peculiar location of the various parts of the gland. Swelling of the gland produces pain in the ear and also in the temporomaxillary articulation. Swelling of the carotid and pterygoid lobes causes pain and fulness in the throat. Opening the lower jaw reduces the space posterior to it in which the gland lies and pinches it against the bony meatus and mastoid process, so that it is impossible to open the jaw widely.

If suppuration occurs it is liable to progress from one lobule to another; when this is the case comparatively small abscesses may appear in different parts of the gland with unaffected tissue between them. As an abscess heals in one lobule, suppuration is apt to occur in another, consequently the disease may persist for a long time. More rarely in the course of or following infectious diseases, particularly in debilitated patients, considerable portions of the gland may slough. This form is apt to be fatal. If the suppurating focus is confined to lobules which are deeply placed, the diagnosis may be obscure because it is difficult to localize the affected spot. If, however, it is near the surface of the gland, the pus does not tend to extend sideways, the fibrous septa prevent this, but it tends to work its way up and perforate the skin. If the glandular lobe is affected, the pus may find an exit through the external auditory meatus or even involve the temporomaxillary joint. If the carotid or pterygoid lobes



are affected, the pus may go between the pterygoid muscles, or around the internal carotid artery and project and open into the pharynx. It may also break into the carotid artery or jugular vein, or perforate through the fascia below and go down the neck. Large abscesses and sloughs may be followed by a parotid fistula.

*Lines of Incision for Abscess.*—The manner of opening a parotid abscess depends on its location and size. If it is desired to open an abscess anterior to a point 1.5 cm. or about half an inch in front of the ear, the structures to be avoided are the duct and facial nerve. The incisions are to be made parallel to the zygoma, and the duct is to be avoided by not cutting on a line joining the lower edge of the cartilage of the ear with the middle of the upper lip. The branches of the facial

nerve lie deep and are to be avoided by making the incision parallel to their course, and not extending it too deeply. After incising the skin, the deeper tissues may be separated by introducing a pointed pair of hæmostatic forceps and opening the blades. In operating in the region below the ear, the blood-vessels are to be avoided. To do this incise the skin longitudinally, not transversely, and open the deep parts carefully with the hæmostatic forceps, as already described. Another method, when the abscess is farther forward, is to make a horizontal incision rather low down on the angle of the jaw and then introduce a grooved director or hæmostatic forceps from below upward.

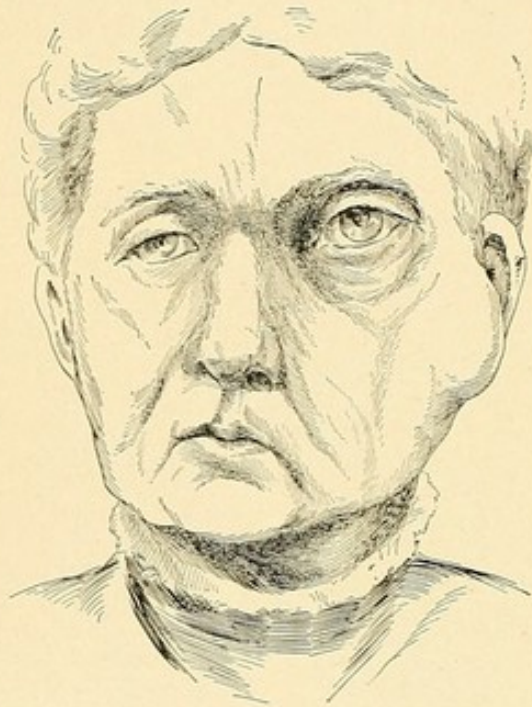

FIG. 63.—Malignant tumor of the parotid gland producing facial paralysis (author's case).

*Tumors* of the parotid gland are liable to be mixed in character, with a sarcomatous element. They are often fairly circumscribed and, particularly if they do not involve the parotid duct, can be removed comparatively readily. If they are malignant and large, complete removal is practically impossible. The possibility of parotid fistula and paralysis of the facial

nerve following operation on this gland should always be borne in mind and explained to patients. The presence of facial paralysis is indicative of malignancy (see Fig. 63).

The parotid lymph nodes on or beneath the capsule may become enlarged and inflamed and resemble true parotiditis. There is one node just below the zygoma and in front of the ear that is not infrequently enlarged in strumous children. This is apt to be involved when affections of the lids or scalp are present. In opening abscesses of these nodes there is little likelihood of injuring either the nerve or the duct, because the nodes are superficial. The transverse facial artery is usually too small to cause trouble. The possibility of its supplying the coronary arteries of the lips, as already described, in which case it would be very large, should be remembered.

### THE UPPER JAW.

The upper jaw carries the upper teeth and contains the maxillary sinus or antrum of Highmore. The affections of the antrum will be alluded to in the chapter on the nose (see page 103). Fractures of the superior maxilla involve the nasal process, the alveolar process, or pass transversely through the body of the bone. The nasal process is sometimes broken in fractures of the nose. In this injury, the lachrymal canal and sac may be injured and the flow of tears through them prevented, causing the tears to run over the cheek.

Fractures of the alveolar process are common enough as a result of blows and extracting teeth. These fractures, as they communicate with the mouth through the broken gums or mucous membrane or tooth socket, are necessarily compound, and



consequently become infected from the mouth and suppurate. This may cause necrosis of the fragment, but the blood supply of the jaws is so good that death of a fragment is rare, and it is not customary to remove fragments not completely detached. The front wall is sometimes driven in.

Fractures occasionally occur in which the line passes through one or both superior maxillary bones from below the malar bone into the nose. If this fracture passes completely backward, it detaches the lower portion of the palate bone and pterygoid processes of the sphenoid bone. The fragment in such cases has a tendency to slip backward. It can be replaced by inserting a hook through the mouth and behind the soft palate and pulling the fragment forward. This injury is produced by a blow on the anterior portion of one or both bones, passing downward and backward. In order to determine the existence of fracture, Guerin recommended inserting the finger in the mouth and feeling for the pterygoid plates. The hamular process of the internal pterygoid plate can readily be felt about one centimetre above and behind the last upper molar tooth. Fractures in the neighborhood of the first and second molar teeth are liable to open the antrum, as the roots of these teeth project into it.

**Resection of Upper Jaw.**—Tumors of the antrum may necessitate a resection of the superior maxilla of one side. Heyfelder was the first to remove both superior maxillæ, in 1844: this was before the discovery of anæsthesia. In removing one superior maxilla, the incision known as Fergusson's is used. This is made through the middle of the upper lip, around the ala of the nose to the inner canthus of the eye, thence outward along the lower border of the orbit to the malar bone. The bleeding from this incision is free. The coronary arteries should be looked for near the mucous surface of the lip toward its free edge. Bleeding will also occur from the *lateralis nasi* and the angular arteries. The soft parts are raised from the bones as far back as the masseter muscle. This is just about level with the outer edge of the bony orbit. In doing so the infra-orbital nerve and artery will be divided. The artery is not large but may bleed freely. The fibrous floor of the orbit is raised and the attachment of the inferior oblique muscle loosened. The malar bone is sawed downward and outward opposite the sphenomaxillary fissure, and the division completed with forceps. The nasal portion of the superior maxilla is sawed through from the orbit into the nose. The soft parts of the roof of the mouth are divided in the median line to the posterior edge of the hard palate, and thence along its edge to the last molar tooth. The soft palate is firmly attached to the hard palate and has to be detached with scissors. An incisor tooth is then drawn, and the bony palate sawed through from the nose into the mouth. The bone with the tumor is wrenched loose with lion-jawed forceps. The union between the posterior portion of the superior maxilla and the pterygoid processes of the sphenoid is not bony, but fibrous, so that the bone is torn away from the processes and the latter are left behind. As the bone comes away, the maxillary nerve should be cut. The bleeding which follows is from the infra-orbital, superior alveolar (posterior dental), and posterior palatine arteries, branches of the internal maxillary. It is not so free as might be expected, provided preliminary ligation of the external carotid has been performed. It will be observed that the facial nerve is not touched nor is the parotid duct wounded.

**Neuralgia of the Maxillary Nerve.**—The pain involves the cheek from the eye to the mouth and as far forward as the median line, also the upper gums and

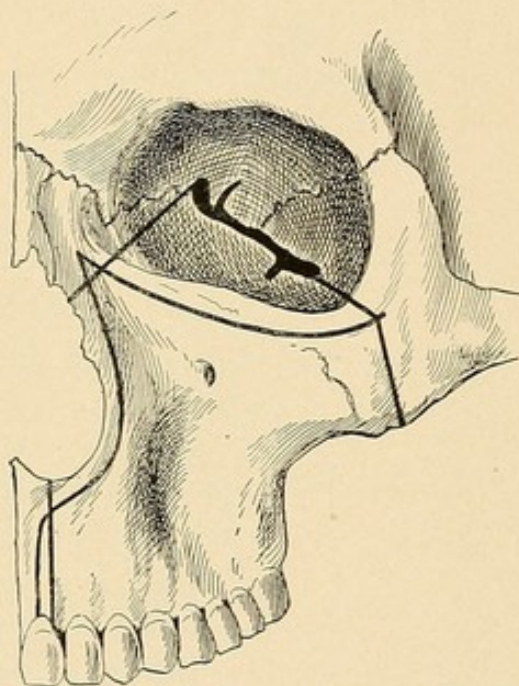


FIG. 64.—Resection of the upper jaw. The curved lines indicate the skin incision and the straight lines where the bones are to be divided.



hard palate. The operations devised for its relief are both numerous and intricate, and necessitate an accurate anatomical knowledge of the parts. The maxillary nerve is the second division of the fifth cranial nerve. It leaves the skull cavity by the foramen rotundum, then crosses the sphenomaxillary fossa, enters the sphenomaxillary fissure and infra-orbital canal to emerge on the cheek, opposite the middle of the lower edge of the orbit and about 6 mm. below it. The intracranial portion is 6 to 8 mm. in length. From the sphenomaxillary fossa to the infra-orbital foramen is about 5 cm. (2 in.). Its branches are as follows: one or two small branches to the dura mater, the *orbital* or *sphenomalar branch* to the cheek and anterior temporal region, *sphenopalatine branches* going to Meckel's ganglion, the *posterior*, *middle*, and *anterior dental* to the upper teeth, and the terminal branches, *labial*, *nasal*, and *palpebral*, on the face.

Its anterior portion has been removed through an incision on the face, and its posterior portion with Meckel's ganglion has been operated on either anteriorly through the maxillary sinus or laterally through the temporal fossa, after removing the zygoma. The writer has removed the intracranial portion by entering the anterior cerebral fossa through the temporal region. Removal of the infra-orbital portion

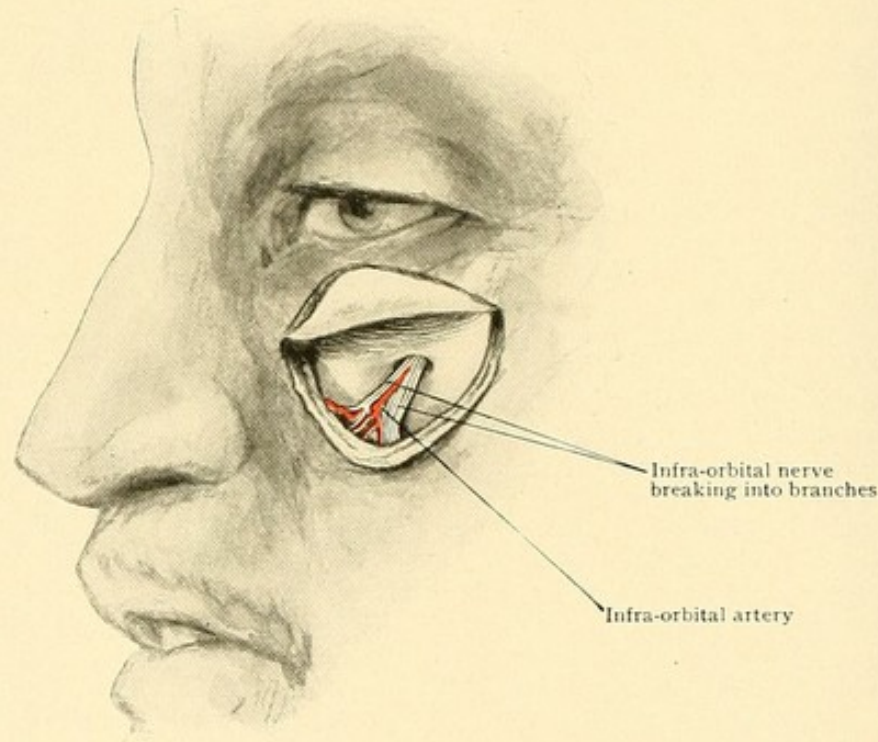


FIG. 65.—Exposure of the infra-orbital nerve and artery.

of the nerve is so liable to be followed by recurrence of the pain and interferes so much with the more complete procedures, as it destroys the guide (the nerve itself) which leads the operator to Meckel's ganglion, that it is doubtful whether it should ever be resorted to. The posterior dental branches are given off so far back that they are not apt to be removed in this operation.

**Removal of the Infra-orbital Nerve.**—An incision 3 cm. in length is made along the lower edge of the orbit. This divides the orbicularis palpebrarum muscle. Arising from the bone, between the infra-orbital foramen and the edge of the orbit, is the levator labii superioris muscle. This should be carefully detached, and the foramen with its artery and nerve will be found opposite the middle of the lower edge of the orbit and about 6 mm. ( $\frac{1}{4}$  in.) below it, on a line drawn from the supra-orbital notch to between the premolar teeth. The position of the foramen having been located, the palpebral ligament and periosteum are divided and the contents of the orbit raised. The canal is next to be opened. This can be done either by chiselling away its roof from the opening on the face and following it backward or by breaking



through its upper wall. This latter procedure is liable to give trouble, because if the track of the canal is not encountered the instrument breaks into the maxillary sinus, the roof of which is very thin. The infra-orbital canal does not pass directly backward but backward and outward, striking the sphenomaxillary fissure about 2 cm. (in a large skull) behind its anterior extremity. Sometimes the roof of the canal is fibrous, in which case the groove so formed can be readily felt, but in others it is bony. The nerve is hooked up and cut as far back as one can, so as to remove, if possible, the posterior dental branches. The terminal branches are then pulled off from the cheek, and the nerve drawn out from the front. It is in the highest degree desirable to avoid wounding the artery, as death is said to have followed it, and

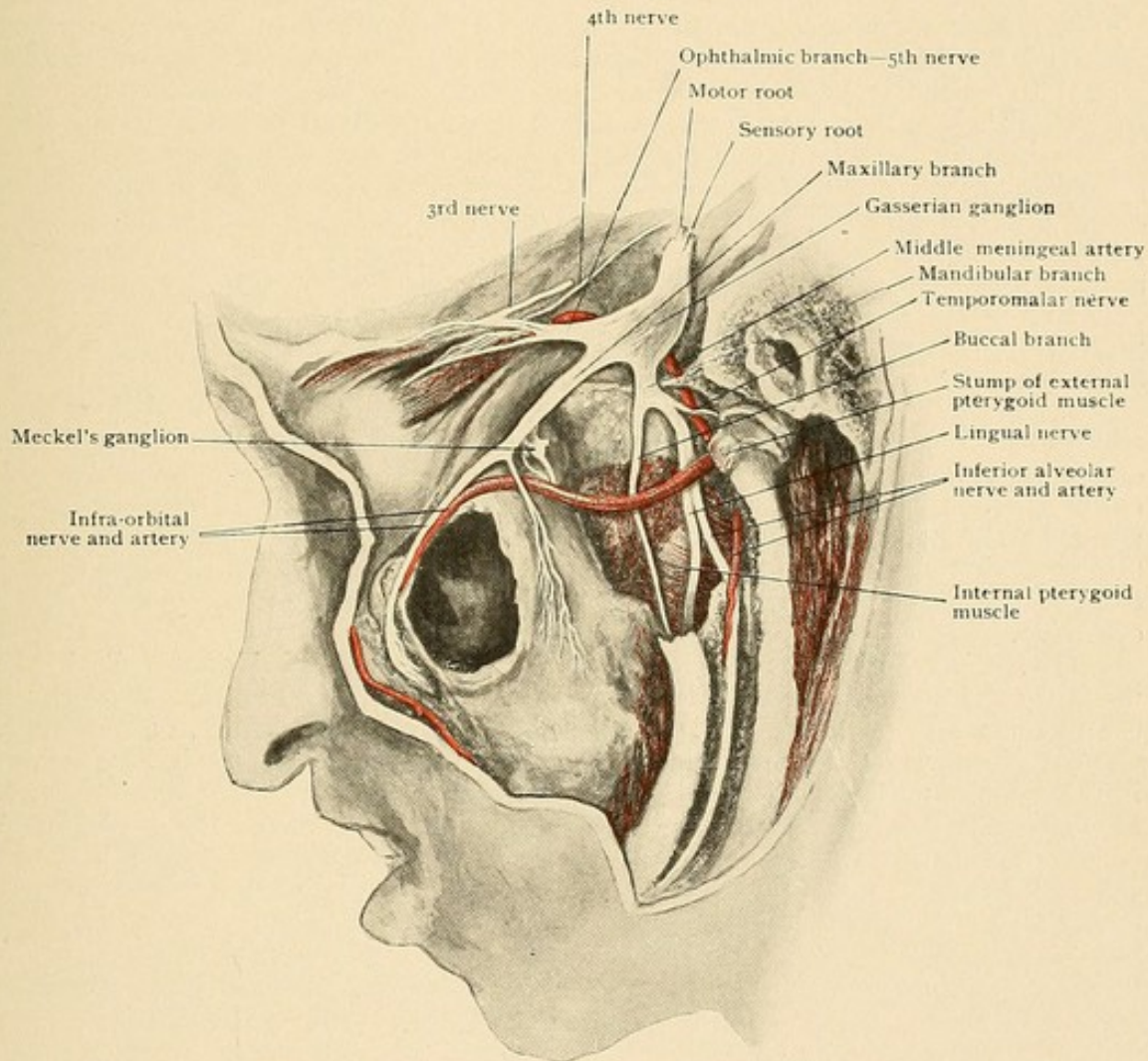


FIG. 66.—The fifth or tri-facial nerve with its various branches.

there may be bleeding into the orbit, causing protrusion of the eye and serious interference with its sight. A better way of removing the nerve, the method of Thiersch (*Verhand. der Deutschen Gesell. für Chir.*, 18 Congress, Berlin, 1889, p. 44), is to grasp it with a pair of slender, curved forceps, then by rotating the forceps very slowly (about 1 turn a minute) both the distal and proximal ends are wound around it and an extremely long portion of the nerve can be removed.

**Removal of Meckel's Ganglion.**—*Operating from the front through the maxillary sinus* (Carnochan's operation, or removal of the sphenopalatine (Meckel's) ganglion and maxillary nerve).—The incision is V-shaped, the apex being 2 cm. above the angle of the mouth, and the branches 3 cm. long. This flap should consist of all tissues down to the bone. The bleeding will be free, as the facial vein and branches of the facial artery will be cut. As the infra-orbital foramen is reached, the nerve is detached from its under surface. The anterior wall of the



maxillary sinus, which is quite thin, is broken with a chisel for an extent of 2 cm. The infra-orbital canal is opened from below, from the surface clear back to the posterior wall of the sinus. The infra-orbital nerve is then brought down into the sinus to serve as a guide to the foramen rotundum. Care should be taken (by opening the canal with comparatively blunt instruments) not to wound the infra-orbital artery. Then break a hole in the posterior wall of the sinus. This is very thin, and not over half a centimetre ( $\frac{1}{2}$  in.) intervenes between it and the anterior wall of the sphenoidal sinus, so that care should be taken not to drive the chisel too far back. The posterior wall having been broken with the chisel and the pieces picked away, the nerve is dragged downward, freed as far back as possible, and pulled loose. Traction on the nerve brings the ganglion forward, and with forceps it is then drawn out. The bleeding, after breaking through the posterior wall of the sinus, may be very free. Meckel's ganglion lies in the sphenopalatine fossa just below the maxillary nerve after it leaves the foramen rotundum. Two short branches unite the ganglion and nerve. It is here that the internal maxillary artery, in the third part of its course, divides into six branches: the *infra-orbital* and *posterior dental*, the *posterior* or *descending palatine* and *Vidian*, and the *pterygopalatine* and *spheno-* or *nasopalatine arteries*. If these arteries are wounded, as they are very apt to be, the bleeding is very free. To control it temporary packing is at first resorted to. If it persists, the nerve is removed as well as possible and the bleeding stopped with gauze. This may be firmly packed into the opening through the posterior wall at the upper inner portion of the sinus, but care should be taken not to push it roughly through the fossa and into the sphenoidal sinus (or cells) beyond.

J. D. Bryant (*Operative Surgery*, vol. i, p. 243) in cases of severe hemorrhage advises the prompt ligation of the external carotid artery, a procedure not, however, often required. It has been suggested that instead of making the incision on the cheek to make it in the mouth above the gums, and pull the cheek and mouth upward and outward. This procedure, while obviating the scar, makes the operation somewhat more difficult. *Kocher* resects the malar bone with the outer wall of the sinus and turns it up, bringing it back into place on the completion of the operation.

**Operating from the Side Through the Pterygoid Fossa.**—Both the maxillary and mandibular branches have been reached by this route; the former at the foramen rotundum and the latter at the foramen ovale. Lücke, of Strasburg, was the pioneer of the operation on the maxillary nerve, and Joseph Pancoast, of Philadelphia, on the mandibular. Lücke's operation was modified by Lossen, of Heidelberg. Recently, Mixer, of Boston, has again advocated the method. A convex flap, base down and reaching  $\frac{1}{2}$  inch below the zygoma, is cut from the external margin of the orbit to the lobe of the ear. The zygoma is sawed through, and, with the masseter, pulled downward. Maurice Richardson, in describing Mixer's operation (*Internat. Textbook of Surg.*, vol. i, p. 863), says that "if the operator is skilled enough in the subsequent manipulations, he may omit cutting the temporal muscle." It will be easier, however, to divide the coronoid process and turn the temporal muscle upward, clearly exposing the infratemporal crest. Detach the upper head of the external pterygoid muscle and push it downward, exposing the external pterygoid plate. Chisel off the spur at the anterior extremity of the infratemporal crest, and immediately in front and to the inner side is the superior maxillary nerve, with the terminal portion of the internal maxillary artery just below it. Immediately posterior to the root of the pterygoid plate is the foramen ovale and mandibular nerve, with the middle meningeal artery a little posterior to it.

**Anatomical Comments.**—The incision at its posterior extremity can be made to avoid cutting the temporal artery by feeling its pulsations, about a centimetre or less in front of the ear, as it passes over the zygoma. The incision should not involve the deep structures—only the skin and superficial fascia. Therefore, the facial nerve and parotid duct (a finger's breadth below the zygoma) will not be injured.

In clearing the upper surface of the zygoma, it will be necessary to cut through the layers of the temporal fascia; between them the orbital branch of the temporal



artery may be encountered and may bleed. The temporal muscle arises not only from the deep layer of the temporal fascia, but may also be attached anteriorly to the inner surface of the zygoma, and in loosening it free bleeding from the deep temporal arteries, branches of the internal maxillary, may be encountered. No trouble need be expected in sawing through the anterior end of the zygoma, but care should be taken not to injure the parotid duct, or the socia parotidis if it is present. In making the division of the posterior end of the zygoma, one must guard against opening the temporomaxillary articulation, for, when the head of the mandible is back in the glenoid fossa, the capsule of the joint extends considerably in front of it. Therefore, it is better to open the mouth and push the jaw on that side forward until it rides on the eminentia articularis, then the anterior limit of the joint can be recognized and avoided. Before one can reach the spur on the anterior extremity of the infratemporal crest, the temporal muscle must be detached from the bone. The

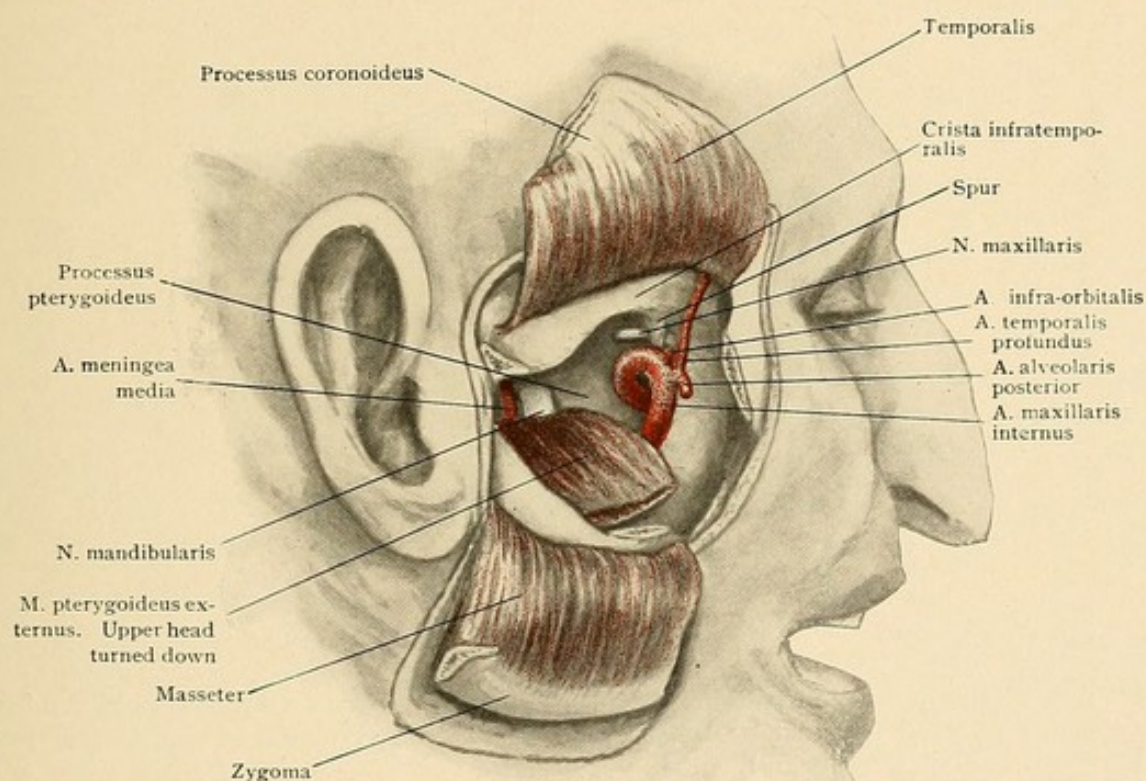


FIG. 67.—Operating through the pterygoid fossa. The skin with the zygoma and masseter have been turned down. The coronoid process is divided and turned up. The upper head of the external pterygoid has been detached and turned down. The maxillary nerve is in front of the pterygoid plate (processus pterygoideus) and the mandibular nerve and middle meningeal artery just behind it.

upper head of the external pterygoid muscle arises from the bone just below the pterygoid ridge (infratemporal crest), and must be loosened from the bone to obtain access to the nerves (see Fig. 67).

The coronoid process rises almost as high as the infratemporal crest, and, therefore, in order to gain space it will be necessary to depress the jaw. Running upward and inward over the internal pterygoid muscle, and passing just in front of the origin of the upper head of the external, is the internal maxillary artery and pterygoid plexus of veins. These vessels lie directly below the maxillary nerve as it crosses the sphenopalatine fossa, and it is to be expected that free hemorrhage will accompany the attempt to fish out the nerve.

In operating in this region, one surgeon found the bleeding so severe as to require the ligation of the external carotid artery.

Intracranial operations are hardly ever done for maxillary neuralgia alone. The mandibular and often the ophthalmic divisions are also usually affected in cases requiring to be approached from the inside of the skull.



**Excision of the Lingual and Inferior Dental Nerves.**—Neuralgia involving the face below the line of the mouth, the lower teeth, and side of the tongue requires the removal of the inferior dental and lingual nerves. To do this, a curved incision following the lower edge of the mandible is made. It ends anteriorly in front of the mandibular foramen, and posteriorly it stops a centimetre below the ear to avoid wounding the facial nerve. The masseter muscle is raised from the bone, and, with the parotid gland, is drawn up. The ramus of the jaw is trephined in its middle, rather high up toward the coronoid notch. The outer table of bone is then to be chiselled off, from the trephine opening as far down as the mental foramen. A delicate, curved, hæmostatic forceps is then made to grasp both nerves through the

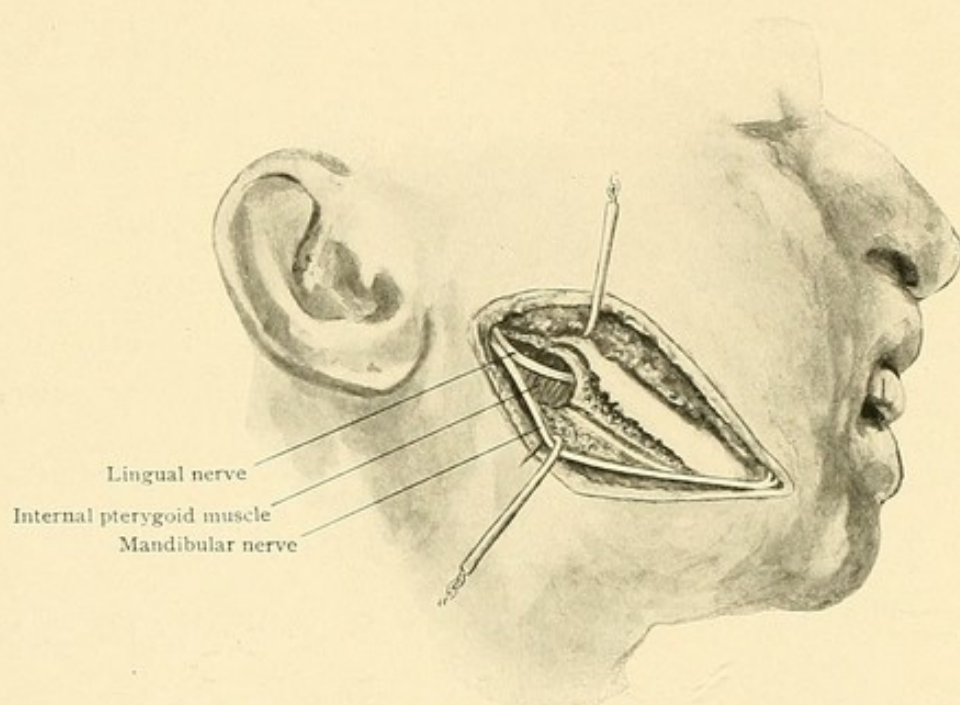


FIG. 68.—Excision of the lingual and mandibular (inferior dental) nerves.

trephine opening, and on rotating very slowly the nerves are wound around the forceps and are gradually torn loose from the base of the skull above to their ultimate branches below (see Fig. 68).

**Operations on the Gasserian Ganglion.**—The Gasserian ganglion lies in its capsule, formed by a splitting of the dura, on the anterior surface of the apex of the petrous portion of the temporal bone and on the root of the greater wing of the sphenoid. From its posterior extremity, which rests on the ridge separating the anterior and posterior surfaces of the petrous portion of the temporal bone, to the foramen rotundum anteriorly is 2.5 to 3 cm. (1 to 1¼ in.). The foramen ovale, which transmits the third or mandibular branch is midway between these two points, and corresponds on the outside of the skull to the eminentia articularis or root of the zygoma. Therefore, in removing the ganglion one works not only inward but also backward. Rose first operated on the ganglion from below. He removed the zygoma and coronoid process, ligated the internal maxillary artery, and trephined the skull in front of the foramen ovale. This operation was succeeded by that of Hartley and Krause. They went in through the temporal fossa. A large horseshoe-shaped flap, with its base above the zygoma, was cut and deepened with chisels through the bone to the dura. This was elevated by breaking across its base, and turning it down. The dura was then lifted from the base of the skull, and the maxillary and mandibular nerves recognized as they passed into the round and oval foramina. The capsule having been incised, these were seized with forceps, and as much of the ganglion as possible torn away.

Other surgeons, like Doyen, Quenu, Poirier, and Cushing, have combined these pterygoid and temporal routes. The bone flap, as made by Hartley and Krause,



embraced the region of the pterion or junction of the coronal with the temporo-sphenoidal sutures. As the bone was lifted from the dura at this point the middle meningeal artery was torn and troublesome bleeding ensued. Also the point of its breaking was too uncertain. Sometimes it broke too high up, sometimes too low down involving the base. It was also found unnecessary to replace the bone as the cavity left was filled up with fibrous tissue. For this reason Tiffany, of Baltimore, advocated the making of an opening in the skull above the zygoma with a trephine or gouge and mallet, and enlarging it with the rongeur forceps; the bone was not replaced. This is the procedure now used.

The operators who used the pterygoid route, by displacing the zygoma downward, were enabled to approach the ganglion from below instead of from above, therefore, a high temporal section of the bone was unnecessary and it has been abandoned; the bone section keeping below the pterion and not wounding the

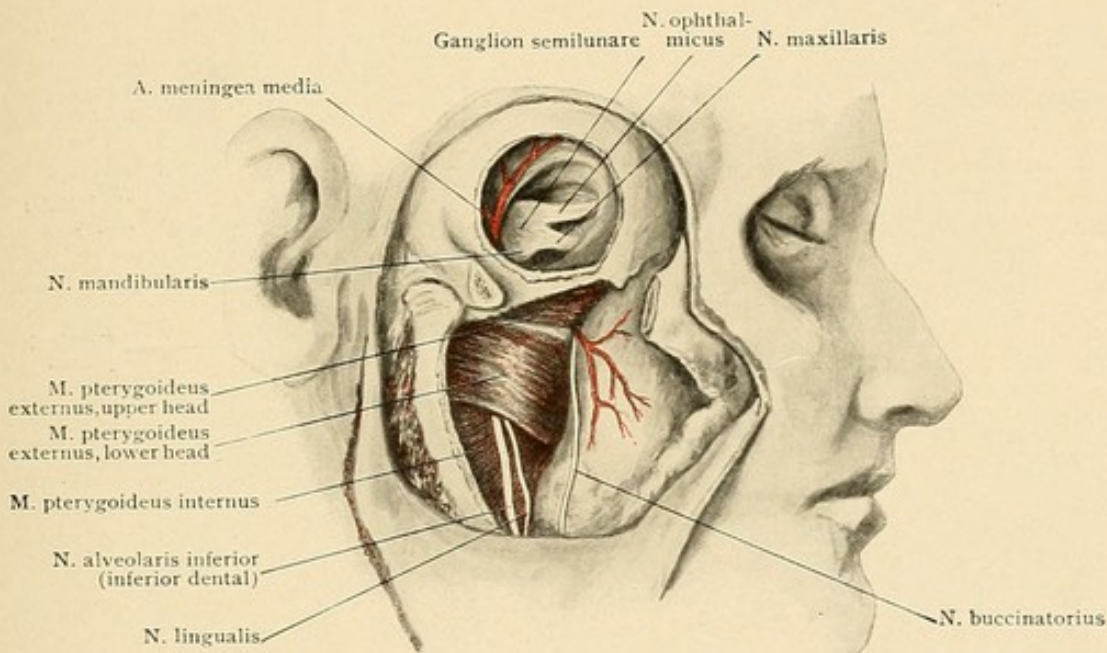


FIG. 69.—The upper portion of the illustration shows the operation of removal of the Gasserian ganglion (ganglion semilunare). The lower portion shows the pterygoid muscles.

middle meningeal artery thus avoids hemorrhage from that locality. Cushing (*Journ. Am. Med. Assoc.*, April 28, 1900) showed that the extensive removal of bone on the base of the skull was unnecessary, and that a displacement of the zygoma and temporal muscle downward, and removal of the bone down to and including part of the infratemporal crest gave sufficient access. Murphy found it unnecessary to resect the zygoma, and this has been our experience.

One of the main difficulties has been the question of bleeding. It has caused death and not infrequently has necessitated the packing of the wound and the deferring of the completion of the operation for two or more days. This bleeding came from the soft parts, the bone, the middle meningeal artery, the veins running from the dura mater to the bone, the cavernous sinus, and the blood-vessels to the ganglion itself. These as given by Cushing are a branch from the middle meningeal soon after its entrance to the skull, a small branch from the carotid, a small branch from the ophthalmic, the small meningeal through the foramen ovale, and occasionally one through the foramen rotundum. He calls attention to the septa in the cavernous sinus as rendering wounds to it less serious than they otherwise would be. If the skin incision is cast too far back, the temporal artery may be cut in front of the ear. Its position can be determined by its pulsation. It or its branches are divided in the upper portion of the incision and bleeding is very free. Division of the temporal muscle is followed by hemorrhage from the deep temporal. The bleeding from the bone is usually not troublesome, but the general oozing from the veins of



the dura mater as it is detached from the bone is sometimes free. If an osteoplastic (bone and skin) flap is raised, the middle meningeal will be torn at the pterion. This is a large vessel and bleeds freely. It may also be torn, while isolating the mandibular division of the nerve, at the foramen spinosum. This foramen is usually a couple of millimetres posterior and to the outer side of the foramen ovale and generally the nerve can be isolated without injuring the artery. In some cases, however, the artery lies so close to the nerve that it is almost certain to be torn. The posterior portion of the ganglion lies on the carotid artery in the middle lacerated foramen, of course separated by a layer of dura mater. Care should, therefore, be taken not to injure the carotid artery. The cavernous sinus has often been injured. This occurs principally in those cases in which it is attempted to excise the ophthalmic division. It is to be avoided by working from behind forward instead of attempting to attack it laterally. Bleeding from the middle meningeal artery can be

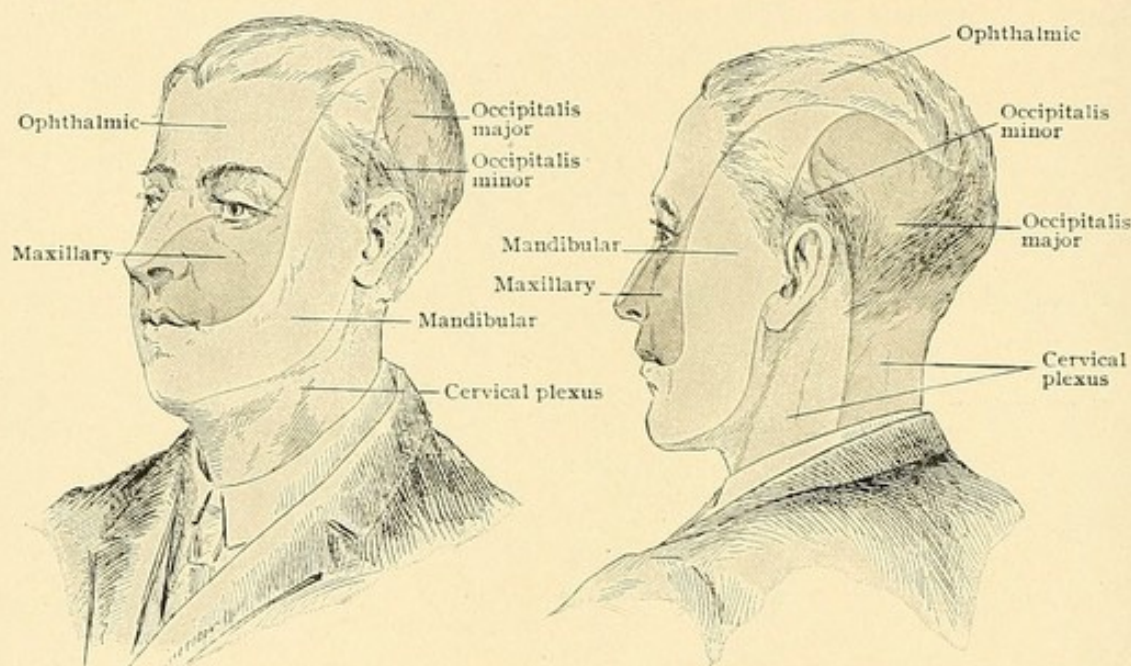


FIG. 70.—Diagrams showing distribution of cutaneous branches of trigeminal and cervical spinal nerves (Piersol).

avoided by biting the skull away with the rongeur forceps and refraining from detaching the dura from the bone where the artery enters it (see Fig. 23).

Cushing states that he makes an opening in the bone only 3 cm. in diameter. Such a small opening is used when the zygoma has been divided and pushed down or removed. Fowler and others have resorted to a preliminary ligation of the external carotid artery. This, while obviating to a great extent troublesome hemorrhage, cuts off the blood supply to the flap and sloughing has followed. In order to overcome this objection, the writer (*Journ. Am. Med. Assoc.*, April 28, 1900) after ligating the external carotid artery above its posterior auricular branch made a temporal skin flap with its base up. The temporal muscle was then divided and turned down and the bone removed with the trephine and rongeur. Hæmostasis was perfect and no ill effects followed the ligation.

It is comparatively easy to isolate the maxillary and mandibular divisions of the nerve. This having been done, the capsule of the ganglion is opened by a cut joining the two. A blunt dissector is then introduced and the upper layer of the dura, less adherent than the lower, is raised from the ganglion. The blunt dissector is then worked beneath the ganglion beginning between the maxillary and mandibular divisions and it is loosened from behind forwards. The sixth nerve is in such close relation to the ophthalmic that a temporary paralysis of it usually follows, causing internal squint. Anæsthesia of the whole side of the face from just in front of the ear to the median line follows complete removal. Frazier and Spiller have divided the root posterior to the ganglion instead of removing the ganglion itself (*Journ. Am. Med. Assoc.*, Oct. 1, 1904, p. 943).



**Area of Distribution of the Fifth Nerve.**—When the ophthalmic division is affected the pain in neuralgia is over the brow and up toward the vertex of the skull; it also involves the eye. The points of exit of the supra-orbital branch at the supra-orbital foramen and of the nasal branch toward the lower portion of the nose are tender to pressure.

When the maxillary division is affected, there is pain in the cheek and ala of the nose. The tender points are the exit of the infra-orbital nerve at and below the infra-orbital foramen, at the exit of the malar branch on the malar bone, and the upper gums and hard palate.

When the mandibular division is affected the pain involves the lower jaw and the side of the head nearly to the top (auriculotemporal branch). The lower gums and tongue are also painful. Pain on pressure is felt over the mental foramen and in the course of the auriculotemporal nerve in front of and above the ear.

### THE LOWER JAW.

The *mandible* or *inferior maxilla* is subject to fractures, dislocation, and tumors. In its composition it is very dense, so that in dividing it a groove should be cut with a saw before the use of the bone-cutting forceps is attempted, otherwise

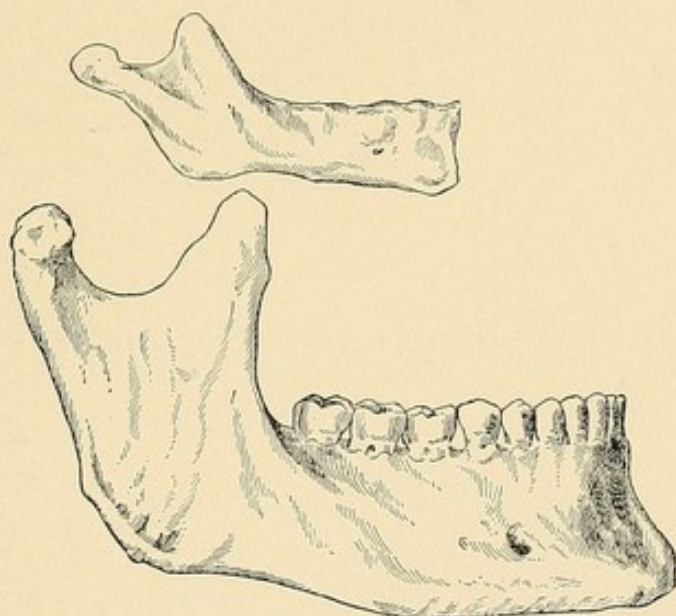


FIG. 71.—Lower jaw of child and adult, showing the mental foramen.

splintering of the bone will ensue. It is the last bone to decay. Its horseshoe shape and exposed position render it unusually liable to fracture. The strongest portion is what one would expect to be the weakest, viz., the symphysis. Its weakest part (or rather the part where it is most often broken) is the region of the mental foramen. The bone is weakened at this point not only by the foramen but also by the deep socket of the canine tooth.

The position of the *mental foramen*, normally between the two bicusps (beneath the second in the negro—Humphry), varies in its vertical location between the alveolar border and lower edge of the body, according to age. In infancy it is low down, in young adults it is midway, and in old people it is high up.

The body of the jaw is composed of two parts, one above and one below the external oblique line, which runs from the base of the anterior border of the coronoid process downward and forward to end at the mental tubercle, to one side of the symphysis. The part above this oblique line is the alveolar and the part below is the basal portion of the body.

The mental foramen opens on the oblique line separating the alveolar and basal portions. In early adult life the two portions, basal and alveolar, are about even in size, so that the foramen is below the middle of the jaw. As the teeth are lost the alveolar process atrophies; this naturally leaves the basal portion with the mental



foramen on or near its upper surface; therefore, in operating for neuralgia in the aged, if it is desired to attack the mandibular nerve in its canal, it should be searched for near the upper border of the bone.

In infancy the teeth, not having erupted, are contained in the jaw, the alveolar portion is, therefore, large. The basal portion, on the contrary, is quite small, serving merely as a narrow shelf on which the unerupted teeth lie. As the mandibular nerve runs beneath the teeth, the mental foramen is of necessity comparatively low. At birth the condyle is about level with the upper portion of the symphysis, and the body forms with the ramus an angle of 175 degrees. At the end of the fourth year the angle has decreased to about 140 degrees. By adult age the angle has decreased to about 115 degrees, and as the teeth are lost the angle gradually increases until it again reaches 140 degrees.

**Temporomandibular Articulation.**—A knowledge of the movements of the jaw is essential to a proper understanding of the fractures and dislocations to which it is subject.

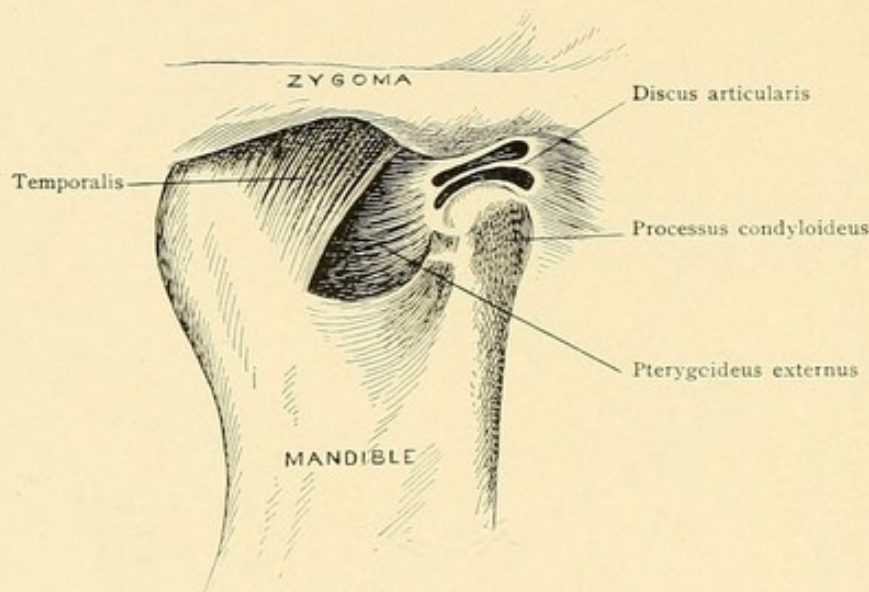


FIG. 72.—The temporomandibular articulation.

The mandible articulates with the glenoid fossa and its anterior edge or eminentia articularis of the temporal bone. Interposed between the condyle below and the bone above, is an interarticular cartilage. This divides the articulation into two portions, an upper and a lower. The ligaments are a capsular, strengthened by an external lateral (temporomandibular) and an internal lateral.

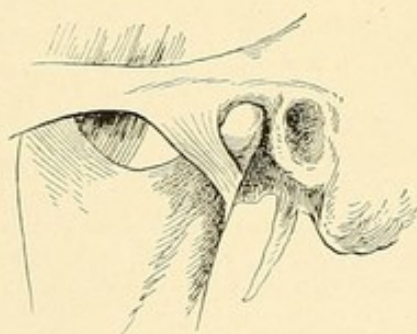


FIG. 73.—External lateral ligament of the lower jaw.

The capsular ligament is weakest anteriorly and strongest on the outer side. The thickening of the capsule on its outer side forms the external lateral or temporomandibular ligament. The sphenomandibular or internal lateral ligament is practically distinct from the articulation. It runs from the alar spine on the sphenoid above to the mandibular spine or lingula, just posterior to the mandibular foramen below. Between it and the neck of the bone run the internal maxillary artery and vein. When the condyle glides forward it puts the posterior portion

of the capsule on the stretch, and if the jaw is dislocated this part of the capsule is torn. The interarticular cartilage is more intimately connected with the lower portion of the articulation. The same muscle that inserts into the neck of the jaw (the external pterygoid) likewise inserts into the cartilage; therefore, the two move together, so that when the condyle goes forward the cartilage goes forward and rides on the eminentia articularis.



**Movements of the Jaw.**—The jaw has four distinct movements. It can be moved directly forward or backward; up and down, a pure hinge motion; a rotary movement on a vertical axis through one of the condyles; and rotation on a transverse axis passing from side to side through the mandibular or inferior dental foramina. The muscles of mastication are the *temporal*, *masseter*, and *pterygoids*; these are supplied by the motor branch of the fifth nerve. To these we may add the *buccinator*, which is supplied by the seventh nerve, and the depressors of the jaw,—the *digastric*, *geniohyoid*, *geniohyoglossus*, *mylohyoid*, and *platysma*. The posterior belly of the digastric receives its nerve supply from the facial; its anterior belly from the mylohyoid branch of the inferior dental from the fifth. The mylohyoid is supplied by the mylohyoid branch of the inferior dental. The geniohyoid and geniohyoglossus are supplied by the hypoglossal nerve. The platysma is supplied by the inframandibular branch of the facial nerve. The upward movement is produced mainly by the masseter and temporal muscles. It is the principal movement in carnivorous animals; therefore, these muscles in them are well developed, and the joint is a pure hinge joint. The internal pterygoid and buccinator likewise aid in closing the mouth; the depressors already mentioned open it. The lateral or rotary movement

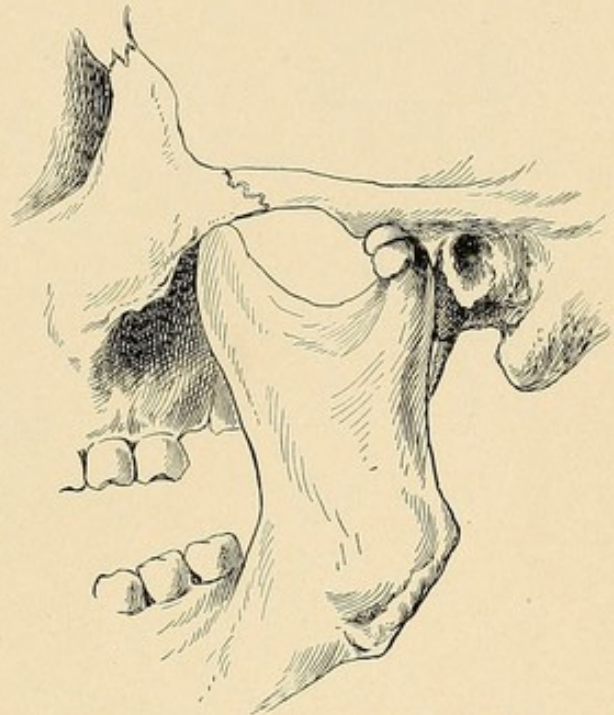


FIG. 74.—Illustrating up-and-down or pure hinge motion of the mandible.

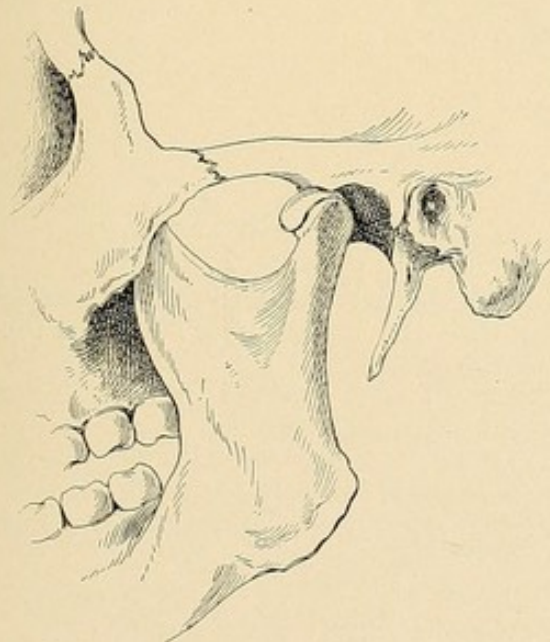

FIG. 75.—Illustrating direct anteroposterior movement of the mandible. The condyle is resting on the eminentia articularis.

around a vertical axis passing through one condyle is used in chewing; therefore, we find the muscles most concerned, the pterygoids, best developed in herbivorous animals, or those which chew the cud. The external pterygoid is especially efficient in pulling the jaw forward; superficial fibres of the masseter help in this. The posterior fibres of the temporal muscle pull the jaw back, as do likewise the depressor muscles of the jaw. In this rotary movement one condyle remains back in its socket while the other is brought forward on the eminentia articularis.

The up-and-down movement of the jaws, when limited in extent, is a pure hinge movement without any anteroposterior displacement, and takes place between the condyle and the interarticular cartilage (Fig. 74). The anteroposterior movement is necessarily accompanied by a slight descent of the jaw, as the condyle glides from the glenoid cavity (Fig. 75) onto the eminentia articularis. It goes nearly, but not quite, to the highest point of the articular



so that as they glide forward the last lower molars strike the second upper ones. The incisors likewise can be kept in contact as the jaw moves backward and forward. It is this movement in the rodent animals which keeps their edges sharp. In chewing, the jaw is depressed, the teeth separated, and the food held between them by the tongue and buccinator muscle. The teeth are then approximated by the lower jaw closing and the condyle sliding upward and backward from the eminentia articularis into the glenoid cavity, carrying with it the articular cartilage.

The hinge motion takes place between the condyle and the interarticular cartilage. The anteroposterior motion takes place between the interarticular cartilage and the eminentia articularis: the cartilage is carried forward with the mandible. A rotary movement occurs when, in chewing, the condyle of one side remains in the glenoid cavity while that of the other rises on the articular eminence. The radius of rotation is a line passing from one condyle to the other. In widely opening the mouth, as in yawning, the condyles are tilted forward while the angles of the mandible are

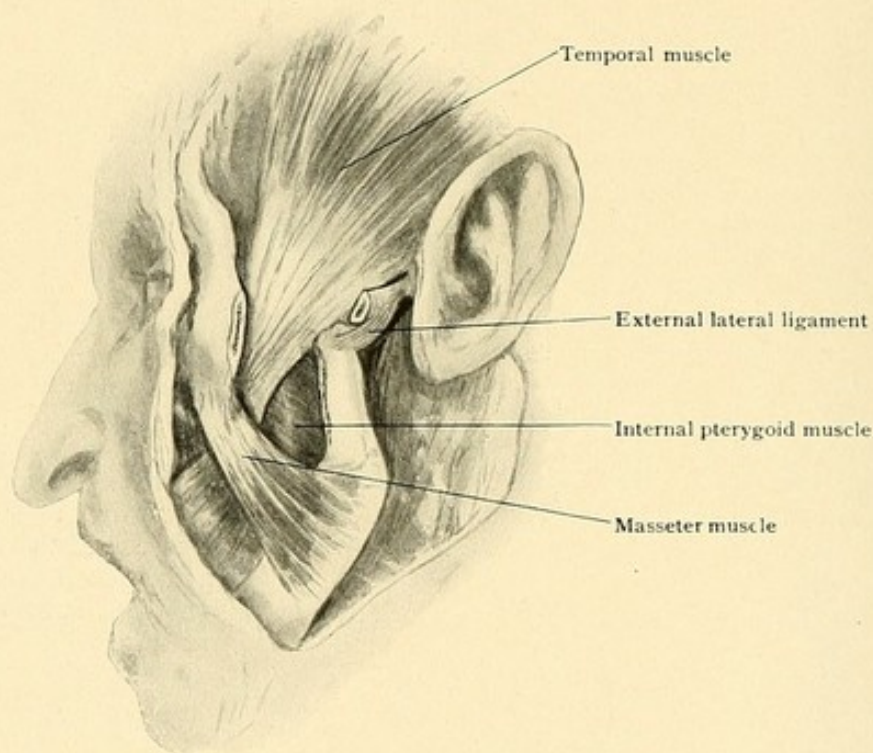


FIG. 76.—Dislocation of the lower jaw; the zygoma and part of the masseter muscle have been cut away.

carried somewhat backward. As the axis of this motion passes from side to side through the mandibular foramina, this portion of the bone moves but little, and the inferior dental vessels and nerve are not put on the stretch.

**Dislocation of the Lower Jaw.**—The forward dislocation is practically the only one to which the jaw is subject. Dislocations in other directions are apt to be accompanied by fractures. An understanding of the mechanism of the production and reduction of this dislocation requires a knowledge of the movements of the jaw, and the influences which the ligaments and muscles exert in limiting them. The normal movements of the jaw have already been discussed.

The ligaments which limit the movements of the jaw are those forming the *capsular ligament*. This is made up of four parts: *anterior*, *posterior*, *internal lateral*, and *external lateral*. The anterior is very weak, hence pus in the joint is most apt to make its exit forwards. It is readily ruptured in dislocations. The posterior ligament, though stronger, may also be torn. The two lateral ligaments, the outer being the stronger, become tense when the condyle slips forward on the articular eminence. In dislocation they remain attached to the mandible and are not ruptured (see Fig. 76).



Dislocation occurs when the mouth has been widely opened and the condyles are forward on the articular eminences. Some sudden jar accompanied by contraction mainly of the external pterygoid muscle causes the condyle to slip forward just in front of the articular eminences. The internal pterygoids and the superficial fibres of the masseter muscles aid in producing the luxation. As the condyle leaves the articulation to jump forward, it will be noted that it does so by an extensive movement, which is one of rotation on a transverse axis passing across in the region of the mandibular foramina. The condyle once out of its socket is kept out by the contraction of the temporal, masseter, and internal and external pterygoid muscles.

**Reduction of Dislocation of the Lower Jaw.**—In reducing the dislocation, the condyles must be depressed and pushed back. This can be done by one of two ways: viz., the thumbs of the surgeon, being protected by wrapping with a towel or bandage, are placed on the last molar teeth, and the jaw firmly grasped with the fingers beneath it. The back part of the jaw is then pressed downward, the chin tilted upward, and the condyles slid back into place.

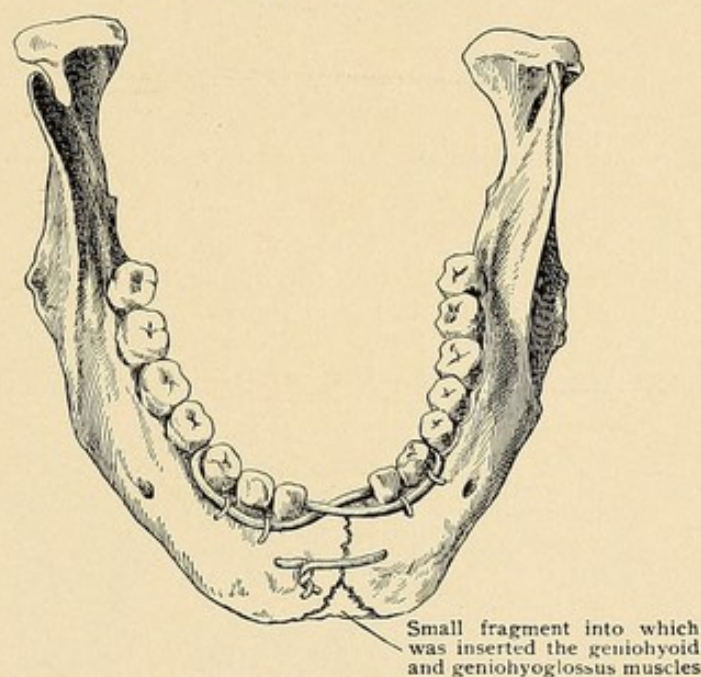


FIG. 77.—Fracture of the mandible through the symphysis (author's sketch).

The other method is to place two corks, one on each side, or a piece of wood, transversely, between the last molar teeth, then raise the chin and push it backward.

The undetached lateral ligaments are put on the stretch when the condyle is luxated forward. Lewis A. Stimson believes that in attempting reduction the jaw should first be opened wider to relax these and then pushed back, but we are not prepared to admit that so doing does relax these ligaments. He has, however, shown that the interarticular cartilage may become displaced and, by filling up the articular cavity, prevent a proper reduction. In rare instances the catching of the coronoid process beneath the malar bone may hinder replacement.

**Fractures of the Lower Jaw (Mandible).**—Fractures of the lower jaw almost never occur through the symphysis; this is on account of its being the thickest and strongest part of the bone. When a fracture of the anterior portion of the jaw detaches a median piece a most dangerous condition is produced. The piece, if sufficiently loosened by the injury, is drawn back into the throat, carrying the tongue with it and tending to suffocate the patient. Such a case is recorded by A. L. Peirson (review by Geo. W. Norris, *Amer. Jour. Med. Sciences*, 1841, N. S. vol. i, p. 186). A man was run over by a wheel which passed over his jaw, fracturing it on each side and forcing the piece into his mouth. The piece was drawn backward and nearly caused death from suffocation.



In the *Annals of Surgery* (vol. xix, 1894, p. 653) is recorded a case of the author's in which a man, while drunk, fell and struck his chin on the curbstone. A fracture was produced through the symphysis above and branching to each side of the genial tubercle below. This small median piece was drawn back into the throat nearly to the hyoid bone, and suffocative symptoms were marked. These disap-

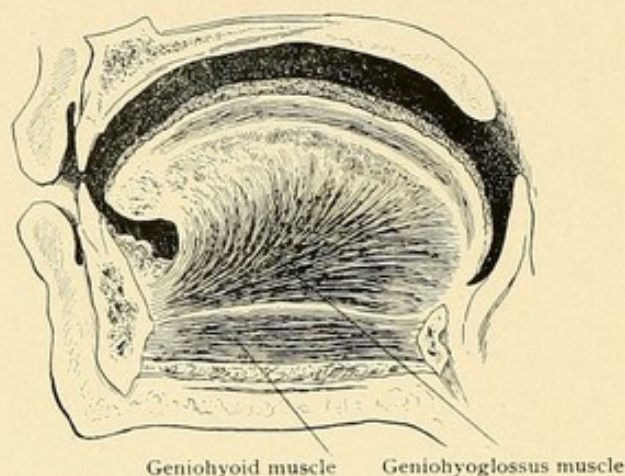


FIG. 78.—Anteroposterior section of the tongue and floor of the mouth, near the midline.

peared when the detached piece was drawn forward and wired in place. The piece was drawn backward by the geniohyoid and geniohyoglossus muscles. The digastrics may also have aided in depressing the fragment (Figs. 77 and 78).

The most usual site of fracture is in the neighborhood of the mental foramen. This is located just below the second premolar tooth (sometimes between the first and second). This foramen and the large socket for the canine tooth farther

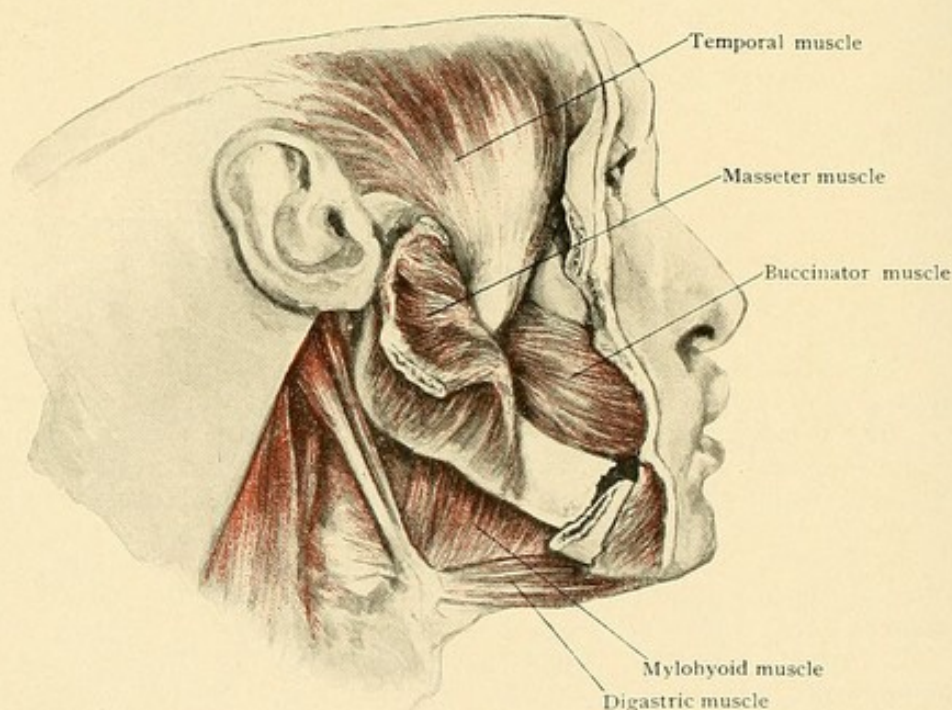


FIG. 79.—Fracture of the lower jaw in the region of the mental foramen, showing the line of fracture and the influence of the muscles in producing displacement.

forward weaken the bone somewhat in this region. The jaw is strengthened behind the mental foramen by the commencement of the anterior portion of the ramus and by an increase in the size of the mylohyoid ridge on the inner surface. The jaw is also protected by the thick masseter muscle and fracture is most liable to occur just in front of it. This constitutes the typical fracture of the lower jaw (Fig. 79).



**Displacement.**—The displacement of the fragments will depend on the line of fracture; and the line of fracture may be determined by the direction and character of the fracturing force. The line of fracture is oblique. It may be oblique from above down or from without in. An examination of the muscles attached to the mandible will show that the elevators of the jaw are attached to it posteriorly and its depressors anteriorly. On this account, when the fracture runs obliquely down and forward there is little or no displacement, because the depressors and elevators tend to press the fragments together. When the fracture runs downward and backward (see Fig. 80), the depressors and elevators tend to separate the fragments. The depression of the anterior fragment is particularly marked when the fracture is double, involving both sides of the jaw. The muscles which tend to depress the anterior fragment are the geniohyoglossus, geniohyoid, mylohyoid (anterior portion), digastric, and platysma. The muscles which elevate the posterior fragment are the temporal, masseter, buccinator, and internal pterygoid.

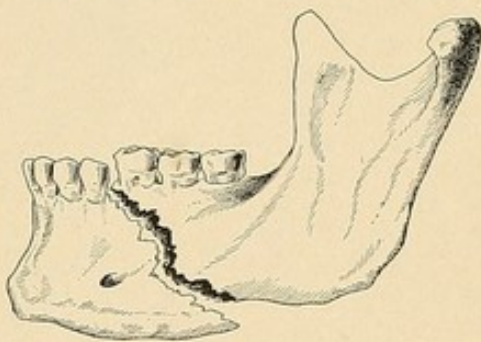


FIG. 80.—Fracture of the lower jaw, showing the line of fracture proceeding downward and backward, favoring displacement.

The displacement may not only be up and down, but may also be lateral. The line of fracture may run from the outside either inward and backward or inward and forward. The jaw is held in place by its own rigidity when intact; when broken, the smaller fragment is liable to be pulled inward by the muscles passing from it toward the median line. These muscles are the internal pterygoid and the mylohyoid. The influence of the former is more marked than of the latter, because the fracture frequently divides the mylohyoid, leaving a part of it attached to each fragment. When the fracture passes from without inward and

backward, then there will be little or no displacement, because the internal pterygoid and mylohyoid draw the fragments together. (See Fig. 81.) When the line of fracture is from without inward and forward, the internal pterygoid of the injured side and the mylohyoid draw the posterior fragment inward, while the internal pterygoid of the opposite side draws the anterior fragment outward (Fig. 82).

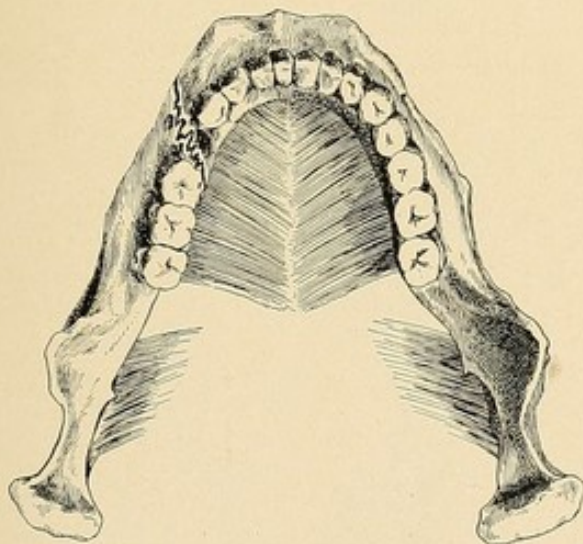


FIG. 81.—Fracture of the jaw, showing absence of displacement when the line of fracture runs from the inside forward and outward.

From a consideration of the foregoing facts, we see that when there is displacement it is because the fracture runs from above downward and backward, and from without inward and forward. The anterior fragment is displaced downward and the posterior fragment is displaced inward.

Fractures through the region of the molar teeth are not particularly uncommon,

and this is likewise the case with fractures obliquely downward and outward through the angle of the jaw. In these injuries the firm attachment of the masseter on the external surface of the jaw and the internal pterygoid on its inner prevent displacement.

Fractures of the coronoid process are exceedingly rare. In them displacement is prevented by the attachment of the temporal muscle, which passes much farther down on the inside than on the outside.

Fractures of the neck of the jaw are particularly serious. Inserted into the condyle and neck of the jaw is the external pterygoid muscle. When a fracture of the neck occurs, this muscle pulls the upper fragment anteriorly and tends to tilt its



inferior surface forward. This displacement is so marked that an excessive amount of callus is thrown out and ankylosis may result. This so seriously interferes

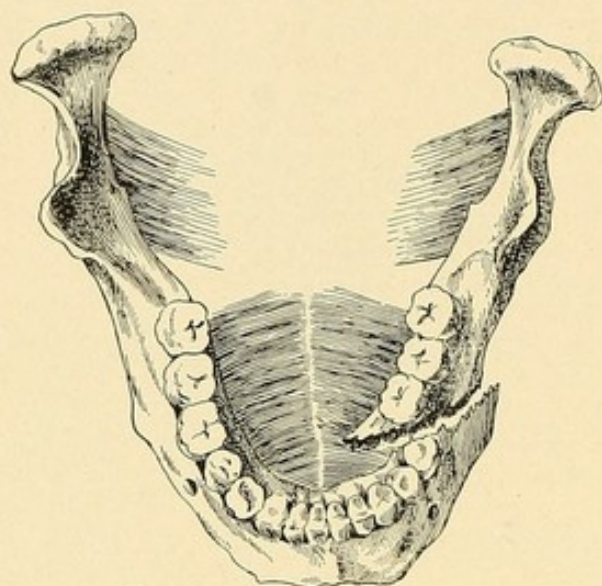


FIG. 82.—Fracture of the jaw, showing the action of the internal pterygoid and mylohyoid muscles in producing displacement when the line of fracture runs from the outside forward and inward.

with the use of the jaws as to justify an operation to remove or replace the upper fragment in proper position. The injury is liable to be overlooked in children, and as they grow up the deformity shown in Fig. 83 develops.



FIG. 83.—Deformity of the face following ankylosis due to fracture of the neck of the lower jaw in infancy (from an original sketch).

*Treatment.*—The lower jaw is held up in place by a bandage, and the upper teeth act as a splint. Sometimes the teeth or fragments are wired in position, or an interdental splint of gutta percha or other material is used.



**Excision of the Condyle of the Jaw.**—The condyle can be removed through an incision 3 cm. long, running from in front of the ear along the lower border of the zygoma. The temporal artery runs a centimetre in front of the ear with the auriculotemporal nerve posterior to it. By care in recognizing the artery, it may be saved and dragged posteriorly. The soft parts on the lower side of the wound with the parotid gland and facial nerve are pushed downward. The condyle can then be dug out, care being taken not to go beyond the bone and wound the internal maxillary artery.

**Excision of the Mandible.**—In removing one-half of the mandible, the incision is made from the symphysis along the lower border of the jaw to the angle and thence upward as high as the lobe of the ear. If it is desired to take extra precautions, the last centimetre of this incision, from the lobule of the ear down, may be carried through the skin only. This will prevent wounding to any great extent the parotid gland tissue, the parotid duct, and positively avoid injuring the facial nerve. The incision, however, is rather far back to wound any large branch of the duct, and is too low down to wound the facial nerve. If it is desired to carry the incision higher than the lobule of the ear, it should go through the skin only. The facial artery and vein will be cut just in front of the masseter muscle. The soft parts,

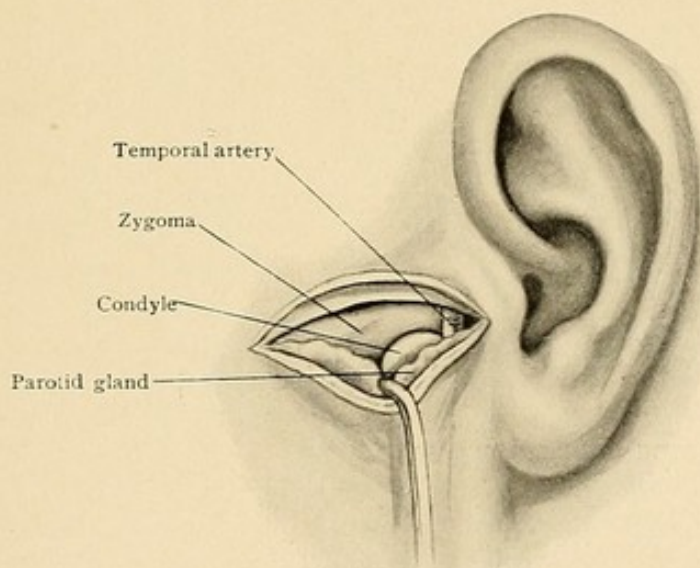


FIG. 84.—Excision of the condyle of the lower jaw.

including the masseter muscle, are raised from the outer surface. In dividing the bone anteriorly, it should be done .5 cm. outside the median line. This will be about through the socket of the second incisor. The object of this is to retain the attachments of the geniohyoid and geniohyoglossus muscles to the genial tubercles, and so prevent any tendency of the tongue to fall back. The jaw is pulled out and separated from the parts beneath, the mylohyoid muscle being made tense. Care should be taken not to injure the submaxillary gland, which lies below the mylohyoid muscle, and the sublingual gland, which lies above it. The lingual nerve is also liable to be wounded if the knife or elevator is not kept close to the bone.

As the detachment proceeds posteriorly, in loosening the internal pterygoid and the superior constrictor, if care is not taken, the pharynx may be wounded. The bone still being depressed and turned outward, the temporal muscle is to be loosened from the coronoid process or else the process is detached and removed later. Access is now to be had to the mandibular foramen at the mandibular spine or spine of Spix. The inferior alveolar artery is then secured and, with the nerve and sphenomandibular ligament, divided. The jaw can now be well depressed and brought inward. The temporomaxillary joint is to be opened from the front, having first cleared off the attachment of the external pterygoid muscle. There is great danger of wounding the internal maxillary artery at this stage of the operation. It lies close to the neck



of the jaw, and it is to avoid bringing it too close to the bone that Jacobson advises that the jaw be not twisted outward when disarticulation is being performed.

The distance between the coronoid process and malar bone varies in different individuals. The process may be displaced by the tumor and thus prevent detachment of the temporal muscle. If so, the process is divided with forceps or saw and removed after the rest of the jaw has been taken away. Injury of the temporomaxillary veins

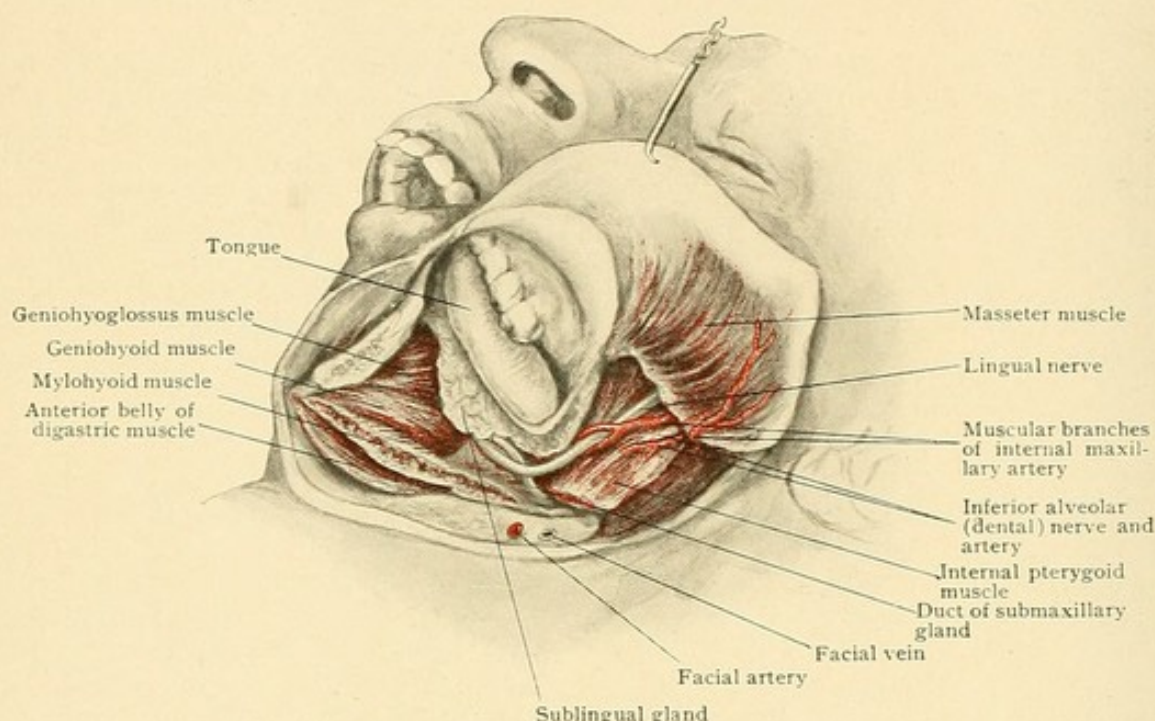


FIG. 85.—Excision of one-half of the lower jaw, showing the structures exposed.

may be avoided by not going behind the posterior edge of the ramus, as is also the case with the external carotid artery. Access to the joint may be facilitated by dragging upward the parotid gland, which carries with it the facial nerve and parotid duct.

## REGION OF THE EYE.

The **eyeball** rests in its socket, which is hollowed out of the soft parts contained in the bony orbit. It is covered in front by the *lids*, which, as they slide over the eye, are lubricated by the tears. These are secreted by the *lachrymal gland* at the upper outer portion of the orbit, flow over the eye, and are drained off by the *lachrymal canals* and *sac* to empty into the nose through the *lachrymonasal duct*.

**The Orbits.**—The orbits are large four-sided cavities, pyramidal in shape. The orbit in an adult male is about 4 cm. in diameter from side to side, and 3.5 cm. from above downward. The depth is 4.5 cm. It is thus seen that the orbit is wider than it is high. On receding into the orbit from its bony edge, the roof arches upward toward the brain to receive the lachrymal gland, thus making the up-and-down diameter slightly longer than the transverse.

The rim of the orbit is very strong and not readily broken by injuries. It is formed by the frontal bone above, the malar bone to the outside, the malar and superior maxillary below, and the superior maxillary and frontal to the inside. The inner (medial) walls of the two orbits are parallel, running distinctly anteroposteriorly. The outer (lateral) walls diverge at an angle of about 45° from the inner ones.

The outer or lateral edge of the orbit is nearly or quite a centimetre and a half posterior to the inner or medial edge. This fact, together with the divergence of the outer wall, is the reason that, in enucleation of the eye, it is always tilted toward the nose, and the scissors introduced and the nerve cut from the outer side.

The outer wall of the orbital cavity is formed mainly by the broad flat surface of the greater wing of the sphenoid bone, and is thick and strong. The other three



walls, on the contrary, are thin and weak. The thin orbital plate of the frontal bone above is frequently fractured in puncture wounds by foreign bodies, and the frontal lobe of the brain injured. Two such instances have come under the writer's care ;

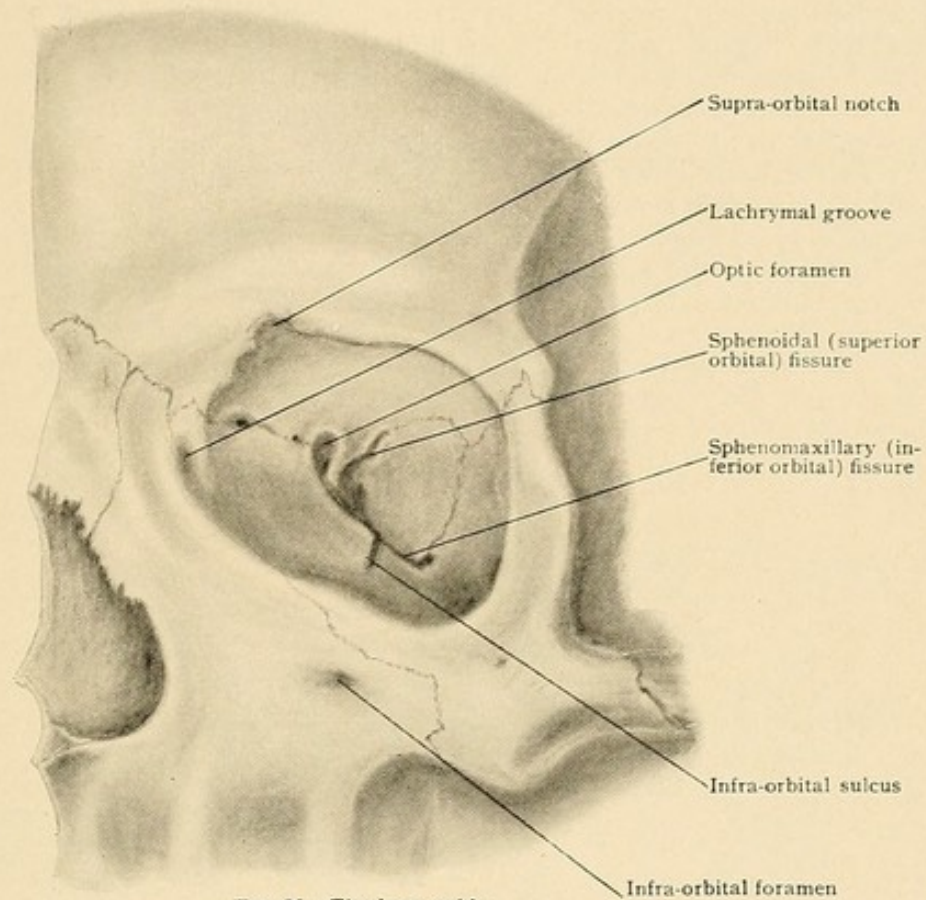


FIG. 86.—The bony orbit.

in the first case, an iron hook had penetrated and caused death from cerebritis ; in the second, the wound was caused by a carriage pole. The patient recovered, notwithstanding a considerable loss of brain tissue.

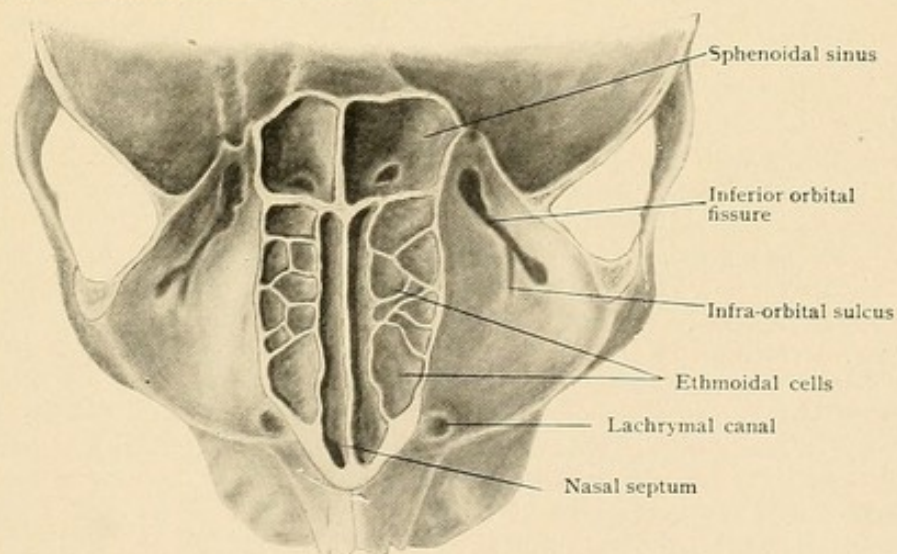


FIG. 87.—Transverse section of the orbital and nasal cavities viewed from above.

To the medial side of the inner wall are the *ethmoid cells*, covered by the thin lachrymal bone and the os planum of the ethmoid. They are readily perforated by suppuration from within those cavities. The floor is chiefly formed by the thin



orbital plate of the superior maxilla. In operations involving the floor of the orbit, care is necessary to avoid breaking through into the maxillary sinus (antrum) beneath.

At the edge of the junction of the outer and lower walls lies the *inferior orbital (sphenomaxillary) fissure*. It runs forward to within 1.5 cm. of the edge of the orbit and extends back to the apex of the orbit, where it unites with the *superior orbital (sphenoidal) fissure*, which lies between the roof and outer wall and extends forward about one-third of the distance to the edge of the orbit. The *optic foramen* enters the apex of the orbit at its upper and inner portion.

At the lower inner edge of the orbit is the lachrymal groove for the lachrymo-nasal duct, leading from the eye to the inferior meatus of the nose. At the junction of the middle and inner thirds of the upper edge is the *supra-orbital notch*. This can be felt through the skin. It transmits the *supra-orbital artery and nerve*. If a complete foramen is present instead of a notch, its location cannot be so readily determined.

**Contents of the Orbit.**—The orbit is lined with a periosteum, and contains the eyeball, the muscles which move it, the veins, arteries, and nerves which go to

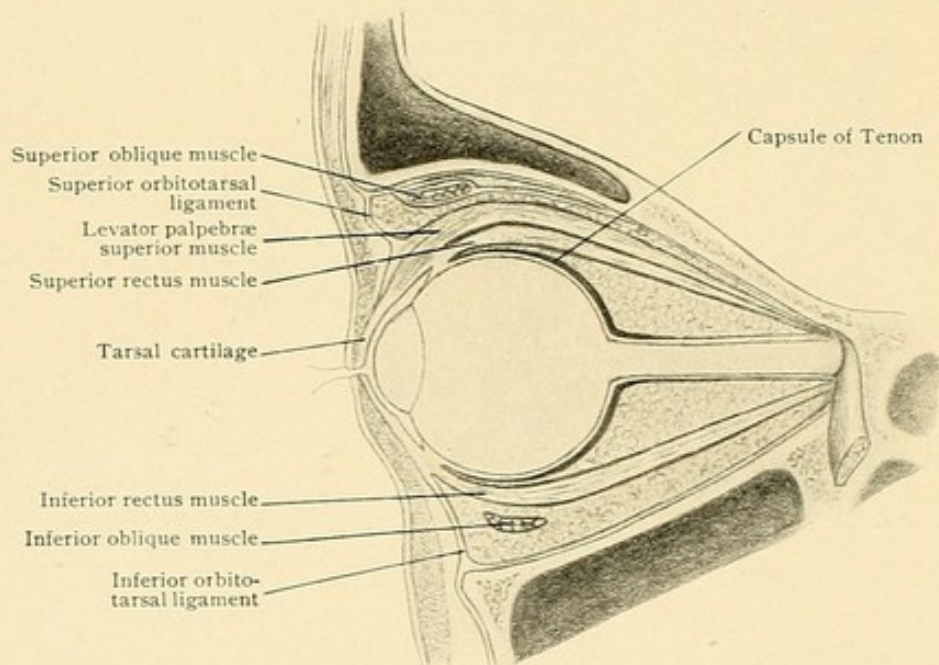


FIG. 88.—Sagittal section through the eye and orbit.

it together with some which traverse the orbit to go to the face, and the lachrymal gland. These structures are more or less surrounded with a fascia which is continuous with the periosteum.

**Periosteum.**—The periosteum of the orbit is not tightly attached and in cases of disease can readily be raised from the bone beneath. Anteriorly, it is continuous at the orbital rim with the periosteum of the bones of the face. Posteriorly, it is continuous through the optic foramen and sphenoidal fissure with the dura mater. It sends prolongations inward, covering all the separate structures in the orbit. From the edge of the orbit it stretches over to the tarsal cartilages, forming the *superior and inferior orbitotarsal ligaments*. These form a barrier (called the *septum orbitale*) to the exit of pus from within the orbit, and for that reason it is advised that orbital abscesses should be opened early. The lower portion, as it reaches the lachrymal groove, splits to cover the lachrymal sac. Another extension from above splits to enclose the lachrymal gland, which is seen to lie comparatively loose in the upper outer portion of the orbit, sustained by its suspensory ligament. It then sends thin fibrous layers which cover the muscles, arteries, veins, nerves, fat pellicles, and finally the eyeball posterior to the insertion of the muscles and optic nerve. This last portion, called the *capsule of Tenon*, begins as far forward as the



insertion of the recti muscles on their under (inner) side, passes over the globe posteriorly, over the optic nerve, and blends with the layer covering the deep surface of the muscles. It is joined to the sclerotic coat of the eye and dural sheath of the nerve by a loose net-work of delicate fibrils. This forms practically a space lined with endothelial plates, similar to the subarachnoid space in the brain. The capsule of Tenon is a distinct, well marked membrane, and the eyeball lies loose and revolves freely within it. It is this space into which the strabismus hook is put when it is desired to cut the recti muscles for squint. Fibrous prolongations are also sent to the sides of the orbit from the internal and external recti muscles. They are the *check ligaments*; and one from the inferior rectus forms the suspensory ligament of the eye.

**Affections of the Orbit.**—The orbit is often invaded by tumors, pus, hemorrhages, and air (producing emphysema).

*Tumors* may either originate in the orbital contents, as sarcomas of the lachrymal gland or eye, or they may come from surrounding regions. It is more rare for them to enter through the natural openings of the orbit than it is for them to push through its thin walls. Coming through natural openings, they may make their entrance: (1) from the brain through the optic foramen or sphenoidal fissure; (2) from the region of the zygomatic and temporal fossæ through the sphenomaxillary fissure; (3) from the nasal cavities (as I have seen), coming up the lachrymonasal canal.

In invading the orbit through its walls they may come: (1) from the nasal cavities and ethmoidal cells, pushing through the thin internal wall; (2) from the frontal sinus, appearing at the upper inner angle; (3) from the sphenoidal cells at the posterior portion of the inner wall; (4) from the brain cavity above, breaking through the roof; (5) from the maxillary sinus below, pushing through the floor.

**Dermoids.**—In the fœtus, the frontonasal process comes from above downward to join the maxillary processes on each side. This leaves an orbitonasal cleft to form the orbit. Owing to defects in the development of this cleft, dermoid tumors may occur in its course. They are seen either at the outer or inner angle of the eye. They are more common at the outer angle near the external angular process, and may have a prolongation to the dura mater. They also occur at the inner angle at the frontonasal suture (Fig. 89). At this point, also, meningoceles are liable to occur. As pointed out by J. Bland Sutton the question of diagnosis is of importance, as an attempt to remove a meningocele by operation is apt to be followed by death, whereas a dermoid, though it may have a fibrous prolongation to the dura mater, can be more safely removed.

**Orbital Abscess.**—Suppuration may either originate within the orbit or extend into it from the neighboring tissues. If the former is the case, it may occur from caries of the bones of the orbit, as in syphilis. It may originate from erysipelas involving the orbit. General inflammation and suppuration of the eye may break through the eye and spread in the orbital tissues (panophthalmitis). If pus enters the orbit from the outside, it is usually from suppuration and caries of the frontal sinus and ethmoidal cells. In this case, the swelling shows itself at the upper portion of the inner angle of the eye. Pus in the maxillary sinus is most apt to discharge into the nose, and not break through the roof into the orbit above. Pus within the orbit tends to push the eyeball forward and even distend the lids. As the orbitotarsal ligament runs from the bony edge of the orbit to the lids, pus does not find an easy exit. The abscess should be opened by elevating the upper lid, and incising the conjunctiva in the sulcus between the globe of the eye and the lid. Pus from suppuration of the lachrymal sac does not tend to invade the orbit but works its way forward to the skin.

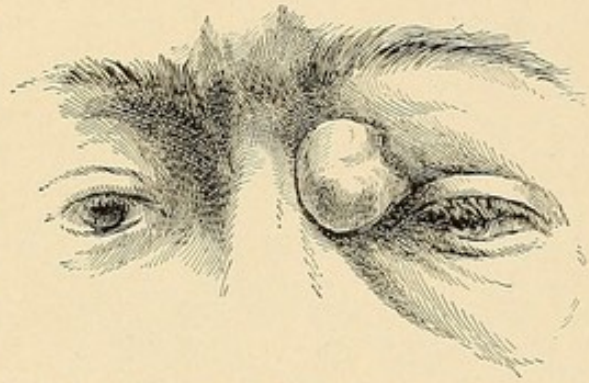


Fig. 89.—Dermoid of orbit. Boy, 15 years of age. It extended back to the body of the sphenoid bone. Case of Dr. Wm. Zentmayer.



*Foreign Bodies in the Orbit.*—Owing to the considerable space which exists between the eye and orbital walls, large foreign bodies may find a lodgment there, often producing serious symptoms for a considerable length of time. The tang of

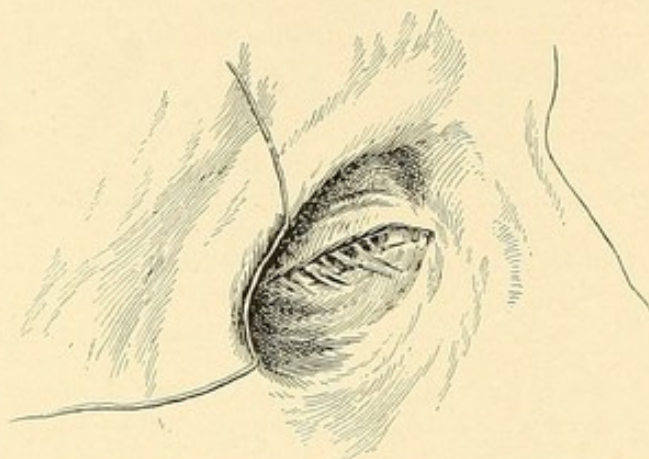


FIG. 90.—Lines of the skin incision. (Krönlein's operation for obtaining access to the retrobulbar region.)

a gun barrel has been so found. This should lead one to search for foreign bodies carefully when this portion of the orbital contents has been wounded.

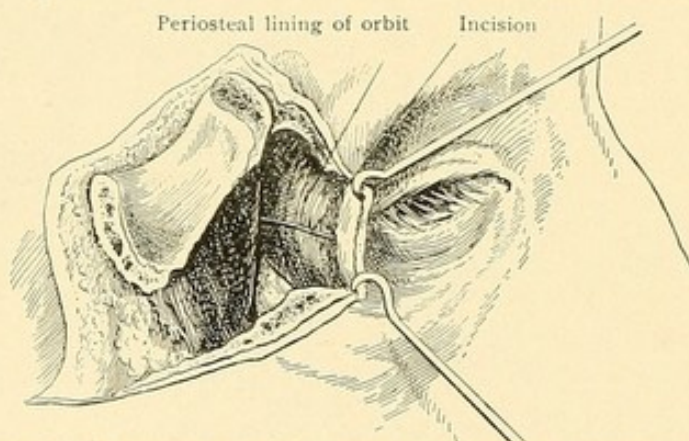


FIG. 91.—The rim of the orbit has been divided and the piece of the bone turned outward; an incision is then made through the periosteal lining. (Krönlein's operation for obtaining access to the retrobulbar region.)

*Emphysema.*—In cases of fracture involving the inner wall and opening up the nasal cavities or sinuses the air, particularly in blowing the nose, may be forced into

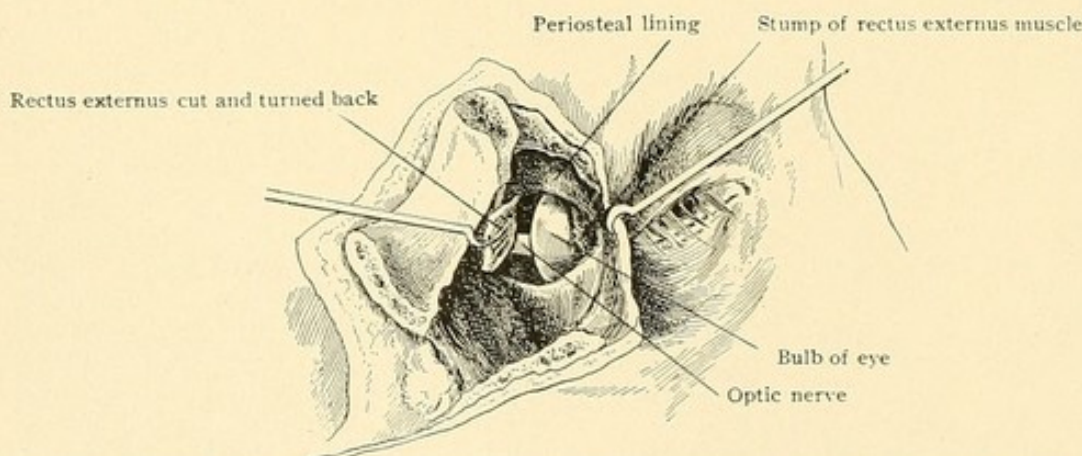


FIG. 92.—The edges of the incised periosteum have been separated and the external rectus muscle divided, exposing the space posterior to the bulb. (Krönlein's operation for obtaining access to the retrobulbar region.)

the orbit, distending the lids and producing a peculiar crackling sensation when palpated. No treatment directed to removal of the air is necessary. It is valuable as a diagnostic sign of fracture communicating with the nasal cavities.



**Hemorrhage.**—Hemorrhage into the orbit may occur either as the result of direct traumatism involving the contents, or from fracture of the base of the skull through the orbital plate. The blood pushes its way anteriorly and shows itself under the conjunctiva surrounding the cornea. It is prevented from appearing on the lids by the orbitotarsal ligament. A subconjunctival hemorrhage alone is not sufficient to justify a diagnosis of fracture of the base of the skull, although it is a significant confirmatory symptom.

**Krönlein's Operation.**—In order to gain access to the back part of the orbit to remove tumors, Krönlein resects the outer wall, divides the periosteum and external rectus muscle, and so gains access to the retrobulbar space. The various steps of the operation are shown in Figs. 90, 91, 92.

### THE EYEBALL AND OPTIC NERVE.

The eyeball has three main coats, viz.: a fibrous outer coat, called the sclerotic; a vascular middle coat, the choroid; and a nervous inner coat, the retina.

**Sclerotic Coat.**—The sclerotic coat forms a firm protective covering or case for the delicate retina within. It is continuous posteriorly with the fibrous coat or dura of the optic nerve, which is a continuation of the dura mater of the brain. At the optic foramen, the dura mater splits into two layers; the outer layer forms the periosteum, while the inner forms the dural coat of the optic nerve. This nerve also, like the brain, has an arachnoid and a pial membrane. The sclerotic coat is continued forward over the front of the eye as the *cornea*. As it is essentially a membrane intended to be protective in its function, its diseases are those of weakness; thus, if the cornea is affected, it bulges forward and is called an *anterior staphyloma*; if the posterior part is affected, the sclera is stretched, and it forms a *posterior staphyloma*.

Anterior staphyloma may occur either rapidly as a small local protrusion, resulting from ulceration of the cornea or a wound, or it may be slow in forming, and involve nearly or quite the whole of the cornea, pushing it forward in the shape of a cone; this is called *conical cornea*. Posterior staphyloma occurs in near-sighted people, the anteroposterior diameter of the eye being longer than normal. If this posterior staphyloma or stretching of the eye becomes marked, the choroid atrophies and the functions of the retina are lost. The white sclera is seen with the ophthalmoscope, surrounding or to one side of the optic nerve.

Although the cornea has no blood-vessels, it still, from its exposed position, becomes inflamed (*keratitis*) and ulcerated, and eventually blood-vessels may develop into it from its periphery, constituting the disease known as *pannus*.

The weakest portion of the globe is at the junction of the sclerotic coat with the cornea. It is here that the sclera is thinnest. On this account, blows on the eye cause it to rupture usually at this point, the tear encircling the edge of the cornea for a variable distance (usually at its upper and inner quadrant) according to the force and direction of the injury. On healing, a staphyloma may form at this point.

The **choroid** or vascular coat of the eye contains the *pigment* or *color* of the eye. It is continued forward as the *ciliary body* (or processes) and *iris*. Being a vascular tissue, its diseases are inflammatory. If the choroid is affected we have *choroiditis*; if the ciliary region is inflamed, it is called *cyclitis*; and if the iris is inflamed we have *iritis*.

The **retina** or nervous coat of the eye is concerned in the function of sight and it, like other nerves, may be affected with inflammation, called *retinitis*. Sometimes it becomes loosened from the choroid beneath by a hemorrhage or rapid stretching of the sclera, constituting a *detachment of the retina*. Outside the disk is the *macula lutea* and fovea centralis or region of distinct vision.

Filling the interior of the eye is the jelly-like transparent *vitreous humor*, enclosed in the *hyaloid membrane*. In front of the vitreous humor is the *lens*; and the clear, limpid liquid between the anterior surface of the lens and the posterior surface of the cornea is the *aqueous humor*.

The **lens**, immediately behind the iris, is suspended in its capsule from the ciliary processes by its suspensory ligament or *zone of Zinn*. Between the ciliary processes and the sclera lies the *ciliary muscle*, which regulates the accommodation



or focussing power of the eye. The ciliary processes are formed of convoluted blood-vessels supported by connective tissue and covered by the pigmented extension of the retina. This ciliary region is an exceedingly sensitive one and a serious wound of it usually means a loss of the eye.

*Cataract*.—When the lens is opaque it constitutes the disease known as cataract: this name is also applied to opacities of the capsule of the lens. When the lens alone is opaque it is called a *lenticular cataract*; when the capsule alone is affected, it is a *capsular cataract*. Both are sometimes involved, constituting a *lenticulocapsular cataract*. The lens is made up of layers like an onion. Some of these layers may become opaque, leaving a surrounding rim of clear tissue. The nucleus within the affected layer is also clear. This form is called a *zonular* or *lamellar cataract*. A capsular cataract may affect the anterior portion of the capsule, forming an *anterior polar cataract*, or the posterior layer of the capsule, forming a *posterior polar cataract*.

If the cornea has been perforated by a central ulceration, the aqueous humor escapes, the lens falls forward, and its anterior capsule becomes adherent at the site

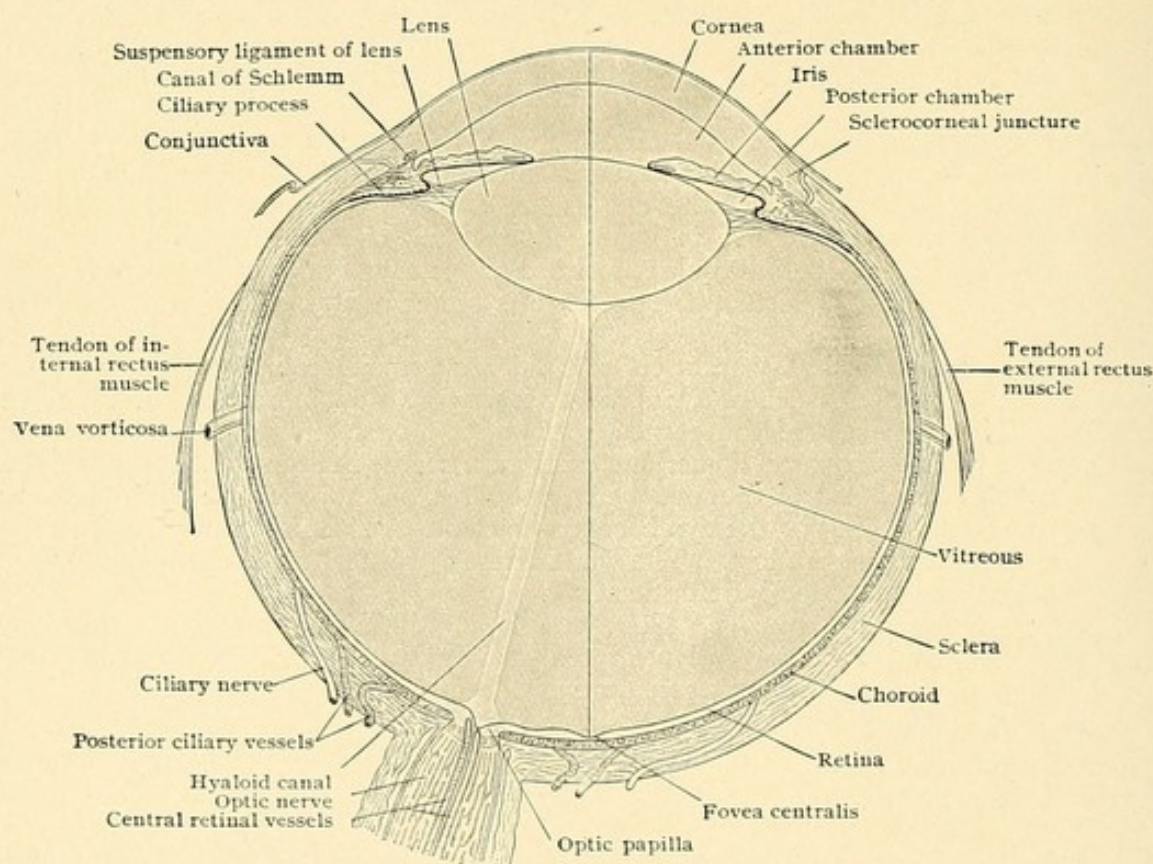


FIG. 93.—Diagrammatic horizontal section of right eye.  $\times 3\frac{1}{2}$ . (Piersol.)

of perforation. As the aqueous humor reaccumulates, it pushes the lens back, leaving a small portion of inflammatory tissue clinging to its anterior capsule, thus forming an anterior polar cataract. A posterior polar cataract is the result either of disease, such as *choroiditis*, in which the posterior capsule becomes involved, or of a persistence of the remains of the *hyaloid artery*, a fetal structure.

*Secondary cataracts* are the opacities of the capsule or inflammatory bands and tissues which are left, or which occur, after the removal of the lens. The lens in childhood is soft; it grows harder as age increases. If the aqueous humor obtains access to the lens through a wound of the anterior capsule, the lens becomes opaque, constituting a *traumatic cataract*. In operating for cataract in childhood, the lens, being soft, is first rendered opaque by the aqueous humor admitted through a puncture made in the capsule; if it is admitted repeatedly to the lens by the surgeon's needle (needling or discission operation) the lens matter is completely dissolved. The fluid lens matter can also be removed by a suction instrument. In old people the nucleus becomes hard and opaque, forming a *senile cataract*.



The aqueous humor does not dissolve the opaque lens after the age of thirty-five years. Senile cataract rarely occurs before the forty-fifth year, so there is a period of ten years in which a cataract may be a nuclear cataract without being senile.

To remove a nuclear or a senile cataract, a slit is made through the cornea near its scleral junction, a piece of the iris may (or may not) be removed, the anterior capsule is cut with a cystotome and the opaque lens pressed out through the opening so made, then through the pupil (either artificial or dilated with atropine), and finally through the sclerocorneal incision. The posterior capsule is not injured, and it prevents the vitreous humor from escaping. If inflammation follows the operation, the iris and ciliary region throw out lymph and the remains of the capsule become opaque, forming a secondary or capsular cataract. This is removed by tearing or cutting it across with needles or extremely fine scissors.

**Iris.**—The iris is the continuation of the choroid through the ciliary body, and extends down to the pupil, its free edge resting on the anterior surface of the lens. The iris is composed of a vascular and fibrous anterior portion, and a muscular and pigmented posterior portion. In consequence of its vascularity, the iris is the frequent site of inflammation. When inflamed it pours out lymph which may cause it to adhere to the lens behind, forming a *posterior synechia*. An *anterior synechia* is where, on account of a perforation of the cornea, the iris washes forward and becomes attached to the cornea in front.

The circular muscle fibres surrounding the pupil are anterior, and form the *sphincter pupillæ muscle*; it contracts the pupil. The radiating muscular fibres, which lie posteriorly, form the *dilator pupillæ*; it dilates the pupil. The dark pigment layer is on the posterior surface of the iris, and after an attack of iritis, as the adherent iris is torn loose from the lens, it leaves patches of pigment adhering to the anterior capsule.

The iris, as it rests at its pupillary margin on the lens, divides the space anterior to the lens into two parts. The part between the posterior surface of the iris and the anterior surface of the lens forms the *posterior chamber*. The *anterior chamber* lies between the anterior surface of the iris and the posterior surface (*Descemet's membrane*) of the cornea. The two chambers communicate through the pupil. The anterior surface of the iris toward its periphery is of the nature of a coarse mesh-work, the spaces of which are the *spaces of Fontana*. They communicate with a venous or lymph canal which passes around the eye at the sclerocorneal junction (*canal of Schlemm*).

**Aqueous Humor and Anterior Lymph Circulation.**—The aqueous humor is of the nature of lymph. It is secreted by the ciliary processes and posterior surface of the iris. It passes through the pupil to the anterior chamber, and enters the spaces of Fontana to empty into the canal of Schlemm. The canal of Schlemm empties its contents into the anterior ciliary veins. In iritis and glaucoma the lymph-current is seriously interfered with. In iritis, the swelling and outpouring of lymph blocks the spaces of Fontana and prevents a free exit of the aqueous humor from the anterior chamber, therefore in this condition the anterior chamber is deep, and the iris is seen to lie far beneath the cornea.

**Glaucoma.**—Glaucoma is a disease accompanied by increased intra-ocular tension. The eyeball feels hard to the touch. It is supposed to be due to disease of the ciliary region interfering with the canal of Schlemm and obstructing it. Therefore, the drainage of the eye and the circulation of the aqueous humor is interfered with. In iritis the anterior chamber becomes deeper, but in glaucoma, as the intra-ocular tension increases, it pushes the lens forward, and it is seen to lie close up to the cornea; so that a shallow anterior chamber causes the ophthalmologist to suspect glaucoma and a deep anterior chamber iritis. The increased pressure within the eye pushes the optic nerve backward at its point of entrance, so that it is seen sunk below the surface of the adjoining retina, forming a distinct cup-shaped cavity or pit. This is *cupping of the disk*.

**Optic Nerve.**—The optic nerve reaches from the *optic chiasm* to the eyeball, a distance of about 5 cm. (2 in.). It enters the apex of the orbit through the optic foramen at the upper inner angle, in company with the ophthalmic artery. The artery crosses the under surface of the nerve from its inner to its outer side. The optic nerve has



as its covering a prolongation of the membranes of the brain. The dura mater when it reaches the foramen splits and gives one layer to form the periosteum lining the orbit and the other to form a fibrous sheath of the nerve. This arrangement prevents pus, forming in the orbit, from passing through the optic foramen into the skull. The *arteria centralis retinae* enters the nerve on its under side and passes through its centre to the interior of the eye. The nerve itself is covered with a fine pial membrane and an arachnoid separating it from the dura, thus forming subdural and subarachnoid spaces. As these membranes and spaces are continuous with those of the brain, hemorrhage or serous effusions occurring within the brain can thus find their way into the sheath of the nerve.

As the nerve enters the eye, it is contracted and forms the *optic disk* or *papilla*.

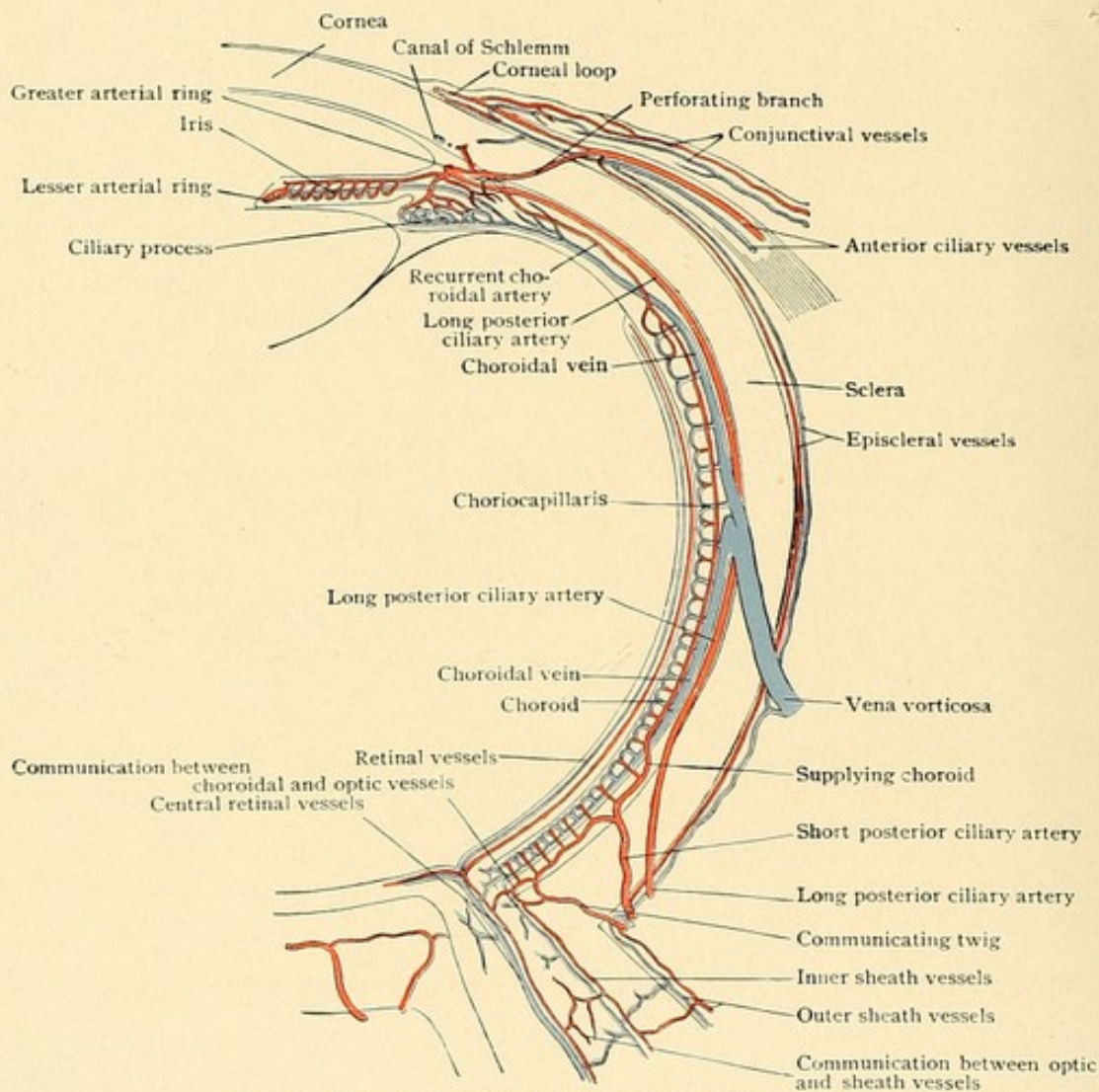


FIG. 94.—Diagram illustrating circulation of eyeball. (Leber.)

It is readily seen with the ophthalmoscope as a round spot somewhat lighter in color than the surrounding eyeground. Coming from a depression or cup in the disk, called the *porus opticus*, are the retinal arteries and veins. A certain amount of cupping is normal, but if wide and deep, with overhanging edges over which the vessels can be seen to dip, it is indicative of glaucoma.

Sometimes the papilla or disk is swollen, constituting an *optic neuritis*. In brain tumor this is frequently the case and is called *choked disk*, or "*stauung papilla*," so named because the circulation was thought to be interfered with owing to the intracerebral pressure being transmitted directly to the nerve. On the subsidence of a severe neuritis the nerve is left in a state of optic atrophy and blindness is the result.



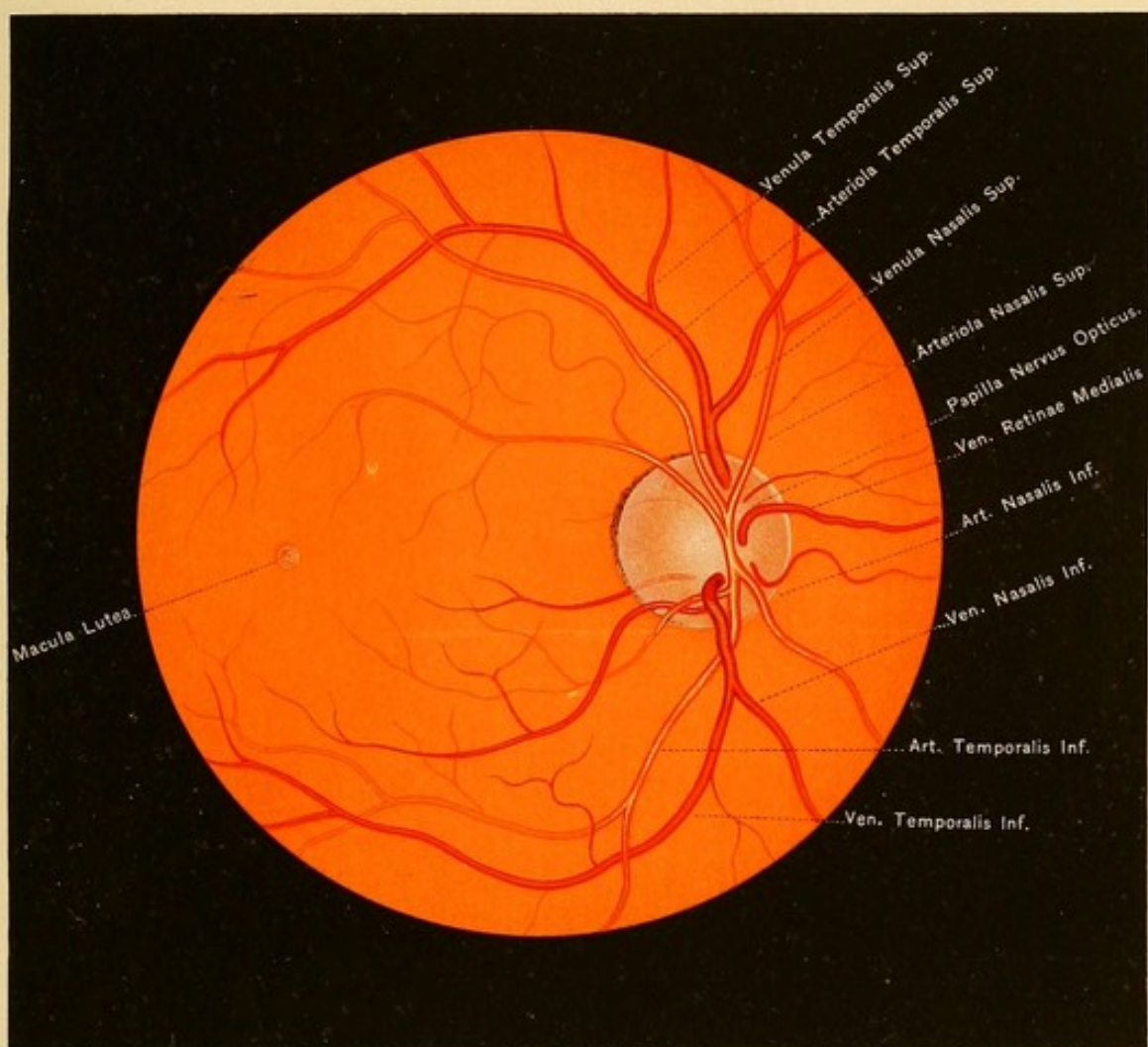



FIG. 95. NORMAL HUMAN FUNDUS OCULI, SHOWING OPTIC PAPILLA AND BLOOD VESSELS; ALSO THE MACULA LUTEA.  
DRAWN BY MR. LOUIS SCHMIDT.







**Muscles of the Orbit.**—Six muscles are connected with the eyeball, four straight and two oblique. One muscle, the *levator palpebræ*, goes to the lid. The four recti muscles, *superior*, *inferior*, *external*, and *internal*, arise from a common tendinous origin, forming a ring or tube called the *ligament of Zinn*. This ligament or tube surrounds the optic foramen and is attached to the opposite side of the sphenoidal fissure. Through it run the optic nerve and ophthalmic artery, the third, fourth, and the nasal branch of the ophthalmic (fifth) nerve.

The *levator palpebræ* and *superior oblique* arise to the inner side and above the optic foramen close to the origin of the other muscles. The superior oblique, after passing through its trochlea or pulley at the inner upper angle of the orbit, continues downward, backward, and outward between the superior rectus and the eye, to be inserted above the extremity of the inferior oblique.

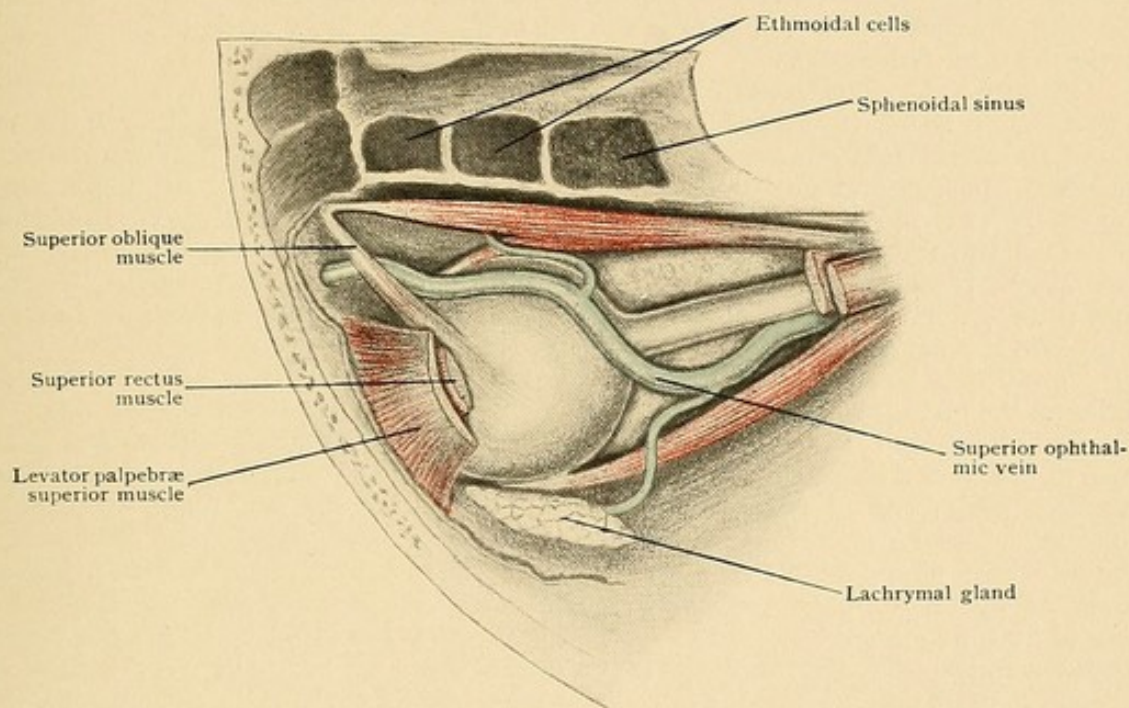


FIG. 46.—The roof of the orbit has been removed, showing the contents.

The *inferior oblique* arises from the anterior edge of the orbit just to the outer side of the lachrymal groove. It passes outward, upward, and backward, over the external surface of the inferior rectus, to be inserted beneath the external rectus.

The *recti muscles* insert into the sclera 5 to 7 mm. back from the cornea. In the operation for internal squint or strabismus, the internal rectus muscle is cut. It possesses the longest tendon of insertion, while the external possesses the shortest. The recti muscles pull the eyes toward their respective sides. The superior oblique turns the cornea down and out and rotates it inwardly. The inferior oblique turns the cornea up and slightly out and rotates the eye outward. A disarrangement of any of these muscles produces diplopia or double vision.

**Blood-Vessels of the Orbit.**—The arteries of the orbit are derived from the *ophthalmic artery*, which breaks up into its various branches soon after it passes through the optic foramen. In enucleation of the eye there is practically no bleeding, because the *arteria centralis* is the only one divided, and it is small. In evisceration, or cleaning out of the contents of the orbit, the main trunk of the ophthalmic will not be cut unless the very apex is invaded. Hemorrhage is readily controlled by packing gauze into the orbital cavity.

The veins of the orbit are the *superior* and *inferior ophthalmic*. The former is much the larger and more important. It not only drains the upper portion of the orbit, but communicates directly with the angular branch of the facial, at the inner canthus of the eye. The infection of erysipelas sometimes travels along these veins directly from the nose, face, and scalp without, to the cavernous sinus and meninges



within, causing thrombosis and death. The inferior ophthalmic usually empties into the superior; its anastomoses at the anterior portion of the orbit with the veins of the face are much smaller and, therefore, not nearly so dangerous.

**Nerves of the Orbit.**—The *optic nerve* is the nerve of sight. Interference with it produces blindness. The *oculomotor* or *third nerve* supplies all the muscles of the orbit except the external rectus and superior oblique. If paralyzed, the eye cannot be moved upward, inward, or to any extent downward. There will be ptosis of the upper lid from paralysis of the levator palpebræ, and dilatation of the pupil and paralysis of the accommodation of the eye. If the *sixth* or *abducens* is paralyzed, the eye cannot be turned outward. If the *fourth* or *pathetic* is paralyzed, the superior oblique fails to act, and the double vision produced is worse when the patient looks down, because it is normally a depressor muscle. The *lachrymal*, *frontal*, and *nasal branches of the fifth* are nerves of sensation, hence, in supra-orbital neuralgia and that affecting the nasal branch, pain is felt in the orbit at the inner angle of the eye and down the side of the nose.

**Retina.**—On the interior of the eye, the expansion of the optic nerve forms the retina. The retina is divided into two lateral halves, each supplied by a corresponding half of the optic nerve. When the nerve reaches the optic chiasm it splits into two parts, one (internal fibres) going to the opposite side of the brain, and the other (external fibres) to the ganglia on the same side of the brain. Posterior to the chiasm, the nerve fibres form the optic tracts. The optic tracts, after leaving the chiasm, wind around the crura cerebri to the external geniculate bodies, thence they pass to the thalami and anterior corpora quadrigemina, and are continued backward into the cuneus lobule of the occipital lobe of the brain.

It will thus be seen that a lesion affecting any portion of the optic pathway posterior to the chiasm will produce blindness of one-half of the retina of both eyes on the side of the injury; a right-sided lesion will produce blindness of the right half of both retinae, and a lesion on the left side, blindness of the left half of both eyes. This is called *hemianopia*. It is *right lateral hemianopia* if the right half of the visual fields is affected, and *left lateral* if the left sides are affected. Affections of the optic nerve produce total blindness of that eye if the whole nerve is involved. If only a part is involved, then a *unilateral hemianopia* may ensue. A *bitemporal hemianopia* may be caused by a tumor involving the anterior or middle portion of the chiasm. A *binasal hemianopia* requires a symmetrical lesion on the outer side of both optic nerves or tracts. A brain tumor located in the cuneus lobule would cause a lateral hemianopia of the same side, right or left, of both visual fields, hence sometimes called *homonymous*.

**The Eyelids and Conjunctiva.**—The eyelids are composed of five layers, viz: (1) *skin*, (2) *subcutaneous tissue*, (3) *orbicularis palpebrarum muscle*, (4) *tarsal cartilage* with the contained *Meibomian glands*, (5) the *conjunctiva*. The juncture of the two lids at each end is called the inner and outer *canthus*.

The skin of the lids is thin and the subcutaneous tissue loose and devoid of fat. For these reasons blood finds its way readily into the lids and shows plainly beneath the skin, constituting the familiar "black eye." The skin lends itself readily to plastic operations, as it is easily raised and the gap left can be readily closed. The blood supply of the lids is abundant, so that the flaps are well nourished and sloughing is not apt to occur. The folds in the skin run parallel to the edge of the lids, therefore the incisions should be made as much as possible in the same direction. The *orbicularis palpebrarum muscle* passes circularly over the lids and lies on the tarsal cartilage toward the edge of the lids and on the orbitotarsal ligament above. The so-called *tarsal cartilage* or *plate* is composed of dense connective tissue and contains no cartilage cells. It is attached externally by the *external (lateral) palpebral ligament* and internally by the *internal (medial) palpebral ligament* or *tendo-oculi*. This latter passes in front of the lachrymal sac. The tarsal plate is continued to the rim of the orbit by the *orbitotarsal ligament* or *septum orbitale*. The expansion of the levator palpebræ muscle ends in the upper edge of the tarsal cartilage and sends some fibres to the tissues immediately in front. The orbitotarsal ligament and tarsal cartilage prevent the fat of the orbit from protruding and also act as a barrier to the exit of pus.

The tarsal cartilage contains the *Meibomian glands*. These can be seen in life, by everting the lid, as yellow streaks passing backward from the edge of the lids.



Frequently these glands become obstructed and their mucus contents dilate the gland, forming a cyst known as *chalazion*. Suppuration may occur and pus instead of mucus is then contained within them. The wall of these cysts is formed by fibrous tissue containing some of the epithelial cells of the glands; therefore, if an uninfamed cyst is simply opened and its contents expressed, it will soon reform. To prevent this recurrence, the lining membrane is curetted in order to remove the mucus-forming cells. The cyst may point and be opened either on the side of the skin or conjunctiva, preferably the latter.

The openings of the Meibomian ducts are on the inner edge of the lids where the conjunctiva joins the skin. At the outer edge of the lids are the *cilia* or *eyelashes* and connected with them are sebaceous and sweat glands. Infection of these

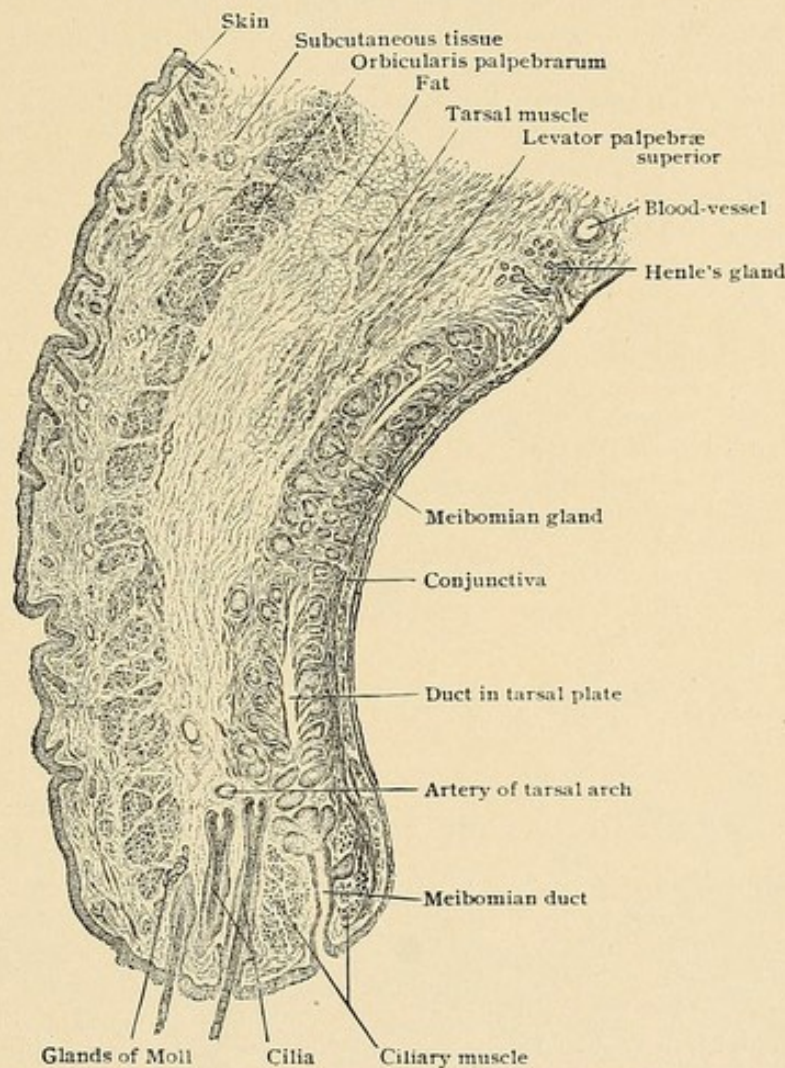


FIG. 97.—Vertical section of upper eyelid of child.  $\times 15$ . (Piersol.)

glands produces a small abscess called a *stye*. As they are on the outer edge of the lids they tend to discharge anteriorly and not toward the conjunctiva.

The *conjunctiva* covers the outer surface of the eye and the inner surface of the lids. The fold where it passes from one to the other is called the *fornix*. The *tarsal* or *palpebral conjunctiva* adheres closely to the tarsus and as it is transparent the Meibomian glands can readily be seen through it. The *ocular* or *bulbar conjunctiva* is loosely adherent to the sclerotic coat and through it the conjunctival vessels, which move with it, can be seen. The straight vessels going toward the cornea do not move when the conjunctiva is moved, because they lie deeper and are attached to the sclera.

**The Lachrymal Apparatus.**—The *lachrymal gland* consists of two portions: an orbital or superior portion and a palpebral or inferior portion. The orbital



portion is enclosed in a capsule and slung from the orbital margin by its suspensory ligament. Beneath, it rests on the fascial expansion of the levator palpebræ muscle. The palpebral portion is smaller than the orbital and is partially separated from it by the fascial expansion. It lies on the conjunctiva at the upper and outer portion of its fornix. The lachrymal gland opens by several fine ducts into the fornix of the conjunctiva. It is sometimes the seat of malignant tumors, but rarely of other troubles. The remaining lachrymal passages running from the eye to the nose are frequently the seat of inflammation, causing suppuration and obstruction.

The *puncta lachrymalia* in the top of each papilla lead into the *canaliculi*. These enter the lids perpendicular to their margin and turning at right angles join just before entering the upper end of the *lachrymal sac*.

The *lachrymal canal*, embracing the sac and lachrymonasal duct, each about 12 mm. in length, extends from just above the internal tarsal ligament or tendo oculi to the inferior meatus of the nose. The sac is strengthened posteriorly by the *tensor tarsi* or *muscle of Horner*, which passes from the lachrymal bone to the *puncta*, and by some fibres of the palpebral ligament. Anteriorly is the strong palpebral ligament. Below the palpebral ligament, the sac is comparatively weak and here it is that distention occurs and pus makes its exit. The duct lies in the lachrymal groove in the bone. It is narrower than the sac, being 3 to 4 mm. in width, and is the usual

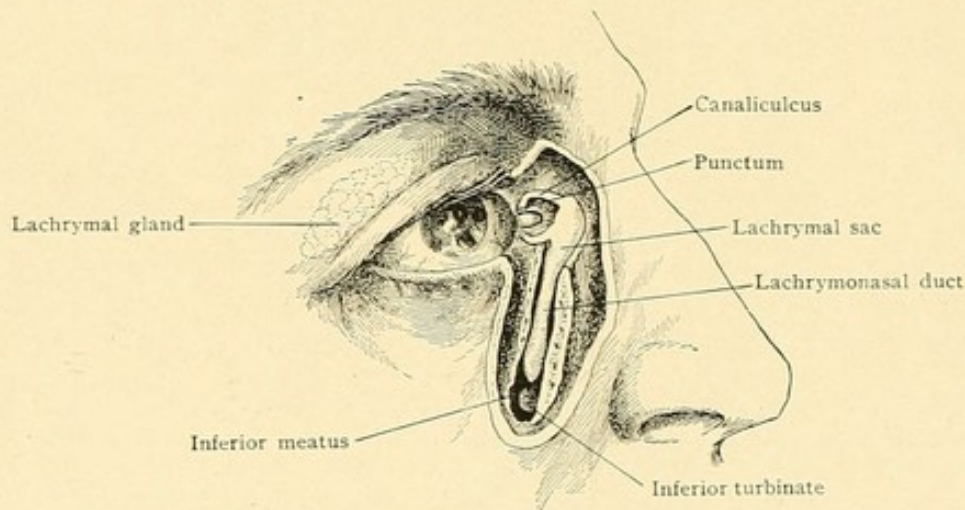


FIG. 98.—Lachrymal apparatus.

seat of obstructions. To keep the passage open in case of stricture probes are passed. The direction of the duct is slightly outward and more markedly backward, being indicated approximately by a line drawn from the inner canthus to just behind the second premolar tooth. In probing the duct it is customary to first open the punctum in the lower lid—which is normally only one mm. in size—by slitting it and the caniculus with a Weber's canaliculus knife. The probe is directed horizontally until the sac is entered, which is recognized by the end of the probe striking the bone; it is then raised vertically and passed downward and backward and sometimes slightly outward until it can be seen in the inferior meatus of the nose about 1 cm. behind the anterior end of the inferior turbinated bone.

## THE EAR.

The *external auditory meatus*, the *tympanum*, and the *Eustachian tube* are the remains of the first branchial cleft in the fœtus. A failure of any portion of the cleft to close normally may leave small sinuses or depressions in the neighborhood of the ear. The *external ear*, also called the *auricle* or *pinna*, is composed mainly of a cartilaginous framework covered with thin skin; the *lobe* or *lobule* forms its lower part and is composed of dense connective tissue containing fat. The large concavity leading into the meatus is the *concha*. The skin of the ear is thin and moder-



ately firmly attached to the cartilage. The subcutaneous tissue contains little or no fat. Although well supplied with blood, the exposed condition of the blood-vessels renders the ear sensitive to cold, and frost-bites are common. Injuries and wounds of the cartilage are slow to heal, and if inflamed the cartilage becomes exceedingly sensitive. Swelling of the ear readily occurs from injury or erysipelas, and the tension is quite painful.

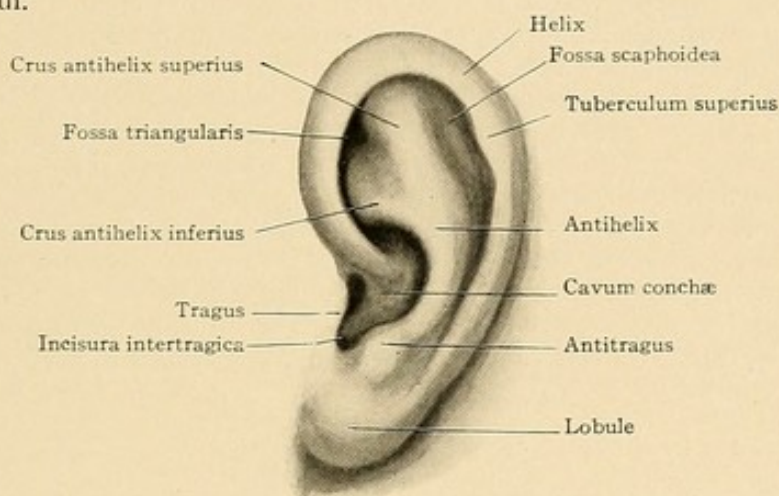


FIG. 99.—The external ear.

*Hæmatoma auris*, or effusions of blood, occur from traumatism, especially in the insane. While a hæmatoma may occur between the skin and perichondrium, on account of the firm binding of the skin to the cartilage it is usually between the perichondrium and cartilage.

*Angioma*, or enlargement of the blood-vessels, not infrequently affects the external ear and may not only be disfiguring but, by showing a tendency to

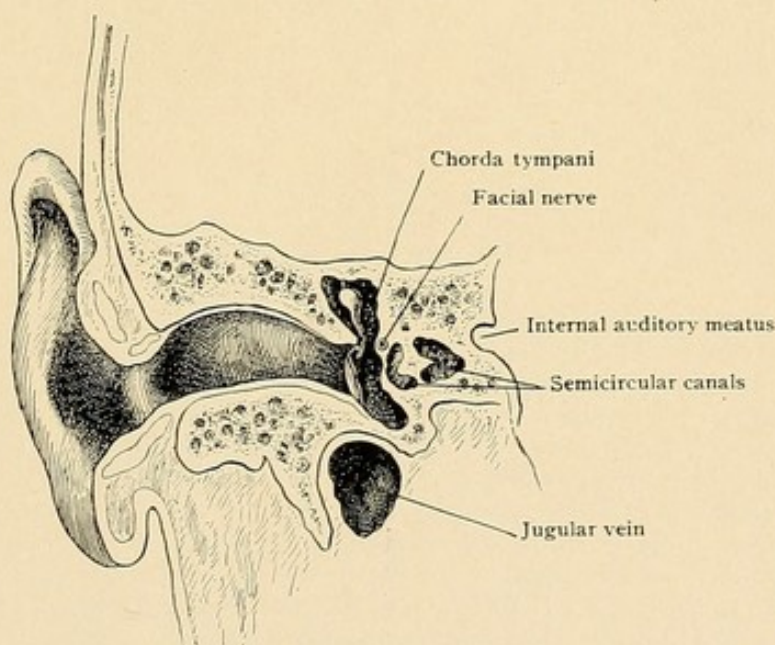


FIG. 100.—Vertical section of the right ear.

extension, may demand operation. The external ear derives its blood supply from the auricular branches of the temporal, internal maxillary, posterior auricular, and occipital arteries. As these are all branches of the external carotid, that artery is sometimes tied as a preliminary step to excising the angiomatic vessels.

**The External Meatus.**—The external auditory meatus extends from the concha to the drumhead, and is about 2.5 cm. in length. A little less than one-half



of it is cartilaginous and a little over one-half bony. Viewed anteroposteriorly the canal has a slight curve with its convexity upward (Fig. 100). Viewed from above (Fig. 101), it is seen first to pass backward and then forward, forming an angle before the bony wall is reached. In order to look into the ear and see the membrane it is necessary to straighten the canal, either by inserting a speculum or by pulling the auricle outward, upward, and backward. In children, upward traction is not so necessary as in the adult. The length of the canal is approximately the same in childhood as in adults, but the bony part is still in a cartilaginous condition. The external opening is oval, while farther in the canal is more circular; hence the Gruber speculum, which is oval in shape, or the round speculum of Wilde can be used with almost equal satisfaction. The point of junction of the bony and cartilaginous parts is narrower than either end, and it is difficult to remove a foreign body which has passed this point. This is particularly true in children, the lumen of the external meatus being quite small and narrow while the tympanic membrane is nearly as large as in adults.

The floor is longer than the roof, owing to the drum membrane inclining at an angle of 140 degrees. Cartilage forms the lower part of the canal, while the upper

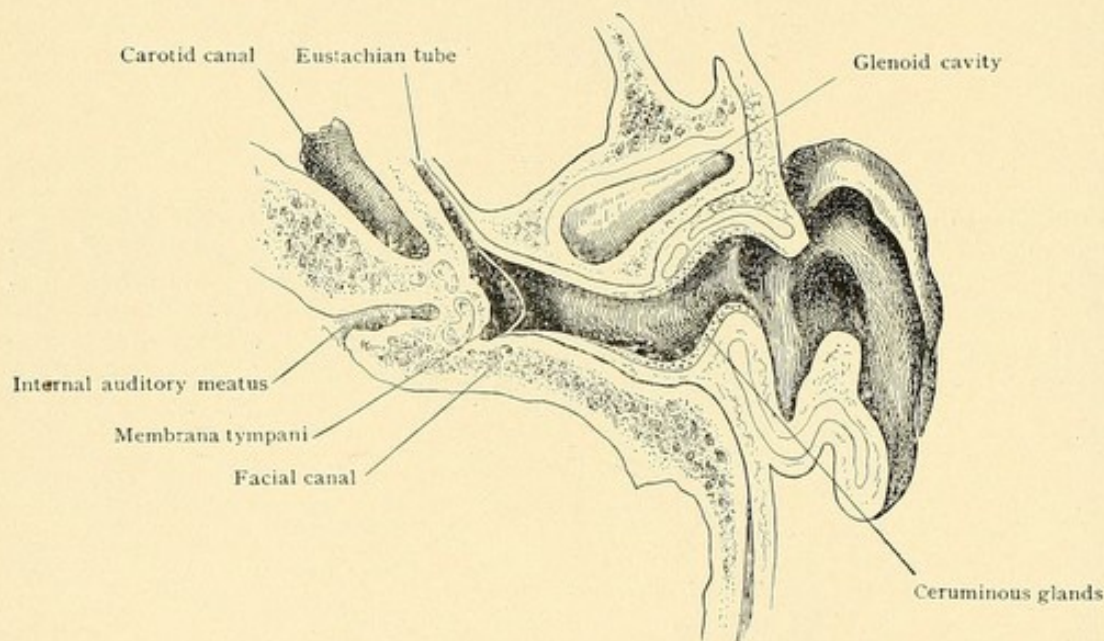


FIG. 101.—Right ear; horizontal transverse section.

part is completed by a fibrous membrane. Below and in front is the temporomaxillary joint, and just posterior is the *glenoid lobe of the parotid gland*. When the gland is inflamed and swollen it presses on the cartilaginous canal and produces pain; and in cases of suppuration pus may discharge through the external meatus, gaining access to the canal through fissures in the cartilage called the *fissures of Santorini*. The cartilaginous portion of the meatus contains sweat-glands, sebaceous glands, and hair-follicles. There are only a few glands in the upper posterior portion of the bony meatus. On account of the location of the glands in the external portion of the canal, accumulations of wax, and abscesses, which result from infection of the glands, occur nearer to the surface than to the drum membrane. It is only when the canal begins to fill up that the wax pushes its way to the membrane. When furuncles occur, the lining membrane swells and by closing the canal prevents a view of the drum being obtained. Incising of furuncles of the auditory meatus is sometimes required. The site of the inflamed spot having been located, an incision can be made where indicated. If care is exercised, one is not likely to injure the drum membrane, because the abscess starts in one of the sebaceous glands, which are located in the external half of the meatus. The membrane lies 2.5 cm. from the surface, and the point of the knife should not be carried so deeply as that for fear of wounding it; there is no necessity of going so far inward.



The meatus is supplied by the *auriculotemporal branch* of the fifth and the *auricular branch* of the pneumogastric nerve. Irritation of the latter nerve is said to be the cause of feeling it in the throat when anything is put in the ear.

**Membrana Tympani.**—The membrana tympani is inclined downward and inward at an angle of about  $140^{\circ}$  to the upper wall (Tröltsch) and  $27^{\circ}$  to the lower wall (Bezold) of the meatus; it does not lie directly transverse, therefore in introducing instruments into the ear the upper posterior part will be first encountered. The membrane is located 2.5 cm. (1 in.) from the surface; this is to be borne in mind in puncturing the membrane or other operations. The membrane has three coats: an outer, continuous with the skin of the meatus; a fibrous or middle layer; and an internal or mucous layer, continuous with the lining of the tympanic cavity. The membrana tympani at birth is fastened at its circumference to the tympanic bone, which unites with the other portions of the temporal bone soon after birth. This ring of bone is incomplete at its upper portion for a distance equaling one-eighth of its circumference. This is called the *notch of Rivinus*. The fibrous layer does not extend across this notch, which is closed by the mucous membrane on the inside and by the skin layer of the membrane on its outer side. The part closing the notch

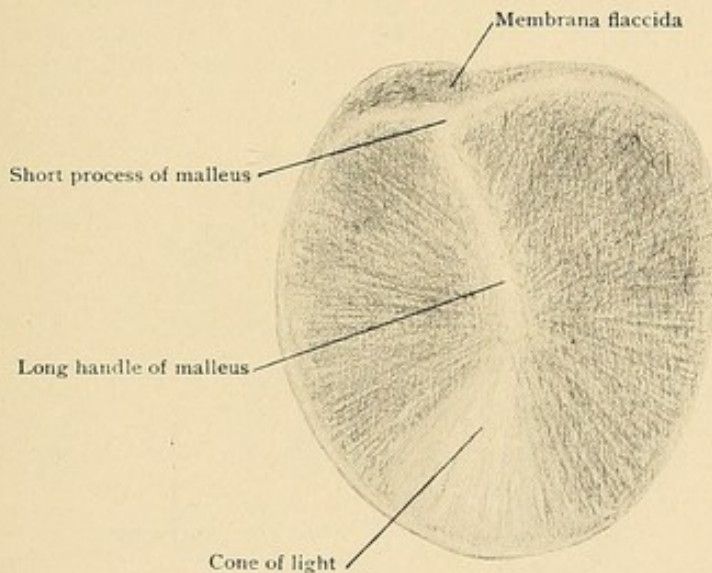


FIG. 102.—Outer surface of the tympanic membrane of the left ear.

is called *Shrapnell's membrane* or *membrana flaccida*. As it possesses no fibrous layer it is weaker than the membrane elsewhere and consequently is a favorite spot for pus to perforate in order to find exit from the middle ear.

In examining the membrane by means of light thrown into the meatus through a speculum by the head mirror, one sees extending downward from its centre a small cone of light; any depression or bulging of the membrane will cause this cone of light to be altered in its position, or even cause it to disappear entirely. From the centre of the membrane upward extends a line which indicates the attachment of the long handle of the malleus, one of the bones of the middle ear. Stretching across the upper portion is the membrane of Shrapnell or *membrana flaccida*, so called on account of its not being so tense as the remaining portion. It is better supplied with blood-vessels than the other portion.

The membrana tympani is of surgical interest on account of its being often distended or perforated. A purulent discharge from the ear usually indicates disease of the middle ear or tympanum. If pus is coming from a furuncle of the meatus, the latter will be swollen and its source can readily be recognized. If it comes from outside of the meatus, as in cases of suppuration of the parotid gland, it will be recognized by an examination of the gland. There is no other source of pus but the middle ear and for it to gain exit it must perforate the membrane; this perforation can usually be seen with the speculum and head mirror, as can also bulging.

In inflammation of the middle ear the effused serum or pus bulges the membrane outward. When this condition is accompanied, as it often is, by intense pain,



*paracentesis* or puncture is resorted to. The preferable spot is the posterior lower quadrant. Paracentesis of the membrane should be done by beginning the incision a little above and behind the centre of the tympanic membrane, which slopes downward and forward at an angle of  $140^{\circ}$  to the upper wall, and cutting downward to its lower edge. One must avoid the long handle of the malleus, which extends directly upward from the centre of the membrane. In the upper posterior part are the incus and stapes, therefore this portion should be avoided; and running across the upper edge beneath the mucous membrane is the *chorda tympani nerve*. Division of this nerve is said to be a matter of not much account. Incision through the anterior part is not considered suitable for drainage.

Perforations frequently occur through Shrapnell's membrane on account of its not having any fibrous layer; thus the pus does not go through the tympanic membrane proper. If perforation with a purulent discharge has existed for a long time granulations come through the opening, forming an aural polyp. To remove these a snare is used or caustic is applied.

**The Tympanum or Middle Ear.**—The tympanic cavity is flat and narrow and is situated directly behind and also above the membrane. It has a floor and roof, and external and internal walls. It is divided into the portion behind the membrane and the portion above the membrane called the *attic*. The *floor* is narrower than the roof and is formed by the *tympanic plate*, which separates it from the jugular

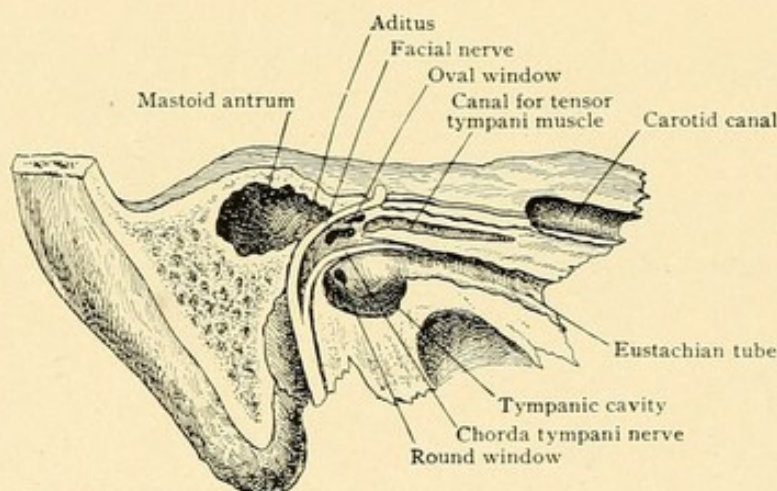


FIG. 103.—Right temporal bone:—The outer surface has been cut away, exposing the tympanic cavity, its inner wall, the mastoid antrum, Eustachian tube, etc.

fossa containing the commencement of the internal jugular vein. The bone forming the floor is more difficult for pus to perforate than is that of the roof, so that extension of middle-ear disease is less frequent through it. The *roof* is comparatively thin and formed of cancellous tissue with a thin and weak outside compact layer; therefore it is a somewhat common site for pus to perforate and thereby obtain access to the middle fossa of the skull. The distance from the floor to the roof is approximately 15 mm. ( $\frac{3}{8}$  in.); half is behind the membrane and the rest forms the attic above.

The *external wall* is formed below by the tympanic membrane and above by the bone. As the membrane is the weakest portion of the walls, collections of pus in the middle ear most often find a vent through it. Immediately behind the membrane are the lower portions of the ossicles, and above is the chorda tympani nerve.

The *internal wall* is formed of bone and is from 2 to 4 mm. ( $\frac{1}{12}$  to  $\frac{1}{6}$  of an inch) behind the membrane. It is so close that in doing the operation of paracentesis care must be taken not to thrust the knife too deeply. In it are the oval and round windows (Fig. 103).

There is no well-defined anterior or posterior wall. The anterior portion of the cavity is continued forward into the Eustachian tube; the canal for the tensor tympani muscle is immediately above it. Posteriorly the cavity of the attic is continuous through the *aditus* with the mastoid antrum and the cells beyond. Posterior



to the opening of the Eustachian tube is an elevation on the internal wall called the *promontory*, formed by one of the semicircular canals. Above the promontory is the *fenestra ovalis*, which lodges the *stapes* bone and communicates with the vestibule. Below and behind is the *fenestra rotunda*, closed by a membrane separating the *cochlea* from the middle ear. Above the fenestra ovalis is a ridge of bone marking the *aqueduct of Fallopius*, in which runs the facial nerve.

The **Eustachian tube** passes from the anterior portion of the tympanic cavity downward, forward, and inward to the upper posterior portion of the pharynx about level with the floor of the nose. It is about 3.5 cm. (approximately  $1\frac{1}{2}$  in.) in length. The outer third, near the ear, is bony and the inner two-thirds are cartilaginous. The point of junction of the bony and cartilaginous portions is the narrowest portion of the tube and is called the *isthmus*. The tube is usually closed, but opens in swallowing, yawning, etc., thus admitting air to the tympanic cavity and mastoid cells. Catarrhal affections of the throat readily travel up the tube and set up an inflammation of the middle ear. Swelling of the lining of the tube follows and air no longer passes to the ear. To open the tube two methods are employed—that of Valsalva, and that of Politzer. The former consists in holding the nostrils and mouth shut and attempting to blow, when the action of the throat and palate muscles opens the tube and allows the air to enter. In the method of Politzer, the patient is

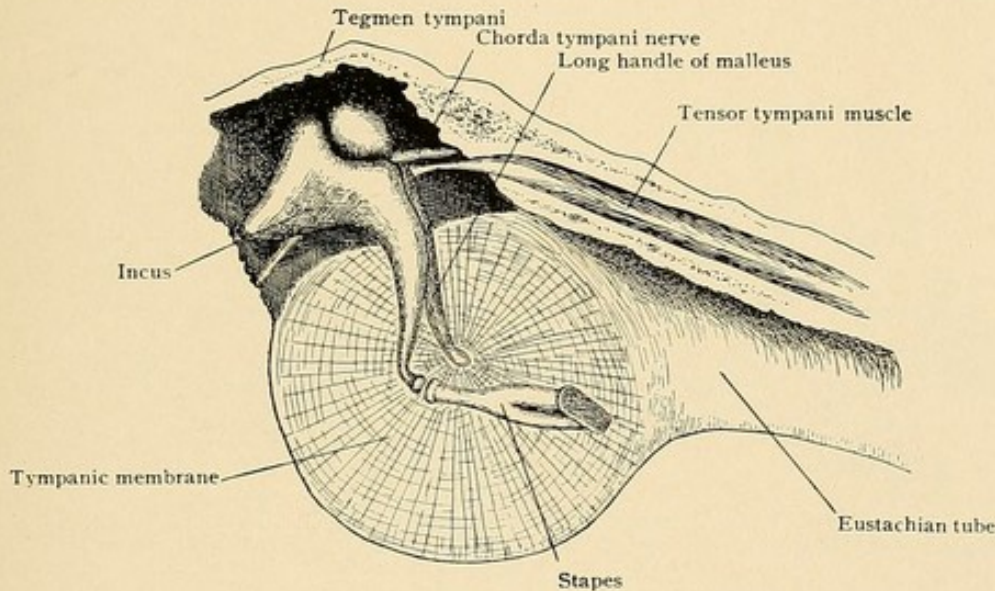


FIG. 104.—View of the tympanic membrane and ossicles of the left ear from within.

given a sip of water which he swallows on command. The nozzle of a rubber air-bag is placed in one nostril and the other held shut. As the patient swallows, the air-bag is compressed and the air enters the Eustachian tube. Sometimes this method is varied by asking the patient to say "hock," thus causing the tube to open, when the air-bag is compressed. The calibre of the tube is sometimes so small that probes are passed up it to dilate it. Care is necessary to avoid introducing the probe too far or it will injure the ossicles of the ear. Pus will sometimes discharge through the tube. I have seen pus coming from the middle ear pass down the tube into the inferior meatus and be blown out the anterior nares.

Lying in a separate canal immediately above and parallel with the Eustachian tube is the canal for the *tensor tympani muscle*.

The **attic** is directly above the tympanic cavity and contains the greater part of the ossicles. Between the two along the inner wall runs a ridge of bone within which is the aquæductus Fallopii, containing the facial nerve. The roof of the attic is called the *tegmen*. It is a thin shell of bone, varying in thickness, and separates the cavity of the ear from the middle cerebral fossa above. Pus frequently eats its way through at this point and forms a subdural abscess, which by working its way backward involves the lateral (transverse) sinus, causing thrombosis and general septic infection.



The **antrum** is a little larger than the attic. The two cavities are continuous through the aditus. The roof of the antrum is level with the roof of the attic and its floor is about level with the top of the membrane. It is thus seen to be directly above and posterior to it.

**Mastoid Cells.**—The mastoid cells are continuous with the antrum and permeate the mastoid process down to its tip. The cells come so close to the surface that suppuration within them often bursts through and discharges behind the ear. The upper, inner, and lower portions of the bone are also sometimes perforated, which will be referred to later.

**Middle-ear Disease.**—Suppuration from middle-ear disease is caused by an infective inflammation travelling up the Eustachian tube from the pharynx and nasal cavities. It may pass to the attic above and thence to the mastoid antrum and mastoid cells. Pus usually finds an exit by perforating the tympanic membrane and discharging through the external auditory meatus. As already stated, it may pass down the Eustachian tube to be blown out of the anterior nares. It has been known to pass down the canal for the tensor tympani muscle, and form a *retropharyngeal abscess*. As the pus reaches the pharynx behind the prevertebral fascia, it may extend laterally and appear externally behind the sternomastoid muscle. Having thus reached the base of the skull, the infection may involve the meninges and brain through the crevices in the bone. It is rare for it to perforate the bone below and

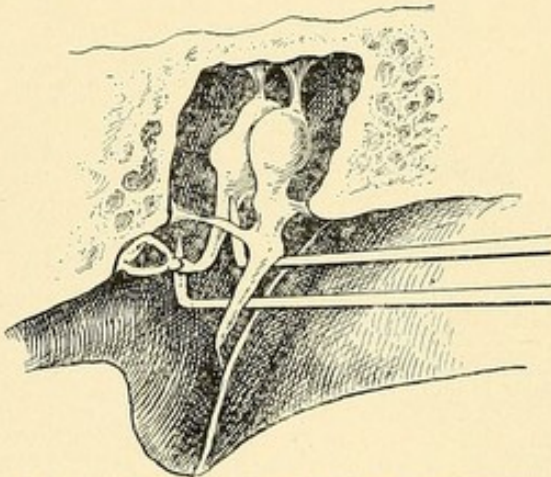


FIG. 105.—Tenotomy of the tensor tympani tendon and separation of the incus from the stapes.

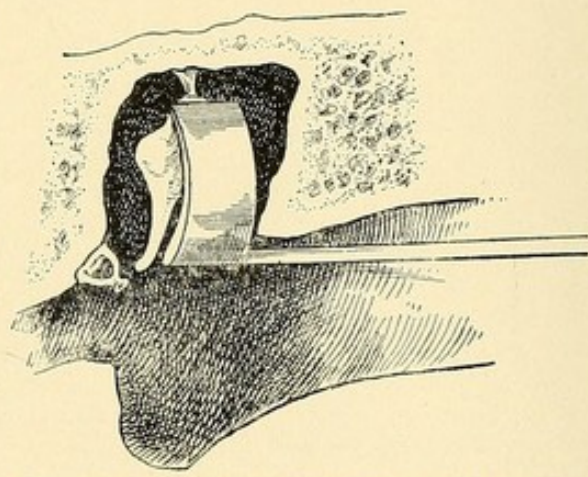


FIG. 106.—Removal of the incus by means of Ludwig's hook.

Modified from Georges Laurens.

anteriorly, and thus implicate the jugular vein and internal carotid artery. It may eat into the posterior wall and involve the facial nerve, which is covered by only a thin shell of bone, and produce facial paralysis, attack the internal ear through the fenestra ovalis and rotunda and pass through the internal meatus to the brain. If it extends upward and involves the attic and antrum, it may perforate the roof, or tegmen, and form a *subdural abscess* in the back part of the middle cerebral fossa, whence it travels a distance of about a centimetre to the lateral sinus, causing a *thrombus* to form, or it may produce an abscess of the temporosphenoidal lobe of the brain. The antrum and mastoid cells being continuous, the posterior and inner walls may be perforated, the pus thereby reaching the posterior cerebral fossa, again involving the lateral sinus, or producing a cerebellar abscess. If it perforates the mastoid process on its inner wall at the groove for the digastric muscle, the pus gains access to the back of the neck, forming what is known as *Bezold's abscess*.

**Operations on the Middle Ear.**—The operations on the middle ear, besides those involving the membrane, are done either for the removal of the remains of the membrane and ossicles, or else to clear out the antrum and mastoid cells and even, if necessary, examine the lateral sinus and jugular vein and explore the brain. They are done for suppurative affections, which may be either chronic, producing local symptoms, or acute, producing in addition constitutional disturbances and even general infection. Caries of the bones is a prominent condition in suppurative cases



of long standing, and the character of the operation is dependent on the extent to which the disease has progressed.

In removal of the ossicles, the tympanic membrane is first separated around its edges. Then the tendon of the tensor tympani muscle is cut, and the incus disarticulated from the stapes. The latter is done by cutting with a bent knife across the axis of the stapes and not of the incus (see Fig. 105). The malleus is seized and drawn first down and then out, bringing the membrane with it, and afterwards the incus, which is detached by Ludwig's hook (see Fig. 106), is removed, and, if desired, the stapes. Granulations and pus are removed by the snare, forceps or curette. Care is to be taken to avoid, if possible, scraping away the thin shell of bone on the internal wall that covers the facial nerve. Any twitching of the muscles of the face indicates that the nerve is being irritated. The chorda tympani nerve, which passes on the inner side of the handle of the malleus and lies beneath the mucous membrane, is of necessity removed. No important symptoms follow its removal.

**Operations on the Antrum and Mastoid Cells.**—In order to understand these operations, one must recall that the *suprameatal crest* is the ridge of bone forming the upper edge of the bony meatus, and a continuation backward of the posterior root

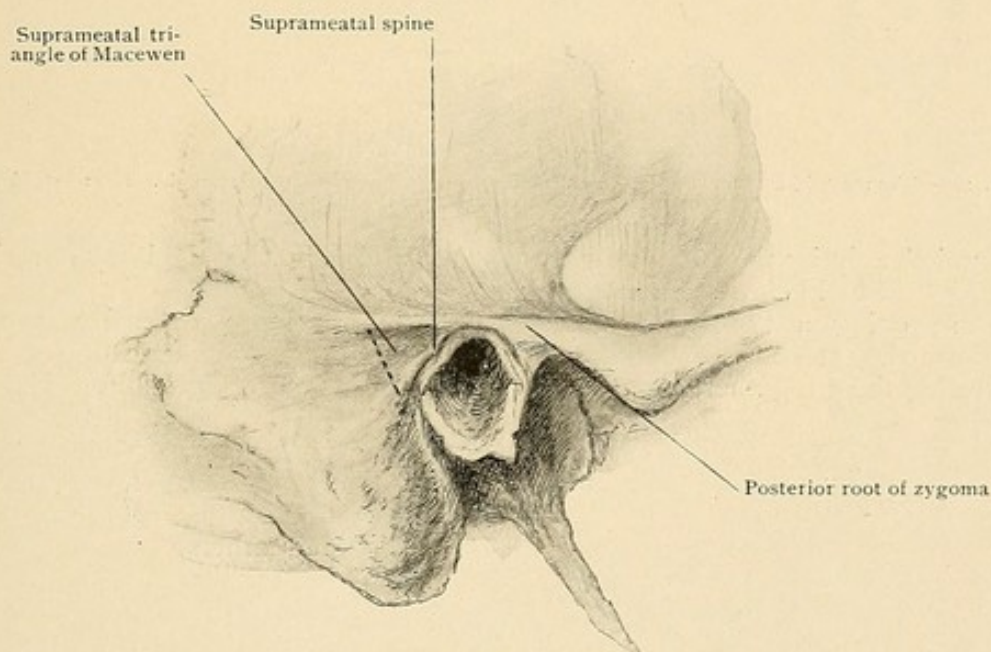


FIG. 107.—Landmarks for operating to enter the mastoid antrum.

of the zygoma. The upper and posterior edge of the meatus is formed by a thin, small shell or edge of bone running from the suprameatal crest downward and backward to the posterior wall; this is the *suprameatal spine*. Behind the suprameatal spine and between it and the posterior portion of the suprameatal crest is a depression, the *suprameatal fossa*. This suprameatal fossa is triangular in shape. The crest forms the upper side, the spine its anterior side, and the ridge of bone, running from the posterior portion of the crest to the lower portion of the spine, forms the posterior side. These three lines form the *suprameatal triangle of Macewen*. It is through this triangle that the antrum may be reached. The operation may be restricted to the antrum and tympanic cavity, or may include the whole or part of the mastoid cells, constituting the operation known as *tympanomastoid exenteration*.

To reach the antrum a semicircular cut is made a centimetre back of the ear and the ear and membranous canal loosened and pushed forward. With a gouge chips of bone are removed from the suprameatal spine backward and from the crest downward as far as desired. This will extend considerably beyond the line marking the posterior boundary of Macewen's triangle. The outer table of bone being removed, the cells are broken through parallel to the meatus and slightly upward,



for the lower level of the antrum corresponds to the upper edge of the meatus. It is hardly safe to penetrate deeper than 1.5 cm. ( $\frac{3}{8}$  in.) from the meatal spine inward, for fear of wounding the facial nerve. The mastoid antrum lies not only above and posterior to the membrane and tympanic cavity, but extends outward along the posterior and upper portion of the canal, and the facial nerve can be

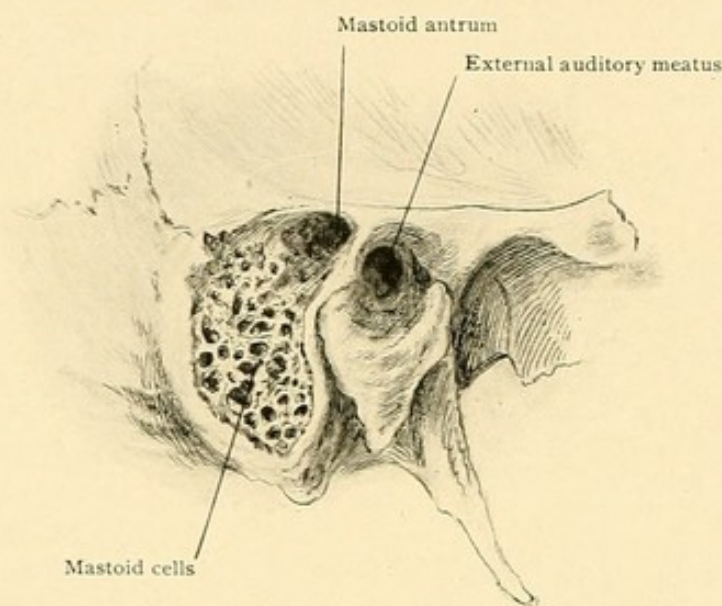


FIG. 108.—The mastoid antrum exposed by chiselling through the suprameatal triangle. The mastoid cells exposed by chiselling off the surface of the mastoid process.

wounded only by passing across the antrum and attacking the bony covering of the Fallopian canal below and anteriorly.

In doing a tympanomastoid exenteration, a more extensive procedure is performed. It consists in cleaning out the various communicating cavities and throwing them together, thus making their interior more accessible. The antrum is

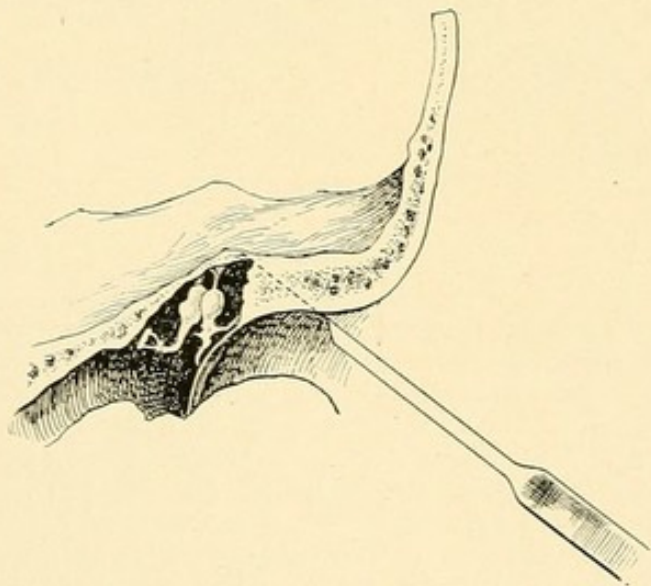


FIG. 109.—Chiselling away the spur of bone between the roof of the external auditory meatus and attic or epitympanum.

reached in one of two ways: either posteriorly, or anteriorly through the meatus. The posterior operation, or that of Schwartz, Zaufal, and others, consists in removing the membranous lining of the bony meatus on its upper and posterior portions down to the tympanic membrane. The antrum is then entered as already described; the posterior bony wall of the meatus is chiselled away, giving access to the tympanum; the ridge of bone separating the roof of the bony meatus from the attic or epitympanum is chiselled away (see Fig. 109), and the membrane and ossicles removed. This gives access to the tympanic cavity, epitympanum, and antrum. As much of the mastoid cells as necessary is

exposed by chiselling away their external covering of bone even down to the tip of the mastoid process.

If the anterior operation of Stacke is performed, the membranous lining of the bony meatus is to be loosened and divided as close to the membrane as possible and drawn forward with the cartilaginous meatus. The drum membrane and as much of the ossicles as possible are then to be removed, and with a chisel or bent gouge the



angle, or ridge of bone between the upper side of the bony meatus and epitympanum, or attic, cut away. The antrum is now entered by chiselling away the upper posterior wall and the chiselling away of bone continued until the mastoid cells have been sufficiently exposed. The final result of these two methods is the same. The external

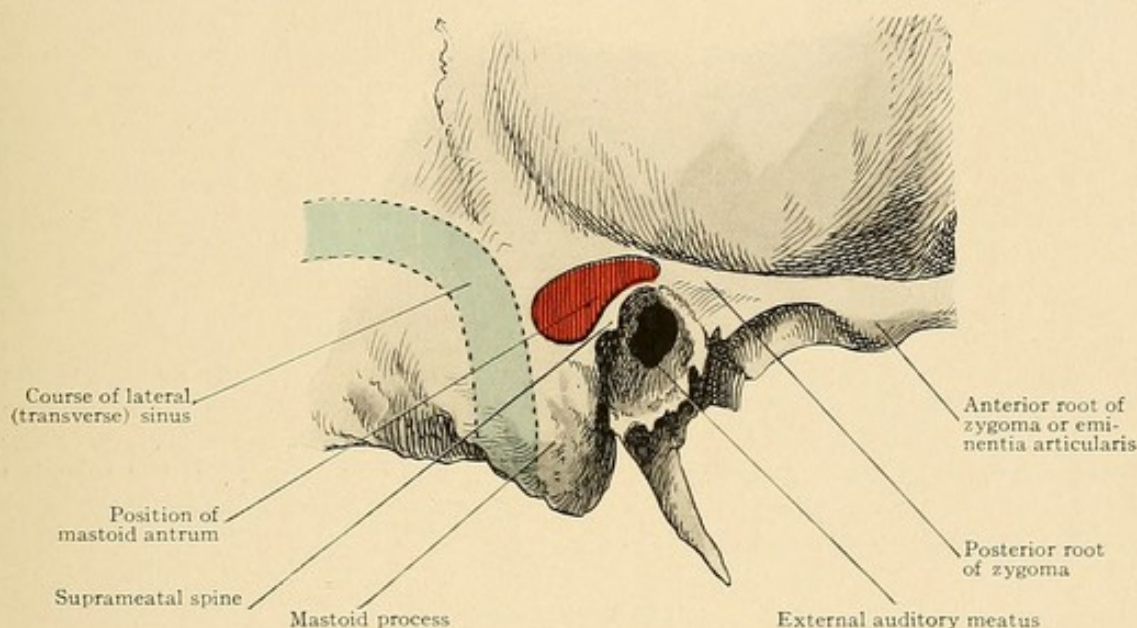


FIG. 110.—Lateral view of the temporal bone, showing the relations of the lateral or transverse sinus and mastoid antrum.

meatus, tympanum, epitympanum, antrum, and mastoid cells are all thrown into one large cavity. Wounding of the facial nerve is to be avoided by first learning its course and then by sponging away the blood and cutting only the structures which are clearly visible. Tracing the facial nerve backward, it is seen (Fig. 103) entering the stylomastoid foramen, passing upward posterior to the tympanic cavity, and crossing at about its upper edge to pass above the oval window. Viewed in Fig. 101, it is seen that the Fallopiian canal lies a trifle nearer to the external surface than does the tympanic membrane, so that in making the opening into the antrum or in connecting the mastoid cells below the antrum with the tympanic cavity, care should be taken to keep a little anterior or superficial to the membrane.

#### Relations of the Brain and Lateral Sinus.

—In operating on the skull for middle-ear disease, it is desirable to know

how to reach and how to avoid the brain and lateral sinus. The lower level of the brain in the region of the ear corresponds to a prolongation directly backward in a straight line of the posterior root of the zygoma. If one keeps below this line, he is not likely to open the brain case. If it is desired to explore the under surface of the

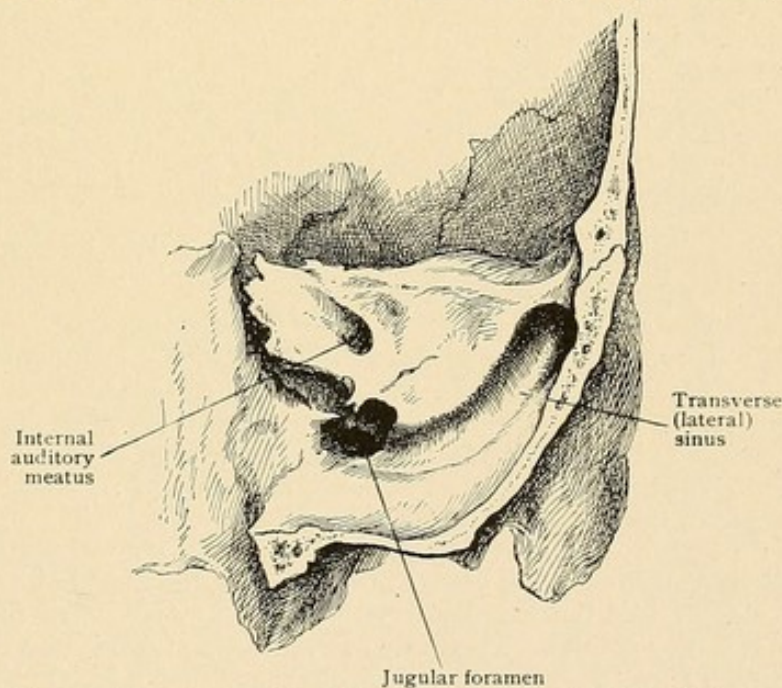


FIG. 111.—Transverse section of the right side of the skull just behind the mastoid process; looking forward.



brain or dura directly over the middle-ear cavity, then one trephines above this line or suprameatal crest, the lower edge of the trephine opening being .5 cm. above it. This will lead to the middle fossa of the skull, occupied by the temporosphenoidal lobe. The sharp upper and posterior edge of the petrous portion of the temporal bone gives attachment to the tentorium and separates the middle cerebral fossa in front from the posterior fossa, containing the cerebellum, behind. The point at which this ridge and tentorium reach the side of the skull is indicated by the point of crossing of a line drawn up from the tip of the mastoid process, midway between its anterior and posterior borders, and the line of the posterior root of the zygoma. The course of the lateral sinus is indicated by a curved line from above and to the right (about .5 to 1 cm.) of the external occipital protuberance to the upper posterior portion of the mastoid process and thence to its tip. The anterior edge of the lateral sinus reaches as far forward as a line drawn from the tip of the mastoid upward, midway between its anterior and posterior borders. The point at which it turns is where this mastoid line intersects the line of the zygoma. Its upper edge rises above this line approximately 1 cm. The sinus is 1 cm. in width. The distance of the sinus from the surface varies from .5 cm., or even less, at the top of the mastoid process to 1.5 cm. at its tip. So uncertain is this that the only safe way to expose the sinus is to cut the bone off with a mallet and gouge in thin chips parallel to the surface. The use of a trephine or other boring instrument is not to be advised. If the infection of the lateral sinus has extended to the jugular vein this latter must be reached by means of a separate incision in the neck.

## THE NOSE.

Externally the nose forms a prominent projection on the face, hence it is frequently injured and its construction should be studied in relation to those injuries. It forms a conspicuous portion of the features, hence deformities or disfigurements of it are very distressing, so that plastic operations are done for their relief. Internally, the nasal cavities are concerned in the sense of smell and form the passage-way to and from the lungs and the various accessory cavities for the air in respiration. It likewise serves as a receptacle for the tears as they come down the lachrymonasal duct. Interference with the flow of air by obstruction of the nasal chambers may cause affections of the pharynx, larynx, lungs, ears, or accessory sinuses—ethmoid, sphenoid, maxillary, and frontal. Catarrhal troubles may start in the nose and invade any of these parts. They may even extend up the Eustachian tube and cause deafness; or up the lachrymonasal duct and cause trouble with the lachrymal canal or conjunctiva. A knowledge of the nose is essential to all those who wish to devote themselves especially to affections of the eye, ear, and throat, because the origin of the affections of these organs may be in the nasal chambers instead of the organ in which they are most manifest.

The skin over the root of the nose is thin and lax. It is well supplied with blood by the frontal and nasal branches of the ophthalmic, and the angular branch of the facial arteries. In reconstructing a nose by means of a flap taken from the forehead, it is these branches that nourish it. The laxity of the skin allows the pedicle to be twisted around without interfering with the circulation.

The skin over the tip and alæ is thick and adherent to the cartilages. It possesses a comparatively scanty blood supply, hence its liability to suffer from cold, and is a favorite site for ulcerations, as lupus, superficial epithelioma (rodent ulcer), etc. Sebaceous and sweat glands are abundant, and stiff hairs guard the inside of the nostrils. These latter are not seldom the seat of small furuncles or boils, which are extremely painful. This is due to the tension caused by the congestion and swelling, which is restricted by the tissues being so firmly bound to the cartilages beneath.

**Nerves.**—In addition to the *olfactory nerve*, the nose is supplied by the *nasal*, *infratrochlear*, and *infra-orbital branches* of the fifth nerve, hence the eyes water when the nose is injured. In certain cases of neuralgia affecting the ophthalmic division of the fifth nerve, pain is felt along the side of the nose. As the nasal nerve enters the skull from the orbit through the anterior ethmoidal foramen, it may be involved in disease of the ethmoidal sinuses.



The **nose proper** consists of a bony and a cartilaginous portion. The *bony portion* is formed by the two nasal bones articulating with the frontal bone above, with each other in the median line, and with the nasal process of the superior maxilla on the side. They are supported on the inside by the upper anterior portion of the perpendicular plate of the ethmoid. This articulation does not extend the whole length of the nasal bones to their tip, but only about half their length.

The *cartilaginous portion* consists of four lateral cartilages, two on each side, upper and lower, and the triangular cartilage, or cartilaginous septum on the inside.

The external shape of the nose viewed in profile is composed of three portions: an upper of bone, a middle of cartilage—the upper lateral cartilages—and a lower, or tip, formed by the lower lateral cartilages. The bridge of the nose is formed by bone; it slopes downward and forward and where it joins the upper lateral cartilage the line changes and slopes more downward, until the tip is reached, here the lower lateral cartilages bulge forward, forming a rounded and more or less projecting tip.

**Injuries to the Nose.**—The bones and cartilages may be fractured or dislocated. This may involve either the outside structures or those forming the septum, and often both. The displacement depends on the character and direction

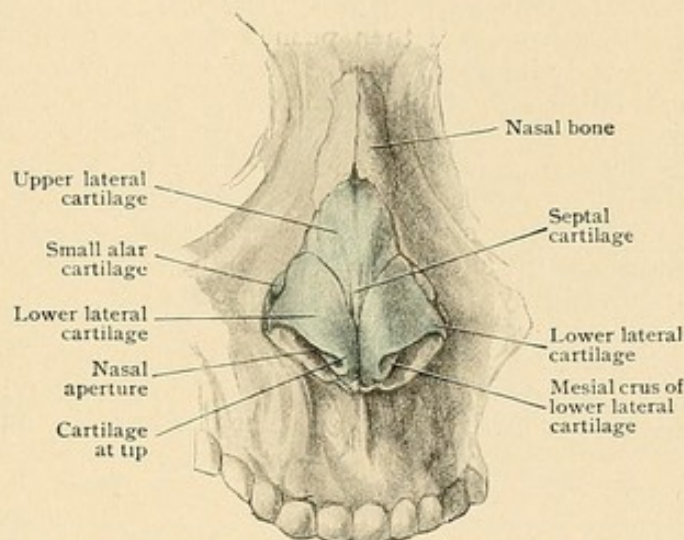


FIG. 112.—Bony and cartilaginous framework of nose, front aspect. (Piersol.)

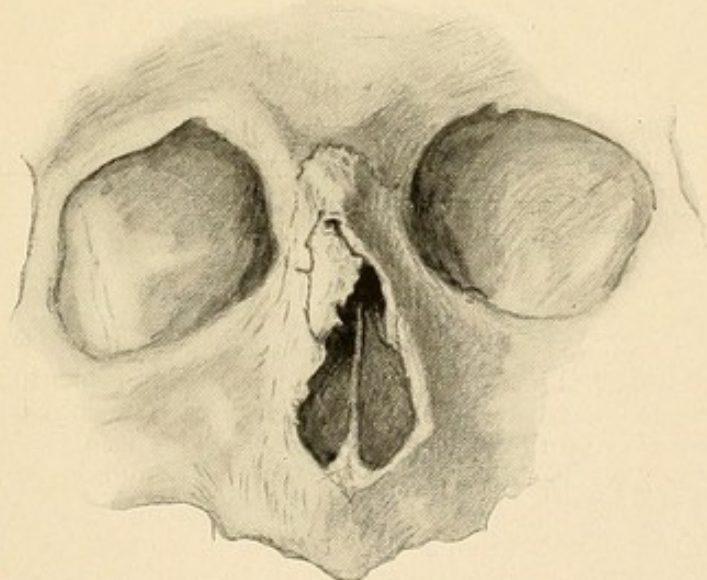


FIG. 113.—Fracture of the nose with deflection of the nasal bone laterally.

of the injury. It is either a displacement to one side, or the nose is crushed, producing a flattening of the bridge. If the displacement is lateral, whether by a dislocation or fracture, there is liable to be a deviation of the septum, because the bony and cartilaginous septum is connected with the bones and is apt to be carried with them to the side. If the displacement is inward, not only are the nasal bones depressed, but the septum beneath may be either bent or fractured. The pushing of the septum toward the floor causes it to buckle and bend or even break at the



junction of the triangular cartilage with the perpendicular plate of the ethmoid and the vomer. In treating these fractures, the most efficient method is to grasp the septum with the flat blades of an Adams forceps (after cocaineization) and lift the bones up or to one side as needed. In cases where it is not desired to use the forceps, the writer grasps the nose with a wet towel, makes traction to loosen the fragments, and then pushes them over into place. The triangular cartilage is frequently injured; with the displacement or loosening of the upper lateral cartilages a great amount of displacement may be caused, so that the nose instead of forming a straight line is bent to one side from the ends of the bones down to the tip. Injuries to the septum in childhood are probably the cause of a large number of the cases of deviation of the septum, spurs, etc., seen later in life.

In fractures the mucous membrane is often torn, thus allowing air to enter the tissues at the site of fracture, producing emphysema. If such a patient blows the nose violently, the air may be forced under the skin of the face, around the eyes and up the forehead.

**Anterior Nares.**—The nostrils or anterior nares in the white race are an elongated oval in shape and run in an anteroposterior direction, being separated from each other by the *columna*. They lie in a direction parallel with the floor of the nose,

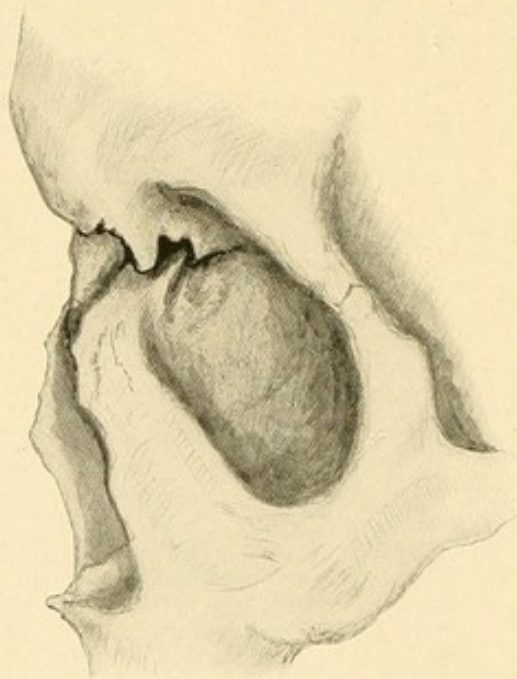


FIG. 114.—Fracture of the nose showing depression of the nasal bone.

so that to examine the nasal fossæ with a speculum the instrument is first introduced from below, then tilting the tip of the nose upward, the speculum is directed backward. To see the floor of the nose, it is necessary to raise the outer end of the speculum still higher, because the floor is below the bony edge. From the outer edge of the nostril the nasal cavities go upward and backward for a distance of .5 to 1 cm. This part, called the vestibule, is covered by skin, not mucous membrane. It bears stiff hairs—*vibrissæ*. Inflammation of these hair-follicles and associated glands produces exceedingly painful pustules. It is here likewise that dried mucus collects and forms scabs, which stick to the hairs and are hard to remove. The attempt to remove them probably is the cause of infection and inflammation around the roots of the hairs. The vestibule leads to the ridge of bone or crest, which is directly posterior to the side of the nasal spine. This ridge of bone is on a higher level than the floor of the nose, and in order to view the latter the nostrils must be raised, by means of the speculum, above it (Fig. 115).

*View from the Anterior Nares.*—In looking into the nose from in front, if the speculum is directed downward, the floor of the nose and the inferior meatus can be seen. On the inner side is the septum, on the outer the anterior end of the



inferior turbinated bone. Still higher is the middle meatus and the anterior end of the middle turbinated bone. The superior turbinated bone is not visible from the front, being in the upper posterior corner and hidden from sight by the middle turbinated. Sometimes in the upper portion of the nose, beneath the outer surface of the anterior extremity of the middle turbinated bone, is seen a small cleft, the *hiatus semilunaris*, leading through the infundibulum into the frontal sinus. If the inferior turbinated has been shrunk with cocaine, and if the inferior meatus is roomy, one can see the posterior wall of the pharynx. This can be seen moving if the patient swallows, pronounces the letter "k," etc., (Fig. 116).

**Septum.**—The *nasal fossæ* are separated from each other by the *septum*. This septum is formed (see Fig. 117) by the triangular cartilage in front, forming the *cartilaginous septum*, and the perpendicular plate of the ethmoid and vomer behind, forming the *bony septum*. The posterior edge of the septum is formed solely

by the edge of the vomer; it can readily be seen with the rhinoscopic mirror. The affections of the septum are hæmatoma, ulcer and abscess, deviation to one side, spurs or outgrowths, and it may be the site of nasal hemorrhages. *Hæmatomas* affect

the cartilage of the septum and resemble those of the ear. They are usually due to traumatism and may become infected, forming a pus-like detritus or abscess. They can readily be recognized as a fluctuating swelling on the septum, one or both sides being affected.

*Deviations of the septum* are bendings toward one side, and cause serious obstruction to breathing. They are probably traumatic in origin and involve the cartilaginous portion. In operating for their correction, incisions are made through the cartilage and the projecting part pushed toward the median line. In some operations care is taken not to cut through the mucous membrane on both sides, as well as through the cartilage. This is done to avoid the formation of a permanent perforation of the septum, the presence of which may cause a very objectionable whistling sound when the patient breathes. As the mucous membrane covering the cartilage is thin, great care is necessary in dividing the cartilage to avoid wounding the side which it is desired to leave intact.

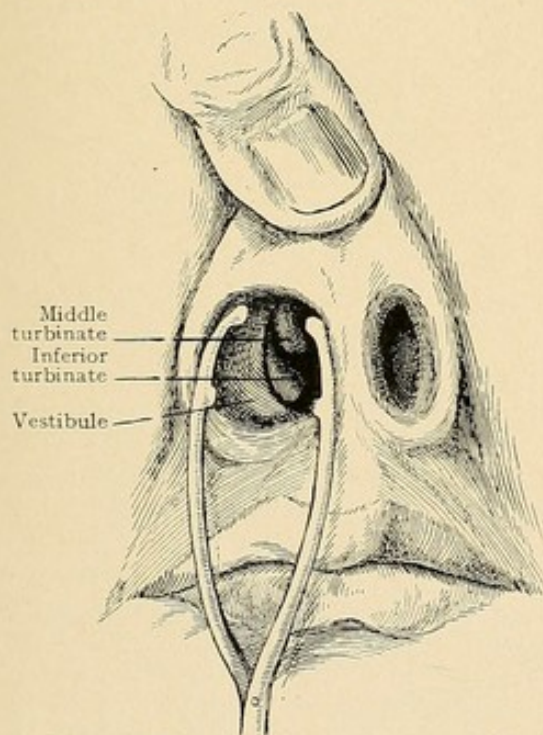


FIG. 116.—Examining the anterior nares. Middle and inferior turbinates exposed to view.

The triangular cartilage is thin at its centre and thick at its edges.

*Spurs* are usually outgrowths of bone or cartilage occurring in the line of juncture of the cartilage and vomer. On the floor of the nose the nasal crest may project quite perceptibly to one side; a cartilaginous projection may likewise occupy this site. As these spurs are found on the anterior edge of the vomer, they some-

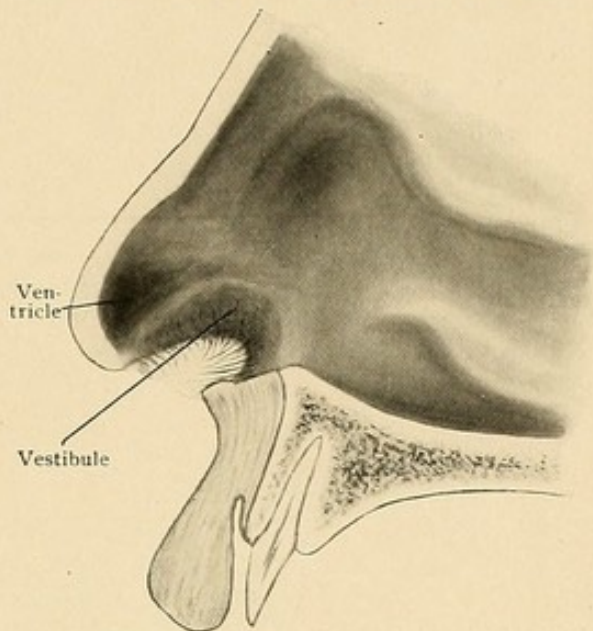


FIG. 115.—Lateral view of the interior of the nose.



times form a distinct ridge of bone running upward and backward. If the spur is short in extent, the farther posterior it is situated, the higher up it is on the septum. If marked, it is often accompanied by deviation of the septum and it may impinge on the lower turbinated bone opposite to it. These spurs are usually removed by sawing. A narrow-bladed saw is introduced with its back on the floor of the nose and the spur removed by sawing upward (Fig. 118).

*Epistaxis* or bleeding from the nose is said to occur in a large percentage of the cases from the septal branch of the sphenopalatine artery. This comes from the internal maxillary artery through the sphenopalatine foramen and passes downward and forward as the nasopalatine or artery of the septum. It anastomoses below with the anterior palatine branch of the descending palatine artery as it comes up from the roof of the mouth through the *foramen of Stenson* (incisor foramen). It also anastomoses with the inferior artery of the septum, a branch of the superior coronary. The bleeding point is to be sought for low down on the anterior portion of the cartilaginous septum near the anterior nares. Hemorrhage can be stopped by packing only the anterior or both the anterior and posterior nares.

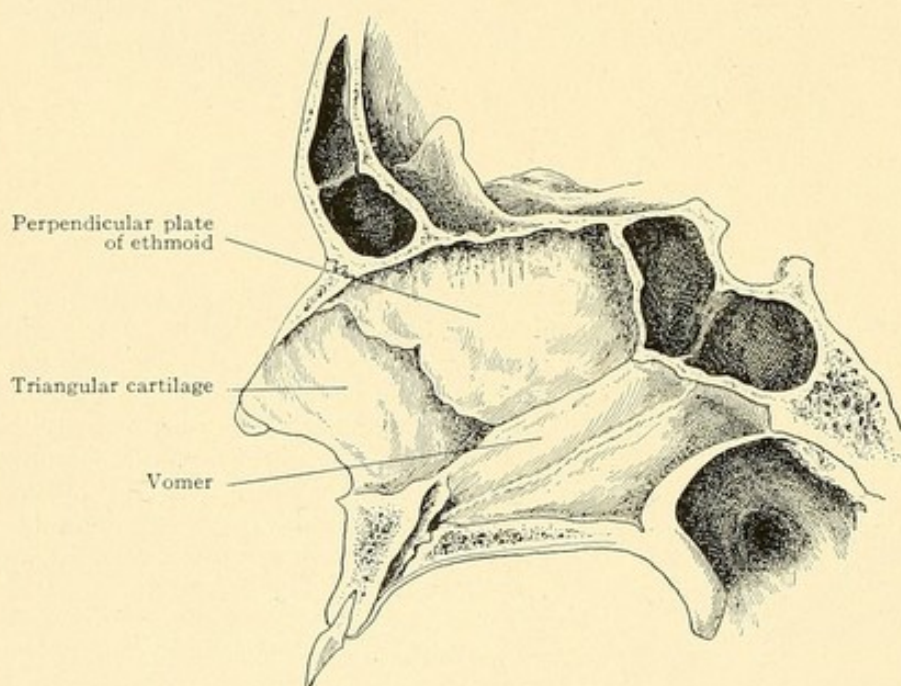


FIG. 117.—Septum of the nose.

The **arteries** supplying the nasal cavities (Fig. 119) come from three directions: superior—the *anterior* and *posterior ethmoidal*, supplying the ethmoidal cells, the upper portion of the septum, the roof, and the outer wall anteriorly; inferior—the *septal branch of the superior coronary artery* and a *branch of the descending palatine artery* coming up through the incisor foramen; posterior—the *sphenopalatine*, giving its *nasopalatine branch* to the septum and also supplying branches to the ethmoidal cells, frontal and maxillary sinuses, and outer wall of nose, the *Vidian* and *pterygo-palatine* going to the posterior portion of the roof, and the *descending palatine* giving branches to the posterior portion of the inferior meatus and posterior end of the inferior turbinated bone.

The **veins**, like the arteries, are in three sets: the *superior* are formed by the *anterior* and *posterior ethmoidal* and some smaller veins passing upward through the foramen in the cribriform plate, or *foramen cæcum*, to the longitudinal sinus; the *inferior* communicate with the facial veins through the anterior nares; the *posterior* drain upward and backward through the sphenopalatine foramen into the pterygoid plexus.

The **lymphatics** drain either anteriorly on the face or posteriorly through the deep lymphatics of the neck. Therefore, acrid secretions causing ulcerations of the anterior nares are liable to be accompanied by swelling of the submaxillary lymphatic



nodes; while enlargement of the deep cervical lymphatics follows disease of the deeper nasal cavities.

*Nasal hypertrophies* are enlargements of the nasal mucous membrane. The mucous membrane of the nose or *Schneiderian membrane* has columnar ciliated cells on its surface and mucous cells beneath. It is prolonged into the various sinuses and cavities in connection with the nasal fossæ. The membrane on the upper third of the septum, the upper portion of the middle turbinated, and the superior turbinated bone, contains the terminal filaments of the olfactory nerve. The membrane over the lower portion of the septum, over the lower edge of the middle, and the greater part of the inferior turbinated bones, contains a venous plexus which renders it erectile. On the slightest irritation this portion of the membrane will swell and obstruct the passage of air through the nostrils. Repeated swelling of the membrane of the septum produces thickenings of the septum, which if anterior may be seen through the nostrils, and if posterior by the rhinoscopic mirror. The membrane

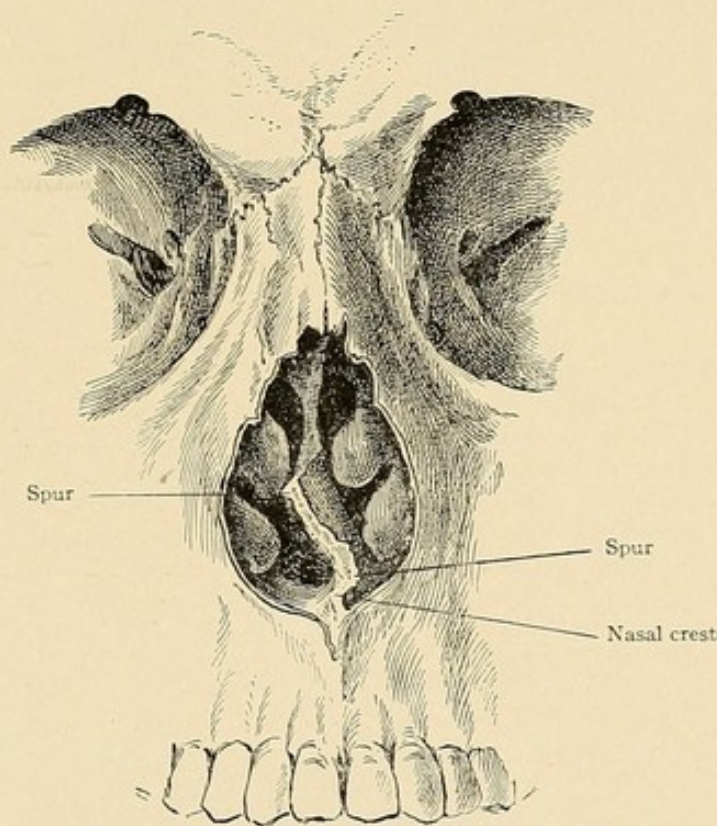


FIG. 118.—Nasal crest and septal spurs.

over the inferior turbinated bones also becomes swollen and enlarged, constituting, if at the forward end, *anterior hypertrophy*, and if at the posterior extremity, *posterior hypertrophy* (Fig. 120). They can be readily seen through the nasal speculum anteriorly and by the rhinoscopic mirror posteriorly. They are treated by applications of acids, as chromic and trichloracetic, by the electrocautery, or are snared off with the cold snare. Snaring is more often employed in reducing posterior hypertrophies, but both the anterior and posterior can be reached by an electrocautery point or a knife introduced through a speculum in the anterior nares.

**The Outer Wall.**—The outer wall has on it the three turbinated bones—superior, middle, and inferior. The inferior is a separate bone, but the middle and superior are parts of the ethmoid bone (Figs. 121 and 122).

The **inferior meatus** is between the inferior turbinated bone and the floor of the nose. The *lachrymonasal duct* enters this meatus just below the anterior end of the inferior turbinated bone. It pierces the mucous membrane obliquely, being guarded by a fold called the *valve of Hasner*. The opening is not visible from the anterior nares and usually it is impossible to introduce a probe into it from them.



The **middle meatus** is between the middle and inferior turbinated bones. The mucous membrane covering the middle turbinated bone lies closer to it than does that of the inferior turbinated bone, so that it is comparatively rare that treatment is necessary to reduce it.

Polypi usually have their origin in this meatus. Beneath the middle turbinated bone on the outer wall of the nose and only to be seen after removal of the bone,

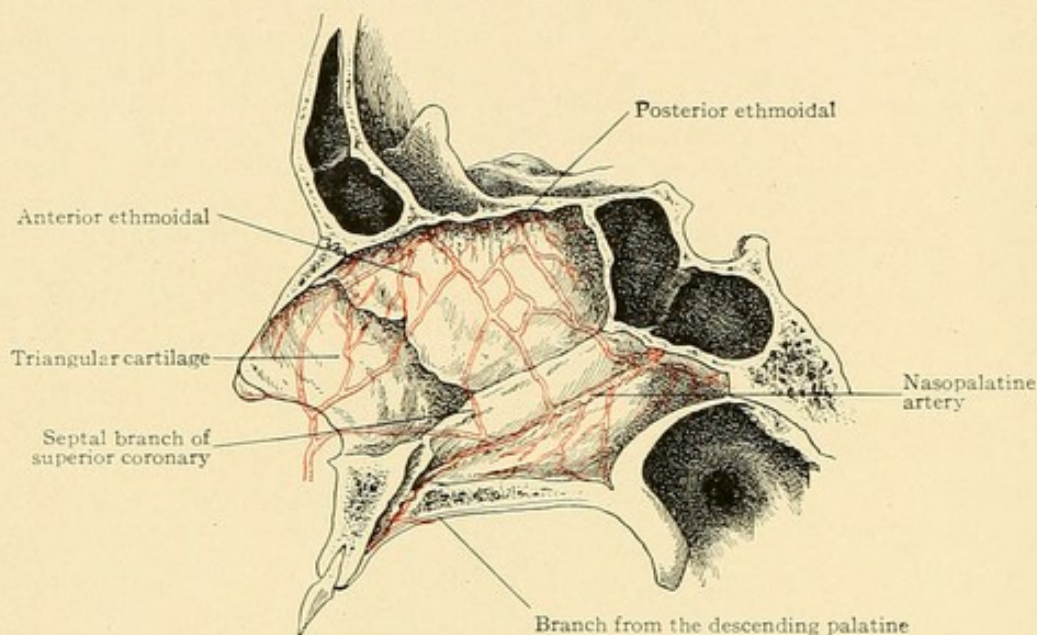


FIG. 119.—Arteries supplying the septum of the nose.

there is, just anterior to its middle, a rounded eminence, the *bulia ethmoidalis*. In it is an opening for the middle ethmoidal cells. Immediately in front is a slit, the *hiatus semilunaris*, into which open the maxillary sinus (*antrum of Highmore*) and the anterior ethmoidal cells. The hiatus is continued above as the *infundibulum*, which enters the frontal sinus. The relation between the hiatus and the opening into

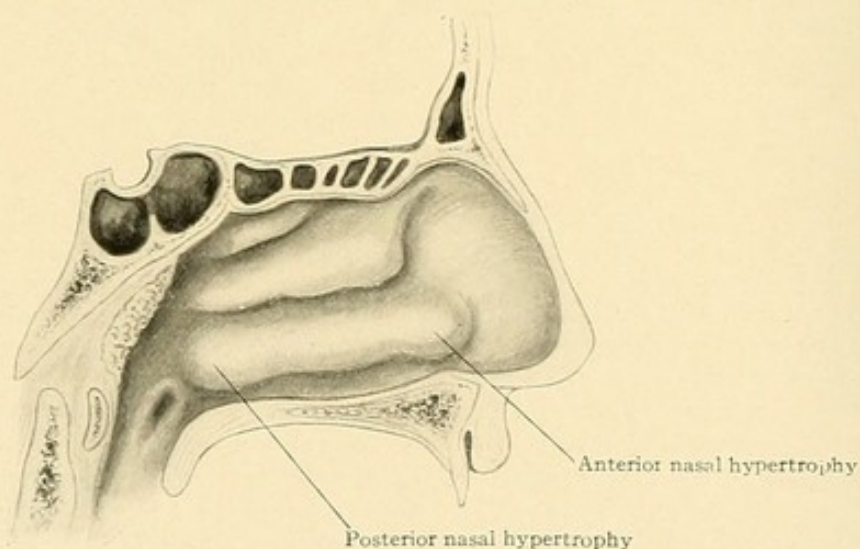


FIG. 120.—View of anterior and posterior hypertrophies of the inferior turbinate.

the maxillary sinus is such, in some cases, that it is possible for pus originating in the frontal sinus to discharge into the maxillary sinus. A knowledge of the relation of these parts is essential to those desirous of treating nasal diseases.

The **superior meatus** is comparatively small and lies above the middle turbinated bone. At the anterior edge of the superior turbinated bone is the opening for the posterior ethmoidal cells. Sometimes there are two or three superior turbinals.



The *spheno-ethmoidal* recess is the cleft above the superior turbinated bone; into it opens the sphenoidal sinus. In order to examine and reach the openings of any of these sinuses, it is practically necessary to take away a part or all of the middle turbinated bone before they can be exposed to view. When this is done, they can be probed, washed out, drained, etc. (see Fig. 125).

The **frontal sinuses** begin to develop about puberty. They occupy the lower anterior portion of the frontal bone. Their size and extent vary considerably. The usual size is from the nasion below to the upper edge of the superciliary ridges above and laterally from the median line to the supra-orbital notch. These limits may be exceeded considerably. They may go as far out as the middle of the upper edge of the orbit or even nearly to the temporal ridge. The anterior and posterior walls are separated a distance of 0.5 to 1 cm. The distance which they extend back over the orbit and upward also varies. The two sinuses are separated by a partition which is often to one side of the median line, so that it is apt to be encountered in opening the sinus through the forehead. The two cells often differ greatly in size and may be divided into various recesses by incomplete septa. They have the infundibulum as their lower extremity, which passes into the hiatus semilunaris beneath the middle turbinated bone and empties into the middle meatus. The frontal sinuses are frequently the seat of suppurative inflammation. This gives rise to pain and tenderness in the supra-orbital region and to a discharge from the corresponding nostril. This discharge can be seen coming from beneath the anterior extremity of the middle turbinated bone. Owing to the proximity of the opening into the maxillary sinus, pus, coming down the hiatus from the frontal sinus, may

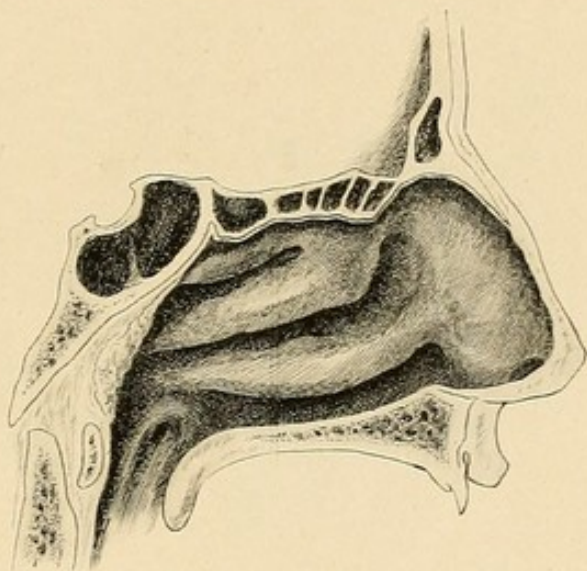


FIG. 121.—Outer wall of nose, showing the superior, middle, and inferior turbinate bones.

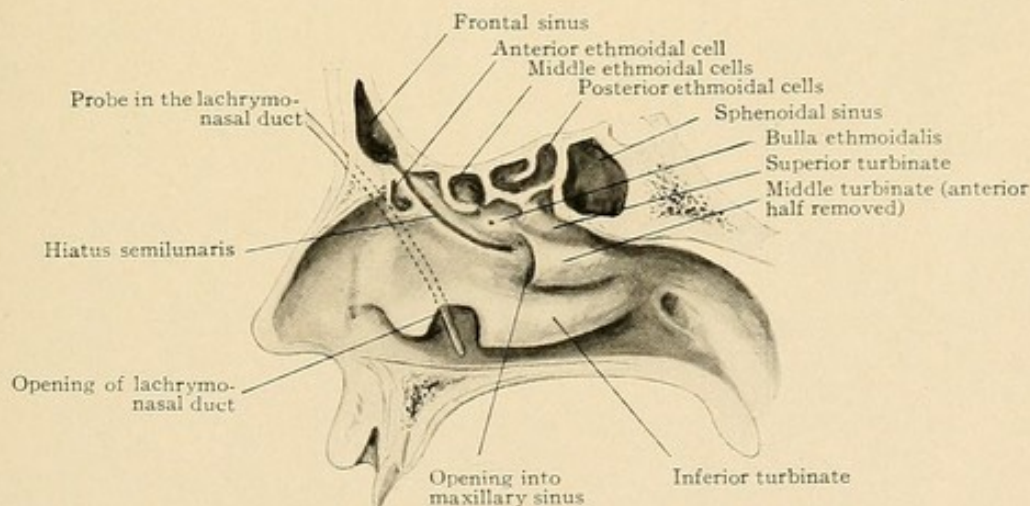
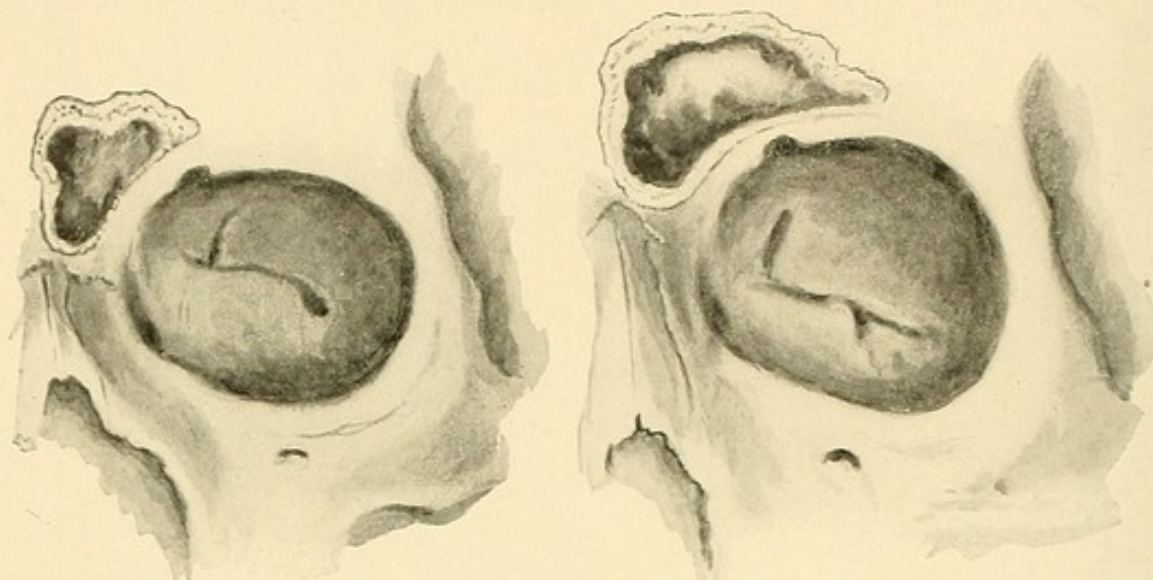


FIG. 122.—View of outer wall of the nose and accessory cavities.

pass into the maxillary sinus, thus simulating disease of that cavity. In order to wash out the sinus, cocaine may be first applied to shrink the nasal membrane; then sometimes one is able to pass a probe or irrigating tube into the hiatus semilunaris and thence up into the sinus. By removing the anterior extremity of the middle turbinated bone access to the hiatus semilunaris is more readily obtained. In certain cases the frontal sinus is opened either through the supra-orbital region or entered through the roof of the orbit at its inner upper corner. The *glabella* is the



depression in the median line separating the superciliary ridges. In operating on the sinus from in front, the opening is to be made just to the outer side of the glabella in order to avoid the septum between the sinuses. In curetting the sinus, the thinness of the upper and posterior wall separating it from the brain, and of the lower wall or roof of the orbit, should be borne in mind, otherwise they are apt to be perforated. The sinus may be divided into recesses by partial septa projecting from



FIGS. 123 and 124.—Two views of the frontal sinus, showing variation in size in different individuals. The anterior wall has been cut away to expose the interior of the sinus.

the sides. Drainage into the nose is obtained by passing an instrument from above downward through the anterior ethmoidal cells. In entering the sinus from below from the outside, the opening is made at the extreme anterior upper edge of the orbit, perforating the bone in a direction upward and inward. The opening into the sinus may be enlarged from within the nose by first inserting a probe to protect the brain and posterior wall and then chiseling or gnawing away the bone in front so that easy access is obtained through the nose for drainage, packing, etc.

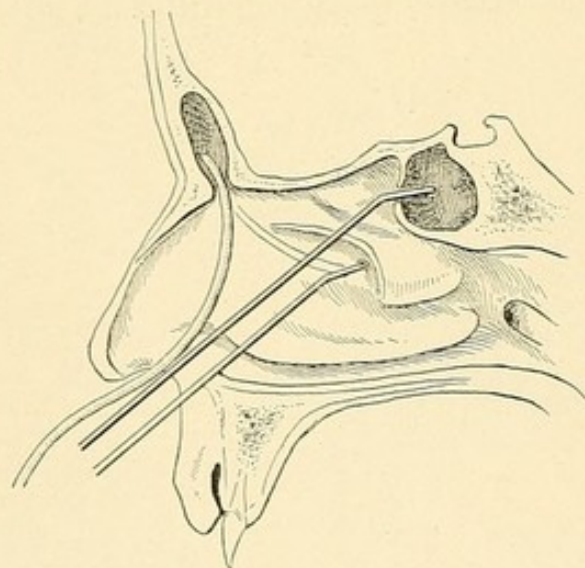


FIG. 125.—Probes introduced into the frontal, maxillary, and sphenoidal sinuses. The anterior portion of the middle turbinate has been removed.

The **ethmoidal sinuses or cells**, three in number on each side, anterior, middle, and posterior, lie between the sphenoidal sinus posteriorly, and the lower extremity of the frontal sinus anteriorly. The anterior cells lie in front of or just above the hiatus and open into it. The middle lie just posterior to the hiatus and open into the outer wall of the middle meatus, perforating the *bulia ethmoidalis*, which is a rounded projection on the outer wall beneath the middle turbinated bone. The posterior cells open still farther back beneath the superior turbinated bone in the superior meatus. In disease of these cells, pus from the middle and anterior ones will show in the middle meatus; from the

posterior cells in the superior meatus. In this latter case it is to be detected posteriorly by means of the rhinoscopic mirror. Access to the cells is obtained by removing the middle turbinated bone. This is done by dividing it into two pieces by a transverse cut with forceps or scissors and then removing the two halves with a snare. By means of probes, curettes, and forceps, the openings into the cells may



be discovered and enlarged as thought necessary. The region of the ethmoidal cells is that from which mucous polypi of the nose take their origin. They are a common accompaniment of suppuration of the accessory nasal cavities. They are usually removed by snares introduced through the anterior nares or more rarely by forceps. Caries affecting the anterior cells may extend into the orbit and the pus may form a fluctuating tumor above the inner canthus of the eye. Care should be taken not to mistake a meningocele for such a tumor.

The **sphenoidal sinuses** are the most posterior, lying still farther back than the ethmoidal. They open into the spheno-ethmoidal recess above and posterior to the superior turbinated bone. Discharge from them goes into the pharynx and is to be seen with the rhinoscopic mirror. They can be reached by first removing the middle turbinated bone and then introducing a probe upward and backward from the anterior nares for a distance of 7.5 cm. (3 in.) in women and 8 cm. in men. They can be drained by cutting away their anterior wall with punch forceps introduced through the anterior nares.

The **maxillary sinus** lies beneath the orbit and to the outer side of the nasal fossæ. It is the seat of tumors, often malignant, and inflammation; the latter accompanied by an accumulation of mucus or pus. The walls of the sinus are thin, so we find tumors bulging forward, causing a protrusion of the cheek. They press inward and obstruct the breathing through that side of the nose, or they push upward and cause protrusion of the eye by encroaching on the orbit. In operating on these tumors, the superior maxilla is usually removed; the lines of the cuts through the bones being shown in Fig. 64. In prying the bone down posteriorly, it may not be torn entirely away from the pterygoid processes and some plates of bone may be left attached. This should be borne in mind in operating for malignant growths. The sphenoidal cells are behind the upper posterior portion of the maxillary sinus, therefore in operating on Meckel's ganglion, if too much force is used in breaking through the posterior wall of the antrum, the instrument may pass across the sphenomaxillary fossa, a distance of about 3 mm., and open the sphenoidal sinus.

The infra-orbital nerve is usually separated from the cavity of the sinus by a thin shell of bone. At the upper anterior portion of the sinus there may be a small cell between the bony canal in which the nerve runs and the bony floor of the orbit. The superior dental nerves reach the upper teeth usually by going through minute canals in the bone, but sometimes, particularly the middle set supplying the bicuspid teeth, may run directly beneath the mucous membrane, and thus be irritated by troubles originating within the sinus.

The inflammatory and infectious diseases of the sinus originate either by extension from the nose or the teeth. The sinus opens into the nose by a slit-like opening into the middle meatus about its middle, posterior to the hiatus semilunaris and 2.5 cm. above the floor of the nose. When the opening is close to the hiatus, liquids may run into it from the hiatus. The bone beneath the hiatus and opening almost down to the floor of the nose is quite thin, so that the sinus can readily be drained by thrusting a trocar and cannula through the outer wall of the nose into the sinus just below the hiatus semilunaris. The sinus is also opened from the front through the canine fossa to the outer side of the canine tooth. This opening affords direct access to the cavity, but is some distance above the floor, thus it does not drain the cavity completely. The roots of the upper teeth project into the antrum forming elevations, usually covered by a thin plate of bone. This is particularly the case of the first and second molars. Disease of the roots of these teeth frequently infects the antrum and drainage is often made through their sockets.

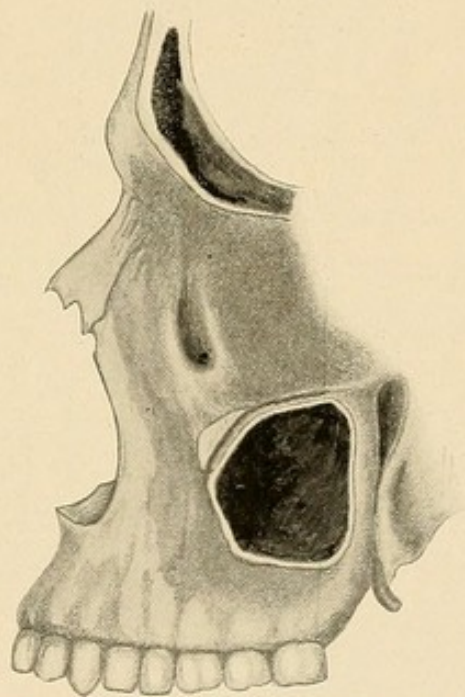


FIG. 126.—Side view of the maxillary and frontal sinuses.



## THE MOUTH AND THROAT.

The **lips** are formed mainly by the *orbicularis oris muscle* with its subdivisions and the *accessory facial muscles* (buccinator, levator and depressor anguli oris, levator labii superioris, levator labii superioris alæque nasi, the zygomaticus major and minor, and the depressor labii inferioris). The orbicularis oris is attached to the superior maxilla in the incisor fossa above the second incisor tooth and also above to the septum. In the lower lip it is attached to the mandible beneath the second incisor tooth. The lips contain, beside muscular tissue, some areolar tissue, arteries, veins, and lymphatics. The muscular fibres are inserted into the skin. The mucous membrane lining the lips has lying beneath it some mucous glands. They sometimes become enlarged and form small, shot-like, cystic tumors containing mucus.

**Affections of the Lips.**—The lips are affected by *wounds*, *angioma* or *blood tumor*, *cancer* (*epithelioma*), and *clefts* (*harelip*). Wounds of the lip when properly approximated heal readily on account of the free blood supply. The arteries sup-

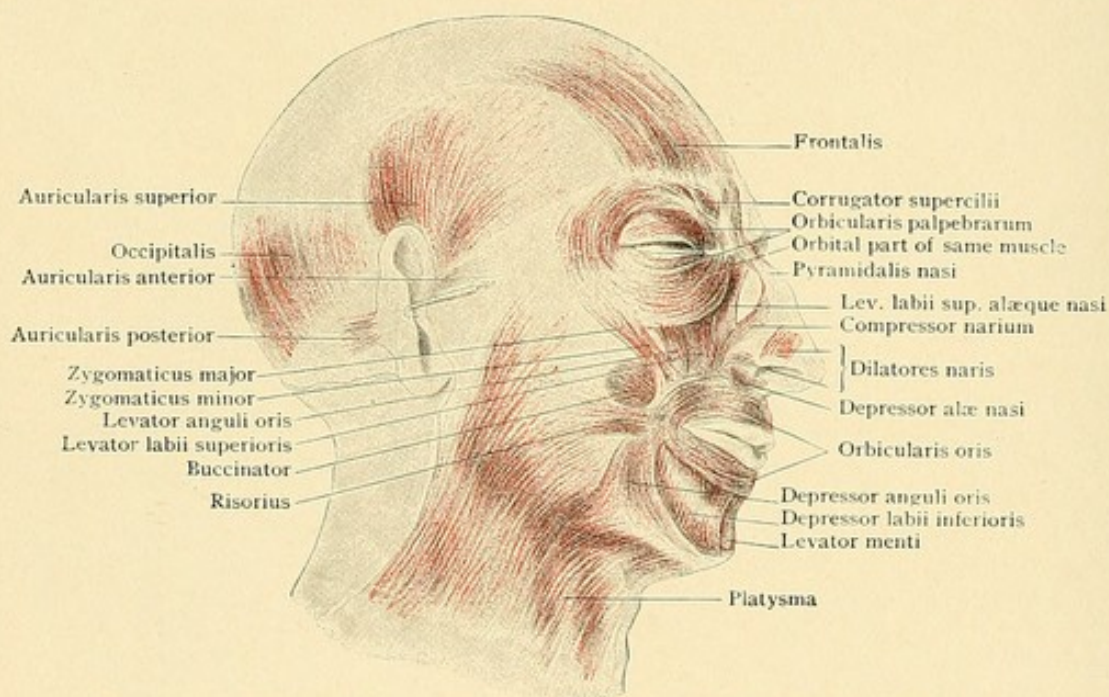


FIG. 127.—Superficial dissection, showing the muscles of the head and face. (Piersol.)

plying the lips are the *superior* and *inferior coronary* branches of the facial. They are given off about opposite the angle of the mouth and pierce the muscle to run beneath the mucous membrane about midway between the edge of the lip and its attachment to the gums or nearer the free border of the lip. Therefore, in operating on the lip, the artery should be looked for in this situation and not toward the skin surface or in the substance of the lip. The superior coronary sends a branch to the nasal septum, called the *inferior artery of the septum*. In the sulcus between the lower lip and chin lies the *inferior labial artery*. The bleeding from this branch is not so free as that from the coronary arteries, because the anastomosis across the median line is not so marked.

**Angioma.**—The blood-vessels, mainly the veins, of the lips sometimes become enlarged, forming a large protrusion. This may be noticed at or soon after birth as a dusky blue, slightly swollen spot on the lip. As the child grows the swelling enlarges. Sometimes it enlarges rapidly and operation is necessary to check its growth; otherwise it may involve a large portion of the face and prove incurable. It is composed of dilated veins with thin walls and large lumen. It does not pulsate and disappears under pressure, only to return when this is removed. It is treated by excision. The thin skin is dissected off and the growth cut away from the tissues beneath, the bleeding being controlled by pressure, hæmostats, and ligatures. In



the case figured, the facial vein, as it crossed the mandible, and the transverse facial vein were obliterated by means of acupressure pins passed beneath them, and the growth was excised.

*Cancer or epithelioma* of the lip almost always affects the lower and not the upper lip. The disease extends through the lymphatics. These pass down and out

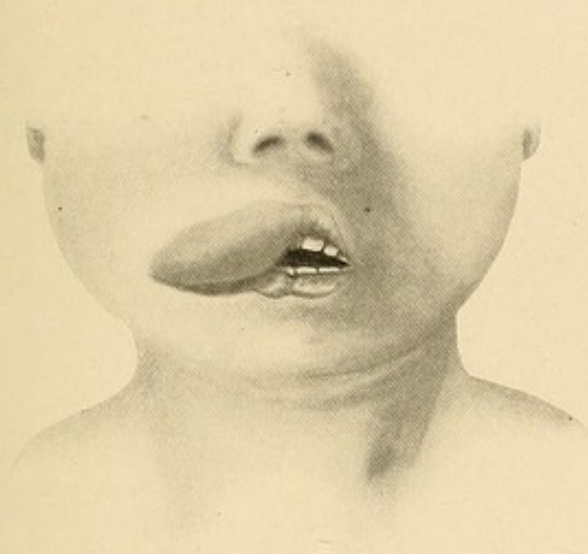


FIG. 128.—Angioma involving the right half of the upper lip in a child. (Personal sketch.)

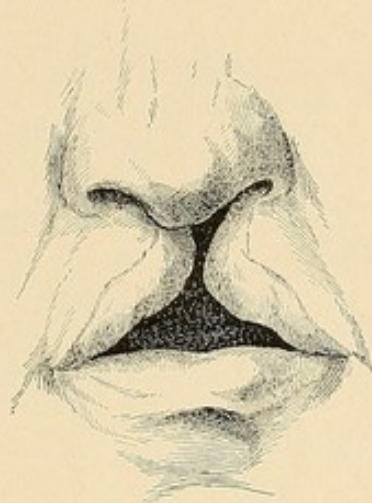


FIG. 129.—Single harelip.

from the lips to the submaxillary lymph-nodes and then to the nodes along the great vessels of the neck. It is in these regions that lymphatic infection is usually seen. The middle of the lower lip is drained into a node in the submental region in front of the submaxillary nodes. This also is sometimes involved. In operating for cancerous growths it is advisable to remove all nodes from both the submental and submaxillary triangles.

*Cleft or harelip* is so named from its resemblance to the lip of a hare. It is a deformity due to lack of development, in which the lip is cleft or split from the mouth up into the nostril, and sometimes even back through the hard and the soft palate. When the cleft is slight, it may not reach the nostril. It is practically always to one side of the middle, going toward one nostril. Sometimes the harelip is double, involving both sides. In such cases the bone between the two clefts may protrude. In the development of the face, the frontonasal process comes down from above to form the middle portion of the nose, upper lip, and upper jaw. It forms a bone known as the premaxilla and bears the incisor teeth. From the sides spring the nasal and maxillary processes. These join together as one process and grow toward the premaxilla. If this process fails to reach the premaxillary

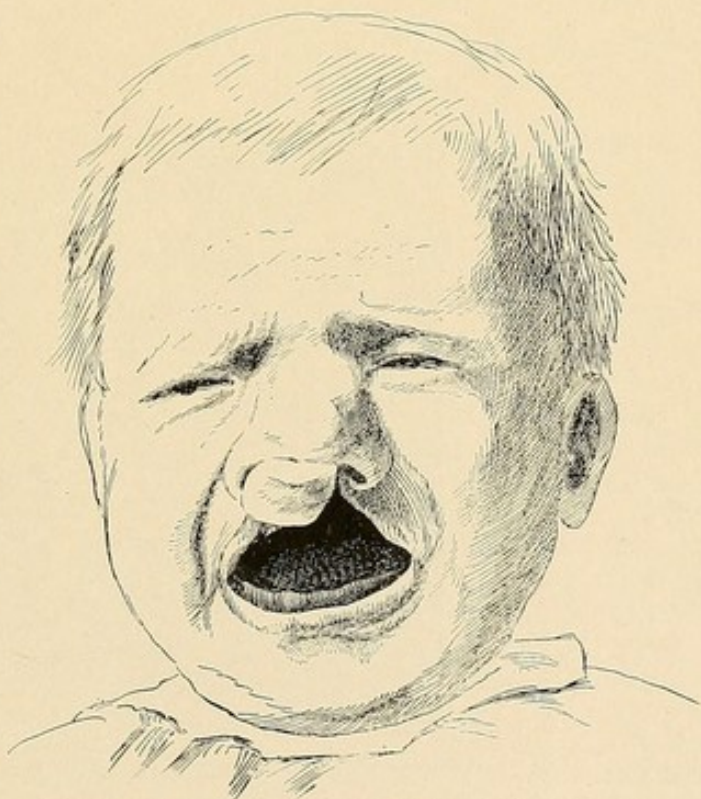


FIG. 130.—Double harelip, showing the projecting premaxilla.



bone, a cleft is left constituting harelip. If both processes fail to reach the premaxilla, a double harelip is formed; the cleft may extend through the hard and the soft palate—

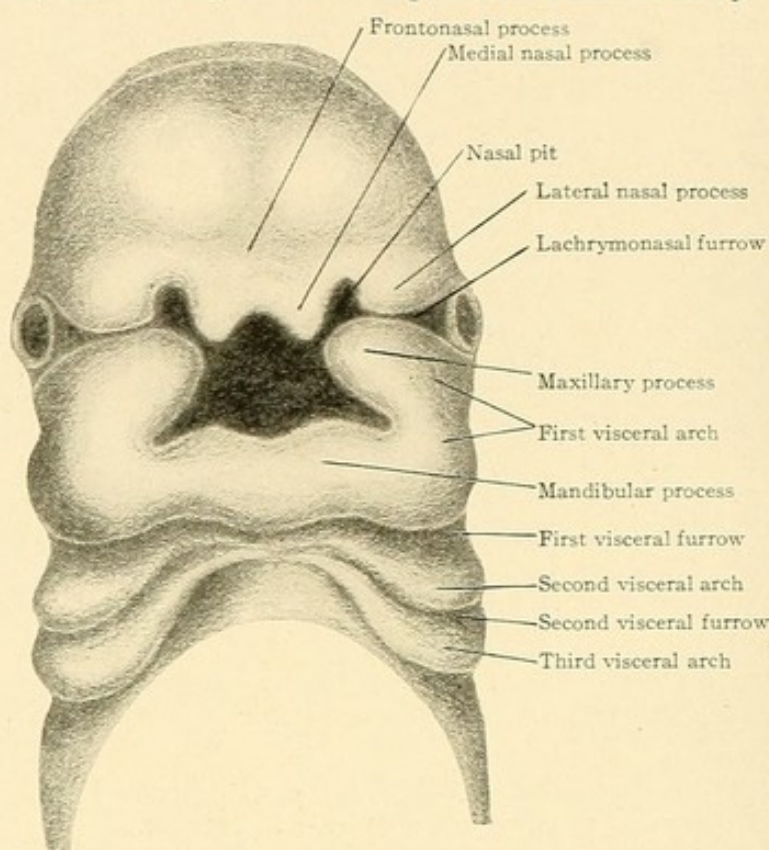


FIG. 131.—Frontal view of human foetus about four weeks old. (After His.)

the cleft palate may alone be present as seen in Fig. 139 (see page 112). In operating for harelip, the two sides of the cleft are freshened and sewed together, thus closing the cleft.

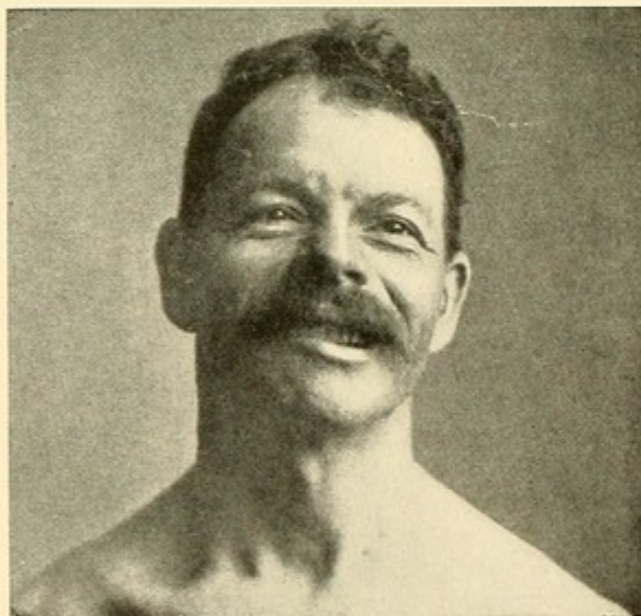


FIG. 132.—Paralysis of depressor labii inferioris from section of the lower filament of the facial nerve. (McDowd.)

*Paralysis of the lips* is due to interference with the functions of the seventh nerve. The muscles of the face and lip are supplied by the seventh or facial nerve. This is frequently paralyzed, for owing to its tortuous passage through the temporal bone in the canal of Fallopius it is injured in fractures of the base of the skull and becomes



affected from middle ear disease or neuritis. When paralyzed, the muscles of the lips, both upper and lower, on the affected side, droop. The drooping of the lower lip may allow the saliva to run out of the mouth. It is also impossible for the patient to pucker his mouth, as in whistling. If the lesion of the facial nerve is inside the skull and not in the Fallopian canal, the *great petrosal nerve* and some of the palatal muscles will be paralyzed, the voice will be altered and swallowing interfered with.

The depressor labii inferioris instead of receiving its nerve supply from the supra-mandibular branch of the facial, frequently is supplied by the inframandibular branch; pressure or injury of this branch in enlargements of or operations on the submandibular lymph-nodes has produced paralysis of the muscle with a peculiar alteration of the facial expression, well shown (see Fig. 132) by a case of Dr. McDowd (*Annals of Surgery*, July, 1905).

**Mouth.**—*Surface Anatomy.*—In looking into the mouth, one sees the tongue below and the roof above, surrounded in front and on the sides by the teeth. On each side are the inner surfaces of the cheeks and posteriorly are seen the uvula, the

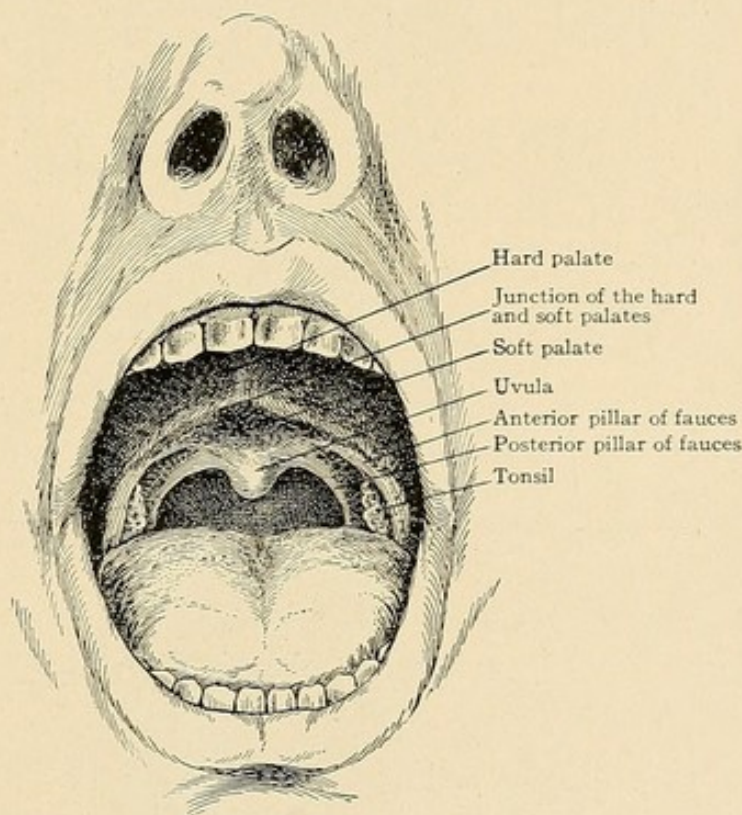


FIG. 133.—Interior of the mouth.

arches of the palate, and the pharynx. On the mucous membrane of the cheek, opposite the second upper molar tooth, is a small papilla in the top of which opens the duct of the parotid gland. A small probe can be inserted into it and passed outward and backward toward the gland.

**Tongue.**—The tongue is covered with a mucous membrane which is modified skin; therefore it is subject to the same diseases as the skin. It is covered with papillæ of three kinds—the *filiform*, *fungiform*, and *circumvallate*. The filiform are the smallest and most numerous and form a sort of ground-work in which the others are imbedded. The fungiform are larger and fewer in number and are scattered on the dorsum, sides, and tip of the tongue among the filiform. The circumvallate, seven to twelve in number, form a V-shaped row at the base of the tongue. In the eruptive fevers, particularly scarlet fever, the tongue gets very red and the papillæ become enlarged, forming what is known as the strawberry or raspberry tongue. Just beyond the apex of the circumvallate papillæ in the median line is the *foramen cæcum*. It is sometimes patulous for a short distance and is the upper extremity of the remains of the *thyroglossal duct*.



On the posterior portion of the tongue behind the circumvallate papillæ, on each side of the median line, is a mass of adenoid tissue which forms what is known as the *lingual tonsil*. It sometimes becomes hypertrophied and is then cut off with a specially curved tonsillotome just as is done with enlarged faucial tonsils. Running from the base of the tongue to the epiglottis are three folds, called the *median* and *lateral glosso-epiglottic folds*.

In the middle of the dorsum of the tongue is a furrow; this is caused by the septum binding the middle of the tongue down and allowing the muscles to rise on each side.

On turning the tip of the tongue up (Fig. 135), a fold of membrane, the *frænum*, is seen extending from the under surface to the floor of the mouth beneath. In newborn children, this frænum appears sometimes to be too short, hence the name *tongue-tie*. In cutting it, the split end of a grooved director is placed over the frænum

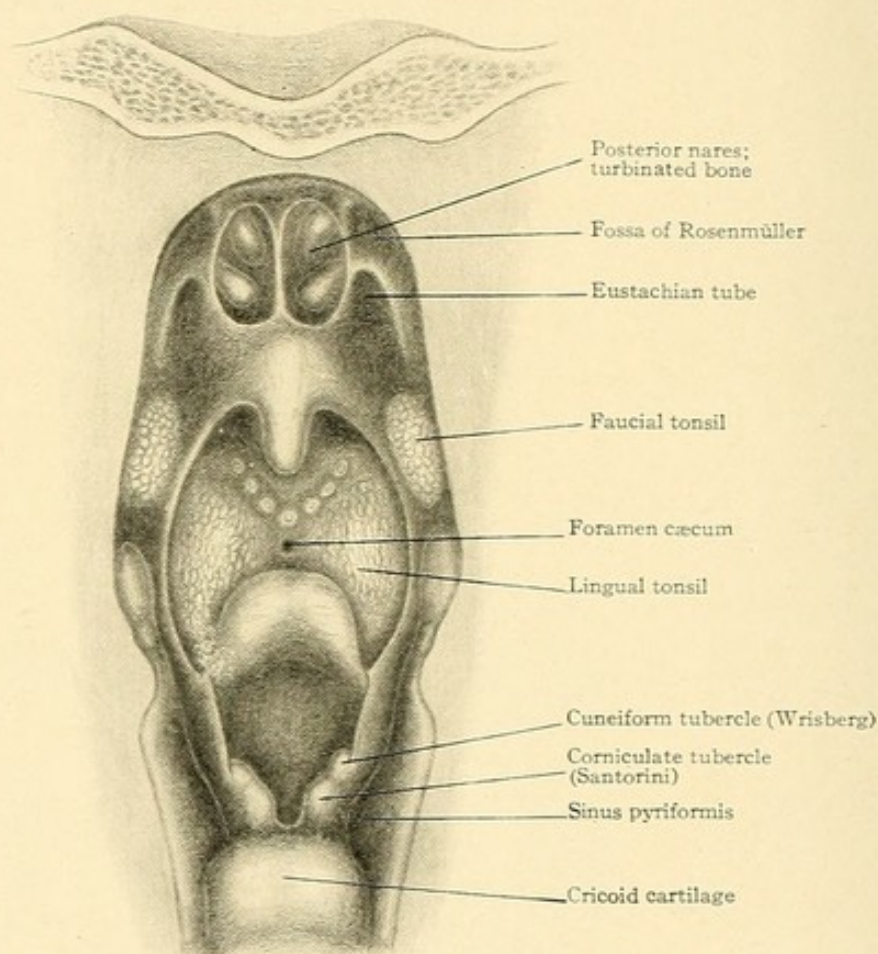


FIG. 134.—View of pharynx, looking forward; posterior wall removed, showing the posterior nares, base of tongue, and opening of the larynx.

and the tongue pushed back. This makes the frænum tense and it can readily be snipped with the scissors. Care should be taken not to cut too deeply, or the ranine artery may be cut and cause troublesome bleeding. Running across the floor of the mouth, between the teeth and tongue, parallel to the alveolus, is the *sublingual ridge*, formed by the *sublingual gland*. This gland lies on the mylohyoid muscle beneath and the lower jaw in front. On each side of the frænum on the sublingual ridge is a papilla into which the duct of the submaxillary gland, *Wharton's duct*, opens. Opening into Wharton's duct, or by a separate duct into the same papilla, is the duct of the sublingual gland, called the *duct of Rivinus* or *Bartholin*. The superficial portion of the gland opens on the sublingual ridge to the outer side of the papilla by a number of small ducts, called the *ducts of Walther*.

*Ranula* is the name given to a cyst occurring in connection with the salivary glands. Such cysts involving the parotid gland are quite rare, so that the term



is usually restricted to those of the submaxillary and sublingual glands. The mylohyoid muscle forms the floor of the mouth and these cysts lie on it beneath the tongue and between the tongue and the gums (Fig. 136). If the cyst is large it causes a protrusion or swelling beneath the jaw. The bulk of the submaxillary gland lies on the side of the mylohyoid muscle nearest the skin; only a small portion of it

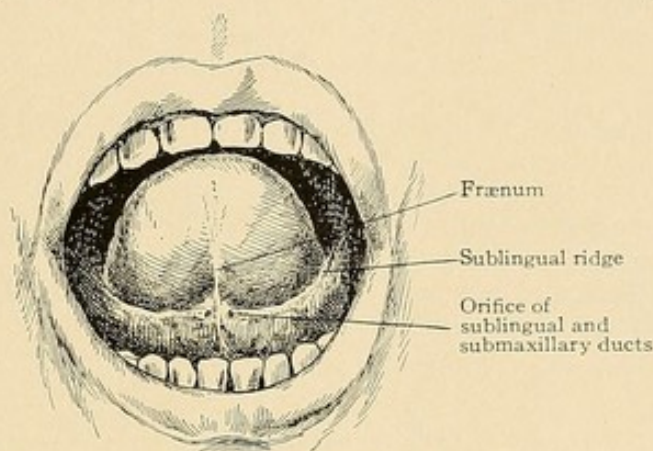


FIG. 135.—Under surface of tongue and floor of mouth.

winds around the posterior edge of the muscle. Therefore, cysts involving the substance of the gland would show in the submaxillary region of one side. If, however, the duct were obstructed (as by a calculus) it would form a cyst, which would bulge into the mouth beneath the tongue and be called a ranula. The sublingual gland is usually the starting point of these cysts, and it will be seen that as they enlarge they

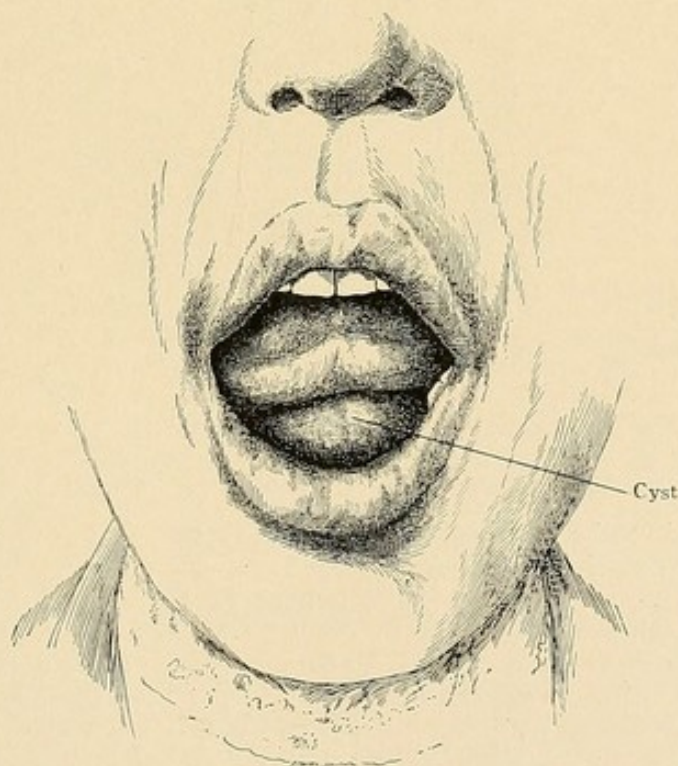


FIG. 136.—Sublingual cyst (ranula). (From a photograph by Dr. Ashhurst.)

push the ranine artery with the tongue backward and are only covered by the mucous membrane. On this account there is little or no danger in operating on them. They are either dissected out or the front wall of the cyst cut away and the interior cauterized or packed with gauze to promote the formation of granulations. The jaw-bone is in front of them and the mylohyoid muscle beneath. Posteriorly lies the duct of the submaxillary gland and the ranine artery.



*Mucous cysts* can occur from the mucous glands of the mouth and tongue itself. There is a gland on the under side of the tip of the tongue, usually larger than the others, called the *anterior lingual gland* or *gland of Nuhn*. As a rule, these mucous cysts are small and are felt as hard rounded bodies beneath the mucous membrane. Dermoid cysts occur in connection with the tongue but very rarely.

*Carcinoma* of the tongue is a moderately frequent disease and as the tongue is covered by modified skin, the cancer is of epithelial type. It begins on the surface of the tongue either by a change in the epithelial covering or else in fissures or ulcers at its edges.

The lymphatics of the tongue pass to the submaxillary nodes beneath the jaw and thence to the deep cervical nodes along the great vessels or directly to the latter without passing through the submaxillary nodes. If the disease exists for any length of time, these are the nodes that become infected. They are only to be reached by an incision in the neck.

The **arteries** of the tongue are the *lingual and its branches*, the *hyoid*, the *dorsalis linguae*, *sublingual*, and *ranine*. In removing the tongue, the lingual

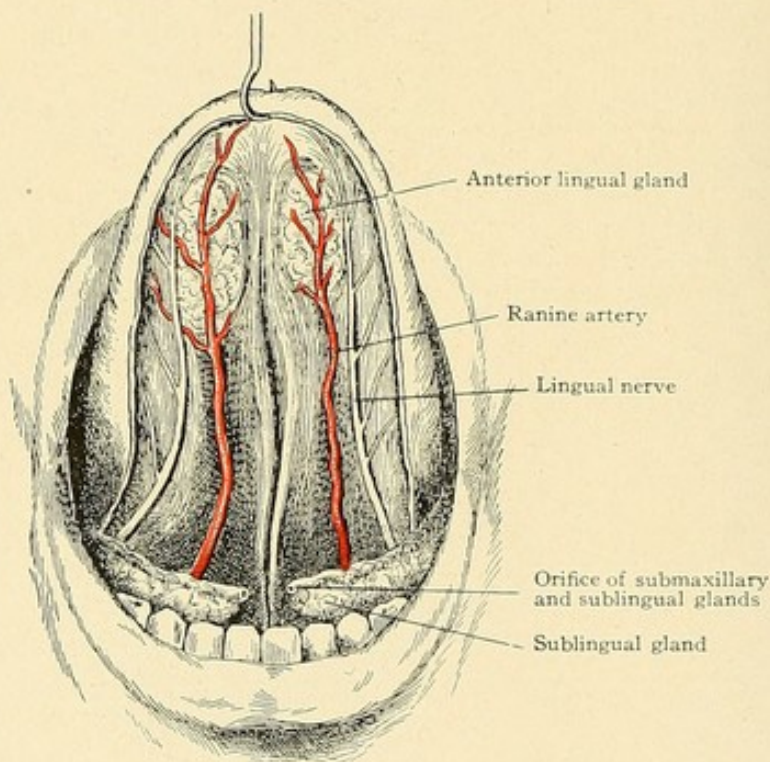


FIG. 137.—Under surface of the tongue, mucous membrane removed.

artery on the side to be removed is sometimes ligated in the neck; this cuts off the blood supply to that side and there is practically no bleeding. There is very little anastomosis between the vessels of the two sides of the tongue. The arteries run lengthwise through the tongue, so that in *glossitis* or *inflammatory swelling* of the tongue, incisions should always be made longitudinally into it.

The ligation of the lingual artery will be found described in the section on the neck. As the lingual artery passes above the hyoid bone, it gives off its *first branch*, the *hyoid*. It is quite small and goes above the hyoid bone superficial to the hyoglossus muscle. The lingual then goes beneath the hyoglossus muscle and near the posterior edge gives off its *second branch* or *dorsalis linguae*.

In *excision*, the tongue is usually cut through on the distal side of the *dorsalis linguae* artery. When this is the case, the bleeding which occurs from the branches of the *dorsalis linguae* is not marked because it is not a large artery.

In order to draw the tongue out, it must be loosened posteriorly by cutting the anterior pillars of the fauces and palatoglossus muscle, and anteriorly at the frænum by cutting the geniohyoglossus muscle. By drawing the tongue up, the ranine



is drawn out of the way and there will be only slight bleeding from small branches of the sublingual, which comes from the main trunk at the anterior edge of the hyoglossus muscle. From this point forward to the tip, the lingual artery is called the ranine. The tongue having been loosened and pulled out, Mr. Jacobson makes a transverse cut through the mucous membrane behind the growth and then, by pushing the tissues aside with a blunt instrument, exposes the lingual nerve and artery lying together beneath the mucous membrane. The artery is then tied and the growth removed.

In order to secure any bleeding points after the tongue has been cut away, the floor of the mouth can be raised and pushed forward by the fingers beneath the chin.

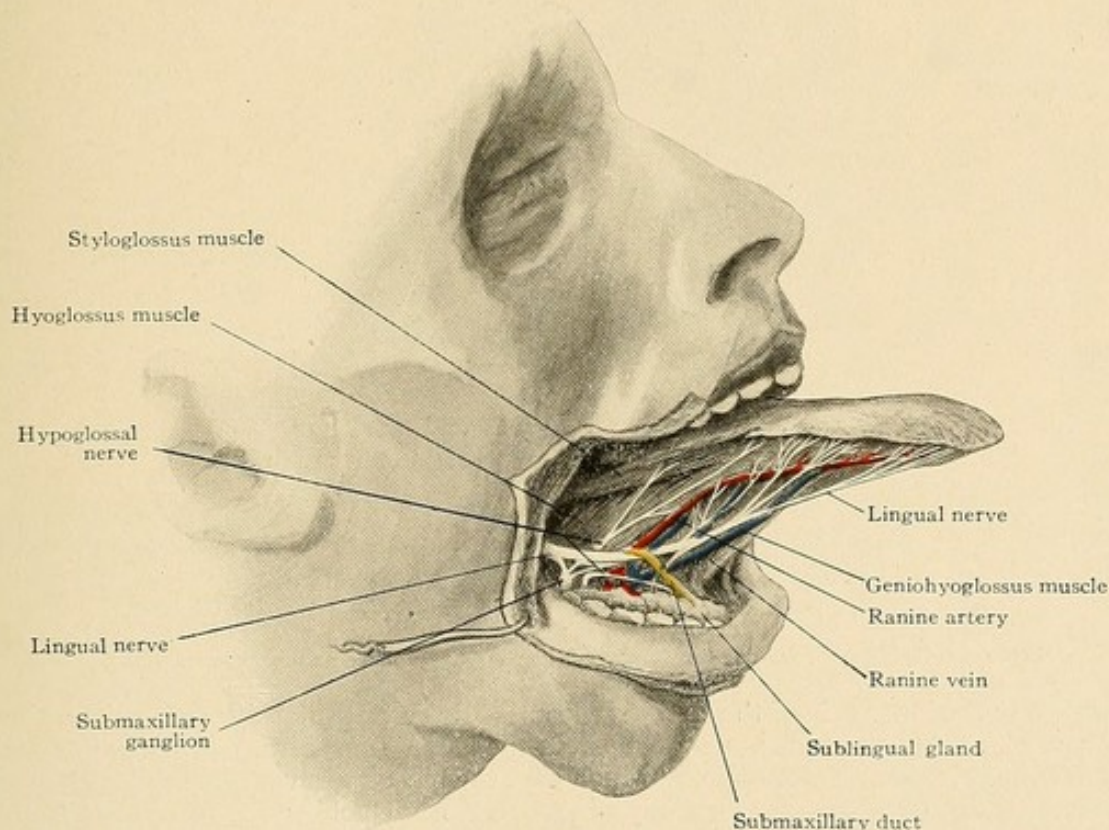


FIG. 138.—The cheek has been split, the tongue drawn forward, and the mucous membrane removed from its under surface, exposing the ranine artery and vein, the lingual and hypoglossal nerves, the sublingual gland, the submaxillary ganglion, and the duct of the submaxillary gland.

This brings the stump into view and within reach. If lymphatic nodes are to be removed, they must be sought for by an additional incision on the outside beneath the jaw.

The **roof of the mouth** is formed by the *hard palate* and the *soft palate*; the former comprising about three-fourths and the latter one-fourth. The hard or bony palate is composed in its anterior two-thirds of the palatal processes of the superior maxillary bones, and in its posterior third of the palatal bones. In the median line close to the incisor tooth, in the dried skull, is the *anterior* or *nasopalatine foramen*. This is subdivided into four foramina, two lateral and two anteroposterior. The former, called the *foramina of Stenson*, transmit the terminal branches of the descending palatine arteries; of the latter, called the *foramina of Scarpa*, the anterior one transmits the left nasopalatine nerve, and the posterior one the right nasopalatine nerve. The soft tissues of the roof of the mouth are thicker than they appear to be, so that when they are raised, as in operating for cleft palate, they form quite a thick layer. Infection of the roof of the mouth when it occurs is usually by extension from neighboring diseased teeth, abscesses being sometimes produced.

The blood supply of the roof is of importance in relation to the operation for *cleft palate* (*staphylorrhaphy*) (Fig. 139). The blood comes anteriorly from the nasopalatine arteries and posteriorly from the descending palatine arteries, which come down



through the pterygopalatine canal from the internal maxillary artery and make their appearance on the hard palate at the posterior palatine foramen. This foramen is on the roof of the mouth opposite the last molar tooth and 0.5 cm. to the inner side and in front of the hamular process (Fig. 140). This hamular process can be felt just pos-

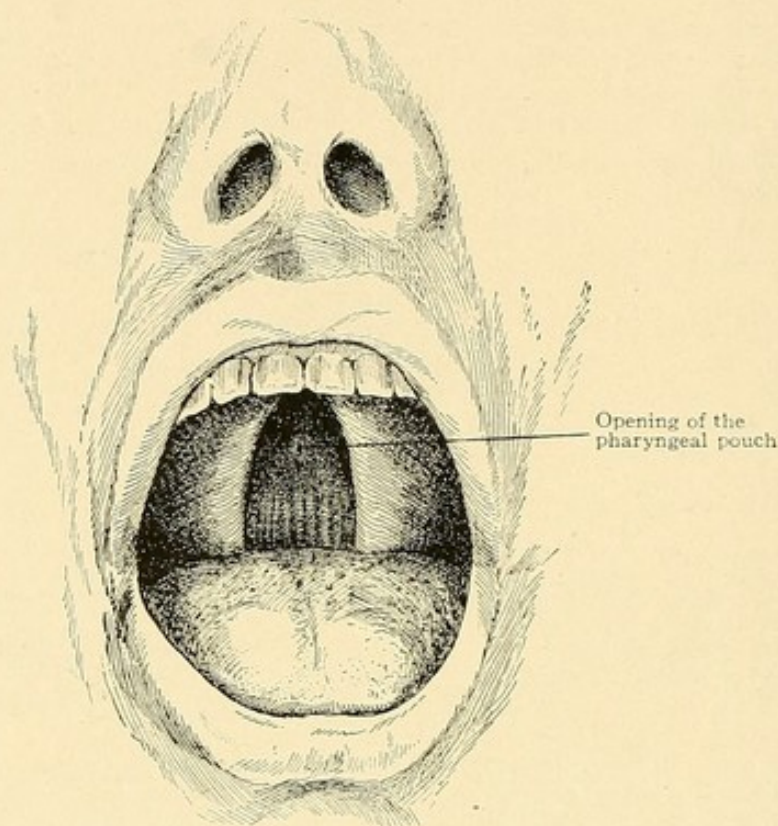


FIG. 139.—Cleft palate, showing the opening of the pharyngeal pouch on the posterior wall.

terior and to the inner side of the last molar tooth. If, in operating for cleft palate, the tissues are loosened from the bone too close to the hamular process, this artery may be torn near its exit from the foramen, in which case the bleeding is very free. To control it, the canal can be plugged with a slip of gauze. In detaching the soft palate from

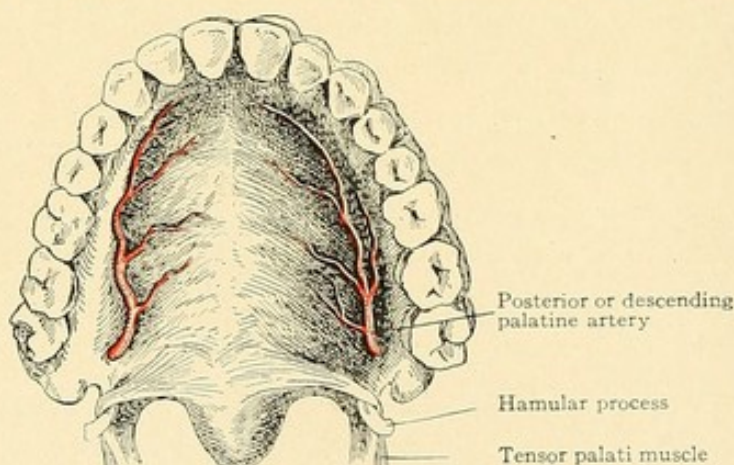


FIG. 140.—Roof of the mouth, mucous membrane removed.

the posterior edge of the hard palate, it should be remembered that this attachment is quite strong. Not only are the muscles of the soft palate themselves attached to the bone, but the pharyngeal aponeurosis which lies under the mucous membrane on the posterior or upper surface of the soft palate is also attached to the bone.

**Palatal Arches.**—Farther back in the mouth, one sees the anterior and posterior arches of the palate or *pillars of the fauces* with the *uvula*. The anterior



pillar runs from the soft palate to the tongue and is formed by the *palatoglossus muscle*. The posterior pillar runs from the soft palate downward to the sides of the pharynx and is formed by the *palatopharyngeus muscle*. In front of these arches and

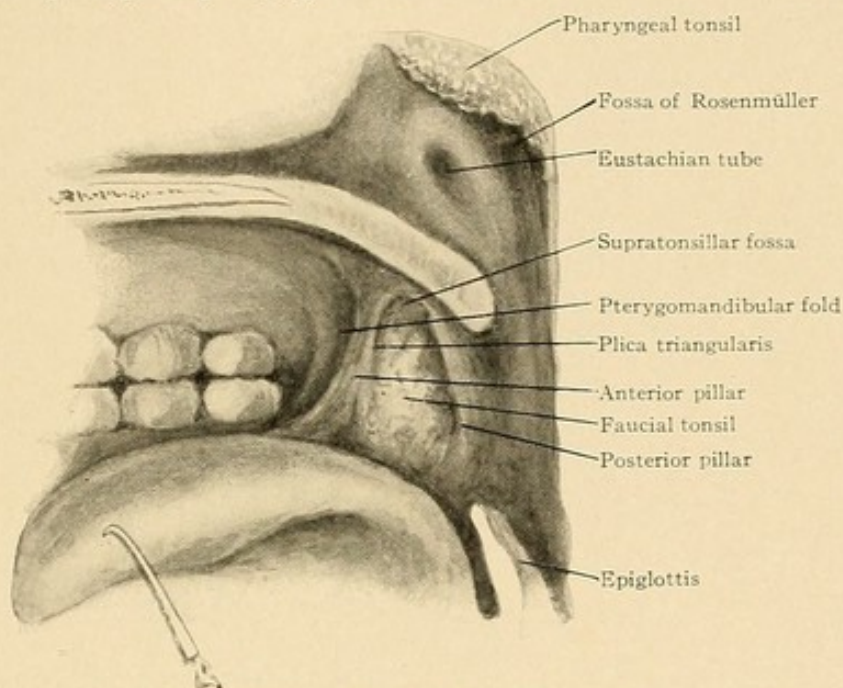


FIG. 141.—Lateral view of the faucial tonsil and pharyngeal region

running from the roof of the mouth opposite the posterior edge of the last molar tooth downward to the posterior edge of the alveolar process of the lower jaw is an elevation of the mucous membrane which shows the line of junction of the hard and soft palates.

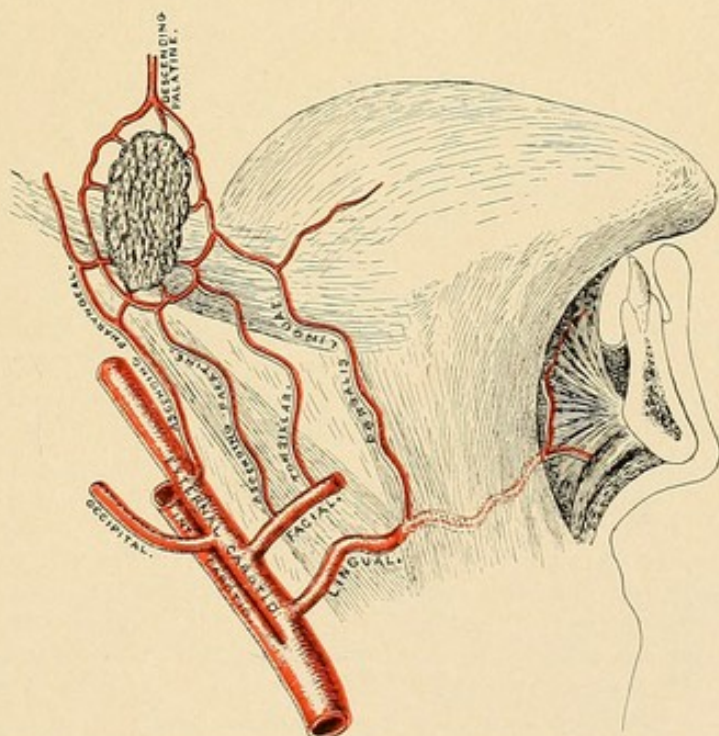


FIG. 142.—Diagram illustrating the blood supply of the faucial tonsil.

**Faucial Tonsils.**—Between the pillars of the fauces lie the *faucial tonsils*. They are limited above by the sulcus, called the *supratonsillar fossa*, formed by the approximation of the pillars and a fold of mucous membrane, called the *plica triangularis* (His), running downward from the anterior pillar and often blending with



the tonsil. Below they extend a variable distance, necessitating depression of the tongue with a spatula in order to make their lower limit accessible. They lie about opposite the angles of the jaw on the superior constrictor muscle with the buccopharyngeal fascia outside of the muscle. A knowledge of their structure is essential to the proper treatment of their diseases. The *tonsils* are oval in shape and when normal in size project but little beyond the pillars of the fauces. They are about 2.5 cm. long by 1 cm. wide and consist of about a dozen recesses or crypts formed by the folding inward of the mucous membrane. From these crypts follicles extend. The walls of the crypts contain adenoid tissue as well as mucous glands. The tonsil is held together by connective tissue which is continuous with its capsule and the submucous fibrous tissue of the pharynx. On this account while an enlarged tonsil can at times be shelled out of its bed, especially its upper portion, at others it is necessary to dissect or cut it out by means of a knife, scissors, or tonsillotome.

The blood-vessels supplying the tonsil are five in number. They are: the *ascending pharyngeal branch* of the *external carotid*, the *ascending palatine* and *tonsillar branches* of the *facial*, the *tonsillar branch* of the *dorsalis linguae*, and the

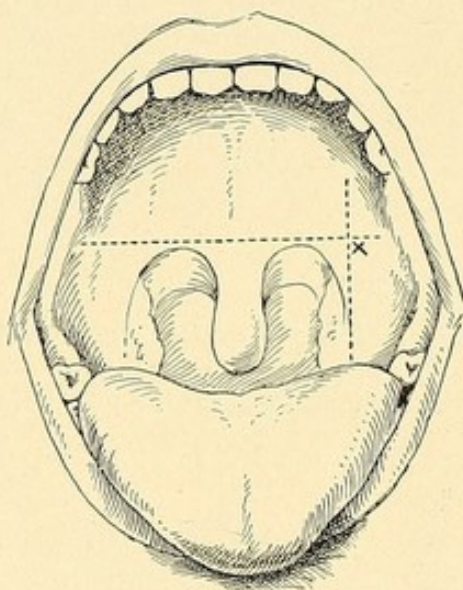


FIG. 143.—Point of puncture for tonsillar abscess. "If an imaginary horizontal line is drawn across the base of the uvula, and another vertically along the anterior faucial pillar, they will intersect at a point overlying the supratonsillar fossa. Just external to this is the best point for opening a quinsy."—St. Clair Thomson, M.D., *Brit. M. J.*, March 25, 1905, p. 645.

*descending palatine branch* of the *internal maxillary*. Ordinarily, these branches are small, but sometimes some of them are large and may cause troublesome hemorrhage. In inflammation of the tonsils, these vessels of course are larger than usual.

The tonsils are subject to inflammation and tumors. Tumors are rare; they grow inward and obstruct breathing and swallowing. Attempts are made to remove them either by scraping, cutting, snaring, or burning them with the electrocautery from the mouth; or they are sometimes removed through an external incision through the neck. This latter is a very severe procedure on account of the depth of the tonsil and the number of important structures which overlie it.

**Tonsillitis** or **quinsy** is an inflammation of the tonsils which leads to the formation of an abscess. In mild cases the crypts or lacunæ are affected, forming a *follicular* or *lacunar tonsillitis*. In this form epithelium and inflammatory matter are poured into the follicles and distend them, often showing as white plugs protruding from the mouth of the crypt. In its treatment, in addition to local applications, surgeons enlarge the openings into the crypts with a small knife and scoop the contents out with a sharp spoon. In severe cases, the whole substance of the tonsil and even the connective tissue around it are involved in the inflammation, forming a *parenchymatous tonsillitis*. It frequently proceeds to the formation of pus. When this forms in the substance of the tonsil it may break into a follicle and discharge into the throat. An abscess of the tonsil may become quite large, bulging toward the



median line, and on breaking may cause suffocation by passage of the pus into the larynx. If, as is usually the case, the pus involves the tissue around the tonsil, forming a peritonsillar abscess, it pushes upward behind the anterior pillar into the supratonsillar fossa and bulges forward, stretching the pillar over it. To evacuate this pus an incision should be made directly anteroposteriorly, with the flat side of the blade parallel with the edge of the pillar, or a slender pair of hæmostatic forceps may be used. A centimetre and a quarter ( $\frac{1}{2}$  in.) is deep enough usually to plunge the knife; the point should not be pointed outwardly but directly backward. The incision should be just above the upper and lateral edge of the anterior pillar (Fig. 143). Some small vessels may bleed, but this will either stop spontaneously or may be controlled by packing. The ascending pharyngeal artery lies beneath the tonsil. The tonsil lies on the pharyngeal aponeurosis and the superior constrictor muscle, while the as-

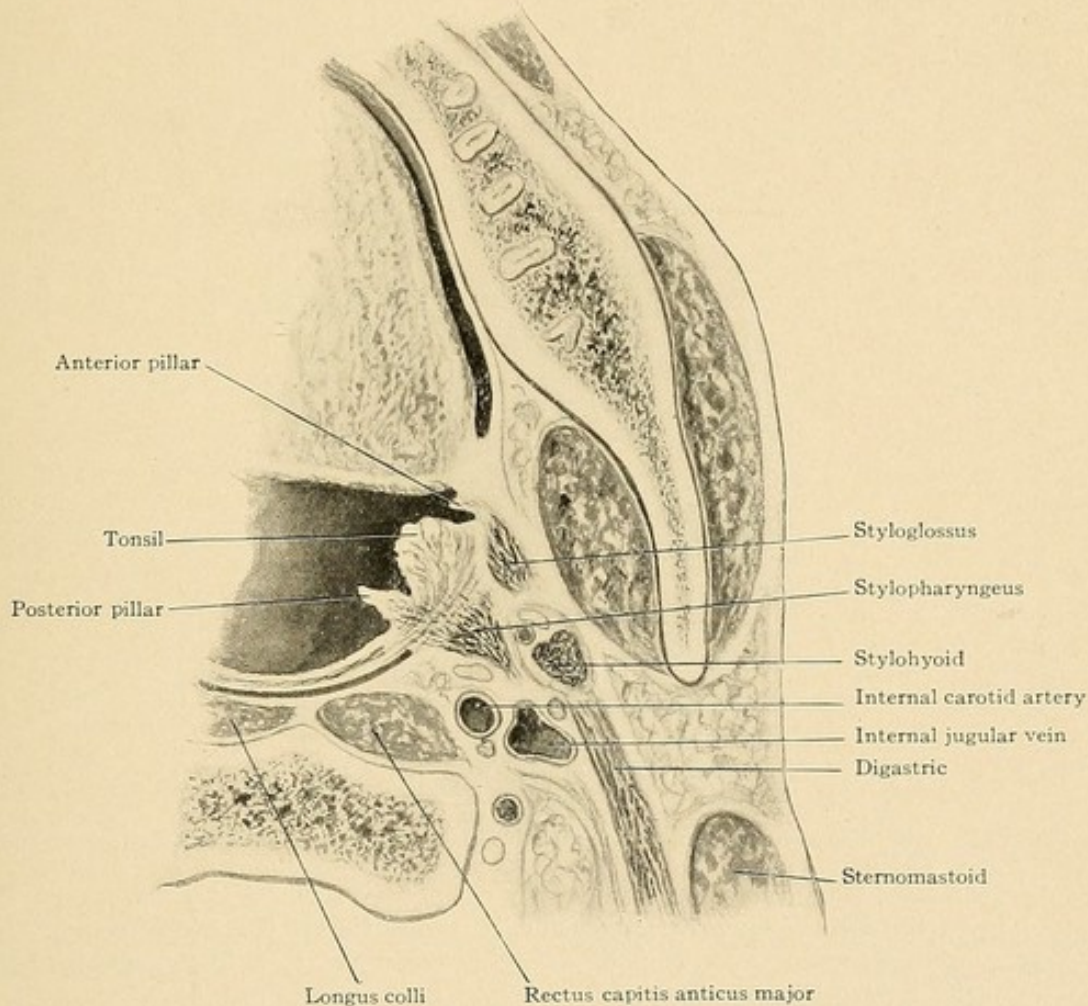


FIG. 144.—Transverse frozen section passing through the faucial tonsil and showing its relation to the internal carotid artery.

ending pharyngeal artery and external carotid lie outside of them, so that both structures would have to be cut before the vessels would be wounded. The internal carotid artery lies still deeper (2 to 2.5 cm.) behind and external to the tonsil. It is usually well out of harm's way unless dilated (see page 123, Fig. 156), but the pus may burrow into it and cause fatal hemorrhage. Sometimes pus may burrow through the constrictor muscle and enter the tissues of the neck. In severe tonsillitis the deep lymphatics beneath the angle of the jaw become enlarged.

*Hypertrophy* of the tonsils is common and is treated by removing them entirely or level with the palatal arches. An instrument called the tonsillotome is used, or it is done with a knife or scissors or snare. Fatal bleeding has followed this operation. The blood supply to the tonsil has already been given. If the bleeding is so free as to threaten the life of a patient, the external carotid artery should be ligated as all the vessels supplying the tonsil are derived from it.



Enucleation is performed by grasping the tonsil with toothed forceps, drawing it out, and cutting it loose with knife or scissors from its attachments to the pillars and aponeurosis beneath. Sometimes after loosening its attachments above it is torn loose or shelled out, from above downward, by the finger or a blunt instrument. On account of the capsule sending prolongations into the tonsil, it cannot readily be "shelled out" and portions may remain and require to be removed with the forceps and scissors or tonsillar punch. It is a disagreeable and bloody procedure and is usually done under a general anæsthetic.

**Retropharyngeal abscess** may arise from any one of three causes,—cervical caries, suppuration of lymphatic nodes, or extension of pus from the middle ear through the canal for the tensor tympani muscle. The pharyngeal aponeurosis lies under the mucous membrane and between it and the constrictor muscle. It is thick above and fades away below. It fills up the gap above between the superior constrictor and the base of the skull and is attached to the pharyngeal spine on the under surface of the basilar process. It is lined with the mucous membrane and covered by the constrictor muscles. Over all is the *buccopharyngeal fascia*, a thin layer continuous forward over the buccinator muscle and separated from the prevertebral fascia

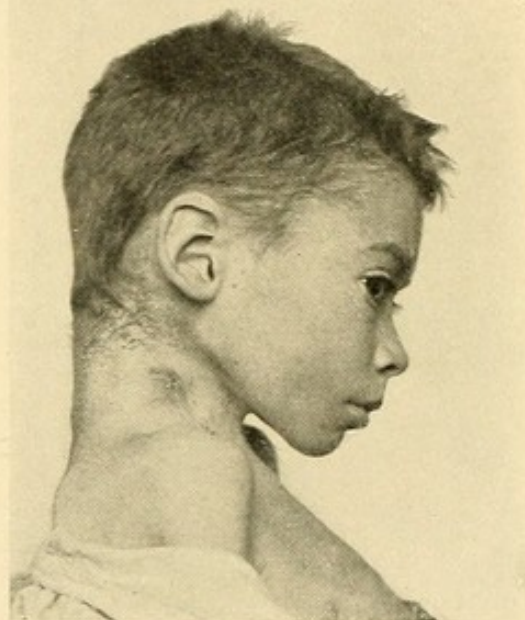


FIG. 145.—Cervical caries with retropharyngeal abscess opening just posterior to the sternomastoid muscle.

by very loose connective tissue. The space between these two layers of fascia is known as the *retropharyngeal space* and pus can follow it downward behind the pharynx and œsophagus into the posterior mediastinum. Retropharyngeal abscesses occur beneath the pharyngeal aponeurosis and bulge into the throat. On account of the looseness of this aponeurosis and its lack of firm attachments, these abscesses may not bulge forward as a distinct circumscribed swelling as abscesses do elsewhere, but are more apt to gravitate downward and hang in a loose bag-like manner opposite the base of the tongue. They are not easily felt, being so soft, and to see them properly the tongue should be held down with a tongue depressor. In looking for their origin, a careful examination of the spine should be made to detect the possible existence of spinal caries or Pott's disease, and the ear should be examined for suppurative otitis media. The lymph-nodes, which sometimes give rise to these abscesses, are one or two lying on the anterior surface of the vertebral column between it and the pharyngeal aponeurosis and constrictor muscles. In evacuating these abscesses the safest way is to place the child on its back with the head hanging, the pus then gravitates toward the roof of the pharynx. The tongue is held out of the way with a tongue depressor and the abscess can be well seen and incised. If the flow of pus is free, as soon as the incision is made, if in a child, the feet may be grasped and elevated, the head hanging downward, and the pus will flow out of the mouth.



The pus may not only point in the mouth but can work its way laterally. In such a case it may pass out behind the sheath of the great vessels and make its appearance, as I have seen it, behind the posterior edge of the sternomastoid muscle. If a tumor is present in this situation, the pus may be evacuated by an incision at this point and the abscess drained there instead of making an opening through the pharynx. This, of course, tends to guard against infection from the mouth.

**Lingual Nerve.**—The lingual nerve or gustatory branch of the fifth can be readily exposed in the mouth. On looking into the mouth, a fold can be seen going up and back just behind the last molar tooth. This is formed by the *pterygomandibular ligament*, running from the tip of the internal pterygoid plate to the posterior extremity of the mylohyoid ridge and joining the buccinator with the superior con-

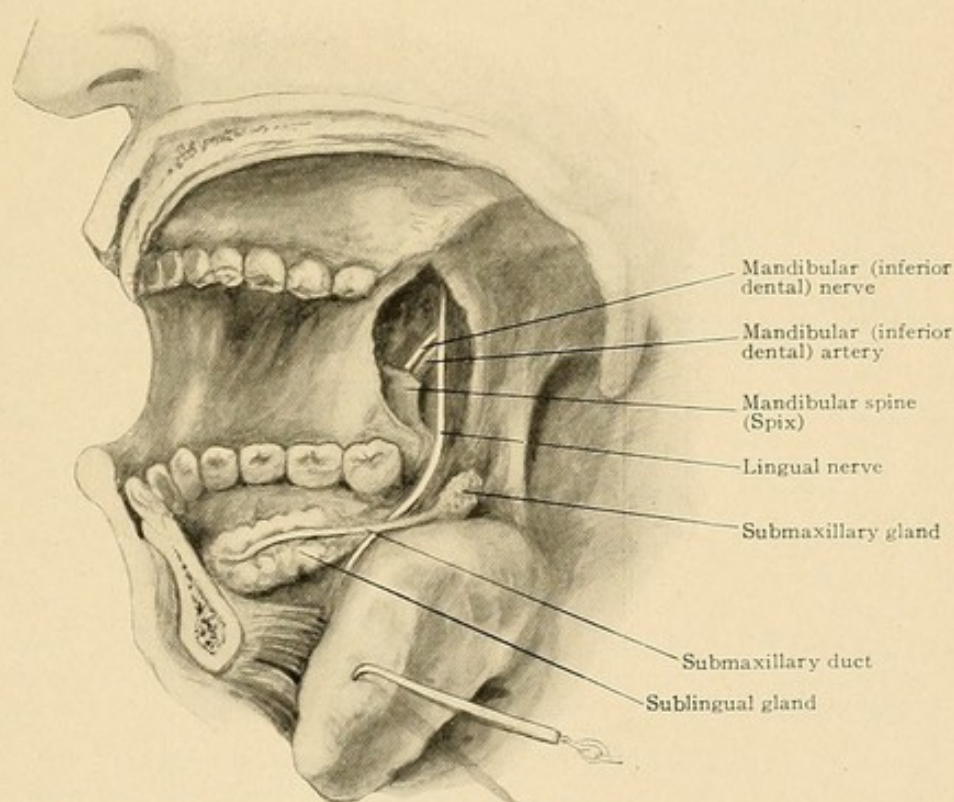


FIG. 146.—View of mandibular and lingual nerves from within.

strictor muscles. An incision made just internal to this fold, below and behind the last molar tooth, will lead one down to the lingual nerve close to the bone.

The **mandibular nerve** is also reached through an incision running from the last upper to the last lower molar tooth. The finger is introduced and the spine of Spix felt at the inferior dental foramen. The nerve and artery enter the mandible at this point, the artery being below and posterior. The operation of Paravicini on this nerve through the mouth is unsatisfactory on account of the lack of proper exposure. It is better to attack the nerve from the outside as detailed on page 60.

## PHARYNX.

The pharynx is the common air and food tract that lies behind the nose, mouth, and larynx. It extends from the base of the skull above to the œsophagus below. Its lower end is at the cricoid cartilage, which is opposite the sixth cervical vertebra. In passing an instrument directly backward through the nose, one strikes the base of the skull or interval between the basilar process and the atlas. In looking into the throat through the mouth, one is level with the body of the second vertebra. If, by means of a hook, the soft palate is raised or pushed aside and the head tilted slightly backward one sees the anterior tubercle of the atlas. The rounded projection can



readily be felt. The pharynx has seven openings into it, viz.: the two posterior nares, the two Eustachian tubes, the mouth, the larynx, and the œsophagus.

**Posterior Nares or Choanæ.**—These can readily be seen by means of the rhinoscopic mirror. They are separated by the posterior edge of the bony septum, the *vomer bone*. They are 2.5 cm. (1 in.) long and 1.25 cm. wide, hence are of sufficient size to allow a well lubricated little finger to pass into them from the anterior nares. The tip of an index finger can be inserted through the mouth below, hence the entire length of the lower meatus of the nose and upper surface of the soft palate can be palpated.

Projecting from each lateral wall toward the septum are the rounded posterior ends of the middle and inferior turbinated bones. Sometimes, high up, the posterior end of the superior turbinate can be seen. The posterior end of the inferior turbinate is frequently enlarged by a swelling of its membrane, forming a *posterior turbi-*

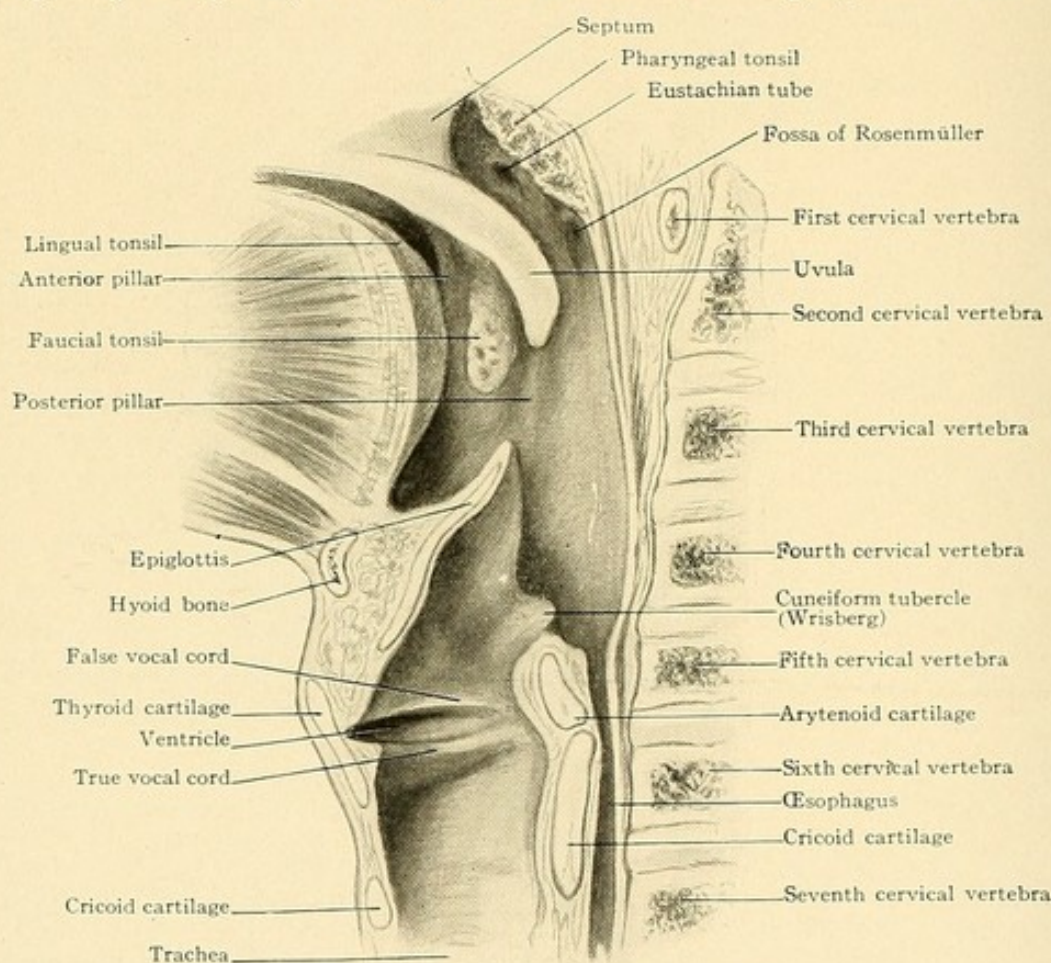


FIG. 147.—Lateral view of pharynx and larynx.

*nate hypertrophy*. Not only does the mucous membrane of the inferior turbinate bones become enlarged, but that on the septum likewise. This constitutes *hypertrophy* or *thickening of the septum*. A polypus may project from the nasal cavities backward into the throat. I removed a very large one by pushing it with the finger into the pharynx and then dragging it out of the mouth.

The posterior nares are quite a distance anterior to the edge of the soft palate, hence it is extremely difficult to make applications by way of the mouth. A much easier way is to make them through a tube introduced into the nose, or even, as when the electrocautery is used, without a protecting tube.

**Eustachian Tube.**—On each side, at a point about opposite the inferior turbinates, are the orifices of the *Eustachian tubes* with the *fossa of Rosenmüller* above. The Eustachian tube runs from the upper portion of the pharynx to the middle ear, opening just behind the tympanic membrane, on the anterior wall. It is about



4 cm. long, 2.5 cm. being cartilaginous (pharyngeal portion) and 1.5 cm. being bony. At the junction of the bony and cartilaginous portions the lumen is slightly diminished, forming the *isthmus*. The tube runs upward, backward, and outward.

The mucous membrane of the throat is continuous with that lining the tube and tympanum, therefore inflammation of the pharynx travels up the tube and affects the middle ear. This is the manner in which earache or inflammation and suppuration

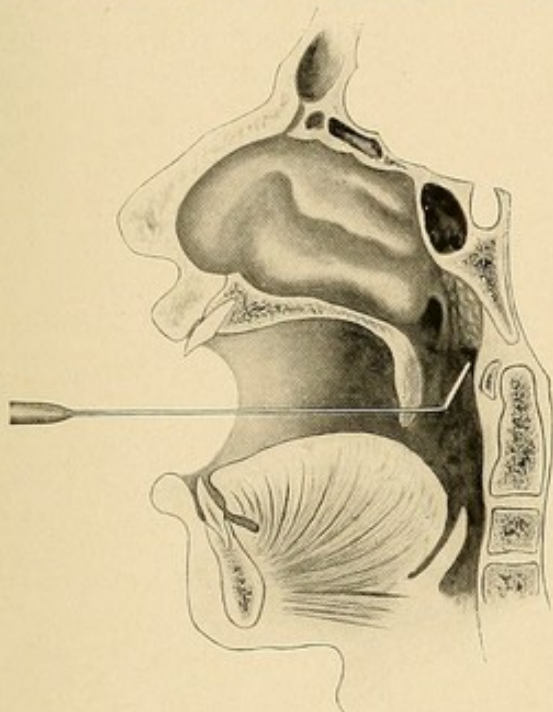


FIG. 148.—Rhinoscopic mirror in position. A view can be obtained of the vault of the pharynx and posterior nares.

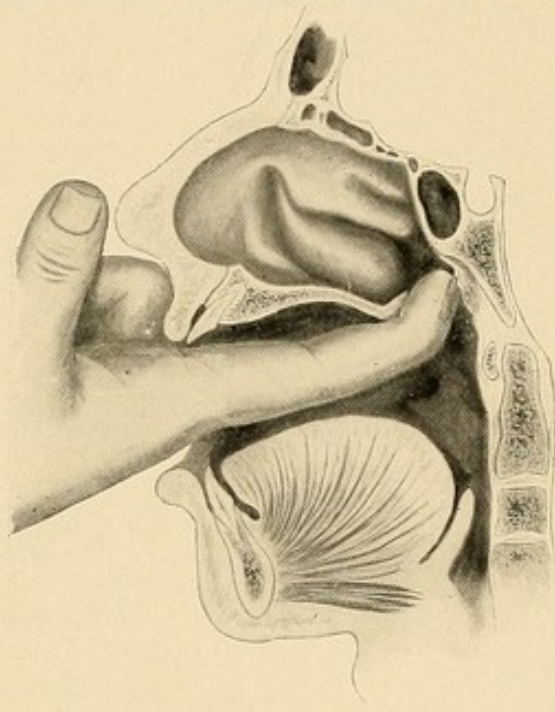


FIG. 149.—Palpation of the posterior nares and pharyngeal tonsil.

of the middle ear is produced. This also explains why impairment of hearing so often accompanies or follows sore throat. When the tube is in a healthy condition, the air finds free access to the ear, in swallowing, sneezing, etc. This is readily demonstrated by closing the nostrils and swallowing, when the pressure of air outside the ear drum will be distinctly felt. When inflammation affects the lining mem-

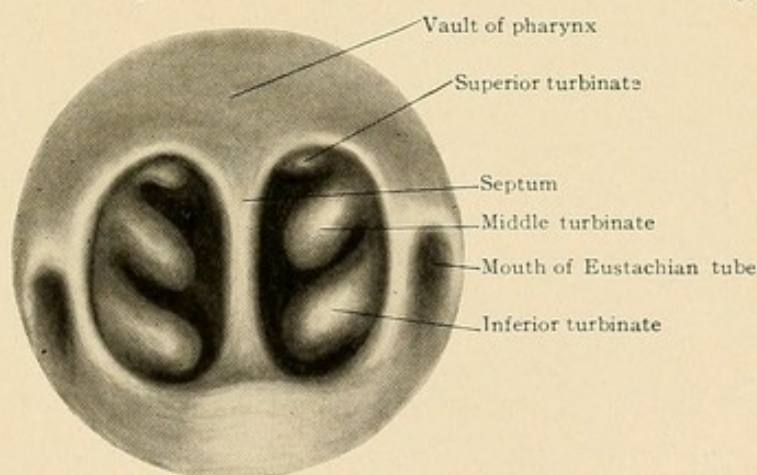


FIG. 150.—View of posterior nares in the pharyngeal mirror.

brane it swells and blocks up the tube and prevents the free access of air to the ear. If the swelling is not too great, air can be forced from the throat to the ear by three different means. The distention of the middle ear by air is called inflating it. The method of Valsalva consists in holding the nostrils and mouth shut and blowing. If the air enters the middle ear, the tympanic membranes will be felt to bulge outward. The method of Politzer is to have the patient hold a small quantity of



water in the mouth. The nozzle of a rubber bag is introduced into one nostril, closing both nostrils with the fingers and thumb of the unengaged hand. On telling the patient to swallow, the bag is compressed and the air enters the Eustachian tube. As the patient swallows, the tensor palati muscle opens the mouth of the tube and as the bag is compressed the air rushes up the tube. Sometimes the vapors of ether, chloroform, etc., are used. The third method is by the Eustachian catheter.

The **Eustachian catheter** is a small, hard rubber or silver tube, slightly bent at the extremity and long enough to reach from the anterior nares in front to the posterior wall of the pharynx. The end of the catheter having been inserted into

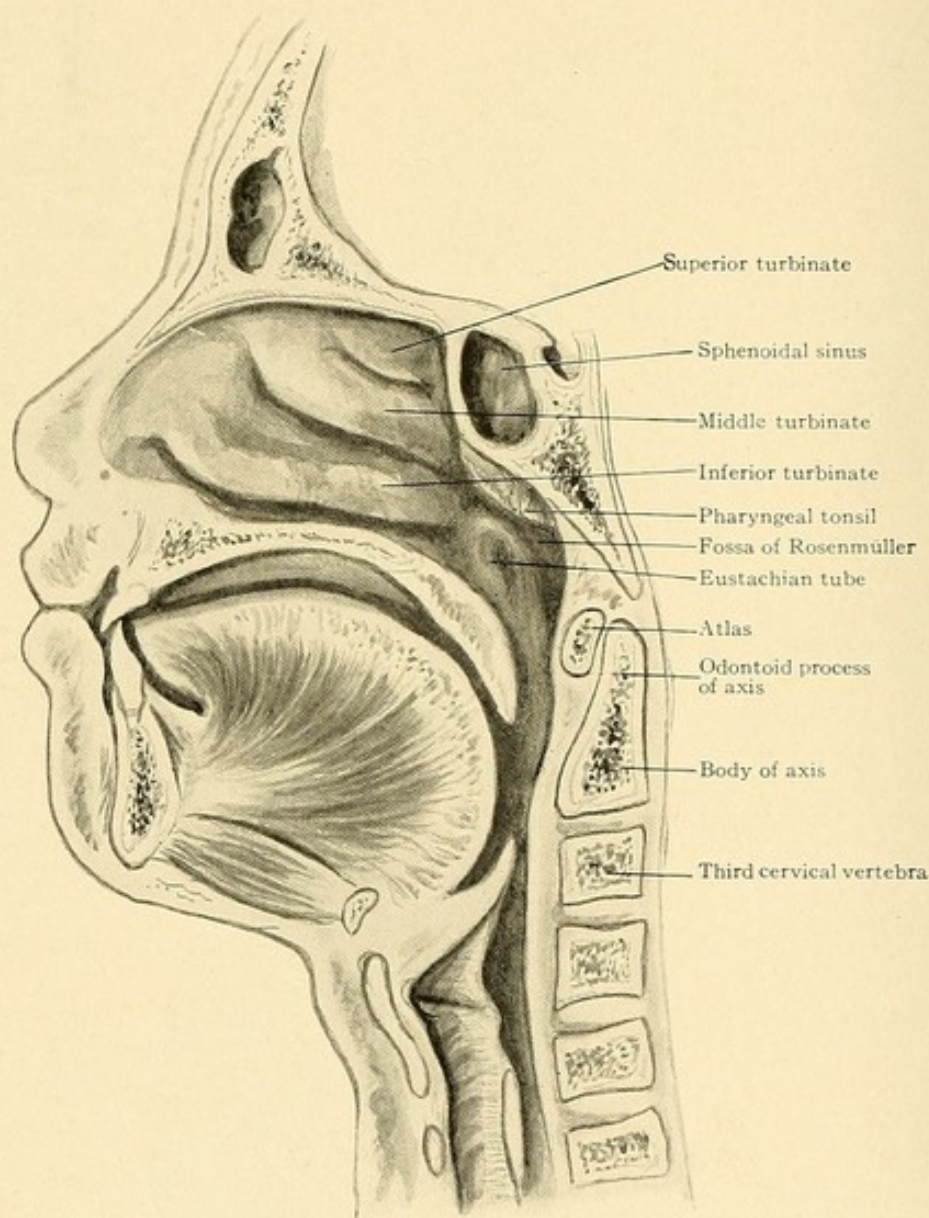


FIG. 151.—Anteroposterior frozen section, showing a lateral view of the pharynx and the relation of the various neighboring structures.

the mouth of the Eustachian tube, air is blown in with the Politzer air-bag. By means of a rubber tube going from the patient's ear to the surgeon's ear, the air can be heard entering the middle ear.

*Introducing the Eustachian Catheter.*—In introducing the Eustachian catheter, the tip of the nose is to be tilted upward until the anterior nares are raised to the level of the floor of the nose. The tip of the catheter is then passed first upward (Fig. 152), then along the floor until it is felt to pass beyond the soft palate and strike the posterior wall of the pharynx (Fig. 153). It is usually advised to enter the



catheter in a vertical position and then change to a horizontal one as soon as the beak passes over the elevation which marks the separation of the vestibule of the nose from the interior. If this method is used, care should be taken to keep the tip of the catheter on the floor of the nose and not pass it up in the region of the middle turbinate bone.

There are three ways of introducing the beak of the catheter into the mouth of the tube after it is felt touching the posterior pharyngeal wall. The first is to withdraw the beak about 2 cm. away from the wall of the pharynx and then turn it upward and outward, pushing it a trifle onward. The second way is to turn the beak directly outward and draw it forward, when it can be felt passing over the cartilaginous opening of the tube. The third way is to turn the beak inward and draw it forward until it catches behind the septum. This is opposite the anterior edge of the mouth of the tube. The beak is then rotated downward and then upward and outward into the tube.

Liquids and sprays are sometimes injected into the ear through the catheter; bougies are also passed into the tube in the same manner as the catheter or, if flexible bougies are used, they are passed through the catheter. As the tip of the bougie passes into the bony portion of the canal, the constriction of the isthmus can be felt 2.5 cm. up from its mouth. The bougie should not be passed farther than 3 cm.

into the tube, otherwise, if the tympanum is entered, the ossicles are apt to be injured.

**Openings of the Mouth, Larynx, and Œsophagus.**—The opening of the mouth into the pharynx is sometimes narrowed from cicatricial contractions, resulting

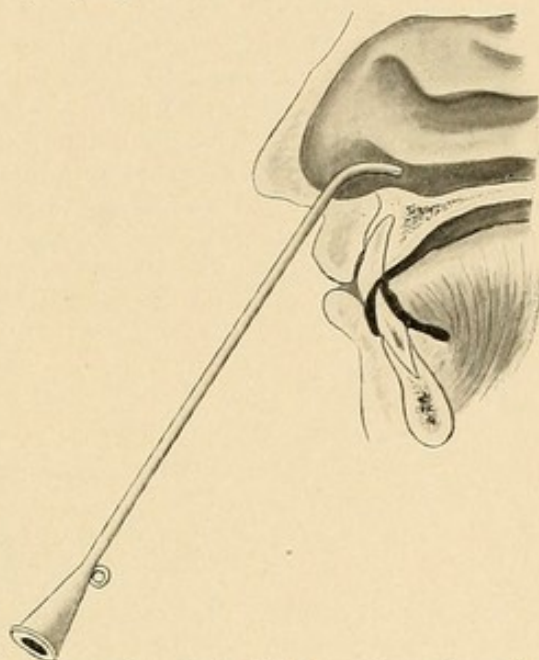


FIG. 152.—Introducing the Eustachian catheter, first step.

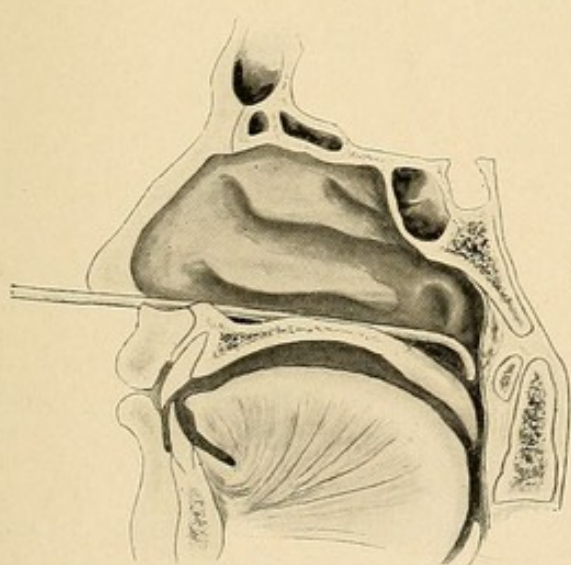


FIG. 153.—Introducing the Eustachian catheter, second step.

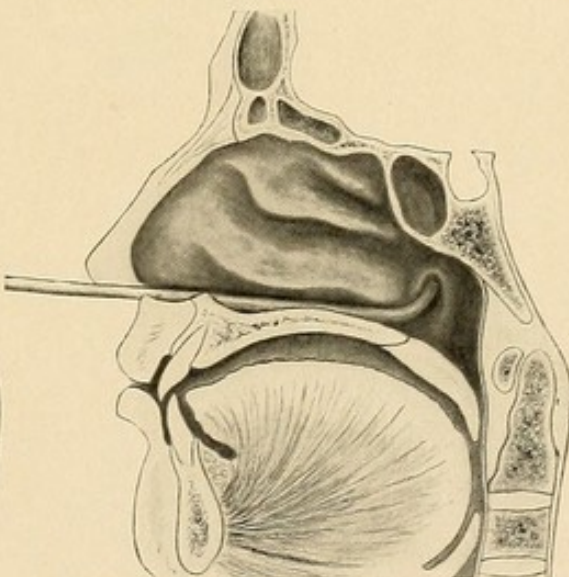


FIG. 154.—Introducing the Eustachian catheter, third step.

from ulcerative processes due to syphilis, caustics, etc. There is rarely obstruction downward, so that these patients can usually swallow, but the cicatrices contract the opening upward, and the soft palate, its arches, and the walls of the pharynx may be all bound together in one cicatricial mass, preventing, as I have seen, all respiration through the nose. This condition is an exceedingly difficult one to remedy, as the contraction tends to recur even after the most radical operations.

The opening into the larynx is more accessible than is often supposed. On drawing the tongue well forward, the tip of the epiglottis can be seen. If a long



straight tongue depressor is used, Kirstein has shown that in many patients the arytenoid cartilages and even a portion of the vocal cords can be seen. The opening into the larynx can readily be felt by a finger introduced into the mouth. In cases of suffocation from a foreign body, as a piece of meat, it is usually lodged at this point, part of the foreign body being in the larynx and part in the pharynx. It can readily be dislodged by the finger, as I have done in impaction of meat, the result of vomiting in ether narcosis. The forefinger should be thrust its full length into the mouth and throat and swept from side to side. The obstructing body can usually be brushed aside and brought up in front of the finger into the mouth.

The opening of the œsophagus is in a line with the long axis of the pharynx; it is at its lower end. The opening of the larynx, on the contrary, is more on its anterior wall. It is for this reason that when an œsophageal tube is introduced, either through the mouth or through the nose, it goes down into the œsophagus and does not enter the larynx. The œsophagus is narrowest at this point.

The **pharyngeal tonsil** stretches across the posterior wall and roof of the pharynx from the opening of one Eustachian tube to that of the other. It is also

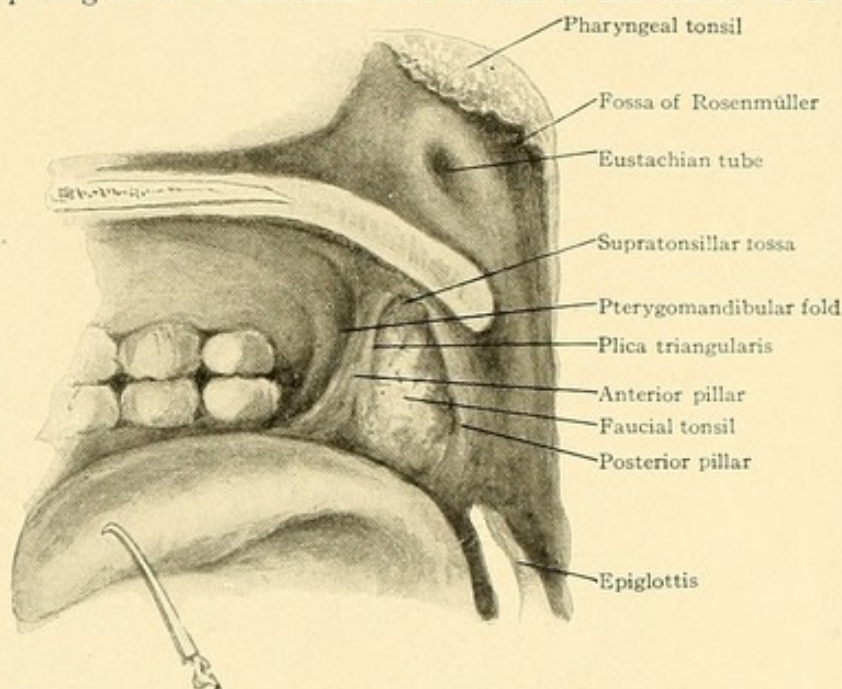


FIG. 155.—Lateral view of the pharyngeal region.

known as *Luschka's tonsil*. It is composed of lymphoid tissue, and when enlarged constitutes the disease known as **adenoids**. It is not true secreting gland tissue, though it contains some mucous glands. It hangs from the vault of the pharynx in a more or less lobulated mass and when large, in children, obstructs nasal respiration. Mouth-breathing results, the child is apt to snore and make queer sounds when sleeping, and the habit of keeping the mouth open causes a peculiar expression of the face almost pathognomonic of the affection. The blood supply at times is abundant. When adenoids are present, their removal is usually undertaken. This is done by introducing an instrument either through the nose or through the mouth and scraping them off. A curette is used for this purpose. That known as Gottstein's consists of an oval-shaped ring set at right angles to a long shaft. It is introduced through the mouth and up behind the soft palate. It is then pushed against the vault of the pharynx and posterior wall and drawn downward cutting and scraping the adenoid tissue away. A much smaller ring curette set on a long, delicate, but stiff handle may be used through the nose for the same purpose. In using the latter instrument, it is common to use an anæsthetic and operate with the head in a hanging position. Free bleeding may occur from this operation. To control it, injections of ice water or a strong alum solution may be tried or gauze may be packed behind the soft palate or pushed in from the anterior nares. A folded pad of



gauze may be attached to the thread of a Bellocq cannula and the pad introduced as is done in plugging the posterior nares. A curved forceps with cutting blades is also used to remove this growth.

**Fossa of Rosenmüller.**—This is the depression above and behind the openings of the Eustachian tubes. The walls of the pharynx are weakest at this point owing to the superior constrictor muscle not coming so high up. Hernia of the mucous membrane sometimes occurs here. When the beak of the Eustachian catheter fails to enter the mouth of the tube it usually enters this fossa.

The **internal carotid artery** runs up the neck outside of the pharynx and opposite the space between the posterior arches of the palate and the posterior wall of the pharynx. It is from 1 to 2 cm. behind and to the outer side of the tonsils. It is separated from the cavity of the throat by its own proper sheath, by the thin buccopharyngeal fascia covering the constrictor muscles, by the constrictor muscles, the pharyngeal aponeurosis, and the mucous membrane. As the tonsils lie between the pillars of the fauces, in opening a tonsillar abscess the knife is not carried either

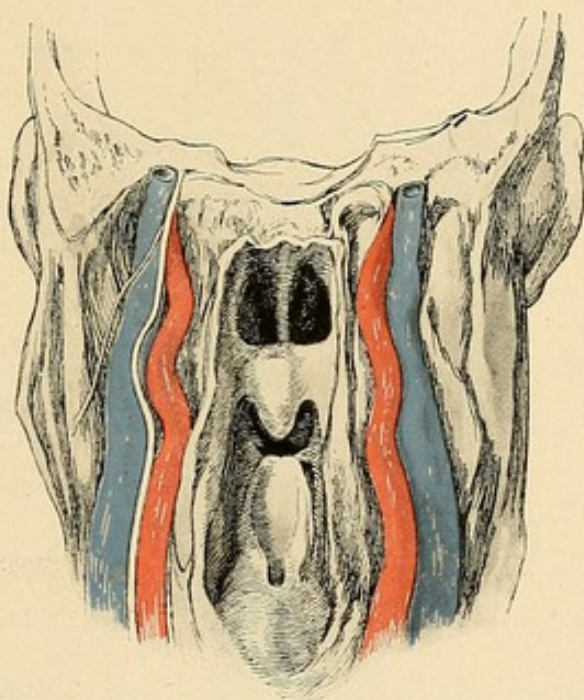


FIG. 156.—Transverse dissection of the neck. The posterior wall of the pharynx has been removed and the vessels exposed. The internal carotids are seen to be abnormally tortuous, with a tendency to bulge into the pharynx.

behind or through the posterior pillar of the fauces. It is practically impossible to wound a normal internal carotid artery. In old people the internal carotid sometimes becomes lengthened and tortuous in the same manner as do the temporal arteries. In such cases the artery may form a pulsating swelling behind and projecting farther inward than the edge of the posterior pillar. This I have once seen. It may be mistaken for a true aneurism, as it pulsates and the pulsation is readily stopped by pressure on the common carotid on the outside of the neck. If, however, the possibility of this condition is borne in mind, the diagnosis can readily be made. The pulsating swelling can readily be seen and felt with the finger just behind the posterior pillar of the fauces.

The **mucous membrane** of the nasopharynx is ciliated columnar; that of the lower portion is squamous. It contains racemose mucous glands and follicles or crypts surrounded by lymphoid tissue. It is well supplied with blood-vessels. It is frequently affected by inflammation or pharyngitis. When the follicles are markedly involved they can be seen studded over the posterior wall of the pharynx. This constitutes a *follicular pharyngitis*. Not infrequently some ulceration may be present, forming an *ulcerative pharyngitis*. Infection attacks it, as in *diphtheritic pharyngitis*. Should pus or pharyngeal abscess form around the pharynx, arising from an infection from the oral cavity, the pus occupies the retropharyngeal space



between the buccopharyngeal fascia and prevertebral fascia. Its spread upward is limited by the skull; laterally it is limited by the sheath of the carotid vessels; hence it passes downward behind the œsophagus and may enter the posterior mediastinum.

**Foreign bodies** may become lodged at the lower end of the pharynx and at the beginning of the œsophagus. As this is about 15 cm. (6 in.) from the teeth, it is beyond the reach of the finger. Luckily, this is below the opening of the larynx and the need for immediate relief is not so urgent.

### THE LARYNX.

The larynx extends from the top of the epiglottis to the lower edge of the cricoid cartilage. It is composed of the three large cartilages—*epiglottis*, *thyroid*, and *cricoid*—and three pairs of small ones—the *arytenoids*, the *corniculæ laryngis* or *cartilages of Santorini*, and the *cuneiform* or *cartilages of Wrisberg*.

The position of the larynx in relation to the spine varies according to age. In the infant it lies opposite the second, third, and fourth cervical vertebræ; in the adult

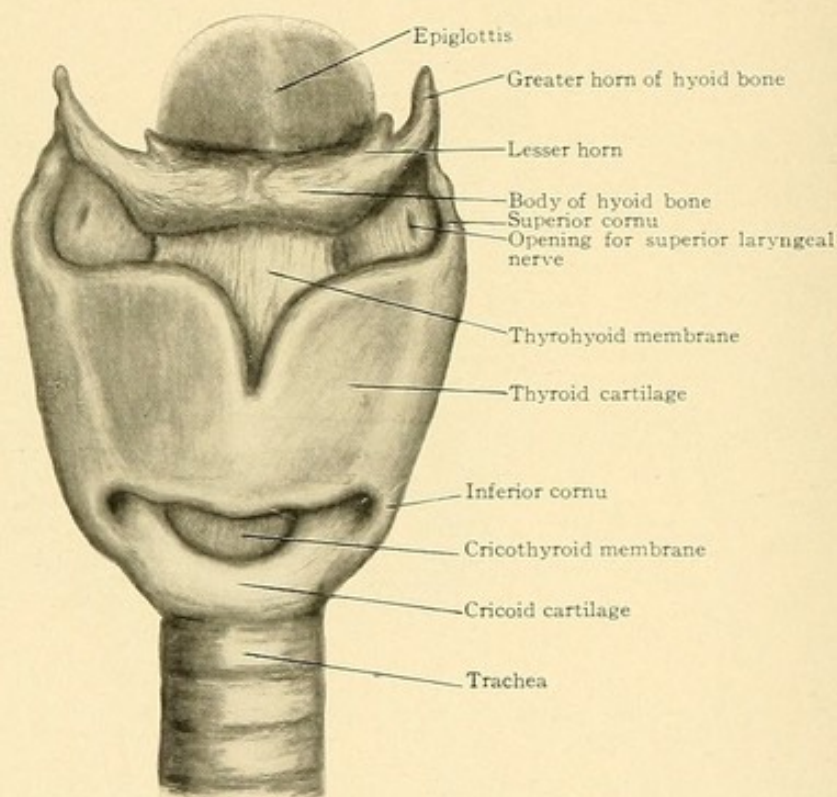


FIG. 157.—Anterior view of hyoid bone and larynx.

it lies opposite the fourth, fifth, and sixth. The larynx being loosely attached varies in relation to the vertebræ according to the position of the head, so that the anterior portion of the cricoid cartilage may be opposite the seventh cervical vertebra in some positions.

**Epiglottis.**—Usually the tip of the epiglottis lies lower than the dorsum of the tongue, so that looking into the mouth it is not seen; it may, however, be brought into view by depressing the base of the tongue and drawing it forward with a long tongue depressor. As the epiglottis rises above the level of the hyoid bone, a cut-throat wound passing above that bone may cut its tip entirely off. In viewing the epiglottis from above downward it is seen to project somewhat backward in its middle. This is visible in the laryngoscopic mirror and is called the cushion of the epiglottis.

Running forward from the epiglottis to the base and the sides of the tongue are three folds of mucous membrane, one median and two lateral, called the glosso-epiglottic folds. These form four fossæ; those on each side of the median line are called the *valleculæ*. In these fossæ foreign bodies, such as fish-bones, etc., may become lodged. They are readily seen by the laryngoscopic mirror.



The **thyrohyoid membrane** passes between the hyoid bone above and the thyroid cartilage below ; crossing it is the hyoid branch of the superior thyroid artery. It is a quite small vessel, of little clinical importance, and ordinarily does not reach the median line.

The posterior edge of this membrane, running from the superior corner of the thyroid cartilage to the hyoid bone, is called the *thyrohyoid ligament*. This ligament has a small cartilaginous nodule in it, the *cartilago triticea*. Piercing the membrane on its side are the internal branches of the superior laryngeal nerve and the superior laryngeal vessels. The *external branch* of the superior laryngeal nerve supplies the cricothyroid muscle, while the *internal* is the nerve of sensation of the larynx.

**Pharyngotomy.**—Sometimes, in order to remove foreign bodies in the larynx or œsophagus, an opening is made through the membrane between the hyoid bone and thyroid cartilage.

**Thyroid Cartilage.**—This is the largest cartilage of the larynx and contains the vocal cords. They lie immediately behind or just below the most prominent

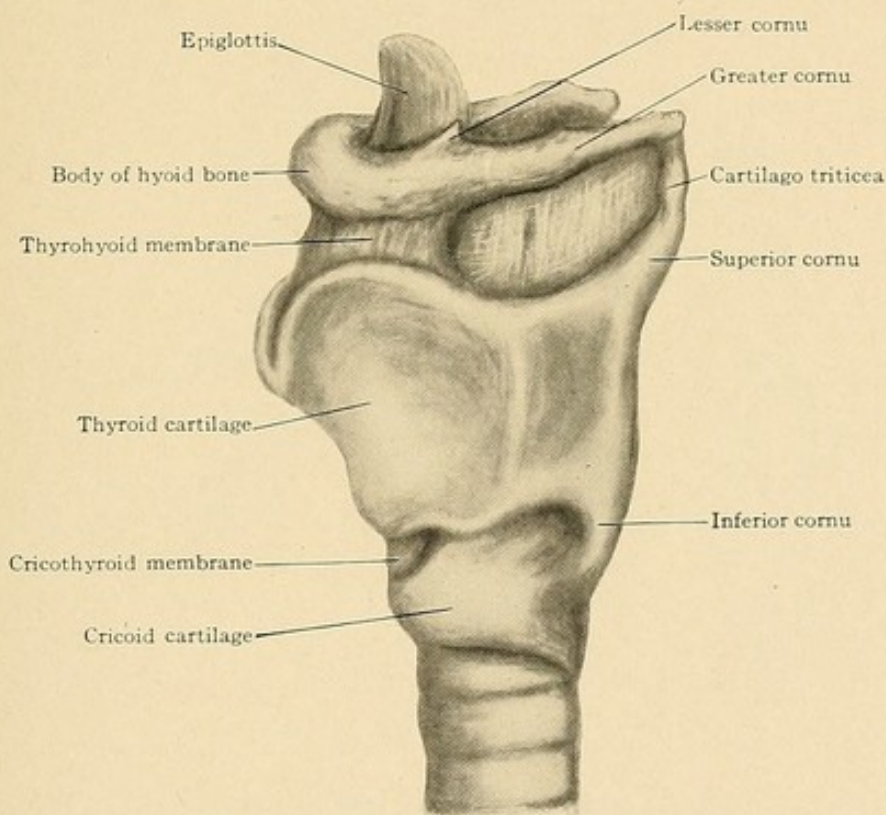


FIG. 158.—Side view of hyoid bone and larynx.

portion of its anterior edge, commonly called "Adam's apple." Since the cartilage is large and strong and as age advances tends to calcify, cut-throat wounds, while opening the cavity within, do not often pass entirely through the cartilage. This cartilage may be fractured by violence. This is often fatal on account of the blood flowing into the trachea and lungs below or on account of œdema of the lining mucous membrane causing obstruction of the breathing. Thyrotomy or division of the thyroid cartilage in the median line is sometimes done to remove foreign bodies or new growths. In these cases the voice will be likely to be impaired by the interference with the vocal cords.

**Cricothyroid Membrane.**—The space between the cricoid and thyroid cartilages is small. This is due to the increase in width of the cricoid as it proceeds backward. The space is readily felt on the living subject between the thyroid above and the cricoid beneath ; the membrane passes between them. It is crossed by a small branch of the superior thyroid artery, the cricothyroid. It is not large enough to cause serious trouble. Introducing a tube through this membrane constitutes the operation



of *laryngotomy*. This operation is but seldom performed. The space is too small in many cases, the opening is not made sufficiently low and it is too close to the vocal cords. It is an operation of emergency. It is much easier to make a quick opening at this point than it is in the trachea below, as it is more superficial and is held steady in place by the cartilage above and below it. Even in adults the space is sometimes too small to introduce a tube without force and the operation should never be done below the age of thirteen. On account of the membrane being nearer the surface than is the trachea, a shorter tube should be used. Before introducing the tube, care must be taken that the mucous membrane has been thoroughly divided, as otherwise the tube will push it before it and slip between the mucous membrane and the cartilage and, therefore, not enter the cavity of the larynx.

**Cricoid Cartilage.**—This is much larger posteriorly than anteriorly and fills the space between the posterior edges of the thyroid cartilage. Its outside diameter is larger than that of the trachea, hence it can readily be felt and forms one of the most important landmarks on the front of the neck. It is about opposite the sixth

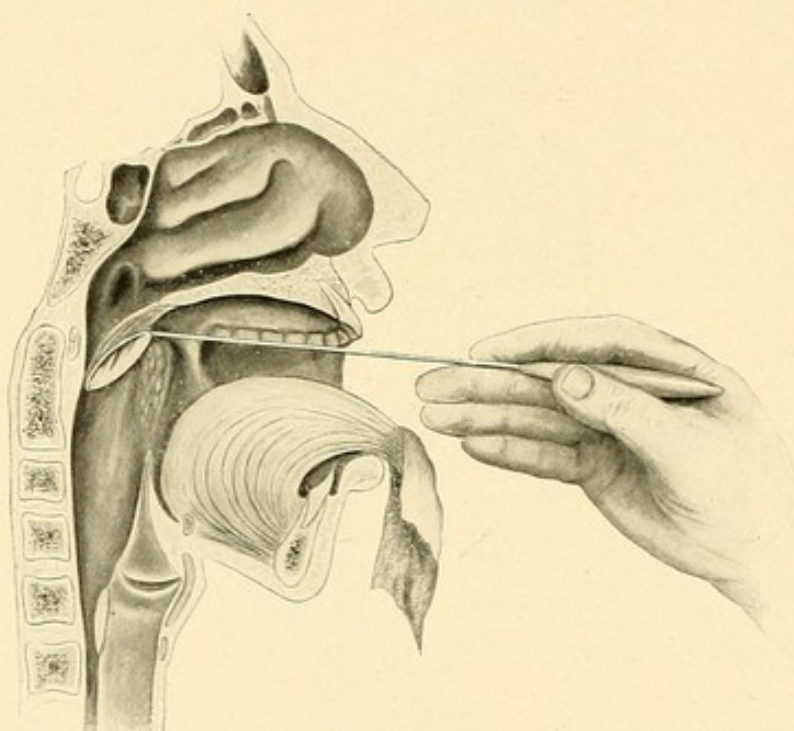


FIG. 159.—Examining the interior of the larynx by means of the laryngoscopic mirror.

cervical vertebra. It is thick and strong and forms a complete circle, being unlike the tracheal rings in this respect. It is rare that it is divided in operations.

For the parts concerned in tracheotomy see the section on the neck.

**Laryngoscopy.**—The interior of the larynx is examined by means of a small mirror, 1 to 3 cm. in diameter, introduced through the mouth and placed just below the uvula at an angle of a little more than 45 degrees. The opening of the larynx is not directly beneath the mirror but slightly anterior. The base of the tongue and lingual tonsils, the glosso-epiglottic folds and pouches, and the epiglottis can be seen in front. Posteriorly one sees the two arytenoid cartilages capped with the cartilages of Santorini. Between the arytenoids is the *commissure* or *interarytenoid space*. To the front and outer side of the tip of the arytenoid cartilages is the cartilage of Wrisberg, and running from it forward are the *aryepiglottic folds*. To the outer side of the aryepiglottic fold is the depression called the *sinus pyriformis*. It is here that congenital cervical fistulæ sometimes open. Near the middle are seen the two, white, *true vocal cords*, and to the outer edge of these are seen the *false vocal cords*. Between these two is the opening of the *ventricle* of the larynx. The rings of the trachea can readily be seen and not infrequently even the point of bifurcation of the trachea opposite about the second rib.



**Diseases of the Larynx.**—*Syphilis* affects the larynx and produces ulcers. These may involve almost any portion but usually they are anterior, involving the epiglottis. They are often associated with syphilitic manifestations in the mouth. *Tuberculosis* affects the posterior portion of the larynx and the bulb-like swellings of the arytenoids are almost pathognomonic. Ulcers when they occur are most marked posteriorly. This affection is associated with a blanching of the mucous membrane of the mouth and the presence of a white frothy mucus, which will lead the laryngologist to suspect the existence of the disease before a view of the larynx is obtained.

*Laryngitis* of a simple nature produces a reddening of the cords and a swelling of the membrane generally.

In *edema* of the larynx, the serous effusion puffs up the loose mucous membrane, particularly of the aryepiglottic folds and epiglottis.

*Tumors* both benign and malignant affect the larynx and can at times be seen to arise from the vocal cords.

*Paralysis* of the muscles is most frequent from interference with the recurrent

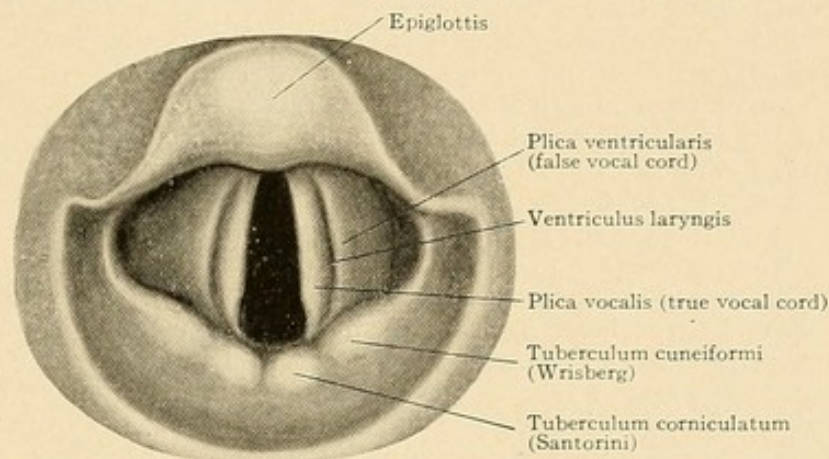


FIG. 160.—View of the larynx as seen in the laryngeal mirror.

laryngeal nerve. This nerve supplies the abductor muscles and when paralyzed the cords tend to fall together. The nerve may be injured in operations on the neck or involved in cancer of the thyroid gland, or œsophagus, or in aneurisms. If one cord is paralyzed, the voice is lost temporarily, and when it returns, it is changed in character. Paralysis of both nerves does not cause entire loss of voice because the cords fall together, but may induce suffocative symptoms ending in death.

## THE NECK.

The neck supports the head. It is a pedestal for the head, and is long in proportion to its thickness; the apparent object of this being to elevate the head and allow it to be moved freely in different directions. The animal is thus better enabled to discover its enemies and to guard itself against them.

The various structures of the neck are mostly long, running between the head above and the trunk below. This is the case with the spine, the air- and food-passages, the blood-vessels, nerves, and even some muscles, as the sternomastoid and trapezius. The shorter structures are either the component parts of the longer ones, as the vertebræ of the spine and the rings of the trachea, or are separate organs like the larynx, thyroid, and submaxillary glands. The presence of these latter organs is not dependent on the length of the neck as is that of the others. In the frog, which practically has no neck, the head being placed directly on the trunk, there still exist both larynx and thyroid gland. In the singing birds the vocal organ or syrinx is placed in the chest at the bifurcation of the trachea. As regards the cervical spine, blood-vessels, air- and food-passages, and muscles, these evidently are proportionate to the length of the neck. In the batrachians or frogs there is but a single cervical vertebra; in the swan there are twenty-five cervical vertebræ, and in the fishes none. In man of course the number of cervical vertebræ remains the same,



seven, no matter what the length of the neck. From a consideration of these facts we may perhaps state that the neck itself is a subsidiary organ, not of any great importance in itself, but rather in relation to some other portion of the body—that portion being the head. It is the staff which supports the head by means of the cervical spine and muscles.

The neck contains the great currents of blood which pass to and fro between the head and trunk. It carries the air- and food-passages, which run from the mouth above to the lungs and stomach below, and incidentally it contains the larynx, the thyroid and submaxillary glands, and some lymphatic nodes. The cerebrospinal nerves of all the body below the head pass either into the neck or through it to the parts beyond. From these facts it becomes evident that, while the neck in itself may be a subsidiary organ, for our purposes it is of the greatest importance, because interference with its structure either by disease or injury—operative or accidental—may destroy the brain above, by interfering with its nourishment, or the body below, by interfering with the vital functions of respiration and nutrition, or may paralyze it by destroying the conductivity of its nerves. The construction of the neck then should be studied with a view of explaining or understanding the diseases and injuries of its various parts and the operations performed for their relief.

**Injuries and Diseases of the Neck.**—Owing to its exposed position the neck is frequently injured by sprains, contusions, cuts, and punctured, gunshot, and all sorts of wounds. The cervical spine may become dislocated or fractured and is frequently the seat of caries. The muscles become contracted, producing torticollis or wry-neck. They may sometimes be ruptured, as in childbirth.

The *arteries* are affected with aneurism, necessitating their ligation. They are also divided in cut-throat cases and wounds. The *veins* are of importance in almost every operation; bleeding from them is dangerous and may be difficult to control.

The *lymphatic nodes* are more numerous than elsewhere in the body. Frequently they are the seat of tuberculous or sarcomatous enlargement, necessitating their removal. They may break down and produce wide-spreading and dangerous abscesses, which are guided in their course by the fascias; hence a knowledge of the construction of the deep fascias of the neck enables us to understand them.

The *submaxillary* and *thyroid glands* are the seat of enlargement and foreign growths requiring the performance of extensive operations for their extirpation. Enlargement of the thyroid gland constitutes the disease known as *goitre*. It is also involved in *exophthalmic goitre* or *Graves's* or *Basedow's disease*.

The *skin* and *subcutaneous tissue* become the seat of inflammation and cellulitis. In cases of wounds this cellular inflammation may involve the structures beneath the deep fascia; this occurs in cut-throat and gunshot wounds.

The neck is also liable to other affections, such as cysts due to embryological defects. Large cysts are formed called *hygromas*, also sinuses or fistulæ, the *congenital fistulæ* of the neck. The larynx may be the seat of malignant disease; hence its removal is undertaken. The operations of *tracheotomy*, *laryngotomy*, and *oesophagotomy* are also at times necessary. In order to understand these various affections and procedures one must be familiar with the construction of the neck, what composes it, where the various structures lie and their relation to one another. In order to utilize this knowledge we must be able to recognize and identify the position of various structures before the skin is incised, for it is rarely that a case presents itself with a wound that permits a view of the deeper structures; hence the importance of a thorough knowledge of its surface and the structures capable of being recognized through the skin.

## SURFACE ANATOMY OF THE NECK.

For convenience of study we may consider the structures in the median line, and those regions anterior and those posterior to the sternomastoid muscle, between it and the trapezius. The posterior portion of the neck will be described in the section devoted to the back.

These regions or triangles are simply arbitrary divisions, made for convenience of description. They are sometimes spoken of in reference to the location



of growths, operative incisions, etc. They comprise the space between the trapezius muscle posteriorly, the median line anteriorly, the clavicle below, and the lower jaw above.

Viewed from in front, the median portion of the neck may be divided into three regions, the *submental*, *laryngeal*, and *tracheal*.

The **submental region** extends from the chin to the lower border of the body of the hyoid bone; it is limited laterally by the anterior belly of the *digastric muscle* on each side. Ranula and other sublingual tumors cause a bulging in this region and it is frequently occupied by an enlarged lymphatic node, which at times suppurates and forms an abscess. The floor of the space is formed by the *mylohyoid muscle* and there are no dangerous structures, so that no hesitancy need be had in incising abscesses in this locality nor in removing diseased lymph-nodes. In carcinoma involving the lower lip near the median line these nodes may be affected and

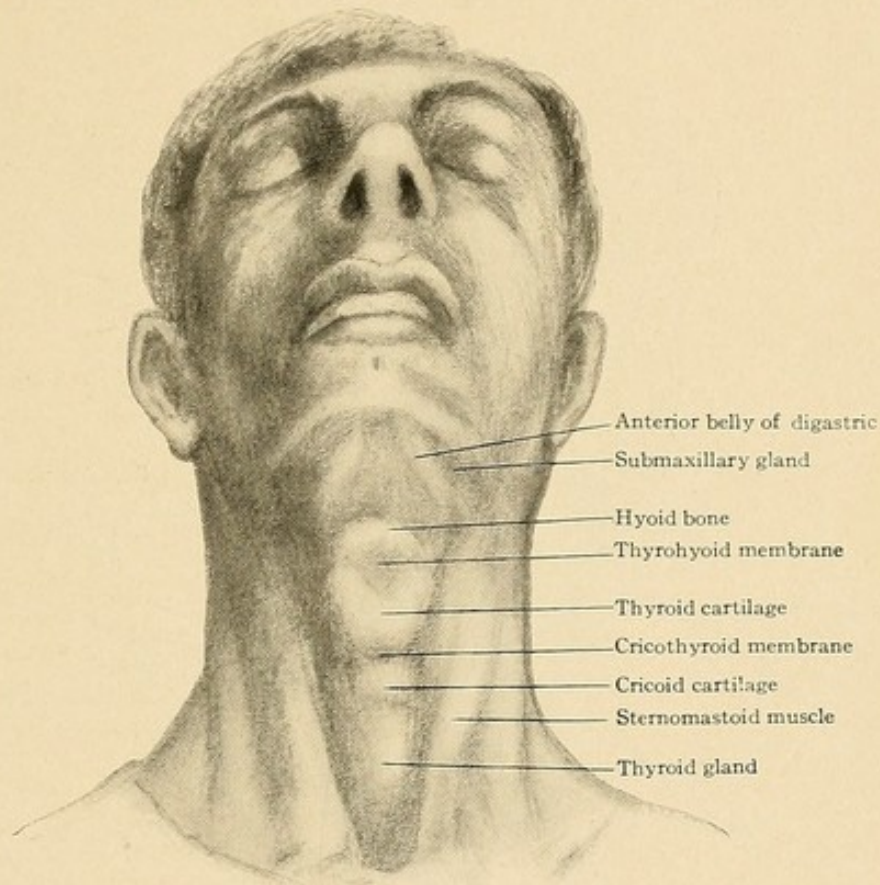


FIG. 161.—Anterior surface of the neck.

their involvement in such cases should always be looked for. The submaxillary lymphatic nodes farther outward may also be implicated. The tip of the epiglottis projects above the hyoid bone in this region.

The **laryngeal region** extends from the under surface of the hyoid bone to the lower edge of the cricoid cartilage. Laterally it is limited to the space occupied by the larynx. The cricoid cartilage is included in this region as a part of the larynx. The vocal cords are just beneath the most prominent part of the thyroid cartilage.

The **tracheal region** extends from the lower edge of the cricoid cartilage to the top of the sternum. Just above the sternum, between the sternal origins of the sternomastoid muscles, is the *suprasternal notch* or, as it is called by the Germans, the *Jugulum*. Laterally the region is limited by the sides of the trachea.

There are seven or eight rings of the trachea between the cricoid cartilage and the top of the sternum. It is covered partly by the *sternohyoid* and *sternothyroid muscles*. The former in the lower half of their course pass outward, leaving a space in which the *sternothyroid muscles* are seen. The sternohyoid muscle arises from



the upper and outer portion of the manubrium, the sternoclavicular ligament, and the inner end of the clavicle. The origin of the sternothyroid is wider than that of the sternohyoid and is lower down. It arises from the first piece of the sternum near the median line, below the sternohyoid, and from the cartilage of the first rib. The first ring of the trachea is not covered by any important structure. The second, third, and fourth rings are covered by the *isthmus* of the thyroid gland; from here down the *inferior thyroid veins* may lie on the trachea for at least part of their course. The *anterior jugular vein* may exist either as a single vein in the median line or to one side of it, or one may pass downward on each side of the median line with a communicating branch from one to the other crossing the median line in the suprasternal notch. The *cricothyroid artery*, a small branch of the superior thyroid, may cross the cricothyroid membrane, but it is usually too small to cause any troublesome bleeding.

**Structures to be Felt in the Median Line.**—On passing the finger downward from the symphysis it sinks into a hollow, on crossing which the hyoid bone is

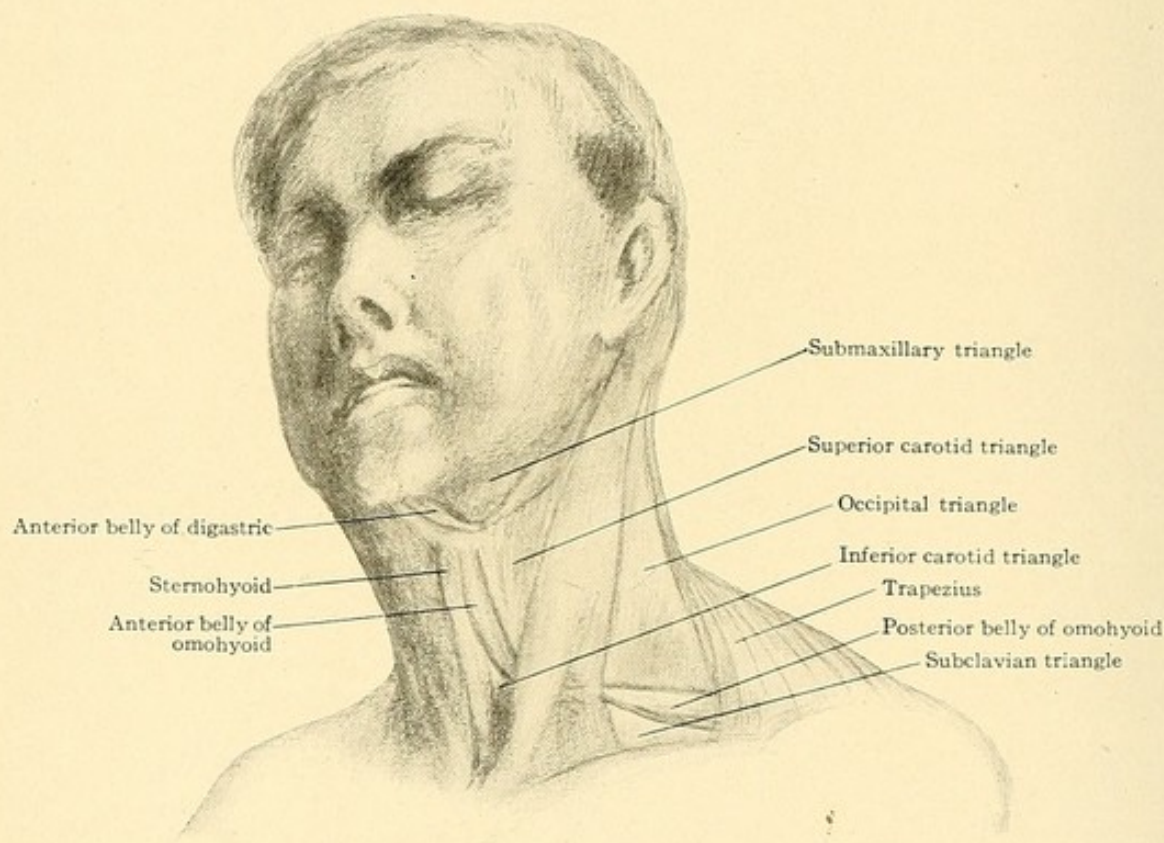


FIG. 162.—Showing anterior and posterior cervical and subsidiary triangles.

felt. On pressing the finger into this hollow it rests between the digastric muscles on each side and the mylohyoid muscles beneath. Still deeper than the mylohyoid are the geniohyoid and geniohyoglossus muscles attached to the genial tubercles on the inner side of the mandible. If the lymphatic nodes at this point are enlarged they may be felt. (Fig. 161.)

The hyoid bone can usually be readily felt in the median line. If it is not easily discovered in the median line it can be felt by a finger and thumb placed on each side of the neck above the thyroid cartilage.

Passing over the hyoid bone the finger then sinks into the space between it and the top of the thyroid cartilage. This space is bridged by the thyrohyoid membrane. Next comes the thyroid cartilage or "Adam's apple." It can readily be seen in adult males and thin people, but in the fat necks of women and children, though it can still be felt, it often cannot be seen. The finger then sinks into the space between the thyroid cartilage above and the cricoid below. They are connected by the cricothyroid membrane, over which runs a small branch (cricothyroid) of the superior thyroid artery.



The prominence of the cricoid cartilage can be seen in thin people and if carefully searched for can be felt in almost all cases. It is opposite the sixth cervical vertebra, a most important landmark. From the cricoid cartilage down to the sternum only soft structures can be felt. The sternum projects forward and the trachea inclines backward so that opposite the top of the sternum the trachea is about 2 cm. behind it. The distance between the top of the sternum and cricoid cartilage in an adult male is about 4.5 cm. ( $1\frac{3}{4}$  in.).

#### THE CERVICAL TRIANGLES.

On viewing the neck from the side the prominent sternocleidomastoid muscle with its thick anterior and thin posterior edge is seen to divide it into two spaces, an anterior and a posterior. They are called the *anterior and posterior cervical triangles*.

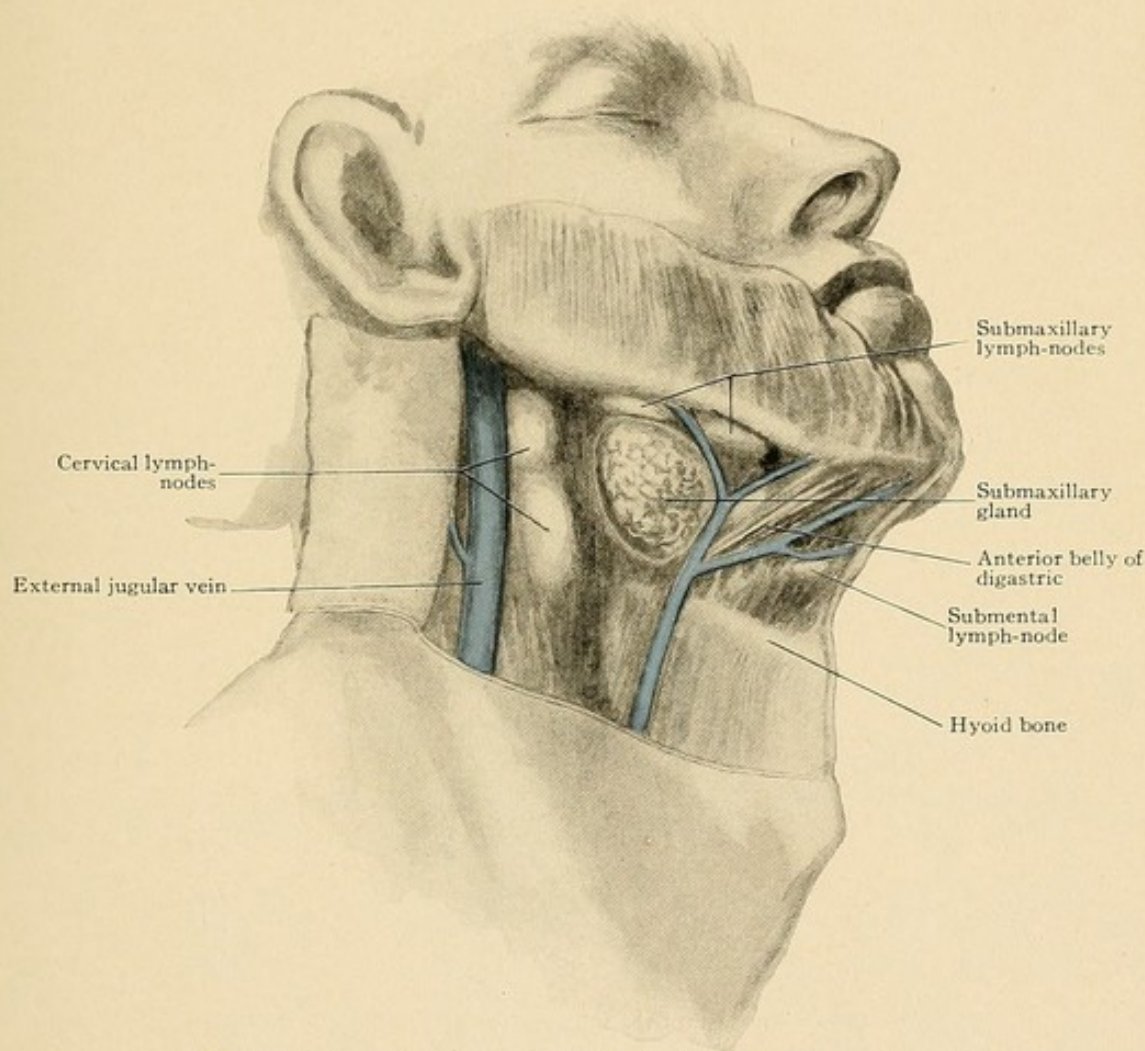


FIG. 163.—Submaxillary region, superficial structures. (From a dissection.)

#### ANTERIOR CERVICAL TRIANGLE.

The anterior cervical triangle has for its anterior side the median line of the neck. Its posterior side is the anterior edge of the sternomastoid muscle. Its upper side is the lower edge of the mandible from the symphysis to the angle and thence across to the mastoid process. The anterior triangle is further divided into the space above the digastric muscle called the *submaxillary triangle*,—from its containing the gland of that name,—the *superior carotid triangle* above the anterior belly of the omohyoid muscle, and the *inferior carotid triangle* below the omohyoid muscle.

The SUBMAXILLIARY TRIANGLE is so called from its containing the submaxillary gland. It is also sometimes called the lingual triangle, from the lingual artery. It



has as its upper side the lower edge of the mandible from near its symphysis around the lower edge of the body to the ramus and thence in a straight line across to the mastoid process. Its anterior side is the anterior belly and its posterior side is the posterior belly of the digastric muscle. The submaxillary gland can usually be felt beneath the jaw. Beneath it runs the facial artery to pass over the body of the mandible in front of the anterior edge of the masseter muscle. The gland lies on the hyoglossus and mylohyoid muscles, which form the floor of this triangle. It is encased in a sort of pocket formed by a splitting of the deep cervical fascia. The posterior portion of this fascia runs from the styloid process to the hyoid bone and is called the *stylohyoid ligament*.

Lymphatic nodes lie on the submaxillary gland and in carcinomatous disease they become enlarged and then can be readily palpated. In operating on these

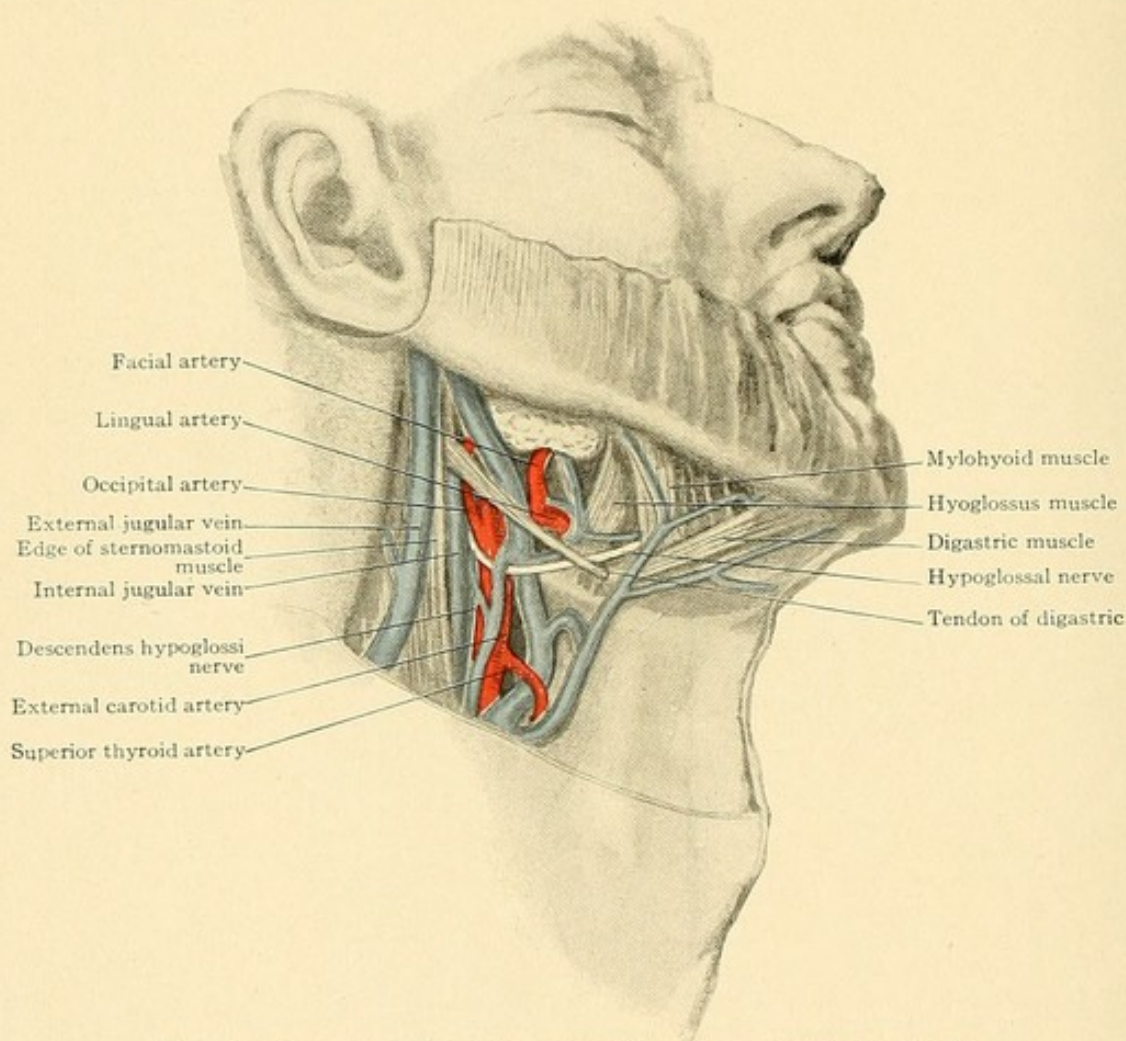


FIG. 164.—Deeper structures of the submaxillary region, especially the vessels.

lymphatic nodes for tuberculous disease, care should be taken to distinguish between them and the submaxillary gland. The tendon of the digastric muscle does not come clear down to the hyoid bone but the loop which binds the two together is sometimes a centimetre or more in length. The lingual artery enters the submaxillary triangle near the apex of the angle formed by the tendon of the digastric. It crosses beneath the posterior belly of the digastric muscle and, particularly if the digastric muscles contract, it may lie close to the tendon. Frequently the search for it is made too high in the triangle and too far away from the hyoid bone. When the submaxillary gland is lifted from its bed the hypoglossal nerve is seen beneath lying on the hyoglossus muscle. The lingual artery lies beneath the hyoglossus muscle and the muscle is cut through in order to find it. The submaxillary region is the seat of *Ludwig's angina*, a septic inflammation involving the cellular



tissues beneath the tongue and jaw around the submaxillary gland and the upper portion of the neck. It is a dangerous affection and may cause death not only by sepsis but also by œdema of the larynx.

Dr. T. Turner Thomas (*Annals of Surgery*, February and March, 1908), has pointed out that the infection passes from the inside of the mouth to the submaxillary region outside by following the connective tissue around the submaxillary gland as it winds around the posterior edge of the mylohyoid muscle through the opening existing between this muscle in front and the anterior portion of the middle constrictor of the pharynx behind.

The SUPERIOR CAROTID TRIANGLE is limited posteriorly by the sternomastoid muscle, superiorly by the posterior belly of the digastric, and inferiorly by the anterior belly of the omohyoid. The location of the omohyoid muscle can be determined by that of the cricoid cartilage, as the muscle crosses the common carotid artery about opposite that point. The sternomastoid muscle can be both seen and felt. It is attached above from the apex of the mastoid process to the middle of the

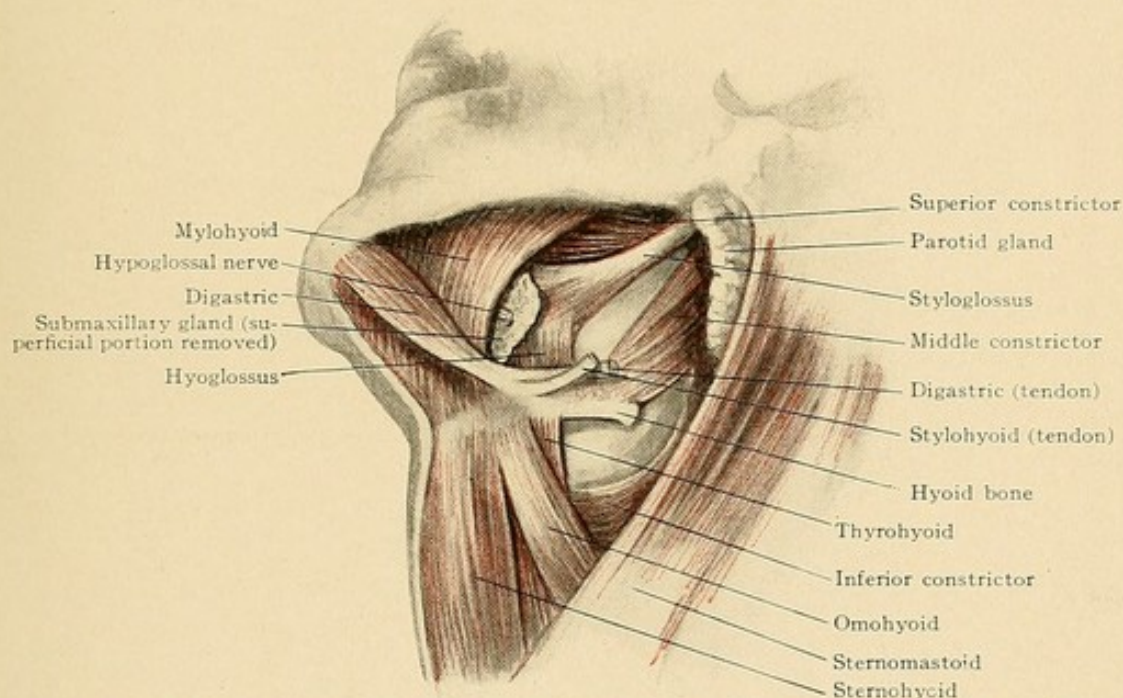


FIG. 165.—Submaxillary region. The anterior portion of the submaxillary gland is seen winding around and beneath the posterior edge of the mylohyoid muscle. The posterior portion of the gland has been cut away. The posterior belly of the digastric and the stylohyoid muscles have also been removed.

superior curved line on the occipital bone. It is attached below by a sternal head to the upper anterior part of the first piece of the sternum, and by a clavicular head to the inner third of the clavicle on its superior and interior border. Its action will be mentioned in discussing wry-neck.

**Arteries.**—The carotid arteries and their branches are found in this triangle. The line of the carotid arteries is from a mid-point between the mastoid process and the angle of the jaw to the sternoclavicular articulation. The line of the sternomastoid muscle is from the mastoid process to near the middle of the upper edge of the sternum. Thus the carotids are internal to the anterior edge of this muscle above, behind the angle of the jaw, and external to it below. The **common carotid** at its upper portion—it ends opposite the upper border of the thyroid cartilage—is just about at or close to the edge of the sternomastoid muscle. From the thyroid cartilage up are the **internal** and **external carotids**. The internal lies behind and to the outer side of the external. The internal gives off no branches until it reaches the skull, while the external is practically all branches. Sometimes the external and the internal carotids are covered by the anterior margin of the sternomastoid muscle. The branches of the external carotid are the *superior thyroid, ascending pharyngeal, lingual, facial, occipital, posterior auricular, internal maxillary, and temporal*. The



superior thyroid or the ascending pharyngeal may either one be the first given off by the external carotid, or may come off from the common carotid itself just before its bifurcation.

The **superior thyroid artery** is given off in the interval between the hyoid bone and upper border of the thyroid cartilage. It gives a small *infrahyoid branch* to the thyrohyoid membrane, also a superior laryngeal branch to the inside of the larynx. This branch pierces the thyrohyoid membrane in company with the superior laryngeal nerve to reach the interior of the larynx. The *sternomastoid branch*, to the muscle of that name, comes off at this point and crosses the common carotid artery. It is of some importance on this account because in ligating the common carotid artery above the omohyoid muscle it is likely to be cut and cause bleeding. Another branch of the superior thyroid artery is the *cricothyroid*. It is small, rests on the cricothyroid membrane, and is the first artery liable to be cut in an incision down the

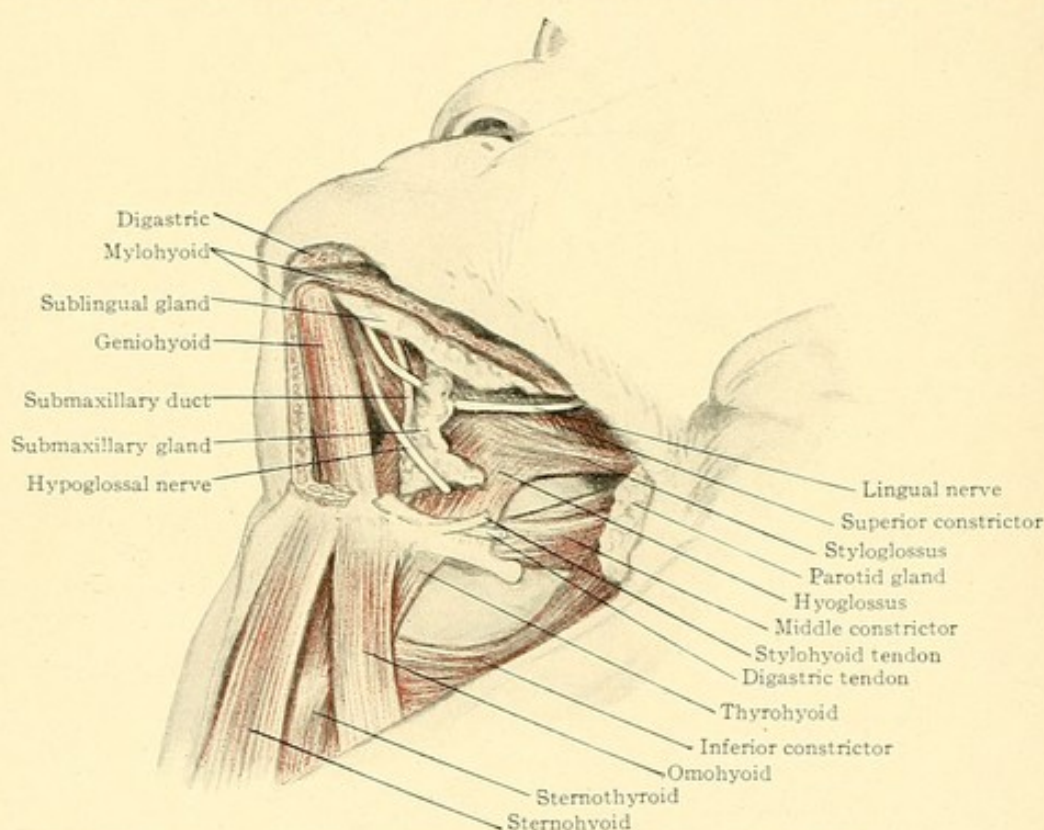


FIG. 166.—Submaxillary region—mylohyoid muscle cut away showing the sublingual gland and anterior portion of submaxillary gland.

median line. Bleeding from it is not apt to be serious. The remainder of the superior thyroid artery supplies the thyroid gland.

The **ascending pharyngeal** is a long slender branch that comes from the under side of the main trunk. It lies on the superior and middle constrictors of the pharynx and goes clear to the skull, giving off some meningeal branches. In ligating the external carotid care should be taken not to include this vessel in the ligature. It also gives branches to the soft palate, tonsil, recti capitis antici muscles, and tympanum.

The **lingual** is given off just below the greater horn of the hyoid bone, and passes forward beneath the hyoglossus muscle to supply the tongue and sublingual tissues. The hypoglossal nerve lies above the artery and on the hyoglossus muscle.

The **facial** comes off just above the lingual artery or often in a common trunk with it. It passes upward and forward in a groove in the under surface of the submaxillary gland and passes over the edge of the jaw at the anterior border of the masseter muscle. The facial vein at this point is posterior to it.

The **occipital artery** comes off almost opposite the facial. It passes upward and backward between the mastoid process and the transverse process of the atlas,



then along in the occipital groove beneath the origin of the sternomastoid muscle, the splenius, trachelomastoid, and digastric to make its appearance a little to the inner side of the middle of a line joining the mastoid process with the external occipital protuberance.

The **posterior auricular** is given off just above the posterior belly of the digastric muscle and runs backward and upward on it, then through the parotid gland and up between the external auditory meatus and the mastoid process. In ligating the external carotid artery with a view of preventing bleeding in removing the Gasserian ganglion, it is endeavored to place the ligature just above the digastric muscle and posterior auricular artery in order to preserve the blood supply of the

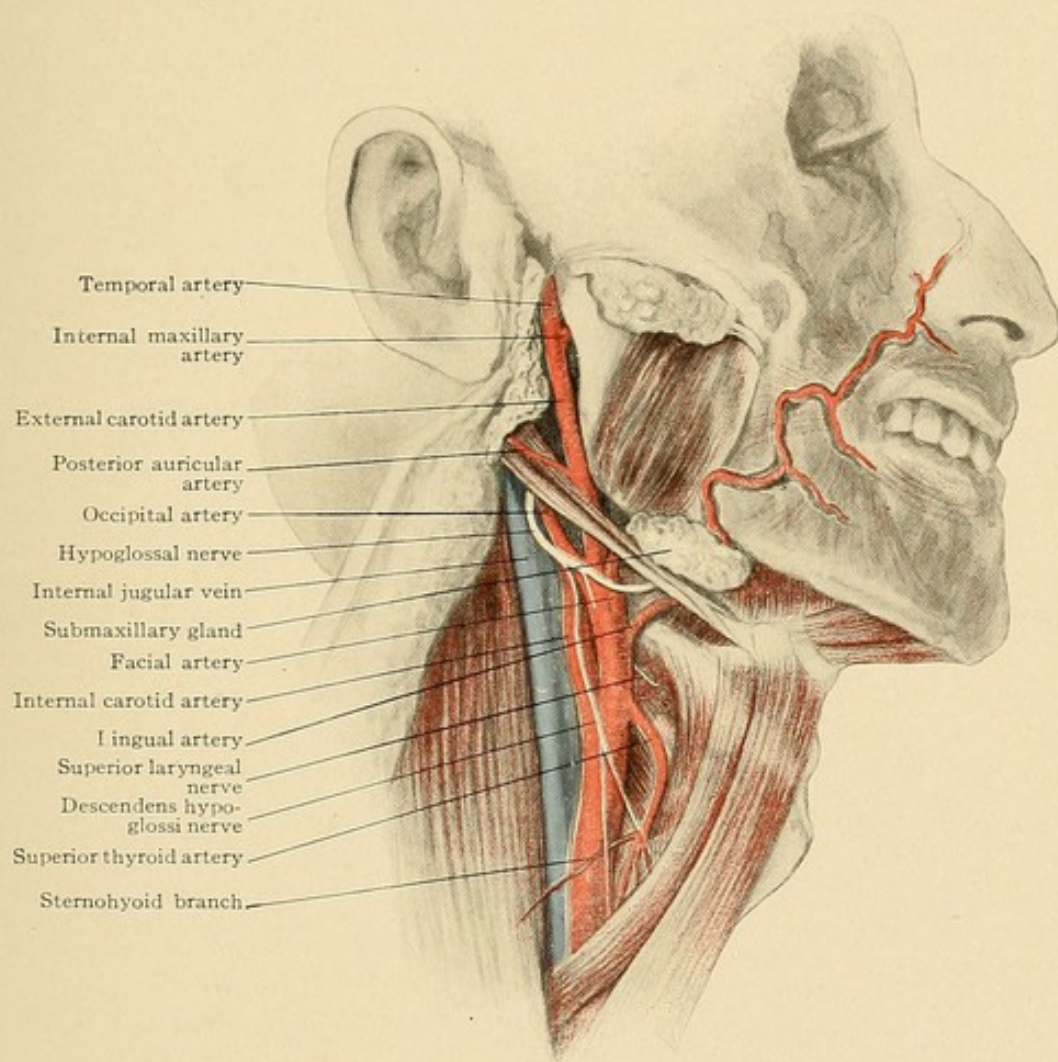


FIG. 167.—Carotid arteries and branches.

tissues above and behind the ear. The internal maxillary and the temporal arteries have already been considered.

**Veins.**—The veins found in and near the superior carotid triangle are the *anterior* and *internal jugulars* and their branches. A small portion of the commencement of the *external jugular* may also be in its extreme upper angle.

The **anterior jugular vein** begins just above the hyoid bone from veins in the submaxillary and submental regions. It lies on the deep fascia and passes down the neck about 1 cm. from the median line, then just above the sternum it turns down and out under the sternomastoid muscle to empty into the external jugular or subclavian. At the point of turning it sends off a branch across the median line to the vein on the opposite side. Thus the blood-current can pass directly across the neck from one external jugular vein to the other. Sometimes there is another communication between the two anterior jugulars through a small branch crossing just above or



below the hyoid bone. Instead of two anterior jugular veins there may be one; in this case it is likely to go down the median line of the neck and so be wounded in tracheotomy. It receives branches from the inferior thyroid veins and hence may bleed freely. It has no valves.

The **internal jugular vein** lies to the outer side of and bulges somewhat anterior to the carotid arteries. It is formed by the junction of the inferior petrosal and lateral sinuses at the jugular foramen, and passes downward posterior to the internal carotid artery and soon reaches its outer side. It receives the facial, lingual, pharyngeal, superior and middle thyroid, and sometimes the occipital veins. A large communicating branch from the external jugular unites either with the facial or with the internal jugular, so that a wound of the external jugular may draw blood directly from the internal jugular.

These tributary veins are superficial to the arteries and in ligating the external carotid artery they will have to be displaced. The internal jugular vein is sometimes

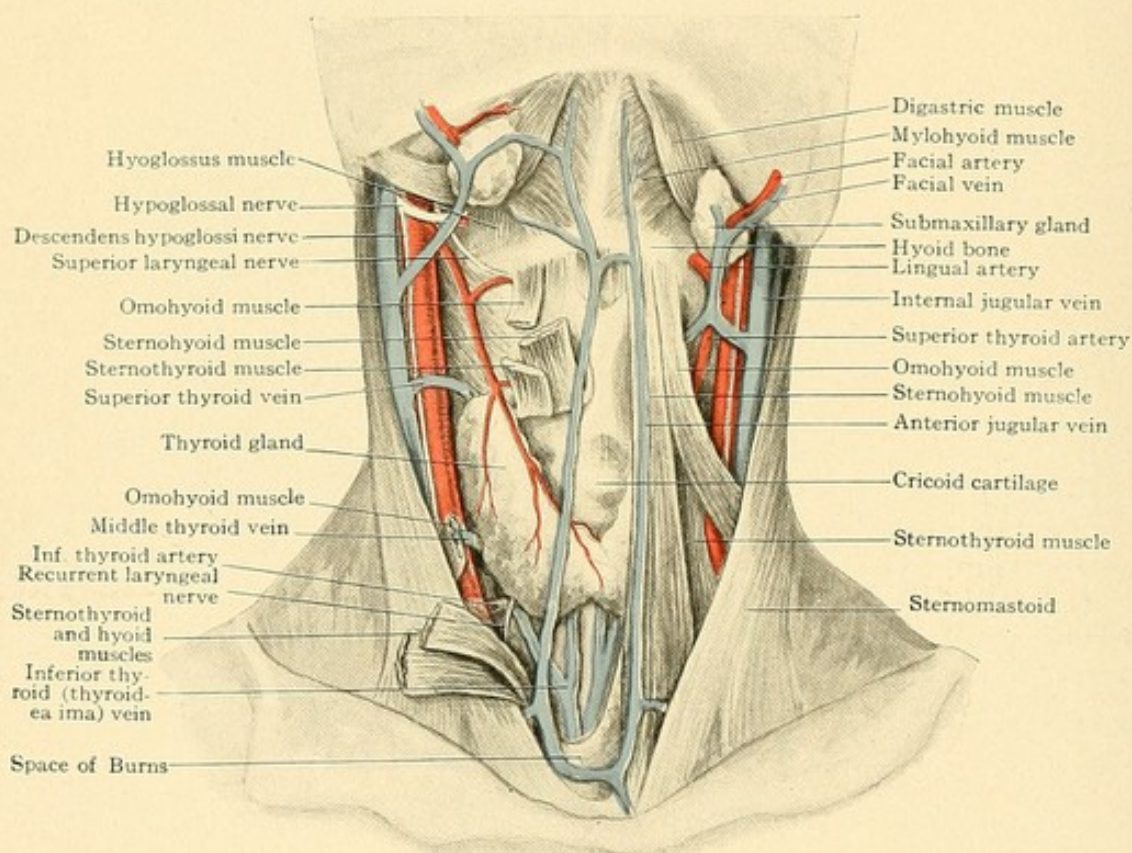


FIG. 168.—Dissection of the deep structures of the front of the neck.

excised in operations for enlarged lymph-nodes or for infective thrombus. It is not so large above the facial vein as below that point. It becomes so involved in enlargements of both tuberculous and carcinomatous lymph-nodes that it may be necessary to excise it along with the tumor. Its removal does not give rise to any serious symptoms.

It becomes thrombosed by the extension of a thrombus from the transverse (lateral) sinus, which in turn becomes affected by the extension of suppurative middle-ear disease through the medium of caries of the bones. When the internal jugular is thrombosed it is evidenced by swelling, redness, and tenderness along the anterior border of the sternomastoid muscle just behind the angle of the jaw. Bleeding from the veins in this region is particularly dangerous because the internal jugular itself is so large and having no valves, will bleed both from the side towards the heart and that towards the head.

The veins also, which are tributary to it in this region, are so large and are wounded so close to the main trunk that the blood from the internal jugular itself



regurgitates. The walls of the veins are thin and, if the fascias happen to be relaxed, fall readily together and thus are difficult to see, and are so adherent to the fascias as not to be readily seized. The surgery of this region requires extreme care and the avoidance of haste.

**Nerves.**—Lying between the internal jugular vein and the internal and common carotid arteries is the *pneumogastric* or *tenth nerve*. It here gives off the *superior laryngeal nerve*, the internal branch of which enters the larynx through the thyrohyoid membrane to endow the interior of the larynx with sensation; the external branch goes to supply the cricothyroid muscle. The pneumogastric nerve is frequently seen in operations in this region. Its division has not been fatal.

The *hypoglossal nerve* winds around the occipital artery and goes forward on the hyoglossus muscle, which separates it from the lingual artery. The *descendens hypoglossi filament* leaves the parent nerve as it winds around the occipital artery. It lies on the carotid artery in the form of a loop formed by the addition of branches from the second and third cervical nerves. As it descends on the sheath of the vessels it gives a branch to the anterior belly of the omohyoid muscle. The loop sends branches to the sternohyoid, sternothyroid, and posterior belly of the omohyoid, and if the nerve is divided paralysis of these muscles will occur. The nerve is to be pushed aside when ligating the artery and not included in the ligature. The superficial branches from the cervical plexus which come from the middle of the posterior edge of the sternomastoid muscle and ramify towards the median line, are nerves of sensation, and their division in operative work causes no serious symptoms, hence they are disregarded. The *inframaxillary branches* of the seventh or *facial nerve* supply the platysma.

**Lymphatics.**—The lymphatics are composed of four sets, a superficial set along the anterior border of the sternomastoid muscle, a deep set accompanying the great vessels, a submaxillary set around and on the submaxillary gland, and a set, two or more in number, beneath the chin.

The *submaxillary gland* itself not infrequently enlarges and is difficult to distinguish from an enlarged lymphatic node. All these glands are at times subjected to operative procedures. Fig. 163 shows the submental, submaxillary, and superficial set of lymphatics enlarged, as well as the submaxillary gland itself. It is taken from a tuberculous subject.

The nodes below and behind the jaw become enlarged from diseases affecting the tongue, mouth, and throat as well as from affections of the face and scalp.

The INFERIOR CAROTID TRIANGLE is limited posteriorly by the lower portion of the sternomastoid muscle, anteriorly by the median line of the neck, and superiorly by the anterior belly of the omohyoid muscle. In this triangle, or reached through it, are the lower portions of the common carotid artery and internal jugular vein, with the pneumogastric nerve between. Anteriorly are the larynx, trachea, thyroid gland, and sternohyoid and sternothyroid muscles. The carotid artery, jugular vein, and pneumogastric nerve lie partly in the triangle but rather under the edge of the sternomastoid muscle. Operations on the air-passages, laryngotomy and tracheotomy; on the thyroid gland, thyroidectomy; and ligation of the common carotid artery and removal of lymph-nodes are all done in this triangle. The superficial and deep lymphatics accompany the vessels; there are also some in Burns's space above the sternum. In children, instead of the innominate artery ceasing at the sternoclavicular articulation, it sometimes rises above it and may be wounded in operation on the trachea. The *thyroidea ima* artery, if present, will lie on the trachea, coming up from the innominate or directly from the aorta.

#### POSTERIOR CERVICAL TRIANGLE.

The posterior cervical triangle has as its base the middle third of the clavicle; its anterior side is the posterior edge of the sternomastoid muscle; its posterior side is the anterior edge of the trapezius; its apex is at the point of junction of these two muscles at the superior curved line of the occiput. It is customary to divide it into two triangles by the posterior belly of the omohyoid muscle. The upper triangle is large and is called the *occipital triangle*. The lower triangle is small and is called the *subclavian triangle*. This division by the posterior belly of the omohyoid muscle is not always satisfactory. The muscle runs upward and inward in a line



from about the junction of the outer and middle thirds of the clavicle to a variable distance, up to 2.5 cm. (1 in.), above the clavicle at the anterior edge of the sternomastoid muscle. The omohyoid muscle has its lower attachment at the posterior edge of the suprascapular notch, which is below the level of the clavicle, and its posterior belly is sometimes concealed behind the clavicle and does not rise above it except at its inner extremity beneath the sternomastoid muscle. It is rare that any distinct triangle is formed, hence as far as the surface markings are concerned there is often no subclavian triangle. Therefore the posterior cervical triangle will be considered as a whole and not divided.

It is covered by the skin, beneath which is the subcutaneous tissue, which at its lower portion contains the fibres of the platysma muscle. Its floor is composed from above downward of the *splenius*, *levator scapulae*, *scalenus posticus*, *scalenus medius*, and *scalenus anticus* muscles. The deep fascia of the neck spans the space and splits anteriorly to enclose the sternomastoid muscle and posteriorly to

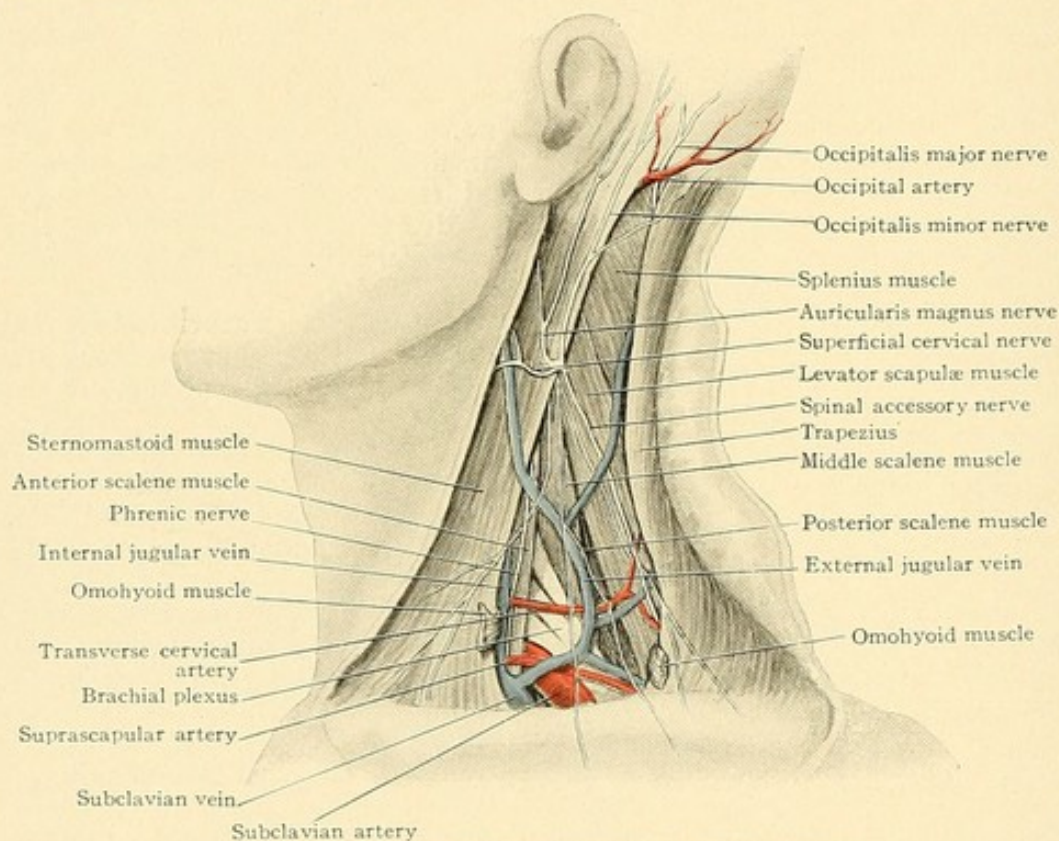


FIG. 169.—Dissection of the posterior cervical triangle.

enclose the trapezius. The space contains important arteries, veins, nerves, and lymphatics.

**External Jugular Vein.**—Lying on the deep fascia and beneath the superficial fascia and platysma is the external jugular vein. This begins below the ear and posterior to the ramus of the jaw, being formed by the union of the temporo-maxillary and posterior auricular veins. It passes downward and slightly backward on the surface of the sternomastoid muscle to its posterior border, which it reaches at about the middle and follows down until about a centimetre above the clavicle; here it pierces the deep fascia and dips behind the clavicular origin of the sternomastoid muscle to empty into the subclavian. It has one pair of valves about 4 cm. above the clavicle, and another pair at its point of entrance into the subclavian. They do not entirely prevent a regurgitation of the blood.

The external jugular vein receives the posterior external jugular vein, and the suprascapular and transverse cervical veins. The occipital may also enter into it. The veins of the neck are exceedingly irregular in their formation and may vary considerably. The external jugular is readily seen through the skin, it may be made more prominent by compressing it just above clavicle. In operations in this



region of the neck in some cases it is necessary to divide this vein; in others one may be able to avoid it, at all events it should be recognized before the incision is made. Behind the angle of the jaw there is usually a branch communicating with the facial, lingual, or internal jugular vein, and just above its lower extremity it is enlarged, forming the part called the sinus. For these reasons, if the vein is cut low down near the clavicle or high up near the angle of the jaw bleeding is liable to be free. The valves are not competent to prevent the reflux of blood and it therefore drains the large internal jugular above and the subclavian below. The attachment of the vein to the deep fascia, as it pierces it above the clavicle, tends to keep its lumen open when the vein is divided and favors the entrance of air into the circulation. The size of the veins in the posterior triangle varies according to those in the anterior. If the anterior and external jugulars are large the posterior and internal jugulars are apt to be small.

**Arteries.**—The arteries in the posterior cervical triangle are the *subclavian*, the *transverse cervical*, and sometimes the *suprascapular* when it runs above the clavicle instead of behind it. The line of the subclavian is from the sternoclavicular joint to the middle of the clavicle. It rises about 1.25 cm. ( $\frac{1}{2}$  in.) above the clavicle. The clavicular origin of the sternomastoid muscle covers the inner third of the clavicle so that the subclavian artery is only visible in the posterior cervical triangle from the outer edge of this muscle to the middle of the clavicle. Both the suprascapular and transverse cervical arteries are given off from the thyroid axis, which arises from the third portion of the subclavian just internal to the scalenus anticus muscle. Therefore at their origin they are both considerably above the level of the clavicle, but as they proceed outward they incline downward, and on leaving the outer edge of the sternomastoid muscle the suprascapular is usually behind the clavicle while the transverse cervical runs parallel to it and a short distance (1 cm.) above it, where it can be felt pulsating.

The posterior belly of the omohyoid muscle can be represented by a line drawn from the anterior edge of the sternomastoid muscle opposite the cricoid cartilage, obliquely down and out to the junction of the middle and outer thirds of the clavicle. It is superficial to the transverse cervical artery and at its inner end is above it. These arteries and their accompanying veins will be encountered in operating in these regions for the removal of lymphatic nodes.

**Nerves.**—The nerves in the posterior cervical triangle are the *spinal accessory*, *branches of the cervical plexus*, and the *brachial plexus*. The position of the spinal accessory is important because it is frequently encountered in operations for the removal of enlarged lymphatic nodes. It enters the under surface of the sternomastoid muscle from 3 to 5 cm. below the tip of the mastoid process and emerges at the posterior edge about its middle or a little above. It is about at this point that the external jugular vein reaches the posterior border of the sternomastoid, and the cervical plexus, formed by the anterior divisions of the four upper cervical nerves, reaches the surface. From this point also the *occipitalis minor* runs upward along the posterior edge of the sternomastoid and the *auricularis magnus* runs upward over the sternomastoid direct to the external ear. The *superficial cervical* runs directly across the muscle towards the median line and the descending branches—the sternal, clavicular, and acromial—pass down beneath the deep cervical fascia to perforate it just above the clavicle and become cutaneous. Care should be taken not to mistake them for the spinal accessory. Still deeper are the cords of the brachial plexus. These cords, sometimes two, at others three in number, are beneath the deep fascia and lie above the subclavian artery. They can be felt and in a thin person, if the head is turned to the opposite side, the prominence which they form under the skin can even be seen.

**Lymphatics.**—The lymphatics of the posterior cervical triangle are numerous and being often enlarged are frequently operated on. They lie along both the outer side of the internal jugular vein and under the posterior edge of the sternomastoid muscle, which they follow clear up to the base of the skull. They also follow the edge of the trapezius muscle and lie in the space between it and the sternomastoid; they extend downward under the clavicle and become continuous with the axillary lymphatics. The right and left lymphatic ducts empty into the venous system at the junction of the innominate and internal jugular veins. That on the left side is



called the *thoracic duct*; it begins as the receptaculum chyli on the body of the second lumbar vertebra and is about 45 cm. (18 in.) long. It drains all the left side of the body and the right as far up as and including the lower surface of the liver.

The duct on the right side is called the *right lymphatic duct*; it is only 1 or 2 cm. in length and drains the right side of the head and neck, the right upper extremity, and the right side of the chest as far down as and including the upper surface of the liver.

#### TORTICOLLIS OR WRY-NECK.

In this affection the head and the neck are so twisted that the face is turned toward the side opposite the contracted muscle and looks somewhat upward. It is usually caused by some affection of the sternomastoid muscle. It is not always the only muscle involved, as the trapezius and others may likewise be affected. It is congenital or acquired. In the congenital cases it is caused by an injury to the

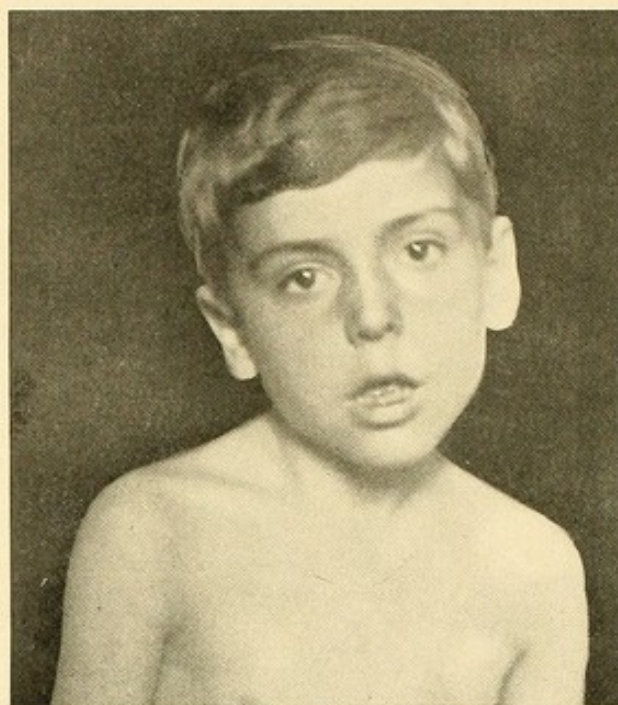


FIG. 170.—Torticollis or wry-neck.

sternomastoid muscle, occurring during childbirth; a swelling or tumor may be present in the course of the muscle. In the acquired form the distortion may be more or less permanent and may be due to caries or other disease of the spine. In such cases it is evident that treatment is to be directed to the diseased spine rather than to the sternomastoid muscle.

Inflammation of the lymph-nodes of the neck may cause the patient to hold the head and neck in a distorted position. The wry-neck in this case will disappear as the cause subsides. Rheumatic affections of the neck are a common cause, and the sternomastoid muscle may then become contracted and require division. In rare instances a nervous affection causes a spasmodic torticollis. The persistent movements render this a very distressing affection, and to relieve it not only has the sternomastoid but also the trapezius been divided, and even the spinal accessory and occipital nerves have been excised.

*Division of the sternomastoid muscle* should be done by open and not by subcutaneous incision. The sternal origin of the sternomastoid muscle is a sharp, distinct cord, but its clavicular origin is a broad, thin band extending outward a third of the length of the clavicle. An incision 2 or 3 cm. or more in length is made over the tendon and the bands are to be carefully isolated before being divided. The structure most important to avoid is the internal jugular vein. It lies close behind the sternal origin of the muscle and great care must be taken to avoid it. In one case in which it was accidentally wounded it was necessary to ligate it. As the



deep fascia of the neck splits to enclose the sternomastoid muscle it is opened by the operation and infection has caused in such cases wide-spread phlegmonous inflammation.

### ARTERIES OF THE NECK.—LIGATION.

**Carotid and Subclavian Arteries and Branches.**—Both these arteries are affected at times with aneurisms, necessitating their ligation. Ligation of the main trunks or their branches is also required in various operations on the head, as in removal of the Gasserian ganglion or maxilla, or excision of the tongue, thyroid gland, etc. The communication between the arteries on the two sides of the body is quite free, as also is that between the arteries above and those lower down. For this reason bleeding from the distal end of a cut artery will be almost as free as from its proximal end. The various branches of the external carotid anastomose across the median line of the body. The vertebrals communicate above through the basilar. The internal carotids communicate through the anterior cerebral and anterior communicating and with the basilar through the posterior communicating and posterior cerebral. Between the parts above and those below we have the superior thyroid anastomosing with the inferior thyroid branch of the thyroid axis from the subclavian artery. The princeps cervicis, a branch of the occipital, anastomoses with the ascending cervical branch of the inferior thyroid, the transverse cervical of the thyroid axis, and the profunda cervicis from the superior intercostal. These free communications enable the surgeon to ligate to any extent without incurring the risk of gangrene. The *line of the carotid arteries* is from a point midway between the mastoid process and the angle of the jaw to the sternoclavicular articulation. At the upper border of the thyroid cartilage the common carotid divides into the internal and external carotids; this is opposite the fifth cervical vertebra.

**Common Carotid Artery.**—This lies on the longus colli muscle and a small portion of the rectus capitis anticus, which separate the artery from the transverse processes of the vertebræ. The artery can be compressed against the vertebræ and its pulsations stopped by pressing backward and slightly inward. It is superficial in the upper portion of its course but becomes deeper as it approaches the chest. The anterior tubercle of the transverse process of the sixth cervical vertebra is called *Chassaignac's tubercle*. It is about opposite the cricoid cartilage. It is one of the guides to the artery. The omohyoid muscle crosses the artery opposite the cricoid cartilage and just above it is the site of election for ligation.

**Ligation of the Common Carotid Artery.**—In making the incision, which should be 5 or 6 cm. long, it should be laid along the anterior edge of the sternomastoid muscle with its middle opposite to or a little above the level of the cricoid cartilage. This incision may be a little anterior to the direct line of the artery as given from midway between the angle of the jaw and mastoid process to the sternoclavicular articulation. This is because the muscle bulges forward and overlaps and hides the artery. The artery is beneath its edge. On cutting through the superficial fascia and platysma the deep fascia is reached, some small veins perhaps being divided in so doing. The deep fascia is divided along the edge of the sternomastoid muscle, which is then pulled outward. Beneath it and running obliquely across the lower portion of the wound is the omohyoid muscle. It is recognized by the direction of its fibres, they being more or less transverse or oblique. Sometimes a small artery, the sternomastoid branch of the superior thyroid, crosses the common carotid just above the omohyoid muscle. The artery is also crossed by veins. The lingual, superior, and middle thyroid veins all pass over it to enter the internal jugular. The middle thyroid vein may be above or just below the omohyoid muscle. These vessels all pass transversely across the artery and beneath the deep fascia. The artery lies in a separate sheath to the inner side of the jugular vein. In the living body it is to be recognized by its pulsations. The vein being filled with blood may overlap the artery. Veins are readily emptied of their blood by pressure on the parts during the operation; hence if the vein happens to be collapsed it may not be recognized and is liable to be wounded. Therefore in examining for the artery see that the pressure from the retractors or other sources does not obstruct the flow of



blood through the jugular vein. Running down on the anterior surface of the artery is the descendens hypoglossi nerve. If seen it should be pushed aside. It supplies the sternohyoid, sternothyroid, and both bellies of the omohyoid muscles. The pneumogastric nerve lies posteriorly, between the artery and the vein. Care will be necessary to avoid including it in the ligature. The ligature is to be carried from the outer to the inner side, the needle being passed between the vein and the artery.

*Ligation of the Common Carotid Artery Below the Omohyoid Muscle.*—The artery below the omohyoid muscle becomes deeper and less accessible. The sternohyoid muscle overlaps it and is less easily displaced. The sternohyoid and sternothyroid muscles likewise tend to encroach on it and have to be drawn inward. The internal jugular vein and carotid artery diverge as they descend, so that at the level of the sternoclavicular joint they are separated 2.5 cm. In this interval the first portion of the subclavian artery shows itself. The anterior jugular vein will probably be encountered along the edge of the sternomastoid muscle, and near the omohyoid

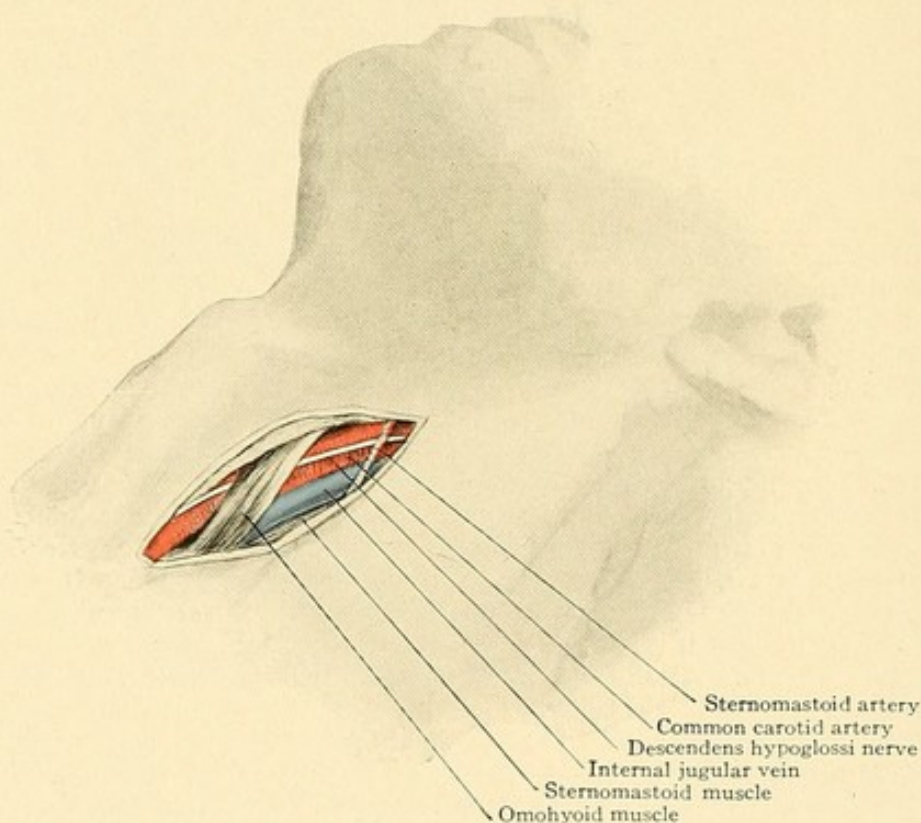


FIG. 171.—Ligation of the common carotid artery.

muscle the artery will be crossed by the middle thyroid vein. Still lower it may be that the inferior thyroid will be encountered. Posterior to the carotid artery is the inferior thyroid artery, coming from the thyroid axis and going to the thyroid gland, and winding around from posteriorly to the inner side is the recurrent laryngeal nerve. The ligating needle is to be passed from without inward.

*Collateral Circulation After Ligation of the Common Carotid Artery.*—When the common carotid has been tied the blood reaches the parts beyond from the branches of the carotid of the opposite side and from the subclavian artery of the same side. The branches of the external carotid anastomose across the median line. This is particularly the case with the superior thyroid and facial. The internal carotids communicate by means of the circle of Willis. From the subclavian the vertebral artery communicates by means of the basilar with the circle of Willis. The thyroid axis by its inferior thyroid branch communicates with the thyroid arteries of the opposite side. An ascending branch of the inferior thyroid as well as one from the transverse cervical, also from the thyroid axis, anastomose with branches of the princeps cervicis, which is a descending branch of the occipital.



Finally the superior intercostal, which, like the vertebral and thyroid axis, is a branch of the first portion of the subclavian, through its profunda cervicis branch anastomoses with a deep descending branch of the princeps cervicis (Fig. 172).

**The Internal Carotid Artery.**—The internal carotid lies posterior and to the outer side of the external. It gives off no branches in the neck. Entering the skull through the *carotid canal*, in the apex of the petrous portion of the temporal bone and directly below and to the inner side of the Gasserian ganglion, it passes through the inner side of the *cavernous sinus* and at the anterior clinoid processes it bends up to divide into the *anterior* and *middle cerebrals*. Before its division it gives off the *posterior communicating artery*, the *anterior choroid artery* to supply the choroid plexus in the lateral ventricles, and the *ophthalmic artery*. The internal

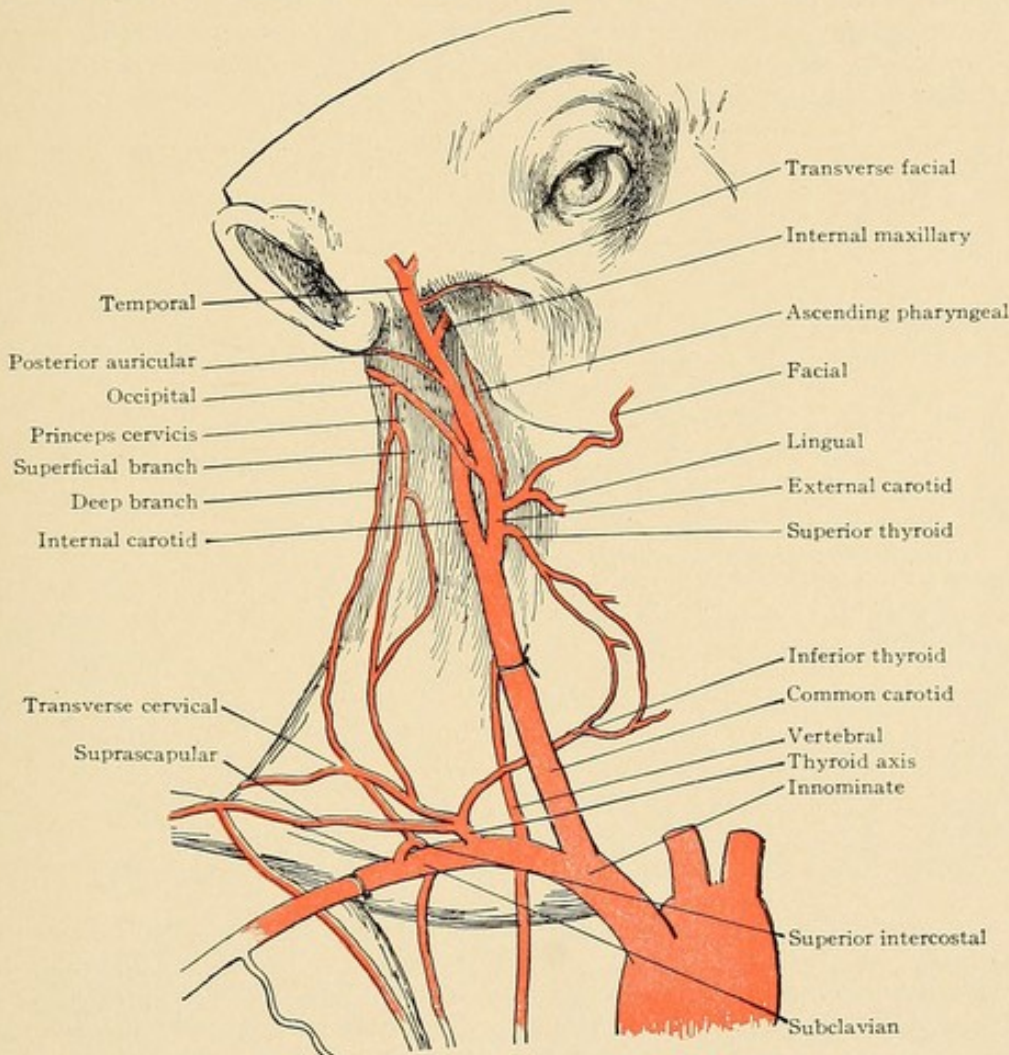


FIG. 172.—Collateral circulation after ligation of the common carotid artery.

carotid artery in the neck is normally straight, but sometimes, particularly in elderly persons, it is tortuous. This may then be mistaken for aneurism. It lies about 2 cm. posterior and a little to the outer side of the tonsil. As the pharynx is the side of least resistance, when the vessel becomes tortuous it bulges into it, and on examination through the mouth a pulsating swelling can be distinctly seen in the pharynx just posterior to the tonsil. The finger introduced can feel the pulsations, and pressure on the carotid in the neck below causes the pulsations to cease. Thus the character of the pulsating swelling can be recognized. This artery is rarely ligated, but if it is desired to do so it can readily be reached through an incision 6 or 7 cm. long behind the angle of the jaw. Aneurism or wounds may necessitate its ligation. At its commencement it is comparatively superficial, but as it ascends it gets quite deep, passing beneath the digastric and stylohyoid muscles. It should therefore be ligated below the angle of the jaw and not over 3 cm. from its origin at the upper



border of the thyroid cartilage. It will be necessary to push the sternomastoid muscle posteriorly, as its anterior margin overlies the vessel. The *internal jugular vein* is to its outer side and between the two and posterior is the *pneumogastric nerve*. The *sympathetic nerve* lies behind it but is separated by a layer of fascia and is not liable to be caught up in passing the aneurism needle. The *lingual*, *facial*, and *laryngeal veins* may be encountered and are apt to cause trouble. They will have to be held aside or ligated and divided. The *ascending pharyngeal artery* may lie close to the internal carotid and care should be taken not to include it in the ligature. The needle is to be passed from without inward.

**The External Carotid Artery.**—Of recent years the external carotid artery has been ligated far more often than formerly, as it was customary to ligate the common carotid instead. The external carotid runs from the upper border of the thyroid cartilage to the neck of the mandible. It supplies the outside of the head, face, and neck. These parts are the seat of various operations for tumors, especially carcinoma of the mouth and tongue, diseased lymph-nodes, and other affections, and

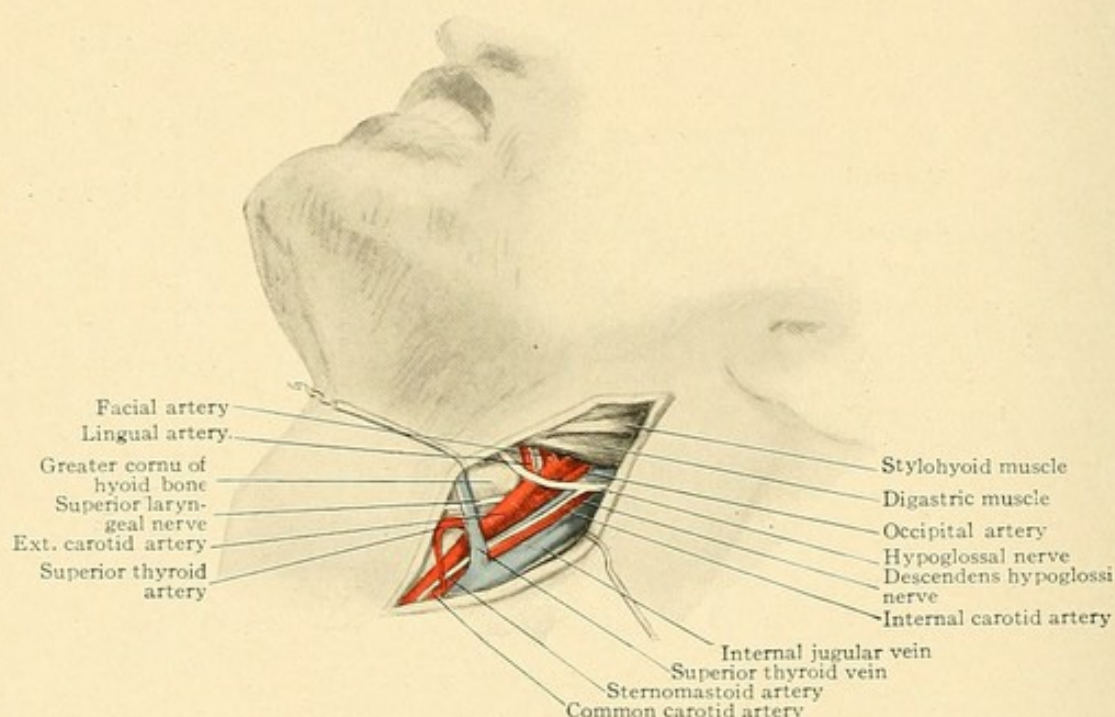


FIG. 173.—Ligation of external carotid artery and its branches.

the external carotid and its branches are not infrequently ligated in order to cut off their blood supply.

In extirpation of the Gasserian ganglion, hemorrhage has been such an annoying and dangerous factor that a preliminary ligation or compression (Crile) of the external carotid is frequently resorted to. This artery may also be ligated for wounds, resection of the upper jaw, hemorrhage from the tonsils, and angiomatous growths affecting the region which it supplies.

Unlike some other arteries the external carotid sometimes seems to have no trunk, consisting almost entirely of branches. Therefore in ligating it one should not expect to find a big artery the size of the internal carotid, but often one only half as large. The branches of the external carotid artery are the *superior thyroid*, *lingual*, and *facial*, which proceed anteriorly toward the median line; the *occipital* and *posterior auricular*, which supply the posterior parts; the *ascending pharyngeal*, which comes off from its deep surface and ascends to the base of the skull; and the *temporal* and *internal maxillary arteries*, which are terminal. It is ligated either near its commencement just above the superior thyroid artery or behind the angle of the jaw above the digastric muscle.

**Ligation of the External Carotid Artery above the Superior Thyroid.**—At its commencement at the upper border of the thyroid cartilage the artery is quite



superficial, being covered by the skin, superficial fascia, platysma, deep fascia, and overlying edge of the sternomastoid muscle. It is to be reached through an incision 5 cm. in length along the anterior edge of the sternomastoid muscle in a line from the sternoclavicular joint to midway between the angle of the jaw and the mastoid process. The middle of the incision is to be opposite the thyrohyoid membrane. The bifurcation of the common carotid artery is an important landmark.

The superior thyroid artery is given off at the very commencement and sometimes even comes from the common carotid just below. The ascending pharyngeal is the next branch, about 1 cm. above the superior thyroid. It comes off from the deep surface of the artery; almost opposite to it and in front is the lingual. It will thus be seen that the distance between the lingual and the superior thyroid, where the ligature is to be placed, is quite small. The superior thyroid is about opposite the upper border of the thyroid cartilage, while the lingual is opposite the hyoid bone. Beneath the artery is the superior laryngeal nerve, but it is not liable to be caught up by the needle in passing the ligature because it lies flat on the constrictors of the pharynx and is apt to be a little above the site of ligation.

The veins are the only structures liable to cause trouble. They are superficial to the arteries. On account of their irregularity more may be encountered than is expected. The superior thyroid and lingual veins both cross the artery to empty into the internal jugular. The facial vein is also liable to be met, as the facial artery frequently springs from a common trunk with the lingual. The communicating branch between the facial and external jugular vein is another one that should be anticipated. These veins, when it is possible, are to be hooked aside; otherwise they are to be ligated and cut. Great care should be taken not to mistake a vein for the artery. It might appear an easy matter to readily recognize the artery and distinguish between it and the veins, but this is not always the case in the living subject. The veins may have some pulsation transmitted to them from the adjacent arteries and the artery may temporarily have its pulsations stopped by pressure from the retractors. The living artery touched by the finger seems soft and does not give the hard, resisting impression felt in palpating the radial in feeling the pulse. The difference in thickness of the coats is also sometimes not apparent at a first glance.

The ligature is to be passed from without inward so as to guard against wounding the internal carotid.

*Ligation of the Superior Thyroid Artery.*—The superior thyroid is the first branch of the external carotid and is given off close down to the bifurcation or even from the common carotid itself just below. It lies quite superficial but of course beneath the deep fascia. At first it inclines upward and then makes a bend and goes downward to the thyroid gland. It gives off three comparatively small branches, the hyoid along the lower border of the hyoid bone, the sternomastoid to the muscle of that name, and the superior laryngeal to the interior of the larynx. The larger portion of the artery goes downward to supply the thyroid gland and muscles over it, therefore the artery is to be looked for at the upper edge of the thyroid cartilage, and not near the hyoid bone. The incision is the same as for ligating the external carotid low down, viz., 5 cm. along the anterior edge of the sternomastoid muscle, its middle being opposite the upper edge of the thyroid cartilage. Veins from the thyroid gland—superior thyroid—will probably cover it. After the deep fascia has been opened, the external carotid is to be recognized at its origin from the common carotid and then the superior thyroid artery found and followed out from that point. The ligature is to be passed from above downward to avoid the superior laryngeal nerve. This nerve lies distinctly above the artery and is not liable to be injured if the thyroid artery is followed out from its origin at the external carotid. Treves suggests ligating it between the sternomastoid and superior laryngeal branches, but it is more readily reached closer to the external carotid artery.

*Ligation of the Lingual Artery.*—The lingual artery may be ligated for wounds, as a preliminary step to excision of the tongue, and to check the growth of or bleeding from malignant growths of the tongue, mouth, or lower jaw.

The lingual artery springs from the external carotid opposite the hyoid bone about 1 cm. above the bifurcation of the common carotid. It is composed of three parts: the first, from its point of origin to the posterior edge of the hyoglossus



muscle; the second, the part beneath the hyoglossus muscle; and the third, the part beyond this muscle to the tip of the tongue.

The artery is usually ligated beneath the hyoglossus muscle in the second part of its course, although it is sometimes desirable to ligate it in the first part of its course.

The *first part* inclines upward and forward, above the greater horn of the hyoid bone, to the hyoglossus muscle, beneath which it passes in a direction somewhat parallel to the upper edge of the hyoid bone. It lies on the middle constrictor of the pharynx and superior laryngeal nerve and is covered by the skin, platysma, and fascia. It lies immediately below the stylohyoid and digastric muscles and is crossed by the hypoglossal nerve and some veins. This portion frequently gives off a hyoid branch which runs above the hyoid bone. It is often missing, in which case the parts are supplied by the hyoid branch of the superior thyroid. From either the end of the first part or the beginning of the second part, the *dorsalis linguæ* branch arises.

The *second part* of the lingual lies on the superior constrictor and geniohyoglossus muscles and is covered by the hyoglossus. It runs in a direction somewhat parallel to the upper edge of the hyoid bone and from 0.5 to 1 cm. above it. In this

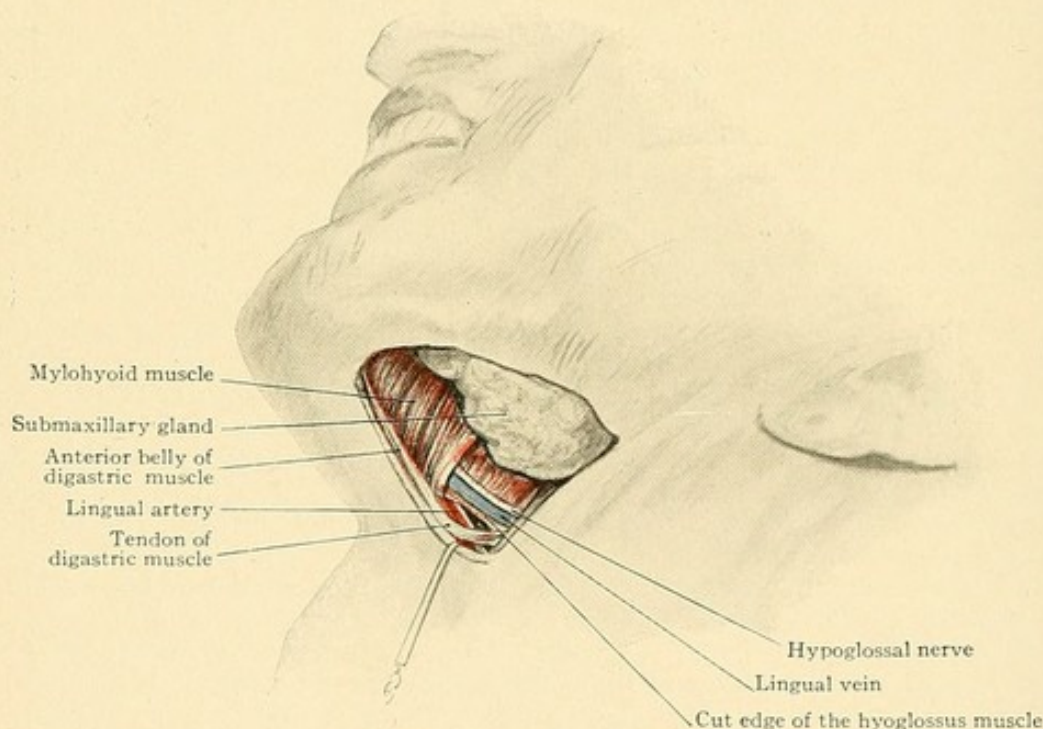


FIG. 174.—Ligation of the lingual artery

part of its course it is usually accompanied by one or two veins and the hypoglossal nerve is superficial to it, the hyoglossus muscle separating them. This is the part of the artery chosen for ligation. An incision is made, convex downward, running from below and to one side of the symphysis nearly down to the hyoid bone and then sloping upward and back, stopping short of the line of the facial artery, which can be determined by the groove on the mandible just in front of the masseter muscle. The skin, superficial fascia, and platysma having been raised, the submaxillary gland is seen covered with a comparatively thin deep fascia. Some veins coming from the submental region may then be encountered. They may be ligated and divided. The submaxillary gland is next to be lifted from its bed and turned upward against the mandible, carrying with it the facial artery, which is adherent to its under surface. The tendon of the digastric will now be seen with the anterior and posterior bellies of the muscle forming an angle with its point toward the hyoid bone. These with the hypoglossal nerve form what has been called the *triangle of Lesser*. It is in this space that the artery is ligated. The floor of the space posteriorly is formed by the hyoglossus muscle, while anteriorly is seen the edge of the mylohyoid muscle. Through the thin fascia overlying the hyoglossus muscle can be seen the hypoglossal



nerve, and below it, sometimes a vein. The artery lies under the muscle, while the veins may be either on or under the muscle or both.

The apex of the angle formed by the tendon of the digastric muscle is held down to the hyoid bone by a slip of fascia which is an expansion of the central tendon of the muscle and the tendon of the stylohyoid muscle. The distance at which the central tendon of the digastric is held away from the hyoid bone varies in different individuals and is an important fact to bear in mind in searching for the artery. If the tendon rests high above the hyoid bone the artery must be looked for low down, sometimes even under the tendon; if, on the contrary, the tendon is low down the artery may be 0.5 to 1 cm. higher up. The hypoglossal nerve lies on the muscle and nearer to the mandible than the artery. If there is a vein on the hyoglossus muscle it is apt to be below the nerve, that is, nearer the hyoid bone, and may lie directly over the artery. The vein and the nerve are to be displaced up towards the jaw and an incision a centimetre long made through the hyoglossus muscle a short distance above the digastric tendon and parallel with the hyoid bone. This incision should not be deep, as the muscle is only 2 or 3 mm. ( $\frac{1}{8}$  in.) thick.

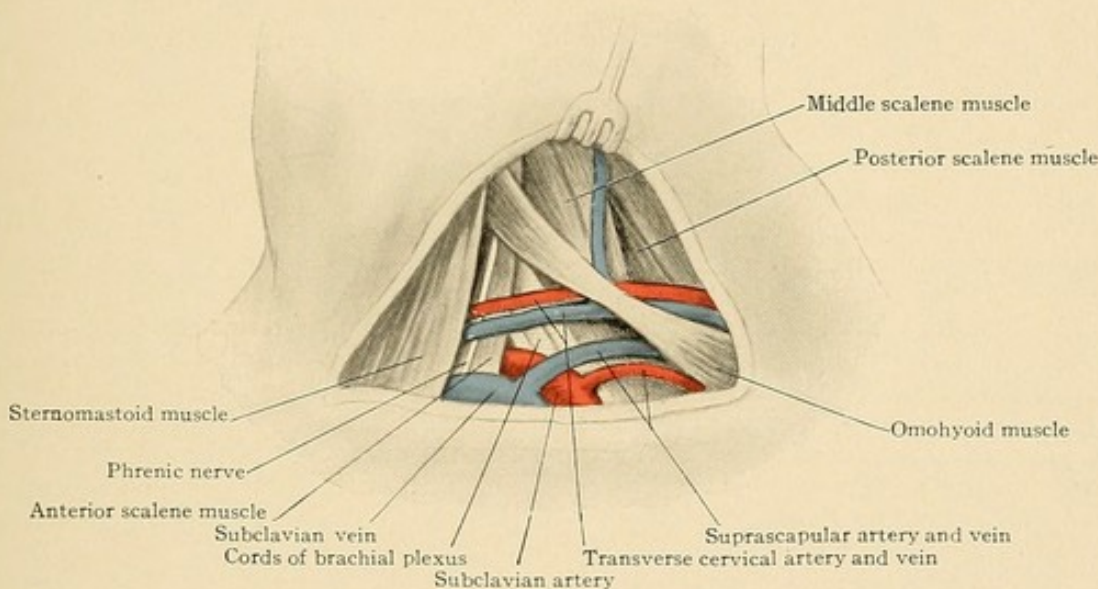


FIG. 175.—Ligation of the subclavian artery

The edges of the incision being raised and displaced upward and downward, the artery will probably be seen running at right angles to the fibres of the muscle and parallel to the hyoid bone. If not seen at once it should be looked for below the incision, nearer to the hyoid bone. Care must be taken not to mistake the vein for the artery. That this is not an unlikely thing is shown by its occurring in the hands of a distinguished surgeon who had had exceptional experience in this same operation. The ligature needle may be passed from above downward to avoid including the hypoglossal nerve.

**Subclavian Artery.**—The right subclavian artery runs from the sternoclavicular articulation in a curved line to the middle of the clavicle. It rises 1.25 cm. ( $\frac{1}{2}$  in., Walsham) above the clavicle. The innominate bifurcates opposite the right sternoclavicular joint. The left subclavian springs directly from the arch of the aorta, therefore it is longer than the right by 4 to 5 cm., this being the length of the innominate. As the subclavian artery passes outward it is crossed by the scalenus anticus muscle, which divides it into three parts: the first part, extending to the inner side of the muscle, gives off three branches, the *vertebral*, *internal mammary*, and *thyroid axis*; the second part, behind the muscle, gives off the *superior intercostal*; the third part has no branches.



The *first portion of the subclavian* lies very deep and operations on it have been so unsuccessful that they have been practically abandoned. As it is frequently involved in aneurisms its relations are worth studying. In approaching the artery from the surface it is seen to be covered by the sternomastoid, the sternohyoid, and the sternothyroid muscles. The outer edge of the sternomastoid muscle corresponds with the outer edge of the scalenus anticus. The three first-named muscles having been raised, the artery is seen to be crossed by the internal jugular, the vertebral, and perhaps the anterior jugular veins. The anterior jugular above the clavicle dips beneath the inner edge of the sternomastoid muscle to pass outward and empty into the external jugular or subclavian. The pneumogastric nerve crosses the artery just to the inner side of the internal jugular vein. Below, the artery rests on the pleura, and on the right side the recurrent laryngeal nerve winds around it. Behind the artery are the pleura and lung, which rise somewhat higher in the neck than does the artery.

On the *left side* the phrenic nerve leaves the scalenus anticus muscle at the first rib, crosses the subclavian at its inner edge, and passes down on the pleura to cross the arch of the aorta. To the inner side of the artery runs the thoracic duct, which, as it reaches the upper portion of the artery, curves over it to cross the scalenus anticus muscle and empty into the junction of the internal jugular and subclavian veins. The trachea and œsophagus are likewise seen to the inner side of the artery. The thyroid axis comes off its anterior surface, the vertebral from its posterior, and the internal mammary below.

The *second portion of the subclavian artery* lies behind the anterior scalene muscle. In front of the anterior scalene is the *subclavian vein*. The *phrenic nerve* runs on the muscle and at the first rib leaves it to continue down between the right innominate vein and pleura. Behind and below, the artery rests on the pleura and the middle scalene muscle is to its outer side. Thus it is seen that the artery passes through a chink formed by the anterior scalene muscle in front and the middle scalene behind. They both insert into the first rib. The posterior scalene is farther back and inserts into the second rib. Above the artery are all the cords of the brachial plexus. One branch of the subclavian, the *superior intercostal artery*, is given off near the inner edge of the anterior scalene muscle.

The *third portion of the subclavian* runs from the outer edge of the anterior scalene muscle to the lower border of the first rib. This part of the artery is the most superficial. The only muscle covering it above is the thin sheet of the platysma, lower down the subclavius muscle and clavicle overlie it; but the operations on the vessel are done above these structures, hence they do not interfere. There are apt to be a number of veins in front of the artery. The external jugular and transverse cervical veins are certain to be present and perhaps the suprascapular and cephalic, which may enter above instead of below the clavicle. These veins may form a regular network in the posterior cervical triangle above the clavicle and prove very troublesome. Above is the brachial plexus and transverse cervical artery and still higher is seen the omohyoid muscle. The suprascapular artery is lower down and usually concealed just below the upper edge of the clavicle. The lowest cord of the brachial plexus, formed by the first dorsal and last cervical nerves, may be posterior to the artery. The nerve to the subclavius muscle passes down in front of it.

*Ligation of the Third Portion of the Subclavian Artery.*—The head is to be turned strongly to the opposite side and the shoulder depressed. This lowers the clavicle and raises the omohyoid muscle and therefore gives more room to work. The skin is to be drawn down and an incision 7.5 cm. long made on the clavicle. The drawing down of the skin is done to avoid wounding the external jugular vein. This vein is really fastened to the deep fascia, and the skin, platysma, and superficial fascia slide over it. On releasing the skin it slides up above the clavicle. The middle of the incision should be a little to the inside of the middle of the clavicle. The deep fascia is to be incised and the clavicular origin of the sternomastoid and trapezius muscles cut to the same extent as the superficial incision. The length of the adult male clavicle is about 15 cm. (6 in.).

The clavicular origin of the sternomastoid extends out on the clavicle one-third of its length. The trapezius inserts into the outer third. This leaves the middle



third or 5 cm. of the clavicle on its upper surface free from muscles. As the incision is 7.5 cm. long this necessitates the division of 2.5 cm. (1 in.) of muscle, and as the middle of the incision is a little to the inner side of the middle of the clavicle this will make it necessary to divide more of the clavicular origin of the sternomastoid than of the trapezius. After the division of the deep fascia, fat and veins are encountered. The scalenus anticus muscle has the subclavian vein in front of it and the artery behind, therefore the vein must be attended to before a search is made for the edge of the scalene muscle. The veins to be encountered are the external jugular vein, which empties into the subclavian in front of or to the outer side of the anterior scalene muscle, and its tributaries, the suprascapular and transverse cervical veins, as well as the anterior jugular and a communicating branch from the opposite side of the neck. The cephalic vein not infrequently sends a communicating branch over the clavicle to empty into the external jugular. The fat is to be picked away with forceps; the veins are to be held out of the way with a blunt hook or ligated and cut. The suprascapular artery may be seen close to or under the clavicle. The transverse cervical artery may perhaps be above the level of the wound. The omohyoid muscle may or may not be seen, as its distance from the clavicle is quite variable. The transverse cervical and suprascapular arteries are not to be cut, as they are needed for the collateral circulation. As was mentioned in speaking of the ligation of the external carotid artery, so also here it is not always easy to distinguish between arteries and veins. The veins being disposed of, the anterior scalene muscle is to be sought at the internal portion of the wound. It runs somewhat like the lower portion of the sternomastoid, the posterior edges of the two muscles coinciding. The phrenic nerve runs down first on the anterior surface and then on the inner surface of the scalenus anticus. The edge of the muscle being recognized, by following it down the finger feels the first rib. The artery lies on the first rib immediately behind the muscle and the vein immediately in front of the muscle. The tubercle on the first rib may not be readily felt because the muscle is inserted into it. The prevertebral fascia coming down the scalenus anticus muscle passes from it to the subclavian artery, forming its sheath; hence, as pointed out by George A. Wright, of Manchester (*Annals of Surgery*, 1888, p. 362), the edge of the muscle may not readily be distinguished and the brachial plexus is a better guide. This is above the artery and the lower cord of the plexus lies directly alongside of the artery. It is closer to the artery above and to its outer side than the subclavian vein is below and to its inner side. The greatest care should be exercised in passing the aneurism needle around the artery. The vein is not so much in jeopardy as are the pleura and lowest cord of the brachial plexus, hence the needle is passed from above down between the nerve and the artery and brought out between the artery and vein.

Wounding of the pleura may cause collapse of the lung and later a septic pleurisy, while including the nerve will cause severe pain, etc.

*Collateral Circulation after Ligation of the Third Portion of the Subclavian Artery.*

—(1) Internal mammary with superior thoracic and long thoracic. (2) The posterior scapular branch of the suprascapular with the dorsalis branch of the subscapular. (3) Acromial branches of suprascapular with acromial branch of acromial thoracic. (4) A number of small vessels derived from branches of the subclavian above with axillary branches of the main axillary trunk below (Gray).

*Ligation of the Inferior Thyroid Artery.*—The inferior thyroid artery, unlike the superior, lies deep from the surface, and it is a far more difficult vessel to reach. It is a branch of the thyroid axis, the other branches being the transverse cervical and suprascapular. The thyroid axis comes from the first part of the subclavian just a little to the inner side of the edge of the scalenus anticus muscle. The inferior thyroid artery ascends on the longus colli muscle, just to the inner side of the scalenus anticus and almost in front of the vertebral artery. When it reaches about the level of the seventh cervical vertebra it bends inward and behind the carotid artery to reach the lower posterior edge of the thyroid gland. The transverse process of the sixth cervical vertebra, called the *carotid tubercle of Chassaignac*, is above it. As it bends to go inward it gives off the ascending cervical artery. In front of the artery are the internal jugular vein, common carotid artery, pneumo-



gastric nerve, and the middle ganglion of the sympathetic. The recurrent laryngeal nerve usually passes upward behind the branches of the artery just before they enter the thyroid gland. The thoracic duct on the left side passes over the front of the artery low down.

*Operation.*—An incision 7.5 cm. long is made along the anterior border of the sternomastoid muscle, extending upward from the clavicle. This will bring the upper extremity up to, or even above, the cricoid cartilage. The anterior jugular vein will have to be ligated and the muscle displaced outward. The common carotid artery should then be isolated and it, together with the pneumogastric nerve and internal jugular vein, drawn outward. The omohyoid muscle may appear at the upper edge of the incision. Feel for the carotid tubercle on the sixth transverse cervical process: the artery lies below the omohyoid muscle and cricoid cartilage and below the tubercle and beneath the sheath of the carotid. If the trunk of the sympathetic or its middle cervical ganglion, which lies on the artery, is encountered, it

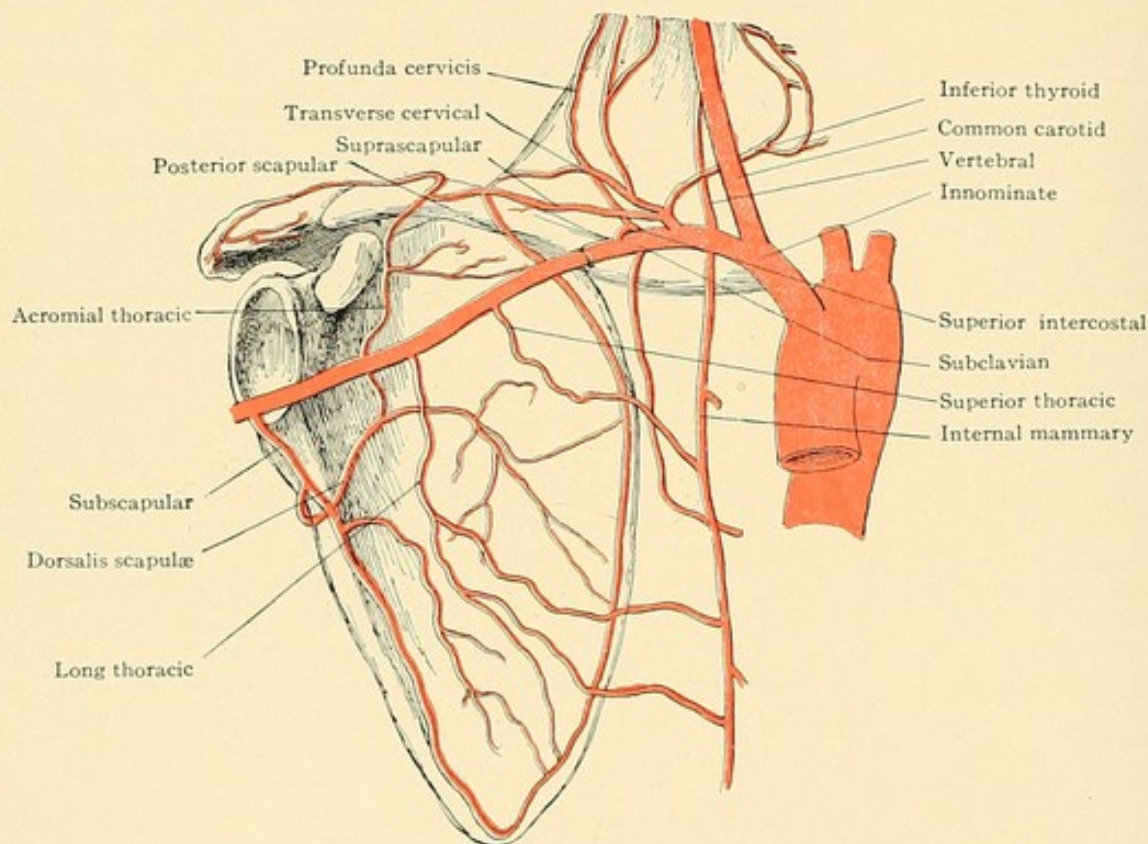


FIG. 176.—Collateral circulation after ligation of the third portion of the subclavian artery.

should be pushed to the inner side, the artery isolated outwardly and ligature applied. Do not go too far out or the scalenus anticus will be reached and the phrenic nerve may be injured, nor too far in, to avoid wounding the recurrent laryngeal.

The *thyroidea ima* (*inferior thyroid*) veins do not cross outward nor accompany the artery, but proceed downward on the trachea to empty into the innominate veins.

### THE CERVICAL FASCIAS.

There are two fascias in the neck, the *superficial* and the *deep*. The superficial fascia has blended with it anteriorly the platysma muscle and the termination of the nerves, arteries, and veins. The main trunks of these structures lie for all practical purposes beneath the superficial fascia and adherent to the surface of the deep fascia. It is for this reason that in raising the superficial structures the larger trunks remain applied to the deep fascia and are thus less liable to be injured in the living and mutilated in the dead. In the superficial fascia and on the deep fascia are the superficial lymphatics.



The superficial lymphatic nodes frequently suppurate. When they do the abscess so formed is prevented by the deep fascia from reaching the parts beneath, so the pus works its way out through the skin. As the superficial fascia is loose, if the abscess is slow in formation, it may extend for a considerable distance under the skin.

*Sebaceous cysts* are common in the neck. As they are superficial to the deep fascia, which is not involved, they can be removed without fear of wounding any important structures. The veins do not overlie them; they are always superficial to the veins, therefore there is no danger of wounding the external jugular.

**The Deep Cervical Fascia.**—The deep cervical fascia completely envelops the neck and sends its branches in between all its various structures. It is the fibrous tissue that both unites and separates all the different structures to and from each other. Where this fascia is abundant it forms a distinct layer, but where it is scant it is simply a small amount of connective tissue between two adjacent parts.

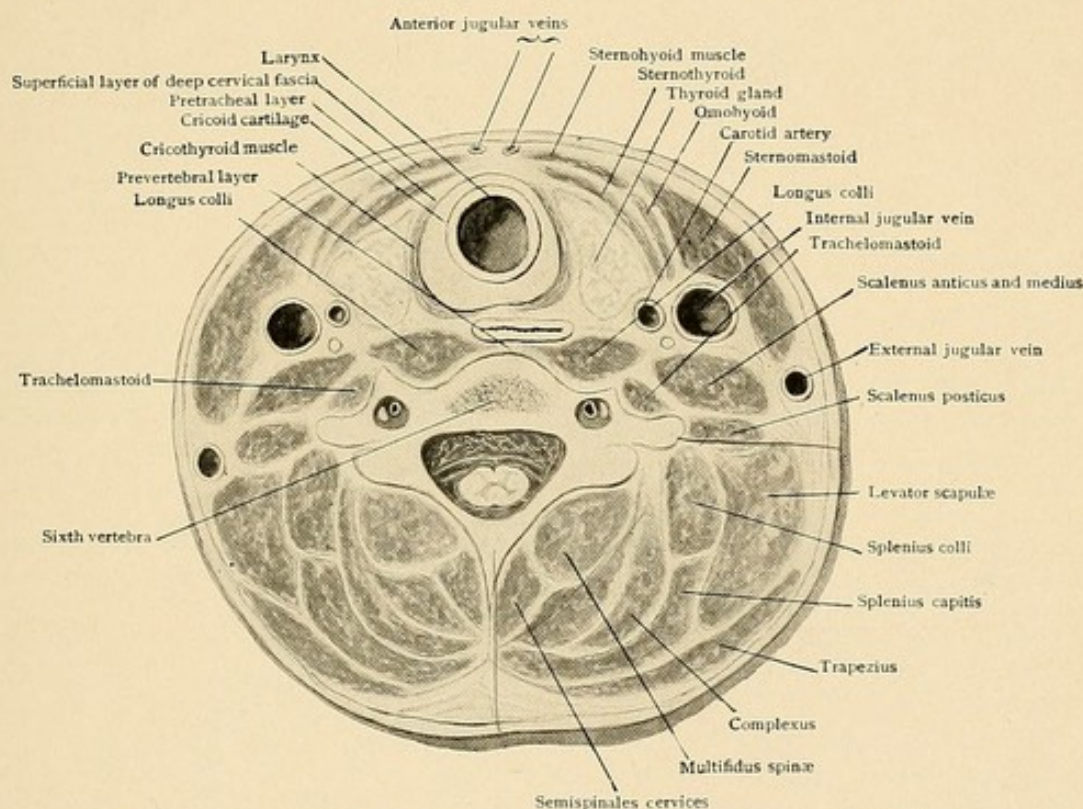


FIG. 177.—Transverse section of the neck through the sixth cervical vertebra.

To follow all the processes of the deep fascia through the neck between its innumerable structures is impossible—nor is it necessary. The main reason for studying the deep cervical fascia and its various parts is to understand the course pursued by abscesses and infections. This is best done by limiting oneself to the main superficial layer and some of the larger layers crossing from side to side.

The principal layers of the deep cervical fascia are the *superficial layer*, which completely encircles and envelops the neck, the *prevertebral layer*, which passes from side to side in front of the spinal column, and the *pretracheal layer*, which passes from side to side in front of the trachea.

**The Superficial Layer.**—The superficial layer of the deep fascia envelops the whole of the neck, with the exception of the skin, platysma, and superficial fascia. It is attached above to the occipital protuberance, the superior curved line of the occiput, the mastoid process, then blends with the capsule of the parotid gland, then passes to the angle of the jaw and along the body of the mandible to the symphysis, whence it proceeds around the opposite side in the same manner. Below it is attached to the sternum, upper edge of the clavicle, acromion process, and spine of the scapula, thence across to the vertebral spines, to which and to the ligamentum



nuchæ it is attached up to the occipital protuberance. In the front of the neck it passes from the mandible down to be attached to the hyoid bone and thence downward to the sternum and clavicle.

From the under side of this superficial layer processes of fascia come off and envelop the various structures of the neck. Every separate structure of the neck is covered by it and therefore separated from the adjacent parts by a more or less distinct layer of the fascia. In many places it is quite thin or almost imperceptible, amounting to but a few shreds of fibrous tissue, in other places it is more distinct, forming more or less marked capsules, as in the case of the thyroid and submaxillary glands, or fibrous layers, as in the case of those in front of the vertebræ and trachea. Posteriorly in the median line the superficial layer of the deep fascia sends a process which covers the under surface of the trapezius muscle. Anteriorly another process is given off to cover the under surface of the sternomastoid muscle. The super-

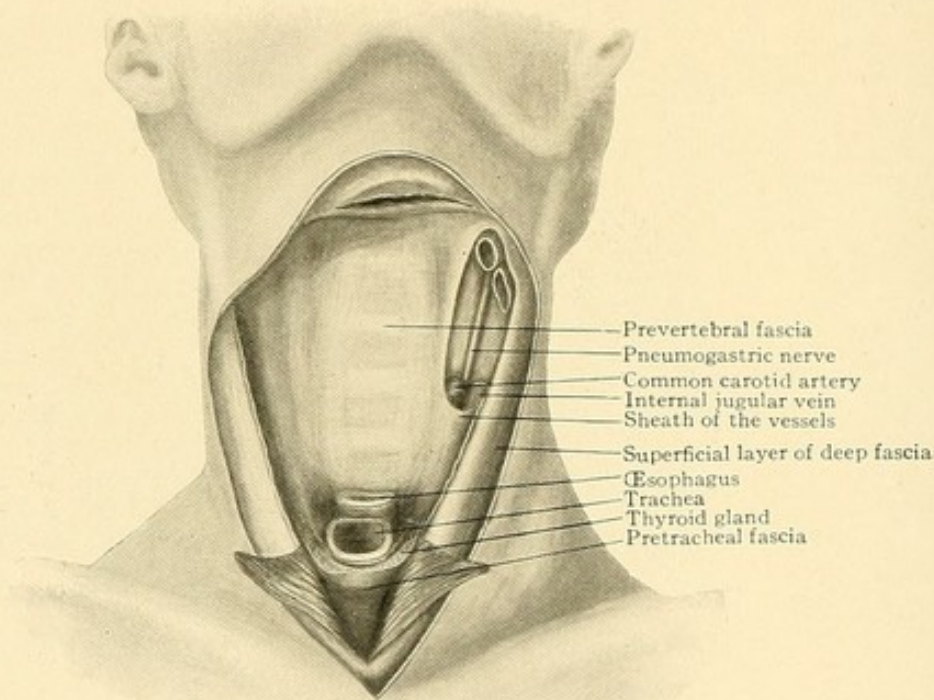


FIG. 178.—Deep cervical fascia. The pharynx and larynx have been cut away, exposing the prevertebral and pretracheal layers.

ficial veins of the neck, the anterior, external, and posterior jugulars, lie on or in the deep fascia, being stuck to or blended with its upper surface.

About 3 cm. ( $1\frac{1}{4}$  in.) above the sternum the deep fascia splits into two layers, one to be attached to the anterior and the other to the posterior edge of the sternum in front of the sternohyoid and sternothyroid muscles. Between these two layers is the *space of Burns*; it contains the lower ends of the anterior jugular veins with the branch that joins them, some fatty tissue and lymphatic nodes, and the sternal origin of the sternomastoid muscle. Sometimes a vein comes up from the surface of the chest below to open into the anterior jugular vein.

The *prevertebral layer* passes from side to side directly on the bodies of the vertebræ. It covers the muscles attached to the spine, as the scalene, longus colli, rectus capitis anticus, and also the nerves, as those of the brachial plexus, coming from the spine. On reaching the carotid artery and jugular vein it helps to form their sheath. Its upper edge is attached to the base of the skull at the jugular foramen and carotid canal and thence across the basilar process to the opposite side. Inferiorly it passes down on the surface of the bodies of the vertebræ into the posterior mediastinum.



From the sheath of the vessels outward, beyond the posterior edge of the sternomastoid muscle, the prevertebral fascia covers the scalene muscles, the brachial plexus of nerves, and the subclavian artery. On reaching the clavicle the fascia is attached to its upper surface, blending with the superficial layer; it is then continued down over the subclavian muscle, forming its sheath, and ends as the costocoracoid membrane. The part over the subclavian artery and vein is continued over them and the brachial plexus and follows them into the axilla. This fascia forms the floor of the posterior cervical triangle; the roof is formed by the superficial layer of the deep fascia. It is between these layers that the suprascapular artery and veins run. The descending branches of the cervical plexus, the spinal accessory nerve, omohyoid muscle, and some fat and lymph-nodes are also found there.

The *pretracheal layer* passes from side to side in front of the trachea. Laterally it too blends with the sheath of the vessels and is continued posteriorly behind the pharynx and œsophagus as the *buccopharyngeal fascia*. In front it blends in the median line with the superficial layer and is attached to the hyoid bone and cricoid cartilage. It splits to enclose and form a capsule for the thyroid gland, and below encloses in its meshes the inferior thyroid veins, and thence passes to the arch of the aorta to be continuous with the pericardium. Laterally it passes under the sternohyoid, omohyoid, and sternothyroid muscles to blend with the sheath of the vessels and the layer on the posterior surface of the sternomastoid muscle. This is its lateral limit. Underneath the sternomastoid muscle a loop of fascia proceeds downward from the omohyoid muscle to the first rib. This is derived from the sheath of the vessels beneath and the layer on the under surface of the sternomastoid superficially.

The *sheath of the vessels* envelops the carotid artery, jugular vein, and pneumogastric nerve. Thin layers of fascia pass between these structures, separating one from the other. The sheath is formed by the union of the outer edge of the pretracheal fascia and the prevertebral fascia, with the fascia lining the under surface of the sternomastoid muscle. This sheath follows the vessels down into the chest and out into the axilla.

The *capsule of the parotid gland* is formed by the splitting of the superficial layer of the deep cervical fascia as it passes from the mastoid process to the angle of the jaw. Its superficial portion is attached to the zygomatic process. Its deep portion passes from the styloid process to the angle of the jaw and is known as the stylomandibular ligament.

The *capsule of the submaxillary gland* is formed by a splitting of the superficial layer at the hyoid bone. It forms the covering of the gland and from the hyoid bone sends a process upward which lies on the digastric and mylohyoid muscles and follows the latter up to be attached along the mylohyoid ridge of the mandible. It proceeds with the submaxillary gland around the posterior edge of the mylohyoid muscle to cover its upper surface. The stylomandibular ligament alluded to above separates the parotid from the submaxillary gland.

The *capsule of the thyroid gland* is not very thick and the gland is readily separated from it, as is also the case with the submaxillary gland. It is continued downward in front of the trachea as the pretracheal layer and laterally it blends with the sheath of the vessels. It follows the vessels downward into the chest and is continuous with the pericardium. The veins of the gland, which are at times very large, run beneath the capsule and bleed freely if wounded.

**The Buccopharyngeal Fascia.**—Between the pharynx in front and the vertebral column behind is the retropharyngeal space. The fascia forming the posterior wall of this space is the prevertebral fascia already described. Forming its anterior wall is a thin layer of connective tissue called the buccopharyngeal fascia. It invests the superior constrictor of the pharynx and is continued forward on the buccinator muscle. It is continued downward behind the pharynx and œsophagus into the posterior mediastinum; laterally it blends with the sheath of the vessels and is continuous with the pretracheal fascia around the larynx, trachea, and thyroid gland (Fig. 179).

**Abscesses of the Neck.**—Abscesses of the neck usually arise in connection with the lymphatic nodes. They may also start from infected wounds, carious



teeth, suppuration of the thyroid gland, and other causes. They may have their course influenced by the various layers of the deep fascia.

*Pus in the Submaxillary Region.*—As the submaxillary space has the mylohyoid muscle as its floor, abscesses here show below the body of the mandible between it and the hyoid bone. Usually they point towards the skin. Infection of this space may occur from the teeth. Tillmans ("Surgery," vol. 1, p. 434) saw a case in which in four days the pus caused death from infection of the mediastinum and pleura. This proceeded downward from a badly extracted tooth and thence under the deep fascia of the neck to the chest.

The pus, filling the submaxillary space, as can also occur in Ludwig's angina, which is an infective inflammation of the submaxillary and sublingual regions, may follow the lingual and facial arteries to the sheath of the great vessels and down into the superior mediastinum. The infection in Ludwig's angina may pass around the posterior edge of the mylohyoid muscle and involve the structures around the

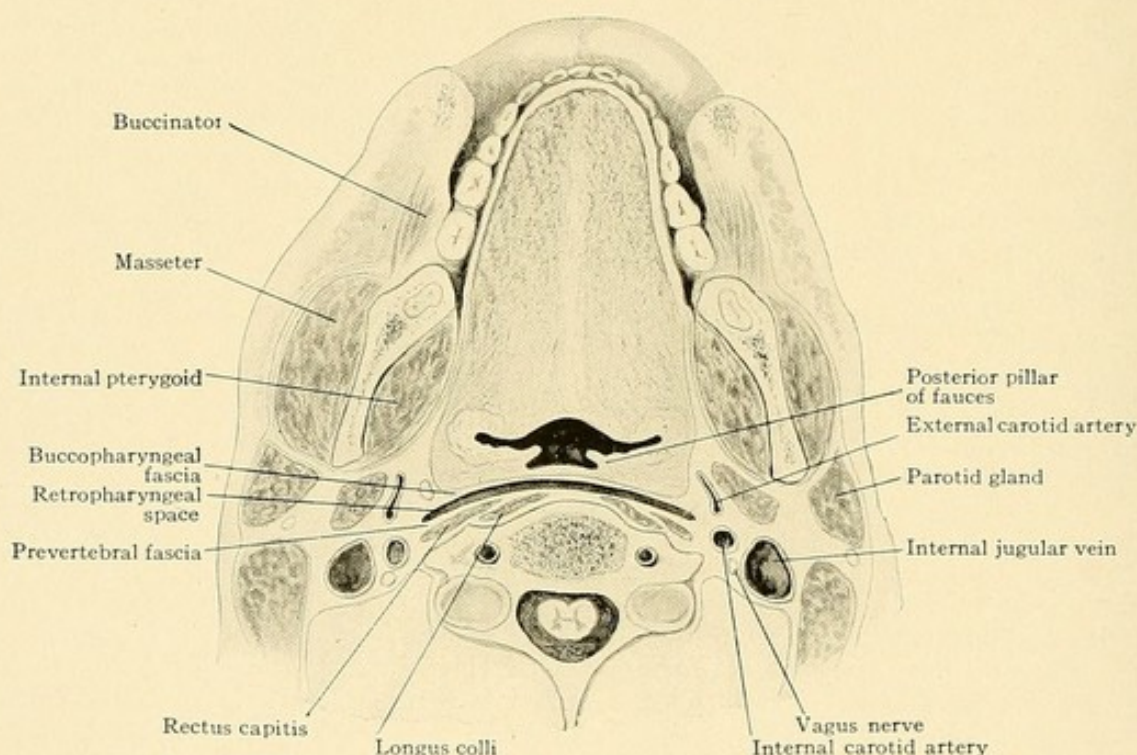


FIG. 179.—Section through the upper portion of the third cervical vertebra, showing the buccopharyngeal and prevertebral fascias and retropharyngeal space.

base of the tongue and pharynx, and produce œdema of the larynx and death (see page 200).

*Pus superficial to the deep fascia* tends to perforate the skin and discharge externally. If it is slow in forming it may sink down and pass over the clavicle onto the upper portion of the chest.

*Pus in the suprasternal notch* or space of Burns bulges anteriorly but may perforate posteriorly. The sternothyroid and sternohyoid muscles are attached to the posterior surface of the sternum; but the layer of fascia on their anterior surface is very thin, so that pus may either pass between the muscles or perforate them and so pass down in front of the pretracheal fascia close to the under surface of the sternum. It would then tend to show itself in the upper intercostal spaces, close to the sternum.

*Pus between the pretracheal and superficial layers*, as may occur from abscesses of the thyroid gland, tends to work its way downward rather than laterally. The pretracheal fascia at the sides blends with the sheath of the vessels and the fascia covering the posterior surface of the sternomastoid muscles. In this space lie the sternohyoid, sternothyroid, and omohyoid muscles. The pretracheal fascia is beneath them and the superficial layer of the deep fascia above. Pus can follow the posterior



surface of these muscles down behind the sternum in front of the innominate veins and arch of the aorta.

*Pus between the pretracheal and prevertebral layers* cannot go further to one side than the sheath of the vessels. Therefore it follows the trachea and œsophagus down into the posterior mediastinum. This space, between these layers, is sometimes called the *visceral space* because it contains the œsophagus, trachea, and thyroid gland. Pus in this space can also perforate into the trachea, pharynx, œsophagus, or even extend laterally and involve the great vessels.

If the anterior portion of the thyroid gland suppurates, the pus may perforate the

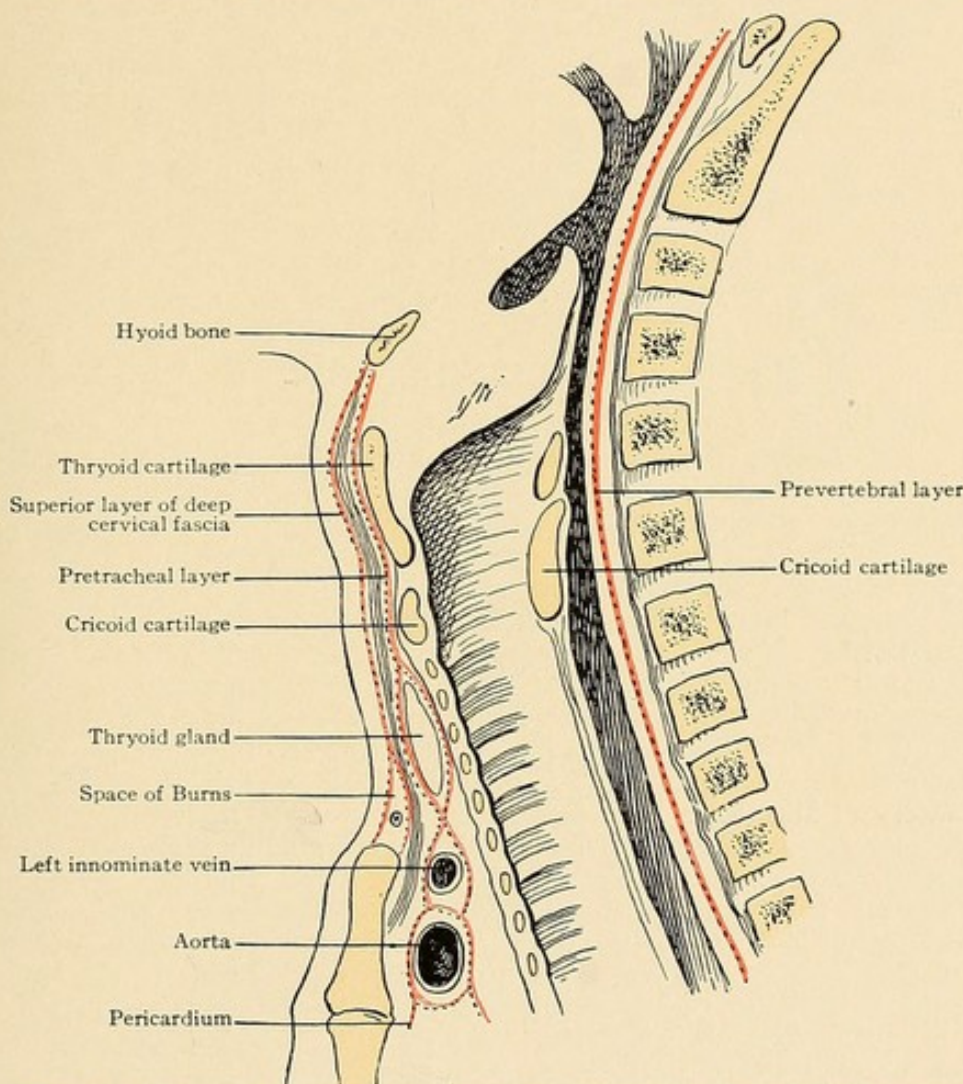


FIG. 180.—The superficial layer, pretracheal layer, and prevertebral layer of the deep cervical fascia.

thin pretracheal fascia covering it and pass down behind the sternohyoid and sternothyroid muscles into the anterior part of the superior mediastinum.

*Pus posterior to the prevertebral fascia*, as from caries of the vertebræ, if high up may bulge into the pharynx, forming a retropharyngeal abscess. It may follow the scaleni muscles and brachial plexus down around the axillary artery into the axilla. In the neck it shows itself posterior to the carotid arteries and to the *outer* edge of the sternomastoid muscles.

*Pus in the sheath of the great vessels*, when originating from lymphatic nodes, may first raise the sternomastoid muscle and show itself along its anterior border; it may perforate the lumen of the vessels; it may pass down with the vessels into the superior mediastinum; or it may bulge into the visceral space between the prevertebral and pretracheal layers and follow the trachea and œsophagus down into the chest. Should it tend outwardly it may break into the posterior cervical triangle between the prevertebral and superficial layers and show itself above the clavicle.



*Retropharyngeal Abscess.*—Pus which tends to point into the pharynx may come from disease of the vertebræ, in which case it is posterior to the prevertebral fascia; or it may originate from the lymphatic nodes in the retropharyngeal space.

When coming from caries of the vertebræ, it may point either in the pharynx or, pushing its way outward, pass behind the great vessels and show itself behind the outer edge of the sternomastoid muscle. I have seen it point in both these places in the same case. When originating in the retropharyngeal space it lies in front of the prevertebral fascia and behind the buccopharyngeal fascia. It either points forward into the pharynx or, going down, follows the posterior surface of the œsophagus into the posterior mediastinum. It may also perforate the œsophagus and enter its lumen.

*Pus in the Posterior Cervical Triangle.*—If above the prevertebral layer this bulges directly forward and tends to open through the skin. Its progress downward is obstructed by the attachment of the superficial layer to the top of the clavicle as it blends with the prevertebral layer. If pus is beneath the prevertebral layer it may then follow the brachial plexus and subclavian artery down beneath the clavicle and appear in the axilla. The attachments of the costocoracoid membrane tend to direct the pus laterally under the pectoralis minor muscle into the axilla rather than to allow it to come forward on the anterior portion of the chest.

### LYMPHATICS OF THE NECK.

The lymphatics of the neck are both superficial and deep. The superficial nodes communicate freely with and end in the deep ones. For the sake of convenience we may divide them into a *transverse set*, embracing the *submental*, *submaxillary*, *superficial upper cervical* (behind the angle of the jaw), *posterior auricular*, and *occipital* nodes; and *two longitudinal sets*, one along the great vessels and another, a posterior set, in the posterior cervical triangle.

**The Transverse Lymphatics.**—The *submental nodes*, also called the suprahyoid, lie beneath the chin and drain the region of the lower lip and chin and anterior part of the floor of the mouth. These will be enlarged in children with ulcerative skin affections of these regions. They may also be involved in carcinoma of the lower lip, especially if near the median line. That the submental nodes drain the tissues of the anterior portion of the mouth and probably the tongue itself is shown by Henry T. Butlin ("Surgery of Malignant Disease," p. 153), who states that the submental nodes are frequently affected in carcinoma of the tongue when its tip is involved.

The *submaxillary nodes* are beneath the body of the mandible in the submaxillary triangle. They drain the lips, nose, floor of the mouth, gums, anterior portion of the tongue and side of the face. These are the nodes most frequently affected in carcinomatous affections of the lips and anterior portion of the tongue. Henry T. Butlin ("Surgery of Malignant Disease," p. 153) calls attention to the fact that in malignant disease of one side of the anterior portion of the tongue the lymphatics of the opposite side may also be involved, thus showing that the lymphatics of the two sides of the tongue freely anastomose. This is contrary to what exists as regards the arteries, which anastomose hardly at all across the median line. He also states that one or more of the lymphatic nodes is frequently imbedded in the substance of the submaxillary gland. Therefore the submaxillary gland is excised at the same time as the affected lymphatic nodes.

The *superficial upper cervical (subparotid) nodes* are just below the parotid lymphatics and behind the angle of the jaw. They drain the region embraced by the masseter muscle as far back as the ear. They may be enlarged in affections of the skin and scalp above. Therefore in children with enlargement of these nodes the source of infection should be sought in those regions.

The *posterior auricular nodes* are behind the ear on the mastoid process and insertion of the sternomastoid muscle. In practice they are encountered as small (1 cm.), round swellings behind the ear, which are usually quite tender to the touch. This is probably due to their being placed on a hard, bony base. When enlarged they are often the subject of operations.



The *superficial occipital nodes* are just below the superior curved line of the occiput or a little lower down in the hollow below the occiput between the posterior edge of the sternomastoid and anterior edge of the trapezius muscles, resting on the splenius. These are the nodes that are enlarged in syphilis and are to be searched for in endeavoring to establish a diagnosis.

*Superficial and Deep Nodes.*—The five sets of nodes just described, viz., the submental, submaxillary, superficial upper cervical, posterior auricular, and superficial occipital, are all regarded as superficial nodes. As a matter of fact this division of the lymphatic nodes into superficial and deep is not of practical value. The communication between the various nodes is quite free. Adjacent nodes communicate and the superficial nodes communicate with the deep ones below.

On account of this an affection is not always limited to a single node but often involves those to each side and those lying still deeper. In the submaxillary region

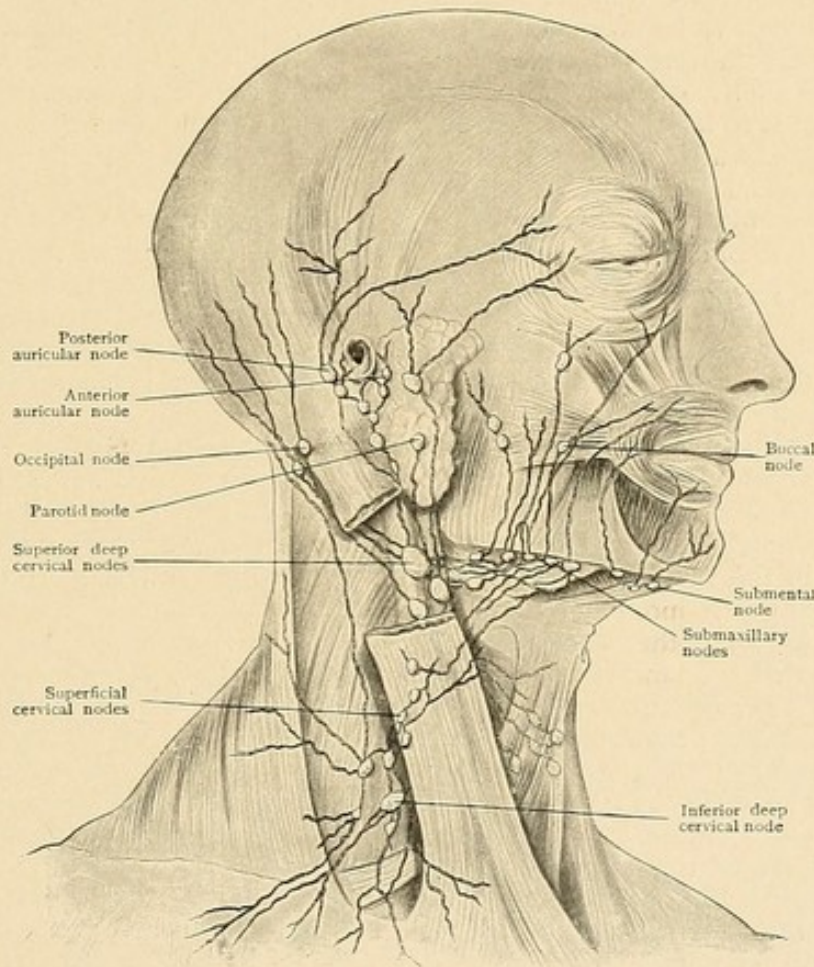


FIG. 181.—Superficial lymphatic vessels and nodes of head and neck; semidiagrammatic. (Piersol.)

the nodes will almost certainly be found to lie under the fascia along with the submaxillary gland. When the occipital nodes are enlarged they may not only be found in the space already described but also on the adjacent trapezius and sternomastoid muscle and even beneath the outer edge of the trapezius below the deep fascia.

**The Longitudinal Lymphatics.**—These are along the great vessels,—the anterior cervical lymphatics,—and in the posterior cervical triangle.

The *anterior cervical lymphatics* is the name given to those which tend to show in the anterior cervical triangle either beneath or in front of the sternomastoid muscle, between it and the median line. There are some nodes in the median line but they are almost all deep down in the neck above the sternum. The other nodes may be either superficial or deep, mostly deep, along the edge of the sternomastoid



muscle. They follow the sheath of the vessels. This is a very extensive chain of nodes. They may extend in all directions. As regards depth they may be on the deep fascia along the edge of the sternomastoid or following the external jugular vein. If deeper they follow the internal jugular vein and carotid artery directly up to the base of the skull, also behind and below the mastoid process and alongside of the transverse process of the atlas (first cervical vertebra). They extend under the sternomastoid posteriorly, deep in the suboccipital region. Should they be enlarged downward they will protrude behind the posterior edge of the sternomastoid into the posterior cervical triangle; if anteriorly they will follow it down into the space of Burns in front of the trachea and thence into the superior mediastinum.

The *posterior cervical nodes* show behind the posterior edge of the sternomastoid, along the edge of the trapezius, and also above the clavicle. They not infrequently fill the posterior cervical triangle and extend beneath the muscles on each side.

Below they may be continuous with enlarged nodes in the axilla and extend anteriorly under the sternomastoid into the pretracheal region and mediastinum. They are frequently excised for both tuberculosis and carcinoma. In so doing particular care is to be taken on account of the transversalis colli and suprascapular arteries and veins, with which they may lie in contact, as well as the terminal portion of the external jugular.

**Postpharyngeal Nodes.**—In the retropharyngeal space, toward the sides, between the buccopharyngeal fascia in front and the prevertebral fascia behind are located one or two nodes (see buccopharyngeal fascia, page 153, and retropharyngeal abscess, page 156). They seem to be the starting point, sometimes, of retropharyngeal abscess. They do not appear to get enlarged and project into the pharynx as tumors, as might be expected, so that they are not subjected to any surgical procedures.

**Operating for the Removal of Enlarged Cervical Nodes.**—This operation may be one of the most serious in surgery. Sir Frederick Treves says: "An operation of this kind should not be undertaken unless the surgeon has perfect confidence in his practical knowledge of the anatomy of the neck. Scarcely an instance can be cited in the range of operative surgery where a knowledge of the structure and of relations is more essential than in these excisions." The main difficulties encountered are in the avoidance of nerves and the control of hemorrhage. Air may enter the veins and cause death, and the thoracic duct may be wounded. The latter accident sometimes results fatally. The difficulty of the operation will depend on the size and number of the nodes, their location, and the character of the inflammation or other changes they have undergone. In an early stage the nodes may be lying loose in the tissues and can be readily turned out when once exposed. Later they may be matted to the surrounding structures by inflammatory deposits and then their separation is a matter of difficulty and danger.

The skin incisions may be either longitudinal or more or less transverse. The longitudinal incisions are usually along either the anterior or posterior border of the sternomastoid muscle, or the anterior edge of the trapezius. The transverse incision may be either opposite the hyoid bone—when it may be prolonged around the angle of the jaw and up to the mastoid process and over the suboccipital glands, or above the clavicle.

As the skin and superficial structures are cut and the deep fascia opened, the superficial veins will be cut, hence the first anatomical fact to be borne in mind is the probable location of the veins. The most important of these is the external jugular. The internal jugular below the hyoid bone lies under the sternomastoid muscle and therefore is protected until the deeper dissection is begun. The external jugular runs about in a line from the angle of the jaw to the middle of the posterior edge of the sternomastoid muscle and thence downward to about the middle of the clavicle. Therefore an incision along the posterior edge of the sternomastoid will divide it at about the middle of the muscle, and the surgeon should be prepared to guard against an undue loss of blood when it is cut. Opening into the external jugular posteriorly between the middle of the sternomastoid muscle and the clavicle below are the posterior jugular, the transverse cervical, and the suprascapular veins.



These latter open into the external jugular 1 or 2 cm. above the clavicle and are almost certain to be cut in operations in the supraclavicular fossa. An incision along the anterior edge of the sternomastoid low down will cut the anterior jugular vein a short distance above the sternum as it winds beneath the sternomastoid to empty into the external jugular. An incision along the anterior border of the sternomastoid from its middle up is bound to cause free hemorrhage. The external jugular behind the angle of the jaw communicates with the facial, which empties into the internal jugular; hence division of the external jugular at this point also drains the blood almost directly from the internal jugular. A carelessly deep incision may wound the internal jugular itself in the region posterior to the hyoid bone. The internal jugular is more superficial at this point than it is lower down. The temporo-maxillary and posterior auricular veins will also be cut behind the ramus of the jaw.

Not only are veins cut but also nerves. The middle of the posterior edge of the sternomastoid is the point of departure of several nerves. The superficial cervical runs directly transversely inward toward the thyroid cartilage. The auricularis magnus goes up to the lobe of the ear, and the occipitalis minor follows the posterior edge of the muscle up to the occiput. These three nerves are nerves of sensation and if they are divided only a certain amount of temporary anæsthesia will be produced over the parts they supply, hence their division is not a matter of much moment. The auricularis magnus is the largest of the three. The descending branches of the cervical plexus, which leave the posterior edge of the sternomastoid muscle immediately below the nerves just mentioned, proceed down under the deep fascia and will be seen only in a deeper dissection. The nerve which it is absolutely important to avoid is the spinal accessory. This enters the sternomastoid muscle on its under surface some little distance back of its anterior edge and 3 to 5 cm. below the mastoid process. It sends a branch to the muscle and leaves its posterior edge about its middle. It then passes downward and outward across the posterior cervical triangle under the deep fascia to enter the deep surface of the trapezius. If this nerve is divided, paralysis of the trapezius will certainly follow and as it is a motor nerve the shoulder of that side will drop considerably. This will be a permanent deformity because motor nerves do not seem to have their functions restored by time as so usually occurs when the nerves of sensation are divided.

If the nodes to be removed are superficial ones there are no other structures to be feared and the operation will be an easy one. If they lie deeper, then the sheath of the sternomastoid muscle is to be divided and the muscle pulled outward. Just above the level of the cricoid cartilage a small artery, the sternomastoid branch of the superior thyroid, enters the muscle and it will be divided. As the sternomastoid is raised and pulled outward care must be taken to avoid wounding the spinal accessory nerve. As this nerve enters the muscle from 3 to 5 cm. below the mastoid process and some distance back from the edge of the muscle, if it is necessary to divide the muscle it is best done high up above the entrance of the nerve, or low down. By so doing the nerve supply (from the spinal accessory) and blood supply are not interfered with and the function of the muscle is not so much impaired as it would be if divided near the middle. The nodes not only possess their own capsule but also a covering from the connective tissue in which they lie. Therefore to remove them they must be detached and separated from it usually by blunt dissection. When these strands of fibrous tissue from the nodes to the surrounding parts are strong they have to be caught with forceps and cut. They are to be clamped, to avoid possible bleeding. When the angle of the jaw is reached the communicating branch between the facial and external jugular veins must be clamped and cut. The parotid gland is to be pulled upward and inward. The nodes may stick to the jugular vein and carotid artery. The vein is on the outside and is likely to be the first encountered. When distended it overlies the artery. If collapsed its presence may not be suspected. Feel for the pulsation of the carotid artery and avoid the structure just to its outer side. The jugular vein may be so involved in the mass as to necessitate its removal. In such a case remember that posteriorly between it and the carotid artery is the pneumogastric nerve.

The sympathetic nerve lies deeper in the fascia toward its posterior surface and is not so likely to be wounded. Its superior cervical ganglion lies opposite the



second and third vertebræ. Working still higher, the transverse process of the atlas or first cervical vertebra will be felt and seen below and to the inner side of the mastoid process. The connective tissue adherent to the nodes is attached to this transverse process and may have to be cut loose or scraped away. In doing so keep to the outer edge because the jugular vein and internal carotid artery lie on its anterior surface.

Beneath the sternomastoid runs the anterior scalene muscle and on it, coming from the third, fourth, and fifth cervical nerves, is the phrenic nerve; so that it is not permitted to dig into and disturb the muscular mass to the outer side of the common carotid artery on which these nodes frequently lie.

In operating *in the submental region* there is nothing to fear. The space between the two anterior bellies of the digastric muscles on the sides, the hyoid bone below, and down to the anterior surface of the mylohyoid muscle beneath, can be cleared out with impunity.

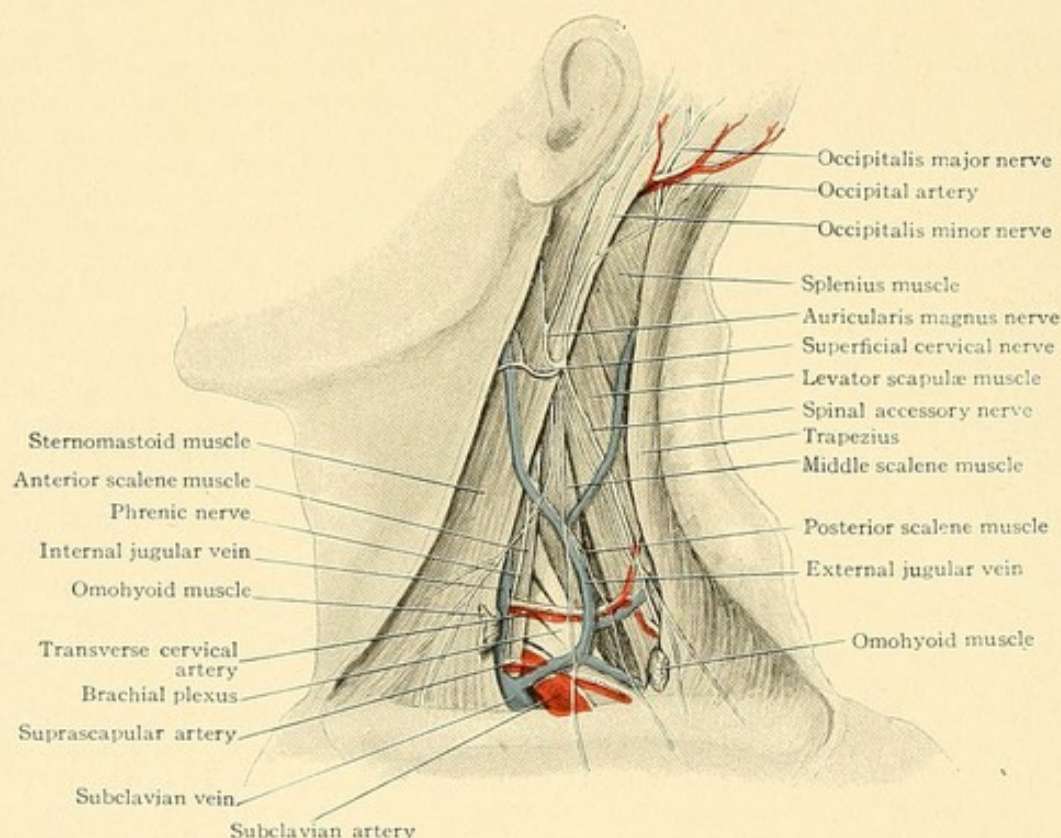


FIG. 182.—The posterior cervical triangle.

*In the submaxillary region* remember that the fascia covering the submaxillary gland is thin, so that the gland will probably be exposed as soon as the superficial structures are raised. As the facial artery and vein cross the mandible just in front of the masseter muscle, the vein is posterior. The artery goes under the gland and is adherent to it, so that as the gland is raised the artery is brought up also. The facial and lingual veins usually empty into the internal jugular, but, as shown in Fig. 168, they may receive a communicating branch from the external jugular and the anterior jugular and continue down as the anterior jugular to empty into the external jugular low down in the neck, beneath the sternomastoid muscle. The hypoglossal nerve will be seen lying on the hyoglossus muscle, but it is readily avoided. The lingual artery is beneath the hyoglossus muscle anteriorly but both it and the facial must be looked for as one nears the posterior belly of the digastric.

*In the lower cervical region*, opposite the cricoid cartilage, the omohyoid muscle will be met. It will sometimes be necessary to divide it. The sternohyoid and sternothyroid muscles and the thyroid gland are to be drawn inward and the sternomastoid outward. One should always keep away from the thyroid gland, as the recurrent



laryngeal nerve runs behind it and on the œsophagus near the trachea. Cutting it will probably cause a permanent alteration in the voice. If the internal jugular vein has been removed, as it may be on one side, but not on both, beneath it one is liable to encounter the inferior thyroid artery below Chassaignac's tubercle on the sixth cervical vertebra, and further out the phrenic nerve on the scalenus anticus muscle, and lower down the transverse cervical and suprascapular arteries. The inferior thyroid veins usually run downward to empty into the innominate veins, but the lower portion of the anterior jugular vein and the middle thyroid veins will probably have to be ligated. The course of the various veins is quite irregular and large venous branches may be encountered at any place.

In the *posterior cervical triangle* the spinal accessory nerve must be avoided as it runs down and back from the middle of the posterior edge of the sternomastoid muscle. The external jugular, posterior jugular, transverse cervical, and suprascapular veins may all require ligation. Beneath the deep fascia (superficial layer) are the descending or supraclavicular branches of the cervical plexus from the third and fourth cervical nerves. Care should be taken not to mistake them for the spinal accessory nerve. If the nerve has been divided it should be sutured together again at the completion of the operation. It is hardly necessary to caution against wounding the subclavian vein; it is in front of the anterior scalene muscle. The artery is behind the muscle. Do not dig under it. It rests on the pleura, a wound or tear of which may mean a septic pleurisy and death. In the angle formed by the junction of the internal jugular vein and subclavian on the left side is the thoracic duct. If wounded death may ensue through persistent leakage of lymph, but not infrequently healing eventually occurs. Wounding of the corresponding lymphatic duct on the right side is not considered so serious, the chyle being carried by the left duct. The cords of the brachial plexus run down and across the posterior cervical triangle above the subclavian artery, but a little care will enable one to avoid them. This is one of the regions of the body in which exact surgery is essential.

### OPERATIONS ON THE AIR-PASSAGES.

The pharynx may be opened just below the hyoid bone,—*subhyoidean pharyngotomy*. The larynx may be opened in the median line,—*thyrotomy*. The cricothyroid membrane may be opened,—*laryngotomy*. The trachea may be opened,—*tracheotomy*.

**Subhyoidean pharyngotomy** is the entering of the pharynx by means of an incision below the hyoid bone. This is an extremely rare operation. It may be performed for the removal of foreign bodies or tumors. The incision may be made just below the hyoid bone and parallel to its border. This will divide the commencement of the anterior jugular vein, perhaps near the median line, perhaps toward the side. A transverse vein usually runs from one anterior jugular vein to the other across the median line at this point. Attached to the hyoid bone nearest to the median line is the sternohyoid muscle, then farther out the omohyoid, and still farther out the thyrohyoid. A small artery, the thyrohyoid, a branch of the superior thyroid, or sometimes of the lingual, will be divided.

The thyrohyoid membrane being incised, access is obtained to the fatty tissue at the base of the epiglottis. If the incision is carried directly backward the epiglottis will be cut through at its base. If, however, it is kept close to the hyoid bone and made upward, the pharynx will be entered in front of the epiglottis and at the root of the tongue. If the incision is carried too far toward the sides the superior thyroid artery and even the external carotid itself will be cut; if carried too low down on the thyrohyoid membrane, then the superior laryngeal artery and nerve may both be wounded. Attention has already been called to the thyrohyoid branch.

**Thyrotomy** is the division of the thyroid cartilage in the median line. The sternohyoid muscles almost touch in the median line. The division should be exactly in the median line. This will avoid wounding the anterior jugular veins. If not in the median line the incision will wound one of the vocal cords. Impairment of the voice certainly follows this operation; it is only performed for the removal of foreign bodies or growths.



**Laryngotomy** is the opening of the cricothyroid membrane. It is rarely done, but it is of service in cases of choking from obstruction of the larynx, foreign bodies, etc.

There is not sufficient room between the cricoid and thyroid cartilages to do this operation properly until puberty has been reached and the larynx has enlarged. The cricoid cartilage is narrow in front but wide behind. Its upper edge rises rapidly as it passes backward, forming an upper crescentic border, the concavity being upward. The lower edge of the thyroid is concave downward. Thus the two edges make an oval opening in front which in children is too small to hold the tracheotomy tube. The nearness to the vocal cords is also a serious objection. Performing a laryngotomy is the easiest and quickest way to enter the air-passages. Both the thyroid and cricoid cartilages in the median line are practically subcutaneous. A longitudinal incision of the skin is usually advised, after which a transverse incision is employed for opening the cricothyroid membrane. The tube is to be shorter than the one ordinarily used for tracheotomy. The cricothyroid artery, running across the membrane, is usually too insignificant to cause any trouble; it is nearer the thyroid cartilage, therefore the cut through the membrane should be close to the cricoid cartilage.

**Tracheotomy** is the opening of the trachea. There are two varieties, the high and the low, according as the tube is inserted above or below the isthmus of the thyroid gland. When in the adult male the neck is in line with the axis of the body the lower border of the cricoid cartilage is about 4 cm. ( $1\frac{1}{2}$  in.) above the sternum. When the head is tilted far back the larynx is drawn upward and the lower border of the cricoid is 6 cm. (about  $2\frac{1}{2}$  in.) above the sternum. Hence in doing a tracheotomy the head is to be tilted far back. The total length of the trachea is 10 to 12 cm. (Morris, Hensman), beginning opposite the sixth cervical vertebra,—upper border in the child and lower in adults,—and ending opposite the fifth dorsal. About half of it is above and half below the top of the sternum. It is composed of 14 to 20 rings. In the adult the isthmus of the thyroid gland covers the second, third, and fourth rings. There are about eight rings above the sternum.

According to Symington and Guersant (Treves) the diameter of the trachea is about as follows:

$1\frac{1}{2}$ to 2 years.....	5 mm.
2 to 4 years.....	6 mm.
4 to 8 years.....	8 mm.
8 to 12 years.....	10 mm.
12 to 15 years.....	12 mm.
Adults.....	12-15 mm.

A knowledge of the size of the trachea is necessary in order to select a tracheotomy tube of a size suitable to the particular case. The liability is to select too large a tube for young children, particularly infants. If this is done it may be very difficult to introduce the tube, or the trachea may even be torn in the attempt. In operating, an incision 2.5 to 3 cm. long is to be made in the median line. This may cut the anterior jugular vein. If carried near to the sternum it will certainly divide the communicating branch between the anterior jugulars at that point. The top of the incision in a child will be over the cricoid cartilage, and as soon as the skin has been divided the finger is to be inserted and the cricoid cartilage felt and recognized. This will show how deep the trachea lies. In very young children the isthmus of the thyroid gland is liable to come up to the cricoid cartilage and the difficulty of displacing it far enough down to allow the tube to be inserted is such that it may be best to divide it. Therefore after the skin and deep fascia have been divided and the cricoid recognized by the finger the soft tissues covering the trachea immediately below the cricoid are grasped on each side with a hæmostatic forceps and divided between them. These tissues may embrace the isthmus of the thyroid gland, the edges of the sternohyoid muscles, some veins, branches from the superior and inferior thyroids, and the fascia covering the gland and overlying the trachea.

The trachea should be cleared before opening it. A sharp hook is inserted into the cricoid cartilage to steady it and an incision is made into the trachea from below upward. In making this incision the utmost care must be taken not to cut through



the trachea and wound the œsophagus behind. The trachea of a child is not the hard resisting structure of the adult. It is a soft tender tube easily compressed and readily torn by roughness, or punctured with a knife. Forceps do not readily hold in it and stitches through it are liable to tear out. Only the very tip of the point of the knife should be allowed to enter the tube. The utmost care must be taken to keep in the median line. This is to be accomplished by using the cricoid cartilage as a guide and by seeing that the position of the head is straight. Cutting to either side of the trachea will cause wounding of the common carotid arteries. Below the isthmus of the thyroid gland and running down on the trachea are the inferior thyroid veins. The superior and middle thyroid veins empty into the internal jugular vein, but the inferior thyroids go downward to empty into the innominate. These veins will be cut if a low tracheotomy is done. In the infant the innominate artery and sometimes, though rarely, the left carotid encroach on the suprasternal notch and may be wounded if the incision is carried too low. The left innominate vein as it crosses to the

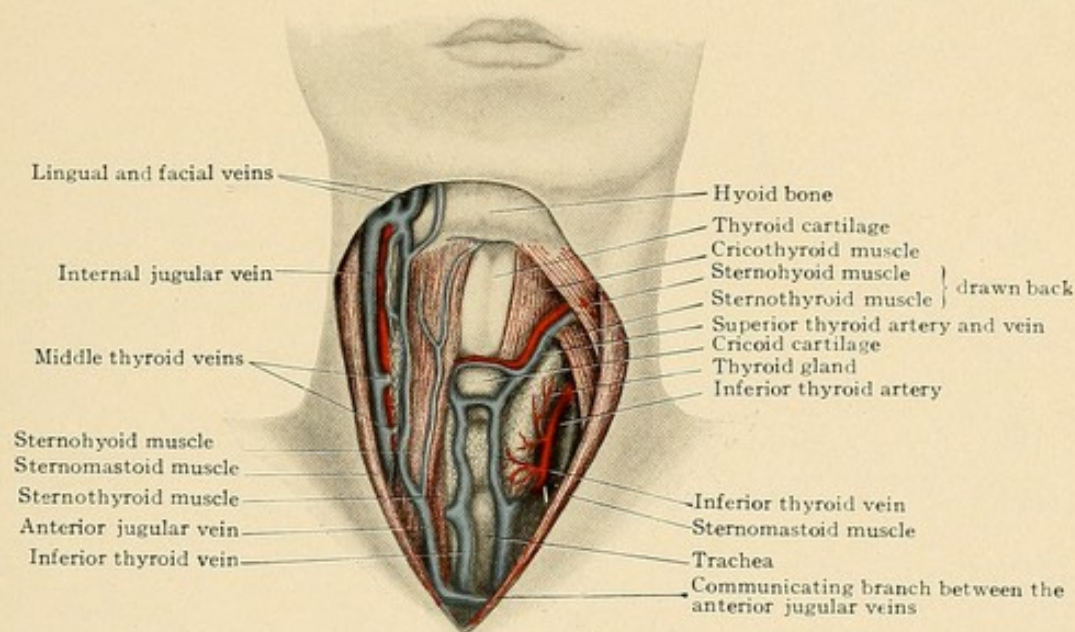


FIG. 183.—Dissection showing the parts involved in operations on the thyroid gland and air-passages.

right side is liable, especially in very young children, to show quite plainly above the sternum and would certainly be cut if the deep incision was carried as far down as the top of the sternum. An anomalous artery, the *thyroidea ima*, a branch of the innominate, sometimes passes upward on the trachea. On account of the presence of all these vessels it is not allowable to do any cutting of the deep parts just above the sternum; they are simply to be depressed by blunt dissection and kept out of the way with retractors while the trachea is being incised. The cricoid cartilage is never to be incised. It is far more firm and resistant than the trachea and it serves to keep the trachea from collapsing. The proximity of the tracheotomy tube to the vocal cords would result in interference with their function.

The *method of Bose* consists in dividing the fascia overlying the trachea near the cricoid cartilage and pushing it down, carrying the isthmus and veins with it, and introducing the tube into the space so cleared. This is so difficult that it is better to divide the isthmus, as already described.

#### OPERATIONS ON THE THYROID GLAND.

The operations which are done on the thyroid gland are ligation of its arterial supply and complete or partial removal. These necessitate a knowledge particularly of its blood supply and structure.

The *thyroid gland* consists of an *isthmus* and two lateral lobes. The isthmus



crosses the second, third, and fourth tracheal rings in the adult. In children it may approach nearer to the cricoid cartilage.

The *lateral lobes* lie under the sternohyoid and the sternothyroid muscles. They rise as high as the oblique line on the sides of the thyroid cartilages which marks the insertion of the sternothyroid muscles. The lobes descend to the level of the sixth ring of the trachea, which is two rings below the isthmus, about two centimetres above the sternum. The inferior constrictor of the pharynx is beneath the gland. The thyroid gland is covered by the *pretracheal fascia* and possesses a *capsule* of its own besides. This fascia envelops the gland and its capsule, and from its posterior surface is prolonged down on the trachea and envelopes the

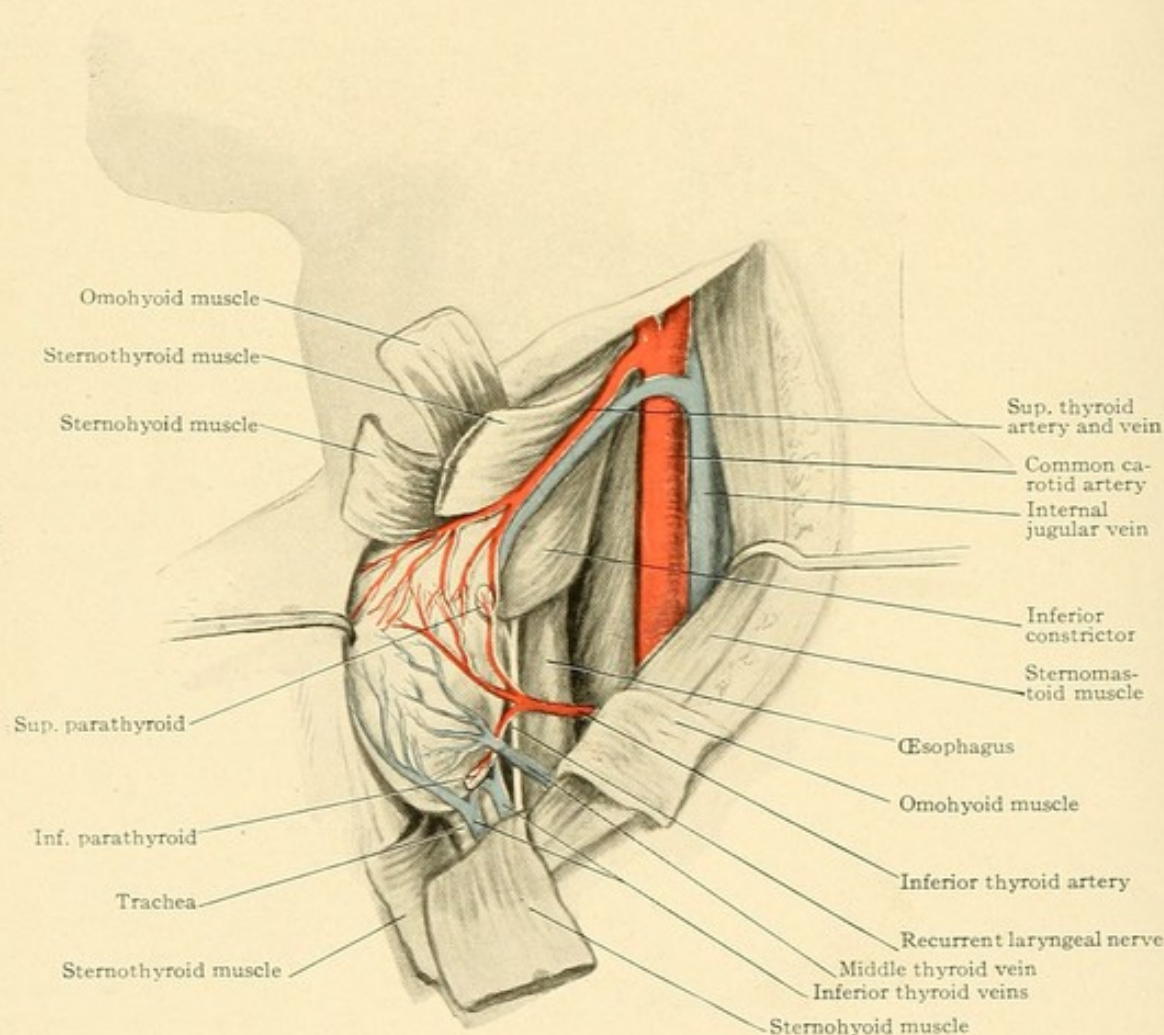


FIG. 184.—Excision of the thyroid gland.

vessels coming to and leaving the gland. Therefore we might say that the inferior thyroid veins are *in* the pretracheal fascia.

As the fascia leaves the gland at the sides one portion of it blends with and helps to form the sheath of the vessels. The other or deeper portion continues around the pharynx and oesophagus, forming the buccopharyngeal fascia. In freeing the gland and its capsule from the overlying pretracheal fascia care must be taken, as pointed out by James Berry ("Diseases of the Thyroid Gland," p. 269), not to be led by this fascia too far posteriorly and therefore wound, as has been done, the pharynx or trachea.

The veins of the gland are more prominent and dangerous than the arteries. They ramify beneath the capsule and as long as the capsule is not torn the bleeding is slight. The *arteries* of the thyroid gland are the superior and inferior thyroids and sometimes the thyroidea ima. The *superior thyroid* comes off the external



carotid just above the bifurcation. It rises almost to the greater horn of the hyoid bone and then descends to the thyroid gland, which reaches to the level of the oblique line on the thyroid cartilage; it supplies the upper portion of the gland, particularly the anterior portion, but also sends a branch down the posterior surface. The vessels crossing the median line, contrary to what is often the case in the arteries of the lip and even the scalp, are very small. The superior thyroid is superficial and presents no special difficulty in ligation. The vein runs beneath it on its course to the internal jugular. The *inferior thyroid* artery, a branch of the thyroid axis, crosses behind the common carotid artery about the level of the seventh cervical vertebra, about on a line with the lower edge of the isthmus. It enters the gland from the side and not from below and ramifies on its posterior surface often as a single large trunk beneath the capsule giving off branches to the parenchyma. Usually it is in front of the recurrent laryngeal nerve, but the middle cervical ganglion of the sympathetic lies on it. Sometimes the artery breaks into branches before it enters the gland. In such cases the recurrent laryngeal nerve may run between these branches and so be injured in removing the gland.

The *thyroidea ima* artery when present enters the gland from below, coming up on the trachea usually from the innominate, in which case the innominate is apt to come off more to the left side and so bring the common carotid closer to the trachea than usual. It may also spring from the aorta or from the right carotid artery.

*The Veins.*—There are three sets of veins, a superior, a middle, and an inferior thyroid, and, as Kocher has pointed out, an accessory thyroid between the middle and inferior ones. The veins ramify under the capsule and form a plexus, which in goitre is much enlarged and communicates freely across the median line at the upper and lower portions of the isthmus. The *superior* and *middle thyroids* pass outward to empty into the internal jugular. Still lower is the *accessory inferior thyroid*, which may empty into the internal jugular, as do the two above it, or it may pass down, as does the inferior thyroid vein, and empty into the innominate. The *inferior thyroid vein* does not follow the artery of the same name but with its fellow of the opposite side passes directly downward in front of the trachea to empty into the innominate vein. Its importance in operations on the trachea has already been alluded to in speaking of tracheotomy.

In removing the gland the superior thyroid artery is found at the upper outer angle, the ligature should be placed sufficiently far out to include the branch to the posterior surface of the gland. In ligating the inferior thyroid arteries they are to be sought at the lower portion of the sides of the gland and are to be ligated either close to the gland or isolated by pulling the carotid artery outward, and tied as they make the bend at the edge of the anterior scalene muscle. Between these two points lies the recurrent laryngeal nerve, usually behind the artery. Halsted advises that each separate branch be ligated as it enters the gland to avoid those supplying the parathyroids. The gland is covered by the omohyoid, sternohyoid, and sternothyroid muscles. If these cannot be drawn aside they should be divided near their upper ends in the same manner as already advised in the case of division of the sternomastoid in removing tuberculous nodes. The sternomastoid muscle will have to be drawn outward.

The internal jugular vein often overlaps the common carotid artery, reaching sometimes even to its inner side, so that the position of the artery is not a sure guide to the location of this vein.

When a goitre dips behind the sternum the presence of the left innominate vein should not be forgotten.

### THE PARATHYROID BODIES.

The parathyroid bodies are usually four in number, but rarely there may be five or six. They are 6 to 7 mm. long, 3 to 4 mm. broad, and 1.5 to 2 mm. thick. The most constant site of the superior parathyroid is at the middle or junction of the upper and middle thirds of the posterior edge of the thyroid gland opposite the cricoid cartilage. The lower parathyroid is near the lower pole, but may be below it. They are small brownish bodies in the meshes of the loose connective tissue forming the outer capsule of the gland. Often they are quite distinct from the gland, but sometimes



they lie in a cleft in the gland and thereby escape recognition. They possess a separate capsule. They are supplied by a separate artery, the parathyroid, a branch of the inferior thyroid. This latter usually gives off two parathyroid arteries, one to each body. Ginsburg (*Univ. Penna. Med. Bulletin*, Jan., 1908) has demonstrated a free anastomosis with the vessels of the opposite side. In many cases it is practically impossible to avoid wounding or removing the parathyroids in operations—Halsted has suggested three means of avoiding their removal, viz.: (1) slice off and leave the piece of thyroid gland supposed to contain the parathyroids; (2) ligate the superior

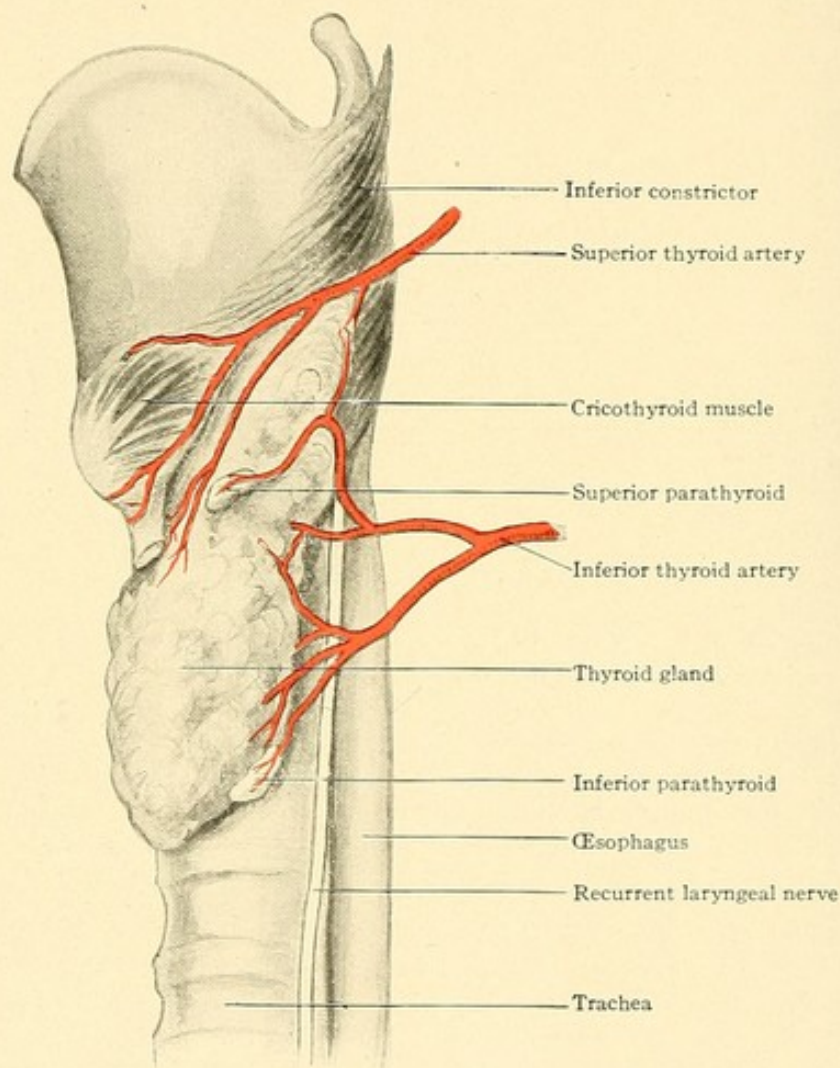


FIG. 185.—Showing the parathyroid bodies.

and inferior thyroids, and a week or two later perform a subcapsular enucleation of the thyroid; (3) search for each parathyroid by following out the ramifications of the inferior thyroid artery—this is the best method of finding them in post-mortem examinations.

#### ÆSOPHAGUS—CERVICAL PORTION.

The œsophagus runs from the level of the cricoid cartilage to the stomach. The cricoid is opposite the sixth cervical vertebra and the cardiac or œsophageal end of the stomach is opposite the lower border of the tenth thoracic vertebra. It is in the median line above, then curves slightly to the left until the root of the neck is reached, when it returns to the median line opposite the fifth thoracic vertebra.

It is in front of the spine and the prevertebral fascia. The layer of fascia between its anterior surface and the trachea is extremely thin. On each side are the common carotid arteries and the sheath of the vessels. The right recurrent laryngeal nerve winds around the commencement of the first portion of the subclavian, and passes



inward and upward behind the common carotid artery to reach the groove between the trachea and œsophagus in which it ascends to the larynx.

On the left side the recurrent laryngeal nerve winds around the arch of the aorta and ascends in the groove on the left side between the trachea and œsophagus. The left carotid artery is closer to the œsophagus than the right. The narrowest point of the lumen is at the cricoid cartilage. Its next narrow point is where it crosses the aorta and left bronchus. This is opposite the upper part of the second piece of the sternum or the upper border of the fifth thoracic vertebra. The third narrow portion is the cardiac opening into the stomach. Mouton (Tillaux, "Anat. Topograph.," p. 418) gives the diameter of the œsophagus at each of these three points as 14 mm.

**Foreign Bodies.**—Foreign bodies if they pass the cricoid cartilage are most liable to stop at the aorta and the left bronchus. This is opposite the angle of Ludwig

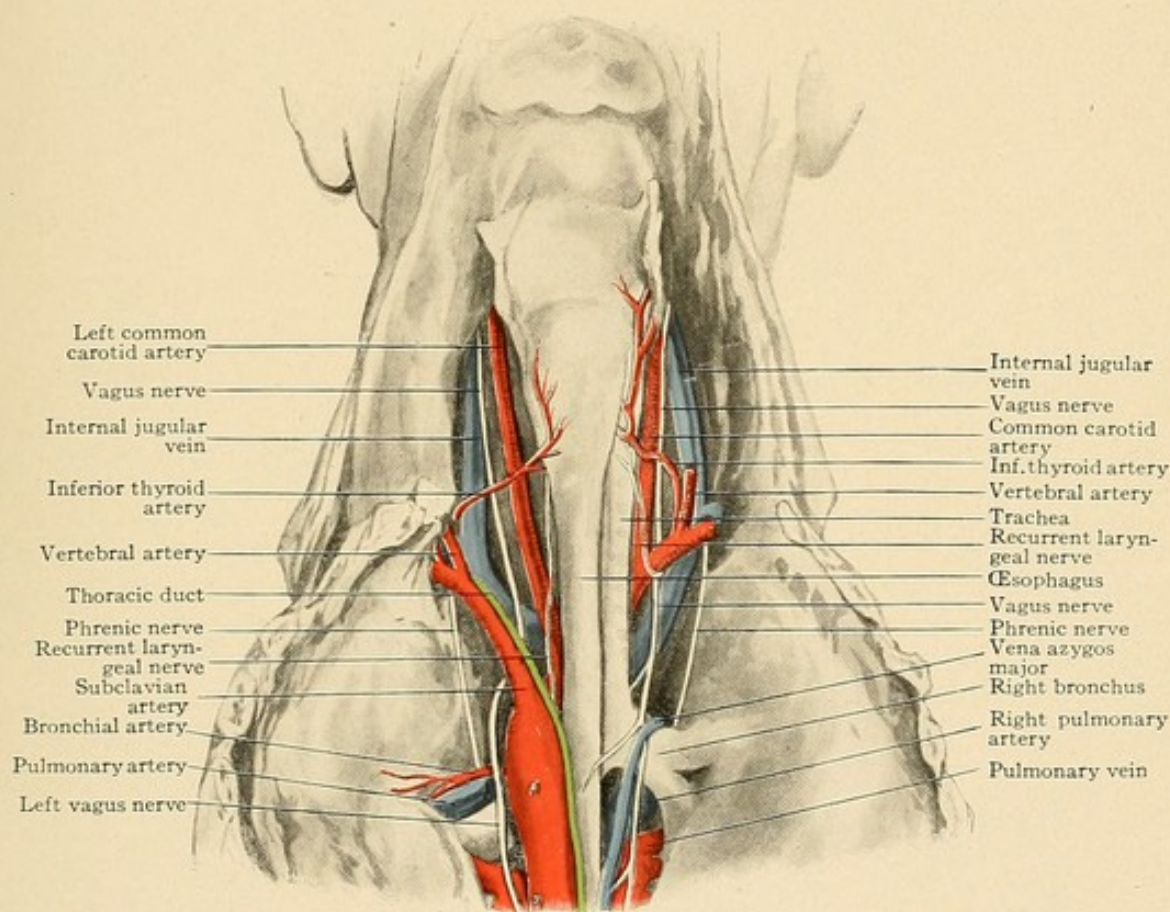


FIG. 186.—Relations of the cervical portion of the œsophagus, viewed posteriorly.

and the second rib, so that the foreign body is either at the root of the neck or just below the top of the sternum. If it passes the two upper constrictions it will probably pass the third, because the cardiac constriction is caused by the diaphragm, which relaxes and allows the body to enter the stomach.

**Œsophagotomy.**—In operating, an incision is made along the anterior border of the left sternomastoid muscle from the sternoclavicular joint upward. The anterior jugular vein will be cut. After opening the deep fascia the sternomastoid is to be pulled outward. The omohyoid is to be drawn up and out and also the lower portion of the sternohyoid and perhaps the sternothyroid.

The middle thyroid and perhaps an accessory thyroid vein are divided and the thyroid gland and trachea drawn inward. The trachea is to be identified by the sense of touch. The inferior thyroid artery is behind the sheath of the vessels and is so high that it is not likely to be injured. The recurrent laryngeal nerve must be looked for between the œsophagus and trachea, and avoided. In going deep down care must be taken not to injure the innominate vein, which comes well up towards the top of the sternum.



## CUT THROAT.

The most frequent site of the incision in cases of cut throat is between the hyoid bone and thyroid cartilage. *If above the hyoid bone*, the incision will divide the mylohyoid, geniohyoid, geniohyoglossus, and hyoglossus muscles, and perhaps the digastric and stylohyoid. If it goes far back it may wound the submaxillary gland or duct, the facial or lingual arteries and veins, and the hypoglossal nerve. The commencement of the anterior jugular will certainly be divided and the external jugular may also be wounded. The cut passes through the base of the tongue and the upper portion of the epiglottis. The tip of the epiglottis is sometimes entirely cut off. *If in the thyrohyoid space*, the incision passes a short distance above the vocal cords. The sternohyoid, omohyoid, and thyrohyoid muscles are divided. If prolonged backward the pharynx will be opened and perhaps the arytenoid cartilages wounded. The superior thyroid artery is likely to be cut. This is the vessel most often divided in suicidal wounds. The carotid arteries and internal jugular veins are deep and far back, lying under the edge of the sternomastoid muscle, and are rarely wounded.

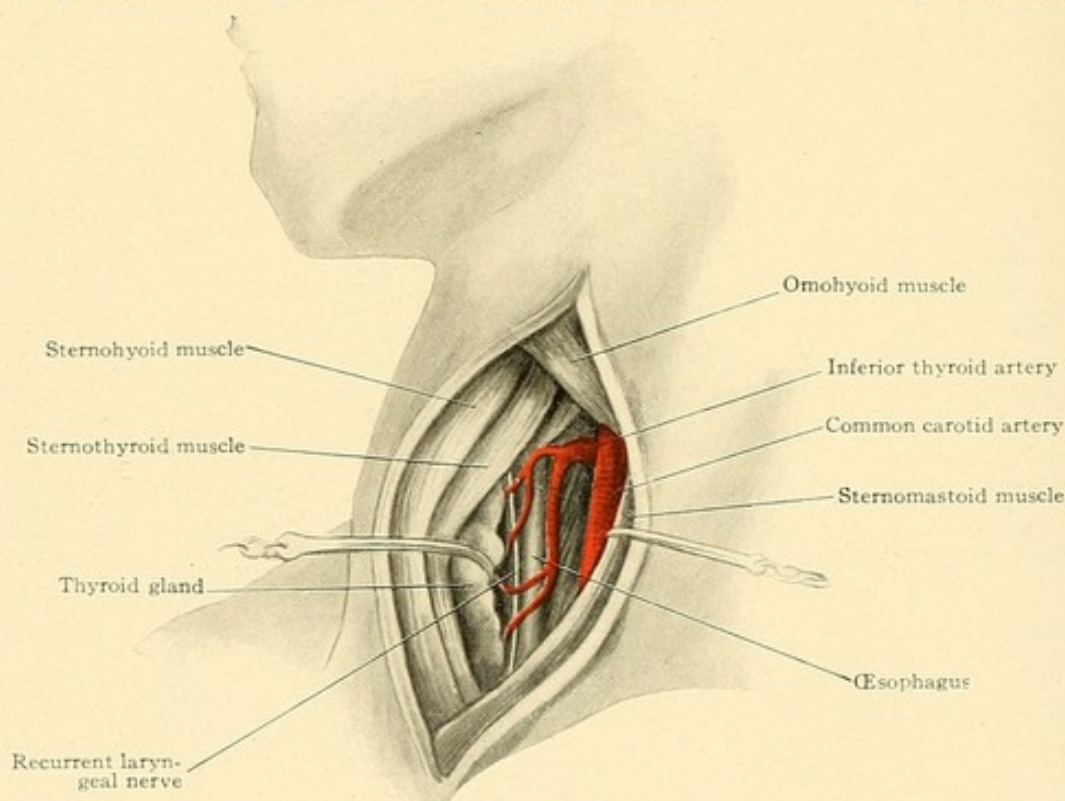


FIG. 187.—Exposing the œsophagus.

If these are cut, death usually rapidly ensues from hemorrhage. The superior laryngeal nerve may be injured as it pierces the thyrohyoid membrane. This nerve is sensory and its division is followed by anæsthesia of that half of the larynx to which it is distributed. This favors the entrance of food and liquids into the larynx and so may cause a fatal septic pneumonia. *If through the thyroid cartilage* the incision may wound the vocal cords. They lie just beneath the most prominent part of the thyroid cartilage and just below its median notch. *If through the trachea*, the incision may wound the thyroid gland, which reaches from about the sixth ring of the trachea to the oblique line on the thyroid cartilage.

Bleeding from the wounded thyroid, if the gland is normal in size, is not likely to be excessive. Below the cricoid cartilage the œsophagus may be wounded, above it the pharynx may be opened. The two large sternomastoid muscles being put on the stretch tend to protect the large vessels beneath. Suppuration not infrequently accompanies these wounds of the neck in which the air and food passages are involved and may give rise to collections of pus which may travel between the fascias, as previously described. In treatment it is customary to cleanse the wounds and approximate the various injured tissues as carefully as possible, and feed by a stomach tube.



## AFFECTIONS OF THE NECK.

**Cervical Cysts and Fistulæ.**—The neck is the seat of some very peculiar cystic tumors and fistulæ which are connected with developmental defects. They

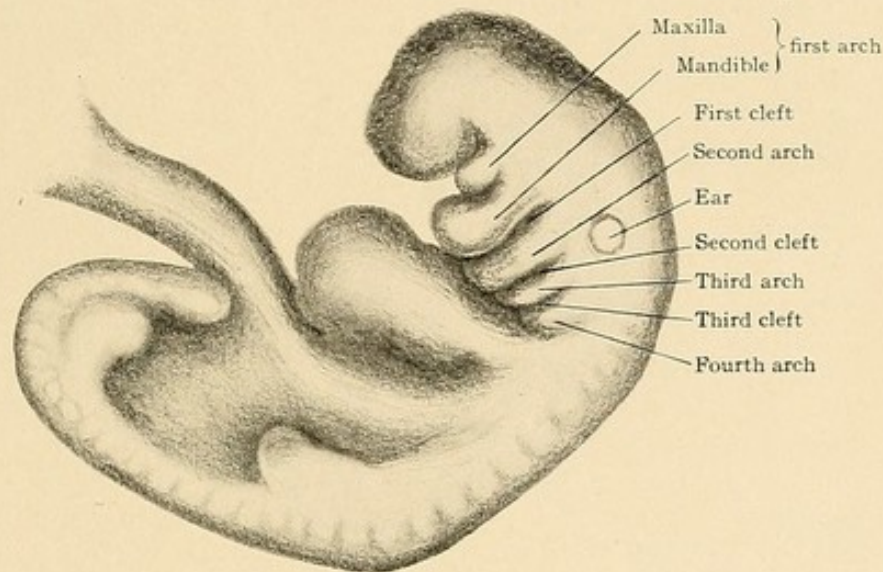


FIG. 188.—Fœtus, 25th day (after His). Showing branchial (visceral) arches and clefts or furrows.

are either lateral or median in location. The lateral originate from the visceral (branchial) clefts, while the median are connected with the thyroglossal duct. The visceral clefts are depressions between the visceral arches. These arches, five in number, spring forward from each side of the embryo to form the neck region. Sometimes these arches are called branchial arches from the fact of their going to form the branchiæ or gills of fishes and some of the other lower orders of animals.

The *first visceral arch* divides into two parts, a maxillary part forming the upper jaw and a mandibular part forming the lower jaw. Defects in the maxillary arch producing harelip and cleft palate have already been described. Two of the ear bones, the incus and malleus, are also formed by the mandibular portion of the first visceral arch.

The *second visceral arch* forms the stapes, the styloid process, the stylohyoid ligament, and the lesser horn of the hyoid bone.

The *third visceral arch* becomes the body and greater horn of the hyoid bone.

The *fourth and fifth visceral arches* blend and form the soft structures of the side of the neck.

The *first visceral cleft*, called the hyomandibular cleft from its being between the hyoid bone and the mandible, forms the middle ear and Eustachian tubes from its inner portion and the external auditory meatus from its outer portion. The membrana tympani is the remains of the membrane which stretched across from one arch to the other. Cervical fistulæ are formed by the persistence of a visceral cleft. As the first visceral cleft persists normally in the structures already named, it

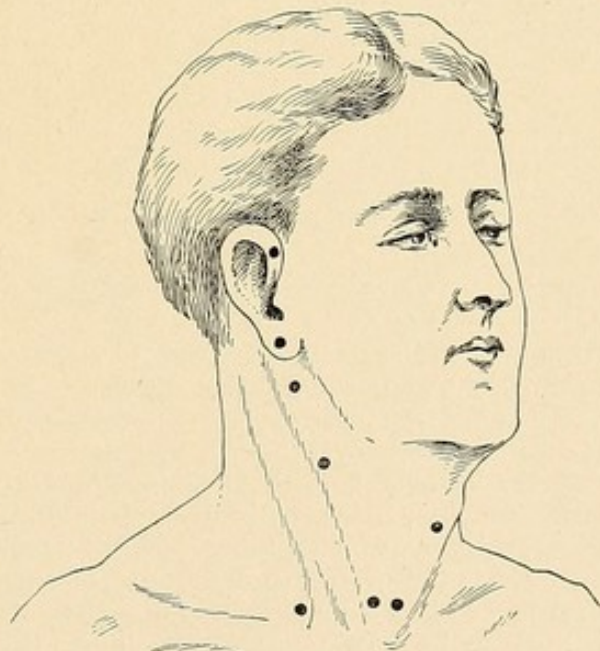


FIG. 189.—Points of opening of sinuses originating from the thyroglossal duct and branchial clefts. (Modified from Sutton.)



in itself does not form pathological fistulæ, but congenital fistulæ are sometimes encountered in the external ear which are the remains of the clefts between the tubercles of which the ear is formed.

**Cervical fistulæ** or sinuses may extend either completely through, from the surface to the pharynx, or may open internally or externally, or be closed at both ends, in which last case the contents accumulate and form a cervical cyst.

*Fistulæ arising from the second visceral cleft* open externally opposite the thyrohyoid space in front of the sternomastoid muscle. Internally they open into the recess holding the tonsil.

*Fistulæ arising from the third and fourth visceral clefts* open externally lower down nearer the sternoclavicular articulation in front of the sternomastoid muscle and internally in the sinus pyriformis. The persistence of the third and fourth visceral clefts internally may produce pharyngeal diverticula, as already noted in discussing that region.

In attempting the cure of cysts and fistulæ due to persistence of the

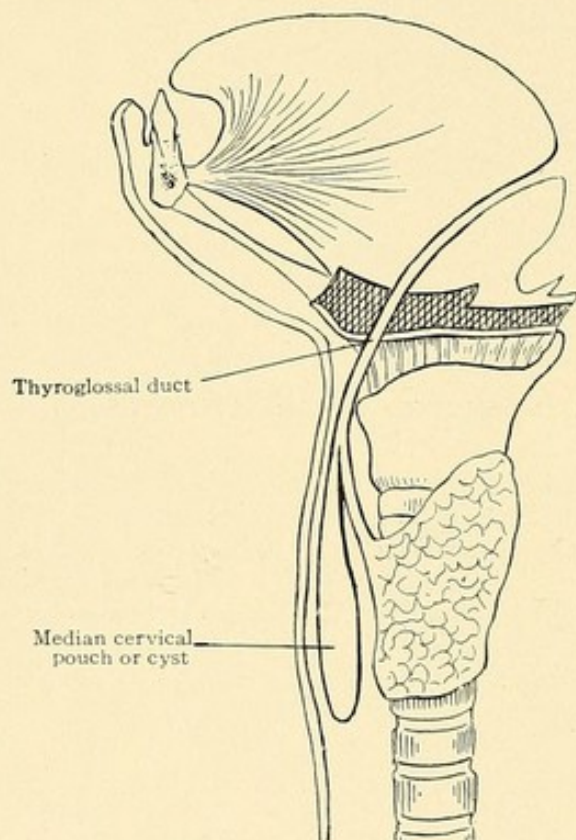


FIG. 190.—Median cervical pouch or cyst arising from the thyroglossal duct.—Marshall's case.

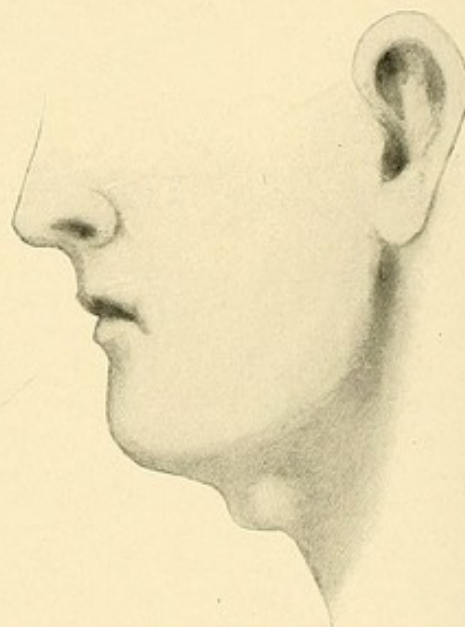

FIG. 191.—Median cervical (thyroglossal) cyst.—Author's case.

visceral clefts it is evident that as they are lined with a secreting epithelium this must be destroyed or removed, or a recurrence will take place. In attempting to dissect them out one must be prepared to follow them through the structures of the neck to the pharynx inside. It is needless to say this may be a serious procedure.

Hueter (quoted by Sutton) followed one between the two carotid arteries into the pharynx. These cysts and fistulæ may be noted at birth or may develop later in life.

**Hydrocele of the Neck.**—There are other cystic tumors of the neck which are congenital, being noticed at birth, and which grow to a large size. They are often wide-spread, extending not only between the tissues of the neck below the deep fascia but even into the axilla. Their walls are thin, consisting sometimes only of a layer of lining epithelium and the surrounding tissues. On this account it is impossible to dissect them out. The use of injections and setons has been abandoned as too dangerous. They rarely require treatment, as they tend to disappear spontaneously. Mr. J. Bland Sutton ascribes their origin *first* to congenitally dilated lymph-spaces; *second* as resembling the cervical air-sacs that exist in the howling monkeys; and *third* that possibly some of them may be related to a persistence of some portion of a branchial cleft.

**Median cervical fistulæ and cysts** originate in connection with the thyroglossal duct. This, in the embryo, leads from the foramen cæcum at the root of the



tongue through to the posterior surface of the hyoid bone and thence downward and forward to the isthmus of the thyroid gland. It begins to atrophy in the fifth week and is obliterated by the eighth. According to Sutton these cysts are never congenital but occur soon after birth or as late as the fourteenth year. They appear as rounded, cystic tumors just below the hyoid bone or over the thyroid cartilage. They either inflame and break of their own accord, discharging externally, or are opened by the surgeon and, contrary to what is the case in hydroceles of the neck, never tend to disappear, but a sinus remains. At times it almost heals, then the contents accumulate and a cyst forms, this again breaks and a sinus results as before. In attempting a cure by operation the sinus should be followed up behind the hyoid bone. In one case after two failures of attempted excision a cure was obtained by destroying the tract by introducing a small galvanocautery point. Unless every portion of the lining membrane be completely destroyed the cells will go on secreting and reproduce, in a short time, the original condition. Failure to cure these sinuses and cysts by excision often occurs, notwithstanding the exercise of the greatest care.

The lower portion of the thyroglossal duct may persist in the form of the pyramid or third lobe of the thyroid gland, which arises from the isthmus or from the left side and ascends as far as the hyoid bone, to which it is attached.

## THE THORAX.

The thorax or chest is that portion of the trunk which lies between the neck and the abdomen. It is composed of a bony framework reinforced by soft parts, and contains the main organs of circulation and respiration. The œsophagus, an organ of the digestive tract, simply passes through it to the regions below. The chest-walls as well as the parts contained within them are affected by wounds and disease, especially the heart and its associated great vessels, and the lungs and pleuræ. These organs are essential to life, like the brain and spinal cord, and like them, are encased in a bony framework. It is an example of bones performing a protecting function in addition to a supporting one.

The functions of the heart and lungs are influenced by constitutional diseases in addition to their own local affections, hence they serve as guides to the general bodily condition, and the condition of the respiration and circulation is continually being examined for the purposes of diagnosis, prognosis, and treatment, even when the heart and lungs themselves are not involved. To make these examinations intelligently, necessitates a knowledge of the organs themselves and their relation to one another and the surrounding parts. This is essential for the physician even more than the surgeon.

The **chest-walls** are composed of a bony framework joined and bound together and covered by soft parts.

The **bones** of the chest consist of the *sternum*, *ribs*, and *thoracic vertebræ*. The clavicle and scapula compose the shoulder-girdle and belong to the upper extremity. The human skeleton is divided into an axial portion and an appendicular portion. The axial portion embraces the skull, the vertebral column, including the sacrum and coccyx, the hyoid bone, the sternum, and the ribs. The appendicular portion consists of the shoulder-girdles and upper extremities and the pelvic girdles and lower extremities.

The bony chest is subject to disease and injury as well as to defects in development, and to deformities due to these causes.

**Shape of the Chest.**—The chest is conical in shape, being small above and large below. In transverse section it is kidney-shaped, the hilus of the kidney being represented by the vertebræ. In the fœtus the anteroposterior diameter is greater than the transverse, thus resembling the thorax in the lower animals. After birth and in infancy the two diameters are nearly equal, hence we have the rounded chest of the child. As growth and development progress the transverse diameter increases more than the anteroposterior, so that at about the second year the chest has become oval and in adults the transverse diameter is one-fourth greater than is the anteroposterior.

Variations in the shape of the chest are mainly the result of disease. In childhood, rachitic disease (rickets) produces a lateral flattening and a projection of the



sternum. If the sternum projects markedly it constitutes what is known as *pigeon breast*, the chest in such a condition being longer from before backward than from side to side. In this disease also there may be a depression on each side of the sternum,

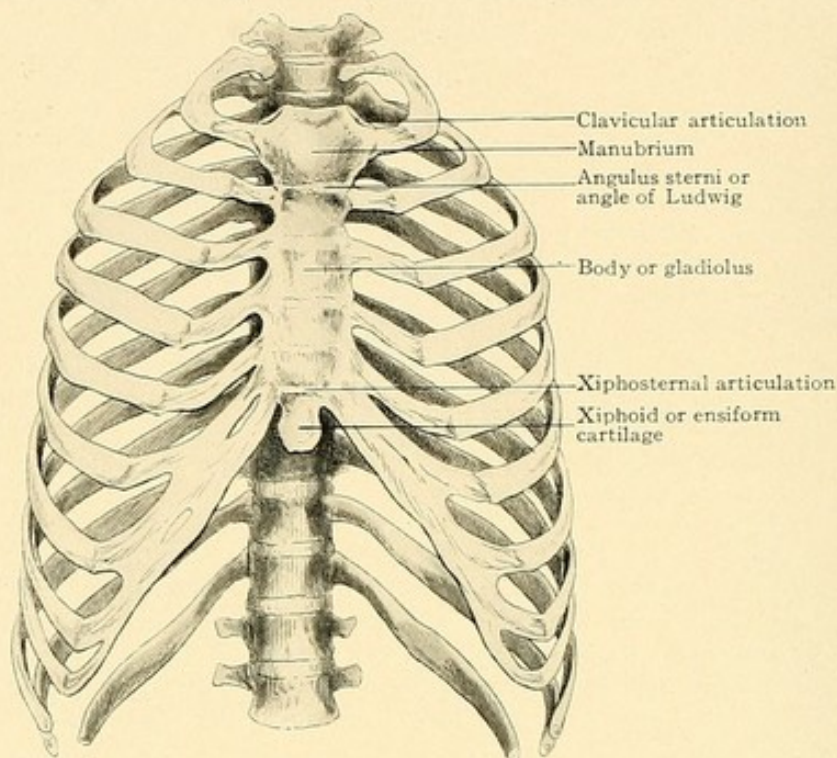


FIG. 192.—The bony thorax.

the back is rounded owing to the bending of the vertebral column, and the points of junction of the ribs and cartilages are enlarged, this latter constituting what is known

as *beading of the ribs*. These beads are felt as rounded enlargements at the sternal extremities of the ribs and form a line parallel to the sternum above and sloping outward below. This line of beads has been called the "*rachitic rosary*." From the level of the ensiform cartilage a groove passes out toward the sides; this has been called "*Harrison's groove*" (see Fig. 193). Sometimes the lower end of the sternum is pressed inward, forming a deep funnel-shaped depression constituting the deformity known as "*funnel chest*" or the "*Trichterbrust*" of the Germans.

This condition of the chest, with the exception of the beading, is also produced in children by obstruction to the breathing from enlargement of the tonsils, from the presence of adenoid growths in the pharynx, and from hypertrophy of the turbinate bones, all of which interfere particularly with nasal respiration.

Diseases of the lungs and pleuræ alter the shape of the chest. In emphysema and when distended by plural effusions, the thorax becomes more rounded in shape, forming what is called the "*barrel-shaped*



FIG. 193.—Child showing Harrison's groove opposite the ensiform cartilage.

*chest*." In phthisis the wasting of the tissues and contraction of the lungs causes the chest to collapse. The ribs slope more sharply downward and the chest becomes



longer and flatter, the anteroposterior diameter being diminished. The angle made by the lower ribs as they ascend to the sternum is called the *costal angle*; this becomes decreased in phthisis. This form of chest is known as the "*phthisical chest*."

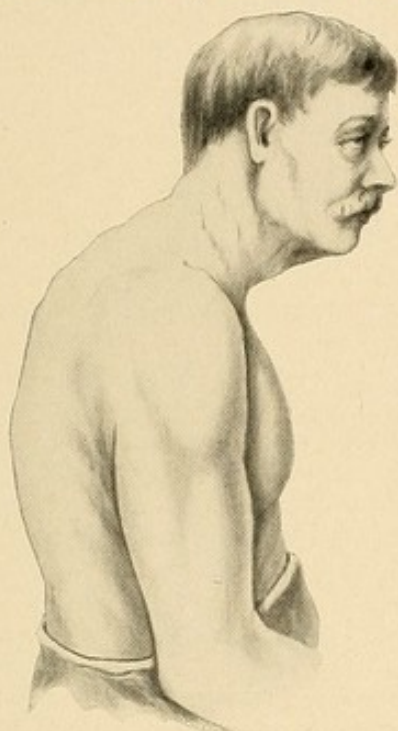


FIG. 194.—Barrel chest of emphysema.

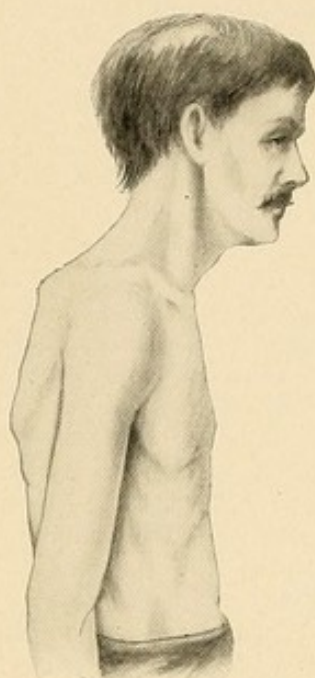


FIG. 195.—Flat chest of phthisis.

When the flatness is marked it is sometimes called the "*flat chest*." When the scapulæ project like wings it is called "*alar*" or "*pterygoid chest*."

In *Pott's disease*, or caries of the spine, as the kyphosis develops the chest falls for-

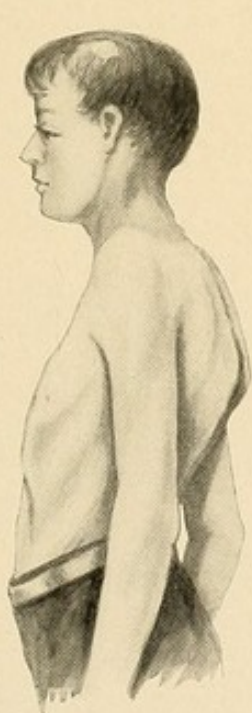


FIG. 196.—Kyphosis from Pott's disease, or caries of the lower thoracic vertebræ. The curvature is an angular anteroposterior one.

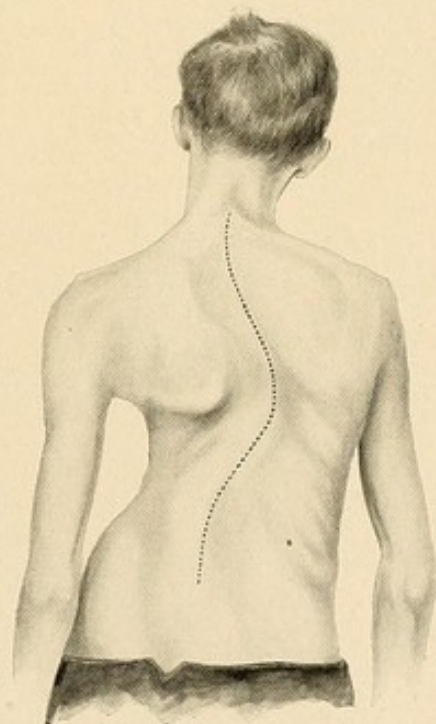


FIG. 197.—Scoliosis, or lateral curvature of the spine.

ward and its anteroposterior diameter is increased. The abdominal contents are crowded up into the chest and push the sternum and lower ribs forward. Associated with this deformity is oftentimes a lateral deviation of the parts above the site of the disease.



In *scoliosis*, or *lateral curvature* of the spine, the distortion is uneven, being a compression of the thorax from above downward and a twisting around a vertical axis. The deformity is frequently so severe as to cause the lower ribs to rest on the iliac crests. It is in order to detect these diseases in their early stages that a knowledge of the shape of the normal chest is so essential.

### THE STERNUM.

The sternum consists of three pieces: the *manubrium* or *presternum*, *gladiolus* or *mesosternum*, and *xiphoid cartilage* or *metasternum*. It is developed in two lateral halves. Should these fail to unite an opening is left in the bone through which the pulsations of the heart have been seen and felt. The junction of the first and second pieces of the sternum is opposite the second rib. The seventh is the last rib to articulate with the sternum directly.

The first and second pieces of the sternum are connected by a joint which persists to advanced age. The projection caused by this joint is called the *angulus sterni* or *angle of Ludwig*. Fractures pass either through this joint, opposite the second rib, or through the bone just below it. They are produced by both direct and indirect force. Usually the upper fragment is beneath the lower one. It is however more true to state that the lower fragment is displaced anteriorly. Any marked posterior displacement of the upper fragment would tend to press on the trachea and interfere with breathing; the trachea bifurcates opposite the joint. As the pleuræ and lungs of the two sides almost or quite touch behind the second piece of the sternum, they may be wounded and emphysema may occur. The heart also may be wounded. Suppuration has followed these injuries, in which case it will be necessary to trephine the sternum to give exit to the pus. The necessity of avoiding wounding of the pleuræ in such a procedure is evident, as it would be followed by collapse of the lung and empyema.

### THE RIBS AND COSTAL CARTILAGES.

The ribs are frequently fractured, sometimes they become affected with caries, and in operating the chest is frequently opened between them or portions of them are excised. They are both elastic and movable, and difficult to break; hence fracture is almost always due to direct violence, and this violence may be so great as sometimes to cause death. Normally there are twelve ribs on each side, but sometimes there is an extra cervical or lumbar rib. These are both rare, the latter the more so.

The seven upper ribs are called *true ribs* because they articulate with the sternum. The remaining five are called *false ribs*, the eleventh and twelfth being *floating ribs*. The eighth, ninth, and tenth ribs each articulate by their cartilages with the rib above. The tenth forms the lower margin of the thorax. The eleventh and twelfth ribs are attached only by their posterior extremities, their anterior portion being imbedded in the soft parts; hence they are called floating ribs. The ribs slope downward and forward. This obliquity increases until the ninth rib, after which it decreases. The first rib in front corresponds to the fourth behind, the second, third, fourth, fifth, sixth, and seventh in front correspond each to the fourth rib lower behind. The first rib is the nearest horizontal in regard to its surface and, being well protected by the clavicle, is rarely broken. The intercostal spaces are broader in front than behind and broader above than below. The third is the largest.

The groove on the lower surface of the ribs holds the intercostal artery, but only as far back as the angle, from which point it occupies the middle of the space.

The extent of the intercostal spaces is considerably influenced by position—flexion of the body brings the ribs together, extension and bending to the opposite side separates them. This point is of importance in reference to the operations of paracentesis and empyema.

The first costal cartilage unites directly with the sternum, there being no joint present. The second and sometimes the third cartilage is joined to the sternum by a ligament with a synovial joint above and below it. The other costal cartilages are



united by a joint with a single cavity. These joints may be the seat of metastatic abscesses in pyæmic infections.

**Cervical ribs** spring from the body and transverse process of the seventh cervical vertebra. They may be long enough to reach to the sternum, but usually are much shorter. One case of this affection was seen by the writer in a man twenty-seven years of age. There was an abnormal fulness above the scapula posteriorly, and above the clavicle anteriorly, just to the inner side of the external jugular vein, a distinct bony process could be felt. This did not move with the scapula or clavicle but did move somewhat with respiration. A skiagraph showed it to be attached to the spine. The patient was seen again five years later,

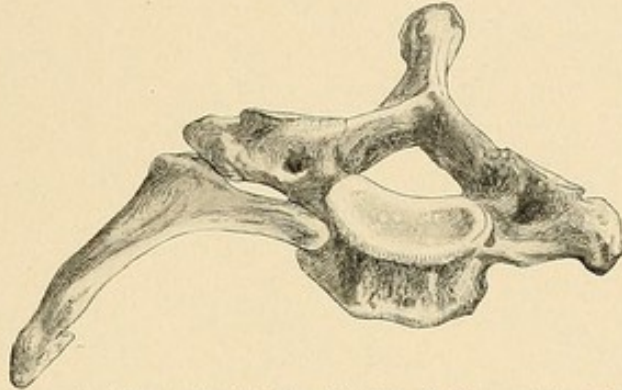


FIG. 198.—A cervical rib attached to the right side of the seventh cervical vertebra.

when the same condition of affairs existed, with the exception that movement on respiration was not so marked. A knowledge of the possible presence of a cervical rib is important in diagnosis, otherwise it may be thought to be a bony or malignant new growth and treatment advised accordingly. The subclavian artery may pass over the cervical rib above and may have its circulation seriously interfered with.

**Fracture of the Ribs.**—The ribs are almost always broken by direct violence; fractures from indirect force, as from coughing, sneezing, and other forms of muscular exertion, are rare. Fracture from compression of the chest is also rare. The site of the fracture is most frequently on the anterior portion of the chest and not the sides

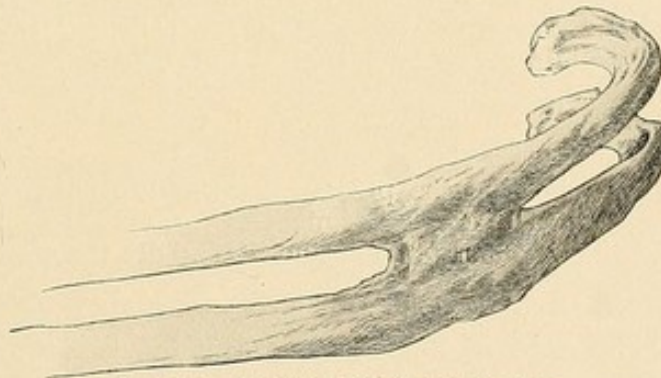


FIG. 199.—Fractured ribs; fusion of callus.

or back. The fourth, fifth, sixth, and seventh ribs are most often broken. The first rib is well protected from direct blows by the clavicle. Lane, however, has shown that it can be broken by pressure of the clavicle when the shoulder is depressed. The eleventh and twelfth, being floating ribs, are rarely broken. The twelfth rib is the least frequently so. In one case we saw the eighth, ninth, tenth, eleventh, and twelfth all broken by the passage of a wheel. The soft parts attached to the fragments prevent much displacement, but there is always some, due to the respiratory movements. Hence callus is always present and it may be so abundant as to join adjacent ribs (see Fig. 199). As already stated, death frequently follows fracture of the ribs and is due to wounding of the chest contents. Rarely the intercostal arteries may be wounded and produce hæmothorax. Wounding of the lung is frequent.



Emphysema of the surface of the body may ensue, but is not dangerous. Pneumothorax, which may be accompanied by infiltration of air into the lung tissue, is more dangerous, favoring collapse of the lung. The object of treatment is to keep the chest-walls from moving. This is accomplished by strapping the chest with adhesive plaster, which is usually laid on almost in the direction of the ribs; but as the chest moves with respiration, the ribs rising, and as they slope downward and forward, I have preferred to lay the straps on from in front downward and backward, this tends to prevent the ribs from rising in inspiration.

### THE THORACIC VERTEBRÆ.

The thoracic or dorsal vertebræ are twelve in number and are so articulated with one another as to form a single, regular curve with its concavity forwards and convexity backward. Any sudden change in the direction of the curve is an evidence of disease; this is seen in the angular curvature of Pott's disease or caries of the spine. The ribs are connected with the vertebræ by the articulation of the head of the rib with the body of the vertebra, and the tubercle of the rib with the *transverse process*. The transverse process is connected with the body by the *pedicle* and with the spinous process by the *lamina*. The spinal cord is exposed in operations by removal of the spinous process and laminae, hence the name *laminectomy*.

The spinous processes are the guides which indicate the position and condition of the vertebræ. Their tips are not covered by muscles but lie close beneath the skin and are readily felt and any abnormality detected. In the normal body the grooves on each side of the spinous processes are filled up with muscle, but in certain diseases, as in infantile paralysis and lateral curvature, they become atrophied and the spine becomes twisted, hence on the convex side of the abnormal lateral curve, to the outer side of the spines, the projection formed by the transverse processes and tubercles of the ribs can be both seen and felt.

The external curve formed by the tips of the spinous processes of the thoracic region in the normal person is not so great as is the curve formed by the anterior portion of the bodies of the thoracic vertebræ. This is because the spinous processes at the upper and lower portions of the chest project out almost at right angles to the long axis of the body, while those of the middle portion slope downward. Hence the tips of the spinous processes of the seventh cervical, first dorsal, and twelfth dorsal vertebræ are opposite the bodies of the same vertebræ, while the others are opposite the bodies of the vertebræ next below. (The spine will be considered more at length in the section devoted to the Back.)

### SOFT PARTS.

The bony thorax is lined by the pleuræ, the ribs are united to each other by the intercostal muscles, and over all are muscles, superficial fascia, and skin. In addition, in front are the mammary glands and behind are the scapulæ.

#### THE INTERCOSTAL MUSCLES AND ARTERIES.

The intercostal spaces are occupied by the two intercostal muscles, with a fascia above them, one below, and one between them.

The *external intercostal muscles* run downward and forward. They begin at the tubercles of the ribs posteriorly and end at the costal cartilages anteriorly. They are continued forward to the sternum by the anterior intercostal membrane, formed by the fusing of the outer and middle intercostal fascias. The *internal intercostal muscles* go downward and backward. They begin at the sternum and end at the angles of the ribs. They are continued to the spine by the posterior intercostal membrane, formed by the fusing of the middle and internal intercostal fascias. The *intercostal arteries* come from both anteriorly and posteriorly. The *anterior intercostals* come from the internal mammary for the upper five or six spaces and from the musculophrenic artery for the remainder. They arise either as a single trunk or as separate superior and inferior branches. At first they are between the pleura and internal intercostal muscle, but they soon perforate that



muscle and run between it and the external intercostal, the superior branch running along the lower edge of the rib and the inferior branch running along the upper edge of the rib below. The aortic or posterior intercostal arises as a single trunk which passes between the external intercostal muscle and the pleura. Arriving opposite the angle of the ribs it divides into superior and inferior branches which unite with those from the internal mammary (*arteria mammaria interna*).

From the vertebræ out to the angle of the ribs the intercostal artery lies about midway between the ribs, hence it is liable to be wounded in paracentesis if the puncture is made too far back. It is for this reason that operations for draining the pleuræ are performed anterior to the costal angles. The superior intercostal branches are larger than the inferior ones. They run under the lower edge of the rib above the space and are therefore protected from injury, particularly stab-wounds.

In opening the chest for empyema it is best to go about midway in the intercostal space and not too close to the lower edge of the rib on account of the liability of wounding the superior intercostal. The inferior branch is usually quite small and causes no serious hemorrhage. Intercostal bleeding may cause a hæmothorax if the wound is

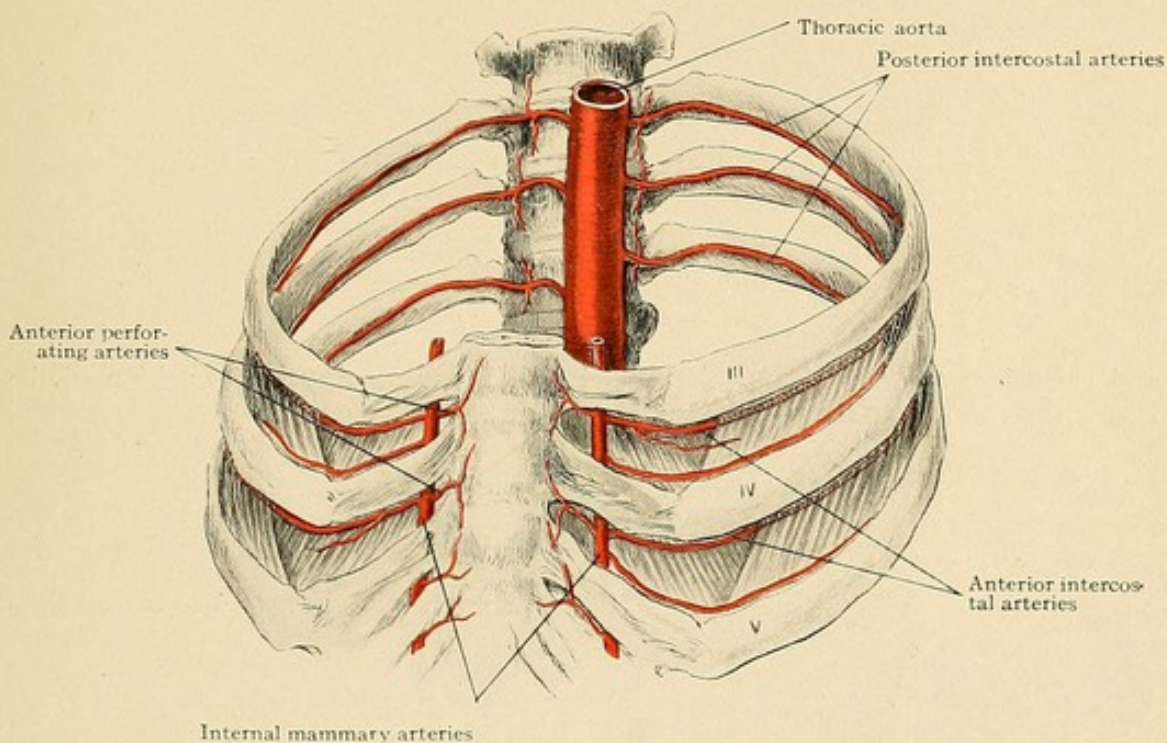


FIG. 200.—Course and distribution of the intercostal arteries.

small. It may be controlled, if the vessel is cut in performing the operation of paracentesis for empyema, by clamping with hæmostatic forceps. If these are allowed to remain on a few minutes the bleeding often does not recur on their removal. If desired a ligature can be applied. If it is undesirable to rely on the clamp or ligature then the wound may be firmly packed with gauze or a piece of gauze may be depressed through the wound into the pleural cavity and then stuffed with more gauze, after which the tampon so formed is pulled firmly outward against the bleeding tissues.

#### MUSCLES.

Covering the chest anteriorly are the *pectoralis major* and *pectoralis minor* muscles. The *serratus anterior* (*magnus*) winds around its side and posteriorly, above is the *trapezius* and below the *latissimus dorsi*. Beneath them are the *erector spinæ* (*sacrospinalis*) muscles on each side of the spinous processes.

The *pectoralis major* muscle arises from the sternal half of the clavicle, from the sternum and costal cartilages as low as the sixth or seventh rib, and from the



aponeurosis of the external oblique muscle and sheath of the rectus muscle. It inserts into the outer lip of the bicipital groove. It is to be noted in regard to this muscle that it is attached only to the inner half of the clavicle and that the clavicular

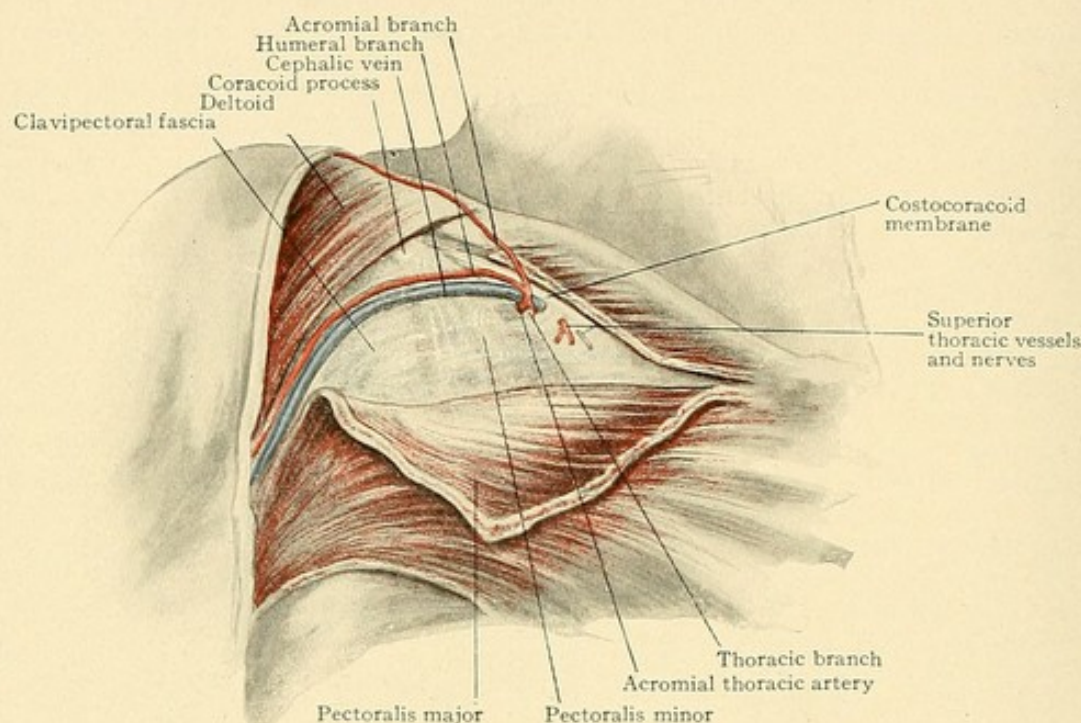


FIG. 201.—The clavipectoral fascia.

and sternal parts are separated by a cleft. When removing it in excision of the breast for carcinoma one separates the muscle by passing through this cleft and detaching the part below. It forms the anterior fold of the axilla and by following this fold to the chest-wall it leads to the fifth rib, as it is at that rib that the muscle leaves the chest-wall.

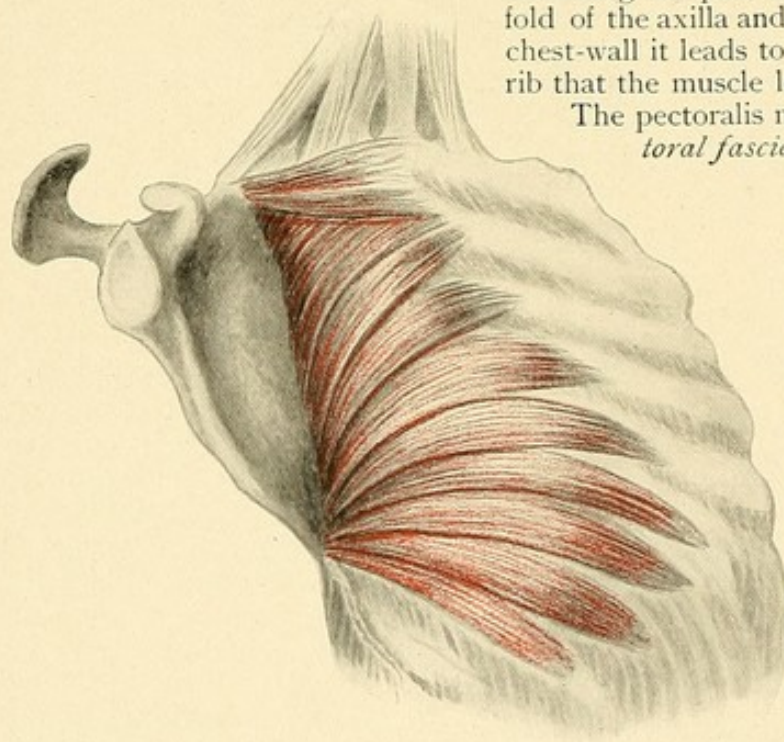


FIG. 202.—The serratus anterior muscle arising by ten digitations from the nine upper ribs.

The pectoralis major is covered by the *pectoral fascia*. When in removal of the female breast for nonmalignant growths the breast is raised, the muscle beneath is seen to be covered with a thin fascia continuous with the fascia of the axilla. Beneath the pectoralis major is the *clavipectoral fascia* continuous with the costocoracoid membrane above and the axillary fascia at the sides.

The **pectoralis minor** passes from the third, fourth, and fifth ribs to the coracoid process. Its origin is well forward toward the anterior extremities of the ribs and, as it is not attached so low on the chest as is the pectoralis

major, it is hidden by the latter and does not aid in forming the anterior axillary fold. This muscle is frequently removed in operations for carcinoma of the mammary gland.



The **serratus anterior (magnus)** muscle (Fig. 202) passes from the side of the chest to the vertebral or posterior border of the scapula, arising by nine or ten digitations from the eight or nine upper ribs, the second having two. The slip arising from the sixth rib is the one most prominently seen on raising the arm away from the side, it passes the farthest forward. The slips into the fifth, seventh, and eighth ribs may also be seen. This muscle passes across the axilla from in front backward,

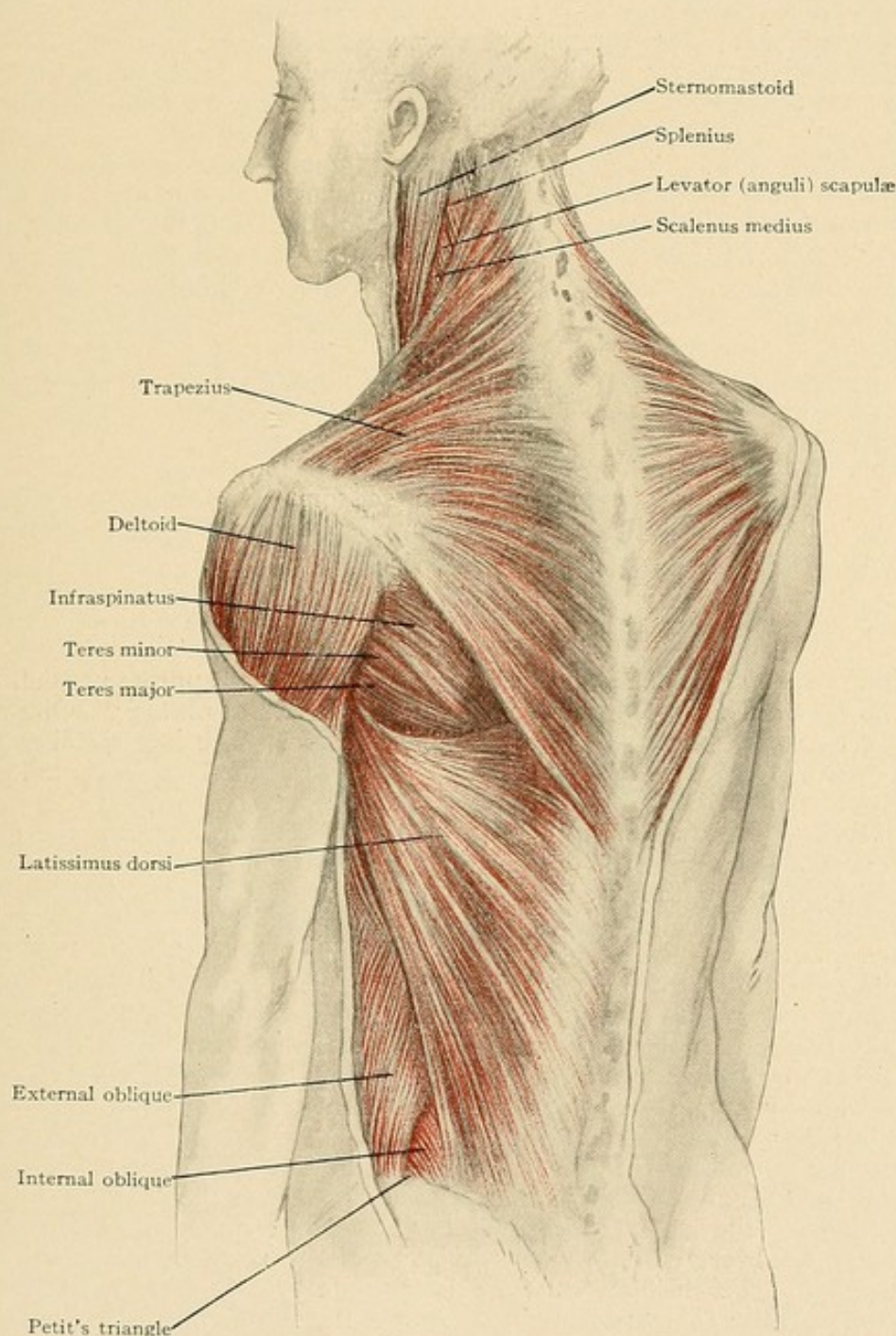


FIG. 203.—Muscles of the back.

lying on the chest-wall. It is supplied by the *posterior thoracic nerve* from the fifth, sixth, and seventh cervicals. This nerve is also called the *long external respiratory nerve of Bell*. The *internal respiratory nerve* is the *phrenic*, which comes from the third, fourth, and fifth cervical nerves. One of the main functions of this muscle is to keep the scapula applied to the chest and to aid in rotating it in elevation



of the arm. When it is paralyzed the arm cannot be raised beyond a right angle and the scapula projects, particularly at its lower angle and posterior edge. This condition is called "*winged scapula*."

The **trapezius** muscle (Fig. 203) has the shape of a triangle, its apex being out on the acromion process and its base in the median line. It arises posteriorly from the inner third of the superior curved line of the occiput, the occipital protuberance, ligamentum nuchæ, and the spines of the seventh cervical and all the thoracic vertebræ.

It inserts into the outer third of the clavicle and the acromion and spinous processes of the scapula. It aids in rotating the scapula and elevating the shoulder; its paralysis is followed by marked dropping of the shoulder. It is supplied by the *spinal accessory nerve*, which is sometimes injured in operations for tumors involving the posterior cervical triangle.

The **latissimus dorsi** muscle arises from the spinous processes of the lower six thoracic vertebræ, from the posterior layer of the lumbar fascia, the outer lip of the posterior third of the iliac crest and by digitations from the lower three or four ribs. Sometimes it is attached to the angle of the scapula. It unites with the tendon of the *teres major* muscle to be inserted into the bottom of the bicipital groove and extends somewhat higher than the tendon of the *pectoralis major*. A bursa, which may become inflamed, sometimes lies between the muscle and the inferior angle of the scapula. The *latissimus dorsi* and *teres major* muscles form the posterior axillary fold.

The **erector spinæ** (*sacrospinalis*) muscle fills up the hollows on each side of the spinous processes. As the various muscular bundles are inserted into the vertebræ by innumerable small tendinous slips, in exposing the vertebræ in performing laminectomy it is necessary to cut them with a knife or scissors. One should not attempt to separate them by blunt dissection. These muscles become atrophied in cases in which the spine becomes distorted.

### SURFACE ANATOMY OF THE THORAX.

On looking at the chest one should note whether or not it appears normal. It may show the rounded form of emphysema or the flat form of phthisis. One side may be larger than the other, suggesting pleural effusion. The intercostal spaces may be obliterated, indicating the same condition. This may be local instead of over the whole chest. Note whether Harrison's groove, funnel and pigeon breast, or beading of the ribs, already described, are present. Aneurism affecting the great vessels may cause a bulging in the upper anterior portion, and cardiac disease may produce marked changes in the apex beat. This may be displaced to the right side by pleural effusion.

The clavicle belongs to the shoulder-girdle and hence will be described with the upper extremity. Both it and the sternum are subcutaneous and can readily be felt beneath the skin. The point of junction of the first and second pieces of the sternum is opposite the second costal cartilage. It forms a distinct prominence, which is readily felt and is a most valuable landmark. It is called the *angulus sterni* or *angle of Ludwig*. There is usually a palpable depression at the junction of the second piece of the sternum and xiphoid cartilage.

The tip of the xiphoid or ensiform cartilage can be felt about 4 cm. below the joint between it and the second piece of the sternum. The top of the sternum is opposite the lower edge of the second thoracic vertebra. The *angulus sterni* is opposite the fifth vertebra, the lower end of the second piece of the sternum is opposite the tenth, and the tip of the ensiform cartilage is opposite the eleventh thoracic vertebra. There is usually comparatively little fat over the sternum, so that in fat and muscular people its level is below that of the chest on each side. Above its upper end is the *suprasternal notch or depression*, below its lower end is the *infrasternal depression* or *epigastric fossa*, sometimes called the *scrobiculus cordis*.

With the upper end of the sternum articulate the clavicles. The sternoclavicular joint possesses an interarticular cartilage between the clavicle and the sternum. This separates them sufficiently to allow the formation of a distinct depression, which can readily be felt. From the sternum to the acromion process the clavicle is subcutaneous. Below the inner end of the clavicle the first rib can be often seen and felt. At



the middle of the clavicle it is so deep from the surface as not to be accessible and here the second rib is the one which shows just below the clavicle. In children the point of junction of the cartilages and ribs can often be distinguished; this is particularly so in cases of rachitis.

The line of junction between the body of the sternum and the ensiform cartilage can be distinguished, and to each side of it is felt the cartilage of the seventh rib, the last that articulates with the sternum. The tenth rib is the lowest which is attached anteriorly, the eleventh and twelfth being shorter and floating ribs. The intercostal spaces are wider anteriorly than posteriorly and the third is the widest.

The nipple is usually in the fourth interspace or on the lower border of the fourth rib and on a line a little to the outer side of the middle of the clavicle. In women its position is variable, owing to the breasts being pendulous. The mammary gland reaches from the third to the seventh rib. As the pectoralis major muscle does not arise lower than the sixth rib it is seen that the mammary gland projects beyond it, an important fact to be remembered in operations for removal of the breast.

Immediately to the outer side of the upper edge of the pectoralis major, beginning at the middle of the clavicle and below it, is a hollow. This is the interval between the pectoralis major and deltoid muscles. At its upper end it is equal in width to one-

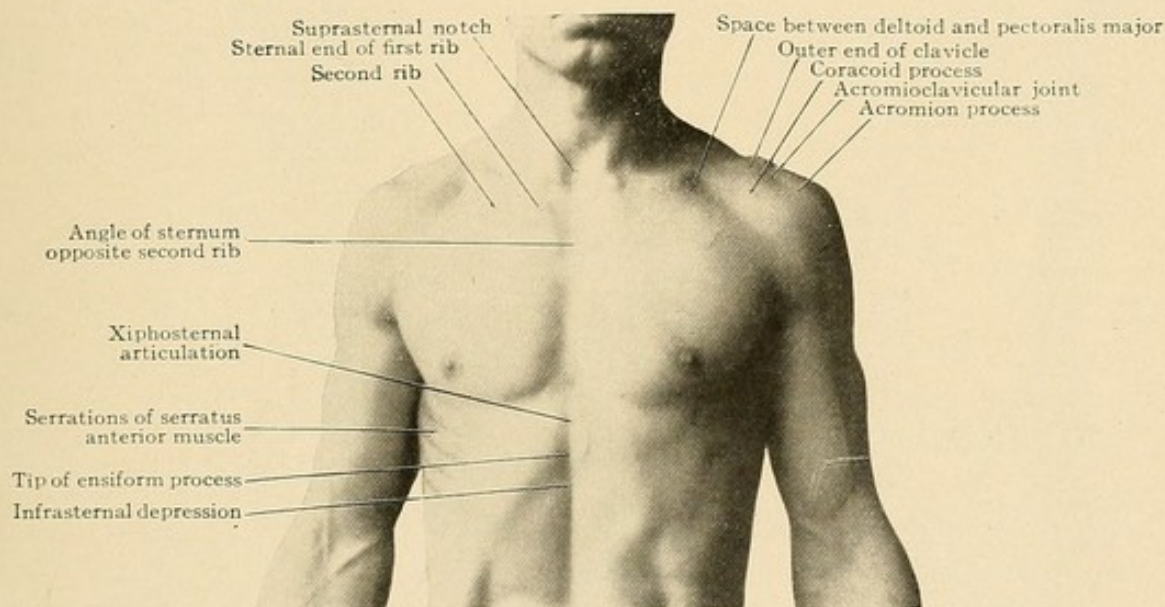


FIG. 204.—Surface anatomy of the thorax.

sixth the length of the clavicle, because the deltoid is attached only to the outer third of the clavicle. Immediately beneath the edge of the deltoid muscle and about 2.5 cm. below the clavicle is the *coracoid process*. On abducting the arm the scapula is rotated and the serratus anterior muscle is put on the stretch; this makes its four lower serrations visible. The serration attached to the fifth rib is the highest, the sixth is the most prominent and extends farthest forward, while below are the last two attached to the seventh and eighth ribs. The operation of paracentesis, or tapping for pleural effusion, is most often done in the sixth interspace in the midaxillary line. This will be about on a level with the nipple. The apex beat of the heart is felt in the fifth interspace, about 2.5 cm. (1 in.) to the inner side of the line of the nipple.

Running down behind the costal cartilages and crossing the intercostal spaces about a centimetre from the edge of the sternum is the *internal mammary artery*. When it reaches the sixth interspace it divides into the *superior epigastric*, which goes downward in the abdominal walls, and the *musculophrenic*, which passes to the attachment of the diaphragm along the edge of the chest.

(The relations of the organs of the chest to the surface will be discussed later. The nervous supply to the surface of the chest is of interest mainly as indicating the probable location of the lesion in cases of fracture of the spine, and it will be described in the section devoted to the Back.)



## THE MAMMA OR BREAST.

The name mammary gland is often given to the breast, yet the latter is composed not only of glandular tissue but also of fibrous and fatty tissue, with the usual vessels, nerves, and lymphatics. In the male the glandular portion is undeveloped, the fat is relatively scanty, and the breast as a whole is insignificant and flat. In the virgin female adult it is more spheroidal. Above the nipple it is flattened and below it is rounded. Its general shape is circular and it covers the chest-wall from the upper border of the third rib to the sixth interspace. Laterally it reaches internally almost to the sternum and externally it overlaps the edge of the pectoralis major. It lies imbedded in the superficial fascia. In its development it is simply a modified sebaceous gland. Beginning by a finger-like growth from the skin it burrows its way into the superficial fascia. It becomes compound and sends its branches in various directions, especially does it extend deeper until finally it pushes away most of the fat and

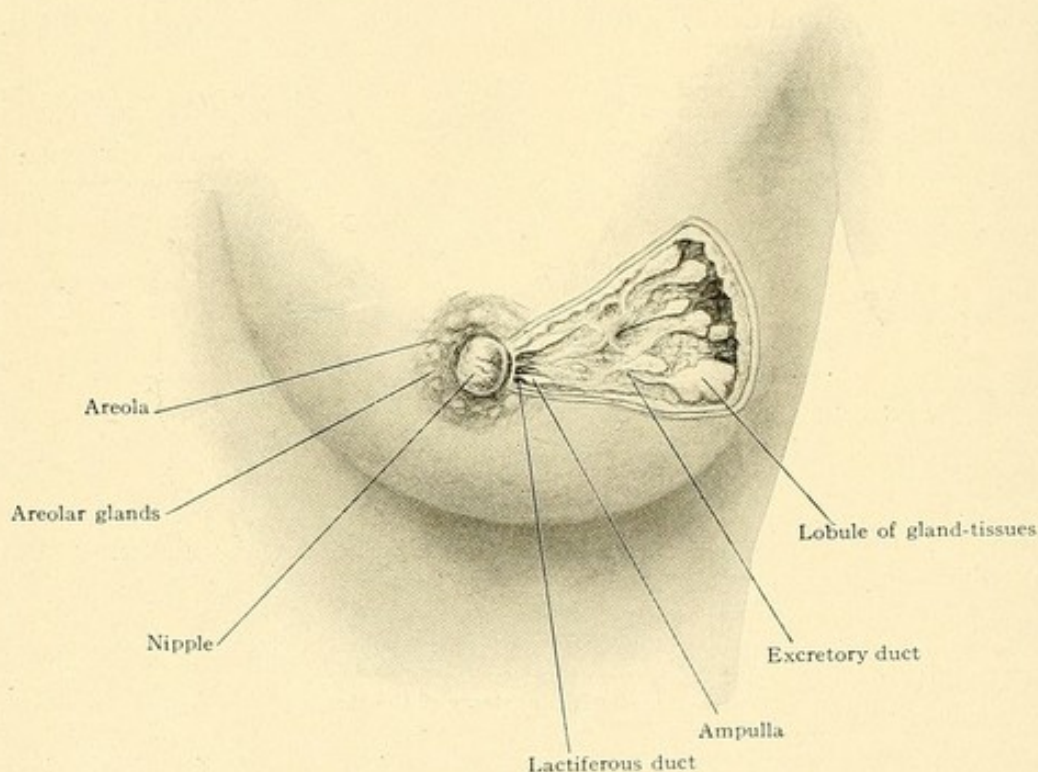


FIG. 205.—The secreting structure of the breast. (Piersol.)

rests on the fascia covering the pectoralis major muscle. This is why we find almost no adipose tissue beneath the gland but mostly between the glandular structure and the skin and around its edges. The shape of the virgin breast is due mainly to its adipose tissue and not to its glandular structure. In those who have borne children the breasts become enlarged, lax, and pendulous. After lactation is completed they again retract but rarely regain their former shape. During lactation the fatty portion of the breast may disappear and leave it apparently in a shriveled condition, yet such a breast may be functionally quite active. Therefore the size of the breast is no criterion of its milk-producing powers.

The **secreting structure**, racemose in character, is divided into ten to sixteen lobules, each of which has its duct. These lactiferous ducts begin in the acini and end in the nipple. Beneath the nipple they are dilated, each forming a sinus or ampulla. While the shape of the breast is regular in its outline the glandular tissue is not so. It possesses three projections or cusps. One of these projects inward nearly or quite to the sternum, while the other two project toward the axilla and side, one being lower than the other. These are the most common



directions in which the glandular tissue is prolonged, but it may extend farther than usual in any direction; hence the wide incisions made in cases of carcinoma.

According to H. J. Stiles (*Ed. Med. Journ.*, 1892, p. 1099), the secreting structure may extend posteriorly into the retromammary tissue between the layers of the pectoral fascia. Anteriorly it is prolonged with the fibrous tissue (*ligaments of Cooper*) almost to the skin.

The **nipple**, located below and to the inner side of the centre of the gland, has connected with it some circular and longitudinal unstriated muscular fibres. The longitudinal ones are attached to the lactiferous ducts and serve to retract the nipple, the circular ones to erect it. Surrounding the nipple is the *areola*. It is pink in the virgin and about 2.5 cm. in diameter. After pregnancy its hue becomes brownish. The *tubercles of Montgomery* are the numerous elevations found on the areola. They are more or less modified sebaceous glands and enlarge during pregnancy. As they secrete a milky fluid, they are often regarded as accessory milk ducts. There is no fat in the nipple or areola.

The **fibrous structure** of the gland envelops the adipose and glandular tissue. It is simply a continuation of the fibrous septa of the superficial fascia. These septa are attached to the skin above, envelop and pass between the fatty and glandular lobules, and form a thin covering for the under surface of the gland. The breast is sometimes spoken of as having a capsule, but that simply refers to the fibrous tissue just described. This fibrous tissue follows largely the ducts, hence when affected with carcinoma it contracts and draws the nipple in. This forms the retracted nipple of that disease. The fibres that go to the skin have been named the ligaments of Cooper. The fibrous tissue forms a net-work in the meshes of which are packed the glandular structure and fat-lobules. It is this which gives the firmness and shape to the virgin breast. In lactation, the fibrous tissue softens and stretches to accommodate the increase in the glandular structure and this, with the loss of fat, causes the breast to become lax and pendulous. In palpating a normal breast between the fingers and the thumb, this firmness may feel like a foreign growth; hence this method of examination is not to be relied on. A better way is to have the patient recline, and lay the fingers flat on the breast, compressing it on the chest-wall beneath.

This flattens the glandular structure and any mass can be more surely detected.

The fibrous tissue between the glandular structure and the pectoralis beneath is quite thin and loose, with large spaces in it which have been called the *submammary bursa*. Pus readily spreads in this loose submammary tissue, but in the gland itself only with difficulty.

**Blood Supply.**—The breast is supplied with blood from above by the *pectoral branch of the acromial thoracic artery*, which leaves the axillary artery at the inner border of the pectoralis minor muscle. The pectoral branch descends between the pectoralis major and minor and anastomoses with the intercostals and long thoracic. It sends branches through the pectoralis major muscle, and in carcinoma of the gland it may be seen much enlarged running downward on the chest-wall beneath the muscle. From the inner side come the *perforating branches of the internal mammary*

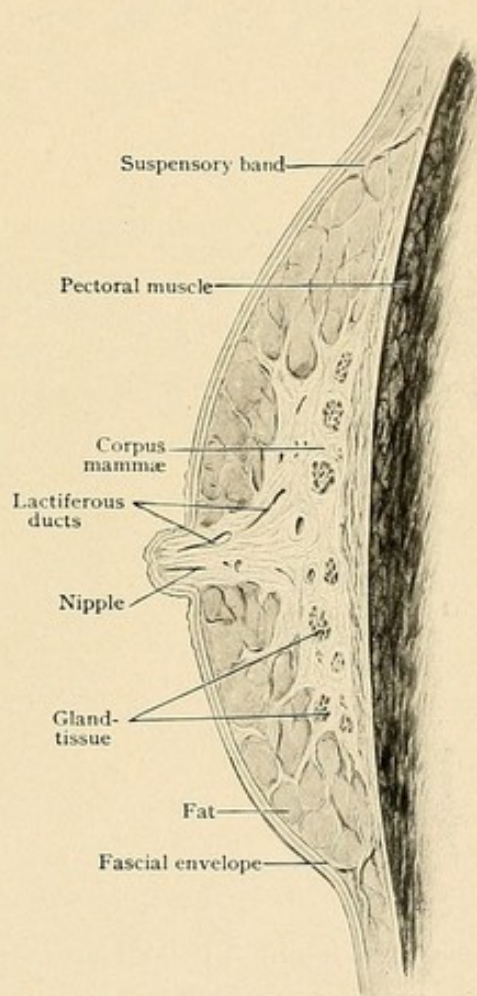


FIG. 206.—Sagittal section of mamma of young woman who had never borne children; hardened in formalin. (Piersol.)



artery from the second to the sixth rib; the second, third, and fourth are the largest and may bleed freely in detaching the pectoralis major. To the outer side and below is the *long thoracic artery*, also called the external mammary; it descends along the outer edge of the pectoralis minor, sending branches inward around the edge of the pectoralis major to the mammary gland. The *intercostal arteries* also contribute somewhat to the blood supply of the gland.

**Lymphatics.**—The breast is exceedingly well supplied with lymphatics. They are composed of a *deep* set around the lobules and ducts, and a *superficial* set which together with the deep lymphatics forms a plexus around the nipple called the *subareolar plexus*. They drain mainly toward the axilla into the lymph-nodes along the edge of the pectoralis major but also communicate with the nodes around the subclavian artery and those in the anterior mediastinum which accompany the internal mammary artery.

The *axillary nodes* are in three sets: one along the edge of the pectoralis major muscle (*pectoral nodes*), another further back along the anterior edge of the scapula (*scapular nodes*), and a third following the course of the axillary artery

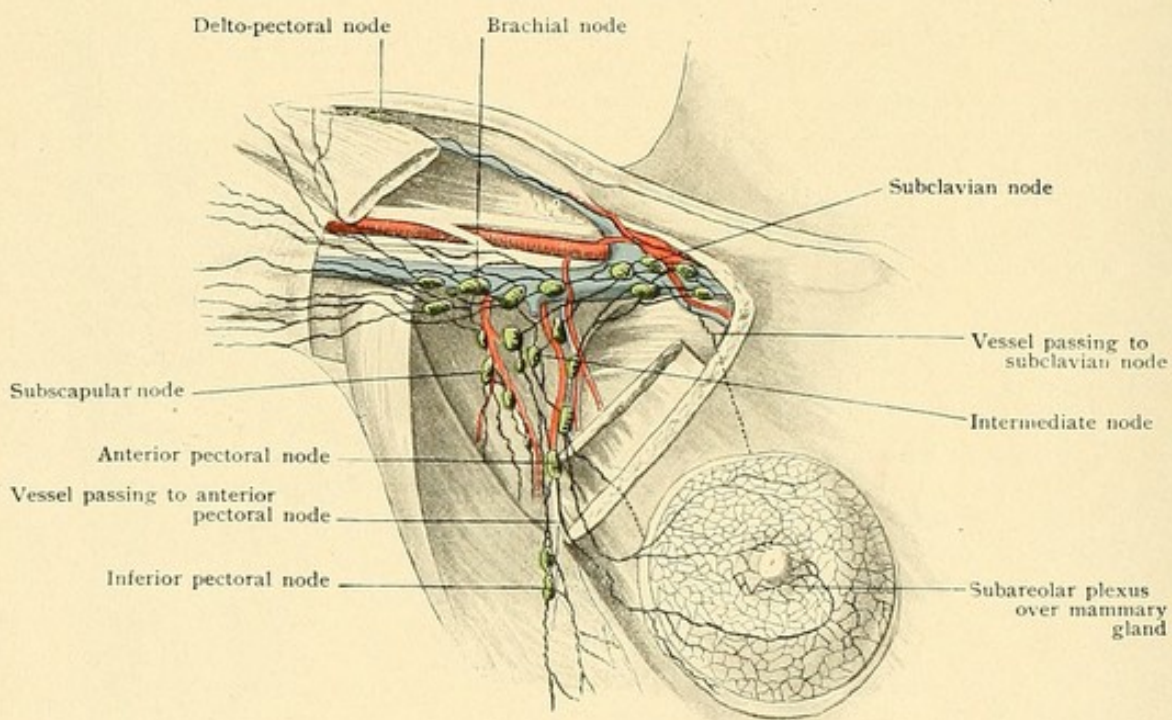


FIG. 207.—Lymphatics of the breast. (Poirier and Cunéo.)

(*humeral nodes*). In addition to these there are some *infraclavicular* or *subclavian nodes* between the deltoid and pectoralis major and at the inner edge of the pectoralis minor muscles; these are comparatively rarely involved primarily. The axillary nodes are continuous and communicate with the subclavian and supraclavicular nodes, and these latter are frequently enlarged subsequent to the axillary infection. The anastomosis of the lymphatics across the median line has been thought to account for the occurrence of the disease in the opposite breast or axilla. As shown by Sappey, some if not all of the lymphatics of even the sternal portion of the breast drain into the axilla and not into the anterior mediastinum, thus accounting for the axillary involvement when the inner portion of the breast is affected. These five sets of nodes communicate with each other, and any one may be alone involved. The supraclavicular set do not become involved primarily because no vessels run directly from the breast to them; they are affected secondarily to involvement of the axillary or subclavian sets.

The deep lymphatics of the breast, according to Sappey, follow the ducts to the areola, there anastomosing with the superficial lymphatics to form what he called the *subareolar plexus*, which drains by two trunks into the axilla. The lymphatics of the



breast anastomose with those of the surrounding structures; hence in certain cases the pectoralis muscles and even the pleura may be affected, and when the disease is widely disseminated by the lymph-channels on the chest-walls there is produced the thickened, brawny, infiltrated condition known as the cancer "*en cuirasse*" of Velpeau.

**Nerves.**—The breast and the skin over it are supplied from the descending branches of the cervical plexus, by thoracic branches from the brachial plexus, and by the second, third, fourth, fifth, and sixth intercostals. These are not of so much practical importance as the lateral branches of the second and third intercostal nerves. That of the second is called the *intercostobrachialis (humeral) nerve*; it crosses the axilla, anastomoses with the *medial brachial (lesser internal) cutaneous nerve*, and supplies the skin of the inner and upper portion of the arm. The third intercostal anastomoses with the second and gives a branch to the arm and to the dorsum of the scapula. These nerves are certain to be seen in clearing out the axilla. Their division is accompanied by no paralysis, but disturbance of them accounts for some of the pain and discomfort following the operation.

#### ABSCESS OF THE BREAST.

Suppuration in the mammary gland is usually due to infection which has entered the gland either through the lymphatics or the lactiferous ducts. The starting point of the infection is thought to be an ulcerated crack or fissure of the nipple. Infection travelling into the gland by way of the lymphatics would cause pus primarily in the pericanalicular tissue but it would soon involve the lactiferous ducts and then pus might exude from the nipple. Infection travelling up the ducts might reach the ultimate lobules and therefore give rise to widespread and multiple abscesses. Suppuration in this gland resembles that in the parotid gland, already described. When the body of the gland is involved it is apt to be so in more than one spot. The infection follows the branching of the ducts and usually there are several small abscesses instead of one large one. If there is a large collection of pus it is not contained in one cavity but more likely in several. This is so often the case that in treating these abscesses it is advised that they should not only be incised but the finger should then be introduced and the partitions separating the various abscess cavities broken through.

In its incipency a lymphatic infection may cause a single collection of pus, but this soon breaks through into the canaliculi and infects and involves the glandular structure. In an early stage of duct infection several inflammatory areas may start up about the same time. The pus soon breaks through the canaliculi and involves the periglandular tissue so that in each mode of infection the condition soon becomes the same. It is for this reason that it is difficult to say whether the infection originated in the lymphatics or the ducts.

When the ducts are inflamed the pus often finds a vent at the nipple. The frequency of this is the reason why direct infection of the ducts is regarded as the more common mode. In incising a mammary abscess the incisions should follow the course of the ducts, that is, they should be made in a direction radiating from the nipple towards the circumference and not transversely, otherwise healthy ducts will be divided.

**Submammary Abscess** (for subpectoral abscess see page 264).—As has been pointed out some of the glandular tissue dips down to the pectoral fascia, hence when some of these deepest lying lobules are inflamed the pus instead of breaking laterally into the adjoining lobules or tissue breaks into the submammary tissue and bursa. Here it spreads rapidly beneath the gland and raises the gland above it. As the pus accumulates it sinks downward and works its way outward to the lower outer quadrant along the edge of the anterior axillary fold. Here is where it should be opened. As the cavity is single one incision is sufficient to drain it.

#### TUMORS OF THE MAMMARY GLAND.

**Benign Tumors.**—There are two main kinds of benign mammary growths, cystic and adenomatous or fibro-adenomatous.

*Cystic* growths due to retention of secretion of the ducts occur as small, rounded tumors, painful and tender to the touch, and are seen between the ages of 25 and 35



years. They are not in any way dangerous. They are composed of a number of dilated acini. Another form is degenerative in character, occurring in the decline of life, and consists of a large number of various sized, usually small, cysts located mostly toward the deep surface of the gland. They contain mucoid and degenerated material produced by the lining membrane of the acini. The whole breast is apt to be studded with small shot-like cysts and both breasts are usually involved. This affection in itself is not malignant, but it may become so by intracanalicular growths springing up from the walls of the cysts.

*Adenomatous* growths are encapsulated, usually single, and are composed of three distinct elements. These are glandular tissue more or less normal in character, glandular tissue cystic in character, and fibrous tissue. The fibrous tissue forms the capsule as well as the stroma in the meshes of which latter glandular tissue, nearly normal, occurs. These are called *fibro-adenomata* and if the glandular tissue is quite abundant they may be called *adenomata*. If the glandular acini are dilated so as to overshadow the fibrous portion, then it is called a *cystic adenoma*. These cystic growths may be quite large.

**Malignant Tumors.**—The malignant growths of the breast are either *sarcomata* or *carcinomata*.

*Sarcomata* originate from the fibrous stroma of the breast surrounding the ducts and acini. As it increases in size it may irritate the glandular structure and obstruct the ducts, thus forming cysts which may be quite large. Such a growth has been called a *cystic sarcoma*. It also shows itself as a single tumor, which may be large but solid. The lymph-nodes are rarely affected. The disease when it wanders from the seat of the primary growth shows itself in some of the internal organs. It is disseminated by the blood and not by the lymphatics.

*Carcinomata* originate from the epithelium lining the ducts and acini. For our purposes we may divide them into two classes, those that grow into the ducts (*intracanalicular*) and those that break through the ducts and invade the surrounding tissues, of these *scirrhus* is the type.

*Intracanalicular growths* have by many authors been considered nonmalignant on account of the rarity of their producing general infection. They grow at times rapidly and produce tumors of considerable size. On section they contain many cysts and into these cysts, which are derived from the dilated milk-ducts, protrude outgrowths from the walls. Sometimes the cavity of the cyst has its liquid contents replaced by the solid tumor which has grown into it. A discharge of bloody serum from the nipple is common in these growths.

*Scirrhus* is the ordinary form of cancer of the breast. It starts in the epithelial structures of the gland, breaks through the basement membrane and involves the structures immediately adjacent to it, and is disseminated more widely by the lymphatics. *Paget's disease* is a true carcinoma which begins as an eczema or ulceration around the nipple and later becomes disseminated.

Carcinoma follows the gland structure, and readily involves the pectoral fascia covering the pectoralis major muscle. Anteriorly, the gland structure in places follows the ligaments of Cooper to the skin above, hence the frequency with which the skin is involved.

The *scirrhus* variety does not involve the ducts in the same manner as does the *intracanalicular* variety, hence bloody discharges from the nipple are not so common as in that affection. The disease, when affecting the region of the nipple, has been considered more dangerous because of the greater development of the lymphatics, particularly the subareolar plexus of Sappey, at that point.

Carcinomatous disease extends especially by way of the lymphatics. These follow the fibrous and canalicular structure, therefore on section the cancerous tissue can be seen extending like roots into the surrounding gland. This tissue shrinks, contracts, and becomes harder as the disease progresses, that is why retraction of the nipple and dimpling of the skin occurs. The most free lymphatic drainage occurs toward the axilla, not toward the mediastinal nodes. The first nodes to show infection are those lying along the edge of the pectoralis major muscle about the level of the third rib. Later, the nodes at the anterior edge of the scapula accompanying the subscapular artery become involved, or those along the axillary vessels. Still later



those along the subclavian vessels may be enlarged and may be felt above the clavicle and farther inward behind the sternomastoid muscle low down.

In rare instances the disease may be carried superficially to the subclavian nodes in the infraclavicular triangle between the deltoid and pectoralis major muscles. Should the disease spread, it may be carried by the lymphatics to the opposite breast directly across the median line. If it involves the lymphatics of the chest-wall generally there is produced the brawny condition of the skin called cancer "*en cuirasse*" of Velpeau already alluded to. A cancerous nodule beyond the edge of the pectoralis major muscle is not necessarily an enlarged node, but may be due to the involvement of one of the cusps of the gland, which sometimes extend even into the axilla.

**Removal of the Cancerous Breast.**—The origin of cancer is now believed to be local and not general and the more complete its removal the greater is the likelihood of cure. Therefore every effort is made to excise every possible infected tissue. This has led to the performance of very extensive operations.

The incision is made so large as to include nearly or quite all of the skin covering the glandular tissue; this is because of the intimate connection of the two, as already pointed out. It is carried out to the arm; this is to facilitate clearing out the axilla and all its contents. The incision is kept close to the skin; this is to avoid any glandular structure which may possibly be beneath. The pectoral fascia covering the pectoral muscle is always removed.

Often both the pectoralis major and minor muscles are removed. In excising them the slight interspace between the clavicular and sternal fibres of the pectoralis major muscle is entered and the muscle detached from the anterior extremities of the ribs and sternum. In so doing the anterior intercostal arteries, particularly those of the second, third, and fourth spaces, are liable to bleed freely. As the pectoralis major is detached and turned outward, the acromial thoracic artery is seen at the inner edge of the pectoralis minor muscle with its pectoral branch running down the surface of the chest. This may be ligated, the finger slipped beneath the pectoralis minor, and this muscle cut loose from the coracoid process above and the third, fourth, and fifth ribs below. At this stage some operators clear the subclavian and axillary vessels of all loose tissues and lymph-nodes.

The vessels are followed out on the arm. When the insertion of the pectoralis major is reached it is detached and the whole mass turned outward and pared loose along the anterior edge of the scapula. Thus it is removed in one piece. The part of the chest-wall which has been cleared off embraces from the middle or edge of the sternum to the anterior edge of the scapula and from near the lower edge of the chest below to the clavicle above. The vessels have been cleared off from the insertion of the axillary folds on the arm to underneath the clavicle. Many operators make an additional incision above the clavicle and clear out the supraclavicular fossa even if no enlarged glands can there be detected. Sometimes the long thoracic artery and thoracalis longus (long external thoracic) nerve may be wounded, but they need not be.

Two nerves will be seen crossing the axilla from the chest to the arm. They are the lateral branches of the second and third intercostal nerves. The second is called the intercostobrachialis (humeral) nerve. If they can conveniently be spared it is to be done, otherwise they are divided. In clearing the axillary vessels, small veins and even arteries may be divided close to the main trunks. These may be expected to bleed freely but are usually readily secured. Care should be taken not to wound unnecessarily the subscapular artery and particularly the vein as they wind around the anterior edge of the scapula 2 to 3 cm. below its neck. Some operators prefer to detach the breast from without in instead of from within out as described.

## THE MEDIASTINUM.

The mediastinum is the middle space of the chest between the spine behind, the sternum in front, and the pleuræ to each side. It is subdivided into a *superior mediastinum*, which is the part above Ludwig's angle, between the first piece of the sternum in front and the vertebræ from the first thoracic to the upper portion of the fifth behind. The part below is divided into the *anterior mediastinum*, the *middle mediastinum*, and the *posterior mediastinum*.



**Superior Mediastinum.**—The upper level of the superior mediastinum is oblique, as it runs from the upper edge of the sternum to the first thoracic vertebra. The lower level of the superior mediastinum runs from the junction of the first and second pieces of the sternum to the upper border of the fifth (or lower border of the fourth) thoracic vertebra. Laterally it is bounded by the pleuræ and apices of the lungs.

The distance from the anterior surface of the spine to the posterior surface of the sternum is quite small, being only 5 to 6 cm. (2 to 2¼ in.). Through this pass most important structures. The *trachea* and *œsophagus* are in the median line as well as the remains of the *thymus gland*. To each side are the great vessels, the *innominate artery* being on the right and the *subclavian* and *carotid* on the left. The *left innominate vein* crosses transversely just below the top of the sternum to meet the *innominate vein of the right side* and form the *superior vena cava*. Into the innominate veins empty the *inferior thyroid*, *vertebral*, *superior intercostal*, *internal mammary*, and

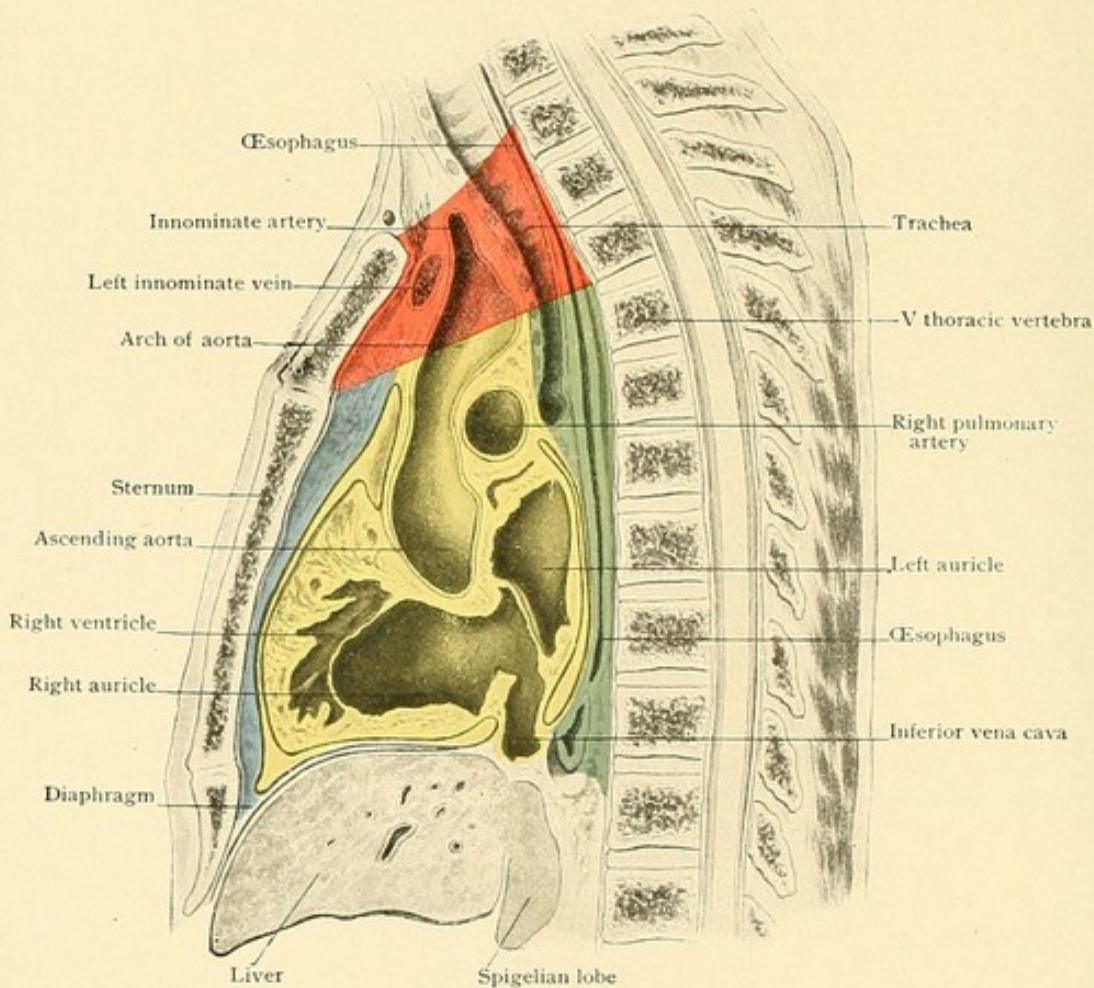


FIG. 208.—The superior (red), anterior (blue), middle (yellow), and posterior (green), mediastina. (Modified from Piersol.)

*pericardial veins*; and into the descending vena cava empties the *vena azygos major*. On the posterior surface of the *œsophagus* and afterwards to its left side passes the *thoracic duct*. The *trachea* bifurcates opposite the junction of the first and second pieces of the sternum, and the transverse portion of the arch of the aorta rises as high as the middle of the manubrium. The *phrenic nerves* lie against the pleura, the right having the vena cava to its inner side.

The *right vagus (pneumogastric) nerve* comes down between the innominate artery and vein and passes downward on the posterior surface of the *œsophagus*. It gives its recurrent laryngeal branch off at about the right sternoclavicular joint. The *left vagus nerve* comes down to the outer side of the left carotid artery and goes over the arch of the aorta, giving off its recurrent laryngeal branch, and thence proceeds to the anterior surface of the *œsophagus*. The presence of the trachea in



the median line and the edges of the lungs which meet opposite the second rib give a resonant percussion note to the first piece of the sternum. With all these important structures crowded in the small space between the vertebræ and sternum it is easy to see why tumors in this region should cause serious symptoms.

*Aneurism* involving the arch of the aorta and the great vessels is common. *Tumors*, such as sarcoma, carcinoma, and glandular, though rare, do occur. *Abscess* from high dorsal Pott's disease has been known to cause serious effects.

The symptoms of all these affections resemble one another to a considerable extent. Interference with the blood-current, usually in the veins, almost never in the arteries, is marked. Alteration in the voice is produced by pressure on the recurrent laryngeal nerves. Dyspnoea from the pressure on the trachea and difficulty in swallowing also occur, as well as interference with the circulation and the

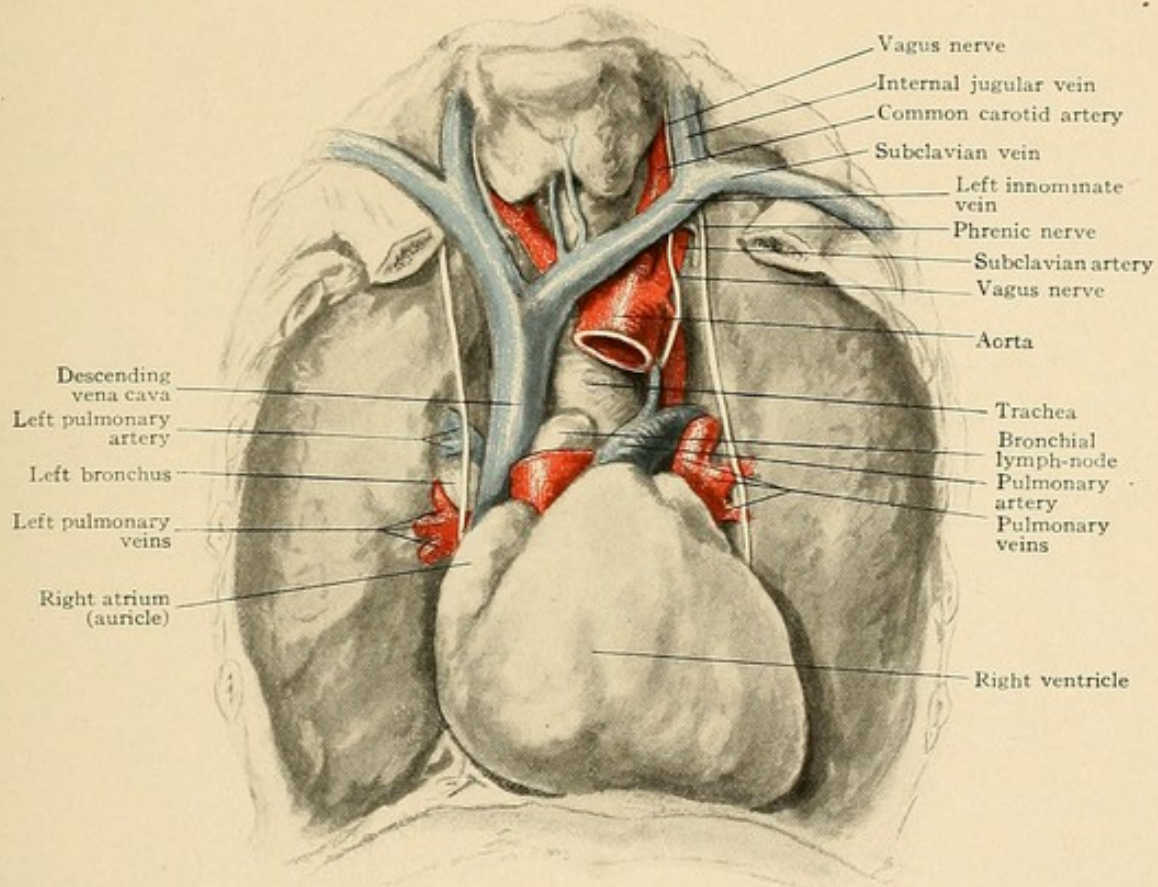


FIG. 209.—Contents of the mediastina viewed from the front.

action of the heart. The presence of growths in this region is indicated also by the presence of dulness over the region of the manubrium.

**Anterior Mediastinum.**—This is the space below the second costal cartilages, between the sternum in front, the pericardium behind, and the two pleuræ on the sides. It is only a narrow slit in the median line above from the second to the fourth costal cartilage; from here the right pleura is prolonged obliquely down and outward to the seventh costal cartilage, which it follows. On the left side the pleura leaves the median line about the fourth cartilage and passes out about 2 cm. to the left of the sternum and then down to the seventh costal cartilage, which it follows. The *triangularis sterni muscle* arises from the under surface of the lower third of the sternum and from the xiphoid cartilage and passes upward and outward to insert into the costal cartilages of the second to the sixth ribs inclusive. The *muscle* lies in front of the anterior mediastinum and the *internal mammary artery* runs down between it and the bone about 1 cm. distant from the edge of the sternum. There are a few lymphatic nodes in the anterior mediastinum on the diaphragm below and



in the superior mediastinum on the arch of the aorta and left innominate vein above. A chain of nodes also accompanies the internal mammary artery along the edge of the sternum between the pleura and chest wall.

*Abscess of the anterior mediastinum* may result from infection due to injury or punctured wounds. It may break into the pleuræ on the sides, into the pericardium posteriorly, work its way down toward the abdomen, or point in the intercostal spaces at the edge of the sternum.

*Paracentesis pericardii* is performed in the sixth interspace close to the sternum; also, the fifth and sixth cartilages may be resected, the internal mammary artery ligated, and the pericardium opened and even drained.

If one attempts to pass a trochar into the pericardium by a puncture through the fifth or sixth interspace sufficiently far out to avoid wounding the internal mammary artery the pleura is apt to be wounded, as it passes farther toward the median line than does the lung.

**The Middle Mediastinum.**—The middle mediastinum is limited in front by the anterior wall of the pericardium and behind by the posterior wall of the pericardium and roots of the lungs. It contains the *heart* with the lower half of the *descending vena cava* and the *vena azygos major* emptying into it, and the *ascending aorta*;

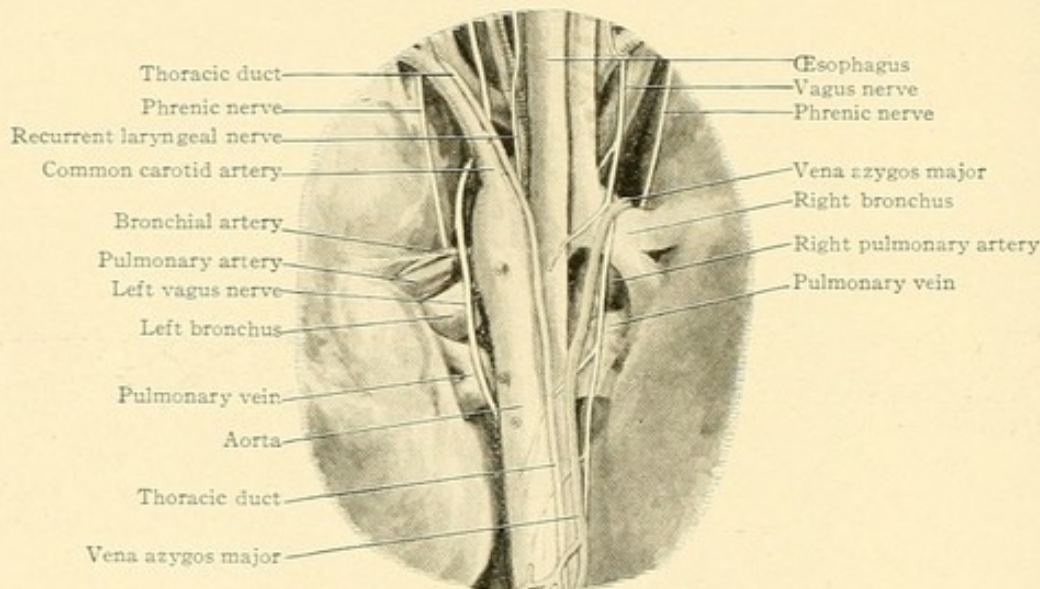


FIG. 210.—Contents of the mediastina viewed from the rear.

also the structures forming the roots of the lungs, viz., the *right* and *left bronchi*, and the *pulmonary arteries* and *veins*.\* The *phrenic nerves* lie between the pericardium and pleuræ anteriorly.

The *bronchial lymphatic nodes* are numerous between the structures forming the roots of the lungs. It is these nodes that are so often enlarged in diseases of the lungs. They are affected in malignant disease as well as in tuberculosis, etc. Enlargements of the heart pressing on the vessels, particularly the *vena azygos major*, are sometimes thought to cause pleural effusions, especially if one-sided.

When the pericardium is distended with fluid it enlarges more in an up and down direction, but when the heart is enlarged its size increases mainly laterally—from side to side.

**Posterior Mediastinum.**—The posterior mediastinum extends from the pericardium and roots of the lungs anteriorly to the vertebræ posteriorly. The pleuræ are on each side. Behind the pericardium runs the *esophagus*, lying in front of the *aorta*, which rests on the vertebræ. In the chink between the aorta and bodies of the vertebræ lies the *thoracic duct* and immediately to its right side is the *vena azygos*

\* The mediastina are arbitrary divisions, and it is a question as to whether the roots of the lungs should not be included in the posterior instead of the middle mediastinum.



*major*. The *vena azygos minor* is on the left side of the vertebræ and crosses the sixth to join the *vena azygos major*. The *descending thoracic aorta* is not infrequently the seat of aneurism.

**Mediastinal Tumors.**—Cancer is the most frequent malignant new growth, then sarcoma and lymphoma. Great enlargement of the lymph-nodes occurs in *Hodgkin's disease* and is probably a factor in causing a fatal issue. Enlargements also result from tuberculosis and other diseases. They give rise to pressure symptoms. Dyspnœa may be due to pressure on the trachea or heart and great vessels. The circulation may be so much impeded that the enlargement of the collateral veins, especially those of the surface, may be very marked. There may also be difficulty of swallowing due to pressure on the œsophagus.

**Pleural Effusions.**—Serous effusions into the pleuræ are also known to accompany heart disease and have been attributed in some instances to obstruction of the circulation. They are apt to be unilateral and are most often found affecting the right pleural cavity. Baccelli attributed the effusion to obstruction of the blood current through the *vena azygos major*; the enlarged heart pulling the superior *vena cava* down drew the *vena azygos major* tightly over the right bronchus, as is well shown in Fig. 210. Steele (*Univ. Med. Mag.*, 1897; *Journ. Am. Med. Asso.*, 1904) and Stengel (*Univ. Penna. Med. Bulletin*, 1901) held that the dilated right heart by extension upward exerts pressure on the root of the right lung and indirectly pinches the *azygos major vein* as it curves over the right bronchus to enter the superior *vena cava*. Fetterolf and Landis (*Am. Journ. Med. Sciences*, 1909) believe that the fluid comes from the visceral pleura and not from the parietal pleura, and that the outpouring, so far as the pressure factor is concerned, is caused by dilated portions of the heart pressing on and partly occluding the pulmonary veins. They point out that Miller (*Am. Journ. of Anat.*, vii) has shown that the veins draining the visceral pleura empty into the pulmonary veins; therefore, if these latter are obstructed, transudation may ensue; this may occur on either side. They point out that if the right atrium (auricle) dilates, it expands upward and backward and compresses the left auricle and root of the right lung; and of the parts composing the root the pulmonary veins are the most anterior, and, therefore, the ones most liable to be compressed. Left-sided effusions are accounted for by compression of the left pulmonary vein by the dilated left atrium (which is the most posterior of the four chambers) and its appendix. The greater frequency of right-sided effusions is due to the more common occurrence of dilatation of the right side of the heart.



## THE CHEST CONTENTS.

For the sake of convenience in description and record, the chest has been divided into various regions and marked by certain longitudinal lines.

### THE LONGITUDINAL LINES.

Seven longitudinal lines are used. They run parallel with the long axis of the body.

1. The **median line** means the midline of the body. This runs down the middle of the sternum anteriorly and the middle of the back posteriorly.
2. The **parasternal line** runs parallel to the edge of the sternum and midway between it and the midclavicular line.
3. The **midclavicular line**, also called the **mammary line**, is a longitudinal

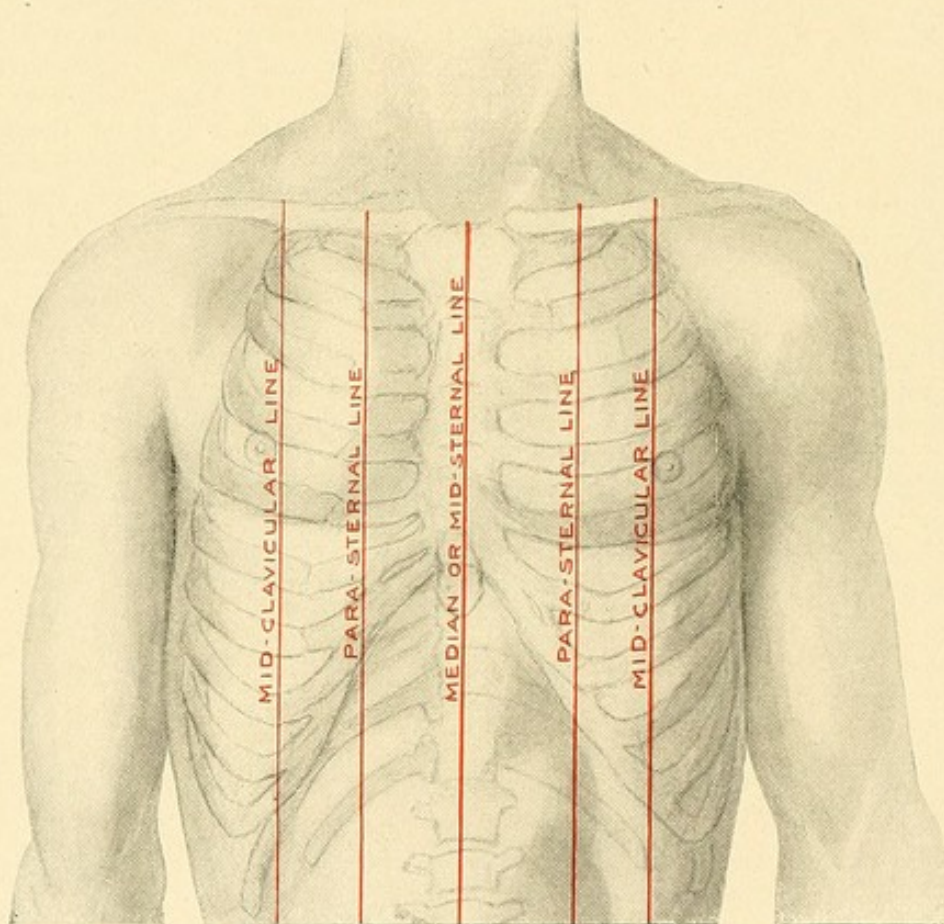


FIG. 211.—The longitudinal lines of the chest used in physical diagnosis.

line passing through the middle of the clavicle. This usually passes 1 to 2 cm. internal to the nipple.

4. The **anterior axillary line** passes through the anterior fold of the axilla.
5. The **midaxillary line** passes through the middle of the axilla.
6. The **posterior axillary line** passes through the posterior fold of the axilla.
7. The **scapular line** passes longitudinally through the lower angle of the scapula.

### THE REGIONS OF THE CHEST.

In the middle of the surface of the chest anteriorly there are three regions:

1. The **suprasternal region** is the part above the sternum between the sternomastoid muscles. It is the suprasternal notch.



2. The **upper sternal region** extends from the suprasternal notch to a line drawn opposite the third costal cartilages.

3. The **lower sternal region** is behind the second piece of the sternum from the third costal cartilages down.

Anteriorly on the chest there are four regions (Fig. 212):

1. The **supraclavicular region**, above the clavicle. This includes the supraclavicular fossa.

2. The **infraclavicular region**, below the clavicle down to the upper edge of the third rib.

3. The **mammary region**, from the upper edge of the third to the upper margin of the sixth rib. This extends from the edge of the sternum to the anterior axillary fold and has the nipple nearly in its centre.

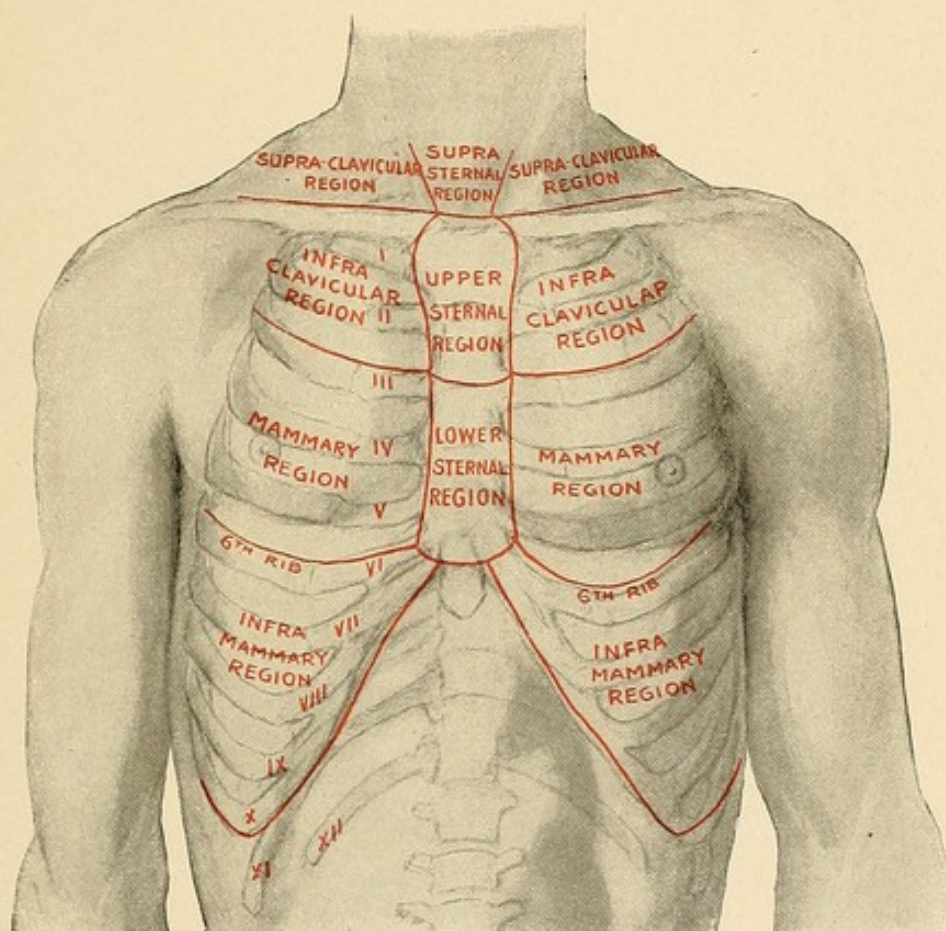


FIG. 212.—The anterior regions of the chest.

4. The **inframammary region** extends from the upper margin of the sixth rib to the lower margin of the thorax.

Laterally on the chest between the folds of the axilla there are two regions:

1. The **upper axillary region** extends down to the upper border of the sixth rib.

2. The **lower axillary region** extends from the upper border of the sixth rib to the lower edge of the thorax.

Posteriorly there are four scapular regions (Fig. 213):

1. The **suprascapular region** is above the spine of the scapula.

2. The **scapular region** is the part covered by the body of the scapula below its spine.

3. The **infrascapular region** is the part of the chest below the scapula between its angle and the lower edge of the chest.

4. The **interscapular region** is the part between the posterior edge of the scapula and the median line.



## THE PLEURÆ.

The pleuræ form closed sacs which line the thorax (parietal pleura) and cover the surface of the lungs (visceral pleura). As the lungs expand and contract, the pleuræ are only completely in contact with the lungs when the latter are fully distended. In ordinary breathing the lungs are not completely expanded, hence the edges of the pleuræ fall together and so prevent the formation of a cavity. This collapsing of the pleuræ takes place mainly along its anterior and lower edges. The apex of the pleura is prevented from collapsing by its attachment to the first rib, and also, as pointed out by Sibson, by the attachment to it of an expansion of the deep cervical fascia and some fibres of the scalenus anticus muscle. Posteriorly the chest wall is unyielding. Anteriorly when the lungs are collapsed they fill out the pleuræ as low down as the fourth costal cartilage; below that, in front of the heart,

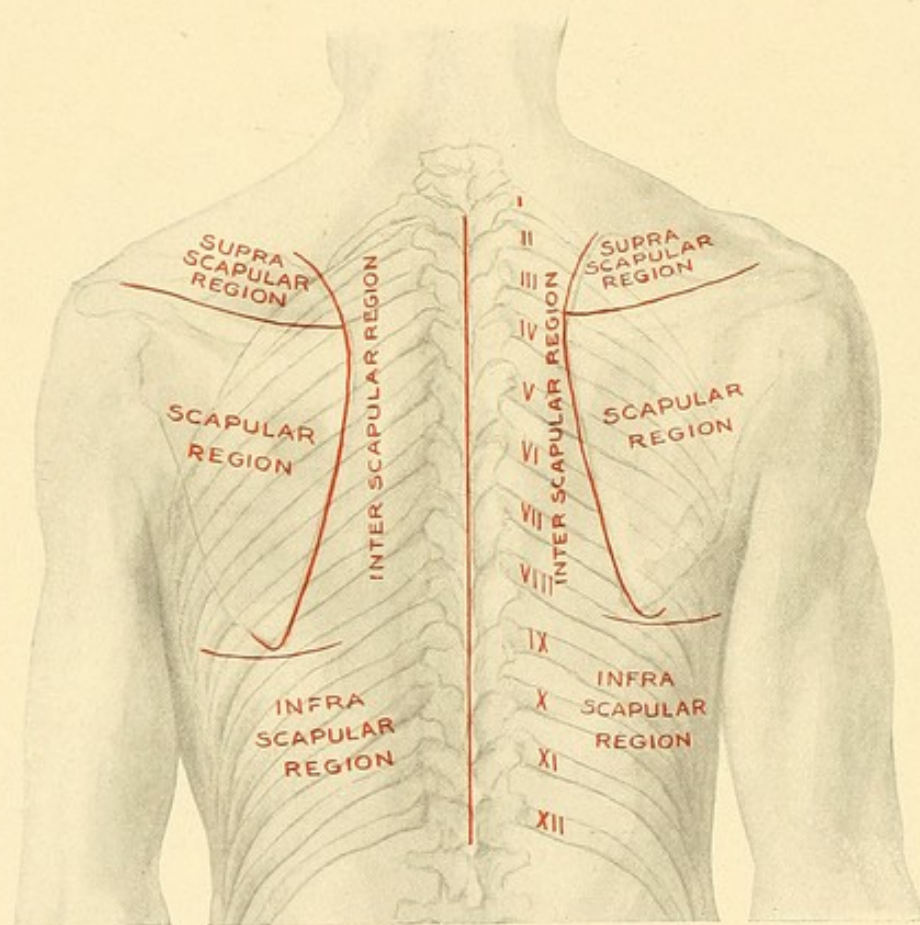


FIG. 213.—The posterior regions of the chest.

a space or sinus is left unoccupied by lung. It is called the *costomediastinal sinus*. Likewise between the diaphragm and chest-walls is another space, in which the parietal or costal and visceral layers of the pleura are in contact, called the *costophrenic sinus* or *complemental space of Gerhardt*. From these facts it follows that the outlines of the pleuræ and lungs are identical posteriorly, superiorly, and anteriorly, as low as the fourth costal cartilage. Here they diverge, the pleuræ descending lower than the lungs.

The top of the pleura is about on a plane with the upper surface of the first rib. This makes its posterior portion at the head of the first rib 5 cm. higher than its anterior portion at the anterior end of the first rib. The upper border of the clavicle is level with a point midway between the anterior and posterior ends of the first rib. This, therefore, shows the pleura to extend 2.5 cm. (1 in.) above the level of the upper surface of the clavicle.



The top of the pleura does not project into the neck in the form of a cone, but resembles a drum-head, being stretched in the form of a plane almost or quite level with the top of the first rib. Its upper surface is strengthened by fibres from the deep fascias of the neck and, according to Sibson, by some fibres from the scalene muscle.

The pleura then slopes forward behind the sternoclavicular joint to meet the pleura of the opposite side at the level of the second costal cartilage, a little to the left of the median line. They then descend until opposite or a little below the fourth costal cartilage, when they each diverge toward the side, reaching the upper border of the seventh costal cartilage near its sternal junction. They then slope down and out, reaching the lower border of the seventh rib in the mammary line, the ninth rib

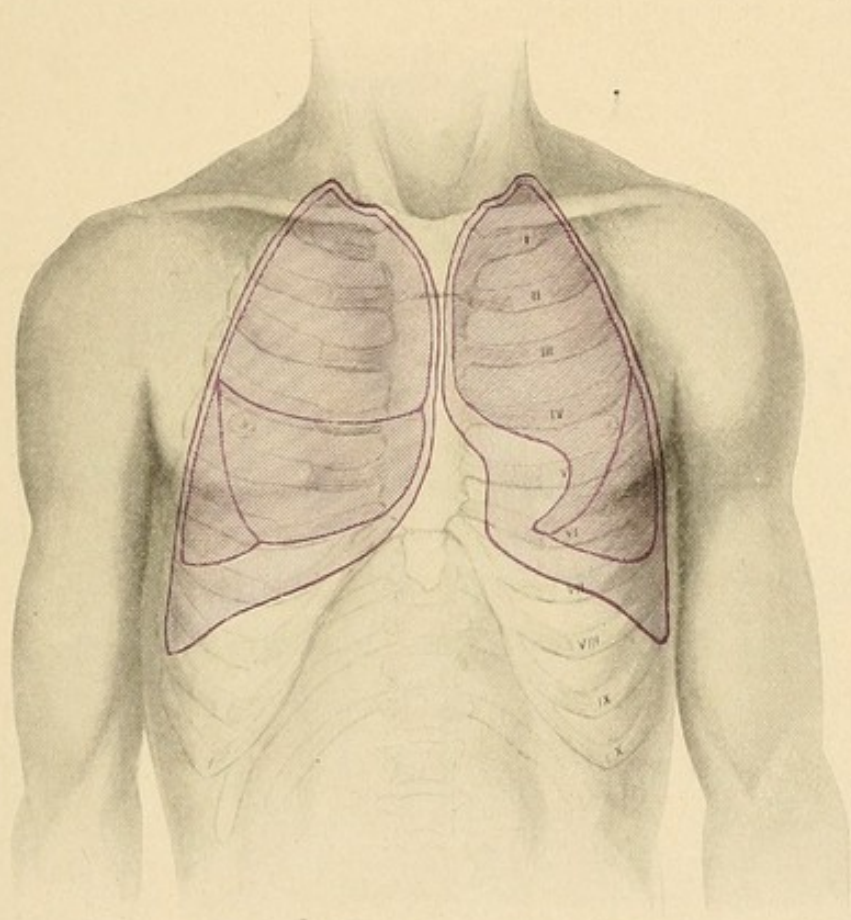


FIG. 214.—Anterior surface relations of the lungs and pleuræ.

in the axillary line, and the twelfth rib posteriorly (Joessel and Waldeyer, page 51). The scapular line intersects the lower edge of the pleura at about the eleventh rib.

In operations involving the lumbar region, if the incision is carried high up posteriorly the pleura may be opened along the lower border of the posterior portion of the twelfth rib. It soon recedes from the costal margin and in the axillary line is about 6 cm. ( $2\frac{2}{3}$  in.) above it.

A heavy body, as a bullet, gravitates to the lowest portion of the pleural cavity, hence it can be removed through an incision in the eleventh interspace posteriorly.

(Paracentesis and empyema will be alluded to after the lungs have been described, see p. 200).



## THE LUNGS

The lungs entirely fill the pleural sacs when completely distended, but only partly so in quiet, ordinary respiration. They are encased in a bony cage that is open below, on account of which, when the lungs distend, they expand mostly downward. To a less extent they expand, in forced respiration, both laterally and anteroposteriorly, due to the elevation of the ribs owing to the traction of the muscles upon them. Ordinary breathing is performed mainly by the diaphragm. It acts like the piston of a cylinder and as it descends the air is drawn into the trachea and lungs. As the diaphragm falls a negative pressure is produced within the chest and were it not for its bony framework, it would collapse. The framework is sufficiently strong to retain its shape in spite of this pressure if the breathing is

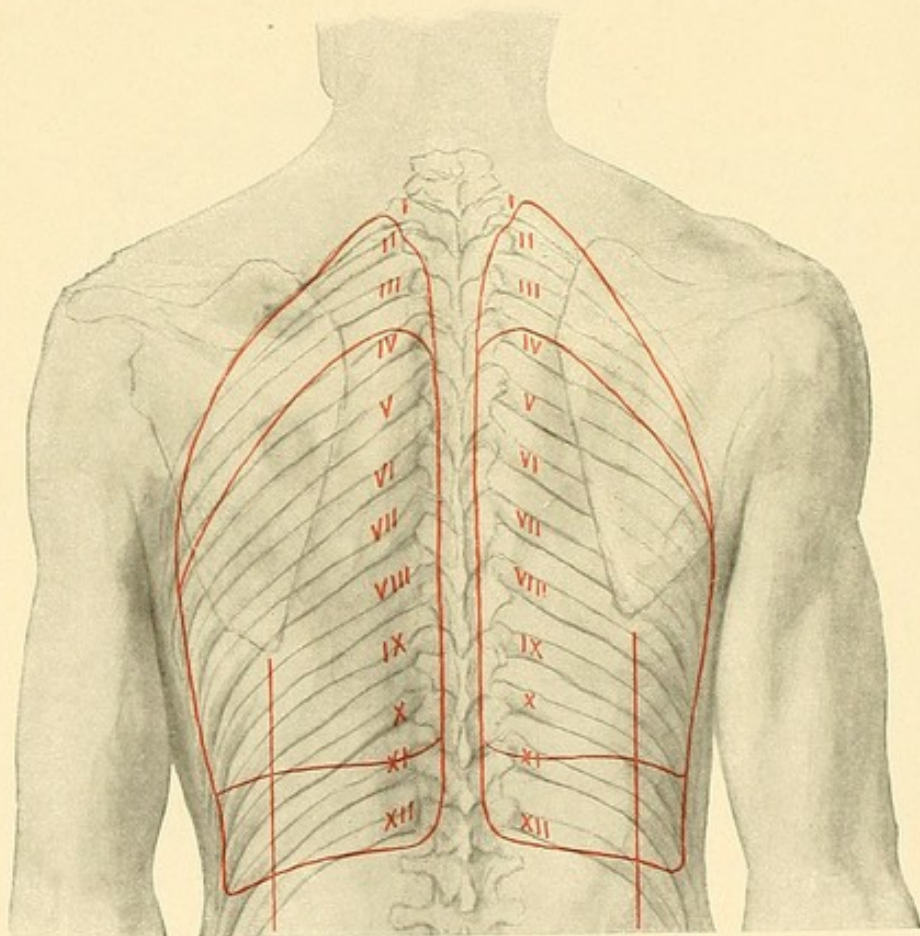


FIG. 215.—Posterior surface relations of the lungs and pleuræ.

normal and the chest-walls are healthy. When, however, obstruction of the air-passages is present, perhaps from enlarged pharyngeal or faucial tonsils or nasal hypertrophies, then the deformities known as funnel-breast, pigeon-breast, etc., already described, arise. They are also produced if there is no obstruction to the breathing but only a weakness in the bony thorax, as occurs in rickets.

Two of the most common of the diseases of the lungs produce changes in the shape of the thorax; they are emphysema and phthisis. Pneumonia, though a frequent enough disease, does not produce any changes, as it is too short in its duration.

In emphysema the lungs are in a state of hyperdistention, hence they fill the chest to its greatest capacity and tend to make the soft parts bulge between the ribs. In phthisis the lungs are contracted, hence the intrathoracic pressure becomes a negative one and the soft parts sink in between their bony support. In emphysema the anteroposterior diameter increases and the chest assumes the barrel-form already described. In phthisis it becomes lessened in its anteroposterior diameter and we



have the flat chest. Enlargement of the chest posteriorly is impossible on account of the support of the ribs, vertebræ, and strong back muscles. Enlargement downward is allowed by a descent of the diaphragm; hence the fulness of the abdomen in those affected with emphysema and conversely the flatness of the abdomen in those having phthisis. In the region of the apices the thorax is closed by the deep fascia, which spreads from the trachea, œsophagus, muscles, and great vessels and blends with the pleura to be attached to the first rib. In the normal condition this is level with the plane of the first rib and rises little if at all above it. Even in disease it is not materially altered. This is certainly so in phthisis and probably so in emphysema. The apparent fulness of the supraclavicular fossæ and intercostal spaces in emphysema and the increased depth of these hollows in phthisis are not due so much to a bulging or to a retraction of the lungs at these points as to the atrophy of the fatty and muscular tissue in phthisis and to the muscular tension in emphysema.

In coughing, the apex of the lung does not jump up into the neck above the clavicle as it appears to do, but remains nearly or quite below the plane of the top of the first rib. The appearance of bulging is caused by the movements of the trachea in the median line and the muscles laterally. This is noticeable particularly in the

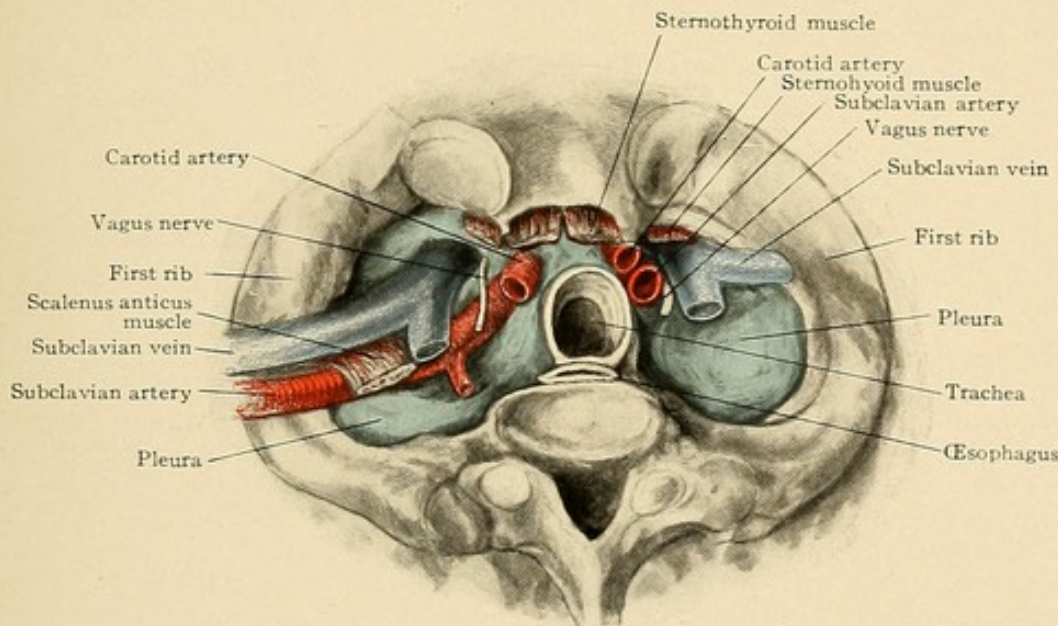


FIG. 216.—Upper end of the thorax, at the level of the first rib.

case of the platysma and omohyoid muscles. In quiet breathing the posterior belly of the omohyoid lies about level with the clavicle, but in coughing it rises 1 or 2 cm. above it. The intercostal membranes and muscles are kept tense by the constant elevation of the ribs due to the muscular tension.

### OUTLINE OF THE LUNGS.

**Apex.**—The apex of the lung has its highest point opposite the posterior extremity of the first rib. It then follows the plane of the top of the first rib down to the sternoclavicular joint, immediately above the junction of the cartilage of the first rib with the sternum. The anterior end of the first rib is 5 cm. lower than the posterior. The upper edge of the clavicle is 2.5 cm. or one inch, above the anterior end of the first rib and 2.5 cm. below the head of the first rib, hence the apex of the lung rises 2.5 cm. (1 in.) above the clavicle, and it lies behind its inner fourth. This distance will vary in different individuals with the obliquity of the ribs. The more oblique the ribs the greater will be the distance between the level of the top of the clavicle and that of the neck of the first rib.

**Anterior Border.**—From the sternoclavicular joint the borders of the lungs pass downward and inward until they almost or quite touch in the median line at the angle of Ludwig opposite the second costal cartilage. They continue downward



almost in a straight line until opposite the fourth costal cartilage, where they begin to diverge. The border of the right lung proceeds downward and begins to turn outward opposite the sixth cartilage.

The left lung on reaching the level of the fourth costal cartilage curves outward and downward across the fourth interspace to a point about 2.5 cm. to the inner side of the nipple in the fourth interspace. From this point it goes downward and inward across the fifth rib and interspace to the top of the sixth rib about 3 cm. to the inner side of the nipple line. This isolated tip of lung just above the sixth rib over the apex beat of the heart is called the *lingula*.

**Lower Border.**—The lower edge of the lung varies in different individuals and in the same individual according to the amount of inflation. In quiet respiration it is about opposite the sixth cartilage and rib from the sternum to the mammary line, opposite the eighth in the midaxillary line, the tenth in the scapular line, and the eleventh near the vertebræ.

**The Fissures and Lobes of the Lungs.**—The left lung has one fissure and two lobes, an upper and a lower.

The right lung has two fissures and three lobes, an upper, a middle, and a lower.

The fissure of the left lung begins above and posteriorly opposite the root of the spine of the scapula; this is level with the fourth rib and third dorsal spine. It passes downward and forward, ending at the sixth rib in the parasternal line. It crosses the fourth in the midaxillary line. The lower lobe of the right lung is of the same size as that of the left side. The lung above it is divided into a middle and upper lobe. The main fissure of the right lung corresponds in its course almost exactly with that of the left lung. It begins above and posteriorly at the root of the spine of the scapula and passing downward crosses the fourth rib in the midaxillary line and ends at the sixth rib in the mammary line (instead of the parasternal line as in the left).

The subsidiary fissure of the right lung leaves the main fissure at the posterior axillary line opposite the fourth rib and follows this rib in an almost horizontal direction to its junction with the sternum.

In order to recognize and appreciate the changes which occur in the lungs in *lobar pneumonia* it is necessary to know the outlines and limits of the various lobes of the lungs. A knowledge of the exact course of the fissures of the lungs is not only necessary to outline the lobes, but it is of service in the diagnosis of pleural effusions. These effusions often are limited to certain localized areas instead of being general.

*Pleurisy* may affect the lung bordering the fissures. When such is the case, the effusion, serous or purulent, may be in the fissure itself and embrace but little of the general pleural cavity. Dry taps from failure to hit the purulent or serous collection are not infrequent, and the possibility of its being interlobular should be borne in mind.

## GENERAL CONSIDERATIONS.

From what has been said it follows that a knowledge of the extent and outlines of the lungs and of the location and course of the fissures is essential to the proper diagnosis and treatment of affections of both the lungs and pleuræ.

The extent of the lungs is determined in the living by percussion. The apex of the lungs forms an oblique plane running upward and backward from just below the lower edge of the inner extremity of the clavicle to the neck of the first rib above and posteriorly. The level of these two points will vary according to the inclination of the ribs, which in turn is influenced by the direction (vertical) of the spine. Ordinarily the distance is 5 cm. (2 in.). It may be even as much as 7 or 8 cm. The top edge of the clavicle passes across the middle of this distance so that the top of the lung is about 2.5 cm. (1 in.) above the clavicle. The highest point of the lung is not in the middle of the space enclosed by the first rib, but is at its posterior border, at the neck of the first rib.

In percussing, one should not strike directly backward but both downward and backward.

If the patient is standing erect the first rib will slope downward and forward at an angle of 65 degrees, or more, with a vertical line. The spine will slope downward and backward from the same vertical line in a normally straight back about 20 degrees.



In people with straight backs and flat chests (often seen in phthisis), the sloping downward of the ribs is marked; in those with rounded backs the chest is apt to be round, as in emphysema, and then the ribs are more horizontal.

Another point to be noticed is the lateral extent of the apex of the lung in relation to the length of the clavicle. The lung does not extend farther out on the clavicle than one-fourth its length. The clavicular origin of the sternomastoid muscle extends out one-third of the length of the clavicle, so that the lung is behind the clavicular origin of the sternomastoid and care should be taken not to percuss too far out. If the finger is laid in the supraclavicular fossa in percussion it should be pressed downward and inward, not backward.

Posteriorly the scapula rises to the second rib and its spine has its root opposite the fourth rib or spinous process of the third thoracic vertebra. Therefore a small portion of the lung is above the upper edge of the scapula and percussion in the supraspinous fossa gives a clear resonant note.

Behind the middle of the first piece of the sternum passes the trachea, crossed by the left innominate vein. The trachea of course contains air; the lungs slope

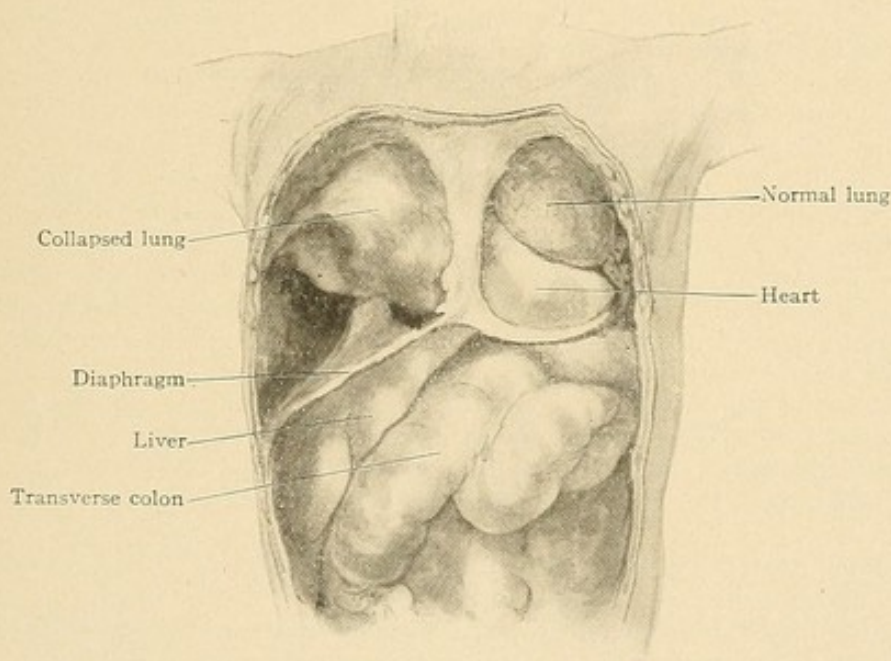


FIG. 217.—Formalin-hardened body, showing the right lung collapsed and compressed by a large pleural effusion.

inward from the sternoclavicular joints to meet nearly or quite in the median line and so continue to the level of the fourth rib; hence it follows that the percussion note on the sternum nearly down to this point is resonant and if it be found to be dull one should look for an aneurismal or other tumor which is displacing or covering the lungs and trachea at this point and thereby subduing their resonance.

Below the fourth rib the area of the absolute heart dulness becomes evident. (This will be alluded to in describing that organ later on.)

In performing abdominal operations, as those involving the gall-bladder and kidney, the surgeon may be tempted to prolong his incision upward into the lower edge of the chest-walls, and it is necessary to know how far he can proceed without opening the pleural cavity. This necessitates his knowing how far from the lower edge of the chest the pleura lies. It reaches to the seventh rib in the mammary line, the ninth in the axillary line, and the twelfth posteriorly, extending to its extreme lower edge.

In the axillary line the pleura is about 6 cm. ( $2\frac{2}{3}$  in.) away from the edge of the thorax. This distance gets less as one proceeds forward to the sternum and backward toward the spine.



In emphysema the lung, being distended, occupies more nearly the outlines of the pleura and its area of resonance is increased. In pleural effusion it is compressed and even sometimes collapsed. As it shrinks it recedes inward and backward and is pushed from the chest-wall by the layer of fluid (Fig. 217). The pressure of the fluid within causes the intercostal spaces to be obliterated and sometimes even to bulge instead of being depressed. As the expansion of the lung is prevented, the chest does not move on the affected side, or expand with the respiration, as it does on the healthy side. This can be demonstrated by measuring the two sides of the chest. At the end of expiration the affected side will be from 1 to 3 cm. greater in circumference than the healthy one. If the pleural effusion is on the right side it may push the heart to the left and raise its apex beat and cause it to pulsate beyond the nipple line and even in the axilla. If it is on the left side the costomediastinal sinus (page 196) becomes distended with fluid or plastic lymph and this obscures or conceals the heart's impulse. If the effusion is very large the heart is pushed over toward the right and its apex beat is seen in the third or fourth interspace on the right side even so far over as the mammary line.

Should the effusion be purulent it may perforate the chest-wall, or open into the pericardium anteriorly, the œsophagus posteriorly, and into the stomach or peritoneal cavity below. If it perforates the chest-wall it usually does so anteriorly between the third and sixth interspaces, most often in the fifth.

**Paracentesis.**—Where the pleural effusion is serous it is usually drawn off by an aspirating needle or trocar.

For diagnostic purposes a hypodermic syringe needle is often used, as the chest-walls are usually thin enough to allow this to be done, particularly if a suitable spot is chosen and the patient is a child. Care should be exercised not to strike a rib. The spot chosen for puncture may be indicated by dulness on percussion. It may be anywhere, but when a choice is permissible the puncture should be made in the sixth interspace about in the middle or postaxillary line. Another preferred spot is in the eighth interspace, below the angle of the scapula. The sixth interspace may be determined in several ways, viz.:

1. Begin at the angulus sterni (angle of Ludwig) and follow out the second rib to the parasternal or midclavicular line, thence count down to the sixth rib and follow it to the midaxillary line.
2. The nipple is in the fourth interspace, follow it to the axillary line and count two spaces down.
3. The apex beat of the heart is in the fifth interspace, follow it around to the axillary line and take the next space below.
4. Find the last rib that articulates with the sternum—it is the seventh; follow it around and take the space above.
5. With the arm to the side the inferior angle of the scapula marks the seventh interspace; take the interspace next above.
6. A horizontal line at the level of the nipple cuts the midaxillary line in about the sixth interspace.
7. The lower edge of the pectoralis major touches the side of the chest at the fifth rib. Follow it to the axillary line and go two spaces lower.
8. By raising the arm the serrations of the serratus anterior muscle attached to the fifth, sixth, seventh, and eighth ribs become visible; that attached to the sixth rib is the most prominent and is attached farthest forward.

**Empyema.**—When the pleural effusion is purulent, tapping is not sufficient, and drainage is resorted to. It is not considered necessary to open the pleural cavity at its lowest part but the sites chosen are usually the sixth or seventh interspace in the mid- or postaxillary line. The movements of the scapula are apt to interfere with drainage immediately below its angle, hence the opening is usually made farther forward. The surgeon may or may not resect a rib.

The ribs may lie so close together as to compress the drainage-tube; in such case a resection is done if the patient's condition permits.

**Incision for Empyema.**—In certain cases the condition of the patient may demand that as little as possible be done, and that quickly. The point of operation is selected by one of the guides already given, perhaps the level of the nipple.



While the finger of one hand marks the interspace, an incision 4 cm. ( $1\frac{1}{2}$  in.) long is made along the upper edge of the rib, this is deepened by a couple of strokes which detach the intercostal muscles and carefully penetrate the pleura. As the pus makes its appearance the knife is withdrawn and the finger is laid on the opening. A drainage-tube held in a curved forceps is then slid along the finger into the chest. Sometimes a rubber tracheotomy tube is used for drainage purposes. Any bleeding will be from the small intercostal branches and can readily be stopped by gauze packing.

The incision is made along the upper edge of the rib because the intercostal artery running along the lower edge of the rib is the larger.

*Resection of a Rib for Empyema.*—For the removal of a part of a rib a more formal operation is necessary. The incision is made directly on the rib down to the bone and five or more centimetres in length. The skin being retracted, the periosteum is incised and detached from the rib with a periosteal elevator which is passed down its posterior surface, pushing the pleura away from the rib. When the elevator reaches the lower border of the rib an incision is made down on it through the intercostal muscles, keeping as close to the rib as possible to avoid wounding the intercostal artery, which lies close to its lower edge. The rib is then divided either with a cutting forceps like Estlander's, or a Gigli saw. The rib, having been divided at one end of the incision, is then lifted up, the pleura stripped off, and divided at the opposite end.

Should the intercostal artery bleed, and it is often sufficiently large to spurt quite actively, it can be caught with a hæmostatic forceps and secured with a ligature if necessary. This is safer than to trust to packing, on account of the lack of support due to the removal of the rib. After the incision is completed, the pleura is incised and the tube introduced. In ligating the intercostal artery, care should be taken not to include the nerve which lies close to but below it; that is, farther away from the rib.

## THE PERICARDIUM.

The pericardium is composed of fibrous tissue lined with a serous membrane.

When affected by inflammation the amount of fluid contained in it becomes increased and it becomes distended and may interfere with the functions of the heart and adjacent structures.

If the effusion is serous it is sometimes drawn off by puncture; if it is purulent drainage is instituted.

The pericardium in shape is somewhat conical. Its base rests on the central tendon of the diaphragm and its apex envelops the great vessels, as they emerge from the base of the heart, for a distance of 4 to 5 cm. The attachment to the diaphragm is most firm at the opening of the inferior vena cava. As the fibrous layer of the pericardium proceeds upward it becomes lost in the fibrous tissue (sheath) covering the great vessels. This is continuous above with the deep cervical fascia, especially with its pretracheal layer. Anteriorly the pericardium is attached above and below to the sternum by the so-called *sternopericardiac ligaments* (Fig. 218).

In front of it above are the remains of the *thymus gland* and *triangularis sterni* muscle of the left side from the third to the seventh costal cartilages. The *internal mammary arteries*, running down behind the costal cartilages about a centimetre from the edge of the sternum above and somewhat more below, are separated from the pericardium by the edges of the lungs and pleuræ, these latter reaching nearly or quite to the median line. The *triangularis sterni* muscle also lies beneath the artery and farther from the surface. As the left pleura slopes more rapidly toward the side than does the right there is a small portion of the pericardium uncovered by the pleura at about the sixth intercostal space close to the sternum. The incisura of the left lung leaves a space where the pericardium is separated from the chest-walls only by the pleura.

On each side the pleura and pericardium are in contact, with the phrenic nerves between them. Posteriorly the pericardium lies on the bronchi, the œsophagus, and the thoracic aorta.



Owing to the fibrous nature of the pericardium it will not expand suddenly. While only about a pint of liquid can be injected into the normal pericardial cavity after death, if a chronic effusion exists in a living person as much as three pints may be present.

Sudden effusion occurring in the living patient will cause obstruction of the circulation at the base of the heart; it may by pressure on the bronchi at the bifurcation produce suffocative symptoms and by pressure on the œsophagus difficulty in swallowing. The lungs are displaced laterally, and the stomach and liver downward. The largest effusions are slow in their formation.

Pressure on the left recurrent laryngeal nerve as it winds around the aorta sometimes produces alteration or loss of the voice.

In children, according to Osler, the præcordia bulges and the anterolateral region of the left chest becomes enlarged as does also the area of the cardiac dulness.

**Paracentesis of the Pericardium.**—Tapping the pericardium by means of a trocar or aspirating needle must be carefully done, or the pleura may be punctured.

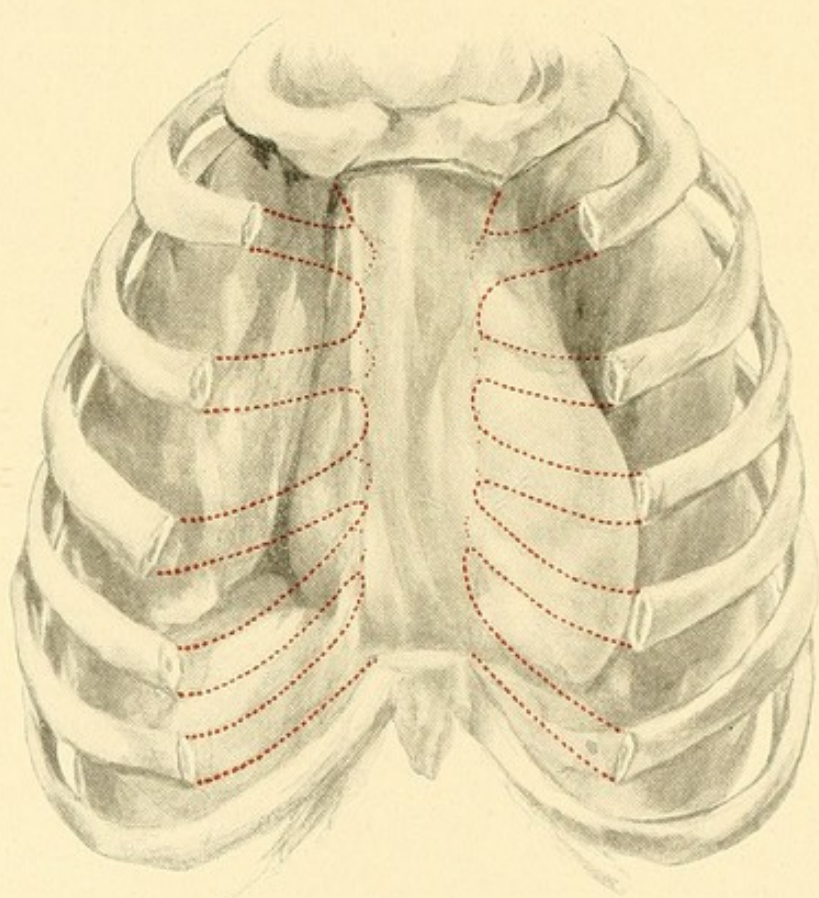


FIG. 218.—View of the pericardium, slightly distended, and its relations to the bony thorax.

The part of the pericardium in contact with the chest-wall and not covered by pleura is very small. It embraces the space between the two pleuræ from the fourth to the seventh ribs. This may be defined by three lines, one in the midline, another from the middle of the sternum opposite the fourth rib to the costosternal junction of the seventh rib, and a third joining these two passing through the articulation of the xiphoid cartilage (Fig. 219).

The left pleural sac may be 1 cm. farther from the edge of the sternum than the right. Thus it is seen that there is hardly a point where a needle can be introduced with the certainty of avoiding the pleura. The safest point is probably close to the left edge of the sternum in the sixth interspace. This interspace may not extend to the sternum, but even if the cartilages are in contact a needle could probably be introduced at this point. As the pericardium is distended it carries the lungs and to a less extent the pleura outwards and increases the area available for puncture both



upward and downward as well as to the sides. When greatly distended the pericardium may reach to the first interspace above, 2.5 cm. (1 in.) to the right of the sternum, to the seventh cartilage below, and to the left nipple line or even beyond. The arching of the diaphragm causes a sternophrenic sinus behind the sternum analogous to the costophrenic sinus at the lower edge of the chest. This becomes distended by pericardial effusions in the same manner as does the costophrenic sinus in pleural effusions. A puncture in the sixth space close to the left edge of the sternum enters this sinus. The increased area in cases of distention from pericardial effusions has led Osler to advise tapping in the fourth interspace, either at the left sternal margin or 2.5 cm. from it, or at the fifth interspace 4 cm. (1½ in.) from the sternal margin; or by thrusting the needle upward and backward close to the costal margin in the left costoxiphoid angle.

It is important to avoid wounding the internal mammary artery, which is usually

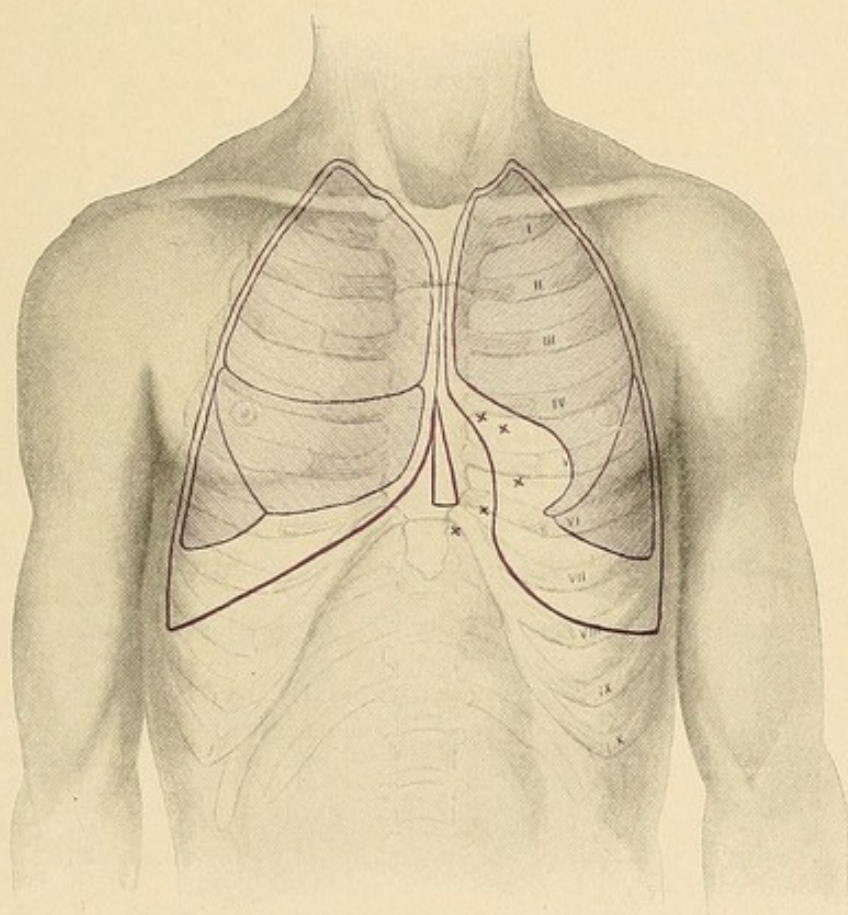


FIG. 219.—Paracentesis of the pericardium.

nearer to the sternum above (0.5 to 1 cm. to its outer side) and farther from it (2 to 3 cm.) below.

The danger of wounding the pleura in aspirating with a needle has probably been overestimated, but when drainage is to be employed the danger is certain.

**Drainage of the Pericardium.**—To drain the pericardium requires the removal usually of at least one of the costal cartilages. A drainage-tube can sometimes be introduced by first making a short incision in the fifth or sixth interspace close to the left edge of the sternum, then puncturing the pericardium, dilating the puncture with forceps, and introducing the tube. The costal cartilages usually lie so close together as to interfere with the proper introduction of a tube, hence the necessity of resection. A flap may be made or a straight incision. The latter is sometimes made over the fifth costal cartilage, which is then resected. If desired the sixth and seventh cartilages are also removed and even a piece of the left edge of the sternum. The intercostal muscles having been raised, the cartilages are removed.



When the internal mammary artery is seen lying beneath, it is to be either ligated or drawn to one side. The triangularis sterni muscle is either incised or drawn to the outer side along with the edge of the left pleura. The pericardium can then be lifted with forceps and incised and the drainage-tube introduced.

## THE HEART.

In size the heart is somewhat larger than the clenched fist. It measures 12.5 cm. (5 in.) in length, 7.75 cm. ( $3\frac{1}{2}$  in.) in width, and 6.25 cm. ( $2\frac{1}{2}$  in.) in thickness. Its weight in the adult male is 250 to 300 Gm. (8 to 10 oz.), in the female it is 60 Gm. (2 oz.) less.

It lies enclosed in its pericardium in the middle mediastinum between the sternum (from the upper edge of the third costal cartilage to the sternoxiphoid articulation) in front, and the bodies of the fifth, sixth, seventh, and eighth thoracic vertebræ behind. Laterally it reaches from two centimetres to the right of the sternum nearly to the left nipple line. On each side of it are the lungs, from which it is separated by the pleuræ and pericardium with the phrenic nerves between. Above are the great vessels and below it rests on the central tendon of the diaphragm.

In shape the heart resembles an acorn, the *atria* (*auricles*), forming the upper right portion and the *ventricles* the lower left portion. It lies with its right side resting on the diaphragm and its apex pointing forward and to the left.

For convenience one speaks of a *base*, an *apex*, a *right border*, a *lower border*, and a *left border*.

### OUTLINES OF THE HEART.

The base of the heart is opposite the upper border of the third costal cartilage. It is here that the superior vena cava ends and the aorta begins. It extends from 1.25 cm. ( $\frac{1}{2}$  in.) to the right of the sternum to 2.5 cm. (1 in.) to the left of the sternum.

The right border of the heart extends from 1.25 cm. ( $\frac{1}{2}$  in.) to the right of the sternum at the upper border of the third costal cartilage in an outwardly curved line to the junction of the seventh rib and the sternum. In the fourth interspace it may reach 2.5 cm. (1 in.) beyond the right edge of the sternum.

The lower border passes from the seventh right chondrosternal junction across the sternoxiphoid joint outward in the fifth interspace to the apex beat, which is 4 to 5 cm. ( $1\frac{1}{2}$  in. to  $1\frac{3}{4}$  in.) below and to the inner side of the nipple and about 8.75 cm. ( $3\frac{1}{2}$  in.) to the left of the median line. This marks the extreme left limit of the heart. In children the apex is higher—it is in the fourth interspace. In old people it is lower.

The left border arches upward from the apex beat, as just given, in an inward and upward direction to 2.5 cm. (1 in.) to the left of the sternum at the upper border of the third costal cartilage.

The atrio- (auriculo-) ventricular groove or line of junction between the atria (auricles) and ventricles runs from the sixth right chondrosternal junction upward and to the left to the third left chondrosternal junction. The atria lie above and to the right of this line and the ventricles below and to the left.

The right atrium (auricle) and right ventricle lie anteriorly and the left atrium and left ventricle lie posteriorly. In the right atrioventricular groove runs the right coronary artery. As it lies on the anterior portion of the heart it is liable to be injured in stab-wounds and give rise to fatal bleeding, as may also the interventricular branch of the left coronary artery as it passes down near the left border of the heart between the right and left ventricles.

*The Portion of the Heart Uncovered by Lung-tissue.*—When the lungs are distended the right lung covers the heart to the median line. The left lung leaves the median line at the level of the fourth costal cartilage and curves outward and downward to about the apex beat in the fifth interspace, 2.5 cm. to the inner side of the nipple line. At this point a small piece of the lung, the *lingula*, sometimes curves around in front of and below the extreme tip of the heart. As the air leaves the lungs they retract and their anterior borders hardly reach the edges of the sternum.



**Area of Cardiac Dulness.**—The area of cardiac dulness corresponds to the area uncovered by lung and in contact with the chest-wall. This is the area of absolute dulness. It begins opposite the fourth costal cartilage and extends down the sternum, between the median line and left edge, to the liver dulness below opposite the sixth costal cartilage. Toward the left side it arches from the fourth left costosternal junction to the apex beat. The area of so-called relative dulness caused by overlapping of the lungs extends along the right edge of the sternum to opposite the upper border of the third rib above, and to the left follows parallel to the left border of the heart to the tip of its apex. Below it blends with the liver dulness (Fig. 221).

The area of cardiac dulness may be increased not only by the enlargement of the heart itself but by pericardial effusions and disease such as aneurism of the great vessels.

In an early stage of pericardial effusion and also in aneurism there may be an

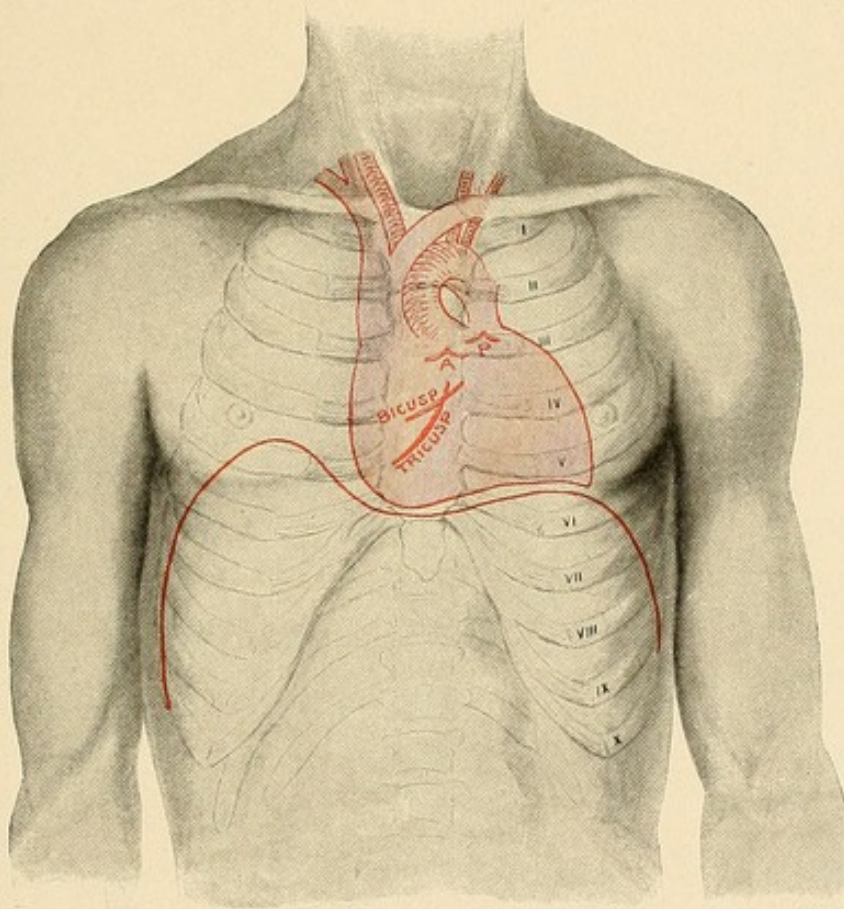


FIG. 220.—Relations of the heart, its valves, and the great blood-vessels to the surface of the chest.

extension of the area of dulness upward. In a later stage of pericarditis the lateral area of dulness becomes increased.

**Cardiohepatic Angle** (Ebstein).—This is the angle formed by the right border of the heart as it meets the liver. It is a more or less resonant area in the fifth right intercostal space. Below it is the liver dulness and above and towards the median line is the heart.

#### VALVES OF THE HEART.

There are two types of valves in the heart: the *bicuspid* (*mitral*) and *tricuspid* between the atria (auricles) and ventricles, and the two sets of *semilunar valves* at the entrance of the pulmonary artery and aorta. (See Fig. 220.)

The **bicuspid valve** is the most important and is the deepest seated. It lies at the edge of the left border of the sternum opposite the fourth costal cartilage. It separates the left atrium and ventricle and lies nearly transversely.



The **tricuspid valve** lies in the middle of the sternum opposite the fourth intercostal space. It runs obliquely downward and to the right from the third left intercostal space to the fifth right costal cartilage. It separates the right atrium and ventricle.

The **pulmonary semilunar valve** lies opposite the sternal end of the third left costal cartilage. It is the most superficial valve and the one highest up on the sternum. It prevents regurgitation of the blood into the right ventricle from the lungs.

The **aortic semilunar valve** lies under the left side of the sternum about level with the lower edge of the third costal cartilage. It is just below and to the right of the pulmonary valve, and above and to the left of the bicuspid valve.

#### LOCATION OF VALVULAR SOUNDS.

The sounds produced by the closure of the valves do not correspond with the position of the valves, but are as follows.

The **bicuspid sound** is heard most distinctly at the apex of the heart as far inward as the parasternal line and as high as the third interspace. It is transmitted around the chest toward the axilla.

The **tricuspid sound** is best heard at the left sternal border between the fifth and sixth costal cartilages (Tyson).

The **pulmonary sound** is best heard in the second interspace to the left of the sternum; the cartilage above is called the pulmonary cartilage.

The **aortic sound** is best heard in the second right intercostal space and the cartilage above is called the aortic cartilage. The aortic sounds are transmitted up the neck in the direction of the great blood-vessels.

#### VARIATION IN SIZE AND POSITION OF THE HEART.

The heart becomes enlarged both by being dilated and by being hypertrophied, usually both conditions are present; and its position is often changed by disease both of itself and of adjacent organs. It is apt to enlarge unequally. In *emphysema* and *bicuspid regurgitation* the right side becomes enlarged, the pulmonary circulation being impeded. In *aortic disease*, *arteriosclerosis*, *muscular exertion*, or any cause impeding the course of the blood through the arteries there is produced an enlargement of the left side of the heart.

The average weight of the healthy heart is in the male 280 Gm. (9 oz.), and in the female 250 Gm. (8 oz.). These may be doubled in cases of enlargement. When the heart is enlarged the apex beat changes its position; it may occupy the sixth, seventh, or eighth interspace instead of the fifth, and may be as far as 5 to 7.5 cm. (2 to 3 in.) to the left of the nipple line.

When it enlarges upward, instead of the absolute dulness beginning opposite the fourth costal cartilage, it is opposite the third or even the second interspace. Toward the right side the absolute dulness may extend a couple of centimetres beyond the right edge of the sternum, instead of being near its left edge as is normal.

The heart is readily displaced by pressure from the surrounding structures. If there is abdominal distention by gas or ascites, or if the liver or spleen is enlarged, the heart is pushed upward. Enlargement of the liver may likewise depress the heart, if the patient is in an upright position, by the weight of the liver dragging it down. Aneurisms of the arch of the aorta, tumors, or emphysema may also depress it. In the aged the apex beat may be normally in the sixth interspace.

Lateral displacement occurs in cases of pleural effusion. Osler says ("Pract. of Med.," p. 594), this is not due to a twisting of the heart on its axis but to a positive lateral dislocation of the heart and pericardium. Pneumothorax or tumors on one side may also push the heart toward the opposite side. It may be pulled to one side by pleural adhesions and in those cases of fibroid phthisis in which the lung becomes markedly retracted. Abscess or tumors of the mediastinum also displace it.

The position of the pulsation of the heart is not always an indication of the position of the apex. In pleural effusion the pulsation may be one, two, or three interspaces higher than normal, while the apex itself may not be elevated.



## WOUNDS OF THE HEART.

Wounds of the heart are usually immediately fatal, but sometimes they are not so. The pleuræ are very liable to be wounded at the same time. The right ventricle, on account of lying anteriorly, is the part most often involved. The atria lie more posteriorly and are most apt to be wounded in stabs through the back. Not only may the substance of the heart itself be injured but also its blood-vessels. The right coronary artery lying in the atrioventricular groove and the anterior interventricular branch of the left coronary running between the two ventricles anteriorly are the vessels most liable to injury. Owing to the heart being enclosed in the pericardium,—a closed sac,—if blood accumulates in it the action of the heart is inter-

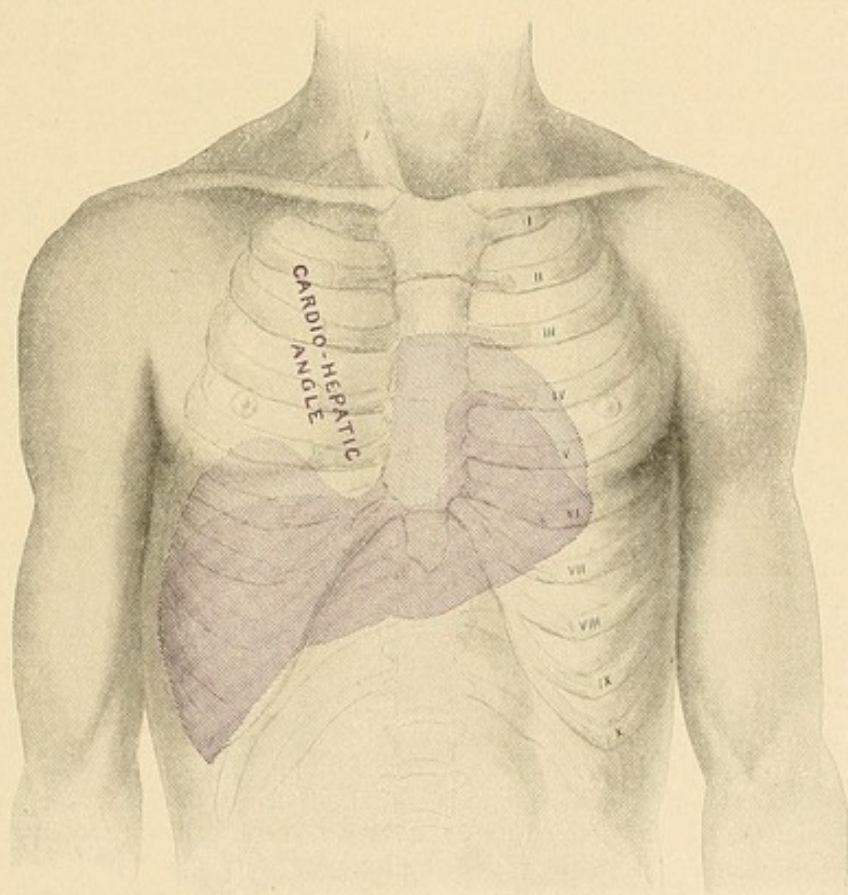


FIG. 221.—Percussion area of the liver and heart. The light shaded area represents the extent of deep or relative dulness and the dark shaded area that of superficial or absolute dulness.

ferred with. To avoid this occurrence, wounds bleeding externally should not be closed, or distention of the pericardium may ensue.

Wounds of the heart have been sutured successfully. In order to reach the heart, a portion of the chest-wall would have to be resected and turned to one side as a flap. This will probably require the opening of the pleural cavity. The pleuræ will in all likelihood already have been involved and found to be filled with blood, as has occurred in at least one case.

A knowledge of the exact outlines of the heart as already given will often enable one to decide as to whether a wound involves the heart or not.



## THE AORTA.

The aorta, as it leaves the left ventricle, begins under the left portion of the sternum opposite the lower border of the third left costal cartilage. This is the location of the aortic semilunar valves as already given. It passes upward toward the right for 5 cm. and then forms an arch, extending backward toward the left, to reach the spine on the left side of the body of the fourth thoracic vertebra. The arch is continued down in front of the spine as the thoracic aorta and pierces the diaphragm in the median line, between the two crura of the diaphragm, opposite the twelfth thoracic vertebra.

The **ascending aorta** begins behind the left half of the sternum on a level with the lower border of the third costal cartilage. It proceeds upward toward the right until it reaches the level of the lower border of the right second costal cartilage, where the arch begins.

Immediately above its commencement it has three enlargements, called the *sinuses* of the aorta (Valsalva), which correspond to the semilunar valves. Of the three semilunar valves two are anterior and one is posterior. From behind the two anterior valves come the *right* and *left coronary arteries*.

Beyond the valves, in the upper right portion of the arch, the aorta is again dilated, forming the *great sinus* of the arch of the aorta.

The right limit of the aorta is about even with the right edge of the sternum; sometimes it projects slightly beyond. When it does so it is liable to be wounded by a stab in the second interspace close to the edge of the sternum. On account of the proximity of the aorta to the second interspace, it is here that the stethoscope is placed to hear aortic murmurs. The aorta at this point is covered only by the thin border of the right lung and pleura and the slight remains of the thymus gland. Below, its commencement is overlapped on the right by the *auricula dextra* (right auricular appendix) of the atrium and on the left by the commencement of the *pulmonary artery*.

The ascending aorta is liable to be the seat of aneurism. It may involve either the lower portion in the region of the sinuses or the region of the great sinus at its upper right anterior portion.

If the aneurism enlarges anteriorly it will show itself first in the second or third interspace. It will bulge the ribs outward in this region. The right lung will be pushed outward and the two layers of the pleura pressed together. It may break externally through the surface or open into the pleural cavity. If it tends to the right it presses on the descending cava and right atrium, thus interfering with the return of the blood from the head and neck and both upper extremities. If it enlarges to the left or backward it may press on the right pulmonary artery and interfere with the free access of blood to the lungs.

The first portion of the aorta is not united with the pericardium, but simply loosely covered by it, so that this portion of the arch is weaker than the other portions, and rupture, with extravasation of blood into the pericardial sac, is not uncommon. An aneurism may also rupture into the superior vena cava.

The **arch of the aorta** passes anteroposteriorly from the upper border of the second right costal cartilage in front to the left side of the body of the fourth thoracic vertebra behind. It is about 5 cm. (2 in.) long. Its under surface is level with the angle of the sternum (angle of Ludwig), opposite the second costal cartilage. Its upper surface rises as high as the middle of the first piece of the sternum, which is opposite the middle of the first costal cartilage, about 2.5 cm. (1 in.) below the top of the sternum.

*Relations.*—*In front* of the arch the right lung and pleura cover it slightly, but the left more so; the remains of the thymus gland is between them. The left superior intercostal vein crosses its upper portion to empty into the left innominate vein. The left phrenic and vagus nerves also cross it, the phrenic being the farther forward and the vagus crossing almost in front of the point of origin of the left subclavian artery. *Behind* lie the trachea, œsophagus, and thoracic duct, also the left recurrent laryngeal nerve. The bifurcation of the trachea is directly behind and below the lower portion of the arch and the left bronchus passes beneath it. The œsophagus lies



compressed between the trachea and vertebræ with the thoracic duct immediately to the left. The left recurrent laryngeal leaves the pneumogastric on the front of the arch, then winds around it and ascends between the trachea and œsophagus to reach the larynx above. *Above*, from the upper surface of the aorta, are given off the innominate, left carotid, and left subclavian arteries. The left innominate vein crosses above its upper edge to unite with the right innominate to form the superior cava. *Below* is the left bronchus coming off from the bifurcation of the trachea, and winding around the arch is the left recurrent laryngeal nerve. Beneath the arch and in front of the bronchi are the right and left pulmonary arteries. From the latter the ductus arteriosus goes to the arch. The cardiac branches of the pneumogastric and sympathetic nerves lie on the anterior, inferior, and posterior sides of the arch.

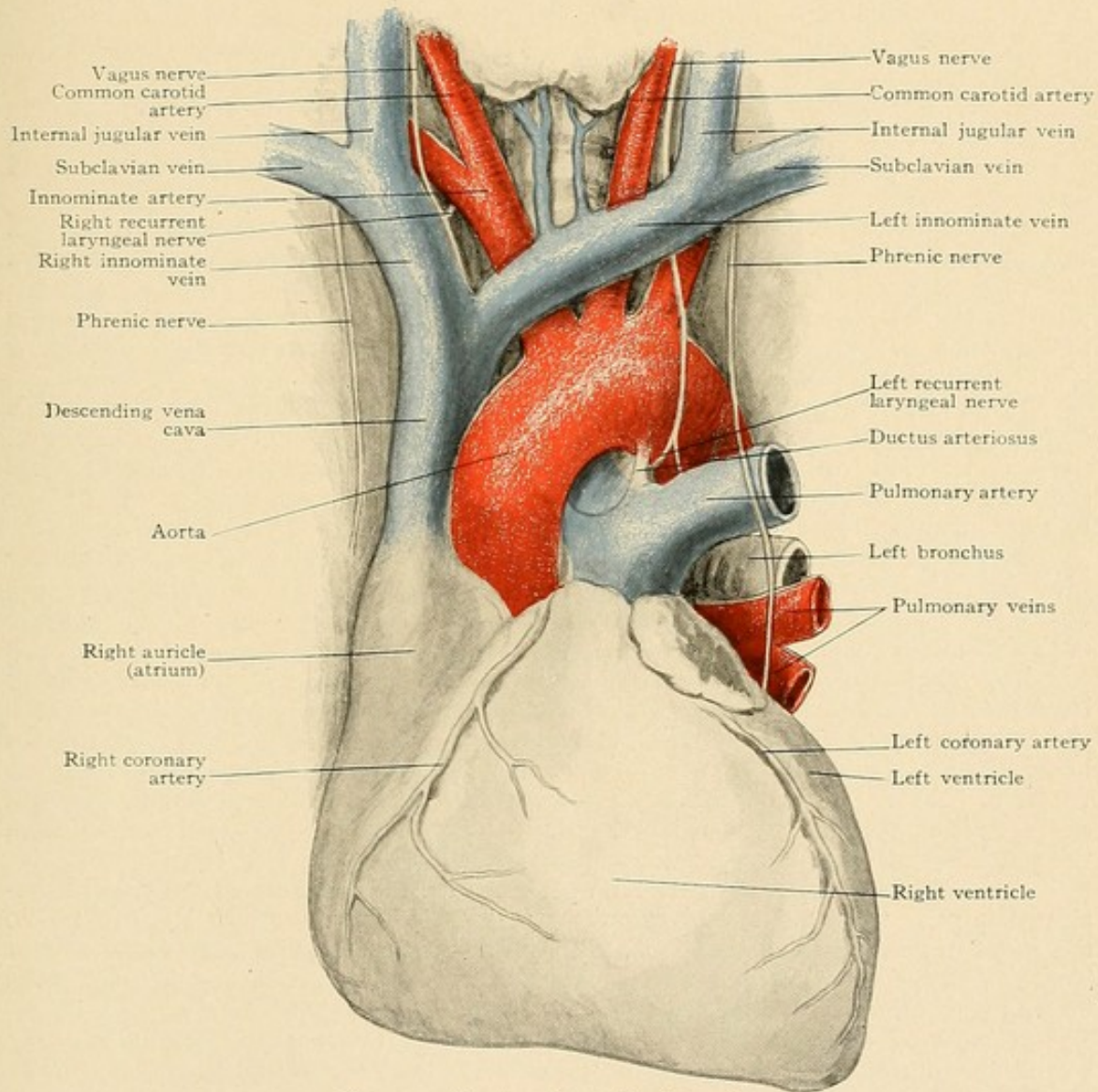


FIG. 222.—Heart and great blood-vessels.

The **ductus arteriosus** at birth is about 1 cm. long and runs from the pulmonary artery to the arch of the aorta below the left subclavian artery. It serves in the fœtus to carry the blood from the trunk of the pulmonary artery direct to the aorta instead of passing into the lungs. When, after birth, the lungs are used the ductus arteriosus becomes obliterated and is found later in life as a cord running to the under side of the arch of the aorta. Congenital defects in the heart are a frequent cause of death at birth and in infancy and childhood. They cause an undue mixture of the venous and arterial blood and give the surface a dusky, bluish hue, hence the term "blue baby" as applied to this condition. It is due to an absence of a part



or the whole of the septa between the atria and ventricles; to a patulous condition of the foramen ovale of the right atrium; and also to a persistent patulous condition of the ductus arteriosus. Children so affected, if they outlive infancy, usually die before reaching adult age.

*Aneurism.*—This portion of the aorta is also a favorite seat of aneurism. The symptoms produced will depend of course on the direction which the tumor takes. If it tends anteriorly it would involve the lungs and pleuræ and the phrenic and vagus nerves, also the sympathetic. The displacement of the left lung would be the more marked. Involvement of the recurrent laryngeal nerve might make a change in the voice, or there might be disturbances of the pupil of the eye due to implication of the sympathetic.

Should the tumor enlarge posteriorly the pressure on the trachea would interfere with the breathing. If the tumor is large this pressure would involve the œsophagus and there might be difficulty in swallowing. Compression of the thoracic duct is said to have led to rapid wasting.

If the aneurism bulges downward it impinges on the left bronchus, which may lead to its dilation and cause *bronchorrhœa*. A large tumor could also interfere with the flow of blood through the pulmonary arteries and so give rise to congestion and dyspnœa.

An enlargement upward would involve the innominate and left carotid and subclavian arteries and also the left innominate vein. Interference with the arteries and veins of the neck and upper extremity frequently gives rise to changes in the pulse on the affected side and also to venous congestion or even œdema. Changes in the voice or even its loss also occur. The sac as it passes upward may show itself in the suprasternal notch.

In all aneurisms of the arch cough is apt to be a prominent symptom. It is often paroxysmal. It is to be accounted for by pressure on the trachea or laryngeal nerves. Difficulty in breathing and swallowing may arise in deep-seated small tumors growing backward and downward. This may be somewhat relieved by sitting up or leaning forward, while reclining or lying on the back may be unendurable.

The great amount of distress which these aneurisms of the arch of the aorta may give rise to is readily appreciated when one recalls that there is only a distance of 5 or 6 cm. ( $2\frac{1}{4}$  in.) between the upper edge of the sternum and the anterior surface of the vertebral column, a space already filled with important structures.

**The Descending Aorta.**—The remaining portion of the aorta, from the lower border of the fourth thoracic vertebra down, is called the *descending aorta*. It is divided into the thoracic and abdominal portions. The thoracic aorta begins at the lower border of the fourth and ends at the lower border of the twelfth thoracic vertebra. At its beginning it lies on the left side of the vertebral column, but as it descends it comes somewhat forward but does not reach the middle line. It lies in the posterior mediastinum more toward the left side than toward the right.

*Relations.*—In *front* above are the pericardium, the pulmonary artery, left bronchus, left pulmonary veins, and œsophagus. *Behind* is the vertebral column. To the *right* are the œsophagus above, the vena azygos major, and the thoracic duct. To the *left* are the left lung and the pleura, which it grooves, and a quite small portion of œsophagus below.

*Aneurism*, when involving the thoracic aorta, tends to cause absorption of the vertebræ and ribs, and to present posteriorly; as the space is not so restricted as is the case higher up the tumor has a freer opportunity to expand and the suffering is not so great nor are the symptoms so marked. It may rupture into the left pleura or œsophagus and may erode through the bodies of the vertebræ into the spinal canal.

These aneurisms may exist many years and attain a large size.



## THE ŒSOPHAGUS.

The Œsophagus begins at the lower edge of the cricoid cartilage, opposite the lower border of the sixth cervical vertebra, and ends at the cardiac opening of the stomach, opposite the eleventh thoracic vertebra.

It is 25 cm. (10 in.) long and begins 15 cm. (6 in.) distant from the teeth. In the neck it inclines to the left, hence œsophagotomy is performed on that side. It reaches the farthest point to the left at the level of the top of the sternum or opposite the second thoracic vertebra. It then inclines to the right, reaching the median line opposite the fifth thoracic vertebra. It then again inclines to the left, to pierce the diaphragm in front of the aortic opening and to the left of the median line opposite the tenth thoracic vertebra, and ends in the cardiac opening of the stomach entirely to the left of the median line and opposite the eleventh thoracic vertebra or tenth dorsal spine. In its passage through the diaphragm it is accompanied by the continuation of the two vagi nerves. At its termination it grooves the posterior surface of the liver.

*Lumen.*—The lumen of the Œsophagus is narrowed at three points, (1) its commencement; (2) where it crosses the aorta and left bronchus; and (3) near its end as it passes through the diaphragm.

The average diameter of the lumen is 2 cm., which at the upper and lower constrictions is reduced to 1.5 cm. The middle constriction is not quite so marked. The lower constriction is most marked at the point of the passage of the Œsophagus through the diaphragm; it enlarges slightly as it enters the stomach. This part of the Œsophagus is quite distensible. The next most distensible part is opposite the left bronchus. This is on a level with the middle of the first piece of the sternum and the third thoracic vertebra. The upper constriction at the cricoid cartilage is the least distensible part of the tube, so that a body passing it may pass entirely down.

In both living and dead bodies the lumen of the Œsophagus is sometimes open and sometimes closed. In the neck the pressure of the soft parts usually keeps it closed, but frozen sections of the dead body show it sometimes closed and sometimes open. Mikulicz in using the œsophagoscope has found the lumen open in the living patient and been able to see down the remainder of the tube when the instrument has only been passed beyond the second constriction.

In passing an œsophageal bougie, one should not be used of a larger diameter than 18 mm. ( $\frac{3}{4}$  in.). It will enter the Œsophagus opposite the lower border of the cricoid cartilage about 15 cm. (6 in.) from the teeth. It will pass the second constriction 7 cm. ( $2\frac{3}{4}$  in.) farther on, opposite the middle of the first piece of the sternum or 2.5 cm. (1 in.) below its upper border, and meet the third constriction 15 cm. (6 in.) lower down, or 37 cm. (14.4 in.) from the teeth, and enter the stomach 3 cm. below, or 40 cm. (16 inches) from the teeth and opposite the eleventh dorsal vertebra.

*Relations.*—In the neck the Œsophagus rests on the longus colli muscle and vertebræ behind and has the trachea in front. On the left side it lies close to the carotid sheath, the lobe of the thyroid gland, and the thoracic duct. The left recurrent laryngeal nerve is in closer relation to it than the right on account of the latter coming over from the right subclavian artery. The left nerve lies on its anterior surface near the left edge. The right carotid artery lies farther from it than does the left. The left inferior thyroid artery is also in closer relation to it than the right on account of the inclination of the Œsophagus to the left side.

*In the thorax* it passes through the superior mediastinum between the trachea and its bifurcation in front and the aorta behind.

In front it has the bifurcation of the trachea and encroaches more on the left than on the right bronchus. The arch of the aorta and the left carotid and subclavian arteries also pass in front of it and in the posterior mediastinum the pericardium and diaphragm are anterior to it.

Posteriorly, above it rests on the spinal column, but below the bifurcation of the trachea the aorta intervenes.



Laterally it is in relation with the left pleura above and the right below and the vena azygos major runs along its right side posteriorly. The arch of the aorta winds around its left side at the root of the lung. The right vagus nerve runs down posteriorly and the left anteriorly, forming a plexus on its surface.

**Dilatation and Diverticula.**—In certain rare cases the œsophagus becomes dilated; this may involve the whole length of the tube or only its lower end. Obstruction low down may be a cause. It has been known to accompany a largely dilated aorta which pressed the œsophagus against the diaphragmatic opening and so hindered the passage of food. Regurgitation of food is a prominent symptom and liquids may regurgitate from the stomach and even enter the mouth.

Diverticula are usually acquired and are but seldom congenital. The point of junction with the pharynx just behind the cricoid cartilage is the most frequent seat. A sac is formed which descends posteriorly behind the part of the tube below and as it increases in size it presses forward and may obstruct its lumen. Obstruction from foreign bodies, stricture, or disease of the cardiac end of the stomach may be a cause. Vomiting is a prominent symptom and the vomited material does not show any evidences of digestion or the presence of acid. The existence of a tumor which forms only on deglutition and which can be emptied by pressure is said to be pathognomonic of an œsophageal diverticulum.

Diverticula have been treated by washing out with a stomach-tube, by excision, or if emaciation is rapid and marked by doing a gastrostomy.

**Carcinoma and Stricture.**—Carcinoma is usually of a flat-celled epitheliomatous type and may surround the œsophagus like a ring. The walls are thickened, a tumor forms, and the internal surface may become ulcerated. Stricture of the affected part may lead to the formation of a dilation or diverticulum above, and ulceration and abscess may perforate and enter surrounding organs.

Dyspnœa may arise from pressure on the air-passages and pus may even penetrate them. Hemorrhage is also sometimes a symptom. It may come either from the inside or outside. In the latter case it may come from the large vessels in the neighborhood.

Septic inflammation may also be set up in the adjacent pleuræ and lungs.

**Foreign Bodies.**—Foreign bodies may become impacted at any part of its course; this is particularly the case if they are hard and rough with irregular outlines. If they are smooth and soft and more or less rounded they are apt to lodge at the constricted parts of the tube. These points are, as already stated, at its commencement, where it crosses the aorta and left bronchus, and where it passes through the diaphragm. The upper constriction is 1.5 cm. (or  $\frac{3}{8}$  in.) in diameter, and is least distensible. It will dilate to the width of 2 cm., and thus will allow a body of about  $\frac{3}{4}$  inch diameter to pass. The two lower constrictions are more distensible and a body that passes the œsophagus can usually pass the ileocæcal valve, so that the upper end of the œsophagus acts as a gauge to prevent the entrance of substances too large for the rest of the alimentary tract. The bodies which become lodged are usually those which have been pushed down beyond the opening of the œsophagus by the contraction of the muscles of the pharynx, and then on account of their irregular form become caught by the contraction of the tube below. With the head moderately extended, the first constriction will be 15 cm. (6 in.) from the teeth. A foreign body at this point will be opposite the cricoid cartilage at the level of the sixth cervical vertebra.

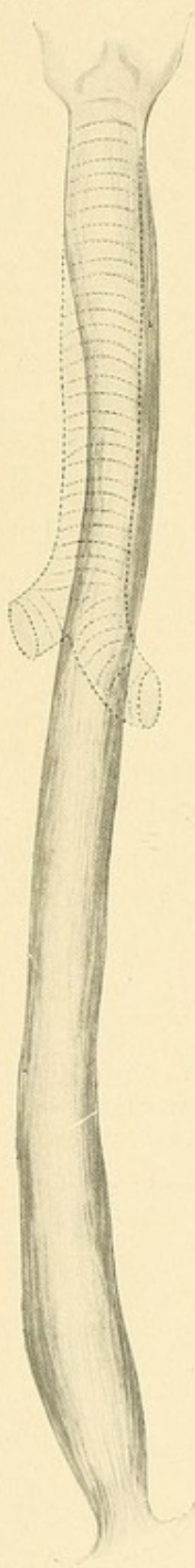


FIG. 223.—The œsophagus. From a plaster cast.



The second constriction is opposite the middle of the first piece of the sternum. This is 7 cm. ( $2\frac{3}{4}$  in.) below the cricoid cartilage. Therefore a foreign body lodged just above it would be just below the top of the sternum.

It would be felt by the probe 22 cm. ( $8\frac{1}{2}$  in.) from the upper teeth and if œsophagotomy was performed it could usually be reached from the wound in the neck.

The third constriction is 15 cm. (6 in.) below the second, or 37 cm. ( $14\frac{1}{3}$  in.) from the teeth, and is accessible from the stomach. This third constriction is more

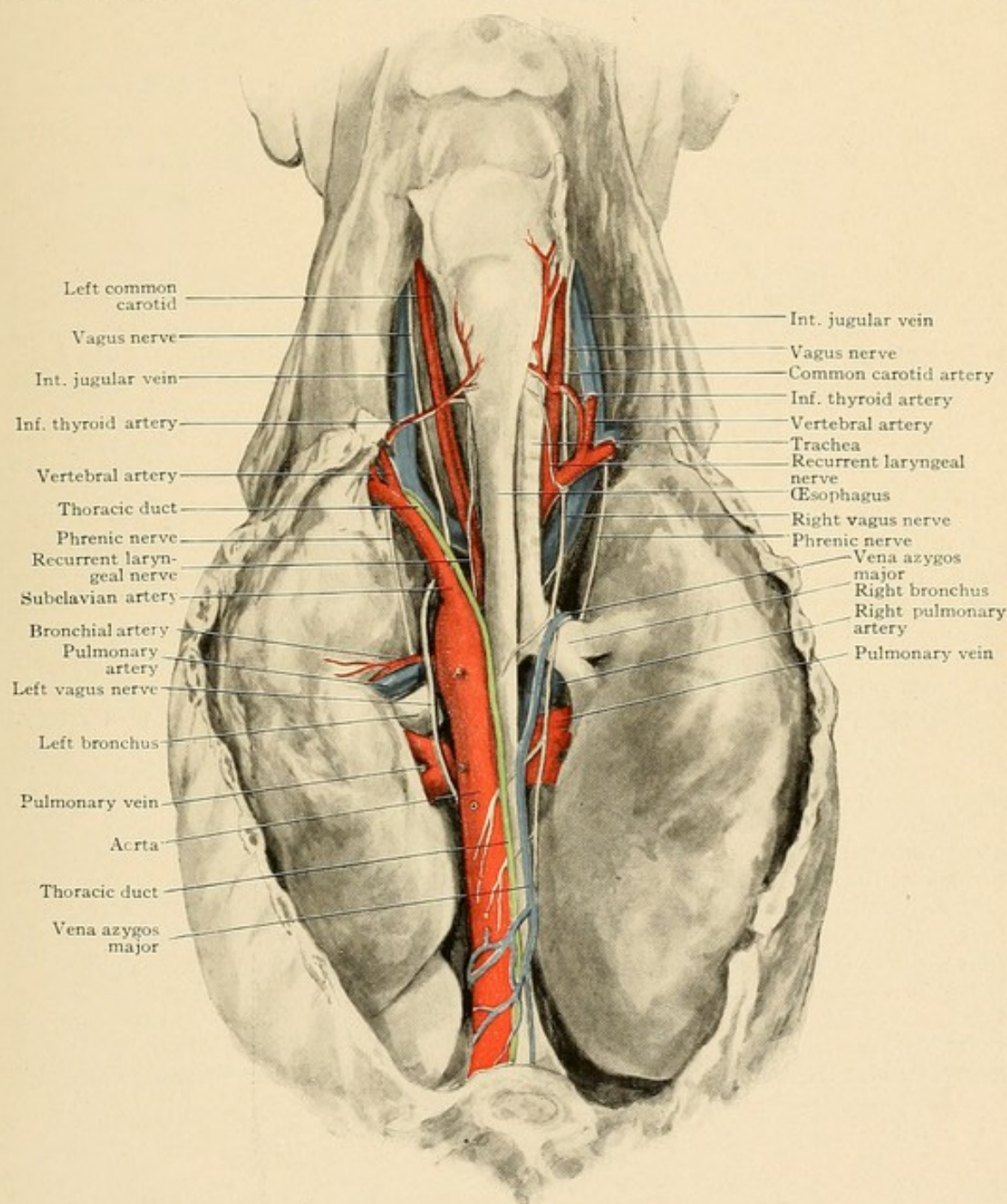


FIG. 224.—Posterior view of the œsophagus, showing its relation to the surrounding structures.

distensible than the two above it. Maurice H. Richardson was able, after introducing the hand into the stomach, to put two fingers into the cardiac opening from below, and so dislodge some impacted false teeth.

Foreign bodies are dangerous on account of the ulceration into the various organs which they cause and also on account of pressure. Pressure on the left bronchus and trachea has caused suffocation.



Ulceration may cause fatal hemorrhage by involving the carotid arteries, more likely the left, the inferior thyroids, the innominate, and even the aorta itself lower down. Low down in the chest the pericardium is in front of the œsophagus, and has been perforated. On the left side above and the right side below, the pleuræ have been perforated and the lungs involved. Abscesses may occur from the ulcerative process and they are particularly dangerous, as the distance between the upper portion of the sternum and anterior portion of the bodies of the vertebræ is so small that compression of the air-passages and suffocation is readily produced.

## THE THORACIC DUCT.

The thoracic duct carries not only *lymph* but also *chyle* which is emptied into the venous system and goes to nourish the body. Therefore a wound of the duct with the escape of its fluid may result fatally from inanition. The lymph coming from all parts of the body is collected into two ducts, the right lymphatic duct and the thoracic duct. Of these two the *right lymphatic duct* is the smaller. It collects the lymph coming from the right side of the head and neck, right upper extremity, right side of the thorax and the upper convex surface of the liver. The several lymphatic branches unite to form a duct, one to two centimetres long, which empties into the venous system at the junction of the right internal jugular and subclavian veins. At its point of entrance it is guarded by a pair of valves. As this duct contains no chyle, and lymph of only a portion of the body, wounds of it have not proved serious.

The *thoracic duct* is much larger and more important. It begins on the bodies of the first and second lumbar vertebræ to the right of the aorta in the *cisterna (receptaculum) chyli*.

The cisterna or receptaculum is 5 to 7.5 cm. long and 7 mm. wide. It receives not only the lymph from the parts below but also the chyle from the intestines. It passes through the aortic opening in the diaphragm with the aorta to the left and the vena azygos major to the right. In the posterior mediastinum it lies on the bodies of the seven lower thoracic vertebræ, with the pericardium, the œsophagus, and the arch of the aorta in front. The thoracic aorta is to its left and the vena azygos major and right pleura to its right. Above the fifth thoracic vertebra it ascends between the œsophagus and left pleura, behind the first portion of the left subclavian artery. On reaching the level of the seventh cervical vertebra it curves downward over the left pleura, subclavian artery, scalenus anticus muscle, and vertebral vein to empty at the junction of the internal jugular and left subclavian veins. It passes behind left internal jugular vein and common carotid artery. At its termination it lies just external to the left sternoclavicular joint and just below the level of the upper border of the clavicle. A punctured wound at this point would injure the duct.

Accompanying the veins of the neck are numerous lymph-nodes which not infrequently become enlarged and require removal. It is in operating on these nodes that wounds of the thoracic duct have been most often produced. When divided, its lumen has appeared to be of the size of a "knitting needle." In some instances the thin walls of the duct have been ligated. In other cases of injury either the oozing point has been clamped with a hæmostatic forceps which has been left in position for a day, or else the wound has been packed with gauze. Recovery usually ensues.



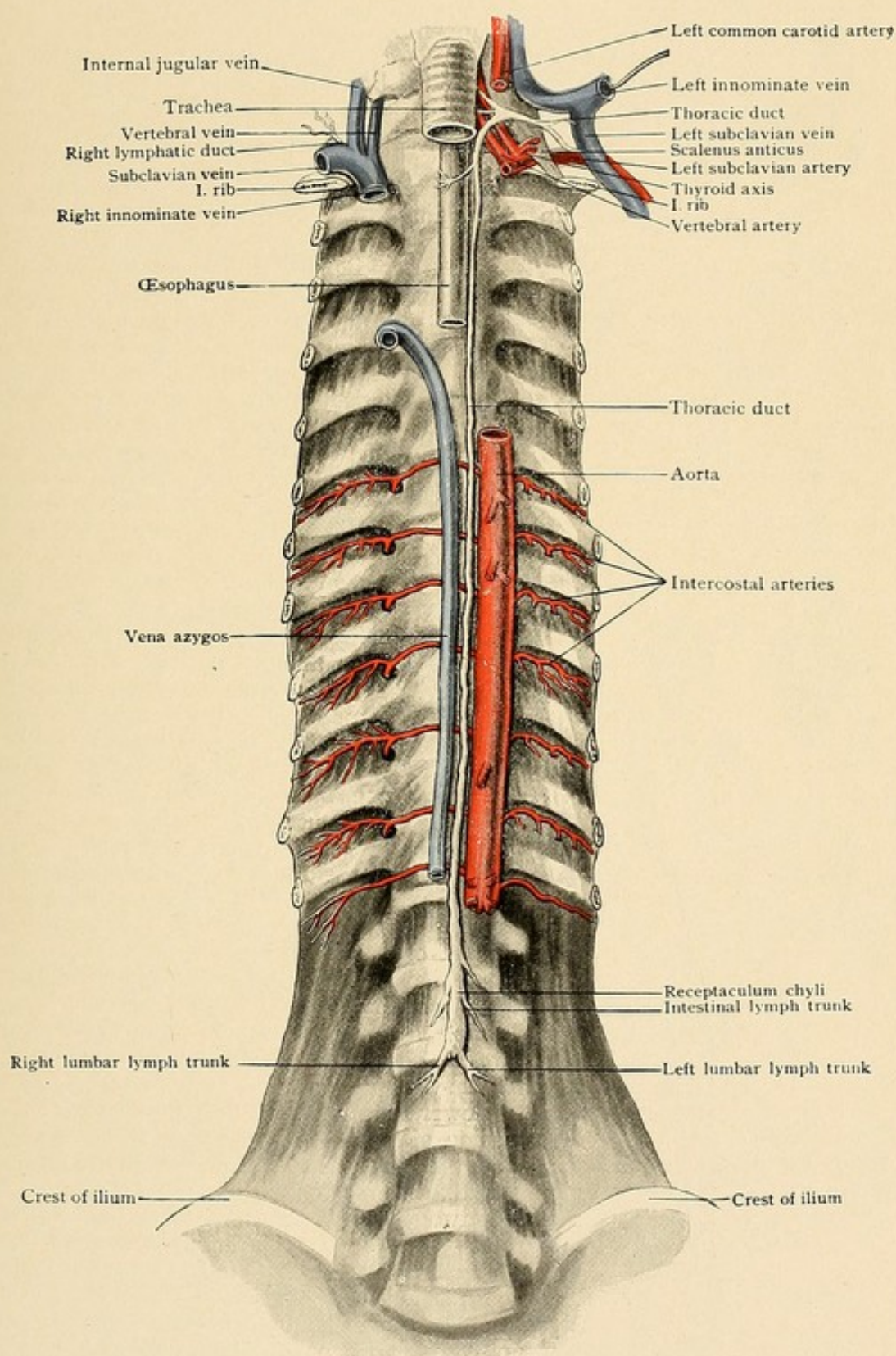


FIG. 225.—Dissection of posterior body-wall, seen from in front, showing thoracic duct and right lymphatic duct; veins have been laterally displaced to expose the terminations of the thoracic duct. (Piersol.)



## THE UPPER EXTREMITY.

**Morphology.**—The human skeleton consists of two parts, called the axial skeleton and the appendicular skeleton.

The *axial skeleton* embraces the bones of the head, the spine, the ribs, the hyoid bone, and the breast bone. In the spine are included not only the vertebræ of the cervical, thoracic, and lumbar regions, but likewise the sacrum and coccyx.

The *appendicular skeleton* embraces the bones of the limbs, or extremities, including the shoulder-girdle, formed by the scapula and clavicle, and the pelvic girdle, formed by the innominate bone (Fig. 226).

**Function.**—The upper extremity in man is an organ of prehension. As such, mobility is its chief characteristic. To permit of this mobility the bones and joints are many, and the latter are comparatively loose; the muscles, also, are both numerous and complex. Hence it is that slight injuries are frequently followed by considerable disturbance of function. They are readily produced and with difficulty repaired, either by nature or by art. Orthopædic surgery has done much for the disabilities and deformities of the lower extremities, but comparatively little for those of the upper. An artificial leg in many cases satisfactorily substitutes the natural one, but an artificial arm is comparatively useless.

The hand is the essential part of the upper extremity, and the rest of the limb is subsidiary. If the forearm were lacking and the hand were attached to the end of the humerus it would still be a very useful appendage, far more so than the stump which is left after the hand has been amputated.

The extremities proper are joined to the trunk by what are called girdles. The upper extremity is attached through the medium of the shoulder-girdle and the lower extremity by the pelvic girdle. The interposition of these girdles adds to the mobility of the extremities, and as the upper extremity is more mobile than the lower we find the shoulder-girdle composed of two bones instead of one as in the pelvic girdle; also, as the lower extremity bears the weight of the body it requires strength in addition to mobility, hence we find that it is joined to the trunk by a single big strong bone, the innominate, instead of by two comparatively slight, narrow bones like the clavicle and scapula which form the shoulder-girdle.

The extremities are termed appendicular because they are simply appendages to the essential part, which is the head and trunk; a person *can* live without extremities.

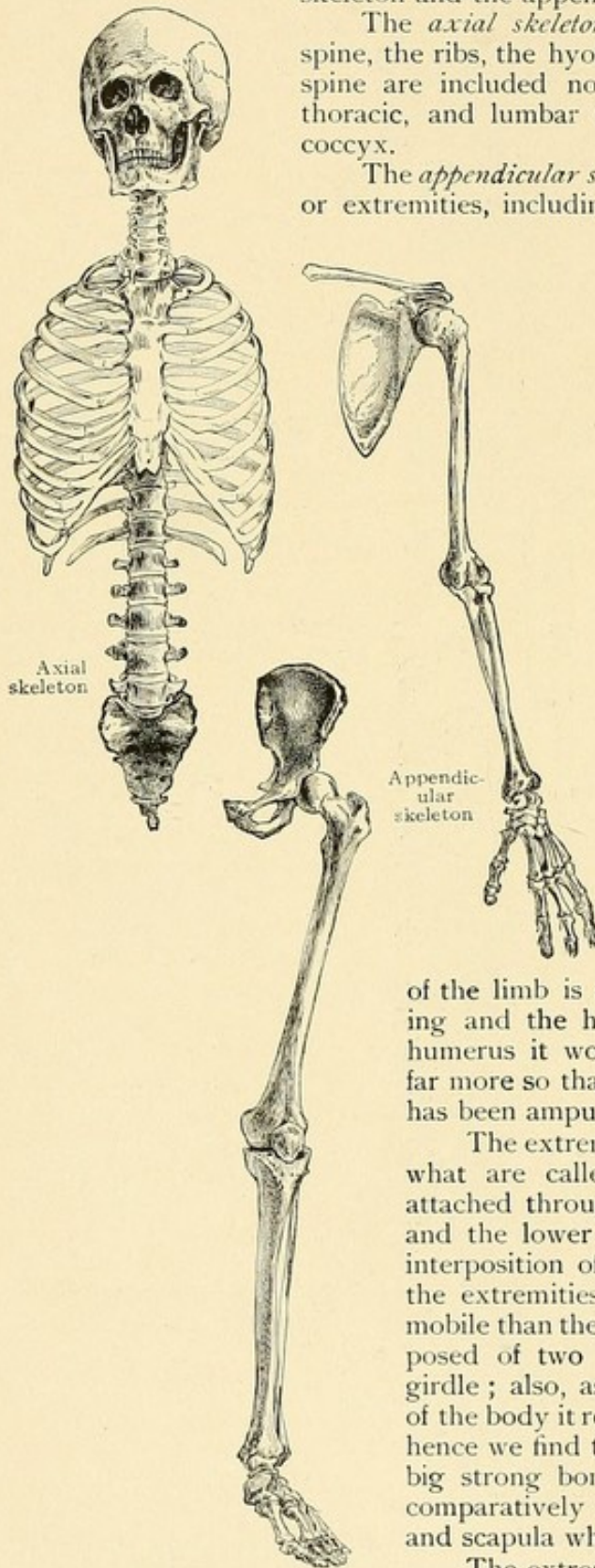


FIG. 226.—The bones of the head and trunk forming the axial skeleton and those of the upper and lower extremities constituting the appendicular skeleton.



## THE SHOULDER-GIRDLE.

The upper extremity is joined to the trunk by the shoulder-girdle, which is composed of the clavicle and scapula. The main movements are anteroposterior, as in swinging the arm, those of abduction and adduction, as in raising and lowering it sidewise, and rotation.

The *scapula* is the more important bone; it is present in all mammals, and the humerus articulates with it.

The scapula in the mole and many other animals may be a comparatively slender bone, but when, as in man, it is necessary to rotate the arm, then the

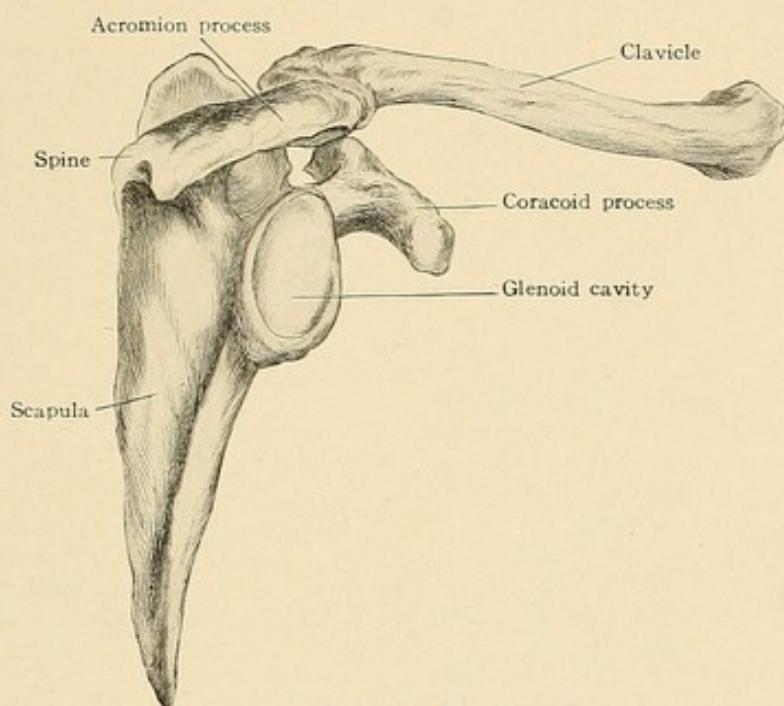


FIG. 227.—Shoulder-girdle of man.

scapula is large so as to form a strong support for the infraspinatus, supraspinatus, teres minor and major, and subscapularis muscles.

The *clavicle* is developed mainly from membrane, partly probably from cartilage, and is the first bone in the body to ossify. It keeps the shoulder out away from the body and increases the range of motion of the upper extremity. It owes its existence to the function of abduction. Without a clavicle abduction is practically wanting and when in man the clavicle is broken, he is temporarily reduced to the condition of those animals which have no clavicles; he is able to move the arm backward and forward but not to elevate it properly, and this is an important diagnostic symptom of that injury.

The clavicle is lacking in the ungulates or hoofed animals. These have an anteroposterior movement, but little abduction. A horse or cow moves its fore-legs back and forward, but not out away from the body. Hence its helplessness when these movements are essential. It is also lacking in seals and whales. In the carnivora, as the lion and the tiger, which possess rudimentary clavicles, sufficient adducting power is present to enable them to hold their food while tearing it apart. In man, apes, bats, rodents, and insectivora the clavicle exists as a well-formed bone;

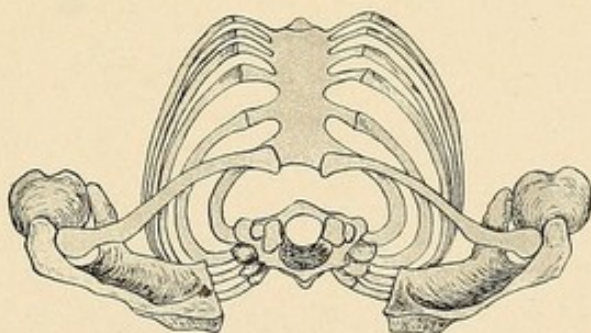


FIG. 228.—Shoulder-girdle of man, showing how the clavicle acts as a prop to keep the shoulder out away from the chest.



hence they can raise the arm well out from the body and even higher than the shoulder. In the rodents, as the squirrel, they are enabled to hold a nut firmly in the paws while eating it. When, as in some of the lower orders, the function of abduction is all important, we find not only the clavicles present and, as in the common fowl, joined, forming the "wish-bone," but in addition, in birds, there is a precoracoid bone formed by the coracoid process, which is enlarged and continued forward to articulate with the sternum; thus in flying animals there are practically two clavicles on each side.

**Affections of the Shoulder.**—The point of the shoulder projects well out from the side of the thorax. Hence it is frequently injured. As the force is resisted

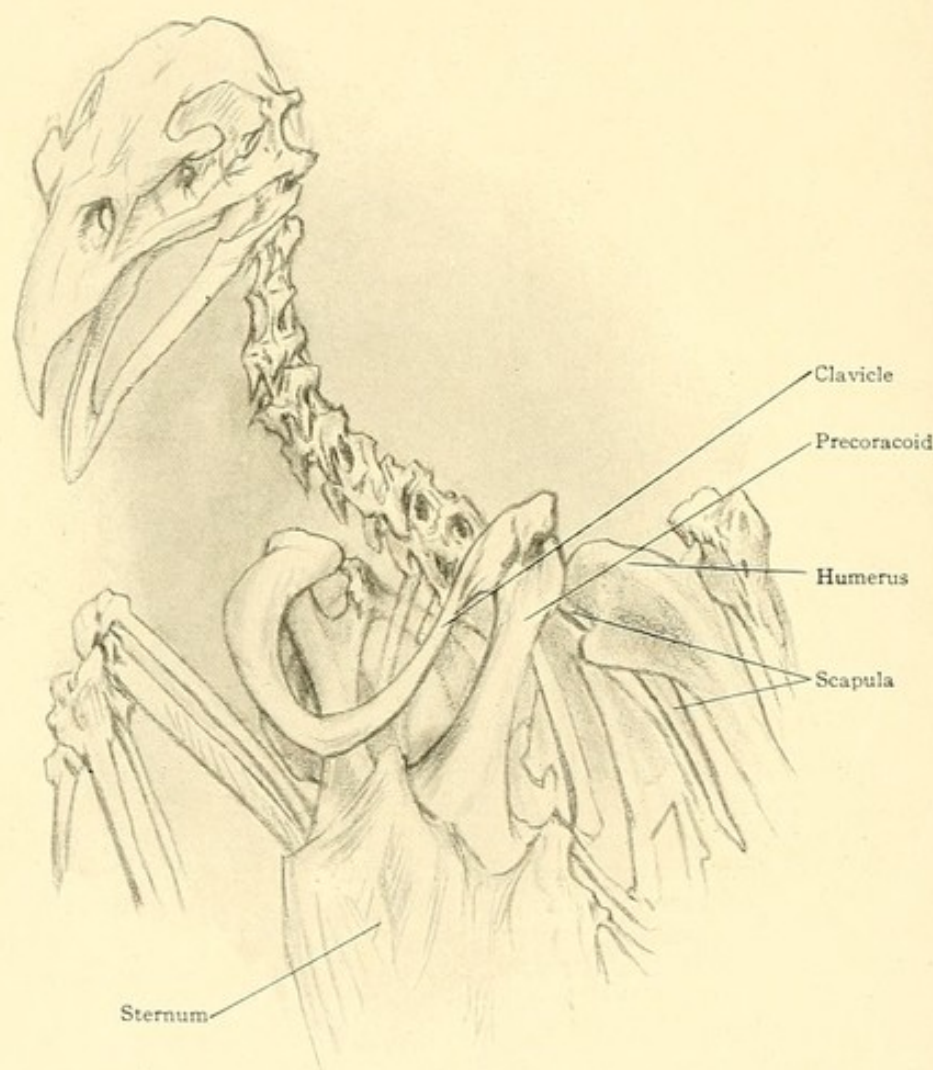


FIG. 229.—Shoulder-girdle in birds. Skeleton of an eagle, from the Wistar Institute; the clavicle, precoracoid, and scapula form the shoulder-girdle; the two clavicles have fused in the median line, forming what is commonly called the "wish-bone."

by the bones, these receive the principal injuries and they are often broken. Fractures of the clavicle dispute with those of the radius the distinction of being the most numerous. Contusions produce more or less complete paralysis of the muscles, not infrequently through lesions of the nerves. The laxity of the joint favors the dislocations to which it is so frequently subject. It likewise becomes the seat of tuberculous disease requiring resection. Crushes of the arm sometimes require its removal at the shoulder-joint, and occasionally as the result of injury or disease operations may be required on the axillary lymph-nodes, nerves, or blood-vessels.

In order to determine the character and extent of injuries to the shoulder, its surface anatomy must be thoroughly known. In order to treat them, a knowledge of the deeper structures and their relation to one another is essential.



The landmarks of the shoulder are formed by the bones and muscles; hence a brief review of their important characters will serve as a basis for the surface anatomy which follows.

### THE BONES OF THE SHOULDER.

The bones entering into the construction of, and forming the basis on which the shoulder is constructed are the clavicle and scapula, forming the shoulder-girdle, and the humerus.

The **clavicle** is a comparatively long and slender bone that acts as a prop to keep the point of the shoulder out from the trunk. The inner extremity is large and rests with its flat surface on the upper outer edge of the sternum, with the interposition of a disk of fibrocartilage. Its outer extremity is flattened; it articulates by

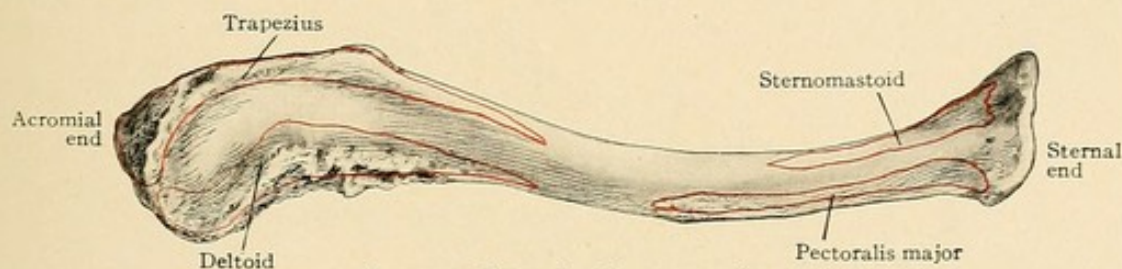


FIG. 230.—Right clavicle, upper surface.

means of a gliding joint with the acromion process of the scapula, and it is connected with the base of the coracoid process beneath by ligaments. It is double curved, the large curve having its convexity forward and embracing the inner two-thirds of the bone, and the small curve having its concavity forward, forming the outer third.

At the deepest part of the concavity of the anterior edge, about at the junction of its outer and middle thirds, is a small rough eminence called the *deltoid tubercle* because of the attachment to it of the deltoid muscle. At a corresponding point on the posterior and under surface of the bone is a prominent projection called the *conoid tubercle*; to this is attached the *conoid ligament*. Running forward and outward from this tubercle on the under surface is a rough line which serves as the point of

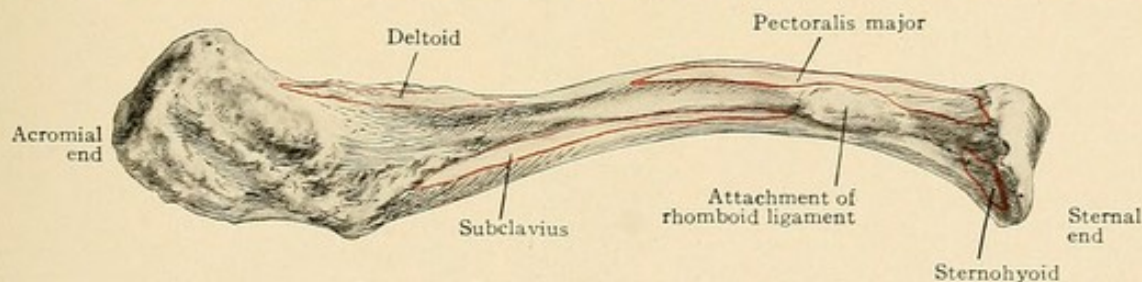


FIG. 231.—Right clavicle, under surface.

attachment of the *trapezoid ligament*. Both these ligaments are of importance in relation to the fractures of this bone.

The middle third of the bone is its weakest part. Attached to the clavicle on its anterior surface are the *deltoid muscle* on its outer third and the *pectoralis major* on its inner half. On its posterior and upper surfaces are the *trapezius* at its outer third, and the clavicular head of the *sternomastoid* on its inner third. The *subclavius muscle* is attached to its under surface. It will thus be seen that there is a space equal to one-sixth of the length of the bone inferiorly and one-third of the bone superiorly which is free from muscular attachments, and it is here that it is most frequently fractured.

**The Scapula.**—The scapula is spoken of as having a body, neck, spine, and acromion, glenoid, and coracoid processes; an upper, an anterior, and a posterior border; and an upper and a lower angle. It is not often spoken of as possessing a head, the glenoid process or that portion being sometimes so called in which the *glenoid cavity* or fossa for the articulation of the humerus is situated.



The constriction surrounding the head of the scapula is known as the *anatomical neck*, in contradistinction to the *surgical neck*, which name has been given to that portion indicated by a line drawn through the suprascapular notch and passing beneath the spine and to the inside of the attachment of the long head of the triceps muscle just below the lower edge of the glenoid cavity.

The angles and borders and spine are important landmarks in physical diagnosis and the coracoid and acromion processes in injuries.

In the upper border of the bone at its junction with the base of the coracoid process is a deep notch called the *suprascapular notch* (*incisura scapulæ*), the supra-

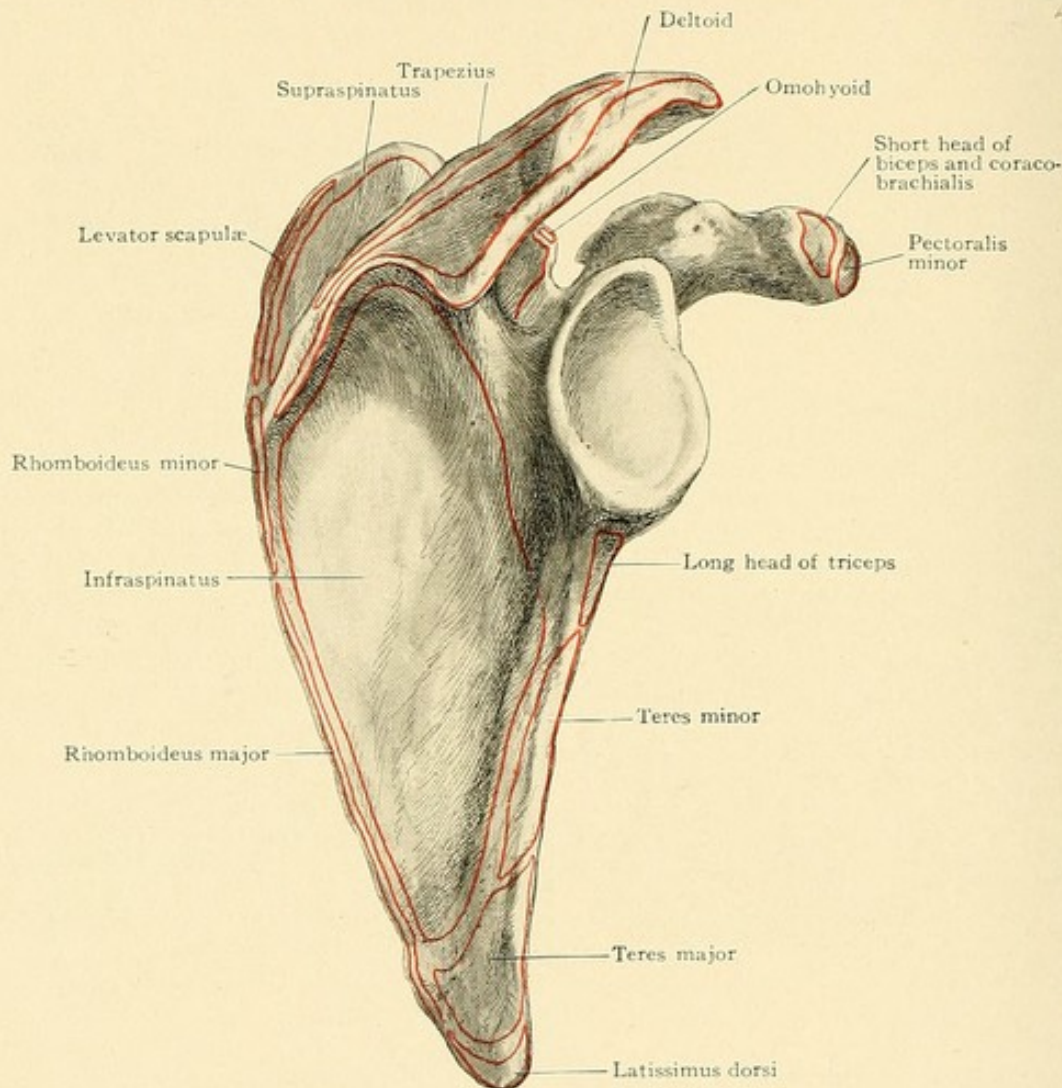


FIG. 232.—Scapula, showing muscular attachments.

scapular nerve passes through it. The artery passes over it. From the edge of the bone just behind the notch arises the *omohyoid muscle*, an important guide in operations on the neck.

The body of the scapula on its under surface is flat and rests on the thorax from the second to the seventh and nearly to the eighth rib. Its movements on the chest are free and follow those of the arm. It rises and falls, glides forward and backward, and also rotates on an anteroposterior axis.

When using any portion of the scapula as a landmark it is customary to have the arm hanging by the side; if it is otherwise the position of the bone will be changed, and the relations of its projections to the surrounding parts are altered. The scapula is sometimes fractured directly across its body below the spine. One should endeavor to fix in mind especially the relation of the acromion and coracoid processes to the head, with its glenoid cavity, and the rest of the bone.



The head is comparatively small and cup-shaped, with the glenoid fossa on its surface for the head of the humerus. It is joined to the body of the bone by a narrow constriction called the neck. Fractures through this neck are rare. Above and posterior to the glenoid fossa is the acromion process and spine of the scapula, and above and anterior is the coracoid process.

The spine of the scapula runs upward and forward across the upper and posterior surface of the bone. Its commencement at the posterior edge of the bone is called its root; this is over the fourth rib and opposite the third thoracic spine. The posterior edge of the scapula opposite the root of the spine projects backward, but this is not the superior angle, which is still higher up. The spine of the scapula ends anteriorly in the acromion process. This projects far beyond the glenoid cavity, overhangs the head of the humerus, and forms the point of the shoulder. It, as well as the rest of the spine, is subcutaneous and is a valuable landmark.

The acromion process is not so often fractured as one would expect. It articulates with the clavicle and the bones are not infrequently luxated at this point.

The coracoid process projects forward underneath the clavicle to the upper and inner side of the head of the humerus. It is about 2.5 cm. (1 in.) below the clavicle and just to the outer side of the junction of its middle and outer thirds. It lies just underneath the inner edge of the deltoid muscle, hence it is not always easily felt. It is almost never fractured, but is especially valuable as a landmark in injuries and operations on the shoulder.

The two great hollows above and below the spine are the *supra-* and *infraspinous fossæ* for the *supra-* and *infraspinatus* muscles. The angles are at the two extremities

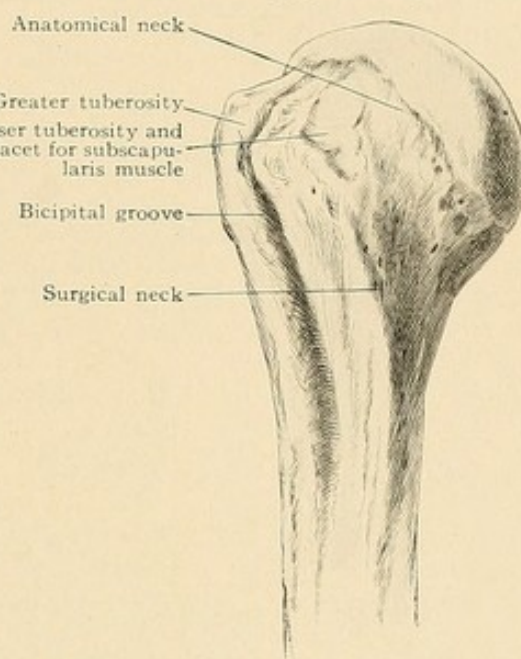


FIG. 233.—Anterior surface of upper end of humerus.

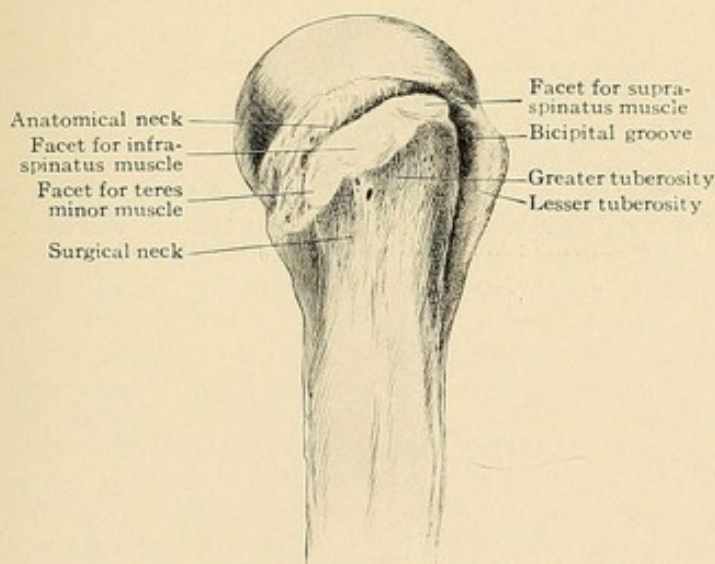


FIG. 234.—Outer surface of upper end of humerus.

of the posterior border. The superior angle receives the insertion of the levator scapulæ muscle and is covered by the *trapezius* which inserts into the spine and thus obscures its outline. The inferior angle is crossed by the upper edge of the *latissimus dorsi* muscle, from which it sometimes receives a few fibres. This angle is rendered prominent when the forearm is flexed on the arm and placed across the back.

**The Humerus.**—The upper end of the humerus is composed of a head joined to the *tuberosities* through the medium of the *anatomical neck*.

The head projects inwardly from

the shaft at an angle of 120 degrees to it. The lesser tuberosity has inserted into it the *subscapularis* muscle; it presents forward. To its outer side and separating it from the greater tuberosity is the *bicipital groove* for the long tendon of the *biceps* muscle. To the outer side of the groove is the greater tuberosity with its three facets for the *supraspinatus*, *infraspinatus*, and *teres minor* muscles.



The greater tuberosity projects considerably beyond the acromion process and therefore forms the most prominent part of the shoulder. Immediately below the tuberosities is the *surgical neck*. It is described as being the portion between the tuberosities above and the insertions of the pectoralis major and latissimus dorsi muscles below. It is a common site for fractures. Half way down the shaft on its outer side is the rough *deltoid eminence* for the insertion of the *deltoid muscle*.

**Sternoclavicular Joint.**—The ligaments uniting the inner end of the clavicle to the thorax at the upper end of the sternum are the *interclavicular*, which passes from one clavicle to the other across the top of the sternum, the *anterior* and *posterior sternoclavicular*, and the *rhomboid* or *costoclavicular ligament* which passes from the clavicle downward and forward to the first rib. This last one limits displacement in cases of luxation. There is a fibrocartilaginous disk between the clavicle and sternum, forming two distinct joint cavities. The line of the joint slopes downward and outward.

**Acromioclavicular Joint.**—The outer end of the clavicle articulates with the acromion process by a joint whose surface inclines down and inward, thus favoring displacements of the clavicle upward. The ligaments joining them are called the *superior* and *inferior acromioclavicular*. In reality they are simply the thickened portions of the *capsular ligament*. This capsular ligament is ruptured in the not infrequent cases of luxation which occur here. Running from the under surface of the clavicle, a short distance from its outer end, to the coracoid process below, is the

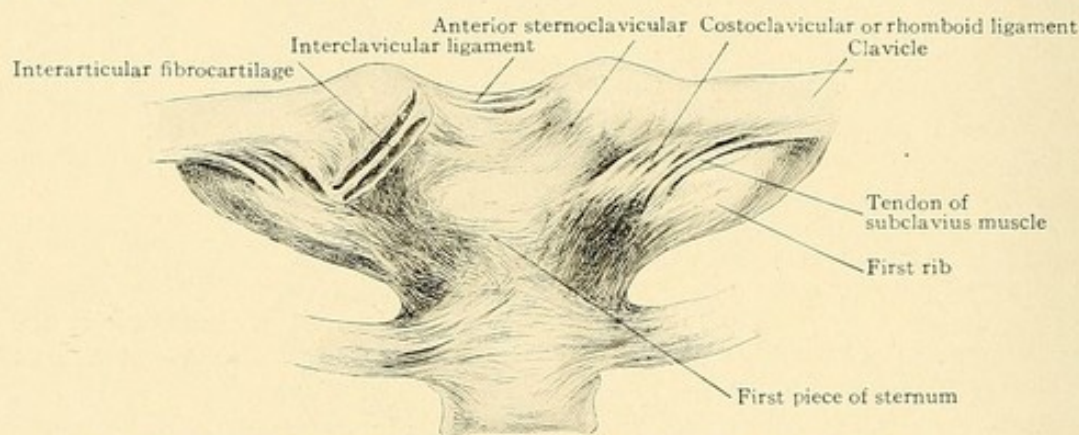


FIG. 235.—Sternoclavicular joint and attachments of the inner end of the clavicle.

*coracoclavicular ligament*. It is composed of two parts, an antero-external square ligament called the *trapezoid*, and a postero-internal conical one called the *conoid*.

The bone may be fractured just external to these ligaments, giving rise to a peculiar deformity to which attention will be called in describing the fractures of the clavicle.

From the coracoid process the *coraco-acromial ligament* runs outward and upward to the acromion process, the *coracohumeral* outward and downward to the neck of the humerus, and the *costocoracoid ligament* inward to the first rib at its cartilage.

**The Shoulder-joint.**—The upper extremity being an organ of prehension and not of support, the shoulder-joint, which is the articulation which connects it with the trunk through the shoulder-girdle, is constructed with the idea in view of favoring and permitting motion, and not of supporting weight or resisting force. Hence we find it to be a ball-and-socket joint, the one which allows of the freest movements.

The glenoid cavity is a shallow excavation, not a deep cup, as in the hip. The articulating surface of the head of the humerus is extensive but not so large as it would have been had the scapula not been made to move on the thorax. The clavicle keeps the joint well out from the side of the body; hence the neck of the humerus is short. The movements of the arm are so extensive and free that we do not have the tuberosities of the humerus so large and set so far away from the articular surface as is the case with the femur and its trochanters.

If the upper portion of the femur was like the upper end of the humerus, the lower extremity would be continually rolling in or out, making walking or running at least difficult if not impossible. Thus we see that the shape of the bones is dependent on the character of their functions.



The ligaments of the joints are inelastic tissues; hence those that enter into the construction of a movable joint must be loose, and the more movable a joint is, the more does its security depend not on its ligaments, but on its muscles.

The shoulder-joint, like other joints, has a capsular ligament which is attached to the adjacent bones and serves to keep the lubricating synovial fluid applied to the articulating surfaces. In certain positions this ligament may also serve to a limited extent to keep the ends of the bones of the joint in contact.

Besides this capsular ligament there are fibrous bands which strengthen it at certain places as they pass from adjacent processes of bone on one side of the joint

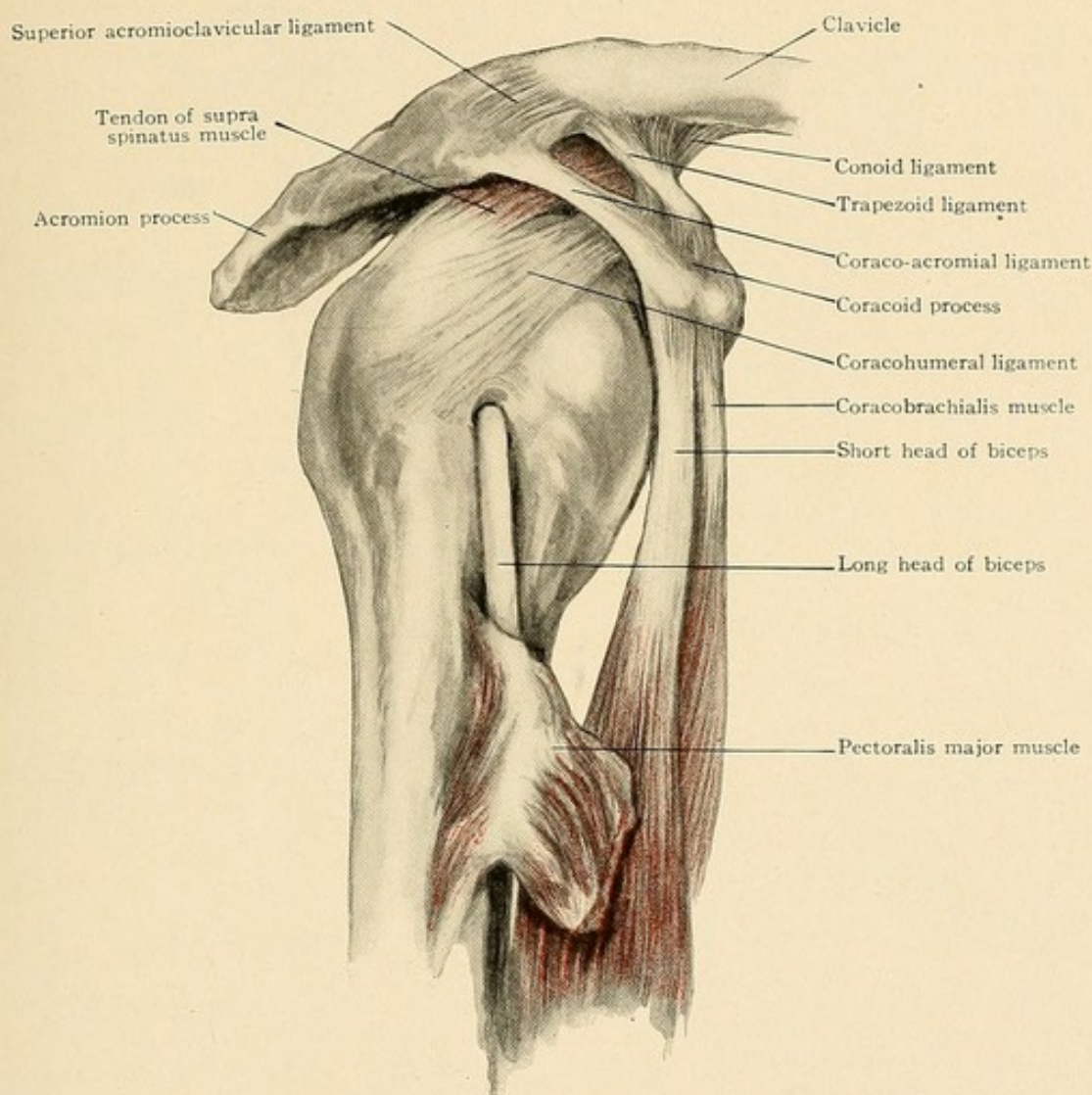


FIG. 236.—Acromioclavicular and shoulder joints.

to those on the other. The muscles and their tendons pass across the capsule and sometimes blend with it, so that there is an intimate relation between the muscles and their tendons and the ligaments; finally, there is a third structure called the *glenoid ligament*, which is in reality a fibrocartilage that serves to deepen the glenoid cavity.

The *capsular ligament* is attached on one side to the edge of the glenoid cavity, the anatomical neck of the scapula, and the rim of the glenoid ligament. On the other side it is attached above or externally to the anatomical neck of the humerus just at the edge of the articulating surface, but on the lower or inner surface it is attached some distance below the articular surface (approximately 1 cm.) and then turns upward toward the edge of the articular cartilage. Thus a fracture through the anatomical neck might pass outside of the joint above, and inside of it below. The positions assumed by the capsule in abduction and adduction are shown in Figs. 237 and 238.



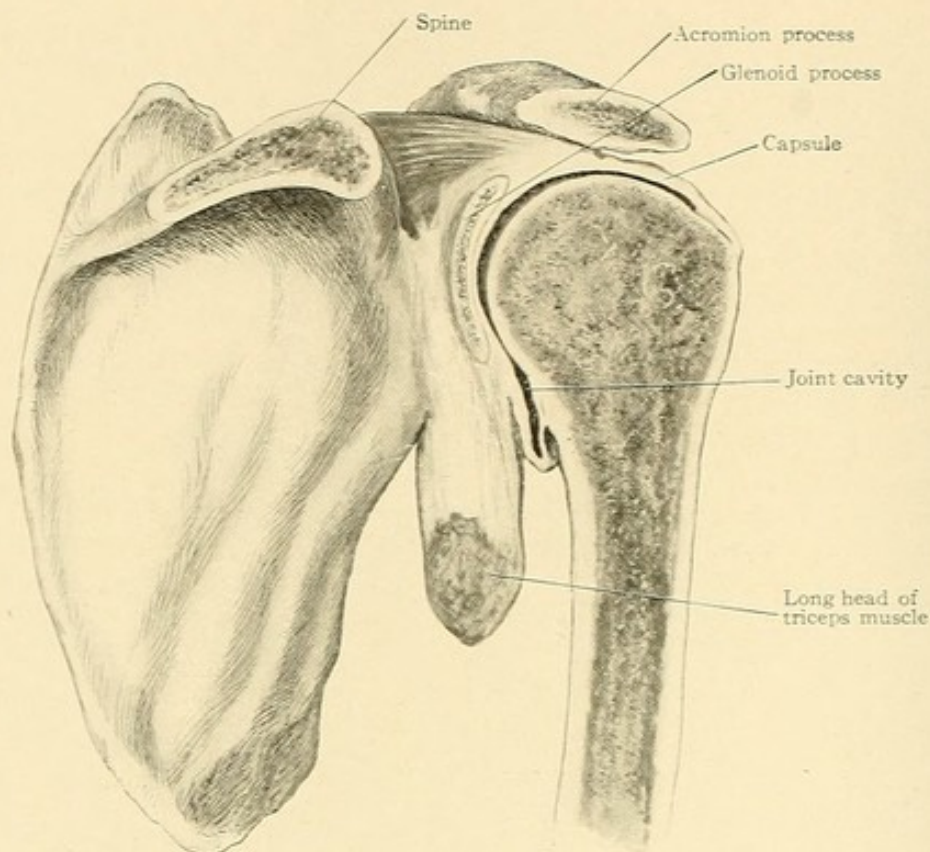


FIG. 237.—Section of shoulder-joint, arm adducted, showing the position assumed by the capsule and the points of its attachment.

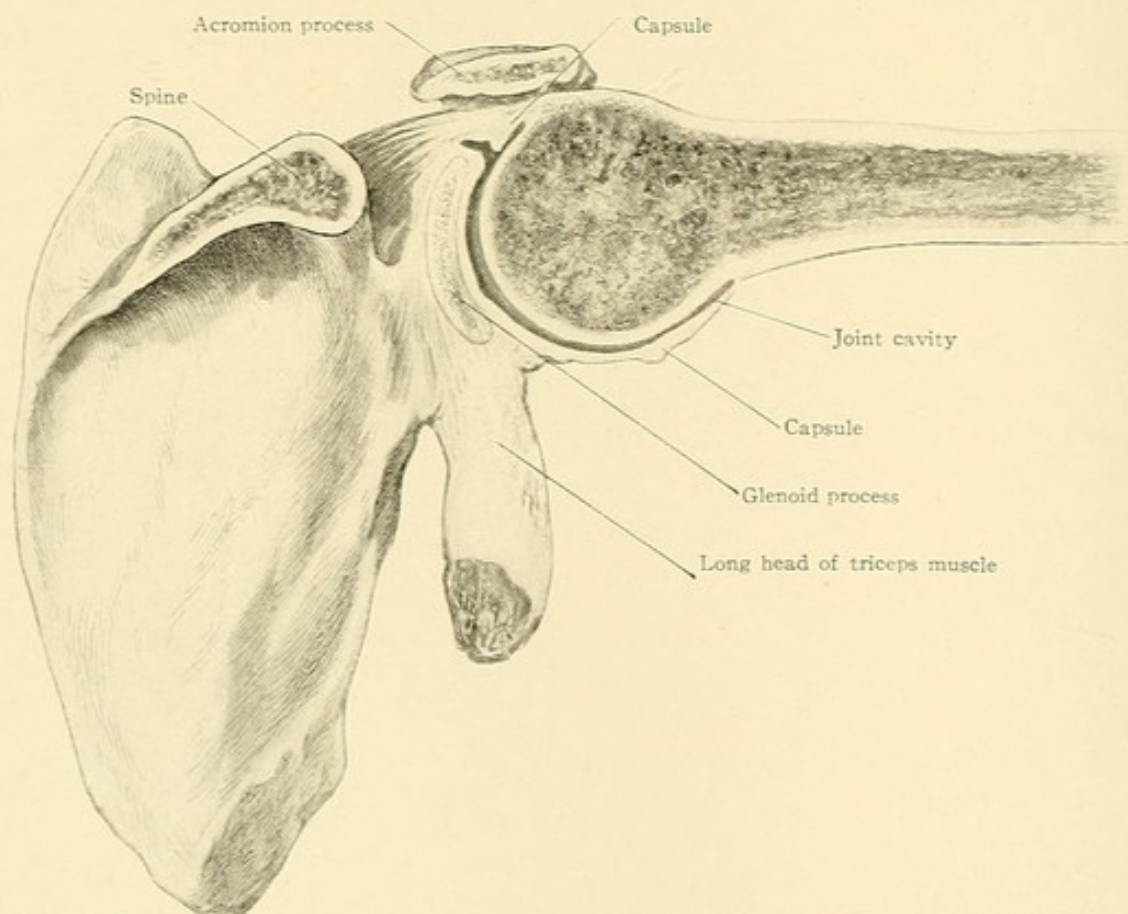


FIG. 238.—Section of shoulder-joint, arm abducted, showing the attachment of the capsule and the position it assumes when the arm is in this position.



The capsular ligament, *per se*, has not much strength. There are two openings in it—one is for the long tendon of the biceps and the other is the opening of the bursa beneath the subscapularis muscle. Sometimes there is a synovial extension beneath the supraspinatus tendon and rarely, in old people, a communication with the subacromial bursa. It is evident that in case of suppuration within the joint the pus would tend to find vent first through these openings.

The laxity of the capsule is such that after the muscles are removed the head can be drawn a considerable distance away from the glenoid cavity. When the mus-

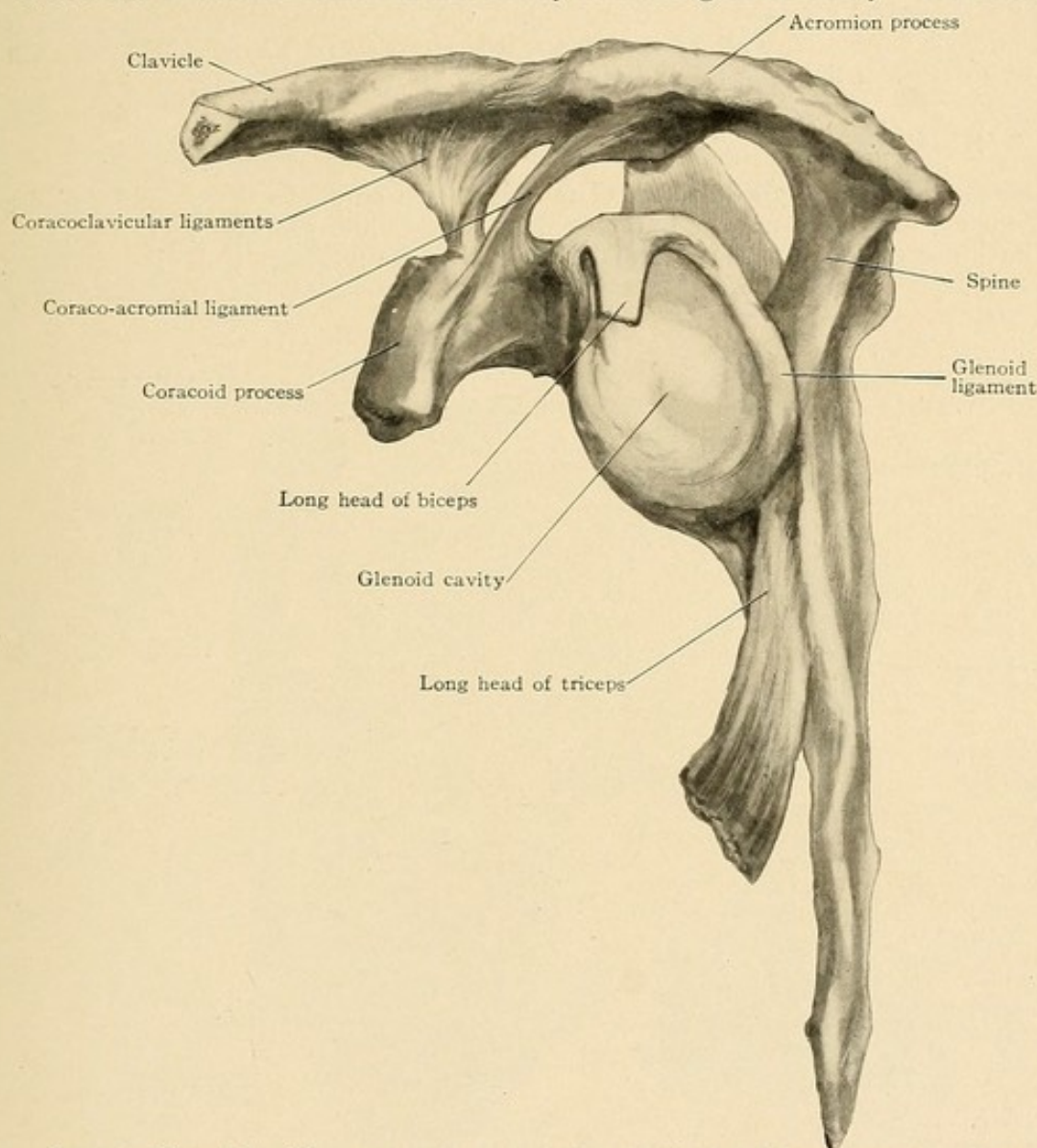


FIG. 239.—View of the left scapula and outer end of the clavicle from in front, showing the ligaments passing from the coracoid process to the clavicle and acromion process, the glenoid ligament, and attachments of the long heads of the biceps and triceps muscles.

cles are paralyzed the weight of the arm causes the head to fall away and a depression is seen beneath the acromion process. The capsule is strengthened by two definite and separate ligamentous bands called the coracohumeral and the glenohumeral ligaments.

The *coracohumeral ligament* passes from the root of the coracoid process to the anterior portion of the greater tuberosity. It is supposed by Sutton to be a regression of the tendon of the pectoralis minor muscle.

The *glenohumeral ligament* is a ribbon-like band seen lying alongside of the inner edge of the biceps tendon as it passes through the interior of the joint. It passes from the root of the coracoid process near the edge of the glenoid cavity to a dimple in the lesser tuberosity of the humerus. Sutton considers it a regression of



the tendon of the subclavius muscle and homologous with the ligamentum teres in the hip. It is also called the superior glenohumeral ligament, in contradistinction to some bands on the lower anterior part of the capsule which are called by some anatomists the middle and inferior glenohumeral ligaments. Between the superior above and the middle and inferior below is the opening by which the bursa of the subscapularis muscle communicates with the joint.

The *glenoid ligament* is the wedge- or cup-shaped ring of fibrocartilage which deepens the glenoid fossa. It is attached around its edge to the rim of the fossa and at its upper end receives the long tendon of the biceps, which divides and blends with it on each side. At its lower part when it is attached to the bone it blends with the anterior edge of the long tendon of the triceps.

### THE MUSCLES OF THE REGION OF THE SHOULDER.

The shoulder embraces two sets of muscles: one connects the shoulder-girdle with the trunk and the other the humerus with the shoulder-girdle.

The inner end of the clavicle articulates with the sternum and gives a bony support to the shoulder-girdle at this point. The rest of the shoulder-girdle,

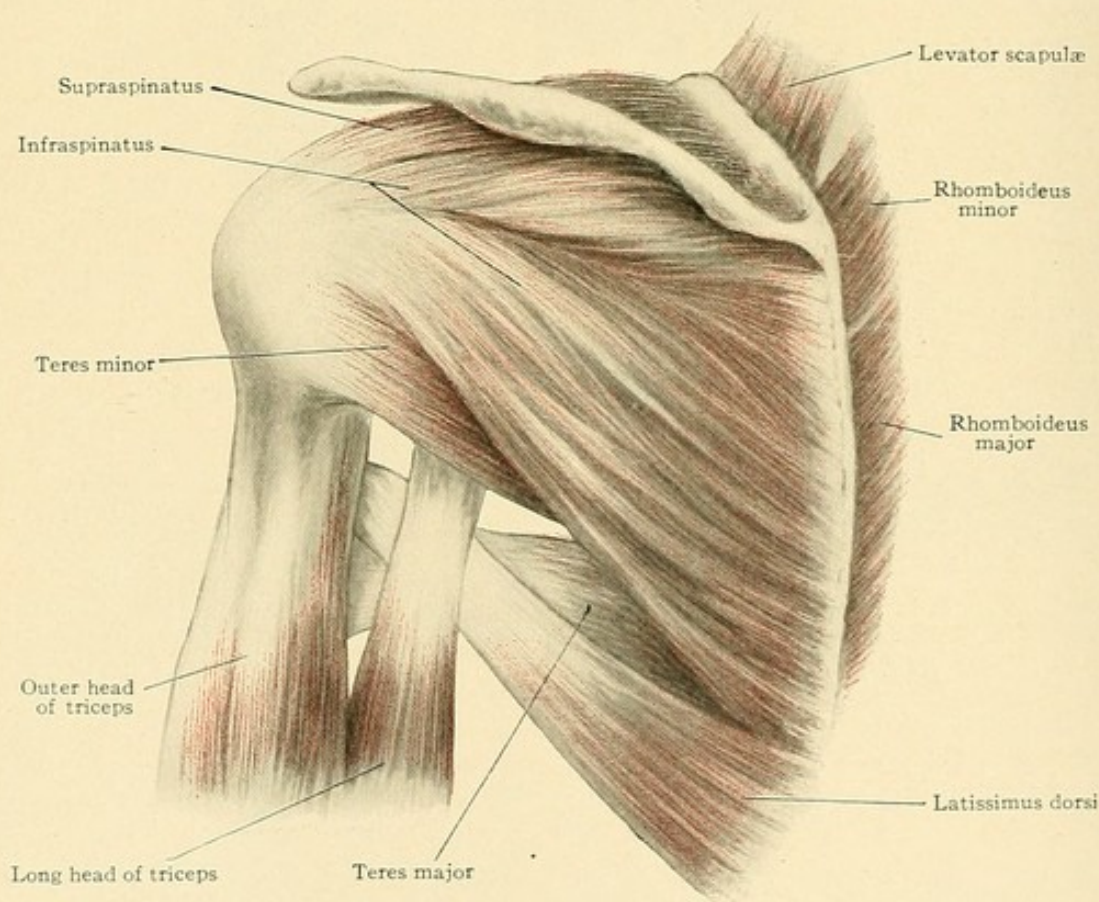


FIG. 240.—Scapular muscles.

comprising the remainder of the clavicle and all of the scapula and bearing the weight of the whole upper extremity, hangs from and is supported and moved by the muscles which pass from it to the vertebræ posteriorly and to the skull, hyoid bone, and ribs anteriorly.

*Anteriorly* the clavicle has attached to its upper inner third the clavicular origin of the sternomastoid muscle; and on its under surface is the subclavius muscle, which arises from the cartilage and anterior end of the first rib. These muscles aid in moving the clavicle. Running from the third, fourth, and fifth ribs to the coracoid process is the *pectoralis minor muscle*; and on the side of the chest, passing to the posterior edge of the scapula, is the *serratus anterior (magnus)* muscle. It will be alluded to again.



*Posteriorly* is the trapezius muscle superficially, and beneath are the *omohyoid*, *levator scapulæ*, and the two *rhomboid muscles*.

The **trapezius** arises from the superior curved line of the occiput, the ligamentum nuchæ, and the spines of the seven cervical and all of the thoracic vertebræ. It inserts into the upper surface of the outer third of the clavicle, acromion process, and spine of the scapula to near its root. Its upper fibres directly aid in sustaining the weight of the upper extremity. It is not infrequently paralyzed, and then falling of the shoulder is marked. It also tends to pull the scapula backward toward the spine, and rotates it.

The **levator scapulæ** arises from the transverse processes of the upper four cervical vertebræ and passes downward to insert into the posterior edge of the scapula between its upper angle and the root of the spine of the scapula.

The scapula is supported largely by this muscle; hence when the trapezius is paralyzed, as occurs in division of its motor nerve, the spinal accessory, this muscle is utilized in counteracting its loss.

The **rhomboid muscles** arise from the lower part of the ligamentum nuchæ and the spines of the seventh cervical and upper five thoracic vertebræ and insert into the posterior edge of the lower three-fourths of the scapula.

The **serratus anterior (magnus) muscle** (Fig. 202), lies beneath the scapula and arises from nine slips from the outer surface of the upper eight or nine ribs; the second rib receives two slips. It passes backward and upward and inserts into the posterior edge of the scapula from its upper to its lower angle.

The serration attached to the sixth rib is the one that reaches farthest forward on the side of the chest.

The **omohyoid muscle** arises posteriorly from the upper border of the scapula, just behind the suprascapular notch, and then runs upward and forward to the under surface of the body of the hyoid bone. It is a digastric or two-bellied muscle and its middle tendon is attached by a pulley-like process of the deep cervical fascia to the first rib.

### MOVEMENTS OF THE SHOULDER-GIRDLE.

While the muscles above enumerated comprise all those directly attached to the shoulder-girdle and trunk, they are of course assisted to some extent by the muscles forming the axillary folds, viz., the pectoralis major anteriorly and the latissimus dorsi and teres major posteriorly.

The shoulder-girdle is elevated by the upper fibres of the trapezius, levator scapulæ, rhomboidei, sternomastoid (clavicular origin), and omohyoid. It is depressed by the lower fibres of the trapezius, latissimus dorsi, lower fibres of the serratus anterior (magnus), pectoralis major, pectoralis minor, and subclavius. It is drawn forward by the pectoralis major, minor, subclavius, serratus anterior, omohyoid, and, if the arm is fixed, by the teres major muscles. It is drawn back by the trapezius, rhomboidei, and latissimus dorsi muscles. Rotation is effected by a combined action of various parts of these muscles.

### SURFACE ANATOMY.

On observing the region of the shoulder it is noticed that it projects well out from the trunk, so that the arm hangs free. It has as its framework three bones—the clavicle and scapula above, forming the shoulder-girdle, and the humerus below. They radiate from the region of the joint, the clavicle toward the front, the scapula toward the back, and the humerus downward, forming the basis of the shape of the shoulder, which is modified by the muscles, fat, and skin.

The skin and fat bridge over and tend to obliterate the hollows and to a less extent obscure the prominences. This is more the case as applied to the muscles than the bones, hence the bones form the better landmarks or guides.

Age and sex modify the surface appearances. In children the bones are but slightly developed and their prominences not marked. Fat is usually abundant and it is often no easy task to recognize by the sense of touch the various anatomical parts and determine whether or not they have been injured. For this reason one should



endeavor to increase his skill by taking advantage of every opportunity that offers for examination. In the case of women the same thing usually exists, but to a less degree. In the somewhat emaciated adult male the structures can be recognized to best advantage.

The clavicle is subcutaneous, and even in children and fat people can be felt throughout its entire length. Its large, knob-like inner extremity projects considerably above the upper edge of the sternum, which can be felt at the suprasternal notch. Take particular notice of its size and compare it with the one on the opposite side so as not to be misled as to its being diseased or luxated. Follow the bone to its outer extremity, which is higher than the inner, more so when lying down than when standing. A prominent ridge marks its outer extremity; if it is difficult to recognize,

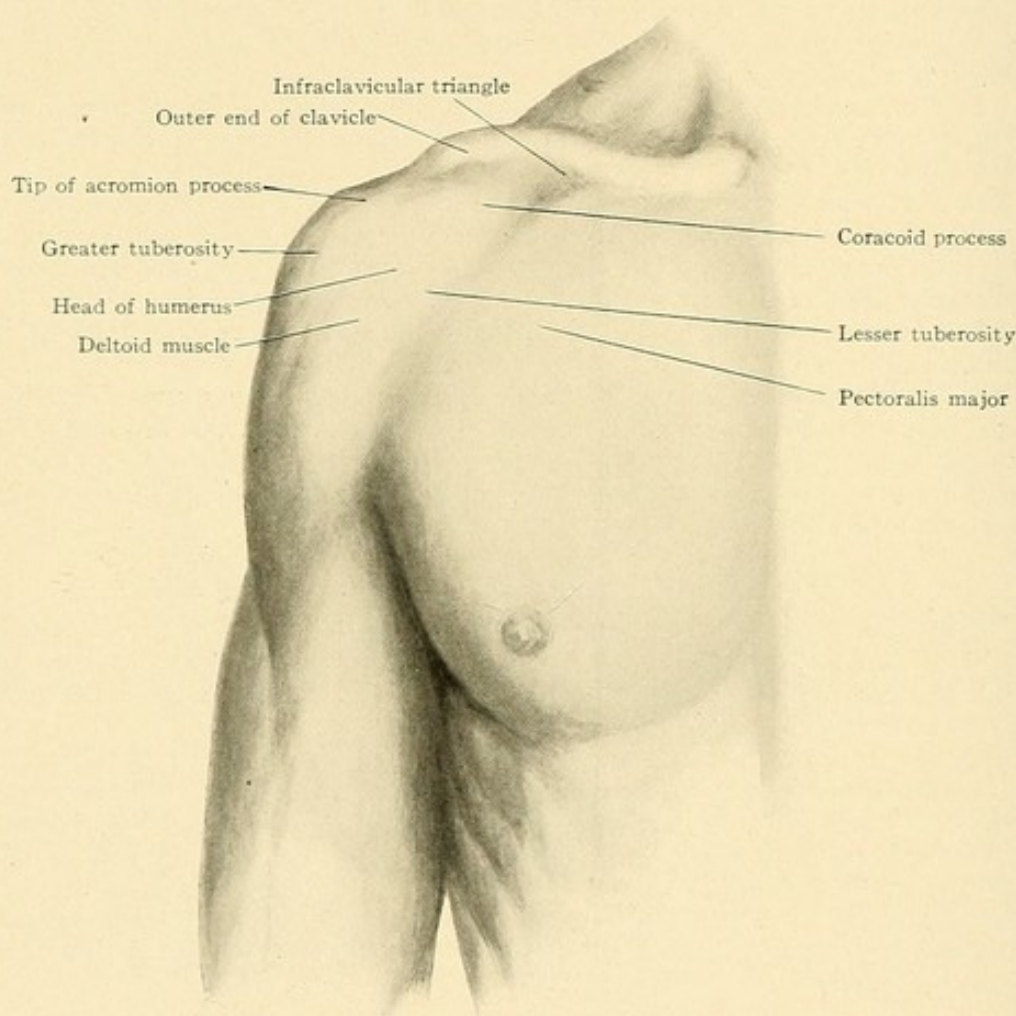


FIG. 241.—Surface anatomy of the shoulder.

as will often be the case, then continue directly outward to the point of the shoulder, which is formed by the tip of the acromion process. Having recognized this point, the end of the clavicle will be found about 2.5 to 3 cm. (1 to 1¼ in.) directly inward from it.

In the median line above the sternum is the suprasternal notch with the prominent sternal origins of the sternomastoid muscles on each side. Just to the outer edge of these tendons lie the sternoclavicular joints. The one on the right side marks the ending of the innominate artery and the commencement of the right common carotid and subclavian. That on the left marks the left carotid with the subclavian directly to its outer side and a little posteriorly.

If the head is extended and turned to the opposite side the clavicular origin of the sternomastoid is made visible. It arises from the *inner third* of the bone.



The inner two-thirds of the clavicle is convex forward. Above this portion is the subclavian triangle in the supraclavicular fossa. The *outer third* of the clavicle is convex backward and from its upper surface the trapezius muscle can be felt proceeding upward. This leaves the middle third of the bone free from muscle.

Under the middle of the bone passes the subclavian artery. It curves upward about 2.5 cm. (1 in.) above the clavicle to descend again to the sternoclavicular joint. The arch so formed indicates the apex of the lung because the subclavian artery rests on the pleura. The internal jugular vein passes down opposite the interval between the sternal and clavicular heads of the sternomastoid muscle.

Just above the clavicle, a little internal to its middle, and behind the clavicular origin of the sternomastoid muscle is seen the external jugular vein. It terminates in the subclavian vein, which lies to the inner (anterior) side of the artery. To the outer side of the artery the cords of the brachial plexus pass upward and inward. They become prominent in emaciated subjects when the head is turned forcibly toward the opposite side. The posterior belly of the omohyoid muscle varies much in its position, sometimes it lies behind the clavicle, at others two or three centimetres above it.

Immediately below the clavicle is the infraclavicular fossa. At its inner extremity can be felt the first rib. As it is exceedingly easy to mistake the ribs, it is best, in counting them, to locate the second rib by recognizing the angle of the sternum, (angle of Ludwig) to which it is opposite, on the surface of the sternum about 5 cm. (2 in.) below its upper edge. Attached to the lower edge of the *inner half* of the clavicle is the pectoralis major muscle and to the *outer third* the deltoid muscle.

This leaves one sixth of the lower edge of the clavicle free from muscular attachments. This forms the base of the subclavicular triangle and its two sides are formed by the adjacent edges of the pectoralis major and deltoid muscles. Beneath this triangle runs the first portion of the axillary artery with the vein to its inner side and the cords of the brachial plexus to its outer side. Deep pressure at this point compresses it against the second rib.

Just to the outer side of the junction of the middle and outer thirds of the clavicle, in front of the deepest part of the concavity of the clavicle and about 2.5 cm. (1 in.) below it, is the coracoid process. It is better felt by pressing the fingers flat on the surface than by digging them in. It is somewhat obscured by the edge of the deltoid muscle, which covers it. Running from the coracoid to the acromion process is the sharp edge of the coraco-acromial ligament. An incision midway between the two processes would open the joint and strike the long biceps tendon as it winds over the head of the humerus to reach the upper edge of the glenoid cavity.

Beneath the acromion process is felt the greater tuberosity of the humerus. If the arm is placed alongside of the body with the palm facing forward, a distinct groove can be felt to the inner side of the acromion process passing downward on a line with the middle of the arm. It is the bicipital groove for the long tendon of the biceps muscle. The bony process of the humerus to its outer side is the greater tuberosity and that to its inner side, between it and the coracoid process, on a slightly lower level, is the lesser tuberosity. It will be noted that the greater tuberosity projects beyond the acromion process and forms the prominence of the shoulder. On rotating the arm the tuberosities can be distinctly felt moving under the deltoid muscle.

Following the acromion process around toward the back it turns abruptly where it joins the spine of the scapula, forming a distinct angle. This angle is quite prominent, can be readily seen and felt, and can be used as a landmark for measuring the length of the humerus. If the spine of the scapula is followed still farther it ends in its root at the posterior border of the bone opposite the upper edge of the fourth rib and third thoracic spine. This marks the upper extremity of the fissure of the lung; with the arm to the side, the lower angle of the scapula lies over the seventh interspace.

**Axilla.**—On raising the arm directly out from the body the armpit and axillary folds become visible. The rounded edge of the anterior axillary fold is formed by the pectoralis major muscle. It follows the fifth rib and its upper end merges with the lower edge of the deltoid muscle.



If firm pressure is made along the inner or lower edge of the outer extremity of the anterior axillary fold the upper end of the biceps muscle can be felt, and lying along with it, to its inner side, is the swell formed by the coracobrachialis muscle.

Along the inner edge of the coracobrachialis muscle lies the axillary artery with its vein to the inner side. This is a little anterior to the middle of the axilla. The artery can be felt pulsating along the inner edge of the coracobrachialis and can be compressed by pressure made in an outward and backward direction against the humerus. The line of the axillary artery is from the middle of the clavicle down along the inner edge of the coracobrachialis muscle, which will be anterior to the middle of the axilla.

The posterior fold of the axilla is formed by the latissimus dorsi and teres major muscles. By deep pressure in the axilla, posterior to the vessels, the arm being abducted, the rounded head of the humerus can be felt.

When the arm is brought more to the side the tissues of the axilla relax and any enlarged lymph-nodes present may be recognized. When normal they cannot be felt.

Winding around the surgical neck of the humerus from behind forward under the deltoid muscle about at the junction of its upper and middle thirds is the pos-

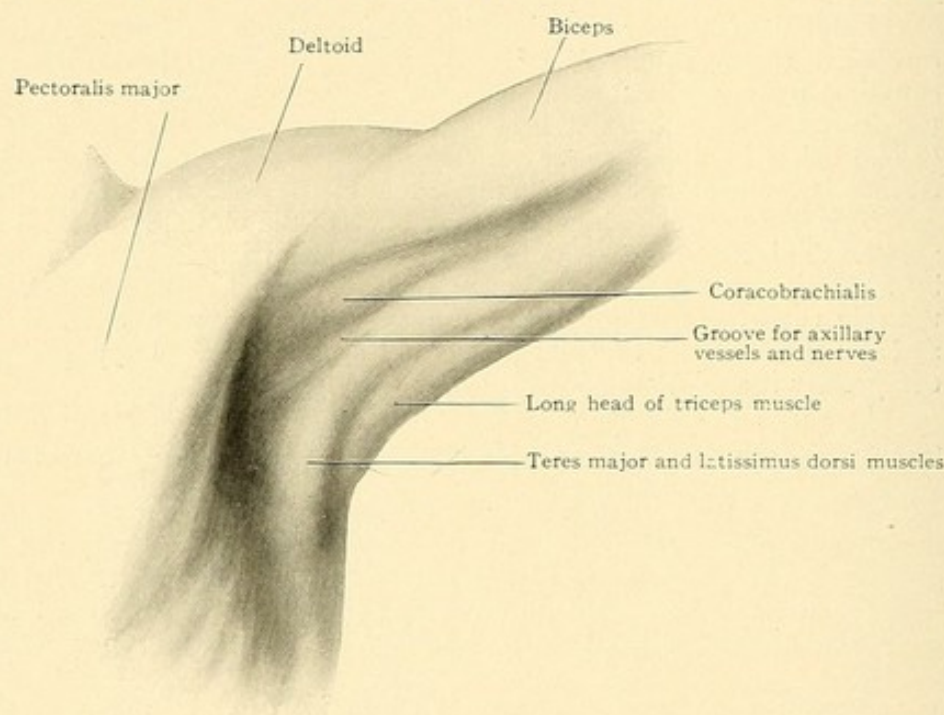


FIG. 242.—Surface anatomy of the axilla.

terior circumflex artery and circumflex nerve. Hence a blow at this point may injure the nerve and cause paralysis of the deltoid muscle. The line of fracture of the surgical neck of the humerus would also lie at this point.

#### DISLOCATIONS OF THE CLAVICLE.

**Dislocation of the Sternal End of the Clavicle.**—The sternal end of the clavicle is most commonly dislocated forward. Other dislocations, which may be upward or backward, are very rare. The range of movement of the clavicle approximates 60 degrees.

The bone is lowest when the elbow is brought forward across the front of the body and highest when the arm is raised and placed behind the neck. The luxation is produced by the shoulder being violently depressed and pushed backward, as in falling on it; in some cases an inward thrust may be added. As the clavicle descends its under surface comes into contact with the first rib, which acts as a fulcrum, and the inner extremity is lifted upward and forward, rupturing the sternoclavicular ligaments. The rhomboid ligament remaining intact prevents a wider displacement of the bone.



As regards treatment, to reduce the luxation the shoulder should be elevated and drawn outward and backward. While pressure is made on the protruding bone the arm is used as a lever and the bone tilted into place. Usually reduction can be readily accomplished, but most people have found it difficult to retain the parts in

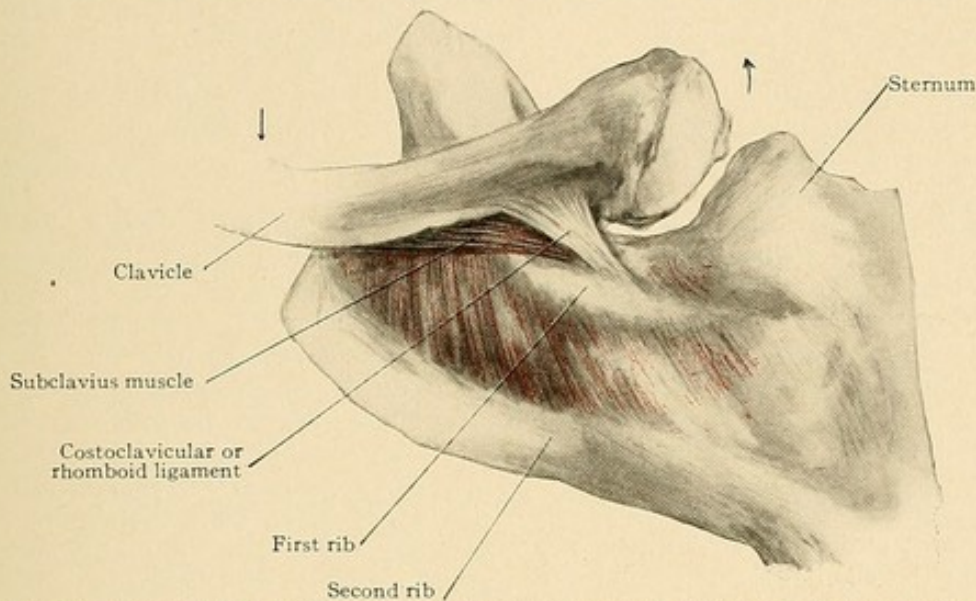


FIG. 243.—Dislocation of the sternal end of the clavicle upward and forward, showing how the first rib acts as a fulcrum and the clavicle as a lever.

place. The only sure way of doing so is to keep the patient in bed on his back. Stimson, following Velpeau and Malgaigne, advises the application of an anterior figure eight bandage of plaster of Paris; Hamilton says deformity remains after any method of treatment, but that function will be but little impaired.

In upward dislocations the case of R. W. Smith has shown that the end of the bone passes behind the sternal origin of the sternomastoid muscle.

In backward dislocations pressure on the trachea and œsophagus have caused difficulty in breathing and swallowing; cyanosis due to pressure on the internal jugular vein has been observed in one case. When one recalls the function of the clavicle in keeping the shoulder out from the body, it is readily seen that when the security of its inner attachment has once been destroyed displacement is favored by the weight of the upper extremity as well as by the action of all the muscles which pass from the head, neck, and trunk to the shoulder-girdle and humerus.

In these dislocations of the sternal end of the clavicle the fibrocartilaginous disk of the joint sometimes is carried out with the clavicle and sometimes remains attached to the sternum, more often it follows the clavicle.

**Dislocation of the Acromial End of the Clavicle.**—The acromial end of the clavicle may be dislocated either upward or downward. Nearly all the dislocations are upward.

The displacement is usually produced by direct violence, a blow on the top or back of the shoulder driving the acromion down and inward. The clavicle not only

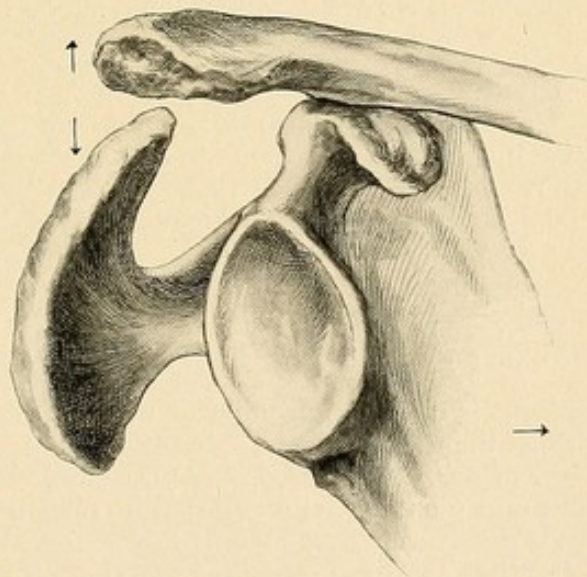


FIG. 244.—Luxation of the outer end of the clavicle upward, showing the coracoid process acting as a fulcrum. As the outer end of the clavicle rises, the lower angle of the scapula is carried toward the median line and the acromion process is depressed and torn loose from the clavicle above.



risks but also goes backward, or the scapula comes forward, so that the end of the clavicle may rest on the acromion process. In this dislocation the base of the coracoid process, on which the clavicle rests and to which it is bound by the conoid and trapezoid ligaments, acts as a fulcrum. The scapula rotates on an anteroposterior axis, passing through the base of the coracoid process, and as the inner portion of the bone rises, its outer portion,—that is, the acromion process,—descends and is torn from the outer end of the clavicle.

The deformity produced by the upwardly projecting end of the clavicle is typical. The luxation may be complete or incomplete. When incomplete the injury is confined to the acromioclavicular joint; when complete the conoid and trapezoid ligaments are partially or wholly ruptured.

The joint usually possesses a poorly developed fibrocartilage and inclines upward and outward so that the inclination favors the rise of the clavicle. When the conoid and trapezoid ligaments are not ruptured they serve as the axis on which the scapula rotates forward so that the outer end of the clavicle slips backward on the acromion process. This led Hamilton to describe these luxations as backward luxations. In rare instances the end of the clavicle seems to be displaced posteriorly without rising above its normal level. We reported one such case in the *Annals of Surgery* several years ago. Reduction of the displacement is easily effected, but the same difficulty in keeping the bone in place has been experienced in this dislocation as in dislocations of the inner extremity. Bandages going over the shoulder and down the arm and under the elbow are commonly employed. The only sure way of keeping the clavicle in its proper position is to operate and fasten it to the acromion with wire or chromicised catgut. When the patient is put in bed the bones are readily replaced.

*Downward dislocation* though rare does seem to have sometimes occurred. From the fact of the under surface of the clavicle resting almost or quite on the coracoid process it is difficult to see how it is possible for this injury to take place. It must take place while the scapula is violently twisted on the clavicle. The displacement is readily reduced and shows but little tendency to recurrence.

### DISLOCATIONS OF THE SHOULDER.

The dislocations of the shoulder are to be studied from the anatomical and not from the clinical standpoint. A knowledge of the anatomical construction of the various parts involved is to be applied to the explanation and elucidation of the methods of production, the signs and symptoms observed, and the procedures necessary for reduction.

*Classification.*—For our purpose there are two forms of dislocations of the shoulder—*anterior* and *posterior*. These two forms are entirely different and must be studied separately.

*Anterior Dislocation.*—An anterior luxation is one in which the head of the humerus is either on or anterior to the long head of the triceps muscle at the lower edge of the glenoid cavity.

*Posterior Dislocation.*—A posterior luxation is one in which the head goes posterior to the glenoid cavity and usually rests beneath the spinous process of the scapula, hence this is called *subspinous dislocation*.

When the head is luxated anteriorly it may pass so far inward as to rest between the coracoid process and the clavicle; hence this form is called *subclavicular*.

When the head does not pass so far inward, but rests on the anterior edge of the glenoid cavity below the coracoid process, it is called a *subcoracoid luxation*.

When it rests on the anterior and lower edge of the glenoid cavity, sometimes on the long head of the triceps muscle or just anterior to it, it is called a *subglenoid luxation*.

### ANTERIOR DISLOCATION OF THE SHOULDER.

The head of the bone almost always comes out through the anterior portion of the capsule and slips beneath the coracoid process. From this point it may shift its position either a little farther inward, when it is called a *subclavicular luxation*, or a little farther downward and outward, when it receives the name of *subglenoid*.



As a matter of fact the head usually comes to rest beneath the coracoid process and permanent fixation of the bone either in the subclavicular or subglenoid positions is very rare. As the symptoms and methods of treatment are identical they will all be included under the one head of subcoracoid luxations. What are commonly regarded as subglenoid luxations are really subcoracoid.

*Method of Production of Anterior Luxations.*—Anterior luxations are produced by the arm being hyperabducted, rotated outward, and the head of the bone pushed or pulled in toward the body. Rotation may not be essential, but it is largely responsible for the wide detachment of the capsule which is present in these injuries. When the arm is raised from the body much beyond a right angle the greater tuberosity strikes the acromion process. If the hyperabduction is continued the acromion process acts as a fulcrum and the head of the bone is lifted from its socket, tearing away the capsule of the joint in front of and below the glenoid cavity.

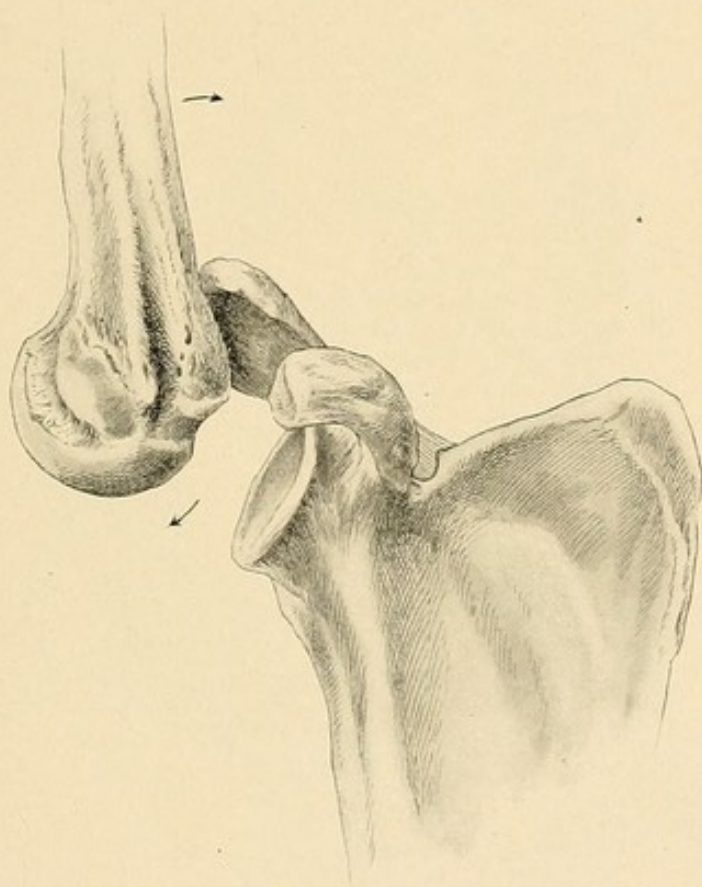


FIG. 245.—Dislocation of the shoulder; action of the bones; by extreme abduction of the humerus over the acromion process as a fulcrum the head is levered out of the socket.

If now the arm rotates, the capsule is still farther detached and if the force continues to act, as in those cases in which a person is thrown forward and alights on the outstretched arm, or if the axillary muscles contract, the head is thrust from its socket. After once leaving the socket, subsequent movements may cause the head to assume various positions around the glenoid cavity; as a matter of fact it is almost always below the coracoid process.

*Parts Injured.*—When the luxation occurs the arm is hyperabducted and, owing to the acromion process being somewhat posterior to the glenoid cavity, pointing backward, this places it up almost or quite alongside of the head. The force which thrusts the bone out acts downward toward the axilla and inward toward the body. The posterior border of the scapula is prevented from descending by the levator scapulæ and rhomboid muscles, hence it is the *joint* which descends and tears loose the capsule already stretched tightly over the head of the humerus.

This is the reason why the lower portion of the capsule is torn; it is the longi-



tudinally acting force that does it. When the transverse force acts it is expended on the anterior portion of the joint because the joint is at the anterior portion of the scapula. Posterior to the joint the scapula rests on the chest, so it is its anterior portion which is forced inward, thus rupturing the capsule at this point. The fulcrum, or acromion process, is also posterior to the midline of the joint.

By a combination of these two forces (longitudinal and transverse) the capsule is ruptured at its lower and especially its anterior portion. Its tearing is favored by a twisting or external rotation of the humerus. The attachment of the capsule is torn from the rim of the glenoid cavity, not from the humerus, and a fragment of the bony rim frequently comes with it. The opening is large and embraces nearly or

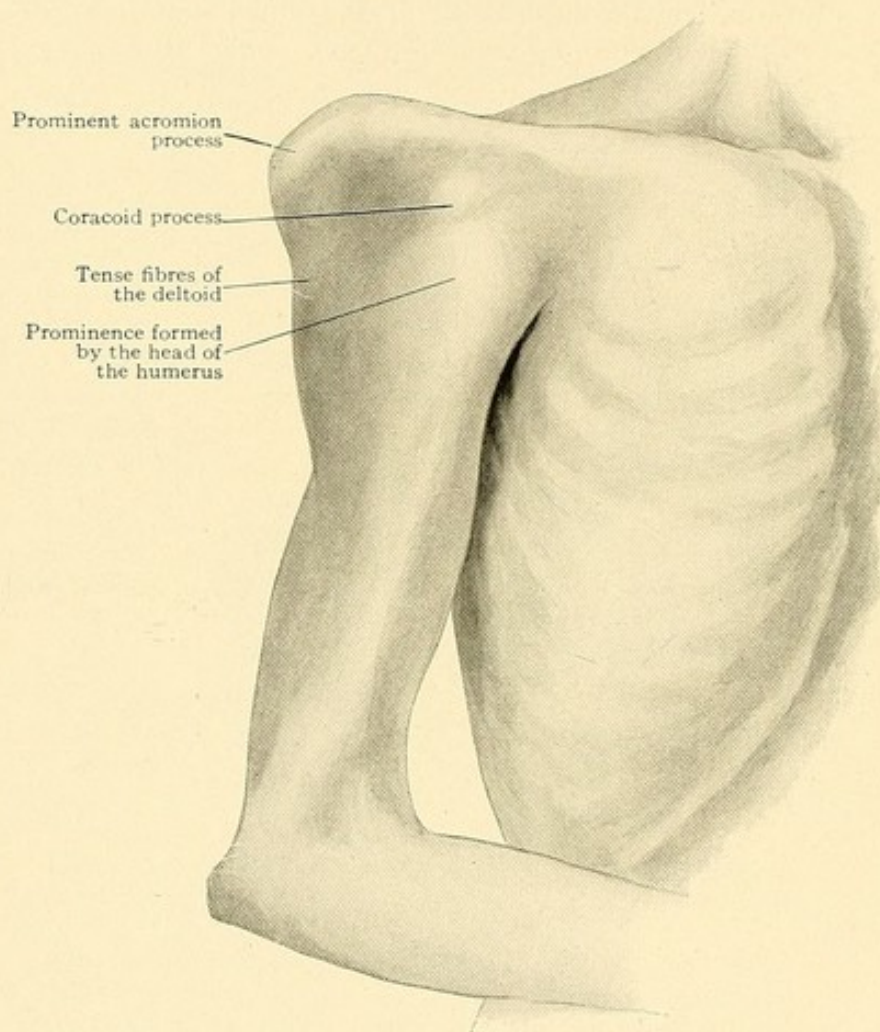


FIG. 246.—Surface view; subcoracoid dislocation of the humerus, showing the elevation of the shoulder, abduction of the arm, prominence of the displaced head below the coracoid process, flattening of the shoulder, and tense fibres of the deltoid muscle.

quite half the circumference of the joint. It is limited above by the coracoid process. The coracohumeral and superior glenohumeral ligaments lying in front of the long tendon of the biceps also limit the tear upwards. If the tear does not extend so high it is because the subscapularis muscle, instead of being torn, is wedged in between the head and the coracoid process. Below, the tear is limited by the insertion of the long head of the triceps. As the head luxates it cannot pierce the triceps tendon, so it slips behind it in a posterior luxation and in front of it in an anterior luxation. The supraspinatus, infraspinatus, and teres minor muscles are all posterior; they blend more or less with the capsule and as the head luxates they are stretched with it over the glenoid cavity.

The long tendon of the biceps, while it may sometimes be torn loose from the bicipital groove after rupture of the transverse ligament, is usually so loose that it



follows the head without being detached from its connections. The subscapularis muscle not infrequently has its lower edge torn.

The brachial plexus and blood-vessels are pushed inward by the head, but when the arm is abducted they are stretched over it, running close to the coracoid process.

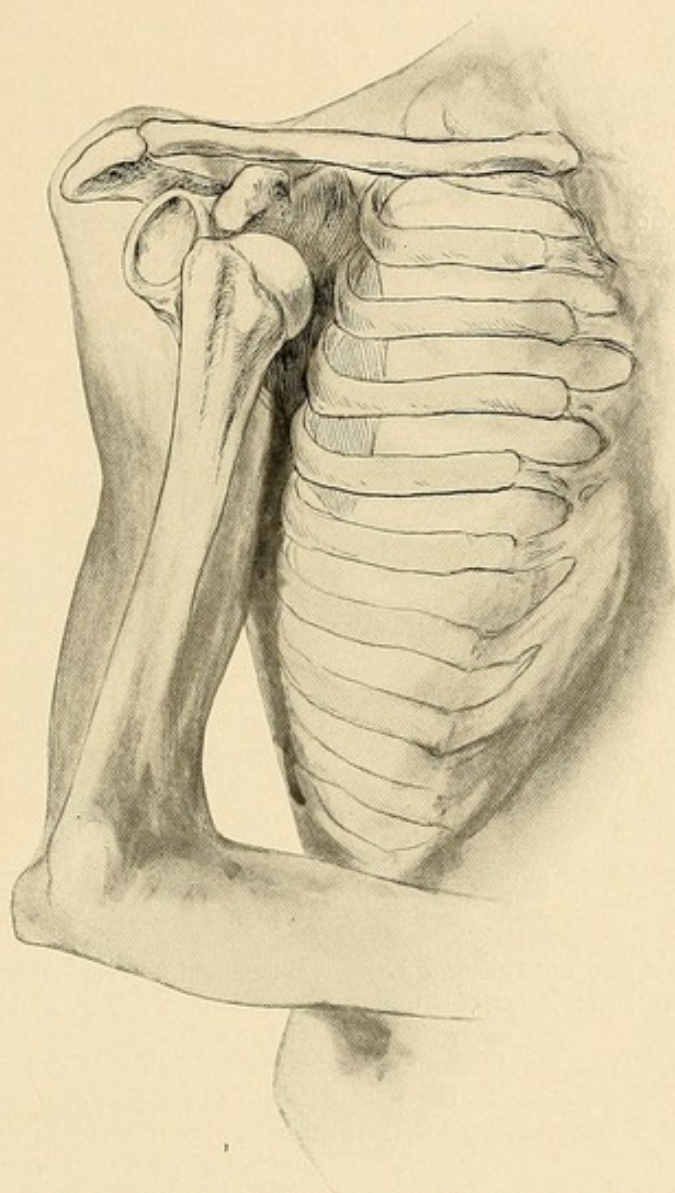


FIG. 247.—Subcoracoid dislocation of the humerus, showing the position of the bones in relation to each other and to the soft parts.

As the circumflex nerve winds around the surgical neck of the humerus, it may be ruptured or tightly stretched over the head of the bone.

Hyperabduction stretches the vessels and nerves so forcibly over the head just prior to its leaving the socket as sometimes to produce serious injury to them.

#### SIGNS AND SYMPTOMS.

There is (1) at first elevation then lowering of the shoulder, (2) flattening of the deltoid muscle, (3) projection of the elbow away from the side. (4) The normal hollow below the outer third of the clavicle is filled up; the head, covered by the deltoid, may sometimes even make a rounded prominence at this point which can frequently be felt. (5) If the elbow is raised and the hand placed on the opposite shoulder and held there the elbow cannot be brought flat on the chest (Dugas's sign), (6) with the



arm to the side the distance from the acromion process to the external condyle is increased, with the arm abducted to a right-angle, the same distance is decreased as compared with the previous position as well as when compared with the arm of the opposite side (see Fig. 248).

1. Lowering the shoulder obviates pain by relaxing the deltoid and preventing it from forcing the head upward in its displaced position.
2. Flattening of the shoulder is due to the head and tuberosities being displaced inward, thus leaving the socket empty. A marked depression can be felt with the fingers below the prominent acromion process.
3. Projection of the elbow from the side is due to tension of the deltoid muscle because the head is lower than normal. In its natural position the top of the head is about level with the coracoid process; when luxated it is below it.
4. The normal hollow below the outer third of the clavicle is lost because here is where the head lies. It may form a distinct prominence and when the arm is rotated

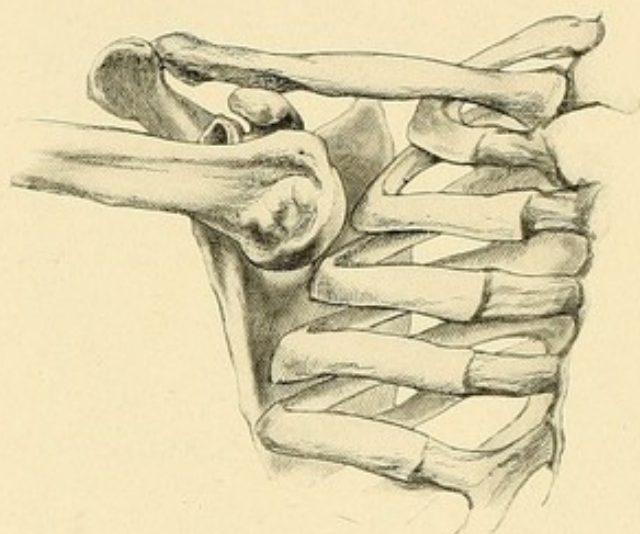


FIG. 248.—Subcoracoid dislocation of the shoulder. The head of the humerus has slipped off its pedestal or shoulder-girdle onto the side of the thorax. This shows how the arm is shortened and why it is necessary to make traction in order to replace the humerus up again on the shoulder-girdle.

if the surgeon lays his hand at this point the tuberosities can be felt to rotate beneath. If the arm is abducted the head can usually be felt in the axilla, where it may even form a prominence.

5. In Dugas's test the elbow cannot be brought to the chest because the outer end of the humerus is held close to the chest-wall. On account of the thorax being rounded like a barrel it is necessary for the outer end of the bone to rise as the inner end falls.

6. The reason for the difference in measurements when the shoulder is luxated is readily seen by the fact that the head is displaced downward and inward as shown in the accompanying figure.

#### TREATMENT.

Reduction of an anterior luxation of the shoulder can be accomplished in two ways, viz., the *direct*, in which the head is pulled or pushed back into the socket, and the *indirect*, in which it is levered back.

**Direct Method.**—This consists in first placing the arm in approximately the position it occupied when luxated (abduction) and then pulling or pushing the head toward and into the socket while the arm is rotated to relax the capsule and allow the head to enter. The usual obstacle to reduction of a recent luxation is muscular contraction. The main muscles acting are the deltoid, pectoralis major, latissimus dorsi, and teres major. To effect reduction the action of these muscles must either be held in abeyance or overcome by force. This may be accomplished in several ways, viz., by the use of general anæsthesia, by such gentle manipulations



as will not incite the muscles to contraction, by a quick movement accomplishing the object before the muscles are able to contract, or, finally, by overcoming the muscular action by steady continuous traction. General anaesthesia is the surest way of obviating muscular contraction.

The question of muscular contraction having been solved by one or more of these expedients the actual replacement is to be accomplished by dragging or pushing the head back over the route it took in coming out. The opening in the capsule is below and anterior, therefore the arm is to be strongly abducted, and traction made upward and backward. This drags the head upward and backward over the rim of the glenoid cavity into its socket. If it does not enter readily it is because of tension

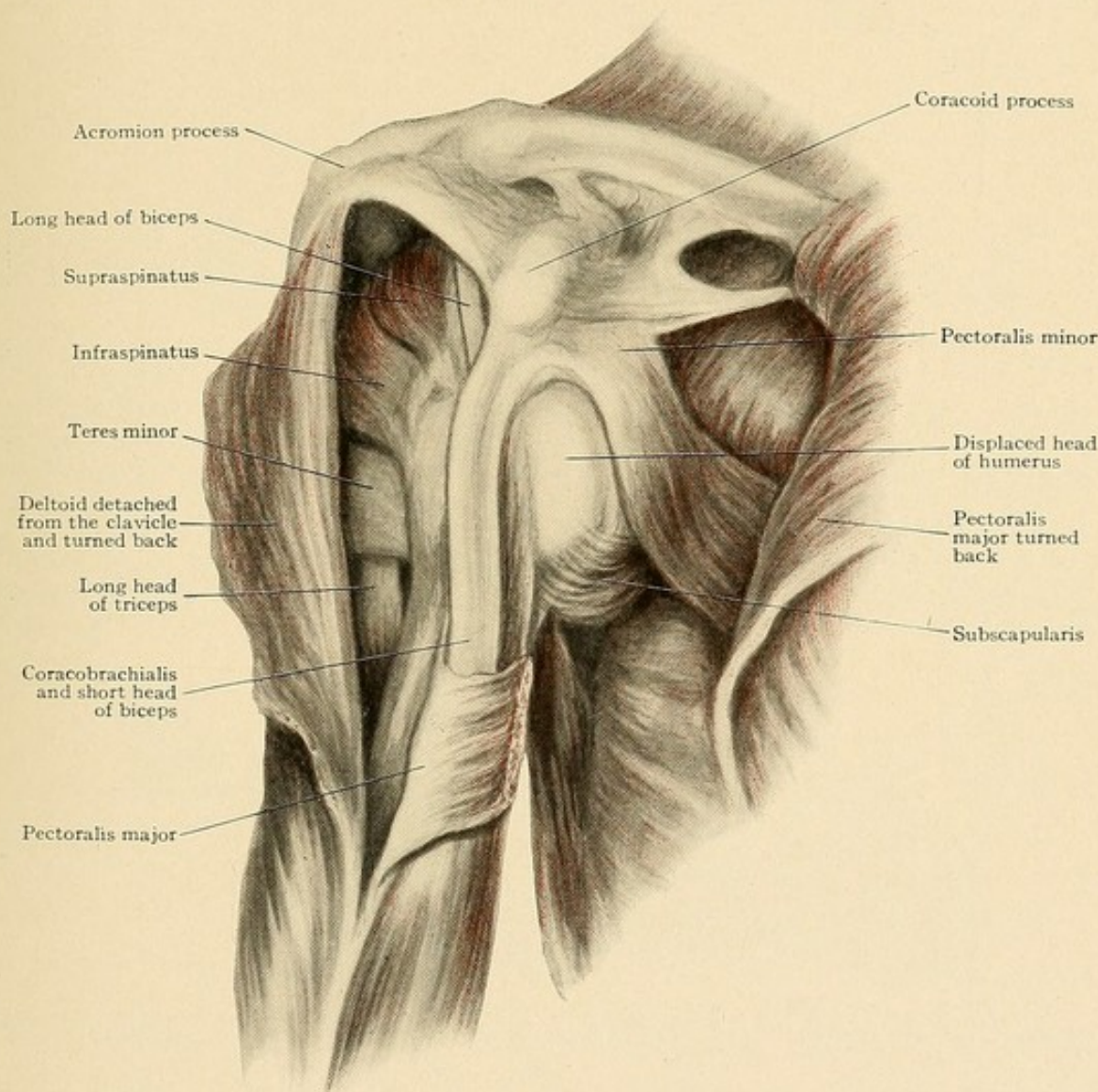


FIG. 249.—Subcoracoid dislocation of the shoulder. Dissection showing the relation of the muscles to the displaced humerus.

of the untorn part of the capsule; this is to be remedied by gently rotating the arm, when the proper position will be revealed by the slipping of the head into place. Rotation in either direction beyond the proper point narrows the tear in the capsule and keeps the head from entering. Traction is necessary in order to replace the head of the humerus on its pedestal or shoulder-girdle from which it has fallen onto the side of the chest (see Figs. 248 and 250).

If it is desired to tire the muscles out, the plan of Stimson is best. Place the patient in a canvas hammock and allow the arm to hang downward through a hole in the canvas. Fasten a ten-pound weight to the wrist and inside of six minutes the



weight will have dragged the head of the humerus into place. This same object can be carried out, but not so well, by having the patient lie on the floor and pulling the arm directly upward by means of a rope and pulley. Here the weight of the body acts as the counter force.

Other means, such as the heel in the axilla, etc., may be found described in works on surgery, but it is to be remembered that the objects to be sought are (1) to overcome the action of the deltoid by abducting the arm, (2) to overcome the axillary muscles—pectoralis major, latissimus dorsi, and teres major—by traction, and (3) to loosen the capsule and open the tear to its widest extent by rotation while the head is pushed with the hand toward and over the lower and anterior edge of the socket.

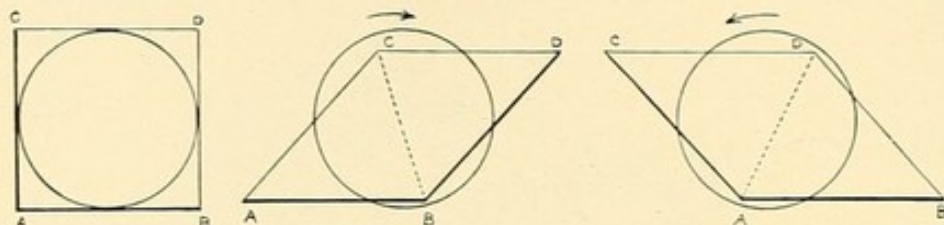


FIG. 250.—Diagram to show how rotation influences the size of the rent in the capsule. The square represents the rent in the capsule and the circle the head of the humerus. If the humerus is rotated too much in the direction of the arrows, either to the right or left, the opening in the capsule is so narrowed as to obstruct the passage of the head.

**Indirect Method.**—The indirect or lever method has been best systematized by Kocher of Berne, although Henry H. Smith, a former professor of surgery in the University of Pennsylvania, taught a similar method previously (see H. H. Smith's "Surgery," 11 vols., also Packard's "Minor Surgery," p. 204, and Ashhurst's "Surgery," 2d Ed., Phila. 1878, p. 284). Kocher's method is as follows: *First Step.*—Flex the forearm until it forms a right angle with the arm, then, with the elbow touching the side of the body, rotate the arm outward 90 degrees until the forearm points directly outward (Fig. 251). This causes the head of the bone to rotate outward and leave the side of the chest to take a position close to the glenoid cavity. *Second Step.*—The arm being held in this position, the elbow is raised forward until

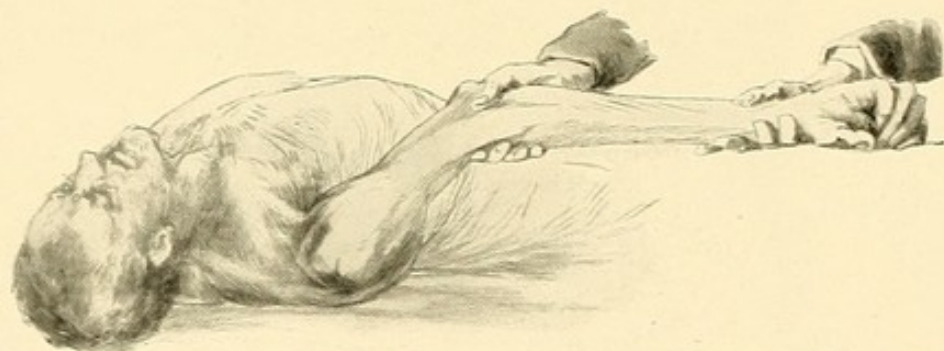

FIG. 251.—Kocher's method of reducing dislocation of the shoulder: First step—Flex the forearm at a right angle to the arm; bring the humerus alongside the chest, the elbow nearly touching the side, and rotate outward as far as the arm will go without undue force.

it forms a right angle or a little more with the long axis of the body. This relaxes the coracobrachialis muscle, releases the lesser tuberosity, which may be caught against it, and allows the head to pass outward and ascend from its low position up into the glenoid cavity (Fig. 252). *Third Step.*—Carry the arm obliquely inward, place the hand on the opposite shoulder and bring the elbow down to the surface of the chest, the humerus pointing diagonally downward and inward as in the Velpeau position for fractured clavicle (Fig. 253).

The mechanism, as readily demonstrated on the cadaver, is as follows: The head lies to the inner side of the glenoid cavity with the tense posterior portion of the capsule passing backward. When external rotation is made the capsule is wound around the head and upper portion of the neck and the head moves out. In some instances the head will not only move out but will likewise move up and be drawn at



once into place. Bringing the arm forward and upward relaxes the coracobrachialis muscle, while bringing it across the chest in the last step assists the head over the rim of the glenoid cavity and restores the member to its normal position. Prof. H. H. Smith brought the elbow forward *before* making the external rotation instead of after, as did Kocher. This is probably the better way because persistence in rotating outward when the lesser tuberosity is caught beneath the tense coracobrachialis muscle is one cause of the frequent fracture of the humerus in attempting to carry

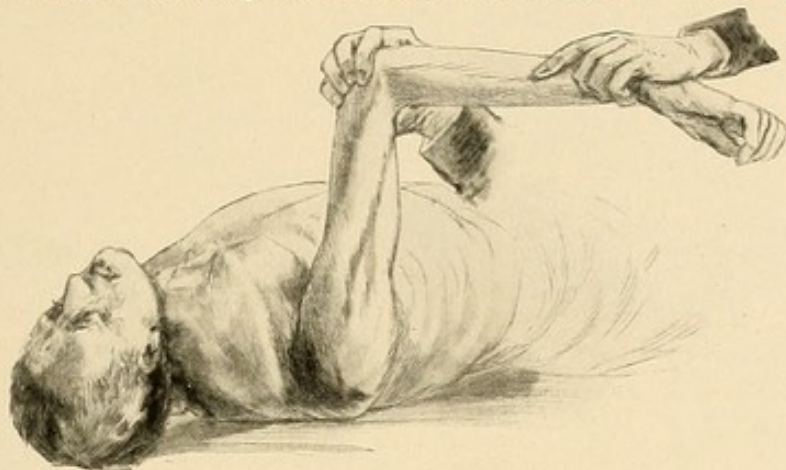

FIG. 252.—Kocher's method of reducing dislocation of the shoulder: Second step—Keeping the arm in external rotation, raise the elbow until the humerus reaches the vertical line or a little beyond.

out Kocher's method; another cause is the violent contraction of the muscles holding the upper end of the bone immovable.

This method can be used without anæsthesia, but it is at times exceedingly painful and savors of cruelty. It is particularly applicable for old and severe cases. It depends for its efficiency on the integrity of the posterior portion of the capsule, if this has been torn loose the method fails and the head simply rotates *in situ*. If this latter is the case, reduction can readily be effected by direct traction and manipulation.

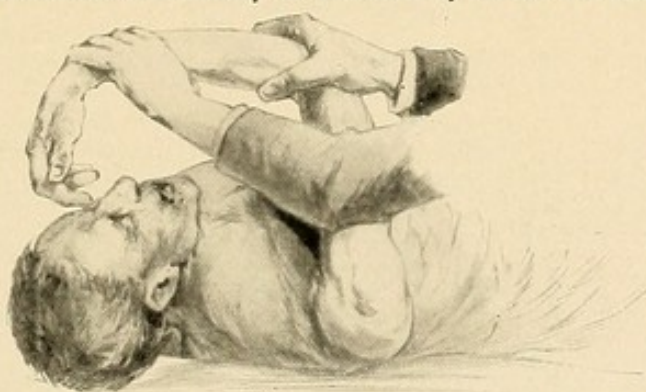

FIG. 253.—Kocher's method of reducing dislocation of the shoulder: Third (final) step—Rotate the arm inward and place the hand on the opposite shoulder bringing the elbow down on the anterior surface of the chest.

#### POSTERIOR DISLOCATIONS OF THE SHOULDER.

Posterior dislocations are always beneath some portion of the spine of the scapula, hence they have been called *subspinous*. When the head lies anteriorly under the posterior portion of the acromion process they have been called *subacromial*.

Posterior luxations are rare. They occur either when the arm is abducted with strong internal rotation or by direct violence, such as a blow on the anterior portion of the shoulder, which forces the head out of its socket backward. The posterior portion of the capsule is torn and the head lies posterior to the glenoid cavity with its anatomical neck resting on the rim and the lesser tuberosity in the glenoid fossa. The arm is inverted and abduction and rotation impaired. The capsule is ruptured by internal rotation while the arm is in a position of abduction, and then a push sends the head posteriorly. We have seen it as a congenital affection resulting from injury in childbirth.



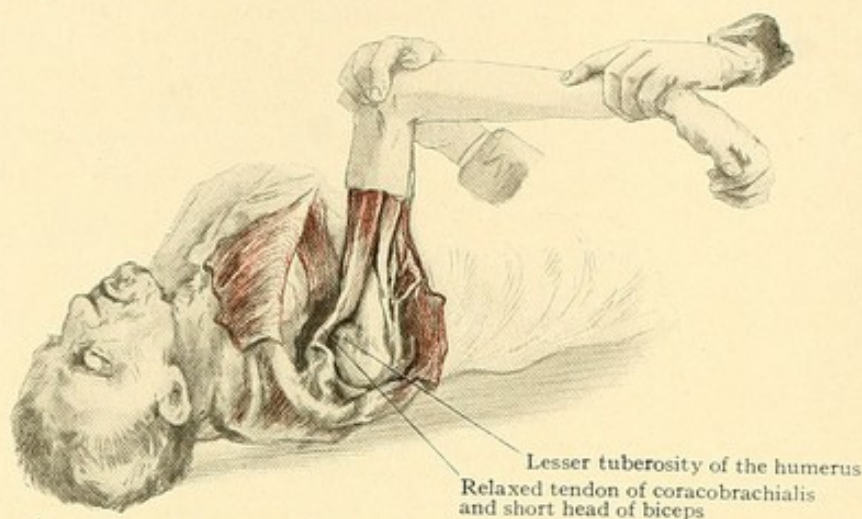


FIG. 254.—Raising the arm to a vertical line or a little more relaxes the tendon of the coracoclavicularis and short head of the biceps muscle and allows the lesser tuberosity of the humerus to pass beneath it when the arm is rotated inward to place the hand on the opposite shoulder.

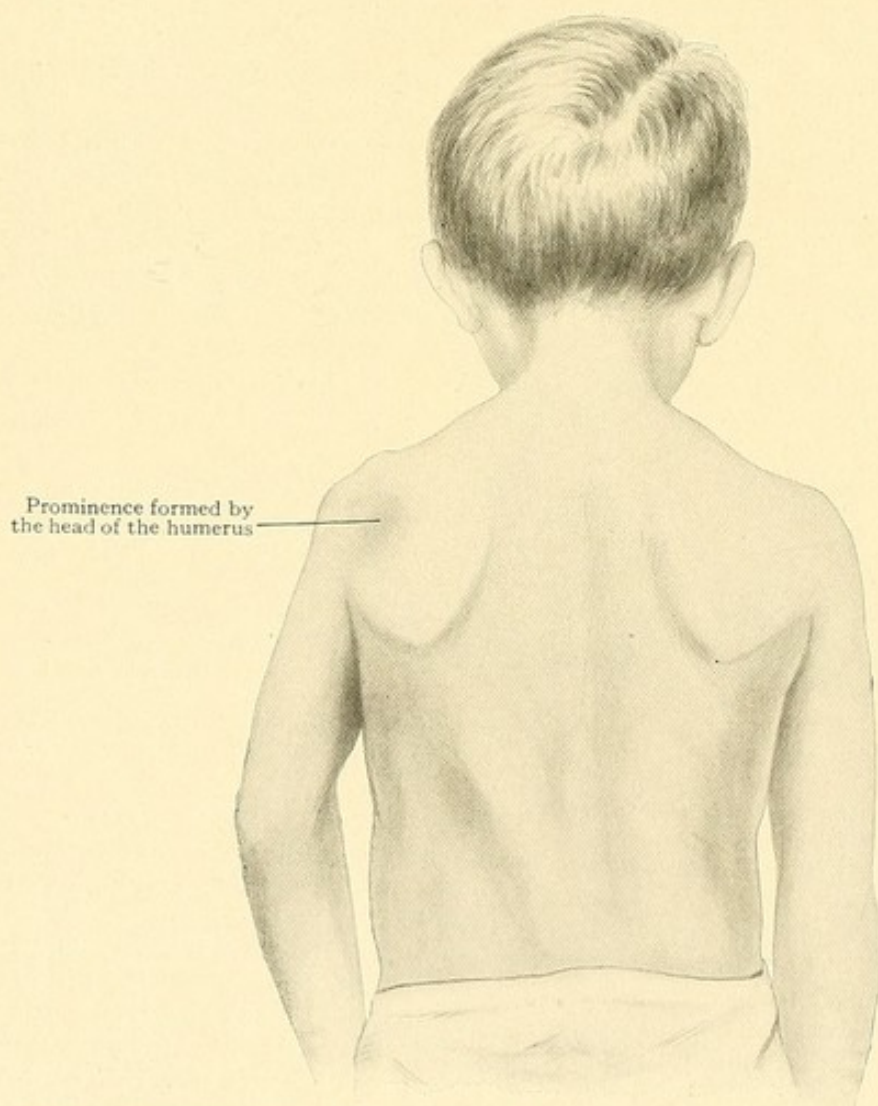


FIG. 255.—Posterior luxation of the shoulder. The head of the humerus makes a prominence beneath the spine of the scapula and the arm is rotated inward. (From a photograph of author's patient by Dr. A. P. C. Ashhurst.)



The infraspinatus, teres minor, and sometimes the subscapularis muscles are ruptured and frequently there are accompanying fractures of the tuberosities or some part of the scapula. The head makes a prominence posteriorly and the arm hangs to the side and in a position of inward rotation. Reduction, if the injury is recent, is likely to be easily effected by pushing the head directly forward into its socket.

## FRACTURES OF THE SHOULDER-GIRDLE AND UPPER END OF THE HUMERUS.

### FRACTURES OF THE CLAVICLE.

Fractures of the clavicle divide with those of the radius the distinction of being the most frequent of any in the body.

The clavicle is most often broken in its middle third, next in its outer, and, lastly, in its inner third.

**Fracture of the Inner Third of the Clavicle.**—This is the rarest fracture of the clavicle and has its main anatomical interest in relation to the costoclavicular ligament. This ligament runs obliquely upward and outward from the upper surface of the cartilage of the first rib to the lower surface of the clavicle, a distance of 2 cm. ( $\frac{1}{3}$  in.).

Immediately in front of the outer portion of this ligament is the insertion of the tendon of the subclavius muscle. The line of the fracture may be either transverse or oblique; if oblique it follows the same direction as do the fractures of the middle third of the bone, viz., from above, downward and inward. The displacement of the inner fragment is upward and of the outer fragment downward. The displace-

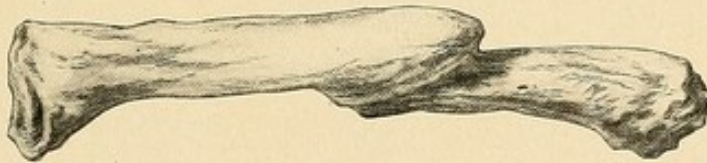


FIG. 256.—Fracture of the clavicle just outside of the middle, with the customary deformity.

ment of the inner fragment upward is promoted by the attachment of the clavicular origin of the sternomastoid muscle: it is opposed by the costoclavicular (rhomboid) ligament and to a less extent by the subclavius muscle.

**Fracture of the Middle Third of the Clavicle.**—The clavicle is most frequently broken in the outer half of its middle third. The bone at this part is most slender; it is here that the anterior curve passes into the posterior; and, finally, it has fewer muscular attachments at this situation. The upper surface has arising from its inner third the clavicular origin of the sternomastoid muscle. Its middle third has no muscular attachments, and on its outer third is the trapezius muscle. On the lower or anterior surface on its inner half is the clavicular origin of the pectoralis major and on its outer third is the deltoid. This leaves the outer half of the middle third free from muscular attachments, with the exception of the subclavius on its under surface. It is through this part of the bone that fractures occur.

Sometimes in children the line of fracture is transverse, but most often it is oblique and always in the direction from above downward and inward.

The *displacement* of the inner fragment is upward, and of the outer fragment downward and inward. This produces the deformity seen in Fig. 256. The inner fragment is pulled up by the clavicular origin of the sternomastoid muscle. The support of the clavicle being gone, the shoulder falls down and in. It is impelled in that direction, first, by the weight of the upper extremity, and, secondly, by the action of the axillary fold muscles,—pectoralis major and minor anteriorly and teres major and latissimus dorsi posteriorly, and by the subclavius to some extent. The anterior edge of the scapula rotates inward and its posterior edge tilts outward.

In this manner overlapping is produced, and measurements of the injured and healthy sides taken from the sternoclavicular to the acromioclavicular joint will show some shortening on the injured side. As the continuity of the shoulder-girdle



has been destroyed and its prop-like action lost, its function of abduction ceases, and the patient is unable properly to elevate the arm. Sometimes the brachial plexus or subclavian vessels are injured by the inner end of the outer fragment. The artery passes beneath the middle of the bone, the vein being to its inner side and the

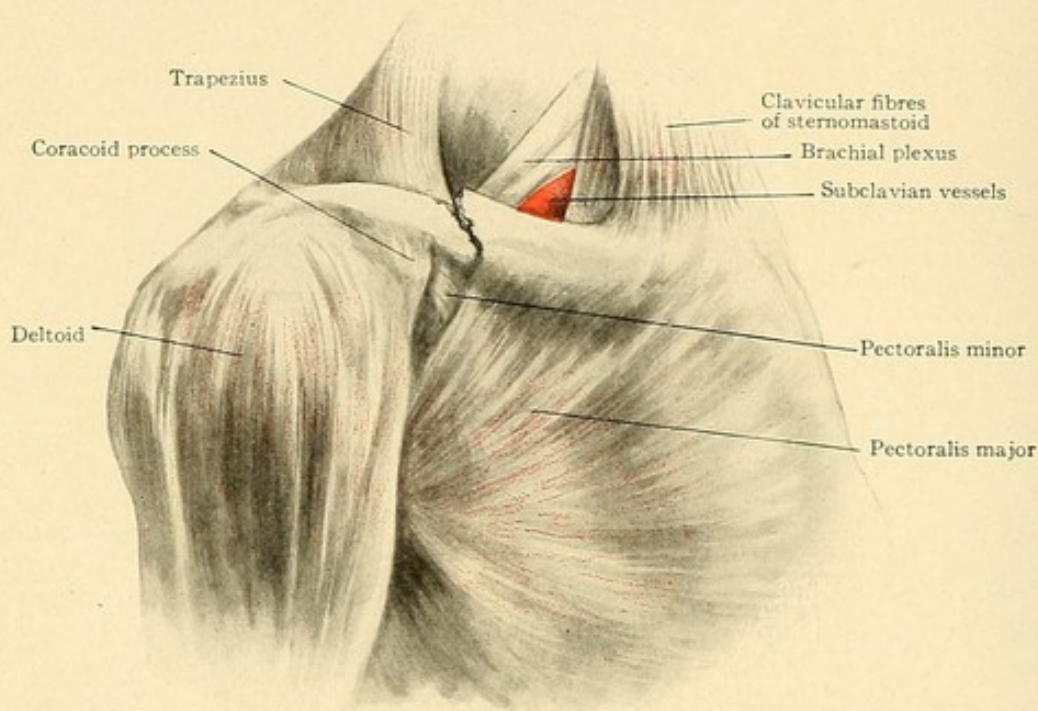


FIG. 257.—Fracture of the clavicle just outside the middle. The outer fragment is displaced downward and inward and the inner fragment upward. The brachial plexus and subclavian vessels are behind the inner end of the outer fragment.

brachial plexus to its outer side. We have operated on one such case of injury to the brachial plexus; and cases of hæmatoma arising from injury to the veins and aneurism from injury to the artery have been recorded.

*Treatment.*—When the line of fracture is oblique and in an adult, healing with a certain, often considerable, amount of deformity is almost constant, the only efficient

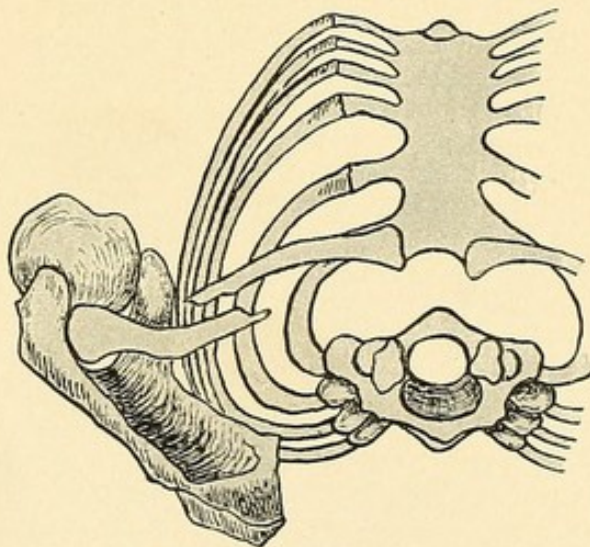


FIG. 258.—Showing how the shoulder falls inward and the posterior edge of the scapula tilts outward when the prop-like action of the clavicle is destroyed by fracture.

way of combating its occurrence is to place the patient in bed on his back. This is the best way of removing the weight of the arm, of quieting the muscles, and by pressure of the scapula close to the thorax of levering the shoulder out (see Fig. 258).



**Fracture of the Outer Third of the Clavicle.**—Attached to the outer third of the clavicle on its under surface, extending not quite to its end, are the coracoclavicular (conoid and trapezoid) ligaments. The conoid inserts into the conoid tubercle near the posterior edge of the clavicle, while the trapezoid is broader and passes from the conoid tubercle outward and anteriorly not quite to the extremity of the bone (see Fig. 267). The bone may be fractured either through the part to which the conoid and trapezoid ligaments are attached, or between them and the end of the bone, a distance of about 2 cm. ( $\frac{1}{2}$  in.). The line of the fracture is either transverse or inclines backward and outward (see Fig. 259).

The displacement of the outer fragment is downward and inward. If the fracture is through the ligaments the displacement is not marked. If beyond the ligaments, the shoulder drops, carrying down the outer fragment, and the inner fragment may be elevated slightly above the outer one, but the up-and-down displacement is not

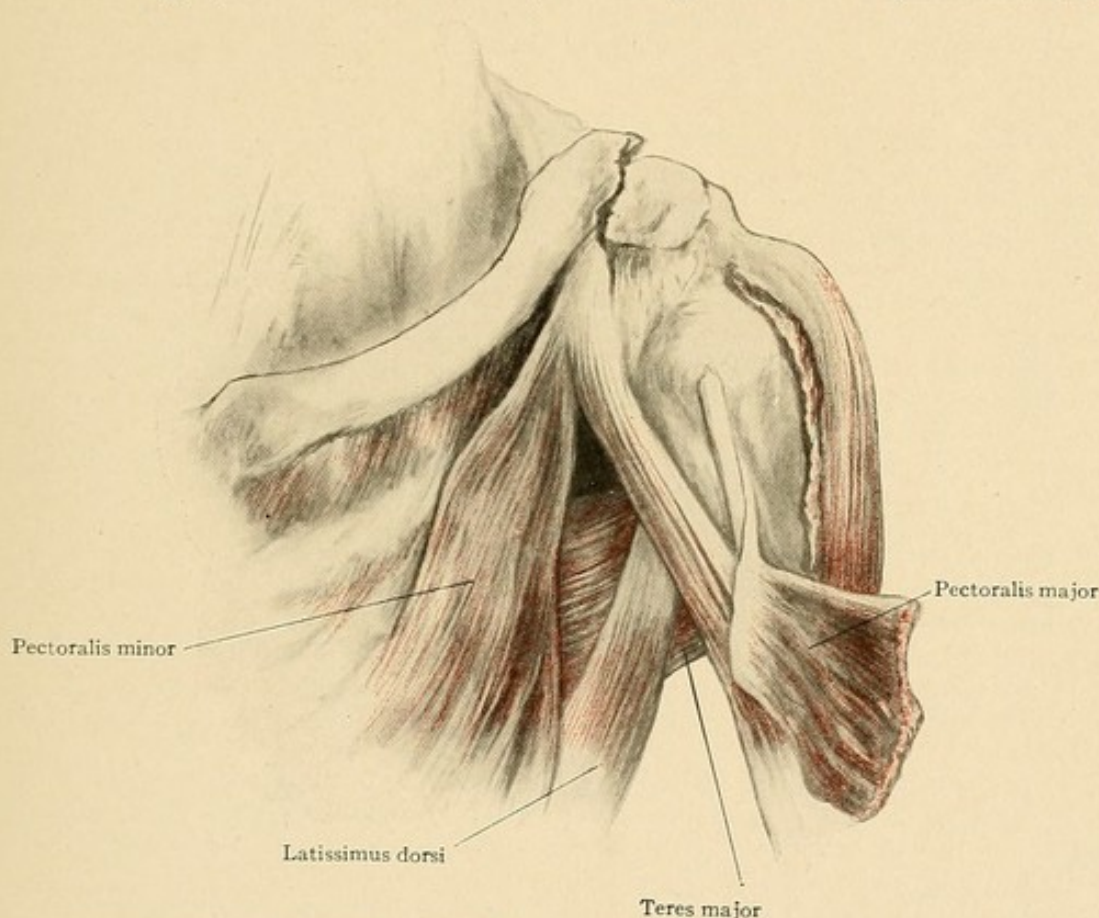


FIG. 259.—Fracture of the outer end of the clavicle. The outer fragment is drawn inward by the pectoralis major latissimus dorsi, and teres major muscles.

conspicuous. In many cases the anteroposterior displacement is very marked and peculiar. The outer fragment is bent sharply inward at the site of fracture, producing a deformity which is pathognomonic. It is caused by the curved shape of the bone at this point, by the weight of the arm, and by the action of the muscles passing from the shoulder to the trunk, especially the pectoralis major (see Fig. 259).

**Treatment.**—As the deformity is not very marked any of the usual bandages, such as those of Velpeau, Desault, or posterior figure eight are fairly satisfactory.

#### FRACTURES OF THE SCAPULA.

While fractures of the scapula are not common, there are a few anatomical facts in reference to the scapula and its muscles which are worth calling attention to.

The scapula is liable to be fractured more or less transversely through the body below the spine; the acromion and coracoid processes have been broken; it has also been fractured through the surgical neck, and the glenoid process has been chipped off.



**Fracture Through the Body.**—The scapula has attached to its under surface the subscapularis muscle, along its posterior border is the serratus anterior (magnus) and rhomboids, to its dorsum and edge below the spine are attached the infraspinatus, teres minor, and teres major muscles. These are covered by a strong, tough fascia which dips between them to be attached to the bone.

Bearing these facts in mind it is readily appreciated why in many of these fractures, which usually traverse the bone below its spine from the axillary to the vertebral border, the displacement is slight, and why healing occurs with some appreciable deformity but with little disability.

If, however, the fracture is low down, breaking off the lower angle, then the teres major and lower portion of the serratus anterior (magnus) muscles displace the fragment toward the axilla, and this is to be borne in mind in treating the injury.

**Fracture of the acromion process** is more rare than would be expected. It is the result of direct violence, and the displacement and disability resulting from the injury are slight. The acromion is covered by a dense fibrous expansion from the trapezius above and the deltoid below, and these prevent a wide separation of the fragments.

**Fracture of the coracoid process** is also rare and may occur from muscular contraction or direct violence, as in luxation of the shoulder. It might be thought that owing to the action of the pectoralis minor, coracobrachialis, and short head of the biceps muscles, which are attached to it, it would be widely displaced, but this is not so, for the conoid and trapezoid ligaments still hold it in place.

**Fractures through the surgical neck** are not common. They pass down through the suprascapular notch and across the glenoid process or head, in front of the base of the spine and behind and parallel with the glenoid fossa. The tendency of the outer fragment to be dragged down by the weight of the arm is resisted by the coraco-acromial and coracoclavicular (conoid and trapezoid) ligaments as well as by the inferior transverse ligament, which runs from one fragment to the other from the base of the spine, on the posterior surface, to the edge of the glenoid cavity. These ligaments all remain intact.

**Fracture through the glenoid process**, chipping off a greater or less portion of the articular surface, is rarely diagnosed. It occurs sometimes in cases of luxation. The long head of the triceps muscle may be fastened to the detached fragment and is liable to pull it downward and therefore some interference with the functions of the joint would be apt to remain and prevent complete recovery.

#### FRACTURES OF THE UPPER END OF THE HUMERUS.

Fractures of the upper end of the humerus may occur through the anatomical neck, through the tuberosities, detaching one or both, and through the surgical neck just below the tuberosities. These fractures are frequently associated with luxation of the head of the bone.

**Fracture through the Anatomical Neck.**—This occurs as the result of direct violence and most often, though not always, in old people. The line of fracture does not always follow exactly the line of the anatomical neck, but may embrace a portion of the tuberosities. The fracture may or may not be an entirely intracapsular one. The capsule in its upper or outer portion is thickened at its humeral end by more or less blending with the tendons of the muscles which pass over it. The capsule at this point is attached to the anatomical neck almost or quite up to the articular surface. On the under side to the contrary it passes about a centimetre below the articular surface and doubles back to be attached somewhat closer to it (see Fig. 266, page 253).

In consequence of this arrangement, a fracture which follows the anatomical neck would be within the joint below and just outside of it above. As a matter of fact, some of these fractures are intra- and some partly extracapsular. This influences the amount and character of the displacement and the course of healing. If the fracture is entirely intracapsular, bony union may not occur, as no callus may be thrown out by the upper fragment and atrophy of the fragment may ensue. The fragment is apt to be much displaced, being tilted and lying to the inner side anteriorly. Sometimes it is entirely extruded from the joint. In one case we have seen it lodged in front under the anterior axillary fold.



The signs and symptoms will vary much, according to the position of the head, and a positive diagnosis may be impossible. A thorough knowledge of the surface anatomy is essential in these cases and a careful comparison should be made with the opposite healthy shoulder. Impaction sometimes occurs, and is said to be most often of the upper fragment into the lower, sometimes splitting it and detaching to a certain extent one of the tuberosities. Sometimes it is the lower fragment which is impacted into the upper.

**Fractures through the Tuberosities.**—Like the former these are often accompanied by luxation, especially if one or both of the tuberosities is detached. These fractures are frequently blended with fracture through the anatomical neck. In this fracture, however, the influence of the muscles is to be remembered. The supraspinatus, infraspinatus, and teres minor insert into the greater tuberosity, and the subscapularis into the lesser. The line of fracture may pass through their insertions and the displacement may be slight.

The upper fragment is, however, liable to be tilted outward by the contraction of the supraspinatus muscle, which is attached to the upper portion of the upper fragment, while there is no muscle attached below to counteract it. In this case the shaft of the humerus is drawn up and out by the deltoid and is felt beneath the acromion process. There is but little rotatory displacement of the upper fragment because the subscapularis anteriorly is neutralized by the infraspinatus and teres minor posteriorly.

In those instances in which there is not much displacement of the upper fragment, the lower one may be drawn inward and forward by the action of the muscles of the axillary folds.

Fractures detaching the tuberosities are almost always accompanied by luxation. If the greater tuberosity alone is detached, it is drawn up beneath the acromion by the supraspinatus.

In all these fractures the subsequent disability is often great and the prognosis is unfavorable. They are amongst the hardest in the body to correctly diagnose. They are treated sometimes with a shoulder-cap and sometimes with the arm in the abducted position while the patient is kept in bed. Epiphyseal separation will be alluded to farther on.

**Fractures of the Surgical Neck.**—These are the most common fractures of the humerus. The surgical neck of the humerus is usually defined as the portion between the lower part of the tuberosities and the upper edge of the tendons of the pectoralis major and latissimus dorsi muscles. Often, however, the tendons of these two muscles continue almost or quite up to the tuberosities, hence there is little or no interval here and the line of fracture then passes through the upper part of these tendons.

The fractures occur both from direct and indirect violence and the direction of the force has probably something to do with the displacement of the fragments.

**Displacement.**—It can readily be seen that if a blow is received on the humerus below the tuberosities while the arm is in a somewhat abducted position the head will be supported by the glenoid process (head) of the scapula and the bone will be fractured through the surgical neck and driven in towards the body, and, as the scapula is supported posteriorly, the movable lower fragment is displaced anteriorly. After the fracture has occurred, and possibly in some cases aided by the peculiar direction of the fracturing force, the lower fragment is drawn upward by the muscles running from one side of the fracture to the other. These are the deltoid, biceps, coracobrachialis, and the long head of the triceps. The typical displacement is for the upper fragment to be abducted and some say rotated out—this latter is not without doubt. The lower fragment is certainly in front and to the inside of its normal position.

The abduction of the upper fragment is due to the unresisted action of the supraspinatus muscle. The subscapularis in front and the teres minor and infraspinatus

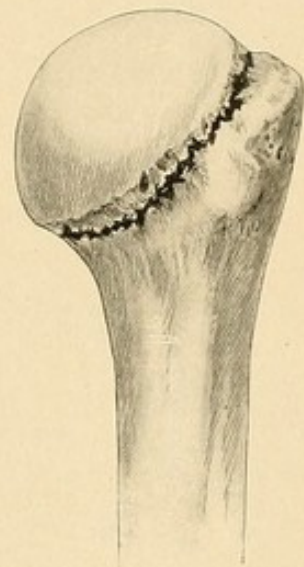


FIG. 260.—Fracture through the anatomical neck of the humerus.



behind nearly or quite balance each other, thus causing little or no lateral displacement. The displacement inward and anteriorly of the lower fragment, is due to the action of the violence as already detailed and is aided by the action of the pectoralis major, the teres major, and latissimus dorsi muscles, all of which pass from the lower fragment just below the seat of fracture inward to the trunk.

The longitudinal displacement is peculiar. As the lower fragment is drawn up its upper end may be felt through the deltoid muscle below and toward the inner side of the acromion. While the displacement in most cases is not marked, in some the lower fragment can readily be felt in the axilla (Fig. 261).

Sometimes instead of the lower fragment being displaced inward it goes outward. In this case as it rises it pushes the head and tilts it inward while it passes farther outward.

The *diagnosis* is to be made by a careful examination and comparison with the opposite healthy member. The head is recognized to be in the glenoid cavity,

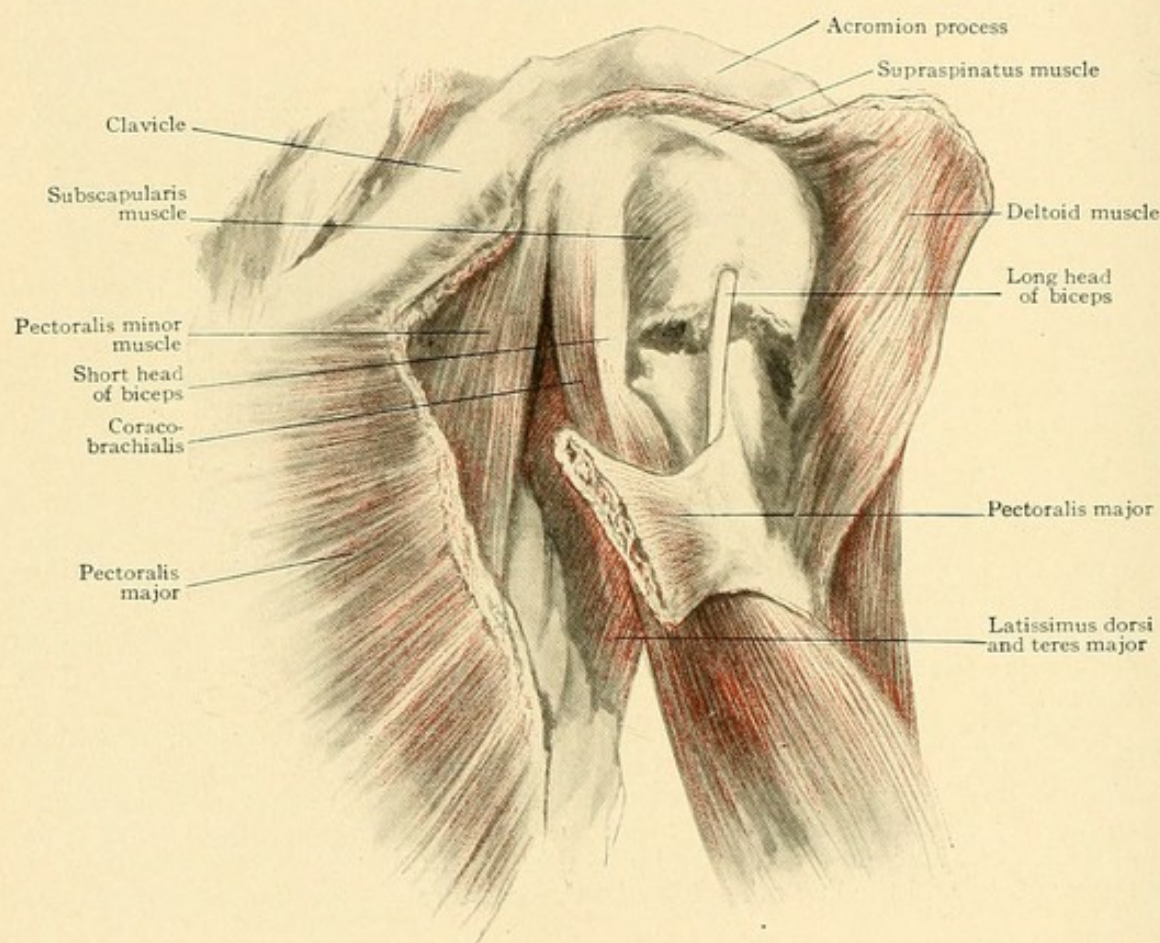


FIG. 261.—Fracture of the surgical neck of the humerus. The upper fragment is held out by the supraspinatus, while the lower fragment is drawn in by the pectoralis major, latissimus dorsi, and teres major muscles and the arm abducted by the deltoid.

crepitus is felt, the upper end of the lower fragment can often be palpated, and on rotating the arm the head of the bone is found to lie stationary.

*Treatment.*—The ideal treatment is extension with the patient in bed and the arm abducted. As the upper fragment cannot be brought in, an effort may be made to bring the lower one out. As these are usually treated as walking cases a common dressing employed is a shoulder-cap with the arm bound to the side; sometimes an axillary pad is used to keep the arm away from the body. In cases of fracture associated with luxation of the head of the bone, replacement can sometimes be effected by traction in the abducted position and pressure on the head, general anæsthesia being used (see description of direct method of reduction under dislocation of the shoulder, page 236).



To aid in the reduction McBurney devised a hook which he inserts into the upper fragment, pulling it toward the glenoid cavity.

### EPIPHYSEAL SEPARATIONS.

The epiphyses that are liable to separation are those of the coracoid process, the acromion process, and the upper end of the humerus.

**Separation of the Coracoid Epiphysis.**—The coracoid process has three separate centres of ossification which fuse with the body of the bone from the fifteenth to the twentieth year. Therefore displacements occurring before the latter age may be separations of the epiphysis and not true fractures, particularly if the line of separation runs through the base of the coracoid.

**Separation of the Acromion Epiphysis.**—The acromion process is cartilaginous up to the fifteenth year. Then two centres appear and the epiphysis unites with the rest of the spine of the scapula about the twentieth year or later. The epiphyseal line runs posterior to the acromioclavicular joint, just behind the angle of the spine of the scapula. It has been suggested that many cases diagnosed as sprains and contusions of the shoulder are really epiphyseal separations of the acromion process.

**Separation of the Epiphysis of the Upper End of the Humerus.**—The upper end of the humerus has three centres of ossification, one for the head and one each for the greater and lesser tuberosities. These three centres are blended by the seventh year, and the whole epiphysis unites with the shaft at about the age of twenty-five years.

The epiphyseal line follows the lower half of the anatomical neck and then passes outward to the insertion of the teres minor muscle. This brings the outer end of the epiphyseal line some distance away from the joint, while the inner portion of the line is within the joint. Disease of this region may therefore follow the epiphyseal cartilage into the joint. A separation of the epiphysis from injury will implicate the joint.

The surgical neck of the humerus lies a short distance below the epiphyseal line and farther away on the outer side than on the inner. The line of the epiphysis rises higher in the centre of the bone than on the surface, making a sort of cap for the end of the diaphysis. The symptoms of epiphyseal separation are almost exactly the same as those of fracture of the surgical neck (see page 245).

The supraspinatus is the main agent in tilting the upper fragment outward, while the muscles inserted into the bicipital ridges,—the pectoralis major into the outer ridge and the latissimus dorsi and teres major into the inner,—draw the lower fragment inward. The relative position of the fragments when the lower is displaced outward is seen in Fig. 262.

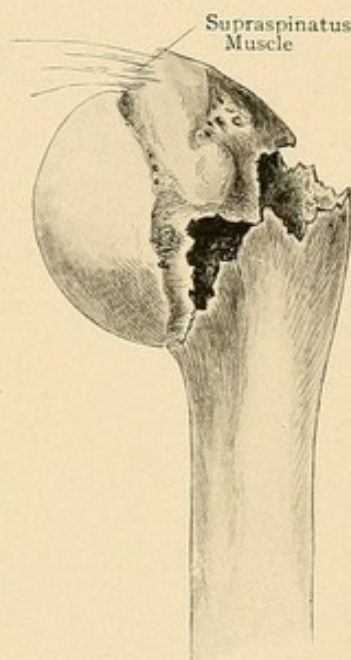


FIG. 262.—Detachment of the epiphysis of the upper end of the humerus.

### AMPUTATIONS AND RESECTIONS OF THE SHOULDER.

#### AMPUTATION AT THE SHOULDER-JOINT.

The many different methods of amputating at the shoulder may for our purposes be divided into two classes,—the flap method and the racket method.

**The Flap Method.**—One large flap may be made to the outer side and a short one to the inner side (Dupuytren) or they may be made anteroposteriorly (Lisfranc). The flap operations were done with long knives by transfixion, as they originated before the discovery of general anæsthesia and by them the member was removed with great rapidity (Fig. 263).

In *Dupuytren's method* the arm was raised to a right angle with the body and the deltoid muscle grasped with one hand while the knife was inserted beneath it, entering



just below the posterior portion of the acromion process (its angle) then passing under the acromion to emerge in front at the coracoid process. This flap was turned up, the capsule and muscles divided, the bone turned out, and while an assistant compressed the remaining tissues they were divided transversely.

*Lisfranc's method* consisted in transfixing the posterior axillary fold from below upward, entering the knife in front of the tendons of the latissimus dorsi and teres major muscles and bringing it out a little in front of the acromion. The joint was opened posteriorly, the bone luxated, and an anterior flap cut from within outward. Sir William Fergusson, probably the most skilful operator of his day, was partial to this operation.

**The Racket Method.**—In this method the incision resembles in shape the

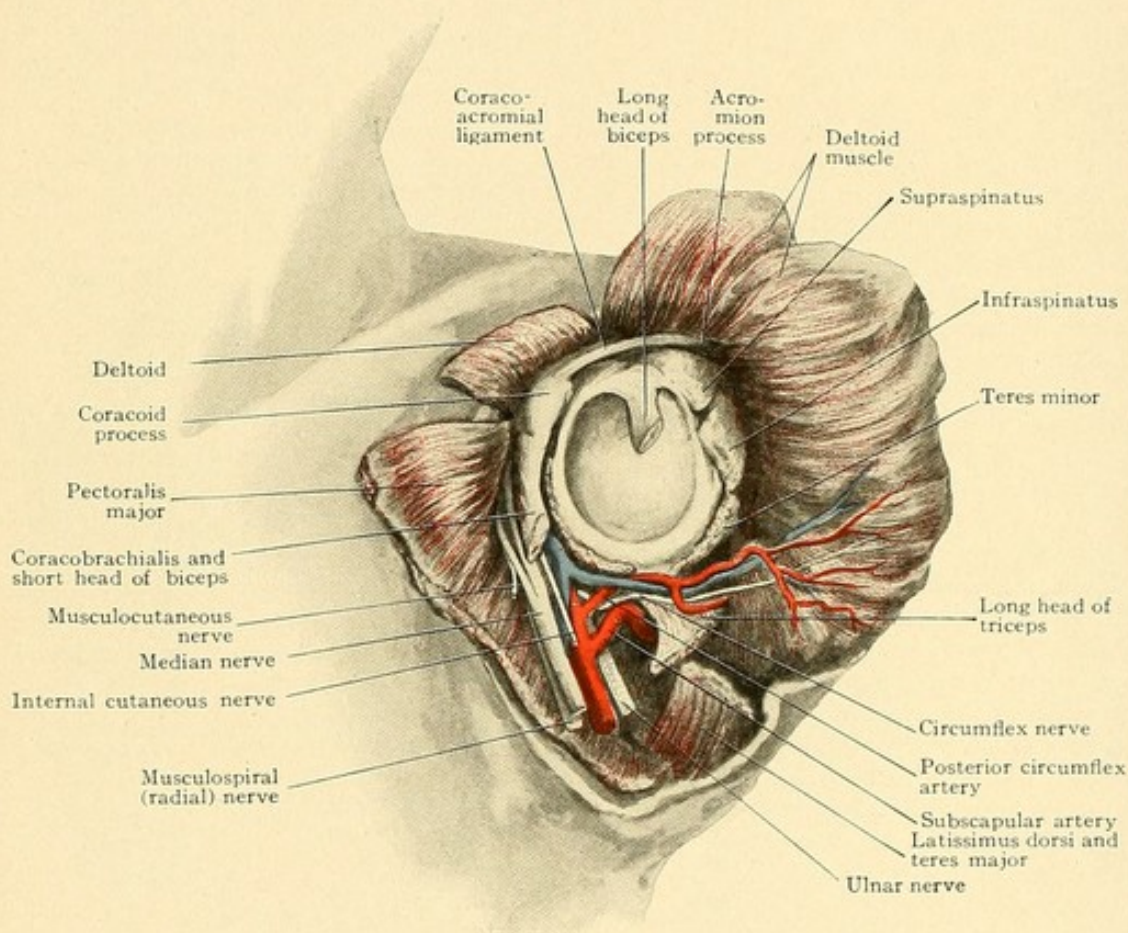


FIG. 263.—Amputation of the shoulder by anteroposterior flaps. The upper extremity of the incision passes between the coracoid and acromion processes. The posterior flap is the larger.

ordinary racket, such as is used in tennis. The loop encircles the arm, while the handle begins above at the point of the shoulder.

There are two operations by the racket method, which differ as to the position from which the upper portion of the incision starts.

*Larrey's Method.*—The operation usually ascribed to Larrey consists in starting the incision at the anterior end of the acromion process and continuing it straight down the arm for three centimetres ( $1\frac{1}{4}$  in.). It then parts, one branch sweeping gradually in a curved line to the anterior axillary fold and the other to the posterior axillary fold, an incision, through the skin only, passes across the inner surface of the arm joining the two branches. The flaps having been turned anteriorly and posteriorly, the joint is opened by cutting on the head of the bone, first posteriorly, then above, and then anteriorly. Tilting the head outward the inferior portion of the capsule is divided and the bone loosened from the soft parts. These are compressed by the fingers of an assistant and cut.



*Spence's Method.*—A modification of Larrey's procedure, attributed to Spence by the British and to S. Fleury by the French, consists in commencing the incision just outside of the coracoid process in the interval between it and the acromion process. This modification is probably the best form of procedure for this locality and is the one which will be discussed here. It will be noticed, however, that it practically changes the operation of Larrey from one with anteroposterior flaps to one with a single external flap, as in the method of Dupuytren. (Fig. 263).

The incision begins just below the coraco-acromial ligament and lies deep in the hollow formed by the anterior concave surface of the outer third of the clavicle. It divides the fibres of the deltoid muscle longitudinally a short distance from its anterior edge. It will be recalled that the deltoid muscle covers the coracoid process and extends just to its inner side to be attached to the outer third of the lower surface of the clavicle. Between it and the adjoining edge of the pectoralis major muscle runs the cephalic vein. This passes downward and outward along the inner edge of the deltoid until it reaches the outer edge of the biceps muscle alongside of which it passes down to the elbow. This vein will be cut as the inner branch of the incision is made. The bicipital groove, when the palm of the hand faces forward, lies almost directly below the coraco-acromial ligament. While the incision is being made the arm is kept rotated slightly outward.

As the knife descends it runs along the inner side of the bicipital groove and divides the tendon of the pectoralis major muscle. As soon as this tendon is cut the incision is inclined laterally. The incision having been carried down to the bone, except on the inside of the arm, the deltoid flap is raised upward and backward. It carries with it the circumflex nerve and posterior circumflex artery.

The disarticulation of the bone is apt to be bungled unless one knows the construction of the parts. It is to be borne in mind that the capsular ligament is to be divided together with the tendons of the muscles inserted into the tuberosities. The capsule does not pass across the anatomical neck to be inserted into the tuberosities beyond, and the mistake is often made of cutting on the anatomical neck and therefore frequently the capsule still remains attached to the proximal side. The cut may be commenced posteriorly and should be made *on the head* of the bone just above the anatomical neck. The arm is to be adducted and rotated inward and the muscles inserting into the greater tuberosity cut in their order, first the teres minor, then the infraspinatus and supraspinatus with the joint capsule beneath them. Then comes the long head of the biceps, and the arm now being rotated outward, the tendon of the subscapularis is divided. In cutting the muscles and capsule across the top of the joint, the arm is to be kept close to the side of the body so as to tilt the upper portion of the capsule out beyond the acromion process.

The head of the bone can now be drawn out sufficiently to allow the knife to be introduced behind it to divide the inferior portion of the capsule. This should be detached close to the bone so as to avoid wounding the axillary artery and especially the posterior circumflex artery and the circumflex nerve, which wind around the surgical neck immediately below and are to be pushed out of the way.

The division is completed by cutting the remaining muscles passing from the trunk to the shaft of the bone. On the inner side may be an uncut portion of the pectoralis major, the coracobrachialis, and short head of the biceps; below is the long head of the triceps and on the outer side are the teres major and latissimus dorsi.

On examining the face of the stump, posteriorly is seen the bulk of the deltoid muscle with the triceps below, and then the latissimus dorsi and teres major tendons lying next to the artery. Anteriorly is the cut edge of the deltoid and pectoralis major with the coracobrachialis and short head of the biceps lying next to the artery.

To the outer side of the artery lie the median and musculocutaneous nerves. To the inner side are the ulnar and lesser internal cutaneous nerves (*cutaneus brachii medialis*) and the axillary vein. Posteriorly are the musculospiral and axillary (circumflex) nerves.

Sometimes the median nerve lies in front instead of to the outer side. The axillary artery is divided below the origin of the anterior and posterior circumflex arteries. The bleeding in the first cut will be from the cephalic vein (which runs between the pectoralis major and deltoid), muscular branches of the posterior and anterior



circumflex, a small ascending branch of the anterior circumflex which runs in the bicipital groove, and the humeral branch of the acromial thoracic which accompanies the cephalic vein.

A glaring and common mistake in the performance of shoulder amputations is the making of the flaps entirely too short, especially when a Larrey operation is attempted.

The avoidance of serious hemorrhage is usually accomplished by clamping the small vessels as the operation proceeds, and before the final division of the axillary vessels slipping the fingers behind the bone and compressing them.

Esmarch's tube has been used by encircling the shoulder as close to the trunk as possible, the tube being kept from slipping by a bandage passed beneath it and fastened to the opposite side. Wyeth's pins have been used for the same purpose. One is inserted through the lower edge of the anterior axillary fold a little internal to its middle and brought out above in front of the acromion process, the other is entered at a corresponding point of the posterior fold and brought out above just behind the angle of the spine of the scapula or acromion process.

**Interscapulothoracic Amputation.**—For malignant growths of the axilla, shoulder, or scapula, and, rarely, for injury, the whole upper extremity with the

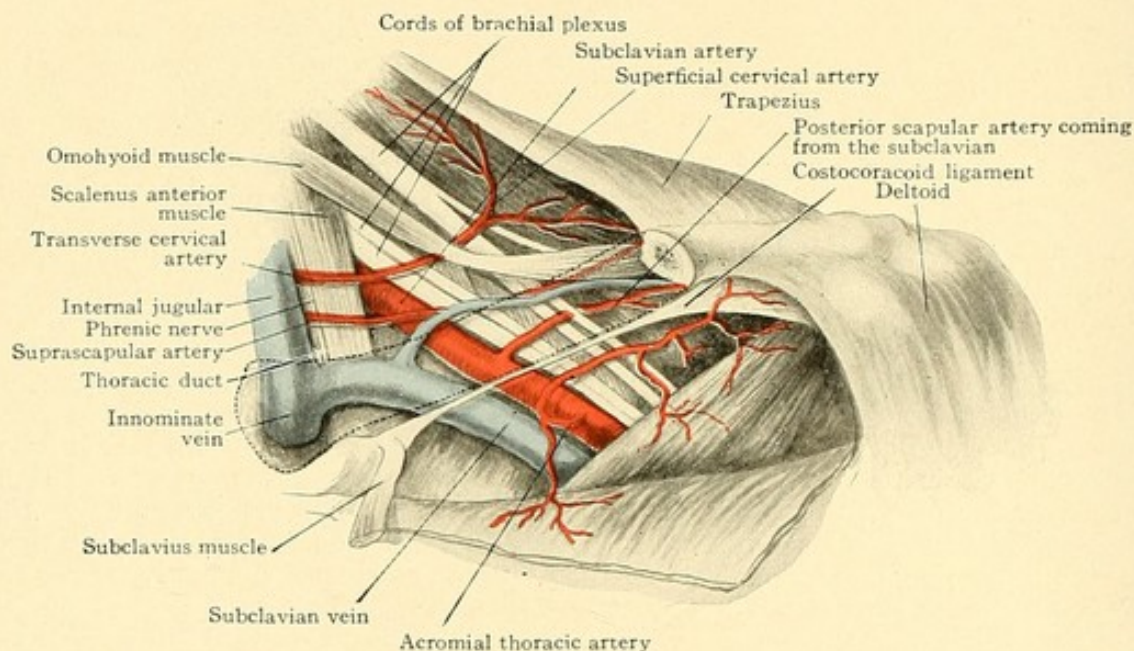


FIG. 264.—Structures exposed by excising the inner portion of the clavicle.

scapula and part or whole of the clavicle have been removed. Anteroposterior flaps are made.

The greatest danger is death from shock and hemorrhage. In order to obtain some idea of the topography and vessels involved, see Fig. 264.

**Excision of the Clavicle.**—Excision of the clavicle in the living body, like tracheotomy, is much more difficult than when practiced on the dead body; this is due to the condition of the parts for which operation is undertaken. It has been often excised for malignant growths. On the upper anterior surface are attached the clavicular origin of the sternomastoid, the deep cervical fascia, and the trapezius muscle. Crossing the clavicle near its middle is the jugulocephalic vein which sometimes connects the cephalic with the external jugular. It is likewise crossed by the superficial descending branches of the cervical plexus. The external jugular vein, about 2.5 cm. (1 in.) above the middle of the clavicle, pierces the deep fascia and turns inward to empty into the internal jugular just behind the outer edge of the sternomastoid muscle; just below it empties the thoracic duct at the junction of the internal jugular and subclavian veins. The subclavian vein is directly behind the clavicle and the left innominate vein crosses behind the left sternoclavicular joint and passes across the posterior surface of the sternum just below or on a level with its



superior border. The omohyoid muscle, if the shoulder is drawn outward and the head turned to the opposite side, is drawn upward above the clavicle.

Behind the upper portion of the clavicle is the suprascapular artery and above it runs the transverse cervical artery, a branch of the thyroid axis. Both these vessels cross over the scalenus anterior muscle on which, toward its inner edge, is lying the phrenic nerve. In front of the scalenus anterior runs the subclavian vein and behind it is the subclavian artery with the cords of the brachial plexus above and to its outer side. Below and in front are attached the pectoralis major and deltoid muscles; the space between them forms the subclavicular triangle and occupies the outer half of the middle third of the bone. The cephalic vein pierces the costocoracoid membrane at this point to enter the subclavian vein.

On the under surface of the bone is the subclavius muscle, covered with a strong membrane. To the inner side of this muscle is the costoclavicular ligament. Beneath the clavicle, about its middle, passes the subclavian artery, separated from the vein in front by the scalenus anterior muscle. Below and beneath the subclavian artery, which rests directly on it, is the pleura. The internal mammary artery passes behind the inner extremity of the clavicle opposite the cartilage of the first rib.

The clavicle is the first bone in the body to ossify, and it has one epiphysis at its sternal end which appears about the seventeenth year and joins the shaft from the twentieth to the twenty-fifth year. In removing the bone it is first loosened at its outer extremity by dividing the acromioclavicular and coracoclavicular (conoid and trapezoid) ligaments.

**Excision of the Scapula.**—The removal of the scapula necessitates the division of a large number of muscles, for which see pages 226 and 227. The subscapular artery at the anterior border, about 2.5 cm. (1 in.) below the head or glenoid process, and the suprascapular at the suprascapular notch, are to be ligated before removing the bone. Skirting the posterior edge is the posterior scapular, the continuation of the transverse cervical artery; it is to be avoided when detaching the muscles. The acromial branches of the acromial thoracic artery ramify over the acromion process; they are not so large as those already mentioned.

Mr. Jacobson suggests that if safety permits one should allow the acromion process to remain, as it preserves the point of the shoulder and to some extent, the functions of the trapezius muscle.

**Excision of the Head of the Humerus.**—The incision for the removal of the head of the humerus should be commenced just outside of the coracoid process and be carried 10 cm. (4 in.) downward in a direction toward the middle of the humerus, where the deltoid inserts. This incision may be made while the arm is somewhat abducted but it does *not* go in the groove between the deltoid and pectoralis major muscles. This groove contains the cephalic vein and the humeral branch of the acromial thoracic artery, and hence is to the *inner* side of the coracoid process and as the incision is to the *outer* side, it passes through the deltoid near its anterior edge (Fig. 265).

The incision goes through the muscle and exposes the capsule of the joint. The sides of the wound are to be retracted and, if the long head of the biceps muscle is not recognized by sight, the finger is inserted and the arm rotated. The bicipital groove can be felt and the tendon identified.

The capsule is to be incised along the *outer* edge of the long tendon of the biceps and as the arm is rotated inward the supraspinatus, infraspinatus, and teres minor muscles are to be detached from the greater (posterior) tuberosity. The biceps tendon is again brought into view by rotating the arm outward and its sheath (transverse ligament) slit up and the tendon luxated inward.

The attachment of the capsule and subscapularis muscle to the lesser (anterior) tuberosity is then divided while the arm is rotated outward. The biceps tendon lies in the bicipital groove between the two tuberosities. When the arm is lying with the palm upward, in a supine position, the bicipital groove looks directly anteriorly in a longitudinal line passing midway between the two condyles of the lower end. The position of the head and groove can be told by observing the position of the condyles. The head is directly above the internal condyle and the groove is on the anterior surface above a point midway between the condyles. After the capsule has been opened



and the attachments of the muscles to the greater and lesser tuberosities divided and the tendon of the biceps luxated inward, the head is thrust directly upward and out of the wound and sawed off as low as desired.

Immediately below the lower edge of the tuberosities is the surgical neck. On it anteriorly winds the anterior circumflex artery, and posteriorly the circumflex (axillary) nerve and posterior circumflex artery. These should not be disturbed, for the artery will bleed and injury of the nerve will cause paralysis of the deltoid muscle.

Posterior and transverse incisions have been suggested for this operation but they are not to be advised. The circumflex nerve and posterior circumflex artery are almost certain to be injured and the functions of the deltoid are liable to be seriously impaired or altogether lost.

If more access is desired than can be obtained by a straight incision as directed, the deltoid can be detached from its origin along the outer end of the clavicle and

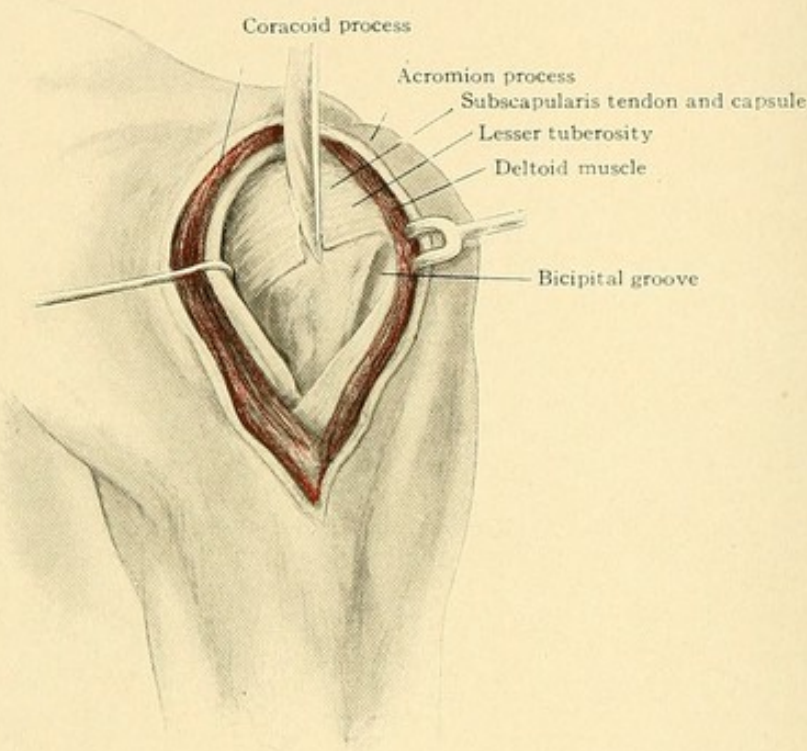


FIG. 265.—Resection of the shoulder-joint. The arm has been rotated outward so as to put the tendon of the subscapularis on the stretch. The long tendon of the biceps has been dislocated from the bicipital groove and is held to the inner side by a hook.

acromion process and turned down. This does not interfere with its nerve supply. The circumflex nerve going to the muscle crosses the humerus at about the junction of the upper and middle thirds of the deltoid or a finger's breadth above its middle. After resection of the bone the deltoid can again be brought up and sewed to its previous attachment.

The character of the operation depends on the nature and extent of the disease. The operator should be familiar with the epiphyseal line, which runs from the inside upward and outward in the line of the anatomical neck as far as the middle of the bone, and then slopes slightly downward and outward to reach the surface almost on a level with the lower (inner) edge of the articular surface. As this is the site of most active growth of the humerus in young subjects this epiphyseal cartilage should be spared as much as possible.

The disability arising from a free resection is so great, owing to the loss of movements resulting from the detachment of muscles and interference with the epiphyseal cartilage, that formal resections are rarely performed, but, instead, the diseased parts are simply gouged away and as much allowed to remain as possible.



It is to be remembered that rotation inward is mostly performed by the subscapularis and outward rotation by the infraspinatus and teres minor. The supraspinatus aids abduction. A too free excision is liable to be followed by a flail-joint, in which case the limb hangs helplessly by the side with the dorsum pointing forward.

The axillary fold muscles insert on the anterior surface of the bone and hence turn the arm inward and draw it in toward the body, they do not compensate for the loss of the muscles attached to the tuberosities.

The bleeding in the operation will be mainly from the acromial branches of the acromial thoracic artery and the bicipital branch of the anterior circumflex artery, which runs in the bicipital groove.

### DISEASES OF THE JOINT AND BURSÆ.

The shoulder-joint, like other joints, is subject to inflammatory and other diseases. These may be (1) traumatic and later septic; (2) rheumatic or gouty; (3) tuberculous, with suppuration.

These affections result in an effusion within the joint-cavity which distends the capsule and finally tends to escape at the weakest points. The joint is not a

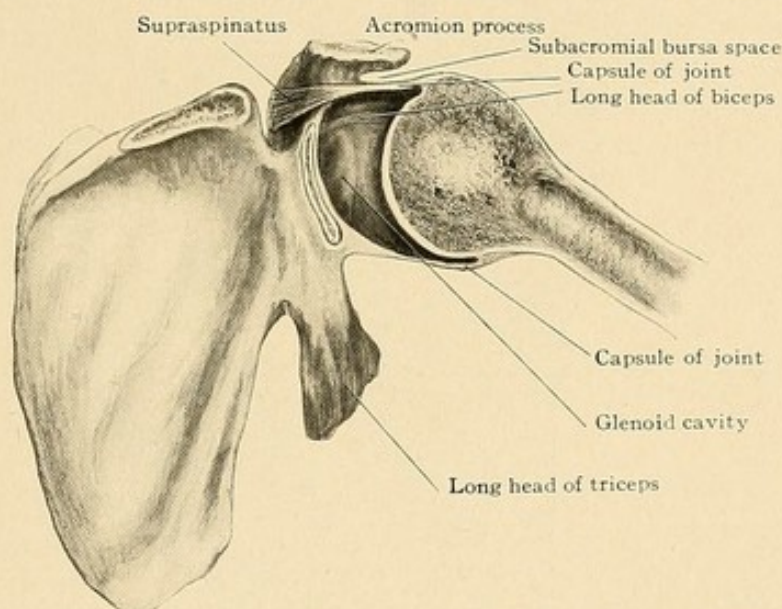


FIG. 266.—Transverse section of shoulder-joint, illustrating the laxity of the capsule of the joint.

complicated one, like the knee, and its synovial membrane is neither so extensive nor so elaborate.

Traumatism may give rise to a synovitis, an inflammation of the synovial membrane, or an arthritis involving the entire joint structures. Sprains and other injuries are not uncommon. A sprain will be caused by a force which acts to a greater extent than the normal movements of the joint will allow.

*Movements of the Joint.*—In abduction the capsule becomes tense at its lower portion when the arm is at 90 degrees to the trunk, greater abduction is resisted by the greater tuberosity impinging on the acromion process and the scapula begins to revolve.

Adduction is resisted both by the muscles and by the ligaments. When the ligaments only remain, the head can be separated for 2 cm. or more from the glenoid cavity (see Fig. 266). Marked adduction is usually limited by the arm coming in contact with the side of the body.

If the humerus is brought diagonally across the chest the scapula begins to move and its posterior edge and lower angle turn forward. As the humerus is adducted the deltoid and supraspinatus are made tense and the head is drawn up in its socket. When the muscles are paralyzed the weight of the upper extremity allows the head to fall and a distinct depression can be seen beneath the acromion process. In paralysis of the deltoid this is particularly noticeable.



If traction is made on the arm, the muscles are the resisting agents. If the arm is in a position of adduction, those going from the humerus to the scapula, as the deltoid, supraspinatus, biceps, and triceps, act. If in abduction, then also those from the humerus to the trunk, like the pectoralis major and latissimus dorsi, are brought into play. The part played by the deltoid and trapezius should be noted. If the arm is down by the side and traction is made on it, the force is transmitted from the humerus in a direct line through the deltoid and the upper fibres of the trapezius to their attachment to the spine and superior curved line of the occiput. If, on the contrary, the traction is made while the arm is raised above the level of the

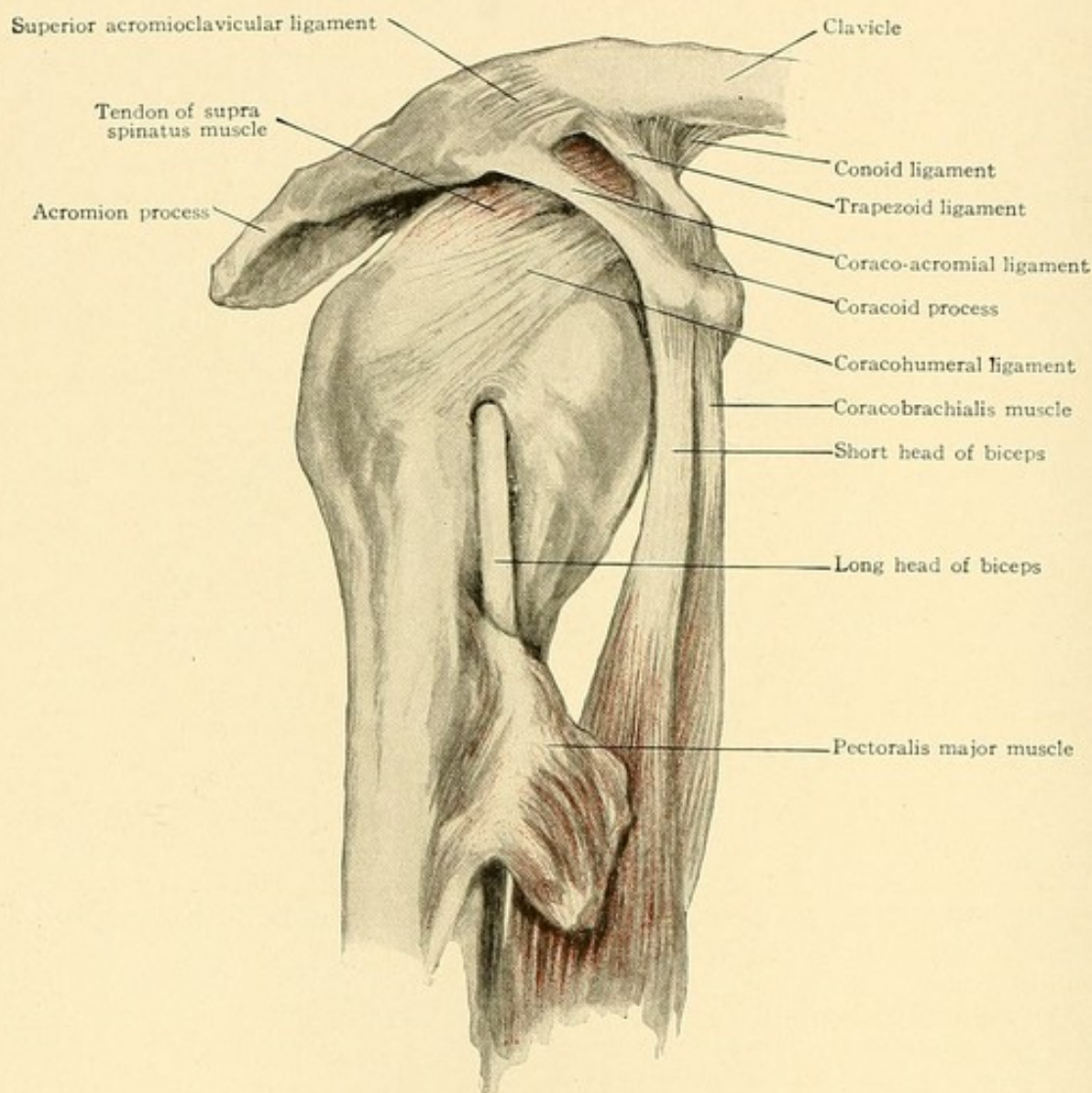


FIG. 267.—Acromioclavicular and shoulder joints.

shoulder, the force is transmitted through the axillary fold muscles as well as by the deltoid and continued through the lower fibres of the trapezius. In either case the muscles are the resisting agents and not the ligaments. Abduction to more than a right angle is resisted by the contact of the greater tuberosity with the under surface of the acromion process and coraco-acromial ligament and the under side of the capsular ligament is made tense. The raising of the arm to 90 degrees is performed by the supraspinatus and deltoid muscles of the scapula and beyond this by the serratus anterior and other muscles.

Inward rotation is limited by the infraspinatus and teres minor muscles and by tension of the upper portion of the capsule. Outward rotation is limited by the subscapularis and upper portion of the capsule.



**Subacromial Bursa.**—Separating the greater tuberosity from the deltoid muscle, the acromion process, and coraco-acromial ligament, is the large subacromial bursa. It does not communicate with the joint, except rarely in old people. Effusions into it cause an increased prominence of the deltoid muscle, and pus seeking an outlet is likely to show itself at the anterior edge of the muscle and less often at its posterior edge. These effusions, which are liable to be present from contusions, sprains, etc., should not be mistaken for intra-articular accumulations.

**Biceps Tendon.**—The long tendon of the biceps muscle enters the joint through the bicipital groove between the two tuberosities. With the arm hanging by the side it points directly forward; it passes over the head of the humerus and under the coraco-acromial ligament about midway between the coracoid and acromion processes to insert into the upper edge of the glenoid cavity. It is covered by a synovial sheath which passes with it through the opening in the capsule and a short distance along the bicipital groove. As this sheath does not communicate with the joint the tendon is in one sense extra-articular. It is held in the groove by a

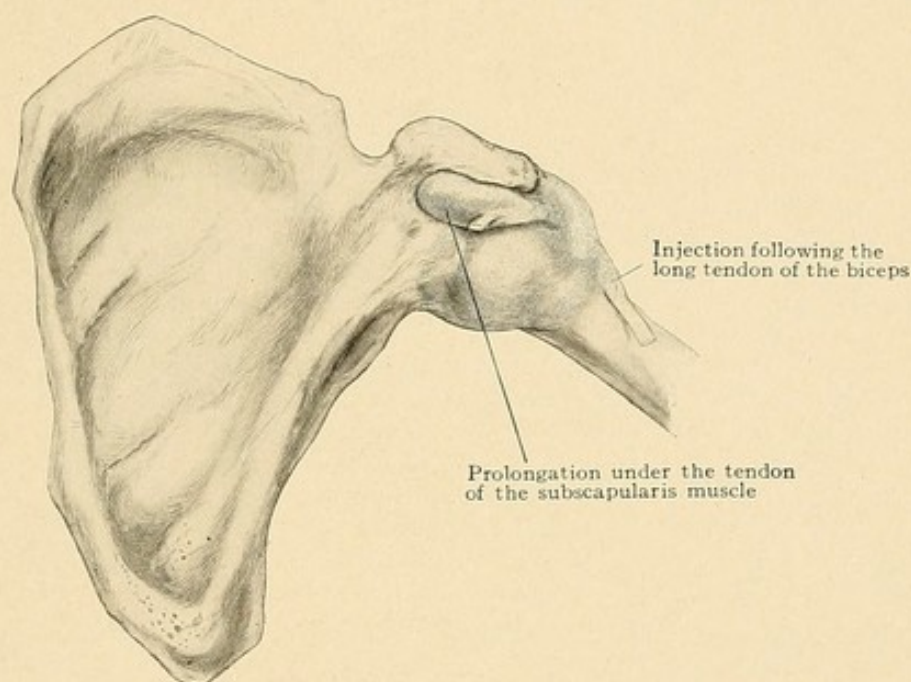


FIG. 268.—Shoulder-joint distended with injection, showing the position assumed by the humerus.

fibrous expansion, extending from the pectoralis major tendon below to the capsule above, called the *transverse humeral ligament*. This ligament is so strong that luxation of the tendon is uncommon; even when the humerus is luxated the tendon is rarely displaced.

**Subscapular Bursa.**—Beneath the tendon of the subscapularis there is a bursa which frequently communicates with the joint. This opening tends to weaken the capsule and it is at this point and just below that the head bursts through in dislocations.

**Infraspinatus Bursa.**—The capsule of the joint and the synovial membrane may be prolonged beyond the rim of the glenoid cavity under the tendon of the infraspinatus, or a bursa at this point may communicate with the joint.

**Other bursæ** may be present, but are unimportant. One is between the coracoid process and the capsule and another under the combined tendon of the coracobrachialis muscle and the short head of the biceps.

**Effusions in the Shoulder-joint.**—Liquid accumulations occur both from injury and disease. The liability of confounding them with those in the subacromial bursa has been alluded to above. As a result of disease, most often osteo-arthritis or tuberculosis, considerable liquid may accumulate in the joint. As the tension increases the arm becomes abducted about 50 degrees and the effusion tends to escape through the openings in the capsule (Fig. 268).



A distention of the joint will cause the deltoid to be more prominent. If the affection is in an old person, as is liable to be the case in osteo-arthritis, there is apt to be a communication with the subacromial bursa and this will become distended. If the liquid is purulent it has a tendency to work its way laterally under the deltoid and break through at its anterior or posterior borders and show itself at the folds of the axilla.

In osteo-arthritis (*arthritis deformans*) the long tendon of the biceps as it passes through the joint may be dissolved and the belly of the muscle then contracts and forms a lump on the middle of the arm anteriorly.

Pus frequently finds an exit along the bicipital groove and follows it downward and shows itself just at the edge of the anterior axillary fold near the middle of the arm.

If the pus passes out by way of the subscapular bursa it passes below the subscapular tendon and into the axilla anteriorly. If it passes backward it may emerge through the bursa beneath the infraspinatus muscle, and then either work its way downward into the posterior portion of the axilla, or if it works upward may travel either above or below the spine of the scapula and show itself on the dorsum.

## THE AXILLA.

The axilla is a wedge-shaped space with its apex upward, formed between the arm and chest at their junction. It serves as a passage-way for the arteries, veins, nerves, and lymphatics passing between the trunk and the upper extremity. It is frequently the site of growths and abscesses, requiring operations which necessitate a knowledge especially of its blood-vessels and lymphatics.

*Extent.*—Its apex lies between the clavicle and scapula above and the first rib beneath. Its base is formed by the skin and fascia stretched between the anterior and posterior axillary folds. It is spoken of as having four walls: inner, outer, anterior, and posterior.

The *inner wall* is formed by the first four ribs and interspaces and the corresponding serrations of the serratus anterior (magnus) muscle.

The *outer wall* is nothing more than the chink formed by the union of the two axillary folds. Above is the lesser tuberosity of the humerus and subscapularis tendon, lower down are the coracobrachial and biceps muscles.

The *anterior wall* is formed by the pectoralis major and minor muscles with the fascia enveloping them.

The *posterior wall* is formed by the subscapularis above and the teres major and latissimus dorsi muscles below.

**Axillary Fascia.**—The name axillary fascia is given to the fascia which closes the axillary space and forms its base. It is stretched across from the lower edge of the pectoralis major in front to the lower edge of the teres major and latissimus dorsi behind. On the inner wall it is continuous with the fascia covering the serratus anterior (magnus) and side of the chest; when it reaches the vessels at the apex of the axilla it is reflected around them to form the sheath.

On the outer wall it passes from the pectoralis major in front, over the coracobrachialis muscle beneath, blends with the sheath of the vessels, and then passes to the posterior wall, covering the subscapularis above and the teres major and latissimus dorsi below. At the lower edge of this latter muscle, which is a little lower than the pectoralis major, it passes across the axilla (Fig. 269).

Anteriorly the fascia covers the pectoralis major muscle; at its lower edge it splits to cover the pectoralis minor muscle and forms a sheath for it. As the axillary fascia approaches the apex of the axilla where the superficial vessels enter, it becomes cribriform in character, the fascia itself being wide-meshed and containing fat in the interstices. If the handle of the scalpel is inserted in the apex of the axilla and worked backward and forward two arches of fascia are readily formed, one convex toward the chest, and called the "Achselbogen," and the other convex toward the arm, called the "Armbogen" (*Langer, Oester. med. Woch.*, 1846, Nos. 15 and 16).

The fascia on the superficial surface of the pectoralis minor is called the *clavipectoral fascia*. At the upper or inner border of the pectoralis minor it is continuous



with the *costocoracoid membrane* which goes up to the clavicle, where it splits to enclose the subclavius muscle and to be attached to the anterior and posterior borders of the clavicle. The upper portion of this costocoracoid membrane is thickened and forms a firm band which runs from the coracoid process to the cartilage of the first rib, and is called the *costocoracoid ligament*.

Between this ligament above and the upper edge of the pectoralis minor below, and piercing the costocoracoid membrane, are the acromiothoracic artery and vein, the cephalic vein, the superior thoracic artery, external anterior thoracic nerve, and a few lymphatics derived from the breast. The superior thoracic artery is often a branch of the acromiothoracic and passes behind the vein to supply the serratus anterior and intercostal muscles and side of the chest.

The fascia on the under surface of the pectoralis minor unites with the layer on its upper surface, and passes upward to the coracoid process and is reflected onto the

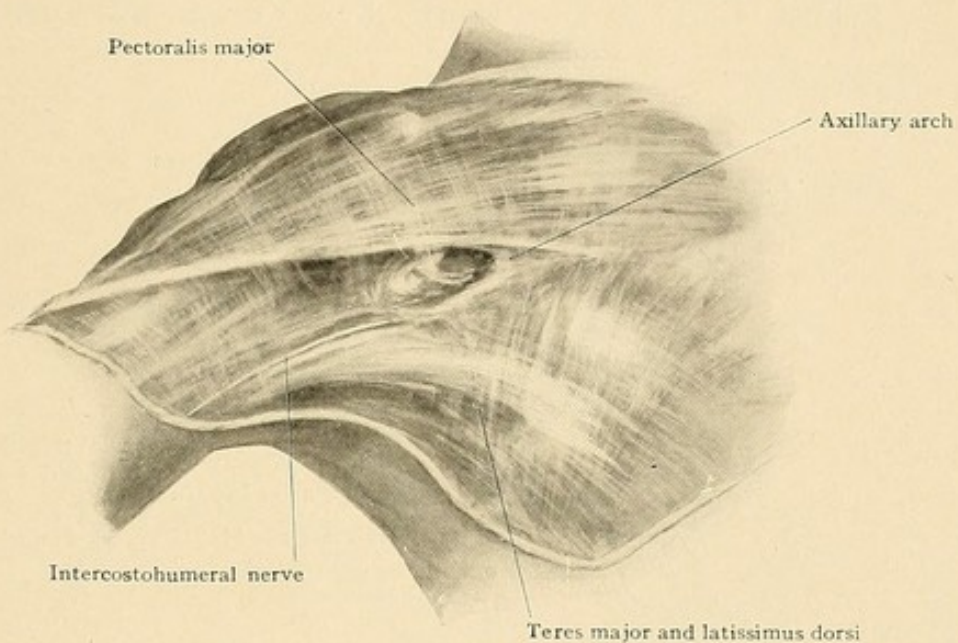


FIG. 269.—Axillary fascia. At the apex of the axilla the fascia is almost lacking, forming a curved arch on the side toward the chest, called the axillary arch or "Achselbogen." The curved edge toward the arm, less distinct than that toward the chest, is called the "Armboogen."

vessels to aid in forming their sheath. It is continuous with the fascia on the under surface of the subclavius muscle and the deep fascia of the neck.

This portion of the fascia is not sufficiently strong to form an absolute barrier between the neck and axilla, consequently abscesses forming in the neck will break through it and passing under the clavicle appear in the axilla, and abscesses starting in the axilla may burrow under the clavicle and up beneath the deep fascia of the neck.

#### THE AXILLARY VESSELS.

The axillary artery and vein are both important. The avoidance of hemorrhage in operations in this locality requires skill and knowledge, and venous bleeding is more apt to be troublesome than arterial. Wounds of the vessels, whether artery or vein, of those portions of the body like the axillæ, groins, or base of the neck are particularly dangerous; the blood current is both large and rapid.

The axillary vein drains the whole upper extremity and part of the chest, while the axillary artery carries all the blood going to those parts. The veins being so much weaker and thinner walled than the arteries is the reason of their being more frequently injured. Ligation of the artery, or vein, or both, may cause gangrene of the extremity and require amputation.

**The Axillary Artery.**—The axillary artery begins at the lower border of the first rib and ends opposite the lower border of the folds of the axilla (teres major). If the arm is lying by the side of the body the artery describes a curve with its



convexity outward. If the arm is placed straight out away from the body, the artery is straight. If the arm is abducted above the level of the shoulder, the artery again becomes curved but with its convexity downward.

The *line of the artery* is straight only when the arm is out from the body, when its course is represented by a line drawn from the middle of the clavicle to the anterior surface of the elbow, midway between the two condyles. It passes down along the inner side of the coracoid process and the coracobrachialis muscle about at the junction of the anterior and middle thirds of the axilla. It is divided into three parts by the pectoralis minor muscle (Fig. 270).

**First Portion.**—The first portion of the axillary is usually stated to be 2.5 cm. (1 in.) in length, and for surgical purposes we may accept this as a working basis.

A. H. Young has pointed out that, with the arm out from the body, the upper border of the pectoralis minor is nearly or quite level with the lower border of the first rib, but the muscle leaves the side of the chest to go to the coracoid process and that makes an interspace, more than 2.5 cm. long, above its upper edge

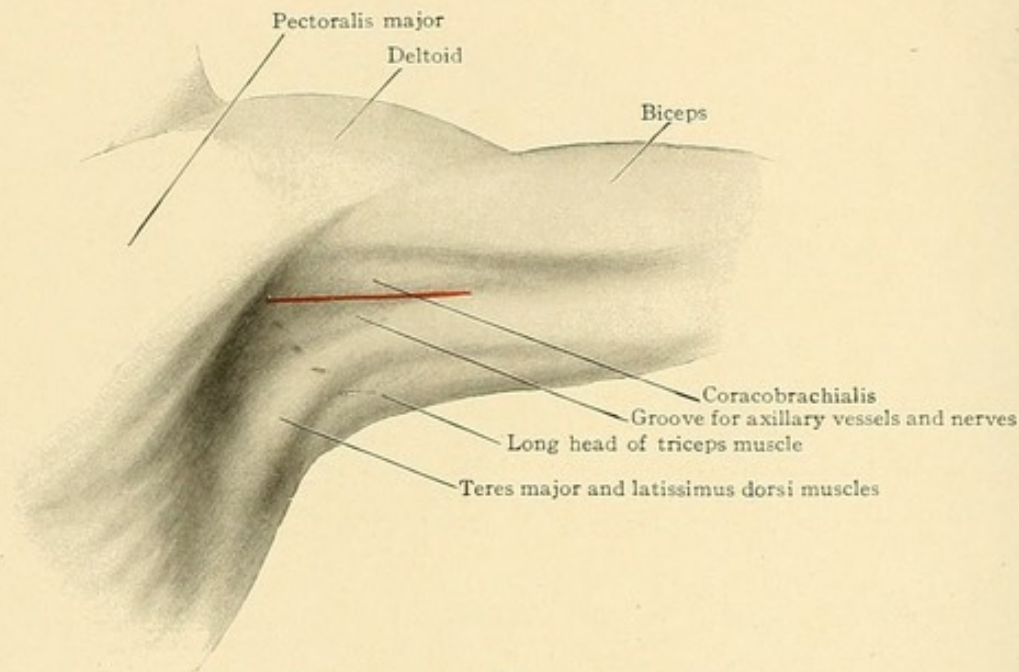


FIG. 270.—Line indicating the course of the axillary artery.

and between it and the lower edge of the subclavius muscle, in which the artery can be ligated. In the first portion the axillary artery above the pectoralis minor lies too deep to be compressed, being on a lower level than the pectoralis major, therefore it is better to compress the subclavian above the clavicle.

**Branches.**—The first portion of the axillary gives off two branches, the superior thoracic and the acromiothoracic (thoraco-acromialis) (Fig. 271).

The *superior thoracic* comes off posteriorly and winds around behind the axillary vein to supply the under surface of the pectoralis minor, intercostal muscles, serratus anterior, and side of the chest. It is a small vessel.

The *acromiothoracic (thoraco-acromialis)* is a short large trunk which comes off anteriorly, winding around the edge of the pectoralis minor and piercing the costo-coracoid membrane to divide into four branches: an acromial, to the acromion process; a humeral, which follows the cephalic vein between the deltoid and pectoralis major; a pectoral, which supplies the under surface of the pectoralis major and gives branches to the mammary gland; and a clavicular, to supply the subclavius muscle.

**Relations.**—*Posteriorly*, the artery lies on the first intercostal space and muscle, the second and part of the third serrations of the serratus anterior, the posterior thoracic nerve (or external respiratory of Bell), and the internal anterior thoracic nerve to the pectoralis minor and major.



*Internally.*—To the inner side of the artery and somewhat anteriorly is the *axillary vein*; between the two runs the *internal anterior thoracic nerve*. As the artery and vein ascend they become separated, the artery to pass behind and the vein in front of the scalenus anterior muscle.

*Externally.*—To the outer side and above the artery lie the cords of the brachial plexus.

*Anteriorly.*—In front of the artery are the skin and superficial fascia, the edge of the pectoralis major muscle and fascia covering it, the costocoracoid membrane pierced by the acromiothoracic artery, cephalic vein, and external anterior thoracic nerve, which goes to supply the pectoralis major muscle.

**Ligation of the First Portion of the Axillary Artery.**—The artery lies deep in the infraclavicular triangle, between the pectoralis major and deltoid muscles. It can be approached by either a transverse or a longitudinal incision. If the former is used it should be made through the skin only, immediately below the clavicle, reaching from just outside the sternoclavicular joint to the coracoid process.

The pectoralis major is detached from the clavicle and pushed downward, it arises from its inner half. This exposes the costocoracoid membrane. At the outer

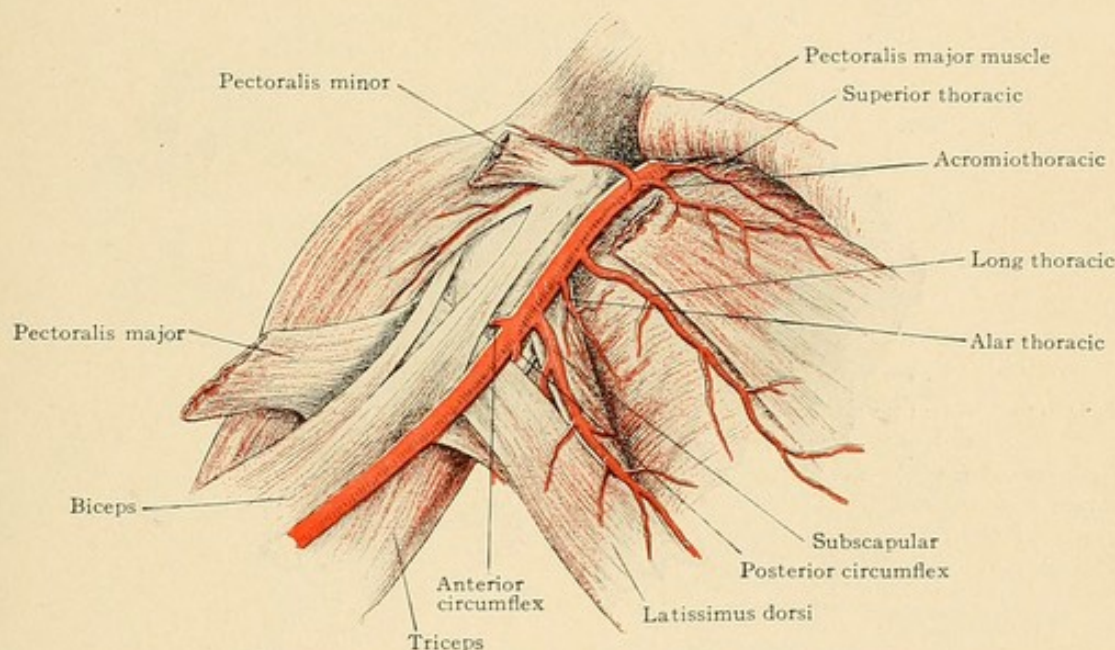


FIG. 271.—Diagrammatic view of axillary artery and its branches.

angle of the wound the cephalic vein and acromiothoracic artery are to be found.

The deltoid muscle is to be detached or pushed outward to expose the coracoid process, this being recognized, the costocoracoid membrane is to be opened to its inner side, between it and the cephalic vein. The acromiothoracic artery if isolated will lead to the artery, while the cephalic vein goes direct to the subclavian vein. The vein and costocoracoid membrane are closely united and great care is necessary to avoid wounding the former in opening the latter. The cords of the brachial plexus are to the outer side of the artery and care is to be exercised not to mistake one of them for the artery. As the vein is the most dangerous structure, it is to be displaced inward and the aneurism needle passed between it and the artery from within outward.

As the external anterior thoracic nerve is a nerve of motion supplying the pectoralis major muscle, if it is seen it should be avoided and not injured.

If it is desired to use a longitudinal instead of transverse incision, it should commence just outside the middle of the clavicle and follow the groove between the deltoid and pectoralis major muscles downward for 10 cm. (6 in.). Great care is then necessary to avoid wounding the cephalic vein and acromiothoracic artery, which lie in this groove.

If sufficient exposure is not given by a single straight incision it can be supplemented by one detaching the pectoralis major from the clavicle.



**Second Portion.**—The second portion of the axillary lies beneath the pectoralis minor muscle. It is 3 cm. ( $1\frac{1}{4}$  in.) long and while never ligated at this point it is nevertheless frequently exposed while clearing out the axilla for malignant growths of the breast. Owing to its being covered by the pectoralis minor and major muscles the artery cannot be compressed at this point in its course.

**Branches.**—Its branches are the alar thoracic and long thoracic. The *alar thoracic* are small branches of little importance supplying the fat and glands of the axilla.

The *long thoracic* or external mammary is of considerable importance on account of its size and because it is encountered in operations on the breast and axilla. It passes down along the lower (outer) border of the pectoralis minor, giving branches to it and the pectoralis major; some branches go to the axilla and serratus anterior, and others, which may be of considerable size in the female, wind around the lower portion of the pectoralis major or pierce it to supply the mammary gland. Posterior

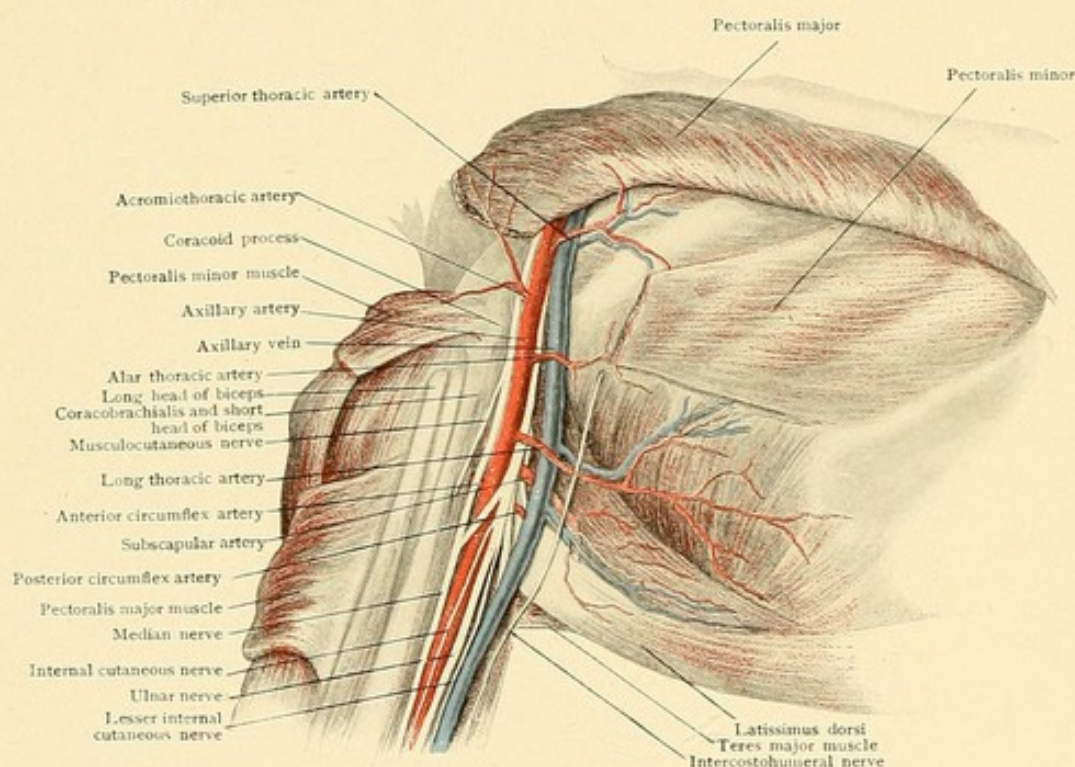


FIG. 272.—Dissection of the axilla.

to it is the long or posterior thoracic nerve, or external respiratory nerve of Bell, going to supply the serratus anterior muscle (Fig. 272).

**Relations.**—*Anteriorly* is the pectoralis minor muscle, superficial to which is the pectoralis major and skin. *Posteriorly* lie the posterior cord of the brachial plexus, the fat of the axilla, and the subscapularis muscle; *internally* is the axillary vein, with the inner cord of the brachial plexus separating the two. *Externally* is the outer cord of the plexus and farther out is the coracoid process.

**Third Portion.**—This is about 7.5 cm. (3 in.) long and runs from the lower border of the pectoralis minor to the lower border of the teres major. Its upper portion is under the pectoralis major but its lower portion is subcutaneous because the teres major, forming the edge of the posterior fold of the axilla, extends lower than the anterior fold. It is here that the axillary artery is most easily reached and most often ligated.

**Branches.**—It gives off three branches, the subscapular, the anterior circumflex, and the posterior circumflex.

The *subscapular* artery is of considerable practical importance; it is the largest branch of the axillary and is given off opposite the lower border of the subscapularis muscle. It follows the lower edge of this muscle down the axillary or outer border



of the scapula to its angle, where it anastomoses with the posterior scapular, one of the terminal branches of the transverse cervical from the thyroid axis.

Four centimetres ( $1\frac{1}{2}$  in.) from its origin the subscapular gives off the *dorsalis scapulæ*, which is as large or larger than the continuation of the artery downward. The position of this artery should be borne in mind in operating. It winds around the outer edge of the scapula between it and the *teres minor* muscle to supply the muscles posteriorly. The subscapular artery is accompanied by the long subscapular nerve to its inner side. (The first or short subscapular nerve supplies the subscapularis muscle, the second supplies the *teres major* and the third or long subscapular supplies the *latissimus dorsi* muscle.)

The posterior axillary chain of lymph-nodes accompanies the subscapular artery, hence it is involved in operations for their removal. The point at which the *dorsalis scapulæ* winds around the axillary border of the bone is at or just above the level of the middle of the deltoid muscle and below the level of the posterior circumflex artery.

The *anterior circumflex* artery is comparatively insignificant. It winds anteriorly around the surgical neck of the humerus beneath the *coracobrachialis* muscle and both heads of the biceps and gives off an ascending bicipital branch which ascends in the bicipital groove and a small descending branch to the tendon of the *pectoralis*

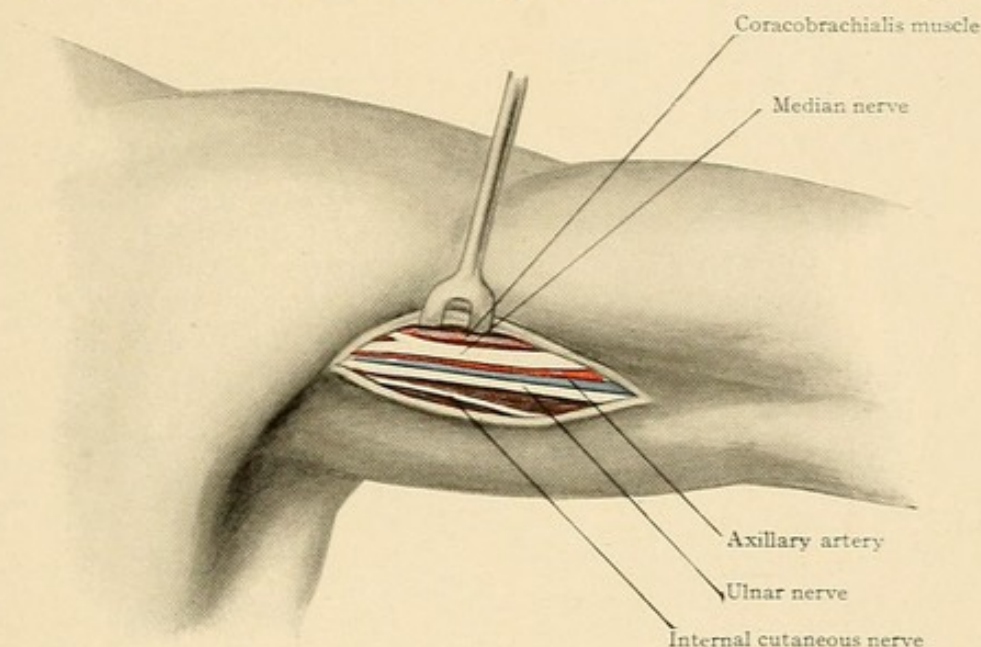


FIG. 273.—Ligation of the third portion of the axillary artery.

major. As pointed out by Walsham, the anterior circumflex artery on account of the closeness with which it hugs the bone may be difficult to secure if wounded in the operation of resection of the humerus.

The *posterior circumflex* artery is much larger than the anterior. It runs around the surgical neck posteriorly, below the *teres minor*, above the *teres major*, and between the long head of the triceps and the humerus. It is accompanied by the circumflex (axillary) nerve and they run transversely around beneath the deltoid muscle on a level with the junction of its upper and middle thirds. It is to avoid wounding these two important structures that the operation of resection is done anteriorly instead of posteriorly. Being covered only by the skin of the axilla and the superficial and deep fascias, it can readily be compressed by pressure directed outwardly against the humerus along the inner edge of the *coracobrachialis* muscle.

**Relations.**—*Posteriorly* the third portion of the axillary artery lies on the subscapularis, the *latissimus dorsi*, and *teres major* muscles, with the musculospiral and circumflex (axillary) nerves between the muscles and the artery.

*Anteriorly* it is covered by the skin and fascia, the *pectoralis major* above, and deep fascia of the arm below. The inner root of the median nerve crosses it and sometimes the outer vena comes.



*Externally* is the coracobrachial muscle (which partly overlaps it and forms its guide), the main trunk and outer head of the median, and the musculocutaneous nerves.

*Internally* is the axillary vein with the ulnar nerve between it and the artery. The internal and lesser internal cutaneous nerves also lie to its inner side with the former the more anterior.

**Ligation of the Third Portion of the Axillary Artery.**—The arm being placed out from the body, palm upward, the incision for ligating the axillary artery in the third portion of its course is laid along the inner border of the coracobrachial muscle, at about the junction of the anterior and middle thirds of the axilla and on a line joining the middle of the clavicle and a point at the bend of the elbow midway between the two condyles of the humerus.

The middle of the incision should be just above the lower edge of the folds of the axilla. The deep fascia having been opened, the coracobrachial muscle with the

musculocutaneous nerve piercing it is pulled outward. Lying on the artery to its outer side is the median nerve; it is to be drawn outward. To the inner side lies the axillary vein with the ulnar nerve beneath it and the internal cutaneous nerve (cutaneus antebrachii medialis) in front of it close to the artery.

The needle is passed from within outward. The artery at this point may be crossed by some muscular fibres coming from the latissimus dorsi and crossing the axilla. The axillary vein is the continuation of the basilic from the lower border of the teres major upward.

Of the two venæ comites of the brachial artery the inner one blends with the basilic at the lower border of the teres major; the outer one crosses the artery to empty into the axillary vein on the opposite side.

The axillary vein receives the subscapular, circumflex, long thoracic, acromiothoracic, alar, and cephalic,

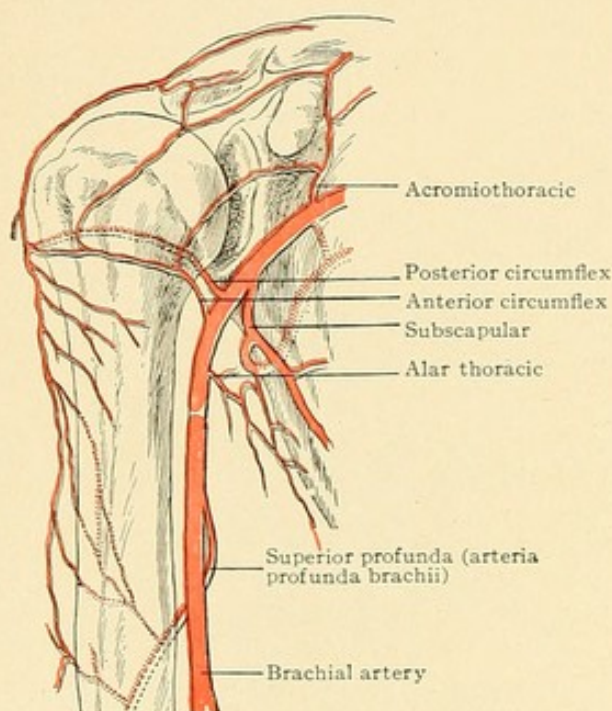


FIG. 274.—Collateral circulation after ligation of the third portion of the axillary artery.

and contains a pair of valves opposite the lower border of the subscapularis muscle.

**Collateral Circulation after Ligature of the Axillary Artery.**—If the first portion of the axillary is tied, the acromiothoracic artery comes off so low down (under the edge of the pectoralis minor muscle almost) that the ligature is placed above it, in which case the collateral circulation is similar to that of the subclavian (see page 149). The second portion of the axillary, lying beneath the pectoralis minor, is not subject to ligation. In the third portion the subscapular and anterior and posterior circumflex arteries come off so close together that the ligature will be placed either just below or just above them (Fig. 274).

If below, then the collateral circulation will be between them above and the superior profunda below. If above the subscapular, then the anastomosis would be as follows:

PROXIMAL VESSELS.	DISTAL VESSELS.
Acromiothoracic, acromial branch . . . . .	with anterior and posterior circumflex
Acromiothoracic, humeral branch . . . . .	with anterior and posterior circumflex
Acromiothoracic, pectoral branch . . . . .	with subscapular
Long thoracic branch . . . . .	with subscapular
Alar thoracic branch . . . . .	with subscapular
Posterior scapular (branch of trans. cervical)	with subscapular and dorsalis scapulæ
Suprascapular . . . . .	with dorsalis scapulæ and posterior circumflex



**Lymphatics of the Axilla.**—There are two sets of lymphatic nodes in the axillary region, the axillary nodes proper and the subclavian nodes.

The number of the nodes varies from about ten or twelve to twenty or more. When enlarged they are readily seen, but after the surgeon has carefully dissected away all the nodes he can possibly find disease may subsequently reveal the existence of others. Hence it is impossible ever to be absolutely sure that *all* nodes have been removed.

The *subclavian nodes*, about two or three in number, lie in the infraclavicular triangle between the pectoralis major and deltoid muscles and on the front of the subclavian vein above the pectoralis minor muscle. They receive radicles from the mammary gland as well as from the axillary groups.

The *axillary nodes proper* are composed of three sets, humeral or external, thoracic or anterior, and scapular or posterior, accompanying the three vessels, axillary, long thoracic, and subscapular.

The *humeral set*, perhaps eight or nine, accompany the axillary artery and vein and lie along them and in the axillary fat. They receive mainly the lymphatics

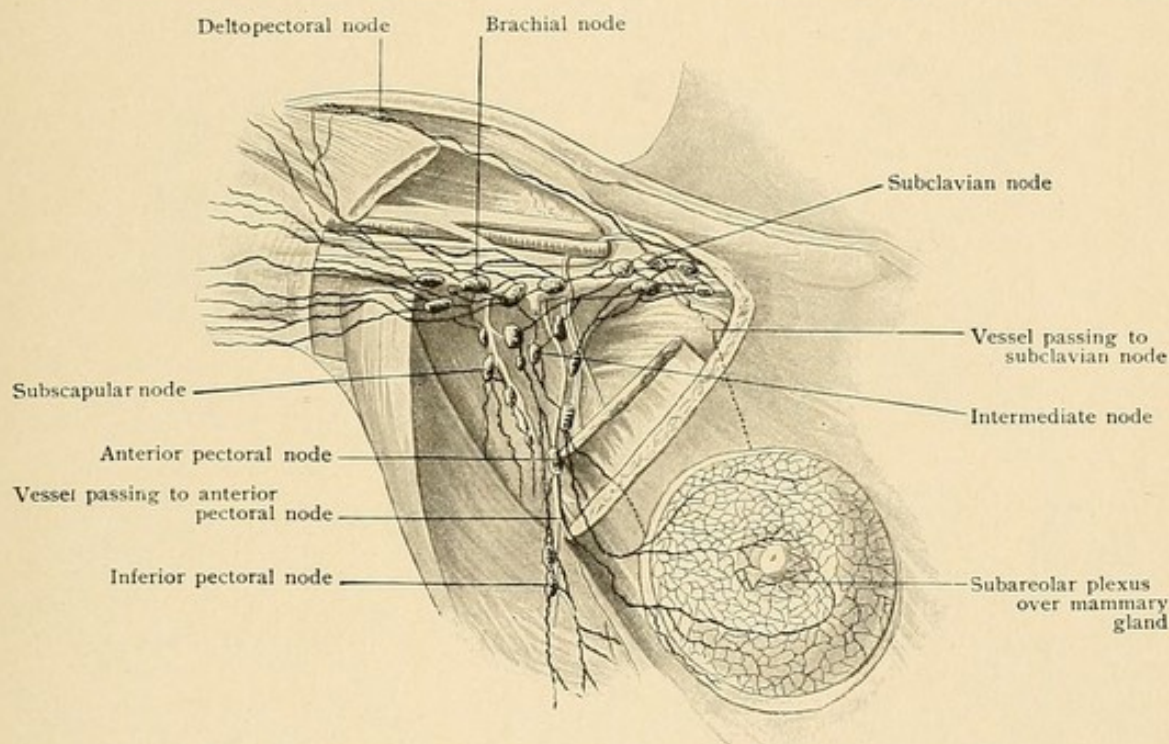


FIG. 275.—Lymphatics of mammary gland, and axillary nodes. (Poirier and Cunéo.)

from the arm. They can often be pared off the vessels with ease, but sometimes are so firmly attached that the vessels are injured in their removal.

The *anterior or thoracic set* accompany the long thoracic artery along the lower border of the pectoral muscles. They are not so numerous as the humeral set, perhaps four or five in number, and drain the anterior upper half of the chest above the umbilicus, including the mammary gland (Fig. 275).

The *posterior or scapular set* accompany the subscapular artery along the posterior portion of the axilla. They are about as numerous as the anterior set and drain the upper posterior portion of the chest, the scapula and lower portion of the neck.

The lymphatics of the middle and lower portion of the back as low down as the umbilicus (3 to 4 cm. above the iliac crest) also drain into the axilla.

These lymphatic nodes communicate with one another, so that it does not of necessity follow that if the part ordinarily drained by a certain set is affected the nearest nodes will be involved. It usually is so, but not always. The infection may pass by or through one set of nodes and involve a neighboring communicating set. It happens in carcinoma of the breast that sometimes the posterior or scapular set are



involved and the anterior or thoracic set escape. This has already been alluded to in the section on the mammary gland (see page 184). These three sets drain into the subclavian nodes and then empty into the subclavian vein near its junction with the jugular.

**Abscess of the Axilla.**—Pus forms in the axillary region from ordinary pyogenic organisms which may or may not be associated with specific organisms like the tubercle bacillus. Abscesses may be either superficial or deep.

The *skin of the axilla* is thin, loose, and abundantly supplied with sebaceous glands connected with the hair-follicles and sweat-glands. These glands are in the deeper layer of the skin and are superficial to the axillary fascia, hence abscesses originating from them tend to break externally; usually they do not become large nor extend deep into the axilla.

Abscesses originating from the lymphatics, on the contrary, may be either deep in the axilla along the axillary, pectoral, or subscapular vessels, or they may be in the axillary fat and tend to point toward the skin. If the lymphatics along the axillary vessels are the point of origin, the abscess may follow them down under the deep fascia to the elbow. If the nodes high up are involved, the abscess may work up under the clavicle into the neck. If, however, the nodes near the apex of the axilla

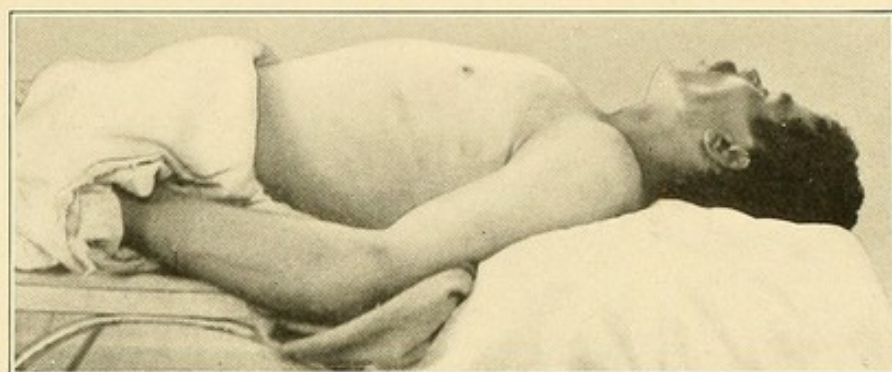


FIG. 276.—Subpectoral abscess.

form the starting-point then the abscess bulges through the cribriform portion of the axillary fascia (between the "Armboogen" and "Achselbogen") into the axilla and tends to discharge through the skin. Abscesses originating in the pectoral group of lymphatics point at the lower margin of the anterior axillary fold. The attachment of the serratus anterior to the side of the chest prevents them from working towards the back.

Abscesses involving the subclavian nodes may cause a *subpectoral abscess* (Fig. 276). The pus collects superficial to the costocoracoid membrane and clavipectoral fascia and pushes the pectoralis major muscle outward, forming a large rounded prominence below the inner half of the clavicle. The pus cannot extend upward or toward the median line on account of the attachment of the pectoralis major muscle. It can burrow through the intercostal spaces and involve the pleural cavity, or break through the fibres of the pectoralis major anteriorly or between the pectoralis major and deltoid, or, as is most commonly the case, work its way under the pectoralis major muscle, over the pectoralis minor, until it reaches the border of the pectoralis major at the anterior fold of the axilla.

In emptying these abscesses an incision is to be made along the anterior axillary fold and a tube introduced beneath the pectoralis major.

**Incision for Axillary Abscess.**—In opening an axillary abscess one should bear in mind that the important veins and nerves accompany the arteries and that the arteries lie in three places, viz., externally along the humerus, anteriorly along the edge of the pectoral muscles, and posteriorly along the edge of the scapula; therefore these three localities are to be avoided and an incision made in the middle of the axilla and short enough not to endanger the brachial vessels on the outside or the long thoracic or subscapular on the inside near the chest-wall.

The incision may divide the skin and if desired the deeper structures can be parted by introducing a closed hæmostatic forceps and separating its jaws.



Axillary abscesses, if of slow formation and unopened, tend to burrow and follow the vessels upward beneath the clavicle and appear in the supraclavicular space beneath the deep cervical fascia, and they may even enter the superior mediastinum. They may also descend the arm under the fascia covering the coracobrachialis muscle.

**Axillary Tumors.**—Tumors of the axilla are almost always due to involvement of the lymph-nodes. They may be either benign and inflammatory in character, forming the ordinary axillary adenitis, or tuberculous, or they may be malignant. As they are due to disease of the lymph-nodes, the parts which the glands drain should be searched for the starting-point of the affection. Aneurism or abscess may be mistaken for a new growth and an inflamed aneurism may readily be thought to be an abscess.

The excision of axillary tumors is difficult. If the tumor is of an inflammatory origin it may be closely adherent to the veins or arteries or nerves, and the same condition may exist in malignant cases.

The blood supply of the axilla is so free that nothing is to be gained by saving small vessels, therefore in paring a tumor off the axillary vessels the various small branches are ligated and divided and the main vessels left bare. This applies to the veins as well as the arteries.

The subscapular artery is so large that it is often allowed to remain. When working in the posterior portion of the axilla it is to be remembered that the posterior circumflex artery is opposite the surgical neck of the humerus, above the tendon of the latissimus dorsi muscle, and that the subscapular artery is on the opposite side of the axillary artery a little higher up. The large subscapular vein will bleed profusely if wounded and it should be looked for at the axillary border of the scapula below the subscapularis muscle.

Wounds of the axillary vein are particularly dangerous on account of the admission of air. The attachment of the vein to the under side of the pectoralis minor and costocoracoid membrane keeps it from collapsing; hence the danger.

**Nerves of the Axilla.**—The *brachial plexus* is above the first portion of the axillary artery. In the second portion one cord is to the inner side, one to the outer, and one behind. In the third portion the *median nerve* is anterior and a little to the outer side of the artery, being formed by two roots, one from the inner and the other from the outer cord of the brachial plexus.

The *musculocutaneous nerve* is to the outer side of the artery, leaving the outer cord to enter the coracobrachialis muscle. The *ulnar, internal cutaneous (cutaneus antebrachii medialis)*, and *lesser internal cutaneous (cutaneus brachii medialis)* come from the inner cord and lie to the inner side of the artery. From the posterior cord come the *axillary (circumflex)* and *radial (musculospiral)* nerves. On the inner wall of the axilla behind the long thoracic artery is the *N. thoracalis longus* (long thoracic, or external respiratory nerve of Bell); it is a motor nerve and supplies the serratus anterior (magnus) muscle, hence it is not to be injured in clearing out the axilla.

Still farther posteriorly, accompanying the subscapular artery, is the *thoraco-dorsalis* or *long subscapular nerve*. It also is a motor nerve supplying the latissimus dorsi muscle; therefore it is to be spared.

Crossing the axilla from the second intercostal space to anastomose with the cutaneus brachii medialis nerve is the *intercostobrachial (humeral) nerve*. It is a nerve of sensation and need not be spared. Sometimes another branch from the third intercostal nerve also crosses the axilla; it is also sensory and can be cut away.

As the *axillary (circumflex) nerve* normally winds around the surgical neck of the humerus, when luxation occurs it is stretched over the head and paralysis of the deltoid may ensue.

The various nerves of the brachial plexus are often injured by pressure resulting from the use of crutches ("crutch palsy"). It is liable to affect any or several of the nerves, the radial (musculospiral) probably the most frequently. Neuritis is common and, as in injuries, the nerves affected are recognized by the motor or sensory symptoms produced.



## THE ARM.

The arm—or upper arm—is formed by a single bone surrounded by muscles, which, with the exception of the biceps, are attached to it. The main vessels and most of the important nerves run down its inner side. It receives from the trunk the insertions of the muscles which move it, and gives origin to the muscles which move

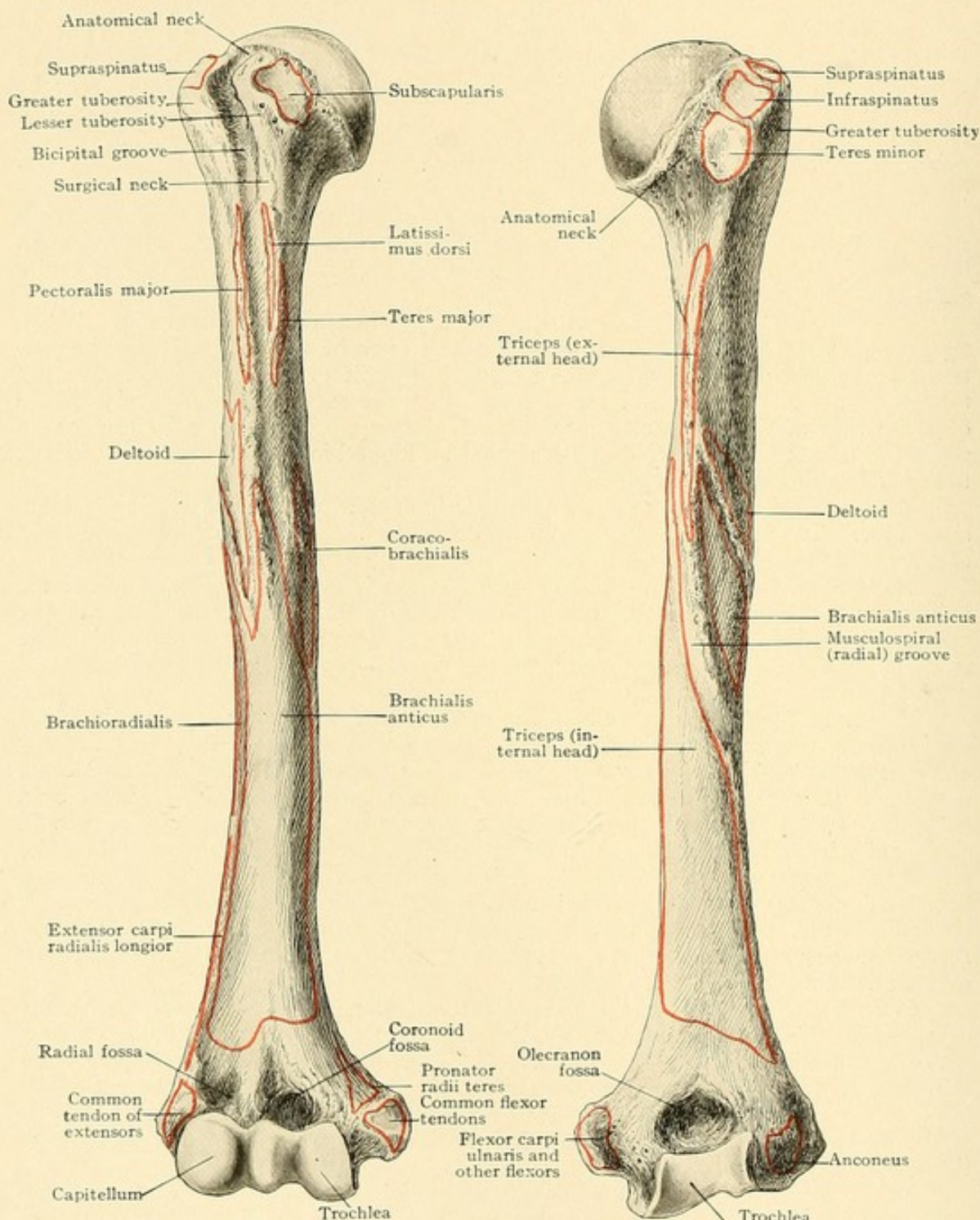


FIG. 277.—Anterior surface of humerus, showing attachment of muscles.

FIG. 278.—Posterior surface of humerus, showing attachment of muscles.

the forearm. It is more subject to injury than to disease; infection, caries, and rickets may attack the bone and rarely new growths may occur, but its common affections are wounds involving the muscles, blood-vessels, or nerves, and fractures of the bone. Severe injuries occasionally necessitate amputation.



## THE HUMERUS.

The humerus is a long bone with a large medullary cavity. Its shaft is composed of compact tissue and its ends of cancellous tissue. In shape it is like the letter *f*, that is, convex anteriorly above and concave anteriorly below. At the middle of the bone on its external surface is the rough deltoid eminence for the insertion of the deltoid muscle.

**Anterior Surface.**—Separating the tuberosities above and running down the anterior surface is the *bicipital groove*. Its external lip receives the insertion of the pectoralis major muscle, its inner lip and floor those of the latissimus dorsi above and the teres major below. On its inner side at and a little below its middle, is the insertion of the coracobrachialis muscle. On the anterior surface from the deltoid

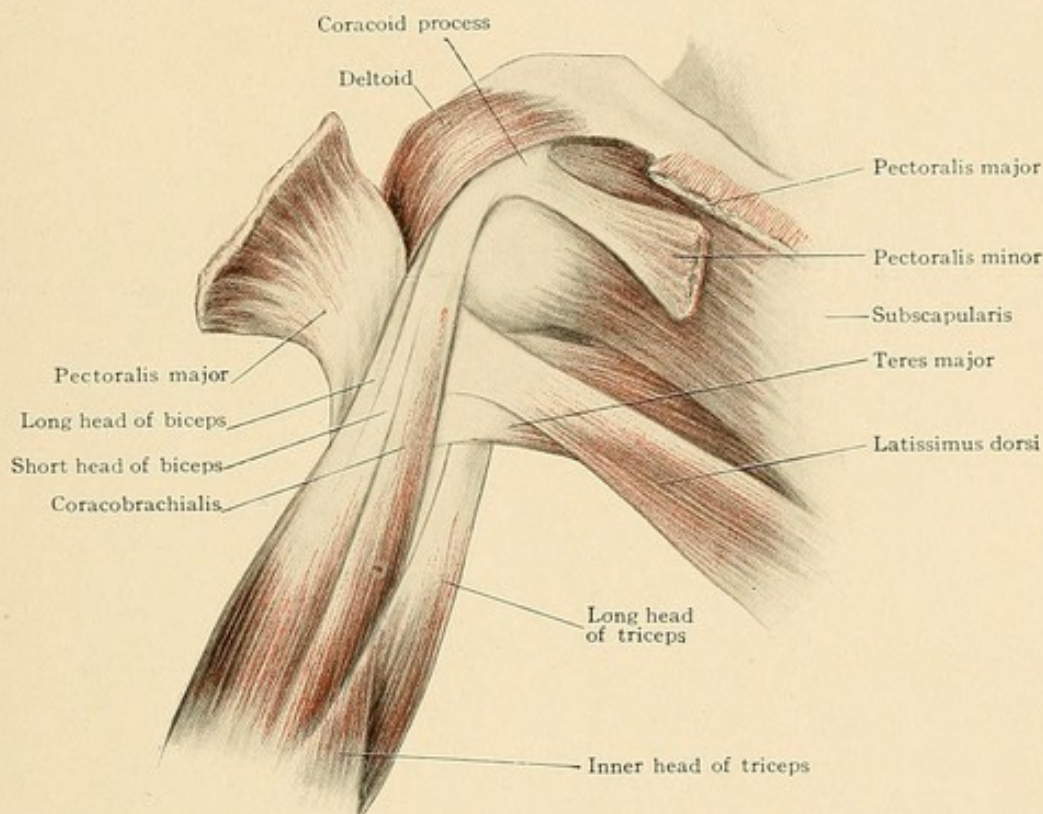


FIG. 279.—Muscles of the anterior and internal aspects of the region of the shoulder.

eminence to the elbow-joint is the origin of the brachialis anticus; it has two heads, which embrace the insertion of the deltoid, one being in front and the other behind it (Fig. 277).

**Posterior Surface.**—On the posterior surface, running obliquely across the bone downward and outward, below the insertion of the deltoid, is a shallow groove, called the *musculospiral groove* (*sulcus radialis*). It holds the *musculospiral* (*radial*) nerve and the *superior profunda artery*. Above the groove and to its outer side is the origin of the outer head of the triceps extensor muscle and the insertion of the deltoid. To its inner side, below, is the origin of the inner head of the triceps. Therefore the groove separates the inner head of the triceps muscle from the outer (Fig. 278).

## MUSCLES OF THE ARM.

In order to operate intelligently it is necessary to know the muscles and interspaces, for the latter carry important structures. The arm possesses four sets of muscles. One, an external set, abducts it, the *deltoid*; another, or internal set, adducts it (and rotates it inward), the *pectoralis major*, *teres major*, *latissimus dorsi*, and *coracobrachialis*; another, anterior set, flexes the forearm, the *biceps*, and the *brachialis anticus*; and the last, or posterior set, extends the forearm, the *triceps*, with, sometimes, the *subanconæus* beneath it.



## THE EXTERNAL, OR ABDUCTOR SET.

This comprises only one muscle, the deltoid; the supraspinatus belongs to the shoulder region.

The **deltoid** forms the large rounded prominence of the shoulder. At its insertion the bone is nearest the surface and can be most readily felt. The posterior edge can be plainly seen when contracted running upward and inward and crossing

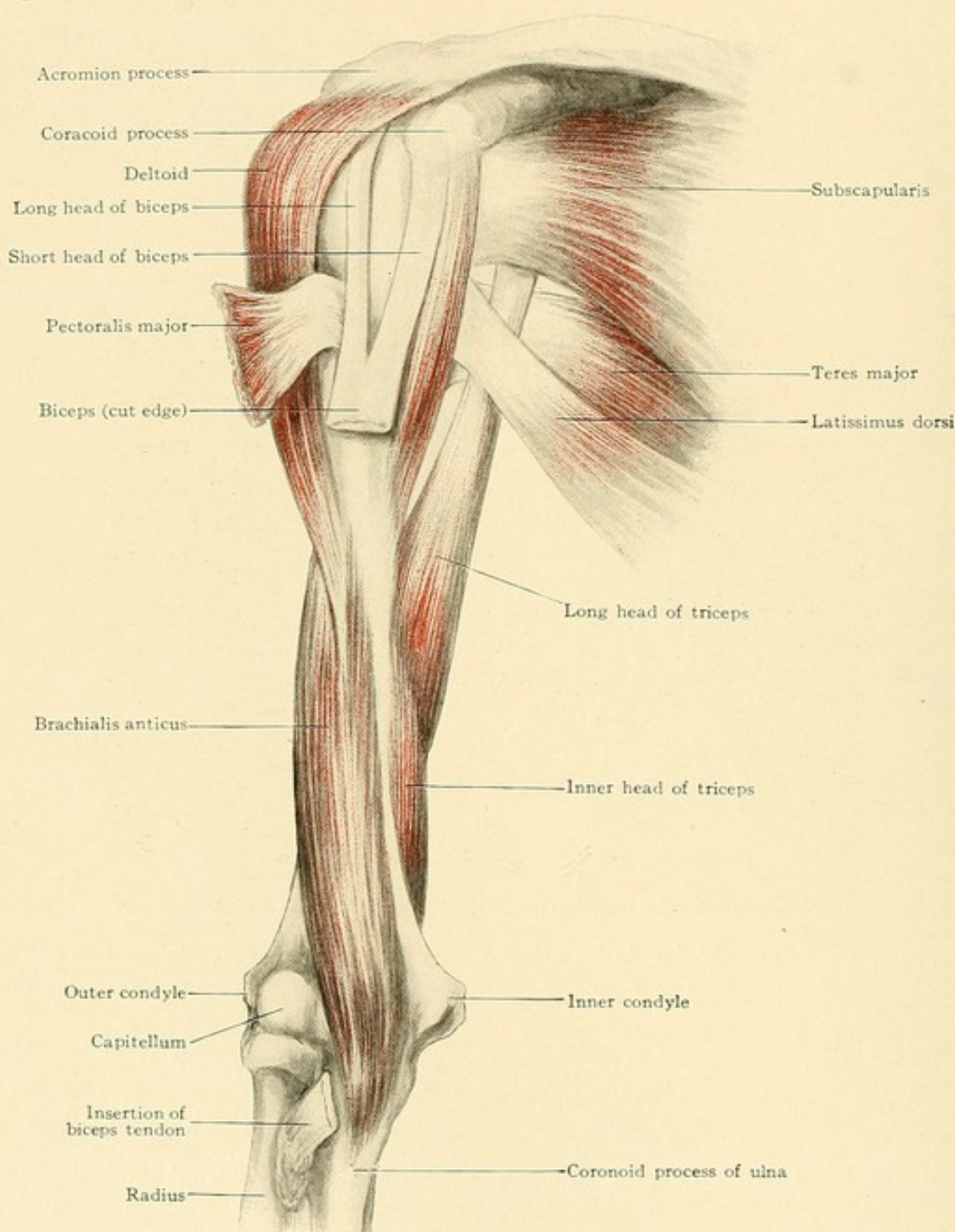


FIG. 280.—Anterior view of muscles of the arm.

the posterior fold of the axilla at right angles. Its anterior edge blends more or less completely with the pectoralis major (Fig. 279).

## THE INTERNAL SET.

The internal set includes the coracobrachialis, with the short head of the biceps, and the pectoralis major, teres major, and latissimus dorsi.



The **coracobrachialis** arises from the coracoid process and tendon of the short head of the biceps and inserts on the inner surface of the humerus for a distance 5 to 7.5 cm. (2 to 3 in.) opposite the insertion of the deltoid, but extending a little lower. In its course from the coracoid process, in its lower part, it is subcutaneous and produces a distinct muscular prominence along the anterior border of the axilla. It occupies about one-third of the width of the axilla and is a guide to the brachial artery. Below the edge of the anterior axillary fold it dips down to insert into the bone and is covered by the biceps muscle. The inner edge of the coracobrachialis is continuous with the inner edge of the biceps. When it contracts it adducts the humerus and brings it forward.

The **pectoralis major**, forming the anterior axillary fold, inserts into the external lip of the bicipital groove from the greater tuberosity above to the insertion of the deltoid below. The tendon is twisted on itself so that the lowest fibres at its origin are inserted the highest, and the highest in origin are the lowest at their insertion.

The **latissimus dorsi** and **teres major** form the posterior axillary fold and their manner of insertion resembles that of the pectoralis major. The tendon of the

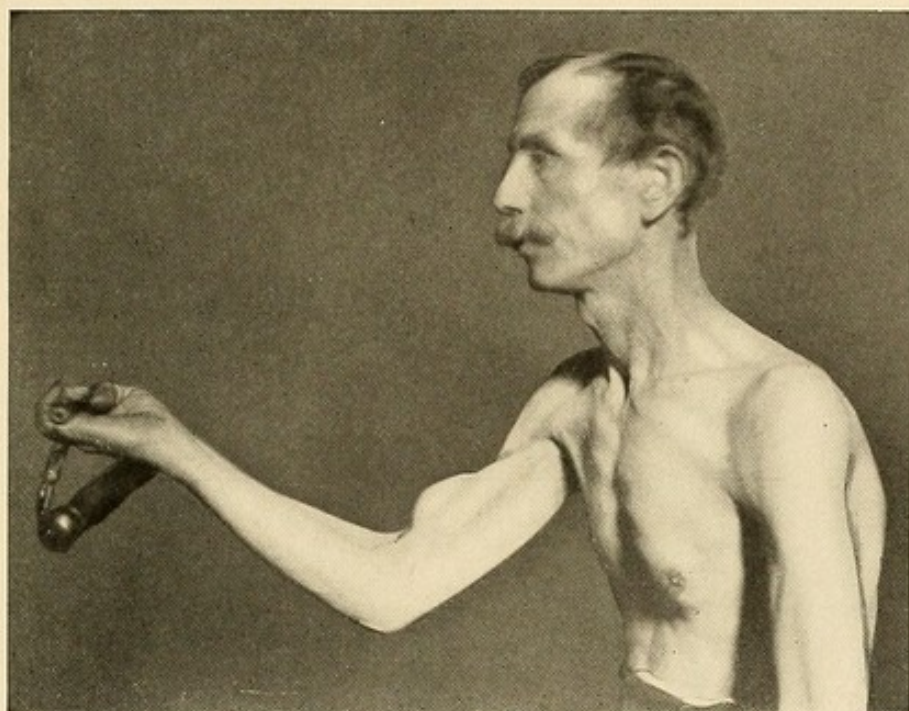


FIG. 281.—Rupture of the tendon of the long head of the biceps muscle, producing a swelling comparatively low down.

**latissimus dorsi** inserts into the bottom of the bicipital groove higher up than the **teres major**. Hence near the humerus the lower edge of the posterior axillary fold is formed by the **teres major** and its lower border marks the lower limit of the *axillary* and the beginning of the *brachial artery*.

As the **pectoralis major**, **latissimus dorsi**, and **teres minor** muscles insert on the anterior surface of the humerus, they tend to rotate it inward as well as to adduct it.

#### THE ANTERIOR SET.

The biceps and brachialis anticus form the muscular mass on the anterior surface of the arm.

The **biceps** has no attachment to the humerus. It spans the bone and is attached to the scapula above and to the radius and deep fascia of the forearm below. In the lower half of the arm it lies on the brachialis anticus. The long head runs up in the *bicipital groove*, and is covered by the tendon of the pectoralis major up to the tuberosities, above that by the transverse humeral ligament up to the capsule, which it perforates, and, crossing over the head of the humerus, is attached to the upper edge of the rim of the glenoid cavity (Fig. 280).

The bicipital branch of the anterior circumflex artery accompanies the tendon in the bicipital groove. This tendon is comparatively rarely luxated, because it is



firmly held in place by the transverse humeral ligament. Pus, in finding an exit from the joint, follows the long tendon of the biceps and passes under the transverse humeral ligament, then beneath the tendon of the pectoralis major to appear on the anterior aspect of the arm at its lower border. Luxation of the tendon outwardly would be opposed by the insertion of the pectoralis major, therefore it is only displaced inwardly. Rupture of the long tendon may occur from violent muscular contraction; or, in rheumatoid arthritis of the shoulder, the tendon may become partly dissolved and break. When this occurs the belly of the muscle contracts and forms a large protuberance on the front of the arm (Fig. 281).

The short head of the biceps fuses with the coracobrachialis muscle, to be attached with it to the coracoid process on its outer portion. The pectoralis minor is the third muscle attached to this process.

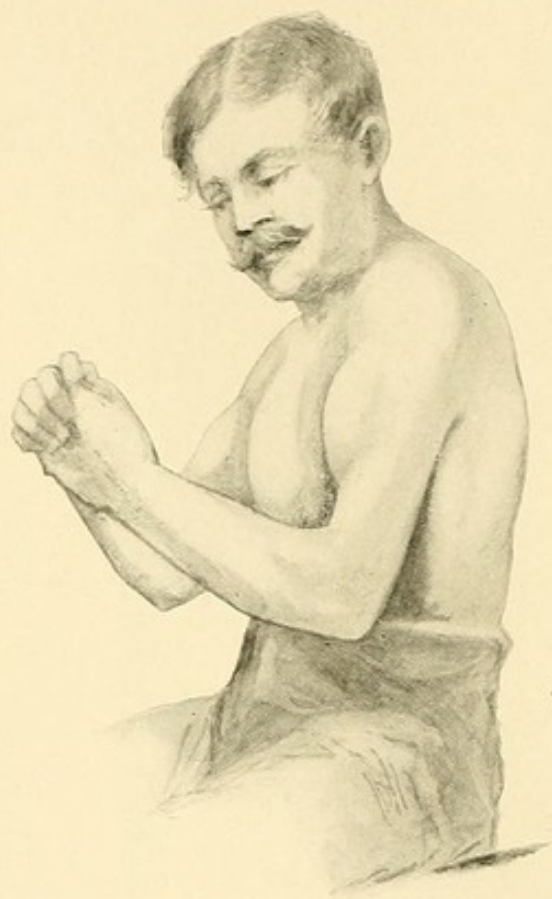

FIG. 282.—Rupture of the lower tendon of the biceps. Contraction of the muscle produces a swelling abnormally high up on the arm. (From a photograph.)

The biceps forms the large muscular

swell on the front of the arm between the anterior fold of the axilla and elbow. At its lower end the biceps inserts by a strong tendon into the posterior border of the bicipital tubercle of the radius. An example of its rupture is shown in Fig. 282. Between it and the bone is a bursa, which does not communicate with the elbow-joint. The *bicipital fascia* is given off from the tendon and passes downward and inward to blend with the deep fascia covering the flexor group of muscles. The biceps not only flexes the radius on the arm but also acts as a powerful supinator.

The **brachialis anticus** covers the lower three-fifths of the humerus and begins with two slips, one on each side of the insertion of the deltoid tendon. It inserts into the inner and lower part of the anterior surface of the coronoid process of the ulna. As the articulation of the ulna and trochlear surface of the humerus is a pure hinge-joint the muscle acts solely as a flexor.

#### THE POSTERIOR OR EXTENSOR SET.

The posterior or extensor set includes the triceps and the subanconeus, when present as a distinct muscle.

#### The Triceps Muscle.—The mus-

cular mass on the posterior surface of the arm is formed solely by the triceps muscle. It arises by three heads and inserts by a single tendon into the olecranon process of the ulna. Its three heads are the long, external, and internal. The long head arises from the lower edge of the glenoid cavity and the scapular border below it for 2.5 cm. (1 in.). It blends with the capsule of the joint and tends to strengthen it at this point. When the arm is abducted, this tendon is closely applied to the capsule and head of the humerus, and when the head escapes in luxation, it slips out anterior to the tendon. The external head arises from the humerus above the musculospiral groove and from the external intermuscular septum; the internal head arises from the humerus below the musculospiral groove and from the internal and the lower part of the external intermuscular septum (Fig. 283).

At its lower end the triceps inserts into the olecranon process, the upper third of the ulna, and the deep fascia of the back of the forearm. The expansion of fascia from the olecranon on the inner side is thin and insignificant, but that on the outer side, on the contrary, is thick and strong, and when fracture of the bone occurs is an important factor in preventing separation of the fragments.



## THE INTERMUSCULAR SEPTA.

The deep fascia of the arm completely encircles it, like a tube. It is continuous above with the fascia covering the deltoid, pectoralis major and teres major muscles, and axillary fascia. Below, it is continuous with the fascia of the forearm and is attached to the olecranon and internal and external condyles.

On each side of the lower half of the humerus, extending from the condyles and the bone above outward to the deep fascia, are two fibrous partitions. They are the *internal* and *external intermuscular septa*. The space in front of them is filled by the flexors, the biceps, and brachialis anticus, and the space behind contains the triceps extensor. The external septum begins at the external condyle and extends above to the tendon of the deltoid, with which it blends. The internal septum begins below at the internal condyle and extends above to the coracobrachialis. The radial (musculospiral) nerve and anterior terminal branch of the (superior) profunda artery, as they wind around the humerus below the insertion of the deltoid, pierce the external septum. The internal septum is pierced high up by the ulnar nerve and superior ulnar collateral (inferior profunda) artery as they emerge at about the level of the lower portion of the insertion of the coracobrachialis to pass down behind the internal condyle.

These intermuscular septa are of importance in operative procedures because they indicate the limits of the muscles and position of nerves and vessels.

## SURFACE ANATOMY.

Inasmuch as the movements of the elbow-joint are anteroposterior only and not lateral, the muscles are principally on the front and back and not on the sides. Hence on looking at an arm a rounded mass is seen anteriorly and posteriorly, and separating them on the sides can be seen in a spare, muscular individual, distinct furrows called the *internal* and *external bicipital furrows*. If these furrows are obscured by fat, one can still feel that the bone is nearer the surface at these points than elsewhere. The anterior muscle mass is formed by the biceps and brachialis anticus muscles, the posterior mass by the triceps. The bone is most readily felt at the insertion of the deltoid at the middle of the outer side of the arm. From this point directly down to the external condyle passes the *external* intermuscular septum and external bicipital furrow. Winding around from the posterior edge of the insertion of the deltoid is the *radial (musculospiral) nerve* and (*superior*) *profunda artery*. They pierce the external intermuscular septum and pass downward in the groove formed by the brachioradialis (supinator longus) and extensor muscles on the outside and the brachialis anticus on the inside. On the inner side of the arm the bicipital furrow, between the biceps in front and the triceps

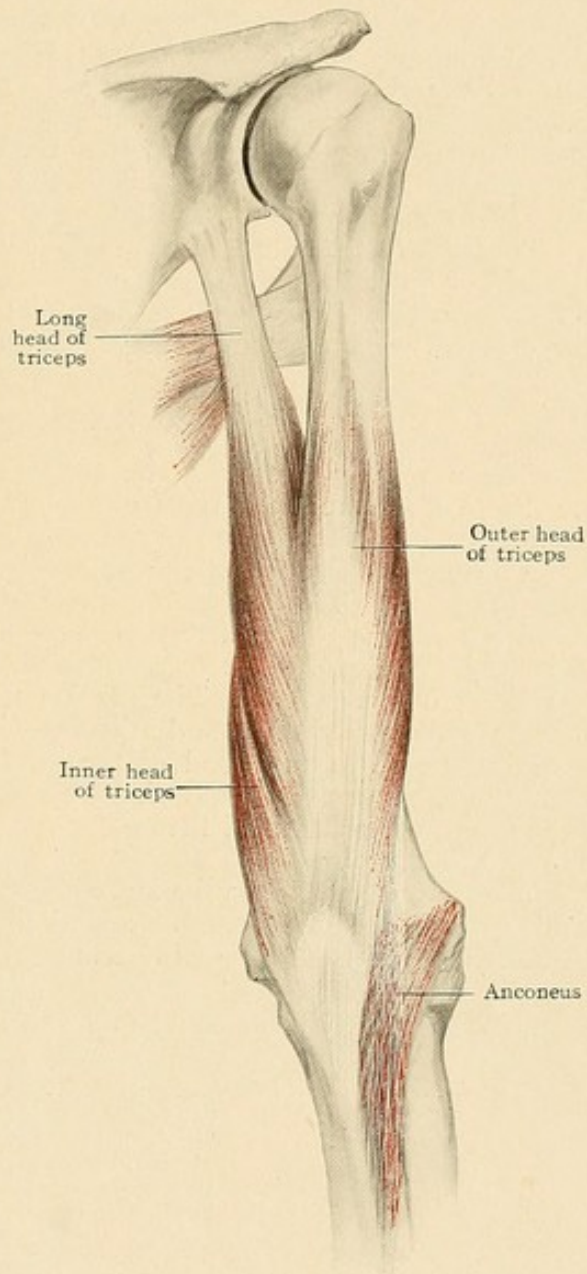


FIG. 283.—Triceps and anconeus muscles.



behind, is quite evident and marks the internal intermuscular septum, which extends to the medial (internal) condyle. In front of it lie the *brachial artery* and *veins*, and *median* and *medial antebrachial (internal) cutaneous nerve*. At the upper portion of the inside of the arm can be seen the swell formed by the coracobrachialis muscle. The inner or posterior border of the coracobrachialis is continuous with the inner border of the biceps, and the brachial artery follows them. The coracobrachialis muscle ends just below the level of the insertion of the deltoid, and, of course, can neither be seen nor felt below that point. It is here that the *ulnar nerve* leaves the artery to pierce the internal intermuscular septum in company with the *superior ulnar collateral (inferior profunda) artery* to reach the groove behind the internal condyle. The brachial artery is covered only by the skin and superficial and deep fascia, and can be felt pulsating along the inner edge of the biceps muscle and tendon; it can be compressed against the bone by pressure directed outwardly above and inclining more posteriorly as the artery progresses down toward the bend of the elbow. It is on the inner side of the arm in the upper two-thirds, and is more anterior in the lower one-third (Fig. 284).

The *cephalic vein* runs up the external bicipital furrow and the *basilic* up the internal. At the junction of the middle and lower thirds of the arm the basilic pierces the deep fascia and from that point runs up beneath it and joins with the *internal vena comes* opposite the lower border of the teres major or subscapularis.

### THE BRACHIAL ARTERY.

The arm being abducted, the course of the brachial artery is indicated by a line drawn from the inner edge of the coracobrachialis muscle, at the junction of the anterior and middle thirds of the axilla, above, to a point just inside the tendon of the biceps at the bend of the elbow, below, midway between the two condyles of the humerus. This lies in the internal bicipital furrow along the inner edge of the biceps muscle. The artery is superficial in its entire course. It is accompanied by two small *venæ comites*, which closely embrace it. The basilic vein runs along its inner side. The median nerve lies on the artery to its outer side above, then directly on it and a little to its inner side at the middle, and passes to its inner side at the bend of the elbow. The medial antebrachial (internal) cutaneous nerve, much smaller than the median, passes down along the inner side of the artery between it and the basilic vein to pierce the fascia about the middle of the arm (Fig. 285).

The *ulnar nerve* lies to the inner side of the artery above and is posterior to the basilic vein. About opposite the insertion of the coracobrachialis it diverges from the artery to pierce the internal intermuscular septum.

#### RELATIONS OF THE BRACHIAL ARTERY

##### *In Front.*

Skin and fascia  
Overlapped by coracobrachialis and biceps  
Median basilic vein  
Bicipital fascia  
Median nerve

##### *Outer Side*

Median nerve, above  
Coracobrachialis  
Biceps  
Vena comes

##### **Brachial Artery**

##### *Inner Side*

Medial antebrachial (int.)  
cutaneous and  
ulnar nerves  
Median nerve below  
Basilic vein  
Vena comes

##### *Behind*

Triceps (long and inner heads)  
Radial (musculospiral) nerve  
(Sup.) profunda artery  
Coracobrachialis muscle  
Brachialis anticus muscle



**Branches of the Brachial Artery.**—The branches of the brachial artery are the profunda (superior), the superior ulnar collateral (inferior profunda), the nutrient, muscular, and inferior ulnar collateral (anastomotica magna).

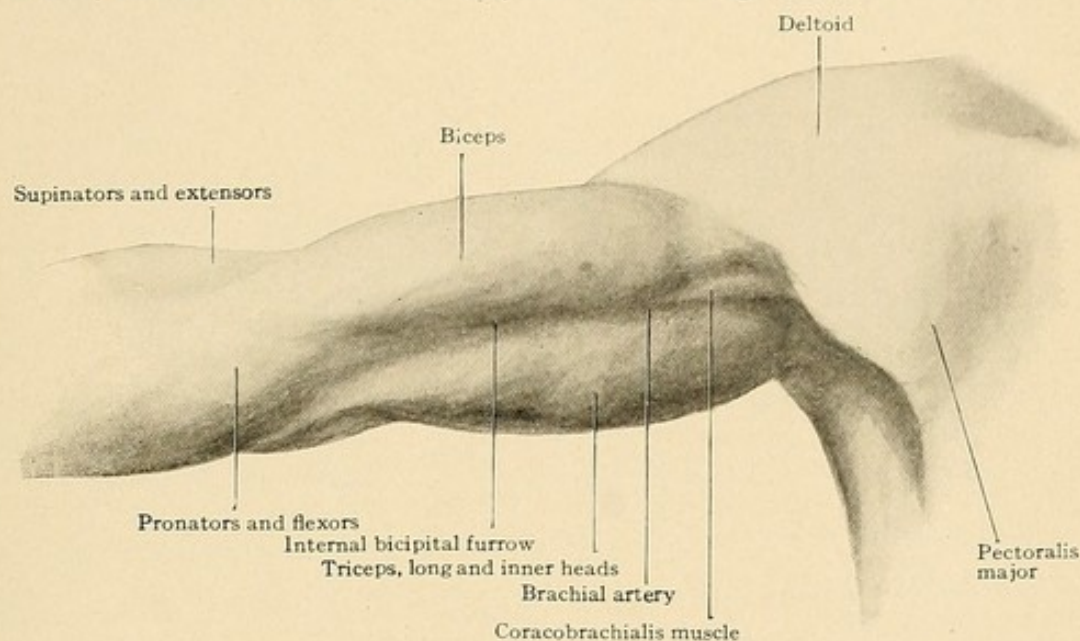


FIG. 284.—Surface anatomy of the arm.

Not infrequently the brachial artery instead of dividing into the radial and ulnar opposite the neck of the radius divides higher up. This is called a high division and is seen most often in the upper third of the arm. The two vessels may follow the

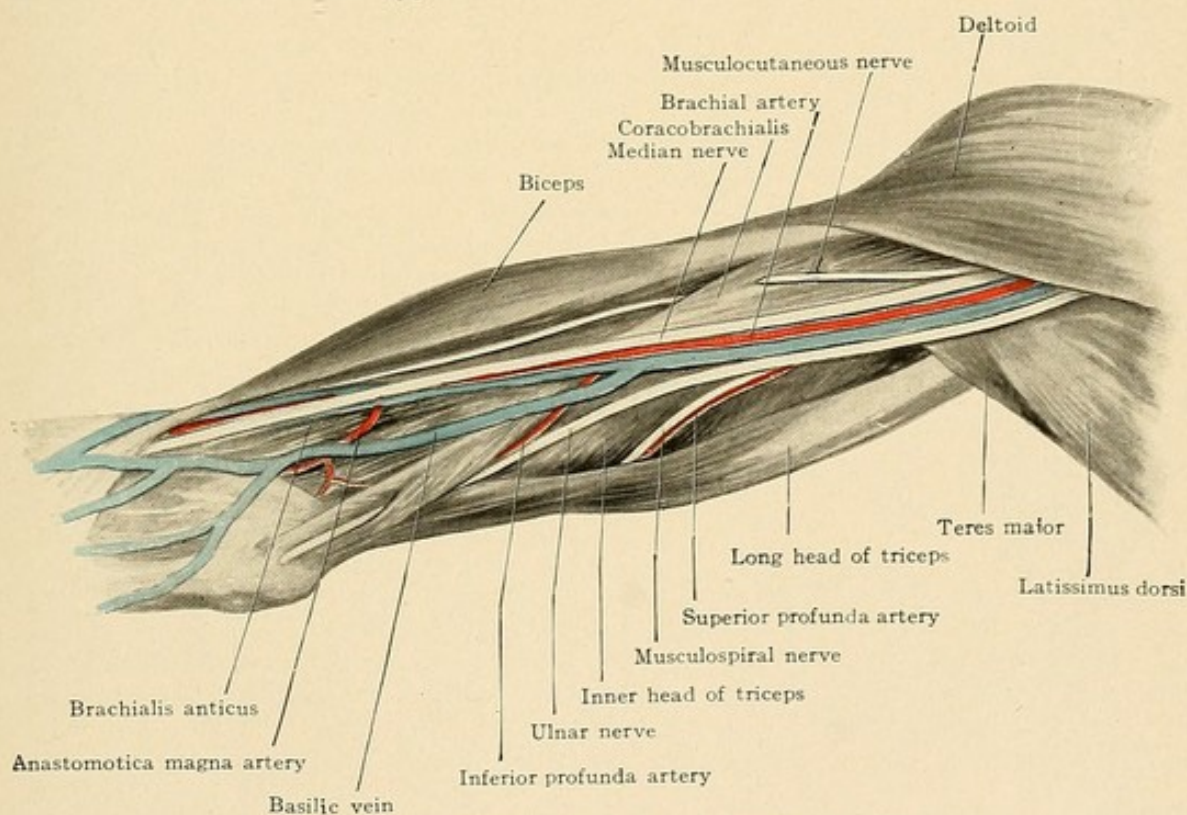


FIG. 285.—Dissection of the arm, viewed from the inner side.

usual course in the arm, or the radial may run under the biceps tendon, instead of over it, and the ulnar may accompany the median nerve in front of the medial condyle or the ulnar nerve behind it.



The *profunda* is given off just below the lower edge of the posterior fold of the axilla (*teres major*). It accompanies the radial (*musculospiral*) nerve around the arm to its outer side; it sends one branch, the radial collateral, to the front of the

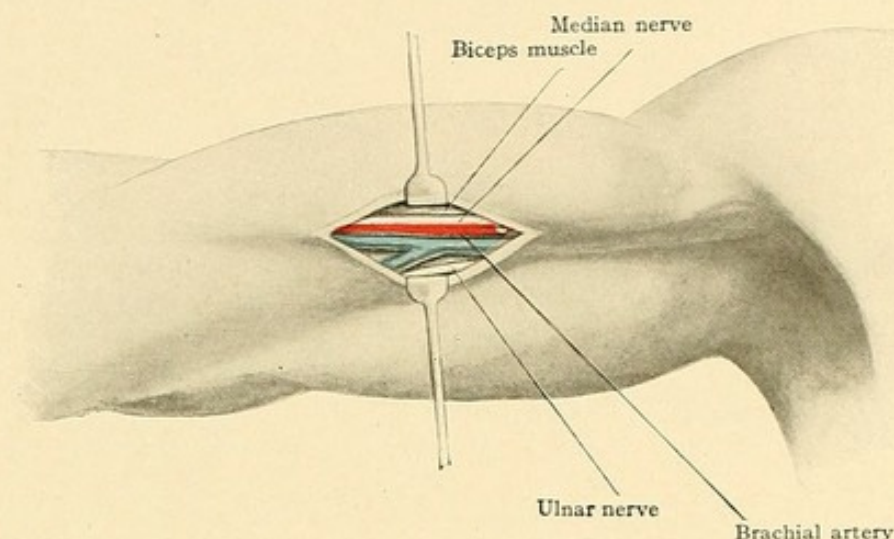


FIG. 286.—Ligation of the brachial artery in the middle of the arm showing the median nerve lying on the artery and the ulnar nerve to its inner side.

elbow and the middle collateral behind it. The *superior ulnar collateral artery* (*inferior profunda*) comes off about opposite the insertion of the *coracobrachialis* muscle. It is much smaller than the *profunda* and with the ulnar nerve pierces the internal intermuscular septum. The *nutrient* artery comes off close to the origin of the superior ulnar collateral (*inferior profunda*) or is a branch of it. It passes downward in the bone in a direction toward the elbow-joint. The *inferior ulnar collateral* (*anastomotica magna*) is given off 5 cm. (2 in.) above the elbow and passes inward over the *brachialis anticus* to divide into two branches, one going down in front and the other behind the elbow.

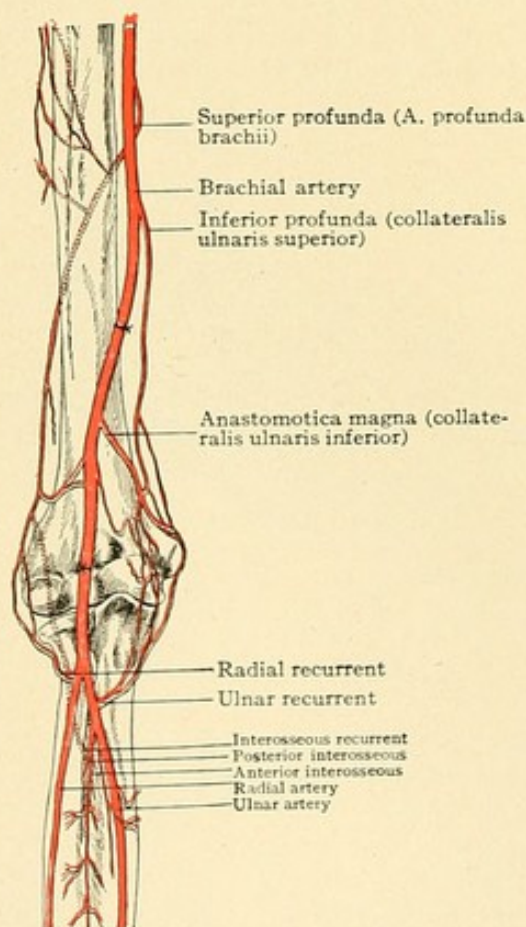


FIG. 287.—Collateral circulation after ligation of the brachial artery at the bend of the elbow.

#### Ligation of the Brachial Artery.

—In ligating the brachial artery, Heath strongly advises that the arm be held by an assistant in an abducted position with the hand supine and not allowed to rest on anything. The object of this is to avoid having the artery overlapped by the triceps being pushed up and thus becoming obscured.

The incision is to be made in the line from the inner edge of the *coracobrachialis* to a point midway between the tips of the condyles. The deep fascia is to be opened and the inner edge of the biceps muscle is to be sought for, recognized, and held outward. The pulsation of the artery may indicate its position in the living; if not, it is to be sought for to the inner side of the edge of the biceps. The median nerve is not to be mistaken for it. It will lie either

over its middle or to its inner side if low down and to its outer side if high up (Fig. 286).

The ulnar nerve lies on the inner side of the artery as far as the middle of the



arm, it then leaves the artery. Below the middle, if the search is made too far posteriorly, the ulnar nerve and basilic vein will be encountered. The ulnar nerve should not be seen, the basilic vein and median nerve—and above the middle of the arm the medial antebrachial (internal) cutaneous nerve—are to be displaced to the inner side.

The needle is to be passed from within outward. Care must be taken not to mistake a large superior or inferior profunda for the main trunk. A high division of the brachial may give two vessels of approximately equal size. Of course, in such a case both must be ligated.

*Collateral Circulation.*—If the ligature is placed above the profunda (superior) branch, the anterior and posterior circumflex will anastomose with the profunda (superior) and superior ulnar collateral (inferior profunda) below. If the ligature is placed between the profunda and superior ulnar collateral arteries, the profunda (superior) will anastomose below with the radial recurrent and posterior interosseous recurrent on the outer side and will also communicate with the inferior ulnar collateral (anastomotica magna) and superior ulnar collateral (inferior profunda) on the inside (Fig. 287). If below the superior ulnar collateral (inferior profunda) then the profunda (superior) would anastomose with the radial and posterior interosseous recurrences on the outside, and the superior ulnar collateral (inferior profunda) with the inferior ulnar collateral (anastomotica magna) and the anterior and posterior ulnar recurrences.

### AMPUTATION OF THE ARM.

In amputation one has to deal with a part of the body that is approximately cylindrical in shape and that contains only a single bone entirely surrounded by soft parts. The circular method is more applicable to amputation of the arm below the insertion of the deltoid than to any other part of the body, but nevertheless in some cases, particularly in muscular arms, difficulty may be experienced in turning back the cuff. In such cases the cuff is slit by the surgeon and the operation becomes one of square skin flaps. For this reason flap amputations are usually to be preferred.

The arm may be amputated at any place, high up or low down. Artificial appliances for the upper extremity are comparatively useless; hence the height of division of the bone is determined by the injury.

As it is desirable to retain the head of the bone and tuberosities, if possible, in order to preserve the shape of the shoulder and retain the attachment of the muscles, amputation may be done through the surgical neck. This is just below the epiphyseal line. In performing a flap amputation the soft parts should cover or cap the bone like a hemisphere: therefore the total length of the flaps should be equal to one-half the circumference of a sphere whose diameter is the diameter of the limb at the point of section of the bone. If the diameter of the limb is 4 inches, then the total length of the flaps should be approximately 6 inches. If the flaps were of equal length then each would be 3 inches long. If there was only one flap, it would be 6 inches long.

It is an axiom in surgery that in flap amputations the artery should be contained in the shorter flap. The operator should accurately know the course of the artery and avoid making his flaps in such a manner as to bring the vessel in the angle of the wound. Otherwise the artery is liable to be split. In a high amputation the external flap may be long and the internal short. In the middle of the arm anteroposterior flaps are preferred and the artery is included in the posterior flap. If the amputation is in the lower third and the flaps are anteroposterior, then the artery of necessity is in the anterior flap.

Above the middle of the arm the deltoid, coracobrachialis, and biceps muscles are free and therefore retract markedly when cut. In the middle the biceps only is free and the same is the case in the lower third. The triceps and brachialis anticus are attached to the bone and therefore retract but little when cut. Surgeons have called attention to the necessity of being careful to see that the radial (musculospiral) nerve is properly divided, otherwise it may be torn by the saw. The groove in which



it lies may be unusually deep and necessitate a special effort to divide it. On the face of the stump the artery is to be looked for to the inner side of the bone in the upper two-thirds of the arm and anteriorly in the lower third. Lying on it will be the median nerve and to its inner side the ulnar nerve. At the level of the insertion of the deltoid the radial (musculospiral) nerve, accompanied by the (superior) profunda artery, will be posterior or toward the outer side. The superior ulnar collateral (inferior profunda) artery is given off at the level of the insertion of the coracobrachialis muscle, which is about opposite the insertion of the deltoid. It accompanies the ulnar nerve. A nerve may be seen lying between the biceps and brachialis anticus. It is the musculocutaneous which becomes superficial just above the bend of the elbow (Fig. 288).

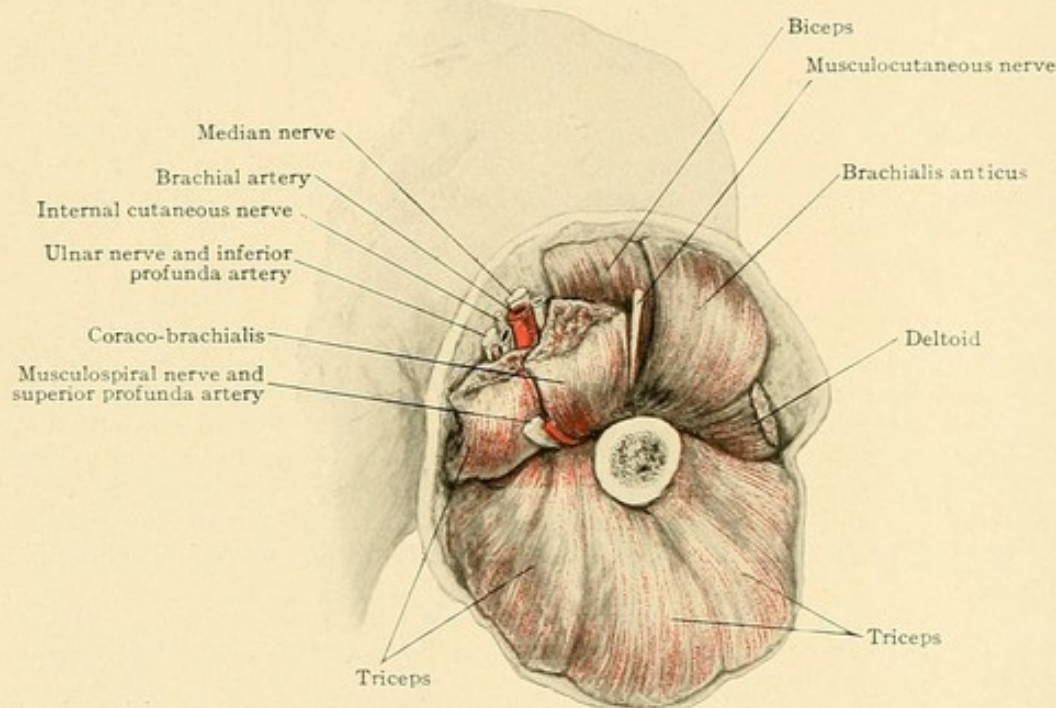


FIG. 288.—Amputation just above the middle of the arm.

Five cm. (2 in.) above the elbow the inferior ulnar collateral (anastomotica magna) artery may be expected to be encountered passing down and in over the brachialis anticus muscle.

## FRACTURES OF THE HUMERUS.

**Fractures of the Shaft of the Humerus.**—There seems to be but little doubt that in many cases the character of displacement of the fragments in fracture of the shaft of the humerus is due to the mode of injury and not to muscular action. This being so accounts for there being less uniformity in these fractures than in those higher up, which have already been considered. There are some cases, however, in which muscular action does play a part and the possible influence of the muscles should be understood.

The line of fracture is usually more or less oblique, in rare cases nearly transverse, but the displacement is often not marked. Notwithstanding this latter fact, non-union of fracture of the shaft of the humerus is one of the most frequent of any in the body.

Muscular action shows its influence most markedly in producing displacements in three directions, viz., in towards the body, out away from the body, and directly anteriorly.



There are two main points where fracture occurs; immediately above the insertion of the deltoid and below it.

*Fracture above the Insertion of the Deltoid.*—The bone may be fractured immediately above the deltoid insertion. In this case the powerful axillary fold muscles, pectoralis major, teres major, and latissimus dorsi, being attached to the upper fragment, tend to draw it toward the body, while the deltoid tends to draw the lower fragment out. The influence of the other muscles, biceps, coracobrachialis, and triceps, would be to increase the overlapping (Fig. 289).

*Fracture below the Deltoid Insertion.*—This is the more common site of fracture. The line of fracture is most apt to be from above downward and outward. The upper fragment is displaced anteriorly by the coracobrachialis and anterior portion

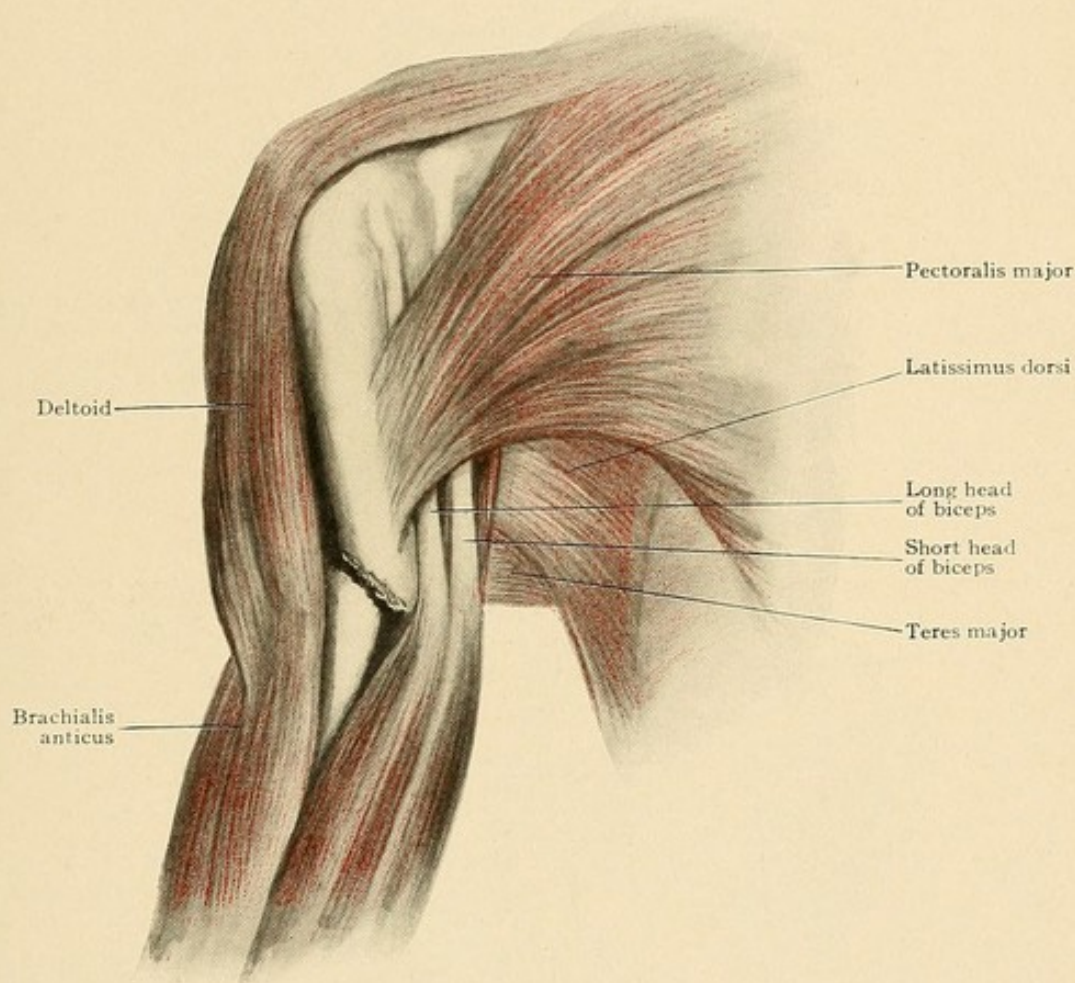


FIG. 289.—Fracture of the shaft of the humerus just above the insertion of the deltoid and below the insertion of the axillary fold muscles. The lower fragment is seen to be drawn outward by the deltoid; the upper fragment is seen to be drawn inward by the pectoralis major, latissimus dorsi, and teres major.

of the deltoid and is drawn outward by the deltoid aided by the supraspinatus. To relax the deltoid the arm is sometimes dressed in an abducted position (Fig. 290).

*Non-Union.*—The humerus has muscles attached to it almost throughout its entire length, and when the sharp ends of the fragments are displaced they probably become fixed in the surrounding muscle, and proper apposition of the fragments is prevented, hence non-union. Hamilton believed that lack of proper fixation was also a prominent cause.

**The Radial (Musculospiral) Nerve.**—In fracture of the shaft of the humerus, paralysis of the extensors due to injury of the radial nerve is comparatively common. It also occurs from pressure due to the use of crutches, to sleeping on the arm, etc. The other nerves are too far removed from the bone to



be injured, but the radial (musculospiral) lies on the bone in the radial (musculospiral) groove in approximately the middle third of the bone. It comes into contact with the bone posteriorly above the insertion of the deltoid and leaves the bone on its outer anterior surface to pass between the brachialis anticus and brachioradialis (supinator longus) muscles. Paralysis may be caused (1) by direct injury to the nerve at the time the fracture is received. (2) By subsequent changes in the nerve due to its being stretched over the sharp edge of a fragment. (3) By being included in callus. The last is probably much more rarely the case than the two former (Fig. 291).

Paralysis should be examined for early in the course of treatment. Too often it is detected only after the splints have been removed, and then it is apt to be ascribed to improper treatment or to misapplied pressure. The symptoms of involvement of

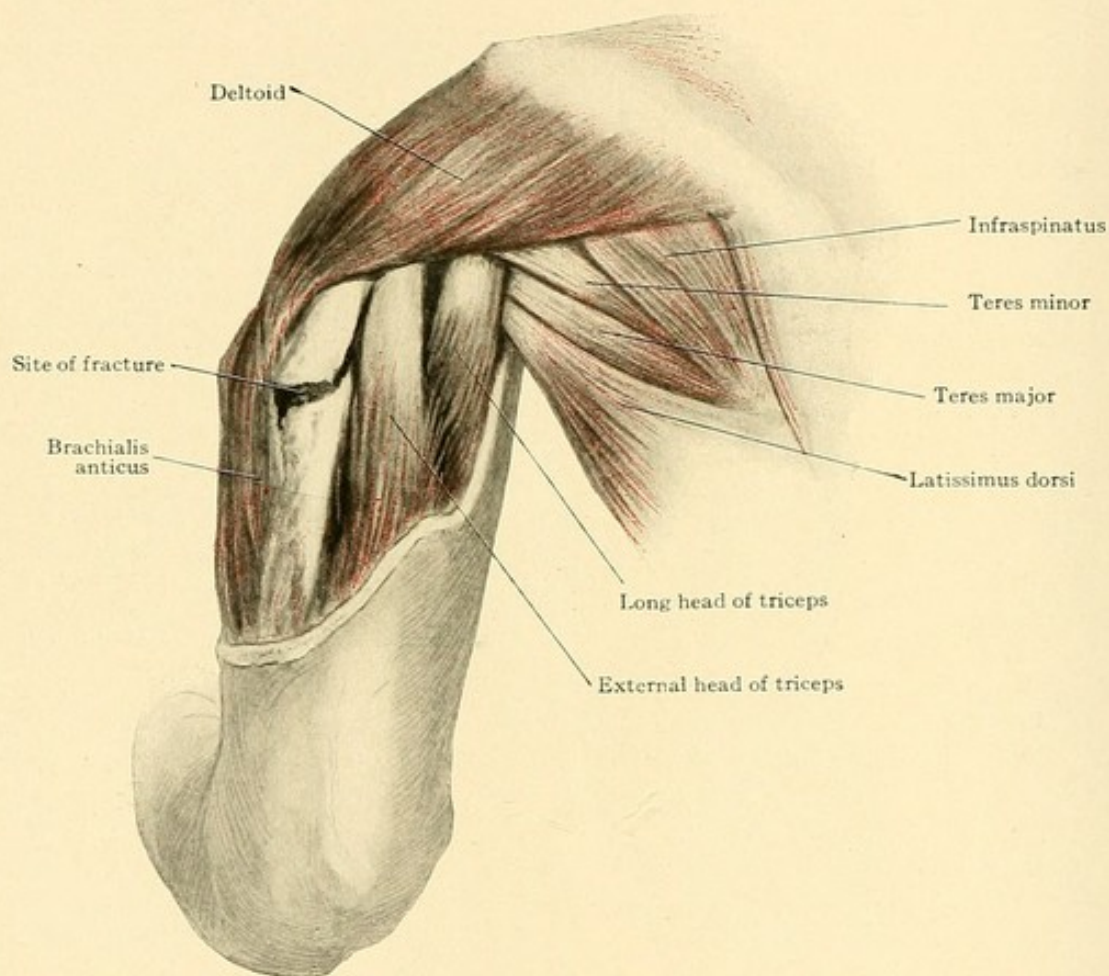


FIG. 290.—Posterior view of a fracture of the shaft of the humerus just below the insertion of the deltoid, showing the influence of that muscle in producing abduction of the upper fragment.

the musculospiral nerve are wrist-drop and diminution of the power of supination, also some sensory changes in the dorsum of the hand and forearm.

This nerve is frequently paralyzed from pressure in cases in which there is no fracture, as from sleeping on the arm, the use of crutches, and also in certain systemic affections, such as lead poisoning. It supplies the triceps, part of the brachialis anticus, brachioradialis (supinator longus), and extensor carpi radialis longior muscles in the arm, and then proceeds to the forearm. The branch to the triceps is given off before the nerve enters the musculospiral groove, hence is not often injured, and loss of extension of the forearm is not often present; even paralysis of the other muscles mentioned is not common, the forearm muscles being mostly affected. The branch to the inner head of the triceps also supplies the anconeus.



## OPERATIONS ON THE ARM.

Caries or necrosis of the humerus may necessitate operative interference at almost any part of the arm. The same may be said of wounds. In operative procedures it is sometimes desirable to avoid important structures and at others to find them.

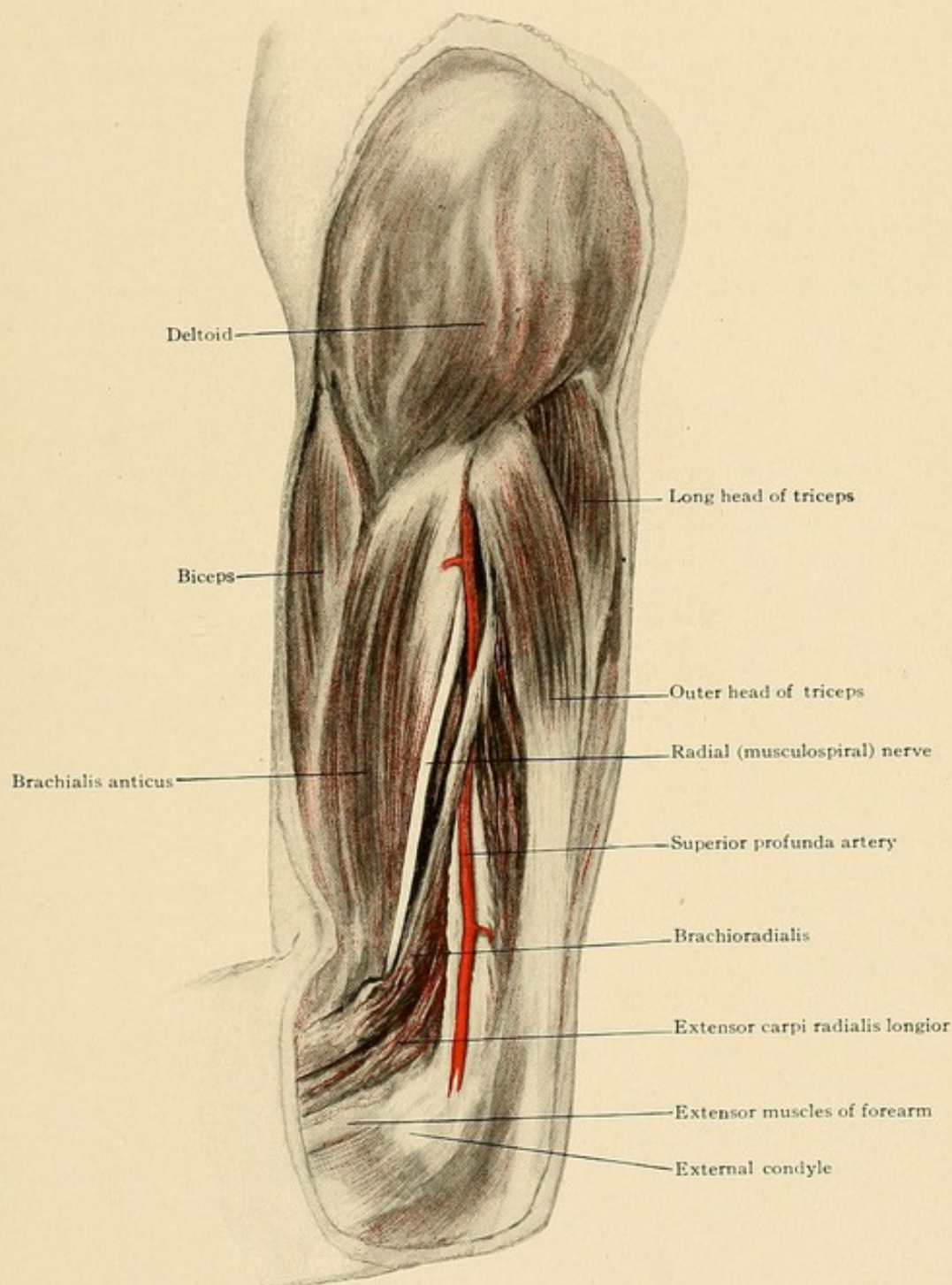


FIG. 291.—The radial (musculospiral) nerve and outer side of arm.

The important structures run lengthwise, hence transverse incisions are not to be used. Most of the large vessels and nerves pass down the inner side of the arm, hence this region is usually avoided. The bone can readily be reached by an incision downward from the insertion of the deltoid, but no operation is to be done in this region without a thorough familiarity with the course of the musculospiral nerve.



A line drawn on the posterior surface of the arm from behind and above the insertion of the deltoid to the groove on the anterior surface between the brachialis anticus and brachioradialis (supinator longus) just above and to the inner side of the external condyle will indicate its course. If exposed during an operation bleeding from the accompanying (superior) profunda artery may be expected. The median and ulnar nerves give off no branches in the upper arm. The median can be readily located by its relation to the artery. It lies to the outer and anterior side of the brachial artery above, then in front, and then to its inner side below. The ulnar nerve lies to the inner side of the artery and between it and the vein posteriorly. In the middle of the arm, it leaves it to pierce and pass beneath the internal intermuscular septum and thence behind the medial (internal) condyle. Operations involving it would be accompanied by bleeding from its companion the superior ulnar collateral artery (inferior profunda).

In operations on the lower portion of the bone the position of the inferior ulnar collateral (anastomotica magna), 5 cm. (2 in.) above the elbow, should be borne in mind. It runs on the brachialis anticus muscle and towards the inner and not the outer side. Incisions on the outer side will encounter the cephalic vein in the external bicipital furrow. Incisions on the inner side will encounter the basilic vein; at the junction of the lower and middle thirds of the arm it pierces the deep fascia.

## REGION OF THE ELBOW.

The elbow is so named because at this point the arm is usually bent. A joint is here inserted which permits of flexion and extension; when the arm is fully extended the "elbow" might be said to have disappeared. The lower end of the humerus forms the proximal portion of the joint and the upper ends of the ulna and radius form its distal portion. Ligaments join these bones together to form the joint, and the blood-vessels and nerves change in character in this region as they pass from the arm to the forearm.

The bones are frequently subject to fractures which are of an exceedingly puzzling and disabling character. The joint becomes luxated and the vessels and nerves are not infrequently injured. A thorough knowledge of the anatomy of the region is absolutely essential to the proper treatment of these affections.

## BONES OF THE ELBOW.

**Humerus.**—The lower end of the humerus broadens laterally and is slightly concave on its anterior surface; this causes the articular surfaces to look downward and forward and not backward. It carries two articular surfaces: one, the *trochlea*, for the ulna, and the other, the *capitellum*, for the radius. The trochlea, descending lower than the capitellum, causes the line of the joint to incline downward and inward instead of being directly transverse, thus producing the "carrying angle" (Fig. 294). Extending from the edges of the articular surfaces outward, one on each side, are the *condyles*, *medial (internal)* and *lateral (external)*.

Chaussier gave the name *epicondyle* to the condyles. He called the medial condyle the *epitrochlea* and the lateral (external) condyle the *epicondyle*. Henle called the internal condyle the *epicondylus medialis* and the external condyle the *epicondylus lateralis*. The name epicondyle is now quite generally employed by both surgical and anatomical writers to designate the projecting extra-articular portion of the condyles, so that the terms are practically synonymous (Fig. 293).

From the condyles two ridges run upward. The *lateral (external) supracondylar ridge* is the more marked of the two and gives origin to the brachioradialis (supinator longus) and the extensor carpi radialis longior muscles, and passes posterior to the deltoid eminence to be continuous with the posterior lip of the radial (musculospiral) groove. The *medial (internal) supracondylar ridge* is much less prominent than the lateral and soon blends with the shaft of the bone. Above the trochlea and capitellum anteriorly are two fossæ, the *coronoid* and the *radial*, to receive the coronoid process and head of the radius when the arm is in complete



flexion. On the posterior surface there is another depression, the *olecranon fossa*, to receive the olecranon process in extreme extension. The projecting hook-like shape of the median condyle causes it to be more frequently fractured than the less prominent lateral condyle. The two condyles are readily felt directly beneath the skin and are the only points of the humerus that are really subcutaneous.

**Ulna.**—The upper extremity of the ulna articulates above with the trochlea of the humerus and on its outer side with the radius. Its upper end is the olecranon process. The posterior portion of this process is called the tip of the olecranon and is continuous with the posterior surface of the ulna, which is subcutaneous. Immedi-

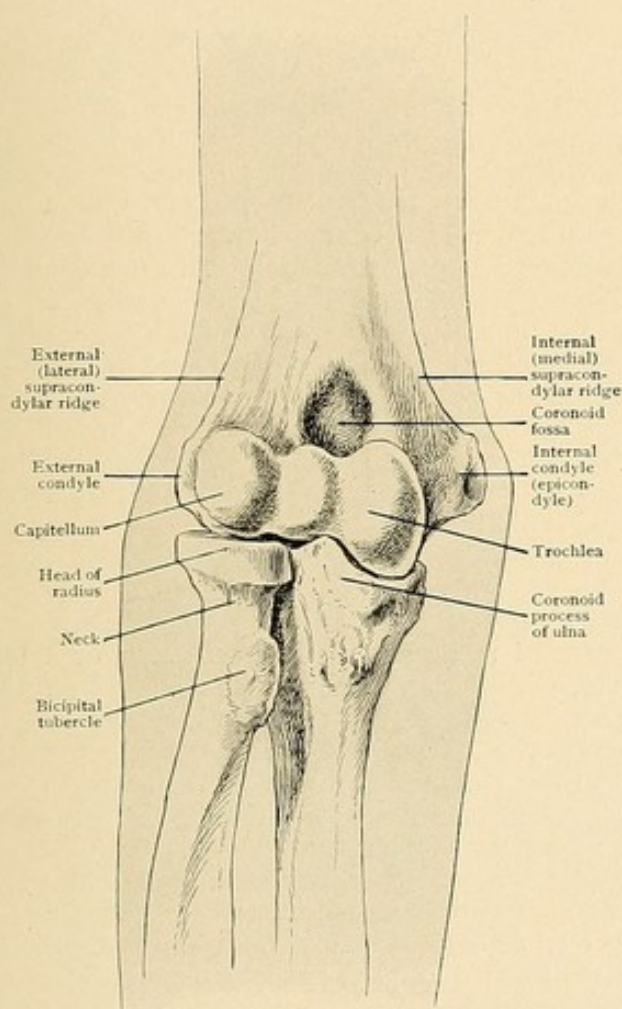


FIG. 292.—Anterior view of bones of right elbow.

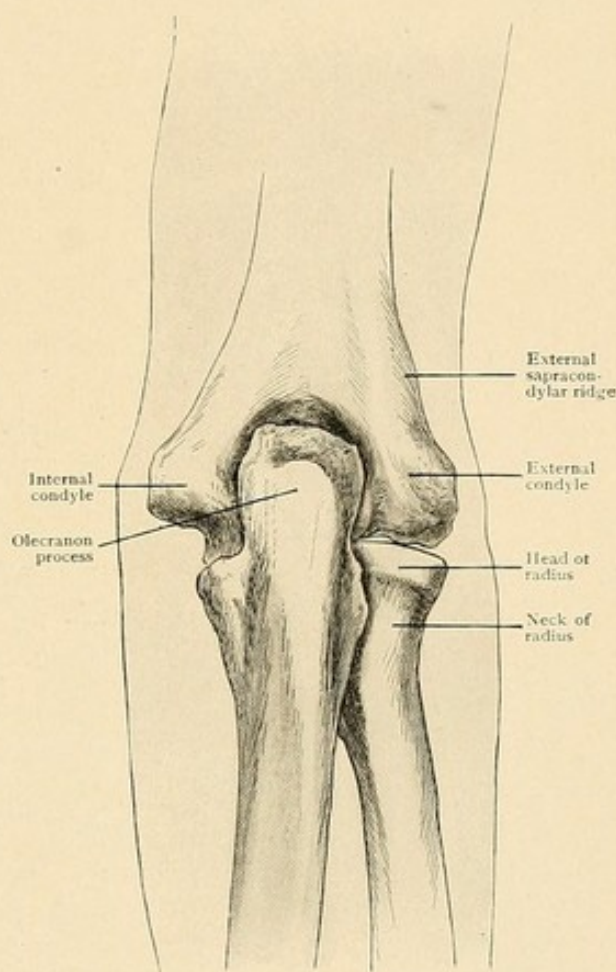


FIG. 293.—Posterior view of bones of elbow.

ately in front of the olecranon is a large hollow, which receives the trochlea. It is called the *greater sigmoid cavity*. The anterior margin of the cavity is called the *coronoid process*. On the outer side of the coronoid process is a hollow called the *lesser sigmoid cavity*, which receives the head of the radius. Fracture of the bone frequently occurs through the narrow portion of the olecranon process into the greater sigmoid cavity.

**Radius.**—The radius ends above in a flat rounded head. The upper surface of this head articulates with the capitulum. The lateral surface articulates internally with the lesser sigmoid cavity of the ulna. The remainder of the circumference of the head is embraced by the orbicular ligament. Immediately below the head is the constricted neck and bicipital tuberosity. To the posterior half of this latter the tendon of the biceps is attached, but its anterior portion is smooth and provided with a bursa. The head of the radius is subcutaneous posteriorly, but the rest is too much covered by muscles to be readily palpated.



## ELBOW-JOINT.

By the term elbow-joint is meant the articulation between the humerus above and the ulna and upper surface of the radius below. The articulation between the upper end of the radius and the ulna forms the *superior radio-ulnar articulation* and does not belong to the elbow-joint proper. As has already been pointed out, the ulna articulates with the trochlea and the radius with the capitellum.

The elbow-joint is a pure hinge-joint. The articulation between the trochlea and ulna is so shaped as to allow no lateral motion, but only an anteroposterior one. The articulation between the capitellum and upper surface of the head of the radius

is, on the contrary, a ball-and-socket joint. The socket, it is true, is shallow, but it is perfectly spherical, made so by the rotary movement of the radius in pronation and supination. Hence it follows that the shape and continuity of the upper extremity depends upon the articulation of the ulna with the humerus: it further follows that if the radius be removed from the elbow-joint the forearm would still be held in its proper relation to the arm, but if the ulna be removed the stability of the joint would be lost and the forearm would move in any direction, laterally as well as anteroposteriorly. It is for this reason that injuries involving the medial condyle and trochlea are more liable to be followed by serious disability than are those of the lateral condyle and capitellum.

The movement of the joint takes place around a transverse axis, which passes from side to side below and in front of the condyles. The forearm can be extended to an angle of 180 degrees, or a straight line, with the arm. It can be flexed to an angle of 30 to 40 degrees. Sometimes it cannot be flexed so much, so that if after an injury to the joint the patient can flex the elbow to half a right angle, or 45 degrees, he may be regarded as having regained a normal amount of motion.

*Carrying Angle.*—The axis of motion of the joint is not exactly transverse, but slopes slightly from the outside downward and inward. The effect of this is to give a slight obliquity to the motions of flexion and extension. This obliquity is not noticeable except in extreme extension and flexion. When the forearm is completely extended it is seen to lie not in the axis of the arm but to bend outward from the elbow at an angle of 170 degrees. This angle is called the "carrying angle,"

because by resting the elbow against the side, any article which is carried in the extended hand is kept away from the body. Sometimes the line of the forearm is almost straight with that of the arm, at others the deflection may amount to 15 degrees. It may vary on the two sides and 10 degrees may be considered an average; Woolsey gives 6 degrees as the average. This carrying angle becomes lost in certain cases of fracture of the elbow, as will be pointed out later. As the elbow is flexed the carrying angle disappears (see Fig. 294).

When flexion is complete the ulna instead of coming up toward the head of the humerus inclines inward at an angle of 10 degrees. Morris states that the hand has a tendency to point to the middle of the clavicle, which would make an angle of 20 degrees. This we believe to be too great.

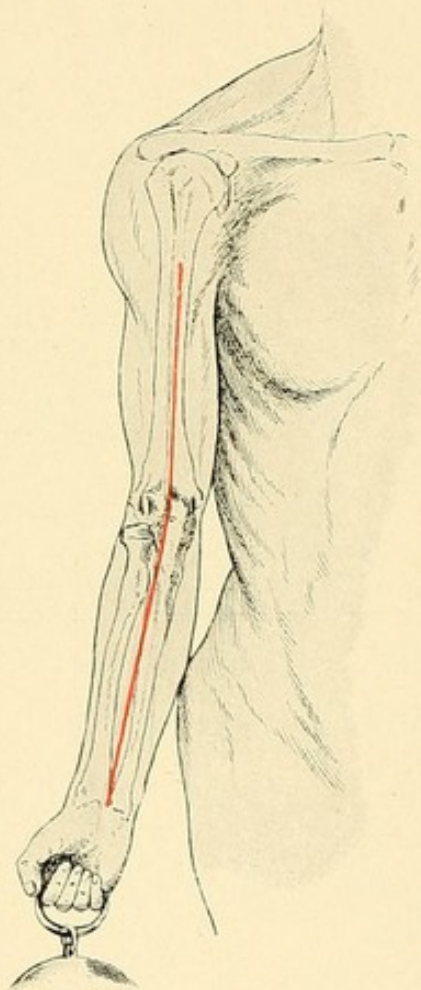


FIG. 294.—The carrying angle; formed by the deviation outward of the axis of the forearm from the axis of the arm.



## LIGAMENTS OF THE ELBOW.

The ligaments of the elbow-joint are four in number—anterior, posterior, internal lateral, and external lateral.

In all joints there are two kinds of ligaments. One kind serves to retain the synovial fluid; it is a capsular ligament and is usually thin; the other kind is thick, firm, and strong, and is intended to bind the bones together and prevent their displacement and to limit movement. These two kinds of ligaments often blend together so that it is impossible to say where one begins and the other ends; at other places they are quite distinct. If an elbow-joint is distended with effusion (or wax) the distinction is readily seen. The capsule becomes distended in front and behind, while at the sides the ligaments remain closely applied to the bones; hence we learn that the anterior and posterior ligaments are capsular in their function while the lateral ligaments are retentive. These will be considered more in detail later.

*Superior Radio-ulnar Articulation.*—While the superior radio-ulnar articulation is not considered a part of the elbow-joint proper, it is nevertheless so closely

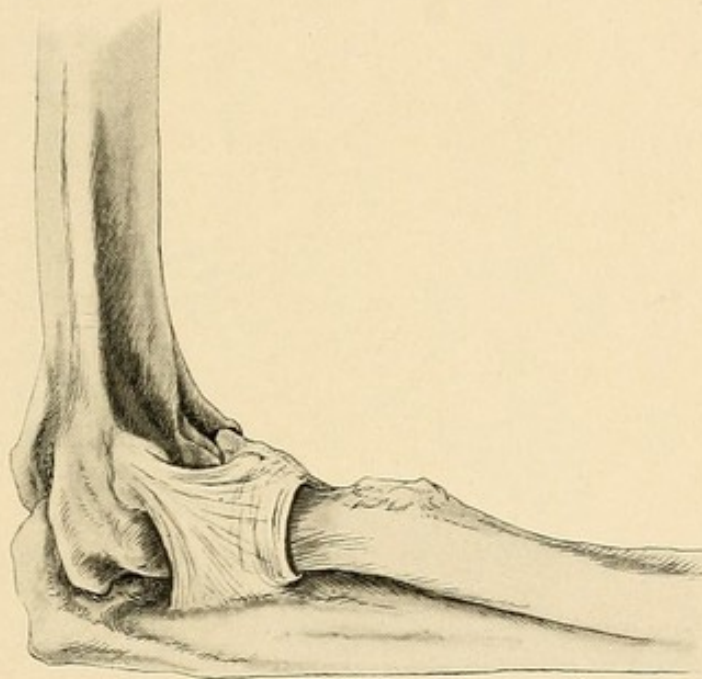


FIG. 295.—The external lateral ligament of the elbow-joint, showing its A shape. Its upper end is attached to the external condyle of the humerus; its lower ends are attached to the ulna. The circular fibres surrounding the head of the radius are called the orbicular ligament.

associated with it that it cannot be ignored. The head of the radius, in addition to its movements of flexion and extension on the humerus, possesses a motion of rotation. In order that it may rotate properly the ligaments are arranged in a peculiar manner. Its motion in respect to the ulna is a purely rotary one, so that it is bound to the ulna by a ligament which encircles its head, called the **orbicular ligament**. The bulk of the ligament encircles three-fourths of the head of the radius and is attached at its ends to the anterior and posterior edges of the lesser sigmoid cavity of the ulna. Its lower fibres are continuous below the lesser sigmoid cavity, forming a complete circle. The upper edge of this orbicular ligament blends with the anterior ligament in front, the posterior behind, and the external lateral at the side. We thus see that as the anterior and posterior ligaments are capsular in their function the radius is kept in place by the external lateral ligament, which branches below in the form of the letter Y to blend with the orbicular ligament. When we consider that these fibres are hardly inserted at all into the radius, but pass over it to the ulna, it is evident that this part of the joint is comparatively weak and not an excessive amount of force would be required to pull the head of the radius from beneath the orbicular



ligament and so luxate it. The *supinator (brevis)* arises partly from the orbicular ligament and strengthens the joint somewhat.

The **external lateral ligament** is a strong band which is attached above to the lower portion of the lateral (external) condyle, blends with the orbicular ligament and is attached below to the ulna along the anterior and posterior edges of the lesser sigmoid cavity (Fig. 295).

The **internal lateral ligament** is a strong band attached above to the lower and anterior portion of the medial (internal) condyle, the groove beneath, and descends in the shape of a fan to insert into the inner edge of the coronoid process and olecranon (Fig. 296).

The **anterior ligament** is capsular in its nature and function, and is a broad, comparatively thin membrane which stretches between the lateral ligaments on the

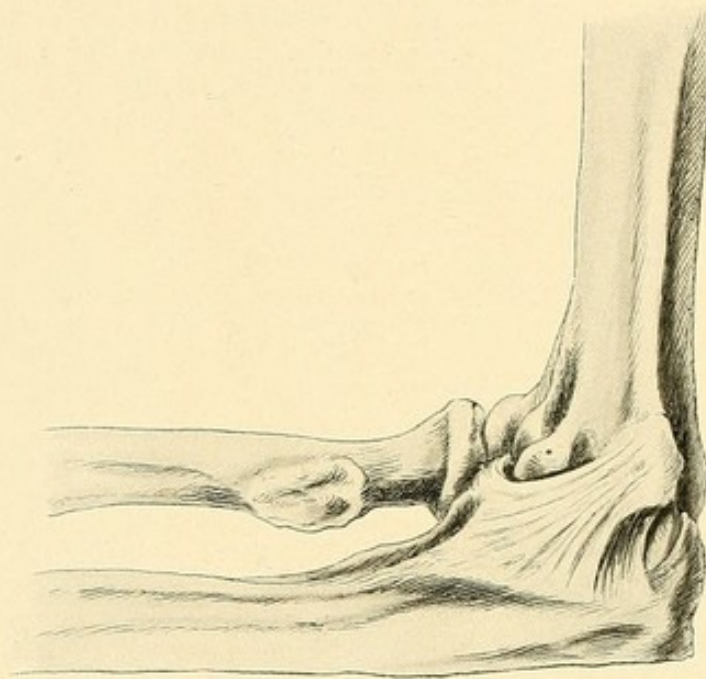


FIG. 296.—The internal lateral ligament of the elbow-joint, showing its fan-like shape.

sides and is attached above to the upper edge of the coronoid fossa and below to the coronoid process and orbicular ligament. It sometimes possesses a few coarse fibres passing downward and outward, but it is mostly very thin, in places barely covering the lining membrane.

The **posterior ligament** resembles the anterior. It blends on each side with the lateral ligaments and is attached above across the upper portion of the olecranon fossa and below to the olecranon and posterior portion of the orbicular ligament. It also has some cross fibres; but, especially at its upper attachment, it is very weak.

### MUSCLES OF THE ELBOW.

The elbow-joint is interposed between the long bones of the forearm below and the long humerus above. The arm muscles come down and pass over the joint to insert close to it in the bones of the forearm. The muscles of the forearm in a similar manner cross the joint and are attached comparatively near it to the humerus above. Thus we see the joint strengthened by the crossing of the various muscular insertions. The elbow having only an anteroposterior motion, the muscles must of necessity be in two main groups, one in front and the other behind the joint.

**Lateral Muscles.**—It is true that there are lateral muscles but they have little or no influence on the movements of the elbow-joint. The medial (internal) condyle gives origin to the flexor muscles of the forearm and the *pronator radii teres*, and the lateral (external) condyle gives origin to the extensor muscles; but the bony



attachment of both these sets of muscles coincides too closely with the axis of motion to allow of their aiding to any marked extent either flexion or extension of the elbow. Their function as far as the elbow is concerned is to aid and strengthen the lateral ligaments of their special sides.

**The Anterior or Flexor Muscles.**—These comprise the *biceps*, *brachialis anticus*, *brachioradialis*, and *extensor carpi radialis longior*. It will be observed that the first two muscles come from above and cross the joint, while the last two arise just above the joint to pass down the forearm (Fig. 297).

The *brachialis anticus* arises from the humerus by two heads, one on each side of the insertion of the deltoid, and from the anterior surface to just above the

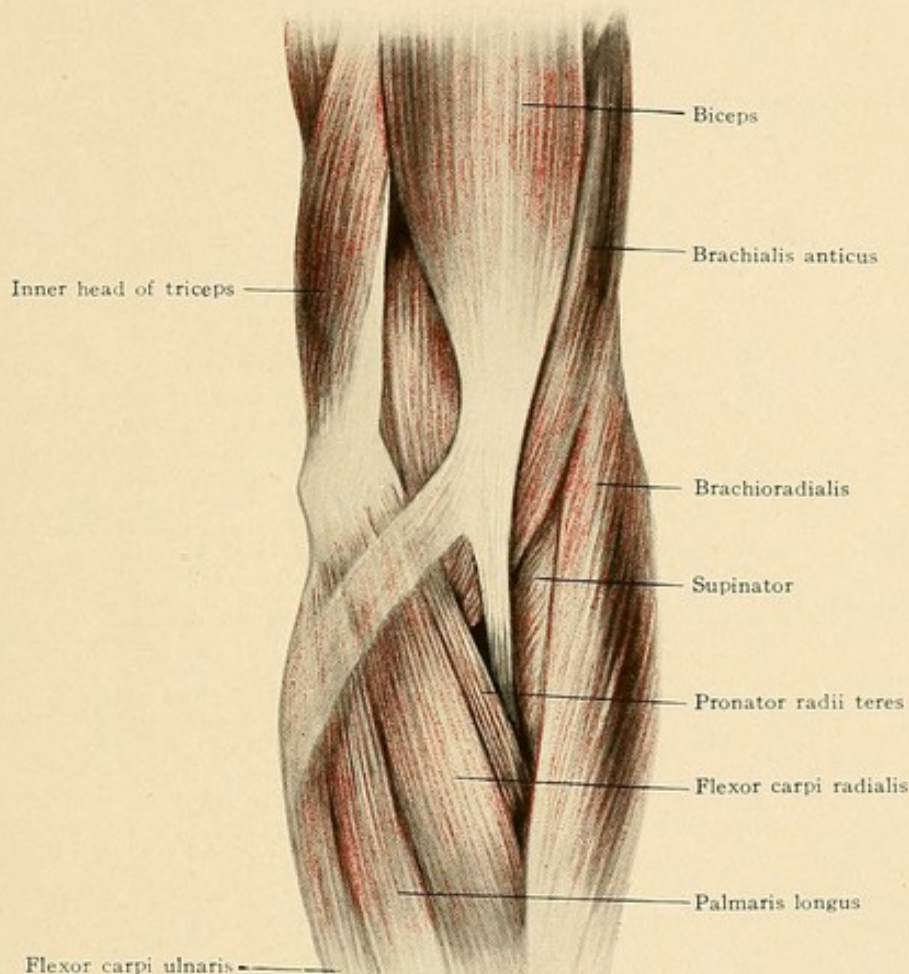


FIG. 297.—View of the antecubital fossa and muscles at the bend of the elbow.

elbow-joint. It passes over the joint and inserts into the base or lower and inner part of the coronoid process. It does *not* insert into the tip, but some distance below. Its function is purely flexion.

The *biceps* arises from the upper rim of the glenoid cavity by its long head and from the coracoid process by its short head. It inserts into the posterior edge of the *bicipital tubercle* of the radius. Between it and the tubercle is a bursa. About 4 cm. ( $1\frac{1}{2}$  in.) above its insertion its tendon gives off a fibrous expansion which passes inward to blend with the deep fascia covering the flexor group of muscles. This is called the *bicipital* or *semilunar fascia*. The biceps tendon passes almost in the middle between the two condyles. Along its inner side is the brachial artery, which is covered by the bicipital fascia; over this fascia passes the median basilic vein, sometimes used for transfusion. The insertion of the biceps is into the radius, which is the *movable* bone, and not into the ulna, which is less so. As a consequence, in addition to its function of flexion it acts also as a powerful supinator of the radius.



The *extensor carpi radialis longior* arises from the lateral condyle and lower third of the supracondyloid ridge and inserts into the base of the second metacarpal bone.

The *brachioradialis* or supinator longus arises from the upper two-thirds of the lateral (external) supracondyloid ridge above the preceding muscle and as high as the insertion of the deltoid. It inserts into the base of the styloid process of the radius.

These two muscles, owing to their high attachment, so much above the axis of motion of the joint, both act as flexors. The *brachioradialis* also supinates the hand.

**The Posterior or Extensor Muscles.**—These comprise the *triceps* and *anconeus muscles* (Fig. 298).

The *triceps* arises by its long head from the lower part of the rim of the glenoid cavity and adjoining border of the scapula; by its external or lateral head from the

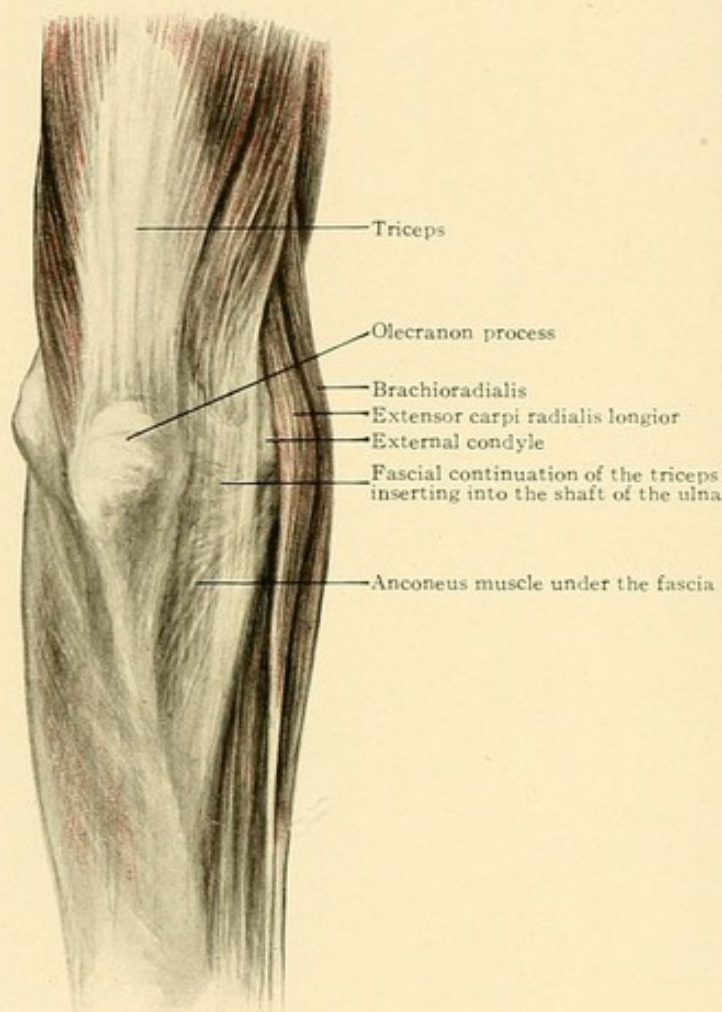


FIG. 298.—Extensor muscles of the back of the elbow.

upper outer portion of the humerus from the greater tuberosity above to the radial (musculospiral) groove below; by its internal or medial head from the posterior surface of the humerus below the radial groove. It inserts into the posterior part of the upper surface of the olecranon. Just above its insertion it is separated from the bone by a bursa. It is continuous from the outer edge of the olecranon as a firm fascia which passes down over the anconeus to be attached to the upper fourth of the ulna and the deep fascia. This is an important structure in fractures of the olecranon.

The *anconeus* passes downward and backward from the lateral (external) condyle to insert into the side of the olecranon and upper fourth of the ulna. Its fibres are practically continuous with the lower fibres of the triceps and it may be considered as a fourth head of that muscle. It covers the posterior portion of the head of the radius and overlaps somewhat the supinator (*brevis*) muscle.



## SURFACE ANATOMY.

Having become acquainted with the bones and muscles, one will be better able to appreciate the surface markings and understand their significance (Fig. 299).

When the elbow is fully extended the bony projections are obscured by the soft tissues, hence in examining an elbow it should be flexed at approximately a right angle. The first object to strike the eye is the prominent olecranon process. It is subcutaneous and the bony ulna beneath can be felt and followed down the back of the forearm. From the tip upward for a couple of centimetres can be felt the upper surface of the olecranon into which the triceps inserts. To feel this distinctly the forearm should be slightly extended to relax the triceps; the outline of the upper portion of the olecranon then becomes perfectly distinct.

Projecting on each side of the elbow are the two condyles of the humerus. These bony projections do not belong to the forearm. The two condyles are nearly on the same level. The medial (internal) is much more prominent and has the appearance of being a trifle higher and slightly anterior. A line joining them

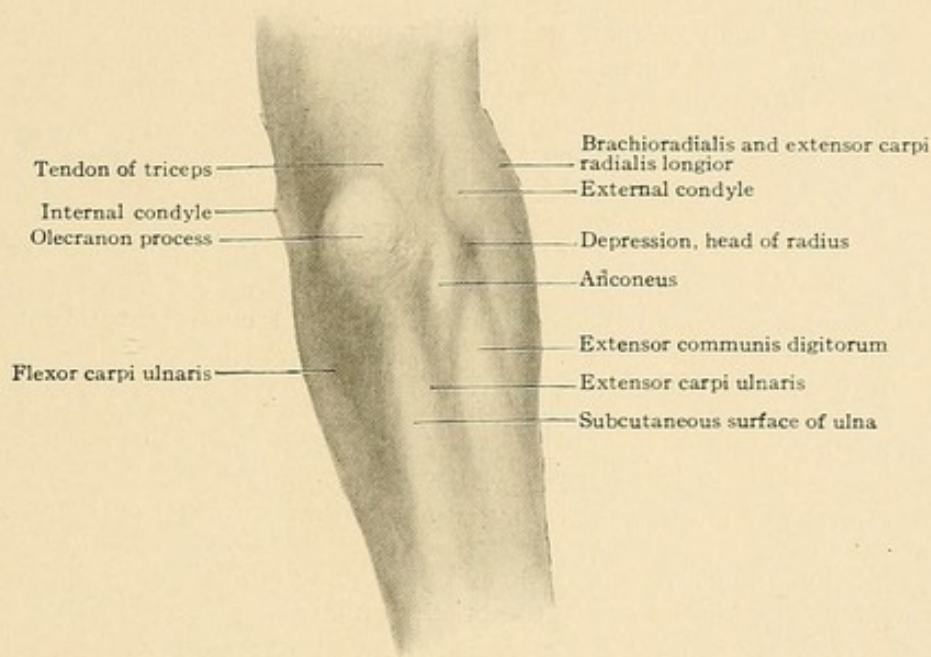


FIG. 299.—Surface anatomy of the back of the elbow.

crosses the long axis of the humerus at an angle of 90 degrees, but makes an angle of only 80 degrees with the forearm. By deep pressure the lateral (external) supracondylar ridge can readily be felt running up the arm somewhat posteriorly from the lateral (external) condyle. The medial (internal) supracondylar ridge is much less easily felt though the intermuscular septum is more evident on this side. When the elbow is flexed at a right angle a line drawn parallel with the humerus and joining the two condyles will pass through the tip of the olecranon. If the forearm is extended the olecranon passes slightly posterior to this line; if the forearm is flexed, the olecranon passes somewhat in front of it. Hence in examining the elbow for injury it is desirable to determine the relation of these points when the elbow is bent at a right angle. The coronoid process lies anteriorly, deep in the flexure of the elbow, and cannot be distinctly felt.

If, now, the elbow is extended, the tip of the olecranon can still be felt with the medial (inner) condyle to its inner side. Between the two is a deep groove in which lies the ulnar nerve. To the outer side of the olecranon is a deep pit or short groove; the bone marking its outer edge is the lateral (external) condyle. In the bottom of this pit at its lower portion, about 2.5 cm. (1 in.) below the tip of the olecranon, can be felt the head of the radius. If the thumb is placed on it and the hand rotated, the



head of the radius can be felt turning beneath. Immediately above the head of the radius, lying to the outer side of the olecranon, if the elbow be again flexed to a right angle, can be seen and felt the bony projection of the capitellum covered by the strong expansion from the triceps. By careful palpation a groove can be felt between the lower edge of the capitellum and the head of the radius which marks the limits and point of articulation of the two bones.

On the posterior aspect of the joint the ulnar nerve is the most important structure; there is, however, a bursa between the upper or posterior surface of the olecranon and the skin and also another on its inferior surface, extending downward, which from its exposed position is frequently injured and enlarged. Such an enlargement occurs from chronic irritation in certain occupations, hence the name "miners' elbow."

With the elbow flexed at a right angle there is seen on its anterior surface a crease which runs from one condyle across to the other. If a knife were held parallel with the forearm and entered at this crease, it would strike the humerus above the level of the joint line, that is, the line of contact of the bones. This joint line runs from 1.25 cm. ( $\frac{1}{2}$  in.) below the lateral (external) condyle to 2.5 cm. (1 in.) below the medial (internal) condyle.

Anteriorly the muscular masses form prominent landmarks. In the middle of the crease can be felt the tendon of the biceps muscle. The muscular swell above the crease is formed by the biceps muscle with the brachialis anticus beneath. The sharp upper edge of the bicipital fascia can be distinctly felt when the muscle contracts. The limits of the biceps can be felt as two lines, radiating like the letter V from the biceps tendon upward. These are the commencing *bicipital furrows* or *grooves*.

The outer branch marks the depression between the outer edge of the biceps and the swell forming the supinator group of muscles. The inner branch marks the inner edge of the biceps, and between it and the medial condyle can be felt a muscular mass which is formed by the inner portion of the brachialis anticus. In the middle of the flexure of the elbow below the crease is a depression called the *antecubital fossa*. To its outer side is the muscular prominence of the extensors and supinator. To its inner side is the muscular prominence of the flexors and pronator. The inner muscular swell ends at the medial (internal) condyle, but the external one passes well up on the arm. The muscles so prolonged upward are the extensor carpi radialis longior for about 5 cm. (2 in.) above the lateral (external) condyle, and the brachioradialis (supinator longus) for 10 cm. (4 in.) higher. The outer limit of the antecubital fossa is formed by the inner edge of the brachioradialis. The inner side is formed by the pronator radii teres muscle.

To the inner side of the biceps tendon lies the brachial artery, which bifurcates opposite the neck of the radius, approximately 2 cm. or a finger's breadth below the crease of the elbow. Still farther to the inner side lies the median nerve. In the groove between the biceps and brachialis anticus on the inner side and brachioradialis (supinator longus) and extensor carpi radialis longior on the outer side lies the radial (musculospiral) nerve; it divides above or opposite the lateral (external) condyle into the superficial branch and posterior interosseous nerve.

### THE VEINS OF THE ELBOW.

The flexure of the elbow is occupied by a number of veins which are of importance from the fact that they are frequently used for purposes of saline infusion, sometimes for blood-letting, and not infrequently they are wounded and give rise to troublesome hemorrhage.

They are made more prominent by allowing the arm to hang and by tying a bandage firmly above the elbow. The larger part of the blood from the parts below is carried by the superficial veins; hence the largest veins lie directly beneath the skin and can be seen through it.

Their arrangement is not always regular but they follow a more or less general plan. The blood from the radial side of the wrist and forearm is carried by the *radial vein*. The *median vein* brings the blood from the anterior surface of the wrist and



parts above. There are two veins on the ulnar side, an *anterior* and a *posterior*. The anterior carries the blood from the anterior ulnar aspect and the posterior ulnar from the posterior ulnar aspect of the wrist and forearm. All these veins contain valves at intervals of a few inches. The median vein passes up the middle of the anterior surface of the forearm, and just below the lower edge of the bicipital fascia communicates with the deep veins accompanying the radial and ulnar arteries. This communication is large, distinct, and always present (Fig. 300).

The median vein then divides into the *median basilic*, which passes upward in the internal bicipital furrow, and the *median cephalic*, which follows the edge of the

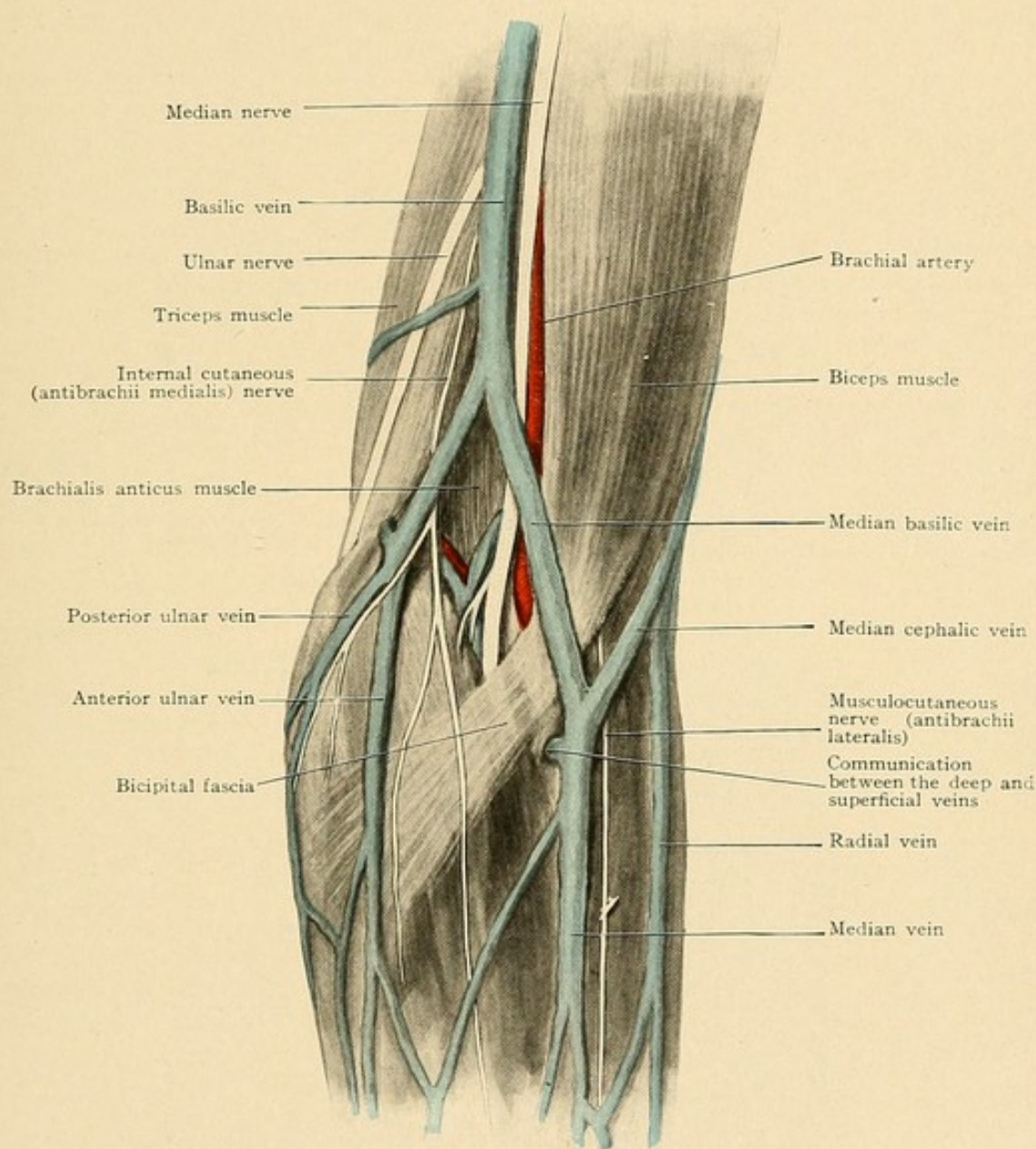


FIG. 300.—Veins at the bend of the elbow.

biceps to the external bicipital furrow. Three or four centimetres above the bifurcation of the median, the median cephalic vein is joined by the radial, and from that point up it is called the *cephalic vein*.

The two *ulnar veins* just below the medial (internal) condyle or sometimes just above it empty into the median basilic vein, which from this point is called the *basilic vein*. Sometimes the two ulnar veins, anterior and posterior, unite and empty into the median basilic by a common trunk. The median basilic vein passes



over the bicipital fascia, which separates it from the brachial artery which lies directly beneath. The median basilic vein (or cephalic when more prominent) is usually chosen for purposes of saline infusion. It lies to the inner side of the biceps tendon and no important structures are liable to be wounded. The terminal filaments of the musculocutaneous nerve pass under the median cephalic vein and are not liable to be wounded. If the median basilic is chosen for infusion or venesection care must be taken not to cut through the bicipital fascia, otherwise a wound of the brachial artery may be produced which may result in the formation of a varicose aneurism or aneurismal varix.

When these veins are wounded the bleeding may be very free. Not only are the superficial parts drained but likewise the deep parts through the communication with the median. We saw one case in which death nearly resulted from such a wound made by a piece of tin. When saline infusion is practised the vein selected is made visible by compressing it above. It is then cut directly down upon and isolated, and the cannula inserted.

### BRACHIAL ARTERY.

At the bend of the elbow the artery lies to the inner side of the biceps tendon. It is beneath the bicipital or semilunar fascia. The upper edge of this fascia can be felt opposite the crease. In the lower third of the arm the median nerve lies close to the artery, but as the bend of the elbow is reached it diverges and becomes separated from it by the coronoid head of the pronator radii teres muscle. Superficial to the deep fascia is the median basilic vein, crossed at its upper portion by the cutaneous antebrachii medialis (internal cuta-

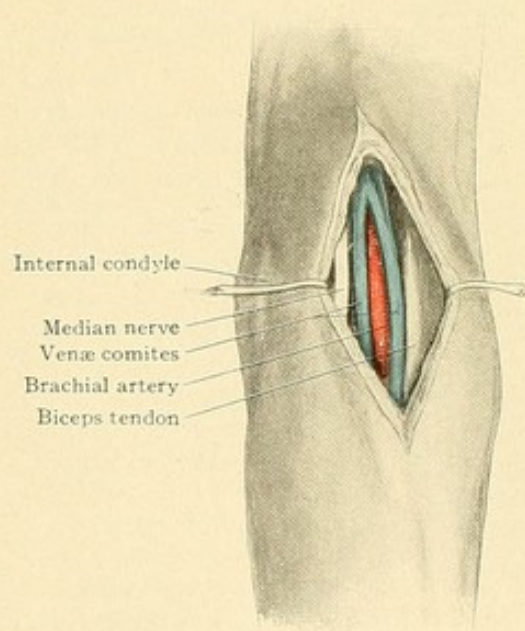


FIG. 301.—Ligation of the brachial artery at the bend of the (left) elbow.

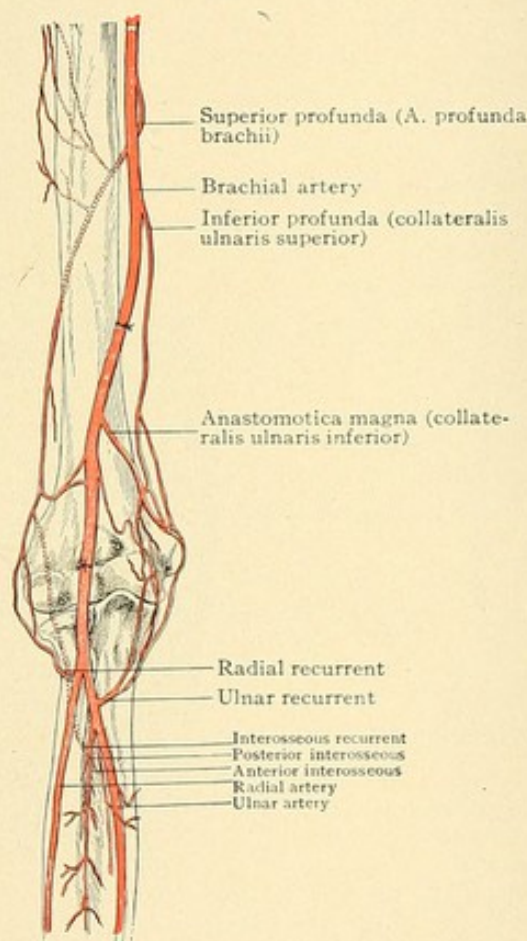


FIG. 302.—Collateral circulation after ligation of the brachial artery at the bend of the elbow.

neous) nerve. The bifurcation of the brachial artery occurs opposite the neck of the radius, which is approximately a finger's breadth, or about 2 cm., below the crease of the elbow.

**Ligation of the Brachial Artery at the Bend of the Elbow.**—The incision is laid along the inner edge of the biceps tendon. The median basilic vein is usually more prominent than the median cephalic and can be seen obliquely crossing



the artery to reach its inner side. This vein is encountered as soon as the skin is divided, hence care is necessary to avoid wounding it. It should be displaced to the inner side along with a filament of the cutaneous nerve if this is present. The incision is then deepened through the upper portion of the bicipital fascia and the artery found beneath, lying in loose fatty tissue and accompanied by two *venæ comites*. The median nerve lies to the inner side but may be sufficiently removed not to be exposed. The needle is passed from the inner towards the outer side (Fig. 301).

*Collateral Circulation.*—On the outer side the profunda (superior) anastomoses with the interosseous recurrent (a branch of the posterior interosseous) and radial recurrent. On the inner side the superior ulnar collateral (inferior profunda) and inferior ulnar collateral (*anastomotica magna*) anastomose with the anterior and posterior ulnar recurrent arteries (Fig. 302).

### DISLOCATIONS OF THE ELBOW.

In dislocation of the elbow the bones of the forearm are most commonly displaced backward. More rarely they may be partially displaced either inwardly or outwardly and with or without an accompanying backward displacement. The lateral ligaments

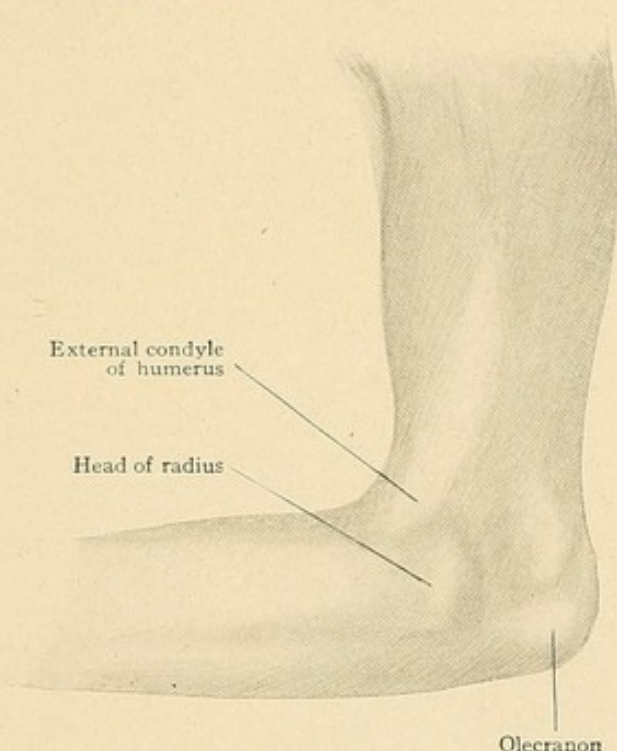


FIG. 303.—Posterior luxation of the elbow; surface view of the outer side.

are strong, the anterior and posterior weak. The formation of the bones permits anteroposterior movement and resists lateral movement; hence the frequency of anteroposterior and the rarity of lateral luxations. To understand and recognize these dislocations and distinguish between them and fractures requires a knowledge of the shape of the bones, the position of the articulations, and especially of the relations and significance of the various bony prominences, in other words, surface anatomy. In doubtful cases compare the normal with the injured elbow.

**Backward Dislocation of the Elbow.**—In backward dislocation the radius and ulna are pushed backward and the lower end of the humerus comes forward. It is most commonly caused by falls on the outstretched hand and not by direct injury to the elbow.

On the cadaver hyperextension with or even without a slight twisting readily produces the displacement.

The internal and external lateral ligaments are torn loose from their respective condyles and the anterior ligament is ruptured. The posterior ligament is stretched



from the olecranon process to the humerus, and with the periosteum may be lifted up but not ruptured. This is especially the case with the periosteum above the external condyle, as shown by Stimson.

The amount of tearing of the muscles depends on the amount of displacement. The flexor muscles may be partly torn from the internal condyle or the extensors from the external. The brachialis anticus probably will be somewhat torn near its insertion in front of the coronoid process. The biceps is not torn but may in some cases be caught behind the external condyle. The orbicular ligament remains intact and holds the radius in its proper relation to the ulna.

*Signs.*—The position assumed by the bones is usually one of slight flexion, approximately 120 degrees (Hamilton).

Viewing the elbow from the side, the anterior portion of the arm above the crease is fuller than is normally the case. Posteriorly the olecranon is seen projecting, and above it is a distinct hollow. On the outer side of the joint immediately in front of the olecranon is seen a prominent projection caused by the head of the radius. It is

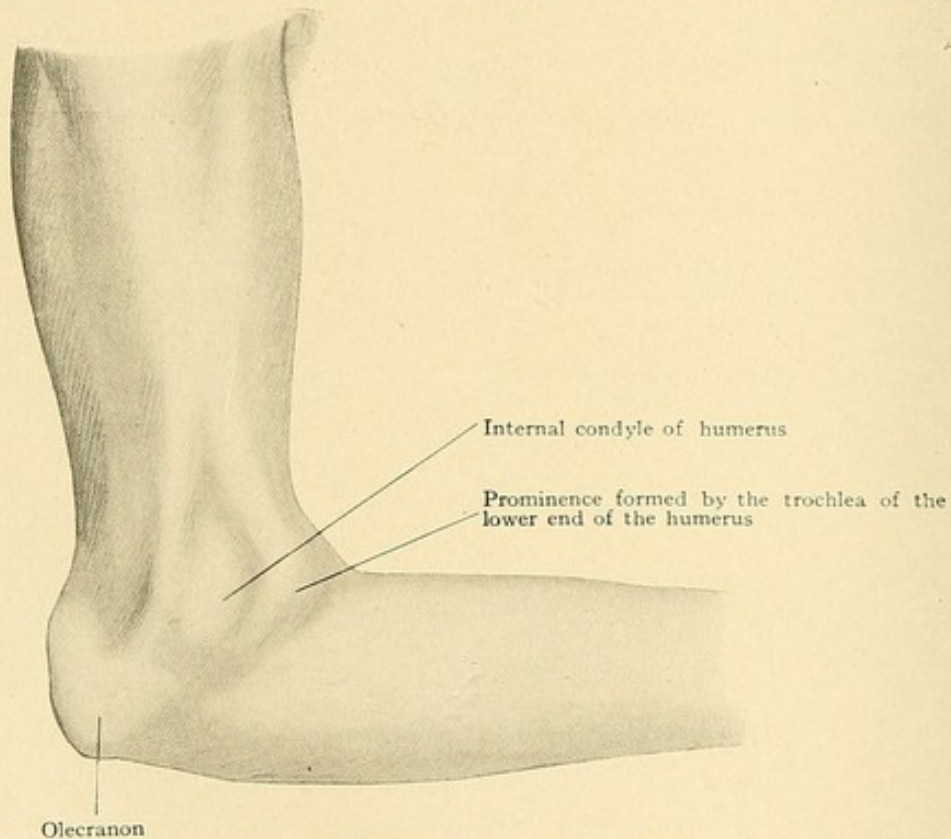


FIG. 304.—Posterior luxation of the elbow; surface view of the inner side.

to be recognized by placing the thumb on it and rotating the hand. Almost directly above it may be felt,—though it is not at all distinct,—the external condyle (Figs. 303 and 305). On the inner side are seen two rounded bony eminences. The posterior and upper of these is the larger; it is the internal condyle. Below and anterior to this is another; it is the inner edge of the trochlear articulating surface (Figs. 304 and 306).

Measurements from the condyle to the acromion process show that they are the same on the injured and the healthy sides. Measurements from the condyle to the styloid process of the ulna show shortening on the injured side. As the lateral ligaments are torn there is abnormal lateral mobility. If the forearm is placed at right angles to the arm, it is seen that the tip of the olecranon no longer lies on a plane drawn through the long axis of the arm and the two condyles, but is considerably posterior to it.

The diagnosis as pointed out by Stimson should be based on the positive recognition of the position of the olecranon, the two condyles, and the head of the radius.

*Treatment.*—The lower end of the humerus rests in front of the coronoid process (rarely fractured). When the forearm is flexed the triceps becomes tense and holds



the bones locked in their displaced position. The coronoid process prevents the humerus from going back into place. To reduce the dislocation, the triceps is to be

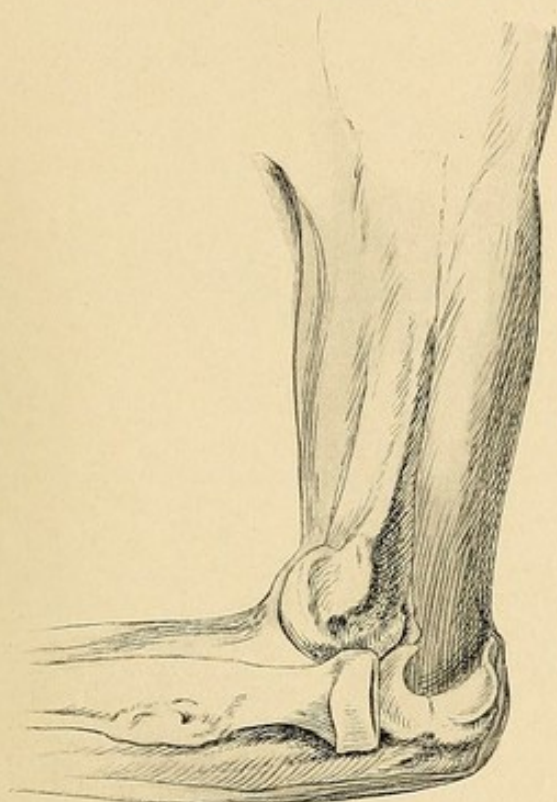

FIG. 305.—Posterior luxation of the elbow, showing the position of the bones as viewed from the outer side.

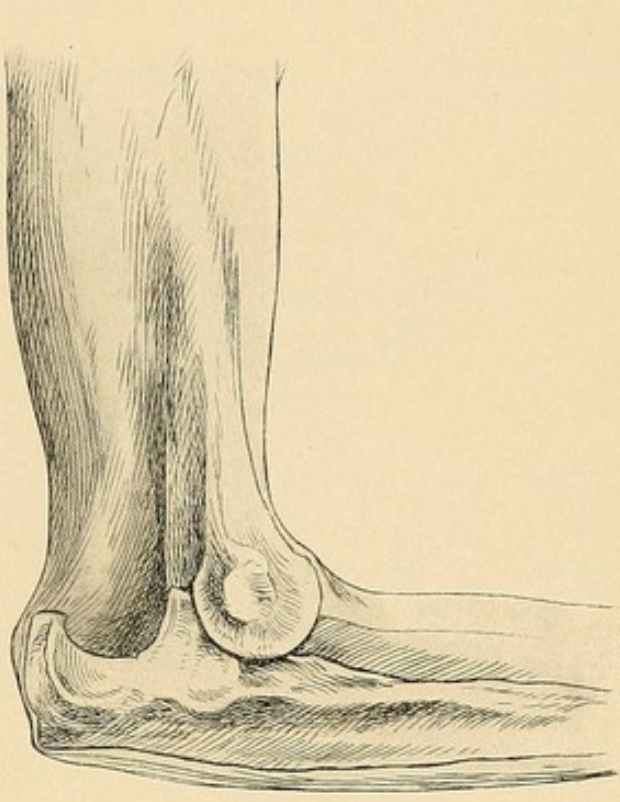


FIG. 306.—Posterior luxation of the elbow, showing the position of the bones as viewed from the inner side.

relaxed by extending the forearm to an angle of about 120 degrees, thus lowering the coronoid process, and extension is to be made on the forearm and counterextension on the arm. Usually an anæsthetic is not required (Fig. 307).

**Inward Dislocation of the Elbow.**—In inward dislocation the ulna and

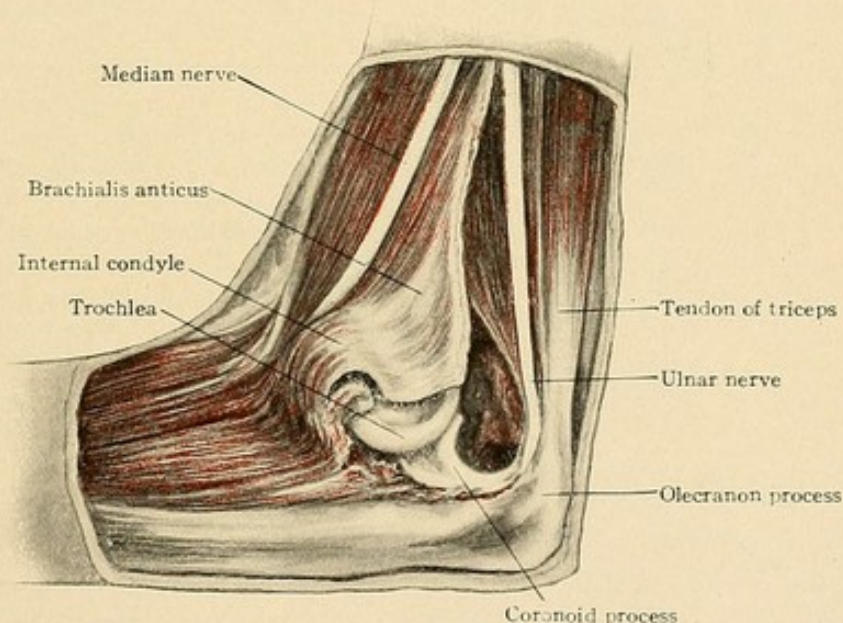


FIG. 307.—Dissected preparation of posterior luxation of the elbow, viewed from the inner side.

radius are pushed toward the inner side. The head of the radius leaves the capitellum to rest on the adjacent portion of the trochlea. The olecranon slides from the



outer to the inner surface of the trochlea. The outer condyle then becomes prominent while the inner becomes confused with the olecranon. The identity of the condyles is always to be established by tracing them up the humerus. This dislocation is always incomplete.

*Treatment.*—Extension and counterextension with the arm slightly flexed to

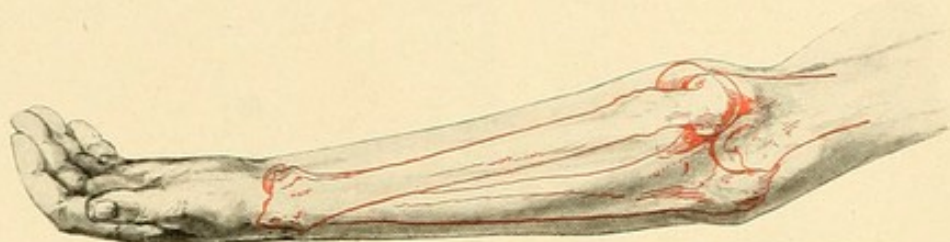

FIG. 308.—Anterior dislocation of the head of the radius. (From author's sketch.)

release the coronoid process aided by direct pressure on the humerus inward and the ulna outward.

**Outward Dislocation of the Elbow.**—In outward dislocation the concave surface of the olecranon rests on the capitellum and in the groove between it and the trochlea. The head of the radius projects far to the outer side of the external condyle. The inner condyle and trochlea become quite prominent and can be readily recognized.

*Treatment.*—Slight flexure of the forearm. Traction and pressure on the radius inward and on the internal condyle and lower end of the humerus outward.

**Dislocation of the Head of the Radius.**—The ulna alone is rarely luxated (when displaced it would practically be a backward and inward luxation of the elbow) but the head of the radius is not infrequently pulled out of place (Fig. 308).

The accident occurs in children, particularly young ones who, in walking with their elders, are frequently lifted or helped along by a pull on the hand. The pull, accompanied by hyperextension of the elbow and some adduction of the hand, draws the head of the radius from beneath the orbicular ligament and then the tension of the biceps drags it forward. The displacement may be either marked or slight. A marked displacement in the well-developed arm of an adult is readily recognized, but in the fat, chubby, undeveloped arm of an infant it is easily overlooked.

*Diagnosis.*—Pain attracts attention to the part. There is apt to be inability to flex the arm beyond a right angle, due to the radius impinging on the lower end of the humerus. Careful palpation reveals a

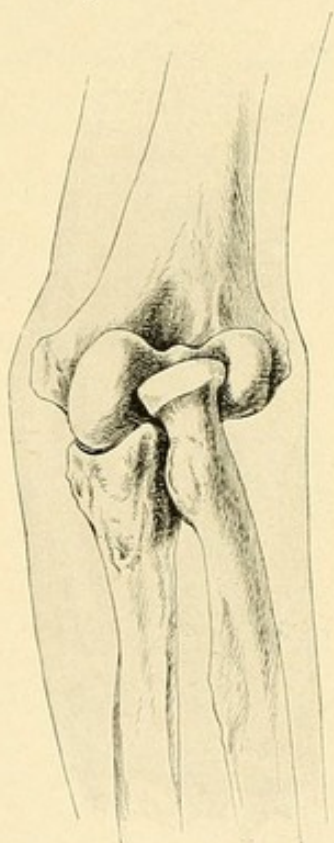


FIG. 309.—Anterior dislocation of the head of the radius. Position of bones when viewed from in front.

hollow below the lateral (external) condyle which should be normally occupied by the head of the radius. The outer side of the forearm at the bend of the elbow may be abnormally full and pressure here may detect the head of the radius displaced forward (Figs. 309 and 310).

*Treatment.*—The forearm is to be extended almost to a straight line. Pressure is to be made with the thumb to force the head of the radius back into place. While this is done the forearm is to be flexed on the arm and if the head is replaced the



elbow can be bent to its normal acute angle. On extension being made the radius frequently again jumps forward, hence the injury is to be subsequently treated with the arm in a flexed position.

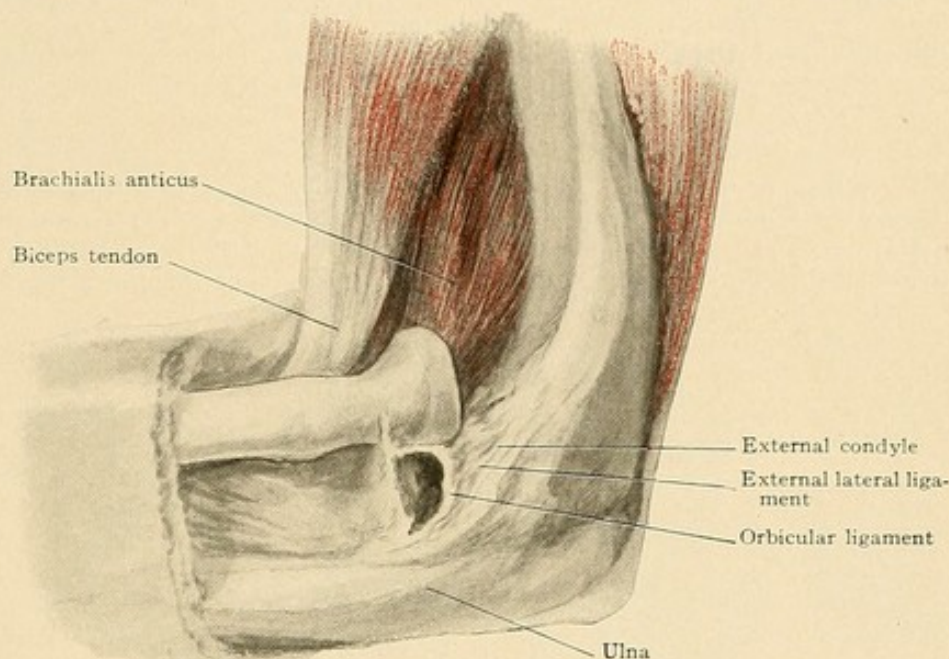


FIG. 310.—Anterior luxation of the head of the radius.

### FRACTURES IN THE REGION OF THE ELBOW.

The elbow is frequently the seat of fractures, especially in children. Their diagnosis and treatment are both difficult and the result sometimes unsatisfactory.

The bony processes are less distinct in children than in adults and fractures sometimes pass unrecognized, being considered sprains, until the persistent disability or marked deformity betrays their presence. Luxations and fractures are at times mistaken for one another. For these reasons a working knowledge of the anatomy of the region is indispensable.

The fractures that occur in this region are transverse fractures above the condyles and oblique fractures through the condyles, which may either involve the condyles proper (epicondyles so called) and be extra-articular, or involve the articular surface of the trochlea or capitellum. Both condyles may be detached by a T- or Y-shaped fracture: the olecranon may be fractured and also the head or neck of the radius.

**Transverse Fracture of the Humerus above the Condyles (Supracondylar).**—This is the most frequent fracture of the lower end of the humerus. The mechanism of its production is not settled. There is little doubt but that it can be produced by hyperextension, as the bone fractures at this point when luxation does not occur. Hamilton regarded a blow on the elbow as the cause. The line of fracture runs transversely across the bone just above the condyles and obliquely from behind downward and forward (Fig. 311, page 296).

**Displacement.**—The lower fragment is drawn upward and backward and sometimes there is an angular lateral deformity with obliteration of the carrying angle (see page 282).

**Signs.**—The overriding of the fragment produces shortening of the humerus as measured from the acromion to the lateral (external) condyle. The olecranon projects backward, causing a hollow above which resembles that produced in backward luxation. The flexure of the elbow is fuller than normal. The relation of the condyles to the tip of the olecranon is not altered. The condyles may, however, lie posterior to a line drawn down the middle of the humerus in its long axis. The sharp edge of the lower fragment can sometimes be felt posteriorly.

Extension of the forearm causes the fragment to be pushed still farther upward.

**Treatment.**—There is no single treatment that is applicable to all cases. If the arm is too much extended, the biceps and brachialis anticus are made tense, and



tension of either the anterior or posterior muscles tends to favor overlapping and to prevent replacement. Full flexion renders the triceps tense. To relax both sets of muscles a position at about right angles is probably best.

Stimson has shown that gunstock (angular) deformity frequently follows this injury, hence especial care should be taken to guard against it. It is caused by a tilting of the lower fragment. Instead of a line joining the condyles being at right angles to the long axis of the humerus, it may be oblique, owing to one condyle being higher than the other. Practically it is not possible to recognize this displacement when the arm is bent at a right angle. The splints will fit the part and everything appears satisfactory, but on removal of the splints and extension of the forearm it may be found that the carrying angle has been destroyed and that a gunstock deformity is present. This accident is to be avoided by extending the arm during the earlier periods of treatment before the fragment becomes fixed by callus, and

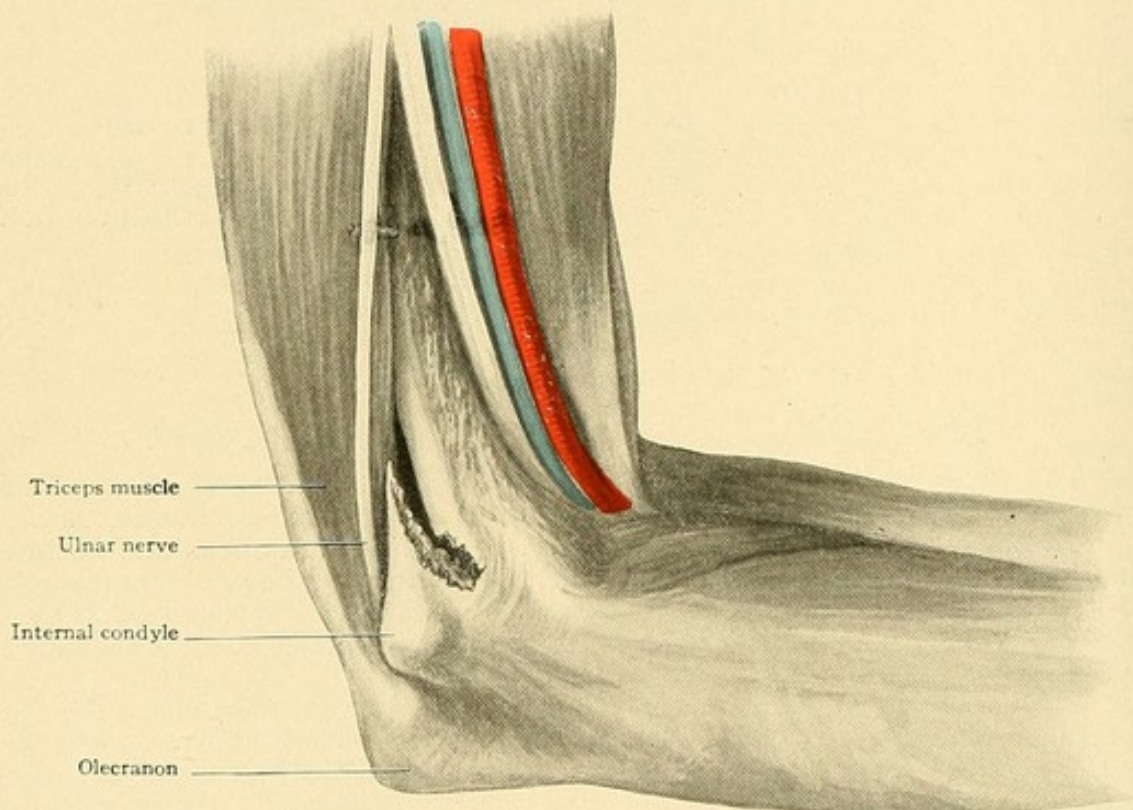


FIG. 311.—Transverse fracture of the lower end of the humerus above the condyles. The upper fragment is seen to be displaced forward and the lower fragment with the olecranon is displaced backward. This posterior displacement is increased by tension of the triceps muscle.

seeing that, on extension, the forearm makes the same angle with the arm as does that of the healthy side.

The common mode of treatment of supracondylar fractures is the use of antero-posterior splints with the elbow bent at a right angle or sometimes acutely flexed.

**Fractures Involving the Condyles.**—The condyles (page 280) have been described as the lateral bony projections of the lower end of the humerus which are extra-articular. Therefore the trochlea and capitellum are not parts of the condyles, and the epicondyles are simply the tips of the condyles.

Bearing this in mind it is evident that fractures involving the condyles may be confined to them and not implicate the articular surfaces. They are then extra-articular fractures of the condyles, or they can with some reason be called fractures of the epicondyles. Other fractures may not only implicate the condyles, but pass through them into the articular surfaces. These will be called intra-articular fractures of the condyles. The internal epicondyle (epicondylus medialis) is sometimes called the epitrochlea.

*Extra-articular Fractures of the Condyles or Fractures of the Epicondyles.*—The medial (internal) condyle projects far beyond the body of the bone as a distinct bony



process, while the lateral (external) condyle is low, flat, and not prominent. For these reasons fractures of the medial condyle not involving the joint are more common than those of the lateral condyle. In fact extra-articular fractures of the lateral condyle (detachment of the epicondyle) are almost unknown, but they have been proven to exist.

In extra-articular fractures of the medial condyle, the fragment has been displaced downward by the flexor muscles which arise from it. To counteract this tendency the arm is treated in a flexed position. As the ulnar nerve runs in the groove on the posterior surface of the condyle it has also been injured, and vesicles and impairment of sensation in the course of the nerve have been observed. As the articular surfaces are not involved, no serious deformity or disability need be expected.

*Intra-articular Fractures of the Condyles.*—The line of fracture in these injuries usually starts above the epicondyle and passes toward the middle of the bone, chipping off a portion of the trochlear surface or the capitellum. Fractures involving the lateral are probably more frequent than those involving the medial condyle.

*Intra-articular Fracture of the Medial Condyle.*—The line of fracture passes obliquely through the condyle, entering just above its tip and emerging on the articular surface of the trochlea either in the groove separating the two portions of the trochlea or the groove between the trochlea and capitellum. As already explained (page 282), the integrity of the joint and the line of the arm depend on the trochlea and not on the capitellum, therefore the farther over toward the capitellum the line of fracture goes the more likely is there to be lateral mobility (Fig. 312).

The fragment may be pushed up; this carries the ulna up with it while the radius is prevented from following by the capitellum. Therefore the forearm bends inward, making a lateral deformity. The carrying angle (page 282) becomes obliterated and what is known as *gunstock deformity* or *cubitus varus* is produced. It is mainly to the researches of Dr. O. H. Allis that we are indebted for our knowledge of the mechanism of this deformity. The attachment of the flexor muscles does not keep the fragment from rising. The deformity is difficult to detect when the elbow is flexed. The condyles and olecranon and shaft of the humerus may all be in the same straight line and still the medial (internal) condyle be higher than normal. If the injury is treated with a right-angled splint the radius and ulna remain in their proper positions but the ulna and medial condyle may both be higher than normal. If this is the case, then, when the forearm is extended, instead of it making an angle of 10 degrees outwardly with the line of the humerus, it may incline 10 degrees or even 20 degrees inwardly; thus it may deviate as much as 30 degrees from the normal direction. To guard against this deformity Allis advised treating the injury with the arm in full extension. Any tendency to lateral deformity will then be at once evident and can be corrected by additional lateral support. Certain it is that no serious fracture of the elbow ought to be treated without frequent examinations of the arm in full or almost complete extension being made from time to time, so as to be sure this deformity is not becoming established.

The treatment of fractures involving the joint by placing the elbow in a position of complete flexion has been strongly advocated, although it has not entirely superseded other methods.

*Intra-articular Fracture of the Lateral (External) Condyle.*—This is also a fairly common injury. The line of the fracture passes from above the tip of the lateral condyle down into the joint through the capitellum or between it and the trochlea. As is to be expected, this does not show the same tendency to lateral deformity as does fracture of the trochlea. When lateral deformity does occur it is because the fracture is so extensive as to also involve the trochlea. This, like the

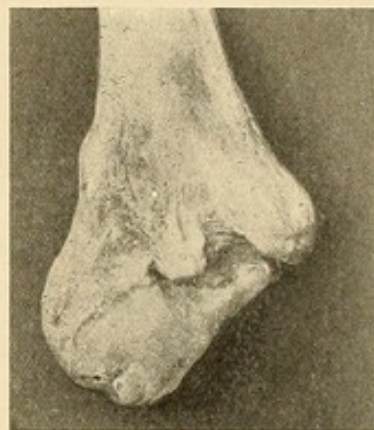


FIG. 312.—Fracture of internal condyle and trochlea, causing gunstock deformity (cubitus varus). From a photograph of a preparation in the Mütter Museum of the College of Physicians.



other fractures of this region, is to be diagnosed by grasping the fractured part and detecting crepitus and excessive mobility. The medial (internal) condyle is felt firmly attached to the humerus and the olecranon to the ulna, but the lateral (external) condyle is felt to move independently of the others. It is efficiently treated by an anterior (not internal) angular splint.

**Intercondylar or T Fracture.**—When both condyles are detached there is produced what is known as a T fracture. In this injury both condyles are detached from each other and from the shaft of the humerus. The line of fracture may vary. Sometimes there is a transverse fracture above the condyles with a second line passing longitudinally into the joint like the letter T. In other cases the lines may be like the letter V or Y (Fig. 313).

In all these cases the mobility is very marked and the limb can be bent at the elbow in any direction. The diagnosis is to be made by grasping the shaft of the humerus with one hand and moving each condyle separately with the other. Having determined that each is detached from the humerus, then one condyle is grasped in each hand and they are moved on one another, thus establishing the fact of a fracture between them.

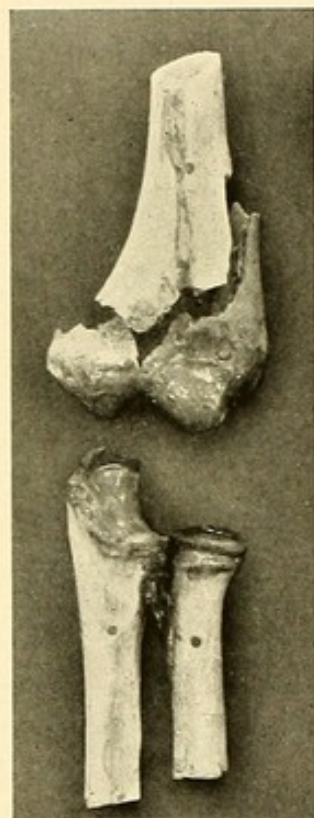


FIG. 313.—Intercondylar or T fracture of the lower end of the humerus. Mütter Museum, College of Physicians.

In treatment the same care must be exercised to detect the occurrence of gunstock deformity as has already been advised in fractures of the medial condyle. In these fractures the fragments are frequently rotated on one another, and disability and deformity so often result that in some cases it is advisable to fix the fragments in place by some operative means.

**Fracture of the Olecranon Process.**—The olecranon process may be fractured either close to its extremity near the insertion of the triceps tendon, through approximately the middle of the greater sigmoid cavity, or toward the coronoid process.

The second is the more common. The fracture which occurs nearer the insertion of the triceps is liable to occur from muscular action, the triceps contracting and tearing off the piece of bone into which it is inserted. The shape of the process should be noted. In the bottom of the greater sigmoid cavity near where the process joins the shaft it is constricted and weakened by a groove which sometimes passes nearly or quite across its surface. This is the weakest point and is most often the site of fracture.

The triceps muscle inserts not only into the upper surface of the olecranon but also along its sides. In addition it sends off a fibrous expansion to each side; the one to the medial condyle is thin, but the one to the lateral condyle forms a broad, tough, fibrous band which stretches from the olecranon to the lateral condyle and passes down over the anconeus to be attached to the outer edge of the upper fourth of the ulna (Fig. 314). In cases of fracture the fragment is only slightly displaced upward by the contraction of the triceps. The reason is that the fibrous expansion of the triceps usually is not sufficiently torn to allow of the retraction of the fragment. The amount of separation of the fragments is directly proportional to the amount of tearing of the lateral fibrous expansion of the triceps tendon. By extending the forearm the triceps is relaxed and by pushing the fragment down crepitus can often be elicited.

**Treatment.**—Fracture of the olecranon process is usually treated with the elbow slightly flexed. Complete extension is not commonly employed. The slight flexion allows for the effusion into the joint and leaves the arm sufficiently extended to relax the triceps.

An adhesive strip placed across the back of the elbow above the fragment and brought down and crossed on the front of the forearm usually suffices to keep the fragment in position.



The bond of union between the fragments is usually so short that it appears to be bony and function is perfect. If the fibrous band is long extension will be incomplete and weak.

**Fracture of the Coronoid Process and Upper End of the Radius.**—

*Fracture of the coronoid process* does occur but it is exceedingly rare. The brachialis anticus does not insert into its tip, but at the lower part of its anterior surface. The fracture is most liable to occur in cases of luxation, the process being knocked off as the humerus comes forward.

*Fractures of the Head and Neck of the Radius.*—The head and neck of the radius are rarely fractured. When broken, the line of fracture through the head is

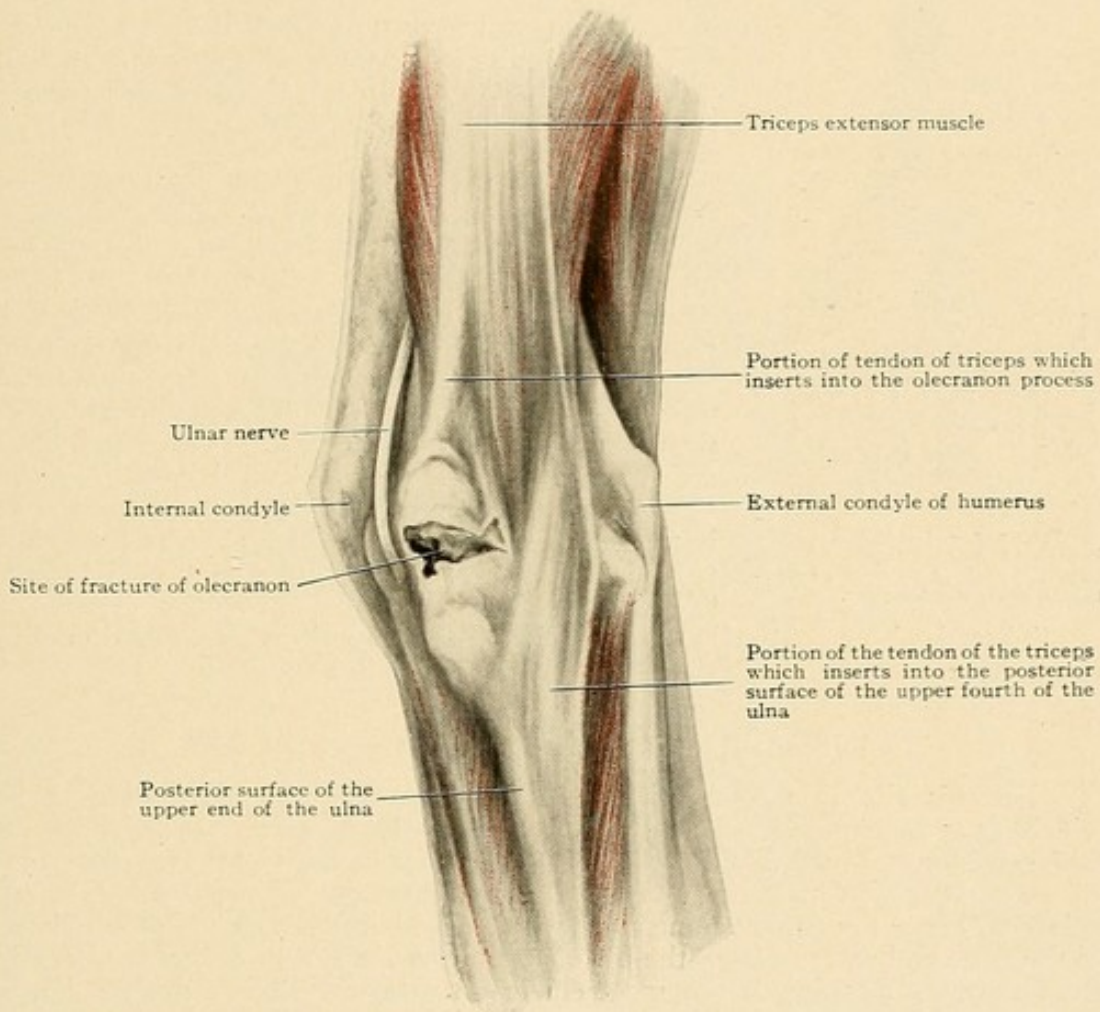


FIG. 314.—Fracture of the olecranon process, showing the insertion of the triceps muscle into the olecranon and upper fourth of the ulna.

usually longitudinal and a portion of the head is chipped off. The fragment is liable to become displaced, and either creates inflammation and suppuration or becomes fixed and greatly interferes with motion. For these reasons the fractured head has been frequently excised. A similar displacement may occur when the neck of the radius is fractured.

In this latter injury an anterior angular deformity is said to have been produced by the action of the biceps pulling the lower fragment, to which it is attached, forwards.

The classical specimen in the Mütter Museum of the College of Physicians of Philadelphia is usually instanced as an example of this action. The possibility of its occurrence suggests the treatment of the injury with the elbow flexed to relax the biceps muscle.

**Epiphyses of the Bones of the Elbow.**—Traumatic epiphyseal separations are possible, but so rare as to be seldom detected. Supracondylar fractures in



children, though not infrequently described as separations of the epiphysis are probably more often true bony fractures.

*Humerus.*—The lower end of the humerus ossifies by four centres. Three of them, those for the lateral (external) condyle, capitellum and outer portion of the trochlea, and inner portion of the trochlea, appear at the twelfth, third, and twelfth years and fuse and unite with the shaft at about the sixteenth year. The fourth, for the internal condyle, appears at the fifth and unites about the seventeenth or eighteenth year. The epiphyseal line runs close to the edge of the articular surface and is below the level of a transverse line joining the upper edges of the two condyles (Fig. 315). A true epiphyseal separation would thus be intra-articular and would involve comparatively only a thin shell of the articular surface. As already stated most of the cases regarded as epiphyseal separations are probably true supracondylar fractures.

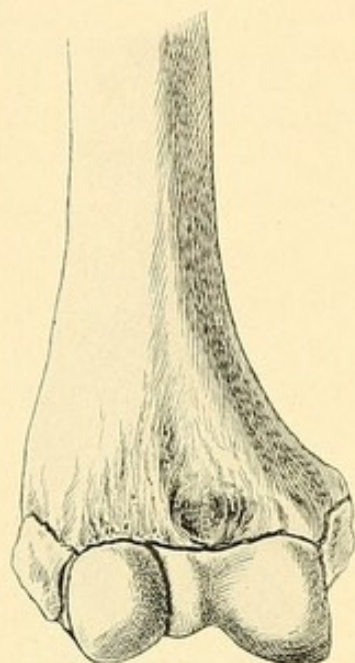


FIG. 315.—Epiphysis of the lower end of the humerus; unites with the shaft at about the seventeenth or eighteenth year.

Destruction or removal of the epiphyseal cartilage is, of course, if possible, to be avoided in operations in young children, as otherwise interference with the growth of the bone will occur.

*Ulna.*—Most of the olecranon process is a direct outgrowth from the shaft of the ulna. At about the tenth year a thin shell forms at its extremity which unites at the sixteenth year. Therefore fractures which pass through the bottom of the greater sigmoid cavity are not separations of the epiphysis but true fractures.

*Radius.*—The upper articular surface of the radius has a centre of ossification which appears from the fifth to the seventh year, and unites at the eighteenth to twentieth year.

There is also a centre for the tubercle. Surgical writers as a rule do not speak of epiphyseal separations of the upper ends of the radius and ulna.

#### DISEASE OF THE OLECRANON BURSA.

Between the skin covering the olecranon process and the bone is a bursa, which, from its exposed position, is not infrequently diseased. It lies in the subcutaneous tissue and resembles in all respects the bursa in front of the patella. In those whose occupation causes them to rest frequently on the elbow, this bursa becomes enlarged, hence the name "miner's elbow." The bursa lies on the posterior surface of the bone and extends from the tip of the olecranon downward in the direction of the forearm. Excision is the most efficient treatment. There are no dangerous structures to be encountered in the operation because the bursa does not communicate with the joint. The position of the ulnar nerve should be borne in mind. It can readily be avoided and usually is not seen. There is sometimes another bursa on the upper surface of the olecranon just below the insertion of the triceps. It is rarely affected.

#### DISEASE OF THE ELBOW-JOINT.

The elbow-joint, like others, is affected with rheumatoid and tuberculous disease. The former frequently causes ankylosis, while the latter frequently causes suppuration. The joint becomes distended and enlarged. The bony prominences of the elbow, while they may not be visible, nevertheless can usually be recognized by palpation. The lateral ligaments are stronger than the anterior and posterior, hence the swelling is most marked in front and behind. As the internal lateral ligament is stronger than the external lateral, swelling will be more marked on the outer side and the medial (internal) condyle will be more easily recognized than the lateral (external).



Pus first works its way posteriorly up behind the tendon of the triceps and then sideways and along the intermuscular septa. As the external supracondylar ridge is nearer the surface than the internal, pus will show itself sooner above the lateral (external) condyle. It may form a protrusion on each side of the triceps tendon and olecranon process.

Later it may show itself anteriorly; when it does so it appears more to the outer than to the inner side, being deflected outwardly through the antecubital space by the attachment of the brachialis anticus to the coronoid process, by the tendon of the biceps and by the bicipital fascia which passes from the tendon over the muscles attached to the medial (internal) condyle.

### RESECTION OF THE ELBOW.

A straight incision is made over the point of the olecranon a little internal to its middle. The upper portion of this incision splits the triceps. Its lower part is

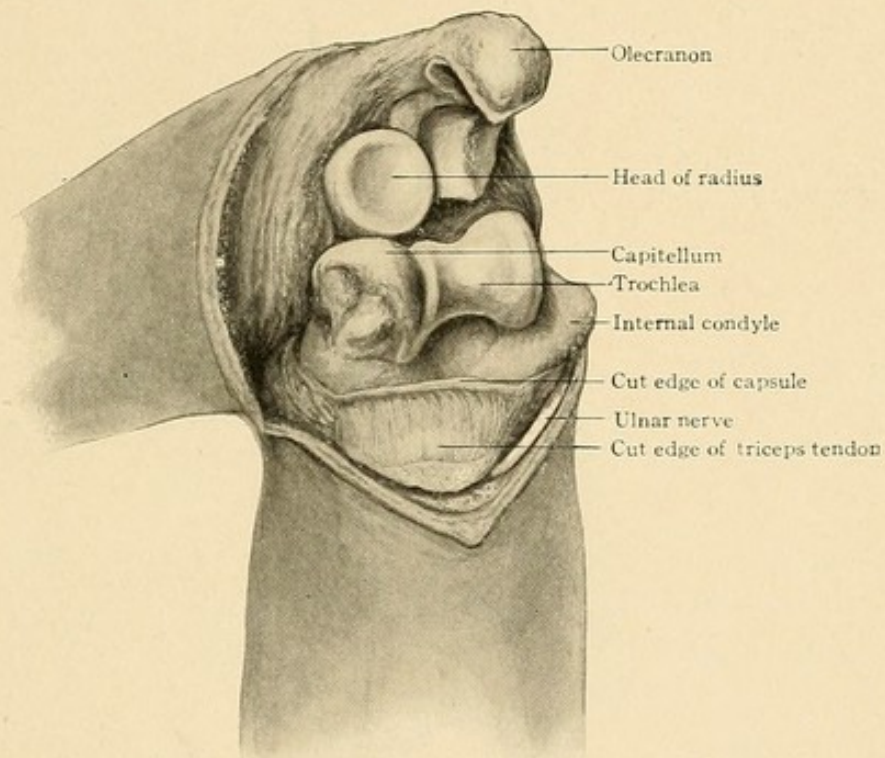


FIG. 316.—Resection of the elbow-joint; the ends of the bones are exposed ready to be removed.

carried down to the bone on the posterior surface of the ulna. The attachment of the triceps to the inner side is then dissected off and the ulnar nerve raised from its groove without injuring it. The medial (internal) condyle is then to be cleared of the muscles attached to it. The parts external to the incision are now to be raised. By means of periosteal elevators aided by the knife the external part of the triceps is detached from the bone as closely as possible, following exactly the edge of the ulna. The anconeus is raised with the triceps and the broad fibrous expansion passing from the olecranon to the lateral (external) condyle and thence over the anconeus to be continuous with the deep fascia is preserved intact. On the care with which this is done depends the amount of subsequent muscular control. As the triceps is turned aside the muscles attached to the lateral condyle are raised in the same manner. The soft parts being drawn to each side the bones are protruded and the remaining soft parts anteriorly can be detached. A flat spatula is then passed beneath the bones and the humerus sawed through opposite the upper edge of the medial (internal) condyle above and the radius and ulna opposite the lower edge of the head of the radius below. The insertions of the biceps and brachialis anticus are not disturbed.



In raising the supinator (*brevis*) from the upper portion of the radius care should be exercised not to wound the posterior interosseous nerve. It runs between two planes of muscular fibres in the substance of the supinator (*brevis*). It is a nerve of motion supplying all the extensor muscles with the exception of the anconeus, brachioradialis (*supinator longus*), and extensor carpi radialis longior; hence its injury will be followed by serious paralysis. Almost no vessels require ligation (Fig. 316).

### AMPUTATION AT THE ELBOW-JOINT.

Amputation at this joint is peculiar from the fact of the width of the lower end of the humerus. The skin is loose and shows a marked tendency to retract, especially on the anterior surface. This, combined with the large, expanded end of the humerus,

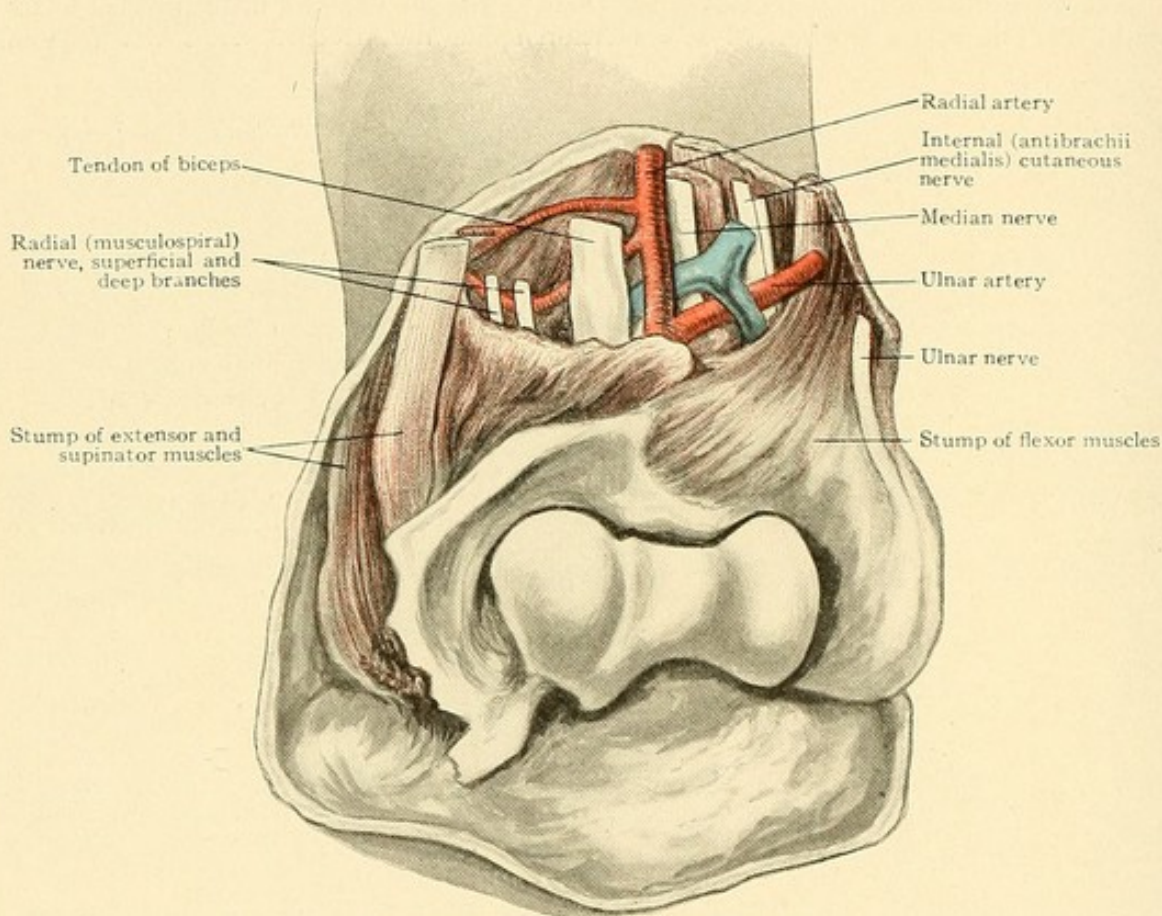


FIG. 317.—Amputation at the elbow-joint.

requires ample flaps to be made or difficulty will be encountered in properly covering the end of the humerus. The irregularity of the line of the joint makes disarticulation somewhat difficult (Fig. 317).

A long anterior flap with or without a short posterior one is usually advised. On account of the tendency to retraction the ends of the incision are not carried up to the condyles but are kept at least 2.5 cm. (1 in.) below them.

If the flap is cut by transfixion the line of the articulation must be borne in mind. Inasmuch as the trochlear surface projects farther down than the capitellum it is customary to incline the knife downward and inward. Also, as the trochlear portion is thicker, wider, and projects farther than the capitellum, the inner side of the flap is made longer than the outer.

The skin on the anterior surface is loose and retracts freely as soon as cut; hence the muscles are often cut by transfixion. The skin on the posterior surface is not so loose and does not exhibit the same tendency to retraction. After the anterior muscles have been raised and the short posterior skin flap turned back the joint is to



be opened. The line of the joint runs from 1.25 cm. below the lateral (ext.) condyle to 2.5 cm. below the medial (int.) condyle and is most readily recognized on the outer side, hence the division of the ligaments is to be made from the outer toward the inner side. The point at which to enter the knife is to be found by first feeling the head of the radius in the pit below the lateral (external) condyle posteriorly and then by pressure just above the head recognizing the groove between the upper edge of the head and capitellum. The knife passes directly transversely along between the head of the radius and capitellum, then across the inner portion of the trochlea and is then directed downward and inward around the projecting inner portion of the trochlea. Division of the internal lateral ligament allows the forearm to be bent back and the triceps attachment becomes exposed and can be divided from the front. The appearance of the stump will depend on the manner in which the flaps have been cut.

On each side will be the muscular masses from the internal and external condyles. Between them will be the tendons of the biceps and brachialis anticus. The median and ulnar nerves are to be found, the former to the inner side of the biceps tendon and the latter behind the medial (internal) condyle. They are to be shortened. The radial (musculospiral) has already divided into its superficial (radial) and deep (posterior interosseous) branches.

The ulnar and radial arteries will probably be found divided well anterior on the face of the stump. Some bleeding may be present from the terminal branches of the profunda in front of the lateral condyle, from the superior ulnar collateral (inferior profunda) behind the medial condyle, or from the interosseous or recurrent branches. It is usually not necessary to apply ligatures to the larger superficial veins.

## THE FOREARM.

The forearm is intimately associated with the functions of the hand. It serves as a sort of pedestal or support, enabling the hand to be carried away from the body, and, by possessing certain movements of its own,—those of pronation and supination,—it increases greatly the range and character of the movements which the hand is capable of executing. The hand is the essential part of the upper extremity and the forearm is subsidiary. Hence we find that, like the neck, the forearm possesses nerves and blood-vessels much larger than its own proper functions would require and which are destined for the more important parts beyond. It is composed of two bones, the radius and the ulna, which act as the bony support of the part, of a few muscles which move these bones and many more which move the hand and fingers beyond, and of certain nerves and blood-vessels that not only supply it but also the parts beyond.

### BONES OF THE FOREARM.

The forearm contains two bones, instead of one as in the arm. One of these bones, the ulna, is directly continuous with the humerus; the other, the radius, is continuous with the hand. In other words, the ulna is associated with the movements of the arm, and the radius with those of the hand. The large end of the ulna articulates with the humerus and its small end is at the wrist, while the large end of the radius is articulated with the hand and its small end with the humerus.

The **ulna** is the bone which acts mainly as a support. It articulates with the humerus by a pure hinge-joint; hence its only motion is one of extension and flexion. It is the fixed bone and does not take part in the movements of pronation and supination, but serves as an anchoring part for the attachment of the muscles which move the radius as well as the hand. At its upper extremity it has attached to it the *brachialis anticus*, *triceps*, and *anconeus muscles*, which flex and extend it.

At its upper extremity on its outer side is the *lesser sigmoid cavity* for the articulation of the radius. Its lower extremity ends in a head tipped with a *styloid process*. The ulna gradually decreases in size from above downward until its lower fourth is reached, when it is slightly enlarged to end in the head. At its lower end, the lateral aspect of the head of the ulna rests in a cavity in the radius to allow of the movements of pronation and supination (Fig. 318).



The **radius** is small above and gradually increases in size until its lower extremity is reached, where it is largest. Its upper portion is composed mainly of compact bone with a medullary cavity; lower down as the bone becomes larger it becomes more cancellous. Hence it does not follow that it is strongest where it is largest; on the contrary it is most often fractured at its lower extremity. About two centimetres below the head of the radius is a tubercle. The biceps tendon is inserted into its posterior portion and a bursa covers its anterior part, over which the tendon of the biceps plays. The radius is the movable bone and to it is attached the hand.

Stretched across from one bone to the other is the *interosseous membrane*. Most of its fibres run from the ulna upward and outward, so that the shocks received on the

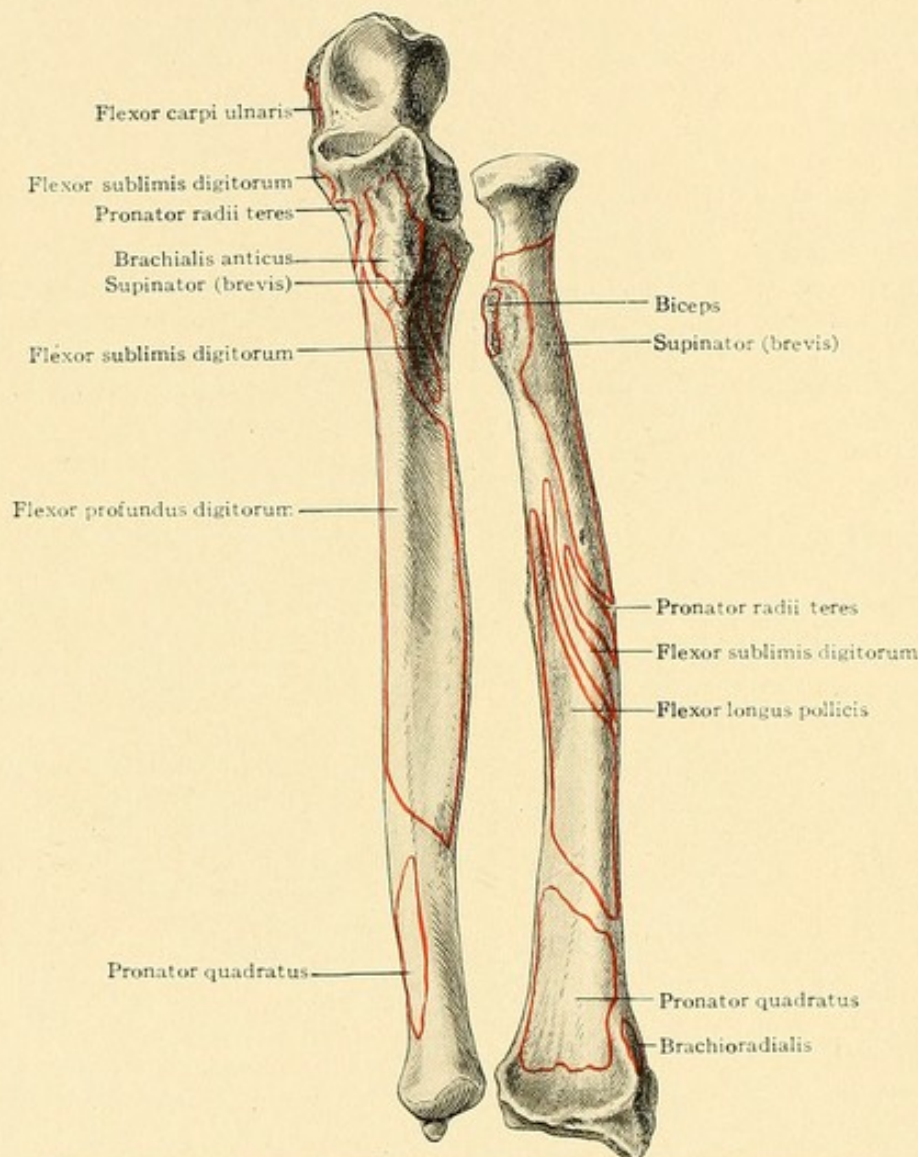


FIG. 318.—Anterior view of radius and ulna with areas of muscular attachments.

hand are transmitted somewhat to the ulna. On its anterior surface run the *anterior interosseous artery and nerve*. About 2.5 cm. (1 in.) above its lower end the artery pierces the membrane to go to the back of the wrist.

#### MOVEMENTS OF PRONATION AND SUPINATION.

The radius revolves on the ulna about an axis which passes through the centre of the head of the radius above and the styloid process of the ulna below, which line if prolonged would pass through the ring finger (Fig. 319). In pronation, the hand lies with the palm down and the radius is crossed diagonally over the ulna; the bones are close together (Fig. 320). In supination the hand lies with the palm up, the



bones lie parallel to one another and widely separated (Fig. 321). In the midposition the radius lies above the ulna and the space between them is at its maximum. The difference in this respect between midpronation and complete supination is slight. The head of the radius rotates in the orbicular ligament, the lower end of the radius revolves around the head of the ulna and rests on the interarticular triangular fibrocartilage. The range of movement is from 140 degrees to 160 degrees. The radius is pronated by the pronator teres and pronator quadratus muscles. It is supinated by the brachioradialis, supinator (brevis), and biceps muscles. Some of the other muscles also aid slightly in these movements, especially the flexor carpi radialis in pronation. In fractures the preservation of the interosseous space is essential for the proper performance of pronation and supination; hence anything

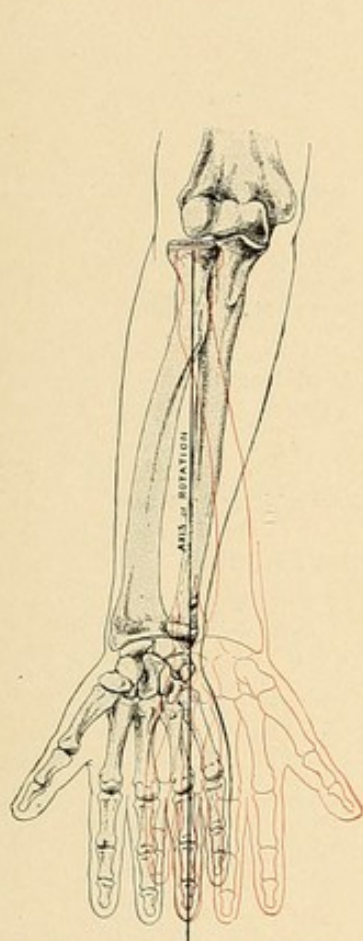


FIG. 319.—The axis of rotation in pronation and supination.

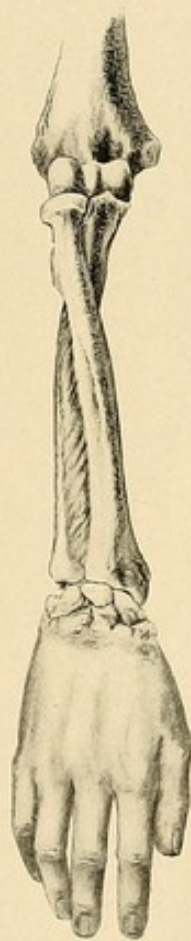

FIG. 320.—Position of the bones of the forearm when the hand is in the position of pronation.

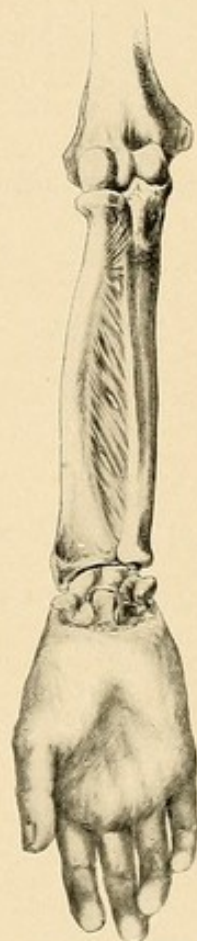

FIG. 321.—Position of the bones of the forearm when the hand is in the position of supination.

which tends to encroach on it, as displacement of the fragments or their position as influenced by the position of the hand, is to be guarded against.

The muscles of supination are much stronger than those of pronation; for this reason instruments intended to be used in a rotary manner turn from the inside toward the outside; that is, in the direction of supination. The screw-driver is an example.

### MUSCLES OF THE FOREARM.

The movements of the hand and fingers are so intricate and complex as to necessitate a large number of muscles for their performance. It is probably easiest in order to understand the construction of the forearm to study these muscles in reference to their functions.

The muscles which occupy the forearm form three groups, which have separate functions: (1) to flex and extend the fingers; (2) to flex and extend the wrist; (3) to pronate and supinate the hand.



## I. THE FLEXORS AND EXTENSORS OF THE FINGERS.

The fingers are moved by two sets of muscles, a long set arising from the forearm and a short set which is confined to the hand. At present we are concerned only with the long extensors and flexors which are found in the forearm.

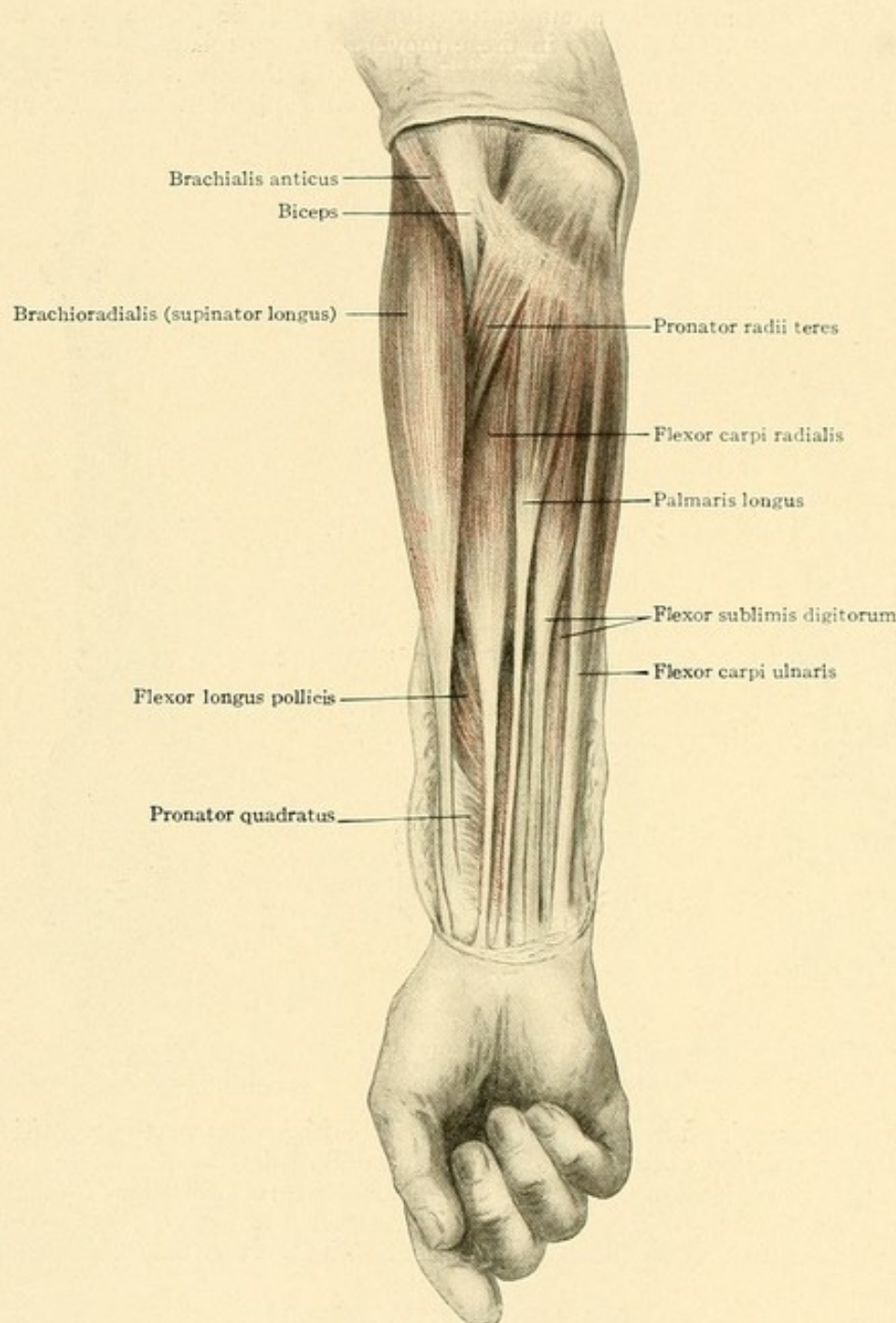


FIG. 322.—Superficial view of the anterior muscles of the forearm.

## THE FLEXORS OF THE FINGERS.

The flexors of the fingers consist of three separate groups of muscles: (1) the *flexor profundus digitorum* and *flexor longus pollicis*, which insert into the distal phalanges; (2) the *flexor sublimis digitorum*; (3) the *palmaris longus* which, spreading out into the palmar fascia, is attached to the heads of the metacarpal



bones and blends with the capsules of the metacarpophalangeal joints. It is an additional perforated flexor muscle (Fig. 322).

1. The **flexor profundus digitorum** is composed of four slips, one for each finger, and the **flexor longus pollicis** (Fig. 323) is a fifth slip that supplies the

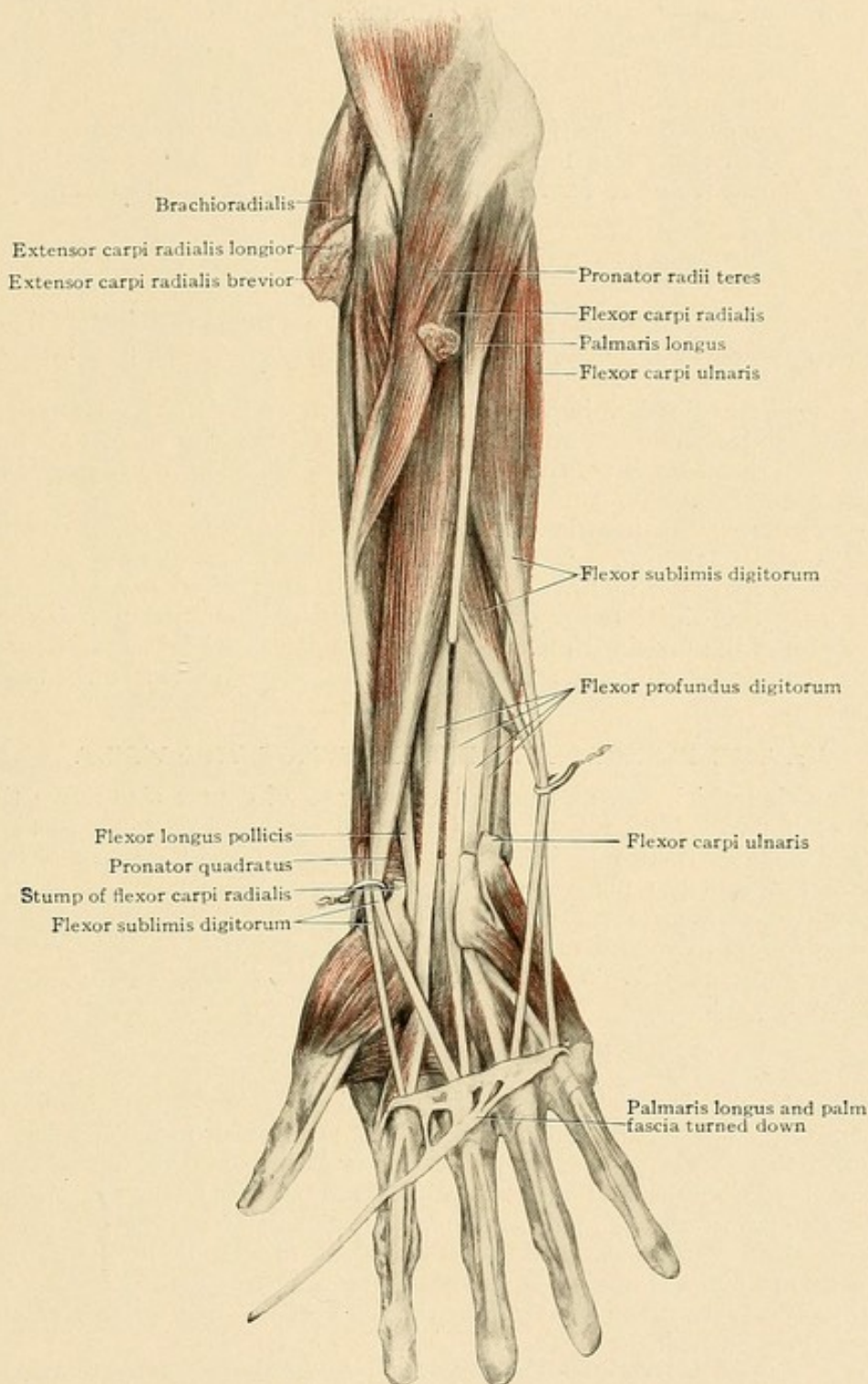


FIG. 323.—Dissection showing the muscles of the forearm, especially the long flexor muscles of the fingers.

thumb. The flexor profundus arises from the anterior surface of the ulna and interosseous membrane while the flexor longus pollicis arises from the anterior surface of the radius and interosseous membrane. Their tendons pass through slits in the flexor sublimis digitorum opposite the proximal phalanges to insert into the bases of the distal phalanges.



2. The **flexor sublimis digitorum** arises from the medial (internal) condyle of the humerus, the coronoid process, the intermuscular septa, and the oblique line of the radius and divides into four tendons which split in front of the proximal phalanges to allow the profundus to pass through and then unite again and insert into the sides of the middle phalanges. There are only four instead of five slips, because the thumb has no middle phalanx but only proximal and distal ones (Fig. 323).

3. The **palmaris longus** arises from the medial (internal) condyle of the humerus and intermuscular septa and inserts into the palmar fascia, which is attached to the base of the proximal phalanges, to the heads of the metacarpal bones, and blends with the capsules of the metacarpophalangeal joints. It is thus seen to be a perforated muscle exactly like the flexor sublimis, which it also resembles in function; its attachment is not so far forward. Traction on it tends to flex the proximal phalanx.

#### THE EXTENSORS OF THE FINGERS.

The extensors of the thumb and fingers arise from the lateral (external) condyle and posterior surface of the ulna, radius, interosseous membrane, and intermuscular septa.

Three separate slips forming the **extensor longus pollicis**, **extensor brevis pollicis**, and **extensor ossis metacarpi pollicis** go to the thumb. The longus inserts into the distal phalanx, the brevis into the proximal, and the ossis into the metacarpal bone of the thumb.

The **extensor communis digitorum** divides into four slips, one for each finger. The slip to the index is reinforced by an additional one called the **extensor indicis proprius muscle**. The slip to the little finger is reinforced by the **extensor minimi digiti (ext. digiti quinti proprius) muscle**. They divide on the dorsum of the proximal phalanges into three parts, the middle one inserts into the base of the middle phalanx, while the two lateral slips insert into the base of the distal phalanx.

#### 2. THE FLEXORS AND EXTENSORS OF THE WRIST.

The muscles which flex and extend the fingers of course also move the hand as a whole, but in addition to these muscles there are five others,—two flexor muscles and three extensor muscles,—which are inserted into the bones of the metacarpus and not into the phalanges. When these muscles contract they tend to move the whole hand and not the fingers alone. They are the *flexor carpi radialis*, *flexor carpi ulnaris*, *extensor carpi radialis longior*, *extensor carpi radialis brevior*, and *extensor carpi ulnaris*. The palmaris longus has already been described as a flexor of the fingers.

#### FLEXORS OF THE WRIST.

**Flexor Carpi Radialis.**—The two flexors of the wrist, the flexor carpi radialis and the flexor carpi ulnaris, are both superficial muscles lying directly beneath the skin. The flexor carpi radialis arises from the medial (internal) condyle of the humerus and intermuscular septa and lies between the pronator radii teres externally and the palmaris longus internally. It runs obliquely across the forearm, striking the wrist at about the junction of the middle and outer thirds. It lies next to and to the outer side of the palmaris longus tendon and to the ulnar side of the radial artery and inserts into the front of the base of the second metacarpal bone (Fig. 324).

**Flexor Carpi Ulnaris.**—The flexor carpi ulnaris arises by two heads, one from the common tendon of the medial (internal) condyle and the other from the olecranon process and upper two-thirds of the ulna. The two heads are separated by the ulnar nerve, which passes down in the groove between the medial condyle and olecranon process. The muscle passes straight down the anterior and inner surface of the ulna to insert first into the pisiform bone and unciform process and then to continue over to the base of the fifth metacarpal bone. The pisiform bone is a sesamoid bone in the tendon of the flexor carpi ulnaris muscle.



Both the flexor carpi radialis and the flexor carpi ulnaris flex the hand at the wrist. When the ulnaris alone acts it tends to tilt the hand inward; when the radialis acts alone it tends to incline the hand outward. Being superficial, these muscles are both important landmarks and guides to the arteries.

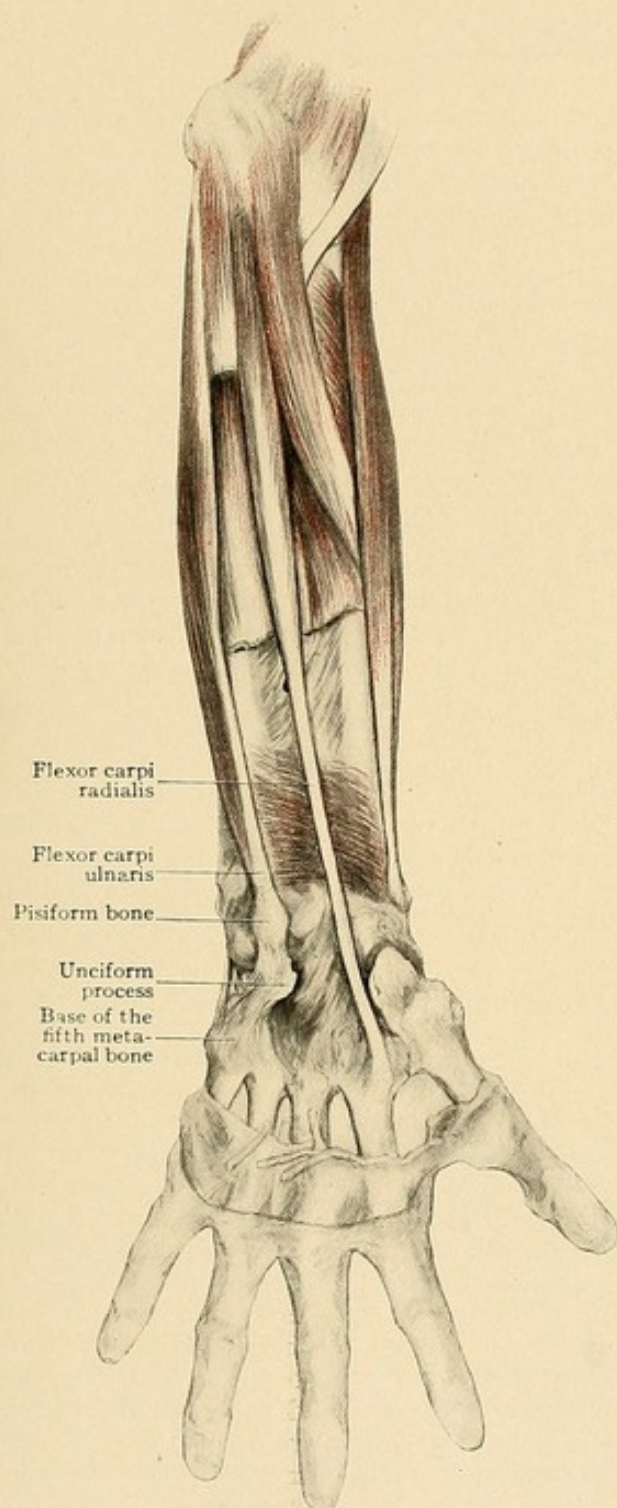


FIG. 324.—The flexor muscles of the wrist.

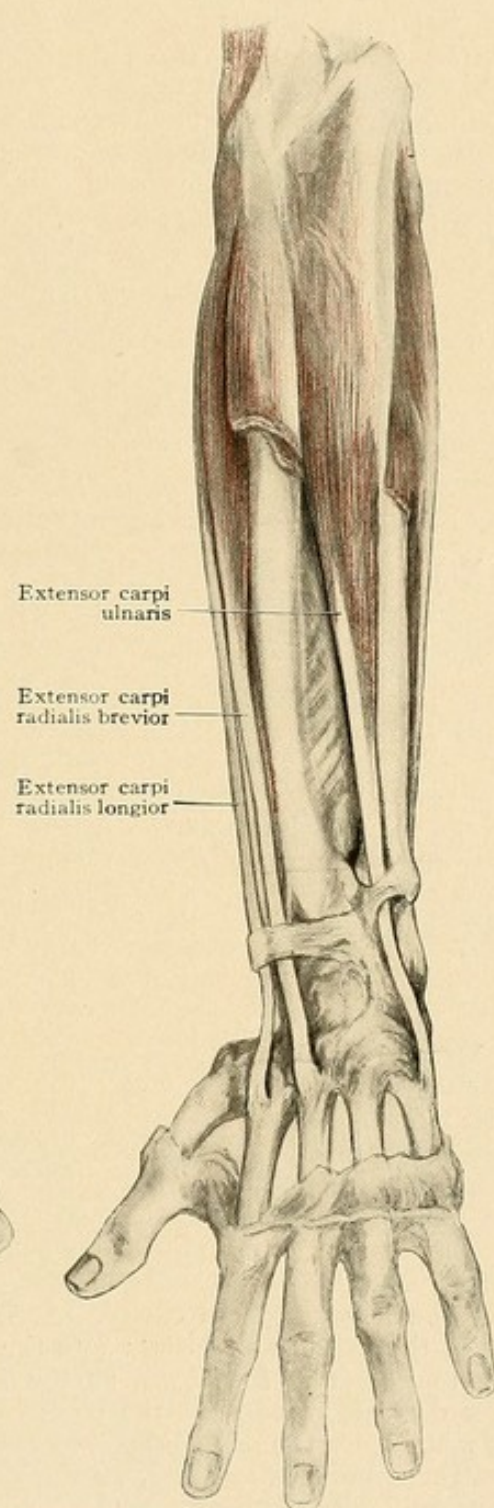


FIG. 325.—The extensor muscles of the wrist.

#### EXTENSORS OF THE WRIST.

**Extensor Carpi Radialis Longior.**—The extensor carpi radialis longior arises from the lower third of the external supracondylar ridge and the lateral (external) condyle and inserts into the back of the base of the second metacarpal bone. When it contracts it tends to tilt the hand toward the radial side as well



as to extend it, and, being attached to the humerus above the line of the elbow-joint, it also aids in flexing the elbow.

**Extensor Carpi Radialis Brevior.**—The extensor carpi radialis brevior arises from the common tendon of the lateral condyle and fascia, and, running down parallel to the longior muscle, inserts into the base of the third metacarpal bone. It is covered by the extensor carpi radialis longior muscle and lies on the supinator (*brevis*). It acts as a pure extensor of the wrist (Fig. 325).

**Extensor Carpi Ulnaris.**—The extensor carpi ulnaris arises by two heads, one from the lateral (external) condyle and the other from the posterior surface of the ulna through the fascia common to it, to the flexor carpi ulnaris, and to the flexor profundus digitorum. It inserts into the base of the fifth metacarpal bone. It extends the wrist and tilts the hand toward the ulnar side.

### 3. PRONATORS AND SUPINATORS OF THE HAND.

The movements of pronation and supination have already been described (page 304). They are performed by five muscles, two pronators and three supinators. The pronators are the *pronator radii teres* and the *pronator quadratus*. The supinators are the *brachioradialis* (*supinator longus*), the *supinator* (*brevis*), and the *biceps*.

#### PRONATORS OF THE HAND.

**Pronator Radii Teres** (*Round Pronator*).—The pronator radii teres arises by two heads, one from the medial (internal) condyle and the other, much smaller, from the inner surface of the coronoid process. The median nerve passes between these two heads. The muscle crosses the forearm obliquely and inserts by a flat tendon into the middle of the outer surface of the radius. It rotates the radius inward and tends to draw it toward the ulna and flex it on the humerus. The influence of this muscle is marked in displacing the radius when fractured.

**Pronator Quadratus** (*Square Pronator*).—The pronator quadratus arises from the volar (palmar) surface of the lower fourth of the ulna and inserts into the lateral and anterior surface of the radius. By its contraction it rotates the radius toward the ulna and in cases of fracture tends to draw the bones together and thus endanger the integrity of the interosseous space (Fig. 326).

#### SUPINATORS OF THE HAND.

**Brachioradialis** (*Supinator Longus*).—The brachioradialis arises from the upper two-thirds of the lateral (external) supracondylar ridge of the humerus and inserts into the base of the styloid process of the radius. When the hand is in a state of pronation contraction of the brachioradialis will tend to supinate it. It also acts as a flexor of the elbow, as has already been pointed out. It is superficial and is an important guide both to the radial (musculospiral) nerve and to the radial artery.

**Supinator** (*Brevis*).—The supinator arises from the lateral condyle, the external lateral and orbicular ligaments, and the triangular surface of the ulna below the lesser sigmoid cavity. It winds around the posterior and external surfaces of the radius and inserts into the upper and outer portion, covering its head, neck, and shaft as low down as the insertion of the pronator radii teres muscle. It lies deep down beneath the mass of extensor muscles and supinates the radius. It is pierced by the deep branch of the radial (posterior interosseous) nerve which bears the same relation to it as does the external popliteal nerve to the peroneus longus muscle in the leg.

**Biceps Muscle.**—The biceps muscle has already been described. Arising by its long head from the upper edge of the glenoid cavity and by its short head from the coracoid process it inserts into the posterior portion of the tubercle of the radius. While its main function is that of flexion of the elbow, still, from the manner in which it winds around the tubercle of the radius, it acts as a powerful supinator when the hand is prone and it is a disturbing factor in the displacements which occur in fractures of the bones of the forearm.



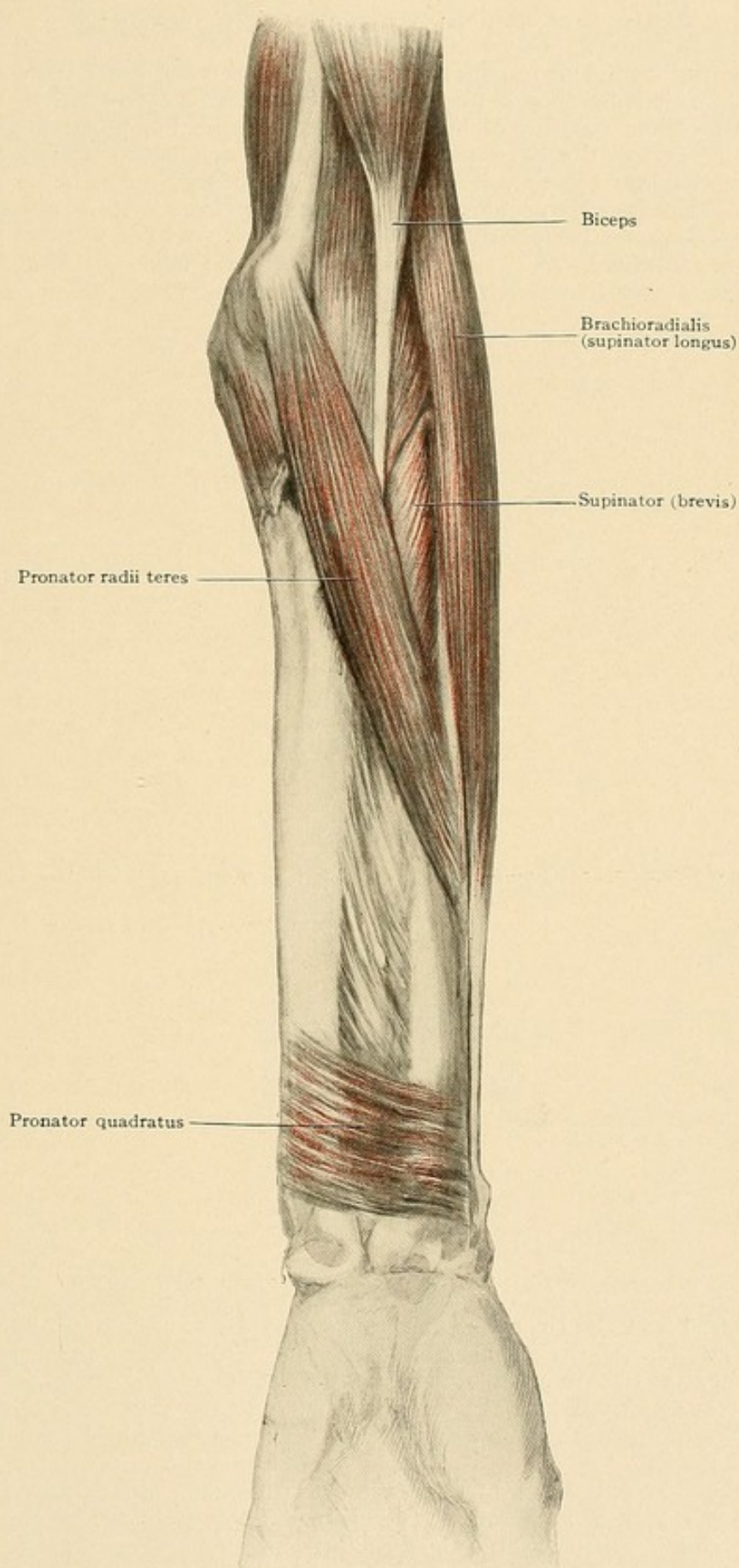


FIG. 326.—The pronator and supinator muscles of the left forearm.



## SURFACE ANATOMY OF THE FOREARM.

The forearm has the shape of a somewhat flattened cone, being large above and small below. This is because the bellies of the muscles lie above and their tendons below. Most of the muscles of the forearm go to the hand and fingers. The prehensile functions of the hand require a strong grasp; hence it is that we find the flexor muscles on the anterior surface of the forearm much larger and more powerful than the extensors posteriorly, and the bones of the forearm, the radius and ulna, nearer the surface posteriorly.

**Anterior Surface.**—Anteriorly nothing is to be felt except muscles and tendons. The extent to which these can be outlined depends on the absence of

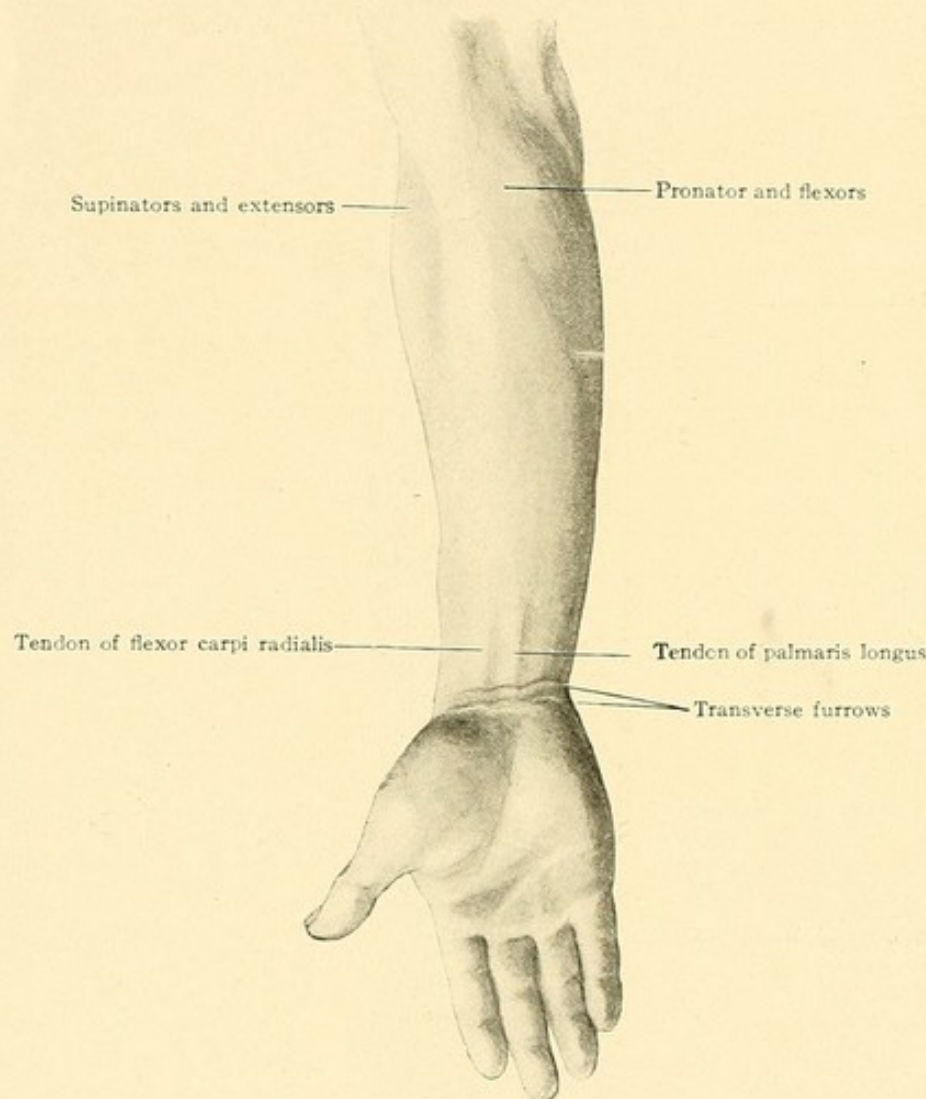


FIG. 327.—Surface anatomy of the forearm.

subcutaneous fat and the degree of development and contraction of the individual muscles. The skin of the forearm is loose and thin. Through it can be seen anteriorly, the median vein going up the middle and the radial vein winding around the back of the wrist and crossing the outer edge of the radius about its middle. On the inner side near the elbow the anterior and posterior ulnar veins are visible passing posteriorly.

Sometimes there is a slight depression on the inner side below the medial (internal) condyle which is caused by the bicipital fascia holding the muscle down. The biceps tendon can be felt at the bend of the elbow, and immediately below it for the distance of 5 cm. (2 in.) can be felt a hollow, the antecubital fossa. The mass of muscles between it and the ulna on the inside and posteriorly are the



flexors and pronator radii teres; the mass of muscles on the outer side between it and the radius posteriorly are the extensors, supinator (brevis), and brachioradialis. The inner edge of the brachioradialis is indicated by a line drawn from the outer side of the biceps tendon to the outer surface of the styloid process of the radius. A line from the medial (internal) condyle running obliquely across the forearm to the middle of the radius indicates the pronator radii teres muscle. A line from the medial condyle to the middle of the wrist indicates the palmaris longus muscle; it is sometimes absent. Another line from the same point above to a centimetre to the radial side of the palmaris longus tendon at the wrist indicates the flexor

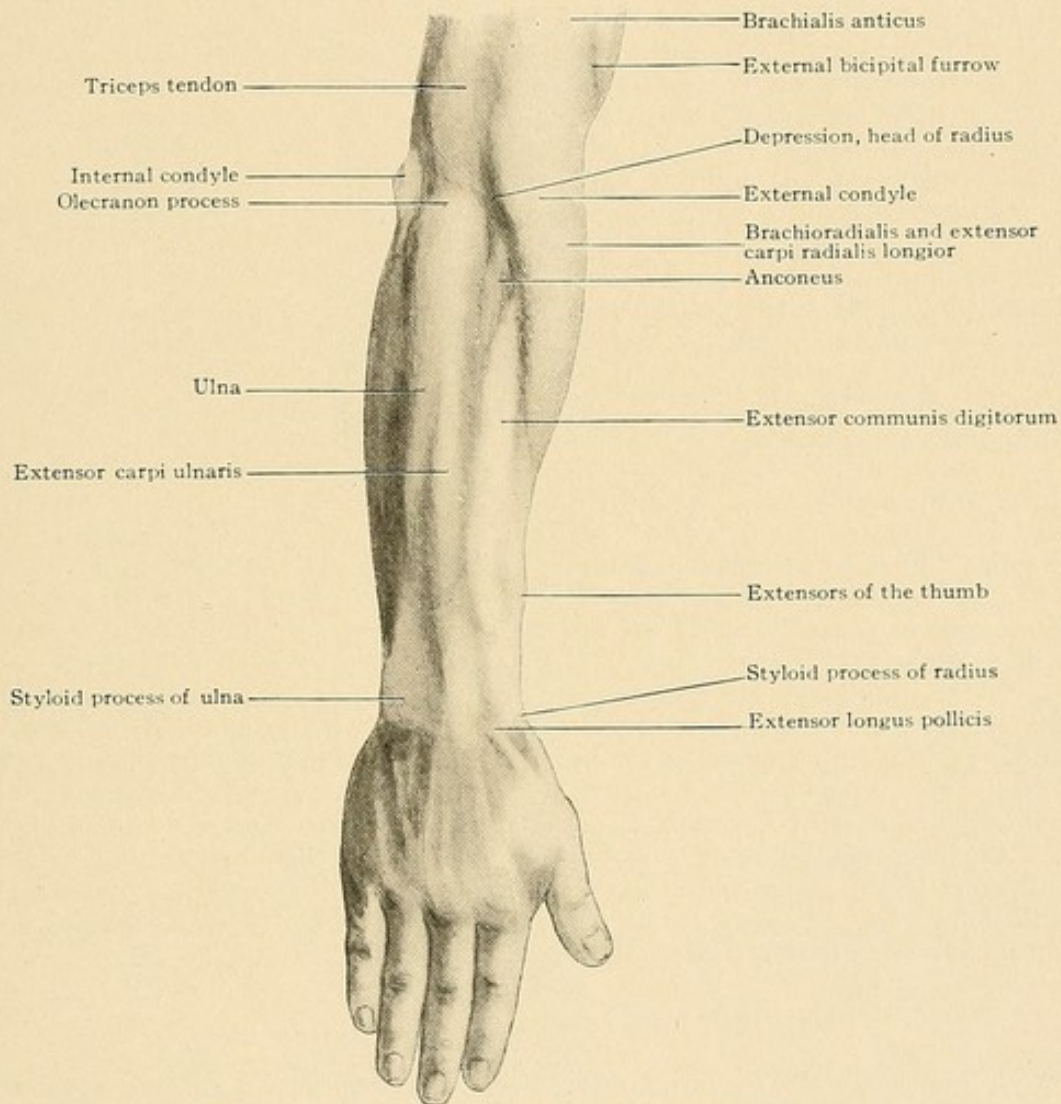


FIG. 328.—Surface anatomy of the back of the forearm.

carpi radialis muscle. The tendons of both these muscles can readily be seen. A line drawn from the medial (internal) condyle to the pisiform bone at the wrist indicates the anterior edge of the flexor carpi ulnaris muscle.

Having located the superficial muscles the arteries and nerves can be traced. The brachial artery bifurcates about a finger's breadth below the bend of the elbow. A line drawn from the inner edge of the biceps tendon, or a point midway between the two condyles, to the anterior surface of the styloid process of the radius indicates the course of the radial artery. In the upper half of the forearm it is overlapped by the edge of the brachioradialis. In the lower half it is uncovered by muscle and lies in the groove formed by the brachioradialis on the outer side and the flexor carpi radialis on the inner. The ulnar artery describes a marked curve toward the ulnar side until it reaches the middle of the forearm, when it passes down in a straight line from the medial (internal) condyle to the radial side of the pisiform bone.



The median nerve runs down the middle of the forearm, lying beneath the groove separating the palmaris longus and flexor carpi radialis tendons. The ulnar nerve runs from the groove between the medial (internal) condyle and olecranon process above to the radial or outer side of the pisiform bone below. It lies to the ulnar side of the ulnar artery in the lower half of the forearm. The rounded muscular mass between the edge of the flexor carpi ulnaris and the palmaris longus is formed by the flexor sublimis digitorum muscle (Fig. 327).

**Posterior Surface.**—The posterior surface differs from the anterior in the bones being more conspicuous—they are subcutaneous. Of the two the ulna is the more evident. At the elbow the olecranon and the capitellum to its outer side are well marked and some distance inwardly is the medial (internal) condyle. By palpation the ulna can be traced down the forearm almost subcutaneous, running from the olecranon process, in a gentle curve toward the median line, down to its styloid process at the back of the wrist. It is covered only by the skin and superficial and deep fascias. About 3 cm. ( $1\frac{1}{4}$  in.) to the outer side of the olecranon can be felt the lateral (external) condyle and capitellum. If the elbow is extended a dimple is seen just below the capitellum; it marks the position of the head of the radius, and by pressure the groove separating the head from the capitellum can be felt.

By placing the thumb of one hand in the dimple on the head of the radius, and rotating the hand of the patient with the other, one can feel the bone rotate and thus be assured that the radius is intact. Whenever fracture of the radius is suspected this is the procedure resorted to in order to determine whether or not it is broken.

The radius can be followed only for an inch or so below the dimple, when it disappears beneath the muscles to again become subcutaneous on the outer side of the forearm, about its middle, from thence it can be followed more or less distinctly down to the styloid process on the outer side of the wrist.

The ulna being subcutaneous, fracture can be determined by palpating it from the olecranon down the back of the forearm to the styloid process.

The line of the ulna is usually marked by the presence of a groove. To the ulnar side of the groove lie the flexor carpi ulnaris and the other flexors; to the radial side lie the extensor carpi ulnaris and the other extensors (Fig. 328).

From the dimple marking the head of the radius a groove in the muscles can be felt which runs to the middle of the outer surface of the radius. Anterior or to the palmar side of this groove lie the brachioradialis and extensor carpi radialis longior with the supinator (brevis) beneath. The muscles posterior or between the groove and the ulna are the extensor carpi radialis brevior, extensor communis digitorum, and extensor carpi ulnaris. Passing over the lower third of the outer side of the radius are the tendons of the extensor ossis metacarpi pollicis and extensor brevis pollicis muscles. As they are here subcutaneous, this is the point at which creaking can be felt when they are affected with tenosynovitis.

## ARTERIES OF THE FOREARM.

A knowledge of the arteries of the forearm is necessary on account of the troublesome hemorrhage which they cause when wounded.

At the bend of the elbow, a finger's breadth below the crease and opposite the neck of the radius, the brachial artery divides into the *radial* and *ulnar arteries*. These are continued through the forearm to enter the hand, the ulnar anteriorly over the annular ligament and the radial posteriorly through the "anatomical snuff-box."

The **ulnar artery** is larger than the radial and in its upper half it describes a curve with its convexity toward the ulnar side passing beneath the pronator radii teres and superficial flexor muscles arising from the medial (internal) condyle. It is accompanied by venæ comites but not by any nerve in this portion of its course. Just above the middle of the forearm the ulnar nerve joins the artery, lying to its ulnar side, and accompanies it down into the hand. In the lower half of its course the ulnar artery lies to the radial side of the flexor carpi ulnaris muscle, being slightly overlapped by it. The flexor sublimis on the radial side also tends to overlap it. The covering of the artery, partially at least, by these muscles, together with the thickness of the deep fascia and the lack of a proper bony support beneath, cause the



pulse from the ulnar artery to be less distinctly felt than that from the radial. When the artery passes beneath the pronator radii teres muscle it is crossed by the median nerve, which lies superficial to the artery, and is separated from it by the deep head of the muscle. The branches of the ulnar artery in the forearm are the anterior and posterior ulnar recurrents, the common interosseous, muscular, nutrient, and anterior and posterior ulnar carpal branches (Fig. 329).

The *anterior ulnar recurrent* runs upward between the edges of the pronator radii teres and brachialis anticus.

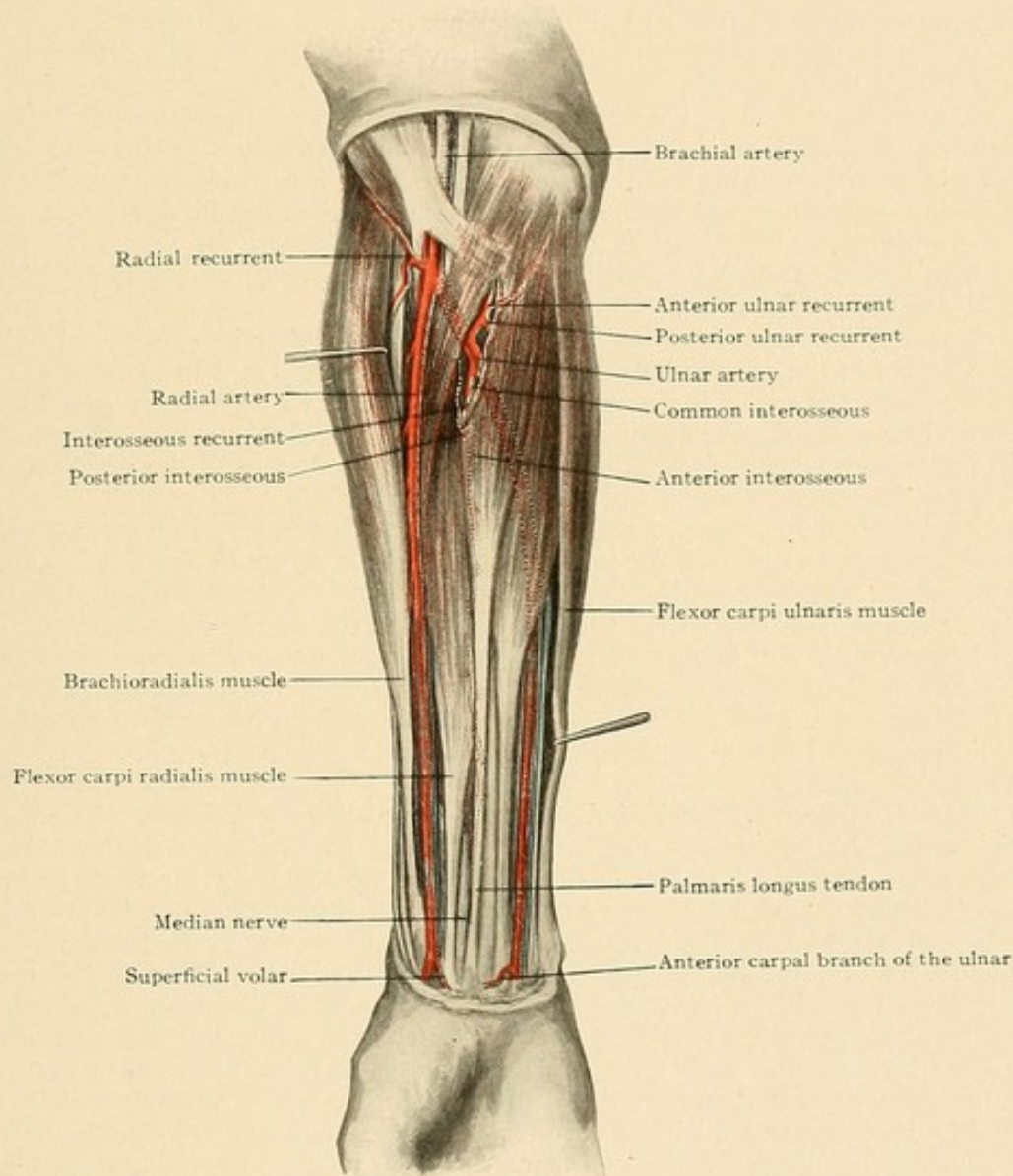


FIG. 329.—Arteries of the forearm.

The *posterior ulnar recurrent* passes upward with the ulnar nerve behind the medial (internal) condyle.

The *common interosseous* artery comes off from the ulnar about 2 to 3 cm. from its origin and divides into the volar (anterior) and dorsal (posterior) interosseous arteries. The anterior gives a branch to the median nerve—the *comes nervi mediani*—a nutrient branch to the radius, and, on reaching the upper edge of the pronator quadratus, sends a posterior terminal branch through the membrane and an anterior terminal branch into the muscle. The posterior interosseous passes beneath the oblique ligament to the back of the forearm and gives off the interosseous recurrent, which runs up between the lateral (external) condyle and the olecranon and then gives branches to the various muscles.



The **radial artery**, though smaller than the ulnar, seems to be a direct continuation of the brachial because it proceeds in the same general direction while the ulnar branches off to one side. It is divided into three parts according to the region it traverses, viz., the forearm, the wrist, and the hand. It describes a slightly outward curved line from a finger's breadth below the middle of the crease of the elbow to a point on the front of the radius at the wrist, 1 cm. ( $\frac{2}{3}$  in.) inside of its styloid process. It is superficial in nearly its entire extent, being overlapped only by the edge of the brachioradialis (supinator longus) in its upper third. This muscle lies to its outer side all the way down to the styloid process. In the middle third the cutaneous branch of the radial nerve lies close to the outer side of the artery, but in the lower third the nerve leaves it to become subcutaneous, passing more toward the dorsum.

To the inner side of the artery is the pronator radii teres muscle in its upper third and the flexor carpi radialis for the rest of its course. At the wrist it rests on the anterior surface of the radius, a centimetre to the inner side of its styloid process. By compressing the vessel against the bone its pulsations can be readily felt, and here is where the finger is applied in taking the pulse.

The branches of the radial artery are the recurrent, muscular, anterior radial-carpal and superficial volar.

The *radial recurrent* arises from the radial soon after its origin and follows the radial nerve, in the groove between the brachialis anticus and brachioradialis.

The *anterior carpal* is a small branch which joins with the corresponding branch of the ulnar and anterior terminal branch of the anterior interosseous to form a so-called anterior carpal arch which anastomoses with branches of the deep palmar arch to supply the bones and joints of the carpus.

The *superficial volar* leaves the radial artery just before it crosses the external lateral ligament. It pierces the muscles of the thumb to anastomose with a superficial branch of the superficial palmar arch. Sometimes this artery is so large that it can be seen pulsating as it passes over the thenar eminence from the wrist downward.

**Ligation of the Ulnar Artery in the Forearm.**—The ulnar artery between the elbow and wrist is so large that when wounded it may require ligation in any part of its course. On account of the artery being deep beneath the flexor muscles in the upper part of the forearm, the middle and lower portions are to be preferred for ligation (Fig. 330).

*Ligation in the Upper Third.*—This is done only for wounds. The superficial incision may be made in a line from the medial (internal) condyle to the middle of the outer border of the radius. The fibres of the pronator radii teres are to be parted, not cut, and the artery searched for crossing the wound almost at right angles, on a line from the bifurcation of the brachial artery to the middle of the inner border of the ulna. The artery is to be found lying between the superficial flexor muscles arising from the medial condyle and the deep muscles arising from the two bones and the interosseous membrane. It lies beneath the ulnar head of the pronator radii teres, which separates it from the median nerve, which is superficial to it and nearer the median line.

*Ligation in the Middle Third.*—The ulnar artery reaches the inner edge of the ulna at its middle and from thence downward runs in a straight line from the medial (internal) condyle to the radial side of the pisiform bone. It lies directly under the deep fascia and along the radial or outer edge of the flexor carpi ulnaris muscle, which can be made tense by extending and abducting the hand.

In the upper part of its middle third the artery lies under the edge of the flexor sublimis digitorum and the ulnar nerve lies a short distance to its ulnar side. In the lower part of the middle third the artery and nerve lie close together, the nerve being next to the tendon of the flexor carpi ulnaris. The tendon to the radial side of the artery is one of the slips of the flexor sublimis digitorum.

If difficulty is found in recognizing the edge of the flexor carpi ulnaris after the skin incision has been made the hand should be extended and abducted: this may make the muscle tense. Sometimes the intermuscular space is marked by a white or yellow (fatty) line or by some small blood-vessels coming to the surface at this point. The edge of the flexor carpi ulnaris is more likely to be to the radial than to



the ulnar side of the skin incision. The needle is to be passed between the nerve and artery from the ulnar toward the radial side.

*Ligation in the Lower Third.*—The relations of the artery are practically the same as in the lower part of the middle third. In the superficial fascia one of the branches of the anterior ulnar vein may be encountered. It should not be mistaken for the artery. The artery lies beneath the deep fascia; the edge of the flexor carpi ulnaris muscle should be clearly recognized. The deep fascia is apt to have two layers, one passing from the edge of the flexor carpi ulnaris over the flexor sublimis while the other, more superficial, goes more to the anterior surface of the annular

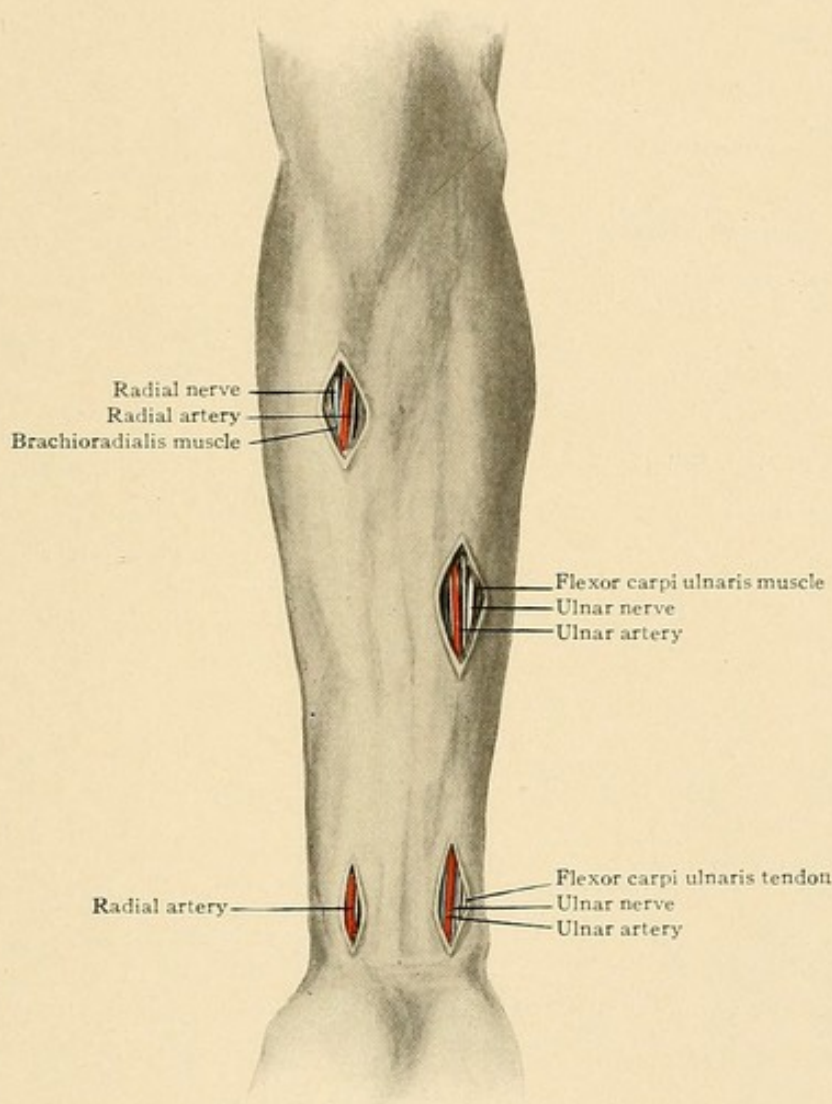


FIG. 330.—Ligation of the radial and ulnar arteries.

ligament. Care is to be taken not to work laterally between these layers but to isolate and recognize the edge of the flexor carpi ulnaris muscle.

The nerve lies between the tendon and artery, which latter has venæ comites. The needle is to be passed from the ulnar toward the radial side.

#### NERVES OF THE FOREARM.

Injuries of the large nerves of the forearm are followed by much disability. When these nerves are divided in wounds it is desirable to unite the ends immediately. The reunion of nerve-trunks which have been divided some time previously is also occasionally necessary.



These operations demand on the part of the surgeon an accurate knowledge of the topography of the part. For our purpose we may consider the nerves of the forearm as being of two kinds—trunks and branches. There are two main trunks—the median and the ulnar; the superficial (radial), and deep (interosseous) branches of the radial (musculospiral), and forearm branches of the median and ulnar form the second class. The main trunks simply traverse the forearm to be distributed in the hand, therefore injury to them shows itself by disabilities of the hand. The branches supplying the forearm, if of sensation, rarely give rise to any serious effects requiring surgical interference. The motor branches enter the muscles of the fore-

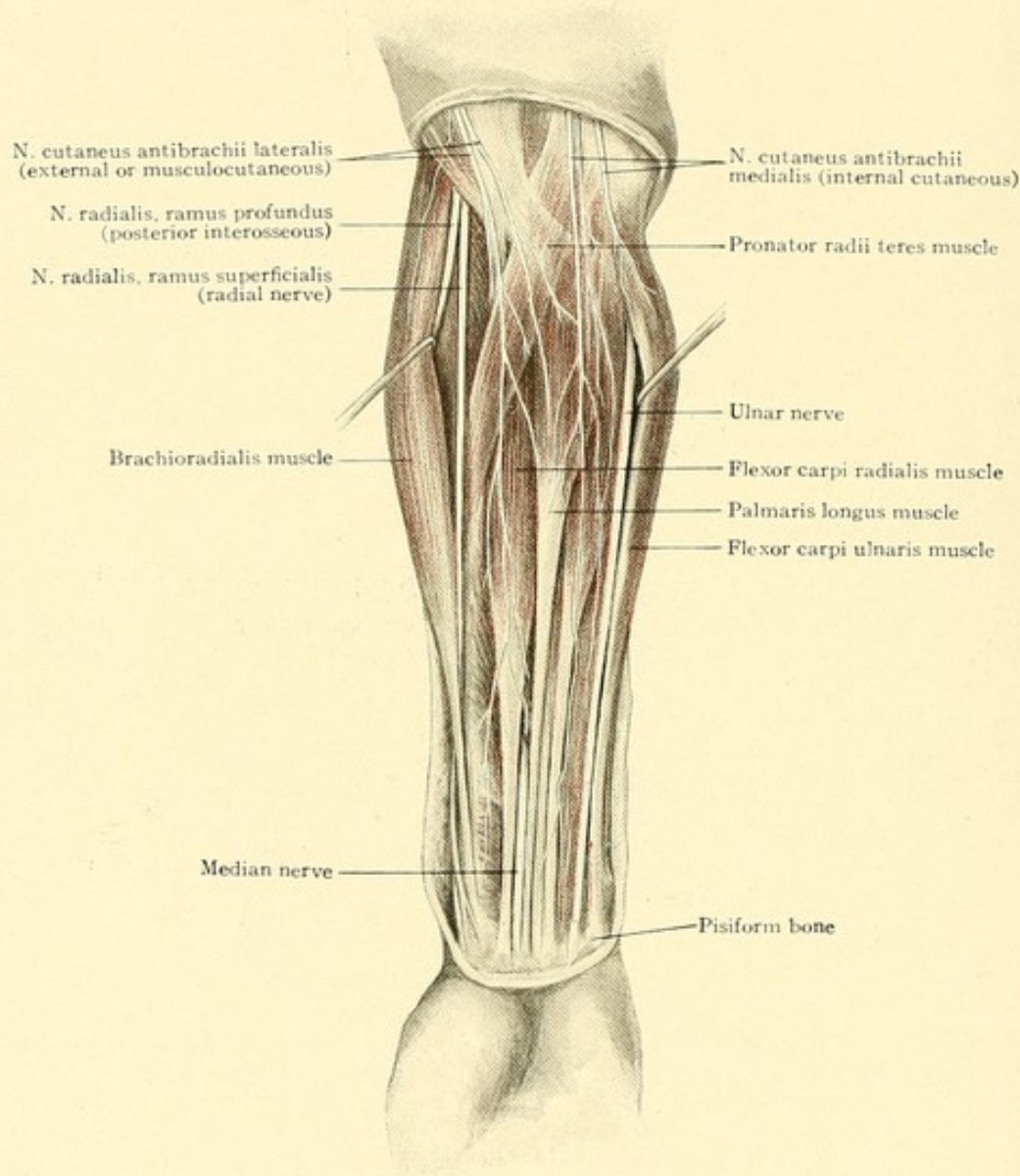


FIG. 331.—The nerves of the forearm.

arm so high up that paralysis usually is seen only when the nerves are injured in the region of the elbow or above. The high entrance is caused by the bellies of the muscles being above and the part below being tendinous (Fig. 331).

**The Median Nerve.**—The median nerve at the elbow-joint lies internal to the brachial artery, which lies next and internal to the biceps tendon. It lies on the brachialis anticus muscle and under the bicipital fascia. It crosses the ulnar artery obliquely a short distance below its origin. The artery curves toward the ulnar side while the nerve has a slight curve toward the radial side; between the two passes the ulnar head of the pronator radii teres muscle. The nerve then proceeds downward



between the superficial and deep layers of muscles. It lies on the flexor profundus digitorum and is covered by the flexor sublimis; about 5 cm. above the annular ligament it becomes more superficial and lies in the interval between the palmaris longus and flexor carpi radialis tendons and touching them. It then passes under the annular ligament to enter the palm of the hand. A branch of the anterior interosseous artery called the *comes nervi mediani* accompanies the nerve in the forearm.

*Branches.*—The median nerve gives off muscular, volar (anterior) interosseous, and palmar cutaneous branches, besides those in the hand.

The superficial flexor muscles, with the exception of the flexor carpi ulnaris, are supplied by branches directly from the main trunk near the elbow; the one to the pronator radii teres usually comes off above the elbow. The deep flexor muscles, with the exception of the inner half of the flexor profundus digitorum, are supplied by the volar (anterior) interosseous branch.

The *volar (anterior) interosseous nerve* leaves the main trunk of the median just below the elbow and accompanies the volar (anterior) interosseous artery, lying on the interosseous membrane between the flexor longus pollicis and the flexor profundus digitorum. It supplies the flexor longus pollicis and radial half of the flexor profundus muscles as well as the pronator quadratus.

The *palmar cutaneous branch* is given off just above the annular ligament and comes to the surface between the palmaris longus and flexor carpi radialis tendons. It passes over the annular ligament to be distributed to the thenar eminence and palm of the hand.

**Wounds of the Median Nerve.**—The median nerve may be wounded in any part of its course in the forearm, but it is superficial only in its lower portion for about 5 cm. above the wrist. From this point up it is covered by the flexor sublimis, the flexor carpi radialis and the pronator radii teres.

While these muscles tend to protect it from injury, if the traumatism is extensive enough to divide it they render it all the more difficult to treat. Accompanying the nerve, especially in the middle third of the forearm, is the *comes nervi mediani* artery, which may cause annoying bleeding. Careless attempts to secure the artery may injure the nerve. Should the nerve be divided, paralysis ensues of all the superficial flexor muscles except the flexor carpi ulnaris, and of the deep muscles, except the inner half of the flexor profundus. This includes the pronator radii teres and pronator quadratus, so that the power of pronating the forearm is impaired as well as the ability to flex the hand. The flexor carpi ulnaris and outer half (that going to the ring and little fingers) of the flexor profundus digitorum are the only flexor muscles not paralyzed.

The paralyzed flexor muscles atrophy and the size of the forearm is much reduced. There will also be impairment of the functions of sensation and motion in the hand, which will be alluded to later.

**Operations.**—To find the nerve in the *upper third* of the forearm an incision may be made at the inner side of the biceps tendon and brachial artery. The median nerve will be found to the inner side of the artery and may be followed down. When the pronator radii teres is reached it must either be drawn to the ulnar side or divided.

The fascial expansion covering the flexor sublimis is next reached; it must be slit up and the muscular fibres parted to reach the nerve lying between it and the flexor profundus, with the volar (anterior) interosseous nerve alongside.

To reach the nerve in the *middle third* of the forearm the guide should be the palmaris longus tendon. The nerve lies in a line joining the outer edge of the palmaris longus tendon at the wrist and the brachial artery at the inner side of the biceps tendon at the elbow. If an incision is made in the middle of the forearm one comes down on the belly of the flexor carpi radialis muscle and it is necessary to part its fibres as well as those of the flexor sublimis beneath. If one goes a little lower down and places the incision between the palmaris longus and flexor carpi radialis the latter may be drawn outward, but the fascia covering the flexor sublimis will still have to be incised. The *comes nervi mediani* artery will be found accompanying the nerve.

To reach the nerve in its *lower third* is the easiest because it becomes superficial about 5 centimetres (2 in.) above the wrist. Here it lies either beneath the



tendon of the palmaris longus or between it and the flexor carpi radialis. The incision should be made between the muscles. A layer of deep fascia will be found beneath them, which must be incised. From this point the nerve can be followed up beneath the flexor sublimis or downward beneath the annular ligament. Care is to be taken not to disturb the tendons of the flexor sublimis at the wrist.

**The Ulnar Nerve.**—The ulnar nerve passes downward in the groove on the back of the medial (internal) condyle and between the condyle and olecranon process. It passes between the two heads of the flexor carpi ulnaris muscle and is covered by it, lying on the flexor profundus digitorum; when half way down the forearm it becomes superficial and lies under or at the edge of the flexor carpi ulnaris muscle with the ulnar artery and flexor sublimis muscle to its outer or radial side. The ulnar artery joins the nerve just above the middle of the forearm. Just below the elbow the artery gives off the posterior ulnar recurrent branch, which passes up with the nerve behind the medial condyle. From the middle of the forearm to the wrist the ulnar nerve lies behind and to the ulnar side of the artery.

**Branches.**—It gives muscular branches in the upper third of the forearm to the flexor carpi ulnaris and ulnar half of the flexor profundus digitorum muscles. It gives small articular branches to both the elbow-joint and wrist-joint.

It also gives off anterior and posterior cutaneous branches. The anterior, one or two, come off about the middle of the forearm; one supplies the anterior surface of the ulnar side of the forearm, while another, called the *palmar cutaneous*, runs down the front of the artery to be distributed to the palm.

The dorsal or posterior cutaneous branch is given off about 5 cm. (2 in.) above the wrist and passes downward and backward beneath the tendon of the flexor carpi ulnaris, across the interval between the pisiform bone and styloid process of the ulna, over the tendon of the extensor carpi ulnaris, and thence to the fingers.

**Wounds.**—This nerve in the forearm is not infrequently wounded. It is especially liable to injury in resecting the elbow-joint. From what has been said of its course and branches it will be seen that in order for paralysis of any of the muscles of the forearm to be produced it must be injured high up in its upper third. Then the flexor carpi ulnaris and inner half of the flexor profundus digitorum will be paralyzed. If injured lower down the only muscular paralysis which will ensue is that of the short muscles of the hand which it supplies.

If the nerve is divided above the middle of the forearm the anterior cutaneous nerves will be involved. If divided between that point and 5 cm. above the wrist the anterior cutaneous escapes but the dorsal cutaneous branch is paralyzed. Below this latter point the dorsal cutaneous branch escapes and the muscular and sensory disturbances produced are on the palmar surface (except the dorsal interossei muscles).

**Operations.**—In all operations on the nerve it should be remembered that its course is a straight line from the medial condyle to the radial edge of the pisiform bone. In the lower half of its course it lies along the outer (radial) edge of the flexor carpi ulnaris and this tendon will serve as a guide to it. It is here covered only by skin and superficial and deep fasciæ, though it may be overlapped by either the artery or the edge of the tendon. If it is desired to reach the nerve in its upper half it can be followed either from above downward or from below upward, the fibres of the flexor carpi ulnaris muscle which cover it being split to the extent necessary for proper exposure. Below the middle of the forearm the ulnar artery lies to its radial side. Near the elbow the posterior ulnar recurrent artery accompanies it upward, but the nerve is far removed from the ulnar artery in this part of its course.

**The Volar Interosseous Nerve and the Superficial and Deep Branches of the Radial (Musculospiral).**—In addition to the large nerve-trunks of the median and ulnar the forearm contains the volar (anterior) interosseous, and the deep and superficial branches of the radial (musculospiral) nerve.

The *volar (anterior) interosseous* nerve leaves the median opposite to or below the bicipital tubercle of the radius; it lies on the interosseous membrane to the ulnar side of the accompanying volar interosseous artery. It supplies the outer half of the flexor profundus digitorum and the flexor longus pollicis muscles, between which it lies, and the pronator quadratus muscle. It is rarely wounded alone.



The deep and superficial branches are the continuation of the radial (musculospiral) which divides in the groove between the brachioradialis (supinator longus) and brachialis anticus muscles just above the elbow.

The *deep branch* (*posterior interosseous*) is the larger and is a muscular nerve; the superficial branch (radial) is smaller and is solely sensory. The deep branch passes down under the brachioradialis and extensor carpi radialis longior and brevior muscles and then enters the substance of the supinator (brevis) through which it passes to supply the extensor muscles on the back of the forearm and terminates in a gangliform enlargement on the back of the wrist. It supplies all the muscles on the back of the forearm except the anconeus, brachioradialis, and extensor carpi radialis longior, which are supplied directly from the radial (musculospiral) nerve. In removing the head of the radius, in resection of the elbow, the supinator (brevis) is to be carefully raised from the bone so as to carry the nerve with it and avoid injuring it. Injury to this nerve causes paralysis of the extensors, and wrist-drop follows.

The *superficial branch* (*radial*) is purely a nerve of sensation. It passes down almost in a straight line and lies to the outer side of the radial artery at the junction of its upper and middle thirds. It lies alongside of the artery to its outer side in its middle third and then, about 7 or 8 cm. (3 in.) above the wrist, quits the artery, passes beneath the tendon of the brachioradialis, and divides into two branches which supply sensation to the dorsal (radial) side of the hand and fingers.

In operating on the radial artery in the middle third of the forearm care should be exercised not to include the nerve in the ligature with the artery.

### FRACTURES OF THE FOREARM.

Fractures of the forearm may involve either the radius or ulna, or both. The radius is the bone most often broken. The preservation of the interosseous space and functions of pronation and supination are prominent points in treatment.

**Fractures of Both Bones.**—These fractures occur either from a direct blow on the part or are due to violence in falling on the outstretched hand. They usually occur in the middle or lower third. The character of the displacement depends more on the manner in which the injury is produced than on the action of the muscles, though in some cases they also have some influence.

The main function of the forearm in addition to that of serving as a pedestal or support for the hand is to perform the movements of pronation and supination. It is these movements that are most apt to be impaired in cases of fracture. When both bones are fractured the interosseous membrane still remains, running transversely from one bone to that of the opposite side. Therefore, while it is common enough to find the fractured ends displaced toward one another, thus narrowing or obliterating the space between them, one never sees a displacement of the fragments producing a widening of the interosseous space. In fracture of both bones four types of deformity or combinations of these types are found.

1. The fractured ends of the distal or proximal fragments may preserve approximately their normal position to one another but be displaced either anteriorly or posteriorly or else to one side. When this is the case the displacement is one simply of overlapping. If the fragments are displaced laterally from one another then the tension of the muscles draws the fragments together and causes them to overlap. There is no special direction which this displacement may take. The lower fragments may be either in front or behind or to either side of the upper ones. The position of the fragments varies according to the direction of the fracturing force.

This displacement is to be remedied by traction on the hand to overcome the muscles and bring the broken ends opposite one another, and then by direct pressure pushing them as completely as possible back into their normal position.

The shafts of both bones have muscles arising from them on both their anterior and posterior surfaces and the sharp fractured ends of the bones not infrequently get stuck in the muscular fibres and so prevent proper approximation; non-union may be produced by this cause.

2. The fractured ends of the distal or proximal fragments may be displaced toward one another, thus lessening or even obliterating the interosseous space. When



the bones are intact they rest on one another at their ends, leaving a space between across which stretches the interosseous membrane. The action of this membrane in preventing a separation of the fragments has already been pointed out, and the influence on the fragments of pronation and supination will be discussed further on. The two bones,—radius and ulna,—traverse the forearm from the elbow to the wrist like two bridges, when they are broken they naturally fall inward toward one another. This approximation of the fragments is aided by the muscles, particularly the pronators and the brachioradialis.

The pronator quadratus and teres both pass from the ulna to the radius, the one at the lower and the other at the upper portion of the forearm. When they contract they naturally tend to draw the bones toward one another. The brachioradialis, arising from the lateral (external) supracondylar ridge of the humerus and inserting into the base of the styloid process of the radius, by its contraction tends to tilt the upper end of the lower fragment toward the ulnar side.

Pressure on the bones by bandages wound around the part likewise causes them to encroach on the interosseous space, hence the desirability of splints which are wider than the forearm so that lateral pressure on the bones by the bandages is prevented.

3. The fragments may be rotated on one another in the direction of pronation or supination and, becoming united in this misplaced position, render the normal movements of rotation either much restricted or altogether impossible.

This axial rotary displacement is due either to the lower fragments being dressed in a position of pronation or to muscular action. As has already been pointed out (see movements of pronation and supination, page 314), in performing the movements of pronation and supination the ulna is the fixed bone and the radius is the movable one. When the hand is pronated the radius crosses the ulna obliquely and lies almost or quite in contact with it, thus obliterating the interosseous space. When the hand is in a position of middle or full supination the bones are widely separated. When fractures are treated in the prone position it is recognized that the callus may bind the bones together in their approximated condition and a loss of motion will result.

This is one reason why it is always required to treat these fractures with the hand midway between supination and pronation or in complete supination, in which position the bones are widely separated. The influence of the supinator muscles, as was pointed out by Lonsdale, is also important. As has already been stated, the supinators are stronger than the pronators. When the fracture occurs above the insertion of the pronator radii teres the upper fragment is rotated outward by the biceps and supinator (brevis). There are no muscles to oppose them. On this account it is necessary to dress the fracture with the hand supinated. When the bones are broken below the middle of the forearm the pronator radii teres remains attached to the upper fragment and tends to oppose the supinating action of the biceps and supinator (brevis). Therefore the fracture is treated with the hand midway between pronation and supination. A diminution or loss of the power of pronation and supination is a common sequel of fractures of the forearm and is due either to an interference with the movement of the bones by callus or displaced fragments or by supination of the upper fragment. It is favored by treating the arm in an unfavorable position.

4. The fragments may be inclined toward one another, producing an angular deformity. Simple bending at the site of injury produces this displacement. It is liable to occur if a narrow band or sling is used to support the injured member. If the hand is supported by the sling the arm sags at the seat of fracture. If the forearm is supported at the site of fracture the hand falls and an angular deformity again occurs. Treatment of the fracture with the hand in a supine position on a splint with a long sling reaching and supporting the entire length of the forearm will obviate and prevent the deformity.

**Fractures of the Shaft of the Radius.**—Fractures of the shaft of the radius are not common. They are produced by both direct and indirect injury. The hand is attached to and articulates mainly with the radius, so that in falls on the hand the force is transmitted to the radius, and the shaft of the bone is not infrequently fractured in this manner.



These fractures are of interest from an anatomical point mainly on account of the influence of rotation and muscular action in displacing the fragments. The forearm possesses the movement of rotation; the radius is the movable bone and rotates around the ulna, hence when it is broken its fractured ends are readily displaced. Fractures of this bone are to be treated with the hand in half or full supination because in these positions the interosseous space is preserved. In pronation the radius crosses the ulna obliquely and lies close upon it and is then most liable to be bound to it by callus. A certain amount of callus or deformity may occur without interfering with the ulna opposite.

It should also not be forgotten that most muscles have more than one action. The biceps is both a flexor and supinator. The brachioradialis flexes, supinates, and exerts a directly upward traction on the outer surface of the lower end of the radius.

The fractures of the shaft of the radius may be divided into those above and those below the insertion of the pronator radii teres. This muscle inserts by a comparatively small tendon into the outer and posterior surface of the middle of the radius.

*Fractures above the Insertion of the Pronator Radii Teres.*—When the bone is fractured above the pronator radii teres insertion, and below the tubercle, the upper fragment is drawn forward and rotated outward by the biceps. If the fracture is down close to the upper edge of the insertion of the pronator radii teres the supinator (brevis) will assist in the supination. The lower fragment will be pronated by the pronator radii teres and quadratus. It will be drawn toward the ulna by the teres, quadratus, and also by the action of the brachioradialis. The pronator radii teres will also tend to draw the lower fragment anteriorly. The injury is to be treated with the elbow flexed to relax the biceps and in a fully supinated position (Fig. 332).

*Fractures below the Insertion of the Pronator Radii Teres.*—When the fracture is below the insertion of the pronator radii teres and above the pronator quadratus we have the lower fragment drawn toward the ulna by the pronator quadratus and the brachioradialis. The quadratus also tends to pronate the hand (Fig. 333).

The upper fragment is displaced anteriorly by the flexing action of both the biceps and pronator radii teres. The supinator (brevis) and biceps both tend to supinate it and the pronator radii teres to pronate it. This tends to place the upper fragment

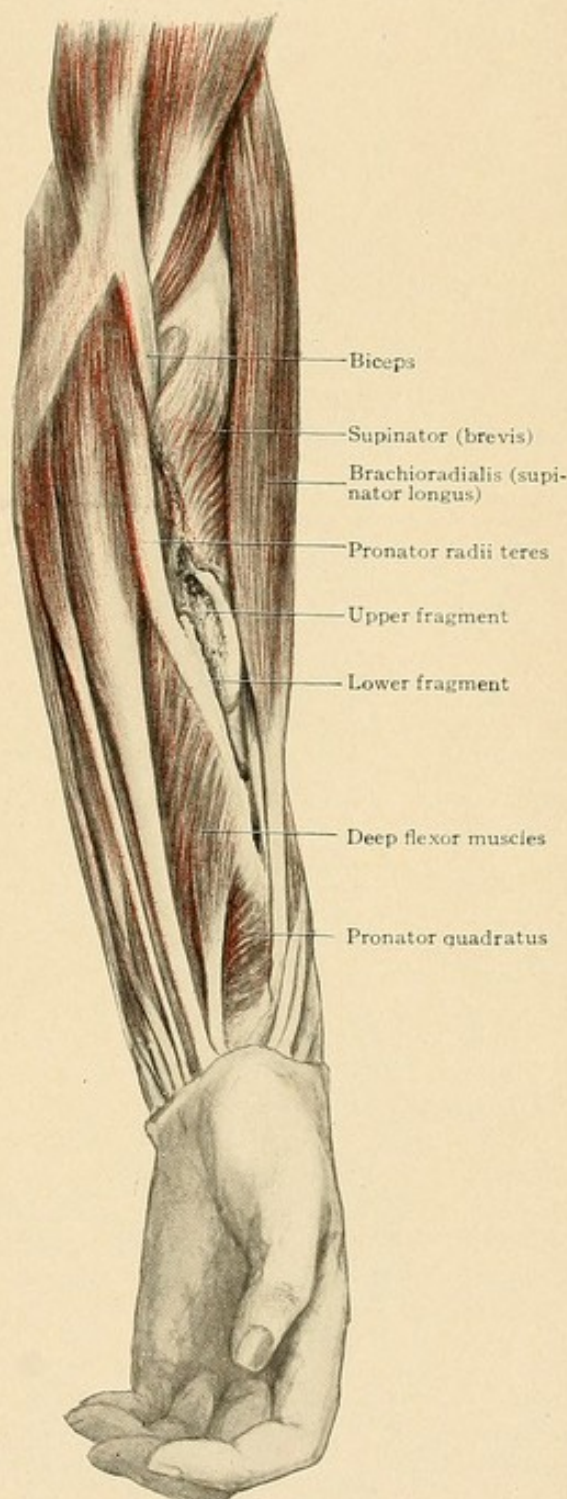


FIG. 332.—Fracture of the shaft of the radius above the insertion of the pronator radii teres muscle. The upper fragment is rotated outward by the biceps and supinator muscles.



midway between pronation and supination. All fractures of the radius are to be treated with the elbow flexed to relax the biceps muscle. It is to be marked that the position of the lower fragment follows the position of the hand in pronation and supination. Also that by bending the hand toward the ulnar side the lower fragment tends to be tilted away from the ulna and thus the interosseous space is increased.

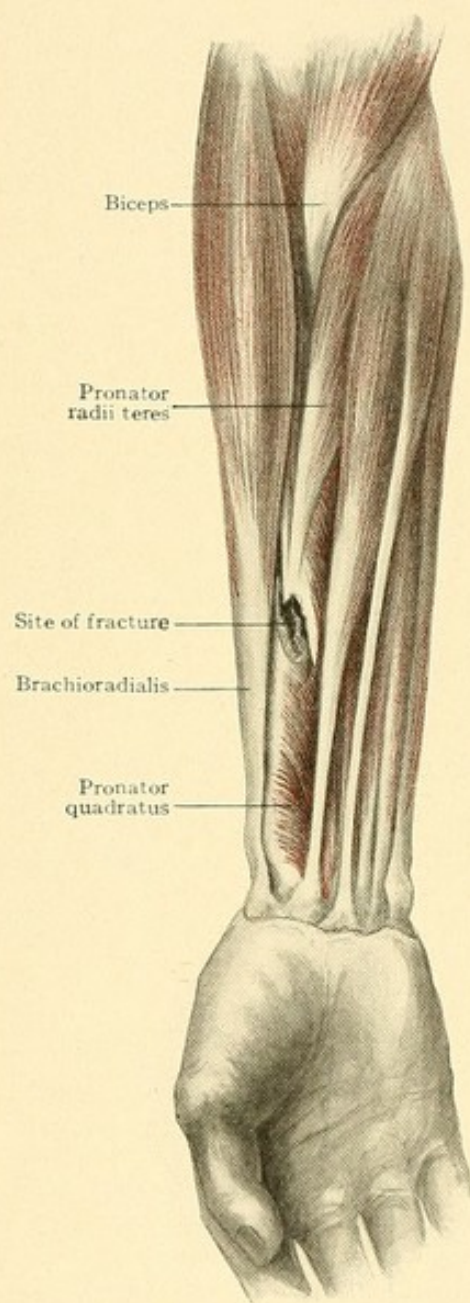


FIG. 333.—Fracture of the radius just below the insertion of the pronator radii teres muscle. The upper fragment is displaced directly forward in a position midway between pronation and supination.

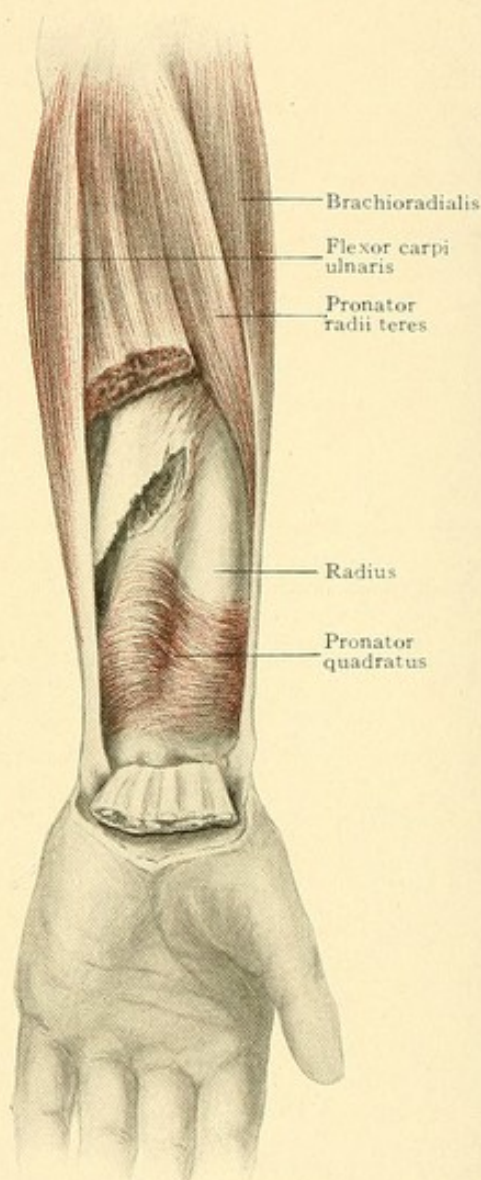


FIG. 334.—Fracture below the middle of the shaft of the ulna, the lower fragment drawn toward the radius by the pronator quadratus muscle.

Pressure with the thumb and fingers between the bones tends to increase the interosseous space and to some extent to counteract the action of the brachioradialis.

On account of the upper fragment assuming a middle position the fracture is dressed in this position with the thumb upward—an internal angular splint is used. Some surgeons prefer using the position of full supination.

The difference in the width of the interosseous space when the hand is in full supination and when it is in semisupination, though it may be slightly in favor of the latter position, is too little to give it any preference on that account.



**Fractures of the Shaft of the Ulna.**—The shaft of the ulna is more often broken by direct violence than is the shaft of the radius. When the arm is raised to ward off a threatened blow the thumb is toward the body and it is the ulna which is presented externally to receive the impact of the blow, hence its more frequent injury. There are two main sites of injury, one just below its middle and the other a short distance below the elbow-joint, about at the junction of its middle and upper thirds. The former results from the fact that the bone below the middle is smaller and weaker than it is above and is not so well covered by muscles.

*Fractures just Below the Middle of the Shaft of the Ulna.*—The bones of the forearm act as props to separate the hand and elbow. The hand is attached to the radius and the radius rests on the capitellum of the humerus, therefore even when the ulna is fractured as long as the radius and attachments of the hand are intact there is usually but little overlapping of the fragments.

The lower fragment is most often displaced to the radial side. This is due to the action of the pronator quadratus muscle (Fig. 334).

The upper fragment articulating with the humerus by a pure hinge-joint cannot be displaced laterally, but the radius and hand can move bodily toward the ulna, being favored in so doing by the pronator radii teres. Thus it is seen that both

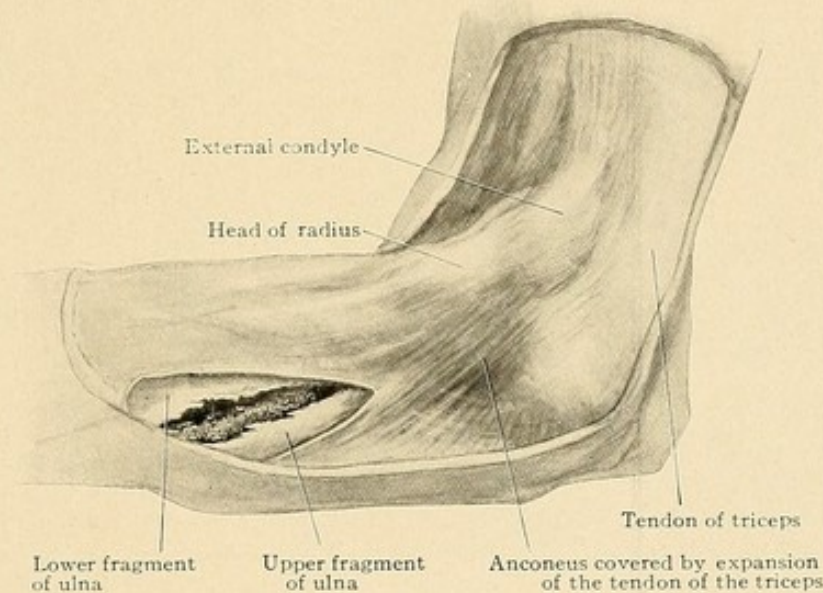


FIG. 335.—Fracture through the upper third of the ulna viewed from the outer side.

upper and lower fragments have a tendency to incline toward the radius and so obliterate the interosseous space and interfere with rotation.

As to whether the lower or upper fragment will be nearer to the radius will depend upon the direction of the line of fracture. If this is from within downward and outward, as is the more usual, then the lower fragment will be to the radial side of the upper one.

The treatment of fractures in this locality should be with the hand placed in the position of full supination. Hamilton ("Fractures and Dislocations," page 319) stated that he had three times seen supination lessened in this injury but never pronation. The ulna is to be pushed away from the radius by pressure made between them with the thumb and fingers and the hand bent toward the radial side.

*Fracture at the Upper Third.*—The radius articulates with the upper end of the ulna in the lesser sigmoid cavity. Immediately below this is a depression in the ulna called the bicipital hollow, intended to accommodate the bicipital tubercle when the forearm is pronated. At this point the bone is slightly narrowed and then widens again toward the middle. This constricted part is 7 or 8 cm. (3 in.) below the tip of the olecranon process and the spot where fracture is likely to occur. When fracture does occur here, if displacement is marked, it produces characteristic lesions. The upper fragment may be displaced either posteriorly or anteriorly.



The carrying angle (page 282) formed by the line of the arm with the line of the forearm, depends on the integrity of the humerus and ulna and their proper articulation. If the ulna is broken high up the forearm is deprived of its support on the inner side and it sags inward, thus approximating the bones, obliterating the interosseous space, and diminishing the carrying angle. In treatment care should be taken that the forearm be not allowed to incline toward the inner side.

*Displacement Posterior.*—When the displacement is posterior the lower end of the upper fragment is tilted backward by the contraction of the triceps muscle. This causes a marked projection on the back of the forearm below the elbow (Fig. 335).




FIG. 336.—Fracture of the upper third of the ulna, with anterior angular displacement of the fragments and anterior dislocation of the head of the radius.

In treating this injury the forearm should be placed in at least partial extension (complete extension is usually not necessary) so as to relax the triceps muscle.

*Displacement Anterior.*—When a person receives a blow in the region of the junction of the upper and middle thirds of the ulna on its posterior surface the fragments are pushed forward and an angular deformity is produced, the apex of the angle pointing toward the anterior surface. The force of the blow is not expended entirely on the ulna but, having broken it, continues and pushes or dislocates the radius forward (Fig. 336).

In these injuries the fracture of the ulna is readily recognized, but the dislocation of the head of the radius is often overlooked. If the dislocation is not reduced subsequent flexion of the elbow will not be possible much if any beyond a right angle. The contraction of the biceps not only favors this luxation by pulling the radius forward but tends to cause it to recur after replacement.

Reduction is to be attempted by supinating and flexing the forearm to relax the biceps and making direct pressure anteroposteriorly on the radius

to force the head back into place. The radius may be kept in place by dressing the arm with the elbow in a position of complete flexion.

### AMPUTATION OF THE FOREARM.

The lower half of the forearm is so largely tendinous that musculocutaneous flaps are unsuitable; by the time the tendons are cut short there is little tissue left but skin, superficial and deep fascia, and a few muscular fibres.

Amputation should be performed as low down as one can so as to save as much as possible. Artificial appliances, so useful in the lower extremity, are, practically, of little value in the upper. The preservation of the power of pronation and supination is to be accomplished when the condition permits. The pronator radii teres has its insertion in the middle of the radius and if the division of the bone is below that point rotary movements will be preserved.

The surgeon should be acquainted with the position of the main arteries and nerves. Four arteries will require ligation: the radial, ulnar, volar (anterior), and dorsal (posterior) interosseous. Their position as well as that of the nerves will vary accordingly to the site of the amputation. The median and ulnar are the only nerves that require shortening.



**Amputation Through the Upper Third.**—The radial artery is to be looked for near the surface under the deep fascia, just beneath the edge of the brachioradialis muscle.

The ulnar artery lies between the superficial and deep flexor muscles somewhat toward the ulnar side of the median line.

The volar interosseous artery lies in front of the interosseous membrane.

The dorsal interosseous lies between the superficial and deep muscles on the back of the forearm more toward the ulnar side.

The median nerve is to be sought in the middle line of the forearm below the superficial flexor muscles.

The ulnar nerve lies to the ulnar side of the ulnar artery on a level with it and beneath the flexor carpi ulnaris muscle.

**Amputation Through the Middle Third.**—The radial artery lies beneath the deep fascia in front of the radius along the inner edge of the brachioradialis.

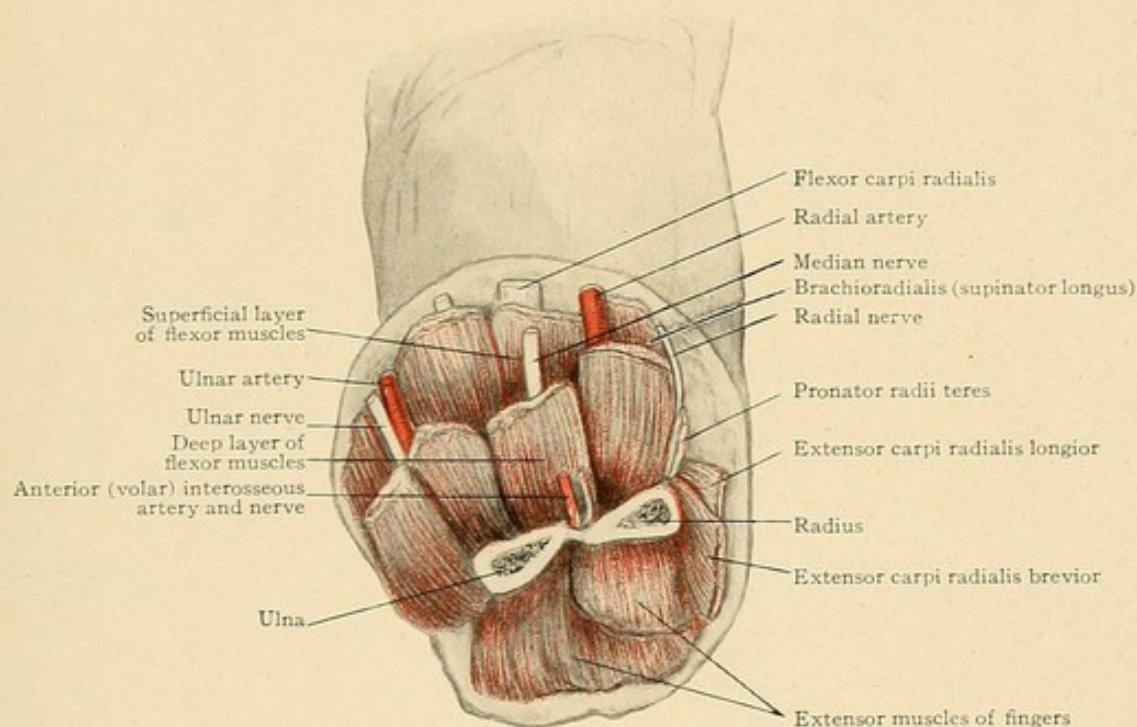


FIG. 337.—Amputation about the middle of the forearm.

The ulnar artery here becomes more superficial and lies beneath the radial edge of the flexor carpi ulnaris muscle.

The volar interosseous is found lying on the anterior surface of the interosseous membrane or the thin edge of the flexor profundus.

The dorsal interosseous lies posterior to the membrane between the superficial and deep extensor muscles.

The median nerve is directly in the midline beneath the flexor sublimis and above the flexor profundus digitorum.

The ulnar nerve lies to the radial side of the ulna, to the ulnar side of the ulnar artery, and under the flexor carpi ulnaris muscle (Fig. 337).

**Amputation Through the Lower Third.**—The radial artery lies beneath the deep fascia between the flexor carpi radialis and brachioradialis.

The ulnar artery lies to the ulnar side under the deep fascia and at the edge of the flexor carpi ulnaris muscle.

The volar and dorsal interosseous arteries are too small to require ligation.

The median nerve lies beneath the palmaris longus muscle. At the wrist it lies beneath the interval between it and the flexor carpi radialis.

The ulnar nerve is superficial along the edge of the flexor carpi ulnaris and accompanies the ulnar artery along its medial (ulnar) side.



## OPERATIONS ON THE BONES AND OTHER STRUCTURES OF THE FOREARM.

The forearm may require to be operated on for disease or injuries of the bones, tumors, foreign bodies, wounds, etc. In operating on this region of the body it is to be constantly borne in mind that it contains a multitude of structures each of which is essential to the proper performance of some special function. Injury to these structures is followed by a corresponding functional disability. Attempts at brilliant operating are out of place and the surgeon should be exact, careful, and even tender in his handling of the various structures.

The forearm is mainly nourished by the volar and dorsal interosseous arteries; the radial and ulnar pass through it to nourish the hand. These latter are to be avoided.

The nerves that supply the forearm are given off high up near the elbow, hence they are not usually in danger of injury. The median, ulnar, and superficial branch of the radial nerve pass to the hand and they, if possible, are to be avoided.

It is therefore evident that as far as the arteries and nerves are concerned operations in the lower part of the forearm are less dangerous than those in the upper. With the muscles it is just the opposite. In the lower half the muscles become tendinous and soon form groups or masses of tendons. These tendons are separated by thin connective-tissue sheaths or synovial membrane which allow them to move freely as the muscles contract. Any interference with these sheaths or their contents causes an outpouring of inflammatory material that binds them together and fetters their action. As healing takes place contraction sets in and the patient is left with a useless claw-like hand. For these reasons large incisions and displacements and interference with tendons are to be avoided whenever possible.

As the muscles mostly run longitudinally the incisions should also be longitudinal. Division of the superficial veins is not liable to cause trouble, but the large radial, median, or ulnar veins on the anterior surface may be plainly visible and then the incision should be made so as to avoid wounding them.

The only superficial nerve to be so avoided is the superficial branch of the radial. It is alongside of the radial artery in its middle third, but about 7 or 8 cm. (3 in.) above the wrist it leaves the artery and winds under the brachioradialis to go down the outer and posterior surface of the radius. It is here to be looked for and avoided, as it furnishes sensation to the thumb, index, middle, and half of the ring fingers.

If it is desired to penetrate the muscles their direction is to be remembered. The superficial flexor muscles arise from the internal condyle, hence the incision should point upward toward it. The direction of the pronator radii teres is from the internal condyle to the middle of the radius. The deep flexors are parallel with the bones.

Posteriorly the extensor group of muscles tends toward the external condyle. A third group on the radial side comprises the brachioradialis and the extensor carpi radialis longior and brevior. The tendon of the first lies on the outer surface of the radius with the other two immediately posterior to it. Crossing the posterior and outer surface of the radius in its lower third are the extensor ossis metacarpi pollicis and extensor brevis pollicis tendons.

If it is desired to reach the bones the ulna can be exposed posteriorly where it is subcutaneous in its entire length by an incision between the flexor carpi ulnaris and extensor carpi ulnaris. The deep fascia is attached to the bone at this point.

If it is desired to expose the radius, H. Morris (*Clin. Soc. Trans.*, vol. x, p. 138) has advised going in between the brachioradialis and the extensor carpi radialis longior. He used the superficial branch of the radial nerve as a guide to the desired interspace.

If an incision were made upward from the outer surface of the styloid process of the radius one would first encounter the tendons of the extensor brevis pollicis and extensor ossis metacarpi pollicis muscles. These being displaced posteriorly would reveal the brachioradialis tendon crossing from beneath the posterior border of the radius; 5 to 7 cm. (2 to 3 in.) above the styloid process would be the superficial



branch of the radial nerve. Following the nerve and edge of the brachioradialis tendon would lead to the interspace between it and the extensor carpi radialis muscle posteriorly. When the middle of the forearm was reached the insertion of the pronator teres would be encountered, and from that point up the bone would be covered by the supinator (*brevis*).

Operations on the median nerve (page 319) and the ulnar nerve (page 320) have already been alluded to.

In operations involving the upper third of the radius the deep branch of the radial (posterior interosseous) nerve is liable to be wounded as it passes through the supinator (*brevis*) muscle. It is best avoided by elevating the muscle from the bone and raising the nerve along with it, for it does not rest immediately on the bone but has some muscular fibres intervening.

The arteries have already been sufficiently described.

#### PUS BENEATH THE DEEP FASCIA.

The deep fascia of the forearm is continuous with that of the arm. It forms a complete covering for the muscles and sends septa between them. It is especially strong posteriorly. It is attached to the medial and lateral condyles of the humerus, the sides of the olecranon process and the whole length of the ulna posteriorly. Below the medial condyle anteriorly it is strengthened by the bicipital fascia. In the antecubital fossa it is pierced by a large communicating vein which connects the superficial and deep veins. Toward its lower end posteriorly, it is strengthened by transverse fibres and becomes attached to the longitudinal ridges on the radius and blends with the posterior annular ligament.

Below anteriorly it is thin and forms a covering for the tendons of the palmaris longus and flexor carpi radialis muscles and at the wrist blends with the annular ligament beneath. This latter, as pointed out by Davies Colley ("Morris's Anatomy," page 311), is a continuation of the layer of fascia covering the flexor sublimis digitorum.

When infection involves the deep tissues of the forearm the pus, being hindered from going externally by the fibrous septa between the various layers of muscles as well as the deep fascia itself, tends to burrow up and down the arm. If in the upper portion of the forearm, it tends to point in the antecubital fossa. If lower down, it tends to come to the surface on the radial side between the flexor carpi radialis and brachioradialis or toward the ulnar side between the palmaris longus and flexor carpi ulnaris.

The three structures,—the tendons of the palmaris longus and flexor carpi radialis and the median nerve,—form a solid barrier anteriorly which inclines the pus to one side. Above posteriorly it may work its way upward behind the internal condyle, following the ulnar nerve.

The fibrous septa of the various muscles hinder the progress of pus laterally, and the attachment of the deep fascia to the ulna prevents its passing around the arm at that point. The many pockets formed by the pus in its burrowing between the muscles render these abscesses difficult to drain and tedious in healing.

Should infection from the thumb travel up the flexor longus pollicis tendon, when it reaches above the wrist it is directly beneath the tendon of the flexor carpi radialis. In such a case an incision should be made along the radial (outer) edge of the tendon, taking care not to wound the radial artery still farther out. If pus infects the forearm by following up the flexor tendons of the fingers beneath the anterior annular ligament, it shows itself above the wrist between the palmaris longus and flexor carpi ulnaris tendons and can here be incised. If it is desired to introduce a drain beneath the flexor muscles, an incision may be made along the side of the ulna and a forceps passed under the flexor tendons and made to project under the skin of the radial side where a counter opening can be made and the drain inserted. (For a discussion of the treatment of purulent affections of the hand and forearm see A. B. Kavel: "Surgery, Gynecology, and Obstetrics," 1909, p. 125, vol. viii, No. 3.) Suppuration around these tendons is very serious, as the effusion binds together the tendons and irritates the nerves and produces disabling contractures which are exceedingly difficult to remedy.



## REGION OF THE WRIST.

By the wrist is meant the constricted portion of the upper extremity by which the hand is joined to the forearm. We will include in its consideration the lower portion of the forearm for about 4 cm. ( $1\frac{1}{2}$  in.) above the radiocarpal joint, and the

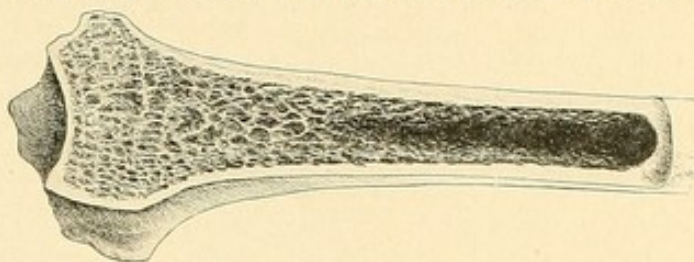


Fig. 338.—Sawn section through the lower end of the radius to show its cancellous structure.

joint itself. The wrist is so constructed as to permit of the movements of pronation and supination of the bones of the forearm, to serve as a support for the hand, and to allow movements of the hand in various directions.

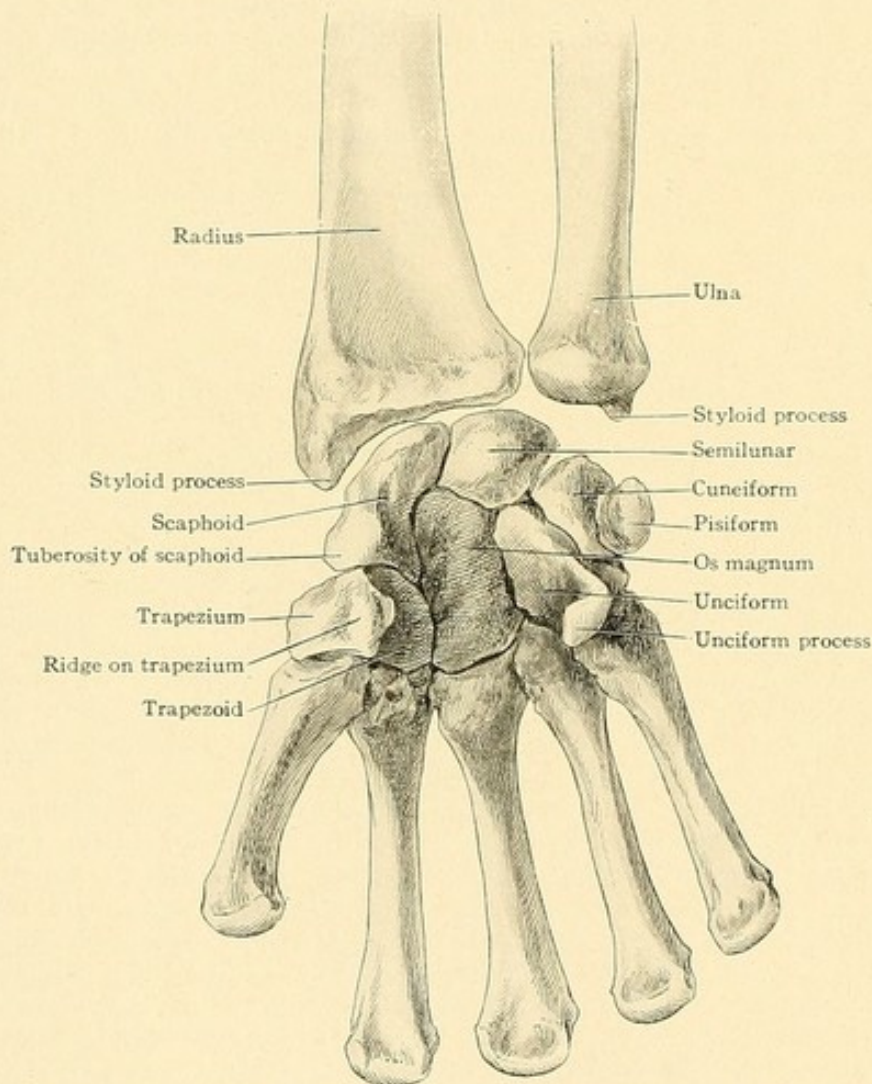


FIG. 339.—Anterior view of the lower ends of the radius and ulna and the carpal bones.

## BONES OF THE WRIST.

We may include among the bones of the wrist the lower ends of the radius and ulna and the first row of bones of the carpus,—the scaphoid, lunate (semilunar), cuneiform, and pisiform.



Of the bones of the forearm—the radius and ulna—we have seen that at the elbow the ulna is the larger of the two. This is because the main function of the ulna is to act as a support to the parts beyond. The radius is intended mainly as a means of enabling the hand to perform the functions of pronation and supination. At the wrist we find the radius supporting the hand and consequently its lower end is large and well developed. The ulna, on the contrary, contributes but little to the support of the hand and does not even enter directly into the wrist-joint, as does the radius at the elbow-joint, but serves as a fixed point around which the radius rotates. The functional value of the ulna at the wrist is so much less than that of the radius as amply to account for its diminished size.

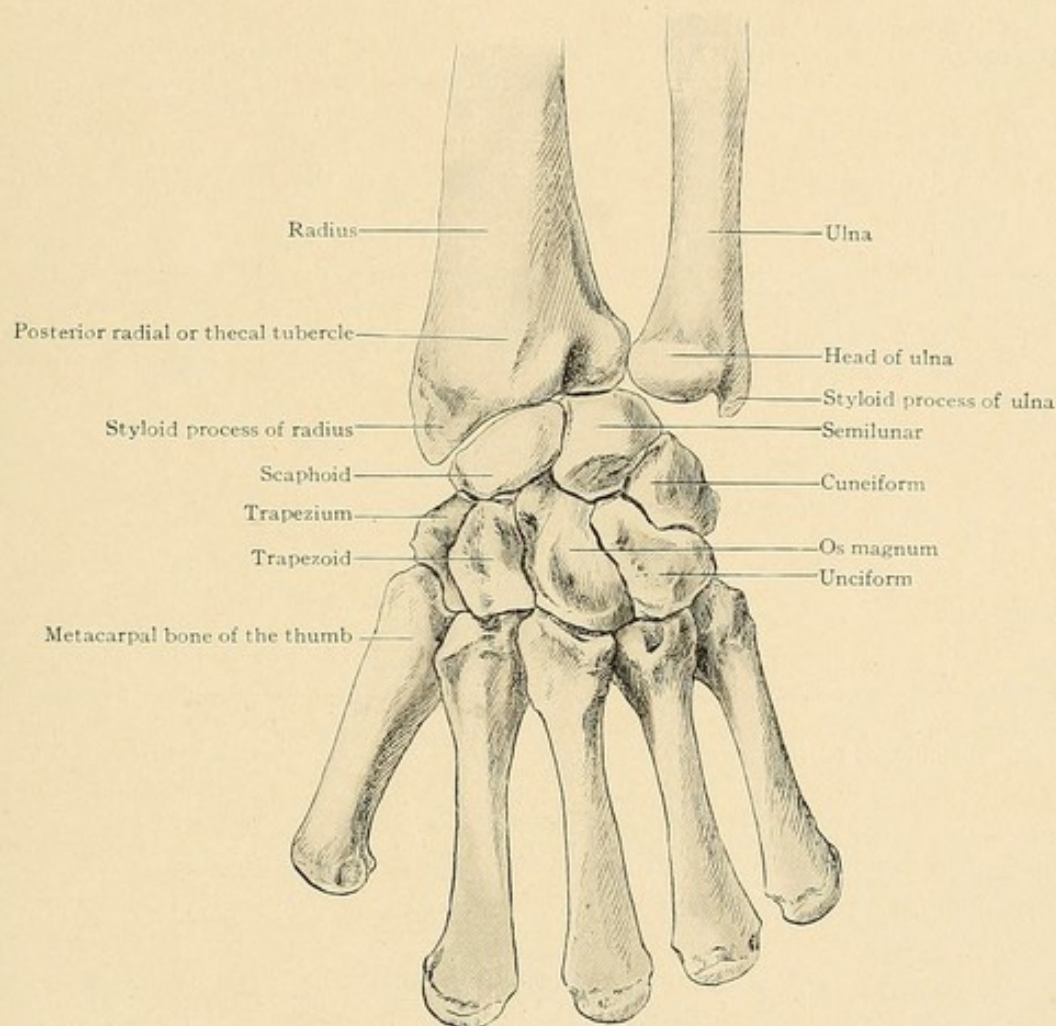


FIG. 340.—Posterior view of the lower end of the radius and ulna and the carpal bones.

**Lower end of the Radius.**—The lower end of the radius is large and spongy. The compact tissue forms a quite thin superficial layer (Fig. 338). Its anterior surface is hollowed out to receive the pronator quadratus muscle, with a prominent articular edge to which is attached the anterior ligament (Fig. 339).

The posterior surface is convex and marked with a number of ridges with grooves between them which lodge the extensor tendons (Fig. 340). In its middle is a prominence, the *dorsal radial tubercle*, which marks the position of the extensor longus pollicis muscle. On its inner side is a concave articular facet, the *ulnar notch* (*sigmoid cavity*), for articulation with the ulna; it is plane from above downward, thus showing that it permits movement in one direction only, like a hinge.

Between the lower edge of the ulnar notch and the articular surface is a rough ridge that gives attachment to the triangular interarticular fibrocartilage.



The lower or radiocarpal articular surface slopes downward and outward to end in the *styloid process*, which is thereby placed lower than the styloid process of the ulna. The articular surface is divided into two facets: the outer is the smaller, is triangular in shape, and articulates with the *navicular (scaphoid) bone*; the inner or larger is quadrilateral and articulates with the *lunate (semilunar) bone*. The styloid process at its base or upper outer portion has inserted into it the tendon of the *brachioradialis muscle*. To its tip is attached the *external lateral ligament*.

**The Ulna.**—The lower extremity of the ulna is rounded in shape, forming its head, with the styloid process projecting downward on its inner and posterior aspect. To its tip is attached the *internal lateral ligament*. On its outer side is a rounded smooth surface for articulation with the ulnar notch of the radius. The inferior or articular surface is flat and rests on the flat interarticular fibrocartilage.

The *navicular (scaphoid)*, *lunate (semilunar)*, *cuneiform*, and *pisiform bones* form the first row of the carpal bones. The pisiform rests on the anterior surface of the cuneiform and does not enter into the articulations between the hand and bones of the forearm.

The navicular and lunate articulate directly with the lower end of the radius, but the cuneiform articulates with the under surface of the triangular interarticular fibrocartilage.

### THE INFERIOR RADIO-ULNAR ARTICULATION.

The joint between the lower ends of the radius and ulna embraces not only the portion between these two bones but also that between the lower end of the ulna and

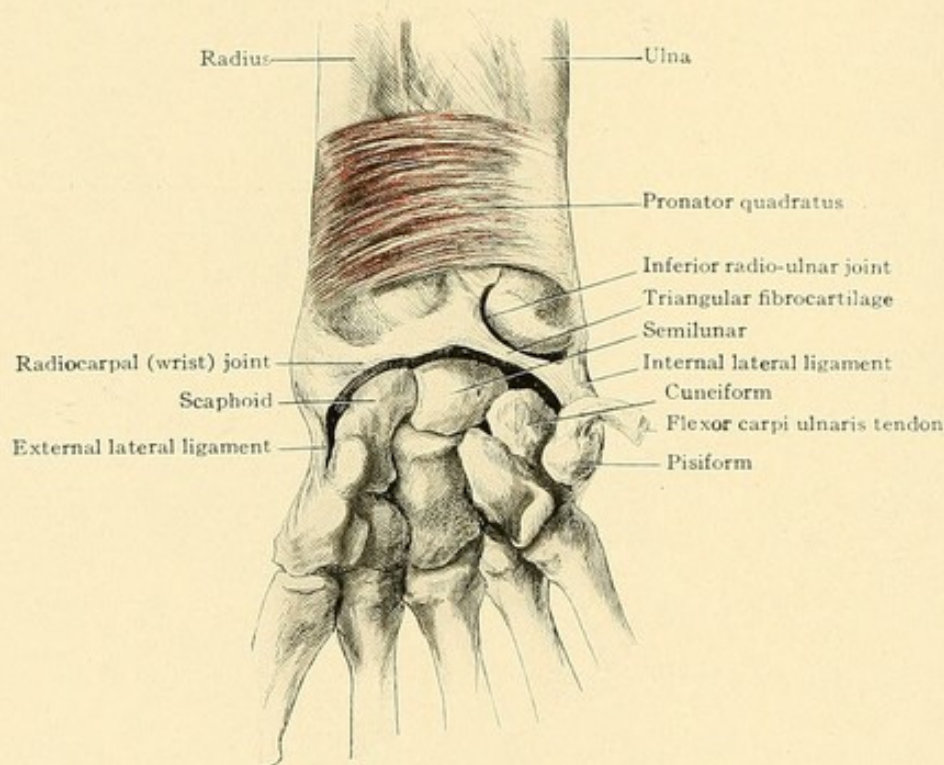


FIG. 341.—The wrist-joint and inferior radio-ulnar articulation.

the upper surface of the triangular fibrocartilage. This latter is attached by its apex to a depression on the outer side of the root of the styloid process of the ulna, and by its base to the rough line on the radius separating the radio-ulnar from the radio-carpal articulation (Fig. 341).

**The Interarticular Triangular Fibrocartilage.**—This serves as the main bond of union between the lower ends of the radius and ulna. It is strong and blends with the internal lateral ligament. Thus the hand has an attachment to the inner side of the radius by means of the internal lateral ligament and triangular cartilage.



**The Capsular Ligament.**—The capsular ligament serves to retain the synovial fluid in the joint. It is thin and filmy and possesses no strength, and therefore is useless in limiting movements.

**Anterior and Posterior Radio-ulnar Ligaments.**—These ligaments are simply a few bands which pass across from the radius to the ulna. They are not strong enough to be efficient in limiting movements of the bones.

**Movements.**—As has already been pointed out (page 304) the movements of pronation and supination have as their axis a line drawn through the middle of the head of the radius, the styloid process of the ulna, and the ring finger. They embrace in ordinary use a range of about 140 degrees which can be increased by forced effort to 160 degrees (Fig. 342).

These movements are limited by various factors, the most prominent being in pronation the contact of the soft parts and bones, as the radius obliquely overlies the ulna, and in supination by the biceps (the most powerful of the supinators) having reached the dead centre.

There is no communication between the radio-ulnar joint above and the radiocarpal joint below, except when, as occasionally happens, the triangular cartilage has a perforation.

During pronation and supination the lower end of the radius moves with the hand, but the lower end of the ulna remains at rest: hence it is that the styloid process of the radius always retains the same position in relation to the hand. When it is desired to identify the styloid process of the radius, one needs only to follow the metacarpal bone of the thumb up to the snuff-box at the upper edge of which the styloid process can always be felt. Also, to identify the styloid process of the ulna, one must not use the hand as a guide because the hand changes its position in relation to the ulna; but, as the ulna remains quiet, its styloid process can be found by following the posterior surface down to its extremity.

As the interarticular triangular cartilage is fastened by its base to the ulnar edge of the radius and by its apex to the base of the styloid process of the ulna, it travels with the hand in the movements of pronation and supination.

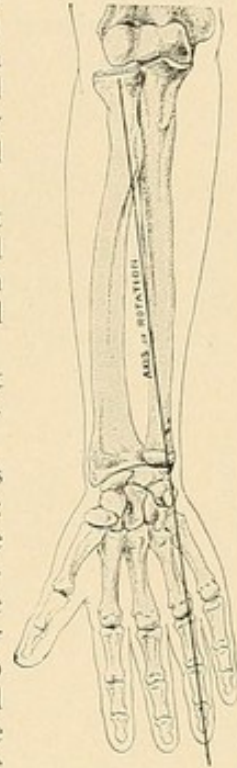


FIG. 342.—Axis of rotation.

## THE RADIOCARPAL OR WRIST-JOINT.

The wrist-joint is formed by the radius and triangular cartilage above and the navicular (scaphoid), lunate (semilunar), and cuneiform bones below. These are joined by the anterior, posterior, internal and external lateral, and capsular ligaments. The two lateral ligaments are strong, well-defined bands, the anterior and posterior ligaments are weaker and are fused with the capsular ligament.

The **internal lateral ligament** is attached above to the tip of the styloid process of the ulna and the tip of the triangular cartilage; below it is attached to the border of the cuneiform bone and is continued on to the pisiform bone.

The **external lateral ligament** is attached above to the tip of the styloid process of the radius and below to the base of the tubercle of the navicular bone.

The **capsular ligament** of the wrist-joint is composed of an anterior and a posterior portion strengthened by the two lateral ligaments just described. The anterior ligament has the bulk of its fibres running downward and inward from the edge of the radius to the palmar surface of the navicular, lunate, and cuneiform bones. It is stronger than the posterior. The posterior ligament likewise has its fibres running downward and inward to be attached to the first row of carpal bones.

**Movements.**—The wrist is classed as a biaxial diarthrosis or condyloid joint. This means that it is a double hinge-joint having movements around two axes, one anteroposterior and the other transverse. A combination of these movements results in circumduction, but it has at least no voluntary movement of rotation.



When rotation of the hand occurs it is accomplished by pronating or supinating the forearm. If the wrist-joint possessed this latter movement it would be a ball-and-socket or enarthrodial joint. The hand can be flexed and extended through an arc of approximately 140 degrees and adducted and abducted about half as much. The position assumed by the bones in flexion and extension is shown in Figs. 343 and 344.

Adduction or bending toward the ulnar side is much greater than is possible toward the radial side. The fact of the ulna not coming so low as the radius

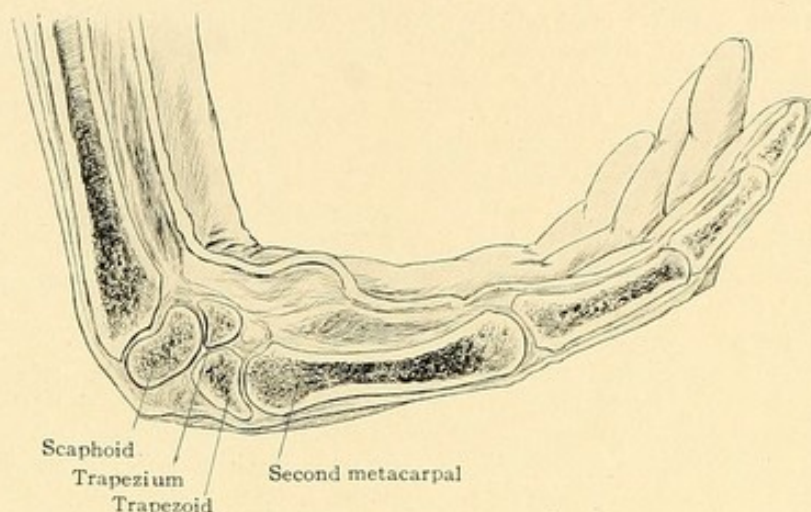


FIG. 343.—Position assumed by the carpal bones in flexion of the wrist.

accounts, at least in part, for this. The lateral ligaments check the movements of abduction and adduction, and in addition the contact of the styloid process of the radius with the trapezium prevents further outward movement.

The extent of the movements of the wrist of course varies much in different individuals. The laxness of the joints in children, women, and those not accustomed to hard manual labor is well known.

The movements of the wrist are performed by two different sets of muscles.

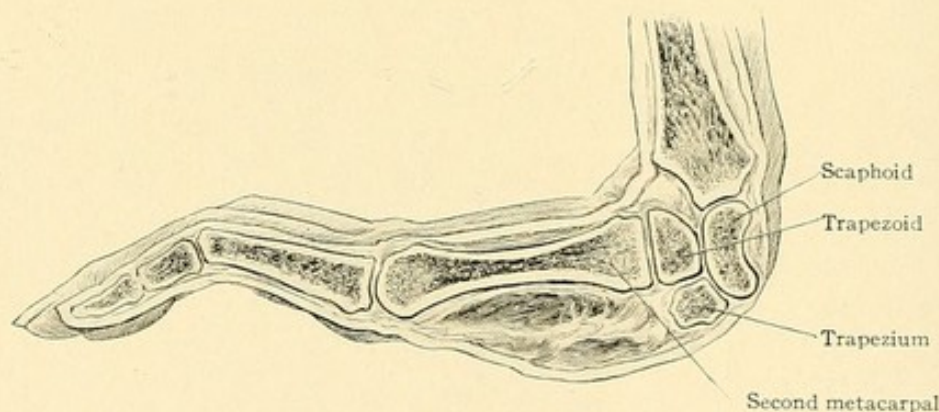


FIG. 344.—Position assumed by the carpal bones in extension of the wrist.

One set comprises the flexors and extensors of the carpus and the other the flexors and extensors of the thumb and fingers.

The first set is composed of the *flexor carpi radialis* and *flexor carpi ulnaris*, with which we may perhaps include the *palmaris longus*,—although it properly belongs with the finger muscles,—and of the *extensor carpi ulnaris*, *extensor carpi radialis longior*, and *extensor carpi radialis brevior*. If the fingers are clinched and the extensors of the fingers contract they aid the three carpal extensors to bend the hand backward. If the fingers are held extended and the flexors of the fingers contract they aid the carpal flexors to bend the hand forward. Contraction of the



flexor and extensor carpi ulnaris adducts the hand and contraction of the flexor carpi radialis and extensor carpi radialis longior and brevior, aided by the short extensor of the thumb and extensor ossis metacarpi pollicis, abducts the hand.

In the affection known as *wrist-drop* all the extensor muscles are paralyzed. It is due to injury, usually from pressure on the radial (musculospiral) nerve, either in the groove of the humerus or in the axilla. Although there are a number of synovial bursæ around the joint in connection with the tendons none communicate with it.

**Muscles.**—The flexor tendons cover the wrist anteriorly and the extensors posteriorly. With the flexor group we may consider the pronator quadratus. A third or radial group comprises the extensor carpi radialis longior and brevior and the brachioradialis.

*Anteriorly.*—The tendons on the front of the wrist occupy four different planes or levels. The most superficial layer embraces the flexor carpi radialis, the palmaris longus, and the flexor carpi ulnaris. Of these three the palmaris longus is the nearest to the skin as it inserts in the palmar fascia in front of the annular ligament. The flexor carpi radialis slips under the upper portion of the annular ligament to insert into the base of the second metacarpal bone. The flexor carpi ulnaris inserts

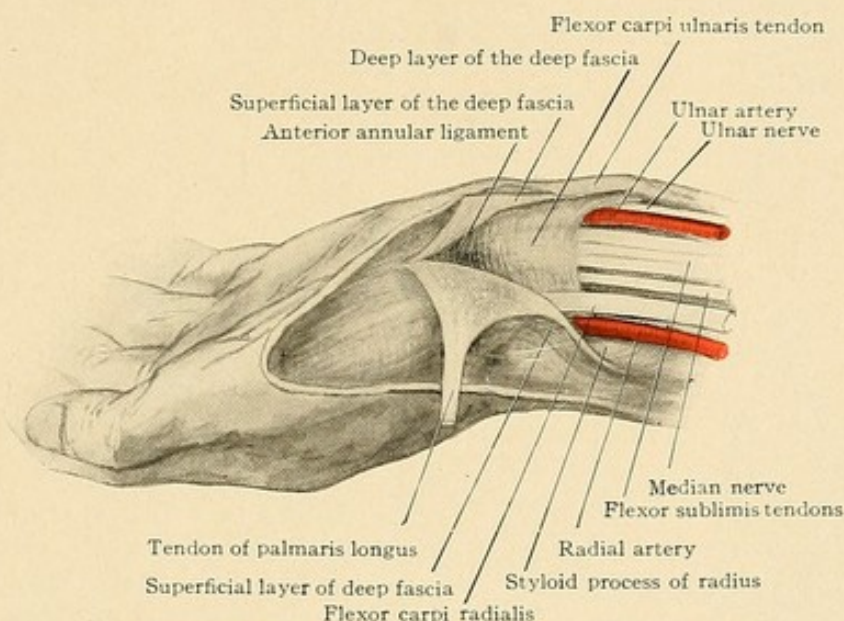


FIG. 345.—Dissection showing the fascias of the anterior portion of the wrist. The superficial layer is continuous with the palmaris longus muscle and palmar fascia; the deep layer is continuous with the anterior annular ligament.

into the pisiform bone and continues onward to the base of the fifth metacarpal bone and the unciform process of the unciform bone.

The second layer of tendons is composed of the four tendons of the flexor sublimis digitorum. They fill the space between the palmaris longus and the flexor carpi ulnaris.

The third layer is composed of the four tendons of the flexor profundus digitorum toward the ulnar side and the flexor longus pollicis toward the radial side.

The fourth and last layer is formed by the pronator quadratus. This lies directly on the bones and covers their lower fourth.

It is sometimes necessary to divide these tendons in cases of contraction of the wrist, hence the desirability of being able to recognize and locate them.

**The Deep Fascia and Anterior Annular Ligament.**—The deep fascia covering the anterior muscles of the forearm is comparatively thin. As it approaches the wrist it divides into two layers. The *superficial layer* is thin and runs over the tendons of the palmaris longus and flexor carpi radialis muscles and the ulnar artery and nerve. It is continuous below with the palmar fascia. To the ulnar side it passes over the flexor carpi ulnaris muscle to be continuous with the posterior annular ligament. It is not attached to the ulna, but slides over it as it follows the movements of the hand in pronation and supination (Fig. 345).



The *deep layer* of the deep fascia covers the flexor sublimis digitorum and passes downward beneath the flexor carpi radialis and brachioradialis muscles. It is continuous below with the anterior annular ligament.

The deep layer blends with the superficial layer to the radial side of the flexor carpi radialis, and then merges with the posterior annular ligament to form the sheath of two of the extensor muscles of the thumb.

On the ulnar side the deep layer passes over the ulnar artery and vein and under the flexor and extensor carpi ulnaris muscles, forming the posterior portion of their sheaths, and then merges with the posterior annular ligament.

The *anterior annular ligament* is attached on the ulnar side to the pisiform bone and unciform process of the unciform bone and on the radial side to the trapezium and tuberosity of the navicular (scaphoid).

Over the anterior annular ligament pass the ulnar artery and nerve, the superficial volar artery, and the palmar cutaneous branch of the median nerve.

Beneath the annular ligament pass the median nerve, the flexor sublimis, flexor profundus, and flexor longus pollicis tendons. These tendons are embraced in two sheaths, one for the flexor longus pollicis and the other for the flexors of the other four fingers, the sheath for the little finger extending to the insertion of the profundus tendon into the distal phalanx. The tendinous sheaths accompany the tendons for a distance of 2.5 to 5 cm. (1 to 2 in.) above the annular ligament.

*Posteriorly.* — On the posterior surface of the wrist the tendons may be divided into two groups, an extensor group and a radial group. The *extensor group* is divided into a superficial and deep set. The superficial set is composed of the extensor communis digitorum, the extensor minimi digiti and the extensor carpi ulnaris. The deep set is composed of the extensor ossis metacarpi pollicis, extensor brevis

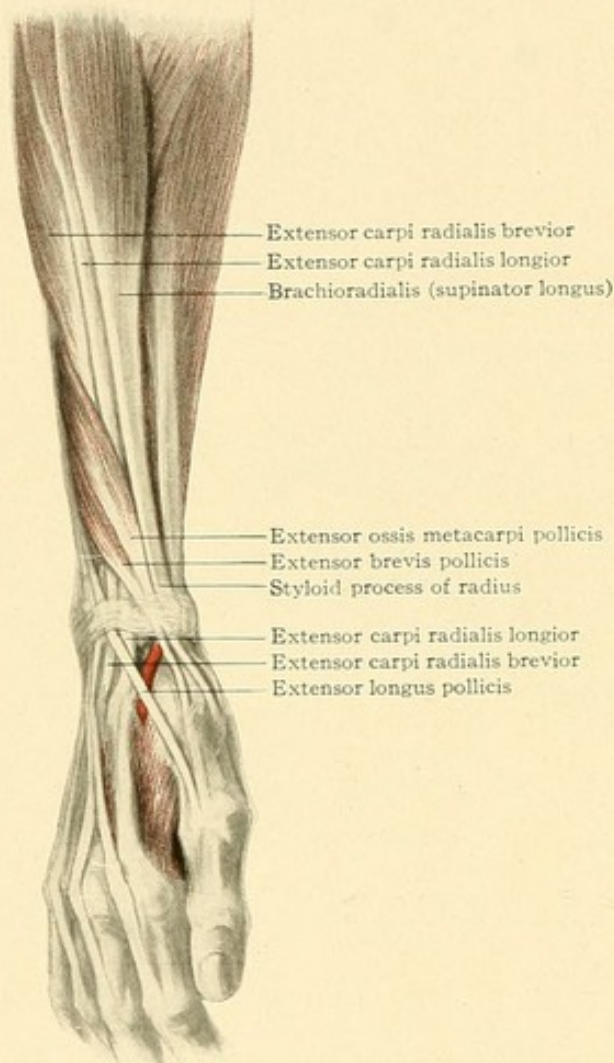


FIG. 346.—Muscles of the radial side of the wrist.

pollicis, extensor longus pollicis, and extensor indicis. The *radial group*, on the posterior and outer surface of the radius, is composed of the extensor carpi radialis longior, the extensor carpi radialis brevis, and the brachioradialis (Fig. 346). The first two lie beneath the deep extensor muscles, thus practically forming a third layer. All the tendons of the posterior and radial group of muscles, with the exception of the brachioradialis, pass beneath the posterior annular ligament into the hand. The brachioradialis inserts into the base of the styloid process of the radius.

**Posterior Annular Ligament.**—As the tendons pass down over the posterior surface of the radius and ulna they are bound down by processes of the deep fascia which form canals in which they run. The deep fascia of the posterior surface of the forearm in the neighborhood of the wrist is strong, and forms the posterior annular ligament. Its lower border is about level with the upper border of the anterior annular ligament. It is attached externally to the posterior and outer edge of the styloid process of the radius and internally to the posterior surface of the



styloid process of the ulna, the internal lateral ligament, the pisiform, and adjacent carpal bones. Beneath this posterior annular ligament are six compartments. From the radial toward the ulnar side they are: (1) One on the outer side of the styloid process of the radius for the extensor ossis metacarpi pollicis and extensor brevis pollicis; (2) for the extensor carpi radialis longior and brevior, then comes the posterior radial tubercle in the middle of the radius, and passing close along its ulnar side is (3) the extensor longus pollicis. To the ulnar side of this tendon is a comparatively broad sheath for (4) the extensor communis digitorum and the extensor

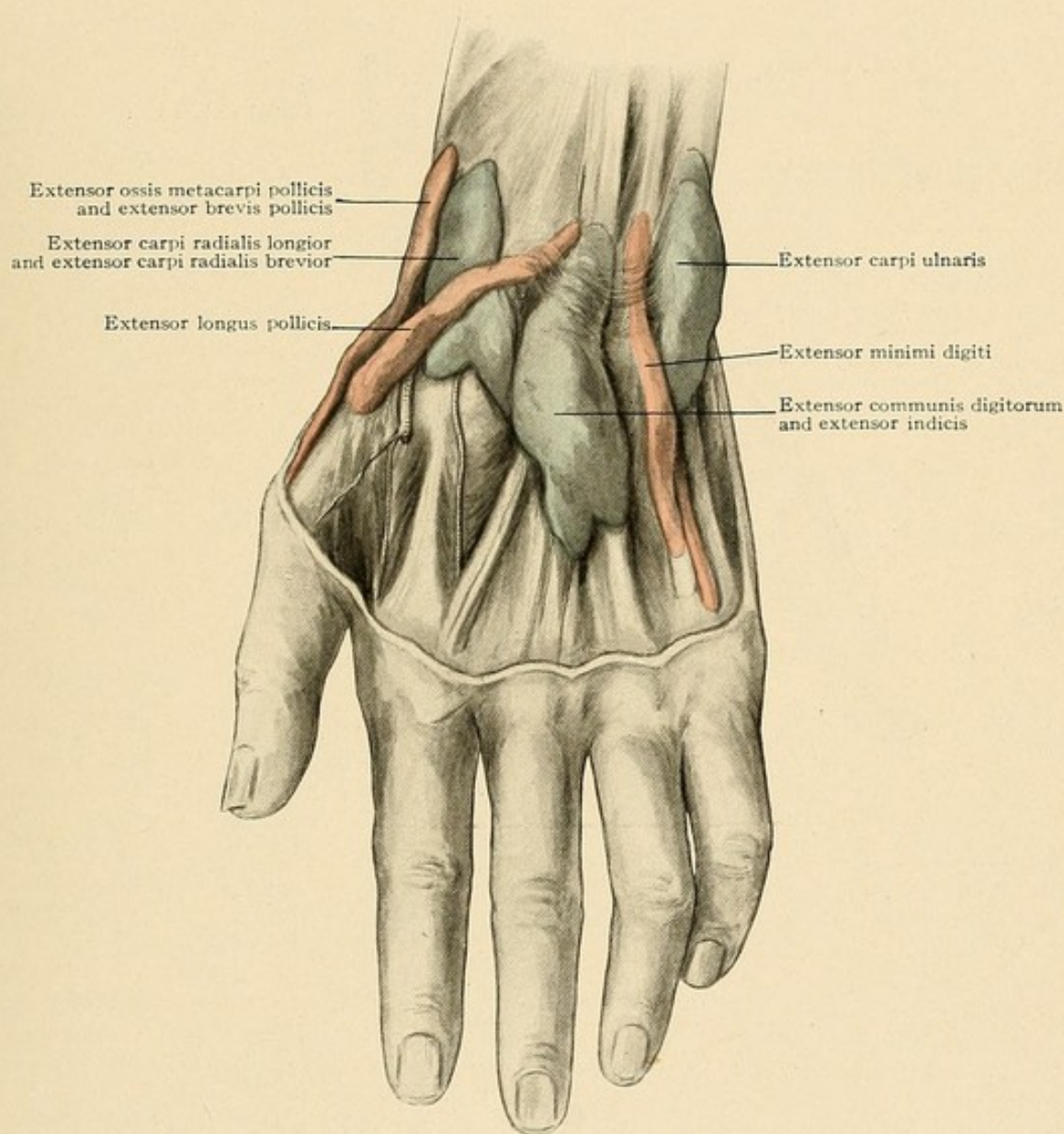


FIG. 347.—The sheaths of the extensor tendons on the back of the wrist distended with wax to show their extent.

indicis muscles. In the interval between the radius and ulna lies (5) the tendon of the extensor minimi digiti, and on the posterior side of the styloid process of the ulna is (6) the tendon of the extensor carpi ulnaris (Fig. 347).

Each of these six compartments is lined with a separate sheath which extends under the annular ligament from a centimetre or two above the joint to about the bases of the metacarpal bones on the dorsal surface of the hand.

**The Anatomical Snuff-Box** (*la tabatière anatomique*, of Cloquet).—On the outer dorsal aspect of the wrist, just below the radius, is a depression particularly noticeable when the thumb is abducted (Fig. 351, page 341). It is triangular in



shape with its base upward. The styloid process of the radius forms its base; the extensor brevis pollicis with the extensor ossis metacarpi pollicis forms its radial or outer side, and the tendon of the extensor longus pollicis forms its ulnar or inner side. Its floor is formed by the navicular (scaphoid) and trapezium bones. Through it, lying on these bones and the external lateral ligament, passes the radial artery on its way to the first interosseous space. Superficial to the artery lies a vein and some fine branches of the radial nerve. In ligating the artery at this point,

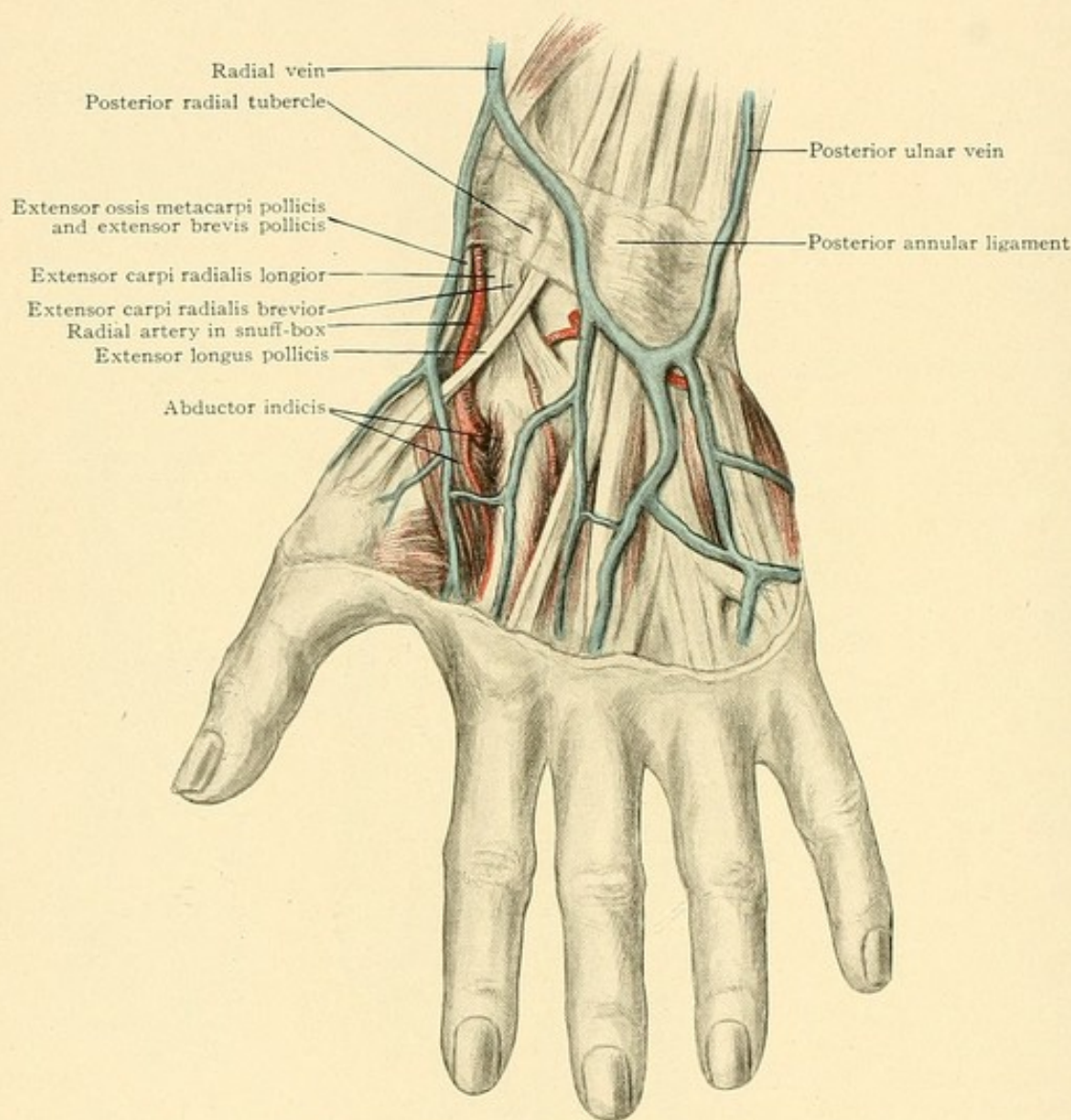


FIG. 348.—View of the anatomical snuff-box and the radial artery passing through it.

care should be taken not to mistake the vein for it; the vein is near the skin, the artery lies deep on the lateral ligament and bones (Fig. 348).

### SURFACE ANATOMY OF THE WRIST.

The bellies of many of the muscles, mainly the superficial ones, cease as they become tendinous about the middle of the forearm. Hence the rapid decrease in size as one descends. When the wrist is reached there is a swelling on each side caused by the expanded lower end of the radius on the outer side and the head of the ulna on the inner. The medial (inner) prominence is rendered more marked by abducting the hand, the lateral (outer) prominence by adducting it. Just beyond these there is a constriction as the wrist passes into the hand.



Above the wrist on the anterior and outer part can be felt the radius. Its lower 2 or 2.5 cm. (1 in.) is sharp and prominent—this is the anterior border of the styloid process. On the outer side at its base is the point of insertion of the brachioradialis tendon. Following the bone down on its outer side, at the upper margin of the anatomical snuff-box, one feels the tip of the styloid process, a most important landmark.

On the outer surface of the radius beginning below between the tip of the styloid process and its sharp anterior border are the extensor ossis metacarpi pollicis and extensor brevis pollicis tendons. They can readily be seen and felt when the thumb is extended as they cross obliquely over the lower end of the radius. The sheaths of these tendons frequently become inflamed from injuries, causing what is termed *tenosynovitis*. If the hand is laid on the lower portion of the radius of a patient so affected, and he is told to move the thumb, a characteristic creaking can be felt as the tendons move in their inflamed sheaths.

The edge of the articular surface of the radius can be indistinctly felt from the tip of the styloid process to the edge of the flexor carpi radialis internally and across the back of the wrist in an upwardly curved line toward the ulna.

On the inner side of the wrist can be felt and seen the prominence made by the head of the ulna. The ulna is subcutaneous and can be followed up the forearm posteriorly its entire length. It is not covered by muscles on its inner border, but on its anterior surface is the flexor carpi ulnaris tendon beneath which is the flexor profundus digitorum, this latter being separated from the bone by the origin of the pronator quadratus. If the posterior surface of the ulna is followed downward the styloid process forming its extremity can be distinctly felt, especially if the hand is placed in the supine position and slightly flexed. Overlying the head of the ulna posteriorly is the tendon of the extensor carpi ulnaris muscle going to the base of the fifth metacarpal bone. This tendon follows the movements of the hand in pronation and supination, but the styloid process of the ulna remains stationary. When the hand is pronated the tendon lies to the anterior side of the styloid process, but when the hand is supinated it lies toward its posterior side. This tendon cannot be readily recognized.

The inner and posterior surface of the cuneiform bone can be felt immediately below the head of the ulna. Some difficulty may be experienced in distinguishing one from the other; if, however, the hand is abducted and adducted the cuneiform bone can be felt to move while the ulna remains stationary. On the palmar surface of the wrist, immediately below the ulna, can be felt the distinct bony prominence formed by the pisiform bone. The flexor carpi ulnaris inserts into it.

About 2 to 2.5 cm. (1 in.) below and to the radial side of the pisiform bone is the unciform process of the unciform bone. It is best detected by laying the ball of the thumb over the spot and making deep pressure with a rolling motion. On the radial side of the anterior surface, directly in line with the tendon of the flexor carpi radialis, is the prominent tubercle of the navicular (scaphoid) bone; a centimetre farther on, in line with the thumb, is the ridge of the trapezium. The anterior annular ligament is attached to its outer surface about 2.5 cm. (1 in.) below the styloid process of the radius; a bony prominence formed by the trapezium marks its junction with the metacarpal bone of the thumb in front.

The ability to locate the carpometacarpal joint of the thumb is of importance in reference to the diagnosis of fractures and other injuries. On comparing the two styloid processes it will be seen that the styloid process of the radius extends 1 cm. ( $\frac{2}{5}$  in.) lower than that of the ulna. This is best observed with the hand in a prone position. Across the front of the wrist there are two transverse lines. The proximal or upper one corresponds with the radiocarpal joint or wrist-joint. The distal or lower one corresponds with the joint between the two rows of carpal bones and marks the upper edge of the anterior annular ligament.

On the posterior surface of the wrist, one-third of the width of the wrist across from the edge of the radius, can be felt a bony prominence. It is the posterior radial tubercle. If the thumb is extended the tendon of the extensor longus pollicis leads directly to the tubercle and lies along its ulnar border. This tubercle marks the middle of the posterior surface of the radius. The radius passes two-thirds across the wrist and the ulna the other third; by firm pressure the interval between them can be felt.



If the hand is firmly clenched and flexed on the forearm the tendons on the anterior surface of the wrist become prominent. The most evident is the palmaris longus which, though sometimes absent, usually stands out clear and sharp. Lying

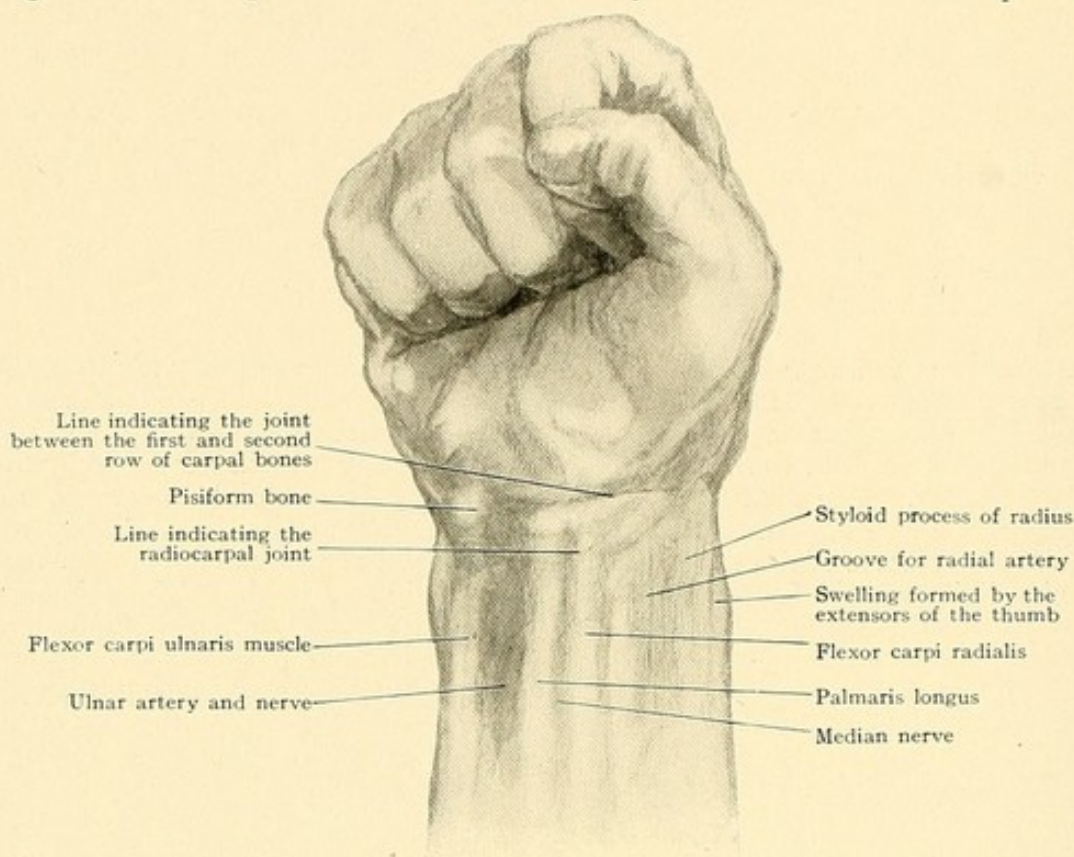


FIG. 349.—Surface anatomy of anterior surface of wrist.

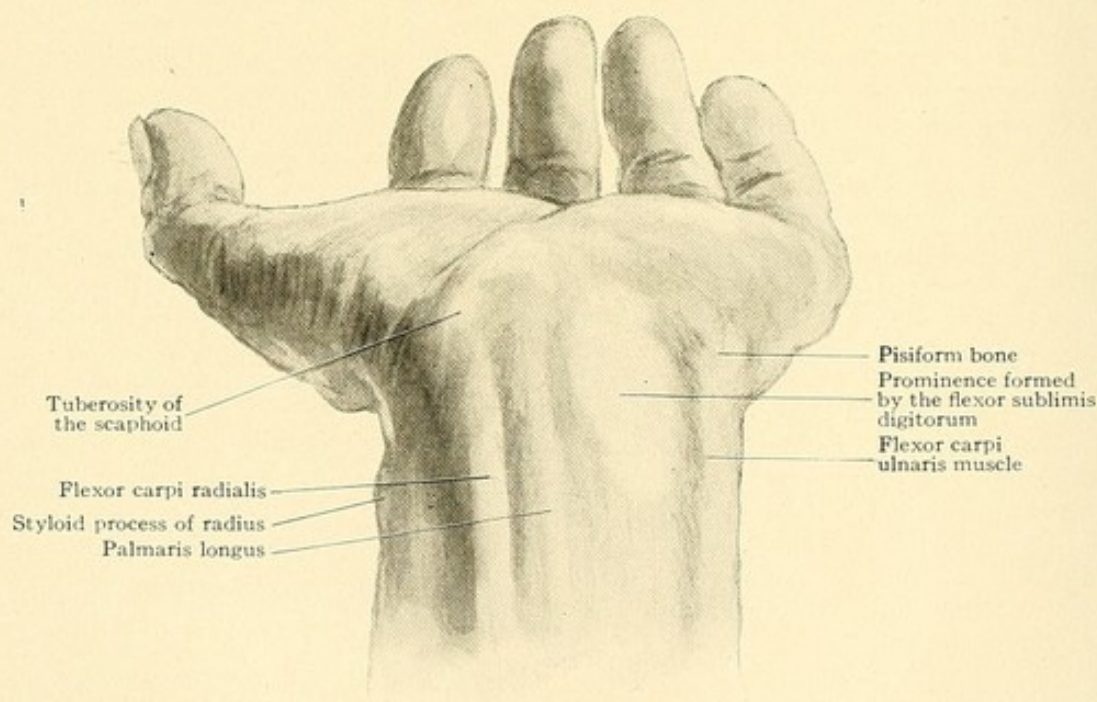


FIG. 350.—Surface anatomy of the anterior portion of the wrist.

along its radial border is the tendon of the flexor carpi radialis; between the two on a lower level lies the median nerve. In front of the ulna, and going directly downward to the pisiform bone, is the tendon of flexor carpi ulnaris (Fig. 349).



If the hand is extended the tendon of the flexor carpi ulnaris stands out clearly. In the hollow to its lateral (outer) side lie the ulnar nerve and artery. A rounded muscular swell fills the space between the ulnar artery and the tendon of the palmaris longus,—it is caused by the flexor sublimis digitorum (see Fig. 350). It is here that abscesses show when they travel up from the hand.

Between the outer edge of the flexor carpi radialis tendon and the anterior outer edge of the radius is a groove in which runs the radial artery. The position of the extensor ossis metacarpi pollicis and extensor brevis pollicis which run together over the outer surface of the radius can best be determined by abducting the thumb and so making these tendons prominent (Fig 351).

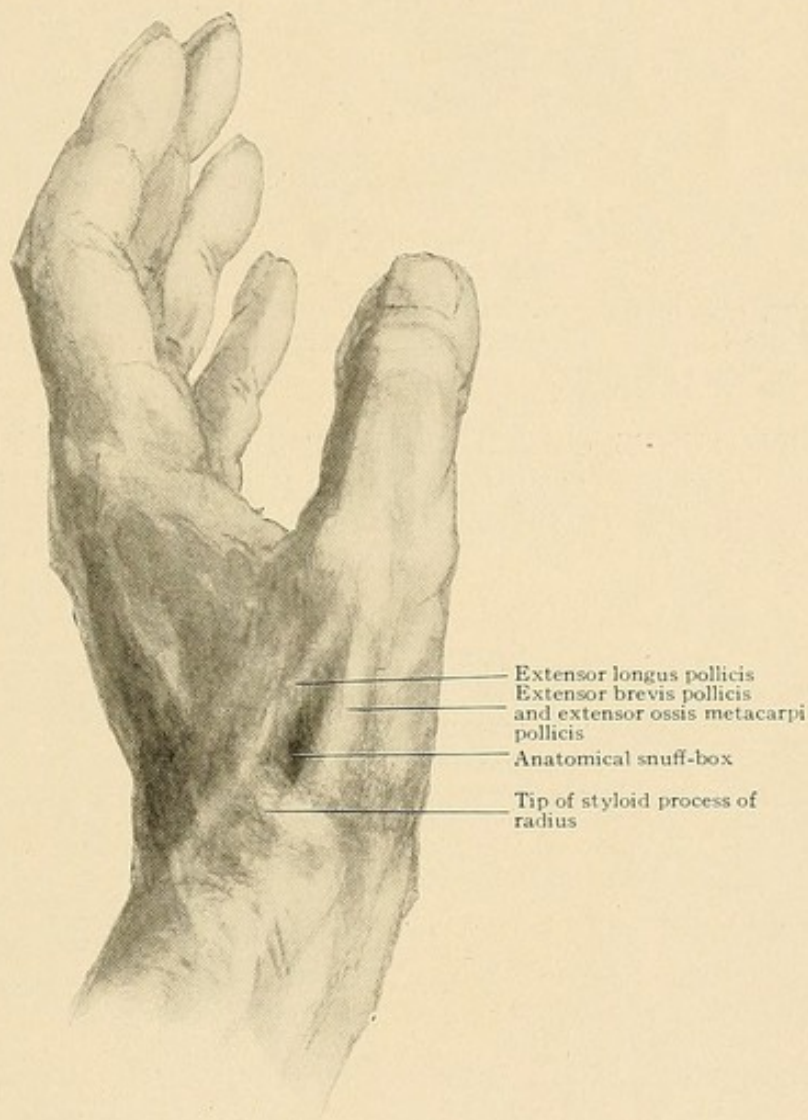


FIG. 351.—Surface anatomy of the outer dorsal portion of the wrist, showing the anatomical snuff-box.

In the same manner the extensor longus pollicis tendon can be made prominent and followed to the posterior radial tubercle. By firm pressure the upper limits of the first and second interosseous spaces can be felt. They mark the bases of the metacarpal bones. The extensor carpi radialis longior passes across the snuff-box to insert into the radial side of the base of the second metacarpal bone. The radial artery as it dips down between the first and second metacarpal bones lies just to its outer side. Crossing under the tendon of the extensor longus pollicis is the extensor carpi radialis brevior, which proceeds to the top of the second interosseous space to insert into the adjoining sides of the second and third metacarpal bones.

In the chink between the radius and ulna lies the tendon of the extensor minimi digiti. Between this tendon and the radial tubercle are the four tendons of the



extensor communis digitorum and extensor indicis muscles. Passing over the head of the ulna to insert into the base of the fifth metacarpal bone is the tendon of the extensor carpi ulnaris. It is best felt just beyond the extremity of the ulna when the hand is drawn toward the ulnar side. It inserts into the base of the fifth metacarpal bone.

**Compound Ganglion.**—Large effusions into the sheath of the flexor tendons of the wrist, usually purulent or tuberculous in character, sometimes cause two swell-

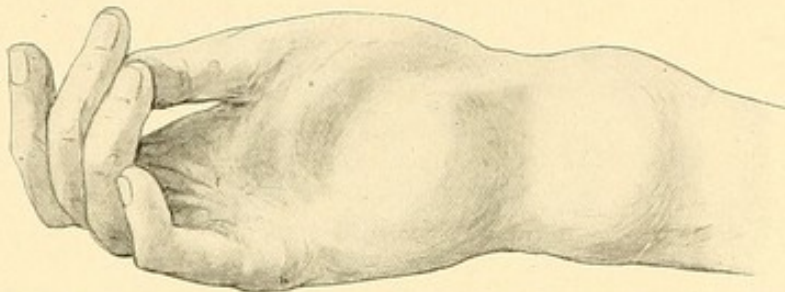


FIG. 352.—Compound ganglion showing swellings above and below the anterior annular ligament. (From author's sketch of a tuberculous case.)

ings, one in the palm of the hand and the other above the wrist. These communicate beneath the anterior annular ligament and form what is called a compound ganglion (Fig. 352).

#### FRACTURES OF THE LOWER END OF THE RADIUS AND ULNA.

The lower end of the ulna is rarely fractured, but that of the radius vies with fracture of the clavicle in being the most frequent of all fractures.

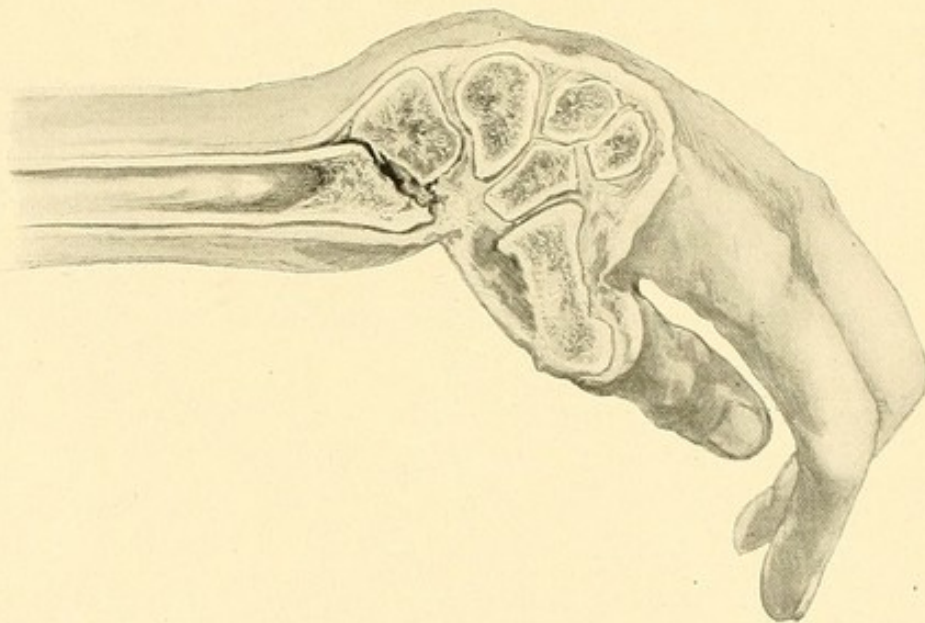


FIG. 353.—Colles's fracture of the lower end of the radius, showing the "silver fork deformity" and displacement of the fragments.

#### COLLES'S FRACTURE.

Fractures of the radius which occur at the wrist possess certain distinct characteristics and were for a long time confounded with dislocations of the wrist. These fractures are generally grouped by modern surgeons under the name of *Colles's fracture*. This fracture was first correctly described, according to both Hamilton and Stimson, by Pouteau ("Œuvres Posthumes," t. 11, p. 251, 1783; also Nèlaton, "Chirurgie Path.," t. 1, p. 739). Mr. Colles, a Dublin surgeon, described the injury most carefully in the *Edinburgh Medical and Surgical Journal*, April, 1814, but it is largely due to Robt. W. Smith's "Treatise on Fractures in the Vicinity



of Joints," Dublin, 1847, that the name Colles's fracture has become generally accepted. Mr. Colles placed the injury  $1\frac{1}{2}$  inches (about 4 cm.) above the joint. Mr. Smith placed it from  $\frac{1}{4}$  in. to 1 in. (6 to 25 mm.) above the joint. Most recent writers include all fractures within 4 cm. ( $1\frac{1}{2}$  in.) of the lower edge of the radius under this name, though some few go still higher. When the line of fracture lies more than 4 cm. above the joint it loses the characteristics of a Colles's fracture and partakes of those of fractures of the shaft; hence we will not go beyond that limit.

The line of fracture is most commonly found, as stated by Robt. W. Smith, from 6 to 25 mm. ( $\frac{1}{4}$  to 1 in.) above the joint. It passes almost transversely across the bone or inclines slightly downward to the ulnar side. It also lies nearer the joint on the anterior surface and inclines backward and upward toward the elbow. Hence the direction is from above downward and forward (Fig. 353).

It is produced while the hand is extended (dorsally flexed) either by direct transmission of the force from the palmar surface of the wrist or by tension of the anterior radiocarpal ligament.

The lower fragment is displaced upward and backward on the shaft of the radius. This causes it to be tilted backward so that the articular surface is rotated on a transverse axis more in the direction of the dorsum than normal and the hand is also carried toward the radial side. The dorsal displacement is due to the direction of the violence and not to muscular action. The radial side of the fragment is displaced upward more than the ulnar because the triangular fibrocartilage retains its

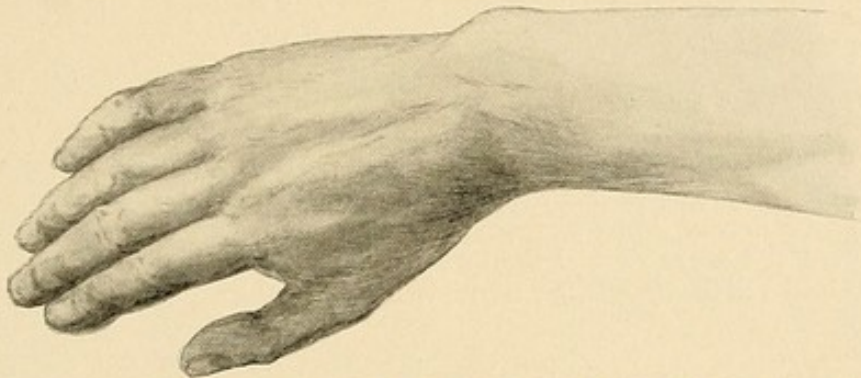

FIG. 354.—Colles's fracture of the radius, showing inclination of hand toward the radial side and prominence of the styloid process of the ulna. (From author's sketch.)

radio-ulnar attachments. This prevents the ulnar side from rising, while the radial side is pulled up by the radial flexor and extensor muscles. If the fracture is not extremely close to the joint the brachioradialis will pull the lower fragment toward the radial side and up toward the elbow.

As the hand is attached to the radius it follows the lower fragment; the extensor muscles of the thumb, the flexor carpi radialis, and the two extensor carpi radialis muscles all tend to aid the brachioradialis in producing the displacement toward the radial side (Fig. 354).

The lower fragment is displaced toward the dorsum and the upper fragment toward the palmar surface. This produces the "silver fork deformity" of Velpeau. This dorsal projection is sometimes increased by the presence of the "carpal tumor," a swelling due to effusion almost directly above the joint. The projection of the upper fragment toward the palmar surface and the effusion in the sheaths of the flexor tendons cause a protrusion on the anterior surface of the wrist and a marked increase in the lower anterior radiocarpal crease.

To reduce the deformity the upper fragment is firmly grasped with one hand while with the other the hand of the patient is forcibly adducted (toward the ulnar side) and then sharply flexed. This drags the distal fragment down and forward off of the proximal one. To retain the fragments in position some surgeons use a pistol-shaped splint to hold the hand turned toward the ulnar side and place a graduated compress on the palmar surface with its base opposite the line of fracture and its apex upward and another pad on the dorsal surface with its apex downward over the hand. Other surgeons place the hand in a flexed position, allowing it to hang.



## SEPARATION OF THE LOWER EPIPHYSIS OF THE RADIUS.

The lower radial epiphysis fuses with the shaft at about the twentieth year; therefore epiphyseal separation can occur up to that time. The epiphyseal line passes across the bone from the base of the styloid process to the upper edge of the radio-ulnar joint (Fig. 355).

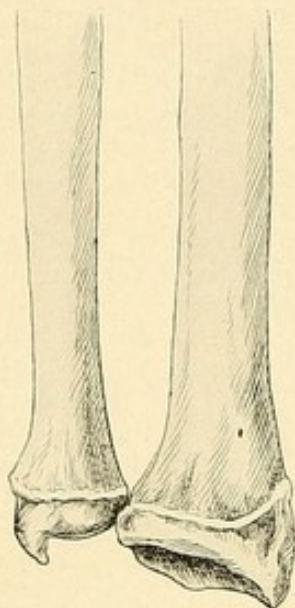


FIG. 355.—Epiphyses of the lower ends of the radius and ulna; union occurs with the shaft of the bones at about the 20th year.

The displacement, symptoms and treatment are the same as in Colles's fracture and it is quite possible that many cases diagnosed as Colles's fracture may be epiphyseal separations.

## FRACTURE OF THE LOWER END OF THE RADIUS WITH DISPLACEMENT FORWARD.

This fracture, though rare, occasionally occurs, and if union has taken place the deformity is marked and the injury is liable to be diagnosed as a luxation. It has been particularly described by Dr. John B. Roberts ("A Clinical, Pathological, and Experimental Study of Fracture of the Lower End of the Radius with Displacement of the Carpal Fragment toward the Flexor or Anterior Surface of the Wrist," Phila., 1897). On account of the difficulties in diagnosis it is well to examine its anatomical peculiarities.

*Displacement.*—The lower fragment is tilted forward toward the palmar surface of the wrist, carrying the radial side of the hand with it (Fig. 356).

*Signs.*—The line of the radius can be followed and felt to curve at its lower portion toward the palmar surface. The hand descending with the displaced fragment causes a groove to appear across the dorsum from one styloid process to the other. The dorsal surface of the lower part of the forearm is on a higher plane than that of the carpus. As the hand is lower than normal this causes the lower end of the ulna to

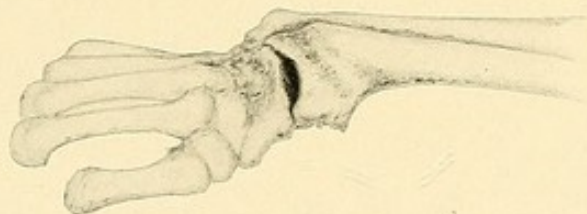

FIG. 356.—Fracture of the lower end of the radius with displacement of the lower fragment toward the palmar surface. (Sketch, by the author, of a specimen in the Mütter Museum of the Philadelphia College of Physicians.)

project much higher than it should. On account of the tension of the extensor carpi radialis longior and brevior the hand is held level with the forearm and does not droop as in Colles's fracture. Displacement to the radial side may or may not be marked.

## FRACTURE OF THE LOWER END OF THE ULNA.

Previous to the use of the X-rays for diagnostic purposes, fracture of the lower end of the ulna was considered extremely rare. Fractures of the ulna above the head resemble practically those of the shaft.

Fracture of the styloid process was observed by D. H. Agnew in one case which was followed by deformity. Inasmuch as the deep fascia slides over the ulna it is readily seen that if it is perforated one or other of the fragments may be caught in the rent. This is probably the explanation of the deformity which occurred in Agnew's case. He advised treatment with the hand bent toward the ulnar side to relax the extensor carpi ulnaris tendon. Fracture of the styloid process of the ulna has been shown by the X-rays to be a more frequent accompaniment of Colles's fracture than was formerly thought to be the case,—it tends to favor displacement of the hand toward the radial side.



## DISLOCATIONS AT THE WRIST.

The dislocations at the wrist may be due to traumatism or may occur spontaneously. There may be either a displacement of the carpus at the radiocarpal joint or of the ulna at the inferior radio-ulnar articulation. These luxations are very rare.

## DISLOCATIONS AT THE RADIOCARPAL JOINT.

It is to Dupuytren that we owe the recognition of the fact that what were previously regarded as luxations of the wrist were really cases of fracture, usually of the radius. True luxations are exceedingly rare; they may be either backward or forward and are often compound. They are usually the result of great violence and the ends of the radius and ulna in many cases protrude on the palmar or dorsal surface.

Backward luxation is the more common of the two. The question of diagnosis is most important in relation to this injury. Many cases which have been diagnosed as luxations afterwards prove to be fractures. In backward luxation the deformity resembles that of Colles's fracture, with the following differences: the palmar swelling in dislocation extends farther down toward the hand than is the case in Colles's fracture,—this is owing to the displacement occurring at the joint instead of some distance above, as in fracture; in luxation the protrusion forming the hump on the dorsal surface has an abrupt upper edge which is lacking in cases of fracture, and both styloid processes—of the radius and the ulna—remain attached to the shaft of the bones.

Anterior luxation may occur from injury, but more commonly it is seen in the form of a subluxation which occurs slowly and spontaneously usually between the ages of 18 and 23 years. It was first described by Dupuytren and later by Madelung. The ulna projects markedly toward the dorsal surface while the radius is somewhat less prominent; there is a marked hollow on the palmar surface of the forearm just above the hand. Fig. 357, from a girl 18 years of age, shows these points clearly.

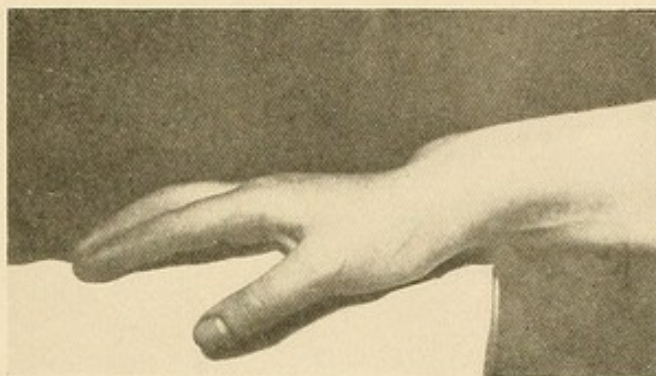


FIG. 357.—Subluxation of the wrist from disease.

## DISLOCATION OF THE ULNA AT THE LOWER RADIO-ULNAR JOINT.

The ulna may be dislocated forwards or backwards. When associated with fracture of the radius it is not so rare, but otherwise it is seldom seen. Posterior luxation is the most common. The internal lateral ligament and triangular cartilage both usually remain attached to the lower end of the ulna, which projects markedly on the dorsal surface. The injury has been produced by falls on the hand and forced pronation.

In recent cases reduction can usually be accomplished by direct pressure and rotation of the hand, with traction. The secret of success in the diagnosis of these obscure fractures and luxations in the region of the wrist lies in knowing the surface anatomy and in being able to recognize the various deeper structures by the sense of touch.

## EXCISION OF THE WRIST.

Formal excisions of the wrist are undertaken for tuberculous disease. It is desirable that all the affected tissues be removed. To do this is difficult, on account of the number and extent of the various carpal bones and joints as well as the danger of injuring the important arteries, nerves, and tendons by which they are



surrounded. To remove the diseased parts without inflicting avoidable injury requires an exact and skilful operator who has a precise knowledge of the anatomy of the region. Interference with the sheaths of the tendons will result in stiffness and loss of control and power in the hand.

Maisonneuve, Boeckel, and Langenbeck operated through a single dorsal incision along the radial side of the extensor indicis tendon. As this incision was found to give insufficient room, Lister, in 1865, advised an additional incision along the ulnar border. Ollier, of Lyons, modified Lister's radial incision by carrying it

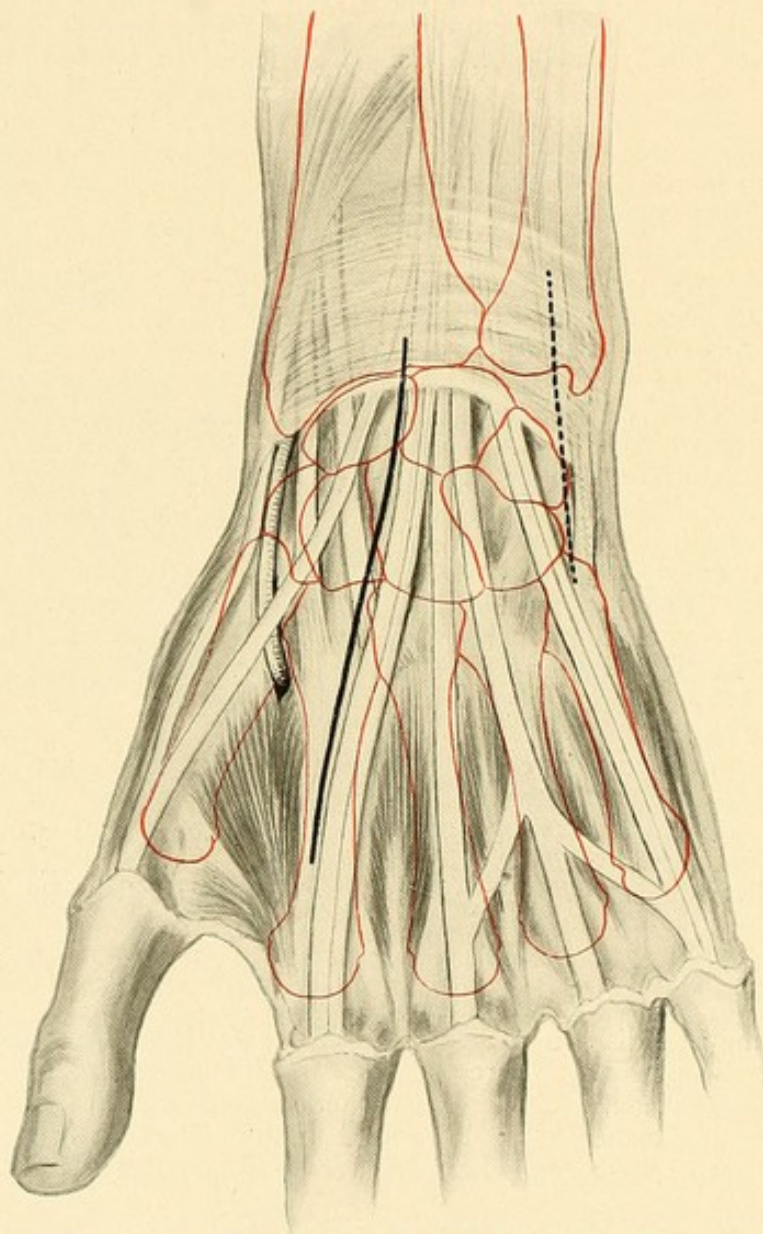


FIG. 358.—Excision of wrist, showing structures involved and Ollier's incisions. The solid line indicates the dorsal radial incision and the dotted line the palmar ulnar incision.

nearer the extensor indicis tendon to better avoid injuring the radial artery and the insertion of the extensor carpi radialis brevis tendon. Ollier also carried his incision somewhat higher on the wrist and raised the tissues with a periosteal elevator, and divided no tendons.

**Ollier's Operation.**—*Radial Incision.*—From a point on the dorsum of the wrist midway between the styloid processes, downward and outward alongside of the extensor indicis tendon to the junction of the middle and lower thirds of the metacarpal bone of the index finger (Fig. 358).



*Ulnar Incision.*—From a point 2.5 cm. (1 in.) above the styloid process of the ulna toward its palmar surface, downward to the base of the fifth metacarpal bone (Fig. 358).

When making the radial incision, branches of the radial nerve may be seen in the lower part of the incision and should if possible be avoided. In making the ulnar incision a cutaneous branch of the ulnar nerve should be avoided as it verges toward the dorsal surface below the styloid process.

The extensor indicis tendon is pulled aside and the extensor carpi radialis brevis beneath detached with the periosteum from the base of the third metacarpal bone. The incision is then extended higher up the wrist, care being taken not to injure the tendon of the extensor longus pollicis at the posterior radial tubercle. The periosteum is to be detached over the lower end of the radius, the radiocarpal joint opened, and the carpal bones removed one after another. The pisiform bone, unciform process, and trapezium are left when possible. In removing the unciform process the deep branch of the ulnar nerve should be avoided. If the trapezium is removed care must be taken not to wound the radial artery as it goes over the bone to dip between the first and second metacarpal bones, and also to avoid the flexor carpi radialis tendon as it crosses to the inner side of the ridge of the trapezium on its palmar surface.

The articular ends of the ulna and radius may be removed with a small saw if necessary. As Jacobson says, this operation is a tedious and difficult one, and we might add that it is liable to be an inefficient one, owing to the inability to remove all of the diseased tissue.

**Operations of Studsgaard and Mynter.**—Studsgaard of Copenhagen in 1891 (*"Hospitalstidenden,"* Jan. 7, 1891) suggested, and Herman Mynter of Buffalo (*Transactions of the American Orthopedic Association*, 1894, vol. vii, p. 253) carried out the method of splitting the hand on the dorsum from the web between the second and third fingers to the lower edge of the radius, and on the palmar surface to the base of the thenar eminence.

Dr. Wm. J. Taylor (*Annals of Surgery*, vol. xxii, 1900, p. 360) modified the operation by employing only the dorsal incision. This operation gives full access and exposure to the parts, and all disease can most readily be recognized and removed with the scissors or other instruments. It is probably the best method of exposure and operation when simple incision and curetting does not suffice.

## AMPUTATION THROUGH THE WRIST-JOINT.

When it is possible to do so the interarticular fibrocartilage over the lower end of the ulna is not to be interfered with. The lower radio-ulnar joint is therefore not injured and the movements of pronation and supination are preserved.

The styloid process of the radius is 1 cm. below that of the ulna. It is directly on the outer side of the radius, while the styloid process of the ulna is toward the posterior surface.

On account of the skin of the palm being thick and well adapted for pressure a long palmar flap is preferred.

**Incision.**—On account of retraction, the knife is entered 1 cm. ( $\frac{3}{8}$  in.) below the radial styloid process—the thumb being abducted to render the tissues tense, and, if the left hand is being operated on, the knife is carried straight down well on the thenar prominence. It is then curved abruptly across the palm on a level almost or quite as low as the web of the thumb. It is continued to the ulnar side and up to within 1 cm. of the styloid process of the ulna. The flap should be an almost square one with rounded ends. The incision goes down to but does not divide the flexor tendons (Fig. 359.)

This flap, embracing the palmar fascia and part of the thenar and hypothenar muscles, is at once raised from the flexor tendons, care being taken not to catch the knife on the unciform and pisiform bones.

The hand is now pronated and a dorsal flap 2.5 cm. (1 in.) long is cut. As the skin is loose and elastic this length is needed to provide against retraction.



The flaps being reflected and the hand flexed, disarticulation is begun by entering the knife on the ulnar side of the dorsum, beneath the styloid process. The joint is followed around to the radial side, bearing in mind that it curves markedly upwards.

If the right hand is being operated on and the knife is entered transversely it will strike the scaphoid bone, therefore it must be at once inclined obliquely upward. Section of the flexor muscles and anterior ligament completes the disarticulation. The radial artery will be cut in the snuff-box. The ulnar will be seen on the inner side of the palmar flap, and on the outer side may be seen the superficial volar. Some small branches of the anterior and posterior carpal and interosseous arteries may require ligation.

Some operators remove the styloid processes of the radius and ulna. If this is done, care is to be taken not to go so high as to injure the insertion of the brachioradialis on the radius and the attachment of the triangular cartilage on the ulna. Usually the styloid processes are not interfered with, in order to avoid impairing the movements of pronation and supination.

**Ligation of the Radial Artery on the Dorsum of the Hand.**—The radial artery can be ligated in the anatomical snuff-box as it crosses the back of the

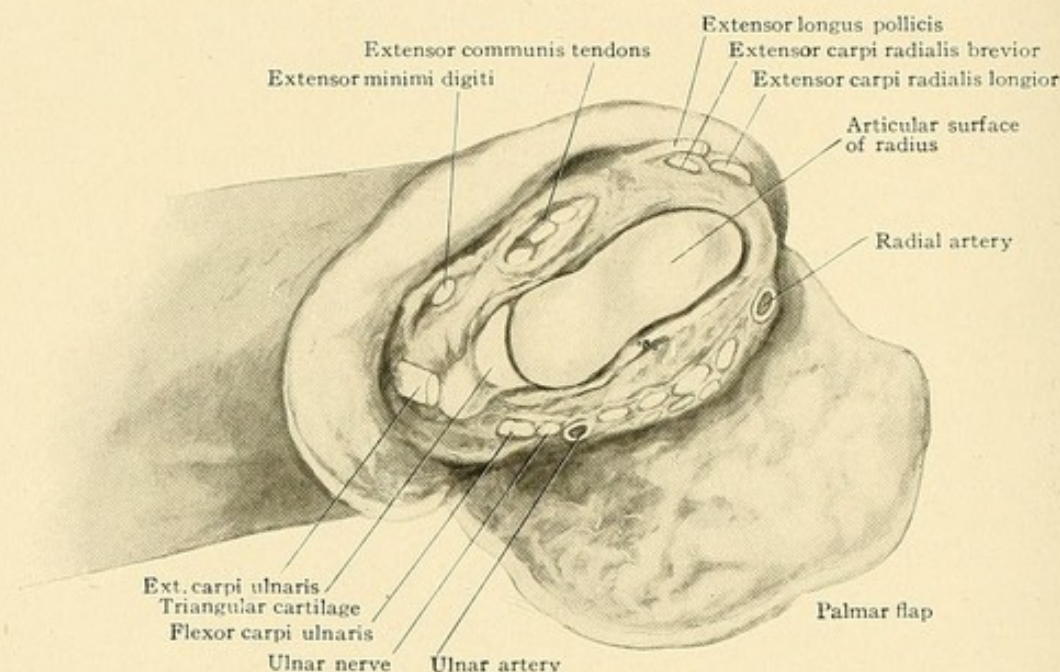


FIG. 359.—Amputation through the wrist-joint of the right side.

hand to dip between the first and second metacarpal bones and the two heads of the abductor indicis muscle. The course of the artery is indicated by a line drawn from the tip of the styloid process of the radius to the upper end of the first interosseous space (see Fig. 348, p. 338).

The incision is usually made in the direction of the tendons from the styloid process down. As soon as the skin is divided there may be exposed in the superficial fascia some branches of the radial nerve and the radial vein. These being pushed aside, the deep fascia is opened and the artery found with its two companion veins lying deep down on the external lateral ligament and trapezium. The most common error in this operation is mistaking the superficial vein for the artery and not searching deep enough.

If the radial artery is wounded as it passes through the snuff-box bleeding will be very free. It is almost impossible to ligate the divided ends in the wound because the proximal end retracts under the short extensor tendons of the thumb and the distal end retracts through the first interosseous space deep into the palm of the hand so that they cannot be reached. When such is the case it is necessary either to ligate the ulnar and radial arteries on the anterior surface just above the wrist or, as we did in one case, pack the wound with antiseptic gauze and keep the hand well elevated.



## THE HAND.

As has already been stated, the hand is the essential part of the upper extremity, and mobility is its main characteristic. It terminates in five digits which possess a bony support or framework. In order that the fingers may perform their many complicated movements numerous joints are inserted which necessitate a still greater number of bones. The movements of the hand and fingers are accomplished not only by the long flexors and extensors of the fingers and the flexors and extensors

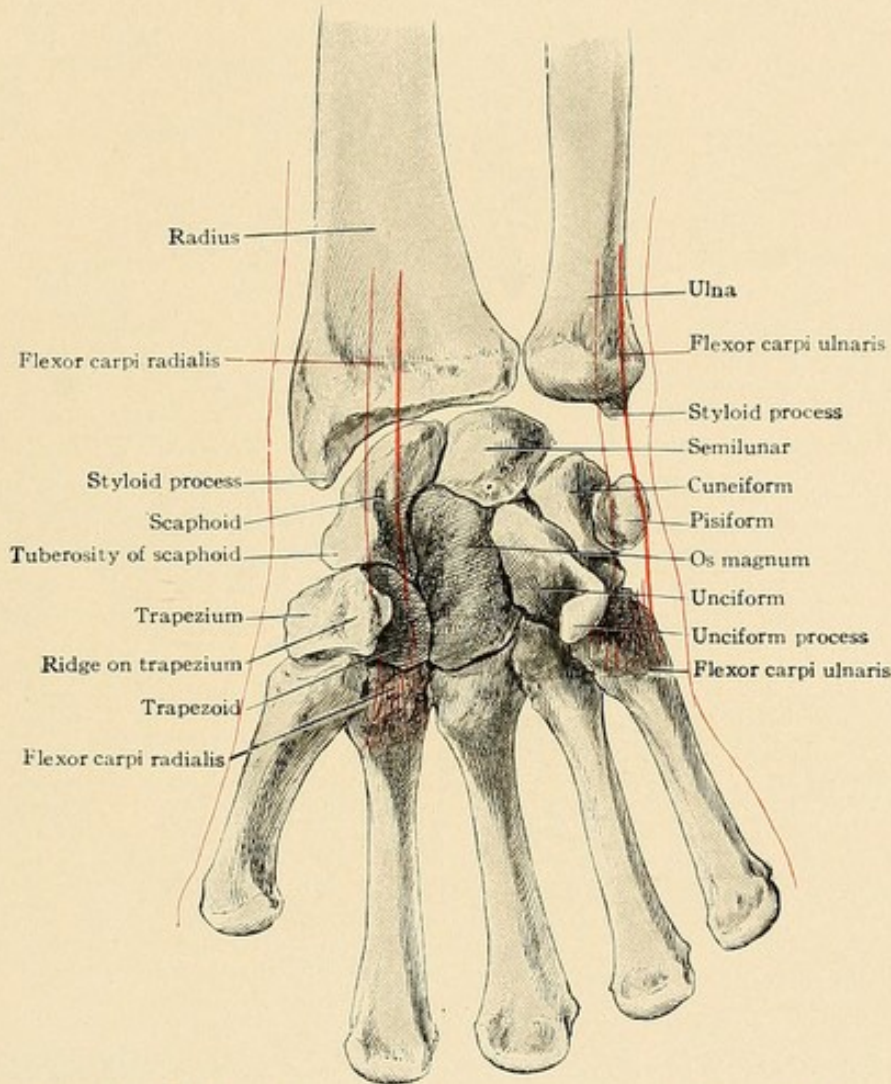


FIG. 360.—Anterior view of the bones of the carpus and metacarpus, showing insertion of the two carpal flexor muscles.

of the carpus, which, as has already been shown, come down from the forearm, but in addition by numerous short muscles situated in the hand itself. An especial peculiarity of the human hand is the ability to oppose the thumb to the other digits.

## BONES OF THE HAND.

The carpus contains 8 bones, the metacarpus 5, the phalanges 14; 27 bones in all.

**The Carpal Bones.**—The carpal bones are in two rows. The upper row is convex above and the lower row is convex below.

The upper row, beginning on the radial side, is composed of the *navicular* (*scaphoid*), *lunate*, *cuneiform*, and *pisiform*. The three first-named articulate with the radius and triangular cartilage, forming the *radiocarpal joint*, but the pisiform is separate. It is perched on the cuneiform bone and is practically a sesamoid bone



developed in the tendon of the flexor carpi ulnaris muscle. The anterior end of the navicular (scaphoid) has on its palmar surface a tuberosity which can be felt immediately below the flexor carpi radialis tendon at the wrist; this tendon passes along the palmar surface to insert in the base of the second metacarpal bone (Fig. 360).

The lower row, beginning on the radial side, is composed of the *trapezium*, *trapezoid*, *os magnum*, and *unciform*. The first three articulate with the first three metacarpal bones but the unciform, like the cuboid in the foot, articulates with two metacarpal bones—the fourth and fifth.

The trapezium articulates with the first metacarpal bone by a saddle-shaped joint and has on its palmar surface a ridge. Along the inner side of this ridge runs the

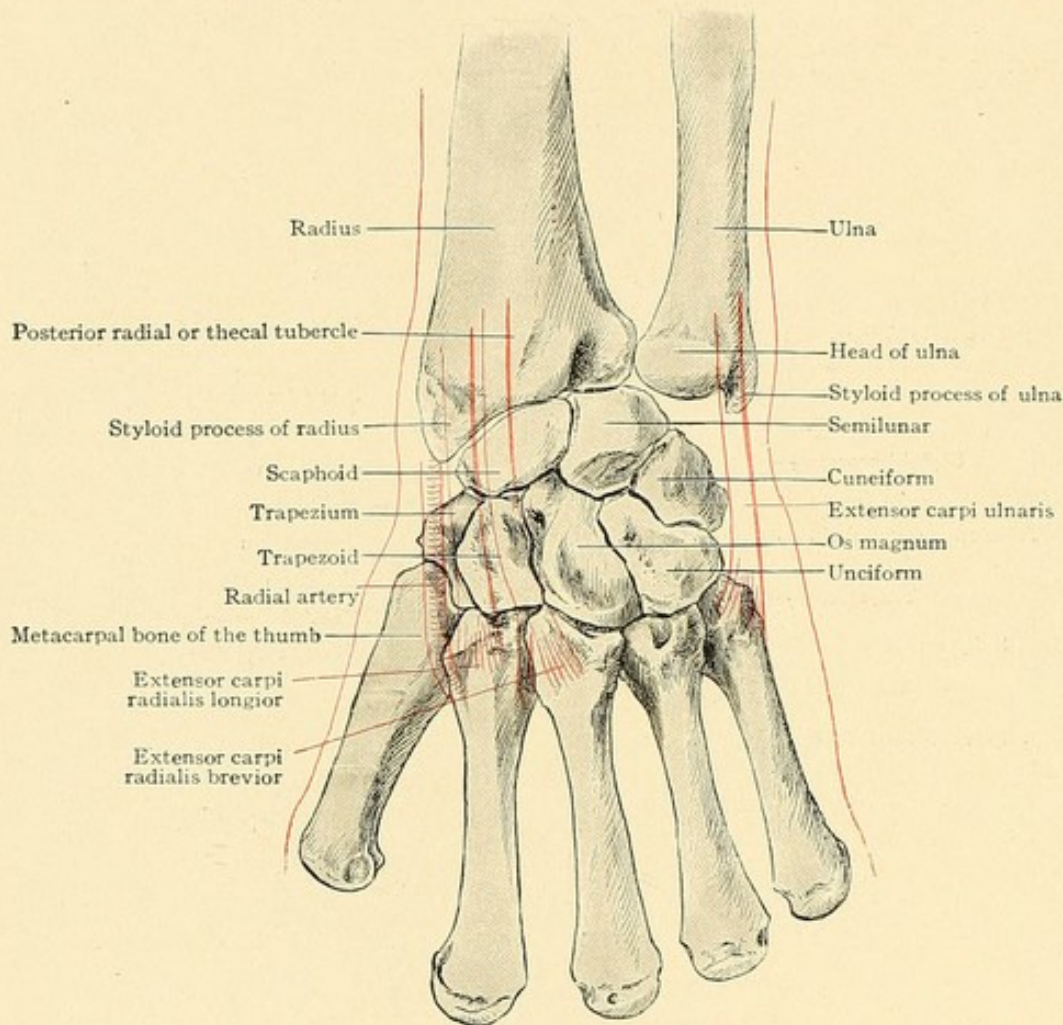


FIG. 361.—Posterior view of the bones of the carpus and metacarpus, showing the insertion of the three carpal extensor muscles.

*flexor carpi radialis tendon*. The ridge of the trapezium and tuberosity of the navicular (scaphoid) give attachment to the radial side of the *anterior annular ligament*.

The unciform bone has a hook-like (unciform) process on its palmar surface. It can be felt by deep pressure 2 cm. (about  $\frac{3}{4}$  in.) below and to the radial side of the pisiform bone. This process and the pisiform bone give attachment to the ulnar side of the anterior annular ligament.

**The Metacarpal Bones.**—The metacarpal bones have their bases at the carpus and their heads toward the phalanges. The shafts are small as compared with the extremities, and hence are not infrequently fractured. On each side of the head is a small projecting tubercle, which, when the bone becomes luxated, catches in the tissues and hinders reduction.

On the palmar surface of the base of the second metacarpal bone is inserted the *flexor carpi radialis* and into the base of the fifth the *flexor carpi ulnaris*, which is continued onward from the pisiform bone. On the dorsal surface, into the base of the



second, is inserted the *extensor carpi radialis longior*; into the base of the third (and part of the second) is inserted the *extensor carpi radialis brevior*, and into the base of the fifth, the *extensor carpi ulnaris* (Fig. 361).

Thus it will be seen that all the flexors and extensors of the wrist have their ultimate insertion into the metacarpal bones.

The metacarpal bone of the thumb has inserting into its base the *extensor ossis metacarpi pollicis tendon*. As this tendon has its origin in the forearm it also acts as

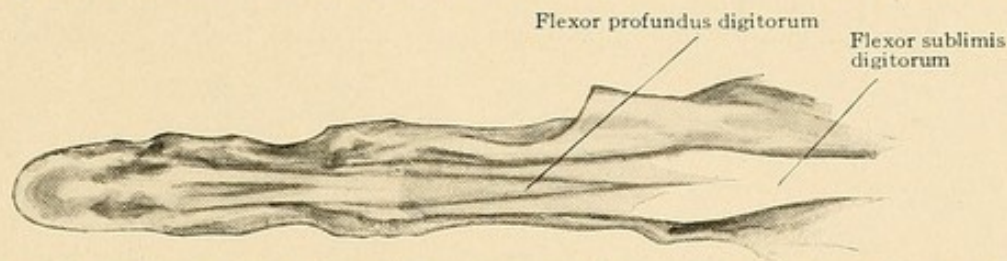


FIG. 362.—Palmar view of the flexor tendons of the finger, showing the insertion of the flexor sublimis into the middle phalanx and the flexor profundus into the distal phalanx.

a carpal extensor, but owing to the movability of the thumb it acts especially as an extensor of the latter, the carpus remaining immovable.

**The Phalanges.**—The thumb has two phalanges and the fingers each three. These are called the *proximal*, *middle*, and *distal phalanges*, also the *first*, *second*, and *third phalanges*. The thumb has only a *proximal* and a *distal phalanx*.

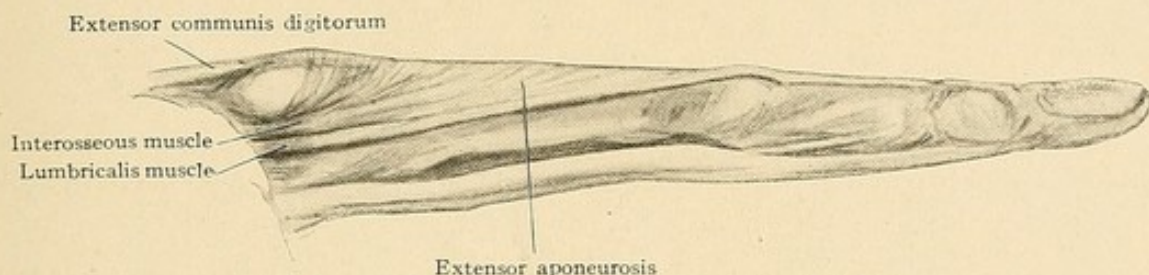


FIG. 363.—Lateral view of the extensor tendons of the finger.

Into the middle phalanges on their palmar surfaces are inserted the *flexor sublimis digitorum tendons* and into the distal the *flexor profundus* (Fig. 362). There is only one long flexor to the thumb and it is inserted into the distal phalanx.

The *extensor communis digitorum* opposite the metacarpophalangeal joints sends off a fibrous expansion which blends with the lateral ligaments of the joints

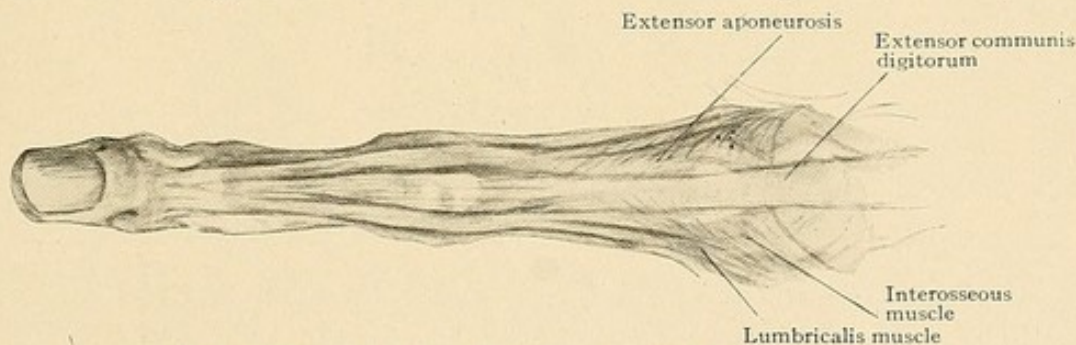


FIG. 364.—Dorsal view of the extensor tendons of the finger.

(Fig. 363). On the dorsum of the proximal phalanx the tendon splits into three parts. The middle slip inserts into the bases of the middle phalanges, while the two lateral slips, after receiving the insertions of the lumbricales and part of the insertions of the interossei, insert into the bases of the distal phalanges of the fingers (Fig. 364). The thumb has two separate extensors, the *extensor brevis pollicis* and the *extensor longus pollicis*.

Into the bases of the proximal phalanges are inserted the remaining portion of the tendons of the interossei muscles, which move the fingers toward and from one another, and slips from the palmar fascia. The main function of the interossei and



lumbrical muscles is to extend the distal and middle phalanges and to flex the proximal ones. When, therefore, most of them are paralyzed, as occurs when the ulnar nerve is divided, the distal and middle phalanges are flexed and the proximal phalanges extended, forming the claw-hand (main griffe) of Duchenne.

### JOINTS OF THE HAND.

The carpal bones besides being connected by short ligaments running from one to another on their dorsal and palmar surface also have their adjacent surfaces con-

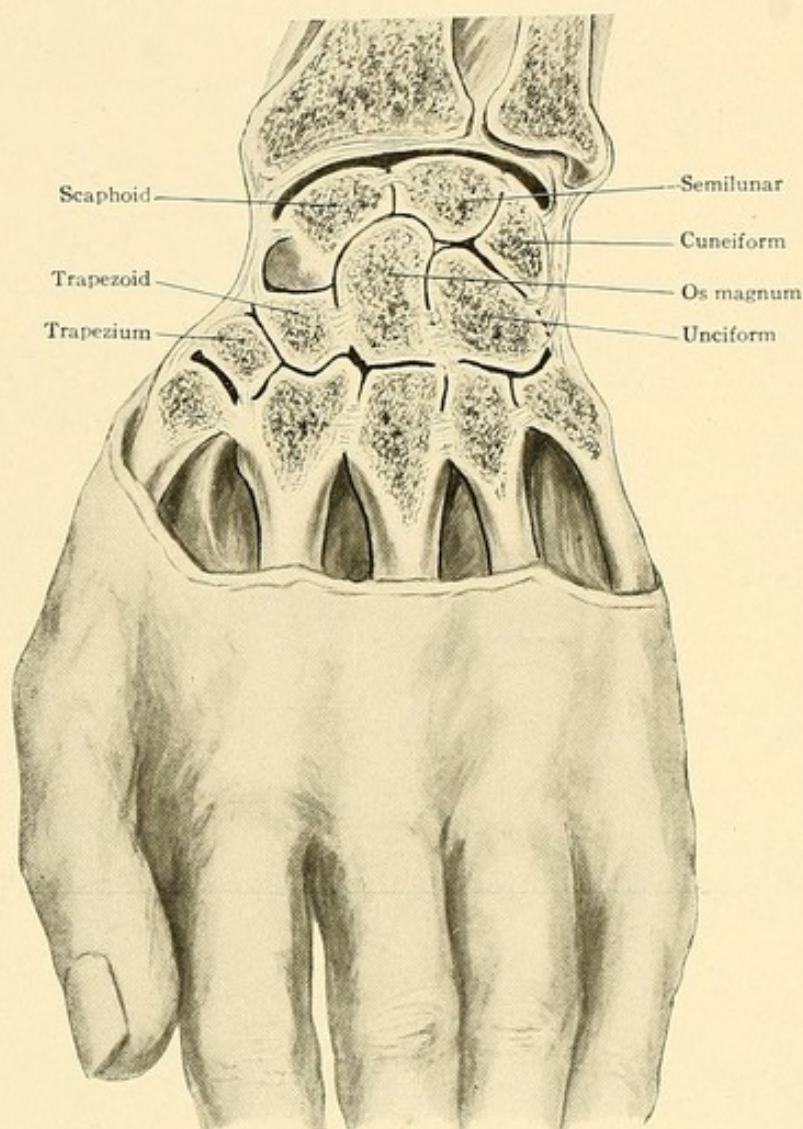


FIG. 365.—The carpal bones and joints.

nected by interosseous ligaments. The three bones of the first row are joined by two ligaments near their proximal surfaces which prevent any communication of the radiocarpal with the midcarpal articulations. The four bones of the second row are joined together by interosseous ligaments (fibrocartilages, Morris) which are not complete. That between the os magnum and the unciform is attached more toward the palmar surface, while that between the os magnum and trapezoid is more toward the dorsal surface. The interosseous ligament between the trapezium and trapezoid is usually lacking (Fig. 365).

**Synovial Membrane.**—From the above description it will be seen that the joints of the carpus (with the exception of the pisiform) all communicate with one another and with the carpometacarpal joints, and that the synovial membrane is practically continuous; hence *suppuration* implicating the synovial membrane at any



point can travel without hindrance between all the carpal (with the exception of the pisiform) and metacarpal bones.

The phalangeal joints have two strong lateral ligaments and an anterior or glenoid ligament, but no posterior ligament.

**Movements.**—While the amount of motion between the individual carpal bones is limited to a slight gliding on one another, still, when taken together, a very considerable range of movement is allowed. The hand can be flexed and extended, abducted and adducted, and circumducted, but not rotated. If the bones of the forearm at the wrist are held immovable it is impossible to rotate the hand.

The radiocarpal joint bends more freely posteriorly (extension) than anteriorly, while the midcarpal bends more freely in the opposite direction (Fig. 343, 344, p. 334), adduction (toward the ulnar side) is more extensive than abduction. The movement between the two rows of carpal bones is quite extensive.

The movements of the inner four carpometacarpal joints are both of flexion and extension, mainly toward the palmar surface, and a lateral flexion and extension which enables a person to "hollow" the hand and so grasp round objects. The palmar flexion of the fourth and fifth metacarpal bones is more marked than that of the index and middle ones. The middle metacarpal bone is the least movable. The metacarpal bone of the thumb articulates with the trapezium by a saddle-shaped joint which allows flexion, extension, abduction, adduction, and circumduction, but little or no rotation.

Abduction, adduction, and circumduction of the thumb occur at the carpometacarpal articulation and *not* at the metacarpophalangeal articulation. This latter is a pure hinge-joint and possesses the movements of flexion and extension only.

The metacarpophalangeal articulations of the fingers are practically saddle-shaped joints resembling somewhat the ball-and-socket joints with all their movements except that of rotation. They can be flexed to an angle of 90 degrees. The interphalangeal joints are hinge-joints and capable only of flexion and extension. The second joint can be flexed to an angle of 150 degrees and the end joint to about a right angle.

In flexion the distal phalanx always passes under the proximal bone, thus causing the prominence of the knuckle to be formed by the proximal phalanx or metacarpal bone (Fig. 366).

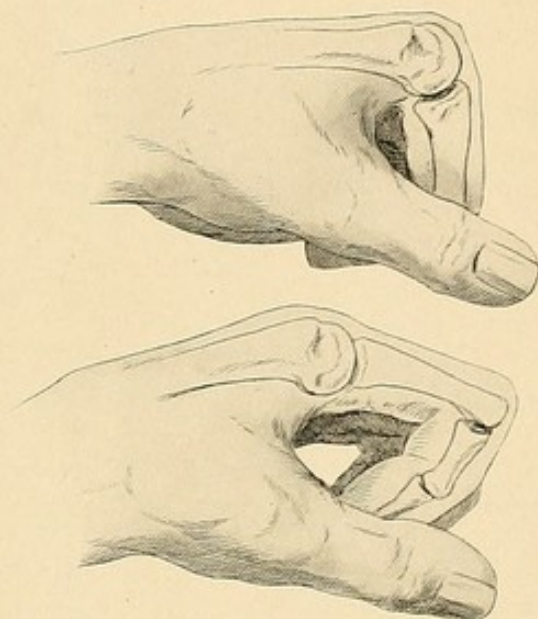


FIG. 366.—Showing how, when the fingers are flexed, the prominence of the knuckles is formed by the projection of the proximal bone.

## MUSCLES OF THE HAND.

The hand contains not only the tendons of the long muscles which descend into it from the forearm, but also some short muscles. They may be divided into *three sets*, viz: a middle set, embracing the *interossei* and *lumbricales*; an external set, embracing the thumb muscles and forming the *thenar eminence*; and an internal set, embracing the little finger muscles and forming the *hypothenar eminence*.

**The Middle Set.**—The *interossei* muscles arise from the adjacent sides of the metacarpal bones; the *lumbricales* arise from the tendons of the flexor profundus digitorum. They all insert into the fibrous expansion of the long extensor tendons at the sides of the proximal phalanges (Fig. 367). When they contract they flex the proximal phalanx and extend the middle and distal phalanges. The *interossei* have a second insertion into the sides of the base of the proximal phalanx. By their action the fingers may be separated one from the other, or approximated. When the fingers are straight the palmar *interossei* act as adductors, while the dorsal *interossei* act as abductors.



**The External Set.**—The thenar or thumb eminence has four muscles, the *abductor pollicis*, *opponens*, *flexor brevis*, and *adductor*. This latter is usually divided into two parts called the *adductor transversus* and *adductor obliquus* (Fig. 368).

The *flexor brevis* has two heads, an outer and an inner. The outer head is inserted into the base of the proximal phalanx on its outer side along with the *abductor*. The inner head, called by some the first volar interosseous, is inserted into the inner side along with the *adductor*; between the two heads runs the tendon of the long flexor of the thumb. The *opponens* inserts into the outer anterior border of the shaft of the first metacarpal bone.

**The Internal Set.**—The little finger, like the thumb, has *abductor*, *opponens*, and *flexor brevis* muscles, but no *adductor*. There is, however, a short

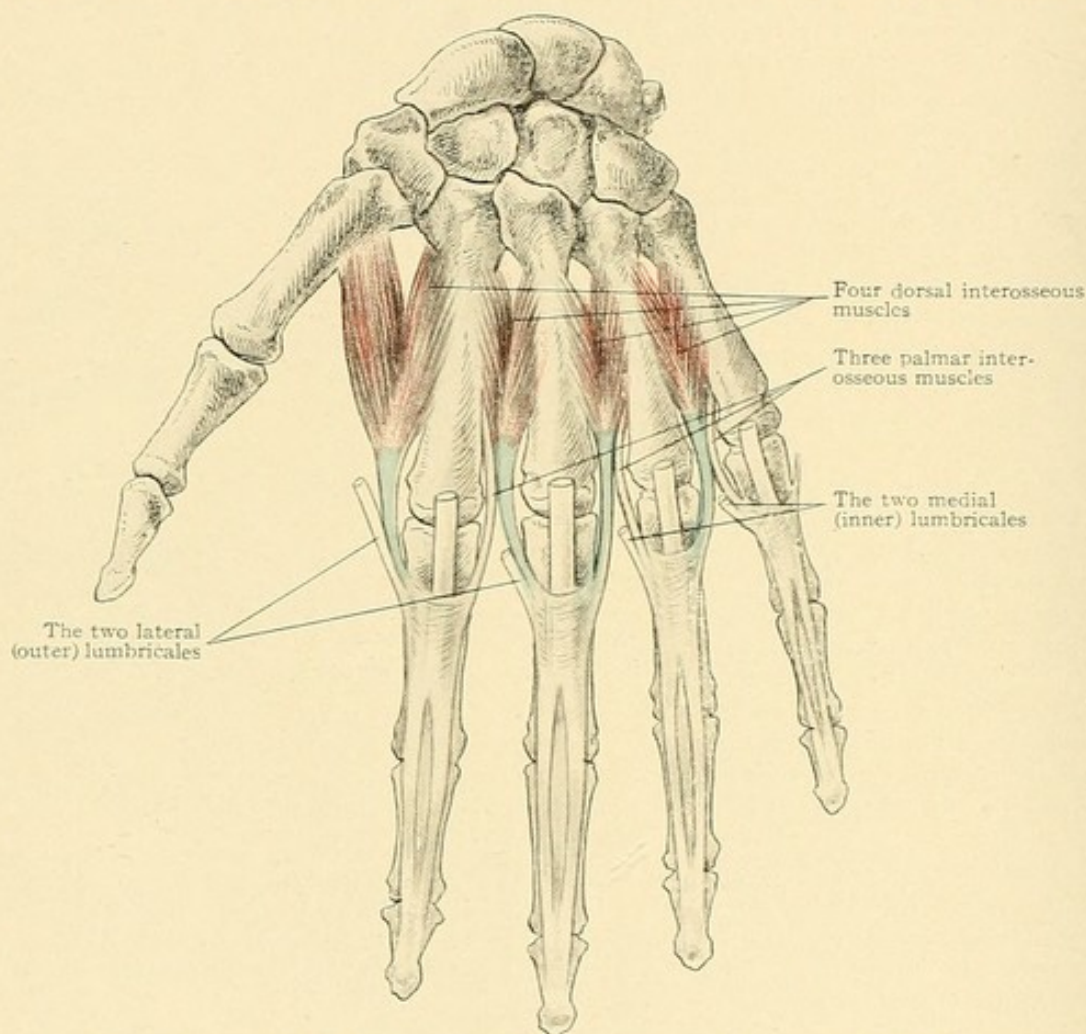


FIG. 367.—Showing the mode of insertion of the interosseous and lumbrical muscles.

muscle, the *palmaris brevis*, which is superficial to the palmar fascia and, passing transversely across the hypothenar eminence, inserts into the skin. It makes a dimple on the ulnar side when the hand is hollowed. The *abductor* and *flexor brevis minimi digiti* muscles insert on the ulnar side of the proximal phalanx, hence when they contract they tend to hollow the hand, as does also the *opponens minimi digiti*, which inserts on the ulnar side of the fifth metacarpal bone.

#### SURFACE ANATOMY OF THE HAND.

The hand is twice as long as it is broad. The length of the middle finger from the metacarpophalangeal joint to its extremity is equal to the distance from the metacarpophalangeal joint to the radiocarpal joint. If the hand is turned with the palm up, the thumb diverges from the median line at an angle of 40 degrees. The



palm is hollow, with a muscular mass on each side. That on the thumb side is called the *thenar* eminence; it is formed by the abductor, opponens, and outer head of the flexor brevis pollicis. The prominence on the ulnar side of the hand is called the *hypothenar* eminence and is formed by the abductor, opponens, and flexor brevis minimi digiti. The palmaris brevis muscle overlies them transversely. The palm is marked by four *creases*, two longitudinal and two transverse. One longitudinal crease begins at the middle of the wrist between the thenar and hypothenar eminences to end on the radial side of the index finger, opposite the head of its metacarpal bone. It is caused by adduction of the thumb. The other longitudinal crease runs somewhat parallel to the first, starting near the wrist and ending in the web

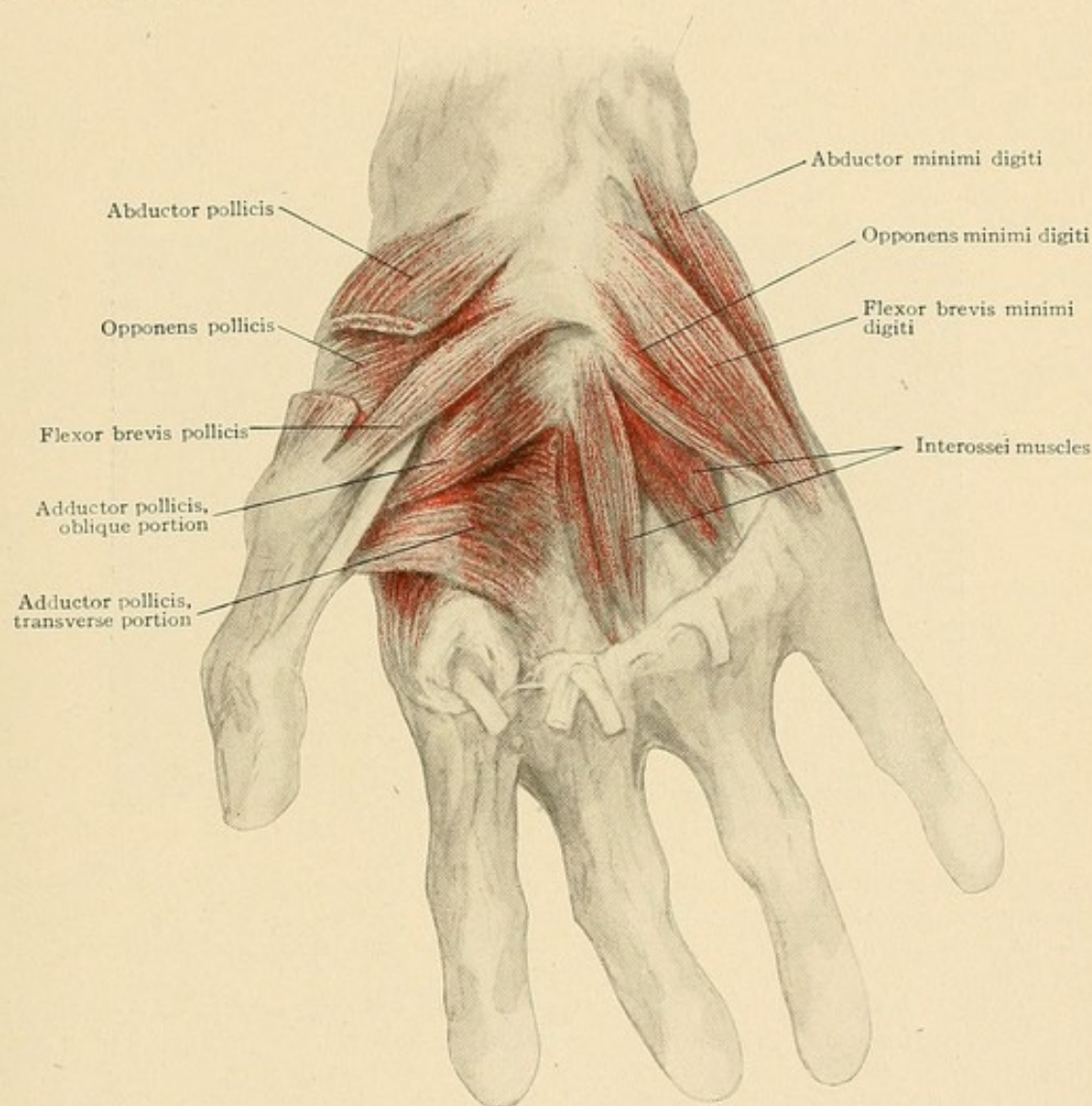


FIG. 368.—Muscles of the hand.

between the index and middle fingers. It is formed by hollowing the hand. The upper transverse crease begins on the radial side of the index finger where the first longitudinal crease ends, and runs obliquely across the palm to the middle of the hypothenar eminence. It is formed by the flexion of the fingers, especially the index, and where it crosses a line drawn through the middle of the middle finger marks the lowest point of the superficial palmar arch. The position of the lowest portion of the superficial palmar arch is also indicated by a line drawn across the palm opposite to the web of the thumb and index finger. The lower transverse crease begins on the hypothenar eminence opposite the head of the fifth metacarpal bone and is formed by the flexion of the middle, ring, and especially the little finger. When it reaches the vicinity of the median line it merges with the second longi-



tudinal crease which passes to the web between the index and middle fingers. Midway between the crease and the webs of the fingers lie the joints of the middle, ring, and little finger. More stress is apt to be laid on a knowledge of these creases than they deserve (Fig. 369).

The position of the metacarpophalangeal joints is best determined by feeling for them on the dorsum of the hand and then taking a corresponding point on the palmar surface. They are sufficiently accurately located by taking a point 2 cm. ( $\frac{3}{4}$  in.) behind the web of the fingers. The creases for the middle phalangeal joints are directly opposite the articulations. The creases for the end phalangeal joints are to the proximal side of the articulations. The deep palmar arch lies about 1.5 cm. ( $\frac{3}{8}$  in.) closer to the wrist than the superficial.

The digital arteries from the superficial palmar arch pass downward with the digital nerves, superficially, in the spaces between the metacarpal bones, to the webs of the fingers. About 1 cm. ( $\frac{2}{5}$  in.) behind the web they sometimes receive branches from the deep palmar arch, and then divide to go to each lateral palmar side of the fingers. The palmar fascia divides into its four slips just below the line of the superficial palmar arch, opposite the web of the thumb.

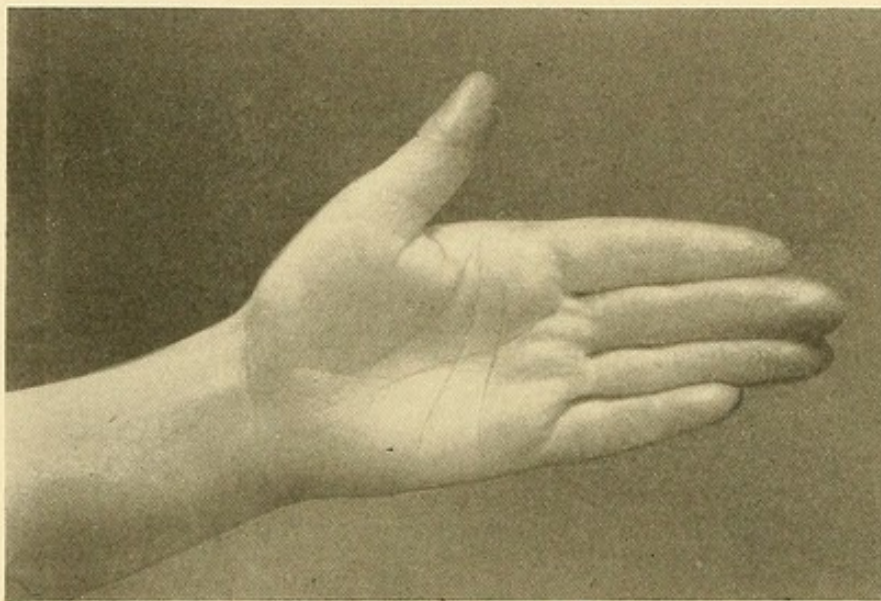


FIG. 369.—The palmar surface of the hand showing thenar and hypothenar eminences and creases.

On the dorsum of the hand the extensor tendons can be seen. Accessory slips usually connect the tendon of the ring finger with that of the little finger and middle finger. A slip also usually passes from the tendon of the middle to that of the index finger.

The slip from the tendon of the ring to that of the little finger has been thought to restrict the freedom of the movement of the ring finger, hence in musicians it sometimes has been divided. The operation is done by first flexing the fingers, which brings the slip well forward near the knuckle, and then introducing a thin knife longitudinally beneath it and cutting toward the skin. The procedure has not found favor among musicians.

The metacarpal bones are subcutaneous and can readily be felt their entire length. The muscular prominence on the dorsum of the hand seen when the thumb and forefinger are approximated is due to the abductor indicis muscle. At its upper extremity the radial artery passes between its two heads to enter the palm. When the thumb is extended the snuff-box becomes evident and the extensor longus pollicis tendon is distinctly seen leading to the ulnar side of the posterior radial (thecal) tubercle on the middle of the dorsum of the radius. The tendons on the radial side of the snuff-box are the extensor brevis and extensor ossis metacarpi pollicis.

When the fingers are flexed, the prominence of the knuckles is formed by the proximal bones; the distal phalanges fold under the proximal ones and the joint line is about 1 cm. ( $\frac{2}{5}$  in.) below the dorsal surface of the metacarpal bones (Fig. 366, page 353).



## THE PALMAR FASCIA.

The palmar fascia is the continuation downward of the palmaris longus tendon. It consists of a thick triangular middle portion and two thin lateral portions which cover the thenar and hypothenar eminences. The *triangular middle portion* can be divided into two layers. Its under layer is composed of transverse fibres, and blends with the anterior annular ligament; its upper layer is composed of longitudinal fibres, the continuation of the palmaris longus, and when it reaches the middle of the palm it divides into four slips which blend with the sheaths of the flexor tendons and

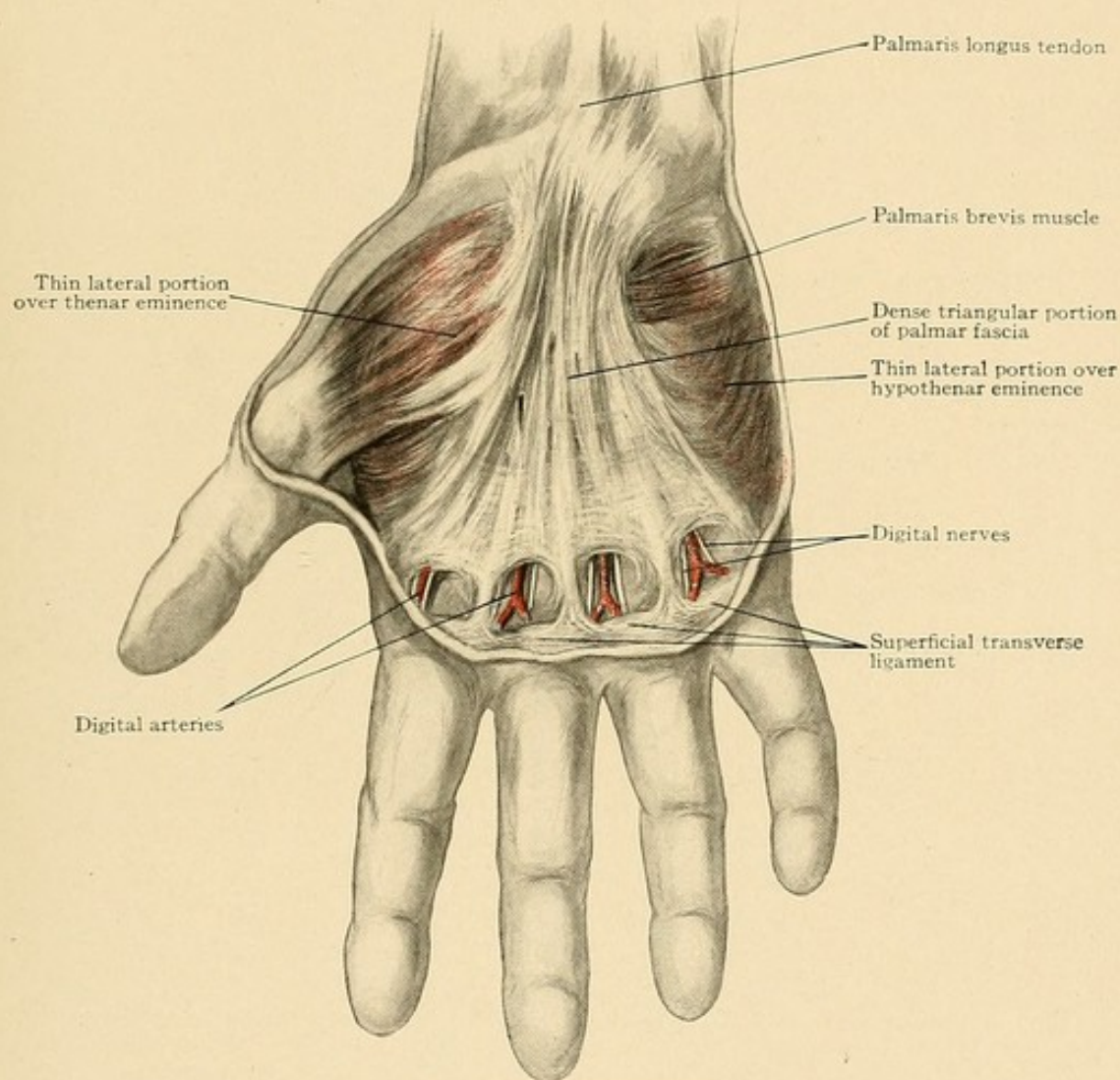


FIG. 370.—The palmar fascia.

lateral ligaments of the metacarpophalangeal joints to insert into the sides of the base of the proximal phalanges, and aid in flexing them. The digital arteries and nerves lie between these slips on their way to the webs of the fingers. The superficial surface is intimately adherent to the skin above, especially at the webs of the fingers, where its fibres form the superficial transverse ligament. The intimate attachment between the skin above and fascia beneath binds these two structures so closely and firmly together that pus cannot travel for any distance between them. It either burrows deeper, or perforates the skin, or collects beneath the epiderm, forming a bleb. A strong band from the palmar fascia frequently goes to the thumb also, and when the palmaris longus contracts it tends to bring the thumb forward. The *lateral portions* covering the thenar and hypothenar eminences are thin and are prolonged beneath the long flexor tendons to become attached to the third and fifth metacarpal bones (Fig. 370).



## ARTERIES OF THE HAND.

The hand receives its blood supply mainly from the radial and ulnar arteries, the amount which it receives from the anterior and posterior interosseous being comparatively insignificant. The continuation of the ulnar in the hand forms the superficial palmar arch and the continuation of the radial forms the deep palmar arch (Fig. 371).

**Ulnar Artery and Superficial Palmar Arch.**—The ulnar artery at the wrist runs along the edge of the flexor carpi ulnaris muscle with the ulnar nerve to its

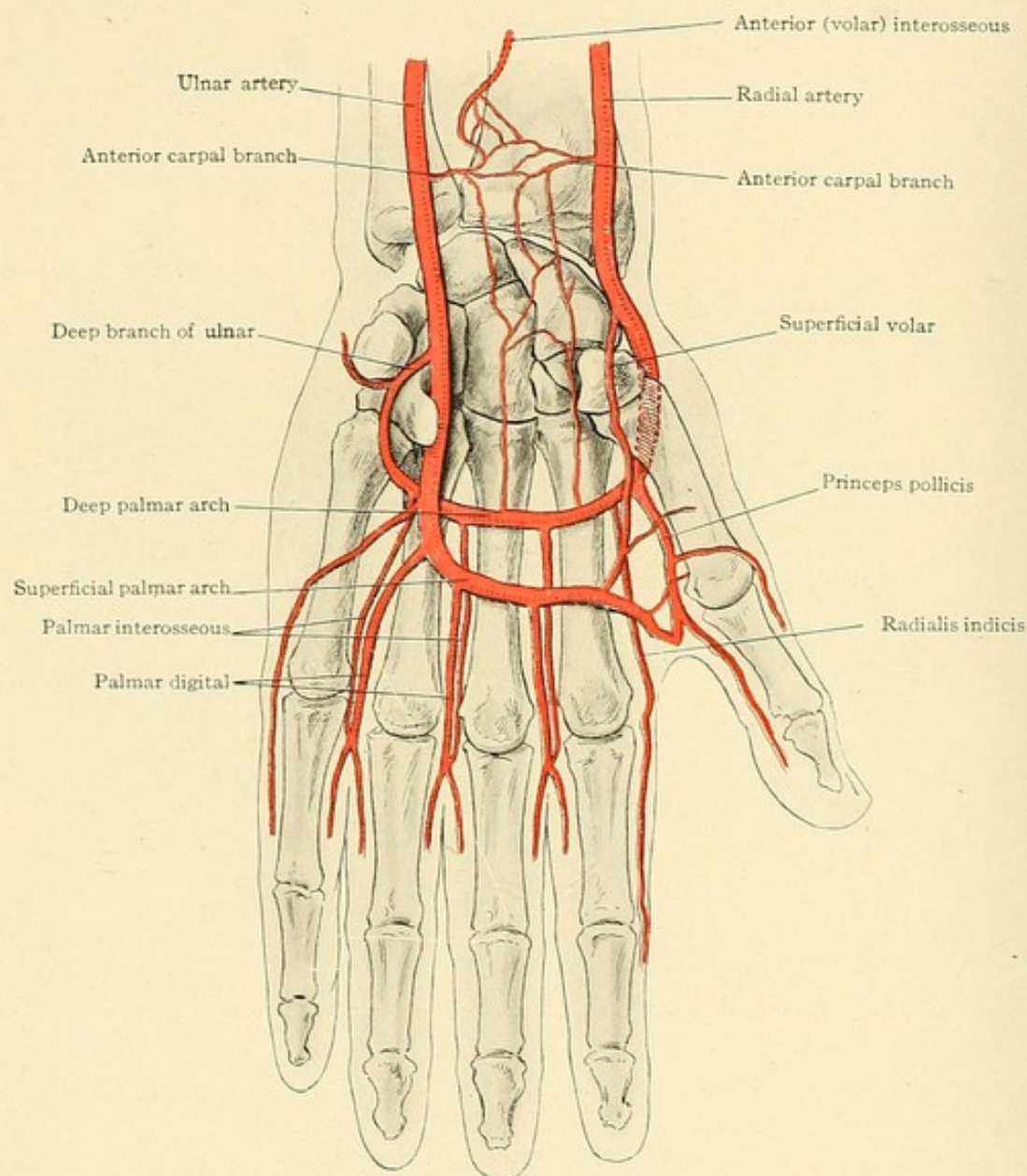


FIG. 371.—The arteries of the hand.

inner or ulnar side. As it enters the hand it lies just to the radial side of the pisiform bone with the nerve intervening. Both the artery and nerve lie *on* the anterior annular ligament. As soon as they pass the pisiform bone they go under the small palmaris brevis muscle and the palmar fascia, and lie on the flexor tendons.

The artery then describes a curve across the palm of the hand toward the web of the thumb. It crosses the middle of the third metacarpal bone at or a little above the level of the web of the thumb and continues on to the radial side of the metacarpal bone of the index finger. Here it receives the superficial volar artery from the radial as well as a communicating branch from the princeps pollicis and



radialis indicis. When one of these branches is large the other two are smaller or lacking altogether. Not infrequently the communication with the radial at this point is in the form of a large branch which passes superficially across the web of the thumb and index finger, and its pulsations can be both seen and felt (Fig. 372).

**Branches.**—As soon as the ulnar artery passes the pisiform bone it gives off its *deep branch* which passes down between the abductor and flexor brevis minimi digiti to join the termination of the radial and form the deep palmar arch. From the convexity of the superficial arch four palmar digital arteries are given off. One goes to the ulnar side of the little finger while the other three go down between the metacarpal bones

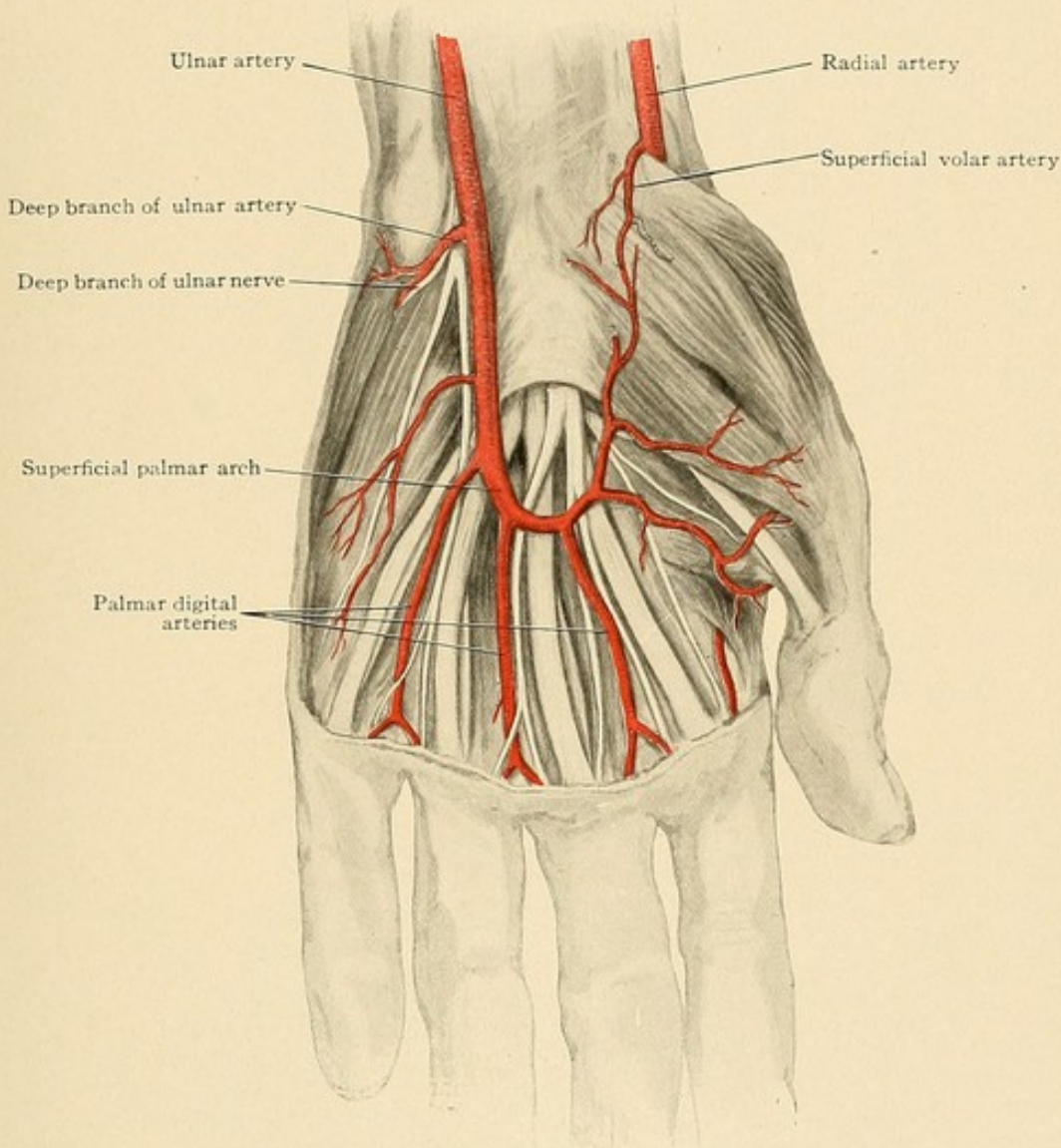


FIG. 372.—Superficial palmar arch.

to the webs of the fingers. Here they may receive a small communicating branch derived from the deep palmar arch, and about 1 cm. ( $\frac{2}{3}$  in.) back from the web divide into collateral digital branches which run along the palmar sides of the fingers. The digital nerves as they accompany the digital arteries are superficial to them.

**The Radial Artery and Deep Palmar Arch.**—The radial artery reaches the wrist between the brachioradialis and flexor carpi radialis tendons. It then turns sharply toward the dorsum around the extremity of the styloid process of the radius. It crosses the external lateral ligaments and the scaphoid and trapezium bones to enter the palm between the bases of the metacarpal bones of the thumb and index finger. It then passes across the palm to the fifth metacarpal bone, where it receives



the deep branch of the ulnar, which completes the formation of the deep arch. It lies beneath the flexor tendons and on the interossei muscles and bases of the metacarpal bones (Fig. 373).

**Branches.**—The radial artery at the wrist gives off a posterior carpal branch which anastomoses with the posterior carpal branch of the ulnar to form a posterior carpal arch. From this arch descend three posterior interosseous arteries. The dorsal interosseous artery lying to the radial side of the index finger is called the *dorsalis indicis*. It comes off separately from the radial, and may be a branch from the radial indicis.

As the radial artery enters the palm it gives off a large branch to the thumb called the *princeps pollicis*, and one to the palmar side of the index called the *radialis indicis*. Farther on, three palmar interosseous branches are given off which communicate at the webs of the fingers with the palmar digital arteries from the superficial arch. The deep palmar arch also sends a few recurrent branches up on the anterior surface of the carpus and three perforating branches between the metacarpal bones to the back of the hand.

### NERVES OF THE HAND.

The hand is supplied by the *median*, *ulnar*, and *radial* (*musculospiral*) nerves. They are of clinical importance on account of the paralysis of the muscles or disturbance of sensation which accompany their injury (Fig. 374).

#### MUSCULAR BRANCHES.

Median Nerve.....	{	Abductor pollicis.
	{	Opponens pollicis.
	{	Outer head of flexor brevis.
	{	First and second lumbricales.
Ulnar Nerve.....	{	To all the rest of the hand muscles.
<i>Superficial Branch</i> .....	{	Palmaris brevis.
	{	Abductor minimi digiti.
	{	Flexor brevis minimi digiti.
	{	Opponens minimi digiti.
<i>Deep Branch</i> .....	{	Adductor transversus and obliquus pollicis.
	{	Inner head of flexor brevis pollicis.
	{	Two inner lumbricales.
	{	All the interossei.

#### CUTANEOUS BRANCHES.

##### *Palmar Surface.*

Median Nerve.....	{	Entire radial side of the palm over to the middle of the ring finger and the groove at the wrist between the thenar and hypothenar eminences.
Ulnar Nerve.....	{	Ulnar side of the little finger, and adjacent sides of little and ring fingers and hypothenar eminence. The adjacent branches of the ulnar and median nerves anastomose.

##### *Dorsal Surface.*

Median Nerve.....	{	Ulnar side of thumb and matrix of nail.
	{	Distal half of the index and middle fingers and distal half of the radial side of the ring finger.
Ulnar Nerve.....	{	Both sides of the little finger and ulnar side of ring finger.
Radial Nerve.....	{	Both sides of thumb as far as the nail, anastomosing with the median on the ulnar side. Proximal half of the index and, with the ulnar, the proximal half of the middle and radial side of the ring finger.



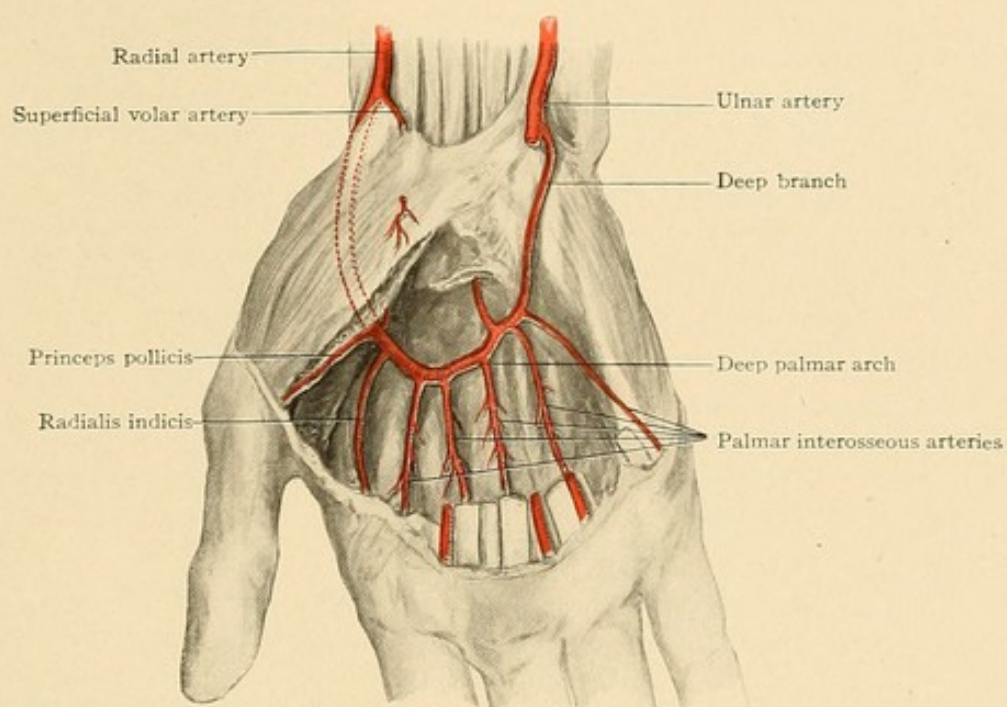


FIG. 373.—The deep palmar arch.

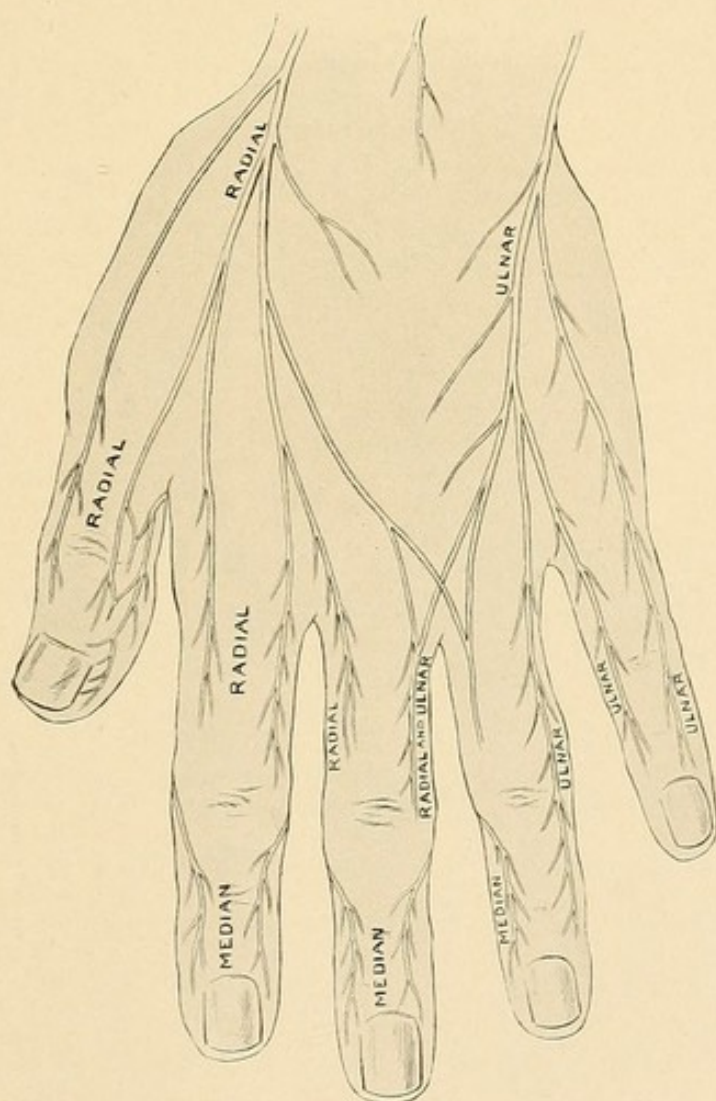


FIG. 374.—Showing the distribution of the nerves of the back of the hand.



## DISLOCATIONS OF THE HAND.

The carpal bones are so firmly held in place by their ligaments that they are rarely luxated. Dislocations of the scaphoid and semilunar however are sometimes encountered.

**Dislocations of the Bases of the Metacarpal Bones.**—Dislocations sometimes occur toward the dorsal surface. The bases of the second and third metacarpal bones in the uninjured hand form a bony prominence on the dorsum of the

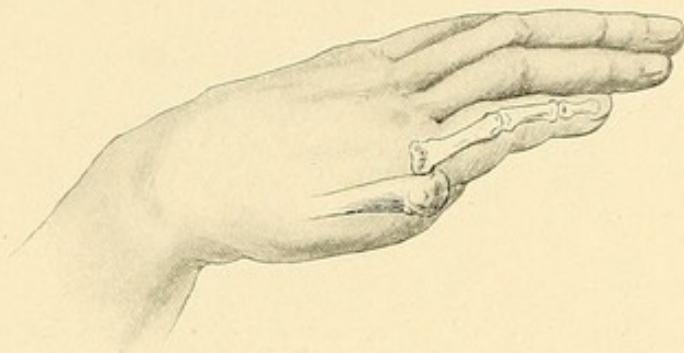


FIG. 375.—Dislocation of proximal phalanx of little finger. (From author's sketch.)

hand which may be mistaken for a luxation. This prominence lies in a direct line with the posterior radial (or thecal) tubercle and about 4 cm. ( $1\frac{1}{2}$  in.) below it.

The bases of the metacarpal bones and carpometacarpal joints are best recognized by following up the interosseous spaces by making firm pressure with the fingers between the bones; when the upper limit of the space is reached the joints can be located 1.25 cm. ( $\frac{1}{2}$  in.) above.

**Dislocations of the Phalanges on the Metacarpal Bones.**—These dislocations occur with moderate frequency. Dislocation of the thumb occurs most frequently and is well known. The little finger is next in frequency, while the other

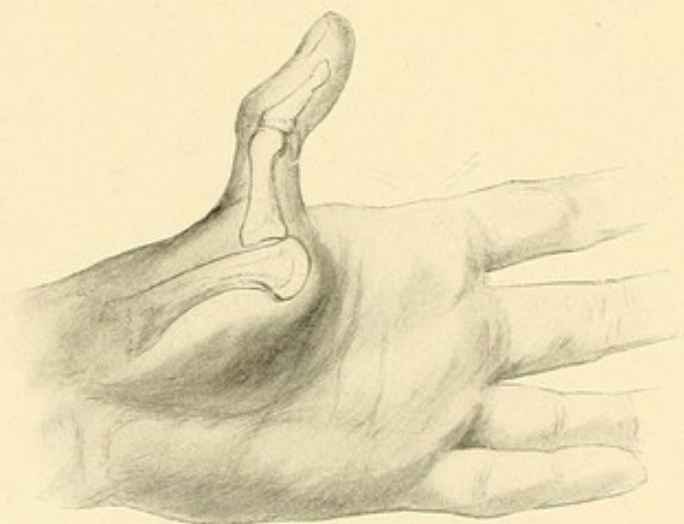


FIG. 376.—Dorsal luxation of the proximal phalanx of the thumb, showing the position of the bones.

three are rarely luxated. When luxation of the proximal phalanx of the little finger occurs it acts precisely as does that of the thumb (as I have seen in one case, Fig. 375). As the thumb dislocation is the most troublesome it alone will be described.

**Dislocation of the Proximal Phalanx of the Thumb.**—This displacement occurs when the thumb is hyperextended on its metacarpal bone (Figs. 376 and 377), and it is often impossible to reduce it without division of the resisting structures. The head of the metacarpal bone is much larger than the shaft immediately behind it and projects especially on its palmar surface toward each side, forming two tubercles.



The joint has two lateral ligaments and an anterior or glenoid ligament. These are more firmly attached to the phalanx than to the metacarpal bone, so that in dislocation they are torn from the latter.

Inserting into the outer side of the base of the proximal phalanx are the tendons of the abductor and outer head of the flexor brevis pollicis. They blend with the lateral ligament and have developed in them a sesamoid bone which rides on the tubercle.

Inserting into the inner side of the base of the proximal phalanx are the inner head of the flexor brevis and the adductor obliquus and transversus pollicis muscles. They blend with the lateral ligament and contain a sesamoid bone which rides on the

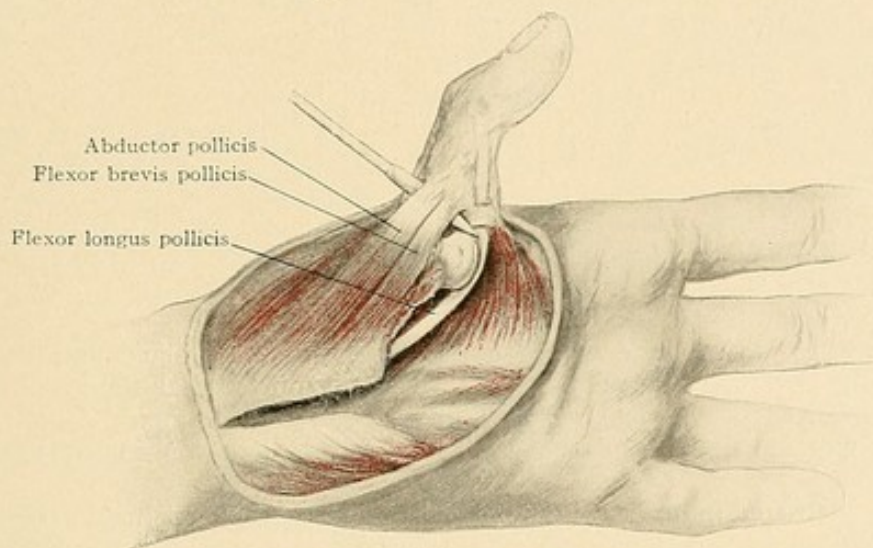


FIG. 377.—Dorsal luxation of the proximal phalanx of the thumb: Division of the tendons of the abductor and flexor brevis pollicis muscles.

inner tubercle. The flexor longus pollicis tendon passes between the two tubercles and sesamoid bones.

When the thumb is hyperextended the glenoid and lateral ligaments are torn loose from the metacarpal bone and carry with them the tendons and sesamoid bones already described. The head of the metacarpal bone projects forward in the palm and can be felt beneath the skin; the flexor longus pollicis tendon slips to the inner side of the bone. As the head pierces the capsule the latter, strengthened by the tendons of the short muscles of the thumb, contracts behind it like a collar and prevents reduction.

Reduction is to be attempted by extending the phalanx until it is at right angles with the metacarpal bone and dragging its base forward over the head of the metacarpal bone and then flexing.

If this is not successful, then by means of a narrow knife, either through an open wound or subcutaneously, the lateral ligament and tendons on one side (the radial) are loosened from the base of the phalanx, which can then be brought forward. This, of course, divides the tendinous collar which prevents reposition (Fig. 377).

**Dislocations of the Middle and Distal Phalanges.**—These frequently occur in playing ball games. In attempting to catch the ball the tip of the finger may be struck and the phalanx hyperextended and thereby luxated (Fig. 378).

These luxations are usually readily reduced by simple traction and flexion. Sometimes, however, reduction is not complete, or there is a concomitant fracture, hence the crippled and deformed fingers so often seen in the case of base-ball players.

A tearing loose of the attachment of the extensor tendon allows the distal phalanx to fall, producing what Stern has called drop phalangette.

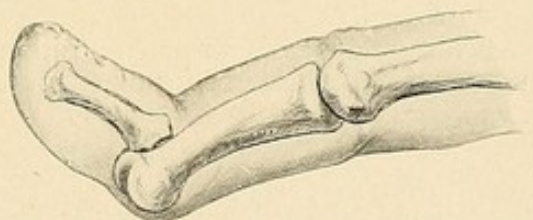


FIG. 378.—Dislocation of the terminal phalanx, showing the position of the bones. (From author's sketch.)



## FRACTURES OF THE HAND.

**Fractures of the carpal bones** are often only suspected or detected by means of a skiagraph. They are quite rare and are almost impossible to distinguish clinically from ordinary sprains.

**Fractures of the metacarpal bones** are more common. The bones are subcutaneous on the dorsum of the hand and can be readily felt throughout their entire length. They are not infrequently broken by a blow on the end of the bone in fighting. Hamilton states that in every case in which the fracture has been produced by a blow on the knuckles the distal end of the distal fragment has been drawn toward the palm and its proximal end projected toward the dorsum. This is accounted for by the greater strength of the flexor muscles.

The first, third, and fourth metacarpophalangeal joints have one extensor tendon, the extensor communis digitorum. The second and fifth have in addition the extensor indicis and the extensor minimi digiti. There are two powerful flexors, the sublimis and profundus, and these are aided by the palmaris longus, interossei, and lumbricales muscles. In one case Hamilton saw a dorsal projection of the proximal fragment which he believed to be due to the action of the extensor carpi radialis muscle because the deformity became less marked when the hand was bent backward and the tendon relaxed.

On anatomical grounds one would expect this dorsal displacement to occur in fractures of the third metacarpal bone. It has only one carpal tendon inserting into it, the extensor carpi radialis brevis. The second has the flexor carpi radialis inserting on its palmar surface and the extensor carpi radialis longior on its dorsal surface.

The fifth metacarpal bone has the flexor carpi ulnaris on its palmar surface and the extensor carpi ulnaris on its dorsal surface. Hence it would be expected that the flexor and extensor muscles would neutralize each other.

In order to relax the parts as well as to allow for the concavity of the palmar surface of the metacarpal bones a rounded pad is to be placed in the palm and the hand placed on a splint; sometimes an additional flat pad and small dorsal splint is of service. Care should be taken not to displace the fragments laterally by constricting the hand with the bandage.

**Fractures of the Phalanges.**—These are frequently compound, necessitating amputation. Fracture of the proximal phalanx necessitates a splint extending into the hand, but for the middle and distal phalanges a short splint is sufficient. The action of the interossei and lumbricales through their insertion into the extensor tendon is liable to draw the distal fragment toward the dorsum if the fracture is left untreated.

A knowledge of the exact position of the joints is essential to avoid mistaking fractures and dislocations for one another.

## WOUNDS OF THE HAND.

Wounds of the hand, owing to the free blood supply, heal rapidly. An exception, however, is to be made in the case of the tendons. These frequently slough. If the tendons are divided they are to be immediately united with sutures, otherwise they retract into their sheaths.

If nerves are divided where they are large, as near the wrist, they should be sutured, because they are partly motor and supply the short muscles of the hand; but if the digital nerves are divided they need not be sutured as they are only sensory. The median nerve enters the palm to the radial side of the median line, and its position can be determined by following down the interval between the tendons of the palmaris longus and flexor carpi radialis muscles.

The ulnar nerve lies immediately to the radial side of the pisiform bone.

Bleeding from wounds of the hand is not infrequently troublesome. The deep arch may be injured in a wound about 2.5 cm. (1 in.) below the lower crease on the anterior surface of the wrist. Its position can also be approximately determined by



feeling for the upper end of the first interosseous space on the dorsum of the hand and selecting a spot at a corresponding level on the palmar surface. It lies deep beneath the palmar fascia and flexor tendons and nerves, and necessitates too great a disturbance of the parts to expose it for ligation; hence, when wounded, bleeding from it is checked by packing the wound with antiseptic gauze. A curved line, convex downward, from the radial side of the pisiform bone to the web of the thumb, describes approximately the course of the superficial palmar arch. It lies immediately beneath the palmar fascia, and if it bleeds freely can be exposed by an incision and tied. The incision should preferably be a longitudinal one to avoid wounding the digital arteries and nerves. The superficial palmar arch lies superficial to the tendons and they should not be disturbed. The digital nerves come down beneath the palmar arch, so that they need not be wounded in ligating it. As they reach the webs of the fingers the nerves become superficial to the arteries, and in the fingers they lie anterior and nearer the median line. The fingers are usually supplied with blood from the superficial palmar arch, and the digital arteries between the palmar arch and webs of the fingers may be quite large. Sometimes the fingers are supplied by large digital branches from the deep palmar arch, then those from the superficial will be correspondingly small.

In uniting the several ends of tendons the two ends of the same tendon should be joined and not the flexor sublimis joined to the profundus and vice versa.

### ABSCESSSES OF THE HAND AND FINGERS.

Purulent collections in the palm of the hand are located either beneath the palmar fascia or are connected with the sheaths of the flexor tendons. When the fingers are affected the pus may be either in the sheaths of the tendons or in the cellular tissue beneath the skin.

**Abscess Beneath the Palmar Fascia.**—As a result of infected wounds pus may accumulate beneath the palmar fascia. The construction of this fascia (see page 357) limits the spread of the pus in some directions and favors it in others. Pus originating beneath the thick middle triangular portion will tend to point to either side, and it may show on the inner side at the hypothenar eminence, or work toward the outer side and point in the web of the thumb (Fig. 379).

It may take an upward course and pass under the annular ligament to point on the anterior surface of the forearm above the wrist.

If it tends downward it escapes through the openings for the exit of the digital arteries and nerves, and shows in the webs of the fingers.

If it extends still farther it burrows between the distal extremities of the metacarpal bones and shows on the back of the hand.

Sometimes the pus works directly toward the surface through small gaps in the fascia. In such cases a small amount of pus may accumulate above the palmar fascia and between it and the skin; so that there is a collection of pus both above and below the fascia, communicating through a hole in the fascia. This is called an hour-glass abscess, or the *abcès en bissac* of the French.

In opening such abscesses, if their character is not recognized the surgeon may only incise the superficial of the two collections and fail to evacuate the deeper and more serious one.

In incising palmar abscesses the only safe way is to limit the incision to the skin and open the deep parts by inserting a closed pair of forceps and then separating its blades. Incisions should not be made nearer to the wrist than on a level with the web of the thumb, or the superficial palmar arch may be cut. The spaces between the metacarpal bones are occupied by the digital arteries and nerves; hence any longitudinal incisions should be made over the tendinous sheaths and metacarpal bones. Usually it is not necessary to carry the incision so deep as to open the sheaths. Incisions over the second, third, and fourth metacarpal bones are tolerably certain to avoid the digital arteries, but an incision over the fifth is liable to wound the artery going to the ulnar side of the little finger as it crosses over from the superficial palmar arch. These arteries of the palm are also liable to be more or less irregular in their location, hence it is better to avoid using the knife in the deeper structures.



**Suppuration in the Sheaths of the Tendons.**—If the sheath of the tendons of the hand or fingers become infected, either by being penetrated by a foreign body or by extension from the surrounding tissues, the pus travels along the tendon as far as the sheath extends.

The sheaths of the tendons vary in their extent. The flexor profundus and sublimis tendons lie together in single sheaths, which commence at the base of the distal phalanx. That of the thumb follows the long flexor tendon up the thumb, beneath the annular ligament, to 3 or 4 cm. ( $1\frac{1}{2}$  in.) above the wrist; that of the little finger passes up to almost opposite the level of the web of the thumb and then spreads over toward the radial side and envelops the remaining tendons of the other three fingers, forming the great carpal bursa which extends up under the annular ligament to 3 or 4 cm. above the wrist (Fig. 380).

The sheaths of the remaining three fingers extend only to the heads of the metacarpal bones, about 2 cm. ( $\frac{3}{4}$  in.) above the webs of the fingers. This would leave

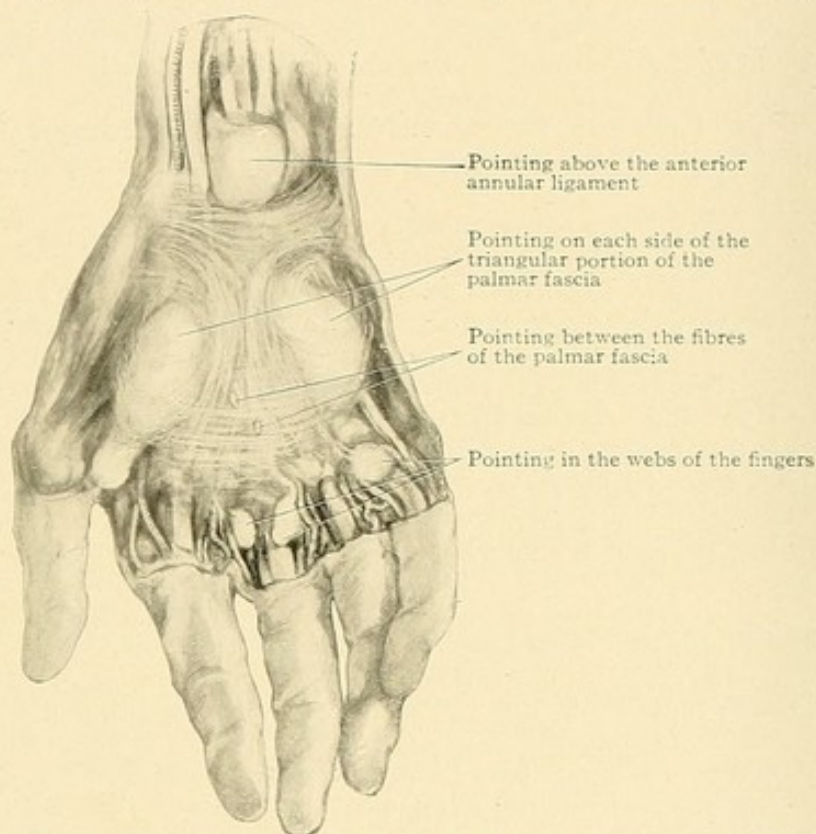


FIG. 379.—Cadaveric preparation with wax injected beneath the palmar fascia to illustrate where palmar abscesses tend to find an exit.

a space of about 2 cm. ( $\frac{3}{4}$  in.) intervening between the proximal ending of the tendon sheaths of the middle three fingers and the great carpal bursa. This is the usual arrangement, but not infrequently the sheath for the little finger ends, as do the other three, opposite the head of the metacarpal bone, or it may go up the entire way to the wrist as a separate sheath, in which case the great carpal bursa envelops only the tendons of the index, middle, and ring fingers.

When suppuration occurs in the sheath of the thumb or little finger it is much more serious than in the other three, because the pus tends to travel directly upward and involve the palm, and go even above the wrist. When suppuration involves the index, middle, or ring fingers it stops when it reaches the vicinity of the metacarpophalangeal joints and involves the palm and carpal bursa only by breaking through its own sheath and breaking into the carpal sheath. This it is not likely to do unless the infection is virulent and the suppuration abundant.

**Suppuration Involving the Fingers.**—When suppuration occurs in the middle or proximal phalanx the pus may occupy the tissue between the skin and tendon, and not involve its sheath, hence is not liable to extend rapidly. When the



end phalanx is affected the affection is known as *panaris*, *whitlow*, *felon*, etc. The pulp of the finger resembles that of the heel, the scalp, the palm of the hand, etc., in the fact that the under surface of the skin sends off firm fibrous bands or fibrils which are attached to the parts beneath. The spaces between these fibrils are filled

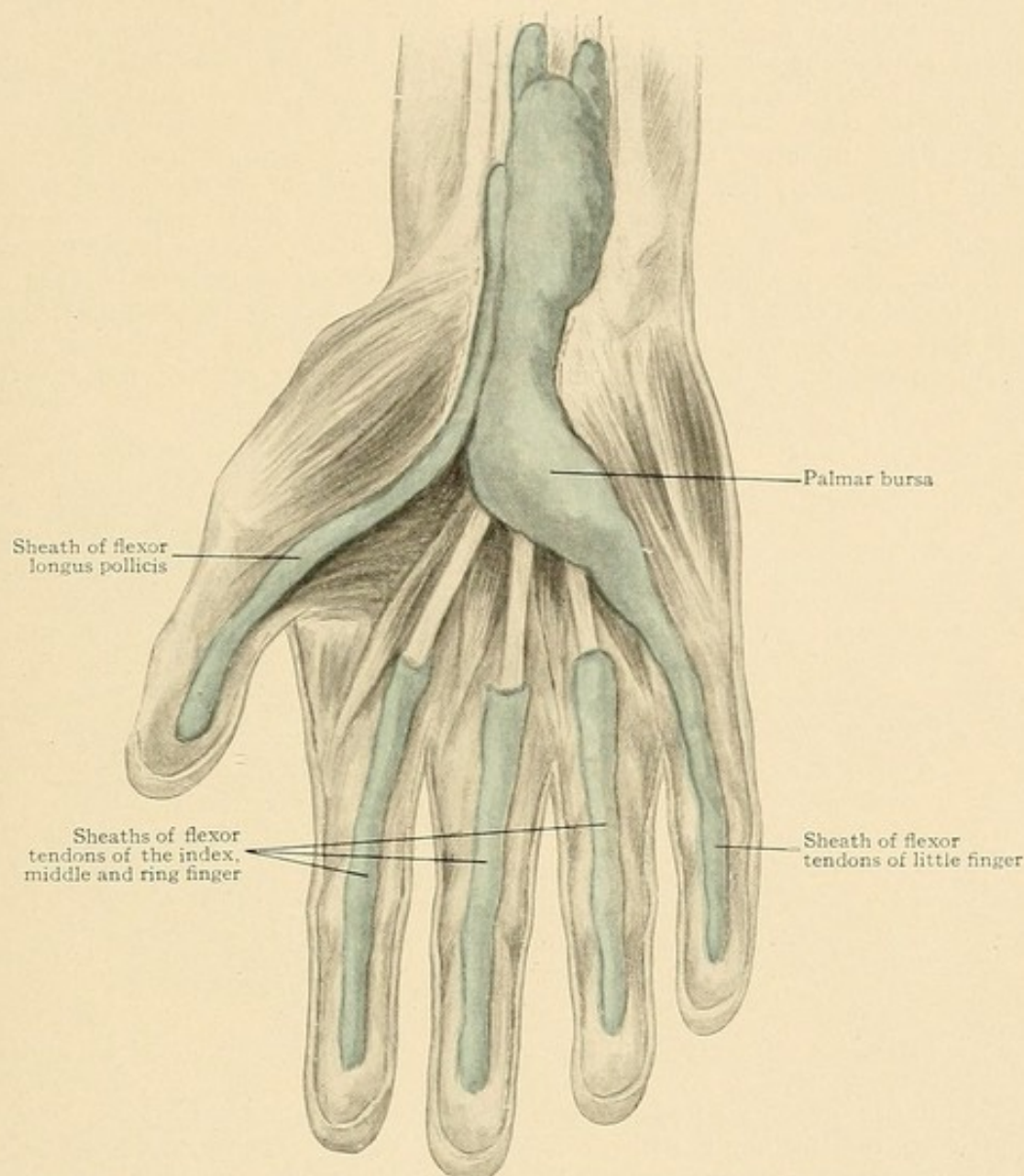


FIG. 380.—Palmar bursa and sheaths of the flexor tendons distended with wax.

in with fatty tissue and vessels, nerves and lymphatics (Fig. 381). Infection begins in the skin through some small wound, as the tearing of the nail, pin-punctures, etc., and involves the fatty tissue beneath. If exit is not given to the pus it is often unable

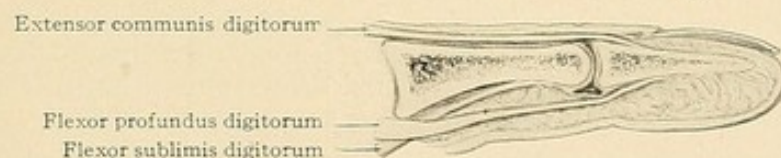

FIG. 381.—Longitudinal section of the end of a finger, showing the pulp and mode of termination of the tendons in the distal phalanx.

to break through the hard skin on the surface. Since the fibrous bands prevent swelling to any extent, it burrows deeper and involves the periosteum along which it proceeds to the region of the joint, here it may enter the sheath of the tendon when it rapidly proceeds upward as far as the sheath extends.



Bone felons are not as a rule primary in their origin, unless syphilitic in character, but arise secondarily by extension from the skin above.

### LYMPHATICS OF THE HAND.

The hand and fingers are abundantly supplied with lymphatics which begin in a plexus around the matrix of the nail and the pulp of the fingers and unite to form lymphatic trunks which proceed up the wrist and forearm. There are both superficial and deep sets, which communicate at the wrist.

The deep set follows the arteries of the forearm and arm to the axilla. This set sometimes possesses a few nodes in the forearm and one at the flexure of the elbow.

The superficial set, both anteriorly and posteriorly, concentrates in the supratrochlear nodes and thence proceeds to the axilla. Some of the lymphatic vessels pass by the supratrochlear nodes and empty direct into the axillary nodes (Fig. 382).

In infections of the fingers or hand the infection follows the lymphatic trunks, which can be seen as red lines running up the forearm. Suppuration may involve the supratrochlear and, later, the axillary nodes. As some of the lymphatic trunks

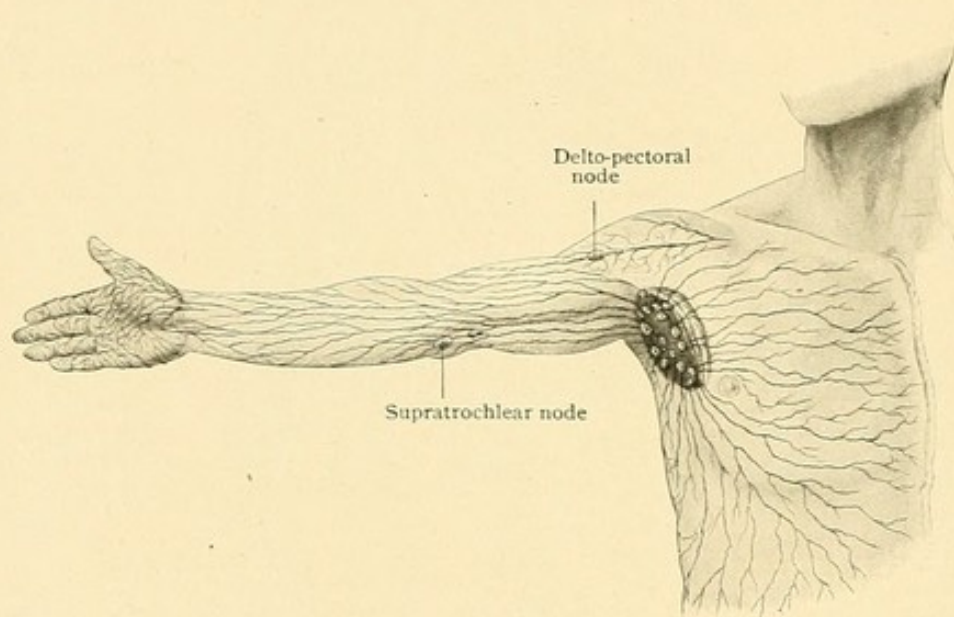


FIG. 382.—Superficial lymphatic vessels of upper limb; semidiagrammatic. (Based on figures of Sappey.)

pass by the supratrochlear nodes to empty direct into the axillary nodes there may be infection of the latter without any implication of the former. Enlargement and inflammation of the occasionally present deep lymphatic nodes of the forearm is clinically unknown, so it may be said that practically there are no lymphatic nodes below the supratrochlear ones.

### AMPUTATIONS OF THE THUMB AND FINGERS.

In these amputations it is particularly necessary to be able to accurately locate the joints. The distal phalanx when flexed always passes under the proximal one. When the flexor and extensor tendons are cut they should be sewed either to their sheaths or united to one another over the ends of the bone.

#### AMPUTATIONS OF THE THUMB.

**Distal Phalanx.**—In removing the distal phalanx the joint is opened by an incision across the dorsum in a line with the middle of the side of the proximal phalanx. A long flap is to be cut from the palmar surface. As the flexor and extensor tendons are inserted into the base of the distal phalanx, it will be an advantage to retain it if possible. The digital arteries may even here require ligation.



**Metacarpophalangeal Amputation.**—Lateral flaps are usually used. They are often made too short because the joint is thought to be higher than it really is. By flexing the thumb to a right angle the joint can be felt on the dorsum about 8 mm. ( $\frac{1}{3}$  in.) below the top of the knuckle. The flaps must be cut as far forward as the middle of the phalanx. The two digital arteries on the palmar surface will require torsion or ligation. If the base of the phalanx can be retained the attachments of the short muscles of the thumb are preserved and additional control is given to the stump.

**Carpometacarpal Amputation.**—The upper limit of the metacarpal bone may often be difficult to recognize. The best way to locate it is to feel for the snuff-box and then feel for the joint a centimetre (say a half inch) in front of it. The dorsalis pollicis artery running on the dorsum of the bone and the princeps pollicis on its palmar aspect may require ligation. In disarticulating, it should be remembered that the joint is curved with its convexity toward the wrist.

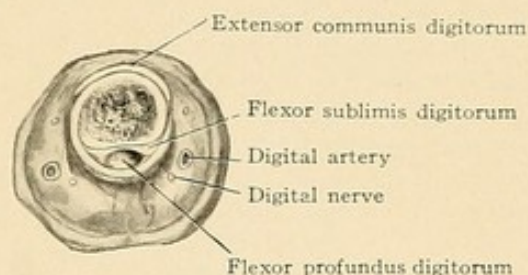


FIG. 383.—A transverse section of the proximal phalanx.

#### AMPUTATIONS OF THE FINGERS.

In amputating the fingers, although it is easier to amputate through the joints, it is better to cut through the bone and save part of the phalanx, because much better control over the movements is obtained on account of the insertion of the tendons into the base and sides of the phalanges. Into the base of the distal phalanx is inserted the common extensor and flexor profundus digitorum. Into the base of the middle phalanx on its dorsal surface is inserted the extensor communis digitorum, which is reinforced by the lumbricales and interossei; on its palmar surface is inserted the flexor sublimis digitorum. Into the bases of the proximal

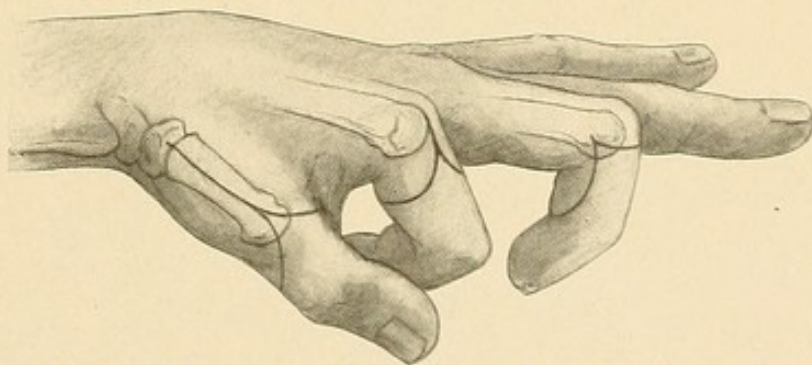


FIG. 384.—Lines of incision for amputations at the carpometacarpal joint of the thumb, the metacarpophalangeal joint of the index finger and between the proximal and middle phalanges of the middle finger.

phalanges are inserted the interossei muscles. The lines of the joints are to be recognized by remembering that the distal phalanx always flexes beneath the proximal one, therefore the prominence is always formed by the head of the proximal bone.

The joint is to be opened by an incision across its anterior surface when flexed, and not on its dorsal surface. Anterior or palmar flaps are always used, except at the metacarpal joints. The digital arteries lie on the lateral palmar surface on each side of the flexor tendons and may require torsion or ligation. The finger-joints have lateral ligaments and a palmar or glenoid ligament. On the dorsal surface there is no ligament, its place being filled by the extensor tendon (Fig. 383).

**Metacarpophalangeal Amputations.**—Lateral flaps are used in disarticulating at the metacarpal joints. In a well-developed hand the line of the joint will be 1.25 cm. ( $\frac{1}{2}$  in.) below the dorsal surface of the metacarpal bone (Fig. 384).

In consequence of not first recognizing the position of the joint the flaps are often cut too short. The incision must not involve the webs of the fingers but should reach as far forward as the middle of the phalanx. If this is not done it will



necessitate resection of the head of the metacarpal bone, which will materially weaken the hand. The two palmar digital arteries will require ligation, and the tendons should be sutured over the face of the bone or to their sheaths, closing them.

## THE ABDOMEN.

The abdomen comprises that part of the body anterior to the spine and erector spinæ and quadratus lumborum muscles, and from the diaphragm above to the rim of the pelvis below. The true pelvis is not included. The *peritoneal cavity* embraces the cavity of the abdomen and also that of the pelvis. An accurate knowledge of the topographical anatomy of the abdomen with its various contained organs is absolutely essential to both the physician and the surgeon for diagnostic purposes, and especially to the latter in carrying out his operative procedures. The *surface* of the abdomen should be studied with reference to physical diagnosis; its *walls*, because herniæ frequently protrude through them, and because they must be traversed in obtaining access to the structures within; its *contents*, in order to properly carry out necessary operative measures.

### SURFACE ANATOMY OF THE ABDOMEN.

The rounded form of the abdomen is influenced by its bony support, by the muscles and fascias attached to these bones, and by the organs within. In the upper portion of the abdomen the tip of the ensiform cartilage can be felt—it is opposite the eleventh dorsal vertebra. Immediately above the ensiform cartilage is its junction with the second piece of the sternum, which is opposite the tenth dorsal vertebra,—the sixth and seventh costal cartilages meet at this point,—the seventh, eighth, ninth, and tenth cartilages can be followed down to the lower border of the chest; just below this, one free rib, the eleventh, can be distinguished and sometimes in thin people the twelfth; but the twelfth is often not palpable because it is buried beneath the erector spinæ muscles. The most certain way of identifying any particular rib is to count from the sternal (Ludwig's) angle, opposite the second rib.

Below, the crest of the ilium can be followed back to the posterior superior spine of the ilium and in front to the anterior superior spine. The spines of the pubes can be recognized, as well as the upper edge of the pubic bones. The depressions for the lineæ alba, lineæ semilunares, and lineæ transversæ are all more marked above the umbilicus. The *umbilicus* lies on the disk between the third and fourth lumbar vertebrae, about 2.5 cm. (1 in.) above a line joining the highest points of the crests of the ilia. It is just below the midpoint between the symphysis and ensiform cartilage.

**Regions.**—For clinical purposes the abdomen has been divided into regions, so that the location of tumors, signs, etc., can be readily indicated. The most convenient division is into nine regions by two transverse and two longitudinal lines. The upper transverse line passes from the tip of the tenth rib—which corresponds to the lower end of the thorax—on one side to that of the other. The lower transverse line passes from the anterior superior spine of the ilium on one side to that of the opposite; it is on a level with the second sacral vertebra. The two longitudinal lines pass directly up on each side from the middle of Poupart's ligament. They strike the cartilages of the eighth ribs, but at too indefinite a point to serve as a guide.

The middle regions are the *epigastric*, the *umbilical*, and the *hypogastric*, or *pubic*. The lateral regions are the right and left *hypochondriac*, the right and left *lumbar*, and the right and left *iliac*.

The abdomen is sometimes divided into four quadrants by a longitudinal median line and a transverse line through the umbilicus. This mode of division is used more by physicians than by surgeons.

The lower transverse line is drawn by Quain and Cunningham from the top of the crest of one ilium to that of the other, but as the umbilicus is often lower than usual this line may pass above it. Anderson (Morris's "Anatomy") suggests using the lineæ semilunares instead of the usual longitudinal lines, but as yet this modification has not been generally accepted.



**Lines, or Lineæ.**—There are certain lines on the abdomen, called *linea alba*, *lineæ semilunares*, *lineæ transversæ*, and sometimes there are present *lineæ albicantes*.

*Linea Alba.*—The linea alba passes in the median line from the ensiform cartilage to the symphysis pubis. It is formed by the fusion of the sheaths of the recti muscles. A little over half way down is the umbilicus.

The linea alba is broad and distinct above the umbilicus, separating the recti muscles a half centimetre ( $\frac{1}{2}$  in.) or more; below, it diminishes and almost or quite disappears, leaving the recti muscles almost in contact with each other. Its fibres run longitudinally, obliquely, and transversely. The transverse fibres are the strongest and not infrequently have gaps between them which allow the subperitoneal fat to protrude and form a *hernia* in the median line which can be felt under the skin as a small, firm, rounded body. When these hernias are operated on they are found to be masses of subperitoneal fat with a somewhat constricted pedicle which emerges

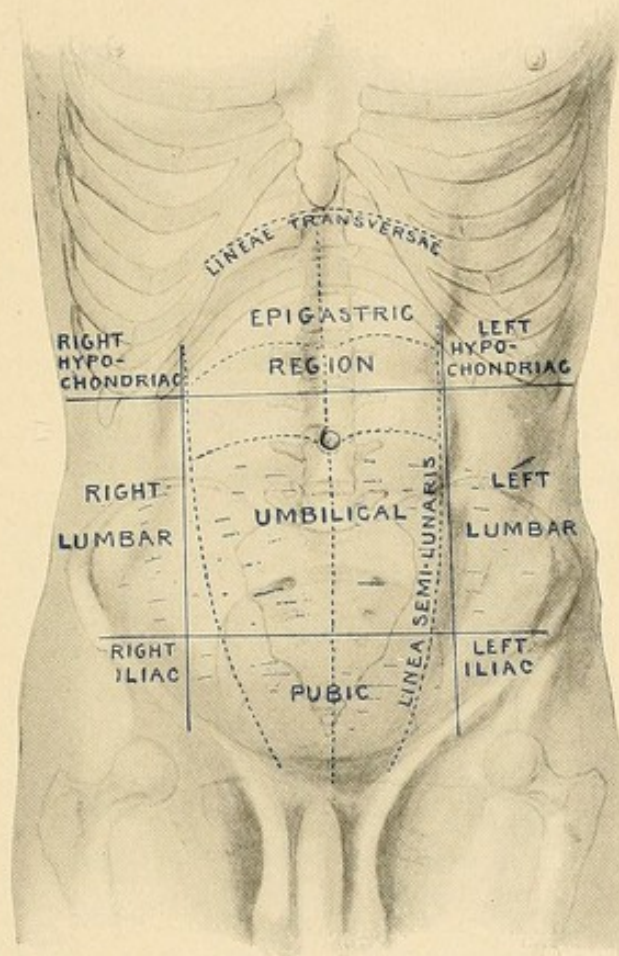


FIG. 385.—Surface anatomy of the abdomen; lines and regions.

from a transverse slit in the linea alba. The peritoneum is not protruded. Some of the fibres of the linea alba are prolonged into the subcutaneous tissue and skin, thus binding it down and forming a groove distinctly visible above the umbilicus but disappearing below it. It does not long prevent extravasated urine from passing from one side to the other (Fig. 385).

*The Umbilicus.*—The umbilicus lies over the disk between the third and fourth lumbar vertebræ, and 2.5 to 4 cm. (1 to 1½ in.) above a line joining the tops of the crests of the ilia. In the fœtus it transmits the *umbilical vein*, the two *umbilical arteries*, and the remains of the *vitelline duct* and stalk of the *allantois*. The umbilical vein becomes the round ligament of the liver and is the only structure passing into the upper half of the umbilicus. The umbilical arteries within the body form the obliterated *hypogastric arteries*, being continuous with the *superior vesicals*. The vitelline duct in fetal life passes from the umbilical vesicle to the small intestine.



Normally it entirely disappears. If its proximal extremity persists it forms a *Meckel's diverticulum*, a projection 3 to 7 cm. long from the small intestine 1 to 3 feet above the ileocaecal valve. It may persist up to the umbilicus and cause a fistula through which feces may discharge, or form a fibrous cord which may cause a fatal strangulation of the intestine. The stalk of the allantois ends as a fibrous cord, called the *urachus*, running down to the fundus of the bladder. If the urachus remains patent urine may be discharged through the umbilicus.

*Lineæ Semilunares.*—There are two lineæ semilunares, which pass from the spines of the pubes in a curve upward and outward along the outer edges of the recti muscles to strike the chest at the ninth costal cartilage. In thin people with little subcutaneous fat their position can be seen, but in fat people, especially females, their location is not readily recognized. Ordinarily they are 6.25 to 7.5 cm. ( $2\frac{1}{2}$  to 3 in.) to the outer side of the umbilicus and midway between the anterior superior spine of the ilium and the median line. The fibrous tendon of the external oblique muscle passes on to the surface of the rectus muscle to blend with its sheath a short distance internal to its lateral border, while the internal oblique blends with the transversalis in the linea semilunaris; so that an incision through the latter would traverse two fibrous layers—one the expansion of the external oblique and the other the blended internal oblique and transversalis. The upper end of the right linea semilunaris indicates the position of the gall-bladder. The point where a line from the umbilicus to the right anterior superior iliac spine is crossed by the linea semilunaris is 2.5 cm. above the root of the appendix and just inside of McBurney's point, or the usual site of greatest tenderness in appendicitis.

*Lineæ Transversæ.*—In thin muscular people when the rectus muscle contracts grooves are seen on its surface which indicate the position of the fibrous lines called the lineæ transversæ. One is opposite the umbilicus, a second opposite the tip of the ensiform cartilage, a third midway between these two, and sometimes a fourth below the umbilicus. The one opposite the umbilicus is the most marked. They are adherent to the sheath of the rectus anteriorly, but pass only part way through the muscle, so that the rectus muscle can be lifted off of the posterior but not off of the anterior portion of its sheath. This fact is to be remembered in operating.

*Lineæ albicantes* are the faint, white, atrophic lines left in the skin of the abdomen after it has been hyperdistended, usually by pregnancy or tumors.

## THE POSITION OF THE ABDOMINAL VISCERA.

**Liver.**—*Upper Border.*—The highest point of the liver is on the right side just to the inner side of the nipple where it rises to the middle of the fourth interspace. To the left it crosses the xiphosternal articulation to follow the lower border of the heart to a little beyond its apex, but hardly to the nipple line, where it reaches the lower border of the sixth rib. Its highest point on the left side is under the fifth rib posteriorly. On the right side it reaches the upper border of the fifth rib in the mammary line, the eighth rib in the midaxillary line, and the tenth rib in the scapular line (Tyson, "Physical Diagnosis," p. 51). In the median line it is about opposite the tenth thoracic spine (Fig. 386).

*Lower Border.*—From just below and to the inner side of the left nipple the lower border of the liver passes across the left eighth costal cartilage, then across the median line midway between the xiphoid articulation and the umbilicus to reach the right ninth costal cartilage, and then follows the edge of the ribs posteriorly. In the upright position, and in women, the liver may project a centimetre or two below the edge of the chest. In the aged it may be slightly retracted.

*Liver Dulness.*—On percussion the liver dulness in the right mammary line extends from the upper border of the sixth rib to the lower edge of the chest. In the axillary line it reaches the upper border of the eighth and in the scapular line the upper border of the tenth rib. From these limits it extends downward to the edge of the ribs.

**Gall-Bladder.**—The gall-bladder reaches the surface at the anterior end of the right ninth costal cartilage, just to the outer edge of the rectus muscle. This is the upper end of the right linea semilunaris.



**Stomach.**—The *cardiac end* lies under the cartilage of the seventh rib, 2.5 cm. (1 in.) from the edge of the sternum and about 10 cm. (4 in.) from the surface. When the stomach is empty the *pylorus* lies in the median line 2.5 to 5 cm. (1 to 2 in.) below the tip of the xiphoid or ensiform cartilage; when distended the pylorus moves 3 to 5 cm. to the right. The *fundus* rises in the left nipple line to the lower edge of the fifth rib. The *lower border* of the stomach crosses the median line 5 to 7.5 cm. (2 to 3 in.) above the umbilicus. In the old it may reach as low as the umbilicus, and when dilated may go far below it.

**Pancreas.**—The pancreas lies beneath the stomach and transverse colon, stretching across from the duodenum on the right of the spine to the spleen on the left. Its body lies over the first and second lumbar vertebræ. This would bring its

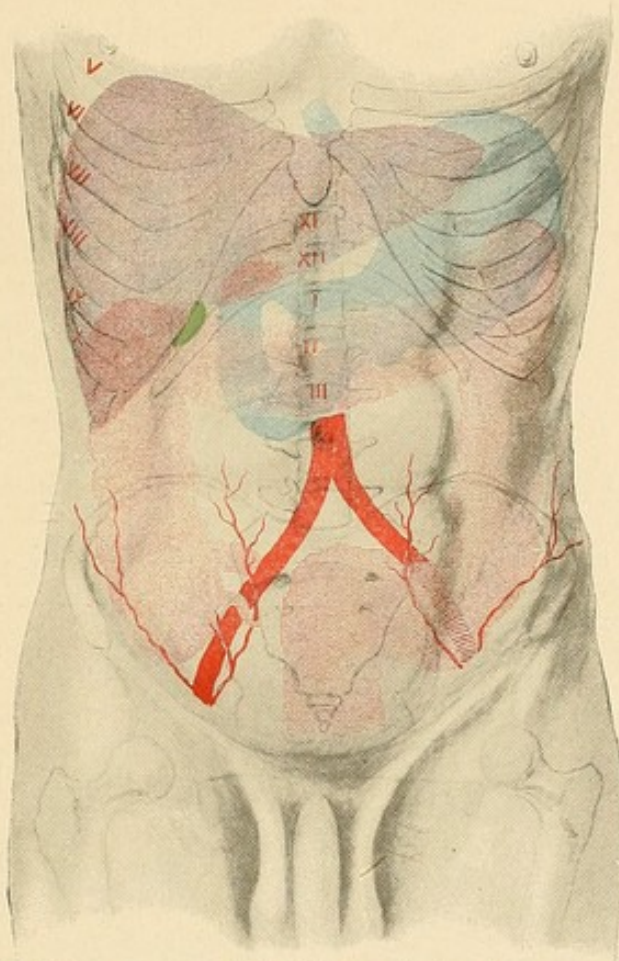


FIG. 386.—Surface anatomy of the abdomen, showing the outlines of the viscera.

lower edge about 5 cm. (2 in.) above the umbilicus and its upper edge about 10 cm. (4 in.) above it.

**Spleen.**—The spleen lies under the ninth, tenth, and eleventh ribs of the left side. Its long axis follows the tenth rib. Its anterior end is at the midaxillary line, while its posterior end reaches to within 4 cm. (1½ in.) of the median line.

**Kidneys.**—The lower edge of the right kidney reaches to within an inch of the level of the umbilicus; this is about opposite the level of the third lumbar spine. The left is 1.25 to 2 cm. (½ to ¾ in.) higher. This leaves about 4 cm. (1½ in.) between the lower edge of the kidneys and the highest point of the iliac crests. Their upper edge is almost or quite up to the level of the tip of the xiphoid cartilage. The pelvis of the kidney and commencement of the ureter are 5 cm. (2 in.) from the median line, about on the level of a line joining the upper ends of the lineæ semilunares. Posteriorly the right kidney rises to the lower border of the eleventh rib, the left kidney to the upper border. The outer edge of the kidney is a little beyond the outer borders of the erector spinæ and quadratus lumborum muscles.



**Small Intestine.**—*Duodenum.*—The duodenum begins at the pylorus and curves first upward and then downward along the right of the spine to the body of the third lumbar vertebra; it then crosses and ascends to the left side of the body of the second. This places it just above the umbilicus in the median line and behind the transverse colon.

*Mesentery.*—The upper extremity of the root or attachment of the mesentery begins 2.5 cm. (1 in.) to the left of the median line and 7.5 cm. (3 in.) above the umbilicus. It runs obliquely downward and to the right for about 15 cm. (6 in.) to a point below and to the right of the umbilicus, over the right sacro-iliac joint, and 8 to 10 cm. (3 to 4 in.) above the middle of a line joining the anterior superior spine and the symphysis pubis.

*Jejunum.*—The coils of the jejunum lie mostly to the left of the median line, but some are also found in the pelvis.

*Ileum.*—The coils of the ileum lie mostly to the right of the median line, and also are found in the pelvis.

**Large Intestine.**—*Cæcum.*—The cæcum lies in the right iliac fossa between the linea semilunaris and the anterior iliac spine.

The *ileocaecal valve* lies 8 to 10 cm. (3 to 4 in.) above the middle of Poupart's ligament.

*McBurney's point* is 4.5 cm. (1¾ in.) above and to the inner side of the right anterior superior iliac spine on a line to the umbilicus.

*Appendix.*—The base of the appendix is 2 cm. (¾ in.) below the ileocaecal valve. This is a little (1 in.) below the point where the linea semilunaris is crossed by a line drawn from the anterior iliac spine to the umbilicus, and is opposite the level of the anterior spine.

*Hepatic Flexure of Colon.*—This lies just to the outer side of the gall-bladder, under the ninth costal cartilage.

*Transverse Colon.*—The lower edge of the transverse colon is about at the level of the umbilicus.

*Splenic Flexure of Colon.*—This rises higher than the hepatic flexure, about to the level of the eighth costal interspace.

**Bladder.**—When empty the bladder sinks into the pelvis. When distended it rises toward the umbilicus, carrying the peritoneal fold with it so as to leave a space of 2.5 to 5 cm. (1 to 2 in.) between it and the top of the pubis.

**Abdominal Vessels.**—The *aorta* bifurcates on the body of the fourth lumbar vertebra 2 cm. (¾ in.) below and to the left of the umbilicus. A line from this point to the middle of one drawn from the anterior superior spine to the symphysis pubis indicates the course of the *iliac arteries*. The upper third of this line is the common iliac and the lower two-thirds the external iliac. The *ureters* cross the points of bifurcation of the common iliac arteries. The *celiac axis* lies just below the tip of the ensiform cartilage. The *renal arteries* are about 5 cm. (2 in.) lower. The *iliac veins* lie along the inner side of the iliac arteries, and the *ascending cava* runs along the right side of the aorta.

The *deep epigastric arteries* run lengthwise at or a little outside of the middle of the recti muscles. They pass beneath the edge of the recti a little below the level of a line joining the umbilicus and middle of Poupart's ligament.

## THE ABDOMINAL WALLS.

The abdominal walls are composed of the skin, superficial fascia, muscles, transversalis fascia, subperitoneal tissue, and peritoneum.

**Skin.**—The skin of the abdomen is moderately thin and lax. It is adherent at the linea alba. In making incisions care is to be taken not to think it thicker than it is and so open the abdominal cavity and perhaps wound the intestines. This is especially liable to occur in the median line—where the subcutaneous fat is not so abundant as elsewhere—and over hernial protrusions, particularly umbilical, where the thinned and distended skin may lie in contact with the peritoneum.

**Superficial Fascia.**—The superficial fascia is composed of an upper fatty layer, and a lower fibrous layer called *Scarpa's fascia*. The superficial vessels run



on this fibrous layer but are too small to cause troublesome hemorrhage; a few minutes' compression with hæmostatic forceps serves to stop bleeding from them. This layer is attached at the linea alba, but not sufficiently closely to prevent extravasated urine from crossing and reaching both flanks. It is also attached to the fascia lata just below Poupart's ligament, and here it *does* prevent urine from passing downward on the thigh. It passes inward over the spermatic cord and is continuous with the dartos of the scrotum and its septum. It is attached to the spines of the pubes and to the symphysis in the median line. This leaves a space or *abdomino-scrotal opening* over the pubic bone on each side of the median line through which extravasated urine rises from the perineum and scrotum to reach the surface of the abdomen.

### MUSCLES OF THE ABDOMEN.

The muscles of the abdomen are arranged in two distinct groups: a longitudinal group embracing the *recti* and *pyramidales* and a transverse group embracing the *external* and *internal oblique* and the *transversalis* of each side.

The **pyramidalis** is small, often undeveloped, and sometimes absent; as its

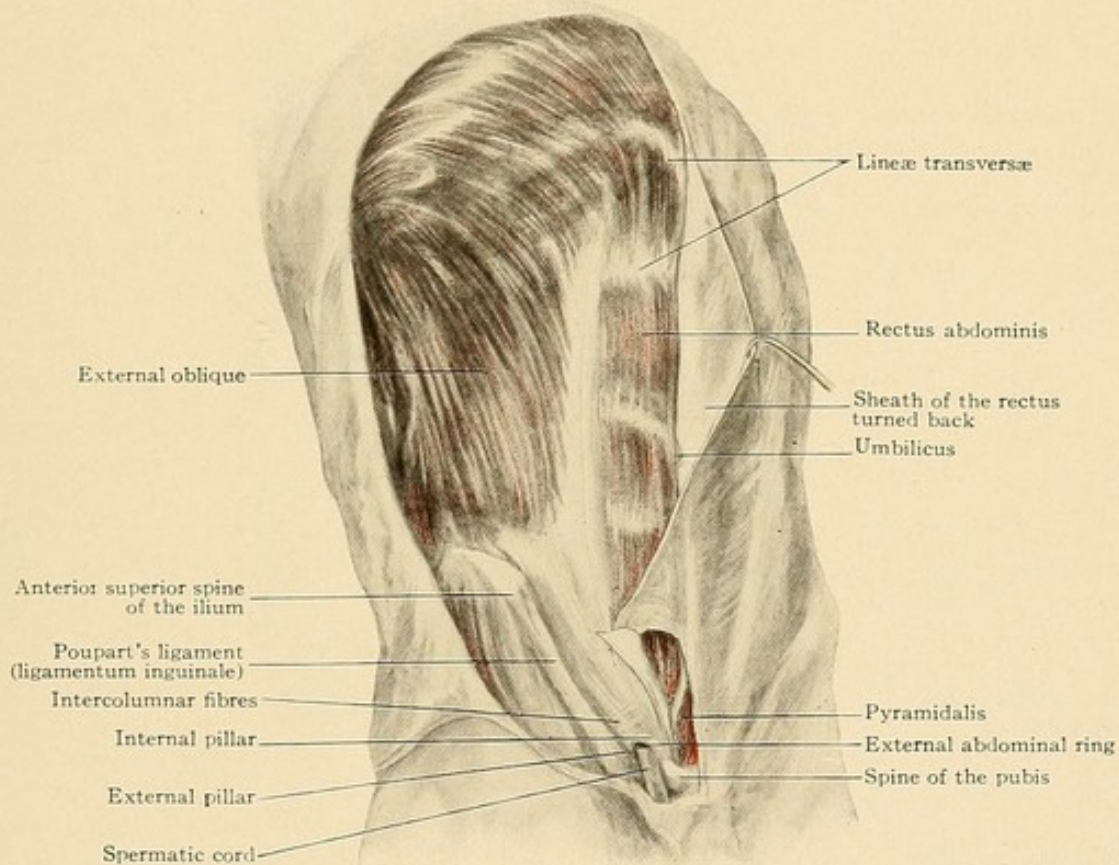


FIG. 387.—The external oblique, rectus abdominis, and pyramidalis muscles.

direction is not markedly different from that of the rectus it may be considered from a surgical point of view as being a part of it.

The **rectus muscle** arises from the crest and symphysis of the pubis and inserts into the cartilages of the fifth, sixth, and seventh ribs and sometimes the ensiform cartilage (Fig. 387).

**Sheath of the Rectus.**—The rectus muscle is enclosed in a fibrous sheath formed by the external and internal oblique and transversalis muscles. The anterior layer is attached to the surface of the muscle by the lineæ transversæ already described (p. 372). The edge of the sheath on one side blends in the median line with that of the other side to form the linea alba. Above the umbilicus, an incision in the median line passes through fibrous tissues only and the muscles on each side are not



exposed, but, as they rapidly approximate each other below, an incision usually passes either through the edge of one muscle or, if it passes exactly between them, may expose the edges of both.

The lateral edge of the sheath is formed primarily by the splitting of the tendon of the internal oblique muscle, one part going in front and the other behind the muscle. The tendon of the external oblique blends with the anterior layer of the tendon of the internal oblique a little to the medial side of the edge of the rectus, and as the pubes is approached the external oblique has its attachment nearer and nearer to the linea alba, so that close to the pubes the external oblique is separated from the internal oblique and goes to form the internal pillar of the external ring and has the conjoined tendon behind it (Fig. 388).

The tendon of the transversalis blends with the posterior layer of the internal oblique tendon until the lower fourth of the rectus is reached, when they both pass in front of the rectus to form the conjoined tendon. The medial portion of the

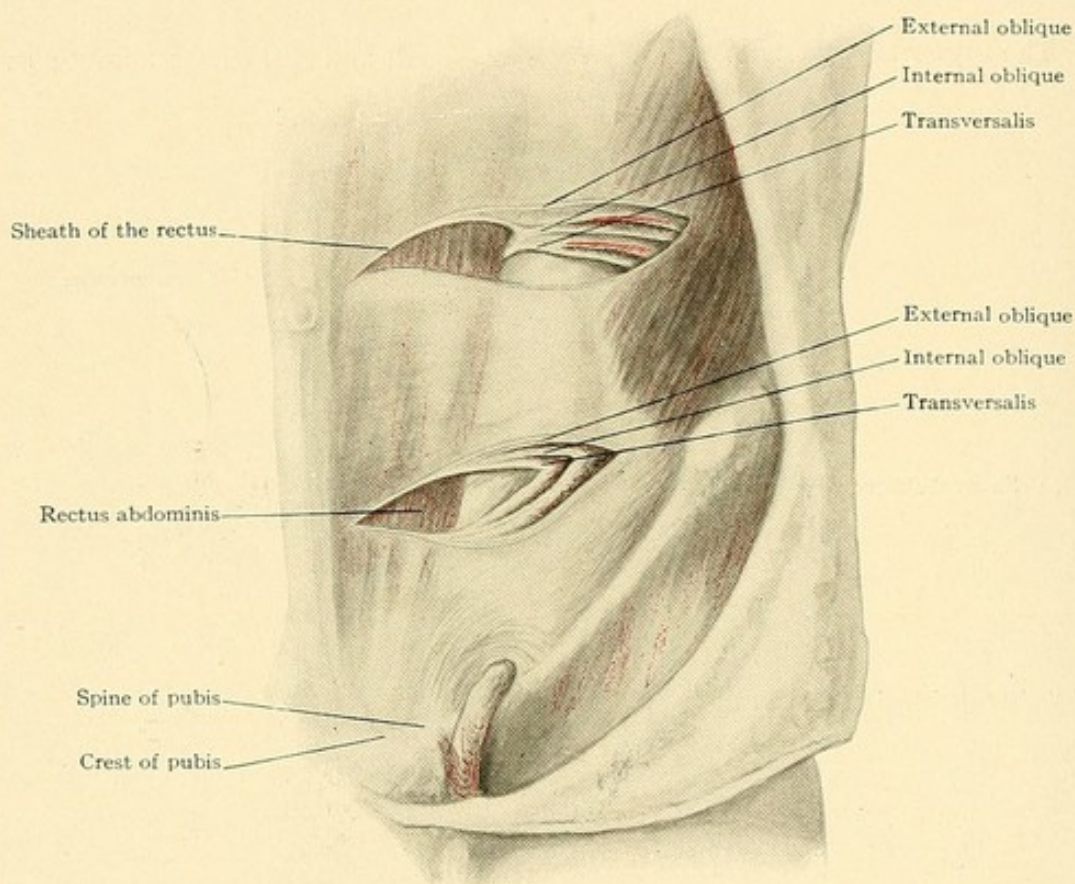


FIG. 388.—Sheath of the rectus abdominis muscle.

sheath of the rectus is attached to the symphysis and crest of the pubis; its lateral portion, forming the conjoined tendon, is attached from the spine of the pubis along the iliopectineal line for the distance of 4 cm. (1½ in.). It lies behind the external abdominal ring.

The lower edge of the posterior portion of the sheath of the rectus is called the semilunar fold of Douglas; the deep epigastric artery ascends beneath this fold about its middle, or a little to its outer side. From this arrangement it will be seen that an incision over or near the lateral edge of the rectus below the umbilicus will pass through two aponeurotic layers, viz., the external oblique and the blended tendons of the internal oblique and transversalis (Fig. 388).

If it is desired to examine the rectus muscle, its sheath can be opened at its edge and the muscle lifted up from the posterior layer, but it cannot be detached from the anterior layer above the umbilicus unless dissected loose from the lineæ transversæ.



The **external oblique** arises from the eight lower ribs. Its posterior portion passes almost directly downward to insert into the anterior half of the crest of the ilium. It is crossed obliquely by the anterior margin of the latissimus dorsi muscle a short distance above the crest, thus leaving a triangular space between them called *Petit's triangle* (*trigonum lumbale*) (see page 394). As the external oblique approaches the linea semilunaris and anterior superior spine it becomes tendinous, its fibres being nearly but not quite parallel with *Poupart's ligament*. Its lower edge forms *Poupart's ligament* (*ligamentum inguinale*) and continues down on the thigh as the *fascia lata*. Its inner portion, above and external to the spine of the pubis, divides to form the external abdominal ring for the passage of the spermatic cord. The outer side of the opening is called the external pillar or column; it is continuous with Poupart's ligament, inserts into the spine of the pubis, and is prolonged along the iliopectineal line for a short distance (2 cm.) to form *Gimbernat's ligament*.

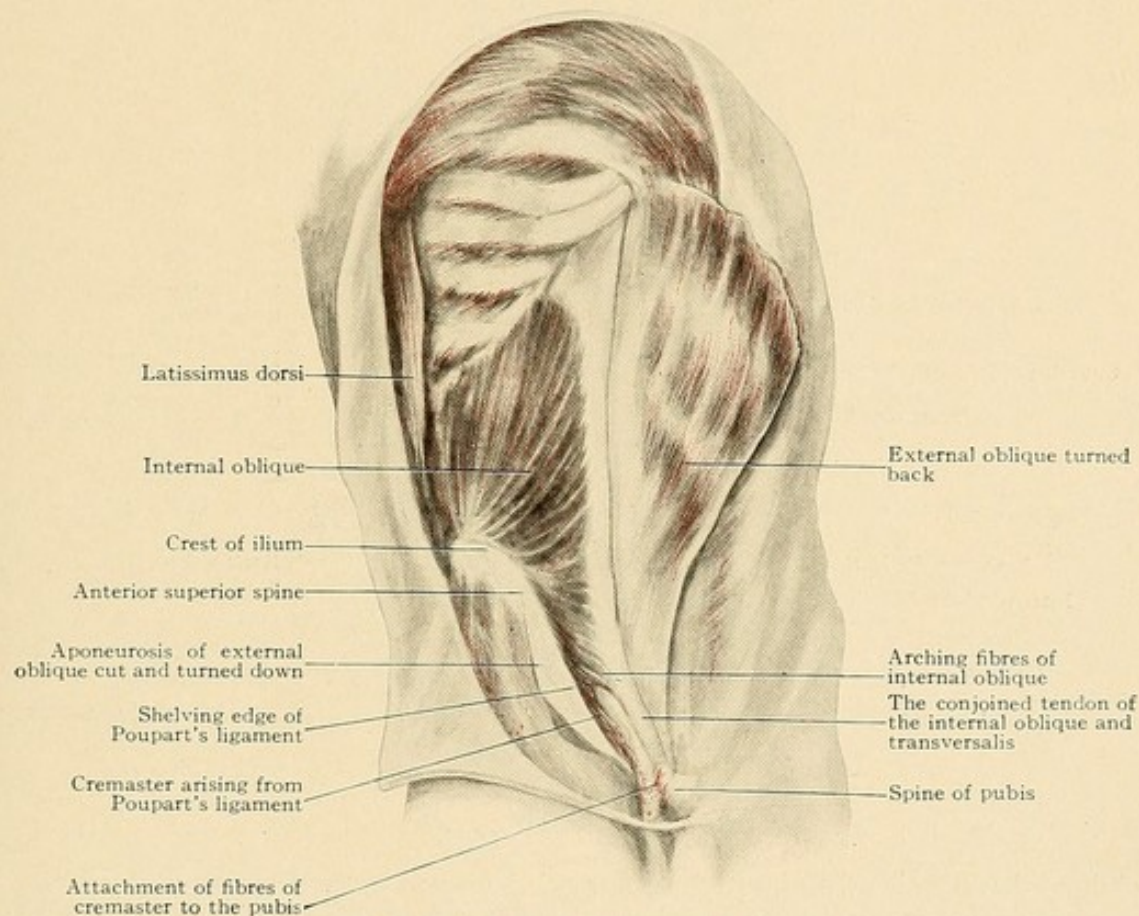


FIG. 389.—Internal oblique muscle.

Sometimes it is continuous upward and inward to the median line on the sheath of the rectus, forming what has been called the *triangular fascia* (Colles). The inner side is called the internal pillar or column. It inserts into the crest of the pubis. The transverse fibres passing from one pillar or column to the other are called *intercolumnar fibres*.

The **internal oblique** (Fig. 389) arises from the lumbar aponeurosis, the anterior two-thirds of the crest of the ilium, and the outer half of Poupart's ligament. It inserts into the lower three ribs and, through the sheath of the rectus and conjoined tendon, into the linea alba, the crest and spine of the pubis, and iliopectineal line for about 4 cm. The fibres arising from the lumbar aponeurosis and the posterior portion of the iliac crest pass upward and inward. Those from the region of the anterior superior iliac spine radiate like a fan; the lower ones, together with the fibres arising from the outer half of Poupart's ligament, arch over the cord and end in the conjoined tendon. Some fibres are continued down over the cord, forming the *cremaster muscle*. The



cremaster muscle usually arises from Poupart's ligament, beneath the spermatic cord, from the lower edge of the internal oblique to near the spine of the pubes, thus obliterating the space usually shown to the under side of the cord, between it and Poupart's ligament. The fibres of the cremaster hang in loops on the cord, and are attached by their distal extremity to the pubic bone in the neighborhood of the spine.

The **transversalis muscle** arises from the six lower ribs, through the lumbar fascia from the transverse processes of the five lumbar vertebræ, and from the anterior two-thirds of the iliac crest and outer third of Poupart's ligament. It *inserts* through the sheath of the rectus in the linea alba and crest of the pubis, and through the conjoined tendon into the spine of the pubis and iliopectineal line for about 4 cm. (1½ in.). The transversalis does not come down so low as the internal

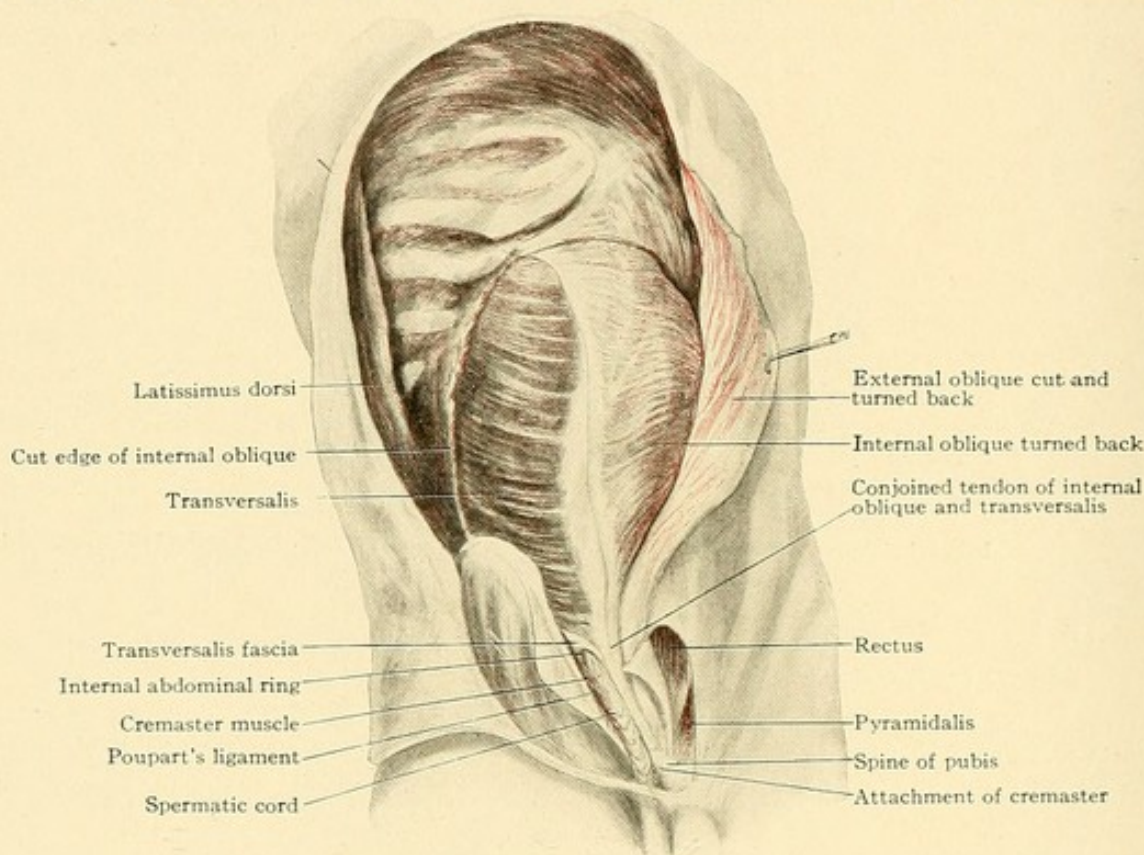


FIG. 390.—Transversalis muscle.

oblique, because it arises from the outer third of Poupart's ligament instead of the outer half, as does the internal oblique. As already stated, the blended tendons of the external and internal oblique and transversalis muscles all pass in front of the rectus in its lower fourth. As the umbilicus is below the middle of the linea alba, this point, where the fold of Douglas is formed, is nearer to the umbilicus than it is to the symphysis (Fig. 390).

### VESSELS OF THE ABDOMINAL WALLS.

The vessels of the abdominal walls comprise arteries, veins, and lymphatics. The *arteries* are superficial and deep; of these the deep are the more important. The arterial twigs in the subcutaneous tissue are small. The superficial epigastric runs in a line from the femoral artery toward the umbilicus. The superficial circumflex iliac runs to its outer side toward the iliac spine, mostly below Poupart's ligament. Branches of these vessels may require the temporary application of a hæmostatic forceps in the operations for hernia or appendicitis.

The deep arteries are important: they are the *superior epigastric*, *deep epigastric*, and *deep circumflex iliac* (Fig. 391).



The **superior epigastric artery** is one of the two terminal branches of the internal mammary. The other is the musculophrenic, which skirts the edge of the thorax. The internal mammary divides opposite the sixth interspace, and the superior epigastric, leaving the thorax at the lower edge of the seventh rib, enters the sheath of the rectus muscle and a few inches lower down enters the substance of the muscle, speedily breaking up into small branches. It is only large in size up toward the thorax, where we have seen it cut by a stab-wound, causing dangerous hemorrhage. It may also be wounded in operations and is to be sought for between the muscle and its posterior sheath, on a line continued downward from a point one centimetre to the outer side of the edge of the sternum.

The **deep epigastric artery** arises from the external iliac at Poupart's ligament and curves inward and upward between the peritoneum and transversalis fascia. It reaches the edge of the rectus below a line joining the femoral artery

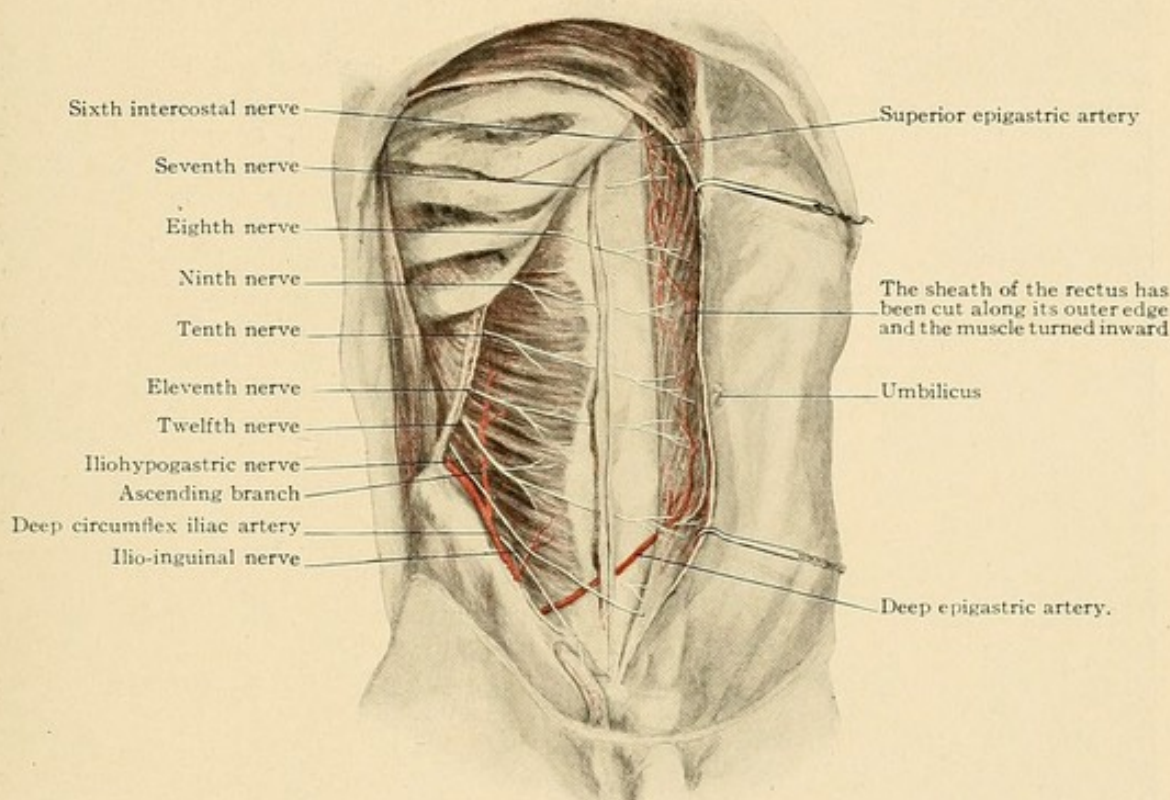


FIG. 391.—The nerves and blood-vessels of the anterior abdominal wall. The nerves are seen piercing the posterior layer of the sheath of the rectus to enter the muscle. The external and internal oblique have been removed exposing the nerves lying on the transversalis.

at Poupart's ligament with the umbilicus. Opposite the fold of Douglas (linea semicircularis) it reaches the middle of the rectus, pierces the transversalis fascia, and enters the substance of the muscle. It sends branches to the outer edge of the muscle which are quite large and bleed freely when cut. It anastomoses above with the superior epigastric. It is a most important artery, as it is liable to be wounded in operations for appendicitis, etc. If cut it will require a ligature, and if pierced by a needle will bleed freely. As it passes upward from Poupart's ligament it lies to the upper and outer side of the femoral canal and may be wounded if the herniotomy knife is turned in that direction. A little higher it crosses the inguinal canal almost midway between the internal and external abdominal rings. An oblique inguinal hernia enters the canal to the outer side of this artery and a direct hernia to its inner side. The fold of the obliterated hypogastric artery is to its inner side.

The **deep circumflex iliac artery** arises from the external iliac almost opposite the deep epigastric and passes outward along the inner side of Poupart's ligament



between the transversalis fascia and the peritoneum. When it reaches the anterior superior spine it passes between the transversalis and internal oblique muscles, and just above the crest divides into an ascending branch which goes upward toward the ribs and a posterior branch passing backward to anastomose with the iliolumbar. The ascending branch is large and bleeds freely when cut. It is not infrequently divided in operations for appendicitis in which the incision is carried far back. Its depth from the surface, between the transversalis and internal oblique muscles, should not be forgotten.

**Superficial Abdominal Veins.**—The upper part of the abdomen is drained by small branches emptying into the superior epigastric, the intercostal, and laterally into the axillary veins. Below, there are the superficial epigastric and superficial circumflex iliac veins. In cases of obstruction to the flow of blood in the large deep veins

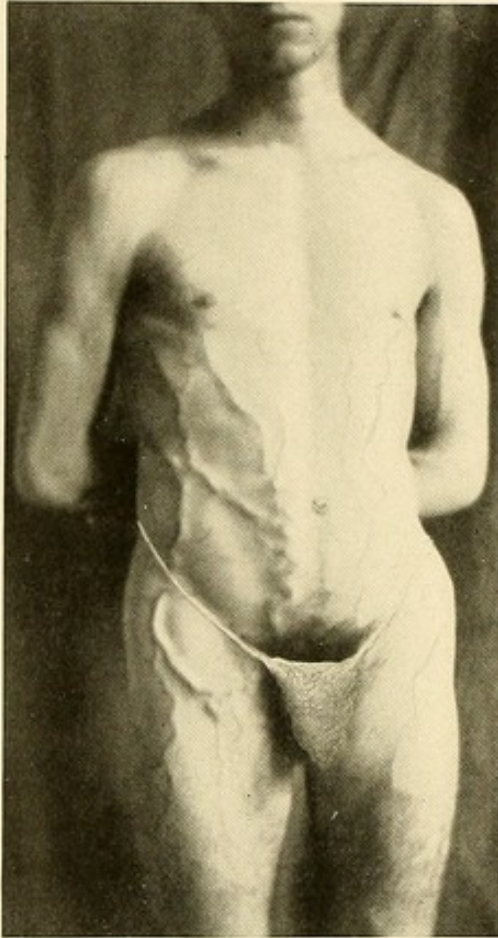


FIG. 392.—Obstruction of the right iliac vein from phlebitis. The vena thoracica epigastrica longa is seen running from the groin up to the axilla.

the superficial veins become visible; thus a branch often becomes visible on the side running from the axillary vein to the superficial epigastric or femoral vein,—it is called by Braune ("Das Venensystem des menschlichen Körpers," 1884, Joessel and Waldeyer, *Topog. chirurg. Anat.*, pp. 22, 147) the *vena thoracica epigastrica longa tegumentosa* (Fig. 392). Other small veins around the umbilicus become very much enlarged, and, branching in various directions around the umbilicus, have given rise to the term *caput Medusæ*.

Kelly ("Operative Gynecology," p. 48) describes two small veins running from the symphysis up to the umbilicus in the subcutaneous tissue on each side of the linea alba, and calls them *celiotomy veins*.

**Deep Veins of the Abdominal Walls.**—The superior epigastric, deep epigastric, and circumflex iliac arteries are accompanied by veins. There is also a vein in the round ligament of the liver emptying into the portal vein, called by Schiff, and later by Sappey, the *vena parumbilicalis* (*Mémoires de l'acad. de méd.*, 1859). In some cases two small veins can be seen on the interior of the abdominal wall, running up to the umbilicus from the symphysis on each side of the median line, and two coming down to the umbilicus on each side of the median line.

**Lymphatics.**—The superficial parts above the umbilicus are drained by lymphatics which empty into the axillary nodes; the vessels below the umbilicus empty into the oblique

set of nodes in the groin. The lymphatics of the deep surface of the abdominal wall above the umbilicus drain into the mediastinal nodes, while those below drain into the pelvic lymphatics along the iliac arteries.

**Nerves.**—The front and sides of the abdomen are supplied by the anterior and lateral cutaneous branches of the sixth, seventh, eighth, ninth, tenth, and eleventh intercostal nerves, the twelfth thoracic or subcostal, and the iliohypogastric and ilioinguinal branches of the first lumbar. The sides of the abdomen are supplied by the *lateral cutaneous branches* which supply the skin as far forward as the rectus muscle. The recti muscles and skin overlying them are supplied by the *anterior branches*. These pass forward between the internal oblique and transversalis muscles to enter the sheath of the rectus, and, after supplying the muscle, pierce the anterior layer and are distributed to the integument above. The sixth and seventh supply the infrasternal region, the eighth about half way down to the umbilicus, the ninth just above the



umbilicus, the tenth the region of the umbilicus, and the eleventh just below,—being about opposite the fold of Douglas, while the twelfth supplies the region above the pubes.

The iliohypogastric emerges through the external oblique about 2 or 3 cm. above the external ring, while the ilio-inguinal emerges through the external ring and supplies the parts adjacent. From this distribution it is evident why disease posteriorly, such as caries of the spine or pleurisy, will cause pain to be complained of in the corresponding distribution anteriorly. Incisions through, or along the outer edge of the rectus, will divide the nerves supplying it, and cause paralysis of the muscle. Incisions made across the lateral muscles of the abdomen cannot be efficiently repaired by sewing the cut muscles together, because this does not restore the function of the nerves which have been divided.

### ABDOMINAL INCISIONS.

These are made through all portions of the abdominal walls according to the organs it is desired to gain access to. They should be so planned as to avoid unnec-

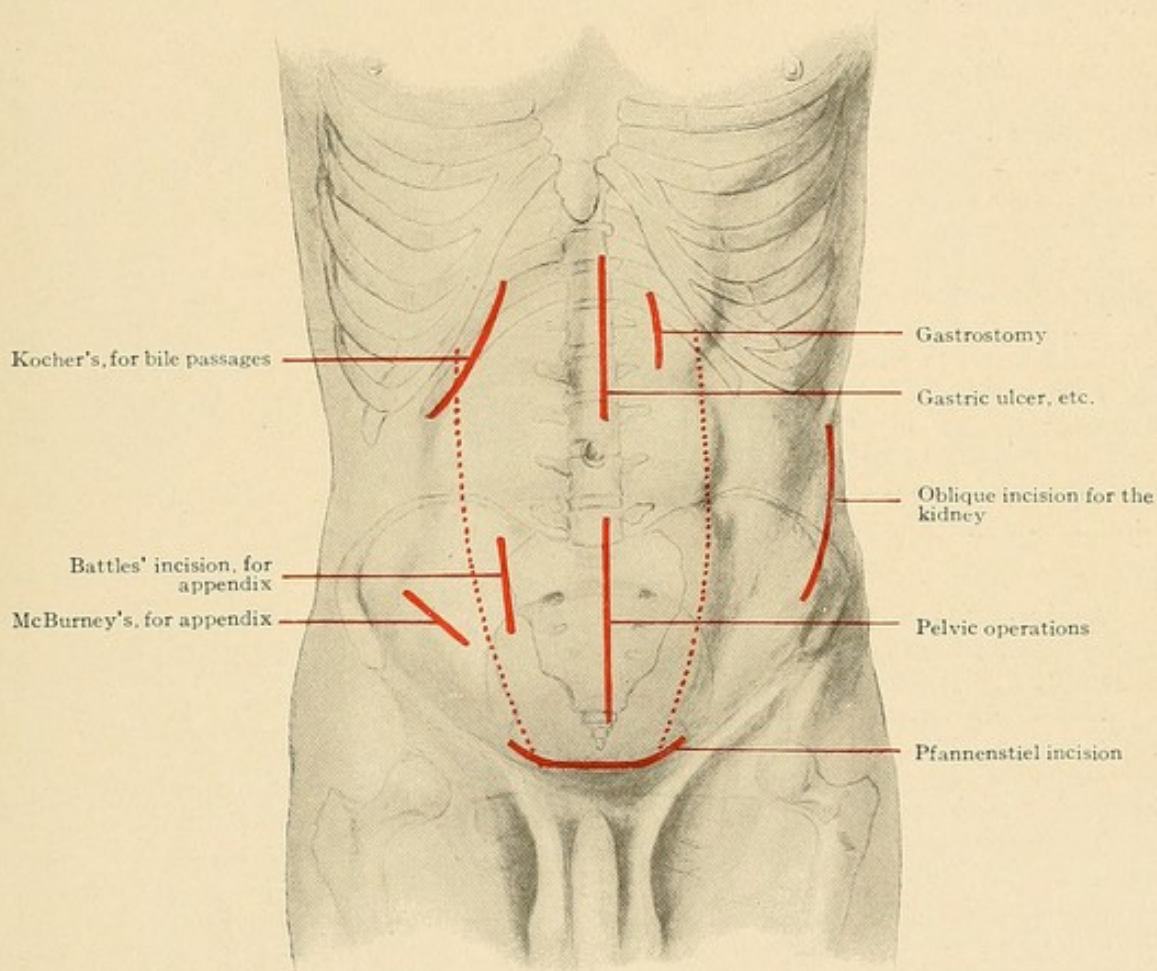


FIG. 393.—Incisions for abdominal operations.

essarily wounding the muscles, arteries, and nerves. It having been found that incisions through fascia alone are more liable to be followed by hernia than those through muscles, incisions through the linea alba and lineæ semilunares are to be avoided. Incisions through the recti muscles are best made near their inner edge. If made in the outer edge the nerves supplying the muscle will be divided, causing subsequent paralysis and weakness. If made through the middle, only the nerves supplying the inner half will be divided, but the main trunks of the deep and superior epigastric arteries will be cut and cause troublesome bleeding. There is least harm



done by making the incision through the inner edge of the muscle. If the method of Battles is resorted to, of dividing the outer edge of the sheath of the rectus longitudinally and displacing the muscle inward, or of dividing the muscle itself longitudinally, then not only are large branches of the deep epigastric arteries met but in dividing the posterior layer of the sheath the nerves are divided. If the rectus is divided transversely (as Kocher advises in operations on the gall-bladder) care must be taken to avoid wounding the nerves; he claims that the scar acts only as an additional linea transversa and does not injure the functions of the muscle. Injury to the nerves and rectus muscle both can be avoided by incising the sheath transversely and then pulling the rectus to one side (Weir), or by dissecting up the sheaths of both recti transversely and separating the muscles in the median line (Pfannenstiel and Stimson).

Incisions through the transverse muscles if made in the same direction through all three muscles are bound to cut some in a direction more or less transverse to their fibres. The incision of McBurney—for appendicitis—avoids wounding the muscles. He separated the external oblique in the direction of its fibres downward and inward, crossing a line from the anterior superior spine to the umbilicus, 4 to 5 cm. ( $1\frac{1}{2}$  to 2 in.) to the inner side of the spine. The internal oblique and transversalis are then separated in the direction of the fibres and drawn in the opposite direction. This method is applicable where small openings suffice; but when large incisions are essential, as in bad suppurating cases of appendicitis and in operations to expose the kidney and ureter, it is customary with many to incise all the muscles in the line of the fibres of the external oblique. Should nerves be encountered they are if possible to be drawn aside. In this incision the internal oblique and transversalis are incised nearly transversely, and bleeding from the deep circumflex iliac artery which runs between them will be encountered.

Edebohl exposes the kidney by incising alongside of the outer edge of the erector spinæ muscle. The latissimus dorsi is separated in the direction of its fibres, the lumbar aponeurosis is incised and kidney exposed. A normal kidney can be delivered through this incision, but not one much enlarged. When the kidney is much enlarged the incision is to be prolonged anteriorly along the crest of the ilium (see page 396). The relation of the pleura is to be borne in mind: it crosses the twelfth rib about its middle to reach its lower edge posteriorly. Hence the upper end of the incision should always be kept anterior to it (see section on Pleura).

## HERNIÆ.

**Abdominal herniæ** occur most often in the umbilical and inguinal regions. Sometimes the recti muscles separate and a median protrusion results; or they may occur at the site of a previous operation.

**Umbilical herniæ** are of three kinds, *congenital*, *infantile*, and *acquired*.

*Congenital umbilical hernia* is due to a developmental defect. In the embryo the umbilicus transmits (1) the vitelline duct, passing from the umbilical vesicle to the small intestines; (2) two umbilical arteries, which inside the abdomen are called hypogastric and pass to the internal iliacs through the superior vesicals; (3) one umbilical vein passing to the liver through the round ligament; (4) the stalk of the allantois, which, on entering the abdomen, is called the urachus, and passes down to the bladder. At birth these structures, with a myxomatous tissue called Wharton's jelly, are covered with amniotic tissues and form the umbilical cord.

If development is interfered with, a cleft is left in the umbilical region into which intestine or other organs may protrude. If only intestine protrudes, it pushes up into the umbilical cord, and constitutes a congenital umbilical hernia. If the intestine is included when the cord is ligated, death from strangulation will ensue; hence the danger of this form of herniæ. If the urachus remains patulous it may form a *urinary fistula*. The hypogastric arteries become obliterated and, opposite Poupart's ligament, have two fossæ, one to their outside and one to their inside. Into these fossæ direct inguinal herniæ may pass. The persistence of the vitelline duct may cause a finger-like projection, called *Meckel's diverticulum*, on the ileum, about 2 or 3 feet above the ileocaecal valve. Sometimes a band passes



from Meckel's diverticulum to the umbilicus and causes strangulation of other coils of the intestine. We have operated on one such case. The umbilical vein becomes obliterated and the small vein found in the round ligament of adults, called by Schiff the *parumbilical*, is a new formation, and not the original fetal umbilical vein.

*Infantile umbilical hernia* is the common form which appears soon after birth. It does not contain omentum so constantly as does adult hernia, because it does not hang so low, nor is it so well developed.

*Acquired umbilical hernia* is the form seen in adults. The presence of the urachus and hypogastric arteries so strengthens the lower edge of the umbilical ring that hernial protrusions make their exit above, hence the hard edge of the ring is nearer the lower end of the hernial sac.

These herniæ almost always contain omentum, and either transverse colon or small intestine. The contents of the herniæ are usually matted together and are adherent. The coverings are very thin, consisting of skin and peritoneum, with a small amount of transversalis fascia and scar-tissue between. Unless extreme care is exercised in operating, the first cut will pass into the sac and wound the intestines or omentum. There are two modes of operating on these herniæ. In one operation the sheaths of the two recti muscles are opened and the muscular fibres and sheaths are brought together and sewed in the median line; in the other, two flaps

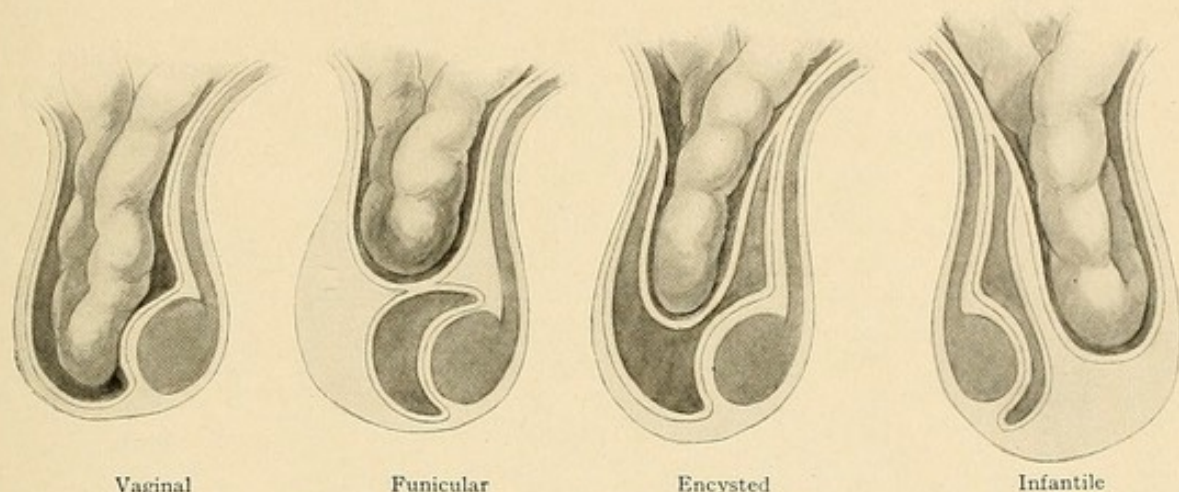


FIG. 394.—The various forms of congenital inguinal hernia.

are made from the fibrous walls of the sac and lapped one over the other, thus closing the hernial opening by two fibrous layers. This may be done either longitudinally or transversely.

**Inguinal Hernia.**—There are two forms of inguinal hernia, the *congenital* and the *acquired*. These are subdivided into several varieties which can only be understood by having a knowledge of the development and construction of the parts involved.

*Development and Descent of the Testis.*—The testicle originates in the lumbar region inside of the abdomen about the third month. It is behind the peritoneum and has a fold of peritoneum, the *plica vascularis*, passing upward from it, containing the spermatic artery and veins, and a fold passing downward to the inguinal region and into the scrotum called the *gubernaculum*. By the fifth or sixth month the testicle has reached the abdominal wall at the internal ring, after which it enters the inguinal canal to pass into the scrotum in the eighth or ninth month of fetal life. A process of peritoneum—the *vaginal process*—precedes the passage of the testicle into the scrotum. The neck of the vaginal process is called the *funicular process*. Soon after birth the vaginal process becomes occluded, first at the internal ring, and thence downward until the testicle is reached, where the unobliterated portion forms the *tunica vaginalis testis*.

*Congenital Herniæ and Hydrocele.*—There are several forms of congenital herniæ. They are so named, not because they exist from birth, but because they are caused by developmental defects which exist at birth (Fig. 394).



The various kinds of herniæ due to developmental defects have been named as follows: *vaginal*—or *congenital*—*funicular*, *encysted*, and *infantile*.

*Vaginal hernia* into the processus vaginalis, commonly known as congenital hernia, is where the vaginal process remains entirely open and the intestine passes down to the testicle. In this form the testicle is found protruding into and at the bottom of the hernial sac. *Funicular Hernia*.—In this form the vaginal process is occluded just above the testicle, but the funicular process above remains open and the intestine descends into it. *Encysted Hernia*.—Here the vaginal process is occluded at the internal ring only, the remainder forming a continuous sac below containing the testicle. When the intestine descends it pushes this septum, like the finger of a glove, down into the cavity containing the testicle. In operation, two serous layers would be incised, within one of which is the testicle and within the other the intestine. *Infantile Hernia*.—In this form also the vaginal process is occluded only at the internal ring. As the intestine descends it forms a sac posterior to the point

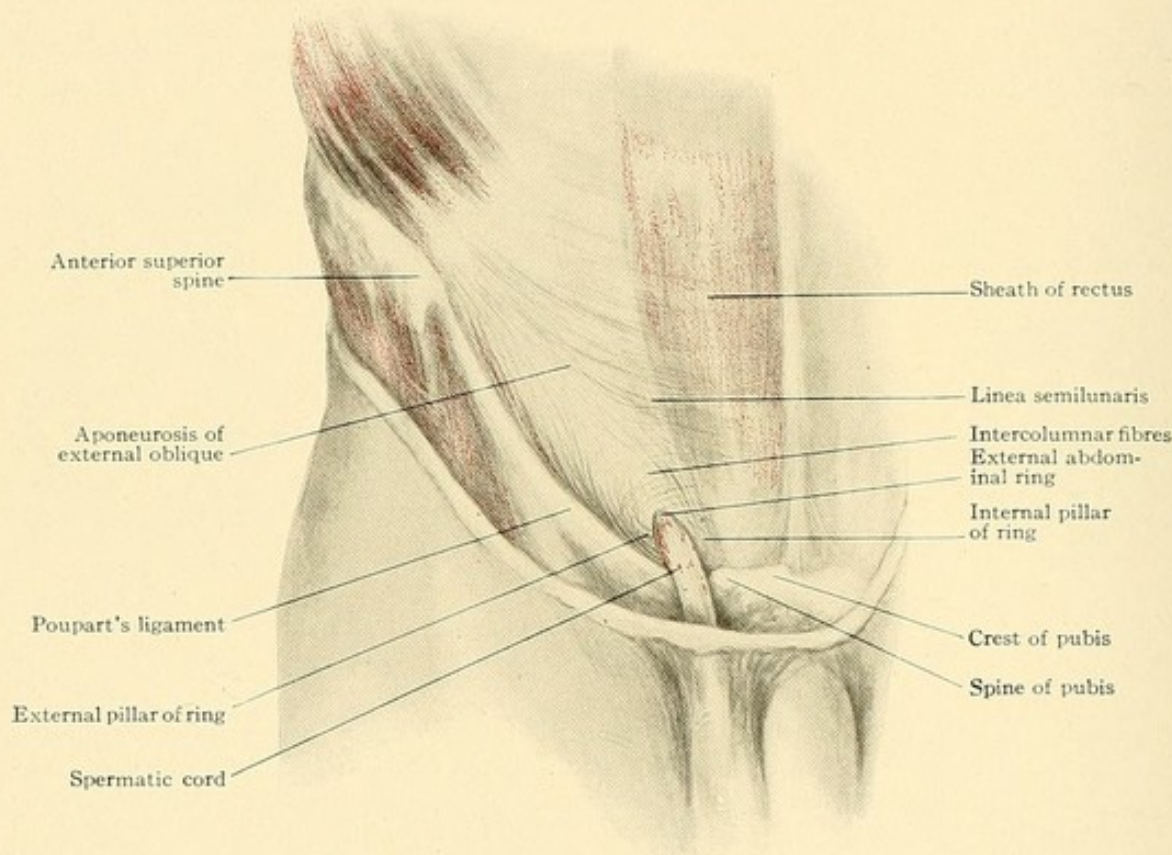


FIG. 395.—Parts concerned in inguinal hernia; the external abdominal ring.

of occlusion and vaginal process. Thus in operation three serous layers are cut through in exposing the intestine and the sac is posterior to the testicle.

*Hydrocele*.—Hydrocele is an accumulation of fluid in the tunica vaginalis testis. It is usually an acquired affection of adult life, and then does not appear to be dependent on congenital anomalies.

*Encysted Hydrocele of the Cord*.—This consists of a cystic collection in the course of the spermatic cord. It makes its appearance in infancy and childhood, and is due to some portion of the funicular or vaginal process failing to become obliterated. Serum accumulates in this unoccluded portion, forming a small serous cyst. Sometimes a small opening furnishes a communication with the abdominal cavity, forming a *congenital hydrocele*. In this case the contents of the cyst can be pressed back into the abdominal cavity only to reappear. Should the communicating opening become dilated by a descending coil of intestine, a hernia into the funicular process would be the result.



*Hydrocele of the Canal of Nuck.*—The inguinal canal in the female transmits the round ligament, and sometimes a finger-like extension of the peritoneum resembling the vaginal process in the male. Accumulation of fluid may occur in this in the same manner as hydrocele of the cord is formed in the male. It is then called hydrocele of the canal of Nuck.

**Acquired Inguinal Hernia.**—Acquired inguinal herniæ may be either of the indirect or direct kind. To understand them one must know the construction of the inguinal canal and spermatic cord.

*The Spermatic Cord.*—As the testicle descends it leaves in its wake the *vas deferens*, the essential part of the spermatic cord. It carries with it the *spermatic artery*, from the aorta, the *pampiniform plexus* of veins, and the *artery of the vas* from the superior vesical. The vas deferens with its artery lies posteriorly and the spermatic artery and pampiniform plexus are anterior. The cremasteric branch of

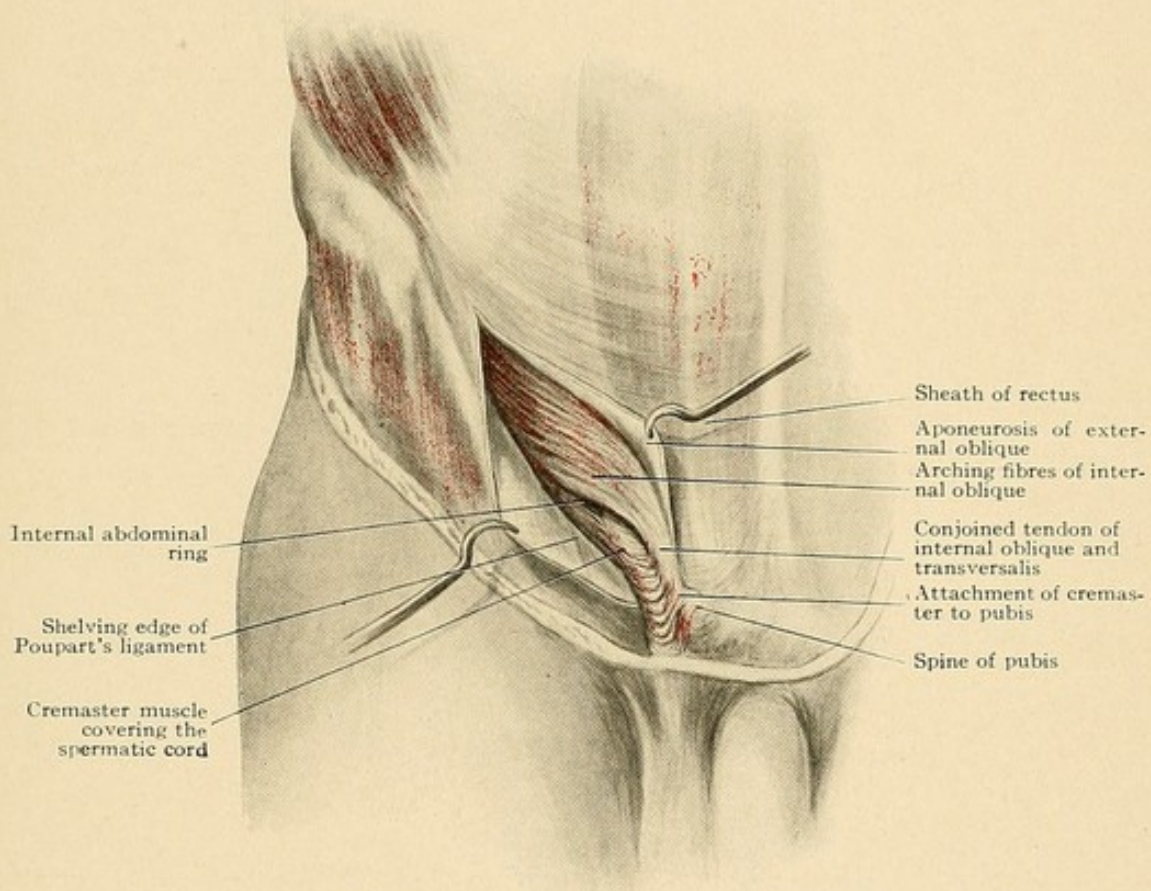


FIG. 396.—Parts concerned in inguinal hernia; the inguinal canal exposed.

the deep epigastric supplies the cremaster muscle. The cord also contains sympathetic nerves, lymphatics, some fibrous remains of the vaginal process, and a few muscular fibres. These structures are imbedded in fatty tissue continuous with the subperitoneal fat and are covered by a fibrous sheath formed by a continuation of the structures of the abdominal walls, viz., the intercolumnar fascia from the external oblique, the cremasteric fascia from the internal oblique, and the transversalis fascia.

*Inguinal Canal (Canalis Inguinalis).*—This runs from the external to the internal abdominal ring and is about 4 cm. (1 3/4 in.) in length. The *external ring (annulus inguinalis subcutaneus)* (Fig. 395) barely admits the tip of the finger; it lies immediately to the outside and above the spine of the pubis. It is formed by a splitting of the fibres of the external oblique aponeurosis into two columns or pillars. The *external column (crus inferius)* blends with Poupart's ligament, passes beneath the cord, and inserts into the spine of the pubis. The *internal column (crus superius)*



inserts into the crest and anterior surface of the body of the pubis. The fibres running across from one column to the other are the *intercolumnar fibres* (*fibræ intercolumnaris*) and are prolonged over the cord as the intercolumnar fascia (Fig. 395).

The *internal ring* (*annulus inguinalis abdominalis*) is the opening in the transversalis fascia where the cord enters the canal. It is 1.25 to 2 cm. ( $\frac{1}{2}$  to  $\frac{3}{4}$  in.) above the middle of Poupart's ligament. This brings it to the outer side of the external iliac artery.

The body being upright, the inguinal canal has an anterior and a posterior wall and a roof and floor. The *anterior wall* (nearest to the skin) is formed by the aponeurosis of the external oblique, and by the internal oblique muscle for its outer third and sometimes even its outer half. The *posterior wall* is nearest to the vertebral column. It is formed by the transversalis fascia and at its inner third the con-

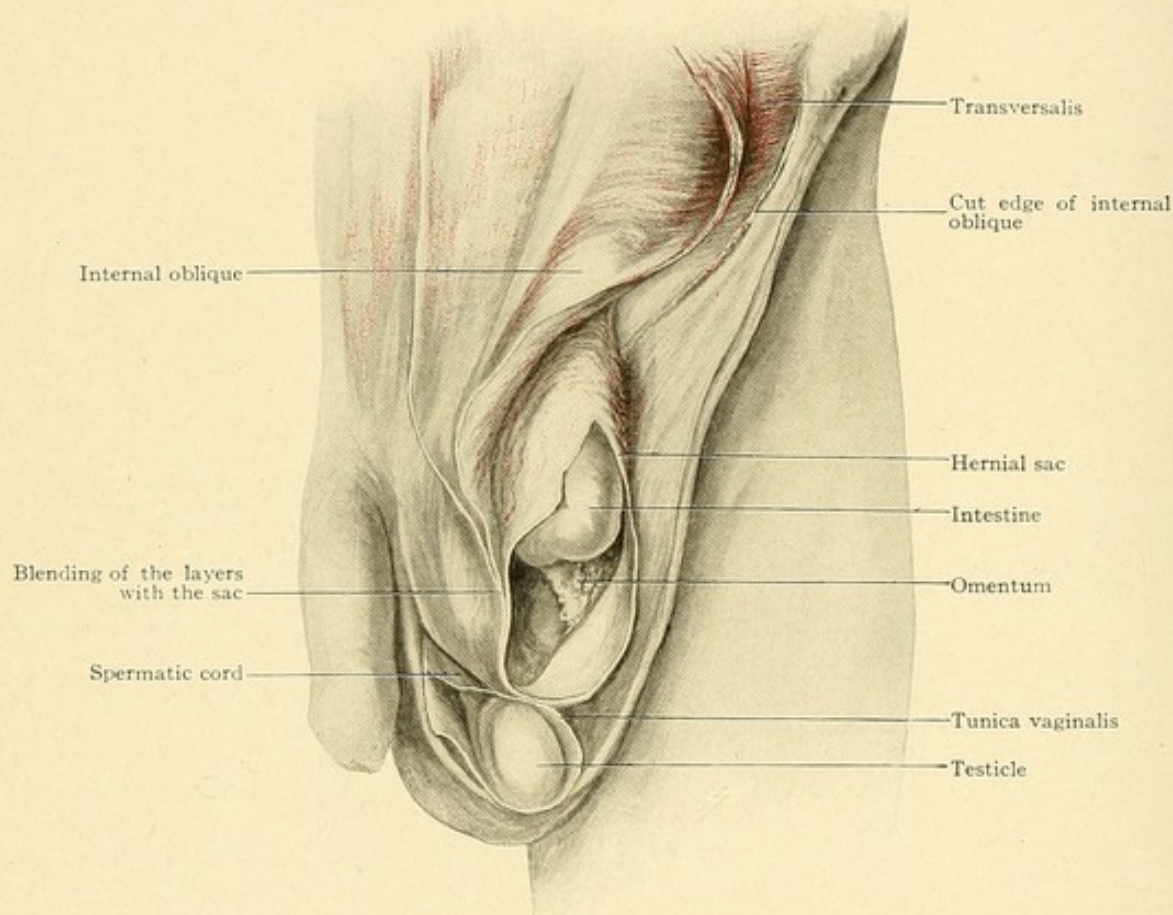


FIG. 397.—The coverings of an acquired oblique inguinal hernia; from an actual dissection. The external and internal oblique have been divided along Poupart's ligament and turned inward exposing the transversalis.

joined tendon. The *roof*, nearest to the head, is formed by the arching fibres of the internal oblique muscle and—still farther above—the transversalis. The *floor* is nearest to the feet. The cord rests on Poupart's ligament with some of the fibres of the cremaster muscle.

To the inner side of the internal ring and almost midway between it and the external ring runs the deep epigastric artery, it is between the transversalis fascia and peritoneum, in the subperitoneal fat.

**Coverings of an Indirect or Oblique Hernia.**—As the intestine descends to form an oblique inguinal hernia it pushes in front of it the following structures: peritoneum, subperitoneal fat, transversalis (infundibuliform) fascia, internal oblique muscle (cremaster), external oblique aponeurosis (intercolumnar fascia), subcutaneous tissue, and skin. These structures are therefore cut in opening the sac to expose the intestine. The hernia always descends in front of the cord and testicle, hence these are posterior. The site of strangulation may be either at the external ring as the hernia passes through the external oblique muscle or at the internal ring



as it passes through the transversalis fascia. The deep epigastric artery is always along the inner side of the neck of the sac, therefore *division of the stricture* must be either upward or up and out, never inward (Fig. 397).

**Operation for Radical Cure.**—This has been systematized by Bassini of Padua. The neck of the sac having been exposed by incising the aponeurosis of the external oblique, and the cord separated from it, the intestine is to be replaced and the sac ligated as high as possible and cut away. The cord is then raised and the arching fibres of the internal oblique (and transversalis) are sutured beneath it to Poupart's ligament. The cord is to be replaced, and the cut edges of the external oblique are sewed together down to the external ring, leaving sufficient room for the exit of the cord (Fig. 398).

**Direct Inguinal Hernia.**—This is so called because it comes directly through the abdominal walls, and not obliquely down through the inguinal canal. It makes its appearance in the neighborhood of the external ring (Fig. 399).

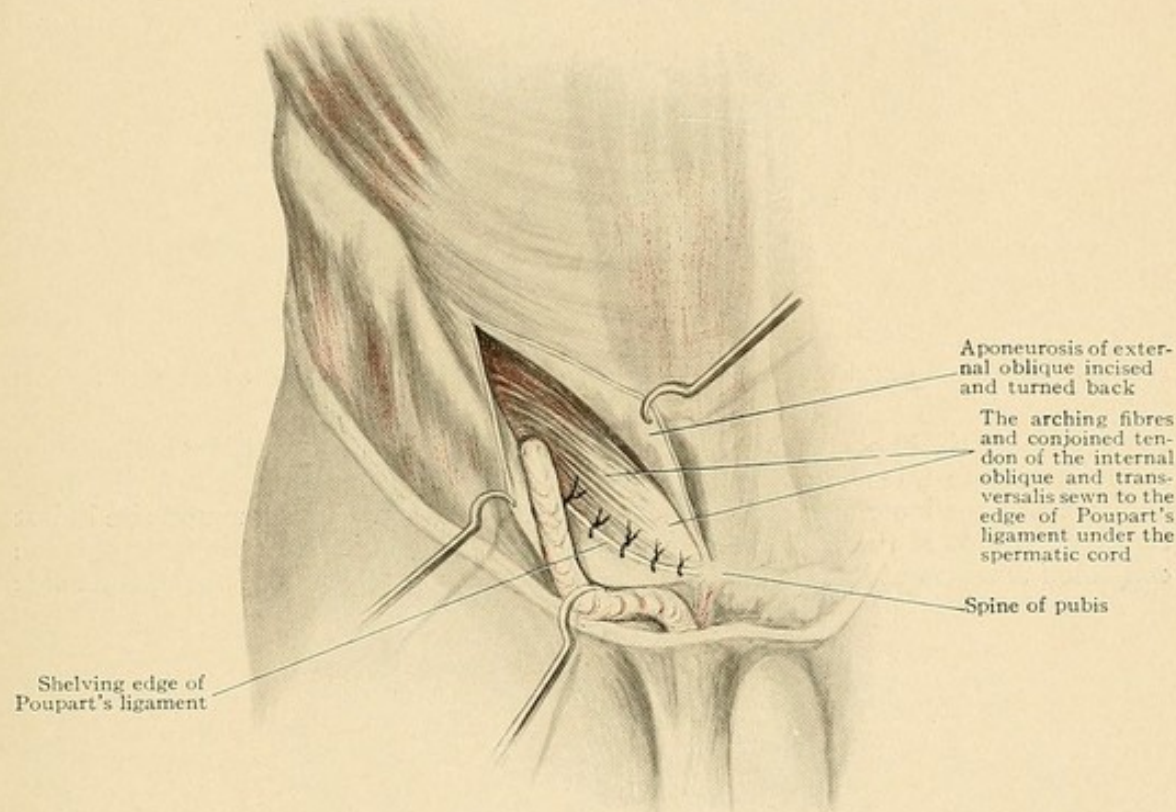


FIG. 398.—Bassini's operation for the radical cure of oblique inguinal hernia.

**Hesselbach's Triangle.**—Hesselbach's triangle is seen from the interior of the abdomen; it has on its outer side the deep epigastric artery, on its inner side the edge of the rectus muscle, and as its base Poupart's ligament. Direct inguinal hernia pierces the abdominal walls through this triangle. On looking at the abdominal wall from the inside, five folds are seen. In the median line the urachus passes from the umbilicus to the top of the bladder; farther out are the folds formed by the obliterated hypogastric arteries (*plica hypogastrica*); and still farther out the folds containing the deep epigastric arteries (*plica epigastrica*). The fossa between the urachus and hypogastric artery is called the *internal inguinal fossa* (*fovea supravesicalis*); that between the hypogastric and deep epigastric arteries, the *middle inguinal fossa* (*fovea inguinalis medialis*), and that to the outside of the epigastric artery the *external inguinal fossa* (*fovea inguinalis lateralis*). An indirect or oblique inguinal hernia enters the abdominal walls at the external inguinal fossa, to the outer side of the epigastric artery. A direct hernia almost always enters the middle inguinal fossa between the hypogastric and epigastric arteries. The hypogastric fold passes up behind the middle of the external ring close to the outer



side of the rectus muscle. On this account a direct hernia rarely enters to the inner side of the hypogastric fold (Fig. 399).

**Coverings of a Direct Inguinal Hernia.**—The conjoined tendon is prolonged outward from the edge of the rectus muscle two-thirds of the distance to the epigastric artery, and sometimes more. A direct hernia piercing the abdominal wall

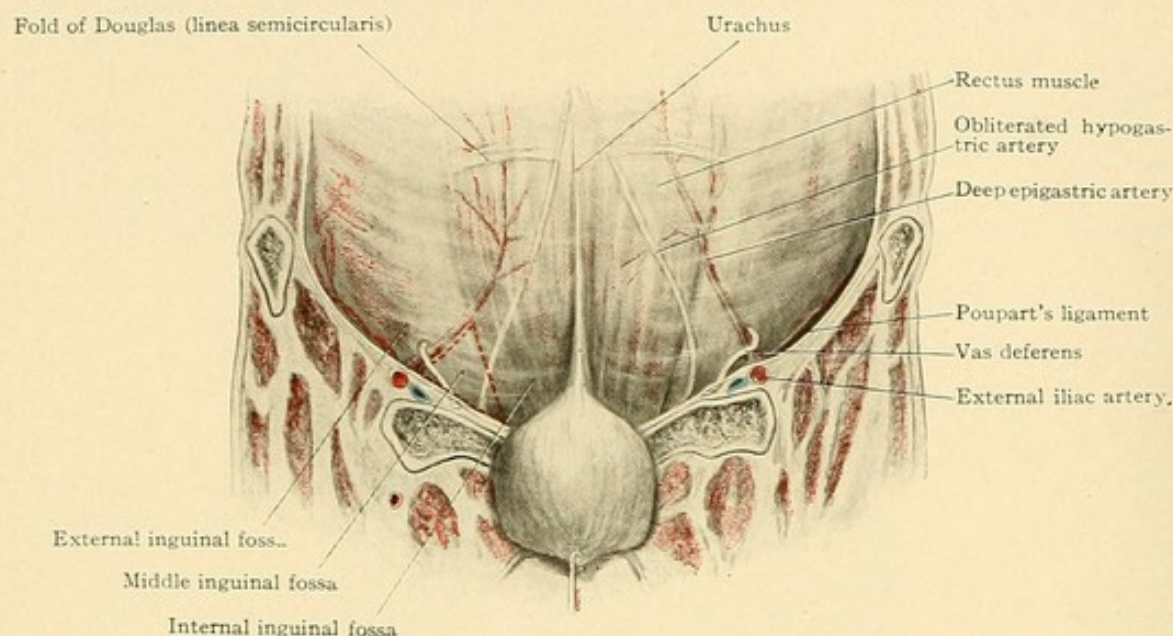


FIG. 399.—View of the posterior surface of the abdominal walls, showing the inguinal fossae and triangle of Hesselbach (the latter in red).

to the inside of the hypogastric artery (very rare) will push in front of it the peritoneum, subperitoneal fat, transversalis fascia, conjoined tendon, and intercolumnar fascia, making its exit at the inner side of the external abdominal ring. The common site is just to the outer side of the obliterated hypogastric artery, and it pushes in front of it the conjoined tendon and intercolumnar fascia, and makes its appearance at the outer side

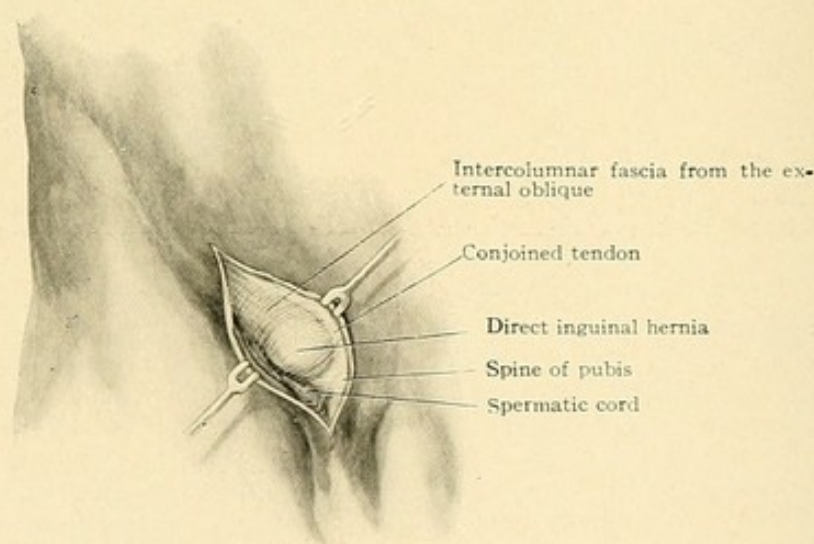


FIG. 400.—Direct inguinal hernia.

of, or through, the external abdominal ring (Fig. 400). If it pierces the middle inguinal fossa farther out, and just to the inside of the epigastric artery, it passes to the outside of the conjoined tendon, and is covered instead by the cremaster muscle.

*Division of the stricture* which occurs here must be made upward and inward, because to its outer side lie the epigastric vessels.



**Radical Cure of Direct Inguinal Hernia.**—When the conjoined tendon is sufficiently thick and strong it is brought down and sewed to Poupart's ligament beneath and behind the cord, thus closing the hernial opening. When it is very weak and

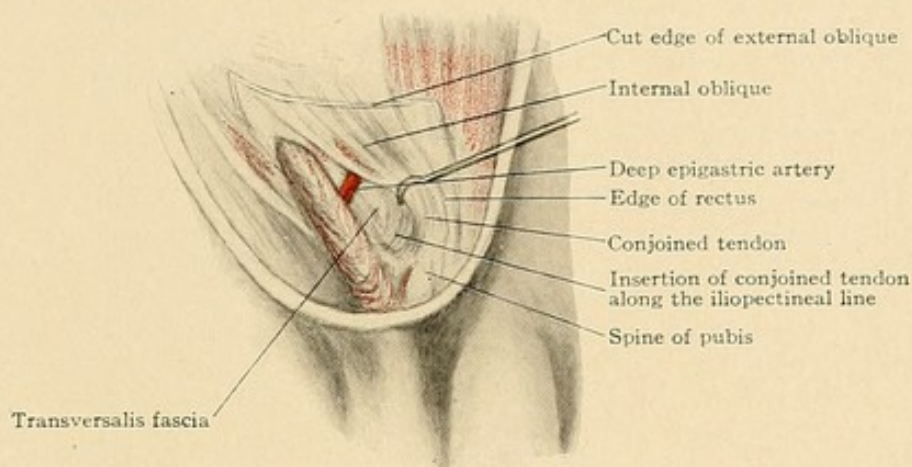


FIG. 401.—The conjoined tendon of the internal oblique and transversalis muscles.

thin, the edge of the rectus muscle is dragged downward and outward and sewed to Poupart's ligament (Bloodgood), then the conjoined tendon (Fig. 401) is brought down in front of it and sewed to Poupart's ligament, and the external ring narrowed so

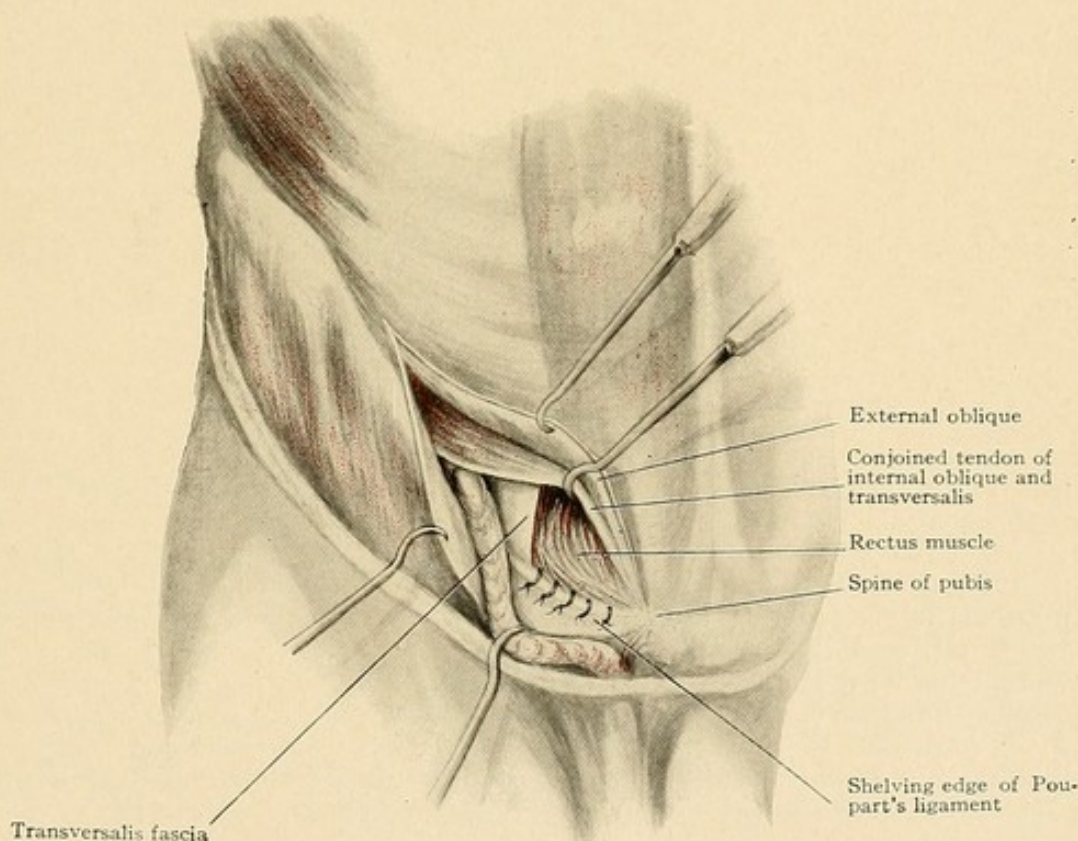


FIG. 402.—Radical cure of direct inguinal hernia. The aponeurosis of the external oblique has been divided and drawn back. The conjoined tendon has been drawn upward toward the median line. The transversalis fascia covering the rectus has been incised and the edge of the muscle has been drawn out and down and sewed to the edge of Poupart's ligament (Bloodgood). The operation is completed by sewing the conjoined tendon to Poupart's ligament, replacing the cord on it, and stitching the edges of the external oblique together down to the external ring.

as to allow room only for the cord to escape (Fig. 402). (The triangular fascia, page 377, is too uncertain and insignificant a structure to be considered in inguinal herniæ).



**Femoral Hernia.**—Femoral hernia is always acquired and descends through the femoral canal beneath Poupart's ligament to make its appearance at the saphenous opening on the thigh. Beneath the inner end of Poupart's ligament is the iliopectineal line of the horizontal ramus of the pubic bone. The two form an angle with the spine of the pubis as its apex. Gimbernats ligament is the prolongation of Poupart's ligament from the spine of the pubis for about 2 cm. ( $\frac{3}{4}$  in.) out on the iliopectineal line. From the iliopectineal line the pectineus muscle proceeds downward and outward beneath Poupart's ligament to below and behind the lesser trochanter of the femur. Farther out beneath Poupart's ligament run the femoral vein and artery, the latter being to the outer side of the vein. Between the femoral vein and Gimbernats ligament is left a space 1 to 2 cm. ( $\frac{2}{3}$  to  $\frac{1}{2}$  in.) wide. This space is called the *femoral canal*. It is through this canal or opening that femoral hernia descends. The *femoral sheath* is the continuation downward of the transversalis fascia which is prolonged from the interior of the pelvis over the femoral artery and vein and between the vein and Gimbernats ligament so as to form three compartments. The outer contains the femoral artery, the middle the femoral vein, and the inner is the femoral canal. The femoral canal is from 1 to 2 cm. ( $\frac{2}{3}$  to  $\frac{1}{2}$  in.) long

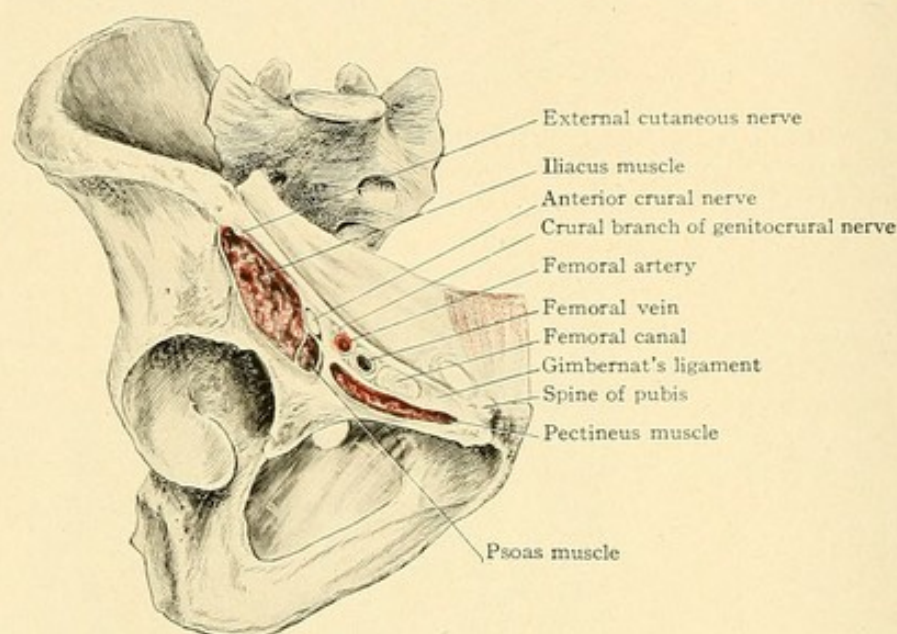


FIG. 403.—The crural arch and the structures which pass beneath it.

and runs from the abdominal side of Poupart's ligament to the upper edge of the saphenous opening and lies between the femoral vein and Gimbernats ligament. Its lower extremity is closed by the meeting of its sides. Above, or superficial to it, is Poupart's ligament, and beneath it is the horizontal ramus of the pubis and pectineal fascia covering the pectineus muscle. It is filled with loose connective tissue, fat, and lymphatics, and sometimes contains a lymphatic node, forming all together what has been called the *septum crurale*. It will thus be seen that the septum crurale is continuous with the subperitoneal fatty tissue (Fig. 403).

**Coverings of a Femoral Hernia.**—When a femoral hernia descends, the intestine pushes in front of it the peritoneum, septum crurale (subperitoneal tissue), and the femoral sheath (transversalis fascia) and makes its appearance at the saphenous opening. The cribriform fascia closing the saphenous opening gives it a covering, and also the subcutaneous tissue and skin above.

**Saphenous Opening.**—This has its centre 4 cm. ( $1\frac{1}{2}$  in.) below and to the outer side of the spine of the pubis. Its margin blends above with Poupart's ligament to proceed to the spine of the pubis. Its outer and upper edge is marked, forming the *falciform process* or *ligament* (of Burns). The upper inner portion of the falciform process is attached to the iliopectineal line and spine of the pubis and, blending with Poupart's ligament above, is called *Gimbernats ligament* (*ligamentum lacunare*) (Fig. 404).



The part of the fascia lata forming the falciform process thins out over the femoral artery and becomes the *cribriform fascia* (*fascia cribrosa*) as it passes from the inner side of the femoral artery on to the femoral vein to blend with the pubic fascia

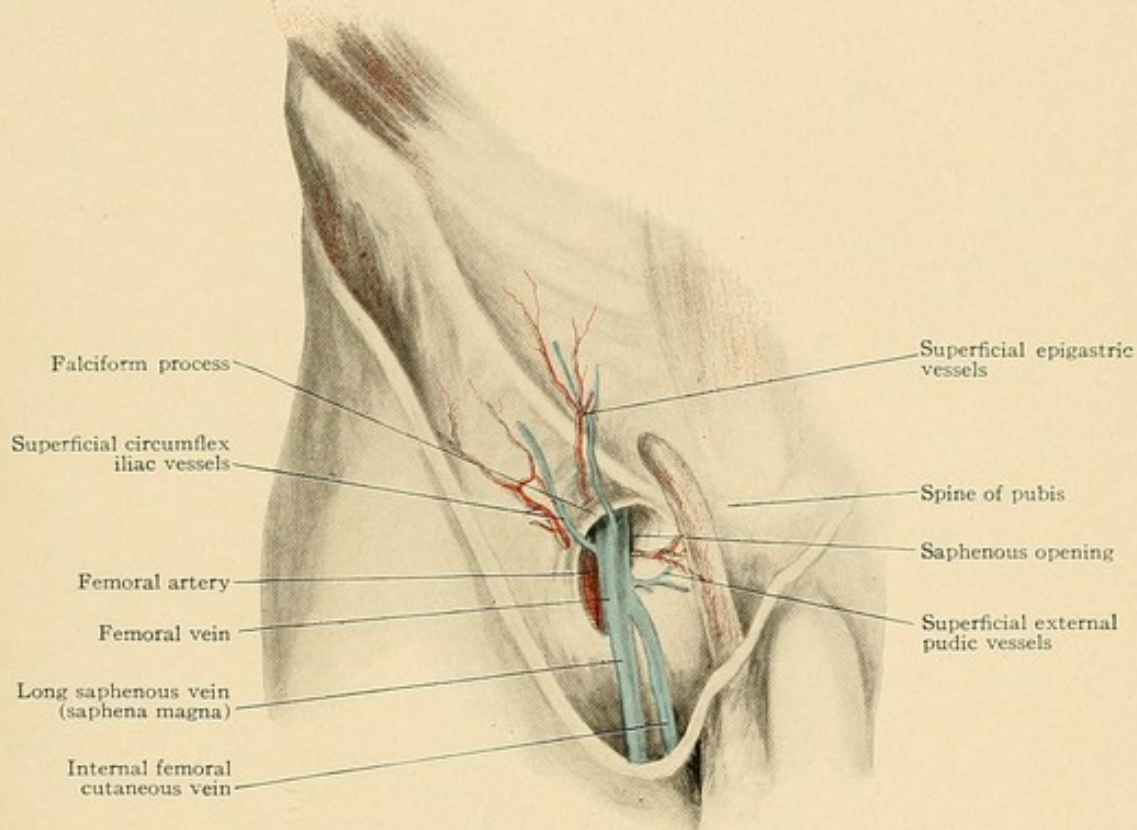


FIG. 404.—The saphenous opening (fossa ovalis).

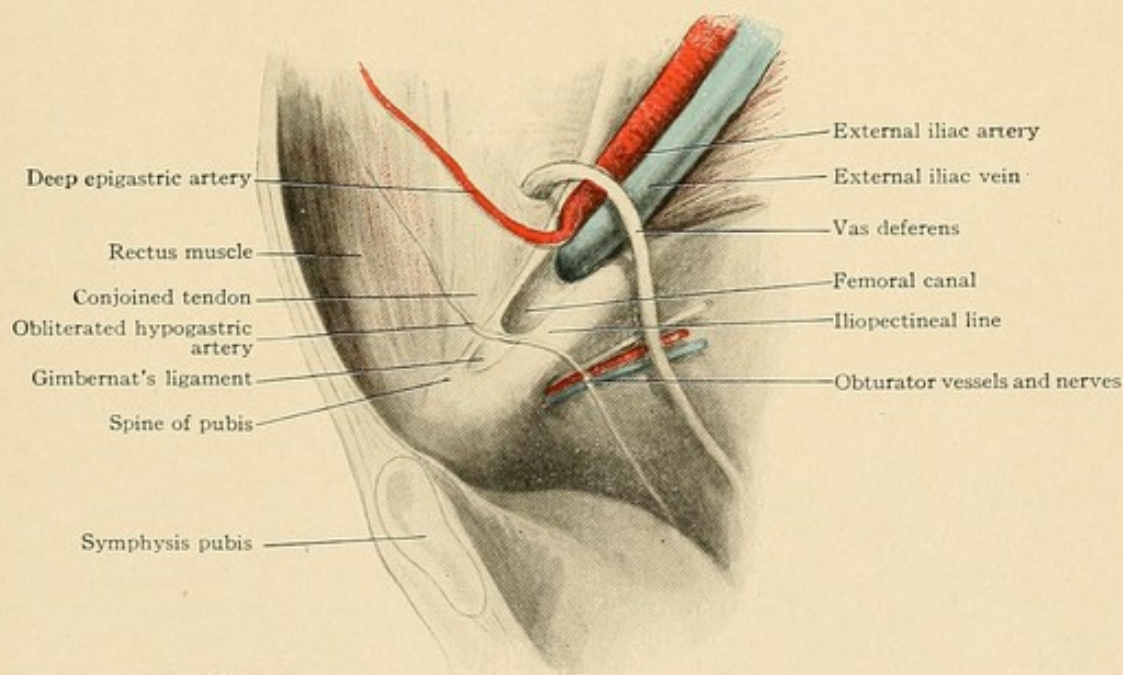


FIG. 405.—View of the inguinal and femoral regions from within; the peritoneum has been removed.

to the inner side. The superficial epigastric, superficial circumflex iliac, and superficial external pudic arteries and veins all pierce this cribriform fascia, as do also the superficial lymphatics and the long or internal saphenous vein.



*Point of Strangulation.*—As a femoral hernia descends it may be strangulated on the sharp edge of Gimbernat's ligament or at the upper portion of the falciform process (Fig. 404).

*Division of Stricture.*—If Gimbernat's ligament is the constricting band the incision is to be made in an upward and inward direction. If the upper portion of the falciform process is the constricting part the incision should be made directly upward into Poupart's ligament.

In order to avoid wounding an anomalous obturator artery which may wind around the neck of the sac, the stricture is best cut from without inward.

**Radical Cure of Femoral Hernia.**—The intestine and omentum having been replaced, the neck of the sac is ligated as high up as possible and cut away or, preferably, the two ends of the ligature are brought up through the aponeurosis of the external oblique and tied on its surface just above Poupart's ligament. To close the femoral canal two or three sutures are inserted as follows: If the hernia is on the right side, the needle is passed downward through the inner end of Poupart's ligament, close to the spine of the pubis, into the pectineal or pubic portion of the fascia lata, and brought out alongside of the femoral vein. It is then inserted again through the edge of the falciform process and the suture tied, thus pulling the falciform

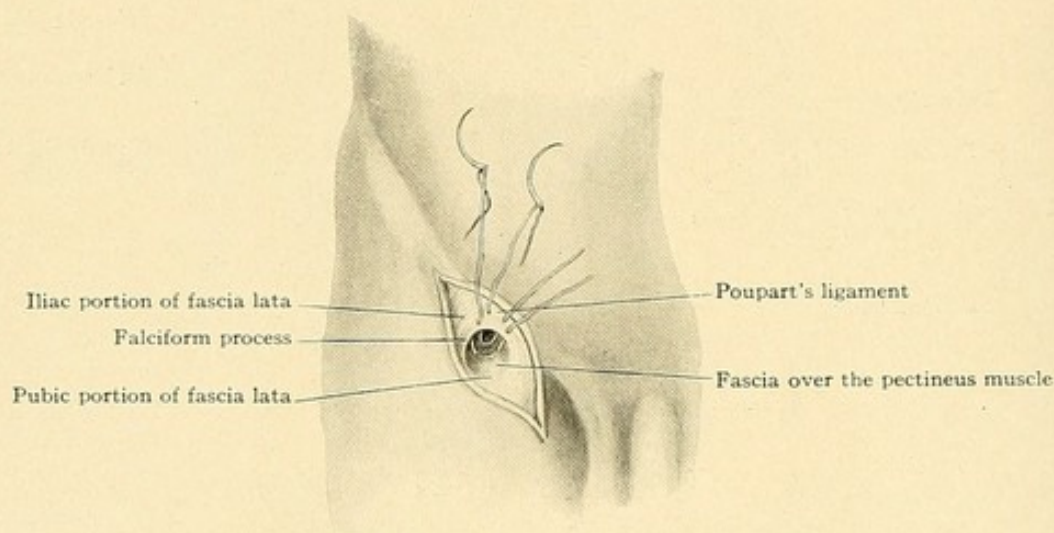


FIG. 406.—Operation for the radical cure of femoral hernia.

form process and the lower edge of Poupart's ligament down on the fascia covering the pectineal muscle. Two or three sutures are all that are required. Another way of inserting the sutures is longitudinally, instead of transversely. The first would be close in to Gimbernat's ligament, the second a little farther out, and the third as close to the femoral vein as possible (Fig. 406).

## THE LUMBAR REGION.

This region is at times affected with abscesses or hernial protrusions and through it incisions are made to reach the kidney (Fig. 407).

**Muscles.**—The **quadratus lumborum muscle** arises from the transverse processes of the lower four lumbar vertebræ, the iliolumbar ligament, and 5 cm. (2 in.) of the iliac crest. It inserts into the posterior half of the last rib and transverse processes of the upper four lumbar vertebræ. The **erector spinæ** is the muscular mass which fills the groove to the outer side of the spinous processes. It arises from the spines of the lumbar vertebræ, the back of the sacrum, the sacrosciatic and sacroiliac ligaments, and about the posterior fourth of the crest of the ilium. It inserts into the posterior portion of the vertebræ and ribs above. The **latissimus dorsi** arises from the spinous processes of the lower six thoracic vertebræ and the vertebral aponeurosis, which is attached to the spinous processes of the lumbar vertebræ, the posterior surface of the sacrum, and the posterior third of the crest of



the ilium. It passes upward and forward to insert into the inner lip of the bicipital groove of the humerus.

It will thus be seen that while the direction of the outer fibres of the latissimus dorsi is from below upward and forward, the direction of those of the quadratus lumborum is upward and backward. It will also be observed that the attachment of the quadratus lumborum is farther out on the crest of the ilium than is that of the latissimus dorsi, reaching about its middle (Figs. 408, 409 and 410).

**Fascias.**—The **lumbar fascia (fascia lumbodorsalis)**, so called, is the continuation backward of the posterior aponeurosis of the transversalis and internal oblique muscles to the spine. When the aponeurosis, from which these two muscles spring, reaches the outer edge of the quadratus lumborum, it splits; one thin layer goes on its ventral surface to be attached to the roots of the transverse processes of the vertebræ; the other thick posterior layer, on reaching the edge of the erector

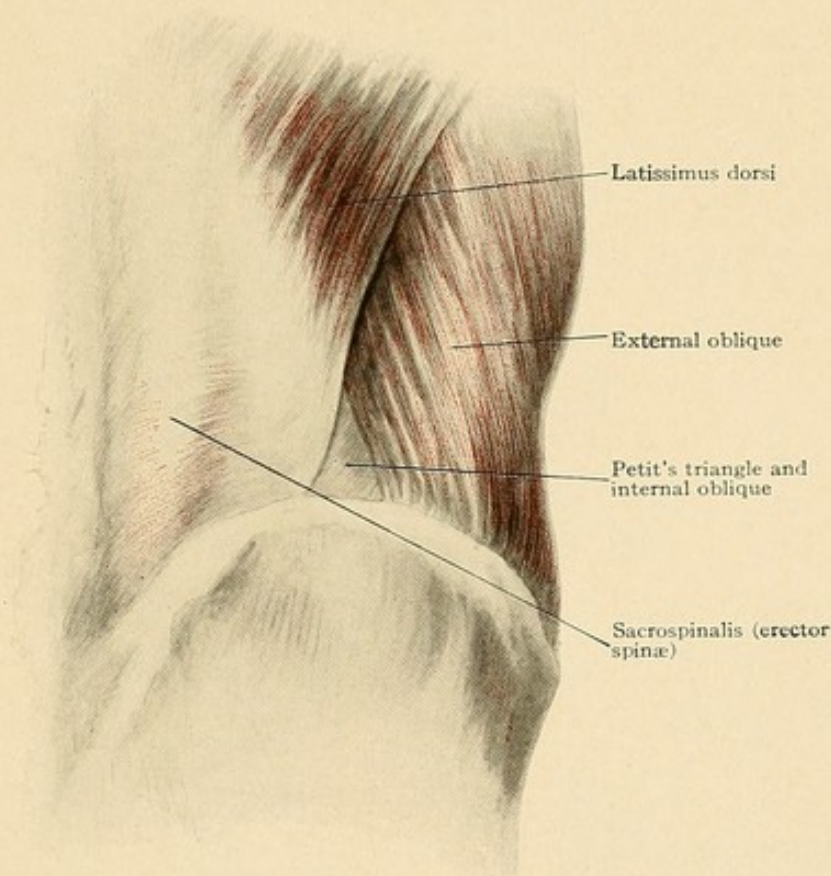


FIG. 407.—The lumbar region, superficial view.

spinæ muscles divides into two, the anterior of which covers the dorsal surface of the quadratus lumborum and the ventral surface of the erector spinæ to attach itself to the tips of the transverse processes, while the posterior layer passes over the dorsal surface of the erector spinæ to be attached to the spinous processes of the lumbar vertebræ. These three layers are called the anterior, middle, and posterior layers of the lumbar fascia (see Fig. 410).

The anterior layer is attached to the tip of the twelfth rib and arches inward to the transverse process of the first or second lumbar vertebra, to form the external arcuate ligament of the diaphragm. It is practically continuous with the transversalis fascia.

The middle layer is attached above to the last rib, and below to the iliac crest, and is very strong.

The posterior layer is continuous above with the vertebral aponeurosis and gives origin to the latissimus dorsi muscle.



**Petit's Triangle** (*trigonum lumbale*).—Above the middle of the crest of the ilium is a small triangular space formed by the edge of the external oblique in front, of the latissimus dorsi behind, and the crest of the ilium below. Its floor is formed by the internal oblique muscle, and it is called the triangle of Petit. It forms a weak point in this region through which collections of pus or, more rarely, ventral herniæ, may make their appearance (Fig. 407).

**Fascial Triangle.**—Above and a little posterior to Petit's triangle is another triangular space. Its base is the twelfth rib, its anterior side is the posterior edge of the internal oblique, and posterior side is the outer edge of the quadratus lumborum. It is also called the triangle of Grynfelt and Lesshaft. The lower portion of the kidney lies immediately beneath it and the latissimus dorsi covers it (Figs. 408 and 409).

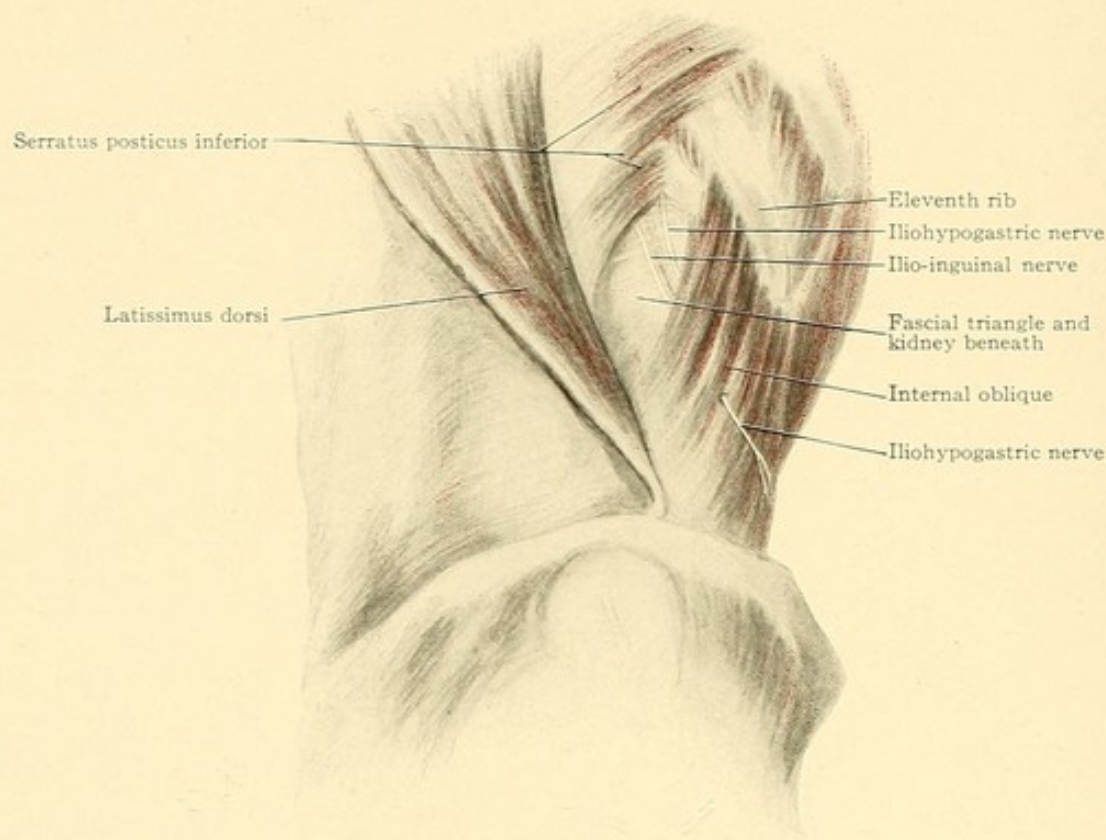


FIG. 408.—The lumbar region; the latissimus dorsi has been turned back and the external oblique cut away, revealing the fascial triangle.

**Lumbar Abscess.**—Pus in the lumbar region usually originates from caries of the vertebræ, from calculus or other renal or perirenal affections, or, if on the right side, sometimes from disease of the appendix. Empyemas may likewise point in this region. Pus starting from the vertebræ may push its way outward under the transversalis aponeurosis (anterior layer of the lumbar fascia) and perforate the transversalis muscle where the iliohypogastric, ilio-inguinal, and last thoracic nerves enter and thus reach the under surface of the internal oblique and perforate this muscle to find its exit at Petit's triangle. Pus may also perforate the floor of the fascial triangle and follow the anterior surface of the latissimus dorsi down until it points in the angle between the posterior portion of the crest of the ilium and the spine. The quadratus lumborum muscle is thin, and its outer edge, which is not covered by the erector spinæ muscle, is readily pierced by pus. The *erector spinæ* is a thick muscle covered both anteriorly and posteriorly by the thick middle and posterior layers of the lumbar fascia, hence pus does not pierce it but always goes around its outer side.

**Lumbar hernia** usually results from the giving way of a scar from an operation.



**Lumbar incisions** are made to evacuate pus or to operate on the kidney. Incisions to evacuate pus should be made obliquely from the outer edge of the quadratus lumborum in order to avoid wounding the nerves.

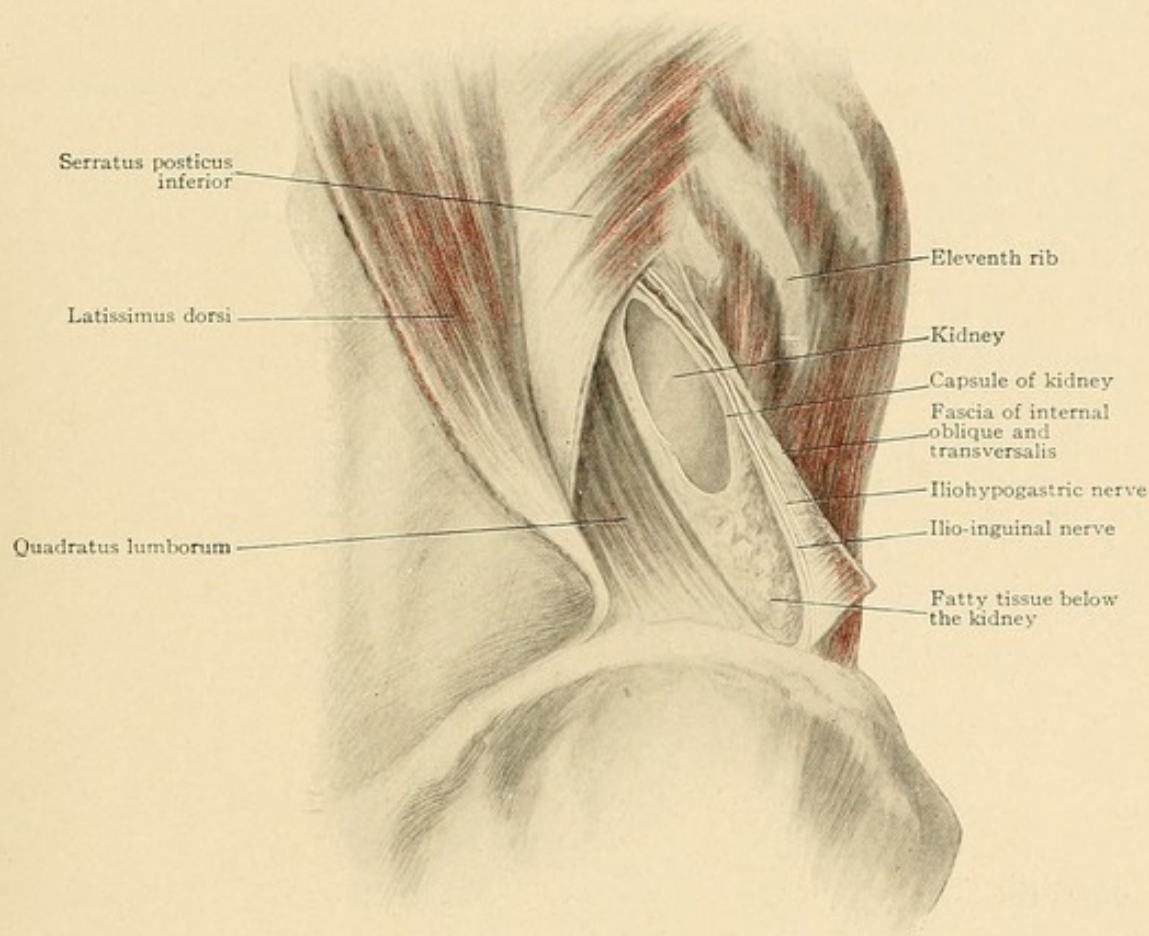


FIG. 409.—Lumbar region, showing the kidney and quadratus lumborum muscle exposed.

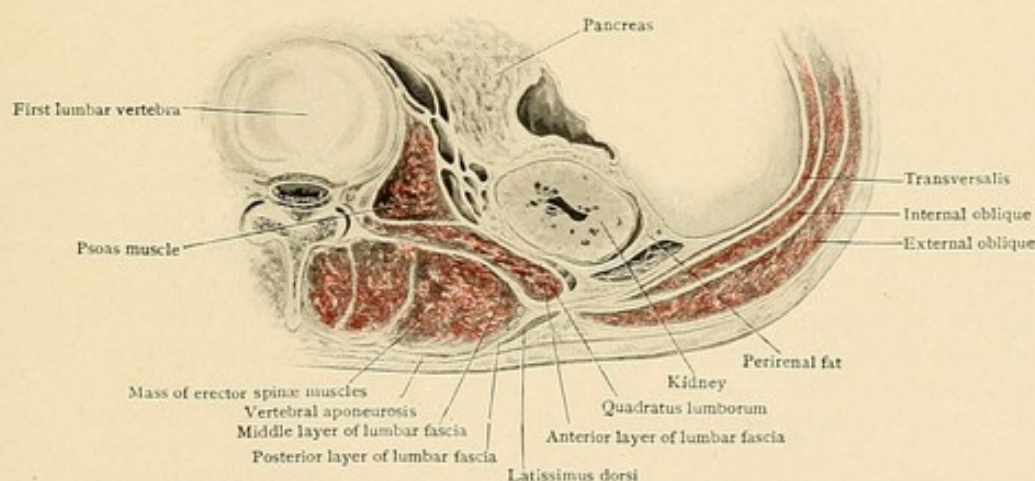


FIG. 410.—Transverse section of the lumbar region, showing the lumbar fascias and muscles.

**Longitudinal Incision.**—If it is desired to expose the kidney, a straight incision 10 cm. (4 in.) long may be made between the last rib and middle of the crest of the ilium along the outer edge of the quadratus lumborum. This may sometimes necessitate cutting the last thoracic nerve near the rib and the iliohypogastric and



ilio-inguinal nerves near the crest. They should if possible be pulled aside, but if cut are to be stitched together again. This gives only sufficient room to bring a normal-sized kidney out of the wound; if the kidney is enlarged, Edebohls recommends prolonging the incision along the crest of the ilium. This longitudinal incision lies just back of the external oblique, traverses in its upper part the latissimus dorsi (the fibres of which may be parted by blunt dissection) then the lumbar fascia or anterior edge of the quadratus lumborum muscle, and lastly the transversalis fascia behind the peritoneum (Fig. 411).

*Oblique Incision.*—When an incision for enlarged kidneys, tumors, or abscesses is desired, it can be made obliquely downward and forward from the twelfth rib—anterior to its middle—toward the anterior portion of the crest of the ilium. This parts the fibres of the external oblique and divides the fibres of the transversalis muscle obliquely, and those of the internal oblique almost transversely, but the nerves (twelfth thoracic and iliohypogastric) are more readily drawn aside than if the longitudinal incision is used. Care is to be taken not to go farther back than the

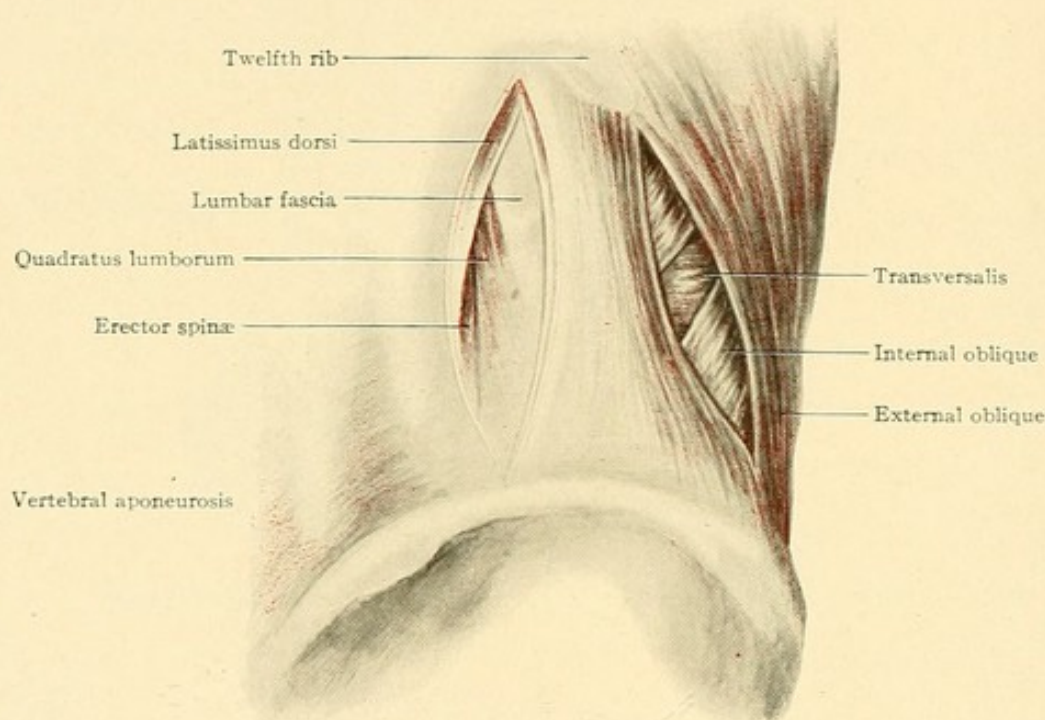


FIG. 411.—Lumbar incisions for operations on the kidney, showing the direction of the muscular fibres.

middle of the twelfth rib, because the pleura usually crosses at that point to reach the lower edge of the rib, or even a little below it at its posterior extremity. As it is sometimes difficult to identify the twelfth rib, because it may be so short as to be hidden beneath the muscles, the most certain way is to count downward from the angle of the sternum opposite the second costal cartilage. There may be some bleeding at the lower portion of the wound from the ascending branch of the deep circumflex iliac artery near the anterior portion of the crest of the ilium.

### THE INTERIOR OF THE ABDOMEN.

The abdominal cavity extends only to the brim of the pelvis; the pelvic cavity is separate. The peritoneal cavity is not synonymous with the abdominal cavity: some of the abdominal organs project comparatively little forward into it and, as in the case of the kidneys, may be only partly covered with the peritoneum. The peritoneal cavity includes the pelvis, so that an infection of the pelvic peritoneum of necessity involves a part of the general peritoneal cavity.

The **peritoneum** is a closed sac lining the abdomen and pelvis into which the



various abdominal and pelvic organs grow. As the organs increase in size they push farther into the abdominal cavity and the peritoneum covers more of their surface, until in some cases the two layers (anterior and posterior) meet; thus the organ is left hanging by its peritoneal pedicle. The peritoneum covering the organs is called the visceral peritoneum, that lining the walls of the abdominal cavity the parietal peritoneum. Those parts of the peritoneum joining the visceral and parietal layers receive various names. Sometimes they are called ligaments,—thus we have the various ligaments of the liver, the coronary, lateral, and suspensory; of the spleen; of the uterus; bladder, etc. Sometimes they are called omenta,—thus we have the greater omentum, the lesser or gastrohepatic omentum and the gastrosplenic omentum. Sometimes they receive the name of mesentery, which is applied to the small intestine, and mesocolon, as applied to the large intestine. From this arrangement

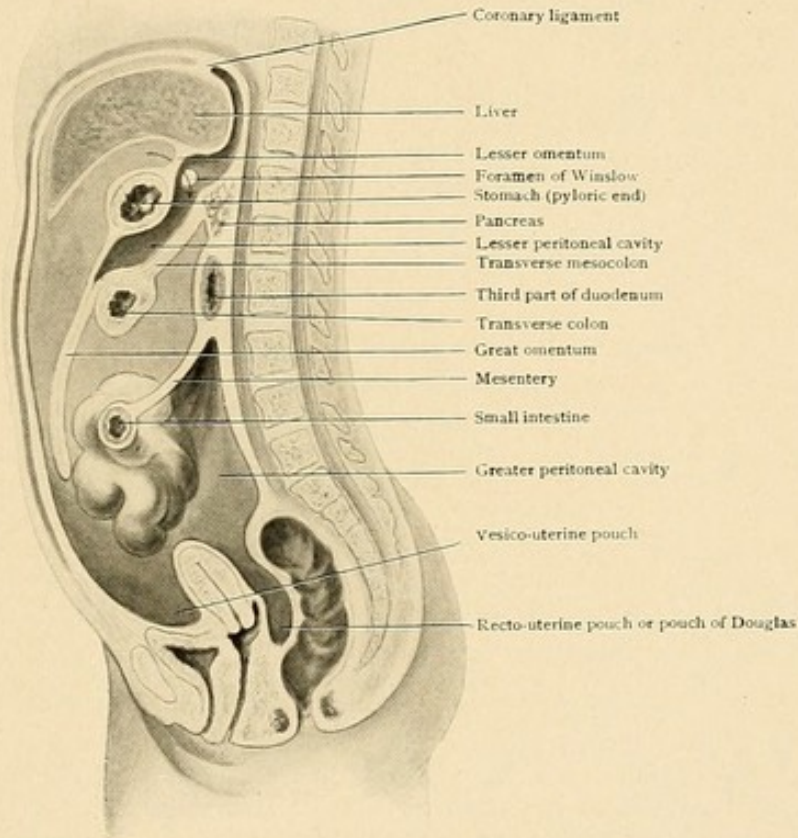


FIG. 412.—Anteroposterior section, showing the peritoneum.

it is evident that there is some portion of every abdominal and pelvic organ that is not covered by peritoneum. In some organs, as the small intestines, the uncovered part is very small, being at the attachment of the mesentery. In other organs, as the kidneys, it is very large, embracing all their posterior surface. In operating on the abdominal or pelvic organs these attachments are of importance, as a knowledge of them enables the surgeon—for example, in operating on the kidney for renal calculus—to complete his procedures without wounding the peritoneum or opening the peritoneal cavity. The upper and lower limits of the peritoneum are also important, as it is liable to be wounded in operations on the chest and the organs of the pelvis.

A knowledge of the course pursued by the peritoneum over the various organs is of service both in diagnosis and operative procedures.

*Viewing the body in an anteroposterior section* (Fig. 412), and beginning at the umbilicus, the peritoneum is seen to pass upward on the posterior surface of the anterior abdominal wall until it reaches the under surface of the diaphragm, which it covers, to the upper posterior surface of the liver, where it forms the *coronary ligament* on



the right side and the *left lateral ligament* on the left. It then covers the upper or parietal surface of the liver and curves around the anterior edge and the under or visceral surface as far as the transverse fissure. Thence it proceeds to the stomach, forming the anterior layer of the lesser or gastrohepatic omentum. After covering the anterior wall of the stomach, it leaves the greater curvature to form the anterior layer of the greater omentum. It next passes to the transverse colon, which it covers and passes back to the spine at the lower border of the pancreas. It then goes downward, covering the transverse portion of the duodenum and forming the anterior layer of the mesentery. Having covered the small intestine, it goes back to the spine, forming the posterior layer of the mesentery, and descends until it reaches the rectum. From the rectum it is reflected forward to the upper part of the vagina and uterus in the female, forming the *recto-uterine pouch* (or *pouch of Douglas*) or on the bladder in the male, being at this point about 7.5 cm. (3 in.) distant from the anus. After covering the fundus and body of the uterus, it is reflected at the level of the internal os to the bladder, forming the *utero-vesical fold*. From the top of the bladder it passes up the abdominal wall to reach the umbilicus.

The peritoneum lining the lesser cavity can be followed upward from the anterior surface to the pancreas. It ascends on the posterior abdominal wall to the under surface of the liver, forming the under layer of the coronary and left lateral ligaments,

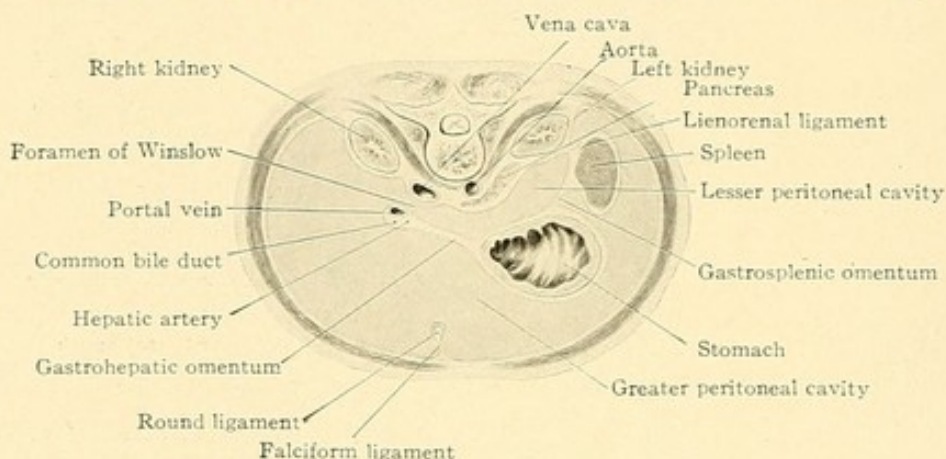


FIG. 413.—Transverse section made through the foramen of Winslow. (Viewed from above.)

and at the transverse fissure is reflected to the posterior surface of the stomach, forming in its course the posterior layer of the gastrohepatic omentum. From the greater curvature it passes downward and then upward to the colon, forming the posterior layer of the greater omentum. From the posterior edge of the transverse colon it passes to the anterior surface of the pancreas, having in its course formed the upper (cephalad) layer of the transverse mesocolon.

*Viewing the body in transverse section.*—On examining a transverse section made below the foramen of Winslow, the peritoneum is seen coming from the parietes and passing over the ascending colon, leaving its posterior surface uncovered. Thence it passes over the vena cava and spine, to go to the mesentery and small intestines. Returning to the spine, it passes over the aorta, and out over the descending colon, usually leaving a portion of its posterior surface uncovered. Thence it returns to the anterior parietes.

In a section made passing through the foramen of Winslow (Fig. 413), the mode of formation of the lesser cavity of the peritoneum and the relation of the peritoneum to the stomach, spleen, and kidneys will be more readily understood. Beginning on the anterior abdominal wall, at the median line and proceeding to the right, the peritoneum is seen to enclose the round ligament of the liver, forming a mesentery for it named the falciform ligament. Continuing around, the peritoneum lines the inner surface of the anterior and lateral abdominal walls, covers the anterior surface of the right kidney, and, after forming the posterior wall of the foramen of Winslow, covers the vena cava, aorta, spine, and pancreas; it then passes over the left kidney



to go to the spleen, forming the anterior layer of the lienorenal ligament. It is then reflected from the spleen to the posterior surface of the stomach, forming the posterior layer of the gastrosplenic omentum. From thence it passes forward on the stomach, past the pylorus to the upper surface of the first portion of the duodenum. Here it winds around the hepatic artery, portal vein, and common bile duct to reach the anterior surface of the stomach. This reflection forms the free anterior edge of the foramen of Winslow. From the fundus of the stomach it passes to the spleen, forming the anterior layer of the gastrosplenic omentum. It winds around the outer or costal surface, and the inner or renal surface of the spleen, and thence passes to the left kidney, forming the posterior layer of the lienorenal ligament. After covering the outer portion of the kidney, it is reflected to the abdominal wall which it follows to the median line.

**The Transversalis Fascia.**—Superficial to the peritoneum and between it and the structures which it covers is a layer of fibrous tissue which varies in thickness. The part which lines the muscles of the abdomen is called the transversalis fascia. It is thickest and most marked in the lower portion of the abdomen and accompanies the femoral vessels down the thigh.

**Subperitoneal Fat.**—In certain locations there is more or less fatty tissue between the transversalis fascia and the peritoneum, and sometimes it is impossible to differentiate them. They blend in the region of the kidneys, the mesenteries, inguinal regions, etc. In the femoral canal the transversalis fascia is continuous with the sheath of the vessels and the subperitoneal fat with the septum crurale. The protrusion of this subperitoneal fat in the median line usually above the umbilicus forms the fatty herniæ alluded to on page 371.

## THE ABDOMINAL VISCERA.

The abdominal contents should first be studied as to their positions and general relations, so that they can be readily found and identified, and then studied as to their intimate relations to the immediate surrounding structures.

By knowing the first, an operator is enabled to expose quickly the affected part, and by knowing the second he is enabled to carry out the desired procedures. While it is true that the presence of tumors or enlargement of the various organs may distort and displace them and so render their exposure and recognition difficult, nevertheless a knowledge of the normal relations is essential in order to solve the difficulties which arise in operating for or studying the various abdominal diseases and injuries.

It must be borne in mind that the extent and position of the various organs is not always the same, even though they are not diseased; it is easier to find a distended than a contracted stomach; in some people the liver though not diseased may be lower than in others, etc.

When the abdominal cavity is freely opened the general relation of the organs is visible as in Fig. 414. In the upper portion is seen the *liver*. Its edge usually is inclined upward toward the left, but sometimes it passes almost transversely across. In the male its lower edge should be about even with the lower edge of the thorax (tenth rib) but in females it may be a finger-breadth lower. Its anterior edge is marked by the *gall-bladder* and *round ligament*. The gall-bladder is liable to be a little to the outside of its normal position at the upper extremity of the right linea semilunaris. The round ligament reaches the liver not at the median line but 2.5 to 4 cm. (1 to 1½ in.) to its right. The point at which the liver crosses the median line is approximately 4 cm. (1½ in.) below the tip of the ensiform cartilage. The *stomach* is seen to the left of the liver, between it and the left costal cartilages. Frequently the stomach is seen to pass a little to the right of the median line, particularly if it is distended. A small portion only, 2.5 to 4 cm. (1 to 1½ in.), is seen in the median line and its lower border slopes up and to the left to disappear under the edge of the ribs. Immediately below the stomach lies the transverse colon, concealed beneath omentum. The *omentum* hangs down from the lower edge of the stomach and spreads over almost the whole of the abdomen below. It is almost always



encountered in operating for appendicitis and is often found in a hernia. The gall-bladder is almost the only organ below the liver and stomach which it is not liable to cover. Not infrequently the omentum is not found spread out, but from the movements of the intestines it may lie between their coils or be displaced largely to the left. The *transverse colon* passes upward and to the left; it crosses the median line just below the stomach and may reach as low as the umbilicus. Not infrequently, however, there may be a coil of small intestine between the level of the umbilicus

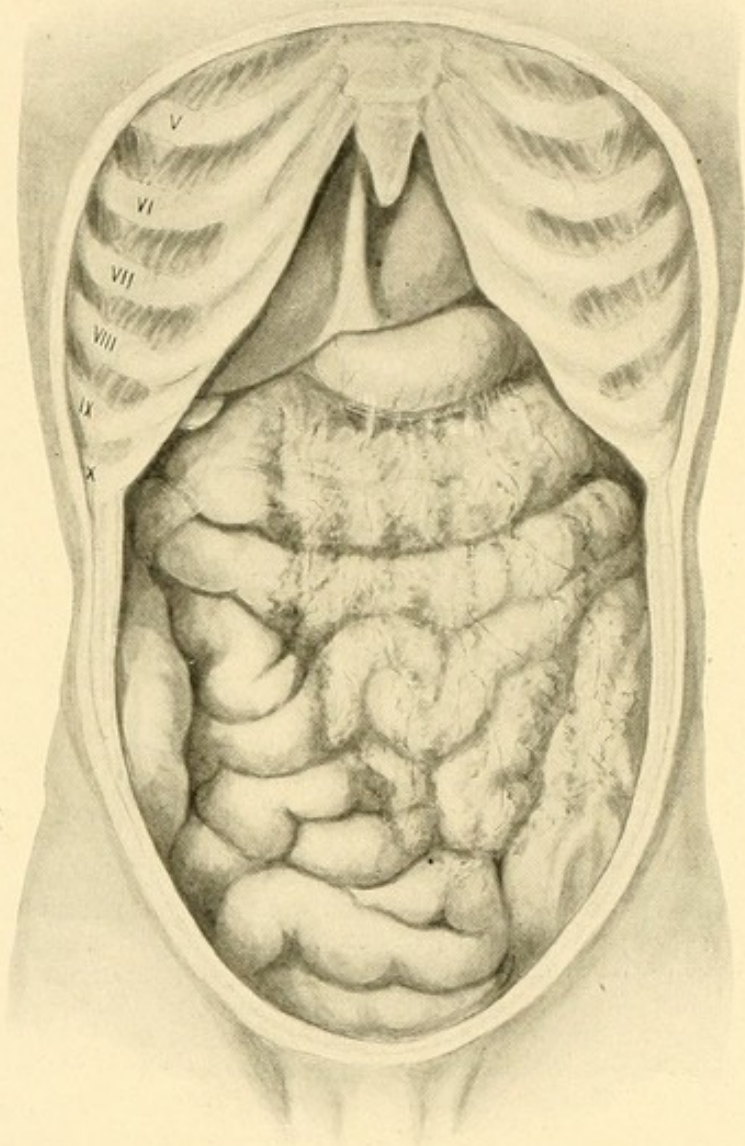


FIG. 414.—View of the abdominal organs *in situ*. Beneath the ensiform process is seen the liver with the round ligament to the right of the median line, below come the stomach, then the transverse colon, and lower down the small intestines, over which is spread the great omentum. In the right iliac region is seen the ascending colon and in the left the termination of the descending colon.

and the transverse colon, or a coil may even push the transverse mesocolon in front of it and show itself between the stomach above and the transverse colon below.

The *cæcum* and the commencement of the *ascending colon* are almost always seen superficially in the right iliac fossa. The lower end of the *cæcum* may reach as far forward as the middle of the inguinal (Poupart's) ligament, but when the ascending colon reaches the upper edge of the iliac crest it sinks backward out of



sight, to reappear again above at the commencement of the transverse colon just below the gall-bladder.

The *descending colon* and *sigmoid flexure* are usually seen lying close to the abdominal wall somewhere between the left iliac crest and approximately the middle of Poupart's ligament. The amount visible is variable,—sometimes a considerable length is seen, at others only a single knuckle. Their presence and location are more uncertain than are those of the cæcum and ascending colon on the right side. The *small intestines* fill the rest of the visible space. They enter the pelvis, usually are found in hernial sacs, and cover both the ascending and descending colon in the flanks. The coils in the upper and left portions of the abdomen are more likely to be jejunum, those in the lower and right portions are more likely to be ileum. Either may be found in the pelvis.

## THE STOMACH.

When the stomach is moderately distended it is a pear-shaped organ lying almost entirely to the left of the median line and occupying the epigastric and left hypochondriac regions. It has an average capacity of 1 to 2 litres (about 2½ pints). Its direction is an oblique one, being downward, forward, and to the right. The

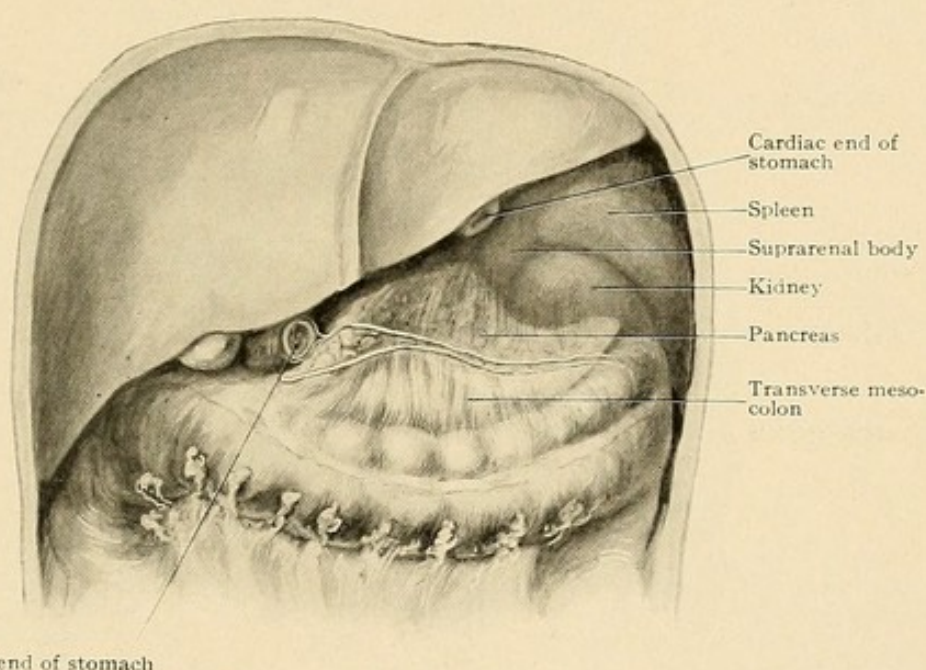


FIG. 415.—The bed of the stomach. The stomach has been removed showing the surrounding structures.

upper two-thirds are more longitudinal, the lower third more transverse, the two parts making an angle of 60 to 70 degrees. The part just adjoining the pylorus is slightly enlarged when the stomach is distended, and is called the *antrum*. The stomach is spoken of as having anterior and posterior walls, but they could just as truthfully be called superior and inferior, especially when the organ is distended. When it is relaxed it tends to hang in a more vertical position, but when it is distended it rotates on a transverse axis, the greater curvature coming forward, and the organ assumes a more horizontal plane. When the stomach is empty it may not be relaxed but contracted. This contraction is liable to be very marked toward the middle of the organ, producing the *hour-glass stomach*. At other times the contraction proceeds a variable distance from the pylorus toward the cardiac extremity. In such cases instead of being pear-shaped the stomach becomes more or less tubular so as to resemble the remainder of the intestinal canal. It then differs but little in appearance from the duodenum, and the position of the pylorus is not readily recognized. If, as may normally occur, the contraction extends well over toward the cardiac end, then liquids do not lodge in the stomach but pass almost immediately through it



into the small intestine beyond. When this condition is found to exist, the stomach is to be recognized by its position, its attachments, and the thickness of its walls. It hangs suspended by its cardiac extremity from the œsophagus. This is beneath the seventh left costal cartilage, about an inch from the edge of the sternum and 10 cm. (4 in.) from the surface; this brings it opposite the eleventh dorsal vertebra immediately in front of the aorta. The pylorus lies just under the edge of the liver, either in the median line when the stomach is empty or, as is more often the case, 2.5 cm. (1 in.) or more to the right of the median line—a little higher up than the gall-bladder or opposite the eighth right costal cartilage and on a level with the first lumbar vertebra. The pylorus is usually a little higher in women than in men. If the liver is contracted the pylorus and adjacent portion of the stomach may be in direct contact with the anterior abdominal wall. The lesser curvature is 7.5 to 12.5 cm. (3 to 5 in.) long and passes downward, forward, and to the right.

**Relations.**—The stomach rests on the transverse mesocolon, which covers the pancreas, solar plexus, aorta, thoracic duct, vena cava, and crura of the diaphragm pos-

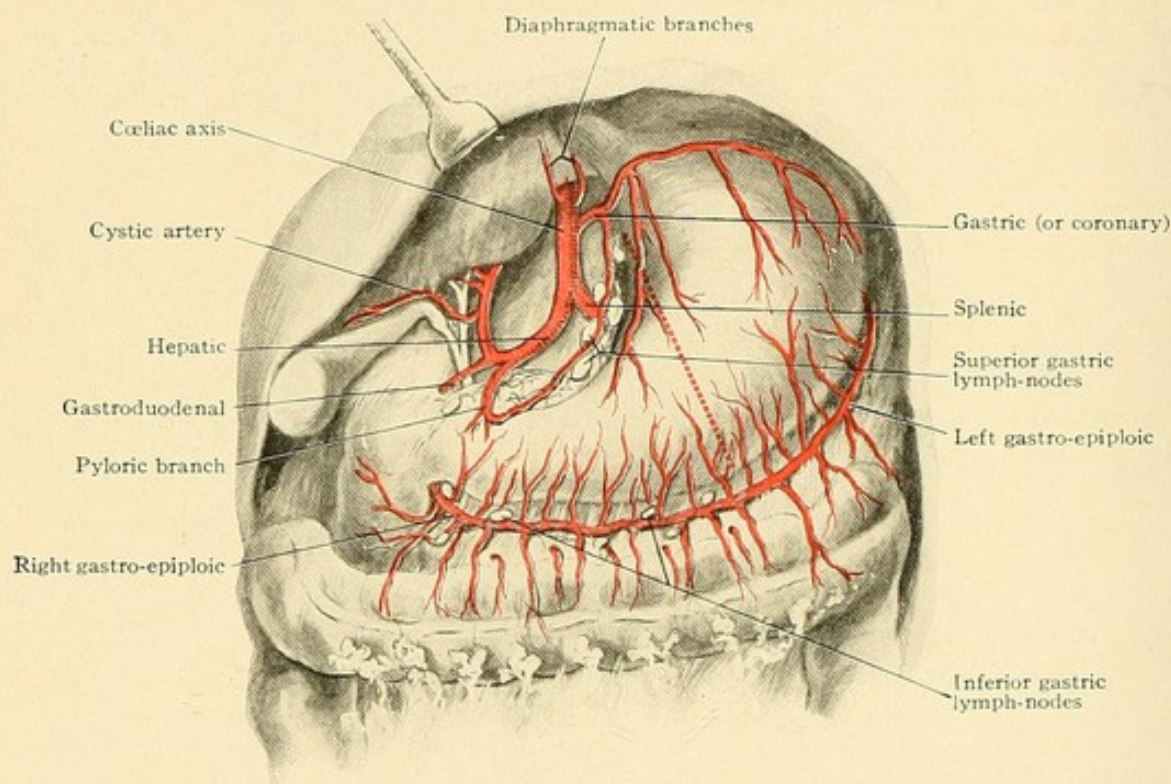


FIG. 416.—Blood supply and lymphatics of the stomach, and Hartmann-Mikulicz line.

teriorly; farther to the left are the left suprarenal body, kidney, and spleen (Fig. 415).

In front are the diaphragm, abdominal parietes, and liver. Above are the lesser or gastrohepatic omentum, liver, and diaphragm. Below is the gastrocolic omentum, transverse colon, and gastrosplenic omentum.

**Percussion.**—In physical diagnosis the size of the stomach is outlined by percussion, it being filled with air or gas to distend it. In the median line its resonance above will be limited by the edge of the liver; below, while usually 5 to 7.5 cm. (2 to 3 in.) above the umbilicus, it is not considered to be dilated, especially in old people, unless it reaches below the umbilicus. It leaves the left costal margin opposite the ninth or tenth costal cartilage. In the left mammary line stomach resonance may reach up to the fifth or sixth rib, while farther to the left it reaches the spleen about in the midaxillary line.

*Traube's semilunar space* is limited above by the edge of the left lung, indicated by the sixth interspace; externally by the spleen, indicated by the midaxillary line; and internally by the costal margin. Normally this area is resonant from the presence of the stomach beneath, but pleural effusion causes it to be dull on percussion.



**Blood Supply.**—The *celiac axis* gives off the gastric, hepatic, and splenic arteries, all of which give branches to the stomach. The *gastric* (or coronary) gives branches to the œsophagus and cardiac end and then runs along the lesser curvature to unite with the pyloric branch of the hepatic. It lies in the gastro-hepatic omentum and sends branches anteriorly and posteriorly over the surface of the stomach (Fig. 416).

The *hepatic artery* as it nears the pylorus gives off a pyloric branch which passes to the left along the lesser curvature, and a gastroduodenal branch, which divides into the superior pancreaticoduodenal to supply the duodenum and head of the pancreas, and the right gastro-epiploic artery which passes to the left along the greater curvature of the stomach.

The *splenic artery* near the spleen gives off the left gastro-epiploic artery which proceeds along the greater curvature to unite with the right gastro-epiploic, a branch of the gastroduodenal artery.

The more the stomach is distended the closer do the arteries of its greater and lesser curvatures lie to its walls. The fundus is supplied by the *vasa brevia*, small branches which leave the splenic artery in the gastrosplenic omentum.

The **veins** follow the course of the arteries. The right gastro-epiploic empties into the superior mesenteric and the left into the splenic; they then enter the portal vein. The pyloric and coronary veins empty into the portal vein direct. The latter receives branches from the œsophagus which become varicose in cirrhosis of the liver.

**Lymphatics.**—The lymphatic nodes of the stomach are found principally around the regions of the pylorus—inferior gastric nodes, and the lesser curvature and cardiac extremity—superior gastric nodes. The inferior nodes drain the greater curvature toward the pylorus while the superior nodes drain the lesser curvature and cardiac end. The fundus is drained by radicles which empty into the nodes which accompany the splenic artery. While some nodes may be found along the greater curvature toward the pyloric end, Cunéo and Poirier state that it is rare to find nodes in the middle portion of the greater curvature and quite exceptional to meet with them in the region of the fundus.

## AFFECTIONS OF THE STOMACH.

In disease the stomach may be contracted or dilated, and is often the seat of ulcer and carcinoma.

**Contracted stomach** occurs either as a normal or pathological condition; it has already been alluded to on page 401. The contraction of the middle, producing the hour-glass shape, results from cicatrices and adhesions due to gastric ulcer. In cases of œsophageal stricture the contraction may be marked. It then embraces mainly the right third of the organ and the affected portion resembles the adjoining duodenum. Abstention from food in the course of an illness may also cause a contracted condition which one should be prepared to encounter in case of operation. A normal contracted condition of the right end of the stomach, often of a more or less hour-glass shape, is frequently encountered in autopsies when death has been caused by disease of other organs (Fig. 417).

**Dilation** results from functional diseases as well as obstructive affections, such as ulcer or carcinoma, involving the pylorus. Distention causes the pylorus to pass from the midline 2.5 to 7.5 cm. (1 to 3 in.) to the right. The organ becomes more horizontal and descends so that its lower border sinks below the umbilicus—its extreme normal level. Sometimes the greater curvature alone is lowered, while in others the gastrohepatic omentum is stretched and the pylorus as well as the greater curvature descends. This is called *gastroptosis*. The amount of distention is recognized by percussion, as pointed out on page 402, or by administering bismuth and examining by the Röntgen rays.

**Ulcer** occurs most frequently along the lesser curvature; then the posterior wall, the region of the pylorus, the anterior wall, cardiac end, fundus, and greater curvature, in the order of frequency. The ulceration may open an artery, producing hemorrhage, or there may be adhesions to neighboring organs, resulting in the



formation of abscess, or direct communication with the greater or lesser peritoneal cavity may be produced. Healing of ulcers near the pylorus may cause stenosis resulting in distention. Hemorrhage may occur from the vessels of the stomach walls or the vessels along the lesser curvature, the splenic or hepatic arteries or even the portal vein. One reason why the arteries along the curvatures are not still more frequently affected is because they often lie a short distance away from and not in immediate contact with the stomach walls. Adhesions to surrounding organs are least liable to form when the perforation is on the anterior wall. Then the larger peritoneal cavity is infected and a general peritonitis quickly ensues. A perforation on the posterior wall involves the lesser cavity of the peritoneum, and the infection must travel first through the foramen of Winslow before a general peritonitis develops. Abscesses may form between the under surface of the liver and the stomach, and they have been known to penetrate the pleura, pericardium, and transverse colon.

**Carcinoma.**—This is located in about 60 per cent. near the pylorus, in 15 per cent. in the lesser curvature, in 10 per cent. at the cardiac end, and in the remaining

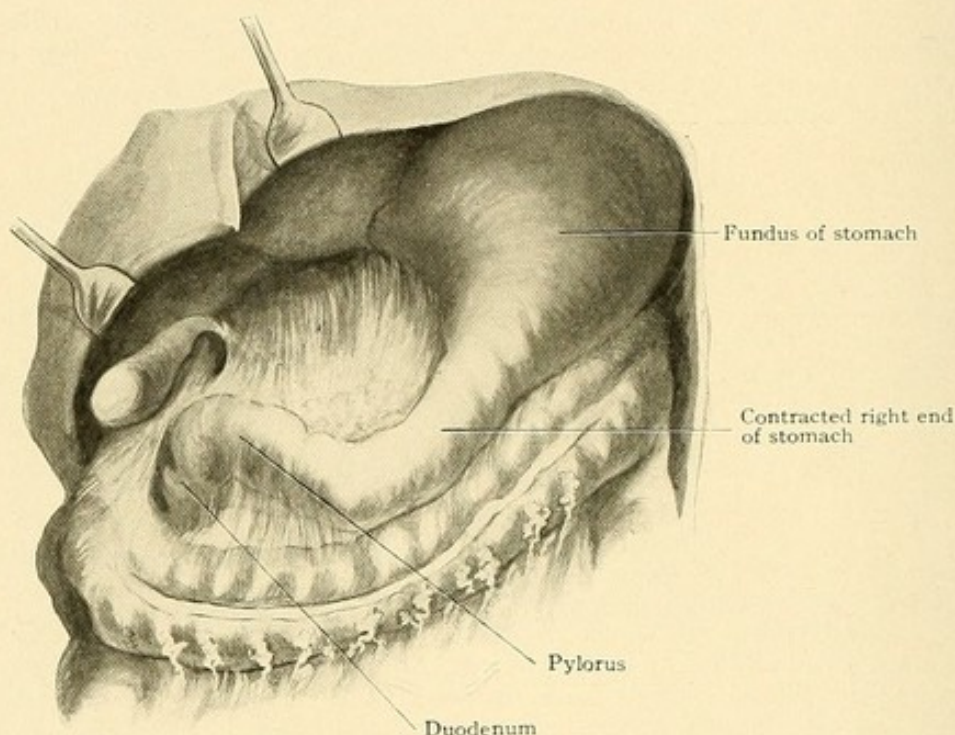


FIG. 417.—Showing the right end of the stomach normally contracted to near the size of the duodenum. From an actual specimen.

15 per cent. in other portions of the organ. Cunéo has shown that extension occurs in the lymphatic nodes along the lesser curvature, in those of the greater curvature along the right third of the stomach adjacent to the pylorus, and in the nodes around the pylorus and head of the pancreas. It has been noticed that there is no tendency to extension to the region of the duodenum. It will thus be seen that a line drawn from the junction of the right and middle thirds of the greater curvature to the cardiac extremity would have nearly all the nodes to the right. It is this portion which is removed in pylorectomy and partial gastrectomy; owing to the extension of the disease up the lymphatics of the œsophagus, enlarged nodes may sometimes be present in the left supraclavicular fossa or even in the left axilla.

The tumor is usually felt in or near the median line, a variable distance above the umbilicus; it may drag the pylorus lower down than normal. If the stomach is distended the tumor may be carried 5 to 7.5 cm. (2 to 3 in.) to the right of the median line. If, as is not uncommon, the disease infiltrates the walls of the stomach, the tumor can be felt passing to the left side, disappearing under the costal margin.



Adhesions and ulceration are common. They are so marked that peritonitis from acute perforation is moderately rare. The adjacent organs are matted together and purulent collections are liable to occur. The ulceration may open into adjacent organs, as the colon. The colon may be adherent to the stomach and the large omentum contracted into a roll. The adhesions and pressure from the growth often interfere with the biliary ducts, and jaundice ensues; interference with the portal vein and vena cava causes ascites, and thrombosis of the veins sometimes occurs. In this disease, as in gastric ulcer, adhesions are least liable to form on the anterior wall, and here perforation requiring operation is most likely.

### OPERATIONS ON THE STOMACH.

The following operations are performed on the stomach: *gastrotomy*, or the opening of the stomach to remove foreign bodies or to treat ulcers; *gastrostomy*, or the making of a gastric fistula to introduce food; *pyloroplasty*, or the widening of a constricted pylorus; *pylorectomy*, for the removal of cancerous or strictured pylorus; *gastrectomy*, or the removal of a part or the whole of the stomach; *gastroplication*, or the folding of the walls to reduce its size; and *gastro-enterostomy*, or the establishing of a fistula between the stomach and the small intestine.

**Technic.**—The incision for gastrostomy is 4 cm. ( $1\frac{1}{2}$  in.) long, over the outer third of the left rectus muscle, beginning 2 cm. ( $\frac{3}{4}$  in.) below the edge of the ribs. The fibres of the rectus are to be parted by blunt dissection from above downward, as this is less apt to tear the lateral branches of the superior epigastric artery than if made in the opposite direction. The incisions for pyloroplasty and partial or complete gastrectomy are made in or near the median line and reach from the tip of the ensiform cartilage to the umbilicus. That for pyloroplasty is placed usually to the right of the median line, all others to the left. In incising to the right of the median line the incision should not be carried down to the umbilicus or the round ligament will be cut. The incisions are placed to one side of the median line in order to open the sheath of the rectus and pass through the muscular fibres, thus allowing of a more secure closure of the wound and diminishing the liability to hernia. In incising the posterior layer of the sheath of the rectus and peritoneum one should avoid wounding the edge of the liver, which crosses the median line midway between the xiphosternal articulation and umbilicus, being higher or lower according to its size. The stomach is recognized as lying immediately below and in contact with the under surface of the left lobe of the liver. If in doubt, follow the under surface of the liver to the transverse fissure, thence over the lesser or gastrohepatic omentum to the lesser curvature of the stomach. The omentum may present in the wound instead of the stomach. It is to be pushed downward and the stomach sought for under the liver. The transverse colon should not be mistaken for the stomach. It lies under the omentum and can be identified by its longitudinal bands. In operating on the pylorus it may be found lying in the median line or 5 cm. (2 in.) or even 7.5 cm. (3 in.) to the right. The normal pylorus will readily admit the index finger. The incision advised by Finney for pyloroplasty is 15 to 20 cm. (6 to 8 in.) long through the right rectus muscle.

*Partial gastrectomy* is the operation usually done for carcinoma. *Pylorectomy* is too incomplete and total gastrectomy is too dangerous. In performing a partial gastrectomy, as done by the Mayo brothers, an incision just to the left of, or in, the median line is made from the ensiform process to the umbilicus. The gastrohepatic omentum is then ligated from the pyloric end toward the cardiac end, well beyond the limits of the tumor. The ligatures are to be placed close to the liver and sufficiently far away from the lesser curvature to allow of the removal of the lymphatic nodes lying along it. The gastric artery is ligated below the cardiac opening, where it reaches the lesser curvature (see Fig. 416, page 402). The pyloric branch of the hepatic is ligated as it reaches the stomach. Ligate the gastroduodenal artery behind the pylorus and the gastro-epiploica sinistra on the greater curvature; the gastrocolic omentum is then to be ligated between the two. Care is to be taken not to ligate the colica media in the transverse mesocolon beneath or gangrene of the colon will result. The duodenum is then clamped and cut, and also the stomach,



in what has been called the Hartmann-Mikulicz line (Fig. 416), which will remove most of the lesser curvature and at least a third of the greater curvature. The two cut ends are then closed with sutures and the lowest portion of the remainder of the stomach connected with the ileum either anteriorly or posteriorly.

In performing a *gastro-enterostomy* the upper portion of the jejunum is brought up and anastomosed with the anterior or posterior wall of the stomach. If the omentum is not seen at once on opening the peritoneum it will, perhaps, be found lying rolled up along the lower border of the stomach. It is to be brought out of the wound and turned upward. On its lower surface is seen the colon running transversely from right to left. Follow the transverse mesocolon down to the spine and the commencement of the jejunum will immediately be felt and can be seen coming through the mesocolon, with the ligament of Treitz running from its upper border to the parietal peritoneum. Follow the jejunum down for 40 cm. (16 in.) and bring it up in front of the great omentum and colon and anastomose with the lower border of the stomach anteriorly, preferably near the pyloric end. If it is

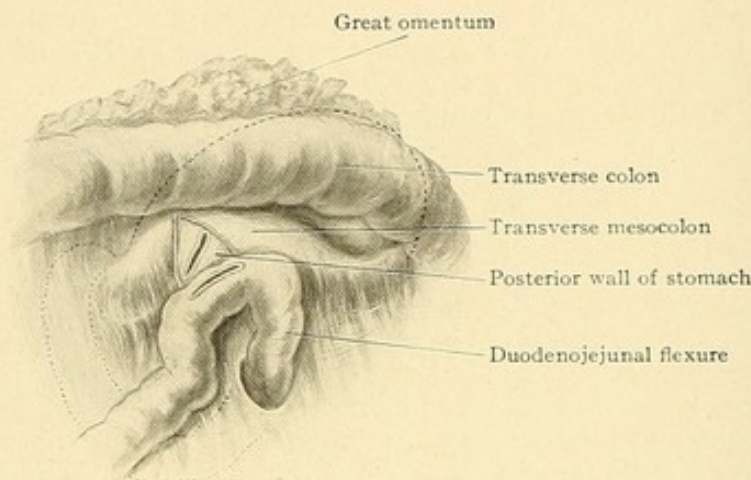


FIG. 418.—Posterior gastro-enterostomy. The omentum and colon have been turned up and the two openings shown in the stomach and commencement of jejunum are to be sewn together along their edges, thus establishing a communication between the stomach and small intestine.

desired to do a posterior gastro-enterostomy the transverse mesocolon is divided and the stomach pushed forward through the opening (Fig. 418). The commencement of the jejunum as it emerges from the transverse mesocolon is then brought up and anastomosed with the posterior wall of the stomach.

## THE SMALL INTESTINE.

The small intestine begins at the pylorus and ends at the ileocaecal valve. It has an average length of 6.75 metres (22 ft. 6 in.) in the adult, independent of the age, weight, and height of the individual (Treves). Jonnesco gives its length as 7.5 metres (24 ft. 7 in.) and Sappey as 8 metres (26 ft. 3 in.). The duodenum is about 25 to 30 cm. (10 to 12 in.) long, and two-fifths of the remainder, or about 8½ ft., is jejunum, and three-fifths, or about 12½ ft., is ileum.

## THE DUODENUM.

The duodenum is the thickest, widest, and most fixed portion of the small intestine. Its diameter is from 3.75 cm. to 5 cm. (1½ to 2 in.) and its muscular and mucous coats are thicker than those of the jejunum or ileum. It also possesses in its upper half the *glands of Brunner* (*glandulae duodenales*) in the submucous coat. It is thus seen that in its structure it resembles more the stomach than the intestine and, like the stomach, is especially prone to ulcer. While carcinoma frequently originates at the pylorus and extends to and involves other parts of the



stomach, it does not tend to involve the duodenum. This is probably due to the lymph stream from the pylorus running toward the stomach and away from the duodenum. The duodenum is also of interest in consequence of its intimate relation to the biliary passages and gall-bladder as well as to the pancreas and its ducts. Inflammations, such as accompany gall-stones, frequently give rise to adhesions, to relieve which operations are performed. The second portion of the duodenum is sometimes opened in order to extract a biliary calculus impacted in the ampulla of Vater at the mouth of the common bile-duct. The upper portion of the duodenum in Finney's operation for pyloroplasty is slit down from the strictured pylorus and sewed to a corresponding slit in the stomach, thus making a large communication between the duodenum and the stomach and eliminating the stricture.

In shape the duodenum resembles a horseshoe. It begins on the right side of the body of the first lumbar vertebra and ends on the left side of the body of the second lumbar vertebra. At its commencement it is suspended from the liver by

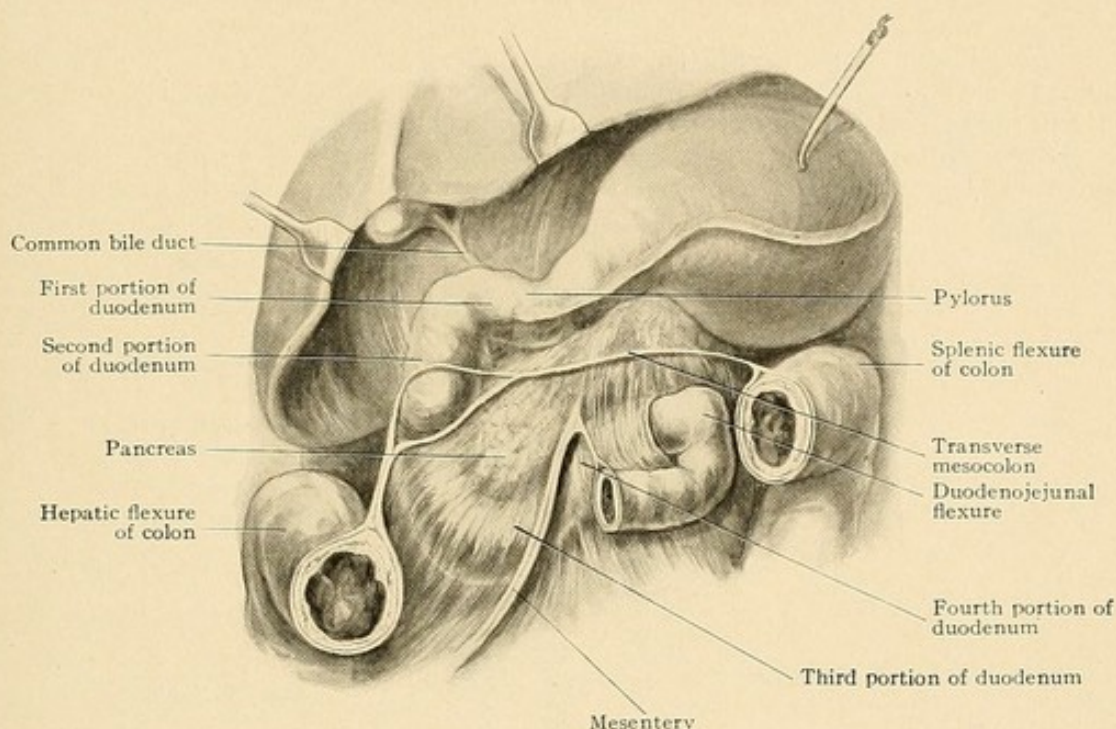


FIG. 419.—The duodenum, showing its course and relation to the surrounding organs.

the duodenohepatic ligament, which is the free edge of the gastrohepatic omentum in which run the hepatic artery, portal vein, and common bile-duct.

The duodenum is composed of four portions. The *first portion* (superior) begins at the pylorus and ends at the neck of the gall-bladder. It is about 5 cm. (2 in.) long, and runs backward along the body of the first lumbar vertebra. The *second portion* (descending) is about 10 cm. (4 in.) long, and runs down the right side of the bodies of the lumbar vertebræ to the lower border of the third. The *third portion* (variously called ascending, transverse, or inferior) runs diagonally upward across the body of the third lumbar vertebra to its left side and then the *fourth portion* ascends to the left side of the second, where it takes a sharp turn and is continued as the jejunum (Fig. 419).

**Relations.**—*First portion:* Above and in front are the quadrate lobe of the liver and the gall-bladder; below is the pancreas; and behind, from left to right, lie the gastroduodenal artery, the portal vein, the common bile-duct, and the vena cava.

*Second portion:* In front is the liver, the neck of the gall-bladder, and the transverse colon. Behind are the renal vessels, ureter, right kidney, and psoas muscle. To its inner side lie the pancreas and vena cava. The common bile-duct runs on the inner side between the duodenum and the pancreas; at the middle of this portion of the duodenum the bile-duct joins with the pancreatic duct to empty into the duodenum through the ampulla of Vater, about 10 cm. (4 in.) from the pylorus.



Third portion: In front are the superior mesenteric artery and root of the mesentery; behind lie the vena cava, aorta, and left psoas muscle. Above, it lies in contact with the pancreas. The termination of the duodenum is usually on the left of the aorta, but Dwight (*Journal of Anatomy and Physiology*, vol. xxxi, p. 576) in fifty-four cases found it twenty-six times on the right of the aorta until just before its terminal flexure. It was wholly on the right side six times, in front of the aorta eleven times, and had crossed the aorta eleven times.

**Peritoneal Covering.**—First part: The pyloric half is almost completely covered by peritoneum, but the distal half only on its anterior surface. Second part: No peritoneum on its inner and posterior surfaces, and only on its outer and anterior where not covered by the transverse colon. Third and fourth parts: The anterior and left sides are covered by peritoneum except where crossed by the root of the mesentery and superior mesenteric vessels.

### JEJUNUM AND ILEUM.

The jejunum is about  $8\frac{1}{2}$  ft. long and the ileum about  $12\frac{1}{2}$  ft. They are bound to the spinal column by the mesentery, which extends from the left side of the body of the second lumbar vertebra to the right sacro-iliac joint.

**Duodenojejunal Flexure and Fossæ.**—The point of ending of the duodenum and beginning of the jejunum is marked by a sharp bend called the *duodeno-*

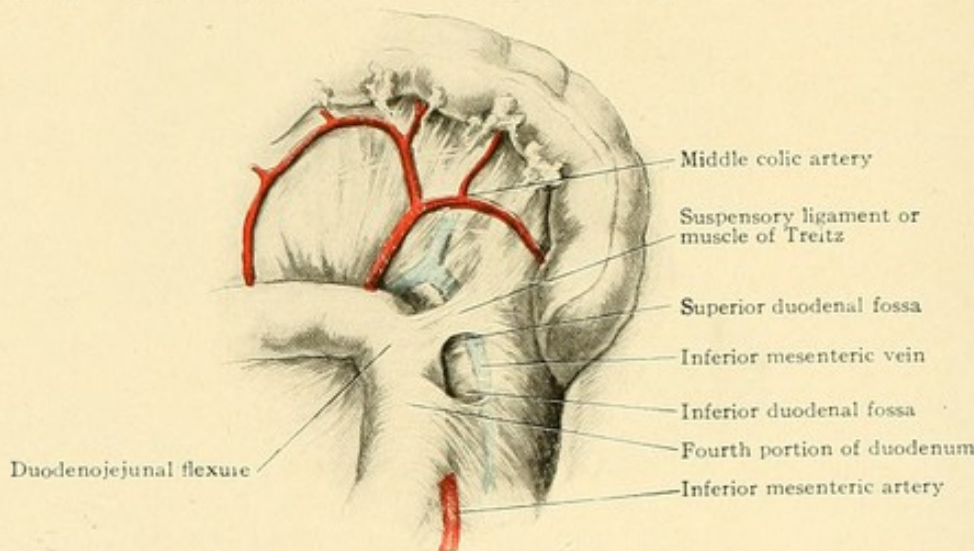


FIG. 420.—The duodenojejunal flexure and duodenal fossæ; the jejunum drawn to the right.

*jejunal flexure.* The beginning of the jejunum passes downward, forward, and usually toward the left. If the transverse colon is thrown upward and the jejunum is pulled sharply to the right, a folded edge of peritoneum containing some muscular fibres is seen passing from the flexure to the parietal peritoneum. This is called the *suspensory ligament or muscle of Treitz*. The fossa which is behind it is the *superior duodenojejunal fossa of Treitz* while that below is the *inferior duodenal fossa*. Below the fossa runs the inferior mesenteric artery and near the left edge of the ligament runs the inferior mesenteric vein. Into the fossæ, if abnormally large, the intestines may enter and produce a retroperitoneal hernia. If the constricting band, which is the ligament of Treitz, is cut, there is danger of dividing the inferior mesenteric vein (see Fig. 420).

The small intestine decreases in size and thickness from its upper to its lower end. The diameter of the jejunum is about 4 cm. ( $1\frac{1}{2}$  in.) while that of the ileum is about 3 cm. ( $1\frac{1}{4}$  in.).

The walls of the jejunum are thicker, redder, and more vascular than those of the ileum and the valvulæ conniventes are better developed. The ileum is thinner, narrower, paler and, particularly when diseased, the large Peyer's patches can be seen.

The **intestinal coils**, while not constant in position, are most apt to be as follows: The commencement of the jejunum is in the upper left portion of the



abdomen. The ileum is more in the right lower quadrant of the abdomen. According to Treves, the intestine from six to eleven feet from its commencement has the longest mesentery and is apt to be found in the pelvis. The lower end of the ileum is also usually found in the pelvis, and rises over its brim to join the cæcum.

There is no certainty, however, of finding a definite piece of the small intestine under any special point on the surface, because the varying distention and movements cause frequent changes of position.

**Meckel's Diverticulum.**—In the embryo the vitello-intestinal duct passes from the umbilicus to the lower end of the small intestine. Normally this disappears, but sometimes a portion of it remains and there is found, one to three feet above the ileocæcal valve, a finger-like projection from the side of the ileum, 5 to 7.5 cm. (2 to 3 in.) long. This is called *Meckel's diverticulum*, and may become the site of disease the same as the rest of the ileum. From its extremity a fibrous band may run to the umbilicus. This has been in rare instances the source of strangulation, causing intestinal obstruction. One such case has been under our care (Fig. 421).

**Peyer's patches** (*noduli lymphatici aggregati*) are most numerous in the lower portion of the ileum. They are ulcerated in typhoid cases and are frequently the site of perforations. These patches are from 1 to 2.5 cm. ( $\frac{1}{2}$  to 1 in.) wide and 2.5 to 7.5 cm. (1 to 3 in.) long. When affected in typhoid fever they can readily be seen through the intestinal walls. By holding the intestine up against the light both Peyer's patches and the *valvulæ conniventes* can readily be seen.

The perforations in typhoid fever occur usually within three feet of the ileocæcal valve, though occasionally they may occur, as we have seen, in the appendix, or higher up in the small intestine, or even in the large intestine.

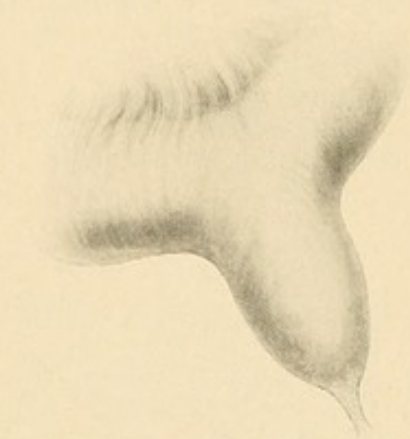

FIG. 421.—Meckel's diverticulum. (From author's sketch.)

## OPERATIONS.

The small intestines are frequently resected and anastomosed with themselves or other portions of the gastro-intestinal canal. Gastro-enterostomy has been alluded to on page 406.

On opening the abdomen, if it is desired to find the upper end of the small intestine, the omentum is pulled out, drawing with it on its under surface the transverse colon. The hand is to be passed backward on the under surface of the transverse mesocolon until the spine is reached; on its left side will be felt the duodenojejunal flexure. On drawing the jejunum to the right, the ligament of Treitz will be seen. A loop 40 cm. (16 in.) down may be taken and brought up in front of the omentum and used for an anterior gastro-enterostomy, or the intestine immediately below the flexure may be used for a posterior gastro-enterostomy (see page 406). If one desires to find the lower end of the small intestine, then a search is made for the colon in the right iliac region. It is recognized by its longitudinal bands and is followed down to the ileocæcal junction. If the case is one of typhoid fever, a rapid examination is then made from the ileocæcal valve upward for perforations. It is desirable at times to determine which is the proximal and which the distal end of an intestinal loop. The best way to do so is to follow the loop down to the mesenteric attachment, as advised by Monks; if the mesentery proceeds up and to the left you have the proximal end; if, however, it is passing down to the right you have the distal end.

The intestine receives its nourishment from the mesentery and will die when detached, hence it is necessary to avoid injury or detachment of the mesentery or its vessels; when this detachment has occurred the involved portion of intestine is resected and removed.



## THE MESENTERY.

The mesentery extends from the left side of the body of the second lumbar vertebra to the right sacro-iliac joint. It is from 15 to 20 cm. (6 to 8 in.) long at its root and spreads out like a fan, to be attached to the small intestine. It is comparatively thick, especially toward its root, and contains the superior mesenteric artery and veins, nerves, and lymphatics. The mesenteric lymphatic nodes are numerous, from 130 to 150 (Quain) in number. They are frequently involved in carcinoma and tuberculosis, and may form masses which may be mistaken either for independent tumors or outgrowths from other organs. They are sometimes inflamed, and even cause abscess, being mistaken for appendix disease. They become calcareous and by the Röntgen rays may cast shadows which have been mistaken for calculi of the urinary organs.

The mesentery has its vessels sometimes ruptured by violence or blocked by emboli or thrombi. This is likely to cause gangrene of the intestine to which they are distributed. In abdominal operations the greatest care is to be taken not to

injure these vessels, and in hemorrhage the least possible amount of ligation is to be done. Obstructions of a mesenteric branch may necessitate the resection of that part of the small intestine which it supplies.

It is particularly important to bear in mind the direction of the mesenteric attachment on account of its influence in directing the course of the blood in cases of hemorrhage. The small intestines are attached at the root of the mesentery like the leaves of a book to its back. Bleeding originating from the right and upper quadrants of the abdomen will pass *over* the intestines and tend to gravitate toward the right iliac fossa. Bleeding originating from the left and lower

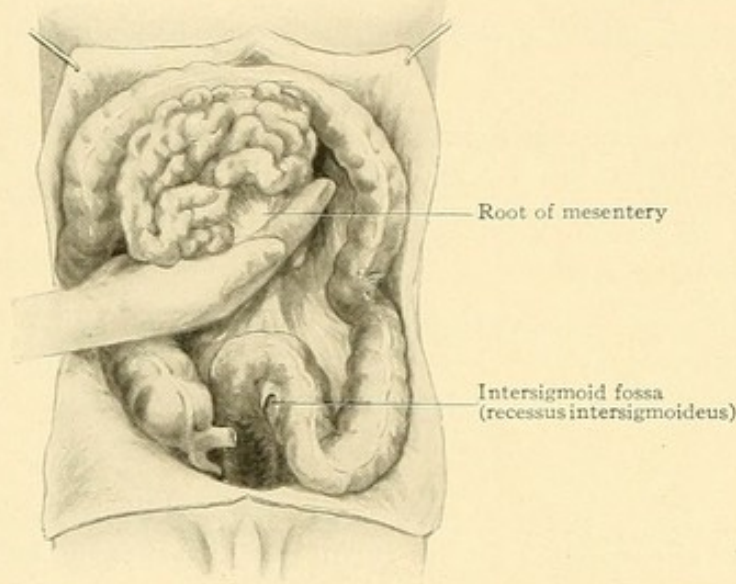


FIG. 422.—The mesentery is seen running downward toward the right sacro-iliac joint; the index finger is below it and the other three fingers above. The small intestines have been raised on the hand and turned upward thus exposing the pelvis and entire left lower half of the abdomen for examination.

quadrants tends to pass under the intestines toward the left iliac fossa. In searching the abdomen through a large median incision for the source of a concealed hemorrhage, the intestines are first to be pushed down and to the left, and the right side of the abdominal wall lifted with retractors. This will expose to view the upper surface of the small intestines, the ascending and transverse colon, the right kidney, liver, stomach, and head of the pancreas. Should additional search be necessary the small intestines are to be raised and turned upward and to the right (Fig. 422), being brought out of the wound if necessary. This will expose the under side of the small intestines and mesentery, the sigmoid flexure, descending colon, left kidney, spleen, and tail of the pancreas, with the left end of the stomach and left lobe of the liver above. The intestines are never to be turned downward to the right nor upward to the left.

The mesentery attains its greatest length, according to Treves, from 6 to 11 feet below the duodenum, where it measures 25 cm. (10 in.) In hernia the mesentery is lengthened to allow of the descent of the gut. Rarely openings are present in the mesentery which may allow the entrance and strangulation of a coil of the intestine.



## THE LARGE INTESTINE.

The large intestine comprises (1) the *cæcum* and *appendix*, (2) *ascending colon*, (3) *transverse colon*, (4) *descending colon*, (5) *sigmoid flexure*, composed of the iliac colon and pelvic colon, and (6) the *rectum* and *anal canal*.

The length of the large intestine exclusive of the rectum and anal canal is 135 cm. (4 ft. 6 in.) in the female, and 140 cm. (4 ft. 8 in.) in the male. If the anterior abdominal wall is removed the *cæcum* and part of the ascending colon are visible, but in the upper part of the lumbar region the colon disappears, being overlaid by the small intestine. Having turned at the hepatic flexure, it again comes into view below the lower edge of the liver and passes superficially across the abdomen to disappear under the left costal margin to form the *splenic flexure*. It is not visible again until it reaches the region of the crest of the ilium, where it once more becomes superficial and follows the inguinal (Poupart's) ligament down to near its lower end, where it turns backward and upward to form the sigmoid loop which descends along the sacrum. In operating it is necessary to be able to distinguish large from small intestine.

**Size.**—The large intestine at its commencement at the *cæcum* may have a diameter of 7.5 cm. (3 in.), but it decreases in size, and, especially if empty, the descending colon and sigmoid flexure may only be 2.5 cm. (1 in.) in diameter. A distended part of the small intestine will be larger than a contracted part of the colon. Inasmuch as operations are frequently done for obstructive conditions which greatly enlarge the involved parts, it is unreliable to depend on size as distinguishing the large intestine. There are three *longitudinal bands* (*tæniæ coli*) on the colon, from 6 to 12 mm. ( $\frac{1}{4}$  to  $\frac{1}{2}$  in.) wide, according to the amount of distention. One is anterior, another postero-external, and the third postero-internal. On the transverse colon they have the same relative position when the great omentum and colon are raised and turned upward. They all begin at the appendix and traverse the large intestine until the rectum is reached, where they blend together, forming a longitudinal layer which is weak at the sides and strong anteriorly and posteriorly.

**Sacculation** of the colon is produced by the longitudinal bands being one-sixth shorter than the rest of the tube. While sacculation tends to become less marked on distension, it is still a valuable means of identification. Dividing the longitudinal bands will cause the sacculation to disappear and the gut to lengthen.

**Appendices epiploicæ** or the small tags of peritoneum containing fat, are found along the large intestine as far as the rectum. They are most numerous along the inner longitudinal band and the transverse colon.

## CÆCUM AND APPENDIX.

The *cæcum* is the blind pouch of the large intestine which extends beyond the opening of the ileum. It is about 7.5 cm. (3 in.) broad and 6.25 cm. ( $2\frac{1}{2}$  in.) long. Its three longitudinal bands converge to the appendix and are continued over it. It lies in the right iliac fossa on the iliacus and psoas muscles, more on the latter, and reaches nearly or quite to its inner edge. It is in contact with the abdominal wall above the outer half of the inguinal (Poupart's) ligament. In fetal life the *cæcum* is cone-shaped and passes gradually and regularly into the appendix. It increases in size more rapidly on its outer side, so that the appendix, which was before opposite the long axis of the gut, becomes placed to the inside just below the ileocæcal valve.

Four varieties of *cæcum* are given by Treves: (1) the conical or fetal type, (2) a globular or quadrilateral type, in which the development of both sides is even, (3) the adult type, in which the outer side is much larger than the inner, (4) an irregular type, in which there is an excess of development of the outer side and an atrophy of the inner side resulting in placing the root of the appendix close to the lower and posterior portion of the ileocæcal junction.

Cunningham makes three varieties: (1) a fetal conical type, (2) an infantile type, in which the outer side is somewhat larger than the inner, and (3) an adult



type, 93 or 94 per cent., in which the outer side is much the larger, and the root of the appendix is on the inner wall just below the ileocaecal valve (in the adult about 2 cm.— $\frac{3}{4}$  in.).

The **ileocaecal valve** marks the emptying of the ileum into the large intestine. On the surface of the body it corresponds to a point 2.5 cm. (1 in.) below the middle of a line joining the anterior superior spine and the umbilicus and the same distance above the middle of a transverse line drawn from the anterior superior spine to the median line. This point is about on the linea semilunaris and directly above the point where the external iliac artery passes under Poupart's ligament. Normally the ileocaecal valve will allow of the passage of gas from the colon into the ileum, as in Senn's hydrogen test for perforation, but not of liquids or solids.

**Vermiform Appendix (processus vermiformis).**—The appendix varies much, both in length and diameter. In health its average length may be given as

from 8.75 cm. ( $3\frac{1}{2}$  in.) to 10 cm. (4 in.) and its diameter as 6 mm. ( $\frac{1}{4}$  in.). It is pale in color and soft in consistence, with its blood-vessels barely visible. In disease it becomes hard and red and the injected vessels are distinctly seen. It becomes much increased in diameter, equalling in size a finger or thumb, and lengthens to 15 cm. (6 in.) or even more. It possesses a serous peritoneal coat, a longitudinal muscular, a circular muscular, a submucous and a mucous coat. The lumen of the appendix has been found to be partially occluded in at least one-fourth of all adults. This occlusion occurring toward its distal extremity is not regarded as pathological, but constrictions occurring elsewhere in the length of the tube are probably the result of previous disease.

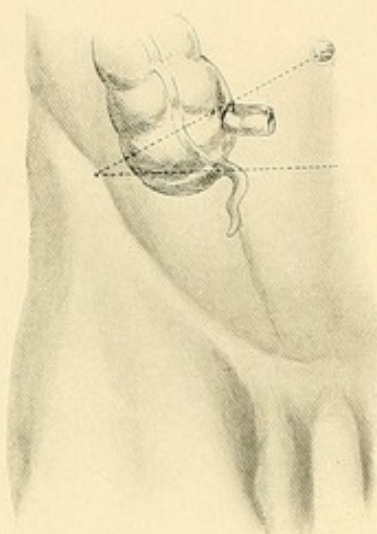


FIG. 423.—The relations of the appendix. The ileocaecal junction is seen to be about one inch below the middle of a line joining the anterior superior spine and umbilicus or where this line crosses the linea semilunaris. The base of the appendix is under the point of crossing of the linea semilunaris and the middle of a horizontal line running from the anterior superior spine to the mid-line of the body; it is one inch below the ileocaecal junction.

cm. ( $\frac{3}{4}$  in.) below the lower edge of the ileum and is often even closer on account of the lower surface of the ilium being in contact with the caecum at that point. It corresponds to a point on the surface of the body where the right semilunar line crosses a line joining the two anterior superior spines (Fig. 423).

The **meso-appendix (mesenteriolum)** comes off the lower surface of the mesentery. It is shorter than the appendix, hence the twisting and curling of the latter. It usually, but not always, extends to the tip and contains toward its left or free border the appendicular artery.

The **ileocolic artery**, from the superior mesenteric, as it approaches the ileocaecal junction divides into five branches: (1) the *colic*, distributed to the colon; (2) the *ileal*, to the upper surface of the ileum; (3) the *anterior ileocaecal branch*, to the front of the caecum, passing through the ileocolic fold; (4) the *posterior ileocaecal artery*, to the posterior part of the caecum; (5) the *appendicular artery*. The appendicular artery descends behind the ileum to enter the meso-appendix and, after sending one recurrent branch to the root of the appendix and another to the ileocaecal fold, passes along the left or free edge of the meso-appendix, and, if this is short, it may be continued on the surface of the appendix to its extremity (Fig. 424).

In removing the appendix this artery requires ligation and if the ligature is not placed close to the root the recurrent branches will not be included and may cause dangerous bleeding.



The veins of the appendix and the cæcum end in the **ileocolic vein**, which joins the superior mesenteric vein and helps to form the portal vein. Hence infection is carried by the blood stream from the appendix and cæcum directly to the liver.

**Position of the Appendix.**—The position and direction of the appendix have been variously described and much discussed. This has arisen from the fact that it is so curled, curved, and twisted on itself that it is impossible to say that it points in any definite direction, and that, being so mobile, it may be found in almost any position, swinging around with its point of attachment to the cæcum as the axis. We agree with Cunningham when he says that it runs generally in one of three directions: (1) over the brim into (or towards) the pelvis; (2) upward behind the cæcum; (3) upward and inward toward the spleen. As he says, each of these has been considered the normal position by one or more observers. It is evident that, as

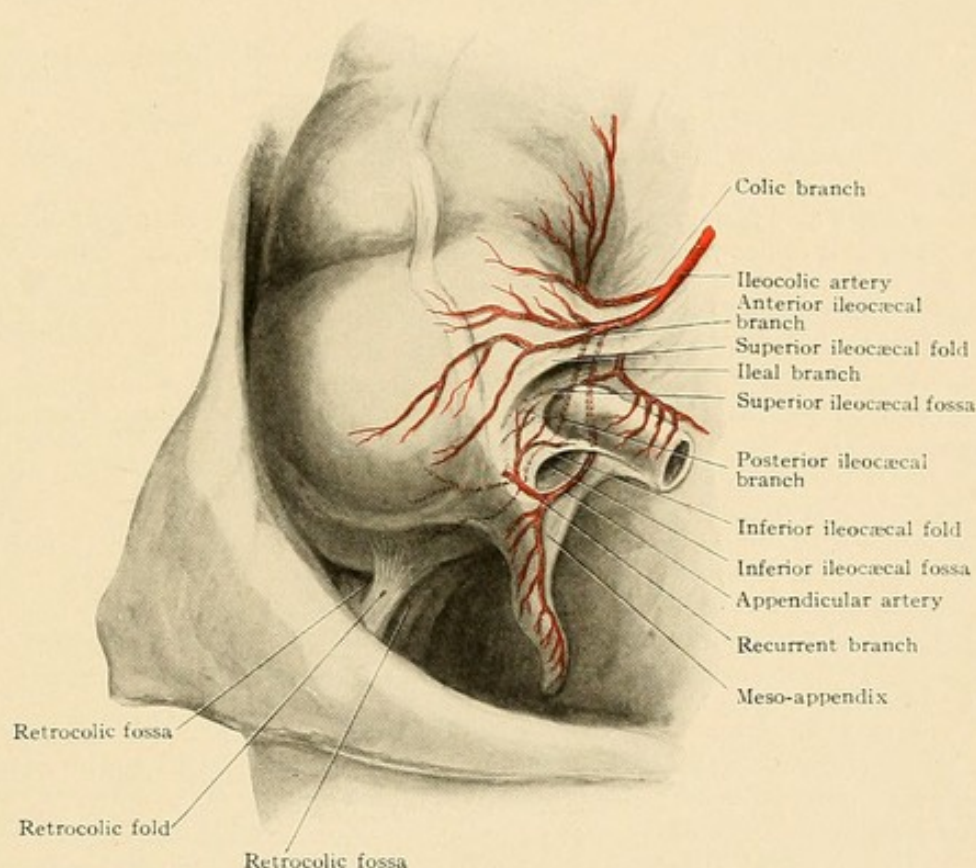


FIG. 424.—The appendix and ileocecal region, showing the folds, fossæ, and arteries.

the appendix comes off close to the ileum, this is its most fixed and constant point. In certain cases the cæcum retains its high fetal position and then the appendix will be higher than usual. If the appendix is long and straight, its tip may reach to or beyond the median line; it may lie in contact with the rectum, ovary, tube, or bladder; it may lie low down close to Poupart's ligament or curved upward behind the colon, reaching in front of the kidney and nearly or quite to the liver. When retro-cæcal it lies on the quadratus lumborum; when lower it may lie on the iliacus or psoas muscle. If it goes over the brim of the pelvis it lies on the external iliac artery. The external iliac vein is below and to the inner side and is largely protected from injury in operating by the stronger and tougher artery.

**Cæcal Folds and Fossæ.**—There are three folds and three fossæ formed by the peritoneum in the neighborhood of the cæcum.

1. The *superior ileocecal (ileocolic)* fold runs from the upper surface of the mesentery just above the ileum to the upper anterior surface of the cæcum. In it runs the *ileocecal (anterior) artery*. Beneath it, with its opening toward the left, is the *superior ileocecal fossa* (Fig. 424).



2. The *inferior ileocæcal fold* passes from the termination of the ileum to the front of the meso-appendix; it contains a small recurrent branch of the appendicular artery. Beneath it and between it and the meso-appendix is the *inferior ileocæcal fossa*, which may sometimes contain the appendix.

3. The *retrocolic fold* is not constant and may be multiple. It passes from the lower and outer surface of the cæcum to the peritoneum beneath. It binds down the end of the cæcum and not infrequently must be divided before the cæcum and appendix can be raised; the fossæ on each side of it are called the *retrocolic fossæ*.

**Lymphatics of the Cæcum and Appendix.**—The lymphatics of the cæcum and appendix drain into a group located in the mesentery of the ileocæcal angle, accompanying the ileocolic artery. According to Poirier and Cunéo there are three sets: an anterior cæcal, a posterior cæcal, and an appendicular.

The *anterior cæcal lymphatics* drain the anterior surface of the cæcum and, after traversing one or two small nodes, pass in the ileocæcal fold up to the main ileocæcal group.

The *posterior cæcal lymphatics* drain the posterior portion of the cæcum and, after traversing three to six small nodes, empty likewise into the ileocæcal group.

The *appendicular lymphatics* form four or five trunks which accompany the artery between the layers of the meso-appendix. They then pass across the posterior surface of the ileum to empty into the ileocæcal group.

Poirier and Cunéo state that these lymph-trunks from the appendix pass through one to three nodes placed in the retro-ileal portion of the meso-appendix, but Kelly and Hurdon state that in the majority of cases these trunks empty into one or two nodes some distance above the ileum in the ileocæcal angle, forming a part of the ileocæcal chain. These latter authors state that there are three sets of lymph-capillaries in the appendix: a superficial or subperitoneal set, another between the submucous and muscular layers, and a deep set in the mucosa around the glands of Lieberkuhn.

The three great lymph-streams, anterior cæcal, posterior cæcal, and appendicular, are quite distinct from each other and from the surrounding lymphatics of the pelvis and colon; when these latter are involved it is not by a lateral extension from these three streams but by direct infection from the regions which they themselves drain. From the ileocæcal nodes the lymphatics follow the arteries to the nodes at the root of the mesentery and empty into the receptaculum chyli. They do not follow the veins to the liver, hence infection of the liver is not caused through the lymph-channels in appendicitis.

**Appendicitis.**—*Diagnosis.*—The most fixed part of the appendix is its root. This corresponds to a point on the linea semilunaris opposite to the anterior superior spine of the ilium. The painful tip of the appendix may be anywhere in a circle around this point 10 cm. (4 in.) in radius. It may be lying posterior and simulate calculus or other kidney trouble; it may be up toward the liver or gall-bladder; it may be toward the left, even beyond the midline; it may be in Douglas's cul-de-sac and be confounded with disease of the uterus, tubes, and bladder. It overlies the ureter and may be mistaken for calculus therein. An enlarged gall-bladder can have its painful apex at McBurney's point. Typhoid ulcers occur close to and, as we have observed, may involve the appendix. All these relations must be remembered. McBurney placed the most tender point 4 to 5 cm. (1½ to 2 in.) from the anterior superior spine in a direction toward the umbilicus. Personally we would place it near the root of the appendix at least 2.5 cm. (1 in.) lower down and a little farther in.

*Operation.*—An incision for appendicitis often used is a longitudinal one over the edge of the rectus muscle, either going directly through it or drawing it to one side (Fig. 425). In McBurney's operation the external oblique is split in the direction of its fibres and the internal oblique and transversalis are parted upward and inward in the direction of their fibres, thus making a square hole through which the appendix is removed. The writer (*Annals of Surgery*, Jan. 1906, p. 106) uses a transverse incision with its centre over the linea semilunaris opposite to or 2.5 cm. (1 in.) above the anterior superior spine. The sheath of the rectus is divided transversely and the muscle displaced toward the median line. The outer portion of the incision



runs slightly oblique to the fibres of the external oblique and almost exactly in the direction of the fibres of the internal oblique and transversalis (Fig. 426).

As soon as the peritoneum is opened the omentum may present itself. This is to be displaced to the left. Some coils of small intestine if present are to be pushed also to the left. The intestine then presenting will be the colon or cæcum, because

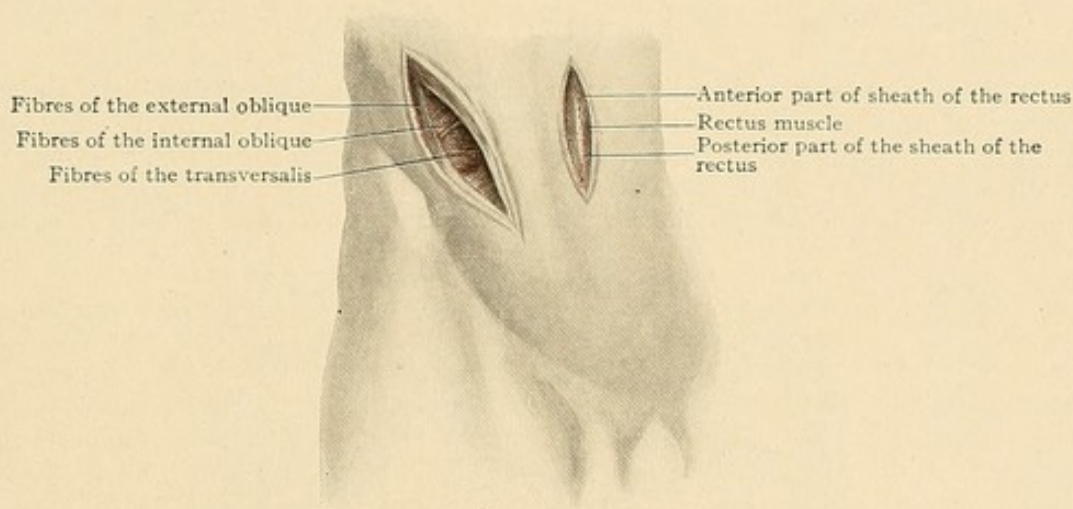


FIG. 425.—Incisions used for operations on the appendix. The longitudinal operation passes through and separates the fibres of the rectus muscle. The oblique operation (that of McBurney) separates the external oblique, internal oblique, and transversalis muscles in the direction of their fibres.

it is fastened to the posterior wall and cannot be moved away. The longitudinal bands will also identify it. Another way is to pass the finger down the inside of the abdominal wall and the floor of the iliac fossa and bring up the cæcum. Always work from the outer toward the inner side, because (see Fig. 422) the ascending

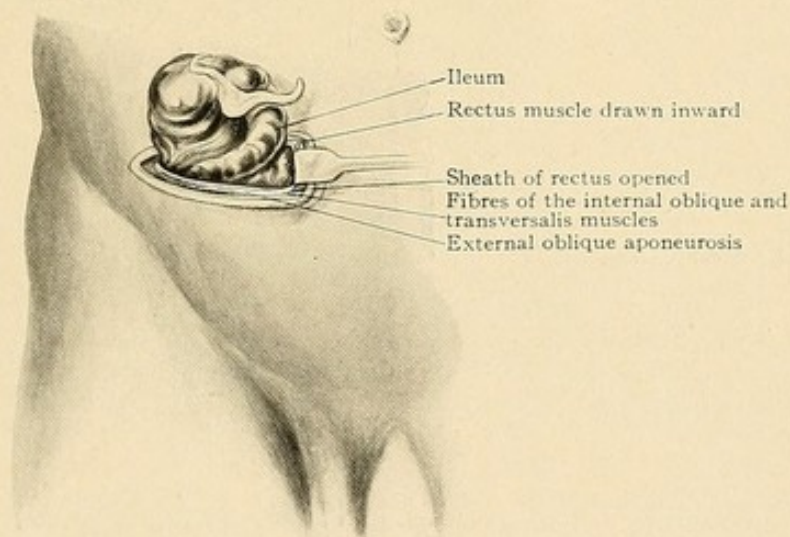


FIG. 426.—Author's incision for appendicitis. The cæcum has been lifted out of the wound, bringing with it the appendix.

colon and cæcum almost always lie against the abdominal wall on the surface of the iliopsoas muscle above the outer half of Poupart's ligament.

The cæcum is to be drawn up and turned toward the head. The longitudinal bands, all of which lead to the appendix, are to be followed down over the cæcum until the appendix is reached. If the bands are not visible, identify the ileocæcal junction and about 2 cm. ( $\frac{3}{4}$  in.) or less below and behind it will be the root of the



appendix; its tip may be anywhere. It can be enucleated from its root out to its tip. A ligature is to be placed around the meso-appendix because the appendicular artery, especially its recurrent branch, may bleed quite freely. The root of the appendix may sometimes be at, instead of below, the ileocaecal junction. The small intestine and caecum almost always overlie the appendix.

### THE COLON.

The **ascending colon** lies in contact with the anterior abdominal wall from its lower end to above the iliac crest; here it dips down to lie on the kidney and form the hepatic flexure above (Fig. 427). At this point some of the coils of the small intestine may lie in front of the hepatic flexure, between the beginning of the transverse colon above and the ending of the ascending colon below. The ascend-

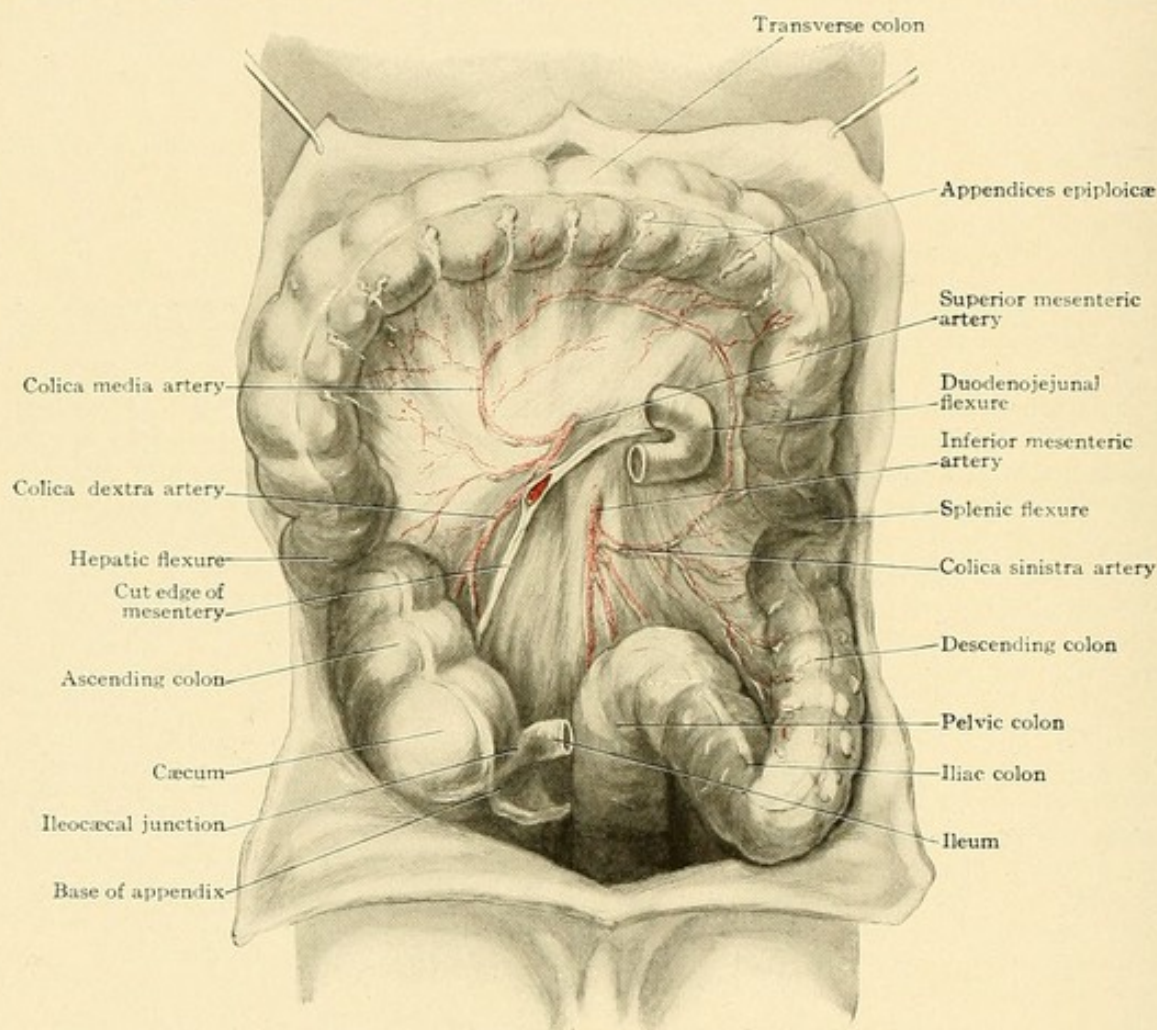


FIG. 427.—View of the interior of the abdomen: the mesentery has been cut, the small intestines removed, and the transverse colon turned upward. The pelvic colon and iliac colon together form the sigmoid flexure.

ing colon lies on the quadratus lumborum muscle and kidney behind and has the psoas to its inner side. It has no mesentery or peritoneum on its posterior surface in 64 per cent. of the cases (Treves) and in tumors of the kidney it may be pushed forward and across their anterior surface. This is a point to be remembered in diagnosis.

The **transverse colon** passes diagonally up and to the left across the abdomen. It starts at the hepatic flexure on the under surface of the liver to the outer side of the gall-bladder. It runs parallel with the lower edge of the liver and stomach and its lower border may reach nearly or quite to the level of the umbilicus. The great omentum passes over the transverse colon, so that to see the latter it is necessary to raise the omentum and look on its under surface. The omentum as it



passes from the colon to the stomach forms the gastrocolic omentum and the two organs may be either close together or some distance apart. The transverse colon instead of running upward and to the left may form a large curve downward, reaching almost to the pelvis. In cases of dilatation and descent (*ptosis*) of the stomach the transverse colon descends with it. The transverse mesocolon passes backward and one layer goes up and covers the pancreas while the other goes down to the mesentery. Its importance in gastro-enterostomy has been pointed out (page 406). Tumors and cysts of the pancreas may push forward above it, or below it, or it may cross directly over the surface of the growth.

The **descending colon** at its commencement at the splenic flexure is much higher and more deeply situated than is the hepatic flexure. It follows the stomach upward and backward and lies against the spleen. From here it descends and is entirely covered by small intestine, the sigmoid flexure coming to the front in the left iliac fossa. The descending colon is much smaller in size than the ascending colon, and like it in the majority (two-thirds) of cases has no mesentery. In doing a colostomy through the loin, the external border of the quadratus lumborum muscle is the guide to the descending colon. It lies 1.25 cm. ( $\frac{1}{2}$  in.) behind the middle of the crest of the ilium.

**Sigmoid Flexure.**—The sigmoid flexure is composed of two parts: one in the iliac fossa, called the iliac colon, and the other in the pelvis, called the pelvic colon, or *omega loop of Treves*.

The *iliac colon* is about 12.5 to 15 cm. (5 to 6 in.) long, and runs from the crest of the ilium to the inner edge of the iliopsoas muscle. It has no mesentery in 90 per cent. of the cases (Jonnesco), and usually comes into contact with the abdominal wall to the inner side of the anterior superior spine sometimes as far down as the middle of Poupart's ligament. In doing an inguinal colostomy this is the portion of the colon it is desired to find. It is then followed down until a part is reached which has sufficient mesentery to allow of its being drawn out of the wound.

The *pelvic colon* is about 40 to 42.5 cm. (16 to 17 in.) long and runs from the edge of the psoas muscle to the level of the third sacral vertebra. It makes a large horseshoe-shaped loop, from which it was named by Treves the *omega loop*, and has a mesentery from 3 to 8 cm. ( $1\frac{1}{4}$  to  $3\frac{1}{2}$  in.) long. The length of the loop as well as its mesentery and its position all vary considerably. Its terminal portion usually runs longitudinally down to end in the rectum, but its intervening portion may pass over the bladder to the right side, or high above the symphysis, or even extend well up in the abdominal cavity. On the under or left side of the loop between its branches is the *intersigmoid fossa* (see Fig. 422, page 410); sometimes it forms a constricted pouch in which a knuckle of intestine has been known to become strangulated.

## THE LIVER.

The liver is wedge-shaped and has three surfaces. These are superior, inferior, and posterior. The posterior forms the base of the wedge and its anterior edge is the apex. The liver is divided into five lobes by five primary fissures and has five ligaments (Fig. 428).

The **lobes of the liver** are: (1) left, (2) right, (3) quadrate, (4) Spigelian, (5) caudate. The *left lobe* is one-sixth the size of the right. It comprises that part to the left of the falciform ligament above and the umbilical and ductus venosus fissures below. The *right lobe* comprises that part to the right of the falciform ligament above and the fissures of the gall-bladder and vena cava below. The *quadrate lobe* is the anterior, small, square-shaped lobe between the fissure of the gall-bladder on the right and the umbilical fissure on the left. It extends from the anterior edge back to the portal fissure. The *Spigelian lobe* is best seen posteriorly, extending from the vena cava on the right to the fissure of the ductus venosus on the left. The *caudate lobe* or process is the name given to the liver tissue running from the lower end of the Spigelian lobe to the right lobe. It passes behind the portal fissure and between it and the vena cava. *Riedel's lobe* is the name given to an abnormal, tongue-like projection of liver tissue from its anterior edge, which may extend downward either over the gall-bladder or external to it. Mayo Robson has seen it extend to the caecal



region, and an inflamed gall-bladder being directly beneath caused pain to be experienced at McBurney's point. This condition is liable to be mistaken for appendicitis.

The **fissures of the liver** are best understood by examining its under surface, where they can be seen arranged in the form of the letter H. They are as follows: (1) The *umbilical fissure*, running from the umbilical notch on the anterior edge to the left end of the portal (transverse) fissure; it contains the round ligament. (2) The *fissure of the ductus venosus*, running upward from the left end of the portal fissure between the left and Spigelian lobes; it contains the remains of the fetal ductus venosus.

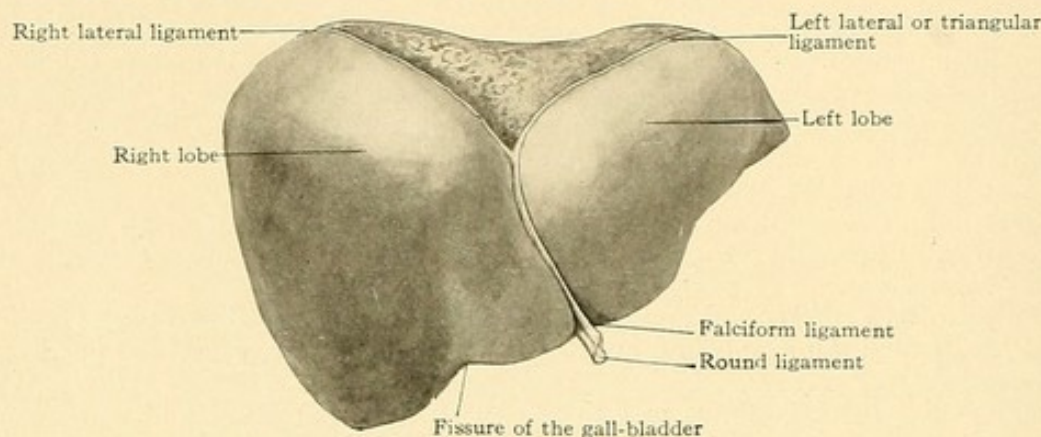


FIG. 428.—View of the anterior and upper surfaces of the liver.

(3) The *fissure of the gall-bladder*, separating the quadrate from the right lobe and ending at the right extremity of the portal fissure; in it lies the gall-bladder. (4) The *fissure of the vena cava*, between the Spigelian and right lobes, lodging the vena cava. (5) The *portal fissure*,—this forms the transverse bar of the H. Its left end receives the umbilical and ductus venosus fissures and its right end the fissures of the gall-bladder and vena cava. It contains the *portal vein*, *hepatic artery*, *hepatic duct*, *nerves*, and *lymphatics*; attached to its sides is the lesser or gastrohepatic omentum. The portal fissure is also called the *transverse fissure*, and the name *longitudinal*

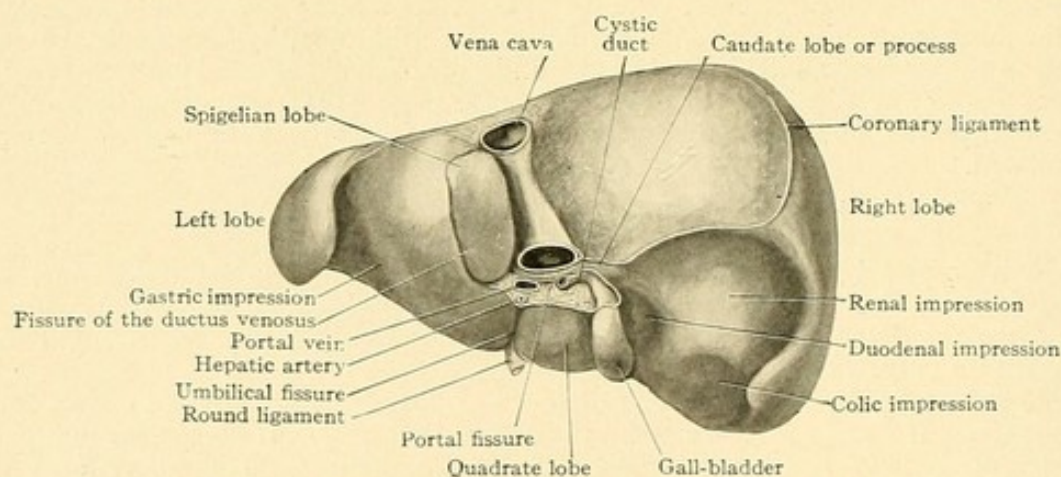


FIG. 429.—View of the posterior and inferior surfaces of the liver.

*fissure* is sometimes applied to the combined umbilical and ductus venosus fissures. (In the recent anatomical nomenclature these fissures are called fossæ.) (Fig. 429.)

The **ligaments of the liver** are five in number: (1) the coronary, (2) the triangular, (3) the falciform, (4) the round, and (5) the ligament of the ductus venosus. The *coronary ligament* surrounds the posterior surface which is not covered by peritoneum. It is 4 to 6 cm. (1½ to 2½ in.) wide and extends from the vena cava 7.5 to 10 cm. (3 to 4 in.) to the right, terminating in a pointed end which has been called the right lateral ligament. The *triangular ligament*, also



called the left lateral, extends as far to the left of the falciform ligament as the coronary does to the right. It is attached to the diaphragm in front of the œsophagus, while the coronary is attached to the back of the diaphragm. The *falciform ligament* starts near the umbilicus, passes to the umbilical notch of the liver 2.5 to 4 cm. (1 to 1½ in.) to the right of the median line and thence over the top of the liver to near its posterior edge, where it blends in front of the vena cava on the right side with the coronary ligament and on the left with the triangular ligament. The *round ligament* is the round cord in the free edge of the falciform ligament which runs from the umbilicus to the umbilical notch and thence to the portal fissure to join the left branch of the portal vein. It is the remains of the fetal umbilical vein. The *ligament of the ductus venosus* runs from the left branch of the portal vein to the vena cava in the fissure of the ductus venosus. The ductus venosus, like the umbilical vein, becomes obliterated at birth.

**Position of the Liver.**—The liver rises to the fourth costal interspace on the right side, to or slightly above the xiphosternal junction in the midline, and the lower border of the fifth rib on the left side, to its extremity, just beyond the apex of the heart, at the lower border of the sixth rib. Its lower border passes from this point to the eighth left cartilage, crosses the middle line about midway between the xiphoid

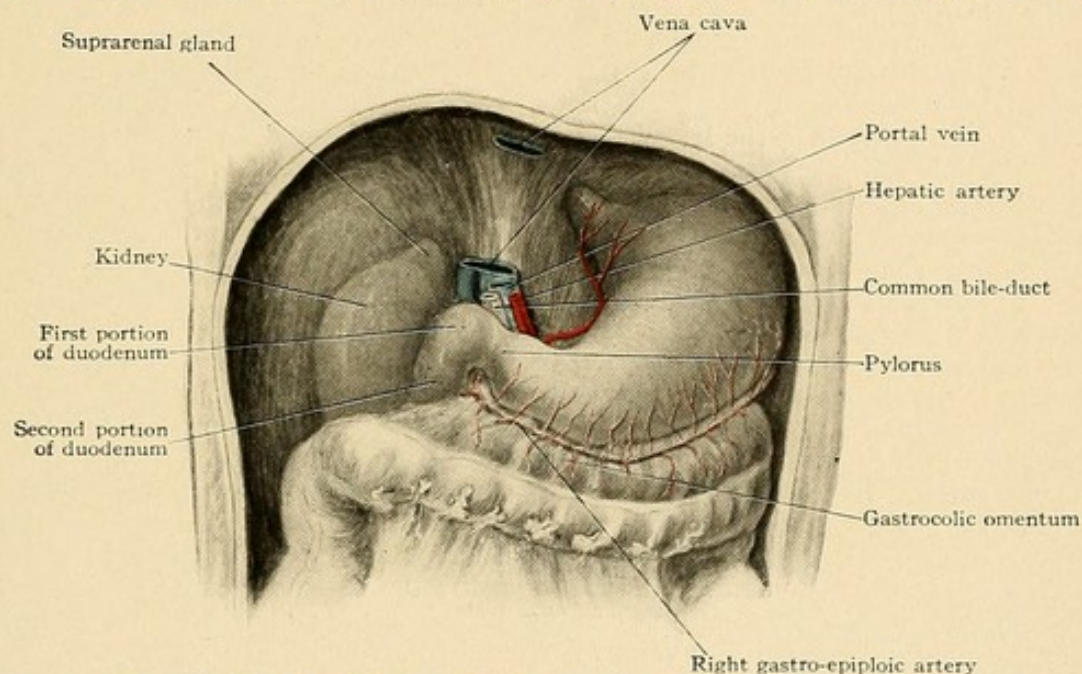


FIG. 430.—The bed of the liver. The liver has been removed to show the surrounding structures.

articulation and umbilicus to the ninth right costal cartilage, and thence follows the edge of the ribs posteriorly, being about 2.5 cm. (1 in.) lower in women. The upper limits of its percussion dullness are the upper border of the sixth rib in the right mammillary line, the eighth in the axillary, and the tenth in the scapular.

**Relations of the Liver.**—The superior surface lies in contact with the diaphragm, except the portion extending about 7.5 cm. (3 in.) below the xiphosternal junction in the median line and sometimes the small projecting edge beyond the ribs, which lies in contact with the abdominal wall. The *posterior surface* lies over the tenth and eleventh thoracic vertebræ, the crura of the diaphragm, the œsophagus, aorta, vena cava, and right suprarenal gland. The *inferior surface* to the left rests on the cardiac end and upper surface of the stomach and gastrohepatic omentum. Beneath the quadrate lobe is the pylorus and beginning of the duodenum. Beneath the caudate lobe is the *foramen of Winslow*, of which it forms the upper boundary. Farther to the right are the depressions for the hepatic flexure of the colon and the right kidney and suprarenal gland (Fig. 430).

The *size* of the liver varies, being small in atrophic diseases and much enlarged in others; therefore, alterations in the area of dullness are frequent. It moves with respiration and sometimes hangs lower than normal (*ptosis*).



**Wounds and Injuries of the Liver.**—The liver is frequently ruptured in falling or by being struck by some body from without. The rupture may involve its anterior edge or upper surface. In all examinations it should not be forgotten that the right and left sides are separated completely by the falciform ligament. On account of the walls of the vessels being imbedded in the liver tissue they do not readily collapse and hemorrhage is often fatal. Rupture of the posterior nonperitoneal surface is not so dangerous as elsewhere.

**Abscesses** may be either one or two large ones or multiple small ones. Pus on the upper surface of the liver, between it and the diaphragm, is called *sub-diaphragmatic abscess*. It may originate either from the liver or other viscera below, or the lung and pleura above. Maydl gives gastric ulcer as the most frequent cause and then affections of the intestines and appendix: we have seen it arise from calculous disease of the kidney. The pus may discharge outward between the ribs, or upward into the pleural cavity, lung, or pericardial sac. In incising for subdiaphragmatic abscess the tenth rib in the axillary line can be resected without opening the pleura, but if the eighth or ninth is chosen the pleural sac may be opened and the two layers of pleura should be stitched together before the incision through the diaphragm into the abscess cavity is made. If the abscess points at the inferior surface it may break into the stomach, duodenum, or colon. It may be reached by an incision through the abdominal walls to the right of the median line. The position of the falciform ligament, about 4 cm. ( $1\frac{1}{2}$  in.) to the right of the median line, should be remembered, and if the left lobe of the liver is to be treated the incision should be made to the left of the ligament.

Multiple abscesses are started in the liver by conveyance of infection through the portal vein, as occurs in appendicitis, or by direct extension up the common duct from the intestine, or from an inflamed gall-bladder or bile-ducts through the hepatic duct and its ramifications.

**Portal Obstruction.**—The veins of the portal system have no valves. The portal vein is formed by the union of the splenic and superior mesenteric veins and the gastric, pyloric, and cystic veins. The splenic receives the blood from the spleen, the stomach, and pancreas, the descending colon, sigmoid flexure, and rectum. The superior hemorrhoidal vein drains the rectum and empties into the inferior mesenteric, which passes into the splenic and finally into the portal vein. The superior mesenteric vein drains the remainder of the large and small intestine.

In cirrhosis, carcinoma, and occasionally gall-stones, the flow of blood through the portal vein is interfered with; hence arise congestions of the various parts which it drains. In the abdomen ascites is produced; the distended and varicose veins of the stomach sometimes rupture, causing hæmatemesis; diarrhœa may occur, and dilatation of the hemorrhoidal veins produces hemorrhoids.

Especially when there also is pressure on the vena cava the superficial and deep veins of the abdominal wall become enlarged (see page 380). The main anastomoses are: (1) between the gastric (coronary) vein of the stomach and the œsophageal veins which empty into the vena azygos major; (2) between the epigastrics (superficial and deep) below and the terminal branch of the internal mammary above; (3) between the epigastric veins and portal vein through the para-umbilical vein (*caput medusæ*, page 380); (4) through the thoracico-epigastrica between the axillary and epigastric (see Fig. 392, page 380); (5) between the superior hemorrhoidal and the middle hemorrhoidal, emptying into the internal pudic.

## GALL-BLADDER AND BILIARY PASSAGES.

The **gall-bladder** lies in the fissure of the gall-bladder, with its fundus just about level with the edge of the liver and its body pointing inward, upward, and backward; its neck, which is S-shaped, is near the right end of the portal fissure. It is 7.5 cm. (3 in.) long and 2.5 to 3 cm. (1 to  $1\frac{1}{4}$  in.) in diameter. It holds one to one and a half ounces. Below, it rests on the transverse colon and first part of the duodenum. It is attached to the liver, but not very strongly, by connective tissue and the peritoneum. According to Brewer (*Annals of Surgery*, 1899, vol. xxix, page 723) one-third to one-fourth of its surface is uncovered by peritoneum: in 5 cases in 100



it had a distinct mesentery. The tip (fundus) of the gall-bladder lies in contact with the abdominal wall at the tip of the ninth costal cartilage, where the right linea semilunaris strikes the costal margin, and just at the outer edge of the rectus muscle, which is about 7.5 cm. (3 in.) from the median line (Fig. 431).

**Hepatic, Cystic, and Common Ducts.**—The *hepatic duct* is formed by the union of the right and left branches in the portal fissure. It is about 2.5 cm. (1 in.) long and 6 mm. ( $\frac{1}{4}$  in.) wide. The *cystic duct* is smaller in diameter than the hepatic and 3 to 4 cm. ( $1\frac{1}{4}$  to  $1\frac{1}{2}$  in.) long and joins it as it emerges from the portal fissure. Both the neck of the gall-bladder and the cystic duct contain constrictions of the mucous membrane—Robson and Moynihan call them valves—which obstruct the passage of a probe or stone. Hence gall-stones are frequently found impacted or lodged in the neck of the gall-bladder or somewhere in the course of the duct. The cystic artery lies above the duct. The *common duct* is formed by the union of the hepatic and cystic ducts at the edge of the portal fissure, and empties into the duodenum about the middle of its second portion on its inner wall. It is 7.5 cm. (3 in.) long and 6 mm. ( $\frac{1}{4}$  in.) or more in width. It passes almost directly downward,

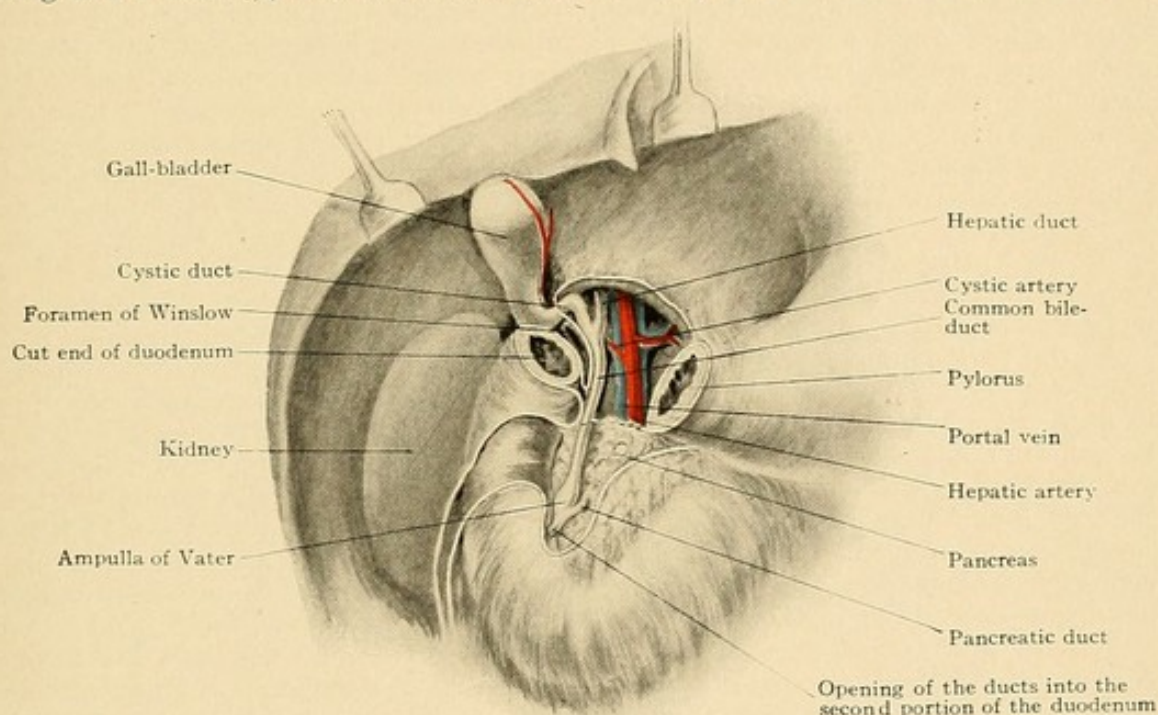


FIG. 431.—The biliary passages. The edge of the liver has been raised, exposing its under surface; the first portion of the duodenum and anterior surface of the pancreas has been removed, exposing the common bile-duct and blood-vessels.

inclining a little to the right, between the folds of the lesser omentum, in front of the foramen of Winslow, behind the first portion of the duodenum, and then between the pancreas and the inner wall of the second portion of the duodenum. It is, at this part, in two-thirds of the cases, completely surrounded by pancreatic tissue. As it passes through the duodenum, which it pierces obliquely, it expands into the *ampulla of Vater* and receives the *pancreatic duct*, or *duct of Wirsung*. Above, it lies directly on the portal vein, with the hepatic artery to its left. About half of the duct, 3 to 4 cm. ( $1\frac{1}{4}$  to  $1\frac{1}{2}$  in.), is above the duodenum and half behind it.

The **hepatic artery** passes along the upper edge of the pancreas, to which it gives branches; it then gives off the superior pyloric to the lesser curvature of the stomach, the gastroduodenal (see page 403), and finally right and left terminal branches. The left supplies the left lobe of the liver, the right crosses usually behind but sometimes in front of the bile-ducts and terminates in the right lobe, after first giving off the *cystic artery*. This runs between the cystic and hepatic ducts and has superficial branches which ramify on the surface of the gall-bladder and deep branches which run up the grooves on each side between the gall-bladder and liver.



It is these branches which bleed when the gall-bladder is removed. One of the deep arteries may be much larger than the other or altogether lacking. Some very fine branches come directly from the liver.

**Lymphatic nodes** are found in the portal fissure and accompanying both the common and cystic ducts. They are especially involved in carcinoma.

The **kidney pouch** is a name given to the space in front of the right kidney. The foramen of Winslow opens into it from the left and the abdominal wall is to its right. The liver is above and the duodenum and transverse colon below. Liquids from the lesser peritoneal cavity and bile-passages flow into this hollow, which can be drained by a tube inserted through a "stab-wound" made through the abdominal wall just to the outside of the right kidney.

**Gall-Stones.**—These and carcinoma are the main affections of the biliary passages. The latter is almost always secondary to pyloric cancer and involves the lymphatic nodes; metastatic deposits may also exist in the liver itself. The diagnosis between the two affections is sometimes difficult. Gall-stones are most frequent in the gall-bladder, next in the common duct, and lastly in the hepatic duct. Obstructive symptoms are not often observed from gall-stones in the hepatic duct alone. Obstruction of the common duct causes jaundice, but this is rare in obstruction of the cystic duct; practically, jaundice is only seen in obstruction of the common duct. Gall-stones usually form in the gall-bladder and, as the cystic duct is smaller than the common duct, if a stone gets out of the former it is frequently passed into the intestine. On account of the contracted opening of the common duct into the duodenum, stones are liable to be retained in the ampulla of Vater. This causes a damming back of the bile, and the common duct increases to the size of a finger. Very large gall-stones may cause ulceration into the duodenum or colon or may press on the portal vein and vena cava, and produce ascites. In operating for gall-stones, Mayo Robson incised through the middle of the right rectus muscle and prolonged the upper part along the edge of the ribs to the outer side of the ensiform cartilage. Where more room was desired Bevan added a transverse cut outward from its lower end. Kocher made a curved incision 4 cm. ( $1\frac{1}{2}$  in.) below the edge of the ribs (see page 382). In order to make the liver project a hard roll is placed beneath the back. To bring the gall-ducts to the surface the liver is dragged down and its edge turned up over the upper extremity of the wound. The gall-bladder can be drawn out and this straightens the curves in the cystic duct. By placing one or two fingers in the foramen of Winslow the thumb can palpate the cystic and the common duct until it disappears behind the duodenum. Gall-stones in the second (retroduodenal) portion of the duct or in the ampulla of Vater can often be felt through the walls of the duodenum. If it is desired to gain access to this portion of the duct, the peritoneum on the outer side of the second portion of the duodenum, binding it to the posterior abdominal wall, must be divided. The duodenum is then turned to the left and the common duct followed down if necessary through the pancreas to the ampulla of Vater. Stones impacted in the ampulla of Vater can be removed by incising the front of the second portion of the duodenum and then cutting down on the stone through the papilla. In some cases it may be impossible to pass a probe down the cystic duct owing to its being caught by the valve-like folds of the mucous membrane. In removing the gall-bladder, bleeding will be less if the cystic artery be first clamped. If this is not possible, then the bleeding will occur from the branches on one or both sides of the gall-bladder. The peritoneum is to be cut through, not torn. Bleeding from the liver substance is slight and readily stopped by pressure. In incising the common duct for calculi the relation of the portal vein behind and the hepatic artery to the left should be remembered. These can be avoided by cutting down on the calculus.

## THE PANCREAS.

The pancreas is composed of two portions joined at right angles to each other. Together they measure about 20 cm. (8 in.). It is divided into a head, neck, body, and tail. The neck is about 2 cm. ( $\frac{3}{4}$  in.) broad, while the head and body are each about 3 cm. ( $1\frac{1}{4}$  in.). The head is about 5 to 6.25 cm. (2 to  $2\frac{1}{2}$  in.) long and lies parallel to the vertebral column on its right side. The body is about 12.5



cm. (5 in.) long and runs transversely from the first portion of the duodenum across to the spleen. The flexure joining the head and body constitutes the neck. It is 2.5 cm. (1 in.) long. The tail is simply the extremity of the body; this is omitted in some descriptions. The body crosses the first lumbar vertebra, while the head lies on the right side of the second and third (Fig. 432).

**Pancreatic Ducts.**—The pancreas has two ducts, a main one called the *pancreatic duct*, or *duct of Wirsung*, and an accessory one called the *duct of Santorini*. The duct of Wirsung runs nearly the whole length of the gland, and, bending somewhat downward at the neck and joining the common bile-duct at the ampulla of Vater, pierces the duodenum obliquely and empties in a common orifice on its mucous surface. It is 3 to 4 mm. ( $\frac{1}{8}$  to  $\frac{1}{4}$  in.) in diameter at its termination. The accessory duct of Santorini comes mainly from the lower portion of the head of the pancreas and empties separately in the duodenum 2 cm. ( $\frac{3}{4}$  in.) above and a little anterior to the biliary papilla. It communicates with the duct of Wirsung in the substance of the pancreas.

**Relations.**—Posteriorly, the head lies on the vena cava while the body crosses the aorta, renal vessels, suprarenal gland, and left kidney. Anteriorly, it is covered with peritoneum and on it lies the stomach; inferiorly, is the attachment of the trans-

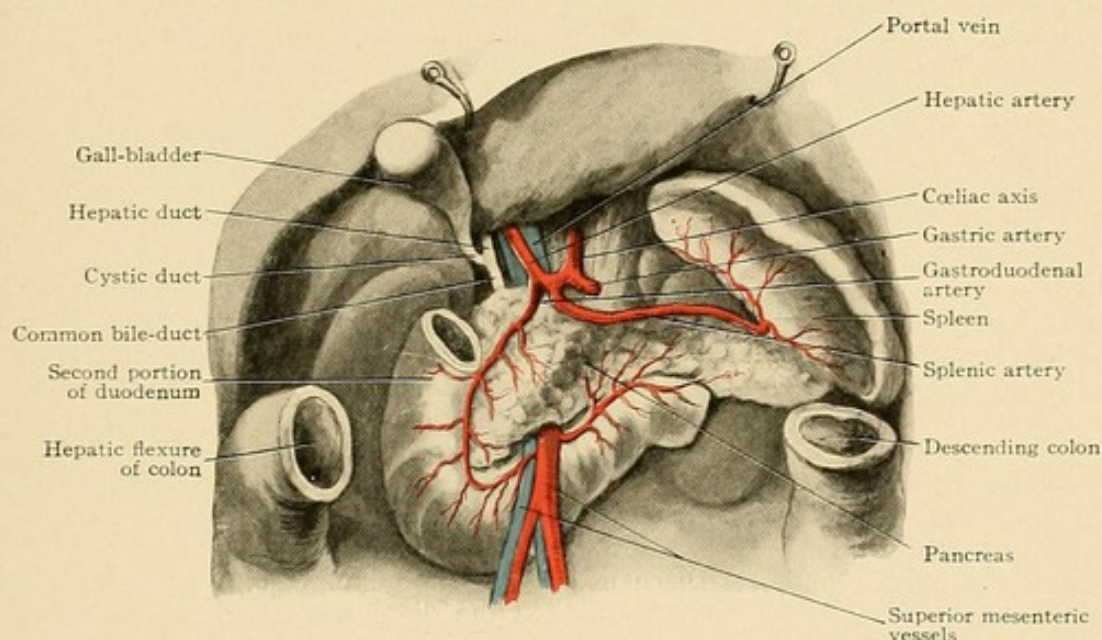


FIG. 432.—The pancreas and spleen.

verse mesocolon, beneath which comes the duodenojejunal flexure. Immediately to the right of this flexure and between it and the head of the pancreas issue the superior mesenteric vessels. At the extreme left is the splenic flexure of the colon.

**Pancreatic Cyst and Abscesses.**—The pancreas is the subject of inflammation (hemorrhagic) which may cause necrosis and abscess; it also is affected with cysts and new growths. Calculus may also occur.

Suppuration may produce a sub-diaphragmatic abscess or perforate the diaphragm and form an empyema. In cases of abscess protruding anteriorly, instead of opening through the peritoneum in front, the pus may be evacuated through a posterior incision made in the right or left costovertebral angle. If the pus has been evacuated through an anterior incision the finger may be introduced into the abscess cavity and used as a guide for a posterior incision.

Pancreatic growths tend to project forward in one of three general directions—viz.: (1) between the liver above and the stomach below; (2) between the stomach above and the transverse colon below; (3) below the transverse colon. The second is the most frequent. When the enlargement comes forward opposite the attachment of the transverse mesocolon it may grow between the layers of the mesocolon and push the transverse colon in front of it instead of going below or above it. After the cyst has been evacuated it may be stitched to the edges of the incision anteriorly and a counter opening made posteriorly on the left side beneath the twelfth rib.



## THE SPLEEN.

The spleen lies high up in the left posterior corner of the abdomen in contact with the diaphragm. It follows the direction of the tenth rib, being covered by the ninth, tenth, and eleventh ribs and extending from a point 4.5 to 5 cm. ( $1\frac{1}{2}$  to 2 in.) external to the median line posteriorly to the midaxillary line anteriorly. Its upper end is opposite the tenth dorsal vertebra, or ninth spine (see Fig. 433).

**Relations.**—It has four surfaces: a posterior one, which lies in contact with the diaphragm; an anterior one toward the stomach; an inferior small one, resting on the splenic flexure of the colon; and an internal one, in contact with the left kidney at its upper anterior portion. The hilum is on its anterior or gastric surface and posterior to it is a depression in which is lodged the tail of the pancreas.

**Ligaments.**—The spleen is covered with peritoneum except at the hilum, which is on its anterior surface; here two ligaments are given off—a posterior one, the *lienorenal*, going from the spleen to the kidney and containing the blood-vessels, and an anterior one, the *gastrosplenic* (also called *omentum*) going to the stomach. The *lienophrenic ligament* (*suspensory ligament*) runs from the left crus of the diaphragm to the upper inner edge of the spleen and blends with the two former ligaments. These three ligaments form a pedicle from which the spleen swings, and it is by their stretching that the spleen at times descends and is detected below the edge of the ribs. A fourth ligament, the *phrenocolic* (*costocolic*) runs from the diaphragm opposite the tenth and eleventh ribs to the splenic flexure of the colon. The upper surface of the colon is concave, forming a fossa (splenic fossa) in which the spleen rests and which, of course, aids in supporting it.

**Splenic Enlargement.**—The spleen is enlarged in many diseases, such as malaria, leukaemia, typhoid fever, and others. This enlargement is to be detected by palpation and percussion. The normal spleen lies under the ribs, therefore it can be palpated only when it enlarges and projects beyond the costal margin or when its pedicle (ligaments) becomes stretched and allows it to wander down. Normal percussion dulness extends anteriorly to the midaxillary line; posteriorly it merges into the kidney dulness and cannot be limited. From above down the dulness would be from the ninth to the eleventh rib in the posterior axillary line.

**Wounds of the Spleen.**—The upper portion of the spleen rises as high as the tenth dorsal vertebra or ninth spine; as the lung posteriorly descends at least one vertebra lower and the pleura still another lower, it follows that a penetrating wound entering the ninth costal interspace in the line of the angle of the scapula would wound first the pleura, then the lung, then the diaphragm, then the spleen, and finally the stomach. If it entered one interspace below—the tenth—it would open the pleural cavity but would probably escape the edge of the lung.

## THE KIDNEYS.

The kidneys when normal are about 12 cm. ( $4\frac{1}{2}$  in.) long, 6 cm. ( $2\frac{1}{2}$  in.) broad and 3 cm. ( $1\frac{1}{4}$  in.) thick. The right is the thicker and the left a little the longer.

They lie in the lumbar regions under the lower portion of the thoracic wall. Their upper ends are nearer the midline than the lower and the inner edges point forward and inward, thus one surface is antero-external and the other postero-internal.

**Relations to the Surface.**—Viewed posteriorly the right kidney has its upper edge opposite the eleventh dorsal spine and the lower edge of the eleventh rib. Its lower edge is opposite the upper edges of the third lumbar spine and vertebral body and about 4 cm. ( $1\frac{1}{2}$  in.) above the highest point of the crest of the ileum, which is opposite the fourth spine (Fig. 433). The left kidney is usually 1.25 cm. ( $\frac{1}{2}$  in.) higher, but being a little longer than the right, its lower limit may not be quite that much higher. The kidney is slightly lower in women and children than in men. The inner border reaches 10 cm. (4 in.) and the hilum 4 to 5 cm. ( $1\frac{1}{2}$  to 2 in.) from the median line, the latter being in front of the interval between the first



and second lumbar spines (H. J. Stiles). Viewed anteriorly, the lower edge of the right kidney is 2.5 cm. (1 in.) above a transverse line through the umbilicus, the left being a little higher. The upper edge is opposite approximately the tip of the ensiform cartilage. The upper end approaches within 3 cm. ( $1\frac{1}{4}$  in.) of the median line. About two-thirds of the kidney lies to the inner side and one-third to the outer of a line drawn longitudinally through the middle of Poupart's ligament. The hilum would be 4 to 5 cm. ( $1\frac{1}{2}$  to 2 in.) out from the middle of a line joining the upper extremities of the two semilunar lines.

**Deep Relations.**—The *posterior surface* at its upper portion rests on the diaphragm; beneath, its lower portion, from within out, rests on the psoas, quadratus lumborum, and transversalis muscles. Between the kidney and the quadratus lumborum run the last thoracic, the iliohypogastric, and the ilio-inguinal nerves. The transversalis fascia as it leaves the body of the first lumbar vertebra arches over the psoas muscle, forming the internal arcuate ligament, and is attached to the trans-

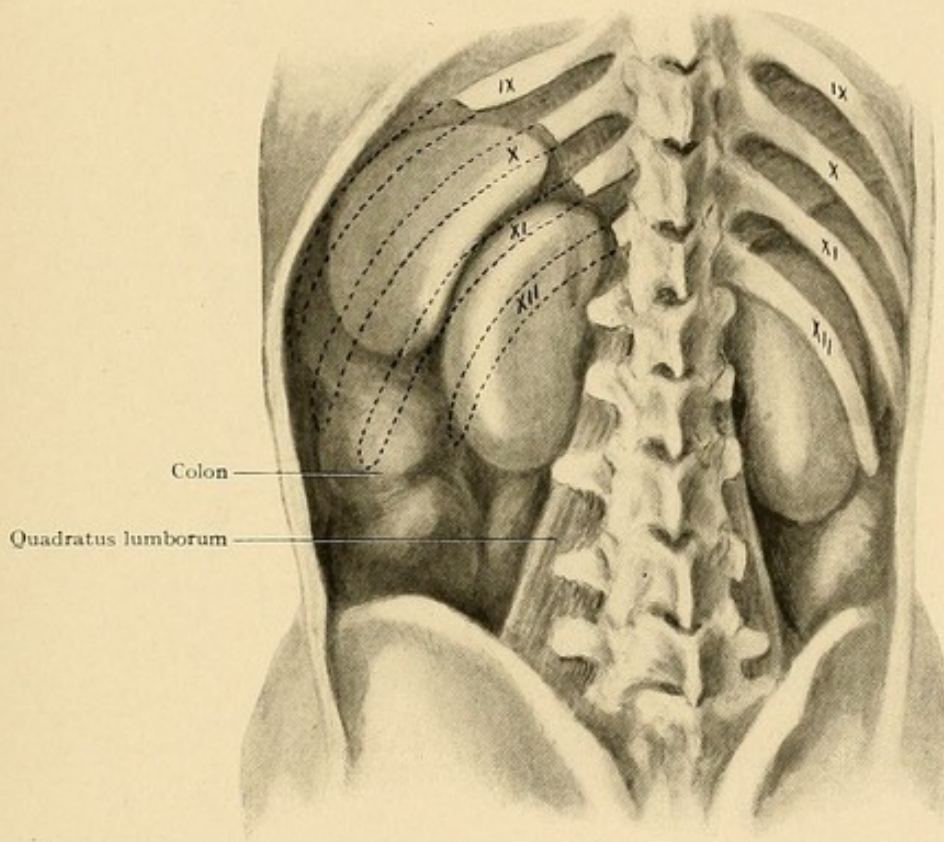


FIG. 433.—Posterior view, showing the relations of the spleen and kidneys.

verse process of the first lumbar vertebra. It then proceeds out over the quadratus lumborum to be attached to the outer portion of the twelfth rib, forming the external arcuate ligament. It then blends with the tendon or fascia, giving origin to the internal oblique and transversalis muscles. Between the fibres of the diaphragm which arise from the external arcuate ligament—over the quadratus lumborum muscle—and the fibres arising from the twelfth rib, a triangular space exists with its base downward. It is called the *hiatus* and if marked allows the pleura and the kidney to come in contact without any muscular fibres intervening. This favors the passage of pus from the region of the kidney into the pleural cavity and lung.

The *anterior surface* relations differ on the two sides. On the *right side* above is the suprarenal gland, then a large area where it is in contact with the liver, then below to the inner side the descending or second part of the duodenum, and below and to the outer side the hepatic flexure of the colon. On the *left side* above and to the inner side is the left suprarenal gland. Beneath it is a small area for the stomach, and still lower a larger one for the left end of the pancreas. On the outer



portion of the anterior surface is an area for the spleen and below one for the splenic flexure of the colon and jejunum.

The **hilum** is the name given to the notch in the inner edge of the kidney. It contains the *pelvis* and commencement of the ureter and the renal vessels and nerves. The *sinus* is the cavity of the kidney. The edges of the pelvis are attached to the borders, or rim, of the hilum.

**Renal Vessels.**—The renal arteries come off opposite the first lumbar vertebra. The right one, a little the longer and higher, passes out beneath the vena cava, head of the pancreas, and second portion of the duodenum. The left one passes behind the pancreas. On reaching the kidney they break into three or four (sometimes more) branches. One of these branches usually proceeds down and enters the kidney on the lower posterior side of the pelvis. The other branches enter anteriorly. The renal vein on leaving the kidney is formed by several branches

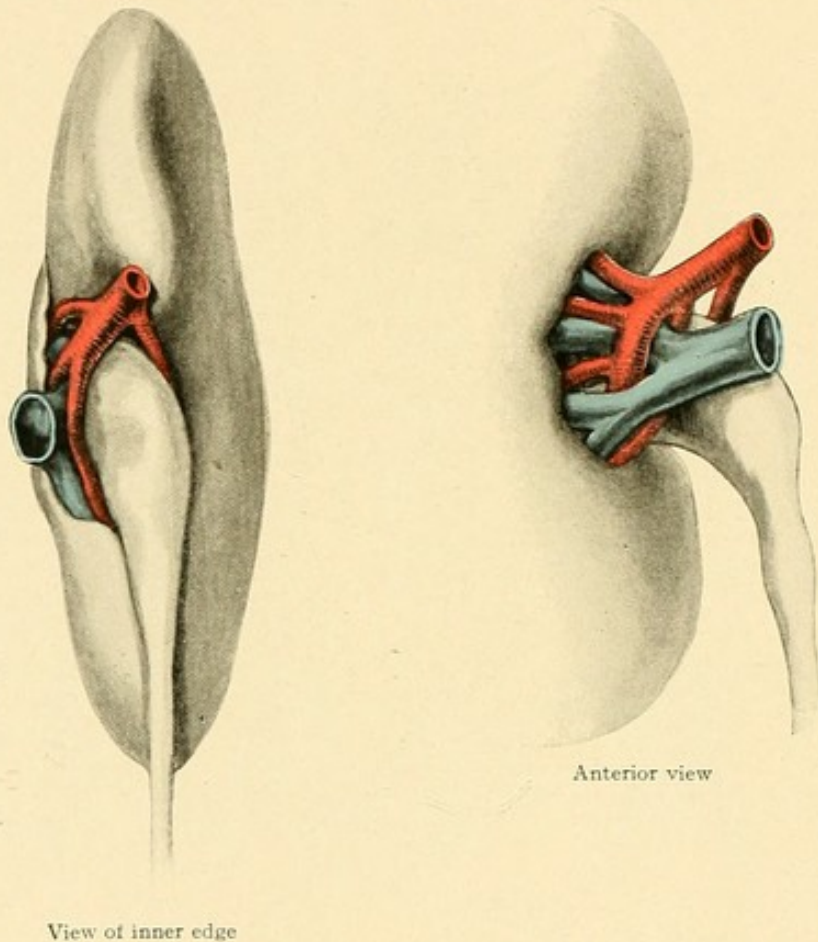


FIG. 434.—The right kidney, showing the relations of the pelvis and blood-vessels.

which pass either in front or posterior to the arterial branches. Greig Smith held ("Abdominal Surgery," vol. ii., p. 799) that the veins were posterior to the arteries. The pelvis is posterior; hence in searching for stone if it is desired to open the pelvis of the kidney it should be incised posteriorly. The usually accepted order is, pelvis posterior, then the arteries, and lastly the veins most anterior (Fig. 434). The blood-vessels of the anterior portion pass out toward the cortex and on passing its middle encroach a little on the posterior side. For this reason incisions through the kidney substance are made on its convex border about 1 cm. ( $\frac{2}{3}$  in.) posterior to its middle (Fig. 435).

**Renal Capsules.**—There are two capsules of the kidney—a fibrous one and a fatty one. The *fibrous capsule* covers the outside of the kidney and is prolonged into the hilum and lines the sinus. It can be stripped from the kidney, but when the organ is diseased it brings small portions of the kidney substance with it. The *fatty capsule* surrounds the kidney, being more abundant around its edges and not so



much on its anterior and posterior surfaces. The kidney lies comparatively loose in this fatty capsule, slipping backward and forward. The fatty capsule is continuous below with the subperitoneal fat.

**Perirenal Fascia of Gerota.**—Covering the fatty capsule is the perirenal fascia, composed of two layers—anterior and posterior. The anterior is continuous with that of the opposite side over the vertebral column. It proceeds outward over the vessels, ureter, and kidney, and fatty capsule, blending at the outer and upper border with the posterior layer; below, it fades away in the subperitoneal tissue of the iliac fossa. The posterior layer passes inward behind the kidney from its outer and upper borders, to be attached to the sides of the vertebral column. Above, these layers are attached to the diaphragm; below, they are continuous with the subperitoneal tissue of the iliac fossa. There is also some perirenal fat behind the perirenal fascia, between it and the muscles beneath (Fig. 436).

**Displacement of the Kidneys.**—The kidney is held in place by the attachment to the diaphragm of the perirenal fascia, by its vessels, peritoneum, ureter, and

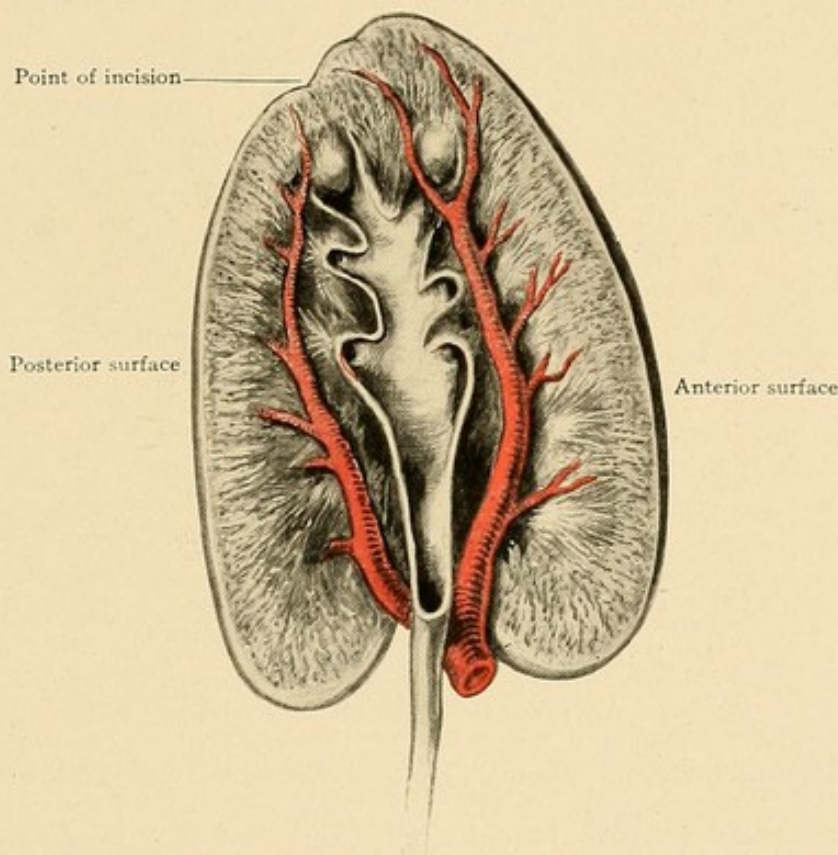


FIG. 435.—Transverse section of the kidney. The renal artery is seen dividing into anterior and posterior branches. Incisions into the organ are to be made as indicated on the posterior surface just back of the prominent edge.

by intra-abdominal pressure. Normally it cannot be felt beneath the edge of the ribs. It, however, readily becomes displaced and slides down so as to be felt below the costal margin; it is then called a *movable kidney*. If the displacement becomes more marked it may descend into the iliac fossa or even toward the median line; then it is called a *floating* or *wandering kidney*. In some instances it slides around without pushing the peritoneum markedly forward, hence it then has no mesentery or pedicle. In other cases it stretches the peritoneum in front of it and has sufficient of a mesentery to allow it to come in contact with the anterior abdominal wall.

**Tumors.**—As the kidney enlarges it does so in a forward and downward direction. As it comes forward it may go to the outer side of the colon, to its inner side, or carry the colon directly in front of it. Greig Smith ("Abdominal Surgery," p. 868) states that on the right side the ascending colon passes over the front and to the *inner* side of the growth, while on the left side the descending colon passes to the front and a little to the *outer* side. Renal tumors may be mistaken for tumors of



the liver and gall-bladder, spleen, and ovaries. A longitudinal coil of resonant intestine passing over the tumor is *prima facie* evidence of its being renal in character. Renal growths appear as more or less spherical tumors which can in some cases be palpated around their entire circumference. If one portion only can be felt, the remainder leads towards the loin; in gall-bladder tumors (cysts) the base of the growth leads toward the liver and is in contact with the abdominal wall, overlying the colon and small intestine. In splenic tumors a notch can sometimes be felt and the growth makes its appearance from above, down under the left costal margin.

**Abscesses.**—The kidney is frequently involved in suppurative affections. Calculi and tuberculous diseases are of that nature, and pyogenic infection may creep up from the bladder, producing *pyelonephritis*, or *surgical kidney*. The pus may be extrarenal, involving the adipose capsule and perirenal fascia; it commonly points in the loin. As this fascia is open below and to the inner side the pus may descend to the iliac fossa or follow inside the sheath of the psoas muscle beneath Poupart's ligament. It may work its way up along the psoas under the ligamentum

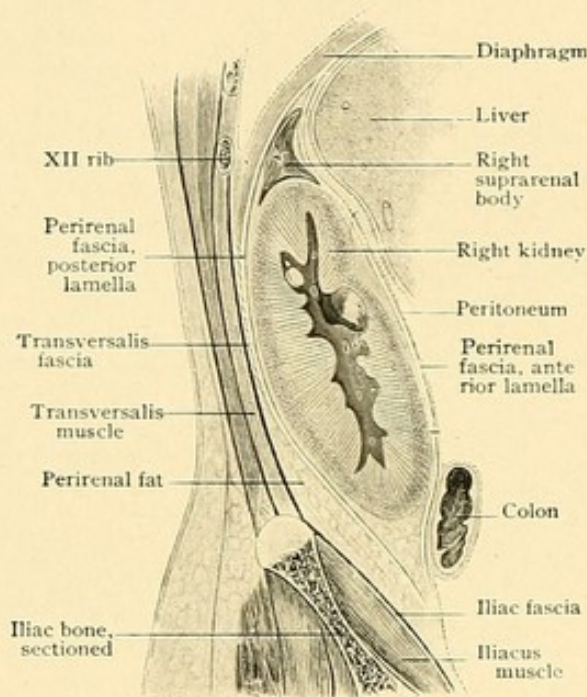


FIG. 436.—Diagrammatic longitudinal section, showing relations of supporting tissue to right kidney. (Gerota.)

arcuatum internum and empty through the lung, or perforate the diaphragm at the hiatus and so reach the lung (page 425). We have seen it work along the under surface of the liver and point anteriorly at the costal margin. It may also rupture into the duodenum or colon. Sometimes it goes posteriorly and perforates the lumbar fascia to appear at the outer edge of the latissimus dorsi and erector spinæ muscles in the iliocostal space, or at the triangle of Petit (page 394).

### OPERATIONS ON THE KIDNEY.

Access to the kidney is demanded for fixing it in place when movable, for the removal of calculus, for the treatment of cystic conditions, abscesses, growths, and even for the entire removal of the organ, which sometimes is greatly enlarged.

**Incision.**—Lumbar incisions have already been discussed (see page 395). There are three things to be borne in mind, viz.: the direction of the muscular fibres and position of the muscles, the position of the nerves, and, last, the pleura. A longitudinal incision along the outer edge of the erector spinæ muscle is large enough to remove a normal-sized kidney, but large kidneys or growths require an oblique incision. This latter begins 2 cm. ( $\frac{3}{4}$  in.) below the last rib, at the edge of



the erector spinæ muscle and passes downward and forward almost or quite parallel to the twelfth rib, toward the anterior extremity of the crest of the ilium. Mayo Robson (*Lancet*, May 14, 1898) made an incision from the inner edge of the anterior superior spine of the ilium to the tip of the last rib. The fibres of the external oblique were then split and retracted. Then the fibres of the internal oblique and transversalis were split, and retracted in the opposite direction. For this method it is claimed that no muscles, nerves, or vessels are divided, and the patient can be operated on while lying on the back. (Consult the Lumbar Muscles, page 392; Fascia, page 393; and Incisions, page 395).

*Nerves.*—The nerves to be avoided in making lumbar incisions are the last thoracic, the iliohypogastric, and the ilio-inguinal. The last thoracic nerve, accompanied by the first lumbar artery, runs parallel to the last rib a short distance below—1.25 cm. ( $\frac{1}{2}$  in.)—and thence pursues a direct course toward a midpoint between the umbilicus and top of the pubes. It emerges from beneath the external arcuate ligament about the middle of the kidney, crossing the quadratus lumborum, pierces the tendon of the transversalis muscle and runs between it and the internal oblique to pierce the sheath of the rectus and be distributed to the skin midway between the umbilicus and top of pubes and supply the pyramidalis muscle. This portion of the nerve will be injured only if the incision is carried up to the twelfth rib. When it is about opposite the tip of the eleventh rib it gives off a lateral (or iliac) branch which goes downward and slightly forward to pierce the internal and external oblique muscles above the crest of the ilium, about 5 cm. (2 in.) posterior to the anterior superior spine. This branch will be cut in making the incision,—but it is only a sensory nerve, not a motor.

The iliohypogastric and ilio-inguinal nerves, from the first lumbar, come out together from beneath the psoas muscle opposite the lower third of the kidney, cross the quadratus lumborum, and pass downward and forward toward the crest of the ilium a little in front of its middle. The iliohypogastric is above the ilio-inguinal, and, piercing the transversalis muscle, divides into the hypogastric and iliac branches. The former pierces the external oblique 2.5 cm. (1 in.) above and a little to the outer side of the external inguinal ring. The latter goes over the crest of the ilium to the gluteal region. The ilio-inguinal pierces the transversalis and enters the inguinal canal to go to the genitals and anterior inner portion of the thigh.

These nerves will probably be seen in making the longitudinal incision, toward its upper portion,—they should be pulled aside. In the oblique incision they will be posterior and not visible.

*Pleura.*—The pleura reaches the lower border of the posterior portion of the twelfth rib; it crosses the rib posterior to its middle, if the rib is of normal length, to pass to the eleventh rib. Therefore, to avoid the pleura the incision must not touch the twelfth rib posterior to its middle. One must not forget that the ribs are irregular in number and especially in length. It is necessary to identify the twelfth rib, this may be extremely difficult, and unless the greatest care is used a mistake is liable to occur. If the eleventh rib is mistaken for the twelfth the pleura comes so much farther forward that it is almost certain to be wounded, as has once occurred, producing a fatal result. The ribs may be counted down from the second at the angle of the sternum (Ludwig), remembering the possibility of there being, as we have seen, fourteen ribs on a side, or thirteen, or only eleven. The twelfth rib is frequently so short as to be completely concealed by the muscles; in that case only one floating rib would be seen.

If it is necessary to excise a rib, begin at its anterior extremity, where it is not in contact with the pleura, and scrape off the periosteum from before backward.

**Delivering the Kidney.**—After getting through the abdominal wall one comes down on the fat surrounding the kidney and its capsules. The kidney is to be felt inward and backward toward the spine. Having been located by touch the perirenal fascia and the fatty capsule are to be opened and the kidney pushed and lifted into the wound. Do not go anterior, because there the colon or peritoneum may bulge forward. Once freed from its fatty capsule the normal-sized kidney is sufficiently movable to be lifted clear out of the wound onto the surface. If it is too large the wound must be enlarged downward. Incisions into the kidney substance



should be made only when the organ is freely accessible, preferably when out on the surface, and in the manner described on page 426. The frequent existence of an additional artery supplying the lower (or other) portion of the kidney should be borne in mind. If it is desired to open the pelvis it should be sought on the posterior surface, because the veins and arteries are in front of it.

*The Suprarenal Glands.*—The right gland is more on the upper anterior surface of the kidney, while the left is more on the upper inner surface above the hilum. The gland rests on the adipose capsule and is not attached to the kidney, so that when the fatty capsule is stripped off in removal of the kidney the suprarenal gland is left behind. They lie opposite the eleventh and twelfth dorsal vertebræ and are 5 to 6 cm. (2 to 2½ in.) apart. A needle thrust into the eleventh interspace close to the spine would penetrate the suprarenal. The right one lies behind the foramen of Winslow.

*Ureter, and Renal Pelvis.*—The *pelvis* of the kidney is the upper expanded end of the ureter. It is not simply funnel-shaped, but it branches like a tree. The lower portion joining the ureter is called the common pelvis, and this divides into

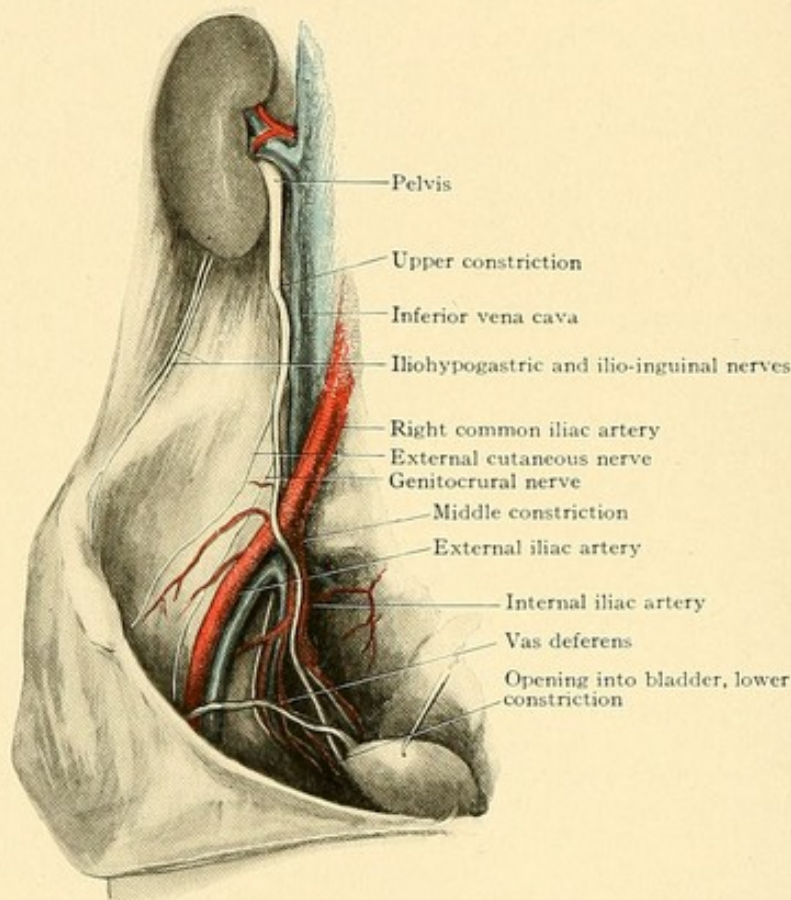


FIG. 437.—The ureter, showing its course and relations.

the superior and inferior pelves; these latter divide into eight or nine calyces which embrace the apices of the pyramids. The deposition of salts in the pelvis causes the formation of renal calculi, which are of the shape of the pelvis in which they occur. The arteries and veins which enter the kidney do so on the anterior surface of the pelvis; hence the incision for the removal of calculi which is sometimes made in the pelvis itself instead of through the kidney substance, is made posteriorly instead of anteriorly. In making the incision care is to be taken to avoid any unusual veins or arteries which may cross the pelvis, especially at its lower portion.

In front of the pelvis of the right kidney is the duodenum, and in front of the left is the pancreas.

The *ureters* are 25 cm. (10 in.) long when in the body, and 27.5 to 32.5 cm. (11 to 13 in.) long when removed from the body (A. Francis Dixon,



"Cunningham's Anatomy"). The left ureter is a little the longer because the left kidney is the higher. They are flattened tubes with a lumen of 3 mm. ( $\frac{1}{8}$  in.) and possess muscular and fibrous walls. The contraction of the marked muscular walls explains the intensity of renal colic. The back-flow of urine from the bladder in diseased conditions may distend the ureters until they approach in size the small intestine. *Course.*—The ureter is in two parts, an abdominal, extending to the brim of the pelvis, and a pelvic part, which is about 2.5 cm. (1 in.) longer than the abdominal. The abdominal portion extends from 4 cm. ( $1\frac{1}{2}$  in.) to the outside of the median line opposite the second lumbar vertebra to 3 cm. ( $1\frac{1}{4}$  in.) outside of the median line on a line joining the anterior superior spines of the ilia. It descends on the psoas muscle almost parallel to the median line but inclining a little inward and crosses the brim of the pelvis at the bifurcation of the common iliac artery (the right being sometimes a little lower). It will be observed that at this point the right ureter lies immediately to the inner side of the base of the appendix. There are three narrowed parts; the first or superior isthmus is 7 cm. ( $2\frac{1}{2}$  in.) below the hilum, where the ureter turns forward on the psoas muscle; the second or inferior isthmus is at the pelvic brim; and the third is where it enters the bladder. Calculi may lodge at any of these points. If this occurs at the brim in the right ureter the case may be mistaken for one of appendicitis, for the location of the two affections would be almost identical. The abdominal ureter does not possess as distinct a sheath as does the pelvic ureter. It is stuck, however, by fibrous tissue to the peritoneum, so that when the latter is raised it comes up with it. The ureters are crossed about their middle and accompanied by the spermatic or ovarian vessels. Just below the middle of the abdominal portion of the ureters the genitocrural nerve emerges from the psoas muscle and passes beneath the ureters from within out. This explains the genital pain in cases of calculi.

**Operations.**—The abdominal portion of the ureter can be reached for operative purposes by prolonging the oblique incision used in kidney procedures downward. It should pass about 2.5 cm. (1 in.) in front of the anterior spine and the same distance above Poupart's ligament. Access to the ureter through the abdominal cavity is not satisfactory because of the presence of the duodenum and, when distended, the ascending colon on the right side and the sigmoid and distended descending colon on the left. The surest way of recognizing the ureter in operations is to follow it downward from the hilum of the kidney or to have it contain an ureteral catheter introduced upward into it from the bladder.

The ureter (with the kidney) is most often excised for tuberculous disease; therefore, instead of its having its normal size of 5 mm. ( $\frac{1}{2}$  in.) when distended, its diameter may be increased to 12 mm. or 18 mm. ( $\frac{1}{2}$  to  $\frac{3}{4}$  in.). Excision has been most often done in women, as in them the pelvic portion is much more accessible. It can be reached through an incision in the anterior vaginal wall at its upper portion instead of using an oblique incision through the abdominal muscles. König advised a transverse incision between the lower edge of the ribs and the crest of the ilium. Bovee (*Journal of Am. Med. Assoc.*, Oct. 23, 1909) gives the following technic: The cervix uteri is to be drawn downward with a volsellum. On the anterior vaginal wall, at the uterovesical juncture, a small dimple will be seen. From the outer side of this dimple an incision from one to one and a half inches in length is made downward and outward. By careful blunt dissection the ureter can be exposed, brought down with a hook, and traction made to liberate it as it passes through the broad ligament. Its lower end may then be ligated and divided. At this stage of the operation the pelvic portion of the ureter may be resected or not as desired. Then a transverse incision, four inches or longer, is made through the extraperitoneal portion of the abdominal wall, opposite the lower pole of the kidney (König); its inner end need not go beyond the semilunar line. Through this wound the kidney is liberated and brought out and the ureter separated by gentle traction and freeing with the fingers.



## THE PELVIS.

The pelvis is composed of the two *innominate bones*, the *sacrum*, and the *coccyx*. It is constructed with a view to connecting the lower extremities with the trunk, to support the weight of the trunk and to promote locomotion, to act as a receptacle and protector of the pelvic viscera and to fulfil the function of parturition.

In infancy locomotion and parturition are in abeyance, hence the pelvis is un-

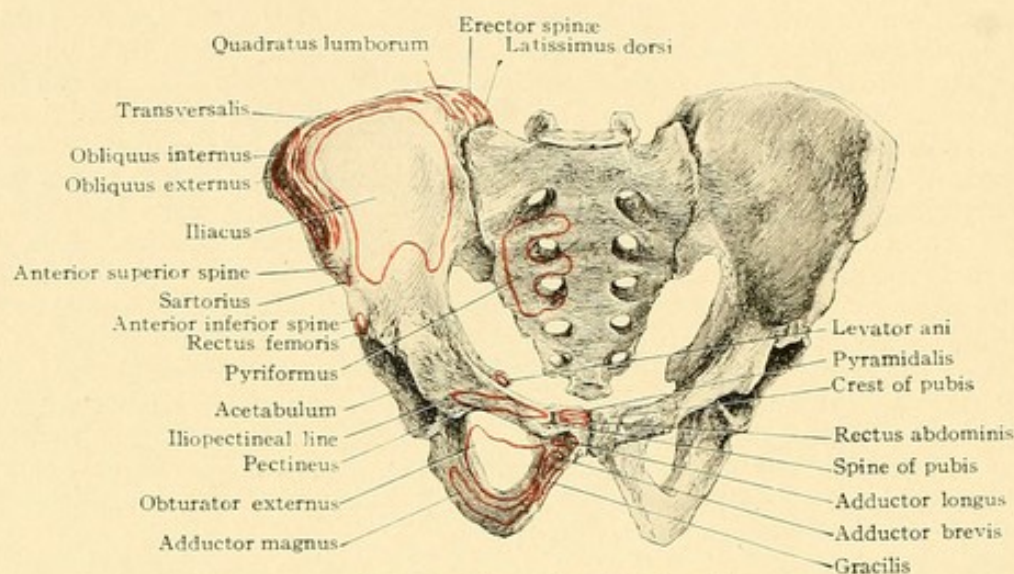


FIG. 438.—The male pelvis, front view.

developed, the bladder and uterus are almost entirely in the abdomen, and the rectum is almost straight. As the child begins to use its lower limbs for locomotion the pelvis increases progressively with the growth of the lower extremities, and with the advent of puberty its development is completed. The structure of the pelvis in

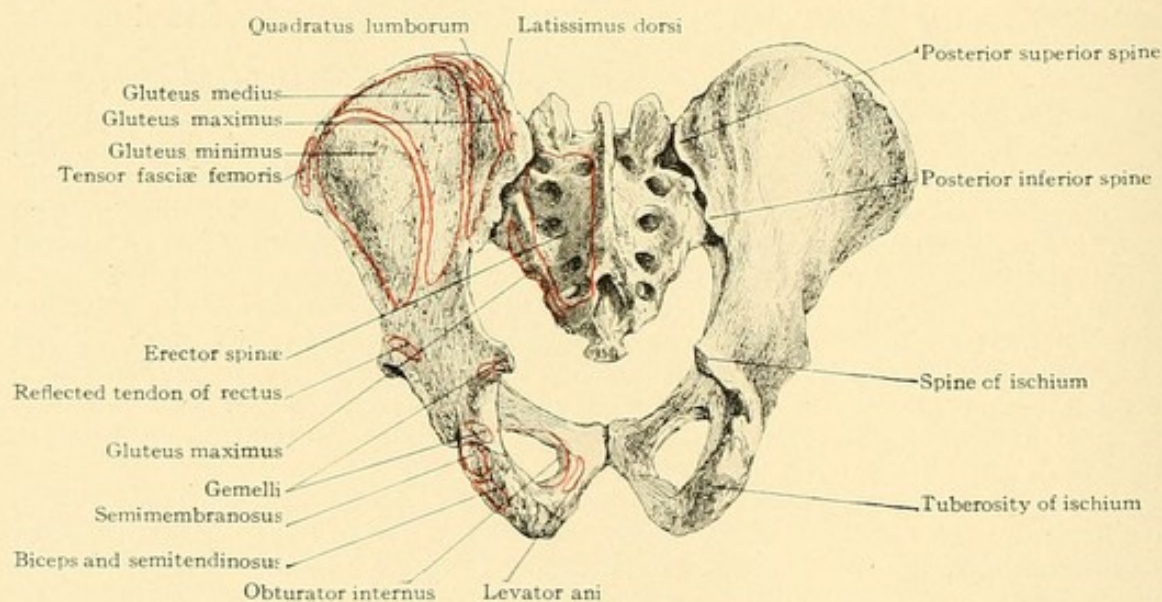


FIG. 439.—The male pelvis, back view.

relation to the function of locomotion will be considered later in connection with the pelvic girdle and lower extremity; here we will consider it in relation to the pelvic viscera and their functions.

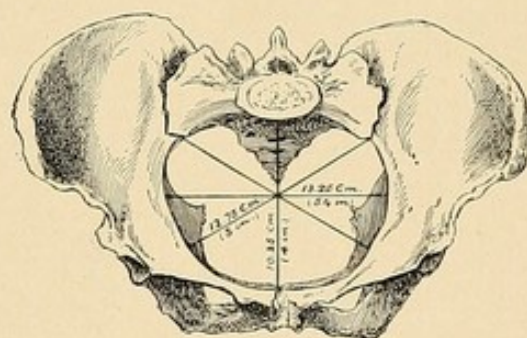
That part of the pelvis above the iliopectineal line has been called the *false pelvis*, while that below is the *true pelvis*. The *inlet* of the pelvis is formed anteriorly by the crest and spine of the pubes, the iliopectineal lines on the sides, and the base



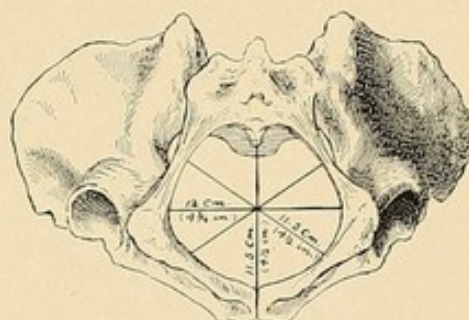
of the sacrum with its promontory posteriorly. The *outlet* is formed by the pubic arch anteriorly with the symphysis in the middle, the rami of the pubes and ischia on the sides, and the great sacrosciatic ligaments and coccyx posteriorly. The viscera above the inlet are abdominal, those below are pelvic. When the body is vertical the inlet forms an angle of 60 degrees with the horizon, and the promontory of the sacrum is 9 to 10 cm. ( $3\frac{1}{2}$  to 4 in.) above the upper edge of the symphysis.

The **male pelvis** is fashioned preëminently for locomotion: man is the more active, hence the pelvis in the male is both heavier and rougher; the false pelvis is broad and shallow, while the true pelvis is deep and narrow and its capacity is less. The inlet is heart-shaped, the tuberosities closer together, and the pubic arch narrower. The obturator foramen is oval (see Figs. 438 and 439).

**The Female Pelvis.**—In addition to the functions of the pelvis and its contents common to the two sexes the female has the function of child-bearing. To fulfil this function the female pelvis is different from that of the male. Owing to the less muscular life of the female the pelvis is smoother, its bony prominences not being so marked (see Fig. 440). The extreme width of the pelvis does not differ much in the two sexes, some authorities giving them as of equal size and some stating that the female is slightly narrower. The main difference consists in the modification of the true pelvis to favor the birth of the child. Its cavity is larger and shallower than in the male. The symphysis pubis is shallower and the sacrum is shorter and less curved. The acetabula are set wider apart as are also the tuberosities of the ischia. This causes the thyroid foramen to be triangular in the female while it has a long diameter parallel with the long axis of the body in the male. It also causes the subpubic angle to be greater in the female, forming an angle of about 90 degrees as against 65 degrees to 70 degrees in the male. The inlet of the female pelvis is more oval and not so heart-shaped as in the male. The cavity is largest at a level between the second and third sacral vertebræ posteriorly and the middle of the symphysis anteriorly. It is smallest between the sacrococcygeal articulation behind and the lower third of the symphysis in front, and the spines of the ischia on the sides. There are three diameters of the pelvis used in obstetrics; an anteroposterior or conjugate, an oblique, and a transverse. The size of these varies according to different authors.



Superior view, inlet.



Inferior view, outlet.

FIG. 440.—The female pelvis, superior and inferior views, with the diameters of the inlet and outlet.

Hirst ("Obstetrics," p. 22), gives the following :

Anteroposterior . . . . .	11 cm. (4.33 in.)	} inlet.
Transverse . . . . .	13.5 cm. (5.32 in.)	
Oblique . . . . .	12.75 cm. (5.02 in.)	
Anteroposterior . . . . .	11 cm. (4.33 in.)	} outlet.
Transverse . . . . .	11 cm. (4.33 in.)	

Dwight, in "Piersol's Anatomy," gives them as follows:

	MALE.			FEMALE.		
	Inlet. cm. (in.)	Cavity. cm. (in.)	Outlet. cm. (in.)	Inlet. cm. (in.)	Cavity. cm. (in.)	Outlet. cm. (in.)
Anteroposterior . . . . .	10.25 (4)	11.5 (4½)	8.25 (3¼)	10.25 (4)	12.75 (5)	11.5 (4½)
Transverse . . . . .	12.75 (5)	12.0 (4¾)	9.00 (3½)	13.25 (5¼)	12.75 (5)	12.0 (4¾)
Oblique . . . . .	12.00 (4¾)	11.5 (4½)	10.25 (4)	12.75 (5)	13.25 (5¼)	11.5 (4½)



The cavity of the pelvis is narrowed somewhat by the soft parts on its sides. The blood-vessels, nerves, and obturator muscles are placed laterally and so usually escape injury. In pregnancy the venous flow is most often interfered with. The first evidence of this is the dusky hue of the vagina; hemorrhoids and varicosities of the veins of the external genitals and lower extremities are common. The rectum and bladder being placed more anteroposteriorly, interference with their functions is frequent. The peculiarities of the female pelvis are evident from birth and are not solely acquired with age.

**Pelvic Walls.**—On looking laterally at the inside of the pelvis, the iliopectineal line is seen separating the abdominal from the pelvic portion. On the iliac or abdominal portion lie the iliacus and psoas muscles. Below the iliopectineal line anteriorly is the body of the pubis with the symphysis in the median line. The descending ramus of the pubis passes down to be continuous with the ramus of the ischium to the tuberosity. A short distance above the tuberosity is the spine of the ischium. Posteriorly are the five vertebræ of the sacrum and the four of the coccyx. Passing upward from the tuberosity of the ischium to the sacrum is the *great sacro-sciatic ligament (ligamentum sacrotuberosum)*; passing backward from the spine of the ischium to the sacrum and coccyx is the *lesser sacro-sciatic ligament (ligamentum sacrospinosum)*. The large opening above the lesser sacro-sciatic ligament is the *great*

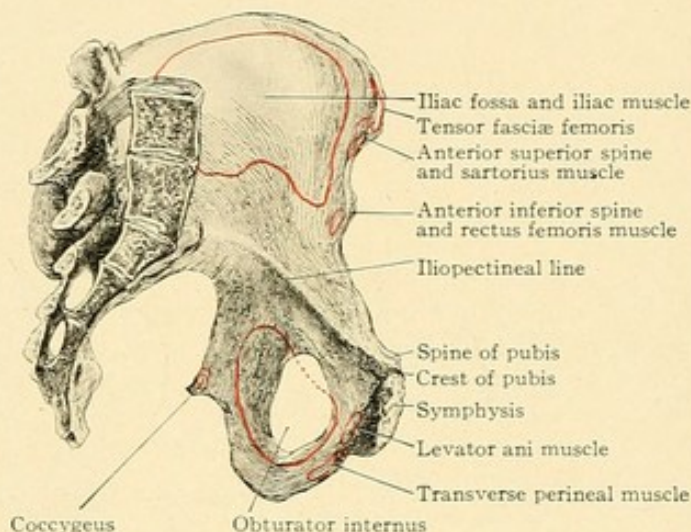


FIG. 441.—View of the pelvis from the inside.

*sacro-sciatic foramen*. Through it pass the piriformis muscle, with the gluteal vessels and superior gluteal nerve above, and, below, the sciatic vessels and nerves, the internal pudic vessels and nerve, the inferior gluteal nerve, and the nerves to the obturator internus and quadratus femoris. The smaller opening below the lesser sacro-sciatic ligament is the *lesser sacro-sciatic foramen*, through which passes the tendon of the obturator internus, the nerve to it, and the internal pudic vessels and nerve. In front of these two foramina is a third, the *obturator*. It is closed by a membrane except at its upper inner portion, which gives exit to the obturator vessels and nerve. Attached to the inner surface of this membrane is the origin of the obturator internus muscle and to its outer surface the obturator externus (Fig. 441).

**Pelvic Floor.**—The pelvic outlet is closed by two muscles, the levator ani and coccygeus. These on each side constitute the pelvic floor. The coccygeus is a comparatively small muscle passing from the spine of the ischium to the coccyx. The *levator ani* is the main muscle which supports and retains the pelvic and abdominal viscera in their normal positions. It arises from the "white line"—which is a thickening of the pelvic fascia extending from the posterior surface of the pubes in front to the spine of the ischium behind—and descends to be attached to the coccyx posteriorly, then around the lower portion of the rectum just above the external sphincter and, farther front, surrounds the vagina of the female or the prostate gland in the male. The part surrounding the prostate has been called the *levator*



*prostatæ*. The anterior edge of the levator ani muscle reaches to the central tendon of the perineum (Fig. 442).

**Pelvic Herniæ.**—Hernial protrusions of the pelvic contents may occur through the upper portion of the obturator membrane, following the vessels and nerve. This is called an *obturator hernia*. The sac is usually to the medial or inner side of the vessels and nerve. It makes its appearance in Scarpa's triangle and is covered by the pectineus muscle. Death has frequently occurred in these cases from strangulation. *Sciatic hernia* is the name given to those forms in which the intestine escapes through the great sciatic notch, passing just above or just below the pyriformis muscle. *Perineal herniæ* are those which work their way downward in other places. Thus the sac may push down between the rectum and bladder and bulge in the perineum. It may pass between the coccygeus and levator ani muscles or between the fibres of the latter and bulge into the ischiorectal fossa or forward into the labium of the female.

**Prolapse.**—The rectum and vagina as they pierce the pelvic floor may prolapse or protrude through the anus or vulva. Prolapse of the *rectum* is a common

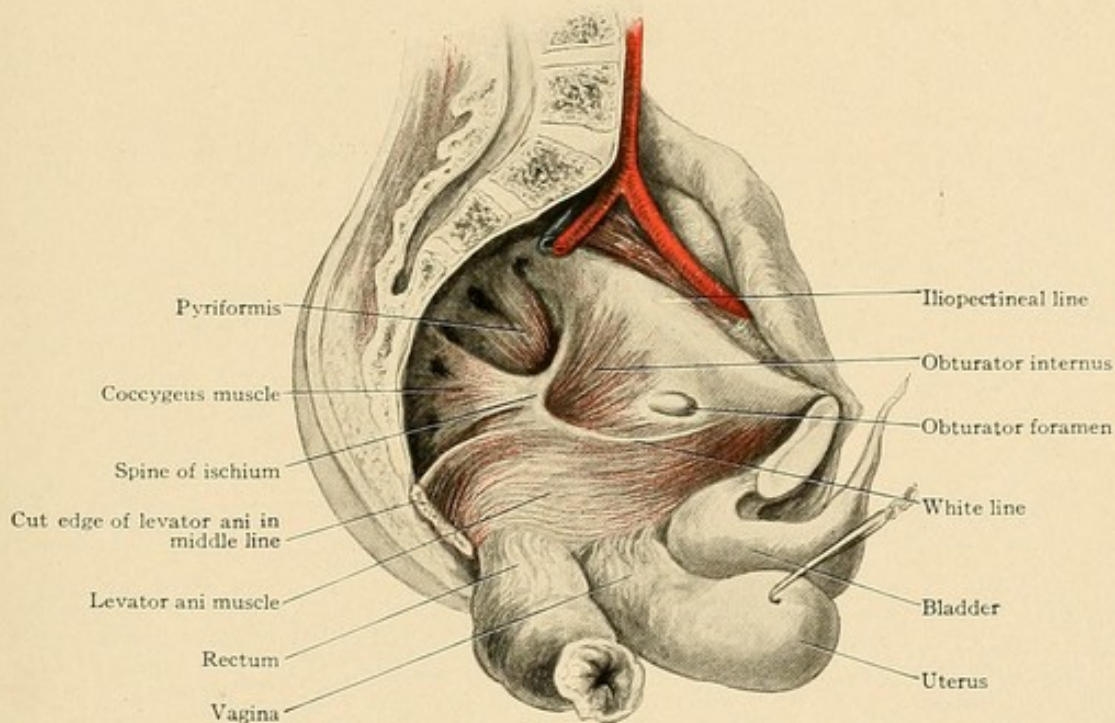


FIG. 442.—Levator ani muscle and interior of pelvis; the bladder, uterus and vagina, and rectum have been loosened and turned down.

affection and if marked may drag down the peritoneum so that some coils of small intestine may be around the prolapsed part. In childbirth the pelvic outlet is frequently torn and the *vagina* prolapses and may drag the uterus down with it, or, the support being lost, the uterus descends and drags the vagina with it and everts it. The vaginal outlet, if much relaxed, allows the rectum to bulge downward and forward, forming a *rectocele*, or the bladder may bulge downward and backward, forming a *cystocele* (see Fig. 466, page 463).

**The Pelvic Fasciæ.**—As the iliac fascia passes over the brim of the pelvis it covers the internal obturator muscle on the walls of the pelvis, hence it is called the *obturator fascia*. From the upper posterior surface of the arch of the pubes anteriorly to the spine of the ischium posteriorly this obturator fascia is thickened, forming the "*white line*" to give origin to the levator ani muscle. At the white line the obturator fascia gives off a visceral layer—the *rectovesical fascia*—which covers the inner or upper surface of the levator ani, then a second layer, the *anal fascia*, covering the under or outer surface of the levator ani muscle, while the obturator fascia itself is continued down on the obturator internus muscle to form



the outer wall of the ischio-rectal space. The *rectovesical fascia* passes downward and inward over the levator ani muscle to cover the pyriformis and coccygeus muscles behind, then the rectum, vagina, and bladder in front. In the male it covers the prostate gland, forming its sheath, and at its anterior portion forms the deep or posterior layer of the triangular ligament of the perineum. This pelvic fascia acts as a barrier between the abdominal and pelvic cavities above and the perineal region below. Pus originating above it tends to form an abscess which rises toward the abdominal cavity, and pus originating below it tends to work toward the surface in the perineum.

**Iliac Vessels.**—The *iliac arteries* commence at the bifurcation of the aorta on the left side of the disk between the third and fourth lumbar vertebræ. This is 2 cm. ( $\frac{3}{4}$  in.) below and to the left of the umbilicus and on a level with a line joining the highest points of the iliac crests. They run in a line drawn from this point to midway between the anterior superior spine of the ilium and the symphysis pubis. This is to the inner side of the middle of Poupart's ligament. They are about 15 cm. (6 in.) in length, the upper third, 5 cm. (2 in.), being the common iliac and the lower two-thirds, 10 cm. (4 in.), being the external iliac arteries. The internal

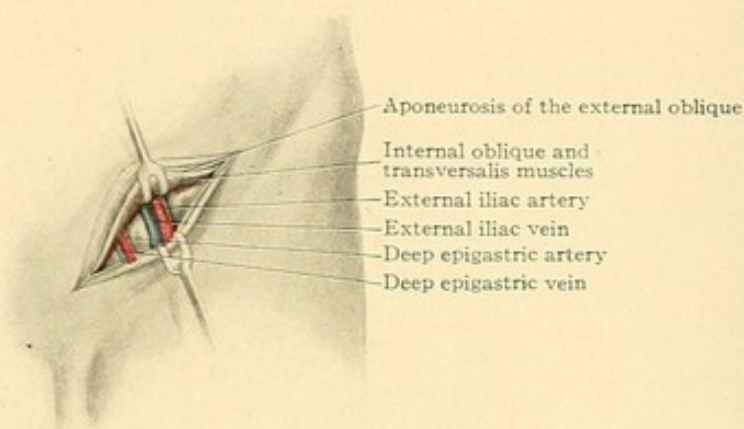


FIG. 443.—Ligation of the external iliac artery.

iliac comes off opposite the sacro-iliac joint on or a little above a line joining the anterior superior spines. The right common iliac artery is a little the longer because it comes from the left side of the vertebral column, and the left common iliac vein is the longer because it goes to the right side. The *left iliac veins* lie to the inner side of the left iliac arteries in their entire course. The *right iliac vein* starts at the inner side of the right external iliac artery and then passes behind it to reach the vena cava on the right side of the vertebral column. The ureters cross the iliac arteries at their bifurcation, and in the female are accompanied by the ovarian arteries and veins. The genitocrural nerve passes downward on the external iliac artery and goes with it beneath Poupart's ligament. Lymphatic nodes accompany the iliac vessels and drain the lower extremity, the abdomen below the umbilicus and the pelvic viscera.

**Ligation of the Iliac Arteries.**—The iliac arteries can be reached for ligation through an incision 2 cm. above and parallel to Poupart's ligament, reaching from the inner side of the external iliac artery to above the anterior superior spine if necessary. If the external iliac only is to be ligated this can be done through a comparatively small incision, but if it is desired to reach the internal or common iliac then the incision must be quite large. When the peritoneum is reached it is lifted up from the iliac fascia beneath and the external iliac artery followed up as far as desired. When the peritoneum is raised the ureter is usually lifted with it; it will be encountered crossing the point of bifurcation of the common iliac into the external and internal iliacs. The relation of the veins to the iliac artery on the two sides is to be borne in mind when passing the needle (Fig. 443).



*Collateral Circulation* (Fig. 444).—When the external iliac artery is ligated the following anastomoses occur :

Iliolumbar . . . . .	with deep circumflex iliac
Gluteal . . . . .	with external circumflex
Obturator . . . . .	with internal circumflex
Sciatic . . . . .	with superior perforating
Internal pudic . . . . .	with deep external pudic
Internal mammary, intercostals, and lumbar . . . . .	with deep epigastric

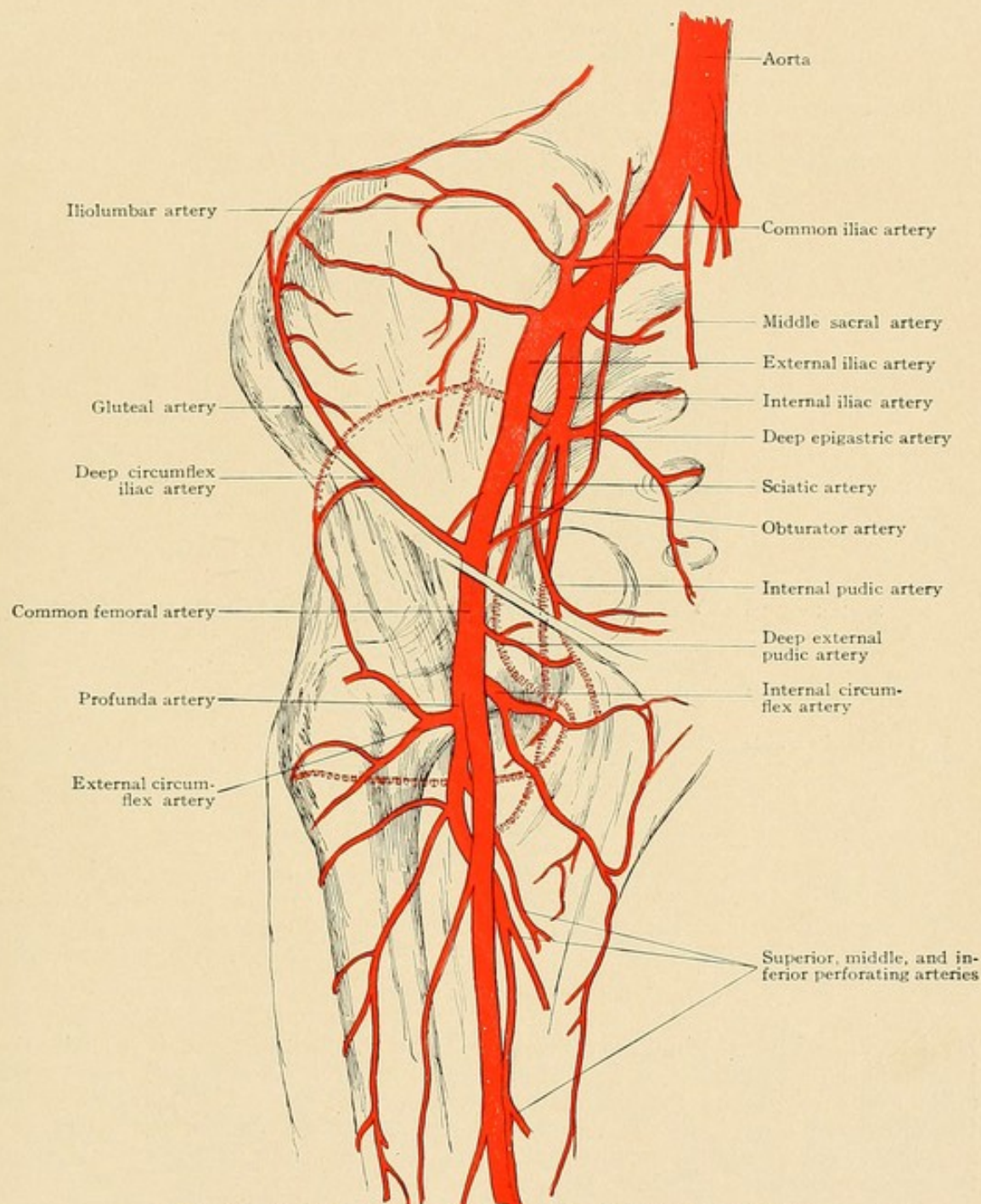


FIG. 444.—Collateral circulation after ligation of the external iliac artery.

Ligation of the iliac arteries by a transperitoneal instead of subperitoneal route has been advocated by Dennis (*Medical News*, Phila., 1886). This lessens the danger of wounding the deep circumflex iliac and deep epigastric arteries, the vas deferens, the ureter, puncturing the veins and loosening up the subperitoneal tissue. Treves has used a median incision from the umbilicus to the pubes.



## THE PELVIC VISCERA.

## RECTUM AND ANAL CANAL.

The **rectum** extends from the level of the third sacral vertebra to where it pierces the levator ani muscle, 3.7 cm. (1½ in.) in front of the tip of the coccyx, but at a lower level, and opposite the lower and anterior part of the prostate. It is 8.75 cm. (3½ in.) long and passes into the anal canal; this latter is 2.5 to 4 cm. (1 to 1½ in.) long, and extends to the skin border (Fig. 445).

When collapsed the rectum appears as a nearly straight tube following the curve of the sacrum, but when distended it becomes distinctly sacculated. It possesses an external longitudinal and internal circular layer of muscular fibres. The longitudinal fibres are continuous with those on the colon but instead of being composed of three

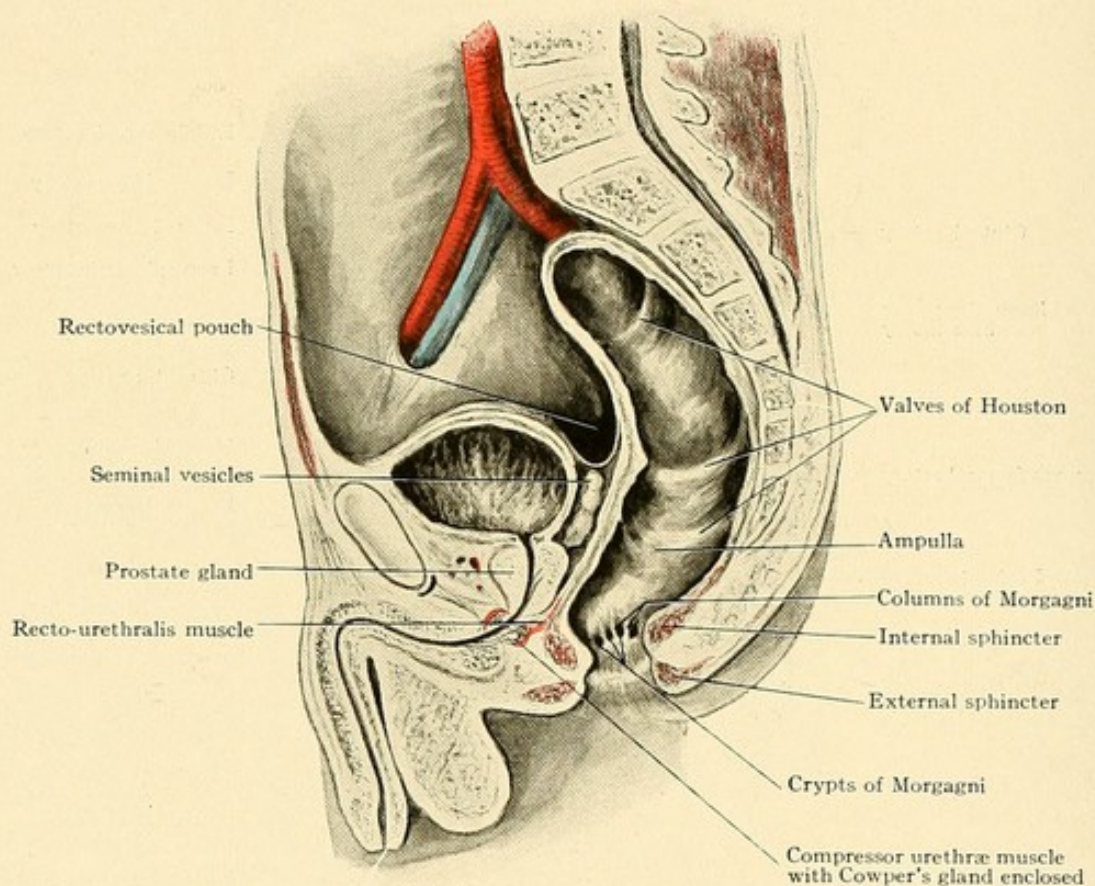


FIG. 445.—Rectum and anal canal.

bands are fused together into two bands, anterior and posterior. On the sides the longitudinal fibres are not so abundant. The circular fibres are continuous on the anal canal as the internal sphincter. For the distance of 4 cm. (1½ in.) between the tip of the coccyx and its termination, the rectum lies on the two levator ani muscles, which join in the median line. The lower portion of the rectum is larger than the upper and is called the *ampulla*.

The anterior surface of the rectum at the ampulla lies against the posterior surface of the prostate but is not intimately adherent to it. At the apex of the prostate the anterior rectal wall makes a more or less sharp turn backward. At this part the rectum and the prostate are embraced by the fibres of the levator ani muscle, which practically blend with the compressor urethrae muscle and surround the membranous urethra. The muscular fibres passing from the longitudinal layer of the rectum to the membranous urethra have been called by Proust the *recto-urethralis muscle*; they



keep the lower extremity of the ampulla of the rectum in close approximation to the apex of the prostate. This is the part of the rectum which has been frequently wounded in the operations of perineal lithotomy and prostatectomy. In the latter operation division of this band allows the rectum to be pushed back and exposes the apex of the prostate.

The sacculation of the rectum is produced by three creases or crescentic folds, called the *rectal valves* or *valves of Houston* (*Dublin Hospital Reports*, 1830). Of these the middle is the largest. It springs from the right anterior quadrant about 5 to 6 cm. (2 to 2¼ in.) above the margin of the anal canal. The superior and inferior valves spring from the left posterior quadrant a short distance above and below the middle valve. At the juncture of the rectum and sigmoid flexure there is another fold on the anterior wall which tends to obstruct the view in making examinations. These valves are composed of connective tissue and circular muscular fibres covered with mucous membrane.

**Peritoneal Relations.**—The posterior portion of the rectum has no peritoneal covering, the mesosigmoid ceasing opposite the third sacral vertebra, about 12.50 cm. (5 in.) from the anus. From this point the peritoneum slopes downward and forward, covering the sides and anterior surface of the rectum 5 cm. (2 in.) lower. The peritoneum is here reflected forward over the bladder in the male forming the rectovesical pouch and over the vagina and uterus in the female forming the pouch of Douglas. It is within 7.5 to 8.5 cm. (3 to 3½ in.) of the anus. This leaves 2.5 cm. (1 in.) or more above the prostate which is not covered by peritoneum. It was through this space that the bladder was formerly tapped with a trocar to relieve it when distended. The peritoneum on the sides is less firmly attached to the rectum and pelvic colon than it is on its anterior surface.

**Rectal Examination.**—The finger can palpate the anal canal and rectum for a distance of 10 cm. (4 in.) from the surface. Anteriorly as soon as the finger passes the sphincters the apex of the prostate can be felt; also the membranous urethra, particularly if it contains a bougie or sound. The prostate can be outlined and its size determined. If the prostate is not enlarged the base of the bladder above can be palpated and the tip of the finger will reach the rectovesical pouch. From the upper or posterior edge of the prostate and extending from near the mid-line upward and outward are the seminal vesicles, sometimes the seat of tuberculous disease. Just to the outer side of the upper end of the seminal vesicles are the lower ends of the ureters. Should a ureteral calculus become impacted at this point it might possibly be felt through the rectum. Posteriorly the coccyx and the hollow of the sacrum can be felt. The segments of the coccyx frequently are luxated or fractured and it is the seat of pain—coccygodynia—for which excision is done. These injuries cause either an ankylosis or a deformity of the coccyx which can often readily be detected by a finger internally and the thumb externally. Laterally the finger can explore the region of the spine of the ischium, the sacrosciatic foramina, and the tuberosities. If a patient is placed in the knee-chest position and a speculum is introduced the rectum immediately distends with air and its interior is visible as far as the promontory of the sacrum. By means of extra long tubes even the sigmoid loop can sometimes be seen. The valves of Houston are readily seen through the speculum.

In introducing tubes and bougies for examination or therapeutic purposes the greatest care is necessary, as death has not infrequently resulted from perforation into the peritoneal cavity.

**The Anal Canal.**—This extends from the rectum to the anus or its opening on the skin, a distance of 2.5 to 4 cm. (1 to 1½ in.). It begins at the level of the levator ani muscles and has the apex of the prostate directly in front of it and the tip of the coccyx behind and a little above. With the body vertical the anal canal has its axis inclining upward and forward toward the bladder; as soon as the sphincter ani is passed the axis of the rectum changes to upward and backward toward the hollow of the sacrum. In introducing a speculum it should always be inclined first anteriorly and then posteriorly. Opposite the level of the levator ani the circular muscular fibres increase to form the *internal sphincter*. This extends down the anal canal for a distance of approximately 2.5 cm. (1 in.) and ends above the skin margin



or, as it has been called, the "white line of Hilton." The *external sphincter* surrounds the lower part of the canal and stretches in a spindle shape from the tip of the coccyx to the central point or tendon of the perineum. Anteriorly it blends with the fibres of the levator ani and the other muscles of the perineum. It is a thick, powerful, voluntary muscle and extends outward from the white line of Hilton or mucocutaneous junction.

*Mucous Membrane.*—The upper half of the mucous membrane of the anal canal has six or eight longitudinal ridges or folds called the *columns of Morgagni or Glisson*. Between the lower ends of these columns are small hollows called the *crypts of Morgagni*, and the free edges of the mucous membrane guarding the crypts are the *anal valves*.

#### BLOOD-VESSELS.

**Arteries.**—The rectum and anal canal are supplied by the superior, middle, and inferior hemorrhoidal, and middle sacral arteries (Fig. 446).

The *superior hemorrhoidal artery* is the terminal branch of the inferior mesen-

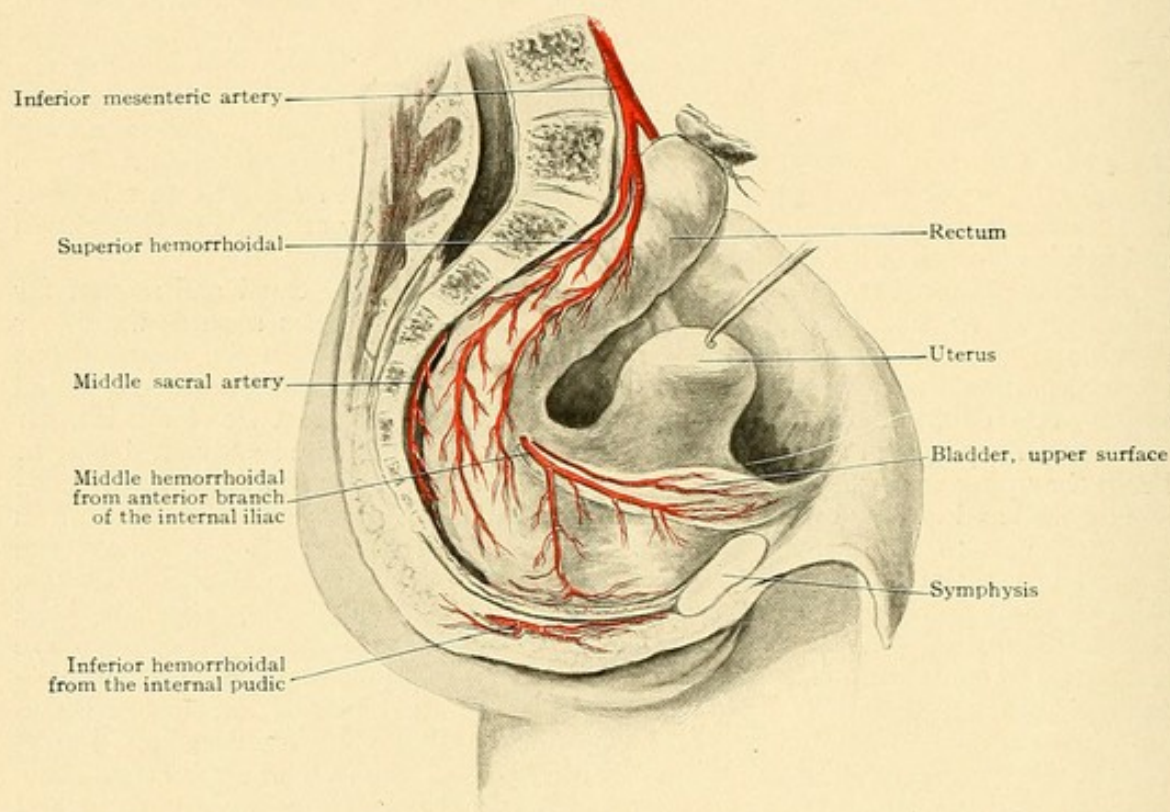


FIG. 446.—The blood supply of the rectum.

teric. It descends in the pelvic mesocolon until it reaches the rectum, when it divides into two lateral branches. These descend on its surface to about its middle, when they subdivide into six or eight branches which pierce the muscular coat and descend in the submucosa, one beneath each column of Morgagni. At the lower end of the rectum and anal canal they anastomose with the terminal branches of the middle and inferior hemorrhoidal arteries.

The *middle hemorrhoidal arteries*, one on each side, come from the anterior branch of the internal iliac. They descend on the lower part of the rectum and supply the posterior portion of the bladder and vagina, or prostate and seminal vesicles, the lower anterior half of the rectum and upper part of the anal canal, and anastomose with the superior hemorrhoidal branches above and the inferior hemorrhoidal below.

The *inferior hemorrhoidal arteries*, two or three on each side, are given off from the internal pudic while in Alcock's canal, at the outer posterior portion of the ischio-rectal fossa; they pass inward and downward to supply the outer surface of the levator ani and internal and external sphincters and lower portion of the rectum and



anal canal. They anastomose with the middle and superior hemorrhoids. They are distributed more to the posterior portion of the lower part of the rectum and anal canal while the middle is distributed more to its anterior portion.

The *middle sacral artery* passes down in the median line from the bifurcation of the aorta to the tip of the coccyx, where it ends in Luschka's gland. It gives a few branches to the rectum at its upper part but they are supposed not to go deeper than the muscular coat. It anastomoses with the superior hemorrhoidal.

**Veins.**—The veins of the rectum and anal canal accompany the corresponding superior, middle, and inferior hemorrhoidal arteries. They form two plexuses, an internal submucous plexus and an external plexus on the surface of the rectum. The internal plexus in the submucous coat begins at the anus in fine venous capillaries which pass upward, mainly in the columns of Morgagni, where they form small dilations or pools and unite into larger branches which pierce the muscular walls about the middle of the rectum to empty into the main superior hemorrhoidal veins and thence into the inferior mesenteric.

The inferior hemorrhoidal veins receive branches from the anus and outer surface

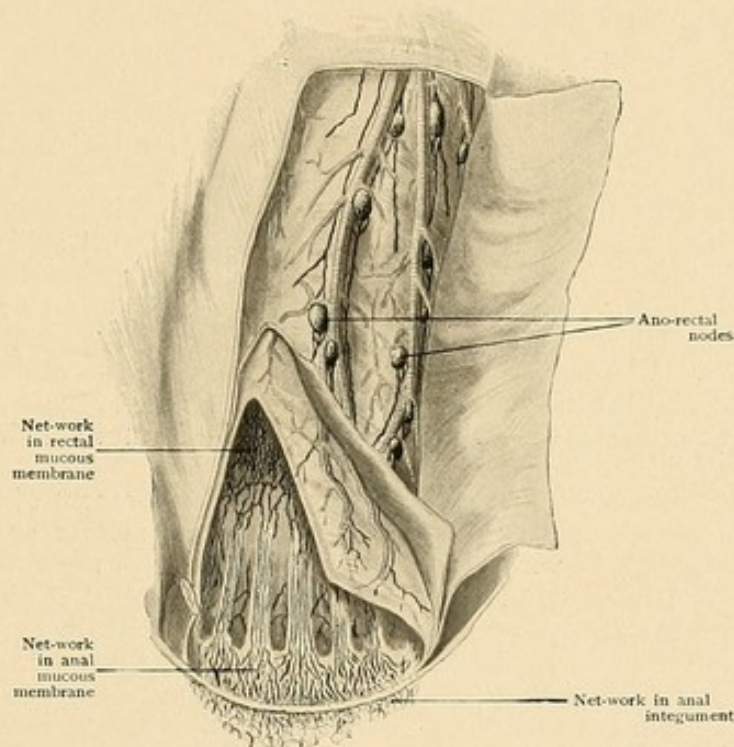


FIG. 447.—Lymphatics of rectum. (Gerota.)

of the sphincters and levator ani muscles and pass thence to the internal pudic veins.

The middle hemorrhoidal vein drains the blood from the external hemorrhoidal plexus on the outer surface of the lower half of the rectum and empties into the internal iliac. It anastomoses with the superior hemorrhoidal above, at about the middle of the rectum, and the inferior hemorrhoidal below, at the upper portion of the anal canal. It is thus seen that the interior of the lower half of the rectum is drained by the superior hemorrhoidal and its exterior by the middle hemorrhoidal. The blood from the upper part of the anal canal drains into the superior hemorrhoidal, that from its lower part into the inferior hemorrhoidal. The blood from the superior hemorrhoidal veins empties into the portal system through the inferior mesenteric, and the blood from the middle and inferior into the general venous system through the internal pudic, internal iliac, and inferior cava. These veins are usually regarded as being without valves, though the opposite view is held by some.

**Lymphatics.**—According to Poirier and Cunéo there is a superior group accompanying the superior hemorrhoidal vessels and draining the mucous membrane of the anal canal and rectum and terminating in the nodes of the pelvic mesocolon after traversing the pararectal lymph-nodes; also a middle group partly communicating



with the above through the pararectal lymph-nodes while the remainder accompany the middle and inferior hemorrhoidal vessels and drain the lower part of the anal canal above the white line. A third group comes from the skin of the margin of the anus and drains into the inguinal nodes. The pararectal (anorectal of Gerota) nodes may become enlarged in cases of nonmalignant ulcer and can be felt in the region of the ampulla by the finger introduced through the anus, thus leading to a mistaken diagnosis of carcinoma (Fig. 447).

**Nerves.**—The anus is supplied by the inferior hemorrhoidal branch of the internal pudic nerve, which, as shown by Hilton, crosses the ischioanal space on the outer surface of the levator ani muscle and passes between the internal and external sphincters to emerge between them at the white line, from whence it sends filaments up on the mucous membrane and down on the skin. This explains the great sensitiveness of the region. It also supplies the external sphincter, hence the association of spasm with pain.

## AFFECTIONS OF THE RECTUM AND ANUS.

**Examination.**—If the buttocks are drawn aside the mucous membrane of the anus is everted and a considerable portion of the anal canal becomes visible. The lower part of the columns and crypts of Morgagni and the anal valves are seen. If the patient strains or bears down, the mucous membrane of the anal canal is brought into view in almost its entire length. One is thus enabled to see dilated veins or hemorrhoids, ulcers, fissures, foreign growths, both benign and malignant, and the openings of fistulæ. By means of a speculum the entire anal canal can be seen. It should be introduced pointing obliquely anteriorly, and if it is desired to view the interior of the rectum above after it has passed the internal sphincter it is to be directed obliquely upward and backward. In digital examination the first resistance encountered is that of the external sphincter; as its edge is passed a sulcus can often be felt, immediately following which the internal sphincter is passed and the finger enters the rectum. The sulcus is about opposite the crypts of Morgagni and is formed by the interval between the contraction of the external sphincter below and the internal sphincter blended with the insertion of the levator ani above. It is just above Hilton's white line.

**Imperforate Anus.**—In an early stage of the development of the embryo the cloaca is the common termination of the genito-urinary system and the intestinal canal. Later the cloaca becomes divided by a septum into the urogenital sinus in front and the rectum behind. A depression in the skin called the anal pit appears opposite the rectum and the membrane between disappears in the fourth month. This membrane is produced by the growing together of the ectoderm and entoderm, the mesoderm being pushed aside. The failure of this membrane to perforate forms imperforate anus. The method of development explains the various malformations of these parts. The anal pit may be absent; the membrane may not perforate; the rectum may end in a blind pouch some distance up from the anus; or it may discharge through a sinus into the bladder or vagina.

**Hemorrhoids.**—Hemorrhoids or piles are varicosities or dilatations of the veins of the anus or anal canal. The middle hemorrhoidal veins are not enlarged because they do not drain the mucous membrane, they are not inside but outside the rectum. When the inferior hemorrhoidal veins are dilated they form external hemorrhoids and are situated at the margin of the anus below the white line and external sphincter, and they cannot be replaced in the rectum. When the superior hemorrhoidal veins are dilated they form internal piles (Fig. 448). The dilatation involves the superior hemorrhoidal veins from the beginning of the mucous membrane at the white line up the entire length of the anal canal and sometimes a short distance up the rectum. There is a natural tendency for external piles to be covered almost wholly by skin and for internal piles to be covered solely by mucous membrane. Inflamed internal piles can be pushed back in the rectum. If an internal pile is continued down over the white line or an external pile is continued up over the white line then they are called intero-external piles. Hemorrhoids consist almost wholly of dilated venous sinuses. The existence of arterial hemorrhoids is now denied although small arterial branches are sometimes encountered in the ordinary



venous pile. The strawberry pile is composed of venous capillaries instead of the larger venous canals usually present. They bleed more freely than does the ordinary venous pile. When external hemorrhoids are operated on they are usually thrombosed. They are then incised and the clots turned out; at other times when not inflamed they are excised and the edges stitched with catgut or the wound packed. Internal piles are either ligated or treated with the clamp and cautery. In applying the ligature the base of the pile is loosened below near the white line and detached for some distance above and then ligated. This is facilitated by the loose attachment of the mucous membrane. Bleeding is not marked because the blood-vessels enter the pile from above. In Whitehead's operation, or excision of the pile-bearing area, the mucous membrane is readily separated by blunt dissection from the parts beneath owing to the laxity of the submucous tissue; it is then excised and the cut edge sewn to the skin at the anus.

**Fistula.**—Fistula in ano may start as an ischiorectal abscess which perforates internally into the rectum or anal canal and externally through the skin. It may also start as an ulcer of the mucous membrane of the rectum or crypts of Morgagni and then produce an ischiorectal abscess which finally opens on the skin. The most common site of the internal opening is just above the anus and below the insertion of the levator ani. This is in the groove between the external and internal sphincters. Sometimes, however, the fistula pierces the levator ani and opens into the

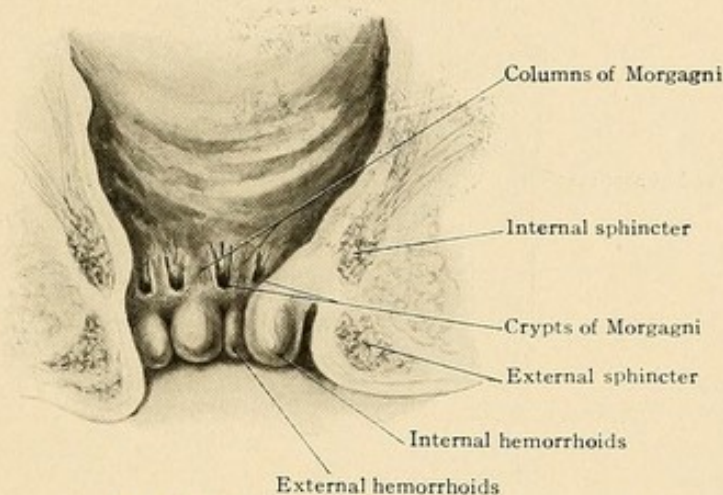


FIG. 448.—Hemorrhoids.

ampulla of the rectum. As the external opening is usually to the outer side of the external sphincter this latter is divided in operating, as is also a part or all of the internal sphincter if the opening is high up. Incontinence of feces is usually avoided if the sphincter is only divided at one place and at right angles to its fibres, not obliquely.

**Anal fissures** occur usually on the posterior wall of the anus associated with a hemorrhoid. Its location, involving the white line, explains its great pain.

**Excision of the Rectum.**—The rectum can be removed either by the perineal or sacral route. In the perineal operation the incision is made from near the base of the scrotum to the coccyx, surrounding the anus. If the incision is made near the white line the external sphincter is saved and turned to each side with the skin flap. The external sphincter is split anteriorly as far as the central point of the perineum and posteriorly to the coccyx. The rectum being drawn forward the levator ani muscle is cut through on its sides and posterior surface about 4 cm. (1½ in.) above the anus, the coccyx, if necessary, being excised. The rectum is then drawn back, the finger slipped beneath the anterior portion of the levator ani, which is farther from the surface than the posterior, and it is divided. These fibres practically constitute the recto-urethralis muscle of Proust. This is near the apex of the prostate; from here up to the peritoneal reflection or rectovesical pouch the rectum is loosely attached but at that point it is necessary to divide the rectal fascia (a part of the rectovesical fascia, p. 435) on the sides, after which the rectum can be drawn still



further down. If it is desired to go still higher the peritoneum may be pushed up off the rectum or it may be opened and the mesorectum detached close to the sacrum so as not to injure its vessels. The detached rectum is then brought down, cut off, and its divided end sutured to the skin.

In approaching the rectum by the sacral route an incision is made across the sacrum opposite the third sacral segment and from its right extremity (Tuttle) down to beyond the tip of the coccyx. The bone is chiselled through opposite the fourth sacral foramina and the flap turned down (Fig. 449). The lateral and middle sacral arteries may have to be ligated. The peritoneum, which is visible in the upper portion of the wound, may then be incised close to the rectum to avoid wounding the ureters, and the mesorectum detached close to the sacrum. This loosens the rectum, which can then be brought out and the opening in the peritoneum sewed

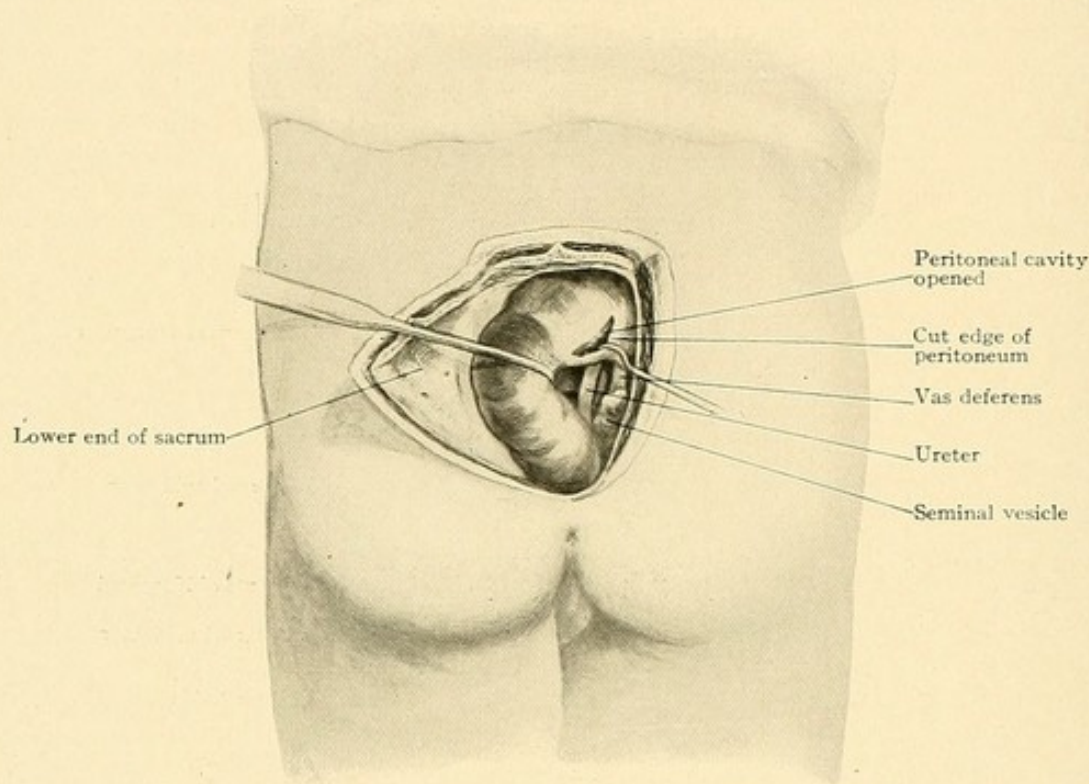


FIG. 449.—Excision of the rectum. The sacrum has been divided and turned aside. The rectum is drawn to the left, exposing the ureter and vas deferens and seminal vesicle, and the peritoneal cavity has been opened above.

shut. As much of the rectum as is desired is removed and the cut ends united by a Murphy button or end-to-end suture.

In carcinoma enlarged lymph-nodes may be found in the mesorectum or hollow of the sacrum and should of course be removed.

## THE BLADDER.

When fully distended the normal bladder contains approximately 500 c.c., or a pint. Its capacity varies much, and it is capable of great distention without rupture. In cases of retention of urine it may reach up to the umbilicus and contain a quart or more, while if its walls are thickened it may be contracted and hold only a few ounces. The shape of the bladder is dependent on the amount of dilatation and its attachments.

**Position.**—In front of the bladder is the symphysis and body of the pubes, below and in front is the prostate gland. Beneath is the posterior portion of the prostate, the seminal vesicles, the termination of the ureters, and the rectum. The upper and posterior surfaces are covered by peritoneum and small intestines, which fill the rectovesical pouch. In the female the bladder rests on the upper half of the vagina and the uterus as far as the internal os.



**Attachments.**—The bladder is fixed at its upper and lower portions. It has true ligaments of fascia and false ligaments of peritoneum. The pelvic fascia is reflected from the levator ani muscles onto the bladder and prostate. Its reflection from the levator ani onto the bladder occurs at its upper portion on each side and is called the *lateral true ligaments* (Fig. 450). The reflection from the anterior part of the bladder and prostate which goes to the posterior surface of the pubes is called the *puboprostatic ligament* or *anterior true ligament* of the bladder. The urachus forms a

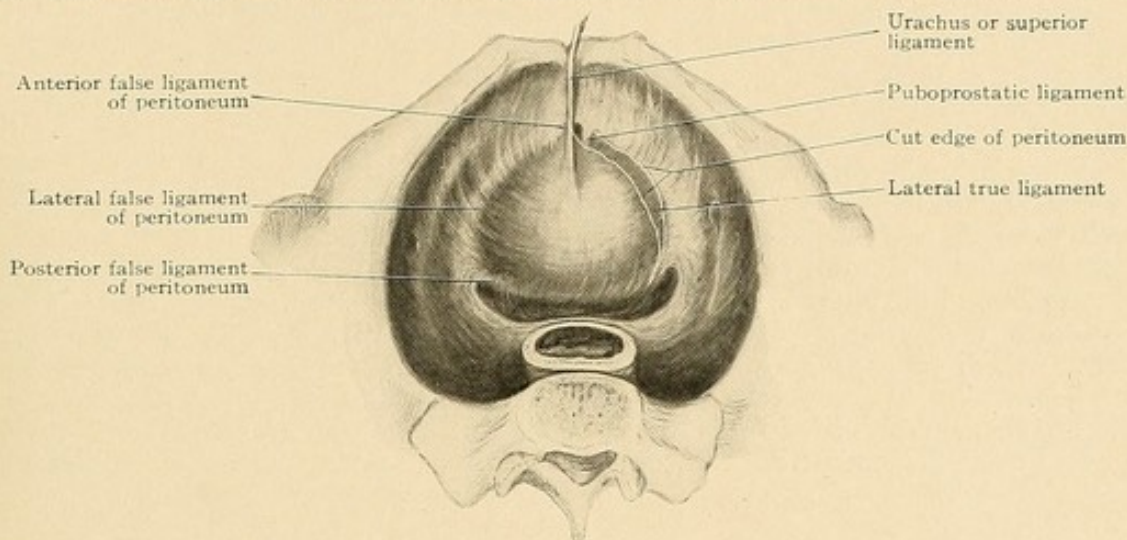


FIG. 450.—View of the interior of the male pelvis, showing the bladder attachments.

*superior ligament.* The false ligaments are simply the peritoneal reflections. That over the urachus is the *anterior false ligament*, and those on the sides, which are reflected from the bladder at about the level of the white line are called the *lateral false ligaments*. When the urachus above is detached the bladder is comparatively loose. Its firmest attachment is at its neck to the prostate and to the rectum above the prostate at the rectovesical pouch. It is this firm attachment which causes the mucous membrane of the base of the bladder to remain smooth while the rest is corrugated.

**Shape.**—The shape of the bladder is influenced by its attachments. As we have just seen these are the urachus in front, the neck below, and the rectovesical pouch behind; therefore, as the bladder collapses it assumes a conical shape with its apex at the neck and its base running from the top of the symphysis anteriorly to the highest point of attachment to the rectum posteriorly. The bladder never sinks entirely below the top of the symphysis, because the urachus holds it there; as its top or fundus descends it sinks behind the symphysis and slopes back to the rectum. If the bladder-walls are actively contracted or much thickened it cannot readily collapse, and then retains a more elongated shape. As it distends it becomes oval and rises toward the umbilicus (Fig. 451).

**Peritoneum.**—In children the bladder is practically an abdominal organ; when it is empty the peritoneum sinks about to the level of the top of the symphysis, but when distended it rises from 2.5 to 6.25 cm. (1 to 2½ in.) above. In the adult the top of the bladder is held to the top of the symphysis by the urachus, and as it becomes empty the upper surface descends until a curved line is formed from the top of the symphysis downward and backward to the rectovesical pouch, which is opposite the insertion of the ureters and corresponds to a point just below

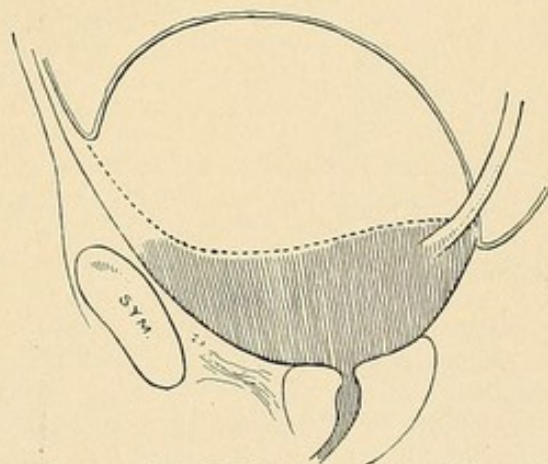


FIG. 451.—The bladder in its empty and distended state. When distended the peritoneal reflection on the anterior abdominal wall is seen to be raised. The posterior or rectovesical reflection remains nearly or quite unchanged.



the extremities of the seminal vesicles and 2.5 to 4 cm. (1 to 1½ in.) above the posterior border of the prostate.

As held by Greig Smith, the main factor in raising the peritoneum from the front of the bladder above the upper edge of the symphysis is its distention, and 450 to 600 c.c. (15 to 20 oz.) will raise the fold 2.5 to 5 cm. (1 to 2 in.).

When the body is placed in the Trendelenburg posture the contents of the bladder gravitate toward the diaphragm, and therefore push the peritoneum up or away from the upper border of the symphysis: hence this position is usually employed when the bladder is to be opened for operative purposes. The use of a rubber bag in the rectum distended with water has been found to raise the peritoneal folds so little that its use has been abandoned in favor of the Trendelenburg posture.

Posteriorly the rectovesical pouch is approximately 8.75 cm. (3½ in.) from the anus, but it may be as little as 7.5 cm. (3 in.), or as much as 10 cm. (4 in.). As has already been stated the attachment of the rectovesical pouch to the rectum is so firm that whether the bladder is distended or collapsed its distance from the prostate is but little altered. It does not change its position markedly as does the peritoneum above the pubes. Waldeyer (Joessel and Waldeyer, *Topog. Chirurg. Anat.*, vol. ii, p. 554) gives 1.5 to 2 cm. (¾ to ⅝ in.) as the greatest possible variation.

*Tapping* the distended bladder is done above the pubes, and care is to be taken to avoid wounding the peritoneum; this is to be done by knowing how its position

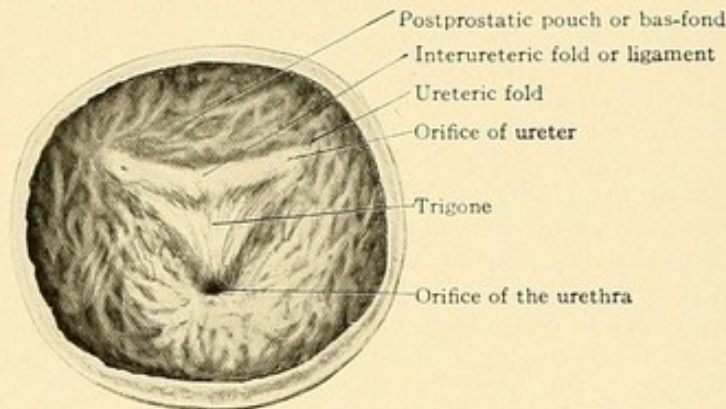


FIG. 452.—View of the interior of the base of the bladder.

is influenced as just detailed above. In front of the anterior bladder wall and between it and the posterior surface of the symphysis and transversalis fascia is the space of Retzius, filled with loose connective tissue. Care is to be taken not to infect it in operative procedures. It readily becomes infiltrated in extravasation of urine.

*Rupture* of the bladder occurs most often through the peritoneum of its posterior surface when the bladder is distended. Extraperitoneal ruptures may occur when it is empty, and are usually the result of wounds by foreign bodies or spicules of bone in fractures.

**Base of the Bladder.**—On the interior of the base of the bladder the ureters open about 2.5 cm. (1 in.) posterior to the urethral orifice, and the same distance (or more if the bladder is distended) from each other. The included triangular space is called the *trigone*. Its mucous membrane is without the rugæ possessed by the rest of the bladder and, if it is distended, is not quite so pale in color. The ureters pass obliquely through the walls a distance of 1.25 cm. (½ in.) and cause slight elevations of the mucous membrane called the *plicæ uretericæ* or *ureteric folds*. Joining the two ureteral orifices is a fold of mucous membrane called by Kelly the *interureteric ligament*. The part immediately posterior to this fold is the *postprostatic pouch* or *bas-fond*. It becomes enlarged in prostatics, and then contains residual urine. Calculi also tend to lodge there (Fig. 452).

**Bladder Walls.**—The bladder is composed of a muscular wall covered externally by the peritoneum and internally by the submucous and mucous coats. In the undistended bladder blood-vessels can be seen in the mucous membrane, which is



in folds. These folds and vessels diminish or disappear when the bladder is distended. The membrane at the trigone is more firmly connected to the muscle beneath than elsewhere in the bladder, hence its smoothness and increased color. The muscular coat is composed of two longitudinal layers with one more or less transverse layer between. The external layer is continuous with the ureters, and over the prostate to be attached to the lower posterior part of the pubes under the name of pubovesical muscle. The circular fibres are continued around the opening of the urethra, forming the internal sphincter. The openings of the ureters are not closed by muscular action, but by the interior pressure. When the bladder is distended, if the ends of the ureters are thickened they do not close as the urine accumulates, but allow it to back up and distend the ureters and pelvis and even cause the kidney itself to become enlarged. Thus infection ascends from the bladder to the kidney and the ureters become distended until they may equal in size the small intestine.

The fibres of the muscular coat pass in various directions, more or less in the form of bundles. When these bundles become hypertrophied they can be seen as distinct ridges on the interior of the bladder. In sounding they can be felt and recognized by the tip of the sound. Such a condition is called a *ribbed bladder*. If the bladder becomes hyperdistended the fibres become separated and the mucous membrane bulges out, forming a sac. It is then called a *sacculated bladder*. These sacs are favorite lodging places for vesical calculi. From diseases of the prostate and urethra the muscular coat becomes thickened. It is then called a *hypertrophied bladder*; such a one is usually contracted.

The bladder walls ordinarily are quite thin, about 3 mm. ( $\frac{1}{8}$  in.) thick. When hypertrophied they are three or four times as thick. When the bladder is viewed in life in abdominal operations it usually appears as a somewhat flaccid sac. It does not assume the globular form until considerably distended and must contain a moderately large amount of urine before showing above the symphysis. The commonly flaccid condition of the bladder leads one to think that its emptying is largely favored by the pressure of the intestines compressing it against the floor of the pelvis, and that it is mainly in case of considerable distention or the pressure of irritation or disease that its own muscular coat is utilized for the purpose. This view is strengthened by the increase in flow when coughing and by the occurrence of bladder troubles (prolapse, etc.) so soon as the integrity of the pelvic floor is injured, as occurs in rupture of the perineum from childbirth. The laxity of the bladder walls allows it to spread sideways to the neighborhood of the inguinal rings, and it has frequently been found in the inguinal canal and has been wounded in operating for hernia. The urethral orifice in the male is about 6.25 cm. ( $2\frac{1}{2}$  in.) from the surface at the upper margin of the symphysis in a downward and backward direction; with the body in a vertical position it might be said to lie on a level with the middle of the symphysis if the bladder is empty, lower if the bladder is distended, and slightly higher if the rectum is distended. It is therefore within easy reach of the finger inserted through a suprapubic incision.

**The Bladder in the Female.**—In the female the vesico-uterine pouch reaches the level of the internal os and the bladder is in contact with the cervix from there down to the cervicovaginal junction or anterior fornix. From here it is in contact with the anterior vaginal wall along its upper half. The trigone extends from the middle of the anterior vaginal wall, which marks the internal orifice of the urethra, to 2 cm. ( $\frac{3}{4}$  in.) below the cervicovaginal junction, the spot where the ureters enter the bladder walls. The absence of the prostate causes the bladder to be lower in the female and the level of the internal urethral orifice is opposite the lower border of the symphysis. It also is smaller in the female and does not show itself so readily above the symphysis on distention. Vesicovaginal fistulæ frequently occur as the result of injuries during childbirth, cancerous ulceration, etc. They are located on the anterior wall of the vagina above its middle. Calculi can be extracted through an incision in the median line of the anterior vaginal wall above its middle. The commencement of the ureters can also be palpated on each side of the cervix anteriorly and impacted calculi may be removed at that point. The bladder is connected with the cervix and vagina posteriorly by comparatively loose connective tissue so that they can be readily separated by blunt dissection as far up as the internal os.



**Cystoscopic Examination.**—The shortness and distensibility of the female urethra make the examination of the interior of the female bladder much easier than that of the male. For purposes of examination it is distended either with air or water. In order to distend it with air it is either injected directly with a rubber bulb or the patient is put in the knee-chest position, or, if on the back, the pelvis is elevated, so that the intestines gravitate toward the diaphragm. If a speculum is then introduced and the obturator withdrawn the bladder at once distends. The walls of the bladder are whitish in color with small vessels running over them. The base (trigone) of the bladder is redder than the surrounding walls. The muscular fasciculi are often seen as distinct ridges and the mucous membrane may be thrown into folds. The internal orifice of the urethra in the female is just below the lower border of the symphysis. The ureteral orifices can be seen as slightly elevated papillæ 2.5 cm. or more behind the urethral orifice and  $30^{\circ}$  to its side, the trigone, when the bladder is not distended, making an equilateral triangle, with the urethra and ureteral papillæ at its angles (Fig. 453).

**Operations.**—Most of the operations on the bladder are done from above. To relieve distention *tapping* is done with a fine trocar or aspirating needle. It is to be inserted close to the upper margin of the symphysis and passed downward and back-

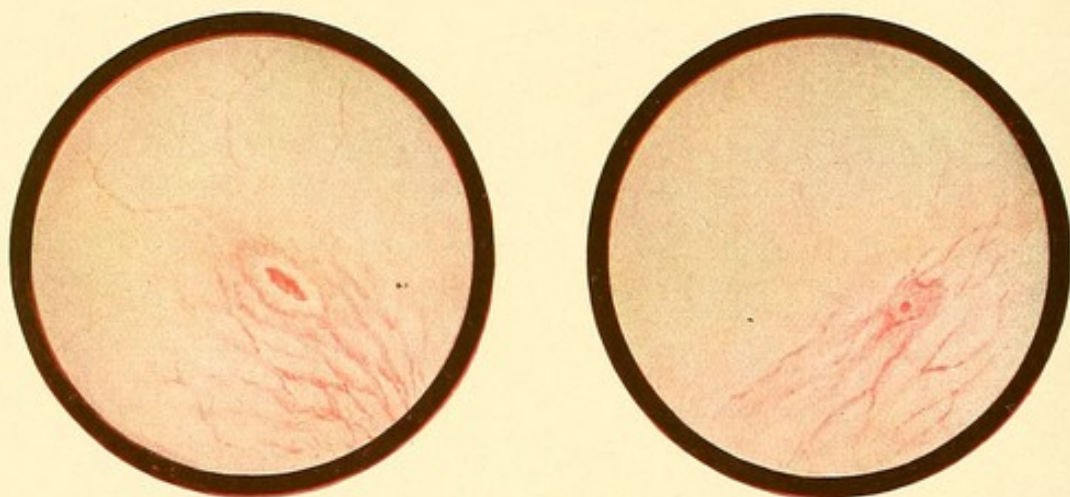


FIG. 453.—The picture on the left demonstrates a normal mucous membrane and ureteral orifice. On the right the ureteral orifice will be observed to be small, round, atrophic, and functionless. (Drawn from a case of Dr. Benj. A. Thomas\* by Mr. Louis Schmidt.)

ward. Cystotomy is performed through the median line. In making the incision three layers of fat are divided; first, the superficial fascia between the skin and muscles; second, the fatty pad between the posterior surface of the muscles and the transversalis fascia; and third, the prevesical fat of the space of Retzius beneath the transversalis fascia and between the anterior wall of the bladder and the symphysis pubis.

**Tumors.**—Growths and prostatic enlargements are often operated on suprapubically. These are usually easily within reach of the finger. In incising the bladder the anterior vesical veins are to be avoided by keeping in the median line.

## THE PROSTATE.

The normal prostate gland is of the shape of a large chestnut. It is 3 to 4 cm. ( $1\frac{1}{4}$  to  $1\frac{1}{2}$  in.) wide, 2.5 to 3 cm. (1 to  $1\frac{1}{4}$  in.) long, and 3 cm. ( $1\frac{1}{4}$  in.) thick. An indistinct furrow on its under surface separates it into two lateral lobes. There is no median lobe, as the prostatic tissue is continued uninterrupted across the median line. For clinical purposes we may consider the prostate as having an apex, a vesical surface or base, and a rectal or posterior surface.

The vesical surface is pierced a little anterior to its centre by the urethral opening, which leads to the apex. Entering below and posteriorly at the fissure are the

\* Diagnosis of Renal Disease and Sufficiency, Dr. Benjamin A. Thomas, *Annals of Surgery*, May, 1903.



ejaculatory ducts. These enter close together near the median line and pass upward and forward to enter the under surface of the prostatic urethra about its middle. It is to the part of the prostatic tissue between the ejaculatory ducts below and the interior of the bladder above, just posterior to the urethral orifice, that the name middle lobe has been applied. This part contains a collection of glands called by Albarran (Albarran and Motz: *Annales des Mal. Génito-Urinaires*, July, 1902) the prespermatic group. Just beneath the mucosa behind the urethra is another group which he calls the subcervical group. In so-called enlargements of the middle lobe these glands form the bulk of the tissue. A slight enlargement produces a bar, a considerable enlargement produces a projecting growth which may even be pedunculated. The glandular portion of the prostate in addition to that just described posterior to the urethral orifice is located centrally, and the fibromuscular part of the gland is mostly outside of the glandular portion, surrounding it and passing across

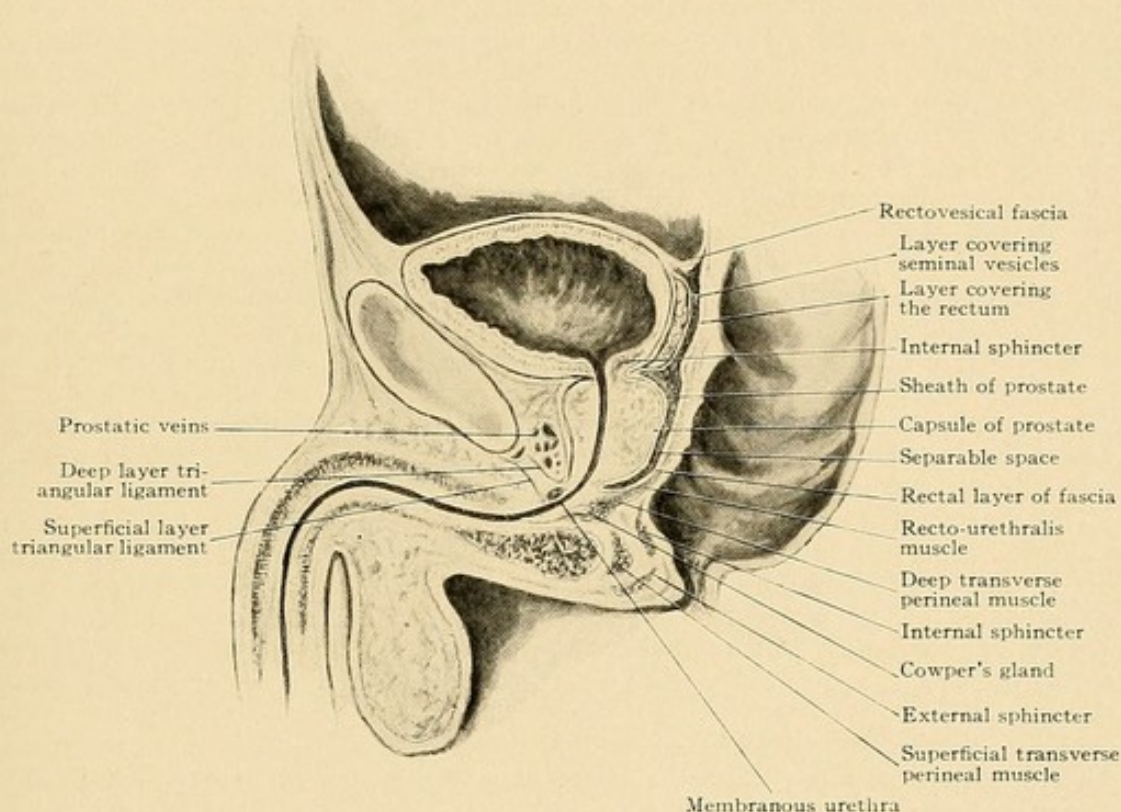


FIG. 454.—The prostate and its fascias.

the median line in front of the urethra to form the anterior commissure. Some fibres cross the median line posteriorly, forming an indistinct posterior commissure.

**Sheath and Capsule.**—The prostate is surrounded by a distinct firm fibrous sheath which is continuous with the rectovesical fascia (*aponeurosis of Denonvilliers*). At the upper portion this blends with the fascia covering the bladder, anteriorly it forms the puboprostatic ligaments, below it is continuous with the deep layer of the triangular ligament of the perineum, posteriorly it is continuous with the rectovesical fascia and covers and binds the seminal vesicles to the bladder. The prostatic plexus of veins is imbedded in this fibrous sheath. (J. W. Thomson Walker, *Brit. Med. Jour.*, July 9, 1904.) (Fig. 454).

Between the veins and the glandular tissue, and covering the latter, is what has been called by Sir Henry Thompson and W. G. Richardson ("Development and Anatomy of the Prostate Gland") the *capsule*. It is a comparatively thin layer of fibrous tissue, insignificant and incomplete in places, which penetrates the substance of the gland. It adheres to and is removed with the lobes of the enlarged prostate in prostatectomy.

C. S. Wallace (*Brit. Med. Jour.*, 1904, i., p. 239) holds that what Sir H. Thompson has called the capsule is the thin, muscular, outer, nonglandular portion of the organ.



**Relations.**—The apex rests on the posterior layer of the triangular ligament 1 to 2 cm. ( $\frac{1}{2}$  to  $\frac{3}{4}$  in.) behind and a little below the subpubic angle and just inside the upper end of the anal canal. This is about 3 to 4 cm. ( $1\frac{1}{4}$  to  $1\frac{1}{2}$  in.) above the white line of Hilton and the prostate is immediately felt by the finger as soon as it enters the rectum. The prostate lies on the rectum, so that it is readily accessible. Its apex being about 3 cm. ( $1\frac{1}{4}$  in.) from the mucocutaneous white line, its upper edge would be 6 cm. ( $2\frac{1}{2}$  in.) and the rectovesical pouch 8.75 cm. ( $3\frac{1}{2}$  in.) above this line. Thus all these structures are usually within reach of the finger. In the median line, extending to each side, the vasa deferentia and seminal vesicles, if diseased, as they sometimes are in tuberculous affections, can readily be felt, but when healthy are too soft to be easily distinguished. On each side is the levator ani muscle, which embraces the prostate as far forward as the membranous urethra, where it practically blends with the deep transverse perineal and compressor urethræ muscles (see recto-urethralis muscle—Perineum, page 475).

**Structure.**—The greater portion of the prostate is composed of unstriped muscular tissue, which is not only arranged peripherally but sends prolongations inward, forming spaces in which the glandular tissue is lodged. There is also a layer surrounding the vesical opening of the urethra. The action of this latter muscle is probably to act as a true sphincter to retain the urine in the bladder. It also by its contraction prevents the regurgitation of the semen into the bladder.

**Veins.**—In the urethral and vesical portions of the prostate are numerous veins. These in the old become varicose, hence the frequency of bleeding in old prostatic cases. Around the anterior portion of the prostate and laterally posteriorly lies the prostatic venous plexus. Into it anteriorly empties the dorsal vein of the penis; from above it receives the vesical veins, and in those advanced in age it communicates also with the hemorrhoidal plexus posteriorly. Fenwick has shown (*Jour. of Anat.* xix. 1885) that in the young these veins possess valves which become incompetent as age supervenes. The prostatic plexus unites in a single large vein on each side which empties into the internal iliac vein.

**Hypertrophy.**—This is the most common affection of the prostate. According to Mansell Moullin it always begins in the glandular elements. It is of two kinds, fibrous and glandular. Both start as glandular but the former in some cases predominates and the glandular element atrophies and leaves a comparatively small hard fibrous prostate. The glandular character of median growths has already been explained on page 449 as originating from the prespermatic and subcervical groups of Albarran.

Glandular hypertrophy of the lateral lobes forms the ordinary large prostates for which prostatectomy is performed. The bleeding, which is so common in these cases of enlarged prostate, is due to the varicose condition of the veins around the posterior portion of the urethra and vesical mucous membrane.

**Prostatectomy.**—This consists in removing the hypertrophied glandular elements. It is performed either suprapubically or through the perineum.

When done through a suprapubic incision a median enlargement (so-called median lobe) can readily be removed by dividing the mucous membrane with the finger-nail or scissors and shelling the growth out with the finger. In this case there is practically no sheath to go through and the amount of bleeding will be proportionate to the varicose condition of the veins. If large lateral growths are to be removed then there is still no fibrous sheath to be entered, but only the thin, filmy capsule and fibromuscular layer of prostatic tissue covering the hypertrophied glandular masses: hence for its division Freyer uses his finger-nail only. As the fibrous sheath is not divided there is no bleeding from the prostatic venous plexus in its layers.

In perineal prostatectomy two methods are used. In the first the membranous urethra is opened by a median incision and then a lateral cut made into the enlarged prostate on each side. The finger is then introduced and the hypertrophied glandular masses enucleated with the finger. In the second method a curved or  $\Lambda$ -shaped incision is made from the central tendon of the perineum toward each side between the rectum and tuberosities. The sphincter ani is then detached from the central tendon and pushed back while the transverse perinei muscles are pulled forward. The muscular fibres between the rectum and membranous portion of the urethra



(page 438, recto-urethralis muscle) are then divided and the rectum pushed back (Fig. 455). This exposes the prostate; its outer capsule or sheath is then incised and the growth removed with the finger or forceps. In order to prevent injury to the ejaculatory ducts Young enucleates through two lateral incisions, thus leaving a middle strip in which the ejaculatory ducts are contained. According to Gosset and Proust (*Manuel de la Prostatectomie*, Paris, 1903) the fascia between the prostate and rectum (aponeurosis of Denonvilliers) is composed of two layers, an anterior one on the prostate—its sheath—and another posterior one on the rectum. When the recto-urethralis muscle is divided the incision should likewise divide the posterior or rectal layer, which is then pushed back with the rectum. Thus is formed the "espace

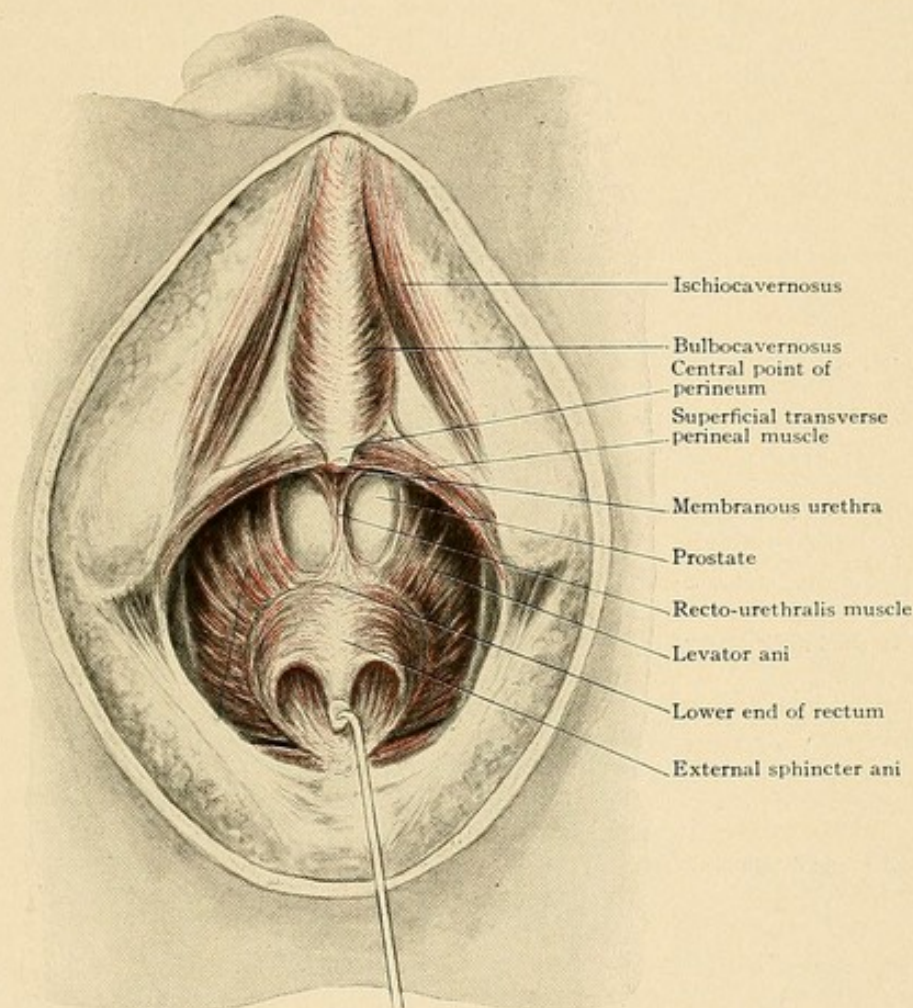


FIG. 455.—The parts involved in prostatectomy. The external sphincter ani has been divided at the central point of the perineum and with the lower portion of the rectum has been drawn back, thus putting the recto-urethralis muscle on the stretch and exposing the prostate to each side.

decollable rétroprostatique" or separable space and the anterior layer or sheath of the prostate is exposed.

**Abscess.**—Inflammation and abscess of the prostate follow injury and infection from the introduction of catheters or bougies and also from gonorrhœa. The hot and enlarged gland can readily be felt through the rectum. The bladder and rectal symptoms are marked. Pus tends to discharge either into the urethra or rectum, more rarely it may point in the perineum behind the triangular ligament and in front of the anus. Abscesses breaking into the urethra may leave a large cavity, which becomes a receptacle for pus, urine, and calculi, and hastens a fatal issue. When breaking into the rectum intractable fistulæ may result. Prostatic abscesses should be opened by an incision in the perineum just anterior to the anus, the finger being introduced into the rectum to avoid wounding it.



## THE SEMINAL VESICLES.

The seminal vesicles are about 5 cm. (2 in.) long and lie on the bladder above the prostate. They diverge on each side toward the ureters, which they overlap and which intervene between the vesicles and bladder wall. The vasa deferentia run along the inner border of the vesicles and join the ducts from the vesicles to form the common ejaculatory ducts just before entering the posterior portion of the prostate. Their upper portion is covered by the peritoneum of the rectovesical pouch. They are fastened to the bladder by the rectovesical fascia, and are in close relation with the prostatic plexus and vesical veins. They are within reach of the finger introduced through the anus and may be massaged and their contents expressed. They have been excised for tuberculous disease. When normal they are not readily recognized by touch, but in disease are easily felt. Operations on them are conducted like those of perineal pros-

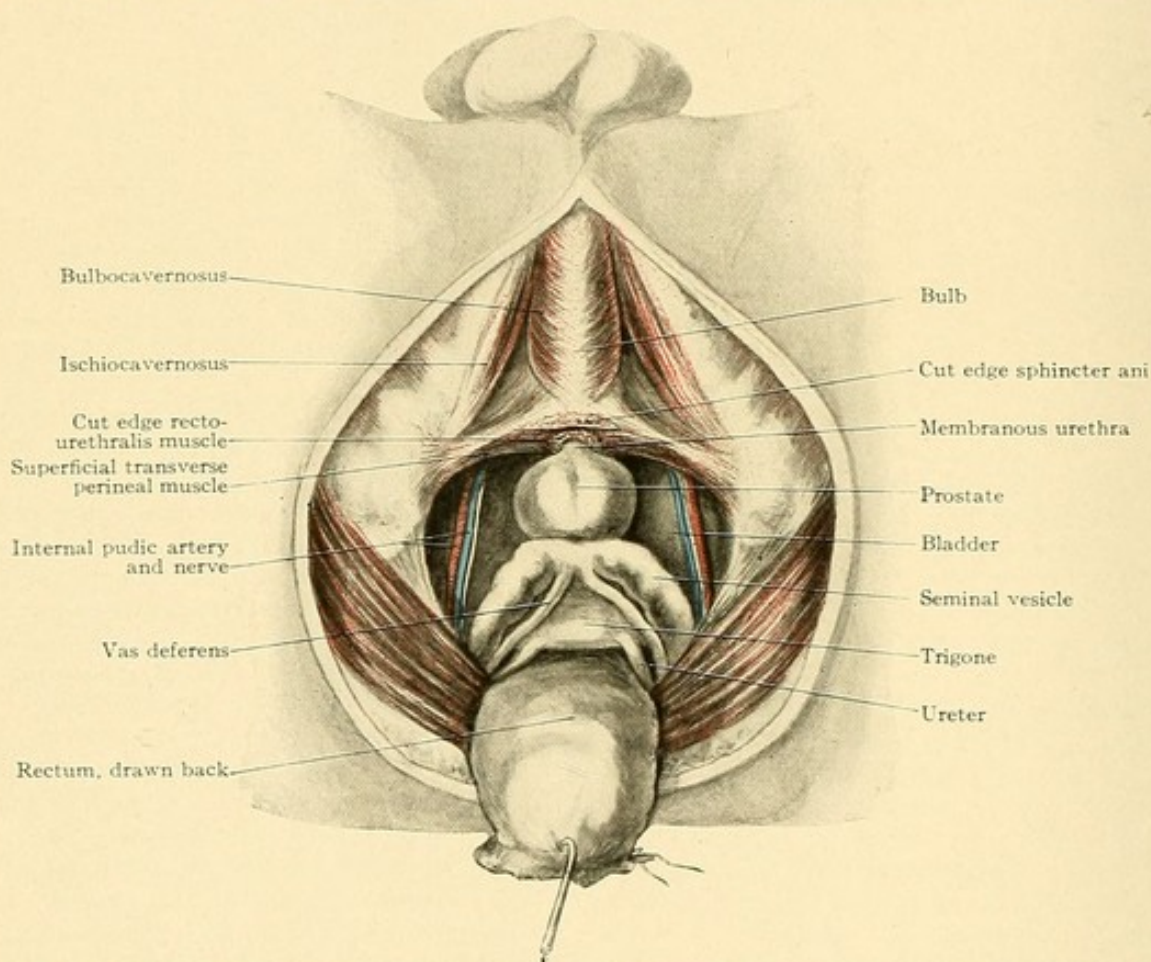


FIG. 456.—The prostate gland and seminal vesicles exposed by dividing the external sphincter and recto-urethralis muscle and pulling the rectum forcibly back.

tectomy, but, as they lie higher, beyond the prostate, it is almost impossible to bring them well into view for operative purposes. The seminal vesicles are nothing more than blind diverticula from the vasa deferentia and partake of its diseases. The epididymis, vas deferens, seminal vesicles, and prostate are all frequently involved in tuberculosis of the genito-urinary tract (Fig. 456).

## THE VAS DEFERENS.

When the vas deferens leaves the internal abdominal ring it winds around the outer side of the deep epigastric artery and dips down over the brim of the pelvis 4 or 5 cm. (1½ to 2 in.) posterior to the pubic spine. It then runs downward and backward on the side of the pelvis, under the peritoneum, crossing superficially the



obliterated hypogastric artery, the obturator vessels and nerve, the vesical arteries, from the inferior of which it receives the artery of the vas, and finally the ureter. In its pelvic course the vas deferens is not often the subject of surgical interference except in cases of undescended testis. In these cases it is often loosened from the firm but thin fibrous bands which retain it in place, after which it is readily drawn forward to allow the testicle to descend.

## DEVELOPMENT OF THE UROGENITAL SYSTEM.

In the early stages of development of the human embryo there arises from the parietal mesothelium on each side a tube known as the *Wolffian duct* with a collection of tubules known as the *Wolffian body*. This reaches its full development in the seventh week. On one side of the Wolffian body develops the *sexual gland*, which later becomes either a *testicle* or *ovary*. At the caudate extremity of the Wolffian body develops the *kidney* by the end of the second month. At this time the bladder is connected by the *urachus* with the stalk of the *allantois*. The lower end of the bladder is connected with the extremity of the intestinal tract through a dilatation

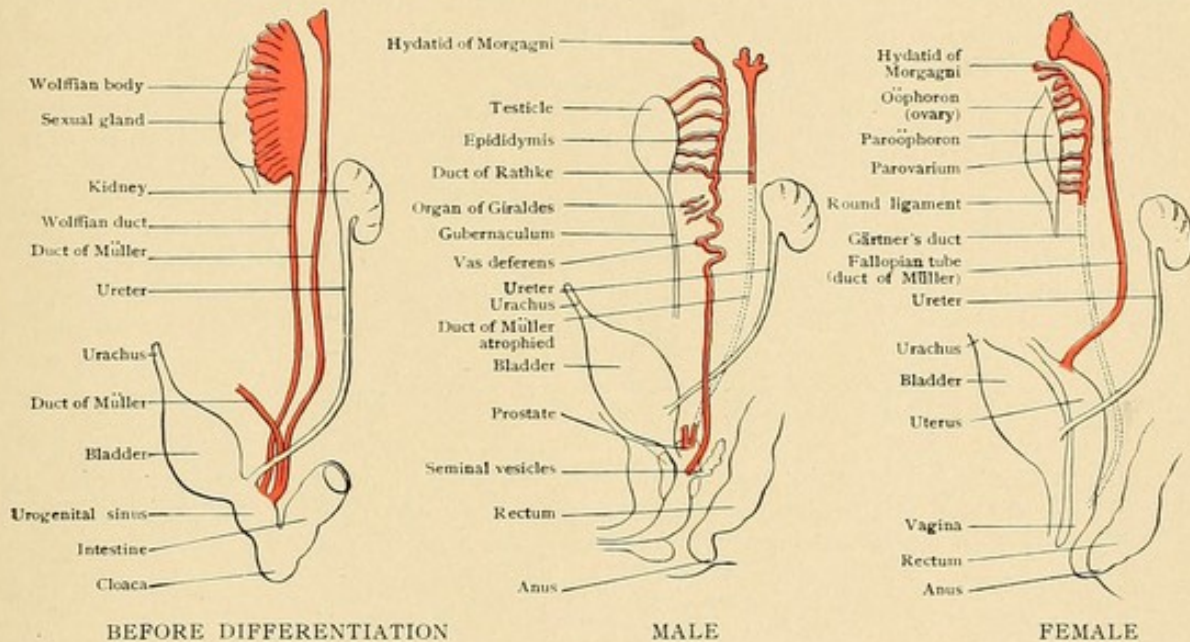


FIG. 457.—The development of the genital organs.

called the *urogenital sinus*. The union of the urogenital sinus and intestine forms the *cloaca*. At the time the Wolffian body is developing there appears alongside of it a tube called the *duct of Müller*. It atrophies in the male but in the female becomes the *Fallopian tube*, *uterus*, and *vagina*. The ureter is developed and becomes connected with the lower portion of the bladder (Fig. 457).

The Wolffian duct and duct of Müller, until about the third month, empty into the urogenital sinus. Differentiation of the sexes begins about the third month and is well advanced in the fifth. The sexual gland in the male becomes the testicle and passing from its lower end is seen the gubernaculum. In the female it becomes the ovary and the round ligament passes from its lower end. The Wolffian body after performing temporarily the functions of a kidney disappears, leaving sometimes a small cyst attached to the upper part of the epididymis in the male and in the broad ligament near the ovary in the female, known as the *hydatid of Morgagni* (*stalked hydatid*). Its lower portion has as its remains some short closed tubes in the tail of the epididymis known as the *paradidymis* or *organ of Giralde*s in the male and the *paroöphoron* of the broad ligament in the female. The Wolffian duct, while forming the vas deferens and part of the epididymis in the male, forms the atrophied paroöphoron in the female to the inner side of the ovary.



The *parovarium* or *organ of Rosenmüller* is the remains of the middle set of Wolffian tubules and in the male forms the epididymis. In the female it is almost always present as a horizontal tube with shorter tubes connected with it, between the layers of the broad ligament near the ovary. The Wolffian duct may persist as a small tube in the broad ligament close to the uterus and vagina and known as the *duct of Gärtner*. The ducts of Müller in the male atrophy and form the *sinus prostaticus* of the prostate. Part of them may persist patulous as the *duct of Rathke*. In the female they form the Fallopian tubes, uterus, and vagina.

A knowledge of the development of the urogenital tract enables one to understand how many of its congenital deformities and subsequent affections are produced. Extrophy of the bladder, epispadias, hypospadias, and various forms of hermaphroditism result when the two lateral halves of the bladder and urethra and external genitals fail to unite in the median line. Should the urachus not close, a fistulous tract leads from the bladder to the umbilicus from which urine discharges. Cysts may also form in its course. Should the partition between the rectum within and the dimple of the anus without not become absorbed there is formed one of the varieties of imperforate anus. In some cases the rectum empties into the urethra or bladder, thus forming a cloaca. Should the testicle become arrested in its descent from the region of the kidney it forms what is known as undescended testicle. It may be arrested within the abdominal cavity, in the inguinal canal, or near the external abdominal ring.

The paroöphoron gives rise to cysts which have a tendency to develop between the layers of the broad ligament and are papillomatous inside. The parovarium also gives rise to cysts which likewise tend to burrow between the layers of the broad ligament. Cysts arising from Gärtner's duct are sometimes found in the vagina. In the male, cysts arising from the Wolffian duct are: (1) encysted hydrocele of the testicle; and (2) general cystic disease of the testicle. Cysts arising from the persistence in the male of the duct of Müller have also been observed in the prostate and seminal vesicles, but they are exceedingly rare.

## THE FEMALE GENERATIVE ORGANS.

The female pelvic organs are so often the subject of operative procedures that an exact knowledge of the relations of the uterus, vagina, ovaries, Fallopian tubes, round and broad ligaments, and ureters is of great importance.

### THE UTERUS.

The normal unimpregnated uterus is approximately 7.5 cm. (3 in.) long, 5 cm. (2 in.) broad, and 2.5 cm. (1 in.) thick. It consists of a fundus, body, and neck. Its fundus is that part above a line joining the two openings of the Fallopian tubes at the cornua. The neck of the uterus or cervix embraces 2.5 cm. (1 in.) of its lower portion. Between the neck and fundus is the body. The cavity of the uterus is small, its anterior and posterior walls being almost in contact, while laterally it extends toward the Fallopian tube openings. The opening through the cervix is the cervical canal; it opens into the vagina by the external os and into the uterus by the internal os; it is round in shape. The external os in the nullipara is round but in those who have borne children it is a transverse slit. The cervical canal is narrowed at both the internal os and the external os while it is larger between; hence in passing instruments into the uterus they traverse with difficulty the external os and the internal os but pass readily between the two and into the uterine cavity beyond.

The cervix enters the upper end of the vagina in its anterior wall and presents downward and backward (Fig. 458). Its posterior lip is longer than the anterior.

**Position.**—The uterus is most firmly fixed to the vagina and its upper portion is the most movable. Lying between the bladder anteriorly and intestines and rectum posteriorly its position varies with the condition of those organs. Normally it inclines anteriorly (anteversion). It lies in contact with the bladder, no intestines intervening. With an empty bladder it may point almost horizontally just above the



top of the symphysis pubis, the external os being almost at the same level. As the bladder distends and the rectum becomes empty the fundus rises more and more until the axis of the uterus may coincide with that of the vagina, or even pass beyond; and then it is said to be retroverted. The uterus is normally almost straight or slightly bent forward. As the result of disease it becomes more or less sharply bent at the region of the internal os either forward or backward. It is then said to be anteverted or retroverted. When retroverted the fundus can frequently be felt as a round hard mass behind the upper posterior portion of the vagina.

**Attachments.**—In addition to being attached to the vagina the uterus has certain folds or ligaments which pass from it to the surrounding parts. Anteriorly the peritoneum is reflected from the uterus at the level of the internal os to the bladder, forming the *utero-vesical fold*. Posteriorly the peritoneum descends from the uterus over the posterior surface of the upper portion of the vagina for 1 or 2 cm. ( $\frac{1}{2}$  in.) and thence onto the rectum constituting the *recto-vaginal* or *recto-uterine fold*. The deep pouch so formed is called *Douglas's pouch*. On each side are three ligaments;

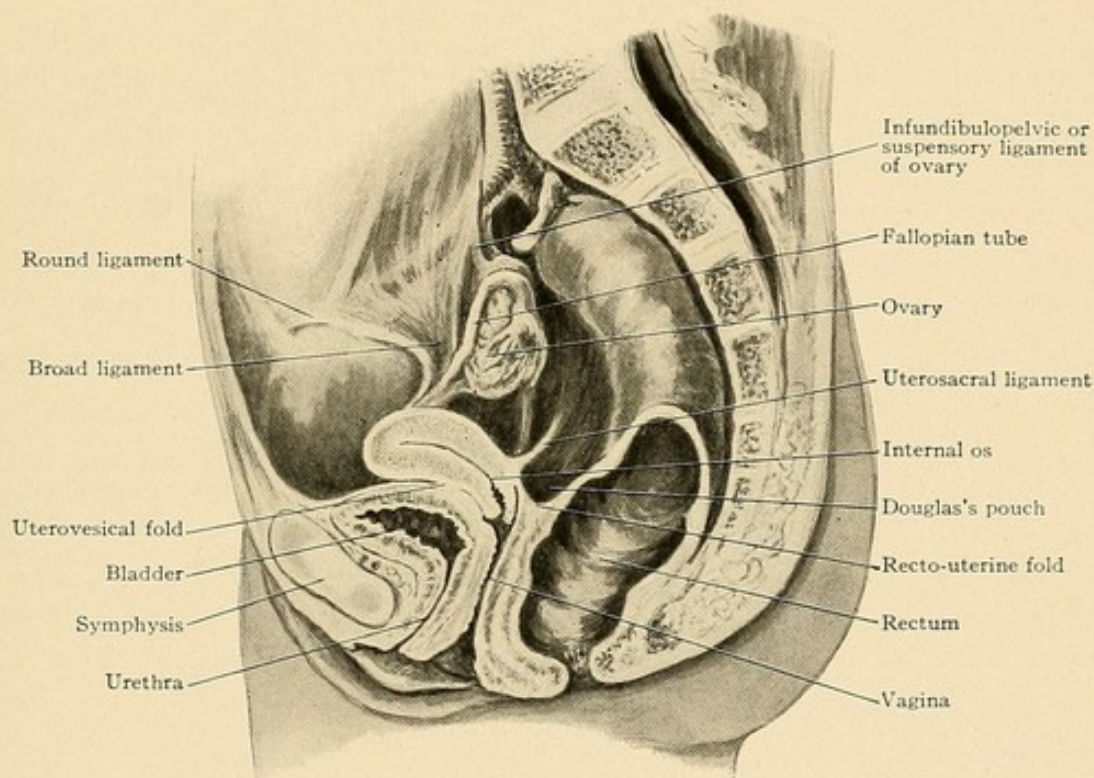


FIG. 458.—Lateral view of the interior of the female pelvis.

the *broad ligament* is the largest and most important. The two broad ligaments and uterus form a diaphragm which extends from one side of the pelvis directly across to the other, thus dividing it into anterior and posterior compartments. On the side of the uterus the broad ligament extends from the round ligament and Fallopian tube above down to below the level of the internal os. The anterior layer blends with the utero-vesical fold at the level of the internal os, while the posterior goes to the bottom of the pouch of Douglas. It passes outward to be attached to the sides of the pelvis from the external iliac vein above down to the floor of the pelvis. Between the two peritoneal layers of the broad ligament at its top is the Fallopian tube, a little lower on the posterior surface is the ovary, going to the ovary are the ovarian vessels; lower still is the round ligament; and running in the base of the broad ligament are the uterine artery and ureter. At its pelvic attachment the broad ligament widens out, having the round ligament as its anterior edge and the *infundibulopelvic* or *suspensory ligament of the ovary* as its posterior edge. This latter runs not to the uterus but to the fimbriated extremity of the Fallopian tube and ovary and contains the ovarian vessels. A little posterior is the *uterosacral ligament* (recto-uterine); it



runs from the uterus backward and contains muscular and fibrous tissue, the muscular tissue goes to the rectal wall while the fibrous goes to be attached to the second and third sacral vertebræ. This ligament on each side forms the outer border of Douglas's pouch.

Contained in the broad ligament between the Fallopian tube and ovary can be seen the remains of the parovarium or organ of Rosenmüller (page 453) and Gärtner's duct. A little farther in are the remains of the paroöphoron not clearly visible to the unaided eye.

The *round ligament* leaves the cornu of the uterus just below and anterior to the Fallopian tube, and passes outward, forward, and slightly upward to reach the internal inguinal ring and canal through which it passes to end in the subcutaneous tissue and skin of the labium majus. Owing to the ovary and Fallopian tube falling backward the round ligament is seen as a distinct cord passing to the sides of the pelvis. It receives a branch from the deep epigastric artery.

## THE OVARY.

The ovary is about 4 cm. ( $1\frac{1}{2}$  in.) long, 2 cm. ( $\frac{4}{5}$  in.) wide, and 1 cm. ( $\frac{2}{5}$  in.) thick. It is connected with the posterior surface of the broad ligament by a very short mesentery, the mesovarium. It is through this that the ovarian vessels pass. It has

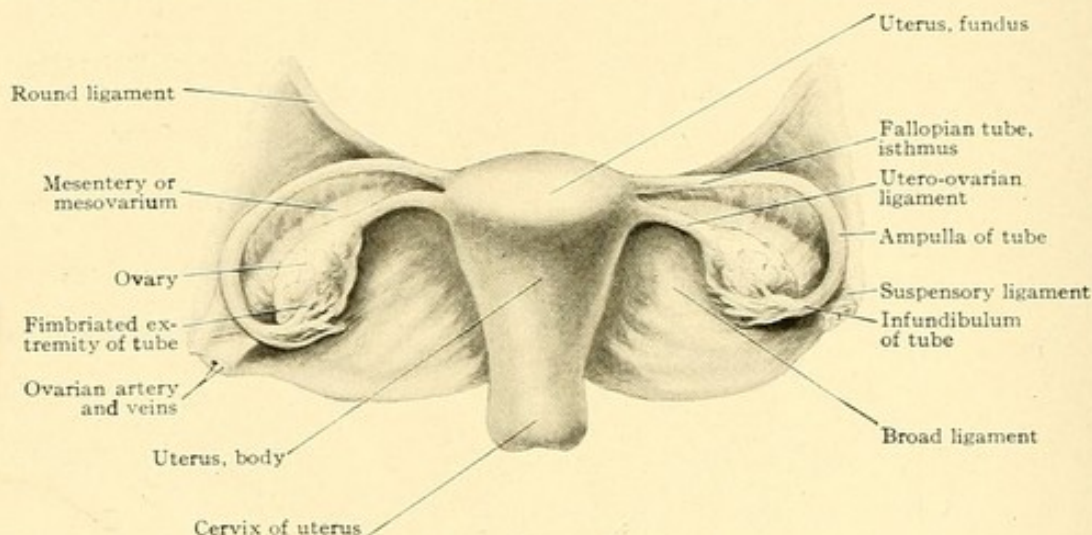


FIG. 459.—The uterus, ovaries, and tubes.

two ligaments, one, the suspensory or infundibulopelvic ligament, is a fold of peritoneum going up to the side of the pelvis above and contains the ovarian vessels; the other, the *utero-ovarian ligament*, going in the broad ligament to enter the uterus just below and behind the Fallopian tube. The ovary lies longitudinally or obliquely against the outer wall of the pelvis with the ureter just behind and below its posterior edge. From its upper end proceeds the suspensory or infundibulopelvic ligament and from its lower end the utero-ovarian ligament. The normal Graafian follicles and corpus luteum should not be mistaken for pathological cysts. The Fallopian tube surrounds the upper end of the ovary and its fimbriated extremity clings to its surface (Fig. 459).

**Fallopian Tubes.**—The Fallopian tube is about 11 cm. ( $4\frac{1}{2}$  in.) long and runs in the broad ligament along its top or free edge from the uterus to the ovary. Its inner portion between the proximal end of the ovary and uterus is straight and smaller in diameter than the rest and is called the *isthmus*. Its lumen is about 3 mm. ( $\frac{1}{8}$  in.). The part beyond, or *ampulla*, curves around the ovary from above downward and is larger than the isthmus and has a lumen of about 8 mm. ( $\frac{1}{3}$  in.). The size of the abdominal opening of the Fallopian tube is about 2 mm. or  $\frac{1}{12}$  in. The part of the broad ligament between the tube and mesovarium is called the *mesosalpinx*.



## THE VAGINA.

The vagina is about 7.5 cm. (3 in.) long; its posterior wall is longer than the anterior, being 8.75 cm. ( $3\frac{1}{2}$  in.) long. It will thus be seen that if the uterus is slightly depressed, as it often is, the cervix is within easy reach of the examining finger, if, however, it is drawn up, as by an abdominal growth, it may only be reached with difficulty. The hollow formed by the anterior wall of the vagina blending with the anterior lip of the cervix is called the *anterior fornix*. The depression behind the posterior lip is the *posterior fornix*, behind which is *Douglas's pouch*. At the vulvar outlet the lumen of the vagina is anteroposterior in direction, it then changes to lateral and at the cervix becomes round. Its walls are in contact. In nulliparæ the tube is more uniform in size, but in multiparæ it is small at each end but large in the middle. It is much more dilatable and larger in the latter, hence operations in nulliparæ are comparatively rarely done through the vagina. Anteriorly the vagina in its upper portion is in relation with the bladder. In its lower portion (about one-third) it is in intimate

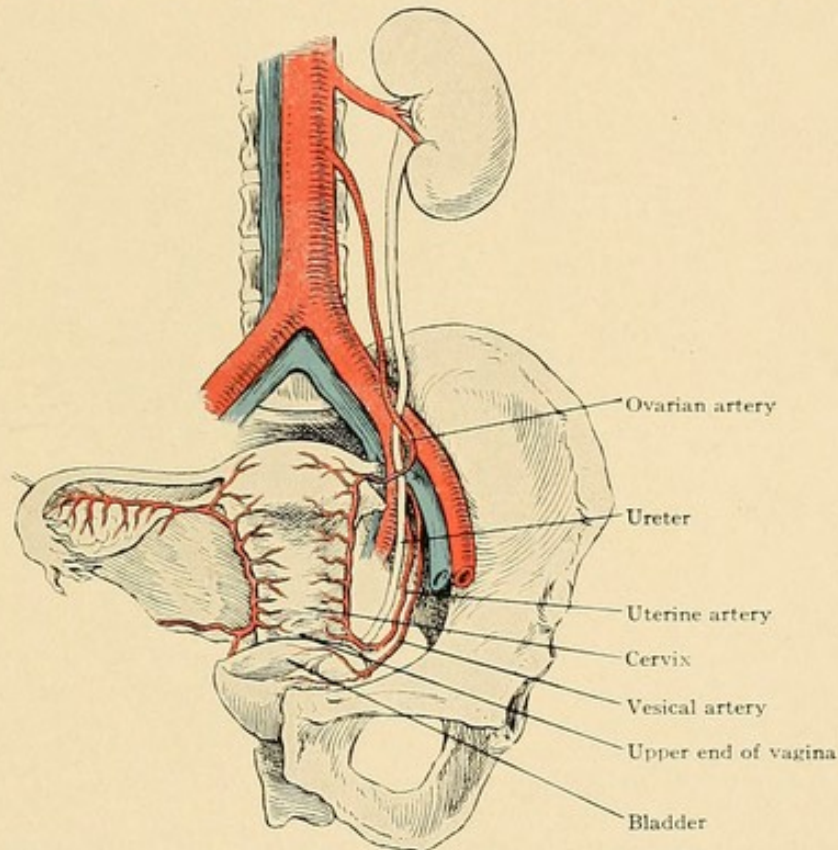


FIG. 460.—The ureter, ovarian artery, and uterine artery; showing their relation to the pelvic organs.

relation with the urethra except at the upper portion of the latter. Posteriorly its upper 1 or 2 cm. ( $\frac{1}{4}$  to  $\frac{3}{4}$  in.) is in front of the peritoneum and Douglas's pouch, below this lies the rectum, and between it and the surface is the perineal body. Laterally the ureters are close to the vagina and about half way up they empty into the bladder. In its lower portion the vagina is joined by the insertion of the levator ani muscle. The connection of the vagina to the bladder in front and rectum behind is loose, so that in performing operations it is readily separated from these organs.

**The Ureter in the Female.**—The pelvic portion of the ureter in the female is about 10 cm. (4 in.) long. It crosses the pelvic brim at a level with the first piece of the sacrum and passes over either the common iliac artery at its bifurcation or the external iliac at its commencement. It then follows the wall of the pelvis downward just posterior to the ovary and, near the floor of the pelvis, bends forward to pass through the base of the broad ligament, traversing the loose connective tissue (parametrium) and being about 1.5 to 2 cm. ( $\frac{1}{2}$  to  $\frac{3}{4}$  in.) outside of the cervix. At that



point it is crossed by the uterine artery. It then inclines somewhat inward and forward along the sides and anterior wall of the vagina to enter the bladder. Its opening in the bladder is about 2.5 cm. (1 in.) below the level of the external os, which is almost as far down as the middle of the anterior vaginal wall. The ureters run in the bladder wall obliquely for about 2 cm. ( $\frac{3}{4}$  in.) and their openings are from 2.5 cm. to 5 cm. (1 to 2 in.) apart according to the amount of vesical distention (Fig. 460).

**Blood-Vessels.**—The main blood-vessels of the pelvic genital organs are the uterine and ovarian arteries, described by some authors as the single utero-ovarian artery.

The **uterine artery** comes from the internal iliac and passes almost horizontally inward toward the lower portion of the cervix. As it approaches the cervix it gives off a cervicovaginal branch passing to the upper part of the vagina. At this point it has just crossed in front of the ureter and is about level with the external os. It then inclines upward, reaching the side of the uterus at its junction with the vagina. It passes up the side of the uterus, in nulliparæ a short distance away from its side, but in multiparæ close to it, until it reaches the cornu above. It here is continuous with the ovarian artery.

The **ovarian artery** comes down from the aorta as does the spermatic artery in

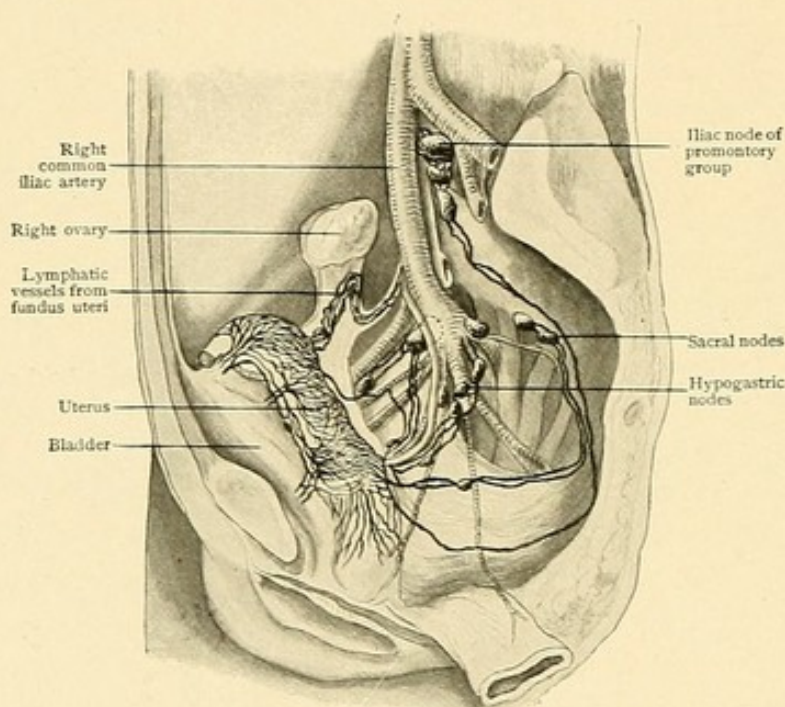


FIG. 461.—Lymphatics of uterus. (Cunéo and Marcille.)

the male. It crosses the brim of the pelvis in front of the ureter, enters the infundibulopelvic or suspensory ligament of the ovary and runs horizontally towards the uterus in the broad ligament between the round ligament and the ovary. It gives branches to the ovary and tube and as it reaches the cornu of the uterus it crosses in front of the round ligament and joins the uterine artery. As the uterine and ovarian arteries are continuous with each other either one may be the larger and they vary considerably in size.

A branch of the deep epigastric artery accompanies the round ligament inward and anastomoses with the uterine and ovarian arteries. It may be enlarged in disease of the ovaries and tubes.

**Lymphatics** (According to Poirier and Cunéo).—The *cervix* has three sets of lymphatics. The first passes outward and upward along the side of the pelvis anterior to the ureter to empty into the nodes along the external iliac artery. The second set passes backward behind the ureter to empty into a node on the anterior division of the internal iliac artery. The third set passes from the posterior surface of the cervix almost directly backward in the uterosacral ligaments to empty, some into the lateral sacral nodes high up in the hollow of the sacrum and some into the nodes of the promontory (Fig. 461).



The lymphatics of the *body of the uterus* communicate with those of the cervix below and at the cornu pass out as four or five trunks along the broad ligament between the ovary and Fallopian tube, being joined by branches from the ovary. They pass through the infundibulopelvic (suspensory) ligament and follow the ovarian vessels to empty into the aortic nodes below the kidney. The *ovarian* lymphatics form four to six trunks which ascend with the ovarian vessels to end in the lower aortic nodes. Opposite the fifth lumbar vertebra they communicate with the trunks from the body of the uterus.

**Pelvic Examinations.**—In making a digital examination the introduced finger recognizes that in the nullipara the vagina is narrow, admitting only one finger, and rugous on its anterior and posterior walls. In multiparæ it is smooth and admits two fingers. As the pulp on the palmar surface of the finger is used and not the side, the finger is to be directed posteriorly into the hollow of the sacrum and then brought anterior (Fig. 462). As the cervix enters the anterior wall and therefore, if normal, points down and back, and is about 6.5 to 7.5 cm. ( $2\frac{1}{2}$  to 3 in.) from the vulvar orifice, it is usually within reach of the tip of the finger. In the nullipara it is felt to be hard, rounded, and projecting distinctly into the vagina with a small os. In multiparæ it is larger, softer, not so prominent, its os is wider and often irregular in shape from lacerations. The uterus is often displaced so that the os may look forward or to one side. The normal uterus is not firmly fixed but is movable and can be readily moved up and down by the examining finger. If it is in a normal anteverted position it

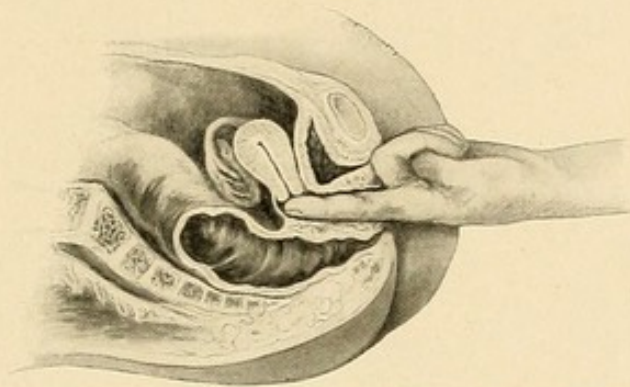


FIG. 462.—Digital vaginal examination. Ovary slightly prolapsed but as yet has not descended entirely into Douglas's pouch.

can be felt between the finger of one hand within and firm pressure with the tips of the fingers of the opposite hand from without just above the symphysis pubis. When the uterus retains its normal almost straight shape and falls either forward or backward it is said to be in a position of anteversion or retroversion. If the uterus is bent on itself in the shape of a curve it is then said to be anteflexed or retroflexed. In *anteversion* the external os points down and back, and the fundus can be felt with the other hand above the pubes. In *retroversion* the os looks downward and forward and the body of the uterus cannot readily be made out by bimanual palpation. If *anteflexed* instead of anteverted it is more difficult to feel the uterus through the abdominal walls but its fundus can be felt through the anterior vaginal wall in front of the anterior lip of the cervix. If *retroflexed* its projecting rounded fundus can readily be felt in Douglas's sac just behind the cervix. By a digital examination one determines the amount of mobility of the uterus, its size, its position, the condition of the cervix, whether or not it is the seat of indurations such as occur from cicatrices and cancer, whether it is lacerated, etc. Growths like fibroid tumors projecting from the anterior or posterior walls can also be felt. Particularly in thin subjects relaxed by anæsthesia the broad ligaments can be followed to the sides and even normal ovaries be recognized. When prolapsed they fall into Douglas's pouch and can be felt posterior to the cervix. Enlarged Fallopian tubes can be felt as distinct masses either fixed to one side of the uterus or prolapsed into Douglas's pouch. Renal calculi impacted in the ureter at its vesical end can be felt between the middle and upper end of the vagina to one side or the other.



## OPERATIONS ON THE FEMALE PELVIC ORGANS.

The most usual operations are the removal of the uterus,—hysterectomy,—removal of the ovary,—oöphorectomy,—removal of the Fallopian tubes,—salpingectomy. The ovaries are often removed with the diseased tubes and also in cases of hysterectomy. These operations are usually done through an abdominal incision near the median line between the umbilicus and the symphysis pubis. Not infrequently they are done through the vagina. After the abdomen is opened it is important to be able to recognize and isolate the individual organs, this is much facilitated by elevating the pelvis so that the intestines gravitate toward the diaphragm—Trendelenburg's position (Fig. 463). The incision having been made and the abdomen opened the first structure seen is the great omentum. This often extends as low as the symphysis. As it hangs from the transverse colon it is to be displaced upward and not toward the sides. The next structures exposed are either the small or large intestines. The transverse colon normally should not come below the umbilicus but it often does come lower and may even descend to the level of the symphysis. When it is low it lies in front with the small intestines behind. It likewise should be displaced upward. Sometimes the sigmoid colon may make its appearance from the left and more rarely the cæcum from the right. It should not be forgotten that both

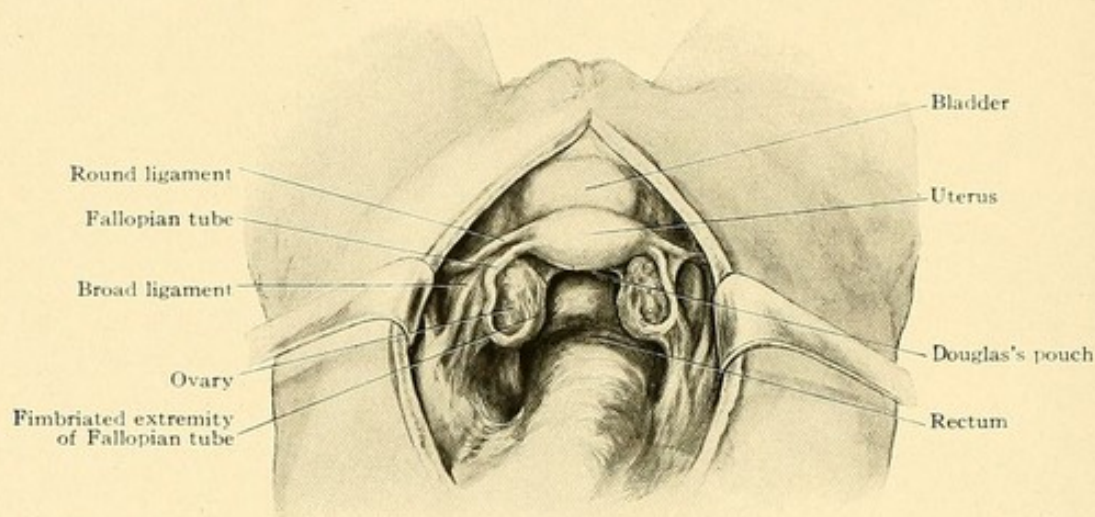


FIG. 463.—View of the interior of the female pelvis in the Trendelenburg position.

these structures are bound to the posterior abdominal walls and may often be covered in front by coils of small intestine. Quite frequently however, the cæcum on the right and iliac colon on the left come in contact with the anterior abdominal walls in the iliac fossa in the neighborhood of the anterior iliac spines and may extend part way down Poupart's ligament. The sigmoid colon if distended may bulge anteriorly but more usually it lies posteriorly covered by the small intestines. If it or the cæcum are encountered they are to be pushed upward and to the side. The small intestines are to be displaced upwards. In the median line anteriorly is now seen the bladder and directly behind it the uterus. If the uterus is drawn to one side the broad ligament of the opposite side is made tense and the round ligament is seen running to the internal ring anteriorly and, more posteriorly, the Fallopian tube. On the posterior surface of the broad ligament below the outer end of the Fallopian tube is seen the ovary. Farther posteriorly, in the hollow of the sacrum, is the rectum, with Douglas's pouch between it and the uterus in front. If it is desired to recognize the structures by touch instead of sight then the anterior abdominal wall is followed down over the bladder and the fundus of the uterus recognized as a hard rounded mass. This can be grasped between the thumb and fingers and followed laterally past the cornu to the broad ligaments. If the tubes and ovaries are enlarged they may be found lying posterior to the uterus in Douglas's pouch instead of laterally.



**Hysterectomy** (abdominal).—The uterus is to be drawn to one side and the posterior portion of the broad ligament is grasped out toward the pelvic wall. As the ovarian artery and veins run along the top of the broad ligament, a ligature is passed through it below them, but posterior or above the round ligament. A clamp may be placed on the side toward the uterus to prevent bleeding from the other side. The ligament is then divided between the ligature and clamp; sometimes the ovaries are allowed to remain, but usually they are removed with the uterus. A ligature is then placed around the round ligament and it is divided; often the round ligament is included in the first ligature. The incisions in the broad ligament are then carried through the peritoneum around the front of the uterus at the vesico-uterine junction and also posteriorly. The bladder being loosely attached can be separated by blunt dissection down to the level of the external os. A clamp close to the side of the cervix controls bleeding from the sides of the uterus, and by pushing away the connective tissue outwardly the uterine artery can be recognized, ligated, and divided. The ureter lies below and behind 1 to 2 cm. ( $\frac{1}{2}$  to  $\frac{3}{4}$  in.) distant from the cervix. The cervix is then detached from the vagina, and the bleeding from the small vaginal vessels controlled first by clamps and then by sutures.

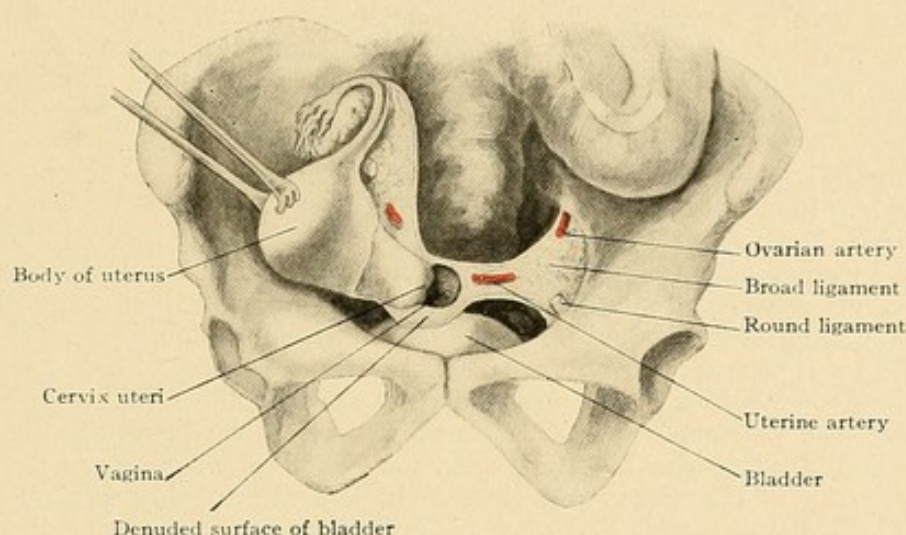


FIG. 464.—Removal of the entire uterus.

The same procedure can be repeated on the opposite side either by continuing from below up, or, as before, from above down (Fig. 464).

**Oophorectomy.**—In removing ovarian tumors any adhesions present are first loosened, and then the tumor raised up and its pedicle ligated. The Fallopian tube is usually adherent to and removed along with the tumor. The pedicle is formed by the utero-ovarian ligament on the inside and the infundibulopelvic on the outside; also the Fallopian tube and part of the broad ligament and branches or trunks of the ovarian artery and veins. As the ovarian vessels run horizontally, if the ligature is not placed low they may not be included, but only the branches which come off from them and proceed to the tumor.

**Salpingectomy.**—In removal of the Fallopian tubes for purulent or other conditions, adhesions are frequently encountered owing to previous inflammation. To remove such a tumor it is better usually to do it by sight rather than by touch alone. If the patient is placed in the Trendelenburg (elevated pelvis) posture the intestines fall out of the pelvis and are kept back by gauze pads. Any coils which are stuck fast to the adjacent organs can then be carefully dissected and peeled loose and the tumor exposed. It will be found either posteriorly in Douglas's pouch, or laterally between the uterus and side of the pelvis, pushing the former toward the opposite side. The distended, enlarged tube with the ovary adherent to it can then be isolated by inserting the finger between it and the pelvic wall, beginning at the posterior edge of the broad ligament and following it around posteriorly, loosening it from the rectum and Douglas's pouch until the uterus is reached. The



finger is then passed beneath the tumor and it is peeled off the pelvic floor, it can then be raised up and its base ligated much like the pedicle of an ovarian tumor. If this is carefully done the parietal peritoneum will not be broken through and there will be little or no bleeding.

**Tumors of the Broad Ligament** (intraligamentary tumors).—Certain tumors originating either from the structures of the broad ligament or ovary, or side of the uterus, grow between the layers of the broad ligament. Parovarian cysts arising from the remains of the Wolffian body are of this character. These intraligamentary cysts are retroperitoneal. The Fallopian tube is spread over and adherent to their upper surface. As they grow down they come in contact with the ureter, which becomes adherent to the bottom and sides of the growth. The liability of injury to the ureter is the greatest danger in these cases, and can only be escaped by searching for, recognizing, and avoiding it. These growths are exposed by splitting the peritoneum covering them and then shelling them out. At times they are large and formidable and extremely difficult to remove.

**Extra-Uterine Pregnancy.**—The most dangerous factor in operating for extra-uterine pregnancy is hemorrhage. The tumor is usually tubal in position. The bleeding comes from the sac, therefore loosening and isolating it should be done with the greatest care to avoid rupturing it. If already ruptured the blood is to be rapidly sponged out, the uterus recognized and grasped with the hand, which is then slid outward until the ruptured tumor is felt and drawn up. The blood comes to the tumor from the ovarian artery and uterine artery. To control the former a clamp is placed on the broad ligament close to the pelvic wall. To control the latter a clamp is placed low down on the broad ligament close to the uterus. The active bleeding then ceases.

**Vaginal Hysterectomy.**—The uterus if not much enlarged can be removed through the vagina when, as is the case in multiparæ, it is lax and capacious.

The cervix is grasped and drawn down to the vulva and the mucous membrane incised in the anterior fornix and posteriorly close to the uterine tissue. The bladder is pushed up and separated from the cervix by dry dissection with occasional snipping of fibrous bands by scissors until the peritoneum at the level of the internal os is reached. The peritoneum, which from this point up is adherent to the uterus, is opened and divided to the broad ligaments on each side. Douglas's sac is next opened posterior to the cervix and close to it, and the opening enlarged with the finger to the broad ligaments. A clamp is now placed on each broad ligament low down to control the uterine arteries. By hooking the finger above the fundus it can be brought back and down and out, the ovaries usually coming with it. The remaining portion of the broad ligaments is then either clamped or tied to control the ovarian arteries. Some operators use clamps alone, others use ligatures. Vaginal branches which bleed are grasped with hæmostats and ligated. The ureters, which lie 1.5 to 2 cm. ( $\frac{1}{2}$  to  $\frac{3}{4}$  in.) away from the cervix, are pushed outward when the opening in Douglas's sac is enlarged, and will be avoided by not placing the clamps too far away from the cervix.

**Laceration of the Cervix.**—The cervix is made accessible for operation by grasping it with tenaculum forceps and drawing it down to the vulva. It is there held to one side, which renders the laceration easily accessible for excision and the introduction of sutures. Bleeding is controlled by the sutures.

## THE FEMALE EXTERNAL GENITALS.

The *labia majora* meet anteriorly in the *anterior commissure* and posteriorly in the *posterior commissure*.

The space between the posterior commissure and the anus, about 3 cm. ( $1\frac{1}{4}$  in.) is the *perineum* (Fig. 465).

The *labia minora* divide anteriorly to form the *prepuce* above the *clitoris* and the *frænum* on its lower surface. Posteriorly they fade away into a thin crescentic fold of mucous membrane called the *fourchette*. The space between the labia minora is the *vestibule*. The *meatus* or *urethra* is in the vestibule 2.5 cm. (1 in.) behind the clitoris. It is surrounded by a ring of mucous membrane and in introducing the



catheter it can be recognized by the sense of touch and so localized. The openings of the *para-urethral ducts* are just below and to the outside of the meatus. The *vulvo-vaginal glands* (of Bartholin) empty on the inner side of the labia minora in the sulcus between them and the hymen. The openings of the ducts are just visible to the naked eye. The openings are about opposite the middle of the vaginal orifice

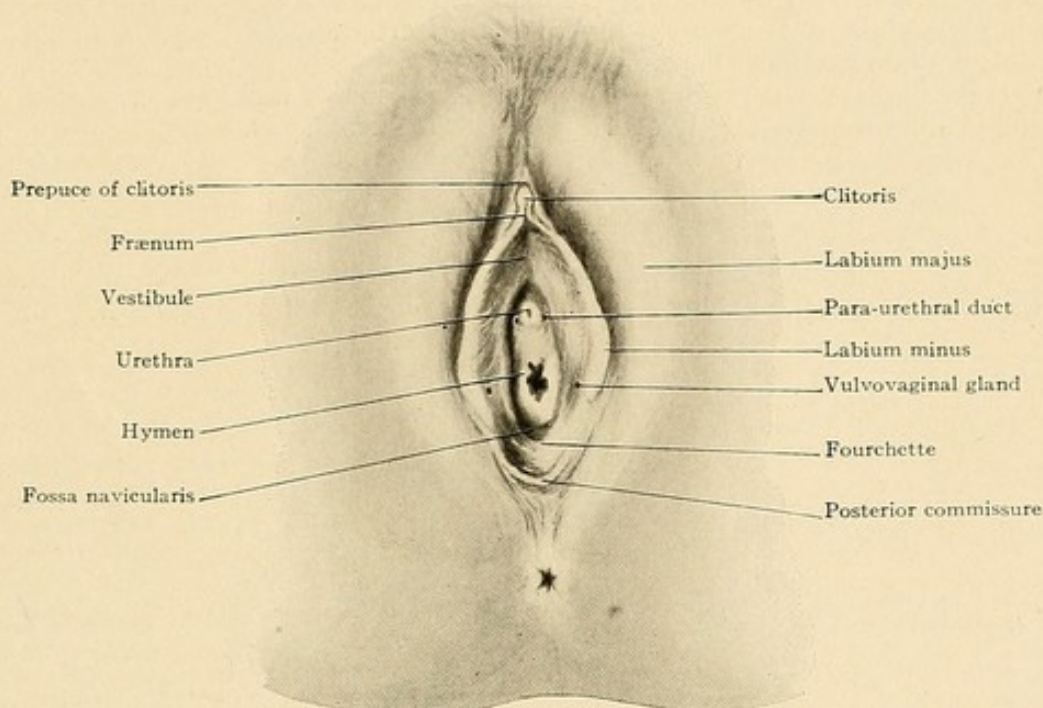


FIG. 465.—External female genitals (vulva).

and the ducts pass down and out to the glands, which are of the size of a bean and lie on each side of the lower end of the vagina.

The *hymen* partly occludes the lower end of the vagina across its posterior portion. The *carunculae hymenales* are the remains of the ruptured hymen. The *fossa navicularis* is the space between the hymen and the fourchette.

#### Clinical Considerations.

—The external genitals are well supplied with veins, and in pregnancy or pelvic growths they may become enlarged and varicose, especially over the labia majora. The fourchette and perineum frequently become ruptured in delivery, the tear, if complete, going into the rectum. The meatus is sometimes the seat of a papillo-angiomatic growth called urethral caruncle. It is treated by removal. The vulvovaginal glands are the seat of cysts and abscesses. They appear as swellings alongside the posterior portion of the vaginal opening. The former are to be carefully and completely excised and the latter opened and packed. The vulvar slit is anteroposterior, the vagina forms a transverse slit and the hymen is placed at the point of transition. In making a vaginal examination (dorsal decubitus) the index finger is to be held vertically until the vestibule is entered. It then is passed horizontally into the vagina and turned palmar surface

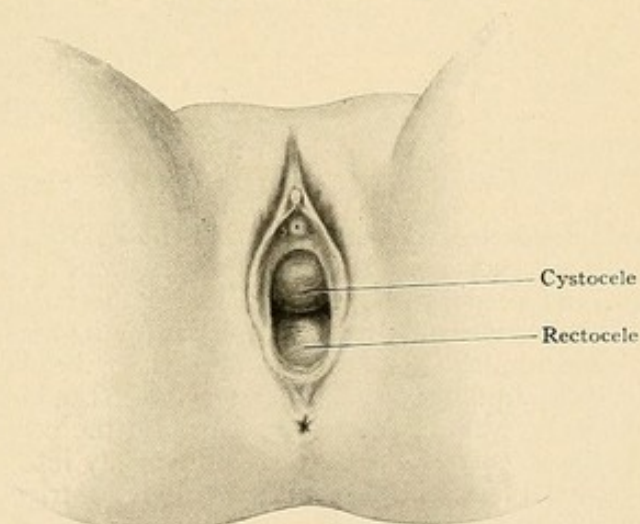


FIG. 466.—Hernia of the bladder (cystocele) and of the rectum (rectocele).



upward to recognize the cervix entering the anterior vaginal wall. Firm pressure with the other hand to depress the external parts is necessary to reach the posterior fornix and Douglas's pouch.

**Cystocele.**—As a result of the relaxation following childbirth the bladder may prolapse through the vaginal orifice. When the uterus prolapses it also drags the bladder down with it. It is to be recognized by passing a sound through the urethra into it. It is treated by excising the mucous membrane covering the cystocele and sewing the sides of the wound together, thus crowding the mucous lining of the bladder up into position (Fig. 466).

**Rectocele.**—The rectum prolapses at the posterior wall of the vagina the same as the bladder does anteriorly and it is treated in a similar manner.

## THE FEMALE PERINEUM.

The perineum in the female is much like that of the male. It has a central point at which converge the external sphincter ani from behind, the superficial transverse

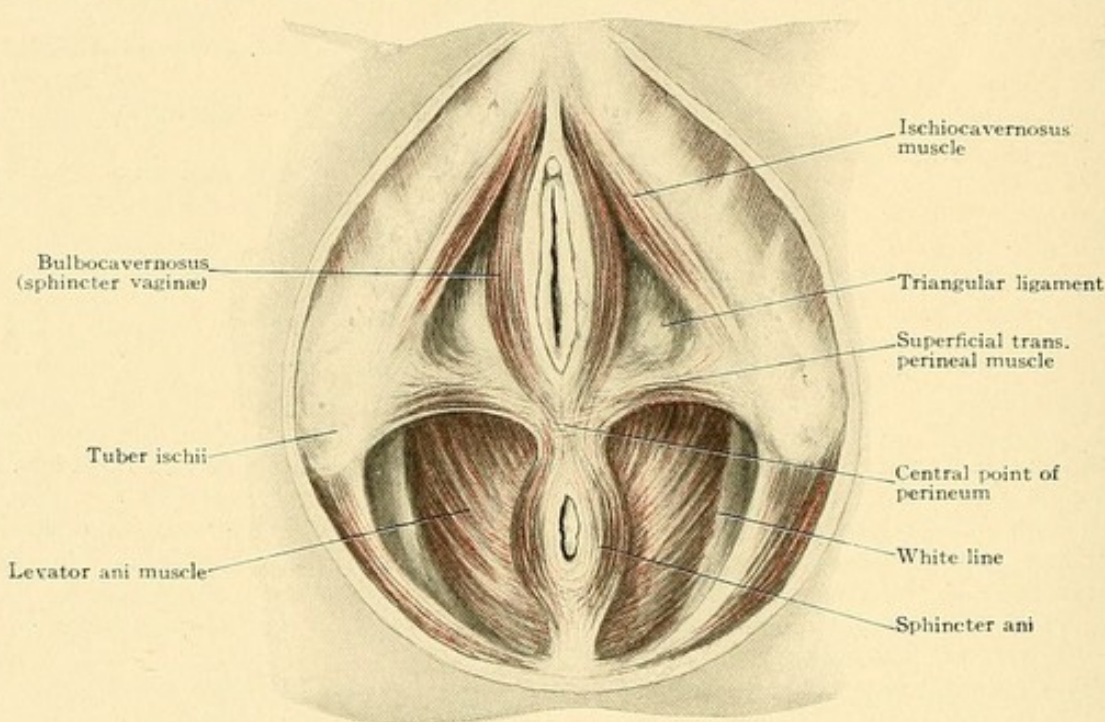


FIG. 467.—Female perineum.

perinei muscles from each side and the bulbocavernosus muscles from the front. The ischiocavernosus muscles lie along the rami of the pubes. These superficial muscles are reinforced by the deep transverse perinei muscle, which comes from the ramus of the ischium on the side to insert by its anterior fibres around the urethra (compressor urethrae), its middle fibres into the vaginal wall, and its posterior fibres at the central point of the perineum. Also the levator ani muscle inserts into the lower end of the vagina anteriorly, then into the central point of the perineum, next into the lower end of the rectum, and finally into the coccyx. The deep layer of the superficial fascia (Colles's fascia) and the triangular ligament being pierced by the vagina are not so marked as in the male—between them lie the ischiocavernosus, bulbocavernosus, and superficial transverse perinei muscles (Fig. 467).

**Rupture or Laceration of the Perineum.**—When the tear goes only part way through the perineum it is called an incomplete laceration; when it goes through into the rectum it is a complete tear.

In an incomplete tear the bulbocavernosus muscles (called also sphincter vaginae) are separated behind and consequently their function of holding the labia majora together is lost and the vulva gapes. In a complete tear all the muscles



helping to form the perineum are divided: they are the bulbocavernosus, the superficial and deep transverse perinei, and the levator ani and external sphincter ani muscles. They draw the sides of the wound apart, sometimes forming a dimple on each side, and thus enlarge the vaginal outlet and allow the anterior wall of the rectum as well as the posterior wall of the bladder to prolapse (Fig. 468).

**Operation.**—The torn area is to be denuded by beginning the incision not higher up than the lower end of the labium minus on one side and carrying it down and then up to a corresponding point on the opposite side. From the extremities of this incision two more are made extending 2.5 to 5 cm. (1 to 2 in.) up the vagina and meeting in the median line. Emmet carried the denudation up each lateral sulcus. The mucous membrane so marked out is then dissected away; to close the wound some operators introduce and bring out the stitches all on the skin surface, while others introduce and tie half of them on the vaginal surface and the other half on the skin surface. The needle is to be carried well out toward the rami of the ischium so as to include a large mass of tissue.

If the mucous membrane of the rectum has been torn it is to be sewed together before the perineal tissues are approximated.

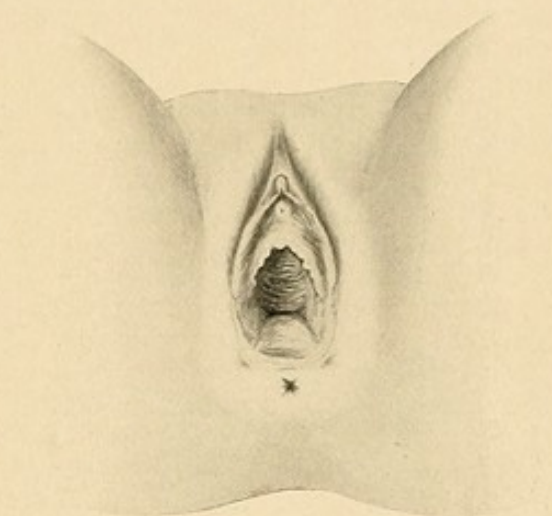


FIG. 468.—Rupture of the perineum. The vulva gapes, showing the rectum bulging forward; the two dimples, one on each side of the anus, are caused by the retracted muscles.

## THE MALE EXTERNAL GENITALS.

**Penis.**—The penis is composed of the two *corpora cavernosa* attached posteriorly to the rami of the ischia and pubes and terminating in blunt ends anteriorly, and the *corpus spongiosum*, commencing at the bulb, at the central point of the perineum posteriorly, and ending in the glans anteriorly. The *glans* is the extended corpus spongiosum and covers the ends of the corpora cavernosa. Its extended rim

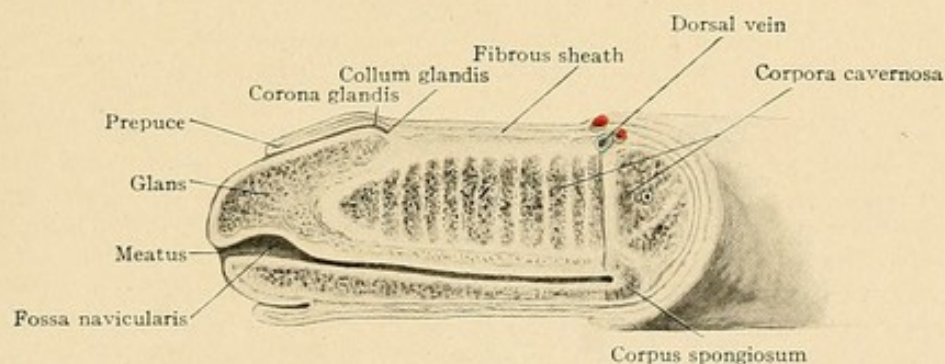


FIG. 469.—Structure of the penis.

is called the *corona glandis* and the groove immediately behind, the neck, or *collum glandis*. In the centre of each corpus cavernosum runs an artery (Fig. 469).

The *skin* is thin, loose, free from hair except at the root, and has beneath it some fibres of the dartos. It projects over the glans, forming the *prepuce* and is attached at the neck or collum glandis and underneath as far forward as the urethra, forming the *frænum*. The connective tissue beneath the skin is loose and free from fat. A *fibrous sheath* (Buck's fascia) surrounds the corpora cavernosa and corpus spongiosum and binds the three together. It is continuous posteriorly with the suspensory ligament and the deep layer of the superficial fascia (Colles's fascia).



Anteriorly it ends at the collum glandis. The corpora cavernosa and corpus spongiosum have each a separate fibrous sheath which separates the two corpora cavernosa forming the *septum pectiniforme*; it is incomplete anteriorly, allowing the blood of the two corpora cavernosa to mingle. The separate sheath of the corpus spongiosum is not as marked as those of the corpora cavernosa. The single dorsal vein of the penis runs in the median line with an artery to each side and the dorsal nerves still farther out. They all lie between the fascial covering of the corpora cavernosa beneath and the fibrous sheath above.

The *lymphatics* of the prepuce and skin drain into the inguinal nodes, those of the glans empty into the nodes in and just above (inside the abdomen) the crural canal; one radicle enters through the inguinal canal running posterior to the cord. As the lymphatic radicles anastomose at the root of the penis a lesion on one side of the organ may involve the lymphatic nodes in the opposite inguinal region.

**Practical Considerations.**—The opening of the prepuce is often constricted, so that the glans cannot be uncovered. This condition is called *phimosis*. A certain amount is normal in young children. At times the prepuce becomes adherent to the glans but it can usually be separated by a blunt instrument without cutting. When the sulcus is reached an accumulation of smegma is seen. This is produced by the subcutaneous glands of the corona and collum glandis and under surface of the prepuce. In performing *circumcision* the prepuce should not be drawn too far forward or too much of the skin and not enough of the mucous surface will be removed; a common

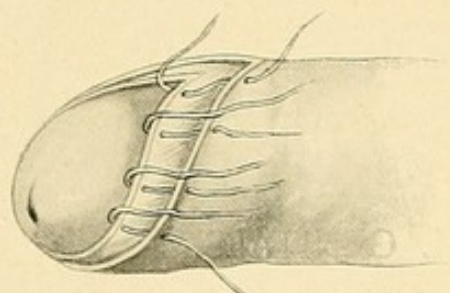


FIG. 470.—Circumcision.

mistake. It is sufficient to remove the skin and mucous membrane two-thirds of the way back to the sulcus and then bring the ends of the incision gradually down and forward to meet at the lower angle of the meatus (Fig. 470). By doing this the *frænum* is not cut and troublesome bleeding from the little artery it contains is avoided. The laxity of the skin, especially of the prepuce, favors rapid swelling. When a contracted prepuce is forcibly drawn behind the glans it constricts the veins and the part beyond the

constriction swells rapidly. This is called *paraphimosis*. To relieve it an incision is made through the skin directly across the constricting band and the prepuce can then be pulled forward over the glans.

*Extravasation of urine* may invade the penis beneath the fibrous sheath but does not invade the glans because the sheath stops at the collum glandis.

*Fracture or rupture* of the corpora cavernosa may occur from violence. The extravasated blood is absorbed and the laceration heals with a scar. In erection this part does not expand, hence deformity and distortion with interference of function may result.

*Chordee*.—When the urethra is inflamed the exudate may involve the corpus spongiosum surrounding it and prevent it from expanding. In erection the organ assumes a downward curve, a condition designated as *chordee*. It disappears with the subsidence of the inflammation.

**Amputation of the Penis.**—The penis is frequently amputated for carcinoma, which disease is favored in the aged by the irritation resulting from a long-existing phimosis. In operating two things are to be guarded against, bleeding and subsequent contraction of the meatus. Bleeding may come from the dorsal arteries or the artery which runs in the middle of each corpus cavernosum. They can first be controlled by a circular rubber band and then later readily ligated. To prevent contraction of the new meatus three methods are available: (1) A long dorsal and short under flap may be cut and the urethra dissected out from the under flap and allowed to project beyond the cut corpora cavernosa. The long dorsal flap is brought down, pierced, and the urethra drawn through. It is then slit up and sewed on each side. A few sutures are then used to unite the upper and lower flaps below the urethra. (2) Two lateral flaps may be made and the split urethra sewed in the line of union between the two flaps. (3) (Writer's, *University Medical Magazine*, January, 1897.) A circular cut is made around the penis and the skin turned back. The penis is then turned up,



the urethra dissected out for 1.25 cm. ( $\frac{1}{2}$  in.), and the corpora cavernosa divided. The arteries being tied, the two outer edges of the corpora cavernosa are brought together in the median line with three catgut sutures. The urethra is then slit up in three places, one below and two above; the three square flaps so formed are then turned back and their corners cut off. This makes three small triangular flaps which when spread out form one large triangle. The skin is then sutured accurately to the edges of this triangle and no raw surface is left (Fig. 471).

#### Scrotum, Testicles, and Spermatic Cord.—

The SCROTUM is the bag in which the testicles are contained. It consists of skin and dartos. The remaining tissues covering the testicles are derived from the layers of the abdominal wall and belong properly to them. The *skin* is thin, loose, wrinkled, and contains sebaceous glands which frequently become occluded, forming small tense cystic tumors. The *dartos* is composed of loose connective tissue and unstriped muscular fibres. It is intimately connected with the skin but moves freely on the parts beneath. It is continuous with the general superficial fascia and with its deep layer or Scarpa's fascia of the abdomen and Colles's fascia of the perineum. It dips between the testicles, forming an incomplete septum (Fig. 472).

*Practical Applications.*—Contraction of the dartos wrinkles the scrotum and if wounded the edges are inverted. For this reason, in operations on the scrotum,

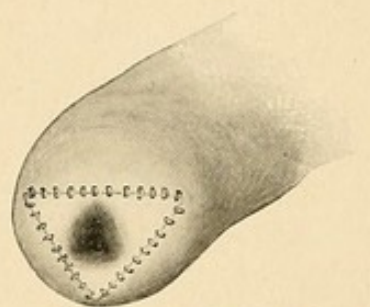


FIG. 471.—Amputation of the penis. Mucous membrane of urethra everted, cut in triangular form and sewed to the skin to avoid cicatricial contraction. (Author's method.)

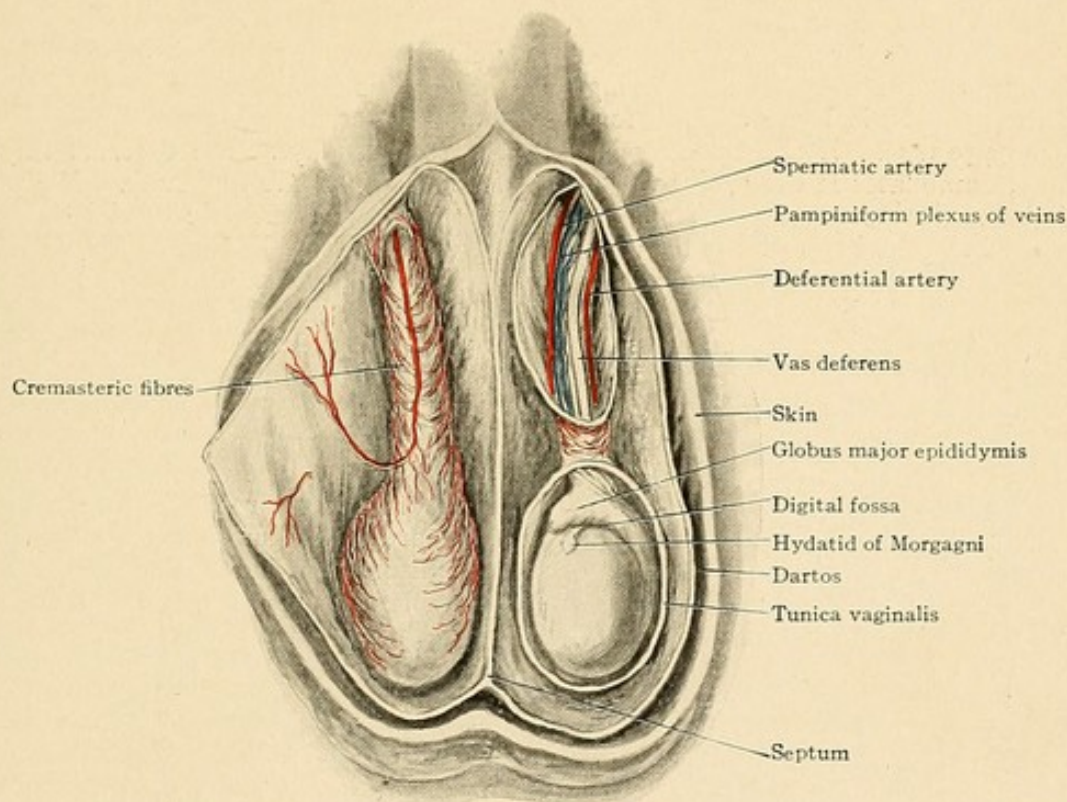


FIG. 472.—Scrotum, testicles, and spermatic cord.

if primary union is desired particular care must be taken to approximate accurately the skin edges and prevent their inversion. The raising of the testicles is done by the cremaster muscle and not by the dartos except incidentally as the scrotum contracts.

The scrotum is supplied by blood through the perineal branches of the internal pudic artery, and by the external pudic. On account of the looseness of the skin attachment, œdema and extravasation of blood and urine may be very extensive and violent. They readily impair the blood circulation and gangrene not infrequently



results. It is for this reason that urinary infiltrations are to be at once incised, and in operations the greatest care is exercised to stop every bleeding vessel. Infection of this region is particularly troublesome and a strict technic is necessary in operating to avoid it. In some cases of varicocele with pendulous scrotum a portion of the scrotum is excised in order to support the testicles.

**TESTICLES.**—The testicles begin to develop early in fetal life—about the third month—below and in front of the kidneys, opposite the second lumbar vertebra.

**Descent of the Testes.**—The testis is covered by peritoneum, which is prolonged at its upper and lower ends. The lower reaches down to the internal ring and later contains fibrous and muscular tissue and passes through the inguinal canal to the lower part of the scrotum: it is called the *gubernaculum testis*. It reaches its highest development in the sixth month and its remains attach the testicle to the lower part of the scrotum as the *ligament of the scrotum*. As the testicle descends, the upper peritoneal band covers the spermatic vessels from the region of the kidney down. The lower portion of the gubernaculum sends branches to the regions of the pubes, perineum, and saphenous opening. The testicle is preceded in its descent through the inguinal canal by a fold of peritoneum—the *vaginal process*—which forms the tunica vaginalis over the testicle, the part above atrophying.

**Practical Applications.**—The testicle may be arrested in some portion of its course, forming an *undescended testicle*, or it may be displaced, as has been suggested, by an abnormal development of one of the subsidiary bands of the gubernaculum. Hence it may be found, not in the scrotum, but in the perineum, in the femoral region, or in the pubic region. It may go through the femoral canal instead of the inguinal. If it is undescended it may be arrested in the abdominal cavity, in the inguinal canal, or at the external ring.

The vaginal process may not entirely close, so that the peritoneal fluid passes down to the tunica vaginalis covering the testicle; this is called a *congenital hydrocele*. If the opening is large enough for intestine to enter, it forms a *congenital hernia* (see page 383). If the opening is closed above, usually at the external ring, and fluid accumulates in the tunica vaginalis it forms an *infantile hydrocele*. If a portion of the vaginal process persists somewhere along the spermatic cord between the internal ring and top of the testis it forms a cyst and is called an *encysted hydrocele of the cord*. The vaginal process closes at its upper portion just before birth and in those cases which are patulous after birth (congenital hernia and hydrocele) there is a tendency to spontaneous closure, hence operative measures are usually deferred. The vaginal process also descends into the inguinal canal in the female and a hydrocele of it is called a *hydrocele of the canal of Nuck*.

**Size, Position, etc.**—The normal testicles are 4 cm. ( $1\frac{1}{2}$  in.) long, 2.5 cm. (1 in.) wide, and 2 cm. ( $\frac{2}{3}$  in.) thick. They are firm to the touch. If larger they are either hypertrophied or diseased. If hypertrophied their consistence is not materially altered, if diseased they are usually harder. If smaller they are usually atrophied and besides the lessening of size are also softer and flabby in consistency.

They lie attached at the inner posterior portion of the scrotum and their long axis points upward, slightly forward, and outward. In all cases of hernia and hydrocele the testicle is to be felt for at the inner posterior aspect of the swelling. In rare instances the testicle is placed anteriorly instead of posteriorly and is liable to be wounded in introducing a trocar into the tunica vaginalis to empty a hydrocele. To avoid this accident the position of the testicle can be determined not only by touch but also by seeing the outline of the testicle by means of a light placed on the opposite side of the scrotum. As the testicle is almost always low down the puncture should be made higher up and preferably on the outer side.

**Epididymis.**—The vas deferens descends to the lower end of the testicle and becoming much convoluted forms the globus minor or tail, thence ascends, forming the body, and finally at the top, receiving the efferent ducts, forms the globus major or head. Between the body of the epididymis and testis is a pocket or depression called the digital fossa. Attached to the upper end of the testis is a small flat body in front of the globus major and attached to the globus major itself is a small cystic pedunculated growth. Both are known as the hydatids of Morgagni, and the former is the remains of the duct of Müller, while the latter is derived from the Wolffian body.



*Practical Application.*—Inflammation of the testis proper is called *orchitis*; of the epididymis, *epididymitis*. When the testicle as a whole is enlarged, if it is due to syphilis or new growth, the testis itself is mainly affected and it is then called *sarcocele*. Inflammations, the result of injury, may produce a true orchitis, but when arising from infections they involve the vas deferens and epididymis and produce an epididymitis. This is the case in gonorrhœa and tubercle, and to a less extent in mumps. An enlarged epididymis can be outlined by careful palpation as being distinct from the testis proper. Advanced tubercle may invade the testis subsequently.

Cystic disease is fairly frequent; it involves the epididymis, especially the globus major. The cysts may be very numerous and may spring either from the ducts of the globus major or from the hydatids of Morgagni.

*Coverings of the Testicle.*—The tunica vaginalis comes from the peritoneum, the tunica albuginea is the continuation of the transversalis fascia (infundibuliform fascia); it is strong, dense, and inelastic. Over this are a few cremasteric fibres from the internal oblique and the intercolumnar fascia from the external oblique. The dartos is continuous with the fascia of Scarpa of the abdomen.

*Application.*—The tunica vaginalis being a closed sac may become distended with serum, forming a hydrocele. The precautions to be taken in tapping it have been alluded to above. It is treated radically by excising the parietal layer and leaving the visceral layer covering the testicle and epididymis. The questions of hemorrhage and skin inversion have also been discussed. Inflammation causes intense pain on account of the unyielding character of the tunica albuginea. To relieve it multiple fine punctures are sometimes made. Abscess (tuberculous) of the testicle opens the tunica albuginea and the testicular tissue protrudes, forming a *hernia testis*. Such testicles are often excised, but if not the hernia eventually shrinks and reduces itself (Holden).

**SPERMATIC CORD.**—The left spermatic cord is longer than the right, hence the left testicle hangs lower. The cord is composed of the vas deferens with its artery, a branch of the superior vesical, and veins; the spermatic artery with its veins; the cremasteric artery; and the layers derived from the abdominal wall (the same as possessed by the testicle). It also possesses nerves, the genital branch of the genitocrural, and branches of the sympathetic, and lymphatics. The *vas deferens* is a small, round, hard cord lying posteriorly. It can be seen when the elements of the cord are separated and can be distinctly felt even through the scrotum. The *deferential artery* accompanies and lies on the cord. The *deferential veins* go with the artery. They unite and form three or four trunks (pampiniform plexus) which pass through the inguinal canal to join and form at the internal ring one large vein, the spermatic, which accompanies the spermatic artery; the right empties into the vena cava, while the left empties into the left renal vein. They possess but few valves, which are imperfect.

The *spermatic artery*, from the aorta, descends in front of the vas deferens and is accompanied by the pampiniform plexus of veins. It lies in the plexus with most of the veins in front of it. These vessels lie in loose, fatty connective tissue derived from the subperitoneal tissue along with the atrophied remains of the peritoneum (ligament of Cloquet).

These structures are covered by the *sheath of the cord*, composed (1) of the transversalis fascia (infundibuliform fascia), (2) cremasteric fibres and fascia from the internal oblique, and (3) intercolumnar fascia from the external oblique.

*Application.*—The cord is involved in operations for varicocele, hernia, and castration. In *varicocele* after the skin incision is made a second incision is required to open the sheath of the cord. This having been done the pampiniform plexus of veins, which are the ones enlarged (varicose) in varicocele, come into view. As many of these as desired are then drawn out, ligated at both ends, and removed. In doing this the spermatic artery may likewise be tied. The circulation is afterwards carried on by the artery and veins of the vas, the cremasteric artery being in the sheath externally. It is wise not to remove all of the enlarged veins. The vas deferens is recognized posteriorly both by sight and touch and is not to be disturbed. In *hernia* the vas deferens sticks close to the sac, on the posterior and inner side. It must be sought for and carefully isolated. In *castration* the testicle is so movable that it can be pushed up into the inguinal region and the incision through the skin for its removal made in that locality. If done for malignant disease a large portion of the vas is removed. This can be done



by incising up to the internal ring and drawing the vas out after freeing it of any restraining fibrous bands. All bleeding vessels are to be ligated and the cord securely held. If the cord slips before all the vessels are secured, the stump may retract in the abdomen and dangerous bleeding result before it can again be secured and the vessels ligated.

## THE URETHRA.

The male urethra is variable in length, as it can be stretched, therefore only average measurements can be given. Its *length* is 20 cm. (8 in.) in the adult, 8 to 10 cm. at 5 years, and 10 to 12 cm. at puberty. Of this, 3 cm. ( $1\frac{1}{4}$  in.) is prostatic, 0.5 cm. ( $\frac{1}{2}$  in.) being in the bladder wall; 1 cm. ( $\frac{2}{3}$  in.) is membranous; 16 cm. (a little over 6 in.) is penile. Its *calibre* varies, being narrowest at the meatus and next narrowest at the membranous portion. The internal meatus is a little larger than the membranous portion. The meatus admits a No. 24 French sound (often

larger), the membranous portion a 26 to 28. The prostatic portion is the largest, admitting a No. 32 sound. The bulbous is almost or quite as large, admitting a 30 to 32. Therefore a sound which passes the meatus should find no further obstruction. The fossa navicularis just beyond the meatus is larger than the urethra beyond (Fig. 473).

**Distensibility.**—The meatus and membranous portions are the least distensible. The former is fibrous in character and will not stretch. In the membranous portion the support of the superficial and deep layers of the triangular ligament prevent dilatation. The prostatic is the most dilatable portion and the bulbous urethra next.

**Relations.**—The internal urethral meatus lies about 6.25 cm. ( $2\frac{1}{2}$  in.) from the surface just behind the middle of the symphysis, if the body is in a vertical position. The membranous portion pierces the triangular ligament, 2.5 cm. (1 in.) or a little less below the subpubic ligament. The lowest portion is just in front of the triangular ligament. The urethra then rises slightly, 0.5 cm. ( $\frac{1}{2}$  in.), and finally drops to the meatus. The subpubic curve of the urethra has a radius of about 5 cm. (2 in.) and urethral instruments are made with approximately this curvature, though they vary much. The membra-

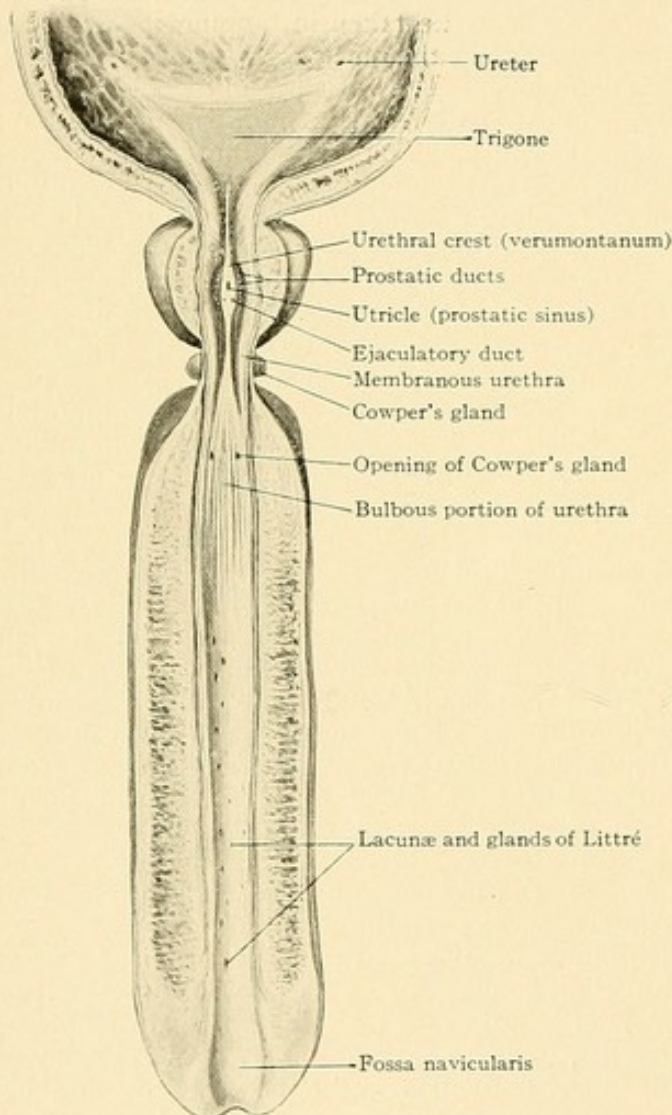


FIG. 473.—The male urethra.

nous urethra can be palpated at the apex of the prostate by the finger in the rectum.

**Structure.**—The urethra is composed of an external layer of erectile tissue covering a muscular layer which is continuous with that of the prostate and bladder. Beneath the muscular layer is the submucous, rich in blood-vessels, on which is laid the mucous layer. This latter is covered with flat, pavement epithelium in the fossa navicularis, and columnar epithelium beyond.



The urethra contains small mucous glands opening on its surface—*glands of Littré*—and small pockets or recesses, called the *lacunæ of Morgagni*, into which the glands of Littré sometimes empty. The lacunæ are mostly in three rows on the roof of the penile portion and open forward toward the meatus. A large one—*lacuna magna*—opens in the posterior portion of the roof of the fossa navicularis, a couple of centimetres behind the meatus. The glands of Cowper open into the bulbous urethra just in front of the triangular ligament. The racemose glands of the prostate open into the sides of the floor of the prostatic urethra, and the ejaculatory ducts open near the middle line just in front of the urethral crest (*verumontanum*), with the utricle (prostatic sinus) between.

The mucous walls of the urethra are normally in contact, making a vertical slit at the external meatus, a transverse one in the penile portion, horseshoe shape in the prostate, and again transverse just before the bladder is reached.

**Urethral Muscles.**—There are two sets of muscles in connection with the urethra; one set might be said to aid in expelling the urine and the other in retaining it. The expulsors are the longitudinal and circular fibres surrounding the urethra just outside the mucous membrane and the *accelerator urinæ* or *bulbocavernosus muscle*. The sphincters are the *compressor urethræ* or *external sphincter muscle*, and the *internal sphincter* at the neck of the bladder, composed of fibres continued from the bladder and prostate. The portion of these fibres surrounding the internal meatus just beneath the mucous membrane is called the *annulus urethralis*.

It has been supposed that if the bladder becomes distended the internal sphincter involuntarily relaxes and allows the urine to enter the prostatic urethra, and it is then stopped by the voluntary contraction of the external sphincter, which is the true sphincter. Leedham Green (*Brit. Med. Jour.*, August, 1906) claims that the internal sphincter holds tight in the living subject even when the bladder is over-distended. Sections made of formalin-hardened bodies seem to support this view.

**Practical Applications.**—A knowledge of both the length and calibre of the urethra is essential in the use of both catheters and bougies or sounds. If urine begins to flow when a catheter is introduced 20 cm. we know the urethra is of normal length. Urine may flow when the bladder is distended as soon as the catheter passes the membranous portion, about 17 cm. ( $6\frac{3}{4}$  in.) from the meatus. In hypertrophy of the prostate the prostatic urethra is much increased in length and it may be impossible to reach the bladder by an ordinary catheter. It may require one 25 or 30 cm. (10 to 12 in.) long. The position of a stricture is located by its distance from the meatus. If a sound is stopped by a stricture inside of 15 cm. (6 in.) from the meatus we know it is anterior to the triangular ligament. Strictures are most frequent where the subpubic curve is lowest, viz., at the bulbomembranous region. They are then called deep strictures. They are next most frequent toward the anterior portion, while strictures of the prostatic portion are almost unknown.

#### Passage of Sounds and Catheters.

—In passing a catheter or sound its beak should be kept applied to the roof of the urethra, otherwise its point will catch in the dilated bulbous portion and strike on the triangular ligament below the opening for the urethra. To aid the beak to follow the subpubic curve the handle is depressed.

In difficult cases the index finger of the opposite hand is introduced in the rectum and the beak is felt at the membranous portion a short distance in front of the apex of the prostate and guided upward into the bladder (Fig. 474). If the penis is grasped near the glans and drawn up the instrument, the urethra may so stretch

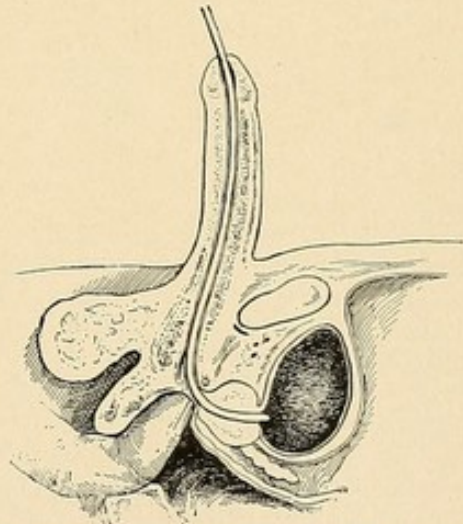


FIG. 474.—Method of passing the sound. The index finger in the rectum is guiding the sound through the membranous urethra.



that the sound will not reach to the bladder. To avoid this it should be grasped lower down toward the scrotum. The urethra is so flexible and loose that straight instruments, such as cystoscopes, can readily be passed by skilful hands. In hypertrophy of the prostate, long instruments, with big curves if of metal, are essential. Many rubber catheters are too short for this purpose. In passing small, filiform bougies they are to be directed at first toward the floor of the urethra to avoid the lacunæ on the roof. If they do catch they are allowed to remain and so prevent the ones subsequently introduced catching in the same place. The vascular net-work in the sub-mucous tissue bleeds readily and the skill evinced by the surgeon in passing urethral instruments is in inverse ratio to the amount of bleeding produced.

Otis claimed that a penis 3 in. in circumference had a normal urethra admitting a No. 30, French scale, sound;  $3\frac{1}{4}$  in. No. 32;  $3\frac{1}{2}$  in. No. 34;  $3\frac{3}{4}$  in. No. 36, and 4 in. No. 38. White and Martin state that a 3 in. circumference admits a No. 26 to No. 28;  $3\frac{1}{4}$  in. Nos. 28 to 30;  $3\frac{1}{2}$  in. Nos. 30 to 32;  $3\frac{3}{4}$  in. Nos. 32 to 34; and a 4 in. Nos. 34 to 36. We agree with the latter, and often the meatus though normal in appearance must be incised to admit the above sizes. The distensibility of the urethra is such, especially in its deeper portions, that after incision of the meatus very large sounds can be introduced. For this reason urethrotomes should not cut to the full size. Teevan's urethrotome only cuts up to 22 French and the additional size is obtained by stretching with sounds. This instrument in one case was made to cut to 26 French but death followed from hemorrhage and a return was made to No. 22. It cuts on the roof, and the dorsal artery of the penis or the artery to the bulb was probably divided. To avoid hemorrhage, deep strictures are treated by dilatation or external urethrotomy and penile strictures only are cut internally. Keegan has shown that the calibre of the urethra in small children is sufficient to allow the use of the lithotrite and so avoid a cutting operation.

*Spasmodic stricture* results from contraction of the urethral muscles due to some irritation. This irritation may be from the urine, from organic stricture, fissure of the anus, hemorrhoids, etc. It causes retention of urine, which can be relieved by passing a full-sized catheter, or by hot baths, etc. Notice the firmness with which the urethra grasps a sound as it is withdrawn.

*Traumatic Stricture.*—This is usually located in the bulbous portion, just in front of the triangular ligament. The urethra is compressed between the pubic bone and the vulnerating body. It is treated by passing in a full-sized catheter either with or without the aid of a perineal incision.

## THE MALE PERINEUM.

The name perineum in its broad sense is applied to the structures of the outlet of the pelvis, superficial to the levator ani muscle. In its restricted anatomical sense it is applied to the subpubic triangle as far back as a line joining the anterior portions of the tuberosities. In its clinical sense it is the space between the anus and scrotum in the male and anus and vulva in the female.

**Bony Landmarks.**—On examining the pelvic outlet the symphysis pubis is seen anteriorly with the descending rami of the pubes and ascending rami of the ischia on the sides, leading to the tuberosities. Posteriorly is seen the coccyx, with the spines of the ischia on each side comparatively close to it. The greater sacro-sciatic ligament runs from the sacrum to the tuberosity of the ischium, the lesser from the sacrum to the spine of the ischium. Taken together a diamond-shaped space is formed. In the female the pubic arch is wider, the tuberosities further apart, the spines of the ischia do not project so markedly inward, and the coccyx is more movable.

**Perineal and Ischio-rectal Regions.**—A line drawn from the anterior portion of one tuberosity to that of the opposite side passes 1.25 cm. ( $\frac{1}{2}$  in.) in front of the anus, and divides the outlet into the urogenital triangle or perineum in front, and the anal triangle or ischio-rectal region behind.

**Urogenital Triangle.**—The urogenital triangle has the symphysis in front, the ischiopubic rami as far back as the anterior portion of the tuberosities on the



sides, and a line joining the two behind. It is closed by a stout fibrous membrane called the triangular ligament.

The **central point of the perineum** is in the median line 2 cm. ( $\frac{3}{4}$  in.) in front of the anus; it marks the posterior edge of the triangular ligament in the median line, and is the point of junction of the anteroposterior and transverse muscles.

**Perineal Fascias.**—There are four perineal fascias, viz.: (1) the superficial layer of the superficial fascia; (2) the deep layer of the superficial fascia, called also Colles's fascia; (3) the superficial layer of the deep fascia, or triangular ligament; and (4) the deep layer of the triangular ligament or pelvic fascia (Fig. 475).

The *superficial layer of the superficial fascia* is the subcutaneous fatty tissue, and is continuous with that of the surrounding parts and the dartos. When thick it makes operations on the deeper structures more difficult and sometimes impossible.

The *deep layer of the superficial fascia or Colles's fascia* is the fibrous under surface of the fatty superficial layer. Posteriorly it unites with the posterior edge of the triangular ligament; laterally it is attached to the ischiopubic rami; and anteriorly it is continuous with the under surface of the dartos of the scrotum, passes forward

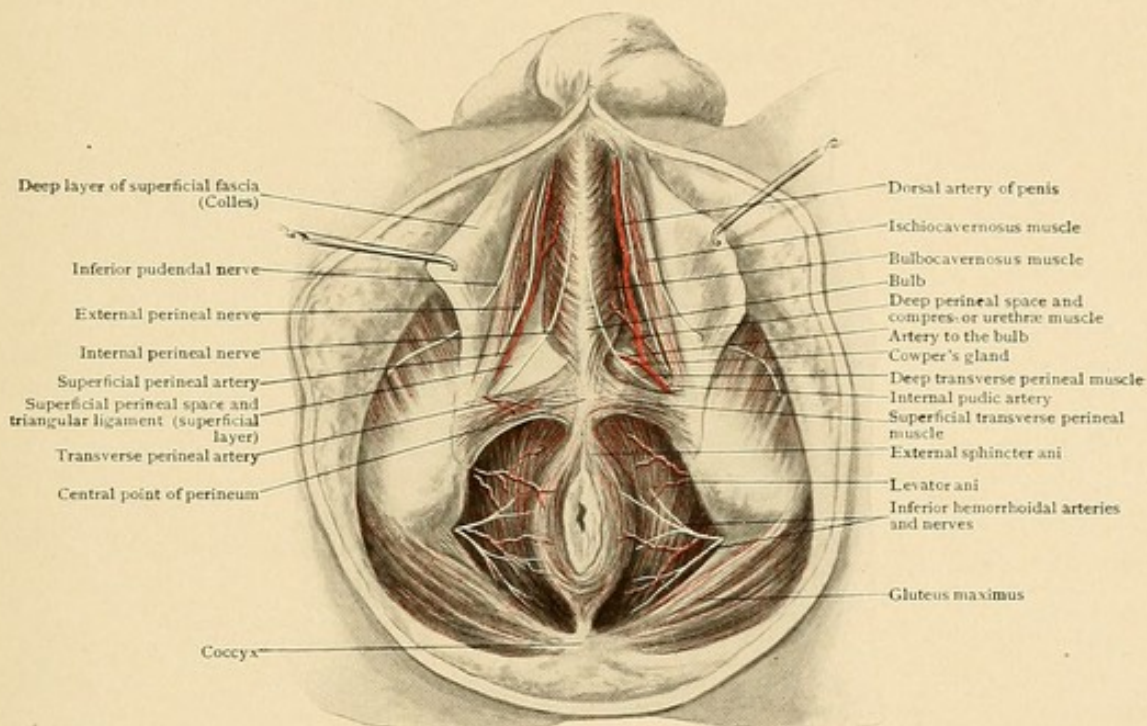


FIG. 475.—The male perineum. The superficial perineal space is shown on the left and the deep perineal space on the right.

to form the suspensory ligament and fibrous sheath (Buck's fascia) of the penis, covers the spermatic cord, and is continuous with Scarpa's fascia (deep layer of the superficial fascia) of the abdomen.

The *anterior layer of the triangular ligament* is a firm fibrous membrane stretching from one tuberosity to the other, and attached to the ischiopubic rami on the sides forward to the pubic arch. Between its upper edge and the symphysis runs the dorsal vein of the penis, the dorsal artery and nerve piercing it a little lower and to the outer side; 2.5 cm. (1 in.) below the symphysis is the urethral opening with the opening for Cowper's ducts close to it below, and those for the vessels to the bulb close to it above. The superficial perineal vessels and nerves pierce its posterior edge. The posterior edge of the triangular ligament blends with the posterior edge of the deep layer of the superficial fascia (Colles).

The *deep layer of the triangular ligament* is a continuation downward of the pelvic fascia. It begins above on the inside of the pelvis, covering the obturator muscle as the obturator fascia; it then passes onto the levator ani muscles as the recto-vesical fascia. As the levator ani muscles do not meet in front, the gap between them is filled in at the median line below or posteriorly by the termination of the



longitudinal fibres of the rectum (prerectalis muscles of Henle, recto-urethralis of Roux, Kalischer, Holl, Proust, and others—see page 438, Rectum), at the sides by the deep transverse perinei and compressor urethræ muscles, and anteriorly by the continuation of the rectovesical fascia. From the deep transverse perinei muscles forward the rectovesical fascia is called the deep layer of the triangular ligament (Fig. 476).

**Perineal Spaces.**—There are two perineal spaces, one superficial space between the triangular ligament (superficial layer) and the deep layer of the superficial fascia (Colles's fascia), and the other, the deep perineal space, between the superficial layer of the triangular ligament and its deep layer.

**Superficial Perineal Space.**—The superficial space has on each side the crura of the penis attached to the ischiopubic rami and covered by the ischiocavernosus (erector penis) muscles. In the median line anteriorly lies the urethra with its erectile tissue covered by the bulbocavernosus (accelerator urinæ) muscle. The posterior portion lying on the triangular ligament is called the *bulb*, and reaches back to the central point of the perineum. From the central point the superficial transverse perineal muscles pass outward and somewhat backward to the rami of the

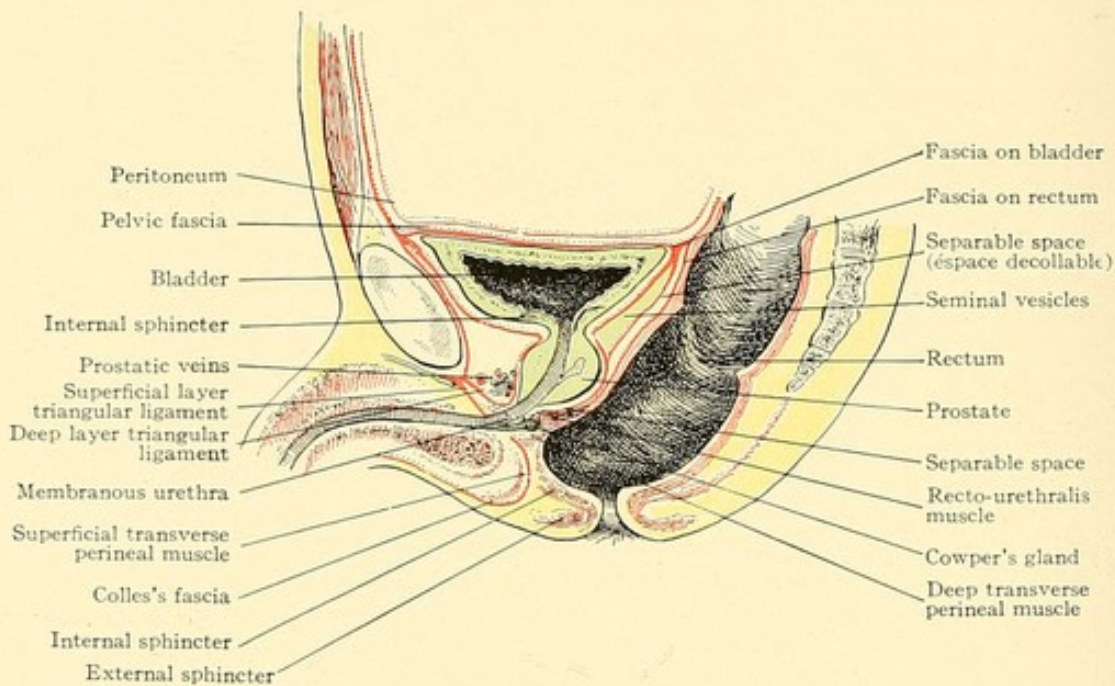


FIG. 476.—Perineal spaces.

ischia, and the sphincter ani passes back to the coccyx. The *internal pudic artery* comes forward from the spine of the ischium through Alcock's canal on the outer wall of the ischio-rectal fossa, 4 cm. (1½ in.) above the lower edge of the tuberosity; when it reaches the posterior edge of the triangular ligament it gives off the superficial perineal artery, which pierces it and enters the superficial perineal space, where it gives off the small transverse perineal artery, and then continues anteriorly to the base of the scrotum. The pudic nerve sends two branches forward in this space, the posterior or internal superficial perineal toward the middle, and the anterior or external along the outer side of the space accompanying the superficial perineal artery forward to the scrotum.

**The Deep Perineal Space.**—This lies between the anterior and posterior layers of the triangular ligament. It contains the compressor urethræ (external vesical sphincter) muscle surrounding the urethra. Embedded in this muscle is *Cowper's gland*. Its duct, 2 cm. (¾ in.) long, pierces the anterior layer of the triangular ligament to empty into the bulbous urethra. Immediately behind the compressor urethræ is the deep transverse perinei muscle passing across from one ischiopubic ramus through the central point of the perineum to the other. Running along the outer side of the space is the continuation of the internal pudic artery. It gives off



the artery to the bulb about 3 cm. ( $1\frac{1}{4}$  in.) in front of the anus, and then about 1.25 cm. ( $\frac{1}{2}$  in.) below the subpubic ligament pierces the anterior layer of the triangular ligament and divides into the artery to the corpus cavernosum and artery to the dorsum of the penis; it is accompanied by the pudic nerve, which divides in like manner. Posteriorly this space is open, not being closed by any fascia except that lining the under or superficial surface of the levator ani muscle in the ischio-rectal fossa. In the mid-line the continuation of the longitudinal fibres of the rectum called the prerectal or recto-urethralis muscle blend with the fibres of the deep transverse perineal muscle.

**Practical Application.**—The perineum is involved in extravasations of blood and urine in cases of rupture of the urethra; also in operations on the deep urethra and bladder for the retention of urine from stricture; also in operations for vesical calculus, enlarged prostate, and disease of the seminal vesicles.

*Extravasation of Urine and Blood.*—Urinary extravasation results most often from stricture and occurs almost always in front of the anterior layer of the triangular ligament. The urine enters the superficial perineal space and is confined superficially by Colles's fascia and beneath by the triangular ligament. It is prevented from going back into the ischio-rectal space by the union of Colles's fascia and the triangular ligament posterior to the superficial transverse perineal muscles; it is prevented from extending laterally by the attachment of Colles's fascia to the ischiopubic rami; hence it works its way forward, distends the scrotum, and follows the spermatic cord up over the crest of the pubis between the spine of the pubis and the median line. Reaching the surface of the abdomen it is prevented from descending on the thigh by the attachment of the deep layer of the superficial fascia (Scarpa's fascia) just below Poupart's ligament, so it flows laterally and makes a collection in the flank of each side above the iliac crests. It may also infiltrate the penis as far forward as the glans. The septum in the median line of the abdomen, perineum, and scrotum hinders but does not prevent the passage of the urine from one side to the other. In treating it, numerous free incisions are made down to the deep fascia.

*Rupture of the Urethra.*—This is produced by falling astride a hard object and jamming the urethra against the subpubic arch, or it results from stricture. The rupture almost always involves the urethra just in front of the triangular ligament and sometimes a part of the membranous urethra. The superficial perineal space becomes infiltrated with blood, and if urine is passed it follows the blood, collecting between Colles's fascia and the triangular ligament.

If the membranous urethra is ruptured the blood and especially the urine may escape into the deep perineal space between the layers of the triangular ligament. It may break or leak through the anterior layer and enter the superficial perineal space; it may work backward into the ischio-rectal regions; it may work up and back between the prostate and rectum or breaking through the deep layer of the triangular ligament it may work up and anterior behind the symphysis pubis, in the pre-vesical space (of Retzius) between the peritoneum and transversalis fascia (see Fig. 476). Ruptured urethra is treated by perineal section or by a retained catheter.

*Perineal Section and Median Lithotomy.*—In these operations the bladder is entered through an incision in the median line into the bulbomembranous urethra. They are done to divide deep strictures, to allow the urine to escape in extravasation and rupture of the urethra, to remove foreign bodies and calculi from the bladder, and to remove enlargements of the prostate gland. The incision is to be made through the raphe in the median line; ordinarily it does not begin farther forward than 3 cm. ( $1\frac{1}{4}$  in.) in front of the anus. As the central point of the perineum is 2 cm. in front of the anus the incision passes through it and divides the posterior fibres of the bulbocavernosus muscle but involves little if at all the erectile tissue of the bulb. There is little bleeding if the incision is kept in the median line. The urethra is entered about 2.5 cm. (1 in.) from the surface, and the knife passed upward and back through the membranous and prostatic urethra into the bladder, a distance of 6.25 to 7.5 cm. ( $2\frac{1}{2}$  to 3 in.) from the surface. In fat people or those with enlarged prostates one may be unable to reach the interior of the bladder with the finger. The membranous and prostatic urethra is distensible, so that when the former is opened the finger can be introduced and pushed into the bladder. In children the



urethra may be too small to permit the entrance of the finger and a blunt guide is introduced, along which forceps may be passed to extract any foreign body. In *Cock's operation* for retention of urine the index finger of one hand is introduced through the rectum and its tip placed at the apex of the prostate. A straight knife is then inserted 2.5 cm. (1 in.) in front of the anus and pushed up and inward into the urethra, being guided by the finger in the rectum. (For removal of enlarged prostate see page 450.)

*Lateral Lithotomy.*—The incision is begun to the left of the median line 3 cm. ( $1\frac{1}{4}$  in.) in front of the anus and carried outward and back midway between the anus and tuberosity of the ischium. The knife is pushed steadily on until it enters the groove in the staff and thence backward into the bladder. The artery to the bulb is to be avoided by not going more than 3 cm. in front of the anus. The rectum is to be avoided by having it empty, by hooking the staff in the urethra well up to the pubic arch, thus drawing the urethra up, and by inclining the knife obliquely outward. The internal pudic artery is to be avoided by keeping away from the ramus of the ischium. Too free an incision of the prostate is bad because urinary infiltration is liable to occur in the pelvic fascia, also an accessory pudic artery, which if present may run along the side of the prostate, may thus be wounded. Usually the bleeding is slight and comes from the division of the superficial transverse perineal and branches of the inferior hemorrhoidal arteries and the prostatic plexus of veins. (For Perineal Prostatectomy see page 450 and Seminal Vesicles page 452.)

**Anal Triangle and Ischiorectal Region.**—The anal triangle is made by the superficial transverse perineal muscles forming its base and the tip of the coccyx its apex. It contains the anal canal with the ischiorectal fossæ on each side.

The **ischiorectal fossa** is wedge-shaped, its base, extending between the tuberosity of the ischium and the anus, is about 2.5 cm. (1 in.) in breadth, and its apex extends up 5 to 7.5 cm. (2 to 3 in.), to the junction of the levator ani and internal obturator muscles. Its inner wall is formed by the levator ani and coccygeus muscles and its outer wall by the obturator internus muscle. Its deepest extreme posterior portion constitutes the *posterior recess*. This communicates superficially, beneath the coccygeal attachment of the external sphincter, with the fossa of the opposite side (see Fig. 475, page 473).

The *anterior recess* (pubic, Waldeyer) runs forward between the prostate gland internally and the ischiopubic ramus externally; the deep and superficial transverse perinei muscles and the deep layer of the triangular ligament are superficial to it.

The *internal pudic vessels and pudic nerve* lie on the internal obturator muscle and ramus of the ischium in a fibrous canal formed by the obturator fascia. It is called *Alcock's canal* and is 4 cm. ( $1\frac{1}{2}$  in.) above the tuberosity.

The *inferior hemorrhoidal vessels and nerves* enter the ischiorectal fossa at its posterior and outer side and run on the surface of the levator ani muscle toward the anus. The *superficial perineal vessels and nerves* enter the fossa anteriorly and immediately pierce the posterior edge of the superficial perineal (Colles's) fascia to supply the structures between it and the superficial layer of the triangular ligament.

**Practical Application.**—The principal affection of the ischiorectal fossa is abscess. This is probably started by violence and infected from the rectum. It commonly tends to point through the skin or open into the rectum. On account of its tendency to burrow it is to be opened early. This is done by making an incision of ample size through the skin and then opening the abscess by blunt dissection in order to empty all pockets. Bleeding is usually slight because the vessels lie deep and escape being wounded. Should the abscess not break externally it may do so internally. If superficial it pierces the anal canal between the external and internal sphincters and makes an opening at about the white line. If it is very deep it may open into the ampulla of the rectum above the internal sphincter (see page 443). It is more common for pus to burrow down into the ischiorectal space through the levator ani than it is for it to burrow up from the ischiorectal fossa (Tuttle). Therefore in extensive ischiorectal abscesses communicating with the interior of the pelvis one should look for the origin of the trouble above. An abscess on one side is liable to be followed by one on the other and pus quite commonly crosses the median line posterior to the anus.



## THE BACK AND SPINE.

## SURFACE ANATOMY.

On examining the back of a person standing upright a *median furrow* is seen (Fig. 477). In the bottom of this the tips of the *spinous processes* can be felt. If the back is bent these processes can be distinctly seen; they should form a straight line. The second cervical spine can be felt by deep pressure in a relaxed neck. The sixth is usually the first one visible and the seventh cervical and first dorsal are very prominent, often the latter the more so. The furrow ends abruptly at the top of the sacrum. From this point down to near the top of the gluteal fold is a *triangular space* with its base above and apex downward. Its apex marks the third sacral spine, and just above this latter, opposite the second sacral spine, on each side can be felt the posterior superior iliac spines. The *erector spinæ* (sacrolumbalis) muscles form elevations on each side of the furrow, most marked in the lumbar region. In muscular people the erector spinæ is seen to consist of two parts: an inner longissimus dorsi muscle, and an outer iliocostalis. Above, the projections of the *scapulæ* are visible. If the arms

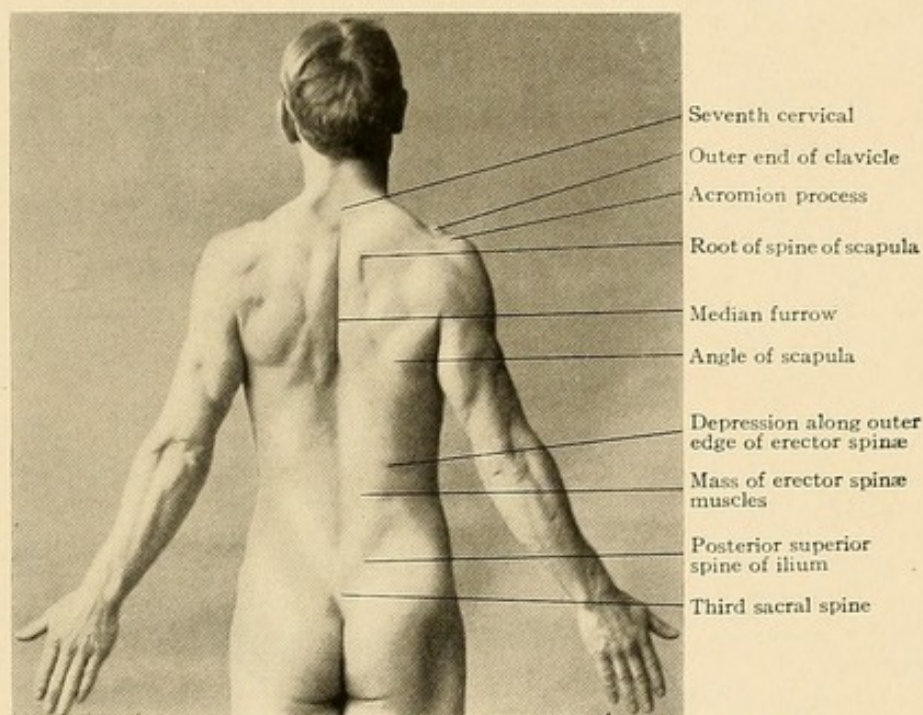


FIG. 477.—Surface anatomy of the back.

are by the sides the posterior border of the scapula is parallel to the median line. The root of the spine of the scapula in a muscular person makes a depression. It is opposite the third dorsal spine or the body of the fourth thoracic vertebra, and marks the upper end of the fissure of the lungs. The spine of the scapula is subcutaneous and can be traced out to the acromion process. The lower angle of the scapula is opposite the upper border of the eighth rib; the upper angle covers the second rib but its tip is level with the first.

In the lumbar region the erector spinæ muscle forms a clearly marked prominence. The twelfth rib usually projects beyond its outer edge, which is marked by a depression separating it from the abdominal muscles in front. It is through this depression that operations on the kidney are performed (see page 428). The distance between the twelfth rib and crest of the ilium is usually 6.25 cm. ( $2\frac{1}{2}$  in.) but it may be more and is often less. Just above the middle of the crest of the ilium is Petit's triangle (page 394); and to the inner side of the lower third of the poste-



rior edge of the scapula is another small triangle. Its upper side is formed by the trapezius, its lower by the latissimus dorsi, and its outer by the posterior edge of the scapula. As the lung is nearest the surface at this point it is often chosen for physical examination, puncture, etc.

## THE VERTEBRAL COLUMN.

Normally the spinal column is composed of seven cervical, twelve dorsal, five lumbar, five sacral, and four to five coccygeal vertebræ. The sacral vertebræ tend to fuse together, forming a single bone, the sacrum. This fusion is complete at the twenty-fifth year. The coccygeal vertebræ join later, fusion occurring in middle life.

Sometimes in advanced age the coccyx and sacrum fuse together. The cervical vertebræ are almost always seven in number, but both the dorsal and lumbar vary much more frequently than is usually supposed. The occurrence of thirteen instead of twelve ribs on a side is not uncommon and I have seen skeletons with only eleven. A rudimentary cervical rib also occasionally occurs.

The tips of the spinous processes of the cervical vertebræ, the first two dorsal, and last four lumbar, pass almost horizontally backward and are therefore nearly opposite the bodies of the vertebræ to which they are attached. The tips of the spines from the third to the last dorsal inclusive, however, are opposite the bodies of the next vertebræ below them, being inclined downward, while the tip of the first lumbar is about opposite the intervertebral disk beneath.

**Curves.**—At the third month of intra-uterine life there is only one large curve, convex posteriorly. At birth there are two curves, each convex posteriorly, a dorsal and sacral, probably to accommodate the thoracic and pelvic viscera; after the erect position is assumed the cervical and lumbar curves become established. The cervical passes into the dorsal curve at the middle of the second thoracic vertebra and the dorsal into the lumbar at the middle of the last thoracic vertebra. (Fig. 478). *Laterally*, there is a slight curve in the dorsal region with its convexity to the right, probably due to the increased use of the right hand.

**Movements.**—Flexion and extension are free in the neck and lumbar region, rotation is slight in the cervical region, free in the upper portion of the dorsal, and gradually diminishes to be absent in the lumbar region.

## DEFORMITIES OF THE SPINAL COLUMN.

The weight of the head is borne on the condyles of the occiput, and a perpendicular let fall from the condyles passes through the points where the spinal curves pass one into the other and thence through the anterior edge of the promontory of the sacrum. Hence if one curve is altered by injury or disease it is of necessity accompanied by a corresponding change in the curve on the opposite side of the perpendicular line. The first is called the primary curve and the other the secondary one. In anteroposterior curvatures these curves are exaggerations of the normal curves but in lateral curvatures they are newly formed because there is, practically,

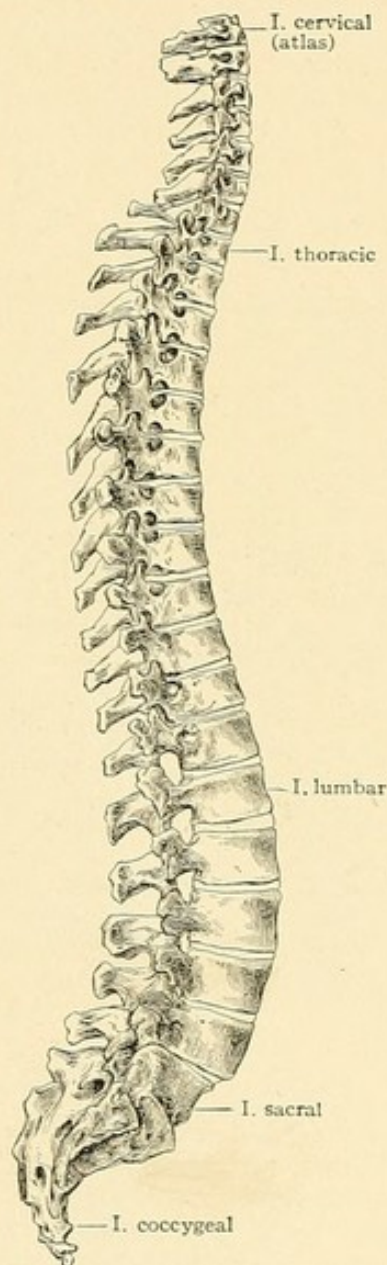


FIG. 478.—Lateral view of the adult spine, showing its curves. (Piersol.)



no normal lateral curve in the spinal column. The spine may project abnormally backward, forming a *kyphosis*; forward, *lordosis*; and more or less laterally, *scoliosis*.

**Kyphosis.**—The vertebrae are supported one above another by two points of contact, a posterior one, formed by the articular processes, and an anterior one, formed by the bodies of the vertebrae separated by the intervertebral disks. Of these two supports, that afforded by the bodies and disks is the more important. The laminae and pedicles with their attached articular processes are frequently fractured, but the shape of the vertebral column is but little altered; even after laminectomy the spine remains comparatively straight. When, however, the bodies of the vertebrae are destroyed, as occurs in tuberculous disease and crushing injuries, the anterior portion of the spine collapses and the parts bend, the spines projecting backward forming a hump (Fig. 479). Thus the angular character of the deformity is explained by the method of construction of the spine.

Besides this *angular kyphosis* there is another form, due to general weakness. This is seen in rachitic children; owing to a weakness of all the tissues the normal curves become increased and, as in young children, the normal spine has one long general curve with its convexity posteriorly, we find this curve greatly increased, forming a *rachitic kyphosis*.

**Lordosis.**—When a child is born and for some time thereafter the spine possesses a slight dorsal and a pelvic curve. When it sits up and begins to hold its head erect and look around, the cervical curve develops. Still later when it begins

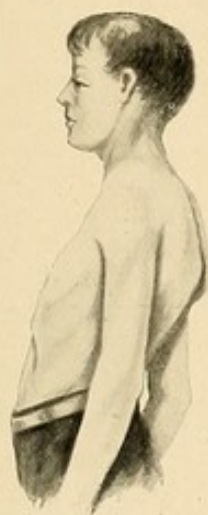

FIG. 479.—Kyphosis or angular anteroposterior curvature, usually due to caries of the bodies of the vertebrae.



FIG. 480.—Lordosis or hollow back, caused by congenital luxation of the hips.

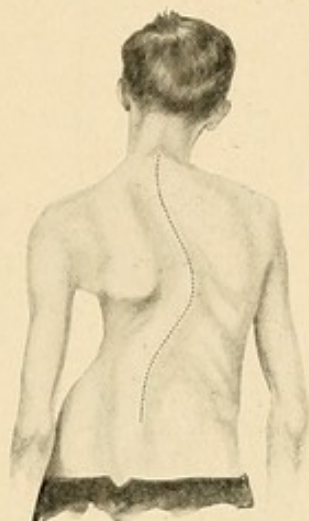


FIG. 481.—Scoliosis or lateral curvature of the spine.

to walk the lumbar curve develops. An increase in the lumbar curve, or lordosis, is caused by general weakness as just described for rachitic kyphosis, or it results from some disease or injury interfering with the lower extremities and thus disturbing the centre of gravity. This occurs in congenital luxation of the hips (Fig. 480), in which the heads of the femurs are set too far back, and also in rachitic deformities of the lower extremities, hip disease, etc. Likewise, if the abdominal viscera are unduly prominent, the thoracic region is carried further back to maintain the balance, and hence a hollow back is produced. Ankylosis of the hip in a flexed position causes lordosis when the limb is brought straight down as in walking. Therefore in cases of lordosis one should remember that it is a secondary condition dependent on diseased conditions of the viscera or extremities and is comparatively rarely an independent affection.

**Scoliosis.**—A normal spine is either absolutely straight or very slightly convex to the right in the dorsal region, probably due to the increased use of the right hand. While scoliosis is called lateral curvature of the spine, it is not a simple lateral bending, but is a complex distortion (Fig. 481). R. W. Lovett has shown that a flexible straight rod can be bent in one plane either anteroposteriorly or laterally, but



that a curved rod cannot be bent laterally without twisting or rotating. Inasmuch as the human spine is curved convexly backward in the dorsal region and convexly forward in the lumbar region, lateral bending is accompanied by rotation of the vertebræ and their attached ribs. The bodies of the vertebræ are carried toward the side of the convexity of the curve and the ribs on that side project backward, producing a marked hump and often an elevation of the shoulder. As a primary curve forms, an attempt is made to restore equilibrium by bending the remaining portion of the spine in the opposite direction, hence the curves, if of long duration, are double or compound, and these secondary curves are called compensating curves. Marked lumbar curves are usually accompanied by prominence of the hip on the side of the convexity, but the pelvis usually remains level. Should the length of the limbs be unequal, allowing tilting of the pelvis, the prominence of the hip would be on the side of concavity. It is obvious that the weight of the body tends to aggravate these pathological curves. The treatment of scoliosis is directed to correcting these faulty curves by exercises and appliances intended to support and stretch the body on the contracted or depressed side and restore the tone and power to the relaxed muscles and tissues of the opposite side.

**Spina Bifida.**—The spinal canal is formed by the laminæ of the vertebræ arching over and uniting posteriorly. This union begins in the dorsal region and progresses towards the head and sacral regions. Failure of union constitutes spina bifida. It is most frequent in the lumbar and sacral regions. Usually a sac formed of the spinal membranes protrudes and contains the spinal cord flattened out like a strap passing down on its posterior surface, but sometimes the sac contains no nervous elements. Frequently the sac is so thin that it soon inflames, ruptures, and allows escape of the cerebrospinal fluid, and death ensues from meningitis. The parts below are not infrequently paralyzed and hydrocephalus may coexist. Operative procedures have been frequently successful in mild cases, but in extensive lesions they have been quite fatal, and even when primarily successful may be followed by the development of hydrocephalus.

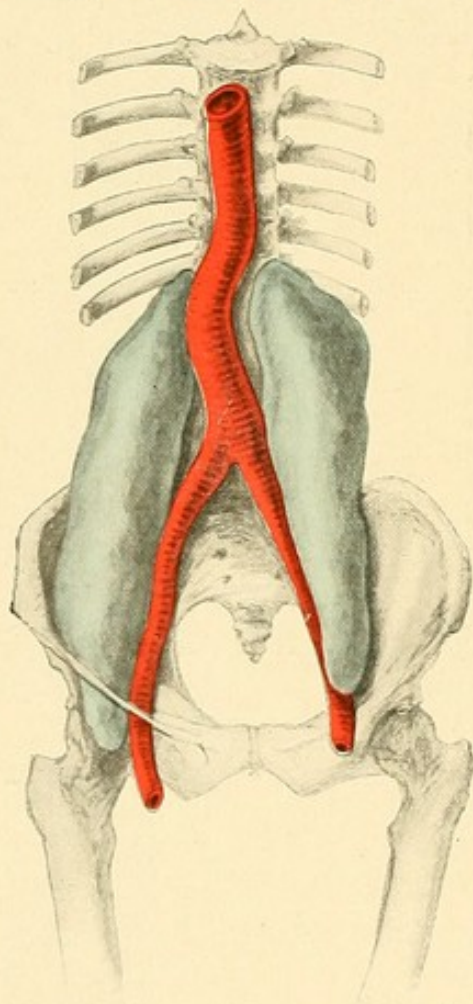


FIG. 482.—Psoas abscess originating from spinal caries of the dorsolumbar vertebræ and following the psoas muscle to the groin. (From a sketch by the author of a specimen in the Mütter Museum of the College of Physicians).

#### AFFECTIONS OF THE SPINAL COLUMN.

**Caries of the Spine.**—While caries of any part of the vertebræ may occur from injury, it is almost always the result of tuberculous disease in the bodies; the pedicles, laminæ, and processes remain unaffected. As the bodies become destroyed the anterior portion of the spine collapses, and this causes a projection of the spines of the affected vertebræ posteriorly or kyphosis. This projection of one or more spinous processes is the surest indication of spinal caries or Pott's disease.

There is also rigidity of the affected region. This is recognized by the attitude assumed and by having the patient, if an adult, bend the back anteroposteriorly. Small children should be placed flat on a table, face down, and then gradually raised by the feet. If the spine is normal the child will readily bend in the lumbar and lumbodorsal regions. The movable regions, embracing the cervicodorsal and dorsolumbar vertebræ, are the sites most frequently affected. Distention of the abdomen



and pain occur from involvement of the spinal nerves. The tenth dorsal nerve arrives anteriorly at the level of the umbilicus, the twelfth is midway between the umbilicus and symphysis and also sends an iliac cutaneous branch a couple of inches behind the anterior superior spine to the skin of the buttock, and below and in front of the great trochanter. The abdomen above the external inguinal ring is supplied by the hypogastric branch of the iliohypogastric from the first lumbar.

**Psoas abscess** is common. The psoas muscle arises from the lower border of the body of the twelfth dorsal and the bodies of all the lumbar vertebræ. The pre-vertebral fascia covering the bodies of the vertebræ is continued downward over the psoas muscle as its sheath. Therefore when pus forms in the bone it enters the sheath and follows it downward under Poupart's ligament, usually just outside, but sometimes, as it gets still lower down, to the inside of the femoral vessels (Fig. 482). At other times it works its way backward and points in the angle between the erector spinæ muscle and the twelfth rib, or along the edge of the erector spinæ lower down, or a little farther out above the top of the middle of the crest of the ilium at Petit's triangle (see page 394). It may also find an exit through the great sacrosclatic notch and point on the posterior aspect of the thigh. Pus originating in the cervical region produces retropharyngeal abscesses, which, if involving the second to the fifth cervical vertebræ, may either point in the pharynx or work outward to the posterior edge of the sternomastoid muscle (see page 156).

### INJURIES OF THE SPINAL COLUMN.

The vertebræ may be dislocated and fractured.

**Dislocation** is rarer than fracture; it is most common in the cervical region. The cervical vertebræ have their articular facets sloping downward and backward, hence dislocation occurs when the upper vertebræ are pushed in front of the lower.

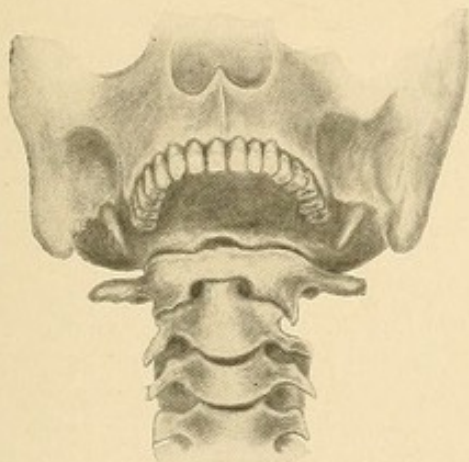


FIG. 483.—Anterior view, showing relation of transverse process of atlas to tip of mastoid process.

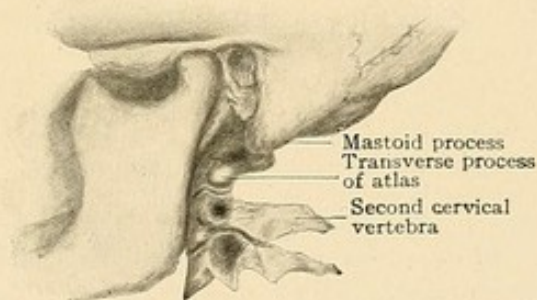


FIG. 484.—Lateral view, showing relation of transverse process of atlas to tip of mastoid process.

The cervical spine normally has but slight rotation, hence when luxated one articular surface is rotated or pushed over and in front of the one below, the opposite articular surface acting as the axis and the distance between the two articulations as the radius of the arch in which the luxated parts move. The elevation of the luxated articular process over the one below is favored by the bending of the spine above toward the opposite side. The head is rotated and inclined toward the uninjured side. Bilateral luxation is rare without associated fracture. It is produced by anterior flexion, and the head and neck are inclined forward while the lower vertebra of the dislocated joints inclines backward, producing a kyphotic condition.

Luxation affects most often the fourth, fifth, and sixth cervical vertebræ. The atlas may be dislocated forward or backward by rupture of the transverse ligament, fracture of the odontoid process, or by a slipping of the process under the ligament.

Luxation of the atlas laterally is very rare, owing to there being normally a total rotation of 60 degrees.



The upper three vertebræ can be palpated on their anterior surfaces by the finger introduced into the mouth.

Posteriorly the second, third, and fourth spines are too deeply placed between the muscles to be palpated.

To reduce the luxation an anæsthetic is given to relax the muscles, and cautious extension is made and the head gently rotated.

**Fracture** of the spine is frequently associated with luxation. It is most frequent low down in the cervical region and at the junction of the dorsal and lumbar vertebræ, these being the places where the

more fixed dorsal portion passes into the more movable cervical and lumbar portions (Fig. 485). The vertebræ are supported at three points—the bodies and the two articular processes. The spinous and articular processes are rarely fractured alone; they may be broken, however, by direct violence. The laminae on each side of the articular processes may be broken and the detached part with the spinous process may be pushed inward, injuring the cord. Fracture of the bodies is most frequent and is due to anterior flexion. The bodies and intervertebral disks are compressed, crushed, and torn. This is accompanied by either luxation or fracture of the articular processes, and occurs most often in the region of the lower dorsal vertebræ. Injury to the cord is common. The parts are not often fixed in a markedly displaced position, as is the case with luxations of the neck, hence attempts at reduction are rarely necessary and fixation is to be aimed for in treatment. The site of injury is determined

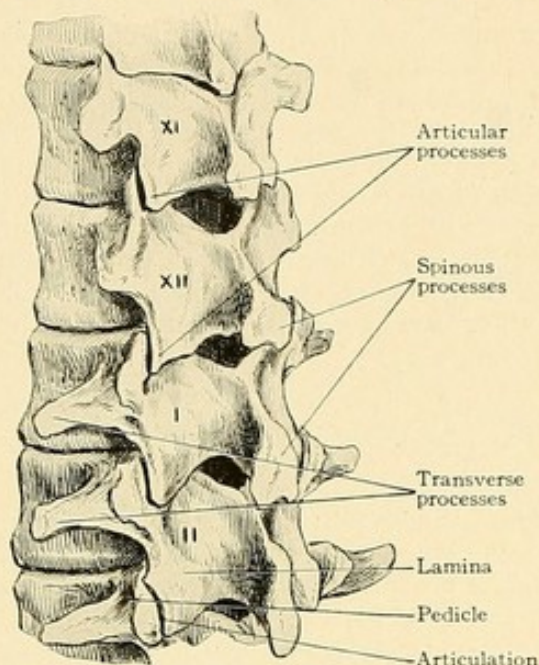


FIG. 485.—Showing the method of articulation of the eleventh and twelfth dorsal and the first and second lumbar vertebræ.

not only by an examination of the spinous processes but also by the extent of interference with the functions of the cord (see page 483).

### SPINAL CORD AND ITS MEMBRANES.

The spinal cord in the male is 45 cm. (18 in.) long. In the fœtus of three months the cord extends to the end of the spinal canal; at birth it has risen to the third lumbar vertebra, and in the adult it is opposite the lower border of the first. It will thus be seen that the point of exit of the spinal nerves from the cord is always some distance higher up than their exit from the intervertebral foramina. The cord is enlarged in the cervical and lumbar regions, the cervical enlargement ending opposite the second dorsal, and the lumbar enlargement beginning about opposite the tenth dorsal vertebra and decreasing gradually. These enlargements correspond with the origin of the nerves to the upper and lower extremities.

The spinal cord is divided into so-called segments. These are thirty-one in number; eight are cervical, twelve thoracic, five lumbar, five sacral, and one coccygeal. Each segment embraces that portion of the cord which gives exit to one pair of anterior or motor root fibres and receives one pair of posterior or sensory root fibres. These segments are a variable distance above the point of exit of the nerves from the bony spinal column. Besides motor and sensory functions they exercise control over certain reflex movements and functions. The control of the bladder and rectum is located in the fifth and sixth sacral segments; the cremasteric reflex is governed by the first and second lumbar; the plantar or Babinski reflex by the first to third sacral, as is also ankle clonus; and the patella reflex by the second and third lumbar segments. They likewise exert a trophic influence, and the appearing of bed or pressure sores without ample cause is presumptive evidence of a spinal lesion of the segments supplying the part.



## TRANSVERSE SPINAL LESIONS.

In endeavoring to localize transverse lesions of the cord, such as result from traumatism, tumors, etc., one must bear in mind that the spinal nerves originate from segments in the cord some distance above where they make their exit from the spinal

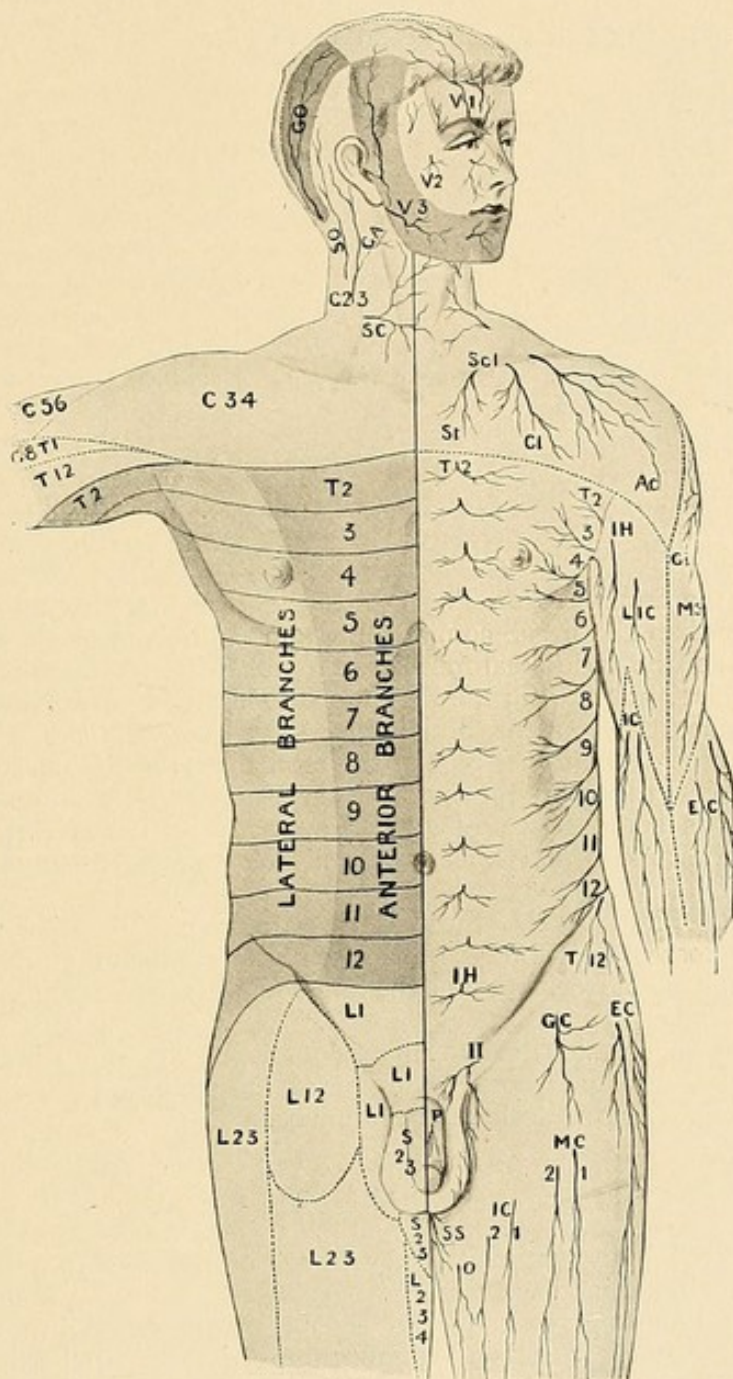


FIG. 486.—Diagram of distribution of cutaneous nerves, based on figures of Hasse and of Cunningham. On right side, areas supplied by indicated nerves are shown; on left side, points at which nerves pierce the deep fascia.  $V^1$ ,  $V^2$ ,  $V^3$ , divisions of fifth cranial nerve; GA, great auricular; GO, SO, greater and smaller occipital; SC, superficial cervical; St, Cl, Ac, sternal, clavicular, and acromial branches of supraclavicular (Sc); Ci, circumflex; MS, musculospiral; IH, intercostohumeral; LIC, IC, lesser internal and internal cutaneous; EC, external cutaneous; IH, iliohypogastric; II, ilio-inguinal;  $T^{12}$ , last thoracic; GC, genitocrural; EC, external cutaneous; MC, middle cutaneous; IC, internal cutaneous; P, pudic; SS, small sciatic; O, obturator; C, T, L, and S, cervical, thoracic, lumbar, and spinal nerves. (Piersol.)

foramina. Chipault (quoted by Starr) gives the following practical rule: "In the cervical region add one to the number of the vertebra, and this will give the segment opposite to it. In the upper dorsal region add two; from the sixth to the eleventh



dorsal vertebra add three. The lower part of the eleventh dorsal spinous process and the space below it are opposite the lower three lumbar segments. The twelfth dorsal spinous process and the space below it are opposite the sacral segments." The spinal cord ends at the lower part of the first lumbar vertebra.

The areas of cutaneous sensibility aid in determining the seat of the lesion. The nerves supplying these various areas are shown in Fig. 486.

Lesions above the fourth cervical nerve are very speedily fatal. The muscular paralyses, as guides to the seat of the lesion in the cervical region, are given by Thorburn as follows:

Supraspinatus and infraspinatus . . . . .	}	Fourth cervical nerve.
Teres minor (?) . . . . .		
{ Biceps . . . . .	}	Fifth cervical nerve.
{ Brachialis anticus . . . . .		
Deltoid . . . . .		
Supinator longus . . . . .	}	Sixth cervical nerve.
Supinator brevis (?) . . . . .		
Subscapularis . . . . .		
Pronators . . . . .	}	Seventh cervical nerve.
Teres major . . . . .		
Latissimus dorsi . . . . .		
Pectoralis major . . . . .	}	Eighth cervical nerve.
{ Triceps . . . . .		
{ Serratus magnus . . . . .		
Extensors of the wrist . . . . .	}	First dorsal nerve.
Flexors of the wrist . . . . .		
Interossei . . . . .		
Other intrinsic muscles of the hand . . . . .		

In fractures of the dorsal region Thorburn has shown that the lesion is usually two vertebræ higher than the nerve coming out from below the displaced vertebra. They cause paralysis of the abdominal muscles, legs, bladder, and rectum.

According to Starr, fractures in the region of the last two dorsal vertebræ cause anæsthesia up to Poupart's ligament, and if the patient recovers the thighs remain paralyzed. In fractures of the upper part of the lumbar region the paralysis may be limited to the legs below the knees but involves the bladder and rectum. Recovery leaves the patient with some power of getting about on crutches with the aid of apparatus to keep the ankles and knees firm, as the thighs are under voluntary control.

Lesions below the first lumbar, those of the cauda equina, give paralysis of the feet and peronei, loss of control of the bladder and rectum, and anæsthesia in the saddle-shaped area on the buttocks, about the anus, and on the posterior part of the genitals.

The diagnosis between lesions of the cauda equina and lower portion of the cord is not always possible. The prognosis of lesions of the cauda equina is, of course, much better than when the cord itself has been injured.

## SPINAL MENINGES.

The cord is covered by a continuation downward of the cerebral meninges. It has a dura mater, arachnoid, and pia mater.

**Dura Mater.**—The outer or endosteal layer of the cerebral dura mater ends posteriorly at the edge of the foramen magnum but anteriorly at the third cervical vertebra. The inner or meningeal layer continues downward as a tough fibrous tube from the foramen magnum to the second or third sacral vertebra, and thence is prolonged downward as a fibrous cord (coccygeal ligament) to be attached to the periosteum over the coccyx. The dura mater in the spine does not, as in the skull, act as a periosteum. The vertebræ have a separate periosteum in addition. Between the dura mater and the bodies of the vertebræ is a somewhat loose space filled with fat, fibrils of connective tissue, and a venous plexus. In injuries these vessels are ruptured and bleed and give rise to clots; the blood, however, does not get inside the membranes and the effusion rarely assumes a sufficient size to produce compression of the cord. These veins pierce the ligamentum subflavum and thus communicate with



the dorsal spinal veins. The dura mater is almost never torn in injuries even though the cord may be crushed (Fig. 487).

**Arachnoid.**—The arachnoid of the spinal cord is a stouter membrane than the cerebral arachnoid. Above it is continuous with the cerebral arachnoid at the foramen magnum. Below it blends with the dura at about the level of the third sacral vertebra. Thus it is seen that while the cord itself ends at the lower border of the first lumbar vertebra the subarachnoid cavity is prolonged nearly or quite to the third sacral. As in the brain, the cavity between the arachnoid and the dura above is slight, the two membranes being practically in contact, so that there is almost no subdural space. Between the arachnoid and pia, however, there is a considerable cavity which is continuous with the same space beneath the cerebral arachnoid. It communicates with the fourth ventricle just above the calamus scriptorius by the foramen of Magendie in the median line, and at the sides by the foramina of Key and Retzius, and also by slits at the descending horns of the lateral ventricles. Hence it is that the ventricular fluid can be drained by a lumbar puncture.

Through this subarachnoid space pass the septum posticum behind and the ligamenta denticulata on each side from the pia to the dura mater. It is also traversed by the anterior and posterior roots of the spinal nerves, the former being in front and the latter behind the ligamentum denticulatum. The arachnoid contains neither vessels nor nerves (Fig. 488).

**Pia Mater.**—The spinal pia mater is thin and closely invests the cord. It carries the blood-vessels of the cord and sends prolongations posteriorly to the dura as the septum posticum, laterally as the two ligamenta denticulata, and also around the anterior and posterior roots of the spinal nerves.

**Spinal Vessels.**—Three arteries supply the spinal cord, an *anterior spinal* in the median line of the anterior surface and two *posterior*

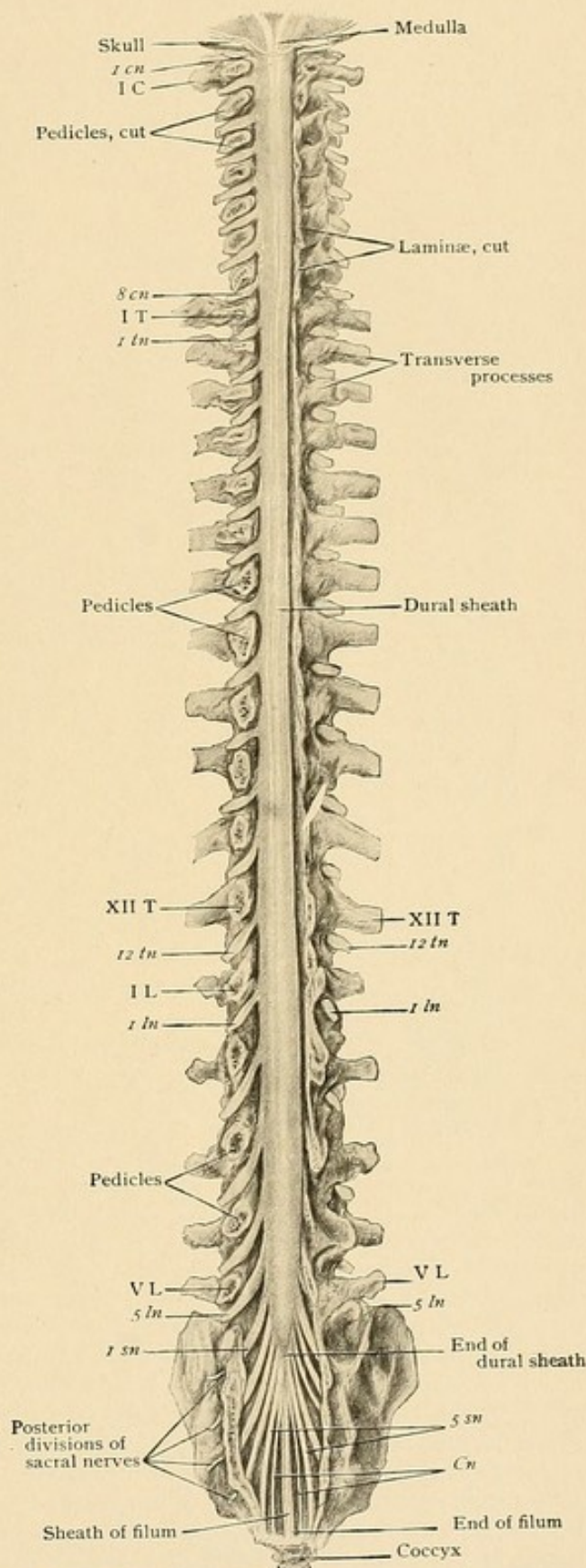


FIG. 487.—Spinal cord enclosed in unopened dural sheath lying within vertebral canal; neural arches completely removed on right side, partially on left, to expose dorsal aspect of dura; first and last nerves of cervical, thoracic, lumbar, and sacral groups are indicated by Italic figures; corresponding vertebrae by Roman numerals. (Piersol.)



*spinal* just behind the posterior spinal roots (Fig. 489). The veins are more numerous. They consist of three sets or plexuses, one on the cord in the meshes of the pia mater, another in the spinal canal between the dura mater and the bone, and the third on and around the outside of the vertebræ. The veins on the cord in the anterior and posterior median fissures communicate above with the veins of the medulla. The lateral veins empty through the radicular veins which accompany the spinal nerve roots. The veins in the spinal canal form anterior and posterior plexuses between the dura and bone and communicate with the extraspinal plexuses around the laminae and spinous processes posteriorly (dorsispinal veins) and the plexus around the bodies anteriorly.

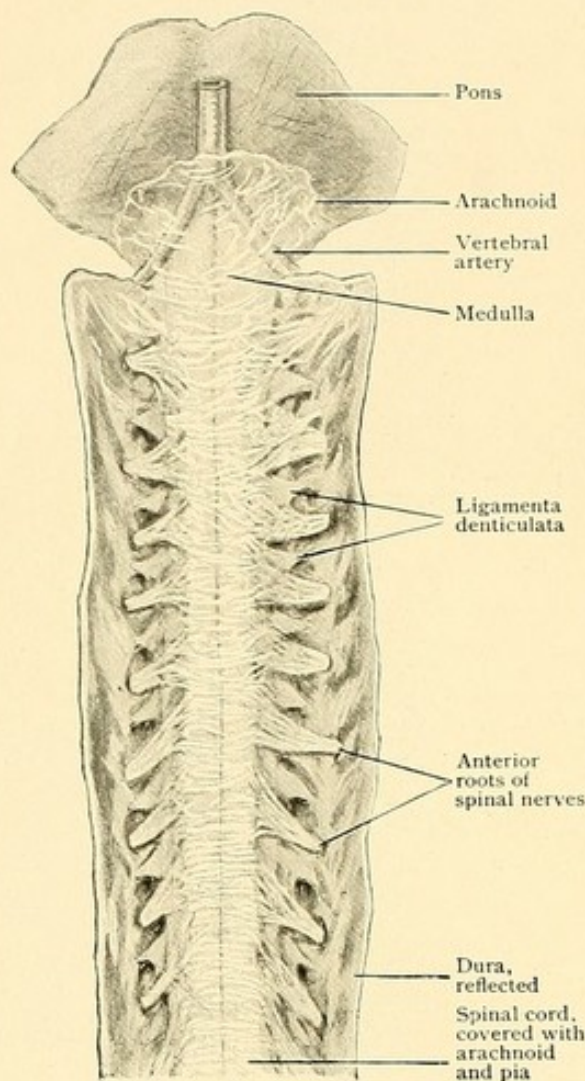


FIG. 488.—Upper part of spinal cord within dural sheath, which has been opened and turned aside; ligamenta denticulata and nerve-roots are shown as they pass outward to dura. (Piersol.)

**Spinal Hemorrhage.**—Spinal hemorrhages, though sometimes caused by disease, are usually the result of injury. They frequently accompany fractures and dislocations. They may be either extradural, intradural, or in the cord—*hæmatomyelia*. They exist either coincident with the original injury or appear within a few hours.

Spinal hemorrhages are rarely large and those in the substance of the cord are the more common. They are usually venous. *Extradural hemorrhage* comes from the plexuses between the dura and bone and the clot may extend through the intervertebral foramina. It is usually of small extent and practically does not produce paralysis from pressure on the cord, hence operation for its relief is useless. *Intradural hemorrhage* comes from the vessels of the pia and may invade not only the subarachnoid but also the subdural space. It may remain localized at the site of injury or the blood may sink and fill a considerable portion of the spinal canal. Owing to the looseness of the cord in its dural sheath the hemorrhage spreads and does not usually give rise to pressure symptoms, hence operation is rarely ad-

visable. Large hemorrhage sometimes comes down from cerebral apoplexy or injuries. *Hæmatomyelia*.—Hemorrhage into the substance of the cord may be caused by extension or accompany the contusion due to dislocation or fracture. The paralysis which follows serious injuries of the spine is usually due to hemorrhage into the gray or white matter of the cord. The gray matter being the softer is the more frequently affected, the blood penetrating it for quite a distance. Hemorrhage into the gray matter destroys it and produces an incurable paralysis. When into the white matter restoration of function through absorption may occur in from four to six weeks. In either case operation usually is of no service. The location of the hemorrhage will be revealed by the interference with the functions of the cord. The hemorrhage can occur in the form of a column of blood infiltrating the gray matter of several segments in one or both directions from the starting-point. The longer extension is usually toward the brain. It is usually limited to one side of the cord. Generally in small and sometimes in large hemorrhages the effect is mainly mechanical, but especially large hemorrhages may be surrounded by areas of softening.







involved, atrophy, and the abolishing of the reflexes. The deformities seen are secondary results of the paralysis.

**Syringomyelia** is an acquired enlargement of the central canal or the formation of new canals in the gray matter. It produces motor, sensory, and trophic disturbances which vary according to the part of the cord attacked.

**Progressive Muscular Atrophy** (Duchenne's Disease).—The atrophy begins most often in the hands and extends to other parts of the body. Then occurs an atrophy of the gray substance of the anterior horns which may extend to the brain; even the white substance of the direct and crossed pyramidal tracts may also show degeneration. There is a type in which there is a lack of demonstrable cord lesions. Among its various forms are those called pseudomuscular hypertrophy, progressive muscular dystrophies (Erb), and primitive progressive myopathies (Charcot).

**Arthritic Muscular Atrophy.**—Disease of the joints often results in marked disturbance of the gray matter of the cord, which in turn is followed by muscular atrophy (Church: Church and Peterson, *Nervous and Mental Diseases*, page 38).

*Lesions Affecting Principally the White Matter of the Cord.*—The principal lesions affecting the white matter are lateral sclerosis, locomotor ataxia, combined posterolateral sclerosis, Friedreich's ataxia, and hereditary spastic paraplegia.

**Lateral sclerosis**, or spastic paraplegia, is almost unknown as a primary affection. It is a sclerosis of the pyramidal tracts. It occurs as a secondary degeneration, the result of cerebral disease, producing the spastic paraplegia of infants—Little's disease—and also follows transverse lesions of the spine from tumors, caries, fractures, etc.

**Locomotor ataxia**, or tabes dorsalis, when advanced may affect the entire portion of the cord between the posterior horns and the commissure, from the filum terminale to the medulla. It begins in Clarke's column (a group of cells in the posterior horn of the cord extending from the seventh cervical to the second lumbar nerves) and may involve the direct cerebellar tracts and Gowers's ascending anterolateral tracts and also the posterior nerve roots. It produces both motor and sensory disturbances as well as trophic changes.

**Combined Posterolateral Sclerosis**—(Ataxic Paraplegia of Gowers).—This produces symptoms combining spastic paraplegia and locomotor ataxia. The following structures are affected: columns of Burdach, Goll, crossed pyramidal tract, direct pyramidal tract, and not always the ascending tract of Gowers.

**Friedreich's ataxia** (family or hereditary ataxia) is a progressive paralysis often appearing through many generations. There is a sclerosis of the columns of Goll and Burdach, crossed pyramidal tract, Gowers's tract, direct cerebellar tract, Lissauer's tract, and often atrophy of the cells of Clarke's column.

**Hereditary Spastic Paraplegia.**—This is a degeneration of the pyramidal tracts, columns of Goll and Burdach, and direct cerebellar tract. The disease has been traced through many generations.

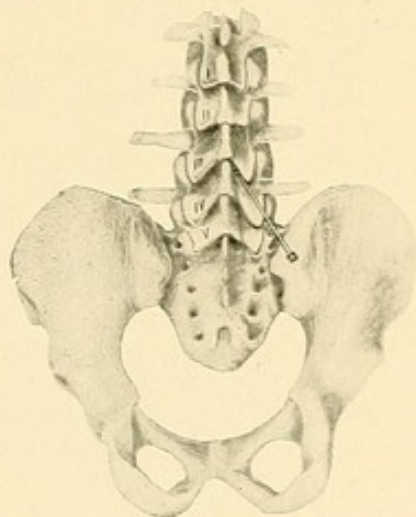


FIG. 490.—Lumbar puncture of the spine.

## OPERATIONS ON THE SPINE.

**Spinal Puncture.**—Spinal puncture may be performed either for diagnostic purposes, for relief of accumulations of subarachnoid fluid, or for the purpose of producing spinal anaesthesia.

The lumbar region is usually selected and the puncture made just to one side of and either above or below the spine of the fourth lumbar vertebra. A line passing from the highest point of the crest of one ilium to that of the opposite side passes through the lower part of the spine of the fourth lumbar vertebra. The puncture should always be made below the upper border of the second lumbar vertebra, because the spinal cord extends down to that point (Fig. 490). The lumbar spines are nearly or quite horizontal and do not incline downward as do those of the cervical



and dorsal regions. The patient should bend the body forward, as by so doing the space between the vertebræ posteriorly is increased.

The needle used should be from 6.25 cm. ( $2\frac{1}{2}$  in.) to 10 cm. (4 in.) long, according to the age and size of the patient. It should be directed slightly toward the median line and upward. In its entrance it pierces the muscles, then the ligamentum subflavum, which passes from one lamina to the other, and finally the dura mater and arachnoid. Failure is liable to occur either from the patient straightening the spine when the puncture is made or from failure to enter the spinal membranes owing to pushing the dura in front of the cannula. A needle enters more readily and surely than does a small trocar with its cannula. The shoulder formed by the cannula, particularly if not well made, is apt to push the tough dura ahead of it instead of puncturing.

**Laminectomy.**—The laminae pass from the transverse and articular processes to the spinous processes. On each side of the median line the erector spinæ muscles form thick masses and the spinous processes lie in the groove between them. Hence, in doing a laminectomy, the depth at which the laminae lie is apt to be found much greater than is expected. An incision is first made directly on the spinous processes and continued down on each side to the laminae. With a chisel-like periosteal elevator the attachments of the muscles and periosteum are detached from the base of the spinous processes and laminae as far out as the transverse processes. The bleeding from the muscles is controlled by packing. The laminae may be divided with a saw inclined inward or the supraspinous, interspinous, and subflava ligaments may be divided, the spinous processes cut close to their base and removed, and finally the laminae removed with bone forceps. When the laminae are removed the dura mater is found separated from the bone by fat and connective tissue. The veins here encountered may bleed freely but cease on pressure being made. If necessary the dura may be opened, in which case the portion of the body toward the head may be lowered to prevent too great loss of cerebrospinal fluid. The roots of the spinal nerves will be found passing out laterally and should if possible be avoided. If the posterior or sensory root is divided it has the same tendency to re-unite as do sensory nerves elsewhere, but division of the anterior root causes permanent motor paralysis. The dura and other structures are then sutured without drainage.

## THE LOWER EXTREMITY.

### GENERAL CONSIDERATIONS.

The lower extremity is designed to bear the weight of the body and serve as a means of locomotion.

It is composed of a pelvic girdle, thigh, leg, and foot.

The pelvic girdle serves as the medium of connection of the lower extremity to the trunk in the same manner as does the shoulder-girdle for the upper extremity.

We saw that prehension, characterized by mobility, was the distinguishing feature of the upper extremity and that the shoulder-girdle was composed of two bones, was loosely joined to the trunk, and held the upper extremity out away from it.

The lower extremity on the contrary has two functions, it must bear the weight of the body and must move this weight around from place to place; hence strength is essential and a less amount of mobility suffices. To meet these changed conditions the lower extremity differs in its construction from the upper in the following respects:

1. The pelvic girdle is composed of one bone—the innominate—instead of two.
2. It also forms a part of a complete bony ring instead of being incomplete posteriorly.
3. It is more firmly joined to the trunk.
4. The hip-joint is placed closer to and in more intimate relation with the trunk than is the shoulder.
5. The bones of the lower extremity are heavier and stronger than those of the upper.
6. The joints are larger and stronger, but their movements are not so extensive.
7. The muscles are coarser and their functions are not so highly specialized.



## THE BONY PELVIS.

The pelvis is composed of the pelvic girdle on each side (innominate bones), and the sacrum and coccyx posteriorly. It serves two purposes. It supports and protects the abdominal and pelvic viscera, and serves as the connection between the trunk and the lower limb. It is divided into two parts—the false pelvis, above the iliopectineal line, and the true pelvis, below the iliopectineal line.

The false pelvis serves to support the abdominal viscera, as its name indicates, like a basin. In man it is large and flaring because his normal position is upright, but in the lower animals, as the quadrupeds, whose normal position is horizontal, it is smaller and less prominent.

The true pelvis contains and protects the pelvic organs and also serves as the connecting link between the trunk above and the extremity below; hence, as it has a double function, it has of necessity a composite structure. In order to contain and protect the pelvic viscera it is made hollow, and in order to support the weight of the body on the legs it is made strong. The pelvic contents are not exposed to injury to the same extent as is the brain; therefore, instead of having a complete covering of bone, like the skull, the bony pelvis is merely a framework comprised solely of those parts essential to strength.

The pelvis supports the trunk in two postures, the standing and sitting. In the former the weight is transmitted through the acetabula, and in the latter to the tuberosities of the ischia.

## MECHANISM OF THE PELVIS.

As was pointed out by Henry Morris ("The Anatomy of the Joints of Man," p. 115), the bony pelvis is composed of arches. The two main arches are the femorosacral and the ischiosacral. These are strengthened by subsidiary arches which join the extremities of the main arches so as to strengthen and fix them.

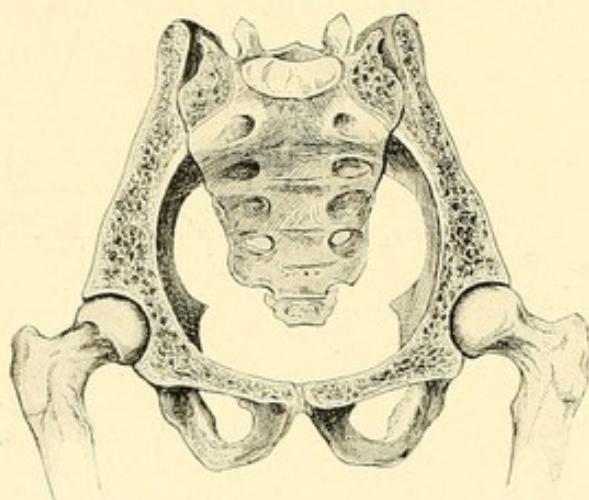


FIG. 491.—The femorosacral arch. The main arch passes upward from one hip-joint to the other through the sacrum: the subsidiary arch passes downward from one hip-joint to the other through the pubes.

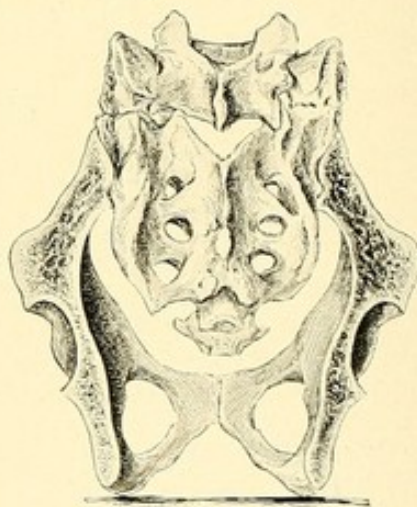


FIG. 492.—The ischiosacral arch. The main arch passes upward from one tuberosity of the ischium through the sacrum down to the opposite tuberosity: the subsidiary arch passes forward from one tuberosity of the ischium through the pubes and back to the opposite tuberosity.

**Femorosacral Arch.**—This arch extends from the acetabula on the sides to the sacrum in the middle, which is its keystone. The weight of the body is transmitted downward through the spine to the sacrum, and then through the two sides of the femorosacral arch to the heads of the femurs. For an arch to be effective its two extremities must be firmly anchored, so that they do not separate when pressure is made on it. In artificial arches, as used in bridges, this separation is guarded against by a rod running from one extremity to the other, forming a chord of the arc. In the pelvis this mechanism is impossible, because this "tie-rod" would



infringe on the cavity of the pelvis, and it is to obviate this that a counter arch is introduced. This secondary arch is formed by the rami and bodies of the pubic bones, and passes anteriorly from one acetabulum to the other on the opposite side. It is much weaker than the primary arch (Fig. 491).

**Ischio-sacral Arch.**—In sitting, the pelvis, viewed laterally, is in much the same position as in standing, being in both almost vertical and beneath the spinal column. The thighs, however, are horizontal and the bulk of the weight is supported by the tuber ischii. From the keystone or sacrum the weight is transmitted through the ilium and body of the ischium to the tuberosities on each side. This primary arch is strengthened by the secondary arch formed on each side by the ramus of the ischium and the descending ramus and body of the pubis. Notice that this likewise is weaker than the primary arch (Fig. 492).

### FRACTURES OF THE PELVIS.

The flaring wings or alæ of the ilium are not infrequently fractured by direct violence. The line of fracture is usually transverse (Fig. 493). The displacement is slight on account of the muscular attachments of the iliacus muscle inside and the glutei muscles outside. The anterior third of the crest of the ilium is subcutaneous and prominent, hence by manipulating it crepitus can usually be elicited and the diagnosis made. Recumbency and the support afforded by adhesive plaster is all the treatment necessary.

The more serious fractures, however, are those of the true pelvis. The pelvic cavity is somewhat heart-shaped; the sacrum projects anteriorly and is so strong that it is rarely fractured. At or just outside of the sacro-iliac joints is, however, one weak point; between the acetabulum and the pubes, through the rami of the pubes and ischium and thyroid foramen, is another; and at the symphysis is a third.

The most frequent fracture passes through the pelvic ring twice, anteriorly through the rami of the pubis and ischium and thyroid foramen and posteriorly through or just external to the sacro-iliac joint. Whenever a fracture of the pelvis is suspected, search for this fracture. Examine the rami of the pubes. Pressure made along Poupert's ligament just external to the spine of the pubes will usually reveal a tender spot and may elicit crepitus. A digital examination through the rectum or vagina may likewise indicate the site of the fracture. The bladder is frequently wounded, the rectum almost never and the urethra rarely.

The symphysis, while comparatively a weak part is rarely the site of injury. In childbirth the attachment of the pubes to each other becomes relaxed and a slight physiological separation occurs.

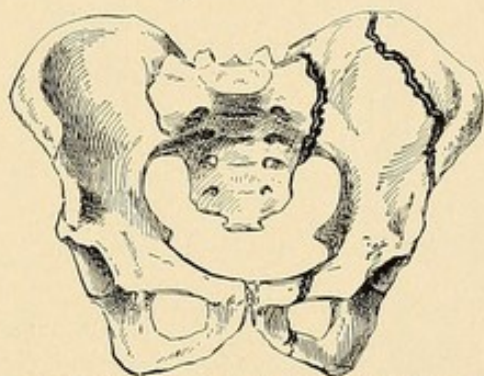


FIG. 493.—Diagram illustrating fracture of the pelvis; one fracture is seen passing through the ilium; the other passes through the sacro-iliac articulation posteriorly and the thyroid foramen anteriorly.

### THE ATTACHMENT OF THE LOWER EXTREMITIES TO THE TRUNK.

The human body usually occupies one of three positions: standing, sitting, or lying. The functions of the lower extremity are to afford support to the body and accomplish locomotion, therefore any disturbance of the normal relation of the extremities to the trunk interferes with the carrying out of those functions and proper support is not given and locomotion is imperfect. In such cases the positions assumed in standing, sitting, and lying are abnormal, often to an extent sufficient to constitute serious deformities, and locomotion, as in walking or running, is seriously impaired or rendered impossible.



The connection of the lower extremities with the trunk is through the means of the pelvic girdle and spinal column; therefore the pelvis and vertebræ above exert a marked influence on the extremities below and must be taken into consideration. The normal upright position of man is obtained by maintaining a proper balance. This balance can be disturbed either anteroposteriorly or laterally. The lower limbs are placed laterally, one on each side; this gives greater stability in that direction, so that when a person falls it is usually in a forward or backward direction rather than toward the side.

**Anteroposterior Equilibrium.**—In the upright position the highest joint is that between the occiput and atlas and the lowest that of the ankle; to enable the body to be in a state of rest, in the upright position, with the use of the least amount

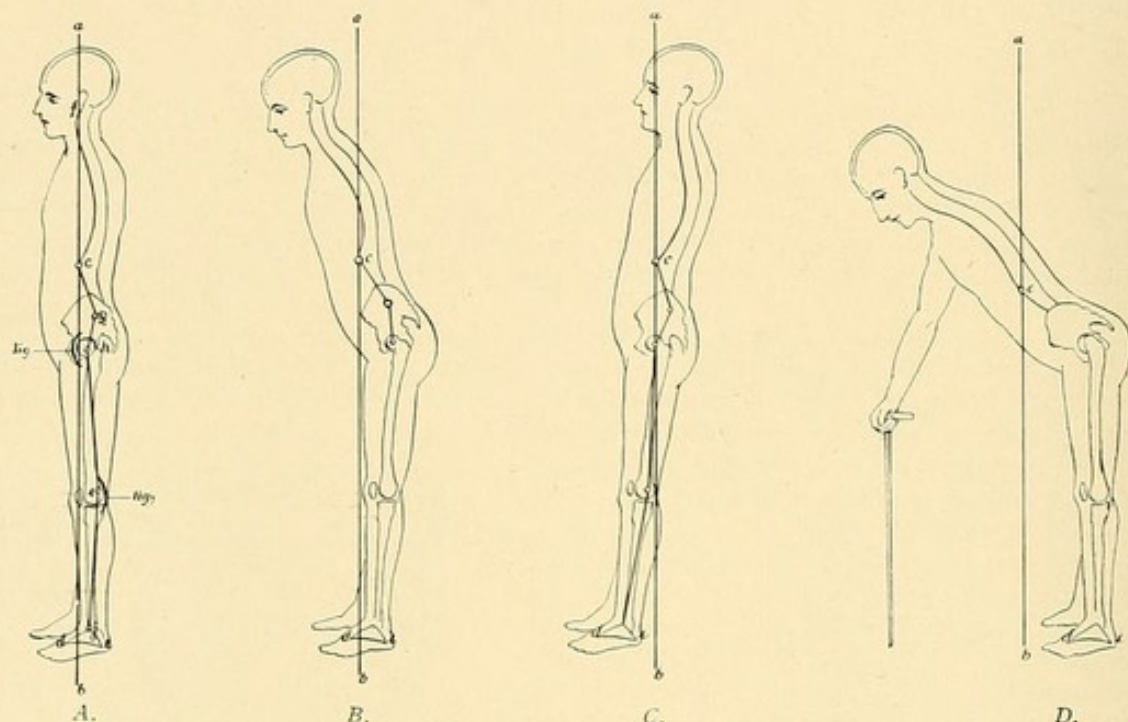


FIG. 494.—Anteroposterior equilibrium.

Fig. A.—The body in the erect position; the centre of gravity *c* is about in the upper lumbar region; *d-e* is the base of support. The vertical line *a-b* through the centre of gravity *c* passes through the occipito-atloid joint above, in front of the sacro-iliac joint *g*, the hip-joint *h*, the knee-joint *i* and the ankle-joint *j* and falls between the points of support *d-e*, passing through the astragaloscaphoid joint. Hyperextension of the hip and knee is prevented by ligaments.

Fig. B.—When the trunk is inclined forward by bending at the hip-joint, the increased projection of the head and upper portion of the trunk in front of the centre of gravity is counterbalanced by the increased projection of the hips and lower portion of the trunk posteriorly. The vertical line through the centre of gravity still cuts the base of support *d-e* and the body remains in a state of equilibrium.

Fig. C.—When the body inclines backward, hyperextension at the hip is prevented by ligaments; therefore, when the vertical line *a-b* through the centre of gravity *c* falls beyond the base of support *d-e*, the body is in unstable equilibrium and it falls.

Fig. D.—If the body, as occurs in some diseases and injuries, is inclined so far forward as to bring the vertical line *a-b* through the centre of gravity *c*, in front of the base of support *d-e*, then it is in a state of unstable equilibrium and additional support is used, in the form of a cane, to prevent falling forward.

of muscular exertion these joints are placed almost vertically one above the other. For the same reason if any part of the skeleton lies in front of a line joining the condyle of the occiput with the astragalo-scapoid joint it is counterbalanced by a projection toward the opposite side. Thus the anterior curve of the cervical region is followed by the posterior curve of the dorsal; the anterior of the lumbar, by the posterior of the sacral. The hip-joint has its centre of motion slightly behind the centre of gravity as has also the knee. A vertical line through the center of gravity must fall within its base of support. This latter is formed by the arch of the foot; its two ends are the tuberosity of the calcaneum posteriorly and the head of the first metatarsal bones anteriorly. The body is in the position of greatest stability when the centre of gravity is midway between those two points, which is when it passes through the astragalo-scapoid joint. As the line of gravity passes from the centre of



the arch toward the ends, equilibrium becomes more unstable until, when it passes beyond them, it is lost and the body begins to fall. In maintaining a normal erect posture hyperextension of the hip-joint is prevented by the anterior or iliofemoral ligament; hyperextension of the knee is prevented by the lateral, posterior, and crucial ligaments (Fig. 494, *A*). The main muscular efforts required are those of the muscles of the back of the neck to hold the head level, owing to the head being heavier anterior to the condyles, and the muscles of the back of the leg to prevent the dorsal flexion at the ankle, due to the centre of gravity falling in front of the ankle-joint. When a person falls asleep in the erect posture the head drops forward and when a soldier is shot his calf muscles give way and he falls forward on his face.

Deformities of the spine affecting its curves have already been alluded to (page 478). When the spine is the part affected it is usually the case that the secondary curve fully compensates for the increased primary one, hence there is no necessity

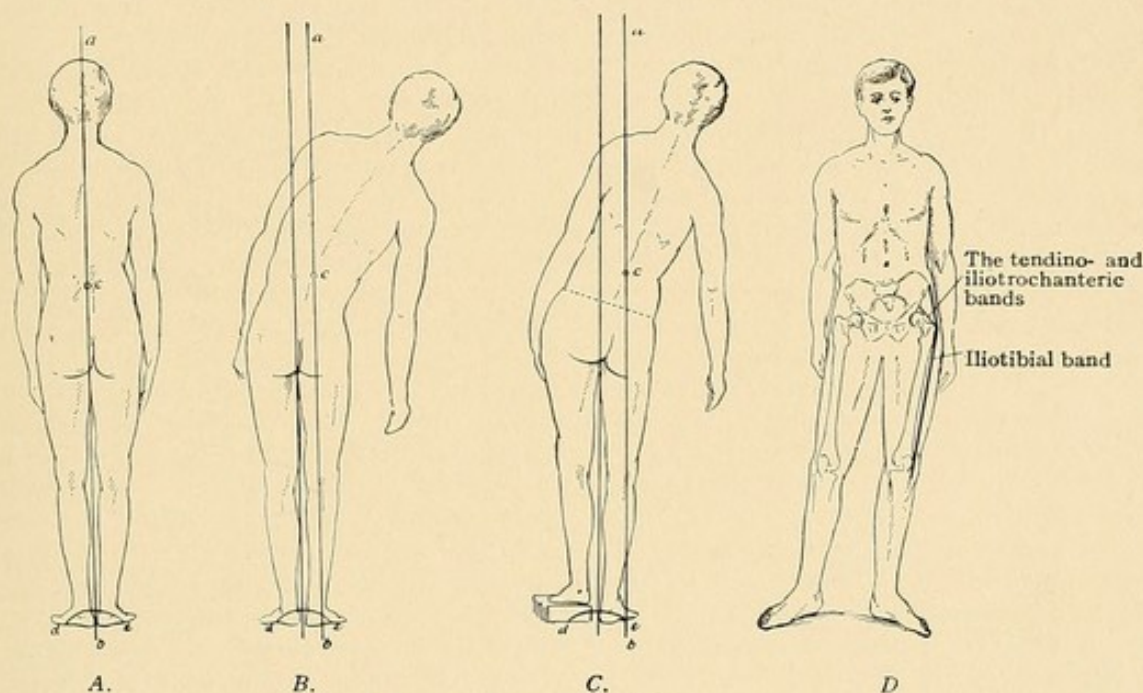


FIG. 495.—Lateral equilibrium.

Fig. *A*.—The body being erect, a vertical line *a-b* through the centre of gravity *c* falls midway between the ankles or base of support *d-e* and the body is in stable equilibrium.

Fig. *B*.—The trunk being inclined to the right, the centre of gravity *c* is shifted to the right and a vertical line *a-b* through it falls still within the line of support *d-e* and the upright position can still be maintained.

Fig. *C*.—If the relative length of the two legs is altered, as by placing a block beneath one of them, the pelvis and upper portion of the body inclines to the opposite side, until a vertical line *a-b* through the centre of gravity *c* falls beyond the extremity of the base of support *d-e* and the body is in a position of unstable equilibrium.

Fig. *D*.—The body in a position of rest. The weight is borne mainly on the left leg; the right side of the pelvis falls until the iliotrochanteric and iliotibial bands are tense, when the position can be maintained without muscular effort.

for any change in the position of the joints below, and we find people with marked deformities of the spine who are normal from the waist down and who stand and walk perfectly well. Occasionally a case presents itself in which the secondary curve has not entirely compensated the primary one and then the body is bent at the hips until the centre of gravity is brought over the base of support (Fig. 494, *B*). If the deformity throws the centre of gravity too far back, by bending the hips it will be brought forward, but if for any reason, such as ankylosis, flexion is impossible, then it cannot be corrected at the hip-joint, and therefore in such cases equilibrium is unstable and the body falls (Fig. 494, *C*). If from deformity the centre of gravity is thrown so far forward as to fall beyond the base of support then a cane or crutches is required (Fig. 494, *D*).

When the hip-joint is involved it is never affected by hyperextension (the iliofemoral ligament prevents that), but always by flexion. This throws the centre of gravity forward; to bring it back a secondary curve is produced in the lumbar region, and we have a condition of lordosis established; if this is insufficient then



the knees may be partly flexed, and if both are insufficient then artificial support or crutches must be used. This is the reason why flexion is sought to be avoided in the treatment of coxalgia, and why osteotomy is done when the hip is ankylosed in a flexed position. Practically speaking there is no efficient compensation occurring at the sacro-iliac joints, the pelvis moving with the lumbar vertebræ.

**Lateral Equilibrium.**—In the upright position the centre of gravity falls midway between the ankles of the two feet. The fact of there being two points of support adds to the stability, which increases as the feet are separated. Hence it is that falls in an anteroposterior direction are more common than sideways. In standing the weight is transmitted from the spine through the femorosacral arches (page 490) to the hip-joint, thence downward through the femur and leg-bones to the astragalus. Here we have to deal with straight lines and angles rather than curves. The spine is normally straight; the line from the spine to the hip-joint is practically straight (no bending being possible), and from the hips to the feet is likewise straight, and the centre of gravity falls midway between the ankles (see Fig. 495, *A*).

The two innominate bones and the sacrum form practically one solid bone, therefore the two hip-joints always maintain the same relative position to each other. When the leg is completely extended there is no lateral movement at the knee-joints. There is a marked more or less lateral movement in the subastragaloid joint which allows the leg to be inclined to one side without moving the foot. From these facts it is evident that lateral equilibrium can be disturbed by a deviation of the spine above the sacrum to one side (Fig. 495, *B*), and also by anything that affects the length of either leg (Fig. 495, *C*). The femorosacral arch is rarely affected, the most usual affection being sacro-iliac disease, or fracture, or relaxation of the sacro-iliac joint, especially in pregnancy.

The lateral equilibrium is maintained almost solely by muscular force except when a position of rest is assumed. The hip-joint is capable of both abduction and adduction, and in the erect position the ligaments on both the upper and lower surfaces of the joint are lax and do not contribute any support. When, however, a position of rest is desired the hips are moved laterally so that the centre of gravity falls on one leg, which is kept extended, the opposite hip then descends until further adduction is stopped by the ligaments on the top of the hip of the other side (Fig. 495, *D*). These ligaments are the outer limb of the iliofemoral (*Y*) ligament and the reinforcing tendinotrochanteric band, an offshoot from the rectus tendon, the iliotrochanteric band, and by the iliotibial band from the crest of the ilium to the outer tuberosity of the tibia.

**Balance.**—For the movements of the body to be properly performed a definite normal relation of the parts to one another must be maintained, whether the body is in a state of motion or at rest. During movement the position of the bones is controlled by the muscles; when at rest, the muscles relax and the position of the bones is controlled by the ligaments. The weight of the body acts as a constant force pressing downward. For this constant pressure not to do harm it is nicely balanced on the bones and ligaments aided by the muscles. If any one of these three is disturbed the balance is altered and disability and ultimate deformity results. A distortion of a bone, as a badly united fracture, throws the weight and muscular action too much to one side and first the action of the part is impaired and then, if use is persisted in, deformity increases. When a person who is standing becomes tired they assume a position of rest, that is, their muscles relax, their joints are extended and the weight is borne on the ligaments. If, now, as in adolescents, these ligaments are weak, they give way. If in the foot, flat-foot results; if in the knees, then knock-knee; if in the back, scoliosis or lateral curvature. If it is the bones which are the primary cause of the lack of proper balance, the surgeon by osteotomy, excisions, etc., will restore them to their proper direction. If it is the muscles, as in infantile and other paralyzes, transplantations, or the taking of a tendon from the strong side and placing it on the weak side, will be resorted to. If it is mainly the ligaments, these will be aided in their function by the use of apparatus, while by means of exercises the muscles are aided in regaining their normal power. The conservative surgery of the extremities has as its underlying principle the restoration of equilibrium to a part whose balance has been disturbed.



## DEVIATIONS OF THE SPINE ABOVE THE SACRUM.

When, as in lateral curvature or scoliosis, there is a pathological curve developed, the centre of gravity is shifted from the midline to one side and it falls nearer the foot of the side toward which the trunk is inclined (see Fig. 496, *A*). This makes the equilibrium unstable so that to restore stability the hips are inclined to the opposite side and the centre of gravity is brought once more midway between the ankles (Fig. 496, *B*). This condition is produced when there is a single incomplete curve or deviation to one side; if, however, the curve is complete and again reaches the median line, as is often the case in scoliosis, then the centre of gravity is not disturbed and there is no lateral shifting of the pelvis (see Fig. 496, *C*). If the primary curve is accompanied by a secondary curve, both being complete and crossing the median line, then also there is no shifting of the pelvis (Fig. 496, *D*). If, however, the curves are so irregular as to shift more of the weight to one side than the other, then the pelvis shifts (Fig. 496, *E*). This causes the hip on the side opposite to the

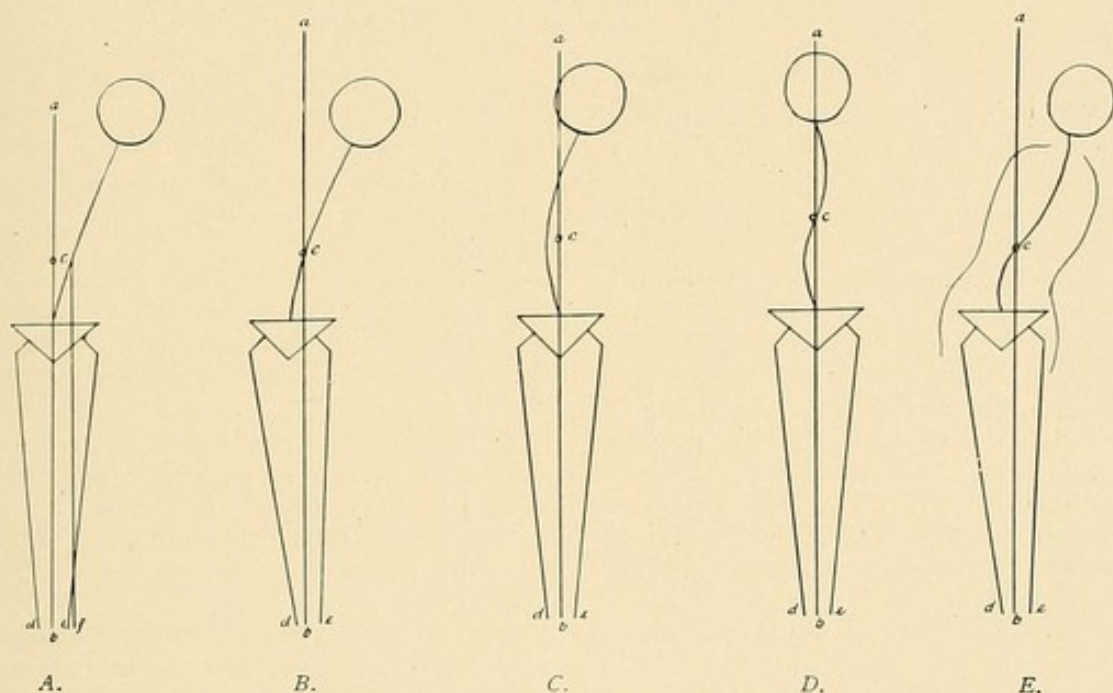


FIG. 496.—Deviation of the spine above the sacrum.

Fig. A.—If the trunk is inclined to one side, a vertical line *a-b* through the centre of gravity is shifted to *c-f*, and therefore falls outside of the base of support *d-e* and unstable equilibrium results.

Fig. B.—The inclining of the trunk to the right has been compensated by shifting the pelvis to the left, and the vertical *a-b* through the centre of gravity *c* falls within the base of support *d-e* and stable equilibrium has again been restored.

Fig. C.—If the deviation of the lower part of the trunk to the left is counterbalanced by a deviation of the upper part to the right then the vertical *a-b* through the centre of gravity *c* falls within the base of support *d-e* and the body remains in stable equilibrium.

Fig. D.—If a complete curve in the lumbar region is compensated by a complete curve in the dorsal and cervical regions above, then the centre of gravity *c* is not shifted and a vertical line through it still falls within the base of support *d-e*, and the body remains in stable equilibrium.

Fig. E.—If the curves are irregular, shifting more of the weight of the upper part of the body to the right, the pelvis is shifted to the left until the centre of gravity *c* is again brought within the base of support *d-e* and stable equilibrium is again restored.

inclination to appear higher than the other, but it is not really so and the pelvis still remains level. It is therefore evident that it is unnecessary and unwise to attempt to correct the deformity by raising the apparently low hip by a high shoe. All these conditions occur in the lateral curvatures or scolioses of childhood and adolescence as well as the deviations which occur from empyema, sciatica, Pott's disease, and other affections. A knowledge of the principles involved is essential to comprehending their production and to directing the exercises and applying the apparatus used in their correction.



## DISTORTIONS ACCOMPANYING AFFECTIONS OF THE LOWER EXTREMITIES.

The hip-joint is capable of flexion, extension, adduction, abduction, and rotation. From the hip to the foot is a straight line; it can be shortened by disease or injury of the bones of the thigh or leg, and in rare cases it can be lengthened by disease at the epiphyses producing a more rapid growth than normal. It is almost unknown for hyperextension of the hip to exist, because if the femur is intact the ilio-femoral ligament prevents it. If the head is gone then the upper end of the femur luxates upward and backward. Rotation likewise produces little effect on the position of the greater trochanter. Deformities due to flexion, abduction, adduction, and shortening are common.

**Increased Flexion.**—Fig. 497, *A* shows the normal position; Fig. 497, *B* shows hyperflexion at the hip. The increased forward bend of the pelvis necessitates an increase in the lumbar curve in order to maintain the anteroposterior equilibrium.

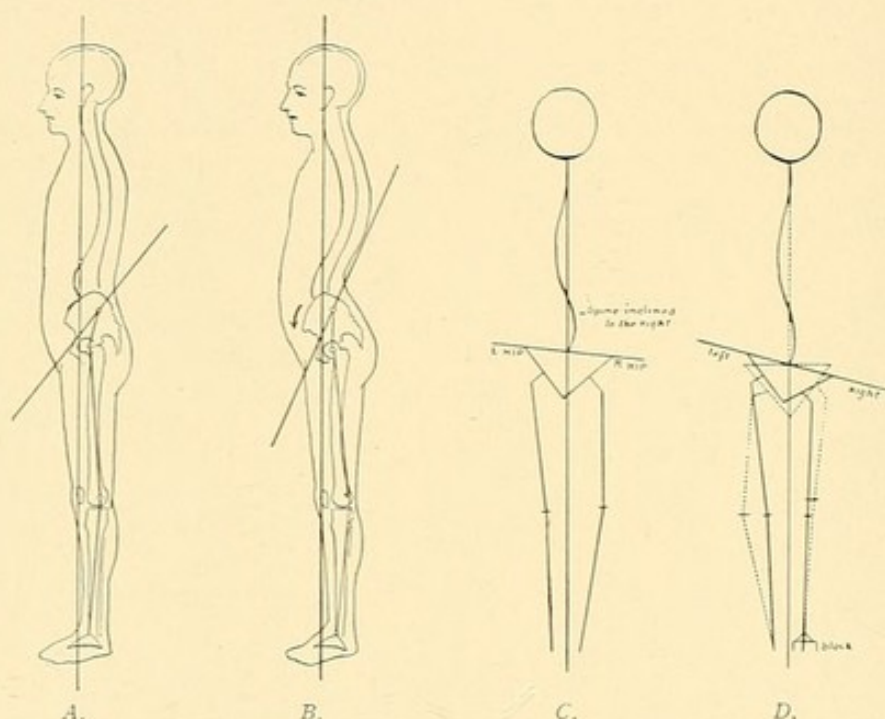


FIG. 497.—Distortions accompanying affections of the lower extremity.

Fig. *A*.—Normal erect position, showing the normal inclination of the pelvis and normal relation of the back and buttocks.

Fig. *B*.—The pelvis has been tilted forward and downward, being flexed on the thighs; this results in an increased hollowing of the back and an increased protrusion of the buttocks.

Fig. *C*.—The left thigh is adducted and the right abducted. If the left hip is ankylosed in a position of adduction, as shown, then the pelvis is tilted down on the right, inclining the spine immediately above in the same direction. This moves the centre of gravity to the right, but is compensated by a shifting of the pelvis to the left, thus bringing the vertical through the centre of gravity within the base of support. If the right hip is ankylosed in abduction, the same condition results. In order to compensate for the uneven lengths of the limbs produced by tilting the pelvis, the knee of the apparently lengthened limb is bent.

Fig. *D*.—The solid outline shows the position assumed when the right leg is shorter than the left. By placing a block under the short right leg the pelvis is raised to a horizontal line and the curves of the spine are straightened, as shown by the dotted outline.

Thus lordosis is produced with the accompanying hollowing of the back and projection of the buttock. This is common in coxalgia and congenital luxations of the hip.

**Hyperadduction and Hyperabduction.**—If there is hyperadduction, as when one hip is ankylosed in a position of adduction, as shown in the left limb (Fig. 497, *C*), the pelvis is carried up toward the left; to restore the balance the spine is inclined to the right. If, however, the right limb is hyperabducted or fixed in a position of abduction, then in assuming the upright posture the right hip descends and the spine is inclined toward the side of the affected limb, as seen in the right hip of Fig. 497, *C*. In treating these conditions the spine can be brought straight by



raising the *abducted* limb, but doing so will increase their inequality still more and shift the pelvis too far to the left. For this reason raising the shoe is not advisable, but an osteotomy and removal of the adduction or abduction is the proper treatment.

**Effects of Shortening or Lengthening of a Lower Extremity.**—The shortening of one limb produces the same effect as the lengthening of the opposite one: in other words it is the inequality of the limbs that counts. In Fig. 497, *D* the right extremity is the shorter; this causes the pelvis to tilt to the right, carrying the lower part of the spine with it and producing a right convex curve which is most marked in the lumbar region. To restore the equilibrium the parts above are carried to the left. Thus a lateral curvature is produced, which, contrary to those which originate in the spine, is accompanied by tilting of the pelvis. In these cases the deformity may be great. If the spinal curvature extends high the shoulders may be uneven, the hips are uneven in height and one projects farther out than the other, the legs may be visibly unequal in length, and there is marked limping of gait. The remedy is obvious. The short limb is to be made equal to the long one by raising the shoe or by other means.

### MEASUREMENT OF THE LOWER LIMBS.

The ability to determine accurately the length of the lower extremities is essential to diagnosis and important in treatment. It is a difficult thing to do and requires knowledge, care, and practice. It may be accepted as a fact that the limbs are nor-

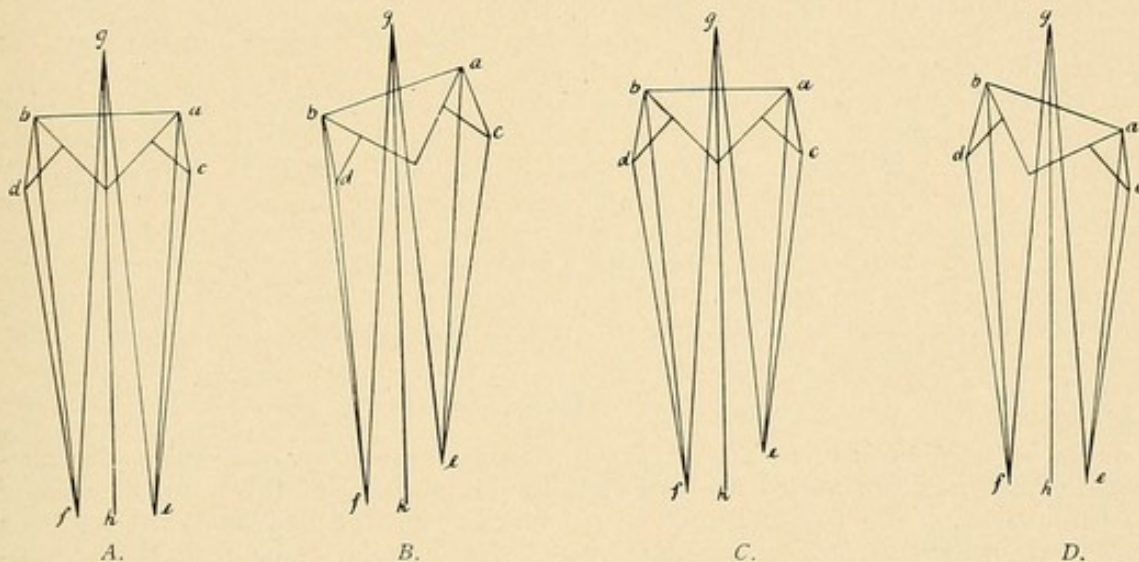


FIG. 498.—Measurements of the lower limbs, viewed from the front. *a*, left anterior superior spine; *b*, right anterior superior spine; *c*, left trochanter; *d*, right trochanter; *e*, left internal malleolus; *f*, right internal malleolus; *g*, umbilicus; *h*, lower end of median line.

Fig. A.—The line of the pelvis *a-b* is in its correct position at a right angle to the long axis of the body *g-h*; *a-e* equals *b-f*, and *g-e* equals *g-f* and *a-c* equals *b-d*.

Fig. B.—The limbs in this figure are of equal length but the pelvis is tilted. The pelvis *a-b* is tilted up on the left and down on the right. Apparent shortening of the left leg is seen by comparing *g-e* with *g-f*. Actual measurement shows *a-e* to be a trifle longer than *b-f* and *a-c* longer than *b-d*.

Fig. C.—One leg shorter than the other, but the pelvis is in the correct position. The actual shortening found by comparing *a-e* with *b-f* corresponds with the apparent shortening found by comparing *g-e* with *g-f*.

Fig. D.—Legs unequal, pelvis tilted down on the side of the short leg. The apparent lengths *g-e* and *g-f*, taken from the umbilicus *g*, show the legs apparently equal, but the distance *b-f* is longer than *a-e* and the absolute or actual amount of shortening is only to be found by levelling the pelvis as in Fig. C, when the apparent and actual amount of shortening will be found to agree.

mally equal in length. It is true that in rare cases there may be a slight inequality, but an amount of inequality readily detected by measurement will usually produce an unevenness in the gait, a slight limp.

To measure accurately, bony landmarks are preferable to the soft parts, such as the umbilicus; these bony points must be carefully identified, they must be in their normal position, and the tape-measure must be accurately applied.

Measurements are usually taken either from the umbilicus or anterior superior spines to the internal malleoli. The latter is the more accurate and shows the actual



shortening, while the former shows the apparent shortening. To identify the tip of the internal malleolus is usually easy enough, but the anterior superior spine is not so evident. The anterior portion of the crest of the ilium should be followed forward until its anterior superior spine can be distinctly felt. In applying the tape it is better not to rest it on the superficial surface of the spine nearest the skin but rather on its inferior surface nearest the feet. It should be placed below the spine and then pushed firmly upward and backward against its lower surface. The superficial surface of the anterior superior spine is often so rounded or flat as to make it an uncertain point to measure from. To put the parts in their normal position it is necessary to see that a line joining the two anterior superior spines is at a right angle with the long axis of the body, otherwise the tilting of the pelvis will vitiate the results. Fig. 498, *A*, front view, shows the normal relation; *g* is the umbilicus; *g-h*, the median line; *a*, left anterior spine; *b*, right anterior spine; *c*, left trochanter; *d*, right trochanter; *e*, left internal malleolus; *f*, right internal malleolus. The line *a-b* is to be at right angles to *g-h*. Then  $a-e = b-f$  and  $g-e = g-f$ .

Fig. 498, *B* shows the effect of tilting of the pelvis, the legs being of equal length. *a-b* instead of being at right angles to *g-h* is inclined upward on the left side and down on the right. Apparent shortening is seen by comparing *g-f* with *g-e*. Actual measurement shows *a-e* to be a trifle longer than *b-f*. This is accounted for by the tilting causing *b-d* to approach each other while *a-c* have separated.

If one hip is ankylosed its femur should be moved laterally until the line joining the two anterior superior spines is at right angles to the median line of the body; the opposite limb is then to be abducted to a similar degree and the measurements of the two limbs can then be compared.

When the legs are unequal and the pelvis is in a correct position, the apparent and actual measurements agree (Fig. 498, *C*).

When the legs are unequal the pelvis is tilted down on the side of the short leg (Fig. 498, *D*). Apparent length taken from the umbilicus shows the legs equal, but the distance *b-f* will be found to be longer than *a-e*. This will not give accurately the actual amount of shortening because of the tilting of the pelvis. It can only be determined by levelling the pelvis so as to make the distances *a-c* and *b-d* equal.

The length of the extremity below the neck of the femur can be determined by feeling for the tip of the greater trochanter on its upper posterior border and measuring to the external malleolus and comparing with the opposite side.

## WALKING.

As locomotion is one of the main functions of the lower extremity, derangements of this function are to be explained by a knowledge of the normal action of its mechanism. The means by which support is accomplished have already been explained in the maintenance of equilibrium. Locomotion embraces walking, running, jumping, etc. Of these walking is the fundamental movement, and the others are only amplifications and modifications of it. In slow normal walking on a level surface the thigh moves on the pelvis, the leg on the thigh, the foot on the leg, and the toes on the rest of the foot. These movements are almost solely in an anteroposterior direction, there being almost no lateral or rotary movements; these begin only when the actions become violent and irregular, such as are necessary in running, overcoming obstacles, etc. It is for this reason that a person may have no limp when walking slowly, but a very perceptible one when walking rapidly. There is always a small amount of lateral motion present which varies with the individual and the sex.

As slow walking necessitates mainly anteroposterior motion, it can be explained by viewing the body laterally.

In ordinary walking the body inclines forward 5 degrees, in fast walking 10 degrees, and in running about 22 degrees (Weber). In walking (Fig. 499, *A*) the body is inclined forward and at the same time one leg begins to advance (the right). This causes flexion of the left ankle and flexion of the right hip (Fig. 499, *B* and *C*). As the right foot touches the ground it extends and the right knee flexes to avoid the shock of impact (Fig. 499, *D*), the left knee begins to flex and flexes more than the right in order for the left foot to swing clear of the ground while being advanced;



if this was not done it would be necessary to raise the limb by tilting the pelvis up on that side. The left continues to advance flexed while the right gradually extends (Fig. 499, *E*), and finally when the right is fully extended the left is likewise fully extended (Fig. 499, *F*) and strikes the ground with the foot about at a right angle to the leg.

The object of flexion of all three joints is, first, to avoid shock in impact, and, secondly, to raise the free foot and allow it to swing forward clear of the ground. The object of extension is to push the body forward.

**Part Played by the Various Joints.**—The *hip*-joint flexes to an extent proportionate to the length of the step (Fig. 499, *A*). If this joint is put out of use by being ankylosed, first, the shock of impact is more severe, no flexion being possible; second, the limb can only be brought forward by bending the pelvis on the opposite hip, and, to a certain extent, the trunk above backward; third, to aid still more to advance the foot forward the pelvis will be rotated laterally on the opposite hip. This causes a swaying of the trunk backward and forward and a side swing or waddle of the pelvis. Fourth, the forward propulsive force is weakened by the loss of the hip extensors. The *knee*, like the hip, lessens the shock of impact by flexing. It raises the foot clear of the ground as it is swung forward, and it aids propulsion by extension. If ankylosed, shock is increased, onward propulsive force is lost, and

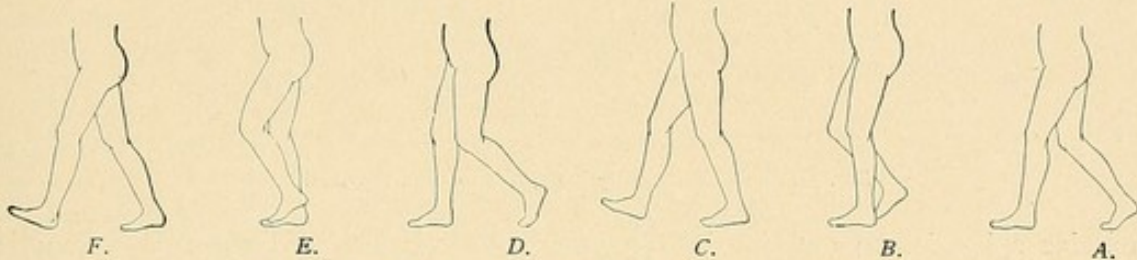


FIG. 499.—Walking. Tracings from photographs by Muybridge.

it is necessary to tilt the pelvis upward in order to raise the foot from the ground and allow it to swing forward. This abducts one or both legs and causes marked waddling. The *ankle* also reduces shock and gives propulsion; if ankylosed, shock is increased and propulsion weakened. This is the least necessary of the three joints and to substitute it artificial appliances are useful, so that in quiet walking limp may be almost lacking, but violent and complicated movements are to a large extent impossible. The toes, especially the big toe, aid in propelling the body forward.

## REGION OF THE HIP.

The hip is that portion of the body joining the lower extremity to the trunk. It differs in construction from the shoulder, because it is designed for strength as well as mobility; hence it is that the bones are heavier, stronger, with their processes more marked, and that the muscles also are bigger and more powerful. It is often the seat of injury and disease, the bones being fractured, the joint luxated, and frequently affected with tuberculosis and other diseases.

## BONES OF THE HIP.

The bones of the hip are the innominate bone and femur. The innominate bone has its shape determined by its relation to the trunk, being adapted to support and protect the viscera, while the femur has its shape determined by its relation to the extremity, being in the nature of a pole to support it.

The **innominate bone** (Figs. 500 and 501) is composed of the *ilium*, *ischium*, and *pubis*. These are united in the acetabulum by the triangular cartilage and become ossified about the sixteenth year. The ilium has a crest which serves for the attachment of the transverse abdominal muscles. At its anterior extremity is



the anterior superior spine, and at its posterior extremity the posterior superior spine. Its large flat portion, called the *ala*, gives origin from both its inner and outer sides to muscles running to the thigh below. The glutei muscles are attached to its outer surface and the iliacus to its inner. Immediately below the anterior

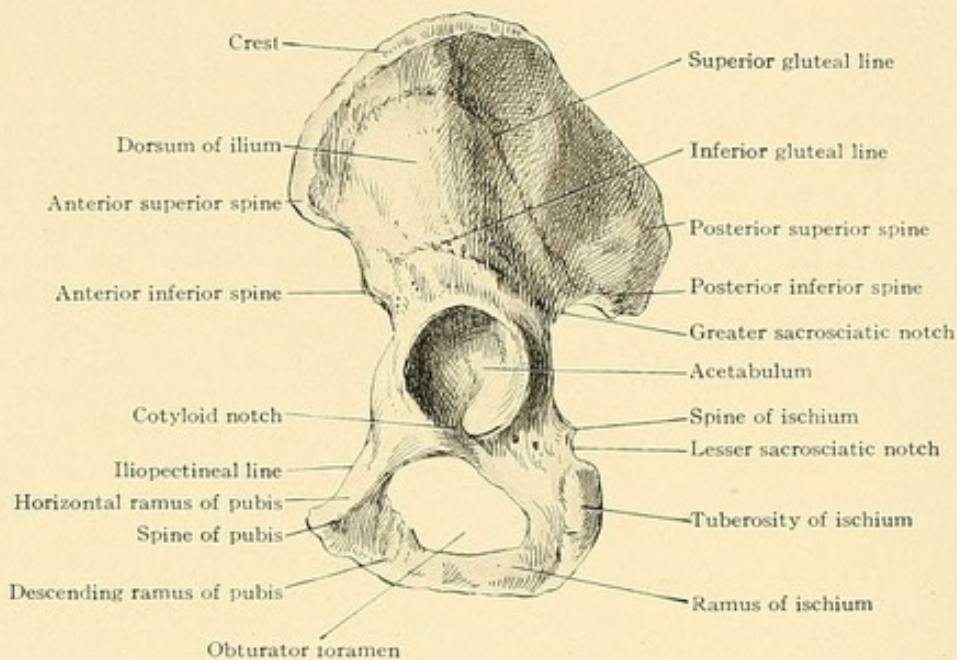


FIG. 500.—The innominate bone, viewed from the outside.

superior spine is the anterior inferior spine; to it is attached the rectus femoris tendon. The ischium is below and behind the acetabulum; its tuberosity gives attachment to the hamstring muscles—biceps (outer), semitendinosus, and semimembranosus (inner). Along the inner surface of the ramus of the ischium, in a

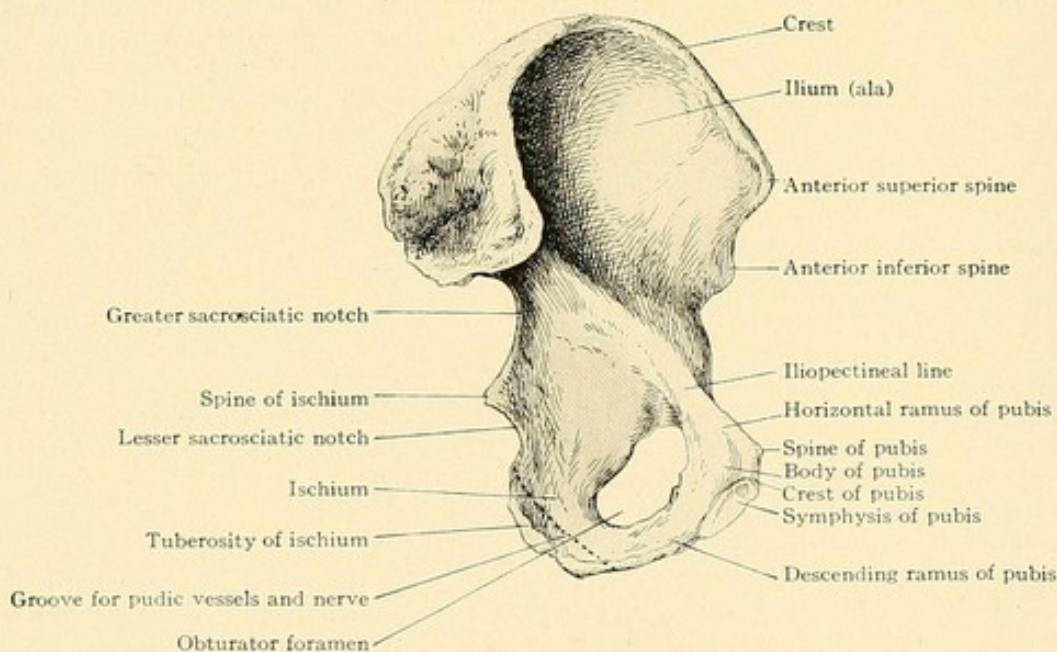


FIG. 501.—The innominate bone, viewed from the inside.

fibrous canal (Alcock's), run the internal pudic vessels and nerve on their way to the perineum. They lie 4 cm. ( $1\frac{1}{2}$  in.) from the surface. The pubis lies below and anterior to the acetabulum. Its upper inner edge forms the iliopectineal line, which is continued back to form the brim of the true pelvis. The superior or



horizontal ramus goes to the ilium, while its inferior or descending ramus goes to the ischium. The upper surface of the superior ramus gives origin to the pectineus muscle; it is over this muscle that femoral hernia descends. The symphysis pubis is the junction of the two pubic bones in the median line. The crest is the upper anterior edge and gives attachment to the rectus and pyramidal muscles (for muscular

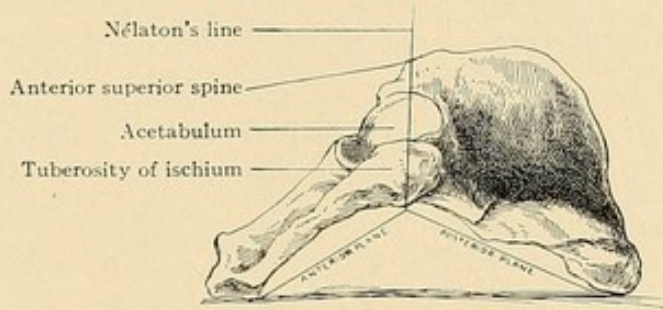


FIG. 502.—Innominate bone, resting on its inner side, to show the wedge-shaped formation of its outer surface. The apex of the wedge is Nélaton's line, running from the anterior superior spine to the tuberosity of the ischium; the anterior plane inclines downward and forward toward the pubis and the posterior plane inclines downward and backward on the ilium.

attachments see Figs. 438 and 439, page 432). The outer extremity of the crest is the spine of the pubis. To it is attached the inner extremity of Poupart's ligament. The obturator foramen, if the body is in an upright position, is just below and a little anterior to the acetabulum; it is closed by a membrane which is incomplete above to give passage to the obturator vessels and nerve. The outer surface

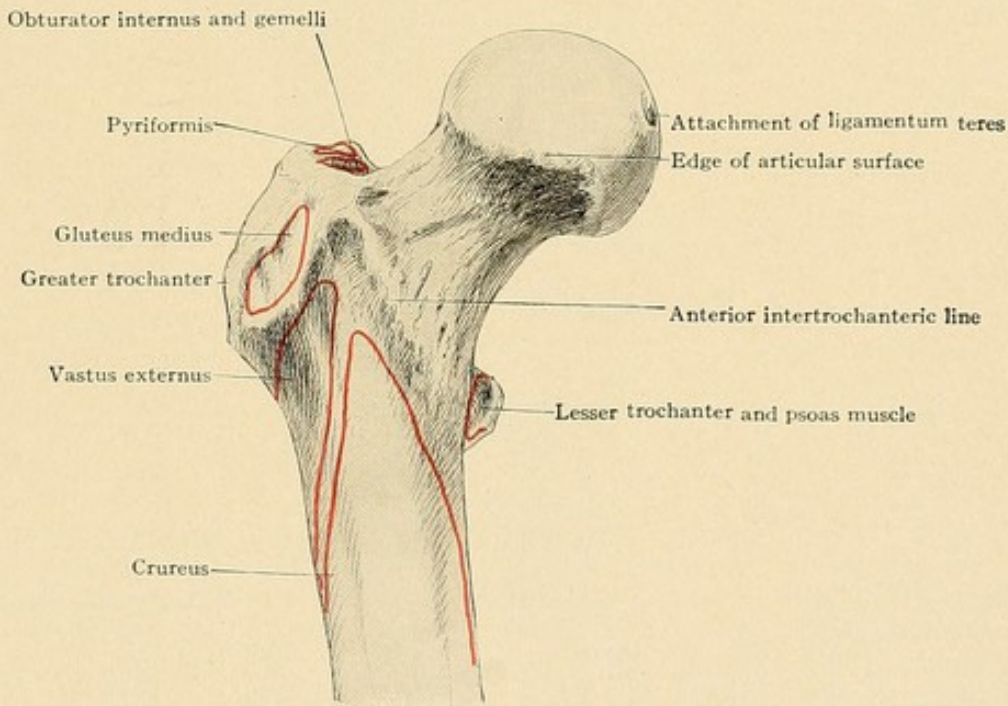


FIG. 503.—Anterior view of the upper end of the femur with muscular attachments.

of the membrane gives origin to the obturator externus muscle and the inner surface to the obturator internus. This latter passes out of the pelvis through the lesser sacrosciatic notch just below the spine of the ischium. Through the greater sacrosciatic notch, above the spine, comes the piriformis muscle and great sciatic nerve. The acetabulum is located at the junction of the ilium, ischium, and pubis, and lies a little to the outer side of the middle of Poupart's ligament, with the femoral artery passing nearer its inner than its outer edge. The obturator foramen is below and a little anterior to the acetabulum when the body is upright and more anterior when it



is horizontal. The bottom of the acetabulum has a large fossa, to the upper portion of which is attached the ligamentum teres, while the lower portion contains a pad of fat. This fossa opens by a large notch, called the *cotyloid notch*, on the side toward the obturator foramen; therefore the bony socket is incomplete at this point.

O. H. Allis has pointed out that a line passing from the anterior superior spine to the tuberosity, called the *Roser-Nélaton line*, forms the apex of a wedge, the ilium sloping down on one side while the ischium and pubes pass down the other. It divides the innominate bone into two parts, an anterior plane and a posterior plane (Fig. 502).

The femur has its neck coming off from the shaft at an upward angle of about 127 degrees (125 degrees to 130 degrees). The head and neck do not lie in the same transverse plane as the line joining the two condyles, but are inclined slightly forward (about 12 degrees). Therefore the neck passes upward, inward, and a little forward. As the result of deformities or disease, the inclination of the neck to the shaft may be reduced, being 90 degrees or less. This condition is known as *coxa*

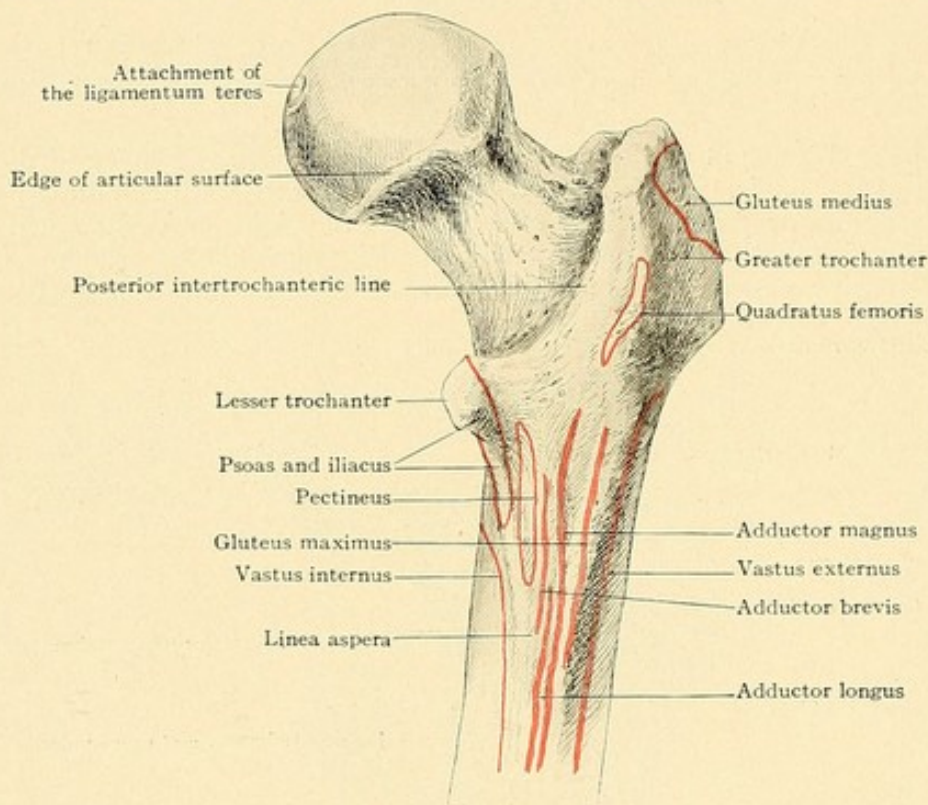


FIG. 504.—Posterior view of the upper end of the femur with muscular attachments.

*vara*. It may be increased, constituting *coxa valga*. The articular surface of the head forms slightly more than a hemisphere and has a pit below and posterior to its centre for the attachment of the ligamentum teres. At the outer upper extremity of the neck where it joins the shaft is the greater trochanter. Its tip or most prominent point is toward its posterior surface and is just about opposite the centre of the hip-joint. Downward and inward from the greater trochanter, on the inner and posterior surface of the shaft, is the lesser trochanter. Between the trochanters anteriorly and posteriorly run the intertrochanteric lines. The great trochanter and the part immediately below and posterior gives attachment to the three glutei muscles, the short rotators (Fig. 504), the piriformis, the obturators, internus with its two gemelli and externus, and the quadratus femoris. The lesser trochanter gives attachment anteriorly to the psoas and the iliacus and immediately below to the pectineus.

The anterior intertrochanteric line marks the lower attachment of the capsule; the posterior has inserted into it the quadratus femoris muscle.



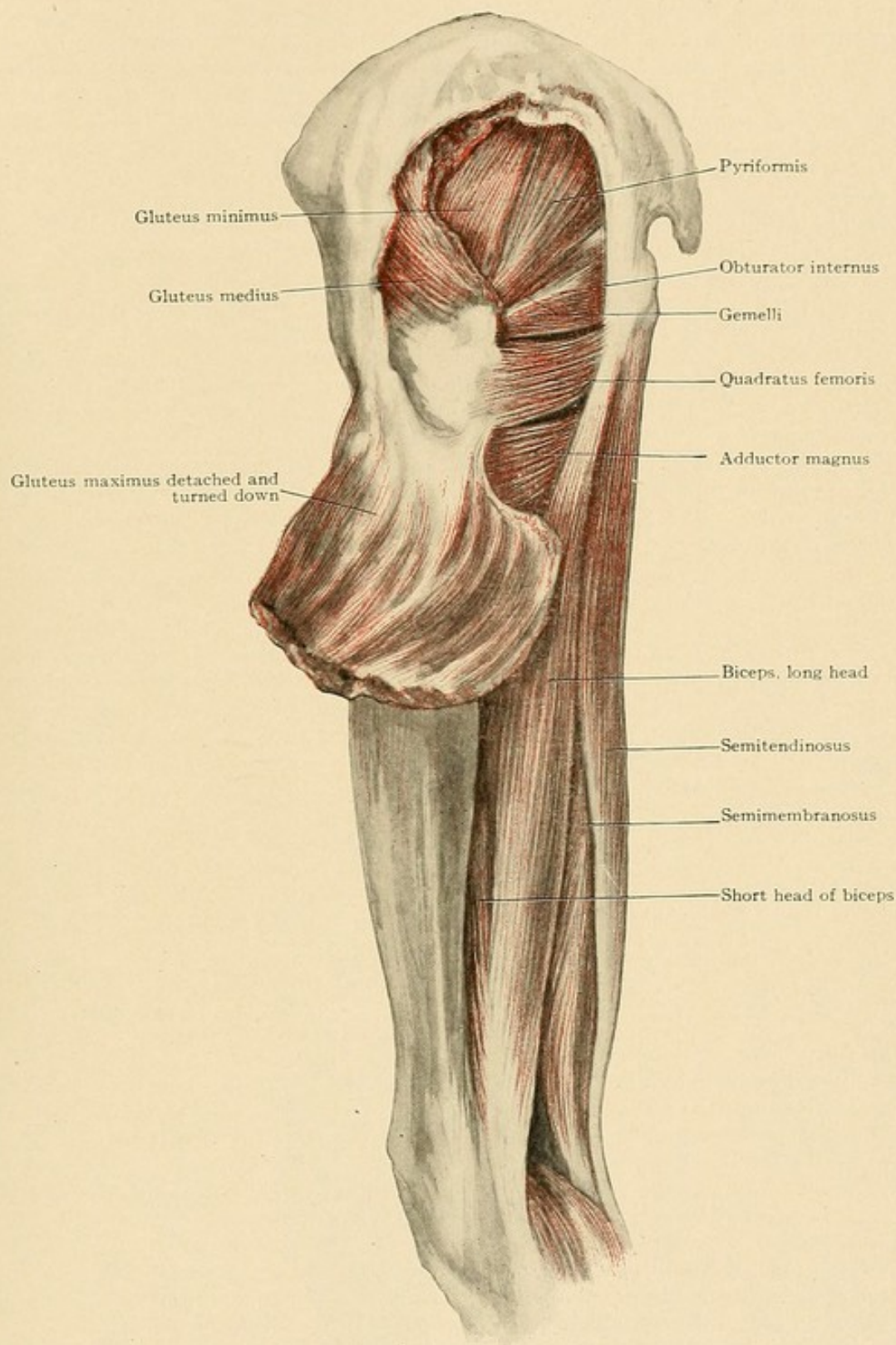


FIG. 505.—Muscles of the region of the hip.

## MUSCLES OF THE HIP.

The muscles of the hip are numerous and their action is often intricate: many muscles are usually used to produce a single movement. Some muscles not only cross the hip-joint but another joint as well. Thus the psoas crosses the hip-joint and pelvis to reach the spine. The hamstring muscles, the rectus femoris, gracilis, and



sartorius cross both the hip-joint and knee-joint, as does practically the tensor fasciæ femoris through its prolongation, the iliotibial band. The movements of the hip are flexion, extension, adduction, abduction, and rotation. Circumduction is a combination of the first four movements.

**Flexion** is mainly the result of the action of the sartorius, iliacus, psoas, rectus femoris, and pectineus.

**Extension** is mainly due to the gluteus maximus, medius, and minimus, biceps, semitendinosus, and semimembranosus.

**Adduction** is accomplished by the pectineus, adductor longus, brevis, and magnus, and to a less extent by the gracilis, quadratus femoris, and lower part of the gluteus maximus.

**Abduction** in the extended position is due to the tensor fasciæ femoris, sartorius, gluteus medius, and gluteus minimus. When flexed the short rotators also aid.

**Internal rotation** is produced mainly by the tensor fasciæ femoris and the anterior portion of the gluteus medius and minimus; three muscles only. The iliopsoas acts as a weak internal rotator if the femur is in a position of extreme external rotation.

**External rotation** is mainly due to the short external rotators—pyriformis, gemelli, obturators, quadratus femoris, the adductors, and the posterior portion of the three gluteals. To a slight extent the sartorius, iliopsoas, pectineus, and biceps may also aid at times.

## SURFACE ANATOMY.

The *crest of the ilium* can be palpated in its entire length. In very thin people it causes an elevation of the surface, but usually it is marked by a depression. Its anterior third is subcutaneous and is more easily seen and felt than the posterior two thirds. A line joining the highest point of the crests passes through the fourth lumbar spine. A line joining the anterior superior spines in front passes below the promontory of the sacrum. The *anterior superior spine* can be readily felt. It lies downward and outward from the umbilicus: as has been said, measurements are best taken by pressing the tape against its lower surface rather than its subcutaneous one.

The *posterior superior spine*, marked by a dimple, is best recognized by following the crest of the ilium to its posterior extremity. It is opposite the middle of the sacroiliac joint and the second sacral spine.

The *posterior inferior spine* is 4 to 5 cm. (1½ to 2 in.) directly below the posterior superior spine. The *spine of the ischium*, which marks the position of the pudic and sciatic arteries, is 8 to 10 cm. (3 to 4 in.) below the posterior superior spine and the *tuberosity of the ischium* is 12 to 15 cm. (5 to 6 in.). Running forward from the posterior inferior spine for a distance of 4 to 5 cm. (1½ to 2 in.) is the *great sciatic notch*; through it pass the pyriformis muscle, gluteal artery and nerves, and sciatic nerve. A line joining the posterior superior spine and the tip of the greater trochanter may be named the *posterior iliotrochanteric line*.

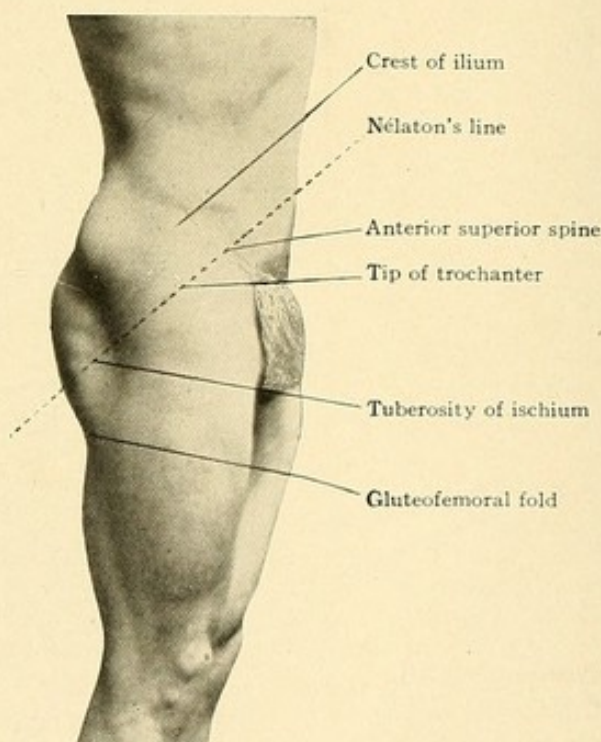


FIG. 506.—Surface anatomy of the region of the hip.



(iliotrochanteric line of Farabeuf). It marks roughly the posterior edge of the gluteus medius muscle and goes through the upper edge of the gluteus maximus. The gluteal artery and superior gluteal nerves cross this line at the junction of the upper and middle thirds, this being about opposite the posterior inferior spine. A line joining the tuberosity of the ischium and tip of the greater trochanter may be called the *ischiotrochanteric line*: it is crossed at the junction of its inner and middle thirds by the sciatic nerve.

The *greater trochanter* is marked by an eminence in thin people and a depression in the plump and fat. Its anterior upper edge is crossed by the tendon of the gluteus medius and cannot be readily outlined. Its upper posterior extremity or tip is readily distinguished and is the spot used for measurements. This point is called the *tip of the greater trochanter* and must be searched for posteriorly. It is opposite the centre of the head of the femur and is on a level with the spine of the pubis.

The *Roser-Nélaton line* is one drawn from the anterior superior spine to the tuberosity of the ischium. It passes through the tip of the greater trochanter. It is of importance in fractures and dislocations (Fig. 507).

*Bryant's triangle* ("Bryant's Surgery", vol. ii, p. 412) is to be drawn while the patient is lying on his back. One side is a perpendicular let fall from the anterior superior spine to the table, the other side is one joining the anterior superior spine and the tip of the greater trochanter, the base is a line running horizontally from the tip of the greater trochanter to the perpendicular line (Fig. 507). If the tip of the trochanter becomes elevated, as in fractures of the neck of the femur, it shortens the base of the triangle on the affected side as compared with the base of the triangle on the sound side.

The *anterior iliotrochanteric line* may be designated as a line joining the anterior superior spine and the tip of the greater trochanter. In normal individuals it slopes downward and backward, forming an *iliotrochanteric angle* ( $b a c$ , Fig. 507) of about 30 degrees. In cases of fracture or luxation this angle becomes reduced as the shortening increases until the tip reaches the level of the anterior superior spine. A rough estimate of this angle by sight and palpation usually enables one to decide immediately as to the presence of shortening from fracture or luxation without the trouble of erecting Bryant's triangle. The anterior iliotrochanteric line forms the anterior side of Bryant's triangle and the anterior half of the Roser-Nélaton line.

The *gluteal cleft* separates the buttocks. In its lower portion can be felt the coccyx. The *gluteal (gluteofemoral) fold* is formed mainly by the subcutaneous fatty tissues and passes horizontally outward from the lower part of the gluteal cleft. A shortening of the leg on either side causes the corresponding fold to incline downward. It is marked in extension and gradually lessens on flexion and disappears when 90 degrees is reached. It is crossed obliquely downward and outward at about its middle by the lower edge of the gluteus maximus. Its disappearance in coxalgia is caused by the flexion incident to that affection.

**Ligation of the Gluteal, Sciatic, and Internal Pudic Arteries.**—To ligate the gluteal artery incise the skin and part the fibres of the gluteus maximus in the upper two-thirds of a line joining the posterior superior spine and the top of the great trochanter (Fig. 508). Pull the lower edge of the gluteus medius up and the artery and superior gluteal nerve will be seen coming out between it and the pyramiformis. To ligate the sciatic and internal pudic arteries an incision parallel to the one

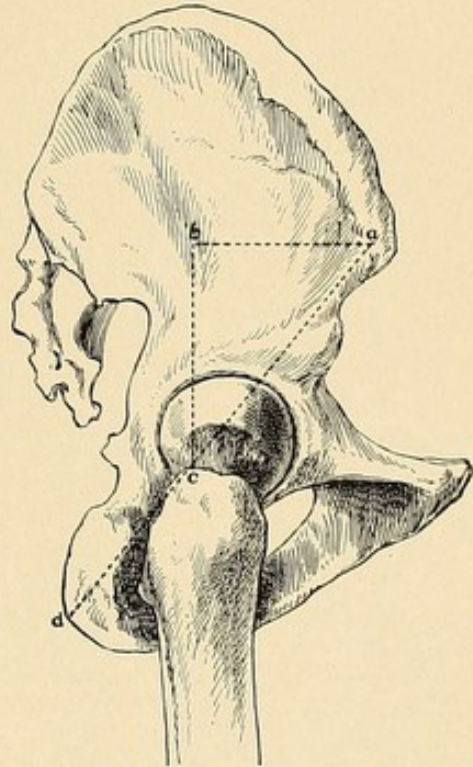


FIG. 507.—View of the outer surface of the bones of the hip showing Roser-Nélaton line ( $a-d$ ), Bryant's triangle ( $a b c$ ), iliotrochanteric line, ( $a c$ ) and the iliotrochanteric angle ( $b a c$ ).



just described but about 7.5 cm. (3 in.) lower is made through the gluteus maximus, and just below the edge of the pyriformis from without inward will be found the great sciatic nerve, lesser sciatic nerve, sciatic artery, and the internal pudic nerve and internal pudic artery crossing the spine of the ischium.

*Bursæ.*—Covering the tuberosity of the ischium is a bursa which sometimes suppurates and forms a sinus. It can readily be excised. These sinuses are often bilateral.

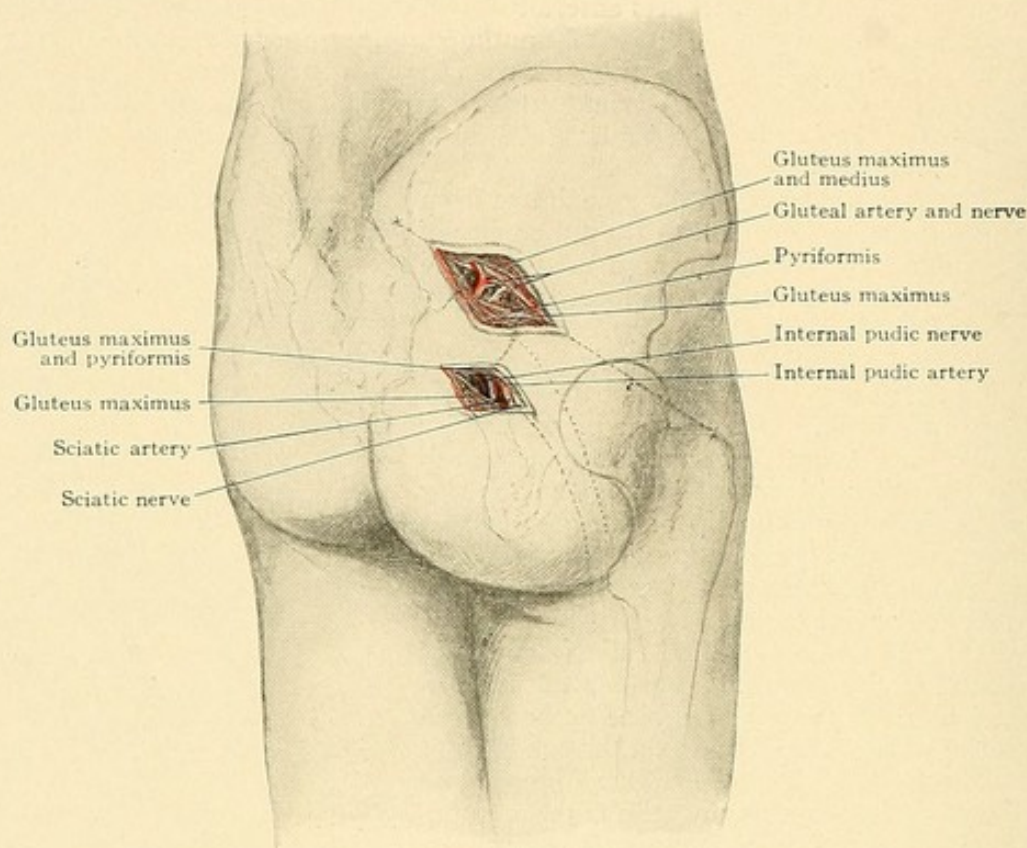


FIG. 508.—Ligation of the gluteal, internal pudic, and sciatic arteries.

## THE HIP-JOINT.

The hip-joint, like the shoulder, is a ball-and-socket joint, and, like it, moves in all directions. The main function of the shoulder is mobility, but the functions of the hip are mobility and support. To give the necessary support and security, the band-like ligaments uniting the bones are strong and the extent of the movements is restricted. Macalister ("Text Book of Human Anatomy," p. 179) points out that while the shoulder has 118 degrees of motion around a sagittal axis, abduction and adduction, the hip has only 90 degrees; around a coronal axis, flexion and extension, the shoulder has 170 degrees and the hip only 140 degrees. In the vertical axis the shoulder rotates 90 degrees, while the hip rotates only 45 degrees. In the upright position the centre of gravity falls in front of the axis of rotation of the hip-joint.

The head of the femur is 5 cm. (2 in.) in diameter and forms  $\frac{5}{7}$  of a sphere. Below and behind its centre is the depression for the attachment of the ligamentum teres. The acetabulum is much deeper than the glenoid cavity of the shoulder-joint and its depth is increased by the cotyloid ligament around its edge. This makes the joint air-tight and holds the femur in place by suction, hence it is called by Allis ("An inquiry into the difficulties encountered in the reduction of dislocations of the hip," Philadelphia, 1896) the sucker ligament. The acetabulum is incomplete at its lower anterior edge, forming the cotyloid notch. The cotyloid ligament bridges



over this notch, and its deeper part loses its cartilaginous cells, becomes fibrous, and is called the transverse ligament.

Beneath the transverse ligament pass vessels, nerves, fatty tissue, and the extremity of the ligamentum teres, which is attached to the ischium just outside.

Running up in the floor of the acetabulum from the cotyloid notch is a depression in which is lodged the ligamentum teres and a pad of fat called the *Haversian gland*. The ligamentum teres is composed of synovial and connective tissue. It is not strong and ruptures at about 14 kilos; the small artery it contains affords nourishment for itself alone, only a very small amount of blood going to the head of the femur. Bland Sutton regards it as a vestigial structure and a regression of the pectineus muscle. It is too weak to add much to the strength of the joint, and the view of Allis that its function is to distribute the synovial fluid and act as a lubri-

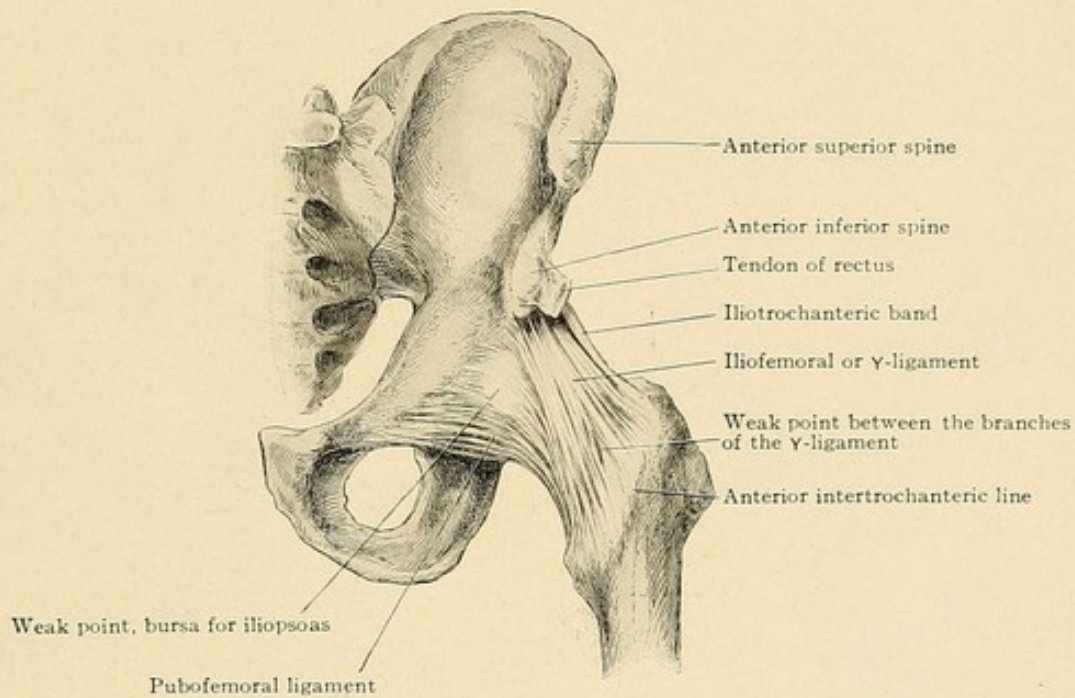


FIG. 509.—Anterior view of the ligaments of the hip-joint.

cating agent is probably correct. The great pressure to which the articulating surfaces of the hip-joint are subjected requires special lubrication and this is furnished by the ligamentum teres and Haversian gland.

Like other joints, the hip has a capsular ligament which is strengthened by bands or ligaments. These ligaments are the iliofemoral, pubofemoral, and ischiofemoral.

**Iliofemoral Ligament** (Bertins' ligament or Y ligament of Bigelow).—This is the strongest ligament in the body. The single stem of the Y ligament is attached to the upper edge of the rim of the acetabulum just below the anterior inferior spine. Its two branches are attached below to the anterior intertrochanteric line. Its upper edge is reinforced by a band from the ilium to the trochanter, the *iliotrochanteric band*, and one from the reflected tendon of the rectus, the *tendinotrochanteric band* (Henry Morris) (Fig. 509).

**The pubofemoral ligament**, also called the pectineofemoral ligament, runs outward into the capsule from the horizontal ramus of the pubes. It is quite weak.

**Ischiofemoral Ligament.**—Allis describes this ligament as follows: "It arises from the ischial portion of the rim of the socket and sends its fibres to the capsule to be blended with them. As its fibres extend upward they separate like two fingers or terminal processes, the one extending forward to the base of the oblique (posterior) line, the other running backward to the digital fossa (Fig. 510)."

It will be observed that this makes it a posterior Y ligament with a distinct bony attachment for its two arms (like the external lateral ligament of the elbow—see



page 283). The web of the two arms is half way down the posterior surface of the neck of the femur.

**Capsular Ligament.**—The capsule of the joint is composed of a thin sac strengthened by the band-like ligaments just described. Wherever there is no reinforcing band the capsule is weak. The posterior and lower portion is weaker than the anterior and upper portion. There is a weak spot between the arms of the iliofemoral ligament anteriorly, a branch of the circumflex artery usually entering here. Between the pubofemoral and inner edge of the iliofemoral ligament is another weak point. A bursa here separates the iliopsoas from the joint and often communicates with the joint. A third weak spot is on the lower posterior part of the neck between the two branches of the ischiofemoral ligament (Fig. 511). Injections into the joint

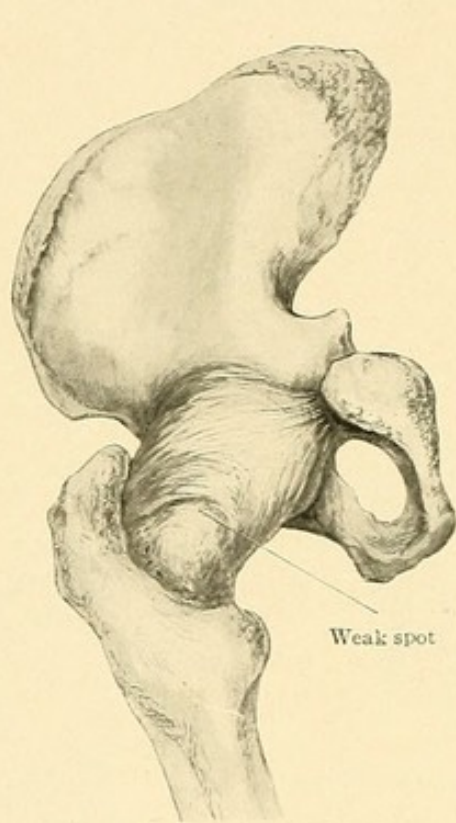


FIG. 510.—The ischiofemoral or posterior Y-ligament. The stem of the Y is attached at the base of the tuberosity of the ischium and one branch is seen going toward the greater trochanter and the other toward the lesser, leaving a weak spot between them half-way down the neck of the bone.

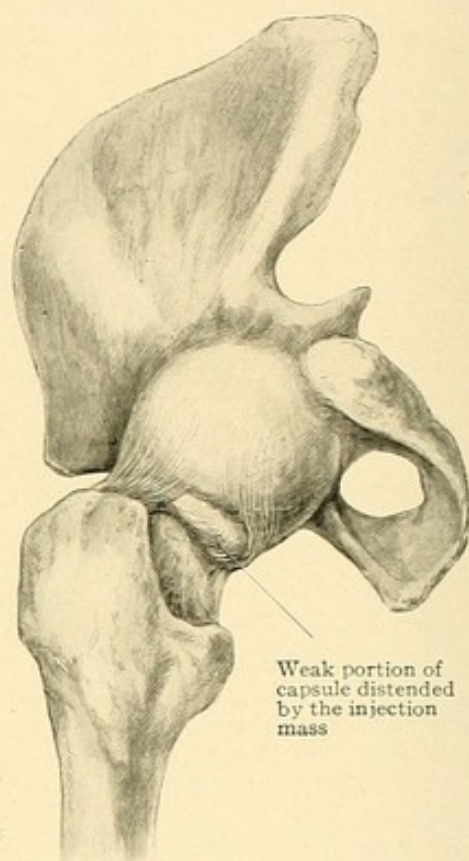


FIG. 511.—Hip-joint distended with wax; the capsule ends posteriorly half-way down the neck and is seen distended by the injection material protruding between the two arms of the ischiofemoral ligament.

protrude very markedly at this point. The weakest part of the joint is the lower anterior, below the pubofemoral ligament and opposite the cotyloid notch; the strongest part is the upper anterior part.

## DISLOCATIONS OF THE HIP.

**Classification.**—Dislocations of the hip are either anterior or posterior (Allis)<sup>1</sup>. If the innominate bone is held horizontally it will be seen that the Roser-Nélaton line from the tuberosity to the anterior superior spine passes through the acetabulum. It forms the apex of a wedge the two sides of which pass down, one anteriorly and the other posteriorly (Fig. 512). Therefore when the head of the

<sup>1</sup> Dr. Oscar H. Allis has given the clearest exposition of dislocations of the hip with which we are acquainted in his Gross Prize Essay entitled, "An Inquiry into the Difficulties Encountered in the Reduction of Dislocations of the Hip," Philadelphia, 1896.



femur leaves its socket it passes down either anteriorly or posteriorly and we have either an anterior or a posterior luxation.

The attachment of the iliofemoral ligament immediately above the acetabulum and of the ischiofemoral directly below also tend to prevent the head's emerging at these places and favor its going anteriorly or posteriorly. Anterior luxations may be either low or high. The primary luxation is a low one into the thyroid foramen.

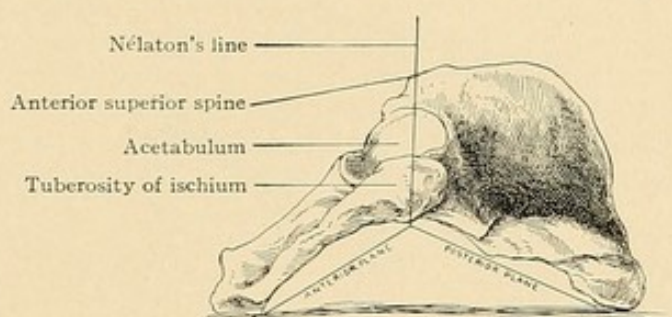


FIG. 512.—Innominate bone, resting on its inner side, to show the wedge-shaped formation of its outer surface. The apex of the wedge is Nélaton's line, running from the anterior superior spine to the tuberosity of the ischium; the anterior plane inclines downward and forward toward the pubis and the posterior plane inclines downward and backward on the ilium.

If then the thigh is rotated outward the head rises, and it becomes a pubic luxation. Posterior luxations may also be either high or low. The primary luxation is a low one either on the spine of the ischium or in the sciatic notch, and by rotation of the thigh inward it becomes a high one on the dorsum of the ilium (Fig. 513). In certain very rare cases in which there has been an excessive amount of twisting the rotation is extreme and a form of dislocation called inverted is produced; it will be explained later.

**Mechanism of the Production of Luxations.**—The following should be borne in mind:

1. The neck of the femur makes with the shaft an angle of approximately 128 degrees.
2. In speaking of inward and outward rotation is meant inward and outward rotation of the *shaft* of the femur. Thus if the head (and neck) is pointing inward and we rotate the shaft inward, the head rotates outward posteriorly. If, however, we rotate the shaft inward while the head is pointing outward then the head moves inward anteriorly. Thus it is seen that in rotating the shaft inward the head is moved inward or outward according to its original position.
3. That while actually the axis of the head and neck does not coincide with a line drawn transversely through the condyles, but inclines forward at an angle of 10 or 12 degrees, nevertheless for practical purposes we may consider that it does so coincide and normally points directly inward.
4. The position of the greater trochanter can be recognized by its being directly above the external condyle, and the position of the head by its being directly above the internal condyle.
5. The muscles may be disregarded in the production of luxations, and the action of only the bones and ligaments considered.
6. A luxation results from the capsule being made tense or even ruptured by a leverage action of the bones, and the head then being thrust out on the anterior or posterior plane.

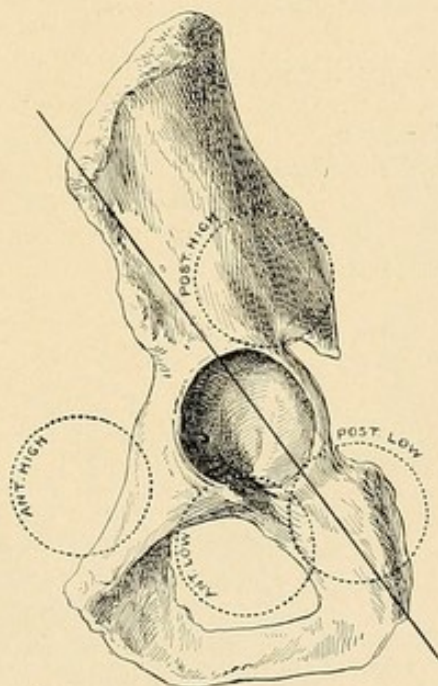


FIG. 513.—Diagram illustrating the position of the head in high and low dislocations on the anterior and posterior planes.



7. The primary luxation is a low anterior or posterior one. This may be changed by subsequent rotation of the thigh.

8. Luxations may occur either when the thigh is in abduction or adduction.

*Luxation by Abduction.*—If the thigh is forcibly abducted the adductor muscles rupture and, the abduction increasing, the head is raised out of the socket by the lever action of the femur as its neck strikes the rim of the acetabulum and its greater

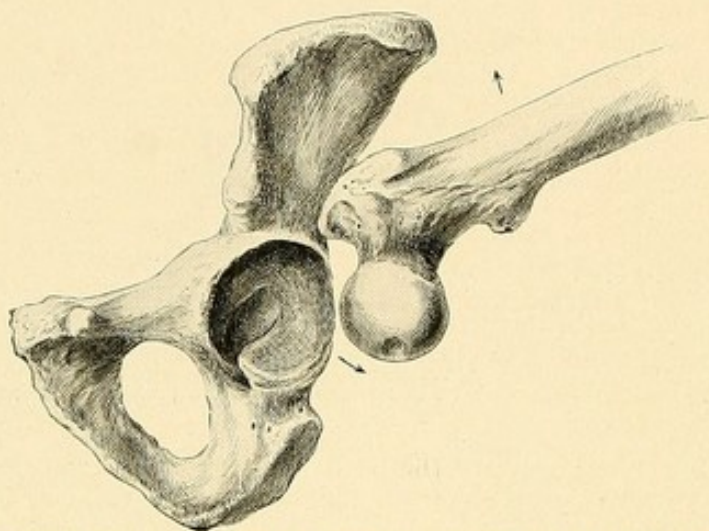


FIG. 514.—Luxation of the hip by indirect or leverage action. The shaft of the femur, from the greater trochanter out, is the long arm of the lever, the head and neck form the short arm and the upper edge of the acetabulum and ilium immediately above is the fulcrum. When the femur is abducted the head is lifted out of its socket rupturing the capsular ligament.

trochanter the ilium above. The head and neck are the short arm of the lever, the rim of the acetabulum or ilium is the fulcrum, and the shaft and distal extremity of the femur are the long arm. The head rises from the socket, ruptures a part at least of the capsular ligament, and then a thrusting force is added which pushes the head forward, producing a thyroid luxation (Fig. 514).

If while the limb is hyperabducted the shaft of the femur is rotated out and the

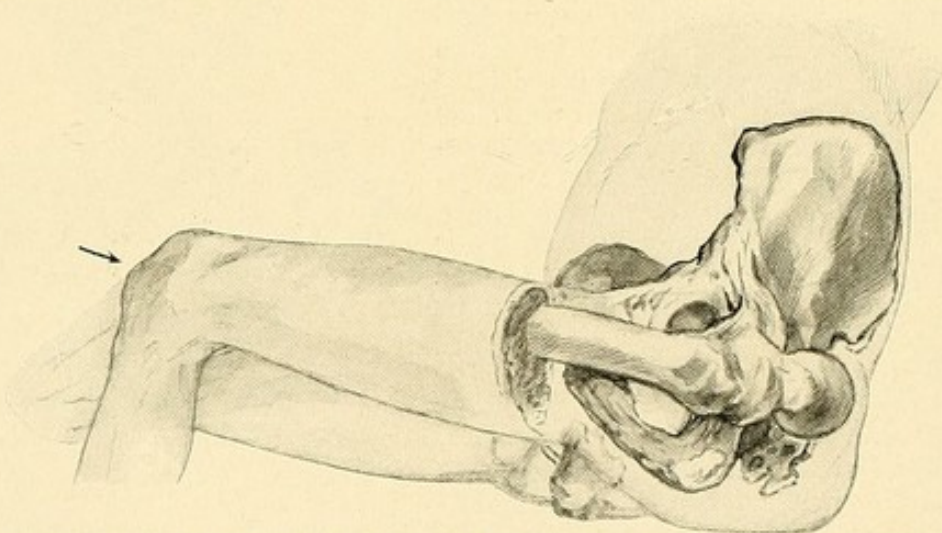


FIG. 515.—Posterior luxation of the hip produced by rotation and direct thrust. The femur is seen to be flexed on the pelvis, adducted and rotated inward; a thrust in the direction of the arrow then sends the head out of the acetabulum onto the posterior plane.

limb brought straight down, parallel with that of the opposite side, then likewise the head may pass forward into the thyroid or pubic position. If while the head is on the anterior plane the thigh is flexed and the shaft rotated inward, then the head follows around the outer edge of the acetabulum and passes from a thyroid to a dorsal position, forming a posterior luxation.



**Luxation by Adduction.**—If the thigh is flexed and adducted the angle of the neck and shaft prevents any bony fulcrum from forming. If now the shaft is strongly rotated inward the iliofemoral or Y ligament becomes tense. It is wound around the neck of the bone and acts as a ligamentous fulcrum. The shaft revolves on its long axis, and as it turns inward the head turns outward and presses against the lower posterior part of the capsule, which ruptures, and a dorsal luxation is produced. A backward thrust in the long axis of the femur also favors the production of the luxation (Fig. 515).

By outward rotation of the shaft the head can be conducted around the edge of the acetabulum until it lies in the thyroid foramen on the anterior plane, thus changing a primary dorsal into a secondary thyroid luxation.

**The Rent in the Capsule.**—The capsule ruptures at its lower anterior or posterior portion according to whether it is primarily an anterior or a posterior luxation. If, however, the limb is rotated while the head is out of its socket, as in the production of a secondary position, then the capsule is torn still further, but the Y ligament is practically never torn either when the original luxation occurs or the secondary.

The rent in the capsule through which the head emerges has been proven both by Robert Morris and Dr. Allis to be always equal in size to the head of the femur and never a slit. Therefore in every case there exists a rent in the capsule large enough to allow of returning the head, provided it is not closed or obstructed by a rotation or malposition of the limb, or by some foreign substance such as torn muscle or infolding of the capsule.

**Injuries to the Muscles.**—When the thigh is abducted the adductor muscles are made tense, and if it is hyperabducted they are torn; these overstretched muscles, some of which may be ruptured, are the three adductors, the pectineus, and the gracilis. If the luxation is an anterior one the obturator externus will be torn because it arises from the outer surface of the thyroid membrane. If a posterior

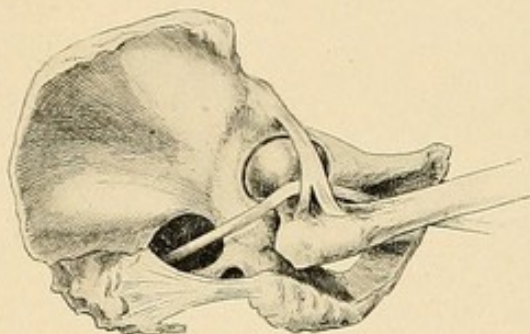


FIG. 516.—Showing the sciatic nerve caught around the neck of the femur. (After an illustration by Dr. Allis in his prize essay on the hip.)

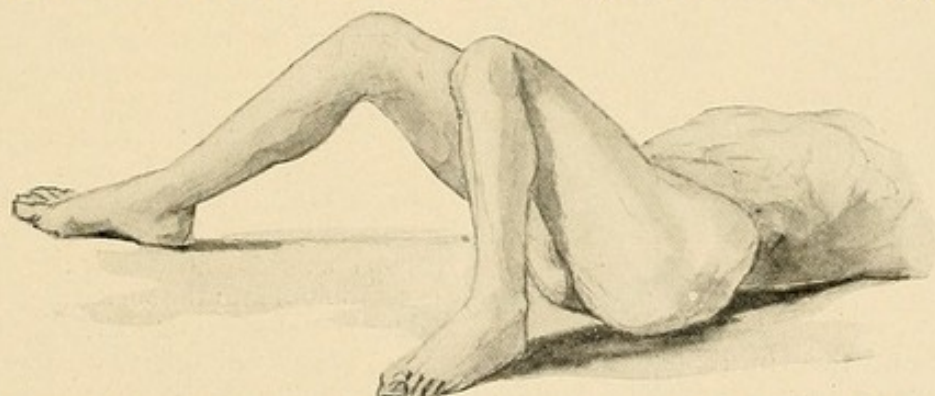


FIG. 517.—Posterior or dorsal luxation of the left hip (From an original sketch by the author). The shortening is seen by comparing the position of the knees, the thigh is adducted and rotated inward.

one the internal obturator may be injured. Allis has pointed out that when the head passes from one plane to another it may tear the obturator externus, quadratus femoris, and upper fibres of the adductor magnus. The tearing of these muscles usually exerts but little influence on the reduction of the luxation.

**Injuries to the Nerves.**—Rarely the anterior crural nerve may be injured by being stretched over the head of the femur. The sciatic nerve has been injured, and Allis has shown how, when a dorsal is rotated into a thyroid luxation, the sciatic nerve is likely to be caught around the neck of the femur (Fig. 516). This is favored by making a large circle while circumducting the knee, and also by extending the leg on the thigh, thus making the nerve tense and causing it to lie closer to the socket.



To detect this accident Allis advises that while an assistant pushes upward on the knee in the direction of the long axis of the femur, the surgeon by flexing and extending the knee will find the nerve alternately made tense and relaxed in the popliteal space.

**Signs of Luxation.**—When luxated *posteriorly* the foot is inverted whether it is a low or high dorsal. The thigh is adducted, bringing the knee of the affected side in front of the sound one. The thigh is usually slightly flexed. There is shortening, and the higher the position of the head the greater the shortening and the farther up the trochanter is above the Roser-Nélaton line. Shortening is best seen with the thighs flexed to a right angle (Fig. 517).

When luxated *anteriorly* the foot is everted or almost straight. If it is a low thyroid there will be little or no eversion; if it is a pubic luxation eversion will be more marked. The thigh is abducted; this is more marked in the thyroid and less in the pubic. The thigh is flexed in the thyroid but may be straight in the pubic. There is no shortening but there may be a slight lengthening difficult to demonstrate (Fig. 518).

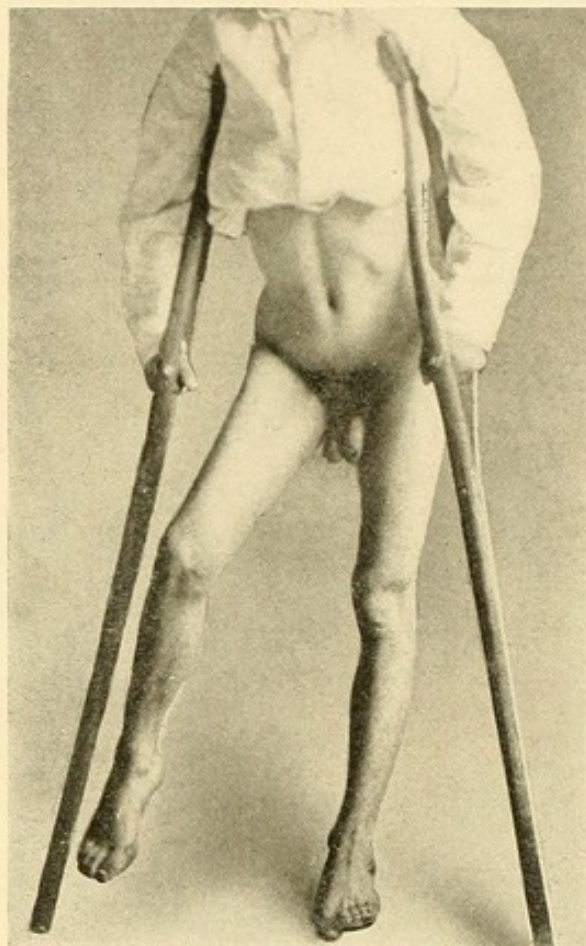


FIG. 518.—Thyroid luxation on the anterior plane. The thigh is flexed and abducted; the toes pointing forward. (From a photograph by Dr. Chas. F. Nassau.)

**Reduction.**—As in the shoulder there are two methods of reducing a dislocated hip, the direct and the indirect. The direct consists in placing the head in as favorable a position as possible and then directly pushing or pulling it towards the socket.

The indirect consists in using the thigh as a lever and rotating the head into place. These methods may be used in combination.

**Direct Method for Dorsal Luxations.**—Patient flat on the floor on his back. Flex the knee on the thigh, and the thigh on the abdomen; this brings the head down from a high position to a low one below the acetabulum. Adduct the thigh slightly; this relaxes the Y ligament and prevents the head catching on the rim of the acetabulum.

Grasp the ankle with one hand, then place the other hand or arm beneath the bent knee and lift upward and inward thus raising the head over the rim of the acetabulum into the socket. If the head does not enter rotate the thigh gently,

first out and then in, lifting at the same time. This rotation is to open the rent in the capsule to its widest extent. Too much rotation narrows the rent and obstructs the entrance of the head. An assistant may at the same time endeavor with his hands to push the head up towards the socket.

Another way of using the direct method (Stimson) is to place the patient face downward on a table with the thigh flexed at a right angle hanging over its end. The leg is then flexed at the knee and pressure made directly downward, gently moving or rotating the head from side to side. This is a safe and efficient method.

**Direct Method for Anterior Luxations.**—In pubic luxations first slightly abduct the thigh and rotate the shaft of the femur inward so as to transform the pubic to a thyroid luxation. For thyroid luxations flex the knee to a right angle, and then flex the thigh on the abdomen to a right angle or even more and slightly abduct (Allis). Then with one hand grasp the ankle and with the other hand or arm in the



flexure of the knee lift up and slightly out, thus guiding the head toward the socket, rotating a little if necessary (Fig. 519).

*The Indirect or Lever Method for Dorsal Luxations.*—Flex the leg on the thigh and the thigh on the abdomen in a position of adduction. Then sweep the

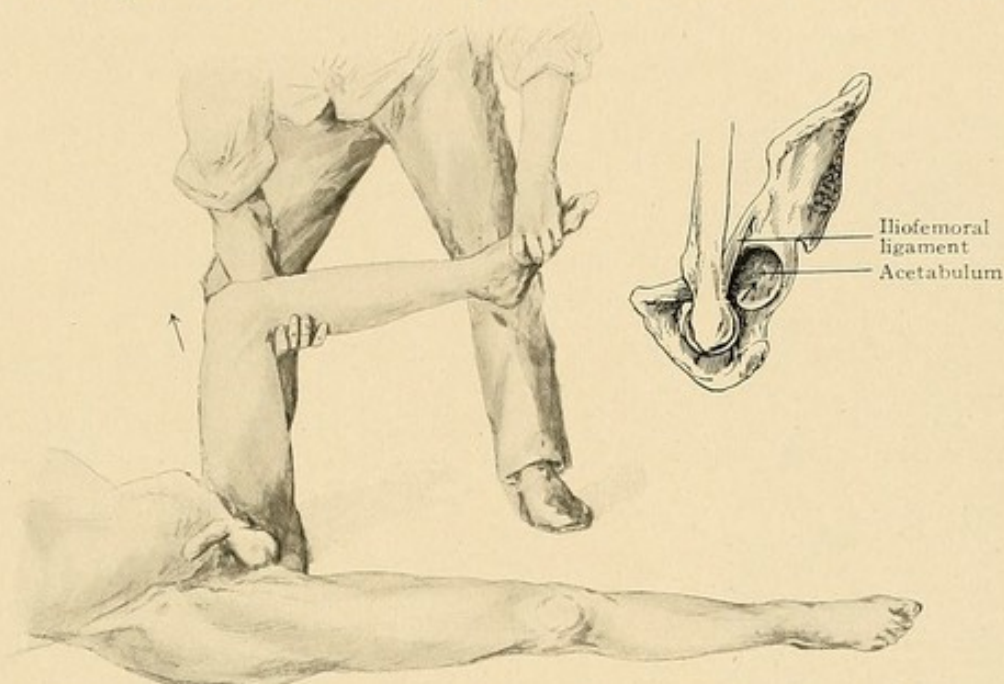


FIG. 519.—Reduction of an anterior (thyroid) luxation by the direct method. The pelvis is to be held firmly to the floor. The thigh is to be flexed, abducted (Allis), and the head lifted upward and outward as shown in the small cut.

knee in a small circle with external rotation, when the knee reaches the point of starting bring the limb down straight. Allis cautions against describing too large a circle with the knee on account of the liability of catching up the sciatic nerve.

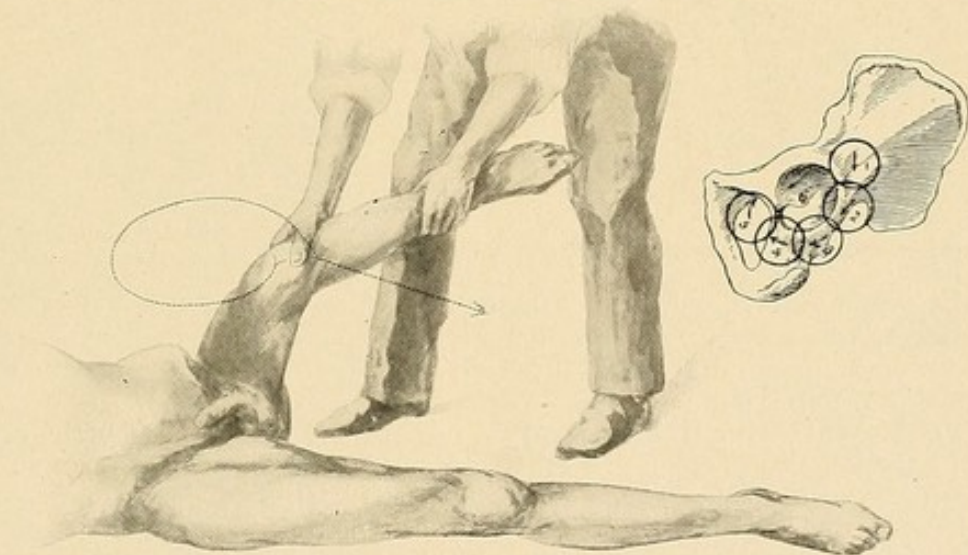


FIG. 520.—Reduction of a posterior (high) dorsal luxation by the indirect (lever) method of circumduction. The thigh is flexed and adducted; the knee describes the circle shown by the dotted line while the head pursues the course shown in the smaller cut to the right.

While rotating the thigh a lifting force may be added, as in the direct method. This method is practically circumduction (Fig. 520).

*The Indirect or Lever Method for Thyroid Luxations.*—Slightly flex the thigh, about to half a right angle, and rotate outward. Slightly abduct or adduct if necessary to relax the capsule before rotating outward.



**Reversed Luxations.**—In certain few cases, either from the peculiar character and direction of the primary injury or from an ordinary anterior or posterior luxation becoming subsequently more widely displaced, there result what are known as reversed luxations. They are of two kinds, reversed thyroid and reversed dorsal.

*Reversed Thyroid.*—In a thyroid luxation the toes point forward; if now the leg is forcibly twisted until the toes point directly backward a reversed thyroid is produced (Fig. 521). In reducing it the head must be first rotated back to its original thyroid position and then reduced by the usual methods.

*Reversed Dorsal.*—In a dorsal luxation the foot is inverted; if now the leg is forcibly twisted outward until the foot is everted, a reversed (or everted) dorsal luxation is produced (Fig. 522). To reduce it the leg must be rotated inward until the head resumes its original position posteriorly and then it may be reduced by the usual dorsal methods. In the production of both these reversed luxations the ligaments are torn still more and the iliofemoral ligament may even be partially detached from its insertion in the femur.

**The Ligamentum Teres.**—In complete luxations the ligamentum teres is torn but it is not large enough to constitute an obstacle to reduction.

**Infolding of the Capsule or Muscle.**—Should the capsule be torn from its attachment to the femur, it may prevent reduction by filling the socket and prevent-

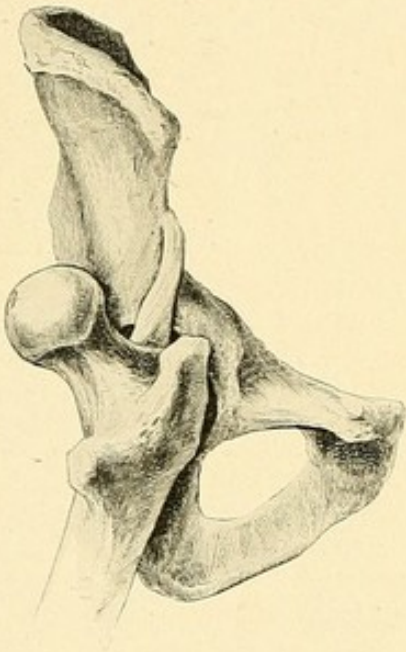


FIG. 521.—Reversed thyroid luxation. (After Allis.)

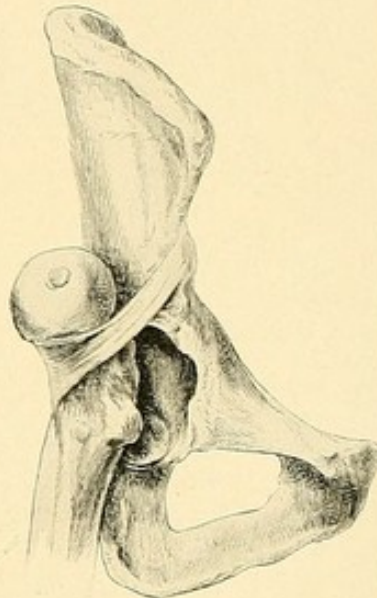


FIG. 522.—Reversed dorsal luxation. (After Allis.)

ing the entrance of the head. Fragments of muscle may act likewise. To clear the socket Allis advises first, rotation to tighten the Y ligament and pressing the head firmly in; second, to rock the head backward and forward and so clear the obstructing material out.

**To Release the Sciatic Nerve.**—If the sciatic nerve is caught around the neck of the femur and cannot be otherwise released, Allis advises extending the leg and cutting down on the nerve at the upper part of the popliteal space. It is then grasped and pulled taut, this releases it from the neck and the thigh can then be flexed and the head replaced: of course, if preferred, an incision can be made directly down on the nerve at the hip.

**To Reduce a Dislocation Complicated by Fracture.**—To accomplish this Allis advises first a trial of the usual direct method of traction and pressure on the head and, if this fails, then while the head is held as near to the socket as possible by an assistant the thigh is brought down and traction is made downward.

**Congenital Luxations of the Hip.**—In congenital luxations the acetabulum may be shallow, the head deformed, and the neck somewhat twisted on its shaft. These luxations are usually posterior.



**Signs.**—There is *no* eversion, no flexion on lying down in young cases, but lordosis is seen on standing (Fig. 523) and in old cases, also on lying down. The main point for diagnosis is shortening. The limb is shorter, measured from the anterior superior spine, and the anterior ilirotrochanteric angle (page 505) is diminished or lost; the tip of the trochanter is above the Roser-Nélaton line, and the base of Bryant's triangle is lessened or even obliterated on the affected side. By careful palpation it can be recognized that the head is absent from its normal position beneath the femoral artery. Frequently the top of the trochanter is on a level with the anterior superior spine. The use of the X-ray is necessary to ascertain accurately the position of the head and as to whether or not the bones possess their normal shape.

**Reduction.**—As the head is usually more or less fixed in its abnormal position, force has to be used to replace it. Paci of Pisa was the first to reduce them systematically by a modification of the circumduction method. He flexed the thigh on the abdomen, then firmly abducted, rotating outward, and used the edge of the table as a fulcrum.

Lorenz used König's padded, wedge-shaped block under the trochanter as a fulcrum to pry the head forward.

The writer combined the direct and indirect methods by placing the child face down on a table with the affected hip on a sand pillow and the leg and thigh hanging over the side. The operator or an assistant then raises (flexes) the knee, bringing it toward the patient's axilla, while the operator presses with his hands and body-weight down on the trochanter. By gradually raising the knee and *keeping it close to the body* and pushing the head forward it eventually slips from the posterior to the anterior plane and into place (Fig 524). When the head has been brought onto the anterior plane it is usually impossible to extend the knee, on account of tension of the hamstring muscles, as pointed out by Lorenz.

After being reduced the thigh cannot be brought down at once to its normal position, as by so doing the head jumps out of its socket; so it is put up in plaster of Paris in an abducted position for some time and brought down gradually.

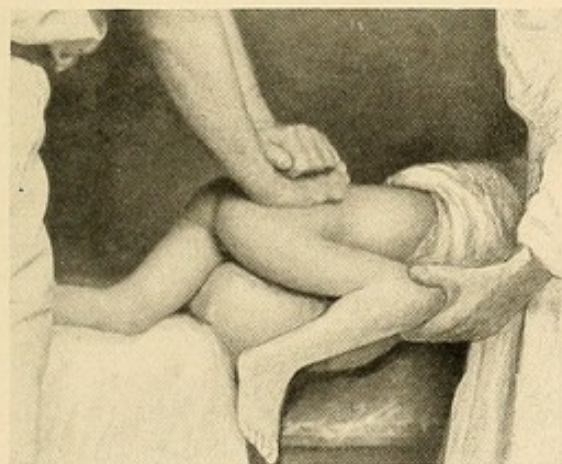

FIG. 524.—Author's method of reducing congenital luxation of the hip.

duction, and slight external rotation. The joint is more or less rigid. The loss of motion is only complete in extreme cases. In mild cases the limitation is only present as a reduction in the normal extent of movements, the joint may move freely and without constraint over a limited arc. The abnormal changes produced are to be recognized by careful inspection, measurements, and comparison with the opposite healthy limb.

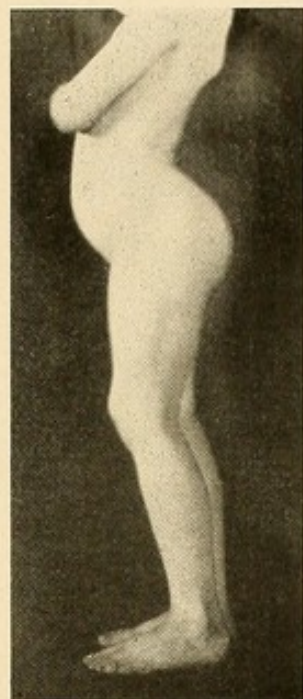


FIG. 523.—Child with congenital luxation of hips, showing characteristic lordosis.

**Hip-Disease (Coxitis or Coxalgia).**—Disease of the hip in its early stage is characterized by pain, limitation of motion, and limping. The pain is either a local one in the hip itself or a referred one. The hip is supplied by branches of the anterior crural, sciatic, and obturator nerves, and as these also supply the region of the knee, disease of the hip causes pains to be felt around the knee, most often on its inner side.

In an early stage the limitation of motion is due to muscular contraction and it disappears under anaesthesia. The limb is held in a position of flexion, ab-



*Attitude.*—Owing to the pain in the affected limb the weight of the body is borne mainly on the healthy limb. Viewing the patient anteriorly in an early case of the disease the external rotation is readily seen in the eversion of the foot. If the foot itself is normal, rotation takes place at the hip-joint and not at the knee or ankle; therefore a foot that is abnormally turned out indicates that there is something in the hip to cause it to turn out. The affected limb is seen to be held in a position of abduction, out away from the healthy one. The flexion is evidenced by the affected limb being placed a little in advance of the other and by the bending at the groin. If the feet are placed together there may also be flexion of the knee (Fig. 525).

Tilting of the pelvis may or may not be apparent, but it exists and can be demonstrated by a careful examination. Viewed posteriorly, besides the position of the limb as seen from in front, there is in addition a change in the gluteal folds and buttock. The gluteal fold on the affected side is lowered in position and shorter than on the healthy side and the buttock is flattened. The flattening of the buttock is caused by the flexion of the hip. This flexion likewise tends to obliterate the gluteal fold. The difference in height of the gluteal folds is caused by the tilting down of the pelvis on the affected side. An inequality in the lower limbs, whether due to shortening or to malposition, such as flexion, will be visible at once by an inequality of the gluteal folds, one being higher than the other. Flexion deformity is recognized when the patient is standing by the bending at the hip-joint and by the lordosis or hollowing of the back. When the patient is recumbent on a flat surface and both legs are brought straight down so that both knees are in contact with the table, then if flexion is present it causes the lumbar vertebræ to arch and the back to rise from the table. If now the thigh of the affected side is elevated until the back again touches the table the degree of elevation necessary to accomplish this will be the measure of flexion.

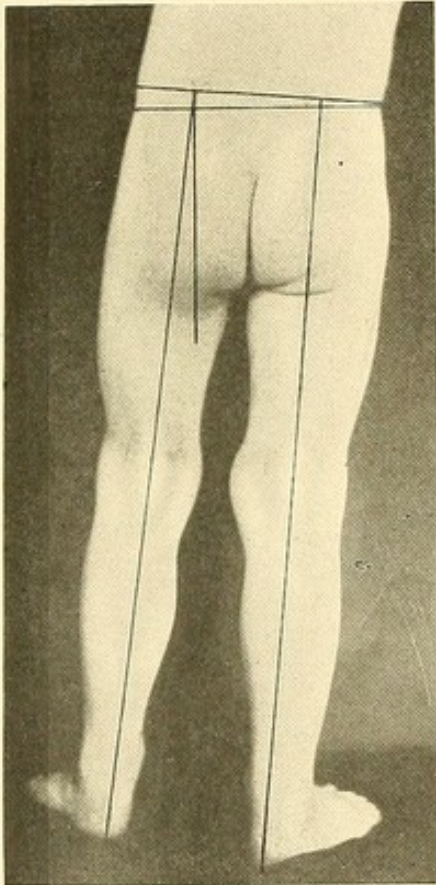


FIG. 525.—Early stage of coxalgia, showing the affected left limb abducted, thus lowering the pelvis on that side; slightly flexed, thus obliterating the gluteofemoral fold, and slightly everted.

*Measurements.*—The child being flat on its back the pelvis is to be made level by seeing that a line joining the two anterior spines is at right angles to the median line. If abduction is present the limb points away from the median line. It cannot be brought straight down parallel with the sound leg without tilting the pelvis. If measured from the umbilicus to the internal malleolus the affected leg measures more than the sound one. This is called apparent lengthening. If when both limbs are placed in the same degree of abduction

and are measured from the anterior spine to the internal malleolus they measure the same, there is no real shortening.

In *advanced disease* adduction is more common than abduction. This produces an apparent shortening, as shown by measurement from the umbilicus to the internal malleolus; if the sound limb is placed in the same degree of adduction as the affected one, the distances from the anterior spines will show no actual shortening unless there is a loss of bone or displacement at the hip-joint. The pelvis, instead of being tilted down on the diseased side, is tilted up. Flexion is usually more marked and the foot is usually inverted instead of everted.

*Hip-Abscess.*—Tuberculosis of the hip probably begins in the neighborhood of the epiphyseal line of the femur and involves the joint secondarily. The epiphysis of the head begins above near the edge of the articular cartilage and runs obliquely across upward and inward. It is thus entirely within the capsule and when



pus forms it first perforates the articular cartilage and enters the joint and then perforates the capsule to point externally. There are three favorite places of exit, viz.: (1) on the posterior surface of the neck between the branches of the ischiofemoral ligament; (2) on the lower anterior surface beneath the iliopsoas tendon, between the pubofemoral and iliofemoral ligaments, through the bursa found here which may communicate with the joint; and (3) at the cotyloid notch.

The head and neck of the femur and also the acetabulum become carious. Pus may find an exit at other places besides those mentioned. It may perforate the acetabulum and show above Poupart's ligament at its outer side, or may break through the upper posterior portion of the capsule. Not often does it break through between the branches of the iliofemoral ligament. When it does break through anteriorly it points in Scarpa's triangle, commonly to the inside of the vessels; when it breaks through posteriorly it descends beneath the fascia lata and points on the posterior or outer portion of the thigh.

**Coxa Vara.**—The normal angle which the head and neck make with the femoral shaft may vary according to Humphry (*Jour. Anat. and Phys.*, xxiii, 236) from 110 to 140 degrees. Sometimes as a result of injury or disease the neck makes a more acute angle than normal, coming off at an angle of 90 degrees or less. This is called coxa vara (Fig. 526). In some cases it is due to a bending of the neck caused by softening of the bone, as in rachitic affections, or to fracture. The limb is shortened, the trochanter raised above the Roser-Nélaton line, and abduction and flexion are restricted. To rectify it Whitman's operation of wedge-shaped resection is done. A wedge of bone with a base of 2 cm. ( $\frac{3}{4}$  in.), apex inward, is removed at a point opposite the lesser trochanter. The femur is then placed in abduction and the bone allowed to heal. When the limb is brought down the angle of the head and neck will be much increased and the deformity and disability will have been removed.

**Coxa Valga.**—The term coxa valga has been applied to the opposite condition, when the neck is nearly parallel with the shaft; it is rarer and of less importance than is coxa vara. Orthopædists regard 135 degrees as the normal limit of the angle between the neck and shaft of the femur, but Humphry placed it at 140 degrees.

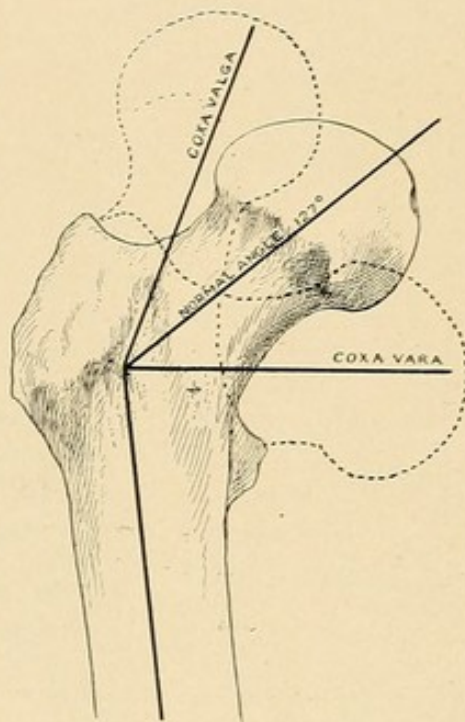


FIG. 526.—Normal angle of the head and neck to the shaft of the femur with the alteration in position in coxa valga and coxa vara shown by dotted lines.

## OPERATIONS ON THE HIP-JOINT.

The operations on the hip are usually done either for hip-disease or congenital luxations. More rarely traumatic or pathological luxations or intracapsular fractures may be operated on. The joint may be approached either anteriorly or laterally. Lateral operations are the more mutilating, while anterior ones are often sufficient and less serious.

**Lateral Operations.**—In approaching the joint from the side the incision of Langenbeck is preferred. It begins well up on the buttocks on a line with the posterior superior spine (page 500) and is continued down over the great trochanter in the axis of the thigh. If made with the limb flexed the line of incision will be straight. The muscular fibres and tendon of the gluteus maximus are cut in the line of the incision. This exposes the posterior edge of the gluteus medius, which is to be pulled forward, and the piriformis, which is to be drawn backward or loosened from its insertion into the trochanter. The capsule can then be incised and the joint examined. Further exposure may be obtained by loosening the gluteus medius and



gluteus minimus from their insertion in the top of the trochanter and pushing them forward. The ligamentum teres is often destroyed by the disease. Removal of the head of the femur enables the acetabulum to be examined and carious bone curetted away if necessary. The incision through the gluteus maximus muscle will be almost parallel to its fibres and near its anterior edge. Care is to be taken not to go too high up between the pyriformis and gluteus medius because the main trunks of the gluteal artery and superior gluteal nerve make their exit there from the great sacro-sciatic notch. The principal bleeding will come from branches of the gluteal artery descending from that point. This operation is practically limited to cases of extensive caries in which it is desired to do a radical operation (Fig. 527).

Boeckmann, of St. Louis, made a large horseshoe-shaped flap over the greater trochanter. Its base was upward and it consisted of skin and superficial fascia. This flap was raised and a chain-saw passed underneath the muscles inserting into the top

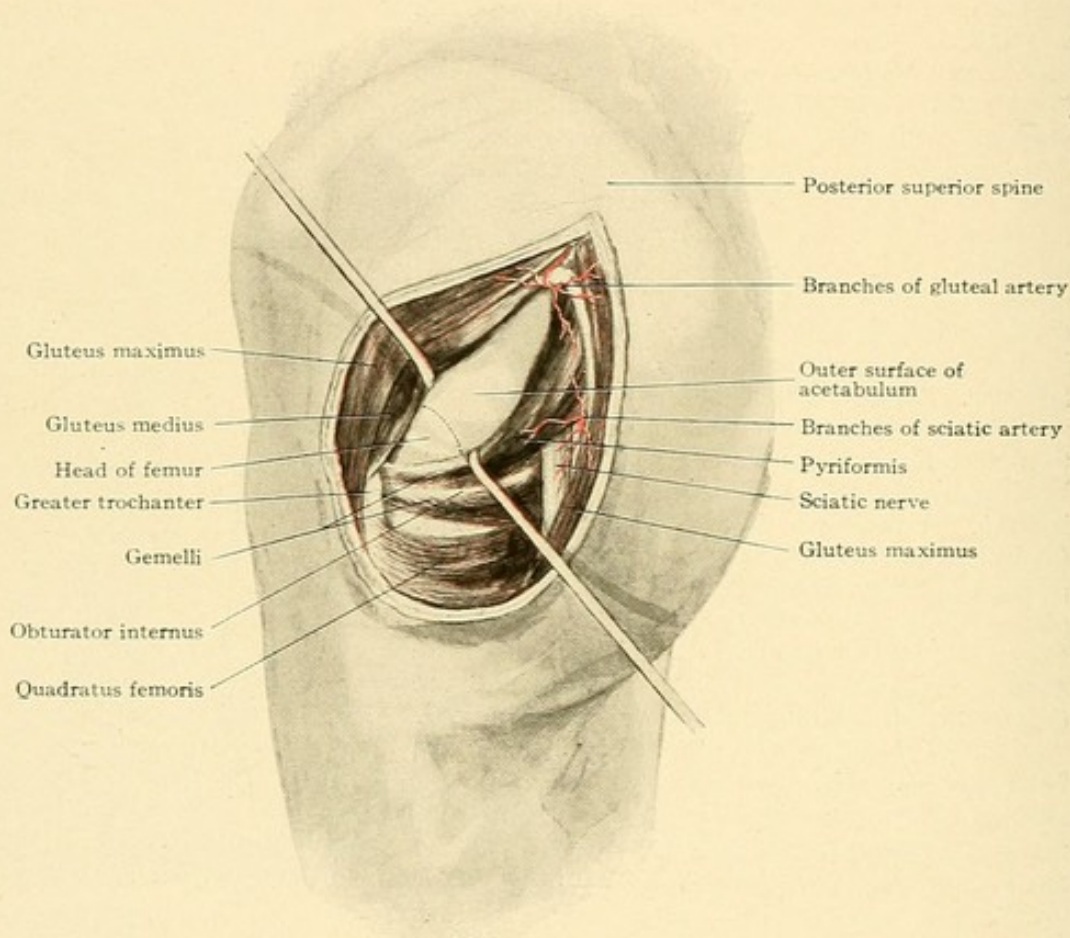


FIG. 527.—The lateral mode of approach in operating on the hip-joint: large incision made to show relation of the parts involved.

of the greater trochanter, and the latter was then sawed off and turned up as a flap. This exposed the upper surface of the head and neck of the femur. The operation was done for intracapsular fracture, the fragments being pinned together with ivory pegs and the trochanter brought down and again fastened in place with ivory pegs. The skin-flap was also brought down and sutured. While good exposure can be obtained by this method, it is almost too severe and has not been generally adopted.

Lorenz, in congenital luxations, incised from the anterior superior spine down and out toward the trochanter. The tensor fasciæ femoris is pushed forward and the glutei muscles backward. Hoffa modified this operation by making his incision along the anterior edge of the greater trochanter. As the hip-joint is nearer the anterior than the lateral surface of the body we believe it to be better to approach it from the front rather than from the side.



**Anterior Operations.**—Lücke made an incision from just below the anterior superior spine running downward and inward along the inner margin of the sartorius. The sartorius and rectus muscles were displaced outward and the iliopsoas inward.

Hüter, Parker, and Barker made the incision directly downward from the anterior superior spine and pulled the sartorius and rectus inward and the tensor fasciæ femoris and gluteus medius and minimus outward (Fig. 528).

The method of Hüter, Parker, and Barker, is not difficult. The only vessel encountered is a branch of the external circumflex. One should not go too low, or some muscular branches of nerves going to the vastus externus will be wounded. No muscles are divided. The writer has used this method with satisfaction in cases of hip disease and intracapsular fracture.

If additional room is desired the fascia lata may be divided laterally and the tensor fasciæ femoris and gluteus medius muscles may be detached from the spine of the ilium and back along the crest, as done by Codivilla. They are to be again sewed back into place before closing the wound.

**Inferior Operations.**—Ludlof, in congenital luxations, abducted the thigh to a right angle and made his incision along the tendon of the adductor longus. This

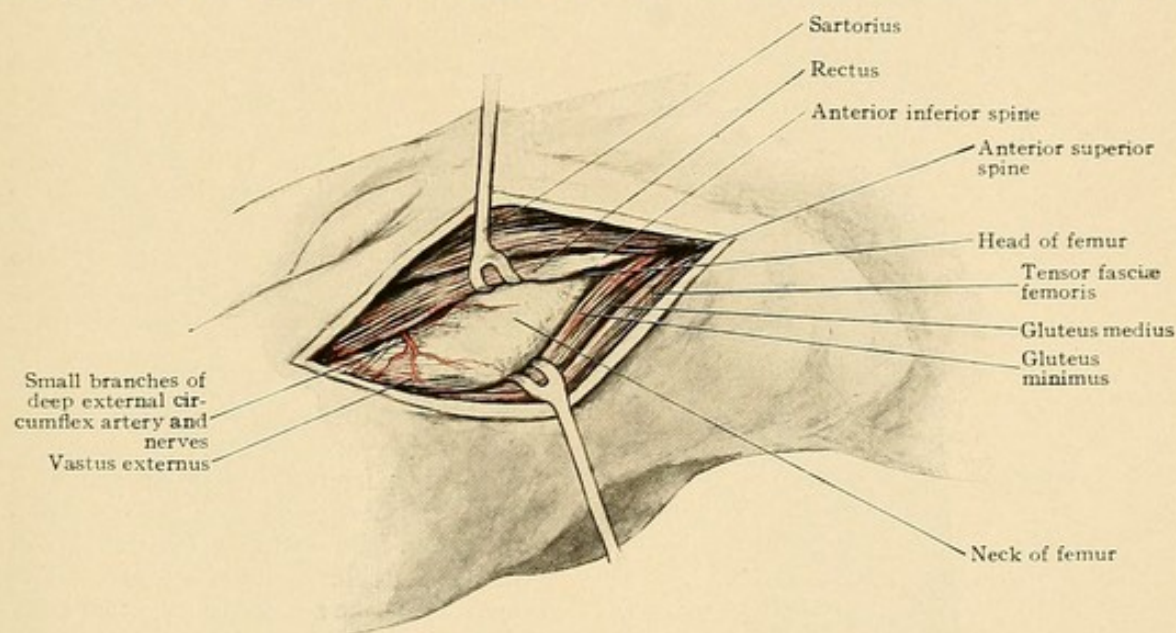


FIG. 528.—Anterior operation on the hip-joint.

muscle was then drawn downward and the pectineus upward and the joint exposed. The writer prefers to make an incision along the inner side of the femoral vein. The vessels are then to be drawn upward and outward and the pectineus downward and inward and the capsule is at once evident.

## THE THIGH.

### STRUCTURE.

The thigh is composed of the femur imbedded in three main sets of muscles, and is supplied and traversed by the femoral vessels and sciatic and anterior crural nerves.

The femur serves as a support and keeps the knee out away from the trunk.

The muscles move the thigh on the trunk, or *vice versa*, and the leg on the thigh.

The blood-vessels and nerves not only supply the structures of the thigh itself, but also serve as channels for the transmission of blood and nervous impulses to and from the parts beyond, hence their large size.



## MUSCLES OF THE THIGH.

There are three main sets of thigh muscles, viz.: extensors, flexors, and adductors. We will limit our consideration to the long muscles.

**Extensor Muscles.**—The extensor muscles consist of the *quadriceps extensor*, composed of the *rectus femoris*, *vastus internus*, *vastus externus* and *crureus* (*vastus intermedius*), and we might add also the *sartorius*. The quadriceps of the thigh is homologous with the triceps extensor of the arm, the fourth head of the latter muscle being the anconeus. The sartorius normally has no homologue in the upper extremity, but is sometimes represented by a slip from the latissimus dorsi to the triceps (dorsi-epitrochlearis—Macalister). The rectus arises by an anterior or straight head from the anterior inferior spine of the ilium and a posterior or reflected head from the upper surface of the rim of the acetabulum. The tendon formed by the union of these two heads passes downward directly over the head of the femur and, in operating on the joint from in front, it must be deflected to one side. The belly of the muscle is separate and not attached to the other muscles (Fig. 529).

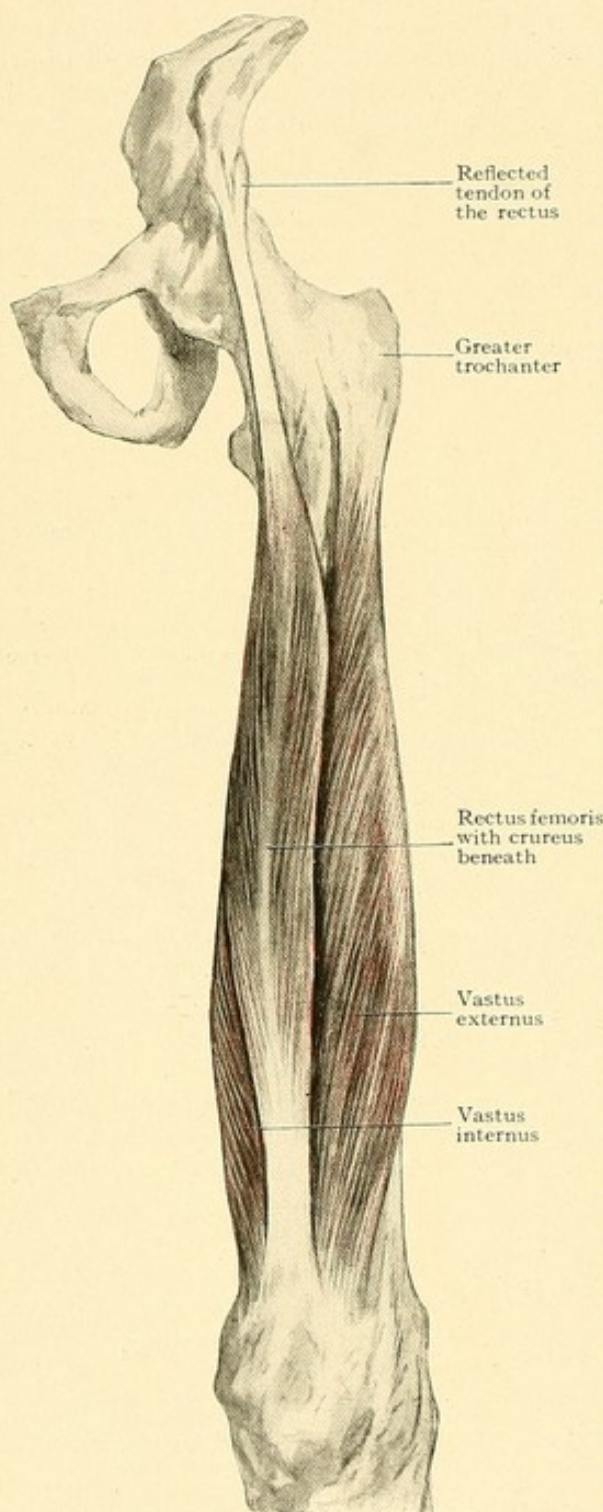


FIG. 529.—The quadriceps extensor muscle of the thigh.

The vastus externus (*vastus lateralis*) forms the muscular mass on the outer surface of the thigh. A bursa separates it from the gluteus maximus above. Superficially it is readily separated from the crureus (*vastus intermedius*) but blends with it close to the bone. The line separating the two muscles is directly upward from the outer edge of the patella. The vastus internus (*vastus medialis*) arises from the inner edge of the linea aspera as high up as the lesser trochanter. Its outer edge blends with the crureus.

The sartorius in the middle third of the thigh lies directly over Hunter's canal. It inserts into the tibia below and internal to its tubercle, hence it spans both the hip-joint and knee-joint. It flexes the thigh on the pelvis and the leg on the thigh. It also rotates the thigh outward and the leg inward especially when the latter is flexed.

The **flexor muscles**, also called the **hamstring muscles**, comprise the *biceps cruris*, the *semitendinosus*, and the *semimembranosus*. The short head of the biceps arises from the outer lip of the linea aspera. Above, the long head is blended with the semitendinosus and arises from the great sacrosacral ligament and the lower inner part of the tuberosity of the ischium.



The semimembranosus arises from the tuberosity just above and external to the biceps and semitendinosus. The biceps, arising by its long head from the tuberosity, lies first to the inner side of the sciatic nerve, and then, as it crosses obliquely to reach the

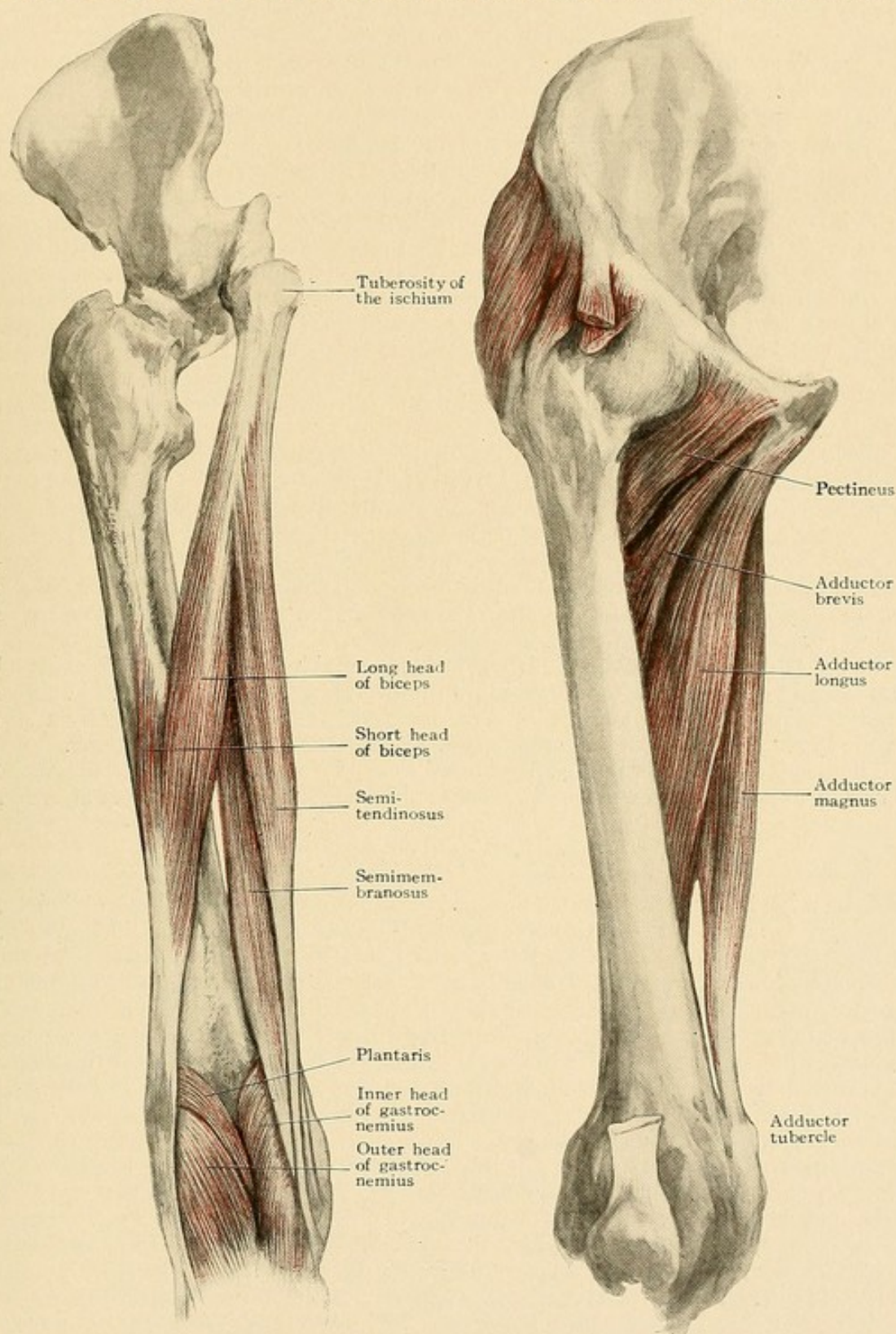


FIG. 530.—The flexor muscles of the thigh.

FIG. 531.—Adductor muscles of the thigh.

outer side of the knee, covers the nerve and finally lies to its outer side. The upper portion of the semimembranosus lies beneath both the long head of the biceps and the semitendinosus, and only comes to the surface between them from the middle of



the thigh down. The tendons of the semimembranosus and semitendinosus form the inner hamstring tendons and the biceps the outer hamstring tendon (Fig. 530).

The **adductor muscles** are the *adductor brevis*, *adductor longus*, *adductor magnus*, and *gracilis*; for clinical purposes the *pectineus* may also be included, although it is morphologically simply a detached portion of the iliacus. The *quadratus femoris* and *obturator externus* belong morphologically to the adductor group, but from a clinical standpoint they are associated more with the external rotators of the hip than the adductors of the thigh. The adductor muscles separate the flexor and extensor groups on the inner side of the thigh. The adductor longus arises by a strong tendon from the body of the pubis just below its spine and inserts into approximately the middle third of the femur in the linea aspera (Fig. 531). When the thigh is abducted the tense edge of its tendon is evident, and if followed upwards it leads to the spine of the pubis. It lies on the same plane as the pectineus, which is immediately above; sometimes, especially in the female, an interval exists between the two through which the adductor brevis may be visible. Near its insertion it forms part of the floor of Scarpa's triangle and the upper part of the floor of Hunter's canal.

The adductor brevis arises from the descending ramus of the pubis just below the origin of the adductor longus and inserts into the femur from the lesser trochanter to the linea aspera. It lies directly behind the upper portion of the adductor longus and in front of the adductor magnus.

The adductor magnus arises from the ramus of the ischium, from the adductor brevis in front to the hamstring tendons on the tuberosity behind. It is inserted into nearly the whole length of the linea aspera, and by a distinct tendinous band into the adductor tubercle at the upper edge of the internal condyle. Its upper portion is sometimes called the adductor minimus. It is pierced near the bone by the perforating branches of the profunda femoris artery and near its lower portion by the femoral artery and vein. It forms part of the floor of Hunter's canal. Its homologue in the upper extremity is the coracobrachialis muscle.

The gracilis arises from the pubis just to the inner side of the adductor brevis and passes straight down the thigh to insert into the tibia, beneath the sartorius and above the semitendinosus. It is sometimes represented in the upper extremity by a slip from the lower border of the pectoralis major called the *chondro-epitrochlearis*.

The pectineus arises from the iliopectineal line to insert just behind and below the lesser trochanter. It lies on the same level as the adductor longus and just above it.

## SURFACE ANATOMY.

If the thigh is flexed and rotated outward the sartorius is seen crossing it obliquely, and Scarpa's triangle is evident as a depression downward from Poupert's ligament. The muscular mass of the upper inner portion of the thigh is composed of the gracilis and adductor muscles. Immediately above the patella is the flat tendon of the rectus, and above and to the inner side of the patella is a rounded mass formed by the vastus internus (Fig. 532). Running upward and inward from the outer edge of the patella to the middle of the thigh is a groove which separates the rectus and vastus externus. On the outer side a flat groove is formed by the iliotibial band of the fascia lata. At its posterior border is the external intermuscular septum between the vastus externus and biceps.

**Scarpa's Triangle.**—This occupies approximately the upper third of the thigh. Its base is formed by Poupert's ligament, its outer side by the sartorius muscle, and its inner side by the adductor longus. Its floor is formed by the iliacus, psoas, pectineus, sometimes a portion of the adductor brevis, and the adductor longus muscles. It contains the femoral artery and vein, the anterior crural nerve, the long saphenous vein, and numerous lymphatics (Fig. 533). At its upper and inner part is the saphenous opening, at which femoral herniæ make their appearance. Psoas abscesses follow the tendon of the psoas muscle down and make their appearance in Scarpa's triangle, sometimes to one side and sometimes to the other of the artery. Pus from hip-joint disease likewise comes to the front at the upper part of the triangle on one side or the other of the femoral artery. The apex of Scarpa's triangle is a favorite site for ligation of the femoral artery.



**Femoral Artery.**—The line of the femoral artery is from a point midway between the anterior superior spine and the symphysis pubis (this brings it to the inner side of the middle of Poupart's ligament) to the adductor tubercle at the inner upper part of the internal condyle. Just below Poupart's ligament it gives off four small branches; the superficial external circumflex, superficial epigastric, and superficial and deep external pudic. About 4 cm. ( $1\frac{1}{2}$  in.) down it gives off the profunda femoris, which is almost as large as the parent trunk. On reaching the edge of the sartorius it passes beneath it to enter Hunter's canal, and at the junction of the middle and lower third of the thigh it pierces the adductor magnus to become the popliteal. At Poupart's ligament the femoral vein lies to the inner side of the artery, but at the apex of the triangle it lies behind it.

**Ligation of the Femoral Artery.**—In ligating the femoral artery an incision is made in the line given above, and the artery sought for beneath the fascia lata. Ligatures are not placed high up, on account of the proximity of the deep femoral; lower down at the apex of the triangle is the preferred point. The crural branch of the genitocrural nerve lies on the artery for a short distance below Poupart's ligament; it is small in size. Just to the outer side of the artery, and sometimes touching it, is

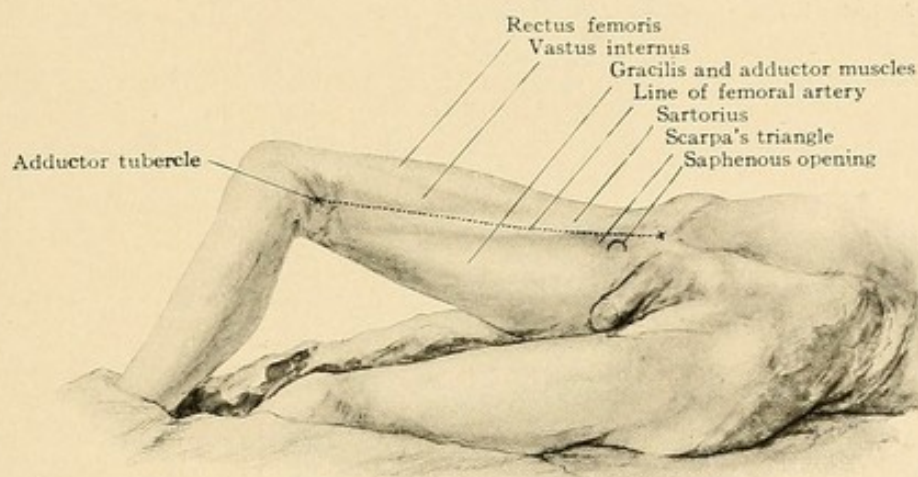


FIG. 532.—Surface anatomy of the thigh.

the anterior crural nerve, and running down its outer side are the internal cutaneous and internal saphenous branches. The femoral vein, which above was internal to the artery, at the apex of the triangle lies posterior to it (Fig. 534).

The **profunda femoris artery** comes off 4 cm. ( $1\frac{1}{2}$  in.) below Poupart's ligament. Its branches are the external (lateral) and internal (medial) circumflex, and four perforating. The last perforating is terminal. The *external circumflex* passes outward over the iliacus and under the sartorius and rectus and divides into three branches; the ascending branch follows the anterior intertrochanteric line and gives off a branch which enters the joint between the limbs of the iliofemoral or Y ligament. The transverse branch goes outward to the upper part of the vastus externus; and the descending branch supplies the muscle lower down. The ascending and transverse branches lie beneath the incision, which is made in operating on the hip-joint anteriorly, and may be cut during the operation. The *internal circumflex* winds inwardly between the psoas and pectineus, then between the adductor brevis and obturator externus, and then between the adductor magnus and quadratus femoris to anastomose with the external circumflex, sciatic, and superior perforating.

The four *perforating arteries* wind around close to the bone from within outward and terminate in the hamstring and vastus externus muscles. They perforate the adductor muscles and send large anastomotic branches to one another near the linea aspera. In operations on the femur, when the soft parts are detached from the posterior portion of the bone, the bleeding from these perforating branches is liable to be very free and on account of their depth difficult to control. It is this which renders operations like those for ununited and compound fractures dangerous.



**Hunter's Canal.**—Hunter's canal occupies approximately the middle third of the thigh. It has an outer wall formed by the vastus internus muscle; a floor formed above by the adductor longus, and below by the adductor magnus; and a

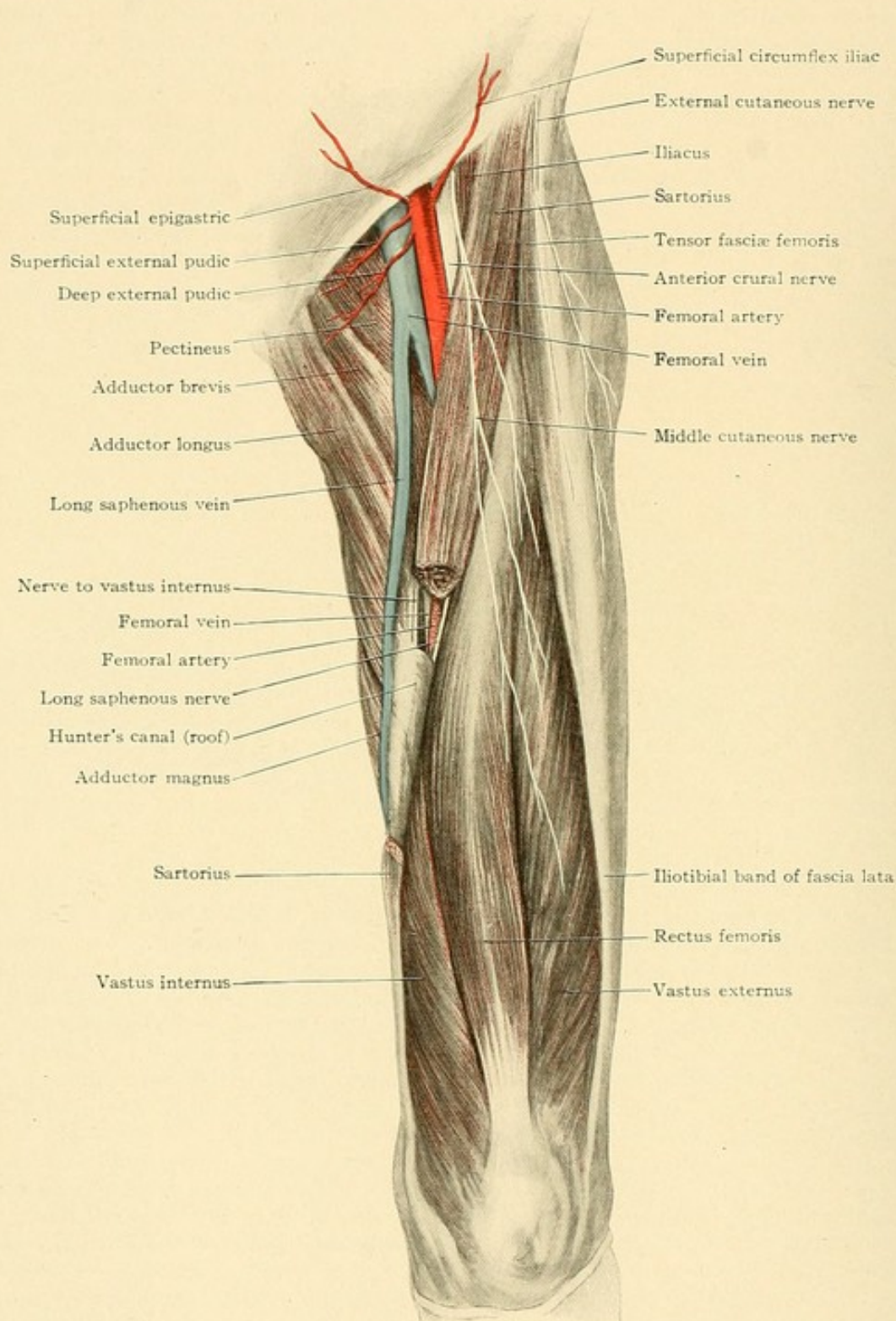


FIG. 533.—Anterior view of the structures of the thigh, Scarpa's triangle and Hunter's canal.

roof formed by a layer of fascia running from the adductor longus and magnus below to the vastus internus on the outer side. The canal runs from the apex of Scarpa's triangle to the opening in the adductor magnus muscle. The sartorius muscle lies on the roof of the canal (Fig. 533).



*The Femoral Artery in Hunter's Canal.*—The femoral artery in Hunter's canal has the vein, to which it is closely bound by fibrous tissue, first posterior and then slightly to its outer side. The internal or long saphenous nerve crosses the artery in front from its outer to its inner side. At the beginning of the canal the nerve to the vastus internus runs alongside of the long saphenous nerve, but it soon leaves it to enter the muscle. The long saphenous nerve leaves the artery as the latter perforates the adductor magnus and passes downward under the sartorius muscle to be distributed to the leg lower down, and to the inner side of the ankle.

*Ligation of the Femoral Artery in Hunter's Canal.*—In ligating the artery the incision is made over the sartorius muscle, which is to be pulled to the outer side; this exposes the roof of the canal, which is then opened. There is no need of

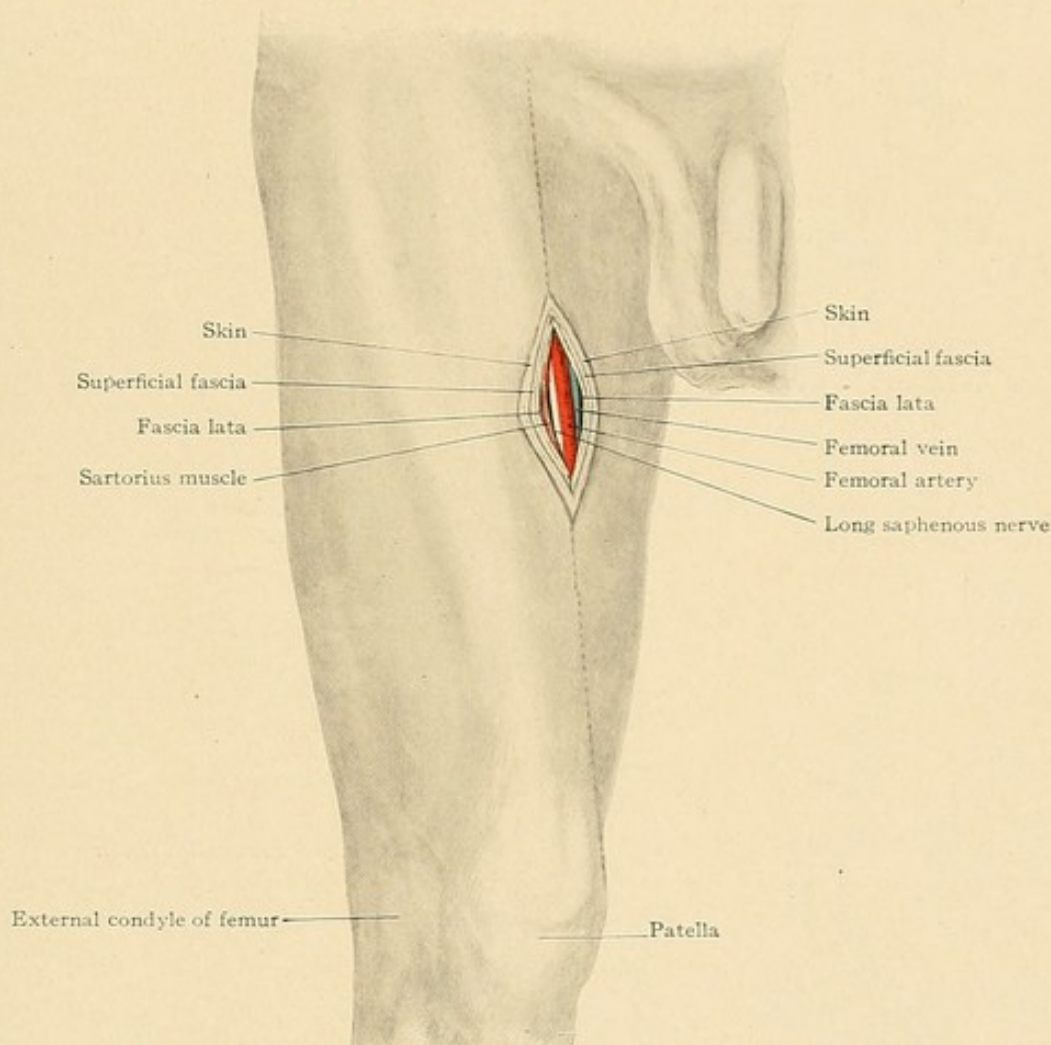


FIG. 534.—Ligation of the femoral artery at the apex of Scarpa's triangle.

including the long saphenous nerve in the ligature. Just before the femoral artery pierces the adductor magnus it gives off the anastomotica magna, whose superficial branch follows the long saphenous nerve, while its deep branch supplies the vastus internus muscle. This latter branch may be the source of troublesome hemorrhage in supracondylar osteotomy.

*Collateral Circulation.*—After ligation of the femoral artery below its profunda branch the external circumflex artery anastomoses with the muscular branches of the femoral, anastomotica magna, and superior articular arteries. The perforating arteries anastomose with the muscular branches below the ligature and with the superior articular arteries (Fig. 535).

**Long or Internal Saphenous Vein.**—The long saphenous vein begins in the venous arch on the dorsum of the foot and passes upward just in front of the internal malleolus, then along the inner posterior edge of the tibia, accompanied by



the long saphenous nerve, then along the posterior border of the internal condyle and up in almost a straight line to the saphenous opening, 4 cm. (1½ in.) below and to the outer side of the spine of the pubis, where it empties into the femoral vein. It is this vein which is involved in varicose veins of the leg, and is frequently operated on. The blood from the inner and outer portions of the thigh collects into two veins which empty into the long saphenous before the saphenous opening is

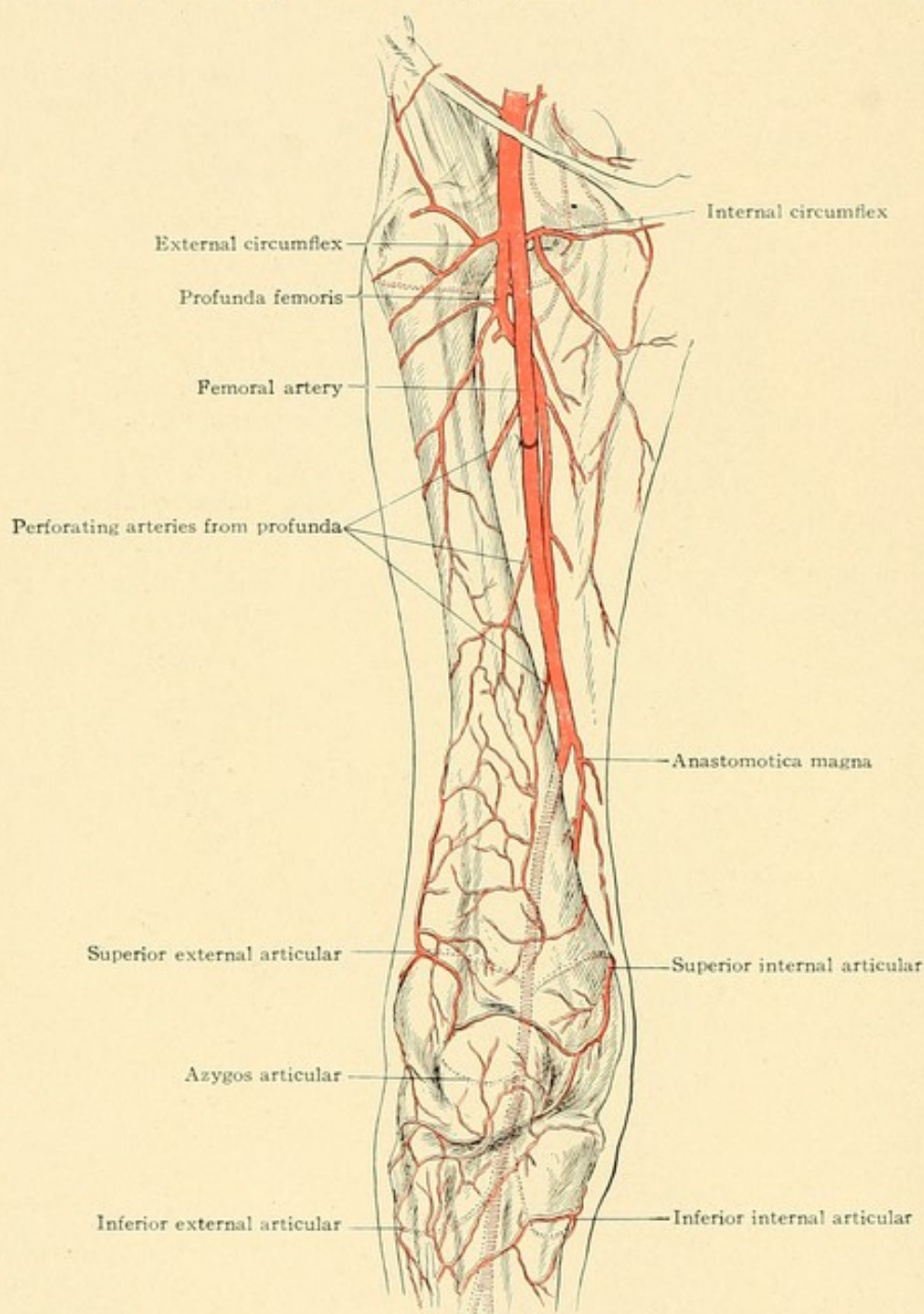


FIG. 535.—Collateral circulation after ligation of femoral artery.

reached, or else join the vein at the saphenous opening, or else open separately into the femoral vein. There are then sometimes two or three veins at the saphenous opening coming from below, instead of one. This is important to bear in mind when operating here, otherwise one of the side veins may be ligated or excised under the impression that it is the main trunk. Every opportunity should be utilized to impress on one's mind the exact course pursued by the vein, as otherwise it may not be readily found if not rendered conspicuous by distention or disease.



**Lymphatics of the Groin.**—The lymphatic nodes of the groin are frequently the seat of infection necessitating operative measures. They are superficial and deep. For clinical purposes there is no better division of the superficial nodes than into an oblique set along Poupart's ligament and a longitudinal set along the blood-vessels (Fig. 536).

While as a general rule it may be stated that the nodes drain the region they are nearest to, this is frequently not the case. Therefore it is not always possible to infer the source of the infection from the location of the infected lymph node. The nodes of the groin drain the lower anterior half of the abdomen, the genitalia, lower limb, and the anal, gluteal, and lumbar regions.

They vary from 10 to 20 in number, and their efferent vessels either pass through the femoral canal to the nodes inside of the abdomen, or may terminate in the deep lymphatic nodes of the femoral canal.

The deep lymphatics consist of one to three nodes in the femoral canal internal to the femoral vessels. They are not constant, and one which is sometimes found at the upper end of the femoral canal is known as the gland or node of Cloquet. They receive the deep lymphatics of the thigh, as well as sometimes a communication from the superficial lymphatics. They rarely become the seat of infection, but if inflamed may be mistaken for strangulated femoral hernia.

**Excision of Inguinal Nodes.**—The inguinal nodes frequently become inflamed and swollen (bubo) from infection transmitted from the parts which they drain. For this they are frequently excised. The superficial nodes are located on the fascia lata around the saphenous opening, and at that point are intimately associated with and surround the veins. On this account it is easy to wound the veins, and the hemorrhage may be so free and so hard to control as to endanger the life of the patient. I know of one such fatal case. This accident is to be avoided by freeing the edge of the mass below the saphenous opening and isolating the long saphenous vein, which is then followed up and exposed at its entrance into the femoral vein. The diseased mass is then to be dissected loose from each side, away from the vein, and removed. The femoral vein itself at this point is superficial, and if the saphenous opening is cleaned out it will of necessity be exposed.

The other veins emptying into the femoral at the saphenous opening above the long saphenous—the superficial circumflex iliac, epigastric, and external pudic—are usually too small and easily secured to cause trouble.

**Sciatic Nerve.**—The sciatic nerve in its descent crosses a line joining the tuberosity of the ischium and greater trochanter at the junction of its inner and middle thirds. It then descends toward the middle of the popliteal space. It divides into the internal and external popliteal nerves at about the middle of the thigh (Fig. 537). Rarely it divides lower down, but more frequently higher up. It is said that it will bear a weight of 183 lbs., but Symington (*Lancet*, 1878—Treves) has pointed out that it will tear out from its spinal attachment before this limit is reached. In exposing it the incision should be made high up at the gluteal fold, to the outer side of the tuberosity of the ischium. At this point it lies to the outer side of the biceps and on the adductor magnus; a little lower down it disappears beneath the biceps, and, if the incision is made here, the muscle must be displaced and it may only be found with difficulty.

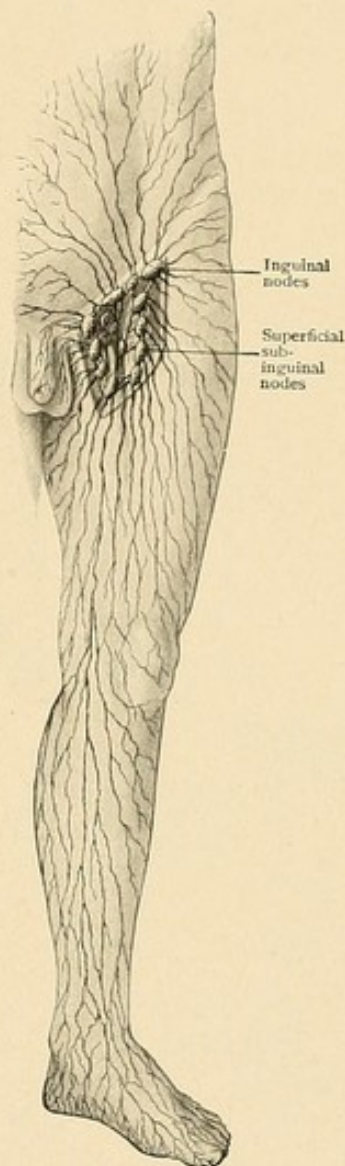


FIG. 536.—Superficial lymphatic vessels of lower limb; semidiagrammatic. (Based on figures of Sappey.)



At the upper end of the popliteal space it again becomes visible, and can be found between the biceps on the outer side and the semimembranosus on the inner side.

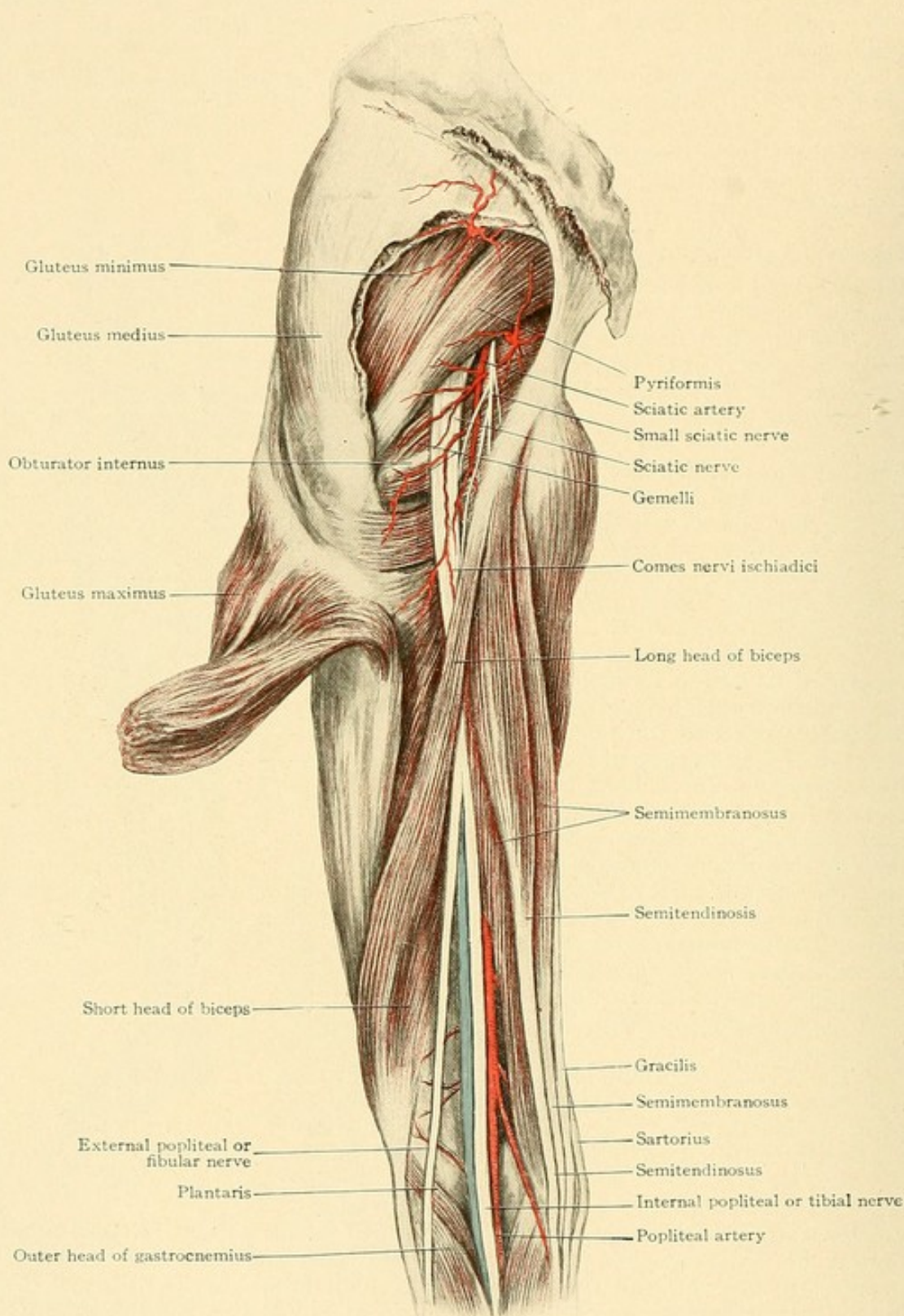


FIG. 537.—Sciatic nerve and structures of the posterior portion of the thigh.

Sciatica may be caused by injury to the sacral plexus in the pelvis, as by labor, or by injury to the nerves as they issue from the spine, as in fractures, luxations, bony outgrowths or tumors. The pain affects the back of the thigh and outer side of the leg.



## FRACTURES OF THE FEMUR.

The femur is usually fractured through the neck, greater trochanter, upper third of the shaft, middle of the shaft, or just above the condyles.

**Fractures of the Neck of the Femur.**—These are often difficult of diagnosis and unsatisfactory in treatment.

The signs peculiar to this fracture are due to the displacement of the fragments. Some shortening occurs in all fractures of the femur (Fig. 538). Comparative measurements to ascertain this will be of no value if the pelvis is tilted (see page 497). If by measurement the limb is shorter than the opposite one, then if the distance from the tip of the greater trochanter to the external malleolus is the same on both sides, the injury must be higher up, or in the neck.

The iliotrochanteric angle instead of being thirty degrees will be diminished or lost. The tip of the greater trochanter will be above the Roser-Nélaton line. The

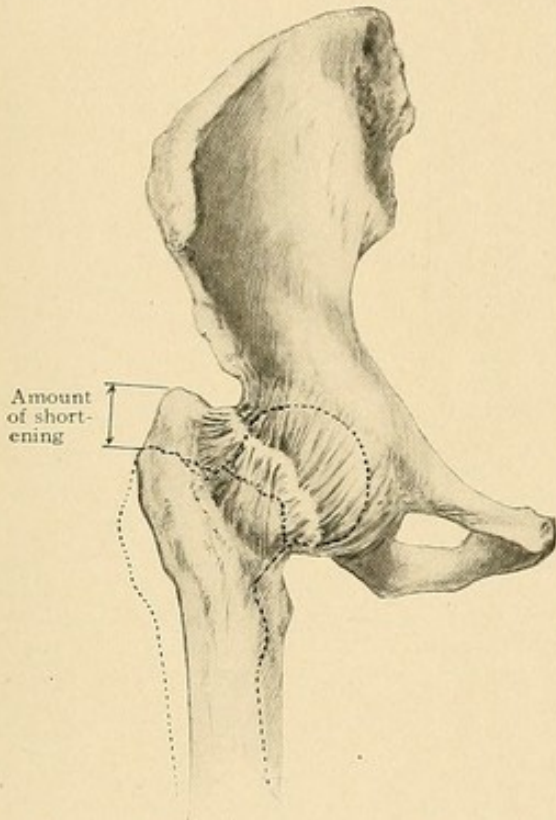


FIG. 538.—Intracapsular fracture of the neck of the femur showing the shortening. The dotted line represents the outline of the normal bone.

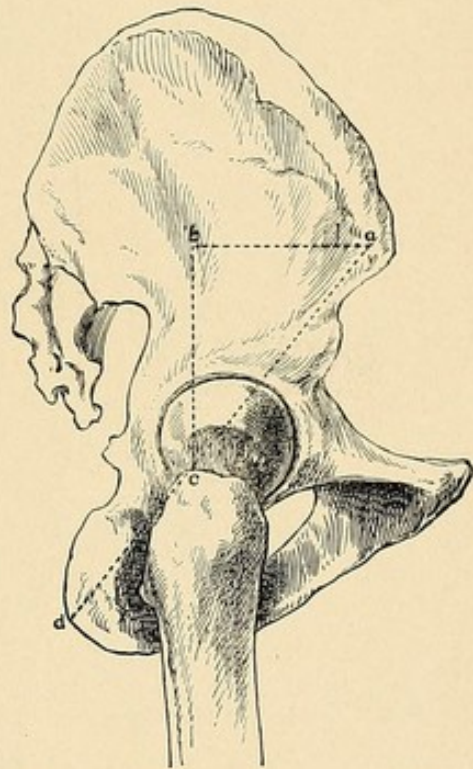


FIG. 539.—View of the outer surface of the bones of the hip, showing Roser-Nélaton line ( $a d$ ); Bryant's triangle ( $a b c$ — $b c$  being its base); the iliotrochanteric line ( $a c$ ) and iliotrochanteric angle ( $b a c$ ).

base of Bryant's triangle will be shorter on the injured side (Fig. 539). If the extended limb is rotated the arc described by the greater trochanter will be smaller on the injured side because the shaft rotates on its axis instead of rotating in the acetabulum. The trochanter of the injured side is usually not so prominent as on the sound side. The iliotibial band is relaxed.

Shortening is well demonstrated by flexing the thighs with the patient on his back: the knee of the sound side will be found to be higher than that of the injured one.

In all fractures of the thigh the foot is placed by gravity in eversion. The rise of the greater trochanter, being nearer to the crest of the ilium, produces a slight fullness in the outer portion of Scarpa's triangle which is absent on the healthy side.

**Line of Fracture.**—The neck is fractured in one of two places, near the head, or near the trochanter. The former is intracapsular entirely, the latter partly intracapsular and partly extracapsular. As the capsule anteriorly descends as low as the



intertrochanteric line and posteriorly only half way down the neck, the high fractures are entirely intracapsular and the low fractures intracapsular in front and extracapsular behind. This causes a marked difference in healing; complete intracapsular fractures do not unite firmly, but the fractures close to the trochanters not infrequently unite firmly with resulting good function.

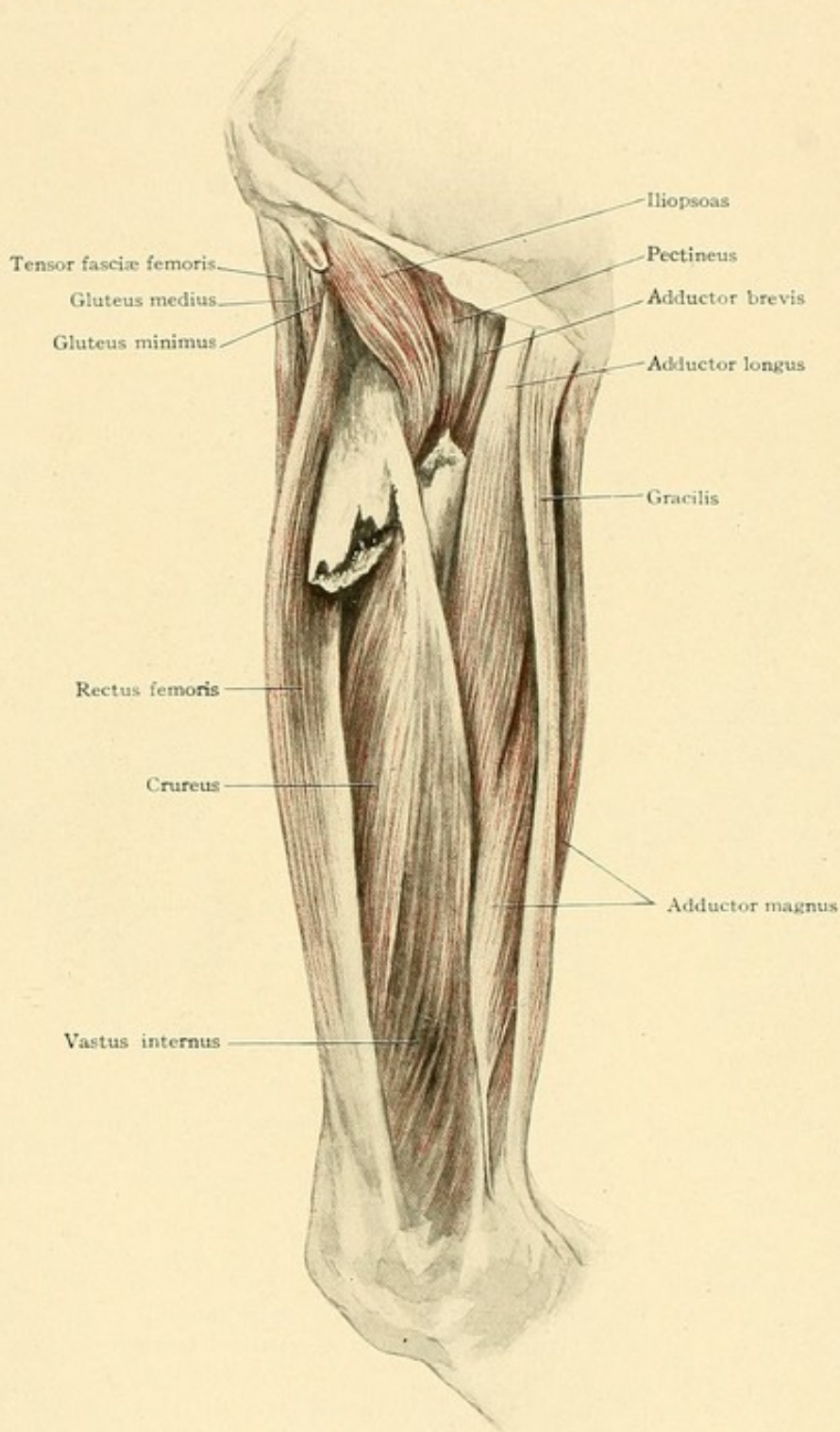


FIG. 540.—Fracture of the femur at the juncture of the upper and middle thirds. Upper fragment drawn forward and outward.

*Impaction.*—Impaction of the other fragment by the neck of the bone is not rare, and firm union may occur. If the fracture is close to the head, the neck is impacted into and penetrates the head, but if the fracture is close to the trochanters the neck penetrates the trochanters, frequently splitting them.



*Mode of Injury.*—In old people the bone is weakened by atrophy and the neck is often fractured by indirect violence, as by twisting, etc. Then the fracture is a high one; if, however, the fracture is by direct violence, as by falling and striking the hip, then the fracture is apt to be close to the trochanters and the prognosis better. Hence the importance of ascertaining the history of the injury. Fracture also occurs in young adults and children, usually from direct injury.

*Treatment.*—The injury is treated (1) by widely abducting the thigh, which elevates the lower fragment to the upper; (2) by adhesive plaster extension combined with lateral weight traction pulling the upper part of the thigh out, which renders tense the capsule and so brings the fractured surfaces in apposition; or (3) by Thomas's splint which is of metal and extends from the level of the axilla to below the knee; this ensures immobility and facilitates handling of the patient.

**Fracture through the Trochanters.**—This is almost always the result of a direct injury or blow on the hip. Impaction is almost the rule, the upper fragment being driven into the lower. Shortening and other symptoms are usually not so marked as in the other fractures and almost any method of treatment is followed by good results.

**Fractures of the Shaft.**—These may be in the upper, middle, or lower third. They all have a common displacement. The upper fragment is displaced forward and outward and the lower fragment backward and usually inward. The foot is usually everted.

*Fractures of the Upper Third.*—The displacement of the upper fragment forward and outward is usually marked. It is caused by the iliacus, psoas, and pectineus pulling it forward and rotating it out and the gluteus minimus and medius abducting it. The lower fragment is pulled in by the adductors and posteriorly by the gastrocnemius and plantaris (Fig. 540). This is a troublesome fracture and is treated either by a double inclined plane or anterior wire splint with the limb in a flexed and abducted position or else the fragments are to be wired or pinned together.

*Fracture of the Middle Third.*—The displacement is the same as in the upper third but to a less extent. It is usually treated by adhesive plaster extension with the leg abducted.

*Fractures of the Lower Third—Supracondylar.*—This is a particularly dangerous fracture because the lower fragment is drawn backward by the gastrocnemius and plantaris, and the popliteal vessels and internal popliteal nerve may either be wounded primarily or stretched over its sharp upper edge (Fig. 541). The artery lying deepest is the most liable to injury, then the vein, and finally the nerve. Gangrene necessitating amputation has occurred. Of course in attempting to replace the fragments the knee should be flexed to relax the gastrocnemius and plantaris. Some cases can be treated by ordinary extension with the knee straight, others with the knee flexed, but others may require operation and fixing by pins or wiring. William Bryant divided the tendo Achillis for the purpose of relaxing the pull of the gastrocnemius.

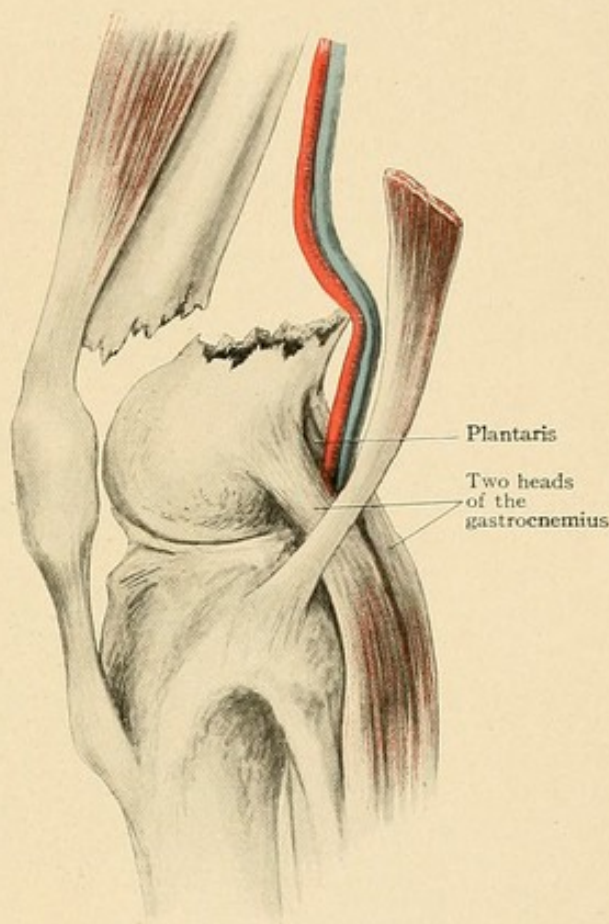


FIG. 541.—Supracondylar fracture of the femur. The lower fragment is seen to be drawn back into the popliteal space by the gastrocnemius and plantaris. The vessels are stretched over the sharp edge of the lower fragment.



## AMPUTATION.

**Amputation at the Hip-Joint.**—In amputating at the hip-joint, hemorrhage is especially to be guarded against. This comes from two sources, the femoral artery anteriorly and the branches of the internal iliac posteriorly. The most reliable way of controlling bleeding is probably by the use of the elastic tourniquet held in place by *Wyeth's pins*. These are two steel pins 5 mm. ( $\frac{3}{16}$  in.) in diameter and 25 cm. (10 in.) long. One is entered 6 mm. ( $\frac{1}{4}$  in.) below the anterior superior spine and slightly to its inner side and traverses the tissues on the outer side of the hip for about 7.5 cm. (3 in.) from the point of entrance; the other is entered through the skin and tendon of the adductor magnus 1.25 cm. ( $\frac{1}{2}$  in.) below the perineum and made to emerge 2.5 cm. (1 in.) below the tuber ischii. The elastic tube is to be wound around the hip above the pins, which prevent its slipping down (Fig. 542). The amputation is then performed as desired. Compression of the aorta or common iliac by instrumental means is obsolete. Sometimes the common iliac is compressed laterally by the finger introduced through an incision in the

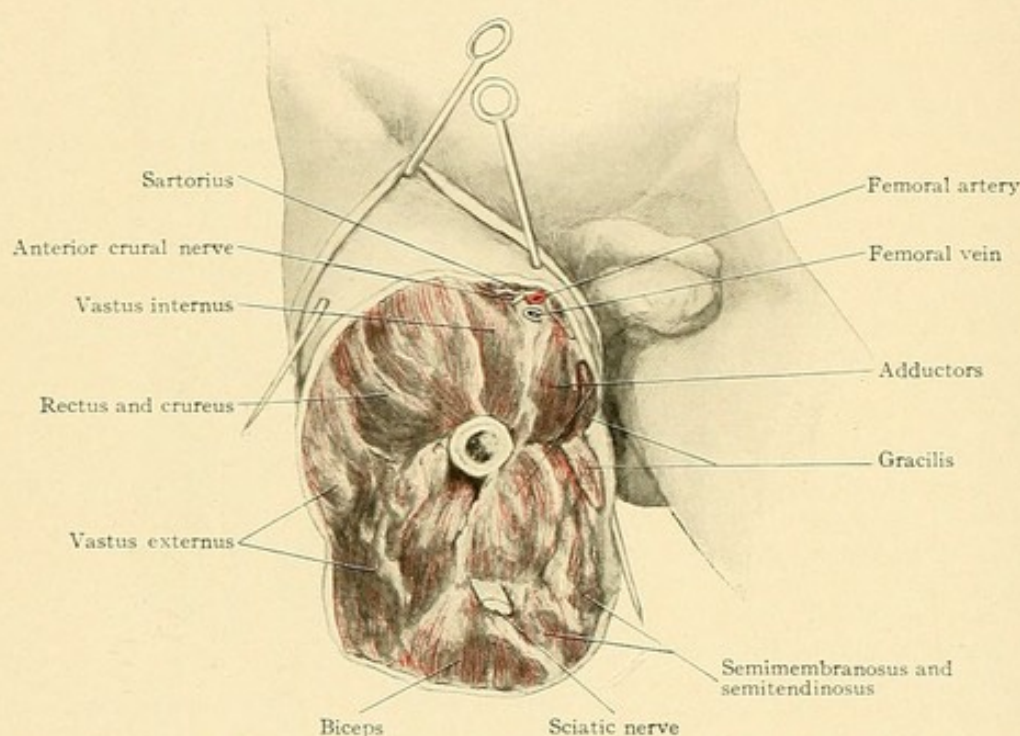


FIG. 542.—Amputation just above the middle of the thigh, showing insertion of Wyeth's pins.

abdominal walls. Another method consists in making lateral flaps with the femoral artery in the angle of the incision—all vessels are then clamped as they are divided.

In some operations the head of the femur is disarticulated before the flaps are made. In this case the first part of the operation is like a resection of the hip by the Langenbeck straight incision.

The bleeding of the posterior flap comes from branches of the gluteal, sciatic, obturator, and internal pudic arteries, derived from the internal iliac.

**Amputation of the Thigh.**—In amputation of the thigh by the flap method care must be taken to avoid splitting the femoral artery. Its position in the various portions of the thigh should be borne in mind. Anteroposterior flaps are to be preferred to lateral ones, and a short anterior flap is to be avoided because the scar is drawn posteriorly (Fig. 542). The muscles of the posterior part of the thigh, the hamstrings, are not attached to the bone, with the exception of the short head of the biceps, they therefore retract when cut and later pull the scar behind the bone. The crureus and vastus externus and internus anteriorly are attached to the bone, and hence cannot draw back either at the time of the operation or afterwards.



The position of the femoral artery will depend on the point at which the amputation is made. It does not lie close to the bone until the popliteal space is reached. Bleeding from the perforating arteries along the *linea aspera* should, however, be looked for and the sciatic nerve should be isolated and cut short.

## REGION OF THE KNEE.

### SURFACE ANATOMY.

The bony landmarks are the patella, the two condyles of the femur, the tibia, and the fibula (Fig. 543).

The patella is pointed below where the *tendo patellæ* is attached, is slightly convex on its upper border, and its lateral edges are prominent, especially the outer. It usually has little tissue over it. With the limb extended and quadriceps relaxed the patella can be moved laterally. There is a hollow above the patella. When the muscle contracts this hollow is filled up by the rectus, and the muscular swells on each side produced by the vastus internus and externus are visible. When the quadriceps muscle is contracted the tense *tendo patellæ* becomes evident, when relaxed the soft fatty pad beneath the tendon can be felt.

About midway between the patella and tubercle of the tibia on each side can be felt a groove which indicates the line of the joint and the location of the semilunar cartilages. On the outer side posteriorly opposite the level of the tibial tubercle can be felt the head of the fibula. Running upward from it is the tendon of the biceps. In front of the biceps can be seen and felt the ilio-tibial band. It is difficult to distinguish the joint-line on the sides, therefore it is better to locate it by recognizing the sulci anteriorly on each side of the *tendo patellæ*; flexing the knee makes these depressions more distinct. The joint on the outer side is about 2 cm. ( $\frac{3}{4}$  in.) above the head of the fibula.

Posteriorly, with the leg extended, the condyles of the femur can readily be outlined; the inner is the more prominent. The upper edge of their articular surfaces can be felt on firm pressure at the sides, and the inner leads to the adductor tubercle, into which the adductor magnus tendon is inserted—this tendon can likewise frequently be felt. The tubercle of the tibia can best be seen and felt when the *tendo patellæ* is relaxed. It is about 4 cm. ( $1\frac{1}{2}$  in.) below the patella. Just above and to its outer side, about 4 cm. ( $1\frac{1}{2}$  in.) distant, is the external tuberosity of the tibia; into it is inserted the lower end of the iliotibial band. To the outer side at a little lower level can be seen and felt the head of the fibula. On the inner side is the flat rounded internal tuberosity of the tibia. Posteriorly is seen the fulness of the popliteal space; on its outer side the tendon of the biceps is readily felt and running with it is the external popliteal

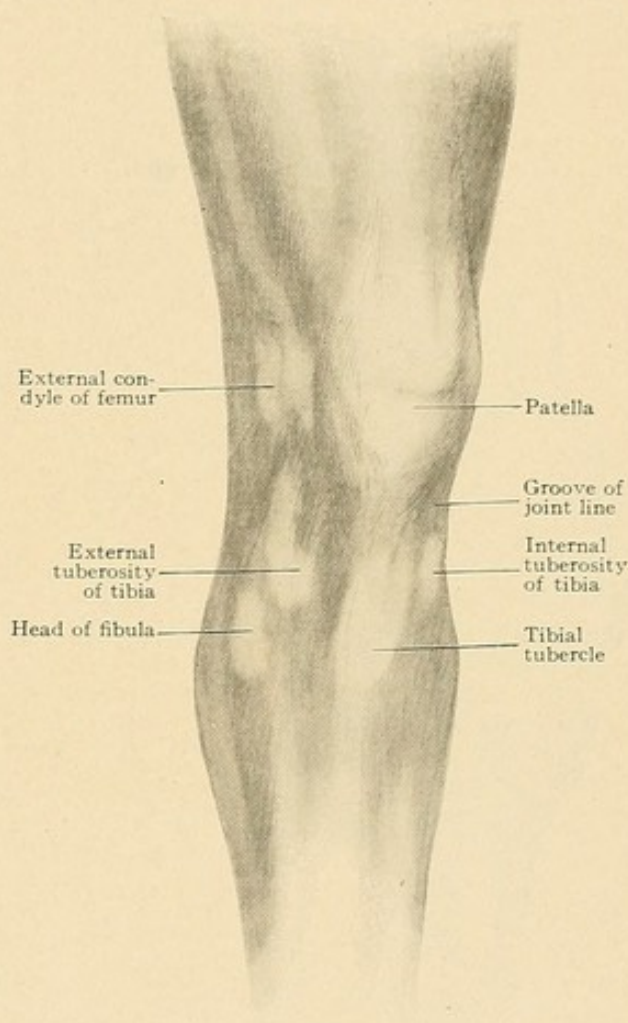


FIG. 543.—Surface anatomy of the knee.



or fibular nerve; on the inner side the most prominent tendon is the semitendinosus with the semimembranosus beneath and the gracilis to the inner side.

### THE KNEE-JOINT.

As the functions of the lower extremity are support and mobility, it is evident that in order to obtain mobility without unduly weakening the limb the ligamentous connection of the bones must be exceptionally strong. The knee is placed half way down the extremity, hence it has the bulk of the body above to support; also, the bones on each side of the joint are the longest in the body, hence their lever action is exceptionally great, which likewise necessitates that the joint be firmly braced by ligaments.

**The Movements of the Knee.**—The knee is primarily a hinge-joint; its main movements are extension and flexion. It can be extended to a straight line (180 degrees) and flexed until the thigh and upper portion of the leg come in contact, at about 45 degrees or even less. The movement is a combined gliding and rolling one. According to Morris ("Joints," p. 375), as extreme extension ends the leg rotates a little outward through a longitudinal axis, passing through the middle of the outer condyle of the femur, and as flexion begins it rotates inward. These rotatory movements are, however, slight, and may practically be ignored. When flexion has proceeded to 150 or 155 degrees, the joint becomes comparatively loose, and this increases as the joint is flexed, until a rotation of 36 degrees (Morris) is allowed. This is of decided practical importance because injuries and treatment are intimately associated with the presence of rotatory movements. No rotation is possible when the knee is fully extended, the bones being then immovable.

#### Bones of the Knee-Joint.

—The knee-joint is between the femur, the tibia, and the patella; the fibula does not enter into it (Fig. 544). The patella is only a sesamoid bone developed in the quadriceps tendon, and is not essential. In some of the lower animals it has a synovial membrane separate from the knee-joint proper.

The joint between the femur and tibia is built up of two separate lateral parts; the condyle and tuberosity of each side forming practically a separate joint and having a crucial ligament as one of its lateral ligaments.

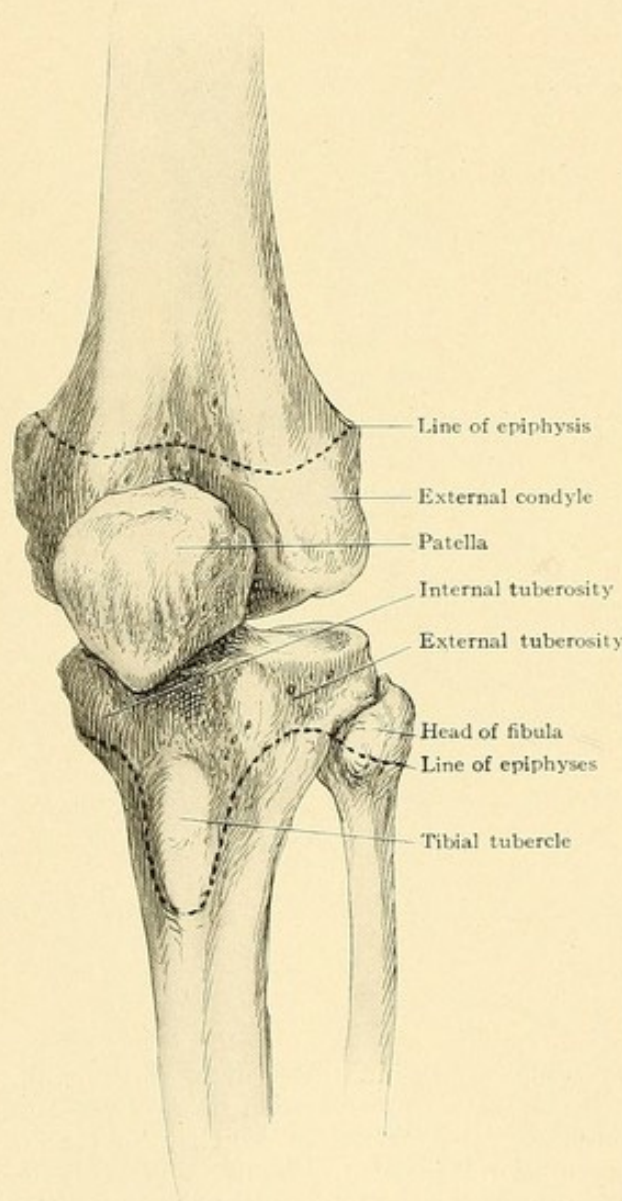


FIG. 544.—Antero-external view of the bones of the knee.

The object of thus combining two joints side by side to form one joint is to add to its strength and lateral stability. The condyles of the femur have their articular surfaces prolonged up on its anterior surface, not to aid in flexion and extension, but simply to facilitate the action of the patella. The outer condyle is the higher, to prevent external luxation of the patella.



The articular surfaces of the condyles are not perfect arcs of a circle. If they were the motion would be solely a gliding one and the lateral ligaments and crucial ligaments would be equally tense in all positions, which is not the case, for, particularly in flexion, they become slightly relaxed. The upper surface of the tibia is slightly hollow and its spine projects upward between the condyles, thus adding to the lateral stability of the joint.

The patella is divided by a longitudinal ridge into two articular facets, the outer for the external condyle being the larger; the ridge lies in the intercondylar space. The inner part of the patella is thicker than the outer because the inner condyle is lower. The patella is a sesamoid bone which is developed more toward the deep surface of the tendon of the quadriceps. The tendon goes over the surface of the patella and is practically continued longitudinally through the superficial portion of the bone. If the dried specimen is hammered the bone can be pulverized and removed, leaving the tendon of the quadriceps continuous with the tendo patellæ. For this reason, when the patella fractures, the torn fibrous fringes are never on the articular surface but always on its superficial surface. The patella has its sharp apex below and fractures frequently tear it off, the small size of the fragment making repair difficult.

**Ligaments of the Knee-Joint.**—To provide for the support required to be given by the lower extremity, the ligaments and tendons binding the bones of the knee together are both numerous and strong. The bond of union is so strong that dislocations from traumatic causes are comparatively rare, and it is only when the ligaments have been weakened by disease that subluxations take place.

The knee possesses the usual *capsular ligament* but so hidden by strengthening bands and tendinous expansions that but little of it is seen. Anteriorly the capsule is strengthened by the tendon of the quadriceps, the patella, and the tendo patellæ (Fig. 545). Viewing these structures as a whole we see that their lower end is firmly attached at the tibial tubercle, but above their attachments are far removed from the joint. They are so strong and thick that pus from within does not tend to go through but goes around them. Their upper attachment is muscular, so they do not act to restrain movements except when the muscle is contracted; hence flexion is limited by contact of the soft parts posteriorly rather than by tension of the ligaments anteriorly. In complete extension the bulk of the patella rises above the articular surface, and connecting its upper edge with the anterior surface of the femur is only the thin capsular ligament, hence effusions into the joint bulge upward at this point. Extending about 5 cm. (2 in.) above the patella is the subfemoral bursa; this in 8 out

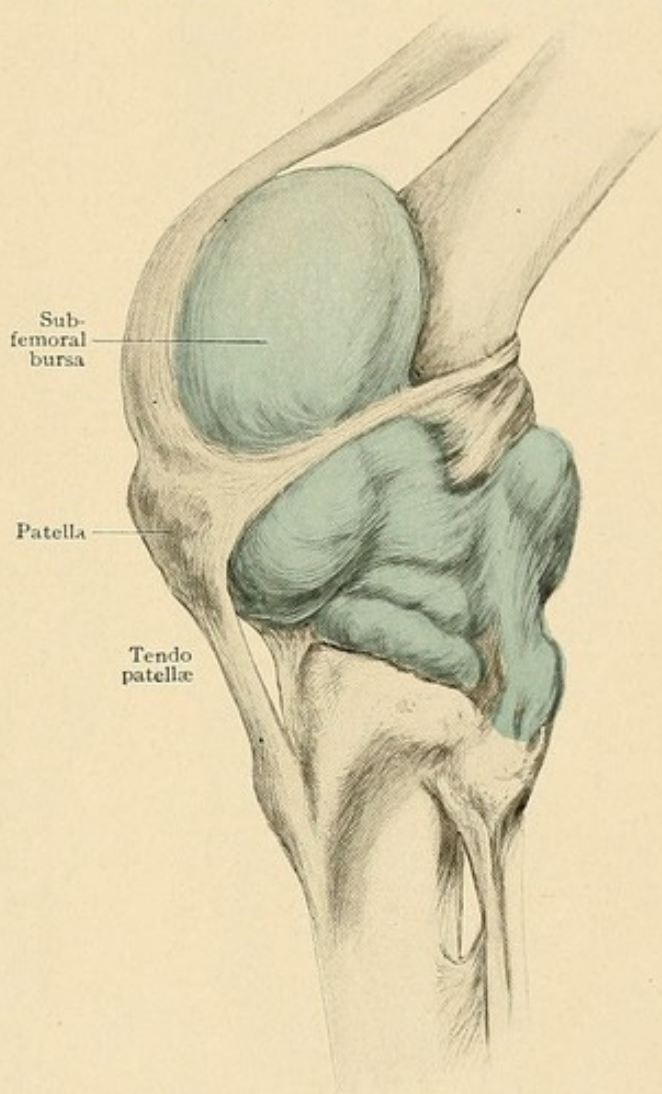


FIG. 545.—Knee-joint distended with wax, showing the extent of its cavity and capsular ligament.



of 10 cases communicates with the joint, and effusions readily distend it. The patella normally lies in contact with the femur but when there is effusion in the joint it is pushed or raised up and is called a *floating patella*. Pressure on it causes it to strike on the femur beneath, which is readily felt and enables one to diagnose effusions within the joint. Posteriorly the capsule is thick, being strengthened by an expansion, called the posterior ligament or ligamentum Winslowii, which goes upward and outward from the tendon of the semimembranosus muscle at the upper edge of the tibia. It is pierced by the branches of the azygos articular artery. The capsular ligament is weak below at the margin of the tibia and here pus may find an exit. It is less liable to come out above, but the bursa under the inner head of the gastrocnemius frequently (17 per cent., Mac-

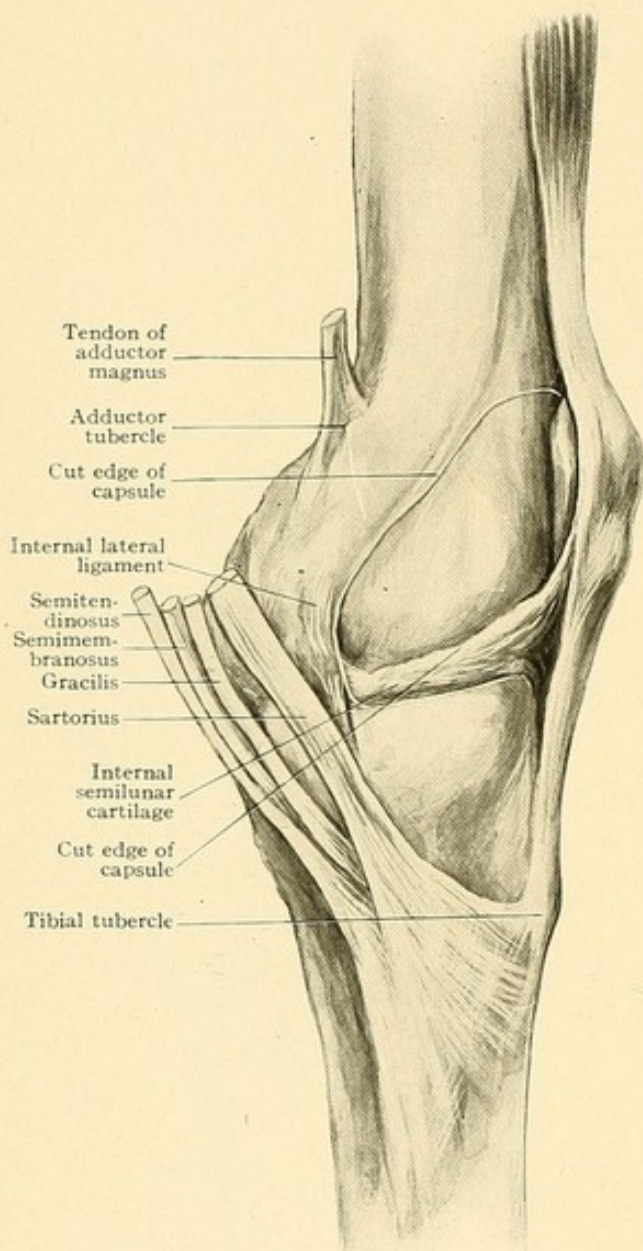


FIG. 546.—View of the inner side of the knee-joint; the capsule has been cut away from the edge of the patella to the internal lateral ligament, exposing the interior of the joint.

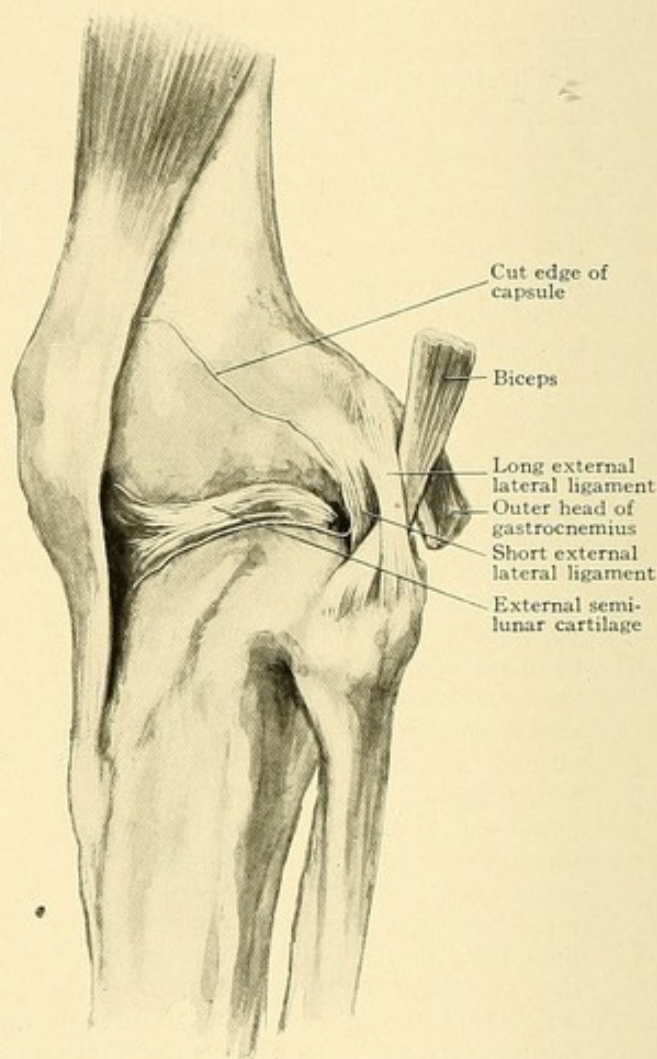


FIG. 547.—View of the outer side of the knee-joint. The capsule has been cut away from the edge of the patella to the external lateral ligament.

alister) communicates with the joint and is usually the origin of the ganglion so often seen in the popliteal region. When the joint becomes subluxated by disease the tibia is drawn backward and this posterior capsular ligament may shorten and prevent reposition forward. So strong is it that forcible attempts are liable to cause fracture.

Internally the capsular ligament is strengthened by the lateral expansion from the side of the patella and from the fascia lata over the vastus internus; these go to the inner tuberosity of the tibia and strengthen the lower part of the joint,



but toward the upper edge of the internal condyle the capsule is again thin and effusions puff it out at that point.

*Internal Lateral Ligament.*—A band of the capsule to which the name internal lateral ligament has been applied runs from beneath the adductor tubercle to the tibia below the internal tuberosity; it is strengthened by fibres from the tendon of the semimembranosus and has the internal articular vessels and nerves passing between it and the tibia. It will be noted that it lies toward the posterior portion of the joint, hence it limits extension (Fig. 546).

Externally the capsule has likewise the fibrous expansion of the quadriceps from the side of the patella and the fascia lata. This latter is the strong iliotibial band and goes downward to insert into the outer tuberosity of the tibia (Fig. 547).

*External Lateral Ligaments.*—There are likewise two band-like ligaments on the outer side, the long and short external lateral ligaments. The long external lateral ligament arises from a tubercle just below and in front of the outer head of the gastrocnemius muscle. It is about 5 cm. (2 in.) long and is attached below to the fibula, anterior to its styloid process. It is embraced on each side by the split tendon of the biceps. Beneath it pass the popliteus tendon in its sheath and the inferior external articular vessels and nerve. Note that this is likewise at the posterior portion of the joint and therefore it too limits extension.

The short or posterior of the two external lateral ligaments is often not to be recognized as a distinct structure, it passes from the styloid process of the fibula over the popliteus tendon to blend with the posterior capsular ligament on the external condyle. The lateral ligaments check extension and outward rotation of the tibia.

*Crucial Ligaments.*—These pass from the tibia, the anterior being attached in front of and the posterior behind the spine, upward to the intercondylar notch of the femur. The anterior or external passes upward, outward, and backward. The posterior or internal passes upward, inward, and forward (Fig. 548). They are never very lax in any position of the joint, but the anterior is most tense in extension and the posterior in flexion. The anterior tends to prevent displacement of the tibia forward and the posterior ligament displacement of the tibia backward. The posterior crucial ligament blends with the posterior capsule and in resecting the knee care should be taken in dividing this ligament that the popliteal artery is not wounded. A ligamentous band runs from the posterior crucial ligament to the external semilunar cartilage; it is called the *ligament of Wrisberg*. The knee-joint in some of the lower animals is composed of two separate joints, one for each condyle, and the crucial ligaments of man are simply the remains of lateral ligaments when separate joints exist. They check inward rotation.

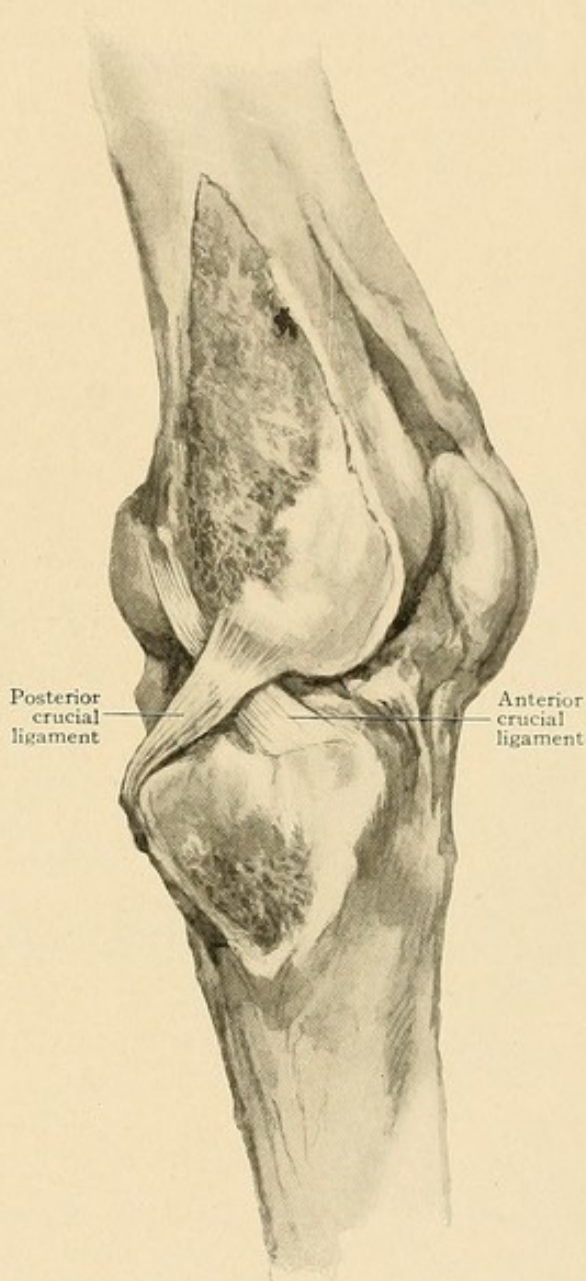


FIG. 548.—The crucial ligaments exposed by sawing off the inner surfaces of the femur and tibia.



*Semilunar Cartilages, Coronary and Transverse Ligaments.*—The semilunar cartilages are used to deepen the joint in the same manner as the cotyloid of the hip and glenoid of the shoulder. It is their method of attachment that is important. The external is nearly circular, the internal is semi-elliptical. The ends are fibrous and are attached in front of and behind the spine of the tibia. The transverse ligament is a band passing across the front from one semilunar cartilage to the other (Fig. 549). As Macalister has pointed out, there is no true coronary ligament. It is the part of the capsular ligament running from the semilunar cartilages to the tibia.

The semilunar cartilages are attached by their outer edges to the capsular ligament. This attachment is less in extent in the case of the external, because its outer surface is obliquely grooved by the tendon of the popliteus muscle, but it has an additional attachment in the ligament of Wrisberg, as stated under the posterior crucial ligament. Humphry ("Human Skeleton," 546) has pointed out that the semilunar cartilages in flexion and extension move with the tibia, but in pronation and supination (rotation) move with the femur.

*Ligamenta Alaria and Mucosum.*—Below the patella is a pad of fat extending under the upper portion of the tendo patellæ; a bursa is under the lower portion. Passing up from this pad to the intercondyloid notch and crucial ligaments is the ligamentum mucosum; below, it is continuous with the synovial fringes at each side of the lower edge of the patella which form the ligamenta alaria. We would suggest that it is possible that these ligaments perform for the knee-joint what Allis has suggested the ligamentum teres does for the hip, viz.: act as a swab to distribute the synovia over the articular surfaces.

**Bursæ of the Knee.**—There are a number of bursæ about the knee-joint, but they are not all of importance. *Anteriorly* there are the prepatellar, suprapatellar, and deep and superficial infrapatellar.

The *prepatellar* bursa lies in the subcutaneous tissue between the skin and patella. It is often enlarged, constituting "housemaid's knee" (Fig. 550). The bursa is almost always

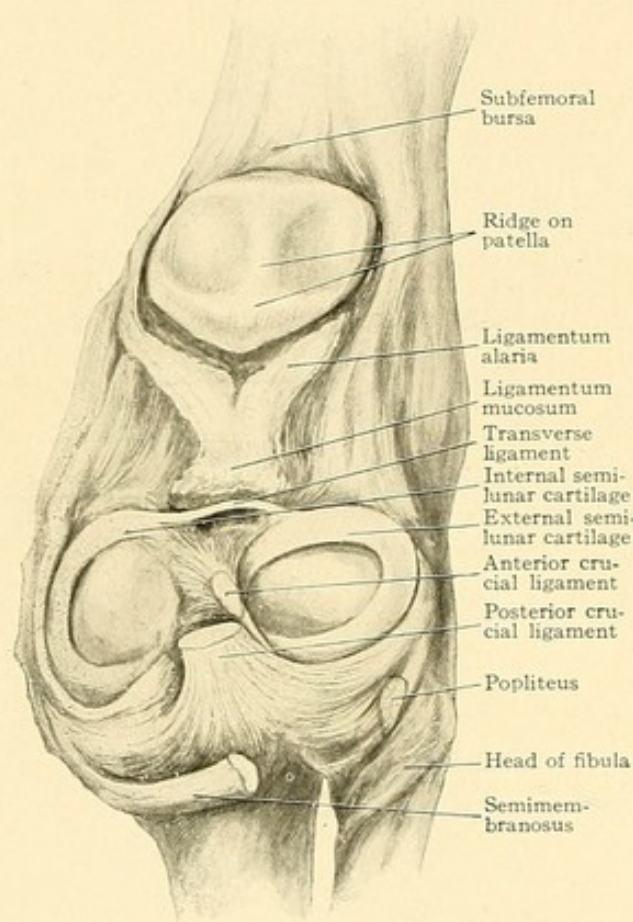


FIG. 549.—View of the interior of the knee-joint, looking forward.

present, but often irregular in shape and character. Injuries frequently cause it to inflame, as do also rheumatoid affections. Sometimes the tendon of the quadriceps over the patella is ossified clear to the surface, which is often irregular and rough, and is felt immediately beneath the skin with apparently no subcutaneous tissue intervening. In these cases the bursa may be very irregular or loculated in shape, or there may be more than one. The sac of the bursa is usually very thin, but becomes thick and distinct as the result of irritation. Excision is usually the quickest way of curing housemaid's knee, but often the easier way of simple incision and drainage with a wick of gauze is sufficient.

The *suprapatellar* or subfemoral bursa extends from 5 to 7.5 cm. (2 to 3 in.) above the patella beneath the crureus muscle. It is liable to be injured by stabs or punctures, and thereby infect the joint with which it communicates in 8 out of 10 cases. It becomes distended in intra-articular effusions.



The *infrapatellar bursæ* are one between the skin and tibial tubercle and the other between the under surface of the tendo patellæ and the upper end of the tibia—they are unconnected with the joint and are not often diseased.

*Posteriorly.*—On the *outer side* of the joint there may be present (1) a bursa beneath the external head of the gastrocnemius which may communicate with the bursa between the popliteus tendon and external lateral ligament. (2) One between the biceps tendon and external lateral ligament, (3) another between the popliteus tendon and external lateral ligament, and (4) one beneath the popliteus, usually an extension of the synovial membrane of the joint. On the *inner side*: (1) one beneath the internal head of the gastrocnemius, which usually communicates with the joint and sends a prolongation between the gastrocnemius and the semimembranosus. This is the most important posterior bursa. (2) There is one beneath the tendons of the sartorius, gracilis, and semitendinosus muscles. (3) One beneath the tendon of the semimembranosus, between it and the tibia; it rarely communicates with the knee-joint. (4) One between the tendons of the semimembranosus and the semitendinosus.

*Ganglion.*—Sometimes a rounded tumor that is called a ganglion appears in the popliteal space. When the knee is flexed it is felt as a round, movable tumor which is hard and cystic. If the knee is extended it slides inward to the edge of the inner condyle and becomes hard and fixed. It usually originates from the bursa beneath the inner head of the gastrocnemius, is prolonged between it and the semimembranosus, and, when the knee is flexed, it either disappears entirely by its contents going into the joint or it can still be felt in the popliteal space. It may be a difficult matter to excise these cysts on account of their ramifications, and when this is impossible it is better to open them up, clean them out, and then sew the wound shut in order to avoid infecting the joint. Care should be taken not to mistake them for solid tumors or enlarged lymph-nodes, both of which are less common than ganglion.

#### Fracture of the Patella.—

The patella may be fractured in two ways, producing different lesions and requiring different treatment. Fracture is produced either by muscular contraction or by direct violence; the former is the more common.

*Fracture by Indirect Violence.*—As pointed out by Humphry, when the knee is fully flexed only the upper third or fourth of the articular surface of the patella is in contact with the condyles of the femur—the remaining two-thirds or three-fourths of the projecting portion of the bone resting on the pad of fat. When semi-flexed the greater part of its surface is in contact with the condyles, or at least the whole of its middle third. In full extension only the lower third or fourth or even less remains in contact.

When semi-flexed the patella is subjected to the greatest leverage strain; hence it is that fractures most often occur in this position and that the fracture occurs so frequently at the junction of the lower and middle portions. When the bone is fractured by indirect force (muscular) the line of fracture traverses its whole thickness and consequently the joint is always involved. Usually there are but two fragments. The extent of separation depends on the amount of laceration of the capsule on each side of the line of fracture (Fig. 551).

On each side of the patella the fibrous expansion of the quadriceps tendon, fascia lata, and joint capsule, if intact, will prevent separation of the fragments. If it is ruptured widely it will permit a separation of about 2.5 cm. (1 in.). It is rare that the primary injury produces a wider separation, and those cases in which the fragments

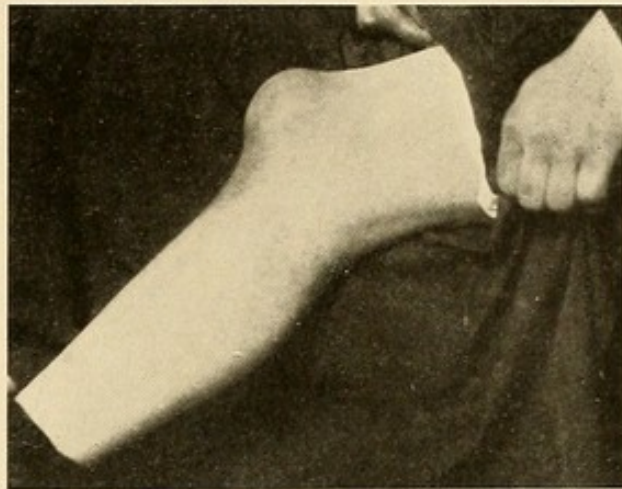


FIG. 550.—Housemaid's knee or enlargement of the prepatellar bursa.



are wider apart are usually those in which the upper fragment has been subsequently pulled up by the contraction of the quadriceps. A fracture which when recent may have had only 1 cm. separation may subsequently show 7.5 to 10 cm. (3 to 4 in.). When the union is fibrous subsequent stretching may occur, also refracture increases the tendency to wide separation.

*Fracture by direct violence* is due to the direct impact of a blow or a crushing of the patella between the femur and some foreign body. In this case the capsule on the sides is but little torn and although there may be several fragments they do not become widely separated.

Macewen has pointed out that the torn fibrous portion of the quadriceps over the patella may hang down between the fragments and hinder union.

*Treatment.*—The method of treatment to be employed varies according to the character of the injury. When the fracture is from indirect force, means must

be employed not only to hold the fragments together, but also to repair the rent in the capsule. Obviously the limb is to be kept in the extended position to relax the quadriceps. The rectus, on account of taking its origin from the pelvis, is also to be relaxed by elevating the limb. A common method of treatment is by open operation. First a flap is raised, exposing the fracture, then the fragments are approximated with wire or other sutures and the rent in the capsule closed with chromic catgut or silk.

In fractures by direct violence, when separation is not marked, the lateral fascial expansion remains untorn and no open operation is necessary; in others, when separation is more marked, and especially if the fracture is compound, a flap may be turned back and the patella surrounded with a strong suture of chromic gut or silk and the fragments thereby drawn together; the suture may also be introduced subcutaneously.

By open operation the blood and clots which usually fill the joint can be removed as well as any fibrous tissue from the tendon of the quadriceps which may lie between the fragments.

**Dislocation of the Patella.**—The articular surface of the patella is divided by a longitudinal ridge into an outer and inner part, which articulate with the corresponding condyles of the femur.

The outer surface for the external condyle is much the larger. The outer condyle is also much higher than the inner and thus tends to prevent luxations. The lateral fibrous expansions on each side of the patella also help to hold it in place.

Favoring dislocation is the inclination inward of the knee and the oblique pull of the quadriceps. When a person is standing upright with the feet together the femurs diverge from the knee as they approach the hip, the knees forming an angle of 165 degrees with its apex in. When the quadriceps muscle contracts it tends to straighten this angle and so pull the patella out. If the ligaments are normal and the pull not too violent, luxation does not occur. When, however, from long disuse or disease the ligaments become relaxed, then a sudden and perhaps unusual contraction of the quadriceps will dislocate the patella. This also occurs if the outer condyle is abnormally flat or if the muscular contraction lifts the patella off or above the condyles, as occurs when the tendo patellæ is too long. In these, as in almost all other cases, the patella is dislocated outward (Fig. 552). Inward dislocation is almost unknown. Direct injury also produces dislocations, practically always outward. The most common form is for the articular surface of the patella to rest on the outer surface of the external condyle. Other forms, which are more rare, are for the inner

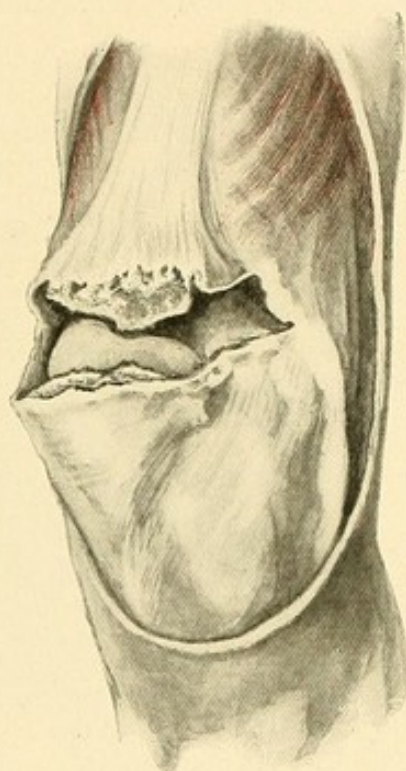


FIG. 551.—Fracture of patella, showing lateral tear of capsule.



edge of the patella to rest against the outer surface of the condyle; for the inner edge to be jammed into the upper portion of the intercondyloid notch with its outer edge sticking up; for the patella to be reversed with its articular surface forward and its anterior surface resting on the condyles.

For treating the affection in slight cases an elastic knee-cap may be of service, but a cure is probably best achieved by the operation of Goldthwait (*Boston Med. and Surg. Journ.*, Feb. 13, 1904). In this the tendo patellæ is split longitudinally and its outer half detached from the tibial tubercle, passed under the remaining half, and sewed fast to the periosteum and expansion of the sartorius at the inner side of the anterior surface of the tibia. This shifts the pull of the quadriceps more inward and the shortening of the tendon holds the outer edges of the patella more firmly against the edge of the external condyle. Simple folding of the inner part of the capsule has been unsuccessful.

**Dislocation of the Knee.**—The knee is rarely luxated and then only by such extreme trauma as sometimes to rupture the popliteal vessels and require amputation. It is frequently compound. The tibia may be luxated anteriorly (the most frequent), posteriorly, to either side, or it may be rotated on the femur.

These displacements are usually due to hyperextension and rotation. The laceration of the surrounding tissues is so extensive that replacement is usually easy by direct traction and manipulation. As a result of weakening of the ligaments by disease the hamstring tendons frequently pull the tibia backward, producing a subluxation often difficult to replace (Fig. 553).

**Dislocation of the Semilunar Cartilages.**—The semilunar cartilages do not become displaced in their entirety, but a portion of one of them is torn partly or completely loose and in moving about gets caught between the bones and produces the characteristic symptoms. The joint becomes useless at once and the patient may fall. The detachment of the cartilage, which is usually the internal one, is caused by either a direct blow on the part or by a twisting of the partly flexed limb. Use of the limb cannot be resumed until the caught cartilage is released. This is most readily achieved by extending the leg and then sharply flexing it. Sometimes the loosened cartilage instead of remaining attached at one end is free in the joint and may make its appearance alongside of the patella. In one of my cases one end of the semilunar cartilage was attached to the crucial ligament while the other was attached to the capsular ligament, thus allowing the part between to stretch across the surface of the condyle and be compressed in walking. These floating cartilages form the "*gelenkmaus*" of the Germans. These two conditions were first described by Hey under the name of internal derangements of the knee-joint. Synovial disease may also produce symptoms closely resembling those of detached cartilage.

**Epiphyseal Separations.**—The epiphyseal line marking the lower epiphysis of the femur starts at the adductor tubercle, at the upper edge of the internal condyle, and passes across transversely just above the edge of the articular surface. It joins with the shaft between the twentieth and the twenty-second year, sometimes as late as

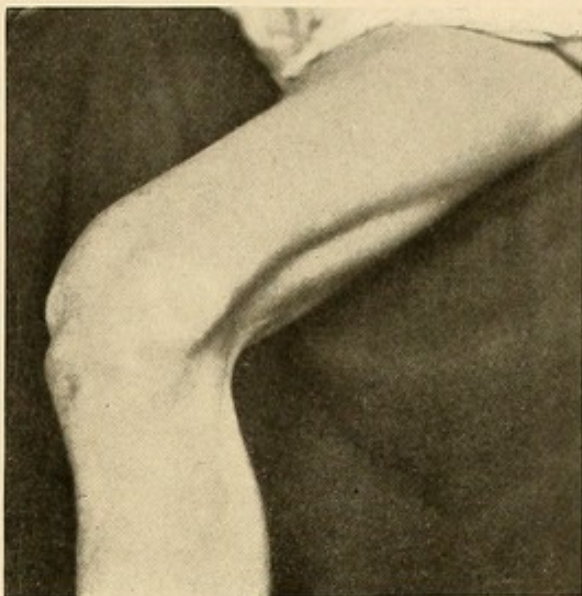


FIG. 552.—Dislocation of patella outward.

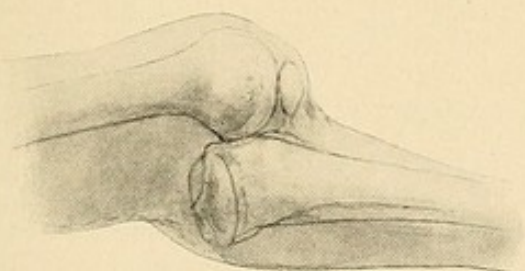


FIG. 553.—Subluxation of the knee from tuberculous disease, showing the relation of the bones. (From an original sketch by the author.)



the twenty-fourth. The epiphysis of the tibia runs transversely across the tibia about 1.5 cm. ( $\frac{5}{8}$  in.) below the articular surface and anteriorly passes down to embrace the tubercle (Fig. 554).

These epiphyseal separations are produced either by direct violence, by force applied laterally, or by twisting—a common way is for the leg to be twisted by being caught between the spokes of a revolving wheel. They never occur later than the age of twenty years and usually occur several years before that age has been reached.

Often the displacement is not serious and is corrected before the patient is seen by the surgeon. Occasionally, especially when the lower epiphysis of the femur is affected, displacement is marked, and the fractured surface of the fragment may lie on the anterior surface of the shaft of the femur. Sometimes the injury is compound and the vessels so injured that amputation is required.

In spite of the fact that the greater part of the growth of the lower extremity occurs from the bones adjacent to the knee-joint epiphyseal separations almost never interfere with it. This is so true that epiphysiolyis or the deliberate separation of the lower epiphysis of the femur by bending the knee laterally over the hard edge of a table is the preferred operation with some surgeons for the correction of lateral deformities of the knee, especially knock-knee. The injury is usually treated as a simple fracture and heals without incident.

**Resection of the Knee.**—In making the skin incision care should be taken to carry it back sufficiently far to allow of division of the lateral ligaments; in so doing, however, one should not divide the long saphenous vein and nerve at the posterior edge of the internal condyle. It is essential to recognize the joint-line; it is just below the lower edge of the patella and thence extends laterally about a finger-breadth above the head of the fibula. It is customary to carry the incision from near the posterior edge of the femur on the inner side to the posterior edge on the outer side at

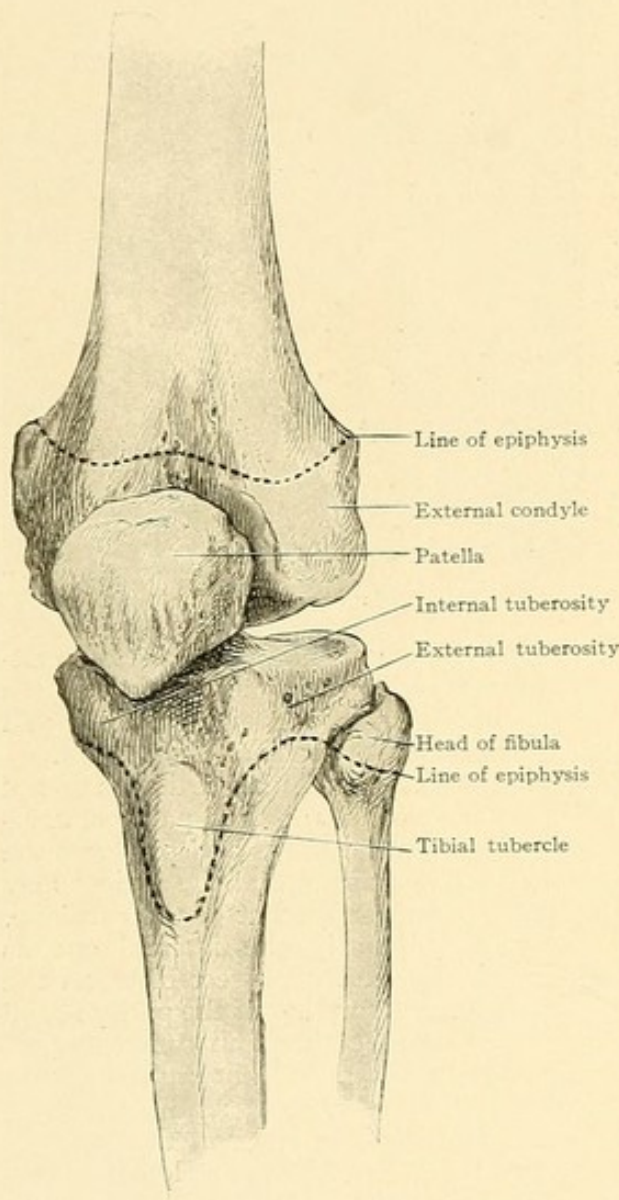


FIG. 554.—Antero-external view of the bones of the knee, showing the lines of the epiphyses.

the joint-line, passing over the middle of the tendo patellæ so as to allow this latter to be readily sutured later if desired.

Care is to be taken to avoid wounding the popliteal artery. This lies close to the posterior part of the capsule; hence the latter is not to be divided transversely but is to be separated by keeping the knife close to the bone. Finally, inasmuch as the bulk of the growth of the lower extremity occurs in the upper end of the tibia and lower end of the femur, it is essential to avoid removing the entire epiphyseal cartilages. For this reason formal resections have been abandoned in young children, and in adolescents as little tissue as possible is removed. The epiphyseal line in the femur runs transversely on a line with the adductor tubercle and passes close to the



upper edge of the articular surface. The epiphyseal line in the tibia lies rather close to the articular surface, being 1.5 cm. ( $\frac{5}{8}$  in.) below in adults and less in children; it slopes down in front to embrace the tibial tubercle (see Fig. 554). When the disease encroaches on the epiphyseal line, rather than remove it the affected parts are to be curetted away and the remainder left. In those cases where the knee is much contracted, either enough of the bone must be removed to allow of straightening or the hamstring tendons must be cut; if this latter is done the external popliteal nerve which runs on the inner posterior surface of the biceps tendon must not be wounded.

**Tuberculous Disease of the Knee-joint.**—The disease begins usually in the epiphyses adjacent to the joint and involves the joint secondarily. The tibia is more frequently the seat than the femur. The swelling and hypertrophy of the synovial membrane and involvement of the adjacent soft parts obliterate the hollows on each side of the patella and cause a bulging below the patella. The knee looks round and swollen, and the condition was formerly called white swelling from the surface being white in color. If liquid accumulates in the joint it becomes distended and flexed, assuming an angle of 120 degrees. The patella is raised from the condyles; it "floats" and if depressed by the finger can be felt striking on the femur beneath, thus demonstrating the presence of liquid in the joint. The swelling extends above the patella to an extent depending on whether or not the subfemoral bursa is involved and whether or not it communicates with the joint.

If pus forms it tends to find an exit beneath the lower edge of the posterior ligament or on either side of the patella at the upper end of the tibia. As the disease progresses the ligaments become weakened. The joint, being already flexed at approximately 120 degrees, is flexed still more by the hamstring muscles, and the head of the tibia in old cases becomes drawn backward in a position of subluxation (see Fig. 553, page 541). The pull of the biceps tendon while the leg is flexed rotates the leg outward and this position may persist: a condition of knock-knee is also sometimes marked.

The disease is treated conservatively by apparatus, but in exceptional cases the lesser operation of erosion or the greater of resection (see above) is done.

**Knock-knee and Bow-legs.**—These conditions most frequently result from rachitis or paralysis. Bowing inward of the knee is called knock-knee or genu valgum. Bowing outward is called bow-legs or in some instances, when the deformity is in the joint, as when the condyles are unequal in length, genu varum.

**Knock-knee (Genu Valgum).** This condition has its point of bending most marked at the knee-joint. When caused by rickets the joint surfaces are often not much altered and the deformity is produced by a bending of the tibia or femur close to the joint; hence when an osteotomy is performed just above the condyles of the femur the joint is again brought level and resumes its functions normally (Fig. 555).

When deformities of the foot or the malpositions due to paralyzes produce knock-knee, then often a certain amount of flexion and external rotation of the leg coexist with perhaps lengthening of the internal condyle. In these cases osteotomy of the femur must often be supplemented or substituted by suitable apparatus, operations on the foot, etc.

**Bow-legs.**—This is almost always caused by softening of the bones, as in rickets. The bending occurs in the bones of both the leg and thigh, and the location of the

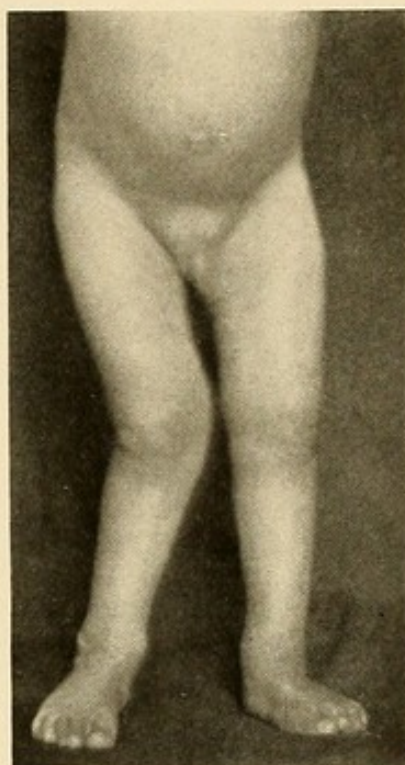


FIG. 555.—Knock-knee or genu valgum.



point of greatest bending is sometimes low down toward the ankles or close up to the knee-joint, or the whole diaphysis of the bones may be curved. They are often curved anteroposteriorly as well as laterally (Fig. 556).

When the point of greatest bending is close to the knee-joint it has been called *genu varum*, but the condyles remain of equal length and the epiphyseal line still remains parallel with the joint line.

As knock-knees and bow-legs so commonly occur in the actively growing period, from the second to the fifth year, apparatus is often of benefit, but frequently forcible straightening by means of an osteoclast or by the hand or epiphysiolysis (see page 542) or osteotomy is resorted to for their correction.

**Osteotomy.**—In osteotomy of the femur the bone is to be divided, as advised by Macewen, a finger-breadth, at least, above the adductor tubercle and 1.25 cm. ( $\frac{1}{2}$  in.) in front of the adductor magnus tendon. In knock-knee many surgeons prefer dividing the bone from the outside of the limb instead of the inside as advised by Macewen. This incision avoids the epiphyseal line, which is opposite the adductor tubercle, and also the anastomotica magna and superior articular arteries. The popliteal vessels are also to be avoided by knowing their position and not directing the osteotome toward them. In performing osteotomy of the bones of the leg the tibia is to be divided by the aid of the chisel, and the fibula is to be broken by manual force. Wedge-shaped resections of bone are commonly not to be advised. They are difficult to do, liable to complications, and, under the most favorable circumstances, are very long in healing and do not give any better results than simple osteotomy or osteoclasis.

#### Ligation of the Popliteal Artery.—

In the *middle* of its course the popliteal artery lies deep between the condyles of the femur and on the posterior capsule and gives off the articular arteries. For these reasons ligation in this part of its course is not performed. To ligate it in the *upper part* of its course an incision is to be made along the outer edge of the semimembranosus muscle near the middle of the upper part of the popliteal space. The muscle being drawn inward the internal popliteal nerve is first seen and drawn outward,

then the vein beneath is also drawn outward and the artery found beneath and a little to the inner side. Don't mistake the semitendinosus for the semimembranosus. The former is a round tendon, the latter is muscular. Another method consists in making the incision immediately behind the adductor magnus tendon. The semimembranosus and semitendinosus are then to be drawn backward and the artery located by its pulsation and the aneurism needle passed from within out. The nerve and vein, being more to the outer side, are not disturbed (Fig. 557).

To ligate the popliteal artery in its *lower third*, make an incision in the midline between the heads of the gastrocnemius muscle, avoiding the short saphenous vein and nerve. Open the deep fascia, draw the internal popliteal nerve to the inner side, the popliteal vein to the outer side, and pass the needle from without in. Flexing the knee will relax the gastrocnemius and enable the artery to be more readily exposed.

**Amputation through the Knee-joint.**—Disarticulation at the knee-joint is usually done either with a long anterior and short posterior or two lateral flaps. This amputation differs from others in the fact that a large rounded mass of bone—the condyles—with no muscles is to be covered by the flap. Therefore the flaps

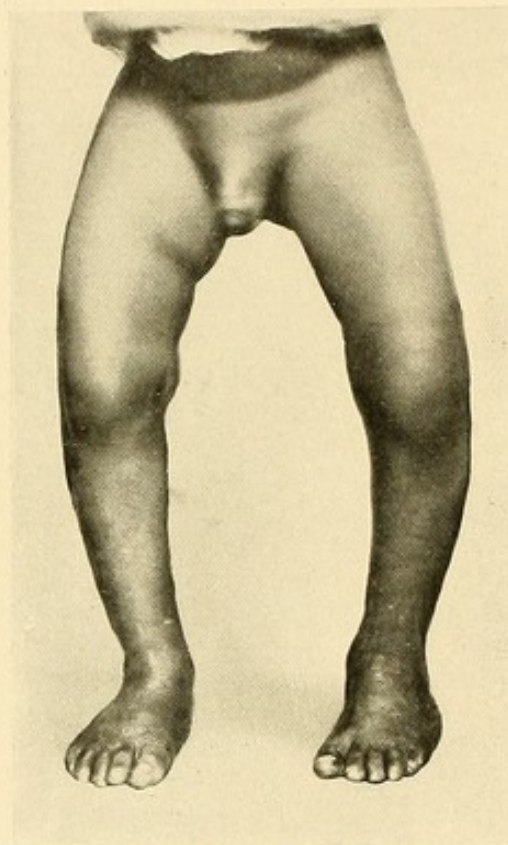


FIG. 556.—Bow-legs.



must be ample and if they are not a piece of the femur must be resected. The internal condyle is larger and projects more than the external. The cicatrix is drawn posteriorly by the hamstring muscles and the resultant stump is good for pressure bearing.

If possible the semilunar cartilages should be left on the femur, the incision for disarticulation being made between them and the tibia. The object of so doing is to prevent the retraction of the soft parts and the resultant protrusion of the bone. The

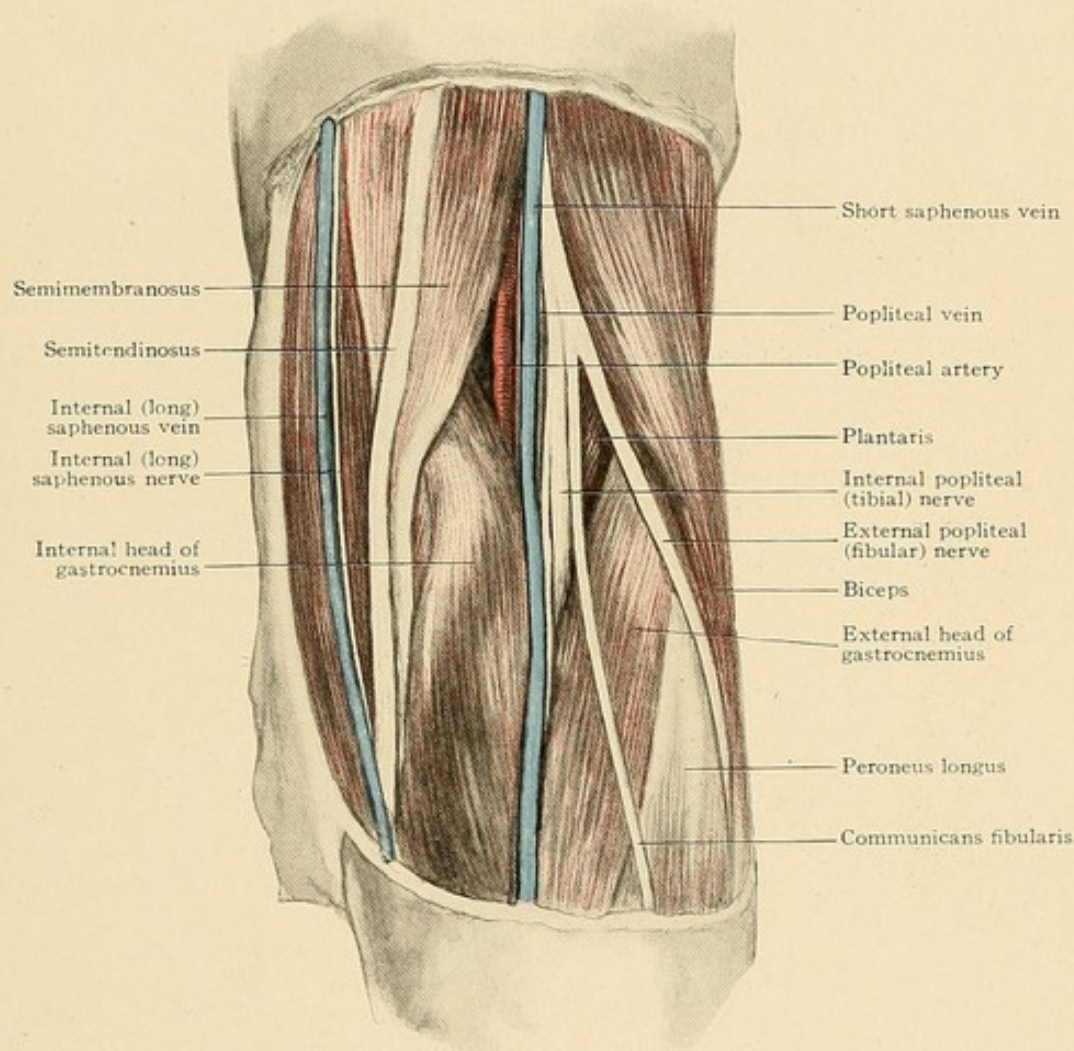


FIG. 557.—The popliteal space.

extremities of the incision should be well back, so that the lateral ligaments can be readily divided, and should not extend higher than the edge of the tibia. If infection follows, pus may collect in the suprapatellar (subfemoral) bursa.

## THE LEG.

The leg having to support the weight of the body has its bones strongly made. The tibia bears nearly all the weight because it articulates with the femur above and astragalus below and transmits the pressure directly from one to the other. The fibula is slight compared to the tibia and lies posterior to it and to the outer side.

The leg bones receive the insertion of the thigh muscles above and give attachment to the muscles which move the foot. The leg therefore is capable of being influenced by the movements of the foot below and the thigh above.



## SURFACE ANATOMY.

At the upper end of the leg can be felt the two tuberosities of the tibia. The lower edge of the tuberosities is on a line with the upper edge of the tubercle. The head of the fibula is almost level with (a little above) the tubercle of the tibia and is situated far posteriorly. Attached to the head of the fibula above is the biceps tendon accompanied by the external popliteal (fibular) nerve and the long external lateral ligament. The tendo patellæ is attached to the tibial tubercle. The tibia is triangular in shape, with a sharp edge—the crest or shin—forward, thus forming two surfaces, an internal and an external. The posterior surface is covered by muscles and is inaccessible. The internal surface is subcutaneous and leads down to the internal malleolus. The external surface has the extensor muscles between it and the fibula. The fibula a short distance below its head becomes covered by the

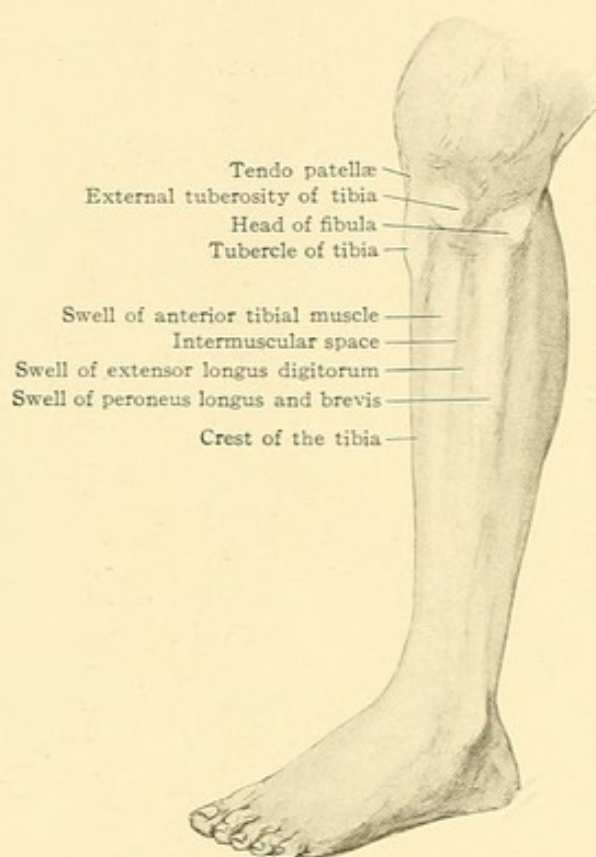


FIG. 558.—Surface anatomy of the leg.

peronei muscles and only becomes subcutaneous in its lower anterior fourth. The upper portion of the leg is largely muscular, but at its lower portion it is mainly tendinous. By placing a finger over the muscles while the foot is moved one is enabled to determine whether or not they are paralyzed (Fig. 558).

## MUSCLES OF THE LEG.

The muscles of the leg are composed of four distinct groups of three each. They are *extensors*, *flexors*, *abductors*, and *muscles of the calf*.

The **extensor group** comprises the *tibialis anterior*, *extensor longus digitorum*, and *extensor longus hallucis*.

The **flexor group** comprises the *tibialis posterior*, *flexor longus digitorum*, and *flexor longus hallucis*.

The **abductor group** comprises the *peroneus longus*, *peroneus brevis*, and *peroneus tertius*.

The **calf muscles** comprise the *gastrocnemius*, *soleus*, and *plantaris*.



It will thus be seen that the extensor and flexor groups are composed of precisely similar muscles only on opposite sides of the leg. They tend to move the foot and toes forward and backward and balance each other. The abductors form a group

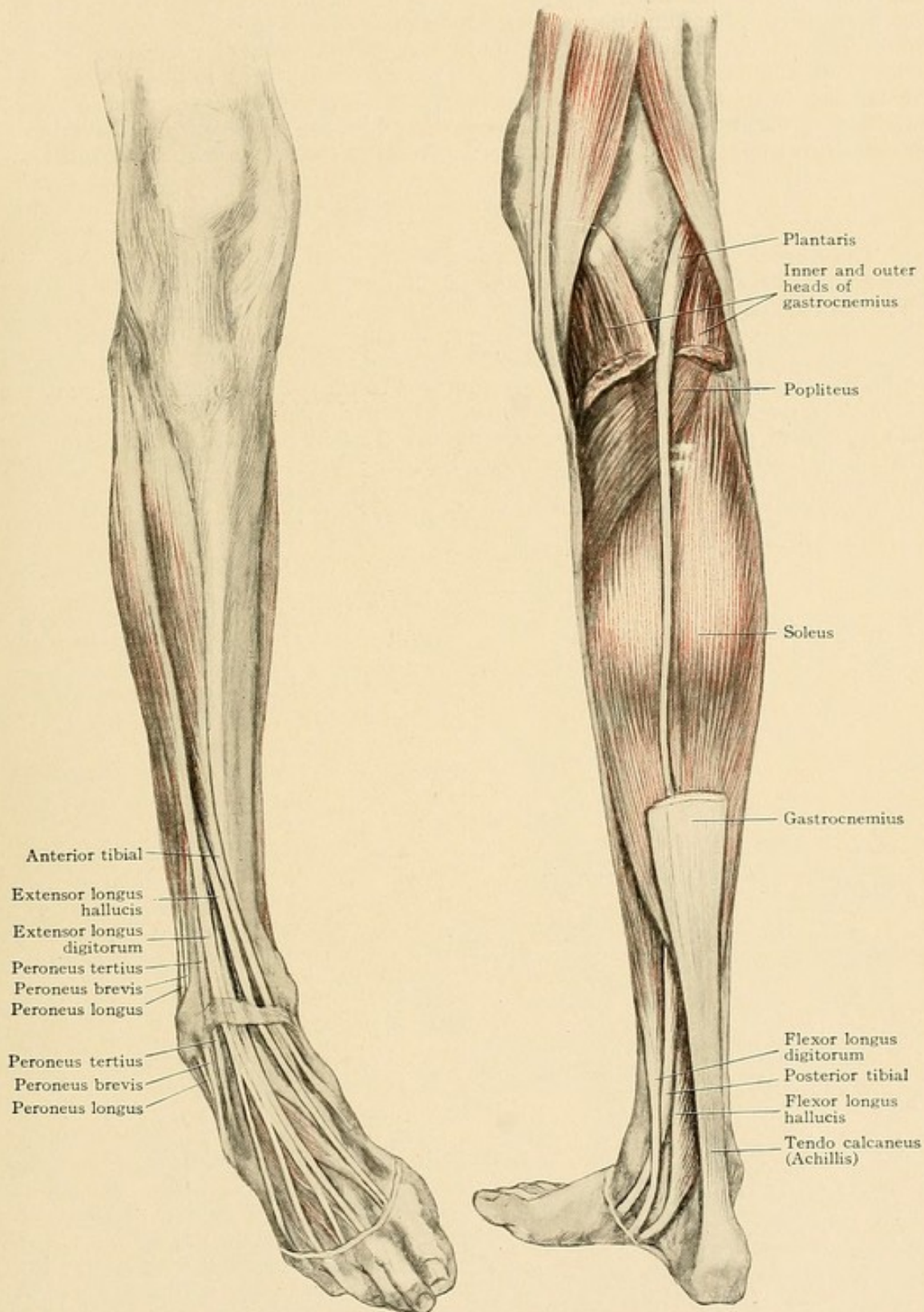


FIG. 559.—Extensor and abductor muscles of the leg.

FIG. 560.—Flexors and muscles of the calf of the leg.

around the fibula on the outer side of the leg and they abduct the foot. They tend to pronate it. The most active agents in adduction are the tibialis anterior and tibialis posterior. The muscles of the calf form a separate posterior group designed



for use in walking and to compensate for the greater length of the foot anterior to the centre of motion at the ankle and its shortness posteriorly.

The extensor group lies between the tibia and fibula anterior to the interosseous membrane. The abductor group forms a mass over the fibula, and the flexor group lies between the tibia and fibula on the posterior surface of the interosseous membrane. The muscles of the calf constitute a superficial layer of muscles which end below in the tendo calcaneus (Achillis). The soleus, with the two heads of the gastrocnemius, is known as the triceps suræ muscle. It is absolutely essential to understand the grouping of these muscles of the leg because thereby its construction is rendered evident and their influence on distortions of the foot can be appreciated.

### FASCIA OF THE LEG.

The deep fascia of the leg is attached above to the tubercle of the tibia, the tuberosities of the tibia, and the head of the fibula. It gives off two septa from its under surface, one in front separating the abductor or peroneal group from the extensor group, and another posterior which separates the abductor group from the soleus posteriorly. This latter covers the deep flexors and separates them from the muscles of the calf and is continued across to be attached to the medial (internal) edge of the tibia. The deep fascia of the leg blends with the periosteum over the medial (internal) surface of the tibia and also with that of the lateral (external) surface of the fibula in its lower fourth. At the ankle the deep fascia is continued on through the annular ligaments.

The muscles of the leg take their origin partly from these fasciæ, and subsidiary septa pass between the muscles.

### ARTERIES OF THE LEG.

The leg has three main arteries, the *anterior tibial*, *posterior tibial*, and *peroneal*. The popliteal artery divides into the anterior and posterior tibial at the lower border of the popliteus muscle just below the lower edge of the tibial tubercle.

Two and a half cm. (1 in.), or a little more, below the edge of the popliteus muscle the peroneal artery is given off from the posterior tibial.

**The Anterior Tibial Artery.—Ligation.**—The line of the anterior tibial artery may be taken as from just internal to the head of the fibula to a point on the front of the ankle midway between the malleoli. The anterior tibial artery pierces the interosseous membrane, but the anterior tibial nerve winds around the head of the fibula and joins the artery 5 to 7 cm. (2 to 3 in.) or more lower down on its outer side.

*In the Upper Third.*—The artery lies between the tibialis anterior and the extensor longus digitorum muscles. This interspace is better recognized by touch than by sight, though a yellowish line of fat or the presence of some small vessels may indicate its position. The tendency is to make the incision too close to the tibia. This

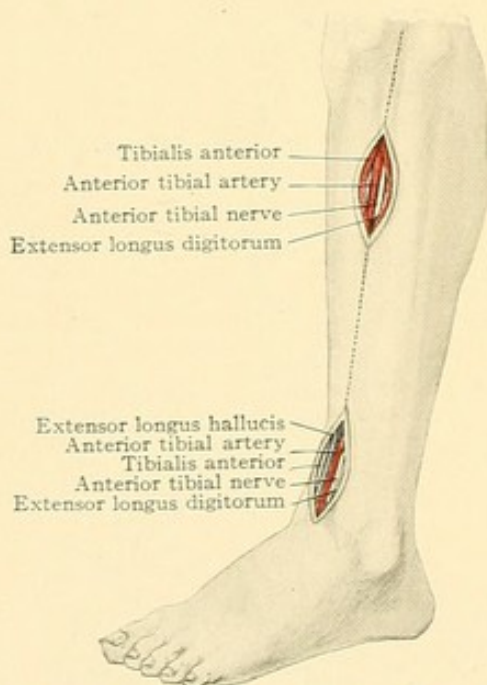


FIG. 561.—Ligation of the anterior tibial artery in its upper and lower thirds.

mistake will be avoided if the line of the artery has been marked and the incision made in it. After separating the muscles, the outer edge of the tibia can be felt and on the membrane close to it is the artery with venæ comites to each side and the nerve farther out. The needle is passed from without inward, and the veins may



be included because they are so firmly bound to the artery and membrane as to be separated only with difficulty (Fig. 561).

*In the Middle Third.*—The incision having been made in the line of the artery, the septum between the tibialis anterior and extensor longus digitorum is usually visible as a depressed line. Flex the foot to relax the tendons, and on drawing the extensor digitorum outward the upper part of the extensor longus hallucis is seen, it also is drawn outward and the artery is found lying on the membrane with the nerve in front of it.

*In the Lower Third.*—Here, above the flexure of the ankle, the artery lies on the tibia between the tibialis anterior and the extensor longus hallucis. The nerve is to its outer or inner side or in front of the artery. Flexing the foot allows the tendons to be more readily separated, and movement of the foot and big toe will assist in identifying the muscles.

**Posterior Tibial Artery.**—*Ligation.*—The line of the posterior tibial artery is from the middle of the popliteal space to the middle of the line joining the internal malleolus and internal tuberosity of the calcaneum; at this latter point it divides into the internal and external plantar arteries (Fig. 562).

*In the Middle of the Leg.*—The incision should be made 2 cm. ( $\frac{3}{4}$  in.) behind the edge of the tibia, avoiding the long saphenous vein. If the edge of the gastrocnemius comes into view draw it outward, incise the soleus muscle through its entire thickness, dividing the tendinous fibres in the body of the muscle. Separate the edges of the incision and seek for the artery on the obliquely running fibres of the flexor longus digitorum muscle. The nerve is to its outer side. The artery lies directly over the outer edge of the tibia, which can be felt with the finger. It is covered with a thin fascia. The ligature is passed from without inward.

*Low Down in the Leg.*—The incision may be made midway between the inner edge of the tibia and the edge of the tendo calcaneus (Achillis). The artery lies beneath the deep fascia on the flexor longus digitorum muscle with the nerve to the outer side. The muscle has fibres as low down as the malleolus and the artery is to the outer side of its tendon. If the artery is sought behind the ankle then it has the

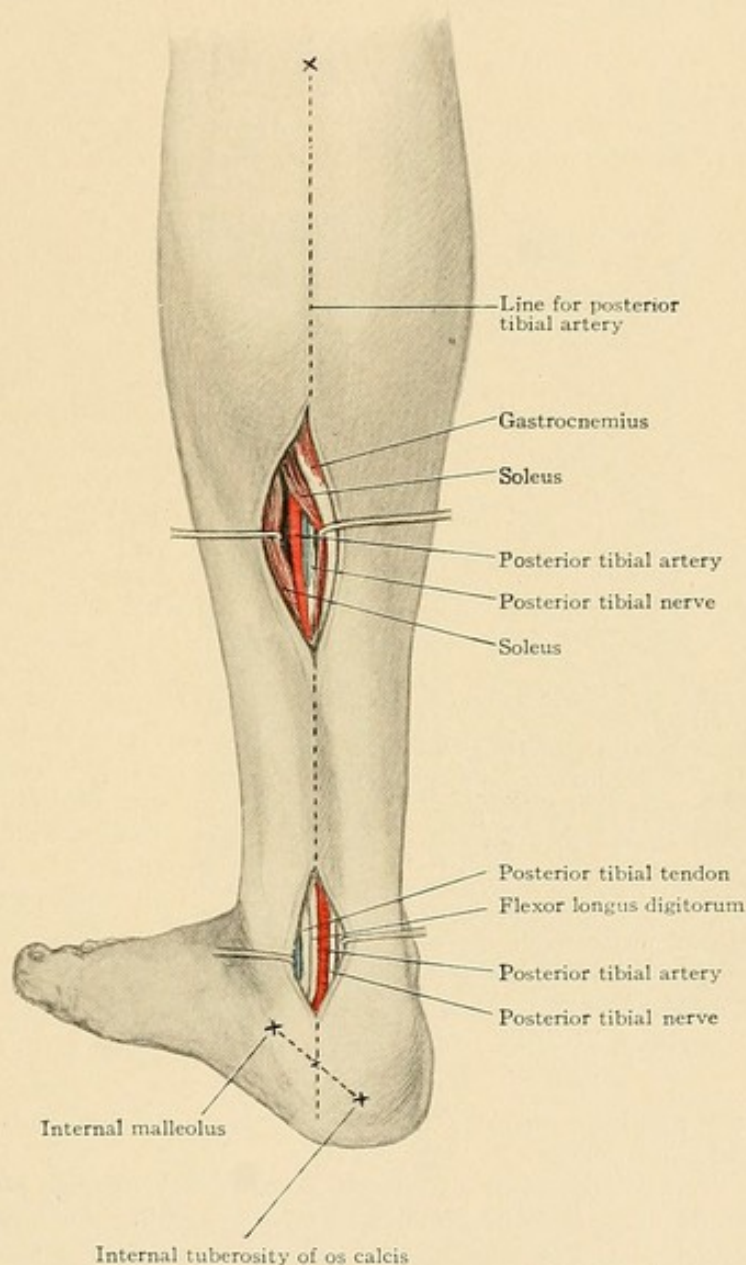


FIG. 562.—Ligation of the posterior tibial artery.



tendons of the tibialis posterior and flexor longus digitorum in front of it. Care should be taken that the main trunk is ligated and not one of its plantar branches in case of a high division.

**Peroneal Artery.**—The peroneal artery is given off from the posterior tibial 2.5 cm. (1 in.) below the lower edge of popliteus muscle. It follows the inner edge of the fibula beneath or in the fibres of origin of the flexor longus hallucis. If it is desired to ligate it, the incision is to be made over the inner edge of the fibula, the edge of the soleus is drawn inward, the fibres of the flexor longus hallucis divided, and the artery found at the junction of the inner edge of the fibula and interosseous membrane. At the lower extremity of the interosseous membrane the artery pierces it to be distributed to the outer anterior portion of the tarsus and ankle.

### VEINS OF THE LEG.

The deep veins of the lower extremity accompany the arteries. The femoral and popliteal veins are single, but the arteries below have *venæ comites*. These deep veins all have valves and there are frequent communications with the superficial veins.

On the dorsum of the foot is a venous arch which unites with the inner dorsal digital vein to form the commencement of the internal or long saphenous vein. The outer extremity unites with the outer dorsal digital vein to form the commencement of the external or short saphenous vein.

The **internal or long saphenous vein** begins just in front of the internal malleolus, ascends on the inner surface of the tibia, passes along the posterior border of the internal condyle and thence up to the saphenous opening. In the leg it communicates with the deep anterior and posterior tibial and external saphenous veins and in the thigh with the femoral. At or near the saphenous opening it receives the external superficial femoral vein from the outer anterior surface of the thigh and the internal superficial femoral vein from the inner posterior portion of the thigh. Not infrequently one of these lateral branches may be almost as large as the internal saphenous itself and may be mistaken for it.

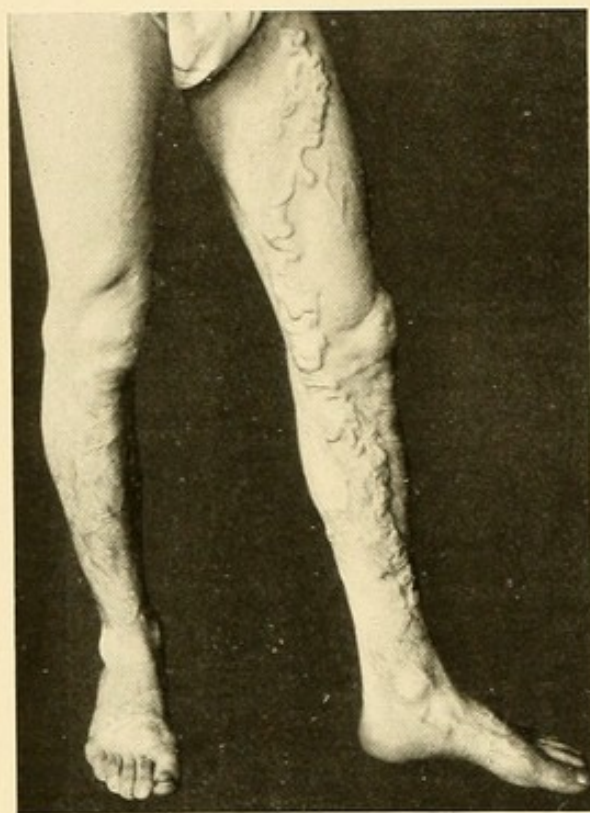


FIG. 563.—Varicose veins, affecting especially the internal or long saphenous vein.

From the knee down the internal saphenous vein is accompanied by the internal saphenous nerve.

The **external or short saphenous vein** begins behind the external malleolus, ascends alongside the tendo calcaneus (Achillis), thence over the gastrocnemius to empty into the popliteal vein. Its branches anastomose with those of the internal saphenous on the inner side of the leg and it communicates through the deep fascia with the deep veins. It is accompanied by the external saphenous nerve.

**Varicose Veins of the Leg.**—A varicose condition of the veins of the leg is very common. Often the cause cannot be ascertained, but not infrequently pelvic tumors, and especially pregnancy, produce the condition by obstructing the blood-current. The veins become distended and the valves, of which there are many, become insufficient. This destroys the valvular support of the blood column and the veins become tortuous and inflamed, the walls thicken and may become adherent to the skin. The walls in places give way, causing hemorrhages. They may become thin



and sacculated and thrombi may form and suppurate. The treatment consists in ligating and excising as many of the affected veins as possible. The internal saphenous is especially to be excised, beginning a short distance below the saphenous opening and extending for the greater portion of its length (Fig. 563).

The operation of Max Schede, of circular incision around the leg just below the knee, dividing everything down to the deep fascia, is usually effective, but we have seen recurrences even after it, due to regurgitation from the deep veins. In fat people the internal saphenous may lie imbedded in the superficial fat some distance beneath the skin.

A varicose condition of the veins of the leg is a causative factor in chronic leg ulcer; hence, in order to cure it, the necessity of elevating the limb in its treatment, or excising the veins.

### LYMPHATICS OF THE LEG.

Sometimes there are one or two lymphatic nodes at the upper extremity of the anterior tibial artery but usually the first to be encountered are around the popliteal vessels,—below that point are only lymphatic radicles or vessels.

### FRACTURES OF THE LEG.

Fractures of the bones of the leg are most often due to direct violence, but sometimes to indirect. The tibia is rarely broken alone, but either it or the fibula may be fractured by a direct blow. On account of the tibia being subcutaneous these fractures are frequently compound. The shafts of the bones, being of compact tissue, are usually broken obliquely. When the fibula is broken above its lower fourth there is usually little displacement because the attached muscles hold it in place.

Fractures of the tibia whether accompanied or not by fracture of the fibula most often occur at the junction of the middle and the lower thirds. The line of fracture is downward, forward, and inward. The displacement of the lower fragment is backward, upward and slightly outward. It is produced mainly by the muscles of the calf pulling on the tendo calcaneus (Achillis). The upper fragment is pulled forward by the quadriceps femoris (Fig. 564).

The difficulty usually encountered in treatment is a persistent projecting forward of the upper fragment with a drawing up and turning outward of the lower fragment and foot. The displacing action of the tendo calcaneus (Achillis) is more powerful than that of the quadriceps. On this account the first attempt at correction should be to place the leg in the

"Pott's position." This consists in flexing the knee to a right angle and placing the leg on its outer side. This relaxes the gastrocnemius and plantaris and is sufficient

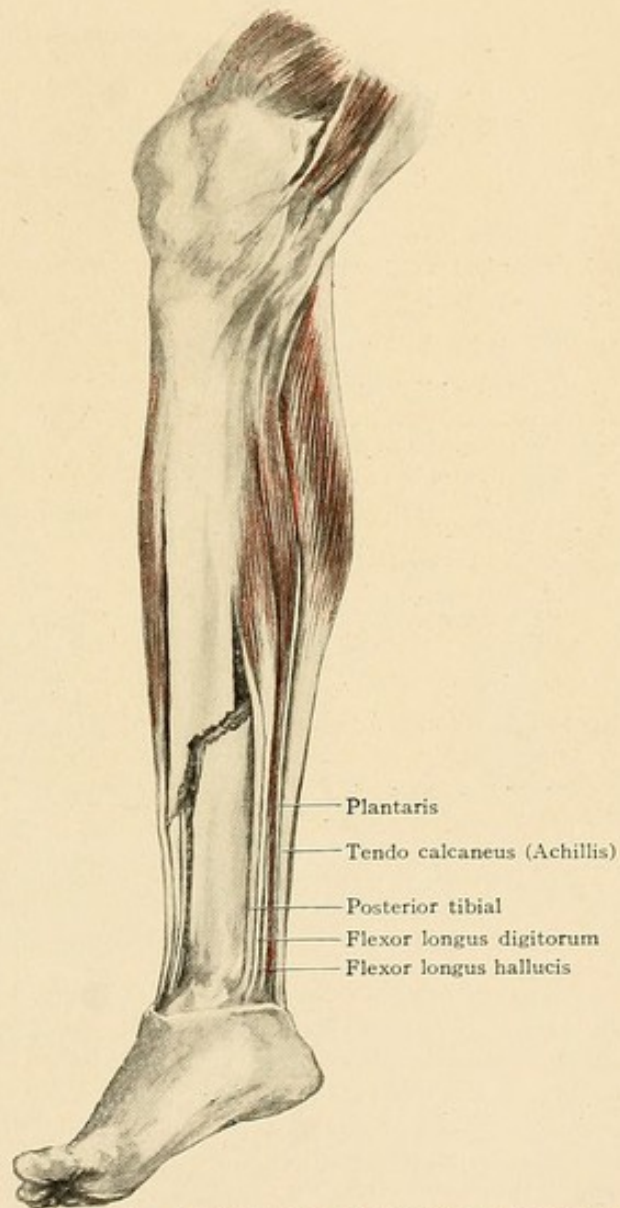


FIG. 564.—Fracture of the tibia with displacement of the upper fragment forward and lower fragment backward and upward.



in some cases to allow of the displacement being remedied. If this fails extension may be tried or tenotomy of the tendo calcaneus should be done and the fragments will at once come into good position.

Woolsey has pointed out that the weight of the foot tends to its outward displacement but another reason is that the insertion of the tendo calcaneus is not beneath the middle of the ankle-joint but more towards its outer side, so that when it contracts it carries the foot outward. The flexor and extensor muscles of the leg balance each other, but the peronei muscles on the outer side have no additional corresponding opponents on the inner side; hence another reason for displacement of the foot and lower fragment outward.

### AMPUTATION OF THE LEG.

Amputation of the leg is best performed at the place of election, a hand's breadth below the knee-joint. This site is preferred because it gives a sufficient

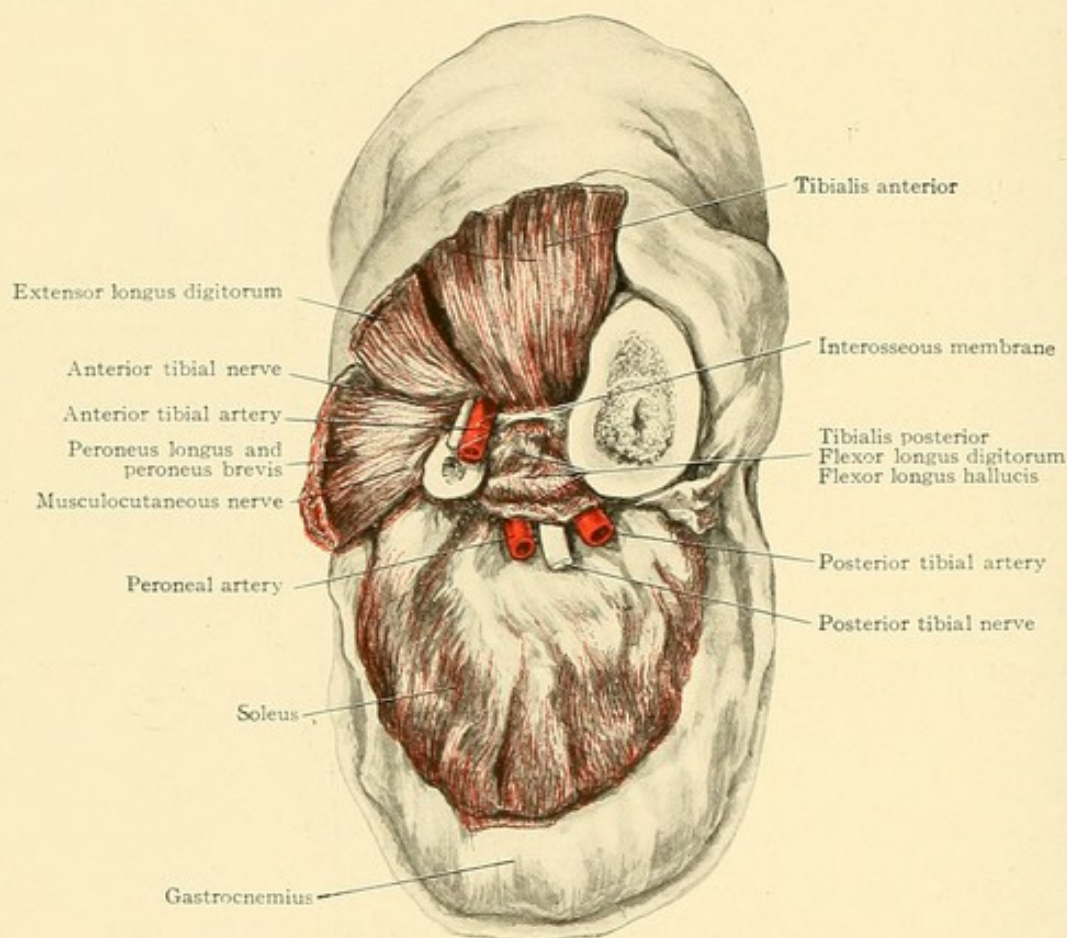


FIG. 565.—Amputation of the upper third of the leg.

length to the stump below the knee and allows sufficient space below for the instrument maker to place the mechanism of the artificial leg which operates the foot. The sharp projecting edge of the crest of the tibia tends to produce ulceration of the tissues or skin in front of it, therefore it is to be cut off obliquely.

The fibula, if divided at the same level as the tibia and especially if antero-posterior flaps are used, tends to project too prominently on the outer side, hence it is preferable to divide it at a higher level than the tibia.

The anterior tibial artery is to be sought for on the interosseous membrane close to the tibia with its nerve to the outer side.

The posterior tibial and peroneal are at the same level on the tibialis posterior muscle with the posterior tibial nerve lying superficial to the posterior tibial artery (Fig. 565).



## REGION OF THE ANKLE.

The ankle-joint is composed of the tibia and fibula above and the astragalus below.

**Surface Anatomy.**—A knowledge of the contour of the ankle aids considerably in determining the character of its diseases and injuries. The malleoli form prominences with distinct hollows above and below them. The sharp anterior edge of the tibia if followed down leads to the tibialis anterior tendon. On the medial (inner) side the malleolus is large and flat. It is subcutaneous and can be readily palpated. At

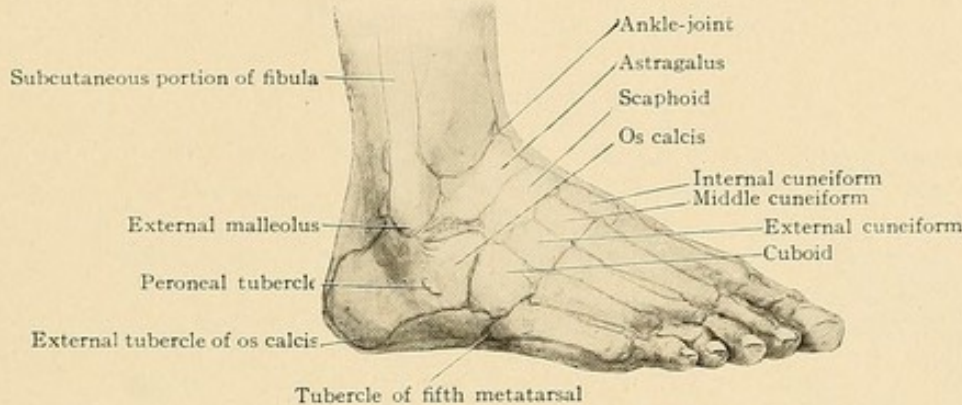


FIG. 566.—Surface anatomy of the outer side of the ankle.

its anterior edge is the commencement of the internal saphenous vein which runs up and slightly back to reach the posterior edge of the tibia 5 to 6 cm. (2 to 2½ in.) above the tip of the malleolus. About 4 cm. (1½ in.) below and in front of the internal malleolus is the prominent tubercle of the scaphoid.

The external malleolus is small and somewhat pointed, and is placed a finger-breadth below and behind the level of the internal malleolus. For a distance of about 7.5 cm. (3 in.) above its tip the fibula is subcutaneous and readily palpated. It is here that it is most often fractured. The transverse line of the joint is level with the upper limit of the swell of the internal malleolus—about 2.5 cm. (1 in.) above

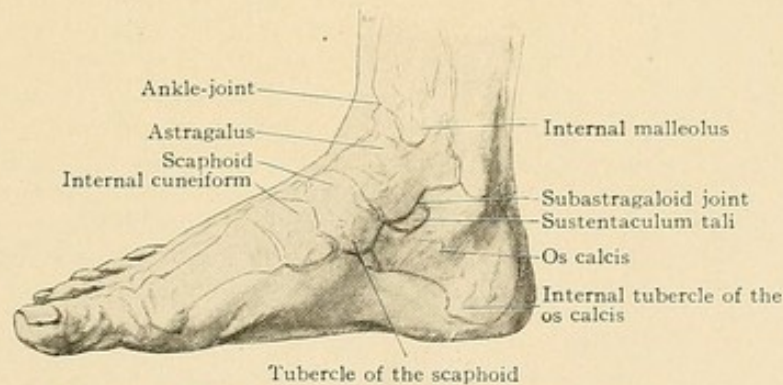


FIG. 567.—Surface anatomy of the inner side of the ankle.

the tip of the external malleolus. The ankle is covered in front and behind by tendons, most of which, especially in thin people, can be felt and seen when they are put on the stretch. Anteriorly the innermost tendon is the tibialis anterior, next the extensor longus hallucis, and then the extensor longus digitorum. Sometimes close to the outer side of the extensor of the little (fifth) toe the contraction of the peroneus tertius tendon can be felt as it goes to be inserted into the fifth metatarsal bone near its base. Running directly downward along the posterior edge of the external malleolus and fibula are the peroneus longus and brevis tendons, the former being the more superficial. About 2.5 cm. (1 in.) below and a little in front of the external malleolus is the peroneal tubercle of the calcaneum; the peroneus brevis passes in



front of it to be inserted into the prominent tuberosity of the fifth metatarsal bone. The long tendon passes behind the tubercle, winds around the cuboid, and crosses the sole to insert into the internal cuneiform and base of the first metatarsal bone.

Posteriorly the tendo calcaneus (Achillis) is large and prominent—along the anterior edge of its lateral (external) side run the external (short) saphenous vein and nerve. Running upward from the posterior border of the internal malleolus the tibialis posterior tendon can sometimes be seen and felt. Posterior to it runs the flexor longus digitorum muscle, then the posterior tibial artery, accompanied by venæ comites, then the posterior tibial nerve, and lastly the flexor longus hallucis. The artery can be felt pulsating midway between the tendo calcaneus and the internal tuberosity of the calcaneum. The anterior tibial artery can be felt pulsating to the lateral (outer) side of the flexor longus hallucis.

### THE ANKLE-JOINT.

**Ligaments and Movements.**—The ankle-joint is a pure hinge-joint and its motion is anteroposterior except in complete extension, when a small amount of lateral movement is possible. The range of movement is 80 degrees; 20 degrees flexion, and 60 degrees extension.

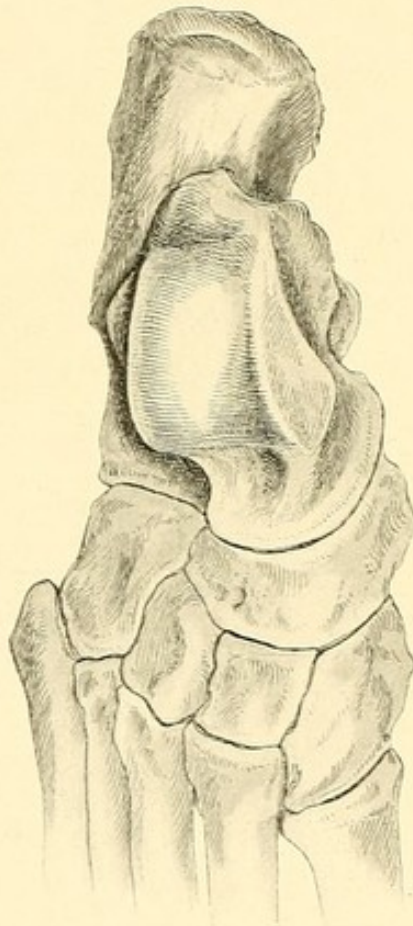


FIG. 568.—The upper articular surface of the astragalus, showing it to be slightly concave and one fourth wider in front than behind.

The tibia and fibula above articulate with the surface of the body of the astragalus below. The articular facet for the fibula is about twice as long from above downward as is that for the internal malleolus. The hollow below the internal malleolus is filled by the internal lateral ligament and the tendon of the tibialis posterior. The inferior tibiofibular joint is sometimes practically lacking, there being almost no continuation of the ankle-joint up between the tibia and fibula. The junction of these two bones is very strong, the ligaments being an anterior, posterior, interosseous, and a transverse inferior tibiofibular ligament which passes across the back of the ankle-joint reinforcing the posterior portion of the capsular ligament. The upper surface of the astragalus is one-fourth wider in front than behind, so that in extension it is not so firmly locked between the malleoli as in flexion (Fig. 568). Its upper surface is slightly concave. Flexion and extension take place on a transverse axis passing through the body of the astragalus at the tip of the external malleolus. This axis is not exactly transverse but is slightly oblique, so that on extension the foot is pointed slightly outward. The ankle has a capsular ligament which is very thin in front and behind the joint. Posteriorly it is reinforced above by the transverse inferior tibiofibular ligament. The flexor longus hallucis also supports it posteriorly. The internal and external lateral ligaments are strong, the internal being the stronger.

The internal lateral or ligamentum deltoideum runs from the malleolus above to the scaphoid, astragalus, and calcaneum below. It is crossed on its surface by the tendons of the tibialis posterior and flexor longus digitorum muscles (Fig. 569).

The external lateral ligament has three fasciculi: an anterior one to the astragalus; a middle one to the side of the calcaneum, and a posterior one to the posterior part of the astragalus (Fig. 570). In both extreme flexion and extension the edges of the tibia come in contact with the astragalus and hence limit further movement. The ligaments also aid in restricting motion.



**Distention of the Joint.**—Fluid tends to find exit from the joint first anteriorly under the extensor tendons, next it tends to exude posteriorly and makes its appearance as a swelling on each side of the tendo calcaneus (Achillis). The ankle-joint is a comparatively tight one and in acute inflammations holds but little effusion. When injected it assumes the position of a right angle and flexion does not occur as

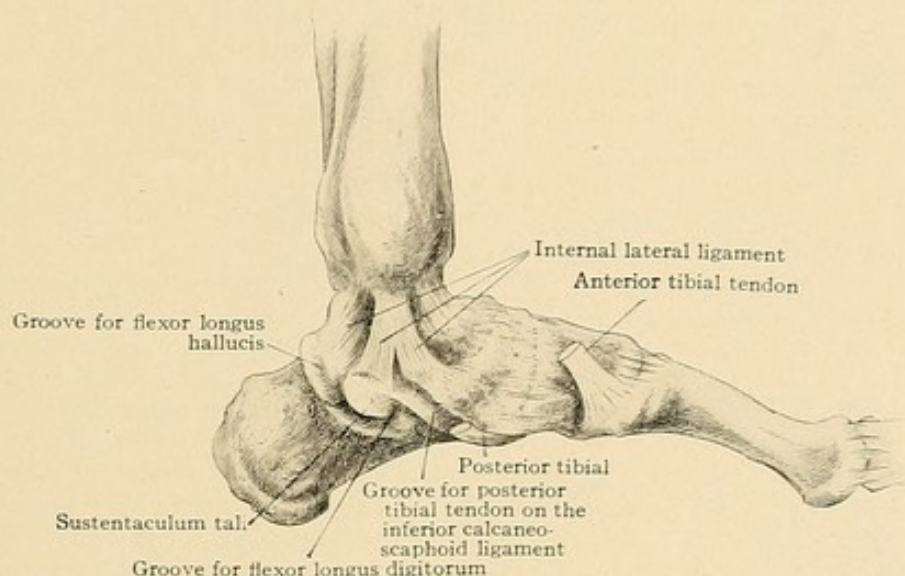


FIG. 569.—View of inner side of ankle-joint, showing the internal lateral ligament.

in other joints (Fig. 571). The rounded appearance of the ankle in tuberculous and other affections is not due so much to effusion within the joint as to inflammatory and tuberculous exudate in the tissues around the joint.

**Tuberculosis of the Ankle.**—This most often affects the body of the astragalus. Sometimes the disease is located in the lower end of the tibia. In the former

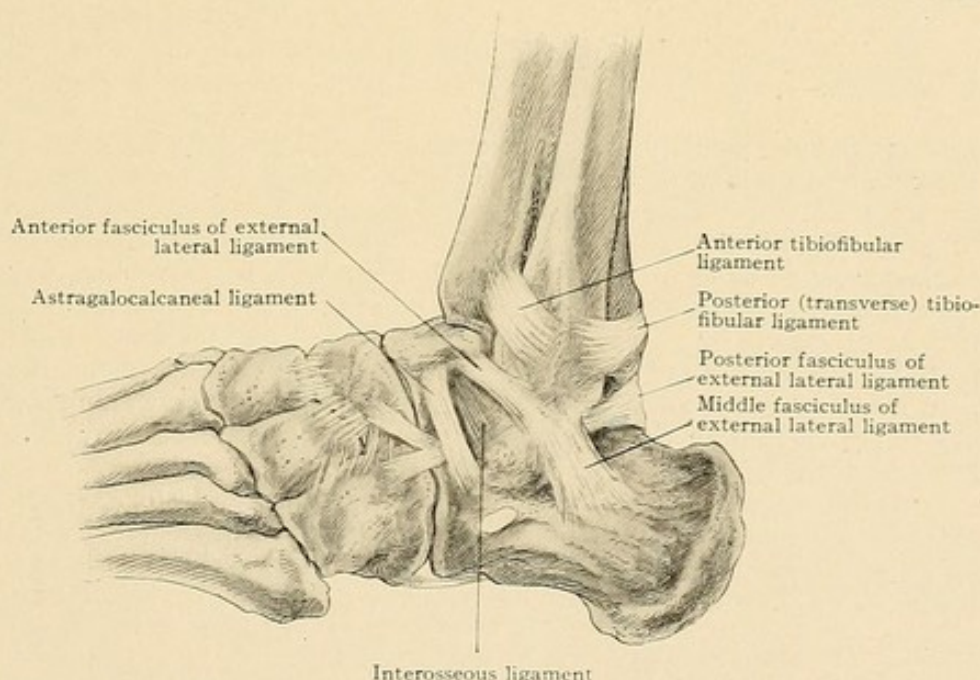


FIG. 570.—Ligaments of the outer side of the ankle.

case other of the tarsal bones are also frequently involved. In the latter an extra-articular operation on the tibia above the internal malleolus may cure the disease, but the motion in the joint often remains impaired.

**Excision of the Ankle.**—Formal resections of the ankle are rarely performed. The joint is difficult to expose without extensive division of the tendons and other



tissues. It is considered best to enlarge any existing sinuses and curette the diseased bone away.

If it is desired to excise the joint it can be done by König's incisions, one along the anterior edge of the internal malleolus and the other along the anterior edge of the external malleolus. Through these incisions all that is necessary can usually be done.

**Sprain of the Ankle.**—In what is usually called a sprain of the ankle the injury is not always confined to the ankle-joint and its ligaments. It has been shown that in many cases there is a tearing off of small fragments of bone, hence the name fracture-sprain (Callender). The ankle-joint has an anteroposterior motion, but the lateral motion of the foot takes place mainly in the subastragaloid joint with some

additional movement allowed by the other tarsal joints. Inasmuch as sprains are usually the consequence of a lateral displacement, the resultant injury is frequently in the subastragaloid and sometimes in the adjacent tarsal joints. This condition can be suspected when the pain and swelling is located below and in front of the ankle rather than around the ankle itself. The sprain is more often the result of inversion than of eversion of the foot. In eversion the plantar ligaments are so strong that the foot moves as a whole and the force is transmitted directly to the ankle and leg bones, and most likely results in the production of a Pott's fracture of the fibula with or without a tearing off of the internal malleolus or rupture of the ligamentum deltoideum (internal lateral).

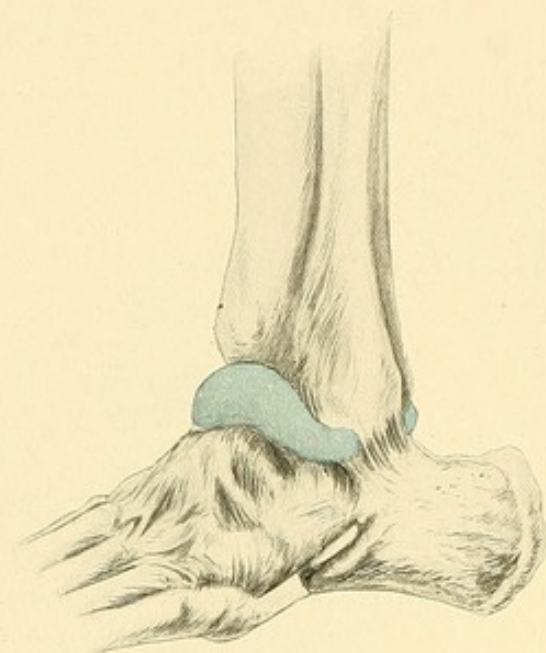


FIG. 571.—Ankle-joint distended with wax, showing that its capsule is weak anteriorly and posteriorly and strong laterally.

**Treatment.**—The principle of treatment in sprains is to prevent the ruptured ligaments and strained tissues being again irritated and kept from healing by subsequent movements of the injured parts. A small degree of movement is usually

painless and unharmed, but a more extensive, and often accidental, movement causes the pain and disability to persist. The failure to apply an efficient dressing which properly limits motion until the primary effect of the injury has passed is the reason of these disabilities becoming chronic. Sometimes fixed dressings like plaster of Paris or silicate of soda are applied for two weeks. Fixation by adhesive plaster has been found very efficient. Gibney demonstrated this. Inasmuch as the injury is usually produced by inversion, the plaster is applied especially to prevent inversion and likewise to give general support. Gibney's method consisted in applying alternate narrow strips of adhesive plaster, one set beginning on the inner side of the foot and going well up on the outer side of the leg, and the other running parallel with the sole of the foot from the heel to the dorsum.

Another method consists in taking a long strip of plaster 7.5 cm. (3 in.) wide, and beginning high up the leg on the inner side, carrying it down under the sole and drawing it firmly up and fastening on the outer side of the leg almost to the knee. This is reinforced by encircling strips around the ankle and instep.

## DISLOCATIONS OF THE ANKLE.

The foot may be dislocated from the leg in nine different manners.

1. The foot as a whole may be carried outward. This is almost always associated with fracture of the fibula, and sometimes of the internal malleolus, constituting Pott's fracture (see page 557).

2. The foot may be carried directly inward. This likewise is associated with fracture of the internal malleolus.



3. The foot may be rotated *out* on its own anteroposterior horizontal axis (parallel with the sole).
4. It may be rotated *in* on its anteroposterior horizontal axis. Both these may be accompanied by fractures.
5. The foot may be rotated inward on a vertical axis longitudinally through the leg.
6. It may be rotated outward on a vertical axis.
7. The foot may be luxated backward, the tibia coming forward on the astragalus (Fig. 572).
8. It may be luxated forward.
9. The astragalus may be pushed up between the bones of the leg.

In Numbers 1 and 2 inward and outward displacement the foot is not immediately beneath the leg, but is to one side of the leg. The outward luxation when accompanied with laceration of the inferior tibiofibular ligaments or tearing off of a small portion of the tibia and fracture of the internal malleolus and fibula constitutes Dupuytren's or Pott's fracture. In Numbers 3 and 4 the foot remains beneath the leg bones and is not displaced much laterally. Numbers 1 and 3 are usually grouped together as outward luxations, and 2 and 4 as inward luxations. Numbers 5 and 6 are very rare. The foot is rotated so that one side looks forward and the other backward.

Number 7 backward luxation is the most common, with the exception of Number 1. When associated with Pott's fracture, backward luxation is produced by hyperextension followed by a thrust and is often compound. The leg is bent backward until the anterior and lateral ligaments rupture, and then the thrust sends the tibia forward on the instep. The articular surface of the astragalus being wider in front opposes the luxation, and fracture of one or both malleoli may result.

Numbers 8 and 9 forward and upward luxations are extremely rare, the former on account of the difficulty in the application of the dislocating force,—the flexion and thrust,—and the latter on account of the extreme strength of the inferior tibiofibular ligaments.

*Treatment.*—In attempting reduction of these luxations the principal thing is to relax the tendo calcaneus (Achillis) by flexing the knee. If this is not sufficient, tenotomy should be practiced. Simple extension with slight rotation and manipulation will then accomplish reposition.

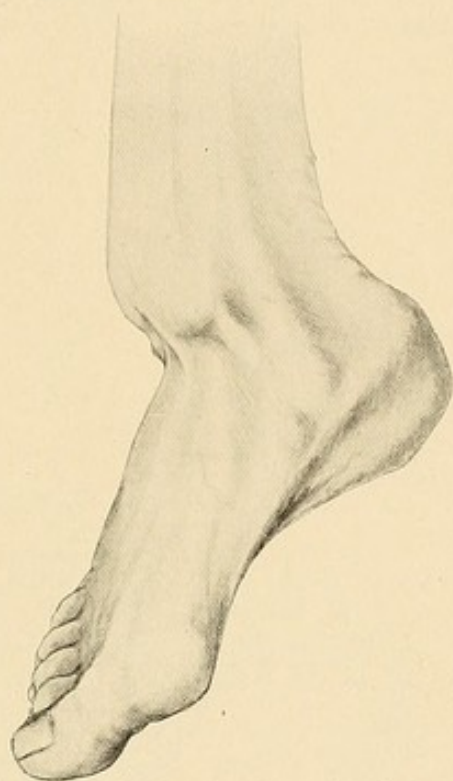

FIG. 572.—Backward luxation of the foot at the ankle-joint.

## FRACTURES OF THE ANKLE.

Fractures of the ankle are usually the result of a force applied laterally, though sometimes a turning of the foot on the vertical axis of the leg may assist. The force applied causes fracture by inversion or eversion of the foot.

**Pott's Fracture or Fracture by Eversion.**—This is named after Sir Percival Pott, Surgeon to St. Bartholomew's Hospital, London, who described the injury, and was himself a victim of it. The French call it Dupuytren's fracture. It is produced by forcing the foot outward, or by having the foot firmly fixed and then bending the limb outward, thus breaking it at the ankle. The fibula is broken 4 to 7.5 cm. (1½ to 3 in.) above its lower end and the ligamentum deltoideum (internal lateral) is either ruptured or the internal malleolus is torn off. Rarely the outer portion of the articular surface of the tibia may be torn off and displaced outward



with the lower fibular fragment. It is to be noted that in this fracture the foot, with the small fragments of tibia and fibula, is practically loosened from the bones of the leg, and the muscles of the calf being unopposed pull the foot backward and upward. Therefore the displacement of the foot is not only outward, but also backward and upward (Fig. 573.)

**Fracture by Inversion.**—This is practically the opposite of the former and is not so frequent. The fibula is fractured by the traction of the external lateral ligaments which remain intact; it may break either above or below the strong inferior tibiofibular ligaments. The internal malleolus may also be torn off. The displacement is toward the inner side and upward and backward (Fig. 574).

**Treatment.**—In these fractures of the ankle replacement is often difficult and resultant deformities frequently cause considerable subsequent disability. For this reason especial efforts are to be made to reduce the displacement and maintain the fragments in proper position.

There are two main points of difficulty. The fractured ends of the fibula become displaced anteroposteriorly and also in the fracture by eversion (Pott's) become pushed inward toward the

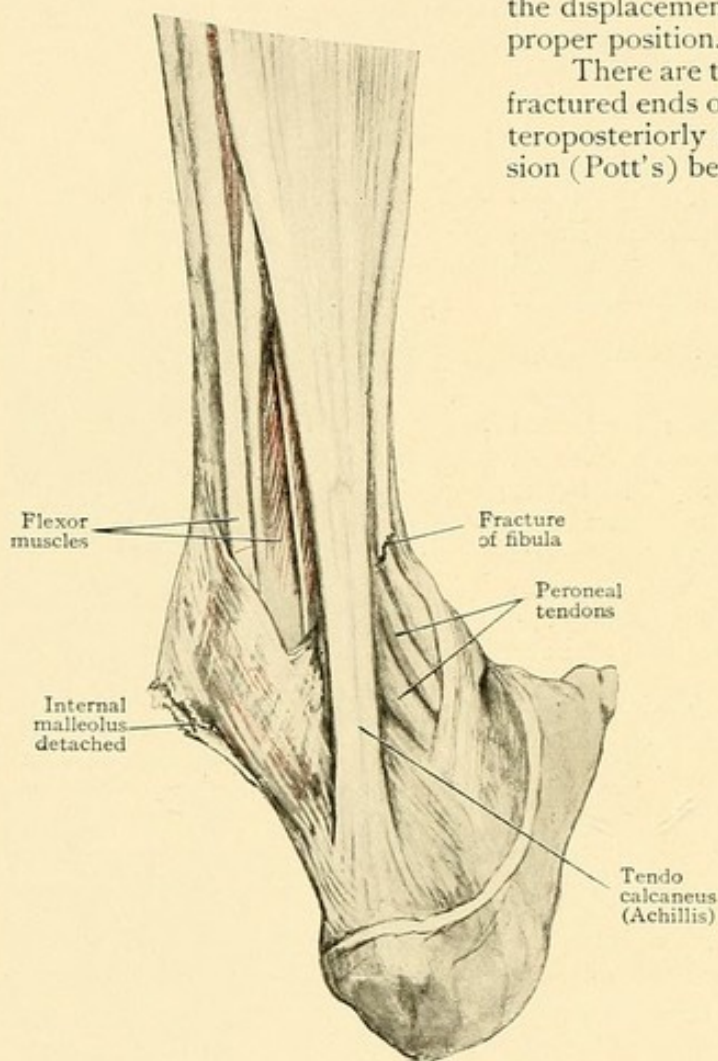


FIG. 573.—Pott's fracture of the fibula, showing eversion of the foot, point of fracture of the fibula, and tearing off of the point of the internal malleolus.

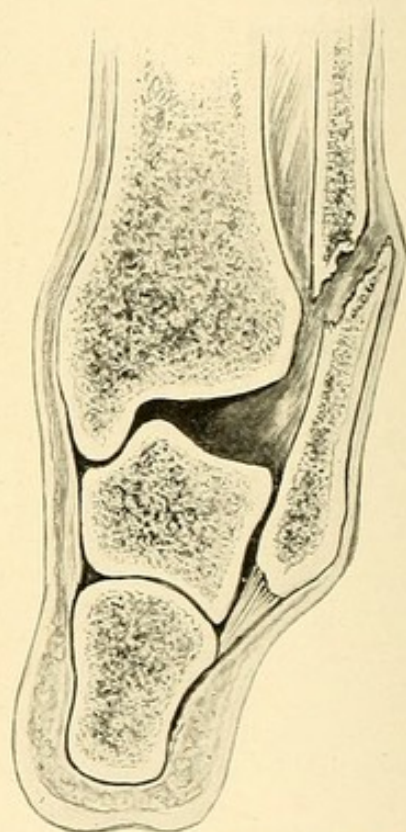


FIG. 574.—Illustrating fracture of the fibula by inversion of the foot.

tibia. The deep fascia of the leg is attached to the fibula and its sharp broken ends may get so fastened or caught in this fascia as to require an open incision before they can be freed sufficiently to allow of their proper replacement. Another difficulty is in the reduction of both the lateral and posterior displacement. Here it is necessary first to relax the muscles of the calf by flexing the leg on the thigh, then by pulling and direct pressure the foot can often be replaced. If this fails tenotomy of the tendo calcaneus (Achillis) is to be done, which relaxes the parts still more by releasing the pull of the soleus, the gastrocnemius and plantaris being already relaxed by flexion of the knee. This is sometimes necessary to prevent the persistent



tendency of the foot to be drawn backward. After reduction not infrequently there is no further tendency to displacement, and the fracture box or any other simple means of retention is sufficient.

In other cases it is better to place the leg in the Pott's position, viz., lying on its outer side with the knee flexed. For similar injuries, Dupuytren advised placing the leg on a straight internal lateral splint on a pad which extended from near the knee down to the seat of fracture. The leg was fastened near the knee to the upper part of the splint, and the foot which projected beyond the pad was drawn by bandages toward the lower part of the splint.

### AMPUTATIONS AT THE ANKLE.

When amputation is performed at the ankle it is usually either by the method of Syme or that of Pirogoff.

**Syme's Amputation.**—"A transverse incision should be carried across the sole of the foot from the tip of the external malleolus or a little posterior to it (rather

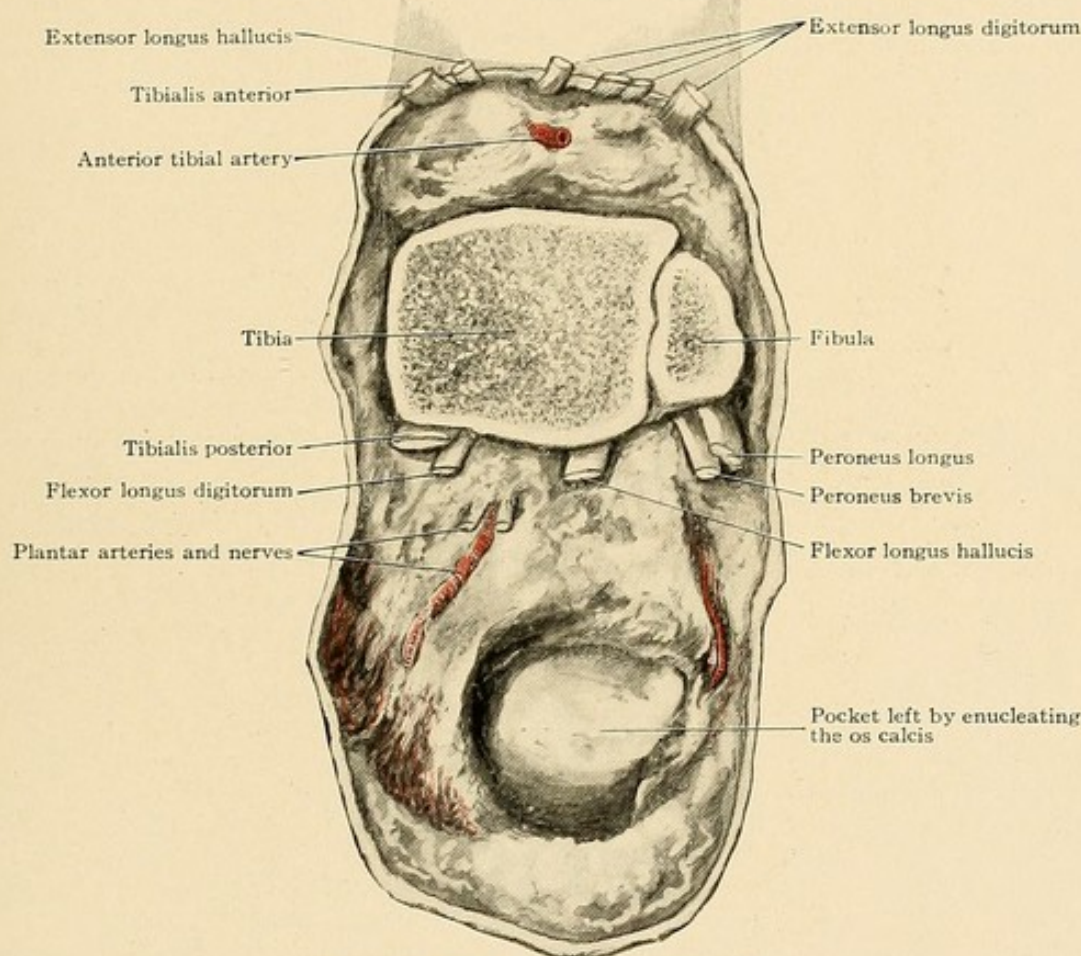


FIG. 575.—Syme's amputation of the ankle.

nearer the posterior than the anterior edge of the bone) to the opposite point on the inner side, which will be rather below the tip of the internal malleolus." The extremities of this incision are connected by another directly across the front of the ankle-joint. The anterior capsule is then divided and the lateral ligaments divided from within outward. The foot being bent down, the tendo calcaneus is cut close to the bone and the calcaneum dissected out. The malleoli are then to be cleared and sawn off with a thin slip of the articular surface of the tibia (Fig. 575).

*Remarks:* The incision across the sole must not go too far back on the inner side, as the internal calcanean branch of the external plantar artery will



be divided and the integrity of the flap threatened. In clearing the calcaneum it is rather an advantage, especially in young people, to take off a thin slice of bone with the tendo calcaneus. In removing the slice from the tibia as little as possible (in growing patients) should be removed, to avoid injuring the epiphyseal cartilage. In dissecting back the flap of the heel, the point of the knife is to be kept close to the bone to avoid cutting the vessels in the flap itself.

**Pirogoff's Amputation.**—The sole incision is carried across from just in front of the external malleolus to just in front of the internal. The anterior incision is made across the front of the joint and the foot disarticulated by dividing the capsular and lateral ligaments. The foot is then bent down and the calcaneum sawn

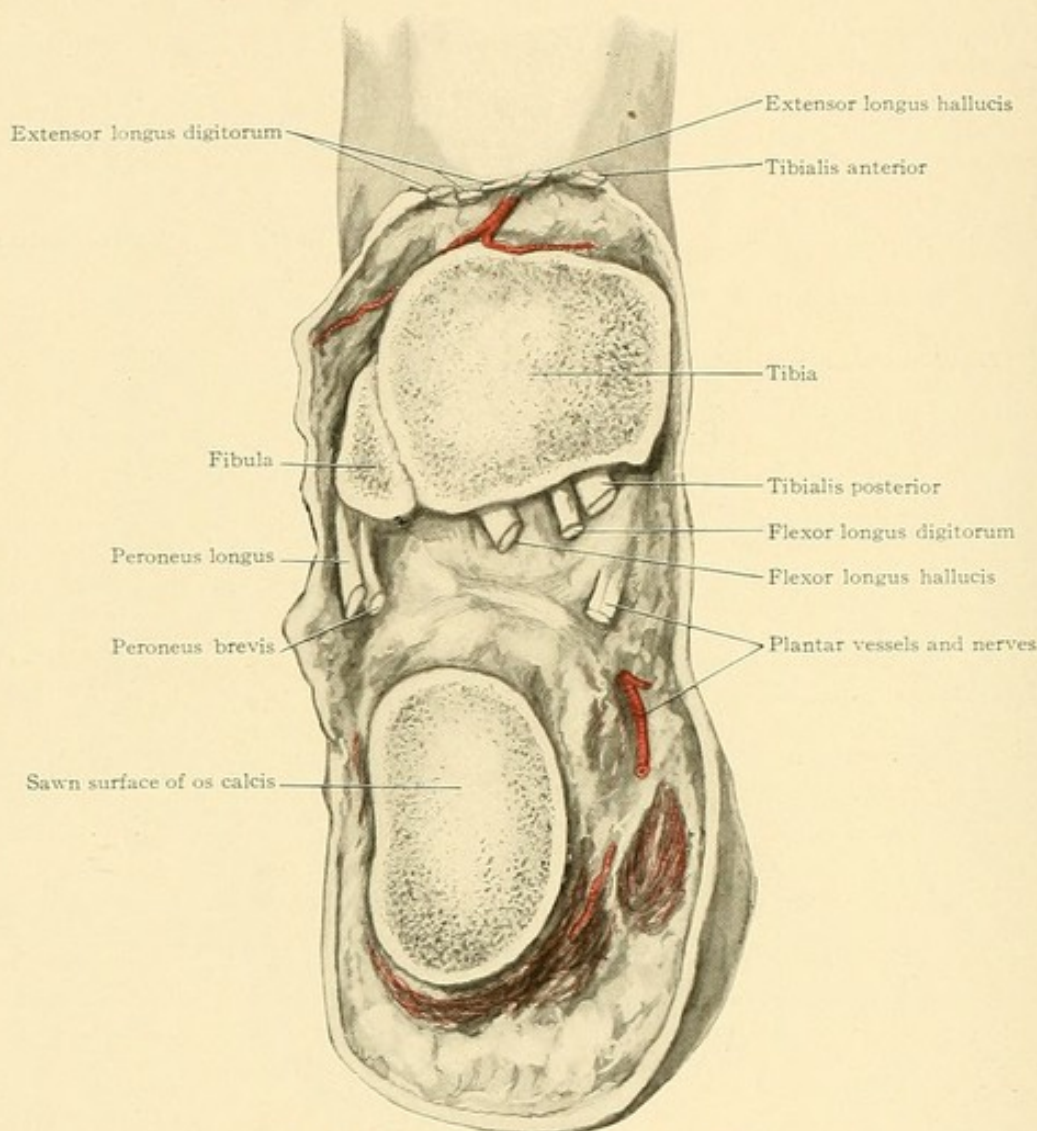


FIG. 576.—Pirogoff's amputation of the ankle.

through the line of the sole incision. A slice is to be removed from the tibia and fibula and the sawn surface of the calcaneum brought up and sutured with chromic catgut (or other) sutures to the sawn surface of the tibia (Fig. 576).

In bringing up the calcaneum to the tibia it may be found difficult to approximate them without undue tension on the tendo Achillis. To provide against this common difficulty it is customary to place the saw on the upper surface of the calcaneum well behind (a finger-breadth) the joint. Also to dissect back the heel-flap .50 to 1 cm. ( $\frac{1}{4}$  to  $\frac{1}{2}$  in.) so that more of the calcaneum can be removed. A larger slice is also taken from the tibia than in Syme's amputation. If the tension remains too great on the tendo calcaneus it is to be divided.



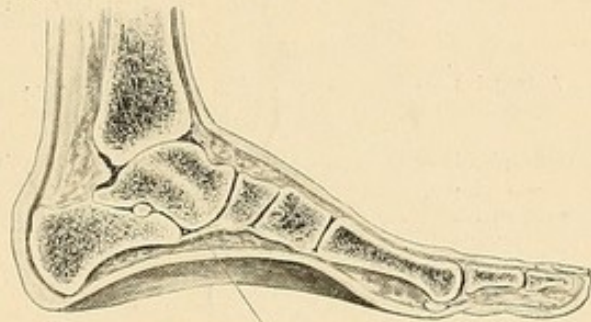
## THE FOOT.

The foot is intended for support and locomotion. The locomotion takes place in the upright position and, in moving, the weight is shifted from one foot to the other. Hence we see that if the foot is to fulfil its function of support it must have strength, because on it rests the weight of almost the whole of the body. If a person is at rest in a standing position the foot is subject to a continuous static pressure which, if any part of the foot is abnormal, whether from congenital or acquired qualities, will eventually result in distortion and impairment of function. If a person is moving about, the foot is subjected to a pressure which is dynamic (movable) in character, and is much greater in amount than is the static pressure of the body at rest.

The movements of the foot in locomotion are not always slow, sometimes they are exceedingly rapid. A person treads on an uneven or unstable surface and the foot must adapt itself instantly or injuries will result; failure to do so results in sprains, fractures, and luxations. In running rapidly the changes in position of the component parts of the foot are instantaneous, otherwise rapid running is impossible. In jumping especially the dynamic pressure plus the inertia causes an enormous strain on the foot. The mobility demanded of the foot is not so great, however, as that of the hand because the movements are neither so intricate nor so numerous. A consideration of these facts enables one to understand: first, the method of construction of the foot; second, its injuries, diseases and deformities; third, the means necessary to employ in preventing and curing them and in obviating to as great extent as possible their consequences.

#### The Construction of the Foot.

The foot is constructed with a view of possessing strength and mobility. Strength is obtained by the bones being short and solid, well compacted together in the form of a double arch, joined by strong ligaments, and supported by powerful muscles. The double arch forms the hollow of the sole of the foot. As pointed out by Ellis ("The Human Foot") when the two feet are placed together there is formed a "dome-shaped space" arching anteroposteriorly from the internal tuberosity of the calcaneum to the head of the first metatarsal bone, and laterally from the inner to the outer edge (Fig. 577). Mobility is obtained by the bones and joints being numerous and the muscles highly specialized.



Inferior calcaneo-scapoid ligament.

FIG. 577.—Section of foot, showing the longitudinal arch.

**Diseases and Injuries of the Foot.**—Disease weakens the foot—sometimes, as in adolescents, the foot is weakened without any apparent disease. In other cases the bones and ligaments become affected, as in rickets, rheumatism, gout, and tuberculous disease. In still others the muscles become affected, either contracted, as in spastic diseases, or relaxed, as in infantile paralysis. When the bones and ligaments are involved they fail to bear the body weight, the arch is crushed and flat-foot and eversion results. Hence valgus is almost always a disease of weakness. If muscles become affected by spasm or paralysis all kinds of deformities are produced. There are many muscles controlling the foot and frequently only one or a few are paralyzed; this leaves the balancing muscles unopposed and they drag the part toward the healthy side. Anything that disturbs the equilibrium or balance of the various muscles results in distortions and deformities. Injuries impair the efficacy of the mechanism of the foot. A crush of the head of the first metacarpal bone destroys the anterior support of the arch and the resultant weakness is marked.

Traumatism produces flat-foot, also sprains, which, while not so deforming, are often disabling. Fractures and luxations occur and may impair the foot permanently. Finally, many children have congenitally deformed feet which require treatment before they can fulfil their functions.



**The Treatment of Affections of the Feet.**—The foot is exceptionally accessible both for diagnosis and treatment. The bones and joints are accessible often to both sight and touch, and one should know where to look and feel for them. Exploratory operations in this portion of the body are out of place. An accurate knowledge of the structures of the foot is absolutely essential to intelligent treatment. The deformities are dependent on muscular action, and one should know the position of the tendons and the influence of the muscles. In amputating, a knowledge of the joints is essential. The problems presented are largely of a mechanical nature, to be solved by a thorough knowledge of the structures and the application of mechanical principles to living tissues.

### BONES OF THE FOOT.

A knowledge of the bony structure of the foot is the key which unlocks its pathology. The bones of the foot are numerous, so as to give it mobility and to

lessen shocks. If the bones become ankylosed the footing becomes insecure, balancing is difficult, the gait is altered, and great care is necessary in locomotion to avoid straining and injury.

The foot is triangular in shape, being broad across the toes and narrow at the heel. Its bones compose the *tarsus*, *metatarsus*, and *phalanges*. Of these the first two are essential, but the third is less so. Phalanges are more or less for prehensile uses, and as man, as we see him, encases his foot in shoes he makes but little use of the toes, hence they are the least important part of the foot. They are used somewhat in walking, and to a greater degree in balancing, climbing, running, etc. They add to the efficiency of the foot, but their loss does not impair it to a great extent. Intricate and delicate movements may be interfered with, but the more deliberate firmer movements, as in walking, may remain almost normal. The big toe has only two phalanges and this increases its strength at the cost of mobility. The remaining portion of the foot is composed of the metatarsus and tarsus—five bones of the former and seven of the latter.

The foot bones are divided longitudinally into two sets, an internal and external. The main

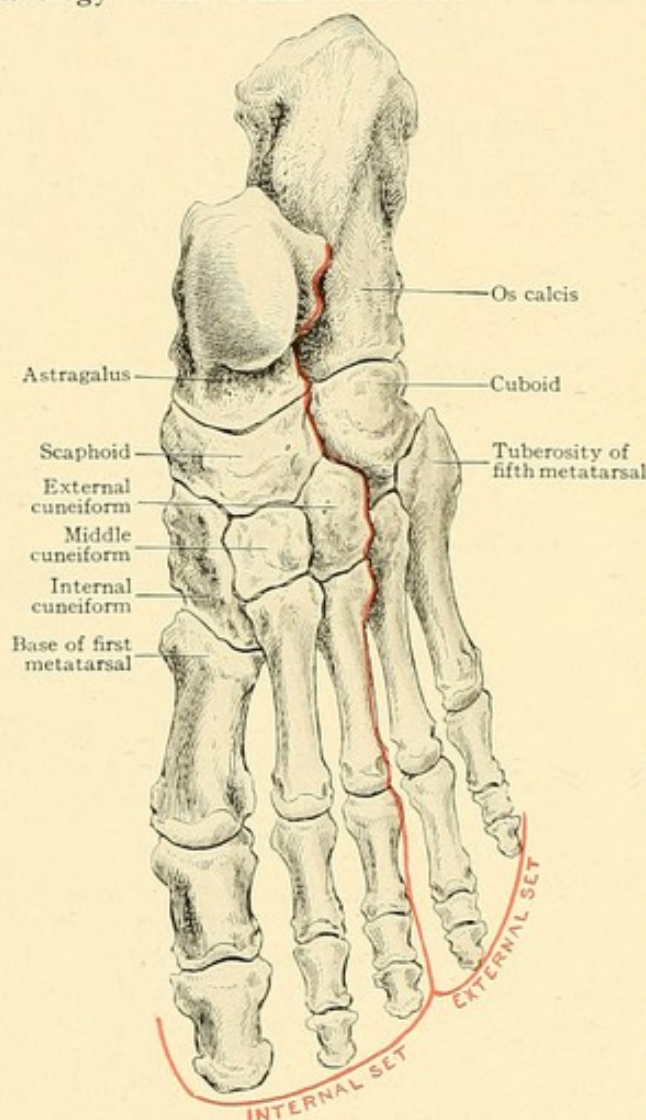


FIG. 578.—Anterior view of the bones of the foot showing their division into internal and external sets.

weight of the body is transmitted through the *internal set*, which is in relation with the tibia. It consists of the *astragalus* (*talus*), *scaphoid* (*navicular*), the three *cuneiform*, and the inner three *metatarsal* bones with their corresponding phalanges (Fig. 578).

The *external set* is in relation with the fibula, and is composed of the *os calcis*, *cuboid*, and outer two *metatarsals* with their corresponding phalanges.

As has been pointed out by Quénu and Kuss (*Revue de Chirurgie*, Jan., 1909, p. 1), while the main function of the internal portion of the foot is support, that of



the external portion is balance. They suggest that from a functional standpoint the foot may be divided into an internal portion composed of all the tarsal bones and the first metatarsal bone with its phalanges, and an external portion consisting of the outer four metatarsal bones and phalanges. They show that in dislocation of the metatarsus the line of division passes between the first and second metatarsal bones; the first metatarsal is usually displaced inwardly, while the second, third, fourth, and fifth metatarsal bones are practically always displaced outwardly, there being a considerable separation between the metatarsal bone of the big toe and the second metatarsal bone adjacent.

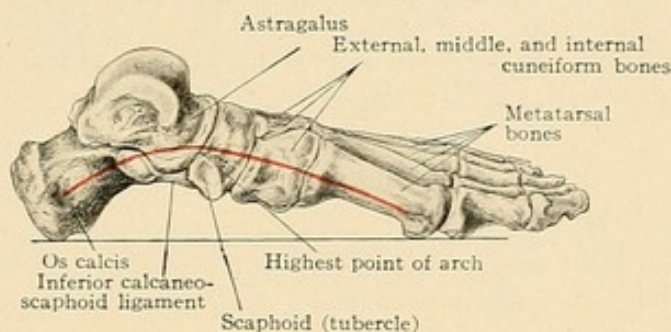


FIG. 579.—The inner arch of the foot.

When there is congenital absence of the tibia the foot bones related to it are also lacking, and when the fibula is lacking there are no bones of the external set. In man both sets contribute to support, but the tibial or inner set is the more important, the fibular or outer set being in a condition of regression.

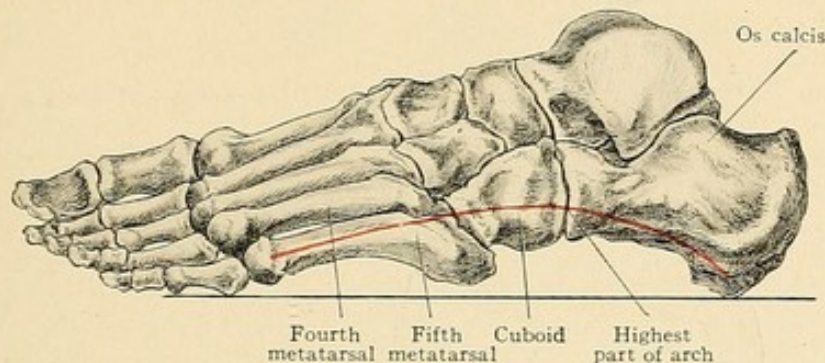


FIG. 580.—The outer arch of the foot.

As has been stated above, the foot is dome-shaped, being arched anteroposteriorly and laterally. The anteroposterior arching has been divided into an inner and outer arch. The *inner arch* is composed of the os calcis, astragalus, scaphoid,

three cuneiform and inner three metatarsal bones. The highest point of this arch is the midtarsal joint between the astragalus and scaphoid (Fig. 579). The *outer arch* is composed of the os calcis, cuboid, and outer two metatarsal bones. It is much lower than the inner arch. The highest point is between the cuboid and os calcis, and when weight is borne on the foot this outer arch becomes obliterated and comes in contact with the ground.

The *lateral arch* has its outer end supported by the outer edge of the foot, which through the medium of the soft parts is in contact with the ground. Its inner end is supported by the inner edge of the foot which is some distance above the ground. Thus it is seen that the weight of the body is transmitted from the body of the astragalus in three directions, viz., backward to the tuberosities of the os calcis, forward to the heads of the metatarsal bones, and laterally toward the base of the fifth metatarsal bone. The posterior pillar of the anteroposterior arch is short, thick, and composed of only two bones, the astragalus and os calcis. It is stiff and strong, but having only two parts is comparatively immovable. The anterior pillar of the arch is longer and has more bones and, while it is not so strong against static pressure as the posterior pillar, is, on account of its elasticity and mobility, far more effective against dynamic (active) pressure. Thus it is that when a person jumps from a

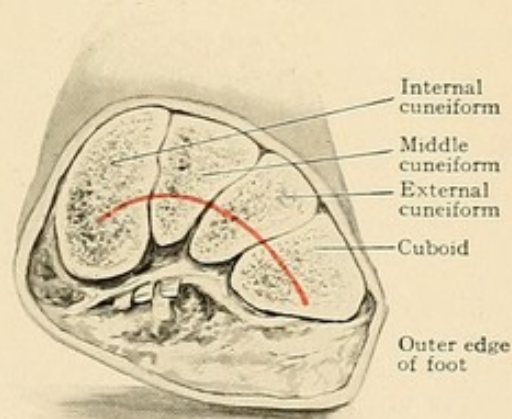


FIG. 581.—Lateral or transverse arch of foot.



height and alights on the sole of the foot the astragalus or os calcis of the posterior pillar is fractured while the bones of the anterior pillar escape. The internal part of the foot is more liable to give way than the external part because the external part is practically in contact with the ground while the internal part has as its support ligaments and muscles, and when these latter give way it is the inner side of the foot which sinks. This is still more favored by the position of the tuberosities of the os calcis with reference to the ankle-joint; they are not directly beneath it, but somewhat to its outer side.

### THE JOINTS AND LIGAMENTS OF THE FOOT.

The amount of movement that takes place between the bones of the foot is not as great as would be expected from their number. It is only in the subastragaloid joint that any considerable motion takes place, while a less amount occurs at the

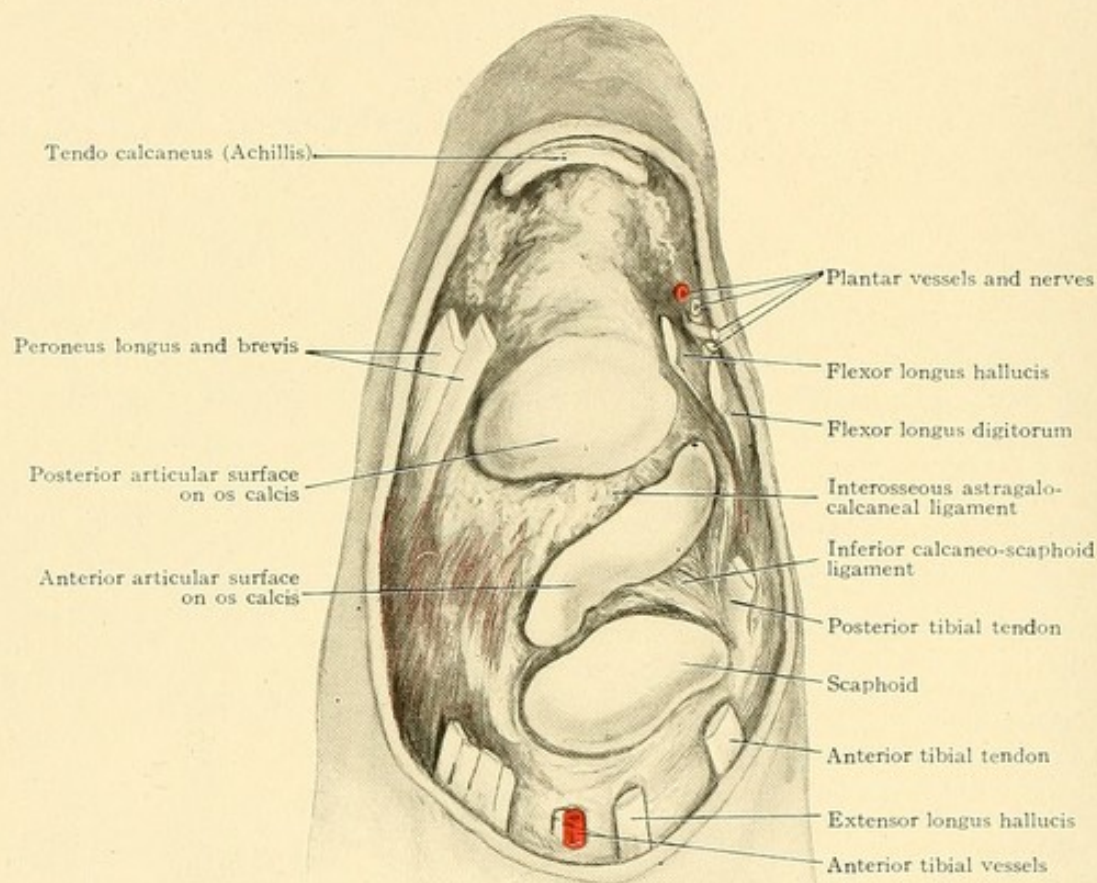


FIG. 582.—The subastragaloid joint; lower surface. The astragalus has been removed.

midtarsal joint. The contiguous tarsal bones are joined by numerous band-like, capsular, and interosseous ligaments which allow a limited amount of movement between them. In the aggregate these movements are considerable and make the foot as a whole quite flexible.

**The Subastragaloid Joint (*Articulatio talo-calcaneo-navicularis*).**—This is a horizontal joint formed by the astragalus above and the os calcis and navicular (scaphoid) below and in front. It runs obliquely forward and inward. The astragalus is not wedged in between the os calcis and scaphoid like the keystone of an arch, but the foot moves freely beneath it. It has an inward motion of adduction around an anteroposterior or longitudinal axis with internal rotation around a vertical axis, and an outward motion of abduction with external rotation. The abduction and adduction movements cannot occur independently of rotation, they are combined. The astragalus is joined to the os calcis below and scaphoid below and in



front by short fibrous bands which help to form the capsule. The under surface of the subastragaloid joint is formed first by the surface of the scaphoid, next by the inferior calcaneoscaphoid ligament, then by the upper surface of the sustentaculum tali, then by the interosseous ligament, and finally by the posterior surface of the os calcis. The inferior calcaneoscaphoid ligament is the most important one in maintaining the integrity of

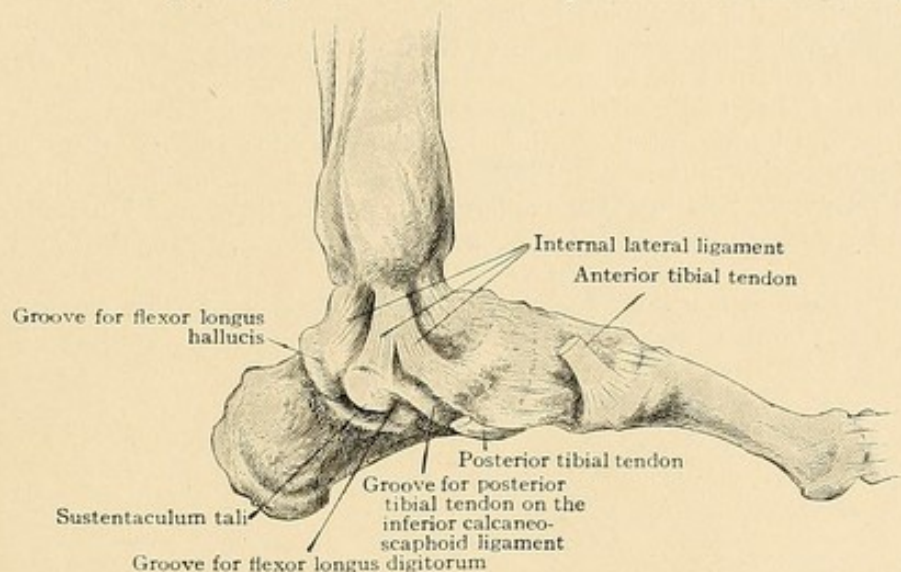


FIG. 583.—View of inner side of ankle-joint, showing the internal lateral ligament.

the arch (Fig. 582). In addition, in order to provide against luxation, which is favored by the superincumbent body weight, the joint is strengthened by three ligaments, viz.:

1. The *interosseous astragalo-calcaneal ligament*, which runs obliquely forward and outward between the os calcis and astragalus and divides the subastragaloid joint into an anterior and posterior portion. It is very strong (Fig. 582).
2. The *internal lateral (deltoid) ligament* of the ankle, which sends fibres by

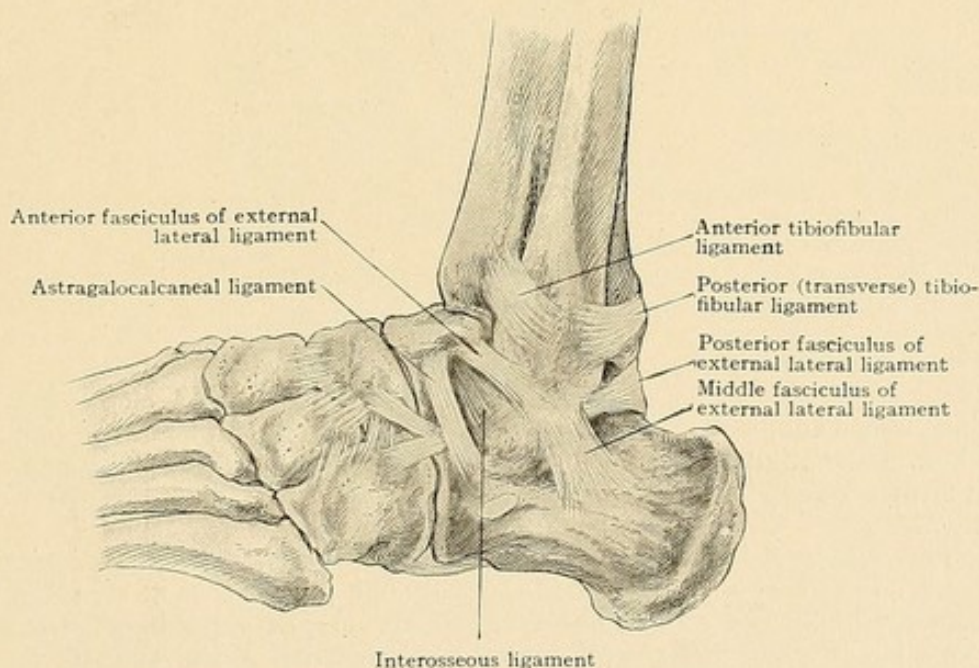


FIG. 584.—Ligaments of the outer side of the ankle.

its deep part from the tibia above to the side of the astragalus below and likewise to the scaphoid in front, and by its superficial part to the sustentaculum tali (Fig. 583).

3. The *external lateral ligament* of the ankle, the anterior and posterior fasciculi of which are both attached to the astragalus and the middle fasciculus of which goes to the os calcis below (Fig. 584).



When the weight of the body is transmitted to the foot it tends to flatten the anteroposterior arch. If the arch descends it can only do so either by pushing the astragalus up—luxating it—or by the ligaments of the arch stretching or rupturing and allowing the two pillars of the arch to separate. In disease the ligaments elongate and by violence they may be ruptured, the arch in each case falls. If the ligaments supporting the astragalus remain intact then excessive lateral movement ruptures those on the side and a sprain of the subastragaloid joint is produced which is often called a sprain of the ankle.

**The Midtarsal Joint (Chopart's Joint).**—This is composed anteriorly of the scaphoid and cuboid bones and posteriorly by the astragalus and os calcis. The movements are not extensive and consist of flexion with inward rotation of the sole, and extension with outward rotation of the sole. The joint is separated into an inner and outer portion by an interosseous ligament where the cuboid, astragalus, and os calcis meet.

**The Ligamentous Support of the Arch of the Foot.**—The bony construction of the arch or dome of the foot has already been explained (page 563). The

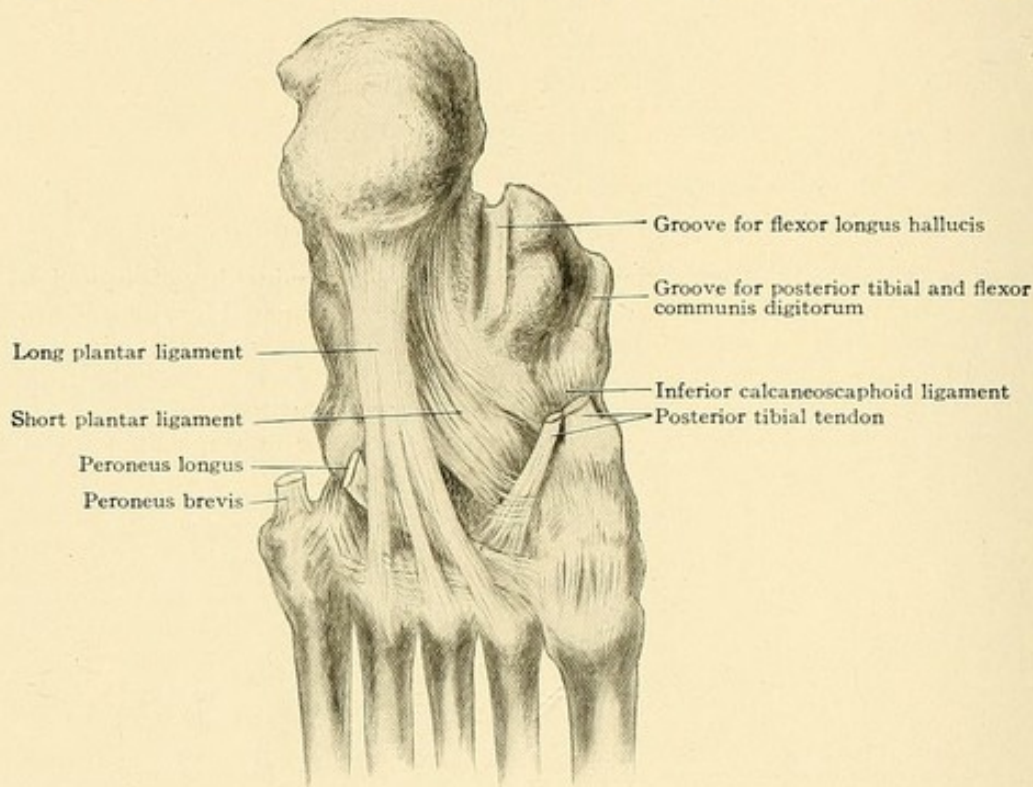


FIG. 585.—Ligaments and tendons of the sole of the foot.

various bones composing it are bound together not only by the short ligaments passing between contiguous bones, but the arch is strengthened by three special ligamentous structures. They are the inferior calcaneoscaphoid ligament, the plantar ligaments, long and short, and the plantar fascia.

The *inferior calcaneoscaphoid ligament* (*ligamentum calcaneonaviculare plantare*) runs from the lower inner portion of the scaphoid, posterior to its tubercle, to the sustentaculum tali. It is an extremely strong fibrocartilaginous band. Anteriorly and above it blends with the internal lateral ligament (deltoid) of the ankle. Together with the posterior surface of the scaphoid it forms a socket for the head of the astragalus. This ligament fills the long gap left in the inner arch of the foot between the scaphoid and os calcis. Running under and supporting it is the tendon of the tibialis posterior (Fig. 585).

The *long plantar or long calcaneocuboid ligament* (*ligamentum plantare longum*) is attached to the under surface of the os calcis in front of its tubercles and thence runs to the peroneal ridge on the cuboid bone and continues onward to



the bases of the second, third, fourth, and fifth metatarsal bones. It makes a canal for the peroneus longus tendon, which runs beneath it.

The *short plantar or short calcaneocuboid ligament* (*ligamentum calcaneocuboideum plantare*) lies beneath the long ligament and is separated from it by a small amount of fatty tissue. It runs obliquely forward and inward from the under surface of the calcaneum to the posterior portion of the cuboid.

The *Plantar Fascia* (*aponeurosis plantaris*).—The middle portion of the plantar fascia runs anteriorly from the inner tubercle of the os calcis to be attached to the sides of the metatarsophalangeal articulations and bases of the proximal phalanges.

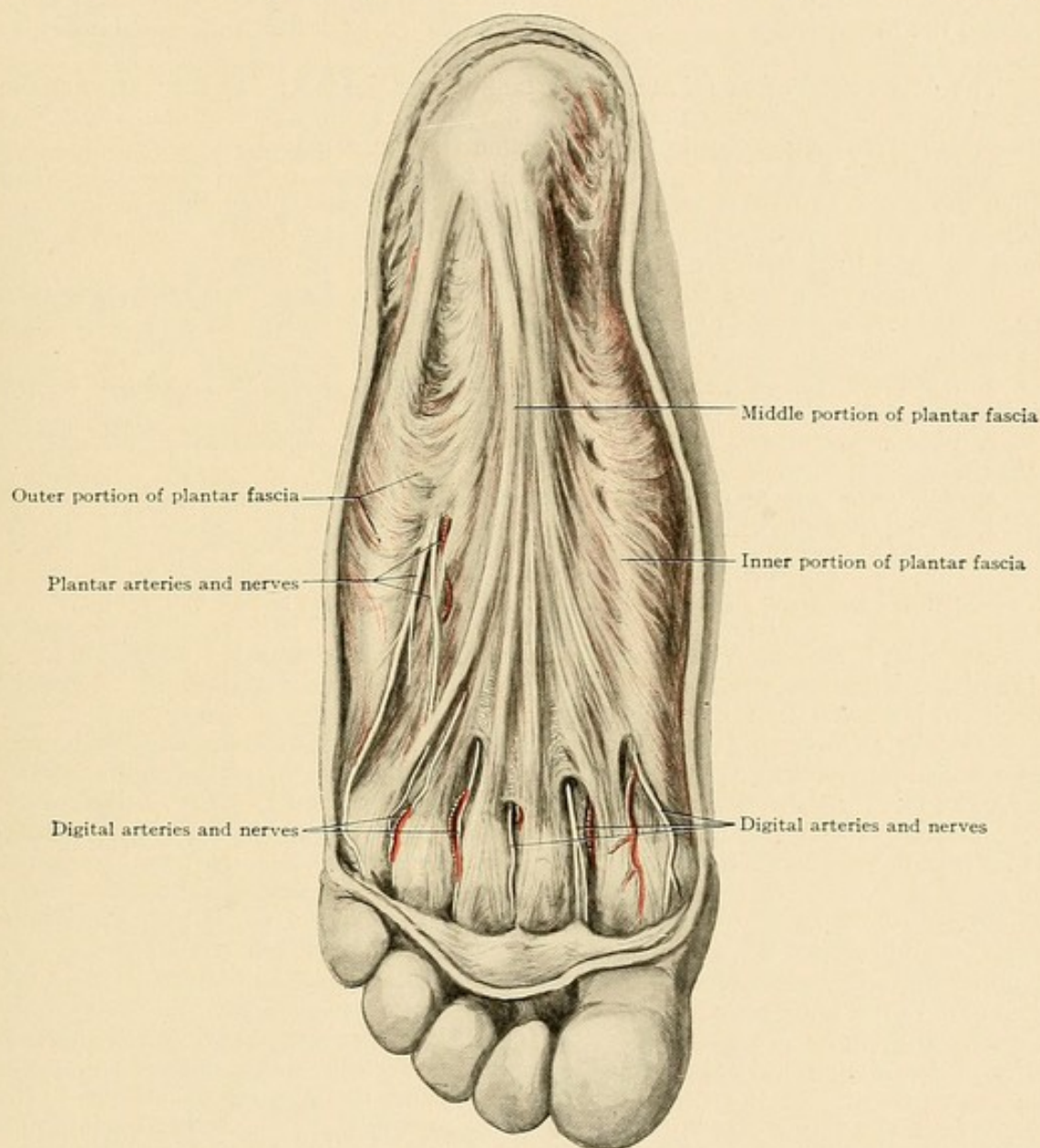


FIG. 586.—The plantar fascia.

It is a thick, strong triangular band. The outer portion is a strong band running from the external tubercle to the tuberosity of the fifth metatarsal bone. The inner portion is thin and weak (Fig. 586).

These three ligamentous structures, the calcaneoscaphoid ligament, plantar ligaments, and plantar fascia are all large, strong, fibrous structures. They join the anterior and posterior pillars of the arches like the string of a bow and prevent them from separating. When a person is standing at rest these are the main ligaments which bear the weight of the body. The static weight is borne by the ligaments but the dynamic weight (movements) is borne by the muscles.



## THE MUSCLES OF THE FOOT.

The foot is acted upon by long muscles which come down from the leg and short muscles which arise in the foot itself. Of these the long muscles are the more important because they influence the position of the foot itself, whereas the short muscles act on the toes; as stated the movements of the toes are of secondary importance (page 562). The functions of the muscles are active or dynamic in character. They bear the weight of the body when in motion and direct the movements of the foot in locomotion. Their function and structure are to be studied together, as one explains the other, and a knowledge of them explains many deformities and indicates their treatment.

The *long muscles* have three distinct actions on the foot: (1) they support the arch of the foot; (2) they flex and extend the foot; (3) they abduct and adduct the foot—this latter being associated with a certain amount of rotation.

The action of the individual muscles is not a simple one. They act on two joints, the ankle and subastragaloid. If the former is stationary they abduct and adduct, if the latter is stationary they flex and extend, but if both move then a combined action of the muscles is necessary.

For our purposes we may divide the muscles into four groups of three each (page 546). They are (1) extensors, (2) flexors, (3) abductors, (4) muscles of the calf.

1. Extensor group: *tibialis anterior*, *extensor longus hallucis*, *extensor longus digitorum*.

2. Flexor group: *tibialis posterior*, *flexor longus digitorum*, *flexor longus hallucis*.

3. Abductor group: *peroneus longus*, *peroneus brevis*, *peroneus tertius*.

4. Muscles of the calf: *gastrocnemius*, *soleus*, *plantaris*.

## THE ACTION OF THE MUSCLES IN SUPPORTING THE TARSAL ARCH.

*Tibialis Anterior*.—The tendon of the anterior tibial descends along the anterior edge of the internal malleolus and inserts into the lower inner surface of the internal cuneiform bone and base of the first metatarsal bone.

*Tibialis Posterior*.—Its tendon passes down close behind the posterior edge of the internal malleolus, crosses the internal lateral ligament of the ankle, passes under the inferior calcaneonavicular (scaphoid) ligament and in front of the sustentaculum tali to insert into the tubercle of the navicular (scaphoid). From the tubercle its tendon sends slips to all the tarsal bones except the talus (astragalus) and to the bases of the second, third, fourth, and sometimes fifth metatarsal bones.

*Flexor Longus Digitorum*.—Its tendon passes behind the internal malleolus immediately posterior to the *tibialis posterior* and then curves around the sustentaculum tali to enter the foot, passing forward to insert into the base of the terminal phalanges of the outer four toes.

*Flexor Longus Hallucis*.—This tendon descends across the middle of the posterior part of the ankle-joint and curves forward under the sustentaculum tali. It is the most posterior of the structures running behind the internal malleolus. It lies deeper than the tendon of the *flexor longus digitorum*, and as it crosses it gives to it a small slip. It then inserts into the base of the terminal phalanx of the big toe.

*Peroneus Longus*.—This tendon overlies the tendon of the *peroneus brevis* as it passes down immediately behind the external malleolus. It then winds around the outer surface of the os calcis behind the peroneal tubercle to pass obliquely inward and forward across the sole of the foot, in a canal formed by the long plantar ligament and a groove in the cuboid bone, to insert into the base of the first metatarsal bone and internal cuneiform.

*Peroneus Brevis*.—This tendon passes down behind the external malleolus beneath and a little anterior to the tendon of the *peroneus longus*. It passes in front of the peroneal tubercle and then goes forward to insert into the tuberosity of the fifth metatarsal bone.



*Peroneus Tertius.*—This tendon descends in front of the external malleolus and inserts into the upper surface of the fifth metatarsal bone near its base.

The other muscles of the leg do not support the tarsal arch. In considering the insertions of these tendons it will be seen that the tibialis anterior, peroneus tertius, and peroneus brevis are practically inserted into the convexity of the tarsal arch and tend to support it by pulling it upward. The flexor longus hallucis and flexor longus digitorum run longitudinally beneath the arch and so directly support it. The tibialis posterior and peroneus longus, one from the inner and the other from the outer side, meet and cross on the sole of the foot, thus forming a double sling immediately beneath the arch on which it rests when those muscles contract.

If these muscles, on which the arch directly relies for its support when subjected to the strain of locomotion, are unable to meet the demands made upon them then the strain falls on the ligaments, and as these are intended for static and not dynamic purposes they weaken and give way and the arch descends. To cure such a condition over use must be avoided and the strength of the muscles is to be restored by exercise, massage, electricity, etc.

#### THE ACTION OF THE MUSCLES AS FLEXORS AND EXTENSORS.

The peroneus group of muscles exert so little influence on flexion and extension that in many cases they may be ignored. The peroneus tertius flexes the ankle, while the longus and brevis extend it. The common movements of the foot when great strength is not required are performed by the flexor and extensor groups of muscles; the muscles of the calf are not so much for adding to the kind of movements as to the amount. The powerful calf muscles have the function of aiding the body in maintaining the upright posture and especially in lifting and propelling it forward in locomotion. When most of the flexors and extensors are paralyzed the foot hangs loose from the leg, the so-called flail-foot. Weakness of the flexor group (tibialis posterior, flexor longus digitorum, and flexor longus hallucis) tends to favor a descent of the arch with consequent pronation or eversion. Weakness of the extensors causes toe-drop and inversion or supination.

Paralysis of the calf muscles deprives the posterior pillar of the arch of its support and the action of the flexors and extensors elevates the arch while the heel descends, so that a condition of hollow foot is produced.

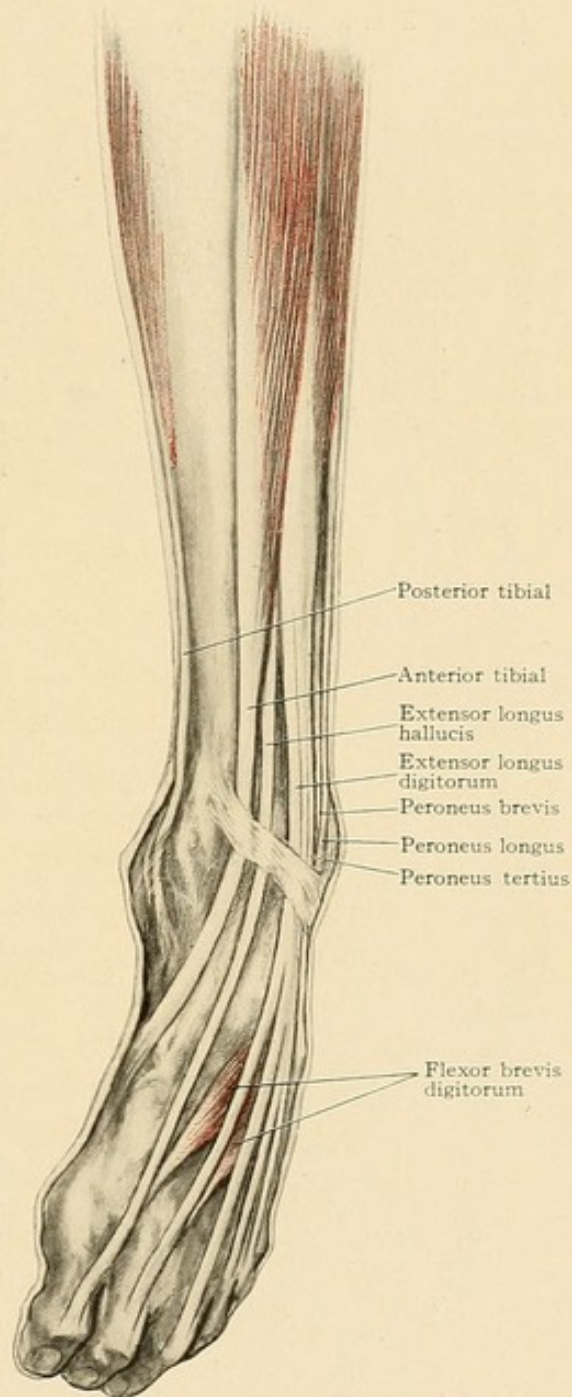


FIG. 387.—The foot in an adducted or supinated position.



Paralysis of the calf muscles is not rare, while that of the deep flexors is less common. The question of paralysis must be studied with reference to each individual case, because the affected muscles are not always completely paralyzed, neither are all the muscles of a group.

#### THE ACTION OF THE MUSCLES AS ABDUCTORS AND ADDUCTORS.

Lateral movements of the foot are comparatively weak when compared with those of flexion and extension. They are intended largely to maintain the balance or equilibrium and to adapt the position of the foot to uneven surfaces, etc. Three muscles act very distinctly as abductors; they are the peroneus longus, brevis, and tertius. Two act as distinct adductors, viz.: the tibialis anterior and the tibialis posterior.

The muscles of the calf act more as abductors than adductors, because the insertion of the tendo calcaneus (Achillis) is not directly behind the ankle-joint but more to its outer side.

When the foot is deformed in the position of inversion, as in club-foot, the tibialis anterior and posterior are usually contracted, but when in the position of eversion, as in flat-foot, then spasm of the peronei or calf muscles is frequent.

Plantar flexion of the foot is a far more powerful movement than extension—flexion is associated with adduction or inversion and extension with abduction or eversion; hence it is that inversion is the position of strength and eversion of weakness. Feats of strength and agility cannot be performed by those who have markedly everted feet.

#### SURFACE ANATOMY OF THE FOOT.

For the clinician and operator an exact knowledge of surface anatomy is absolutely essential. It can readily be acquired because the various bony points and tendons are usually evident both to touch and sight.

**Bony Landmarks.**—There are five prominent bony points: they are the *internal* and *external malleoli*, the *tubercles of the os calcis* and *navicular (scaphoid)* and the *tuberosity of the fifth metatarsal bone*.

The *internal malleolus* is large and flat and has a somewhat rounded lower edge.

It is above and anterior to the external malleolus. Immediately in front of its anterior edge runs the commencement of the long saphenous vein. Around its lower posterior border runs the tendon of the tibialis posterior muscle on its way to the tubercle of the scaphoid.

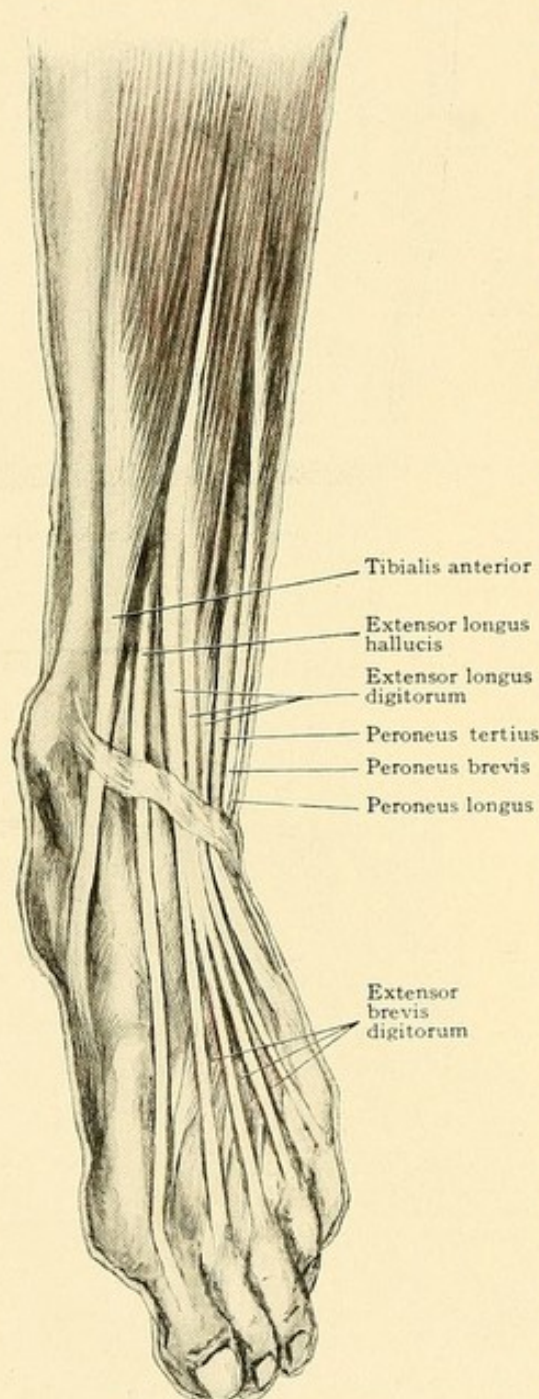


FIG. 588.—The foot in an abducted or pronated position.



The *external malleolus* is more prominent than the internal, smaller, and more pointed. The fibula above for its lower fourth is subcutaneous. The tip of the external malleolus is 2 cm. ( $\frac{3}{4}$  in.) below and behind the internal. Around its posterior and lower edge run the peroneus longus and brevis tendons.

The *tubercles of the os calcis* can be felt posteriorly and at the sides. The external surface can be followed forward, but the internal is buried beneath the soft tissues. Of the two tubercles on its under surface the internal can be felt by firm pressure.

The *tubercle of the scaphoid (navicular)* lies on the plantar rather than on the lateral aspect of the bone. It can be felt 4 cm. ( $1\frac{1}{2}$  in.) below and in front of the

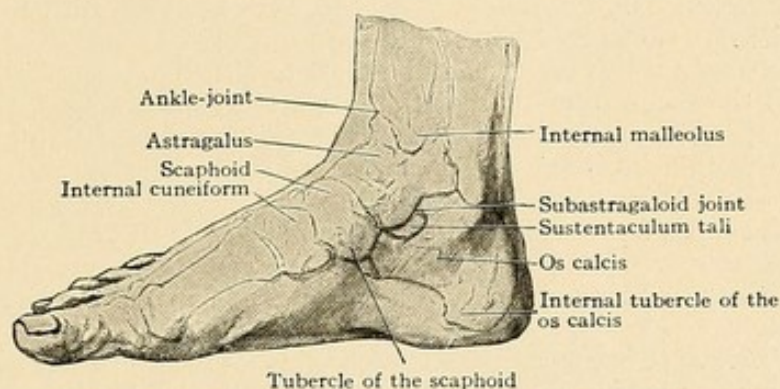


FIG. 589.—Surface anatomy of the inner side of the ankle.

internal malleolus. It is the landmark for the tarsal joints on the inner side of the foot. The *tibialis posterior* muscle runs from it to the posterior edge of the internal malleolus.

The *sustentaculum tali* can be found by feeling 2.5 cm. (1 in.) below the internal malleolus. It is not very distinct.

The *tuberosity of the fifth metatarsal bone* is the large bony prominence 6 cm. ( $2\frac{1}{2}$  in.) below and in front of the external malleolus. It is the guide to the tarsal

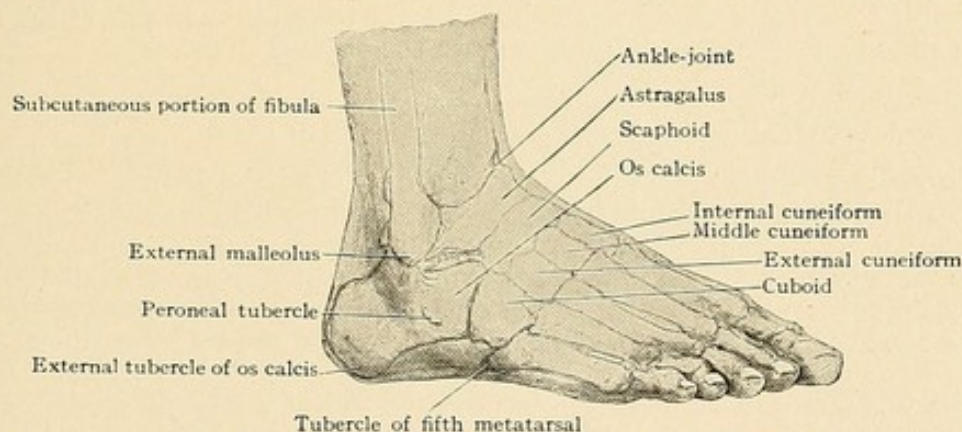


FIG. 590.—Surface anatomy of the outer side of the ankle.

joints on the outside of the foot. The tendon of the *peroneus brevis* runs from it to the posterior edge of the external malleolus.

The *peroneal spine* (tubercle) can be felt indistinctly as a small bony prominence 2.5 cm. (1 in.) below and a little in front of the external malleolus. In front of it runs the *peroneus brevis* and behind it the *peroneus longus*.

**The Tendons.**—It is difficult to identify the position of the tendons, especially if one does not know where to look for them.

The *tendo calcaneus* (Achillis) is usually easily recognized, as it can be made tense, even in fat, chubby children, by dorsally flexing the foot.



The *flexor longus digitorum* and *flexor longus hallucis* lie too deeply behind the internal malleolus to be recognized; the latter is the more posterior.

The *tibialis posterior*, on strongly abducting the foot, can often be seen and felt along the posterior border of the internal malleolus and between the latter and the tubercle of the scaphoid, into which it inserts.

The *tibialis anterior* is the tendon nearest the anterior edge of the internal malleolus. It runs down to the internal cuneiform bone about 2.5 cm. (1 in.) in front of the tubercle of the scaphoid.

The *extensor longus hallucis* lies just to the outside of the *tibialis anterior* and can often be made prominent by flexing the big toe.

The *extensor longus digitorum* tendons at the ankle lie close together just outside of the *extensor longus hallucis*. The *peroneus tertius* runs from them to the dorsum of the fifth metatarsal bone a little in front of its base.

The *peroneal tendons* can usually be made visible by sharply adducting the foot. The *brevis* is then seen running back to the peroneal spine 2.5 cm. (1 in.) below and a little in front of the external malleolus and from this point up to behind the malleolus; in thin people both the *brevis* and *longus* can be seen and followed up the lower part of the fibula.

The soft rounded prominence about 5 cm. (2 in.) in front of the external malleolus is the *extensor brevis digitorum muscle*.

**The Joints.**—The *ankle-joint* lies 1.25 cm. ( $\frac{1}{2}$  in.) above the tip of the internal malleolus.

The *midtarsal* (Chopart's) joint is best found on the inner side of the foot; here it passes immediately behind the tubercle of the scaphoid. On the outer side it is approximately at the middle of a line joining the external malleolus and tuberosity of the fifth metatarsal bone. At this point there is frequently a bony prominence formed by the anterior edge of the *os calcis*.

The *tarsometatarsal* (Lisfranc's) joint is best found on the outer side of the foot. It lies immediately behind the tuberosity of the fifth metatarsal bone, between it and the cuboid.

Its inner extremity can be found either by following up the first metatarsal bone from its head for about 5 cm. (2 in.) when a ridge of bone will be felt on its base, the joint being immediately behind it; or by identifying the tubercle of the scaphoid and allowing 2.5 cm. (1 in.) from its anterior edge for the internal cuneiform bone. Its exact location is to be recognized by pressing with the edge of the thumb at the suspected spot and moving the metatarsal bone with the opposite hand.

## THE ARTERIES OF THE FOOT.

The **dorsalis pedis artery** runs from the middle of the front of the ankle to the base of the first metatarsal interspace. The *extensor longus hallucis* tendon is on the medial side and the *extensor longus digitorum* on the lateral. An incision made midway between these tendons exposes the muscular fibres of the *extensor brevis digitorum*; this is pulled to the outer side and the artery will be found lying on the bone beneath. The *extensor brevis digitorum* crosses it near its termination.

This artery is rarely the subject of ligation, but one frequently endeavors to feel its pulsation in order to determine whether the artery above is intact.

**The Plantar Arteries.**—The *tibialis posterior* divides into the internal and external plantar arteries at a point midway on a line joining the internal malleolus and internal tubercle of the *os calcis*. From this point the **internal plantar artery** runs forward along the medial side of the *flexor longus hallucis* in the groove between the *abductor hallucis* and *flexor brevis digitorum*. It is much the smaller of the two plantar arteries (Fig. 591).

The **external plantar artery** runs from the same point as the internal to the inner side of the base of the fifth metatarsal bone. To this point it lies beneath the *flexor brevis digitorum* and above the *accessorius*. It then dips deeper, lying on the *interossei*, and curves inward to end in the communicating artery which pierces the base of the first metatarsal space to anastomose with the *dorsalis pedis*.



It can be ligated by making an incision at the medial side of the base of the fifth metatarsal bone between the flexor brevis digitorum and the flexor brevis minimi digiti.

Formal ligation of the plantar arteries is not often required. If wounded the bleeding can be stopped by packing the wound, applying pressure, and elevating the foot as high as possible. Care is to be exercised in making incisions in the sole of

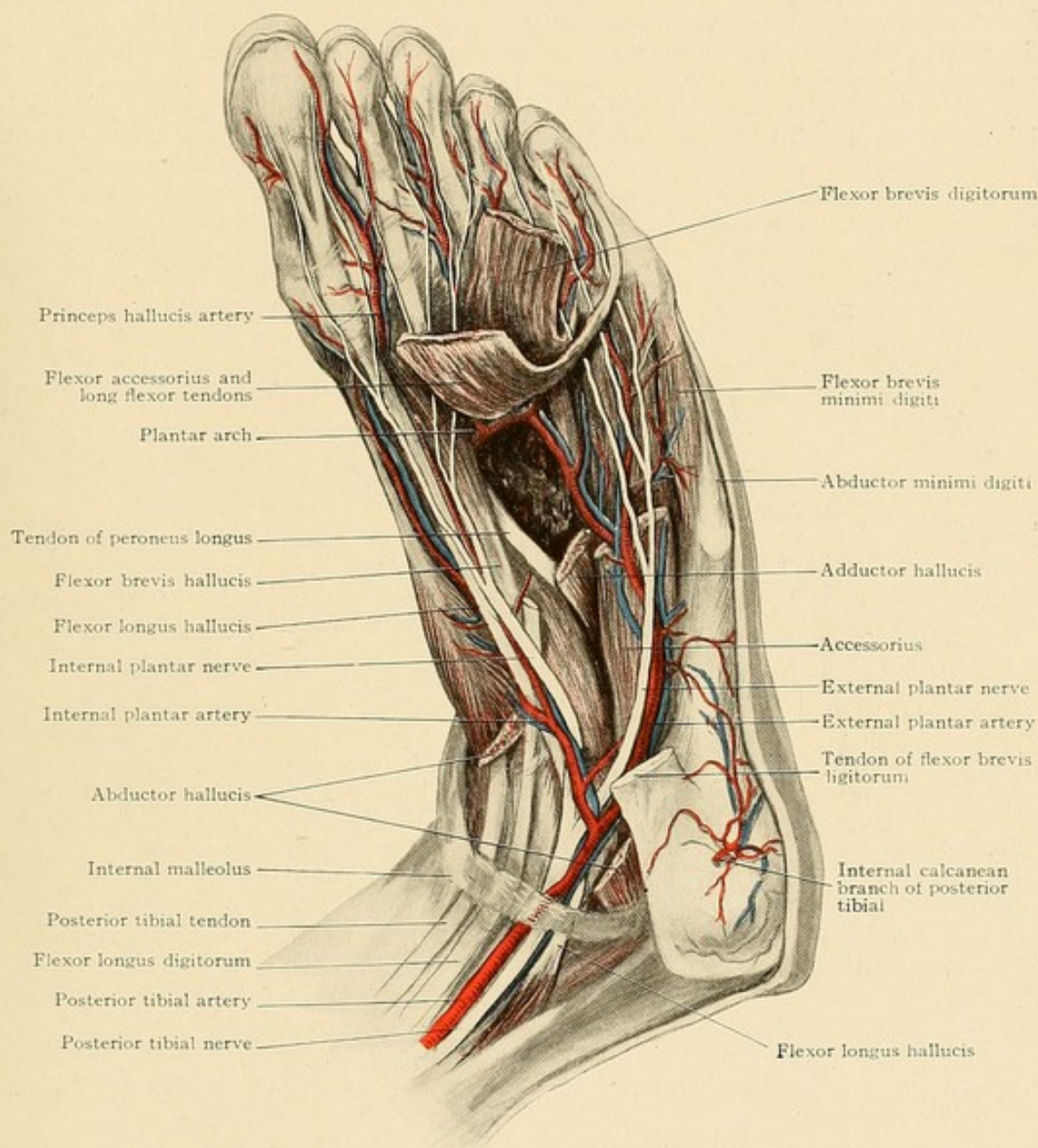


FIG. 591.—Plantar arteries and nerves.

the foot in the grooves to the inner and outer side of the flexor brevis digitorum for fear of wounding the plantar arteries. The external plantar is, however, not liable to be wounded if the incision is made back toward the tubercle of the os calcis.

The plantar arteries usually escape division in operating subcutaneously on the plantar fascia because the plantar fascia is above the flexor brevis while the arteries are below. It is so difficult to ligate bleeding arteries in the foot that it is usually better to pack the wound with an antiseptic gauze and elevate the limb.



## AMPUTATIONS OF THE FOOT.

The foot may be amputated through the midtarsal or tarsometatarsal joints. Ordinarily they give unsatisfactory stumps owing to the heel being pulled up by the tendo calcaneus (Achillis), and the shape of the inner part of the tarsal arch. This causes the patient to walk on the end of the stump, which soon becomes painful.

To perform these operations skilfully it is essential that one be familiar with the lines of the joints. Plantar flaps are used because the skin of the sole is tougher than that of the dorsum and the cicatrix is out of the line of pressure.

**Midtarsal (Chopart's) Amputation.**—This is made through the midtarsal joint. The guides to the joint are the tubercle of the scaphoid (navicular) on the

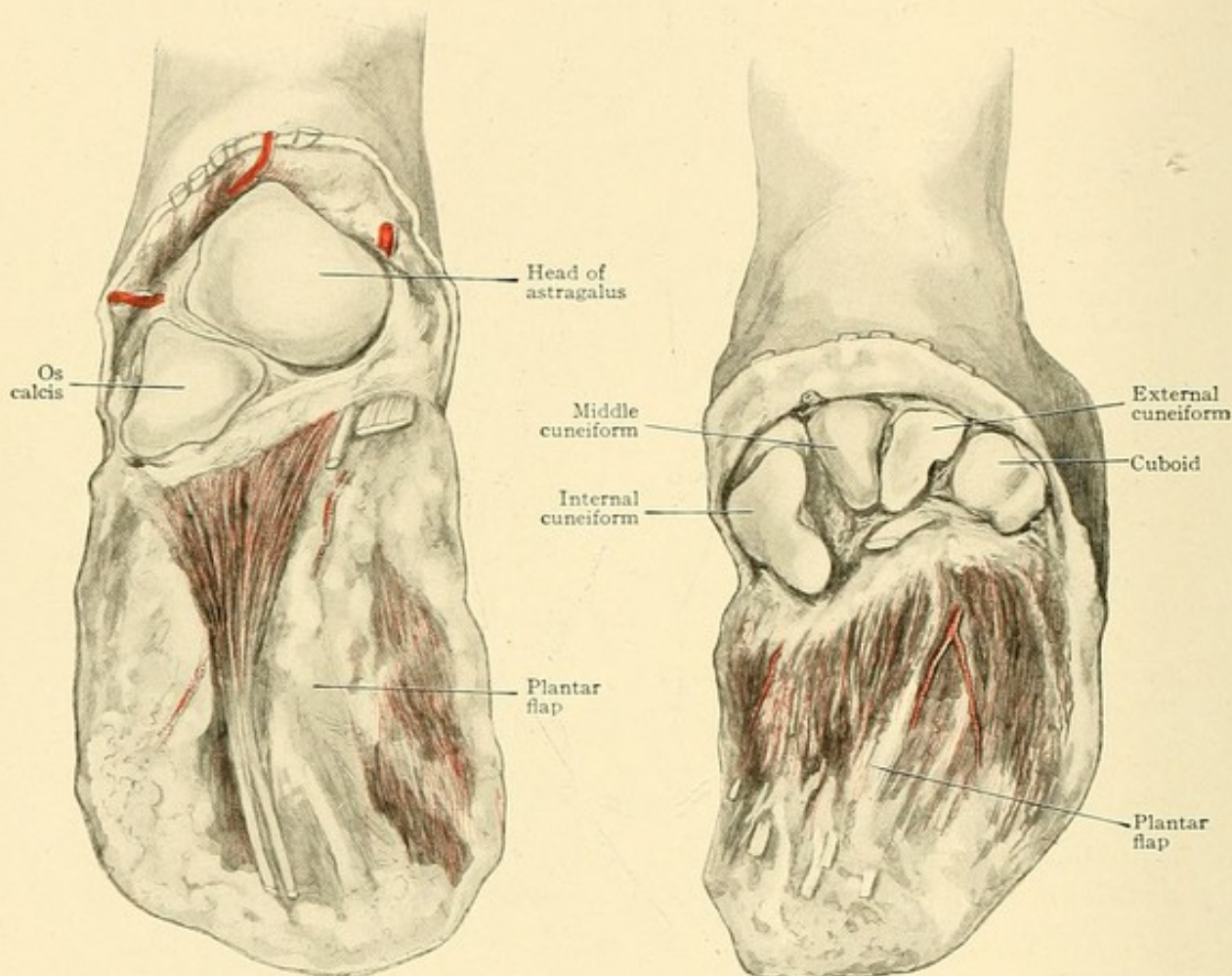


FIG. 592.—Chopart's midtarsal amputation of the foot.

FIG. 593.—Lisfranc's tarsometatarsal amputation of the foot.

inside and the ridge on the anterior end of the os calcis, midway between the external malleolus and the fifth metatarsal bone, on the outer side. A short dorsal and a long plantar flap are cut. The plantar flap is longer on its inner side to allow for the greater thickness of the foot on that side. It is easier to begin the disarticulation on the inside, going in just behind the tubercle of the scaphoid (navicular). This part of the joint is convex forward. On reaching the outer edge of the astragalus (talus) care should be taken not to slip posteriorly between the astragalus and os calcis, but to continue laterally. The extensor tendons are to be sutured to the end of the stump and frequently the tendo calcaneus (Achillis) is cut in an attempt to prevent subsequent elevation of the heel. (Fig. 592).

Carelessness may result in opening the joint in front instead of behind the scaphoid (navicular).



**Tarsometatarsal (Lisfranc's) Amputation.**—The guide to this joint is the tuberosity of the fifth metatarsal bone on the outer side and the ridge on the base of the first metatarsal on the inner side. This latter is about 4 cm. (1½ in.) in front of the highest point of the tubercle of the scaphoid.

The joint is best entered from the outer side. The knife is to be passed first forward and then carried inward. Trouble is usually experienced when the base of the second metatarsal is to be disarticulated. It lies behind the others and some surgeons advise skipping it and opening the first metatarsal joint and then completing the disarticulation by opening the second last. The sawing off of the projecting internal cuneiform bone as proposed by Hey is objected to on account of weakening the attachment of the tibialis anterior tendon. The same precaution is to be taken of making the plantar flap longer on its inner side, as was advised in Chopart's amputation, on account of the greater depth of the foot on this side. The line of the joint is best understood by reference to the position of the bones (Fig. 578). Tenotomy of the tendo calcaneus (Achillis) is not so often resorted to in this amputation as in that through the midtarsal joint (Fig. 593).

### PLANTAR ABSCESS.

Abscesses of the sole of the foot are usually caused by infected punctured wounds, or by the extension of infection from wounds of the toes, etc.

The plantar fascia lies on the flexor brevis digitorum while the long flexor tendons lie beneath it. A punctured wound may perforate the plantar fascia and penetrate the flexor brevis which arises from its under surface, yet if this muscle is not entirely traversed by the wound the tendons of the long flexors beneath escape infection and the pus accumulates beneath the plantar fascia.

#### Superficial Plantar Abscess.—

In the superficial form of plantar abscess the pus tends to point in four directions: (1) it may come directly up through gaps between the fibres of the plantar fascia and make an hour-glass abscess, a small amount of pus being above the plantar fascia, between it and the skin, while a larger collection is beneath the fascia in the substance of the muscle; (2) it may burrow its way forward showing between the tendons in the direction of the webs of the toes; (3) it may appear in the groove on the outer side of the foot between the flexor brevis and abductor minimi digiti; (4) it may appear on the inner side of the foot between the abductor hallucis and flexor brevis (Fig. 594).

**Deep Plantar Abscess.**—In deep infection the pus accumulates around the deep flexor tendons and beneath the flexor brevis muscle. Its greatest tendency is to extend up the leg by following the flexor tendons behind the internal malleolus. It may also show itself in the grooves on either side of the flexor brevis, or between the tendons at the webs of the toes.

**Incision of Plantar Abscess.**—The safest way to open these abscesses is by the method of Hilton. The skin is first incised and the abscess opened by inserting a pointed hæmostatic forceps and opening its blades, or using some similar blunt instrument. This is done to avoid wounding the arteries. If necessary the whole

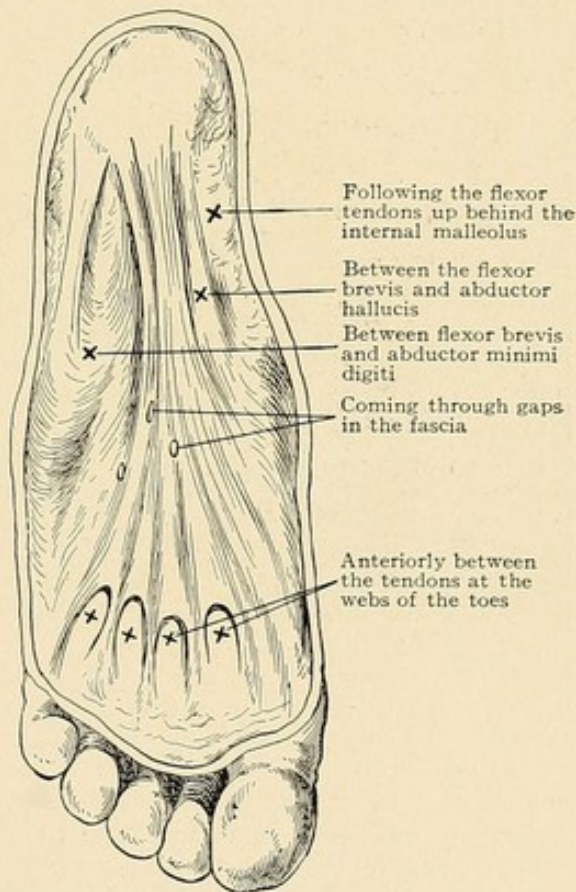


FIG. 594.—Diagram showing the points of exit of suppuration beneath the plantar fascia.



thickness of the foot may be traversed by this means and a drainage-tube passed through from one side to the other.

Incisions should not be made over bony points where they would be subjected to pressure. Hence the heads of the metatarsal bones and the prominent outer edge of the foot are avoided. Incisions in the hollow of the foot and between the forward ends of the metatarsal bones are to be preferred. In opening a subcutaneous collection one should not be satisfied with simply incising the skin, but the fascia should be widely split to guard against a larger collection of pus beneath.

Collections which present to the outer side of the flexor brevis are to be opened a little distance behind the base of the fifth metatarsal bone because the external plantar artery becomes somewhat superficial at its inner side.

### DEFORMITIES OF THE FOOT.

The common deformities of the foot are those in which the parts affected are deformed or turned to an abnormal degree in the direction of their normal movements. Thus in *talipes varus* the foot is turned inward, hyperadducted; *talipes valgus* and flat-foot, turned out, hyperabducted; *talipes equinus* or hyperextended, *talipes calcaneus* or hyperflexed, and *talipes cavus* or increase of the arch of the foot.

These deformities may be either congenital or acquired, and it is not always easy to separate the two. A deformity may be thought by the parents to have existed from birth, when it may have been caused by an infantile paralysis occurring before the period of walking.

Foot deformities likewise possess two characteristics which are marked, they are those of paralysis or weakness and contraction or strength. They are usually

associated but sometimes separate. There can be a paralysis without contraction, but inasmuch as the muscular system is built on the principle of balance it is obvious that if one muscle or set of muscles is paralyzed it is only a question of time until the opposing muscles become contracted. In a similar manner if contraction exists as the most prominent element and perhaps the primary one, it will usually be found that the opposing muscles and ligaments are stretched and weakened.

These conditions furnish the indications for treatment. Where weakness is the predominant feature then support is to be given and contraction of the relaxed tissue favored. Where

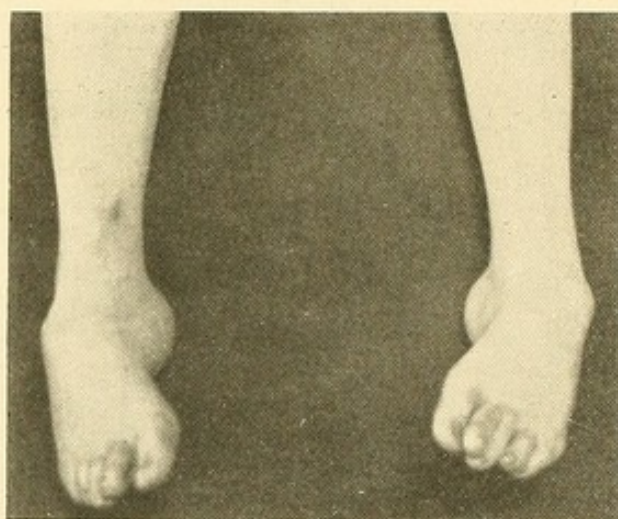


FIG. 595.—*Talipes equinovarus*.

strength and contraction is predominant then operations and forcible measures are necessary to overcome them. Also, when in a contracted case the contracted tissues have been overcome, there still remains the weakness of the opposing tissues to be remedied. It may be possible to bring the foot to a perfectly normal position, but until the previously weakened and overstretched tissues have regained their tone normal function will not be possible.

While the deformities may be simple they are usually compound; thus an equinus may be associated with a varus or valgus, and is then called an equinovarus or equinovalgus. Cavus or hollow-foot and calcaneus or lowering of the heel are often associated, so that it is difficult to draw a line separating them.

**Talipes Varus.**—*Talipes varus* in its most common form is congenital and is often associated with equinus or a drawing up of the heel. The prevailing deformity is one of adduction, with a certain amount of inward rotation (Fig. 595). The muscles favoring it are the tibialis anterior and tibialis posterior; therefore the tendons of these muscles are sometimes cut to prevent their drawing the foot upward and



inward. Division of the plantar fascia is also often necessary. The main principles of treatment are to stretch the contracted tissues forcibly, either by manual or instrumental force, and then maintain the foot in its corrected position, often at first by plaster of Paris and later by apparatus, until the weakened opposing muscles have resumed their functions. This often takes so long that transplanting of tendons has been resorted to; thus the tendon of the tibialis anterior has been detached from its insertion on the inner side of the foot and transplanted to the outer side, so that the contracting force on the inner side of the foot is weakened, while the correcting force of the abducting muscles has been increased.

If equinus is present either tenotomy of the tendo calcaneus (Achillis) or forcible stretching of it allows the heel to descend.

**Talipes Valgus.**—In talipes valgus the foot is abducted or everted. It is sometimes associated with equinus and sometimes with calcaneus. It is more usually an acquired than a congenital deformity. It is a deformity that has weakness as its primary cause and most marked characteristic. This weakness is either a more or less general one affecting the ligaments and muscles, as shown by its occurring in adolescents, or else primarily a muscular one caused by spinal infantile paralysis (anterior poliomyelitis) (Fig. 596).

From what has been said of the normal movements of the joints (page 569 and *ante*) it is evident that a weakness of either the muscles or ligaments shows itself first

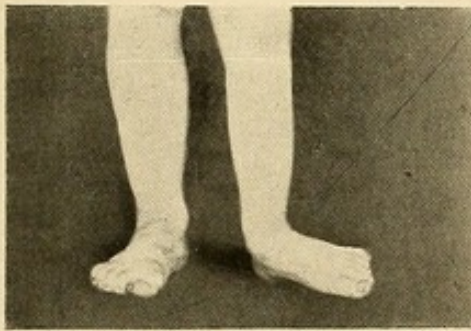


FIG. 596.—Paralytic talipes valgus.

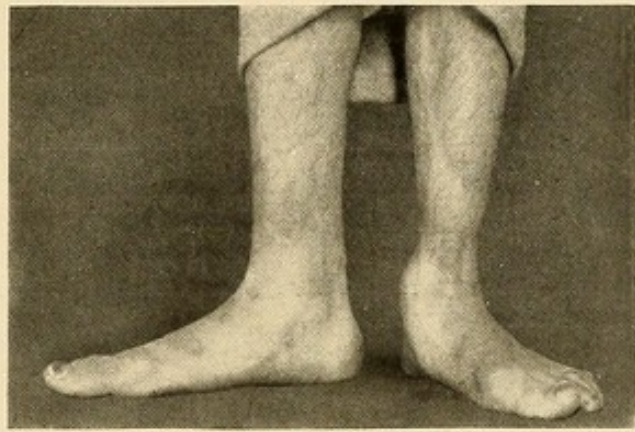


FIG. 597.—Flat-foot.

by an eversion of the foot called the *pronated foot* which is followed by a descent of the tarsal arch or *flat-foot* and later by a more complete eversion or *pes valgus*. They are the three stages of the same process.

When a young person with apparently normal feet is subjected to excessive strain, as by long standing, etc., the muscles and ligaments are unable to bear the burden. The muscles give way first and the foot everts, mainly at the subastragaloid joint, thus is produced the pronated foot. The patient, unable to support the body weight sufficiently on the weakened muscles, relaxes them and allows the body weight to be borne on the ligaments. This excess of weight on the ligaments supporting the arch causes them to give way and the arch descends and flat-foot results. The process often stops here in the adolescent form or even if rheumatism is the weakening element (Fig. 597).

When paralysis—usually of the extensors and tibialis posterior—is the cause, then the ligaments not being so much affected may maintain the arch intact, but the whole foot is drawn outward by the peroneal and flexor muscles, aided also by the centre of gravity being shifted inward. The deformity is increased by walking and a true valgus results.

In the pronated foot and flat-foot of adolescents pain is often marked so that the relaxation of the inverting muscles is often accompanied by spasm of the everting muscles and the peronei muscles are frequently found markedly contracted. In paralytic valgus the eversion of the foot relaxes the peronei and they gradually shorten. It should be noted that the contraction of the peroneal muscles in one case is active, in the other passive.



*Treatment.*—In painful pronated and flat feet the contracted muscles can be relaxed by perfect rest in bed. Next the arch can be supported by pads or plates beneath the instep and the weakened muscles strengthened by massage, electricity, or appropriate exercises while the exciting cause of overwork is removed. In paralytic valgus, the foot may be brought straight by forcible stretching and held there by appropriate apparatus; or an artificial ankylosis (arthrodesis) of the subastragaloid

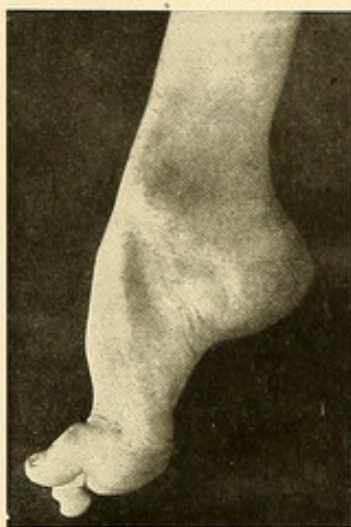


FIG. 598.—Talipes equinus.

and ankle-joints may be made to hold the foot in position; or the peroneal or other tendons, on the outer side of the foot, may be transplanted to the inner.

**Talipes Equinus.**—This sometimes exists as a pure form but it often accompanies varus and sometimes valgus. It is caused by a paralysis of the extensor muscles. The tendo calcaneus is contracted and the patient walks on the toes. By division or lengthening of the tendo calcaneus and forcible flexion of the foot the

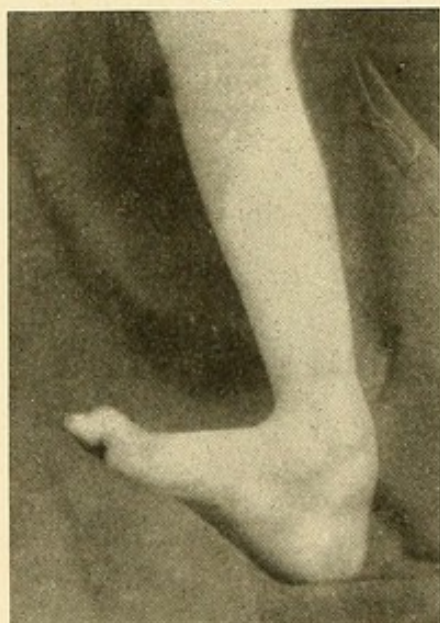


FIG. 599.—Talipes calcaneus.

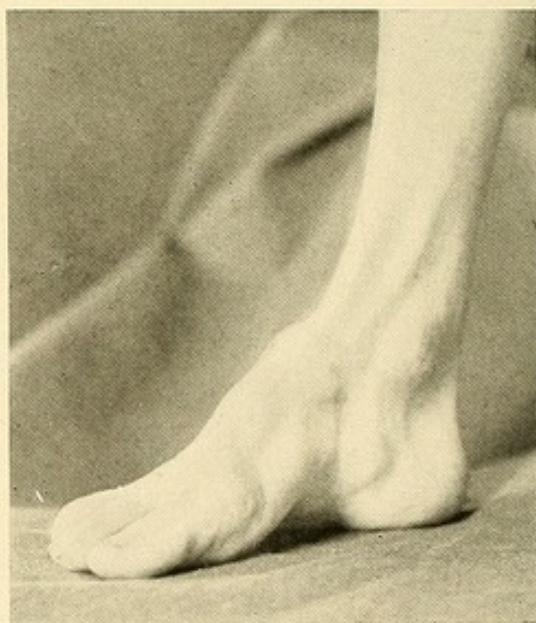


FIG. 600.—Talipes cavus.

heel may be brought down but the foot will "flop" in a more or less flail-like condition from the leg. To remedy this either an apparatus is employed or sometimes the peroneal muscles or some of the flexor tendons are brought forward and the effort made to have them fulfil the function of the paralyzed extensors, which latter may also be shortened (Fig. 598).

**Talipes Calcaneus and Talipes Cavus.**—These result from paralysis of the muscles of the calf or of most of the flexor and extensor muscles (Figs. 599 and 600).



If the calf muscles are paralyzed the contraction of the tibialis anterior and tibialis posterior pull up the arch and the contraction of the flexor brevis digitorum pulls the pillars closer together, therefore the heel descends, the arch ascends, and the plantar ligaments contract. If the extensor muscles are also paralyzed the toes drop and the anterior deformity is increased.

The *treatment* of this condition is as yet not entirely settled. The plantar fascia must be divided and the pillars of the arch separated and the arch depressed by forcible manual or instrumental means. To retain the foot in its corrected position the tendo calcaneus is sometimes shortened and even the tibialis anterior and posterior and peroneal muscles transplanted anteriorly into the extensor longus digitorum so as to increase the power of dorsal flexion of the anterior pillars of the tarsal arch. At times some of these tendons are grafted on the tendo calcaneus in order to pull the heel up. Operations on the bones and joints are also performed.

**Hallux valgus** is a subluxation of the big toe outward. There is usually a deformity of the bone, the joint surface of the head of the first metatarsal being inclined obliquely out. As the toe becomes displaced outward the extensor hallucis longus by its contraction tends to increase the deformity. On the side of the head of the protruding metatarsal bone a bursa develops and becomes painful, forming a *bunion*. This bursa sometimes suppurates (Fig. 601).

In some cases hallux valgus is due apparently to ill-shaped shoes, but in many cases, and these the worst, a rheumatic-gouty condition is the main factor. In treatment the articular surface of the head of the first metatarsal bone is first resected. This enables the toe to be brought straight. To keep it straight the tendon of the extensor hallucis is displaced inward so that by its contraction it keeps the toe from again going outward.

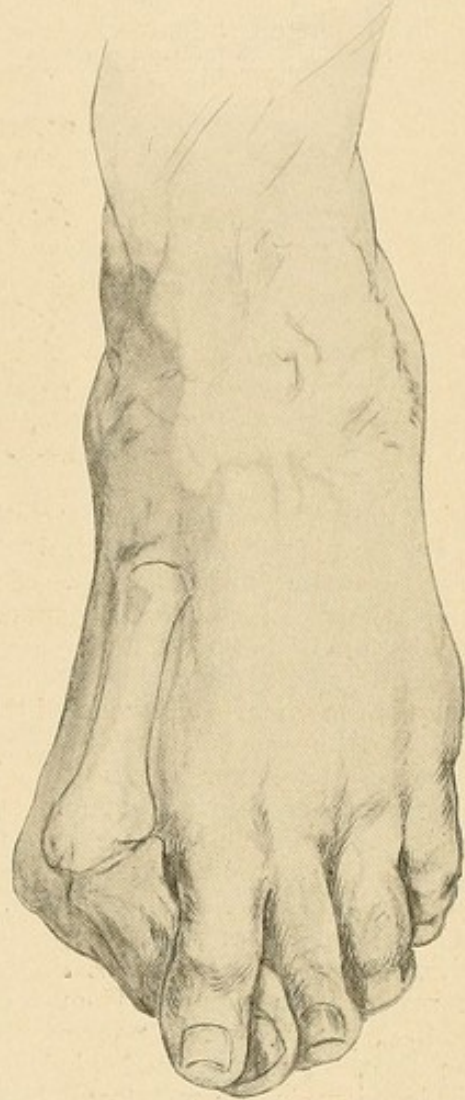


FIG. 601.—Hallux valgus, showing the position of the bones.

## THE TOES.

The toes are shorter than the fingers and are not so often injured. When injured or diseased healing may be delayed by the constant motion to which they are subjected. For this reason rest should be enforced in obstinate cases by the application of bandages or splints.

**Ingrown Nail.**—This usually affects the big toe. It is caused commonly by the irritation and pressure of badly-shaped shoes. To cure it the side of the nail is sometimes removed. In so doing the nail should be removed well beyond the skin margin at the matrix otherwise it is reproduced in a distorted form. It requires several months for a new nail to grow out from the matrix. Packing cotton soaked in a solution of nitrate of silver, 10 grains to the ounce, beneath the edge of the nail destroys the infection, lessens the pressure, and usually relieves the acute trouble in a few days.

**Hammer Toe.**—This is a contraction of one of the toes, most often the second. The deformity is usually consecutive to the use of badly fitting shoes. Walsham ("Deformities of the Human Foot"), Shattock, and Anderson believe it to depend



on a contraction of the plantar fibres of the lateral ligaments and glenoid ligament on the under side of the joint. Others hold it to be a contraction of the tendons. In treatment both conditions have to be considered. On pulling the toes the extensor tendon is put on the stretch, it should be divided, the remaining contractures are then either cut or broken by forcible stretching and the toe kept straight by band-

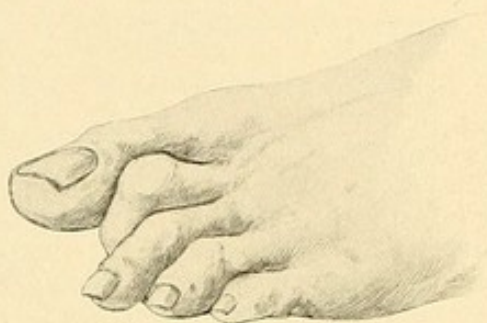

FIG. 602.—Hammer-toe. (From author's sketch.)

aging until all tendency to contraction has been corrected. As a last resort resection of the joint is performed (Fig. 602).

**Luxation of the Toes.**—The big toe may become dislocated by direct violence; the lesion is often compound. The displacement is most often backward on the dorsum of the metatarsal bone. When the injury is not compound the same difficulty may be experienced in reducing it as occurs in dislocation of the thumb. The cause is the same. The head of the metatarsal bone becomes caught in the fibrous tissues of the capsule and between the two heads of the flexor brevis hallucis muscle. These each contain a sesamoid bone. The detachment of one of these heads from the base of the first phalanx may be necessary before replacement can be effected.

Dislocation of the other individual toes is not nearly so rare as it is thought to be. It results from jumping from a height and landing, perhaps on an uneven surface, with the toes. The proximal phalanx may be displaced upon the metatarsal bone and the resulting pain is often considered to be merely a sprain.

The head of the affected metatarsal bone can be felt projecting in the sole, the toe is shortened and the space between it and the adjacent one usually increased; but the diagnosis is difficult and is best established by means of a skiagraph. Reduction is difficult and even when accomplished is not apt to remain (Fig. 603). Resection may be required.

#### **Metatarsalgia or Morton's Disease.**

—This is a painful affection of one of the metatarsophalangeal joints, usually the fourth. Its pathology is not settled, but treatment is based on the supposition that the heads of the metatarsal bones become pressed together, usually by tight shoes. Relief is often afforded by separating the toes with cotton; by winding adhesive plaster—several thicknesses—around the affected toe; by supporting the arch by pads or plates; by inserting a narrow longitudinal pad; or by resection or amputation.

**Resection of the Metatarsophalangeal Joint.**—In hallux valgus resection of the head of the metatarsal bone may give rise to a stiff joint. If the ankylosis is in a somewhat extended position, walking may not be impaired.

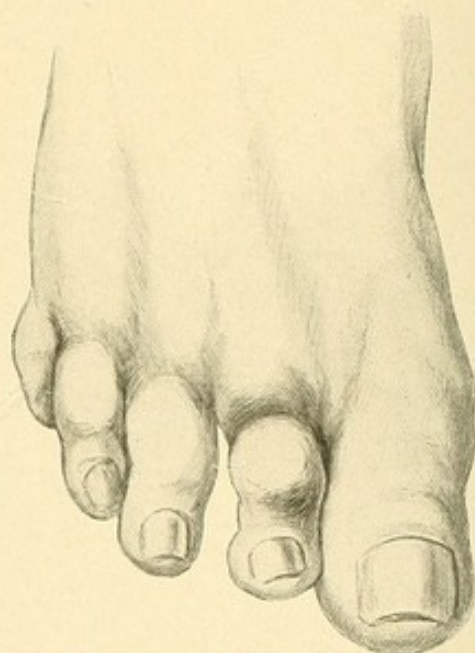

FIG. 603.—Dorsal luxation of the proximal phalanx of the second toe. Notice the shortening of the toe, its separation from the third toe, and the fulness over the head of the metatarsal bone. (From a sketch by the author.)



Excision of these joints may, and often does, give rise to a flail-like condition. The affected toe is deprived of its support and becomes displaced. Sometimes it gets beneath the adjoining toes and pain is caused by their superincumbent pressure. In other cases the toe is squeezed up above the level of the adjoining ones and is rubbed by the shoe above, causing painful corns. In either case the toe affected is a source of misery and not infrequently may require to be amputated. For these reasons excisions are seldom resorted to except in cases of hallux valgus.

**Amputation of the Toes.**—Amputation of the phalanges does not cause serious disability, but the loss of the head of the first metatarsal bone seriously weakens the foot.

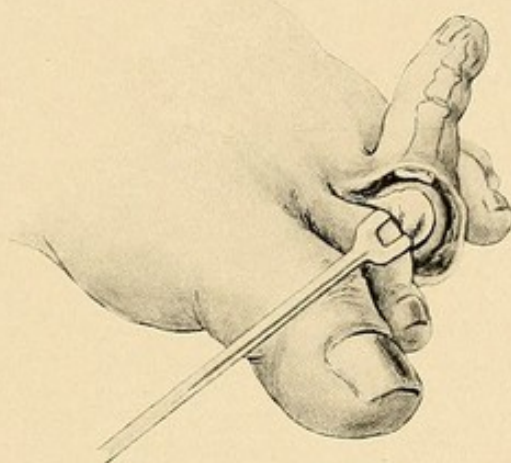


FIG. 604.—Amputation of a toe at the metatarsophalangeal joint, with lateral flaps, showing method of disarticulating.

Amputation of the outer four toes at the metatarsophalangeal joint is a difficult operation because, unless one is well informed, it will be hard to strike the joint. It should be sought about 1 cm. ( $\frac{2}{5}$  in.) behind the web on the dorsal aspect, and if approached on the plantar aspect especial care is to be exercised not to go too far back and search for it on the neck of the metatarsal bone (Fig. 604). As in the hand so also in the foot when the proximal phalanx is bent the prominence (or knuckle) is formed by the head of the proximal (metatarsal) bone.







FROZEN SECTIONS.







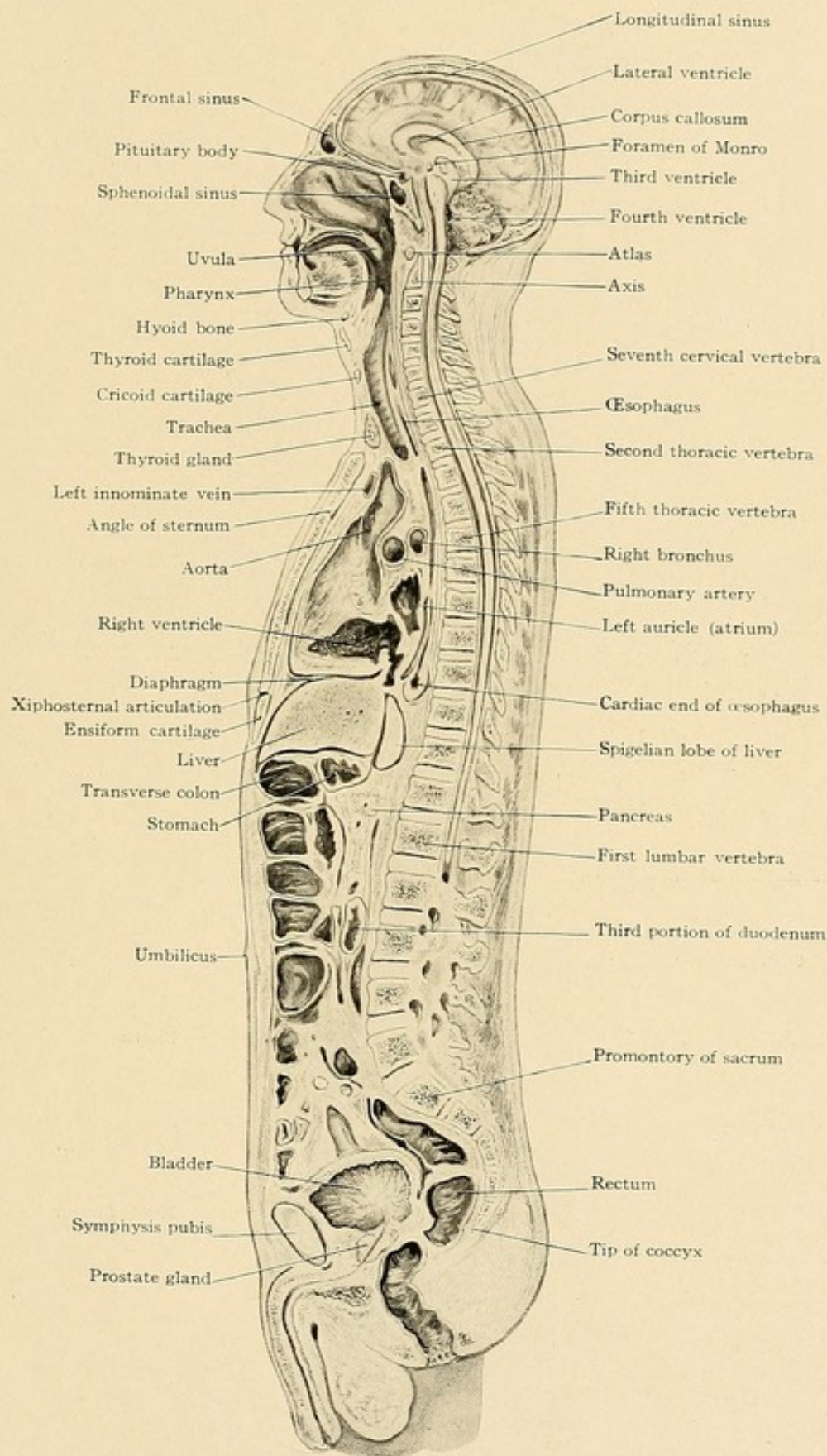


FIG. 605.—Median sagittal section.



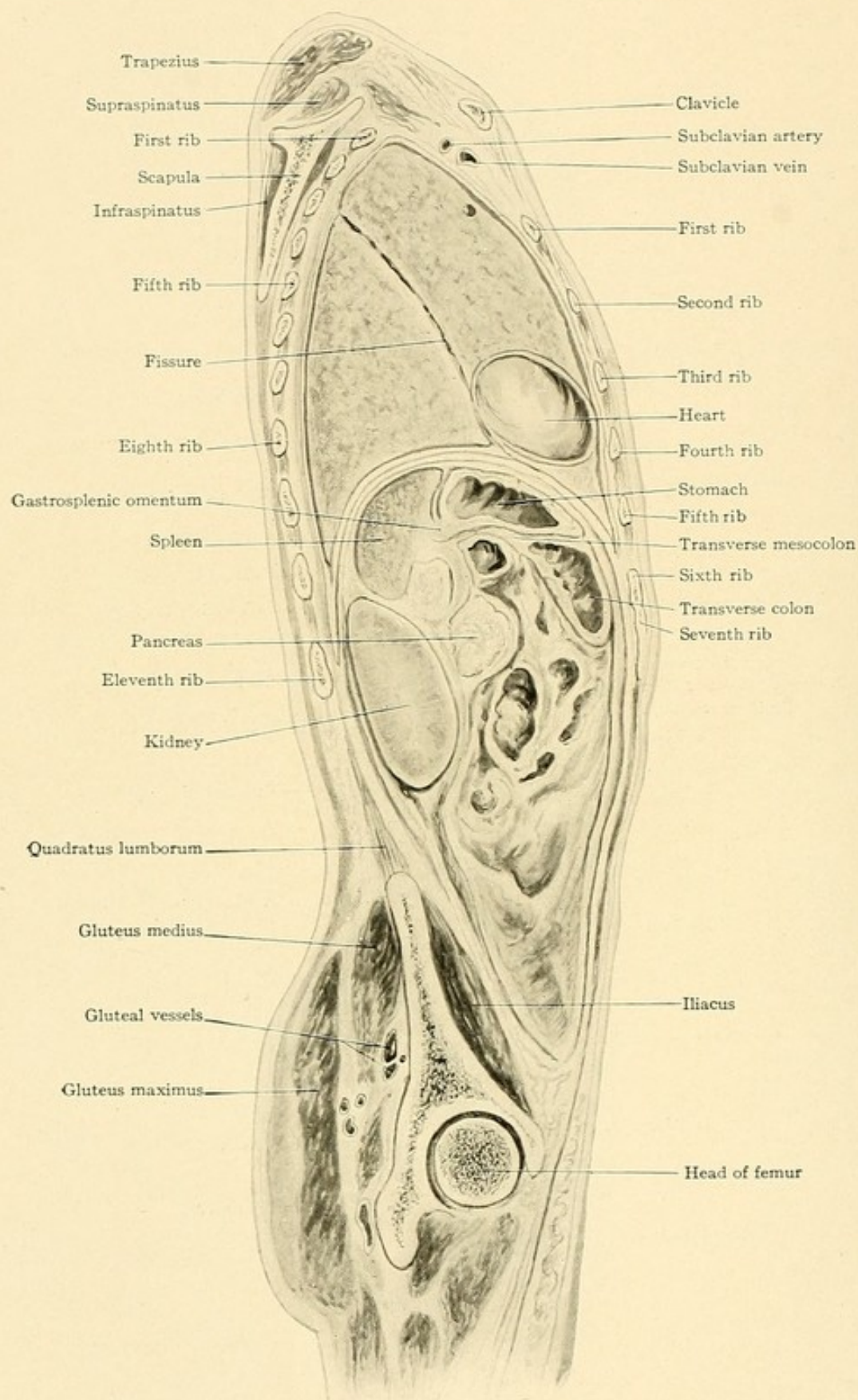


FIG. 606.—Sagittal section through about the middle of the left clavicle.



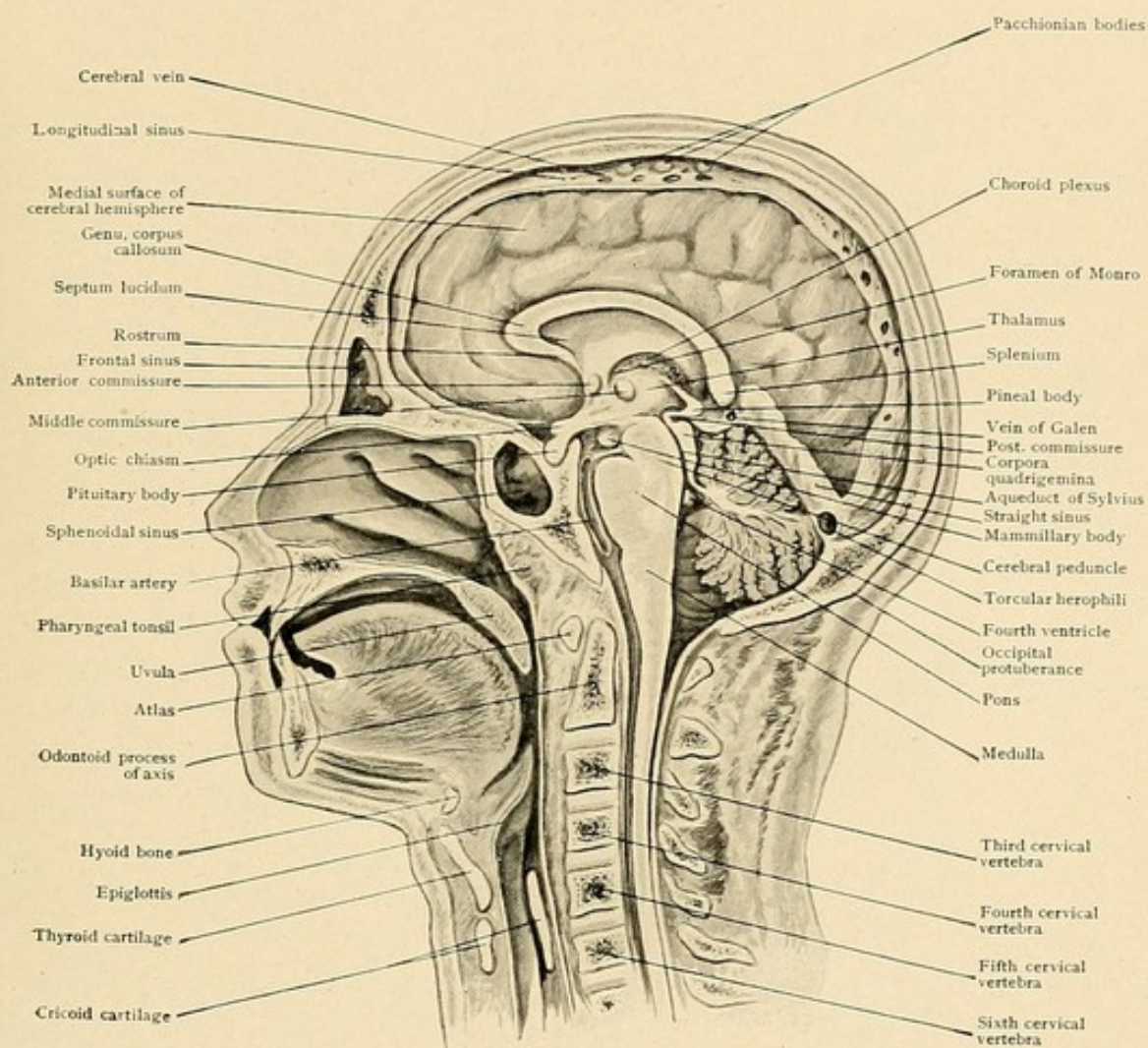


FIG. 607.—Median sagittal section of the head and neck.



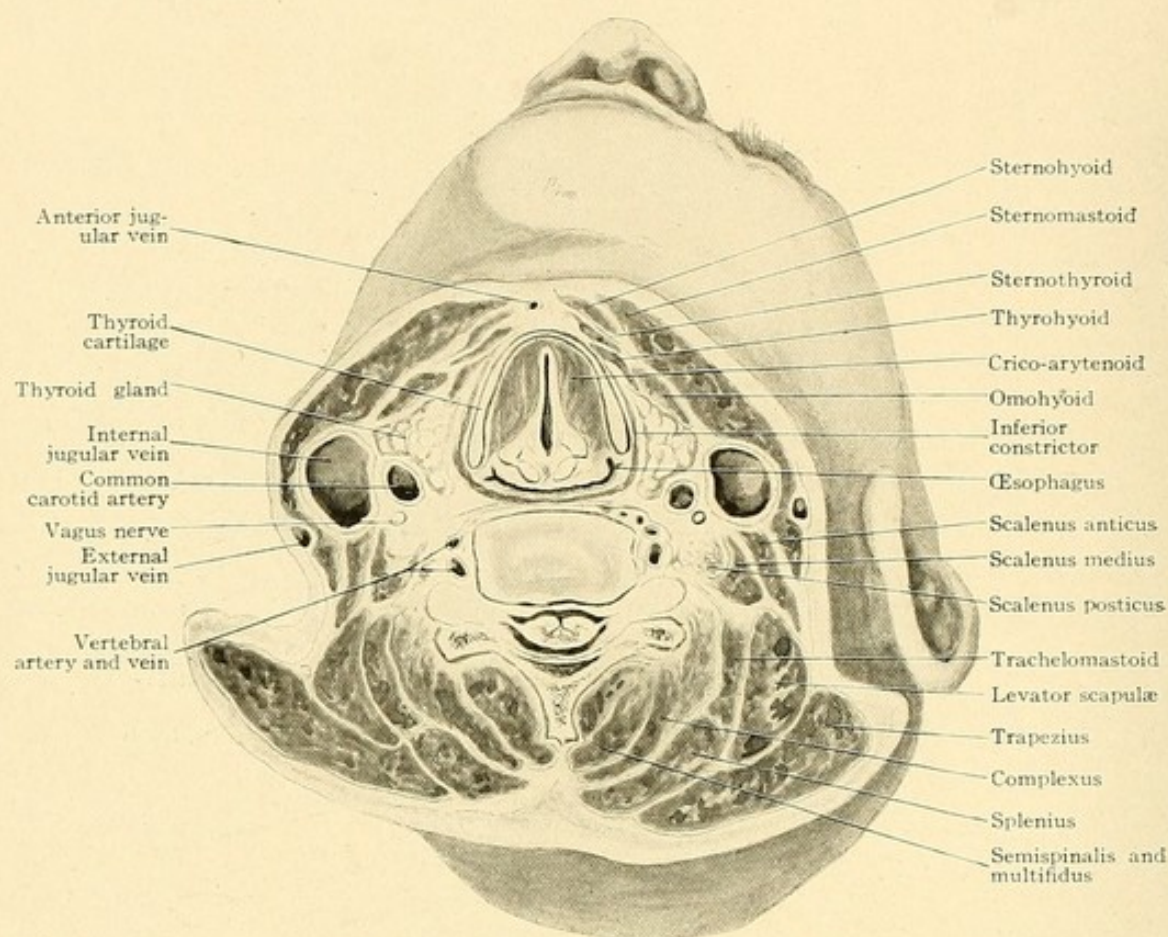


FIG. 608.—Transverse section through the intervertebral cartilage between the fifth and sixth cervical vertebrae.



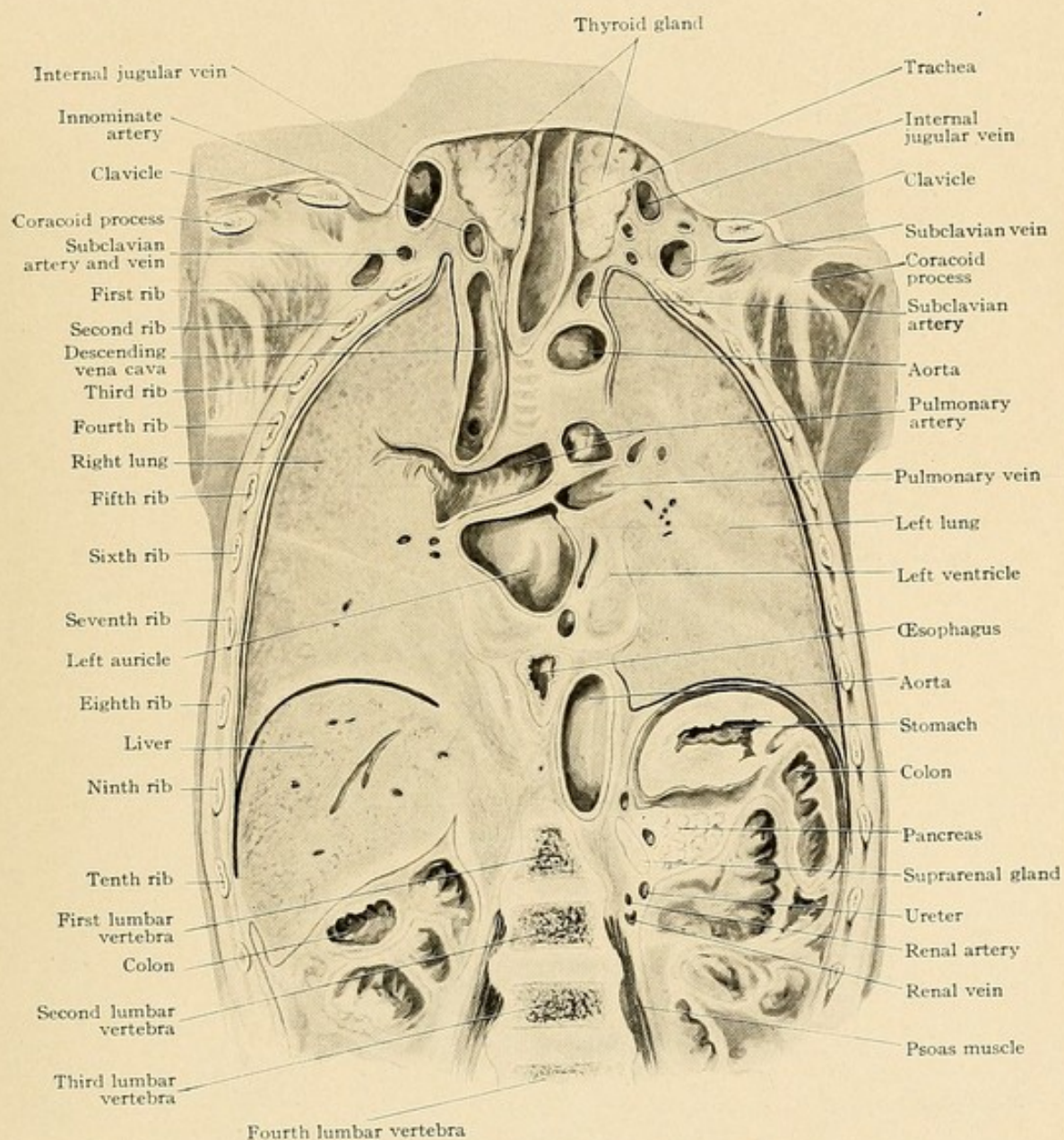


FIG. 609.—Coronal section through the thorax.



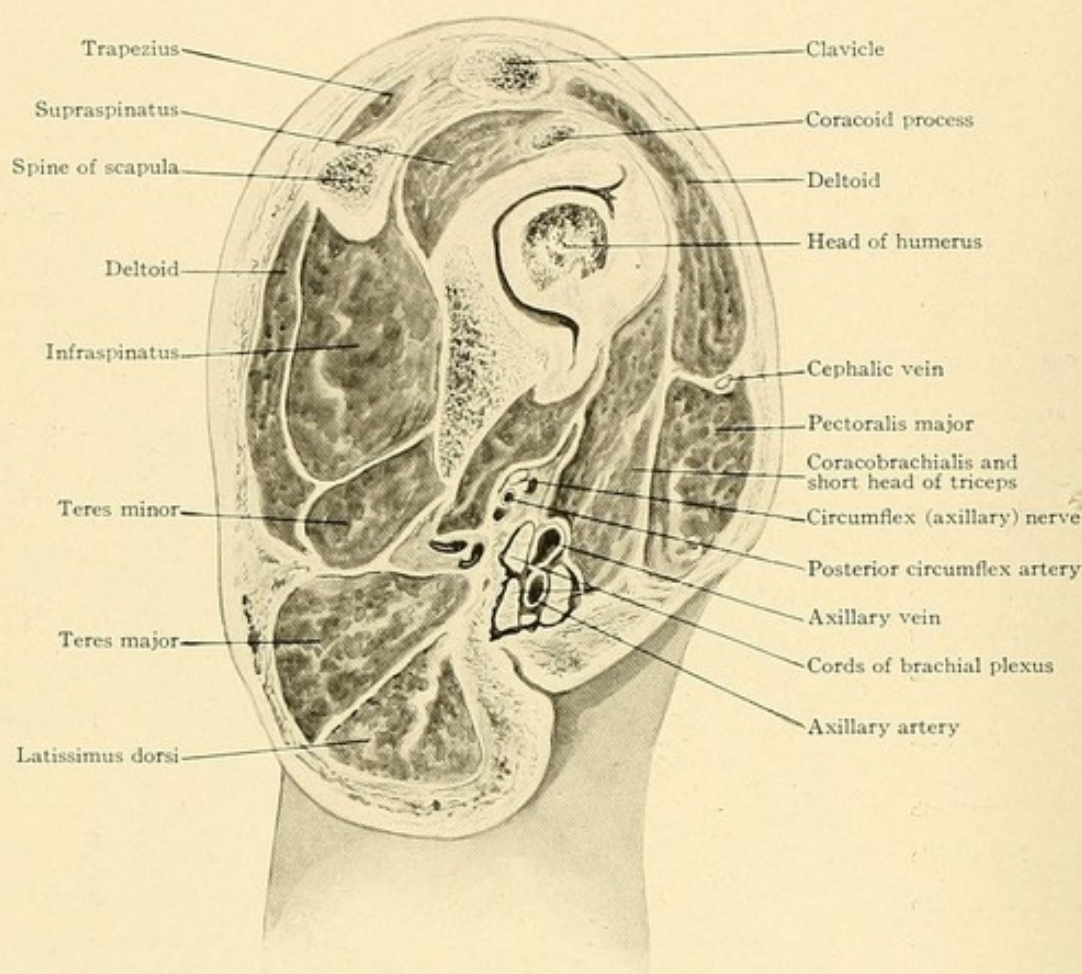


FIG. 610.—Sagittal section through the left shoulder.

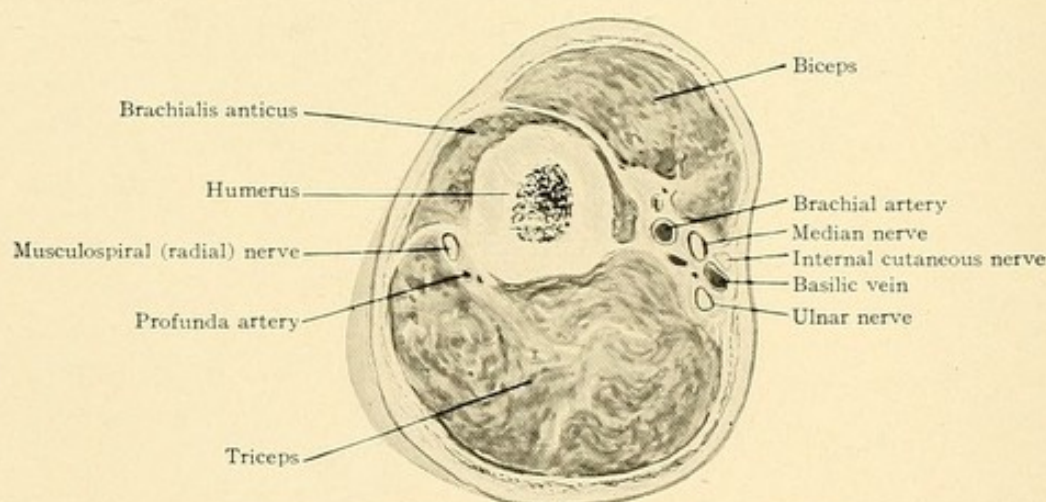


FIG. 611.—Transverse section through the middle of the arm.



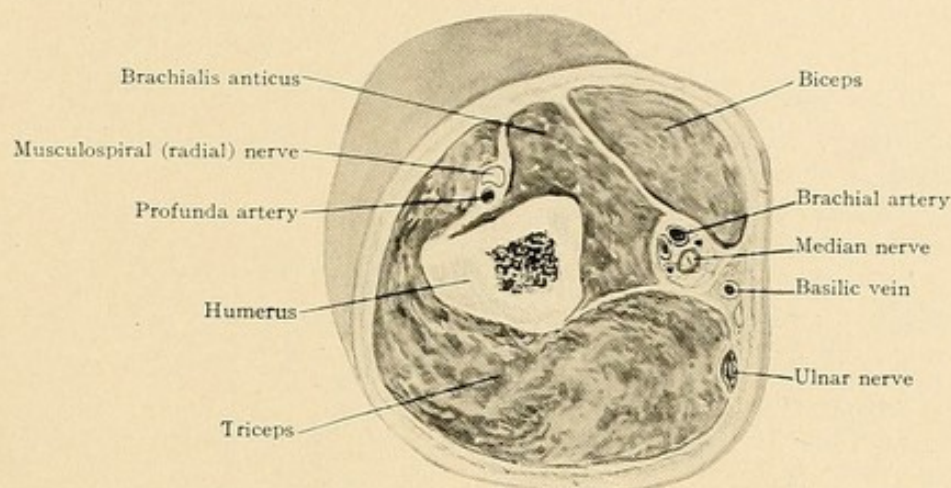


FIG. 612.—Transverse section through the lower third of the arm.

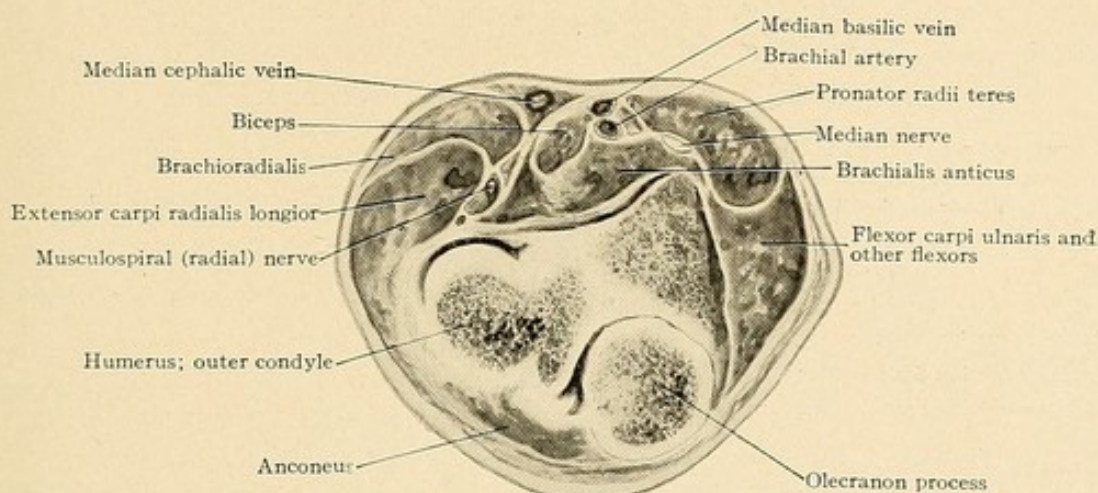


FIG. 613.—Transverse section through the olecranon process.

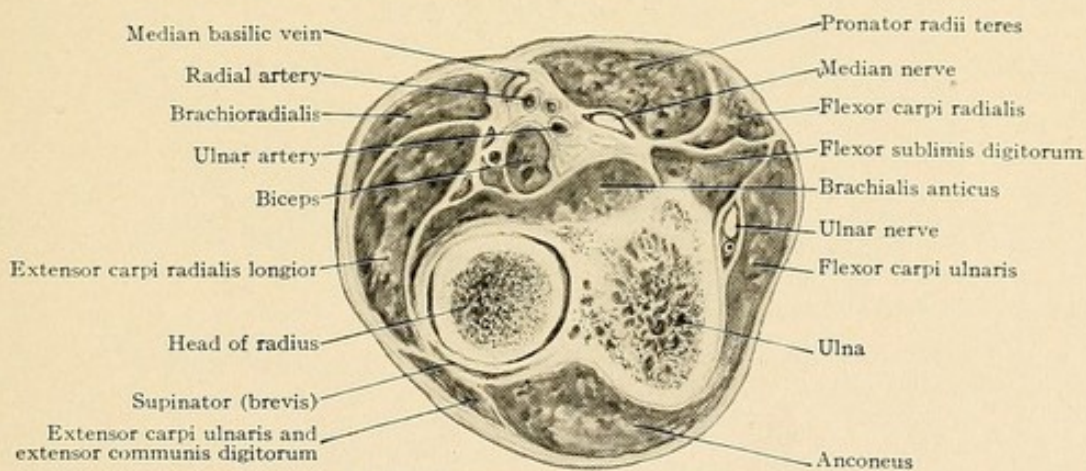


FIG. 614.—Transverse section through the head of the radius.



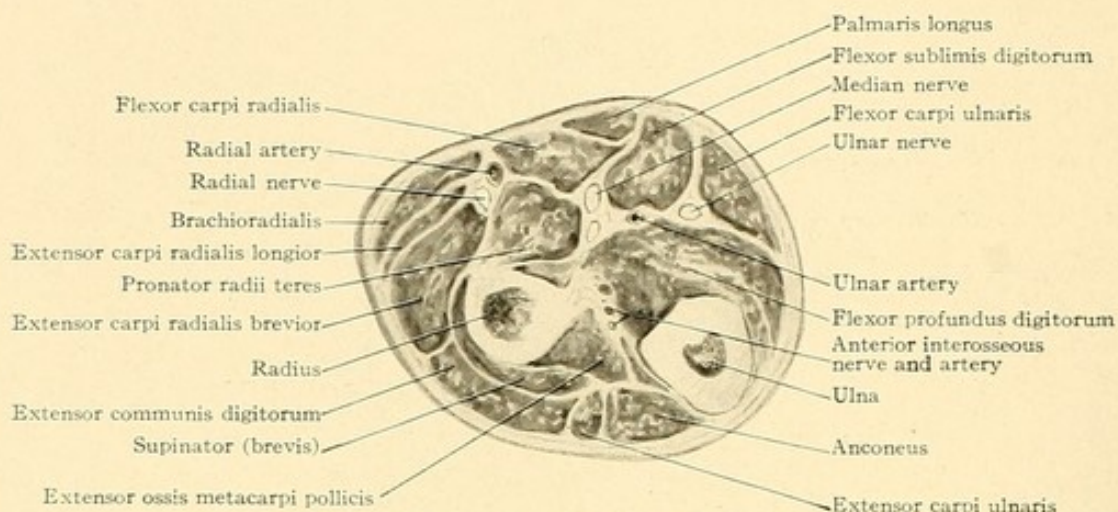


FIG. 615.—Transverse section through the upper third of the forearm.

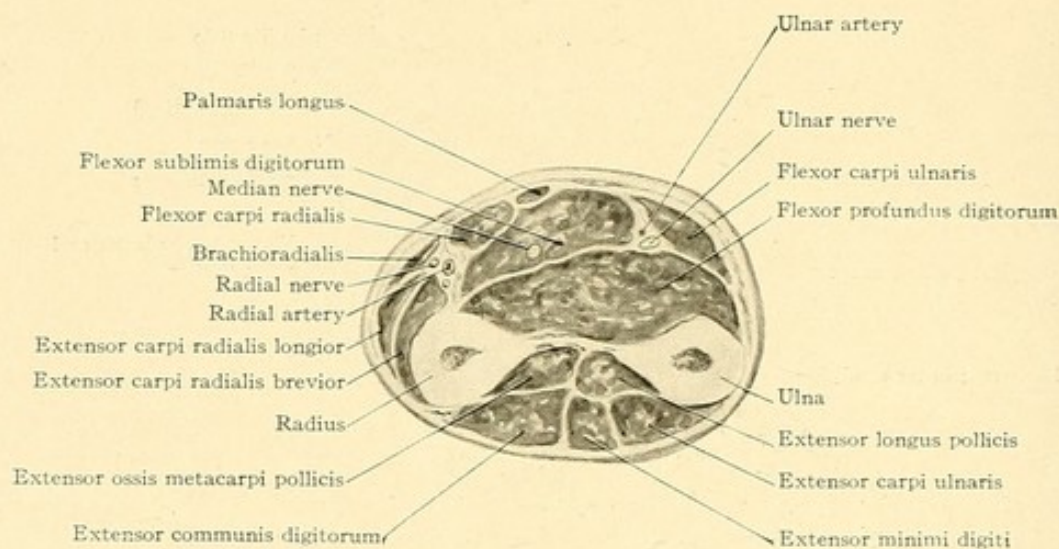


FIG. 616.—Transverse section about the middle of the forearm.

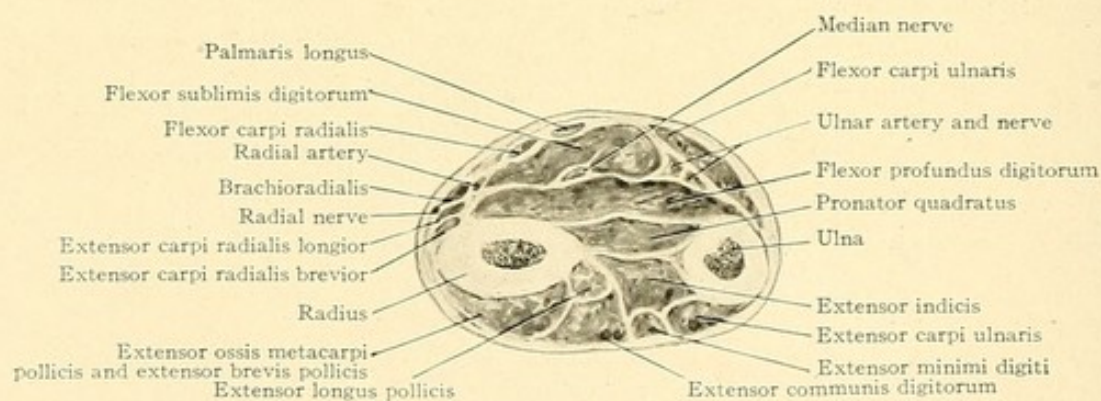


FIG. 617.—Transverse section of upper part of lower third of forearm.



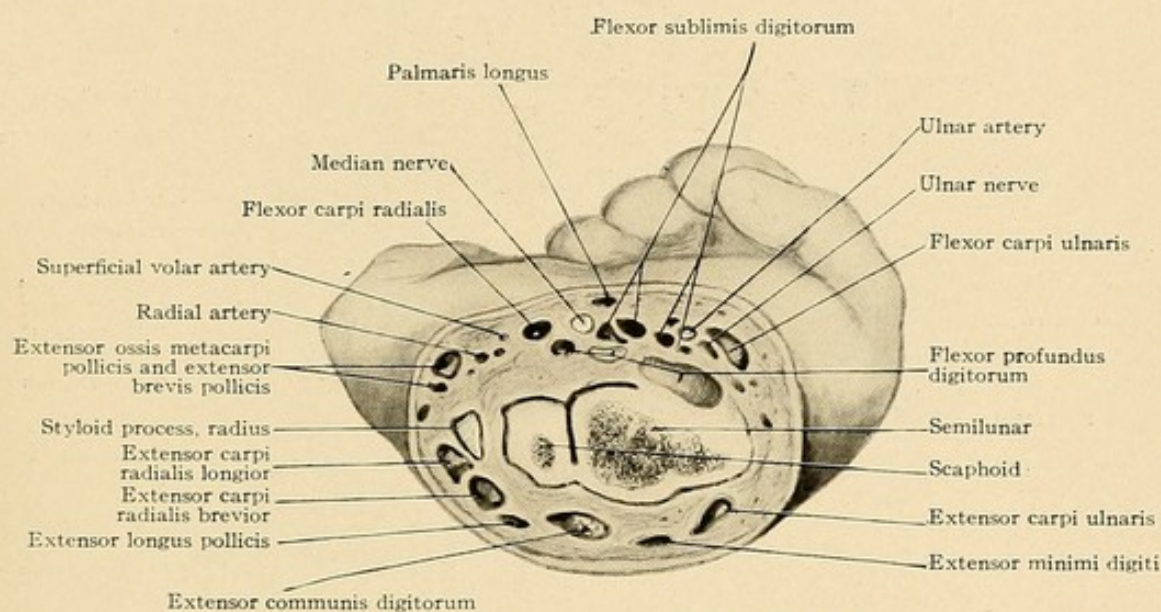


FIG. 618.—Transverse section through the wrist-joint.

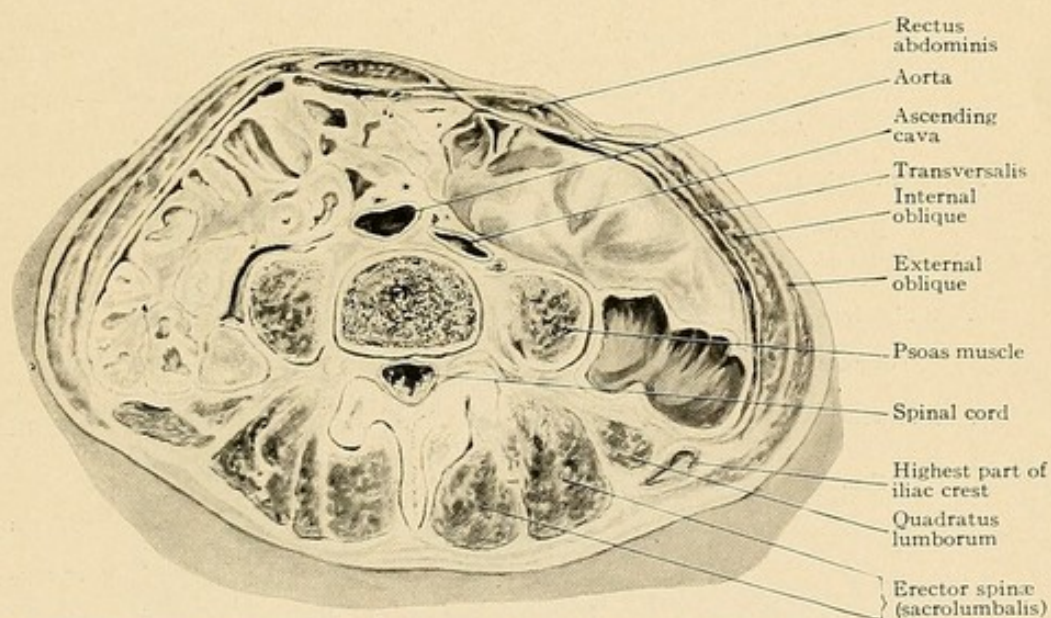


FIG. 619.—Horizontal transverse section through the body of the fourth lumbar vertebra.



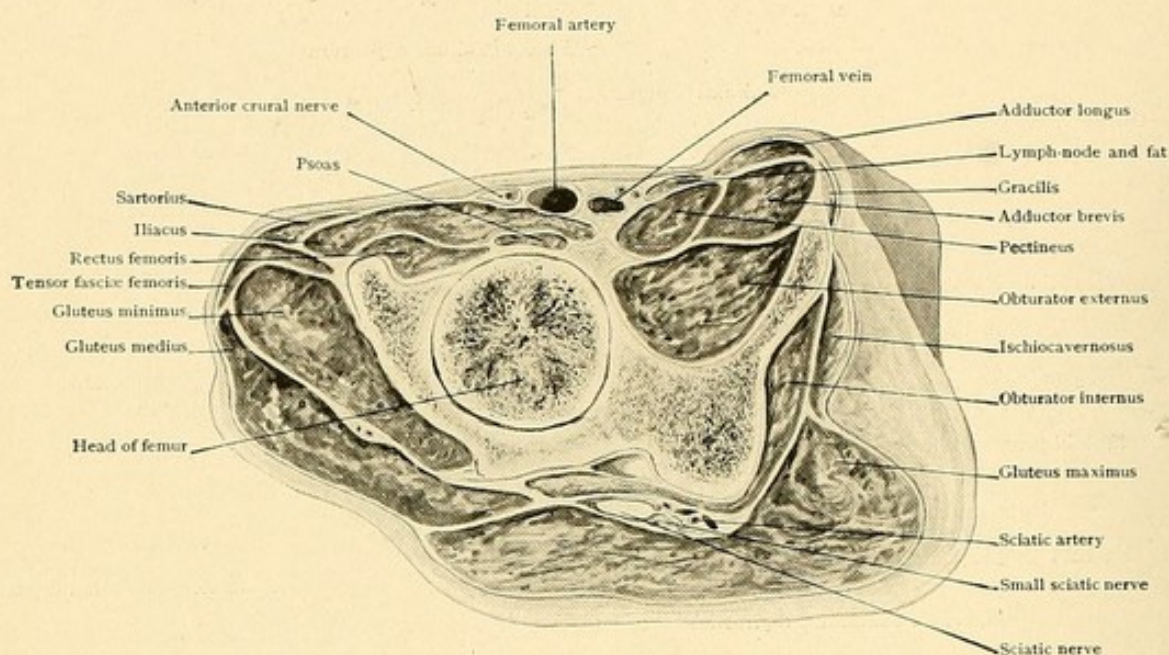


FIG. 620.—Oblique section of the upper part of thigh parallel to and just below Poupart's ligament.

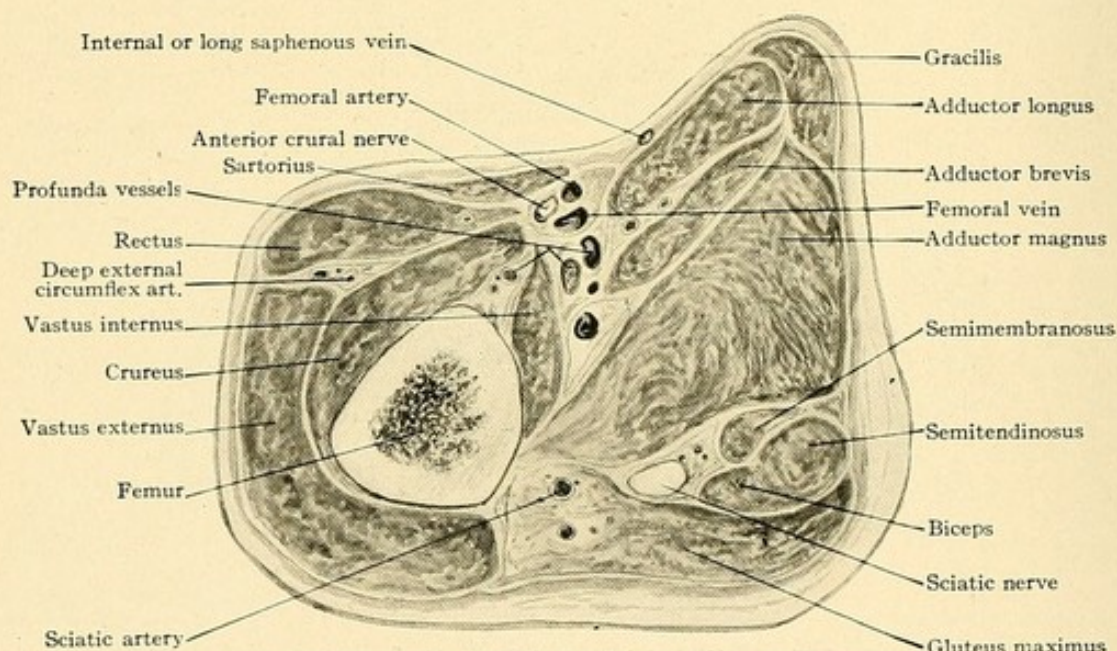


FIG. 621.—Transverse section of thigh high up through Scarpa's triangle.



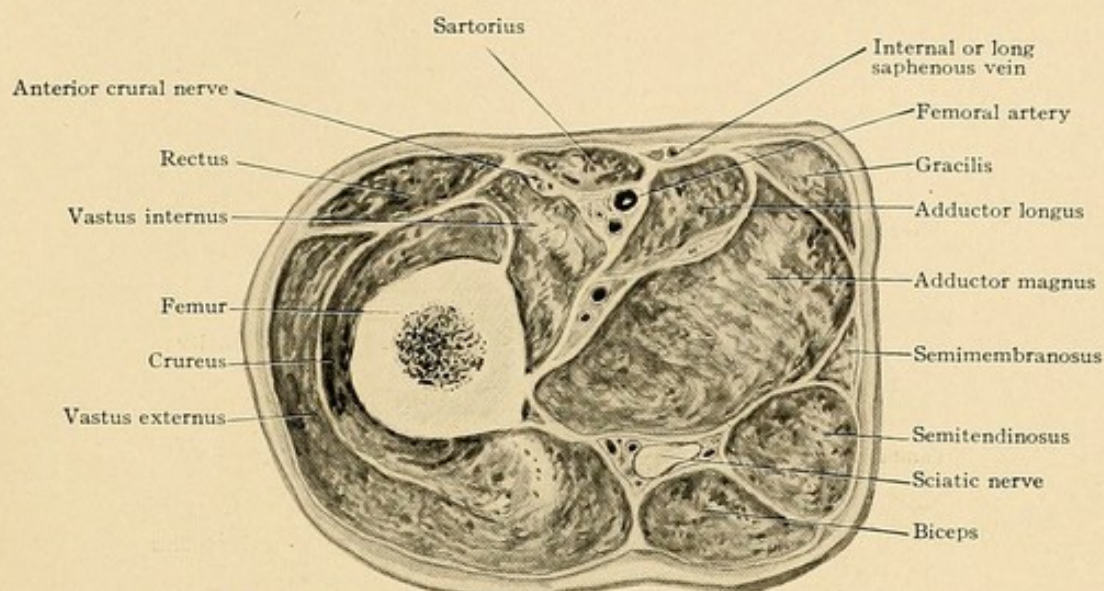


FIG. 622.—Section of thigh about at the apex of Scarpa's triangle.

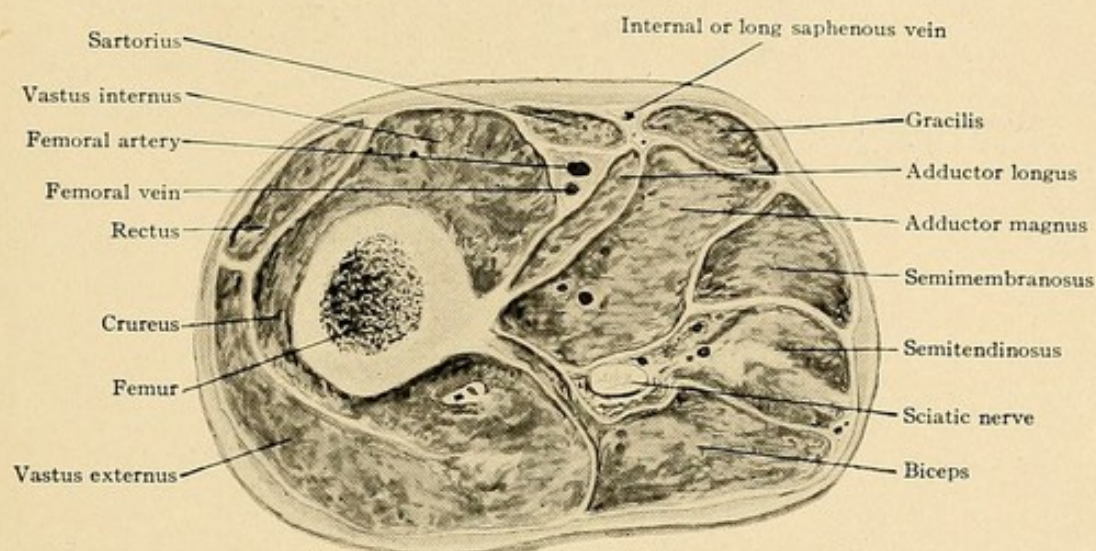


FIG. 623.—Section of thigh about the middle.

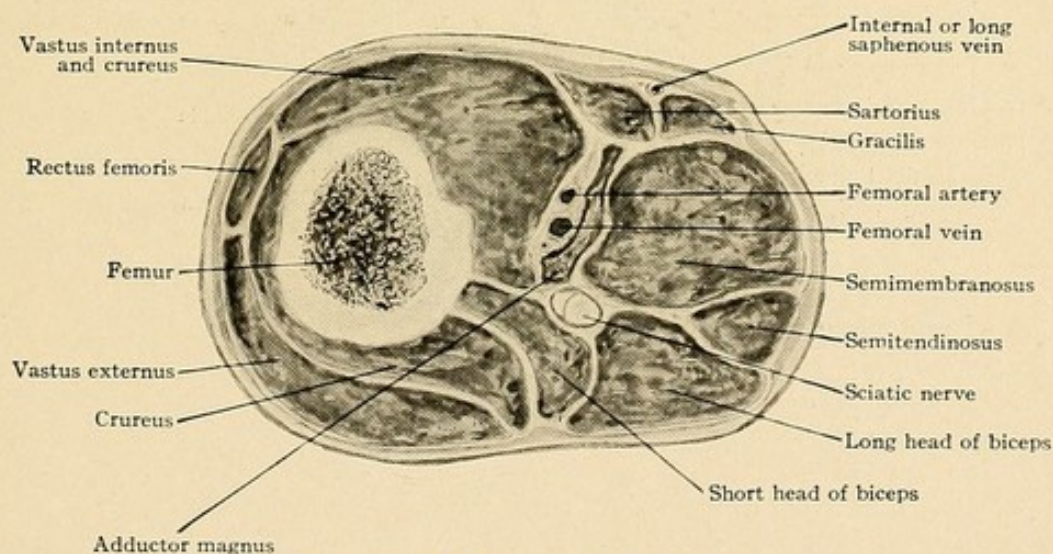


FIG. 624.—Section of thigh through its lower third.



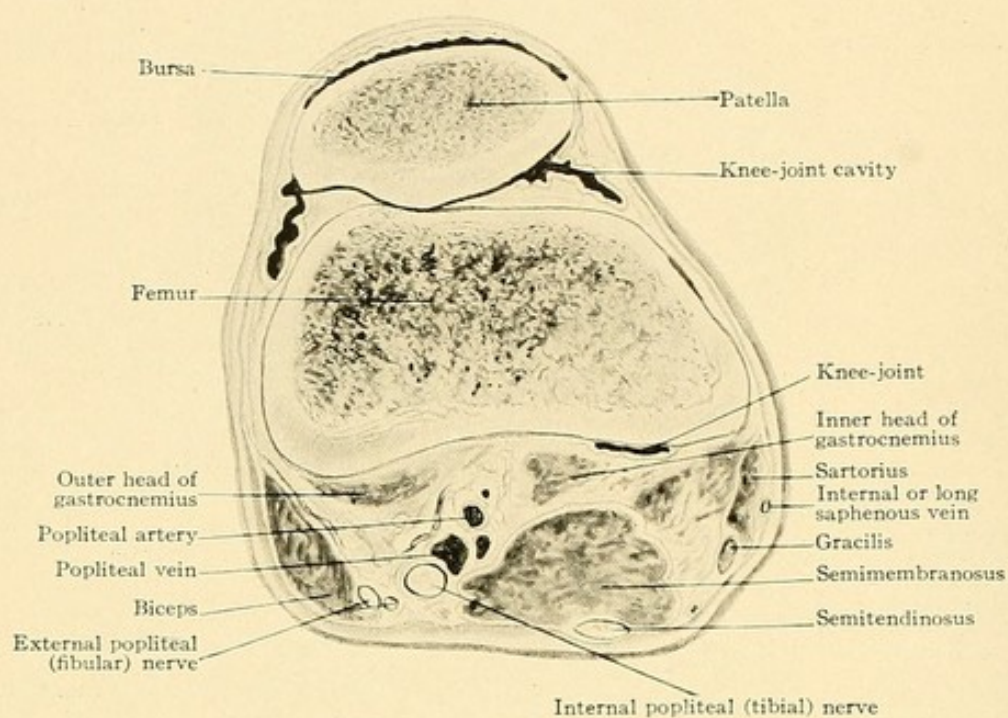


FIG. 625.—Transverse section through the patella.

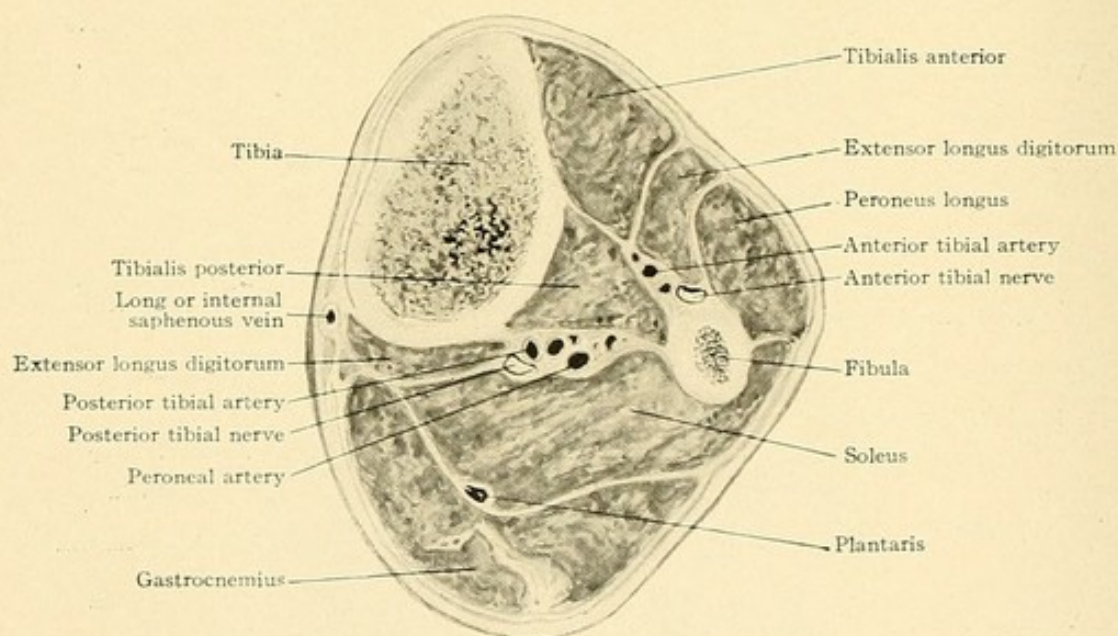


FIG. 626.—Section through upper third of leg.



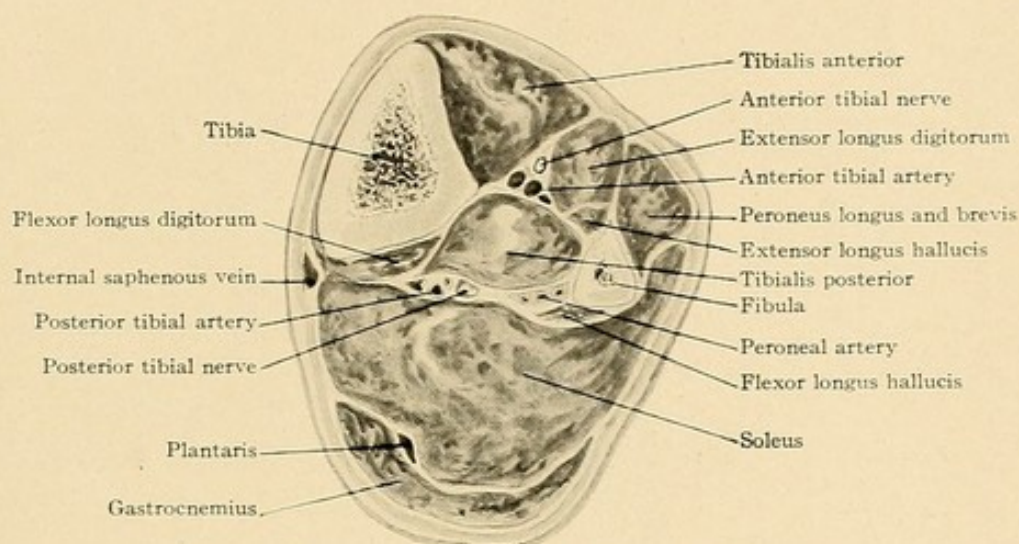


FIG. 627.—Transverse section through the middle of the leg.

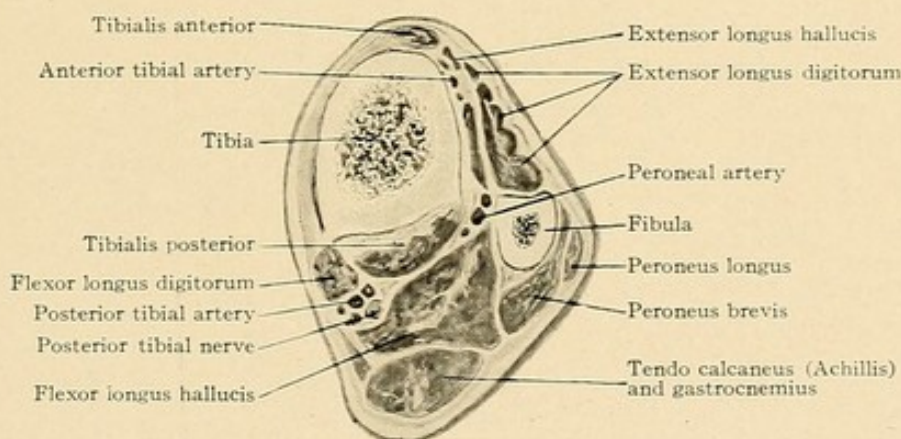


FIG. 628.—Transverse section through the lower third of the leg.



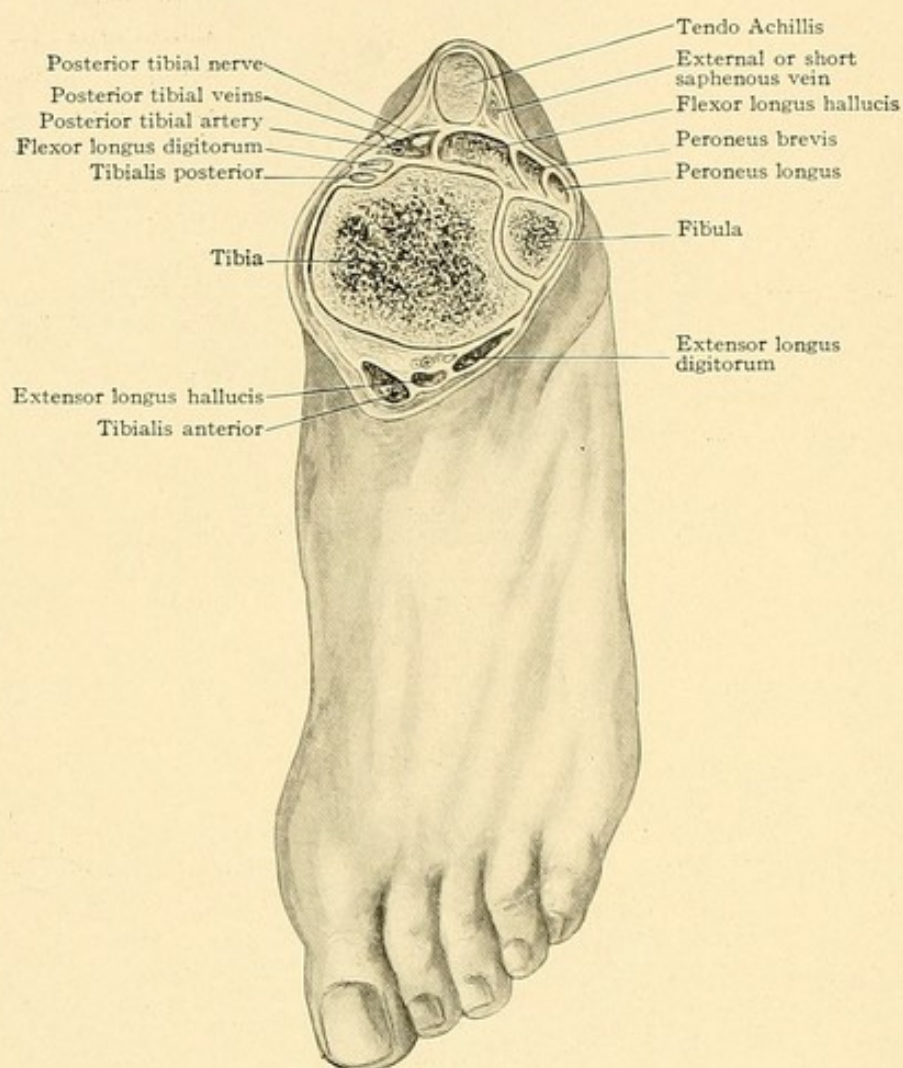


FIG. 629.—Transverse section through the ankle.



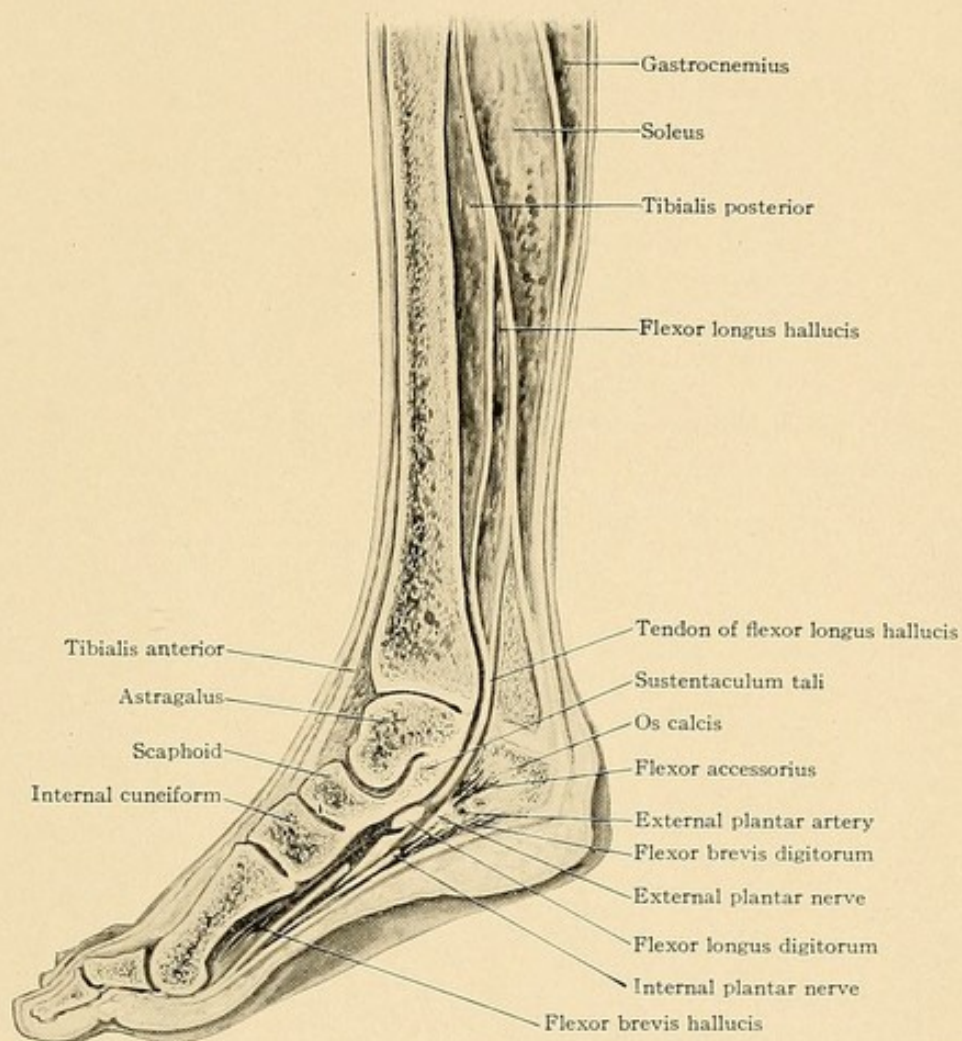


FIG. 630.—Anteroposterior section through the tibia and first metatarsal bone.







# INDEX.

- Abdomen, 370  
 abdominal incisions, 381  
 abdominal ring, external, 377, 385  
     internal, 386  
 fascia of, superficial, 374  
     transversalis, 399  
 herniæ of (see Hernia)  
 Hesselbach's triangle, 387  
 inguinal canal, 385  
 interior of, 396  
 lines of, 371  
     linea alba, 371  
     lineæ albicantes, 372  
     lineæ semilunares, 372  
     lineæ transversæ, 372  
 lumbar region of (see Lumbar)  
     incisions, 395  
     longitudinal, 395  
     oblique, 396  
 McBurney's point, 374  
 muscles of, 375  
 nerves of, 380  
 regions of, 370  
 surface anatomy of, 370  
 vessels of, 374  
 viscera of, 399  
     position of, 372, 399  
 walls of, 374  
     lymphatics of, 380  
     nerves of, 380  
     vessels of, 378  
     arteries, 378  
     veins, 380  
 Abdominal ring, external, 377, 385  
     external pillar of, 377, 385  
     intercolumnar fibres of, 377, 386  
     internal pillar of, 377, 385  
     internal, 386  
 Abdominoscrotal opening, 375  
 Abducens nerve, injury to, in fractures of skull, 20  
 Abscess of axilla, 264  
     incision for, 264  
     Bezold's, 90  
     of breast, 185  
     cerebellar, 13  
     cerebral, 44  
     of fingers, 366  
     of hand, 365  
     beneath palmar fascia, 365  
     involving the fingers, 366  
     involving sheaths of tendons, 366  
     of hip, 516  
     ischio-rectal, 476  
     of kidney, 428  
     points of pointing of, 428  
     of liver, 420  
     lumbar, 394  
     of neck, 153  
     influence of cervical fascia on, 154  
     of orbit, 75  
     palmar, 365  
     of pancreas, 423  
     evacuation of, 423  
     of parotid gland, 53  
     incisions for, 54  
 Abscess, peritonsillar, 114  
     plantar, 575  
     deep, 575  
     incision for, 575  
     superficial, 575  
     in posterior cervical triangle, 156  
     of prostate, 451  
     psoas, 481  
     retropharyngeal, 90, 116, 156  
     of scalp, 5  
     subaponeurotic, 6  
     subcutaneous, 5  
     subpericranial, 6  
     subdiaphragmatic, 420, 423  
     subdural, 90  
     submammary, 185  
     in tendon sheaths of hand, 366  
     of testicle, 469  
 Acetabulum, 501  
 Achilles' tendon, 551  
     action in fractures of tibia, 551  
     tenotomy of,  
     in fractures of the tibia, 552  
     in Pott's fracture, 558  
 Acromioclavicular joint, 222  
     ligament, 222  
 Adenoids, 122  
     removal of, 122  
 Aditus, 88  
 Air-passages, operations on, 161  
 Alcock's canal, 474, 476  
 Allantois, 371,  
     stalk of, 382  
 Allis:  
     method of reduction of dislocation of hip, 512  
     method of releasing sciatic nerve, 514  
 Ampulla of Vater, 407  
     stone in, 422  
 Amputation  
     of ankle, 559  
     Pirogoff's, 560  
     Syme's, 559  
     of arm, 275  
     at elbow, 302  
     of fingers, 369  
     metacarpophalangeal, 369  
     of foot, 574  
     midtarsal (Chopart's), 574  
     tarsometatarsal (Lisfranc's), 575  
     of forearm, 326  
     through lower third, 327  
     through middle third, 327  
     through upper third, 327  
     at hip-joint, 532  
     interscapulothoracic, 250  
     at knee-joint, 544  
     of leg, 552  
     of penis, 466  
     of shoulder-joint,  
     flap method, 247  
     Dupuytren's, 247  
     Lisfranc's, 248  
     racket method, 248  
     Larrey's, 248  
     Spence's, 249



- Amputation of thigh, 532  
 of thumb, 368  
   carpometacarpal, 369  
   metacarpophalangeal, 369  
 of toes, 581  
 at wrist, 347
- Anal canal (see Intestine, large)  
 fissures, 443  
 triangle (see Male perineum)
- Anconeus muscle, 286
- Anderson and Makin, method of locating fissures of brain, 42
- Aneurism of aorta,  
   arch, 210  
   ascending, 208  
   descending, 210  
   arteriovenous, 7  
   cirroid, of scalp, 7
- Aneurismal varix, 7
- Angioma of ear, 85  
 of lips, 104
- Angle, cardiohepatic, 205  
 of Ludwig, 180
- Ankle, 553  
 amputation of, 559  
   Pirogoff's, 560  
   Syme's, 559  
 ankle-joint, 554  
   distention of, 555  
   ligaments of, 554  
   movements of, 554  
 dislocations of, 556  
   treatment, 557  
 excision of, 555  
 fractures of, 557  
   Pott's fracture by eversion, 557  
   by inversion, 558  
 sprain of, 556  
   treatment, 556  
 surface anatomy of, 553  
 tuberculosis of, 555
- Annular ligament,  
   of wrist, anterior, 335  
   posterior, 336
- Anterior poliomyelitis, 487
- Antrum, mastoid, 90  
 operations, 91  
 of Highmore (see Maxillary sinus)
- Anus (see Intestine, large)
- Aorta, 208  
   arch of, 208  
     aneurism of, 210  
     ductus arteriosus, 209  
   ascending, 208  
     aneurism of, 208  
   bifurcation of, 374  
   descending, 210  
     aneurism of, 210
- Apoplexy, 30, 31  
 cortical, 32
- Appendicitis, 414  
 operation for, 414
- Appendicular artery, 412
- Appendix vermiformis (see Intestine, large)
- Arachnoid, 21
- Aran's law for fractures of the skull, 15
- Arch: of aorta, 208  
   femorosacral, 490  
   of foot, 561, 563  
     external, 563  
     internal, 563  
     lateral or transverse, 563  
     ligaments of, 566
- Arch of foot, muscles supporting, 568  
   ischiosacral, 491  
   palmar, deep, 359  
   superficial, 358  
   plantar, 572
- Arm, 266  
 amputation of, 275  
 brachial artery, 272  
 humerus, 267  
   fractures of, 276  
 intermuscular septa of, 271  
 muscles of, 267  
 operations on, 279  
 surface anatomy of, 271
- Arterial varix, 7
- Arteriovenous aneurism, 7
- Artery or arteries,  
   acromiothoracic, 258  
   alarthoracic, 260  
   alveolar, inf., 50  
   anastomotica magna, 274  
   anterolateral perforating, 28  
   aorta, 208  
   appendicular, 412  
   arteria centralis retinae, 80  
   artery to bulb, 475  
   auricular, deep, 50  
     posterior, 3, 135  
   axillary, 257  
   basilar, 25  
   brachial, 272, 290  
   buccal, 50  
   carotid, common, 141  
     external, 144  
     internal, 25, 27, 143  
   carpal, anterior, 316  
   cerebral, anterior, 25, 27  
     middle, 28  
     posterior, 25, 28  
   choroid, anterior, 28  
   circle of Willis, 25  
   circumflex, anterior, 261  
     external, 523  
     internal, 523  
     posterior, 261  
     superficial external, 523  
   coeliac axis, position of, 374  
   colic, 412  
   communicating, anterior, 25  
     posterior, 25  
   coronary, inferior, of facial, 104  
     superior, of facial, 104  
     of stomach, 403  
   of corpus cavernosum, 475  
   cystic, 421  
   deferential, 469  
   dental, 50  
     posterior, 50, 58  
   dorsal, of penis, 475  
   dorsalis indicis, 360  
     linguae, 110  
     pedis, 572  
     scapulae, 261  
   epigastric, deep, 379  
     superficial, 523  
     superior, 181, 379  
     wounds of, 379  
   ethmoidal, anterior, 98  
     posterior, 98  
   facial, 50, 134  
   femoral, 523  
   frontal, 3  
   gastric, 403



- Artery, gastroduodenal, 403  
   gastro-epiploic, dextra, 403  
   gluteal, 505  
     ligation of, 505  
   hemorrhoidal, inferior, 440, 476  
     middle, 440, 476  
     superior, 440  
   hepatic, 403, 421  
   hyoid, 110  
   hypogastric, obliterated, 307, 371, 382  
   ileal, 412  
   ileocaecal, anterior, 412  
     posterior, 412  
   ileocolic, 412  
   iliac, 436  
   iliac, deep circumflex, 379  
     wounds of, in operating on the ap-  
       pendix, 380  
     line of, 374  
   infra-orbital, 50, 58  
   intercostal, 176  
     anterior, 176  
     posterior, 177  
     superior, 147  
   labial, inferior, 104  
   lachrymal, 3  
   lenticulostriate, 28  
   lingual, 110, 134, 145  
   mammary, internal, 147, 181  
   masseteric, 50  
   maxillary, internal, 50, 58  
   meningeal, middle, 17, 21, 50  
     small, 50  
   musculophrenic, 181  
   nasopalatine, 50, 58, 98  
   occipital, 3, 4, 134  
   ophthalmic, 3, 81  
   ovarian, 458  
   palatine, ascending, 98  
     descending, 50, 58, 98, 114  
   palmar arch, deep, 359  
     superficial, 358  
   pancreatico-duodenal, superior, 403  
   perforating, of profunda femoris, 523  
   perineal, superficial, 476  
     transverse, 474, 476  
   peroneal, 550  
     ligation of, 550  
   pharyngeal, ascending, 114, 134  
   plantar, external, 572  
     internal, 572  
     ligation of, 573  
   popliteal, 544  
   posterolateral, 29  
   posteromedian, 28  
   princeps pollicis, 360  
   profunda, femoris, 522  
     inferior, 274  
     (superior), 274  
   pterygoid, 50  
   pterygopalatine, 50, 58, 98  
   pudic, deep external, 523  
     internal, 440, 474, 476  
     superficial external, 523  
   pyloric, 403  
   radial, 316, 359  
     carpal, 316  
     recurrent, 316  
   radialis indicis, 360  
   ranine, 110  
   renal, 426  
   sacral, middle, 441  
   sciatic, 505
- Artery, septal, 98, 104  
   spermatic, 385, 469  
   sphenopalatine, 50, 58, 98  
   spinal, anterior, 485  
     posterior, 485  
   splenic, 403  
   subclavian, 139, 147  
   sublingual, 110  
   subscapular, 260  
   superficial volar, 316  
   superior ulnar collateral, 274  
   supra-orbital, 3  
   suprascapular, 139  
   temporal, 3, 48, 52  
     deep anterior, 50  
     posterior, 50  
   thoracic, long, 260  
     superior, 258  
   thyroid axis, 147  
   thyroidea ima, 165  
   thyroid, inferior, 149, 165  
     superior, 134  
   tibial, anterior, 548  
     posterior, 549  
   tonsillar, of dorsalis linguae, 114  
     of facial, 114  
   transverse cervical, 139  
   tympanic, 50  
   ulnar, 314, 358  
     collateral, inferior, 274  
     superior, 274  
     recurrent, anterior, 315  
     posterior, 315  
   umbilical, 371, 382  
   uterine, 458  
   vasa brevia, 403  
   of the vas deferens, 385  
   vertebral, 25, 147  
   vesicle, superior, 371  
   Vidian, 50, 58, 98
- Arthritic muscular atrophy, 488  
 Articulations (see Joints)  
 Arytenoid cartilages, 129  
 Ascites, 420  
 Asterion, 39  
 Attic of middle ear, 88  
   tegmen of, 89  
   perforation of, by pus, 89
- Auditory area of brain, 37  
   nerve, 20  
   injury to, in fractures of skull, 20
- Auriculotemporal branch of fifth nerve, 3, 52
- Axilla, 229, 256  
   abscess of, 264  
   incision for, 264  
   axillary fascia, 256  
   lymphatics of, 263  
   nerves of, 265  
   tumors of, 265  
   vessels of, 257
- Axillary artery, 257  
   collateral circulation after ligation of, 262  
   first portion, 258  
     ligation of, 259  
   second portion, 260  
   third portion, 260  
     ligation of, 262
- Axillary nerve, 265
- Back, 477  
   surface anatomy of, 477
- Balance, 494  
   disturbance of, 494



- Balance, methods of restoring, 494  
 Bartholin, duct of, 108  
 Basal ganglia of brain, 37  
     functions of, 37  
 Bassini's operation for hernia, 387  
 Battle's abdominal incision, 382  
 Biceps muscle, 269, 285, 310  
     tendon of, 255  
     dislocation of, 269  
     rupture of, 270  
 Bicapital fascia, 285  
     groove, 221, 267  
     tubercle, 285  
 Bigelow, Y ligament of, 507  
 Bladder, 444  
     attachments of, 445  
     base of, 446  
     cystoscopic examination, 448  
     in female, 447  
     calculi in, 447  
     vesico-vaginal fistulæ of, 447  
     hypertrophy of, 447  
     interureteric ligament of, 446  
     ligaments of, 445  
     operations on, 448  
     peritoneum of, 445  
     plicæ uretericæ or ureteric folds, 446  
     position of, 374, 444  
     of internal urethral orifice, 447  
     postprostatic pouch or bas-fond, 446  
     rectovesical pouch, 446  
     ribbed, 447  
     rupture of, 446  
     sacculated, 447  
     shape of, 445  
     tapping of, 446, 448  
     Trendelenburg position in operation on, 446  
     trigone of, 446  
     tumors of, 448  
     walls of, 446  
 Bloodgood's operation for hernia, 389  
 Boeckman's operation on the hip, 518  
 Bone or bones:  
     astragalus, or talus, 562  
     of base of skull, 8  
     carpal, 348  
     of chest, 171  
     clavicle, 219  
     coccyx, 432, 434  
     of cranium, 8  
     cuboid, 562  
     cuneiform, of tarsus, 562  
     external, 562  
     internal, 562  
     middle, 562  
     of wrist, 332, 349  
     of elbow, 280  
     ethmoid, 8  
     of face, 8, 44  
     femur, 502  
     fibula, 534, 571  
     external malleolus of, 571  
     fracture of, 551  
     frontal, 8  
     external angular process of, 40  
     internal angular process of, 46  
     of hand, 349  
     carpal bones, 349  
     metacarpal bones, 350  
     phalanges, 351  
     humerus, 221, 267, 280  
     ilium, 499  
     ala of, 500  
     Bones: ilium, anterior superior spine of, 500, 504  
     crest of, 499, 504  
     posterior superior spine of, 500, 504  
     innominate, 432, 434, 499  
     planes of, 502  
     ischium, 434, 500  
     tuberosity of, 500  
     bursa covering, 506  
     lachrymal, 8, 44  
     malar, 8, 44, 49  
     fracture of, 49  
     maxilla, inferior, 8, 44  
     fracture of, 67  
     maxilla, superior, 8, 44  
     fracture of, 54  
     metacarpal, 350  
     dislocations of, 362  
     metatarsal, 562  
     nasal, 8, 44, 94  
     occipital, 8  
     os calcis, 562  
     sustentaculum of, 571  
     tubercles of, 571  
     os magnum, 300  
     palate, 8, 44  
     parietal, 8  
     patella, 534, 535  
     phalanges of foot, 562  
     of hand, 351  
     dislocation of, on metacarpal bones, 262  
     fracture of, 364  
     pisiform, 332, 349  
     pubis, 434, 500  
     crest of, 501  
     iliopectineal line of, 500  
     ramus, descending, of, 501  
     horizontal, of, 501  
     spine of, 501  
     radius, 281, 304  
     lower end of, 331  
     ribs, 174  
     sacrum, 434  
     scaphoid, of foot, or navicular, 562  
     tubercle of, 571  
     of wrist, 332, 349  
     scapula, 219  
     semilunar, 332, 349  
     sphenoid, 8  
     sternum, 174  
     tarsal, 562  
     fracture of, 563  
     temporal, 8  
     tibia, 534  
     fracture of, 551  
     internal malleolus of, 573  
     trapezium, 350  
     trapezoid, 350  
     turbinate, inferior, 8, 44, 97, 118  
     hypertrophy of, 118  
     middle, 97, 118  
     superior, 97  
     ulna, 281, 303  
     lower end of, 332  
     unciform, 350  
     vomer, 8, 44  
     of wrist, 330  
 Bony landmarks of foot, 570  
     of skull, 39  
 Bovee's operation for excision of ureter, 451  
 Bow-legs, 543  
     treatment, 544  
 Brachial artery, 272, 290



- Brachial artery, branches of, 273  
 ligation of, 274  
   collateral circulation after, 275  
 ligation of, at bend of elbow, 290  
   collateral circulation after, 291  
 plexus, 265  
 Brachialis anticus muscle, 270, 286  
 Brain, 25  
   apoplexy, 30  
     cortical, 32  
   basal ganglia, blood supply of, 28  
   blood supply of, in obstruction to circle of Willis, 25  
   caudate nucleus, 30, 31  
     blood supply of, 28  
   cerebral abscess, 44  
     lobes, 32  
   cerebral localization, 34  
     functions of basal ganglia, 37  
     convolutions on surface of cerebrum, 35  
     corona radiata, 38  
     crura cerebri, 38  
     internal capsule, 38  
     motor tract, 38  
     pons Varolii, 38  
   cerebral softening, 30  
   choroid plexus, 30  
   circulation of, 25  
   convolutions of, 33  
     angular gyrus, 33, 42  
     Broca's convolution, 33  
     frontal convolution, 33, 41  
     gyrus fornicatus, 34  
     marginal convolution, 34  
     occipital convolutions, 33, 42  
     parietal convolutions, 33  
     supramarginal gyrus, 33, 41  
     temporal convolutions, 33, 41  
   corpus striatum, 30, 31  
   cortex, blood supply of, 28  
     functions of, 34  
   craniocerebral topography, 39  
     bony landmarks, 39  
     convolutions, main, 40  
       subsidiary, 41  
     fissures in children, 42  
       main, 39  
       subsidiary, 41  
     lower level of brain, 40  
     ventricles, lateral, 43  
     topographical points, 40  
   crus cerebri, 31  
   decussation, motor, 31  
   external capsule, 31  
   fissures of, 33  
     calcarine, 34  
     longitudinal, 33, 39  
     parieto-occipital, 33, 40  
     of Rolando, 33, 40  
     of Sylvius, 33, 40  
     transverse, 33  
   foramen lacerum medium, 27  
     Monro, 30  
   fornix, pillars of, 30  
   hemispheres, lateral surface of, 33  
     medial surface of, 34  
   internal capsule, 31  
   lenticular nucleus, 31  
   lobes of, 32  
   lower level of, 40  
   medulla, 31  
   paralysis, crossed, 32  
 Brain, perforated space, anterior, 28  
   pons, 31  
     hemorrhage into, 32  
   relations of, to lateral sinus, 93  
   septum lucidum, 30  
   tænia semicircularis, 30  
   thalamus, 30, 31  
   trephining, 44  
   veins of Galen, 31  
   velum interpositum, 31  
   venous sinuses of, 12  
   ventricles, 30  
     fifth ventricle, 30  
     lateral ventricles, 30, 43  
     third ventricle, 30  
 Breast (see Mammary gland)  
 Bregma, 39  
 Broad ligament, 455  
   tumors of, 462  
 Broca's convolution of brain, 35  
   functions of, 35  
 Brunner, glands of, 406  
 Bryant's triangle, 505  
 Buccopharyngeal fascia, 153  
 Bulla ethmoidalis, 100  
 Bunion, 579  
 Burns, ligament of, 390  
 Bursa or bursæ:  
   covering tuberosity of ischium, 506  
     disease of, 506  
   great carpal, 366  
   infraspinatus, 255  
   of knee, 538, 539  
     infrapatellar, 539  
     posterior bursæ, 539  
     prepatellar, 538  
       inflammation of, 538  
     suprapatellar, 538  
   of olecranon, 300  
     disease of, 300  
   of shoulder, 255  
   subacromial, 255  
   subfemoral, 535  
   subscapular, 255  
 Cæcal folds, 413  
   fossæ, 413  
 Cæcum (see Intestine, large)  
 Calcaneus, tendo (see Achilles')  
 Canal,  
   Alcock's, 474, 476  
   femoral, 390  
   Hunter's, 524  
   inguinal (see Inguinal)  
   lachrymal, 72, 84  
   of Schlemm, 79  
 Canaliculi, lachrymal, 84  
 Cancer  
   of breast, 185  
     operation for, 187  
   of lips, 105  
     treatment, 105  
   of oesophagus, 212  
   of stomach, 404  
     adhesion in, 405  
     perforation in, 405  
     ulceration in, 405  
   of tongue, 110  
 Cancrum oris, 49  
 Capitellum, 280  
 Capsule, external, 31  
   internal, 31  
   of kidney, 426



- Capsule of parotid gland, 153  
   of prostate gland, 449  
   of submaxillary gland, 153  
   Tenon's, 74  
   of thyroid gland, 153  
 Caput medusæ, 380  
   succedaneum, 5  
 Carcinoma (see Cancer)  
 Cardiohepatic angle, 205  
 Caries of the spine, 480  
 Carotid artery, common, 141  
   collateral circulation after ligation  
     of, 142  
     in superior carotid triangle, 133  
     ligation of, 141  
     ligation of, below omohyoid muscle,  
       142  
   external, 144  
     in superior carotid triangle, 133  
     ligation of, 144  
   internal, 25, 27, 143  
     in cavernous sinus, 14  
     in superior carotid triangle, 133  
     ligation of, 143  
     relations of, to pharynx, 123  
     relations of, to tonsil, 123  
   tubercle, 149  
 Carpal bursa, great, 366  
 Carpometacarpal joints,  
   movements of, 353  
 Carrying angle, 282  
 Cartilage or cartilages:  
   arytenoid, 124  
   cricoid, 126  
   of Santorini, 124  
   of septum, 97  
   tarsal, 82  
   thyroid, 125  
     fracture of, 125  
   of Wrisberg, 124  
 Castration, 469  
 Cataract, 78  
   operations for, 79  
   varieties of: capsular, 78  
     lamellar, 78  
     lenticular, 78  
     lenticulocapsular, 78  
     polar, 78  
     secondary, 78  
     senile, 78  
     traumatic, 78  
     zonular, 78  
 Catheter, passage of, 471  
 Caudate nucleus, 30, 31  
   blood supply of, 28  
 Cavernous sinus, 13  
 Cells, ethmoid, 73, 102  
   disease of, 102  
   mastoid, 11, 90  
     operation on, 91  
 Central lobe of brain, 33  
 Cephalhæmatoma, 5  
 Cephalhydrocele, 7  
 Cerebellar abscess, 13  
 Cerebral abscess, 44  
 Cerebral lobes, 32  
   central, or island of Reil, 33  
   frontal, 32  
   occipital, 32  
   parietal, 32  
   temporosphenoidal, 32  
   localization (see Brain)  
   softening, 30  
 Cerebral venous sinuses, 12  
   cavernous sinus, 13  
   lateral or transverse sinus, 12  
   superior longitudinal sinus, 12  
   torcular Herophili, 12  
 Cerebritis, 23  
 Cerebrospinal fluid in fractures of skull, 19  
   meningitis, 23  
 Cervical adenitis, 158  
   operation for, 158  
   cysts, 169  
   fascias, 150  
     influence of, on pus in neck, 154  
   fistulæ, 168  
   triangles, 131  
     anterior, 131  
       inferior carotid, 131, 137  
       submaxillary, 131  
       superior carotid, 131, 133  
     posterior, 137  
       occipital, 137  
       subclavian, 131, 137  
 Chalazion, 83  
 Cheek, 49  
   contusions of, 49  
   wounds of, 49  
 Chest, 171, 192  
   bones of, 171  
     ribs, 174  
     sternum, 174  
   costal cartilages, 174  
   heart, 204  
   lines of, 192  
   lungs, 196  
   mammary gland, 182  
   mediastinum, 187  
   muscles of, 177  
   œsophagus, 211  
   paracentesis of, 200  
   pericardium, 201  
   pleuræ, 194  
   regions of, 192  
   shape of, 171  
   soft parts, 176  
   surface anatomy of, 180  
   vertebræ of, 176  
   walls of, 171  
 Chiene's method of finding the fissure of Rolando,  
   42  
 Choked disk, 80  
 Chopart's amputation, 574  
 Chordee, 466  
 Choroid coat of eye, 77  
   affections of, 77  
   plexus, 30  
 Circle of Willis, 25  
 Circulation of the brain, 25  
 Circumcision, 466  
 Circumflex iliac artery, deep, 379  
   wound of, in operating on ap-  
   pendix, 380  
   nerve, 265  
 Cirroid aneurism, 7  
 Clavicle, 219  
   dislocations of, 230  
     acromial end, 231  
     sternal end, 230  
   excision of, 250  
   fractures of, 241  
     inner third, 241  
     middle third, 241  
     outer third, 241  
 Clavipectoral fascia, 256



- Cleft palate, 111  
     operation on, 112  
 Clitoris, 462  
 Cloaca, 453  
 Coccygodynia, 439  
 Coeliac axis, 403  
     position of, 374  
 Colles's fascia, 377  
     fracture, 342  
     reduction of, 343  
 Colon (see Intestine, large)  
 Colostomy, 417  
     inguinal, 417  
 Columns of Morgagni or Glisson, 440  
 Combined posterolateral sclerosis, 488  
 Common bile-duct, 421  
 Complementary space of Gerhardt, 194  
 Compound ganglion, 342  
 Condyle of lower jaw, 64  
     excision of, 71  
 Condyles of humerus, 280  
 Congenital dislocation of hips, 514  
     hernia, 383  
     hydrocele, 384  
 Conjoined tendon, 376  
 Conjunctiva, 82, 83  
     bulbar, 83  
     fornix of, 83  
     palpebral, 83  
 Conoid ligament, 222, 257  
 Contusions of cheek, 49  
     of scalp, 5  
 Convolutions of brain, 33  
     in craniocerebral topography, 40, 41, 42  
 Coraco-acromial ligament, 222  
 Coracohumeral ligament, 194  
 Corona radiata, 38  
     functions of, 38  
 Coronary ligament of liver, 397, 418  
 Coronoid fossa, 280  
 Corpora quadrigemina, 38  
     blood supply of, 29  
 Corpus striatum, 30, 31  
     functions of, 37  
 Costocoracoid ligament, 257  
     membrane, 257  
 Costomediastinal sinus, 194  
 Costophrenic sinus, 194  
 Cowper's gland, 471, 474  
 Coxalgia or coxitis, 515  
     abscess in, 516  
     attitude, 516  
     measurements, 516  
     symptoms, 515  
 Coxa valga, 517  
     vara, 517  
 Craniocerebral topography (see Brain)  
 Cranium, 8  
     bones of, 8  
 Cremaster muscle, 377  
 Crest, infratemporal, 47  
 Cribriform fascia, 391  
 Cricoid cartilage, 126  
 Cricothyroid membrane, 125  
 Crus cerebri, 31  
     blood supply of, 29  
     functions of, 38  
 Crutch palsy, 265  
 Crypts of Morgagni, 440  
 Cubitus varus, 297  
 Cuneiform bone  
     of carpus, 349  
     of tarsus, 562  
 Cuneus lobe of brain, 34  
 Cushing's operation on the Gasserian ganglion, 60  
 Cut throat, 168  
 Cyclitis, 77  
 Cystic duct, 421  
 Cystocele, 435, 464  
 Cystotomy, 448  
 Cysts of neck, 169  
     median, 170  
     of salivary glands, 108  
     treatment, 109  
 Davis: method of amputation of penis, 466  
     method of reduction of congenital dislocation  
     of hips, 515  
     transverse incision for appendicitis, 414  
 Decussation, motor, 31  
 Deltoid ligament of ankle, 554, 565  
     muscle, 268  
 Dental nerve, inferior, excision of, 60  
 Dermoid tumor of scalp, 8  
 Development of urogenital system, 553  
 Diaphragm, hiatus in, 425  
     relation of, to pus in kidney region, 425  
 Diploë of skull, 10, 15  
 Dislocation of ankle, 556  
     treatment, 557  
     of bases of metacarpal bones, 362  
     of clavicle, 230  
         acromial end, 231  
         sternal end, 230  
     of elbow, 291  
         backward, 291  
         treatment, 292  
         inward, 293  
         treatment, 294  
         outward, 294  
         treatment, 295  
     of fingers, 363  
     of head of radius, 294  
     of hip (see Hip)  
     of jaw, lower, 66  
         reduction of, 67  
     of knee, 541  
     of nose, treatment of, 96  
     of patella, 540  
         treatment of, 541  
     of phalanges on metacarpal bones, 362  
     of shoulder, 232  
         anterior, 232  
         method of production of, 233  
         parts injured, 233  
         reduction of, 236  
             direct method, 236  
             indirect method, 238  
         signs and symptoms of, 235  
         posterior, 239  
     of spine, 481  
     of toes, 580  
         of big toe, 580  
     of wrist, 345  
         at radio-carpal joint, 345  
         at radio-ulnar joint, 345  
 Douglas's pouch, 398, 454  
 Douglas, semilunar folds of, 376  
 Duct or ducts:  
     of Bartholin, 108  
     common bile-duct, 421  
         stone in, 422  
         operation for, 422  
     cystic, 421  
         stone in, 422  
         operation for, 422



- Duct, ejaculatory, 471  
 of Gartner, 454  
 hepatic, 421  
   stone in, 422  
     operation for, 422  
 lachrymonasal, 72, 84, 99  
 lymphatic, right, 140  
 of Müller, 453  
 pancreatic, 423  
 para-urethral, 463  
 parotid, 51  
   calculus in, 51  
 of Rathke, 454  
 of Rivinus (see Bartholin)  
 of Santorini, 423  
 Stenson's, 51  
 thoracic, 140, 214  
   wounds of, 214  
 thyroglossal, 107  
   in fistulæ of neck, 170  
 vitelline, 371, 382  
 of Walther, 108  
 Wharton's, 108  
 of Wirsung, 423  
 Ductus arteriosus, 209  
 Duodenojejunal flexure, 408  
   fossæ, 408  
 Duodenum (see Intestine, small)  
 Dupuytren's splint in fracture of ankle, 557  
 Dural hemorrhage,  
   of brain, 23  
   of cord, 486  
 Dura mater, 20  
   in children, 9  
 Ear, 84  
   Eustachian catheter, 120  
     tube, 84, 89, 118  
   external, 84  
     affections of, 85  
     angioma of, 85  
     hæmatoma of, 85  
   meatus, external auditory, 84, 85  
     fissures of Santorini, 86  
     furuncles of, 86  
     nerves of, 87  
     wax in, 86  
   membrana tympani, 87  
     paracentesis of, 88  
     perforation of, 87, 88  
   middle, 88  
     aditus, 88  
     antrum, 90  
       operations on, 91  
     aqueduct of Fallopius, 89  
     attic, 88, 89  
     disease of, 90  
     fenestra ovale, 89  
     fenestra rotundum, 89  
     mastoid cells, 90  
       operation on, 91  
     operations on, 90  
     walls of, 88  
   suprameatal fossa, 91  
     spine, 91  
     triangle of Macewen, 91  
   tympanum (see Ear, middle)  
 Ear-wax, 86  
 Edebohls's incision, 382, 396  
 Ejaculatory ducts, 471  
 Elbow, 280  
   amputation at, 302  
   bones of, 280  
   Elbow, bones of, epiphyses of, 299  
     brachial artery, 290  
       ligation of, at elbow, 290  
   carrying angle, 282  
   dislocations of, 291  
     backward, 291  
       treatment, 292  
   of head of radius, 295  
     treatment, 295  
   inward, 293  
     treatment, 294  
   outward, 294  
     treatment, 294  
   elbow-joint, 282  
     disease of, 300  
     ligaments of, 283  
   fractures in the region of, 295  
   muscles of, 284  
   olecranon bursa, 300  
     disease of, 300  
   radio-ulnar articulation, superior, 283  
     ligaments of, 283  
   resection of, 301  
   surface anatomy, 287  
   veins of, 288  
 Eminence, frontal, 8, 45  
   hypothenar, 353  
   thenar, 353  
 Emphysema of orbit, 76  
 Empyema, 200  
   operation for, 200  
   resection of rib for, 201  
 Encephalitis, 23  
 Encephalocele, 7  
 Epididymis, 468  
   epididymitis, 469  
 Epidural hemorrhage, 17  
 Epigastric artery, deep, 379  
   position of, 374  
   relations to Hesselbach's triangle,  
     387  
     to inguinal hernia, 379, 387  
     to internal ring, 386  
   wounds of, 379  
   superior, 379  
   wounds of, 379  
   region of abdomen, 370  
 Epiglottis, 124  
 Epiphyseal separations of acromium, 247  
   of coracoid process, 247  
   of elbow, 299  
   of humerus, upper end, 247  
   of knee, 541  
   of radius, lower end, 344  
 Epistaxis, 98  
 Epithelioma of lips (see Cancer)  
 Equilibrium, anteroposterior, 492  
   effect of ankylosis of hip-joint on, 493  
   effect of spinal deformities on, 493  
   lateral, 494  
   deviations of spine above sacrum, 495  
 Erector spinæ muscle, 392  
 Ethmoid bone, 8  
   cells or sinus (see Sinus)  
 Eustachian catheter, 120  
   tube, 84, 89, 118  
   catheterization of, 120  
   inflammation of, 89, 119  
   methods of inflating, 89, 119  
 Excision (see Resection)  
 Extensor carpi radialis brevis, 286  
   longior, 286  
 External oblique muscle, 377



- Extradural hemorrhage of brain, 17  
     of cord, 486  
 Extra-uterine pregnancy, 462  
 Extravasation of blood into perineum, 475  
     of urine into penis, 466  
     of urine into perineum, 475  
 Extremity, lower, 489  
     ankle, 553  
     attachment of, to trunk, 491  
     balance, 494  
     distortions resulting from affections of, 496  
     equilibrium, anteroposterior, 492  
     lateral, 494  
     foot, 561  
     general considerations of, 489  
     hip, 499  
     knee, 533  
     leg, 545  
     lengthening of, 497  
     measurement of lower limbs, 497  
     pelvis, 490  
     shortening of, 497  
     thigh, 519  
     walking, 498  
     upper, 216  
     functions of, 216  
     morphology of, 216  
     shoulder, 217  
 Eye, 72  
     anterior chamber, 79  
     anterior lymph circulation of, 79  
     aqueous humor, 77, 79  
     canthus of, 82  
     cataract (see Cataract)  
     choked disk, 80  
     choroid, 77  
     choroiditis, 77  
     ciliary body, 77  
     conjunctiva, 83  
     cornea, 77  
     cyclitis, 77  
     eyeball, 72, 77  
     glaucoma, 79  
     hyaloid membrane, 77  
     iris, 77, 79  
     affections of, 79  
     keratitis, 77  
     lacrimal apparatus, 83  
     lens, 77  
     lids, 72  
     ligament of Zinn, 81  
     macula lutea, 77  
     muscles of,  
         ciliary, 77  
         dilator pupillæ, 79  
         oblique, inferior, 81  
             superior, 81  
         rectus, external, 81  
             inferior, 81  
             internal, 81  
             superior, 81  
         sphincter pupillæ, 79  
     optic disk, 80  
     optic nerve, 79  
         optic neuritis, 80  
     orbits (see Orbit)  
     posterior chamber, 79  
     retina, 77  
         detachment of, 77  
         retinitis, 77  
     sclerotic coat, 77  
     spaces of Fontana, 79  
 Eye, staphyloma, anterior, 77  
     posterior, 77  
     synechia anterior, 79  
     posterior, 79  
     vitreous humor, 77  
     zone of Zinn, 77  
 Eyelids, 82  
     chalazion, 83  
     eyelashes, 83  
     layers of, 82  
     Meibomian glands, 82  
     stye, 83  
     tarsal plates, 82  
 Face, 44  
     blood-vessels of, 44  
     bones of, 8, 44  
     facial artery, 50  
     frontal region of, 45  
     infra-orbital nerve, 56  
         removal of, 56  
     internal maxillary artery, 50  
     jaw, lower, 63  
     jaw, upper, 54  
         fractures of, 54  
         resection of, 55  
     maxillary nerve, 56  
         neuralgia of, 55  
     nerves of, 44  
     region of cheek, 49  
     region of eye, 72  
     removal of Meckel's ganglion, 57  
     soft parts, 44  
         blood-vessels, 44  
         nerves, 44  
         temporal region, 46  
 Facial artery, 50, 134  
     nerve, 20, 52  
         injury to, in fracture of skull, 20  
         paralysis of, 82  
 Falciform process, 390  
 Fallopian tubes, 456  
     development of, 453  
     operation on, 460, 461  
 Falx cerebri, 20  
 Fascia, anal, 435  
     axillary, 256  
     bicipital, 285  
     buccopharyngeal, 153  
     Buck's, 465  
     clavipectoral, 178, 256  
     Colles's, 473  
     cribriform, 391  
     deep, of forearm, 329  
         pus beneath, 329  
     intercolumnar, 377  
     lata, 377  
     of leg, 548  
     lumbar, 393  
         anterior layer of, 393  
         middle layer of, 393  
         posterior layer of, 393  
     of neck, 150  
         influence of, on pus in neck, 154  
         layers of, deep, 151  
         superficial, 150  
     obturator, 435  
     palmar, 357  
         abscess beneath, 365  
     parotid, 52  
     pectoral, 178  
     pelvic, 435  
     perineal, 473



- Fascia, perirenal, 426  
 plantar, 567  
   abscess beneath, 575  
 pretracheal, 153  
   pus above, 154  
   pus beneath, 155  
 prevertebral, 153  
   pus in front of, 155  
   pus posterior to, 155  
 rectovesical, 435, 436  
 Scarpa's, 374  
 superficial, of abdomen, 374  
 temporal, 47  
 transversalis, 399  
 triangular, 377  
   of wrist, deep, 335  
 Fascial triangle, 394  
 Fat, subperitoneal, 399  
 Fauces, pillars of, 112  
 Felon, 367  
 Femoral artery, 523  
   collateral circulation after ligation of, 525  
   in Hunter's canal, 525  
   ligation of, in Hunter's canal, 525  
   in Scarpa's triangle, 523  
   canal, 390  
   sheath, 390  
 Femorosacral arch, 490  
 Femur, 502  
   coxa valga, 502  
   coxa vara, 502  
   fractures of, 529  
     neck, 529  
     shaft, 531  
     trochanters, 531  
   osteotomy of, 544  
 Fibula, 534, 571  
   fracture of, 551  
 Fifth nerve (see Trifacial)  
 Fingers, amputations of, 369  
   metacarpophalangeal, 369  
   dislocations of distal and middle phalanges, 363  
   phalanges on metacarpal bones, 362  
   suppuration involving, 366  
 Fissure or fissures, anal, 443  
   of brain, 33  
     calcarine, 34  
     longitudinal, 33  
     parieto-occipital, 33  
     of Rolando, 33  
     of Sylvius, 33  
     transverse, 33  
   of liver, 418  
   orbital, inferior, 74  
     superior, 74  
   of Santorini, 86  
   sphenoidal, 74  
   sphenomaxillary, 74  
 Fistula in ano, 443  
 Fistulæ of neck, 169, 170  
   median, 170  
   urinary, 382  
   vesicovaginal, 447  
 Flat-foot, 577  
   treatment, 578  
 Floating kidney, 427  
 Fontana, spaces of, 79  
 Fontanelles, 8  
   anterior, 8  
   anterolateral, 9  
   posterior, 8  
   posterolateral, 9  
 Foot, 561  
   amputations of, 574  
     midtarsal (Chopart's), 574  
     tarsometatarsal (Lisfranc's), 575  
   arch of, 561, 563  
     external arch, 563  
     internal arch, 563  
     lateral or transverse arch, 563  
     ligaments of, 566  
     muscles supporting, 568  
   arteries of, 572  
   bones of, 562  
   construction of, 561  
   deformities of, 576  
     flat-foot, 577  
     hallux valgus, 579  
     pronation of, 577  
     talipes calcaneus, 578  
       cavus, 578  
       valgus, 577  
       varus, 576  
   diseases and injuries of, 561  
     treatment of, 562  
   joints of, 569  
     midtarsal or Chopart's, 566  
     subastragaloid, 564  
     ligaments of, 565  
     sprain of, 566  
   ligaments of, 564  
   metatarsalgia, 580  
   muscles of, 568  
     action of, as abductors and adductors, 570  
     action of, as flexors and extensors, 569  
     action of, in supporting tarsal arch, 568  
   plantar abscess, 575  
     deep, 575  
     superficial, 575  
       incision for, 575  
   plantar fascia, 567  
     abscess beneath, 575  
   surface anatomy of, 570  
     bony landmarks, 570  
     joints, 572  
     tendons, 571  
   toes, 579  
     amputation of, 581  
     dislocations of, 580  
     hammer toe, 579  
     ingrown nail, 579  
     metatarsalgia, 580  
     resection of metatarsophalangeal joint, 580  
 Foramen of Key, 22  
   of Magendie, 22  
   mental, 63  
   of Monro, 31  
   nasopalatine, 111  
   obturator, 434, 501  
   optic, 74  
   ovale, 60  
   palatine, posterior, 112  
   of Retzius, 22  
   rotundum, 60  
   sacrosciatic, greater, 434  
     lesser, 434  
     structures passing through, 434  
   of Winslow, 398  
 Foramina of Scarpa, 111  
   of Stenson, 98, 111  
 Forearm, 303  
   amputation of, 326  
     through lower third, 327  
     through middle third, 327



- Forearm, amputation of, through upper third, 327  
 arteries of, 314  
 bones of, 303  
 deep fascia of, 329  
   pus beneath, 329  
 fractures of, 321  
   both bones, 321  
     treatment, 322  
   shaft of radius, 322  
     treatment, 324  
   shaft of ulna, 325  
     treatment, 325, 326  
 movements of pronation and supination, 304  
 muscles of, 305  
   extensors and flexors of fingers, 306  
   extensors and flexors of wrist, 308  
   pronators and supinators of hand, 310  
 nerves of, 317  
 operations on bones and other structures, 328  
 surface anatomy of, 312  
   anterior surface, 312  
   posterior surface, 314
- Foreign bodies:  
   in larynx, 125  
   in orbit, 76  
   in pharynx, 124
- Fornix, pillars of, 30
- Fossa or fossæ:  
   cæcal, 413  
   ileocæcal fossa, inferior, 414  
     superior, 413  
   retrocolic fossæ, 414  
   duodenojejunal, inferior, 408  
     superior, 408  
   epigastric, 180  
   inguinal,  
     external, 387  
     internal, 387  
     middle, 387  
   intersigmoid, 417  
   of Rosenmüller, 123  
   suprameatal, 91  
   supratonsillar, 113
- Fourchette, 462
- Fracture  
   of alveolar process of upper jaw, 54  
   of both bones of forearm, 321  
     treatment, 322  
   of clavicle, 241  
     inner third, 241  
     middle third, 241  
     outer third, 243  
   Colles's, 342  
     reduction of, 343  
   of coronoid process and upper end of radius, 299  
   of femur, 529  
     neck, 529  
       impaction in, 530  
       treatment, 531  
     shaft, 531  
       treatment, 531  
     trochanters, 531  
       treatment, 531  
   of humerus  
     above the condyles, 295  
       treatment, 295  
     intercondylar or T fracture, 298  
     involving the condyles, 296  
       extra-articular, 296  
       intra-articular, 297  
     shaft, 276  
       above insertion of deltoid, 277  
       of humerus, shaft, below insertion of deltoid, 277  
       injury to radial nerve in, 277  
       non-union in, 277  
       treatment, 277  
     upper end, 244  
       anatomical neck, 244  
       surgical neck, 245  
       through the tuberosities, 245  
       treatment, 246  
   of jaw, lower, 67  
     displacement, 69  
     treatment, 70  
     upper, 54  
   of malar bone, 49  
   of maxilla, inferior (see Jaw)  
     of maxilla, superior (see Jaw)  
   of metacarpal bones, 364  
   of nose, 95  
     treatment, 96  
   of olecranon, 298  
     treatment, 298  
   of patella, 539  
     by direct violence, 540  
     by indirect violence, 539  
     treatment of, 540  
   of pelvis, 491  
   of phalanges, 363  
   Pott's, by eversion, 557  
     by inversion, 558  
     treatment, 558  
   of radius, Colles's, 342  
     coronoid process, 299  
     head and neck, 299  
     lower end with forward displacement, 344  
     shaft, 322  
       above pronator radii teres, 323  
       below pronator radii teres, 323  
       treatment, 324  
   of ribs, 175  
   of scapula, acromion process, 244  
     body, 244  
     coracoid process, 244  
     glenoid process, 244  
     surgical neck, 244  
   of skull, 15  
     Aran's law in, 15  
     in adults, 15  
     bleeding from sinuses in, 19  
     cerebrospinal fluid in, 19  
     in childhood, 14  
     by contrecoup, 16  
     emphysema, in 19  
     hemorrhage in, 16  
     injuries to nerves in, 19  
     through anterior cerebral fossa, 16  
     through middle cerebral fossa, 17  
     through posterior cerebral fossa, 17  
     trephining for middle meningeal hemorrhage in, 18  
     trephining for posterior branch of middle meningeal artery in, 18  
   of spine, 482  
   of sternum, 174  
   of tarsal bones, 563  
   of thyroid cartilage, 125  
   of tibia, 551  
     action of tendo calcaneus in, 551  
     treatment, 551  
   of ulna, lower end, 344  
     olecranon, 298  
     treatment, 298  
     shaft, 325



- Fracture of ulna, shaft, below middle, 325  
treatment, 325  
upper third, 326  
treatment, 327
- Friedreich's ataxia, 488
- Frontal bone, 8  
convolutions of brain, 33  
eminences, 45  
lobe of brain, 32  
blood supply of, 28  
process, external, 40  
internal, 46  
region, 45  
sinuses (see Sinus)  
suture, 45
- Funnel chest, 172
- Galen, veins of, 31
- Gall-bladder, 372, 420  
common bile-duct, 421  
cystic duct, 421  
gall-stones, 422  
operation for, 422  
position of, 372, 399
- Gall-stones, 422  
operations for, 422
- Ganglion, compound, of wrist, 342  
Gasserian, 60  
operations on, 60  
of knee, 539  
Meckel's, 57  
removal of, 57
- Gasserian ganglion (see Ganglion)
- Gastrectomy, 405
- Gastric artery, 403  
ulcer, 403  
perforation of, 404
- Gastro-enterostomy, 406
- Gastroplication, 405
- Gastroptosis, 403
- Gastrotomy, 405
- Generative organs, female, 454  
blood-vessels of, 458  
broad ligament, 455  
development of, 453  
external, 462  
clinical considerations of, 464  
Fallopian tube, 456  
lymphatics of, 458  
operations on, 460  
ovary, 456  
pelvic examination, 459  
perineum, 464  
uterus, 454  
vagina, 457  
male, 465  
development of, 453  
penis, 465  
perineum, 472  
scrotum, 467  
spermatic cord, 469  
testicle, 468  
urethra, 470
- Gerhardt, complemental space of, 194
- Gerota, perirenal fascia of, 427
- Gimbernat's ligament, 377, 390
- Glabella, 39
- Gland or glands:  
Bartholin's, 463  
of Brunner, 406  
Cowper's, 471  
Haversian, 507  
lachrymal, 72, 83
- Glands of Littre, 471  
mammary, 182  
meibomian, 82  
parotid, 3, 51  
capsule of, 153  
prostate, 448  
sublingual, 108  
submaxillary, 132  
capsule of, 153  
thymus, 188  
thyroid, 164  
vulvovaginal, 463
- Glaucoma, 79
- Glosso-epiglottic folds, 108, 124
- Glossopharyngeal nerve, 20  
injury to, in fractures of skull, 20
- Gluteal cleft, 505  
fold, 505
- Goitre, 128
- Goldthwait's operation for dislocation of patella, 541
- Groin, lymphatics of, 527  
excision of, 527
- Gunstock deformity, 297
- Gustatory area of brain, 37
- Gyrus fornicatus, 34
- Hæmatemesis, 420
- Hæmatoma of ear, 85  
neonatorum, 8  
of scalp, 5
- Hæmatomyelia, 486
- Hallux valgus, 579  
treatment, 579
- Hammer toe, 579
- Hand, 349  
abscesses of, 365  
beneath palmar fascia, 365  
involving fingers, 366  
suppuration in tendon sheaths, 366  
amputation of fingers, 369  
of thumb, 368  
arteries of, 358  
bones of, 349  
dislocations of, 362  
bases of metacarpal bones, 362  
distal and middle phalanges, 363  
phalanges on metacarpal bones, 362  
proximal phalanx of thumb, 362  
fractures of, 364  
metacarpal bones, 364  
phalanges, 364  
treatment, 364  
joints of, 352  
movements of, 353  
synovial membrane of, 352  
suppuration of, 352  
lymphatics of, 368  
muscles of, 353  
nerves of, 360  
palmar fascia, 357  
surface anatomy of, 354  
wounds of, 364
- Harelip, 105  
treatment, 106
- Harrison's groove, 172
- Hartmann-Mikulicz line, 406
- Heart, 204  
area of dulness of, 205  
cardiohepatic angle, 205  
dilatation of, as cause of pleural effusion, 191  
location of valvular sounds of, 206  
outlines of, 204  
portion uncovered by lung-tissue, 204



- Heart, valves of, 206  
 variation in size and position of, 206  
 wounds of, 207  
 operation for, 207
- Hemianopia, 82  
 binasal, 82  
 bitemporal, 82  
 homonymous, 82  
 lateral, 82
- Hemispheres of brain,  
 lateral surface, 33  
 medial surface, 34
- Hemorrhage, dural, 23  
 epidural, 17  
 middle meningeal, 17  
 into orbit, 77  
 pial, 23  
 from plantar arteries, 573  
 into pons, 32  
 from sinuses in fracture of skull, 19  
 into spinal cord, 486
- Hemorrhoidal arteries, 440  
 inferior, 440, 476  
 middle, 440, 476  
 superior, 440  
 veins, 441
- Hemorrhoids, 420, 442  
 external, 442  
 internal, 442  
 strawberry, 443  
 treatment of, 443
- Hepatic artery, 403, 421  
 duct, 421  
 flexure of colon, 374
- Hereditary spastic paraplegia, 488
- Hernia, 382  
 abdominal, 382  
 congenital, 383  
 descent of testis, 383  
 encysted, 384  
 funicular, 384  
 infantile, 384  
 umbilical, 382  
 vaginal, 384  
 femoral, 390  
 coverings of, 390  
 radical cure of, 392  
 saphenous opening in, 390  
 strangulation of, 392  
 division of, 392  
 inguinal, 383  
 acquired, 385  
 direct, 385, 387  
 coverings of, 388  
 Hesselbach's triangle, 387  
 radical cure of, 389  
 strangulation of, 388  
 division of, 388  
 indirect, 385  
 coverings of, 386  
 radical cure of, 387  
 strangulation of, 386  
 division of, 387  
 lumbar, 394  
 obturator, 435  
 pelvic, 435  
 perineal, 435  
 retroperitoneal, 408  
 sciatic, 435  
 of testicle, 469  
 umbilical, 382  
 acquired, 383  
 infantile, 383
- Hernia, umbilical, infantile, treatment, 383  
 operation on, 383
- Hesselbach's triangle, 387
- Hiatus semilunaris, 97, 100
- Hip, 499  
 abscess of, 516  
 acetabulum, 501  
 ankylosis of, 479  
 bones of, 499  
 femur, 582  
 innominate, 499  
 Bryant's triangle, 505  
 coxalgia or coxitis, 515  
 abscess in, 516  
 attitude, 516  
 measurements, 516  
 symptoms, 515  
 coxa valga, 517  
 vara, 517  
 dislocations of, 508  
 catching of sciatic nerve in, 514  
 freeing of, 514  
 classifications of, 508  
 complicated by fracture, 514  
 reduction of, 514  
 congenital, 514  
 reduction of, 515  
 signs of, 515  
 infolding of capsule or muscle in, 514  
 injuries to muscles in, 511  
 injuries to nerves in, 511  
 mechanism of production, 509  
 reduction, direct method, 512  
 indirect method, 513  
 rent in capsule, 511  
 reversed dislocations, 514  
 signs of, 512
- hip-joint, 506  
 amputation at, 532  
 disease of, 515  
 hyperabduction of, 496  
 hyperadduction of, 496  
 hyperflexion of, 496  
 ligaments of, 507  
 capsular, 508  
 iliofemoral, 507  
 ischiofemoral, 507  
 pubofemoral, 507  
 movements of, 504  
 muscles controlling, 504  
 operations on, 517  
 anterior, 519  
 Boeckman's, 518  
 inferior, 519  
 lateral, 517  
 Lorenz's, 518  
 iliotrochanteric line, anterior, 505  
 posterior, 504  
 ligation of gluteal artery, 505  
 of internal pudic artery, 505  
 of sciatic artery, 505  
 muscles of, 503  
 Roser-Nélaton line, 502, 505  
 surface anatomy of, 504
- Hour-glass stomach, 401
- Housemaid's knee, 538
- Houston, valves of, 439
- Humerus, 221, 267, 280  
 epiphysis of, lower, 300  
 separation of, 300  
 separation of upper, 247  
 excision of head of, 251  
 fracture of, above the condyles, 295



- Humerus, fracture of, above the condyles, treatment, 295  
intercondylar or T fracture, 298  
treatment, 298  
involving the condyles, 296  
extra-articular, 296  
intra-articular, 297  
treatment, 297  
shaft, 276  
above insertion of deltoid, 277  
below insertion of deltoid, 277  
injury to radial nerve, 277  
non-union in, 277  
upper end, 244  
anatomical neck, 244  
surgical neck, 245  
tuberosities, 245  
lower end of, 280  
shaft of, 207  
upper end of, 221  
Hunter's canal, 524  
Hydatid of Morgagni, 453  
Hydrocele, 384  
of canal of Nuck, 385, 468  
congenital, 384, 468  
encysted, of cord, 384, 468  
of neck, 170  
Hydrocephalus, acute, 23  
Hymen, 463  
Hypochondriac region of abdomen, 370  
Hypogastric region of abdomen, 370  
Hypoglossal nerve, 20, 137  
injury to, in fractures of skull, 20  
Hypothenar eminence, 353  
Hysterectomy, 460, 461  
vaginal, 462  
Ileocaecal fold, 413  
inferior, 414  
superior, 413  
fossa, inferior, 414  
superior, 413  
valve, 374, 412  
Ileocolic artery, 412  
Ileum (see Intestine, small)  
Iliac arteries, 436  
ligation of, 436  
collateral circulation after, 437  
line of, 374, 436  
region of abdomen, 370  
veins, position of, 374  
Iliohypogastric nerve, 381  
injury to, in abdominal incisions, 381  
Ilio-inguinal nerve, 381  
Iliopectineal line, 434  
Iliotrochanteric angle, 505  
line, anterior, 505  
posterior, 504  
Ilium, 499  
Imperforate anus, 442  
Incisions, abdominal, 381  
for abscess of axilla, 264  
in abscess of parotid gland, 54  
Battles, abdominal, 382  
Edebohls, for kidney, 382  
for empyema, 200  
for glands of neck, 158  
for glossitis, 110  
Kocher's, for gall-bladder, 382  
lumbar, 395, 428  
longitudinal, 395  
oblique, 396  
McBurney's, for appendix, 382, 414  
Incisions for operating on the forearm, 328  
Pfannenstiel's abdominal, 382  
for palmar abscess, 365  
for plantar abscess, 575  
for removal of breast, 187  
Stimson's abdominal, 382  
transverse, for appendicitis, 414  
Weir's abdominal, 382  
Inflammation of dura, 22  
of pia mater, 23  
of scalp, 5  
Infra-orbital nerve, 56, 94  
removal of, 56  
Infraspinatus bursa, 255  
Infrasternal depression, 180  
Infratemporal crest, 47  
Infundibulum of nose, 100  
Ingrown toe-nail, 579  
Inguinal adenitis, 527  
canal, 385  
columns of, external, 385  
internal, 385  
walls of, 386  
anterior, 386  
floor, 386  
posterior, 386  
roof, 386  
fossæ, external, 387  
internal, 387  
middle, 387  
hernia (see Hernia)  
Inion, 39  
Interarticular cartilage of jaw, 64  
triangular fibrocartilage, 332  
Intercolumnar fascia, 377, 386  
Intercondylar fracture of humerus, 298  
Intercostal arteries, 176  
anterior, 176  
posterior, 177  
nerves, 380  
anterior branches, 380  
lateral cutaneous branches, 380  
Internal capsule, 38  
functions of, 38  
oblique muscle, 377  
pudic artery, 440, 474, 476  
ligation of, 505  
nerve, 476  
Interossei muscles, 353  
Interosseous membrane between radius and ulna, 304  
Intersigmoid fossa, 417  
Intestine, large, 374, 411  
anal canal, 439  
blood-vessels of, 440  
examination of, 442  
external sphincter, 440  
fissures of, 443  
fistula in ano, 443  
hemorrhoids, 442  
imperforate anus, 442  
internal sphincter, 439  
lymphatics of, 441  
mucous membrane of, 440  
nerves of, 442  
valves of, 440  
white line of Hilton, 440  
appendix, 374, 412  
appendicitis, 414  
operation for, 414  
blood supply of, 412  
lymphatics of, 414  
mesoappendix, 412



- Intestine, large, appendix, position of, 374, 413  
     veins of, 413  
     blood supply of, 412  
     caecal folds, 413  
     fossae, 413  
     caecum, 374, 401, 411  
     lymphatics of, 414  
     position of, 374, 400  
     types of, 411  
     colon, ascending, 416  
         position of, 400  
         relation of, to tumors of kidney, 427  
     descending, 417  
         in colostomy, 417  
         position of, 401  
     hepatic flexure, 411  
         position of, 374  
     iliac, 417  
         in inguinal colostomy, 417  
     intersigmoid fossa, 417  
     pelvic, 417  
     sigmoid flexure, 417  
     splenic flexure, 411  
         position of, 374  
     transverse, 416  
         position of, 374, 400  
     ileocaecal valve, 374, 412  
         position of, 374  
     rectum, 438  
         ampulla of, 438  
         blood-vessels of, 440  
         excision of, 443  
         lymphatics of, 441  
         mucous membrane of, 440  
         peritoneal relations of, 439  
         prolapse of, 435  
         rectal examination, 439, 442  
         recto-urethralis muscle, 438  
         valves of Houston, 439  
     sacculations of, 411  
     size of, 411  
     small, 374, 406  
         coils of, 408  
         duodenum, 374, 486  
             duodenojejunal flexure, 408  
             fossa, 408  
             peritoneal covering of, 408  
             position of, 374  
             relations of, 407  
     ileum, 374, 408  
         position of, 374  
     jejunum, 374, 408  
         duodenojejunal flexure, 408  
         fossa, inferior, 408  
         superior, 408  
         muscle or ligament of Treitz, 408  
         constriction of intestine by, 408  
         position of, 374  
     Meckel's diverticulum, 409  
         strangulation of intestines by, 409  
     operations on, 409  
     Peyer's patches, 409  
     position of, 374, 401  
 Intradural hemorrhage of cord, 486  
 Iris, 77, 79  
     affections of, 77, 79  
 Ischiorectal abscess, 476  
     treatment, 476  
     fossa, 476  
 Ischiosacral arch, 491  
 Ischium, 499  
 Jaw, lower, 63  
     dislocation of, 66  
         reduction of, 67  
     excision of, 71  
     excision of condyle of, 71  
     fractures of, 67  
     ligaments of, 64, 66  
         influence on pus in joint, 66  
     movements of, 65  
     temporomandibular articulation, 64  
     upper, 54  
         excision of lingual nerve, 60  
         mandibular nerve, 60  
         fractures of, 54  
         maxillary nerve, 56  
             removal of, through the ptery-  
             goid fossa, 58  
         operations on Gasserian ganglion, 60  
         removal of infra-orbital nerve, 56  
         removal of Meckel's ganglion, 57  
         resection of, 55  
 Jejunum (see Intestine, small)  
 Joint or joints, acromioclavicular, 222  
     ligaments of, 222  
     ankle, 554  
         distention of, 555  
         ligaments of, 554  
         movements of, 554  
     carpometacarpal, movements of, 353  
     elbow, 282  
         ligaments of, 284  
         movements of, 282  
     of foot, 564  
         ligaments of, 564, 566  
         location of, 571  
     of hand, 352  
         movements of, 353  
         synovial membrane of, 352  
             suppuration of, 352  
     metacarpophalangeal, position of, 353  
     midtarsal or Chopart's, 566, 572  
     radio-ulnar, inferior, 332  
         superior, 283  
     shoulder, 222  
         ligaments of, 223  
         movements of, 227  
     sternoclavicular, 222  
     subastragaloid, 564  
         ligaments of, 565  
         sprain of, 566  
     tarsometatarsal (Lisfranc's), 572  
     temporomandibular, 64  
     tibiofibular, inferior, 554  
         ligaments of, 554  
     wrist-joint, 333  
         ligaments of, 333  
         movements of, 333  
 Keratitis, 77  
 Key, foramen of, 22  
 Kidneys, 373, 424  
     abscesses of, 428  
         points of pointing of, 428  
     capsules of, 426  
         fatty, 426  
         fibrous, 426  
     displacements of, 427  
         floating kidney, 427  
         movable kidney, 427  
     hilum of, 426  
     lower border of, 373  
     operations on, 428  
         delivering the kidney, 429



- Kidneys, operations on, incisions, 395, 428  
     nerves encountered, 429  
     pleura in, 429  
     incisions into kidney substance, 429  
     outer edge of, 373  
     pelvis of, 426, 430  
     position of, 373  
     perirenal fascia, 427  
     position of, 373  
     pyelonephritis, 428  
     relations, deep, 425  
         anterior surface, 425  
         posterior surface, 425  
     to surface, 424  
     sinus of, 426  
     suprarenal glands, 430  
     tumors of, 427  
     upper border of, 373  
     ureter, 430  
         course, 431  
         operations on, 431  
     vessels of, 426
- Knee, 533  
     amputation through knee-joint, 544  
     bow-legs, 543  
         treatment, 544  
     bursæ of, 538  
     dislocation of, 541  
         subluxation, 541  
     epiphyseal separations of, 541  
     ganglion of, 539  
     knee-joint, 534  
         ligaments of, 535  
         lines of, 534  
         movements of, 534  
         pus in, 535, 536  
         semilunar cartilages of, 538  
             dislocation of, 541  
     knock-knee, 543  
         treatment, 544  
     osteotomy of femur, 544  
     patella, 535  
         dislocation of, 540  
         fractures of, 539  
     resection of, 542  
     surface anatomy of, 533  
     tuberculous disease of, 543
- Knock-knee, 543  
     treatment, 544
- Kocher's incision for gall-bladder, 382  
     for removal of Meckel's ganglion, 58
- Krönleins operation, 77
- Kyphosis, 479  
     rachitic, 479
- Labia majora, 462  
     minora, 462
- Laceration of perineum, 464  
     operation for, 465
- Lachrymal bones, 8  
     canals, 72, 84  
     gland, 72, 83  
     sac, 72, 84
- Lachrymonasal duct, 72, 84, 99  
     stricture, 7, 84
- Lambda, 39
- Laminectomy, 489
- Laryngitis, 127
- Laryngoscopy, 126
- Laryngotomy, 126, 162
- Larynx, 124  
     cricoid cartilage, 126  
     cricothyroid membrane, 125
- Larynx, diseases of, 127  
     epiglottitis, 124  
     foreign bodies in, 122  
     operations on, 161  
     paralysis of muscles of, 127  
     thyrohyoid membrane, 125  
     thyroid cartilage, 125  
         fracture of, 125  
     valleculæ of, 124  
         foreign bodies in, 124
- Lateral curvature of spine (see Scoliosis)  
     sclerosis, 488  
     sinuses (see Sinus)
- Latissimus dorsi muscle, 269, 392
- Leg, 545  
     amputation of, 552  
     arteries of, 548  
     fascia of, 548  
     fractures of, 551  
     lymphatics of, 551  
     muscles of, 546  
         actions of, 547  
     surface anatomy of, 546  
     veins of, 550  
         varicosities of, 550  
         operation for, 551
- Lens of eye, 77  
     cataract of, 78
- Lenticular nucleus, 31
- Lenticulostriate ganglion, 28  
     blood supply of, 28
- Lesser, triangle of, 146
- Levator ani muscle, 434
- Ligament or ligaments:  
     acromioclavicular, 222  
     alaria, of knee, 538  
     annular, anterior, of wrist, 335  
         structures passing beneath, 336  
         structures passing over, 336  
     annular, posterior, of wrist, 336  
         structures passing beneath, 337  
     anterior, of elbow, 284  
     of Bigelow, 507  
     of bladder, 445  
         false, 445  
         true, 445  
     broad, 455  
     of Burns, 390  
     calcaneoscapoid, inferior, 566  
     capsular, of ankle, 554  
         of hip, 508  
         of inferior radio-ulnar articulation, 333  
         of knee, 535  
         of shoulder, 223  
         of wrist, 333  
     conoid, 222  
     coraco-acromial, 222  
     coracoclavicular, 222  
     coracohumeral, 222, 225  
     coronary, of knee, 538  
         of liver, 397, 418  
     costocoracoid, 222, 257  
     cotyloid of hip, 506  
     crucial of knee, 537  
     deltoid of ankle, 554, 565  
     denticulate, 485  
     of ductus venosus, 419  
     falciform of liver, 419  
     of foot, 564  
     Gimbernat's, 377, 390  
     glenohumeral, 222, 225  
     glenoid of shoulder, 223, 226  
     of hip, 507



- Ligament, iliofemoral, 507  
 infundibulopelvic or suspensory of the ovary, 455, 456  
 interclavicular, 222  
 interosseous astragalo-calcaneal, 565  
 ischiofemoral, 507  
 of knee, 535  
 lateral, external, of ankle, 554, 565  
   of elbow, 284  
   of knee, 537  
   of wrist, 333  
 internal, of ankle, 554, 565  
   of elbow, 284  
   of knee, 537  
   of wrist, 333  
 left, of liver, 398  
 lienophrenic, 424  
 lienorenal, 399, 424  
 ligamentum mucosum of knee, 538  
 ligamentum teres, 506  
 of liver, 418  
 mucosa of knee, 538  
 orbicular, 283  
 orbitotarsal, 6, 74, 82  
 of ovary, 456  
 palpebral, external, 82  
   internal, 82, 84  
 phrenocolic, 424  
 plantar, long, 567  
   short, 566  
 posterior of elbow, 284  
 Poupart's, 377  
 pubofemoral, 507  
 puboprostatic, 445  
 radio-ulnar, anterior, 333  
   posterior, 333  
 rhomboid, 222  
 round, of liver, 419  
   of uterus, 456  
 sacrosciatic, great, 434  
   lesser, 434  
 of shoulder-joint, 223  
 of spleen, 424  
 sternoclavicular, 222  
 of sternoclavicular joint, 222  
 stylohyoid, 132  
 suspensory, of jejunum, 408  
 temporomandibular, 64  
 of tempormandibular articulation, 64  
 transverse, of knee, 538  
 trapezoid, 222  
 of Treitz, 406  
 triangular, 473  
   anterior layer, 473  
   deep layer, 473  
 utero-ovarian, 456  
 uterosacral, 455  
 of uterus, 455  
 of Wrisberg, 537  
 of Zinn, 81
- Ligation of axillary artery, first portion, 259  
 third portion, 262  
 of brachial artery in arm, 274  
   at elbow, 290  
 of carotid artery, common, 141  
   external, 144  
   internal, 143  
 of femoral artery in Hunter's canal, 525  
   in Scarpa's triangle, 523  
 of gluteal artery, 505  
 of iliac arteries, 436  
 of internal pudic artery, 505  
 of lingual artery, 145
- Ligation of peroneal artery, 550  
 of popliteal artery, 544  
 of radial artery, on dorsum of hand, 348  
 of sciatic artery, 505  
 of subclavian, 147, 148  
 of thyroid, inferior, 149  
   superior, 145  
 of tibial artery, anterior, 548  
   posterior, 549  
 of ulnar artery, 316  
   lower third, 317  
   middle third, 316  
   upper third, 316
- Linea alba, 371  
 Lineæ albicantes, 372  
   semilunares, 372  
   transversæ, 372
- Lingual nerve, excision of, 60  
 exposure through mouth, 117
- Lips (see Mouth)
- Lisfranc's amputation, 575
- Lithotomy, lateral, 476  
 median, 475
- Liver, 372, 417  
 abscesses of, 420  
 biliary passages, 420  
   common duct, 421  
   cystic duct, 421  
   hepatic duct, 421  
 fissures of, 418  
 gall-bladder, 420  
 gall-stones, 422  
   operations for, 422  
 hepatic artery, 421  
 injuries to, 420  
 kidney pouch, 422  
 ligaments of, 418  
 liver dulness, 372  
 lobes of, 417  
 lower border of, 372  
 lymphatic nodes of, 422  
 portal obstruction, 420  
   anastomosis of superficial veins in, 420  
 position of, 372, 399, 419  
 relations of, 419  
 size of, 419  
 upper border of, 372  
 wounds of, 420
- Lobes of brain, 32  
 of liver, 417
- Locomotor ataxia, 488
- Longitudinal fissure of brain, 33, 39
- Lordosis, 479
- Lorenz's operation on hip, 518
- Lower level of the brain, 40
- Ludwig's angina, 132
- Ludwig, angle of, 180
- Lumbar abscess, 394  
 fascia, 393  
   anterior layer of, 393  
   middle layer of, 393  
   posterior layer of, 393  
 hernia, 394  
 incisions, 395  
   longitudinal, 395  
   oblique, 396  
 puncture, 488  
 region of abdomen, 370  
   fascias of, 393  
   herniæ of, 394  
   incisions in, 395  
   muscles of, 392  
   Petit's triangle, 394



- Lumbricales muscles, 353
- Lungs, 196  
   in emphysema, 196  
   empyema, 201  
   general considerations of, 198  
   lobes of, 198  
   outline of, 197  
     anterior border, 198  
     apex, 198  
     lower border, 199  
   in phthisis, 197
- Lymphatics of abdominal walls, 380  
   of anal canal, 441  
   of appendix, 414  
   of axilla, 263  
   of cæcum, 414  
   of groin, 527  
     excision of, 527  
   of hand, 368  
   of leg, 551  
   of liver, 422  
   of mammary gland, 184  
   of neck, 156  
     abscess of, 154  
     operation on, 158  
   of nose, 98  
   of ovary, 459  
   of rectum, 441  
   of scalp, 4  
   of stomach, 403  
   of uterus, 458
- Macewen, suprameatal triangle of, 91
- Magendie, foramen of, 22
- Malar bone, 8, 44, 49  
   fracture of, 49  
   tubercle, 40
- Mammary gland, 182  
   abscess of, 185  
   blood supply of, 183  
   fibrous structure of, 183  
   lymphatics of, 184  
   nerves of, 185  
   nipple, 183  
   removal for carcinoma, 187  
   secreting structure of, 182  
   tumors of, 185  
     benign, 185  
     malignant, 186  
     removal of, 187
- Mandible (see Jaw, lower)
- Mandibular nerve, 60  
   excision of, 60  
   exposure of, through the mouth, 117
- Marginal convolution of brain, 34
- Masseter muscle, 65
- Mastoid antrum, in adults, 11  
   in childhood, 9  
   operations on, 91  
   cells, 11, 90  
   operation on, 91  
   process, 4, 11
- Maxilla, inferior (see Jaw, lower)  
   superior (see Jaw, upper)
- Maxillary artery, internal, 50, 58  
   nerve, 56  
     neuralgia of, 55  
     operations on, through pterygoid fossa, 58  
   sinus (see Sinus)
- Mayo incision for gastrectomy, 405
- Mayo Robson's incision for kidney, 429
- McBurney's incision for appendix, 382, 414  
   point, 374, 414
- Measurement of lower limbs, 497
- Meatus, auditory, external, 84  
   inferior, of nose, 99  
   middle, of nose, 100  
   superior, of nose, 100
- Meckel's diverticulum, 372, 382, 409  
   strangulation of intestines by, 383, 409  
   ganglion, 58  
   removal of, 57
- Median nerve, 318  
   branches of, 319  
   distribution of, in hand, 360  
   operations on, 319  
   wounds of, 319
- Mediastinum, 187  
   anterior, 189  
     abscess of, 190  
     paracentesis of the pericardium through, 190  
   middle, 190  
     enlarged glands in, 190  
   posterior, 190  
   superior, 188  
     abscess in, 189  
     aneurism in, 189  
     tumors in, 189  
   tumors of, 191
- Medulla, 31
- Meibomian glands, 82
- Meninges of brain, 20  
   affections of, 22  
   arachnoid, 21  
   dura mater, 20  
     hemorrhage into, 23  
   pia mater, 22  
   of spinal cord, 484  
     arachnoid, 485  
     dura mater, 484  
     pia mater, 485  
     subarachnoid space, 485  
     subdural space, 485
- Meningitis, 23  
   tuberculous, 23
- Meningocele, 7
- Mesentery, 374, 398, 410  
   influence of, upon blood in abdominal cavity, 210  
   lymph-nodes of, 410
- Mesocolon, 398
- Mesosalphinx, 456
- Metacarpal bones, 350  
   dislocations of, 362  
   fractures of, 364  
     treatment of, 364
- Metacarpophalangeal joints, position of, 356
- Metatarsalgia, 580
- Middle meningeal hemorrhage, 17  
   trephining for, 18
- Midfrontal area of brain, 35  
   function of, 38
- Miner's elbow, 300
- Monro, foramen of, 30
- Morgagni, columns of, 440  
   crypts of, 440
- Morton's disease, 580
- Motor track of brain, 39  
   functions of, 39
- Mouth, 104  
   cysts of, mucous, 110  
   lingual nerve, 117  
   lips, 104  
     angioma of, 104  
     blood supply of, 104



- Mouth, lips, cancer of, 105  
 harelip, 105  
 paralysis of, 106  
 wounds of, 104  
 mandibular nerve, 117  
 palatal arches, 112  
 palate, 111  
 blood supply of, 111  
 cleft, 111  
 operation for, 112  
 foramina in, 111  
 hard, 111  
 soft, 111  
 roof of, 111  
 blood supply of, 111  
 foramina in, 111  
 surface anatomy of, 107  
 tongue, 107  
 tonsils, faucial, 113  
 lingual, 108
- Movable kidney, 427
- Muscle or muscles:
- abductor minimi digiti, 354
  - abductor pollicis, 354
  - accelerator urinæ, 471
  - adductor brevis, 522
    - longus, 522
    - magnus, 522
    - pollicis, 354
  - anconeus, 286
  - biceps, 269, 284, 310
    - tendon of, 255
    - dislocation of, 269
    - rupture of, 270
    - of thigh, 520
  - brachialis anticus, 270, 284
  - brachioradialis, 285, 286, 310
  - buccinator, 65
  - bulbocavernosus, 471, 474
  - ciliary, 77
  - coccygeus, 434
  - compressor urethræ, 471, 474
  - coracobrachialis, 269
  - cremaster, 377
  - crureus, 520
  - deltoid, 268
  - digastric, 65
  - dilator pupillæ, 79
  - erector spinæ, 180, 392, 477
  - extensor brevis digitorum, 572
  - extensor brevis pollicis, 308
  - extensor carpi radialis brevior, 310, 334
  - extensor carpi radialis longior, 286, 309, 334
  - extensor carpi ulnaris, 310, 334
  - extensor communis digitorum, 308
  - extensor longus digitorum, 546, 572
  - extensor longus hallucis, 546, 572
  - extensor longus pollicis, 308
  - extensor minimi digiti, 308
  - extensor ossis metacarpi pollicis, 308
  - flexor brevis minimi digiti, 354
  - flexor brevis pollicis, 354
  - flexor carpi radialis, 308, 334
  - flexor carpi ulnaris, 308, 334
  - flexor longus digitorum, 546, 568, 572
  - flexor longus hallucis, 546, 568, 572
  - flexor longus pollicis, 307
  - flexor profundus digitorum, 307
  - flexor sublimis digitorum, 308
  - gastrocnemius, 596
    - bursa of, 539
  - geniohyoglossus, 65
  - geniohyoid, 65
  - Muscle, gluteus maximus, 504
    - medius, 504
    - minimus, 504
  - gracilis, 522
  - iliacus, 434, 504
  - intercostal, external, 176
  - internal, 176
  - interossei of hand, 353
  - ischiocavernosus, 474
  - latissimus dorsi, 180, 269, 392
  - levator anguli scapulæ, 138, 227
  - levator ani, 434
    - palpebræ, 81
  - masseter, 65
  - mylohyoid, 65
  - oblique, external, 377
    - inferior, of eye, 81
    - internal, 377
    - superior, of eye, 81
  - obturator externus, 504, 522
    - internus, 504
  - occipitofrontalis, 2
  - omohyoid, 227
  - opponens minimi digiti, 354
  - opponens pollicis, 354
  - orbicularis oris, 104
  - orbicularis palpebrarum, 82
  - palatoglossus, 113
  - palatopharyngeus, 13
  - palmaris brevis, 354
    - longus, 308, 334
  - pectineus, 522
  - pectoralis major, 177, 269
    - minor, 178
  - perineal, deep, transverse, 474
  - superficial, 474
  - peroneus brevis, 546, 568, 572
    - longus, 546, 568, 572
    - tertius, 546, 568, 572
      - action of, 569
  - plantaris, 546
  - platysma, 65
  - pronator quadratus, 310
    - radii teres, 284, 310
  - psoas, 434, 504
  - pterygoid, 65
  - pyramidalis, 375
  - pyriformis, 504
  - quadratus femoris, 504, 522
    - lumborum, 392
  - quadriceps extensor, 520
  - recto-urethralis, 438
  - rectus abdominis, 375
    - sheath of, 375
    - external, of eye, 81
    - femoris, 520
    - inferior, of eye, 81
    - internal, of eye, 81
    - superior, of eye, 81
  - rhomboid, 227
  - sartorius, 520
  - scalenus anticus, 138
    - medius, 138
    - posticus, 138
  - semimembranosus, 521
  - semitendinosus, 520
  - serratus anterior (magnus), 179, 227
  - soleus, 546
  - sphincter ani, external, 440
    - internal, 439
  - internal, of bladder, 471
  - pupillæ, 79
  - splenius, 138



- Muscle, sternohyoid, 122  
 sternomastoid, 4  
   division of, for torticollis, 4  
 subclavius, 226  
 supinator brevis, 316  
 temporal, 48, 65  
 tensor tarsi, 84  
 tibialis anterior, 546, 568, 572  
   posterior, 546, 568, 572  
 transversalis, 378  
 trapezius, 4, 180, 227  
 of Treitz, 408  
   constriction of intestines by, 408  
 triceps, 270, 286  
 vastus externus, 520  
   internus, 520
- Musculospiral  
 groove, 267  
 nerve, 265, 277  
   paralysis of, 277
- Mynter, operation for excision of wrist, 347
- Nævus, 7
- Nares, anterior, 96  
 posterior, 118
- Nasal bones, 8
- Nasion, 39, 46
- Neck, 127  
 abscess of, 153  
   influence of cervical fascias on, 154  
 arteries of, 141  
 cervical ribs, 175  
   triangles, 131  
 cut throat, 168  
 cysts of, 169  
   median, 170  
   sebaceous, 151  
 diseases affecting, 128  
 fascias of, 150  
   influence on pus in neck, 154  
 fistulæ of, 169  
   median, 170  
 hydrocele of, 170  
 injuries to, 128  
 lymphatics of, 156  
   abscess of, 153  
   operation on, 156  
 œsophagus, cervical portion, 166  
   foreign bodies in, 167  
   œsophagotomy, 167  
 sheath of vessels of, 153  
   pus in, 155  
 surface anatomy of, 128  
   laryngeal region, 129  
   structures felt in median line, 130  
   submental region, 129  
   tracheal region, 129  
 torticollis, 140  
   treatment of, 140  
 triangles, cervical, 131
- Nerve or nerves:  
 abducens, 20, 82  
 auditory, 20  
 auricularis magnus, 44, 52, 139  
 auriculotemporal branch of fifth, 3, 52  
 axillary (see Nerve, circumflex)  
 circumflex, 265  
 cutaneous, internal, of arm, 265  
   internal, of leg, 523  
   lesser internal, 265  
 dental, anterior, 56  
   inferior (see Mandibular nerve)  
   posterior, 56  
 Nerve, descendens hypoglossi, 137  
   facial, 20, 52  
   paralysis of, 82  
   fourth (see Pathetic nerve)  
   frontal branch of fifth, 82  
   genitocrural, 451  
   glossopharyngeal, 20  
   hemorrhoidal, inferior, 442, 476  
   humeral, 265  
   hypoglossal, 20, 137  
   iliohypogastric, 387, 429  
   injury to, in abdominal incisions, 381  
   ilio-inguinal, 381, 429  
   infraorbital, of maxillary, 56, 94  
   removal of, 56  
   infratrochlear, 94  
   intercostal, 380  
   anterior branches, 380  
   lateral branches, 380  
   intercostobrachialis, 185, 265  
   interosseus, anterior (volar), 320  
   posterior, 321  
   labial, of maxillary, 56  
   lacrimal of fifth, 82  
   laryngeal, superior, 125, 137  
   lingual, 60  
   excision of, 60  
   exposure in mouth, 117  
   long subscapular, 265  
   mandibular, 60  
   excision of, 60  
   exposure of, through mouth, 117  
   operations on, through pterygoid fossa, 58  
   maxillary, 56  
   neuralgia of, 55  
   operations on, through pterygoid fossa, 58  
   medial brachial cutaneous, 185  
   median, 318  
   distribution of, in hand, 360  
   operations on, 319  
   wounds of, 319  
   musculocutaneous, 265  
   musculospiral, 265, 277  
   paralysis of, 278  
   nasal, of maxillary, 56, 82, 94  
   occipitalis major, 4  
   minor, 44, 139  
   oculomotor, 19, 82  
   injury to, in fracture of skull, 19  
   paralysis of, 82  
   olfactory, 19, 94  
   injuries to, in fracture of skull, 19  
   optic, 19, 79, 82  
   injury to, in fracture of skull, 19  
   orbital, of maxillary, 56  
   palpebral, of maxillary, 56  
   pathetic, 20, 82  
   paralysis of, 82  
   perineal, external or anterior, 474, 476  
   internal or posterior, 474, 476  
   phrenic, 179  
   pneumogastric, 137  
   pudic, 474, 475, 476  
   radial, 265  
   in arm, 277  
   in forearm, 321  
   in hand, 360  
   respiratory, long external of Bell, 179  
   saphenous, internal, 523  
   long, 526  
   sciatic, large, 527  
   sciatica, 528  
   sphenomalar, of maxillary, 56



- Nerve, sphenopalatine branch of maxillary, 56  
 spinal accessory, 20, 139  
 superficial cervical, 139  
 supra-orbital, 45  
   operation on, 46  
 terminal, of maxillary, 56  
 third (see Oculomotor)  
 thoracic, last, 429  
   posterior, 179  
 thoracodorsalis, 265  
 trifacial, 20  
   area of distribution of, 63  
 ulnar, 265, 320  
   distribution in hand, 360  
   operations on, 320  
   wounds of, 320  
 vagus, 20, 137  
 Neuralgia of maxillary nerve, 55  
 Nipple, 181, 183  
 Noma, 49  
 Nose, 94  
   arteries of, 98  
   bleeding from, 98  
   bony portion, 95  
   bulla ethmoidalis, 100  
   cartilaginous portion, 95  
   epistaxis, 98  
   ethmoidal sinuses, 102  
   frontal sinuses, 101  
   hiatus semilunaris, 97, 100  
   injuries to, 95  
     dislocations, 95  
     fracture, 95  
   lachrymonasal duct, 99  
   lymphatics of, 98  
   maxillary sinus or antrum, 103  
   meatus, inferior, 99  
     middle, 100  
     superior, 100  
   mucous membrane of, 99  
     hypertrophies of, 99  
   nares, anterior, 96  
     view of, 96  
     posterior, 118  
   nasal hypertrophies, 99  
     anterior, 99  
     posterior, 99  
   nerves of, 94  
   obstruction of, 94  
   septum, 97  
     deviations of, 97  
     hematomas of, 97  
     hypertrophies of, 118  
     spurs of, 97  
   spheno-ethmoidal recess, 101  
   sphenoidal sinus, 103  
   turbinate bone, inferior, 96  
     hypertrophy of, anterior, 99  
     posterior, 99, 118  
     middle, 97  
     superior, 97  
   veins of, 98  
   wall, outer, 99  
 Notch, suprasternal, 180  
 Occipital artery, 3, 4  
   bone, 8  
   convolutions of brain, 33  
   lobe of brain, 32  
     blood supply of, 29  
   protuberance, 4  
   sinus, 13  
 Occipitalis major nerve, 4  
 Occipitofrontalis muscle, 2  
 Oculomotor nerve, 19, 82  
   injury to, in fractures of skull, 19  
   paralysis of, 82  
 Oesophagotomy, 167  
 Oesophagus, 166, 211  
   carcinoma of, 212  
   cervical portion, 166  
   dilatation of, 212  
   diverticula of, 212  
   foreign bodies in, 167, 212  
   oesophagotomy, 167  
   relations of, 211  
   structure of, 212  
   tumors of, 211  
 Olecranon, 281  
   bursa of, 300  
     disease of, 300  
   fracture of, 298  
 Olfactory area of brain, 37  
   nerve, 19, 94  
     injuries to, in fracture of skull, 19  
 Ollier, operation for excision of wrist, 346  
 Omentum, gastrohepatic, 397  
   gastrosplenic, 399  
   greater, 398, 399  
     anterior layer of, 398  
     posterior layer of, 398  
   lesser, 398  
 Oophorectomy, 460, 461  
 Ophthalmic artery, 3, 81  
 Optic chiasm, 79  
   disk, 80  
     affections of, 80  
   nerve, 19, 79, 82  
     injuries to, in fractures of skull, 19  
     neuritis of, 80  
 Orbicular ligament, 283  
 Orbitotarsal ligaments, 6, 74  
 Orbits, 72  
   abscess of, 75  
   affections of, 75  
   blood-vessels of, 81  
   contents of, 74  
   dermoids, 75  
   emphysema of, 76  
   foreign bodies in, 76  
   hemorrhage into, 77  
   inferior orbital fissure, 74  
   Kronlein's operation, 77  
   margins of, 45  
   muscles of,  
     levator palpebræ, 81  
     oblique, inferior, 81  
     superior, 81  
     rectus, external, 81  
     inferior, 81  
     internal, 81  
     superior, 81  
   nerves of, 82  
   periosteum of, 74  
   rim of, 72  
   sphenoidal fissure, 74  
   sphenomaxillary fissure, 74  
   superior orbital fissure, 74  
   tumors of, 75  
   walls of, 72  
 Orchitis, 469  
 Os magnum, 350  
 Osteotomy of femur, 544  
   of tibia, 544  
 Ovarian artery, 458  
 Ovary, 456



- Ovary, blood-supply of, 458  
 development of, 453  
 ligaments of, 456  
 lymphatics, 459  
 oophorectomy, 460, 461
- Pacchionian bodies, 21
- Pachymeningitis, 22  
 externa, 22  
 interna, 22
- Palate, arches of, 112  
 blood-supply of, 111  
 cleft palate, 111  
     operation for, 112  
 hard, 111  
 palate bone, 8  
 soft, 111
- Palmar abscess, 365  
     incisions for, 365  
 arch, deep, 359  
     superficial, 358  
 fascia, 357  
     abscess beneath, 365
- Pampiniform plexus, 385
- Panaris, 367
- Pancreas, 373, 422  
 abscess of, 423  
     evacuation of, 423  
 cysts of, 423  
 directions of enlargement of growths of, 423  
 ducts of, 423  
 position of, 373  
 relations of, 423
- Pannus, 77
- Paracentesis of chest, 201  
     pericardii, 190, 202
- Paracentral lobule of brain, 34
- Paradidymis, 453
- Paralysis, crossed, of pons, 32  
     of larynx, 127  
     of lips, 106  
     of musculospiral nerve, 278
- Parathyroid bodies, 165
- Parietal bones, 8  
 eminences, 8  
 lobe of brain, 32  
     blood-supply of, 28
- Paroöphoron, 453  
 cysts of, 454
- Parotid duct, 51  
     calculus of, 51  
     fascia, 52  
     gland, 3, 51  
     abscess of, 53  
     incisions for, 54  
     affections of, 53  
     capsule of, 53  
     lobes of, 52  
     lymphatics of, 53  
     nerves traversing, 52  
     tumors of, 54  
     vessels traversing, 52
- Parotiditis, 53  
     suppurative, 53
- Parovarium or organ of Rosenmüller, 454
- Patella, 534, 535  
 dislocations of, 540  
     treatment, 541  
 floating patella, 536  
 fractures of, 439  
     by direct violence, 540  
     by indirect violence, 539  
     treatment, 540
- Pathetic nerve, 20, 82  
     injuries to, in fractures of skull, 20  
     paralysis of, 82
- Pectoralis major muscle, 269
- Pectoralis minor, 178
- Pelvic examination, 459
- Pelvis, 432  
 bones of, 432, 499  
 bony pelvis, 489  
     arches of, 490  
     femorosacral, 490  
     ischiosacral, 491  
 distortions of, due to affections of lower  
     extremity, 496  
     correction of, 496, 497  
 effect on, of shortening or lengthening the  
     lower extremity, 497  
 tilting of, in deviations of spine, 495  
     correction of, 495  
 false, 432  
 fascia of, 435  
     influence of, on pointing of pus, 436  
 female, 433  
     diameters of, 433  
 floor of, 434  
 foramina of, 434  
     structures passing through, 434  
 fractures of, 491  
 herniæ of, 435  
 iliac vessels, 436  
 iliopectineal line, 434  
 influence of sex on, 433  
 inlet of, 432  
 ligaments of, 434  
 male, 433  
 outlet of, 433  
 prolapse of rectum and vagina, 435  
 true, 432  
 viscera of, 438  
 walls of, 434  
 white line of, 435
- Penis, 465  
 amputation of, 466  
 chordee, 466  
 circumcision, 466  
 crura of, 474  
 extravasation of urine into, 466  
 lymphatics of, 466  
 paraphimosis, 466  
 phimosis, 466  
 rupture of, 466
- Pericardium, 201  
 drainage of, 203  
 paracentesis of, 190, 202
- Pericranium, 3
- Perineal section, 475  
     spaces (see Perineum, male)
- Perineum, female, 464  
     laceration of, 464  
     operation for, 465  
 male, 472  
     anal triangle, 476  
     bony landmarks, 472  
     central point of, 473  
     extravasation of blood and urine into, 475  
     fascias of, 473  
     Colles's, 473  
     superficial, 473  
     triangular ligament, 473  
     ischioanal abscess, 476  
     treatment, 476  
     ischioanal fossa, 476  
     nerves of, 476



- Perineum, male, operations on, 475  
 lithotomy, lateral, 476  
 median, 475  
 perineal section, 475  
 perineal spaces, 474  
 deep, 474  
 superficial, 474  
 urogenital triangle, 472  
 vessels of, 476
- Periosteum of orbit, 74
- Peritoneum, 396  
 anteroposterior section of, 397  
 cæcal folds, 413  
 ileocæcal fold, inferior, 414  
 ileocæcal fold, superior, 413  
 retrocolic fold, 414  
 cæcal fossæ, 413  
 ileocæcal fossa, inferior, 414  
 ileocæcal fossa, superior, 413  
 retrocolic fossæ, 414  
 cavity of, greater, 397, 398  
 lesser, 398  
 coronary ligament, 397  
 foramen of Winslow, 398  
 left lateral ligament of liver, 398  
 lienorenal ligament, 399  
 mesentery, 374, 398  
 mesocolon, transverse, 398  
 omentum, gastrosplenic, 399  
 greater, 398  
 lesser, 398  
 recto-uterine (Douglas's) pouch, 398  
 transverse section of, 398  
 uterovesical fold, 398
- Peritonsillar abscess, 115
- Perivascular lymph-sheath,
- Peroneal artery, 550  
 ligation of, 550
- Petit's triangle, 377, 394
- Petrosal sinus, inferior, 13
- Peyer's patches, 409
- Pfannenstiel, abdominal incision of, 382
- Phalanges, 351  
 dislocation of,  
 distal and middle phalanges, 363  
 on metacarpal bones, 362  
 proximal, of thumb, 362  
 fractures of, 364  
 treatment of, 364
- Pharyngitis, 123
- Pharyngotomy, 125  
 subhyoidæan, 161
- Pharynx, 117  
 adenoids, 122  
 removal of, 122  
 Eustachian tube, 118  
 foreign bodies in, 124  
 fossa of Rosenmüller, 123  
 mucous membrane of, 123  
 openings into  
 larynx, 121  
 obstruction at, 122  
 mouth, 121  
 contractures of, 121  
 œsophagus, 122  
 posterior nares, 118  
 pharyngeal tonsil, 122  
 pharyngitis, 123  
 relation of internal carotid artery to, 123  
 retropharyngeal abscess (see Abscess)
- Phimosis, 466
- Pial hemorrhage, 23
- Pia mater, 22
- Pigeon breast, 172
- Piles (see Hemorrhoids)
- Pirogoff's amputation, 560
- Pisiform bone, 349
- Plantar abscess, 575  
 deep, 575  
 incision for, 575  
 superficial, 575  
 arteries, 572  
 external, 572  
 internal, 572  
 ligation of, 573  
 fascia, 567  
 abscess beneath, 575
- Pleura, 194  
 boundaries of, 195  
 empyema, 200  
 in lumbar incisions, 195, 429  
 paracentesis of, 200  
 pleural effusion, 191
- Pleural effusion, 191  
 dilatation of heart as cause of, 191
- Plexus, brachial, 225  
 choroid, 30  
 pampiniform, 385
- Pneumogastric nerve, 137
- Point, pre-auricular, 40  
 Rolandic, inferior, 40  
 superior, 40, 42  
 Sylvian, 40, 42
- Pons, 31  
 crossed paralysis of, 32  
 hemorrhage into, 32
- Popliteal artery, 544  
 ligation of, 544
- Portal obstruction, 420  
 anastomosis of superficial veins in, 420  
 vein, 420
- Postcentral convolution of brain, 33
- Postprostatic pouch, 446
- Pott's disease of spine, 480  
 fracture, 557  
 treatment, 558  
 position, in fractures of tibia, 551  
 in Potts' fracture, 559
- Pouch of Douglas, 398, 454  
 kidney, 422  
 recto-uterine, 398
- Poupart's ligament, 377
- Pre-auricular point, 40
- Precentral convolution of brain, 33
- Precuneus, 34
- Prefrontal area of brain, 35  
 functions of, 35
- Prepatellar bursa, 538  
 inflammation of, 538
- Process, angular, external, of frontal bone, 40  
 internal, of frontal bone, 46  
 coracoid, 181  
 falciform, 390  
 hamular, 112  
 mastoid, 4  
 styloid, of radius, 332  
 of ulna, 303
- Progressive spinal muscular atrophy, 488
- Prolapse of rectum, 434  
 of vagina, 434
- Pronated foot, 577  
 treatment, 578
- Pronators of forearm, 304
- Prostatectomy, 450  
 perineal, 450  
 suprapubic, 450



- Prostate gland, 448  
 abscess of, 451  
 capsule of, 449  
 hypertrophy of, 449, 450  
 prostatectomy, 450  
   perineal, 450  
   suprapubic, 450  
 relations of, 450  
 separable space, 451  
 sheath of, 449  
 structure of, 450  
 veins of, 450
- Psoas abscess, 481  
 muscle, 434, 504
- Pterion, 39, 42
- Pubic bone, 499
- Puncta lachrymalia, 84
- Pyelonephritis, 428
- Pylorotomy, 405
- Pyloroplasty, 405
- Quadrangle lobule of brain, 34
- Quadratus lumborum muscle, 392
- Rachitic kyphosis, 479  
 rosary, 172
- Radial artery, 316, 359  
 in hand, 359  
   branches, 360  
   ligation of, on dorsum of hand, 348  
   fossa, 280  
 nerve, 265, 277, 321  
   branches in forearm, 320  
     deep, 321  
     superficial, 321  
     volar interosseous, 320  
 distribution in hand, 360  
 paralysis of, 277  
 tubercle, dorsal, 331
- Radiocarpal joint (see Wrist), 333
- Radio-ulnar articulation, inferior, 332  
 dislocation of, 345  
 ligaments of, 333  
 movements of, 333  
 superior, 283  
 ligaments of, 283
- Radius, 281, 304  
 dislocation of head of, 295  
   treatment, 295  
 epiphysis of, lower, 344  
   separation of, 344  
   upper, 300  
     separation of, 299  
 fractures of, Colles's, 342  
   treatment, 343  
   head and neck, 299  
     treatment, 299  
   lower end with forward displacement, 344  
   shaft, 322  
     above insertion of pronator radii  
       teres, 323  
     below insertion of pronator radii  
       teres, 323  
     treatment, 323  
   lower end of, 331
- Ranula, 108  
 treatment, 109
- Rectal examinations, 439
- Rectocele, 435, 464
- Recto-urethralis muscle, 438
- Recto-uterine fold, 455  
 pouch, 398
- Rectovesical pouch, 446
- Rectum (see Intestine, large)
- Rectus abdominis muscle, 375  
 sheath of, 375
- Region or regions:  
 of abdomen, 370  
   epigastric, 370  
   hypochondriac, 370  
   hypogastric, 370  
   iliac, 370  
   lumbar, 370  
   umbilical, 370  
 of ankle, 553  
 of arm, 266  
 of back, 477  
 of cheek, 49  
 of chest, 192  
 of elbow, 280  
 of eye, 72  
 of forearm, 303  
 frontal, 45  
 of hip, 499  
 of knee, 533  
 laryngeal, 129  
 lumbar, 392  
 of neck, 127  
 of shoulder, 217  
 spine, 477  
 submaxillary, pus in, 154  
 submental, 129  
 temporal, 46  
 of thigh, 519  
 tracheal, 129  
 of wrist, 330
- Reil, island of, 28, 33
- Renal arteries, 426
- Resection of ankle, 555  
 of clavicle, 250  
 of condyle of lower-jaw, 71  
 of elbow, 301  
 of humerus, upper end, 251  
 of inferior dental nerve, 60  
 of jaw, lower, 71  
   upper, 55  
 of knee, 542  
 of lingual nerve, 60  
 of maxilla, superior (see Jaw)  
 of metatarsophalangeal joint of foot, 580  
 of rectum, 443  
 of rib, 201  
 of scapula, 251  
 of tongue, 110  
 of ureter, 431
- Retina, 77, 82  
 affections of, 77, 82  
 detachment of, 77  
 hemianopia, 82  
   binasal, 82  
   bitemporal, 82  
   homonymous, 82  
   lateral, 82
- Retrocolic fold, 414  
 fossa, 414
- Retropharyngeal abscess, 90, 116, 123, 156  
 treatment, 116  
 space, 116
- Retzius, foramen of, 22
- Ribs, 174  
 cervical, 175  
 fracture of, 175
- Ridge, sublingual, 108  
 superciliary, 45
- Rings, abdominal (see Abdomen)
- Rivinus, duct of, 108



- Rolandic area of brain, 35  
 functions of, 35  
 point, inferior, 40  
   superior, 40, 42  
 Rolando, fissure of, 33  
 Rosenmüller, fossa of, 123  
 Roser-Nélaton line, 502, 505  
 Rupture of biceps tendon, 270  
   of bladder, 446  
   of penis, 466
- Sacrosciatic foramen, greater, 434  
   lesser, 434  
   structures passing through, 434  
 ligament, greater, 434  
   lesser, 434
- Salpingectomy, 460, 461  
 Santorini, cartilages of, 124  
   duct of, 423  
   fissures of, 86
- Saphenous opening, 390  
 Sarcocele, 469
- Scalp, 1  
   abscess of, 5  
     subaponeurotic, 6  
     subcutaneous, 5  
     subpericranial, 6  
   affections of blood-vessels of, 6  
     aneurismal varix, 6  
     arterial aneurism, 6  
     cirroid aneurism, 6  
     telangiectasis, 6  
     treatment, 7  
     varicose aneurism, 6  
     venous angioma, 6  
   arteries of, 3  
   contusions of, 5  
   hæmatomas of, 5  
   inflammation of, 5  
   layers of, 1  
     affections involving, 4  
   lymphatics of, 4  
   pericranium, 2  
   tumors of, 7  
     cephalhydrocele, 7  
     dermoid tumors, 7  
     encephalocele, 7  
     meningocele, 7  
     sebaceous cyst, 7  
   wounds of, 4  
     treatment of, 5
- Scaphoid bone of hand, 349  
   of foot, 562
- Scapula, 219  
   excision of, 251  
   fractures of, 243  
     acromion process, 244  
     body, 244  
     coracoid process, 244  
     glenoid process, 244  
     surgical neck, 244  
   separation of epiphysis of acromion process, 247  
     coracoid process, 247  
   winged, 180
- Scarpa's fascia, 374  
   triangle, 522
- Schede's operation for varicose veins, 557
- Schlemm, canal of, 79
- Schneiderian membrane, 99
- Sciatica, 528
- Sciatic nerve, 527  
   exposure of, 527
- Sciatic notch, great, 504
- Sclerotic coat of eye, 77  
   affections of, 77
- Scoliosis, 479, 495
- Serobiculus cordis, 180
- Scrotum, 467  
   blood-supply of, 467  
   dartos of, 467  
   extravasation of blood and urine into, 467  
     treatment of, 468  
   operations on, 467  
   skin of, 467
- Sebaceous cyst of neck, 151  
   of scalp, 7
- Semilunar bone, 349  
   cartilages of knee, 538  
     dislocation of, 541  
   fold of Douglas, 376
- Seminal vesicles, 452  
   operations on, 452
- Sensory area of brain, 37
- Septum lucidum, 30
- Septum of nose (see Nose)
- Sheath of vessels of neck, 153  
   pus in, 155
- Shoulder, 217  
   acromioclavicular joint of, 222  
   affections of, 218  
   amputation of, 247  
     flap method, 247  
     interscapulothoracic, 250  
     racket method, 248  
   axilla, 229  
   bones of, 219  
   bursæ of, 255  
   diseases of the joint and bursæ, 253  
   dislocations of, 232  
     anterior, 232  
       treatment, 236  
     posterior, 239  
   epiphyseal separations of, 247  
     acromium, 247  
     coracoid, 247  
     upper end of humerus, 247  
   muscles of, 226  
   shoulder-girdle, 217  
     fractures of, 241  
     movements of, 227  
   shoulder-joint, 222  
     effusions into, 255  
     ligaments of, 223  
     movements of, 253  
   sternoclavicular joint, 222  
   surface anatomy of, 227
- Shrapnell's membrane, 87
- Sigmoid cavity, greater, 281  
   lesser, 303  
   flexure, 417  
     position of, 401  
   notch, 331  
   sinus, 13
- Silver fork deformity, 343
- Sinus or sinuses:  
   cavernous, 14  
   costomediastinal, 194  
   costophrenic, 194  
   ethmoidal, 73, 102  
     in childhood, 10  
     suppuration in, 102  
       drainage of, 102  
   frontal, 10, 45, 101  
     in childhood, 10  
     operation on, 102



- Sinuses, frontal, suppurative in, 101  
 drainage of, 102  
 lateral, 12  
 relations of brain to, 93  
 thrombosis of, 89, 90  
 maxillary, 101, 103  
 disease of, 103  
 in childhood, 10  
 operations on, 103  
 occipital, 13  
 petrosal, inferior, 13  
 superior, 13  
 pocularis, 454  
 sigmoid, 13  
 sphenoidal, 103  
 in childhood, 10  
 suppuration in, 103  
 drainage of, 103  
 sphenoparietal, 13  
 straight, 13  
 superior longitudinal, 12  
 transverse, 12  
 urogenital, 453  
 Skin of abdomen, 374  
 Skull, 8  
 in adults, 10  
 cerebral venous sinuses, 12  
 cavernous, 13  
 lateral or transverse, 12  
 occipital, 13  
 sigmoid, 13  
 straight, 13, 31  
 superior longitudinal, 12  
 superior and inferior petrosal, 13  
 torcular Herophili, 12  
 fractures of, 15  
 by contrecoup, 16  
 hemorrhage in, 16  
 injury to nerves in, 19  
 frontal sinuses, 10, 101  
 mastoid cells, 11  
 operations on, 91  
 mastoid process, 11  
 suprameatal triangle, 12, 91  
 sutures, 11  
 tables of, 10  
 trephining, 18, 44  
 in childhood, 8  
 cells and air sinuses, 9  
 ethmoidal sinus, 9  
 frontal sinus, 9  
 mastoid antrum, 9  
 maxillary sinus, 9  
 sphenoidal sinus, 9  
 dura, 9  
 fontanelles, 8  
 fractures of, 14  
 Snuff-box, 337  
 Sound, urethral, passage of, 471  
 Speech centre, 35  
 Spermatic artery, 385  
 cord, 385, 469  
 sheath of, 469  
 varicocele, 469  
 operations for, 469  
 vessels of, 469  
 Spheno-ethmoidal recess, 101  
 Sphenoidal sinus (see Sinus)  
 Sphenoid bone, 8  
 Sphenoparietal sinus, 13  
 Spina bifida, 480  
 operation on, 480  
 Spinal accessory nerve, 20  
 Spinal accessory nerve, injury to, in fractures of skull, 20  
 column, 478  
 caries of, 480  
 curves of, 478  
 deformities of, 478  
 kyphosis, 479  
 lordosis, 479  
 scoliosis, 479  
 spina bifida, 480  
 deviations of, above the sacrum, 495  
 injuries to, 481  
 dislocations of, 481  
 fractures of, 482  
 nervous lesions in, 484  
 laminectomy, 489  
 movements of, 478  
 psoas abscess, 481  
 spinal cord, 482  
 meninges, 484  
 spinous processes, 477  
 vertebrae of, 478  
 cord, 482  
 cervical enlargement, 482  
 functions of, 487  
 hemorrhage into, 486  
 extradural, 486  
 hematomyelia, 486  
 intradural, 486  
 lesions of, 487  
 of gray matter, 487  
 transverse, 483  
 localization of, 483, 484  
 muscular paralysis in, 484  
 of white matter, 488  
 lumbar enlargement, 482  
 meninges of, 484  
 arachnoid, 485  
 dura, 484  
 pia, 485  
 operations on, 488  
 laminectomy, 489  
 spinal puncture, 488  
 segments of, 483  
 lesions of, 484  
 spinal localization, 487  
 tracts of, 487  
 vessels of, 485  
 localization, 487  
 meninges (see Spinal cord)  
 puncture, 488  
 Spine, anterior inferior, of ilium, 500, 504  
 superior, of ilium, 500, 504  
 posterior inferior, of ilium, 504  
 superior, of ilium, 500, 504  
 of Spix, 117  
 suprameatal, 91  
 Spleen, 373, 424  
 ligaments of, 424  
 position of, 374  
 relations of, 424  
 splenic enlargements, 424  
 wounds of, 424  
 Splenic artery, 403  
 flexure of colon, 374  
 Sprain of ankle, 556  
 treatment, 556  
 of subastragaloid joint, 565  
 Staphyloma, anterior, 77  
 posterior, 77  
 Stenson's duct, 51  
 Stephanion, 40  
 Sternoclavicular joint, 222



- Sternomastoid muscle, 4  
     division of, for torticollis, 140  
 Sternum, 174  
     fractures of, 174  
 Stimson, abdominal incision of, 382  
 Stomach, 373, 401  
     blood-supply of, 403  
     carcinoma of, 404  
         adhesions in, 405  
         perforation of, 405  
         ulceration in, 405  
     cardiac end, 373, 402  
     contracted stomach, 401, 403  
     dilatation of, 403  
     fundus of, 373  
     gastroptosis, 403  
     hour-glass deformity of, 401  
     lower border, 373  
     lymphatics of, 403  
     operations on, 405  
         gastrectomy, 405  
         gastro-enterostomy, 406  
         gastropliation, 405  
         gastrostomy, 405  
         gastrotomy, 405  
         pylorectomy, 405  
         pyloroplasty, 405  
     percussion of, 482  
     position of, 399, 402  
     pylorus, 373, 402  
     relations of, 402  
     Traube's semilunar space, 402  
     ulcer of, 403  
         perforation of, 404  
     veins of, 403  
 Straight sinus, 13, 31  
 Stricture of œsophagus, 212  
     of urethra, 472  
 Studsgaard operation for excision of wrist, 347  
 Sty, 83  
 Styloid process of radius, 332  
     of ulna, 303  
 Subacromial bursa, 255  
 Subaponeurotic layer of scalp, 2  
 Subarachnoid space, 22  
 Subastragaloid joint, 564  
     ligaments of, 565  
     sprain of, 566  
 Subclavian artery, 147  
     ligation of, 148  
 Subdiaphragmatic abscess, 420, 423  
 Subfemoral bursa, 535  
 Submammary abscess, 185  
 Submaxillary gland, 132  
     capsule of, 153  
 Submental region, 129  
 Subpericranial tissue of scalp, 3  
 Subperitoneal fat, 399  
 Subscapular artery, 260  
     bursa, 255  
 Superciliary ridges, 45  
 Superficial fascia of scalp, 1  
     of abdomen, 374  
 Superior longitudinal sinus, 12  
     parietal gyrus, 33  
     petrosal sinus, 13  
 Supination of forearm, 304  
 Supramarginal gyrus, 33  
 Suprameatal spine, 91  
     triangle, 12, 91  
 Supra-orbital nerve, 45  
     operation on, 46  
     neuralgia, 45  
 Supra-orbital neuralgia, operation for, 46  
 Suprarenal gland, 430  
 Suprasternal notch, 180  
     pus in, 154  
 Surgical kidney, 428  
 Sustentaculum tali, 571  
 Sutures of skull, 11  
 Sylvian point, 40, 42  
 Sylvius, fissure of, 28, 33  
 Syme's amputation, 559  
 Synechia, anterior, 79  
     posterior, 79  
 Siringomyelia, 488  
 Tabes dorsalis, 488  
 Tænia semicircularis, 30  
 Talipes calcaneus and cavus, 578  
     treatment, 579  
     equinus, 578  
         treatment, 578  
     planus, 577  
         treatment, 578  
     valgus, 577  
         treatment, 578  
     varus, 576  
         treatment, 576  
 Tarsometatarsal amputation, 575  
 Telangiectasis, 7  
 Temporal artery, 3, 48, 52  
     bones, 8  
     convolutions of the brain, 334  
     fascia, 47  
     muscle, 65  
     region, 46  
     ridge, 39  
 Temporomandibular articulation, 64  
     ligaments of, 64  
 Temporosphenoidal lobe of brain, 32  
     blood-supply of, 29  
 Tendon or tendons:  
     conjoined, 388  
     of foot, 571  
         location of, 571  
     of hand, 356  
         wounds of, 364  
     sheaths of hand, suppuration in, 366  
     tendo Achillis, 557  
         action in fracture of fibula, 558  
         of tibia, 551  
         tenotomy of, 552, 558  
     tendo calcaneus (Achillis), 557  
 Tendo-oculi, 82  
 Tenon, capsule of, 74  
 Tentorium cerebelli, 20  
 Testicle, 468  
     abscess of, 469  
     castration, 469  
     coverings of, 469  
     descent of, 383, 468  
     development of, 383, 453  
     epididymis, 468  
         epididymitis, 469  
     hernia of, 469  
     hydrocele, 384, 468  
     orchitis, 469  
     size and position of, 468  
     undescended, 468  
 Thalamus, 30, 31  
     blood-supply of, 28  
     functions of, 37  
 Thenar eminence, 353  
 Thigh, 519  
     amputation, 532



- Thigh, amputation of, at hip-joint, 532  
 femoral artery, 523  
 femur, fractures of (see Fractures)  
 Hunter's canal, 524  
 lymphatics of groin, 527  
 excision of, 527  
 muscles of, 520  
 adductors, 522  
 extensors, 520  
 flexors, 520  
 saphenous vein, long or internal, 525  
 varicosities of, 526  
 Scarpa's triangle, 522  
 sciatic nerve, 527  
 sciatica, 528  
 structure of, 519  
 surface anatomy of, 522  
 Thoracic duct, 140, 214  
 wounds of, 214  
 Thorax (see Chest), 171  
 surface anatomy of, 18  
 Thumb,  
 amputation of, 368  
 carpometacarpal, 369  
 distal phalanx, 368  
 metacarpophalangeal, 369  
 dislocation of proximal phalanx of, 362  
 Thyroglossal duct, 107  
 in cervical fistulæ, 170  
 Thyroid cartilage, 125  
 fracture of, 125  
 gland, 164  
 arteries of, 164  
 capsule of, 153  
 operations on, 163  
 parathyroid, 166  
 veins of, 165  
 Thyrotomy, 161  
 Tibia, 534  
 fractures of, 551  
 Tibial artery, anterior, 598  
 ligation of, 548  
 posterior, 549  
 ligation of, 549  
 Tibiofibular joint, inferior, 554  
 ligaments of, 554  
 Toes (see Foot)  
 Tongue, 107  
 arteries of, 110  
 cancer of, 110  
 excision of, 110  
 foramen cæcum of, 107  
 glossitis, 110  
 incisions in, 110  
 glosso-epiglottic folds, 108  
 lingual tonsil, 108  
 mucous cysts of, 110  
 papillæ of, 107  
 circumvallate, 107  
 filiform of, 107  
 fungiform of, 107  
 removal of, 110  
 tongue-tie, 108  
 treatment, 108  
 Tonsil, faucial, 113  
 blood-supply of, 114  
 enucleation of, 115  
 hypertrophy of, 115  
 peritonsillar abscess, 115  
 relation to internal carotid artery, 315  
 removal of, 115  
 supratonsillar fossa, 113  
 tumors of, 114  
 Tonsil, lingual, 108  
 Luschka's, 122  
 pharyngeal, 122  
 Tonsillitis, 114  
 Topographical points of brain, 40  
 Topography, craniocerebral, 39  
 Torcular Herophili, 12  
 Torticollis, 140  
 Tracheal region, 129  
 Tracheotomy, 162  
 Transversalis fascia, 399  
 muscle, 378  
 Transverse sinuses, 12  
 spinal lesions, 483  
 Trapezium, 350  
 Trapezius muscle, 4  
 Trapezoid bone, 350  
 ligament, 222  
 Traube's semilunar space, 402  
 Treitz, ligament of, 406  
 Trephining, 44  
 for middle meningeal hemorrhage, 18  
 for posterior branch of middle meningeal, 18  
 Triangle, anal (see Perineum, male)  
 Bryant's, 505  
 fascial, 394  
 Hesselbach's, 387  
 of Lesser, 146  
 of neck, 131  
 anterior, 131  
 posterior, 137  
 Petit's, 377, 394  
 Scarpa's, 522  
 suprameatal, 12  
 urogenital (see Perineum, male)  
 Triangular fascia, 377  
 ligament, 473  
 anterior or superficial layer, 473  
 posterior or deep layer, 473  
 Triceps muscle, 270, 286  
 fascial expansion of, 270  
 in resection of elbow, 301  
 Trifacial nerve, area of distribution of, 63  
 Gasserian ganglion, 60  
 operations on, 60  
 infraorbital branch, 56  
 removal of, 56  
 injury to, in fractures of skull, 20  
 lingual branch, 60  
 excision of, 60  
 mandibular branch, 60  
 excision, 60  
 maxillary branch, 56  
 operation on, 58  
 Meckel's ganglion, 57  
 removal of, 57  
 supra-orbital branch, 45  
 removal of, 45  
 Trigone of bladder, 446  
 Trochlea, 280  
 Tube, Eustachian, 84, 89  
 Fallopian, 456  
 Tubercle, carotid, 149  
 dorsal radial, 331  
 of os calcis, 571  
 of scaphoid bone, 571  
 Tuberculosis of ankle, 555  
 of hip, 515  
 of knee, 543  
 of meninges, 23  
 Tuberosity of fifth metatarsal bone, 571  
 of ischium, 501  
 Tumors of axilla, 265



- Tumors of bladder, 448  
   of broad ligament, 462  
   of kidney, 427  
   of mammary gland, 185  
   of parotid gland, 54  
   of scalp, 7  
 Tunica albuginea, 469  
   vaginalis, 469  
 Turbinate bone, inferior, 8, 44, 97, 118  
   hypertrophy of, 118  
   middle, 97, 118  
   superior, 97  
 Tympanic membrane (see Ear)  
 Tympanomastoid exenteration, 91, 92  
 Tympanum (see Ear)  
 Ulcer, gastric, 403  
 Ulna, 281, 303  
   dislocation of, at inferior radio-ulnar joint, 345  
   epiphysis of, upper, 300  
     separation of, 300  
   fracture of lower end, 344  
     treatment, 344  
   olecranon process, 298  
     treatment, 298  
   shaft, 325  
     below middle, 325  
       treatment, 325  
     upper third, 325  
       treatment, 326  
   lower end of, 332  
   upper end of, 281  
 Ulnar artery, 314, 358  
   in hand, 358  
     branches of, 359  
   ligation of, in forearm, 316  
     lower third, 317  
     middle third, 316  
     upper third, 316  
   nerve, 320  
     distribution in hand, 360  
     operations on, 320  
     wounds of, 320  
 Umbilical arteries, 371, 382  
   hernia (see Hernia)  
   region of abdomen, 370  
   veins, 371  
 Umbilicus, 371  
 Unciform bone, 350  
 Urachus, 382, 387  
 Ureter, 430  
   abdominal portion, 431  
     course of, 431  
     excision of, 431  
     operation on, 431  
   calculi in, 431  
   in female, 457  
   points of narrowing, 431  
   relation of, to genitocrural nerve, 431  
 Urethra, male, 470  
   calibre of, 470  
   distensibility, 470  
   length of, 470  
   muscles of, 471  
   passage of catheters and sounds, 471  
   practical applications, 471  
   relations of, 470  
   rupture of, 475  
     treatment of, 475  
   stricture of, 471  
     spasmodic, 472  
     traumatic, 472  
   structure, 470  
   Urethral crest, 471  
 Urogenital system, development of, 453  
   triangle (see Perineum, male)  
 Uterine artery, 458  
 Uterovesical fold, 398  
 Uterus, 454  
   antelexion of, 459  
   anteversion of, 459  
   attachments of, 455  
   blood-supply of, 458  
   broad ligament of, 455  
   cervix, 454  
     lacerations of, 462  
   development of, 453  
   hysterectomy, 460, 461  
     vaginal, 462  
   ligaments of, 455  
   lymphatics of, 458  
   position of, 454  
   retroflexion, 459  
   retroversion, 459  
 Uvula, 112  
 Vagina, 457  
   development of, 453  
   fornix, anterior, 457  
     posterior, 457  
 Vagus nerve, 20  
   injury to, in fractures of skull, 20  
 Valve or valves:  
   Gerlach, 412  
   ileocaecal, 374, 412  
   of heart, 206  
   of rectum (Houston), 439  
 Varicocele, 469  
 Varicose aneurism, 7  
   veins of leg, 526, 550  
     operation for, 551  
 Vas deferens, 385, 452, 469  
 Vater, ampulla of, 407  
   stone in, 422  
 Vein or veins:  
   of abdominal walls, 380  
   celiotomy, 380  
   choroid plexus of, 30  
   coronary, 403  
   cystic, 420  
   deferential, 469  
   of elbow, 288  
   epigastric, deep, 380  
     superficial, 380  
     superior, 380  
   ethmoidal, anterior, 98  
     posterior, 98  
   femoral, 523  
   of Galen, 31  
   gastric, 420  
   gastro-epiploic, left, 403  
     right, 403  
   hemorrhoidal,  
     inferior, 441  
     middle, 441  
     superior, 420, 441  
   ileocolic, 413  
   iliac, 436  
     position of, 374  
   iliac, circumflex, deep, 380  
     superficial, 380  
   jugular, anterior, 135  
     external, 138  
     internal, 136  
       thrombosis of, 136  
       wounds of, 136



- Veins of leg, 550  
   median, 288  
   median basilic, 289  
   median cephalic, 289  
   mesenteric, superior, 420  
   of nose, 98  
   ophthalmic, inferior, 81  
     superior, 81  
   pampiniform plexus of, 385  
   portal, 420  
   of prostate gland, 450  
   pyloric, 403, 420  
   radial, 288  
   renal, 426  
   saphenous, long or internal, 525, 550  
     excision of, for varicose veins, 551  
     short or external, 550  
   of spinal cord, 480  
   splenic, 420  
   of thyroid gland, 165  
   ulnar, 289  
   umbilical, 371  
   vena parumbilicalis, 380  
   vena thoracica epigastrica longa tegumen-  
     tosa, 380  
   venous plexuses of rectum, 441  
   vertebral plexuses, 484, 486  
 Velum interpositum, 31  
 Venous angioma, 7  
 Ventricles, fifth, of brain, 30  
   lateral, of brain, 30, 43  
     tapping of, 43  
   third, of brain, 30  
     blood-supply of, 28  
 Vertebrae, thoracic, 176  
 Vertebral artery, 25, 147  
   column (see Spinal column)  
 Vestibule of vagina, 462  
 Viscera, abdominal, 372, 399  
   position of, 372, 399  
   pelvic, 438  
 Visual area of brain, 37  
 Vitelline duct, 371, 382  
 Vomer, 8  
 Vulvo-vaginal glands, 463  
  
 Walking, 498  
   part played by various joints in, 499  
 Walther, ducts of, 108  
 Weir's abdominal incision, 382  
  
 Wharton, duct of, 108  
 Whitlow, 367  
 Winslow, foramen of, 398  
 Wirsung, duct of, 423  
 Wolffian body, 453  
   duct, 453  
 Wounds of cheek, 49  
   of epigastric artery, deep, 379  
     in abdominal operations, 380  
     superior, 379  
   of hand, 364  
   of heart, 207  
     operation for, 207  
   of lips, 104  
   of liver, 420  
   of parotid duct, 51  
   of scalp, 4  
   of spleen, 424  
   of thoracic duct, 214  
 Wrisberg, cartilages of, 124  
   ligament of, 537  
 Wrist, 330  
   amputation at, 347  
   annular ligament, anterior, 335  
     structures passing beneath, 336  
     structures passing over, 336  
   posterior, 336  
     structures passing beneath, 337  
   bones of, 330  
   compound ganglion of, 342  
   deep fascia of, 335  
   dislocations of, 345  
     at radiocarpal joint, 345  
     at radio-ulnar joint, 345  
     wrist-drop, 334  
   excision of, 345  
   fractures of, Colles's, 342  
     lower end of radius and ulna, 342  
   inferior radio-ulnar articulation, 332  
     ligaments of, 333  
     movements of, 333  
   ligation of radial artery on dorsum of hand,  
     348  
   muscles of, 335  
   snuff-box, 337  
   surface anatomy of, 338  
   tendons of, 336  
 Wrist-joint, 333  
   ligaments of, 333  
   movements of, 333
















## COLUMBIA UNIVERSITY LIBRARIES

This book is due on the date indicated below, or at the expiration of a definite period after the date of borrowing, as provided by the library rules or by special arrangement with the Librarian in charge.

DATE BORROWED	DATE DUE	DATE BORROWED	DATE DUE
C28 (1149) 100M			



QM531

D29  
1910



