

Operative surgery on the cadaver / by Jasper Jewett Garmany.

Contributors

Garmany, Jasper Jewett.
Augustus Long Health Sciences Library

Publication/Creation

New York : Appleton, 1887.

Persistent URL

<https://wellcomecollection.org/works/vet8fw6p>

License and attribution


This material has been provided by This material has been provided by the Augustus C. Long Health Sciences Library at Columbia University and Columbia University Libraries/Information Services, through the Medical Heritage Library. The original may be consulted at the the Augustus C. Long Health Sciences Library at Columbia University and Columbia University. where the originals may be consulted.

This work has been identified as being free of known restrictions under copyright law, including all related and neighbouring rights and is being made available under the Creative Commons, Public Domain Mark.


You can copy, modify, distribute and perform the work, even for commercial purposes, without asking permission.




Wellcome Collection
183 Euston Road
London NW1 2BE UK
T +44 (0)20 7611 8722
E library@wellcomecollection.org
<https://wellcomecollection.org>










D. H. McAlpin Jr.

21 East 21 St.



OPERATIVE SURGERY

ON THE CADAVER

BY

JASPER JEWETT GARMANY,

A. M., M. D., F. R. C. S.,

ATTENDING SURGEON TO OUT-DOOR POOR DISPENSARY OF BELLEVUE HOSPITAL;
VISITING SURGEON TO NINETY-NINTH STREET RECEPTION HOSPITAL,
BRANCH OF BELLEVUE HOSPITAL; MEMBER OF THE
BRITISH MEDICAL ASSOCIATION, ETC.

NEW YORK
D. APPLETON AND COMPANY
1887

66

G18

1887

c.1

Spec Coll

Hist Coll

Webster Library

R2

66

G18

COPYRIGHT, 1887,

By D. APPLETON AND COMPANY.

DL
APR 28 1943

IN MEMORIAM.

TO MY PRECEPTOR,

PROFESSOR JAMES R. WOOD, M. D., LL. D.,


IN RECOGNITION OF

HIS ACTS OF KINDNESS DURING MY THREE YEARS' PUPILAGE,

AND WHILE INTERNE OF BELLEVUE HOSPITAL,

THIS VOLUME IS REVERENTLY DEDICATED

BY THE AUTHOR.




PREFACE.

It is my endeavor to present a guide to the manipulative procedures of the ordinary surgical operations.

Acknowledgment of indebtedness is chiefly due to Stephen Smith's "Operative Surgery."

NEW YORK CITY, *September, 1887.*



CONTENTS.

	PAGES
CHAPTER I.	
USE OF SPECULA, CATHETERS, SOUNDS, BOUGIES, ETC.—PLUGGING OF POSTERIOR NARES.—I. Aural, Nasal, Vaginal, and Rectal Specula—II. Catheterization of Eustachian Tube, Nasal Duct; Catheterization of Larynx; Intubation of Larynx; Use of Stomach-Tube, Œsophageal Probang, Urethral Sound or Catheter, Rectal Bougies—III. Plugging of Posterior Nares . . .	1-9
CHAPTER II.	
PARACENTESIS, HYPODERMIC NEEDLE.—I. Corneæ, Tympani, Thoracis, Pericardii, Abdominis, Vesicæ, Urethræ, Aspiration—II. Hypodermic Needle	10-16
CHAPTER III.	
MANIPULATION OF THE SCALPEL—INCISIONS—DRAINAGE—SUTURES—KNOTS	17-27
CHAPTER IV.	
OPERATIONS ON THE HEAD AND NECK.—Trephining—Operation for Strabismus—Excision of the Eye—Extraction of Teeth—Perforation of the Antrum—Excision of the Tongue—Bronchotomy—External Œsophagotomy	28-42
CHAPTER V.	
OPERATIONS ON THE TRUNK.—Excision of the Mammary Gland—Median Laparotomy—Enterorrhaphy—Enterectomy—Enterotomy—Enterostomy—Colectomy—Colostomy—Nephrorrhaphy—Nephrotomy—Nephrectomy—Symphysiotomy . . .	42-53

CHAPTER VI.

GENITO-VESICAL.—External Perineal Urethrotomy—Sounding for Vesical Calculus—Lithotrity—Cystotomy—Posterior Catheterization—Resection of the Scrotum—Circumcision—Amputation of the Penis—Shortening of the Round Ligaments—Castration—Oöphorectomy 54-66

CHAPTER VII.

OPERATIONS ON MUSCLES.—Manipulation of the Tenotome—Myotomy (Tenotomy and Fasciatomy)—Suturing of Tendons:—Sterno-cleido-Mastoid; Flexors of Digits; Extensors of Digits; Flexors of Carpus; Biceps Cubiti; Flexors of Toes; Extensor Longus Digitorum; Extensor Proprius Hallucis; Tibialis Anticus; Tibialis Posticus; Peroneus Longus and Brevis; Tendo Achillis; Biceps Femoris; Inner Hamstrings; Quadriceps Femoris; Adductor Longus; Plantar Fascia—Suturing of the Tendon of the Biceps Femoris 67-72

CHAPTER VIII.

OPERATIONS ON NERVES.—Neurotomy—Neurectomy—Nerve-Stretching—Nerve-Suturing—Neurotomy of Lingual—Neurectomy of Spinal Accessory—Stretching of Great Sciatic—Suturing of Median 73-75

CHAPTER IX.

OPERATIONS ON THE CIRCULATORY SYSTEM.—Compression of Vessels (Tourniquet and Elastic Band)—Torsion of Vessels—Ligature: (a) Cut Vessels, (b) Vessels in their Continuity—Ligature of Special Arteries in their Continuity:—Radial, Ulnar, Brachial, Axillary, Subclavian, Vertebral, Common Carotid, Internal Carotid, External Carotid, Superior Thyroid, Lingual, Facial, Occipital, Temporal, Common Iliac, Internal Iliac, Gluteal, Sciatic, Internal Pudic, External Iliac, Deep Epigastric, Femoral, Profunda Femoris, Popliteal, Posterior Tibial, Peroneal, Anterior Tibial, Dorsalis Pedis—Phlebotomy—Arteriotomy—Transfusion 76-102


CHAPTER X.

OPERATIONS ON THE OSSEOUS SYSTEM.—Manipulation of the Saw—Osteotomy (Tibia)—Wiring of Bones (Patella)—Excision of

	PAGES
Superior Maxilla—Excision of Inferior Maxilla—Resection of Rib—Resection of Articulating Ends of Bones:—Shoulder, Elbow, Wrist, Metacarpo-Phalangeal, Phalangeal, Hip, Knee, Ankle	103-121

CHAPTER XI.

AMPUTATIONS AND DISARTICULATIONS.—Manipulation of the Amputating-Knife—Steps in Operating—I. Amputations and Disarticulations of the Upper Limb: Fingers; Wrist (Dubreuil's Operation); Forearm; Elbow; Arm; Shoulder (Spence's Operation) — II. Amputations and Disarticulations of the Lower Limb: Toes; Metatarsus (Lisfranc's Operation); Tarsus (Chopart's Operation); Ankle (Syme's Operation), (Pirogoff's Operation); Leg (Teale's Operation); Knee (Bauden's Operation); Thigh (Carden's Operation), (Gritti's Operation), (Lister's Operation); Hip (Liston's Operation), (Jordan's Operation)		122-146
--	--	---------



OPERATIVE SURGERY ON THE CADAVER.

CHAPTER I.

USE OF SPECULA, CATHETERS, SOUNDS, BOUGIES, AND PLUGGING OF POSTERIOR NARES.

I. INTRODUCTION OF AURAL, NASAL, VAGINAL, AND RECTAL SPECULA.

Aural Speculum (Gruber, Toynbee).—Before the speculum can be introduced, the canal must be straightened by seizing the auricle by its upper part and drawing it upward, backward, and outward.

Moisten the speculum with water, and gently insert the small end into the canal. The speculum is to be introduced into the canal to the required extent by gently screwing it forward and backward in a small arc, and by slight pressure.

To examine the drum, it is best to use reflected light. The speculum must be manipulated to bring the different parts of the canal and of the drum into view.

An ear-syringe must have its nozzle introduced in the same manner as the speculum. Apply the nozzle to the roof of the canal while injecting the fluid.

Nasal Speculum (Fraenkel).—Insert the speculum along the floor of the naris, having first pushed

up the tip of the nose to straighten the canal. The floor of the naris extends horizontally backward.

When the speculum has been introduced to the extent of one to one and a half inch, the blades are to be separated by the screw.

Both nostrils may be dilated at once by putting one blade of the speculum on each side of the septum, and then separating them.

Vaginal Speculum (Fergusson, Sims).—Place the subject on the back, with the hip-joints and knees semiflexed and the thighs separated, in order to use the ordinary specula. Lubricate the cylindrical speculum (Fergusson). Press the posterior edge of the vaginal entrance downward with the convex side of the tip of the instrument. Push the speculum horizontally to examine the canal and manipulate to bring into view the cervix.

Place the subject on the left side with the left arm drawn posteriorly so that she rests upon the left chest-wall; flex the thighs and legs to about a right angle. The right knee rests above the left, so that the right hip-joint is more flexed than the left. Lubricate the blade of Sims's speculum which is to be introduced. Grasp the isthmus of the instrument between the fingers and thumb of the left hand, and let the blade to be introduced rest in the concavity of the extended thumb and index-finger of the right hand with the pulp of the index-finger extending beyond the lip of the instrument. The right forefinger is thus in the concavity of the blade to be introduced. Press against the posterior wall of the vagina with the back of the right index-finger and guide the blade into the vagina with the convexity toward its

posterior and superior lateral wall. The walls of the vagina are separated, allowing air to distend the canal.

To hold the speculum, the assistant must stand behind the body and use the width of his hand like a wedge between the buttock and upper blade of the speculum. The isthmus lies against the palm of the hand, and the superior part between the index-finger and thumb, leaving the other fingers free.

An instrument to depress the vaginal folds obstructing the view may be necessary.

Rectal Speculum.—Place the subject on the back with the thighs separated; or on the side with the knees pushed up close to the abdomen. A reflecting cylindrical speculum with a portion of its circumference deficient, or one of the valve specula, may be used. Lubricate the point of the instrument. Insert, directing the point of the instrument toward the bladder, hence somewhat forward, for the first inch and a half. Now the point of the instrument is to be directed nearly horizontally backward, toward the hollow of the sacrum.

If a valve-speculum is used, it is to be opened, after it is fully introduced, and again shut before beginning to be removed. Manipulate the speculum to bring into view every part.

The nozzle of a syringe must follow this same course during its introduction.

II. CATHETERIZATION OF EUSTACHIAN TUBE, NASAL DUCT; INTUBATION OF TRACHEA; USE OF STOMACH-TUBE, ŒSOPHAGEAL PROBANG, URETHRAL SOUND OR CATHETER, RECTAL BOUGIES.

Eustachian Catheter (Noyes).—Pass the catheter, keeping its point against the floor of the naris until

it reaches the pharynx. Push the catheter until it touches the posterior wall of the pharynx; withdraw the instrument about one half of an inch, and direct its point outward and slightly upward toward the corresponding ear, touching the side wall of the pharynx. A sensation, as if the catheter is grasped, is felt when its point engages in the orifice of the canal. Generally the opening is sought for too far posteriorly. The catheter may be passed from the opposite nostril, or from the mouth.

Confirm the introduction, if desirable, by using the otoscope, to hear the rush of air when forced through the catheter into the tympanum.

Probing of the Nasal Duct.—Pull down the lower lid to expose the punctum with the orifice of the lower canaliculus. Introduce a small silver probe perpendicularly, into the orifice and then turn its point horizontally inward, following the canal until it touches the inner bony wall of the lachrymal sac. The point is now directed downward almost perpendicularly, with a slight inclination backward and outward, and advanced until it appears in the inferior meatus of the corresponding nostril. The canal traversed is about an inch in length.

Catheterism of the Larynx.—The mouth is held open by means of a mouth-gag if necessary. With the left index-finger passed back to the root of the tongue, feel and hook forward the epiglottis. Pass the catheter, keeping its beak against the finger, until it reaches the epiglottis. Direct the beak of the catheter over the epiglottis, and down its posterior surface into the larynx.

Intubation of the Larynx.—Direct O'Dwyer's tube

of suitable size by the foregoing manipulations into the larynx. Push the tube loose from the obturator, and sink it down into the larynx until the epiglottis can close over its opening. A piece of thread passed through the opening in the anterior angle of the tube, and out of the mouth, prevents its descent into the œsophagus if the introduction has been faulty. Withdraw the thread, if the tube has been correctly introduced, holding the finger against the tube to prevent the thread drawing upon it.

To withdraw the tube, the extractor is guided into the opening in the tube, and its blades separated, to hold it firmly. It can now be removed, keeping the blades of the extractor separated during the removal.

Stomach-Tube, Œsophageal Probang, or Bougie.—Push the head of the subject back so as to make the canal to be traversed as straight as possible. Pass the tube, probang, or bougie, to the posterior wall of the pharynx. Place the left index-finger so as to protect the larynx, until the instrument has been directed down the œsophagus along the posterior pharyngeal wall for several inches. Remove the finger from the mouth. Bend the head forward to make a curve in the cervical region corresponding to the dorsal curve. Gently introduce about eighteen inches of tubing when the stomach will be entered.

The œsophageal probang is introduced beyond the body to be removed, when the bristles are spread and the body drawn up.

If the tube is passed through the nostril, give it a slight bend downward, so that, when it meets the posterior wall of the pharynx, it will be directed downward.

Catheterization of the Urethra.—To pass a cathe-

ter or sound through the male urethra, the body must be laid on the back, the shoulders elevated, and the hip-joints slightly flexed and rotated outward, the thighs being separated. Stand on the left side facing the head of the subject, and grasp the penis behind the corona glandis between the middle and ring fingers of the left hand with the palm turned upward. Separate the lips of the meatus with the left thumb and index-finger, and raise the penis. Hold lightly by its extremity the oiled catheter or sound between the right thumb and index and middle fingers. Enter the beak of the instrument into the meatus, keeping the handle depressed and the shaft horizontally lying over the left groin. By pulling the penis over the instrument thus held, with slight pressure, it will be "swallowed" until its beak is below the pubes. Revolve the shaft of the instrument horizontally until it occupies the median plane of the body lying on a line which would run from the umbilicus to the symphysis pubis. The beak being fairly engaged under the symphysis, begin to raise the handle of the instrument, supporting more than its weight, so that the beak will follow the roof of the canal. The left index-finger can support the convexity of the instrument by pressure over it through the rectal wall or perinæum. The handle is made to revolve through a semicircle in the vertical plane running through the median line of the body. While the handle is being depressed between the thighs, the finger supporting the convexity makes the beak of the instrument continue to follow the roof of the canal. If the beak circles around the shaft when turned, the catheter is in the viscus.

On a fat subject the *tour du maître* is convenient. The body is placed as before, but the operator stands on the right side facing the head of the subject. The handle of the instrument may be held between the thighs, or over the left thigh, with the shaft lying horizontally. The instrument is introduced as before until the beak reaches the bulb, when the handle is made to describe an arc toward the umbilicus, being continually raised until the median vertical plane is reached, when it is depressed as before between the thighs.

To introduce rubber catheters requires no manipulative skill.

Tunneled Sounds and Catheters.—These are introduced upon a guide of rubber or whalebone. Inject so as to distend with oil the urethra. Introduce a filiform bougie, avoiding the lacunæ, on the roof of the urethra, for the first inch. If it is arrested, introduce another, and so on until six or eight are introduced. Alternate the ends introduced—first straight, then spiral and angular. By withdrawing and then advancing with a screwing motion, one of the bunch will enter the bladder; withdraw the others. The protruding end is now threaded through the tunnel of the catheter, and held firmly between the left thumb and index-finger. The sound is made to follow the same manœuvres as the ordinary sound, but is guided by the filiform bougie, without force, into the bladder.

To catheterize the female urethra, turn the subject on the back, semiflex the hip and knee joints, and separate the thighs. Stand on the right side, facing the head of the subject. Hold the oiled catheter

near its beak between the right thumb and index-finger, overlapping its end with the index-finger. Pass the hand holding the catheter under the right knee, and separate the labia with the index-finger from below upward, until the upper edge of the vagina is felt. Feel for the prominent urethral papilla, about one half of an inch above this, and place the pulp of the index-finger at its lower border. The catheter can now be easily guided over the pulp of the finger into the urethra and on into the bladder. It may be necessary to follow the cord-like urethra, felt through the anterior vaginal wall, up to the papilla.

If a soft catheter is used, pass the left hand over the thigh, to aid in its introduction.

Introduction of Rectal Bougies.—Place the subject on the back with the knees and hip-joints flexed, and the buttock at the edge of the table; or on the side with the hip-joints and knees semiflexed. Gently enter the oiled point of the bougie into the anal orifice, inclining it slightly forward. Direct the point for the first inch and a half forward toward the bladder. Now introduce the bougie until five inches have entered the rectum with the point directed nearly horizontally toward the middle of the sacrum. If the bougie is to be further introduced, its point should be directed a little forward and to the left, as if to strike the abdominal wall two inches to the left of the umbilicus.

III. PLUGGING THE POSTERIOR NARES.

Place the subject on the back with the head slightly raised upon a block. Separate the jaws by

means of a mouth-gag. Prepare a firm plug of cotton or cloth, one half of an inch thick and three quarters of an inch long, and tie it in the middle of a doubled cord eighteen inches long. Pass a Bellocq's sound threaded with a cord a foot long, keeping its beak applied to the floor through the naris, until it reaches the pharynx. Protrude the spring from the canula, and the eye carrying the cord will be curved into the mouth. Attach to this cord one end of the doubled cord attached to the plug, while the other end of the doubled cord may be cut until it measures six inches in length. Draw the spring into the canula, which will pull the oiled plug into the mouth. Now begin to withdraw the Bellocq's sound, directing, if necessary, the plug up, around, and over the soft palate, with the left index-finger.

Detach the end of the doubled cord protruding from the nostril, and separate it so that there will be two strings. Now stuff into the nostril between the two strings a plug of cotton, over which tie the strings, thus holding in place this anterior plug. Care must be taken not to pull the posterior plug too far into the nostril. It must only engage itself in the posterior naris. The other end of the doubled cord hangs down into the pharynx.

To remove the plugs, cut the string holding the anterior plug and withdraw this plug. Catch with forceps the end of the doubled cord hanging in the pharynx and draw gently upon the posterior plug. The detachment of the posterior plug may be aided by a probe passed through the anterior naris, pressing it backward into the pharynx.

CHAPTER II.

PARACENTESIS.

I. CORNEÆ, TYMPANI, THORACIS, PERICARDII, ABDOMINIS, VESICÆ; ASPIRATION. II. HYPODERMIC NEEDLE.

Paracentesis Corneæ.—Place the subject on the back, and stand behind the head. Raise the upper lid of the eye, and apply the pulp of the left index-finger horizontally to the lid and partly to the globe. Depress the lower lid, and apply the middle finger of the same hand in like manner. Now by pressure, keeping the fingers apart, the globe of the eye is controlled.

The puncture is made with a broad needle held lightly between the right thumb and index-finger. Enter the needle with its flat surface parallel to the iris at either lower lateral margin of the cornea, and direct the point downward as if to puncture the lower margin a little beyond its central point. The needle must never be passed in front of the pupil in traversing the anterior chamber. While withdrawing, rotate the needle as soon as its point has left the anterior chamber, in order to make the wound patulous.

Paracentesis Tympani.—Expose the tympanic membrane by reflected light through an ear-specu-

lum. Puncture the tympanum posterior to the handle of the malleus with a small, double-edged knife, held between the right thumb and index-finger. Enlarge the puncture vertically, not allowing the point of the knife to scarify the inner wall of the tympanum.

Paracentesis Thoracis.—Prepare the subject for this and the following paracenteses by injecting water into the cavities.

Place the subject on the side. Find the sixth intercostal space, and select a point just above the lower rib bounding this space equidistant from the sternum and from the spine. Puncture with a lancet the skin at this spot. Enter the trocar and canula in this puncture and push through the thoracic wall, determining to what extent the instrument shall be introduced by the right index-finger laid along the upper surface of the instrument. Direct the point of the instrument upward to avoid the upper edge of the lower rib. Withdraw the trocar. The fluid may be allowed to run away, or it can be removed by suction. The intercostal space sinks below the puncture through the skin as the fluid is removed.

Keep the integument pushed against the shaft of the instrument, in order to close the puncture immediately after it is withdrawn.

If a lower intercostal space be chosen, be careful to direct the point of the trocar upward, to avoid puncturing the diaphragm.

Paracentesis Pericardii.—Puncture the skin in the center of the fifth intercostal space at any point three quarters of an inch to two inches from the border of the sternum on the left side. The internal

mammary artery is situated about half an inch from the sternum. Hold the trocar and canula in the right hand with the right index-finger laid along the instrument to prevent its entering the sac any greater distance than that determined upon. Enter the point of the instrument into the puncture and push the instrument upward and inward into the sac with great care. Withdraw the trocar and allow the fluid to run out, or to be sucked out through the canula. The same precautions against the entrance of air, on the withdrawal of the trocar, must be taken as in paracentesis thoracis.

Paracentesis Abdominis.—Place the subject in the sitting posture, and surround the abdomen with a broad, many-tailed bandage, with an opening through which to operate. Make a puncture through the skin with a lancet at the point bisecting a line drawn from the umbilicus to the symphysis pubis. In this puncture enter the trocar and canula, holding the instrument in the right hand, with the index-finger applied to its upper surface where you wish to limit its introduction. Push the instrument into the abdominal cavity. Withdraw the trocar, leaving in the canula until sufficient fluid has escaped.

The canula may be moved about, or a catheter-perforated tube introduced through the canula, to promote the evacuation of the fluid; withdraw the canula, preventing the introduction of air.

Paracentesis Vesicæ.—The bladder may be tapped above or below the pubes, through the anterior vaginal wall, or through the anterior wall of the male rectum.

Suprapubic.—Place the subject on the back;

puncture with a lancet the skin just above the symphysis pubis. Enter the trocar and canula through the puncture, and direct its point downward and backward, while pushing it into the bladder. Limit the introduction of the instrument to about an inch; and if a curved instrument is used, keep the convexity uppermost. Withdraw the trocar, and allow the fluid to escape.

While withdrawing the canula, close its orifice with the pulp of the index-finger, to prevent urine or air being sucked out along its track. Guard against the entrance of air, as in the other paracenteses.

Subpubic.—Pull the penis down, and puncture the skin just under the symphysis pubis with a lancet. Enter the point of a small curved trocar and canula, with its concavity turned upward, into the puncture, and push the instrument directly backward through the tissues for about two inches; withdraw the trocar. After the urine has escaped, withdraw the canula, with the same precautions as in the previous puncture.

Vaginal.—Place the subject on the back with the thighs and legs semiflexed and strongly abducted. Stand between the legs and introduce into the vagina the left index-finger with its palmar surface turned upward until its tip reaches a point an inch posterior to the posterior surface of the pubis. Shield the point of a curved trocar by withdrawing it a little into the canula. Introduce the instrument with its concavity turned upward, and its end following the palmar surface of the left index-finger. When the end reaches the tip of the finger, protrude the point of the trocar. Push the instrument upward and back-

ward into the bladder; withdraw the trocar, and allow the urine to flow. In order to prevent the escape of urine into the tissues, take the same precautions as before, while removing the canula.

Rectal.—Place the subject in the lithotomy position. Introduce the left index-finger into the rectum, and feel for the prostate, and then feel beyond a space bounded on each side by the cord-like vesiculæ seminales converging toward the prostate. Introduce a curved trocar and canula with the convexity downward, and the point of the trocar sheathed in the canula, along the palmar surface of the finger until the end of the canula is applied to the anterior rectal wall just beyond the prostate in the median line. Protrude the point of the trocar, and push the instrument upward into the bladder. Do not allow urine to escape from the canula while the canula is being withdrawn.

Paracentesis Urethrae.—Place the subject in the lithotomy position. Introduce the left index-finger into the rectum, and apply the pulp of the finger to the rectal wall where the anterior extremity or apex of the prostate is felt. With a double-edged knife held as a pen, but with cutting edges held vertically, pierce the perinæum in the median line a little less than an inch in front of the anus. Push the knife boldly forward, directing the point toward the tip of the left index-finger. The knife may be given a slight up-and-down motion of the handle to enlarge the wound as the point advances; when the point is felt to be near the tip of the finger, by directing it obliquely to the right or left, the urethra is opened.

To catheterize through this puncture, withdraw

the knife and insert a director into the bladder, when the left index-finger can be removed from the rectum, and the left hand given charge of the director. On the director guide a catheter into the bladder.

If the urethra is tapped through the rectum, the lateral walls of the rectum may be held apart by two Sims's specula, and the left index-finger must direct the point of the knife toward the apex of the prostate.

Aspiration (Dieulafoy).—Draw the piston back, producing thus a vacuum in the cylinder of the instrument. Grasp the needle in the same manner as a trocar, and push it through the skin and tissues into the cavity to be explored. If its use is substituted for the trocar and canula, the direction and situation of the punctures are the same for both instruments. By drawing the skin to one side before making the puncture, the opening in the skin on removing the needle will not correspond with the course of the needle through the deeper tissues, thus presenting a valvular arrangement against the entrance of air. After the opening in the needle is buried in the tissues, open the stop-cock, which will cause the vacuum to extend into the needle. Now advance slowly, "vacuum in hand," in search of the effusion. As soon as a cavity is entered, the point of the needle must remain stationary until the needle is removed.

II. HYPODERMIC NEEDLE.

The hypodermic needle should always be made use of before the trocar and canula as a means of diagnosis. It must enter the same spot, and have its point directed as that of the trocar in the various tappings. Withdraw the piston after the point is in the fluid,

and allow the syringe to fill. The needle must be withdrawn quickly, and the left index-finger placed immediately over the point of puncture.

If the needle is used for medication, the manipulation is different. Put the nozzle of the syringe into the solution to be injected, and withdraw the piston beyond the mark denoting the required number of minims. Adjust the needle, and force out the superfluous solution and air, holding the syringe with the point upward.

If the medication is special, the point of the needle is introduced to the spot, and the syringe slowly emptied. If the medication is general, the skin and areolar tissue are pinched up preferably on the outer side of the arm or thigh into a fold about one quarter of an inch broad. The needle is entered in front of and between the tips of the left thumb and index-finger which are holding the fold, avoiding veins, and pushed obliquely downward until the sensation is obtained that the point is in loose tissue. Slowly inject the fluid. Withdraw the needle, and slightly rub the part, to diffuse the solution into a greater area of the areolar tissue.

CHAPTER III.

MANIPULATION OF THE SCALPEL.—DRAINAGE.— SUTURES.—KNOTS.

MANIPULATION OF THE SCALPEL.

1. *How to hold the Scalpel.*—Three methods of holding the scalpel are necessary to graceful operation:

(a) The first is where the scalpel is held as a pen. The handle of the instrument passes upward to the radial side of the index-finger. The lower part of the handle and the upper part of the blade are held between the pulp of the thumb on one side, the index-finger on the back, and the middle finger overlapping the other side. The ring and middle fingers are semiflexed, and are used as rests to steady the hand.

This method is useful in the limited and precise cuts of a dissection.

The edge of the scalpel is turned forward when used to cut from within outward after puncturing, as in opening an abscess.

(b) The second method is where the scalpel is held like the bow of the violin. The direction of the instrument is almost parallel to the surface. The handle is held between the pulp of the thumb on

one side and the pulps of all the other fingers on the other. The pulp of the index-finger may be placed on the back of the blade if firmness is required.

This method allows the greatest freedom to the hand, hence is used in making long incisions.

In dividing tissue over the director, this method is used, with the edge turned upward. If the tissue is divided from the distal to the proximal end, the handle of the instrument points forward.

(c) In the third method the scalpel is held as a table-knife. The handle of the scalpel is kept against the palmar surface of the hand by the ends of the middle and ring fingers. The index-finger bears upon the back of the blade, while the thumb presses the instrument against the side of the middle finger.

This position allows a great deal of force to be exerted, as in separating muscular attachments from bones.

2. *How to use the Scalpel; Incisions.*—The foregoing methods of holding the scalpel should be practiced while making incisions into the abdominal wall. Avoid incising the median line of the abdomen, in order not to interfere with other operations.

Enter the point of the scalpel perpendicularly where the incision is to begin, through the integument, stretched equally between the left index-finger and thumb. Lower the handle so that the belly of the scalpel will be applied to the tissues. Cut the integument without much pressure, but with slight sawing motion to the desired extent. The incision is completed as it was begun, with the scalpel held perpendicularly to avoid "tailing."

Incisions may be made by pinching up the skin,

and then transfixing and cutting outward, or by cutting the fold from the surface to the desired extent.

In making the incision deeper, make the cuts of the same length as the first, and as important structures are approached use the director. With a pair of thumb-forceps pinch up very superficially the tissue at the bottom of the wound. Nick the tissue as close to the ends of the forceps as possible, the scalpel being held short, with the blade flatwise to the surface, and making a right angle with the forceps. Enter the end of the director into the opening formed, and gradually, with slight pressure and lateral movements, introduce it to the angle of the wound. The end of the director should be inclined slightly, as if to push through, the layer of tissue being raised during its introduction. Place the point of the knife into the groove, and incline the handle toward the director as much as possible, without allowing the point to escape the groove. Advance the knife held in this manner with a slight sawing motion, until its point is arrested in the *cul-de-sac* at the end of the groove. Raise the handle of the knife to the perpendicular position to divide completely the tissues up to the angle of the wound.

This procedure is repeated in order to divide the tissues to the other angle of the wound.

Let each cut advance the operation systematically.

If a loose layer underlie a fascia, as is the case with the peritonæum, be careful that a fold of the underlying tissue does not override the point of the director.

Tissues overlying the director should be examined before being divided.

The overlying tissues may be divided with scissors, one blade being kept in the groove. Hold the scissors with the thumb and middle fingers in the rings, and the index-finger on the blade to direct.

DRAINAGE.

To illustrate this principle, prepare a piece of rubber tubing with free openings cut into its lumen along its sides at short intervals. Introduce, if necessary with a probe or thumb-forceps, one end of the tubing down to the bottom of the wound. This end must be cut slanting, to facilitate its introduction. Bring the other end out of the most dependent part of the wound. Fasten a safety-pin through the tubing as it leaves the wound, or pierce the tubing with a needle carrying a ligature, which is to be tied loosely around the member, or fastened by plaster to the surface. Cut the tubing flush with the surface.

Introduce in like manner a piece of prepared tubing into the superior angle of the wound and secure it.

Strands of horse-hair, long enough to extend beyond the angles of the wound while lying in its deepest part, or, when doubled, to reach from the bottom to the most dependent angle of the wound, may be used to illustrate correctly the principle of drainage.

Patulous openings can be made by removing a column of tissue, with an instrument cutting like a leather-punch, from the deeper parts of the wound to the surface in dependent positions (canalization).

SUTURES.

1. *The continuous or glover's suture* is made by piercing one lip of the wound from without and the other correspondingly from within, thus bringing the armed needle out, so that the points of entry and exit are opposite and equidistant from the margin.

When the next and subsequent stitches are to be taken, the needle is entered on the same side as for the first stitch, and at equal distances apart. The ligature extends diagonally across the line of the wound from one point of exit to the next of entry.

Care must be taken to pierce the integument perpendicularly.

Use a curved or half-curved needle, if the stitches are to run deep through the tissues.

The left hand steadies and affords counter-pressure, enabling the needle to pierce the tissues.

Accurate apposition of thin-lipped wounds is best attained by this suture where there is little force required to maintain coaptation.

To remove this suture, cut each diagonal turn at its entry and then withdraw by means of forceps, holding the left index-finger applied closely to the point of exit to prevent the lip of the wound from bearing any strain.

When these sutures are used to bring together the deeper parts of a wound, they are called *buried sutures*.

2. *The interrupted suture* is made like the continuous, except that it does not run from one exit to the next entry of the suture, but is cut after each complete passage of the needle, and the two ends

are united by a knot. The knots should fall on one side of the wound, either the side of the entries or that of the exits of the sutures.

To remove the suture, cut the ligature at its point of entry if the knot is over the exit, and then by means of forceps draw upon the knot, the left index-finger being applied near the exit to prevent dragging on the lip of the wound.

3. *The quilled suture* is made by passing a stout needle, fitted into a handle, through the tissues from one side to the corresponding point of the other side of the wound. Thread the eye which is near the point with a double ligature, and withdraw the needle, thus carrying one end of the double ligature through to the other side of the wound. A curved needle is best adapted for making this suture. Through the loop of the double ligature pass a piece of catheter, and secure it by drawing on the double ligature from the other side of the wound. Tie the two free ends of the double ligature over a similar piece of catheter.

If a number of sutures are used, run a piece of bougie through all the loops, which will, of course, run parallel to the wound, and secure a similar piece of bougie on the other side between the ends of the double ligatures.

This suture holds the deeper parts in apposition; hence, the pieces of bougie must be removed about an inch from the margin of the wound, to make the course of the ligatures as nearly straight as possible.

The continuous or interrupted suture is used, in conjunction with the quilled suture, to secure apposition of the superficial parts of the wound.

If buttons are used instead of quills, the suture is called the *button-suture*.

4. *The twisted suture* is made by passing metal pins through the lips of the wound. The pins should cross the wound as deep as possible, and, if the tissue is completely divided into flaps, they should pierce almost to the other surface. Enter the pins some distance from the margin, and bring them out at corresponding points on the other side of the wound. The pins being placed, wrap around them cotton yarn, in a figure of eight, making the crossings of the yarn correspond to the line of incision. As each pin is sufficiently wrapped, the yarn is continued diagonally from the lower turn of that pin to the upper of the next. Clip the points of the pins, and protect the skin by placing beneath the ends small pieces of adhesive plaster.

This suture keeps the whole surface of a wound in apposition, and from being used in hare-lip is called *hare-lip suture*.

The pins should be pointed, or a pin-carrier will be necessary (Buck, Post) to guide them into position.

5. *The quilt or fold suture* is made by passing the needle through the lips of the wound at equidistant and opposite points. A knot is now made, which must lie over the point of exit. Now enter the needle on the side through which the needle has just made its exit, and bring it out at a point exactly opposite and equidistant from the margin of the wound. In this suture the loops lie parallel to the wound.

Secure the last stitch, as in the case of the glover's suture, by tying together the free end of the loop

which holds the needle, and the double end made by cutting the needle loose from the ligature. Before making the last stitch, pull several inches more of the ligature through the eye of the needle, so that the free end will not be carried through the puncture when the needle makes it exit.

The quilled or button, the twisted, and the quilt sutures, are sutures of relaxation, and require the glover's or interrupted suture to be used in conjunction to appose the more superficial parts of the wound.

If wire is used as a suture, the ends are twisted together, and the twisted portion of the suture is placed as the knot of the silk ligature, away from the line of incision. Make the wire lie flat across the wound by bending it to make an angle at the entry and exit. The ends may be clipped to one quarter of an inch, or all run into a piece of rubber tubing.

The suture must be cut near the twist when it is to be removed. Straighten as much as possible the wire and run it into the slit of an applicator. Press the applicator firmly enough to prevent any force being exerted on the flap, while the twist of the suture is caught in the forceps and steadily drawn upon.

Always aim at having no more strain on sutures than is required to establish perfect coaptation without any wrinkling of the lips of the wound.

6. The special sutures for organs covered by serous membrane will be practiced in connection with the operations performed upon the intestine. The needles should have rounded edges.

(a) *Lembert's Suture*.—Enter the needle about one third of an inch from the cut edge and pierce a fold of

peritonæum. This fold should include nearly a quarter of an inch of the peritonæum between the point of entrance of the needle and the cut edge. Enter the needle near the other edge, and pierce a similar fold of peritonæum exactly opposite. Invert the edges of the wound, and either make the suture continuous or interrupted.

This suture brings into contact narrow surfaces perpendicular to the cut margin.

(b) *Gely's Suture*.*—Enter the needle about a quarter of an inch from the margin and advance it parallel to the wound, piercing a fold of peritonæum. The entrance and exit of the needle should be separated about a quarter of an inch. Enter the needle on the other side, at a point corresponding to the exit, and pierce a similar fold of peritonæum, bringing the needle out at a point opposite and corresponding to the first entrance of the needle. The beginning and ending of the suture are thus opposite each other across the wound, and are to be secured by a knot after the edges of the wound have been inverted.

A continuous Gely's suture may be made by threading a needle on each end of a ligature and then entering the needles on opposite sides of the wound at corresponding points. Take up similar folds of peritonæum by advancing the needles parallel to the edges of the wound. The two needles may now change sides, or, better, the ends may be tied and the suture made secure. The needles must enter at the points of exit of the last suture, and similar folds of peritonæum be pierced as before.

* These sutures, if made to pierce into the lumen of the gut, are objectionable.

This suture secures the contact of a surface of peritonæum extending parallel to the wound.

(c) *Jobert's Suture*.—Strip the mesentery two thirds of an inch back from the ends of a divided gut. Insinuate into the lumen of the upper gut one end of a piece of tallow-candle, and into that of the lower the other end of the candle. Pierce the upper end of gut from without inward, about a quarter of an inch from the margin through the surface from which the mesentery was stripped. Invaginate one half inch of the cut end of the lower gut into its own lumen. Pierce the invaginated gut near its cut margin, and the invaginating gut lying over it, from within outward through the surface from which the mesentery was stripped.

Similar sutures are to be passed all around the whole circumference of the divided ends of the intestine. The upper ends of the ligatures are now passed through the lower gut near the folded margin. The candle is slipped down the alimentary canal, and the ends of the ligature are secured.

Serous surfaces are brought into contact except where the mesentery was attached, where raw surfaces are apposed.

The divided upper gut is invaginated into the invaginated portion of the lower divided gut, imitating intussusception.

(d) *Double Continuous*.—This is the ordinary continuous suture carried around the circumference, and then continued back in the middle of the spaces left between the former entrances and exits of the ligature.

The edges are inverted to bring together serous surfaces.

(e) *Czerny's suture* may be used in connection with most of the foregoing sutures with advantage. Enter the needle through the peritoneal surface near the margin of the wound, and bring it out through the wound-surface near the edge of the mucous membrane. Pierce the opposite wound-surface near the mucous edge, and bring the needle out through the peritoneal surface near the margin of the wound. Invert the peritoneal edge of the wound and secure the ends of the ligature by means of a knot.

These stitches are to be made one eighth of an inch apart.

KNOTS.

1. *Reef-Knot*.—The reef-knot is a double knot. The first knot is made by making a loop and carrying the end of the ligature held in the right hand forward over the end held in the left hand, so as to be turned through the loop backward. The second knot is made (the ends of the ligature having changed hands) by carrying the end held in the right hand backward over that held in the left hand, so as to be passed through the loop forward.

The second turn of the knot should not be drawn upon with great force.

2. *Surgeon's Knot*.—This is a double knot having the end of the ligature turned through the first loop twice. The second knot is made by turning the end of the ligature in the same manner once through the second loop.

The first knot, having two turns, is not liable to slip.

CHAPTER IV.

OPERATIONS ON THE HEAD AND NECK.

TREPHINING.

*Crown Trephine, Galt's Trephine.**

SHAVE the part. Make semilunar, crucial, or Λ -shaped incisions down to the bone, and raise all the tissues in flaps with a periosteum elevator. Make the flaps sufficiently large to expose a surface of bone which will allow the crown of the trephine to be applied. Hold the flaps from the wound by tenacula, or by ligatures passed through them near their edges. Project the central pin of the trephine slightly beyond the crown, and make it fast. Hold the handle of the trephine between the palm of the hand and the middle, ring, and little fingers, and apply the thumb and index-finger along the shaft.

The operator must work from a higher level than the part to be trephined, in order to bear upon the instrument.

Place the central pin of the trephine in the center of the surface, and with a few turns of the handle from left to right and right to left, and with slight pressure, make it bore into the bone. After a few more turns, the instrument being held perpen-

* See chapter x, use of saw.

dicularly to the surface, the teeth of the crown will make a circular track. When this groove is of sufficient depth to keep the instrument from slipping, the central pin is retired and made fast before advancing farther. Now begin again to saw, removing the trephine often to clean its teeth with a brush, and to ascertain the depth of the groove by means of a probe or a quill toothpick.

The color of the dust will change from white to a reddish color when the cancellous tissue is reached.

When the instrument is well advanced in the bone, screw into the small, central hole, made by the pin in the first part of the operation, one of Heine's tirefonds (a small screw with an eye in its head). The screw must not be longer than the circular groove is deep.

Continue to advance with the trephine until the toothpick discloses the complete section of the bone in a part of the groove. The trephine must be slightly slanted and made to saw only on the undivided part.

A Galt's trephine is in the shape of a truncated cone, and becomes wedged as soon as the bone is completely severed, hence is a safe instrument.

Examine frequently to find if the section is complete. When the section is completed, fasten a hook (Roser) into the eye of the tirefond, and pull gently on the disk, aiding in its removal with the elevator.

Make the sawn edge perfectly smooth.

If two walls of bone are to be sawn through, the first must be sawn with a large trephine, and the second with a much smaller one, as when trephining the frontal sinuses.

In trephining the long bones, as, for example, the head of the tibia, the small crown trephine is used.

To study trephining for depressed fracture of the skull, fracture with a hammer the skull in various localities. Expose the parts as directed. Place the point of the pin of the trephine near the margin on the solid, undepressed bone, and, if possible, away from sinuses, or the middle meningeal artery.

Select a spot where the line of fracture between two depressed fragments meets the margin. The crown of the trephine must overlap the margin of the depression. Remove the disk or portion of a disk of bone, which will allow the elevator to raise the depressed fragments. Remove all detached fragments and small fragments which have been considerably depressed. Make the bony margin smooth with the rongeur, gouges, chisels, or scoops. Saw any sharp angles of bone with Hey's saw, using the straight toothed edge for straight section, and the rounded edge for curved section.

If the wound is made with a pick, the fragments removed must be fitted together to ascertain if any pieces have been driven into the brain.

Provide for drainage from the wound, and stitch together the flaps.

OPERATION FOR STRABISMUS.

Place the subject on the back. Stand facing the subject. Keep the eyelids separated by means of a stop-speculum.

Catch up the conjunctiva just external to the cornea with toothed forceps, and rotate the eye outward. An assistant, standing behind the head of the sub-

ject, must hold these forceps. This places the eye in position for operation upon the tendon of the internal rectus.

To operate upon the tendon of the external rectus, the conjunctiva is seized internally to the cornea and the globe rotated inward.

Pinch up with a pair of ordinary dissecting forceps a vertical fold of conjunctiva and sub-conjunctival tissue, at the point of intersection of the lower horizontal and the vertical tangents to the cornea. With a small pair of blunt-pointed scissors, snip this fold, cutting it down to its base, thus making a horizontal wound. This cut divides the capsule of Tenon, thus opening into the lymph-space around the sclerotic.

Still holding the forceps in the left hand, insert a strabismus-hook into the opening. Direct the end of the hook downward slightly, and then horizontally backward, half the distance on the globe toward the entrance of the optic nerve. Bring the hook upward and forward until its end bulges the conjunctiva just above the upper edge of the tendon.

In these manœuvres, the end of the instrument must be kept applied to the surface of the sclerotic.

Pull slightly upon the tendon toward the cornea. The hook is retained posterior to the corneal margin by the tendon. With the small, probe-pointed scissors curved on the flat, divide the tendon from below upward between the hook and the cornea. The lower blade of the scissors must be kept in contact with the hook, and the upper between the tendon and the conjunctiva. The curve of the scissors must follow the curve of the hook.

Search to find if any part of the tendon is undivided, which bands would prevent the hook from advancing to the corneal margin.

EXCISION OF THE EYE.

Keep the eyelids apart by means of a stop-speculum.

With a pair of toothed forceps catch hold of the conjunctiva and sub-conjunctival tissue external to the cornea. Divide these tissues all around the cornea, keeping close to the corneal margin. Draw up with a strabismus-hook the tendon of the external rectus, which is to be divided about an eighth of an inch from its attachment to the sclerotic. Grasp with forceps the stump of tendon of the external rectus left attached to the sclerotic in order to control the globe in the subsequent steps of the operation.

Hook up the tendons of the superior and inferior recti muscles, and divide them close to the sclerotic.

Pass posteriorly a pair of probe-pointed scissors curved on the flat with their curve following the external surface of the globe until their point touches the optic nerve. Separate the blades of the scissors and include the nerve, which must then be divided.

The globe is now easily drawn forward, when the attachment of the oblique and internal rectus muscles and any fibrous bands must be divided close to the sclerotic.

EXTRACTION OF TEETH.

Place the subject on the back, with a block under the head during the extraction of the lower teeth.

The head must hang over a block during the extraction of the upper teeth.

Grasp the forceps in the right hand, with the thumb laid along one bar somewhat between the two bars of the handle, to prevent a crushing force being exerted on the tooth.

Stand on the right-hand side of the table.

Lightly apply suitable forceps to the neck of the tooth. Push the sharp edges of the blades of the forceps between the gum and the tooth, until arrested by the alveolar process of the maxilla. Tighten the grasp on the tooth when the different motions for the different extractions are begun.

Upper Incisors and Canine.—To extract these, use straight forceps with blades having one groove. These teeth have conical roots, hence are loosed by slight rotation. The blades of the forceps are crowded down into the socket so as to catch hold nearer the root. To extract, pull downward and slightly forward, after the tooth has been loosened sufficiently by slight rotation.

Upper Bicuspids.—Use forceps with narrow blades, and with the handle curved to avoid coming in contact with the lower teeth. The tooth has a root which is flattened laterally. Apply the forceps; force the tooth outward and then tilt it outward and inward until loose. Crowd the forceps-blades toward the root, and extract by pulling downward.

Upper Molars.—Right and left forceps are necessary. The outer blade has two grooves corresponding to the roots of the tooth. The blades make an obtuse angle with the handle. The internal edge of the alveolar process being the stronger and the palatine root liable to fracture, apply the forceps and force the tooth outward. Move the tooth from side

to side, push the blades of the forceps deeper into the socket, and extract by pulling downward,

Lower Incisors.—The tooth has a root flattened laterally. Apply the forceps; pull outward, and then, by rocking the tooth inward and outward, loosen it sufficiently to allow the blades of the forceps to be forced deeper toward its root. Extract by drawing upward and slightly outward.

Lower Canine.—The root is conical, hence the tooth is removed in the same manner as the upper canine, except that the pull is upward.

Lower Bicuspid.—Use forceps with narrow blades, which form almost a right angle with the handle. These teeth are extracted like the upper bicuspid, except that they are pulled upward.

Lower Molars.—The roots are one internal and one external. Apply the forceps and force the tooth outward. Rock the tooth forward and backward, because the roots incline backward. Push the blades of the forceps deeper toward the roots, and extract by drawing upward. Protect the roof of the mouth by holding the forceps near the blades.

Extract broken roots of teeth by an elevator, having a short, thin blade, which is grooved on the inner side. The blade has a sharp-pointed or broad edge, and bends so as to make an obtuse angle with the shaft. Two are necessary, right and left. In extracting the root, make the internal plate of the alveolar process the fulcrum for the elevator.

PERFORATION OF THE ANTRUM.

Place the subject on the back, with the head hanging over a block. Stand on the right-hand side of

the table. Extract the first or second molar tooth of the upper jaw, the rule being to choose the one most decayed.

Hold the bone-drill, or, as Fergusson recommends, an ordinary gimlet in the right hand, with the index-finger applied along the shaft. Enter the instrument into the socket of the tooth extracted, and by boring upward and slightly inward, keeping up uniform pressure, perforate the floor of the antrum.

The index-finger, applied along the shaft, prevents the instrument from plunging through the cavity of the antrum against the floor of the orbit.

The antrum may be perforated from the canine fossa by dissecting off the tissues, the upper lip being turned upward, until the bone is cleared, and then by using a trephine or drill to bore horizontally backward.

EXCISION OF THE TONGUE.

Partial Excision.—The only partial excision which claims notice is that of a longitudinal half of the organ.

The lingual artery of the corresponding side must be ligated in the triangle formed by the hypoglossal nerve and the tendon of the digastric muscle, as a step of the operation (see ligation of linguals).

Retain the jaws widely separated by means of a mouth-gag. Pass two stout ligatures through the front half of the tongue, one on each side of the median line. Pull the tongue forward and upward. Cut with a scalpel the mucous membrane in the median line of the under surface of the tongue from the tip to the frænum. Divide with the scissors the frænum, also the mucous membrane reflected from the

under surface of the half of the organ to be removed to the floor of the mouth. Divide the mucous membrane reflected from this side to the fauces, also the underlying muscles. Pull the tongue forward and downward, and cut with a scalpel the mucous membrane, and slightly the underlying muscular tissue along the dorsum in the median line from the root to the tip.

With the fingers separate the two halves of the tongue all the way to the hyoid bone. Tear with the fingers the attachments to the under and lateral surfaces.

Sever the part from the hyoid bone by means of scissors, blunt-pointed, and curved on the flat.

By traction on the ligature through the remaining half of the organ, the cut surface is brought into view.

Complete Excision.—Ligate the lingual arteries and perform tracheotomy as steps of the operation (see tracheotomy and ligation of linguals).

Keep the jaws separated by means of a gag. Pass a stout ligature through the anterior part of the tongue and draw, by pulling on the ligature, the tongue upward and forward.

Cut the mucous membrane on the inner surface of the symphysis menti, and separate the tissues from the bone with an elevator, until the origins of the muscles attached to the genial tubercles are exposed. Cut these tendons close to the bone.

Draw the tongue forward, and pass a ligature through each lateral glosso-epiglottidean ligament. Bring these ligatures out of the angles of the mouth and fasten them to the cheeks by plaster.

Divide with scissors the frænum and the mucous membrane at its reflection from the under surface of the tongue to the floor of the mouth, also the mucous membrane and muscular attachments to the sides of the organ. Tear with the fingers all tissues necessary to free the tongue to its base.

Slip the noose of an *écraseur* over the tongue down to its attachment to the hyoid bone. Prevent the *écraseur* from slipping forward by passing hare-lip pins through the tongue in front of the noose. Begin slowly to divide the tissues in the loop of the *écraseur*, by making about two turns of the handle every minute.

By drawing on the ligatures passed through each lateral glosso-epiglottidean fold the stump attached to the hyoid bone may be inspected.

If removal beneath the inferior maxilla is practiced, Kocher's method is recommended (see text-books on surgery).

BRONCHOTOMY.

Thyrotomy, Laryngotomy, Tracheotomy.

Place the subject on the back with the shoulders depressed. Place a block under the neck and allow the head to hang backward. Stand on the right-hand side facing the subject.

1. *Thyrotomy*.—Steady the thyroid cartilage between the index-finger and thumb of the left hand. Make an incision in the median line from the hyoid bone to the cricoid cartilage through the skin and fasciæ. Divide the fibrous connection between the sterno-hyoid muscles. Separate the sides of the wound by means of retractors. Ligate, if present, the communicating branch between the two hyoid

arteries just below the hyoid bone, also that of the crico-thyroid arteries below the thyroid cartilage.

Locate with the left index-finger the notch on the superior border of the thyroid cartilage which marks the junction of its halves. Divide the thyroid cartilage from this notch downward, never deviating from the median line. Open into the larynx through the mucous membrane exactly in the median line, to avoid wounding the vocal cords. Retract the alæ of the cartilage.

In closing the wound the halves of the cartilage must be accurately joined by sutures. Provide for drainage, and stitch the integument and fascia together.

2. *Laryngotomy*.—Locate the cricoid cartilage. The space just above this cartilage and below the thyroid in the median line is the site of the operation.

Make an incision in the median line extending three quarters of an inch above and below the center of the crico-thyroid space. Divide the integument and fasciæ covering the crico-thyroid membrane. Retract the sides of the incision. Steady the part by means of a tenaculum hooked under the lower border of the thyroid cartilage. Pierce the membrane above the middle of the cricoid cartilage and enlarge the opening into the air-passage by lateral incisions through the membrane just above the cricoid cartilage.

Dilate the opening and insert a laryngeal tube, directing its end horizontally backward into the air-passage and then downward. If the opening does not readily admit the tube, divide the cricoid cartilage in the median line.

The operation may be performed by steadying the part, and then piercing with a knife, held with the middle finger applied to the blade one half inch from the point as a guard, all the tissues into the larynx. This puncture must be made a little below the thyroid cartilage in the median line, the blade of the knife being held crosswise. Turn the edge of the knife and cut downward, following the median line to or through the cricoid cartilage.

In the child the incision must be prolonged in the same line downward through two or three rings of the trachea (laryngo-tracheotomy).

The communicating branch between the crico-thyroid arteries may be divided below the thyroid cartilage. The superior thyroid veins communicate above the isthmus of the gland, and hence have their communicating branches divided in laryngo-tracheotomy.

Insert the tube and secure it in position by means of a tape encircling the neck. Stitch the upper and lower angles of the wound.

3. *Tracheotomy*.—Locate the cricoid cartilage with the left index-finger. Make an incision extending from above the cricoid cartilage downward two inches in the median line. Divide the integument and fasciæ and separate the sterno-hyoid muscles. Retract the sides of the wound. Cut the fascia transversely on the cricoid cartilage and strip it downward with the isthmus of the thyroid gland, (Bose). Hook the trachea below the cricoid cartilage with a tenaculum and draw it upward and forward.

Pierce the trachea with a scalpel held with its cutting edge upward in the lower angle of the wound,

and divide it upward in the median line to the extent of three quarters of an inch.

Dilate the opening and insert a tracheotomy-tube with its convexity turned upward. Secure the tube by means of a tape, and stitch the angles of the wound.

In the child the incision reaches nearly to the upper border of the sternum. The trachea being small, avoid wounding its posterior wall.

If the isthmus of the thyroid gland can not readily be displaced downward, catch it with serrefines on each side and divide it in the median line.

The communicating branches between the superior thyroid veins are divided as they cross the median line above the isthmus of the thyroid gland.

It is seldom necessary to operate below the isthmus of the thyroid gland in the living, and the operation on the cadaver gives an inadequate idea of the difficulties encountered in this location. The incisions must be made in the median line through the integument and fasciæ. Separate the sterno-hyoid and sterno-thyroid muscles. Make the incisions from below upward, using the left index-finger to locate the trachea and to guide the incisions.

In the lower angle of the wound the left innominate vein, the innominate artery, a plexus formed by the inferior thyroid veins, the thyroidea ima, and the thymus gland may be encountered.

When the trachea, which is deeply situated, is exposed, hook it forward and open it to the extent of an inch in the median line. The tube is now inserted and secured.

The operation of tracheotomy may be performed

by bolder incisions. Include the trachea between the left index-finger on the left and the thumb on the right side. By approximating the fingers and pressing backward, the trachea is made to bulge forward, and the tissues anterior to it are put on the stretch. Locate the cricoid cartilage. Make an incision in the median line two inches in length from the cricoid cartilage downward. Divide all the tissues until the trachea is exposed. Apply clamps to the divided isthmus of the thyroid gland. Hook the trachea forward, and complete the operation as before described.

Before inserting the tube in these operations, suck the mucus from the air-passage by means of a rubber tube attached to the nozzle of an ordinary syringe.

EXTERNAL ŒSOPHAGOTOMY.

Place the subject on the back, with the shoulders slightly raised on a block. Turn the face to the right, as the œsophagus is most easily approached from the left side, to which it inclines. Operate from the left side.

Locate the cricoid cartilage, close below which the œsophagus is to be opened. Make an incision between the anterior border of the left sterno-mastoid muscle and the larynx, beginning at the level of the upper border of the thyroid cartilage, and continue this incision downward two inches between the same muscle and the trachea. Cut the integument, platysma, and fasciæ. Draw the sterno-mastoid muscle outward. Separate the omo-hyoid muscle, and either divide it or draw it outward with the sterno-mastoid.

Elevate slightly the head, to relax the tissues, so

that the sides of the wound can be retracted. Divide on a director the deep fascia, and draw the carotid sheath outward. Separate the attachments of the thyroid lobe and turn it toward the right.

Pass a bulbous bougie through the mouth and pharynx into the œsophagus to the location where the opening is to be made. Draw the trachea forward, slightly twisting it over toward the right side. The bulb of the bougie can now be cut directly upon, or the wall of the œsophagus may be raised and a small opening made through it to admit the finger. Enlarge the opening vertically, either upward or downward.

In making the opening do not divide the recurrent laryngeal nerve, and in cutting downward guard against wounding the inferior thyroid artery.

In closing the wound into the œsophagus, stitch the opening with a continuous suture and invert the edges. Bring together the separated muscles by means of buried sutures, providing for drainage. Stitch the integumentary wound.

Pharyngotomy is performed if the incision into the œsophagus is prolonged upward above the level of the cricoid cartilage into the pharynx.

If the external incision is continued upward, avoid cutting the superior thyroid artery and the superior laryngeal nerve.

CHAPTER V.

OPERATIONS ON THE TRUNK.

EXCISION OF THE MAMMARY GLAND.

THE removal of the areolar tissue of the axilla should be practiced in conjunction with this operation.

Place the subject on the back, with the thorax slightly raised on a block. The pectoralis major is made tense by the arm being abducted to a right angle with the body. Operate standing on the side from which the gland is to be removed.

Begin internal to the gland to make a curved incision, concave upward, following closely the direction of the fibers of the pectoralis major, and extending below the nipple external to the gland. Dissect the integument and fascia downward until the lower border of the pectoralis major is reached, which is the best guide to the lower border of the gland. Separate the lower and posterior connections of the gland.

Begin a second curved incision, concave downward, at the same point as the first, and extend it in the direction of the fibers of the pectoralis major above the nipple, joining the first incision at a point external to the gland. Dissect up the integument and fascia until the upper border of the gland is ex-

posed. Separate the upper and internal connections of the gland.

Grasp the gland and draw it outward. Throw a ligature around the external connections, and sever the tissue distal to the ligature.

Extend the incision upward and outward to the middle of the axilla. Tease out and separate by means of the fingers the stump of the gland, the areolar tissue along the inferior border of the pectoralis major, and in the whole of the axillary space.

If in the upper part of the axillary space any attachments require cutting, they must first be ligatured and then cut on the distal side of the ligature.

The axillary vessels are situated in the anterior third of this space. In the operation branches of the long and alar thoracic, intercostals, and internal mammary arteries are divided.

Puncture the lower flap through its most dependent part. Provide for drainage through this puncture and through the inner angle of the wound.

Suture the flaps together, using sutures of relaxation if there is any tension.

MEDIAN LAPAROTOMY.

Place the subject on the back. Evacuate the bladder. Stand on the right side, facing the abdomen.

Make an incision with a scalpel in the median line of the abdomen from just below the umbilicus to a point about an inch above the symphysis pubis. Divide the integument and fascia to bring into view the linea alba. Cut in the linea alba, through its fibrous tissue and the underlying transversalis fascia,

until the areolar tissue over the peritonæum is uncovered. Tease through this areolar tissue, or divide it on a director. Catch up very superficially the peritonæum and nick it near the end of the forceps. With a second pair of forceps seize the opposite side of the small opening, and tear it large enough to admit the finger.

Introduce the left index-finger, and apply its palmar surface to the peritonæum in the line of the incision. Introduce a probe-pointed bistoury flatwise along the palmar surface of the finger. Turn its cutting edge forward and divide the peritonæum.

The further division of the peritonæum is best made with a probe-pointed bistoury, cutting between the left index and middle fingers, which draw it forward and at the same time prevent the intestines slipping in front of the knife.

If the incision is not large enough, it must be prolonged upward. Divide the integument and fascia in the median line, avoiding the umbilicus by a curved incision around its left semi-circumference. The incision can now be completed by dividing the peritonæum and the remaining undivided tissues between the index and middle fingers in the manner described.

The contents of the peritoneal cavity are all accessible, and can be examined. To close the wound, bring together the divided peritonæum, apposing serous surfaces by means of the quilt or the continuous sutures. Draw together the recti muscles by means of buried sutures or silver sutures of relaxation. Provide for drainage from the superficial wound. Suture the integument and fascia, bringing them together, if necessary, by sutures of relaxation.

If the linea alba is obscure, and the sheath of the rectus is opened, remember that posteriorly, about midway between the umbilicus and the pubes, the sheath ends inferiorly in the semilunar fold of Douglas.

ENTERORRHAPHY.

Prepare the subject by stabbing through the abdominal wall or shooting with a revolver to wound the intestine.

Expose the abdominal contents by means of median laparotomy.

The different sutures considered in Chapter III for wounded intestine may be practiced to close the wounds.

Enterorrhaphy may be employed in cases where it does not reduce the caliber of the gut to less than one half of its normal size.

ENTERECTOMY.

Expose the abdominal contents by median laparotomy.

Remove the part to be operated upon out of the peritoneal cavity. Apply intestinal pincers two inches below the line of the proposed lower division of the intestine. Strip the intestinal contents upward and prevent their descent by applying intestinal pincers two inches above the line of the proposed upper division of the intestine. The gut to be excised, now being empty of any fecal contents, is divided by scissors.

The mesentery attached to the excised intestine may be ligated in sections near its attachment and then separated by cutting between the ligatures and

the intestine. A triangular piece of the mesentery may be removed, the base of the triangle being the border of the mesentery attached to the excised portion of intestine. The sides of the triangle are then joined by sutures.

A divided vessel may be found near the mesenteric border of the divided ends of the intestine.

Appose the ends of the intestine by means of the Jobert, Czerny-Lembert, or double interrupted suture if enterorrhaphy is proposed.

The division of the intestine may be made obliquely, and the mesenteric border of one end sutured to the free border of the other (Morris). This fulfills the requirement of good blood-supply to the ends of the gut. The division of the gut is ordinarily made near a loop of the mesenteric artery to meet this same demand.

Both ends of the intestine may be secured to the external wound, and a fecal fistula be established as is about to be described.

ENTEROTOMY.

Expose the intestines by median laparotomy.

Follow the mesentery downward to determine one of the lower loops of the small intestine. It is necessary to be guided by the mesentery, as Treves has shown that the long mesentery of the lower portion of the jejunum allows it to occupy the pelvic cavity.

Remove the loop selected for the operation from the peritoneal cavity. Open into its lumen by nicking a fold picked up by means of forceps.

Enlarge the wound by means of probe-pointed

scissors, using the probe-pointed blade in the lumen of the intestine.

The wound may be closed by performing enterorrhaphy, or a fecal fistula may be established.

ENTEROSTOMY, WITH ENTEROTOMY OR ENTERECTOMY.

In this operation the loop of intestine is brought to the lower angle of the laparotomy incision, or a second opening is made in a line with the fibers of the external oblique muscle which will act slightly as a sphincter. An opening one inch and a half long through the abdominal walls is made to lead into the lumen of the gut.

After median laparotomy the loop of intestine is secured by piercing it with a ligature, both ends of which are brought out of the abdominal opening to which the gut is to be sutured.

Prevent the bulging of the intestines by inserting a sponge through the wound. Detach the peritonæum around the wound and draw it up, stitching it to the integument so that the walls of the wound will present a serous surface. Remove the sponge from the abdominal cavity and draw upon the ends of the ligature to engage the loop of gut in the wound. A quarter of an inch from the margin pass a needle into the wound through almost the entire thickness of the walls of the abdomen. Pierce a small fold of the apposed circumference of the intestine. Carry the ligature from within outward through the wall of the abdomen, and secure its ends by means of a knot. In like manner, at intervals of one quarter of an inch, stitch the intestine to the walls of the wound.

Open the intestine nearly to the extent of the

wound, and pass a sponge into its lumen to prevent the escape of any matter. Suture the cut edges of the intestine and of the skin together, by means of the continuous suture.

If a fistula is to be established with enterectomy, the enterectomy may first be performed, and the two ends of the intestine brought to the abdominal wound. The lower end is sutured by means of the quilt suture to one side-wall of the wound, with its end flush with the integument. The upper end must be sutured as after enterotomy, no regard being paid to the presence of the lower end.

The lumen of the lower end may be closed by the Czerny-Lembert suture, and the end then allowed to remain free in the abdominal cavity.

COLECTOMY.

Follow the same rules given for the performance of enterectomy. It is best to establish a fecal fistula by attaching the upper end of the gut to the wound, the lower end being returned into the abdominal cavity after closing its lumen by the Czerny-Lembert suture.

Colotomy is governed by the same rules as those for enterotomy.

LUMBAR COLOSTOMY.

This operation may be performed either on the right side into the ascending colon, or on the left side into the descending colon.

Place the subject midway between the side and prone positions, with a block under the loin to render tense and prominent the site of the operation.

Bisect a line joining the anterior and posterior superior spinous processes of the ilium, and one half

inch posterior to this point erect a perpendicular extending to the last rib.

Make an incision about four inches long, having the median point of the perpendicular line as its median point. This incision should extend downward and forward parallel to the last rib. Divide the integument and fasciæ, the outer edge of the latissimus-dorsi muscle, and the posterior free edge of the external oblique muscle. Divide the internal oblique and transversalis muscles, and expose the external borders of the erector spinæ and quadratus lumborum muscles. Divide the transversalis fascia, and expose the areolar tissue lying posterior to the colon.

Retract toward the spine the quadratus lumborum muscle. Tease through the areolar tissue, and above feel the lower rounded end of the kidney.

Inflate the colon by forcing air by the anus through the rectum. The colon is felt immediately below and in front of the lower end of the kidney.

Divide slightly the outer border of the quadratus lumborum muscle. Tease through the areolar tissue until the colon is uncovered.

Draw up into the wound by means of forceps the posterior and inner wall of the colon. One inch from each angle of the wound pass a ligature deeply through the tissues to corresponding points on the other side of the wound. These ligatures will pierce the portion of gut engaged in the wound. Make a longitudinal opening, about one inch long, into the lumen of the gut. Hook up the ligatures as they traverse the lumen of the intestine and divide them, thus making four sutures. Secure these sutures, which will prevent the gut from receding.

Insert a sponge into the lumen of the intestine, and stitch the edges of the intestinal opening to the integument on each side of the wound. Appose the angles of the wound by sutures.

If the peritoneal cavity is opened, stitch the peritoneal wound, providing for drainage, and bring the abdominal wound together. The operation should be tried in the opposite loin. The ascending more often than the descending colon is attached to the abdominal parietes by a meso-colon.

The incision for colostomy, when prolonged into the quadratus lumborum muscle until the finger can touch the transverse process of a lumbar vertebra, is to be recommended in opening a psoas abscess. Tease a way with the finger along the anterior surface of the transverse process, where an opening into the sheath of the psoas muscle can be made.

NEPHRORRHAPHY.

Place the subject in the same position as for lumbar colostomy.

Make an incision, parallel and similar to that for lumbar colostomy, one inch nearer the lower border of the twelfth rib. The tissues are divided, and the fat enveloping the kidney teased through to expose the posterior surface of the capsule.

Press on the abdominal wall to engage the kidney in the wound. Divide on a director the capsule of the kidney and strip it from the organ to the extent of one half of an inch or more. Draw upon the capsule and stitch it to the sides of the wound.

Leave the wound open.

NEPHROTOMY.

Expose the posterior surface of the kidney as in the last operation.

Cut through the cortical substance as if to expose a calculus. The location of the incision is determined by systematic search with the exploring needle.

The pelvis of the kidney should be explored by dividing the organ parallel to the Malpighian pyramids.

NEPHRECTOMY.

Expose the kidney. Separate by means of the fingers the kidney from the surrounding areolar tissue. Separate the ureter from the vessels. With an aneurism-needle pass a ligature around the vessels and ligate them a little distance from the kidney. Divide the vessels distal to the ligature, and remove the kidney still attached to the ureter. Divide the ureter near the pelvis of the kidney. Invert the edges and close the caliber of the ureter by stitches, after which it can be returned into the wound. Ligate separately the vessels in the pedicle. Provide drainage, and close the wound.

After the vessels are ligated, the kidney may be removed in halves if it is enlarged.

SYMPHYSIOTOMY.

Place the subject on the back. Shave the hair from over the pubes. Distend the bladder. Stand on the right-hand side of the patient.

Make an incision in the median line of the body from a point one inch above the upper margin to the level of the lower margin of the symphysis pubis.

Divide the integument and fascia above and all the tissues over the symphysis. By means of a periosteal elevator push aside the tissues on each side of the incision over the symphysis, clearing the bones to the extent of one half of an inch. Separate the pyramidales and recti muscles at their junction in the median line.

Evacuate the bladder. With the fingers clear the attachments above, behind, and below the symphysis pubis. Pass a chain-saw behind the symphysis. Protect the tissues behind and below by means of spatulæ while the symphysis is sawn through.

The diameters of the pelvis may be increased or the anterior vesical wall uncovered by separating the pubic bones.

The ligaments joining the ilia to the spinal column are stretched or partially ruptured when the pubic bones are drawn apart.

To close the wound, the pubic bones are to be wired, drainage provided, and the wound stitched (see Chapter IX).

CHAPTER VI.

GENITO-VESICAL.

EXTERNAL PERINEAL URETHROTOMY.

PLACE the subject on the back, and tie the wrist and ankle of each side together. Draw the buttock to the edge of the table and separate the thighs. Shave the perinæum. Sit facing the perinæum.

Pass a sound having a groove on its convexity into the bladder. An assistant must hold the sound perpendicularly in the median line, drawing slightly toward the pubes, at the same time holding up the scrotum. Make an incision in the median line of the perinæum one inch and a half long, ending one half inch anterior to the anus. Divide the integument and fasciæ. Incise the tissues in the median line until the groove of the instrument can be felt. Guide with the left index-finger the point of a narrow knife into the groove.

1. Run the knife along the groove to the apex of the prostate.

2. Cut an opening three quarters of an inch long into the urethra by running the knife along the groove. Pass a ligature through each side of the urethral wound. Withdraw the sound to imitate the case of an impassable obstruction. By drawing on the ligatures the

urethral canal is opened. Pass a probe into the bladder as a guide.

3. Dissect in the median line to the apex of the prostate, or upon the end of a bougie passed by posterior catheterization to imitate cases where no external opening can be discovered.

Leave the wound open.

SOUNDING FOR STONE.

Place the subject on the back, with the buttock elevated on a block. Pass into the bladder through the perineal wound a small piece of chalk.

Stand on the left side and introduce a Thompson's searcher. Its passage through the membranous urethra occurring when the searcher is vertical may be aided by pressure over the pubes to relax the suspensory ligament of the penis, or by pressure over the convexity of the curve of the searcher as it bulges the perinæum. Inject through the searcher about five ounces of water.

Stand between the thighs. Make the beak of the instrument follow every part of the walls of the bladder. By twirling the handle slightly, the beak is made to rap lightly against the walls. To explore behind the prostate, insert the left index-finger into the rectum and push upward toward the inverted beak of the searcher. Aid the exploration of the anterior wall by pressing above the pubes.

In the female, pass the searcher as a catheter. Aid the exploration by the finger in the vagina.

The click made by striking the stone may be increased by attaching a sounding-board, or by fastening one end of a rubber tube to the instrument and

inserting the other end into the ear. If more than one piece of chalk be inserted, a click may be obtained after one piece is held in the forceps.

LITHOTRITY.

Remove the searcher and introduce a lithotrite, allowing it to enter the bladder by its own weight.

Lithotritry may be performed through the urethra or through the opening made by external urethrotomy.

When the lithotrite touches the chalk, turn the beak away and open its blades. Turn the separated blades toward the chalk, and engage it between them. Close the blades to confine the chalk. Raise the chalk from the mucous membrane and crush it by screwing the lever quickly once or twice. The large fragments fall close to the instrument and can be easily picked up. The chalk may be caught by pressing the convexity of the lithotrite against the base of the bladder and allowing it to fall between the open blades. The crushing should be done in the center of the cavity of the bladder.

The *débris* of the chalk may be removed at once by means of an evacuator ("rapid lithotritry" of Bigelow). Remove the lithotrite and introduce an evacuating catheter (Keyes's). Attach the washer filled with water. By pressing the bulb of the washer, it is partially emptied into the bladder. When the pressure is removed, the bulb, resuming its shape, causes a current of water into the washer, which carries with it small particles of the chalk. The particles sink into the receptacle below the washer.

Large fragments cause a "click" when carried against the catheter. The remaining fragments must

be crushed, and the washing continued until all are removed. Hold the lithotrite steady while crushing the chalk, and be sure that the blades are in contact before beginning its removal. Bryant's catheter and crusher combined prevents the change of instruments after the first crushing.

In perineal lithotripsy, a large lithotrite and evacuating catheter may be used without lacerating the tissues; also the same applies to lithotripsy through the female urethra.

CYSTOTOMY.

1. *Median Perineal Cystotomy*.—Place the subject as for external urethrotomy.

Pass a grooved staff into the bladder which is held as in external urethrotomy. Insert the oiled left index-finger into the rectum to feel the apex of the prostate.

Puncture the perinæum one half inch above the anus in the median line, directing the point of the knife with its edge turned upward nearly to the apex of the prostate. While withdrawing the knife, cut upward in the median line to the extent of one inch.

Remove the finger from the rectum. Guide the knife with its edge directed downward, until its point is in the groove of the staff. *a.* Push the knife along the groove into the bladder. *b.* After the urethra has been divided, a grooved director may be passed along the staff, after which the staff may be withdrawn. The neck of the bladder may now be incised upward.

Introduce the finger along the guide into the bladder, and examine the interior.

(Removal of a piece of chalk by means of forceps may be practiced. Introduce the forceps along a guide and grasp the chalk in its long axis. In removing the forceps holding the chalk, draw downward, moving the handle of the forceps from side to side without rotation.)

Introduce through the wound a chemise catheter into the bladder. Pack the catheter by filling the space between the chemise and the catheter, thus exerting pressure on the walls of the wound.

2. *Vaginal Cystotomy*.—Place the subject as in the last operation. Retract the posterior vaginal wall with a Sims's speculum. Inject into the bladder four or five ounces of water through a catheter and then plug the catheter.

Hold the catheter so that it bulges the anterior vaginal wall. Through the vagina divide the tissues in the median line, cutting on the catheter to the extent of an inch. The incision should be made from behind forward, and care must be taken not to incise the cervix posteriorly, nor the urethra anteriorly. The interior of the bladder is readily explored by the finger.

Close the wound by the continuous suture from behind forward. Draw the vaginal wall forward by means of tenacula, to facilitate the closing of the wound by sutures.

3. *Lateral Perineal Cystotomy*.—The subject is placed in the same position as for the median operation.

a. *In the Male*.—Pass a grooved staff into the bladder, which is to be held perpendicularly, the scrotum being raised by the same hand of the assistant.

Begin an incision just to the left of the median

point of the raphe, which extends from the anus to the scrotum, and continue it downward and outward to a point half-way between the tuber ischii and the anus. Divide the tissues in this line until the groove in the staff can be felt. Guide the point of the knife, with its edge turned downward, into the groove. Push the knife, depressing its handle if the staff is curved, to make the point run in the groove into the bladder. Incise the neck of the bladder and the prostate, while withdrawing the knife in a more horizontal line than the skin incision. The finger introduced along the staff can now examine the interior of the bladder.

The left transversus perinei and superficial perineal arteries may be ligated.

To avoid wounding the rectum, introduce the left index-finger while cutting the tissues.

Introduce a chemise catheter as in the last operation.

b. In the Female.—The position is the same as that for operation on the male subject.

Pass a grooved staff into the bladder. Begin an incision just to the left of the clitoris, and continue it downward and outward one inch and a half parallel to the descending ramus of the pubes and ascending ramus of the ischium. Incise the tissues in this line until the groove of the staff can be felt near the neck of the bladder. Guide the point of the knife along the nail of the left index-finger into the groove of the staff, and incise the neck of the bladder downward and outward in the line of the incision. To avoid wounding the vagina, introduce the finger while incising the tissues.

The finger can easily explore the interior of the bladder through the incision.

Suprapubic Cystotomy.—Place the subject on the back, and shave the hair from over the pubes. Insert into the rectum beyond the external sphincter a rubber bag. Distend the bag with about twelve ounces of water, after introducing a catheter into the bladder. Inject into the bladder through the catheter from six to ten ounces of water, and plug the catheter.

Stand on the left-hand side and begin an incision over the symphysis pubis, extending upward three inches in the median line of the body. Divide the integument and fasciæ. Separate the pyramidales and recti muscles. Divide the fascia transversalis on a director, and tease through the areolar tissue immediately above the symphysis pubis, until the bladder-wall is uncovered. The bladder is recognized by its muscular fibers, its vessels, its color, and its feel against the beak of the catheter.

With the fingers separate the areolar tissue from the bladder upward, to the extent of two inches. Retract the areolar tissue, and hook a tenaculum into the bladder on each side of the median line. Make the point of the catheter to bulge in the wound, and examine the overlying tissue.

Direct with the left index-finger the point of the knife to the upper limit of the exposed bladder-wall. Pierce the bladder-wall, holding the knife with its edge turned downward. Divide the bladder-wall in the median line down to the symphysis pubis.

Examine the interior of the organ with the finger. (In introducing the forceps the tenacula must still retain their hold to prevent the walls of the bladder

from being pushed backward.) Allow the water to escape from the rubber bag.

Insert into the bladder through the wound the end of a large drainage-tube, leaving the other end outside. Stitch the wound. Remove the bag from the rectum.

In the adult female, the vagina instead of the rectum may be distended with the rubber bag.

POSTERIOR CATHETERIZATION.

This requires a suprapubic cystotomy. The opening into the bladder is made large enough to admit the index-finger and a bougie.

Follow with the left index-finger the anterior wall of the bladder downward in the median line. Feel the smooth floor of the bladder at the neck (trigone) and hook the finger forward into the urethral opening. Pass a bougie along the finger, and direct it into the urethra.

The end of the bougie can be felt through the perinæum. The bougie may be passed through the whole length of the urethra.

RESECTION OF THE SCROTUM.

Place the subject on the back. If the operation be practiced on one side, the testicle of that side must be pushed up to the external abdominal ring.

Stretch uniformly the half of the scrotum to be operated upon. Make a row of interrupted quilt sutures one half inch above the proposed section at intervals of one quarter of an inch. Allow sufficient space for the introduction of drainage-tubes, by omitting the first and last sutures. The line of sutures

should make an acute angle with the median raphe of the scrotum.

Sever the part of the scrotum one half inch below the line of quilt sutures. Introduce the drainage-tubes, and bring the edges together by means of the continuous suture.

If the operation be bilateral, both testicles are pushed upward near the external abdominal rings. The row of sutures is made horizontally or slightly curved, with the concavity upward, across the stretched scrotum. Allow for drainage at each end. Sever the portion of the scrotum one half inch below the row of quilt sutures, and proceed as in case of the unilateral operation. Several small arteries may be found and ligated.

Henry's clamp, if used, simplifies the operation.

CIRCUMCISION.

Place the subject on the back. Mark the skin of the prepuce on a level with the meatus of the urethra.

Catch the end of the foreskin above with a pair of forceps, and with a second pair catch the end below. One of the blades of each forceps should fasten the mucous membrane, and the other the skin. Pull upon the forceps, at the same time separating them to put the foreskin on the stretch. Clamp the foreskin on a line with the mark made before it was stretched. (The clamp should be placed perpendicularly and not obliquely, as often advised.) Sever the portion of the foreskin beyond the clamp. The artery of the frænum may be ligated.

The skin will retract so as to uncover about one

half of the glans penis. Slit up the mucous membrane in the median line along the dorsum to the level of the retracted skin. Pare off the mucous membrane in a line from the lower border of the meatus urinarius to the central point of a line along the middle of the dorsum of the glans penis.

Separate any adhesions of the mucous membrane to the glans. Stitch the contiguous cut edges of the skin and mucous membrane together.

The mucous membrane is shortest along the dorsum, and the skin is cut circularly, hence the resulting foreskin slants obliquely downward and forward. The frænum permanently secures this shape to the new foreskin.

AMPUTATION OF THE PENIS.

Place the subject on the back.

Pierce the penis horizontally from side to side, between the corpora cavernosa and the corpus spongiosum, with an acupuncture-needle. The penis must be pierced nearer the body than the line of the amputation. Tie a tape around the penis above the acupuncture-needle. Divide the integument circularly one half inch below the proposed division of the corpora cavernosa. Retract the skin and divide with a narrow-bladed knife the corpora cavernosa. Turn the edge of the knife forward and cut between the corpora cavernosa and the corpus spongiosum. Divide the corpus spongiosum one half inch in front of the division of the corpora cavernosa. The dorsal arteries of the penis and the arteries of the corpora cavernosa may be ligated.

Divide the protruding corpus spongiosum verti-

cally, and stitch the angles to the integument. Remove the acupuncture-needle, also the tape.

SHORTENING OF THE ROUND LIGAMENTS.

Place the subject on the back. Shave the hair from the mons veneris.

Begin an incision just above the spine of the pubes, and continue it three inches outward and slightly upward, parallel to Poupart's ligament. Cut the integument and fasciæ, and expose the aponeurosis of the external oblique with the intercolumnar fibers joining the two pillars of the external abdominal ring. Divide the intercolumnar fascia, and nick the aponeurosis of the external oblique, to expose the contents of the inguinal canal.

The round ligament is readily known by the direction of its fibers. It is enveloped in fat.

Carefully separate the exposed portion of the round ligament from its attachments. Draw upon the round ligament, at the same time having the uterus pushed forward by an assistant's finger in the vagina. The ligament will become relaxed. If a loop of an inch or more in circumference is now formed, the remainder of the ligament becomes taut.

Repeat the operation on the opposite round ligament.

Draw the loops of the ligaments inward, and stitch them to the deep fascia above the pubes.

Stitch the divided aponeuroses of the external obliques; also the pillars of the rings.

Provide for drainage, and stitch the wounds.

CASTRATION.

Place the subject on the back.

Stretch the scrotal coverings over the testis. Begin an incision just below the external abdominal ring, and continue it downward over the testis to the bottom of the scrotum. Divide the tissues over the cord. Separate the cord, and throw around it a silk ligature, leaving the ends of the ligature hanging. Divide the cord between the ligature and the testis. Seize the testis by means of forceps, and cut its attachments to the scrotum. Ligate the spermatic artery, artery of the vas deferens, and the cremasteric artery.

Separate the silk ligature from the cord. Provide for drainage from the bottom of the wound. Approximate the cut edges by means of the continuous suture. A row of quilt sutures should be made one half inch from the margin of the wound, as after resection of the scrotum.

OÖPHORECTOMY.

Place the subject on the back. Shave the hair from the hypogastric region and from the mons veneris. Empty the bladder.

Perform a median laparotomy, beginning the incision one inch above the pubes, and continuing it upward four inches. (Remember that the sheath of the rectus is deficient for the lower half of the distance between the umbilicus and the symphysis.) If muscular fibers are divided in the wound, the above caution is pertinent.

Push the intestines aside, and feel along the pos-

terior surface of the broad ligament for the ovary. Separate any accidental attachments, and draw the ovary up to the wound. Transfix the attachment of the ovary by a needle carrying a double ligature. Any large vein or the tube must be avoided. The needle should not have cutting edges. Cut the ligature from the needle, and tie each half of the transfixed tissue separately. Sever the attachment of the ovary between the ligatures and the ovary.

The contiguous portion of the Fallopian tube is generally removed with the ovary. Ligate any vessel that can be discovered. Remove with a small scoop or cauterize the lining mucous secreting cells of the Fallopian tube on the cut surface of the pedicle. Allow the pedicle to drop back into the peritoneal cavity.

The other ovary may be likewise removed.

Perform the abdominal toilet, and then close the external wound after providing for superficial drainage.

CHAPTER VII.

MANIPULATION OF TENOTOME, MYOTOMY, TENOTOMY, FASCIATOMY, SUTURING OF TENDONS.

MANIPULATION OF TENOTOME.

1. *How to hold.*—Hold the tenotome as a pen.

2. *How to use.*—Enter the point of the tenotome perpendicularly to the surface. The blade must be advanced with its side parallel to the tissue to be divided. The point must reach to the distal border of, but not beyond, the tissue to be divided. When the flat of the blade is in contact with the whole tissue to be severed, turn the handle of the tenotome to present the edge at a right angle.

Make the edge cut with a slight sawing movement.

When the tissue is divided, withdraw the tenotome in the same manner that it was introduced.

Sterno-cleido-mastoid.—Place the subject on the back. Turn the head from the side to which the muscle belongs, to make it taut. Stand on the same side as the muscle.

The muscle can be clearly located. Draw the integument inward over the sternal attachment. Enter the sharp point of the tenotome over the external border of the tendon, and with a slight move-

ment of the point cut the fascia along the external border. Withdraw the tenotome, and introduce a probe-pointed tenotome to the outer border of the tendon. Relax the muscle by turning the head slightly to the side of the operation. Introduce the probe-pointed tenotome beneath the tendon, following its posterior surface to its inner border. Place the left thumb so that the tendon will lie between it and the tenotome. Make the tendon taut by turning the head away. Divide the tendon, making pressure with the left thumb at the same time over the tendon.

The thumb can appreciate with great accuracy the advancing edge, and regulate accordingly the required movement of the tenotome and pressure of the tissue against its edge.

When the tendon is divided, begin to withdraw the tenotome. Follow the tenotome as it is being withdrawn with the left thumb, until the thumb is over the wound. As soon as the wound is uncovered, close it with a square piece of plaster, to prevent the entrance of air into the track of the knife and the space made by the retracted tendon.

To divide the clavicular attachment, draw the integument inward, and pass the tenotome as before from without inward beneath the tissue to be divided. Proceed as in the former operation.

The division of this muscle at the level of the spinal accessory nerve will be considered in the operation of neurotomy of the spinal accessory.

Flexors Sublimis and Profundus Digitorum and Longus Pollicis.—Supinate the forearm, to bring the palm of the hand uppermost.

Pinch up the tissues over the middle of the proxi-

mal phalanx with the left index-finger and thumb. Enter the tenotome beneath the fold of tissue pinched up. Extend the finger, and divide the tendons toward the bone. Close the wound as described.

Extensor Communis Digitorum, Extensors Primi and Secundi Internodii Pollicis.—Pronate the forearm to bring the dorsum of the hand uppermost.

Pinch up the integument near the head of the metacarpal bone. Divide the tendon against the bone. Close the wound as described.

Flexor Carpi Radialis.—Supinate the forearm, and pass the tenotome from the radial artery beneath the tendon from without inward.

Flexor Carpi Ulnaris.—Supinate the forearm, and pass the tenotome beneath the tendon from without inward, avoiding the ulnar artery.

The extensors of the wrist need no special mention.

Biceps Flexor Cubiti.—Supinate the forearm. Extend the elbow to locate the tendon.

Pinch up the integument about an inch above the bend of the elbow over the tendon. Pass the tenotome from within outward beneath the tendon, facilitating its passage by semiflexing the elbow.

Extend the elbow, and divide the tendon toward the surface.

After the inner border of the tendon has been exposed in this operation, it is better to use a probe-pointed tenotome.

Flexors Longus and Brevis Digitorum and *Flexor Longus Hallucis* may be divided as the corresponding tendons in the hand; also the extensor proprius hallucis.

Extensor Longus Digitorum Pedis.—Place the subject on the back.

Locate the tendon by extending the ankle. Pass the tenotome beneath the tendon from within outward about an inch above the bend of the ankle.

Tibialis Anticus.—Pass the tenotome from without inward beneath the tendon about an inch above the ankle.

By adducting the foot and flexing the ankle, the passage of the tenotome beneath the tendon is facilitated.

Tibialis Posticus.—Place the subject on the abdomen. Stand between the legs. Rotate the leg inward, and flex the ankle.

Locate the tendon immediately behind the internal border of the tibia. Draw the integument backward over the tendon, where it is felt about an inch above the inner malleolus. Pierce the tissues to the tendon, and then with a probe-pointed tenotome divide it against the tibia.

The tendon is made taut during its division by abducting the foot and flexing the ankle.

Peroneus Longus and Brevis.—With the subject lying on the abdomen, stand facing the outside of the leg.

Draw the integument backward over the tendons, as they are felt just posterior to the fibula about an inch above the outer malleolus. Make the tendons taut by adducting the foot and flexing the ankle. Cut toward the fibula.

Tendo Achillis.—Place the subject on the abdomen. Stand between the legs.

Pinch up a fold of integument over the tendon.

Introduce the tenotome beneath the tendon against its anterior surface a little above the level of the malleoli. Place the left thumb over the tendon, which is put on the stretch by flexing the ankle. Divide the tendon, taking care that the tenotome does not cut through the integument.

Biceps Femoris.—The subject on the abdomen, locate the tendon with the knee extended.

Push the tendon outward with the left thumb. Enter the point of the tenotome about two inches above the head of the fibula to the inner border of the tendon. By slightly moving the point of the tenotome, make the opening in the fascia larger. Pass a probe-pointed tenotome internally, and then beneath the tendon, the knee being slightly flexed. Care must be taken to hug the tendon to avoid the perineal nerve. Extend the knee and divide the tendon.

Semitendinosus and Semimembranosus.—Locate the tendons, the subject being placed as in the last operation. Stand on the outside of the limb.

Draw the integument outward. Enter the tenotome from without inward on a level with the condyles of the femur. Divide the tendons.

The semitendinosus alone may be divided, or, by advancing the blade more and more inward, the semimembranosus and other internal ham-string muscles may simultaneously be divided.

Quadriceps Extensor.—Place the subject on the back. Stand on the outside of the limb.

Draw the integument above the patella inward. Enter the tenotome, or preferably a fasciatome, just external to the tendon above the patella, and advance

it over the tendon. Partially divide the tendon, cutting downward until the deeper fibers can be ruptured.

It is best to avoid dividing the deeper fibers with the knife, lest the joint be opened.

Adductor Longus.—Locate the tendon just below the spine of the pubes, the hip being abducted. Draw the integument over its tendinous origin outward. Enter the tenotome from without inward beneath the tendon. Cut upward and inward.

From the foregoing operations it may be noticed that, when cutting in the proximity of important structures, the probe-pointed tenotome is used and passed from these structures.

Plantar Fascia (Fasciatomy).—Pass the fasciatome from within outward along the deeper surface of the band of fascia arising from the inner tuberosity of the os calcis. Divide the fascia, following the same rules given in tenotomy.

EXAMPLE OF TENDON SUTURING.

Biceps Femoris.—Make an incision three inches long over the course of the divided tendon. Expose the ends of the tendon, and cut them so that they will, when approximated, present oblique surfaces to each other. Securely stitch the ends together, making the sutures extend deeply into the substance of the tendon. The hip being extended, and knee flexed, the divided ends of the tendon are easily drawn together.

CHAPTER VIII.

OPERATIONS ON NERVES (NEUROTOMY, NEURECTOMY, STRETCHING, AND SUTURING).

NEUROTOMY OF THE LINGUAL.

SEPARATE the jaws by means of a gag.

Introduce the left index-finger into the mouth, and place it on the inner surface of the inferior maxilla in a line from the last molar tooth to the angle. Introduce a curved bistoury, and cut the tissues anterior to the finger.

The incision should be an inch in length, and parallel to the line in which the finger lies, and extend nearly to the last molar tooth. It should divide all the tissues through to the bone. The finger acts as a guide.

NEURECTOMY OF THE SPINAL ACCESSORY.

Place the subject on the back, and turn the head away from the side of the operation.

Make an incision three inches long just external to the anterior border of the sterno-cleido-mastoid muscle, with its middle point on a level with the angle of the jaw. Divide the integument and fasciæ, and open into the sheath of the sterno-cleido-mastoid muscle. Retract the sides of the wound. Divide the muscular fibers in the middle of the wound on a di-

rector until the nerve is exposed. Excise an inch or more of the nerve.

The nerve is sometimes found between the sternal and clavicular fibers, but generally beneath this septum. Sometimes the nerve is beneath the whole muscle. By searching the posterior border of the muscle, the nerve can be found and followed back into the muscle. Provide drainage, and close the wound.

NERVE-STRETCHING OF THE GREAT SCIATIC.

Place the subject on the abdomen.

Begin an incision a little above the gluteal fold, and extend it downward four inches in the middle line of the thigh. Divide the integument and fasciæ, and expose the border of the gluteus-maximus muscle. Divide the cellular tissue along the outer border of the long head of the biceps femoris, and retract the sides of the wound. The nerve is seen resting on the adductor magnus. Separate the nerve with the fingers. Raise the leg from the table by pulling on the nerve hooked up by the fingers. If the limb is very heavy, it need not be quite raised. Provide for drainage, and close the wound.

NERVE-SUTURING OF THE MEDIAN.

Supinate the forearm.

Begin an incision about two inches above the wrist, between the tendons of the palmaris longus and the flexor carpi radialis. The incision should extend upward three inches, dividing the integument and fasciæ. Separate the tendons of the palmaris longus and the flexor carpi radialis, and raise the

flexor sublimis digitorum muscle. Retract the sides of the wound to expose the nerve. (Excise an inch of the nerve.)

Both ends of the nerve being exposed, should be stretched by means of forceps to approximate them. Freshen the ends of the nerve by cutting away the tips which were crushed by the forceps. Bring the ends into apposition by means of stitches extending through the nerve-sheath only. Provide for drainage, and close the wound.

CHAPTER IX.

OPERATIONS ON THE CIRCULATORY SYSTEM.

COMPRESSION OF VESSELS.

1. **PRESSURE** is applied to a particular vessel by various means, of which Petit's tourniquet will be considered.

Apply the tourniquet by encircling the limb with the strap, placing under the strap and over the vessel a compress. A roller-bandage will act as a compress, and should be placed so as to engage the vessel between it and the bone. The lumen of the vessel is closed by turning the screw of the tourniquet to tighten the strap.

2. The soft tissues of a part may be compressed by various means, of which the elastic bandage and tubing are in most common use.

Apply the bandage spirally, overlapping each turn to a very slight extent. The bandage must be stretched before the turn is applied.

If a limb is to be rendered bloodless, apply the bandage from the extremity toward the trunk. The last two or three turns of the bandage may be tied together, and the bandage removed from below, or the limb may be encircled by rubber tubing just above the bandage, when the bandage may be entirely removed.

At the shoulder the tubing must run under the axilla and over the clavicle.

At the groin the tubing must run between the anus and the tuber ischii of the side to be compressed, and over the middle of the crest of the ilium. It can be held above the ilium or secured to a belt or bandage encircling the body just above the crests of the ilia.

The tubing, like the bandage, must be stretched before the turns are applied to the part.

TORSION OF VESSELS.

A vessel of considerable size must be seized at its end by means of forceps and separated from the surrounding tissue to an extent to allow of being seized at a right angle to its course by a second pair of forceps. A quarter of an inch of the vessel should separate the forceps if the vessel is of large size. Turn the forceps holding the end of the vessel until but slight resistance is offered, after which the other pair of forceps are removed. The forceps holding the end of the vessel is last removed. On the cadaver the effect of the torsion can only be surmised.

Vessels of small size are caught by means of forceps, and twisted until their ends (and the little tissue always included in the bite of the forceps) separate from the cut surface.

LIGATURE OF VESSELS.

I. *Ligature of a Divided Vessel.*—Ligature of a severed vessel is performed by catching the end of the vessel by means of forceps, and then compressing the vessel in the loop of a knot.

If the vessel is large, it should be separated from surrounding tissues, and accurately ligatured.

When catgut is used, a third knot should be tied to insure against the loosening of the ligature.

If the vessel is of small size, some of the surrounding tissue is included in the loop of the knot.

Care must be exercised to prevent including the instrument in the loop of the knot. A tenaculum may be used to pick up the vessel and adjacent tissue, when, if the tissue is nicked for the ligature, it is not liable to slip.

The first knot should be drawn upon until, in the case of a large vessel, its inner coats are felt to crush. The second knot should never be drawn upon with great force, for the ligature is then very readily broken.

If a vessel is cut, but not severed, and the vessel be a large vein, the opening is pinched together by means of forceps, and the ligature applied as for a small vessel. The caliber of the vein is thus not occluded. In case of arteries, the section must be completed, and both ends treated with a ligature. On the cadaver a partially severed vessel is hardly noticed.

II. *Ligature of a Vessel in its Continuity.*—The position of a vessel is determined by certain "guides":

1. The surface guide is a line drawn joining certain fixed points, as bony eminences.

2. The deep guides are the contiguous anatomical structures.

3. The feel and color of the vessel.

General Rules.—When the location is chosen, the incision is made usually in the surface guide, its

length being determined by the depth of the vessel from the surface. The central point of this incision should correspond as nearly as possible to the part of the vessel to be included in the ligature. All the tissues must be divided to the same extent, important structures being pushed aside. As the vessel is approached, the tissues may be divided on a director.

When the sheath or areolar tissue contiguous to the vessel is reached, it is picked up by forceps and nicked; a director is introduced through the opening, and the tissue divided for a quarter of an inch. If the vessel is still enveloped in tissue, an opening is made into it as just described. Catch the edge of the wound in the sheath on the side toward the vein or other important structure by means of forceps. Roll, by means of a probe or director, the vessel away from the sheath thus securely fixed. The probe or director should be held at a right angle to the vessel, and be moved between the vessel and the sheath to an extent less than the opening in the sheath. It may be necessary to catch the opposite edge of the wound in the sheath to separate the vessel completely around its whole circumference.

An aneurism-needle carrying a ligature is passed under the vessel from the side on which the most vulnerable structure is situated. The sheath should be caught first on the side of the introduction of the needle by means of forceps, and then again on the side of exit, to make way for the point of the needle. If the vessel is deeply situated, the point of the needle is caught after it has passed beneath the vessel, and the handle of the instrument is unscrewed to allow the curved end of the needle carrying the liga-

ture to be drawn under the vessel. One end of the ligature is held to prevent the whole ligature being drawn under the vessel.

The ligature being under the vessel, the first loop of the knot is applied at a right angle to the course of the vessel. Draw upon the knot by means of the fingers, which must press upon the ends of the ligature close to the vessel. The second knot is not to be drawn upon very forcibly. Do not allow the tightening of the knots to raise the vessel from its bed.

(Prove the operation by opening into the vessel to discover the thickness of its walls, etc.)

LIGATURE OF SPECIAL ARTERIES IN THEIR CONTINUITY.

RADIAL ARTERY.—Supinate the forearm and extend the wrist.

The surface guide is a line drawn from a point midway between the tips of the condyles of the humerus to a point about one half of an inch internal to the tip of the styloid process of the radius.

1. *Lower Third.*—Make an incision two inches long in the line of the artery, extending to within one inch of the wrist. Divide the integument and superficial fascia. Push aside any veins which appear, and divide on a director the deep fascia. Expose the artery between the tendons of the flexor carpi radialis and supinator longus. Nick the areolar tissue enveloping the artery, and pass the needle, avoiding the venæ comites. Ligate the vessel. Close the wound, providing for drainage.

2. *Middle Third.*—Divide the integument and fascia in the line of the artery. Look for the inner edge of the supinator longus, which is near the mid-

dle line of the forearm. Retract the supinator longus outward to uncover the artery. Pass the needle from without inward, to avoid the radial nerve.

The radial artery may lie on the deep fascia, or on the supinator longus muscle.

ULNAR ARTERY.—Supinate the forearm and extend the wrist.

The surface guide to the vessel, for the lower two thirds of its course, is a line drawn from the internal condyle of the humerus to the radial side of the pisiform bone.

1. *Lower Third*.—Make an incision three inches long in the line of the artery, extending to within one inch of the wrist. Divide the integument and superficial fascia. Push aside any veins which may be present, and divide the deep fascia on a director. Flex the wrist and retract the flexor carpi ulnaris muscle toward the ulnar side to uncover the artery. Pass the needle from within outward, to avoid the ulnar nerve.

2. *Middle Third*.—Make an incision three inches long in the line of the vessel. Find the interspace between the flexor carpi ulnaris and the flexor sublimis digitorum. Avoid mistaking the palmaris longus or the supinator longus for the flexor sublimis digitorum. Separate the muscles and retract the sides of the wound. Pass the needle from within outward.

The artery may lie superficial to the muscles or deep fascia.

BRACHIAL ARTERY.—Abduct the arm and rotate it outward, also supinate the forearm.

The surface guide is a line drawn from the junc-

tion of the anterior and middle thirds of the axilla to a point midway between the condyles of the humerus.

1. *Bend of Elbow.*—Make an incision two inches long in the line of the artery, at the bend of the elbow. Divide the integument and superficial fascia, pushing aside the median basilic vein. Divide on a director the deep fascia and the bicipital fascia. Slightly flex the elbow. Find the artery with the bicipital tendon situated externally and the median nerve internally. Pass the needle from within outward.

2. *Lower Half of the Arm.*—Make an incision three inches long in the line of the artery, dividing the integument and superficial fascia. Divide the deep fascia internal to the biceps muscle. Slightly flex the elbow, and retract the biceps muscle outward. Find the artery with the median nerve situated above, which is to be retracted outward with the muscle.

Pass the needle from within outward, avoiding the veins.

3. *Upper Arm.*—Make an incision three inches long in the line of the artery, dividing the integument and superficial fascia. Divide the deep fascia internal to the coraco-brachialis muscle. Retract outward the coraco-brachialis muscle, and find the artery with the median nerve situated above and externally, and the ulnar nerve internally.

Retract the median nerve outward, and the basilic vein and ulnar nerve inward. Pass the needle from within outward.

The brachial artery may divide high in its course or run superficially to the median nerve, etc.

AXILLARY ARTERY (third portion).—Abduct and rotate outward the arm.

The surface guide to the portion of the artery for ligation is a line drawn between the anterior and middle thirds of the axilla.

Make an incision three inches long in the line of the artery, extending an inch above the anterior fold of the axilla. Divide the integument and superficial fascia. Divide the deep fascia along the internal border of the coraco-brachialis muscle, and retract this muscle outward. Find the artery with the median and the musculo-cutaneous nerves situated externally and the ulnar and the internal cutaneous nerves internally. The axillary vein is posterior and situated more superficially. Pass the needle from within outward.

SUBCLAVIAN ARTERY (*second and third portions*).—Place a small block under the back of the subject. Turn the face to the opposite side and draw downward the shoulder.

The surface guide is a line four inches long, drawn one half inch above and parallel to the clavicle. The line should be drawn outward from a point two inches external to the sternal end of the clavicle.

Stand behind the shoulder. Draw the integument downward, and incise it against the clavicle. Allow the integument to retract so as to bring the incision above the clavicle. Divide the superficial fascia and platysma, pushing aside the external jugular vein. Partially sever the sterno-cleido-mastoid and trapezius muscles if necessary. Tease a way through the areolar tissue with its plexus of veins formed by the supra-scapular and transverse cervical veins until the omo-hyoid muscle is uncovered. Divide on a director the deep fascia, and retract the

omo-hyoid muscle upward. Feel the taut scalenus anticus muscle, and follow its outer border downward to the tubercle of the first rib. The artery is situated immediately behind the muscle, as it is inserted into this tubercle,

Tease the tissues from the vessel. The cords of the brachial plexus and the omo-hyoid muscle are to be retracted backward. The subclavian vein is not seen, as it lies in front of the scalenus anticus muscle and at a lower level. Pass the needle from before backward.

If the second portion is to be ligated, divide the scalenus anticus muscle, guarding against injuring the phrenic nerve or transversus colli artery. On the left side the thoracic duct also lies on the scalenus anticus muscle. Hug the artery with the needle to avoid the pleura.

Sometimes the vein and artery change situations; also, large branches given off from the artery may complicate the operation.

VERTEBRAL ARTERY.—Place the subject on the back, and turn the face to the opposite side.

The surface guide is the depression between the posterior border of the sterno-cleido-mastoid and the scalenus anticus muscles.

Make an incision four inches long, following the posterior border of the sterno-mastoid muscle downward to within one half inch of the clavicle. Divide the integument, platysma, and superficial fascia, and retract inward the external jugular vein. Separate the sterno-cleido-mastoid muscle from the scalenus anticus muscle. The muscle must be relaxed, by turning the face of the subject forward. The phrenic

nerve, transversalis colli artery, and on the left side the thoracic duct, may be seen on the surface of the scalenus anticus. Avoid wounding these structures, and separate the scalenus anticus from the longus colli muscle. In the interspace between these muscles, the vertebral vein will first be uncovered. In the lower angle of the wound the pleura is uncovered. Retract the vein and pass the needle from the vein before backward, being mindful of the proximity to the pleura, and of the thoracic duct crossing from within outward.

The vertebral vessels vary in regard to which foramen in the transverse processes of the cervical vertebræ they enter. The arteries vary often in their origin, and hence in their manner of reaching the intermuscular space between the longus colli and scalenus anticus muscle.

COMMON CAROTID ARTERY.—Place the subject on the back, with a block between the shoulders, and turn the face to the opposite side.

The surface guide is included in a line drawn from a point midway between the angle of the jaw and the mastoid process, to a point over the sterno-clavicular articulation. That portion of the line below the level of the superior border of the thyroid cartilage is the surface guide.

Stand behind the shoulder.

1. *Ligature over the Carotid Tubercle.*—Make an incision four inches long in the line of the artery, beginning one half inch above the clavicle. Divide the integument, platysma, and superficial fascia. Retract the edges of the wound and divide the fascia at the anterior border of the sterno-mastoid muscle.

Separate the muscle by means of the fingers from its attachments. Divide the fibers near the sternal origin with a probe-pointed bistoury, guided on the left index-finger. Raise the head, to allow the muscle to be retracted outward. Push aside or divide between ligatures the anterior jugular vein. Divide the fascia on a director, at the outer border of the sterno-hyoid muscle, and retract the sterno-hyoid and sterno-thyroid muscles inward.

Feel for the carotid tubercle (the anterior tubercle of the transverse process of the sixth cervical vertebra) about two inches above the clavicle. The artery is readily felt lying upon this tubercle. Expose the carotid sheath, avoiding the recurrent laryngeal nerve and the inferior thyroid artery internally, and remembering that the left internal jugular may lie over the artery in this location. Open the sheath through its inner side directly over the artery. The pneumogastric nerve is situated behind and externally, and the internal jugular vein in front and externally, hence the needle is passed from without inward.

2. *Ligature at the Level of the Cricoid Cartilage.*—Make an incision about four inches long in the line of the artery, having its central point at the level of the cricoid cartilage. Divide the integument, platysma, and superficial fascia. Divide the fascia at the anterior border of the sterno-mastoid muscle, and retract the muscle outward. The sterno-mastoid artery may be seen divided. Avoid the middle thyroid vein or divide it between ligatures. In the upper angle of the wound avoid injuring the superior thyroid, lingual, and facial veins, and in the lower an-

gle the anterior jugular vein. Divide the deep fascia on a director, and retract inward the sterno-thyroid and sterno-hyoid muscles.

The omo-hyoid muscle is known by its fibers extending across the carotid sheath upward and inward. On the inner side of the sheath the descendens noni nerve is seen. The omo-hyoid muscle is retracted upward or downward, or may be divided. Open the carotid sheath on its inner aspect, avoiding the descendens noni nerve. Pass the needle from without inward, avoiding the internal jugular vein and the pneumogastric nerve.

If the artery be ligated above the level of the cricoid cartilage, the superior thyroid artery must be avoided. If the ligature is placed below the level of the cricoid cartilage, remember that the recurrent laryngeal nerve and the inferior thyroid artery are located behind and internally.

The artery may bifurcate at a lower level than the upper border of the thyroid cartilage. The omo-hyoid muscle may cross the artery at a different level. The artery may give off branches, usually arising from the external carotid.

INTERNAL CAROTID ARTERY.—Place the subject as in the last operation.

The surface guide is the portion of the previously drawn line, extending from the level of the upper border of the thyroid cartilage to the point midway between the angle of the jaw and the mastoid process. Begin an incision at the upper extremity of this line, and continue it downward, following the line to the level of the body of the thyroid cartilage. Divide the integument, platysma, and superficial fascia.

Divide the fascia at the anterior border of the sternomastoid muscle, and retract the muscle outward, raising the head slightly to relax the muscle. Avoid the facial, lingual, and inferior thyroid veins. Divide the deep fascia on a director, and retract upward and inward the posterior belly of the digastric and the stylo-hyoid muscles. The external carotid crossed by the hypoglossal nerve is now exposed and must be retracted inward. The internal carotid can be felt posterior and external to the external carotid.

Apply the ligature about one inch above the origin of the artery, passing the needle from without inward, to avoid the internal jugular vein and the pneumogastric nerve.

The artery may begin at different levels. The artery may be situated internal to the external carotid.

EXTERNAL CAROTID ARTERY.—Place the subject as in the previous operation. Expose the artery as described. Ligate the vessel fully an inch above the bifurcation of the common carotid. Pass the needle from without inward. Before tightening the ligature find a branch given off from the vessel, to eliminate the internal carotid. Tie any branches given off near the location of the ligature.

SUPERIOR THYROID ARTERY.—The subject is placed as in the previous operations.

Make an incision nearly three inches long, following the anterior border of the sternomastoid muscle, and having its middle point on a level with the upper border of the thyroid cartilage. Divide the integument, platysma, and superficial fascia. Divide the fascia along the anterior border of the sternomastoid muscle. Retract outward the sternomastoid

muscle to expose the artery crossing the floor of the superior carotid triangle between the common carotid artery and the lobe of the thyroid gland. Avoid the lingual, facial, and superior thyroid veins. Pass the needle, directing its point toward the lobe of the thyroid gland.

LINGUAL ARTERY.—Turn the face of the subject away from the side of the operation, and draw the chin upward.

Make an incision about three inches long, following the superior border of the hyoid bone. This incision should be slightly concave superiorly, and should begin at a point one half inch external to the median line. Divide the integument, platysma, and superficial fascia. Separate the fascia from the lower part of the submaxillary gland, and hook the gland upward. The hypoglossal nerve, making a triangle with the looped tendon of the digastric muscle, is seen in the bottom of the wound. The lingual vein generally lies upon the floor of this triangle, following the hypoglossal nerve. Divide on a director the fibers of the hyoglossus muscle just above the looped tendon of the digastric muscle. The lingual artery may be encountered in the fibers of the muscle, or will be seen running horizontally beneath the muscle.

If the lingual vein should be found in company with the artery, pass the needle from the vein.

FACIAL ARTERY.—Turn the face of the subject away from the side of the operation.

Draw the skin upward over the ramus of the jaw. Make an incision two inches long, following the lower border of the bone. A point over the junction of the posterior with the middle third of the body of the

bone should mark the middle of the incision. Divide the integument, platysma, and superficial fascia, being careful not to bear upon the knife as it crosses the artery. The fascia had better be divided on a director. Retract the sides of the incision, when the artery can be found crossing the ramus of the jaw at the lower part of the anterior border of the masseter muscle.

Pass the needle from behind forward, to avoid the facial vein.

OCCIPITAL ARTERY.—Turn the face of the subject away from the side of the operation; shave the part.

Begin an incision posteriorly to and a little below the apex of the mastoid process, and continue it three inches in the direction of the external occipital protuberance. Divide the integument and fascia. Divide the sterno-mastoid and splenius muscles to the extent of the wound. Retract the edges of the wound, when the tortuous artery will be seen.

TEMPORAL ARTERY.—Turn the face of the subject away from the side of the operation.

Make an incision about two inches long at a right angle to the zygoma, having its middle point just in front of the tragus, between the tragus and the root of the zygoma.

Divide the integument and superficial fascia, when the artery can be felt surrounded by dense fascia. Divide on a director the fascia over the artery, and pass the needle from behind forward, to avoid the temporal vein and the auriculo-temporal nerve.

COMMON ILIAC ARTERY.—Place the subject on the back, inclined somewhat to the opposite side.

The surface guide to the common and external

iliac arteries is a line drawn from a point a little to the left of the umbilicus to a point midway between the symphysis pubis and the anterior superior spinous process of the ilium. The upper limit of this line may also be determined by taking a point an inch to the left of the middle point of a line drawn from the highest portion of one iliac crest to that of the other. The upper two or three inches of this line correspond to the course of the vessel.

Make an incision concave internally from the cartilage of the eleventh rib to a point two inches above the middle of Poupart's ligament. Divide the integument and fascia, the external oblique aponeurosis, the internal oblique, and the transversalis muscles. Divide the transversalis fascia on a director to the full extent of the wound. With the fingers separate the peritonæum and subserous areolar tissue from the iliac fossa until the psoas muscle covered by the psoas fascia is seen. Along the inner border of this muscle, above the level of the sacro-iliac synchondrosis, the artery can be felt.

On the left side the superior hæmorrhoidal vessels and the attachment of the sigmoid mesocolon must be pushed aside, and the needle passed from within outward.

On the right side pass the needle from without inward, to avoid the iliac veins which have crossed under the artery to form the vena cava.

The ureter generally adheres to the tissues raised, but, if found crossing the lower part of the artery, it may be retracted downward.

The arteries vary in length, and may give off branches.

INTERNAL ILIAC ARTERY.—The operation is the same as that to expose the common iliac. The artery can be felt as it runs down into the pelvis over the sacro-iliac synchondrosis at the inner side of the psoas muscle. The needle should be passed nearly an inch below the origin of the artery from within outward and from behind forward. Special precautions are to be taken to avoid the external iliac vein and the ureter in front. The needle should have its curve set at a right angle to the shaft, and should be made for right and left arteries.

The common and internal iliacs may be more conveniently ligated by performing a median laparotomy, retracting or removing from the abdominal cavity the intestines, incising the posterior wall of the peritonæum, and by passing the ligature as already described.

GLUTEAL ARTERY.—Place the subject on the belly, and rotate the hip-joint inward.

The surface guide is a line drawn from the posterior superior spinous process of the ilium to the middle of the trochanter major. At the junction of the upper and middle thirds of this line the artery emerges from the pelvis.

Begin an incision about an inch from the upper limit of this line, and extend it downward five inches, following the line. Divide the integument and fascia, separate the fibers of the gluteus maximus muscle, and divide the fascia covering its under surface. Search for the intermuscular septum between the gluteus medius and the pyriformis muscles, in which the artery and its veins will be found. By rotating the hip-joint outward, the wound can be held open more

readily. Ligate the artery as near its exit from the pelvis as possible, as it soon gives off its branches.

SCIATIC ARTERY.—Place the subject on the belly.

The surface guide to the operation is a line drawn from the posterior superior spinous process of the ilium to the tuber ischii.

Make an incision four inches long parallel to the fibers of the gluteus maximus, having as its middle point the junction of the lower and middle thirds of this line. Divide the integument and fascia, and separate the fibers of the gluteus maximus muscle. Divide the fascia covering the under surface of the gluteus maximus muscle. The artery will be seen emerging from under the pyriformis muscle. Internally will be seen the pudic vessels, and externally situated will be seen the sciatic nerve. Pass the needle from without inward to avoid the vein.

INTERNAL PUDIC ARTERY.—1. The artery may be exposed by the last operation. It is found just internal to the sciatic artery, emerging from under the pyriformis muscle, accompanied by its veins and the pudic nerve.

2. *In the Perinæum.*—Place the subject in the lithotomy position.

The surface guide is a line drawn from below the symphysis pubis to the inner side of the tuberosity of the ischium.

Make an incision in this line three inches long, following the ramus of the pubis and ischium, and extending nearly to the tuberosity of the ischium. Divide the integument and the thick layer of adipose tissue. Separate the tissues from the inner side of the ramus. Avoid injuring the crus penis. The

artery can be felt about an inch and a half above the tuber ischii. The ridge formed by the falciform process of the great sacro-sciatic ligament is below the artery. Divide the obturator fascia which covers the artery, and pass the ligature, avoiding the veins and the pudic nerve.

The pudic nerve is situated internally to the artery, and its branch, the perineal nerve, runs below the artery.

EXTERNAL ILIAC ARTERY.—Place the subject on the back, inclined to the opposite side, and slightly flex the hip-joint.

The surface guide is the lower part of the line given as the guide to the common and external iliac arteries.

Begin an incision a little internal to and an inch above the middle point of Poupart's ligament, and continue it upward and outward four inches. The incision should extend nearly parallel to Poupart's ligament, but slightly more concave upward. Divide the skin and fascia. Divide on a director the aponeurosis of the external oblique, the internal oblique muscle, and the transversalis muscle. Divide the transversalis fascia to the extent of the wound. Separate the peritonæum and subserous fat upward and inward from the iliac and psoas fasciæ. The artery is found at the inner border of the psoas muscle. Pass the needle from within outward to avoid the vein, which is situated internally on a lower level. Avoid the genital branch of the genito-crural nerve, and apply the ligature about two inches above the level of Poupart's ligament.

DEEP EPIGASTRIC ARTERY.—Place the subject on the back.

The surface guide to the course of the artery is the line of the iliac arteries.

Make an incision three inches long one inch above and parallel to Poupart's ligament. The incision should have its middle point over the course of the artery. Divide the integument and fascia, the aponeurosis of the external oblique, and a few fibers of the internal oblique and transversalis muscles. Divide on a director the transversalis fascia to the extent of the wound. The artery will be seen extending in the direction of the umbilicus. Separate the veins, and pass the needle.

The deep circumflex iliac may be secured through the same wound.

FEMORAL ARTERY.—Place the subject on the back. Semiflex the knee, and rotate outward the hip-joint slightly flexed.

The surface guide to the artery is the upper two thirds of a line drawn from a point midway between the anterior superior spinous process of the ilium and the symphysis pubis to the adductor tubercle on the inner condyle of the femur.

1. *Common Femoral*.—Begin an incision one half inch above Poupart's ligament, and continue it downward three inches in the line of the artery. Divide the integument and superficial fascia, avoiding the lymphatic glands. Feel Poupart's ligament, and divide on a director the fascia lata, which is attached to its lower border. The sheath of the vessels is now exposed, and should be opened one half inch below Poupart's ligament. Pass the needle from within outward, to avoid the vein which is inclosed in a separate compartment of the sheath just internal to the artery.

2. *Superficial Femoral in Scarpa's Triangle.*—Three inches below Poupart's ligament begin an incision, and extend it downward three inches in the line of the artery. Divide the integument and superficial fascia, avoiding the internal saphenous vein. Divide the fascia lata, and recognize the sartorius muscle by its fibers extending downward and inward. Locate the artery where the sartorius and the adductor longus muscles meet. Separate and retract outward the sartorius muscle. Pass the needle from within outward, remembering that the vein is behind as well as internal, and hence directing the point of the needle toward the artery.

3. *Superficial Femoral in Hunter's Canal.*—Begin an incision in the middle of the thigh, and extend it downward four inches in the line of the artery. Divide the integument, superficial fascia, and the fascia lata. Recognize the sartorius muscle by its fibers extending downward and inward. Separate and retract inward the sartorius to expose the dense fascia forming the roof of Hunter's canal. Search for a branch of the artery which perforates this fascia to locate the artery. Divide the fascia over the artery. Retract outward the long saphenous nerve. Pass the needle from without inward to avoid the vein which is in contact externally and posteriorly with the artery.

The femoral artery may divide in the upper part of its course, or give off its branches irregularly. It has been found situated posteriorly to its usual course.

PROFUNDA FEMORIS ARTERY.—Place the subject as if for ligation of the femoral artery.

Begin an incision one inch below Poupart's ligament, and extend it downward three inches in the line of the femoral artery. Uncover the femoral artery and find on its outer side, or posteriorly, the origin of the profunda femoris. Avoid the profunda vein which is situated in front of the artery. Pass the ligature around the artery about three quarters of an inch from its origin.

POPLITEAL ARTERY.—Turn the subject on the abdomen.

The surface guide is a line drawn from a point one inch internal to the upper angle, to the lower angle of the popliteal space.

1. *Above the Knee-Joint.*—Begin an incision at the upper part of the popliteal space and extend it downward four inches, following the course of the artery. Divide the integument and fascia. Expose the fleshy fibers of the semimembranosus and retract the muscle inward. Tease a way through the areolar tissue, until the sciatic nerve is encountered. Internal to the nerve and nearer the femur, the vein resting upon the artery will be found. The artery is situated internally to the vein resting upon the femur. Retract the nerve and vein outward, and pass the needle from without inward.

2. *Below the Knee-Joint.*—Make an incision four inches long, extending in the course of the artery to the lower end of the line drawn as the surface guide. Divide the integument and fascia, avoiding the external saphenous vein. Tease a way through the areolar tissue between the heads of the gastrocnemius muscle, until the posterior tibial nerve is uncovered. External and deeper in the tissues, the popliteal vein,

resting on the artery, is to be found. The artery is situated externally beneath the vein resting upon the popliteus muscle. Retract the nerve and vein inward, and pass the needle from within outward.

POSTERIOR TIBIAL ARTERY.—Turn the subject on the back. Slightly flex the knee and hip joints, and rotate outward to make the limb rest upon its outer surface.

The surface guide is a line drawn from the lower angle of the popliteal space, to a point one half inch posterior to the inner malleolus.

1. *In Middle of Leg.*—Make an incision four inches long, parallel to and one inch posterior to the inner border of the tibia. Divide the integument and fascia, avoiding the internal saphenous vein. The inner border of the gastrocnemius can be seen resting upon the soleus. Cut through the muscular and tendinous fibers of the soleus in the line of the primary incision, until the deep fascia is reached. Separate the soleus and retract it outward, the muscle being made lax by extending the ankle-joint. Divide on a director the deep fascia when the artery may be seen. Retract the nerve outward, and pass the needle from without inward, avoiding the venæ comites.

2. *Posterior to Inner Malleolus.*—Flex the ankle-joint. Make an incision three inches long, midway between the inner border of the tibia and the tendo Achillis. The incision should extend down to the level of the lower end of the internal malleolus. Divide the integument and superficial fascia. Divide on a director the deep fascia. Separate the tissues, to uncover the artery external to the tendon of the

flexor longus digitorum muscle. The nerve situated behind and externally is retracted outward, and the needle passed from without inward, avoiding the venæ comites.

PERONEAL ARTERY.—Slightly flex the knee and hip joints, and rotate inward to make the limb lie with its outer surface uppermost. The course of the artery is just internal to the fibula.

In Middle of Leg.—Make an incision four inches long, parallel to and one half inch posterior to the fibula. Divide the integument and fascia. Cut the filular attachment of the soleus to the extent of the wound. Separate the soleus from the fascia covering the flexor longus hallucis. Extend the ankle-joint and retract the soleus inward. The artery will be found just internal to the fibula under the deep fascia. It may be found in the substance of the flexor longus hallucis. Pass the needle.

ANTERIOR TIBIAL ARTERY.—Place the subject on the back, with the limb extended.

The surface guide is a line drawn from a point on the anterior surface of the limb, one half inch internal to the head of the fibula, to a point midway between the malleoli in front of the ankle-joint.

1. *Middle Third of Leg.*—Make an incision four inches long obliquely downward and outward, having its middle point over the course of the artery. Divide the integument and superficial fascia. Divide on a director the deep fascia which will require horizontal cuts to allow its retraction. Search for the outer border of the tibialis anticus muscle, which may be made more evident in the lower part of the wound, by extending the ankle and turning the foot

outward. Separate the tibialis anticus from the extensor longus digitorum, down to the interosseous membrane. The artery will be found on this membrane with its veins, and with the anterior tibial nerve in front. Retract the nerve outward, and pass the needle from without inward.

2. *Lower Third of Leg.*—Make an incision three inches long in the line of the artery. Find the outer border of the tibialis anticus tendon. Separate the tibialis anticus from the extensor proprius hallucis, whose tendon has commenced to cross over to the inner side of the artery. The artery is found on the interosseous membrane, with the nerve situated externally. Pass the needle from without inward, avoiding the venæ comites.

DORSALIS PEDIS ARTERY.—Extend the ankle-joint.

The surface guide is a line drawn from a point in front of the ankle, midway between the malleoli to the first metatarsal interosseous space.

Make an incision two inches long, beginning one inch from the upper end of this line. Divide the integument and superficial fascia. Divide on a director the dense deep fascia along the outer border of the tendon of the extensor proprius hallucis, made prominent by flexing the great toe. Separate and retract outward the extensor brevis digitorum, the inner tendon of which crosses over the artery. The nerve is external. Pass the needle avoiding the venæ comites.

PHLEBOTOMY.

Tie a ligature tightly around the arm just above the elbow, and try to make the veins prominent by

pressing any blood which is fluid in the forearm, up toward the elbow.

Select the median cephalic vein, which can be seen or felt. Grasp the forearm just below the elbow with the left hand, and steady the vein with the left thumb. Hold the lancet between the right thumb and index-finger, with its blade making an obtuse angle with the hand. Puncture the vein obliquely, and tilt the point of the lancet while removing it, in order to enlarge the opening.

If the external jugular is chosen for operation, the puncture must divide the fibers of the platysma myoides. Open the vein as it crosses the sterno-cleido-mastoid muscle, making the length of the opening to run upward and outward. The vein is made prominent for operation by placing a pad above the middle of the clavicle to make pressure on the vein.

The internal saphenous vein is cut obliquely above the inner malleolus.

ARTERIOTOMY.

Locate the anterior temporal artery. The artery is subcutaneous, and can be readily followed upward and forward from the temporal artery.

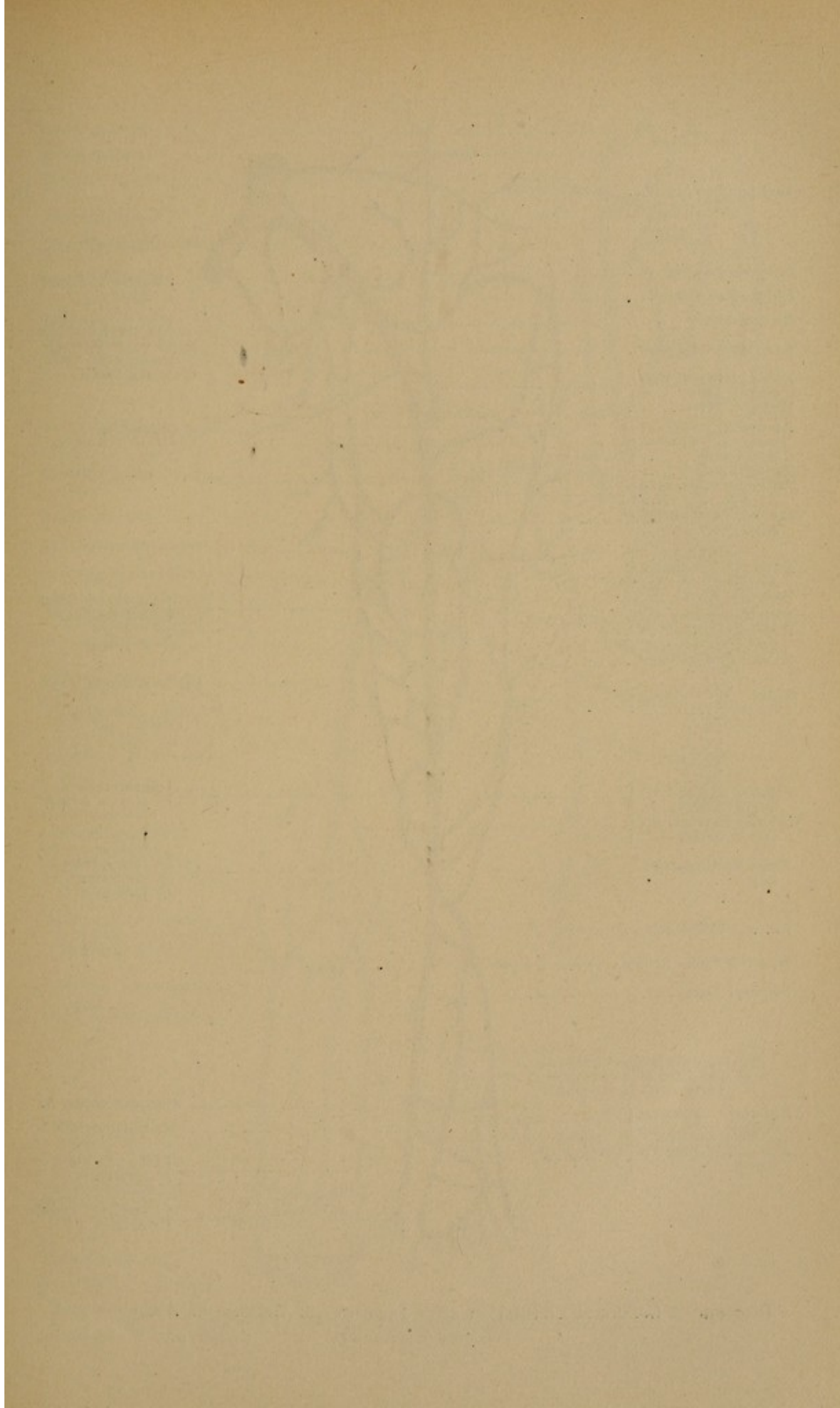
Divide the integument over the artery. Partially divide the artery by an oblique incision. When the wound is to be closed the artery must be completely divided and closed by compression, torsion, or the ligature.

TRANSFUSION.

One of the various methods may be practiced on the subject.

Arterial Transfusion.—(Prepare a fluid for trans-

fusion by adding to a pint of distilled water one and a half drachm of common salt and fifteen grains of carbonate of soda. Keep the temperature of the fluid at 104° Fahr.) Expose the radial artery, and ligature it in the lowest part of the wound. Occlude the artery by means of forceps applied above the ligature, and divide the vessel between the forceps and the ligature. Separate the artery from its bed to the extent of an inch. Compress the artery above the wound. Remove the forceps, and introduce into the artery, and secure with a ligature, the end of a trocar. Place the receptacle holding the fluid six feet above the body, and attach it to the trocar by means of rubber tubing. Allow the tubing to fill with fluid to expel the air before attaching it to the trocar. Remove the pressure on the artery above the wound. Allow several ounces of the fluid slowly to enter the arterial system. When the trocar is to be removed, the artery above the end of the instrument must first be ligated.



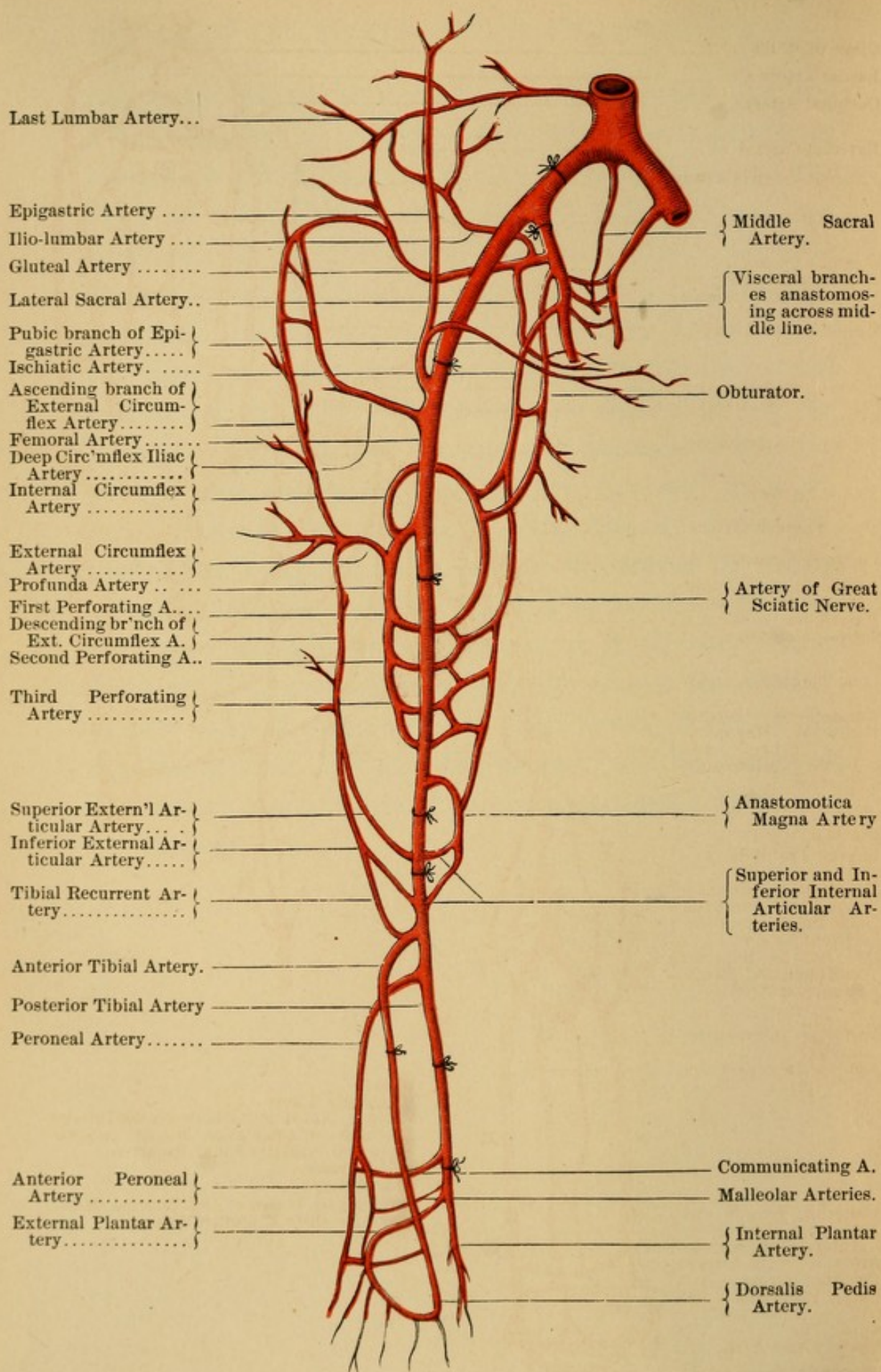
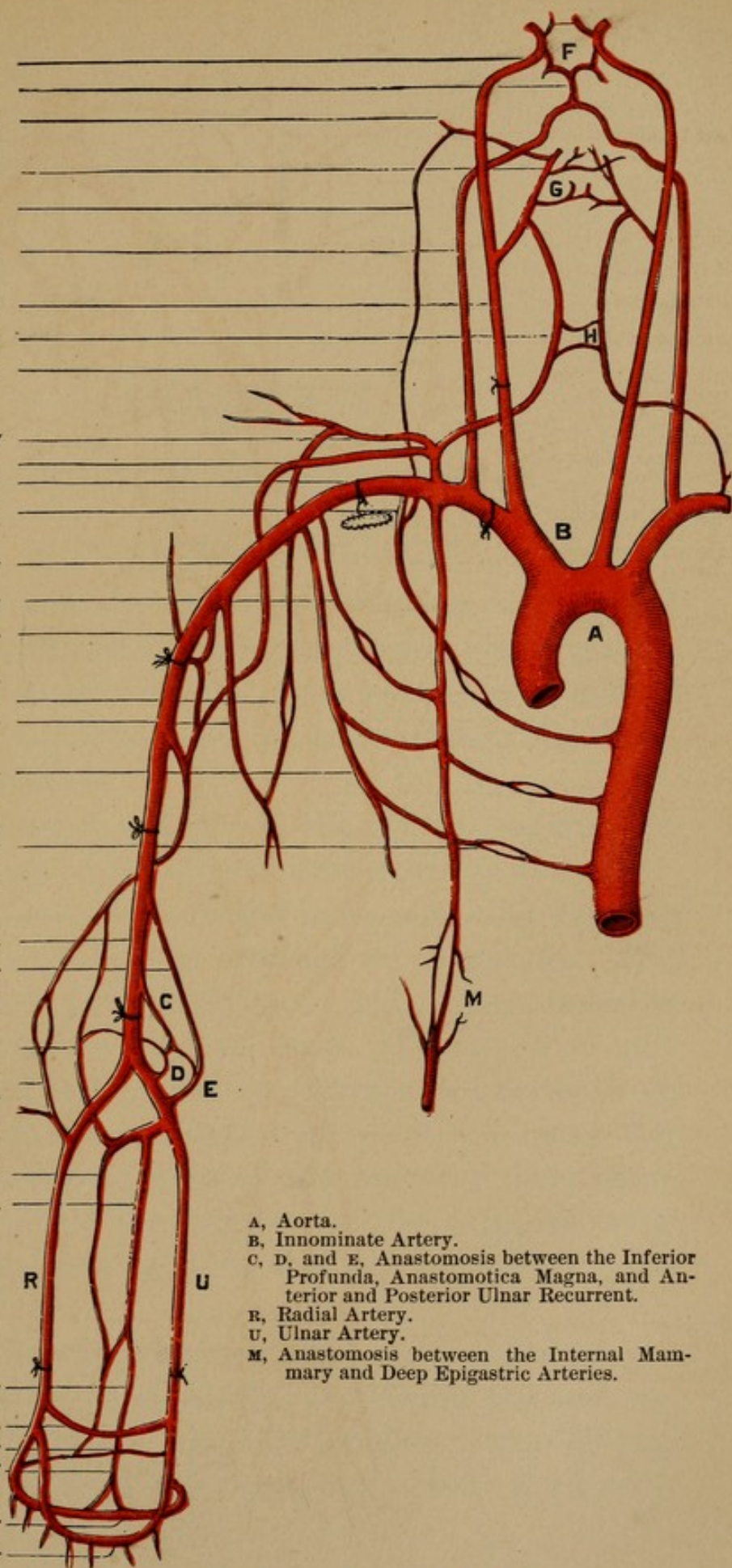


Diagram of Collateral Circulation after Ligatures of Arteries of Abdomen and Lower Extremity. (Smith and Walsham.)


Circle of Willis
 Basilar Artery
 Occipital Artery
 External Carotid
 Princeps Cervicis Artery
 Vertebral Artery
 Common Carotid
 Anastomosis between }
 Superior and Inferior }
 Thyroid Arteries
 Deep Cervical Artery
 Posterior Scapular Artery
 Suprascapular Artery
 Subclavian Artery
 Superior Intercostal Ar- }
 tery
 Axillary Artery
 Short Thoracic Artery
 Posterior Circumflex A.
 Anastomosis between }
 the Posterior Scapular }
 and Dorsalis Scapulae }
 Subscapular Artery
 Long Thoracic Artery
 Anastomosis between }
 Internal Mammary, }
 Long Thoracic, and }
 Aortic Intercostals }
 Arteries
 Brachial Artery
 Inferior Profunda
 Anastomosis between }
 Superior Profunda }
 and Interosseous Re- }
 current Artery
 Ditto between Superior }
 Profunda and Radial }
 Recurrent Arteries
 Posterior Interosseous }
 Artery
 Anterior Interosseous A.
 R
 U
 Posterior Branch and }
 Anterior Branch of }
 Anterior Interosseous }
 Artery
 Posterior Carpal
 Carpal Recurrent
 Deep Palmar Arch
 Superficial Palmar Arch



A, Aorta.
 B, Innominate Artery.
 C, D, and E, Anastomosis between the Inferior
 Profunda, Anastomotica Magna, and An-
 terior and Posterior Ulnar Recurrent.
 R, Radial Artery.
 U, Ulnar Artery.
 M, Anastomosis between the Internal Mam-
 mary and Deep Epigastric Arteries.

Diagram of the Collateral Circulation of the Arm.

(Smith and Walsham.)



CHAPTER X.

OPERATIONS ON THE OSSEOUS SYSTEM.

MANIPULATION OF THE SAW.

1. *How to hold.*—Hold the saw in the full grasp of the hand, with the index-finger placed along the side.

2. *How to use.*—Before a saw can be freely moved to and fro, a groove must be made in the bone to retain it in position.

In the case of a trephine, the central pin controls the movement of the crown until a groove is cut.

A chain-saw is conducted into position by a needle or probe, to which it is attached by a ligature. The chain should not be twisted, and its cutting-edge must be presented to the bone. The chain should be kept taut, and as nearly straight as the depth of the wound in the soft parts will allow. To keep the chain taut, the two arms of the operator must move in unison. Hold the handles in the palm, allowing the chain to pass between the middle and ring fingers.

The ordinary saw must be steadied, and a groove in the bone be established, by drawing the saw toward the operator. The left thumb-nail, applied just above the level of the teeth, will steady the instrument.

If the saw is moved rapidly, the heat, which would be excessive, must be prevented by irrigation. When the bone is nearly severed, the undivided portion bends and the track of the saw is narrowed, hence the saw should then be presented to the bone at a different angle.

OSTEOTOMY.

Various instruments are used to cut bones, as saws, chisels, osteotomes, scoops, etc. The use of the osteotome, in making a section of the bone in this operation, must be considered a matter of choice.

EXAMPLE: *Middle of the Tibia*.—Place the subject on the back. Shave the part. Adjust a sand-pillow under the limb at the site of the operation.

Select the subcutaneous portion of the tibia. Draw the skin upward so that the wound will be valvular. Make an incision in the long axis of the limb through all the tissues. There are no important structures to be avoided. The incision should be long enough to admit the osteotome, which should be inserted with its cutting edge in the axis of the wound until it touches the bone. Hold the osteotome at a right angle to the bone, and turn it so that its cutting edge is presented to the bone crosswise. Strike the head of the osteotome with a mallet, and then move the osteotome in the axis of its cutting edge to prevent its becoming wedged. When the section is deep and the osteotome is moved with difficulty, a narrower and thinner osteotome must be substituted. The smaller osteotome can be directed backward and outward and backward and inward in the wound made by the larger osteotome. When the

section is nearly completed, the bone is broken with *slight* force.

Place the limb in the desired position, and close the wound, providing for drainage.

WIRING OF BONES.

EXAMPLE: *Fractured Patella*.—Prepare the subject by fracturing or subcutaneously dividing the patella and separating its fragments by flexing the knee-joint. Place the subject on the back.

Make a horizontal incision from the posterior part of the lateral surface of one condyle of the femur across the front of the joint, to the corresponding point on the other condyle. The incision should cross the joint on the level of the upper margin of the lower fragment of the patella. Divide all the tissues, thus freely opening the joint. Turn the fractured surface of each bone upward, and make them smooth by means of a bone-scoop.

Enter a bone-drill in the middle line of the anterior surface of the patella, a third of an inch from the anterior margin of the fractured surface. Bore the bone obliquely, piercing through the fractured surface near the layer of cartilage which covers its posterior surface. After each fragment is perforated, a stout silver wire is pushed through the track of the drill, following the point of the drill as it is withdrawn. A single wire is sufficient. Approximate the fragments by drawing the ends of the wire forward. Use care to be assured that no tissue nor foreign substance is included between the fractured surfaces. Twist the ends of the wire together until all the slack is taken up.

Cut the twisted ends of the wire one half inch from the surface of the patella, and bend them down against the bone, a cut through the periosteum being made over the bone to receive them. Cut along the wire as it lies over the patella, so that the wire can be pressed flat against the bone.

Provide for drainage from the joint at the two angles of the wound. Stitch accurately together the capsule of the joint and the tissue on the fragments of the patella, by means of a continuous suture of cutgut. The joint is thus closed and separated from the wound of the superficial tissues. Close the superficial wound, after providing for drainage. No vessels of importance are divided in this operation.

EXCISION OF THE SUPERIOR MAXILLA.

Place the subject on the back, with the head slightly elevated on a block. Operate from the right-hand side, facing the subject.

Extract the middle incisor tooth of the bone to be removed. Make an incision through the median line of the upper lip to the septum nasi, and extend it into the nostril of the side from which the bone is to be excised. Curve the incision around the corresponding ala, and extend it upward in the furrow between this side of the nose and the cheek, to a point one half of an inch below the inner canthus of the eye. Join to the upper end of this incision an incision extending just below the inferior margin of the orbit to the malar bone (Fergusson). These incisions should divide all the tissues to the bone. Ligate the divided angular artery. Dissect the tissues from the bone, leaving undivided the reflexion

of mucous membrane from the external surface of the alveolar process to the flap.

Begin at a point one half of an inch from the middle of the posterior margin of the hard palate to make an incision through the periosteum extending along the median line to the space caused by the extraction of the middle incisor tooth. Extend this incision up over the alveolar process until it meets the incision dividing the upper lip.

Separate the ala and side of the nose attached to the nasal process of the bone, and retract these parts in toward the septum. Incise the tissues on the floor of the nostril along the side of the septum, and, with a narrow saw, divide the alveolar process and hard palate in this line.

Strip up with an elevator the periosteum from the floor of the orbit, and expose the speno-maxillary fissure. Protect the eye by holding the tissues of the orbit upward with the elevator, while the nasal process is sawn through to the internal inferior angle of the orbit. Divide with a scalpel the floor of the orbit from the internal inferior angle to the speno-maxillary fissure, cutting close to the margin. Saw from a point opposite the speno-maxillary fissure the malar bone downward and outward, just internal to the most prominent part of the bone.

Cut with a scalpel the mucous membrane reflected from the external surface of the alveolar process to the flap formed by the cheek, to a point posterior to the last molar tooth. Make a transverse incision through the periosteum, joining this incision behind the last molar tooth to the median incision through the hard palate.

Grasp the bone by means of lion forceps and force it down, to break the palatine and pterygoid attachments. Twist the bone and tear it from its other attachments.

Cut the superior maxillary nerve short, and ligate the internal maxillary artery in the location of the spheno-maxillary fossa.

The cutting forceps may supplement the use of the saw, and a saw may be used to divide the floor of the orbit instead of the scalpel.

An excision leaving the inferior margin of the orbital fossa may be made. The operation is performed in every respect like the last, except in separating the bone superiorly. Drill or trephine the antrum just below the middle of the inferior margin of the orbital fossa, so as to admit a narrow saw. Proceeding internally, saw horizontally the anterior wall of the antrum and through the nasal process into the nasal fossa. Proceeding externally, saw horizontally through the anterior wall of the antrum and obliquely downward and outward when the malar bone is reached.

An excision may be performed, leaving the inter-maxillary bone. In this case the canine tooth is drawn, and the alveolar process sawn through the incisor fissure. The other steps of the operation are the same as those just described.

These excisions may be practiced sub-periosteally, by incising the gum down to the bone along the alveolar process internally and externally, just above the teeth. Join the incisions behind the last molar, and through the space left after either the incisor or canine tooth has been extracted. Separate the tissues from

the external surface of the alveolar process, leaving them attached to the flap. Separate the tissues from the internal surface of the alveolar process, and from the hard palate as far as the median line. In the operation where the intermaxillary bone is to remain, an incision is carried from the socket of the extracted canine tooth to the median line following the incisor fissure. In sawing the alveolar process and hard palate, be careful that the gum and periosteal flap are protected. In stitching together the wound, the flaps removed from each side of the alveolar process are brought in apposition.

The part of the facial flap made by dividing the upper lip will need stitches of relaxation.

If both bones are removed simultaneously, the same incisions (Fergusson) are to be made on the other side. Separate the septum from the nasal crest. The two maxillæ are not to be sawn between, but removed together.

EXCISION OF THE INFERIOR MAXILLA.

Place the subject on the back, with the head slightly raised upon a block. Stand on the right-hand side, facing the subject.

First, one half of the bone is removed as follows: Extract the middle incisor tooth of the half to be removed. Make an incision through the middle of the lower lip to a point just below the symphysis menti, cutting down to the bone. Join to the lower end of this incision another extending along the lower border of the body, around the angle, and upward, immediately posterior to the ramus of the bone, until the level of the lobe of the ear is reached. The fa-

cial artery is divided between ligatures, as it crosses the bone in a line with the anterior edge of the masseter muscle. Separate the flap thus marked out from the bone, by means of the scalpel and elevator, and reflect it upward.

Divide with a narrow saw the bone downward and outward from the space formed by the extraction of the middle incisor tooth to a point external to the genial tubercles.

Catch the divided end of the bone with the lion forceps and draw it upward and outward, while the tissues from the inner surface and inferior border of the body are separated by means of the scalpel and elevator. Guard against the division of the lingual nerve, by keeping the edge of the knife directed toward the bone while separating the tissues below the molar teeth. Turn the bone outward, and cut the muscular insertions from the internal surface, and the anterior edge of the coronoid process, also the insertion of the internal pterygoid. Cut the inferior dental vessels and nerve as they enter their canal. Grasp the bone and depress it. Cut the muscular attachment and the capsular ligament on the anterior surface of the neck of the bone. Dislocate the condyle and twist it loose, cutting any attachments not torn or peeled off. Keep the edge of the knife against the bone, as the internal maxillary artery is just behind and internal to the neck. Tie the inferior dental artery.

If it is necessary to prolong the external incision upward to the condyle, to effect the disarticulation, Stenson's duct, the transverse facial artery, and branches of the facial nerve will be divided.

Before beginning the removal of the other half of the bone, pass a ligature through the anterior part of the tongue and draw it forward.

Separate the attachments of the muscles arising from the genial tubercles, and proceed as in the removal of the first half. Stitch the mucous membrane together, and provide for drainage externally. Use stitches of relaxation to secure the coaptation of the incision through the lip.

Resections of different portions of the bone are best performed through external incisions following the course of that for excision. It is never necessary in these partial excisions to divide the lip.

Before the muscular attachments to the genial tubercles are severed, always secure the tongue by means of a ligature passed through its anterior part. After the operation, suture these muscles to the tissues removed anteriorly from the symphysis menti.

RESECTION OF RIB.

Place the subject in such a position that the portion of bone to be removed is uppermost.

Make an incision along the middle of the body of the rib, extending a little beyond each end of the portion to be removed. Join to each end of this incision a vertical incision, extending from the upper to the lower border of the rib. These incisions must divide the periosteum. Raise all the tissues from the bone by means of a periosteum elevator until the external surface and upper and lower borders are bare. Proceed with care to separate the periosteum, covered by the pleura, from the internal surface. The intercostal vessels run in the groove near the lower border,

from which they must be dislodged by means of the elevator and scalpel.

When the portion of bone is separated from all of its attachments, carry a chain-saw under it and saw through one end. Protect the pleura with a spatula while sawing. Seize the divided end of the portion of bone to be removed with lion forceps to steady it while the resection is completed. Provide for drainage, and stitch the flaps together.

RESECTION OF THE ARTICULATING ENDS OF BONES.*

Shoulder-Joint.—Place the subject on the back, with the shoulders raised on a block. Draw the shoulder near the edge of the table, and stand on the side of the operation facing the subject. Rotate the joint inward, so that the external condyle of the humerus is directed forward.

Begin an incision just below the acromio-clavicular articulation, and extend it four or five inches downward in the middle of the anterior surface of the limb. Divide the integument and fascia, and the inner fibers of the deltoid muscle. Retract the sides of the wound, and feel the bicipital groove of the humerus. Open the sheath of the tendon of the long head of the biceps, and the capsule of the joint up to the acromion process, by cutting along the external edge of the tendon from below upward. Raise the tendon from the bicipital groove and retract it outward.

Incise the periosteum along the inner margin of the bicipital groove, and separate it from the bone

* These operations should be modified in young subjects to preserve the epiphyseal cartilages.

as far internally as possible, by means of an elevator rotating the joint outward. The elevator should not be pointed, nor have a sharp edge. The attachment of the subscapularis muscle to the lesser tuberosity is separated by means of a scalpel. The edge of the scalpel must always be directed toward the bone.

Rotate the joint inward and retract inward the tendon of the long head of the biceps muscle. Incise the periosteum along the external margin of the bicipital groove. Separate the periosteum as far outward as possible, rotating the joint inward. The attachments of the supra-spinatus, infra-spinatus, and teres minor muscles to the greater tuberosity of the humerus must be separated by means of the scalpel. The anterior and posterior circumflex vessels, and the posterior circumflex nerve, are not in danger if the edge of the elevator and scalpel are directed toward the bone during their use.

Care must be exercised that the periosteum is not lacerated during its separation from the surgical neck of the bone.

Pass a chain-saw over the head, behind the surgical neck of the bone. Protect the sides of the wound by means of spatulas to prevent the friction of the chain-saw against them. Saw the bone through and remove it from its cavity. The glenoid cavity is to be examined.

If the separation of the tissues posteriorly is impracticable, the upper extremity of the bone may be sawn off and removed. The divided upper end may now be directed to the wound and the tissues separated, when the saw can be carried over the end to the surgical neck. Provide for drainage, and close the wound.

Elbow-Joint (Park).—Extend the joint and raise the limb so that the posterior surface is accessible. Stand on the outside of the limb.

Make an incision five inches long in the middle of the posterior surface of the limb, having its middle point over the olecranon process near to its internal border. Divide all the tissues to the bone.

Internally to the wound, separate the tissues from the posterior surface of the humerus and the olecranon process by means of a scalpel and periosteum elevator. Carefully separate the tissues in the groove between the olecranon and the internal condyle. The ulnar nerve is not to be exposed. Separate the muscular attachments from the internal condyle, flexing the joint when convenient. The ulnar nerve is protected by the left thumb-nail, and the edge of the scalpel is to be directed toward the bone. Retract the tissues and divide the internal lateral ligament of the joint.

Externally to the wound separate the tissues from the bones by means of the scalpel and periosteum elevator. Detach the muscles from the external condyle, preserving as before their attachment to the periosteum. Retract the tissues and divide the external lateral ligament along the lower border of the external condyle of the humerus.

Separate from the ulna the olecranon process, by means of bone-cutting forceps or the saw. In using bone-cutting forceps, the flat surface should be placed toward the shaft of the bone to prevent splintering.

Flex the joint and force the lower end of the humerus out of the wound. Separate the tissues attached to the anterior surface, no special care being

taken to preserve the periosteum. Avoid the brachial artery and the median nerve. Saw the bone through at a right angle to the shaft above the condyles. Allow the humerus to return into the wound cavity.

Push the ends of the radius and ulna into the opening of the wound. Detach the tissues from the ulna and radius, down to the level of the lower border of the coronoid process. Saw the bones through at this level. The tubercle of the radius is not to be sacrificed, and special care must be given to preserve the attachment of the brachialis anticus to the periosteum. Draw the bones into the wound cavity, and approximate them to the humerus at a right angle.

Wrist.—(Excision of the carpus with resection of the carpal ends of the radius and ulna, and of those of the metacarpus.) Place the hand prone and adducted upon the table.

Begin an incision one half of an inch above the wrist-joint, a little nearer to the inner than to the outer border of the dorsal surface of the radius, and continue it downward to the middle of the dorsal surface of the second metacarpal bone. Divide the integument and fascia, the tendon of the extensor carpi radialis brevis muscle, the periosteum, and posterior ligaments.

On the radial side of the incision, detach by means of a scalpel the extensor carpi radialis longior from the second metacarpal bone. Extend the wrist, and use an elevator to separate the remaining attachments, guarding against wounding the radial artery. Retract the tissues and separate by means of bone-nippers the trapezium from the remainder of the carpus.

On the ulnar side of the incision, the wrist being extended, separate by means of an elevator the tissues from the bones.

Begin a second incision two inches above the wrist-joint, between the flexor carpi ulnaris and the ulna, and continue it downward to the level of the middle of the fifth metacarpal bone. This incision should run just anterior to the ulna and the fifth metacarpal bone. Separate by means of a scalpel the attachment of the extensor carpi ulnaris from the fifth metacarpal bone. Extend the wrist, and complete the separation of the tissues from the dorsal surface of the bones.

Flex the wrist and separate the tissues from the palmar surface, cutting the pisiform bone and the unciform process from the rest of the carpus, by means of the bone-cutting forceps. Do not use the scalpel in separating the tissues below the heads of the metacarpal bones, on account of the proximity of the deep palmar arch.

Retract the tissues above and below, and by means of cutting forceps separate the carpus from the radius and triangular cartilage above and from the metacarpus below. The carpus can now be removed through the wound on the ulnar side. Dissect out the trapezium, avoiding the radial vessels, and the pisiform bone and the unciform process, avoiding the ulnar vessels and nerve.

Push the metacarpal bones into the wound, and saw off their articular surfaces. Separate the tissues from the head of the ulna, avoiding the ulnar vessels and nerve, and saw off its articulating surfaces. Separate the tissues from the carpal end of the ra-

dus, avoiding the radial vessels. Protrude the bone and saw off its articulating surface on a level with the sawn end of the ulna.

Search for the detached tendons of the extensors of the carpus, shave off slightly their surface toward the dorsum of the hand, and attach them with catgut to the periosteum over the sawn ends of their respective metacarpal bones. Appose to the sawn ends of the radius and ulna those of the metacarpus.

Metacarpo-phalangeal.—Place the hand, with the fingers extended, prone upon the table.

Make an incision two inches long over the dorsal surface of the bones, with its middle point over the joint. In the case of the thumb, the incision should be a little to the radial side, and in case of the little finger, a little to the ulnar side of the middle of the dorsal surface. Divide the integument and fascia. Push aside the dorsal tendons and incise the periosteum. Separate by means of an elevator the periosteum from the ends of the bones for half an inch, and cut the ligaments of the joint. Forcibly flex the joint to protrude the head of the metacarpal bone. Saw off the articular surface. Protrude the base of the phalanx through the wound, and saw off its articular surface.

Phalangeal.—Extend the finger.

Make longitudinal incisions, about an inch long, on the sides of the finger nearer the dorsal than the palmar surface. The middle of the incisions should correspond to the joint. Divide the tissues to the bones. Elevate the tissues from the head of the proximal phalanx, and divide the lateral ligaments of the joint. Bend the finger laterally to protrude the

head of the proximal phalanx. Saw off the head of the proximal phalanx. Push the base of the more distal phalanx into the opening, and separate the tissues from its base by means of a scalpel. Protrude the end of the bone and saw off the articular surface.

Hip (Langenbeck).—Place the subject on the back, inclined to the opposite side. Flex the hip-joint until the thigh is at an angle of 45° with the axis of the body.

Make an incision about six inches long in the axis of the limb, with its middle point over the middle of the superior border of the great trochanter. Divide the integument and fasciæ. Incise the periosteum on the trochanter, and separate, by means of the scalpel and elevator, the tissues from the superior border and outer surface. Separate the fibers of the gluteus maximus muscle, and divide on a director the fascia covering its deep surface.

Push aside the tissues to expose the neck of the femur and retract the sides of the wound. Incise the capsule and periosteum, cutting on the long axis of the neck of the femur. Separate the tissues from the neck. The attachment of the obturator externus muscle must be cut from the digital fossa with care.

1. Incise in several places the cotyloid ligament, so that air can enter the acetabulum. Adduct and forcibly rotate inward the joint, partially dislocating the head of the femur. Divide the ligamentum teres against the head of the femur, when the dislocation is easily completed.

Pass a chain-saw around the neck of the femur, and saw through the bone, protecting the soft parts.

The acetabulum is readily examined, the sides of the wound being retracted.

2. If an excision is to include the division of the bone just above the level of the lesser trochanter, other attachments must be separated before the head of the bone is dislocated. Cut the periosteum at a right angle to the longitudinal incision, carrying the knife as far around the bone as possible. This horizontal incision of the periosteum should be on the level of the middle of the trochanter. Separate all the tissues down to the level of the lesser trochanter. Now the head of the bone is to be dislocated, and the chain-saw passed behind the bone above the lesser trochanter. Divide the bone just above the level of the lesser trochanter, protecting the soft parts from contact with the saw.

Knee.—Place the subject on the back, with the knee-joint semi-flexed.

Begin an incision just below the adductor tubercle on the internal condyle, and extend it across the front of the limb below the patella to a corresponding part of the external condyle of the femur. Divide all the tissues to the bone, opening widely the joint. Flex the joint, and carefully cut the crucial ligaments.

The lateral ligaments having been completely divided against the condyles, the posterior surface of the femur is readily reached. Separate the tissues as far back as the posterior surfaces of the condyles, protecting with the thumb the popliteal artery. Retract the tissues and divide the bone by means of a Butcher's saw from behind forward. Do not remove so much bone as to include the posterior articular surfaces of

the condyles, nor the upper portion of the patellar articular surface. Saw the bone horizontally to the surfaces of the condyles, and not to the axis of the bone; the same amount of bone in length is removed from each condyle, thus preserving the obliquity of the axis to the plane of the lower end of the femur.

Separate the tissues from the upper end of the tibia to the extent of one half inch. Retract the tissues, and, by means of a Butcher's saw, divide the bone from behind forward. The saw should remove the articular surface and a thin layer of bone at a right angle to the long axis of the tibia. The section of bone is above the level of the head of the fibula.

Turn upward the flap containing the patella, and, by making parallel incisions toward the bone beginning from above, enucleate the bone from its capsule. By putting the fingers under the upturned flap, the patella is made prominent and its separation expedited.

Bring the sawn surfaces of the femur and tibia into exact apposition, and wire them together. Suture with catgut the divided ligamentum patellæ. Provide drainage from the pouch above the bones to the lower angles of the wound. Suture the deep tissues (capsule) together by means of buried sutures of catgut. Close the external wound, providing for drainage from the superficial parts of the wound.

Ankle-Joint.—Turn the leg upon its inner surface.

Make an incision three inches long over the lower subcutaneous portion of the fibula, down along the posterior border of the external malleolus. Extend the incision to the tip and up along the anterior bor-

der of the malleolus. Divide all the tissues against the bone. Separate the tissues from the bone up to the interosseous space by means of an elevator. Pass a wide director through the interosseous space to protect the tissues while the bone is sawn by means of a chain-saw. Grasp the lower sawn end of the fibula, and separate its lower and internal attachments, keeping the edge of the knife against the bone.

Turn the leg upon its outer surface. Make an incision three inches long over the tibia near its inner border, extending over the internal malleolus near its posterior border. Continue the incision over the lower to the anterior border of the malleolus. Divide the tissues and separate them from the bone to a level above the joint. Saw the internal malleolus, and complete its division by means of cutting forceps. Remove the internal malleolus, cutting toward the bone to avoid the tendons and vessels in close proximity. Protrude the tibia and saw off its articular surface.

Push the astragalus into the opening, and remove its articular surface by means of the rongeur. Appose the cut end of the astragalus to that of the tibia.

CHAPTER XI.

AMPUTATIONS AND DISARTICULATIONS.

MANIPULATION OF THE AMPUTATING-KNIFE.

1. *How to hold the Knife.*—In operating gracefully, several methods of holding the amputating-knife are practiced :

(a) The knife is held ordinarily as a table-knife. This method was discussed as practiced with the scalpel.

(b) The knife is held with the handle in the full grasp of the hand. If the edge of the knife be turned from the palm of the hand, the thumb should be placed as a support on the back of the handle.

(c) The handle of the knife near its extremity is held between the pulps of the index and middle fingers and the thumb. The extremity of the handle can be made to describe an arc in the space between the index-finger and thumb without touching the palm of the hand. The knife, pointing upward, has its edge turned toward the palm of the hand.

This method is used in making a circular incision around a limb.

2. *How to cut with the Knife.*—In cutting with the amputating-knife the blade should be given a free sawing movement.

When the knife is used to pierce, its point should be steadily advanced; never partially withdrawn and again advanced, because the first thrust may have wounded some important structure.

STEPS IN OPERATING.

1. Tissues belonging to the part distal to the site of the operation must be left in continuity, to serve as a covering for the wound-surface caused by the amputation.

(a) *Circular Method*.—In this method one or more cellulo-cutaneous flaps are raised to cover the wounded surface. All the tissues are divided at a right angle to the long axis of the limb near the level of the base of this cellulo-cutaneous covering. The soft parts are divided at a lower level, and the bone is sacrificed up to a little higher level than the base of the covering.

(b) *Flap Method*.—In this method other tissues besides skin and subcutaneous fascia enter into the formation of the covering provided for the wound-surface. The covering may be formed by transfixion and cutting toward the surface, or by cutting from the surface toward the bone, and may consist of one or more flaps.

2. *Periosteal Flap*.—The bone is provided with a covering of periosteum for its sawn surface by raising this tissue from the bone to be sacrificed before applying the saw.

(This flap is made to prevent the atrophy of the end of the bone; it also lessens the chance of an adherent cicatrix.)

3. *Interosseous Flap*.—Where two bones are to

be sawn through, the tissues between should be divided transversely at a level one half inch lower than the saw-cut, and then separated from the bones up to this level.

The vessels in this flap are easily controlled.

4. The bone is generally removed up to a little higher level than that of the divided soft parts. If the bone is to be divided, it is sawn off ordinarily at a right angle to the long axis of the limb.

The sacrifice of the soft parts is not necessarily in fixed proportion to that of the bone.

AMPUTATIONS AND DISARTICULATIONS OF THE UPPER LIMB.

Amputation and Disarticulation of Fingers.—During all the operations on the hand, compress the arteries at the wrist. The three rows of knuckles are formed by the heads of the proximal bones entering into the articulations.

Disarticulation at the Distal Phalanx.—Pronate the hand. The finger should point toward the operator, and be held between his thumb above and his index-finger beneath.

Make incisions in the long axis of the finger in the middle of the lateral surfaces which begin over the expanded base, and continue downward two thirds of the length of the phalanx. Flex the joint to a right angle, and join the proximal ends of the lateral incisions by a dorsal incision over the line of the joint. Open the joint by an incision slightly convex toward the body, and divide the lateral ligaments.

Pass the finger-knife, with its edge directed to-

ward the end of the finger, under the disarticulated base of the phalanx. Extend the finger and cut the palmar flap, keeping close to the bone and following the lateral incisions. Turn the edge of the knife perpendicularly to the flap and cut it off from the phalanx.

Remove any portion of the flexor tendon contained in the flap. Occlude the digital arteries. Close the wound by bending the palmar flap over the end of the second phalanx. Provide for drainage.

Amputation and Disarticulation of the Second Phalanx.

1. *Amputation*.—Make a circular incision through the integument and fascia, as near the end of the phalanx as possible. Divide the flap on each side, so that it can be rolled up like a cuff to the extent of one half the diameter of the phalanx. Divide the tissues circularly at the level of the base of the flaps. Saw the bone at a right angle to its long axis.

Occlude the digital arteries. Round off the angles of the flaps, and stitch the flaps accurately together, providing for drainage.

2. *Disarticulation*.—Make two lateral incisions as in disarticulation of the distal phalanx. In making the dorsal incision, divide only the integument and fascia over the line of the joint. Elevate a flap, including the common extensor tendon and the periosteum, from the dorsal surface of the second phalanx. This flap should be of sufficient size to cover the head of the phalanx. Disarticulate the bones and form the palmar flap, as in case of the distal phalanx.

Occlude the digital arteries. Cover the head of the bone with the periosteal and tendinous flap,

which in turn must be covered by the palmar flap. Stitch the palmar flap to the tissue on the dorsal surface, making the sutures in such a manner as to include the dorsal tendon.

Amputation and Disarticulation of the Proximal Phalanx.

1. *Amputation.*—This amputation is performed similarly to that of the second phalanx, except that a dorsal periosteal and tendinous flap should be secured of sufficient size to cover the sawn end of the bone. Stitch the dorsal tendinous flap to the divided flexor tendons. Stitch the palmar to the dorsal flap, providing for drainage.

2. *Disarticulation.*—This operation is best performed by a pyriform incision. The other fingers are separated from the one to be removed.

Begin an incision on the dorsal surface at the anterior extremity of the head of the metacarpal bone, and extend it obliquely downward toward the palmar surface, one quarter of an inch beyond the junction of the web to the finger. Make a similar incision on the opposite side of the finger. Join the ends of these incisions by a transverse incision across the palmar surface of the finger. These incisions should include the tissues to the bone. Join to the upper angle of this pyriform incision, an incision three quarters of an inch long, extending along the dorsal surface of the metacarpal bone.

Separate the tissues from the bone, without preserving the periosteum. Open the joint by a dorsal incision concave toward the body. Divide the lateral ligaments, and disarticulate the bones. Occlude the digital arteries.

The head of the metacarpal bone is often removed when symmetry is more desirable than strength.

In the case of the thumb or the index-finger, an external flap may be fashioned to cover the wound-surface, and an internal one in case of the little finger.

The heads of the second or fifth metacarpal bones should be cut off obliquely toward the contiguous bone.

The practice of set amputations or disarticulations of the metacarpal bones is of doubtful expediency. In amputating through these bones the bases of the second, third, and fifth should be preserved, on account of their tendinous attachments. In disarticulating the first metacarpal the saddle-shape of the articulation should be remembered, and the proximity of the radial artery. The sesamoid bones should not be included in the flap.

Disarticulation at the Wrist.—Compress the brachial artery. Supinate the hand.

Begin an incision at the styloid process of the radius and extend it straight down in the palm of the hand to within one half inch of the level of the head of the second metacarpal bone. Begin a second incision at a corresponding point on the ulnar side of the wrist, and extend it into the palm to within one half inch of the level of the head of the fifth metacarpal bone. Join the distal ends of these incisions by means of a transverse incision across the palm of the hand. Divide the tissues until the flexor tendons are encountered.

Raise this rectangular flap from the palm up to the level of the wrist-joint. The pisiform bone and

the unciform process of the unciform bone may be cut with bone-nippers, and afterward dissected from the flap.

Pronate the hand, and connect the proximal ends of the longitudinal incisions by a dorsal incision slightly convex downward. Reflect this short dorsal cellulo-cutaneous flap to the level of the wrist-joint.

Grasp the hand and strongly flex the wrist. Divide the extensor tendons and open into the joint by an incision slightly convex toward the body. Divide the lateral ligaments. Retract the palmar flap, and divide with one sweep, *not push*, of the knife, all the flexor tendons.

Cut short the divisions of the ulnar and median nerves. Occlude the radial artery, and any small dorsal or palmar arteries which may be seen. The superficial arch is included in the palmar flap. The styloid processes may be nipped off. Stitch the palmar to the dorsal flap, providing for drainage.

Dubreuil's Operation.—Make a flap convex downward, whose base shall extend from the junction of the outer to the middle third of the wrist anteriorly, to a corresponding point on the dorsum. The lower convex border of the flap extends to the level of the head of the first metacarpal bone. Reflect this cellulo-cutaneous flap up to the level of the wrist.

Make an incision from one extremity of the base of the flap around the ulnar side of the wrist to the other extremity. Retract the cellulo-cutaneous tissue up to the level of the wrist, and remove the hand, as already described. Occlude the radial and ulnar arteries, and fit the flap to the surface of the wound, providing for drainage.

Amputation through the Forearm (circular).—Compress the brachial artery. Extend the arm and hold it between supination and pronation. Measure the circumference of the forearm at the site of the amputation. The length of the flap should be one quarter of this measurement.

The operator, standing on the right-hand side of the limb, with his right foot forward, and stooping slightly, should carry the knife under and up on the other side of the forearm until, by extending his wrist, the edge of the knife lies horizontally on the upper surface of the limb. With a slight sawing motion the knife is made to divide circularly the integument and cellular tissue around the limb. As the knife cuts under the limb and on the side nearest to the operator, the handle describes an arc between the index-finger and thumb, so that at the completion of the incision it points forward. The operator at the same time assumes the erect position.

Elevate the flap, keeping the edge of the knife directed perpendicularly to the muscular tissue. Slit the flap in a line corresponding to the long axis of the ulna, so that it may be rolled up like a cuff to the desired extent. Make a circular division of the muscles at a level one half inch below the base of the flap. With a catlin form an interosseous flap as already described. Form periosteal flaps for each bone.

Retract the soft parts by means of a retractor, made by partially tearing into three strips a rather wide bandage. One of the strips should go between the bones, and lie over the other strips crossed above. Grasp with the left hand the limb just above the proposed division of the bone. Saw the bones, begin-

ning and ending on the more fixed. The radius is more fixed below, and the ulna above.

Remove any spiculum by means of the bone-nippers. Occlude the radial, ulnar, and the two interosseous arteries. Remember that the posterior interosseous artery lies between the superficial and deep layer of muscles. Provide for drainage, and stitch the flap accurately together, making the line of union vertical, rounding off the angles of the flap made by the ulnar incision, and where the flap is doubled upon itself superiorly.

In the middle of the forearm preserve, if possible, the insertion of the pronator radii teres muscle, and in the upper part the insertions of the biceps and brachialis anticus.

Disarticulation at the Elbow-Joint (circular).—Extend the elbow and abduct the limb. Compress the brachial artery above the middle of the arm.

Measure the circumference of the limb around the joint, to determine the length of the flap. Remember that the line of the articulation is oblique, and is fully one half inch below the internal epicondyle.

Make a circular division of the integument and superficial fascia, as described in the last operation. Raise the flap and roll it up like a cuff above the joint. Forcibly extend the joint, and divide the tissues in front in the line of the joint obliquely downward and inward. Divide the lateral ligaments. Hyperextend the joint and dislocate forward the olecranon. Retract the flap, and divide with a sweep of the knife the triceps tendon.

Occlude the brachial and the profunda arteries. Pull out and cut short the median, ulnar, and mus-

culo-spiral nerves. Bring the flap together vertically, and round off the superior and inferior folded angles. Stitch the apposed edges, providing for drainage.

Amputation through the Arm.—The amputation through the arm by the circular method is performed by following the same general rules already described.

This amputation should also be practiced by the flap method. Compress the vessels above the site of the proposed amputation. Abduct and rotate outward the shoulder-joint. Stand on the right-hand side of the limb.

Grasp the arm one inch below the proposed level of the saw-cut, between the left thumb and index-finger. The thumb should be placed over the biceps, and the index-finger over the triceps muscle, the humerus being situated about midway between. Begin an incision just below the tip of the index-finger, and extend it downward the length of one half the diameter of the limb. Make a similar incision downward, from just below the tip of the thumb. Join the lower ends of these incisions by a transverse incision somewhat convex downward. These incisions should divide the integument and superficial fascia, which will immediately retract. Complete the internal flap by beginning at the level of the retracted integument to cut obliquely to the bone situated between the tips of the thumb and index-finger.

The brachial artery may be caught by means of forceps as soon as it is divided. The base of this internal flap thus formed includes the semi-circumference of the limb. The flap includes the inner borders of the biceps and triceps muscles.

Through the anterior angle of the wound push the point of the amputating-knife across the outer surface of the humerus—the edge of the knife being directed downward. Advance the point of the knife to the posterior angle of the wound, the tissues being pressed external to the track of the knife. Carry the knife downward along the external surface of the humerus with a free sawing movement, supporting the flap with the left hand. When the knife has reached a level about an inch below the extremity of the internal flap, turn its edge perpendicularly toward the surface, and form the extremity of the external flap by cutting directly to the surface.

Retract the flaps, and form a periosteal flap. Clear the bone, being sure that the musculo-spiral nerve is divided. Saw through the bone.

Occlude the brachial and the two profunda arteries. Draw upon the median, ulnar, and musculo-spiral nerves, and cut them off at the wound-surface. Stitch the flaps together, providing for drainage.

Disarticulation at the Shoulder-Joint (Spence).—Place the subject near the edge of the table, with the back raised upon a high block. Compress the vessels in the axilla by the elastic tubing, as already described. Slightly abduct and rotate outward the limb.

Begin an incision, as for resection of the head of the humerus, a little above and external to the coracoid process, and extend it three or four inches downward in the axis of the limb. This incision should divide the tissues down to the bone, uncovering the tendon of the long head of the biceps, and enabling the operator to inspect the shoulder-joint.

From the lower end of this incision make a transverse incision slightly convex downward, dividing all the tissues external to the humerus and extending to the posterior fold of the axilla. This incision cuts through the deltoid muscle just above its insertion.

Begin a second incision at the lower end of the vertical incision, and carry it transversely and slightly convex downward, around the inner side of the limb, to meet the external incision at the posterior axillary fold. This incision should only divide the integument and the subcutaneous fascia.

Elevate the deltoid portion of the flap up to the level of the acromion process. Rotate the limb inward, and, with a forcible sweep of the knife above the greater tuberosity, divide the capsule and the tendons of muscles, opening widely the joint. Rotate the limb outward, and divide the capsule of the joint and the tendon of the subscapularis.

Pass the knife over the head of the humerus to its inner side. Cut downward, following the humerus to the level of the divided integument on the inner side of the limb. Place the thumb between the flap and the humerus, and compress the axillary artery against the fingers of the same hand placed in the axilla. Turn the edge of the knife perpendicularly to the flap and cut straight through the tissues on the inner side of the limb.

AMPUTATIONS AND DISARTICULATIONS OF THE LOWER LIMB.

Amputations and Disarticulations of Toes.—Compress the vessels of the leg during these operations.

The rules given for performing the amputations

and disarticulations of the fingers are applicable to those of the toes. Disarticulations are to be preferred in operating on the toes, with the one exception of amputation through the proximal phalanx of the great toe.

In the disarticulation of the first metatarso-phalangeal joint the pyriform incision should cross the plantar surface of the great toe at least one half inch below the web, on account of the great size of the head of the metatarsal bone. It is preferable to remove the heads of the metatarsal bones after disarticulations.

Amputation and Disarticulation of Metatarsus.—

1. *Amputation.*—Grasp the toes with the left hand, and stand facing the sole of the foot.

Make an incision through the soft parts from one side of the foot to the other, following the groove at the junction of the toes to the sole. Join to the ends of this incision two lateral incisions, one along the inner side of the foot over the first metatarsal bone, and the other along the outer side of the foot over the fifth metatarsal bone. These lateral incisions should extend to the level of the proposed amputation through the metatarsus. Reflect the plantar flap thus marked out, cutting close to the metatarsal bones.

Reflect a dorsal cellulo-cutaneous flap inverse in length to the plantar flap. The dorsal flap should be slightly convex downward, and its base should extend from one side to the other of the base of the plantar flap. Divide the dorsal tendons at the level of the base of the dorsal flap.

Incise the tissues in the interosseous spaces to al-

low four strips of a six-tailed retractor to be passed through the spaces. Retract the flaps and the tissues in the interosseous spaces and saw through the metatarsal bones.

Cut off the protruding part of any tendon and stitch the plantar to the dorsal flap, providing for drainage.

2. *Disarticulation*.—Disarticulation of separate metatarsal bones should be performed by a pyriform incision, as for disarticulation of the proximal phalanx, supplemented by a dorsal incision over the bone up to the level of the tarso-metatarsal joint. Avoid wounding the plantar arch.

In disarticulating the first tarso-metatarsal joint, avoid wounding the communicating branch between the dorsalis pedis and the external plantar artery.

Lisfranc's Operation.—Extend the ankle and grasp the sides of the foot, with the left index-finger and thumb resting over the bases of the fifth (tuberosity) and first metatarsal bones. The base of the first metatarsal bone is situated one and a half inch below the tubercle of the scaphoid.

Cut a dorsal cellulo-cutaneous flap slightly convex downward, whose base shall extend to the middle of the sides of the foot at the level of the tarso-metatarsal articulations. Reflect this dorsal flap.

Grasp the toes in the left hand and flex the ankle, to render the sole of the foot accessible. Join to the ends of the dorsal incision an incision extending down the sides of the foot and across the sole through the center of the balls of the toes. This incision divides all the soft parts, and in crossing the sole is on a level with the heads of the metatarsal bones. The incision

will be slightly convex downward and reach a lower level internally than externally.

Extend the ankle and bear down on the metatarsal bones. Divide the dorsal tendons at the level of the base of the dorsal flap. Begin the disarticulation by carrying the knife around the tuberosity of the fifth metatarsal bone to its inner side, where its articular surface is situated. Disarticulate in a line downward and inward until the knife is arrested by the second metatarsal bone. Disarticulate from the inner side the first tarso-metatarsal joint.

Pierce with the knife, having its edge directed forward, the tissue between the bases of the first and second metatarsal bones, and, by making the handle of the knife describe an arc toward the ankle, divide the attachments of the second metatarsal bone to the first metatarsal and internal cuneiform bones. The same manœuvre is practiced on the other side of the second metatarsal bone. Divide the dorsal ligament between the middle cuneiform and the base of the second metatarsal bone by making transverse parallel cuts at short intervals until the line of the articulation is found.

All resistance is now overcome and the articular surfaces exposed. Sever the inferior attachments to the bones together with the insertion of the peroneus longus into the base of the first metatarsal bone.

Pass a narrow-bladed knife behind and then beneath the disarticulated bases of the metatarsal bones and cut downward, following closely the bones until the plantar flap is completed.

The lateral arching of the metatarsal bones is destroyed by this disarticulation, hence the knife can

follow the bones while piercing the foot from side to side. Occlude the dorsalis pedis, the internal plantar, and external plantar arteries. Stitch the plantar to the dorsal flap, providing for drainage.

Amputation and Disarticulation through the Tarsus.—1. *Amputation.*—Molière and Hancock recommend sawing through the tarsus without considering the line of the articulations.

Form a plantar flap of large size and an inversely large dorsal flap, following Lisfranc's operation as a model. Make the section of the bones as if operating upon a single bone.

2. *Chopart's Operation (Disarticulation at the Medio-tarsal Joint).*—Grasp the sides of the extended foot just posterior to the tubercle of the scaphoid and over a point one inch posterior to the tuberosity of the fifth metatarsal bone between the left thumb and index-finger. Make a short dorsal cellulo-cutaneous flap with its base extending to the middle of the lateral surfaces of the foot at the points over which the left thumb and index-finger are applied. The flap should be slightly convex downward.

Flex the ankle, grasping the toes to present the sole of the foot to the operator. Join the ends of the dorsal incision by an incision extending down the sides of the foot and across the sole just posterior to the balls of the toes. This incision should divide all the tissues down to the bones, and should extend across the sole about one-half inch from the heads of the metatarsal bones.

Reflect the dorsal flap. Forcibly extend the foot and divide the dorsal tendons over the line of the articulations. Disarticulate the bones in a line ex-

tending across the tarsus from half an inch below the peroneal tubercle to a point just above the tubercle of the scaphoid.

Pass a narrow-bladed knife between the disarticulated surfaces and turn its edge toward the toes. Cut the plantar flap, keeping close to the bones.

The plantar flap is often fashioned more symmetrically by including only a portion of the tissues internally, making the internal and external edges of equal thickness.

Occlude the dorsalis pedis, internal plantar, and the external plantar arteries.

Disarticulation at the Ankle-Joint (Syme's Operation).—Grasp the foot with the left hand and flex the ankle until the foot is at a right angle with the leg.

Begin an incision at the tip of the external malleolus and extend it downward and across the sole of the foot to a corresponding point on the inner side of the limb. The incision will terminate at a point a little below the posterior border of the inner malleolus, and should divide all the tissues to the bone.

Connect the ends of this incision by an incision across the instep in a line which bisects the angle made by the foot and leg. This incision should only divide the skin and subcutaneous fascia.

Raise the heel-flap, keeping the edge of the knife always directed toward the os calcis and using the left thumb in the wound to push back the flap. Avoid wounding the posterior tibial artery. Separate the attachment of the tendo Achillis and reflect the flap over the tuberosity of the os calcis.

Forcibly extend the ankle, and having raised the

skin and cellular tissue, cut the tendons anteriorly in the line of the joint. The bones may now be cleared at a level just above the ankle-joint and the two malleoli with a thin slice of the tibia sawn off at a right angle to the axis of the leg.

The joint may be disarticulated by dividing the ligaments anteriorly and around the malleoli, and only the malleoli sawn off obliquely upward. If the joint is to be disarticulated, it may be done before the heel-flap is raised, and then the flap separated from above downward.

Occlude the anterior tibial, external plantar, and internal plantar arteries. Cut off any protruding tendon. Make a longitudinal slit one half inch long through the posterior thin part of the flap, just external to the tendo Achillis. Cover the ends of the bone with the heel-flap, providing for drainage on each side and posteriorly.

Pirogoff's Operation.—Flex the ankle so that the foot is brought to a right angle with the leg.

Make an incision from the tip of one malleolus across the sole of the foot to the tip of the other malleolus dividing the tissues to the bone. Join the ends of this incision by an incision across the instep, at an angle of 45° to the axis of the leg, dividing the integument and cellular tissue.

Reflect the short dorsal flap, and forcibly extend the ankle. Divide the dorsal tendons and disarticulate the joint.

Separate from above downward the tissues from the os calcis, until the sustentaculum tali is uncovered. Saw the os calcis obliquely, from just behind the astragalus to the edge of the incision through the soft

parts across the sole of the foot. Clear the bones to a level just above the joint, and saw off the malleoli and a thin slice of the tibia.

Occlude the anterior tibial, external plantar, and the internal plantar arteries. Cut off any protruding tendon. Wire the retained portion of the os calcis to the end of the tibia. Provide for drainage, and close the wound as in the case of Syme's operation.

The os calcis may be sawn through from below upward and backward, the dorsal flap raised, and the malleoli sawn off without disarticulating the ankle.

It is of advantage to make the incision across the sole more anteriorly, when a greater portion of the os calcis is preserved in its oblique section.

If the dorsal and plantar incisions are made broadly convex downward to the level of the mediotarsal joint, the os calcis may be sawn through horizontally just below the sustentaculum tali, as recommended by Le Fort. When the section of the os calcis is complete, the joint between the cuboid and os calcis is disarticulated. The stump has a broad base already accustomed to pressure.

Amputations through the Leg.—The circular method of amputating may be practiced, the rules for which have already been considered.

Teale's Operation.—Compress the vessels above the site of the operation. Stand on the right side of the limb. Measure the circumference of the limb at the proposed site of the amputation.

Make an anterior *square* flap, whose sides are equal to one half this circumference. (The flap will, of course, include more than half of the circumfer-

ence of the limb below.) Reflect the flap, which should include all the tissues anterior to the bones and to the interosseous membrane. Avoid nicking the anterior tibial artery, while separating the tissues from the interosseous membrane.

A periosteal flap may be formed for the tibia and raised with the anterior flap.

Connect the sides of the anterior flap at a quarter of its length from its base, by a transverse incision through all the tissues posterior to the bones. Reflect this posterior, rectangular flap, the base of which is one half and the length one eighth the circumference of the limb.

Form an interosseous flap, and retract the tissues by means of a three-tailed retractor. Clear the bones at the junction of the flaps, and begin the section of the tibia at a right angle to its long axis. Complete the section of the fibula while sawing through the tibia. Some prefer the section of the fibula at a little higher level.

Occlude the anterior tibial, the posterior tibial, and the peroneal arteries. Cut off any protruding tendon and pull out and divide the anterior tibial nerve as high up as possible. The angle formed by the crest of the tibia may be rounded off by means of bone-nippers. Double the anterior flap upon itself over the ends of the bones, and stitch together the contiguous edges of the flaps, providing for drainage.

In amputations near the knee, preserve the tubercle of the tibia, and avoid opening into the superior tibio-fibular articulation, which may communicate with the knee-joint.

Disarticulation at the Knee-Joint (Circular Meth-

od).—Extend the knee, and compress the vessels above the site of the operation.

Form a circular, cellulo-cutaneous flap, the length of one quarter the circumference of the limb over the joint. The incision will be made about one inch below the level of the tubercle of the tibia. Slit the flap posteriorly, and roll it upward like a cuff.

Flex the knee, and divide the ligamentum patellæ close to the patella, and the capsule of the joint against the condyles of the femur. Sever the lateral ligaments completely, by cutting to the posterior surface of the condyles, and divide the crucial ligaments as they appear in the interior of the joint.

Divide from behind forward, the tissues posteriorly, against the upper extremity of the tibia, about half an inch below the level of the joint. Pass the knife through the joint to divide the posterior ligament, and direct its edge downward along the posterior surface of the head of the tibia, to complete the operation.

Occlude the popliteal artery and vein. Push a director into the synovial pouch above the patella, to its upper and inner limit, and cut down upon the end of the director to make an opening to admit a large drainage-tube.

Bring the edges of the flap together antero-posteriorly; round off the lower angles formed by slitting, and the upper by doubling the flap, and enter the sutures after providing for drainage, above and below.

Bauden's Operation.—Extend the knee and control the vessels above.

Make an oval incision around the limb from one

inch below the tubercle of the tibia anteriorly, to one half inch above the level of the head of the tibia posteriorly. The incision should extend almost transversely across the limb below, so as to form a broad end to the flap.

Reflect the flap up to the ligamentum patellæ. Semiflex the knee, and divide the ligamentum patellæ, the capsule, and the lateral ligaments, to open widely the joint. Sever the crucial ligaments. Pass the knife between the ends of the bones and divide the tissues posteriorly, cutting downward and then backward.

Occlude the popliteal artery and vein. Provide for drainage from the joint-cavity above, and internal to the patella, as in the last operation. Cover the end of the femur with the flap, and stitch the edges of the wound together, providing for drainage.

Amputations through the Thigh (Carden's Operation).—Control the vessels above, and extend the knee-joint; stand on the right-hand side of the limb. Grasp the femur over the condyles between the left index-finger and thumb.

Begin an incision through the skin and cellular tissue at the posterior and lower border of the condyle, over which the index-finger rests, and extend it downward, in a broad, convex curve, below the patella, and then upward to a corresponding point over the other condyle, over which the thumb has been placed. The end of the flap should extend to the tubercle of the tibia, and should be very broad. Reflect the flap up to the ligamentum patellæ. Flex the knee-joint, and divide the ligamentum patellæ, the capsule of the joint, and the lateral ligaments.

The joint can now be examined, as was the case after the first incision of Spence's operation at the shoulder.

Sever the crucial ligaments. Pass the knife through the joint, then extend the joint, and divide the tissues posteriorly, cutting directly backward, thus forming no posterior flap. (The operation is often modified by forming a short posterior flap.)

Grasp the end of the femur by means of lion-forceps and saw the bone through the condyles. The bone may be sawn through without disarticulating the posterior tissues, being cut from behind forward. The patella may be dissected out of its capsule.

Occlude the popliteal artery and vein by separate ligatures. Close the wound, providing for drainage.

Gritti's Operation.—A rectangular flap, instead of a convex flap, is fashioned from the front of the limb as in Carden's operation. The femur is divided just above the condyles, and the cartilaginous surface of the patella is sawn off.

The sawn surface of the patella is applied to that of the femur, as in Pirogoff's osteo-plastic operation at the ankle.

Circular Method.—This method of amputation should be practiced, following the rules already discussed. The muscles should be divided fully an inch below the base of the flap, on account of their great contraction.

Lister's Operation.—Control the vessels of the thigh, above the site of the operation. Extend the limb. Measure the circumference of the thigh at the site of the proposed amputation.

Raise an anterior convex flap, consisting of integument, and a moderately thick layer of muscular tissue, the length of two thirds the measurement of the circumference of the limb. Reflect a posterior cellululo-cutaneous convex flap, one third the circumference of the limb in length.

Divide the remainder of the soft parts circularly. Provide a periosteal flap and retract the tissues about two inches. Saw the bone. Occlude the femoral and profunda arteries.

Esmarch's Operation.—Raise two lateral flaps of moderate length. Divide all the soft parts circularly to the bone. Push up the periosteum to the extent of an inch or more, and saw through the bone.

Suture the periosteal flap over the end of the bone, and then the muscles together by means of buried sutures. Suture the flaps together, making no provision for drainage.

Disarticulation at the Hip-Joint.—Bring the nates over the edge of the table; control the vessels as described by means of the elastic tubing (Lloyd).

Jordan's Operation.—Hold the thigh at an angle of 45° with the axis of the body. Begin an incision three inches above the middle of the upper border of the great trochanter, and continue it downward, along the outer surface of the thigh, dividing all the tissues to the bone. Separate the periosteum from the bone down to the proposed level of division of the soft parts (Ollier).

Disarticulate the hip-joint as in resection. Divide the soft parts by the circular method at as low a level as possible. Occlude the femoral and profunda arteries.

This method of amputating is applicable to the shoulder-joint.

Transfixion (Liston).—Place the subject so that the nates project beyond the table. Abduct the opposite limb, and lift up the scrotum. Slightly flex the hip-joint, and rotate the limb inward.

On the left side transfix the tissues in front of the joint, from a point midway between the anterior superior spine of the ilium and the great trochanter, to a point anterior to the tuberosity of the ischium. Guard against piercing through the foramen ovale. On the right side, the point of the knife is entered anterior to the tuber ischii.

Cut downward, following the bone closely, for five or six inches. (An assistant can now pass his fingers under the flap, and press the vessels against his thumbs, placed over the flap.) Turn the edge of the knife perpendicularly to the flap, and cut directly to the surface.

Abduct and rotate strongly outward the joint. The capsule may have been opened by the first thrust of the knife. Divide the capsule, and partially dislocate the head of the femur, when the ligamentum teres can be divided, and the disarticulation completed.

Pass the knife behind the head of the bone. Adduct and rotate inward, when the trochanter major will not interfere with the formation of a posterior flap four or five inches in length.

(Guthrie cuts the flaps from the surface toward the bone.)

Occlude the femoral vessels, the profunda, the obturator, and sciatic arteries.

INDEX.

- Abdominis, paracentesis, 12.
 Adductor longus, tenotomy of, 72.
 Amputation of arm, 131.
 of forearm, 129.
 of leg, 140.
 of metatarsus, 134.
 of penis, 63.
 of proximal phalanx, 126.
 of second phalanx, 125.
 of tarsus, 134.
 of thigh, 143.
 of toes, 133.
 Ankle, disarticulation at, 138.
 Antrum, perforation of, 34.
 Arm, amputation through, 131.
 Arteriotomy, 101.
 Artery, ligation of axillary, 82.
 brachial, 81.
 common carotid, 85.
 external carotid, 88.
 internal carotid, 87.
 deep epigastric, 94.
 facial, 89.
 femoral, 95.
 gluteal, 92.
 common iliac, 90.
 external iliac, 94.
 internal iliac, 92.
 lingual, 89.
 occipital, 90.
 dorsalis pedis, 100.
 peroneal, 99.
 popliteal, 97.
 internal pudic, 93.
 radial, 80.
 sciatic, 93.
 subclavian, 83.
 temporal, 90.
 superior thyroid, 88.
 anterior tibial, 99.
 posterior tibial, 98.
 ulnar, 81.
 vertebral, 84.
 Aspiration (Dieulafoy), 15.
 Aural specula (Gruber and Toynbee), 1.
 Axillary artery, ligation of, 82.
 Bauden's operation, 142.
 Bones, wiring of, 105.
 Bougies, œsophageal, 5.
 rectal, 8.
 Brachial artery, ligation of, 81.
 Bronchotomy, 37.
 Canalization, 20.
 Carden's operation, 143.
 Carotid artery, ligation of common, 85.
 external, 88.
 internal, 87.
 Castration, 65.
 Catheterization of Eustachian canal, 3.
 of larynx, 4.
 of urethra, 5.
 of posterior urethra, 61.
 Catheter, tunneled, 7.
 Chopart's operation, 137.
 Circumcision, 62.
 Colectomy, 49.
 Colostomy, lumbar, 49.
 Compression of vessels, 76.
 Corneal paracentesis, 10.
 Cystotomy, lateral perineal, 58.
 median perineal, 57.
 suprapubic, 60.
 Disarticulation at ankle-joint, 138.
 at elbow, 130.
 at hip, 145.
 at knee, 141.
 at metatarsus, 134.
 of distal phalanx, 124.
 of proximal phalanx, 126.
 of second phalanx, 125.
 of tarsus, 137.
 of toes, 133.
 of wrist, 127.
 Drainage, 20.
 Dubreuil's operation, 128.

- Elbow, disarticulation at, 130.
 Enterectomy, 46.
 Enterorrhaphy, 46.
 Enterostomy, with enterotomy or enterectomy, 48.
 Enterotomy, 47.
 Epigastric artery, ligation of deep, 94.
 Esmarch's operation, 145.
 Eustachian catheter (Noyes), 3.
 Excision of breast, 43.
 of eye, 32.
 of inferior maxilla, 109.
 of superior maxilla, 106.
 of tongue, 35.
 Extensor communis digitorum, tenotomy of, 69.
 longus digitorum pedis, tenotomy of, 70.
 quadriceps femoris, tenotomy of, 71.
 primi and secundi internodii pollicis, 69.
 Extraction of teeth, 32.
 Eye, excision of, 32.

 Facial artery, ligation of, 89.
 Fasciatomy, plantar fascia, 72.
 Femoral artery, ligation of, 95.
 Flexor cubiti, tenotomy of biceps, 69.
 carpi radialis, tenotomy of, 69.
 carpi ulnaris, tenotomy of, 69.
 longus and brevis digitorum, tenotomy of, 69.
 profundus digitorum, tenotomy of, 68.
 sublimis digitorum, tenotomy of, 68.
 biceps femoris, tenotomy of, 71.
 biceps femoris, suture of tendon, 72.
 pollicis longus, tenotomy of, 68.
 Forearm, amputation through, 129.

 Gluteal artery, ligation of, 92.
 Gritti's operation, 144.

 Hip, disarticulation at, 145.
 Hypodermic needle, 15.

 Iliac artery, ligation of common, 90.
 external, 94.
 internal, 92.
 Intubation of larynx (O'Dwyer's tubes), 4.

 Joint, resection at ankle, 120.
 elbow, 114.
 hip, 118.
 knee, 119.
 metacarpo-phalangeal, 117.
 phalangeal, 117.

 Joint, resection at shoulder, 112.
 wrist, 115.
 Jordan's operation, 145.

 Knee, disarticulation at, 141.
 Knife, manipulation of amputating, 122.
 Knot, reef, 27.
 surgeon's, 27.

 Laparotomy, median, 44.
 Laryngotomy, 38.
 Laryngo-tracheotomy, 39.
 Larynx, catheterization of, 4.
 intubation of (O'Dwyer's tubes), 4.
 Leg, amputation through, 140.
 Ligaments, shortening of round, 64.
 Ligation of arteries, 80.
 of vessels, 77.
 Lingual artery, ligation of, 89.
 nerve, neurotomy of, 73.
 Lisfranc's operation, 135.
 Lister's operation, 144.
 Liston's operation, 146.

 Mammary gland, excision of, 43.
 Maxilla, excision of superior, 109.
 of inferior, 106.
 Median nerve, suturing of, 74.
 Metatarsus, amputation and disarticulation of, 134.

 Nares, plugging of posterior, 8.
 Nasal duct, probing of, 4.
 specula (Fraenkel), 1.
 Needle, hypodermic, 15.
 Nephrectomy, 52.
 Nephorrhaphy, 51.
 Nephrotomy, 52.
 Neurectomy of spinal accessory, 73.
 Neurotomy of lingual, 73.
 Nerve, stretching of great sciatic, 74.
 suturing of median, 74.

 Occipital artery, ligation of, 90.
 Œsophageal probang or bougie, 5.
 Œsophagotomy, external, 41.
 Oöphorectomy, 65.
 Operations, steps in, 123.
 Osteotomy, 104.

 Paracentesis abdominis, 12.
 corneæ, 10.
 pericardii, 11.
 thoracis, 11.
 tympani, 10.
 urethræ, 14.
 vesicæ, 12.

- Pedis, ligation of dorsalis, 100.
 Penis, amputation of, 63.
 Pericardii, paracentesis, 11.
 Perineal cystotomy, lateral, 58.
 cystotomy, median, 57.
 urethrotomy, external, 54.
 Peroneal artery, ligation of, 99.
 Peroneus longus and brevis, tenotomy of, 70.
 Phalanx, disarticulation of distal, 124.
 proximal, 126.
 second, 125.
 Pharyngotomy, 42.
 Phlebotomy, 100.
 Pirogoff's operation, 139.
 Plantar fascia, fasciatomy of, 72.
 Popliteal artery, ligation of, 97.
 Probing nasal duct, 4.
 Pudic internal artery, ligation of, 93.

 Radial artery, ligation of, 80.
 Rectal bougie, 8.
 specula, 3.
 Resection at ankle, 120.
 bones, articulating ends, 112.
 elbow, 114.
 hip, 118.
 knee, 119.
 metacarpo-phalangeal, 117.
 phalangeal, 117.
 of rib, 111.
 of scrotum, 61.
 shoulder, 112.
 wrist, 115.
 Rib, resection of, 111.

 Saw, manipulation of, 103.
 Scalpel, manipulation of, 17.
 Sciatic artery, ligation of, 93.
 nerve, great, stretching of, 74.
 Scrotum, resection of, 61.
 Semimembranosus and semitendinosus, tenotomy of, 71.
 Shoulder (Spence), disarticulation at, 132.
 Sounding for stone, 55.
 Sounds, tunneled, 7.
 Specula, aural (Gruber, Toynbee), 1.
 nasal (Fraenkel), 1.
 rectal, 3.
 vaginal (Fergusson's, Sims's), 2.
 Spinal accessory, neurectomy of, 73.
 Sterno-cleido-mastoid, tenotomy of, 67.
 Stomach-tube, 5.
 Stone, sounding for, 55.
 Strabismus, 30.
 Subclavian artery, ligation of, 83.

 Suprapubic cystotomy, 60.
 Suture, continuous or glover's, 21.
 Czerny's, 27.
 double continuous, 26.
 Gely's, 25.
 interrupted, 21.
 Jobert's, 26.
 Lembert's, 24.
 quilled, 22.
 quilt or fold, 23.
 twisted, 23.
 Syme's operation, 138.
 Symphysiotomy, 52.
 Syringe, aural, 1.
 rectal, 3.

 Tarsus, amputation and disarticulation through, 137.
 Teale's operation, 140.
 Teeth, extraction of, 32.
 Temporal artery, ligation of, 90.
 Tendo Achillis, tenotomy of, 70.
 Tendon suturing, flexor biceps femoris, 72.
 Tenotome, manipulation of, 67.
 Tenotomy of adductor longus, 72.
 of flexor carpi radialis, 69.
 of flexor carpi ulnaris, 69.
 of flexor biceps cubiti, 69.
 of extensor communis digitorum, 69.
 of flexor longus and brevis digitorum, 69.
 of flexor sublimis and profundus digitorum, 68.
 of extensor longus pedis digitorum, 70.
 of flexor biceps femoris, 71.
 of quadriceps extensor femoris, 71.
 of longus hallucis, 69.
 of peroneus longus and brevis, 70.
 of flexor longus pollicis, 68.
 of primi and secundi internodii pollicis, 69.
 of semitendinosus and semimembranosus, 71.
 of sterno-cleido-mastoid, 67.
 of tendo Achillis, 70.
 of tibialis anticus, 70.
 of tibialis posticus, 70.
 Thigh, amputation through, 143.
 Thoracis, paracentesis, 11.
 Thyroid artery, ligation of superior, 88.
 Thyrotomy, 37.
 Tibialis artery, ligation of anterior, 99.
 anticus, tenotomy of, 70.
 posterior artery, ligation of, 98.
 posticus, tenotomy of, 70.

- | | |
|--|---|
| Toes, amputation and disarticulation of, 133.
Tongue, excision of, 35.
Torsion of vessels, 77.
Tracheotomy, 39.
Transfusion, 101.
Trepining, 28.
Tunneled sounds or catheters, 7.
Tympani, paracentesis, 10.

Ulnar artery, ligation of, 81.
Urethra, catheterization of, 5.
paracentesis of, 14. | Urethrotomy, perineal external, 54.

Vaginal specula (Fergusson's, Sims's),
2.
Vertebral artery, ligation of, 84.
Vesicæ, paracentesis, 12.
Vessels, compression of, 76.
ligation of, 77.
torsion of, 77.

Wiring of bones, 105.
Wrist, disarticulation at, 127. |
|--|---|

THE END.

MEDICAL

AND

HYGIENIC WORKS

PUBLISHED BY

D. APPLETON & CO., 1, 3, & 5 Bond Street, New York.

BARKER (FORDYCE). On Sea-Sickness. A Popular Treatise for Travelers and the General Reader. Small 12mo. Cloth, 75 cents.

BARKER (FORDYCE). On Puerperal Disease. Clinical Lectures delivered at Bellevue Hospital. A Course of Lectures valuable alike to the Student and the Practitioner. Third edition. 8vo. Cloth, \$5.00; sheep, \$6.00.

BARTHOLOW (ROBERTS). A Treatise on Materia Medica and Therapeutics. **Sixth edition.** Revised, enlarged, and adapted to "The New Pharmacopœia." 8vo. Cloth, \$5.00; sheep, \$6.00.

BARTHOLOW (ROBERTS). A Treatise on the Practice of Medicine, for the Use of Students and Practitioners. **Sixth edition,** revised and enlarged. 8vo. Cloth, \$5.00; sheep, \$6.00.

BARTHOLOW (ROBERTS). On the Antagonism between Medicines and between Remedies and Diseases. Being the Cartwright Lectures for the Year 1880. 8vo. Cloth, \$1.25.

BASTIAN (H. CHARLTON). Paralysis: Cerebral, Bulbar, and Spinal. Illustrated. Small 8vo. Cloth, \$4.50.

BASTIAN (H. CHARLTON). The Brain as an Organ of the Mind. 12mo. Cloth, \$2.50.

BELLEVUE AND CHARITY HOSPITAL REPORTS. Edited by W. A. Hammond, M. D. 8vo. Cloth, \$4.00.

BENNET (J. H.). On the Treatment of Pulmonary Consumption, by Hygiene, Climate, and Medicine. Thin 8vo. Cloth, \$1.50.

BILLINGS (F. S.). The Relation of Animal Diseases to the Public Health, and their Prevention. 8vo. Cloth, \$4.00.

BILLROTH (THEODOR). General Surgical Pathology and Therapeutics. A Text-Book for Students and Physicians. Translated from the tenth German edition, by special permission of the author, by Charles E. Hackley, M. D. **Fifth American edition, revised and enlarged.** 8vo. Cloth, \$5.00; sheep, \$6.00.

BRAMWELL (BYROM). Diseases of the Heart and Thoracic Aorta. Illustrated with 226 Wood-Engravings and 68 Lithograph Plates—showing 91 Figures—in all 317 Illustrations. 8vo. Cloth, \$8.00; sheep, \$9.00.

BRYANT (JOSEPH D.). A Manual of Operative Surgery. **New edition, revised and enlarged.** 793 Illustrations. 8vo. Cloth, \$5.00; sheep, \$6.00.

- BUCK (GURDON). Contributions to Reparative Surgery, showing its Application to the Treatment of Deformities produced by Destructive Disease or Injury; Congenital Defects from Arrest or Excess of Development; and Cicatricial Contractions following Burns. Illustrated by Thirty Cases and fine Engravings. 8vo. Cloth, \$3.00.
- CARPENTER (W. B.). Principles of Mental Physiology, with their Application to the Training and Discipline of the Mind, and the Study of its Morbid Conditions. 12mo. Cloth, \$3.00.
- CARTER (ALFRED H.). Elements of Practical Medicine. **Third edition**, revised and enlarged. 12mo. Cloth, \$3.00.
- CHAUVEAU (A.). The Comparative Anatomy of the Domesticated Animals. Translated and edited by George Fleming. Illustrated. 8vo. Cloth, \$6.00.
- COMBE (ANDREW). The Management of Infancy, Physiological and Moral. Revised and edited by Sir James Clark. 12mo. Cloth, \$1.50.
- COOLEY. Cyclopædia of Practical Receipts, and Collateral Information in the Arts, Manufactures, Professions, and Trades, including Medicine, Pharmacy, and Domestic Economy. Designed as a Comprehensive Supplement to the Pharmacopœia, and General Book of Reference for the Manufacturer, Tradesman, Amateur, and Heads of Families. **Sixth edition**, revised and partly rewritten by Richard V. Tuson. With Illustrations. 2 vols., 8vo. Cloth, \$9.00.
- CORNING (J. L.). Brain Exhaustion, with some Preliminary Considerations on Cerebral Dynamics. Crown 8vo. Cloth, \$2.00.
- CORNING (J. L.). Local Anæsthesia in General Medicine and Surgery. Being the Practical Application of the Author's Recent Discoveries. With Illustrations. Small 8vo. Cloth, \$1.25.
- DAVIS (HENRY G.). Conservative Surgery. With Illustrations. 8vo. Cloth, \$3.00.
- ELLIOT (GEORGE T.). Obstetric Clinic: A Practical Contribution to the Study of Obstetrics and the Diseases of Women and Children. 8vo. Cloth, \$4.50.
- EVETZKY (ETIENNE). The Physiological and Therapeutical Action of Ergot. Being the Joseph Mather Smith Prize Essay for 1881. 8vo. Limp cloth, \$1.00.
- FLINT (AUSTIN). Medical Ethics and Etiquette. Commentaries on the National Code of Ethics. 12mo. Cloth, 60 cents.
- FLINT (AUSTIN). Medicine of the Future. An Address prepared for the Annual Meeting of the British Medical Association in 1886. With Portrait of Dr. Flint. 12mo. Cloth, \$1.00.
- FLINT (AUSTIN, JR.). Text-Book of Human Physiology; designed for the Use of Practitioners and Students of Medicine. Illustrated by three Lithographic Plates, and three hundred and thirteen Woodcuts. **Third edition, revised.** Imperial 8vo. Cloth, \$6.00; sheep, \$7.00.
- FLINT (AUSTIN JR.). The Physiological Effects of Severe and Protracted Muscular Exercise; with Special Reference to its Influence upon the Excretion of Nitrogen. 12mo. Cloth, \$1.00.
- FLINT (AUSTIN, JR.). Physiology of Man. Designed to represent the Existing State of Physiological Science as applied to the Functions of the Human Body. Complete in 5 vols.
 Vol. I. Introduction; The Blood; Circulation; Respiration. 8vo.
 Vol. II. Alimentation; Digestion; Absorption; Lymph; and Chyle. 8vo.

Vol. III. Secretion; Excretion; Ductless Glands; Nutrition; Animal Heat; Movements; Voice and Speech. 8vo.

Vol. IV. The Nervous System. 8vo.

Vol. V. (With a General Index to the five volumes.) Special Senses; Generation. Per vol., cloth, \$4.50; sheep, \$5.50.

** Vols. I and II can be had in cloth and sheep binding; Vol. III in sheep only. Vol. IV is at present out of print.

FLINT (AUSTIN, JR.). The Source of Muscular Power. Arguments and Conclusions drawn from Observation upon the Human Subject under Conditions of Rest and of Muscular Exercise. 12mo. Cloth, \$1.00.

FLINT (AUSTIN, JR.). Manual of Chemical Examinations of the Urine in Disease; with Brief Directions for the Examination of the most Common Varieties of Urinary Calculi. Revised edition. 12mo. Cloth, \$1.00.

FOTHERGILL (J. MILNER). Diseases of Sedentary and Advanced Life. 8vo. Cloth, \$2.00.

FOURNIER (ALFRED). Syphilis and Marriage. Translated by P. Albert Morrow, M. D. 8vo. Cloth, \$2.00; sheep, \$3.00.

FREY (HEINRICH). The Histology and Histochemistry of Man. A Treatise on the Elements of Composition and Structure of the Human Body. Translated from the fourth German edition by Arthur E. J. Barker, M. D., and revised by the author. With 608 Engravings on Wood. 8vo. Cloth, \$5.00; sheep, \$6.00.

FRIEDLANDER (CARL). The Use of the Microscope in Clinical and Pathological Examinations. Second edition, enlarged and improved, with a Chromo-lithograph Plate. Translated, with the permission of the author, by Henry C. Coe, M. D. 8vo. Cloth, \$1.00.

GAMGEE (JOHN). Yellow Fever a Nautical Disease. Its Origin and Prevention. 8vo. Cloth, \$1.50.

GARMANY (JASPER J.). Operative Surgery on the Cadaver. (*In press.*)

GERSTER (ARPAD G.). The Rules of Aseptic and Antiseptic Surgery. A Practical Treatise for the Use of Students and the General Practitioner. 8vo. Illustrated with over two hundred fine Engravings. (*In press.*)

GROSS (SAMUEL W.). A Practical Treatise on Tumors of the Mammary Gland. Illustrated. 8vo. Cloth, \$2.50.

GUTMANN (EDWARD). The Watering-Places and Mineral Springs of Germany, Austria, and Switzerland. Illustrated. 12mo. Cloth, \$2.50.

GYNÆCOLOGICAL TRANSACTIONS. 8vo. Cloth, per volume, \$5.00.

Vol. VIII. Being the Proceedings of the Eighth Annual Meeting of the American Gynæcological Society, held in Philadelphia, September 18, 19, and 20, 1883.

Vol. IX. Being the Proceedings of the Ninth Annual Meeting of the American Gynæcological Society, held in Chicago, September 30, and October 1 and 2, 1884.

Vol. X. Being the Proceedings of the Tenth Annual Meeting of the American Gynæcological Society, held in Washington, D. C., September 22, 23, and 24, 1885.

Vol. XI. Being the Proceedings of the Eleventh Annual Meeting of the American Gynæcological Society, held in Baltimore, Maryland, September, 21, 22, and 23, 1886.

- HAMILTON (ALLAN McL.). Clinical Electro-Therapeutics, Medical and Surgical. A Hand-Book for Physicians in the Treatment of Nervous and other Diseases. 8vo. Cloth, \$2.00.
- HAMMOND (W. A.). A Treatise on Diseases of the Nervous System. **Eighth edition**, rewritten, enlarged, and improved. 8vo. Cloth, \$5.00; sheep, \$6.00.
- HAMMOND (W. A.). A Treatise on Insanity, in its Medical Relations. 8vo. Cloth, \$5.00; sheep, \$6.00.
- HAMMOND (W. A.). Clinical Lectures on Diseases of the Nervous System. Delivered at Bellevue Hospital Medical College. Edited by T. M. B. Cross, M. D. 8vo. Cloth, \$3.50.
- HART (D. BERRY). Atlas of Female Pelvic Anatomy. With Preface by Alexander J. C. Skene, M. D. 37 Plates with 150 Figures, and 89 pages descriptive text. Large 4to. Cloth, \$15.00. (*Sold only by subscription.*)
- HARVEY (A.). First Lines of Therapeutics. 12mo. Cloth, \$1.50.
- HOFFMANN-ULTZMANN. Analysis of the Urine, with Special Reference to Diseases of the Urinary Apparatus. By M. B. Hoffmann, Professor in the University of Gratz; and R. Ultzmann, Tutor in the University of Vienna. **Second enlarged and improved edition.** 8vo. Cloth, \$2 00.
- HOWE (JOSEPH W.). Emergencies, and how to treat them. Fourth edition, revised. 8vo. Cloth, \$2.50.
- HOWE (JOSEPH W.). The Breath, and the Diseases which give it a Fetid Odor. With Directions for Treatment. **Second edition**, revised and corrected. 12mo. Cloth, \$1.00.
- HUEPPE (FERDINAND). The Methods of Bacteriological Investigation. Written at the request of Dr. Robert Koch. Translated by Hermann M. Biggs, M. D. Illustrated. 8vo. Cloth, \$2.50.
- HUXLEY (T. H.). The Anatomy of Vertebrated Animals. Illustrated. 12mo. Cloth, \$2.50.
- HUXLEY (THOMAS HENRY). The Anatomy of Invertebrated Animals Illustrated. 12mo. Cloth, \$2.50.
- JACCOUD (S.). The Curability and Treatment of Pulmonary Phthisis. Translated and edited by Montagu Lubbock, M. D. 8vo. Cloth, \$4.00.
- JONES (H. MACNAUGHTON). Practical Manual of Diseases of Women and Uterine Therapeutics. For Students and Practitioners. 188 Illustrations. 12mo. Cloth, \$3.00.
- KEYES (E. L.). The Tonic Treatment of Syphilis, including Local Treatment of Lesions. 8vo. Cloth, \$1.00.
- KINGSLEY (N. W.). A Treatise on Oral Deformities as a Branch of Mechanical Surgery. With over 350 Illustrations. 8vo. Cloth, \$5.00; sheep, \$6.00.
- LEGG (J. WICKHAM). On the Bile, Jaundice, and Bilious Diseases. With Illustrations in Chromo-Lithography. 8vo. Cloth, \$6.00; sheep, \$7.00.
- LITTLE (W. J.). Medical and Surgical Aspects of In-Knee (Genu-Valgum): its Relation to Rickets, its Prevention, and its Treatment, with and without Surgical Operation. Illustrated by upward of Fifty Figures and Diagrams. 8vo. Cloth, \$2.00.

- LORING (EDWARD G.). A Text-Book of Ophthalmoscopy. Part I. The Normal Eye, Determination of Refraction, and Diseases of the Media. With 131 Illustrations, and 4 Chromo-Lithographs. 8vo. Cloth, \$5.00.
- LUSK (WILLIAM T.). The Science and Art of Midwifery. With 246 Illustrations. **Second edition, revised and enlarged.** 8vo. Cloth, \$5.00; sheep, \$6.00.
- LUYS (J.). The Brain and its Functions. With Illustrations. 12mo. Cloth, \$1.50.
- MARKOE (T. M.). A Treatise on Diseases of the Bones. With Illustrations. 8vo. Cloth, \$4.50.
- MAUDSLEY (HENRY). Body and Mind: an Inquiry into their Connection and Mutual Influence, specially in reference to Mental Disorders. An enlarged and revised edition, to which are added Psychological Essays. 12mo. Cloth, \$1.50.
- MAUDSLEY (HENRY). Physiology of the Mind. Being the first part of a third edition, revised, enlarged, and in great part rewritten, of "The Physiology and Pathology of the Mind." 12mo. Cloth, \$2.00.
- MAUDSLEY (HENRY). Pathology of the Mind. Third edition. 12mo. Cloth, \$2.00.
- MAUDSLEY (HENRY). Responsibility in Mental Disease. 12mo. Cloth, \$1.50.
- NEFTTEL (WM. B.). Galvano-Therapeutics. The Physiological and Therapeutical Action of the Galvanic Current upon the Acoustic, Optic, Sympathetic, and Pneumogastric Nerves. 12mo. Cloth, \$1.50.
- NEUMANN (ISIDOR). Hand-Book of Skin Diseases. Translated by Lucius D. Bulkley, M. D. Illustrated by 66 Wood-Engravings. 8vo. Cloth, \$4.00; sheep, \$5.00.
- THE NEW YORK MEDICAL JOURNAL (weekly). Edited by Frank P. Foster, M. D. Terms per annum, \$5.00.
- GENERAL INDEX, from April, 1865, to June, 1876 (23 vols.) 8vo. Cloth, 75 cents.
- NIEMEYER (FELIX VON). A Text-Book of Practical Medicine, with particular reference to Physiology and Pathological Anatomy. Containing all the author's Additions and Revisions in the eighth and last German edition. Translated by George H. Humphreys, M. D., and Charles E. Hackley, M. D. 2 vols., 8vo. Cloth, \$9.00; sheep, \$11.00.
- NIGHTINGALE'S (FLORENCE). Notes on Nursing. 12mo. Cloth, 75 cents.
- PEASLEE (E. R.). A Treatise on Ovarian Tumors: their Pathology, Diagnosis, and Treatment, with reference especially to Ovariectomy. With Illustrations. 8vo. Cloth, \$5.00; sheep, \$6.00.
- PEREIRA'S (Dr.) Elements of Materia Medica and Therapeutics. Abridged and adapted for the Use of Medical and Pharmaceutical Practitioners and Students, and comprising all the Medicines of the British Pharmacopœia, with such others as are frequently ordered in Prescriptions, or required by the Physician. Edited by Robert Bentley and Theophilus Redwood. Royal 8vo. Cloth, \$7.00; sheep, \$8.00.

- PEYER (ALEXANDER). An Atlas of Clinical Microscopy. Translated and edited by Alfred C. Girard, M.D. First American, from the manuscript of the second German edition, with Additions. Ninety Plates, with 105 Illustrations, Chromo-Lithographs. Square 8vo. Cloth, \$6.00.
- POMEROY (OREN D.). The Diagnosis and Treatment of Diseases of the Ear. With One Hundred Illustrations. **Second edition**, revised and enlarged. 8vo. Cloth, \$3.00.
- POORE (C. T.). Osteotomy and Osteoclasia, for the Correction of Deformities of the Lower Limbs. 50 Illustrations. 8vo. Cloth, \$2.50.
- QUAIN (RICHARD). A Dictionary of Medicine, including General Pathology, General Therapeutics, Hygiene, and the Diseases peculiar to Women and Children. By Various Writers. Edited by Richard Quain, M.D., In one large 8vo volume, with complete Index, and 138 Illustrations. (*Sold only by subscription.*) Half morocco, \$8.00.
- RANNEY (AMBROSE L.). Applied Anatomy of the Nervous System, being a Study of this Portion of the Human Body from a Standpoint of its General Interest and Practical Utility, designed for Use as a Text-Book and as a Work of Reference. Profusely illustrated. 8vo. Cloth, \$4.00; sheep, \$5.00.
- RANNEY (AMBROSE L.). Lectures on Electricity in Medicine, delivered at the Medical Department of the University of Vermont, Burlington. Numerous Illustrations. 12mo. Cloth, \$1.00.
- RANNEY (AMBROSE L.). Practical Suggestions respecting the Varieties of Electric Currents and the Uses of Electricity in Medicine, with Hints relating to the Selection and Care of Electrical Apparatus. With Illustrations and 14 Plates. 16mo. Cloth, \$1.00.
- RIBOT (TH.). Diseases of Memory: an Essay in the Positive Psychology. Translated from the French by William Huntington. 12mo. Cloth, \$1.50.
- RICHARDSON (B. W.). Diseases of Modern Life. 12mo. Cloth, \$2.00.
- RICHARDSON (B. W.). A Ministry of Health and other Addresses. 12mo. Cloth, \$1.50.
- ROBINSON (A. R.). A Manual of Dermatology. Revised and corrected. 8vo. Cloth, \$5.00.
- ROSCOE-SCHORLEMMER. Treatise on Chemistry.
 Vol. 1. Non-Metallic Elements. 8vo. Cloth, \$5.00.
 Vol. 2. Part I. Metals. 8vo. Cloth, \$3.00.
 Vol. 2. Part II. Metals. 8vo. Cloth, \$3.00.
 Vol. 3. Part I. The Chemistry of the Hydrocarbons and their Derivatives. 8vo. Cloth, \$5.00.
 Vol. 3. Part II. The Chemistry of the Hydrocarbons and their Derivatives. 8vo. Cloth, \$5.00.
 Vol. 3. Part III. This part commences the consideration of the complicated but most important series of bodies known as the Aromatic Compounds. 8vo. Cloth, \$3.00.
- ROSENTHAL (I.). General Physiology of Muscles and Nerves. With 75 Woodcuts. 12mo. Cloth, \$1.50.
- SAYRE (LEWIS A.). Practical Manual of the Treatment of Club-Foot. **Fourth edition**, enlarged and corrected. 12mo. Cloth, \$1.25.

- SAYRE (LEWIS A.). Lectures on Orthopedic Surgery and Diseases of the Joints, delivered at Bellevue Hospital Medical College. **New edition**, illustrated with 324 Engravings on Wood. 8vo. Cloth, \$5.00; sheep, \$6.00.
- SCHROEDER (KARL). A Manual of Midwifery, including the Pathology of Pregnancy and the Puerperal State. Translated into English from the third German edition, by Charles H. Carter, M.D. With 26 Engravings on Wood. 8vo. Cloth, \$3.50; sheep, \$4.50.
- SHOEMAKER (JOHN V.). A Text-Book of Diseases of the Skin. 8vo. Six Chromo-Lithographs and numerous Engravings. (*In press.*)
- SIMPSON (JAMES Y.). Selected Works: Anæsthesia, Diseases of Women. 3 vols., 8vo. Per volume. Cloth, \$3.00; sheep, \$4.00.
- SKENE (ALEXANDER J. C.). A Text-Book on the Diseases of Women. 8vo. Illustrated with over two hundred fine Engravings. (*In press.*)
- SMITH (EDWARD). Foods. 12mo. Cloth, \$1.75.
- SMITH (EDWARD). Health: A Hand-Book for Households and Schools. Illustrated. 12mo. Cloth, \$1.00.
- STEINER (JOHANNES). Compendium of Children's Diseases: a Hand-Book for Practitioners and Students. Translated from the second German edition, by Lawson Tait. 8vo. Cloth, \$3.50; sheep, \$4.50.
- STEVENS (GEORGE T.). Functional Nervous Diseases: their Causes and their Treatment. Memoir for the Concourse of 1881-1883, Académie Royal de Médecine de Belgique. With a Supplement, on the Anomalies of Refraction and Accommodation of the Eye, and of the Ocular Muscles. Small 8vo. With six Photographic Plates and twelve Illustrations. Cloth, \$2.50.
- STONE (R. FRENCH). Elements of Modern Medicine, including Principles of Pathology and of Therapeutics, with many Useful Memoranda and Valuable Tables of Reference. Accompanied by Pocket Fever Charts. Designed for the Use of Students and Practitioners of Medicine. In wallet-book form, with pockets on each cover for Memoranda, Temperature Charts, etc. Roan, tuck, \$2.50.
- STRECKER (ADOLPH). Short Text-Book of Organic Chemistry. By Dr. Johannes Wislicenus. Translated and edited, with Extensive Additions, by W. H. Hodgkinson and A. J. Greenaway. 8vo. Cloth, \$5.00.
- STRÜMPPELL (ADOLPH). A Text-Book of Medicine, for Students and Practitioners. With 111 Illustrations. 8vo. Cloth, \$6.00; sheep, \$7.00.
- SWANZY (HENRY R.). A Hand-Book of the Diseases of the Eye, and their Treatment. With 122 Illustrations, and Holmgren's Tests for Color-Blindness. Crown 8vo. Cloth, \$3.00.
- TRACY (ROGER S.). The Essentials of Anatomy, Physiology, and Hygiene. 12mo. Cloth, \$1.25.
- TRACY (ROGER S.). Hand-Book of Sanitary Information for Householders. Containing Facts and Suggestions about Ventilation, Drainage, Care of Contagious Diseases, Disinfection, Food, and Water. With Appendices on Disinfectants and Plumbers' Materials. 16mo. Cloth, 50 cents.
- TRANSACTIONS OF THE AMERICAN LARYNGOLOGICAL ASSOCIATION, VOL. VI. Being the Proceedings of the Sixth Annual Meeting, held in Detroit, June 24, 25, and 26, 1885. 8vo. Cloth, \$2.50.

TRANSACTIONS OF THE NEW YORK STATE MEDICAL ASSOCIATION, VOL. I. Being the Proceedings of the First Annual Meeting of the New York State Medical Association, held in New York, November 18, 19, and 20, 1884. Small 8vo. Cloth, \$5.00.

TYNDALL (JOHN). Essays on the Floating Matter of the Air, in Relation to Putrefaction and Infection. 12mo. Cloth, \$1.50.

ULTZMANN (ROBERT). Pyuria, or Pus in the Urine, and its Treatment. Translated by permission, by Dr. Walter B. Platt. 12mo. Cloth, \$1.00.

VAN BUREN (W. H.). Lectures upon Diseases of the Rectum, and the Surgery of the Lower Bowel, delivered at Bellevue Hospital Medical College. **Second edition, revised and enlarged.** 8vo. Cloth, \$3.00; sheep, \$4.00.

VAN BUREN (W. H.). Lectures on the Principles and Practice of Surgery. Delivered at Bellevue Hospital Medical College. Edited by Lewis A. Stimson, M. D. 8vo. Cloth, \$4.00; sheep, \$5.00.

VAN BUREN AND KEYES. A Practical Treatise on the Surgical Diseases of the Genito-Urinary Organs, including Syphilis. Designed as a Manual for Students and Practitioners. With Engravings and Cases. By W. H. Van Buren, M. D., and Edward L. Keyes, M. D. 8vo. Cloth, \$5.00; sheep, \$6.00.

VOGEL (A.). A Practical Treatise on the Diseases of Children. Translated and edited by H. Raphael, M. D. **Third American from the eighth German edition, revised and enlarged.** Illustrated by six Lithographic Plates. 8vo. Cloth, \$4.50; sheep, \$5.50.

VON ZEISSL (HERMANN). Outlines of the Pathology and Treatment of Syphilis and Allied Venereal Diseases. **Second edition,** revised by Maximilian von Zeissl. Authorized edition. Translated, with Notes, by H. Raphael, M. D. 8vo. Cloth, \$4.00; sheep, \$5.00.

WAGNER (RUDOLF). Hand-Book of Chemical Technology. Translated and edited from the eighth German edition, with extensive Additions, by William Crookes. With 336 Illustrations. 8vo. Cloth, \$5.00.

WALTON (GEORGE E.). Mineral Springs of the United States and Canadas. Containing the latest Analyses, with full Description of Localities, Routes, etc. **Second edition, revised and enlarged.** 12mo. Cloth, \$2.00.


WEBBER (S. G.). A Treatise on Nervous Diseases: Their Symptoms and Treatment. A Text-Book for Students and Practitioners. 8vo. Cloth, \$3.00.


WEEKS (CLARA S.). A Text-Book of Nursing. For the Use of Training-Schools, Families, and Private Students. 12mo. With 13 Illustrations, Questions for Review and Examination, and Vocabulary of Medical Terms. 12mo. Cloth, \$1.75.

WELLS (T. SPENCER). Diseases of the Ovaries. 8vo. Cloth, \$4.50.

WYETH (JOHN A.). A Text-Book on Surgery: General, Operative, and Mechanical. Profusely illustrated. (*Sold by subscription only.*) 8vo. Buckram, uncut edges, \$7.00; sheep, \$8.00; half morocco, \$8.50.

WYLIE (WILLIAM G.). Hospitals: Their History, Organization, and Construction. 8vo. Cloth, \$2.50.





COLUMBIA UNIVERSITY LIBRARIES



0050195379

