

**A radiographic atlas of the pathologic changes of bones and joints / by  
Amédée Granger.**

**Contributors**

Granger, Amédée, 1879-  
Augustus Long Health Sciences Library

**Publication/Creation**

New York : The A. L. Chatterton co., [1911], [©1911]

**Persistent URL**

<https://wellcomecollection.org/works/e52tgrxg>

**License and attribution**

This material has been provided by This material has been provided by the Augustus C. Long Health Sciences Library at Columbia University and Columbia University Libraries/Information Services, through the Medical Heritage Library. The original may be consulted at the the Augustus C. Long Health Sciences Library at Columbia University and Columbia University. where the originals may be consulted.

This work has been identified as being free of known restrictions under copyright law, including all related and neighbouring rights and is being made available under the Creative Commons, Public Domain Mark.

You can copy, modify, distribute and perform the work, even for commercial purposes, without asking permission.



Wellcome Collection  
183 Euston Road  
London NW1 2BE UK  
T +44 (0)20 7611 8722  
E [library@wellcomecollection.org](mailto:library@wellcomecollection.org)  
<https://wellcomecollection.org>

COLUMBIA LIBRARIES OFFSITE  
HEALTH SCIENCES STANDARD



HX64056228

RD36 G762

A radiographic atlas

**RECAP**

# RADIOGRAPHIC ATLAS

AMÉDÉE GRANGER



RD36

G762

Columbia University  
in the City of New York

College of Physicians and Surgeons

Library



Gift of

DR. MARY L. H. A. SNOW


Wm. Bulham Snow.











Ex Libris  
William Bayard Snow

# A RADIOGRAPHIC ATLAS

OF THE

## Pathologic Changes of Bones and Joints

BY

AMÉDÉE GRANGER, M. D.

Lecturer on Radiology and Electro-physics, New  
Orleans Polyclinic; Physician-in-charge of the  
X-ray Department of the Charity Hospital;  
Associate Editor of the Journal of Ad-  
vanced Therapeutics; Member of  
Société Française d'Electro-  
thérapie, Paris

---

NEW YORK:

THE A. L. CHATTERTON CO.



RD 36  
G 762

COPYRIGHT, 1911,

BY

AMÉDÉE GRANGER, M.D.

# CONTENTS

	PAGE
PREFACE .....	11
INTRODUCTION .....	13
SKIAGRAPHY .....	17
NORMAL JOINTS.....	27

## PART II.

### DISEASES OF THE JOINTS AND BONES


OSTEO-MYELITIS .....	53
TUBERCULOSIS .....	67
OSTEO-SARCOMA .....	77
SYPHILIS .....	91
PERIOSTITIS .....	105
RICKETS .....	109
SCURVY .....	117
OSTEOMATA .....	123
OSTEOID-CHONDROMA .....	123
CYST .....	128
DIFFERENTIAL DIAGNOSIS.....	130
ARTHRITIS .....	131
RHEUMATOID ARTHRITIS.....	141
TUBERCULAR ARTHRITIS.....	147
LOOSE SEMI-LUNAR CARTILAGE.....	158

## PART III.

### FRACTURES, DISLOCATIONS, FOREIGN BODIES.

FRACTURES .....	161
DISLOCATIONS .....	183
FOREIGN BODIES.....	195





Digitized by the Internet Archive  
in 2010 with funding from  
Open Knowledge Commons

## INDEX TO PLATES

PLATE	PAGE
I. The Author's Radiologic Frame.....	23
II. The Author's Radiologic Frame.....	25
III. Normal Shoulder Joint—Antero-Posterior Position....	29
IV. Normal Shoulder Joint—Posterior-Anterior View—Head of Humerus Rotated Outwards.....	31
V. Normal Elbow Joint—Antero-Posterior View—Forearm in Supination.....	33
VI. Normal Elbow Joint—Lateral View—Internal Condyle Lying on the X-Ray Plate.....	35
VII. Normal Wrist Joint—Palmar View.....	37
VIII. Normal Hand—Palmar View.....	39
IX. Normal Sacro-Lumbar and Sacro-Iliac Joints—Dorsal Position .....	41
X. Normal Hip Joint—Dorsal Position.....	43
XI. Normal Knee Joint—Antero-Posterior View.....	45
XII. Normal Knee Joint—Lateral View—The Leg Lying On Its External Surface.....	47
XIII. Normal Ankle Joint—Lateral View—Fracture of the Lower End of the Fibula.....	49
XIV. Normal Foot—Plantar View.....	51
XV. Osteomyelitis of the Lower End of the Humerus.....	55
XVI. Osteomyelitis of the Radius—Presence of Sequestrum..	57
XVII. Osteomyelitis of the Radius—Total Destruction of the Bone—Secondary Involvement of the Soft Parts...	59
XVIII. Chronic Osteomyelitis of the Ulna—Extensive Destruc- tion of the Shaft, with the Presence of a Large Sequestrum .....	61
XIX. Osteomyelitis of the Metacarpal Bone of the Thumb— Involvement of the Soft Parts.....	63
XX. Osteomyelitis of the Entire Shaft of the Humerus Sepa- ration of the Upper Epiphysis—Presence of Large Sequestra—Secondary Involvement of the Soft Parts .....	65
XXI. Tuberculosis of the Lower End of the Femur—Sec- ondary Involvement of the Knee Joint.....	69
XXII. Tuberculosis of the Bones of the Wrist—Presence of Sequestra .....	71
XXIII. Tubercular Osteomyelitis of the Tibia—This Case Had Suffered with an Undiagnosed Pain in the Knee for Over One Year, During Which Time He Was Sub- jected to Numerous and Varied Treatments.....	73



PLATE	PAGE
XXIV. Tubercular Osteitis of the Tibia.....	75
XXV. Sarcoma of the Soft Parts of the Thigh—No Involvement of the Femur—X-Ray Finding Confirmed by a Careful Examination of the Limb After a Hip Amputation .....	79
XXVI. Osteo-Sarcoma of the Upper End of the Humerus—Secondary Involvement of the Soft Parts.....	81
XXVII. Immense Osteo-Sarcoma of the Lower End of the Femur—Involvement of the Knee Joint.....	83
XXVIII. Osteo-Sarcoma of the Upper End of the Humerus—Pathological Fracture.....	85
XXIX. Osteo-Sarcoma of the Femur—Pathological Fracture...	87
XXX. Osteo-Sarcoma of the Lower End of the Radius—Giant Cell Variety.....	89
XXXI. Syphilitic Gummata of the Muscles of the Thigh.....	93
XXXII. Syphilitic Periostitis of the Tibia.....	95
XXXIII. Syphilis of the Lower End of the Radius.....	97
XXXIV. Syphilis of the Femur—Calcareous Degeneration of the Popliteal Artery—Presence of a Phlebolith in the Popliteal Veins.....	99
XXXV. Syphilis of the Femur—Necrosis of Bone—Involvement of the Soft Parts.....	101
XXXVI. Syphilis of the Ulna—Extensive Loss of Substance....	103
XXXVII. Periostitis of the Tibia.....	107
XXXVIII. Rachitic Bones.....	111
XXXIX. Rachitic Bones.....	113
XL. Rachitic Bones.....	115
XLI. Sub-Periosteal Hemorrhage in Scurvy—Acute Stage....	119
XLII. Extensive Sub-Periosteal Hemorrhage in Scurvy—Chronic Stage.....	121
XLIII. Multiple Exostoses of the Bones of the Forearm.....	125
XLIV. Osteoid Chondroma of the Femur.....	127
XLV. Cyst of Bone.....	129
XLVI. Arthritis of the Knee Joint.....	133
XLVII. Arthritis of Knee Joint—Small Adhesion.....	135
XLVIII. Fibrous Ankylosis of the Elbow Joint.....	137
XLIX. Bony Ankylosis of the Ankle Joint.....	139
L. Rheumatoid Arthritis of the Wrist—Hypertrophic Type.	143
LI. Rheumatoid Arthritis of the Knee—Atrophic Type....	145
LII. Tubercular Arthritis of the Knee—Early Stage.....	149
LIII. Tubercular Arthritis of the Hip.....	151
LIV. Tubercular Coxitis of the Right Hip—First Stage—Child Four Years Old.....	153
LV. Tubercular Coxitis of the Right Hip—Second Stage—Bone Involvement—Child Four Years Old.....	155
LVI. Tubercular Coxitis of the Right Hip—Third Stage—Bone Destruction—Child Four Years Old.....	157
LVII. Loose Semi-Lunar Cartilage.....	159
LVIII. Fracture of the Right Femur—Antero-Posterior View—Same Case as Plate LIX.....	163
LIX. Fracture of the Right Femur—Lateral View—Same Case as Plate LVIII.....	165

PLATE	PAGE
LX. Gun-Shot Fracture of the Lower End of the Humerus— Antero-Posterior View—Same Case as Plate LXI..	167
LXI. Gun-Shot Fracture of the Lower End of the Humerus— Lateral View—Same Case as Plate LX.....	169
LXII. Impacted Fracture of the Surgical Neck of the Femur— Clinical Diagnosis was Contusion of Hip.....	171
LXIII. Fracture of the Anatomical Neck of the Femur—Clinical Diagnosis was Contusion of Hip.....	173
LXIV. Fracture of the Pelvic Bones—Fracture Line Runs Through the Acetabulum.....	175
LXV. Fracture of the Upper End of the Shaft of the Femur— The Fracture Runs Through the Inter-Trochanteric Line of the Femur.....	177
LXVI. Fracture of the Astragalus—Clinical Diagnosis, Contu- sion of the Ankle.....	179
LXVII. Fracture of the Patella—Skiagram Taken About Three Months After Suturing of the Capsule.....	181
LXVIII. Dislocation Backwards and Upwards of Both Bones of the Forearm—Antero-Posterior View—Fracture of the Olecranon—Same Case as Plate LXIX.....	185
LXIX. Dislocation Backwards and Upwards of Both Bones of the Forearm—Lateral View—Fracture of the Ole- cranon—Same Case as Plate LXVIII.....	187
LXX. Dislocation Downwards, Forwards and Inward of the Head of the Humerus—Old Dislocation.....	189
LXXI. Double Congenital Dislocation of the Hips—Exotosis on the Shaft of the Left Femur.....	191
LXXII. Reduced Congenital Dislocation of the Right Hip.....	193
LXXIII. Gun-Shot Wound of the Right Thigh—Bullet Lodger in the Greater Trochanter.....	197
LXXIV. Gun-Shot Wound of the Knee—Bullet Lodged in the Upper End of the Tibia.....	199
LXXV. Gun-Shot Wound of the Arm—Gun-Shot Fracture of the Humerus—Antero-Posterior View—Same Case as Plate LXXVI.....	201
LXXVI. Gun-Shot Wound of the Arm—Gun-Shot Fracture of the Humerus—Lateral View—Same Case as Plate LXXV.....	203
LXXVII. Gun-Shot Wound of the Left Knee—Antero-Posterior View—Same Case as Plate LXXVIII.....	205
LXXVIII. Gun-Shot Wound of the Knee—Lateral View—Same Case as Plate LXXVII.....	207





## PREFACE

The Roentgen Ray is no longer employed merely to locate foreign bodies, to diagnose fractures and to render valuable assistance in the treatment of the latter. By its means we can detect pathological changes taking place in Bones and Joints and differentiate between those due to different diseases. Its importance to the surgeon and the physician in the diagnosis, prognosis and treatment of the pathological conditions of Bones and Joints is therefore of paramount importance. With a just and increasing appreciation of its usefulness in these cases the X-ray is made use of more frequently, and it becomes necessary for the medical profession to be able to correctly interpret X-ray negatives.

This atlas has been prepared with the hope that it might prove of valuable assistance to the surgeon, the physician, and the X-ray operator, with limited experience and facilities in interpreting skiagrams.

The author has tried to be practical both in the writing and general arrangement of the work, and, with the exception of the Chapter on Skiagraphy, which was prepared with the view of being of still further assistance to the beginner in X-ray work, all theoretical and technical descriptions and discussions have been omitted.

The cuts are correct reproductions of photographic prints of X-ray negatives made by the author, and have not been retouched. They were carefully selected so as best to illustrate the various subjects treated, and help most in establishing the diagnosis of abnormal conditions of bone or joint as seen on the X-ray negative under examination. Facing each cut is a concise and accurate description of same, and throughout the work, whenever necessary, are descriptive notes.

To those gentlemen who are expert in this field of medicine the author hopes that the varied collection of skiagrams, especially those illustrating different stages of the changes due to disease occurring in Bones and Joints, may prove of interest.

The author is indebted to the Administrators of the Charity Hospital for the rare opportunities afforded in observation and experimentation in this important and interesting field. Also to his Assistants in the X-Ray Department of that institution and to others for their valuable assistance and the many courtesies extended to him.

AMÉDÉE GRANGER, M. D  
Maison Blanc Building, New Orleans, La.



## INTRODUCTION

Since the discovery of the X-ray by Roentgen in 1895, and its practical application to the diagnosis of fractures and to the detection of foreign bodies, its field of usefulness as a diagnostic agent has steadily enlarged with the improvements in apparatus and operating technic. The latest advance, and I believe the most important, is its use as a practical and almost infallible means of diagnosing the diseases of bones and joints.

Without detracting from the value of the X-ray in locating calculi and foreign bodies, in the diagnosis of affections of the thoracic viscera, and as a guide to the proper treatment of fractures, its superior advantage to the surgeon in establishing the diagnosis of the affection and the extent of bone and joint involvement before operation, enabling him to make a prognosis and to select the proper treatment, becomes at once apparent, and of immense importance to the patient.

We must become trained in the examination of the X-ray negative, because no process of printing can bring out all the gradations in tone that appear on a good negative. Nothing must be lost even though it should show up indistinctly. Of course, the most satisfactory manner of making this examination is by viewing the plate in a negative illuminator or shadow-box placed in a dark or darkened room. The shadow-box consists of a contrivance in which plates of different sizes can be viewed in different positions and at different angles by a controllable reflected light. The arrangement is very simple and the intensity of the light easily controlled by means of a rheostat. The control of light is very important. Without it the details in very thin negatives would be lost. The light should be turned on very gradually, and the differences in tone of the shadows carefully looked for and their contour, size, etc., noted. The advantage of being able to examine the plates at different angles will be appreciated by all those who have had experience in this line of work, as it often enables one to see slight differences in shadings, denoting abnormalities, which otherwise would have escaped the examina-



tion, no matter how minute. If we have no shadow-box, the next best thing would be to replace a pane of glass in a window having a good and clear view of the sky by a piece of ground glass. When examining an X-ray negative by this means, it should be placed against the ground glass window, if it is dense, and held away from it if thin, and should also be held at various angles. Still another and very satisfactory way is to hold a large piece of ground glass in front of an incandescent or other brilliant light and proceed with the examination of the X-ray plate, as in the case of a ground glass window. In any case, the film side of the plate should be turned towards the light and it should be viewed from the glass side. In that manner we examine a plate as we would a patient with the fluoroscope. The plate replaces the fluorescent screen with the image on it of a patient, placed between the light or tube and the plate or screen, as the case may be. By so doing we establish a more accurate basis of comparison between our skiagraphic and our fluoroscopic work. The shadows appear on the screen or plate as the parts which cause them exist in the subject; that is, what is seen on the right side of the plate or screen is on the right side of the subject, or vice versa.

Still another reason for viewing the X-ray negatives through their glass sides is that the image, in photographic prints made by exposing to some light a sensitized piece of paper held firmly against the film side of the X-ray negative, appears as when seen through the glass side of the negative. The advantages from this constant association of ideas, and because we do not have to transpose the images or shadows, more than counterbalance the slight disadvantages of looking at the shadow on the film through the glass of the plate.

INTERPRETATION. Before one is competent correctly to interpret an X-ray plate, he must know and thoroughly appreciate:

First. That an X-ray negative is a shadowgraph.

Second. The necessity of being familiar with the appearance of radiographs of the normal anatomy.

Third. To be familiar with the pathology of bones and joints. This is important because, as will be shown throughout the discussion of the various diseases, the abnormal X-ray shadows are always easily accounted for by definite pathological changes in the bone or joint.

Fourth. The importance of the relative positions of the tube, the patient and the plate to each other.

1. The X-ray picture is a shadowgraph. The X-rays that reach the plate affect the film as do ordinary light rays. When we interpose between X-rays and the photographic plates objects



of different atomic weight, the heavier substances prevent the passage of the rays more than the light ones, and the film being unequally acted upon, shows not an image, but shadows of various tones. Precisely the same thing occurs when we skiagraph any part of the human body, composed as it is of structures of varying densities. The bones appear white on the plates, the other tissues vary in tone from light to dark gray. Therefore, a good negative would show not only foreign bodies and gross pathological lesions of the skeleton, such as fractures, dislocations, but would also show changes in bone structure, the presence of callous, of effusions and exudates, tubercular involvements, etc.

2. A thorough and minute knowledge of the appearance of the human anatomy, seen with the X-rays, is of paramount importance. Dr. E. W. Shenton, in an admirable article in the *Physician and Surgeon*, says: "The surgeon who relies on his anatomical knowledge to translate a radiographic appearance will find that he depends upon a broken reed." Possibly the most striking instance of this is found in the appearance of a normal knee-joint. We are immediately struck by the high position of the patella, accustomed to seeing it pictured in all text-books on anatomy as covering the joint. The epiphyseal line in children and young adults could be mistaken for fractures. The appearance of the pelvis of a young child, with the apparent separation between the pelvic bones, and the absence of the femoral head, all due to unossified cartilage, is striking. Another source of error could be made in the acromio-clavicular articulation. Unless the normal appearance of joints and of bone textures of individuals, from children to adult life, is known, the diagnosis of pathological conditions becomes impossible.

3. We must know what changes in the structures of bones and joints the different diseases produce. The general course of the affection, its predilection for certain bones or joints and for particular parts or structures of these.

For example, new bone formations, callous, cartilage before ossification, throw a shadow which is only slightly more dense than that of the surrounding soft parts, but becomes denser as ossification takes place. In such diseases as rickets, where proper calcification does not take place, tuberculosis, where we find absorption of the lime salts and a rarifying osteitis, the bone shadow becomes paler than normal.

In syphilis, around bone abscesses, the walls of circumscribed osteomyelitis, we find a denser bone shadow, due to bone sclerosis.

Effusions and extravasation cause shadows, the density of which depends upon the nature of the effusions or extravasation.

Hemorrhages, producing blood cysts or pigmented areas of extravasated blood, so commonly seen in sarcoma, show as irregular shadows, which are of considerable diagnostic importance.

4. The importance of the relative position of tube, patient and plate to each other. The X-rays are given off as a cone of light from the target or anticathode of the tube, the most central ray, or ray of normal incidence, produces a perfect shadow, that is, one without distortion; the farther we get away from this ray, the more oblique the ray employed becomes, the greater the distortion of the shadow produced by them. From the above, it becomes obvious that the normal ray should be known, and that it should be made to pass through the centre of the plate or part being examined. Besides, we must also know at what distance the tube was when the skiagraphs were taken, as the closer the tube to the plate, the greater the shadow produced, and this enlarged shadow, although free from distortion, may become the source of error. The part should always lie as near to the plate as possible, because, first, the farther away from the plate, the greater the shadow; second, the greater the angle it forms with the plate, the more distorted the shadow. For that reason, the hip and shoulder present unusual difficulties. No comparison of value could be made between the skiagraph of a sound hip taken while rotated inwards and that of an affected hip rotated outwards.

Dr. John Hall Edwards, in a highly interesting article in the September, 1906, number of the *Archives of the Roentgen Rays*, says: "As long as surgeons are content to accept the evidence of a radiograph taken under unknown conditions and by an unskilled operator, so long will mistakes be made and the way kept open for fraud and quackery.

"The value of the interpretation of the radiograph depends entirely upon the knowledge and experience of the expert who is asked to give an opinion, and a good opinion cannot be formed from viewing a radiograph produced from a Crooke's tube held in an unknown position. A large amount of distortion is easily detected by anyone used to the examination of X-ray pictures, but a small amount is frequently difficult to recognize, even by an expert."



## SKIAGRAPHY

Skiagraphy is the art of taking images of the different parts of the human body on sensitized plates by means of the X-ray. It is of course impossible in a book of the nature of this one to enter into descriptions of the apparatus necessary for the production of the X-ray. Several excellent text-books treating of these subjects in a thorough and scientific manner have been published, and the reader desiring this information is referred to them. In this chapter only a few practical hints are given, and it was written in the hope that it might prove useful to the inexperienced X-ray operator.

When making skiagraphs the X-ray plate, enclosed in its envelopes of black and orange paper, must be placed in as close contact with the part to be skiagraphed as possible and with the film side of the plate turned towards it. Under the X-ray plate place a sheet of lead the size of the plate, this will prevent the fogging of the X-ray plate, which might take place if any secondary rays are given off by its glass surface. These secondary rays are produced whenever any X-rays which have not been absorbed by the tissues and by the sensitized film reach the glass surface of the X-ray plate.

Whenever possible, the part to be examined should be skiagraphed lying in two positions, which are at right angles to each other. This is of great importance not only in locating foreign bodies and pathological conditions, but also in showing the extent of the latter, or the results of treatment or operation.

No exception to this rule should be made when skiagraphing the hand. I know that the current practice is to take a palmar, then a dorsal view. Very little additional information is gained by the second view.

Remember that the X-rays are given off as a cone of light from a point on the anticathode or target of the X-ray tube. This part of the anticathode, which can be recognized as a small, roughened, or indented spot on it, should be placed over the center of the part to be skiagraphed and over the center of the X-ray plate. When making use of a compression diaphragm the X-ray tube should be focussed; that is, the point of emission of the rays placed over the center of the upper opening of the diaphragm. The use of a diaphragm will give much finer and clearer negatives, because the secondary rays, given off from the surface of the X-ray tube, which blur the image by the production on the sensitized plate of secondary and indistinct shadows,

are not permitted to reach the plate. In some cases, for instance, when making skiagraphs of the hip, spine, or pelvis, and of the renal, hepatic, and vesical regions, when looking for calculi, a compression diaphragm is an absolute necessity.

Therefore the best results are only obtainable when we can accurately focus the ray of normal incidence, *i. e.*, the normal or central ray, cut out the secondary X-rays, and, as far as possible, prevent the passage of the inverse discharge through the X-ray tube. (See text-books on Radiology, also description of author's Radiologic Frame.)

Always bear in mind that to produce an even illumination of an X-ray plate, the target—the point of emission of the cone of X-ray light—must be placed over its center and at a distance from it of not less than twice that of its longest diameter. For example, when using an X-ray plate 11 x 14 ins., if the anticathode of the tube is not placed over its center and at a distance of not less than 28 ins., the shadows thrown on the plate although clear and distinct in the center would be indistinct at the edges of the plate. Moreover, if the target was not well over the center of the plate the shadows would be distorted, and the more so the greater the obliquity of the rays producing them. Note that we always mention the distance from the anticathode to the plate and not from the glass surface of the X-ray tube to the plate. The size of X-ray tubes vary from 5 ins. to 9 ins. in diameter, but the X-rays are always given off from a point on the anticathode, and if one operator using a 5-in. diameter tube stated that he made a skiagraph at a distance of 20 ins. from the plate—measuring from glass surface of tube to plate—another observer with exactly the same installation and under the same conditions, but using a 9-in. diameter tube, would not duplicate the results in the same time, because the target of his tube would be 2 ins. farther off from the plate—*i. e.*, in the first instance the target would be at 22½ ins. and the second 24½ ins. from the plate.

A very important factor in all skiagraphic work, the one factor which gives more trouble to the inexperienced operator than any other, is the length of time that the X-ray exposure should last in order to obtain a good skiagraph. This depends upon

First. The intensity of the X-ray light, which depends upon the energy of the current which activates the X-ray tube. This will vary with the size and style of the generating apparatus, whether static machine, induction coil, X-ray transformers or generators. If an induction coil upon the style of interrupter and the amount of current in the primary.

Second. The penetration of the X-rays. This depends upon the state of vacuum of the X-ray tube.



Third. The distance from anticathode to plate.

Fourth. The subject to be skiagraphed, *i. e.*, the nature of the part, the age, weight, size and sex of the patient. Also the condition of the part and the presence of dressing, splints, etc.

It is at once apparent that if all these factors are varying continually it is impossible to do anything but guesswork, and the correct timing of an X-ray exposure becomes a physical impossibility. It is necessary therefore to render all these factors constant as much as possible. Fortunately for all practical purposes this is possible with all except the constantly changing factor of the subject, here the experience and observation of the operator alone will overcome the difficulty. In our Department at the Charity Hospital where, in the last four years, we have made over 3,500 skiagraphs, we have adopted the following plan with very satisfactory results, *viz.*: We make use of a coil, because it is not influenced by atmospheric and temperature conditions as is the case with the static machine, and because the output of current is so much greater than with the latter type of apparatus. The coil, interrupter and rheostat are regulated to give a certain output through the secondary terminals. The auto-regulable X-ray tubes which we employ are regulated to furnish when activated by the coil a ray of medium penetration. We always make use of a Roentgen ammeter in the secondary circuit with the X-ray tube. The reading on the scale of this instrument will indicate at once any change in the vacuum of the X-ray tube, hence in the penetrating power of the rays given off by it, provided that the first factor, the energizing current produced by the coil, has remained constant. The reading of the meter will be greater when the vacuum of the tube is lowered, and less when the vacuum of the tube is higher. Within certain limits the higher the vacuum of the tube the more penetrating the X-rays produced by it, the lower the vacuum the less penetrating the rays.

Besides any sudden and marked variation in the reading of the Roentgen ammeter—the needle dropping to 0, or just as suddenly jumping up 3 or more ma., is an indication that the X-ray tube is very overtaxed and is either about to puncture or to have its vacuum lowered to a point which renders it useless for future work. The warning should be heeded and the current turned off at once.

In the Department an assistant remains at the switchboard and keeps a watchful eye on the Roentgen ammeter, especially when doing work which we know will put the X-ray tube on more or less of a strain.

The two factors, the current output and the degree of vacuum



of the tube, can for all practical purposes be regulated and made constant. This having been done we render the third factor, that of the distance from anticathode to plate, constant by always working at stated distances. We do practically all of our work in the following distances:—22 ins., 25 ins. and 28 ins., respectively. We employ the smaller distance when making use of compression, the middle one for most of the work, and the greater one when making exposures on X-ray plates 11 x 14 ins. in size.

Since the action of the X-rays on the sensitized plate is inversely as the square of the ratio of the distance then, where we would expose, say one time at a distance of 22 ins., we would have to expose one and a third times as long at 25 ins., and one and two-third times as long at 28 ins. to obtain the same result. This ratio, one time for 22 ins., one and a third times for 25 ins., and one and two-third times for 28 ins., can be easily remembered, and it gives us three convenient and practical distances and at the same time makes the third factor, that of distance, constant also.

To assist in the practical working out of the last factor, that of the subject, I have prepared the following table of comparative exposures for the different parts of the adult body of medium size and weight.

TABLE OF COMPARATIVE EXPOSURES.

Ankle .....	2 times	Neck .....	8 times
Arm .....	3 "	Pelvis .....	12 "
Elbow .....	3 "	Shoulder .....	4½ "
Foot .....	2½ "	Skull .....	7 "
Forearm .....	2 "	Spine .....	12 "
Hip .....	11 "	Teeth .....	6 "
Kidney .....	6 "	Thigh .....	7 "
Knee .....	6 "	Thorax .....	6 "
Leg .....	5 "	Wrist and hand .....	1 time

This table has proved of inestimable value to us during the past three years.

Proceed in the following manner, after installing your outfit, if a new one, or after cleaning and overhauling it, if one already in use, regulate it so as to give a certain discharge at the secondary terminals. When this has been done connect up your X-ray tube to these terminals, with a Roentgen ammeter in circuit, and take a skiagraph of a normal hand and wrist of a medium-sized adult at a distance of 22 ins. Note carefully the amount of current in the primary of the inductor, as shown by reading the ammeter on the switchboard, the read-

ing of the Roentgen ammeter, and the degree of penetration of the rays emitted by the tube. This last information is obtained by means of a penetrameter scale. We make use of the Benoist. This data once obtained is of positive and practical value as long as the conditions remain the same. Any change in these will be at once indicated by a change in the reading of one or both ammeters, and will, of course, require either readjusting of the apparatus or correction of the time of the exposure. With a good apparatus and auto-regulable X-ray tubes this will only have to be done at long intervals.

Repeat the experiment of taking a skiagraph of the hand and wrist until you find the correct exposure necessary to give you a good and well contrasted negative. You are now in a position to make skiagraphs of any part of the body with every chance of success.

#### EXAMPLE.

Let us say that it took 15 seconds to make a good negative of the hand and wrist at 22 ins. distance. Then at 25 ins. distance it would require an exposure of 20 seconds ( $15'' \times 1 \frac{1}{3}$ ); and at 28 ins. distance it would require an exposure of 25 seconds ( $15'' \times 1 \frac{2}{3}$ ). To make a good skiagraph of an elbow we find by consulting the Table of Comparative Exposure that it takes three times as long; then 45 seconds ( $15'' \times 3$ ) exposure would give a good skiagraph of the elbow joint at a distance of 22 ins.; 60 seconds ( $20'' \times 3$ ) at a distance of 25 ins.; and 75 seconds ( $25'' \times 3$ ) at a distance of 28 ins.

As already stated, the duration of the exposure will have to vary from the above, depending upon the age, size, and weight of the patient. Here no set rule can be suggested, experience and observation alone will guide the operator.

It is often necessary to make skiagraphs of cases of fractures and dislocations through dressings and splints; in such cases expose longer than what the normal exposure for the affected part would be, and be guided by the quantity and kind of splint and dressings employed. No satisfactory skiagraphs of bones and joints affected by disease can be made through dressings or splints. In this class of cases, where we are looking for deviations from the normal bone or joint shadows, the shadows produced by the dressings or splints would be very troublesome and misleading.

In the following pages we describe an apparatus which we have devised after long continued observation and experimentation. We believe that it will prove of valuable assistance to the X-ray worker, especially in the field of skiagraphy.



PLATE I.

THE AUTHOR'S X-RAY LABORATORY.

Showing the Author's sliding Universal X-ray frame in position to do radiographic or radiotherapeutic work, with the patient lying on the operating table. The X-ray tube is clamped inside of the box, which is lined with X-ray proof material. This box is also provided with a lead glass window, through which the operator can observe the functioning of the tube. The tube containing box can be placed over any given point of the operating table by causing the whole frame to slide between its tracks from end to end of the table, and by moving the cradle holder of the box on the hinged frame overlooking the table from side to side of the latter. The vertical movement, i. e., the movement to and from the table is obtained by turning the pilot wheel placed at the right hand of the operator and on his side of the operating table. It becomes self-evident that this apparatus not only insures adequate protection to the operator but permits him to accomplish his work from his side of the table without having to reach over or beyond his patient, and with the greatest accuracy, speed and convenience.



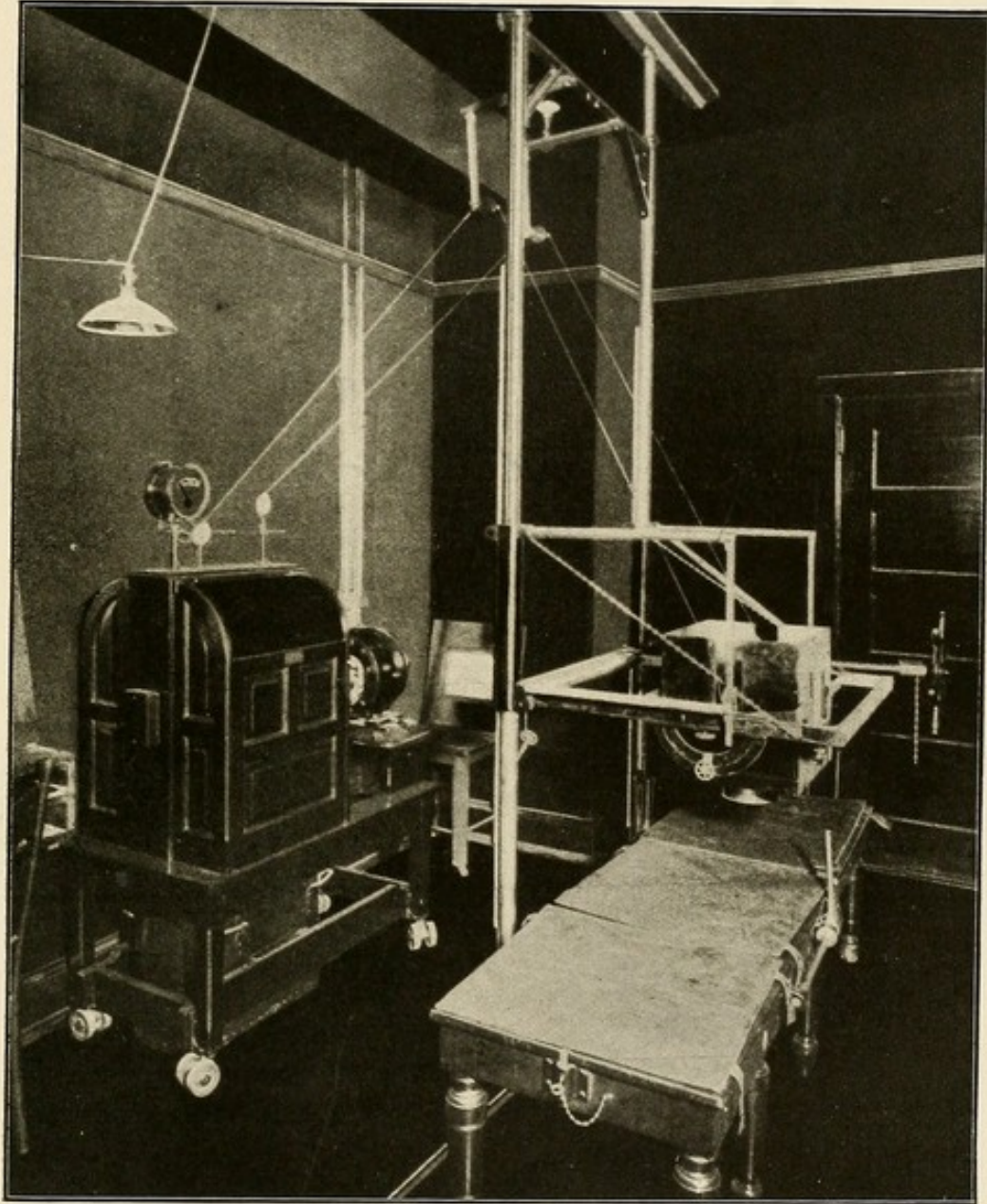


PLATE I.

PLATE II.

THE AUTHOR'S X-RAY LABORATORY.

Showing the Author's sliding Universal X-ray frame in position for fluoroscopic work, or radiography or radiotherapy, with the patient in the sitting posture. As the fluorescent screen and plate holders are interchangeable, either can be used without disturbing the patient or the remainder of the apparatus. The opening in the front of the tube holding box is fitted with an X-ray proof iris diaphragm, and on the outside of this opening is a channel holder which receives various attachments used for special work, such as orthodiagraphic tracings, localization, etc. The screen and the plate holder are attached to the carriage which supports the tube holding box, and it follows that every movement imparted to them causes a similar movement of the tube, and vice versa. The operating table is shown open, with a subject seated upon a stool ready to be fluoroscoped. This stool has a revolving seat, which can be lowered or raised as required. A lateral movement is imparted to the screen and tube by taking hold of the screen holder and causing the whole frame to slide on its tracks; a vertical movement by turning the pilot wheel to the right or left. Reaching overhead, the lights in the room are controlled by appropriate switches, reaching back, the current passing through the tube is controlled by a suitable switchboard table. All of this is done by the operator from one stand, with the greatest ease and convenience, in a minimum of time and without having to reach to the side or beyond the patient.







PLATE II.





### NORMAL JOINTS.

Appreciating the immense advantage of always having handy for comparison a set of normal skiagraphs when studying abnormal ones, especially those of the different joints, we have prepared this chapter, trusting that it will prove of real help to the reader.

In it are only described the normal adult joints. There are several atlases of normal skiagraphy, which give skiagrams of normal joints and bones from childhood to adult life.

The period at which ossification takes place, and hence the shadows depending upon same, vary so much, even in children of the same age, that we have found it best and most practical whenever in doubt when examining skiagraphs in which the pathological changes were not well marked to compare the doubtful negative with one made from the corresponding healthy part of the same patient.

For obvious reasons we have inserted this chapter in this part of the work, before those in which pathological conditions are described.

PLATE III.

NORMAL SHOULDER JOINT—ANTERO-POSTERIOR POSITION.

Note the position of the head of the humerus with reference to the glenoid cavity.

The articular surface of the head of the humerus, its anatomical neck, and the bicipital groove show plainly.

The neck and spine of the scapula, the glenoid cavity, the acromion and coracoid process can be easily made out.

Notice particularly the apparent separation at the acromio-clavicular articulation



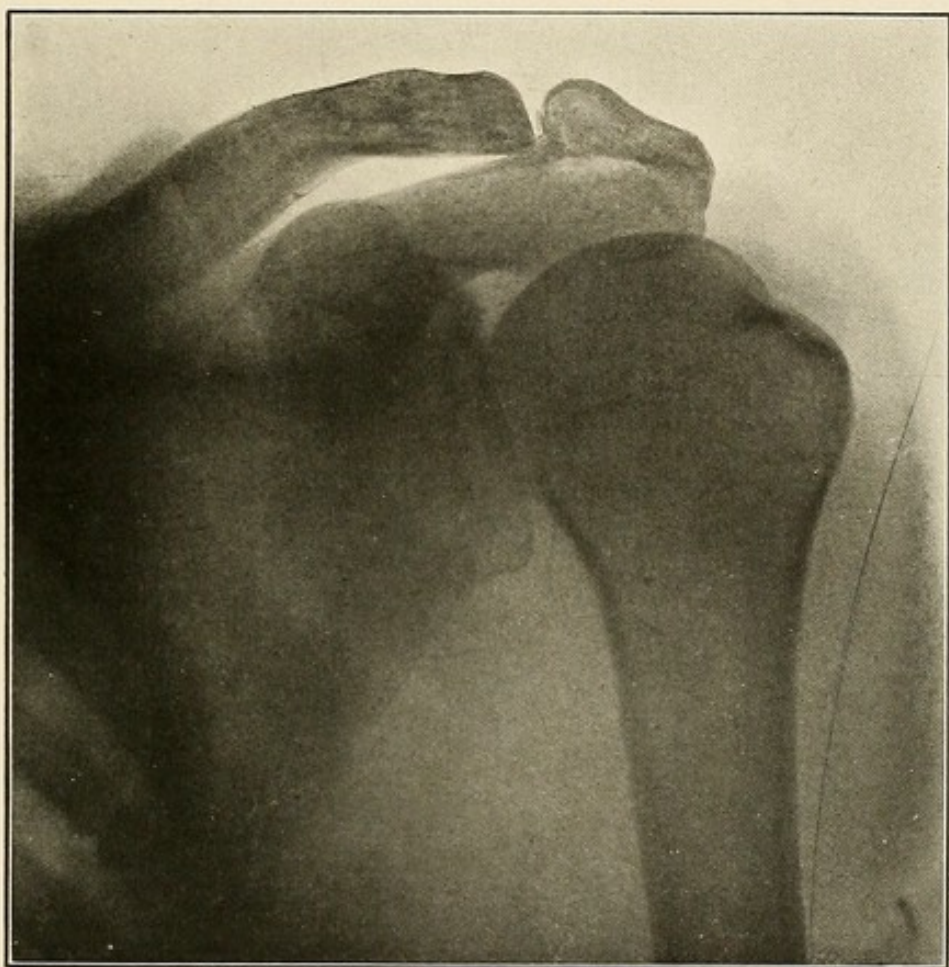


PLATE III.

PLATE IV.

NORMAL SHOULDER JOINT—POSTERIOR-ANTERIOR VIEW—HEAD OF HUMERUS  
ROTATED OUTWARDS.

As in Plate III, the articular surface of the head of the humerus, its anatomical neck, the bicipital groove, the glenoid cavity, the neck and spine of the scapula, acromion and coracoid processes all show up very distinctly. The apparent separation of the acromio-clavicular articulation is not so noticeable.

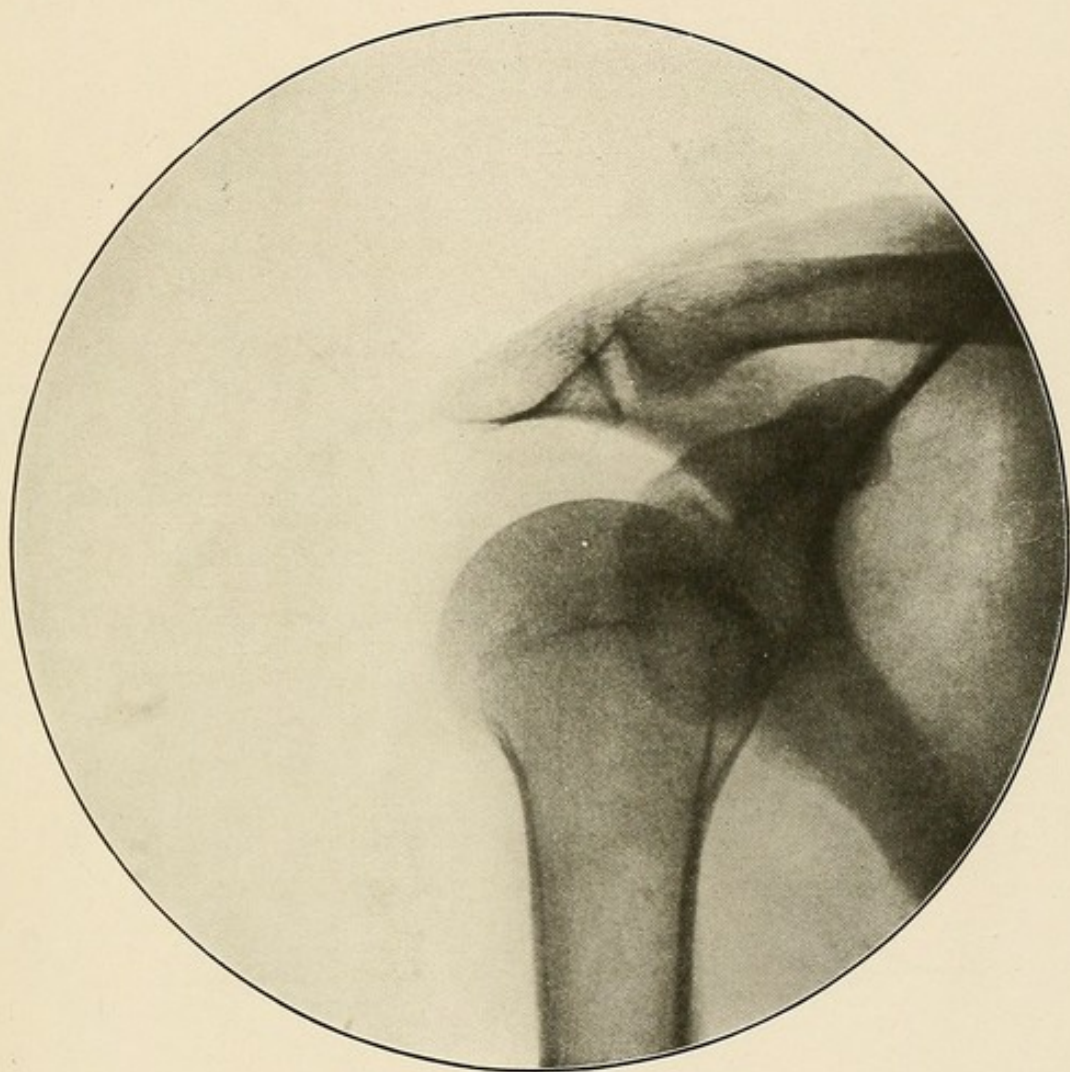


PLATE IV.



PLATE V.

NORMAL ELBOW JOINT—ANTERO-POSTERIOR VIEW—FOREARM IN SUPINATION.

The humerus articulates with the ulna and radius, and the head of the radius articulates with the lesser sigmoid cavity of the ulna.

We see distinctly the external and internal condyles, the olecranon fossa, the trochlear and the radial head of the humerus; the olecranon and coronoid processes of the ulna; the head, neck and bicipital tuberosity of the radius.

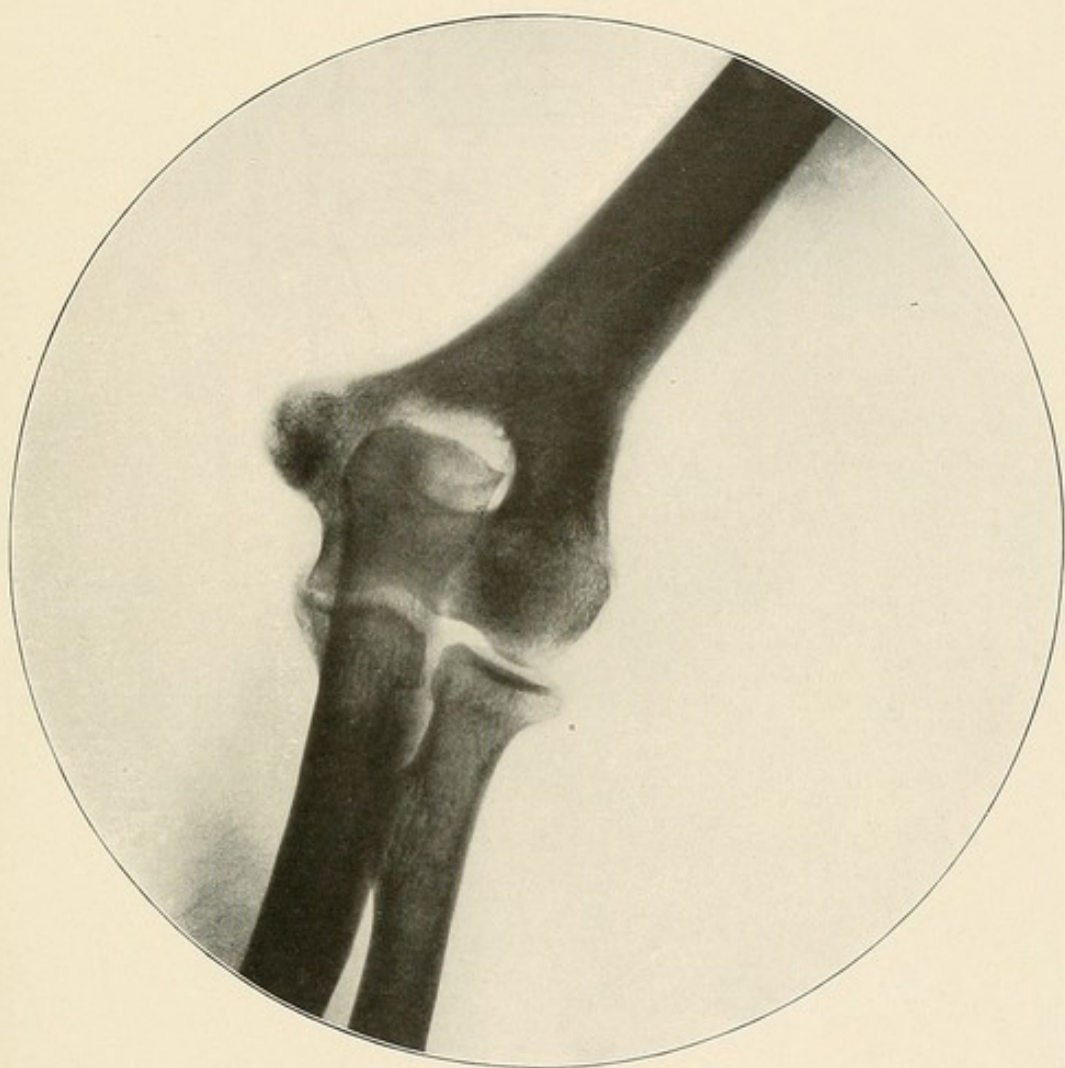


PLATE V.

PLATE VI.

NORMAL ELBOW JOINT—LATERAL VIEW—INTERNAL CONDYLE LYING ON THE  
X-RAY PLATE—THE FOREARM MIDWAY BETWEEN PRONATION AND  
SUPINATION, ITS ULNA SURFACE LYING ON THE PLATE,  
THE THUMB LOOKING UP.

The trochlear surface of the humerus articulates with the greater sigmoid cavity of the ulna, and the radial head of the humerus articulates with the head of the radius.

The olecranon and coronoid processes, and the greater sigmoid cavity of the ulna, and the head and neck of the radius, are distinctly visible.

The radial head of the humerus and the head of the radius are larger and their contour not so sharp, because they were lying farther from the X-ray plate than the ulna during the exposure.



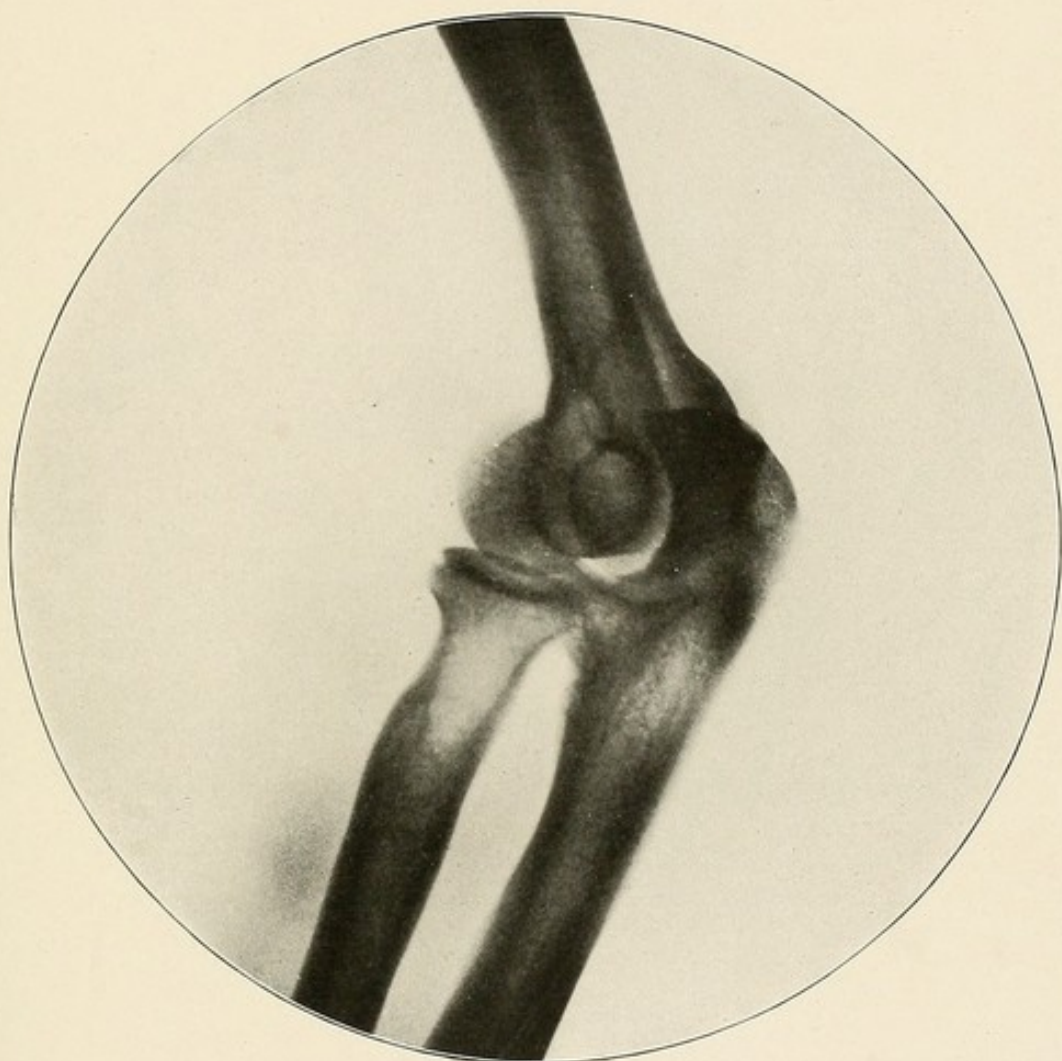


PLATE VI.

PLATE VII.

NORMAL WRIST JOINT—PALMAR VIEW.

The sigmoid cavity of the radius receives the head of the ulna.

The radius articulates with the scaphoid and the semi-lunar.

The cuneiform is separated from the lower end of the ulna by the triangular ligament, which throws no shadow on the skiagram.

The first row of carpal bones seen on the skiagram from without inwards are the scaphoid, the semi-lunar, the cuneiform and the pisiform. The last bone can be distinguished as an almost round shadow overlapping the inner half of the cuneiform.

The lower row of carpal bones proceeding from the meta-carpal bone of the thumb inwards are the trapezium, the trapezoid, the os magnum, and the unciform.

The unciform or hook-like process of the unciform bone, the small sesamoid bone of the thumb, and the styloid process can all be plainly seen.

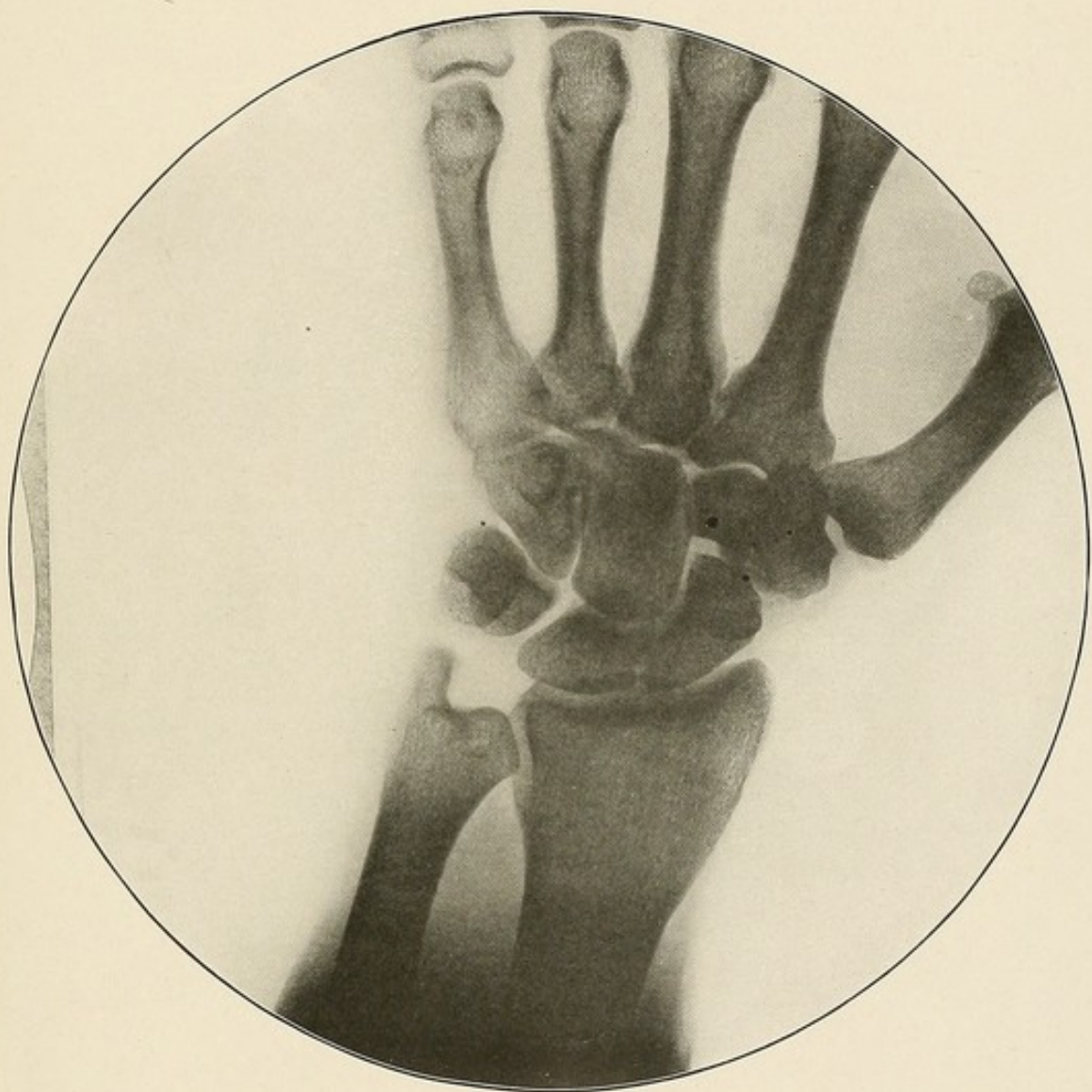


PLATE VII.



PLATE VIII.

NORMAL HAND—PALMAR VIEW.

Note the shape and the structural detail of the metacarpal bones and of the phalanges.

Note, also, the articulation of the various bones composing the hand.

The sesamoid bone of the thumb shows well.

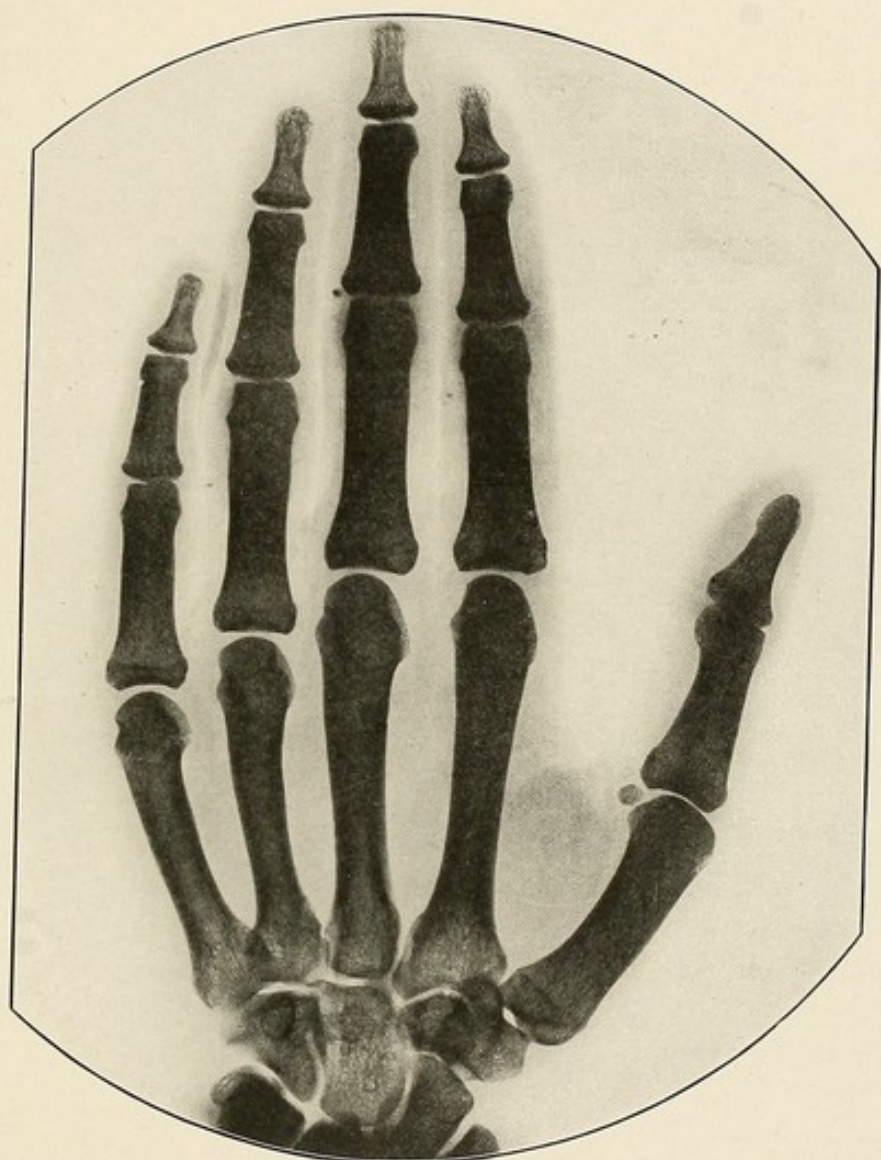

PLATE VIII.

PLATE IX.

NORMAL SACRO-LUMBAR AND SACRO-ILIAC JOINTS—DORSAL POSITION.

The sacrum articulates above with the last lumbar, and on either side with the ilia.

The sacral spines and the posterior sacral foramen can be distinctly seen.

At the lower part of the skiagram the articulation between the sacrum and the coccyx can be seen, and just above this the light shadow, partially surrounded by a darker border, is the posterior median sacral groove.



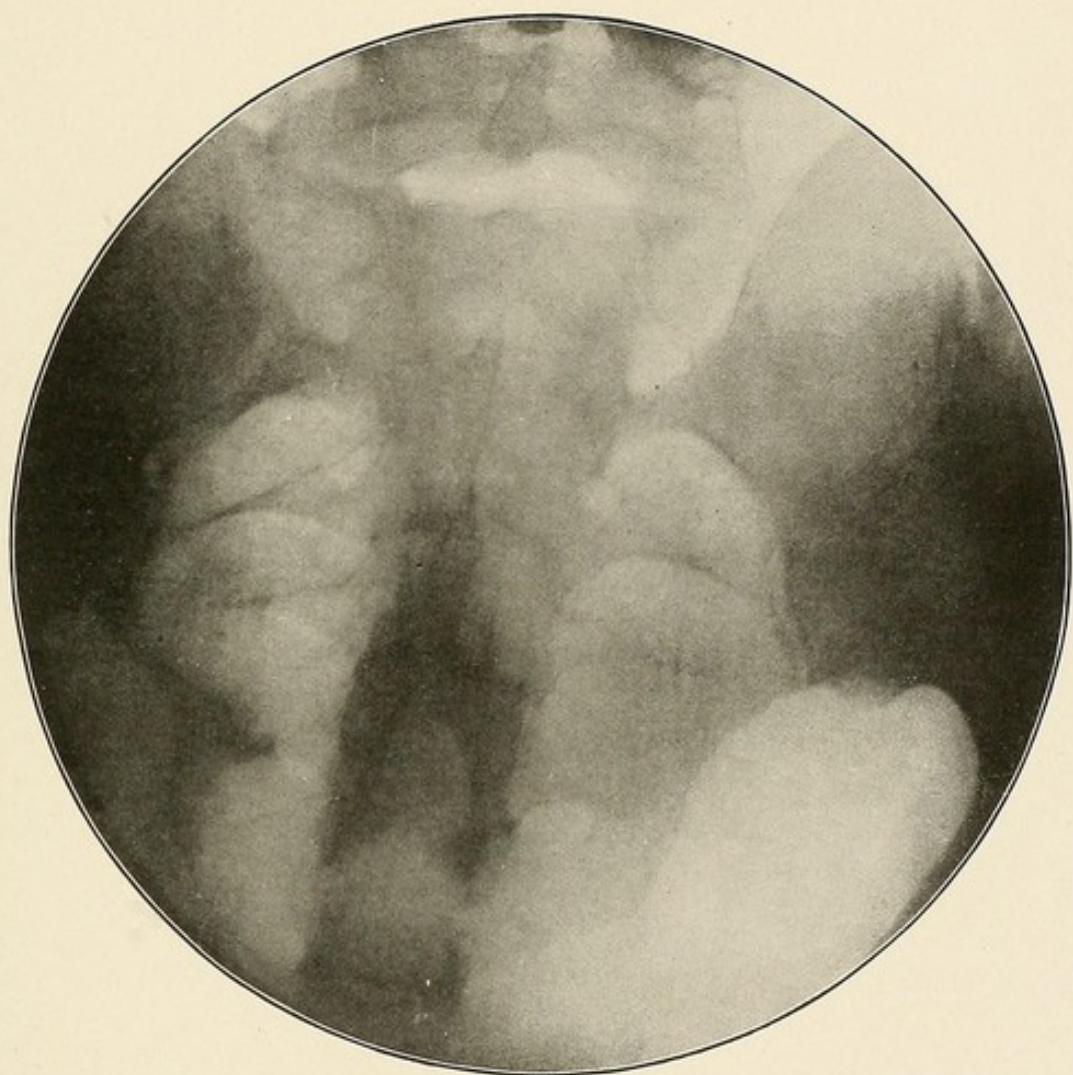


PLATE IX.

PLATE X.

NORMAL HIP JOINT—DORSAL POSITION.

The head of the femur articulates with the acetabulum.

The obturator foramen, the anatomical neck of the femur, its surgical neck, its greater and lesser trochanters, the intertrochanteric line, are all plainly visible.

At the upper extremity of the intertrochanteric line, at a point where the shadow of the neck of the femur meets that of the shaft, a V-shaped dark line indicates the position of the digital fossa. Above the outer margin of the acetabulum is the groove for the tendon of the rectus muscle.

Note particularly the angle formed by the head and the neck of the femur with the shaft of that bone.

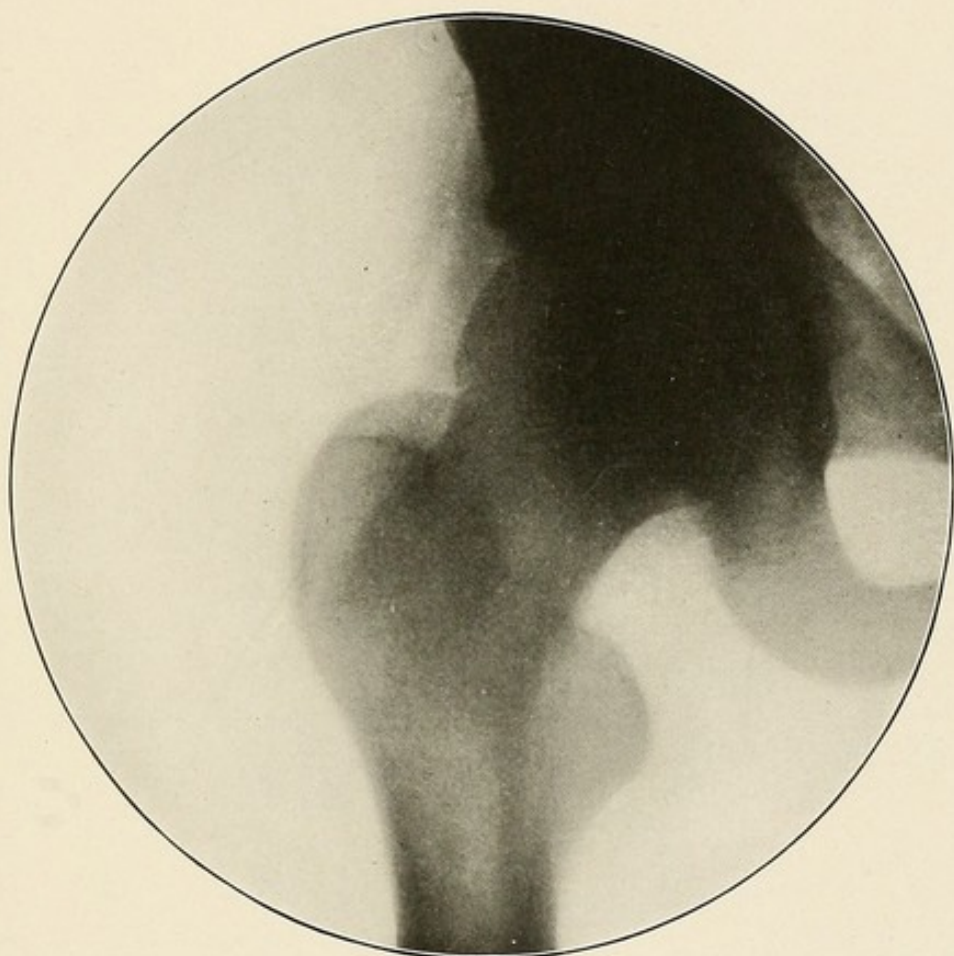


PLATE X.



PLATE XI.

NORMAL KNEE JOINT—ANTERO-POSTERIOR VIEW.

The clear space between the femur and the tibia is due to the fact that the interarticular cartilage does not produce a shadow on the X-ray plate, which can be distinguished from that of the surrounding soft parts.

The shadow of the patella can be plainly seen, and shows that bone lying over the lower extremity of the femur with only a very small part of its lower end extending over the interarticular space.

The spine of the tibia, the epiphyseal line running horizontally across its upper end, and the head of the styloid process of the fibula, are all visible.

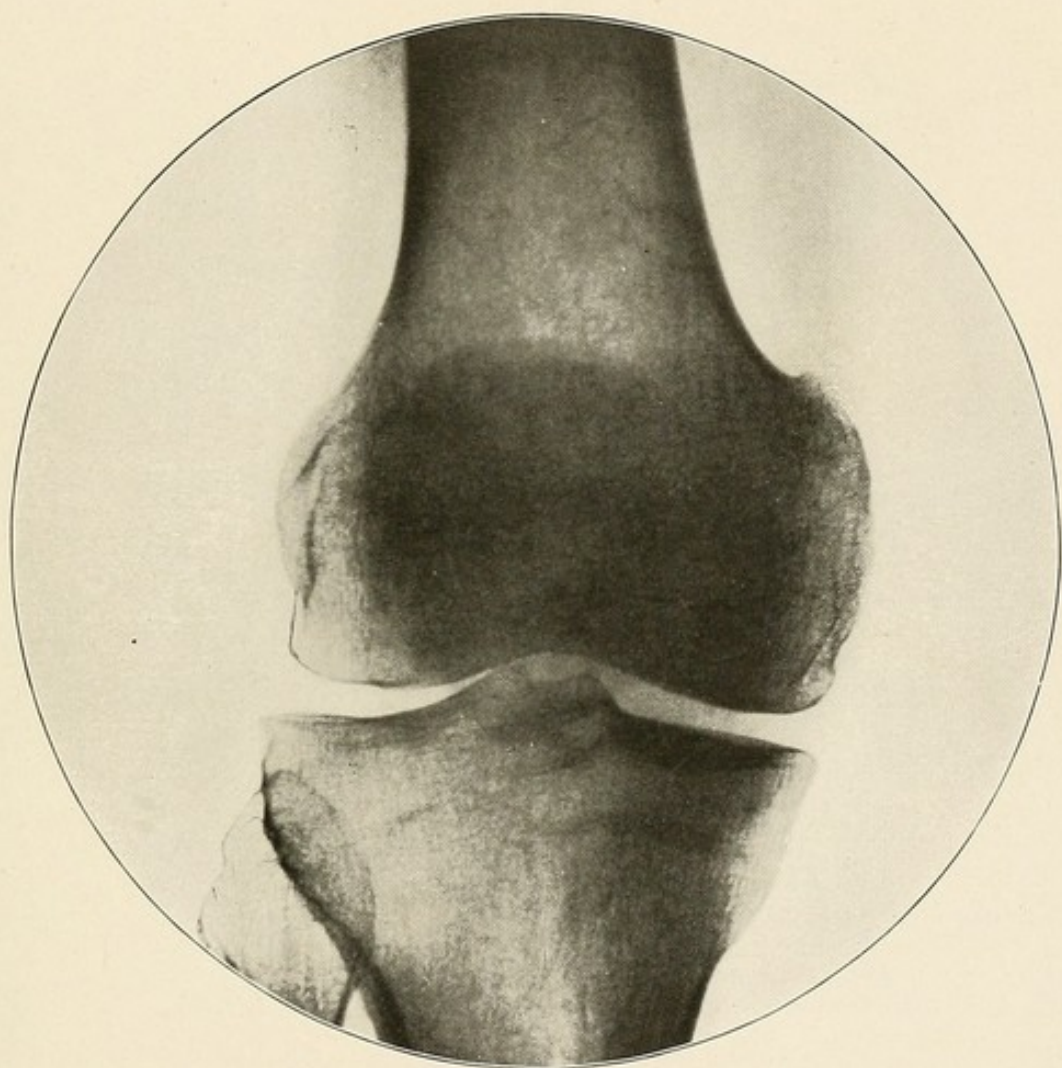


PLATE XI.

PLATE XII.

NORMAL KNEE JOINT—LATERAL VIEW—THE LEG LYING ON ITS EXTERNAL SURFACE.

The patella is seen in its high position, lying over the lower end of the femur.

The external condyle of the femur, which was lying closest to the X-ray plate during the exposure, is easily recognized as the smaller, denser and more distinct shadow.

The head and styloid process of the fibula can be seen in the lower part of the skiagram.

The spine of the tibia is also visible.

Note particularly the clear space lying between the lower end of the patella, and the lower end of the femur and the upper end of the tibia. •



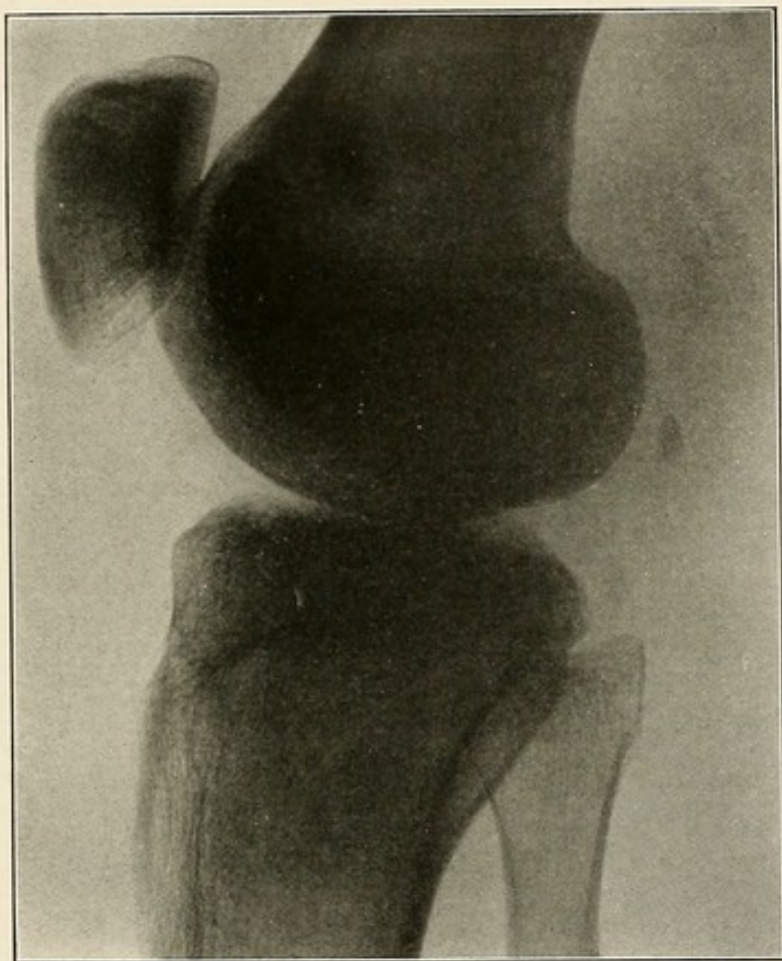


PLATE XII.

PLATE XIII.

NORMAL ANKLE JOINT—LATERAL VIEW—FRACTURE OF THE LOWER END OF THE  
FIBULA.

The bone structure and the articular surfaces and facets show with remarkable clearness.

The astragalus articulates with the tibia and fibula above, with the os calcis below, and with the scaphoid in front.

Its head, neck and body can be plainly made out.

The os calcis articulates with the astragalus above and with the cuboid in front. Its tuberosity, grooves and articular facets, and its rough lower posterior surface for the attachment of the tendo Achillis, all show distinctly.

The deep groove on the inferior surface of the cuboid bone, which lodges the tendon of the Peroncus longus, can also be seen.

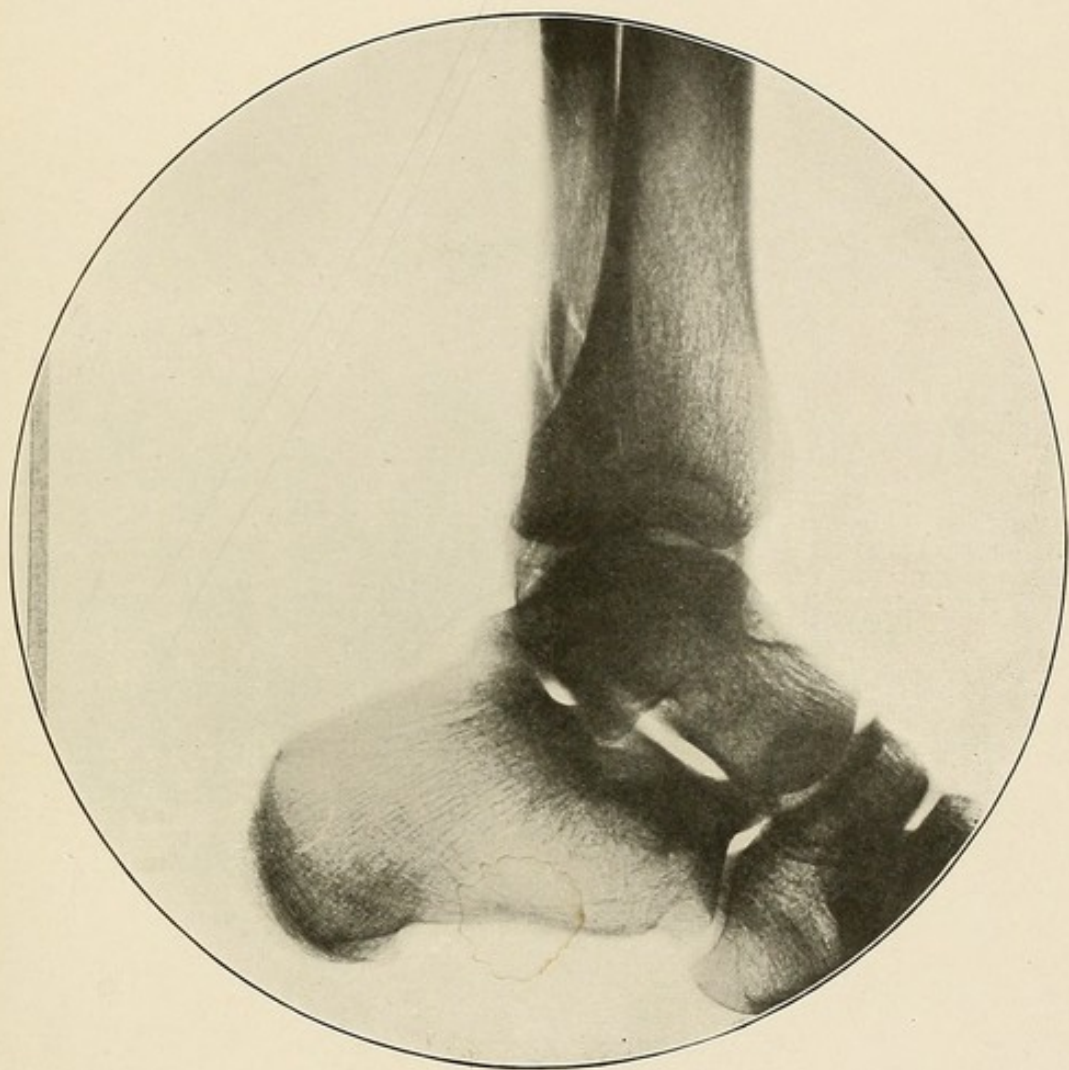


PLATE XIII.



PLATE XIV.

NORMAL FOOT—PLANTAR VIEW.

The cuboid articulates with the os calcis behind, with the external cuneiform on the inner side, and with the 4th and 5th metatarsal bones in front.

The scaphoid articulates with the astragalus behind and the three cuneiform bones in front.

The internal cuneiform articulates with the metacarpal bone of the big toe, the middle cuneiform and the scaphoid.

The external cuneiform is hidden by the middle cuneiform and by the cuboid, but its rectangular shadow, articulating with the cuboid, the scaphoid, the middle cuneiform, and the 2d, 3d and 4th metatarsal bones, can be distinctly made out.

Note the structure and the articulation of the metatarsal bones and phalanges.

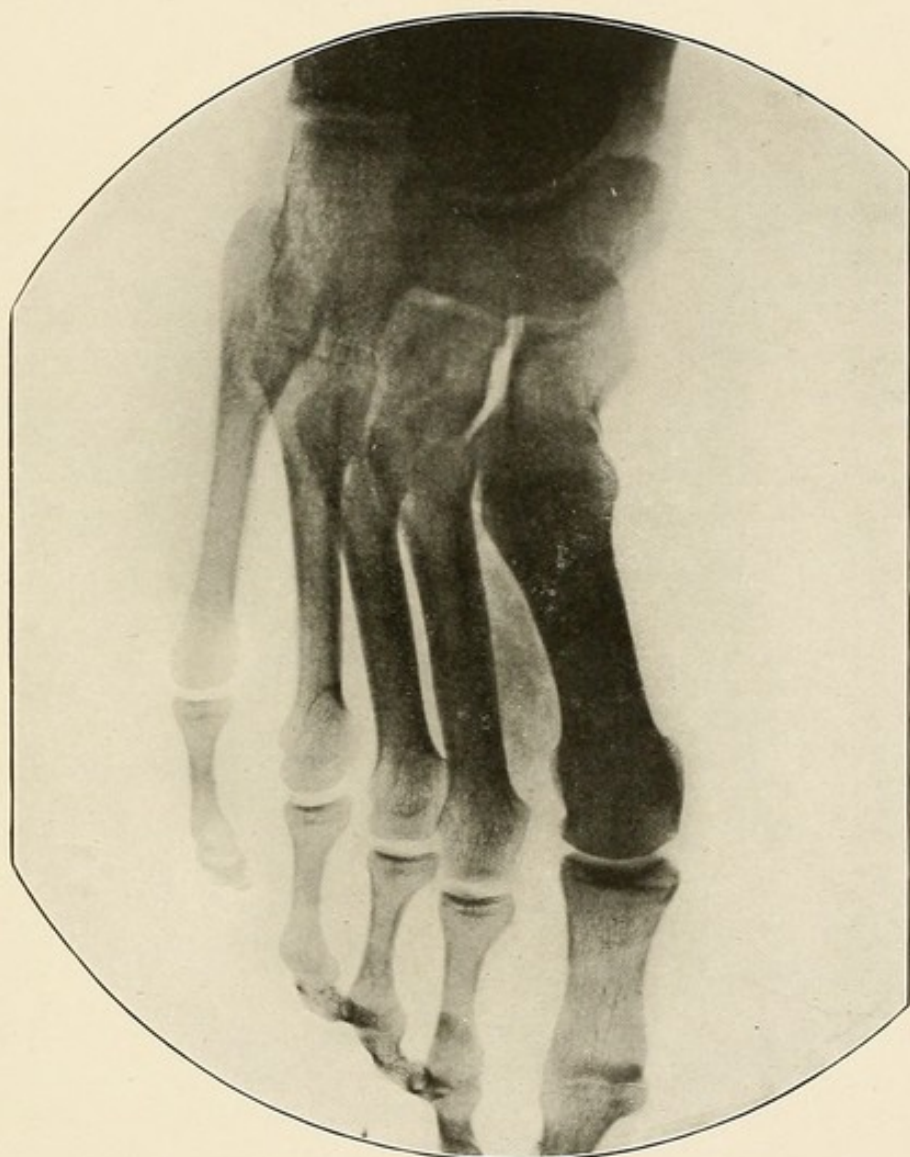


PLATE XIV.





## PART II.

### DISEASES OF BONES AND JOINTS.

---

#### OSTEOMYELITIS.

Osteomyelitis usually affects the shaft of one of the long bones, it may be in close proximity to the joint, but rarely involves the latter, except secondarily in cases of long standing. It is recognized on the radiogram by the lighter area of bone and marrow rarefaction, the surrounding darker areas of bone condensation and in some cases the presence of sequestra (Plate XVI).

The affection causes a softening of the marrow and a suppurative osteitis, which in some cases becomes circumscribed by a process of osteosclerosis. The periosteum is usually swollen and œdematous (Plate XV).

In other cases the medullary cavity becomes involved as the pus accumulates and the walls of the bones may be broken through permitting the discharge of pus outward, with secondary involvement of the soft parts (Plates XVII, XIX, XX). As a result of these changes, necrosis of greater or lesser portions of the bone may ensue with the formation of larger or smaller sequestra (Plates XVI, XVII, XVIII).

In more malignant cases the entire bone marrow becomes involved. The cancellous tissue of one or both of the epiphyses usually becomes involved and secondary involvement of the joint may result (Plate XIX). In young persons the epiphyses very frequently become separated from the diseased shaft by the destruction of the cartilage which binds them together (Plate XX).

PLATE XV.

OSTEOMYELITIS OF THE LOWER END OF THE HUMERUS.

At the lower end of the humerus, a short distance above the epiphyseal line, can be seen a light shadow, due to softening of the bone marrow and to a suppurative osteitis.

The medullary cavity is enlarged, because of the destruction and loss of substance of the cancellous tissue of the bone, caused by the osteomyelitic process.

The light affected area is circumscribed by a dark zone of bone sclerosis. The periosteum is swollen and œdematous.

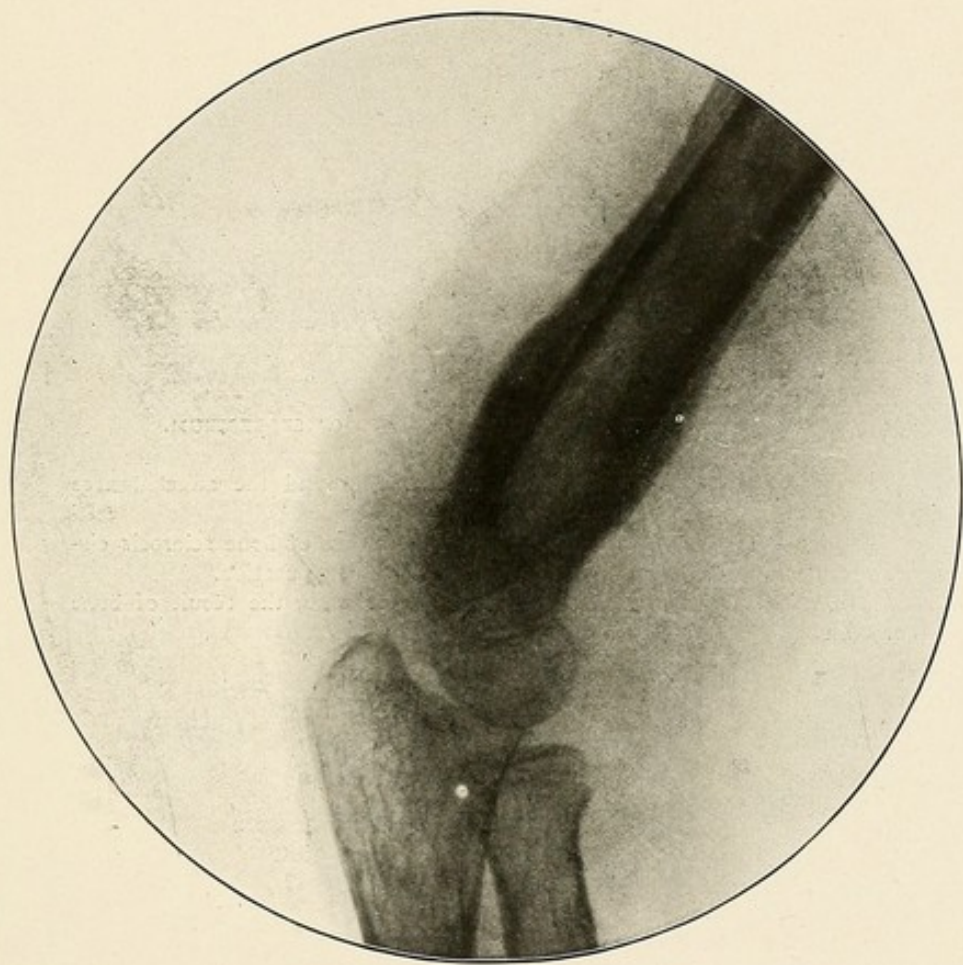


PLATE XV.



PLATE XVI.

OSTEOMYELITIS OF THE RADIUS—PRESENCE OF SEQUESTRUM.

The periosteum is swollen and cedematous around the affected area of the radius.

The bone is swollen, and a dark and dense area of bone sclerosis circumscribes the lighter area of bone and marrow suppuration.

Within this light area is seen a small sequestrum, the result of bone necrosis.

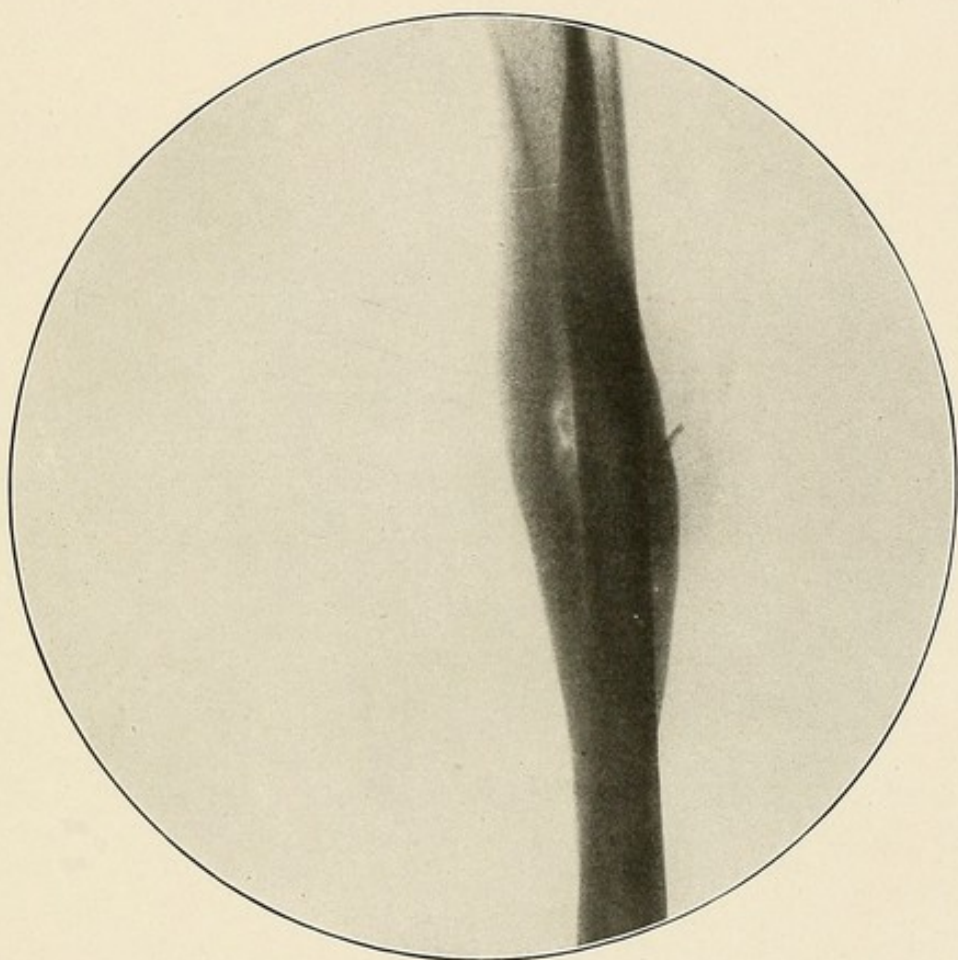


PLATE XVI.

PLATE XVII.

OSTEOMYELITIS OF THE RADIUS—TOTAL DESTRUCTION OF THE BONE—SECONDARY  
INVOLVEMENT OF THE SOFT PARTS.

The entire radius is enlarged and necrosed.

The light areas over the necrosed bone indicate the holes bored by the pus through the walls of the bone.

The secondary involvement of the soft parts is indicated by their darker shadow.



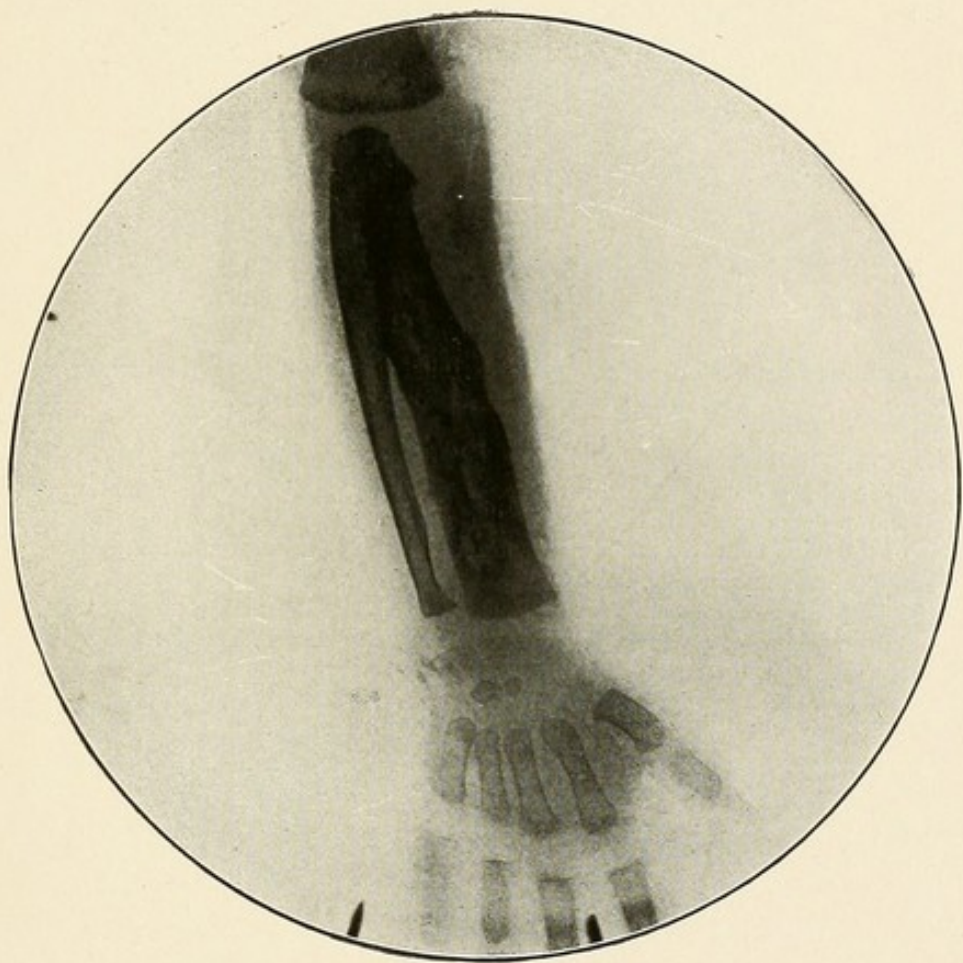


PLATE XVII.

PLATE XVIII.

CHRONIC OSTEOMELITIS OF THE ULNA—EXTENSIVE DESTRUCTION OF THE SHAFT  
WITH THE PRESENCE OF A LARGE SEQUESTRUM.

There is little or no swelling of the soft parts.

The lighter shadow in the soft parts on the ulna side of the forearm, and with its center lying opposite the space between the two fragments of the ulna, indicates the loss of substance in the soft parts and the position of the discharging sinus.

The large sequestrum shows the extent of bone destruction.

Nature's effort at repair is seen in the presence of a new bone formation, starting from the ends of both fragments of the ulna.

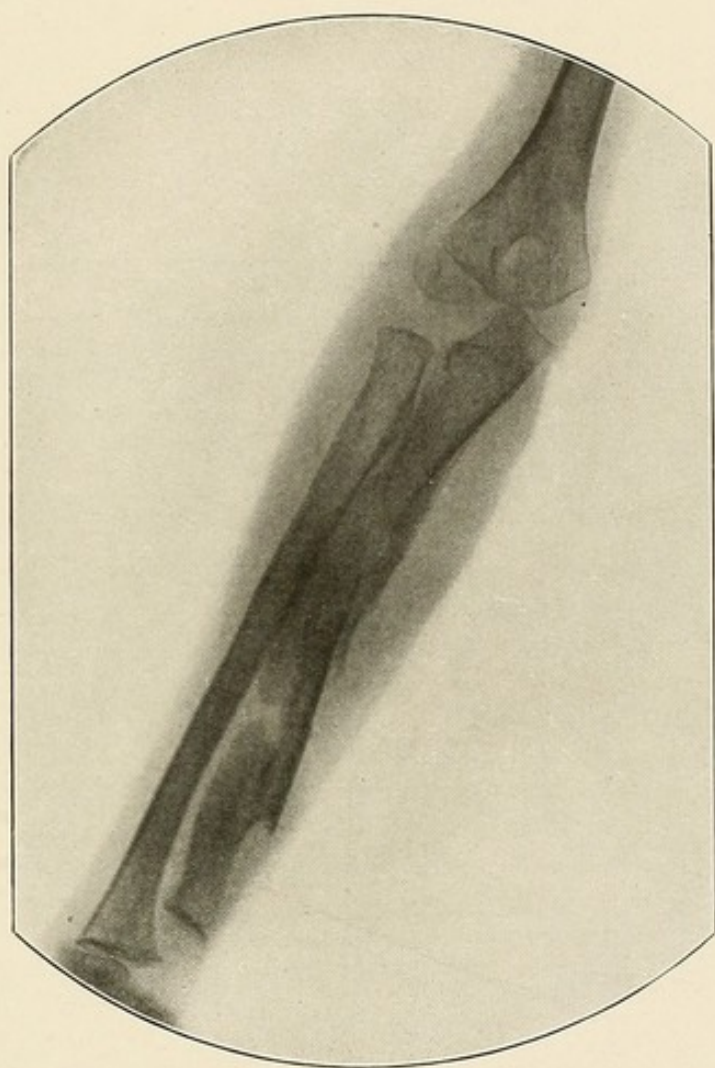


PLATE XVIII.



PLATE XIX.

OSTEOMYELITIS OF THE METACARPAL BONE OF THE THUMB—INVOLVEMENT OF  
THE SOFT PARTS.

The entire bone is involved.

The places through which the pus has bored through the walls of the bone can be plainly seen.

The cancellous tissue of both epiphyses is involved.

The first carpo-metacarpal joint is also involved.

The extent of the secondary involvement of the soft parts is well marked.

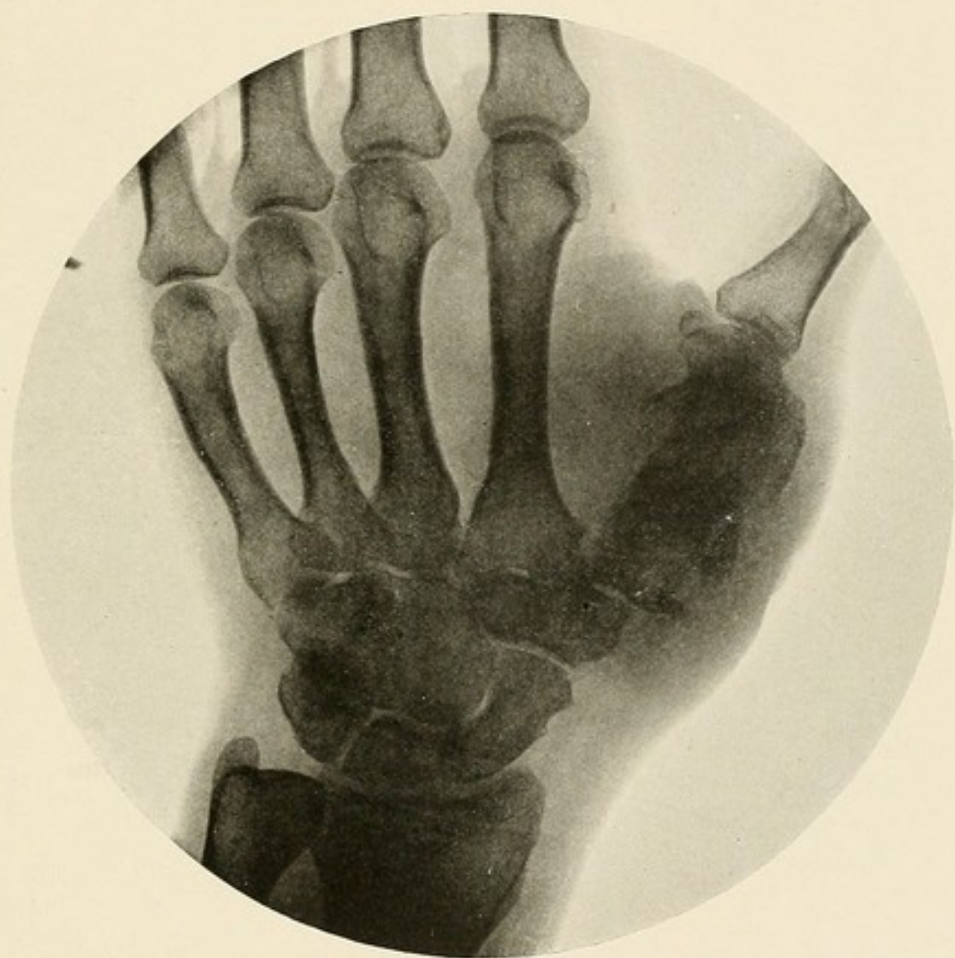


PLATE XIX.

PLATE XX.

OSTEOMYELITIS OF THE ENTIRE SHAFT OF THE HUMERUS—SEPARATION OF THE  
UPPER EPIPHYSIS—PRESENCE OF LARGE SEQUESTRA—SECONDARY  
INVOLVEMENT OF THE SOFT PARTS.

Involvement and destruction of the entire shaft of the bone.

The darker areas indicate the presence of large sequestra, the result of the bone necrosis.

The holes bored by the pus through the walls of the bone are represented by the lighter circumscribed areas in the bone.

The upper epiphysis has become separated from the diseased shaft and remains unaffected by the disease.

The darker shadow of the soft parts shows their secondary involvement.



Ex Libris  
William Benham Snow

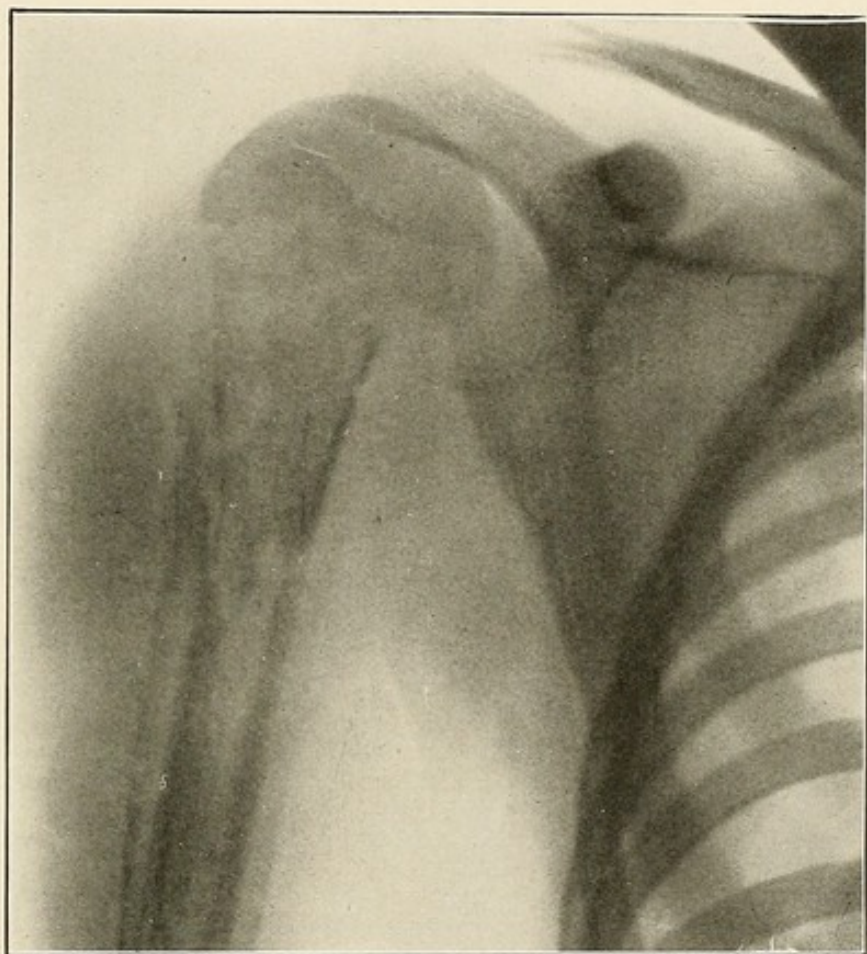


PLATE XX.



### TUBERCULOSIS.

Recognized on the radiogram by the paler hue of the bone shadow, the atrophy of bone, the epiphyseal prominence and, in the later stages of the disease, bone destruction.

Primary tubercular infection of the shaft of bones rarely occurs, except in the phalanges, metacarpal and metatarsal bones. It occurs most frequently in early life and is often associated with involvement of the joints. The tuberculous process causes a disappearance of the lime salts associated with a rarifying and formative process in the bone. This new tissue formation is simple granulation tissue. Whether in or near a joint, the disease often simulates epiphyseal growth, which shows on the radiograph as enlarged, pale and squared (Plate XXI), when compared with the normal side. As the process advances bone destruction takes place, with sometimes the formation of sequestra (Plate XXII). The pus cavity may become circumscribed by a process of bone condensation (Plate XXIII), or may invade the joints and soft parts (Plate XXIV).



PLATE XXI.

TUBERCULOSIS OF THE LOWER END OF THE FEMUR—SECONDARY INVOLVEMENT  
OF THE KNEE JOINT.

The lower end of the femur is enlarged and its lighter shadow indicates bone rarefaction.

The epiphyseal line is lost.

The epiphyses of both the femur and the tibia are pale, enlarged and squared.

New formation granulation is present between the patella and the femur, between the femur and tibia, and in the peri-articular tissues.

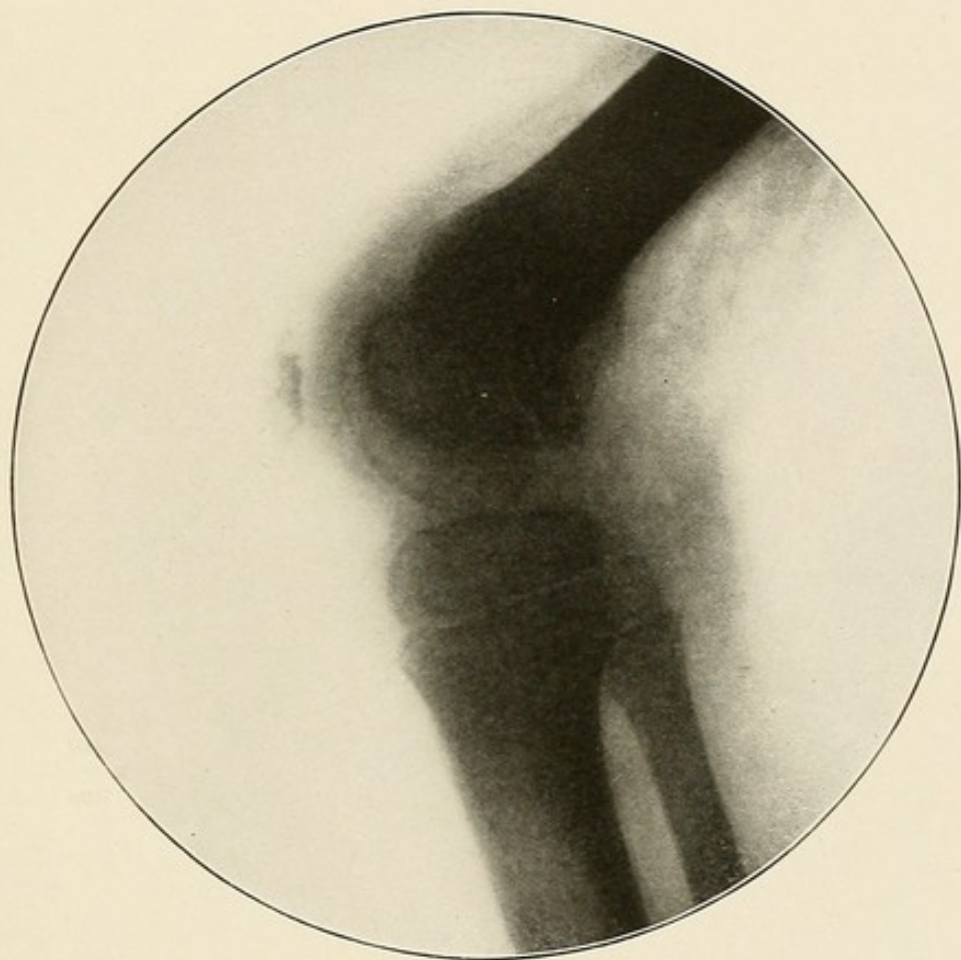


PLATE XXI.

PLATE XXII.

TUBERCULOSIS OF THE BONES OF THE WRIST—PRESENCE OF SEQUESTRA.

Tubercular involvement of the lower end of the radius, with destruction of its articular surface, and loss of bone substance on the outer surface of the bone.

Extensive involvement and destruction of the carpal bones.

The trapezium is the only one of these that can be distinctly made out.

The whole wrist presents the appearance of one mass of tubercular granulation tissue, with irregular darker areas of bone necrosis.

On the ulna side the secondary involvement of the soft parts and the presence of pus are well marked.



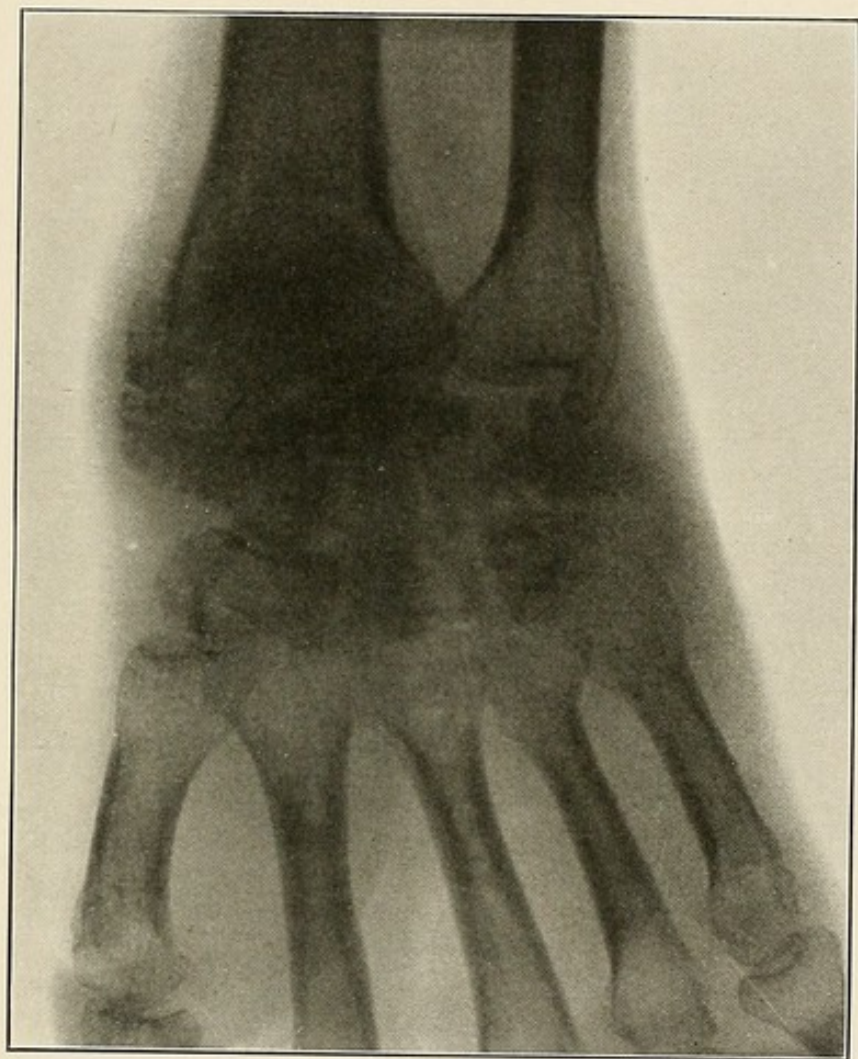


PLATE XXII.

PLATE XXIII.

TUBERCULAR OSTEOMELITIS OF THE TIBIA—THIS CASE HAD SUFFERED WITH AN  
UNDIAGNOSED PAIN IN THE KNEE FOR OVER ONE YEAR, DURING  
WHICH TIME HE WAS SUBJECTED TO NUMEROUS  
AND VARIED TREATMENTS.

Below the epiphyseal line and in a position corresponding to the tubercle  
of the tibia is a light shadow of bone rarefaction, surrounded by a well-  
marked, dense shadow of bone sclerosis.

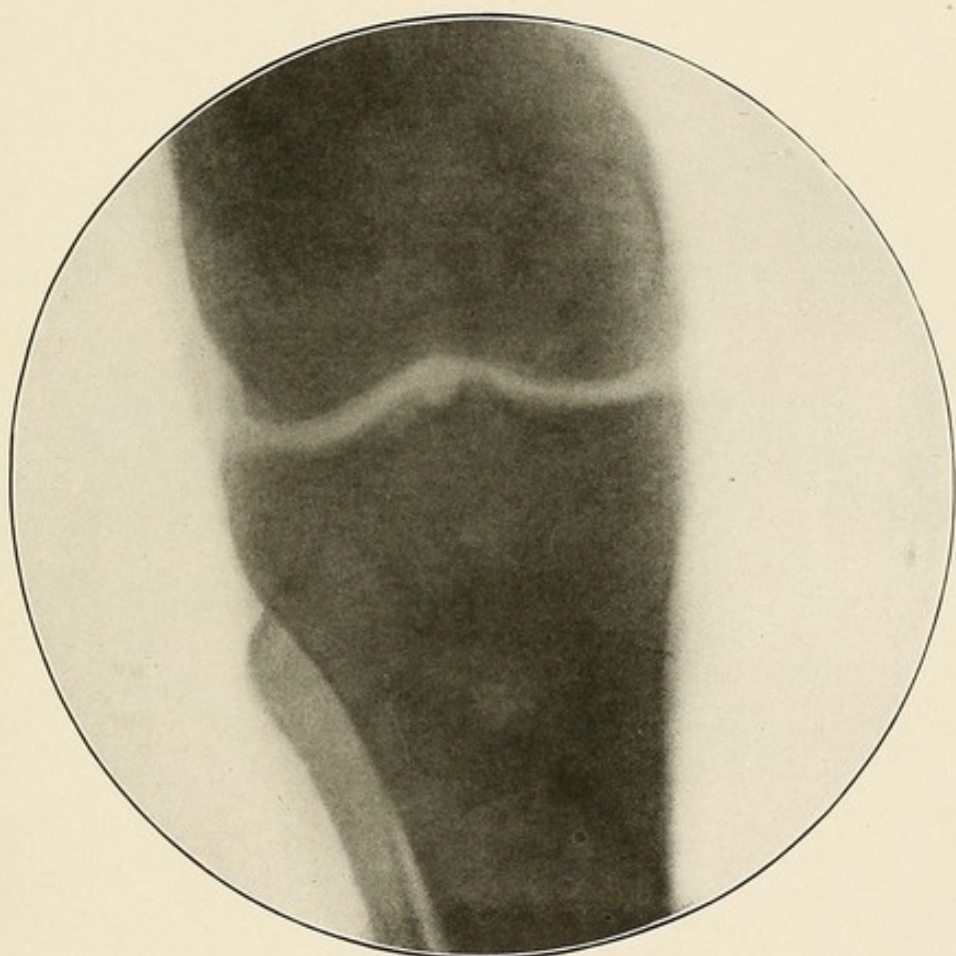


PLATE XXIII.



PLATE XXIV.

TUBERCULAR OSTEITIS OF THE TIBIA.

Below the epiphyseal line, on the anterior and inner surfaces of the tibia, is the light shadow of bone rarefaction.

The extent of the bone involvement and the loss of bony substance can be plainly seen.

The darker shadow of the soft parts to the inner side of the tibia shows the secondary involvement of these parts and the presence of granulation tissue.

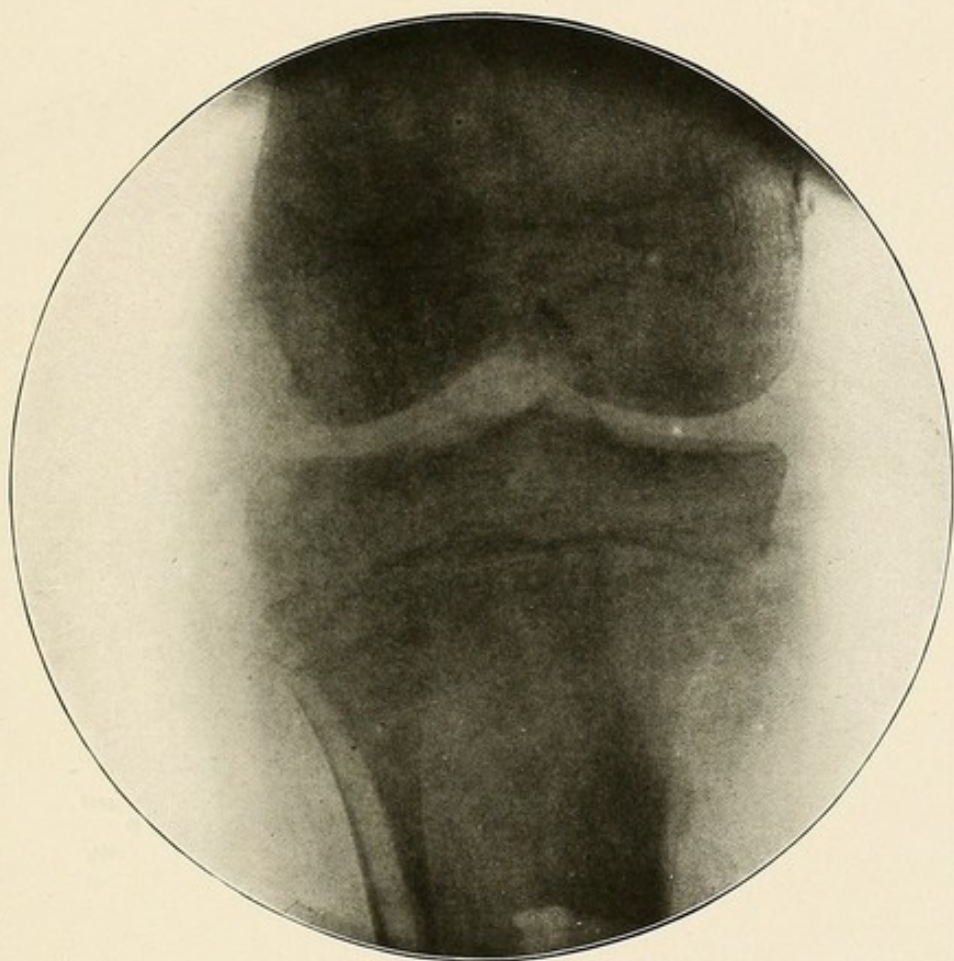


PLATE XXIV.





### SARCOMA.

Osteo-Sarcoma is recognized on the radiogram by a shadow usually paler than that of normal bone and *resembling in appearance that of white paint frosted on a pane of glass by means of a piece of absorbent cotton*. This appearance is regarded as characteristic by the author. It is due to the fact that on account of the degenerative changes as well as from the hemorrhagic extravasation, larger or smaller cystic cavities develop and the extravasated blood causes areas of pigmentation. Besides this, in some types of the disease, new bone formation takes place in the mass in the shape of small calcified plates surrounded by a softer zone.

The disease starts in the bone or in the periosteum and may even start from the outside layers of the periosteum, involving the soft parts, itself remaining intact between the bone and the growth (Plate XXV). Most frequently a new bone is formed beneath the periosteum, so that the tumor is encased in a thin bony shell (Plates XXVI, XXVIII, XXX). Perforating this and the periosteum the tumor invades the soft parts, its outline becomes lost and its shadow fades away, blending with that of the soft parts.

In upwards of two-thirds of the cases of sarcoma of the long bones, the growth will be found in one end of the bone, the lower end in the femur and the upper end in the tibia and humerus, probably starting in the epiphyses, *but very rarely invading the joint*, except in the later stages of the disease (Plate XXVII). In a few cases, especially those of the femur and tibia, it begins in the middle of the shaft and here it is always of the periosteal type, forming a fusiform enlargement of the shaft in the early stages. Pathological fractures due to this disease are not infrequent (Plates XXVIII, XXIX).

In one case of sarcoma (Plate XXX), in which *the characteristic frosted-like appearance* was not present operation revealed a cavity walled by a thin shell of bone and filled with a homogeneous substance resembling unorganized granulation tissue which could be easily scooped out. The pathologist's report was *giant cell sarcoma*.

This type of sarcoma, the myelogenous or medullary giant cell, is prone to develop cysts in bone, and these cysts are often filled with blood and comprise the so-called bone aneurisms. The absence of cystic cavities and pigmentation, the result of degenerative changes and hemorrhagic extravasation and of calcified plates so generally found in the other types of osteo-sarcoma, account for the absence of the characteristic appearance mentioned above.

PLATE XXV.

SARCOMA OF THE SOFT PARTS OF THE THIGH—NO INVOLVEMENT OF THE FEMUR  
—X-RAY FINDING CONFIRMED BY A CAREFUL EXAMINATION  
OF THE LIMB AFTER A HIP AMPUTATION.

The dark mottled shadow surrounding the femur and seen more especially behind that bone is a sarcomatous tumor of the soft parts of the thigh.

The bone is not involved.

Its normal outline can be distinctly made out through the abnormal shadow.



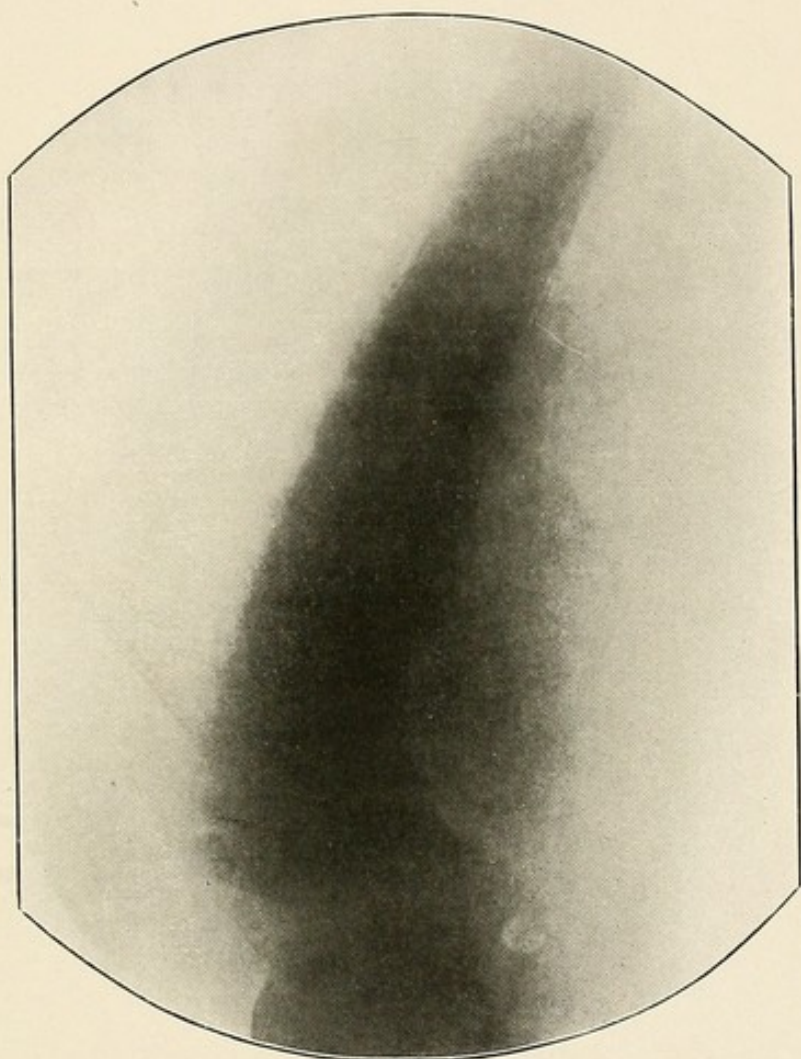


PLATE XXV.



PLATE XXVI.

OSTEO-SARCOMA OF THE UPPER END OF THE HUMERUS—SECONDARY INVOLVEMENT OF THE SOFT PARTS.

The upper extremity of the humerus is enormously enlarged, and its normal structure is replaced by the characteristic appearance of osteosarcoma.

The disease has perforated the thin, bony envelope encasing the tumor notably on the inner and outer borders, and in these places it invades the soft parts; its outline is lost, and its shadow blends with that of the latter tissues.

The shoulder joint is not involved.

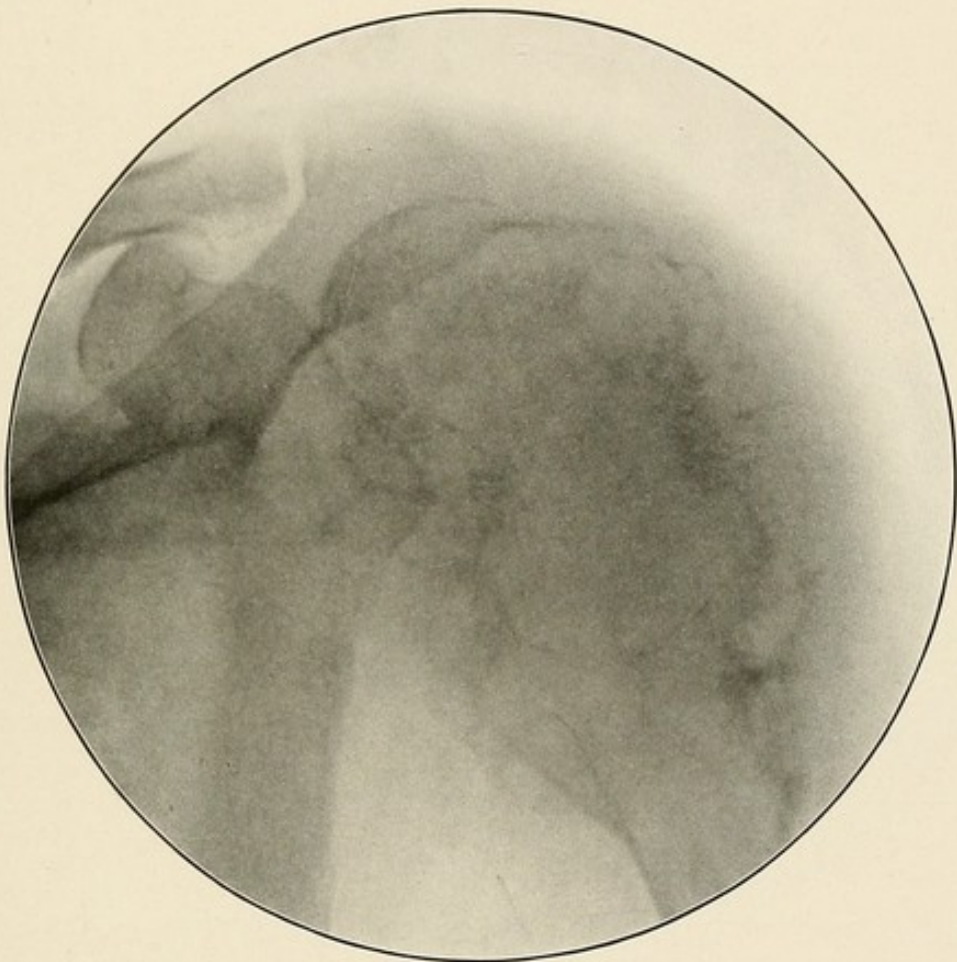


PLATE XXVI.

PLATE XXVII.

IMMENSE OSTEO-SARCOMA OF THE LOWER END OF THE FEMUR—INVOLVEMENT  
OF THE KNEE JOINT.

This skiagram shows the latter stages of osteo-sarcoma.

A large mass, presenting the characteristic appearance of osteo-sarcoma, replaces the normal shadows of the lower end of the femur and of the knee joint.

The peri-articular tissues and surrounding soft parts are involved.



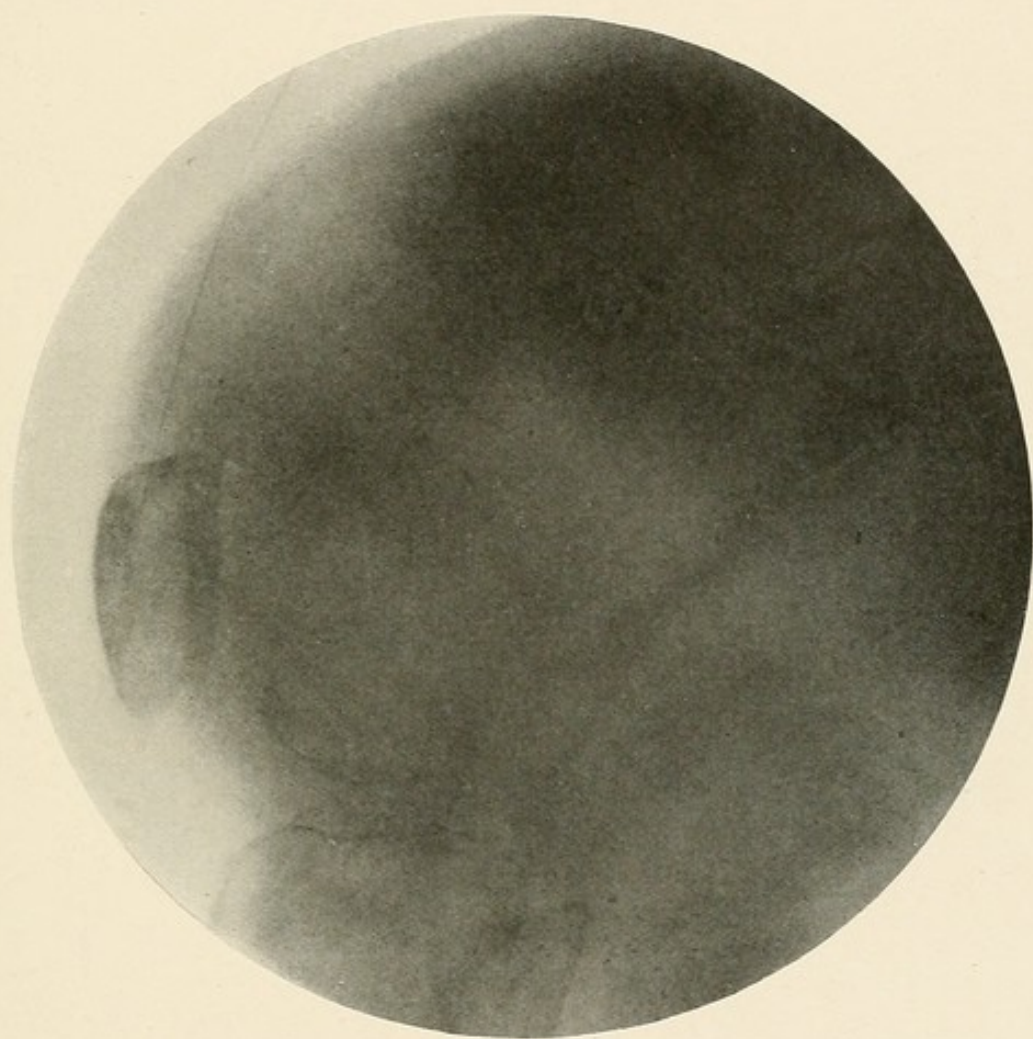


PLATE XXVII.

PLATE XXVIII.

OSTEO-SARCOMA OF THE UPPER END OF THE HUMERUS—PATHOLOGICAL  
FRACTURE.

The upper end of the humerus is enlarged, and its normal shadow is replaced by the characteristic appearance of osteo-sarcoma.

The disease has perforated the thin, bony envelope encasing the growth on the inner border, and in that location it invades the soft parts.

There is a pathological fracture present.

The contrast between the diseased bone above the fracture and the unaffected shaft below it is well marked.

The soft parts about the fractured ends of the diseased bone are involved by the disease.

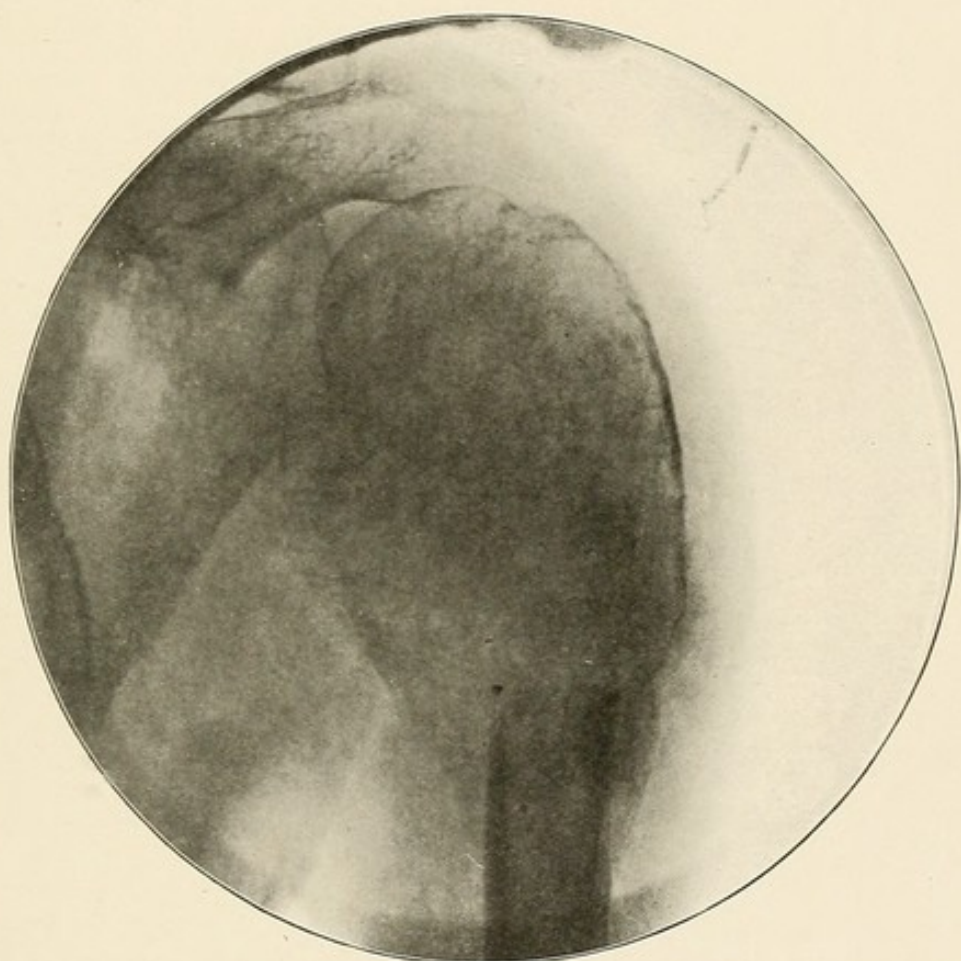


PLATE XXVIII.



PLATE XXIX.

OSTEO-SARCOMA OF THE FEMUR—PATHOLOGICAL FRACTURE.

The tumor mass, including the ends of the fractured bone and involving the surrounding soft parts, presents the characteristic appearance of osteo-sarcoma.

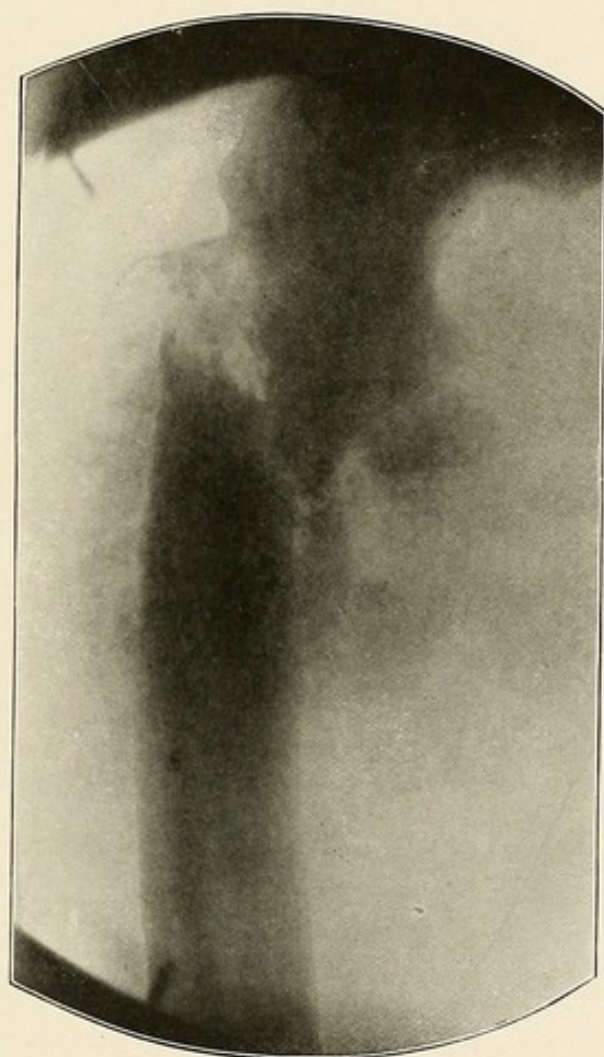


PLATE XXIX.

PLATE XXX.

OSTEO-SARCOMA OF THE LOWER END OF THE RADIUS—GIANT CELL VARIETY.

The characteristic appearance of sarcoma is absent.

A tumor, encased in a thin bony shell and filled with tissue resembling the tubercular granulation tissue, replaces the normal bony shadow of the lower end of the radius.

The outline of the tumor is distinct, and it can be well made out, separated from the normal soft parts above it by a thin bony wall.

The normal inner border of the radius is lost in the new growth.

Its articular surface remains intact.



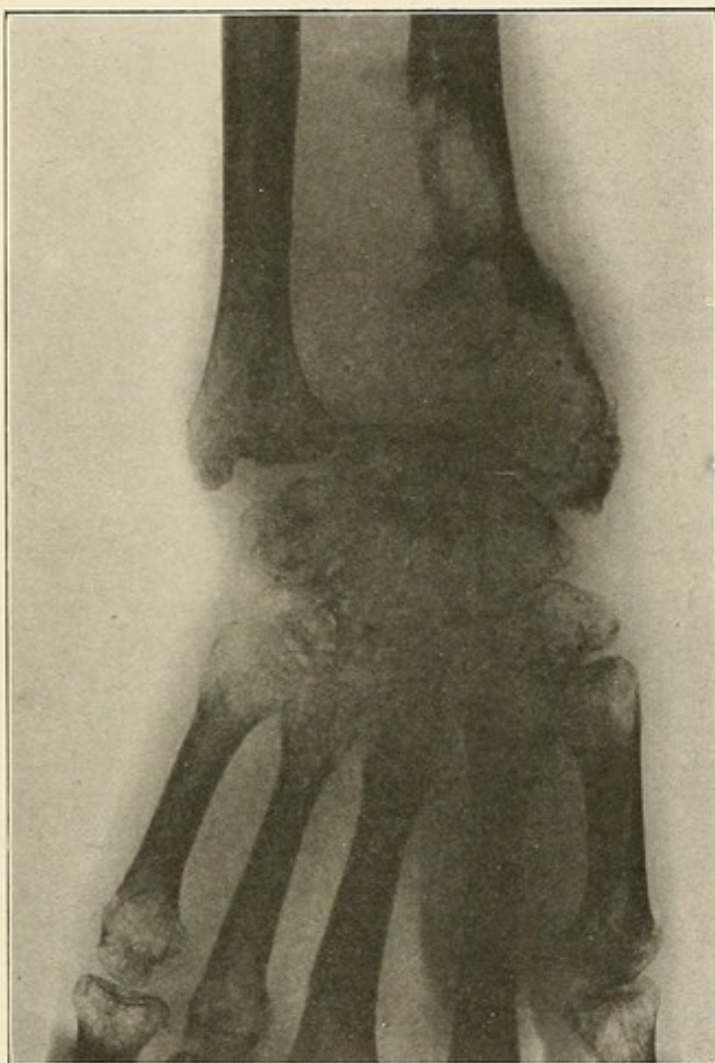


PLATE XXX.



### SYPHILIS.

Distinguished on the radiogram by the darker hue of bone and the thickened and irregular outline of the periosteal covering, due to the condensing osteitis in and on the surface of the bone and the deposit of new bone under the periosteum. The disease usually commences in the periosteum, which becomes thickened and infiltrated (Plate XXXII), with or without the formation of the bony matter. As the disease progresses, the channels in the bone, enlarged by a rarefying osteitis, forming irregular defects, are filled with new fibrous tissue (Plates XXXIII, XXXIV). The process is not infrequently associated with suppuration (Plate XXXV, and the necrosis of a larger or smaller portion of bone (Plate XXXVI).



PLATE XXXI.

SYPHILITIC GUMMATA OF THE MUSCLES OF THE THIGH.

The shadow seen in the muscles of the anterior surface of the thigh is a mass of sclerotic tissue of syphilitic origin.

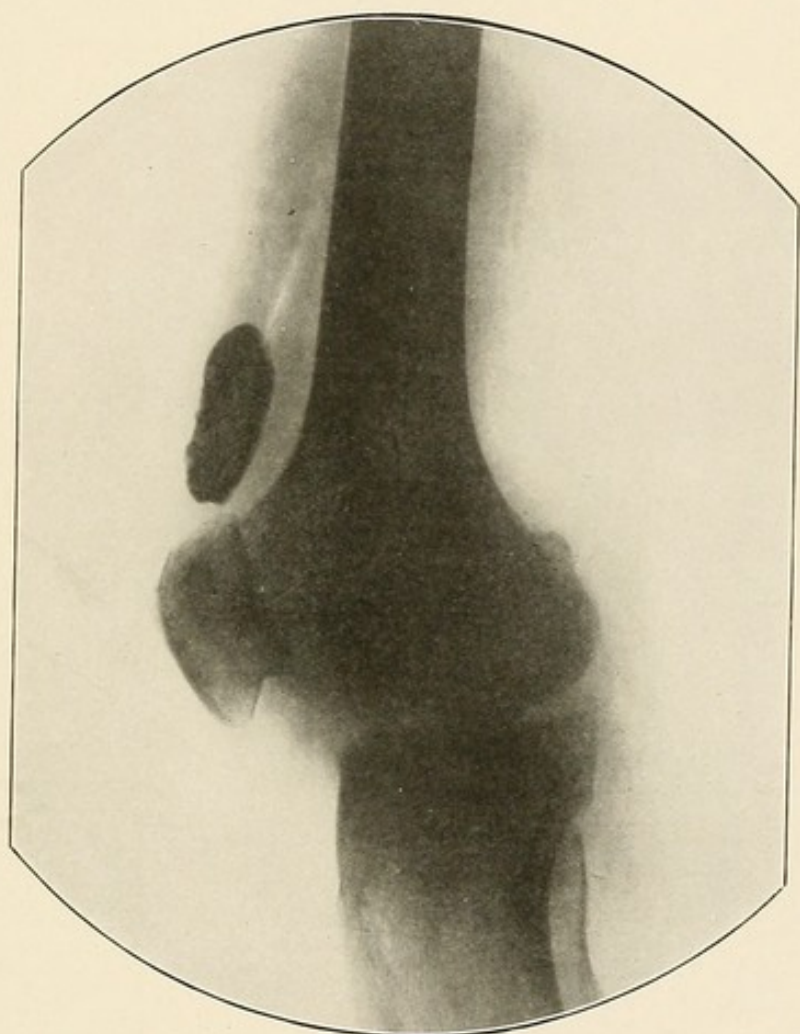


PLATE XXXI.

PLATE XXXII.

SYPHILITIC PERIOSTITIS OF THE TIBIA.

The periosteum is swollen and raised.

The shadow is darker than in the other forms of periostitis, and its outline is rough instead of smooth (see Plate XXXVII).

The irregular darker areas indicate the presence under the periosteum of new formation sclerotic or bone tissue, due to the syphilitic process.



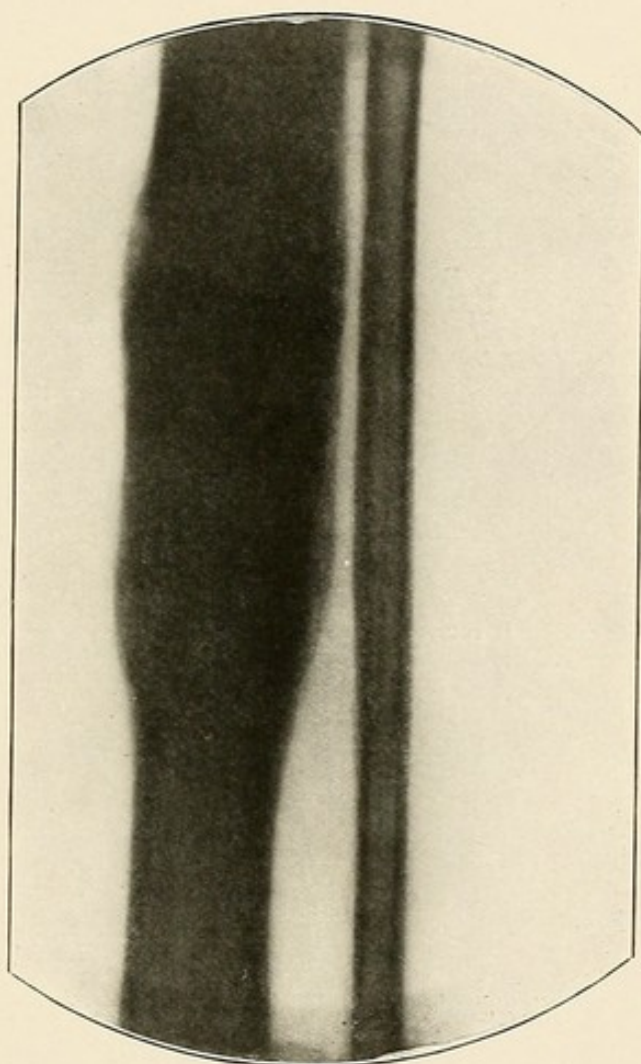


PLATE XXXII.

PLATE XXXIII.

SYPHILIS OF THE LOWER END OF THE RADIUS.

The bone shadow is much darker than the normal.  
Its outline is rough and presents irregularities.

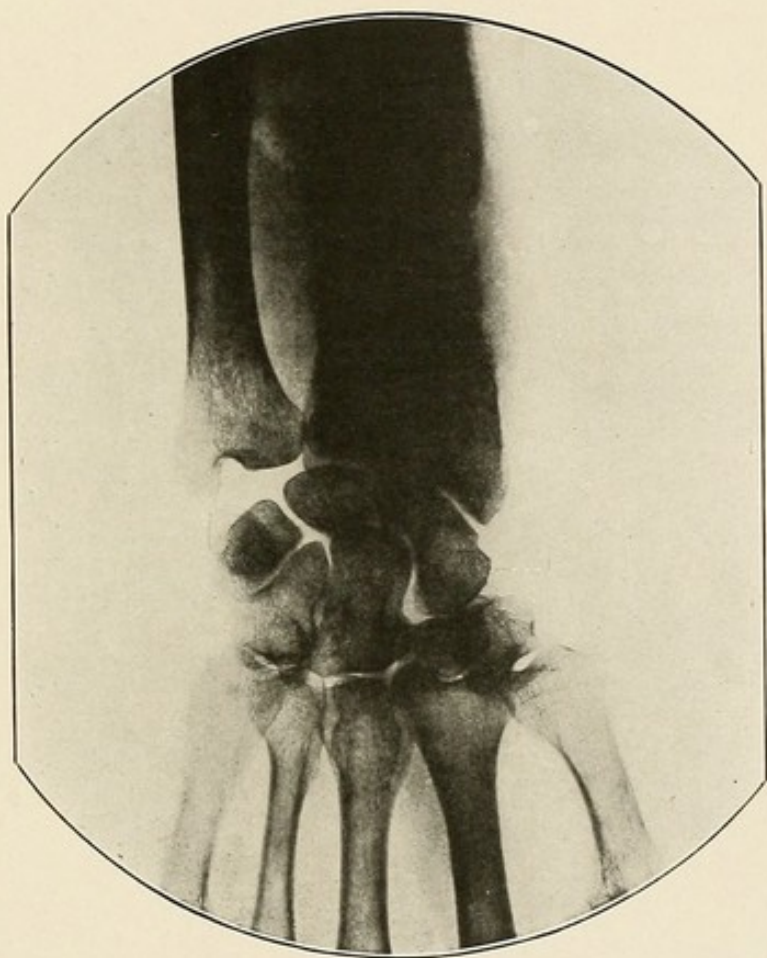


PLATE XXXIII.



PLATE XXXIV.

SYPHILIS OF THE FEMUR—CALCAREOUS DEGENERATION OF THE POPLITEAL  
ARTERY—PRESENCE OF A PHLEBOLITH IN THE POPLITEAL VEINS.

The normal shadow of the femur is replaced by the darker shadow of osteo-sclerosis. Its outline is rough and presents irregularities.

The popliteal artery has undergone calcareous degeneration, and is visible in its whole course throughout the skiagram.

The small oval shadow behind the femoral condyle is a phlebolith in one of the popliteal veins.

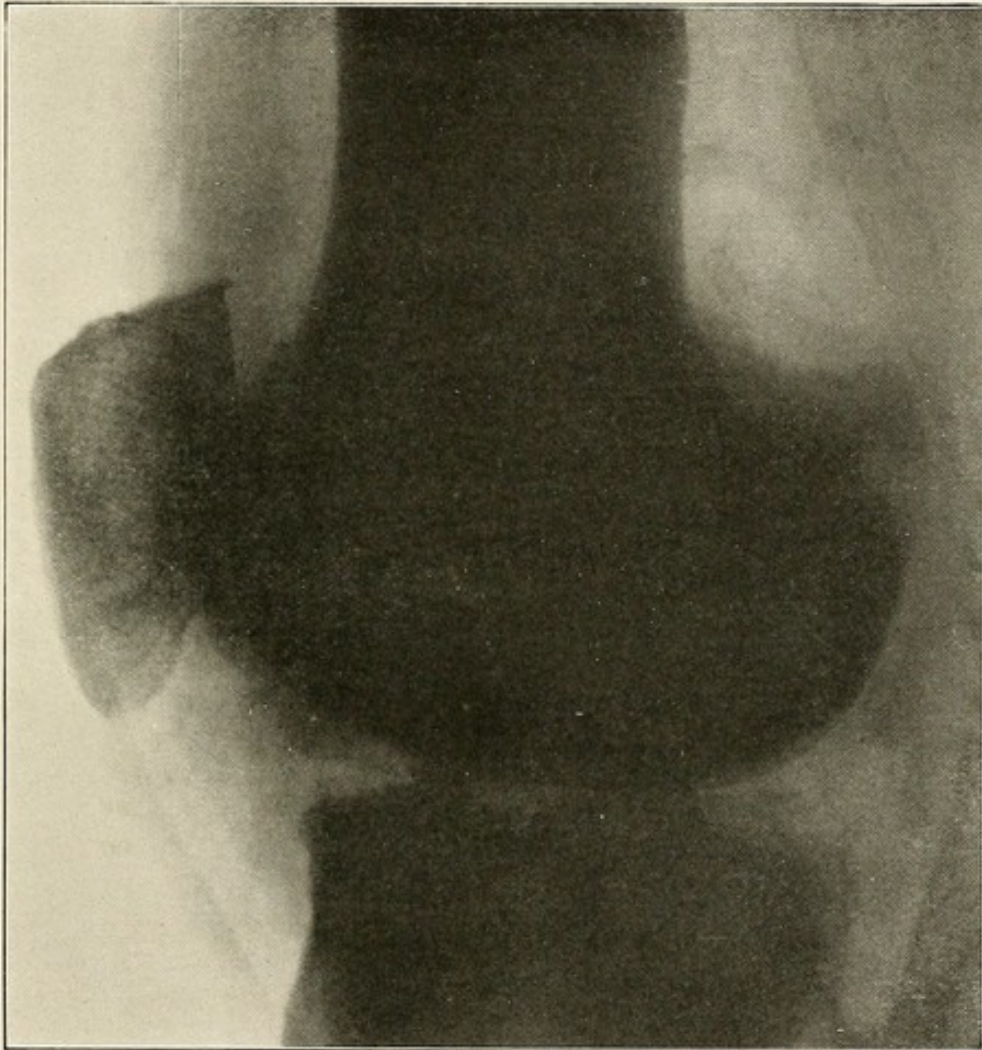


PLATE XXXIV.

PLATE XXXV.

SYPHILIS OF THE FEMUR—NECROSIS OF BONE—INVOLVEMENT OF THE SOFT  
PARTS.

The darker shadow of the bone, its rough outline presenting irregularities, forms a typical picture.

Evidence is also present of destruction of bone, with loss of substance and of suppuration, with secondary involvement of the soft parts.



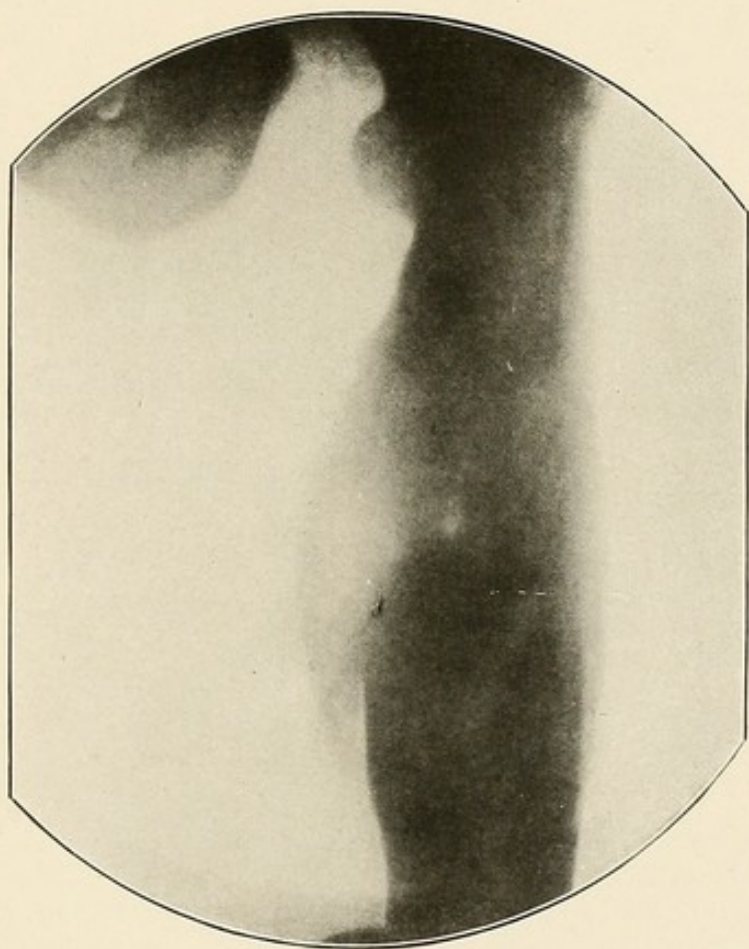


PLATE XXXV.

PLATE XXXVI.

SYPHILIS OF THE ULNA—EXTENSIVE LOSS OF SUBSTANCE.

Compare the darker shadow of the ulna with the normal shadow of the radius.

The skiagram also shows the extent of the loss in bony substance and the presence of necrosed bone.

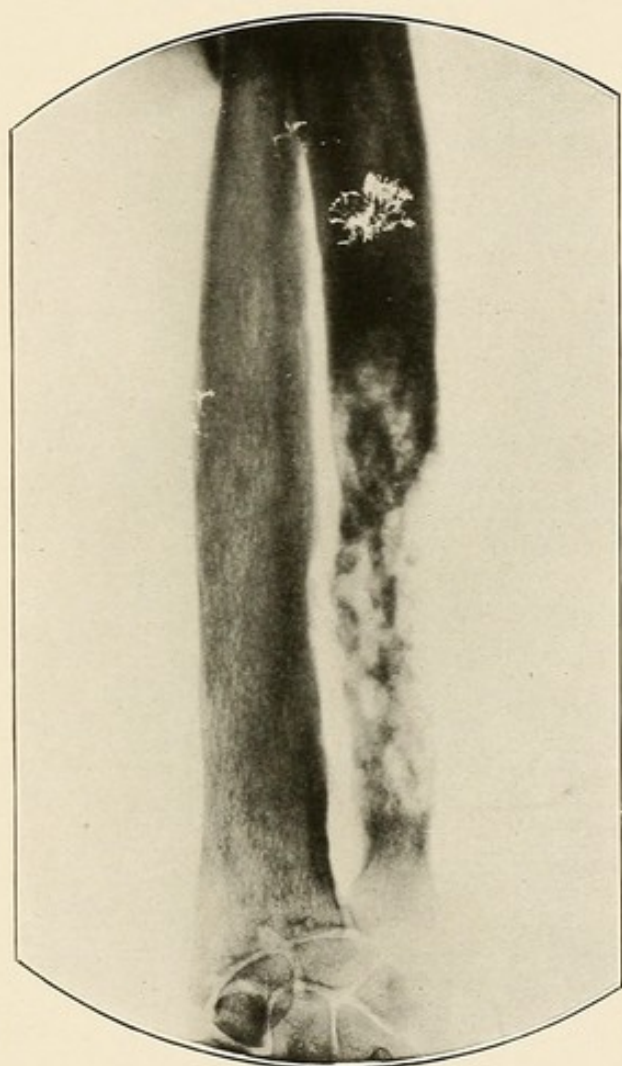


PLATE XXXVI.





### PERIOSTITIS.

(Plate XXXVII): Periostitis can only be distinguished on the radiogram when there is considerable thickening of the periosteum or some exudate existing between it and the bone. It is then recognized as a circumscribed shadow, darker than the normal soft parts. This shadow may be large or small, entirely surround the bone or appear only as a raised dark shadow upon one of the bone surfaces. If there is secondary involvement or caries of the bone this will also show plainly in the radiogram. The results of periostitis, the formation of fibrous or osseous tissue between the periosteum and the bone, can also be plainly seen as dark circumscribed areas next the bone.

PLATE XXXVII.

PERIOSTITIS OF THE TIBIA.

The periosteum is swollen and raised, and there is an exudate between it and the anterior surface of the tibia.

The darker circumscribed area on the anterior border of the bone is a new bone formation, caused by the periostitis.



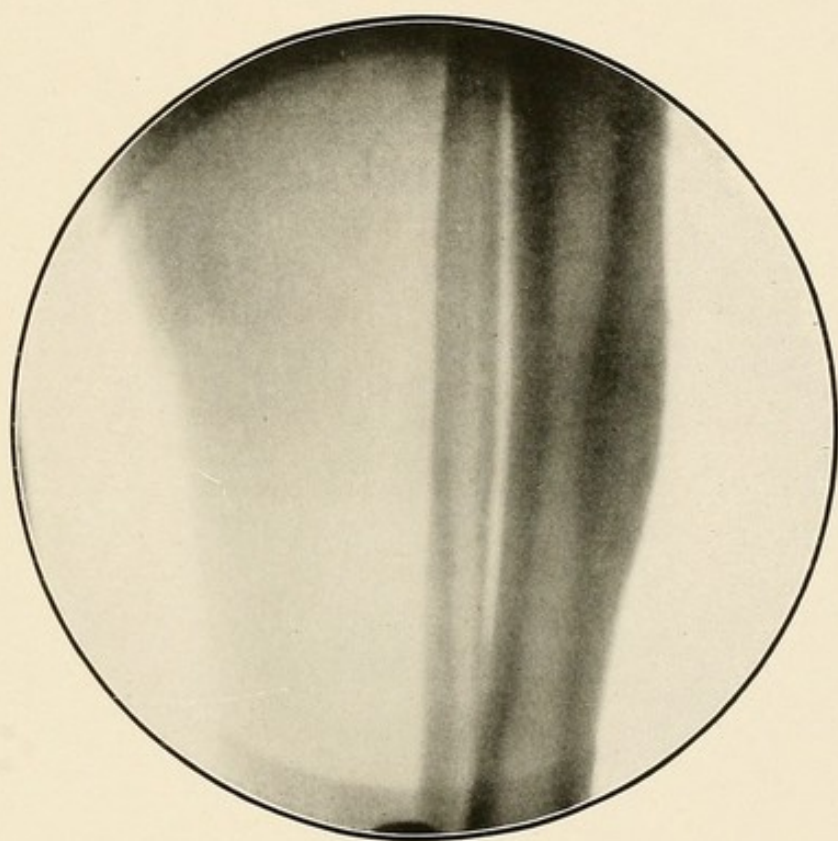


PLATE XXXVII.



### RICKETS.

Rickets is recognized by the pale bone shadow, the enlarged medullary canal and the bending of the epiphyses or the shaft or both of the long bone.

The condition usually occurs during the first two years of life, but it may be congenital or may occur as late as the twelfth year. Proper calcification does not take place. At the same time, the dilatation of the medullary cavity goes on irregularly and often to an excessive degree. The cartilaginous and sub-periosteal cells grow with increased rapidity and exuberance and in an irregular manner. As a result the bones do not possess solidity and cannot resist the traction of the muscles (Plate XXXVIII) or outside pressure. The epiphyses may be displaced or bent, especially in the ribs, less frequently in the long bone. The long bones or the pelvic bones may be bent in a variety of forms (Plates XXXIX, XL).

PLATE XXXVIII.

RACHITIC BONES.

The shadow of the bones is paler than normal.

The upper and inner end of both tibias; just below the epiphyseal line, is bent downwards.

There is a slight bending of the shafts of both tibias.



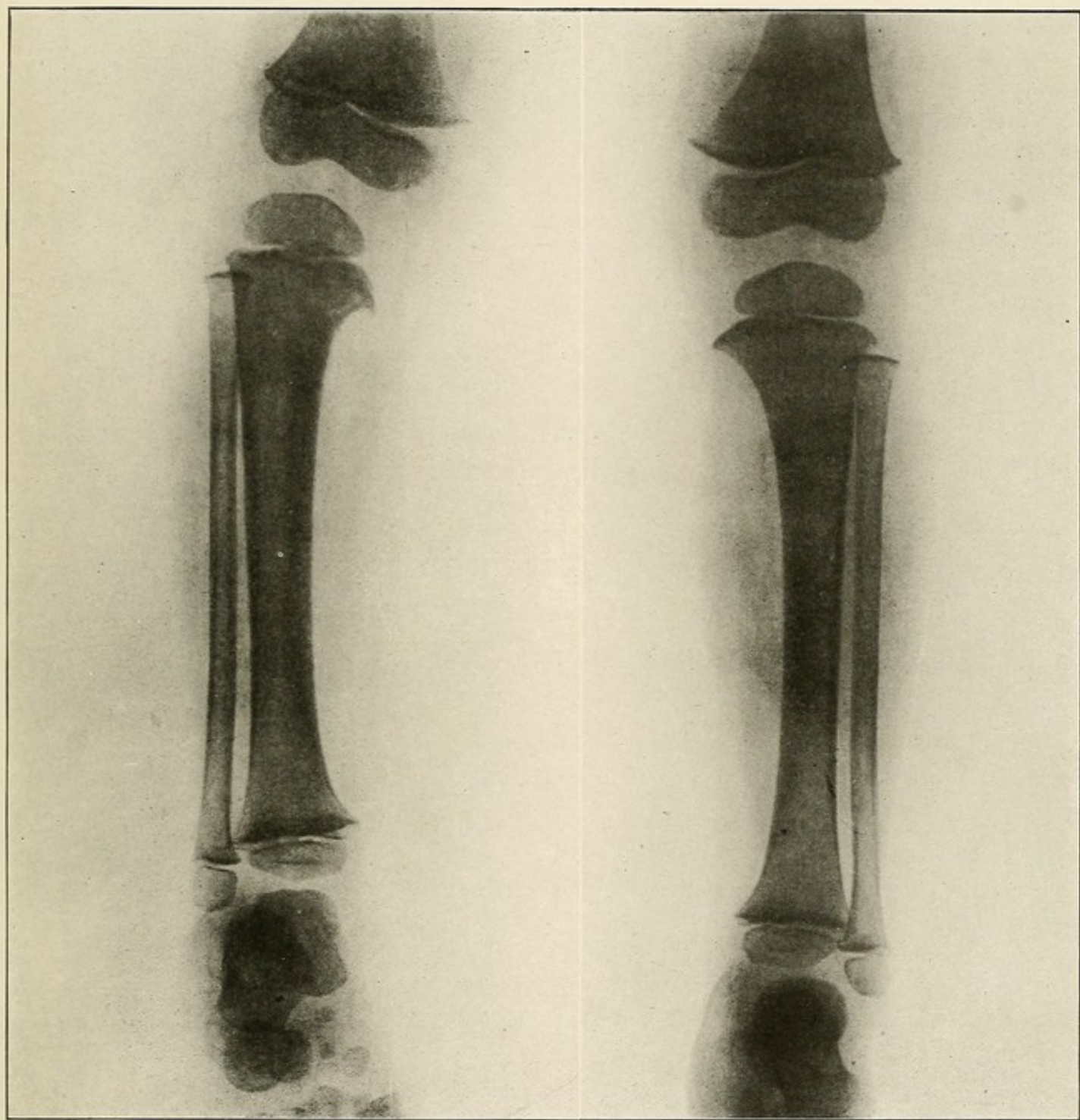


PLATE XXXVIII.

PLATE XXXIX.

RACHITIC BONES.

The lower and inner end of both femurs, just above the epiphyseal line, is bent upwards, and the upper and inner end of both tibias, just above the epiphyseal line, is bent downwards.

The shafts of both femurs and tibias are slightly bent.

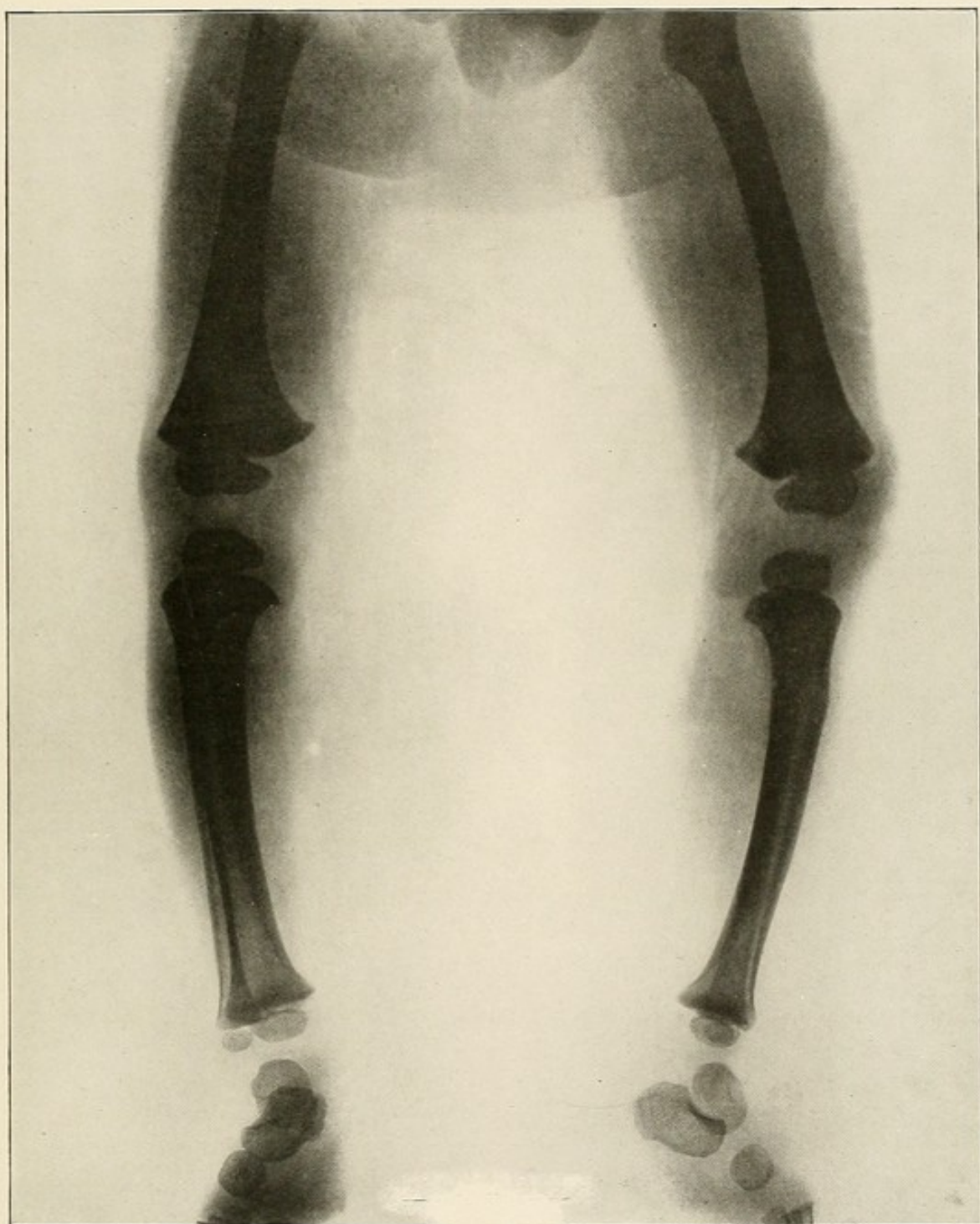


PLATE XXXIX.



PLATE XL.

RACHITIC BONES.

This skiagram shows the pale shadow and the enlarged medullary cavities of both tibias.

There is a marked bending of the shafts of both tibias.



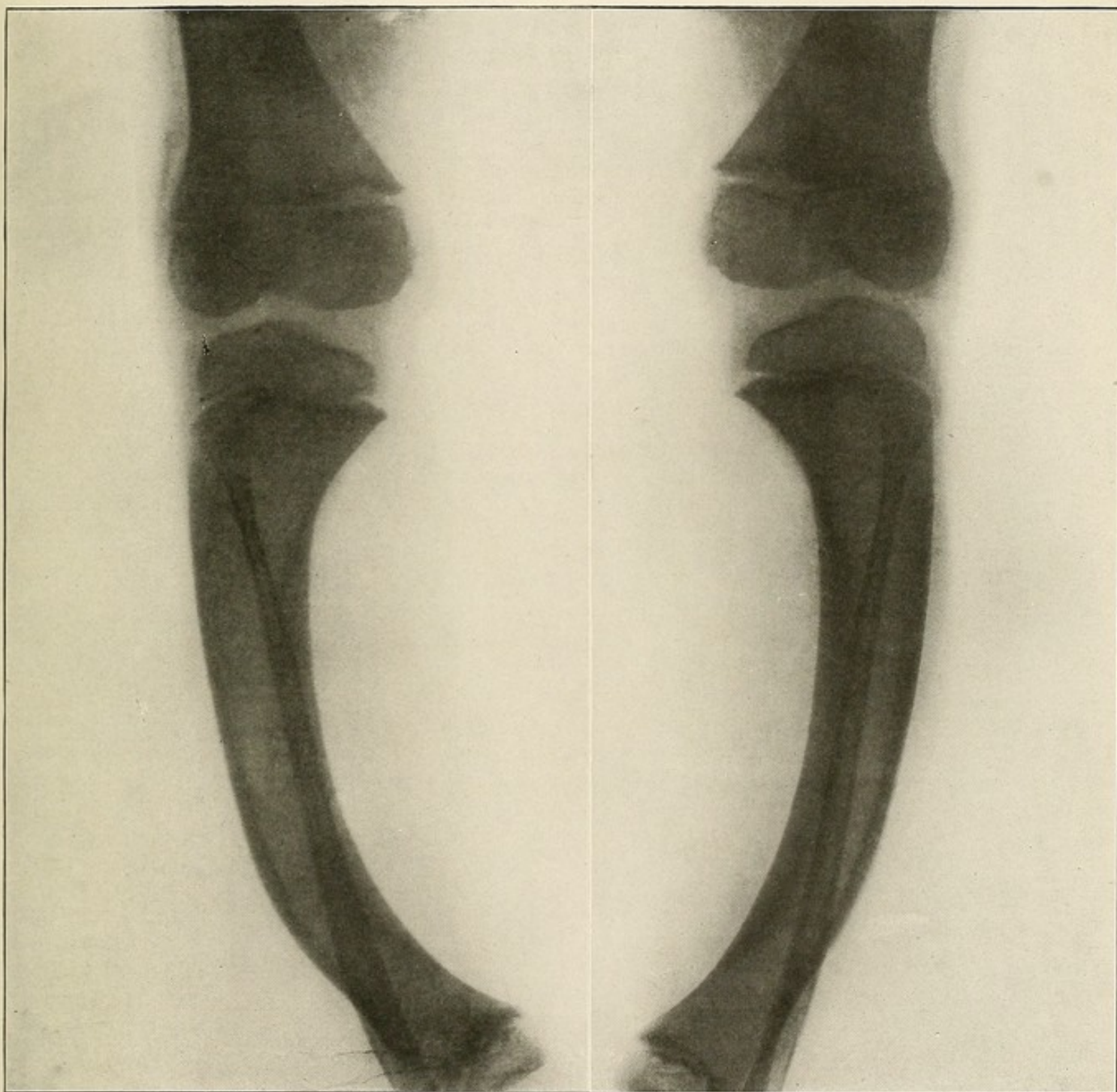



PLATE XL.



### SCURVY.

Scurvy, although not truly a disease of bones, causes frequently sub-periosteal hemorrhages, which are most generally found at the lower extremity of the long bones (Plates XLI, XLII).

PLATE XLI.

SUB-PERIOSTEAL HEMORRHAGE IN SCURVY—ACUTE STAGE.

The sub-periosteal hemorrhage is represented on the skiagram as a light fusiform shadow, lying between the anterior surface of the femur and the soft parts on the anterior surface of the thigh.



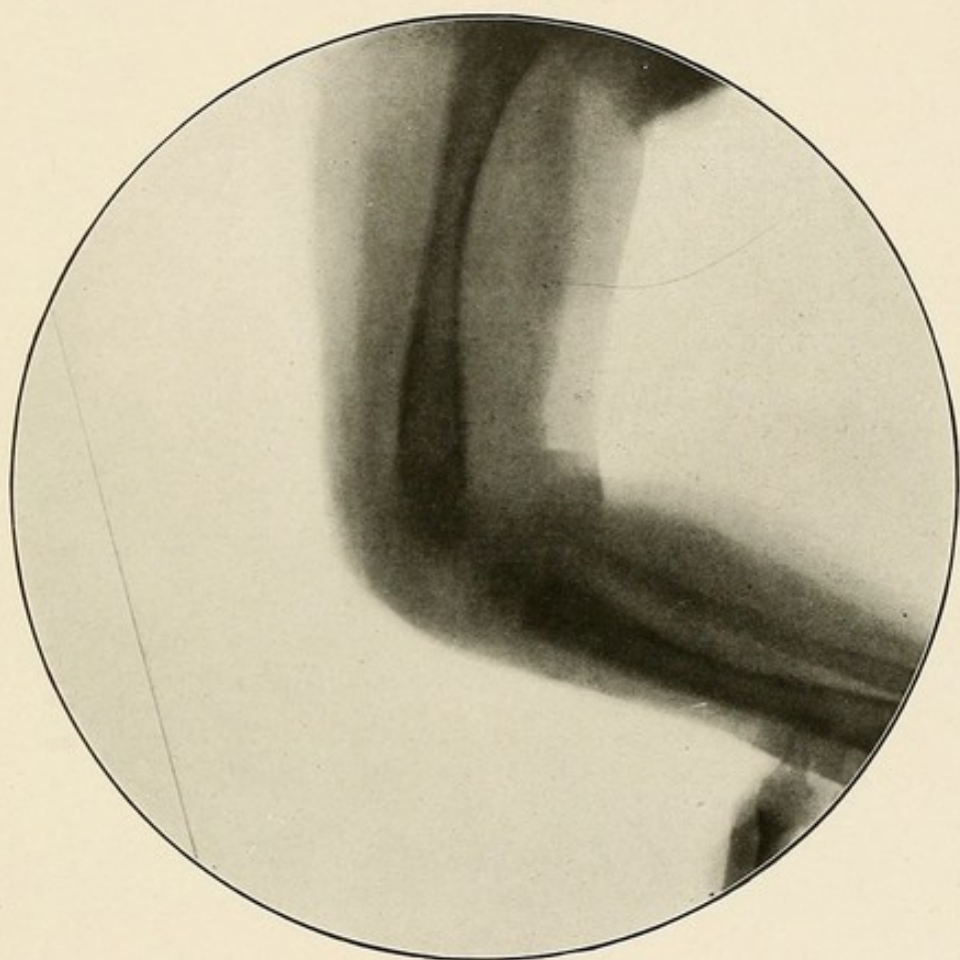


PLATE XLI.

PLATE XLII.

EXTENSIVE SUB-PERIOSTEAL HEMORRHAGE IN SCURVY—CHRONIC STAGE.

The hemorrhage shows as a dark gray shadow, between the bone and the raised periosteum. It extends from the level of the lesser trochanter to the epiphyseal line of the right femur.

The shadow of the bone is darker than that of the other unaffected side, because the hemorrhage surrounded the bone.

The shadow of the hemorrhagic area is darker than in the preceding plate, because the clot was larger and organized.

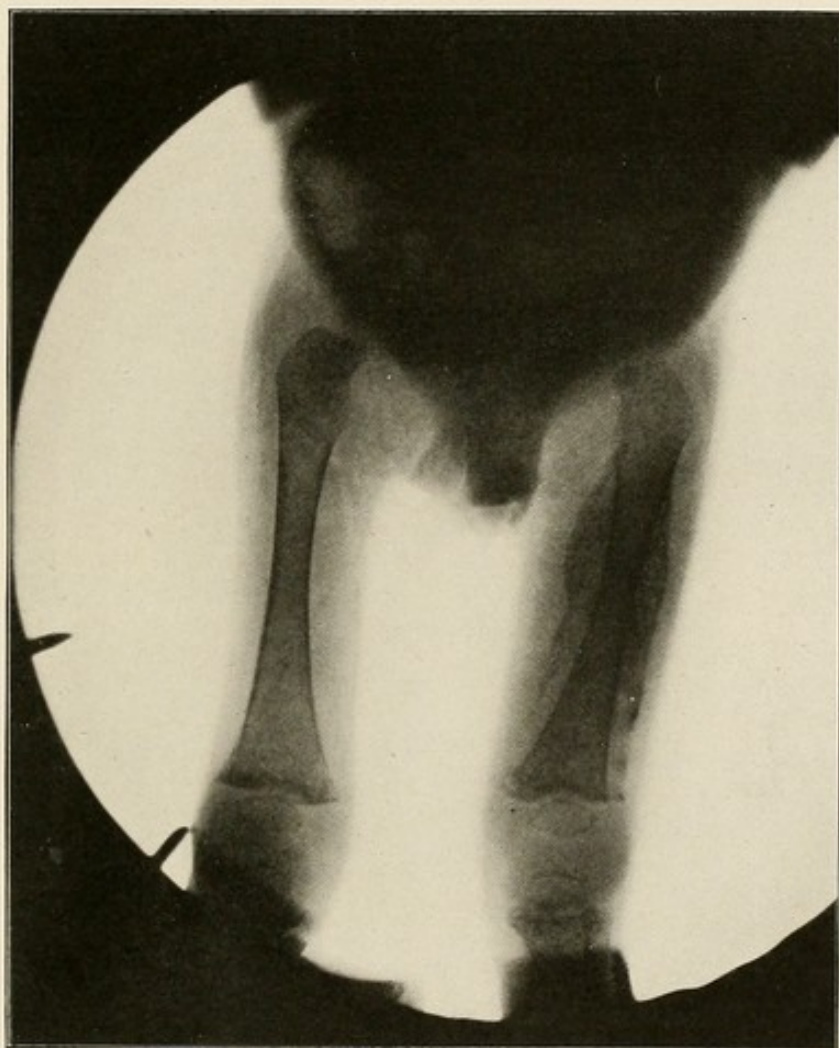


PLATE XLII.





### OSTEOMATA.

(Plate XLIII: New bone growths may start from the periosteum—exostosis—or they may start from the interior of the bone—enostosis. The former may appear anywhere; the latter are seldom found outside of the bones of the head. They would be recognized on the skiagram as irregular, dark masses, attached to the bone.

### OSTEOID CHONDROMA.

(Plate XLIV): Osteoid chondroma develop beneath the periosteum most frequently in the femur or tibia, near the knee joint, forming a club-shaped enlargement of the bone, resembling somewhat the immature bone tissue seen beneath the periosteum in developing bone.

PLATE XLIII.

MULTIPLE EXOSTOSES OF THE BONES OF THE FOREARM.

The irregular dark shadows projecting from the sides of the ulna and radius, near their lower ends, represent the new bone growth from the periosteum.

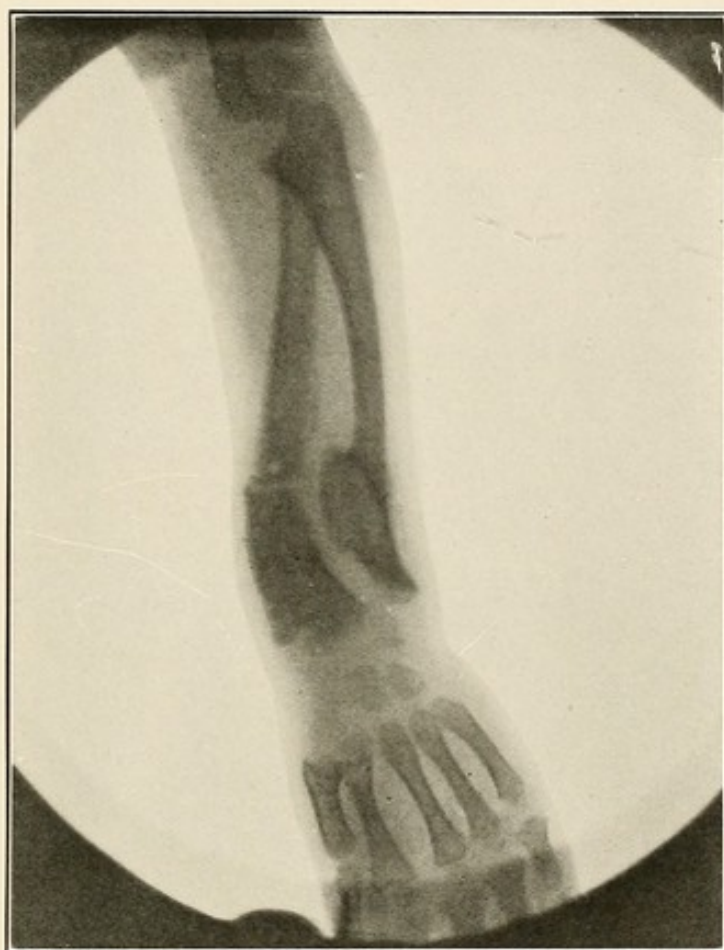

PLATE XLIII.

PLATE XLIV.

OSTEOID CHONDROMA OF THE FEMUR.

The enlargement of the inner condyle of the femur is well marked.



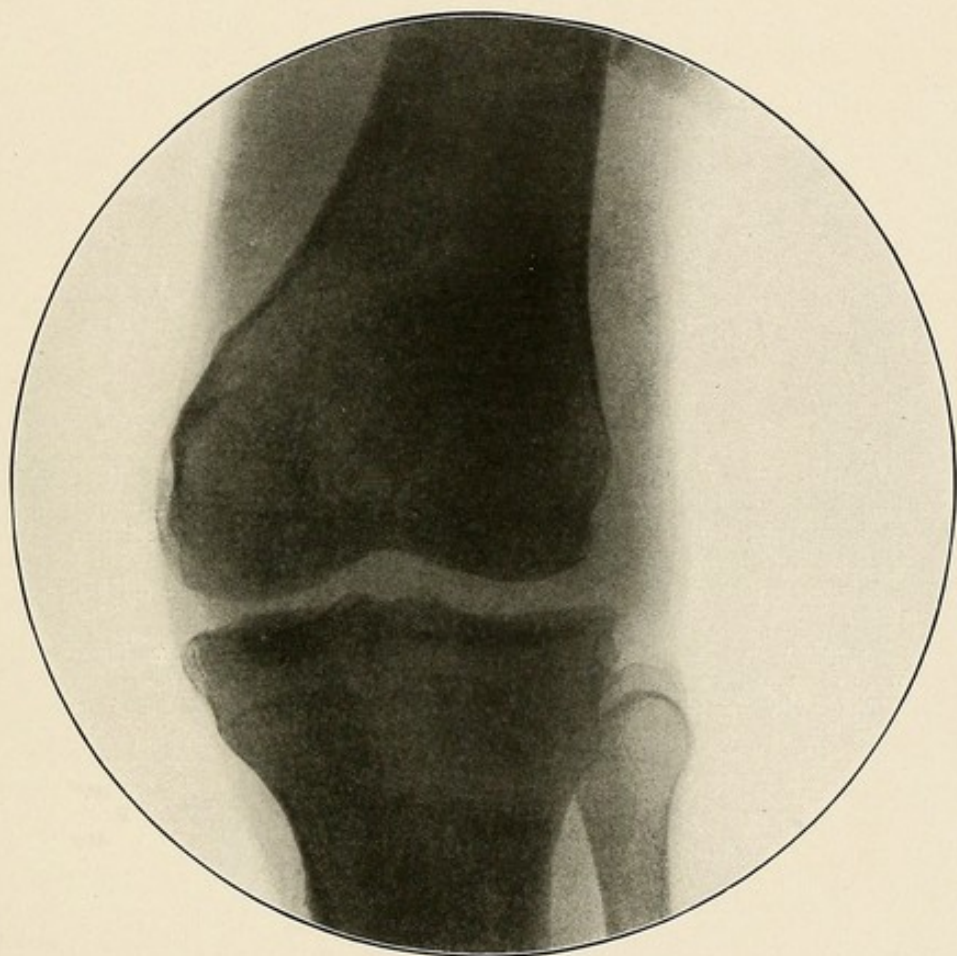


PLATE XLIV.

PLATE XLV.

CYST OF BONE.

Cyst of bones is rarely found outside of the bones of the head. It is usually the result of a former osteitis. It could not be diagnosed on a radiogram from a small medullary giant cell sarcoma before the latter breaks through the bony wall.

In the Plate a cystic cavity can be seen in the radius about its middle third.

The walls of the cavity are thin and throw a very faint shadow. They were formed of periosteum and thin new bone formation.

The cavity was filled with a bloody and serous liquid.

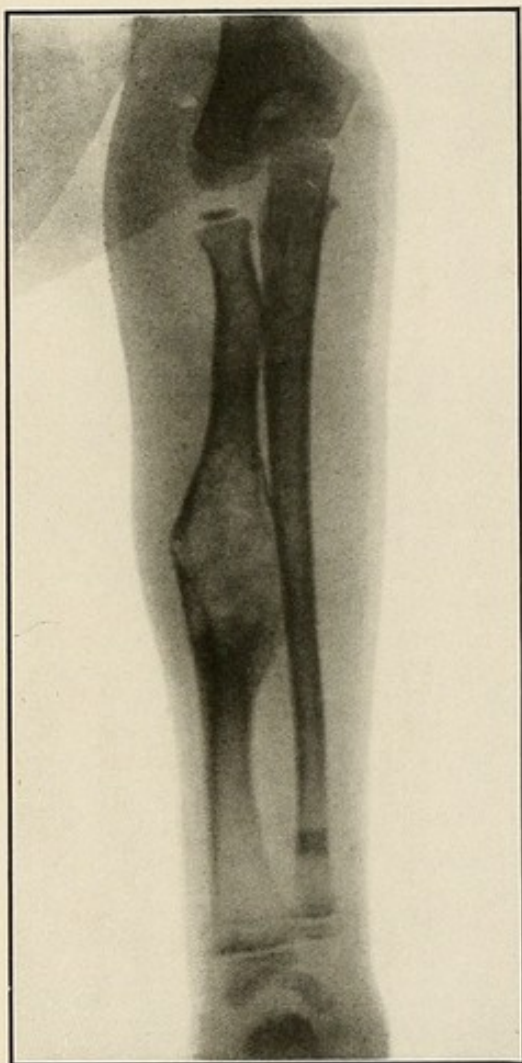


PLATE XLV.



## DIFFERENTIAL DIAGNOSIS.

Of the disease discussed in this part the one which is most likely to be confounded with some other disease is osteo-sarcoma; because of that and because of the serious import of such a mistake, we shall devote a few lines to its differential diagnosis.

Asteo-sarcoma must be differentiated from osteo-myelitis, tuberculosis of bone, syphilis of bone, osteomata, cyst of bone, scurvy and exhubrant callous formations.

All cases of osteo-sarcoma seen by the author, with the exception of one case of medullary giant cell sarcoma, presented the characteristic frost-like appearance.

*Large Osteomata:* Either exostosis or enostosis are the only other diseases of the bone presenting shadows which have any resemblance to the characteristic appearance of sarcoma. This shadow, however, is much denser, does not involve the entire bone segment and does not merge into the soft parts.

*Osteomyelitis* shows in circumscribed cases the light central shadow surrounded by the dark rim of osteosclerosis; in extensive cases, with extension of inflammation to the soft parts, there is a honeycombed appearance of the bone, with or without the presence of sequestra. While in sarcoma the normal bone shadow disappears and is replaced by the characteristic shadow, which fades away into the surrounding soft parts.

*Tuberculosis of Bone* shows the indefinite pale shadow and the bone atrophy. It nearly always begins at the epiphyses and very frequently spreads to the joint. Sarcoma, quite the contrary, very rarely involves the joint, except in the later stages (see Plate XXX).

*Syphilis of Bones* shows darker shadows. The periosteum often presents an irregular raised appearance over a greater area than is seen in sarcoma, and there is no blending or extension to the soft parts as in the latter disease.

*Cyst of Bone* cannot be differentiated from a small medullary giant-celled sarcoma. It lacks the characteristic appearance present in other types of sarcoma.

*Scurvy:* When the sub-periosteal hemorrhage is extensive and the clot organized, could be mistaken for the form of sarcoma, beginning in the outer layers of the periosteum and invading the soft parts, leaving the bone intact. The bone outline is clearer and more distinct, and the outline of the tumor is sharp in scurvy



and does not blend with and become lost in that of the soft parts. The periosteum is raised, but smooth, not close to the bone, and its outer layer rough and forming part of the tumor mass, as is the case in sarcoma (see Plates XXV and XLII)

*Exuberant Callous Formation* could be mistaken for a sarcoma of bone with pathological fracture. The characteristic appearance of osteo-sarcoma would be absent (see Plate XXIX).

### ARTHRITIS.

The synovial sac becomes filled with serum, sero-fibronous fluid or pus, depending upon the nature of the infective agency. The skiagram shows the increased interosseous space and the distended joint capsule. The density of the shadow will, of course, depend upon the nature of the fluid in the synovial sac.

Mild cases undergo resolution. The more malignant ones cause extensive destruction of cartilage and bone. The majority of cases become chronic. Here we find the following joint changes: At first the synovial membrane is congested and its tufts are prominent (Plate XLVI). Later there is more or less destruction of the synovia, with the formation of small adhesions (Plate XLVII) and the tufts become large and projecting. As the disease advances the cartilaginous surface is destroyed and replaced by granulation tissue. Fibrous (Plate XLVIII) and bony (Plate XLIX) ankylosis often result.

PLATE XLVI.

ARTHRITIS OF THE KNEE JOINT.

The congestion of the synovial membrane and the prominence of its tufts are well represented on the skiagram by the gray shadow with fringe-like lower free border, in what is normally a clear space between the lower extremities of the patella and femur and the upper extremity of the tibia.

The tendon patella is also visible.

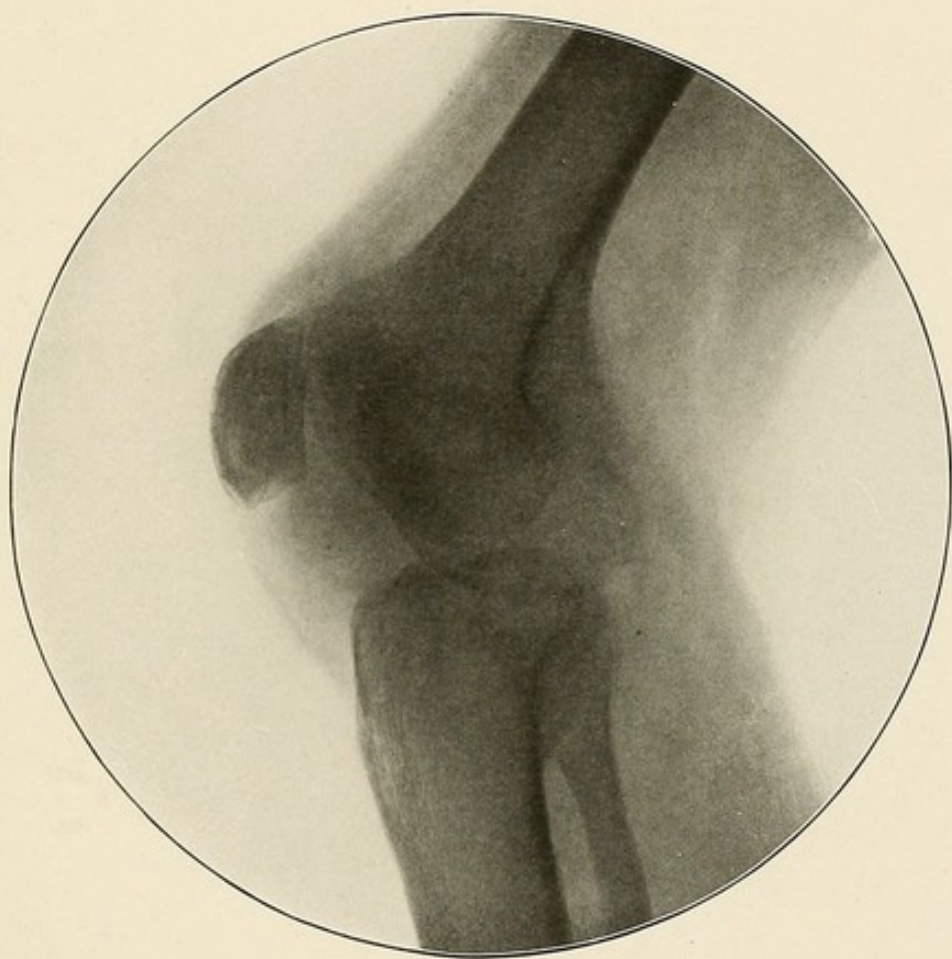


PLATE XLVI.

PLATE XLVII.

ARTHRITIS OF KNEE JOINT—SMALL ADHESION.

A small band of adhesion between the spine of the tibia and the external femoral condyle can be plainly seen.

The shadow of the inter-articular space is darker than normal.



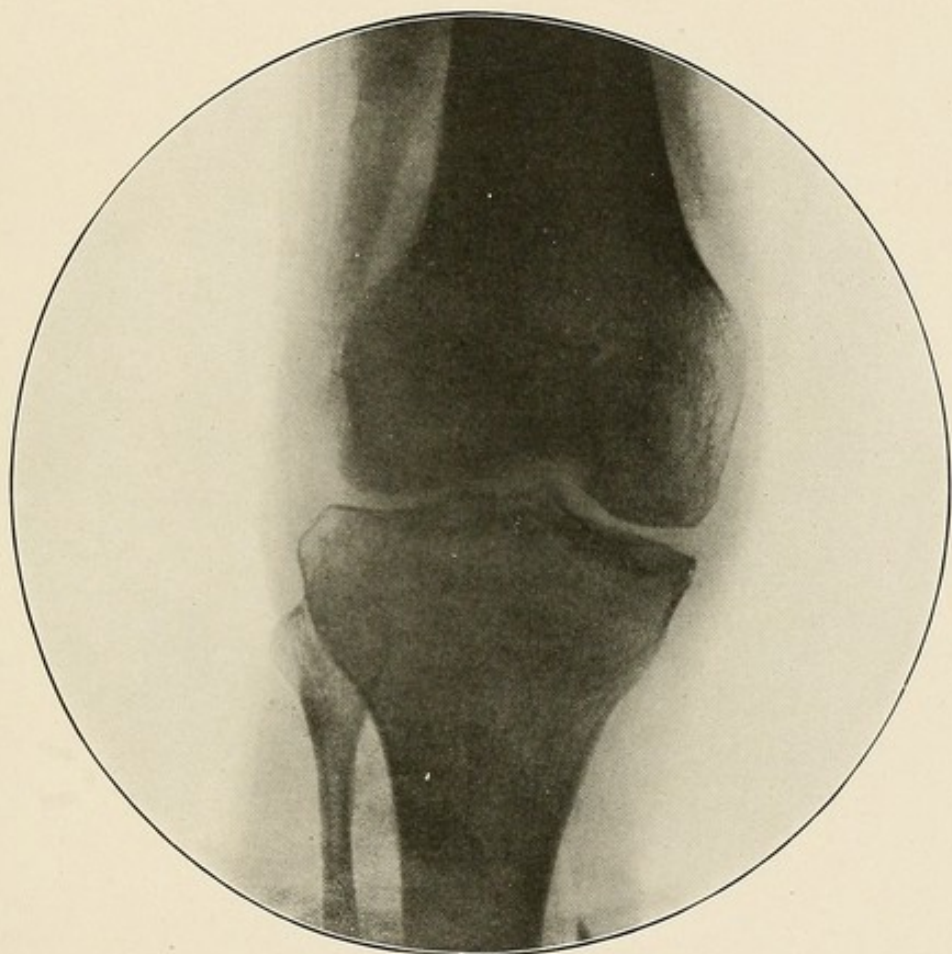


PLATE XLVII.

PLATE XLVIII.

FIBROUS ANKYLOSIS OF THE ELBOW JOINT.

The fibrous bands of adhesions between the articular surfaces of the humerus and ulna can be distinctly made out.

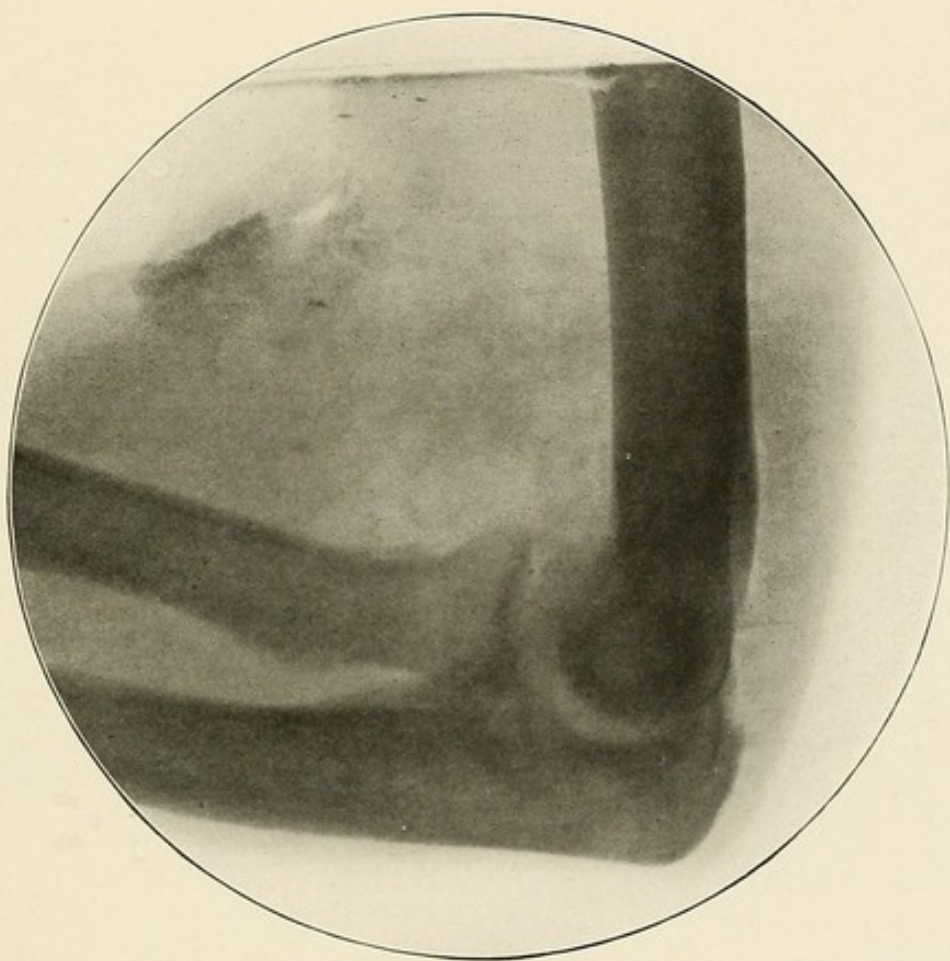


PLATE XLVIII.

PLATE XLIX.

BONY ANKYLOSIS OF THE ANKLE JOINT.

The joint is destroyed, and one mass of bony tissue is present.



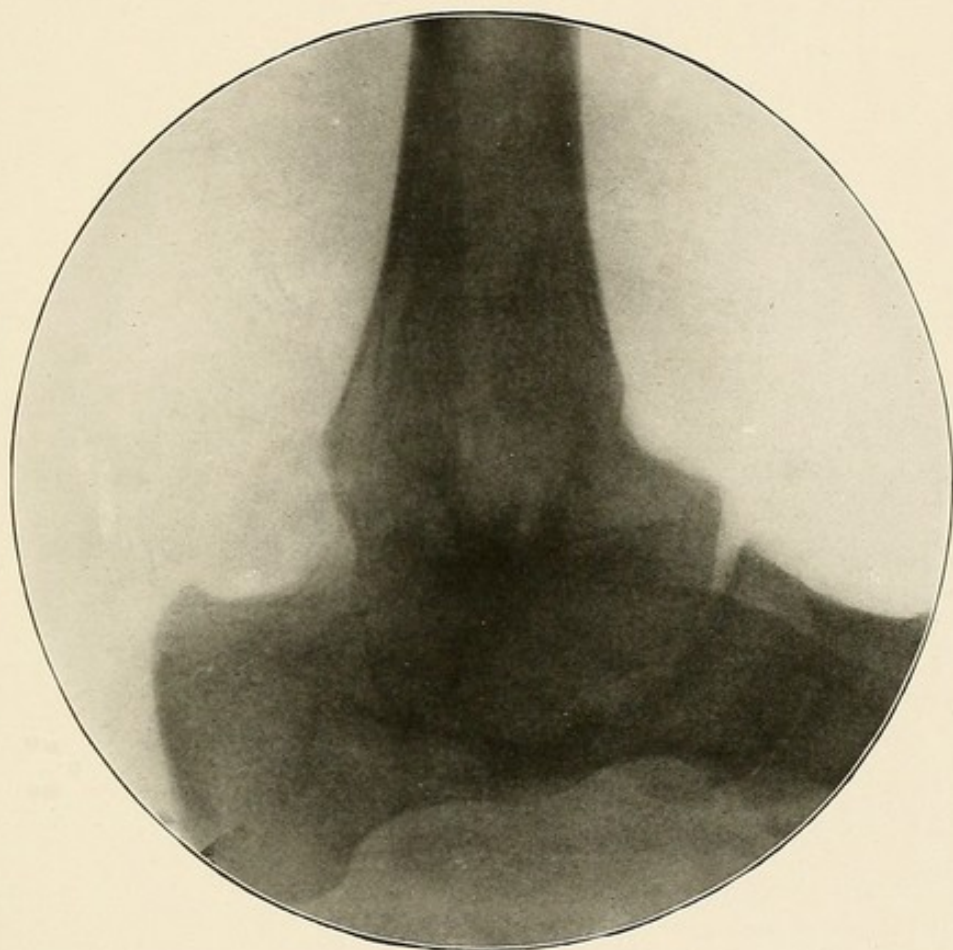


PLATE XLIX.



### RHEUMATOID ARTHRITIS.

This name has been applied to a variety of chronic inflammation of joints which combine with degeneration of parts of the joint and the new formation of bone may result in marked deformities of the part. The capsules are thickened and sclerosed, the tufts of the synovial membrane are changed into cartilage, new bone grows from the articular cartilages, from the joint capsules, and even from the ligaments (Plate L).

As a result of the changes which take place in the basement membrane and in the cartilages, the latter become destroyed from pressure during the movements of the joint and the bone is laid bare. This is shown in the skiagraph by disappearance of the normal articular shadow (Plate LI).

The ends of the bones are much deformed. They are flattened and made broader by irregular new growth of bone, while at the same time they atrophy. The new growth of bone starts from the articular cartilage.

PLATE L.

RHEUMATOID ARTHRITIS OF THE WRIST—HYPERTROPHIC TYPE.

There is a marked deformity of the wrist.

The articular cartilage of the radius is destroyed.

The normal inter-articular shadows are absent. The carpal bones cannot be made out from each other, and they can barely be separated from the radius and ulna above and the metacarpal bones below.

New growth formations, starting from the margins of the articular cartilages of the radius and ulna and from the ligaments, can be seen.



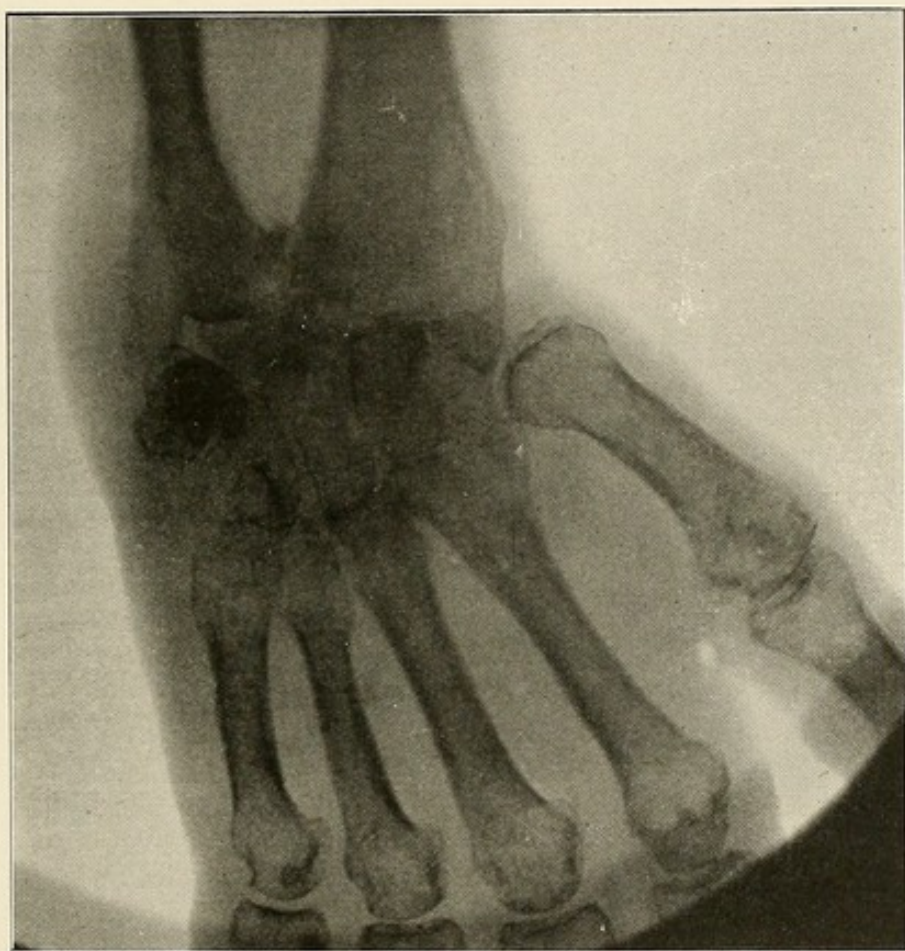

PLATE L.

PLATE LI.

RHEUMATOID ARTHRITIS OF THE KNEE—ATROPHIC TYPE.

The inter-articular shadow in the external half of the joint is darker than normal.

In the inner half the absence of the inter-articular clear shadow indicates the almost complete destruction and disappearance of the articular cartilage.

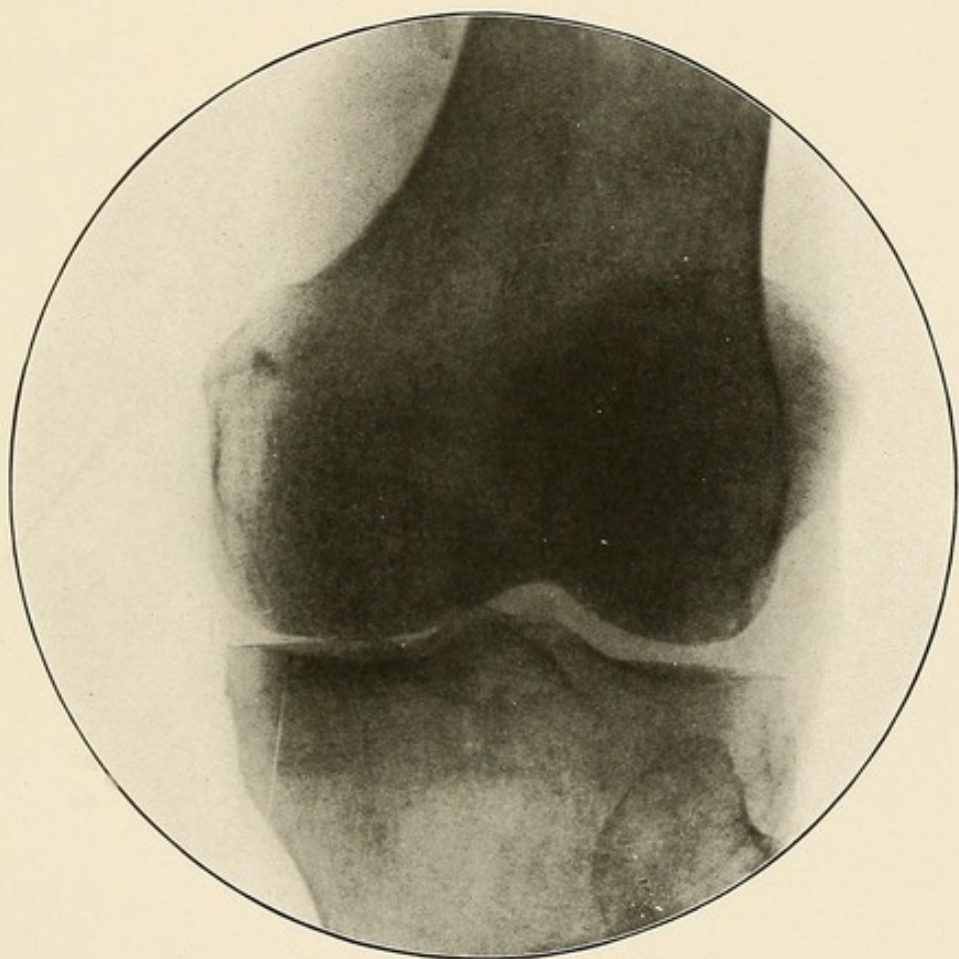


PLATE LI.





### TUBERCULAR ARTHRITIS.

This affection usually begins in the synovial membrane of the joint (Plate LII), or it may extend to the joint from adjacent bone. It is characterized by the formation of tubercle tissue and granulation tissue and is usually associated with secondary inflammation and degenerative changes of the surrounding part. This disease is most common in children and young persons, and usually affects one of the larger joints (Plate LIII). It is recognized on the radiogram by the paler hue of granulation tissue. As the disease advances and the articular ends of the bones become involved this is plainly seen on the X-ray negative by the paler shadow and the atrophy of the affected bone (Plate LIV). Later the area and extent of the bone destruction (Plate LV), with resulting deformities, show distinctly (Plate LVI).

PLATE LII.

TUBERCULAR ARTHRITIS OF THE KNEE--EARLY STAGE.

The dark oval shadow, including the knee joint and the peri-articular tissues, indicates the presence of tubercular granulation formations in the synovial membrane of the joint, associated with secondary inflammation of the surrounding soft parts.

The lower epiphyses of the femur is pale.

The inter-articular space is much greater than normal.

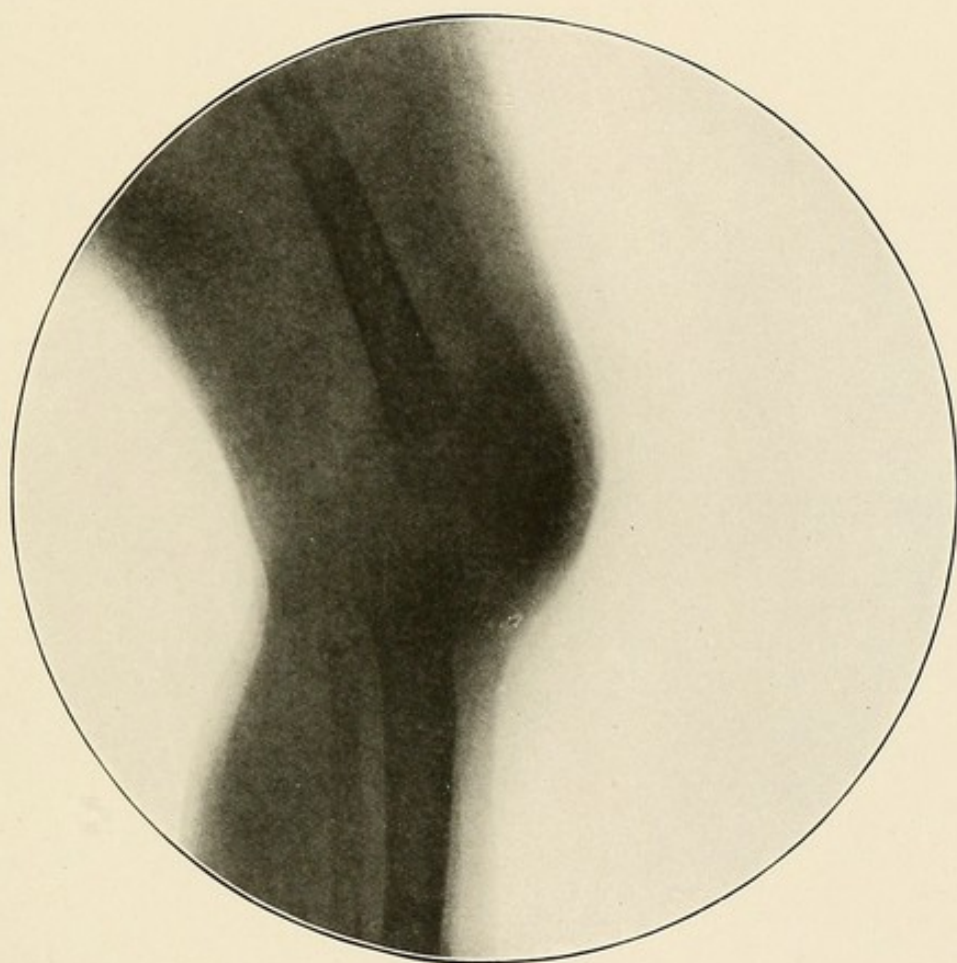


PLATE LII.

PLATE LIII.

TUBERCULAR ARTHRITIS OF THE HIP.

The normal, clear, inter-articular space is replaced by the light gray shadow, indicative of synovial congestion and infiltration.

The head and neck of the femur and the pelvic bones are paler than normal.

The light gray hue of the bones, just above and to the inner side of the acetabulum, denotes bone rarefaction and the presence of new formation tubercular granulation tissue.



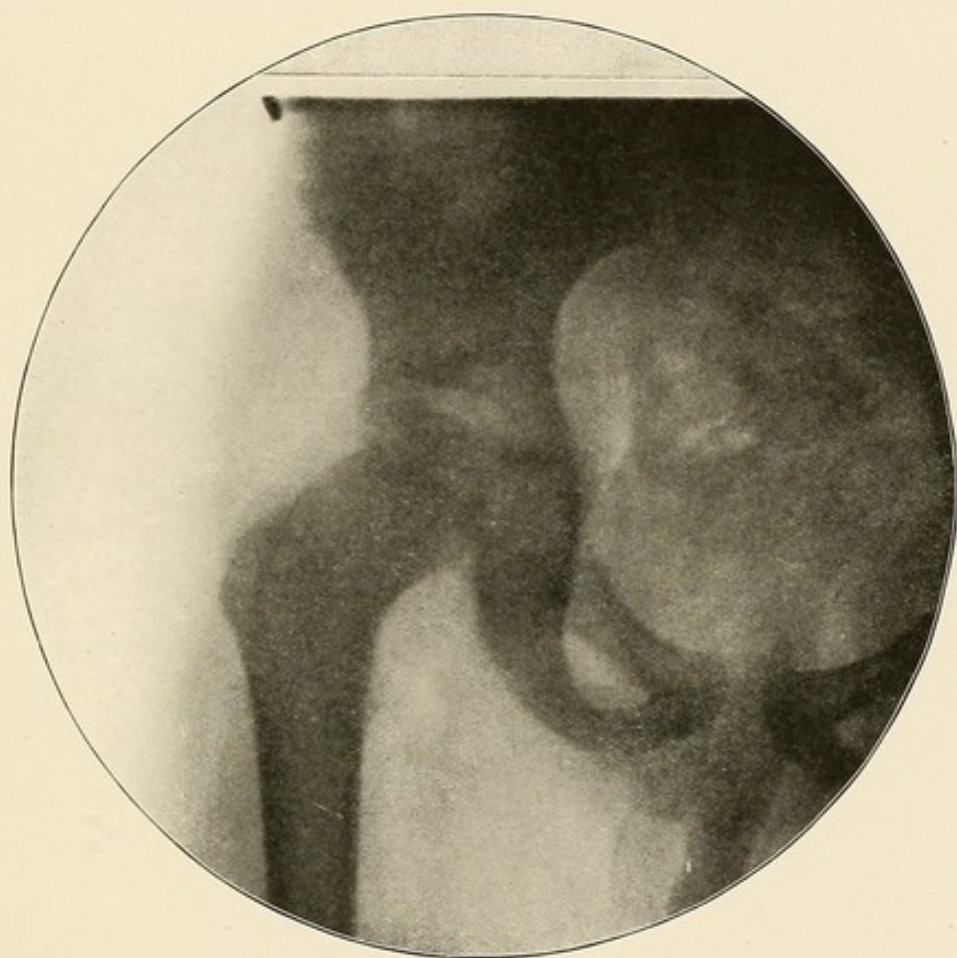


PLATE LIII.

PLATE LIV.

TUBERCULAR COXITIS OF THE RIGHT HIP—FIRST STAGE—CHILD 4 YEARS OLD.

The difference in the size of the hip and the pelvis in the right side is not real, it is due to the tilting of the pelvis, caused by the rigid and fixed position of the affected hip.

The bones are paler on the right side.

The inter-articular and epiphyseal lines, so distinct on the healthy side, are indistinct and blocked on the affected one.

A distinct oval light-gray shadow embracing the acetabulum and the head and neck of the femur, is seen on the right side.

This is indicative of congestion of the synovial membrane and of the presence of fluid in the joint.

There is no involvement of the bones. The white line surrounding the upper epiphysis of the femur is produced by a tracing on the X-ray negative made to indicate the position of this epiphysis.

This little patient died of pneumonia about one week after this skia-gram was made, and the X-ray findings were confirmed at the autopsy.

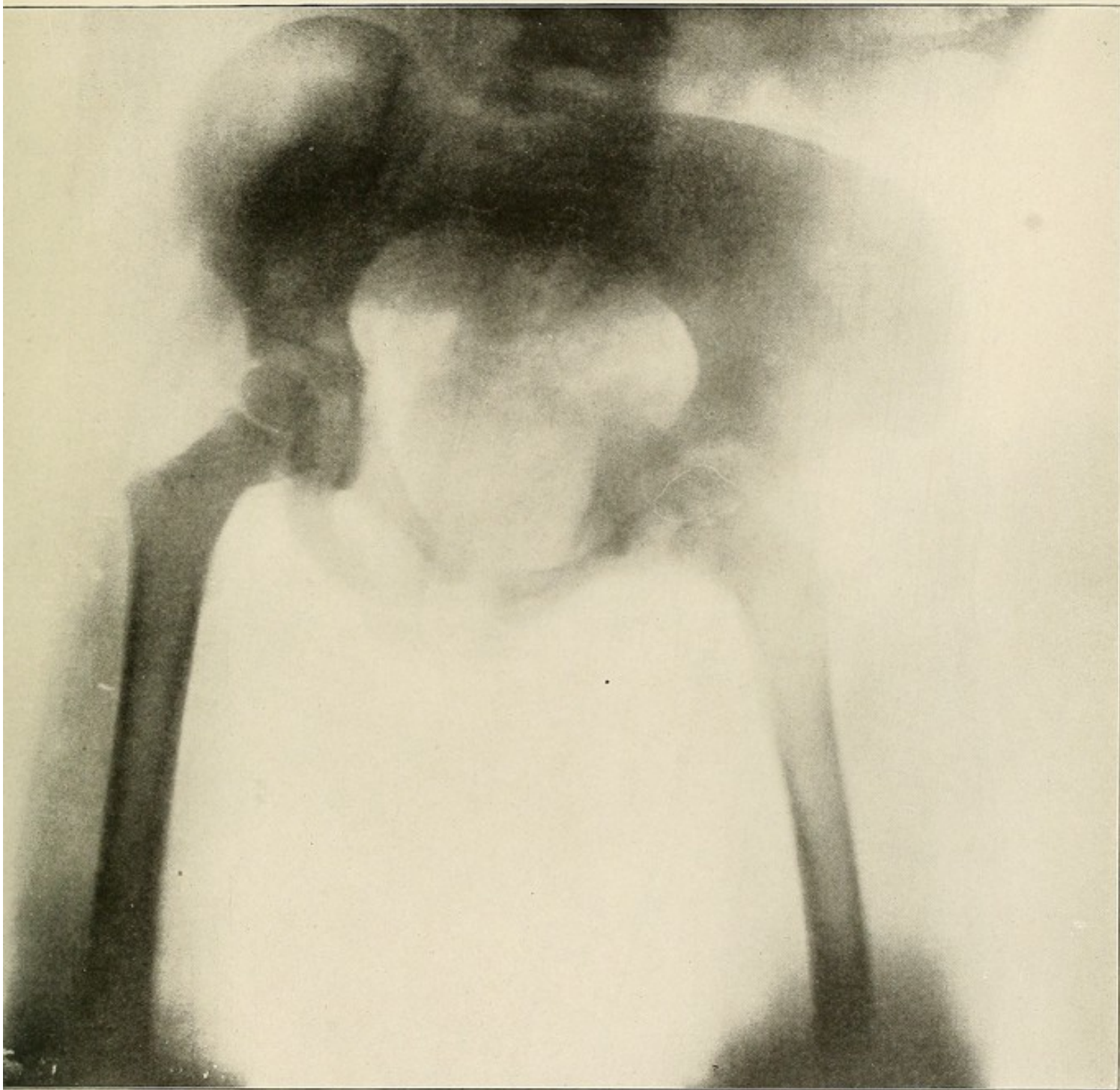

PLATE LIV.



PLATE LV.

TUBERCULAR COXITIS OF THE RIGHT HIP—SECOND STAGE—BONE INVOLVEMENT—  
CHILD 4 YEARS OLD.

The femur and the pelvic bones are pale and atrophied on the affected side.

The gray shadow on the right side, including the hip joint and the surrounding soft parts, shows the extent of the tubercular involvement of the joint and the peri-articular tissues.

The acetabulum, the head, neck and great trochanter of the femur are involved; the bone rarefaction and infiltration, with the new formation tubercular granulation tissue, can be seen extending to a line slightly below the inter-trochanteric line.



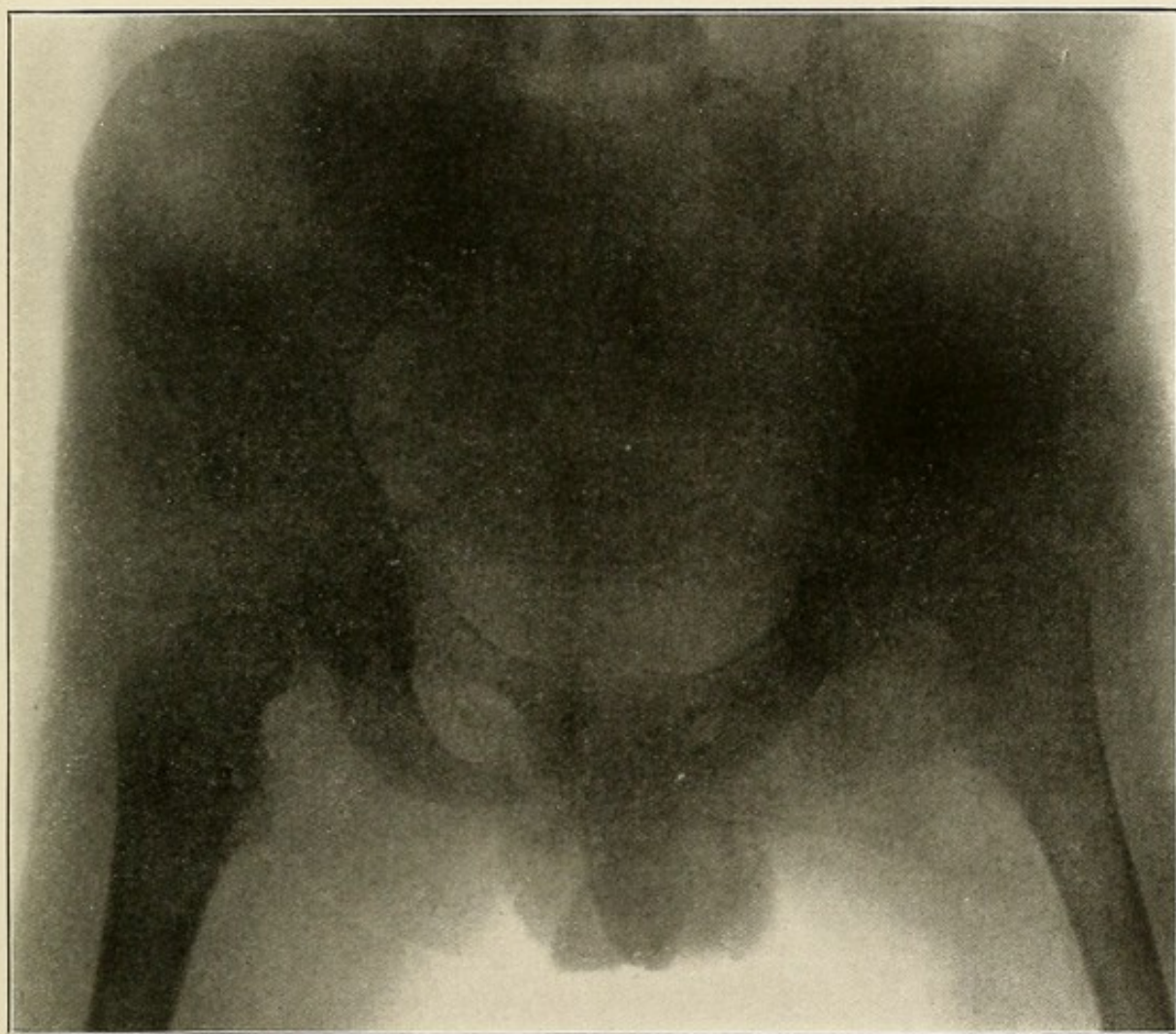


PLATE LV.

PLATE LVI.

TUBERCULAR COXITIS OF THE RIGHT HIP—THIRD STAGE—BONE DESTRUCTION—  
CHILD 4 YEARS OLD.

The affected femur is paler than the normal one.

The right pelvic bones and femur are atrophied.

The acetabulum and the head of the femur are destroyed.

The involvement of the femur extends to a point below the inter-trochanter line.

The gray shadows in the soft parts surrounding the upper extremity of the femur and the hip joint show the extent of involvement of these parts.

The destruction of the pelvic bones and the involvement of the pelvic tissues are clearly visible.

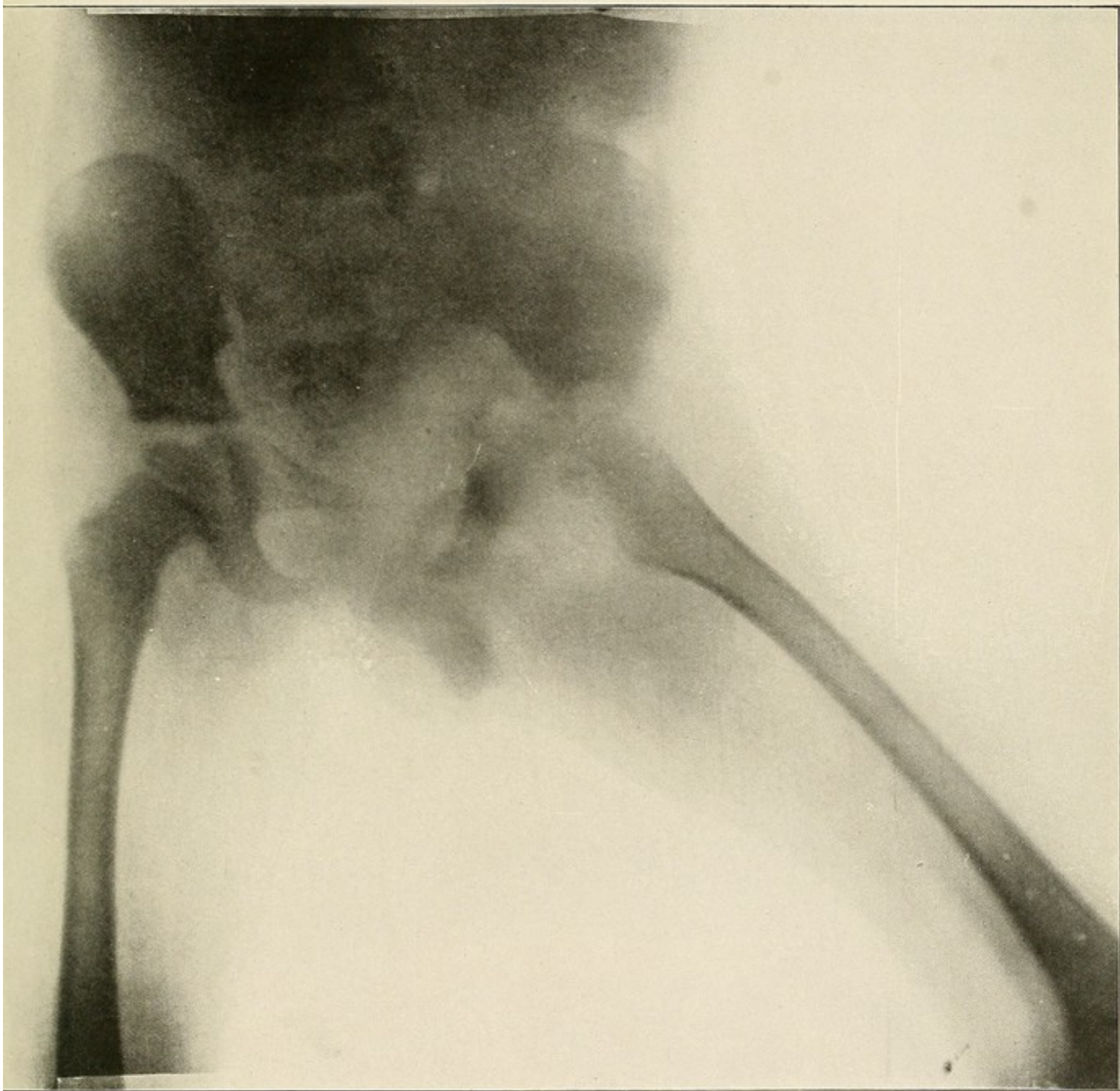


PLATE LVI.



PLATE LVII.

LOOSE SEMI-LUNAR CARTILAGE.

This Plate shows a loose outer semi-lunar cartilage slightly dislocated inwards.

The dislocation inwards of the external semi-lunar cartilage of the tibia can be distinctly made out.

The separation between the loose semi-lunar cartilage and the upper end of the tibia is well marked.



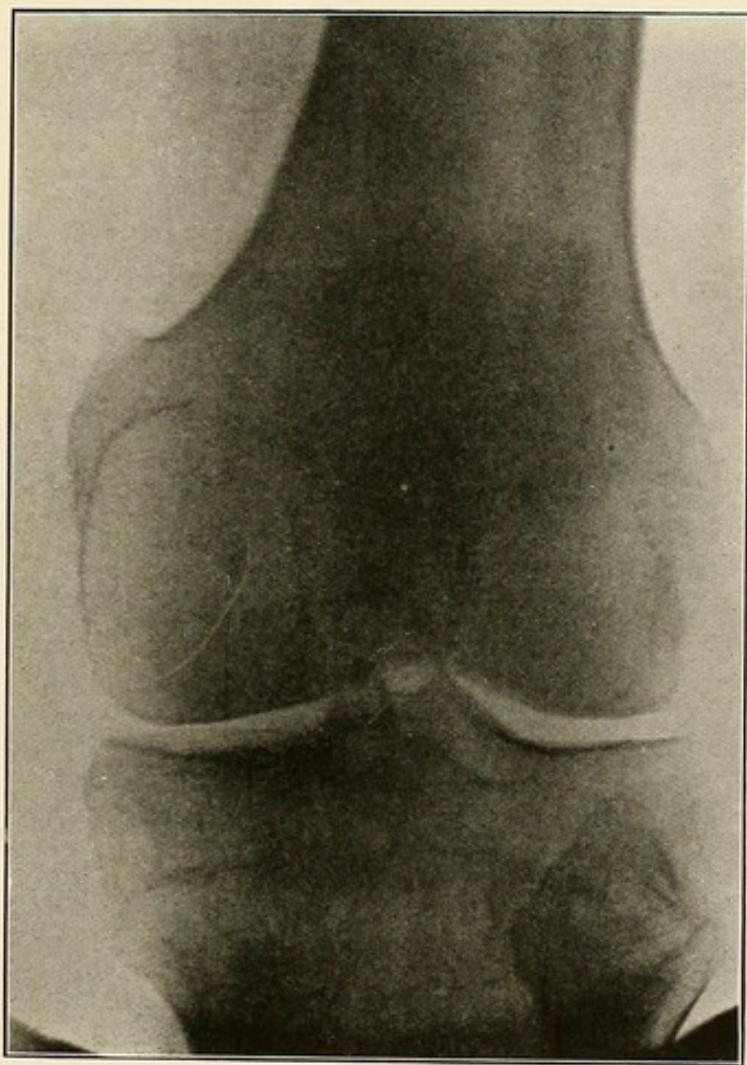


PLATE LVII.



### PART III.

#### FRACTURES, DISLOCATIONS, FOREIGN BODIES.

---

##### FRACTURES.

In establishing the diagnosis of fracture two skiagrams of the affected part should always be made whenever this is possible. One of these must be an antero-posterior view of the limb, and the other a lateral view. No exception to this rule should be made when skiagraphing the wrist and hand. The practice to take a palmar and then a dorsal view is faulty. The second exposure in every instance should be made with the part lying in a position which is at right angles to that assumed during the first exposure.

In that way alone accurate information can be obtained about the nature of the fracture, the position of the fragments and the formation of callous, and, in some rare cases, the presence of a fracture.

One view may show the fragments in apparently perfect opposition, while the other shows considerable displacement (Plates LVIII and LIX). Or one view may show a fracture, and the other view shows none (Plates LX and LXI).

Whenever from the nature of the part (hip, spine, shoulder, ribs, clavicle, scapula), or from ankylosis or deformity (fixed flexed knee, etc.), only one view can be made, this should be done with the part lying as close to the plate as possible and in as near the normal position as possible. In such cases a correct diagnosis can, as a rule, only be made after a careful study of the skiagrams and after comparison with normal skiagrams (Plates LXII and LXVI).

PLATE LVIII.

FRACTURE OF THE RIGHT FEMUR—ANTERO-POSTERIOR VIEW—SAME CASE AS  
PLATE LIX.

A shadow darker than that of the soft parts, but not as dark as that of the bone, can be seen on each side of the femur, about midway between its epiphyseal line and the upper border of the skiagram. At that same point the bone shadow is much darker.

The explanation of these shadows is seen in the next *Plate*. The first shadow is due to callous formation, and the darker shadow of the bone is due to overlapping of the fractured ends of the femur.



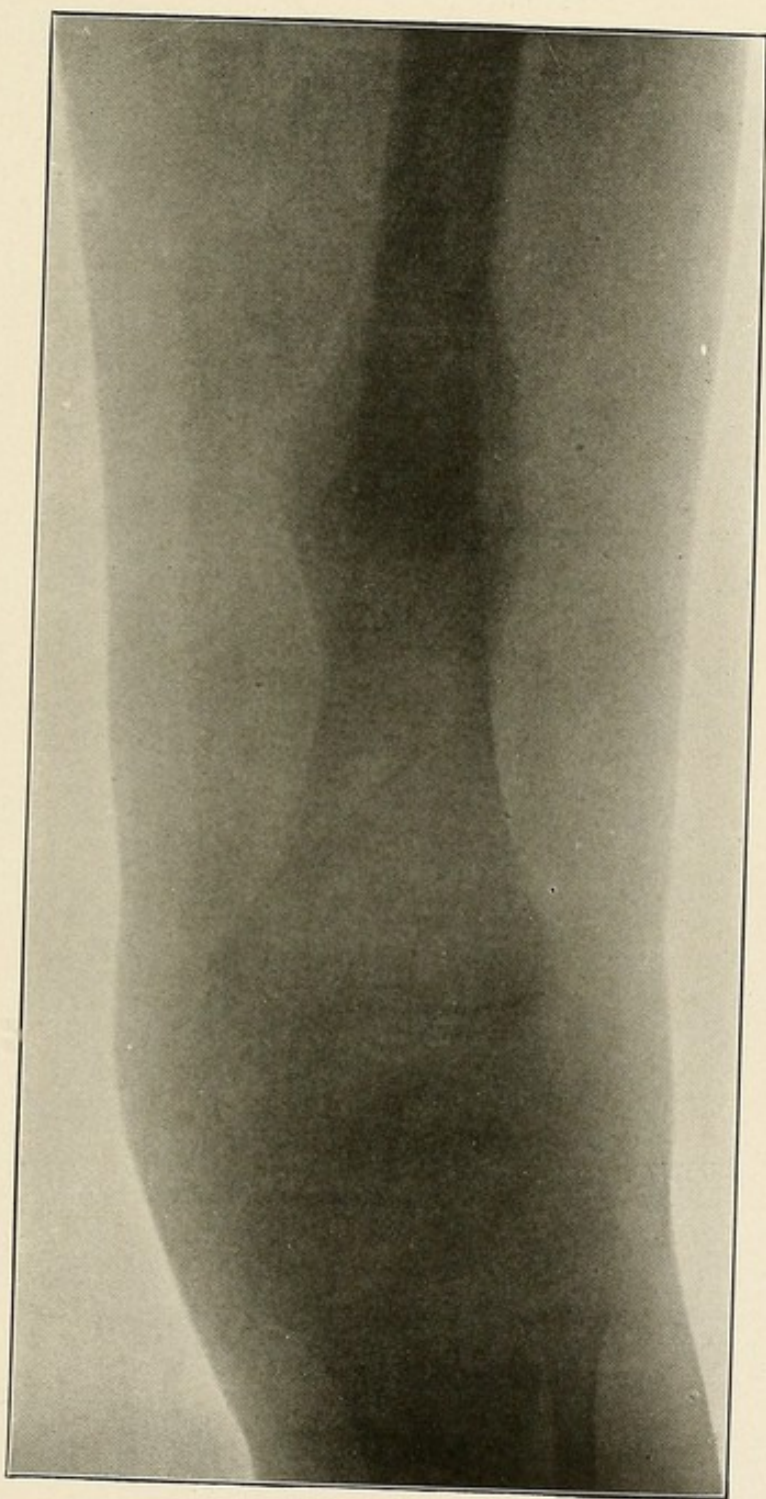


PLATE LVIII.

PLATE LIX.

FRACTURE OF THE RIGHT FEMUR—LATERAL VIEW—SAME CASE AS PLATE LVIII.

The fractured ends of the femur overlap and are displaced in an antero-posterior direction.

Callous is thrown out from the ends of both fragments and holds the bones together.

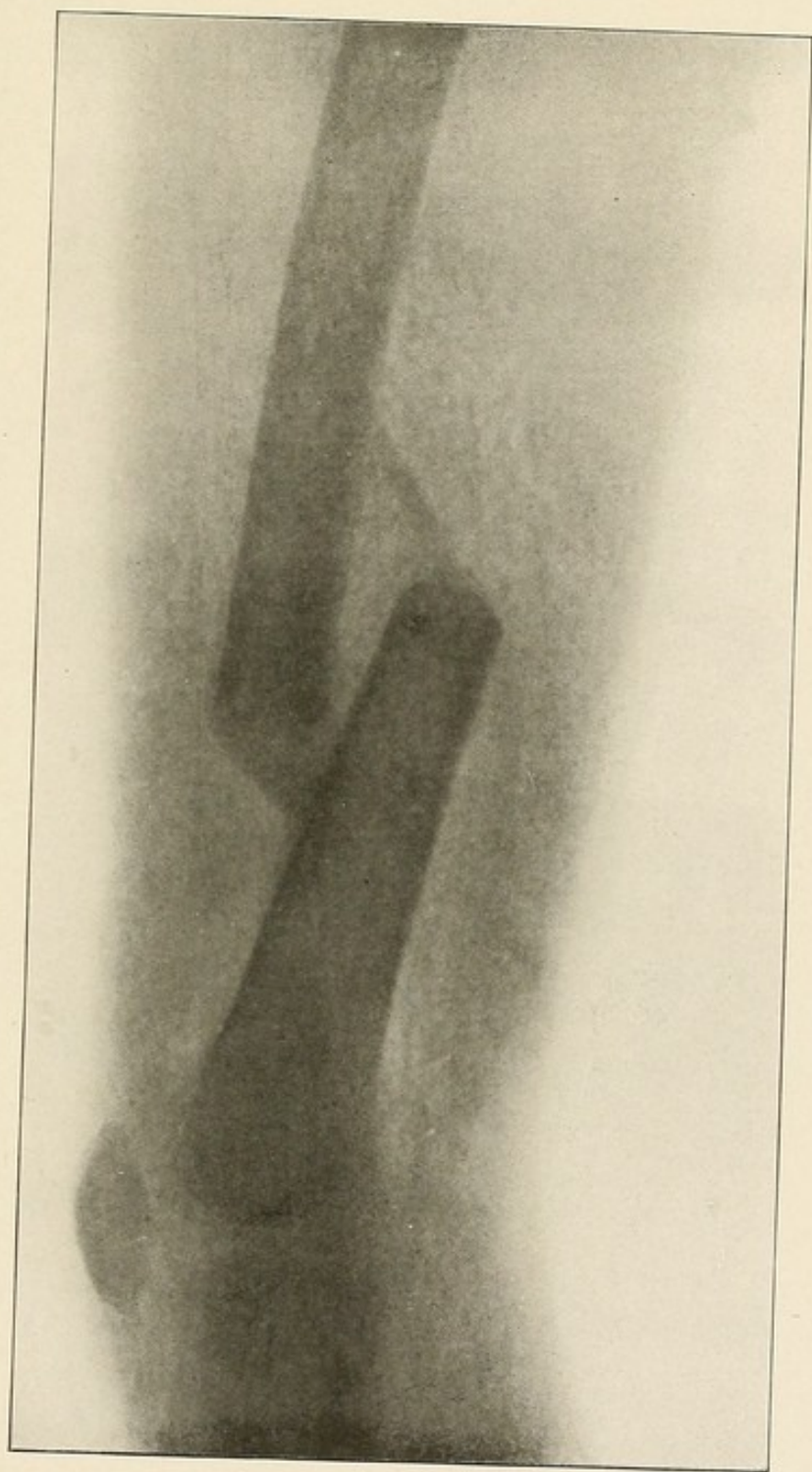


PLATE LIX.

PLATE LX.

GUN-SHOT FRACTURE OF THE LOWER END OF THE HUMERUS—ANTERO-POSTERIOR  
VIEW—SAME CASE AS PLATE LXI.

The fracture line runs into the joint.

The splintered bullet lies close to the upper end of the fracture.



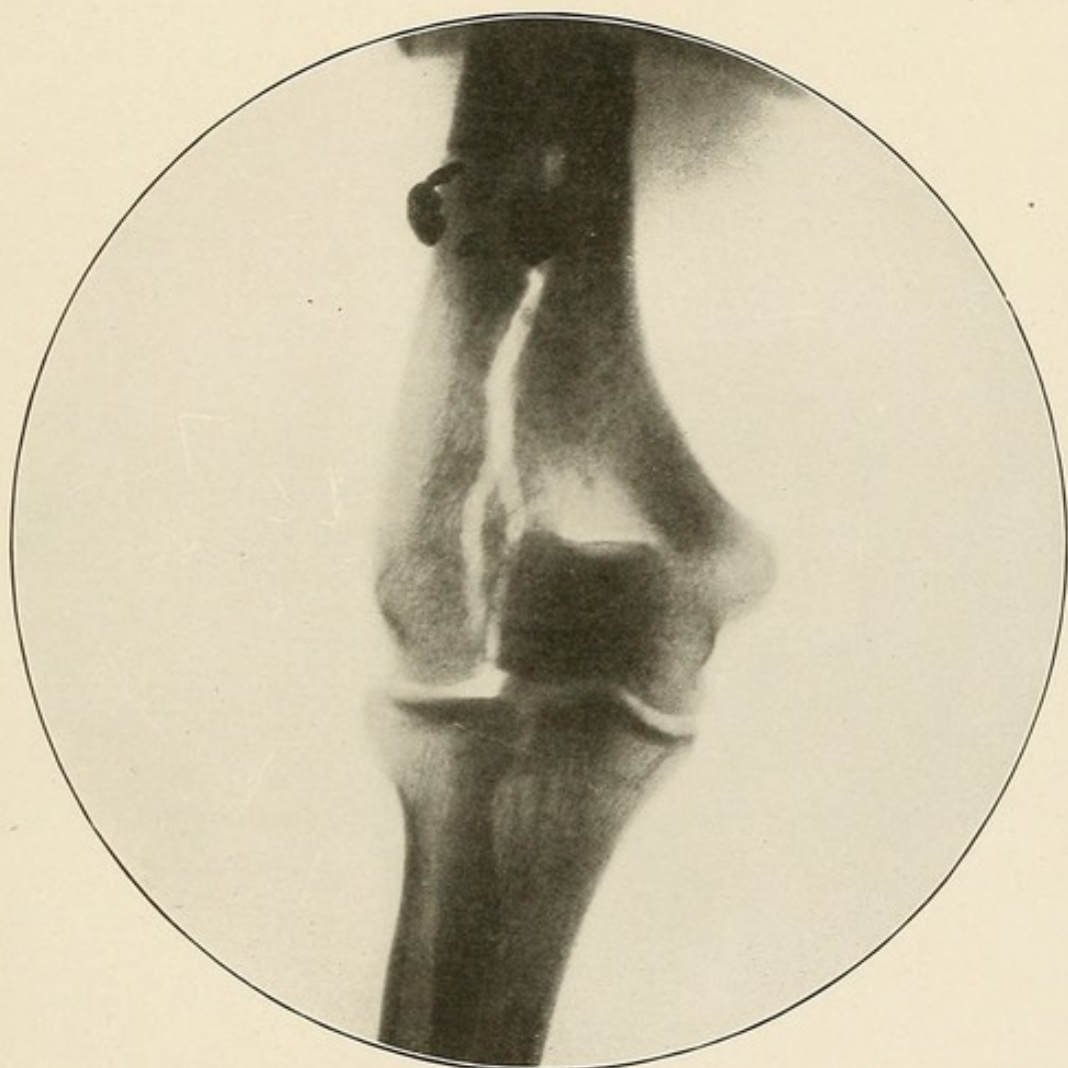


PLATE LX.

PLATE LXI.

GUN-SHOT FRACTURE OF THE LOWER END OF THE HUMERUS—LATERAL VIEW—  
SAME CASE AS PLATE LX.

No fracture can be detected in this skiagram.

There is no shadow due to callous formation or to the overlapping of the fractured ends of bone as in the preceding case (Plates LVIII-LIX).

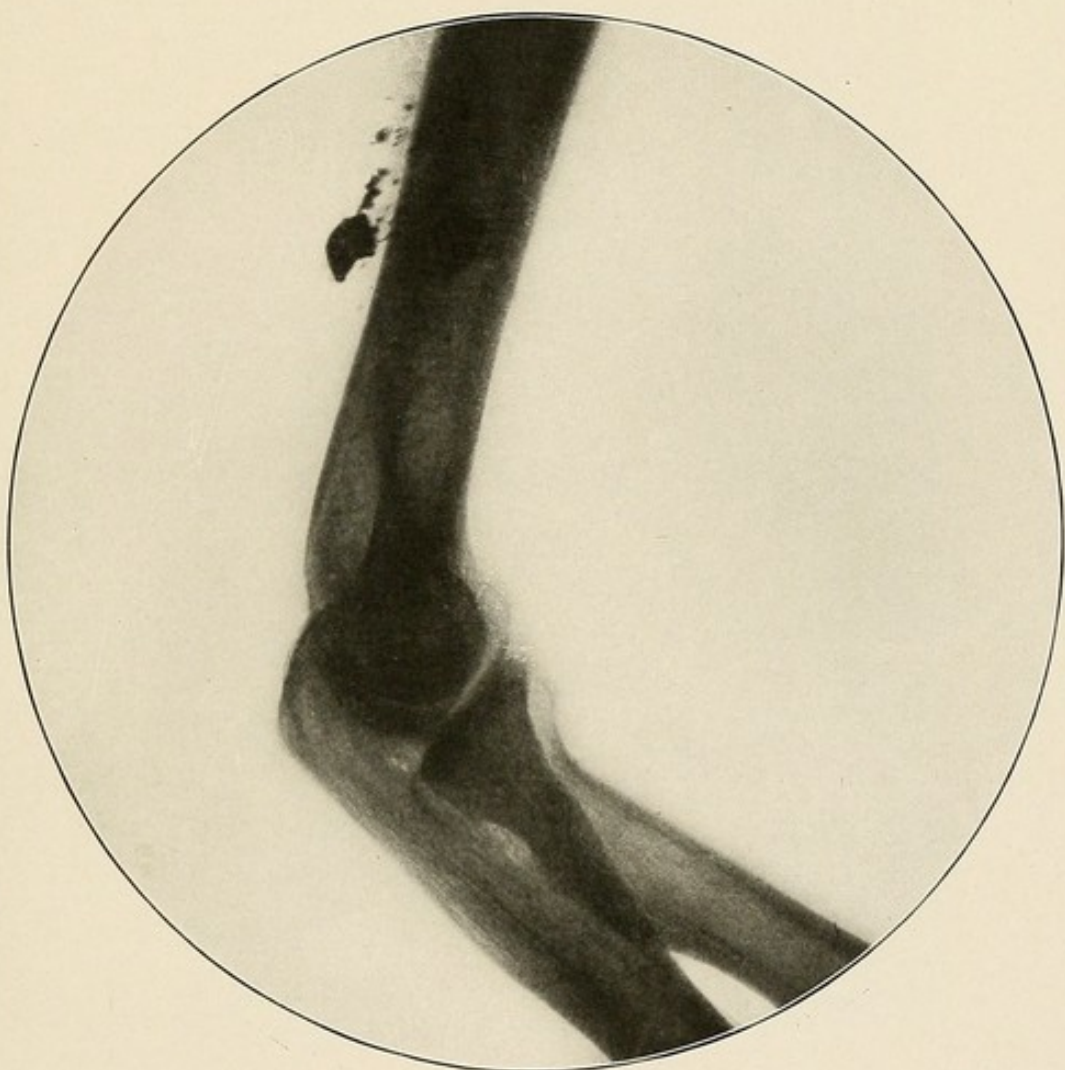

PLATE LXI.

PLATE LXII.

IMPACTED FRACTURE OF THE SURGICAL NECK OF THE FEMUR—CLINICAL  
DIAGNOSIS WAS CONTUSION OF HIP.

Compare with the skiagram of a normal hip (Plate X). Notice the higher position of the greater trochanter and the abnormal angle formed by the head and neck of the femur with the shaft.



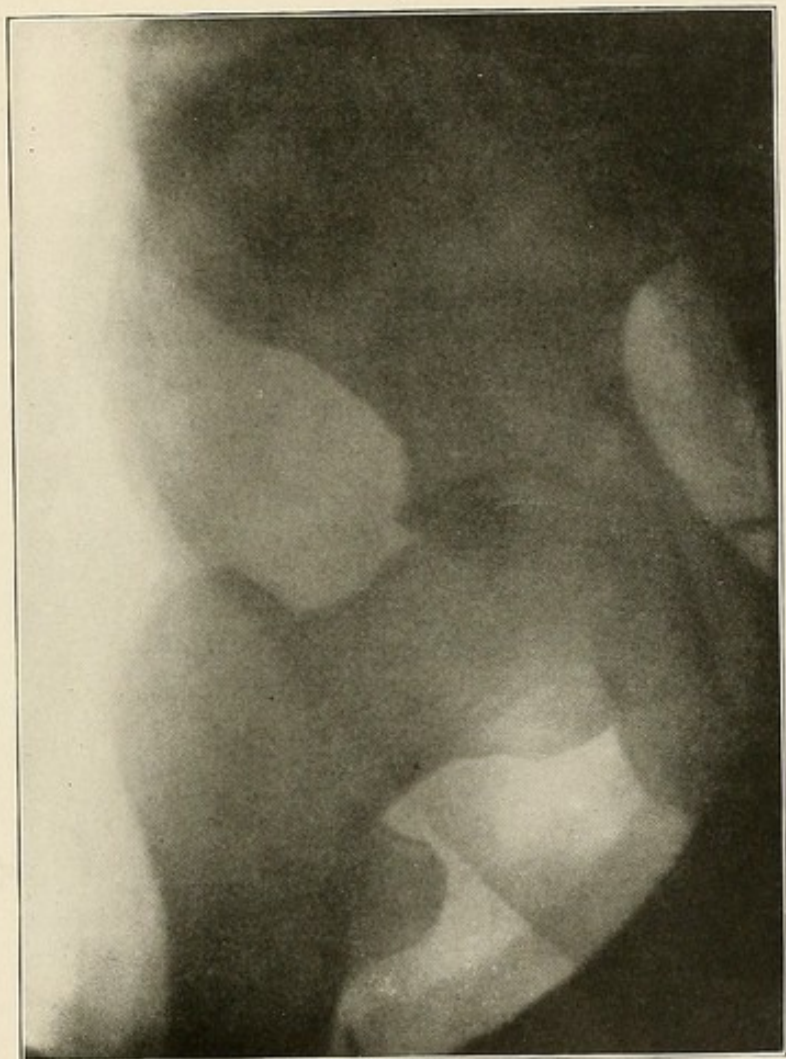


PLATE LXII.

PLATE LXIII.

FRACTURE OF THE ANATOMICAL NECK OF THE FEMUR—CLINICAL DIAGNOSIS  
WAS CONTUSION OF HIP.

The greater trochanter is in a higher position than normal.

The head is in the acetabulum.

The fracture line runs through the neck of the femur.

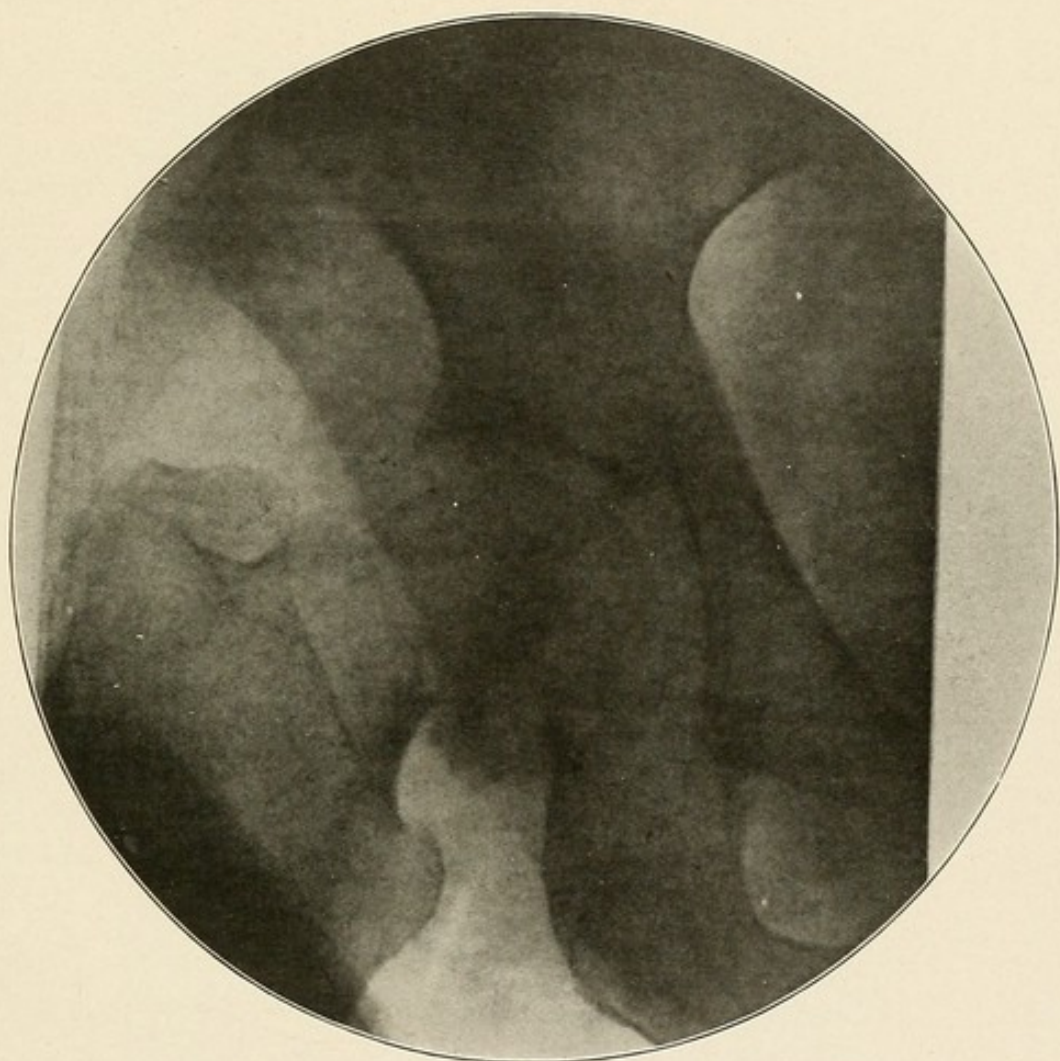


PLATE LXIII.

PLATE LXIV.

FRACTURE OF THE PELVIC BONES—FRACTURE LINE RUNS THROUGH THE  
ACETABULUM.



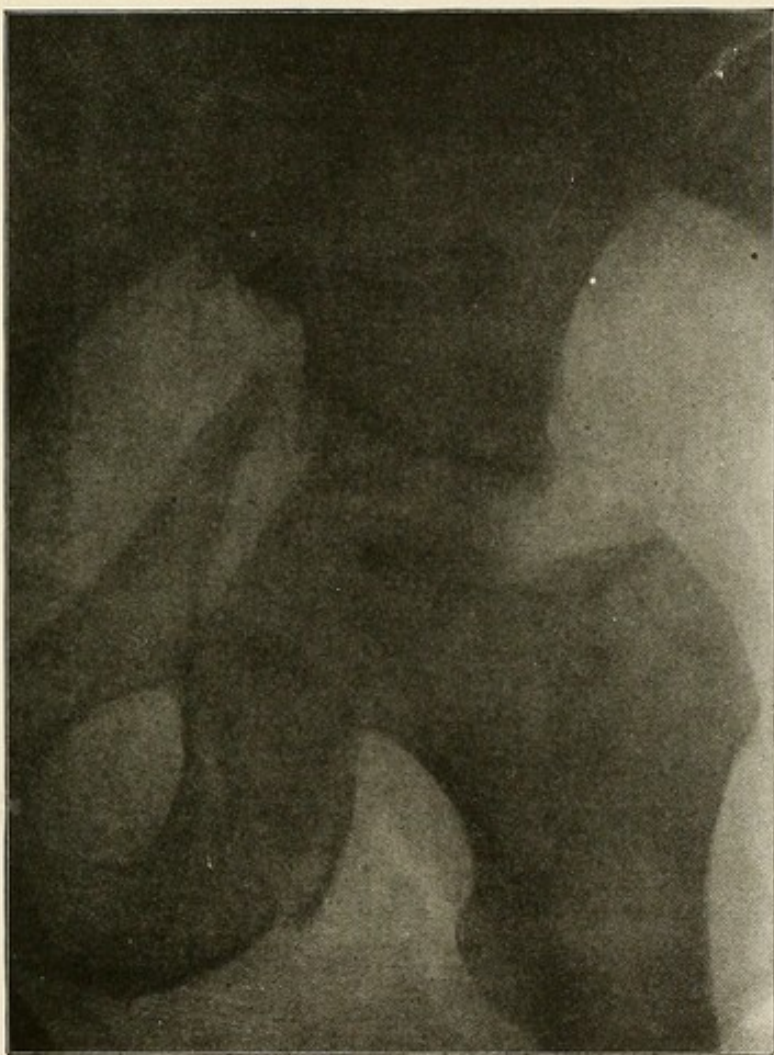

PLATE LXIV.

PLATE LXV.

FRACTURE OF THE UPPER END OF THE SHAFT OF THE FEMUR—THE FRACTURE  
RUNS THROUGH THE INTER-TROCHANTERIC LINE OF THE FEMUR.

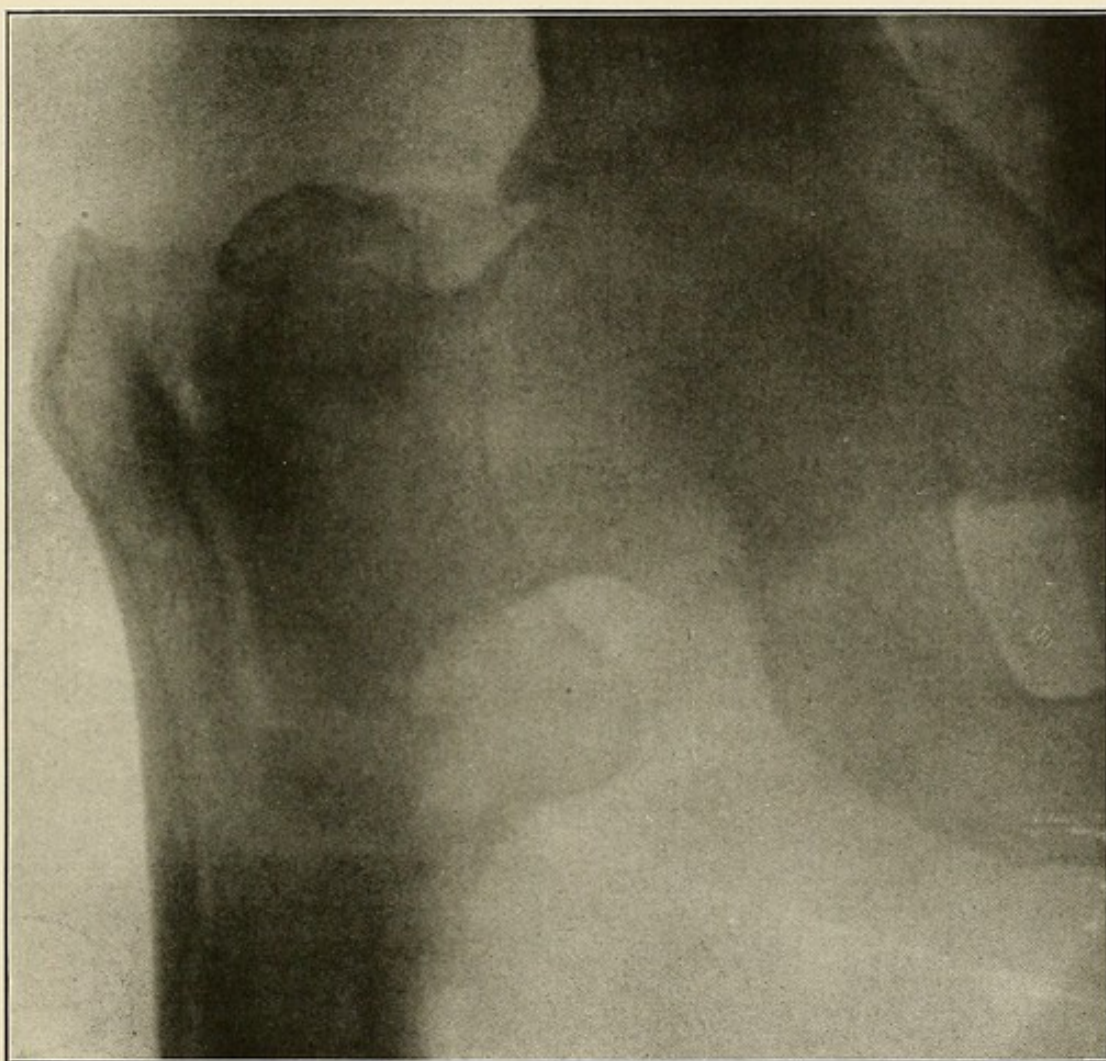


PLATE LXV.



PLATE LXVI.

FRACTURE OF THE ASTRAGALUS—CLINICAL DIAGNOSIS, CONTUSION OF THE  
ANKLE.

The fracture becomes at once apparent when comparison is made with the skiagram of a normal ankle (Plate XIII). Without such assistance this is a very difficult plate to interpret.



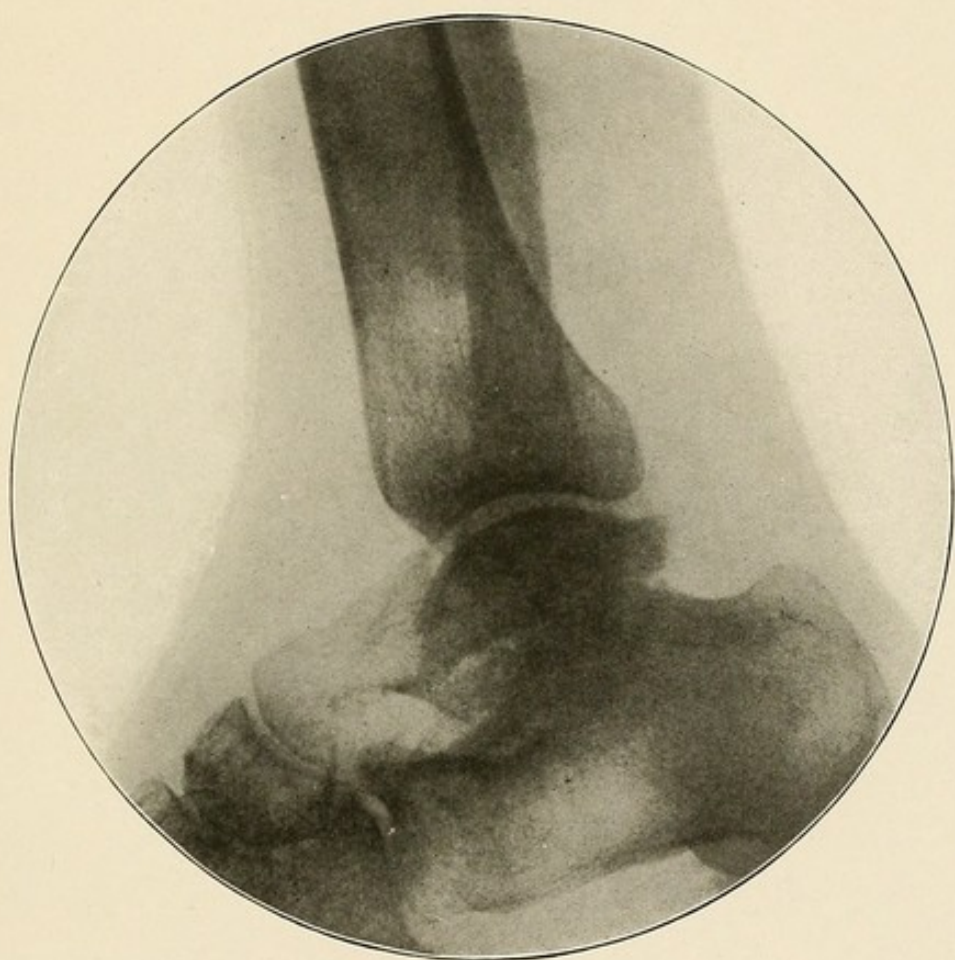


PLATE LXVI.

PLATE LXVII.

FRACTURE OF THE PATELLA—SKIAGRAM TAKEN ABOUT 3 MONTHS AFTER  
SUTURING OF THE CAPSULE.

The functional result was perfect.

Notice the separation and apparent lack of union between the two fragments.

This is due to the fact that the callous does not become completely ossified before between nine and twelve months.

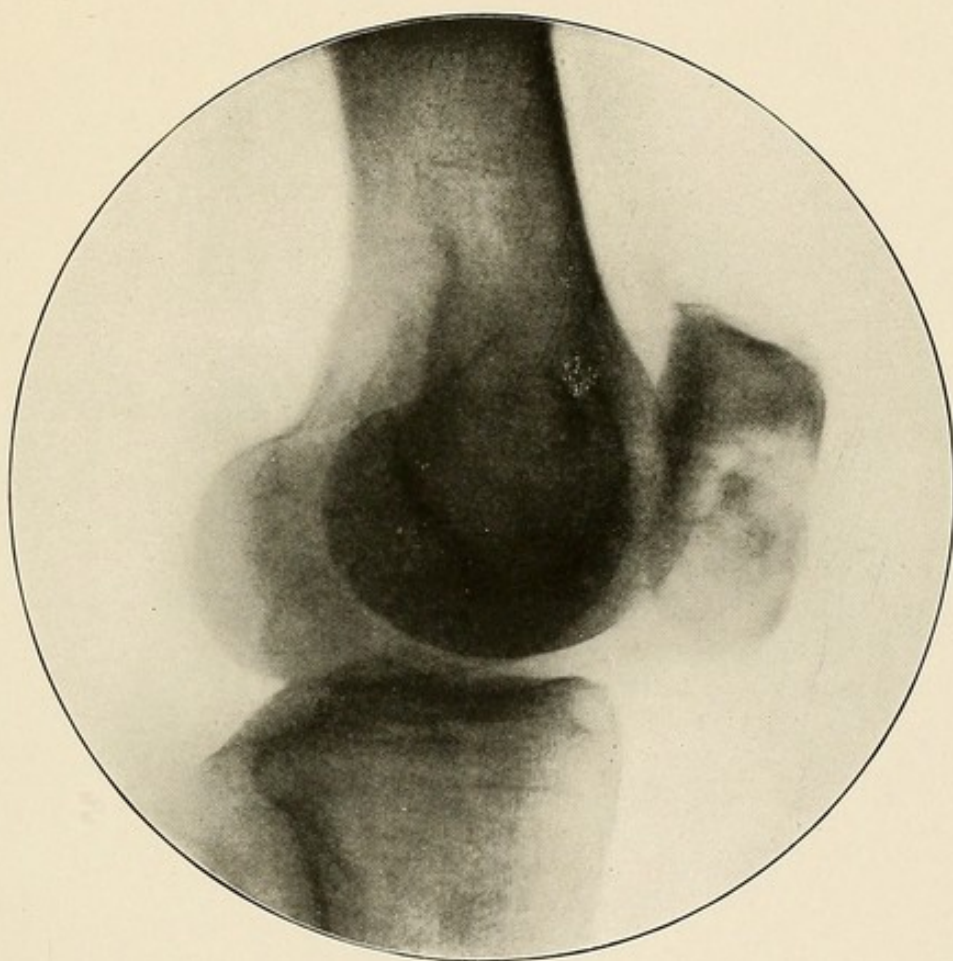


PLATE LXVII.





### DISLOCATIONS.

With the exception of the hip and shoulder two skiagrams should be made of the affected joints.

The diagnosis can, as a rule, be readily made from these skiagrams.

In cases of the hip and shoulder dislocations, the empty acetabular and glenoid cavities, and the abnormal position of the heads of the femur and humerus, can be easily made out. In old dislocations the new joint can be distinctly made out (Plate LXX).

In congenital dislocations of the hip joints, which have been reduced, the former position of the head of the femur and the lessened depth of the acetabular cavity are distinctly visible on the affected side (Plate LXXII).

PLATE LXVIII.

DISLOCATION BACKWARDS AND UPWARDS OF BOTH BONES OF THE FOREARM—  
ANTERO-POSTERIOR VIEW—FRACTURE OF THE OLECRANON—  
SAME CASE AS PLATE LXIX.

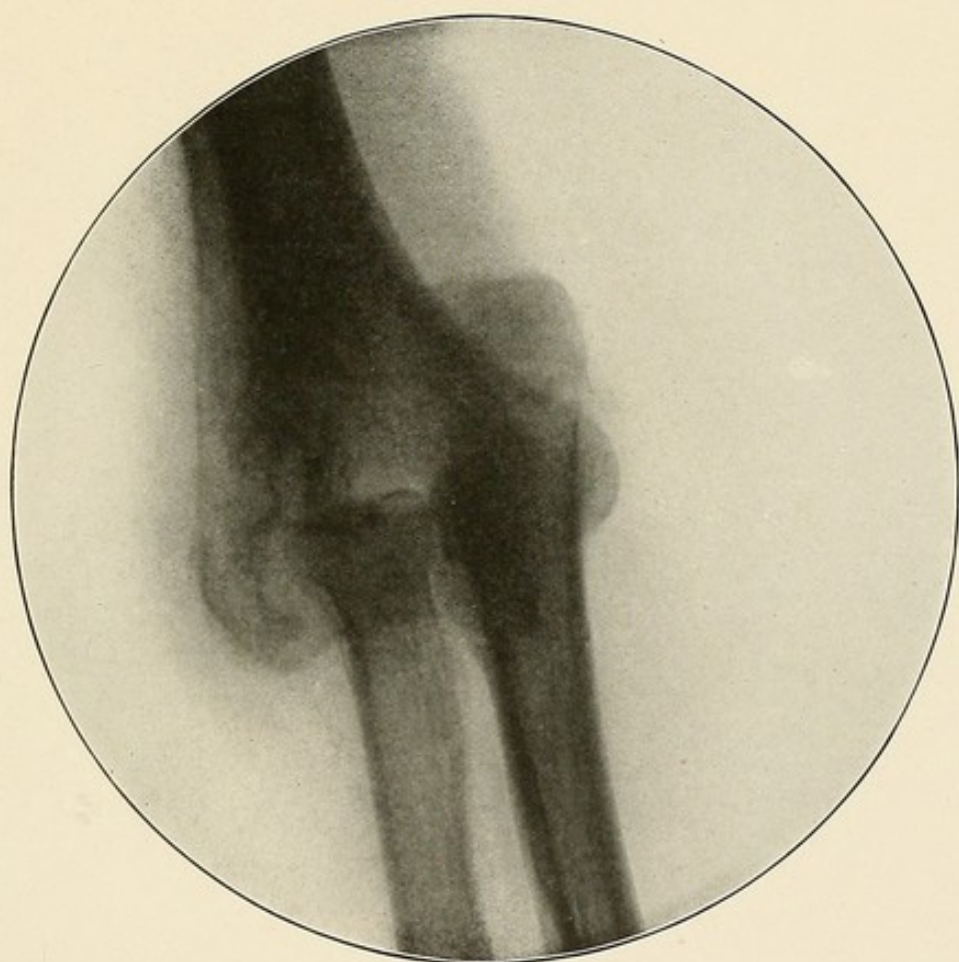


PLATE LXVIII.

PLATE LXIX.

DISLOCATION BACKWARDS AND UPWARDS OF BOTH BONES OF THE FOREARM—  
LATERAL VIEW—FRACTURE OF THE OLECRANON—SAME  
CASE AS PLATE LXVIII.



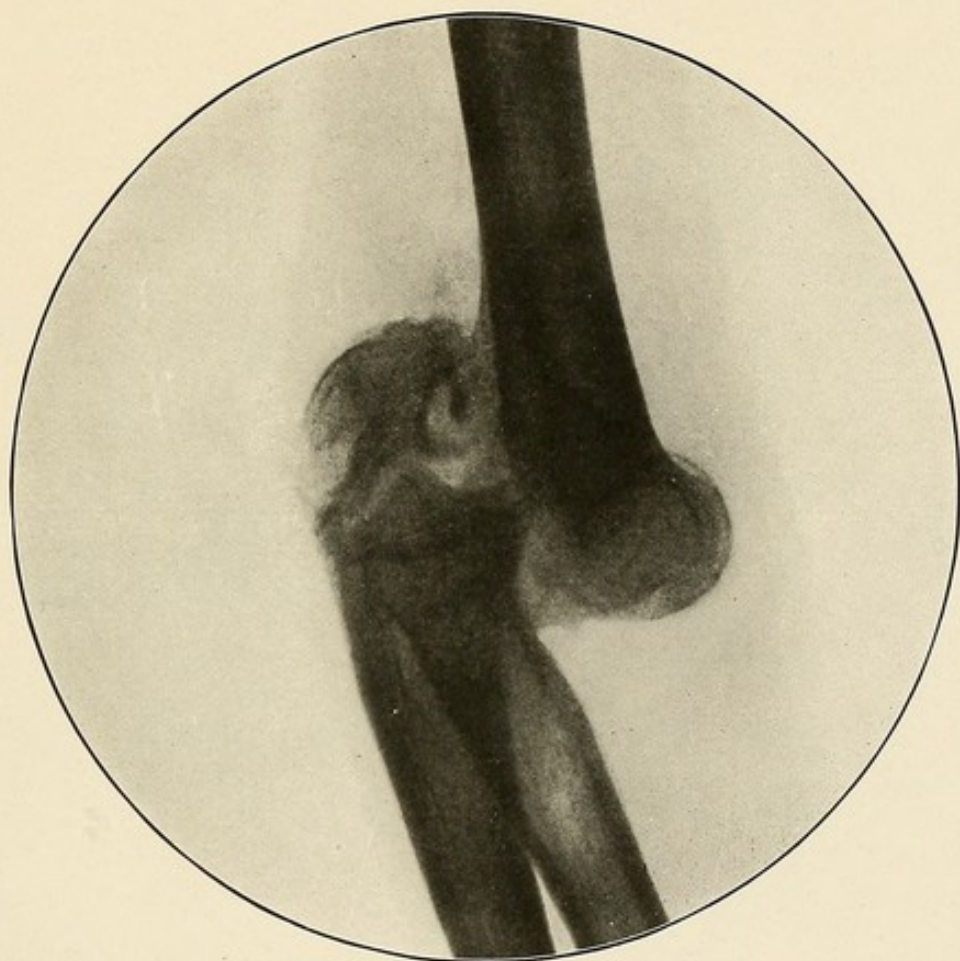


PLATE LXIX.

PLATE LXX.

DISLOCATION DOWNWARDS, FORWARDS AND INWARD OF THE HEAD OF THE  
HUMERUS—OLD DISLOCATION.

The glenoid cavity is empty.

The new joint can be distinctly made out.

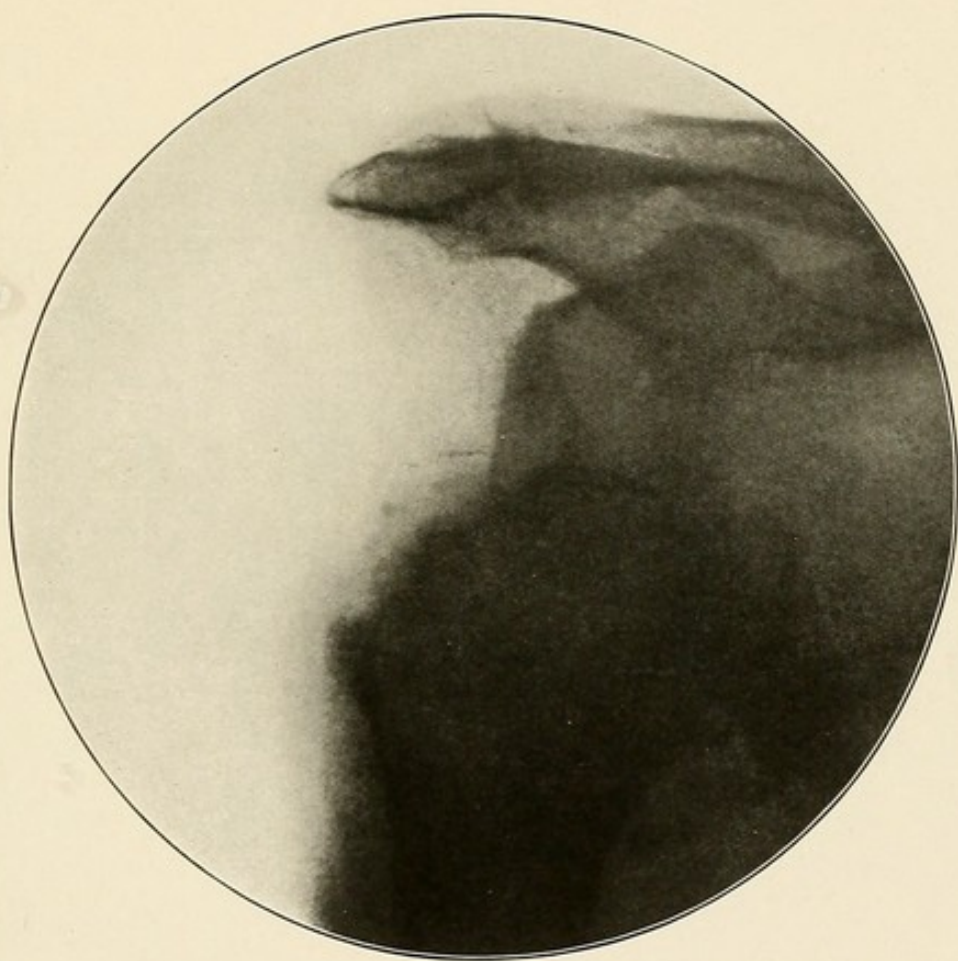


PLATE LXX.

PLATE LXXI.

DOUBLE CONGENITAL DISLOCATION OF THE HIPS—EXOSTOSIS ON THE SHAFT OF  
THE LEFT FEMUR.

Both acetabular cavities are empty.

The new joints above on the dorsum of the ilium can be plainly seen.



Ex Libris  
William Benham

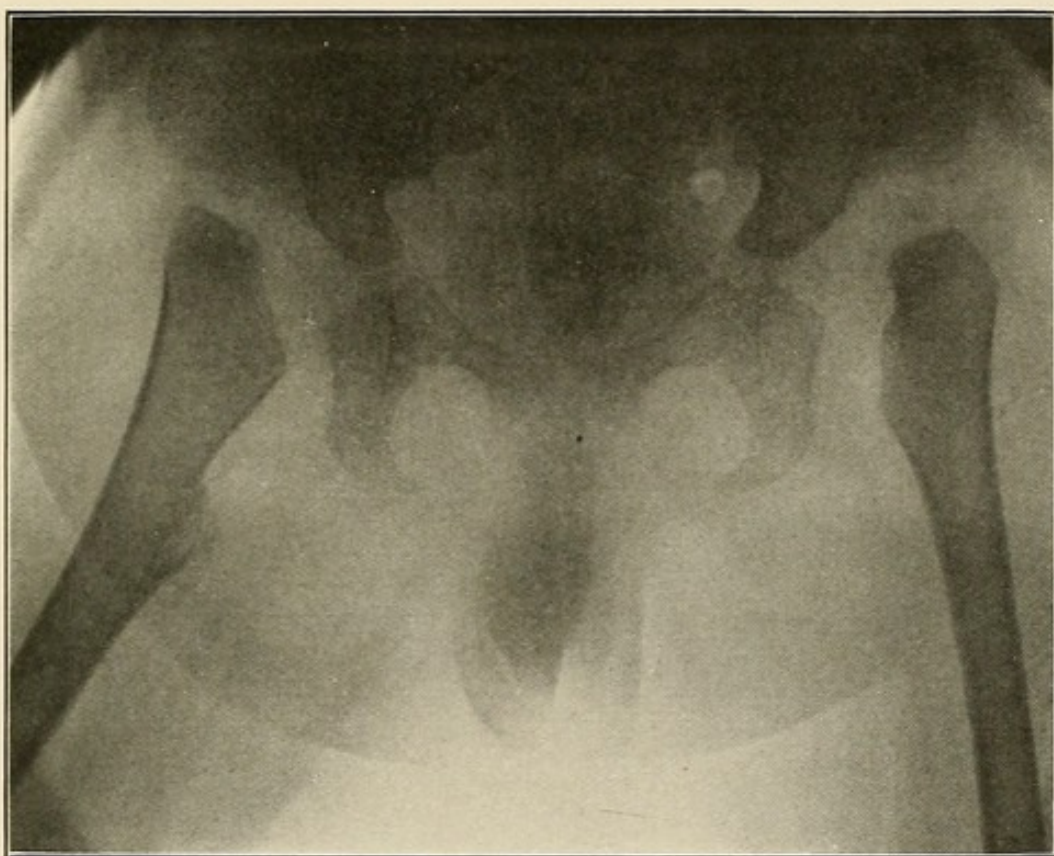


PLATE LXXI.

PLATE LXXII.

REDUCED CONGENITAL DISLOCATION OF THE RIGHT HIP.

The acetabular cavity on the right side is not as deep as on the normal side.

Just below the acetabulum is a depression, which represents the situation of the abnormal position of the head before reduction.

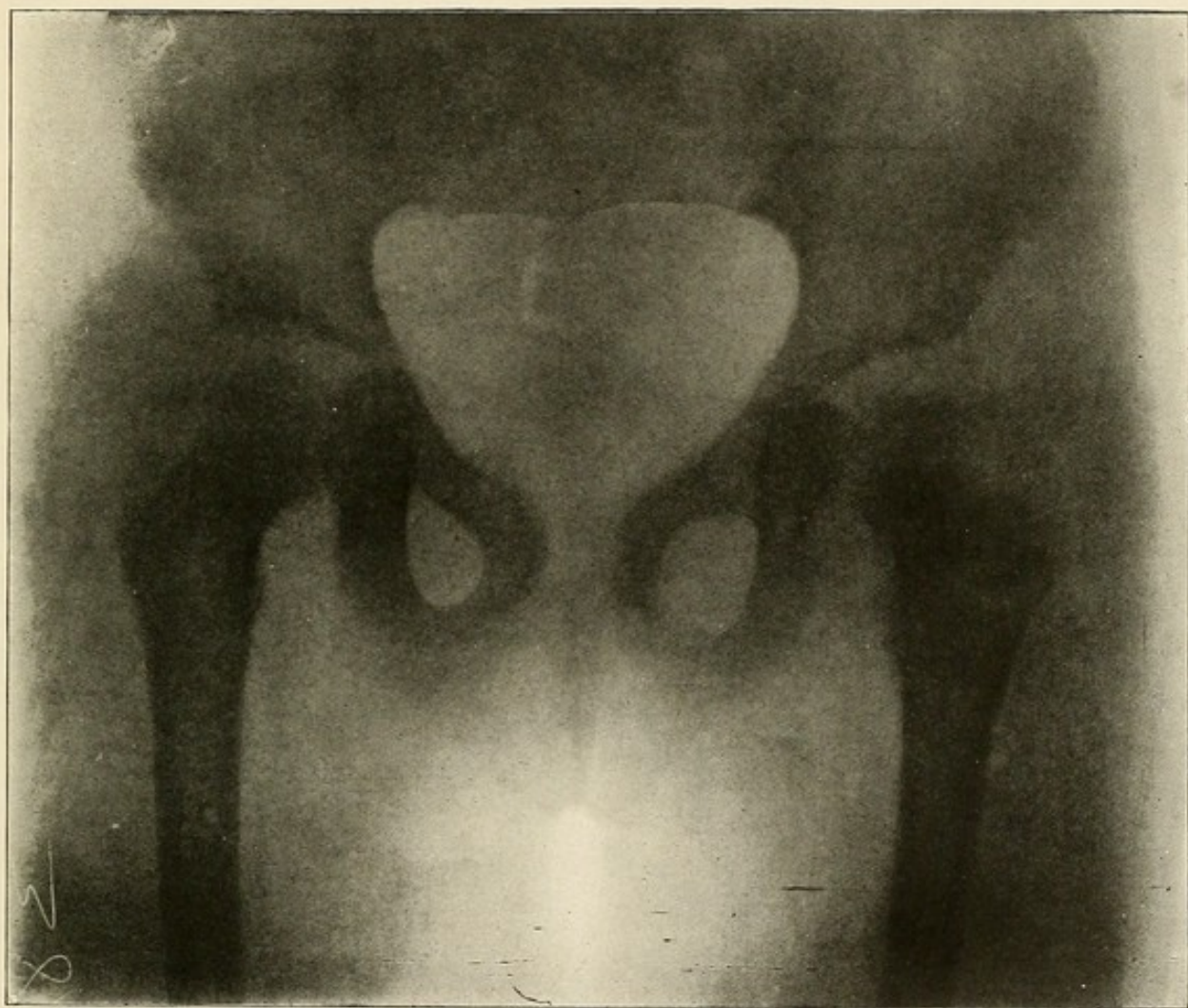


PLATE LXXII.





## FOREIGN BODIES.

We are only concerned in this chapter with the location of Foreign Bodies in or near the bones and joints of the extremities.

This, we believe, can be done in every instance from skiagrams taken in the usual manner, without the use of any special instrument, by remembering and applying the two following rules:

First. Whenever a foreign body is imbedded in the bone it is always surrounded by a light zone, first described by the author.

Second. The closer the foreign body lies to the X-ray plate the smaller, the darker, and the sharper will its shadow be.

When the foreign body is imbedded in the bone, a good skiagraph shows a zone completely surrounding it. This zone is of a lighter shade than that of the bone in which the foreign body is imbedded. Such is not the case if the foreign body is not imbedded in the bone, even though the latter and the foreign body both lie in the path of the X-rays and show in the negative in such a manner that from one single skiagraph, taken without special device and in only one position of the tube and part, it would be impossible to tell whether the foreign body was in front or behind or in the bone, except for the presence of this zone (Plates LXXIII and LXXIV).

It follows that if the foreign body is not imbedded in the bone, and that its shadow is more distinct and sharp than that of the latter, it must necessarily lie closer to the X-ray plate or between the bone and the X-ray plate. In an antero-posterior view this would mean that it was situated behind or posterior to the bone (Plates LXXVII and LXXVIII).

For example, we suppose a skiagram of the hip taken in the usual antero-posterior position and showing the presence of a foreign body. The absence of the light gray zone would indicate that the foreign body was not imbedded in the femur. A large, indistinct shadow with an outline not as sharp as that of the bone would indicate further that the foreign body was in front of the latter, *i. e.*, farther removed from the X-ray plate than the bone.

If for any reason the location of the foreign body seemed doubtful after the examination of this skiagram, and as it cannot be confirmed by a lateral view, another skiagram should be made with the patient lying face down, that is, a posterior-anterior view of the hip, instead of the usual antero-posterior view.

If for any reason the location of the foreign body seemed the second the shadow of the foreign body would be smaller, darker and more distinct and sharp, because the foreign body would be lying closer to the X-ray plate.

PLATE LXXIII.

GUN-SHOT WOUND OF THE RIGHT THIGH—BULLET LODGED IN THE GREATER  
TROCHANTER.

The light-gray zone completely surrounds the bullet.

This negative, made over two years ago, had not been properly washed after fixing and it turned yellow. This accounts for the poor detail and the fact that the acetabulum head and neck of the femur are lost.

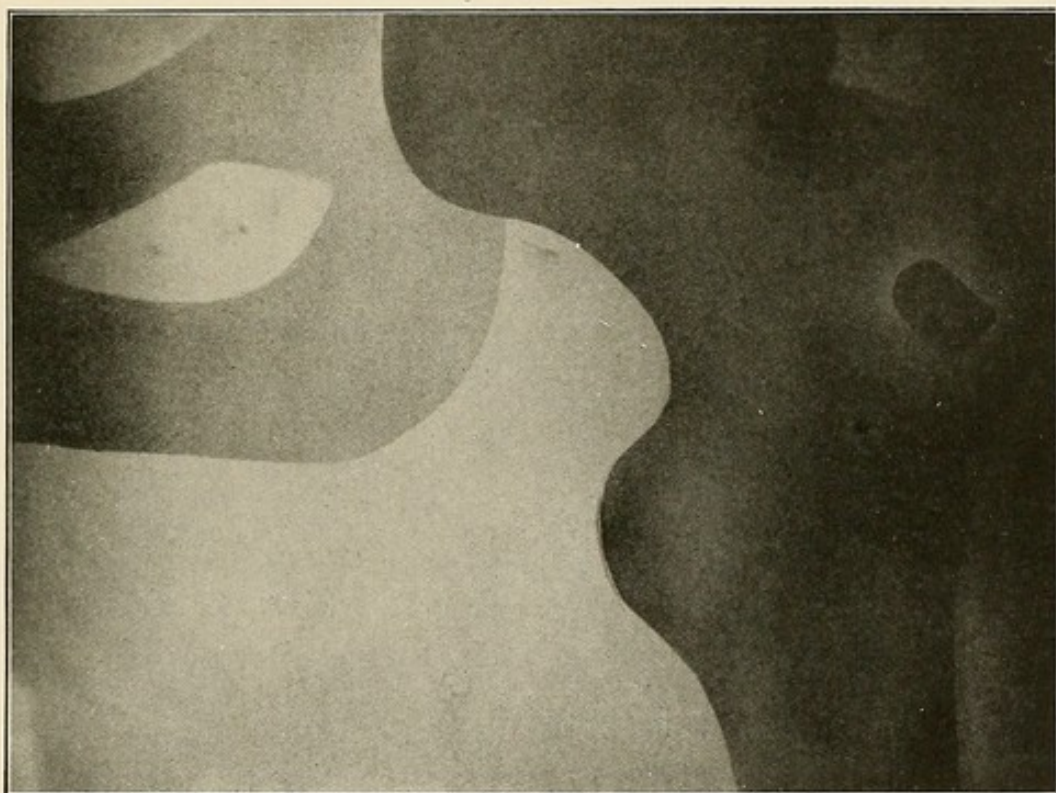


PLATE LXXIII.



PLATE LXXIV.

GUN-SHOT WOUND OF THE KNEE—BULLET LODGED IN THE UPPER END  
OF THE TIBIA.

The light gray zone completely surrounds the bullet.



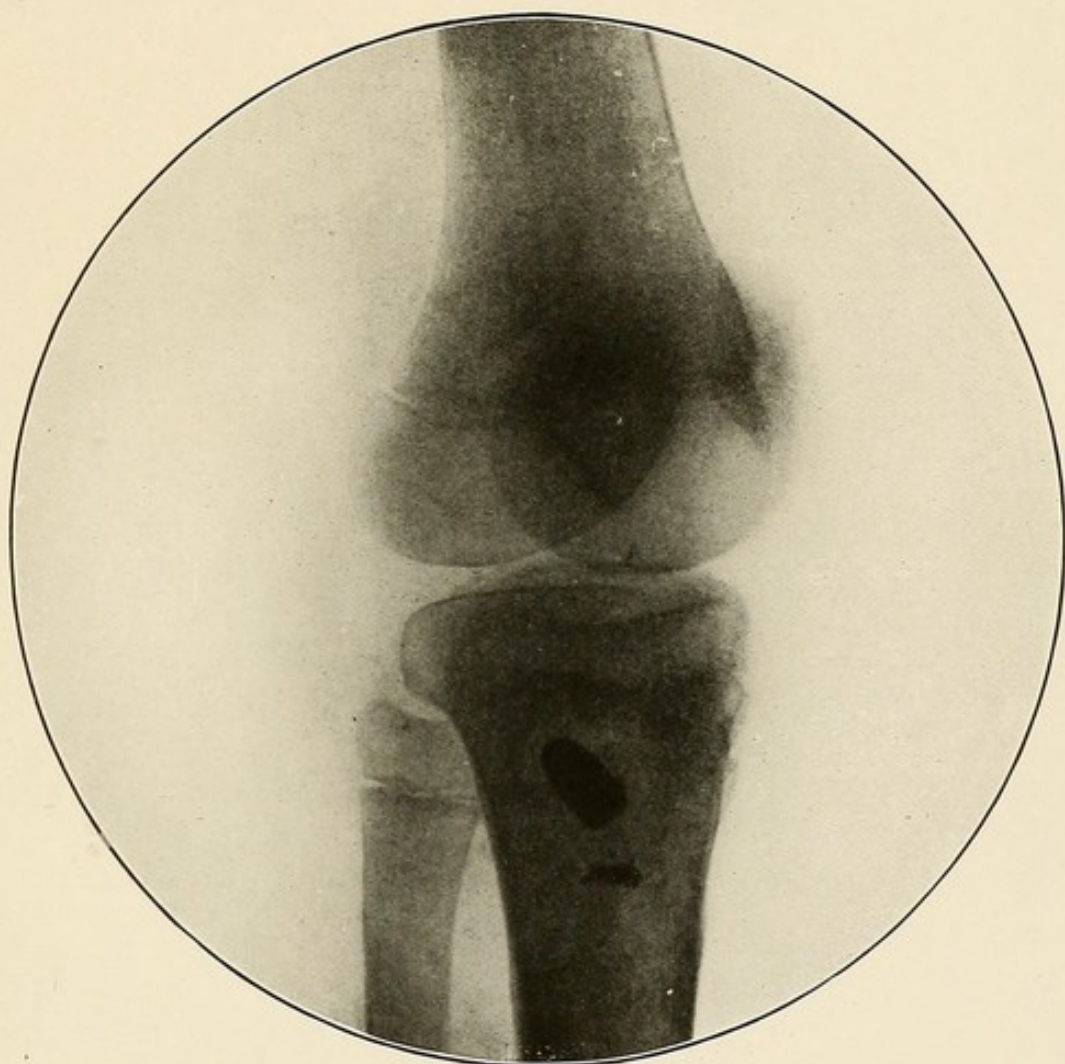


PLATE LXXIV.

PLATE LXXV.

GUN-SHOT WOUND OF THE ARM—GUN-SHOT FRACTURE OF THE HUMERUS—  
ANTERO-POSTERIOR VIEW—SAME CASE AS PLATE LXXVI.

The small circumscribed black shadow at the upper end of the fracture line is a fragment of the splintered bullet. As it is not surrounded by a light gray zone it is not lodged in the bone, but lies posterior to the bone, as shown in the next *Plate*.

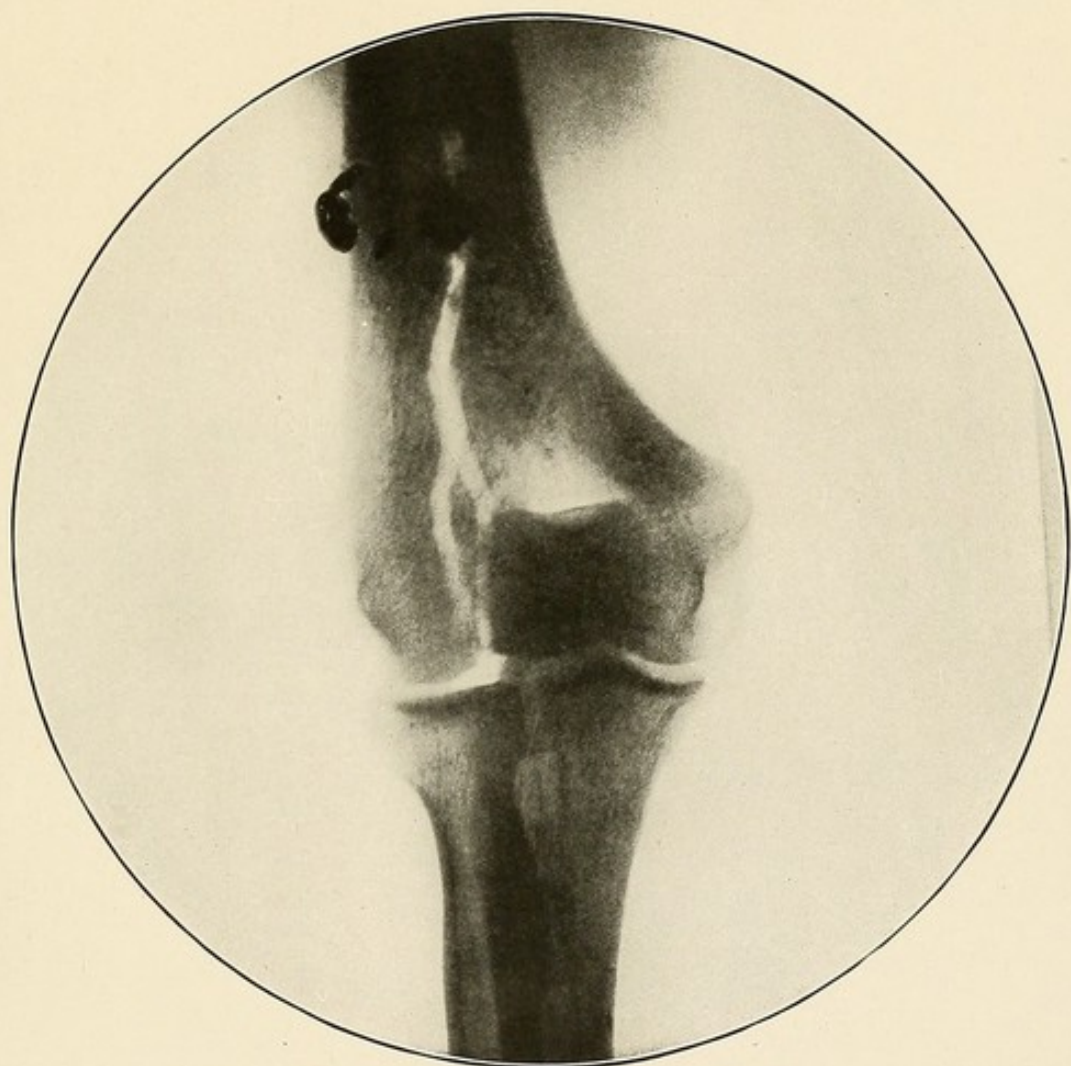


PLATE LXXV.

PLATE LXXVI.

GUN-SHOT WOUND OF THE KNEE—LATERAL VIEW—SAME CASE AS PLATE LXXVII.  
LATERAL VIEW—SAME CASE AS PLATE LXXV.

The small circumscribed black shadow seen in the center of the bone shadow is a fragment of the splintered bullet. As it is not surrounded by a *light gray zone* it is not in the bone, but must be internal or external to it. When the negative was taken the ulnar surface was lying on the plate, and the shadow lying behind the humerus, having a more distinct outline, was lying closer to the plate, i. e., closer to the ulnar or inner border of the bone, and the other was closer to the radial or outer border. Plate LXXV shows this.



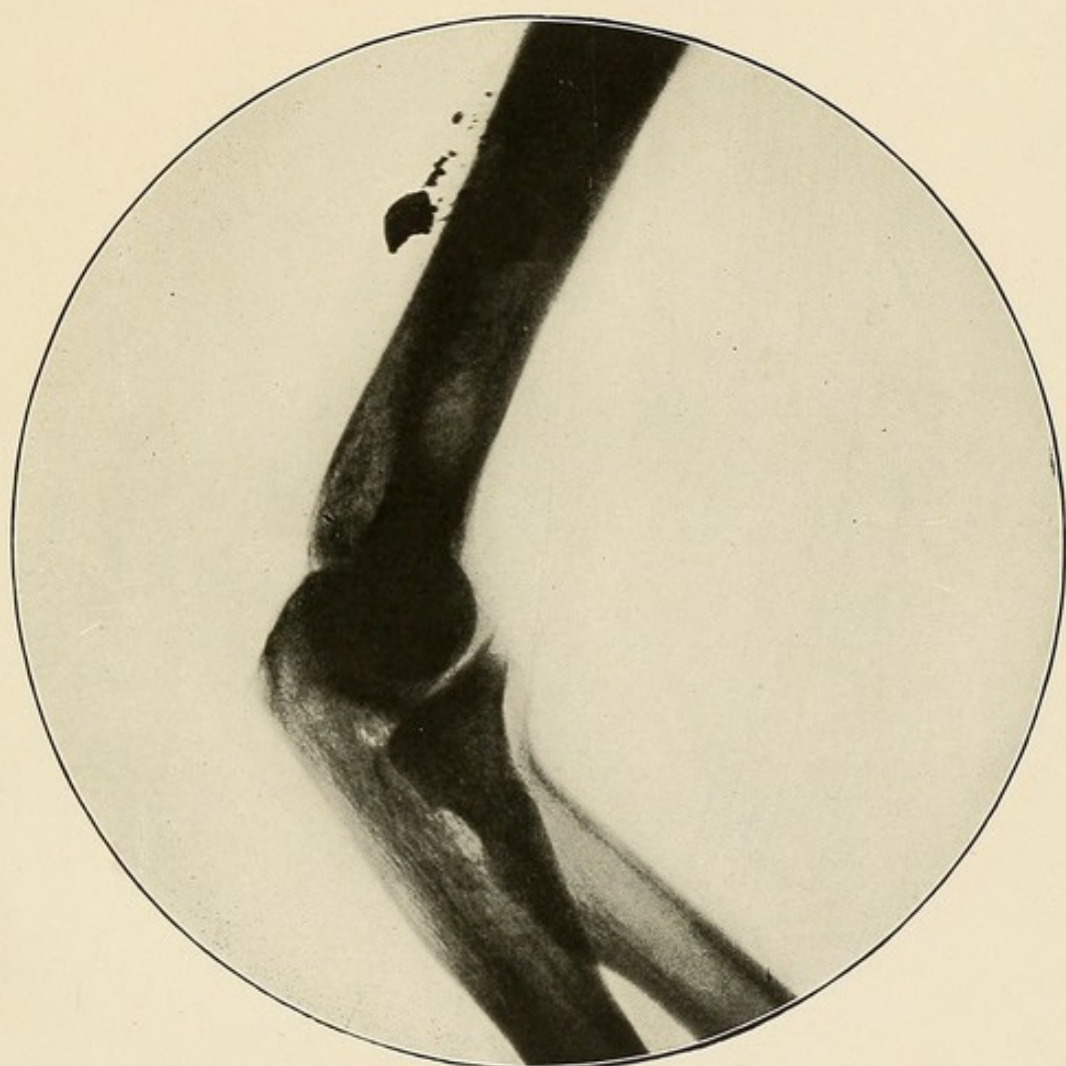


PLATE LXXVI.

PLATE LXXVII.

GUN-SHOT WOUND OF THE LEFT KNEE—ANTERO-POSTERIOR VIEW—SAME CASE  
AS PLATE LXXVIII.

The small circumscribed black shadow seen above the condyles is the bullet.

As it is not surrounded by a light gray zone it is not imbedded in the bone, but must lie anterior or posterior to it. Since the outline of the bullet is sharper than that of the bone it must have been lying between the latter and the plate during the exposure. It must therefore lie behind the bone. The correctness of this interpretation is seen in the next *Plate*.

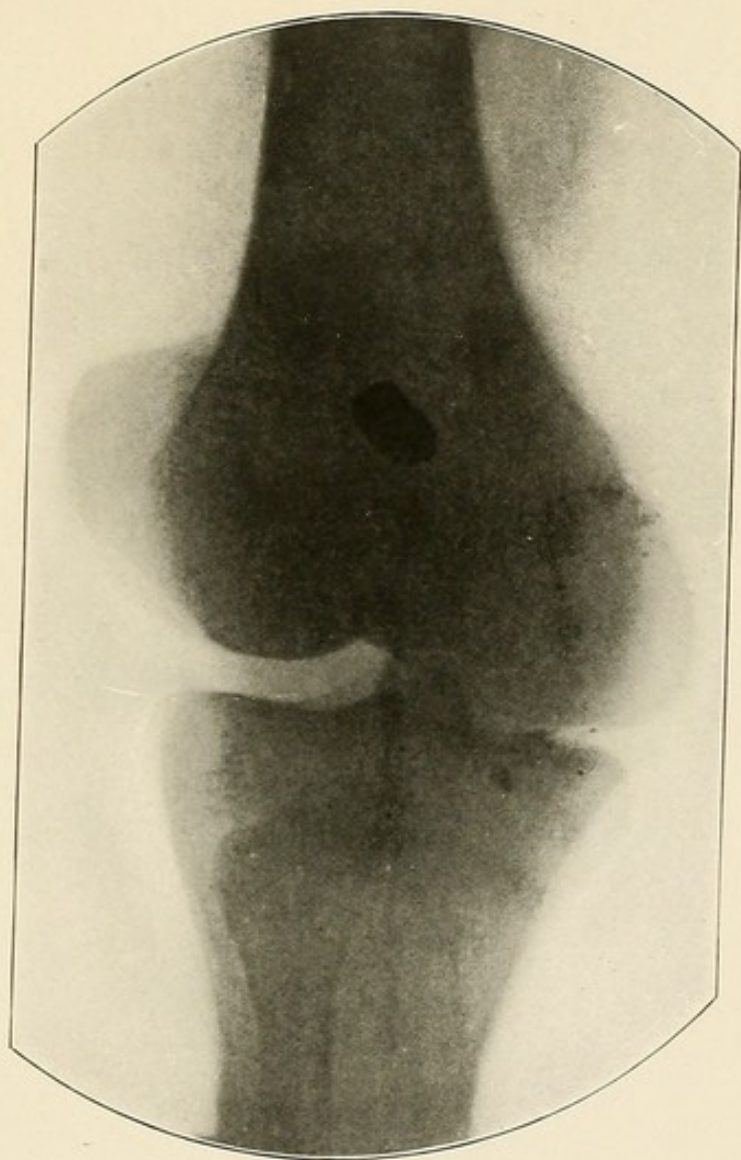


PLATE LXXVII.

PLATE LXXVIII.

GUN-SHOT WOUND OF THE KNEE—LATERAL VIEW—SAME CASE AS PLATE LXXVII.

The small circumscribed dark gray shadow lying behind the femur and above the condyles is the bullet.

As its outline is neither more nor less distinct than that of the bone it must be lying in a position about opposite the center of the bone. See preceding *Plate*.



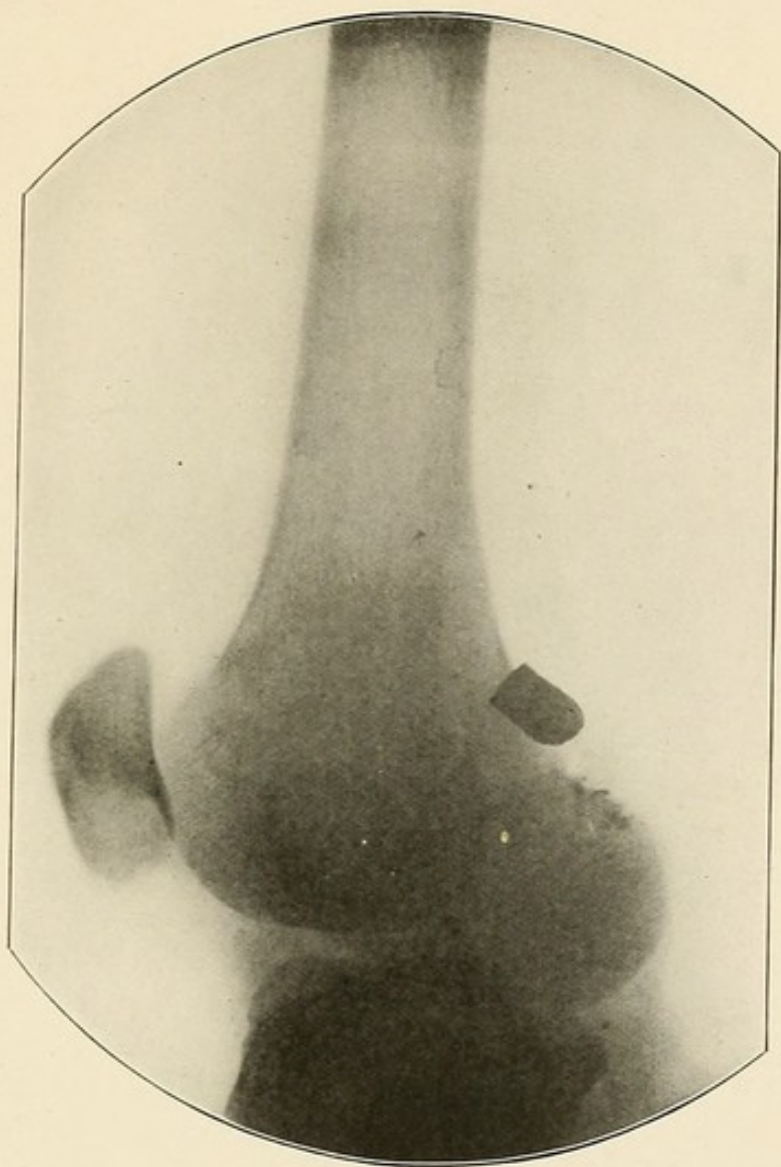




PLATE LXXVIII.










COLUMBIA UNIVERSITY LIBRARIES (hsl, str)

**Rd 36 G762 C.1**

A radiographic atlas of the pathologic c



2002124432

RD36

G762

Granger

