Anatomy, descriptive and surgical / Edited by T. Pickering Pick and Robert Howden.

Contributors

Gray, Henry, 1827-1861
Howden, Robert, 1856-1941
Pick, T. Pickering (Thomas Pickering), 1841-1919
Augustus Long Health Sciences Library

Publication/Creation

Philadelphia : Lea brothers, 1901.

Persistent URL

https://wellcomecollection.org/works/jsmf3ddb

License and attribution

This material has been provided by the Augustus C. Long Health Sciences Library at Columbia University and Columbia University Libraries/Information Services, through the Medical Heritage Library. The original may be consulted at the the Augustus C. Long Health Sciences Library at Columbia University and Columbia University.
This work has been identified as being free of known restrictions under copyright law, including all related and neighbouring rights and is being made available under the Creative Commons, Public Domain Mark.

You can copy, modify, distribute and perform the work, even for commercial purposes, without asking permission.

Wellcome Collection
183 Euston Road
London NW1 2BE UK
T +44 (0)20 7611 8722
E library@wellcomecollection.org
https://wellcomecollection.org

DUPLICATE
HX00060739

QM23 G79 1901

Columbia University
in the City of New York
College of Physicians and Surgeons



Reference Library

ANATOMY,

DESCRIPTIVE AND SURGICAL

BY

HENRY GRAY, F.R.S.,

FELLOW OF THE ROYAL COLLEGE OF SURGEONS; LECTURER ON ANATOMY AT ST. GEORGE'S HOSPITAL MEDICAL SCHOOL.

EDITED BY

T. PICKERING PICK, F.R.C.S.,

CONSULTING SURGEON TO ST. GEORGE'S HOSPITAL AND TO THE VICTORIA HOSPITAL FOR CHILDREN; H. M. INSPECTOR OF ANATOMY IN ENGLAND AND WALES,

AND

ROBERT HOWDEN, M.A., M.B., C.M.,

PROFESSOR OF ANATOMY IN THE UNIVERSITY OF DURHAM; EXAMINER IN ANATOMY IN THE UNIVERSITIES OF DURHAM AND EDINBURGH, AND TO THE BOARD OF EDUCATION, SOUTH KENSINGTON.

A REVISED AMERICAN, FROM THE FIFTEENTH ENGLISH, EDITION.

WITH 780 ILLUSTRATIONS, MANY OF WHICH ARE NEW.



LEA BROTHERS & CO.,

PHILADELPHIA AND NEW YORK.

1901.

TO

SIR BENJAMIN COLLINS BRODIE, BART.,

F.R.S., D.C.L.,

SERJEANT-SURGEON TO THE QUEEN,

CORRESPONDING MEMBER OF THE INSTITUTE OF FRANCE,

This Work is Dedicated

IN ADMIRATION OF

HIS GREAT TALENTS

AND IN REMEMBRANCE OF

MANY ACTS OF KINDNESS SHOWN TO THE AUTHOR

FROM AN

EARLY PERIOD OF HIS PROFESSIONAL CAREER.

PUBLISHERS' NOTE TO THE NEW AMERICAN EDITION.

In his masterpiece Henry Gray left undying evidence of his anatomical knowledge and of his comprehension of the best method of imparting it to other minds. It is appropriate that a new and thoroughly revised edition of such a work should appear in the opening of the new century—for forty-five years it has easily held the front place among works on Anatomy, and its merits are only brightened by the numerous works which have endeavored to contest its supremacy. During that time it has had the benefit of the careful scrutiny of many leading anatomists of the English-speaking race. Anatomy is far from stationary, either in its facts or in improvements in the method of their presentation; hence any work which would faithfully reflect the existing position of the science must be revised at comparatively frequent intervals. Fortunately for students and practitioners, *Gray's Anatomy* enjoys a continuous demand rendering frequent revision possible.

The splendid illustrations in *Gray* have long been known as the most effective and intelligible presentations of anatomical structures ever produced. In the present revision this series has been vastly improved, special attention having been given to those for the portion on General Anatomy and Embryology.

The practical application of anatomical facts in medicine and surgery has always been a prominent feature of the work, and this distinctive characteristic has received especial care.

This *new century* edition is presented to the medical public with the absolute confidence that it will be found worthy in every respect to maintain the exalted [illegible] work has for so many years enjoyed as the most convenient and [illegible] of its subject.

PREFACE TO THE FIFTEENTH ENGLISH EDITION.

In this edition the entire work has undergone a careful revision. The section on Embryology has been somewhat amplified, and its text rendered more intelligible by the introduction of some sixty additional illustrations after His, Kollmann, Duval, and others. Throughout the rest of the work a considerable number of the diagrams have been redrawn and new illustrations here and there added.

The Editors are indebted to Dr. R. Bolam, Lecturer on Physiology and Histology, and to Dr. W. Turnbull, Demonstrator of Anatomy, both of the University of Durham College of Medicine, for their valuable help. The former kindly undertook the revision of the chapter on General Anatomy or Histology; while the latter rendered great assistance in the revision and proof-reading of some of the other portions of the work.

It is hoped that this edition will maintain the reputation which the work has for so many years enjoyed.

CONTENTS.

DESCRIPTIVE AND SURGICAL ANATOMY.

OSTEOLOGY.—THE SKELETON.

PAGE

The Skeleton 33
Number of the Bones 33
Form of Bones 33

THE SPINE.

General Characters of a Vertebra 34
Characters of the Cervical Vertebræ 35
Atlas 36
Axis 37
Seventh Cervical 39
Characters of the Dorsal Vertebræ 39
Peculiar Dorsal Vertebræ 41
Characters of the Lumbar Vertebræ 41
Structure of the Vertebræ 43
Development of the Vertebræ 43
" " Atlas 44
" " Axis 44
" " Seventh Cervical 45
" " Lumbar Vertebræ 45
Progress of Ossification in the Spine 45
Sacral and Coccygeal Vertebræ 45
Sacrum 45
Coccyx 50
Of the Spine in General 51
Surface Form of Spine 53
Surgical Anatomy of Spine 53

THE SKULL.

Bones of the Cranium 55
Occipital Bone 55
Parietal Bones 59
Frontal Bone 61
Temporal Bones 65
Sphenoid Bone 72
Ethmoid Bone 77
Development of the Cranium 80
The Fontanelles 80
Wormian Bones 81
Congenital Fissures and Gaps 81
Bones of the Face:
Nasal Bones 81
Superior Maxillary Bones 83
Changes produced in Upper Jaw by Age . 88
Lachrymal Bones 88
Malar Bones 89
Palate Bones 91
Inferior Turbinated Bones 94
Vomer 95
Inferior Maxillary Bone 96
Changes produced in the Lower Jaw by Age 99
Sutures of the Skull 101
Vertex of the Skull 103
Base of the Skull, Internal Surface 103
Anterior Fossa 103
Middle Fossa 105
Posterior Fossa 106
Base of Skull, External Surface 106
Lateral Region of the Skull 110
Temporal Fossa 110
Mastoid Portion 111
Zygomatic Fossa 111

PAGE

Spheno-maxillary Fossa 112
Anterior Region of the Skull 112
Orbits 113
Nasal Fossæ 115
Surface Form of Skull 118
Surgical Anatomy of Skull 119
Os Hyoides 122

THE THORAX.

The Sternum 124
The Ribs 128
Peculiar Ribs 130
Costal Cartilages 132
Surface Form of Chest 132
Surgical Anatomy of Chest 133

THE UPPER EXTREMITY.

The Shoulder and Pelvic Girdles 134
The Clavicle 135
Surface Form 137
Surgical Anatomy 137
The Scapula 138
Surface Form 143
Surgical Anatomy 143
The Humerus 144
Surface Form 149
Surgical Anatomy 149
The Forearm 150
The Ulna 150
Surface Form 155
The Radius 155
Surface Form 157
Surgical Anatomy of Bones of Forearm . 157
The Hand 158
The Carpus 158
Bones of the Upper Row 161
Bones of the Lower Row 163
The Metacarpus 165
Peculiar Characters of the Metacarpal Bones . 166
Phalanges 169
Surface Form of Bones of Hand 169
Surgical Anatomy of Bones of Hand . . 170
Development of the Bones of the Hand . . . 170

THE LOWER EXTREMITY.

Os Innominatum 171
Ilium 172
Ischium 174
Os Pubis 176
Development of the Os Innominatum 177
The Pelvis 179
Differences between the Male and Female Pelvis 182
Surface Form of Bones of Pelvis 182
Surgical Anatomy of Bones of Pelvis . . 183
The Femur or Thigh-bone 183
Surface Form 190
Surgical Anatomy 190
The Leg 191
Patella 191
Surface Form 192
Surgical Anatomy 192

PAGE

Tibia 192
Surface Form 196
Fibula 196
Surface Form 198
Surgical Anatomy of Bones of Leg . . . 198
The Foot 199
Tarsus 199
Os Calcis 199
Astragalus 203
Cuboid 204
Navicular 205
Internal Cuneiform 206
Middle " 206
External " 207
Metatarsal Bones 208
Phalanges 210
Development of the Bones of the Foot . . . 211
Construction of the Foot as a whole . . . 211
Surface Form of Foot 213
Surgical Anatomy of Foot 213
Sesamoid Bones 214

THE ARTICULATIONS.

Structures composing the Joints 217
Articular Lamella of Bone 217
Ligaments 217
Synovial Membrane 217
Bursæ 218
Synovia 218
Forms of Articulation:
Synarthrosis 218
Amphiarthrosis 219
Diarthrosis 219
Movements of Joints 220

Articulations of the Trunk.

Articulations of the Vertebral Column . . . 223
" " Atlas with the Axis . . 227
" " Spine with the Cranium 229
" " Atlas with the Occipital Bone 229
Articulation of the Axis with the Occipital Bone 230
Surgical Anatomy of Articulations of the Spine 231
Tempero-mandibular Articulation 231
Surface Form 234
Surgical Anatomy 234
Articulations of the Ribs with the Vertebræ:
Costo-central 234
Costo-transverse 236
Articulations of the Cartilages of the Ribs with the Sternum and Ensiform Cartilage . 238
Interchondral Articulations 239
Articulations of the Ribs with their Cartilages 239
Ligaments of the Sternum 239
Articulation of the Pelvis with the Spine . . 240
Articulations of the Pelvis:
Articulation of the Sacrum and Ilium . . 241
Ligament between the Sacrum and Ischium 242
Articulation of the Sacrum and Coccyx . 244
Articulation of the Pubes 244

Articulations of the Upper Extremity.

Sterno-clavicular 245
Surface Form 247
Surgical Anatomy 247
Acromio-clavicular 248
Surface Form 249
Surgical Anatomy 249
Proper Ligaments of the Scapula 249
Shoulder-joint 251
Surface Form 254
Surgical Anatomy 254
Elbow-joint 255
Surface Form 258
Surgical Anatomy 358
Superior Radio-ulnar Articulations 259
Middle Radio-ulnar Articulation 259
Inferior Radio-ulnar Articulation 260
Surface Form 261
Wrist-joint 262
Surface Form 263
Surgical Anatomy 263
Articulations of the Carpus 263
" of the first row of Carpal Bones 263
" of the second row of Carpal Bones 264
" of the two rows of Carpal Bones 264
Carpo-metacarpal Articulations 265
of the Metacarpal Bone of Thumb and Trapezium 265
of the four inner Metacarpal Bones and Carpus 266
Articulations of the Metacarpal Bones 267
Metacarpo-phalangeal Articulations 267
Surface Form 268
Articulations of the Phalanges 268

Articulations of the Lower Extremity.

Hip-joint 268
Surface Form 272
Surgical Anatomy 272
Knee-joint 274
Surface Form 280
Surgical Anatomy 280
Superior Tibio-fibular Articulation 282
Middle Tibio-fibular Articulation 282
Inferior Tibio-fibular Articulation 282
Articulations between the Tibia and Fibula . 282
Ankle-joint 283
Surface Form 285
Surgical Anatomy 285
Articulations of the Tarsus 287
" of the Os Calcis and Astragalus 287
" of the Os Calcis and Cuboid . 287
" of the Os Calcis and Navicular 288
Surgical Anatomy 288
" of the Astragalus and Navicular 289
" of the Navicular and Cuneiform 289
" of the Navicular and Cuboid . . 289
" of the Cuneiform with each other 290
" of the External Cuneiform and Cuboid 290
Tarso-metatarsal Articulations 290
Articulations of the Metatarsal Bones 291
Synovial Membranes in Tarsal and Metatarsal Joints 291
Metatarso-phalangeal Articulations 292
Articulations of the Phalanges 293
Surface Form 293

MUSCLES AND FASCIÆ.

General Description of Muscle 295
" " Tendons 296
" " Aponeuroses 296
" " Fascia 296

Muscles and Fasciæ of the Cranium and Face.

Subdivision into Groups 297

Cranial Region.

Dissection 298
Occipito-frontalis 298

Auricular Region.

Dissection 300
Attrahens Auriculum 300
Attollens Auriculum 301

PAGE

Retrahens Auriculum 301
Actions 301

Palpebral Region.

Dissection 301
Orbicularis Palpebrarum 301
Corrugator Supercilii 302
Tensor Tarsi 302
Actions 302

Orbital Region.

Dissection 303
Levator Palpebræ 303
Rectus Superior, Inferior, Internal, and External Recti 304
Superior Oblique 304
Inferior Oblique 305
Actions 305
Surgical Anatomy 306

Nasal Region.

Pyramidalis Nasi 306
Levator Labii Superioris Alæque Nasi 306
Dilatator Naris, Anterior and Posterior . . . 306
Compressor Nasi 306
Compressor Narium Minor 306
Depressor Alæ Nasi 306
Actions 307

Superior Maxillary Region.

Levator Labii Superioris Proprius 307
Levator Anguli Oris 307
Zygomaticus, Major and Minor 307
Actions 307

Inferior Maxillary Region.

Dissection 308
Levator Labii Inferioris 308
Depressor Labii Inferioris 308
Depressor Anguli Oris 308
Actions 308

Intermaxillary Region.

Dissection 308
Orbicularis Oris 308
Buccinator 309
Risorius 310
Actions 310

Temporo-mandibular Region.

Masseteric Fascia 310
Masseter 310
Temporal Fascia 310
Dissection 311
Temporal 311

Pterygo-mandibular Region.

Dissection 312
External Pterygoid 312
Internal Pterygoid 312
Actions 313
Surface Form of Muscles of Head and Face . 313

MUSCLES AND FASCIÆ OF THE NECK.

Subdivision in Groups 313

Superficial Region.

Dissection 314
Superficial Cervical Fascia 314
Platysma Myoides 314
Surgical Anatomy 315
Actions 315
Deep Cervical Fascia 315
Surgical Anatomy 317
Sterno-mastoid 317
Boundaries of the Triangles of the Neck . . 318
Actions 319
Surface Form 319
Surgical Anatomy 319

Infra-hyoid Region.

Dissection 319
Sterno-hyoid 319

PAGE

Sterno-thyroid 319
Thyro-hyoid 320
Omo-hyoid 320
Actions 321

Supra-hyoid Region.

Dissection 321
Digastric 321
Stylo-hyoid 322
Stylo-hyoid Ligament 322
Mylo-hyoid 322
Genio-hyoid 322
Actions 323

Lingual Region.

Dissection 323
Genio-hyo-glossus 323
Hyo-glossus 324
Chrondro-glossus 324
Stylo-glossus 324
Palato-glossus 325
Muscular Substance of Tongue 325
Superior Lingualis 326
Transverse Lingualis 326
Vertical Lingualis 326
Inferior Lingualis 326
Surgical Anatomy 327
Actions 327

Pharyngeal Region.

Dissection 327
Inferior Constrictor 327
Middle Constrictor 328
Superior Constrictor 328
Stylo-pharyngeus 329
Actions 329

Palatal Region.

Dissection 329
Levator Palati 329
Tensor Palati 329
Palatine Aponeurosis 330
Azygos Uvulæ 330
Palato-glossus 331
Palato-pharyngeus 331
Salpingo-pharyngeus 331
Actions 331
Surgical Anatomy 332

Vertebral Region (Anterior).

Rectus Capitis Anticus Major 332
Rectus Capitis Anticus Minor 332
Rectus Capitis Lateralis 333
Longus Colli 333

Vertebral Region (Lateral).

Scalenus Anticus 334
Scalenus Medius 335
Scalenus Posticus 335
Actions 335
Surface Form of Muscles of Neck 335

MUSCLES AND FASCIÆ OF THE TRUNK.

Subdivision into Groups 336

The Back.

Subdivision into Layers 336

First Layer.

Dissection 336
Superficial and Deep Fasciæ 337
Trapezius 337
Ligamentum Nuchæ 339
Latissimus Dorsi 339

Second Layer.

Dissection 340
Levator Anguli Scapulæ 340
Rhomboideus Minor 340
Rhomboideus Major 340
Actions 340

Third Layer.

Dissection 341
Serratus Posticus Superior 341

PAGE

Serratus Posticus Inferior 341
Vertebral Aponeurosis 341
Lumbar Fascia 342
Splenius 342
Splenius Capitis 342
Splenius Colli 342
Actions 342

Fourth Layer.

Dissection 343
Erector Spinæ 343
Ilio-costalis 343
Musculus Accessorius ad Ilio-costalem 343
Cervicalis Ascendens 345
Longissimus Dorsi 345
Transversalis Cervicis 345
Trachelo-mastoid 345
Spinalis Dorsi 345
Spinalis Colli 345
Complexus 345
Biventer Cervicis 346

Fifth Layer.

Dissection 346
Semispinalis Dorsi et Colli 346
Multifidus Spinæ 346
Rotatores Spinæ 347
Supraspinales 347
Interspinales 347
Extensor Coccygis 347
Intertransversales 347
Rectus Capitis Posticus Major 347
Rectus Capitis Posticus Minor 348
Obliquus Capitis Inferior 348
Obliquus Capitis Superior 348
Suboccipital Triangle 348
Actions 348
Surface Form of Muscles of Back 349

THE THORAX.

Intercostal Fasciæ 350
Intercostal Muscles 350
External Intercostals 350
Internal Intercostals 350
Infracostales (subcostales) 351
Triangularis Sterni 351
Levatores Costarum 352
Diaphragm 352
Actions 354
Muscles of Inspiration and Expiration . . . 355

Superficial Muscles of the Abdomen.

Dissection 356
Superficial Fascia 356
External or Descending Oblique 356
External Abdominal Ring 357
The Intercolumnar Fibres 358
The Intercolumnar Fascia 359
Poupart's Ligament 359
Gimbernat's Ligament 359
Triangular Fascia 359
Ligament of Cooper 359
Internal or Ascending Oblique 360
Cremaster 361
Transversalis 362
Rectus 362
Pyramidalis 364
Linea Alba 365
Lineæ Semilunares, Lineæ Transversæ . . . 365
Actions 365
Fascia Transversalis 365
Internal Abdominal Ring 366
Inguinal Canal 366
Surface Form of Muscles of Abdomen . . . 366

Deep Muscles of the Abdomen.

Quadratus Lumborum 367
Actions 367

Muscles of the Pelvic Outlet.

Corrugator Cutis Ani 368
External Sphincter Ani 368

PAGE

Internal Sphincter Ani 368
Levator Ani 369
Coccygeus 369

Muscles of the Perinæum in the Male.

Superficial Perineal Fascia 370
Transversus Perinæi 371
Accelerator Urinæ 371
Erector Penis 372
Triangular Ligament 373
Compressor Urethræ 374

Muscles of the Perinæum in the Female.

Transversus Perinæi 375
Sphincter Vaginæ 375
Erector Clitoridis 375
Triangular Ligament 375
Compressor Urethræ 375

MUSCLES AND FASCIÆ OF THE UPPER EXTREMITY.

Subdivision into Groups 376
Dissection of Pectoral Region and Axilla . . 376
Fasciæ of the Thorax 377

THE SHOULDER.

Anterior Thoracic Region.

Pectoralis Major 378
Costo-coracoid Membrane 378
Pectoralis Minor 379
Subclavius 380
Actions 381

Lateral Thoracic Region.

Serratus Magnus 381
Actions 382
Superficial Fascia 382

Acromial Region.

Deep Fascia 382
Deltoid 382
Actions 383
Surgical Anatomy 383

Anterior Scapular Region.

Subscapular Fascia 383
Subscapularis 383
Actions 384

Posterior Scapular Region.

Dissection 384
Supraspinous Fascia 384
Supraspinatus 384
Infraspinous Fascia 384
Infraspinatus 384
Teres Minor 385
Teres Major 386
Actions 386

THE ARM.

Anterior Humeral Region.

Dissection 386
Deep Fascia of Arm 386
Coraco-brachialis 387
Biceps 387
Brachialis Anticus 388
Actions 388

Posterior Humeral Region.

Triceps 388
Subanconeus 389
Actions 389
Surgical Anatomy 389

THE FOREARM.

Dissection 389
Deep Fascia of Forearm 390

Anterior Radio-ulnar Region, Superficial Layer.

Pronator Radii Teres 390
Flexor Carpi Radialis 391

Superficial Temporal Artery. PAGE
Course and Relations . . . 495
Branches . . . 495
Surgical Anatomy . . . 496

Internal Maxillary Artery.
Course and Relations . . . 496
Branches from First Portion . . . 496
" " Second Portion . . . 498
" " Third Portion . . . 499

SURGICAL ANATOMY OF THE TRIANGLES OF THE NECK.

Anterior Triangular Space.
Inferior Carotid Triangle . . . 500
Superior Carotid Triangle . . . 500
Submaxillary Triangle . . . 501

Posterior Triangular Space.
Occipital Triangle . . . 501
Subclavian Triangle . . . 502

Internal Carotid Artery.
Cervical Portion . . . 502
Petrous Portion . . . 503
Cavernous Portion . . . 503
Cerebral Portion . . . 503
Peculiarities . . . 504
Surgical Anatomy . . . 505
Branches . . . 505
Ophthalmic Artery . . . 505
Cerebral Branches of Internal Carotid . 510
The Blood-vessels of the Brain . . . 512

ARTERIES OF THE UPPER EXTREMITY.

Subclavian Arteries.
First Part of Right Subclavian Artery . . . 514
First Part of Left Subclavian Artery . . . 516
Second Part of Subclavian Artery . . . 516
Third Part of Subclavian Artery . . . 516
Peculiarities . . . 517
Surface Marking . . . 518
Surgical Anatomy . . . 518
Branches . . . 520
Vertebral Artery . . . 520
Basilar Artery . . . 522
Circle of Willis . . . 523
Thyroid Axis . . . 523
Inferior Thyroid . . . 523
Suprascapular Artery . . . 524
Transversalis Colli . . . 524
Internal Mammary . . . 526
Superior Intercostal . . . 527
THE AXILLA . . . 527
Surgical Anatomy of the Axilla . . . 529

Axillary Artery.
First Portion . . . 530
Second Portion . . . 530
Third Portion . . . 531
Peculiarities . . . 531
Surface Marking . . . 531
Surgical Anatomy . . . 531
Branches . . . 532

Brachial Artery.
Relations . . . 533
Bend of the Elbow . . . 534
Peculiarities of Brachial Artery . . . 534
Surface Form . . . 535
Surgical Anatomy . . . 535
Branches . . . 536

Radial Artery.
Relations . . . 538
Deep Palmar Arch . . . 538
Peculiarities . . . 539
Surface Marking . . . 539
Surgical Anatomy . . . 539
Branches . . . 539

Ulnar Artery. PAGE
Relations . . . 542
Peculiarities of Ulnar Artery . . . 542
Surface Marking . . . 542
Surgical Anatomy . . . 542
Branches . . . 543
Superficial Palmar Arch . . . 544

ARTERIES OF THE TRUNK.

DESCENDING AORTA . . . 546

THORACIC AORTA.
Course and Relations . . . 546
Surgical Anatomy . . . 547
Branches . . . 547

ABDOMINAL AORTA.
Course and Relations . . . 549
Surface Marking . . . 550
Surgical Anatomy . . . 550
Branches . . . 550
Cœliac Axis . . . 551
Gastric Artery . . . 551
Hepatic Artery . . . 551
Splenic Artery . . . 551
Superior Mesenteric Artery . . . 553
Inferior Mesenteric Artery . . . 555
Suprarenal Arteries . . . 556
Renal Arteries . . . 556
Spermatic Arteries . . . 557
Ovarian Arteries . . . 557
Phrenic Arteries . . . 557
Lumbar Arteries . . . 558
Middle Sacral Artery . . . 558
Luschka's Gland . . . 558

COMMON ILIAC ARTERIES.
Course and Relations . . . 559
Branches . . . 559
Peculiarities . . . 559
Surface Marking . . . 560
Surgical Anatomy . . . 560

Internal Iliac Artery.
Course and Relations . . . 561
Peculiarities . . . 562
Surgical Anatomy . . . 562
Branches . . . 563
Vesical Arteries . . . 563
Hemorrhoidal Arteries . . . 563
Uterine Arteries . . . 563
Vaginal Arteries . . . 564
Obturator Artery . . . 564
Peculiarities . . . 565
Internal Pudic Artery . . . 565
In the Male . . . 565
Peculiarities . . . 566
Surgical Anatomy . . . 566
Branches . . . 566
In the Female . . . 567
Sciatic Artery . . . 567
Lumbar Artery . . . 569
Lateral Sacral Artery . . . 569
Gluteal Artery . . . 569
Surface Marking of Branches of Internal Iliac 569
Surgical Anatomy of Branches of Internal Iliac . . . 570

External Iliac Artery.
Course and Relations . . . 570
Surgical Anatomy . . . 570
Deep Epigastric Artery . . . 571
Deep Circumflex Iliac Artery . . . 572

ARTERIES OF THE LOWER EXTREMITY.

Femoral Artery.
Course and Relations . . . 572
Scarpa's Triangle . . . 572
Hunter's Canal . . . 573

PAGE
Common Femoral 573
Superficial Femoral 574
Peculiarities 575
Surface Marking 575
Surgical Anatomy 575
Branches 578
Deep Femoral 578
Branches 579

Popliteal Artery.

Popliteal Space 581
Course and Relations 581
Peculiarities 582
Surface Marking 582
Surgical Anatomy 582
Branches 583

Anterior Tibial Artery.

Course and Relations 585
Peculiarities 586
Surface Marking 586
Surgical Anatomy 586
Branches 586

Dorsalis Pedis Artery.

Course and Relations 587
Peculiarities 587
Surface Marking 587
Surgical Anatomy 587
Branches 588

Posterior Tibial Artery.

Course and Relations 588
Peculiarities 589
Surface Marking 589
Surgical Anatomy 589
Branches 590

Peroneal Artery.

Course and Relations 590
Peculiarities 590
Plantar Arteries 591
Surface Marking 592
Surgical Anatomy 592

THE VEINS.

General Anatomy.

Subdivision into Pulmonary, Systemic, and Portal 593
Anastomoses of Veins 593
Superficial Veins 593
Deep Veins, Venæ Comites 594
Sinuses 594
Pulmonary Veins 594
Systemic Veins 594

Veins of the Head and Neck.

Frontal Vein 595
Facial Vein 596
Surgical Anatomy 596
Temporal Vein 596
Internal Maxillary Vein 596
Temporo-maxillary Vein 597
Posterior Auricular Vein 597
Occipital Vein 597

Veins of the Neck.

External Jugular Vein 597
Surgical Anatomy 597
Posterior External Jugular Vein 598
Anterior Jugular Vein 598
Internal Jugular Vein 598
Lingual Vein 598
PAGE
Pharyngeal Vein 598
Thyroid Veins 598
Surgical Anatomy of Internal Jugular Vein . 599
Vertebral Veins 599
Veins of the Diploë 599

Cerebral Veins.

Superficial Cerebral Veins 600
Deep Cerebral Veins 601
Cerebellar Veins 601

Sinuses of the Dura Mater.

Superior Longitudinal Sinus 602
Inferior Longitudinal, Straight Sinuses . . . 602
Lateral Sinus 602
Occipital Sinuses 603
Cavernous Sinuses 603
Surgical Anatomy 604
Circular Sinus 604
Superior Petrosal Sinus 604
Inferior Petrosal Sinus 605
Transverse Sinuses 605
Emissary Veins 605
Surgical Anatomy 606

Veins of the Upper Extremity and Thorax.

Superficial Veins 607
Deep Veins 607
Axillary Vein 609
Surgical Anatomy 609
Subclavian Vein 609
Innominate Veins 609
Peculiarities of 610
Internal Mammary Veins 610
Inferior Thyroid Veins 610
Superior Intercostal Veins 611
Superior Vena Cava 611
Azygos Veins 611
Bronchial Veins 611
Spinal Veins 612

Veins of the Lower Extremity—Abdomen and Pelvis.

Internal Saphenous Vein 614
External Saphenous Vein 614
Popliteal Vein 615
Femoral Vein 616
External Iliac Vein 616
Deep Epigastric Veins 616
Deep Circumflex Iliac Veins 616
Internal Iliac Vein 616
Internal Pudic Veins 616
Common Iliac Veins 617
Peculiarities 617
Inferior Vena Cava 617
Peculiarities 618
Lumbar Veins 618
Spermatic Veins 618
Surgical Anatomy 618
Ovarian Veins 618
Renal and Suprarenal Veins 619
Phrenic Veins 619
Hepatic Veins 619

Portal System of Veins.

Superior Mesenteric Vein 619
Splenic Vein 619
Inferior Mesenteric Vein 619
Gastric Veins 619
Portal Vein 621
Cystic Vein 621

Cardiac Veins 621
Coronary Sinus 622

THE LYMPHATICS.

General Anatomy. PAGE

Subdivision into Deep and Superficial 623
Lymphatic or Conglobate Glands 623
Thoracic Duct 624
Right Lymphatic Duct 625

Lymphatics of Head, Face, and Neck.

Lymphatic Glands of Head 625
Lymphatics of the Head 625
Superficial Lymphatics of the Face 626
Deep Lymphatics of the Face 626
Lymphatics of the Cranium 626
Lymphatic Glands of the Neck 627
Superficial Cervical Glands 627
Deep Cervical Glands 628
Superficial and Deep Cervical Lymphatics . . 628
Surgical Anatomy 628

Lymphatics of the Upper Extremity.

Superficial Lymphatic Glands 628
Deep Lymphatic Glands 628
Axillary Glands 628
Surgical Anatomy 629
Superficial Lymphatics of Upper Extremity . 630
Deep Lymphatics of Upper Extremity . . . 630

Lymphatics of the Lower Extremity.

Superficial Inguinal Glands 630
Surgical Anatomy 630
Deep Lymphatic Glands 630
Anterior Tibial Gland 631
Popliteal Glands 631
Deep Inguinal Glands 631
Gluteal and Ischiatic Glands 631
Superficial Lymphatics of Lower Extremity 631
Internal Group 631
External Group 631
Deep Lymphatics of Lower Extremity . . . 632

Lymphatics of Pelvis and Abdomen.

Lymphatic Glands of Pelvis 632
External Iliac Glands 632
Internal Iliac Glands 632
Sacral Glands 632
Lumbar Glands 632

PAGE

Superficial Lymphatics of Wall of Abdomen 632
" " of Gluteal Region . . 632
" " of Scrotum and Perinæum 633
" " of Penis 633
" " of Labia Nymphæ, and Clitoris . . 634
Deep Lymphatics of Pelvis and Abdomen . . 634
Lymphatics of Bladder 634
" of Rectum 634
" of Uterus 634
" of Testicle 634
" of Kidney 634
" of Liver 634
Lymphatic Glands of Stomach 635
Lymphatics of Stomach 635
Lymphatic Glands of Spleen 635
Lymphatics of Spleen 635

Lymphatic System of the Intestine.

Lymphatic Glands of Small Intestine (Mesenteric Glands) 635
Lymphatic Glands of Large Intestine 635
Lymphatics of Small Intestine (Lacteals) . . 635
" of Large Intestine 635

Lymphatics of Thorax.

Lymphatic Glands of Thorax 636
Intercostal Glands 636
Internal Mammary Glands 636
Anterior Mediastinal Glands 636
Posterior Mediastinal Glands 636
Superior Lymphatics on Front of Thorax . . 636
Deep Lymphatics of Thorax 636
Intercostal Lymphatics 636
Internal Mammary Lymphatics 636
Lymphatics of Diaphragm 636
Bronchial Glands 636
Lymphatics of Lung 637
Cardiac Lymphatics 637
Thymic Lymphatics 637
Thyroid Lymphatics 637
Lymphatics of Œsophagus 637

THE NERVOUS SYSTEM.

Subdivision into Cerebro-spinal Centres, Ganglia, and Nerves, etc. 639

THE BRAIN AND ITS MEMBRANES.

Membranes of the Brain 639

The Dura Mater.

Structure 639
Arteries, Veins, Nerves 640
Processes of the Dura Mater 640
Falx Cerebri 640
Tentorium Cerebelli 640
Falx Cerebelli 641
Diaphragma Selli 641

The Arachnoid Membrane.

General Description 641
Subdural Space 641
Subarachnoid Space 641
Cerebro-spinal Fluid 642
Structure 642
Glandulæ Pacchioni 642

The Pia Mater.

General Description and Structure 642
Lymphatics and Nerves 643

THE BRAIN.

General Considerations and Divisions 643

The Hemispheres.

Surface of the Cerebrum 643
Longitudinal Fissure 645
Sylvian Fissure 645
Fissure of Rolando 646
Parieto-occipital Fissure 646
Calloso-marginal Fissure 646
Internal Parieto-occipital Fissure 647
Calcarine Fissure 647
Collateral Fissure 647
Dentate or Hippocampal Fissure 647
Frontal Lobe 648
Parietal Lobe 650
Occipital Lobe 651
Temporal Lobe 652
Central Lobe or Island of Reil 652
Limbic Lobe 652
Olfactory Lobe 654
Base of the Encephalon 655
Longitudinal Fissure 655
Corpus Callosum 655
Lamina Cinera 656
Optic Commissure 656
Tuber Cinereum 656
Infundibulum 656
Corpora Albicantia 656
Posterior Perforated Space 657
Pons Varolii 657
Crura Cerebri 658
Hemispheres of Cerebellum . . . . . 6[illegible]

PAGE

The Interior of the Cerebrum. . . . 658
Corpus Callosum . . . 659
Lateral Ventricles . . . 660
Corpus Striatum . . . 662
Nucleus Caudatus . . . 662
Medulla Oblongata . . . 656
Optic Tracts . . . 657
Nucleus Lenticularis . . . 662
Internal Capsule . . . 663
External Capsule . . . 664
Claustrum . . . 664
Tænia Semicircularis . . . 664
Fornix . . . 664
Anterior Commissure . . . 665
Septum Lucidum . . . 665
Fifth Ventricle . . . 666
Hippocampus Major . . . 666
Corpus Fimbriatum . . . 667
Choroid Plexus . . . 667
Transverse Fissure . . . 669
Velum Interpositum . . . 669

The Inter-brain. . . . 669
Third Ventricle . . . 670
Middle Commissure . . . 671
Posterior Commissure . . . 671
Optic Thalami . . . 671
Pineal Gland . . . 672

The Mid-brain. . . . 673
Crustæ . . . 674
Tegmentum . . . 674
Substantia Nigra . . . 675
Corpora Quadrigemina . . . 675
Corpora Geniculata . . . 676
Aqueduct of Sylvius . . . 676
Subthalamic Region . . . 676

The Structure of the Cerebrum . . . 677
White Matter of the Cerebrum . . . 677
Projection Fibres . . . 677
Commissural Fibres . . . 677
Association Fibres . . . 677
Gray Matter of the Cerebrum . . . 678
" " of the Cortex . . . 678
Special Types of Gray Matter . . . 680

The Hind-brain . . . 681
Pons Varolii . . . 681
Superior Olivary Nucleus . . . 683
Nuclei of the Fifth Nerve . . . 683
Nucleus of the Sixth Nerve . . . 683
Nucleus of the Facial Nerve . . . 683
Nuclei of the Auditory Nerve . . . 684
Nuclei Pontis . . . 684

The Cerebellum . . . 684
Lobes . . . 684
Upper Surface of the Cerebellum . . . 686
Lingula . . . 686
Lobulus Centralis . . . 686
Culmen Monticuli . . . 686
Clivus Monticuli . . . 686
Folium Cacuminis . . . 686
Under Surface of the Cerebellum . . . 686
Nodule and Flocculus . . . 688
Uvula and Amygdalæ . . . 688
Pyramid and Biventral Lobes . . . 689
Tuber Valvulæ, and Posterior Inferior Lobes . . . 689
Internal Structure of the Cerebellum . . . 689
Peduncles . . . 689
Gray Matter of the Cortex . . . 691
Independent Centres . . . 693
Weight of the Cerebellum . . . 693

The Medulla Oblongata . . . 693
Pyramids . . . 694
Lateral Columns . . . 694
Olivary Body . . . 694
Funiculus of Rolando . . . 694
Funiculus Cuneatus . . . 694

PAGE
Funiculus Gracilis . . . 696
Restiform Body . . . 696
Arciform Fibres . . . 696
Fourth Ventricle . . . 697
Internal Structure of the Medulla . . . 699
Weight of the Encephalon . . . 703
Cerebral Topography . . . 705

THE SPINAL CORD AND ITS MEMBRANES.
Dissection . . . 707

The Membranes of the Cord. . . . 707
Dura Mater . . . 707
Arachnoid . . . 708
Pia Mater . . . 709
Ligamentum Denticulatum . . . 709

The Spinal Cord. . . . 710
Fissures . . . 711
Columns . . . 711
Structure . . . 712
Minute Anatomy . . . 713
Neuroglia . . . 713
White Substance . . . 713
Gray Substance . . . 715
Origin of the Spinal Nerves . . . 717
Nerve-tracts . . . 717
Motor, Efferent, or Descending Tract . . . 718
Other Descending Tracts . . . 719
Sensory, Afferent, Ascending Tract . . . 719
Other Ascending Tracts . . . 719

THE CRANIAL NERVE.
Enumeration . . . 720
Olfactory Nerve . . . 720
Surgical Anatomy . . . 721
Optic Nerve . . . 721
Tracts . . . 721
Commissure . . . 721
Surgical Anatomy . . . 722
Motor Oculi Nerve . . . 722
Surgical Anatomy . . . 724
Pathetic Nerve . . . 725
Surgical Anatomy . . . 725
Trifacial Nerve . . . 725
Gasserian Ganglion . . . 726
Ophthalmic Nerve . . . 726
Lachrymal and Frontal Branches . . . 726
Nasal Branches . . . 727
Ophthalmic Ganglion . . . 729
Superior Maxillary Nerve . . . 729
Spheno-palatine Ganglion . . . 732
Inferior Maxillary Nerve . . . 734
Auriculo-temporal Branch . . . 735
Lingual Branch . . . 735
Inferior Dental Branch . . . 736
Otic Ganglion . . . 736
Submaxillary Ganglion . . . 737
Surgical Anatomy of Fifth Nerve . . . 738
Abducens Nerve . . . 738
Relations of the Orbital Nerves in the Cavernous Sinus . . . 739
Relations, etc., in the Sphenoidal Fissure . . . 739
" in the Orbit . . . 739
Surgical Anatomy . . . 740
Facial Nerve . . . 740
Branches of Facial Nerve . . . 741
Surgical Anatomy . . . 744
Auditory Nerve . . . 745
Surgical Anatomy . . . 746
Glosso-pharyngeal Nerve . . . 746
Pneumogastric (Vagus) Nerve . . . 749
Surgical Anatomy . . . 752
Spinal Accessory Nerve . . . 753
Surgical Anatomy . . . 754
Hypoglossal Nerve . . . 754
Surgical Anatomy . . . 756

THE SPINAL NERVES.
Roots of the Spinal Nerves . . . 756
Origin of Anterior Roots . . . 756
" of Posterior Roots . . . 756

PAGE

Ganglia of the Spinal Nerves 757
Posterior Divisions of the Spinal Nerves . . 758
Anterior Divisions of the Spinal Nerves. . . 758
Points of Emergence of Spinal Nerves . . . 758

THE CERVICAL NERVES.

Roots of the Cervical Nerves 758
Posterior Divisions of the Cervical Nerves . 759
Anterior Divisions of the Cervical Nerves . 760

THE CERVICAL PLEXUS.

Superficial Branches of the Cervical Plexus . 762
Deep Branches of the Cervical Plexus. . . . 763

THE BRACHIAL PLEXUS.

Branches above the Clavicle.

Posterior Thoracic 768
Suprascapular 768

Branches below the Clavicle.

Anterior Thoracic 769
Subscapular Nerves 769
Circumflex Nerve 769
Musculo-cutaneous Nerve 770
Internal Cutaneous Nerve 770
Lesser Internal Cutaneous Nerve 771
Median Nerve 771
Ulnar Nerve. 772
Musculo-spiral Nerve. 774
Radial Nerve 775
Posterior Interosseous Nerve 775
Surgical Anatomy of Brachial Plexus 776

THE DORSAL NERVES.

Roots of the Dorsal Nerves 776
Posterior Divisions of the Dorsal Nerves . . 777
Anterior Divisions of the Dorsal Nerves . . 777
First Dorsal Nerve. 777
Upper Dorsal Nerves. 778
Lower Dorsal Nerves. 779
Last Dorsal Nerve 780
Surgical Anatomy 780

THE LUMBAR NERVES.

Root of Lumbar Nerves 780
Posterior Divisions of Lumbar Nerves . . . 781
Anterior Divisions of Lumbar Nerves. . . . 781

THE LUMBAR PLEXUS.

Branches of Lumbar Plexus 782
Ilio-hypogastric Nerve 782
Ilio-inguinal Nerve 783
Genito-crural Nerve 783
External Cutaneous Nerve 785
Obturator Nerve 785
Accessory Obturator Nerve 786
Anterior Crural Nerve 786
Branches of Anterior Crural 786
Middle Cutaneous 786
Internal Cutaneous 786
Long Saphenous 787
Muscular and Articular Branches 787

THE SACRAL AND COCCYGEAL NERVES. PAGE

Roots of, origin of 788
Posterior Divisions of Sacral Nerves 788
Coccygeal Nerve 789
Anterior Divisions of Sacral Nerves 789

THE SACRAL PLEXUS.

Superior Gluteal Nerve 791
Inferior Gluteal Nerve 791
Small Sciatic Nerve 791
Pudic Nerve 793
Great Sciatic Nerve 793
Internal Popliteal Nerve 794
External Saphenous Nerve 794
Posterior Tibial Nerve 794
Plantar Nerves 795
External Popliteal or Peroneal Nerve 796
Anterior Tibial Nerve 796
Musculo-cutaneous Nerve 796
Surgical Anatomy of Lumbar and Sacral Plexus 797

THE SYMPATHETIC NERVE.

Subdivision of, into Parts 798
Branches of the Ganglia, General Description of 799
CERVICAL PORTION OF THE GANGLIATED CORD 799
Superior Cervical Ganglion 799
Carotid Plexus 801
Cavernous Plexus 801
Middle Cervical Ganglion 803
Inferior Cervical Ganglion 803
THORACIC PART OF THE GANGLIATED CORD 804
Great Splanchnic Nerve 804
Lesser Splanchnic Nerve 804
Smallest Splanchnic Nerve 804
LUMBAR PORTION OF THE GANGLIATED CORD 805
PELVIC PORTION OF THE GANGLIATED CORD 805

THE GREAT PLEXUSES OF THE SYMPATHETIC.

Cardiac Plexuses 805
Great Cardiac Plexs 806
Superficial Cardiac Plexus 806
Coronary Plexuses 806
Epigastric, or Solar Plexus 806
Phrenic Plexus 808
Suprarenal Plexus 808
Renal Plexus 808
Spermatic Plexus 808
Cœliac Plexus 808
Superior Mesenteric Plexus 809
Aortic Plexus 809
Inferior Mesenteric Plexus 809
Hypogastric Plexus 809
Pelvic Plexus 809
Inferior Hemorrhoidal Plexus 809
Vesical Plexus 809
Prostatic Plexus 809
Vaginal Plexus 810
Uterine Plexus 810

THE ORGANS OF SPECIAL SENSE.

THE TONGUE.

Structure of 811
Papillæ of 813
Glands of 815
Fibrous Septum of 815
Hyo-glossal Membrane 815
Arteries and Nerves of 815
Muscles of 815
Nerves of 816
Surgical Anatomy 816

THE NOSE.

Cartilages of 818
Muscles of 819
Skin 819
Mucous Membrane 819
Arteries, Veins, and Nerves 819

The Nasal Fossæ.

Outer Wall of 820
Mucous Membrane of 820
Superior, Middle, and Inferior Meatuses . . . 822
Arteries and Veins of Nasal Fossæ 822
Nerves of Nasal Fossæ 823
Surgical Anatomy of Nose and Nasal Fossæ . 823

THE EYE.

Situation, Form of 824
Capsule of Tenon 824

PAGE

Tunics of, sclerotic . . . 825
Cornea . . . 826
Choroid . . . 828
Ciliary Body . . . 829
Ciliary Muscle . . . 830
Iris . . . 830
Membrana Pupillaris . . . 832
Ciliary Muscle . . . 832
Retina . . . 832
Structure of Retina . . . 833
Structure of Retina at Yellow Spot . . . 838
Arteria Centralis Retinæ . . . 839

The Humors of the Eye.

Aqueous Humor . . . 839
Anterior Chamber . . . 839
Posterior Chamber . . . 839
Vitreous Body . . . 839
Suspensory Ligament of Lens . . . 840
Canal of Petit . . . 840
Crystalline Lens and its Capsule . . . 840
Changes produced in the Lens by Age . . . 841
Vessels of the Globe of the Eye . . . 841
Nerves of the Eyeball . . . 841
Surgical Anatomy of Eye . . . 841

The Appendages of the Eye.

Eyebrows . . . 843
Eyelids . . . 843
Eyelashes . . . 843
Structure of the Eyelids . . . 843
Tarsal Plates . . . 843
Meibomian Glands . . . 844
Conjunctiva . . . 845
Caruncule Lachrymales . . . 845

The Lachrymal Apparatus.

Lachrymal Gland . . . 846
" Canals . . . 846
" Sac . . . 847
Nasal Duct . . . 847
Surface Form of Papebral Fissure . . . 847
Surgical Anatomy . . . 847

THE EAR.

The External Ear.

Pinna, or Auricle . . . 848
Structure of Auricle . . . 849

PAGE

Ligaments of the Pinna . . . 849
Muscles of the Pinna . . . 850
Arteries, Veins, and Nerves of the Pinna . . . 850
Auditory Canal . . . 851
Surface Form . . . 852

The Middle Ear, or Tympanum.

Cavity of Tympanum . . . 852
Roof of the Tympanic Cavity . . . 853
Floor of the Tympanic Cavity . . . 853
Outer Wall of the Tympanic Cavity . . . 853
Internal Wall of the Tympanic Cavity . . . 853
Posterior Wall of the Tympanic Cavity . . . 854
Anterior Wall of the Tympanic Cavity . . . 854
Eustachian Tube . . . 855
Membrana Tympani . . . 855
Structure of . . . 855
Ossicles of the Tympanum . . . 856
Ligaments of the Ossicula . . . 857
Muscles of the Tympanum . . . 857
Mucous Membrane of Tympanum . . . 858
Arteries of Tympanum . . . 858
Veins and Nerves of Tympanum . . . 858

The Internal Ear, or Labyrinth.

Osseous Labyrinth . . . 859
Vestibule . . . 859
Semicircular Canals:
Superior Semicircular Canal . . . 860
Posterior Semicircular Canal . . . 860
External Semicircular Canal . . . 860
Cochlea:
Central Axis of, or Modiolus . . . 861
Bony Canal of . . . 861
Osseous Lamina Spiralis . . . 862
Membranous Labyrinth . . . 862
Utricle and Saccule . . . 862
Semicircular Canals . . . 862
Cochlea . . . 863
Scala Tympani, Scala Vestibuli, and Scala Media . . . 863
Organ of Corti . . . 864
Vessels of the Labyrinth . . . 866
Auditory Nerve . . . 866
Vestibular Nerve . . . 867
Cochlear Nerve . . . 867
Surgical Anatomy . . . 867

THE ORGANS OF DIGESTION.

Subdivisions of the Alimentary Canal . . . 869
The Mouth . . . 869
The Lips . . . 869
The Cheeks . . . 870
The Gums . . . 870

THE TEETH.

General Characters of . . . 871
Permanent Teeth . . . 871
Incisors . . . 871
Canine . . . 872
Bicuspids . . . 872
Molars . . . 873
Temporary, or Milk Teeth . . . 873
Structure of the Teeth . . . 874
Ivory or Dentine . . . 876
Enamel . . . 877
Cortical Substance . . . 878
Development of the Teeth . . . 878
" of the Permanent Teeth . . . 881
Eruption of the Teeth . . . 881

THE PALATE.

Hard Palate . . . 883
Soft Palate . . . 883
Uvula, Pillars of the Soft Palate . . . 883
Mucous Membrane and Aponeurosis . . . 883
Muscles of Soft Palate . . . 884

The Tonsils.

Arteries . . . 884
Veins and Nerves of Tonsils . . . 884

THE SALIVARY GLANDS.

Parotid Gland.

Situation and Relations . . . 884
Stenson's Duct . . . 885
Surface Form . . . 886
Vessels and Nerves of Parotid Gland . . . 886

The Submaxillary Gland.

Situation and Relations . . . 886
Wharton's Duct . . . 886
Vessels and Nerves of Submaxillary Gland . . . 887

The Sublingual Gland.

Situation and Relations . . . 887
Vessels and Nerves of . . . 887
Structure of Salivary Glands . . . 887
Surface Form of Mouth . . . 888

THE PHARYNX AND ŒSOPHAGUS.

Situation and Relations . . . 890
Structure of Pharynx . . . 890
Surgical Anatomy . . . 891
Relations of Œsophagus . . . 891
Structure . . . 892

PAGE
Vessels . . . 892
Nerves of . . . 893
Surgical Anatomy . . . 893

THE ABDOMEN.

Boundaries . . . 895
Apertures of . . . 895
Regions . . . 895

The Peritoneum.

Reflections traced . . . 898
Lesser Sac of Peritoneum . . . 899
Ligaments formed by Peritoneum . . . 901
Omenta . . . 901
Lesser Omentum . . . 901
Great Omentum . . . 902
Gastro-splenic Omentum . . . 902
Mesenteries . . . 902
Mesocolon, Mesorectum, Appendices Epiploicæ . . . 903
Retro-peritoneal Fossæ . . . 904

The Stomach.

Situation . . . 905
Surfaces . . . 905
Greater and Lesser Curvatures . . . 906
Cardiac and Pyloric Orifices . . . 906
Alterations in Position . . . 907
Pylorus . . . 908
Structure of Stomach . . . 908
Serous Coat . . . 908
Muscular Coat and Mucous Membrane . . . 908
Gastric Follicles . . . 909
Vessels and Nerves of Stomach . . . 910
Surface Marking . . . 910
Surgical Anatomy . . . 911

The Small Intestines.

Duodenum . . . 912
First or Superior Portion . . . 912
Second or Descending Portion . . . 912
Third or Transverse Portion . . . 914
Fourth or Ascending Portion . . . 914
Vessels and Nerves of Duodenum . . . 914
Jejunum and Ileum . . . 914
Meckel's Diverticulum . . . 915
Structure of Small Intestines . . . 915
Serous and Muscular Coats . . . 915
Mucous Membrane and Epithelium . . . 915
Valvulæ Conniventes . . . 916
Villi—their Structure . . . 917
Simple Follicles . . . 918
Duodenal Glands . . . 918
Solitary Glands . . . 919
Peyer's Glands . . . 919
Vessels and Nerves . . . 921

The Large Intestine.

Cæcum . . . 922
Appendix Cæci Vermiformis . . . 922
Ileo-cæcal Valve . . . 923
Colon . . . 923
Ascending . . . 923
Transverse . . . 924
Descending . . . 925
Sigmoid Flexure . . . 925
Rectum . . . 925
Structure of Large Intestine . . . 928
Serous Coat . . . 928
Muscular Coat . . . 928
Areolar and Mucous Coats . . . 928
Simple Follicles . . . 929

PAGE
Solitary Glands . . . 929
Vessels and Nerves . . . 929
Surface Form . . . 930
Surgical Anatomy . . . 930

THE LIVER.

Size, Weight, Position of . . . 933
Its Surfaces and Borders . . . 934

Fissures.

Longitudinal . . . 935
Fissure of Ductus Venosus . . . 936
Portal Fissure . . . 936
Fissure for Gall-bladder . . . 936
Fissure for Inferior Vena Cava . . . 936

Lobes.

Right . . . 937
Quadratus . . . 937
Spigelii . . . 937
Caudatus . . . 937
Left . . . 937

Ligaments.

Falciform . . . 937
Lateral and Coronary . . . 937
Round Ligament . . . 938
Vessels of Liver . . . 938
Structure of Liver . . . 938
Serous Coat . . . 938
Fibrous Coat . . . 938
Lobules . . . 938
Hepatic Cells . . . 939
Hepatic Artery . . . 940
Portal Vein . . . 940
Hepatic Veins . . . 940
Biliary Ducts . . . 940
Lymphatics of the Liver . . . 941
Nerves of Liver . . . 941

EXCRETORY APPARATUS OF THE LIVER.

Hepatic Duct . . . 942
Gall-bladder . . . 942
Structure . . . 942
Cystic Duct . . . 943
Ductus Communis Choledochus . . . 943
Structure . . . 943
Surface Marking of Liver . . . 943
Surgical Anatomy . . . 944

THE PANCREAS.

Dissection . . . 945
Relations . . . 945
Duct . . . 947
Structure . . . 948
Vessels and Nerves . . . 948
Surface Marking . . . 948
Surgical Anatomy . . . 948

THE SPLEEN.

Relations . . . 949
Size and Weight . . . 950
Structure of Serous and Fibrous Coats . . . 950
Proper Substance . . . 951
Splenic Artery, Distribution . . . 952
Malpighian Bodies . . . 952
Capillaries of Spleen . . . 953
Veins of Spleen . . . 953
Lymphatics . . . 953
Nerves . . . 954
Surface Marking of Spleen . . . 954
Surgical Anatomy . . . 954

THE ORGANS OF VOICE AND RESPIRATION.

The Larynx.

Cartilages of the Larynx . . . 955
Thyroid Cartilage . . . 955
Cricoid Cartilage . . . 956
Arytenoid Cartilages, Cartilages of Santorini . . . 957
Cartilage of Wrisberg . . . 958
Epiglottis . . . 958
Ligaments of the Larynx . . . 958
Ligaments Connecting the Thyroid Cartilage with the Hyoid Bone . . . 958
Ligaments Connecting the Thyroid Cartilage with the Cricoid . . . 958

PAGE

Ligaments Connecting the Arytenoid Cartilages to the Cricoid 959
Ligaments of the Epiglottis 959
Superior Aperture of the Larynx 959
Rima Glottidis 959
False Vocal Cords 960
True Vocal Cords 961
Ventricle of Larynx, Sacculus Laryngis . . . 961
Muscles of Larynx 961
Crico-thyroid 961
Crico-arytenoideus posticus 962
Crico-arytenoideus lateralis 962
Arytenoideus 962
Thyro-arytenoideus 962
Muscles of the Epiglottis 963
Thyro-epiglottideus 963
Aryteno-epiglottideus, superior 963
" inferior 963
Actions of Muscles of Larynx 963
Mucous Membrane of Larynx 964
Glands, Vessels, and Nerves of Larynx . . . 964

The Trachea.

Relations 965
Bronchi 966
Structure of Trachea 966
Cartilages 966
Fibrous Membrane 967
Muscular Fibres 967
Mucous Membrane 967
Glands 967
Vessels and Nerves 967
Surface Form 968
Surgical Anatomy of Laryngo-tracheal Region 968

The Pleura.

Reflections 969
Vessels and Nerves 971
Surgical Anatomy 971

The Mediastina.

PAGE

Superior Mediastinum 971
Anterior Mediastinum 972
Middle Mediastinum 972
Posterior Mediastinum 973

The Lungs

Surfaces 973
Borders and Lobes 973
Root of Lung 974
Weight, Color, and Properties of Substance of Lung 975
Structure of Lung 975
Serous Coat and Subserous Areolar Tissue . . 975
Parenchyma and Lobules of Lung 976
Bronchi, Arrangement of, in Substance of Lung 976
Structure of Smaller Bronchial Tubes 976
The Air-cells 976
Pulmonary Artery 976
Pulmonary Capillaries and Veins 976
Bronchial Arteries 976
Bronchial Veins 977
Lymphatics and Nerves of Lung 977
Surface Form of Lungs 977
Surgical Anatomy 977

The Thyroid Gland.

Surface and Relations 979
Structure 980
Vessels and Nerves 981
Surgical Anatomy 981

The Thymus Gland.

Relations 981
Structure 982
Vessels and Nerves 982

THE URINARY ORGANS.

The Kidneys.

Relations 985
Dimensions, Weight 985
General Structure 986
Cortical Substance 987
Medullary Substance 987
Minute Structure 987
Malpighian Bodies 988
" Tufts 988
" Capsule 988
Tubuli Uriniferi, Course 988
" " Structure 990
Renal Blood-vessels 992
Renal Veins 992
Venæ Rectæ 992
Nerves 993
Lymphatics 993
Surface Form 993
Surgical Anatomy 993

The Ureters.

Situation 994
Calices 995
Course 995
Relations 995
Structure 995
Surgical Anatomy 996

The Suprarenal Capsules.

Relations 997
Structure 997
Vessels and Nerves 998

THE PELVIS.

Boundaries 998
Contents 998

The Bladder.

Shape, Position, Relations 998
Subdivisions 1001
Urachus 1002
Ligaments 1002
Structure 1002
Interior of Bladder 1003
Vessels and Nerves 1004
Surface Form 1004
Surgical Anatomy 1004

The Male Urethra.

Divisions 1005
Structure 1006
Surgical Anatomy 1007
Bladder and Urethra in the Female 1007

THE MALE ORGANS OF GENERATION.

Prostate Glands 1009
Structure 1010
Vessels and Nerves 1010
Surgical Anatomy 1011
Cowper's Gland 1011
Structure 1011

THE PENIS.

Root 1011
Glans Penis 1011
Body 1012
Structure of Penis 1012
Corpora Cavernosa 1012
Structure 1012
Arteries of the Penis 1013
Corpus Spongiosum 1013
The Bulb 1013
Structure of Corpus Spongiosum 1014
Lymphatics of the Penis 1011

PAGE

Nerves of the Penis 1014
Surgical Anatomy 1014

THE TESTES AND THEIR COVERINGS.

Scrotum 1015
Coverings of the Testis 1015
Vessels and Nerves of the Coverings of the Testis 1016

The Spermatic Cord.

Its Composition 1016
Relations of, in Inguinal Canal 1016
Arteries of the Cord 1016
Veins of the Cord 1016
Lymphatics and Nerves of the Cord 1017
Surgical Anatomy 1017

THE TESTES.

Form and Situation 1017
Size and Weight 1018
Coverings 1018
Tunica Vaginalis 1018
Tunica Albuginea 1018
Mediastinum Testis 1018
Tunica Vasculosa 1019
Structure of the Testis 1019
Lobulus of the Testis 1019
Tubuli Seminiferi 1019
Arrangement in Lobuli 1019
" in Mediastinum Testis 1019
" in Epididymis 1019
Spermatogenesis 1020
Vas Deferens, Course, Relations 1021
Structure 1021
Vas Aberrans 1021
Surgical Anatomy 1021

Vesiculæ Seminales.

Form and Size 1022
Relations 1022
Structure 1022
Ejaculatory Ducts 1023

THE FEMALE ORGANS OF GENERATION.

Mons Veneris, Labia Majora 1025
" " Labia Minora 1026
Clitoris 1026
Meatus Urinarius 1027
Hymen, Glands of Bartholin 1027

The Vagina.

Relations 1028
Structure 1028

The Uterus.

Situation, Form, Dimensions 1028
Fundus, Body, and Cervix 1029
Ligaments 1029
Cavity of the Uterus 1030
Cavity of the Cervix 1031
Structure 1031
Vessels and Nerves 1032
Its Form, Size, and Situation in the Fœtus . 1033
" " " at Puberty . . 1033
Its Form, Size, etc., during Menstruation . . 1033
Its Form during Pregnancy 1033
" after Parturition 1033
" in Old Age 1033

The Appendages of the Uterus.

Fallopian Tubes 1034
Structure 1035
Ovaries 1035
Structure 1036
Graafian Vesicles 1036
Discharge of the Ovum 1037
Ligament of the Ovary 1038
Round Ligaments 1038
Vessels and Nerves of Appendages 1038

The Mammary Glands.

Situation and Size 1038
Nipple 1039
Structure of Mamma 1039
Vessels and Nerves 1040

THE SURGICAL ANATOMY OF HERNIA.

INGUINAL HERNIA.

COVERINGS OF INGUINAL HERNIA.

Dissection 1041
Superficial Fascia 1041
Superficial Vessels and Nerves 1041
Deep Layer of Superficial Fascia 1042
Aponeurosis of External Oblique 1042
External Abdominal Ring 1043
Pillars of the Ring 1043
Intercolumnar Fibres 1043
" Fascia 1043
Poupart's Ligament 1044
Gimbernat's Ligament 1044
Triangular Ligament 1044
Internal Oblique Muscle 1045
Cremaster 1045
Transversalis Muscle 1045
Spermatic Canal 1046
Transversalis Fascia 1046
Internal Abdominal Ring 1047
Subperitoneal Areolar Tissue 1047
Deep Epigastric Artery 1047
Peritoneum 1047

Oblique Inguinal Hernia.

Course and Coverings of Oblique Hernia . . 1049
Seat of Stricture 1051
Scrotal Hernia 1051
Bubonocele 1051
Congenital Hernia 1051
Infantile and Encysted Hernia 1051
Hernia into the Funicular Process 1051

Direct Inguinal Hernia.

Course and Coverings of the Hernia 1052
Seat of Stricture 1053
Incomplete Direct Hernia 1053
Comparative Frequency of Oblique and Direct Hernia 1053
Division of Stricture in Inguinal Hernia . . 1053

FEMORAL HERNIA.

Dissection 1053
Superficial Fascia 1053
Cutaneous Vessels 1054
Internal Saphenous Vein 1054
Superficial Inguinal Glands 1055
Cutaneous Nerves 1055
Deep Layer of Superficial Fascia 1055
Cribriform Fascia 1055
Fascia Lata 1055
Iliac Portion 1055
Pubic Portion 1056
Saphenous Opening 1056
Crural Arch 1057
Gimbernat's Ligament 1058
Femoral Sheath 1059
Deep Crural Arch 1059
Crural Canal 1059

PAGE
Femoral or Crural Ring 1060
Position of Parts around the Ring 1060
Septum Crurale 1060
Descent of Femoral Hernia 1061
Coverings of Femoral Hernia 1061
Varieties of Femoral Hernia 1061
Seat of Stricture 1061

SURGICAL ANATOMY OF THE PERINÆUM.

Ischio-rectal Region.
Dissection of 1063
Boundaries of 1063
Superficial Fascia 1063
Ischio-rectal Fossa 1064
Position of Parts contained in 1064

The Perinæum Proper in the Male.
Boundaries and Extent 1064
Deep Layer of Superficial Fascia 1065
Course taken by the Urine in Rupture of the Urethra 1065
Muscles of the Perinæum (Male) 1065
Deep Perineal Fascia 1065
Superficial Layer 1066
Deep Layer 1066
Parts between the two Layers 1066
Compressor Urethræ 1067
Cowper's Glands 1067
Pudic Vessels and Nerves 1067
Artery of the Bulb 1067
Position of the Viscera at Outlet of Pelvis . 1067
Prostate Gland 1068
Surgical Anatomy of Lithotomy 1068
Parts divided in the Operation 1069
Parts to be avoided in the Operation 1069
Abnormal Course of Arteries in the Perinæum 1069

The Female Perinæum.
Superficial Fascia 1069
Deep Fascia 1069
Compressor Urethræ 1070
Perineal Body 1070
Pelvic Fascia 1070
Obturator Fascia 1071
Recto-vesical Fascia 1071

GENERAL ANATOMY OR HISTOLOGY.

The Animal Cell 1073
The Nutritive Fluids 1077
Blood 1077
Lymph and Chyle 1082
Epithelium 1082
Connective Tissue 1086
The Connective Tissues proper 1086
Adipose Tissue 1091
Pigment 1092
Cartilage 1092
White Fibro-cartilage 1094
Yellow or Reticular, Elastic Cartilage . 1094
The Bone 1096
Development of Bone 1099
Muscular Tissue 1104
Striped Muscle 1 1105
Unstriped Muscle 1109
Cardiac Muscular Tissue 1110
Nervous Tissue 1111
The Brain 1118
The Nerves 1118
The Sympathetic Nerve 1120
Origin and Termination of Nerves . . . 1120
The Ganglia 1124
The Vascular System 1126
The Arteries 1126
The Capillaries 1128
The Veins 1130
The Lymphatics 1131
The Lymphatic Glands 1133
The Skin and its Appendages 1135
The Nails 1139
The Hair 1140
The Sebaceous Glands 1142
The Sudoriferous Glands 1142
Serous Membranes 1143
Synovial Membranes 1145
Mucous Membranes 1145
Secreting Glands 1146

EMBRYOLOGY.

The Ovum 1149
Maturation of 1150
Impregnation of 1151
Segmentation of 1152
Formation of the Mesoblast 1154
First Rudiments of the Embryo 1155
Formation of Membranes 1160
The Amnion 1160
The Chorion 1161
The Allantois 1162
The Decidua 1162
The Placenta 1164
Development of the Embryo 1165
The Spine 1165
The Ribs and Sternum 1166
The Cranium and Face 1166
The Nervous Centres 1172
The Nerves 1178
The Eye 1180
The Ear 1183
The Nose 1184
The Skin, Glands, and Soft Parts 1186
The Limbs 1187
The Muscles 1187
The Blood-vascular System 1187
Vitelline Circulation 1187
Placental Circulation 1189
The Alimentary Canal and its Appendages . 1198
The Respiratory Organs 1206
The Urinary and Generative Organs 1207
Ovaries and Testicles 1209
Descent of the Testes 1211
External Organs 1212
Chronological Tables of the Development of the Fetus 1215

INDEX 1217

DESCRIPTIVE AND SURGICAL ANATOMY.

OSTEOLOGY—THE SKELETON.

THE entire skeleton in the adult consists of 200 distinct bones. These are—

The spine or vertebral column (sacrum and coccyx included)	26
Cranium	8
Face	14
Hyoid bone, sternum, and ribs	26
Upper extremities	64
Lower extremities	62
	200

In this enumeration the patellæ are included as separate bones, but the smaller sesamoid bones and the ossicula auditûs are not reckoned. The teeth belong to the tegumentary system.

These bones are divisible into four classes: *Long*, *Short*, *Flat*, and *Irregular*.

The **Long Bones** are found in the limbs, where they form a system of levers, which have to sustain the weight of the trunk and to confer the power of locomotion. A long bone consists of a shaft and two extremities. The *shaft* is a hollow cylinder, contracted and narrowed to afford greater space for the bellies of the muscles; the walls consist of dense, compact tissue of great thickness in the middle, but becoming thinner toward the extremities; the spongy tissue is scanty, and the bone is hollowed out in its interior to form the *medullary canal*. The *extremities* are generally somewhat expanded for greater convenience of mutual connection, for the purposes of articulation, and to afford a broad surface for muscular attachment. Here the bone is made up of spongy tissue with only a thin coating of compact substance. The long bones are not straight, but curved, the curve generally taking place in two directions, thus affording greater strength to the bone. The bones belonging to this class are the *clavicle*, *humerus*, *radius*, *ulna*, *femur*, *tibia*, *fibula*, *metacarpal* and *metatarsal* bones, and the *phalanges*.

Short Bones.—Where a part of the skeleton is intended for strength and compactness, and its motion is at the same time slight and limited, it is divided into a number of small pieces united together by ligaments, and the separate bones are short and compressed, such as the bones of the *carpus* and *tarsus*. These bones, in their structure, are spongy throughout, excepting at their surface, where there is a thin crust of compact substance. The *patellæ* also, together with the other sesamoid bones, are by some regarded as short bones.

Flat Bones.—Where the principal requirement is either extensive protection or the provision of broad surfaces for muscular attachment, we find the osseous structure expanded into broad, flat plates, as is seen in the bones of the skull and the shoulder-blade. These bones are composed of two thin layers of compact tissue enclosing between them a variable quantity of cancellous tissue. In the cranial bones these layers of compact tissue are familiarly known as the *tables* of the

skull; the outer one is thick and tough; the inner one thinner, denser, and more brittle, and hence termed the *vitreous table*. The intervening cancellous tissue is called the *diploë*. The flat bones are: the *occipital*, *parietal*, *frontal*, *nasal*, *lachrymal*, *vomer*, *scapula*, *os innominatum*, *sternum*, *ribs*, and *patella*.

The **Irregular** or **Mixed Bones** are such as, from their peculiar form, cannot be grouped under either of the preceding heads. Their structure is similar to that of other bones, consisting of a layer of compact tissue externally, and of spongy cancellous tissue within. The irregular bones are: the *vertebræ*, *sacrum*, *coccyx*, *temporal*, *sphenoid*, *ethmoid*, *malar*, *superior maxillary*, *inferior maxillary*, *palate*, *inferior turbinated*, and *hyoid*.

Surfaces of Bones.—If the surface of any bone is examined, certain eminences and depressions are seen to which descriptive anatomists have given the following names.

These eminences and depressions are of two kinds: *articular* and *non-articular*. Well-marked examples of articular eminences are found in the heads of the humerus and femur and of articular depressions in the glenoid cavity of the scapula and the acetabulum. Non-articular eminences are designated according to their form. Thus, a broad, rough, uneven elevation is called a *tuberosity;* a small, rough prominence, a *tubercle;* a sharp, slender, pointed eminence, a *spine;* a narrow, rough elevation, running some way along the surface, a *ridge* or *line*.

The non-articular depressions are also of very variable form, and are described as *fossæ*, *grooves*, *furrows*, *fissures*, *notches*, etc. These non-articular eminences and depressions serve to increase the extent of surface for the attachment of ligaments and muscles, and are usually well marked in proportion to the muscularity of the subject.

A prominent process projecting from the surface of a bone, which it has never been separate from or movable upon is termed an *apophysis* (from ἀπόφυσις, an excrescence); but if such process is developed as a separate piece from the rest of the bone, to which it is afterward joined, it is termed an *epiphysis* (from ἐπίφυσις, an accretion). The main part of the bone, or shaft, which is formed from the primary centre of ossification, is termed the *diaphysis*, and is separated, during growth, from the epiphysis by a layer of cartilage, at which growth in length of the bone takes place.

THE SPINE.

The **Spine** is a flexuous and flexible column formed of a series of bones called *vertebræ* (from *vertere*, to turn).

The **Vertebræ** are thirty-three in number, and have received the names *cervical*, *dorsal*, *lumbar*, *sacral*, and *coccygeal*, according to the position which they occupy; seven being found in the cervical region, twelve in the dorsal, five in the lumbar, five in the sacral, and four in the coccygeal.

This number is sometimes increased by an additional vertebra in one region, or the number may be diminished in one region, the deficiency being supplied by an additional vertebra in another. These observations do not apply to the cervical portion of the spine, the number of bones forming which is seldom increased or diminished.

The vertebræ in the upper three regions of the spine are separate throughout the whole of life; but those found in the sacral and coccygeal regions are in the adult firmly united, so as to form two bones—*five* entering into the formation of the upper bone or *sacrum*, and *four* into the terminal bone of the spine or *coccyx*.

General Characters of a Vertebra.

Each **vertebra** consists of two essential parts—an anterior solid segment or *body*, and a posterior segment or *arch*. The arch (*neural*) is formed of two *pedicles* and two *laminæ*, supporting seven *processes*—viz. four *articular*, two *transverse*, and one *spinous*.

The bodies of the vertebræ are piled one upon the other, forming a strong

pillar for the support of the cranium and trunk; the arches forming a hollow cylinder behind the bodies for the protection of the spinal cord. The different vertebræ are connected together by means of the articular processes and the intervertebral fibro-cartilages; while the transverse and spinous processes serve as levers for the attachment of muscles which move the different parts of the spine. Lastly, between each pair of vertebræ apertures exist through which the spinal nerves pass from the cord. Each of these constituent parts must now be separately examined.

The **Body** or **Centrum** is the largest part of a vertebra. Above and below, it is flattened; its upper and lower surfaces are rough for the attachment of the intervertebral fibro-cartilages, and present a rim around their circumference. In front, it is convex from side to side, concave from above downward. Behind, it is flat from above downward and slightly concave from side to side. Its anterior surface is perforated by a few small apertures, for the passage of nutrient vessels; whilst on the posterior surface is a single large, irregular aperture, or occasionally more than one, for the exit of veins from the body of the vertebra—the *venæ basis vertebræ*.

The **Pedicles** are two short, thick pieces of bone, which project backward, one on each side, from the upper part of the body of the vertebra, at the line of junction of its posterior and lateral surfaces. The concavities above and below the pedicles are the *intervertebral notches;* they are four in number, two on each side, the inferior ones being generally the deeper. When the vertebræ are articulated the notches of each contiguous pair of bones form the intervertebral foramina, which communicate with the spinal canal and transmit the spinal nerves and blood-vessels.

The **Laminæ** are two broad plates of bone which complete the neural arch by fusing together in the middle line behind. They enclose a foramen, the *spinal foramen*, which serves for the protection of the spinal cord; they are connected to the body by means of the pedicles. Their upper and lower borders are rough, for the attachment of the *ligamenta subflava*.

The **Spinous Process** projects backward from the junction of the two laminæ, and serves for the attachment of muscles and ligaments.

The **Articular Processes**, four in number, two on each side, spring from the junction of the pedicles with the laminæ. The two superior project upward, their articular surfaces being directed more or less backward; the two inferior project downward, their articular surfaces looking more or less forward.[1]

The **Transverse Processes**, two in number, project one at each side from the point where the lamina joins the pedicle, between the superior and inferior articular processes. They also serve for the attachment of muscles and ligaments.

Character of the Cervical Vertebræ (Fig. 1).

The **Cervical Vertebræ** are smaller than those in any other region of the spine, and may readily be distinguished by the foramen in the transverse process, which does not exist in the transverse process of either the dorsal or lumbar vertebræ.

The **Body** is small, comparatively dense, and broader from side to side than from before backward. The anterior and posterior surfaces are flattened and of equal depth; the former is placed on a lower level than the latter, and its inferior border is prolonged downward, so as to overlap the upper and fore part of the vertebræ below. Its upper surface is concave transversely, and presents a projecting lip on each side; its lower surface is convex from side to side, concave from before backward, and presents laterally a shallow concavity which receives the corresponding projecting lip of the adjacent vertebra. The *pedicles* are directed outward and backward, and are attached to the body midway between the upper and lower borders, so that the superior intervertebral notch is as deep as the inferior, but it is, at the same time, narrower. The *laminæ* are narrow,

[1] It may, perhaps, be as well to remind the reader that the direction of a surface is determined by that of a line drawn at right angles to it.

long, thinner above than below, and overlap each other, enclosing the spinal foramen, which is very large, and of a triangular form. The *spinous process* is short, and bifid at the extremity to afford greater extent of surface for the attachment of muscles, the two divisions being often of unequal size. They increase in length from the fourth to the seventh. The *articular processes* are flat, oblique, and of an oval form: the superior are directed backward and upward; the inferior forward and downward. The *transverse processes* are short, directed downward, outward, and forward, bifid at their extremity, and marked by a groove along their upper surface, which runs downward and outward from the superior intervertebral notch, and serves for the transmission of one of the cervical nerves. They are situated in front of the articular processes and on the outer side of the pedicles. The transverse processes are pierced at their base by a foramen, for the transmission of the vertebral artery, vein, and plexus of nerves.

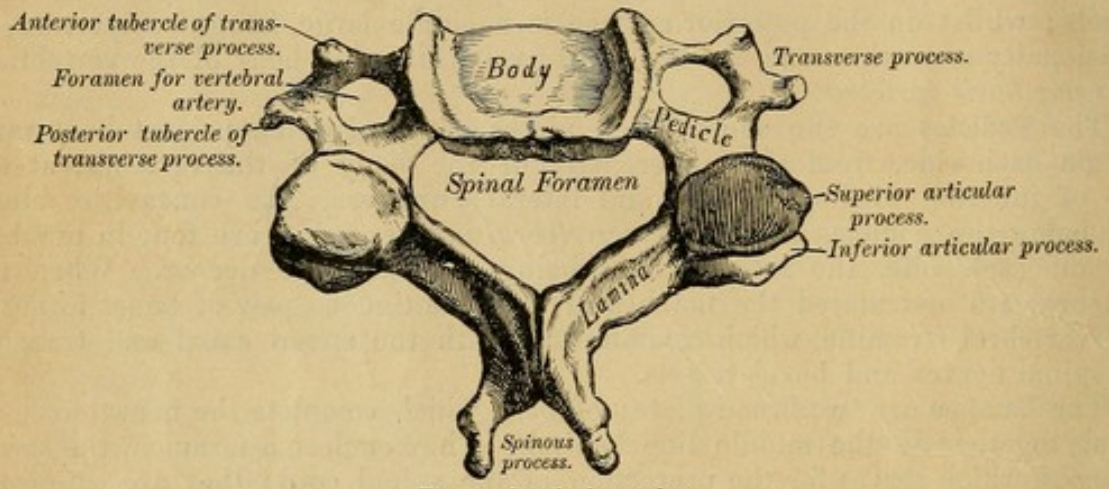

FIG. 1.—Cervical vertebra.

Each process is formed by two roots: the anterior root, sometimes called the *costal process*, arises from the side of the body, and is the homologue of the rib in the dorsal region of the spine; the posterior root springs from the junction of the pedicle with the lamina, and corresponds with the transverse process in the dorsal region. It is by the junction of the two that the foramen for the vertebral vessels is formed. The extremity of each of these roots forms the *anterior* and *posterior tubercles* of the transverse processes.[1]

The peculiar vertebræ in the cervical region are the first, or *Atlas;* the second, or *Axis;* and the seventh, or *Vertebra prominens*. The great modifications in the form of the atlas and axis are designed to admit of the nodding and rotatory movements of the head.

The **Atlas** (Fig. 2) is so named from supporting the globe of the head. The chief peculiarities of this bone are that it has neither body nor spinous process. The body is detached from the rest of the bone, and forms the odontoid process of the second vertebra; while the parts corresponding to the pedicles join in front to form the anterior arch. The atlas is ring-like, and consists of an anterior arch, a posterior arch, and two lateral masses. The *anterior* arch forms about one-fifth of the ring: its anterior surface is convex, and presents about its centre a *tubercle*, for the attachment of the Longus colli muscle; posteriorly it is concave, and marked by a smooth, oval or circular facet, for articulation with the odontoid process of the axis. The upper and lower borders give attachment to the anterior occipito-atlantal and the anterior atlanto-axial ligaments, which connect it with the occipital bone above and the axis below. The *posterior* arch forms about two-fifths of the circumference of the bone; it terminates behind in a *tubercle*,

[1] The anterior tubercle of the transverse process of the sixth cervical vertebra is of large size, and is sometimes known as "Chassaignac's" or the "carotid tubercle." It is in close relation with the carotid artery, which lies in front and a little external to it; so that, as was first pointed out by Chassaignac, the vessel can with ease be compressed against it.

which is the rudiment of a spinous process, and gives origin to the Rectus capitis posticus minor. The diminutive size of this process prevents any interference in the movements between the atlas and the cranium. The posterior part of the arch presents above and behind a rounded edge for the attachment of the posterior occipito-atlantal ligament, while in front, immediately behind each superior articular process, is a groove, sometimes converted into a foramen by a *delicate bony spiculum* which arches backward from the posterior extremity of the superior articular process. These grooves represent the superior intervertebral notches, and are peculiar from being situated behind the articular processes, instead of in front of them, as in the other vertebræ. They serve for the transmission of the vertebral artery, which, ascending through the foramen in the transverse process, winds round the lateral mass in a direction backward and inward. They also transmit the suboccipital (first spinal) nerve. On the under surface of the posterior arch, in the same situation, are two other grooves, placed behind the lateral masses, and representing the inferior intervertebral notches of other vertebræ. They are much less marked than the superior. The lower border also gives attachment to the posterior atlanto-axial ligament, which connects it with the axis. The *lateral masses* are the most bulky and solid parts of the atlas, in order to support the weight of the head; they present two articulating processes above, and two below. The two superior are of large size, oval,

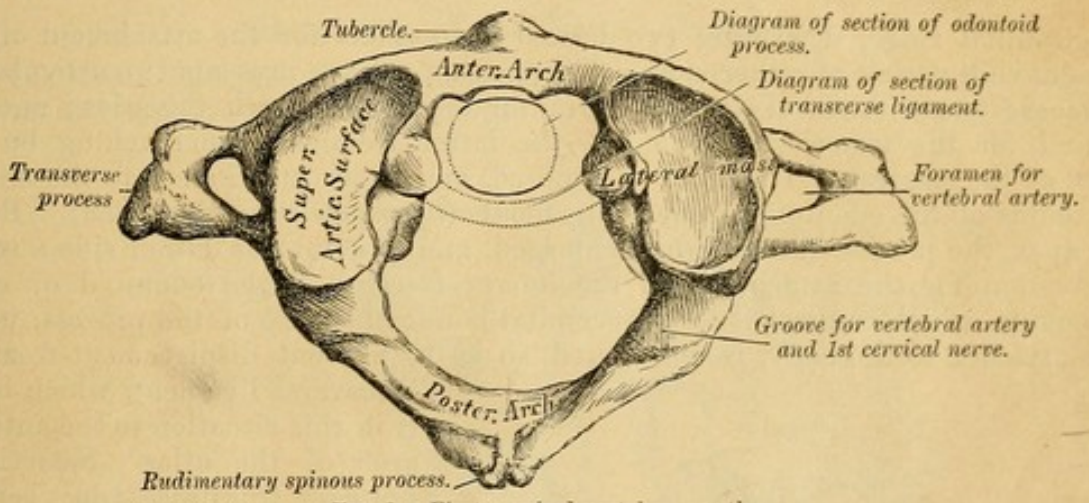

FIG. 2.—First cervical vertebra, or atlas.

concave, and approach each other in front, but diverge behind; they are directed upward, inward, and a little backward, each forming a kind of cup for the corresponding condyle of the occipital bone, and are admirably adapted to the nodding movements of the head. Not infrequently they are partially subdivided by a more or less deep indentation which encroaches upon each lateral margin. The inferior articular processes are circular in form, flattened or slightly concave, and directed downward and inward, articulating with the axis, and permitting the rotatory movements. Just below the inner margin of each superior articular surface is a small tubercle, for the attachment of the transverse ligament, which, stretching across the ring of the atlas, divides it into two unequal parts; the anterior or smaller segment receiving the odontoid process of the axis, the posterior allowing the transmission of the spinal cord and its membranes. This part of the spinal canal is of considerable size, to afford space for the spinal cord; and hence lateral displacement of the atlas may occur without compression of this structure. The *transverse processes* are of large size, project directly outward and downward from the lateral masses, and serve for the attachment of special muscles which assist in rotating the head. They are long, not bifid, and perforated at their base by a canal for the vertebral artery, which is directed from below, upward and backward.

The **Axis** (Fig. 3) is so named from forming the pivot upon which the first vertebra, carrying the head, rotates. The most distinctive character of this bone

is the strong, prominent process, tooth-like in form (hence the name al
which rises perpendicularly from the upper surface of the body. is
deeper in front than behind, and prolonged downward anteriorly so -
the upper and fore part of the next vertebra. It presents in fr n

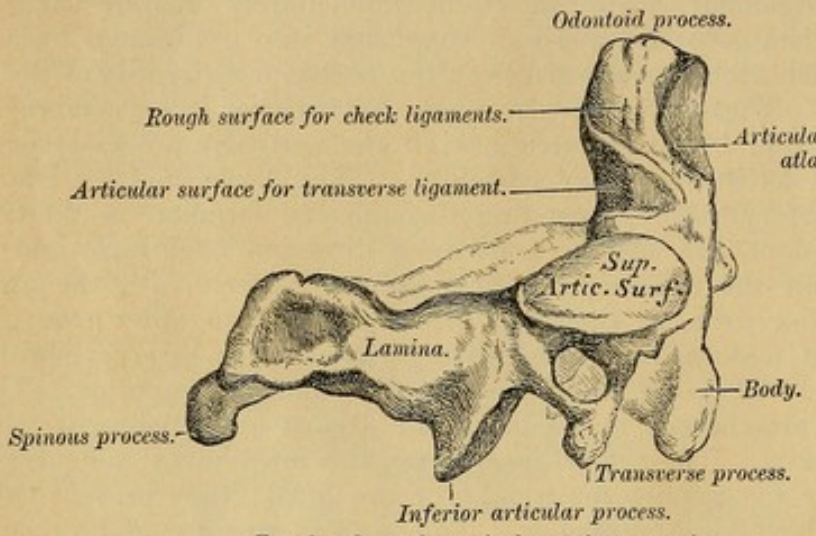

FIG. 3. — Second cervical vertebra, or axis.

longitudinal ridge, separating two lateral depressions for the attachment of the Longus colli muscle of either side. The *odontoid process* presents two articulating surfaces: one in front, of an oval form, for articulation with the atlas; another behind, for the transverse ligament—the latter frequently encroaching on the sides of the process. The apex is pointed, and gives attachment to the middle fasciculus of the odontoid or check ligaments (*ligamentum suspensorium*). Below the apex the process is somewhat enlarged, and presents on either side a rough impression for the attachment of the *lateral* fasciculi of the odontoid or *check* ligaments, which connect it to the occipital bone; the base of the process, where it is attached to the body, is constricted, so as to prevent displacement from the transverse ligament, which binds it in this situation to the anterior arch of the atlas. Sometimes, however, this process does become displaced, especially in children, in whom the ligaments are more relaxed: instant death is the result of this accident. The internal structure of the odontoid process is more compact than that of the body. The *pedicles* are broad and strong, especially their anterior extremities, which coalesce with the sides of the body and the root of the odontoid process. The *laminæ* are thick and strong, and the spinal foramen large, but smaller than that of the atlas. The *transverse processes* are very small, not bifid, and perforated by the foramen for the vertebral artery, which is directed obliquely upward and outward. The *superior articular surfaces* are round, slightly convex, directed upward and outward, and are peculiar in being supported on the body, pedicles, and transverse processes. The *inferior articular surfaces* have the same direction as those of the other cervical vertebræ. The *superior*

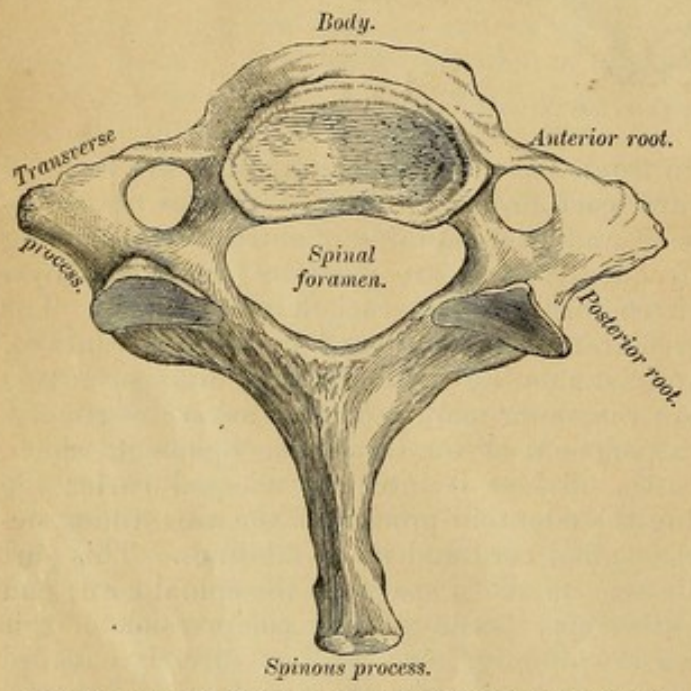

FIG. 4. — Seventh cervical vertebra, or vertebra prominens.

intervertebral notches are very shallow, and lie behind the articular processes; the *inferior* in front of them, as in the other cervical vertebræ. The *spinous process* is of large size, very strong, deeply channelled on its under surface, and presents a bifid, tubercular extremity for the attachment of muscles which serve to rotate the head upon the spine.

Seventh Cervical (Fig. 4).—The most distinctive character of this vertebra is the existence of a very long and prominent spinous process; hence the name "vertebra prominens." This process is thick, nearly horizontal in direction, not bifurcated, and has attached to it the lower end of the ligamentum nuchæ. The *transverse process* is usually of large size, its posterior tubercles are large and prominent, while the anterior are small and faintly marked; its upper surface has usually a shallow groove, and it seldom presents more than a trace of bifurcation at its extremity. The foramen in the transverse process is sometimes as large as in the other cervical vertebræ, but is usually smaller on one or both sides, and sometimes wanting. On the left side it occasionally gives passage to the vertebral artery; more frequently the vertebral vein traverses it on both sides; but the usual arrangement is for both artery and vein to pass in front of the transverse process, and not through the foramen. Occasionally the anterior root of the transverse process exists as a separate bone, and attains a large size. It is then known as a "cervical rib."

Characters of the Dorsal Vertebræ.

The **Dorsal Vertebræ** are intermediate in size between those in the cervical and those in the lumbar region, and increase in size from above downward, the upper

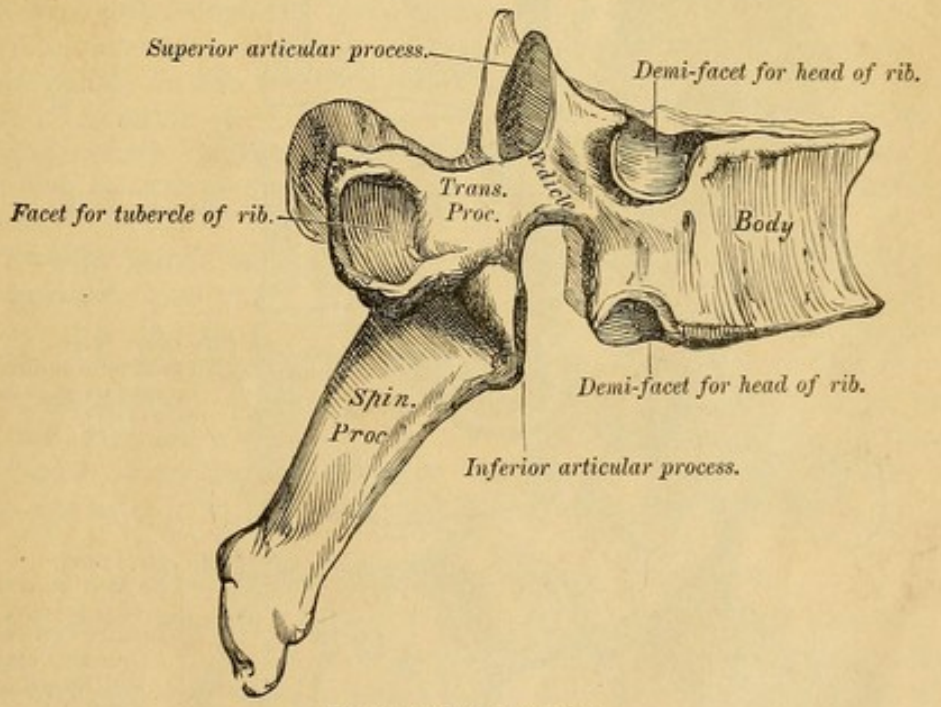

FIG. 5.—A dorsal vertebra.

vertebræ in this segment of the spine being much smaller than those in the lower part of the region. The dorsal vertebræ may be at once recognized by the presence on the sides of the body of one or more facets or half-facets for the heads of the ribs.

The **bodies** of the dorsal vertebræ resemble those in the cervical and lumbar regions at the respective ends of this portion of the spine; but in the middle of the dorsal region their form is very characteristic, being heart-shaped, and as broad in the antero-posterior as in the lateral direction. They are thicker behind than in front, flat above and below, convex and prominent in front, deeply concave behind, slightly constricted in front and at the sides, and marked on each side,

near the root of the pedicle, by two demi-facets, one above, the other below. are covered with cartilage in the recent state, and, when articulated with the ing vertebræ, form, with the intervening fibro-cartilage, oval surfaces reception of the heads of the corresponding ribs. The *pedicles* are directe ward, and the inferior intervertebral notches are of large size, and deeper tha any other region of the spine. The *laminæ* are broad, thick, and imbricated– that is to say, overlapping one another like tiles on a roof. The spinal foramen is

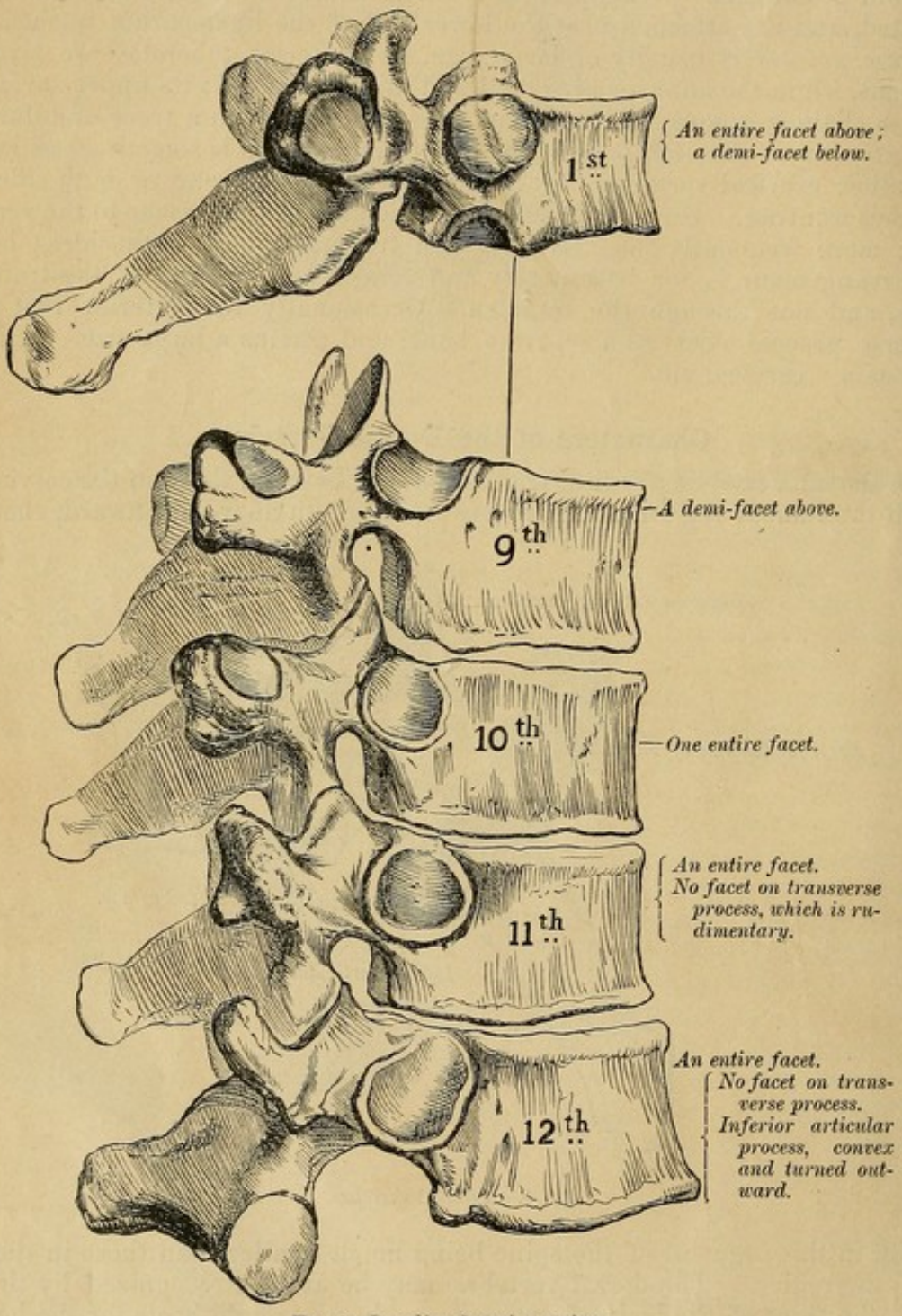

FIG. 6.—Peculiar dorsal vertebræ.

small, and of a circular form. The *spinous processes* are long, triangular on transverse section, directed obliquely downward, and terminate in a tubercular extremity. They overlap one another from the fifth to the eighth, but are less oblique in direction above and below. The *articular processes* are flat, nearly vertical in direction, and project from the upper and lower part of the pedicles; the superior being directed backward and *slightly* outward and upward, the inferior

forward and a little inward and downward. The *transverse processes* arise from the same parts of the arch as the posterior roots of the transverse processes in the neck, and are situated behind the articular processes and pedicles; they are thick, strong, and of great length, directed obliquely backward and outward, presenting a clubbed extremity, which is tipped on its anterior part by a small concave surface, for articulation with the tubercle of a rib. Besides the articular facet for the rib, *three indistinct tubercles* may be seen rising from the transverse processes, one at the upper border, one at the lower border, and one externally. In man they are comparatively of small size, and serve only for the attachment of muscles. But in some animals they attain considerable magnitude, either for the purpose of more closely connecting the segments of this portion of the spine or for muscular and ligamentous attachment.

The peculiar dorsal vertebræ are the *first*, *ninth*, *tenth*, *eleventh*, and *twelfth* (Fig. 6).

The **First Dorsal Vertebra** presents, on each side of the *body*, a single entire articular facet for the head of the first rib and a half facet for the upper half of the second. The body is like that of a cervical vertebra, being broad transversely; its upper surface is concave, and lipped on each side. The *articular surfaces* are oblique, and the *spinous process* thick, long, and almost horizontal.

The **Ninth Dorsal** has no demi-facet below. In some subjects, however, the ninth has two demi-facets on each side; when this occurs the tenth has only a demi-facet at the upper part.

The **Tenth Dorsal** has (except in the cases just mentioned) an entire articular facet on each side, above, which is partly placed on the outer surface of the pedicle. It has no demi-facet below.

In the **Eleventh Dorsal** the body approaches in its form and size to the lumbar. The articular facets for the heads of the ribs, one on each side, are of large size, and placed chiefly on the pedicles, which are thicker and stronger in this and the next vertebra than in any other part of the dorsal region. The *spinous* process is short, and nearly horizontal in direction. The *transverse* processes are very short, tubercular at their extremities, and have no articular facets for the tubercles of the ribs.

The **Twelfth Dorsal** has the same general characters as the eleventh, but may be distinguished from it by the inferior articular processes being convex and turned outward, like those of the lumbar vertebræ; by the general form of the body, laminæ, and spinous process, approaching to that of the lumbar vertebræ; and by the transverse processes being shorter, and marked by three elevations, the superior, inferior, and external tubercles, which correspond to the mammillary, accessory, and transverse processes of the lumbar vertebræ. Traces of similar elevations are usually to be found upon the other dorsal vertebræ (*vide ut supra*).

Characters of the Lumbar Vertebræ.

The **Lumbar Vertebræ** (Fig. 7) are the largest segments of the vertebral column, and can at once be distinguished by the absence of the foramen in the transverse process, the characteristic point of the cervical vertebræ, and by the absence of any articulating facet on the side of the body, the distinguishing mark of the dorsal vertebræ.

The **body** is large, and has a greater diameter from side to side than from before backward, slightly thicker in front than behind, flattened or slightly concave above and below, concave behind, and deeply constricted in front and at the sides, presenting prominent margins, which afford a broad basis for the support of the superincumbent weight. The *pedicles* are very strong, directed backward from the upper part of the bodies; consequently, the inferior intervertebral notches are of considerable depth. The *laminæ* are broad, short, and strong, and the spinal foramen triangular, larger than in the dorsal, smaller than in the cervical, region. The *spinous processes* are thick and broad, somewhat quadrilateral, horizontal in direction, thicker below than above, and terminating by a rough, uneven border.

The *superior articular processes* are concave, and look backward and inwa. the *inferior*, convex, look forward and outward; the former are separated by a much wider interval than the latter, embracing the lower articulating processes of the vertebra above. The *transverse processes* are long, slender, directed trans-

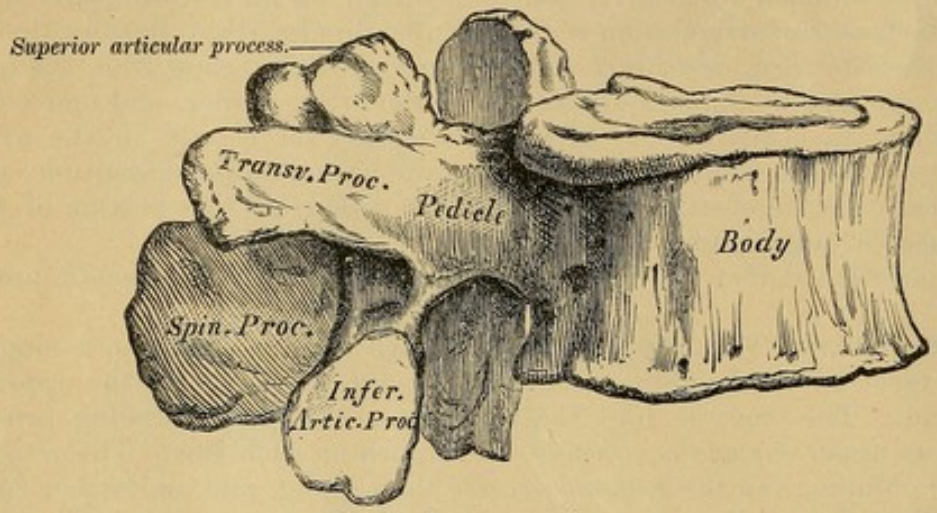

FIG. 7.—Lumbar vertebra.

versely outward in the upper three lumbar vertebræ, slanting a little upward in the lower two. They are situated in front of the articular processes, instead of behind them as in the dorsal vertebræ, and are homologous with the ribs. Of the three tubercles noticed in connection with the transverse processes of the twelfth dorsal vertebra, the *superior* ones become connected in this region with the back

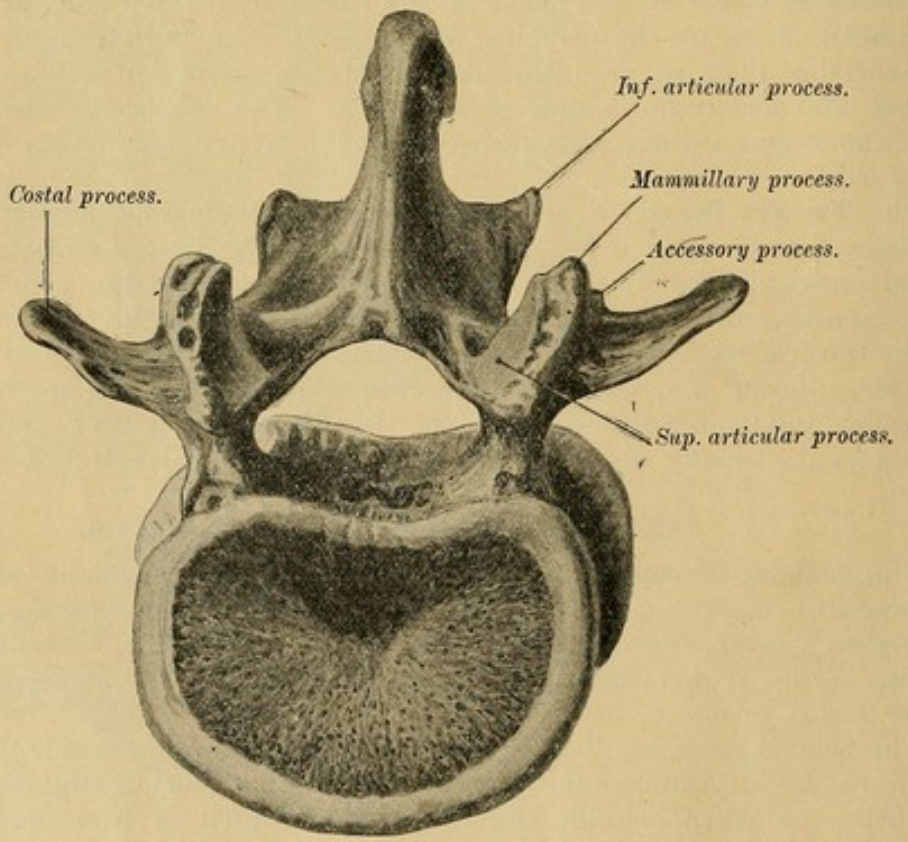

FIG. 8.—Lumbar vertebræ.

part of the superior articular processes, and have received the name of *mammillary* processes; the *inferior* are represented by a small process pointing downward, situated at the back part of the base of the transverse process, and called the *accessory* processes: these are the true transverse processes, which are rudimental in this region of the spine; the *external* ones are the so-called transverse processes,

the homologue of the rib, and hence sometimes called costal processes (Fig. 8). Although in man these are comparatively small, in some animals they attain considerable size, and serve to lock the vertebræ more closely together.

The **Fifth Lumbar** vertebra is characterized by having the body much thicker in front than behind, which accords with the prominence of the sacro-vertebral articulation; by the smaller size of its spinous process; by the wide interval between the inferior articulating processes; and by the greater size and thickness of its transverse processes, which spring from the body as well as from the pedicles.

Structure of the Vertebræ.—The body is composed of light, spongy, cancellous tissue, having a thin coating of compact tissue on its external surface perforated by numerous orifices, some of large size, for the passage of vessels; its interior is traversed by one or two large canals, for the reception of veins, which converge toward a single large, irregular aperture or several small apertures at the posterior part of the body of each bone. The arch and processes projecting from it have, on the contrary, an exceedingly thick covering of compact tissue.

Development.—Each vertebra is formed of four primary centres of ossification (Fig. 9), one for each lamina and its processes, and two for the body.[1] Ossification commences in the laminæ about the sixth week of fœtal life, in the situation where the transverse processes afterward project, the ossific granules shooting backward to the spine, forward into the pedicles, and outward into the transverse and articular processes. Ossification in the body commences in the middle of the cartilage about the eighth week by two closely approximated centres, which speedily coalesce to form one central ossific point. According to some authors, ossification commences in the laminæ only in the upper vertebræ—*i. e.*, in the cervical and upper dorsal. The first ossific points in the lower vertebræ are those which are to form the body, the osseous centres for the laminæ appearing at a subsequent period. At birth these three pieces are perfectly separate. During the first year the laminæ become united behind, the union taking place first in the lumbar region and then extending upward through the dorsal and lower cervical regions. About the third year the body is joined to the arch on each side in such a manner that the body is formed from the three original centres of ossification, the amount contributed by the pedicles increasing in extent from below upward. Thus the bodies of the sacral vertebræ are formed almost entirely from the central nuclei; the bodies of the lumbar are formed laterally and behind by the pedicles; in the dorsal region the pedicles advance as far forward as the articular depressions for the head of the ribs, forming these cavities of reception; and in the neck the

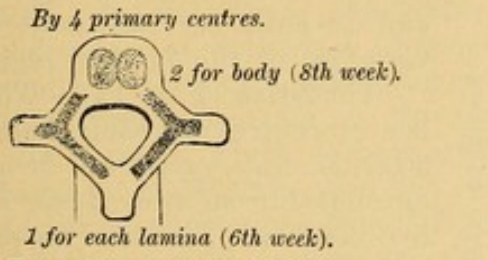

FIG. 9.—Development of a vertebra.

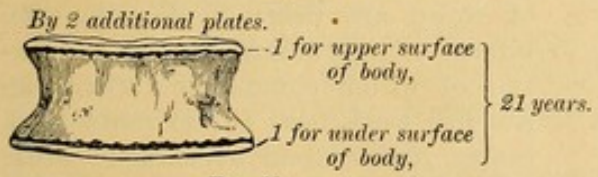

FIG. 10.

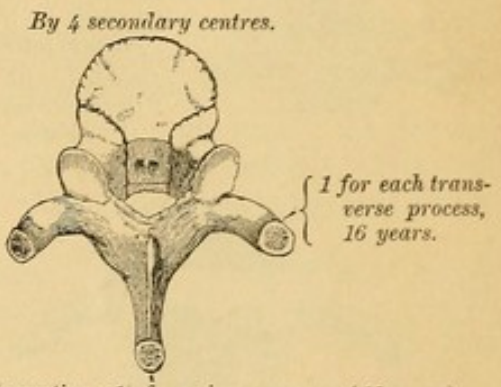

FIG. 11.

[1] By many observers it is asserted that the bodies of the vertebra are developed from a single centre which speedily becomes bilobed, so as to give the appearance of two nuclei; but that there are two centres, at all events sometimes, is evidenced by the fact that the two halves of the body of the vertebra may remain distinct throughout life and be separated by a fissure through which a protrusion of the spinal membrane may take place, constituting an anterior spina bifida.

lateral portions of the bodies are formed entirely by the advance of the pedicles. The line along which union takes place between the body and the neural arch is named the *neuro-central suture*. Before puberty no other changes occur, excepting a gradual increase in the growth of these primary centres; the upper and under surfaces of the bodies and the ends of the transverse and spinous processes being tipped with cartilage, in which ossific granules are not as yet deposited. At sixteen years (Fig. 11) three secondary centres appear, one for the tip of each transverse process, and one for the extremity of the spinous process. In some of the lumbar vertebræ, especially the first, second, and third, a second ossifying centre appears at the base of the spinous process. At twenty-one years (Fig. 10) a thin circular epiphysial plate of bone is formed in the layer of cartilage situated on the upper and under surfaces of the body, the former being the thicker of the two. All these become joined, and the bone is completely formed between the twenty-fifth and thirtieth year of life.

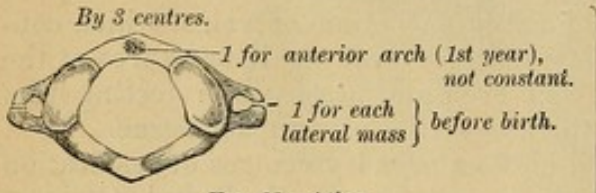

Fig. 12.—Atlas.

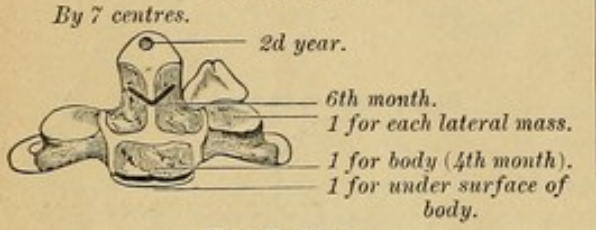

Fig. 13.—Axis.

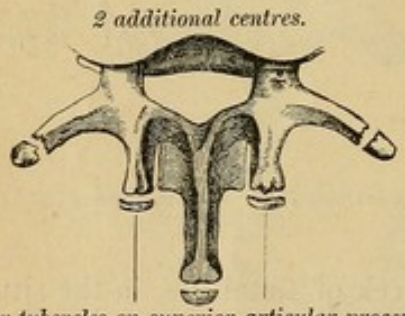

Fig. 14.—Lumbar vertebra.

Exceptional cases.

Exceptions to this mode of development occur in the first, second, and seventh cervical, and in the vertebræ of the lumbar region.

The **Atlas** (Fig. 12).—The number of centres of ossification of the atlas is very variable. It may be developed from two, three, four, or five centres. The most frequent arrangement is by three centres. Two of these are destined for the two lateral or neural masses, the ossification of which commences about the seventh week near the articular processes, and extend backward; these portions of bone are separated from one another behind, at birth, by a narrow interval filled in with cartilage. Between the third and fourth years they unite either directly or through the medium of a separate centre developed in the cartilage in the middle line. The anterior arch, at birth, is altogether cartilaginous, and in this a separate nucleus appears about the end of the first year after birth, and, extending laterally, joins the neural processes in front of the pedicles. Sometimes there are two nuclei developed in the cartilage, one on either side of the median line, which join to form a single mass. And occasionally there is no separate centre, but the anterior arch is formed by the gradual extension forward and ultimate junction of the two neural processes.

The **Axis** (Fig. 13) is developed by *seven* centres. The body and arch of this bone are formed in the same manner as the corresponding parts in the other vertebræ: one centre (or two, which speedily coalesce) for the lower part of the body, and one for each lamina. The centres for the laminæ appear about the seventh or eighth week, that for the body about the fourth month. The odontoid process consists originally of an extension upward of the cartilaginous mass in which the lower part of the body is formed. At about the sixth month of fœtal life two osseous nuclei make their appearance in the base of this process: they are placed laterally, and join before birth to form a conical bilobed mass deeply cleft above; the interval between the cleft and the summit of the process is formed by a wedge-shaped piece of cartilage, the base of the process being separated from the body by a cartilaginous interval, which

gradually becomes ossified at its circumference, but remains cartilaginous between centre until advanced age.[1] Finally, as Humphry has demonstrated, the the odontoid process has a separate nucleus, which appears in the second than the joins about the twelfth year. In addition to these there is a secondary a thin epiphysial plate on the under surface of the body of the bone.

The **Seventh Cervical.**—The anterior or costal part of the transverse of the seventh cervical is developed from a separate osseous centre at about sixth month of fœtal life, and joins the body and posterior division of the transverse process between the fifth and sixth years. Sometimes this process continues as a separate piece, and, becoming lengthened outward, constitutes what is known as a cervical rib. This separate ossific centre for the costal process has also been found in the fourth, fifth, and sixth cervical vertebræ.

The **Lumbar Vertebræ** (Fig. 14) have *two additional centres* (besides those peculiar to the vertebræ generally) for the mammillary tubercles, which project from the back part of the superior articular processes. The transverse process of the first lumbar is sometimes developed as a separate piece, which may remain permanently unconnected with the remaining portion of the bone, thus forming a lumbar rib—a peculiarity that is rarely met with.

Progress of Ossification in the Spine generally.—Ossification of the laminæ of the vertebræ commences in the cervical region of the spine, and proceeds gradually downward. Ossification of the bodies, on the other hand, commences a little below the centre of the spinal column (about the ninth or tenth dorsal vertebra), and extends both upward and downward. Although, however, the ossific nuclei make their first appearance in the lower dorsal vertebræ, the lumbar and first sacral are those in which these nuclei are largest at birth.

Attachment of Muscles.—To the *Atlas* are attached nine pairs: the Longus colli, Rectus capitis anticus minor, Rectus lateralis, Obliquus capitis superior and inferior, Splenius colli, Levator anguli scapulæ, First Intertransverse, and Rectus capitis posticus minor.

To the *Axis* are attached eleven pairs: the Longus colli, Levator anguli scapulæ, Splenius colli, Scalenus medius, Transversalis colli, Intertransversales, Obliquus capitis inferior, Rectus capitis posticus major, Semispinalis colli, Multifidus spinæ, Interspinales.

To the remaining vertebræ, generally, are attached thirty-five pairs and a single muscle: *anteriorly*, the Rectus capitis anticus major, Longus colli, Scalenus anticus medius and posticus, Psoas magnus and parvus, Quadratus lumborum, Diaphragm, Obliquus abdominis internus, and Transversalis abdominis—*posteriorly*, the Trapezius, Latissimus dorsi, Levator anguli scapulæ, Rhomboideus major and minor, Serratus posticus superior and inferior, Splenius, Erector spinæ, Ilio-costalis, Longissimus dorsi, Spinalis dorsi, Cervicalis ascendens, Transversalis colli, Trachelo-mastoid, Complexus, Biventer cervicis, Semispinalis dorsi and colli, Multifidus spinæ, Rotatores spinæ, Interspinales, Supraspinales, Intertransversales, Levatores costarum.

Sacral and Coccygeal Vertebræ.

The **Sacral** and **Coccygeal Vertebræ** consist, at an early period of life, of nine separate pieces, which are united in the adult so as to form two bones, five entering into the formation of the sacrum, four into that of the coccyx. Occasionally, the coccyx consists of five bones.[2]

The **Sacrum** (sacer, sacred) is a large, triangular bone (Fig. 15), situated at the lower part of the vertebral column, and at the upper and back part of the pelvic cavity, where it is inserted like a wedge between the two innominate bones; its upper part or base articulating with the last lumbar vertebræ, its apex with the coccyx. The sacrum is curved upon itself, and placed very obliquely, its upper

[1] See Cunningham, *Journ. Anat.*, vol. xx. p. 238.

[2] Sir George Humphry describes this as the usual composition of the coccyx.—*On the Skeleton*, p. 456.

44 projecting forward, and forming, with the last lumbar vertebra, a very
ıt angle, called the *promontory* or *sacro-vertebral angle;* whilst its central
lateral p irected backward, so as to give increased capacity to the pelvic cavity.
The line its for examination an anterior and posterior surface, two lateral surfaces,
named th n apex, and a central canal.

ing a g **Anterior Surface** is concave from above downward, and slightly so from
unde to side. In the middle are seen four transverse ridges, indicating the original
beinsion of the bone into five separate pieces. The portions of bone intervening
Atween the ridges correspond to the bodies of the vertebræ. The body of the
first segment is of large size, and in form resembles that of a lumbar vertebra; the
succeeding ones diminish in size from above downward, are flattened from before
backward, and curved so as to accommodate themselves to the form of the sacrum,
being concave in front, convex behind. At each end of the ridges above mentioned
are seen the *anterior sacral foramina*, analogous to the intervertebral foramina,

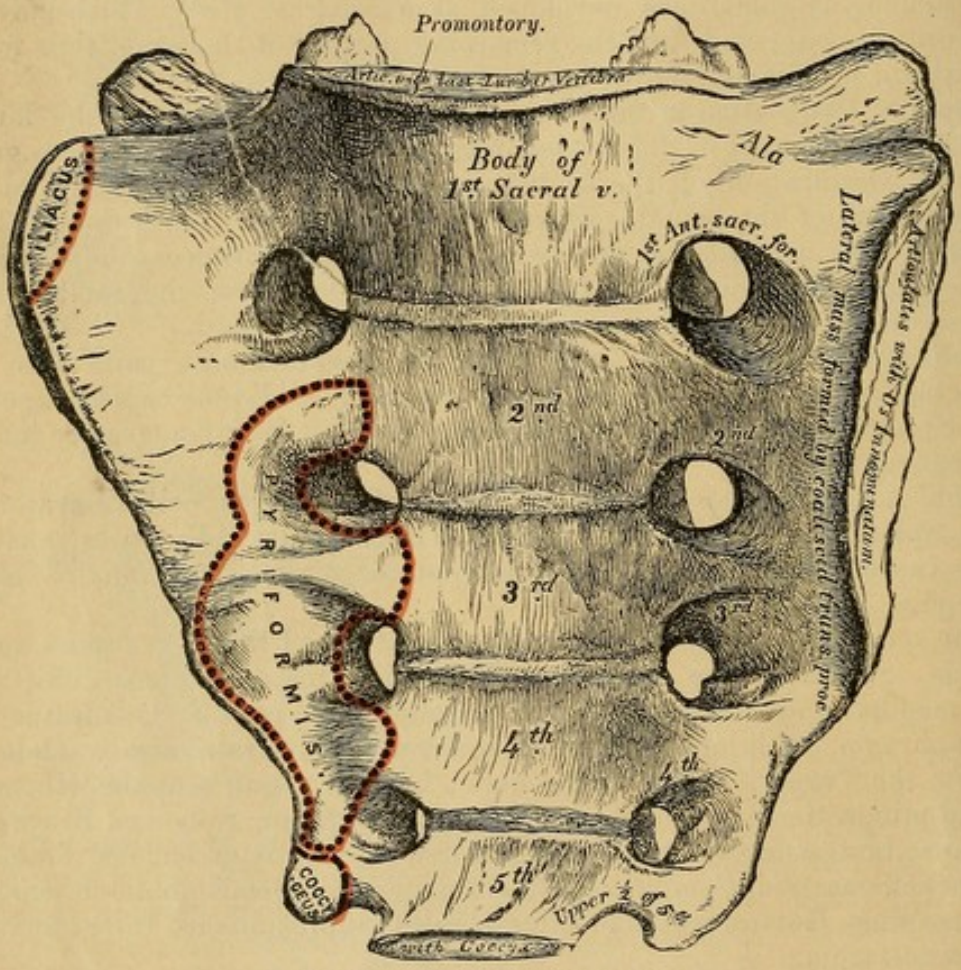

FIG. 15.—Sacrum, anterior surface.

four in number on each side, somewhat rounded in form, diminishing in size from above downward, and directed outward and forward; they transmit the anterior branches of the sacral nerves and the lateral sacral arteries. External to these foramina is the *lateral mass*, consisting at an early period of life of separate segments; these become blended, in the adult, with the bodies, with each other, and with the posterior transverse processes. Each lateral mass is traversed by four broad, shallow grooves, which lodge the anterior sacral nerves as they pass outward, the grooves being separated by prominent ridges of bone, which give attachment to the slips of the Pyriformis muscle.

If a vertical section is made through the centre of the sacrum (Fig. 16), the bodies are seen to be united at their circumference by bone, a wide interval being left centrally, which, in the recent state, is filled by intervertebral substance. In

some bones this union is more complete between the lower segments than between the upper ones.

The **Posterior Surface** (Fig. 17) is convex and much narrower than the anterior. In the middle line are three or four tubercles, which represent the rudimentary spinous processes of the sacral vertebræ. Of these tubercles, the first is usually prominent, and perfectly distinct from the rest; the second and third are either separate or united into a tubercular ridge, which diminishes in size from above downward; the fourth usually, and the fifth always, remaining undeveloped. External to the spinous processes on each side are the *laminæ*, broad and well marked in the first three pieces; sometimes the fourth, and generally the fifth, are only partially developed and fail to meet in the middle line. These partially developed laminæ are prolonged downward as rounded processes, the *sacral cornua*, and are connected to the cornua of the coccyx. Between them the bony wall of the lower end of the sacral canal is imperfect, and is liable to be opened in the sloughing of bed-sores. External to the laminæ is a linear series of indistinct tubercles representing the *articular processes;* the upper pair are large, well developed, and correspond in shape and direction to the superior articulating processes of a lumbar vertebra; the second and third are small; the fourth and fifth (usually blended together) are situated on each side of the sacral canal and assist in forming the sacral cornua. External to the articular processes are the four *posterior sacral foramina;* they are smaller in size and less regular in form than the anterior, and transmit the posterior branches of the sacral nerves. On the outer side of the posterior sacral foramina is a series of tubercles, the rudimentary *transverse processes* of the sacral vertebræ. The first pair of transverse tubercles are large, very distinct, and correspond with each *superior angle* of the bone; they together with the second pair, which are of small size, give attachment to the horizontal part of the sacro-iliac ligament; the third give attachment to the oblique fasciculi of the posterior sacro-iliac ligaments; and the fourth and fifth to the great sacro-sciatic ligaments. The interspace between the spinous and transverse processes on the back of the sacrum presents a wide, shallow concavity, called the *sacral groove;* it is continuous above with the vertebral groove, and lodges the origin of the Multifidus spinæ.



FIG. 16.—Vertical section of the sacrum.

The **Lateral Surface**, broad above, becomes narrowed into a thin edge below. Its upper half presents in front a broad, ear-shaped surface for articulation with the ilium. This is called the *auricular* surface, and in the fresh state is coated with fibro-cartilage. It is bounded posteriorly by deep and uneven impressions, for the attachment of the posterior sacro-iliac ligaments. The lower half is thin and sharp, and terminates in a projection called the *inferior lateral angle;* below this angle is a notch, which is converted into a foramen by articulation with the transverse process of the upper piece of the coccyx, and transmits the anterior

division of the fifth sacral nerve. This lower, sharp border gives attachment to the greater and lesser sacro-sciatic ligaments, and to some fibres of the Gluteus maximus posteriorly, and to the Coccygeus in front.

The **Base** of the sacrum, which is broad and expanded, is directed upward and forward. In the middle is seen a large oval articular surface, which is connected with the under surface of the body of the last lumbar vertebra by a fibro-cartilaginous disk. It is bounded behind by the large, triangular orifice of the sacral canal. The orifice is formed behind by the laminæ and spinous process of the first sacral vertebra: the superior articular processes project from it on each side; they are oval, concave, directed backward and inward, like the superior articular processes of a lumbar vertebra; and in front of each articular process is an intervertebral notch, which forms the lower part of the foramen between the last lumbar and first sacral vertebra. Lastly, on each side of the large oval articular

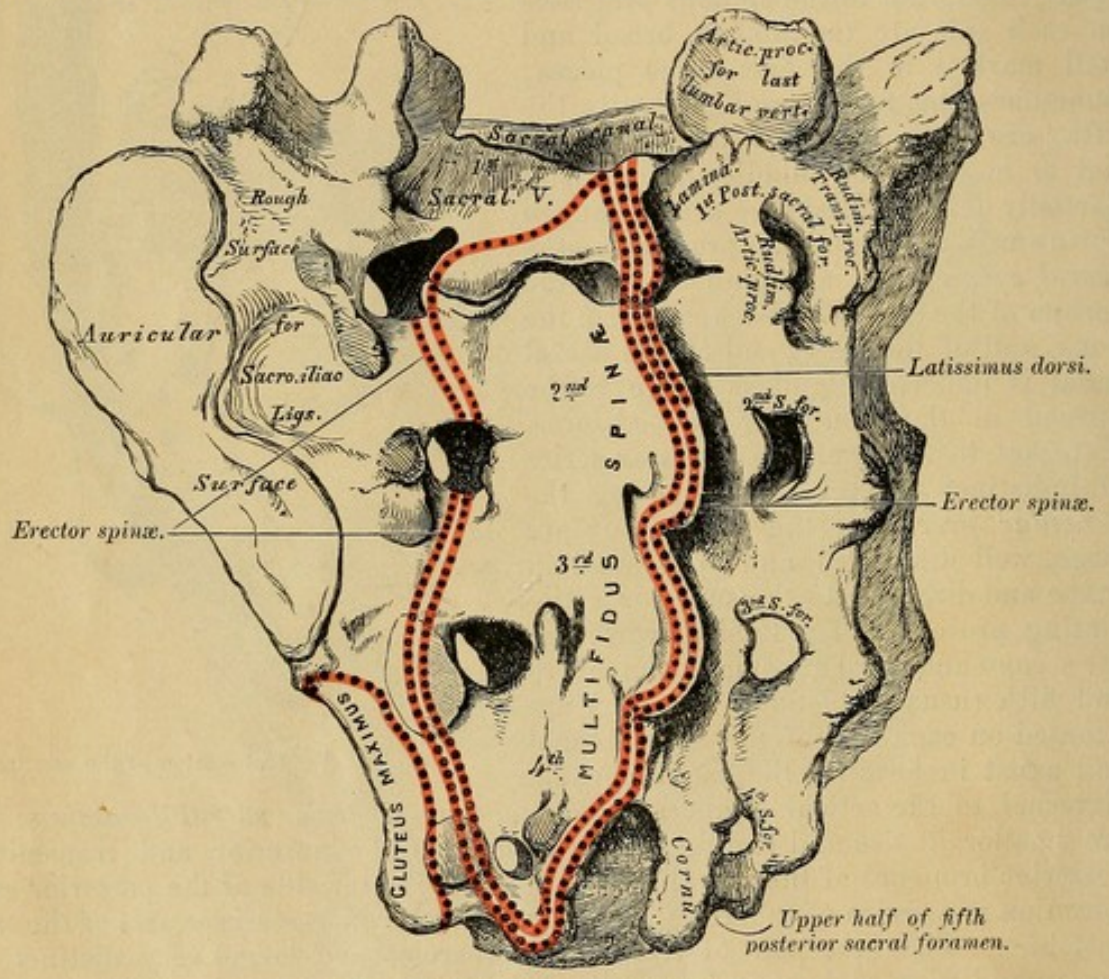

FIG. 17.—Sacrum, posterior surface.

plate is a broad and flat triangular surface of bone, which extends outward, supports the Psoas magnus muscle and lumbo-sacral cord, and is continuous on each side with the iliac fossa. This is called the *ala* of the sacrum, and gives attachment to a few of the fibres of the Iliacus muscle. The posterior part of the ala represents the transverse process of the first sacral segment.

The **Apex,** directed downward and slightly forward, presents a small, oval, concave surface for articulation with the coccyx.

The **Spinal Canal** runs throughout the greater part of the bone; it is large and triangular in form above, small and flattened, from before backward, below. In this situation its posterior wall is incomplete, from the non-development of the laminæ and spinous processes. It lodges the sacral nerves, and is perforated by the anterior and posterior sacral foramina, through which these pass out.

Structure.—It consists of much loose, spongy tissue within, invested externally by a thin layer of compact tissue.

Differences in the Sacrum of the Male and Female.—The sacrum in the female is shorter and wider than in the male; the lower half forms a greater angle with the upper, the upper half of the bone being nearly straight, the lower half presenting the greatest amount of curvature. The bone is also directed more obliquely backward, which increases the size of the pelvic cavity; but the sacro-vertebral angle projects less. In the male the curvature is more evenly distributed over the whole length of the bone, and is altogether greater than in the female.

Peculiarities of the Sacrum.—This bone, in some cases, consists of six pieces; occasionally, the number is reduced to four. Sometimes the bodies of the first and second segments are not joined or the laminæ and spinous processes have not coalesced. Occasionally the upper pair of transverse tubercles are not joined to the rest of the bone on one or both sides; and, lastly, the sacral canal may be open for nearly the lower half of the bone, in consequence of the imperfect development of the laminæ and spinous processes. The sacrum, also, varies considerably with respect to its degree of curvature. From the examination of a large number of skeletons it would appear that in one set of cases the anterior surface of this bone was nearly straight, the curvature, which was very slight, affecting only its lower end. In another set of cases the bone was curved throughout its whole length, but especially toward its middle. In a third set the degree of curvature was less marked, and affected especially the lower third of the bone.

Development (Fig. 18).—The sacrum, formed by the union of five vertebræ, has *thirty-five* centres of ossification.

The *bodies* of the sacral vertebræ have each three ossific centres: one for the central part, and one for the epiphysial plates on its upper and under surface. Occasionally the primary centres for the bodies of the first and second piece of the sacrum are double.

The arch of each sacral vertebra is developed by two centres, one for each lamina. These unite with each other behind, and subsequently join the body.

The *lateral masses* have six additional centres, two for each of the first three vertebræ. These centres make their appearance above and to the outer side of the anterior sacral foramina (Fig. 18), and are developed into separate segments

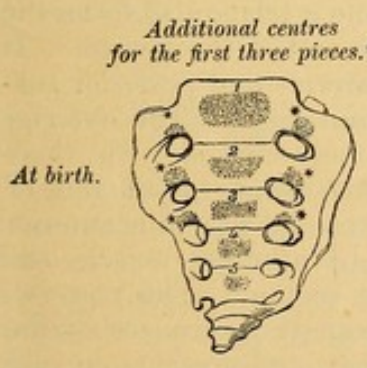

FIG. 18.—Development of the sacrum.

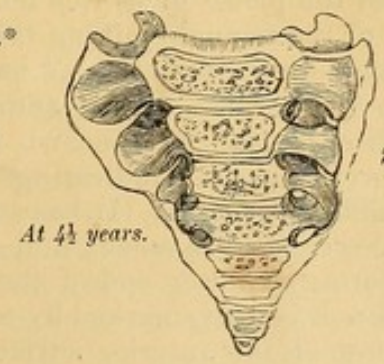

FIG. 19.

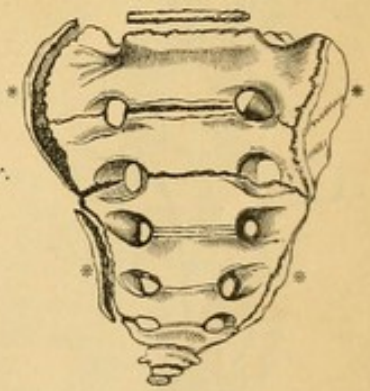

FIG. 20.

(Fig. 19); they are subsequently blended with each other, and with the bodies and transverse processes to form the lateral mass.

Lastly, each *lateral surface* of the sacrum is developed by two epiphysial plates (Fig. 20): one for the auricular surface, and one for the remaining part of the thin lateral edge of the bone.

Period of Development.—At about the eighth or ninth week of fœtal life ossification of the central part of the bodies of the first three vertebræ commences, and at a somewhat later period that of the last two. Between the sixth and eighth months ossification of the laminæ takes place; and at about the same period the centres for the lateral masses for the first three sacral vertebræ make their appearance. The period at which the arch becomes completed by the junction

of the laminæ with the bodies in front and with each other behind varies in different segments. The junction between the laminæ and the bodies takes place first in the lower vertebræ as early as the second year, but is not effected in the uppermost until the fifth or sixth year. About the sixteenth year the epiphyses for the upper and under surfaces of the bodies are formed, and between the eighteenth and twentieth years those for each lateral surface of the sacrum make their appearance. The bodies of the sacral vertebræ are, during early life, separated from each other by intervertebral disks. But about the eighteenth year the two lowest segments become joined together by ossification extending through the disk. This process gradually extends upward until all the segments become united, and the bone is completely formed from the twenty-fifth to the thirtieth year of life.

Articulations.—With four bones: the last lumbar vertebra, coccyx, and the two innominate bones.

Attachment of Muscles.—To eight pairs: in front, the Pyriformis and Coccygeus, and a portion of the Iliacus to the base of the bone; behind, the Gluteus maximus, Latissimus dorsi, Multifidus spinæ, and Erector spinæ, and sometimes the Extensor coccygis.

The Coccyx.

The **Coccyx** (*κόκκυξ*, cuckoo), so called from having been compared to a cuckoo's beak (Fig. 21), is usually formed of four small segments of bone, the most rudimentary parts of the vertebral column. In each of the first three segments may be traced a rudimentary body, articular and transverse processes; the last piece (sometimes the third) is a mere nodule of bone, without distinct processes. All the segments are destitute of pedicles, laminæ, and spinous processes, and, consequently, of intervertebral foramina and spinal canal. The first segment is the largest; it resembles the lowermost sacral vertebra, and often exists as a separate piece; the last three, diminishing in size from above downward, are usually blended together so as to form a single bone. The gradual diminution in the size of the pieces gives this bone a triangular form, the base of the triangle joining the end of the sacrum. It presents for examination an anterior and posterior surface, two borders, a base, and an apex. The *anterior surface* is slightly concave, and marked with three transverse grooves, indicating the points of junction of the different pieces. It has attached to it the anterior sacro-coccygeal ligament and Levator ani muscle, and supports the lower end of the rectum. The *posterior surface* is convex, marked by transverse grooves similar to those on the anterior surface; and presents on each side a lineal row of tubercles, the rudimentary articular processes of the coccygeal vertebræ. Of these, the superior pair are large, and are called the *cornua of the coccyx;* they project upward, and articulate with the cornua of the sacrum, the junction between these two bones completing the fifth posterior sacral foramen for the transmission of the posterior division of the fifth sacral nerve. The *lateral borders* are thin, and present a series of small eminences, which represent the transverse processes of the coccygeal vertebræ. Of these, the first on each side is the largest, flattened from before backward, and often ascends to join the lower part of the thin lateral edge of the sacrum, thus completing the fifth anterior sacral foramen for the transmission of the anterior division of the fifth sacral nerve; the others diminish in size from above downward, and are often wanting. The *borders*

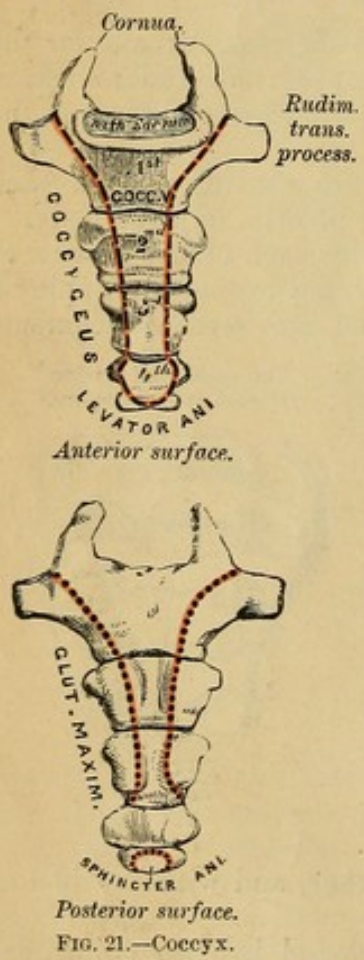

Anterior surface.

Posterior surface.

FIG. 21.—Coccyx.

of the coccyx are narrow, and give attachment on each side to the sacro-sciatic ligaments, to the Coccygeus muscles in front of the ligaments, and to the Gluteus maximus behind them. The *base* presents an oval surface for articulation with the sacrum. The *apex* is rounded, and has attached to it the tendon of the external Sphincter muscle. It is occasionally bifid, and sometimes deflected to one or other side.

Development.—The coccyx is developed by *four* centres, one for each piece. Occasionally one of the first three pieces of this bone is developed by two centres, placed side by side. The ossific nuclei make their appearance in the following order: in the first segment, shortly after birth; in the second piece, at from five to ten years; in the third, from ten to fifteen years; in the fourth, from fifteen to twenty years. As age advances these various segments become united with each other from below upward, the union between the first and second segments being frequently delayed until after the age of twenty-five or thirty. At a late period of life, especially in females, the coccyx often becomes joined to the end of the sacrum.

Articulation.—With the sacrum.

Attachment of Muscles.—To four pairs and one single muscle: on either side, the Coccygeus; behind, the Gluteus maximus and Extensor coccygis, when present; at the apex, the Sphincter ani; and in front, the Levator ani.

The Spine in General.

The **Spinal Column**, formed by the junction of the vertebræ, is situated in the median line, at the posterior part of the trunk; its average length is about two feet two or three inches, measuring along the curved anterior surface of the column. Of this length the cervical part measures about five, the dorsal about eleven, the lumbar about seven inches, and the sacrum and coccyx the remainder. The female spine is about one inch less than that of the male.

Viewed in front, it presents two pyramids joined together at their bases, the upper one being formed by all the vertebræ from the second cervical to the last lumbar, the lower one by the sacrum and coccyx. When examined more closely, the upper pyramid is seen to be formed of three smaller pyramids. The uppermost of these consists of the six

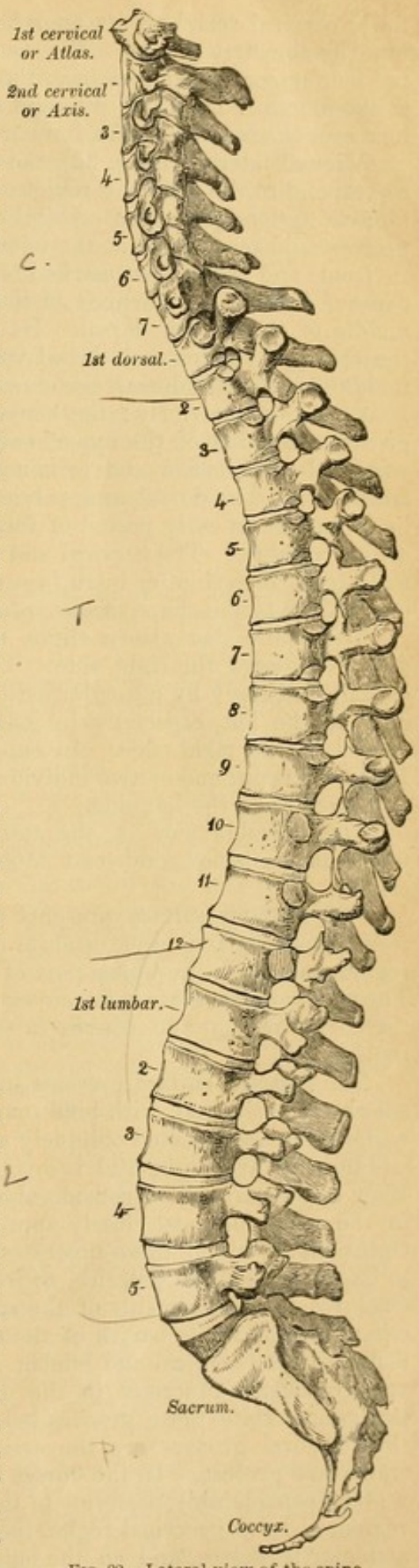

FIG. 22.—Lateral view of the spine.

lower cervical vertebræ, its apex being formed by the axis or second cervical, its base by the first dorsal. The second pyramid, which is inverted, is formed by the four upper dorsal vertebræ, the base being at the first dorsal, the smaller end at the fourth. The third pyramid commences at the fourth dorsal, and gradually increases in size to the fifth lumbar.

Viewed laterally (Fig. 22), the spinal column presents several curves, which correspond to the different regions of the column, and are called *cervical*, *dorsal*, *lumbar*, and *pelvic*. The *cervical* curve commences at the apex of the odontoid process, and terminates at the middle of the second dorsal vertebra; it is convex in front, and is the least marked of all the curves. The *dorsal* curve, which is concave forward, commences at the middle of the second, and terminates at the middle of the twelfth dorsal. Its most prominent point behind corresponds to the spine of the seventh dorsal vertebra. The *lumbar* curve commences at the middle of the last dorsal vertebra, and terminates at the sacro-vertebral angle. It is convex anteriorly; the convexity of the lower three vertebræ being much greater than that of the upper two. The *pelvic* curve commences at the sacro-vertebral articulation and terminates at the point of the coccyx. It is concave anteriorly. The dorsal and pelvic curves are the primary curves, and begin to be formed at an early period of fœtal life, and are due to the shape of the bodies of the vertebræ. The cervical and lumbar curves are compensatory or secondary, and are developed after birth in order to maintain the erect position. They are due mainly to the shape of the intervertebral disks.

The spine has also a slight lateral curvature, the convexity of which is directed toward the right side. This is most probably produced, as Bichat first explained, chiefly by muscular action, most persons using the right arm in preference to the left, especially in making long-continued efforts, when the body is curved to the right side. In support of this explanation it has been found by Béclard that in one or two individuals who were left-handed the lateral curvature was directed to the left side.

The movable part of the spinal column presents for examination an anterior, a posterior, and two lateral surfaces; a base, a summit, and spinal canal.

The **anterior surface** presents the bodies of the vertebræ separated in the recent state by the intervertebral disks. The bodies are broad in the cervical region, narrow in the upper part of the dorsal, and broadest in the lumbar region. The whole of this surface is convex transversely, concave from above downward in the dorsal region, and convex in the same direction in the cervical and lumbar regions.

The **posterior surface** presents in the median line the spinous processes. These are short, horizontal, with bifid extremities, in the cervical region. In the dorsal region they are directed obliquely above, assume almost a vertical direction in the middle, and are horizontal below, as are also the spines of the lumbar vertebræ. They are separated by considerable intervals in the loins, by narrower intervals in the neck, and are closely approximated in the middle of the dorsal region. Occasionally one of these processes deviates a little from the median line—a fact to be remembered in practice, as irregularities of this sort are attendant also on fractures or displacements of the spine. On either side of the spinous processes, extending the whole length of the column, is the vertebral groove formed by the laminæ in the cervical and lumbar regions, where it is shallow, and by the laminæ and transverse processes in the dorsal region, where it is deep and broad. In the recent state these grooves lodge the deep muscles of the back. External to the vertebral grooves are the articular processes, and still more externally the transverse process. In the dorsal region the latter processes stand backward, on a plane considerably posterior to the same processes in the cervical and lumbar regions. In the cervical region the transverse processes are placed in front of the articular processes, and on the outer side of the pedicles, between the interver-

tebral foramina. In the dorsal region they are posterior to the pedicles, intervertebral foramina, and articular processes. In the lumbar they are placed also in front of the articular processes, but behind the intervertebral foramina.

The **lateral surfaces** are separated from the posterior by the articular processes in the cervical and lumbar regions, and by the transverse processes in the dorsal. These surfaces present in front the sides of the bodies of the vertebræ, marked in the dorsal region by the facets for articulation with the heads of the ribs. More posteriorly are the intervertebral foramina, formed by the juxtaposition of the intervertebral notches, oval in shape, smallest in the cervical and upper part of the dorsal regions, and gradually increasing in size to the last lumbar. They are situated between the transverse processes in the neck, and in front of them in the back and loins, and transmit the spinal nerves.

The **base** of that portion of the vertebral column formed by the twenty-four movable vertebræ is formed by the under surface of the body of the fifth lumbar vertebra; and the **summit** by the upper surface of the atlas.

The **vertebral** or **spinal canal** follows the different curves of the spine; it is largest in those regions in which the spine enjoys the greatest freedom of movement, as in the neck and loins, where it is wide and triangular; and narrow and rounded in the back, where motion is more limited.

Surface Form.—The only part of the vertebral column which lies closely under the skin, and so directly influences surface form, is the apices of the spinous processes. These are always distinguishable at the bottom of a median furrow, which, more or less evident, runs down the mesial line of the back from the external occipital protuberance above to the middle of the sacrum below. In the neck the furrow is broad, and terminates in a conspicuous projection, which is caused by the spinous process of the seventh cervical vertebra (vertebra prominens). Above this the spinous process of the sixth cervical vertebra may sometimes be seen to form a projection; the other cervical spines are sunken, and are not visible, though the spine of the axis can be felt, and generally also the spines of the third, fourth, and fifth cervical vertebræ. In the dorsal region the furrow is shallow, and during stooping disappears, and then the spinous processes become more or less visible. The markings produced by these spines are small and close together. In the lumbar region the furrow is deep, and the situation of the lumbar spines is frequently indicated by little pits or depressions, especially if the muscles in the loins are well developed and the spine incurved. They are much larger and farther apart than in the dorsal region. In the sacral region the furrow is shallower, presenting a flattened area which terminates below at the most prominent part of the posterior surface of the sacrum, formed by the spinous process of the third sacral vertebra. At the bottom of the furrow may be felt the irregular posterior surface of the bone. Below this, in the deep groove leading to the anus, the coccyx may be felt. The only other portions of the vertebral column which can be felt from the surface are the transverse processes of three of the cervical vertebræ—viz. the first, the sixth, and the seventh. The transverse process of the atlas can be felt as a rounded nodule of bone just below and in front of the apex of the mastoid process, along the anterior border of the sterno-mastoid. The transverse process of the sixth cervical vertebra is of surgical importance. If deep pressure be made in the neck in the course of the carotid artery, opposite the cricoid cartilage, the prominent anterior tubercle of the transverse process of the sixth cervical vertebra can be felt. This has been named *Chassaignac's tubercle*, and against it the carotid artery may be most conveniently compressed by the finger. The transverse process of the seventh cervical vertebra can also often be felt. Occasionally the anterior root, or costal process, is large and segmented off, forming a cervical rib.

Surgical Anatomy.—Occasionally the coalescence of the laminæ is not completed, and consequently a cleft is left in the arches of the vertebræ, through which a protrusion of the spinal membranes (dura mater and arachnoid), and sometimes of the spinal cord itself, takes place, constituting a malformation known as *spina bifida*. This disease is most common in the lumbo-sacral region; but it may occur in the dorsal or cervical region, or the arches throughout the whole length of the canal may remain unapproximated. In some rare cases, in consequence of the non-coalescence of the two primary centres from which the body is formed, a similar condition may occur in front of the canal, the bodies of the vertebræ being found cleft and the tumor projecting into the thorax, abdomen, or pelvis, between the lateral halves of the bodies affected.

The construction of the spinal column of a number of pieces, securely connected together and enjoying only a slight degree of movement between any two individual pieces, though permitting of a very considerable range of movement as a whole, allows a sufficient degree of mobility without any material diminution of strength. The many joints of which the spine is composed, together with the very varied movements to which it is subjected, render it liable to

sprains; but so closely are the individual vertebræ articulated that these sprains are rarely or ever severe, and any amount of violence sufficiently great to produce tearing of the ligaments would tend rather to cause a dislocation or fracture. The further safety of the column and its less liability to injury is provided for by its disposition in curves, instead of in one straight line. For it is an elastic column, and must first bend before it breaks: under these circumstances, being made up of three curves, it represents three columns, and greater force is required to produce bending of a short column than of a longer one that is equal to it in breadth and material. Again, the safety of the column is provided for by the interposition of the intervertebral disk between the bodies of the vertebræ, which act as admirable buffers in counteracting the effects of violent jars or shocks. Fracture-dislocation of the spine may be caused by direct or indirect violence, or by a combination of the two, as when a person, falling from a height, strikes against some prominence and is doubled over it. The fractures from indirect violence are the more common, and here the bodies of the vertebræ are compressed, whilst the arches are torn asunder; whilst in fractures from direct violence the arches are compressed and the bodies of the vertebræ separated from each other. It will therefore be seen that in both classes of injury the spinal marrow is the part least likely to be injured, and may escape damage even where there has been considerable lesion of the bony framework. For, as Mr. Jacobson states, "being lodged in the centre of the column, it occupies neutral ground in respect to forces which might cause fracture. For it is a law in mechanics that when a beam, as of timber, is exposed to breakage and the force does not exceed the limits of the strength of the material, one division resists compression, another laceration of the particles, while the third, between the two, is in a negative condition."[1] Applying this principle to the spine, it will be seen that, whether the fracture-dislocation be produced by direct violence or indirect, one segment, either the anterior or posterior, will be exposed to compression, the other to laceration, and the intermediate part, where the cord is situated, will be in a neutral state. When a fracture-dislocation is produced by indirect violence the displacement is almost always the same, the upper segment being driven forward on the lower, so that the cord is compressed between the body of the vertebra below and the arch of the vertebra above.

The parts of the spine most liable to be injured are (1) the dorsi-lumbar region, for this part is near the middle of the column, and there is therefore a greater amount of leverage, and moreover the portion above is comparatively fixed, and the vertebræ which form it, though much smaller, have nevertheless to bear almost as great a weight as those below; (2) the cervico-dorsal region, because here the flexible cervical portion of the spine joins the more fixed dorsal region; and (3) the atlanto-axial region, because it enjoys an extensive range of movement, and, being near the skull, is influenced by violence applied to the head. In fracture-dislocation it has been proposed to trephine the spine and remove portions of the laminæ and spinous processes. The operation can only be of use when the paralysis is due to the pressure of bone or the effusion of blood, and not to cases, which are by far the most common, where the cord is crushed to a pulp. And even in those cases where the cord is compressed by bone the portion of displaced bone which presses on the cord is generally the body of the vertebra below, and is therefore inaccessible to operation. The operative proceeding is one of great severity, involving an extensive and deep wound and great risk of septic meningitis, and, as the advantages to be derived from it are exceedingly problematical and confined to a very few cases, it is not often resorted to. Trephining has also been resorted to in some cases of paraplegia due to Pott's disease of the spine. Here the paralysis is due to the pressure of inflammatory products, and where this is new scar-tissue, formed by the organization of granulation tissue, its removal has been attended with a very considerable amount of success.

THE SKULL.

The **Skull** is supported on the summit of the vertebral column, and is of an oval shape, wider behind than in front. It is composed of a series of flattened or irregularly shaped bones which, with one exception (the lower jaw), are immovably joined together. It is divided into two parts, the Cranium and the Face, the former of which constitutes a case for the accommodation and protection of the brain, while opening on the face are the orifices of the nose and mouth; between the cranium above and the face below the orbital cavities are situated. The Cranium (*κράνος*, a helmet) is composed of *eight* bones—viz., the *occipital*, two *parietal*, *frontal*, two *temporal*, *sphenoid*, and *ethmoid*. The Face is composed of *fourteen* bones—viz., the two *nasal*, two *superior maxillary*, two *lachrymal*, two *malar*, two *palate*, two *inferior turbinated*, *vomer*, and *inferior maxillary*. The *ossiculi auditûs*, the *teeth*, and *Wormian bones* are not included in this enumeration.

[1] Holmes's *System of Surgery*, vol. i., p. 529, 1883.

- *Skull*, 22 *bones*
  - *Cranium*, 8 *bones*
    - Occipital.
    - Two Parietal.
    - Frontal.
    - Two Temporal.
    - Sphenoid.
    - Ethmoid.
  - *Face*, 14 *bones*
    - Two Nasal.
    - Two Superior Maxillary.
    - Two Lachrymal.
    - Two Malar.
    - Two Palate.
    - Two Inferior Turbinated.
    - Vomer.
    - Inferior Maxillary.

The Hyoid Bone, situated at the root of the tongue and attached to the base of the skull by ligaments, has also to be considered in this section.

THE CRANIUM.

The Occipital Bone.

The **Occipital Bone** (*ob*, *caput*, against the head) is situated at the back part

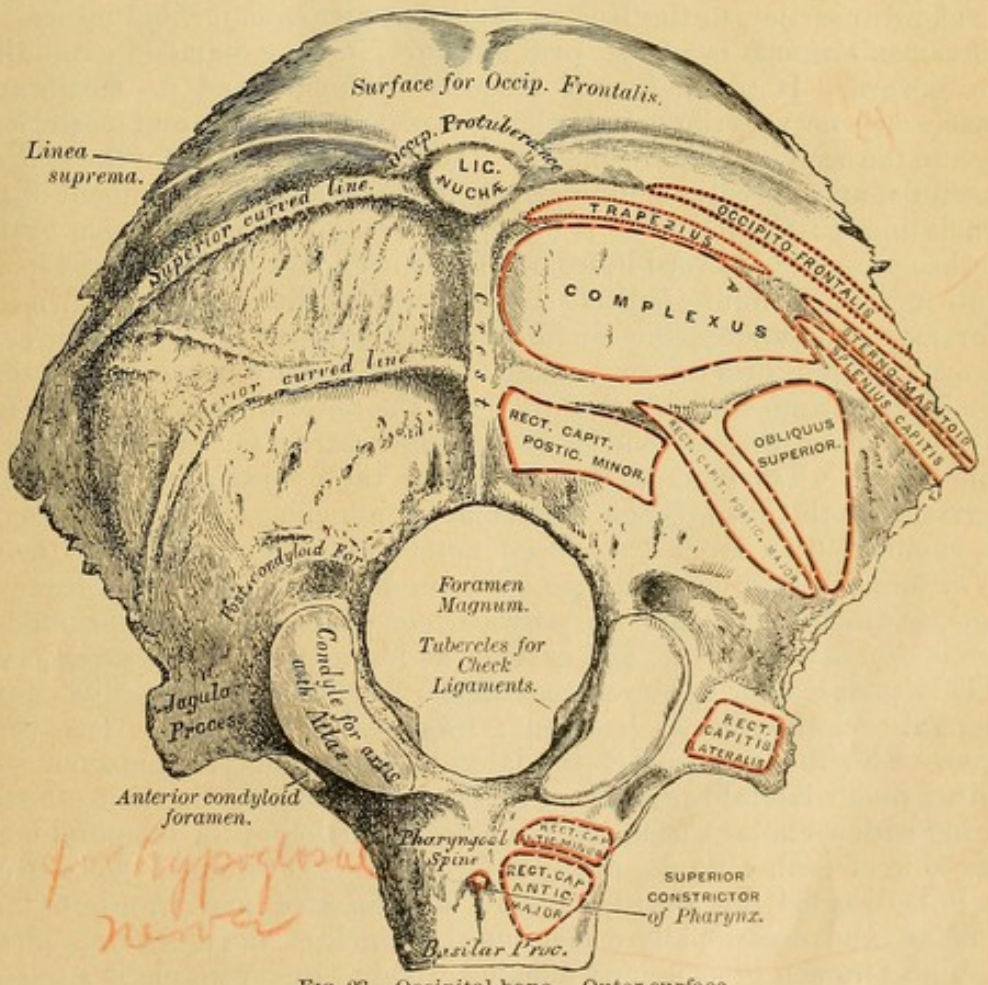

FIG. 23.—Occipital bone. Outer surface.

and base of the cranium, is trapezoid in shape and is much curved on itself (Fig. 23). It presents at its front and lower part a large oval aperture, the *foramen magnum*, by which the cranial cavity communicates with the spinal canal. The portion of bone behind this opening is flat and expanded and forms the *tabula*; the portion in front is a thick, elongated mass of bone, the *basilar process*; while on either side of the foramen are situated processes bearing the

condyles, by which the bone articulates with the atlas. These processes are known as the *condylar portions*. It presents for examination two surfaces, four borders, and four angles.

The **external surface** is convex. Midway between the summit of the bone and the posterior margin of the foramen magnum is a prominent tubercle, the *external occipital protuberance*, and, descending from it as far as the foramen, a vertical ridge, the *external occipital crest*. This protuberance and crest give attachment to the Ligamentum nuchæ, and vary in prominence in different skulls. Passing outward from the occipital protuberance is a semicircular ridge on each side, the *superior curved line*. Above this line there is often a second less distinctly marked ridge, called the *highest curved line* (*linea suprema*); to it the epicranial aponeurosis is attached. The bone between these two lines is smoother and denser than the rest of the surface. Running parallel with these from the middle of the crest is another semicircular ridge on each side, the *inferior curved lines*. The surface of the bone above the linea suprema is rough and porous, and in the recent state is covered by the Occipito-frontalis muscle, while the superior and inferior curved lines, together with the surfaces of bone between and below them, serve for the attachment of several muscles. The superior curved line gives attachment internally to the Trapezius, externally to the muscular origin of the Occipito-frontalis, and to the Sterno-cleido-mastoid to the extent shown in Fig. 23; the depressions between the curved lines to the Complexus internally, the Splenius capitis and Obliquus capitis superior externally. The inferior curved line and the depressions below it afford insertion to the Rectus capitis posticus, major and minor.

The **foramen magnum** is a large, oval aperture, its long diameter extending from before backward. It transmits the medulla oblongata and its membranes, the spinal accessory nerves, the vertebral arteries, the anterior and posterior spinal arteries, and the occipito-axial ligaments. Its back part is wide for the transmission of the medulla, and the corresponding margin rough for the attachment of the dura mater enclosing it; the fore part is narrower, being encroached upon by the condyles; it has projecting toward it, from below, the odontoid process, and its margins are smooth and bevelled internally to support the medulla oblongata. On each side of the foramen magnum are the *condyles*, for articulation with the atlas; they are convex, oval, or reniform in shape, and directed downward and outward; they converge in front, and encroach slightly upon the anterior segment of the foramen. On the inner border of each condyle is a rough tubercle for the attachment of the ligaments (*check*) which connect this bone with the odontoid process of the axis; whilst external to them is a rough tubercular prominence, the *transverse* or *jugular process*, channelled in front by a deep notch, which forms part of the jugular foramen or foramen lacerum posterius. The under surface of this process presents an eminence which represents the *paramastoid process* of some mammals. The eminence is occasionally large, and extends as low as the transverse process of the atlas. This surface affords attachment to the Rectus capitis lateralis muscle and to the lateral occipito-atlantal ligament; its upper or cerebral surface presents a deep groove which lodges part of the lateral sinus, whilst its external surface is marked by a quadrilateral rough facet, covered with cartilage in the fresh state, and articulating with a similar surface on the petrous portion of the temporal bone. On the outer side of each condyle, near its fore part, is a foramen, the *anterior condyloid*; it is directed downward, outward, and forward, and transmits the hypoglossal nerve, and occasionally a meningeal branch of the ascending pharyngeal artery. This foramen is sometimes double. Behind each condyle is a fossa,[1] sometimes perforated at the bottom by a foramen, the *posterior condyloid*, for the transmission of a vein to the lateral sinus. In front of the foramen magnum is a strong quadrilateral plate of bone, the *basilar process*, wider behind than in front; its under surface, which is rough, presenting in the median line a tubercular ridge,

[1] This fossa presents many variations in size. It is usually shallow, and the foramen small; occasionally wanting on one or both sides. Sometimes both fossa and foramen are large, but confined to one side only; more rarely, the fossa and foramen are very large on both sides.

the *pharyngeal spine*, for the attachment of the tendinous raphe and Superior constrictor of the pharynx; and on each side of it rough depressions for the attachment of the Rectus capitis anticus, major and minor.

The **Internal** or **Cerebral Surface** (Fig. 24) is deeply concave. The posterior part or tabulur is divided by a crucial ridge into four fossæ. The two superior fossæ receive the occipital lobes of the cerebrum, and present slight eminences and depressions corresponding to their convolutions. The two inferior, which receive the hemispheres of the cerebellum, are larger than the former, and comparatively smooth; both are marked by slight grooves for the lodgment of arteries. At the point of meeting of the four divisions of the crucial ridge is an eminence, the *internal occipital protuberance*. It nearly corresponds to that on the outer surface, and is perforated by one or more large vascular foramina. From this eminence the superior division of the crucial ridge runs upward to the superior angle of the bone; it presents a deep groove for the superior longitudinal sinus, the margins of which give attachment to the falx cerebri. The inferior division, the *internal occipital crest*, runs to the posterior margin of the foramen magnum,

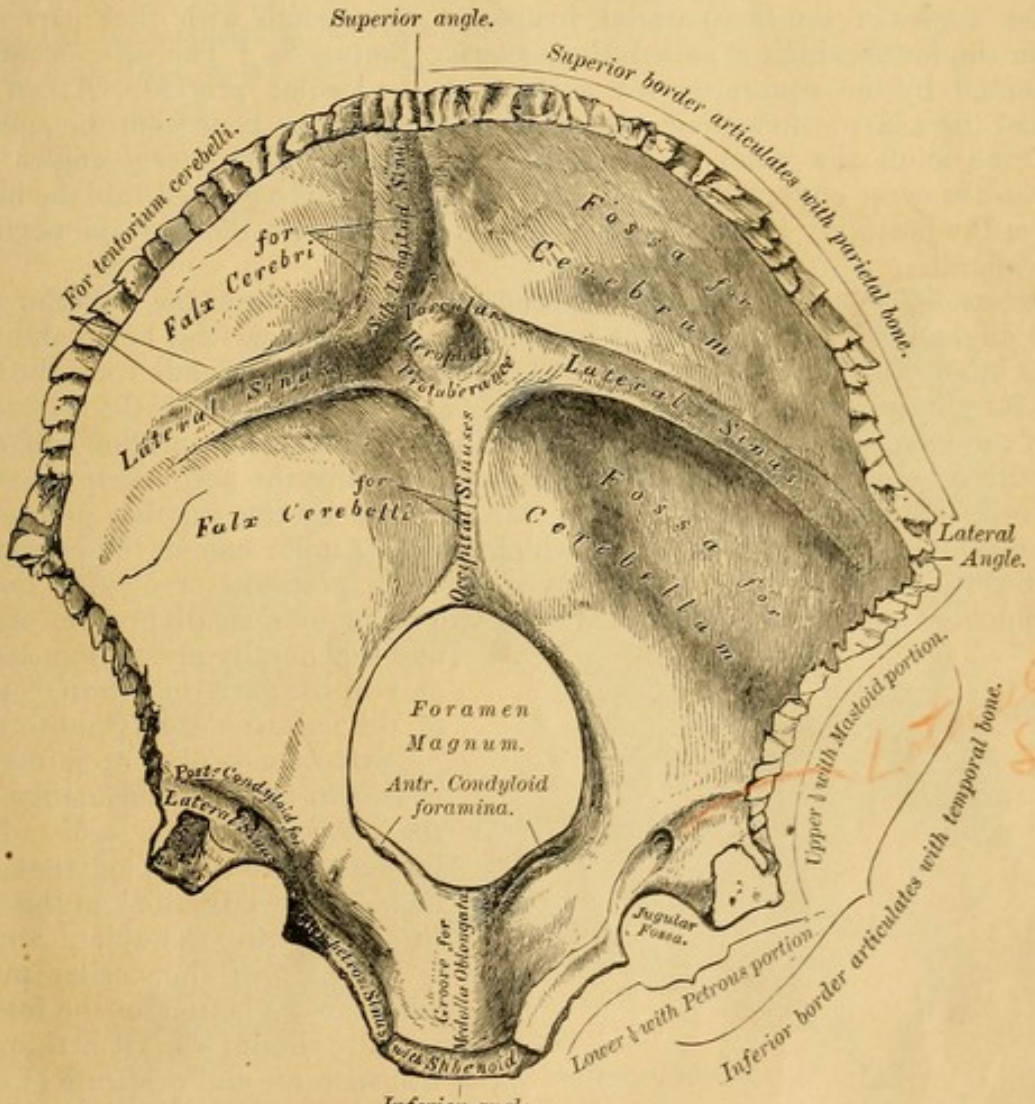

FIG. 24.—Occipital bone. Inner surface

on the edge of which it becomes gradually lost; this ridge, which is bifurcated below, serves for the attachment of the falx cerebelli. It is usually marked by a single groove, which commences at the back part of the foramen magnum and lodges the occipital sinus. Occasionally the groove is double where two sinuses exist. The transverse grooves pass outward to the lateral angles; they are deeply channelled for the lodgment of the lateral sinuses, their prominent margins afford-

ing attachment to the tentorium cerebelli.[1] At the point of meeting of these grooves is a depression, the *torcular Herophili*,[2] placed a little to one or the other side of the internal occipital protuberance. More anteriorly is the foramen magnum, and on each side of it, but nearer its anterior than its posterior part, the internal openings of the anterior condyloid foramen; the internal openings of the posterior condyloid foramina are a little external and posterior to them, protected by a small arch of bone. At this part of the internal surface there is a very deep groove in which the posterior condyloid foramen, when it exists, has its termination. This groove is continuous, in the complete skull, with the transverse groove on the posterior part of the bone, and lodges the end of the same sinus, the lateral. In front of the foramen magnum is the basilar process, presenting a shallow depression, the *basilar groove*, which slopes from behind, upward and forward, and supports the medulla oblongata and part of the pons Varolii, and on each side of the basilar process is a narrow channel, which, when united with a similar channel on the petrous portion of the temporal bone, forms a groove which lodges the inferior petrosal sinus.

Angles.—The *superior* angle is received into the interval between the posterior superior angles of the two parietal bones: it corresponds with that part of the skull in the fœtus which is called the *posterior fontanelle*. The *inferior* angle is represented by the square-shaped surface of the basilar process. At an early period of life a layer of cartilage separates this part of the bone from the sphenoid, but in the adult the union between them is osseous. The *lateral* angles correspond to the outer ends of the transverse grooves, and are received into the interval between the posterior inferior angles of the parietal and the mastoid portion of the temporal.

Borders.—The *superior* border extends on each side from the superior to the lateral angle, is deeply serrated for articulation with the parietal bone, and forms, by this union, the lambdoid suture. The *inferior* border extends from the lateral to the inferior angle; its upper half is rough, and articulates with the mastoid portion of the temporal, forming the masto-occipital suture; the inferior half articulates with the petrous portion of the temporal, forming the petro-occipital suture; these two portions are separated from one another by the jugular process. In front of this process is a deep notch, which, with a similar one on the petrous portion of the temporal, forms the *foramen lacerum posterius* or *jugular foramen*. This notch is occasionally subdivided into two parts by a small process of bone, and it generally presents an aperture at its upper part, the internal opening of the posterior condyloid foramen.

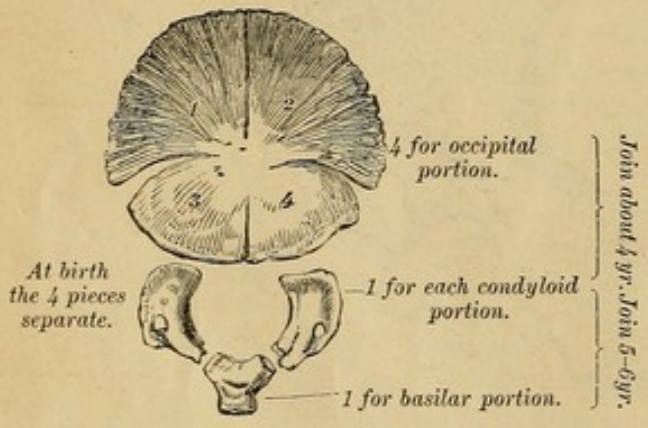

FIG. 25.—Development of occipital bone. By seven centres.

Structure.—The occipital bone consists of two compact laminæ, called the *outer* and *inner tables*, having between them the diploic tissue; this bone is especially thick at the ridges, protuberances, condyles, and anterior part of the basilar process; while at the bottom of the fossæ, especially the inferior, it is thin, semi-transparent, and destitute of diploë.

Development (Fig. 25).—At birth the bone consists of four distinct parts: a *tabular* or expanded portion, which lies behind the foramen magnum; two *condylar* parts, which form the sides of the foramen; and a *basilar* part, which lies in front of the foramen. The number of nuclei for the tabular part vary. As

[1] Usually one of the transverse grooves is deeper and broader than the other; occasionally, both grooves are of equal depth and breadth, or both equally indistinct. The broader of the two transverse grooves is nearly always continuous with the vertical groove for the superior longitudinal sinus.

[2] The columns of blood coming in different directions were supposed to be *pressed* together at this point (*torcular*, a wine-press).

a rule, there are four, but there may be only one (Blandin) or as many as eight (Meckel). They appear about the eighth week of fœtal life, and soon unite to form a single piece, which is, however, fissured in the direction indicated in the figure. The basilar and two condyloid portions are each developed from a single nucleus, which appears a little later. The upper portion of the tabular surface—that is to say, the portion above the transverse fissure—is developed from membrane, and may remain separated from the rest of the bone throughout life, when it constitutes the *interparietal bone;* the rest of the bone is developed from cartilage. At about the fourth year the tabular and the two condyloid pieces join, and about the sixth year the bone consists of a single piece. At a later period, between the eighteenth and twenty-fifth years, the occipital and sphenoid become united, forming a single bone.

Articulations.—With six bones: two parietal, two temporal, sphenoid, and atlas.

Attachment of Muscles.—To twelve pairs: to the superior curved line are attached the Occipito-frontalis, Trapezius, and Sterno-cleido-mastoid. To the space between the curved lines, the Complexus,[1] Splenius capitis, and Obliquus capitis superior; to the inferior curved line, and the space between it and the foramen magnum, the Rectus capitis posticus, major and minor; to the transverse process, the Rectus capitis lateralis; and to the basilar process, the Rectus capitis anticus, major and minor, and Superior constrictor of the pharynx.

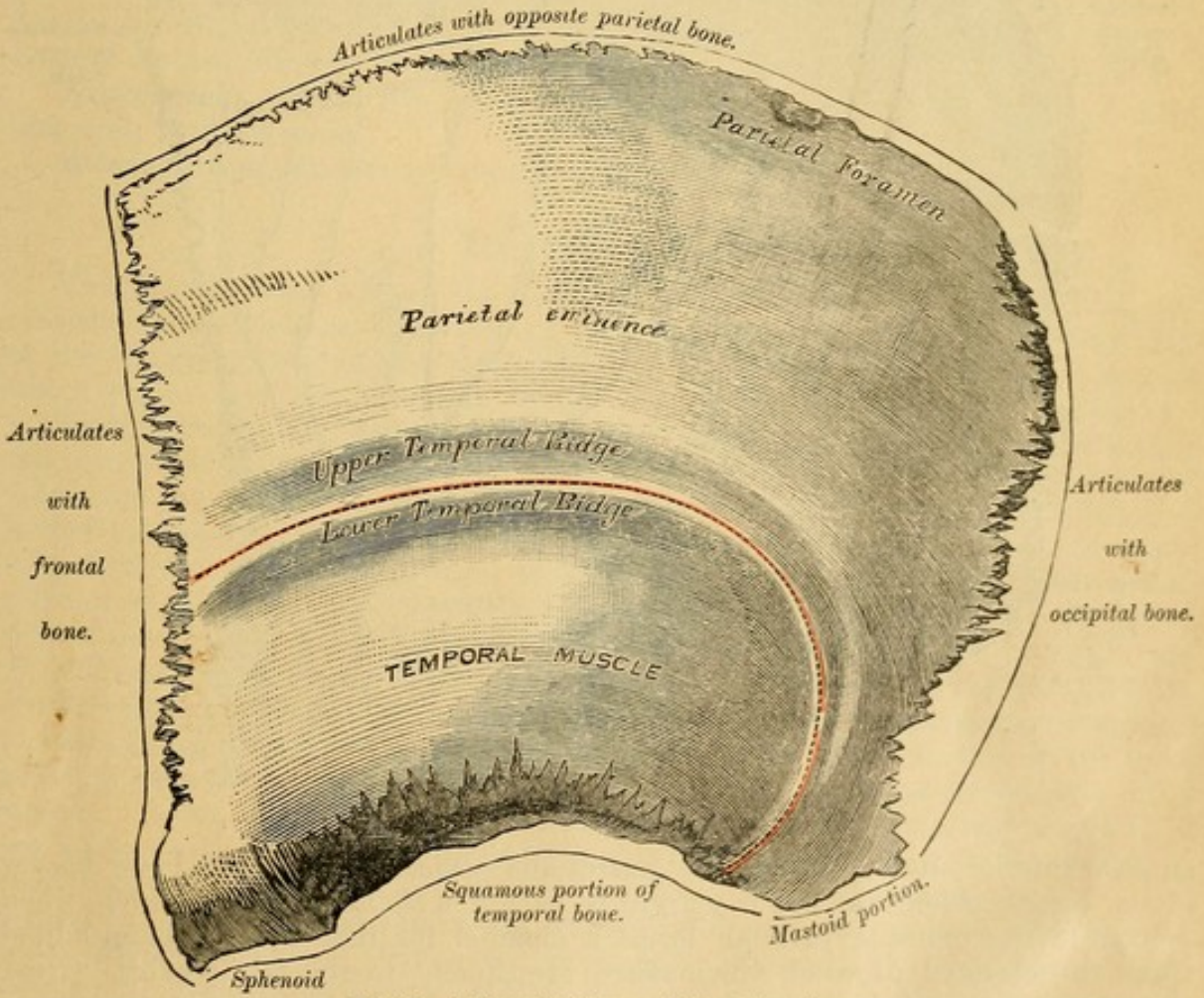

FIG. 26.—Left parietal bone. External surface.

The Parietal Bones.

The **Parietal Bones** (*paries*, a wall) form, by their union, the sides and roof of the skull. Each bone is of an irregular quadrilateral form, and presents for examination two surfaces, four borders, and four angles.

[1] To these the Biventer cervicis should be added, if it is regarded as a separate muscle.

Surfaces.—The *external surface* (Fig. 26) is convex, smooth, and marked about its centre by an eminence called the *parietal eminence*, which indicates the point where ossification commenced. Crossing the middle of the bone in an arched direction are two well-marked curved lines or ridges, the *upper* and *lower temporal ridges;* the former gives attachment to the temporal fascia, while the latter indicates the upper limit of the origin of the temporal muscle. Above these ridges the surface of the bone is rough and porous, and covered by the aponeurosis of the Occipito-frontalis; between them the bone is smoother and more polished than the rest; below them the bone forms part of the temporal fossa, and affords attachment to the temporal muscle. At the back part of the superior border, close to the sagittal suture, is a small foramen, the *parietal foramen*, which transmits a vein to the superior longitudinal sinus, and sometimes a small branch of the occipital artery. Its existence is not constant, and its size varies considerably.

The **internal surface** (Fig. 27), concave, presents depressions for lodging the convolutions of the cerebrum and numerous furrows for the ramifications of the middle meningeal artery; the latter runs upward and backward from the

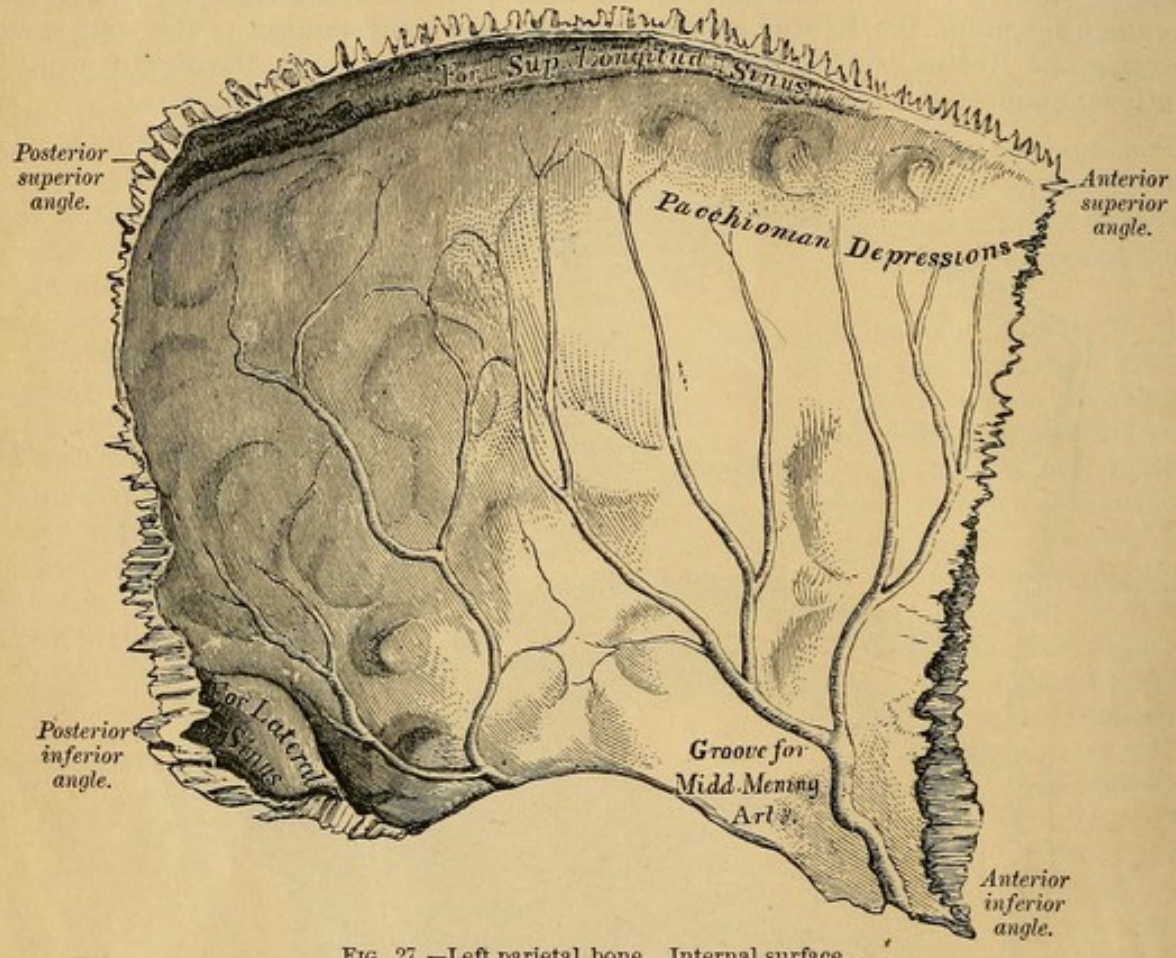

FIG. 27.—Left parietal bone. Internal surface.

anterior inferior angle and from the central and posterior part of the lower border of the bone. Along the upper margin is part of a shallow groove, which, when joined to the opposite parietal, forms a channel for the superior longitudinal sinus, the elevated edges of which afford attachment to the falx cerebri. Near the groove are seen several depressions, especially in the skulls of old persons; they lodge the Pacchionian bodies. The internal opening of the parietal foramen is also seen when that aperture exists.

Borders.—The *superior*, the longest and thickest, is dentated to articulate with its fellow of the opposite side, forming the sagittal suture. The *inferior* is divided into three parts: of these, the anterior is thin and pointed, bevelled at the expense of the outer surface, and overlapped by the tip of the great wing of the sphenoid; the middle portion is arched, bevelled at the expense of the outer surface, and

overlapped by the squamous portion of the temporal; the posterior portion is thick and serrated for articulation with the mastoid portion of the temporal. The *anterior* border, deeply serrated, is bevelled at the expense of the outer surface above and of the inner below; it articulates with the frontal bone, forming the *coronal suture*. The *posterior* border, deeply denticulated, articulates with the occipital, forming the *lambdoid suture*.

Angles.—The *anterior superior* angle, thin and pointed, corresponds with that portion of the skull which in the fœtus is membranous and is called the *anterior fontanelle*. The *anterior inferior* angle is thin and lengthened, being received in the interval between the great wing of the sphenoid and the frontal. Its inner surface is marked by a deep groove, sometimes a canal, for the anterior branch of the middle meningeal artery. The *posterior superior* angle corresponds with the junction of the sagittal and lambdoid sutures. In the fœtus this part of the skull is membranous, and is called the *posterior fontanelle*. The *posterior inferior* angle articulates with the mastoid portion of the temporal bone, and generally presents on its inner surface a broad, shallow groove for lodging part of the lateral sinus.

Development.—The parietal bone is formed in membrane, being developed by *one* centre, which corresponds with the parietal eminence, and makes its first appearance about the seventh or eighth week of fœtal life. Ossification gradually extends from the centre to the circumference of the bone: the angles are consequently the parts last formed, and it is in their situation that the fontanelles exist previous to the completion of the growth of the bone. Occasionally the parietal bone is divided into two parts, upper and lower, by an antero-posterior suture.

Articulations.—With five bones: the opposite parietal, the occipital, frontal, temporal, and sphenoid.

Attachment of Muscles.—One only, the Temporal.

The Frontal Bone.

The **Frontal Bone** (*frons*, the forehead) resembles a cockle-shell in form, and consists of two portions—a *vertical* or *frontal* portion situated at the anterior part of the cranium, forming the forehead; and a *horizontal* or *orbito-nasal* portion which enters into the formation of the roof of the orbits and nasal fossæ.

Vertical Portion.—*External Surface* (Fig. 28).—In the median line, traversing the bone from the upper to the lower part, is occasionally seen a slightly-elevated ridge, and in young subjects a suture, which represents the line of union of the two lateral halves of which the bone consists at an early period of life; in the adult this suture is usually obliterated and the bone forms one piece; traces of the obliterated suture are, however, generally perceptible at the lower part. On either side of this ridge, a little below the centre of the bone, is a rounded eminence, the *frontal eminence*. These eminences vary in size in different individuals, and are occasionally unsymmetrical in the same subject. They are especially prominent in cases of well-marked cerebral development. The whole surface of the bone above this part is smooth, and covered by the aponeurosis of the Occipito-frontalis muscle. Below the frontal eminence, and separated from it by a slight groove, is the *superciliary ridge*, broad internally, where it is continuous with the nasal eminence, but less distinct as it arches outward. These ridges are caused by the projection outward of the frontal air sinuses,[1] and give attachment to the Orbicularis palpebrarum and Corrugator supercilii. Between the two superciliary ridges is a smooth surface, the *glabella* or *nasal eminence*. Beneath the superciliary ridge is the *supraorbital arch*, a curved and prominent margin, which forms

[1] Some confusion is occasioned to students commencing the study of anatomy by the name "sinuses" having been given to two perfectly different kinds of spaces connected with the skull. It may be as well, therefore, to state here, at the outset, that the "sinuses" in the interior of the cranium which produce the grooves on the inner surface of the bones are venous channels along which the blood runs in its passage back from the brain, while the "sinuses" external to the cranial cavity (the frontal, sphenoidal, ethmoidal, and maxillary) are hollow spaces in the bones themselves which communicate with the nostrils, and contain air.

the upper boundary of the orbit and separates the vertical from the horizontal portion of the bone. The outer part of the arch is sharp and prominent, affording to the eye, in that situation, considerable protection from injury; the inner part is less prominent. At the junction of the internal and middle third of this arch is a notch, sometimes converted into foramen, and called the *supraorbital notch* or *foramen*. It transmits the supraorbital artery, vein, and nerve. A small aperture is seen in the upper part of the notch, which transmits a vein from the diploë to join the supraorbital vein. The supraorbital arch terminates externally in the *external angular process* and internally in the *internal angular process*. The external angular process is strong, prominent, and articulates with the malar bone; running upward and backward from it are two well-marked lines, which, commencing together from the external angular process, soon diverge from each other and run in a curved direction across the bone. These are the *upper* and *lower temporal ridges;* the upper gives attachment to the temporal fascia, the

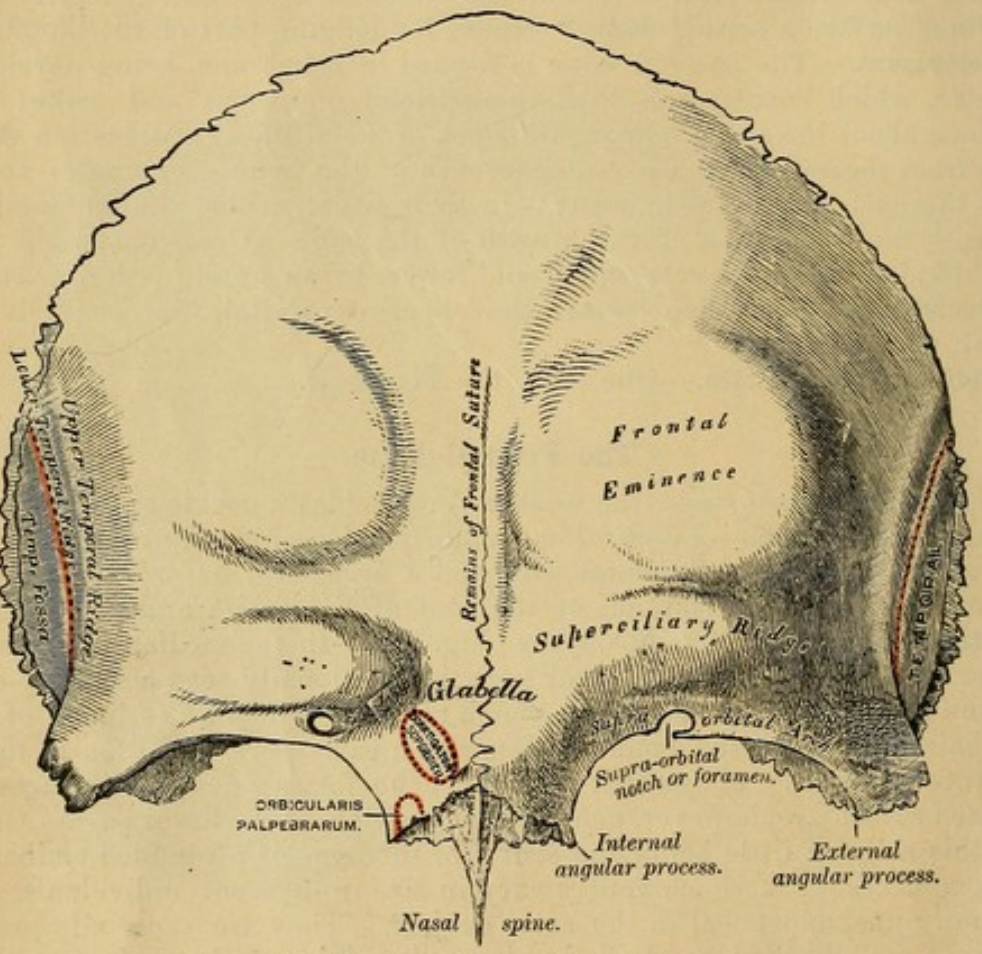

FIG. 28.—Frontal bone. Outer surface.

lower to the temporal muscle. Beneath them is a slight concavity that forms the anterior part of the temporal fossa and gives origin to the Temporal muscle. The internal angular processes are less marked than the external, and articulate with the lachrymal bones. Between the internal angular processes is a rough, uneven interval, the *nasal notch*, which articulates in the middle line with the nasal bone, and on either side with the nasal process of the superior maxillary bone. From the concavity of this notch projects a process, the *nasal process*, which extends beneath the nasal bones and nasal processes of the superior maxillary bones and supports the bridge of the nose. On the under surface of this is a long pointed process, the *nasal spine*, and on either side a small grooved surface enters into the formation of the roof of the nasal fossa. The nasal spine forms part of the septum of the nose, articulating in front with the nasal bones and behind with the perpendicular plate of the ethmoid.

Internal Surface (Fig. 29).—Along the middle line is a vertical groove, the edges of which unite below to form a ridge, the *frontal crest;* the groove lodges the superior longitudinal sinus, whilst its margins afford attachment to the falx cerebri. The crest terminates below at a small notch which is converted into a foramen by articulation with the ethmoid. It is called the *foramen cæcum*, and varies in size in different subjects: it is sometimes partially or completely impervious, lodges a process of the falx cerebri, and when open transmits a vein from the lining membrane of the nose to the superior longitudinal sinus. On either side of the groove the bone is deeply concave, presenting depressions for the convolutions of the brain, and numerous small furrows for lodging the ramifications of the anterior meningeal arteries. Several small, irregular fossæ are seen also on either side of the groove, for the reception of the Pacchionian bodies.

Horizontal Portion.—This portion of the bone consists of two thin plates, *the orbital plates*, which form the vault of the orbit, separated from one another by a median gap, the ethmoidal notch. The *external surface* of each orbital plate consists of a smooth, concave, triangular lamina of bone, marked at its anterior and external part (immediately beneath the external angular

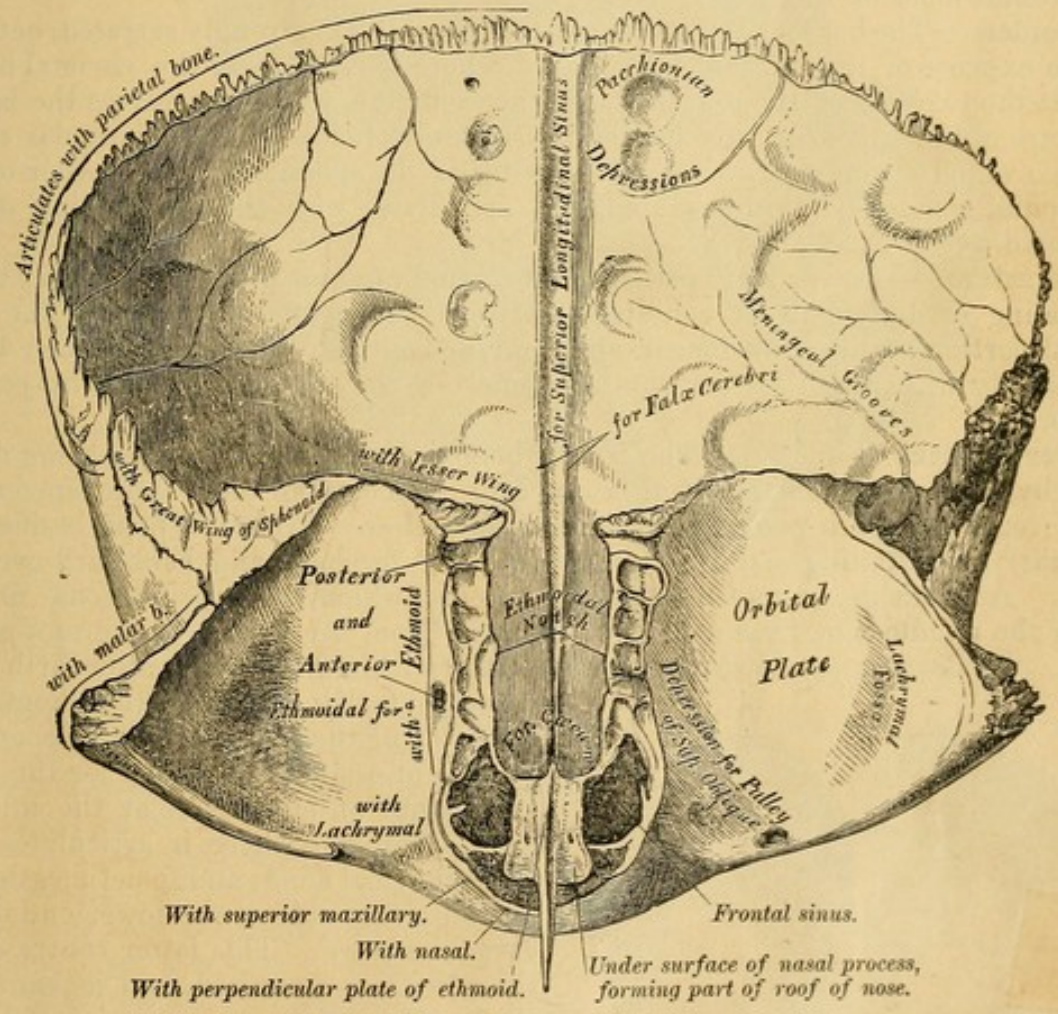

FIG. 29.—Frontal bone. Inner surface.

process) by a shallow depression, the *lachrymal fossa*, for lodging the lachrymal gland; and at its anterior and internal part by a depression (sometimes a small tubercle), the *trochlear fossa*, for the attachment of the cartilaginous pulley of the Superior oblique muscle of the eye. The ethmoidal notch separates the two orbital plates; it is quadrilateral, and filled up, when the bones are united, by the cribriform plate of the ethmoid. The margins of this notch present several half-cells, which, when united with corresponding half-cells on the upper surface of the ethmoid, complete the ethmoidal cells; two grooves are also seen crossing these

edges transversely; they are converted into canals by articulation with the ethmoid, and are called the *anterior* and *posterior ethmoidal* canals: they open on the inner wall of the orbit. The anterior one transmits the nasal nerve and anterior ethmoidal vessels, the posterior one the posterior ethmoidal vessels. In front of the ethmoidal notch, on either side of the nasal spine, are the openings of the frontal sinuses. These are two irregular cavities, which extend upward and outward, a variable distance, between the two tables of the skull, and are separated from one another by a thin, bony septum, which is often displaced to one side. They give rise to the prominences above the supraorbital arches called the *superciliary ridges*. In the child they are generally absent, and they become gradually developed as age advances. These cavities vary in size in different persons, are larger in men than in women, and are frequently of unequal size on the two sides, the right being commonly the larger. They are lined by mucous membrane, and communicate with the nose by the infundibulum, and occasionally with each other by apertures in their septum.

The **internal surface of the horizontal portion** presents the convex upper surfaces of the orbital plates, separated from each other in the middle line by the ethmoidal notch, and marked by eminences and depressions for the convolutions of the frontal lobes of the brain.

Borders.—The border of the vertical portion is thick, strongly serrated, bevelled at the expense of the internal table above, where it rests upon the parietal bones, and at the expense of the external table at each side, where it receives the lateral pressure of those bones; this border is continued below into a triangular rough surface which articulates with the great wing of the sphenoid. The border of the horizontal portion is thin, serrated, and articulates with the lesser wing of the sphenoid.

Structure.—The vertical portion and external angular processes are very thick, consisting of diploic tissue contained between two compact laminæ. The horizontal portion is thin, translucent, and composed entirely of compact tissue; hence the facility with which instruments can penetrate the cranium through this part of the orbit.

Development (Fig. 30).—The frontal bone is formed in membrane, being developed by *two* centres, one for each lateral half, which make their appearance about the seventh or eighth week, above the orbital arches. From this point ossification extends, in a radiating manner, upward into the forehead and backward over the orbit. At birth the bone consists of two pieces, which afterward become united, along the middle line, by a suture which runs from the vertex to the root of the nose. This suture usually becomes obliterated within a few years after birth; but it occasionally remains throughout life, constituting the *metopic* suture. Secondary centres of ossification appear for the nasal spine—one on either side at the internal angular process where it articulates with the lachrymal bone; and sometimes there is one on either side at the lower end of the coronal suture. This latter centre sometimes remains ununited, and is known as the pterion ossicle, or it may join with the parietal, sphenoid, or temporal bone.

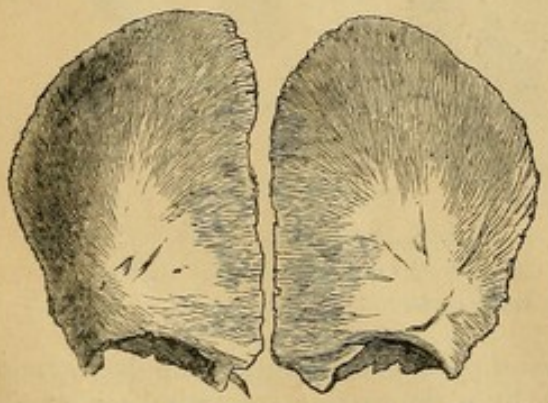

FIG. 30.—Frontal bone at birth. Developed by two lateral halves.

Articulations. — With twelve bones: two parietal, the sphenoid, the ethmoid, two nasal, two superior maxillary, two lachrymal, and two malar.

Attachment of Muscles.—To three pairs: the Corrugator supercilii, Orbicularis palpebrarum, and Temporal, on each side.

The Temporal Bones.

The **Temporal Bones** (*tempus*, time) are situated at the sides and base of the skull, and present for examination a *squamous*, *mastoid*, and *petrous* portion.

The **squamous portion** (*squama*, a scale), the anterior and upper part of the bone, is scale-like in form, and thin and translucent in texture (Fig. 31). Its *outer surface* is smooth, convex, and grooved at its back part for the deep temporal arteries; it affords attachment to the Temporal muscle and forms part of the temporal fossa. At its back part may be seen a curved ridge—part of the *temporal ridge;* it serves for the attachment of the temporal fascia and limits the origin of the Temporal muscle. The boundary between the squamous and mastoid portions

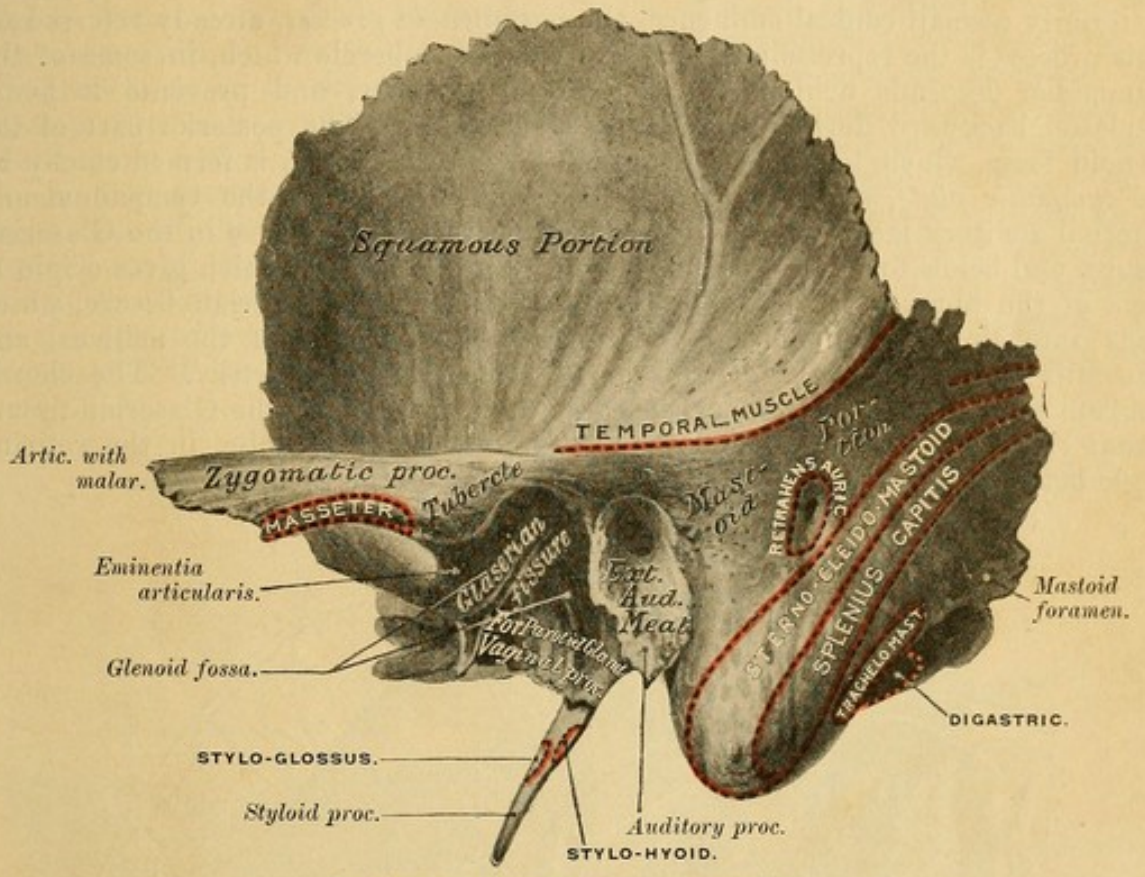

FIG. 31.—Left temporal bone. Outer surface.

of the bone, as indicated by traces of the original suture, lies fully half an inch below this ridge. Projecting from the lower part of the squamous portion is a long, arched process of bone, the *zygoma* or zygomatic process. This process is at first directed outward, its two surfaces looking upward and downward; it then appears as if twisted upon itself, and runs forward, its surfaces now looking inward and outward. The superior border of the process is long, thin, and sharp, and serves for the attachment of the temporal fascia. The inferior, short, thick, and arched, has attached to it some fibres of the Masseter muscle. Its outer surface is convex and subcutaneous; its inner is concave, and also affords attachment to the Masseter. The extremity, broad and deeply serrated, articulates with the malar bone. The zygomatic process is connected to the temporal bone by three divisions, called its *roots*—an anterior, middle, and posterior. The anterior, which is short, but broad and strong, is dir[illegible]ted inward, to terminate in a rounded eminence, the *eminentia articulari[illegible]*, as[illegible] eminence forms the front boundary of the glenoid fossa, and [illegible]ese cells ar[illegible]te is covered with cartilage. The middle root is known as the [illegible]oward the lower [illegible], and is very prominent in young bones. It separates th[illegible] process being quite [illegible] the glenoid fossa from the external auditory meatus, a[illegible]ey are entirely absent, an[illegible]encement of a well-marked fissure, the *Glaserian fis[illegible]*hese may be seen a larg[illegible] which is strongly marked,

runs from the upper border of the zygoma backward over the external auditory meatus. It is termed the *supra-mastoid crest*, and forms the posterior part of the lower temporal ridge. At the junction of the anterior root with the zygoma is a projection, called the *tubercle*, for the attachment of the external lateral ligament of the lower jaw; and between the anterior and middle roots is an oval depression, forming part of the glenoid fossa (γλήνη, a socket), for the reception of the condyle of the lower jaw. This fossa is bounded, in front, by the eminentia articularis; behind, by the tympanic plate, which separates it from the external auditory meatus; it is divided into two parts by a narrow slit, the *Glaserian fissure*. The anterior or mandibular part, formed by the squamous portion of the bone, is smooth, covered in the recent state with cartilage, and articulates with the condyle of the lower jaw. This part of the glenoid fossa presents posteriorly a small conical eminence, the *post-glenoid process*, already referred to. This process is the representative of a prominent tubercle which, in some of the mammalia, descends behind the condyle of the jaw, and prevents it being displaced backward during mastication (Humphry). The posterior part of the glenoid fossa, which lodges a portion of the parotid gland, is formed chiefly by the *tympanic plate*, which constitutes the anterior wall of the tympanum and external auditory meatus. The plate of bone terminates above in the Glaserian fissure, and below forms a sharp edge, the *vaginal* process, which gives origin to some of the fibres of the Tensor palati muscle. The Glaserian fissure, which leads into the tympanum, lodges the processus gracilis of the malleus, and transmits the tympanic branch of the internal maxillary artery. The chorda tympani nerve passes through a separate canal, parallel to the Glaserian fissure (*canal of Huguier*), on the outer side of the Eustachian tube, in the retiring angle between the squamous and petrous portions of the temporal bone.[1]

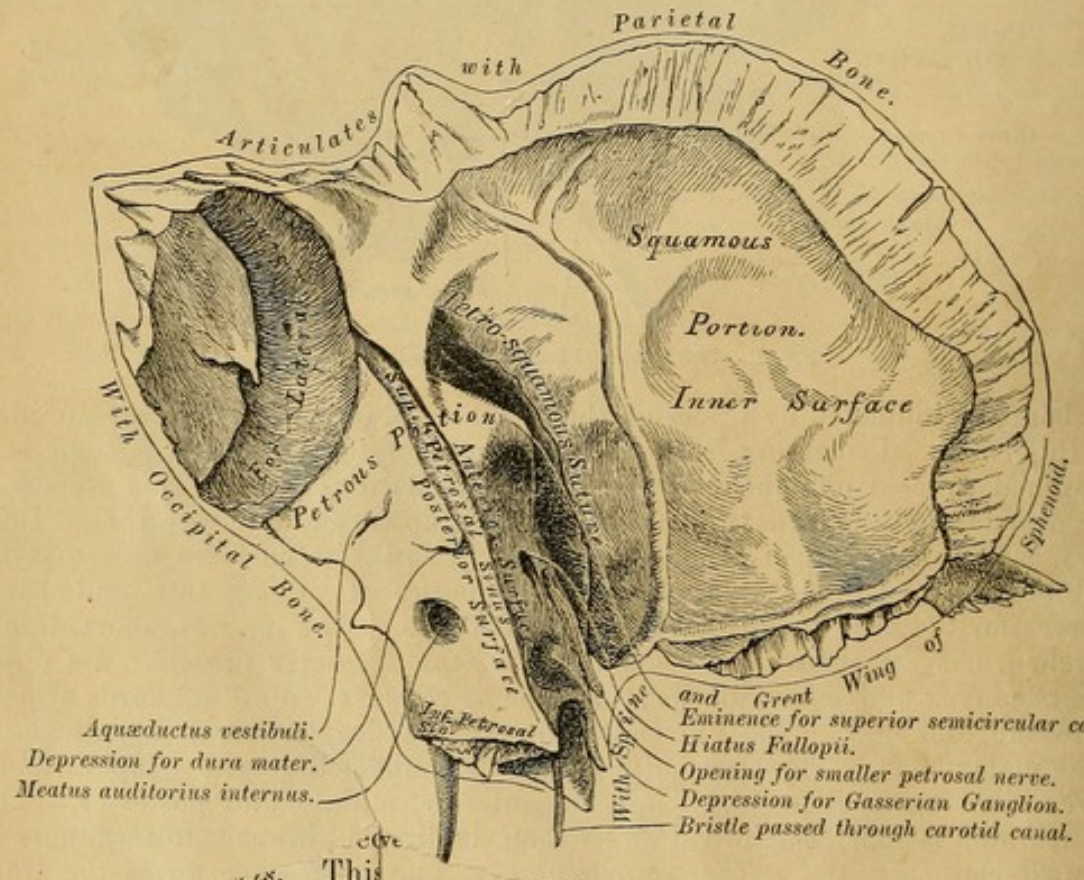

...s. This ... bone Inner surface.
in the recent sta... To three pairs: ...
The *post-glenoid process* ... poral, on each side. ... (Fig. 32) is concave, presents
... mandibular portion of ...
... terminates at the comm... ...l which lies above the Eustachian
...ure. The posterior root, ...

numerous eminences and depressions for the convolutions of the cerebrum, and two well-marked grooves for the branches of the middle meningeal artery.

Borders.—The superior border is thin, bevelled at the expense of the internal surface, so as to overlap the lower border of the parietal bone, forming the squamous suture. The anterior inferior border is thick, serrated, and bevelled, alternately at the expense of the inner and outer surfaces, for articulation with the great wing of the sphenoid.

The **Mastoid Portion** (*μαστός*, a nipple or teat) is situated at the posterior part of the bone; its outer surface is rough, and gives attachment to the Occipito-frontalis and Retrahens aurem muscles. It is perforated by numerous foramina; one of these, of large size, situated at the posterior border of the bone, is termed the *mastoid foramen;* it transmits a vein to the lateral sinus and a small artery from the occipital to supply the dura mater. The position and size of this foramen are very variable. It is not always present; sometimes it is situated in the occipital bone or in the suture between the temporal and the occipital. The mastoid portion is continued below into a conical projection, the *mastoid process*, the size and form of which vary somewhat. This process serves for the attachment of the Sterno-mastoid, Splenius capitis, and Trachelo-mastoid muscles. On the inner side of the mastoid process is a deep groove, the *digastric fossa*, for the attachment of the Digastric muscle; and, running parallel with it, but more internal, the *occipital groove*, which lodges the occipital artery. The internal surface of the mastoid portion presents a deep, curved groove, the *fossa sigmoidea*, which lodges part of the lateral sinus; and into it may be seen opening the mastoid fora-

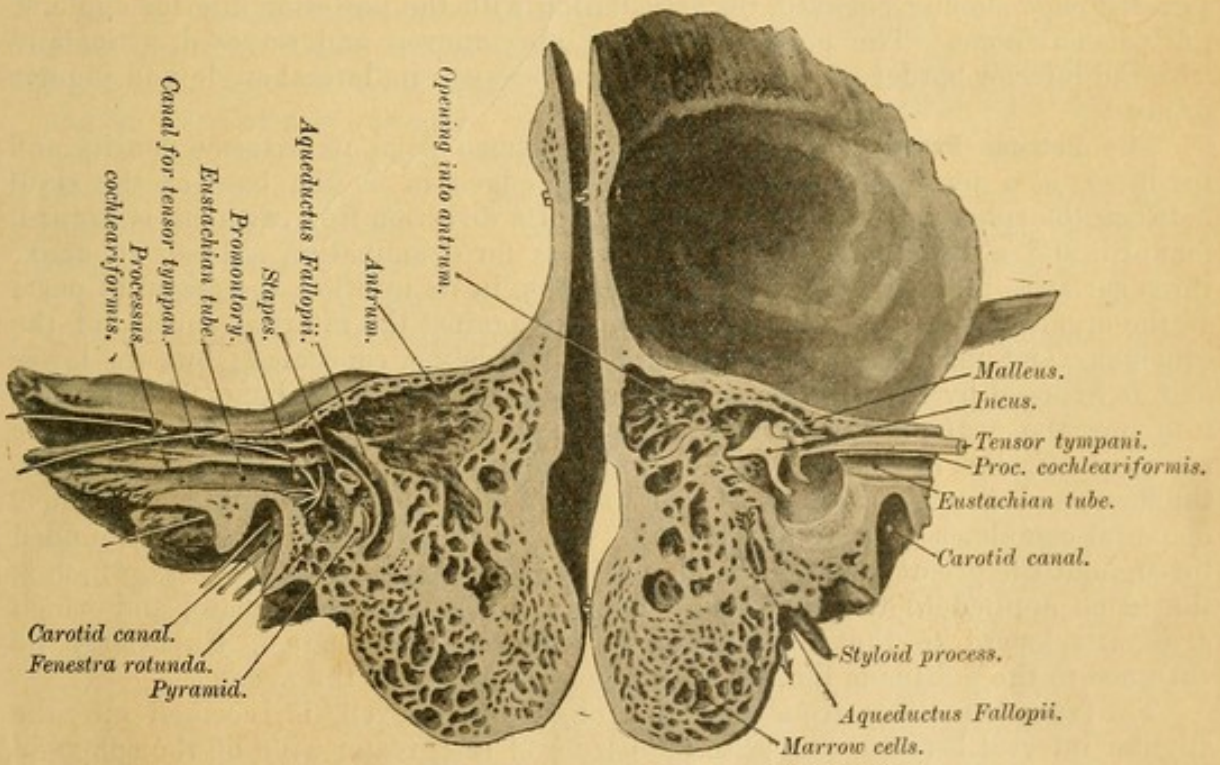

FIG. 33.—Section through the petrous and mastoid portions of the temporal bone, showing the communication of the cavity of the tympanum with the mastoid antrum.

men. The groove for the lateral sinus is separated from the innermost of the mastoid air-cells by only a thin lamina of bone, and even this may be partly deficient. A section of the mastoid process shows it to be hollowed out into a number of cellular spaces, communicating with each other, called the *mastoid cells*, which exhibit the greatest possible variety as to their size and number. At the upper and front part of the bone these cells are large and irregular, and contain air. They diminish in size toward the lower part of the bone, those situated at the apex of the mastoid process being quite small and usually containing marrow. Occasionally they are entirely absent, and the mastoid is solid throughout. In addition to these may be seen a large irregular cavity (Fig. 33),

situated at the upper and front part of the section. It is called the *mastoid antrum*, and must be distinguished from the mastoid cells, though it communicates with them. It is filled with air, and is lined with a prolongation of the mucous membrane of the tympanum, which extends into it through an opening, by which it communicates with the cavity of the tympanum. The mastoid antrum is bounded above by a thin plate of bone, which separates it from the middle fossa of the base of the skull on the anterior surface of the petrous portion of the temporal bone; below by the mastoid process; externally by the squamous portion of the bone just below the supra-mastoid crest; and internally by the external semicircular canal of the internal ear which projects into its cavity. The opening by which it communicates with the tympanum is situated at the superior internal angle of the posterior wall of that cavity, and opens into that portion of the tympanic cavity which is known as the *attic* or *epitympanic recess;* that is to say, that portion of the tympanum which is above the level of the membrana tympani.

The mastoid cells, like the other sinuses of the cranium, are not developed until after puberty; hence the prominence of this process in the adult: the mastoid antrum, on the other hand, is of large size at birth.

In consequence of the communication which exists between the tympanum and mastoid cells, inflammation of the lining membrane of the former cavity may easily travel backward to that of the antrum, leading to caries and necrosis of their walls and the risk of transference of the inflammation to the lateral sinus or encephalon.

Borders.—The superior border of the mastoid portion is broad and rough, its serrated edge sloping outward, for articulation with the posterior inferior angle of the parietal bone. The posterior border, also uneven and serrated, articulates with the inferior border of the occipital bone between its lateral angle and jugular process.

The **Petrous Portion** (*πέτρος*, a stone), so named from its extreme density and hardness, is a pyramidal process of bone wedged in at the base of the skull between the sphenoid and occipital bones. Its direction from without is inward, forward, and a little downward. It presents for examination a base, an apex, three surfaces, and three borders, and contains, in its interior, the essential parts of the organ of hearing. The *base* is applied against the internal surface of the squamous and mastoid portions, its upper half being concealed; but its lower half is exposed by the divergence of those two portions of the bone, which brings into view the oval expanded orifice of a canal leading into the tympanum, the *meatus auditorius externus*. The curved tympanic plate forms the anterior wall, the floor, and a part of the posterior wall of this meatus, while the squamous temporal completes it above and behind. The entrance to the meatus is bounded throughout the greater part of its circumference by the *auditory process*, which is the name applied to the free rough margin of the tympanic plate, and which gives attachment to the cartilaginous portion of the meatus. Superiorly the entrance to the meatus is limited by the posterior root of the zygoma.

The **apex** of the petrous portion, rough and uneven, is received into the angular interval between the posterior border of the greater wing of the sphenoid and the basilar process of the occipital; it presents the anterior or internal orifice of the carotid canal, and forms the posterior and external boundary of the foramen lacerum medium.

The **anterior surface** of the petrous portion (Fig. 32) forms the posterior part of the middle fossa of the skull. This surface is continuous with the squamous portion, to which it is united by a suture, the *petro-squamous suture*, the remains of which are distinct even at a late period of life. It presents six points for examination: 1, an eminence near the centre, which indicates the situation of the superior semicircular canal; 2, in front and a little to the outer side of this eminence a depression indicating the position of the tympanum; here the layer of bone which separates the tympanum from the cranial cavity is extremely thin, and is known as the *tegmen tympani;* 3, a shallow groove, sometimes

double, leading outward and backward to an oblique opening, the *hiatus Fallopii*, for the passage of the greater petrosal nerve and the petrosal branch of the middle meningeal artery; 4, a smaller opening, occasionally seen external to the latter, for the passage of the smaller petrosal nerve; 5, near the apex of the bone, the termination of the carotid canal, the wall of which in this situation is deficient in front; 6, above this canal a shallow depression for the reception of the Gasserian ganglion.

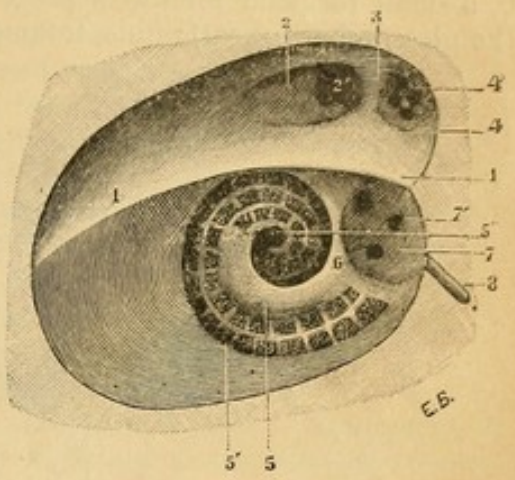

FIG. 34.—Diagrammatic view of the Fundus of the internal auditory meatus (Testut): 1. Falciform crest. 2, Anterior superior cribriform area. 2'. Internal opening of the Aquæductus Fallopii. 3. Vertical crest which separates the anterior and posterior superior cribriform areas. 4. Posterior superior cribriform area, with (4') openings for nerve-filaments. 5. Anterior inferior cribriform area. 5'. Spirally arranged, sieve-like openings for the nerves to the cochlea. 5''. Opening of the central canal of the cochlea. 6. Crest which separates the anterior and posterior inferior cribriform areas. 7. Posterior inferior cribriform area. 7' Orifices for the branches of the nerve to the saccule. 8. Foramen singulare of Morgagni, with the anterior portion of the canal which gives passage to the nerve to the posterior semicircular canal.

The **posterior surface** forms the front part of the posterior fossa of the skull, and is continuous with the inner surface of the mastoid portion of the bone. It presents three points for examination: 1. About its centre, a large orifice, the *meatus auditorius internus*, whose size varies considerably; its margins are smooth and rounded, and it leads into a short canal, about four lines in length, which runs directly outward and is closed by a vertical plate, the *lamina cribrosa*, which is divided by a horizontal crest, the *crista falciformis*, into two unequal portions. Each portion is subdivided by a little vertical crest into two parts, named respectively anterior and posterior. The *lower* portion presents three sets of foramina; one group just below the posterior part of the crest, the *area cribrosa media*, consisting of a number of small openings for the nerves to the saccule; below and posterior to this, the *foramen singulare*, or opening for the nerve to the posterior semicircular canal; in front and below the first, the *tractus spiralis foraminosus*, consisting of a number of small spirally arranged openings which terminate in the canalis centralis cochleæ and transmit the nerve to the cochlea; the upper portion, that above the crista, presents behind a series of small openings, the area cribrosa superior, for the passage of filaments to the utricle and superior and external semicircular canal, and, in front, one large opening, the commencement of the aquæductus Fallopii, for the passage of the facial nerve. 2. Behind the meatus auditorius, a small slit, almost hidden by a thin plate of bone, leading to a canal, the *aquæductus vestibuli*, which transmits the *ductus endolymphaticus* together with a small artery and vein. In the interval between these two openings, but above them, is an angular depression which lodges a process of the dura mater, and transmits a small vein into the cancellous tissue of the bone. In the child this depression is represented by a large fossa, the *flocculer fossa*, which extends backward as a blind tunnel under the superior semicircular canal.

The **inferior** or **basilar surface** (Fig. 35) is rough and irregular, and forms part of the base of the skull. Passing from the apex to the base, this surface presents eleven points for examination: 1, a rough surface, quadrilateral in form, which serves partly for the attachment of the Levator palati and Tensor tympani muscles; 2, the large, circular aperture of the carotid canal, which ascends at first vertically, and then, making a bend, runs horizontally forward and inward; it transmits the internal carotid artery and the carotid plexus; 3, the *aquæductus cochleæ*, a small, triangular opening, lying on the inner side of the latter, close to the posterior border of the petrous portion; it transmits a vein from the cochlea which joins the internal jugular; 4, behind these openings a deep depression, the *jugular fossa*, which varies in depth and size in different skulls; it lodges the

lateral sinus, and, with a similar depression on the margin of the jugular process of the occipital bone, forms the foramen lacerum posterius or jugular foramen; 5, a small foramen for the passage of Jacobson's nerve (the tympanic branch of the glosso-pharyngeal): this foramen is seen in front of the bony ridge dividing

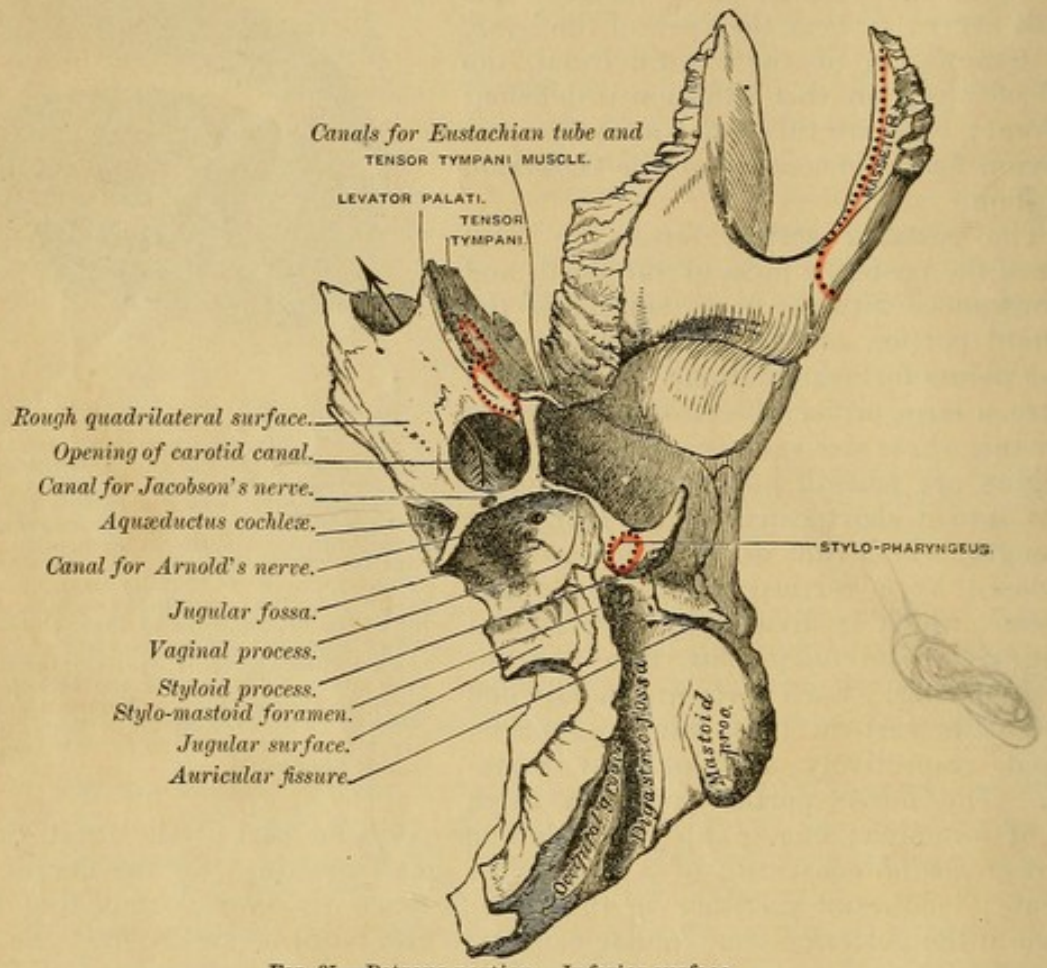

FIG. 35.—Petrous portion. Inferior surface.

the carotid canal from the jugular fossa; 6, a small foramen on the wall of the jugular fossa, for the entrance of the auricular branch of the pneumogastric (Arnold's) nerve; 7, behind the jugular fossa a smooth, square-shaped facet, the *jugular surface;* it is covered with cartilage in the recent state, and articulates with the jugular process of the occipital bone; 8, the *vaginal process*, a very broad, sheath-like plate of bone, which extends backward from the carotid canal and gives attachment to part of the Tensor palati muscle; this plate divides behind into two laminæ, the outer of which is continuous with the tympanic plate, the inner with the jugular process; 9, between these laminæ is the ninth point for examination, the *styloid process*, a sharp spine, about an inch in length: it is directed downward, forward, and inward, varies in size and shape, and sometimes consists of several pieces united by cartilage; it affords attachment to three muscles, the Stylo-pharyngeus, Stylo-hyoideus, and Stylo-glossus, and two ligaments, the stylo-hyoid and stylo-maxillary; 10, the *stylo-mastoid foramen*, a rather large orifice, placed between the styloid and mastoid processes: it is the termination of the aquæductus Fallopii, and transmits the facial nerve and stylo-mastoid artery; 11, the *auricular fissure*, situated between the tympanic plate and mastoid processes, for the exit of the auricular branch of the pneumogastric nerve.

Borders.—The *superior*, the longest, is grooved for the superior petrosal sinus, and has attached to it the tentorium cerebelli; at its inner extremity is a semilunar notch, upon which the fifth nerve lies. The *posterior* border is intermediate in length between the superior and the anterior. Its inner half is marked by a groove, which, when completed by its articulation with the occipital, forms the channel

for the inferior petrosal sinus. Its outer half presents a deep excavation—the *jugular fossa*—which, with a similar notch on the occipital, forms the foramen lacerum posterius. A projecting eminence of bone occasionally stands out from the centre of the notch, and divides the foramen into two parts. The *anterior* border is divided into two parts—an outer joined to the squamous portion by a suture, the remains of which are distinct; an inner, free, articulating with the spinous process of the sphenoid. At the angle of junction of the petrous and squamous portions are seen two canals, separated from one another by a thin plate of bone, the *processus cochleariformis;* they both lead into the tympanum, the upper one transmitting the Tensor tympani muscle, the lower one forming the bony part of the Eustachian tube.

Structure.—The squamous portion is like that of the other cranial bones: the mastoid portion, cellular; and the petrous portion, dense and hard.

Development (Fig. 36).—The temporal bone is developed by *ten* centres, exclusive of those for the internal ear and the ossicula—viz., one of the squamous portion including the zygoma, one for the tympanic plate, six for the petrous and mastoid parts, and two for the styloid process. Just before the close of fœtal life the temporal bone consists of four parts: 1. The *squamo-zygomatic*, which is ossified in membrane from a single nucleus, which appears at its lower part about the second month. 2. The *tympanic plate*, an imperfect ring, in the concavity of which is a groove, the *sulcus tympanicus*, for the attachment of the circumference of the tympanic membrane. This is also ossified from a single centre, which appears about the third month. 3. The *petro-mastoid*, which is developed from six centres, which appear about the fifth or sixth month. Four of these are for the petrous portion, and are placed around the labyrinth, and two for the mastoid (Vrolik). According to Huxley, the centres are more numerous, and are disposed so as to form three portions: (1) including most of the labyrinth, with a part of the petrous and mastoid, he has named *prootic;* (2) the rest of the petrous, the *opisthotic;* and (3) the remainder of the mastoid, the *epiotic*. The petro-mastoid is ossified in cartilage. 4. The *styloid process* is also ossified in cartilage from two centres: one for the base, which appears before birth, and is termed the *tympano-hyal;* the other, comprising the rest of the process, is named the *stylo-hyal*, and does not appear until after birth. Shortly before birth the tympanic plate joins with the squamous. The petrous and mastoid join with the squamous during the first year, and the tympano-hyal portion of the styloid process about the same time. The stylo-hyal does not join the rest of the bone until after puberty, and in some skulls never becomes united. The subsequent changes in this bone are, that the tympanic plate extends outward and backward, so as to form the meatus auditorius. The extension of the tympanic plate, however, does not take place at an equal rate all round the circumference of the ring, but occurs most rapidly on its anterior and posterior portions, and these outgrowths meet and blend, and thus, for a time, there exists in the floor of the meatus a foramen, the *foramen of Huschke:* this foramen may persist throughout life. The glenoid cavity is at first extremely shallow, and looks outward as well as downward; it becomes deeper and is ultimately directed downward. Its change in direction is accounted for

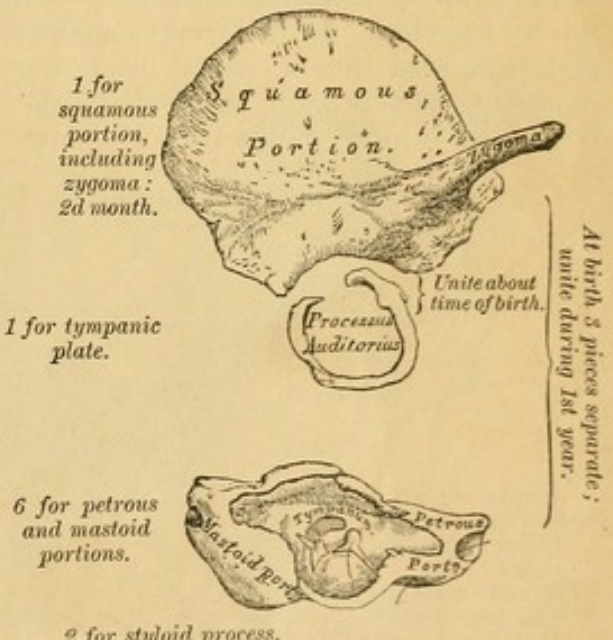

FIG. 36.—Development of the temporal bone. By ten centres.

as follows: the part of the squamous temporal which supports it lies at first *below* the level of the zygoma. As, however, the base of the skull increases in width, this lower part of the squama is directed horizontally inward to contribute to the middle fossa of the skull, and its surfaces therefore come to look upward and downward. The mastoid portion is at first quite flat, and the stylo-mastoid foramen and rudimentary styloid process lie immediately behind the entrance to the auditory meatus. With the development of the air-cells the outer part of the mastoid portion grows downward and forward to form the mastoid process, and the styloid process and stylo-mastoid foramen now come to lie on the under surface. The descent of the foramen is necessarily accompanied by a corresponding lengthening of the aqueduct of Fallopius.

The downward and forward growth of the mastoid process also pushes forward the tympanic plate, so that the portion of it which formed the original floor of the meatus and containing the foramen of Huschke is ultimately found in the anterior wall. With the gradual increase in size of the petrous portion the floccular fossa or tunnel under the superior semicircular canal becomes filled up and almost obliterated.

Articulations.—With five bones—occipital, parietal, sphenoid, inferior maxillary, and malar.

Attachment of Muscles.—To fifteen: to the squamous portion, the Temporal; to the zygoma, the Masseter; to the mastoid portion, the Occipito-frontalis, Sterno-mastoid, Splenius capitis, Trachelo-mastoid, Digastricus, and Retrahens aurem; to the styloid process, the Stylo-pharyngeus, Stylo-hyoideus, and Stylo-glossus; and to the petrous portion, the Levator palati, Tensor tympani, Tensor palati, and Stapedius.

The Sphenoid Bone.

The **Sphenoid Bone** (*σφήν*, a wedge) is situated at the anterior part of the base of the skull, articulating with all the other cranial bones, which it binds firmly and solidly together. In its form it somewhat resembles a bat with its wings extended; and is divided into a central portion or body, two greater and two lesser wings extending outward on each side of the body, and two processes—the pterygoid processes—which project from it below.

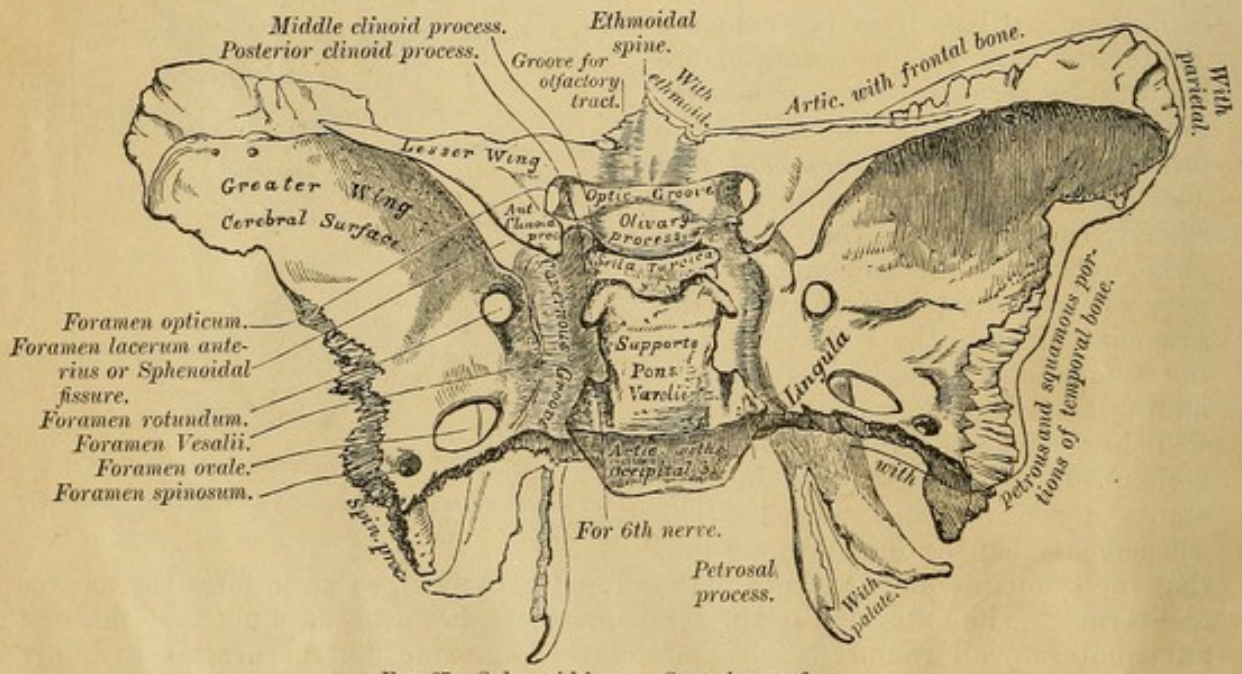

FIG. 37.—Sphenoid bone. Superior surface.

The **body** is of large size, and hollowed out in its interior so as to form a mere shell of bone. It presents for examination *four* surfaces—a superior, an inferior, an anterior, and a posterior.

The Superior Surface (Fig. 37).—In front is seen a prominent spine, the

ethmoidal spine, for articulation with the cribriform plate of the ethmoid; behind this a smooth surface presenting, in the median line, a slight longitudinal eminence, with a depression on each side for lodging the olfactory lobes. This surface is bounded behind by a ridge, which forms the anterior border of a narrow, transverse groove, the *optic groove*, behind which lies the optic commissure; the ridge terminates on either side of the *optic foramen*, for the passage of the optic nerve and ophthalmic artery. Behind the optic groove is a small eminence, olive-like in shape, the *olivary process;* and still more posteriorly, a deep depression, the *pituitary fossa*, or *sella turcica*, which lodges the pituitary body. This fossa is perforated by numerous foramina, for the transmission of nutrient vessels into the substance of the bone. It is bounded in front by two small eminences, one on either side, called the *middle clinoid processes* (*κλίνη*, a bed), which are sometimes connected by a spiculum of bone to the anterior clinoid processes, and behind by a square-shaped plate of bone, the *dorsum ephippii* or *dorsum sellæ*, terminating at each superior angle in a tubercle, the *posterior clinoid processes*, the size and form of which vary considerably in different individuals. These processes deepen the pituitary fossa, and serve for the attachment of prolongations from the tentorium cerebelli. The sides of the dorsum ephippii are notched for the passage of the sixth pair of nerves, and below present a sharp process, the *petrosal process*, which is joined to the apex of the petrous portion of the temporal bone, forming the inner boundary of the middle lacerated foramen. Behind this plate the bone presents a shallow depression, which slopes obliquely backward, and is continuous with the basilar groove of the occipital bone; it is called the *clivus*, and supports the upper part of the pons Varolii. On either side of the body is a broad groove, curved something like the italic letter *f;* it lodges the internal carotid artery and the cavernous sinus, and is called the *carotid* or *cavernous groove*. Along the outer margin of this groove, at its posterior part, is a ridge of bone in the angle between the body and greater wing, called the *lingula*. The **posterior surface**, quadrilateral

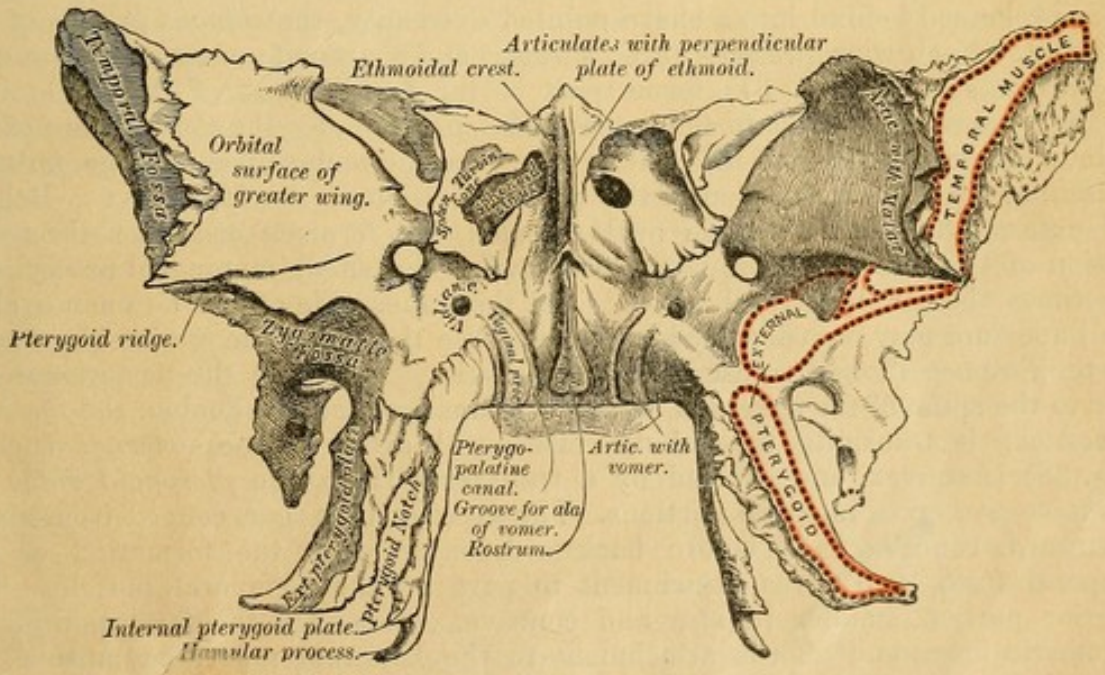

FIG. 38.—Sphenoid bone. Anterior surface.[1]

in form, is joined to the basilar process of the occipital bone. During childhood these bones are separated by a layer of cartilage; but in after-life (between the eighteenth and twenty-fifth years) this becomes ossified, ossification commencing above and extending downward; and the two bones then form one piece. The **anterior surface** (Fig. 38) presents, in the middle line, a vertical ridge of bone, the

[1] ...re, both the anterior and inferior surfaces of the body of the sphenoid bone are ... being held with the pterygoid processes almost horizontal.

ethmoidal crest, which articulates in front with the perpendicular plate of the ethmoid, forming part of the septum of the nose. On either side of it are irregular openings leading into the *sphenoidal cells* or *sinuses*. These are two large irregular cavities hollowed out of the interior of the body of the sphenoid bone, and separated from one another by a more or less complete perpendicular bony septum. Their form and size vary considerably; they are seldom symmetrical, and are often partially subdivided by irregular osseous laminæ. Occasionally, they extend into the basilar process of the occipital nearly as far as the foramen magnum. The septum is seldom quite vertical, being commonly bent to one or the other side. These sinuses do not exist in children, but they increase in size as age advances. They are partially closed, in front and below, by two thin, curved plates of bone, the *sphenoidal turbinated* bones, leaving a round opening at their upper parts, by which they communicate with the upper and back part of the nose, and occasionally with the posterior ethmoidal cells or sinuses. The lateral margins of this surface present a serrated edge, which articulates with the os planum of the ethmoid, completing the posterior ethmoidal cells; the lower margin, also rough and serrated, articulates with the orbital process of the palate bone, and the upper margin with the orbital plate of the frontal bone. The **inferior surface** presents, in the middle line, a triangular spine, the *rostrum*, which is continuous with the sphenoidal crest on the anterior surface, and is received into a deep fissure between the alæ of the vomer. On each side may be seen a projecting lamina of bone, which runs horizontally inward from near the base of the pterygoid process: these plates, termed the *vaginal processes*, articulate with the edges of the vomer. Close to the root of the pterygoid process is a groove, formed into a complete canal when articulated with the sphenoidal process of the palate bone; it is called the *pterygo-palatine canal*, and transmits the pterygo-palatine vessels and pharyngeal nerve.

The **Greater Wings** are two strong processes of bone which arise from the sides of the body, and are curved in a direction upward, outward, and backward, being prolonged behind into a sharp-pointed extremity, the *spinous process* of the sphenoid. Each wing presents three surfaces and a circumference. The *superior* or *cerebral* surface (Fig. 37) forms part of the middle fossa of the skull; it is deeply concave, and presents eminences and depressions for the convolutions of the brain. At its anterior and internal part is seen a circular aperture, the *foramen rotundum*, for the transmission of the second division of the fifth nerve. Behind and external to this is a large oval foramen, the *foramen ovale*, for the transmission of the third division of the fifth nerve, the small meningeal artery, and sometimes the small petrosal nerve.[1] At the inner side of the foramen ovale a small aperture may occasionally be seen opposite the root of the pterygoid process; it is the *foramen Vesalii*, transmitting a small vein. Lastly, in the posterior angle, near to the spine of the sphenoid, is a short canal, sometimes double, the *foramen spinosum*; it transmits the middle meningeal artery. The *external* surface (Fig. 38) is convex, and divided by a transverse ridge, the *pterygoid ridge* or *infratemporal crest*, into two portions. The superior or larger, convex from above downward, concave from before backward, enters into the formation of the temporal fossa, and gives attachment to part of the Temporal muscle. The inferior portion, smaller in size and concave, enters into the formation of the zygomatic fossa, and affords attachment to the External pterygoid muscle. It presents, at its posterior part, a sharp-pointed eminence of bone, the *spinous process*, to which are connected the internal lateral ligament of the lower jaw and the Tensor palati muscle. The pterygoid ridge, dividing the temporal and zygomatic portions, gives attachment to part of the External pterygoid muscle. At its inner and anterior extremity is a triangular spine of bone which serves to increase the extent of origin of this muscle. The *anterior* or *orbital* surface, smooth and quadrilateral in form, assists in forming the outer wall of the orbit. It is bounded

[1] The small petrosal nerve sometimes passes through a special foramen between the foramen ovale and foramen spinosum.

above by a serrated edge, for articulation with the frontal bone; below, by a rounded border which enters into the formation of the spheno-maxillary fissure. Internally, it presents a sharp border, which forms the lower boundary of the sphenoidal fissure, and has projecting from about its centre a little tubercle of bone, which gives origin to one head of the External rectus muscle of the eye; and at its upper part is a notch for the transmission of a recurrent branch of the lachrymal artery; externally it presents a serrated margin for articulation with the malar bone. One or two small foramina may occasionally be seen for the passage of branches of the deep temporal arteries; they are called the *external orbital foramina*. *Circumference of the great wing* (Fig. 37), commencing from behind, that portion of the circumference from the body of the sphenoid to the spine, is serrated and articulates by its outer half with the petrous portion of the temporal bone, while the inner half forms the anterior boundary of the foramen lacerum medium, and presents the posterior aperture of the Vidian canal for the passage of the Vidian nerve and artery. In front of the spine the circumference of the great wing presents a serrated edge, bevelled at the expense of the inner table below and of the external above, which articulates with the squamous portion of the temporal bone. At the tip of the great wing a triangular portion is seen, bevelled at the expense of the internal surface, for articulation with the anterior inferior angle of the parietal bone. Internal to this is a triangular, serrated surface, for articulation with the frontal bone: this surface is continuous internally with the sharp inner edge of the orbital plate, which assists in the formation of the sphenoidal fissure, and externally with the serrated margin for articulation with the malar bone.

The **Lesser Wings** (*processes of Ingrassias*) are two thin, triangular plates of bone which arise from the upper and lateral parts of the body of the sphenoid, and, projecting transversely outward, terminate in a sharp point (Fig. 37). The superior surface of each is smooth, flat, broader internally than externally, and supports part of the frontal lobe of the brain. The inferior surface forms the back part of the roof of the orbit and the upper boundary of the sphenoidal fissure or foramen lacerum anterius. This fissure is of a triangular form, and leads from the cavity of the cranium into the orbit; it is bounded internally by the body of the sphenoid—above, by the lesser wing; below, by the internal margin of the orbital surface of the great wing—and is converted into a foramen by the articulation of this bone with the frontal. It transmits the third, the fourth, the three branches of the ophthalmic division of the fifth, the sixth nerve, some filaments from the cavernous plexus of the sympathetic, the orbital branch of the middle meningeal artery, a recurrent branch from the lachrymal artery to the dura mater, and the ophthalmic vein. The anterior border of the lesser wing is serrated for articulation with the frontal bone; the posterior, smooth and rounded, is received into the fissure of Sylvius of the brain. The inner extremity of this border forms the *anterior clinoid process*. The lesser wing is connected to the side of the body by two roots, the upper thin and flat, the lower thicker, obliquely directed, and presenting on its outer side, near its junction with the body, a small tubercle, for the attachment of the common tendon of origin of three of the muscles of the eye. Between the two roots is the *optic foramen*, for the transmission of the optic nerve and ophthalmic artery.

The **Pterygoid Processes** (*πτέρυξ*, a wing; *εἶδος*, likeness), one on each side, descend perpendicularly from the point where the body and greater wing unite (Fig. 39). Each process consists of an external and an internal plate, which are joined together by their anterior borders above, but are separated below, leaving an angular cleft, the *pterygoid notch*, in which the pterygoid process or tuberosity of the palate bone is received. The two plates diverge from each other from their line of connection in front, so as to form a V-shaped fossa, the *pterygoid fossa*. The *external pterygoid plate* is broad and thin, turned a little outward, and, by its outer surface, forms part of the inner wall of the zygomatic fossa, giving attachment to the External pterygoid; its inner surface forms part

of the pterygoid fossa, and gives attachment to the Internal pterygoid. The *internal pterygoid plate* is much narrower and longer, curving outward, at its extremity, into a hook-like process of bone, the *hamular process*, around which turns the tendon of the Tensor palati muscle. The outer surface of this plate forms part of the pterygoid fossa, the inner surface forming the outer boundary of the posterior aperture of the nares. On the posterior surface of the base of the process, above the pterygoid fossa, is a small, oval, shallow depression, the *scaphoid fossa*, from which arises the Tensor palati, and above which is seen the

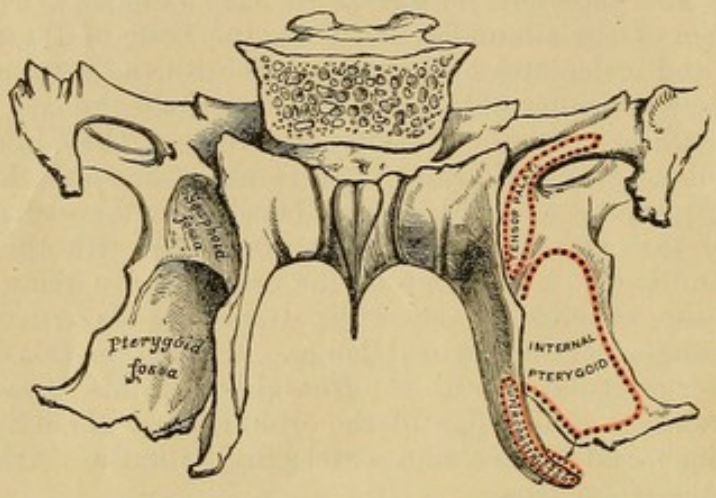

FIG. 39.—Sphenoid bone. Posterior surface.

posterior orifice of the Vidian canal. Below and to the inner side of the Vidian canal, on the posterior surface of the base of the internal plate, is a little prominence, which is known by the name of the *pterygoid tubercle*. The Superior constrictor of the pharynx is attached to the posterior edge of the internal plate. The anterior surface of the pterygoid process is very broad at its base, and forms the posterior wall of the spheno-maxillary fossa. It supports Meckel's ganglion. It presents, above, the anterior orifice of the Vidian canal; and below, a rough margin, which articulates with the perpendicular plate of the palate bone.

The **Sphenoidal Spongy Bones** are two thin, curved plates of bones, which exist as separate pieces until puberty, and occasionally are not joined to the sphenoid in the adult. They are situated at the anterior and inferior part of the body of the sphenoid, an aperture of variable size being left in their anterior wall, through which the sphenoidal sinuses open into the nasal fossæ. They are irregular in form and taper to a point behind, being broader and thinner in front. Their upper surface, which looks toward the cavity of the sinus, is concave; their under surface convex. Each bone articulates in front with the ethmoid, externally with the palate; its pointed posterior extremity is placed above the vomer, and is received between the root of the pterygoid process on the outer side and the rostrum of the sphenoid on the inner.[1]

Development.—Up to about the eighth month of fœtal life the sphenoid bone consists of two distinct parts: posterior or *post-sphenoid* part, which comprises the pituitary fossa, the greater wings, and the pterygoid processes; and an anterior or *pre-sphenoid* part, to which the anterior part of the body and lesser wings belong. It is developed by fourteen centres: eight for the posterior sphenoid division, and six for the anterior sphenoid. The eight centres for the posterior sphenoid are—one for each greater wing and external pterygoid plate, one for each internal pterygoid plate, two for the posterior part of the body, and

[1] A small portion of the sphenoidal turbinated bone sometimes enters into the formation of the inner wall of the orbit, between the os planum of the ethmoid in front, the orbital plate of the palate below, and the frontal above.—Cleland, *Roy. Soc. Trans.*, 1862.

one on each side for the lingula. The six for the anterior sphenoid are one for each lesser wing, two for the anterior part of the body, and one for each sphenoidal turbinated bone.

Post-sphenoid Division.—The first nuclei to appear are those for the greater wings (*ali-sphenoids*). They make their appearance between the foramen rotundum and foramen ovale about the eighth week, and from them the external pterygoid plates are also formed. Soon after, the nuclei for the posterior part of the body appear, one on either side of the sella turcica, and become blended together about the middle of fœtal life. About the fourth month the remaining four centres appear, those for the internal pterygoid plates being ossified in membrane and becoming joined to the external pterygoid plate about the sixth month. The centres for the lingulæ speedily become joined to the rest of the bone.

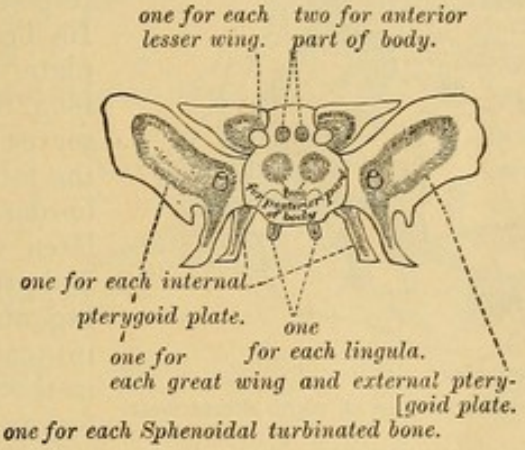

FIG. 40.—Plan of the development of sphenoid. By fourteen centres.

Pre-sphenoid Division.—The first nuclei to appear are those for the lesser wings (*orbito-sphenoids*). They make their appearance about the ninth week, at the outer borders of the optic foramina. A second pair of nuclei appear on the inner side of the foramina shortly after, and, becoming united, form the front part of the body of the bone. The remaining two centres for the sphenoidal turbinated bones make their appearance about the fifth month. At birth they consist of small triangular laminæ, and it is not till the third year that they become hollowed out and cone-shaped. About the fourth year they become fused with the lateral masses of the ethmoid, and hence, from an embryological point of view, may be regarded as belonging to the ethmoid.

The pre-sphenoid is united to the body of the post-sphenoid about the eighth month, so that at birth the bone consists of three pieces—viz. the body in the centre, and on each side the great wings with the pterygoid processes. The lesser wings become joined to the body at about the time of birth. At the first year after birth the greater wings and body are united. From the tenth to the twelfth year the spongy bones are partially united to the sphenoid, their junction being complete by the twentieth year. Lastly, the sphenoid joins the occipital from the eighteenth to the twenty-fifth year.

Articulations.—The sphenoid articulates with *all* the bones of the cranium, and five of the face—the two malar, two palate, and vomer: the exact extent of articulation with each bone is shown in the accompanying figures.[1]

Attachment of Muscles.—To eleven pairs: the Temporal, External pterygoid, Internal pterygoid, Superior constrictor, Tensor palati, Levator palpebræ, Obliquus oculi superior, Superior rectus, Internal rectus, Inferior rectus, External rectus.

The Ethmoid Bone.

The **Ethmoid** (ἠθμός, a sieve) is an exceedingly light, spongy bone, of a cubical form, situated at the anterior part of the base of the cranium, between the two

[1] It also sometimes articulates with the tuberosity of the superior maxilla.

orbits, at the root of the nose, and contributing to form each of these cavities. It consists of three parts: a horizontal plate, which forms part of the base of the cranium; a perpendicular plate, which forms part of the septum nasi; and two lateral masses of cells.

The **Horizontal** or **Cribriform Plate** (Fig. 41) forms part of the anterior fossa of the base of the skull, and is received into the ethmoid notch of the frontal bone between the two orbital plates. Projecting upward from the middle line of this plate is a thick, smooth, triangular process of bone, the *crista galli*, so called from its resemblance to a cock's comb. Its base joins the cribriform plate. Its posterior border, long, thin, and slightly curved, serves for the attachment of the falx cerebri. Its anterior border, short and thick, articulates with the frontal bone, and presents two small projecting alæ, which are received into corresponding depressions in the frontal, completing the foramen cæcum behind. Its sides are smooth and sometimes bulging; in which case it is found to enclose a small sinus.[1] On each side of the crista galli the cribriform plate is narrow and deeply grooved, to support the bulb of the olfactory tract, and perforated by foramina for the passage of the olfactory nerves. These foramina are arranged in three rows: the innermost, which are the largest and least numerous, are lost in grooves on the upper part of the septum; the foramina of the outer row are continued on to the surface of the upper spongy bone. The foramina of the middle row are the smallest; they perforate the bone and transmit nerves to the roof of the nose. At the front part of the cribriform plate, on each side of the crista galli, is a small fissure, which transmits the nasal branch of the ophthalmic nerve; and at its posterior part a a triangular notch, which receives the ethmoidal spine of the sphenoid.

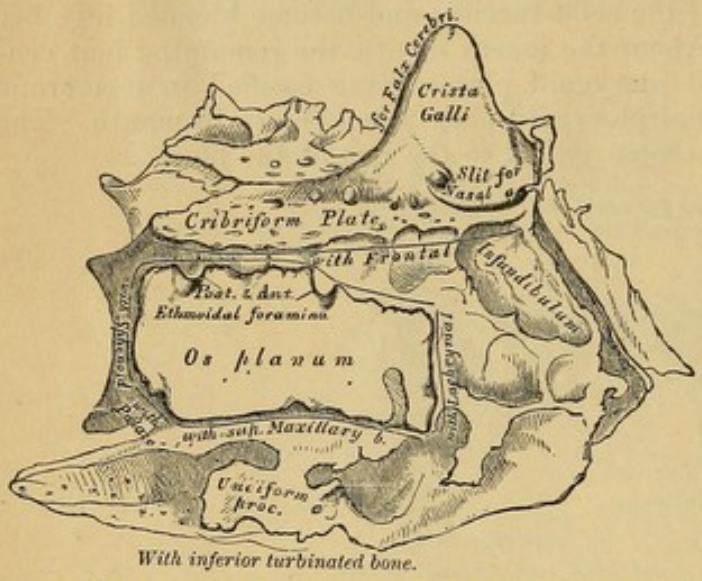

FIG. 41.—Ethmoid bone. Outer surface of right lateral mass (enlarged).

The **Perpendicular Plate** (Fig. 42) is a thin, flattened lamella of bone, which descends from the under surface of the cribriform plate, and assists in forming the septum of the nose. It is much thinner in the middle than at the circumference, and is generally deflected a little to one side. Its anterior border articulates with the nasal spine of the frontal bone and crest of the nasal bones. Its posterior border, divided into two parts, articulates by its upper half with the sphenoidal crest of the sphenoid, by its lower half with the vomer. The inferior border serves for the attachment of the triangular cartilage of the nose. On each side of the perpendicular plate numerous grooves and canals are seen, leading from foramina on the cribriform plate; they lodge filaments of the olfactory nerves.

The **Lateral Masses** of the ethmoid consist of a number of thin-walled cellular cavities, the *ethmoidal cells*, interposed between two vertical plates of bone, the outer one of which forms part of the orbit, and the inner one part of the nasal fossa of the corresponding side. In the disarticulated bone many of these cells appear to be broken; but when the bones are articulated they are closed in at every part, except where they open into the nasal fossæ. The upper surface of each lateral mass presents a number of apparently half-broken cel-

[1] Sir George Humphry states that the crista galli is commonly inclined to one side, usually the opposite to that toward which the lower part of the perpendicular plate is bent.—*The Human Skeleton*, 1858, p. 277.

lular spaces; these are closed in when articulated by the edges of the ethmoidal notch of the frontal bone. Crossing this surface are two grooves on each side, converted into canals by articulation with the frontal; they are the *anterior* and *posterior ethmoidal* canals, and open on the inner wall of the orbit. The posterior surface also presents large, irregular cellular cavities, which are closed in by articulation with the sphenoidal turbinated bones and orbital process of the palate. The cells at the anterior surface are completed by the lachrymal bone and nasal process of the superior maxillary, and those below also by the superior maxillary. The outer surface of each lateral mass is formed of a thin, smooth, oblong plate of bone, called the *os planum;* it forms part of the inner wall of the orbit, and articulates, above, with the orbital plate of the frontal; below, with the superior maxillary; in front, with the lachrymal; and behind, with the sphenoid and orbital process of the palate.

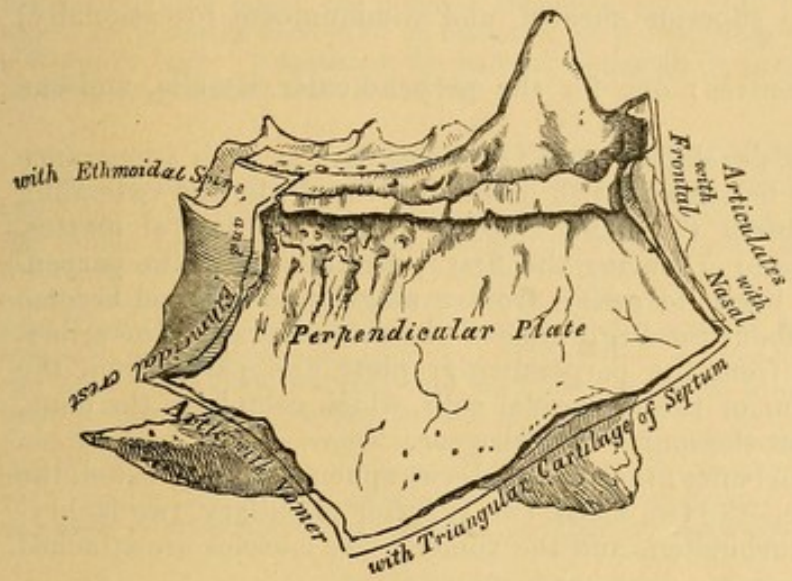

FIG. 42.—Perpendicular plate of ethmoid (enlarged), shown by removing the right lateral mass.

From the inferior part of each lateral mass, immediately beneath the os planum, there projects downward and backward an irregular lamina of bone, called the *unciform process*, from its hook-like form: it serves to close in the upper part of the orifice of the antrum, and articulates with the ethmoidal process of the inferior turbinated bone. It is often broken in disarticulating the bones.

The inner surface of each lateral mass forms part of the outer wall of the nasal fossa of the corresponding side. It is formed of a thin lamella of bone, which descends from the under surface of the cribriform plate, and terminates below in a free, convoluted margin, the *middle turbinated* bone. The whole of this surface is rough and marked above by numerous grooves, which run nearly vertically downward from the cribriform plate; they lodge branches of the olfactory nerve, which are distributed on the mucous membrane covering the bone. The back part of this surface is subdivided by a narrow oblique fissure, the *superior meatus* of the nose, bounded above by a thin, curved plate of bone, the *superior turbinated* bone. By means of an orifice at the upper part of this fissure the posterior ethmoidal cells open into the nose. Below, and in front of the superior meatus, is seen the convex surface of the middle turbinated bone. It extends along the whole length of the inner surface of each lateral mass; its lower margin is free and thick, and its concavity, directed outward, assists in forming the middle meatus. It is by a large orifice at the upper and front part of the middle meatus that the anterior ethmoidal cells, and through them the frontal sinuses, communicate with the nose by means of a funnel-shaped canal, the *infundibulum*.

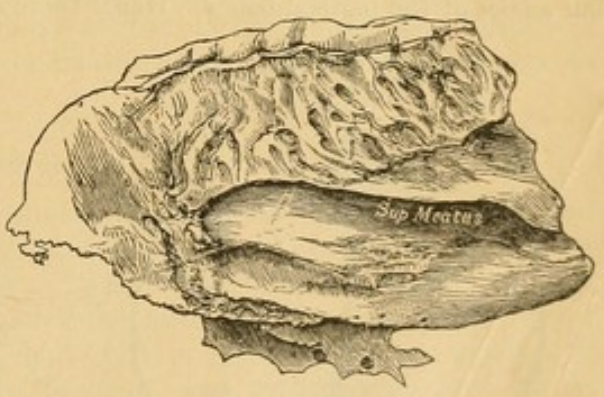

FIG. 43.—Ethmoid bone. Inner surface of right lateral mass (enlarged).

The cellular cavities of each lateral mass, thus walled in by the os planum on the outer side and by the other bones already mentioned, are divided by a thin transverse bony partition into two sets, which do not communicate with each other; they are termed the *anterior* and *posterior ethmoidal cells* or *sinuses*. The former, more numerous, communicate with the frontal sinuses above and the middle meatus below by means of a long, flexuous canal, the *infundibulum;* the posterior, less numerous, open into the superior meatus, and communicate (occasionally) with the sphenoidal sinuses.

Development.—By *three* centres: one for the perpendicular lamella, and one for each lateral mass.

The lateral masses are first developed, ossific granules making their appearance in the os planum between the fourth and fifth months of fœtal life, and extending into the spongy bones. At birth the bone consists of the two lateral masses, which are small and ill-developed. During the first year after birth the perpendicular plate and crista galli begin to ossify, from a single nucleus, and become joined to the lateral masses about the beginning of the second year. The cribriform plate is ossified partly from the perpendicular plate and partly from the lateral masses. The formation of the ethmoidal cells, which completes the bone, does not commence until about the fourth or fifth year.

Articulations.—With fifteen bones: the sphenoid, two sphenoidal turbinated, the frontal, and eleven of the face—the two nasal, two superior maxillary, two lachrymal, two palate, two inferior turbinated, and the vomer. No muscles are attached to this bone.

DEVELOPMENT OF THE CRANIUM.

The early stages of the development of the cranium have already been described. We have seen that it is formed from a layer of mesoblast, derived from the protovertebral plates of the trunk, which is spread over the whole surface of the rudimentary brain. That portion of this layer from which the bones of the skull are to be developed consists of a thin, membranous capsule.

Ossification commences in the roof, and is preceded by the deposition of a membranous blastema upon the surface of the cerebral capsule, in which the ossifying process extends, the primitive membranous capsule becoming the internal periosteum, and being ultimately blended with the dura mater. The ossification of the bones of the base takes place for the most part in cartilage, and although the bones of the vertex of the skull appear before those at the base, and make considerable progress in their growth, at birth ossification is more advanced in the base, this portion of the skull forming a solid, immovable groundwork.

The Fontanelles.

Before birth the bones at the vertex and side of the skull are separated from each other by membranous intervals in which bone is deficient. These intervals are principally found at the four angles of the parietal bones. Hence there are six fontanelles. Their formation is due to

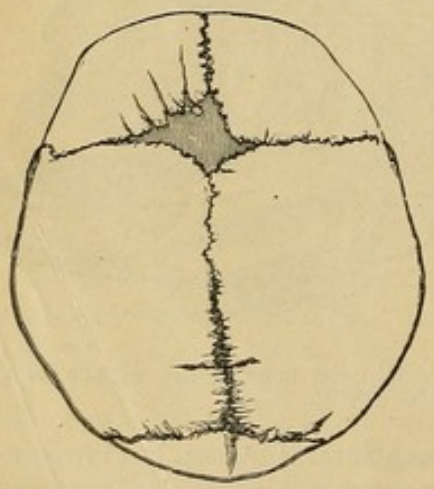

FIG. 44.—Skull at birth, showing the anterior and posterior fontanelles.

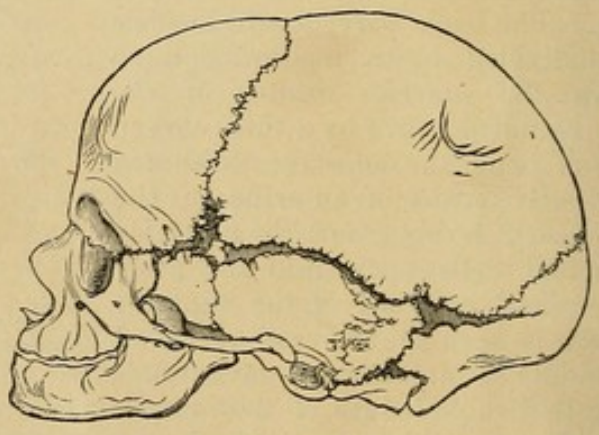

FIG. 45.—The lateral fontanelles.

the wave of ossification being circular and the bones quadrilateral; the ossific matter first meets at the margins of the bones, at the points nearest to their centres of ossification, and vacuities

or spaces are left at the angles, which are called *fontanelles*, so named from the pulsations of the brain, which are perceptible at the anterior fontanelle, were likened to the rising of water in a fountain. The anterior fontanelle is the largest; it is lozenge-shaped, and corresponds to the junction of the sagittal and coronal sutures; the posterior fontanelle, of smaller size, is triangular, and is situated at the junction of the sagittal and lambdoid sutures; the remaining ones are situated at the inferior angles of each parietal bone. The latter are closed soon after birth; the two at the two superior angles remain open longer; the posterior being closed in a few months after birth; the anterior remaining open until the first or second year. These spaces are gradually filled in by an extension of the ossifying process or by the development of a Wormian bone. Sometimes the anterior fontanelle remains open beyond two years, and is occasionally persistent throughout life.

Supernumerary or Wormian[1] Bones.

In addition to the constant centres of ossification of the skull, additional ones are occasionally found in the course of the sutures. These form irregular, isolated bones, interposed between the cranial bones, and have been termed *Wormian bones* or *ossa triquetra*. They are most frequently found in the course of the lambdoid suture, but occasionally also occupy the situation of the fontanelles, especially the posterior and, more rarely, the anterior. Frequently one is found between the anterior inferior angle of the parietal bone and the greater wing of the sphenoid, the *pterion ossicle* (Fig. 45). They have a great tendency to be symmetrical on the two sides of the skull, and they vary much in size, being in some cases not larger than a pin's head, and confined to the outer table; in other cases so large that one pair of these bones may form the whole of the occipital bone above the superior curved lines, as described by Béclard and Ward. Their number is generally limited to two or three, but more than a hundred have been found in the skull of an adult hydrocephalic skeleton. In their development, structure, and mode of articulation they resemble the other cranial bones.

Congenital Fissures and Gaps.

An arrest in the ossifying process may give rise to deficiencies or gaps; or to fissures, which are of importance in a medico-legal point of view, as they are liable to be mistaken for fractures. The fissures generally extend from the margins toward the centre of the bone, but the gaps may be found in the middle as well as at the edges. In course of time they may become covered with a thin lamina of bone.

BONES OF THE FACE.

The Facial Bones are fourteen in number—viz. the

Two Nasal.	Two Palate.
Two Superior Maxillary.	Two Inferior Turbinated.
Two Lachrymal.	Vomer.
Two Malar.	Inferior Maxillary.

"Of these, the upper and lower jaws are the fundamental bones for mastication, and the others are accessories; for the chief function of the facial bones is to provide an apparatus for mastication, while subsidiary functions are to provide for the sense-organs (eye, nose, tongue) and a vestibule to the respiratory and vocal organs. Hence the variations in the shape of the face in man and the lower animals depend chiefly on the question of the character of their food and their mode of obtaining it."[2]

The Nasal Bone.

The **Nasal** (*nasus*, the nose) are two small oblong bones, varying in size and form in different individuals; they are placed side by side at the middle and upper part of the face, forming, by their junction, "the bridge" of the nose (Fig. 46). Each bone presents for examination two surfaces and four borders. The *outer* surface is concave from above downward, convex from side to side; it is covered by the Pyramidalis and Compressor nasi muscles, and gives attachment at its upper part to a few fibres of the Occipito-frontalis muscle (Theile). It is marked by numerous small arterial furrows, and perforated about its centre by a foramen, sometimes double, for the transmission of a small vein. The *inner* surface is concave from side to side, convex from above downward; in which direction

[1] Wormius, a physician in Copenhagen, is said to have given the first detailed description of these bones.

[2] W. W. Keen, American edition p. 185.

it is traversed by a longitudinal groove (sometimes a canal), for the passage of a branch of the nasal nerve. The *superior* border is narrow, thick, and serrated, for articulation with the nasal notch of the frontal bone. The *inferior*

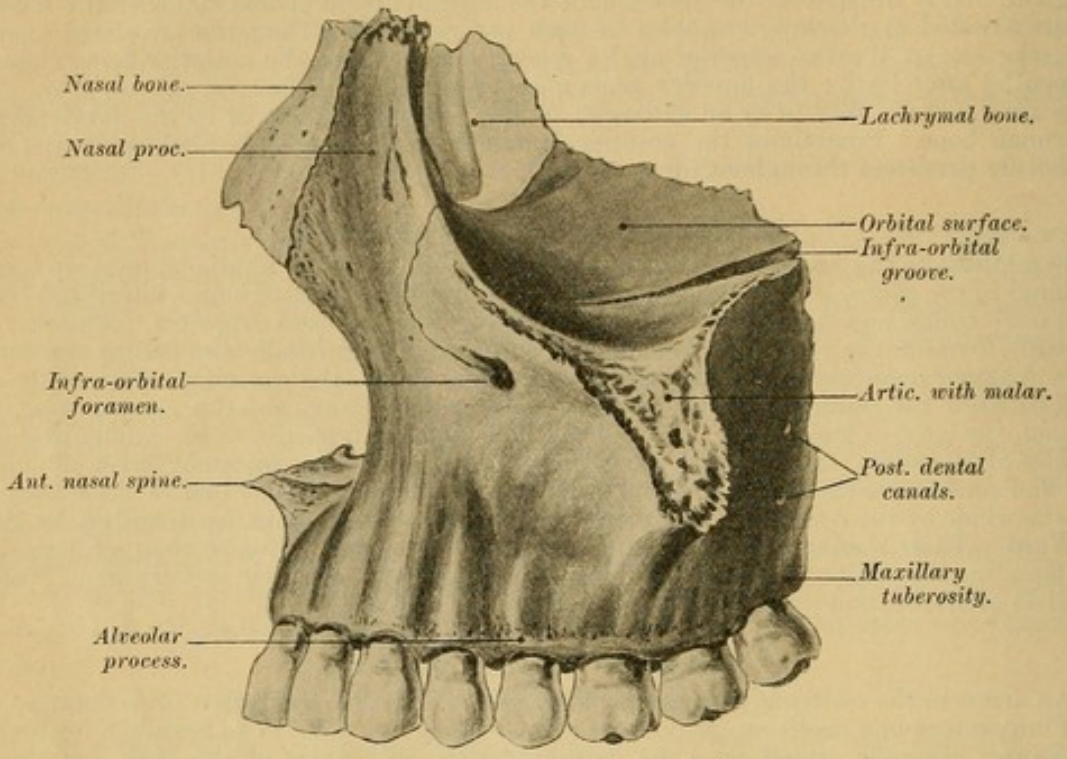

FIG. 46.—Nasal and lachrymal bone *in situ*.

border is broad, thin, sharp, inclined obliquely downward, outward, and backward, and serves for the attachment of the lateral cartilage of the nose. This border presents, about its middle, a notch, through which passes the branch of the nasal nerve above referred to, and is prolonged at its inner extremity into a sharp spine, which, when articulated with the opposite bone, forms the *nasal angle*. The *external* border is serrated, bevelled at the expense of the internal surface above and of the external below, to articulate with the nasal process of the superior maxillary. The *internal* border, thicker above than below, articulates with its fellow of the opposite side, and is prolonged behind into a vertical crest which forms part of the septum of the nose; this crest articulates above downward with the nasal spine of the frontal above, and the perpendicular plate of the ethmoid, and the triangular septal cartilage of the nose.

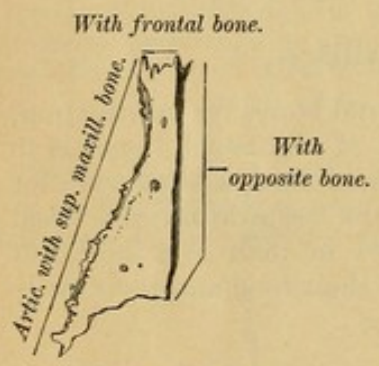

Outer Surface.

FIG. 47.—Right nasal bone.

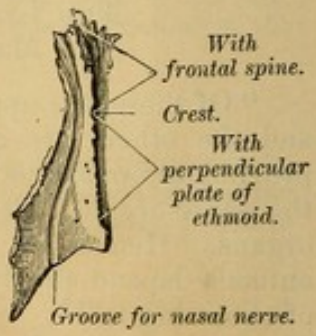

Inner Surface.

FIG. 48.—Left nasal bone.

Development.—By *one* centre for each bone, which appears about the eighth week.

Articulations.—With four bones: two of the cranium, the frontal and ethmoid, and two of the face, the opposite nasal and the superior maxillary.

Attachment of Muscles.—A few fibres of the Occipito-frontalis muscle.

The Superior Maxillary Bones or Maxillæ.

The **Superior Maxillary** (*maxilla*, the jaw-bone) are the most important bones of the face from a surgical point of view, on account of the number of diseases to which some of their parts are liable. Their careful examination becomes, therefore, a matter of considerable interest. They are the largest bones of the face, excepting the lower jaw, and form, by their union, the whole of the upper jaw. Each bone assists in the formation of three cavities, the roof of the mouth, the floor and outer wall of the nasal fossæ, and the floor of the orbit, and also enters into the formation of two fossæ, the zygomatic and spheno-maxillary, and two fissures, the spheno-maxillary and pterygo-maxillary.

The bone presents for examination a body and four processes—malar, nasal, alveolar, and palate.

The **body** is somewhat cuboid, and is hollowed out in its interior to form a large cavity, the *antrum of Highmore*. Its surfaces are four—an external or facial, a posterior or zygomatic, a superior or orbital, and an internal or nasal.

The **external** or **facial surface** (Fig. 49) is directed forward and outward. It presents at its lower part a series of eminences corresponding to the position of the teeth. Just above those for the incisor teeth is a depression, the *incisive* or *myrtiform fossa*, which gives origin to the Depressor alæ nasi; and below it to the alveolar border is attached a slip of the Orbicularis oris. Above and a little external to it the Compressor nasi arises. More external is another depression, the *canine fossa*, larger and deeper than the incisive fossa, from which

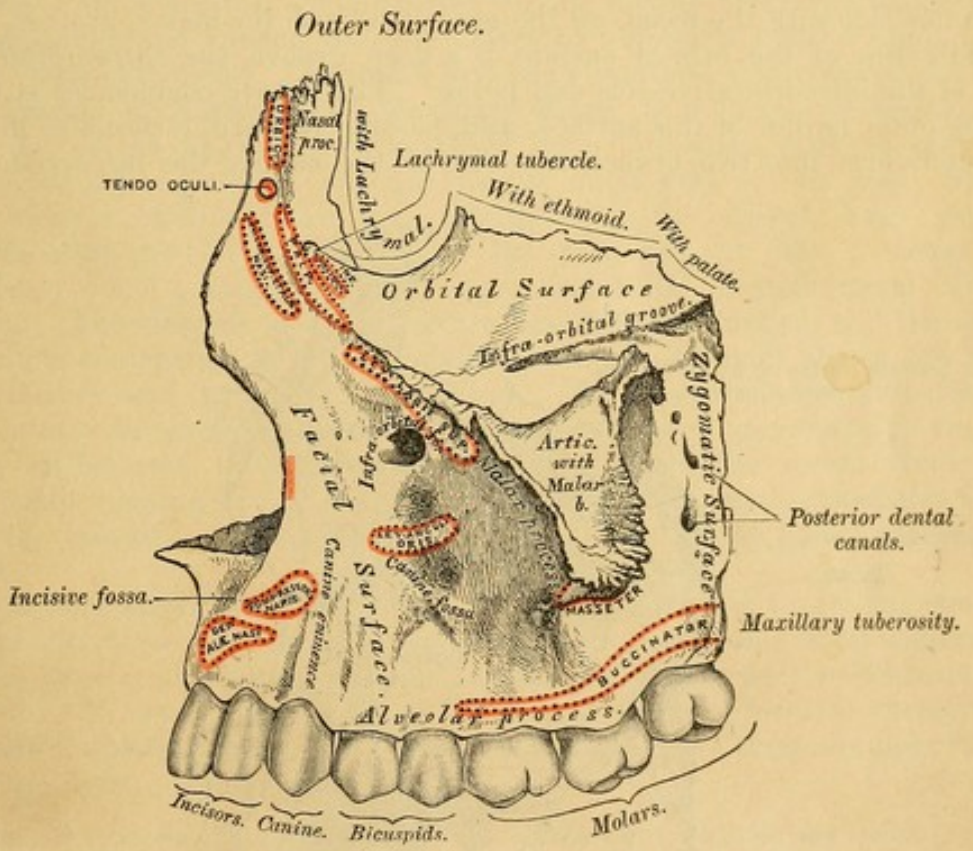

FIG. 49.—Left superior maxillary bone. Outer surface.

it is separated by a vertical ridge, the *canine eminence*, corresponding to the socket of the canine tooth. The canine fossa gives origin to the Levator anguli oris. Above the canine fossa is the *infraorbital foramen*, the termination of the infraorbital canal; it transmits the infraorbital vessels and nerve. Sometimes the infraorbital canal opens by two, very rarely by three, orifices on the face. Above the infraorbital foramen is the margin of the orbit, which affords partial attachment to the Levator labii superioris proprius. To the sharp margin of bone

which bounds this surface in front and separates it from the internal surface is attached the Dilator naris posterior.

The **posterior** or **zygomatic surface** is convex, directed backward and outward, and forms part of the zygomatic fossa. It is separated from the facial surface by a strong ridge of bone, which extends upward from the socket of the second molar tooth. It presents about its centre several apertures leading to canals in the substance of the bone; they are termed the *posterior dental canals*, and transmit the posterior dental vessels and nerves. At the lower part of this surface is a rounded eminence, the *maxillary tuberosity*, especially prominent after the growth of the wisdom-tooth, rough on its inner side for articulation with the tuberosity of the palate bone, and sometimes with the external pterygoid plate. It gives attachment to a few fibres of origin of the Internal pterygoid muscle. Immediately above this is a smooth surface, which forms the anterior boundary of the spheno-maxillary fossa; it presents a groove which, running obliquely downward, is converted into a canal by articulation with the palate-bone, forming the *posterior palatine* canal.

The **superior** or **orbital surface** is thin, smooth, triangular, and forms part of the floor of the orbit. It is bounded internally by an irregular margin which in front presents a notch, the *lachrymal notch*, which receives the lachrymal bone; in the middle articulates with the os planum of the ethmoid, and behind with the orbital process of the palate bone; bounded externally by a smooth, rounded edge which enters into the formation of the spheno-maxillary fissure, and which sometimes articulates at its anterior extremity with the orbital plate of the sphenoid; bounded in front by part of the circumference of the orbit, which is continuous on the inner side with the nasal, on the outer side with the malar, process. Along the middle line of the orbital surface is a deep groove, the *infraorbital*, for the passage of the infraorbital vessels and nerve. The groove commences at the middle of the outer border of this surface, and, passing forward, terminates in a canal, which subdivides into two branches. One of the canals, the *infraorbital*, opens

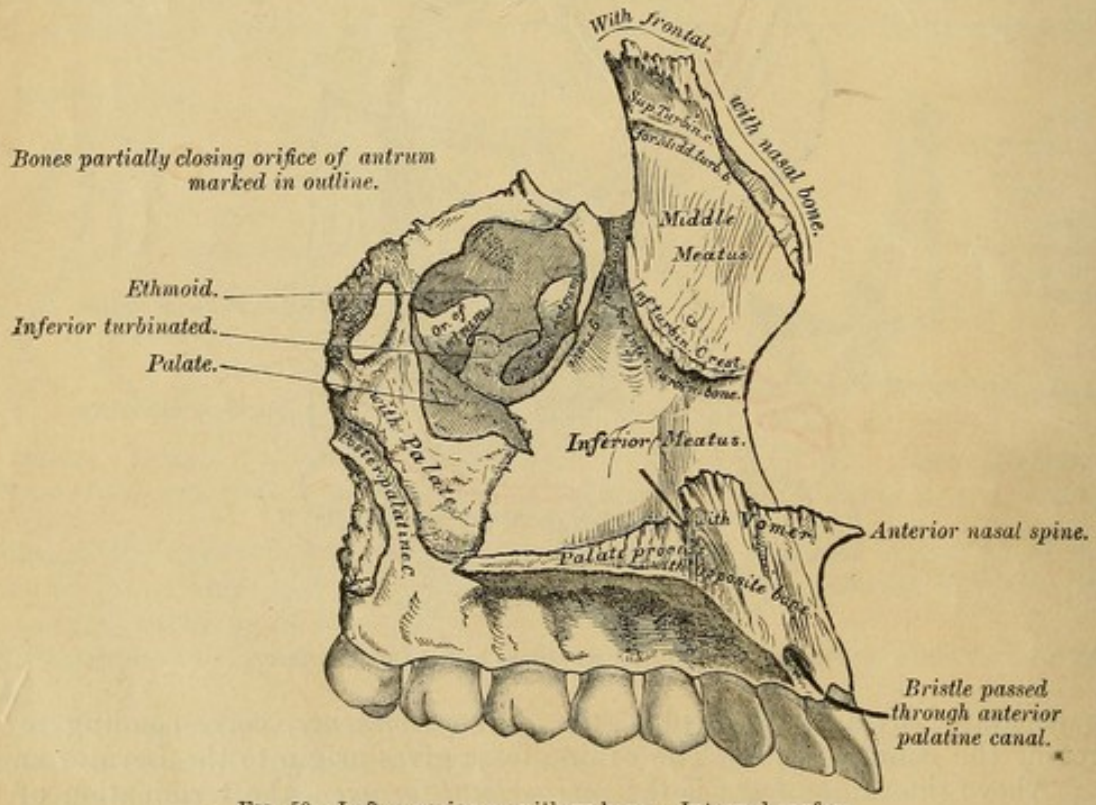

FIG. 50.—Left superior maxillary bone. Internal surface.

just below the margin of the orbit; the other, which is smaller, runs downward in the substance of the anterior wall of the antrum; it is called the *anterior dental* canal, and transmits the anterior dental vessels and nerve to the front teeth of

the upper jaw. From the back part of the infraorbital canal a second small canal is sometimes given off, which runs downward in the outer wall of the antrum, and conveys the middle dental nerve to the bicuspid teeth. Occasionally this canal is derived from the anterior dental. At the inner and fore part of the orbital surface, just external to the lachrymal groove for the nasal duct, is a depression which gives origin to the Inferior oblique muscle of the eye.

The **internal surface** (Fig. 50) is unequally divided into two parts by a horizontal projection of bone, the *palate process:* the portion above the palate process forms part of the outer wall of the nasal fossæ; that below it forms part of the cavity of the mouth. The superior division of this surface presents a large, irregular opening leading into the *antrum of Highmore.* At the upper border of this aperture are numerous broken cellular cavities, which in the articulated skull are closed in by the ethmoid and lachrymal bones. Below the aperture is a smooth concavity which forms part of the inferior meatus of the nasal fossæ, and behind it is a rough surface which articulates with the perpendicular plate of the palate bone, traversed by a groove which, commencing near the middle of the posterior border, runs obliquely downward and forward, and forms, when completed by its articulation with the palate bone, the *posterior palatine canal.* In front of the opening of the antrum is a deep groove, converted into a canal by the lachrymal and inferior turbinated bones. It is called the *lachrymal groove*, and lodges the nasal duct. More anteriorly is a well-marked rough ridge, the *inferior turbinated crest*, for articulation with the inferior turbinated bone. The shallow concavity above this ridge forms part of the middle meatus of the nose, while that below it forms part of the inferior meatus. The portion of this surface below the palate process is concave, rough and uneven, and perforated by numerous small foramina for the passage of nutrient vessels. It enters into the formation of the roof of the mouth.

The **Antrum of Highmore**, or **Maxillary Sinus**, is a large, pyramidal cavity hollowed out of the body of the maxillary bone: its apex, directed outward, is formed by the malar process; its base, by the outer wall of the nose. Its walls are everywhere exceedingly thin, and correspond to the orbital, facial, and zygomatic surfaces of the body of the bone. Its inner wall, or base, presents, in the disarticulated bone, a large, irregular aperture, which communicates with the nasal fossa. The margins of this aperture are thin and ragged, and the aperture itself is much contracted by its articulation with the ethmoid above, the inferior turbinated below, and the palate bone behind.[1] In the articulated skull this cavity communicates with the middle meatus of the nasal fossæ, generally by two small apertures left between the above-mentioned bones. In the recent state usually only one small opening exists, near the upper part of the cavity, sufficiently large to admit the end of a probe, the other being closed by the lining membrane of the sinus.

Crossing the cavity of the antrum are often seen several projecting laminæ of bone, similar to those seen in the sinuses of the cranium; and on its posterior wall are the *posterior dental canals*, transmitting the posterior dental vessels and nerves to the teeth. Projecting into the floor are several conical processes, corresponding to the roots of the first and second molar teeth;[2] in some cases the floor is perforated by the teeth in this situation.

It is from the extreme thinness of the walls of this cavity that we are enabled to explain how a tumor growing from the antrum encroaches upon the adjacent parts, pushing up the floor of the orbit, and displacing the eyeball, projecting inward into the nose, protruding forward on to the cheek, and making its way backward into the zygomatic fossa and downward into the mouth.

The **Malar Process** is a rough, triangular eminence, situated at the angle of

[1] In some cases, at any rate, the lachrymal bone encroaches slightly on the anterior superior portion of the opening, and assists in forming the inner wall of the antrum.

[2] The number of teeth whose fangs are in relation with the floor of the antrum is variable. The antrum "may extend so as to be in relation to all the teeth of the true maxilla, from the canine to the *dens sapientiæ*." (See Mr. Salter on Abscess of the Antrum, in a *System of Surgery*, edited by T. Holmes, 2d ed. vol. iv. p. 356.)

separation of the facial from the zygomatic surface. In front it is concave, forming part of the facial surface; behind it is also concave, and forms part of the zygomatic fossa; above it is rough and serrated for articulation with the malar bone; whilst below a prominent ridge marks the division between the facial and zygomatic surfaces. A small part of the Masseter muscle arises from this process.

The **Nasal Process** is a strong, triangular plate of bone, which projects upward, inward, and backward by the side of the nose, forming part of its lateral boundary. Its *external* surface is concave, smooth, perforated by numerous foramina, and gives attachment to the Levator labii superioris alæque nasi, the Orbicularis palpebrarum, and Tendo oculi. Its *internal* surface forms part of the outer wall of the nasal fossæ: at its upper part it presents a rough, uneven surface, which articulates with the ethmoid bone, closing in the anterior ethmoidal cells; below this is a transverse ridge, the *superior turbinated crest*, for articulation with the middle turbinated bone of the ethmoid, bounded below by a shallow smooth concavity which forms part of the middle meatus; below this again is the inferior turbinated crest (already described), where the process joins the body of the bone. Its upper border articulates with the frontal bone. The *anterior* border of the nasal process is thin, directed obliquely downward and forward, and presents a serrated edge for articulation with the nasal bone; its *posterior* border is thick, and hollowed into a groove, the *lachrymal groove*, for the nasal duct: of the two margins of this groove, the inner one articulates with the lachrymal bone, the outer one forms part of the circumference of the orbit. Just where the latter joins the orbital surface is a small tubercle, the *lachrymal tubercle;* this serves as a guide to the position of the lachrymal sac in the operation for fistula lachrymalis. The lachrymal groove in the articulated skull is converted into a canal by the lachrymal bone and lachrymal process of the inferior turbinated; it is directed downward, and a little backward and outward, is about the diameter of a goose-quill, slightly

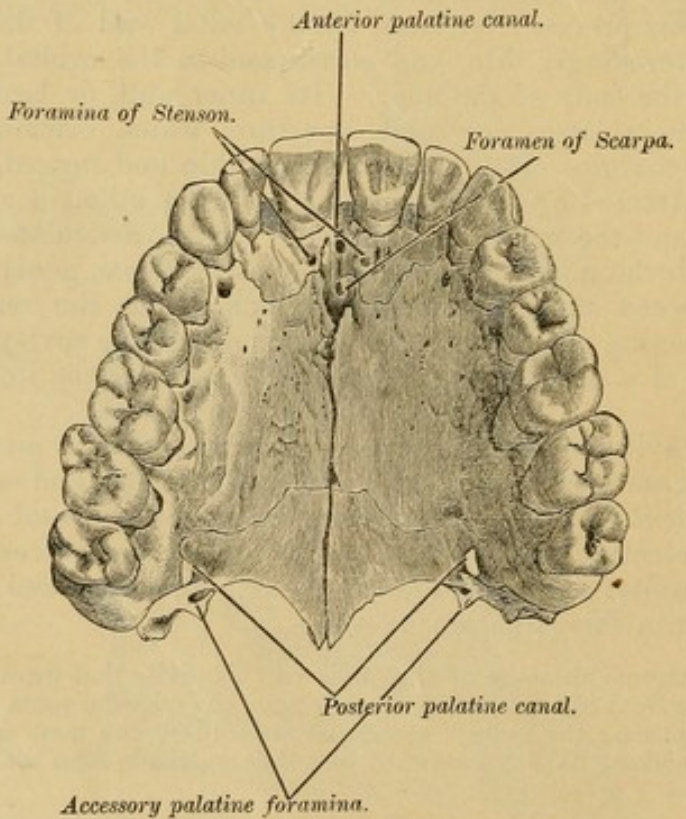

FIG. 51.—The palate and alveolar arch.

narrower in the middle than at either extremity, and terminates below in the inferior meatus. It lodges the nasal duct.

The **Alveolar Process** is the thickest and most spongy part of the bone, broader behind than in front, and excavated into deep cavities for the reception of the teeth.

These cavities are eight in number, and vary in size and depth according to the teeth they contain. That for the canine tooth is the deepest; those for the molars are the widest, and subdivided into minor cavities; those for the incisors are single, but deep and narrow. The Buccinator muscle arises from the outer surface of this process, as far forward as the first molar tooth.

The **Palate Process**, thick and strong, projects horizontally inward from the inner surface of the bone. It is much thicker in front than behind, and forms a considerable part of the floor of the nostril and the roof of the mouth.

Its *inferior* surface (Fig. 51) is concave, rough and uneven, and forms part of the roof of the mouth. This surface is perforated by numerous foramina for the passage of the nutrient vessels, channelled at the back part of its alveolar border by a longitudinal groove, sometimes a canal, for the transmission of the posterior palatine vessels, and the anterior and external palatine nerves from Meckel's ganglion, and presents little depressions for the lodgement of the palatine glands. When the two superior maxillary bones are articulated together, a large orifice may be seen in the middle line, immediately behind the incisor teeth. This is the *anterior palatine canal* or *fossa*. On examining the bottom of this fossa four canals are seen: two branch off laterally to the right and left nasal fossæ, and two, one in front and one behind, lie in the middle line. The former pair of these canals are named the *foramina of Stenson*, and through them passes the anterior or terminal branch of the descending or posterior palatine arteries, which ascend from the mouth to the nasal fossæ. The canals in the middle line are termed the *foramina of Scarpa*, and transmit the naso-palatine nerves, the left passing through the anterior, and the right through the posterior, canal. On the palatal surface of the process a delicate linear suture may sometimes be seen extending from the anterior palatine fossa to the interval between the lateral incisor and the canine tooth. This marks out the intermaxillary or incisive bone, which in some animals exists permanently as a separate piece. It includes the whole thickness of the alveolus, the corresponding part of the floor of the nose, and the anterior nasal spine, and contains the sockets of the incisor teeth. The *upper* surface is concave from side to side, smooth, and forms part of the floor of the nose. It presents the upper orifices of the foramina of Stenson and Scarpa, the former being on each side of the middle line, the latter being situated in the intermaxillary suture, and therefore not visible unless the two bones are placed in apposition. The *outer* border of the palate process is incorporated with the rest of the bone. The *inner* border is thicker in front than behind, and is raised above into a ridge, the *nasal crest*, which, with the corresponding ridge in the opposite bone, forms a groove for the reception of the vomer. In front this crest rises to a considerable height, and this portion is named the *incisor crest*. The *anterior* margin is bounded by the thin, concave border of the opening of the nose, prolonged forward internally into a sharp process, forming, with a similar process of the opposite bone, the *anterior nasal spine*. The *posterior* border is serrated for articulation with the horizontal plate of the palate bone.

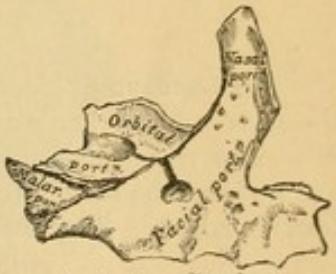

Anterior Surface.



Inferior Surface.

FIG. 52.—Development of superior maxillary bone. At birth.

Development.—This bone commences to ossify at a very early period, and ossification proceeds in it with great rapidity, so that it is difficult to ascertain with certainty its precise number of centres. It appears, however, probable that it is ossified from four centres, which are deposited in membrane. 1. One which forms that portion of the body of the bone which lies internal to the infra-orbital canal, including the floor of the orbit, the outer wall of the nasal fossa, and the nasal process; 2. A second which gives origin to that portion of the bone which lies external to the infra-orbital canal

and the malar process; 3. A third from which is developed the palatine process posterior to Stenson's canal and the adjoining part of the nasal wall; 4. And a fourth for the front part of the alveolus which carries the incisor teeth and corresponds to the pre-maxillary bone of the lower animals. These centres appear about the eighth week, and by the tenth week the three first-named centres have become fused together and the bone consists of two portions, one the maxilla proper, and the other the pre-maxillary portion. The suture between these two portions on the palate persists till middle life, but is not to be seen on the facial surface. This is believed by Callender to be due to the fact that the front wall of the sockets of the incisive teeth is not formed by the pre-maxillary bone, but by an outgrowth from the facial part of the superior maxilla. The antrum appears as a shallow groove on the inner surface of the bone at an earlier period than any of the other nasal sinuses, its development commencing about the fourth month of fœtal life. The sockets for the teeth are formed by the growing downward of two plates from the dental groove, which subsequently becomes divided by partitions jutting across from the one to the other.

Articulations.—With *nine* bones: two of the cranium, the frontal and ethmoid, and seven of the face—viz. the nasal, malar, lachrymal, inferior turbinated, palate, vomer, and its fellow of the opposite side. Sometimes it articulates with the orbital plate of the sphenoid, and sometimes with its external pterygoid plate.

Attachment of Muscles.—To twelve: the Orbicularis palpebrarum, Obliquus oculi inferior, Levator labii superioris alæque nasi, Levator labii superioris proprius, Levator anguli oris, Compressor nasi, Depressor alæ nasi, Dilatator naris posterior, Masseter, Buccinator, Internal pterygoid, and Orbicularis oris.

CHANGES PRODUCED IN THE UPPER JAW BY AGE.

At birth and during infancy the diameter of the bone is greater in an antero-posterior than in a vertical direction. Its nasal process is long, its orbital surface large, and its tuberosity well marked. In the adult the vertical diameter is the greater, owing to the development of the alveolar process and the increase in size of the antrum. In old age the bone approaches again in character to the infantile condition: its height is diminished, and after the loss of the teeth the alveolar process is absorbed, and the lower part of the bone contracted and diminished in thickness.

The Lachrymal Bones.

The **Lachrymal** (*lachryma*, a tear) are the smallest and most fragile bones of the face. They are situated at the front part of the inner wall of the orbit (Fig. 46). and resemble somewhat in form, thinness, and size a finger-nail; hence they are termed the *ossa unguis*. Each bone presents for examination two surfaces and four borders. The **external** or **orbital** surface (Fig. 53) is divided by a vertical ridge, the *lachrymal crest*, into two parts. The portion of bone in front of this ridge presents a smooth, concave, longitudinal groove, the free margin of which unites with the nasal process of the superior maxillary bone, completing the lachrymal groove. The upper part of this groove lodges the lachrymal sac; the lower part lodges the nasal duct. The portion of bone behind the ridge is smooth, slightly concave, and forms part of the inner wall of the orbit. The ridge, with a part of the orbital surface immediately behind it, affords attachment to the Tensor tarsi muscle: it terminates below in a small, hook-like projection, the *hamular process*, which articulates with the lachrymal tubercle of the superior maxillary bone, and completes the upper orifice of the lachrymal groove. It sometimes exists as a separate piece, which is then called the *lesser lachrymal bone*. The *internal* or *nasal* surface presents a depressed furrow, corresponding to the ridge on its outer surface. The surface of bone in front of this forms part of

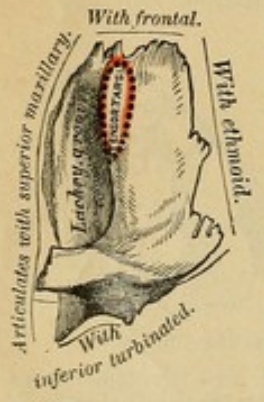

FIG. 53.—Left lachrymal bone. External surface. (Slightly enlarged.)

the middle meatus, and that behind it articulates with the ethmoid bone, filling in the anterior ethmoidal cells. Of the *four borders*, the *anterior* is the longest, and articulates with the nasal process of the superior maxillary bone. The *posterior*, thin and uneven, articulates with the os planum of the ethmoid. The *superior*, the shortest and thickest, articulates with the internal angular process of the frontal bone. The *inferior* is divided by the lower edge of the vertical crest into two parts; the posterior part articulates with the orbital plate of the superior maxillary bone; the anterior portion is prolonged downward into a pointed process, which articulates with the lachrymal process of the inferior turbinated bone and assists in the formation of the lachrymal groove.

Development.—By a single centre, which makes its appearance soon after ossification of the vertebræ has commenced.

Articulations.—With four bones: two of the cranium, the frontal and ethmoid, and two of the face, the superior maxillary and the inferior turbinated.

Attachment of Muscles.—To one muscle, the Tensor tarsi.

The Malar Bones.

The **Malar** (*mala*, the cheek) are two small, quadrangular bones, situated at the upper and outer part of the face: they form the prominence of the cheek, part of the outer wall and floor of the orbit, and part of the temporal and zygomatic fossæ (Fig. 54). Each bone presents for examination an external and an internal surface; four processes, the frontal, orbital, maxillary, and zygomatic; and four borders. The **external surface** (Fig. 55) is smooth, convex, perforated near its

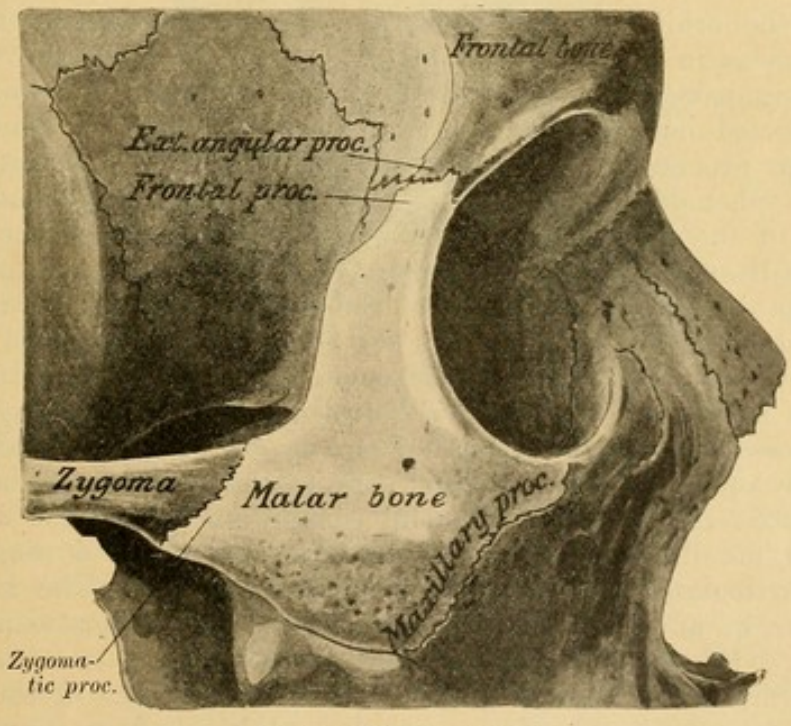

FIG. 54.—Malar bone *in situ*.

centre by one or two small apertures, the *malar foramina*, for the passage of nerves and vessels, covered by the Orbicularis palpebrarum muscle, and affords attachment to the Zygomaticus major and minor muscles.

The **internal surface** (Fig. 56), directed backward and inward, is concave, presenting internally a rough, triangular surface, for articulation with the superior maxillary bone; and externally, a smooth concave surface, which above forms the anterior boundary of the temporal fossa, and below, where it is wider, forms part of the zygomatic fossa. This surface presents, a little above its centre, the aperture of one or two malar canals, and affords attachment to a portion of the

Masseter muscle at its lower part. Of the four processes, the **frontal** is thick and serrated, and articulates with the external angular process of the frontal bone. To its orbital margin is attached the external tarsal ligament. The **orbital** process is a thick and strong plate, which projects backward from the orbital margin of the bone. Its *supero-internal* surface, smooth and concave, forms, by its junction with the orbital surface of the superior maxillary bone and with the great wing of the sphenoid, part of the floor and

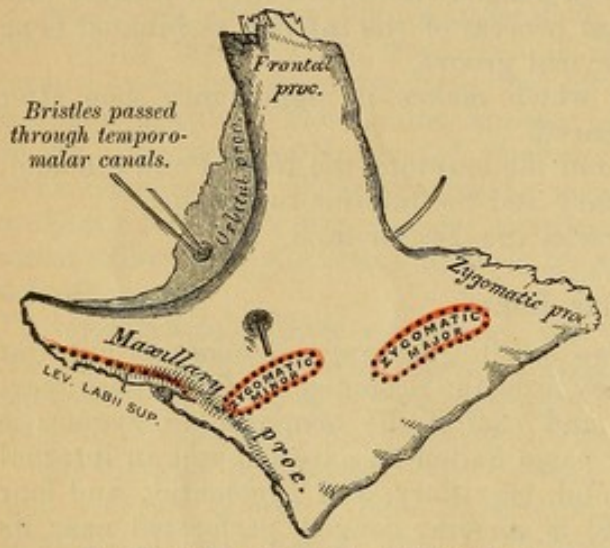

FIG. 55.—Left malar bone. Outer surface.

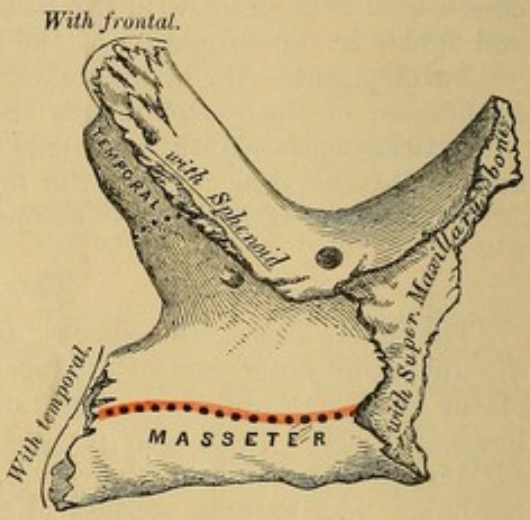

FIG. 56.—Left malar bone. Inner surface.

outer wall of the orbit. Its *infero-external* surface, smooth and convex, forms part of the zygomatic and temporal fossæ. Its *anterior* margin is smooth and rounded, forming part of the circumference of the orbit. Its *superior* margin, rough and directed horizontally, articulates with the frontal bone behind the external angular process. Its *posterior* margin is rough, and serrated for articulation with the sphenoid; *internally* it is also serrated for articulation with the orbital surface of the superior maxillary. At the angle of junction of the sphenoidal and maxillary portions a short, rounded, non-articular margin is generally seen; this forms the anterior boundary of the spheno-maxillary fissure: occasionally, no such non-articular margin exists, the fissure being completed by the direct junction of the maxillary and sphenoid bones or by the interposition of a small Wormian bone in the angular interval between them. On the *upper* surface of the orbital process are seen the orifices of one or two temporo-malar canals; one of these usually opens on the posterior surface, the other (occasionally two) on the facial surface: they transmit filaments (temporo-malar) of the orbital branch of the superior maxillary nerve. The **maxillary** process is a rough, triangular surface which articulates with the superior maxillary bone. The **zygomatic** process, long, narrow, and serrated, articulates with the zygomatic process of the temporal bone. Of the **four borders,** the *antero-superior* or *orbital* is smooth, arched, and forms a considerable part of the circumference of the orbit. The *antero-inferior* or *maxillary* border is rough, and bevelled at the expense of its inner table, to articulate with the superior maxillary bone; affording attachment by its margin to the Levator labii superioris proprius, just at its point of junction with the superior maxillary. The *postero-superior* or *temporal* border, curved like an italic letter *f*, is continuous above with the commencement of the temporal ridge; below, with the upper border of the zygomatic arch: it affords attachment to the temporal fascia. The *postero-inferior* or *zygomatic* border is continuous with the lower border of the zygomatic arch, affording attachment by its rough edge to the Masseter muscle.

Development.—The malar bone ossifies generally from three centres, which appear about the eighth week—one for the zygomatic and two for the orbital portion—and fuse about the fifth month of fœtal life. The bone is sometimes,

after birth, seen to be divided by a horizontal suture into an upper and larger and a lower and smaller division. In some quadrumana the malar bone consists of two parts, an orbital and a malar, which are ossified by separate centres.

Articulations.—With four bones: three of the cranium, frontal, sphenoid, and temporal; and one of the face, the superior maxillary.

Attachment of Muscles.—To four: The Levator labii superioris proprius, Zygomaticus major and minor, and Masseter.

The Palate Bones.

The **Palate Bones** (*palatum*, the palate) are situated at the back part of the nasal fossæ: they are wedged in between the superior maxillary bones and the pterygoid processes of the sphenoid (Fig. 57). Each bone assists in the for-

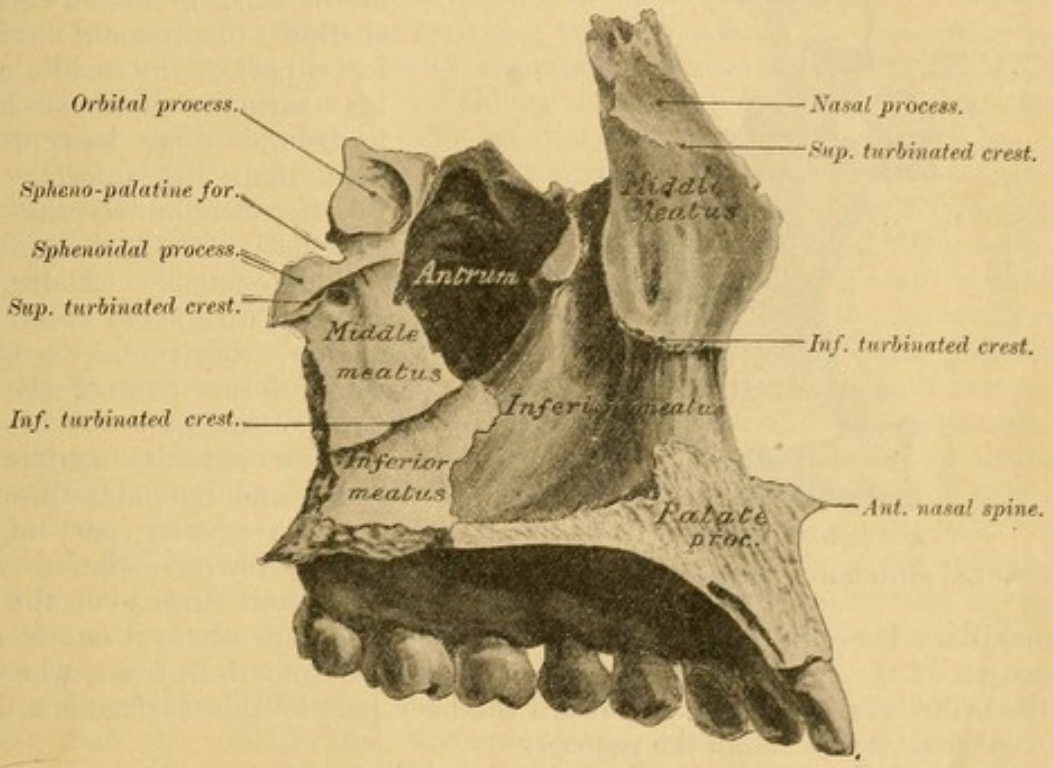

FIG. 57.—Palate bone *in situ*.

mation of three cavities: the floor and outer wall of the nose, the roof of the mouth, and the floor of the orbit, and enters into the formation of two fossæ, the spheno-maxillary and pterygoid; and one fissure, the spheno-maxillary. In form the palate bone somewhat resembles the letter L, and may be divided into an inferior or horizontal plate and a superior or vertical plate.

The **Horizontal Plate** is of a quadrilateral form, and presents two surfaces and four borders. The *superior* surface, concave from side to side, forms the back part of the floor of the nose. The *inferior* surface, slightly concave and rough, forms the back part of the hard palate. At its posterior part may be seen a transverse ridge, more or less marked, for the attachment of part of the aponeurosis of the Tensor palati muscle. At the outer extremity of this ridge is a deep groove converted into a canal by its articulation with the tuberosity of the superior maxillary bone, and forming the *posterior palatine canal*. Near this groove the orifices of one or two small canals, *accessory posterior palatine*, may be seen. The *anterior* border is serrated, bevelled at the expense of its inferior surface, and articulates with the palate process of the superior maxillary bone. The *posterior* border is concave, free, and serves for the attachment of the soft palate. Its inner extremity is sharp and pointed, and, when united with the opposite bone, forms a projecting process, the *posterior nasal spine*, for the attachment of the Azygos uvulæ muscle. The *external* border is united with the lower part of the perpen-

dicular plate almost at right angles. The *internal* border, the thickest, is serrated for articulation with its fellow of the opposite side; its superior edge is raised into a ridge, which, united with the opposite bone, forms a crest in which the vomer is received.

The **Vertical Plate** (Fig. 58) is thin, of an oblong form, and directed upward and a little inward. It presents two surfaces, an external and an internal, and four borders.

The **internal surface** presents at its lower part a broad, shallow depression, which forms part of the inferior meatus of the nose. Immediately above this is a well-marked horizontal ridge, the *inferior turbinated crest*, for articulation with the inferior turbinated bone; above this, a second broad, shallow depression, which forms part of the middle meatus, surmounted above by a horizontal ridge less prominent than the inferior, the *superior turbinated crest*, for articulation with the middle turbinated bone. Above the superior turbinated crest is a narrow, horizontal groove, which forms part of the superior meatus.

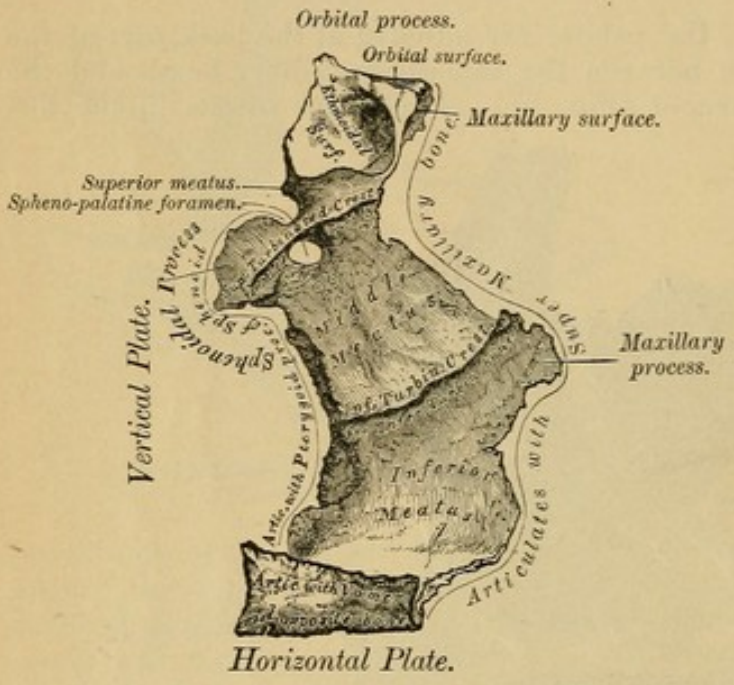

FIG. 58.—Left palate bone. Internal view. (Enlarged.)

The **external surface** is rough and irregular throughout the greater part of its extent, for articulation with the inner surface of the superior maxillary bone, its upper and back part being smooth where it enters into the formation of the spheno-maxillary fossa; it is also smooth in front, where it covers the orifice of the antrum. Toward the back part of this surface is a deep groove, converted into a canal, the *posterior palatine*, by its articulation with the superior maxillary bone. It transmits the posterior or descending palatine vessels and one of the descending palatine branches from Meckel's ganglion.

The *anterior* border is thin, irregular, and presents, opposite the inferior turbinated crest, a pointed, projecting lamina, the *maxillary process*, which is directed forward, and closes in the lower and back part of the opening of the antrum. The *posterior* border (Fig. 59) presents a deep groove, the edges of which are serrated for articulation with the pterygoid process of the sphenoid. At the lower part of this border is seen a pyramidal process of bone, the *pterygoid process* or tuberosity of the palate, which is received into the angular interval between the two pterygoid plates of the sphenoid at their inferior extremity. This process presents at its back part a median groove and two lateral surfaces. The groove is smooth, and forms part

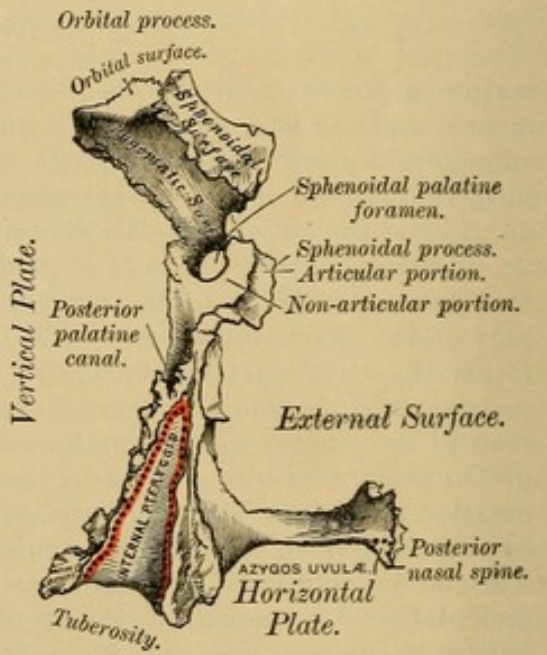

FIG. 59.—Left palate bone. Posterior view. (Enlarged.)

of the pterygoid fossa, affording attachment to the Internal pterygoid muscle; whilst the lateral surfaces are rough and uneven, for articulation with the anterior border of each pterygoid plate. A few fibres of the Superior constrictor arise from the tuberosity of the palate bone. The base of this process, continuous with the horizontal portion of the bone, presents the apertures of the *accessory descending palatine canals*, through which pass the two smaller descending branches of Meckel's ganglion; whilst its outer surface is rough for articulation with the inner surface of the body of the superior maxillary bone.

The *superior* border of the vertical plate presents two well-marked processes separated by an intervening notch or foramen. The anterior, or larger, is called the *orbital process;* the posterior, the *sphenoidal.*

The **Orbital Process,** directed upward and outward, is placed on a higher level than the sphenoidal. It presents five surfaces, which enclose a hollow cellular cavity, and is connected to the perpendicular plate by a narrow, constricted neck. Of these five surfaces, three are articular, two non-articular or free surfaces. The three articular are the *anterior* or *maxillary* surface, which is directed forward, outward, and downward, is of an oblong form, and rough for articulation with the superior maxillary bone. The *posterior* or *sphenoidal* surface is directed backward, upward, and inward. It ordinarily presents a small, open cell, which communicates with the sphenoidal cells, and the margins of which are serrated for articulation with the vertical part of the sphenoidal turbinated bone. The *internal* or *ethmoidal* surface is directed inward, upward, and forward, and articulates with the lateral mass of the ethmoid bone. In some cases the cellular cavity above mentioned opens on this surface of the bone; it then communicates with the posterior ethmoidal cells. More rarely it opens on both surfaces, and then communicates both with the posterior ethmoidal and the sphenoidal cells. The non-articular or free surfaces are the *superior* or *orbital*, directed upward and outward, of triangular form, concave, smooth, and forming the back part of the floor of the orbit; and the *external* or *zygomatic* surface, directed outward, backward, and downward, of an oblong form, smooth, lying in the spheno-maxillary fossa, and looking into the zygomatic fossa. The latter surface is separated from the orbital by a smooth, rounded border, which enters into the formation of the spheno-maxillary fissure.

The **Sphenoidal Process** of the palate bone is a thin, compressed plate, much smaller than the orbital, and directed upward and inward. It presents three surfaces and two borders. The *superior* surface, the smallest of the three, articulates with the under surface of the sphenoidal turbinated bone; it presents a groove, which contributes to the formation of the pterygo-palatine canal. The *internal* surface is concave, and forms part of the outer wall of the nasal fossa. The *external* surface is divided into an articular and a non-articular portion: the former is rough, for articulation with the inner surface of the internal pterygoid plate of the sphenoid; the latter is smooth, and forms part of the spheno-maxillary fossa. The *anterior* border forms the posterior boundary of the spheno-palatine foramen. The *posterior* border, serrated at the expense of the outer table, articulates with the inner surface of the internal pterygoid plate.

The orbital and sphenoidal processes are separated from one another by a deep notch, which is converted into a foramen, the *spheno-palatine*, by articulation with the sphenoidal turbinated bone. Sometimes the two processes are united above, and form between them a complete foramen, or the notch is crossed by one or more spiculæ of bone, so as to form two or more foramina. In the articulated skull this foramen opens into the back part of the outer wall of the superior meatus, and transmits the spheno-palatine vessels and the superior nasal and naso-palatine nerves.

Development.—From a single centre, which makes its appearance about the second month at the angle of junction of the two plates of the bone. From this point ossification spreads inward to the horizontal plate, downward into the tuberosity, and upward into the vertical plate. In the fœtus the horizontal plate

is much longer than the vertical, and even after it is fully ossified the whole bone is at first remarkable for its shortness.

Articulations.—With six bones: the sphenoid, ethmoid, superior maxillary, inferior turbinated, vomer, and opposite palate.

Attachment of Muscles.—To four: the Tensor palati, Azygos uvulæ, Internal pterygoid, and Superior constrictor of the pharynx.

The Inferior Turbinated Bones.

The **Inferior Turbinated Bones** (*turbo*, a whirl) are situated one on each side of the outer wall of the nasal fossæ. Each consists of a layer of thin, spongy bone, curled upon itself like a scroll—hence its name "turbinated"—and extends horizontally along the outer wall of the nasal fossa, immediately below the orifice of

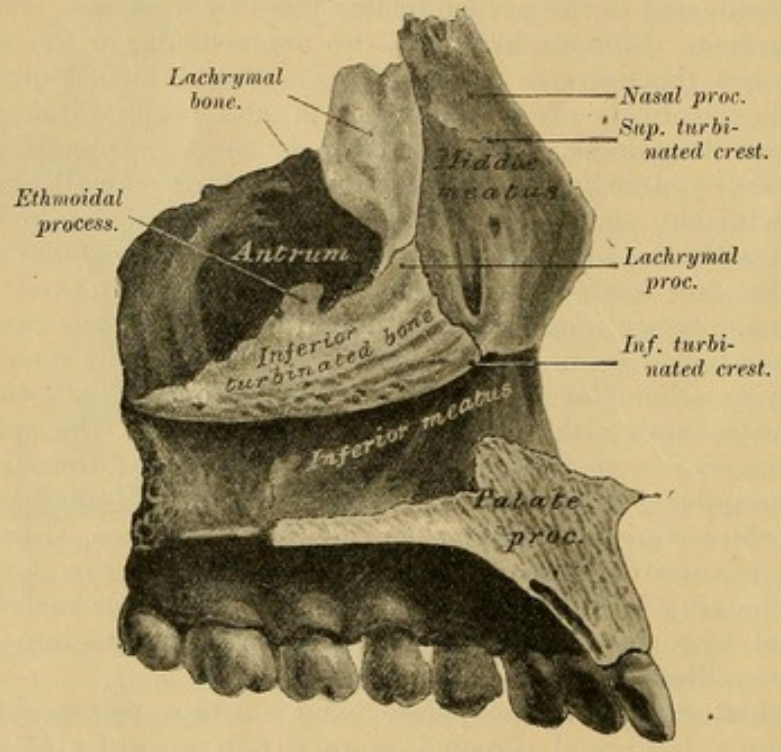

FIG. 60.—Inferior turbinated bone and Lachrymal bone *in situ*.

the antrum (Fig. 60). Each bone presents two surfaces, two borders, and two extremities.

The **internasal surface** (Fig. 61) is convex, perforated by numerous apertures, and traversed by longitudinal grooves and canals for the lodgement of arteries and



FIG. 61.—Right inferior turbinated bone. Internal surface.

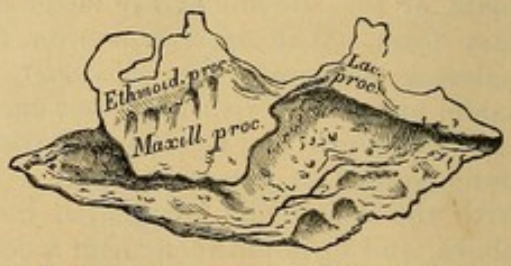

FIG. 62.—Right inferior turbinated bone. External surface.

veins. In the recent state it is covered by the lining membrane of the nose. The **external surface** is concave (Fig. 62), and forms part of the inferior meatus. Its *upper border* is thin, irregular, and connected to various bones along the outer wall of the nose. It may be divided into three portions: of these, the anterior articulates with the inferior turbinated crest of the superior maxillary bone; the posterior with the inferior turbinated crest of the palate bone; the middle portion

of the superior border presents three well-marked processes, which vary much in their size and form. Of these, the anterior and smallest is situated at the junction of the anterior fourth with the posterior three-fourths of the bone: it is small and pointed, and is called the *lachrymal process;* it articulates by its apex with the anterior inferior angle of the lachrymal bone, and by its margins with the groove on the back of the nasal process of the superior maxillary, and thus assists in forming the canal for the nasal duct. At the junction of the two middle fourths of the bone, but encroaching on its posterior fourth, a broad, thin plate, the *ethmoidal process*, ascends to join the unciform process of the ethmoid; from the lower border of this process a thin lamina of bone curves downward and outward, hooking over the lower edge of the orifice of the antrum, which it narrows below: it is called the *maxillary process*, and fixes the bone firmly to the outer wall of the nasal fossa. The *inferior border* is free, thick, and cellular in structure, more especially in the middle of the bone. Bone *extremities* are more or less narrow and pointed, the posterior being the more tapering. If the bone is held so that its outer concave surface is directed backward (*i. e.*, toward the holder), and its superior border, from which the lachrymal and ethmoidal processes project, upward, the lachrymal process will be directed to the side to which the bone belongs.[1]

Development.—By a single centre, which makes its appearance about the middle of fœtal life.

Articulations.—With four bones: one of the cranium, the ethmoid, and three of the face, the superior maxillary, lachrymal, and palate.

No muscles are attached to this bone.

The Vomer.

The **Vomer** (*vomer*, a ploughshare) is a single bone, situated vertically at the back part of the nasal fossæ, forming part of the septum of the nose (Fig. 63).

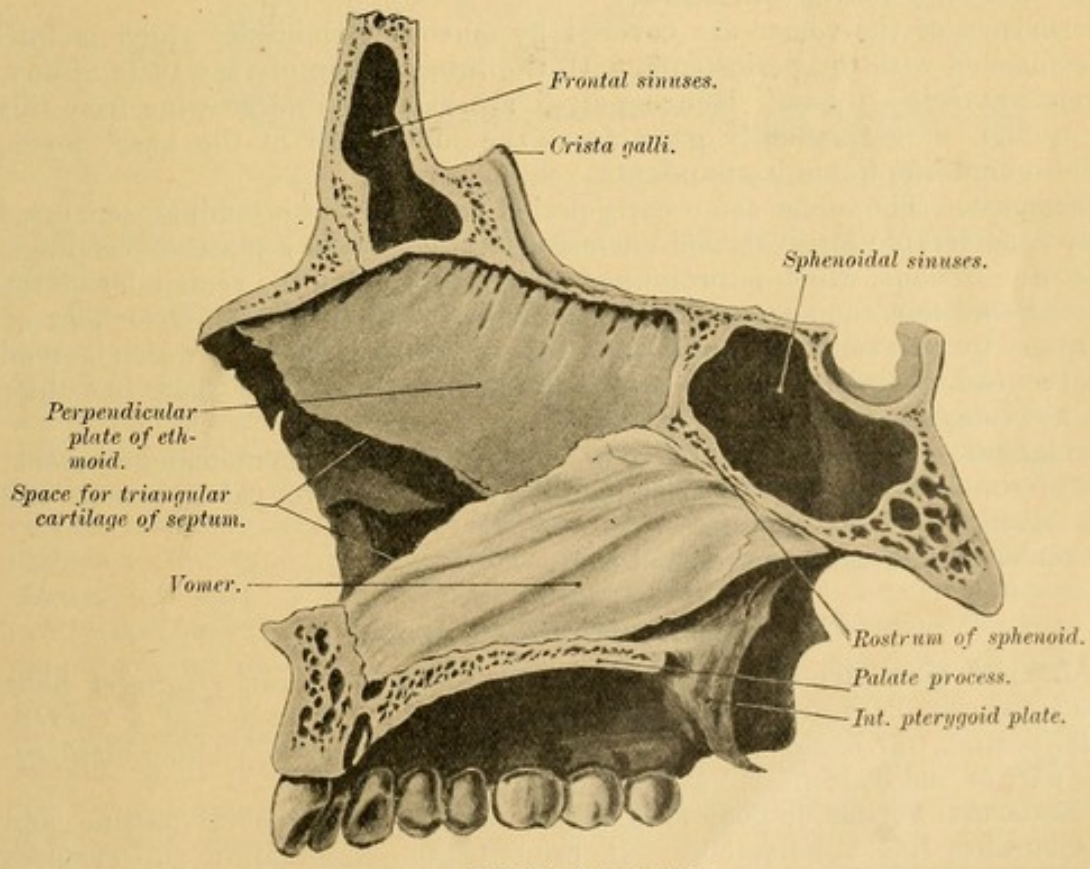

FIG. 63.—Vomer *in situ*.

It is thin, somewhat like a ploughshare in form; but it varies in different indi-

[1] If the lachrymal process is broken off, as is often the case, the side to which the bone belongs may be known by recollecting that the maxillary process is nearer the back than the front of the bone.

viduals, being frequently bent to one or the other side; it presents for examination two surfaces and four borders. The *lateral surfaces* are smooth, marked by small furrows for the lodgement of blood-vessels, and by a groove on each side, sometimes a canal, the *naso-palatine*, which runs obliquely downward and forward to the intermaxillary suture; it transmits the naso-palatine nerve. The *superior border*, the thickest, presents a deep groove, bounded on each side by a horizontal projecting ala of bone; the groove receives the rostrum of the sphenoid, while the alæ are overlapped and retained by the *vaginal processes* which project from the under surface of the body of the sphenoid at the base of the pterygoid processes. At the front of the groove a fissure is left for the transmission of blood-vessels to the substance of the bone. The *inferior border*, the longest, is broad and uneven in front, where it articulates with the two superior maxillary bones; thin and sharp behind, where it joins with the palate bones. The upper half of the *anterior border* usually consists of two laminæ of bone, between which is received the perpendicular plate of the ethmoid; the lower half, also separated into two lamellæ, receives between them the lower margin of the septal cartilage of the nose. The *posterior border* is free, concave, and separates the nasal fossæ behind. It is thick and bifid above, thin below.

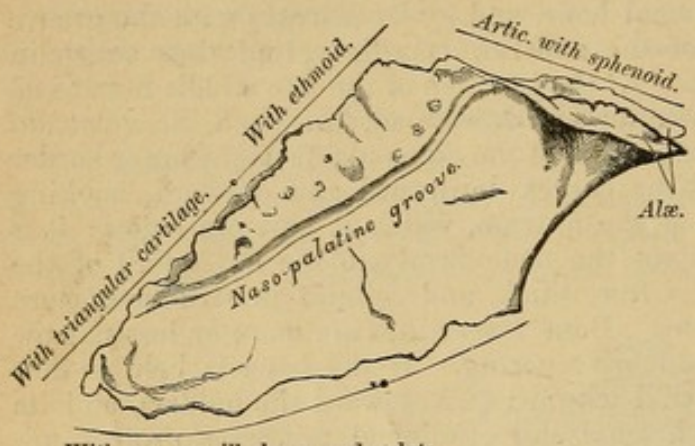

FIG. 64.—The vomer.

The surfaces of the vomer are covered by mucous membrane, which is intimately connected with the periosteum, with the intervention of very little, if any, submucous connective tissue. Hence polypi are rarely found growing from this surface, though they frequently grow from the outer wall of the nasal fossæ, where the submucous tissue is abundant.

Development.—The vomer at an early period consists of two laminæ, separated by a very considerable interval, and enclosing between them a plate of cartilage, the *vomerine cartilage*, which is prolonged forward to form the remainder of the septum. Ossification commences in the membrane at the postero-inferior part of this cartilage by two centres, one on each side of the middle line, which extend to form the two laminæ. They begin to coalesce at the lower part, but their union is not complete until after puberty.

Articulations.—With six bones: two of the cranium, the sphenoid and ethmoid; and four of the face, the two superior maxillary and the two palate bones; and with the cartilage of the septum.

The vomer has no muscles attached to it.

The Inferior Maxillary Bone.

The **Inferior Maxillary Bone** (the *Mandible*), the largest and strongest bone of the face, serves for the reception of the lower teeth. It consists of a curved, horizontal portion, the *body*, and two perpendicular portions, the *rami*, which join the back part of the body nearly at right angles.

The **Horizontal Portion** or **Body** (Fig. 65) is convex in its general outline, and curved somewhat like a horseshoe. It presents for examination two surfaces and two borders. The **external surface** is convex from side to side, concave from above downward. In the median line is a vertical ridge, the *symphysis*, which extends from the upper to the lower border of the bone, and indicates the point of junction of the two pieces of which the bone is composed at an early period of life.

The lower part of the ridge terminates in a prominent triangular eminence, the *mental process*. This eminence is rounded below, and often presents a median depression separating two processes, the *mental tubercles*. It forms the chin, a feature peculiar to the human skull. On either side of the symphysis, just below the cavities for the incisor teeth, is a depression, the *incisive fossa*, for the attachment of the Levator menti (or Levator labii inferioris); more externally is attached a portion of the Orbicularis oris (*Accessorii Orbicularis inferioris*), and, still more externally, a foramen, the *mental foramen*, for the passage of the mental vessels and nerve. This foramen is placed just below the interval between the two bicuspid teeth. Running outward from the base of the mental process on each side is a ridge, the *external oblique* line. The ridge is at first nearly horizontal, but afterward inclines upward and backward, and is continuous with the anterior border of the ramus: it affords attachment to the Depressor

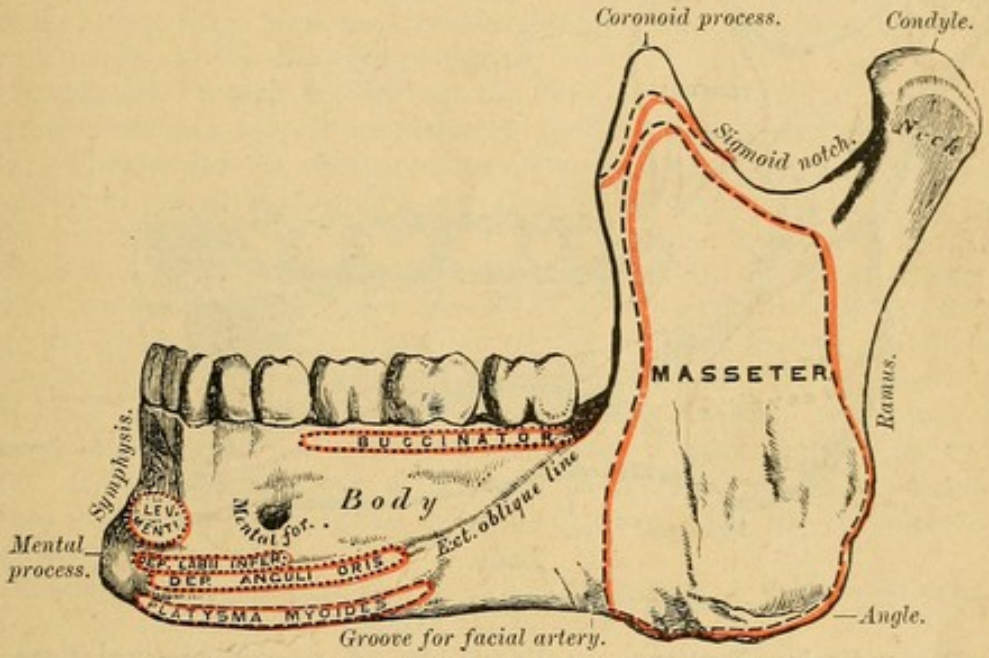

FIG. 65. — Inferior maxillary bone. Outer surface. Side view.

labii inferioris and Depressor anguli oris; below it the Platysma myoides is attached.

The **internal surface** (Fig. 66) is concave from side to side, convex from above downward. In the middle line is an indistinct linear depression, corresponding to the symphysis externally; on either side of this depression, just below its centre, are four prominent tubercles, placed in pairs, two above and two below; they are called the *genial tubercles*, and afford attachment, the upper pair to the Genio-hyo-glossi, the lower pair to the Genio-hyoidei, muscles. Sometimes the tubercles on each side are blended into one; at others they all unite into an irregular eminence; or, again, nothing but an irregularity may be seen on the surface of the bone at this part. On either side of the genial tubercles is an oval depression, the *sublingual fossa*, for lodging the sublingual gland; and beneath the fossa a rough depression on each side which gives attachment to the anterior belly of the Digastric muscle. At the back part of the sublingual fossa the *internal oblique line* (*mylo-hyoidean*) commences; it is at first faintly marked, but becomes more distinct as it passes upward and outward, and is especially prominent opposite the last two molar teeth; it affords attachment throughout its whole extent to the Mylo-hyoid muscle; the Superior constrictor of the pharynx with the pterygo-maxillary ligament being attached above its posterior extremity, near the alveolar margin. The portion of the bone above this ridge is smooth, and covered by the mucous membrane of the mouth; the portion below presents an oblong depression, the *submaxillary fossa*, wider behind than in front, for the lodgement of the submaxillary gland. The external oblique line and the internal or mylo-hyoidean line

divide the body of the bone into a superior or alveolar and an inferior or basilar portion.

The **superior** or **alveolar** border is wider, and its margins thicker, behind than in front. It is hollowed into numerous cavities, for the reception of the teeth; these cavities are sixteen in number, and vary in depth and size according to the teeth which they contain. To its outer side, the Buccinator muscle is attached as far forward as the first molar tooth. The **inferior** border is rounded, longer than the superior, and thicker in front than behind; it presents a shallow groove, just where the body joins the ramus, over which the facial artery turns.

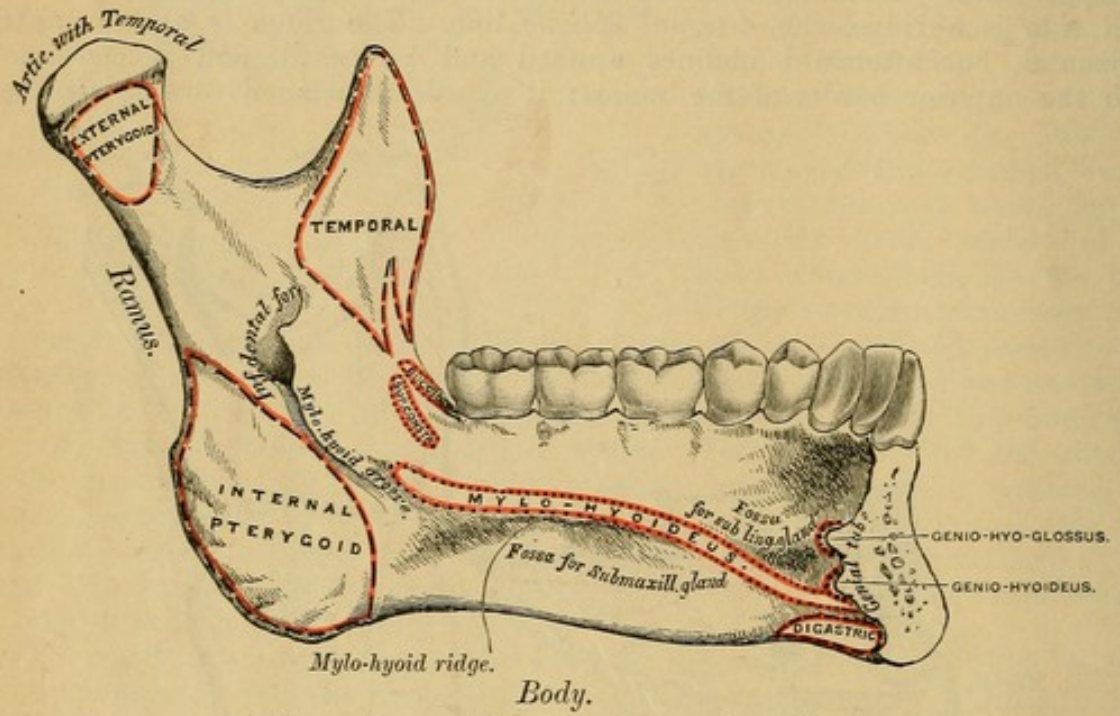

FIG. 66. — Inferior maxillary bone. Inner surface. Side view.

The **Perpendicular Portions,** or **Rami,** are of a quadrilateral form. Each presents for examination two surfaces, four borders, and two processes. The *external surface* is flat, marked with ridges, and gives attachment throughout nearly the whole of its extent to the Masseter muscle. The *internal surface* presents about its centre the oblique aperture of the inferior dental canal, for the passage of the inferior dental vessels and nerve. The margin of this opening is irregular; it presents in front a prominent ridge, surmounted by a sharp spine, the *lingula*, which gives attachment to the internal lateral ligament of the lower jaw, and at its lower and back part a notch leading to a groove, the *mylo-hyoidean*, which runs obliquely downward to the back part of the submaxillary fossa, and lodges the mylo-hyoid vessels and nerve. Behind the groove is a rough surface, for the insertion of the Internal pterygoid muscle. The inferior dental canal runs obliquely downward and forward in the substance of the ramus, and then horizontally forward in the body; it is here placed under the alveoli, with which it communicates by small openings. On arriving at the incisor teeth, it turns back to communicate with the mental foramen, giving off two small canals, which run forward, to be lost in the cancellous tissue of the bone beneath the incisor teeth. This canal, in the posterior two-thirds of the bone, is situated nearer the internal surface of the jaw; and in the anterior third, nearer its external surface. Its walls are composed of compact tissue at either extremity, and of cancellous in the centre. It contains the inferior dental vessels and nerve, from which branches are distributed to the teeth through small apertures at the bases of the alveoli. The *lower border* of the ramus is thick, straight, and continuous with the body of the bone. At its junction with the posterior border is the *angle of the jaw*, which is either inverted or everted, and marked by rough, oblique ridges on each side, for

the attachment of the Masseter externally, and the Internal pterygoid internally; the stylo-maxillary ligament is attached to the angle between these muscles. The *anterior border* is thin above, thicker below, and continuous with the external oblique line. The *posterior border* is thick, smooth, rounded, and covered by the parotid gland. The *upper border* of the ramus is thin, and presents two processes, separated by a deep concavity, the *sigmoid notch*. Of these processes, the anterior is the *coronoid*, the posterior the *condyloid*.

The **Coronoid Process** is a thin, flattened, triangular eminence of bone, which varies in shape and size in different subjects, and serves chiefly for the attachment of the Temporal muscle. Its *external surface* is smooth, and affords attachment to the Temporal and Masseter muscles. Its *internal surface* gives attachment to the Temporal muscle and presents the commencement of a longitudinal ridge, which is continued to the posterior part of the alveolar process. On the outer side of this ridge is a deep groove, continued below on the outer side of the alveolar process; this ridge and part of the groove afford attachment, above, to the Temporal; below, to the Buccinator muscle.

The **Condyloid Process**, shorter but thicker than the coronoid, consists of two portions; the *condyle*, and the constricted portion which supports the condyle, the *neck*. The *condyle* is of an oblong form, its long axis being transverse, and set obliquely on the neck in such a manner that its outer end is a little more forward and a little higher than its inner. It is convex from before backward and from side to side, the articular surface extending farther on the posterior than on the anterior aspect. At its outer extremity is a small tubercle for the attachment of the external lateral ligament of the temporo-mandibular joint. The *neck* of the condyle is flattened from before backward, and strengthened by ridges which descend from the fore part and sides of the condyle. Its lateral margins are narrow, the external one giving attachment to part of the external lateral ligament. Its posterior surface is convex; its anterior is hollowed out on its inner side by a depression (the *pterygoid fossa*), for the attachment of the External pterygoid muscle.

The **Sigmoid Notch**, separating the two processes, is a deep semilunar depression, crossed by the masseteric vessels and nerve.

Development.—The lower jaw is developed principally from membrane, but partly from cartilage. The process of ossification commences early—earlier than in any other bone except the clavicle. The greater part of the bone is formed from a centre of ossification (dentary), which appears between the fifth and sixth week in the membrane on the outer surface of Meckel's cartilage. A second centre (*splenial*) appears in the membrane on the inner surface of the cartilage, and from this centre the inner wall of the sockets of the teeth is formed; this terminates above in the lingula. The anterior extremity of Meckel's cartilage becomes ossified, forming the body of the bone on each side of the symphysis. Two supplemental patches of cartilage appear at the condyle and at the angle, in each of which a centre of ossification for these parts appears; the coronoid process is also ossified from a separate centre. At birth the bone consists of two halves, united by a fibrous symphysis, in which ossification takes place during the first year.

Articulation.—With the glenoid fossæ of the two temporal bones.

Attachment of Muscles.—To fifteen pairs: to its external surface, commencing at the symphysis, and proceeding backward: Levator menti, Depressor labii inferioris, Depressor anguli oris, Platysma myoides, Buccinator, Masseter; a portion of the Orbicularis oris (Accessorii orbicularis inferioris) is also attached to this surface. To its internal surface, commencing at the same point: Genio-hyoglossus, Genio-hyoideus, Mylo-hyoideus, Digastric, Superior constrictor, Temporal, Internal pterygoid, External pterygoid.

CHANGES PRODUCED IN THE LOWER JAW BY AGE.

The changes which the lower jaw undergoes after birth relate (1) to the alterations effected in the body of the bone by the first and second dentitions, the loss of the teeth in the aged, and

Side View of the Lower Jaw at Different Periods of Life.

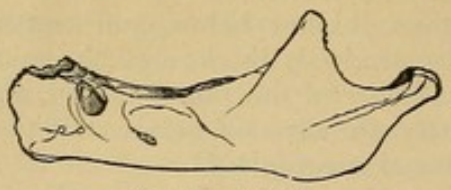

Fig. 67.—At birth.

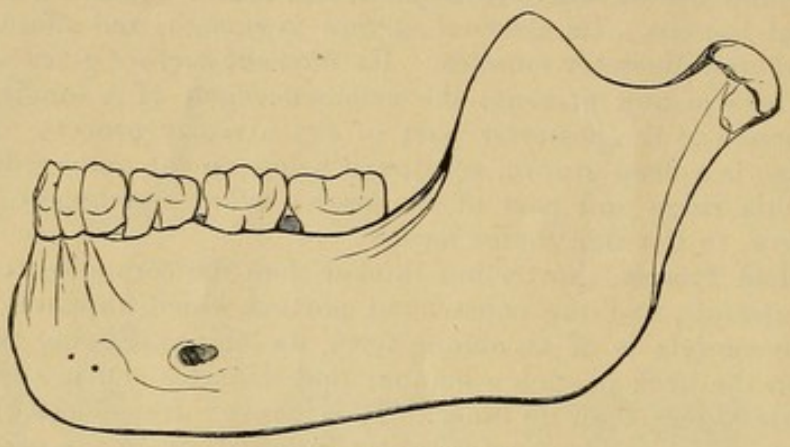

Fig. 68.—At seven years.

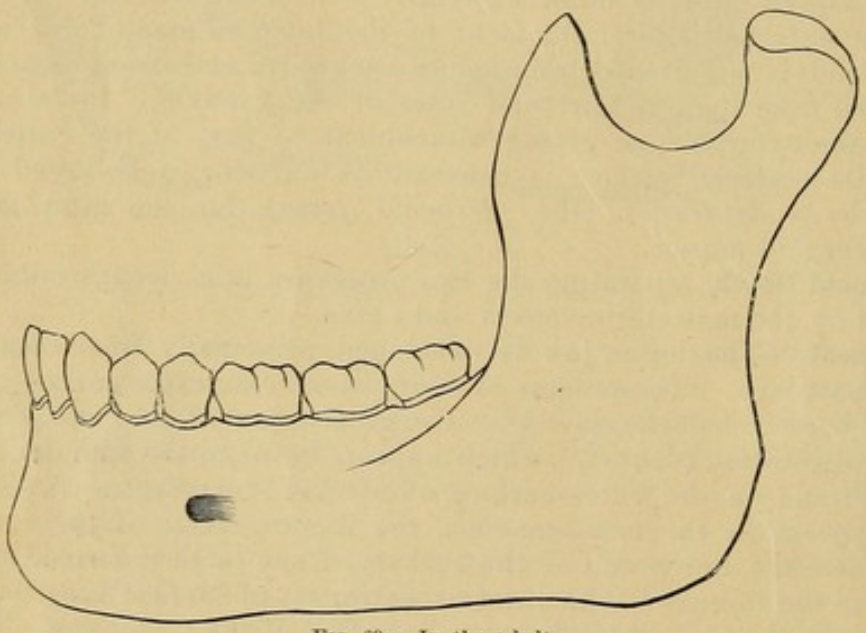

Fig. 69.—In the adult.

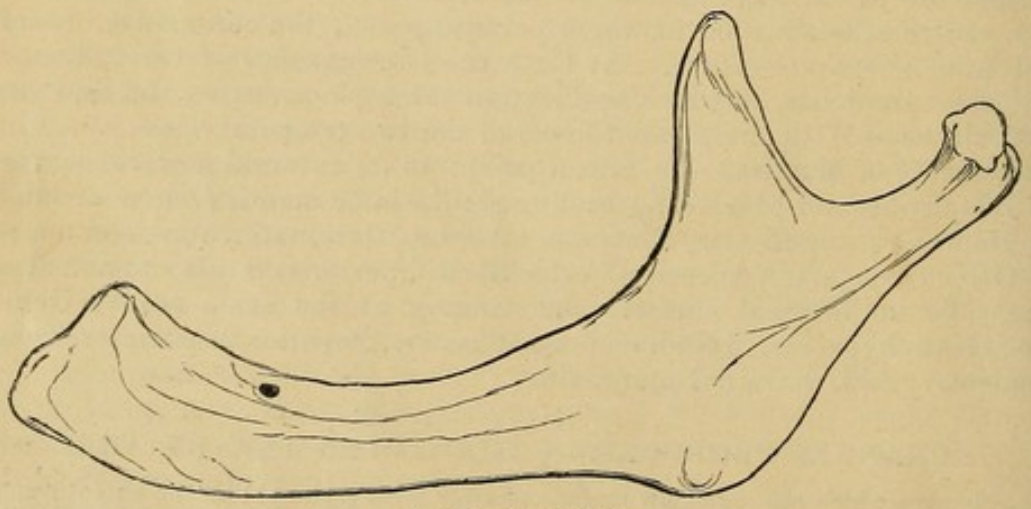

Fig. 70.—In old age.

the subsequent absorption of the alveoli; (2) to the size and situation of the dental canal; and (3) to the angle at which the ramus joins with the body.

At birth (Fig. 67) the bone consists of lateral halves, united by fibrous tissue. The body is a mere shell of bone, containing the sockets of the two incisor, the canine, and the two temporary molar teeth, imperfectly partitioned from one another. The dental canal is of large size, and runs near the lower border of the bone, the mental foramen opening beneath the socket of the first molar. The angle is obtuse (175°), and the condyloid portion nearly in the same horizontal line with the body; the neck of the condyle is short, and bent backward. The coronoid process is of comparatively large size, and situated at right angles with the rest of the bone.

After birth (Fig. 68) the two segments of the bone become joined at the symphysis, from below upward, in the first year; but a trace of separation may be visible in the beginning of the second year near the alveolar margin. The body becomes elongated in its whole length, but more especially behind the mental foramen, to provide space for the three additional teeth developed in this part. The depth of the body becomes greater, owing to increased growth of the alveolar part, to afford room for the fangs of the teeth, and by thickening of the subdental portion, which enables the jaw to withstand the powerful action of the masticatory muscles; but the alveolar portion is the deeper of the two, and, consequently, the chief part of the body lies above the oblique line. The dental canal after the second dentition is situated just above the level of the mylo-hyoid ridge, and the mental foramen occupies the position usual to it in the adult. The angle becomes less obtuse, owing to the separation of the jaws by the teeth. (About the fourth year it is 140°.)

In the adult (Fig. 69) the alveolar and basilar portions of the body are usually of equal depth. The mental foramen opens midway between the upper and lower border of the bone, and the dental canal runs nearly parallel with the mylo-hyoid line. The ramus is almost vertical in direction, and joins the body nearly at right angles.

In old age (Fig. 70) the bone becomes greatly reduced in size; for with the loss of the teeth the alveolar process is absorbed, and the basilar part of the bone alone remains; consequently, the chief part of the bone is *below* the oblique line. The dental canal, with the mental foramen opening from it, is close to the alveolar border. The rami are oblique in direction, the angle obtuse, and the neck of the condyle more or less bent backward.

The Sutures.

The bones of the cranium and face are connected to each other by means of *Sutures*. That is, the articulating surfaces or edges of the bones are more or less roughened or uneven, and are closely adapted to each other, a small amount of intervening fibrous tissue, the *sutural ligament*, fastening them together. The *Cranial Sutures* may be divided into three sets: 1. Those at the vortex of the skull. 2. Those at the side of the skull. 3. Those at the base.

The sutures at the vertex of the skull are three: the *sagittal*, *coronal*, and *lambdoid*.

The **Sagittal Suture** (*interparietal*) is formed by the junction of the two parietal bones, and extends from the middle of the frontal bone backward to the superior angle of the occipital. In childhood, and occasionally in the adult, when the two halves of the frontal bone are not united, it is continued forward to the root of the nose. This suture is sometimes perforated, near its posterior extremity, by the parietal foramen; and in front, where it joins the coronal suture, a space is occasionally left which encloses a large Wormian bone.

The **Coronal Suture** (*fronto-parietal*) extends transversely across the vertex of the skull, and connects the frontal with the parietal bones. It commences at the extremity of the greater wing of the sphenoid on one side, and terminates at the same point on the opposite side. The dentations of the suture are more marked at the sides than at the summit, and are so constructed that the frontal rests on the parietal above, whilst laterally the frontal supports the parietal.

The **Lambdoid Suture** (*occipito-parietal*), so called from its resemblance to the Greek letter *Λ*, connects the occipital with the parietal bones. It commences on each side at the mastoid portion of the temporal bone, and inclines upward to the end of the sagittal suture. The dentations of this suture are very deep and distinct, and are often interrupted by several small Wormian bones.

The sutures at the side of the skull extend from the external angular process of the frontal bone to the lower end of the lambdoid suture behind. The anterior portion is formed between the lateral part of the frontal bone above and the malar and great wing of the sphenoid below, forming the *fronto-malar* and *fronto*

sphenoidal sutures. These sutures can also be seen in the orbit, and form part of the so-called *transverse facial* suture. The posterior portion is formed between the parietal bone above and the great wing of the sphenoid, the squamous and mastoid portions of the temporal bone below, forming the *spheno-parietal*, *squamo-parietal*, and *masto-parietal* sutures.

The **Spheno-parietal** is very short; it is formed by the tip of the great wing of the sphenoid, which overlaps the anterior inferior angle of the parietal bone.

The **Squamo-parietal**, or **Squamous Suture**, is arched. It is formed by the squamous portion of the temporal bone overlapping the middle division of the lower border of the parietal.

The **Masto-parietal** is a short suture, deeply dentated, formed by the posterior inferior angle of the parietal and the superior border of the mastoid portion of the temporal.

The sutures at the base of the skull are the *basilar* in the centre, and on each side the *petro-occipital*, the *masto-occipital*, the *petro-sphenoidal*, and the *squamo-sphenoidal*.

The **Basilar Suture** is formed by the junction of the basilar surface of the occipital bone with the posterior surface of the body of the sphenoid. At an early period of life a thin plate of cartilage exists between these bones, but in the adult they become fused into one. Between the outer extremity of the basilar suture and the termination of the lambdoid an irregular suture exists, which is subdivided into two portions. The inner portion, formed by the union of the petrous part of the temporal with the occipital bone, is termed the **petro-occipital**. The outer portion, formed by the junction of the mastoid part of the temporal with the occipital, is called the **masto-occipital**. Between the bones forming the petro-occipital suture a thin plate of cartilage exists; in the masto-occipital is occasionally found the opening of the mastoid foramen. Between the outer extremity of the basilar suture and the spheno-parietal an irregular suture may be seen, formed by the union of the sphenoid with the temporal bone. The inner and smaller portion of this suture is termed the **petro-sphenoidal**; it is formed between the petrous portion of the temporal and the great wing of the sphenoid: the outer portion, of greater length and arched, is formed between the squamous portion of the temporal and the great wing of the sphenoid; it is called the **squamo-sphenoidal.**

The cranial bones are connected with those of the face, and the facial bones with each other, by numerous sutures, which, though distinctly marked, have received no special names. The only remaining suture deserving especial consideration is the **transverse.** This extends across the upper part of the face, and is formed by the junction of the frontal with the facial bones: it extends from the external angular process of one side to the same point on the opposite side, and connects the frontal with the malar, the sphenoid, the ethmoid, the lachrymal, the superior maxillary, and the nasal bones on each side.

The sutures remain separate for a considerable period after the complete formation of the skull. It is probable that they serve the purpose of permitting the growth of the bones at their margins, while their peculiar formation, together with the interposition of the sutural ligament between the bones forming them, prevents the dispersion of blows or jars received upon the skull. Humphry remarks, "that, as a general rule, the sutures are first obliterated at the parts in which the ossification of the skull was last completed—viz. in the neighborhood of the fontanelles; and the cranial bones seem in this respect to observe a similar law to that which regulates the union of the epiphyses to the shafts of the long bones." The same author remarks that the time of their disappearance is extremely variable: they are sometimes found well marked in skulls edentulous with age, while in others which have only just reached maturity they can hardly be traced. The obliteration of the sutures takes place sooner on the inner than on the outer surface of the skull. The sagittal and coronal sutures are as a rule the first to become ossified—the process starting near the posterior extremity of the former and the lower ends of the latter.

THE SKULL AS A WHOLE.

The Skull, formed by the union of the several cranial and facial bones already described, when considered as a whole is divisible into five regions: a superior region or vertex, an inferior region or base, two lateral regions, and an anterior region, the face.

The Vertex of the Skull.

The **Superior Region,** or **Vertex,** presents two surfaces, an external and an internal.

The **external surface** is bounded, in front, by the glabella and supraorbital ridges; behind, by the occipital protuberance and superior curved lines of the occipital bone; laterally, by an imaginary line extending from the outer end of the superior curved line, along the temporal ridge, to the external angular process of the frontal. This surface includes the greater part of the vertical portion of the frontal, the greater part of the parietal, and the superior third of the occipital bone; it is smooth, convex, of an elongated oval form, crossed transversely by the coronal suture, and from before backward by the sagittal, which terminates behind in the lambdoid. The point of junction of the coronal and sagittal sutures is named the *bregma*, and is represented by a line drawn vertically upward from the external auditory meatus, the head being in its normal position. The point of junction of the sagittal and lambdoid sutures is called the *lambda*, and is about $2\frac{3}{4}$ inches above the external occipital protuberance. From before backward may be seen the frontal eminences and remains of the suture connecting the two lateral halves of the frontal bone; on each side of the sagittal suture are the parietal foramen and parietal eminence, and still more posteriorly the convex surface of the occipital bone. In the neighborhood of the parietal foramen the skull is often flattened, and the name of *obelion* is sometimes given to that point of the sagittal suture which lies exactly opposite to the parietal foramen.

The **internal surface** is concave, presents depressions for the convolutions of the cerebrum, and numerous furrows for the lodgement of branches of the meningeal arteries. Along the middle line of this surface is a longitudinal groove, narrow in front, where it commences at the frontal crest, but broader behind, where it lodges the superior longitudinal sinus, and by its margin affords attachment to the falx cerebri. On either side of it are several depressions for the Pacchionian bodies, and at its back part the internal openings of the parietal foramina. This surface is crossed, in front, by the coronal suture; from before backward by the sagittal; behind, by the lambdoid.

The Base of the Skull.

The **Inferior Region,** or **Base of the Skull,** presents two surfaces—an internal or cerebral, and an external or basilar.

The **internal** or **cerebral surface** (Fig. 71) presents three fossæ, called the *anterior*, *middle*, and *posterior* fossæ of the cranium.

The **Anterior Fossa** is formed by the orbital plates of the frontal, the cribriform plate of the ethmoid, the anterior third of the superior surface of the body, and the upper surface of the lesser wings of the sphenoid. It is the most elevated of the three fossæ, convex externally where it corresponds to the roof of the orbit, concave in the median line in the situation of the cribriform plate of the ethmoid. It is traversed by three sutures, the *ethmo-frontal*, *ethmo-sphenoidal*, and *fronto-sphenoidal*, and lodges the frontal lobe of the cerebrum. It presents, in the median line, from before backward, the commencement of the groove for the superior longitudinal sinus and the frontal crest for the attachment of the falx cerebri; the *foramen cæcum*, an aperture formed between the frontal bone and the crista galli of the ethmoid, which, if pervious, transmits a small vein from the nose to the superior longitudinal sinus; behind the foramen cæcum, the *crista galli*, the posterior margin of which affords attachment to the falx cerebri; on either side of the crista galli, the cribriform plate, which supports the olfactory bulb, and

presents three rows of foramina for the transmission of its nervous filaments, and in front a slit-like opening for the nasal branch of the ophthalmic division

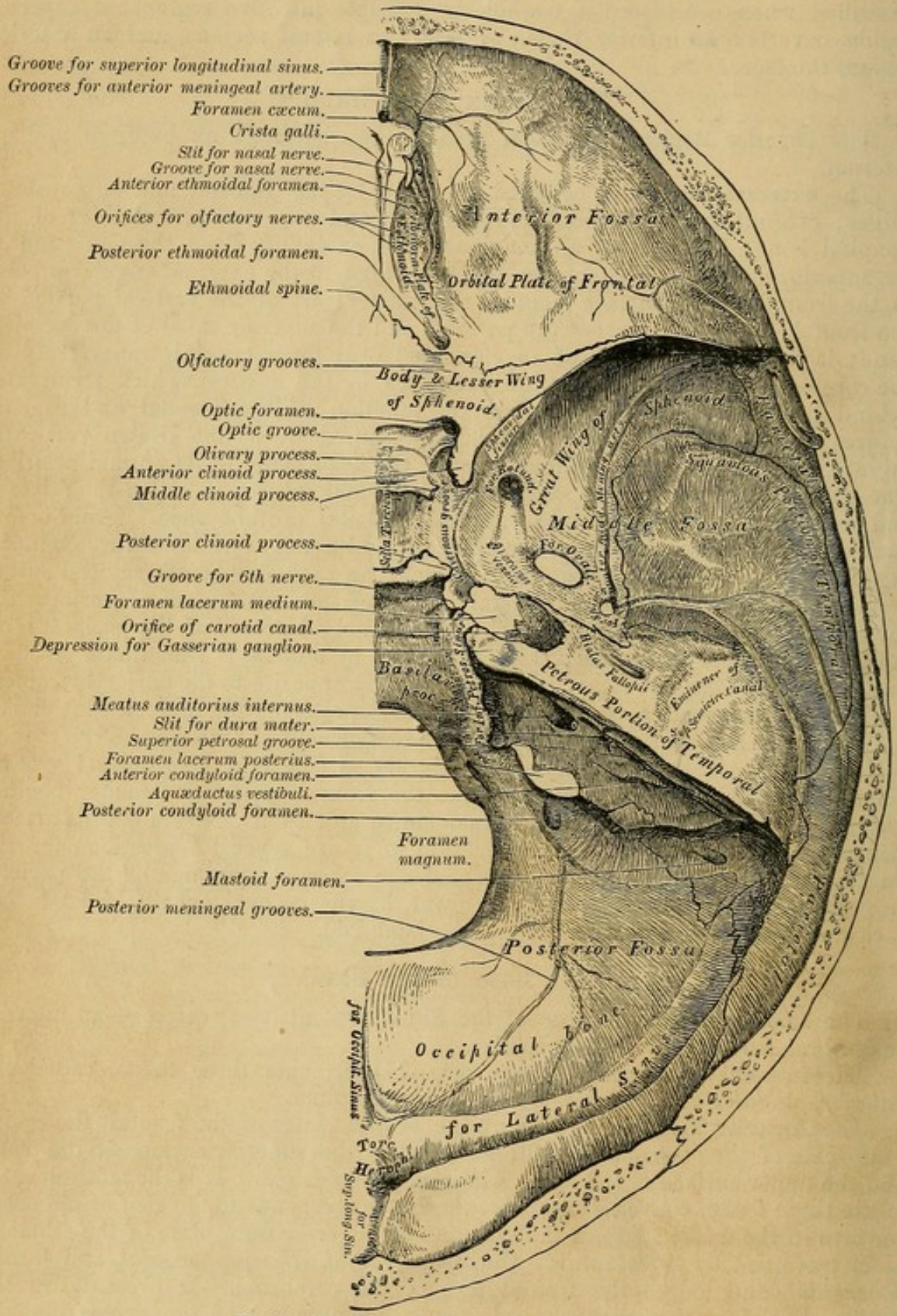

FIG. 71.—Base of the skull. Inner or cerebral surface.

of the fifth nerve. On the outer side of each olfactory groove are the internal openings of the *anterior* and *posterior ethmoidal foramina;* the former, situated about the middle of the outer margin of the olfactory groove, transmits the anterior ethmoidal vessels and the nasal nerve, which latter runs in a depression

along the surface of the ethmoid to the slit-like opening above mentioned; while the posterior ethmoidal foramen opens at the back part of this margin under cover of the projecting lamina of the sphenoid, and transmits the posterior ethmoidal vessels. Farther back in the middle line is the *ethmoidal spine*, bounded behind by a slight elevation, separating two shallow longitudinal grooves which support the olfactory lobes. Behind this is a transverse sharp ridge, running outward on either side to the anterior margin of the optic foramen, and separating the anterior from the middle fossa of the base of the skull. The anterior fossa presents, laterally, depressions for the convolutions of the brain and grooves for the lodgement of the anterior meningeal arteries.

The **Middle Fossa,** deeper than the preceding, is narrow in the middle line, but becomes wider at the side of the skull. It is bounded in front by the posterior margin of the lesser wing of the sphenoid, the anterior clinoid process, and the ridge forming the anterior margin of the optic groove; behind, by the superior border of the petrous portion of the temporal and the dorsum ephippi; externally by the squamous portion of the temporal, anterior inferior angle of the parietal bone, and greater wing of the sphenoid. It is traversed by four sutures, the squamo-parietal, spheno-parietal, squamo-sphenoidal, and petro-sphenoidal.

In the middle line, from before backward, is the *optic groove*, behind which lies the optic commissure; the groove terminates on each side in the optic foramen, for the passage of the optic nerve and ophthalmic artery; behind the optic groove is the *olivary process*, and laterally the *anterior clinoid processes*, to which are attached processes of the tentorium cerebelli. Farther back is the *sella turcica*, a deep depression which lodges the pituitary gland, bounded in front by a small eminence on either side, the *middle clinoid process*, and behind by a broad square plate of bone, the *dorsum ephippi*, surmounted at each superior angle by a tubercle, the *posterior clinoid process;* beneath the latter process is a notch, for the sixth nerve. On each side of the sella turcica is the *cavernous groove:* it is broad, shallow, and curved somewhat like the Italic letter *f;* it commences behind at the foramen lacerum medium, and terminates on the inner side of the anterior clinoid process, and presents along its outer margin a ridge of bone. This groove lodges the cavernous sinus, the internal carotid artery, and the nerves of the orbit. The sides of the middle fossa are of considerable depth; they present depressions for the convolutions of the brain and grooves for the branches of the middle meningeal artery; the latter commence on the outer side of the foramen spinosum, and consist of two large branches, an anterior and a posterior; the former passing upward and forward to the anterior inferior angle of the parietal bone, the latter passing upward and backward. The following foramina may also be seen from before backward: Most anteriorly is the *foramen lacerum anterius*, or *sphenoidal fissure*, formed above by the lesser wing of the sphenoid; below, by the greater wing; internally, by the body of the sphenoid; and sometimes completed externally by the orbital plate of the frontal bone. It transmits the third, the fourth, the three branches of the ophthalmic division of the fifth, the sixth nerve, some filaments from the cavernous plexus of the sympathetic, the orbital branch of the middle meningeal artery, a recurrent branch from the lachrymal artery to the dura mater, and the ophthalmic vein. Behind the inner extremity of the sphenoidal fissure is the *foramen rotundum*, for the passage of the second division of the fifth or superior maxillary nerve; still more posteriorly is seen a small orifice, the *foramen Vesalii*, an opening situated between the foramen rotundum and ovale, a little internal to both: it varies in size in different individuals, and is often absent; when present, it transmits a small vein. It opens below into the pterygoid fossa, just at the outer side of the scaphoid depression. Behind and external to the latter opening is the *foramen ovale*, which transmits the third division of the fifth or inferior maxillary nerve, the small meningeal artery, and the small petrosal nerve.[1] On the outer side of the foramen ovale is the *foramen spinosum*, for the passage of the middle meningeal artery; and

[1] See footnote, p. 74.

on the inner side of the foramen ovale, the *foramen lacerum medium*. The lower part of this aperture is filled with cartilage in the recent state. The Vidian nerve and a meningeal branch from the ascending pharyngeal artery pierce this cartilage. On the anterior surface of the petrous portion of the temporal bone is seen, from without inward, the eminence caused by the projection of the superior semicircular canal; in front of and a little outside this is a depression corresponding to the roof of the tympanum; the groove leading to the hiatus Fallopii, for the transmission of the petrosal branch of the Vidian nerve and the petrosal branch of the middle meningeal artery; beneath it, the smaller groove, for the passage of the lesser petrosal nerve; and, near the apex of the bone, the depression for the Gasserian ganglion; and the orifice of the carotid canal, for the passage of the internal carotid artery and carotid plexus of nerves.

The **Posterior Fossa**, deeply concave, is the largest of the three, and situated on a lower level than either of the preceding. It is formed by the posterior third of the superior surface of the body of the sphenoid, by the occipital, the petrous and mastoid portions of the temporal, and the posterior inferior angle of the parietal bone; it is crossed by four sutures, the petro-occipital, the masto-occipital, the masto-parietal, and the basilar; and lodges the cerebellum, pons Varolii, and medulla oblongata. It is separated from the middle fossa in the median line by the dorsum ephippii, and on each side by the superior border of the petrous portion of the temporal bone. This border serves for the attachment of the tentorium cerebelli, is grooved for the superior petrosal sinus, and at its inner extremity presents a notch, upon which rests the fifth nerve. The circumference of the fossa is bounded posteriorly by the grooves for the lateral sinuses. In the centre of this fossa is the *foramen magnum*, bounded on either side by a rough tubercle, which gives attachment to the odontoid or check ligaments; and a little above these are seen the internal openings of the *anterior condyloid foramina*, through which pass the hypoglossal nerve and a meningeal branch from the ascending pharyngeal artery. In front of the foramen magnum is a grooved surface, formed by the basilar process of the occipital bone and by the posterior third of the superior surface of the body of the sphenoid, which supports the medulla oblongata and pons Varolii, and articulates on each side with the petrous portion of the temporal bone, forming the petro-occipital suture, the anterior half of which is grooved for the inferior petrosal sinus, the posterior half being encroached upon by the *foramen lacerum posterius*, or *jugular foramen*. This foramen presents three compartments: through the anterior passes the inferior petrosal sinus; through the posterior, the lateral sinus and some meningeal branches from the occipital and ascending pharyngeal arteries; and through the middle, the glosso-pharyngeal, pneumogastric, and spinal accessory nerves. Above the jugular foramen is the *internal auditory meatus*, for the facial and auditory nerves and auditory artery; behind and external to this is the slit-like opening leading into the aquæductus vestibuli, which lodges the ductus endolymphaticus; while between the two latter, and near the superior border of the petrous portion, is a small, triangular depression, the remains of the floccular fossa, which lodges a process of the dura mater and occasionally transmits a small vein into the substance of the bone. Behind the foramen magnum are the *inferior occipital fossæ*, which lodge the hemispheres of the cerebellum, separated from one another by the *internal occipital crest*, which serves for the attachment of the falx cerebelli and lodges the occipital sinus. The posterior fossæ are surmounted, above, by the deep transverse grooves for the lodgment of the *lateral sinuses*. These channels, in their passage outward, groove the occipital bone, the posterior inferior angle of the parietal, the mastoid portion of the temporal, and the jugular process of the occipital, and terminate at the back part of the jugular foramen. Where this sinus grooves the mastoid portion of the temporal bone the orifice of the *mastoid foramen* may be seen, and just previous to its termination it has opening into it the *posterior condyloid foramen*. Neither foramen is constant.

The **External Surface** of the Base of the Skull (Fig. 72) is extremely irregular.

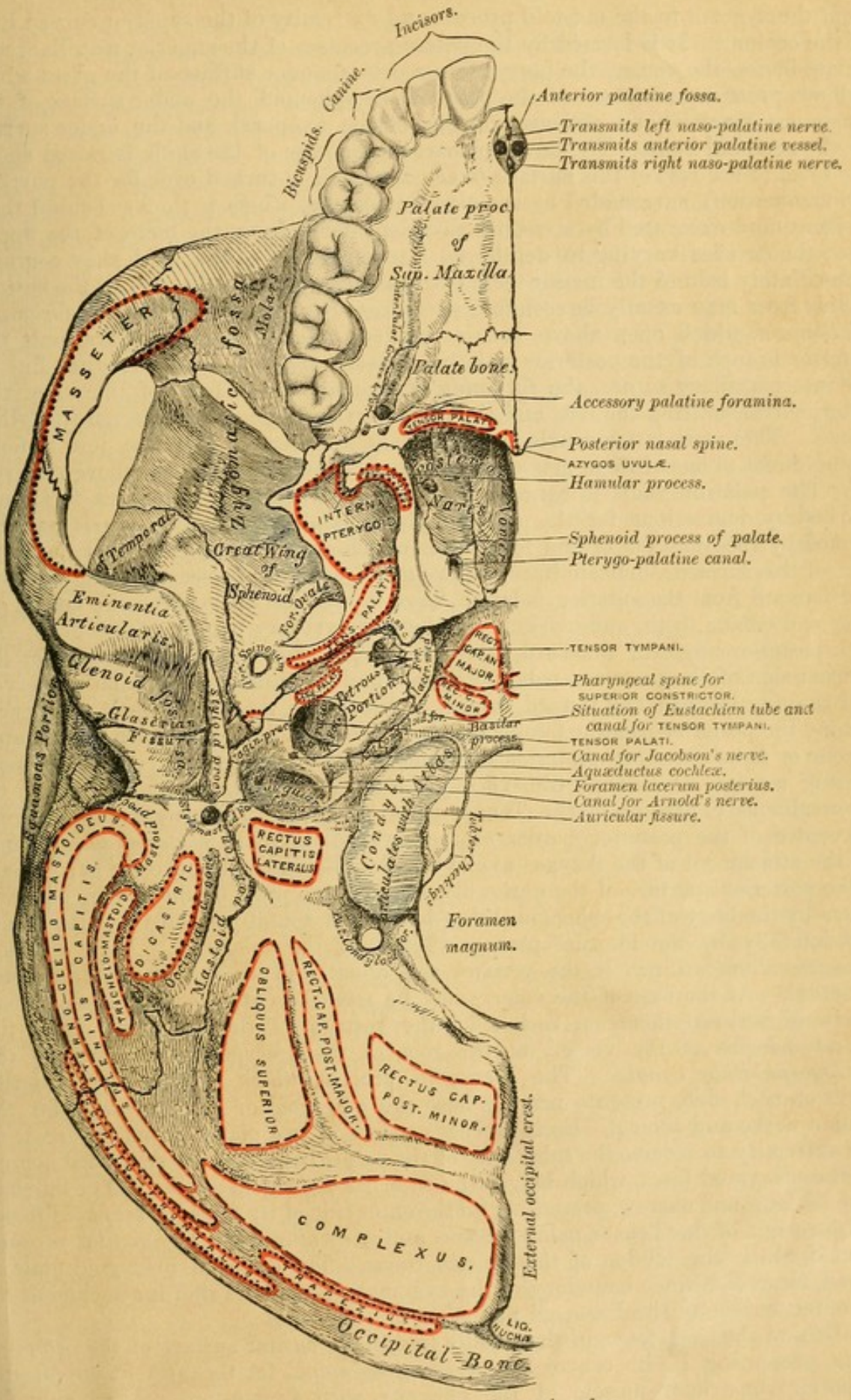

FIG. 72.—Base of the skull. External surface.

It is bounded in front by the incisor teeth in the upper jaw; behind by the superior curved lines of the occipital bone; and laterally by the alveolar arch, the lower border of the malar bone, the zygoma, and an imaginary line extending

from the zygoma to the mastoid process and extremity of the superior curved line of the occiput. It is formed by the palate processes of the superior maxillary and palate bones, the vomer, the pterygoid processes, under surface of the great wing, spinous processes and part of the body of the sphenoid, the under surface of the squamous, mastoid, and petrous portions of the temporal, and the under surface of the occipital bone. The anterior part of the base of the skull is raised above the level of the rest of this surface (when the skull is turned over for the purpose of examination), surrounded by the alveolar process, which is thicker behind than in front, and excavated by sixteen depressions for lodging the teeth of the upper jaw, the cavities varying in depth and size according to the teeth they contain. Immediately behind the incisor teeth is the *anterior palatine fossa*. At the bottom of this fossa may usually be seen four apertures: two placed laterally, the *foramina of Stenson*, which open above, one in the floor of each nostril, and transmit the anterior branch of the posterior palatine vessels, and two in the median line in the intermaxillary suture, the *foramina of Scarpa*, one in front of the other, the anterior transmitting the left, and the posterior (the larger) the right, naso-palatine nerve. These two latter canals are sometimes wanting, or they may join to form a single one, or one of them may open into one of the lateral canals above referred to. The palatine vault is concave, uneven, perforated by numerous foramina, marked by depressions for the palatine glands, and crossed by a crucial suture, formed by the junction of the four bones of which it is composed. At the front part of this surface a delicate linear suture may frequently be seen, passing outward and forward from the anterior palatine fossa to the interval between the lateral incisor and canine teeth, and marking off the pre-maxillary portion of the bone. At each posterior angle of the hard palate is the *posterior palatine foramen*, for the transmission of the posterior palatine vessels and large descending palatine nerve; and running forward and inward from it a groove, for the same vessels and nerve. Behind the posterior palatine foramen is the *tuberosity of the palate bone*, perforated by one or more accessory posterior palatine canals, and marked by the commencement of a ridge, which runs transversely inward, and serves for the attachment of the tendinous expansion of the Tensor palati muscle. Projecting backward from the centre of the posterior border of the hard palate is the *posterior nasal spine*, for the attachment of the Azygos uvulæ muscle. Behind and above the hard palate is the posterior aperture of the nares, divided into two parts by the vomer, bounded above by the body of the sphenoid, below by the horizontal plate of the palate bone, and laterally by the internal pterygoid plate of the sphenoid. Each aperture measures about an inch in the vertical and about half an inch in the transverse direction. At the base of the vomer may be seen the expanded alæ of this bone, receiving between them, on each side, the rostrum of the sphenoid. Near the lateral margins of the vomer, at the root of the pterygoid processes, are the *pterygo-palatine canals*. The pterygoid process, which bounds the posterior nares on each side, presents near its base the *pterygoid* or *Vidian canal*, for the Vidian nerve and artery. Each process consists of two plates, which bifurcate at the extremity to receive the tuberosity of the palate bone, and are separated behind by the pterygoid fossa, which lodges the Internal pterygoid muscle. The internal plate is long and narrow, presenting on the outer side of its base the *scaphoid fossa*, for the origin of the Tensor palati muscle, and at its extremity the *hamular process*, around which the tendon of this muscle turns. The external pterygoid plate is broad, forms the inner boundary of the zygomatic fossa, and affords attachment by its outer surface to the External pterygoid muscle.

Behind the nasal fossæ in the middle line is the basilar surface of the occipital bone, presenting in its centre the *pharyngeal spine*, for the attachment of the Superior constrictor muscle of the pharynx, with depressions on each side for the insertion of the Rectus capitis anticus major and minor. At the base of the external pterygoid plate is the *foramen ovale*, for the transmission of the third division of the fifth nerve, the small meningeal artery, and sometimes the small petrosal nerve; behind this, the *foramen spinosum*, which transmits the middle

meningeal artery, and the prominent spinous process of the sphenoid, which gives attachment to the internal lateral ligament of the lower jaw and the Tensor palati muscle. External to the spinous process is the *glenoid fossa*, divided into two parts by the Glaserian fissure (page 66), the anterior portion concave, smooth, bounded in front by the eminentia articularis, and serving for the articulation of the condyle of the lower jaw; the posterior portion rough, bounded behind by the tympanic plate, and serving for the reception of part of the parotid gland. Emerging from between the laminæ of the vaginal process of the tympanic plate is the *styloid process*, and at the base of this process is the *stylo-mastoid foramen*, for the exit of the facial nerve and entrance of the stylo-mastoid artery. External to the stylo-mastoid foramen is the *auricular fissure*, for the auricular branch of the pneumogastric, bounded behind by the mastoid process. Upon the inner side of the mastoid process is a deep groove, the *digastric fossa;* and a little more internally the *occipital groove*, for the occipital artery. At the base of the internal pterygoid plate is a large and somewhat triangular aperture, the *foramen lacerum medium*, bounded in front by the great wing of the sphenoid, behind by the apex of the petrous portion of the temporal bone, and internally by the body of the sphenoid and basilar process of the occipital bone: it presents in front the posterior orifice of the Vidian canal; behind, the aperture of the carotid canal. The basilar surface of this opening is filled in the recent state by fibro-cartilaginous substance; across its upper or cerebral aspect passes the internal carotid artery. External to this aperture the *petro-sphenoidal suture* is observed, at the outer termination of which is seen the orifice of the canal for the Eustachian tube and that for the Tensor tympani muscle. Behind this suture is seen the under surface of the petrous portion of the temporal bone, presenting, from within outward, the quadrilateral, rough surface, part of which affords attachment to the Levator palati and Tensor tympani muscles; external to this surface the orifices of the carotid canal and the aquæductus cochleæ, the former transmitting the internal carotid artery and the ascending branches of the superior cervical ganglion of the sympathetic, the latter serving for the passage of a small artery and vein to the cochlea. Behind the carotid canal is a large aperture, the *jugular foramen*, formed in front by the petrous portion of the temporal, and behind by the occipital; it is generally larger on the right than on the left side, and is divided into three compartments by processes of dura mater. The anterior is for the passage of the inferior petrosal sinus; the posterior, for the lateral sinus and some meningeal branches from the occipital and ascending pharyngeal arteries; the central one, for the glosso-pharyngeal, pneumogastric, and spinal accessory nerves. On the ridge of bone dividing the carotid canal from the jugular foramen is the small foramen for the transmission of Jacobson's nerve; and on the wall of the jugular foramen, near the root of the styloid process, is the small aperture for the transmission of Arnold's nerve. Behind the basilar surface of the occipital bone is the *foramen magnum*, bounded on each side by the condyles, rough internally for the attachment of the check or odontoid ligaments, and presenting externally a rough surface, the *jugular process*, which serves for the attachment of the Rectus capitis lateralis muscle and the lateral occipito-atlantal ligament. On either side of each condyle anteriorly is the *anterior condyloid fossa*, perforated by the anterior condyloid foramen, for the passage of the hypoglossal nerve and a meningeal artery. Behind each condyle is the *posterior condyloid fossa*, perforated on one or both sides by the posterior condyloid foramina, for the transmission of a vein to the lateral sinus. Behind the foramen magnum is the *external occipital crest*, terminating above at the *external occipital protuberance*, whilst on each side are seen the *superior* and *inferior curved lines;* these, as well as the surfaces of bone between them, are rough for the attachment of the muscles, which are enumerated on page 59.

The Lateral Region of the Skull.

The **Lateral Region** of the Skull is of a somewhat triangular form, the base of the triangle being formed by a line extending from the external angular process of the frontal bone along the temporal ridge backward to the outer extremity of the superior curved line of the occiput: and the sides by two lines, the one drawn downward and backward from the external angular process of the frontal bone to the angle of the lower jaw, the other from the angle of the jaw upward and

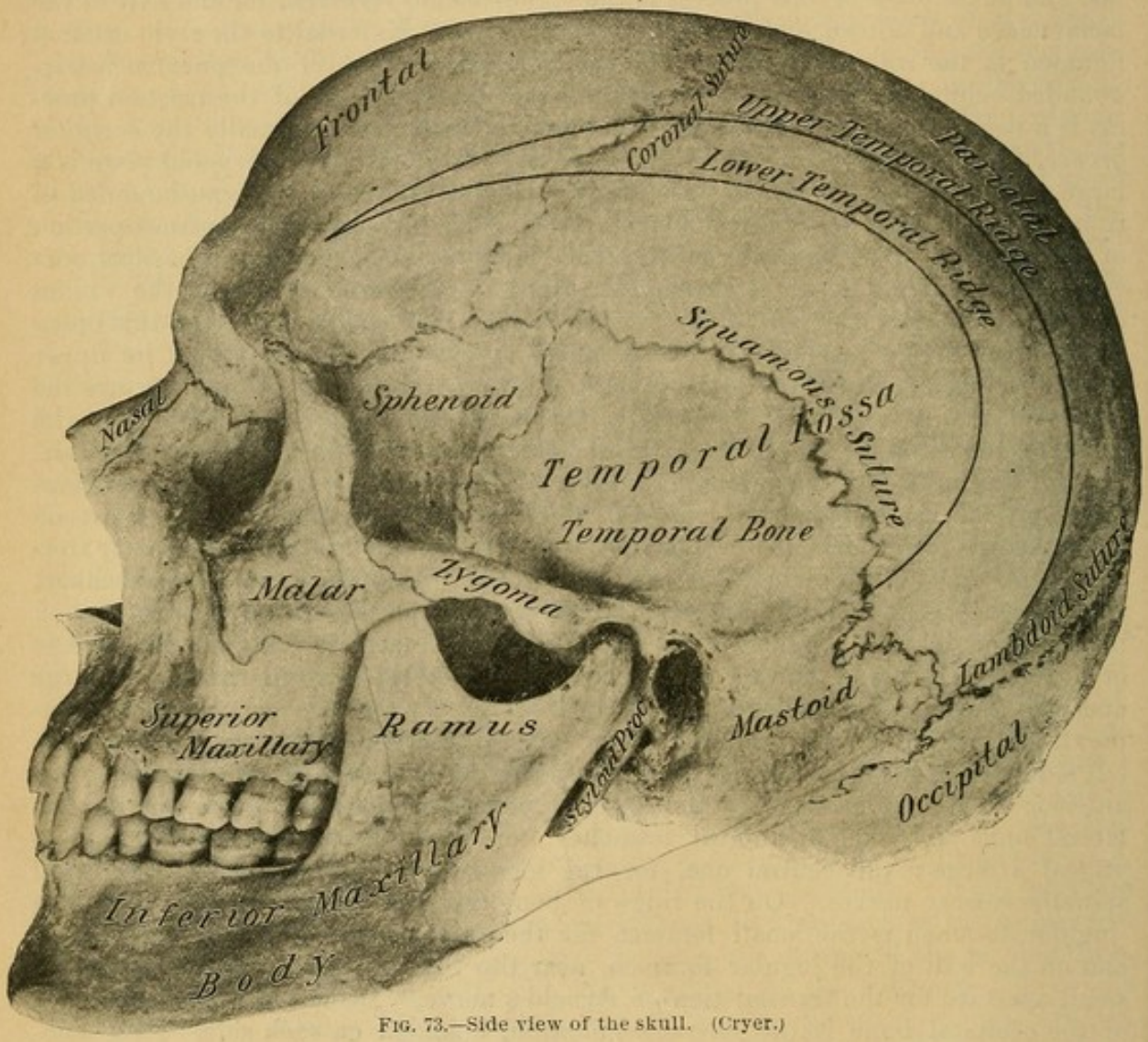

FIG. 73.—Side view of the skull. (Cryer.)

backward to the outer extremity of the superior curved line. This region is divisible into three portions—temporal fossa, mastoid portion, and zygomatic fossa.

The Temporal Fossa.

The **Temporal Fossa** is bounded above and behind by the temporal ridges, which extend from the external angular process of the frontal upward and backward across the frontal and parietal bones, curving downward behind to terminate in the posterior root of the zygomatic process (*supra-mastoid crest*). In front it is bounded by the frontal, malar, and great wing of the sphenoid; externally by the zygomatic arch formed conjointly by the malar and temporal bones; below, it is separated from the zygomatic fossa by the pterygoid ridge, seen on the outer surface of the great wing of the sphenoid. This fossa is formed by five bones, part of the frontal, great wing of the sphenoid, parietal, squamous portion of the temporal, and malar bones, and is traversed by six sutures, part of the transverse facial, spheno-malar, coronal, spheno-parietal, squamo-parietal, and squamo-sphenoidal. The point

where the coronal suture crosses the superior temporal ridge is sometimes named the *stephanion;* and the region where the four bones, the parietal, the frontal, the squamous, and the greater wing of the sphenoid, meet, at the anterior inferior angle of the parietal bone, is named the *pterion.* This point is about on a level with the external angular process of the frontal bone and about one and a half inches behind it. This fossa is deeply concave in front, convex behind, traversed by grooves which lodge branches of the deep temporal arteries, and filled by the Temporal muscles.

The Mastoid Portion.

The **Mastoid Portion** of the side of the skull is bounded in front by the tubercle of the zygoma; above, by a line which runs from the posterior root of the zygoma to the end of the mastoid-parietal suture; behind and below by the masto-occipital suture. It is formed by the mastoid and part of the squamous and petrous portions of the temporal bone; its surface is convex and rough for the attachment of muscles, and presents, from behind forward, the mastoid foramen, the mastoid process, the external auditory meatus surrounded by the tympanic plate, and, most anteriorly, the temporo-maxillary articulation.

The point where the posterior inferior angle of the parietal meets the occipital bone and mastoid portion of the temporal is named the *asterion.*

The Zygomatic Fossa.

The **Zygomatic Fossa** is an irregularly shaped cavity, situated below and on the inner side of the zygoma; bounded, in front, by the zygomatic surface of the superior maxillary bone and the ridge which descends from its malar process; behind, by the posterior border of the external pterygoid plate and the eminentia articularis; above, by the pterygoid ridge on the outer surface of the great wing

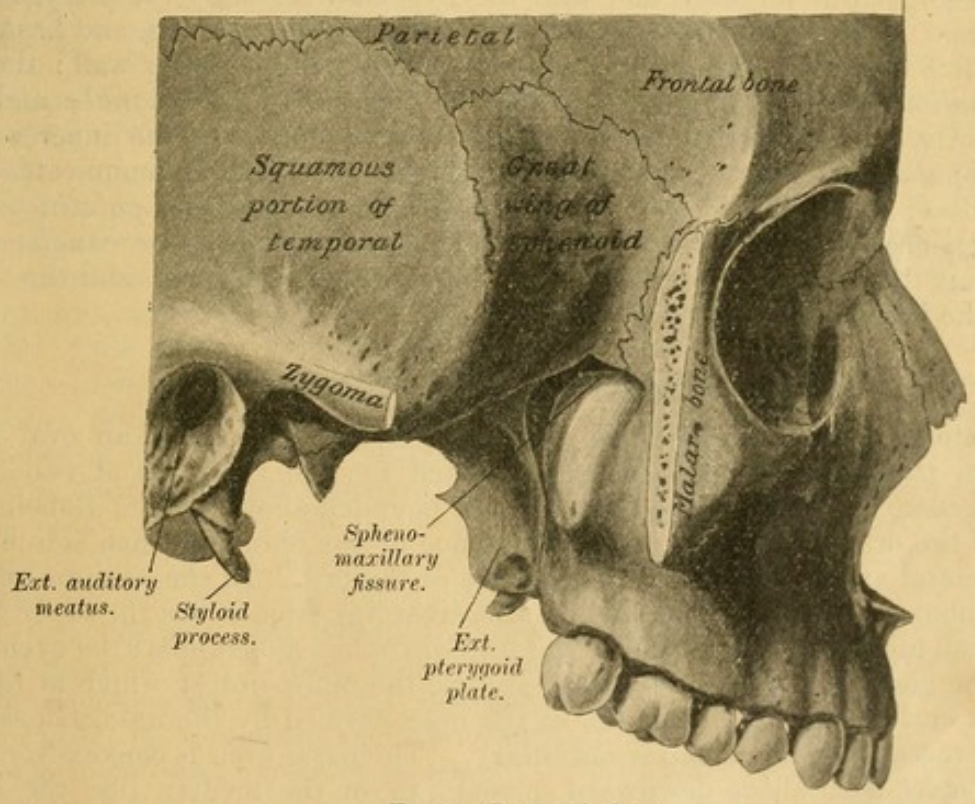

FIG. 74.—Zygomatic fossa.

of the sphenoid and the under part of the squamous portion of the temporal; below, by the alveolar border of the superior maxilla; internally, by the external pterygoid plate; and externally, by the zygomatic arch and ramus of the lower jaw (Fig. 74). It contains the lower part of the Temporal, the External and Internal pterygoid muscles, the internal maxillary artery and vein, and inferior max-

illiary nerve and their branches. At its upper and inner part may be observed two fissures, the spheno-maxillary and pterygo-maxillary.

The **Spheno-maxillary Fissure,** horizontal in direction, opens into the outer and back part of the orbit. It is formed above by the lower border of the orbital surface of the great wing of the sphenoid; below, by the external border of the orbital surface of the superior maxilla and a small part of the palate bone; externally, by a small part of the malar bone:[1] internally, it joins at right angles with the pterygo-maxillary fissure. This fissure opens a communication from the orbit into three fossæ—the temporal, zygomatic, and spheno-maxillary; it transmits the superior maxillary nerve and its orbital branch, the infraorbital vessels, and ascending branches from the spheno-palatine or Meckel's ganglion.

The **Pterygo-maxillary Fissure** is vertical, and descends at right angles from the inner extremity of the preceding; it is a V-shaped interval, formed by the divergence of the superior maxillary bone from the pterygoid process of the sphenoid. It serves to connect the spheno-maxillary fossa with the zygomatic fossa, and transmits branches of the internal maxillary artery.

The Spheno-maxillary Fossa.

The **Spheno-maxillary Fossa** is a small, triangular space situated at the angle of junction of the spheno-maxillary and pterygo-maxillary fissures, and placed beneath the apex of the orbit. It is formed above by the under surface of the body of the sphenoid and by the orbital process of the palate bone; in front, by the superior maxillary bone; behind, by the anterior surface of the base of the pterygoid process and lower part of the anterior surface of the great wing of the sphenoid; internally, by the vertical plate of the palate. This fossa has three fissures terminating in it—the *sphenoidal*, *spheno-maxillary*, and *pterygo-maxillary;* it communicates with the orbit by the spheno-maxillary fissure; with the nasal fossæ by the spheno-palatine foramen, and with the zygomatic fossa by the pterygo-maxillary fissure. It also communicates with the cavity of the cranium, and has opening into it five foramina. Of these, there are three on the posterior wall: the *foramen rotundum* above; below and internal to this, the *Vidian canal;* and still more inferiorly and internally, the *pterygo-palatine canal.* On the inner wall is the *spheno-palatine foramen*, by which the spheno-maxillary communicates with the nasal fossa; and below is the superior orifice of the *posterior palatine canal*, besides occasionally the orifices of the *accessory posterior palatine canals.* The fossa contains the superior maxillary nerve and Meckel's ganglion, and the termination of the internal maxillary artery.

The Anterior Region of the Skull.

The **Anterior Region** of the Skull, which forms the face, is of an oval form, presents an irregular surface, and is excavated for the reception of two of the organs of sense, the eye and the nose. It is bounded above by the glabella and margins of the orbit; below, by the prominence of the chin; on each side by the malar bone and anterior margin of the ramus of the jaw. In the median line are seen from above downward the glabella, and diverging from it are the *superciliary ridges*, which indicate the situation of the frontal sinuses and support the eyebrows. Beneath the glabella is the fronto-nasal suture, the mid-point of which is termed the *nasion*, and below this is the arch of the nose, formed by the nasal bones, and the nasal processes of the superior maxillary. The nasal arch is convex from side to side, concave from above downward, presenting in the median line the internasal suture formed between the nasal bones, laterally the naso-maxillary suture formed between the nasal bone and the nasal process of the superior maxillary bone. Below the nose is seen the opening of the anterior nares, which is heart-shaped, with the narrow end upward, and presents laterally the thin, sharp

[1] Occasionally the superior maxillary bone and the sphenoid articulate with each other at the anterior extremity of this fissure; the malar is then excluded from entering into its formation.

margins serving for the attachment of the lateral cartilages of the nose, and in the middle line below a prominent process, the *anterior nasal spine*, bounded by two deep notches. Below this is the *intermaxillary suture*, and on each side of it the *incisive fossa*. Beneath this fossa are the alveolar processes of the upper and lower jaws, containing the incisor teeth, and at the lower part of the median line the *symphysis of the chin*, the *mental process*, with its two *mental tubercles*, separated by a median groove, and the *incisive fossa* of the lower jaw.

On each side, proceeding from above downward, is the *supraorbital ridge*, terminating externally in the external angular process at its junction with the malar, and internally in the internal angular process; toward the inner third of this ridge is the *supraorbital notch* or *foramen*, for the passage of the supraorbital vessels and nerve. Beneath the supraorbital ridge is the opening of the orbit, bounded externally by the orbital ridge of the malar bone; below, by the orbital ridge formed by the malar and superior maxillary bones; internally, by the nasal process of the superior maxillary and the internal angular process of the frontal bone. On the outer side of the orbit is the quadrilateral anterior surface of the malar bone, perforated by one or two small malar foramina. Below the inferior margin of the orbit is the *infraorbital foramen*, the termination of the infraorbital canal, and beneath this the *canine fossa*, which gives attachment to the Levator anguli oris; still lower are the alveolar processes, containing the teeth of the upper and lower jaws. Beneath the alveolar arch of the lower jaw is the *mental foramen*, for the passage of the mental vessels and nerve, the *external oblique line*, and at the lower border of the bone, at the point of junction of the body with the ramus, a shallow groove for the passage of the facial artery.

The Orbits.

The **Orbits** (Fig. 75) are two quadrilateral pyramidal cavities, situated at the upper and anterior part of the face, their bases being directed forward and outward, and their apices backward and inward, so that the axes of the two, if continued backward, would meet over the body of the sphenoid bone. Each orbit is formed of *seven* bones, the frontal, sphenoid, ethmoid, superior maxillary, malar, lachrymal, and palate; but three of these, the frontal, ethmoid, and sphenoid, enter into the formation of *both* orbits, so that the two cavities are formed of *eleven* bones only. Each cavity presents for examination a roof, a floor, an inner and an outer wall, four angles, a circumference or base, and an apex. The roof is concave, directed downward and slightly forward, and formed in front by the orbital plate of the frontal; behind by the lesser wing of the sphenoid. This surface presents internally the depression for the cartilaginous pulley of the Superior oblique muscle; externally, the depression for the lachrymal gland; and posteriorly, the suture connecting the frontal and lesser wing of the sphenoid.

The **floor** is directed upward and outward, and is of less extent than the roof; it is formed chiefly by the orbital process of the superior maxillary; in front, to a small extent, by the orbital process of the malar, and behind, by the superior surface of the orbital process of the palate. This surface presents at its anterior and internal part, just external to the lachrymal groove, a depression for the attachment of the Inferior oblique muscle; externally, the suture between the malar and superior maxillary bones; near its middle, the infraorbital groove; and posteriorly, the suture between the maxillary and palate bones.

The **inner wall** is flattened, nearly vertical, and formed from before backward by the nasal process of the superior maxillary, the lachrymal, os planum of the ethmoid, and a small part of the body of the sphenoid. This surface presents the lachrymal groove and crest of the lachrymal bone, and the sutures connecting the lachrymal with the superior maxillary, the ethmoid with the lachrymal in front, and the ethmoid with the sphenoid behind.

The **outer wall** is directed forward and inward, and is formed in front by the orbital process of the malar bone; behind, by the orbital surface of the greater

wing of the sphenoid. On it are seen the orifices of one or two malar canals, and the suture connecting the sphenoid and malar bones.

Angles.—The *superior external angle* is formed by the junction of the upper and outer walls; it presents, from before backward, the suture connecting the frontal with the malar in front and with the great wing of the sphenoid behind; quite posteriorly is the foramen lacerum anterius, or sphenoidal fissure, which transmits the third, the fourth, the three branches of the ophthalmic division of the fifth, the sixth nerve, some filaments from the cavernous plexus of the sympathetic, the orbital branch of the middle meningeal artery, a recurrent branch

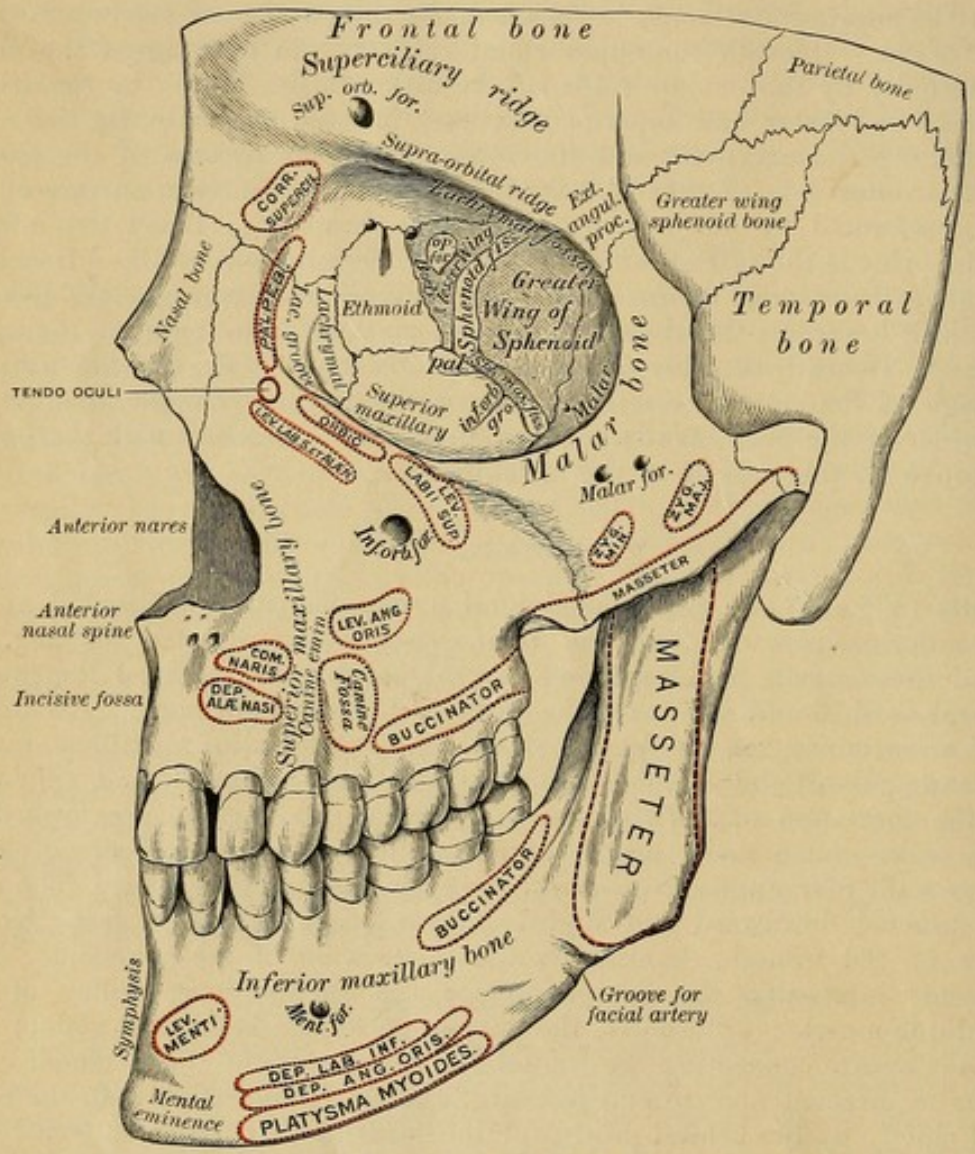

FIG. 75.—Antero-lateral region of the skull. (Cryer.)

from the lachrymal artery to the dura mater, and the ophthalmic vein. The *superior internal angle* is formed by the junction of the upper and inner wall, and presents the suture connecting the frontal bone with the lachrymal in front and with the ethmoid behind. The point of junction of the *anterior* border of the lachrymal with the frontal has been named the *dacryon*. This angle presents two foramina, the anterior and posterior ethmoidal, the former transmitting the anterior ethmoidal vessels and nasal nerve, the latter the posterior ethmoidal vessels. The *inferior external angle*, formed by the junction of the outer wall and floor, presents the spheno-maxillary fissure, which transmits the superior maxillary nerve and its orbital branches, the infraorbital vessels, and the ascending branches from the spheno-palatine or Meckel's ganglion. The *inferior internal angle* is formed by the union of the lachrymal and os planum of the ethmoid with the superior max-

illary and palate bones. The *circumference*, or base, of the orbit, quadrilateral in form, is bounded above by the supraorbital ridge; below, by the anterior border of the orbital plate of the malar and superior maxillary bones; externally, by the external angular process of the frontal and malar bones; internally, by the internal angular process of the frontal and the nasal process of the superior maxillary. The circumference is marked by three sutures, the fronto-maxillary internally, the fronto-malar externally, and the malo-maxillary below; it contributes to the formation of the lachrymal groove, and presents, above, the supraorbital notch (or foramen), for the passage of the supraorbital vessels and nerve. The *apex*, situated at the back of the orbit, corresponds to the optic foramen,[1] a short, circular canal which transmits the optic nerve and ophthalmic artery. It will thus be seen that there are *nine* openings communicating with each orbit—viz. the optic foramen, sphenoidal fissure, spheno-maxillary fissure, supraorbital foramen, infraorbital canal, anterior and posterior ethmoidal foramina, malar foramina, and canal for the nasal duct.

The Nasal Fossæ.

The **Nasal Fossæ** are two large, irregular cavities situated on either side of the middle line of the face, extending from the base of the cranium to the roof of the mouth, and separated from each other by a thin vertical septum. They communicate by two large apertures, the anterior nares, with the front of the face, and by the two posterior nares with the naso-pharynx behind. These fossæ are much

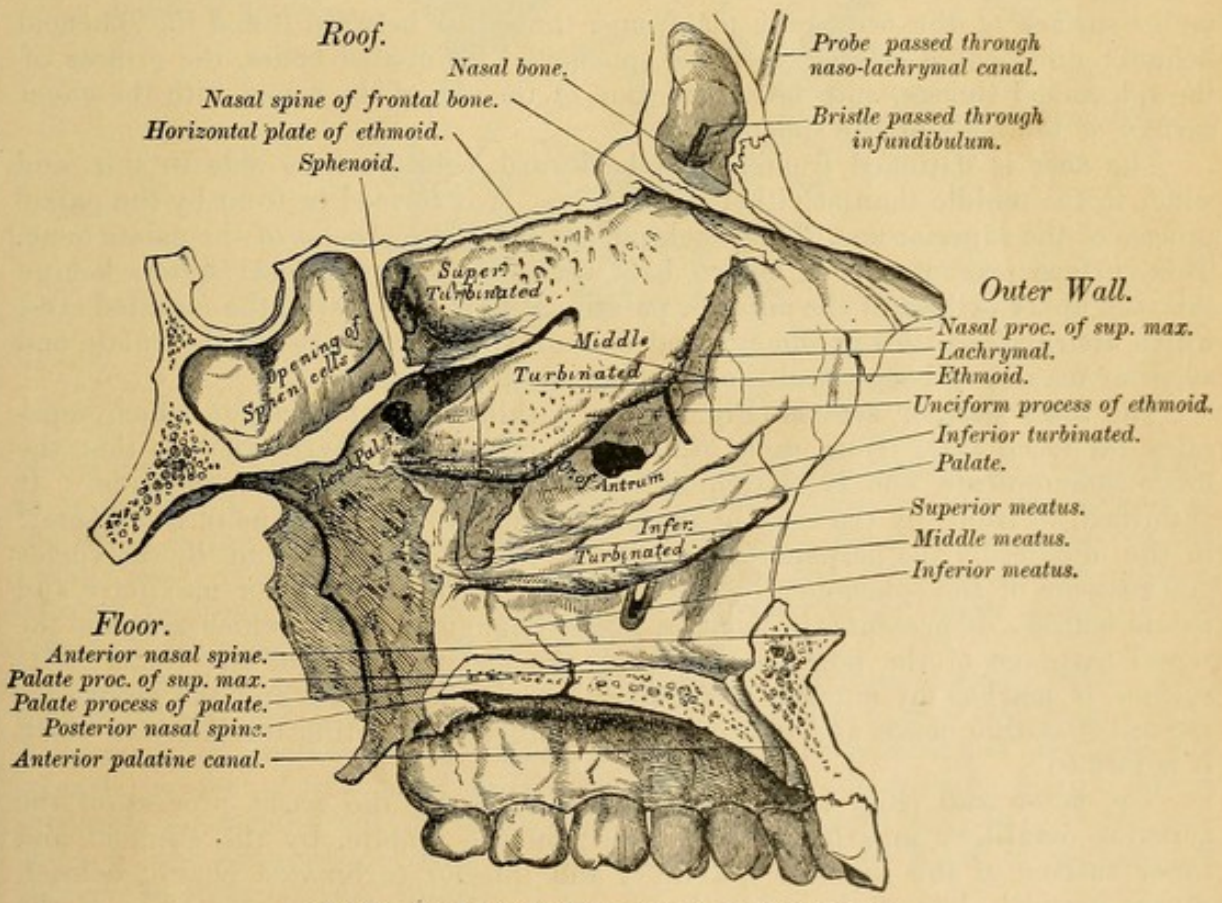

FIG. 76.—Roof, floor, and outer wall of left nasal fossa.

narrower above than below, and in the middle than at the anterior or posterior openings; their depth, which is considerable, is much greater in the middle than at either extremity. Each nasal fossa communicates with four sinuses, the frontal above, the sphenoidal behind, and the maxillary and ethmoidal on the outer wall.

[1] Quain, Testut, and others give the apex of the orbit as corresponding with the inner end of the sphenoidal fissure. It seems better, however, to adopt the statement in the text, since the muscles of the eyeball take origin around the optic foramen, and diverge from it to the globe of the eye.

Each fossa also communicates with four cavities: with the orbit by the lachrymal groove, with the mouth by the anterior palatine canal, with the cranium by the olfactory foramina, and with the spheno-maxillary fossa by the spheno-palatine foramen; and they occasionally communicate with each other by an aperture in the septum. The bones entering into their formation are fourteen in number: three of the cranium, the frontal, sphenoid, and ethmoid, and all the bones of the face, excepting the malar and lower jaw. Each cavity is bounded by a roof, a floor, an inner and an outer wall.

The **upper wall**, or **roof** (Fig. 76), is long, narrow, and horizontal in its centre, but slopes downward at its anterior and posterior extremities; it is formed in front by the nasal bones and nasal spine of the frontal, which are directed downward and forward; in the middle, by the cribriform plate of the ethmoid, which is horizontal; and behind, by the under surface of the body of the sphenoid and sphenoidal turbinated bones, the ala of the vomer and the sphenoidal process of the palate bone, which are directed downward and backward. This surface presents, from before backward, the internal aspect of the nasal bones; on their outer side, the suture formed between the nasal bone and the nasal process of the superior maxillary; on their inner side, the elevated crest which receives the nasal spine of the frontal and the perpendicular plate of the ethmoid, and articulates with its fellow of the opposite side; whilst the surface of the bones is perforated by a few small vascular apertures, and presents the longitudinal groove for the nasal nerve; farther back is the transverse suture, connecting the frontal with the nasal in front, and the ethmoid behind, the olfactory foramina and nasal slit on the under surface of the cribriform plate, and the suture between it and the sphenoid behind; quite posteriorly are seen the sphenoidal turbinated bones, the orifices of the sphenoidal sinuses, and the articulation of the alæ of the vomer with the under surface of the body of the sphenoid.

The **floor** is flattened from before backward, concave from side to side, and wider in the middle than at either extremity. It is formed in front by the palate process of the superior maxillary; behind, by the palate process of the palate bone. This surface presents, from before backward, the anterior nasal spine; behind this, the upper orifices of the anterior palatine canal; internally, the elevated crest which articulates with the vomer; and behind, the suture between the palate and superior maxillary bones, and the posterior nasal spine.

The **inner wall**, or **septum** (Fig. 77), is a thin vertical partition which separates the nasal fossæ from each other; it is occasionally perforated, so that the fossæ communicate, and it is frequently deflected considerably to one side.[1] It is formed, in front, by the crest of the nasal bones and nasal spine of the frontal; in the middle, by the perpendicular plate of the ethmoid; behind, by the vomer and rostrum of the sphenoid; below, by the crests of the superior maxillary and palate bones. It presents, in front, a large, triangular notch, which receives the septal cartilage of the nose; and behind, the grooved edge of the vomer. Its surface is marked by numerous vascular and nervous canals and the groove for the naso-palatine nerve, and is traversed by sutures connecting the bones of which it is formed.

The **outer wall** (Fig. 76) is formed, in front, by the nasal process of the superior maxillary and lachrymal bones; in the middle, by the ethmoid and inner surface of the superior maxillary and inferior turbinated bones; behind, by the vertical plate of the palate bone and the internal pterygoid plate of the sphenoid. This surface presents three irregular longitudinal passages, or *meatuses*, termed the superior, middle, and inferior meatuses of the nose. The *superior meatus*, the smallest of the three, is situated at the upper and back part of each nasal fossa, occupying the posterior third of the outer wall. It is situated between the superior and middle turbinated bones, and has opening into it two foramina, the *spheno-palatine* at the back of its outer wall, and the *posterior ethmoidal cells* at the front part of the outer wall. The sphenoidal sinus opens

[1] See footnote, p. 78.

into a recess, the *spheno-ethmoidal recess*, which is situated above and behind the superior turbinated bone. The *middle meatus* is situated between the middle and inferior turbinated bones, and extends from the anterior end of the inferior turbinated bone to the spheno-palatine foramen of the outer wall of the nasal fossa. It presents in front the orifice of the *infundibulum*, by which the middle meatus communicates with the anterior ethmoidal cells, and through these with the frontal sinuses. The middle ethmoidal cells also open into this meatus, while

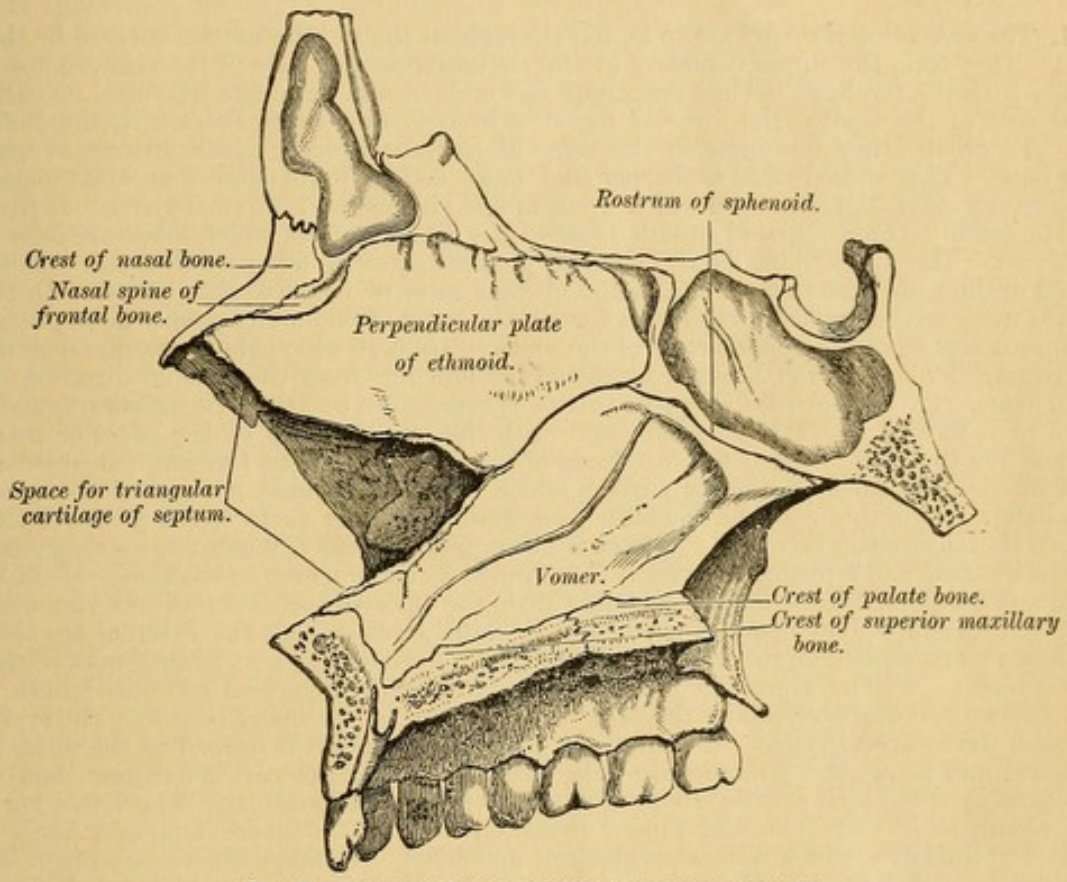

FIG. 77.—Inner wall of nasal fossæ, or septum of nose.

at the centre of the outer wall is the *orifice of the antrum*, which varies somewhat as to its exact position in different skulls. The *inferior meatus*, the largest of the three, is the space between the inferior turbinated bone and the floor of the nasal fossa. It extends along the entire length of the outer wall of the nose, is broader in front than behind, and presents anteriorly the lower *orifice of the canal for the nasal duct.*

The **anterior nares** present a heart-shaped or pyriform opening whose long axis is vertical and narrow extremity upward. This opening in the recent state is much contracted by the cartilages of the nose. It is bounded above by the inferior border of the nasal bone; laterally by the thin, sharp margin which separates the facial from the nasal surface of the superior maxillary bone; and below by the same border, where it slopes inward to join its fellow of the opposite side at the anterior nasal spine.

The **posterior nares**, or **choanæ**, are the two posterior oval openings of the nasal fossæ, by which they communicate with the upper part of the pharynx. They are situated immediately in front of the basilar process, and are bounded above by the under surface of the body of the sphenoid and alæ of the vomer; below, by the posterior border of the horizontal plate of the palate bone; externally, by the inner surface of the internal pterygoid plate; and internally, in the middle line, they are separated from each other by the posterior border of the vomer.

Surface Form.—The various bony prominences or landmarks which are to be easily felt and recognized in the head and face, and which afford the means of mapping out the important structures comprised in this region, are as follows:

1. Supraorbital arch.
2. Internal angular process.
3. External angular process.
4. Zygomatic arch.
5. Mastoid process.
6. External occipital protuberance.
7. Superior curved line of occipital bone.
8. Parietal eminences.
9. Temporal ridge.
10. Frontal eminences.
11. Superciliary ridges.
12. Nasal bones.
13. Lower margin of orbit.
14. Lower jaw.

1. The *supraorbital arches* are to be felt throughout their entire extent, covered by the eyebrows. They form the upper boundary of the circumference or base of the orbit, and separate the face from the forehead. They are strong and arched, and terminate internally on each side of the root of the nose in the *internal angular process*, which articulates with the lachrymal bone. Externally they terminate in the *external angular process*, which articulates with the malar bone. This arched ridge is sharper and more defined in its outer than in its inner half, and forms an overhanging process which protects and shields the lachrymal gland. It thus protects the eye in its most exposed situation and in the direction from which blows are most likely to descend. The supraorbital arch varies in prominence in different individuals. It is more marked in the male than in the female, and in some races of mankind than others. In the less civilized races, as the forehead recedes backward, the supraorbital arch becomes more prominent, and approaches more to the characters of the monkey tribe, in which the supraorbital arches are very largely developed, and acquire additional prominence from the oblique direction of the frontal bone. 2. The *internal angular process* is scarcely to be felt. Its position is indicated by the angle formed by the supraorbital arch with the nasal process of the superior maxillary bone and the lachrymal bone at the inner side of the orbit. Between the internal angular processes of the two sides is a broad surface which assists in forming the root of the nose, and immediately above this a broad, smooth, somewhat triangular surface, the *glabella*, situated between the superciliary ridges. 3. The *external angular process* is much more strongly marked than the internal, and is plainly to be felt. It is formed by the junction or confluence of the supraorbital and temporal ridges, and, articulating with the malar bone, it serves to a very considerable extent to support the bones of the face. In carnivorous animals the external angular process does not articulate with the malar, and therefore this lateral support to the bones of the face is not present. 4. The *zygomatic* arch is plainly to be felt throughout its entire length, being situated almost immediately under the skin. It is formed by the malar bone and the zygomatic process of the temporal bone. At its anterior extremity, where it is formed by the malar bone, it is broad and forms the prominence of the cheek; the posterior part is narrower, and terminates just in front and a little above the tragus of the external ear. The lower border is more plainly to be felt than the upper, in consequence of the dense temporal fascia being attached to the latter, which somewhat obscures its outline. Its shape differs very much in individuals and in different races of mankind. In the most degraded type of skull—as, for instance, in the skull of the negro of the Guinea Coast—the malar bones project forward and not outward, and the zygoma at its posterior extremity extends farther outward before it is twisted on itself to be prolonged forward. This makes the zygomatic arch stand out in bold relief, and affords greater space for the Temporal muscle. In skulls which have a more pyramidal shape, as in the Esquimaux or Greenlander, the malar bones do not project forward and downward under the eyes, as in the preceding form, but take a direction outward, forming with the zygoma a large, rounded sweep or segment of a circle. Thus it happens that if two lines are drawn from the zygomatic arches, touching the temporal ridges, they meet above the top of the head, instead of being parallel, or nearly so, as in the European skull, in which the zygomatic arches are not nearly so prominent. This gives to the face a more or less oval type. 5. Behind the ear is the *mastoid portion of the temporal bone*, plainly to be felt, and terminating below in a nipple-shaped process. Its anterior border can be traced immediately behind the concha, and its apex is on about a level with the lobule of the ear. It is rudimentary in infancy, but gradually develops in childhood, and is more marked in the negro than in the European. 6. The *external occipital protuberance* is always plainly to be felt just at the level where the skin of the neck joins that of the head. At this point the skull is thick for the purposes of safety, while radiating from it are numerous curved arches or buttresses of bone which give to this portion of the skull further security. 7. Running outward on either side from the external occipital protuberance is an arched ridge of bone, which can be more or less plainly perceived. This is the *superior curved line* of the occipital bone, and gives attachment to some of the muscles which keep the head erect on the spine; accordingly, we find it more developed in the negro tribes, in whom the jaws are much more massive, and therefore require stronger muscles to prevent their extra weight carrying the head forward. Below this line the surface of bone at the back of the head is obscured by the overlying muscles. Above it, the vault of the cranium is thinly covered with soft structures, so that the form of this part of the head is almost exactly that of the upper portion of the occipital, the parietal, and the frontal bones themselves; and in bald persons even the lines of junction of the bones, especially the junction of the occipital and parietal at the lambdoid suture, may be defined as a slight depression, caused by the thickening of the borders of the bones in this situation. 8. In the line of the greatest transverse diameter of the

head, on each side of the middle line, are generally to be found the *parietal eminences*, one on each side of the middle line, though sometimes these eminences are not situated at the point of the greatest transverse diameter, which is at some other prominent part of the parietal region. They denote the point where ossification of the parietal bone began. They are much more prominent and well-marked in early life, in consequence of the sharper curve of the bone at this period, so that it describes the segment of a smaller circle. Later in life, as the bone grows, the curve spreads out and forms the segment of a larger circle, so that the eminence becomes less distinguishable. In consequence of this sharp curve of the bone in early life, the whole of the vault of the skull has a squarer shape than it has in later life, and this appearance may persist in some rickety skulls. The eminence is more apparent in the negro's skull than in that of the European. This is due to greater flattening of the temporal fossa in the former skull to accommodate the larger Temporal muscle which exists in these races. The parietal eminence is particularly exposed to injury from blows or falls on the head, but fracture is to a certain extent prevented by the shape of the bone, which forms an arch, so that the force of the blow is diffused over the bone in every direction. 9. At the side of the head may be felt the *temporal ridge*. Commencing at the external angular process, it may be felt as a curved ridge, passing upward and then curving backward, on the frontal bone, separating the forehead from the temporal fossa. It may then be traced, passing backward in a curved direction, over the parietal bone, and, though less marked, still generally to be recognized. Finally, the ridge curves downward, and terminates in the posterior root of the zygoma, which separates the squamous from the subcutaneous mastoid portion of the temporal bone. Mr. Victor Horsley has recently shown, in an article on the "Topography of the Cerebral Cortex," that the second temporal ridge (see page 62) can be made out on the living body. 10. The *frontal eminences* vary a good deal in different individuals, being considerably more prominent in some than in others, and they are often not symmetrical on the two sides of the body, the one being much more pronounced than the other. This is often especially noticeable in the skull of the young child or infant, and becomes less marked as age advances. The prominence of the frontal eminences depends more upon the general shape of the whole bone than upon the size of the protuberances themselves. As the skull is more highly developed in consequence of increased intellectual capacity, so the frontal bone becomes more upright and the frontal eminences stand out in bolder relief. Thus they may be considered as affording, to a certain extent, an indication of the development of the hemispheres of the brain beneath, and of the mental powers of the individual. They are not so much exposed to injury as the parietal eminences. In falls forward the upper extremities are involuntarily thrown out, and break the force of the fall, and thus shield the frontal bone from injury. 11. Below the frontal eminences on the forehead are the *superciliary ridges*, which denote the position of the frontal sinuses, and vary according to the size of the sinuses in different individuals, being, as a rule, small in the female, absent in children, and sometimes unusually prominent in the male, when the frontal sinuses are largely developed. They commence on either side of the glabella, and at first present a rounded form, which gradually fades away at their outer ends. 12. The *nasal bones* form the prominence of the nose. They vary much in size and shape, and to them is due the varieties in the contour of this organ and much of the character of the face. Thus, in the Mongolian or Ethiopian they are flat, broad and thick at their base, giving to these tribes the flattened nose by which they are characterized, and differing very decidedly from the Caucasian, in whom the nose, owing to the shape of the nasal bones, is narrow, elevated at the bridge, and elongated downward. Below, the nasal bones are thin and connected with the cartilages of the nose, and the angle or arch formed by their union serves to throw out the bridge of the nose, and is much more marked in some individuals than others. 13. The *lower margin of the orbit*, formed by the superior maxillary bone and the malar bone, is plainly to be felt throughout its entire length. It is continuous internally with the nasal process of the superior maxillary bone, which forms the inner boundary of the orbit. At the point of junction of the lower margin of the orbit with the nasal process is to be felt a little tubercle of bone, which can be plainly perceived by running the finger along the bone in this situation. This tubercle serves as a guide to the position of the lachrymal sac, which is situated above and behind it. 14. The outline of the *lower jaw* is to be felt throughout its entire length. Just in front of the tragus of the external ear, and below the zygomatic arch, the condyle can be made out. When the mouth is opened this prominence of bone can be perceived advancing out of the glenoid fossa on to the eminentia articularis, and receding again when the mouth is closed. From the condyle the posterior border of the ramus can be felt extending down to the angle. A line drawn from the condyle to the angle would indicate the exact position of this border. From the angle to the symphysis of the chin the lower, rounded border of the body of the bone is plainly to be felt. At the point of junction of the two halves of the bone is a well-marked triangular eminence, the *mental process*, which forms the prominence of the chin.

Surgical Anatomy.—An arrest in the ossifying process may give rise to deficiencies or gaps; or to fissures, which are of importance in a medico-legal point of view, as they are liable to be mistaken for fractures. The fissures generally extend from the margin toward the centre of the bone, but gaps may be found in the middle as well as at the edges. In course of time they may become covered with a thin lamina of bone.

Occasionally a protrusion of the brain or its membranes may take place through one of these gaps in an imperfectly developed skull. When the protrusion consists of membranes only, and is filled with cerebro-spinal fluid, it is called a *meningocele;* when the protrusion consists of brain

as well as membranes, it is termed an *encephalocele ;* and when the protruded brain is a prolongation from one of the ventricles, and is distended by a collection of fluid from an accumulation in the ventricle, it is termed an *hydrencephalocele.* This latter condition is frequently found at the root of the nose, where a protrusion of the anterior horn of the lateral ventricle takes place through a deficiency of the fronto-nasal suture. These malformations are usually found in the middle line, and most frequently at the back of the head, the protrusion taking place through the fissures which separate the four centres of ossification from which the tabular portion of the occipital bone is originally developed (see page 61). They most frequently occur through the upper part of the vertical fissure, which is the last to ossify, but not uncommonly through the lower part, when the foramen magnum may be incomplete. More rarely these protrusions have been met with in other situations than those two above mentioned, both through normal fissures, as the sagittal, lambdoid, and other sutures, and also through abnormal gaps and deficiencies at the sides, and even at the base of the skull.

Fractures of the skull may be divided into those of the vault and those of the base. Fractures of the vault are usually produced by direct violence. This portion of the skull varies in thickness and strength in different individuals, but, as a rule, is sufficiently strong to resist a very considerable amount of violence without being fractured. This is due to several causes: the rounded shape of the head and its construction of a number of secondary elastic arches, each made up of a single bone; the fact that it consists of a number of bones, united, at all events in early life, by a sutural ligament, which acts as a sort of buffer and interrupts the continuity of any violence applied to the skull; the presence of arches or ridges, both on the inside and outside of the skull, which materially strengthen it; and the mobility of the head upon the spine which further enables it to withstand violence. The elasticity of the bones of the head is especially marked in the skull of the child, and this fact, together with the wide separation of the individual bones from each other, and the interposition between them of other softer structures renders fracture of the bones of the head a very uncommon event in infants and quite young children; as age advances and the bones become joined, fracture is more common, though still less liable to occur than in the adult. Fractures of the vault may, and generally do, involve the whole thickness of the bone; but sometimes one table may be fractured without any corresponding injury to the other. Thus, the outer table of the skull may be splintered and driven into the diploë, or in the frontal or mastoid regions into the frontal or mastoid cells, without any injury to the internal table. And on the other hand, the internal table has been fractured, and portions of it depressed and driven inward, without any fracture of the outer table. As a rule, in fractures of the skull the inner table is more splintered and comminuted than the outer, and this is due to several causes. It is thinner and more brittle; the force of the violence as it passes inward becomes broken up, and is more diffused by the time it reaches the inner table; the bone, being in the form of an arch, bends as a whole and spreads out, and thus presses the particles together on the convex surface of the arch—*i. e.* the outer table—and forces them asunder on the concave surface or inner table; and, lastly, there is nothing firm under the inner table to support it and oppose the force. Fractures of the vault may be simple fissures or starred and comminuted fractures, and these may be depressed or elevated. These latter cases of fracture with elevation of the fractured portion are uncommon, and can only be produced by direct wound. In comminuted fracture a portion of the skull is broken into several pieces, the lines of fracture radiating from a centre where the chief impact of the blow was felt; if depressed, a fissure circumscribes the radiating line, enclosing a portion of skull. If this area is circular, it is termed a "pond" fracture, and would in all probability have been caused by a round instrument, as a life-preserver or hammer; if elliptical in shape, it is termed a "gutter fracture," and would owe its shape to the instrument which had produced it, as a poker.

Fractures of the base are most frequently produced by the extension of a fissure from the vault, as in falls on the head, where the fissure starts from the part of the vault which first struck the ground. Sometimes, however, they are caused by direct violence, when foreign bodies have been forced through the thin roof of the orbit, through the cribriform plate of the ethmoid from being thrust up the nose, or through the roof of the pharynx. Other cases of fracture of the base occur from indirect violence, as in fracture of the occipital bone from impaction of the spinal column against its condyles in falls on the buttocks, knees, or feet, or in cases where the glenoid cavity has been fractured by the violent impact of the condyle of the lower jaw against it from blows on the chin.

The most common place for fracture of the base to occur is through the middle fossa, and here the fissure usually takes a fairly definite course. Starting from the point struck, which is generally somewhere in the neighborhood of the parietal eminence, it runs downward through the parietal and squamous portion of the temporal bone and across the petrous portion of this bone, frequently traversing and implicating the internal auditory meatus, to the middle lacerated foramen. From this it may pass across the body of the sphenoid, through the pituitary fossa to the middle lacerated foramen of the other side, and may indeed travel round the whole cranium, so as to completely separate the anterior from the posterior part. The course of the fracture should be borne in mind, as it explains the symptoms to which fracture in this region may give rise; thus, if the fissure pass across the internal auditory meatus, injury to the facial and auditory nerves may result, with consequent facial paralysis and deafness; or the tubular prolongation of the arachnoid around these nerves in the meatus may be torn, and thus permit of the escape of the cerebro-spinal fluid should there be a communication between the internal ear

and the tympanum and the membrana tympani be ruptured, as is frequently the case; again, if the fissure passes across the pituitary fossa and the muco-periosteum covering the under surface of the body of the sphenoid is torn, blood will find its way into the pharynx and be swallowed, and after a time vomiting of blood will result. Fractures of the anterior fossa, involving the bones forming the roof of the orbit and nasal fossa, are generally the results of blows on the forehead; but fracture of the cribriform plate of the ethmoid may be a complication of fracture of the nasal bone. When the fracture implicates the roof of the orbit, the blood finds its way into this cavity, and, travelling forward, appears as a subconjunctival ecchymosis. If the roof of the nasal fossa be fractured, the blood escapes from the nose. In rare cases there may be also escape of cerebro-spinal fluid from the nose where the dura mater and arachnoid have been torn. In fractures of the posterior fossa extravasation of blood may appear at the nape of the neck.

The bones of the skull are frequently the seat of nodes, and not uncommonly necrosis results from this cause, also from injury. Necrosis may involve the entire thickness of the skull, but is usually confined to the external table. Necrosis of the internal table alone is rarely met with. The bones of the skull are also frequently the seat of sarcomatous tumor.

The skull in rickets is peculiar: the forehead is high, square, and projecting, and the antero-posterior diameter of the skull is long in relation to the transverse diameter. The bones of the face are small and ill-developed, and this gives the appearance of a larger head than actually exists. The bones of the head are often thick, especially in the neighborhood of the sutures, and the anterior fontanelle is late in closing, sometimes remaining unclosed till the fourth year. The condition of *craniotabes* has by some been also believed to be the result of rickets, by others is believed to be due to inherited syphilis. In all probability it is due to both. In these cases the bone undergoes atrophic changes in patches, so that it becomes greatly thinned in places, generally where there is pressure, as from the pillow or nurse's arm. It is, therefore, usually met with in the parietal bone and vertical plate of the occipital bone.

In congenital syphilis deposits of porous bone are often found at the angles of the parietal bones and two halves of the frontal bone which bound the anterior fontanelle. These deposits are separated by the coronal and sagittal sutures, and give to the skull an appearance like a "hot cross bun." They are known as Parrot's nodes, and such a skull has received the name of *natiform*, from its fancied resemblance to the buttocks.

In connection with the bones of the face a common malformation is *cleft palate*, owing to the non-union of the palatal processes of the maxillary or pre-oral arch. This cleft may involve the whole or only a portion of the hard palate, and usually involves the soft palate also. The cleft is in the middle line, except it involves the alveolus in front, when it follows the suture between the main portion of the bone and the pre-maxillary bone. Sometimes the cleft runs on either side of the pre-maxillary bone, so that this bone is quite isolated from the maxillary bones and hangs from the end of the vomer. The malformation is usually associated with hare-lip, which, when single, is almost always on one side, corresponding to the position of the suture between the lateral incisor and canine tooth. Some few cases of median hare-lip have been described. In double hare-lip there is a cleft on each side of the middle line.

The bones of the face are sometimes fractured as the result of direct violence. The two most commonly broken are the nasal bone and the inferior maxilla, and of these the latter is by far the most frequently fractured of all the bones of the face. Fracture of the *nasal* bone is for the most part transverse, and takes place about half an inch from the free margin. The broken portion may be displaced backward or more generally to one side by the force which produced the lesion, as there are no muscles here which can cause displacement. The *malar* bone is probably never broken alone; that is to say, unconnected with a fracture of the other bones of the face. The *zygomatic arch* is occasionally fractured, and when this occurs from direct violence, as is usually the case, the fragments may be displaced inward. This lesion is often attended with great difficulty or even inability to open and shut the mouth, and this has been stated to be due to the depressed fragments perforating the temporal muscle, but would appear rather to be caused by the injury done to the bony origin of the Masseter muscle. Fractures of the *superior maxilla* may vary much in degree, from the chipping off of a portion of the alveolar arch, a frequent accident when the "old key" instrument was used for the extraction of teeth, to an extensive comminution of the whole bone from severe violence, as the kick of a horse. The most common situation for a fracture of the *inferior maxillary bone* is in the neighborhood of the canine tooth, as at this spot the jaw is weakened by the deep socket for the fang of this tooth; it is next most frequently fractured at the angle; then at the symphysis, and finally the neck of the condyle or the coronoid process may be broken. Occasionally a double fracture may occur, one in either half of the bone. The fractures are usually compound, from laceration of the mucous membrane covering the gums. The displacement is mainly the result of the same violence as produced the injury, but may be further increased by the action of the muscles passing from the neighborhood of the symphysis to the hyoid bone.

The superior and inferior maxillary bones are both of them frequently the seat of necrosis, though the disease affects the lower much more frequently than the upper jaw, probably on account of the greater supply of blood to the latter. It may be the result of periostitis, from tooth irritation, injury, or the action of some specific poison, as syphilis, or from salivation by mercury; it not unfrequently occurs in children after attacks of the exanthematous fevers, and a special form occurs from the action of the fumes of phosphorus in persons engaged in the manufacture of matches.

Tumors attack the jaw-bones not infrequently, and these may be either innocent or malignant: in the upper jaw cysts may occur in the antrum, constituting the so-called dropsy of the antrum; or, again, cysts may form in either jaw in connection with the teeth: either cysts connected with the roots of fully-developed teeth, the "dental cyst;" or cysts connected with imperfectly developed teeth, the "dentigerous cyst." Solid innocent tumors include the fibroma, the chondroma, and the osteoma. Of malignant tumors there are two classes, the sarcomata and the epithelioma. The sarcoma are of various kinds, the spindle-celled and round-celled, of a very malignant character, and the myeloid sarcoma, principally affecting the alveolar margin of the bone. Of the epitheliomata we find the squamous variety spreading to the bone from the palate or gum, and the cylindrical epithelioma originating in the antrum or nasal fossæ.

Both superior and inferior maxillary bones occasionally require removal for tumors and in some other conditions. The upper jaw is removed by an incision from the inner canthus of the eye, along the side of the nose, round the ala, and down the middle line of the upper lip. A second incision is carried outward from the inner canthus of the eye along the lower margin of the orbit as far as the prominence of the malar bone. The flap thus formed is reflected outward and the surface of the bone exposed. The connections of the bone to the other bones of the face are then divided with a narrow saw. They are (1) the junction with the malar bone, passing into the spheno-maxillary fissure; (2) the nasal process; a small portion of its upper extremity, connected with the nasal bone in front, the lachrymal bone behind, and the frontal bone above, being left; (3) the connection with the bone on the opposite side and the palate in the roof of the mouth. The bone is now firmly grasped with lion-forceps, and by means of a rocking movement upward and downward the remaining attachments of the orbital plate with the ethmoid, and the back of the bone with the palate, broken through. The soft palate is first separated from the hard with a scalpel, and is not removed. Occasionally in removing the upper jaw it will be found that the orbital plate can be spared, and this should always be done if possible. A horizontal saw-cut is to be made just below the infraorbital foramen and the bone cut through with a chisel and mallet. Removal of one-half of the lower jaw is sometimes required. If possible, the section of the bone should be made to one side of the symphysis, so as to save the genial tubercles and the origin of the genio-hyo-glossus muscle, as otherwise the tongue tends to fall backward and may produce suffocation. Having extracted the central or preferably the lateral incisor tooth, a vertical incision is made down to the bone, commencing at the free margin of the lip, and carried to the lower border of the bone; it is then carried along its lower border to the angle and up the posterior margin of the ramus to a level with the lobule of the ear. The flap thus formed is raised by separating all the structures attached to the outer surface of the bone. The jaw is now sawn through at the point where the tooth has been extracted, and the knife passed along the inner side of the jaw, separating the structures attached to this surface. The jaw is then grasped by the surgeon and strongly depressed, so as to bring down the coronoid process and enable the operator to sever the tendon of the temporal muscle. The jaw can be now further depressed, care being taken not to evert it nor rotate it outward, which would endanger the internal maxillary artery, and the external pterygoid torn through or divided. The capsular ligament is now opened in front and the lateral ligaments divided, and the jaw removed with a few final touches of the knife.

The antrum of Highmore occasionally requires tapping for suppuration. This may be done through the socket of a tooth, preferably the first molar, the fangs of which are most intimately connected with the antrum, or through the facial aspect of the bone above the alveolar process. This latter method does not perhaps afford such efficient drainage, but there is less chance of food finding its way into the cavity. The operation may be performed by incising the mucous membrane above the second molar tooth, and driving a trocar or any sharp-pointed instrument into the cavity.

THE HYOID BONE.

The **Hyoid bone** is named from its resemblance to the Greek upsilon; it is also called the *lingual bone*, because it supports the tongue and gives attachment to its numerous muscles. It is a bony arch, shaped like a horseshoe, and consisting of five segments, a body, two greater cornua, and two lesser cornua. It is suspended from the tip of the styloid processes of the temporal bone by ligamentous bands, the *stylo-hyoid* ligaments.

The **Body** (*basi-hyal*) forms the central part of the bone, and is of a quadrilateral form; its *anterior surface* (Fig. 78), convex, directed forward and upward, is divided into two parts by a vertical ridge which descends along the median line, and is crossed at right angles by a horizontal ridge, so that this surface is divided into four spaces or depressions. At the point of meeting of these two lines is a prominent elevation, the *tubercle*. The portion above the horizontal ridge is directed upward, and is sometimes described as the superior border. The anterior surface gives attachment to the Genio-hyoid in the greater part of its extent; above, to the Genio-hyo-glossus; below, to the Mylo-hyoid, Styly-hyoid, and

aponeurosis of the Digastric (suprahyoid aponeurosis); and between these to part of the Hyo-glossus. The *posterior surface* is smooth, concave, directed backward and downward, and separated from the epiglottis by the thyro-hyoid membrane and by a quantity of loose areolar tissue. The *superior border* is rounded, and gives attachment to the thyro-hyoid membrane, part of the Genio-hyo-glossi and Chondro-glossi muscles. The *inferior border* gives attachment, in front, to the Sterno-hyoid; behind, to the Omo-hyoid and to part of the Thyro-hyoid at its junction with the great cornu. It also gives attachment to the Levatore glandulæ thyroideæ when this muscle is present. The *lateral surfaces* after middle life are joined to the greater cornua. In early life they are connected to the cornua by cartilaginous surfaces, and held together by ligaments, and occasionally a synovial membrane is found between them.

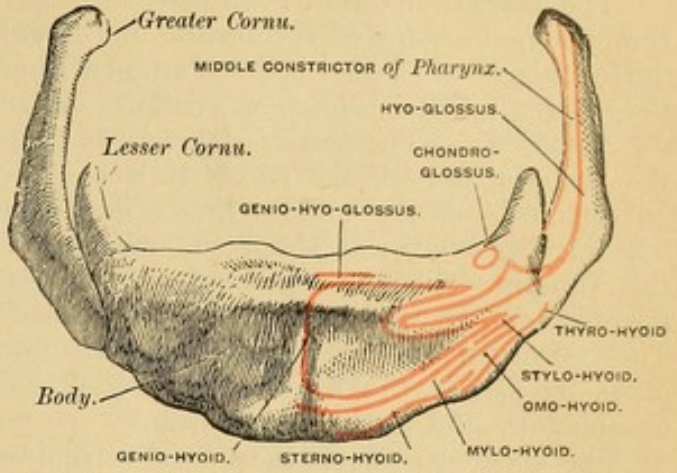

FIG. 78.—Hyoid bone. Anterior surface. (Enlarged.)

The **Greater Cornua** (*thyro-hyal*) project backward from the lateral surfaces of the body; they are flattened from above downward, diminish in size from before backward, and terminate posteriorly in a tubercle for the attachment of the lateral thyro-hyoid ligament. The outer surface gives attachment to the Hyo-glossus, their upper border to the Middle constrictor of the pharynx, their lower border to part of the Thyro-hyoid muscle.

The **Lesser Cornua** (*cerato-hyals*) are two small, conical-shaped eminences attached by their bases to the angles of junction between the body and greater cornua, and giving attachment by their apices to the stylo-hyoid ligaments.[1] The smaller cornua are connected to the body of the bone by a distinct diarthrodial joint, which usually persists throughout life, but occasionally becomes ankylosed.

Development.—By *five* centres: one for the body, and one for each cornu. Ossification commences in the body about the eighth month, and in the greater cornua toward the end of fœtal life. Ossification of the lesser cornua commences some years after birth. Sometimes there are two centres for the body.

Attachment of Muscles.—Sterno-hyoid, Thyro-hyoid, Omo-hyoid, aponeurosis of the Digastric, Stylo-hyoid, Mylo-hyoid, Genio-hyoid, Genio-hyo-glossus, Chondro-glossus, Hyo-glossus, Middle constrictor of the pharynx, and occasionally a few fibres of the Inferior lingualis. It also gives attachment to the thyro-hyoidean membrane and the stylo-hyoid, thyro-hyoid, and hyo-epiglottic ligaments.

Surface Form.—The hyoid bone can be felt in the receding angle below the chin, and the finger can be carried along the whole length of the bone to the greater cornu, which is situated just below the angle of the jaw. This process of bone is best perceived by making pressure on one cornu, and so pushing the bone over to the opposite side, when the cornu of this side will be distinctly felt immediately beneath the skin. This process of bone is an important landmark in ligature of the lingual artery.

Surgical Anatomy.—The hyoid bone is occasionally fractured, generally from direct violence, as in the act of garrotting or throttling. The great cornu is the part of the bone most frequently broken, but sometimes the fracture takes place through the body of the bone. In consequence of the muscles of the tongue having important connections with this bone, there is great pain upon any attempt being made to move the tongue, as in speaking or swallowing.

[1] These ligaments in many animals are distinct bones, and in man are occasionally ossified to a certain extent.

THE THORAX.

The **Thorax**, or **Chest**, is an osseo-cartilaginous cage containing and protecting the principal organs of respiration and circulation. It is conical in shape, being narrow above and broad below, flattened from before backward, and longer behind than in front. It is somewhat reniform on transverse section.

Boundaries.—The *posterior* surface is formed by the twelve dorsal vertebræ and the posterior part of the ribs. It is concave from above downward, and presents on each side of the middle line a deep groove in consequence of the direction backward and outward which the ribs take from their vertebral extremities to their angles. The *anterior* surface is flattened or slightly convex, and inclined forward from above downward. It is formed by the sternum and costal cartilages. The *lateral* surfaces are convex; they are formed by the ribs, separated from each other by spaces, the *intercostal spaces*. These are eleven in number, and are occupied by the intercostal muscles.

The *upper opening* of the thorax is reniform in shape, being broader from side to side than from before backward. It is formed by the first dorsal vertebra behind, the upper margin of the sternum in front, and the first rib on each side. It slopes downward and forward, so that the anterior part of the ring is on a lower level than the posterior. The antero-posterior diameter is about two inches, and the transverse about four. The *lower* opening is formed by the twelfth dorsal vertebra behind, by the twelfth rib at the sides, and in front by the cartilages of the eleventh, tenth, ninth, eighth, and seventh ribs, which ascend on either side and form an angle, the *subcostal angle*, from the apex of which the ensiform cartilage projects. It is wider transversely than from before backward. It slopes obliquely downward and backward, so that the cavity of the thorax is much deeper behind than in front. The Diaphragm closes in the opening forming the floor of the thorax.

In the female the thorax differs as follows from the male: 1. Its general capacity is less. 2. The sternum is shorter. 3. The upper margin of the sternum is on a level with the lower part of the body of the third dorsal vertebra, whereas in the male it is on a level with the lower part of the body of the second dorsal vertebra. 4. The upper ribs are more movable, and so allow a greater enlargement of the upper part of the thorax than in the male.

The Sternum.

The **Sternum** (*στέρνον*, the chest) (Figs. 79, 80) is a flat, narrow bone, situated in the median line of the front of the chest, and consisting, in the adult, of three portions. It has been likened to an ancient sword; the upper piece, representing the handle, is termed the *manubrium;* the middle and largest piece, which represents the chief part of the blade, is termed the *gladiolus;* and the inferior piece, which is likened to the point of the sword, is termed the *ensiform* or *xiphoid appendix*. In its natural position its inclination is oblique from above downward and forward. It is slightly convex in front, concave behind, broad above, becoming narrowed at the point where the first and second pieces are connected, after which it again widens a little, and is pointed at its extremity. Its average length in the adult is about seven inches, being rather longer in the male than in the female.

The **First Piece** of the sternum, or **Manubrium** (*pre-sternum*), is of a somewhat triangular form, broad and thick above, narrow below at its junction with the middle piece. Its *anterior surface*, convex from side to side, concave from above downward, is smooth, and affords attachment on each side to the Pectoralis major and sternal origin of the Sterno-cleido-mastoid muscle. In well-marked bones the ridges limiting the attachment of these muscles are very distinct. Its *posterior surface*, concave and smooth, affords attachment on each side to the Sterno-hyoid and Sterno-thyroid muscles. The *superior border*, the thickest, presents at its centre the *pre-sternal notch;* and on each side an oval articular surface, directed

upward, backward, and outward, for articulation with the sternal end of the clavicle. The *inferior border* presents an oval, rough surface, covered in the recent state with a thin layer of cartilage, for articulation with the second portion of the bone. The *lateral borders* are marked above by a depression for the first costal cartilage, and below by a small facet, which with a similar facet on the upper angle of the middle portion of the bone, forms a notch for the reception of the costal cartilage of the second rib. These articular surfaces are separated by a narrow, curved edge, which slopes from above downward and inward.

The **Second Piece** of the sternum, or **Gladiolus** (*meso-sternum*), considerably longer, narrower, and thinner than the first piece, is broader below than above. Its *anterior surface* is nearly flat, directed upward and forward, and marked by three transverse lines which cross the bone opposite the third, fourth, and fifth articular depressions. These lines are produced by the union of the four separate pieces of which this part of the bone consists at an early period of life. At the junction of the third and fourth pieces is occasionally seen an orifice, the *sternal foramen;* it varies in size and form in different individuals, and pierces the bone from before backward. This surface affords attachment on each side to the sternal origin of the Pectoralis major. The *posterior surface*, slightly concave, is also marked by three transverse lines, but they are less distinct than those in front: this surface affords attachment below, on each side, to the Triangularis sterni muscle, and occasionally presents the posterior opening of the sternal foramen. The *superior border* presents an oval surface for articulation with the manubrium. The *inferior border* is narrow, and articulates with the ensiform appendix. Each *lateral border* presents, at each superior angle, a small facet, which, with a similar facet on the manubrium, forms a cavity for the cartilage of the second rib; the four succeeding angular depressions receive the cartilages of the third, fourth, fifth, and sixth ribs; whilst each inferior angle presents a small facet, which, with a corresponding one on the ensiform appendix, forms a notch for the cartilage of the seventh rib. These articular depressions are separated by a series of curved interarticular intervals, which diminish in length from above downward, and correspond to the intercostal spaces. Most of the cartilages belonging to the true ribs, as will be seen from the foregoing description, articulate with the sternum at the line of junction of two of its primitive component segments. This is well seen in many of the lower animals, where the separate parts of the bone remain ununited longer than in man. In this respect a striking analogy exists between the mode of connection of the ribs with the vertebral column and the connection of the costal cartilages with the sternum.

The **Third Piece** of the sternum, the **Ensiform** or **Xiphoid Appendix** (*meta-sternum*), is the smallest of the three; it is thin and elongated in form, cartilaginous in structure in youth, but more or less ossified at its upper part in the adult Its *anterior surface* affords attachment to the chondro-xiphoid ligament; its *posterior surface*, to some of the fibres of the Diaphragm and Triangularis sterni muscles; its *lateral borders*, to the aponeurosis of the abdominal muscles. Above it articulates with the lower end of the gladiolus, and at each superior angle presents a facet for the lower half of the cartilage of the seventh rib; below, by its pointed extremity it gives attachment to the linea alba. This portion of the sternum is very various in appearance, being sometimes pointed, broad, and thin, sometimes bifid or perforated by a round hole, occasionally curved or deflected considerably to one or the other side.

Structure.—The bone is composed of delicate cancellous structure, covered by a thin layer of compact tissue, which is thickest in the manubrium between the articular facets for the clavicles.

Development.—The cartilaginous sternum originally consists of two bars, situated one on either side of the mesial plane and connected with the rib cartilages of its own side. These two bars fuse with each other along the middle line, and the bone, including the ensiform appendix, is developed by *six* centres; one for the first piece or manubrium, four for the second piece or gladiolus, and one for the ensiform

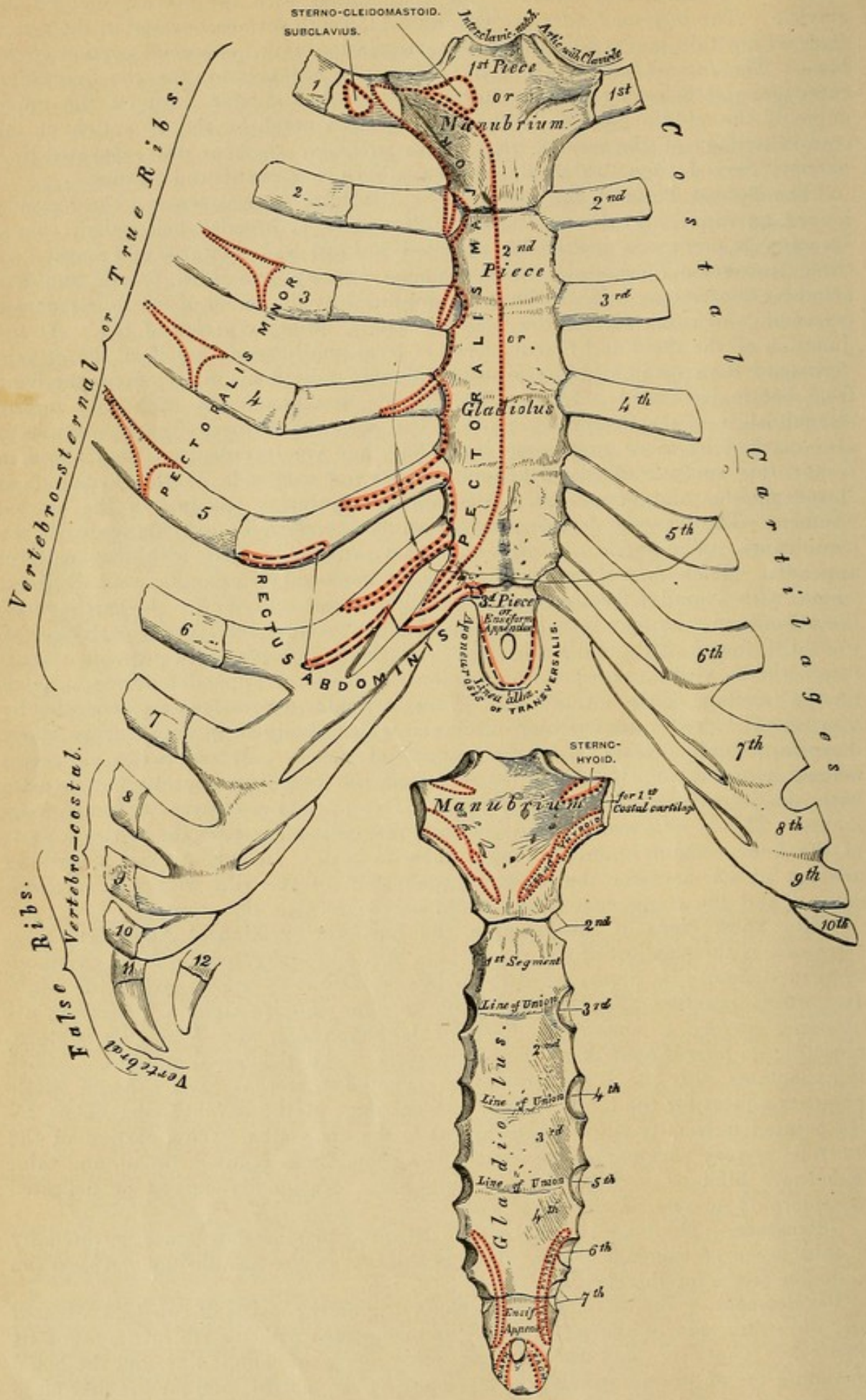

FIG. 79.—Sternum and costal cartilages.

FIG. 80.—Posterior surface of sternum.

appendix. Up to the middle of fœtal life the sternum is entirely cartilaginous, and when ossification takes place the ossific granules are deposited in the middle of the intervals between the articular depressions for the costal cartilages, in the following order (Fig. 81): In the first piece, between the fifth and sixth months; in the second and third, between the sixth and seventh months; in the fourth piece, at the ninth month; in the fifth, within the first year or between the first and second years after birth; and in the ensiform appendix, between the second and the seventeenth or eighteenth years, by a single centre which makes its appearance at the upper part and proceeds gradually downward. To these may be added the

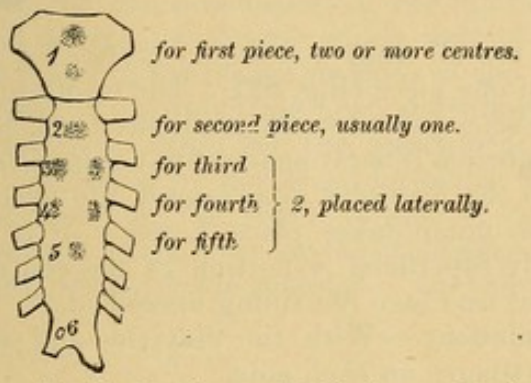

FIG. 81.—Development of the sternum by six centres. Time of appearance.

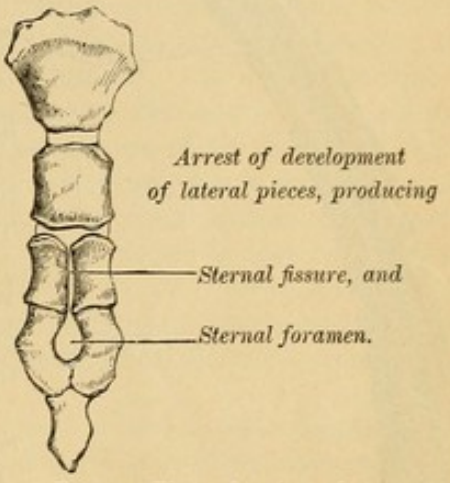

FIG. 82.—Time of union of sternum.

occasional existence, as described by Breschet, of two small episternal centres, which make their appearance one on each side of the presternal notch. They are

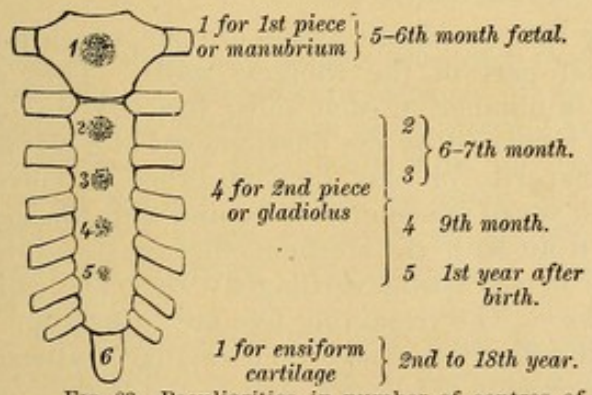

FIG. 83.—Peculiarities in number of centres of sternum.

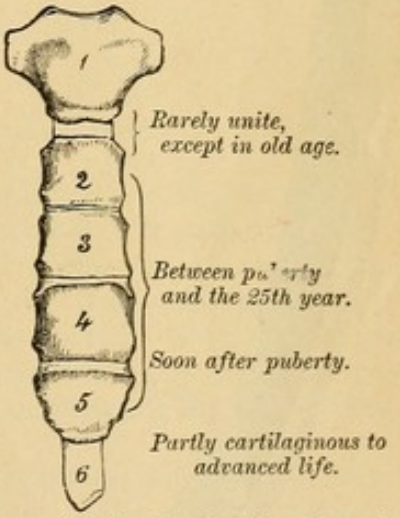

FIG. 84.—Peculiarities in mode of union of sternum.

probably vestiges of the episternal bone of the monotremata and lizards. It occasionally happens that some of the segments are formed from more than one centre, the number and position of which vary (Fig. 83). Thus, the first piece may have two, three, or even six centres. When two are present, they are generally situated one above the other, the upper one being the larger;[1] the second piece has seldom more than one; the third, fourth, and fifth pieces are often formed from two centres placed laterally, the irregular union of which will serve to explain the occasional occurrence of the sternal foramen (Fig. 84), or of the vertical fissure which occasionally intersects this part of the bone, and which is further explained by the manner in which the cartilaginous matrix, in which ossification takes place, is formed. Union of the various centres of the gladiolus commences about puberty, from below, and proceeds upward, so that by the age of twenty-

[1] Sir George Humphry states that this is "probably the more complete condition."

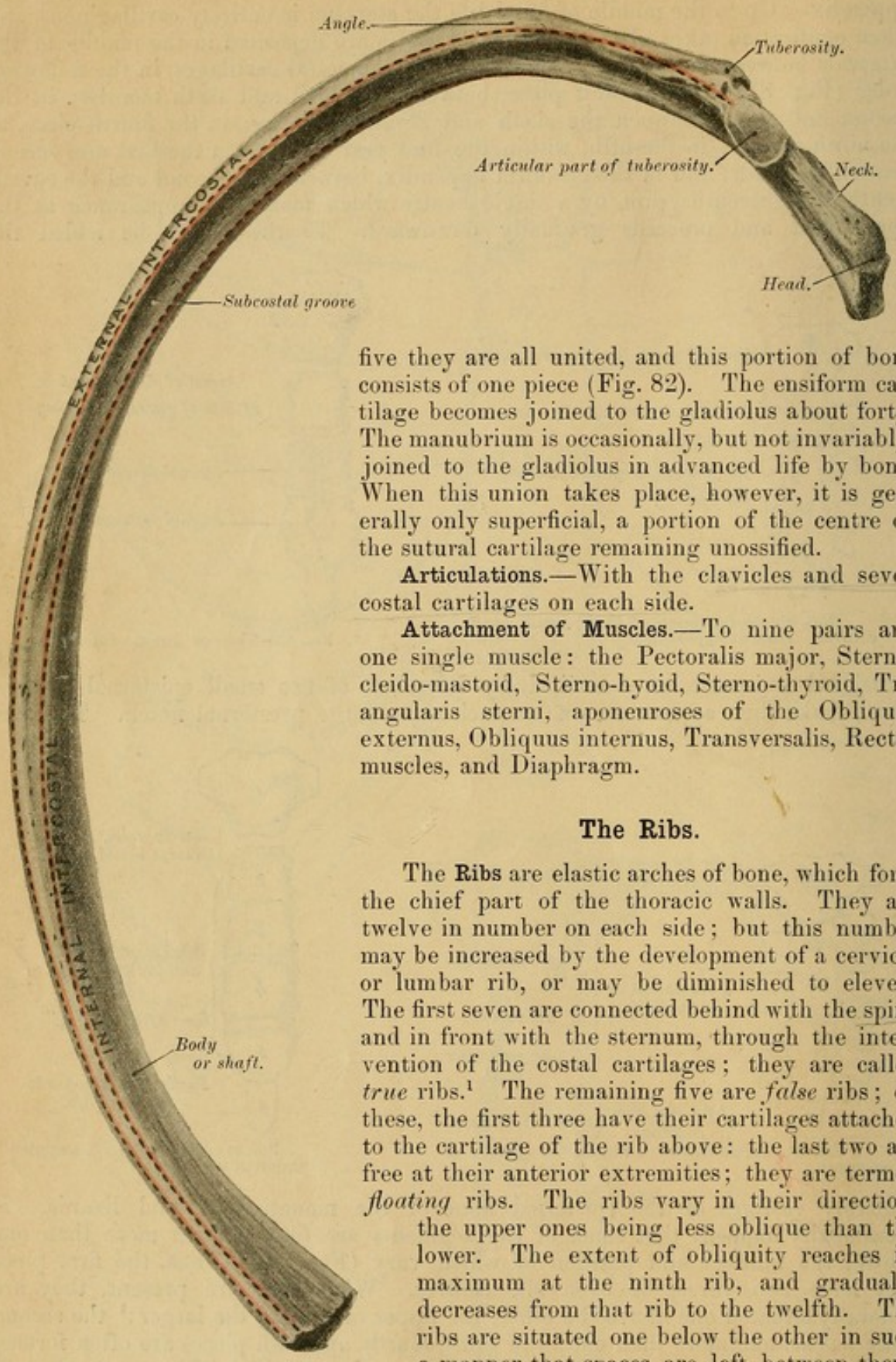

FIG. 85.—A central rib of left side.

five they are all united, and this portion of bone consists of one piece (Fig. 82). The ensiform cartilage becomes joined to the gladiolus about forty. The manubrium is occasionally, but not invariably, joined to the gladiolus in advanced life by bone. When this union takes place, however, it is generally only superficial, a portion of the centre of the sutural cartilage remaining unossified.

Articulations.—With the clavicles and seven costal cartilages on each side.

Attachment of Muscles.—To nine pairs and one single muscle: the Pectoralis major, Sterno-cleido-mastoid, Sterno-hyoid, Sterno-thyroid, Triangularis sterni, aponeuroses of the Obliquus externus, Obliquus internus, Transversalis, Rectus muscles, and Diaphragm.

The Ribs.

The **Ribs** are elastic arches of bone, which form the chief part of the thoracic walls. They are twelve in number on each side; but this number may be increased by the development of a cervical or lumbar rib, or may be diminished to eleven. The first seven are connected behind with the spine and in front with the sternum, through the intervention of the costal cartilages; they are called *true* ribs.[1] The remaining five are *false* ribs; of these, the first three have their cartilages attached to the cartilage of the rib above: the last two are free at their anterior extremities; they are termed *floating* ribs. The ribs vary in their direction, the upper ones being less oblique than the lower. The extent of obliquity reaches its maximum at the ninth rib, and gradually decreases from that rib to the twelfth. The ribs are situated one below the other in such a manner that spaces are left between them, which are called *intercostal spaces*. The length of these spaces corresponds to the length of the ribs and their cartilages; their breadth is greater in front than behind, and between the upper than between the lower ribs. The ribs increase in length from the first to the seventh, when

[1] Sometimes the eighth rib cartilage articulates with the sternum; this condition occurs more frequently on the right than on the left side.

they again diminish to the twelfth. In breadth they decrease from above downward; in the upper ten the greatest breadth is at the sternal extremity.

Common Characters of the Ribs (Fig. 85).—A rib from the middle of the series should be taken in order to study the common characters of the ribs.

Each rib presents two extremities, a posterior or vertebral, an anterior or sternal, and an intervening portion—the body or shaft.

The **posterior** or **vertebral extremity** presents for examination a head, neck, and tuberosity. The **head** (Fig. 86) is marked by a kidney-shaped articular surface, divided by a horizontal ridge into two facets for articulation with the costal cavity formed by the junction of the bodies of two contiguous dorsal vertebræ; the upper facet is small, the inferior one of larger size; the ridge separating them serves for the attachment of the interarticular ligament. The **neck** is that flattened portion of the rib which extends outward from the head; it is about an inch long, and is placed in front of the transverse process of the lower of the two vertebræ with which the head articulates. Its *anterior surface* is flat and smooth, its *posterior* rough for the attachment of the middle costo-transverse ligament, and perforated by numerous foramina, the direction of which is less constant than those found on the inner surface of the shaft. Of its two borders the *superior* presents a rough crest for the attachment of the anterior costo-transverse ligament; its *inferior border* is rounded. On the posterior surface of the neck, just where it

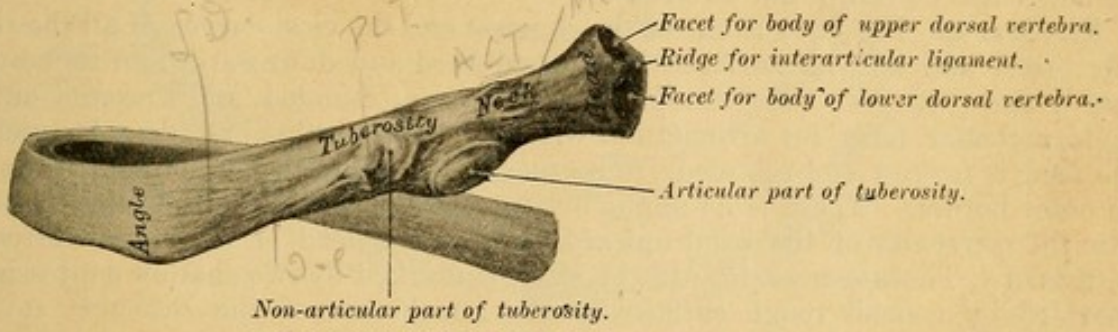

FIG. 86.—Vertebral extremity of a rib. External surface.

joins the shaft, and nearer the lower than the upper border, is an eminence—the **tuberosity,** or **tubercle**; it consists of an articular and a non-articular portion. The *articular portion*, the more internal and inferior of the two, presents a small, oval surface for articulation with the extremity of the transverse process of the lower of the two vertebræ to which the head is connected. The *non-articular portion* is a rough elevation, which affords attachment to the posterior costo-transverse ligament. The tubercle is much more prominent in the upper than in the lower ribs.

The **shaft** is thin and flat, so as to present two surfaces, an external and an internal, and two borders, a superior and an inferior. The *external surface* is convex, smooth and marked at its back part, a little in front of the tuberosity, by a prominent line, directed obliquely from above downward and outward; this gives attachment to a tendon of the Ilio-costalis muscle or of one of its accessory portions, and is called the *angle*. At this point the rib is bent in two directions. If the rib is laid upon its lower border, it will be seen that the portion of the shaft in front of the angle rests upon this border, while the portion of the shaft behind the angle is bent inward and at the same time tilted upward. The interval between the angle and the tuberosity increases gradually from the second to the tenth rib. The portion of bone between these two parts is rounded, rough, and irregular, and serves for the attachment of the Longissimus dorsi muscle. The portion of bone between the tubercle and sternal extremity is also slightly twisted upon its own axis, the external surface looking downward behind the angle, a little upward in front of it. This surface presents, toward its sternal extremity, an oblique line, the *anterior angle*. The *internal surface* is concave, smooth, directed a little upward behind the angle, a little downward in front of it. This surface

is marked by a ridge which commences at the lower extremity of the head; it is strongly marked as far as the inner side of the angle, and gradually becomes lost at the junction of the anterior with the middle third of the bone. The interval between it and the inferior border presents a groove, *subcostal*, for the intercostal vessels and nerve. At the back part of the bone this groove belongs to the inferior border, but just in front of the angle, where it is deepest and broadest, it corresponds to the internal surface. The superior edge of the groove is rounded; it serves for the attachment of the Internal intercostal muscle. The inferior edge corresponds to the lower margin of the rib and gives attachment to the External intercostal. Within the groove are seen the orifices of numerous small foramina which traverse the wall of the shaft obliquely from before backward. The *superior border*, thick and rounded, is marked by an external and an internal lip, more distinct behind than in front; they serve for the attachment of the External and Internal intercostal muscles. The *inferior border*, thin and sharp, has attached to it the External intercostal muscle. The **anterior** or **sternal extremity** is flattened, and presents a porous, oval, concave depression, into which the costal cartilage is received.

Peculiar Ribs.

The ribs which require especial consideration are five in number—viz. the first, second, tenth, eleventh and twelfth.

The **first rib** (Fig. 87) is one of the shortest and the most curved of all the ribs; it is broad and flat, its surfaces looking upward and downward, and its borders inward and outward. The *head* is of small size, rounded, and presents only a single articular facet for articulation with the body of the first dorsal vertebra. The *neck* is narrow and rounded. The *tuberosity*, thick and prominent, rests on the outer border. There is no angle, but in this situation the rib is slightly bent, with the convexity of the bend upward, so that the head of the bone is directed downward. The *upper surface* of the shaft is marked by two shallow depressions, separated by a small rough surface for the attachment of the Scalenus anticus muscle—the groove in front of it transmitting the subclavian vein, that behind it the subclavian artery. Between the groove for the subclavian artery and the tuberosity is a rough surface, for the attachment of the Scalenus medius muscle. The *under surface* is smooth, and destitute of the groove observed on the other ribs. The *outer border* is convex, thick, and rounded, and at its posterior part gives attachment to the first serration of the Serratus magnus; the *inner* is concave, thin, and sharp, and marked about its centre by the commencement of the rough surface for the Scalenus anticus. The *anterior extremity* is larger and thicker than any of the other ribs.

The **second rib** (Fig. 88) is much longer than the first, but bears a very considerable resemblance to it in the direction of its curvature. The non-articular portion of the tuberosity is occasionally only slightly marked. The *angle* is slight and situated close to the tuberosity, and the shaft is not twisted, so that both ends touch any plane surface upon which it may be laid; but there is a similar though slighter bend, with its convexity upward, to that found in the first rib. The shaft is not horizontal, like that of the first rib, its *outer surface*, which is convex, looking upward and a little outward. It presents, near the middle, a rough eminence for the attachment of the second and third digitations of the Serratus magnus; behind and above which is attached the Scalenus posticus. The *inner surface*, smooth and concave, is directed downward and a little inward; it presents a short groove toward its posterior part.

The **tenth rib** (Fig. 89) has only a single articular facet on its head.

The **eleventh** and **twelfth ribs** (Figs. 90 and 91) have each a single articular facet on the head, which is of rather large size; they have no neck or tuberosity, and are pointed at the extremity. The eleventh has a slight angle and a shallow groove on the lower border. The twelfth has neither, and is much shorter than the eleventh, and the head has a slight inclination downward. Sometimes the twelfth rib is even shorter than the first.

Structure.—The ribs consist of cancellous tissue enclosed in a thin, compact layer.

Development.—Each rib, with the exception of the last two, is developed by *three* centres: one for the shaft, one for the head, and one for the tubercle. The last two have only *two* centres, that for the tubercle being wanting. Ossification commences in the shaft of the ribs at a very early period, before its appearance in the vertebræ. The epiphysis of the head, which is of slightly angular shape, and that for the tubercle, of a lenticular form, make their appearance between the six-

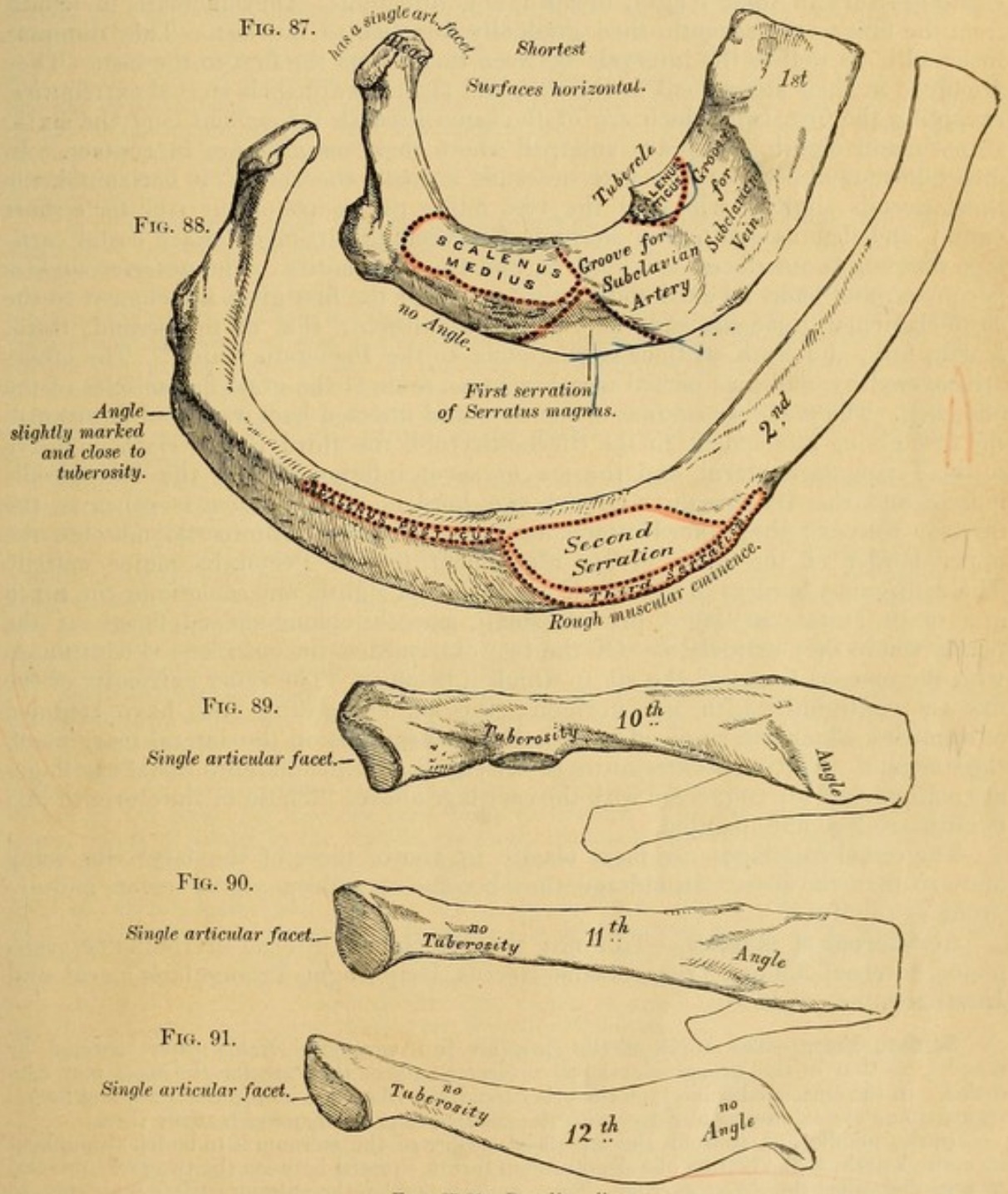

Figs. 87–91.—Peculiar ribs.

teenth and twentieth years, and are not united to the rest of the bone until about the twenty-fifth year.

Attachment of Muscles.—To nineteen: The Internal and External intercostals, Scalenus anticus, Scalenus medius, Scalenus posticus, Pectoralis minor, Serratus magnus, Obliquus externus, Quadratus lumborum, Diaphragm, Latissimus dorsi, Serratus posticus superior, Serratus posticus inferior, Ilio-costalis, Musculus accessorius ad ilio-costalem, Longissimus dorsi, Cervicalis ascendens, Levatores costarum, and Infracostales.

The Costal Cartilages.

The **Costal Cartilages** (Fig. 79, p. 126) are bars of white, hyaline cartilage, which serve to prolong the ribs forward to the front of the chest, and contribute very materially to the elasticity of its walls. The first seven are connected with the sternum, the next three with the lower border of the cartilage of the preceding rib. The cartilages of the last two ribs have pointed extremities, which terminate in free ends in the walls of the abdomen. Like the ribs, the costal cartilages vary in their length, breadth, and direction. They increase in length from the first to the seventh, then gradually diminish to the last. They diminish in breadth, as well as the intervals between them, from the first to the last. They are broad at their attachment to the ribs, and taper toward their sternal extremities, excepting the first two, which are of the same breadth throughout, and the sixth, seventh, and eighth, which are enlarged where their margins are in contact. In direction they also vary: the first descends a little, the second is horizontal, the third ascends slightly, while all the rest follow the course of the ribs for a short extent, and then ascend to the sternum or preceding cartilage. Each costal cartilage presents two surfaces, two borders, and two extremities. The *anterior surface* is convex, and looks forward and upward: that of the first gives attachment to the costo-clavicular ligament and the Subclavius muscle; that of the second, third, fourth, fifth, and sixth, at their sternal ends, to the Pectoralis major.[1] The others are covered by, and give partial attachment to, some of the great flat muscles of the abdomen. The *posterior surface* is concave, and directed backward and downward, the first giving attachment to the Sterno-thyroid, the third to the sixth inclusive to the Triangularis sterni, and the six or seven inferior ones to the Tranversalis muscle and the Diaphragm. Of the two borders, the *superior* is concave, the *inferior* convex: they afford attachment to the internal Intercostal muscles, the upper border of the sixth giving attachment to the Pectoralis major muscle. The contiguous borders of the sixth, seventh, and eighth, and sometimes the ninth and tenth, costal cartilages present small, smooth, oblong-shaped facets at the points where they articulate. Of the two extremities, the *outer* one is continuous with the osseous tissue of the rib to which it belongs. The *inner* extremity of the first is continuous with the sternum; the six succeeding ones have rounded extremities, which are received into shallow concavities on the lateral margins of the sternum. The inner extremities of the eighth, ninth, and tenth costal cartilages are pointed, and are connected with the cartilage above. Those of the eleventh and twelfth are free and pointed.

The costal cartilages are most elastic in youth, those of the false ribs being more so than the true. In old age they become of a deep yellow color, and are prone to calcify.

Attachment of Muscles.—To nine: the Subclavius, Sterno-thyroid, Pectoralis major, Internal oblique, Transversalis, Rectus, Diaphragm, Triangularis sterni, and Internal intercostals.

Surface Form.—The bones of the chest are to a very considerable extent covered by muscles, so that in the strongly-developed muscular subject they are for the most part concealed. In the emaciated subject, on the other hand, the ribs, especially in the lower and lateral region, stand out as prominent ridges with the sunken, intercostal spaces between them.

In the middle line, in front, the superficial surface of the sternum is to be felt throughout its entire length, at the bottom of a deep median furrow situated between the two great pectoral muscles and called the *sternal furrow*. These muscles overlap the anterior surface somewhat, so that the whole of the sternum in its entire width is not subcutaneous; and this overlapping is greater opposite the centre of the bone than above and below, so that the furrow is wider at its upper and lower parts, but narrower in the middle. The centre of the upper border of the sternum is visible, constituting the pre-sternal notch, but the lateral parts of this border are obscured by the tendinous origins of the Sterno-mastoid muscles, which present themselves as oblique tendinous cords, which narrow and deepen the notch. Lower down on the subcutaneous surface a well-defined transverse ridge, the angle of Ludovic, is always to be felt. This denotes the line of junction of the manubrium and body of the bone, and is a useful guide to the second costal cartilage, and thus to the identity of any given rib. The second rib being found through its

[1] The first and seventh also, occasionally, give origin to the same muscle.

costal cartilage, it is easy to count downward and find any other. From the middle of the sternum the furrow spreads out, and, exposing more of the surface of the body of the bone, terminates below in a sudden depression, the *infrasternal depression* or *pit of the stomach* (*scrobiculus cordis*), which corresponds to the ensiform cartilage. This depression lies between the cartilages of the seventh rib, and in it the ensiform cartilage may be felt. The sternum in its vertical diameter presents a general convexity forward, the most prominent point of which is at the joint between the manubrium and gladiolus.

On each side of the sternum the costal cartilages and ribs on the front of the chest are partially obscured by the great pectoral muscle; through which, however, they are to be felt as ridges, with yielding intervals between them, corresponding to the intercostal spaces. Of these spaces, the one between the second and third ribs is the widest, the next two somewhat narrower, and the remainder, with the exception of the last two, comparatively narrow.

The lower border of the Pectoralis major muscle corresponds to the fifth rib, and below this, on the front of the chest, the broad, flat outline of the ribs, as they begin to ascend, and the more rounded outline of the costal cartilages, are often visible. The lower boundary of the front of the thorax, the *abdomino-thoracic arch*, which is most plainly seen by arching the body backward, is formed by the ensiform cartilage and the cartilages of the seventh, eighth, ninth, and tenth ribs, and the extremities of the eleventh and twelfth ribs or their cartilages.

On each side of the chest, from the axilla downward, the flattened external surfaces of the ribs may be defined in the form of oblique ridges, separated by depressions corresponding to the intercostal spaces. They are, however, covered by muscles, which obscure their outline to a certain extent in the strongly developed. Nevertheless, the ribs, with the exception of the first, can generally be followed over the front and sides of the chest without difficulty. The first rib, being almost completely covered by the clavicle and scapula, can only be distinguished in a small portion of its extent. At the back the angles of the ribs form a slightly-marked oblique line on each side of and some distance from the vertebral spines. This line diverges somewhat as it descends, and external to it is a broad, convex surface caused by the projection of the ribs beyond their angles. Over this surface, except where covered by the scapula, the individual ribs can be distinguished.

Surgical Anatomy.—Malformations of the sternum present nothing of surgical importance beyond the fact that abscesses of the mediastinum may sometimes escape through the sternal foramen. Fractures of the sternum are by no means common, owing, no doubt, to the elasticity of the ribs and their cartilages, which support it like so many springs. When broken it is frequently associated with fracture of the spine, and may be caused by forcibly bending the body either backward or forward until the chin becomes impacted against the top of the sternum. It may also be fractured by direct violence or by muscular action. The fracture usually occurs in the upper half of the body of the bone. Dislocation of the gladiolus from the manubrium also takes place, and is sometimes described as a fracture.

The bone, being subcutaneous, is frequently the seat of gummatous tumors, and not uncommonly is affected with caries. Occasionally the bone, and especially its ensiform appendix, becomes altered in shape and driven inward by the pressure, in workmen, of tools against their chest.

The ribs are frequently broken, though from their connections and shape they are able to withstand great force, yielding under the injury and recovering themselves like a spring. The middle of the series are the ones most liable to fracture. The first, and to a less extent the second, being protected by the clavicle, are rarely fractured; and the eleventh and twelfth, on account of their loose and floating condition, enjoy a like immunity. The fracture generally occurs from indirect violence, from forcible compression of the chest-wall, and the bone then gives way at its weakest part—*i. e.* just in front of the angle. But the ribs may also be broken by direct violence, when the bone gives way and is driven inward at the point struck, or they may be broken by muscular action. It seems probable, however, that in these latter cases the bone has undergone some atrophic changes. Fracture of the ribs is frequently complicated with some injury to the viscera contained within the thorax or upper part of the abdominal cavity, and this is most likely to occur in fractures from direct violence.

Fracture of the costal cartilages may also take place, though it is a comparatively rare injury.

The thorax is frequently found to be altered in shape in certain diseases.

The *rickety* thorax is caused chiefly by atmospheric pressure. The balance between the air on the inside of the chest and the outside during some stage of respiration is not equal, the preponderance being in favor of the air outside; and this, acting on the softened ribs, causes them to be forced in at the junction of the cartilages with the bones, which is the weakest part. In consequence of this the sternum projects forward, with a deep depression on either side caused by the sinking in of the softened ribs. The depression is less on the left side, on account of the ribs being supported by the heart. The condition is known as "pigeon-breast." The lower ribs, however, are not involved in this deformity, as they are prevented from falling in by the presence of the stomach, liver, and spleen. And when the liver and spleen are enlarged, as they sometimes are in rickets, the lower ribs may be pushed outward: this causes a transverse constriction just above the costal arch. The anterior extremities of the ribs are usually enlarged in rickets, giving rise to what has been termed the "rickety rosary." The *phthisical chest* is often long and narrow, flattened from before backward, and with great obliquity of the ribs and projection of the scapulæ. In *pulmonary emphysema* the chest is enlarged in all its diameters, and presents on section an almost circular outline. It has received the name of the

"barrel-shaped chest." In severe cases of *lateral curvature of the spine* the thorax becomes much distorted. In consequence of the rotation of the bodies of the vertebræ which takes place in this disease the ribs opposite the convexity of the dorsal curve become extremely convex behind, being thrown out and bulging, and at the same time flattened in front, so that the two ends of the same rib are almost parallel. Coincident with this, the ribs on the opposite side, on the concavity of the curve, are sunk and depressed behind and bulging and convex in front. In addition to this the ribs become occasionally welded together by bony material.

The ribs are frequently the seat of necrosis leading to abscesses and sinuses, which may burrow to a considerable extent over the wall of the chest. The only special anatomical point in connection with these is that care must be taken in dealing with them that the intercostal space is not punctured and the pleural cavity opened or the intercostal vessels wounded, as the necrosed portion of bone is generally situated on the internal surface of the rib.

In cases of empyema the chest requires opening to evacuate the pus. There is considerable difference of opinion as to the best position to do this. Probably the best place in most cases will be found to be between the fifth and sixth ribs, in or a little in front of the mid-axillary line. This is the last part of the cavity to be closed by the expansion of the lung; it is not thickly covered by soft parts; the space between the two ribs is sufficiently great to allow of the introduction of a fair-sized drainage-tube, and the opening is in a dependent position, when the patient is confined to bed, as he usually inclines toward the affected side, so as to allow the sound lung the freest possible play, and so permits of efficient drainage.

THE EXTREMITIES.

The extremities, or limbs, are those long, jointed appendages of the body which are connected to the trunk by one end and free in the rest of their extent. They are *four* in number: an *upper* or *thoracic pair*, connected with the thorax through the intervention of the shoulder, and subservient mainly to prehension; and a *lower pair*, connected with the pelvis, intended for support and locomotion. Both pairs of limbs are constructed after one common type, so that they present numerous analogies, while at the same time certain differences are observed between the upper and lower pair, dependent on the peculiar offices they have to perform.

The bones by which the upper and lower limbs are attached to the trunk are named respectively the *shoulder* and *pelvic girdles*, and they are constructed on the same general type, though presenting certain modifications relating to the different uses to which the upper and lower limbs are respectively applied. The *shoulder girdle* is formed by the scapula and clavicle, and is imperfect in front and behind. In front, however, the girdle is completed by the upper end of the sternum, with which the inner extremities of the clavicle articulate. Behind, the girdle is widely imperfect and the scapula is connected to the trunk by muscles only. The *pelvic girdle* is formed by the innominate bones, and is completed in front through the symphysis pubis, at which the two innominate bones articulate with each other. It is imperfect behind, but the intervening gap is filled in by the upper part of the sacrum. The pelvic girdle, therefore, presents, with the sacrum, a complete ring, comparatively fixed, and presenting an arched form which confers upon it a solidity manifestly intended for the support of the trunk, and in marked contrast to the lightness and mobility of the shoulder girdle.

With regard to the morphology of these girdles, the blade of the scapula is generally believed to correspond to the ilium; but with regard to the clavicles there is some difference of opinion: formerly it was believed that they corresponded to the ossa pubis, meeting at the symphysis, but it is now generally taught that the clavicle has no homologue in the pelvic girdle, and that the os pubis and ischium are represented by the small coracoid process in man and most mammals.

THE UPPER EXTREMITY.

The bones of the upper extremity consist of those of the shoulder girdle, of the arm, the forearm, and the hand.

THE SHOULDER GIRDLE.

The shoulder girdle consists of two bones, the clavicle and the scapula.

The Clavicle.

The **Clavicle** (*clavis*, a key), or collar-bone, forms the anterior portion of the shoulder girdle. It is a long bone, curved somewhat like the italic letter *f*, and placed nearly horizontally at the upper and anterior part of the thorax, immediately above the first rib. It articulates by its inner extremity with the upper border of the sternum, and by its outer extremity with the acromion process of the scapula, serving to sustain the upper extremity in the various positions which it assumes, whilst at the same time it allows of great latitude of motion in the arm.[1] It presents a double curvature when looked at in front, the convexity being forward at the sternal end and the concavity at the scapular end. Its outer third is flattened from above downward, and extends, in the natural position of the bone, from a point opposite the coracoid process to the acromion. Its inner two-thirds are of a prismatic form, and extend from the sternum to a point opposite the coracoid process of the scapula.

External or Flattened Portion.—The *outer third* is flattened from above downward, so as to present two surfaces, an upper and a lower; and two borders, an anterior and a posterior. The *upper surface* is flattened, rough, marked by impressions for the attachment of the Deltoid in front and the Trapezius behind; between these two impressions, externally, a small portion of the bone is subcutaneous. The *under surface* is flattened. At its posterior border, a little external to the point where the prismatic joins with the flattened portion, is a rough eminence, the *conoid tubercle;* this, in the natural position of the bone, surmounts the coracoid process of the scapula and gives attachment to the conoid ligament. From this tubercle an oblique line, occasionally a depression, passes forward and outward to near the outer end of the anterior border; it is called the *oblique line* or *trapezoid ridge*, and affords attachment to the trapezoid ligament. The *anterior border* is concave, thin, and rough, and gives attachment to the Deltoid; it occasionally presents, at its inner end, at the commencement of the deltoid impression, a tubercle, the *deltoid tubercle*, which is sometimes to be felt in the living subject. Tho *posterior border* is convex, rough, broader than the anterior, and gives attachment to the Trapezius.

Internal or Prismatic Portion.—The prismatic portion forms the *inner two-thirds* of the bone. It is curved so as to be convex in front, concave behind, and is marked by three borders, separating three surfaces. The *anterior border* is continuous with the anterior margin of the flat portion. At its commencement it is smooth, and corresponds to the interval between the attachment of the Pectoralis major and Deltoid muscles; at the inner half of the clavicle it forms the lower boundary of an elliptical space for the attachment of the clavicular portion of the Pectoralis major, and approaches the posterior border of the bone. The *superior border* is continuous with the posterior margin of the flat portion, and separates the anterior from the posterior surface. At its commencement it is smooth and rounded, becomes rough toward the inner third for the attachment of the Sterno-mastoid muscle, and terminates at the upper angle of the sternal extremity. The *posterior* or *subclavian border* separates the posterior from the inferior surface, and extends from the conoid tubercle to the rhomboid impression. It forms the posterior boundary of the groove for the Subclavius muscle, and gives attachment to a layer of cervical fascia covering the Omo-hyoid muscle. The *anterior surface* is included between the superior and anterior borders. It is directed forward and a little upward at the sternal end, outward and still more upward at the acromial extremity, where it becomes continuous with the upper surface of the flat portion. Externally, it is smooth, convex, nearly subcutaneous, being covered only by the

[1] The clavicle acts especially as a fulcrum to enable the muscles to give lateral motion to the arm. It is accordingly absent in those animals whose fore limbs are used only for progression, but is present for the most part in those animals whose anterior extremities are clawed and used for prehension, though in some of them—as, for instance, in a large number of the carnivora—it is merely a rudimentary bone suspended among the muscles, and not articulating either with the scapula or sternum.

Platysma; but, corresponding to the inner half of the bone, it is divided by a more or less prominent line into two parts: a lower portion, elliptical in form, rough, and slightly convex, for the attachment of the Pectoralis major; and an upper part, which is rough, for the attachment of the Sterno-cleido-mastoid. Between the two muscular impressions is a small subcutaneous interval. The *posterior* or *cervical surface* is smooth, flat, and looks backward toward the root of the neck. It is limited, above, by the superior border; below, by the subclavian border; internally, by the margin of the sternal extremity; externally, it is continuous with the posterior border of the flat portion. It is concave from within outward, and is in relation, by its lower part, with the suprascapular vessels. This surface, at about the junction of the inner and outer curves, is also in close relation with the brachial plexus and subclavian vessels. It gives attachment, near the sternal extremity, to part of the Sterno-hyoid muscle; and presents, at or near the middle, a foramen, directed obliquely outward, which transmits the chief nutrient artery of the bone. Sometimes there are two foramina on the posterior surface, or one on the posterior, the other on the inferior surface. The *inferior* or *subclavian*

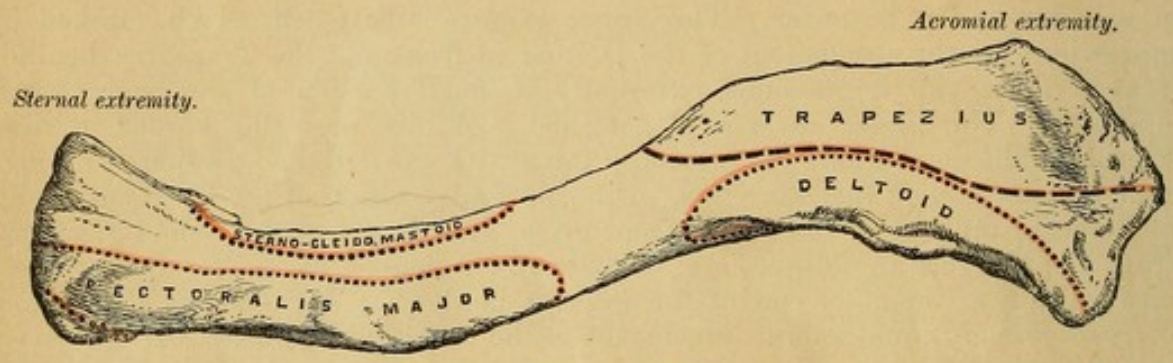

FIG. 92.—Left clavicle. Superior surface.

surface is bounded, in front, by the anterior border; behind, by the subclavian border. It is narrow internally, but gradually increases in width externally, and

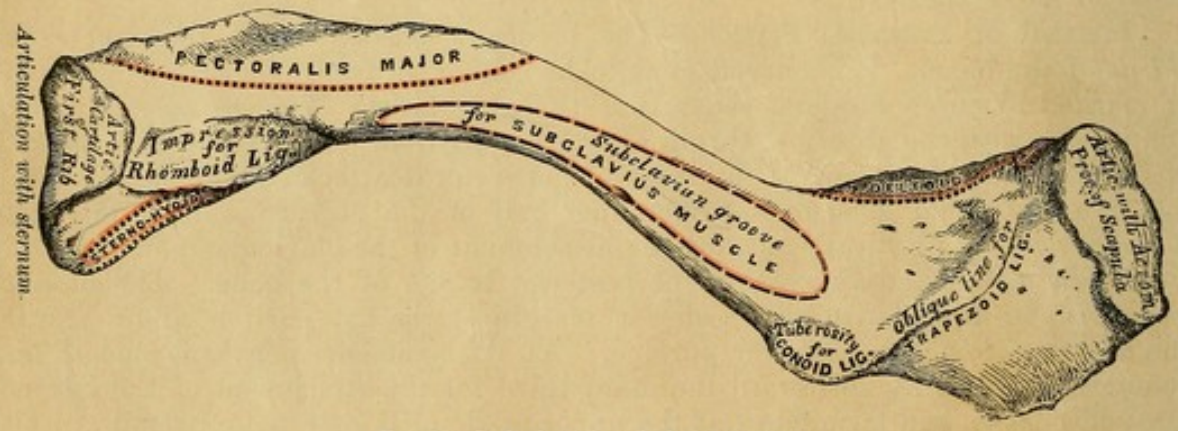

FIG. 93.—Left clavicle. Inferior surface.

is continuous with the under surface of the flat portion. Commencing at the sternal extremity may be seen a small facet for articulation with the cartilage of the first rib. This is continuous with the articular surface at the sternal end of the bone. External to this is a broad, rough surface, the *rhomboid impression*, rather more than an inch in length, for the attachment of the costo-clavicular (rhomboid) ligament. The remaining part of this surface is occupied by a longitudinal groove, the *subclavian groove*, broad and smooth externally, narrow and more uneven internally; it gives attachment to the Subclavius muscle, and by its margins to the costo-coracoid membrane, which splits to enclose a muscle. Not infrequently this groove is subdivided into two parts by a longitudinal line, which gives attachment to the intermuscular septum of the Subclavius muscle.

The **internal** or **sternal extremity** of the clavicle is triangular in form, directed

inward and a little downward and forward; and presents an articular facet, concave from before backward, convex from above downward, which articulates with the sternum through the intervention of an interarticular fibro-cartilage; the circumference of the articular surface is rough, for the attachment of numerous ligaments. The posterior border of this surface is prolonged backward, so as to increase the size of the articular facet; the upper border gives attachment to the interarticular fibro-cartilage, and the lower border is continuous with the costal facet on the inner end of the inferior or subclavian surface, which articulates with the cartilage of the first rib.

The **outer** or **acromial extremity,** directed outward and forward, presents a small, flattened, oval facet, which looks obliquely downward, for articulation with the acromion process of the scapula. The circumference of the articular facet is rough, especially above, for the attachment of the acromio-clavicular ligaments.

Peculiarities of the Bone in the Sexes and in Individuals.—In the female the clavicle is generally shorter, thinner, less curved, and smoother than in the male. In those persons who perform considerable manual labor, which brings into constant action the muscles connected with this bone, it becomes thicker and more curved, its ridges for muscular attachment become prominently marked. The right clavicle is generally longer, thicker, and rougher than the left.

Structure.—The shaft, as well as the extremities, consists of cancellous tissue, invested in a compact layer much thicker in the middle than at either end. The clavicle is highly elastic, by reason of its curves. From the experiments of Mr. Ward it has been shown that it possesses sufficient longitudinal elastic force to project its own weight nearly two feet on a level surface when a smart blow is struck on it; and sufficient transverse elastic force, opposite the centre of its anterior convexity, to throw its own weight about a foot. This extent of elastic power must serve to moderate very considerably the effect of concussions received upon the point of the shoulder.

Development.—By *two* centres: one for the shaft and one for the sternal extremity. The centre for the shaft appears very early, before any other bone—according to Béclard, as early as the thirtieth day. The centre for the sternal end makes its appearance about the eighteenth or twentieth year, and unites with the rest of the bone about the twenty-fifth year.

Articulations.—With the sternum, scapula, and cartilage of the first rib.

Attachment of Muscles.—To six: the Sterno-cleido-mastoid, Trapezius, Pectoralis major, Deltoid, Subclavius, and Sterno-hyoid.

Surface Form.—The clavicle can be felt throughout its entire length, even in persons who are very fat. Commencing at the inner end, the enlarged sternal extremity, where the bone projects above the upper margin of the sternum, can be felt, forming with the sternum and the rounded tendon of the Sterno-mastoid a V-shaped notch, the *pre-sternal notch.* Passing outward, the shaft of the bone can be felt immediately under the skin, with its convexity forward in the inner two-thirds, the surface partially obscured above and below by the attachments of the Sterno-mastoid and Pectoralis major muscles. In the outer third it forms a gentle curve backward, and terminates at the outer end in a somewhat enlarged extremity which articulates with the acromial process of the scapula. The direction of the clavicle is almost, if not quite, horizontal when the arm is lying quietly by the side, though in well-developed subjects it may incline a little upward at its outer end. Its direction is, however, very changeable with the varying movements of the shoulder-joint.

Surgical Anatomy.—The clavicle is the most frequently broken of any single bone in the body. This is due to the fact that it is much exposed to violence, and is the only bony connection between the upper limb and the trunk. The bone, moreover, is slender, and is very superficial. The bone may be broken by direct or indirect violence or by muscular action. The most common cause is, however, from indirect violence, and the bone then gives way at the junction of the outer with the inner two-thirds of the bone; that is to say at the junction of the two curves, for this is the weakest part of the bone. The fracture is generally oblique, and the displacement of the outer fragments is inward, away from the surface of the body; hence compound fracture of the clavicle is of rare occurrence. The inner fragment as a rule is little displaced. Beneath the bone the main vessels of the upper limb and the great nerve-cords of the brachial plexus lie on the first rib, and are liable to be wounded in fracture, especially in fracture from direct violence, when the force of the blow drives the broken ends inward. Fortunately, the Subclavius muscle is interposed between these structures and the clavicle, and this often protects them from injury.

The clavicle is not uncommonly the seat of sarcomatous tumors, rendering the operation of excision of the entire bone necessary. This is an operation of considerable difficulty and danger. It is best performed by exposing the bone freely, disarticulating at the acromial end, and turning it inward. The removal of the outer part is comparatively easy, but resection of the inner part is fraught with difficulty, the main danger being the risk of wounding the great veins which are in relation with its under surface.

The Scapula.

The **Scapula** (*σκαπάνη*, a spade) forms the back part of the shoulder girdle. It is a large, flat bone, triangular in shape, situated at the posterior aspect and side of

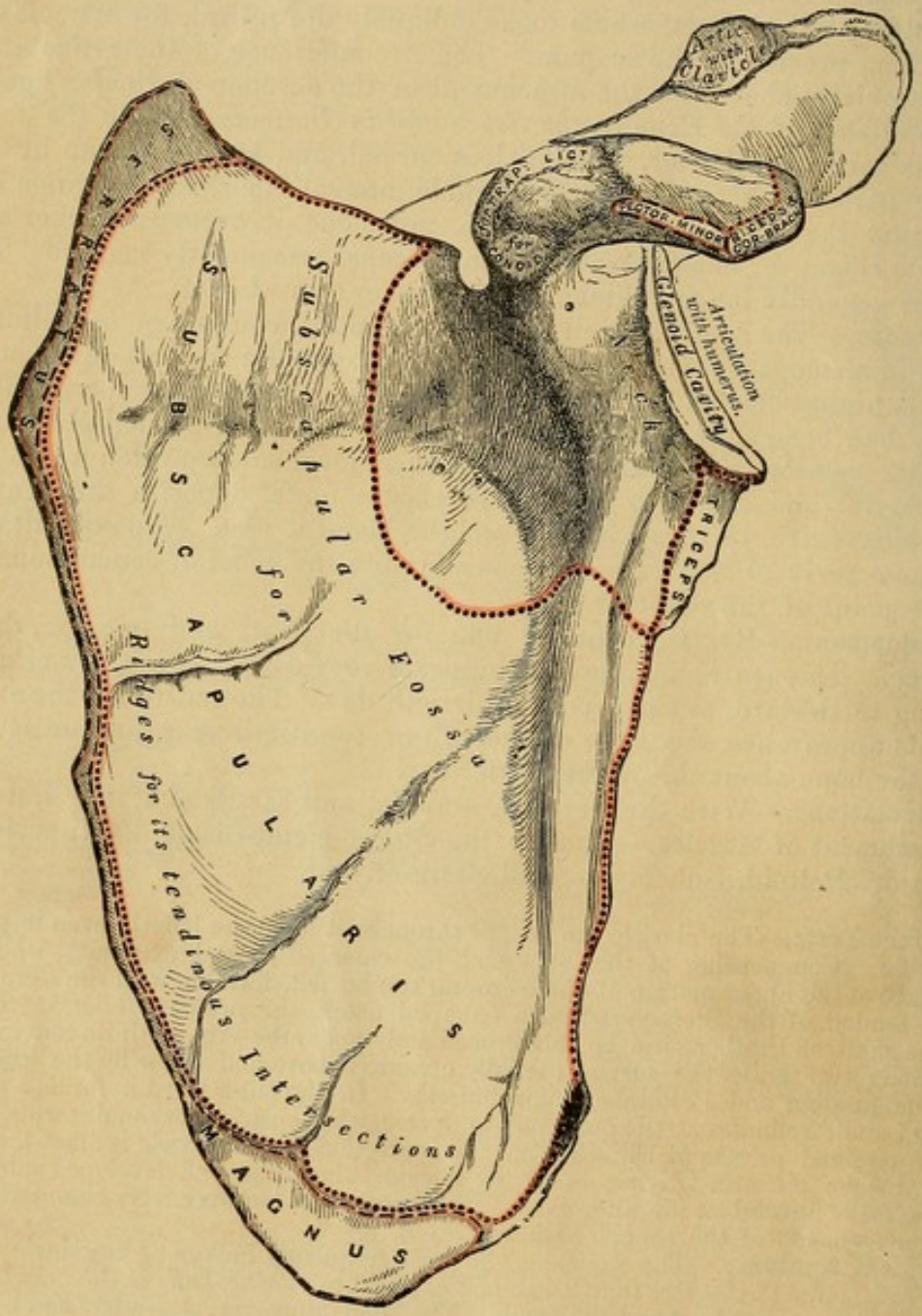

FIG. 94.—Left scapula, anterior surface, or venter.

the thorax, between the second and seventh, or sometimes the eighth, ribs, its internal border or base being about an inch from, and nearly, but not quite parallel with the spinous processes of the vertebræ, so that it is rather closer to them above than below. It presents for examination two surfaces, three borders, and three angles.

The **anterior surface**, or **venter** (Fig. 94), presents a broad concavity, the *sub-*

scapular fossa. It is marked, in the inner two-thirds, by several oblique ridges, which pass from behind outward and upward; the outer third is smooth. The oblique ridges give attachment to the tendinous intersections, and the surfaces between them to the fleshy fibres, of the Subscapularis muscle. The anterior third of the fossa, which is smooth, is covered by, but does not afford attachment to, the fibres of this muscle. The venter is separated from the internal border by a smooth, triangular margin at the superior and inferior angles, and in the interval between these by a narrow edge which is often deficient.

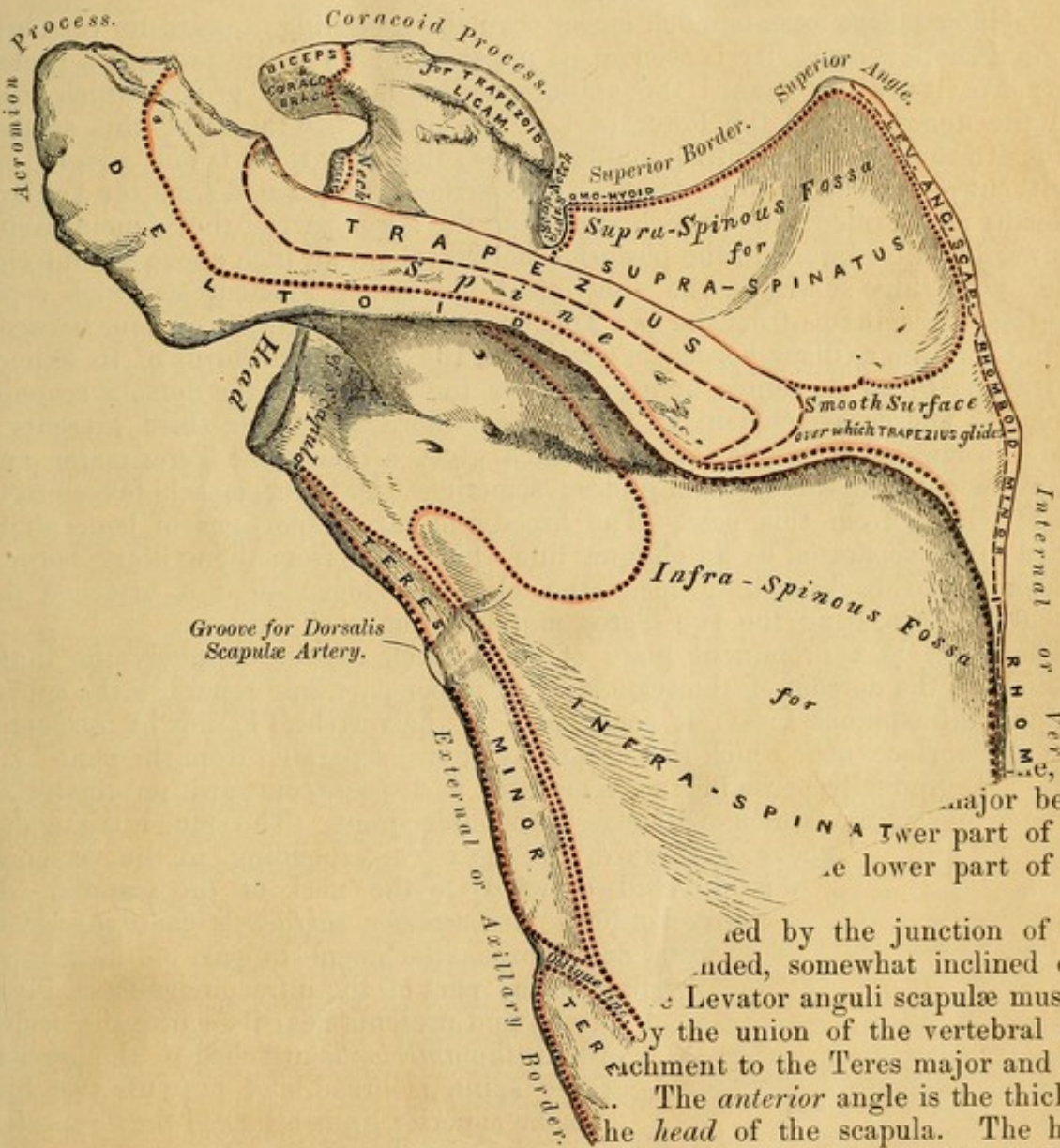

FIG. 95.—

...e, the ...ajor being ...wer part of the ...e lower part of the

...ed by the junction of the ...nded, somewhat inclined out- ...e Levator anguli scapulæ muscle. ...y the union of the vertebral and ...achment to the Teres major and fre- ... The *anterior* angle is the thickest ...he *head* of the scapula. The head ...face, the *glenoid cavity* (γλήνη, a socket), downward, and its direction outward and for- ...oove; at its apex is a slight impression (*supra-* ...tached the long tendon of the Biceps muscle. It is recent state; and its margins, slightly raised, give ...ginous structure, the *glenoid ligament*, by which its ... *neck* of the scapula is the slightly depressed surface

This marginal surface a...; it is more distinct on the posterior than on the anterior Serratus magnus muscle, ...above. In the latter situation it has arising from it a thick at its upper part, wher... id process. able angle, called the ...ess, so called from its fancied resemblance to a crow's beak of the bone from its ... thick, curved process of bone which arises by a broad base the spine and acrom... of the neck of the scapula; it is directed at first upward and so that the thickest

to the plane of the glenoid cavity, and must consequently operate most effectively on the head of the humerus, which is contained in that cavity.

The **posterior surface**, or **dorsum** (Fig. 95), is arched from above downward, alternately concave and convex from side to side. It is subdivided unequally into two parts by the *spine:* the portion above the spine is called the *supraspinous fossa*, and that below it the *infraspinous fossa.*

The **supraspinous fossa**, the smaller of the two, is concave, smooth, and broader at the vertebral than at the humeral extremity. It affords attachment by its inner two-thirds to the Supraspinatus muscle.

The **infraspinous fossa** is much larger than the preceding; toward its vertebral margin a shallow concavity is seen at its upper part; its centre presents a prominent convexity, whilst toward the axillary border is a deep groove which runs from the upper toward the lower part. The inner two-thirds of this surface affords attachment to the Infraspinatus muscle; the outer third is only covered by it, without giving origin to its fibres. This surface is separated from the axillary border by an elevated ridge, which runs from the lower part of the glenoid cavity downward and backward to the posterior border, about an inch above the inferior angle. The ridge serves for the attachment of a strong aponeurosis which separates the Infraspinatus from the two Teres muscles. The surface of bone between this line and the axillary border is narrow in the upper two-thirds of its extent, and traversed near its centre by a groove for the passage of the dorsalis scapulæ vessels; it affords attachment to the Teres minor. Its lower third presents a broader, somewhat triangular surface, which gives origin to the Teres major, and over which the Latissimus dorsi glides; sometimes the latter muscle takes origin by a few fibres from this part. The broad and narrow portions of bone above alluded to are separated by an oblique line which runs from the axillary border, downward and backward, to meet the elevated ridge: to it is attached the aponeurosis separating the two Teres muscles from each other.

The **Spine** is a prominent plate of bone which crosses obliquely the inner four-fifths of the dorsum of the scapula at its upper part, and separates the supra- from the infraspinous fossa: it commences at the vertebral border by a smooth, [illegible]angular surface, over which the Trapezius glides, separated from the bone by a [illegible] gradually becoming more elevated as it passes outward, terminates in [illegible]rocess, which overhangs the shoulder-joint. The spine is triangular [illegible] above downward, its apex corresponding to the vertebral [illegible]h is directed outward) to the neck of the scapula. It [illegible]hree borders. Its *superior surface* is concave, assists [illegible]fossa, and affords attachment to part of the Supra- [illegible]*urface* forms part of the infraspinous fossa, gives [illegible] muscle, and presents near its centre the orifice [illegible] orders, the *anterior* is attached to the dorsum [illegible]f the spine, is broad, and presents two lips [illegible]To the superior lip is attached the Trapezius [illegible]gh tubercle is generally seen occupying [illegible] insertion of the middle and inferior [illegible]ghout its whole length, is attached [illegible]artly covered by the tendinous [illegible], the shortest of the three, is [illegible]s above with the under sur- [illegible] the scapula. The narrow

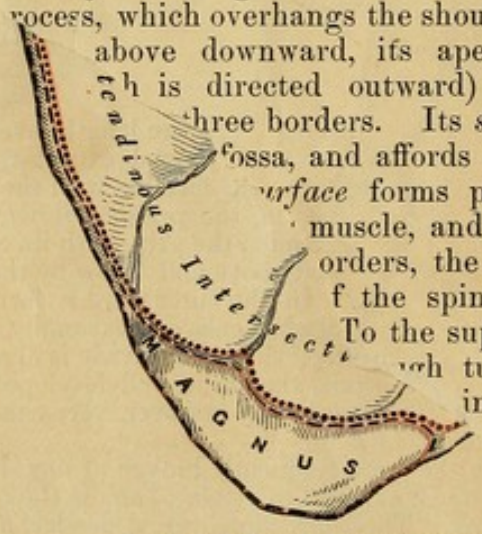

FIG. 94.—Left scapula, anterior surface, or

the thorax, between the second and seventh, or someti from the glenoid cavity, internal border or base being about an inch from, and supra- and infraspinous parallel with the spinous processes of the vertebræ, so that them above than below. It presents for examination two sui mit of the shoulder and three angles. [illegible]what triangular or

The **anterior surface**, or **venter** (Fig. 94), presents a broad [illegible]st a little outward, [illegible]lenoid cavity. Its

upper surface, directed upward, backward, and outward, is convex, rough, and gives attachment to some fibres of the Deltoid, and in the rest of its extent it is subcutaneous. Its *under surface* is smooth and concave. Its *outer border* is thick and irregular, and presents three or four tubercles for the tendinous origins of the Deltoid muscle. Its *inner margin*, shorter than the outer, is concave, gives attachment to a portion of the Trapezius muscle, and presents about its centre a small oval surface for articulation with the acromial end of the clavicle. Its *apex*, which corresponds to the point of meeting of these two borders in front, is thin, and has attached to it the coraco-acromial ligament.

Borders.—Of the three borders of the scapula, the *superior* is the shortest and thinnest; it is concave and extends from the superior angle to the coracoid process. At its outer part is a deep, semicircular notch, the *suprascapular*, formed partly by the base of the coracoid process. This notch is converted into a foramen by the transverse ligament, and serves for the passage of the suprascapular nerve. Sometimes this foramen is entirely surrounded by bone. The adjacent margin of the superior border affords attachment to the Omo-hyoid muscle. The *external*, or *axillary*, *border*, is the thickest of the three. It commences above at the lower margin of the glenoid cavity, and inclines obliquely downward and backward to the inferior angle. Immediately below the glenoid cavity is a rough impression (the *infraglenoid tubercle*), about an inch in length, which affords attachment to the long head of the Triceps muscle; in front of this is a longitudinal groove, which extends as far as its lower third and affords origin to part of the Subscapularis muscle. The inferior third of this border, which is thin and sharp, serves for the attachment of a few fibres of the Teres major behind and of the Subscapularis in front. The *internal*, or *vertebral*, *border*, also named the *base*, is the longest of the three, and extends from the superior to the inferior angle of the bone. It is arched, intermediate in thickness between the superior and the external borders, and the portion of it above the spine is bent considerably outward, so as to form an obtuse angle with the lower part. The vertebral border presents an anterior lip, a posterior lip, and an intermediate space. The *anterior lip* affords attachment to the Serratus magnus; the *posterior lip*, to the Supraspinatus above the spine, the Infraspinatus below; the interval between the two lips, to the Levator anguli scapulæ above the triangular surface at the commencement of the spine, the Rhomboideus minor to the edge of that surface; the Rhomboideus major being attached by means of a fibrous arch connected above to the lower part of the triangular surface at the base of the spine, and below to the lower part of the posterior border.

Angles.—Of the three angles, the *superior*, formed by the junction of the superior and internal borders, is thin, smooth, rounded, somewhat inclined outward, and gives attachment to a few fibres of the Levator anguli scapulæ muscle. The *inferior* angle, thick and rough, is formed by the union of the vertebral and axillary borders, its outer surface affording attachment to the Teres major and frequently to a few fibres of the Latissimus dorsi. The *anterior* angle is the thickest part of the bone, and forms what is called the *head* of the scapula. The head presents a shallow, pyriform, articular surface, the *glenoid cavity* (γλήνη, a socket), whose longest diameter is from above downward, and its direction outward and forward. It is broader below than above; at its apex is a slight impression (*supraglenoid tubercle*), to which is attached the long tendon of the Biceps muscle. It is covered with cartilage in the recent state; and its margins, slightly raised, give attachment to a fibro-cartilaginous structure, the *glenoid ligament*, by which its cavity is deepened. The *neck* of the scapula is the slightly depressed surface which surrounds the head; it is more distinct on the posterior than on the anterior surface, and below than above. In the latter situation it has arising from it a thick prominence, the coracoid process.

The **Coracoid Process**, so called from its fancied resemblance to a crow's beak (κόραξ, a crow), is a thick, curved process of bone which arises by a broad base from the upper part of the neck of the scapula; it is directed at first upward and

inward, then, becoming smaller, it changes its direction and passes forward and outward. The ascending portion, flattened from before backward, presents in front a smooth, concave surface over which passes the Subscapularis muscle. The horizontal portion is flattened from above downward, its upper surface is convex and irregular, and gives attachment to the Pectoralis minor; its under surface is smooth; its inner border is rough, and gives attachment to the Pectoralis minor; its outer border is also rough for the coraco-acromial ligament, while the apex is embraced by the conjoined tendon of origin of the short head of the Biceps and of the Coraco-brachialis and gives attachment to the Costo-coracoid ligament. At the inner side of the root of the coracoid process is a rough impression for the attachment of the conoid ligament; and running from it obliquely forward and outward on the upper surface of the horizontal portion, an elevated ridge for the attachment of the trapezoid ligament.

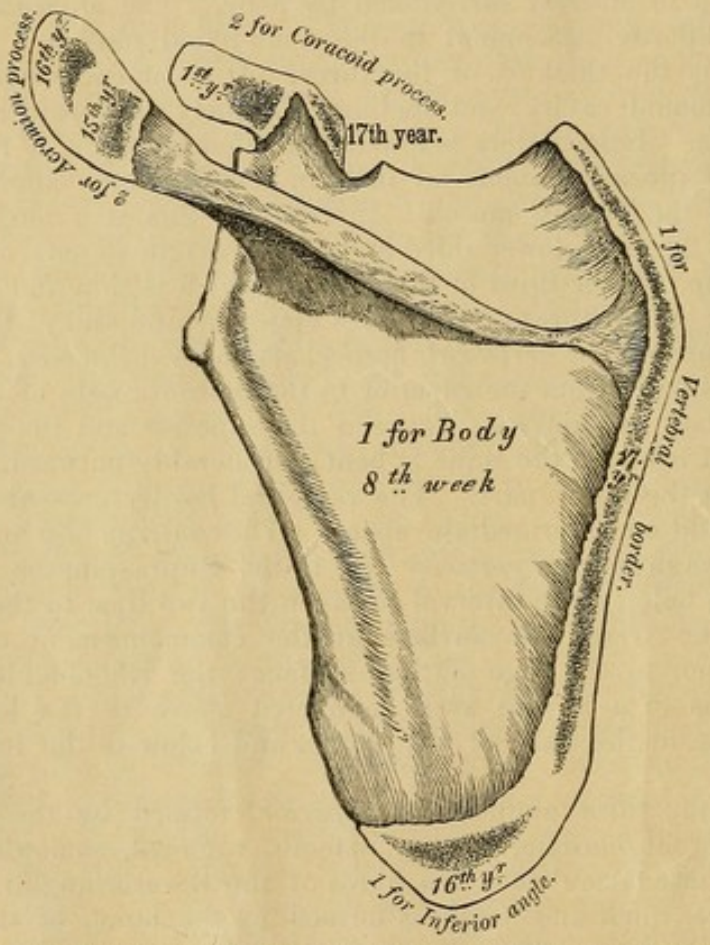

FIG. 96.—Plan of the development of the scapula. By seven centres. The epiphyses (except one for the coracoid process) appear from fifteen to seventeen years, and unite between twenty-two and twenty-five years of age.

Structure.—In the head, processes, and all the thickened parts of the bone the scapula is composed of cancellous tissue, while in the rest of its extent it is composed of a thin layer of dense, compact tissue. The centre part of the supra-spinous fossa and the upper part of the infra-spinous fossa, but especially the former, are usually so thin as to be semitransparent; occasionally the bone is found wanting in this situation, and the adjacent muscles come into contact.

Development (Fig. 96).—By *seven* or more centres: one for the body, two for the coracoid process, two for the acromion, one for the vertebral border, and one for the inferior angle.

Ossification of the body of the scapula commences about the second month of fœtal life by the formation of an irregular quadrilateral plate of bone immediately behind the glenoid cavity. This plate extends itself so as to form the chief part of the bone, the spine growing up from its posterior surface about the third month.

At birth a large part of the scapula is osseous, but the glenoid cavity, coracoid and acromion processes, the posterior border, and inferior angle are cartilaginous. From the fifteenth to the eighteenth month after birth ossification takes place in the middle of the coracoid process, which usually becomes joined with the rest of the bone at the time when the other centres make their appearance. Between the fourteenth and twentieth years ossification of the remaining centres takes place in quick succession, and in the following order: first, in the root of the coracoid process, in the form of a broad scale; secondly, near the base of the acromion process; thirdly, in the inferior angle and contiguous part of the posterior border; fourthly, near the extremity of the acromion; fifthly, in the posterior border. The acromion process, besides being formed of two separate nuclei, has its base formed by an extension into it of the centre of ossification which belongs to the spine, the extent of which varies in different cases. The two separate nuclei unite, and then join with the extension from the spine. These various epiphyses become joined to the bone between the ages of twenty-two and twenty-five years. Sometimes failure of union between the acromion process and spine occurs, the junction being effected by fibrous tissue or by an imperfect articulation; in some cases of supposed fracture of the acromion with ligamentous union it is probable that the detached segment was never united to the rest of the bone. The upper third of the glenoid cavity is usually ossified from a separate centre (subcoracoid) which makes its appearance between the tenth and eleventh years. Very often, in addition, an epiphysis appears for the lower part of the glenoid cavity.

Articulations.—With the humerus and clavicle.

Attachment of Muscles.—To seventeen: to the anterior surface, the Subscapularis; posterior surface, Supraspinatus, Infraspinatus; spine, Trapezius, Deltoid; superior border, Omo-hyoid; vertebral border, Serratus magnus, Levator anguli scapulæ, Rhomboideus minor and major; axillary border, Triceps, Teres minor, Teres major; apex of glenoid cavity, long head of the Biceps; coracoid process, short head of the Biceps, Coraco-brachialis, Pectoralis minor; and to the inferior angle occasionally a few fibres of the Latissimus dorsi.

Surface Form.—The only parts of the scapula which are truly subcutaneous are the spine and acromion process, but, in addition to these, the coracoid process, the internal or vertebral border and inferior angle, and, to a less extent, the axillary border, may be defined. The acromion process and spine of the scapula are easily felt throughout their entire length, forming, with the clavicle, the arch of the shoulder. The acromion can be ascertained to be connected to the clavicle at the acromio-clavicular joint by running the finger along it, its position being often indicated by an irregularity or bony outgrowth from the clavicle close to the joint. The acromion can be felt forming the point of the shoulder, and from this can be traced backward to join the spine of the scapula. The place of junction is usually denoted by a prominence, which is sometimes called the angle. From here the spine can be felt as a prominent ridge of bone, marked on the surface as an oblique depression, which becomes less and less distinct, and terminates a little external to the spinous processes of the vertebræ. Its termination is usually indicated by a slight dimple in the skin on a level with the interval between the third and fourth dorsal spines. Below this point the vertebral border of the scapula may be traced, running downward and outward, and thus diverging from the vertebral spines, to the inferior angle of the bone, which can be recognized, although covered by the Latissimus dorsi muscle. From this angle the axillary border can usually be traced through this thick muscular covering, forming, with the muscles, the posterior fold of the axilla. The coracoid process may be felt about an inch below the junction of the middle and outer third of the clavicle. Here it is covered by the anterior border of the deltoid and lies a little to the outer side of a slight depression which corresponds to the interval between the Pectoralis major and Deltoid muscles. When the arms are hanging by the side, the upper angle of the scapula corresponds to the upper border of the second rib or the interval between the first and second dorsal spines, the inferior angle to the upper border of the eighth rib or the interval between the seventh and eighth dorsal spines.

Surgical Anatomy.—Fractures of the body of the scapula are rare, owing to the mobility of the bone, the thick layer of muscles by which it is encased on both surfaces, and the elasticity of the ribs on which it rests. Fracture of the neck of the bone is also uncommon. The most frequent course of the fracture is from the suprascapular notch to the infraglenoid tubercle, and it derives its principal interest from its simulation to a subglenoid dislocation of the humerus. The diagnosis can be made by noting the alteration in the position of the coracoid process. A fracture of the neck external to, and not including, the coracoid process is said to occur, but it is exceedingly doubtful whether such an accident ever takes place. The acromion process is more frequently broken than any other part of the bone, and there is some-

times, in young subjects, a separation of the epiphysis. It is believed that many of the cases of supposed fracture of the acromion, with fibrous union, which have been found on post-mortem examination are really cases of imperfectly united epiphysis. Sir Astley Cooper believed that most fractures of this bone united by fibrous tissue, and the cause of this mode of union was the difficulty there was in keeping the fractured ends in constant apposition. The coracoid process is occasionally broken off, either from direct violence or perhaps, rarely, from muscular action.

Tumors of various kinds grow from the scapula. Of the innocent form of tumors probably the osteomata are the most common. When it grows from the venter of the scapula, as it sometimes does, it is of the compact variety, such as usually grows from membrane-formed bones, as the bones of the skull. This would appear to afford evidence that this portion of the bone is formed from membrane, and not, like the rest of the bone, from cartilage. Sarcomatous tumors sometimes grow from the scapula, and may necessitate removal of the bone, with or without amputation of the upper limb. The bone may be excised by a T-shaped incision, and, the flaps being reflected, the removal is commenced from the posterior or vertebral border, so that the subscapular vessels which lie along the axillary border are among the last structures divided, and can be at once secured.

THE ARM.

The **arm** is that portion of the upper extremity which is situated between the shoulder and the elbow. Its skeleton consists of a single bone, the humerus.

The Humerus.

The **Humerus** is the longest and largest bone of the upper extremity; it presents for examination a shaft and two extremities.

The **Upper Extremity** presents a large, rounded *head*, joined to the shaft by a constricted portion, called the *neck*, and two other eminences, the *greater* and *lesser tuberosities* (Fig. 97).

The **head,** nearly hemispherical in form,[1] is directed upward, inward, and a little backward, and articulates with the glenoid cavity of the scapula; its surface is smooth and coated with cartilage in the recent state. The circumference of its articular surface is slightly constricted, and is termed the *anatomical neck*, in contradistinction to the constriction which exists below the tuberosities. The latter is called the *surgical neck*, from its often being the seat of fracture. It should be remembered, however, that fracture of the *anatomical neck* does sometimes, though rarely, occur.

The **anatomical neck** is obliquely directed, forming an obtuse angle with the shaft. It is more distinctly marked in the lower half of its circumference than in the upper half, where it presents a narrow groove, separating the head from the tuberosities. Its circumference affords attachment to the capsular ligament and is perforated by numerous vascular foramina.

The **greater tuberosity** is situated on the outer side of the head and lesser tuberosity. Its upper surface is rounded and marked by three flat facets, separated by two slight ridges: the highest facet gives attachment to the tendon of the Supraspinatus; the middle one, to the Infraspinatus; the inferior facet and the shaft of the bone below it, to the Teres minor. The outer surface of the great tuberosity is convex, rough, and continuous with the outer side of the shaft.

The **lesser tuberosity** is more prominent, although smaller than the greater: it is situated in front of the head, and is directed inward and forward. Its summit presents a prominent facet for the insertion of the tendon of the Subscapularis muscle. The tuberosities are separated from one another by a deep groove, the *bicipital groove*, so called from its lodging the long tendon of the Biceps muscle, with which runs a branch of the anterior circumflex artery. It commences above between the two tuberosities, passes obliquely downward and a little inward, and terminates at the junction of the upper with the middle third of the bone. It is deep and narrow at the commencement, and becomes shallow and a little broader as it descends. Its borders are called, respectively, the anterior

[1] Though the head is nearly hemispherical in form, its margin, as Sir G. Humphry has shown, is by no means a true circle. Its greatest measurement is from the top of the bicipital groove in a direction downward, inward, and backward. Hence it follows that the greatest elevation of the arm can be obtained by rolling the articular surface in this direction—that is to say, obliquely upward, outward, and forward.

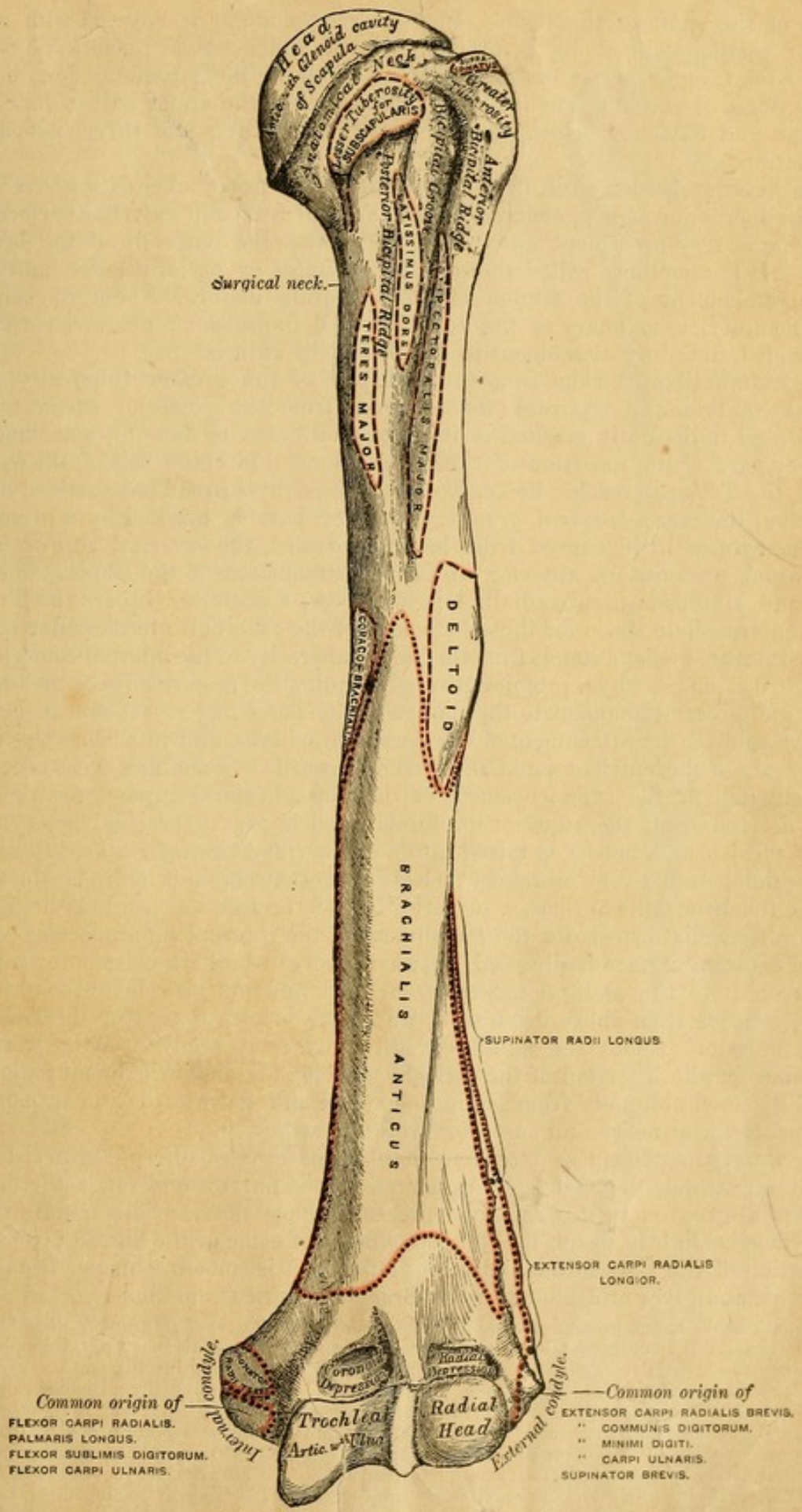

FIG. 97.—Left humerus. Anterior view.

and posterior *bicipital ridges*, and form the upper part of the anterior and internal

borders of the shaft of the bone. In the recent state it is covered with a thin layer of cartilage, lined by a prolongation of the synovial membrane of the shoulder-joint, and receives the tendon of insertion of the Latissimus dorsi muscle.

The **Shaft** of the humerus is almost cylindrical in the upper half of its extent, prismatic and flattened below, and presents three borders and three surfaces for examination.

The **anterior border** runs from the front of the great tuberosity above to the coronoid depression below, separating the internal from the external surface. Its upper part is very prominent and rough, and forms the outer lip of the bicipital groove. It is sometimes called the *anterior bicipital* or *pectoral ridge*, and serves for the attachment of the tendon of the Pectoralis major. About its centre it forms the anterior boundary of the rough deltoid impression; below, it is smooth and rounded, affording attachment to the Brachialis anticus.

The **external border** runs from the back part of the greater tuberosity to the external condyle, and separates the external from the posterior surface. It is rounded and indistinctly marked in its upper half, serving for the attachment of the lower part of the insertion of the Teres minor, and below this of the external head of the Triceps muscle; its centre is traversed by a broad but shallow, oblique depression, the *musculo-spiral groove;* its lower part is marked by a prominent, rough margin, a little curved from behind forward, the *external supracondylar ridge*, which presents an anterior lip for the attachment of the Supinator longus above and Extensor carpi radialis longior below, a posterior lip for the Triceps, and an intermediate space for the attachment of the external intermuscular septum.

The **internal border** extends from the lesser tuberosity to the internal condyle. Its upper third is marked by a prominent ridge, forming the posterior lip of the bicipital groove, and gives attachment to the tendon of the Teres major. About its centre is an impression for the attachment of the Coraco-brachialis, and just below this is seen the entrance of the nutrient canal, directed downward. Sometimes there is a second canal, situated at the commencement of the musculo-spiral groove, for a nutrient artery derived from the superior profunda branch of the brachial artery. The inferior third of this border is raised into a slight ridge, the *internal supracondylar ridge*, which becomes very prominent below; it presents an anterior lip for the attachment of the Brachialis anticus, a posterior lip for the internal head of the Triceps, and an intermediate space for the attachment of the internal intermuscular septum.

The **external surface** is directed outward above, where it is smooth, rounded, and covered by the Deltoid muscle; forward and outward below, where it is slightly concave from above downward, and gives origin to part of the Brachialis anticus muscle. About the middle of this surface is seen a rough, triangular impression for the insertion of the Deltoid muscle; and below it the musculo-spiral groove, directed obliquely from behind, forward and downward, and transmitting the musculo-spiral nerve and superior profunda artery.

The **internal surface**, less extensive than the external, is directed inward above, forward and inward below; at its upper part it is narrow and forms the floor of the bicipital groove: to it is attached the Latissimus dorsi. The middle part of this surface is slightly rough for the attachment of some of the fibres of the tendon of insertion of the Coraco-brachialis; its lower part is smooth, concave from above downward, and gives attachment to the Brachialis anticus muscle.[1]

[1] A small, hook-shaped process of bone, the *supracondylar process*, varying from $\frac{1}{10}$ to $\frac{3}{4}$ of an inch in length, is not infrequently found projecting from the inner surface of the shaft of the humerus two inches above the internal condyle. It is curved downward, forward, and inward, and its pointed extremity is connected to the internal border, just above the inner condyle, by a ligament or fibrous band, which gives origin to a portion of the Pronator radii teres; through the arch completed by this fibrous band the median nerve and brachial artery pass when these structures deviate from their usual course. Sometimes the nerve alone is transmitted through it, or the nerve may be accompanied by the ulnar artery in cases of high division of the brachial. A well-marked groove is usually found behind the process in which the nerve and artery are lodged. This space is analogous to the supracondyloid foramen in many animals, and probably serves in them to protect the nerve and artery from compression during the contraction of the muscles in this region. A detailed account of this process is given by Dr. Struthers, in his *Anatomical and Physiological Observations*, p. 202. An accessory portion of the Coracobrachialis muscle is frequently connected with this process, according to Mr. J. Wood (*Journal of Anat. and Phys.*, No. 1, Nov., 1866, p. 47).

The **posterior surface** (Fig. 98) appears somewhat twisted, so that its upper part is directed a little inward, its lower part backward and a little outward. Nearly the whole of this surface is covered by the external and internal heads of the Triceps, the former of which is attached to its upper and outer part, the latter to its inner and back part, the two being separated by the musculo-spiral groove.

The **Lower Extremity** is flattened from before backward, and curved slightly forward; it terminates below in a broad, articular surface which is divided into two parts by a slight ridge. Projecting on either side are the external and internal condyles. The articular surface extends a little lower than the condyles, and is curved slightly forward, so as to occupy the more anterior part of the bone; its greatest breadth is in the transverse diameter, and it is obliquely directed, so that its inner extremity occupies a lower level than the outer. The outer portion of the articular surface presents a smooth, rounded eminence, which has received the name of the *capitellum*, or *radial head* of the humerus; it articulates with the cup-shaped depression on the head of the radius, and is limited to the front and lower part of the bone, not extending as far back as the other portion of the articular surface. On the inner side of this eminence is a shallow groove, in which is received the inner margin of the head of the radius. Above the front part of the capitellum is a slight depression, the *radial fossa*, which receives the anterior border of the head of the radius when the forearm is flexed. The inner portion of the articular surface, the *trochlea*, presents a deep depression between two well-marked borders. This surface is convex from before backward, concave from side to side, and occupies the anterior, lower, and posterior parts of the bone. The external border, less prominent than the internal, corresponds to the interval between the radius and the ulna. The internal border is thicker, more prominent, and consequently of greater length, than the external. The grooved portion of the articular surface fits accurately within the greater sigmoid cavity of the ulna: it is broader and deeper on the posterior than on the anterior aspect of the bone, and is inclined obliquely from behind forward and from without inward. Above the front part of the trochlear surface is seen a smaller depression, the *coronoid fossa*, which receives the coronoid process of the ulna during flexion of the forearm. Above the back part of the trochlear surface is a deep, triangular depression, the *olecranon fossa*, in which is received the summit of the olecranon process in extension of

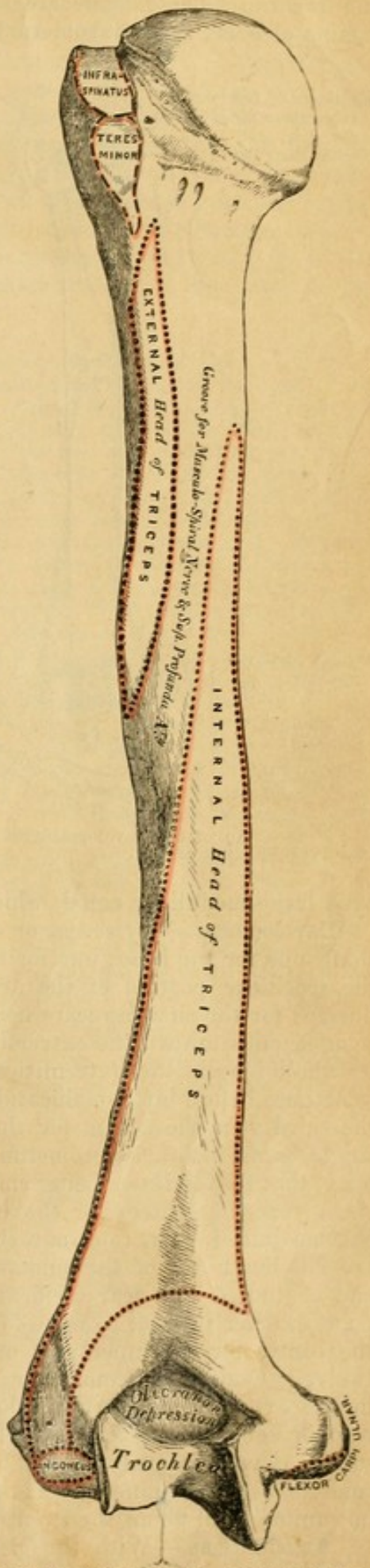

FIG. 98.—Left humerus. Posterior surface.

the forearm. These fossæ are separated from one another by a thin, transparent lamina of bone, which is sometimes perforated, forming the *supratrochlear foramen;* their upper margins afford attachment to the anterior and posterior ligaments of the elbow-joint, and they are lined, in the recent state, by the synovial membrane of this articulation. The articular surfaces, in the recent state, are covered with a thin layer of cartilage. The external condyle (*epicondyle*) is a small, tubercular eminence, less prominent than the internal, curved a little forward, and giving attachment to the external lateral ligament of the elbow-joint, and to a tendon common to the origin of some of the extensor and supinator muscles. The internal condyle (*epitrochlea*), larger and more prominent, and therefore more liable to fracture, than the external, is directed a little backward: it gives attachment to the internal lateral ligament, to the Pronator radii teres, and to a tendon common to the origin of some of the flexor muscles of the forearm. The ulnar nerve runs in a groove at the back of the internal condyle, or between it and the olecranon process. These condyles are directly continuous above with the external and internal supracondylar ridges.

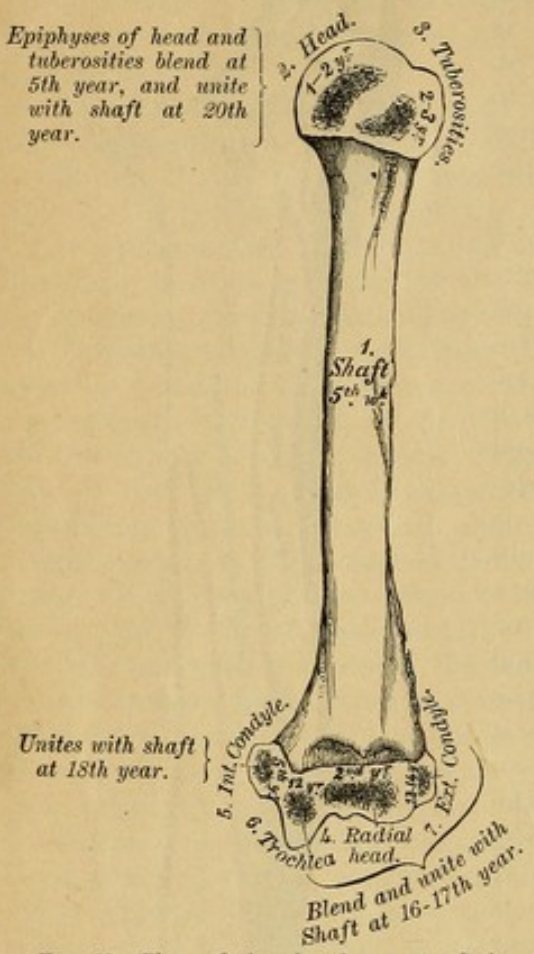

FIG. 99.—Plan of the development of the humerus By seven centres.

Structure.—The extremities consist of cancellous tissue, covered with a thin compact layer; the shaft is composed of a cylinder of compact tissue, thicker at the centre than at the extremities, and hollowed out by a large medullary canal, which extends along its whole length.

Development.—By *seven*, or occasionally *eight*, centres (Fig. 99), one for the shaft, one for the head, one for the tuberosities, one for the radial head, one for the trochlear portion of the articular surface, and one for each condyle. The nucleus for the shaft appears near the centre of the bone in the eighth week, and soon extends toward the extremities. At birth the humerus is ossified nearly in its whole length, the extremities remaining cartilaginous. During the first year, sometimes before birth, ossification commences in the head of the bone, and during the third year the centre for the tuberosities makes its appearance, usually by a single ossific point, but sometimes, according to Béclard, by one for each tuberosity, that for the lesser being small and not appearing until the fifth year. By the sixth year the centres for the head and tuberosities have increased in size and become joined, so as to form a single large epiphysis.

The lower end of the humerus is developed in the following manner: At the end of the second year ossification commences in the capitellum, and from this point extends inward, so as to form the chief part of the articular end of the bone, the centre for the inner part of the trochlea not appearing until about the age of twelve. Ossification commences in the internal condyle about the fifth year, and in the external one not until about the thirteenth or fourteenth year. About sixteen or seventeen years the outer condyle and both portions of the articulating surface (having already joined) unite with the shaft: at eighteen years the inner condyle becomes joined; while the upper epiphysis, although the first formed, is not united until about the twentieth year.

Articulations.—With the glenoid cavity of the scapula and with the ulna and radius.

Attachment of Muscles.—To twenty-four: to the greater tuberosity, the Supraspinatus, Infraspinatus, and Teres minor; to the lesser tuberosity, the Subscapularis; to the anterior bicipital ridge, the Pectoralis major; to the posterior bicipital ridge, the Teres major; to the bicipital groove, the Latissimus dorsi; to the shaft, the Deltoid, Coraco-brachialis, Brachialis anticus, external and internal heads of the Triceps; to the internal condyle, the Pronator radii teres, and common tendon of the Flexor carpi radialis, Palmaris longus, Flexor sublimis digitorum, and Flexor carpi ulnaris; to the external condyloid ridge, the Supinator longus and Extensor carpi radialis longior; to the external condyle, the common tendon of the Extensor carpi radialis brevior, Extensor communis digitorum, Extensor minimi digiti, Extensor carpi ulnaris, and Supinator brevis; to the back of the external condyle, the Anconeus.

Surface Form.—The humerus is almost entirely clothed by the muscles which surround it, and the only parts of this bone which are strictly subcutaneous are small portions of the internal and external condyles. In addition to these, the tuberosities and a part of the head of the bone can be felt under the skin and muscles by which they are covered. Of these the greater tuberosity forms the most prominent bony point of the shoulder, extending beyond the acromion process and covered by the Deltoid muscle. It influences materially the surface form of the shoulder. It is best felt while the arm is lying loosely by the side; if the arm be raised, it recedes from under the finger. The lesser tuberosity, directed forward and inward, is to be felt to the inner side of the greater tuberosity, just below the acromio-clavicular joint. Between the two tuberosities lies the bicipital groove. This can be defined by placing the finger and making firm pressure just internal to the greater tuberosity; then, by rotating the humerus, the groove will be felt to pass under the finger as the bone is rotated. With the arm abducted from the side, by pressing deeply in the axilla the lower part of the head of the bone is to be felt. On each side of the elbow-joint, and just above it, the internal and external condyles of the bone are to be felt. Of these the internal is the more prominent, but the ridge passing upward from it, the internal condyloid ridge, is much less marked than the external, and, as a rule, is not to be felt. Occasionally, however, we find along this border the hook-shaped process mentioned above. The external condyle is most plainly to be seen during semiflexion of the forearm, and its position is indicated by a depression between the attachment of the adjacent muscles. From it is to be felt a strong bony ridge running up the outer border of the shaft of the bone. This is the external supracondylar ridge; it is concave forward, and corresponds with the curved direction of the lower extremity of the humerus.

Surgical Anatomy.—There are several points of surgical interest connected with the humerus. First, as regards its development. The upper end, though the first to ossify, is the last to join the shaft, and the length of the bone is mainly due to growth from this upper epiphysis. Hence, in cases of amputation of the arm in young subjects the humerus continues to grow considerably, and the end of the bone which immediately after the operation was covered with a thick cushion of soft tissue, begins to project, thinning the soft parts and rendering the stump conical. This may necessitate the removal of a couple of inches or so of the bone, and even after this operation a recurrence of the conical stump may take place.

There are several points of surgical interest in connection with fractures. First, as regard their causation: the bone may be broken by direct or indirect violence like the other long bones, but, in addition to this, it is probably more frequently fractured by muscular action than any other of this class of bone in the body. It is usually the shaft, just below the insertion of the Deltoid, which is thus broken. I have seen the accident happen from throwing a stone, and in an apparently healthy adult from cutting a piece of hard "cake tobacco" on a table. In this latter case there was no disease of the bone that could be discovered. Fractures of the upper end may take place through the anatomical neck, through the surgical neck, or separation of the greater tuberosity may occur. Fracture of the anatomical neck is a very rare accident; in fact, it is doubted by some whether it ever occurs. These fractures are usually considered to be intracapsular, but they are probably partly within and partly without the capsule, as the lower part of the capsule is inserted some little distance below the anatomical neck, while the upper part is attached to it. They may be impacted or non-impacted. In most cases there is little or no displacement on account of the capsule, in whole or in part, remaining attached to the lower fragment. But occasionally a very remarkable alteration in position takes place; the upper fragment turns on its own axis, so that the cartilaginous surface of the head rests against the upper end of the lower fragment. When the fractured end is entirely separated from all its surroundings, its vascular supply must be entirely cut off, and one would expect it, theoretically, to necrose. But this must be exceedingly rare, for Gurlt was unable to find a single authenticated case recorded. Separation of the upper epiphysis of the humerus sometimes occurs in the young subject, and is marked by a characteristic deformity by which the lesion may be at once recognized. This consists in the presence of an abrupt projection at the front of the joint some short distance below the coracoid process, caused by the upper end of the lower fragment. In fractures of the shaft of the humerus the lesion may take place at any point, but appears to be more common in the lower than in the upper part of the bone. The points of interest in con

nection with these fractures are—(1) that the musculo-spiral nerve may be injured as it lies in the groove on the bone, or may become involved in the callus which is subsequently thrown out; and (2) the frequency of non-union. This is believed to be more common in the humerus than in any other bone, and various causes have been assigned for it. It would seem most probably to be due to the difficulty that there is in fixing the shoulder-joint and the upper fragment, and possibly the elbow-joint and lower fragment also. Other causes which have been assigned for the non-union are: (1) that in attempting passive motion of the elbow-joint to overcome any rigidity which may exist, the movement does not take place at the articulation, but at the seat of fracture; or that the patient, in consequence of the rigidity of the elbow, in attempting to flex or extend the forearm moves the fragment and not the joint. (2) The presence of small portions of muscular tissue between the broken ends. (3) Want of support to the elbow, so that the weight of the arm tends to drag the lower fragment away from the upper. An important distinction to make in fractures of the lower end of the humerus is between those that involve the joint and those which do not; the former always serious, as they may lead to impairment of the utility of the limb. They include the T-shaped fracture and oblique fractures which involve the articular surface. The fractures which do not involve the joint are the transverse above the condyles and the so-called epitrochlear fracture, when the tip of the internal condyle has broken off, generally from direct violence.

Under the head of separation of the epiphysis two separate injuries have been described. One where the whole of the four ossific centres which form the lower extremity of the bone are separated from the shaft; and secondly, where the articular portion is alone separated, the two condyles remaining attached to the shaft of the bone. The epiphysial line between the shaft and lower end runs across the bone just above the tips of the condyles, a point to be borne in mind in performing the operation of excision.

Tumors originating from the humerus are of frequent occurrence. A not uncommon place for a chondroma to grow from is the shaft of the bone somewhere in the neighborhood of the insertion of the deltoid. Sarcomata frequently grow from this bone.

THE FOREARM.

The **Forearm** is that portion of the upper extremity which is situated between the elbow and the wrist. Its skeleton is composed of two bones, the ulna and radius.

The Ulna.

The **Ulna** (Figs. 100, 101), so called from its forming the elbow (*ὠλένη*), is a long bone, prismatic in form, placed at the inner side of the forearm, parallel with the radius. It is the larger and longer of the two bones. Its upper extremity, of great thickness and strength, forms a large part of the articulation of the elbow-joint; it diminishes in size from above downward, its lower extremity being very small, and excluded from the wrist-joint by the interposition of an interarticular fibro-cartilage. It is divisible into a shaft and two extremities.

The **Upper Extremity,** the strongest part of the bone, presents for examination two large, curved processes, the Olecranon process and the Coronoid process; and two concave, articular cavities, the greater and lesser sigmoid cavities.

The **Olecranon Process** (*ὠλένη*, elbow; *χρανίον*, head) is a large, thick, curved eminence situated at the upper and back part of the ulna. It is curved forward at the summit so as to present a prominent tip which is received into the olecranon fossa in extension of the forearm; its base being contracted where it joins the shaft. This is the narrowest part of the upper end of the ulna, and, consequently, the most usual seat of fracture. The posterior surface of the olecranon, directed backward, is triangular, smooth, subcutaneous, and covered by a bursa. Its upper surface is of a quadrilateral form, marked behind by a rough impression for the attachment of the Triceps muscle; and in front, near the margin, by a slight transverse groove for the attachment of part of the posterior ligament of the elbow-joint. Its interior surface is smooth, concave, covered with cartilage in the recent state, and forms the upper and back part of the great sigmoid cavity. The lateral borders present a continuation of the same groove that was seen on the margin of the superior surface; they serve for the attachment of ligaments; viz., the back part of the internal lateral ligament internally, the posterior ligament externally. To the inner border is also attached a part of the Flexor carpi ulnaris, while to the outer border is attached the Anconeus.

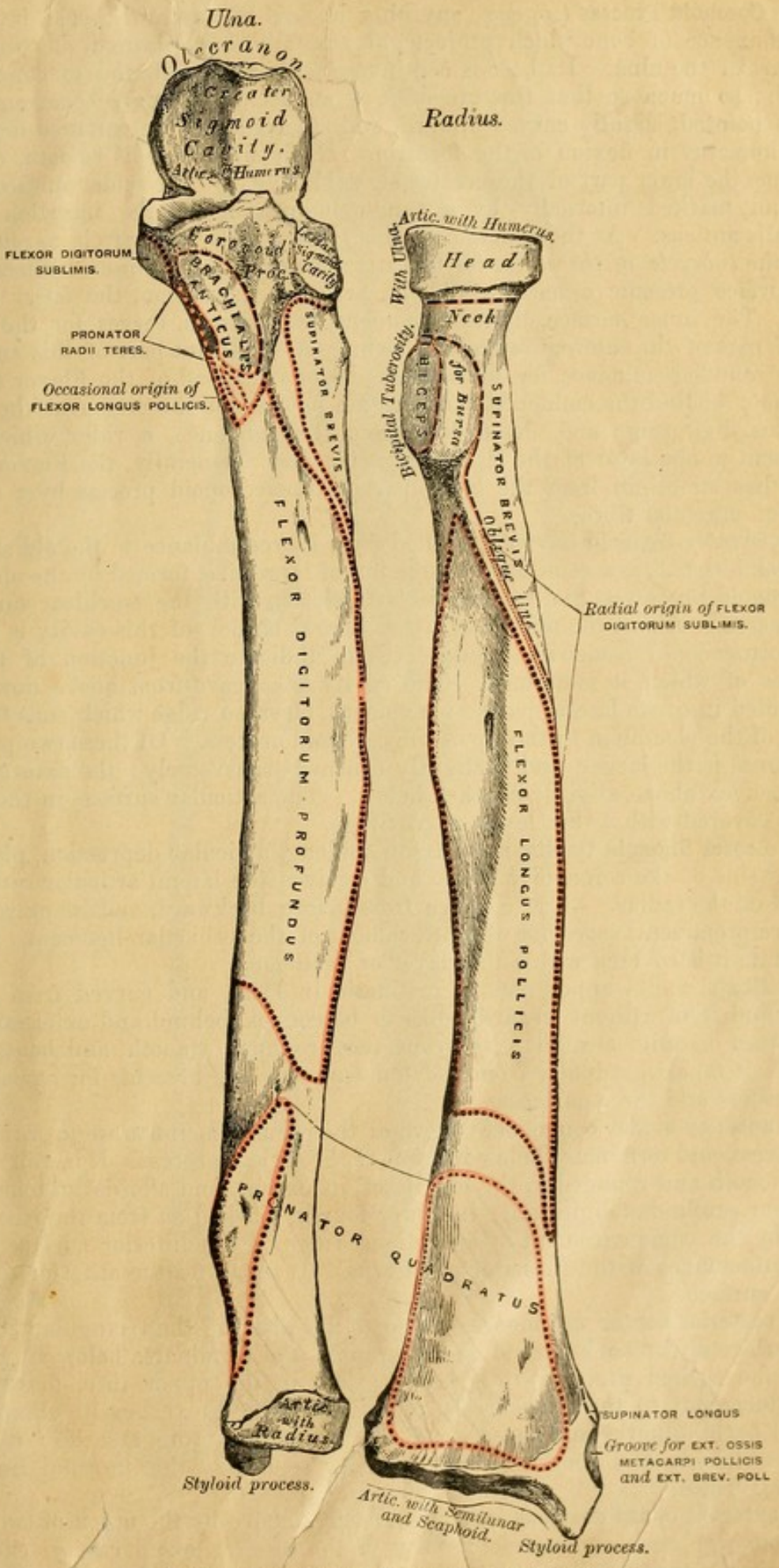

FIG. 100.—Bones of the left forearm. Anterior surface.

The **Coronoid Process** (*κορώνη*, anything hooked like a crow's beak) is a triangular eminence of bone which projects horizontally forward from the upper and front part of the ulna. Its base is continuous with the shaft, and of considerable strength; so much so that fracture of it is an accident of rare occurrence. Its apex is pointed, slightly curved upward, and received into the coronoid depression of the humerus in flexion of the forearm. Its upper surface is smooth, concave, and forms the lower part of the greater sigmoid cavity. The under surface is concave, and marked internally by a rough impression for the insertion of the Brachialis anticus. At the junction of this surface with the shaft is a rough eminence, the *tubercle of the ulna*, for the attachment of the oblique ligament. Its outer surface presents a narrow, oblong, articular depression, the *lesser sigmoid* cavity. The inner surface, by its prominent, free margin, serves for the attachment of part of the internal lateral ligament. At the front part of this surface is a small, rounded eminence for the attachment of one head of the Flexor sublimis digitorum; behind the eminence, a depression for part of the origin of the Flexor profundus digitorum; and, descending from the eminence, a ridge which gives attachment to one head of the Pronator radii teres. Generally, the Flexor longus pollicis has an origin from the lower part of the coronoid process by a rounded bundle of muscular fibres.

The **Greater Sigmoid Cavity**, so called from its resemblance to the old shape of the Greek letter Σ, is a semilunar depression of large size, formed by the olecranon and coronoid processes, and serving for articulation with the trochlear surface of the humerus. About the middle of either lateral border of this cavity is a notch which contracts it somewhat, and serves to indicate the junction of the two processes of which it is formed. The cavity is concave from above downward, and divided into two lateral parts by a smooth, elevated ridge which runs from the summit of the olecranon to the tip of the coronoid process. Of these two portions, the internal is the larger, and is slightly concave transversely; the external portion is convex above, slightly concave below. The articular surface, in the recent state, is covered with a thin layer of cartilage.

The **Lesser Sigmoid Cavity** is a narrow, oblong, articular depression, placed on the outer side of the coronoid process, and receives the lateral articular surface of the head of the radius. It is concave from before backward, and its extremities, which are prominent, serve for the attachment of the orbicular ligament. In the recent state it is covered with a thin layer of cartilage.

The **Shaft**, at its upper part, is prismatic in form, and curved from behind forward and from without inward, so as to be convex behind and externally; its central part is quite straight; its lower part rounded, smooth, and bent a little outward; it tapers gradually from above downward, and presents for examination three borders and three surfaces.

The **anterior border** commences above at the prominent inner angle of the coronoid process, and terminates below in front of the styloid process. It is well marked above, smooth and rounded in the middle of its extent, and affords attachment to the Flexor profundus digitorum: its lower fourth, marked off from the rest of the border by the commencement of an oblique ridge on the anterior surface, serves for the attachment of the Pronator quadratus. It separates the anterior from the internal surface.

The **posterior border** commences above at the apex of the triangular subcutaneous surface at the back part of the olecranon, and terminates below at the back part of the styloid process; it is well marked in the upper three-fourths, and gives attachment to the aponeurosis common to the Flexor carpi ulnaris, the Extensor carpi ulnaris, and the Flexor profundus digitorum muscles; its lower fourth is smooth and rounded. This border separates the internal from the posterior surface.

The **external** or **interosseous border** commences above by the union of two lines, which converge one from each extremity of the lesser sigmoid cavity, enclosing between them a triangular space for the attachment of part of the Supinator brevis,

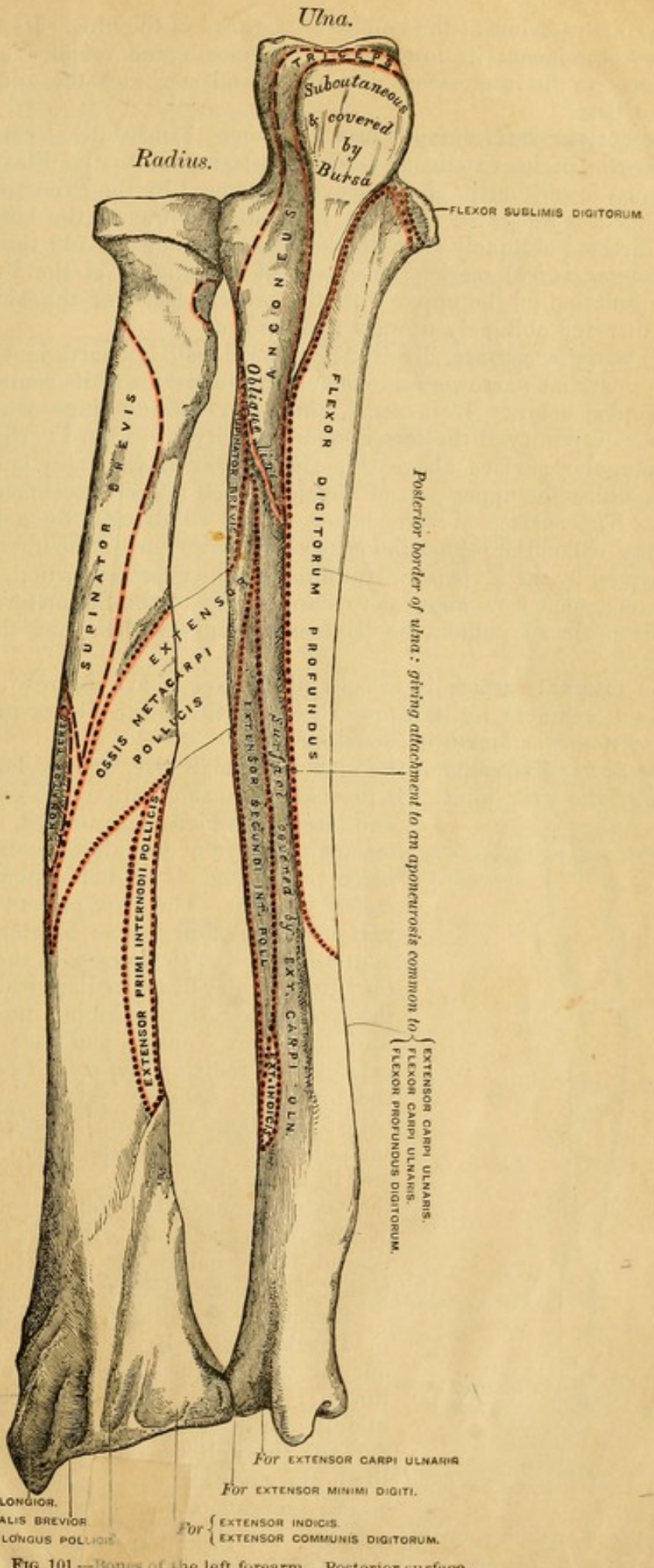

FIG. 101.—Bones of the left forearm. Posterior surface.

and terminates below at the middle of the head of the ulna. Its two middle fourths are very prominent; its lower fourth is smooth and rounded. This border gives attachment to the interosseous membrane, and separates the anterior from the posterior surface.

The **anterior surface,** much broader above than below, is concave in the upper three-fourths of its extent, and affords attachment to the Flexor profundus digitorum; its lower fourth, also concave, is covered by the Pronator quadratus. The lower fourth is separated from the remaining portion of the bone by a prominent ridge, directed obliquely from above downward and inward; this ridge (the *oblique* or *Pronator ridge*) marks the extent of attachment of the Pronator quadratus. At the junction of the upper with the middle third of the bone is the nutrient canal, directed obliquely upward and inward.

The **posterior surface,** directed backward and outward, is broad and concave above, somewhat narrower and convex in the middle of its course, narrow, smooth, and rounded below. It presents, above, an oblique ridge, which runs from the posterior extremity of the lesser sigmoid cavity, downward to the posterior border; the triangular surface above this ridge receives the insertion of the Anconeus muscle, whilst the upper part of the ridge itself affords attachment to the Supinator brevis. The surface of bone below this is subdivided by a longitudinal ridge, sometimes called the *perpendicular line*, into two parts: the internal part is smooth, and covered by the Extensor carpi ulnaris; the external portion, wider and rougher, gives attachment from above downward to part of the Supinator brevis, the Extensor ossis metacarpi pollicis, the Extensor longus pollicis, and the Extensor indicis muscles.

The **internal surface** is broad and concave above, narrow and convex below. It gives attachment by its upper three-fourths to the Flexor profundus digitorum muscle: its lower fourth is subcutaneous.

The **Lower Extremity** of the ulna is of small size, and excluded from the articulation of the wrist-joint. It presents for examination two eminences, the outer and larger of which is a rounded, articular eminence, termed the *head* of the ulna, the inner, narrower and more projecting, is a non-articular eminence, the *styloid process*. The *head* presents an articular facet, part of which, of an oval or semilunar form, is directed downward, and articulates with the upper surface of the interarticular fibro-cartilage which separates it from the wrist-joint; the remaining portion, directed outward, is narrow, convex, and received into the sigmoid cavity of the radius. The *styloid process* projects from the inner and back part of the bone, and descends a little lower than the head, terminating in a rounded summit, which affords attachment to the internal lateral ligament of the wrist. The head is separated from the styloid process by a depression for the attachment of the triangular interarticular fibro-cartilage; and behind, by a shallow groove for the passage of the tendon of the Extensor carpi ulnaris.

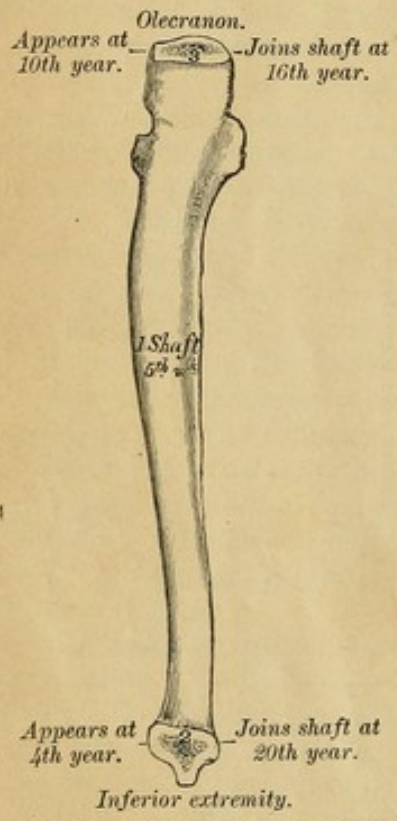

FIG. 102.—Plan of the development of the ulna. By three centres.

Structure.—Similar to that of the other long bones.

Development.—By *three* centres: one for the shaft, one for the inferior extremity, and one for the olecranon (Fig. 102). Ossification commences near the middle of the shaft about the eighth week, and soon extends through the greater part of the bone. At birth the ends are cartilaginous. About the fourth year a separate osseous nucleus appears in the middle of the head, which soon extends into the styloid process. About the tenth year ossific matter appears in the olecranon near its extremity, the chief part of this

process being formed from an extension of the shaft of the bone into it. At about the sixteenth year the upper epiphysis becomes joined, and at about the twentieth year the lower one.

Articulations.—With the humerus and radius.

Attachment of Muscles.—To sixteen: to the olecranon, the Triceps, Anconeus, and one head of the Flexor carpi ulnaris. To the coronoid process, the Brachialis anticus, Pronator radii teres, Flexor sublimis digitorum, and Flexor profundus digitorum; generally also the Flexor longus pollicis. To the shaft, the Flexor profundus digitorum, Pronator quadratus, Flexor carpi ulnaris, Extensor carpi ulnaris, Anconeus, Supinator brevis, Extensor ossis metacarpi pollicis, Extensor longus pollicis, and Extensor indicis.

Surface Form.—The most prominent part of the ulna on the surface of the body is the olecranon process, which can always be felt at the back of the elbow-joint. When the forearm is flexed, the upper quadrilateral surface can be felt, directed backward; during extension it recedes into the olecranon fossa, and the contracting fibres of the triceps prevent its being perceived. At the back of the olecranon is the smooth, triangular, subcutaneous surface, which below is continuous with the posterior border of the shaft of the bone, and felt in every position of the forearm. During extension the upper border of the olecranon is slightly above the level of the internal condyle, and the process itself is nearer to this condyle than the outer one. Running down the back of the forearm, from the apex of the triangular surface which forms the posterior surface of the olecranon, is a prominent ridge of bone, the posterior border of the ulna. This is to be felt throughout the entire length of the shaft of the bone, from the olecranon above to the styloid process below. As it passes down the forearm it pursues a sinuous course and inclines to the inner side, so that, though it is situated in the middle of the back of the limb above, it is on the inner side of the wrist at its termination. It becomes rounded off in its lower third, and may be traced below to the small, subcutaneous surface of the styloid process. Internal to this border the lower fourth of the inner surface is to be felt. The styloid process is to be felt as a prominent tubercle of bone, continuous above with the posterior subcutaneous border of the ulna, and terminating below in a blunt apex, which lies a little internal and behind, but on a level with, the wrist-joint. The styloid process is best felt when the hand is in the same line as the bones of the forearm, and in a position midway between supination and pronation. If the forearm is pronated while the finger is placed on the process, it will be felt to recede, and another prominence of bone will appear just behind and above it. This is the head of the ulna, which articulates with the lower end of the radius and the triangular interarticular fibro-cartilage, and now projects between the tendons of the Extensor carpi ulnaris and the Extensor minimi digiti muscles.

The Radius.

The **Radius** (*radius*, a ray, or spoke of a wheel) is situated on the outer side of the forearm, lying side by side with the ulna, which exceeds it in length and size. (Figs. 100 and 101.) Its upper end is small, and forms only a small part of the elbow-joint; but its lower end is large, and forms the chief part of the wrist. It is one of the long bones, prismatic in form, slightly curved longitudinally, and, like other long bones, has a shaft and two extremities.

The **Upper Extremity** presents a head, neck, and tuberosity. The *head* is of a cylindrical form, depressed on its upper surface into a shallow cup which articulates with the capitellum or radial head of the humerus. In the recent state it is covered with a layer of cartilage which is thinnest at its centre. Around the circumference of the head is a smooth, articular surface, broad internally where it articulates with the lesser sigmoid cavity of the ulna; narrow in the rest of its circumference, where it rotates within the orbicular ligament. It is coated with cartilage in the recent state. The head is supported on a round, smooth, and constricted portion of bone, called the *neck*, which presents, behind, a slight ridge, for the attachment of part of the Supinator brevis. Beneath the neck, at the inner and front aspect of the bone, is a rough eminence, the *bicipital tuberosity*. Its surface is divided into two parts by a vertical line—a posterior, rough portion, for the insertion of the tendon of the Biceps muscle; and an anterior, smooth portion, on which a bursa is interposed between the tendon and the bone.

The **Shaft** of the bone is prismoid in form, narrower above than below, and slightly curved, so as to be convex outward. It presents three surfaces, separated by three borders.

The **anterior border** extends from the lower part of the tuberosity above to the anterior part of the base of the styloid process below. It separates the anterior from the external surface. Its upper third is very prominent; and from its oblique direction, downward and outward, has received the name of the *oblique line of the radius*. It gives attachment externally to the Supinator brevis, internally to the Flexor longus pollicis, and between these to the Flexor sublimis digitorum. The middle third of the anterior border is indistinct and rounded. Its lower fourth is sharp, prominent, affords attachment to the Pronator quadratus and to the posterior annular ligament of the wrist, and terminates in a small tubercle, into which is inserted the tendon of the Supinator longus.

The **posterior border** commences above at the back part of the neck of the radius, and terminates below at the posterior part of the base of the styloid process; it separates the posterior from the external surface. It is indistinct above and below, but well marked in the middle third of the bone.

The **internal** or **interosseous border** commences above at the back part of the tuberosity, where it is rounded and indistinct, becomes sharp and prominent as it descends, and at its lower part divides into two ridges, which descend to the anterior and posterior margins of the sigmoid cavity. This border separates the anterior from the posterior surface, and has the interosseous membrane attached to it throughout the greater part of its extent.

The **anterior surface** is concave for its upper three-fourths, and gives attachment to the Flexor longus pollicis muscle; it is broad and flat for its lower fourth, and gives attachment to the Pronator quadratus. A prominent ridge limits the attachment of the Pronator quadratus below, and between this and the inferior border is a triangular rough surface for the attachment of the anterior ligament of the wrist-joint. At the junction of the upper and middle third of this surface is the nutrient foramen, which is directed obliquely upward.

The **posterior surface** is rounded, convex, and smooth in the upper third of its extent, and covered by the Supinator brevis muscle. Its middle third is broad, slightly concave, and gives attachment to the Extensor ossis metacarpi pollicis above, the Extensor brevis pollicis below. Its lower third is broad, convex, and covered by the tendons of the muscles, which subsequently run in the grooves on the lower end of the bone.

The **external surface** is rounded and convex throughout its entire extent. Its upper third gives attachment to the Supinator brevis muscle. About its centre is seen a rough ridge, for the insertion of the Pronator radii teres muscle. Its lower part is narrow, and covered by the tendons of the Extensor ossis metacarpi pollicis and Extensor brevis pollicis muscles.

The **Lower Extremity** of the radius is large, of quadrilateral form, and provided with two articular surfaces—one at the extremity, for articulation with the carpus, and one at the inner side of the bone, for articulation with the ulna. The carpal articular surface is of triangular form, concave, smooth, and divided by a slight antero-posterior ridge into two parts. Of these, the external is of a triangular form, and articulates with the scaphoid bone; the inner, quadrilateral, articulates with the semilunar. The articular surface for the ulna is called the *sigmoid cavity* of the radius; it is narrow, concave, smooth, and articulates with the head of the ulna. The circumference of this end of the bone presents three surfaces —an anterior, external, and posterior. The *anterior surface*, rough and irregular, affords attachment to the anterior ligament of the wrist-joint. The *external surface* is prolonged obliquely downward into a strong, conical projection, the *styloid process*, which gives attachment by its base to the tendon of the Supinator longus, and by its apex to the external lateral ligament of the wrist-joint. The outer surface of this process is marked by a flat groove, which runs obliquely downward and forward, and gives passage to the tendons of the Extensor ossis metacarpi pollicis and the Extensor brevis pollicis. The *posterior surface* is convex, affords attachment to the posterior ligament of the wrist, and is marked by three grooves. Proceeding from without inward, the first groove is broad but

shallow, and subdivided into two by a slightly elevated ridge: the outer of these two transmits the tendon of the Extensor carpi radialis longior, the inner the tendon of the Extensor carpi radialis brevior. The second, which is near the centre of the bone, is a deep but narrow groove, bounded on its outer side by a sharply-defined ridge; it is directed obliquely from above, downward and outward, and transmits the tendon of the Extensor longus pollicis. The third, lying most internally, is a broad groove, for the passage of the tendons of the Extensor indicis and Extensor communis digitorum.

Structure.—Similar to that of the other long bones.

Development (Fig. 103).—By *three* centres: one for the shaft and one for each extremity. That for the shaft makes its appearance near the centre of the bone, about the eighth week of fœtal life. About the end of the second year ossification commences in the lower epiphysis, and about the fifth year in the upper end. At the age of seventeen or eighteen the upper epiphysis becomes joined to the shaft, the lower epiphysis becoming united about the twentieth year.

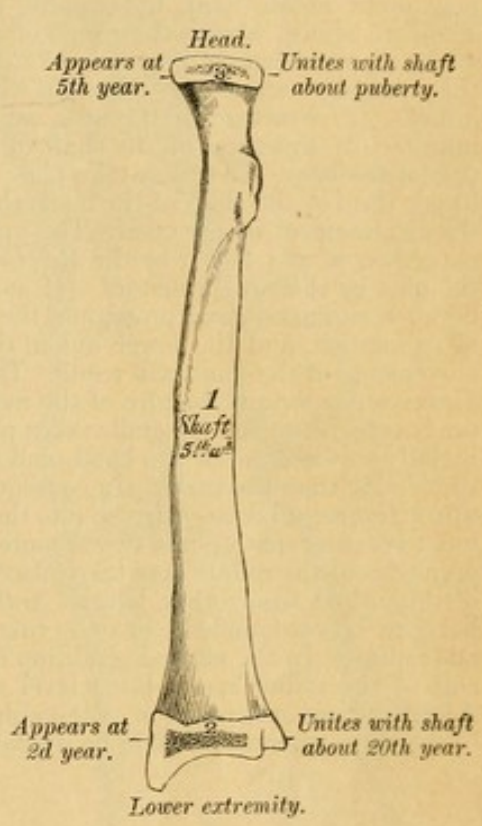

FIG. 103.—Plan of the development of the radius. By three centres.

Articulation.—With four bones: the humerus, ulna, scaphoid, and semilunar.

Attachment of Muscles.—To nine: to the tuberosity, the Biceps; to the oblique ridge, the Supinator brevis, Flexor sublimis digitorum, and Flexor longus pollicis; to the shaft (its anterior surface), the Flexor longus pollicis and Pronator quadratus; (its posterior surface), the Extensor ossis metacarpi pollicis and Extensor brevis pollicis; (its outer surface), the Pronator radii teres; and to the styloid process, the Supinator longus.

Surface Form.—Just below and a little in front of the posterior surface of the external condyle a part of the head of the radius may be felt, covered by the orbicular and external lateral ligaments. There is in this situation a little dimple in the skin, which is most visible when the arm is extended, and which marks the position of the head of the bone. If the finger is placed on this dimple and the forearm pronated and supinated, the head of the bone will be distinctly perceived rotating in the lesser sigmoid cavity. The upper half of the shaft of the radius cannot be felt, as it is surrounded by the fleshy bellies of the muscles arising from the external condyle. The lower half of the shaft can be readily examined, though covered by tendons and muscles and not strictly subcutaneous. If traced downward, the shaft will be felt to terminate in a lozenge-shaped, convex surface on the outer side of the base of the styloid process. This is the only subcutaneous part of the bone, and from its lower extremity the apex of the styloid process will be felt bending inward toward the wrist. About the middle of the posterior aspect of the lower extremity of the bone is a well-marked ridge, best perceived when the hand is slightly flexed on the wrist. It forms the outer boundary of the oblique groove on the posterior surface of the bone, through which the tendon of the Extensor longus pollicis runs, and serves to keep that tendon in its place.

Surgical Anatomy.—The two bones of the forearm are more often broken together than is either the radius or ulna separately. It is therefore convenient to consider the fractures of these two bones together in the first instance, and subsequently to mention the principal fractures which take place in each bone individually. These fractures may be produced by either direct or indirect violence, though more commonly by direct violence. When indirect force is applied to the forearm the radius generally alone gives way, though both bones may suffer. The fracture from indirect force generally takes place somewhere about the middle of the bones; fracture from direct violence may occur at any part, more often, however, in the lower half of the bone. The fracture is usually transverse, but may be more or less oblique. A point of interest in connection with these fractures is the tendency that there is for the two bones to unite across the interosseous membrane; the limb should therefore be put up in a position midway between supination and pronation, which is not only the most comfortable position, but also separates the bones most widely from each other, and therefore diminishes the risk of the bones becoming united across the interosseous membrane. The splints, anterior and posterior, which are

applied in these cases should be rather wider than the limb, so as to prevent any lateral pressure on the bones. For in these cases there is a greater liability to gangrene from the pressure of the splints than in other parts of the body. This is no doubt due principally to two causes: (1) the flexion of the forearm compressing to a certain extent the brachial artery and retarding the flow of blood to the limb; and (2) the superficial position of the two main arteries of the forearm in a part of their course, and their liability to be compressed by the splints. The special fractures of the ulna are—(1) Fracture of the olecranon. This may be caused by direct violence, falls on the elbow with the forearm flexed, or by muscular action by the sudden contraction of the triceps. The most common place for the fracture to occur is at the constricted portion where the olecranon joins the shaft of the bone, and the fracture may be either transverse or oblique; but any part may be broken, even a thin shell may be torn off. Fractures from direct violence are occasionally comminuted. The displacement is sometimes very slight, owing to the fibrous structures around the process not being torn. (2) Fracture of the coronoid process sometimes occurs as a complication of dislocation backward of the bones of the forearm, but it is doubtful if it ever occurs as an uncomplicated injury. (3) Fractures of the shaft of the ulna may occur at any part, but usually take place at the middle of the bone or a little below it. They are almost always the result of direct violence. (4) The styloid process may be knocked off by direct violence. Fractures of the radius consist of—(1) Fracture of the head of the bone; this generally occurs in conjunction with some other lesion, but may occur as an uncomplicated injury. (2) Fracture of the neck may also take place, but is generally complicated with other injury. (3) Fractures of the shaft of the radius are very common, and may take place at any part of the bone. They may take place from either direct or indirect violence. In fractures of the upper third of the shaft of the bone, that is to say, above the insertion of the Pronator radii teres, the displacement is very great. The upper fragment is strongly supinated by the Biceps and Supinator brevis, and flexed by the Biceps; while the lower fragment is pronated and drawn toward the ulna by the two pronators. If such a fracture is put up in the ordinary position, midway between supination and pronation, the fracture will unite with the upper fragment in a position of supination, and the lower one in the mid-position, and thus considerable impairment of the movements of the hand will result. The limb should be put up with the forearm supinated. (4) The most important fracture of the radius is that of the lower end (Colles's fracture). The fracture is transverse, and generally takes place about an inch from the lower extremity. It is caused by falls on the palm of the hand, and is an injury of advanced life, occurring more frequently in the female than the male. In consequence of the manner in which the fracture is caused, the upper fragment becomes driven into the lower, and impaction is the result; or else the lower fragment becomes split up into two or more pieces, so that no fixation occurs. Separation of the lower epiphysis of the radius may take place in the young. This injury and Colles's fracture may be distinguished from other injuries in this neighborhood—especially dislocation, with which it is liable to be confounded—by observing the relative positions of the styloid processes of the ulna and radius. In the natural condition of parts, with the arm hanging by the side, the styloid process of the radius is on a lower level than that of the ulna; that is to say, nearer the ground. After fracture or separation of the epiphysis this process is on the same or higher level than that of the ulna, whereas it would be unaltered in position in dislocation.

THE HAND.

The skeleton of the **Hand** is subdivided into three segments—the Carpus or wrist-bones; the Metacarpus or bones of the palm; and the Phalanges or bones of the digits.

The Carpus.

The bones of the **Carpus** (*καρπός*, the wrist), eight in number, are arranged in two rows. Those of the upper row, enumerated from the radial to the ulnar side, are the scaphoid, semilunar, cuneiform, and pisiform; those of the lower row, enumerated in the same order, are the trapezium, trapezoid, os magnum, and unciform.

Common Characters of the Carpal Bones.

Each bone (excepting the pisiform) presents six surfaces. Of these the *anterior* or *palmar* and the *posterior* or *dorsal* are rough for ligamentous attachment, the dorsal surface being the broader, except in the scaphoid and semilunar. The *superior* or *proximal* and *inferior* or *distal* are articular, the superior generally convex, the inferior concave; and the *internal* and *external* are also articular when in contact with contiguous bones, otherwise rough and tubercular. The structure in all is similar, consisting of cancellous tissue enclosed in a layer of compact bone. Each bone is also developed from a single centre of ossification.

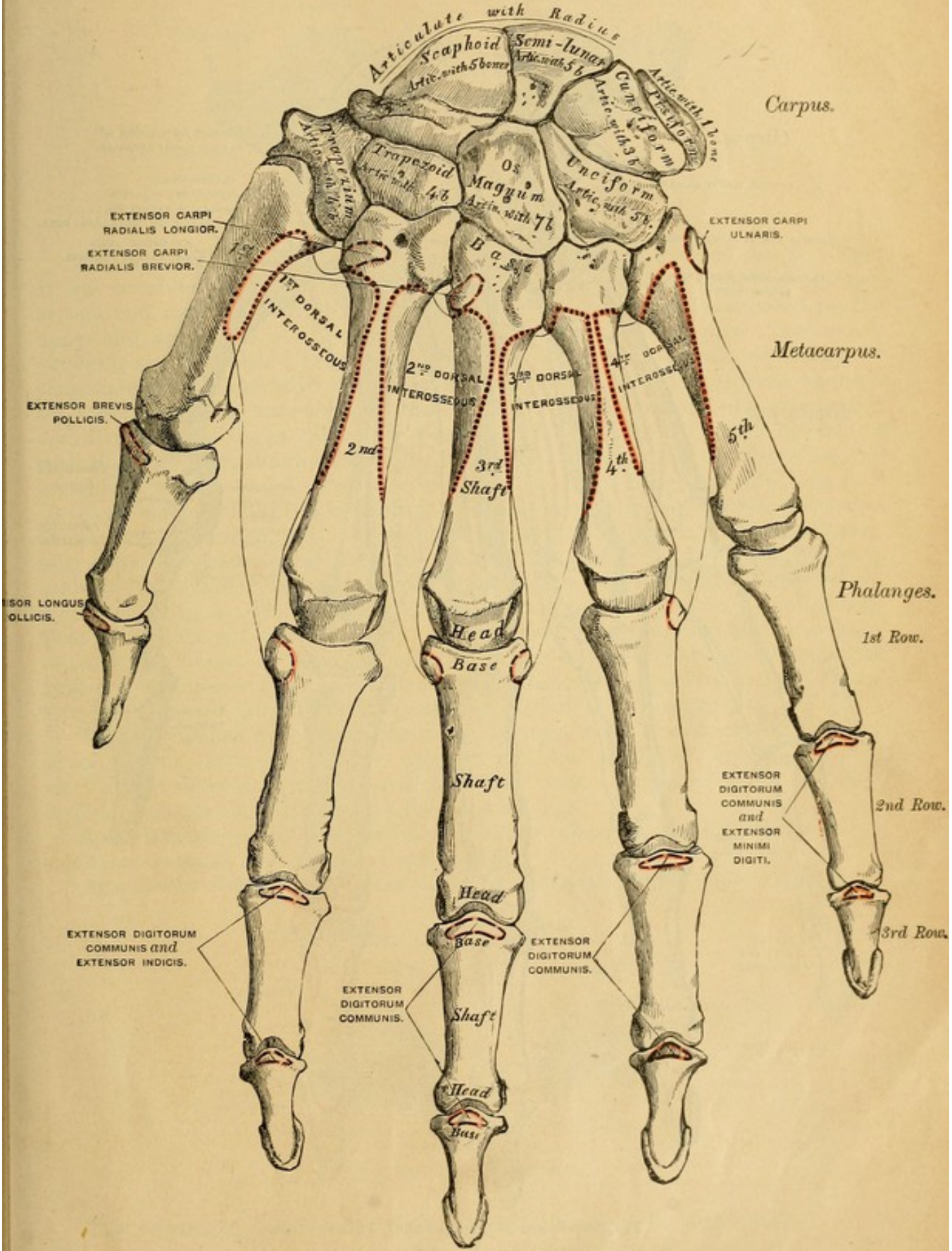

FIG. 104.—Bones of the left hand. Dorsal surface.

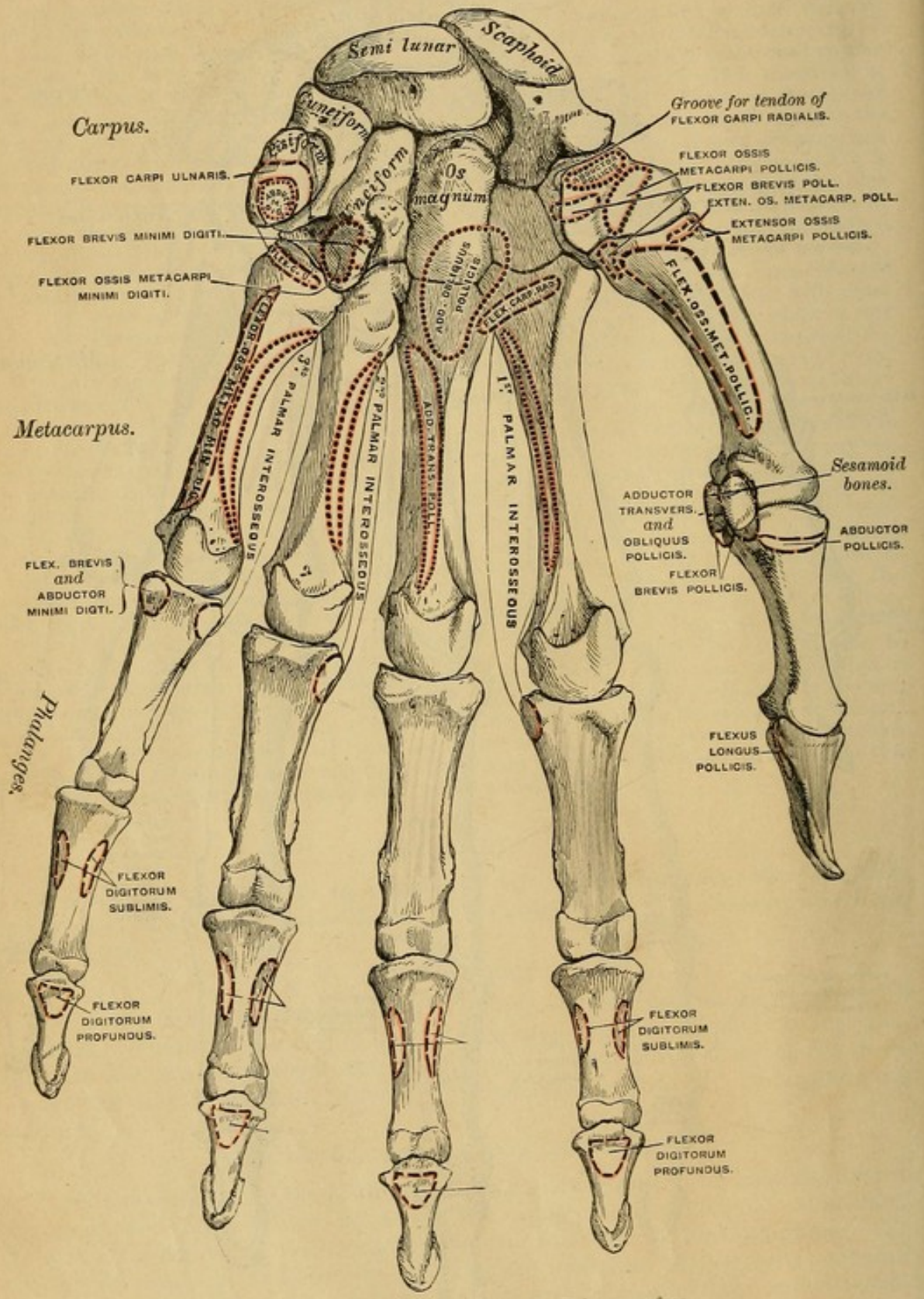

FIG. 105.—Bones of the left hand. Palmar surface.

Bones of the Upper Row.

Scaphoid (Fig. 106).

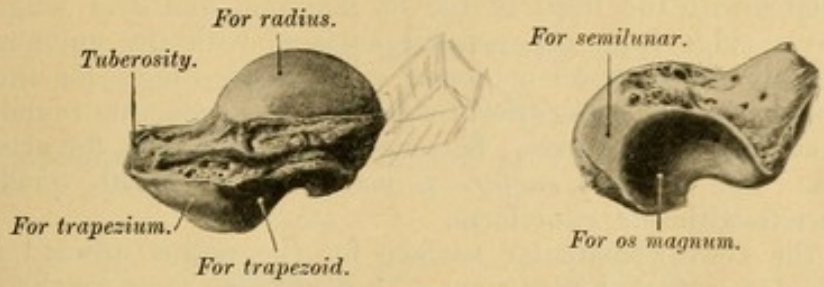

Fig. 106.—The left scaphoid.

The **Scaphoid** (*σκάφη*, a boat, *εἶδος*, like) is the largest bone of the first row. It has received its name from its fancied resemblance to a boat, being broad at one end and narrowed like a prow at the opposite. It is situated at the upper and outer part of the carpus, its long axis being from above downward, outward, and forward. The *superior surface* is convex, smooth, of triangular shape, and articulates with the lower end of the radius. The *inferior surface*, directed downward, outward, and backward, is smooth, convex, also triangular, and divided by a slight ridge into two parts, the external of which articulates with the trapezium, the inner with the trapezoid. The *posterior* or *dorsal surface* presents a narrow, rough groove which runs the entire length of the bone and serves for the attachment of ligaments. The *anterior* or *palmar surface* is concave above, and elevated at its lower and outer part into a prominent rounded tuberosity, which projects forward from the front of the carpus and gives attachment to the anterior annular ligament of the wrist and sometimes a few fibres of the Abductor pollicis. The *external surface* is rough and narrow, and gives attachment to the external lateral ligament of the wrist. The *internal surface* presents two articular facets: of these, the superior or smaller one is flattened, of semilunar form, and articulates with the semilunar; the inferior or larger is concave, forming, with the semilunar bone, a concavity for the head of the os magnum.

To ascertain to which side the bone belongs, hold it with the superior or radial convex, articular, surface upward, and the posterior surface—*i. e.*, the narrow, non-articular, grooved surface—toward you. The tubercle on the outer surface points to the side to which the bone belongs.[1]

Articulations.—With five bones: the radius above, trapezium and trapezoid below, os magnum and semilunar internally.

Attachment of Muscles.—Occasionally a few fibres of the Abductor pollicis.

Semilunar (Fig. 107).

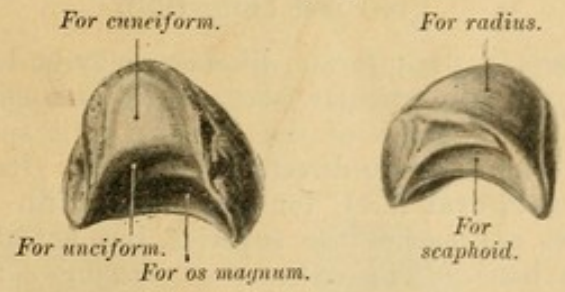

Fig. 107.—The left semilunar.

The **Semilunar** (*semi*, half; *luna*, moon) bone may be distinguished by its deep concavity and crescentic outline. It is situated in the centre of the upper

[1] In these directions each bone is supposed to be placed in its natural position—that is, such a position as it would occupy when the arm is hanging by the side, the forearm in a position of supination, the thumb being directed outward, and the palm of the hand looking forward.

row of the carpus, between the scaphoid and cuneiform. The *superior surface*, convex, smooth, and bounded by four edges, articulates with the radius. The *inferior surface* is deeply concave, and of greater extent from before backward than transversely: it articulates with the head of the os magnum and by a long, narrow facet (separated by a ridge from the general surface) with the unciform bone. The *anterior* or *palmar* and *posterior* or *dorsal surfaces* are rough, for the attachment of ligaments, the former being the broader and of a somewhat rounded form. The *external surface* presents a narrow, flattened, semilunar facet for articulation with the scaphoid. The *internal surface* is marked by a smooth, quadrilateral facet, for articulation with the cuneiform.

Hold it with the convex articular surface for the radius upward, and the narrowest non-articular surface toward you. The semilunar facet for the scaphoid will be on the side to which the bone belongs.

Articulations.—With five bones: the radius above, os magnum and unciform below, scaphoid and cuneiform on either side.

Cuneiform (Fig. 108).

The **Cuneiform** (*cuneus*, a wedge; *forma*, likeness) may be distinguished by its pyramidal shape (*os pyramidale*), and by its having an oval, isolated facet for articulation with the pisiform bone. It is situated at the upper and inner side of the carpus. The *superior surface* presents an internal, rough, non-articular portion, and an external or articular portion, which is convex, smooth, and articulates with the triangular interarticular fibro-cartilage of the wrist. The *inferior surface*, directed outward, is concave, sinuously curved, and smooth for articulation with the unciform. The *posterior* or *dorsal surface* is rough, for the attachment of ligaments. The *anterior* or *palmar surface* presents, at its inner side, an oval facet, for articulation with the pisiform; and is rough externally, for ligamentous attachment. The *external surface*, the base of the pyramid, is marked by a flat, quadrilateral, smooth facet, for articulation with the semilunar. The *internal surface*, the summit of the pyramid, is pointed and roughened, for the attachment of the internal lateral ligament of the wrist.

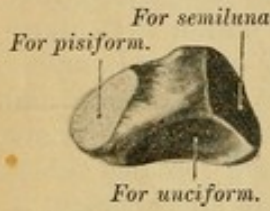

Fig. 108.—The left cuneiform.

Hold the bone with the surface supporting the pisiform facet away from you, and the concavo-convex surface for the unciform downward. The base of the wedge (*i. e.*, the broad end of the bone) will be on the side to which it belongs.

Articulations.—With three bones: the semilunar externally, the pisiform in front, the unciform below; and with the triangular, interarticular fibro-cartilage which separates it from the lower end of the ulna.

Pisiform (Fig. 109).

The **Pisiform** (*pisum*, a pea; *forma*, likeness) may be known by its small size and by its presenting a single articular facet. It is situated on a plane anterior to the other bones of the carpus; it is spheroidal in form, with its long diameter directed vertically. Its *posterior surface* is a smooth, oval facet, for articulation with the cuneiform. This facet approaches the superior, but not the inferior, border of the bone. The *anterior* or *palmar surface* is rounded and rough, and gives attachment to the anterior annular ligament and to the Flexor carpi ulnaris and Abductor minimi digiti muscles. The *outer* and *inner surfaces* are also rough, the former being concave, the latter usually convex.



Fig. 109.—The left pisiform.

Hold the bone with the posterior surface—that which presents the articular facet—toward you, in such a manner that the faceted portion of the surface is uppermost. The outer, concave surface will point to the side to which it belongs.

Articulations.—With one bone, the cuneiform.

Attachment of Muscles.—To two: the Flexor carpi ulnaris and Abductor minimi digiti; and to the anterior annular ligament.

Bones of the Lower Row.

Trapezium (Fig. 110).

The **Trapezium** (*τράπεζα*, a table) is of very irregular form. It may be distin-

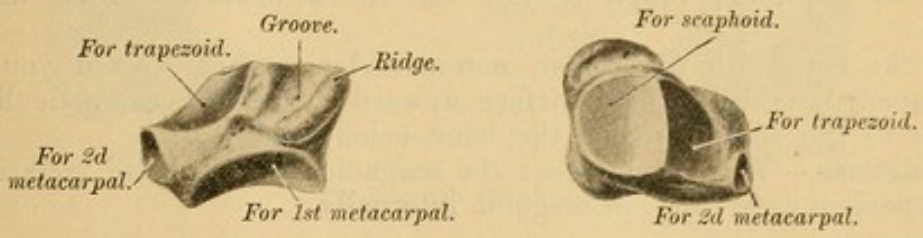

Fig. 110.—The left trapezium.

guished by a deep groove, for the tendon of the Flexor carpi radialis muscle. It is situated at the external and inferior part of the carpus, between the scaphoid and first metacarpal bone. The *superior surface*, concave and smooth, is directed upward and inward, and articulates with the scaphoid. The *inferior surface*, directed downward and inward, is oval, concave from side to side, convex from before backward, so as to form a saddle-shaped surface, for articulation with the base of the first metacarpal bone. The *anterior* or *palmar surface* is narrow and rough. At its upper part is a deep groove running from above obliquely downward and inward; it transmits the tendon of the Flexor carpi radialis, and is bounded externally by a prominent ridge, the oblique ridge of the trapezium. This surface gives attachment to the Abductor pollicis, Flexor ossis metacarpi pollicis, and Flexor brevis pollicis muscles, and the anterior annular ligament. The *posterior* or *dorsal surface* is rough. The *external surface* is also broad and rough, for the attachment of ligaments. The *internal surface* presents two articular facets: the upper one, large and concave, articulates with the trapezoid; the lower one, small and oval, with the base of the second metacarpal bone.

Hold the bone with the saddle-shaped surface downward and the grooved surface away from you. The prominent, rough, non-articular surface points to the side to which the bone belongs.

Articulations.—With four bones: the scaphoid above, the trapezoid and second metacarpal bones internally, the first metacarpal below.

Attachment of Muscles.—Abductor pollicis, Flexor ossis metacarpi pollicis, and part of the Flexor brevis pollicis.

Trapezoid (Fig. 111).

The **Trapezoid** is the smallest bone in the second row. It may be known by its wedge-shaped form, the broad end of the wedge forming the dorsal, the narrow

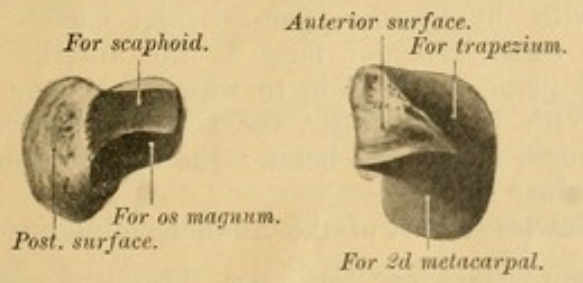

Fig. 111.—The left trapezoid.

end the palmar, surface, and by its having four articular surfaces touching each

other and separated by sharp edges. The *superior surface*, quadrilateral in form, smooth, and slightly concave, articulates with the scaphoid. The *inferior surface* articulates with the upper end of the second metacarpal bone; it is convex from side to side, concave from before backward, and subdivided by an elevated ridge into two unequal lateral facets. The *posterior* or *dorsal* and *anterior* or *palmar surfaces* are rough, for the attachment of ligaments, the former being the larger of the two. The *external surface*, convex and smooth, articulates with the trapezium. The *internal surface* is concave and smooth in front, for articulation with the os magnum; rough behind, for the attachment of an interosseous ligament.

Hold the bone with the larger, non-articular surface toward you, and the smooth, quadrilateral articular surface upward. The convex, articular surface will point to the side to which the bone belongs.[1]

Articulations.—With four bones: the scaphoid above, second metacarpal bone below, trapezium externally, os magnum internally.

Os Magnum (Fig. 112).

The **Os Magnum** is the largest bone of the carpus, and occupies the centre of the wrist. It presents, above, a rounded portion or head, which is received into

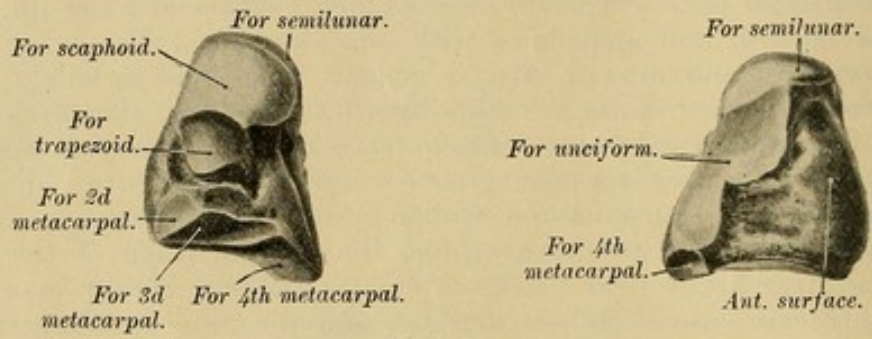

Fig. 112.—The left os magnum.

the concavity formed by the scaphoid and semilunar bones; a constricted portion or neck; and, below, the body. The *superior surface* is rounded, smooth, and articulates with the semilunar. The *inferior surface* is divided by two ridges into three facets, for articulation with the second, third, and fourth metacarpal bones, that for the third (the middle facet) being the largest of the three. The *posterior* or *dorsal surface* is broad and rough; the *anterior* or *palmar*, narrow, rounded, and also rough, for the attachment of ligaments and a part of the Adductor obliquus pollicis. The *external surface* articulates with the trapezoid by a small facet at its anterior inferior angle, behind which is a rough depression for the attachment of an interosseous ligament. Above this is a deep and rough groove, which forms part of the neck and serves for the attachment of ligaments, bounded superiorly by a smooth, convex surface, for articulation with the scaphoid. The *internal surface* articulates with the unciform by a smooth, concave, oblong facet which occupies its posterior and superior parts, and is rough in front, for the attachment of an interosseous ligament.

Hold the bone with the broader, non-articular surface toward you, and the head upward. The small, articular facet at the anterior inferior angle of the external surface will point to the side to which the bone belongs.

Articulations.—With seven bones: the scaphoid and semilunar above; the second, third, and fourth metacarpal below; the trapezoid on the radial side; and the unciform on the ulnar side.

Attachment of Muscles.—Part of the Adductor obliquus pollicis.

[1] Occasionally in a badly marked bone there is some difficulty in ascertaining to which side the bone belongs; the following method will sometimes be found useful: Hold the bone with its broader, non-articular surface upward, so that its sloping border is directed toward you. The border will slope to the side to which the bone belongs.

Unciform (Fig. 113).

The **Unciform** (*uncus*, a hook; *forma*, likeness) may be readily distinguished

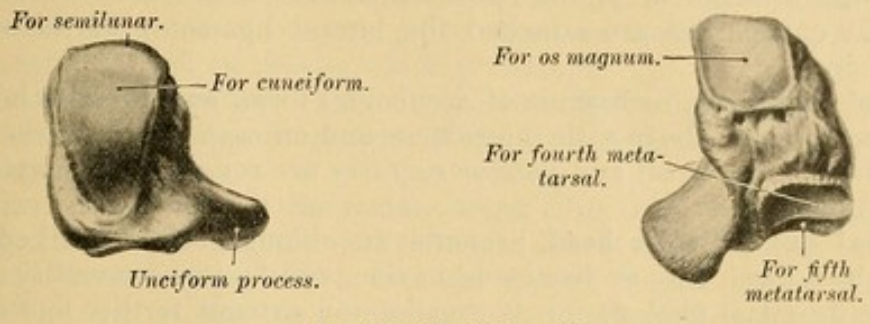

Fig. 113.—The left unciform.

by its wedge-shaped form and the hook-like process that projects from its palmar surface. It is situated at the inner and lower angle of the carpus, with its base downward, resting on the two inner metacarpal bones, and its apex directed upward and outward. The *superior surface*, the apex of the wedge, is narrow, convex, smooth, and articulates with the semilunar. The *inferior surface* articulates with the fourth and fifth metacarpal bones, the concave surface for each being separated by a ridge which runs from before backward. The *posterior* or *dorsal surface* is triangular and rough, for ligamentous attachment. The *anterior* or *palmar surface* presents, at its lower and inner side, a curved, hook-like process of bone, the *unciform process*, directed from the palmar surface forward and outward. It gives attachment by its apex to the annular ligament and Flexor carpi ulnaris; by its inner surface to the Flexor brevis minimi digiti and the Flexor ossis metacarpi minimi digiti; and is grooved on its outer side, for the passage of the Flexor tendons into the palm of the hand. This is one of the four eminences on the front of the carpus to which the anterior annular ligament is attached, the others being the pisiform internally, the oblique ridge of the trapezium and the tuberosity of the scaphoid externally. The *internal surface* articulates with the cuneiform by an oblong facet cut obliquely from above, downward and inward. The *external surface* articulates with the os magnum by its upper and posterior part, the remaining portion being rough, for the attachment of ligaments.

Hold the bone with the hooked process away from you, and the articular surface, divided into two parts, for the metacarpal bones, downward. The concavity of the process will be on the side to which the bone belongs.

Articulations.—With five bones: the semilunar above, the fourth and fifth metacarpal below, the cuneiform internally, the os magnum externally.

Attachment of Muscles.—To three: the Flexor brevis minimi digiti, the Flexor ossis metacarpi minimi digiti, the Flexor carpi ulnaris.

The Metacarpus.

The **Metacarpal Bones** are five in number: they are long, cylindrical bones, presenting for examination a shaft and two extremities.

Common Characters of the Metacarpal Bones.

The **Shaft** is prismoid in form and curved longitudinally, so as to be convex in the longitudinal direction behind, concave in front. It presents three surfaces: two lateral and one posterior. The *lateral surfaces* are concave, for the attachment of the Interossei muscles, and separated from one another by a prominent anterior ridge. The *posterior* or *dorsal surface* presents in its distal half a smooth, triangular, flattened area which is covered, in the recent state, by the tendons of the Extensor muscles. This triangular surface is bounded by two lines, which commence in small tubercles situated on the dorsal aspect on either side of the

digital extremity, and, running backward, converge to meet together a little behind the centre of the bone and form a ridge which runs along the rest of the dorsal surface to the carpal extremity. This ridge separates two lateral, sloping surfaces for the attachment of the Dorsal interossei muscles.[1] To the tubercles on the digital extremities are attached the lateral ligaments of the metacarpo-phalangeal joints.

The **carpal extremity,** or **base,** is of a cuboidal form, and broader behind than in front; it articulates above with the carpus, and on each side with the adjoining metacarpal bones; its *dorsal* and *palmar surfaces* are rough, for the attachment of tendons and ligaments.

The **digital extremity,** or **head,** presents an oblong surface, markedly convex from before backward, less so from side to side, and flattened laterally; it articulates with the proximal phalanx; it is broader and extends farther forward on the palmar than on the dorsal aspect. It is longer in the antero-posterior than in the transverse diameter. On either side of the head is a tubercle for the attachment of the lateral ligament of the metacarpo-phalangeal joint. The *posterior surface*, broad and flat, supports the Extensor tendons; the *anterior surface* is grooved in the middle line for the passage of the Flexor tendons, and marked on each side by an articular eminence continuous with the terminal articular surface.

Peculiar Characters of the Metacarpal Bones.

The **metacarpal bone of the thumb** (Fig. 114) is shorter and wider than the rest, diverges to a greater degree from the carpus, and its *palmar surface* is directed inward toward the palm. The *shaft* is flattened and broad on its dorsal aspect, and does not present the ridge which is found on the other metacarpal bones; it is concave from above downward, on its palmar surface. The *carpal extremity*, or *base*, presents a concavo-convex surface, for articulation with the trapezium; it has no lateral facets, but presents externally a tubercle for the insertion of the Extensor ossis metacarpi pollicis. The *digital extremity* is less convex than that of the other metacarpal bones, broader from side to side than from before backward. It presents on its palmar aspect two distinct articular eminences for the two sesamoid bones in the tendons of the Flexor brevis pollicis, the outer one being the larger of the two.

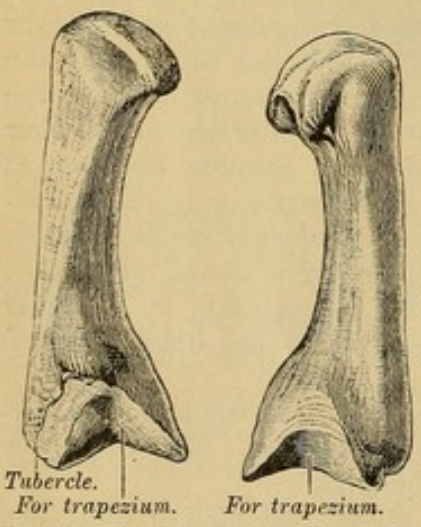

FIG. 114.—The first metacarpal. (Left.)

The side to which this bone belongs may be known by holding it in the position it occupies in the hand, with the carpal extremity upward and the dorsal surface backward; the tubercle for the Extensor ossis metacarpi pollicis will point to the side to which it belongs.

Attachment of Muscles.—To four: the Flexor ossis metacarpi pollicis, the Extensor ossis metacarpi pollicis, the Flexor brevis pollicis, and the First dorsal interosseous.

The **metacarpal bone of the index finger** (Fig. 115) is the longest and its base the largest of the other four. Its *carpal extremity* is prolonged upward and inward, forming a prominent ridge. The dorsal and palmar surfaces of this extremity are rough, for the attachment of tendons and ligaments. It presents four articular facets: three on the upper aspect of the base: the middle one of the three is the largest, concave from side to side, convex from before backward, for articulation with the trapezoid; the external one is a small, flat, oval facet, for articulation with the trapezium; the internal one on the summit of the ridge is

[1] By these sloping surfaces the metacarpal bones of the hand may be at once differentiated from the metatarsal bone of the foot.

long and narrow, for articulation with the os magnum. The fourth facet is on the inner or ulnar side of the extremity of the bone, and is for articulation with the third metacarpal bone.

The side to which this bone belongs is indicated by the absence of the lateral facet on the outer (radial) side of its base, so that if the bone is placed with its base toward the student and the palmar surface upward, the side on which there is no lateral facet will be that to which it belongs.

Attachment of Muscles.—To six: Flexor carpi radialis, Extensor carpi radialis longior, Adductor obliquus pollicis, First and Second dorsal interosseous, and First palmar interosseous.

The **metacarpal bone of the middle finger** (Fig. 116) is a little smaller than the preceding: it presents a pyramidal eminence (the styloid process) on the radial side of its base (dorsal aspect) which extends upward behind the os magnum; immediately below this, on the dorsal aspect, is a rough surface for the attachment of

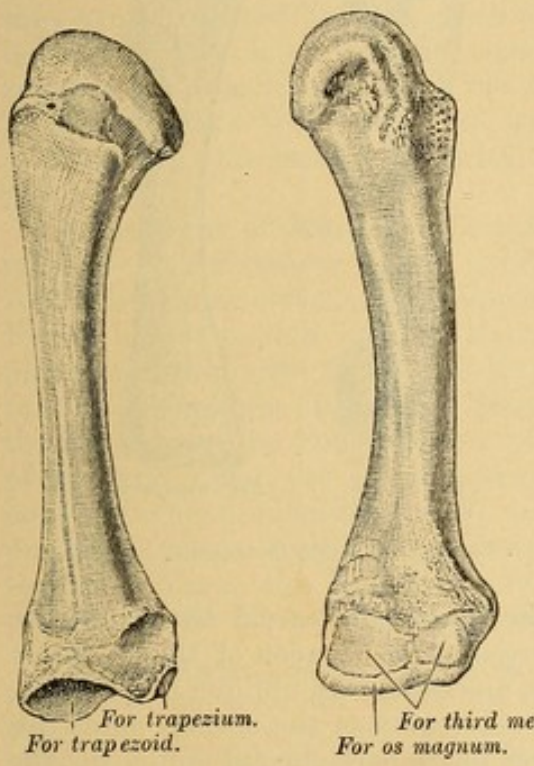

FIG. 115.—The second metacarpal. (Left.)

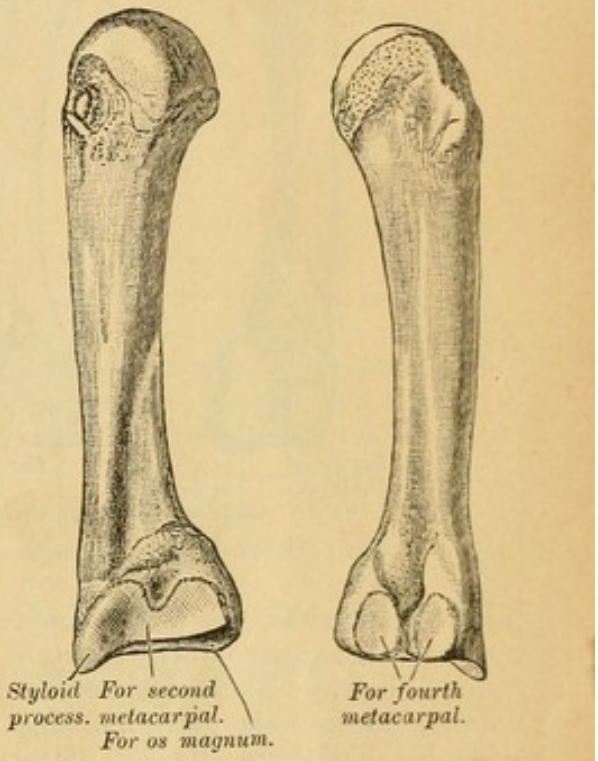

FIG. 116.—The third metacarpal. (Left.)

the Extensor carpi radialis brevior. The carpal, articular facet is concave behind, flat in front, and articulates with the os magnum. On the radial side is a smooth, concave facet, for articulation with the second metacarpal bone, and on the ulnar side two small, oval facets, for articulation with the fourth metacarpal.

The side to which this bone belongs is easily recognized by the styloid process on the radial side of its base. With the palmar surface uppermost and the base toward the student, this process points toward the side to which the bone belongs.

Attachment of Muscles.—To six: Extensor carpi radialis brevior, Flexor carpi radialis, Adductor transversus pollicis, Adductor obliquus pollicis, and Second and Third dorsal interosseous.

The **metacarpal bone of the ring finger** (Fig. 117) is shorter and smaller than the preceding, and its base small and quadrilateral; the carpal surface of the base presenting two facets, a large one externally, for articulation with the unciform, and a small one internally, for the os magnum. On the radial side are two oval facets, for articulation with the third metacarpal bone; and on the ulnar side a single concave facet, for the fifth metacarpal.

If this bone is placed with the base toward the student and the palmar surface

upward, the radial side of the base, which has two facets for articulation with the third metacarpal bone, will be on the side to which it belongs. If, as sometimes happens in badly marked bones, one of these facets is indistinguishable, the side may be known by selecting the surface on which the larger articular facet is present. This facet is for the fifth metacarpal bone, and would therefore be situated on the ulnar side—that is, the one to which the bone does *not* belong.

Attachment of Muscles.—To three: the Third and Fourth dorsal and Second palmar interosseous.

The **metacarpal bone of the little finger** (Fig. 118) presents on its base one facet, which is concavo-convex, and which articulates with the unciform bone, and one

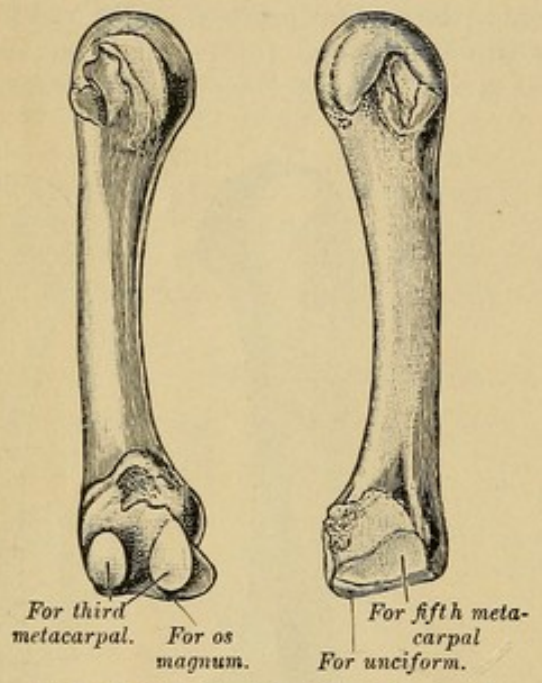

FIG. 117.—The fourth metacarpal. (Left.)

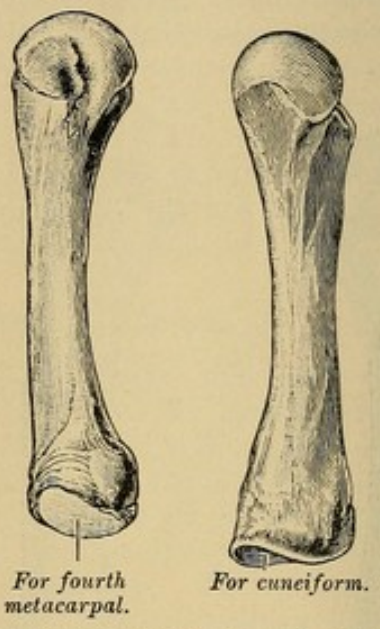

FIG. 118.—The fifth metacarpal. (Left.)

lateral, articular facet, which articulates with the fourth metacarpal bone. On its ulnar side is a prominent tubercle, for the insertion of the tendon of the Extensor carpi ulnaris. The dorsal surface of the shaft is marked by an oblique ridge which extends from near the ulnar side of the upper extremity to the radial side of the lower. The outer division of this surface serves for the attachment of the Fourth dorsal interosseous muscle; the inner division is smooth and covered by the Extensor tendons of the little finger.

If this bone is placed with its base toward the student and its palmar surface upward, the side of the head which has a lateral facet will be that to which the bone belongs.

Attachment of Muscles.—To five: the Extensor carpi ulnaris, Flexor carpi ulnaris, Flexor ossis metacarpi minimi digiti, Fourth dorsal, and Third palmar interosseous.

Articulations.—Besides the phalangeal articulations, the first metacarpal bone articulates with the trapezium; the second with the trapezium, trapezoid, os magnum, and third metacarpal bones; the third with the os magnum and second and fourth metacarpal bones; the fourth with the os magnum, unciform, and third and fifth metacarpal bones; and the fifth with the unciform and fourth metacarpal.

The *first* has no lateral facets on its carpal extremity; the *second* has no lateral facet on its radial side, but one on its ulnar side; the third has one on its radial and two on its ulnar side; the fourth has two on its radial and one on its ulnar side; and the fifth has only one on its radial side.

The Phalanges.

The **Phalanges** (*internodia*) are the bones of the fingers; they are fourteen in number, three for each finger, and two for the thumb. They are long bones, and present for examination a shaft and two extremities. The *shaft* tapers from above downward, is convex posteriorly, concave in front from above downward, flat from side to side, and marked laterally by rough ridges, which give attachment to the fibrous sheaths of the Flexor tendons. The *metacarpal extremity*, or *base*, in the first row presents an oval, concave, articular surface, broader from side to side than from before backward; and the same extremity in the other two rows, a double concavity, separated by a longitudinal median ridge, extending from before backward. The *digital extremities* are smaller than the bases, and terminate, in the first and second rows, in two small, lateral condyles, separated by a slight groove; the articular surface being prolonged farther forward on the palmar than on the dorsal surface, especially in the first row.

The **Ungual Phalanges** are convex on their dorsal, flat on their palmar, surfaces; they are recognized by their small size and by a roughened, elevated surface of a horseshoe form on the palmar aspect of their ungual extremity, which serves to support the sensitive pulp of the finger.

Articulations.—The first row, with the metacarpal bones and the second row of phalanges; the second row, with the first and third; the third, with the second row.

Attachment of Muscles.—To the base of the first phalanx of the thumb, five muscles: the Extensor brevis pollicis, Flexor brevis pollicis, Abductor pollicis, Adductor transversus and obliquus pollicis. To the second phalanx, two: the Flexor longus pollicis and the Extensor longus pollicis. To the base of the first phalanx of the index finger, the First dorsal and the First palmar interosseous; to that of the middle finger, the Second and Third dorsal interosseous; to that of the ring finger, the Fourth dorsal and the Second palmar interosseous; and to that of the little finger, the Third palmar interosseous, the Flexor brevis minimi digiti, and Abductor minimi digiti. To the second phalanges, the Flexor sublimis digitorum, Extensor communis digitorum, and, in addition, the Extensor indicis to the index finger, the Extensor minimi digiti to the little finger. To the third phalanges, the Flexor profundus digitorum and Extensor communis digitorum.

Surface Form.—On the front of the wrist are two subcutaneous eminences, one on the radial side, the larger and flatter, due to the tuberosity of the scaphoid and the ridge on the trapezium; the other, on the ulnar side, caused by the pisiform bone. The tubercle of the scaphoid is to be felt just below and in front of the apex of the styloid process of the radius. It is best perceived by extending the hand on the forearm. Immediately below is to be felt another prominence, better marked than the tubercle; this is the ridge on the trapezium which gives attachment to some of the short muscles of the thumb. On the inner side of the front of the wrist the pisiform bone is to be felt, forming a small but prominent projection in this situation. It is some distance below the styloid process of the ulna, and may be said to be just below the level of the styloid process of the radius. The rest of the front of the carpus is covered by tendons and the annular ligament, and entirely concealed, with the exception of the hooked process of the unciform, which can only be made out with difficulty. The back of the carpus is convex and covered by the Extensor tendons, so that none of the posterior surfaces of the bones are to be felt, with the exception of the cuneiform on the inner side. Below the carpus the dorsal surfaces of the metacarpal bones, except the fifth, are covered by tendons, and are scarcely visible except in very thin hands. The dorsal surface of the fifth is, however, subcutaneous throughout almost its whole length, and is plainly to be perceived and felt. In addition to this, slightly external to the middle line of the hand, is a prominence, frequently well marked, but occasionally indistinct, formed by the base of the metacarpal of the middle finger. The heads of the metacarpal bones are plainly to be felt and seen, rounded in contour and standing out in bold relief under the skin, when the fist is clenched. It should be borne in mind that when the fingers are flexed on the hand, the articular surfaces of the first phalanges glide off the heads of the metacarpal bones on to their anterior surfaces, so that the heads of these bones form the prominence of the knuckles and receive the force of any blow which may be given. The head of the third metacarpal bone is the most prominent, and receives the greater part of the shock of the blow. This bone articulates with the os magnum, so that the concussion is carried through this bone to the scaphoid and semilunar, with which the head of the os magnum articulates, and by these bones is transferred to the radius, along which it may be carried to the capitellum of the humerus. The enlarged extremities of the phalanges are to be plainly felt: they form the

joints of the fingers. When the digits are bent the proximal phalanges of the joints form prominences, which in the joint between the first and second phalanges is slightly hollowed, in accordance with the grooved shape of their articular surfaces, whilst at the last row the prominence is flattened and square-shaped. In the palm of the hand the four inner metacarpal bones are covered by muscles, tendons, and the palmar fascia, and no part of them but their heads is to be distinguished. With regard to the thumb, on the dorsal aspect the base of the metacarpal bone forms a prominence below the styloid process of the radius; the shaft is to be felt, covered by tendons, terminating at its head in a flattened prominence, in front of which can be felt the sesamoid bones.

Surgical Anatomy.—The carpal bones are little liable to fracture, except from extreme violence, when the parts are so comminuted as to necessitate amputation. Occasionally they are the seat of tubercular disease. The metacarpal bone and the phalanges are not unfrequently broken from direct violence. The first metacarpal bone is the one most commonly fractured; then the second, the fourth, and the fifth, the third being the one least frequently broken. There are two diseases of the metacarpal bones and phalanges which require special mention on account of the frequency of their occurrence. One is tubercular dactylitis, consisting in a deposit of tubercular material in the medullary canal, expanding the bone, with subsequent caseation and resulting necrosis. The other is chondroma, which is perhaps more frequently found in connection with the metacarpal bones and phalanges than with any other bones. They are commonly multiple, and may spring either from the medullary canal or from the periosteum.

Development of the Bones of the Hand.

The **Carpal Bones** are each developed by a *single* centre. At birth they are all cartilaginous. Ossification proceeds in the following order (Fig. 119): In the

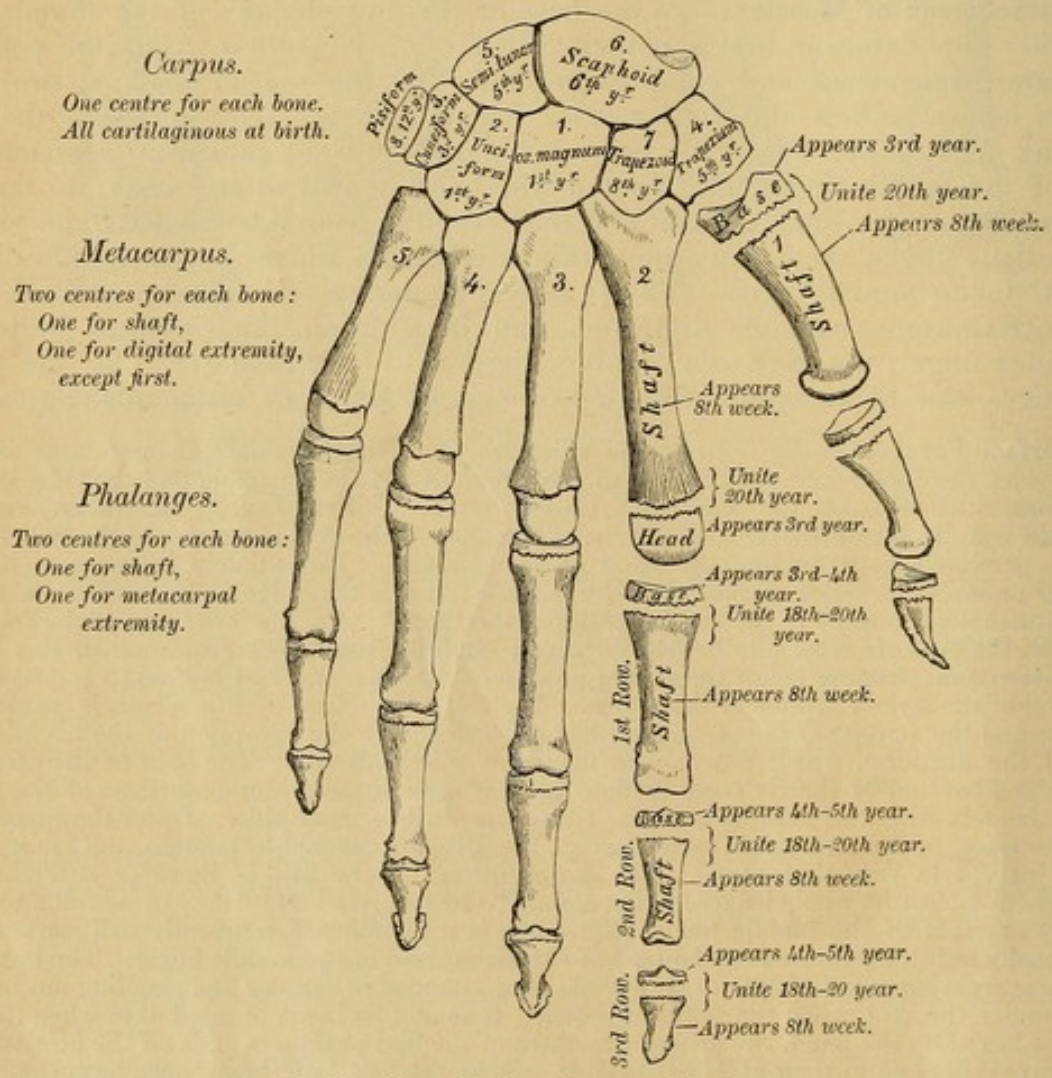

FIG. 119.—Plan of the development of the hand.

os magnum and unciform an ossific point appears during the first year, the former preceding the latter; in the cuneiform, at the third year; in the trapezium and semilunar, at the fifth year, the former preceding the latter; in the scaphoid, at

the sixth year; in the trapezoid, during the eighth year; and in the pisiform, about the twelfth year.

Occasionally an additional bone, the *os centrale*, is found in the carpus, lying between the scaphoid, trapezoid, and os magnum. During the second month of fœtal life it is represented by a small cartilaginous nodule, which, however, fuses with the cartilaginous scaphoid about the third month. Sometimes the styloid process of the third metacarpal is detached and forms an additional ossicle.

The **Metacarpal Bones** are each developed by *two* centres: one for the shaft and one for the digital extremity for the four inner metacarpal bones; one for the shaft and one for the base for the metacarpal bone of the thumb, which in this respect resembles the phalanges.[1] Ossification commences in the centre of the shaft about the eighth or ninth week, and gradually proceeds to either end of the bone: about the third year the digital extremities of the four inner metacarpal bones and the base of the first metacarpal begin to ossify, and they unite about the twentieth year.

The **Phalanges** are each developed by *two* centres: one for the shaft and one for the base. Ossification commences in the shaft, in all three rows, at about the eighth week, and gradually involves the whole of the bone excepting the upper extremity. Ossification of the base commences in the first row between the third and fourth years, and a year later in those of the second and third rows. The two centres become united, in each row, between the eighteenth and twentieth years.

In the ungual phalanges the centre for the shaft appears at the distal extremity of the phalanx, instead of at the middle of the shaft, as is the case with the other phalanges.

THE LOWER EXTREMITY.

The bones of the lower extremity consist of those of the pelvic girdle, of the thigh, of the leg, and of the foot.

The Pelvic Girdle.

The **Pelvic Girdle** consists of a single bone, the *os innominatum*, by which the thigh is connected to the trunk.

The Os Innominatum.

The **Os Innominatum** (*in*, not; *nomino*, I name), or *nameless bone*, so called from bearing no resemblance to any known object, is a large, irregularly shaped, flat bone, constricted in the centre and expanded above and below. With its fellow of the opposite side it forms the sides and anterior wall of the pelvic cavity. In young subjects it consists of three separate parts, which meet and form the large, cup-like cavity, the *acetabulum*, situated near the middle of the outer surface of the bone; and, although in the adult these have become united, it is usual to describe the bone as divisible into three portions—the ilium, the ischium, and the os pubis.

The **ilium**, so called from its supporting the flank (*ilia*), is the superior, broad, and expanded portion which runs upward from the acetabulum and forms the prominence of the hip.

The **ischium** (*ἰσχίον*, the hip) is the inferior and strongest portion of the bone; it proceeds downward from the acetabulum, expands into a large tuberosity, and then, curving forward, forms, with the descending ramus of the os pubis, a large aperture, the obturator foramen.

The **os pubis** is that portion which extends inward and downward from the acetabulum to articulate in the middle line with the bone of the opposite side: it

[1] Allan Thomson has demonstrated the fact that the first metacarpal bone is often developed from three centres; that is to say, there is a separate nucleus for the distal end, forming a distinct epiphysis, visible at the age of seven or eight years. He also states that there are traces of a proximal epiphysis in the second metacarpal bone.—*Journal of Anatomy*, 1869.

forms the front of the pelvis, supports the external organs of generation, and has received its name from the skin over it being covered with hair.

The **Ilium** presents for examination two surfaces, an external and an internal; a crest, and two borders, an anterior and a posterior.

External Surface or Dorsum of the Ilium (Fig. 120).—The posterior part of this surface is directed backward and outward; its front part. downward and outward.

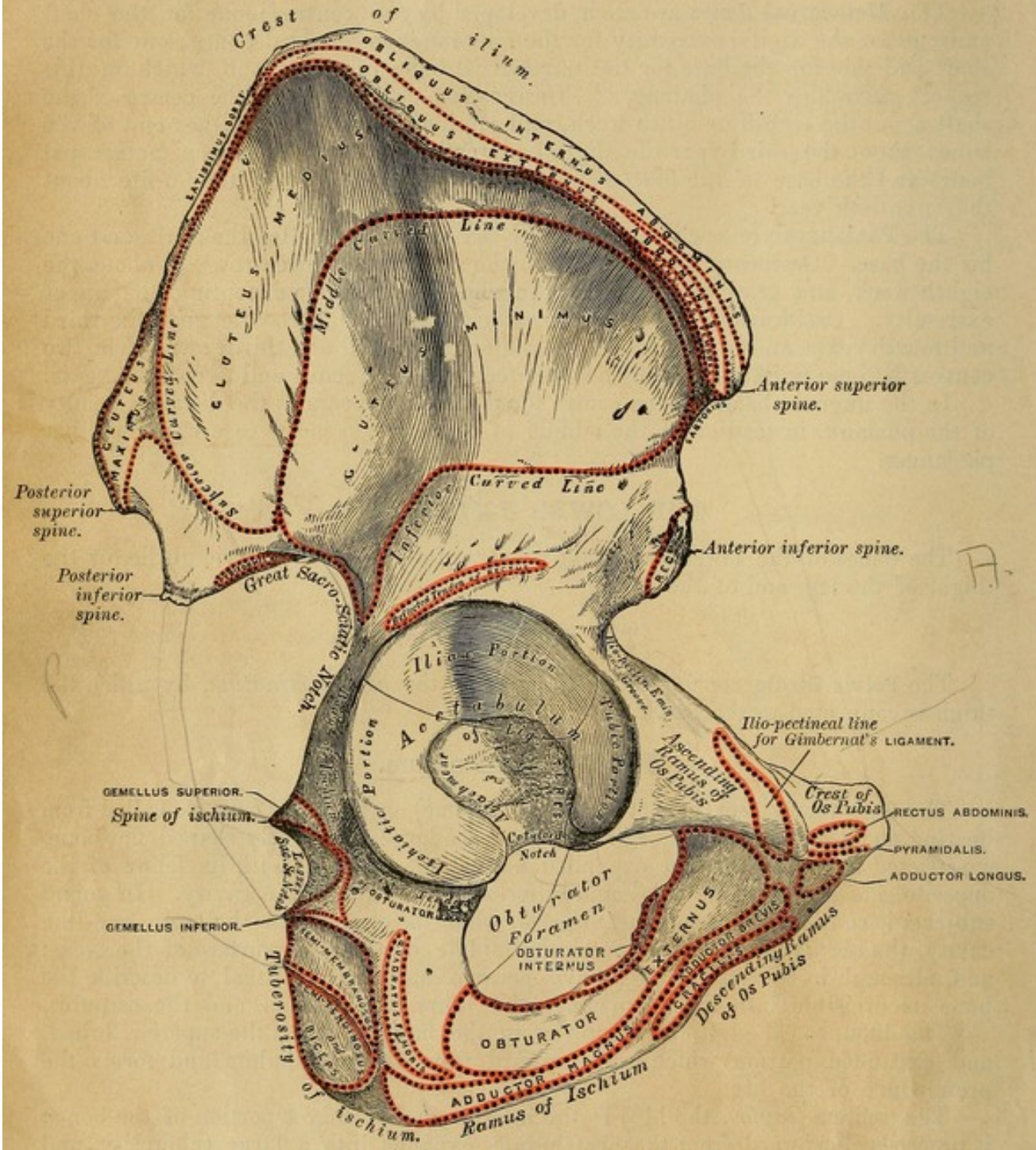

FIG. 120.—Right os innominatum. External surface.

It is smooth, convex in front, deeply concave behind; bounded above by the crest, below by the upper border of the acetabulum; in front and behind by the anterior and posterior borders. This surface is crossed in an arched direction by three semicircular lines—the superior, middle, and inferior curved lines. The *superior curved line*, the shortest of the three, commences at the crest, about two inches in front of its posterior extremity; it is at first distinctly marked, but as it passes downward and backward to the upper part of the great sacro-sciatic notch, where

it terminates, it becomes less marked, and is often altogether lost. Behind this line is a narrow semilunar surface, the upper part of which is rough and affords attachment to part of the Gluteus maximus; the lower part is smooth and has no muscular fibres attached to it. The *middle curved line*, the longest of the three, commences at the crest, about an inch behind its anterior extremity, and, taking a curved direction downward and backward, terminates at the upper part of the great sacro-sciatic notch. The space between the superior and middle curved lines and

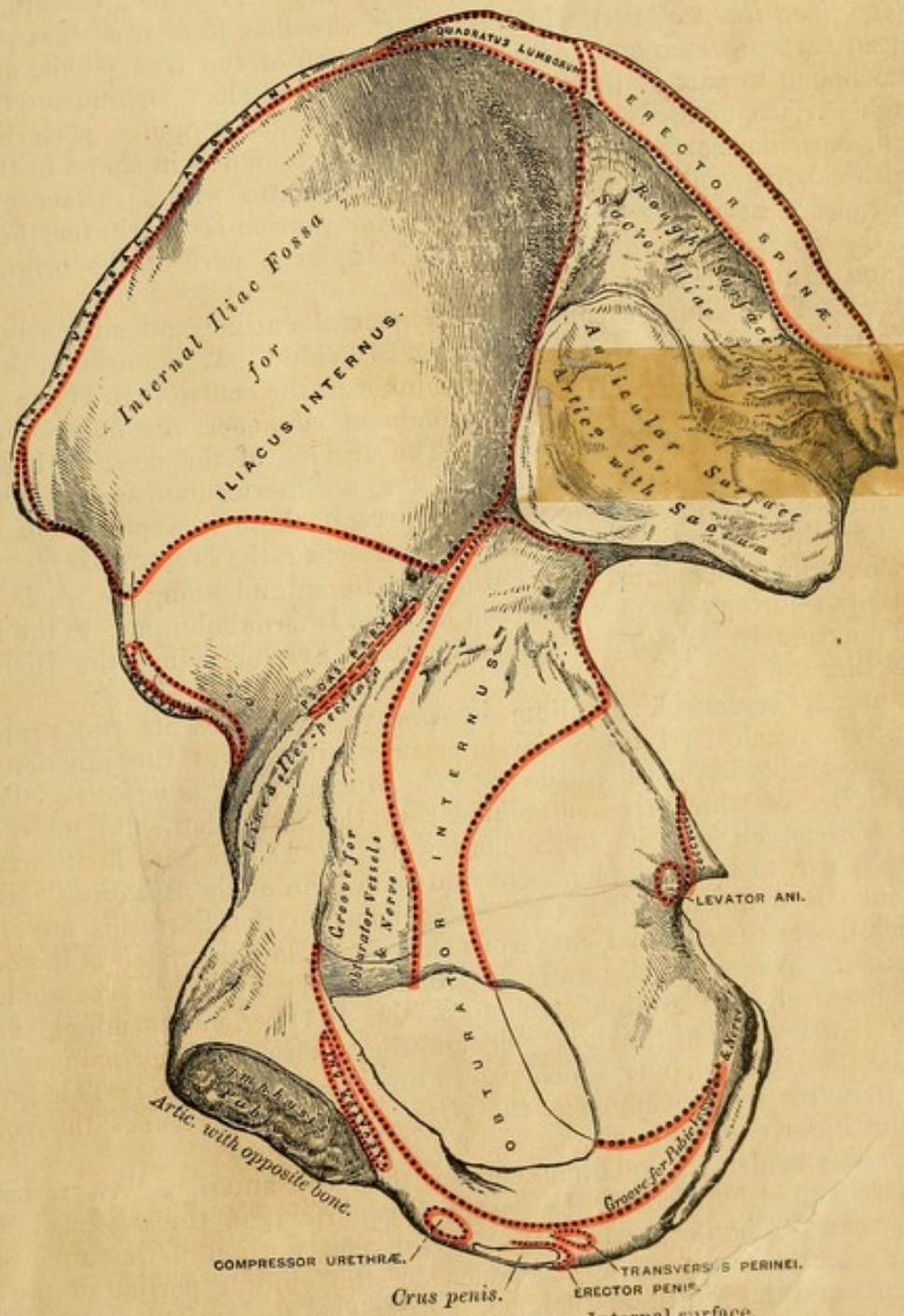

FIG. 121.—Right os innominatum. Internal surface.

the crest is concave, and affords attachment to the [illegible]uteus medius muscle. Near the central part of this line may often be observe[illegible] [illegible]rifice of a nutrient foramen. The *inferior curved line*, the least distinct of [illegible]ower rough, somewh[illegible] in front at the notch on the anterior border, and, taking [illegible]n. The anterior portion is su[illegible]divided ward, terminates at the middle of the [illegible]om base to apex, into two parts: the bone included between the middle a[illegible]tor magnus; the inner to the great sacro- downward, convex from before b[illegible]is subdivided into two facets by an oblique minimus muscle. Beneath the [illegible]utward: from the u[illegible]per and outer facet arises [illegible]ferior

part of the acetabulum, is a roughened surface (sometimes a depression), to which is attached the reflected tendon of the Rectus femoris muscle.

The **Internal Surface** (Fig. 121) of the ilium is bounded above by the crest; below it is continuous with the pelvic surface of the os pubis and ischium, a faint line only indicating the place of union; and before and behind it is bounded by the anterior and posterior borders. It presents a large, smooth, concave surface, called the *iliac fossa*, or *venter ilii*, which lodges the Iliacus muscle, and presents at its lower part the orifice of a nutrient canal; and below this a smooth, rounded border (the *linea ilio-pectinea*), which separates the iliac fossa from that portion of the internal surface which enters into the formation of the true pelvis, and which gives attachment to part of the Obturator internus muscle. Behind the iliac fossa is a rough surface divided into two portions, an anterior and a posterior. The anterior or auricular surface, so called from its resemblance in shape to the ear, is coated with cartilage in the recent state, and articulates with a surface of similar shape on the side of the sacrum. The posterior portion is rough, for the attachment of the posterior sacro-iliac ligaments and for a part of the origin of the Erector and Multifidus spinæ.

The **crest** of the ilium is convex in its general outline and sinuously curved, being concave inward in front, concave outward behind. It is longer in the female than in the male, very thick behind, and thinner at the centre than at the extremities. It terminates at either end in a prominent eminence, the *anterior superior* and *posterior superior spinous process*. The surface of the crest is broad, and divided into an external lip, an internal lip, and an intermediate space. About two inches behind the anterior superior spinous process there is a prominent tubercle on the outer lip. To the external lip is attached the Tensor fasciæ femoris, Obliquus externus abdominis, and Latissimus dorsi, and along its whole length, the fascia lata; to the space between the lips, the Internal oblique; to the internal lip, the Transversalis, Quadratus lumborum, and Erector spinæ, the Iliacus, and the fascia iliaca.

The **anterior border** of the ilium is concave. It presents two projections, separated by a notch. Of these, the uppermost, situated at the junction of the crest and anterior border, is called the *anterior superior spinous process* of the ilium, the outer border of which gives attachment to the fascia lata and the origin of the Tensor fasciæ femoris; its inner border, to the Iliacus; while its extremity affords attachment to Poupart's ligament and the origin of the Sartorius. Beneath this eminence is a notch which gives attachment to the Sartorius muscle, and across which passes the external cutaneous nerve. Below the notch is the *anterior inferior spinous process*, which terminates in the upper lip of the acetabulum; it gives attachment to the straight tendon of the Rectus femoris muscle and the ilio-femoral ligament. On the inner side of the anterior inferior spinous process is a broad, shallow groove, over which passes the Ilio-psoas muscle. This groove is bounded internally by an eminence, the *ilio-pectineal*, which marks the point of union of the ilium and os pubis.

The **posterior border** of the ilium, shorter than the anterior, also presents two projections separated by a notch, the *posterior superior* and the *posterior inferior spinous processes*. The former corresponds with that portion of the inner surface of the ilium which serves for the attachment of the oblique portion of the sacro-iliac ligaments and the Multifidus spinæ; the latter, to the auricular portion which articulates with the sacrum. Below the posterior inferior spinous process is a deep notch, the *great sacro-sciatic*.

The **Ischium** forms the lower and back part of the os innominatum. It is divisible into three portions—the *body*; a large, rough eminence, on the upper border of the acetabulum, the *tuberosity*; and a thin part which passes in front, between the anterior and posterior borders. This surface is crossed by three semicircular lines—the superior, middle, and inferior. The *inferior curved line*, the shortest of the three, commences in front of its posterior extremity; it is at first directed downward and backward to the upper part of the acetabulum formed by the

The **Ischium** presents three surfaces, external, internal, and posterior. The

ischium; it is smooth and concave, and forms a little more than two-fifths of the acetabular cavity; its outer margin is bounded by a prominent rim or lip, the external border, to which the cotyloid fibro-cartilage is attached. Below the acetabulum, between it and the tuberosity, is a deep groove, along which the tendon of the Obturator externus muscle runs as it passes outward to be inserted into the digital fossa of the femur. The *internal surface* is smooth, concave, and enters into the formation of the lateral boundary of the true pelvic cavity. This surface is perforated by two or three large, vascular foramina, and affords attachment to part of the Obturator internus muscle. The *posterior surface* is quadrilateral in form, broad and smooth. Below, where it joins the tuberosity, it presents a groove continuous with that on the external surface, for the tendon of the Obturator externus muscle. The lower edge of this groove is formed by the tuberosity of the ischium, and affords attachment to the Gemellus inferior muscle. This surface is limited, externally, by the margin of the acetabulum; behind, by the posterior border; it supports the Pyriformis, the two Gemelli, and the Obturator internus muscles in their passage outward to the great trochanter. The *external border* forms the prominent rim of the acetabulum, and separates the posterior from the external surface. To it is attached the cotyloid fibro-cartilage. The *internal border* is thin, and forms the outer circumference of the obturator foramen. The *posterior border* of the body of the ischium presents, a little below the centre, a thin and pointed, triangular eminence, the *spine of the ischium*, more or less elongated in different subjects; its external surface gives attachment to the Gemellus superior, its internal surface to the Coccygeus and Levator ani; whilst to the pointed extremity is connected the lesser sacro-sciatic ligament. Above the spine is a notch of a large size, the *great sacro-sciatic*, converted into a foramen by the lesser sacro-sciatic ligament; it transmits the Pyriformis muscle, the gluteal vessels, and superior and inferior gluteal nerves; the sciatic vessels, the greater and lesser sciatic nerves, the internal pudic vessels and nerve, and the nerves to the Obturator internus and Quadratus femoris. Of these, the gluteal vessels and superior gluteal nerve pass out above the Pyriformis muscle, the other structures, below it. Below the spine is a smaller notch, the *lesser sacro-sciatic;* it is smooth, coated in the recent state with cartilage, the surface of which presents two or three ridges corresponding to the subdivisions of the tendon of the Obturator internus, which winds over it. It is converted into a foramen by the sacro-sciatic ligaments, and transmits the tendon of the Obturator internus, the nerve which supplies that muscle, and the internal pudic vessels and nerve.

The **tuberosity** presents for examination three surfaces: external, internal, and posterior. The *external surface* is quadrilateral in shape, and rough for the attachment of muscles. It is bounded above by the groove for the tendon of the Obturator externus; in front it is limited by the posterior margin of the obturator foramen, and below it is continuous with the ramus of the bone; behind, it is bounded by a prominent margin which separates it from the posterior surface. In front of this margin the surface gives attachment to the Quadratus femoris, and anterior to this to some of the fibres of origin of the Obturator externus. The lower part of the surface gives origin to part of the Adductor magnus. The *internal surface* forms part of the bony wall of the true pelvis. In front it is limited by the posterior margin of the obturator foramen. Behind, it is bounded by a sharp ridge, for the attachment of a falciform prolongation of the great sacro-sciatic ligament; it sometimes presents a groove on the inner side of this ridge for the lodgement of the internal pudic vessels and nerve; and, more anteriorly, has attached the Transversus perinæi and Erector penis muscles. The *posterior surface* is divided into two portions—a lower rough, somewhat triangular part, and an upper smooth, quadrilateral portion. The anterior portion is subdivided by a prominent vertical ridge, passing from base to apex, into two parts: the outer one gives attachment to the Adductor magnus; the inner to the great sacro-sciatic ligament. The upper portion is subdivided into two facets by an oblique ridge which runs downward and outward: from the upper and outer facet arises

.terior

the Semimembranosus; from the lower and inner, the Biceps and Semitendinosus.

The **ramus** is the thin, flattened part of the ischium which ascends from the tuberosity upward and inward, and joins the descending ramus of the os pubis, their point of junction being indicated in the adult by a rough line. The outer surface of the ramus is rough, for the attachment of the Obturator externus muscle, and also some fibres of the Adductor magnus; its inner surface forms part of the anterior wall of the pelvis. Its inner border is thick, rough, slightly everted, forms part of the outlet of the pelvis, and presents two ridges and an intervening space. The ridges are continuous with similar ones on the descending ramus of the os pubis: to the outer one is attached the deep layer of the superficial perineal fascia, and to the inner, the superficial layer of the triangular ligament of the urethra. If these two ridges are traced downward, they will be found to join with each other just behind the point of origin of the Transversus perinæi muscle; here the two layers of fascia are continuous behind the posterior border of the muscle. To the intervening space, just in front of the point of junction of the ridges, is attached the Transversus perinæi muscle, and in front of this a portion of the crus penis vel clitoridis and the Erector penis vel clitoridis muscle. Its outer border is thin and sharp, and forms part of the inner margin of the obturator foramen.

The **Os Pubis** forms the anterior part of the os innominatum, and, with the bone of the opposite side, forms the front boundary of the true pelvic cavity. It is divisible into a body, an ascending and a descending ramus.

The **body** is somewhat quadrilateral in shape, and presents for examination two surfaces and three borders. The *anterior surface* is rough, directed downward and outward, and serves for the attachment of various muscles. To the upper and inner angle, immediately below the crest, is attached the Adductor longus; lower down, from without inward, are attached the Obturator externus, the Adductor brevis, and the upper part of the Gracilis. The *posterior surface*, convex from above downward, concave from side to side, is smooth, and forms part of the anterior wall of the pelvis. It gives attachment to the Levator ani, Obturator internus, a few muscular fibres prolonged from the bladder, and the pubo-prostatic ligaments. The *upper border* presents for examination a prominent tubercle, which projects forward and is called the *spine;* to it are attached the outer pillar of the external abdominal ring and Poupart's ligament. Passing upward and outward from this is a prominent ridge, forming part of the *ilio-pectineal line*, which marks the brim of the true pelvis: to it are attached a portion of the conjoined tendon of the Internal oblique and Transversalis muscles, Gimbernat's ligament, and the triangular fascia of the abdomen. Internal to the spine of the os pubis is the *crest*, which extends from this process to the inner extremity of the bone. It affords attachment, anteriorly, to the conjoined tendon of the Internal oblique and Transversalis; and posteriorly, to the Rectus and Pyramidalis muscles. The point of junction of the crest with the inner border of the bone is called the *angle;* to it, as well as to the symphysis, is attached the internal pillar of the external abdominal ring. The *internal border* is articular; it is oval, covered by eight or nine transverse ridges, or a series of nipple-like processes arranged in rows, separated by grooves; they serve for the attachment of a thin layer of cartilage, placed between it and the central fibro-cartilage. The *outer border* presents a sharp margin, which forms part of the circumference of the obturator foramen and affords attachment to the obturator membrane.

The **ascending** or **superior ramus** extends from the body to the point of junction of the os pubis with the ilium, and forms the upper part of the circumference of the obturator foramen. It presents for examination a superior, inferior, and posterior surface, and an outer extremity. The *superior surface* presents a continuation of the ilio-pectineal line, already mentioned as commencing at the pubic spine. In front of this ridge the surface of bone is triangular in form, wider externally than internally, and is covered by the Pectineus muscle.

part

The surface is bounded externally by a rough eminence, the *ilio-pectineal*, which serves to indicate the point of junction of the ilium and os pubis, and gives attachment to the Psoas parvus, when this muscle is present. The triangular surface is bounded below by a prominent ridge, the *obturator crest*, which extends from the cotyloid notch to the spine of the os pubis. The *inferior surface* forms the upper boundary of the obturator foramen, and presents externally a broad and deep oblique groove, for the passage of the obturator vessels and nerve; and internally a sharp margin which forms part of the circumference of the obturator foramen, and to which the obturator membrane is attached. The *posterior surface* forms part of the anterior boundary of the true pelvis. It is smooth, convex from above downward, and affords attachment to some fibres of the Obturator internus. The *outer extremity*, the thickest part of the ramus, forms one-fifth of the cavity of the acetabulum.

The **descending** or **inferior ramus** of the os pubis is thin and flattened. It passes outward and downward, becoming narrower as it descends, and joins with the ramus of the ischium. Its *anterior surface* is rough, for the attachment of muscles—the Gracilis along its inner border; a portion of the Obturator externus where it enters into the formation of the foramen of that name; and between these two muscles the Adductores brevis and magnus from within outward. The *posterior surface* is smooth, and gives attachment to the Obturator internus, and, close to the inner margin, to the Compressor urethræ. The *inner border* is thick, rough, and everted, especially in females. It presents two ridges, separated by an intervening space. The ridges extend downward, and are continuous with similar ridges on the ascending ramus of the ischium; to the external one is attached the deep layer of the superficial perineal fascia, and to the internal one the superficial layer of the triangular ligament of the urethra. The *outer border* is thin and sharp, forms part of the circumference of the obturator foramen, and gives attachment to the obturator membrane.

The **cotyloid cavity**, or **acetabulum**, is a deep, cup-shaped, hemispherical depression, directed downward, outward, and forward; formed internally by the os pubis, above by the ilium, behind and below by the ischium, a little less than two-fifths being formed by the ilium, a little more than two-fifths by the ischium, and the remaining fifth by the pubic bone. It is bounded by a prominent, uneven rim, which is thick and strong above, and serves for the attachment of the *cotyloid ligament*, which contracts its orifice and deepens the surface for articulation. It presents below a deep notch, the *cotyloid notch*, which is continuous with a circular depression, the *fossa acetabuli*, at the bottom of the cavity: this depression is perforated by numerous apertures, lodges a mass of fat, and its margins, as well as those of the notch, serve for the attachment of the ligamentum teres. The notch is converted, in the natural state, into a foramen by a dense ligamentous band which passes across it. Through this foramen the nutrient vessels and nerves enter the joint.

The **obturator** or **thyroid foramen** is a large aperture situated between the ischium and os pubis. In the male it is large, of an oval form, its longest diameter being obliquely from before backward; in the female it is smaller and more triangular. It is bounded by a thin, uneven margin, to which a strong membrane is attached, and presents, anteriorly, a deep groove which runs from the pelvis obliquely inward and downward. This groove is converted into a foramen by the obturator membrane, and transmits the obturator vessels and nerve.

Structure.—This bone consists of much cancellous tissue, especially where it is thick, enclosed between two layers of dense, compact tissue. In the thinner parts of the bone, as at the bottom of the acetabulum and centre of the iliac fossa, it is usually semitransparent, and composed entirely of compact tissue.

Development (Fig. 122).—By *eight* centres: three primary—one for the ilium, one for the ischium, and one for the os pubis; and *five* secondary—one for the crest of the ilium, one for the anterior inferior spinous process (said to occur more

frequently in the male than the female), one for the tuberosity of the ischium, one for the symphysis pubis (more frequent in the female than the male), and one or more for the Y-shaped piece at the bottom of the acetabulum. These various centres appear in the following order: First, in the ilium, at the lower part of the bone, immediately above the sciatic notch, at about the eighth or ninth week; secondly, in the body of the ischium, at about the third month of fœtal life; thirdly, in the body of the os pubis, between the fourth and fifth months. At birth the three primary centres are quite separate, the crest, the bottom of the acetabulum, the ischial tuberosity, and the rami of the ischium and pubes being still cartilaginous. At about the seventh or eighth year the rami of the os pubis and ischium are almost completely united by bone. About the thirteenth or fourteenth year the three divisions of the bone have extended their growth into the bottom of the acetabulum, being separated from each other by a Y-shaped portion of cartilage, which now presents traces of ossification, often by two or more centres. One of these, the *os acetabuli*, appears about the age of twelve, between the ilium and os pubis, and fuses with them about the age of eighteen. It forms the pubic part of the acetabulum. The ilium and ischium then become joined, and lastly the os pubis to the ischium, through the intervention of this Y-shaped portion. At about the age of puberty ossification takes place in each of the remaining portions, and they become joined to the rest of the bone between the twentieth and twenty-fifth years. Separate centres are frequently found for the pubic and ischial spines.

Articulations.—With its fellow of the opposite side, the sacrum, and femur.

By eight centres { *Three primary (Ilium, Ischium, and Os Pubis).*
Five Secondary.

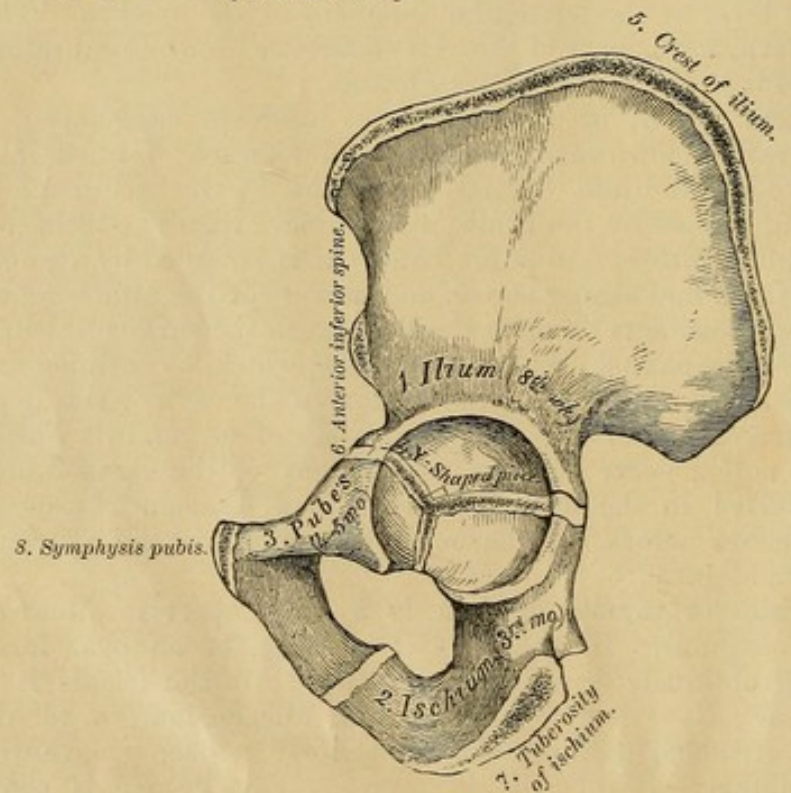

The three primary centres unite through Y-shaped piece about puberty.
Epiphyses appear about puberty, and unite about 25th year.

FIG. 122.—Plan of the development of the os innom. natum.

Attachment of Muscles.—To the *ilium*, sixteen. To the outer lip of the crest, the Tensor vaginæ femoris, Obliquus externus abdominis, and Latissimus dorsi; to the internal lip, the Iliacus, Transversalis, Quadratus lumborum, and Erector spinæ; to the interspace between the lips, the Obliquus internus. To the outer surface of the ilium, the Gluteus maximus, Gluteus medius, Gluteus minimus, reflected tendon of the Rectus; to the upper part of the great sacro-sciatic notch, a portion of the Pyriformis; to the internal surface, the Iliacus; to that portion of

the internal surface below the linea ilio-pectinea, the Obturator internus to the internal surface of the posterior superior spine, and the Multifidus spinæ; to the anterior border, the Sartorius and straight tendon of the Rectus. To the *ischium*, thirteen. To the outer surface of the ramus, the Obturator externus and Adductor magnus; to the internal surface, the Obturator internus and Erector penis. To the spine, the Gemellus superior, Levator ani, and Coccygeus. To the tuberosity, the Biceps, Semitendinosus, Semimembranosus, Quadratus femoris, Adductor magnus, Gemellus inferior, Transversus perinæi, Erector penis. To the *os pubis*, sixteen: Obliquus externus, Obliquus internus, Transversalis, Rectus, Pyramidalis, Psoas parvus, Pectineus, Adductor magnus, Adductor longus, Adductor brevis, Gracilis, Obturator externus and internus, Levator ani, Compressor urethræ, and occasionally a few fibres of the Accelerator urinæ.

The Pelvis (Figs. 123, 124).

The **Pelvis,** so called from its resemblance to a basin (L. *pelvis*), is stronger and more massively constructed than either the cranial or thoracic cavity; it is a bony ring, interposed between the lower end of the spine, which it supports, and the lower extremities, upon which it rests. It is composed of four bones: the two ossa innominata, which bound it on either side and in front, and the sacrum and coccyx, which complete it behind.

The pelvis is divided by an oblique plane passing through the prominence of the sacrum, the linea ilio-pectinea, and the upper margin of the symphysis pubis into the false and true pelvis.

The **false pelvis** is the expanded portion of the pelvic cavity which is situated above this plane. It is bounded on each side by the ossa ilii; in front it is

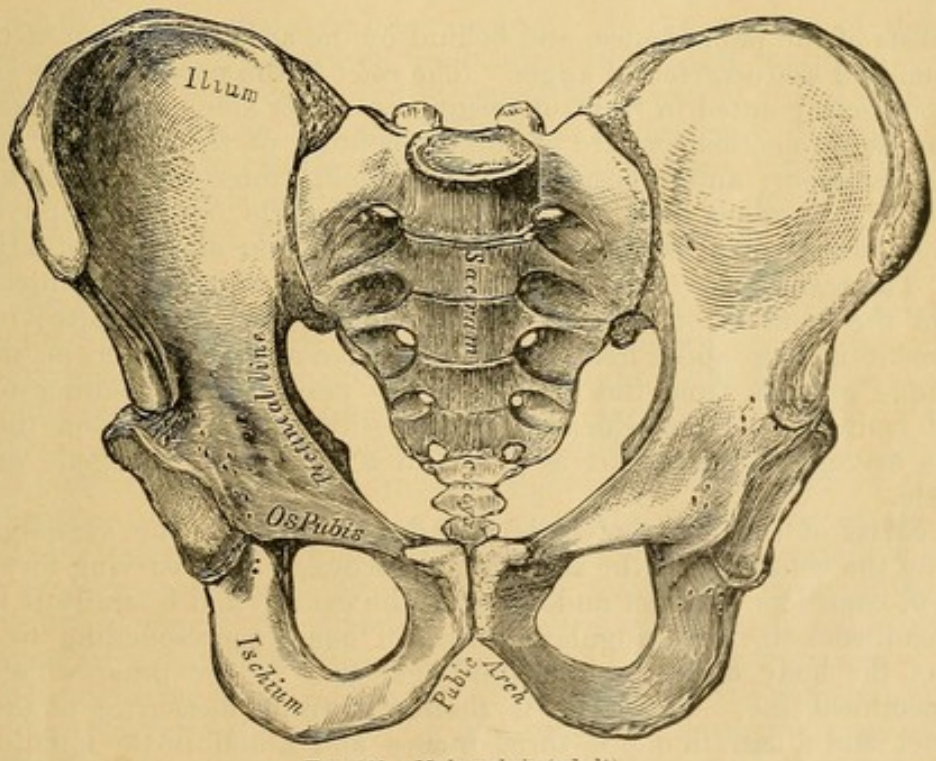

FIG. 123.—Male pelvis (adult).

incomplete, presenting a wide interval between the spinous processes of the ilia on either side, which is filled up in the recent state by the parietes of the abdomen; behind, in the middle line, is a deep notch. This broad, shallow cavity is fitted to support the intestines and to transmit part of their weight to the anterior wall of the abdomen, and is, in fact, really a portion of the abdominal cavity. The term false pelvis is incorrect, and this space ought more properly to be regarded as part of the hypogastric and iliac regions of the abdomen.

The **true pelvis** is that part of the pelvic cavity which is situated beneath the

plane. It is smaller than the false pelvis, but its walls are more perfect. For convenience of description it is divided into a superior circumference or inlet, an inferior circumference or outlet, and a cavity.

The **superior circumference** forms the brim of the pelvis, the included space being called the *inlet*. It is formed by the linea ilio-pectinea, completed in front

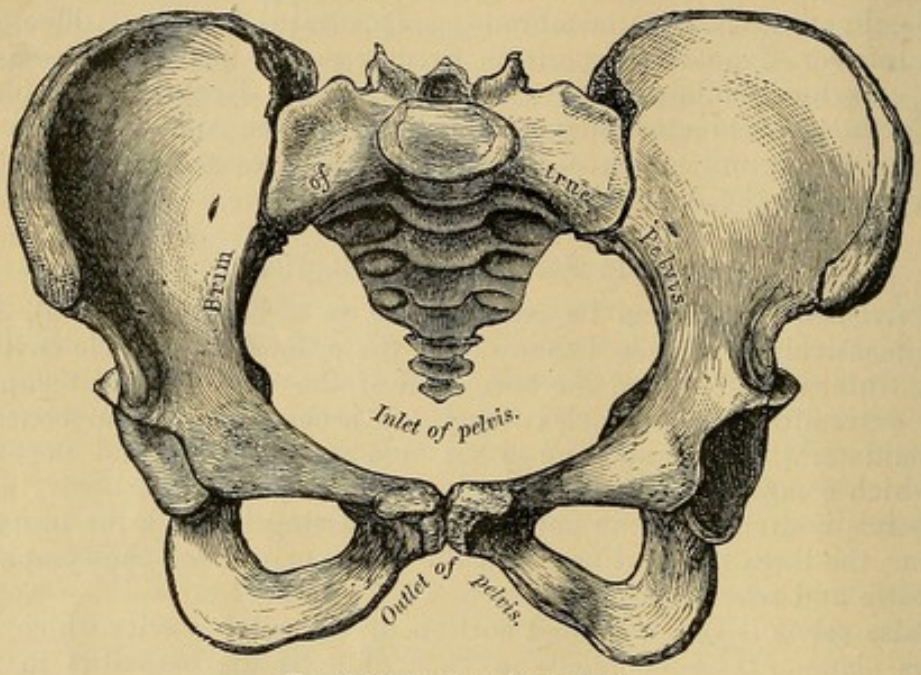

FIG. 124.—Female pelvis (adult).

by the crests of the pubic bones, and behind by the anterior margin of the base of the sacrum and sacro-vertebral angle. The *inlet* of the pelvis is somewhat heart-shaped, obtusely pointed in front, diverging on either side, and encroached upon behind by the projection forward of the promontory of the sacrum. It has three principal diameters: antero-posterior (sacro-pubic), transverse, and oblique. The antero-posterior extends from the sacro-vertebral angle to the symphysis pubis; its average measurement is four inches in the male, four and three-quarters in the female. The transverse extends across the greatest width of the inlet, from the middle of the brim on one side to the same point on the opposite; its average measurement is four and a half in the male, five and a quarter in the female. The oblique extends from the margin of the pelvis, corresponding to the ilio-pectineal eminence on one side, to the sacro-iliac articulation on the opposite side; its average measurement is four and a quarter in the male and five in the female.

The **cavity** of the true pelvis is bounded in front by the symphysis pubis; behind, by the concavity of the sacrum and coccyx, which, curving forward above and below, contracts the inlet and outlet of the canal; and laterally it is bounded by a broad, smooth, quadrangular surface of bone, corresponding to the inner surface of the body of the ischium and that part of the ilium which is below the ilio-pectineal line. The cavity is shallow in front, measuring at the symphysis an inch and a half in depth, three inches and a half in the middle, and four inches and a half posteriorly. From this description it will be seen that the cavity of the pelvis is a short, curved canal, considerably deeper on its posterior than on its anterior wall. This cavity contains, in the recent subject, the rectum, bladder, and part of the organs of generation. The rectum is placed at the back of the pelvis, and corresponds to the curve of the sacro-coccygeal column; the bladder in front, behind the symphysis pubis. In the female the uterus and vagina occupy the interval between these viscera.

The **lower circumference** of the pelvis is very irregular, and forms what is called the *outlet*. It is bounded by three prominent eminences: one posterior, formed by the point of the coccyx; and one on each side, the tuberosities of the

ischia. These eminences are separated by three notches; one in front, the *pubic arch*, formed by the convergence of the rami of the ischia and pubic bones on each side. The other notches, one on each side, are formed by the sacrum and coccyx behind, the ischium in front, and the ilium above; they are called the *sacro-sciatic notches;* in the natural state they are converted into foramina by the lesser and greater sacro-sciatic ligaments. In the recent state, when the ligaments are *in situ*, the outlet of the pelvis is lozenge-shaped, bounded in front by the subpubic ligament and the rami of the os pubis and ischium; on each side by the tuberosities of the ischia; and behind by the great sacro-sciatic ligaments and the tip of the coccyx.

The diameters of the outlet of the pelvis are two, antero-posterior and transverse. The *antero-posterior* extends from the tip of the coccyx to the lower part of the symphysis pubis; its average measurement is three and a quarter inches in the male and five in the female. The antero-posterior diameter varies with the length of the coccyx, and is capable of increase or diminution on account of the mobility of that bone. The *transverse* extends from the posterior part of one ischiatic tuberosity to the same point on the opposite side: the average measurement is three and a half inches in the male and four and three-quarters in the female.[1]

Position of the Pelvis.—In the erect posture the pelvis is placed obliquely with regard to the trunk of the body: the bony ring, which forms the brim of the true pelvis, is placed so as to form an angle of about 60° to 65° with the ground on which we stand. The pelvic surface of the symphysis pubis looks upward and backward, the concavity of the sacrum and coccyx downward and forward, the base of the sacrum in well-formed female bodies being nearly four inches above the upper border of the symphysis pubis, and the apex of the coccyx a little more than half an inch above its lower border. In consequence of this obliquity of the pelvis the line of gravity of the head, which passes through the middle of the odontoid process of the axis and through the points of junction of the curves of the vertebral column to the sacro-vertebral angle, descends toward the front of the cavity, so that it bisects a line drawn transversely through the middle of the heads of the thigh-bones. And thus the centre of gravity of the head is placed immediately over the heads of the thigh-bones on which the trunk is supported.

Axes of the Pelvis (Fig. 125).—The plane of the inlet of the true pelvis will be represented by a line drawn from the base of the sacrum to the upper margin of the symphysis pubis. A line carried at right angles with this at its middle would correspond at one extremity with the umbilicus, and at the other with the middle of the coccyx: the axis of the inlet is therefore directed downward and backward. The axis of the outlet, produced upward, would touch the base of the sacrum, and is therefore directed downward and forward. The axis of the cavity is curved like the cavity itself: this curve corresponds to the concavity of the sacrum and coccyx, the extremities being indicated by the central points of the inlet and outlet. A knowledge of the direction of these axes serves to explain the course of the fœtus in its passage through the pelvis during parturition. It is also important to the surgeon, as indicating the direction of the force required in the removal of calculi from the bladder by the sub-pubic operation, and as determining the direction in which instruments should be used in operations upon the pelvic viscera.

[1] The measurements of the pelvis given above are, I believe, fairly accurate, but different measurements are given by various authors, no doubt due in a great measure to differences in the physique and stature of the population from whom the measurements have been taken. The accompanying chart has been formulated to show the measurements of the pelvis which are adopted by many obstetricians.—Ed.

	A. P.	Obl.	Tr.
Inlet	4	4½	5
Cavity	4½	4½	4½
Outlet	5	4½	4

Differences between the Male and the Female Pelvis.—The *female* pelvis, looked at as a whole, is distinguished from the *male* by the bones being more delicate, by its width being greater and its depth smaller. The whole pelvis is less massive, and its bones are lighter and more slender, and its muscular impressions are slightly marked. The iliac fossæ are shallow, and the anterior iliac spines widely separated; hence the greater prominence of the hips. The *inlet* in the female is larger than in the male; it is more nearly circular, and the sacro-vertebral angle projects less forward. The *cavity* is shallower and wider; the sacrum is shorter, wider, and less curved; the obturator foramina are triangular, and smaller in size than in the male. The *outlet* is larger and the coccyx more movable. The spines of the ischia project less inward. The tuberosities of the ischia and the acetabula are wider apart. The *pubic arch* is wider and more rounded than in the male, where it is an angle rather than an arch. In consequence of this the width of the fore part of the pelvic outlet is much increased and the passage of the fœtal head facilitated.

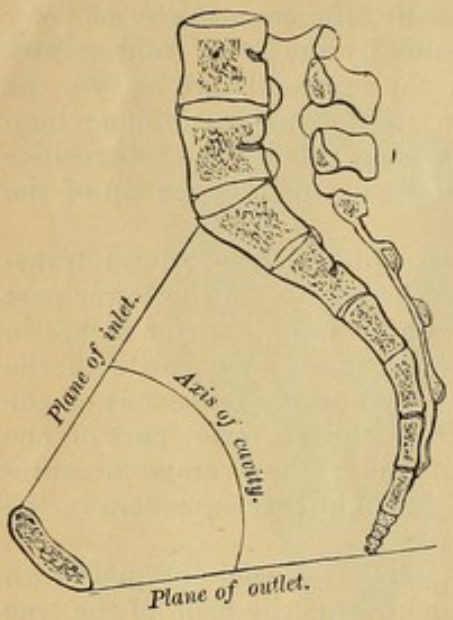

FIG. 125.—Vertical section of the pelvis, with lines indicating the axis of the pelvis.

The size of the pelvis varies, not only in the two sexes, but also in different members of the same sex. This does not appear to be influenced in any way by the height of the individual. Women of short stature, as a rule, have broad pelves. Occasionally the pelvis is equally contracted in all its dimensions, so much so that all its diameters measure an inch less than the average, and this even in women of average height and otherwise well formed. The principal divergences, however, are found at the inlet, and affect the relation of the antero-posterior to the transverse diameter. Thus we may have a pelvis the inlet of which is elliptical either in a transverse or antero-posterior direction; the transverse diameter in the former and the antero-posterior in the latter greatly exceeding the other diameters. Again, the inlet of the pelvis in some instances is seen to be almost circular.

The same differences are found in various races. European women are said to have the most roomy pelves. That of the negress is smaller, circular in shape, and with a narrow pubic arch. The Hottentots and Bushwomen possess the smallest pelves.

In the *fœtus* and for several years after birth the pelvis is small in proportion to that of the adult. The cavity is deep, and the projection of the sacro-vertebral angle less marked. The generally accepted opinion that the female pelvis does not acquire its sexual characters until after puberty has been shown by recent observations[1] to be erroneous, the characteristic differences between the male and female pelvis being distinctly indicated as early as the fourth month of fœtal life.

Surface Form.—The pelvic bones are so thickly covered with muscles that it is only at certain points that they approach the surface and can be felt through the skin. In front, the anterior superior spinous process is easily to be recognized; a portion of it is subcutaneous, and in thin subjects may be seen to stand out as a prominence at the outer extremity of the fold of the groin. In fat subjects its position is marked by an oblique depression amongst the surrounding fat, at the bottom of which the bony process may be felt. Proceeding upward and outward from this process, the crest of the ilium may be traced throughout its whole length, sinuously curved. It is represented, in muscular subjects, on the surface, by a groove or furrow, the *iliac furrow*, caused by the projection of fleshy fibres of the External oblique muscle of the abdomen; the iliac furrow lies slightly below the level of the crest. It terminates behind in the posterior superior spinous process, the position of which is indicated by a slight depression on a level with the spinous process of the second sacral vertebra. Between the two posterior superior spinous processes, but at a lower level, is to be felt the spinous process of the third sacral vertebra (see page 53). Another part of the bony pelvis which is easily accessible to the

[1] Fehling, *Zeitschr. für Geburt. u. Gynaek.*, Bd. ix. und x.; and Arthur Thomson, *Journal of Anatomy and Physiology*, vol. xxxiii.

touch is the tuberosity of the ischium, situated beneath the gluteal fold, and, when the hip is flexed, easily to be felt, as it is then to a great extent uncovered by muscle. Finally, the spine of the os pubis can always be readily felt, and constitutes an important surgical guide, especially in connection with the subject of hernia. It is nearly in the same horizontal line with the upper edge of the great trochanter. In thin subjects it is very apparent, but in the obese it is obscured by the pubic fat. It can, however, be detected by following up the tendon of origin of the Adductor longus muscle.

Surgical Anatomy.—There is arrest of development in the bones of the pelvis in cases of extroversion of the bladder; the anterior part of the pelvic girdle being deficient, the bodies of the pubic bones imperfectly developed, and the symphysis absent. The pubic bones are separated to the extent of from two to four inches, the superior rami shortened and directed forward, and the obturator foramen diminished in size, narrowed, and turned outward. The iliac bones are straightened out more than normal. The sacrum is very peculiar. The lateral curve, instead of being concave, is flattened out or even convex, with the ilio-sacral facets turned more outward than normal, while the vertical curve is straightened.[1]

Fractures of the pelvis are divided into fractures of the false pelvis and of the true pelvis. Fractures of the false pelvis vary in extent: a small portion of the crest may be broken or one of the spinous processes may be torn off, and this may be the result of muscular action; or the bone may be extensively comminuted. This latter accident is the result of some crushing violence, and may be complicated with fracture of the true pelvis. These cases may be accompanied by injury to the intestine as it lies in the hollow of the bone, or to the iliac vessels as they course along the margin of the true pelvis. Fractures of the true pelvis generally occur through the ascending ramus of the os pubis and the ramus of the ischium, as this is the weakest part of the bony ring, and may be caused either by crushing violence applied in an antero-posterior direction, when the fracture occurs from direct force, or by compression laterally, when the acetabula are pressed together, and the bone gives way in the same place from indirect violence. Occasionally the fracture may be double, occurring on both sides of the body. It is in these cases that injury to the contained viscera is liable to take place: the urethra, the bladder, the rectum, the vagina in the female, the small intestines, and even the uterus, have all been lacerated by a displaced fragment. Fractures of the acetabulum are occasionally met with: either a portion of the rim may be broken off, or a fracture may take place through the bottom of the cavity, and the head of the femur driven inward and project into the pelvic cavity. Separation of the Y-shaped cartilage at the bottom of the acetabulum may also occur in the young subject, separating the bone into its three anatomical portions.

The sacrum is occasionally, but rarely, broken by direct violence—*i. e.*, blows, kicks, or falls on the part. The lesion may be complicated with injury to the nerves of the sacral plexus, leading to paralysis and loss of sensation in the lower extremity, or to incontinence of fæces from paralysis of the sphincter ani.

The pelvic bones often undergo important deformity in rickets, the effect of which in the adult woman may interfere seriously with childbearing. The deformity is due mainly to the weight of the spine and trunk, which presses on the sacro-vertebral angle and greatly increases it, so that the antero-posterior diameter of the pelvis is diminished. But, in addition to this, the weight of the viscera on the venter ilii causes them to expand and the tuberosities of the ischia to be incurved. In osteomalacia also great deformity may occur. The weight of the trunk causes an increase in the sacro-vertebral angle and a lessening of the antero-posterior diameter of the inlet, and at the same time the pressure of the acetabula on the heads of the thigh-bones causes these cavities, with the adjacent bone, to be pushed upward and backward, so that the oblique diameters of the pelvis are also diminished, and the cavity of the pelvis assumes a triradiate shape, with the symphysis pubis pushed forward.

THE THIGH.

The **Thigh** is that portion of the lower extremity which is situated between the pelvis and the knee. It consists in the skeleton of a single bone, the femur.

The Femur, or Thigh-Bone.

The **Femur** (*femur*, the thigh) is the longest,[2] largest, and strongest bone in the skeleton, and almost perfectly cylindrical in the greater part of its extent. In the erect posture it is not vertical, being separated from its fellow above by a considerable interval, which corresponds to the entire breadth of the pelvis, but inclining gradually downward and inward, so as to approach its fellow toward its lower part, for the purpose of bringing the knee-joint near the line of gravity of the body. The degree of this inclination varies in different persons, and is greater in the female than the male, on account of the greater breadth of the pelvis. The femur, like other long bones, is divisible into a shaft and two extremities.

[1] Wood. Heath's *Dictionary of Practical Surgery*, i., 426.

[2] In a man six feet high it measures eighteen inches—one-fourth of the whole body.

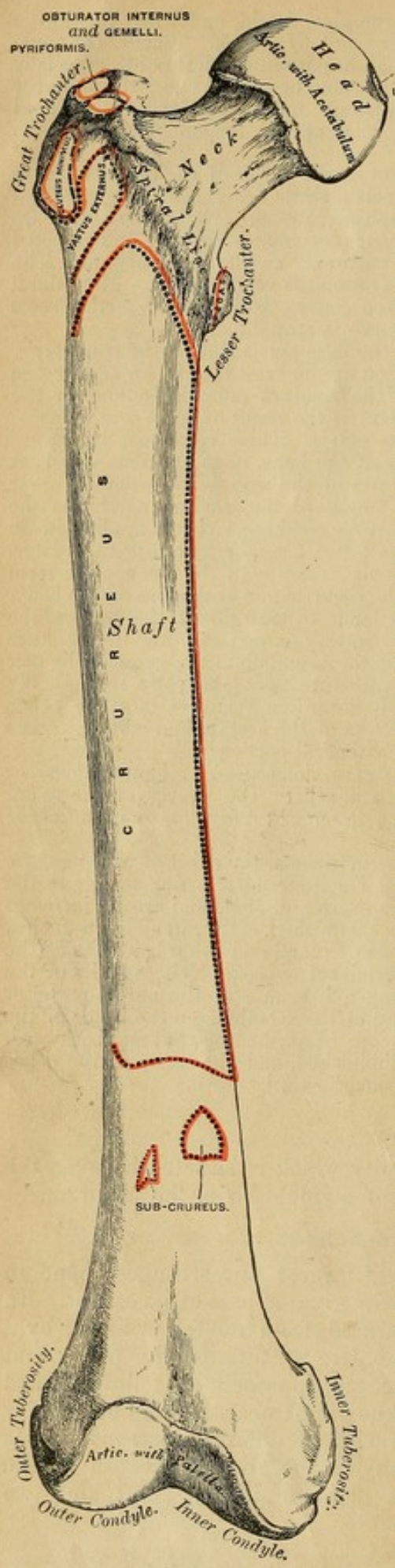

FIG. 126.—Right femur. Anterior surface.

The **Upper Extremity** presents for examination a head, a neck, and a great and lesser trochanters.

The **head**, which is globular, and forms rather more than a hemisphere, is directed upward, inward, and a little forward, the greater part of its convexity being above and in front. Its surface is smooth, coated with cartilage in the recent state, except at a little behind and below its centre, where is an ovoid depression, for the attachment for the ligamentum teres. The **neck** is a flattened pyramidal process of bone which connects the head with the shaft. It varies in length and obliquity at various periods of life and under different circumstances. The angle is widest in infancy, and becomes lessened during growth, so that at puberty it forms a gentle curve from the axis of the shaft. In the adult it forms an angle of about 130° with the shaft, but varies in inverse proportion to the development of the pelvis and the stature. In consequence of the prominence of the hips and widening of the pelvis in the female, the neck of the thigh-bone forms more nearly a right angle with the shaft than it does in man. It has been stated that the angle diminishes in old age and the direction of the neck becomes horizontal, but this statement is founded on insufficient evidence. Sir George Humphry states that the angle decreases during the period of growth, but after full growth has been attained it does not usually undergo any change, even in old age. He further states that the angle varies considerably in different persons of the same age. It is smaller in short than in long bones, and when the pelvis is wide.[1] The neck is flattened from before backward, contracted in the middle, and broader at its outer extremity, where it is connected with the shaft, than at its summit, where it is attached to the head. The vertical diameter of the outer half is increased by the thickening of the lower edge, which slopes downward to join the shaft at the lesser trochanter, so that the outer half of the neck is flattened from before backward, and its vertical diameter measures one-third more than the antero-posterior. The inner half is smaller and of a more circular shape. The *anterior surface* of the neck is perforated by numerous vascular foramina. The *posterior surface* is smooth, and is broader and more concave than the anterior; it gives attachment to the posterior part of the capsular ligament of the hip-joint, about half an inch above the posterior

[1] *Journal of Anatomy and Physiology.*

intertrochanteric line. The *superior border* is short and thick, and terminates externally at the great trochanter; its surface is perforated by large foramina. The *inferior border*, long and narrow, curves a little backward, to terminate at the lesser trochanter.

The **Trochanters** (*τροχάω*, to run or roll) are prominent processes of bone which afford leverage to the muscles which rotate the thigh on its axis. They are two in number, the great and the lesser.

The **Great Trochanter** is a large, irregular, quadrilateral eminence, situated at the outer side of the neck, at its junction with the upper part of the shaft. It is directed a little outward and backward, and in the adult is about three-quarters of an inch lower than the head. It presents for examination two surfaces and four borders. The *external surface*, quadrilateral in form, is broad, rough, convex, and marked by a prominent diagonal impression, which extends from the posterior superior to the anterior inferior angle, and serves for the attachment of the tendon of the Gluteus medius. Above the impression is a triangular surface, sometimes rough for part of the tendon of the same muscle, sometimes smooth for the interposition of a bursa between that tendon and the bone. Below and behind the diagonal line is a smooth, triangular surface, over which the tendon of the Gluteus maximus muscle plays, a bursa being interposed. The *internal surface* is of much less extent than the external, and presents at its base a deep depression, the *digital* or *trochanteric fossa*, for the attachment of the tendon of the Obturator externus muscle; above and in front of this an impression for the attachment of the Obturator internus and Gemelli. The *superior border* is free; it is thick and irregular, and marked near the centre by an impression for the attachment of the Pyriformis. The *inferior border* corresponds to the point of junction of the base of the trochanter with the outer surface of the shaft; it is marked by a rough, prominent, slightly curved ridge, which gives attachment to the upper part of the Vastus externus muscle. The *anterior border* is prominent, somewhat irregular, as well as the surface of bone immediately below it; it affords attachment at its outer part to the Gluteus minimus. The *posterior border* is very prominent, and appears as a free, rounded edge, which forms the back part of the digital fossa.

The **Lesser Trochanter** is a conical eminence which varies in size in different subjects; it projects from the lower and back part of the base of the neck. Its base is triangular, and connected with the adjacent parts of the bone by three well-marked borders: two of these are above—the *internal* continuous with the lower border of the neck, the *external* with the posterior intertrochanteric line—while the *inferior border* is continuous with the middle division of the linea aspera. Its summit, which is directed inward and backward, is rough, and gives insertion to the tendon of the Ilio-psoas. The Iliacus is also inserted into the shaft below the lesser trochanter between the Vastus internus in front and the Pectineus behind.

A well-marked prominence of variable size, which projects from the upper and front part of the neck at its junction with the great trochanter, is called the *tubercle of the femur;* it is the point of meeting of five muscles: the Gluteus minimus externally, the Vastus externus below, and the tendon of the Obturator internus and Gemelli above. Running obliquely downward and inward from the tubercle is the *spiral line* of the femur, or *anterior intertrochanteric line;* it winds round the inner side of the shaft, below the lesser trochanter, and terminates in the linea aspera, about two inches below this eminence. Its upper half is rough, and affords attachment to the ilio-femoral ligament of the hip-joint; its lower half is less prominent, and gives attachment to the upper part of the Vastus internus. Running obliquely downward and inward from the summit of the great trochanter on the posterior surface of the neck is a very prominent, well-marked ridge, the *posterior intertrochanteric line*. Its upper half forms the posterior border of the great trochanter, and its lower half runs downward and inward to the upper and back part of the lesser trochanter. A slight ridge sometimes commences about the

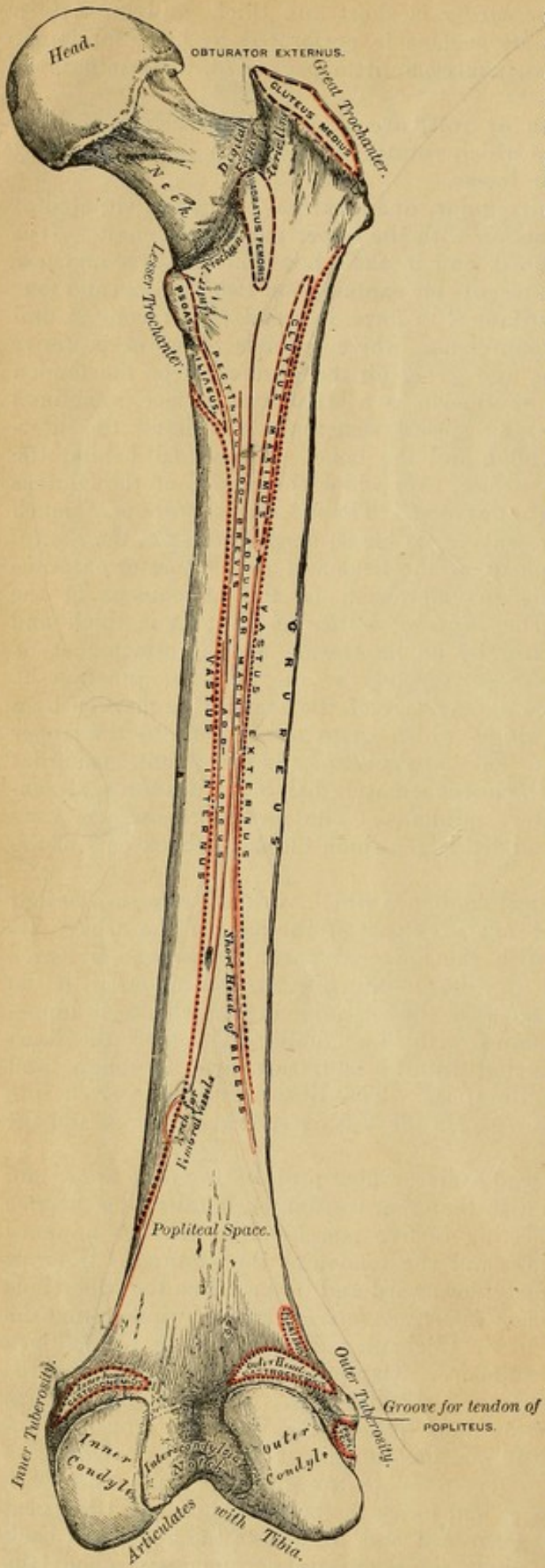

FIG. 127.—Right femur. Posterior surface.

middle of the posterior intertrochanteric line, and passes vertically downward for about two inches along the back part of the shaft: it is called the *linea quadrati*, and gives attachment to the Quadratus femoris and a few fibres of the Adductor magnus muscles.[1]

The **Shaft**, almost cylindrical in form, is a little broader above than in the centre, and somewhat flattened below, from before backward. It is slightly arched, so as to be convex in front and concave behind, where it is strengthened by a prominent longitudinal ridge, the *linea aspera*. It presents for examination three borders, separating three surfaces. Of the three borders, one, the linea aspera, is posterior; the other two are placed laterally.

The **linea aspera** (Fig. 127) is a prominent longitudinal ridge or crest, on the middle third of the bone, presenting an external lip, an internal lip, and a rough intermediate space. Above, this crest is prolonged by three ridges. The most external one is very rough, and is continued almost vertically upward to the base of the great trochanter. It is sometimes termed the *gluteal ridge*, and gives attachment to part of the Gluteus maximus muscle; its upper part is often elongated into a roughened crest, on which is a more or less well-marked, rounded tubercle, a rudimental third trochanter. The middle ridge, the least distinct, is continued to the base of the trochanter minor, and the internal one is lost above in the spiral line of the femur. Below, the linea aspera is prolonged by two ridges, which enclose between them a triangular space, the *popliteal surface*, upon which rests the popliteal artery. Of these two ridges, the outer one is the more prominent, and de-

[1] Generally there is merely a slight thickening about the centre of the intertrochanteric line, marking the point of attachment of the Quadratus femoris. This is termed by some anatomists the *tubercle of the Quadratus*.

scends to the summit of the outer condyle. The inner one is less marked, especially at its upper part, where it is crossed by the femoral artery. It terminates, below, at the summit of the internal condyle, in a small tubercle, the *Adductor tubercle*, which affords attachment to the tendon of the Adductor magnus.

To the inner lip of the linea aspera and its inner prolongation above and below is attached the Vastus internus, and to the outer lip and its outer prolongation above is attached the Vastus externus. The Adductor magnus is attached to the linea aspera, to its outer prolongation above and its inner prolongation below. Between the Vastus externus and the Adductor magnus are attached two muscles—viz. the Gluteus maximus above, and the short head of the Biceps below. Between the Adductor magnus and the Vastus internus four muscles are attached: the Iliacus and Pectineus above, the Adductor brevis and Adductor longus below. The linea aspera is perforated a little below its centre by the nutrient canal, which is directed obliquely upward.

The *two lateral borders* of the femur are only slightly marked, the outer one extending from the anterior inferior angle of the great trochanter to the anterior extremity of the external condyle; the inner one from the spiral line, at a point opposite the trochanter minor, to the anterior extremity of the internal condyle. The internal border marks the limit of attachment of the Crureus muscle internally.

The **anterior surface** includes that portion of the shaft which is situated between the two lateral borders. It is smooth, convex, broader above and below than in the centre, slightly twisted, so that its upper part is directed forward and a little outward, its lower part forward and a little inward. To the upper three-fourths of this surface the Crureus is attached; the lower fourth is separated from the muscle by the intervention of the synovial membrane of the knee-joint and a bursa, and affords attachment to the Subcrureus to a small extent. The *external surface* includes the portion of bone between the external border and the outer lip of the linea aspera: it is continuous above with the outer surface of the great trochanter, below with the outer surface of the external condyle; to its upper three-fourths is attached the outer portion of the Crureus muscle. The *internal surface* includes the portion of bone between the internal border and the inner lip of the linea aspera; it is continuous above with the lower border of the neck, below with the inner side of the internal condyle: it is covered by the Vastus externus muscle.

The **Lower Extremity,** larger than the upper, is of a cuboid form, flattened from before backward, and divided into two large eminences, the *condyles* (*κόνδυλος*, a knuckle), by an interval which presents a smooth depression in front called the *trochlea*, and a notch of considerable size behind—the *intercondyloid notch*. The *external condyle* is the more prominent anteriorly, and is the broader both in the antero-posterior and transverse diameters. The *internal condyle* is the narrower, longer, and more prominent inferiorly. This difference in the length of the two condyles is only observed when the bone is perpendicular, and depends upon the obliquity of the thigh-bones, in consequence of their separation above at the articulation with the pelvis. If the femur is held obliquely, the surfaces of the two condyles will be seen to be nearly horizontal. The two condyles are directly continuous in front, and form a smooth trochlear surface, which articulates with the patella. It presents a median groove, which extends downward and backward to the intercondyloid notch; and two lateral convexities, of which the external is the broader, more prominent, and prolonged farther upward upon the front of the outer condyle. The external border of this articular surface is also more prominent, and ascends higher than the internal one. The intercondyloid notch lodges the crucial ligaments; it is bounded laterally by the opposed surfaces of the two condyles, and in front by the lower end of the shaft.

Outer Condyle.—The *outer surface* of the external condyle presents, a little behind its centre, an eminence, the *outer tuberosity;* it is less prominent than the inner tuberosity, and gives attachment to the external lateral ligaments of the knee. Immediately beneath it is a groove which commences at a depression a

little behind the centre of the lower border of this surface: the front part of this depression gives origin to the Popliteus muscle, the tendon of which is lodged in the groove during flexion of the knee. The groove is smooth, covered with cartilage in the recent state, and runs upward and backward to the posterior extremity of the condyle. The *inner surface* of the outer condyle forms one of the lateral boundaries of the intercondyloid notch, and gives attachment, by its posterior part, to the anterior crucial ligament. The *inferior surface* is convex, smooth, and broader than that of the internal condyle. The posterior extremity is convex and smooth: just above and to the outer side of the articular surface is a depression for the tendon of the outer head of the Gastrocnemius, above which is the origin of the Plantaris.

Inner Condyle.—The *inner surface* of the inner condyle presents a convex eminence, the *inner tuberosity*, rough for the attachment of the internal lateral ligament. The *outer side* of the inner condyle forms one of the lateral boundaries of the intercondyloid notch, and gives attachment, by its anterior part, to the posterior crucial ligament. Its *inferior* or *articular surface* is convex, and presents a less extensive surface than the external condyle. Just above the articular surface of the condyle, behind, is a depression for the tendon of origin of the inner head of the Gastrocnemius.

Structure.—The shaft of the femur is a cylinder of compact tissue, hollowed by a large medullary canal. The cylinder is of great thickness and density in the middle third of the shaft, where the bone is narrowest and the medullary canal well formed; but above and below this the cylinder gradually becomes thinner, owing to a separation of the layers of the bone into cancelli, which project into the medullary canal and finally obliterate it, so that the upper and lower ends of the shaft, and the articular extremities more especially, consist of cancellated tissue invested by a thin, compact layer.

The arrangement of the cancelli in the ends of the femur is remarkable. In the upper end they are arranged in two sets. One, starting from the top of the head, the upper surface of the neck, and the great trochanter, converge to the inner circumference of the shaft (Fig. 128); these are placed in the direction of greatest pressure, and serve to support the vertical weight of the body. The second set are planes of lamellæ intersecting the former nearly at right angles, and are situated in the line of the greatest tension—that is to say, along the lines in which the muscles and ligaments exert their traction. In the head of the bone these

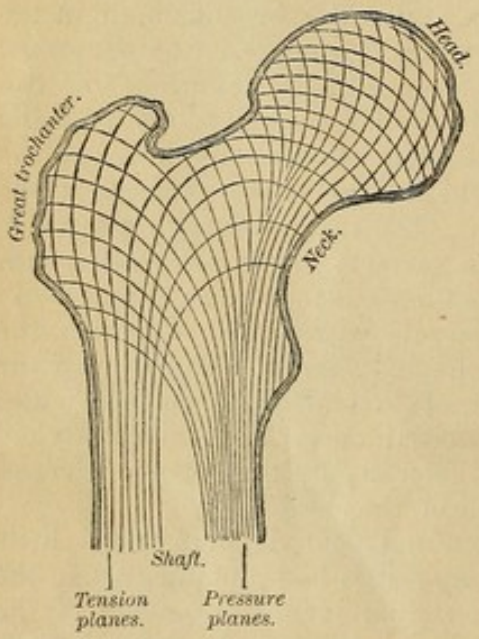

FIG. 128.—Diagram showing the arrangement of the cancelli of the neck of the femur.

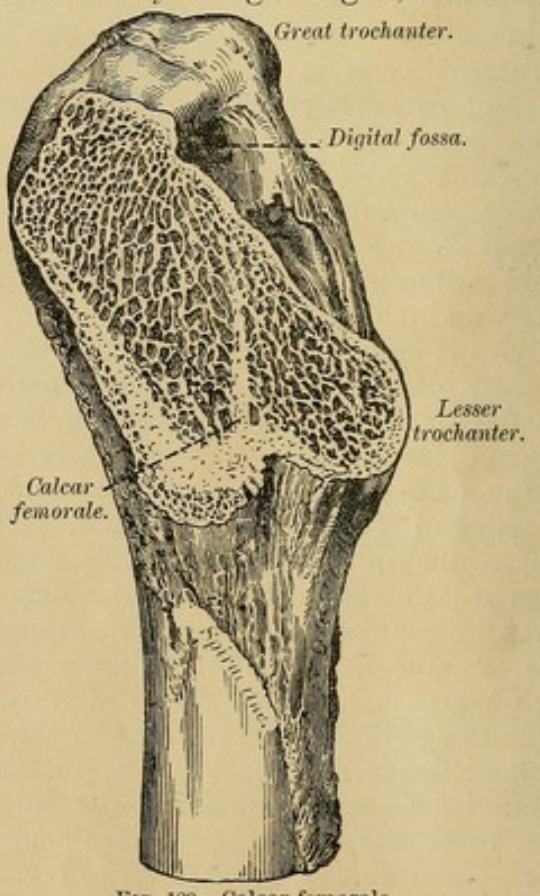

FIG. 129.—Calcar femorale.

planes are arranged in a curved form, in order to strengthen the bone when exposed to pressure in all directions. In the midst of the cancellous tissue of the neck is a vertical plane of compact bone, the *femoral spur* (*calcar femorale*) which commences at the point where the neck joins the shaft midway between the lesser trochanter and the internal border of the shaft of the bone, and extends in the direction of the digital fossa (Fig. 129). This materially strengthens this portion of the bone. Another point in connection with the structure of the neck of the femur requires mention, especially on account of its influence on the production of fracture in this situation. It will be noticed that a considerable portion of the great trochanter lies behind the level of the posterior surface of the neck; and if a section be made through the trochanter at this level, it will be seen that the posterior wall of the neck is prolonged into the trochanter. This prolongation is termed by Bigelow the "true neck,"[1] and forms a thin, dense plate of bone, which passes beneath the posterior intertrochanteric ridge toward the outer surface of the bone.

In the lower end the cancelli spring on all sides from the inner surface of the cylinder, and descend in a perpendicular direction to the articular surface, the cancelli being strongest and having a more accurately perpendicular course above the condyles. In addition to this, however, horizontal planes of cancellous tissue are to be seen, so that the spongy tissue in this situation presents an appearance of being mapped out into a series of rectangular areas.

Articulations.—With three bones: the os innominatum, tibia, and patella.

Development (Fig. 130).—The femur is developed by *five* centres: one for the shaft, one for each extremity, and one for each trochanter. Of all the long bones, except the clavicle, it is the first to show traces of ossification: this commences in the shaft, at about the seventh week of fœtal life, the centres of ossification in the epiphyses appearing in the following order: First, in the lower end of the bone, at the ninth month of fœtal life[2] (from this the condyles and tuberosities are formed); in the head at the end of the first year after birth; in the great trochanter, during the fourth year; and in the lesser trochanter, between the thirteenth and fourteenth. The order in which the epiphyses are joined to the shaft is the reverse of that of their appearance: their junction does not commence until after puberty, the lesser trochanter being first joined, then the great, then the head, and, lastly, the inferior extremity (the first in which ossification commenced), which is not united until the twentieth year.

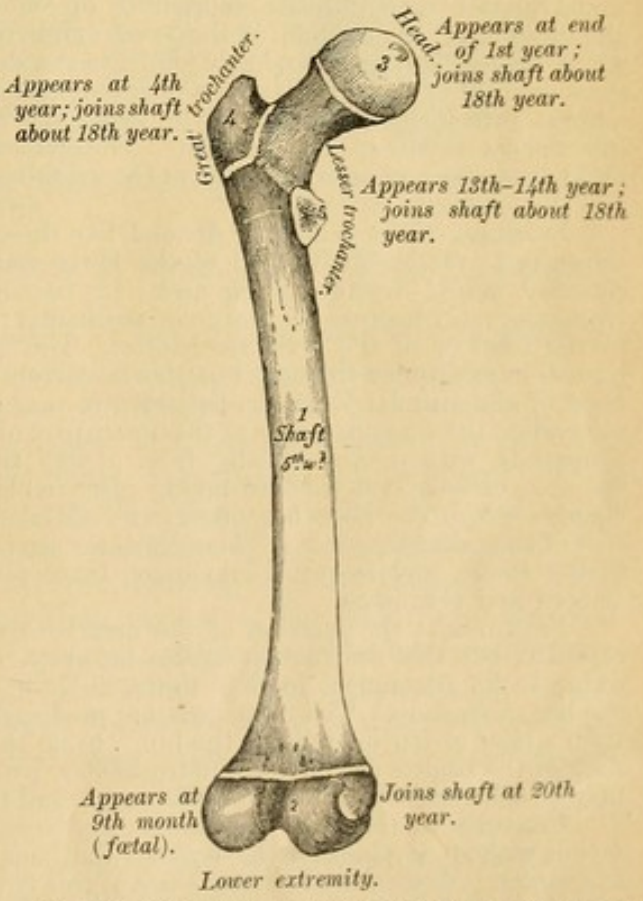

FIG. 130.—Plan of the development of the femur. By five centres.

Attachment of Muscles.—To twenty-three. To the great trochanter: the Gluteus medius, Gluteus minimus, Pyriformis, Obturator internus, Obturator externus, Gemellus superior, Gemellus inferior, and Quadratus femoris. To the lesser trochanter: the Psoas magnus and the Iliacus below it. To the shaft:

[1] *Bigelow on the Hip*, p. 121.

[2] This is said to be the only epiphysis in which ossification begins before birth; though according to some observers, the centre for the upper epiphysis of the tibia also appears before birth.

the Vastus externus, Gluteus maximus, short head of the Biceps, Vastus internus, Adductor magnus, Pectineus, Adductor brevis, Adductor longus, Crureus, and Subcrureus. To the condyles: the Gastrocnemius, Plantaris, and Popliteus.

Surface Form.—The femur is covered with muscles, so that in fairly muscular subjects the shaft is not to be detected through its fleshy covering, and the only parts accessible to the touch are the outer surface of the great trochanter and the lower expanded end of the bone. The external surface of the great trochanter is to be felt, especially in certain positions of the limb. Its position is generally indicated by a depression, owing to the thickness of the Gluteus medius and minimus, which project above it. When, however, the thigh is flexed, and especially if crossed over the opposite one, the trochanter produces a blunt eminence on the surface. The upper border is about on a line with the spine of the os pubis, and its exact level is indicated by a line drawn from the anterior superior spinous process of the ilium, over the outer side of the hip, to the most prominent point of the tuberosity of the ischium. This is known as Nélaton's line. The outer and inner condyles of the lower extremity are easily to be felt. The outer one is more subcutaneous than the inner one, and readily felt. The tuberosity on it is comparatively little developed, but can be more or less easily recognized. The inner condyle is more thickly covered, and this gives a general convex outline to this part, especially when the knee is flexed. The tuberosity on it is easily felt, and at the upper part of the condyle the sharp tubercle for the insertion of the tendon of the Adductor magnus can be recognized without difficulty. When the knee is flexed, and the patella situated in the interval between the condyles and the upper end of the tibia, a part of the trochlear surface of the femur can be made out above the patella.

Surgical Anatomy.—There are one or two points about the ossification of the femur bearing on practice to which allusion must be made. It has been stated above that the lower end of the femur is the only epiphysis in which ossification has commenced at the time of birth. The presence of this ossific centre is, therefore, a proof, in newly-born children found dead, that the child has arrived at the full period of utero-gestation, and is always relied upon in medico-legal investigations. The position of the epiphysial line should be carefully noted. It is on a level with the adductor tubercle, and the epiphysis does not, therefore, form the whole of the cartilage-clad portion of the lower end of the bone. It is essential to bear this point in mind in performing excision of the knee, since growth in length of the femur takes place chiefly from the lower epiphysis, and any interference with the epiphysial cartilage in a young child would involve such ultimate shortening of the limb, from want of growth, as to render it almost useless. Separation of the lower epiphysis may take place up to the age of twenty, at which time it becomes completely joined to the shaft of the bone; but, as a matter of fact, few cases occur after the age of sixteen or seventeen. The epiphysis of the head of the femur is of interest principally on account of its being the seat of origin of a large number of cases of tuberculous disease of the hip-joint. The disease commences in the majority of cases in the highly vascular and growing tissue in the neighborhood of the epiphysis, and from here extends into the joint.

Fractures of the femur are divided, like those of the other long bones, into fractures of the upper end; of the shaft; and of the lower end. The fractures of the upper end may be classified into (1) fracture of the neck; (2) fracture at the junction of the neck with the great trochanter; (3) fracture of the great trochanter; and (4) separation of the epiphysis, either of the head or of the great trochanter. The first of these, fracture of the neck, is usually termed intracapsular fracture, but this is scarcely a correct designation, as, owing to the attachment of the capsular ligament, the fracture may be partly within and partly without the capsule, when the fracture occurs at the lower part of the neck. It generally occurs in old people, principally women, and usually from a very slight degree of indirect violence. Probably the main cause of the fracture taking place in old people is in consequence of the degenerative changes which the bone has undergone. Merkel believes that it is mainly due to the absorption of the calcar femorale. These fractures are occasionally impacted. As a rule they unite by fibrous tissue, and frequently no union takes place, and the surfaces of the fracture become smooth and eburnated.

Fractures at the junction of the neck with the great trochanter are usually termed extracapsular, but this designation is also incorrect, as the fracture is partly within the capsule, owing to its attachment in front to the anterior intertrochanteric line, which is situated below the line of fracture. These fractures are produced by direct violence to the great trochanter, as from a blow or fall laterally on the hip. From the manner in which the accident is caused, the neck of the bone is driven into the trochanter, where it may remain impacted, or the trochanter may be split up into two or more fragments, and thus no fixation takes place.

Fractures of the great trochanter may be either "oblique fracture through the trochanter major, without implicating the neck of the bone" (Astley Cooper), or separation of the great trochanter. Most of the recorded cases of this latter injury occurred in young persons, and were probably cases of separation of the epiphysis of the great trochanter. Separation of the epiphysis of the head of the femur has been said to occur, but has probably never been verified by post-mortem examination.

Fractures of the shaft may occur at any part, but the most usual situation is at or near the centre of the bone. They may be caused by direct or indirect violence or by muscular action.

Fractures of the upper third of the shaft are almost always the result of indirect violence, whilst those of the lower third are the result, for the most part, of direct violence. In the middle third fractures occur from both forms of injury in about equal proportions. Fractures of the shaft are generally oblique, but they may be transverse, longitudinal, or spiral. The transverse fracture occurs most frequently in children. The fractures of the lower end of the femur include transverse fracture above the condyles, the most common; and this may be complicated by a vertical fracture between the condyles, constituting the T-shaped fracture. In these cases the popliteal artery is in danger of being wounded. Oblique fracture, separating either the internal or external condyle, and a longitudinal incomplete fracture between the condyles, may also take place.

The femur as well as the other bones of the leg are frequently the seat of acute necrosis in young children. This is no doubt due to their greater exposure to injury, which is often the exciting cause of this disease. Tumors not unfrequently are found growing from the femur: the most common forms being sarcoma, which may grow either from the periosteum or from the medullary tissue within the interior of the bone; and exostosis, which is commonly found originating in the neighborhood of the epiphysial cartilage of the lower end.

THE LEG.

The skeleton of the Leg consists of three bones: the Patella, a large sesamoid bone, placed in front of the knee; the Tibia; and the Fibula.

The Patella (Figs. 131, 132).

The **Patella** (*patella*, a small pan) is a flat, triangular bone, situated at the anterior part of the knee-joint. It is usually regarded as a sesamoid bone, developed in the tendon of the Quadriceps extensor. It resembles these bones (1) in its being developed in a tendon; (2) in its centre of ossification presenting a knotty or tuberculated outline; (3) in its structure being composed mainly of dense cancellous tissue, as in the other sesamoid bones. It serves to protect the front of the joint, and increases the leverage of the Quadriceps extensor by making it act at a greater angle. It presents an anterior and a posterior surface, three borders, and an apex.



FIG. 131.—Right patella. Anterior surface.

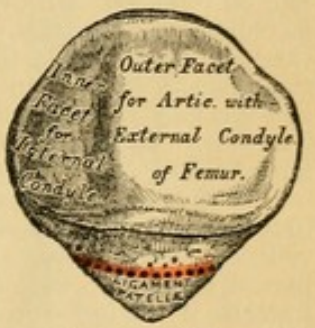

FIG. 132.—Right patella. Posterior surface.

The **anterior surface** is convex, perforated by small apertures, for the passage of nutrient vessels, and marked by numerous rough, longitudinal striæ. This surface is covered, in the recent state, by an expansion from the tendon of the Quadriceps extensor, which is continuous below with the superficial fibres of the ligamentum patellæ. It is separated from the integument by a bursa. The **posterior surface** presents a smooth, oval-shaped, articular surface, covered with cartilage in the recent state, and divided into two facets by a vertical ridge, which descends from the superior border toward the inferior angle of the bone. The ridge corresponds to the groove on the trochlear surface of the femur, and the two facets to the articular surfaces of the two condyles; the outer facet, for articulation with the outer condyle, being the broader and deeper. This character serves to indicate the side to which the bone belongs. Below the articular surface is a rough, convex, non-articular depression, the lower half of which gives attachment to the ligamentum patellæ, the upper half being separated from the head of the tibia by adipose tissue.

The **superior border** is thick, and sloped from behind, downward and forward: it gives attachment to that portion of the Quadriceps extensor which is derived from the Rectus and Crureus muscles. The **lateral borders** are thinner, converging below. They give attachment to that portion of the Quadriceps extensor derived from the external and internal Vasti muscles.

The **apex** is pointed, and gives attachment to the ligamentum patellæ.

Structure.—It consists of a nearly uniform dense cancellous tissue covered by a thin compact lamina. The cancelli immediately beneath the anterior surface are arranged parallel with it. In the rest of the bone they radiate from the posterior articular surface toward the other parts of the bone.

Development.—By a single centre, which makes its appearance, according to Béclard, about the third year. In two instances I have seen this bone cartilaginous throughout, at a much later period (six years). More rarely, the bone is developed by two centres, placed side by side. Ossification is completed about the age of puberty.

Articulations.—With the two condyles of the femur.

Attachment of Muscles.—To four: the Rectus, Crureus, Vastus internus, and Vastus externus. These muscles, joined at their insertion, constitute the Quadriceps extensor cruris.

Surface Form.—The external surface of the patella can be seen and felt in front of the knee. In the extended position of the limb the internal border is a little more prominent than the outer, and if the Quadriceps extensor is relaxed, the bone can be moved from side to side and appears to be loosely fixed. If the joint is flexed, the patella recedes into the hollow between the condyles of the femur and the upper end of the tibia, and becomes firmly fixed against the femur.

Surgical Anatomy.—The main surgical interest about the patella is in connection with fractures; which are of common occurrence. They may be produced by muscular action; that is to say, by violent contraction of the Quadriceps extensor while the limb is in a position of semi-flexion, so that the bone is snapped across the condyles; or by direct violence, such as falls on the knee. In the former class of cases the fracture is transverse; in the latter it may be oblique, longitudinal, stellate, or the bone variously comminuted. The principal interest in these cases attaches to their treatment. Owing to the wide separation of the fragments, and the difficulty there is in maintaining them in apposition, union takes place by fibrous tissue, and this may subsequently stretch, producing wide separation of the fragments and permanent lameness. Various plans, including opening the joint and suturing the fragments, have been advocated for overcoming this difficulty.

In the larger number of cases of fracture of the patella the knee-joint is involved, the cartilage which covers its posterior surface being also torn. In some cases of fracture from direct violence, however, this need not necessarily happen, the lesion involving only the superficial part of the bone; and, as Morris has pointed out, it is an anatomical possibility, in complete fracture, if the lesion involve only the lower and non-articular part of the bone, for it to take place without injury to the synovial membrane.

The Tibia (Figs. 133, 134).

The **Tibia** (*tibia*, a flute or pipe) is situated at the front and inner side of the leg, and, excepting the femur, is the longest and largest bone in the skeleton. It is prismoid in form, expanded above, where it enters into the knee-joint, more slightly enlarged below. In the male its direction is vertical and parallel with the bone of the opposite side; but in the female it has a slightly oblique direction downward and outward, to compensate for the oblique direction of the femur inward. It presents for examination a shaft and two extremities.

The **Upper Extremity,** or **Head,** is large, and expanded on each side into two lateral eminences, the *tuberosities*. *Superiorly*, the tuberosities present two smooth, concave surfaces, which articulate with the condyles of the femur; the internal, articular surface is longer, deeper, and narrower than the external, oval from before backward, to articulate with the internal condyle; the external one is broader and more circular, concave from side to side, but slightly convex from before backward, especially at its posterior part, where it is prolonged on to the posterior surface for a short distance, to articulate with the external condyle. Between the two articular surfaces, and nearer the posterior than the anterior aspect of the bone, is an eminence, the *spinous process* of the tibia, surmounted by a prominent tubercle on each side, on to the lateral aspect of which the facets just described are prolonged; in front and behind the spinous process is a rough depression for the attachment of the anterior and posterior crucial ligaments and the semilunar fibro-cartilages. The *anterior surfaces* of the tuberosities are continuous with one another, forming a single large surface, which is somewhat

flattened: it is triangular, broad above, and perforated by large vascular foramina; narrow below, where it terminates in a prominent oblong elevation of large size, the *tubercle* of the tibia; the lower half of this tubercle is rough, for the attachment of the ligamentum patellæ; the upper half presents a smooth facet supporting, in the recent state, a bursa which separates the ligament from the bone. *Posteriorly* the tuberosities are separated from each other by a shallow depression, the *popliteal notch*, which gives attachment to part of the posterior crucial ligament and part of the posterior ligament of the knee-joint. The *inner tuberosity* presents posteriorly a deep transverse groove, for the insertion of one of the fasciculi of the tendon of the Semi-membranosus. Its *lateral surface* is convex, rough, and prominent: it gives attachment to the internal lateral ligament. The *outer tuberosity* presents posteriorly a flat articular facet, nearly circular in form, directed downward, backward, and outward, for articulation with the fibula Its lateral surface is convex and rough, more prominent in front than the internal: it presents a prominent rough eminence, situated on a level with the upper border of the tubercle of the tibia at the junction of its anterior and outer surfaces, for the attachment of the ilio-tibial band. Just below this the Extensor longus digitorum and a slip from the Biceps are attached.

The **Shaft** of the tibia is of a triangular prismoid form, broad above, gradually decreasing in size to its most slender part, at the commencement of its lower fourth, where fracture most frequently occurs; it then enlarges again toward its lower extremity. It presents for examination three borders and three surfaces.

The **anterior border**, the most prominent of the three, is called the *crest of the tibia*, or, in popular language, the *shin*; it commences above at the tubercle, and terminates below

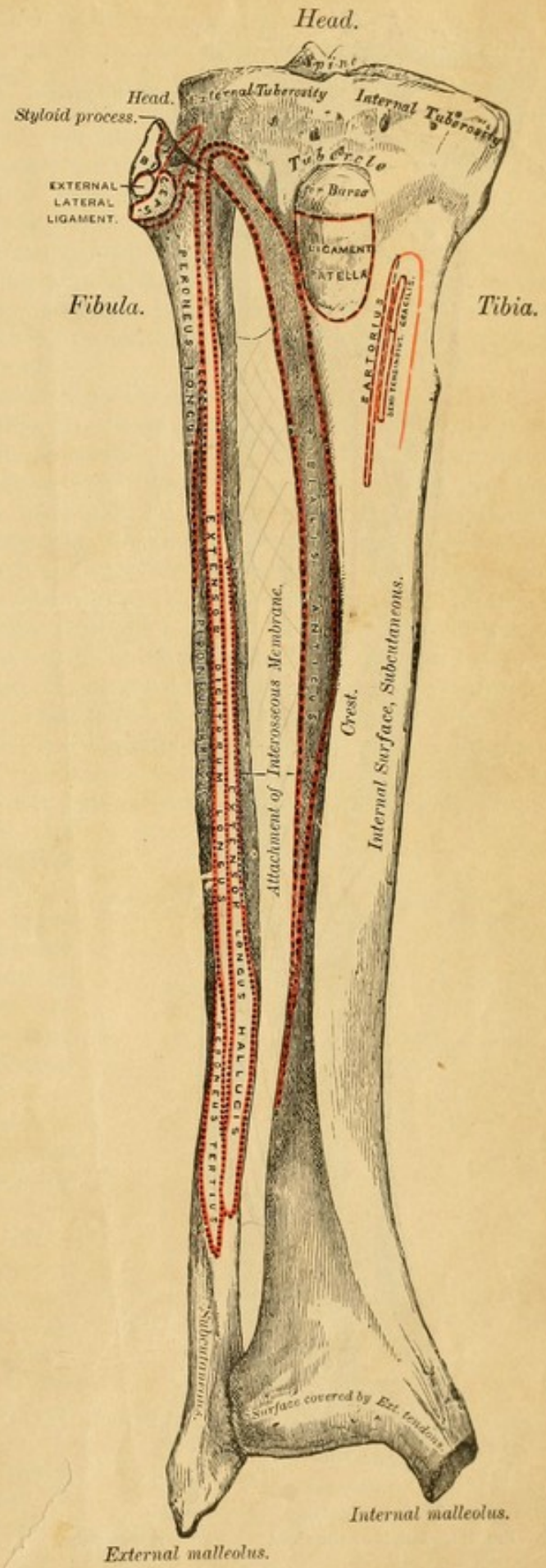

FIG. 133.—Bones of the right leg. Anterior surface.

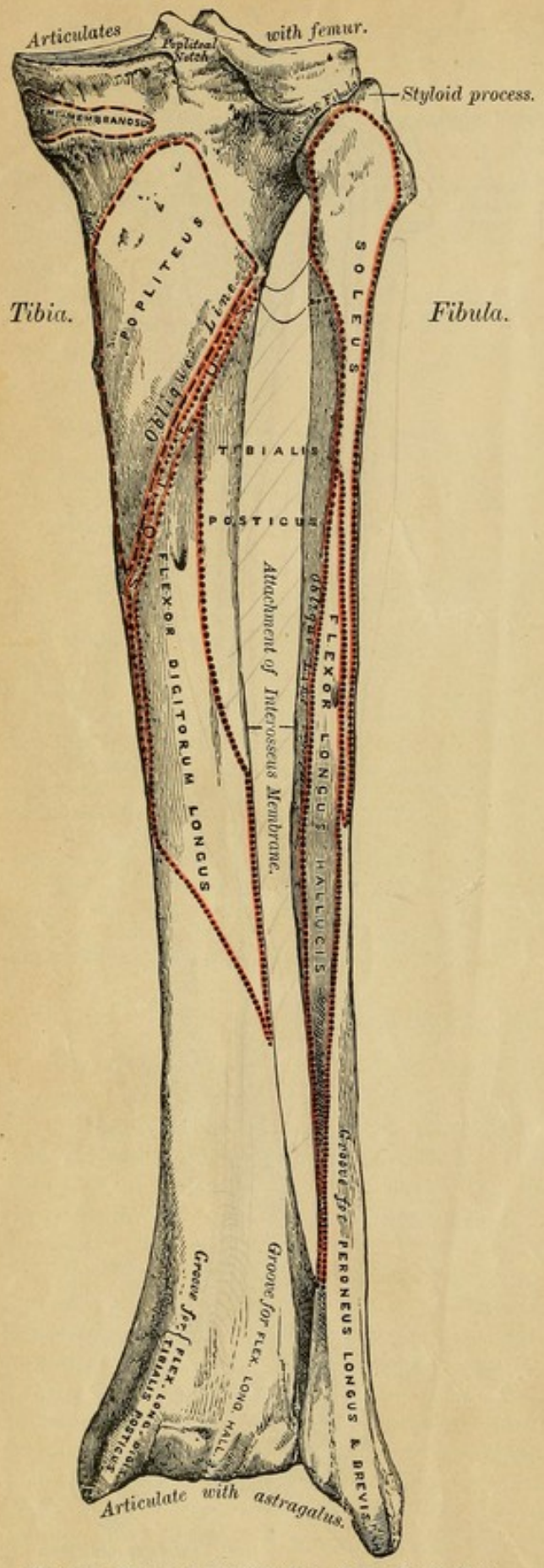

FIG. 134.—Bones of the right leg. Posterior surface.

at the anterior margin of the inner malleolus. This border is very prominent in the upper two-thirds of its extent, smooth and rounded below. It presents a very flexuous course, being usually curved outward above and inward below; it gives attachment to the deep fascia of the leg.

The **internal border** is smooth and rounded above and below, but more prominent in the centre; it commences at the back part of the inner tuberosity, and terminates at the posterior border of the internal malleolus; its upper part gives attachment to the internal lateral ligament of the knee to the extent of about two inches, and to some fibres of the Popliteus muscle; its middle third to some fibres of the Soleus and Flexor longus digitorum muscles.

The **external border,** or **interosseous ridge,** is thin and prominent, especially its central part, and gives attachment to the interosseous membrane; it commences above in front of the fibular articular facet, and bifurcates below, to form the boundaries of a triangular rough surface, for the attachment of the interosseous ligament connecting the tibia and fibula.

The **internal surface** is smooth, convex, and broader above than below; its upper third, directed forward and inward, is covered by the aponeurosis derived from the tendon of the Sartorius, and by the tendons of the Gracilis and Semitendinosus, all of which are inserted nearly as far forward as the anterior border; in the rest of its extent it is subcutaneous.

The **external surface** is narrower than the internal; its upper two-thirds presents a shallow groove for the attachment of the Tibialis anticus muscle; its lower third is smooth, convex, curves gradually forward to the anterior aspect of the bone, and is covered from within outward by the tendons of the following muscles: Tibialis anticus, Extensor proprius hallucis, Extensor longus digitorum.

The **posterior surface** (Fig. 134) presents, at its upper part, a prominent ridge, the *oblique line* of the tibia, which extends from the back part of the articular

facet for the fibula obliquely downward, to the internal border, at the junction of its upper and middle thirds. It marks the lower limit for the insertion of the Popliteus muscle, and serves for the attachment of the popliteal fascia and part of the Soleus, Flexor longus digitorum, and Tibialis posticus muscles; the triangular concave surface, above and to the inner side of this line, gives attachment to the Popliteus muscle. The middle third of the posterior surface is divided by a vertical ridge into two lateral halves: the ridge is well marked at its commencement at the oblique line, but becomes gradually indistinct below; the inner and broader half gives attachment to the Flexor longus digitorum, the outer and narrower to part of the Tibialis posticus. The remaining part of the bone presents a smooth surface covered by the Tibialis posticus, Flexor longus digitorum, and Flexor longus hallucis muscles. Immediately below the oblique line is the medullary foramen, which is large and directed obliquely downward.

The **Lower Extremity,** much smaller than the upper, presents five surfaces; it is prolonged downward, on its inner side, to a strong process, the *internal malleolus.* The *inferior surface* of the bone is quadrilateral, and smooth for articulation with the astragalus. This surface is concave from before backward, and broader in front than behind. It is traversed from before backward by a slight elevation, separating two lateral depressions. It is narrow internally, where the articular surface becomes continuous with that on the inner malleolus. The *anterior surface* of the lower extremity is smooth and rounded above, and covered by the tendons of the Extensor muscles of the toes; its lower margin presents a rough transverse depression, for the attachment of the anterior ligament of the ankle-joint; the *posterior surface* presents a superficial groove directed obliquely downward and inward, continuous with a similar groove on the posterior surface of the astragalus, and serving for the passage of the tendon of the Flexor longus hallucis; the *external surface* presents a triangular rough depression for the attachment of the inferior interosseous ligament, connecting it with the fibula; the lower part of this depression is smooth, covered with cartilage in the recent state, and articulates with the fibula. This surface is bounded by two prominent borders, continuous above with the interosseous ridge; they afford attachment to the anterior and posterior inferior tibio-fibular ligaments. The *internal surface* of the lower extremity is prolonged downward to form a strong pyramidal process, flattened from without inward—the *internal malleolus.* The *inner surface* of this process is convex and subcutaneous; its *outer surface* is smooth and slightly concave, and articulates with the astragalus; its *anterior border* is rough, for the attachment of the anterior fibres of the internal lateral or Deltoid ligament; its *posterior border* presents a broad and deep groove, directed obliquely downward and inward, which is occasionally double: this groove transmits the tendons of the Tibialis posticus and Flexor longus digitorum muscles. The *summit* of the internal malleolus is marked by a rough depression behind, for the attachment of the internal lateral ligament of the ankle-joint.

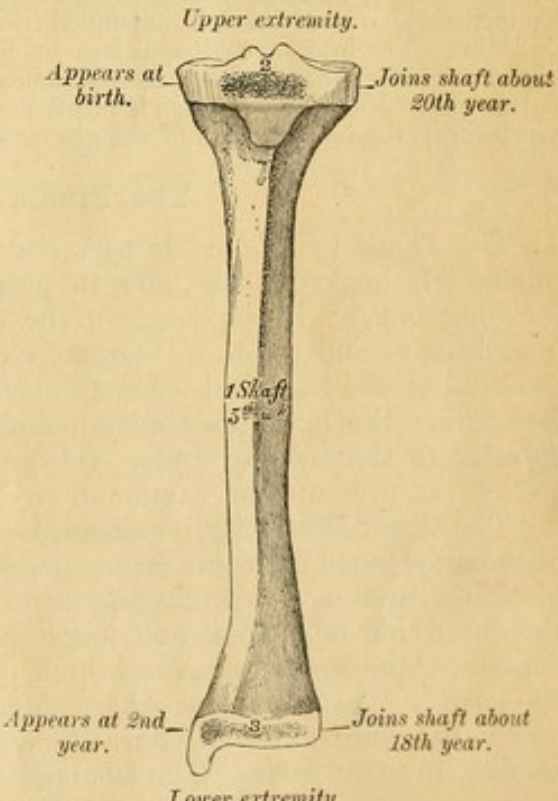

FIG. 135.—Plan of the development of the tibia. By three centres.

Structure.—Like that of the other long bones. At the junction of the middle and lower third, where the bone is smallest, the wall of the shaft is thicker than in other parts, in order to compensate for the smallness of the calibre of the bone.

Development.—By *three* centres (Fig. 135): one for the shaft, and one for each extremity. Ossification commences in the centre of the shaft about the seventh week, and gradually extends toward either extremity. The centre for the upper epiphysis appears before or shortly after birth; it is flattened in form, and has a thin, tongue-shaped process in front which forms the tubercle. That for the lower epiphysis appears in the second year. The lower epiphysis joins the shaft at about the eighteenth, and the upper one about the twentieth, year. Two additional centres occasionally exist—one for the tongue-shaped process of the upper epiphysis, which forms the tubercle, and one for the inner malleolus.

Articulations.—With three bones: the femur, fibula, and astragalus.

Attachment of Muscles.—To twelve: to the inner tuberosity, the Semimembranosus: to the outer tuberosity, the Tibialis anticus and Extensor longus digitorum and Biceps; to the shaft, its internal surface, the Sartorius, Gracilis, and Semitendinosus; to its external surface, the Tibialis anticus; to its posterior surface, the Popliteus, Soleus, Flexor longus digitorum, and Tibialis posticus; to the tubercle, the ligamentum patellæ, by which the Quadriceps extensor muscle is inserted into the tibia. In addition to these muscles, the Tensor fasciæ femoris is inserted indirectly into the tibia, through the ilio-tibial band, and the Peroneus longus occasionally derives a few fibres of origin from the outer tuberosity.

Surface Form.—A considerable portion of the tibia is subcutaneous and easily to be felt. At the upper extremity the tuberosities are to be recognized just below the knee. The internal one is broad and smooth, and merges into the subcutaneous surface of the shaft below. The external one is narrower and more prominent, and on it, about midway between the apex of the patella and the head of the fibula, may be felt a prominent tubercle for the insertion of the ilio-tibial band. In front of the upper end of the bone, between the tuberosities, is the tubercle of the tibia, forming an oval eminence which is continuous below with the anterior border or crest of the bone. This border can be felt, forming the prominence of the shin, in the upper two-thirds of its extent as a sharp and flexuous ridge, curved outward above and inward below. In the lower third of the leg the border disappears, and the bone is concealed by the tendons of the muscles on the front of the leg. Internal to the anterior border is to be felt the broad internal surface of the tibia, slightly encroached upon by the muscles in front and behind. It commences above at the wide expanded inner tuberosity, and terminates below at the internal malleolus. The internal malleolus is a broad prominence situated on a higher level and somewhat farther forward than the external malleolus. It overhangs the inner border of the arch of the foot. Its anterior border is nearly straight; its posterior border presents a sharp edge, which forms the inner margin of the groove for the tendon of the Tibialis posticus muscle.

The Fibula (Figs. 133, 134).

The **Fibula** (*fibula*, a clasp) is situated at the outer side of the leg. It is the smaller of the two bones, and, in proportion to its length, the most slender of all the long bones; it is placed on the outer side of the tibia, with which it is connected above and below. Its upper extremity is small, placed toward the back of the head of the tibia and below the level of the knee-joint, and excluded from its formation; the lower extremity inclines a little forward, so as to be on a plane anterior to that of the upper end, projects below the tibia, and forms the outer ankle. It presents for examination a shaft and two extremities.

The **Upper Extremity,** or **Head,** is of an irregular quadrate form, presenting above a flattened articular facet, directed upward, forward, and inward, for articulation with a corresponding facet on the external tuberosity of the tibia. On the outer side is a thick and rough prominence, continued behind into a pointed eminence, the *styloid process*, which projects upward from the posterior part of the head. The *prominence* gives attachment to the tendon of the Biceps muscle and to the long external lateral ligament of the knee, the ligament dividing the tendon into two parts. The *summit* of the styloid process gives attachment to the short external lateral ligament. The remaining part of the circumference of the head is rough, for the attachment of muscles and ligaments. It presents in front a tubercle for the origin of the upper and anterior part of the Peroneus longus, and the adjacent surface gives attachment to the anterior superior tibio-fibular ligament; and behind, another tubercle for the attachment of the posterior superior tibio-fibular ligament and the upper fibres of the Soleus muscle.

The **shaft** presents four borders—the antero-external, the antero-internal, the postero-external, and the postero-internal; and four surfaces—anterior, posterior, internal, and external.

The antero-external border commences above in front of the head, runs vertically downward to a little below the middle of the bone, and then, curving somewhat outward, bifurcates so as to embrace the triangular subcutaneous surface immediately above the outer surface of the external malleolus. This border gives attachment to an intermuscular septum, which separates the extensor muscles on the anterior surface of the leg from the Peroneus longus and brevis muscles on the outer surface.

The **antero-internal border,** or **interosseous ridge,** is situated close to the inner side of the preceding, and runs nearly parallel with it in the upper third of its extent; but diverges from it so as to include a broader space in the lower two-thirds. It commences above, just beneath the head of the bone (sometimes it is quite indistinct for about an inch below the head), and terminates below at the apex of a rough triangular surface immediately above the articular facet of the external malleolus. It serves for the attachment of the interosseous membrane, which separates the extensor muscles in front from the flexor muscles behind.

The **postero-external border** is prominent; it commences above at the base of the styloid process, and terminates below in the posterior border of the outer malleolus. It is directed outward above, backward in the middle of its course, backward and a little inward below, and gives attachment to an aponeurosis which separates the Peronei muscles on the outer surface of the shaft from the flexor muscles on its posterior surface.

The **postero-internal border,** sometimes called the *oblique line*, commences above at the inner side of the head, and terminates by becoming continuous with the antero-internal border or interosseous ridge at the lower fourth of the bone. It is well marked and prominent at the upper and middle parts of the bone. It gives attachment to an aponeurosis which separates the Tibialis posticus from the Soleus above and the Flexor longus hallucis below.

The **anterior surface** is the interval between the antero-external and antero-internal borders. It is extremely narrow and flat in the upper third of its extent; broader and grooved longitudinally in its lower third; it serves for the attachment of three muscles, the Extensor longus digitorum, Peroneus tertius, and Extensor proprius hallucis.

The **external surface** is the space between the antero-external and postero-external borders. It is much broader than the preceding, and often deeply grooved, is directed outward in the upper two-thirds of its course, backward in the lower third, where it is continuous with the posterior border of the external malleolus. This surface is completely occupied by the Peroneus longus and brevis muscles.

The **internal surface** is the interval included between the antero-internal and the postero-internal borders. It is directed inward, and is grooved for the attachment of the Tibialis posticus muscle.

The **posterior surface** is the space included between the postero-external and the postero-internal borders; it is continuous below with the rough triangular surface above the articular facet of the outer malleolus; it is directed backward above, backward and inward at its middle, directly inward below. Its upper third is rough, for the attachment of the Soleus muscle; its lower part presents a triangular rough surface, connected to the tibia by a strong interosseous ligament, and between these two points the entire surface is covered by the fibres of origin of the Flexor longus hallucis muscle. At about the middle of this surface is the nutrient foramen, which is directed downward.

The **Lower Extremity,** or **external malleolus,** is of a pyramidal form, somewhat flattened from without inward, and is longer, and descends lower than the internal malleolus. Its *external surface* is convex, subcutaneous, and continuous with the triangular (also subcutaneous) surface on the outer side of the shaft. The *internal surface* presents in front a smooth triangular facet, broader above than below, and

convex from above downward, which articulates with a corresponding surface on the outer side of the astragalus. Behind and beneath the articular surface is a rough depression which gives attachment to the posterior fasciculus of the external lateral ligament of the ankle. The *anterior border* is thick and rough, and marked below by a depression for the attachment of the anterior fasciculus of the external lateral ligament. The *posterior border* is broad and marked by a shallow groove, for the passage of the tendons of the Peroneus longus and brevis muscles. The *summit* is rounded, and gives attachment to the middle fasciculus of the external lateral ligament.

In order to distinguish the side to which the bone belongs, hold it with the lower extremity downward and the broad groove for the Peronei tendons backward—*i. e.* toward the holder: the triangular subcutaneous surface will then be directed to the side to which the bone belongs.

Articulations.—With two bones: the tibia and astragalus.

Development.—By *three* centres (Fig. 136): one for the shaft, and one for each extremity. Ossification commences in the shaft about the eighth week of fœtal life, a little later than in the tibia, and extends gradually toward the extremities. At birth both ends are cartilaginous. Ossification commences in the lower end in the second year, and in the upper one about the fourth year. The lower epiphysis, the first in which ossification commences, becomes united to the shaft about the twentieth year; the upper epiphysis joins about the twenty-fifth year. Ossification appearing first in the lower epiphysis is contrary to the rule which prevails with regard to the commencement of ossification in epiphyses—viz. that that epiphysis toward which the nutrient artery is directed commences to ossify last; but it follows the rule which prevails with regard to the union of epiphyses, by uniting first.

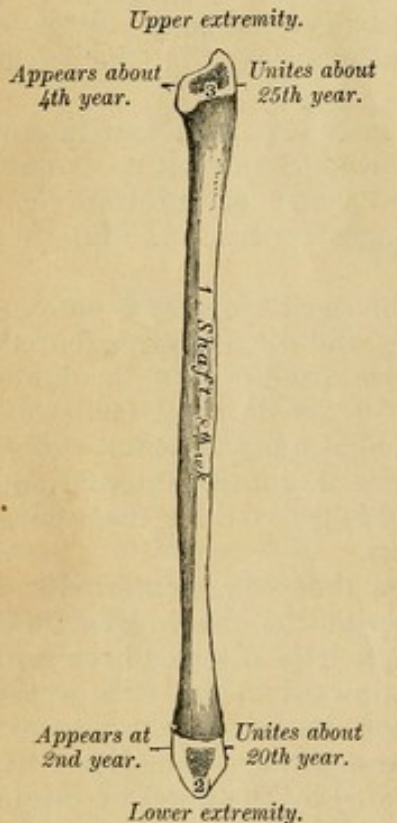

FIG. 136.—Plan of the development of the fibula. By three centres.

Attachment of Muscles.—To nine: to the head, the Biceps, Soleus, and Peroneus longus; to the shaft, its anterior surface, the Extensor longus digitorum, Peroneus tertius, and Extensor proprius hallucis; to the internal surface, the Tibialis posticus; to the posterior surface, the Soleus and Flexor longus hallucis; to the external surface, the Peroneus longus and brevis.

Surface Form.—The only parts of the fibula which are to be felt are the head and the lower part of the external surface of the shaft and the external malleolus. The head is to be seen and felt behind and to the outer side of the outer tuberosity of the tibia. It presents a small, prominent triangular eminence slightly above the level of the tubercle of the tibia. The external malleolus presents a narrow elongated prominence, situated on a plane posterior to the internal malleolus and reaching to a lower level. From it may be traced the lower third or half of the external surface of the shaft of the bone in the interval between the Peroneus tertius in front and the other two Peronei tendons behind.

Surgical Anatomy.—In fractures of the bones of the leg both bones are usually fractured, but each bone may be broken separately, the fibula more frequently than the tibia. Fracture of both bones may be caused either by direct or indirect violence. When it occurs from indirect force, the fracture in the tibia is at the junction of the middle and lower third of the bone. Many causes conduce to render this the weakest part of the bone. The fracture of the fibula is usually at rather a higher level. These fractures present great variety, both as regards their direction and condition. They may be oblique, transverse, longitudinal, or spiral. When oblique, they are usually the result of indirect violence, and the direction of the fracture is from behind, downward, forward, and inward in many cases, but may be downward and outward or downward and backward. When transverse, the fracture is often at the upper part of the bone, and is the result of direct violence. The spiral fracture usually commences as a vertical fissure, involving the ankle-joint, and is associated with fracture of the fibula higher up. It is the result of torsion, from twisting of the body whilst the foot is fixed.

Fractures of the tibia alone are almost always the result of direct violence, except where the malleolus is broken off by twists of the foot. Fractures of the fibula alone may arise from indirect or direct force, those of the lower end being usually the result of the former, and those higher up being caused by a direct blow on the part.

The tibia and fibula, like the femur, are frequently the seat of acute necrosis. Chronic abscess is more frequently met with in the cancellous tissue of the head and lower end of the tibia than in any other bone of the body. The abscess is of small size, very chronic, and probably the result of tuberculous osteitis in the highly vascular growing tissue at the end of the shaft near the epiphyseal cartilage in the young subject.

The tibia is the bone which is most frequently and most extensively distorted in rickets. It gives way at the junction of the middle and lower third, its weakest part, and presents a curve forward and outward.

THE FOOT (Figs. 137, 138).

The skeleton of the Foot consists of three divisions: the Tarsus, Metatarsus, and Phalanges.

The Tarsus.

The bones of the **Tarsus** are seven in number: viz., the calcaneum or os calcis, astragalus, cuboid, navicular, internal, middle, and external cuneiform bones.

The Calcaneum (Fig. 139).

The **Calcaneum**, or **Os Calcis** (*calx*, the heel), is the largest and strongest of the tarsal bones. It is irregularly cuboidal in form, having its long axis directed forward and outward. It is situated at the lower and back part of the foot, serving to transmit the weight of the body to the ground, and forming a strong lever for the muscles of the calf. It presents for examination six surfaces: superior, inferior, external, internal, anterior, and posterior.

The **superior surface** is formed behind by the upper aspect of that part of the os calcis which projects backward to form the heel. It varies in length in different individuals; is convex from side to side, concave from before backward, and corresponds above to a mass of adipose substance placed in front of the tendo Achillis. In the middle of the superior surface are two (sometimes three) articular facets, separated by a broad shallow groove, which is directed obliquely forward and outward, and is rough for the attachment of the interosseous ligament connecting the astragalus and os calcis. Of the two articular surfaces, the *external* is the larger, and situated on the body of the bone: it is of an oblong form, wider behind than in front, and convex from before backward. The *internal articular surface* is supported on a projecting process of bone, called the *lesser process* of the calcaneum (*sustentaculum tali*); it is also oblong, concave longitudinally, and sometimes subdivided into two parts, which differ in size and shape. More anteriorly is seen the upper surface of the *greater process*, marked by a rough depression for the attachment of numerous ligaments, and a tubercle for the origin of the Extensor brevis digitorum muscle.

The **inferior surface** is narrow, rough, uneven, wider behind than in front and convex from side to side; it is bounded posteriorly by two tubercles separated by a rough depression; the *external*, small, prominent, and rounded, gives attachment to part of the Abductor minimi digiti: the *internal*, broader and larger, for the support of the heel, gives attachment, by its prominent inner margin, to the Abductor hallucis, and in front to the Flexor brevis digitorum muscles and plantar fascia; the depression between the tubercles gives attachment to the Abductor minimi digiti. The rough surface in front of the tubercles gives attachment to the long plantar ligament and to the outer head of the Flexor accessorius muscle; while to a prominent tubercle nearer the anterior part of this surface, as well as to a transverse groove in front of it, is attached the short plantar ligament.

The **external surface** is broad, flat, and almost subcutaneous; it presents near its centre a tubercle, for the attachment of the middle fasciculus of the external lateral ligament. At its upper and anterior part this surface gives attachment to

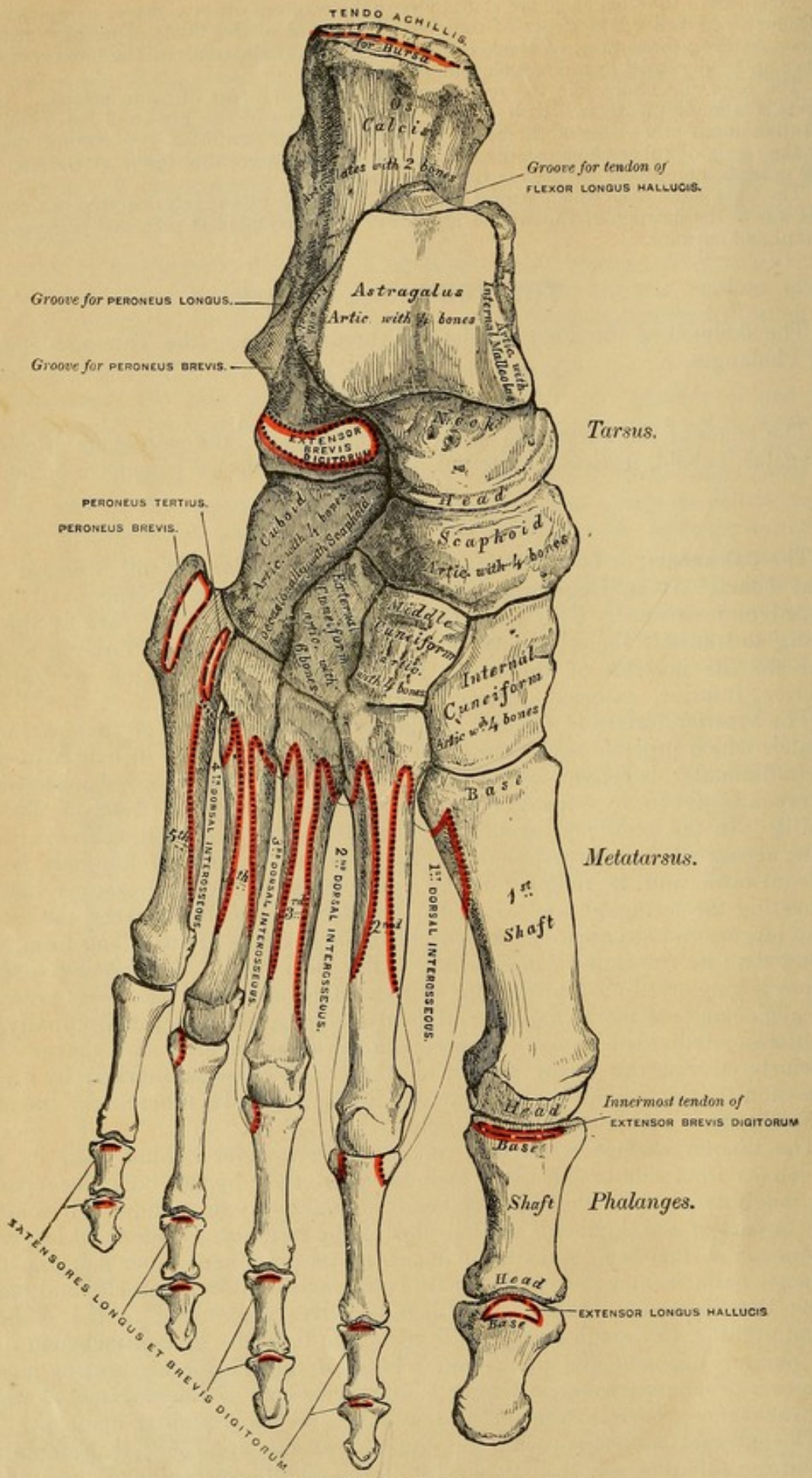

FIG. 137.—Bones of the right foot. Dorsal surface.

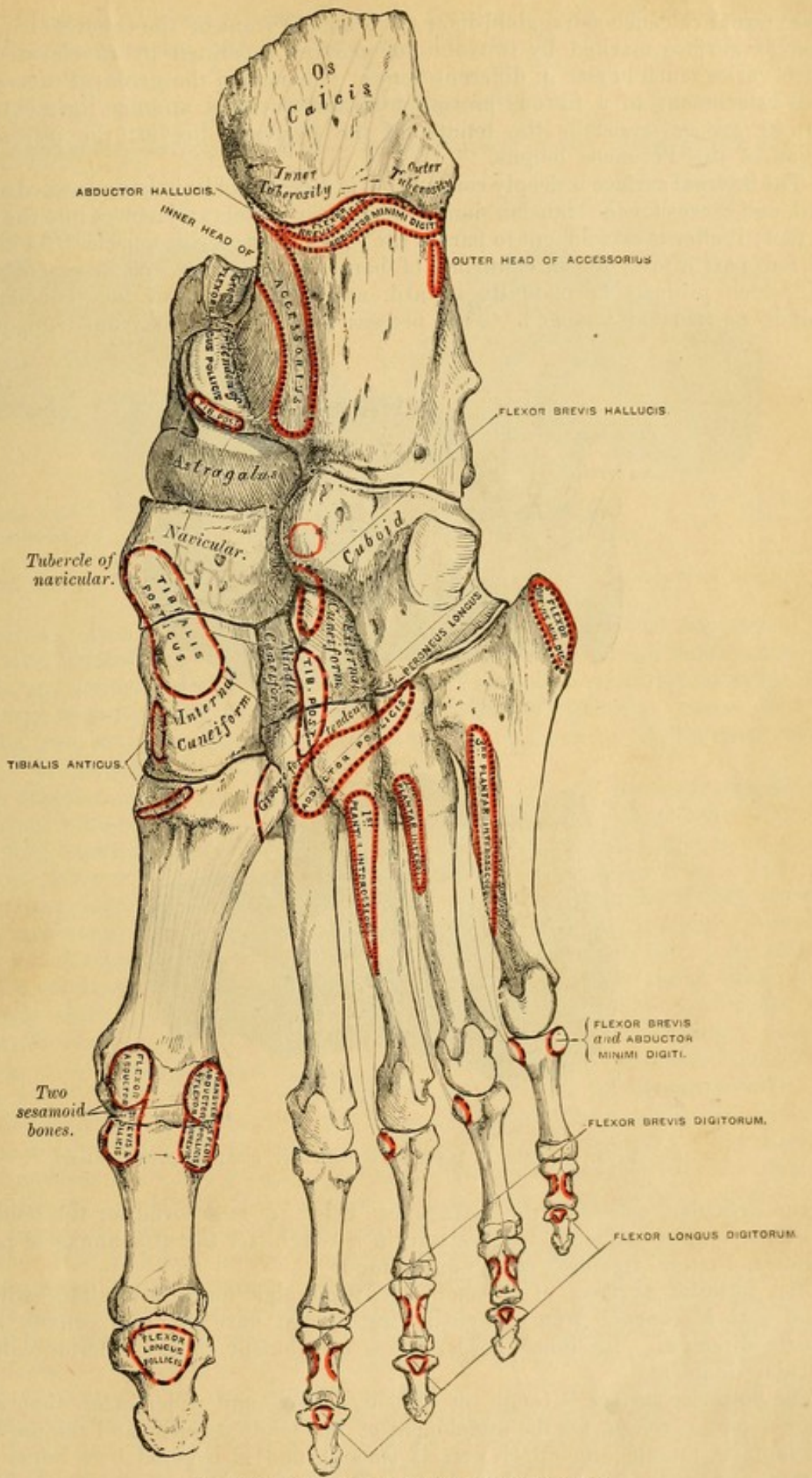

FIG. 138.—Bones of the right foot. Plantar surface.

the external calcaneo-astragaloid ligament: and in front of the tubercle it presents a narrow surface marked by two oblique grooves, separated by an elevated ridge which varies much in size in different bones; it is named the *peroneal tubercle*, and gives attachment to a fibrous process from the external annular ligament. The *superior groove* transmits the tendon of the Peroneus brevis; the *inferior*, the tendon of the Peroneus longus.

The **internal surface** is deeply concave; it is directed obliquely downward and forward, and serves for the transmission of the plantar vessels and nerves into the sole of the foot; it affords attachment to part of the Flexor accessorius muscle. At its upper and fore part it presents an eminence of bone, the *lesser process* or *sustentaculum tali*, which projects horizontally inward, and to it a slip of the tendon of the Tibialis posticus is attached. This process is concave above, and supports the

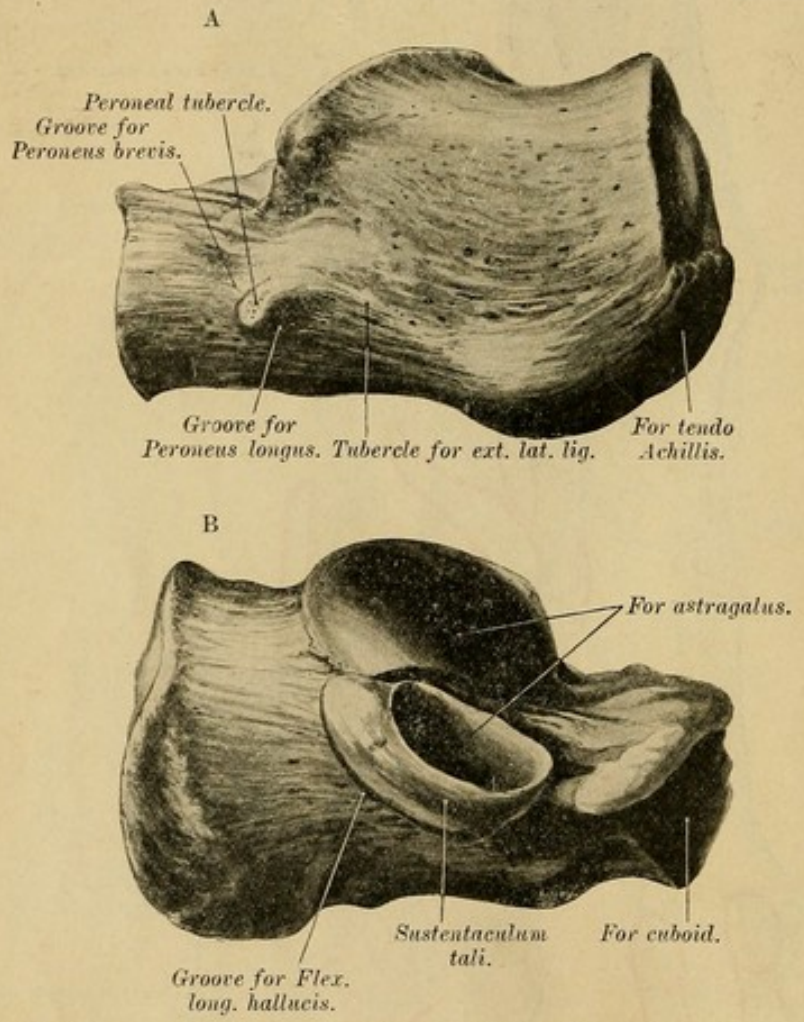

FIG. 139.—The left os calcis. A. Postero-external view. B. Antero-internal view.

anterior articular surface of the astragalus; below, it is grooved for the tendon of the Flexor longus hallucis. Its free margin is rough, for the attachment of part of the internal lateral ligament of the ankle-joint.

The **anterior surface**, of a somewhat triangular form, articulates with the cuboid. It is concave from above downward and outward, and convex in the opposite direction. Its inner border gives attachment to the inferior calcaneo-navicular ligament.

The **posterior surface** is rough, prominent, convex, and wider below than above. Its lower part is rough, for the attachment of the tendo Achillis and the tendon of the Plantaris muscle; its upper part is smooth, and is covered by a bursa which separates the tendons from the bone.

Articulations.—With two bones: the astragalus and cuboid.

Attachment of Muscles.—To eight: part of the Tibialis posticus, the tendo

Achillis, Plantaris, Abductor hallucis, Abductor minimi digiti, Flexor brevis digitorum, Flexor accessorius, and Extensor brevis digitorum.

The Astragalus (Fig. 140).

The **Astragalus** (*ἀστράγαλος*, a die) is the largest of the tarsal bones, next to

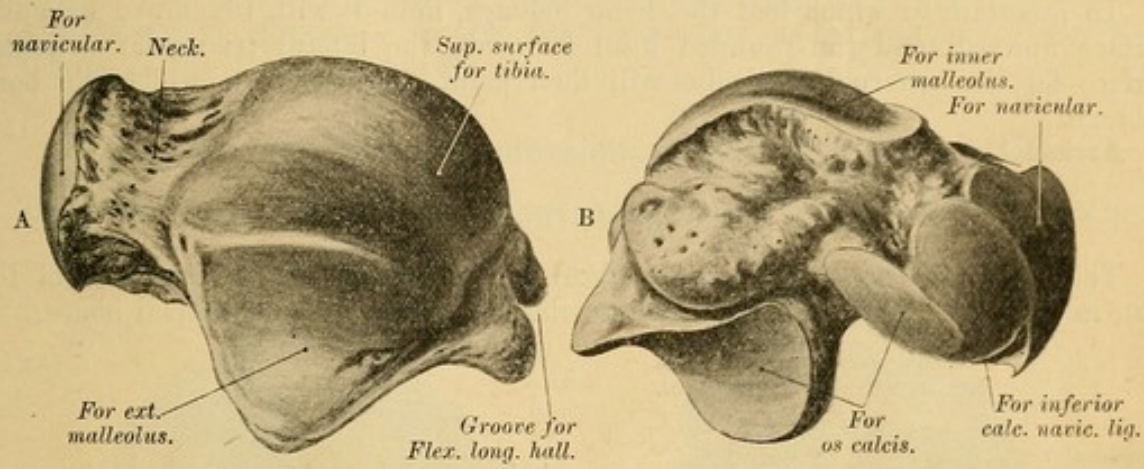

FIG. 140.—The left astragalus. A. Superior and external view. B. Inferior and internal view.

the os calcis. It occupies the middle and upper part of the tarsus, supporting the tibia above, articulating with the malleoli on either side, resting below upon the os calcis, and joined in front to the navicular. This bone may easily be recognized by its large rounded head, by the broad articular facet on its upper convex surface, or by the two articular facets separated by a deep groove on its under concave surface. It presents six surfaces for examination.

The **superior surface** presents, behind, a broad smooth trochlear surface for articulation with the tibia. The trochlea is broader in front than behind, convex from before backward, slightly concave from side to side; in front of it is the upper surface of the neck of the astragalus, rough for the attachment of ligaments. The *inferior surface* presents two articular facets separated by a deep groove. The groove runs obliquely forward and outward, becoming gradually broader and deeper in front: it corresponds with a similar groove upon the upper surface of the os calcis, and forms, when articulated with that bone, a canal, filled up in the recent state by the interosseous calcaneo-astragaloid ligament. Of the two articular facets, the posterior is the larger, of an oblong form and deeply concave from side to side; the anterior is shorter and narrower, of an elongated oval form, convex longitudinally, and often subdivided into two by an elevated ridge; of these, the posterior articulates with the lesser process of the os calcis; the anterior, with the upper surface of the inferior calcaneo-navicular ligament. The *internal surface* presents at its upper part a pear-shaped articular facet for the inner malleolus, continuous above with the trochlear surface; below the articular surface is a rough depression, for the attachment of the deep portion of the internal lateral ligament. The *external surface* presents a large triangular facet, concave from above downward for articulation with the external malleolus; it is continuous above with the trochlear surface; and in front of it is a rough depression for the attachment of the anterior fasciculus of the external lateral ligament of the ankle-joint. The *anterior surface*, convex and rounded, forms the *head* of the astragalus; it is smooth, of an oval form, and directed obliquely inward and downward; it articulates with the navicular. On its under and inner surface is a small facet, continuous in front with the articular surface of the head, and behind with the smaller facet for the os calcis. This rests on the inferior calcaneo-navicular ligament, being separated from it by the synovial membrane, which is prolonged from the anterior calcaneo-astragaloid joint to the astragalo-navicular joint. The head is surrounded

by a constricted portion, the *neck* of the astragalus. The *posterior surface* is narrow, and traversed by a groove, which runs obliquely downward and inward, and transmits the tendon of the Flexor longus hallucis, external to which is a prominent tubercle, to which the posterior fasciculus of the external lateral ligament is attached. This tubercle is sometimes separated from the rest of the astragalus, and is then known as the *os trigonum*. To the inner side of the groove is a second, but less marked, tubercle.

To ascertain to which foot the bone belongs, hold it with the broad articular surface upward, and the rounded head forward; the lateral triangular articular surface for the external malleolus will then point to the side to which the bone belongs.

Articulations.—With four bones: tibia, fibula, os calcis, and navicular.

The Cuboid (Fig. 141).

The **Cuboid** (κύβος, a cube; εἶδος, like) bone is placed on the outer side of the foot, in front of the os calcis, and behind the fourth and fifth metatarsal bones. It

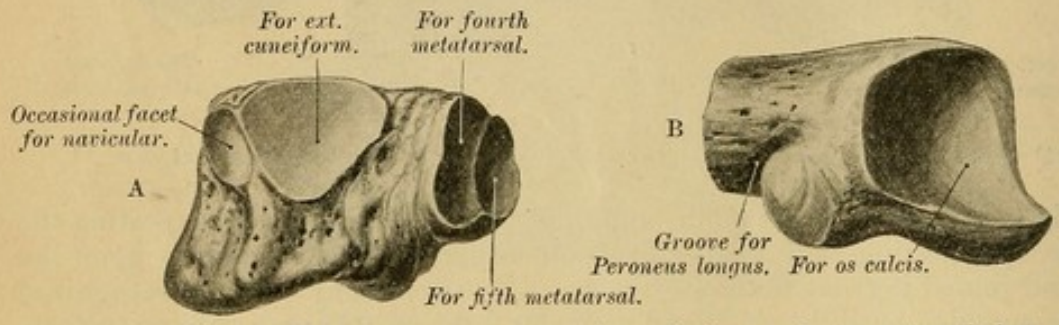

FIG. 141.—The left cuboid. A. Antero-internal view. B. Postero-external view.

is of a pyramidal shape, its base being directed inward, its apex outward. It may be distinguished from the other tarsal bones by the existence of a deep groove on its under surface, for the tendon of the Peroneus longus muscle. It presents for examination six surfaces: three articular and three non-articular.

The **non-articular surfaces** are the superior, inferior, and external. The *superior* or *dorsal surface*, directed upward and outward, is rough, for the attachment of numerous ligaments. The *inferior* or *plantar surface* presents in front a deep groove, which runs obliquely from without, forward and inward; it lodges the tendon of the Peroneus longus, and is bounded behind by a prominent ridge, to which is attached the long calcaneo-cuboid ligament. The ridge terminates externally in an eminence, the *tuberosity of the cuboid*, the surface of which presents a convex facet, for articulation with the sesamoid bone of the tendon contained in the groove. The surface of bone behind the groove is rough, for the attachment of the short plantar ligament, a few fibres of the Flexor brevis hallucis, and a fasciculus from the tendon of the Tibialis posticus. The *external surface*, the smallest and narrowest of the three, presents a deep notch formed by the commencement of the peroneal groove.

The **articular surfaces** are the posterior, anterior, and internal. The *posterior surface* is smooth, triangular, and concavo-convex, for articulation with the anterior surface of the os calcis. The *anterior*, of smaller size, but also irregularly triangular, is divided by a vertical ridge into two facets: the inner one, quadrilateral in form, articulates with the fourth metatarsal bone; the outer one, larger and more triangular, articulates with the fifth metatarsal. The *internal surface* is broad, rough, irregularly quadrilateral, presenting at its middle and upper part a smooth oval facet, for articulation with the external cuneiform bone; and behind this (occasionally) a smaller facet, for articulation with the navicular; it is rough in the rest of its extent, for the attachment of strong interosseous ligaments.

To ascertain to which foot the bone belongs, hold it so that its under surface, marked by the peroneal groove, looks downward, and the large concavo-convex articular surface backward toward the holder: the narrow non-articular surface, marked by the commencement of the peroneal groove, will point to the side to which the bone belongs.

Articulations.—With four bones: the os calcis, external cuneiform, and the fourth and fifth metatarsal bones; occasionally with the navicular.

Attachment of Muscles.—Part of the Flexor brevis hallucis and a slip from the tendon of the Tibialis posticus.

The Navicular (Fig. 142).

The **Navicular** or **Scaphoid bone** is situated at the inner side of the tarsus,

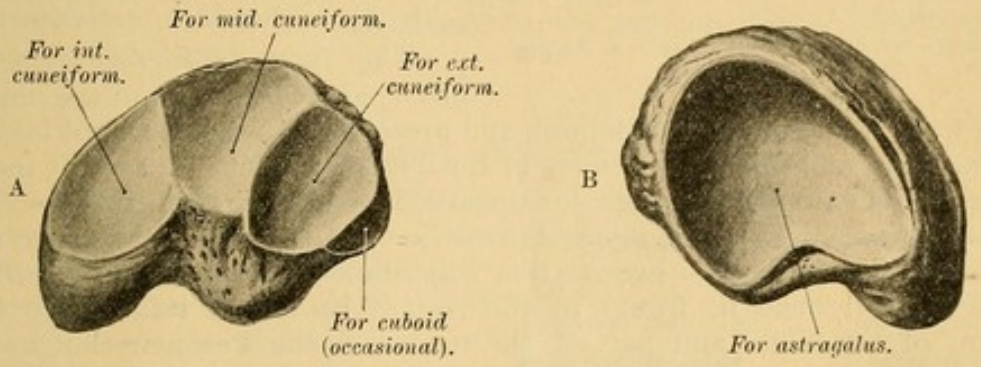

FIG. 142.—The left navicula r. A. Antero-external view. B. Postero-internal view.

between the astragalus behind and the three cuneiform bones in front. It may be distinguished by its form, being concave behind, convex and subdivided into three facets in front.

The *anterior surface*, of an oblong form, is convex from side to side, and subdivided by two ridges into three facets, for articulation with the three cuneiform bones. The *posterior surface* is oval, concave, broader externally than internally, and articulates with the rounded head of the astragalus. The *superior surface* is convex from side to side, and rough for the attachment of ligaments. The *inferior* is irregular, and also rough for the attachment of ligaments. The *internal surface* presents a rounded tubercular eminence, the *tuberosity* of the navicular, the lower part of which projects, and gives attachment to part of the tendon of the Tibialis posticus. The *external surface* is rough and irregular, for the attachment of ligamentous fibres, and occasionally presents a small facet for articulation with the cuboid bone.

To ascertain to which foot the bone belongs, hold it with the concave articular surface backward, and the convex dorsal surface upward; the external surface—*i. e.* the surface opposite the tubercle—will point to the side to which the bone belongs.

Articulations.—With four bones: astragalus and three cuneiform; occasionally also with the cuboid.

Attachment of Muscles.—Part of the Tibialis posticus.

The Cuneiform Bones.

The **Cuneiform Bones** have received their name from their wedge-like shape (*cuneus*, a wedge; *forma*, likeness). They form, with the cuboid, the anterior row of the tarsus, being placed between the navicular behind, the three innermost metatarsal bones in front, and the cuboid externally. They are called the *first*, *second*, and *third*, counting from the inner to the outer side of the foot, and, from their position, *internal*, *middle*, and *external*.

The Internal Cuneiform (Fig. 143).

The **Internal Cuneiform** is the largest of the three. It is situated at the inner side of the foot, between the navicular behind and the base of the first metatarsal in front. It may be distinguished from the other two by its large size, and by its not presenting such a distinct wedge-like form. Without the others it may be known by the large, kidney-shaped anterior articulating surface and by the prominence on the inferior or plantar surface for the attachment of the Tibialis posticus. It presents for examination six surfaces.

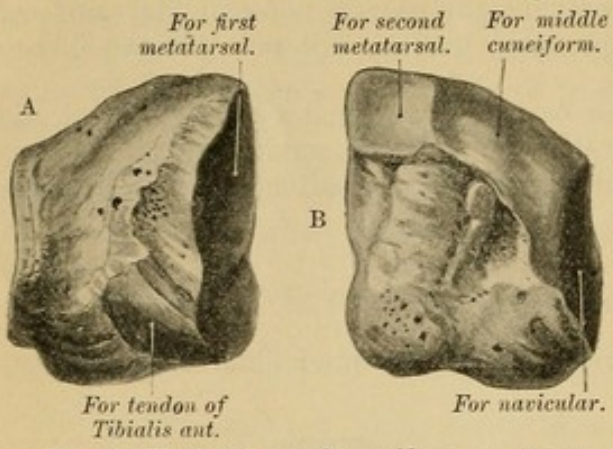

FIG. 143.—The left internal cuneiform. A. Antero-internal view. B. Postero-external view.

The *internal surface* is subcutaneous, and forms part of the inner border of the foot; it is broad, quadrilateral, and presents at its anterior inferior angle a smoot oval facet, into which the tendon of the Tibialis anticus is partially inserted; in the rest of its extent it is rough, for the attachment of ligaments. The *external surface* is concave, presenting, along its superior and posterior borders, a narrow reversed L-shaped surface for articulation with the middle cuneiform behind, and second metatarsal bone in front; in the rest of its extent it is rough for the attachment of ligaments and part of the tendon of the Peroneus longus. The *anterior surface*, kidney-shaped, much larger than the posterior, articulates with the metatarsal bone of the great toe. The *posterior surface* is triangular, concave, and articulates with the innermost and largest of the three facets on the anterior surface of the navicular. The *inferior* or *plantar surface* is rough, and presents a prominent tuberosity at its back part for the attachment of part of the tendon of the Tibialis posticus. It also gives attachment in front to part of the tendon of the the Tibialis anticus. The *superior surface* is the narrow-pointed end of the wedge, which is directed upward and outward; it is rough for the attachment of ligaments.

To ascertain to which side the bone belongs, hold it so that its superior narrow edge looks upward, and the long, kidney-shaped, articular surface forward; the external surface, marked by its vertical and horizontal articular facets, will point to the side to which it belongs.

Articulations.—With four bones: navicular, middle cuneiform, first and second metatarsal bones.

Attachment of Muscles.—To three: the Tibialis anticus and posticus, and Peroneus longus.

The Middle Cuneiform (Fig. 144).

The **Middle Cuneiform**, the smallest of the three, is of very regular wedge-like form, the broad extremity being placed upward, the narrow end downward. It is situated between the other two bones of the same name, and articulates with the navicular behind and the second metatarsal in front. It is smaller than the external cuneiform bone, from which it may be further distinguished by the L-shaped articular facet, which runs round the upper and back part of its inner surface.

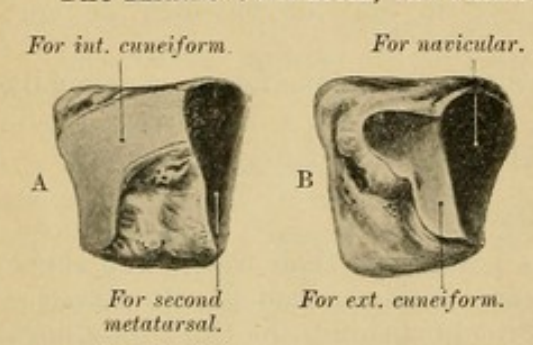

FIG. 144.—The left middle cuneiform. A. Antero-internal view. B. Postero-external view.

The *anterior surface*, triangular in form and narrower than the posterior, articulates with the base of the second metatarsal bone. The *posterior surface*, also triangular, articulates with the navicular.

The *internal surface* presents a reversed L-shaped articular facet, running along the superior and posterior borders, for articulation with the internal cuneiform, and is rough in the rest of its extent for the attachment of ligaments. The *external surface* presents posteriorly a smooth facet for articulation with the external cuneiform bone. The *superior surface* forms the base of the wedge; it is quadrilateral, broader behind than in front, and rough for the attachment of ligaments. The *inferior surface*, pointed and tubercular, is also rough for ligamentous attachment and for the insertion of a slip from the tendon of the Tibialis posticus.

To ascertain to which foot the bone belongs, hold its superior or dorsal surface upward, the broadest edge being toward the holder: the smooth facet (limited to the posterior border) will then point to the side to which it belongs.

Articulations.—With four bones: navicular, internal and external cuneiform, and second metatarsal bone.

Attachment of Muscles.—A slip from the tendon of the Tibialis posticus is attached to this bone.

The External Cuneiform (Fig. 145).

The **External Cuneiform**, intermediate in size between the two preceding, is of a very regular wedge-like form, the broad extremity being placed upward, the narrow end downward. It occupies the centre of the front row of the tarsus, between the middle cuneiform internally, the cuboid externally, the navicular behind, and the third metatarsal in front. It is distinguished from the internal cuneiform bone by its more regular wedge-like shape and by the absence of the kidney-shaped articular surface: from the middle cuneiform, by the absence of the reversed L-shaped facet, and by the two articular facets which are present on both its inner and outer surfaces. It has six surfaces for examination.

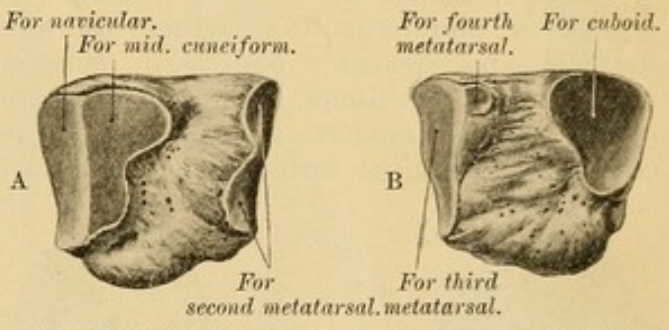

Fig. 145.—The left external cuneiform. A. Postero-internal view. B. Antero-external view.

The *anterior surface*, triangular in form, articulates with the third metatarsal bone. The *posterior surface* articulates with the most external facet of the navicular, and is rough below for the attachment of ligamentous fibres. The *internal surface* presents two articular facets, separated by a rough depression; the anterior one, sometimes divided into two, articulates with the outer side of the base of the second metatarsal bone; the posterior one skirts the posterior border and articulates with the middle cuneiform; the rough depression between the two gives attachment to an interosseous ligament. The *external surface* also presents two articular facets, separated by a rough non-articular surface; the anterior facet, situated at the superior angle of the bone, is small, and articulates with the inner side of the base of the fourth metatarsal; the posterior and larger one articulates with the cuboid; the rough, non-articular surface serves for the attachment of an interosseous ligament. The three facets for articulation with the three metatarsal bones are continuous with one another, and covered by a prolongation of the same cartilage; the facets for articulation with the middle cuneiform and navicular are also continuous, but that for articulation with the cuboid is usually separate. The *superior* or *dorsal surface* is of an oblong square form, its posterior external angle being prolonged backward. The *inferior* or *plantar surface* is an obtuse rounded margin, and serves for the attachment of part of the tendon of the Tibialis posticus, part of the Flexor brevis hallucis, and ligaments.

To ascertain to which side the bone belongs, hold it with the broad dorsal

surface upward, the prolonged edge backward; the separate articular facet for the cuboid will point to the proper side.

Articulations.—With six bones: the navicular, middle cuneiform, cuboid, and second, third, and fourth metatarsal bones.

Attachment of Muscles.—To two: part of the Tibialis posticus, and Flexor brevis hallucis.

The number of tarsal bones may be reduced owing to congenital ankylosis, which may occur between the os calcis and cuboid, the os calcis and navicular, the os calcis and astragalus, or the astragalus and navicular.

The Metatarsal Bones.

The **Metatarsal Bones** are five in number, and are numbered one to five, in accordance with their position from within outward; they are long bones, and present for examination a shaft and two extremities.

Common Characters.—The *shaft* is prismoid in form, tapers gradually from the tarsal to the phalangeal extremity, and is slightly curved longitudinally, so as to be concave below, slightly convex above. The *posterior extremity*, or *base*, is wedge-shaped, articulating by its terminal surface with the tarsal bones, and by its lateral surfaces with the contiguous metatarsal bones, its dorsal and plantar surfaces being rough for the attachment of ligaments. The *anterior extremity*, or *head*, presents a terminal rounded articular surface, oblong from above downward, and extending farther backward below than above. Its sides are flattened and present a depression, surmounted by a tubercle, for ligamentous attachment. Its under surface is grooved in the middle line for the passage of the Flexor tendon, and marked on each side by an articular eminence continuous with the terminal articular surface.

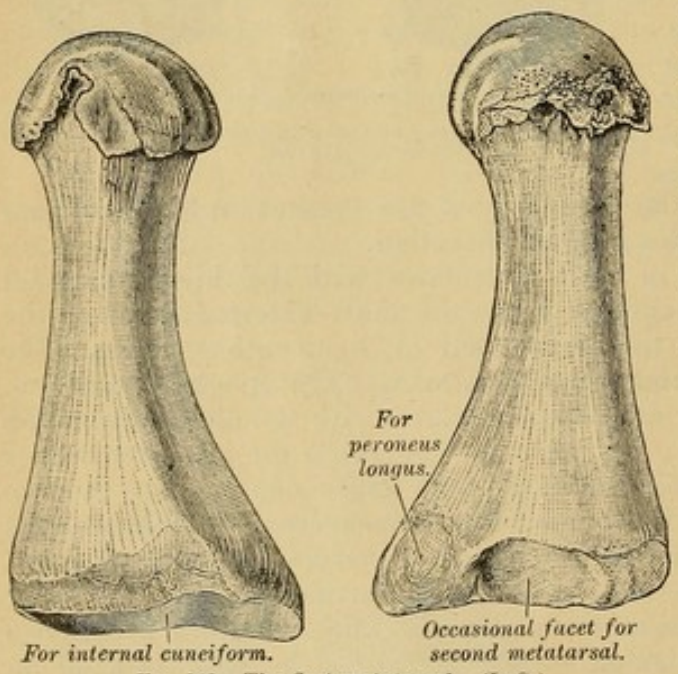

FIG. 146.—The first metatarsal. (Left.)

Peculiar Characters.—The **First** (Fig. 146) is remarkable for its great thickness, but is the shortest of all the metatarsal bones. The *shaft* is strong and of well-marked prismoid form. The *posterior extremity* presents, as a rule, no lateral articular facet, but occasionally on the outer side there is an oval facet by which it articulates with the second metatarsal bones. Its terminal articular surface is of large size, kidney-shaped; its circumference is grooved, for the tarso-metatarsal ligaments, and internally gives attachment to part of the tendon of the Tibialis anticus: its inferior angle presents a rough oval prominence for the insertion of the tendon of the Peroneus longus. The *head* is of large size; on its plantar surface are two grooved facets, over which glide sesamoid bones; the facets are separated by a smooth elevated ridge.

This bone is known by the single kidney-shaped articular surface on its base, the deeply grooved appearance of the plantar surface of its head, and its great thickness relatively to its length. When it is placed in its natural position, the concave border of the kidney-shaped articular surface on its base points to the side to which the bone belongs.

Attachment of Muscles.—To three: part of the Tibialis anticus, the Peroneus longus, and the First dorsal interosseous.

The **Second** (Fig. 147) is the longest and largest of the remaining metatarsal bones, being prolonged backward into the recess formed between the three cuneiform bones. Its *tarsal extremity* is broad above, narrow and rough below. It presents four articular surfaces: one behind, of a triangular form, for articulation with the middle cuneiform; one at the upper part of its internal lateral surface, for articulation with the internal cuneiform: and two on its external lateral surface—an upper and a lower, separated by a rough non-articular interval. Each of these articular surfaces is divided by a vertical ridge into two facets, thus making four facets; the two anterior of these articulate with the third metatarsal; the two posterior (sometimes continuous) with the external cuneiform. In addition

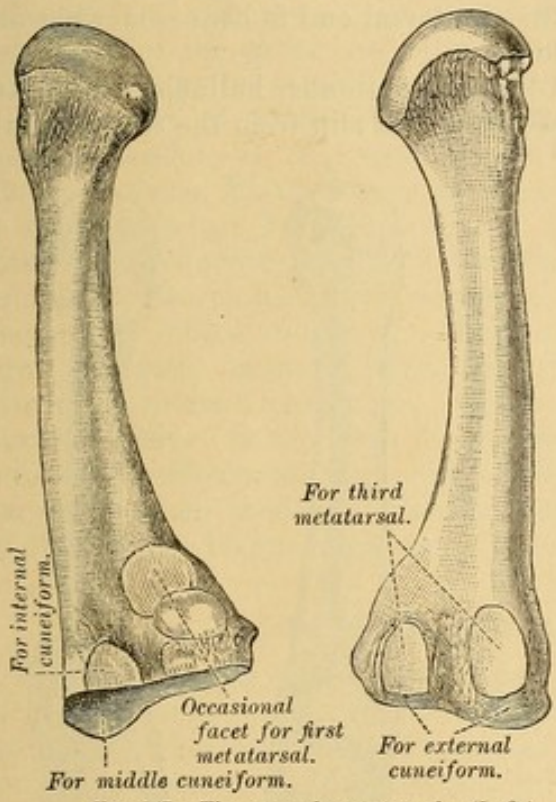

FIG. 147.—The second metatarsal. (Left.)

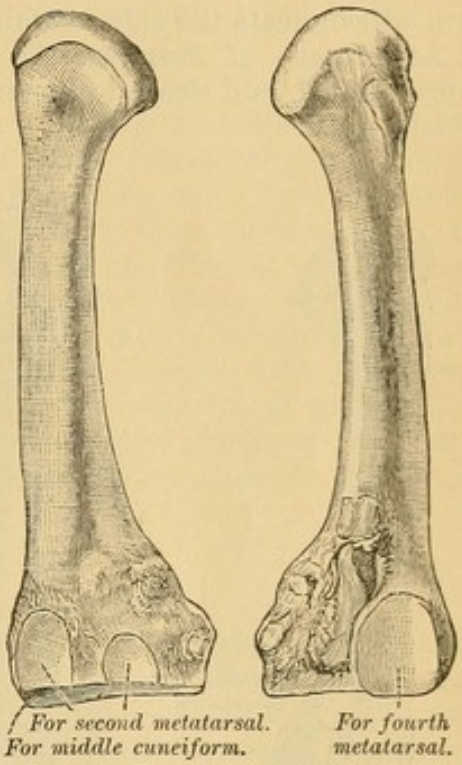

FIG. 148.—The third metatarsal. (Left.)

to these articular surfaces there is occasionally a fifth when this bone articulates with the first metatarsal bone. It is oval in shape, and is situated on the inner side of the shaft near the base.

The facets on the tarsal extremity of the second metatarsal bone serve at once to distinguish it from the rest, and to indicate the foot to which it belongs; there being one facet at the upper angle of the internal surface, and two facets, each subdivided into two parts, on the external surface, pointing to the side to which the bone belongs. The fact that the two posterior subdivisions of these external facets sometimes run into one should not be forgotten.

Attachment of Muscles.—To four: the Adductor obliquus hallucis, First and Second dorsal interosseous, and a slip from the tendon of the Tibialis posticus; occasionally also a slip from the Peroneus longus.

The **Third** (Fig. 148) articulates behind, by means of a triangular smooth surface, with the external cuneiform; on its inner side, by two facets, with the second metatarsal; and on its outer side, by a single facet, with the fourth metatarsal. The latter facet is of circular form and situated at the upper angle of the base.

The third metatarsal is known by its having at its tarsal end two undivided facets on the inner side, and a single facet on the outer. This distinguishes it from the second metatarsal, in which the two facets, found on one side of its tarsal end, are each subdivided into two. The single facet (when the bone is put in its natural position) is on the side to which the bone belongs.

Attachment of Muscles.—To five: Adductor obliquus hallucis, Second and Third dorsal, and First plantar interosseous, and a slip from the tendon of the Tibialis posticus.

The **Fourth** (Fig. 149) is smaller in size than the preceding; its *tarsal extremity* presents a terminal quadrilateral surface, for articulation with the cuboid; a smooth facet on the inner side, divided by a ridge into an anterior portion for articulation with the third metatarsal, and a posterior portion for articulation with the external cuneiform; on the outer side a single facet, for articulation with the fifth metatarsal.

The fourth metatarsal is known by its having a single facet on either side of the tarsal extremity, that on the inner side being divided into two parts. If this subdivision be not recognizable, the fact that its tarsal end is bent somewhat outward will indicate the side to which it belongs.

Attachment of Muscles.—To five: Adductor obliquus hallucis, Third and Fourth dorsal, and Second plantar interosseous, and a slip from the tendon of the Tibialis posticus.

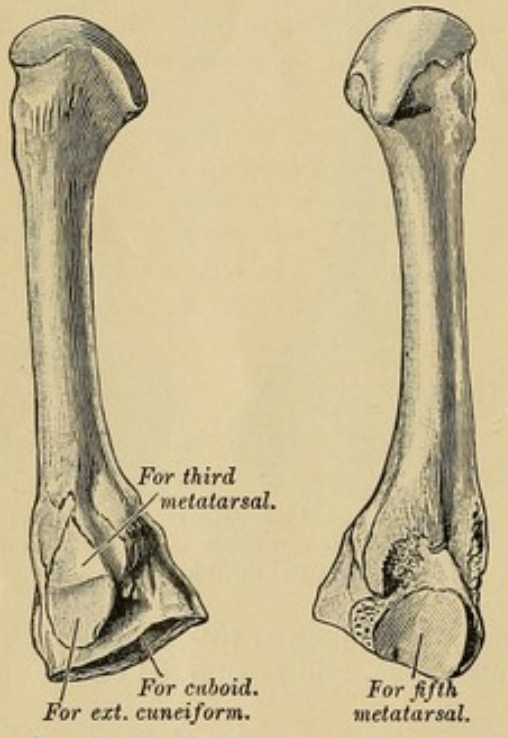

FIG. 149.—The fourth metatarsal. (Left.)

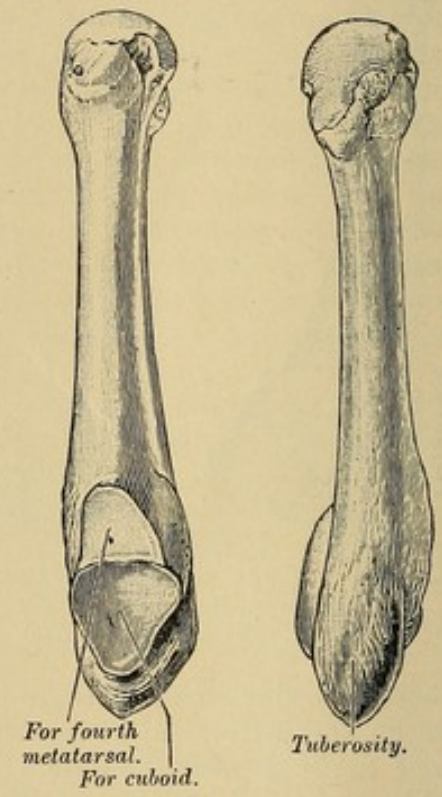

FIG. 150.—The fifth metatarsal. (Left.)

The **Fifth** (Fig. 150) is recognized by the tubercular eminence on the outer side of its base. It articulates behind, by a triangular surface cut obliquely from without inward, with the cuboid, and internally with the fourth metatarsal.

The projection on the outer side of this bone at its tarsal end at once distinguishes it from the others, and points to the side to which it belongs.

Attachment of Muscles.—To six: the Peroneus brevis, Peroneus tertius, Flexor brevis minimi digiti, Adductor transversus hallucis, Fourth dorsal, and Third plantar.

Articulations.—Each bone articulates with the tarsal bones by one extremity, and by the other with the first row of phalanges. The number of tarsal bones with which each metatarsal articulates is one for the first, three for the second, one for the third, two for the fourth, and one for the fifth.

The Phalanges.

The **Phalanges** of the foot, both in number and general arrangement, resemble those in the hand; there being two in the great toe and three in each of the other toes.

The phalanges of the *first row* resemble closely those of the hand. The *shaft* is compressed from side to side, convex above, concave below. The *posterior extremity* is concave; and the *anterior extremity* presents a trochlear surface, for articulation with the second phalanges.

The phalanges of the *second row* are remarkably small and short, but rather broader than those of the first row.

The *ungual* phalanges in form resemble those of the fingers; but they are smaller, flattened from above downward, presenting a broad base for articulation with the second row, and an expanded extremity for the support of the nail and end of the toe.

Articulation.—The first row, with the metatarsal bones behind and second phalanges in front; the second row of the four outer toes, with the first and third phalanges; of the great toe, with the first phalanx; the third row of the four outer toes, with the second phalanges.

Attachment of Muscles.—To the first phalanges. Great toe, five muscles: innermost tendon of Extensor brevis digitorum, Abductor hallucis, Adductor obliquus hallucis, Flexor brevis hallucis, Adductor transversus hallucis. Second toe, three muscles: First and Second dorsal interosseous and First lumbrical. Third toe, three muscles: Third dorsal and First plantar interosseous and Second lumbrical. Fourth toe, three muscles: Fourth dorsal and Second plantar interosseous and Third lumbrical. Fifth toe, four muscles: Flexor brevis minimi digiti, Abductor minimi digiti, and Third plantar interosseous, and Fourth lumbrical.—Second phalanges. Great toe; Extensor longus hallucis, Flexor longus hallucis. Other toes; Flexor brevis digitorum, one slip of the common tendon of the Extensor longus and brevis digitorum.[1]—Third phalanges: two slips from the common tendon of the Extensor longus and Extensor brevis digitorum, and the Flexor longus digitorum.

Development of the Foot (Fig. 151).

The **Tarsal bones** are each developed by a single centre, excepting the os calcis, which has an epiphysis for its posterior extremity. The centres make their appearance in the following order: os calcis, at the sixth month of fœtal life; astragalus, about the seventh month; cuboid, at the ninth month; external cuneiform, during the first year; internal cuneiform in the third year; middle cuneiform and navicular in the fourth year. The epiphysis for the posterior tuberosity of the os calcis appears at the tenth year, and unites with the rest of the bone soon after puberty.

The **Metatarsal bones** are each developed by *two* centres: one for the shaft and one for the digital extremity in the four outer metatarsal; one for the shaft and one for the base in the metatarsal bone of the great toe.[2] Ossification commences in the centre of the shaft about the ninth week, and extends toward either extremity. The centre in the proximal end of the first metatarsal bone appears about the third year, the centre in the distal end of the other bones between the fifth and eighth years; they become joined between the eighteenth and twentieth years.

The **Phalanges** are developed by *two* centres for each bone: one for the shaft and one for the metatarsal extremity. The centre for the shaft appears about the tenth week, that for the epiphysis between the fourth and tenth years; they join the shaft about the eighteenth year.

Construction of the Foot as a Whole.

The foot is constructed on the same principles as the hand, but modified to form a firm basis of support for the rest of the body when in the erect position. It

[1] Except the second phalanx of the fifth toe, which receives no slip from the Extensor brevis digitorum.

[2] As was noted in the first metacarpal bone, so in the first metatarsal, there is often to be observed a tendency to the formation of a second epiphysis in the distal extremity. (See footnote, p. 171.)

is more solidly constructed, and its component parts are less movable on each other than in the hand. This is especially the case with the great toe, which has to assist in supporting the body, and is therefore constructed with greater solidity; it lies parallel with the other toes, and has a very limited degree of mobility, whereas the thumb, which is occupied in numerous and varied movements, is constructed in such a manner as to permit of great mobility. Its metacarpal bone is directed away from the others, so as to form an acute angle with the second, and it enjoys a considerable range of motion at its articulation with the carpus. The foot is placed at right angles to the leg—a position which is almost peculiar to man, and has relation to the erect position which he maintains. In order to allow of its supporting the weight of the whole body in this position with the least expenditure of material, it is constructed in the form of an arch. This arch is not, however, made up of two equal limbs. The hinder one, which is made up of the os calcis and the posterior part of the astragalus, is about half the length of the anterior limb, and measures about three inches. The anterior limb consists of the rest of

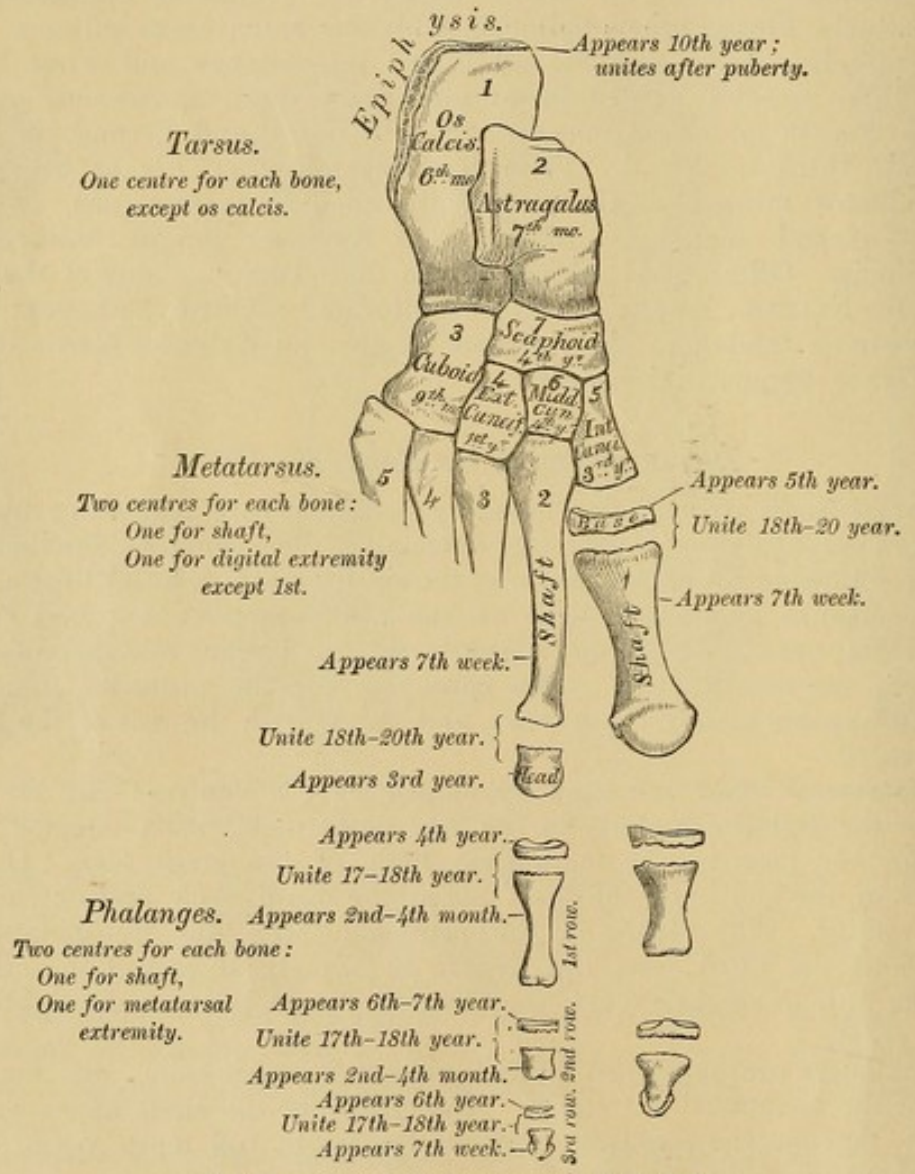

FIG. 151.—Plan of the development of the foot.

the tarsal and the metatarsal bones, and measures about seven inches. It may be said to consist of two parts, an inner segment made up of the head of the astragalus, the navicular, the three cuneiform, and the three inner metatarsal bones; and an outer segment composed of the os calcis, the cuboid, and the two outer metatarsal bones. The summit of the arch is at the superior articular surface of the astragalus; and its two extremities—that is to say, the two piers on which the arch rests in standing—are the tubercles on the under surface of the os calcis posteriorly, and

the heads of the metatarsal bones anteriorly. The weakest part of the arch is the joint between the astragalus and scaphoid, and here it is more liable to yield in those who are overweighted, and in those in whom the ligaments which complete and preserve the arch are relaxed. This weak point in the arch is braced on its concave surface by the inferior calcaneo-navicular ligament, which is more elastic than most other ligaments, and thus allows the arch to yield from jars or shocks applied to the anterior portion of the foot and quickly restores it to its pristine condition. This ligament is supported internally by blending with the Deltoid ligament, and inferiorly by the tendon of the Tibialis posticus muscle, which is spread out into a fan-shaped insertion, and prevents undue tension of the ligament or such an amount of stretching as would permanently elongate it.

In addition to this longitudinal arch the foot presents a transverse arch, at the anterior part of the tarsus and hinder part of the metatarsus. This, however, can scarcely be described as a true arch, but presents more the character of a half-dome. The inner border of the central portion of the longitudinal arch is elevated from the ground, and from this point the bones arch over to the outer border, which is in contact with the ground, and, assisted by the longitudinal arch, produce a sort of rounded niche on the inner side of the foot, which gives the appearance of a transverse as well as a longitudinal arch.

The line of the foot, from the point of the heel to the toes, is not quite straight, but is directed a little outward, so that the inner border is a little convex and the outer border concave. This disposition of the bones becomes more marked when the longitudinal arch of the foot is lost, as in the disease known under the name of "flat-foot."

Surface Form.—On the dorsum of the foot the individual bones are not to be distinguished with the exception of the head of the astragalus, which forms a rounded projection in front of the ankle-joint when the foot is forcibly extended. The whole surface forms a smooth convex outline, the summit of which is the ridge formed by the head of the astragalus, the navicular, the middle cuneiform, and the second metatarsal bones; from this it gradually inclines outward and more rapidly inward. On the inner side of the foot, the internal tuberosity of the os calcis and the ridge separating the inner from the posterior surface of the bone may be felt most posteriorly. In front of this, and below the internal malleolus, may be felt the projection of the sustentaculum tali. Passing forward is the well-marked tuberosity of the navicular bone, situated about an inch or an inch and a quarter in front of the internal malleolus. Further toward the front, the ridge formed by the base of the first metatarsal bone can be obscurely felt, and from this the shaft of the bone can be traced to the expanded head articulating with the base of the first phalanx of the great toe. Immediately beneath the base of this phalanx, the internal sesamoid bone is to be felt. Lastly, the expanded ends of the bones forming the last joint of the great toe are to be felt. On the outer side of the foot the most posterior bony point is the outer tuberosity of the os calcis, with the ridge separating the posterior from the outer surface of the bone. In front of this the greater part of the external surface of the os calcis is subcutaneous; on it, below and in front of the external malleolus, may be felt the peroneal ridge, when this process is present. Farther forward, the base of the fifth metatarsal bone forms a prominent and well-defined landmark, and in front of this the shaft of the bone, with its expanded head, and the base of the first phalanx may be defined. The sole of the foot is almost entirely covered by soft parts, so that but few bony parts are to be made out, and these somewhat obscurely. The hinder part of the under surface of the os calcis and the heads of the metatarsal bones, with the exception of the first, which is concealed by the sesamoid bones, may be recognized.

Surgical Anatomy.—Considering the injuries to which the foot is subjected, it is surprising how seldom the tarsal bones are fractured. This is no doubt due to the fact that the tarsus is composed of a number of bones, articulated by a considerable extent of surface and joined together by very strong ligaments, which serve to break the force of violence applied to this part of the body. When fracture does occur, these bones, being composed for the most part of a soft cancellous structure, covered only by a thin shell of compact tissue, are often extensively comminuted, especially as most of the fractures are produced by direct violence. And having only a very scanty amount of soft parts over them, the fractures are very often compound, and amputation is frequently necessary.

When fracture occurs in the anterior group of tarsal bones, it is almost invariably the result of direct violence; but fractures of the posterior group, that is, of the calcaneum and astragalus, are most frequently produced by falls from a height on to the feet; though fracture of the os calcis may be caused by direct violence or by muscular action. The posterior part of the bone, that is, the part behind the articular surfaces, is almost always the seat of the fracture, though some few cases of fracture of the sustentaculum tali and of vertical fracture between the two articulating facets have been recorded. The neck of the astragalus, being the weakest

part of the bone, is most frequently fractured, though fractures may occur in any part and almost in any direction, either associated or not with fracture of other bones.

In cases of club-foot, especially in congenital cases, the bones of the tarsus become altered in shape and size, and displaced from their proper positions. This is especially the case in congenital equino-varus, in which the astragalus, particularly about the head, becomes twisted and atrophied, and a similar condition may be present in the other bones, more especially the navicular. The tarsal bones are peculiarly liable to become the seat of tuberculous caries from comparatively trivial injuries. There are several reasons to account for this. They are composed of a delicate cancellated structure, surrounded by intricate synovial membranes. They are situated at the farthest point from the central organ of the circulation and exposed to vicissitudes of temperature; and, moreover, on their dorsal surface are thinly clad with soft parts which have but a scanty blood-supply. And finally, after slight injuries, they are not maintained in a condition of rest to the same extent as similar injuries in some other parts of the body. Caries of the calcaneum or astragalus may remain limited to the one bone for a long period, but when one of the other bones is affected, the remainder frequently become involved, in consequence of the disease spreading through the large and complicated synovial membrane which is more or less common to these bones.

Amputation of the whole or a part of the foot is frequently required either for injury or disease. The principal amputations are as follow: (1) Syme's: amputation at the ankle-joint by a heel-flap, with removal of the malleoli and sometimes a thin slice from the lower end of the tibia. (2) Roux's: amputation at the ankle-joint by a large internal flap. (3) Pirogoff's amputation: removal of the whole of the tarsal bones, except the posterior part of the os calcis and a thin slice from the tibia and fibula including the two malleoli. The sawn surface of the os calcis is then turned up and united to the similar surface of the tibia. (4) Subastragaloid amputation: removal of the foot below the astragalus through the joint between it and the os calcis. This operation has been modified by Hancock, who leaves the posterior third of the os calcis and turns it up against the denuded surface of the astragalus. This latter operation is of doubtful utility and is rarely performed. (5) Chopart's or medio-tarsal: removal of the anterior part of the foot with all the tarsal bones except the os calcis and astragalus; disarticulation being effected through the joints between the astragalo-scaphoid and calcaneo-cuboid in joints. (6) Lisfranc's: amputation of the anterior part of the foot through the tarso-metatarsal joints. This has been modified by Hey, who disarticulated through the joints of the four outer metatarsal bones with the tarsus, and sawed off the projecting internal cuneiform; and by Skey, who sawed off the base of the second metatarsal bone and disarticulated the others.

The bones of the tarsus occasionally require removal individually. This is especially the case with the astragalus and os calcis for disease limited to the one bone, or again the astragalus may require excision in cases of subastragaloid dislocation, or, as recommended by Mr. Lund, in cases of inveterate talipes. The cuboid has been removed for the same reason by Mr. Solly. But both these two latter operations have fallen very much into disuse, and have been superseded by resection of a wedge-shaped piece of bone from the outer side of the tarsus. Finally, Mickulicz and Watson have devised operations for the removal of more extensive portions of the tarsus. Mickulicz's operation consists in the removal of the os calcis and astragalus, along with the articular surfaces of the tibia and fibula, and also of the scaphoid and cuboid. The remaining portion of the tarsus is then brought into contact with the sawn surfaces of the tibia and fibula, and fixed there. The result is a position of the shortened foot resembling talipes equinus. Watson's operation is adapted to those cases where the disease is confined to the anterior tarsal bones. By two lateral incisions he saws through the bases of the metatarsal bones in front and opens up the joints between the scaphoid and astragalus, and the cuboid and os calcis, and removes the intervening bones.

The metatarsal bones and phalanges are nearly always broken by direct violence, and in the majority of cases the injury is the result of severe crushing accidents, necessitating amputation. The metatarsal bones, and especially that of the great toe, are frequently diseased, either in tubercular subjects or in perforating ulcer of the foot.

Sesamoid Bones.

These are small rounded masses, cartilaginous in early life, osseous in the adult, which are developed in those tendons which exert a great amount of pressure upon the parts over which they glide. It is said that they are more commonly found in the male than in the female, and in persons of an active muscular habit than in those who are weak and debilitated. They are invested throughout their whole surface by the fibrous tissue of the tendon in which they are found, excepting upon that side which lies in contact with the part over which they play, where they present a free articular facet. They may be divided into two kinds: those which glide over the articular surfaces of joints, and those which play over the cartilaginous facets found on the surfaces of certain bones.

The sesamoid bones of the joints in the upper extremity, are two on the palmar surface of the metacarpo-phalangeal joint in the thumb, developed in the tendons of the Flexor brevis pollicis; occasionally one or two opposite the metacarpo-phalangeal articulations of the fore and little fingers; and, still more rarely, one opposite the same joints of the third and fourth fingers. In the lower extremity, the patella, which is developed in the tendon of the Quadriceps extensor; two small sesamoid bones, found in the tendons of the Flexor brevis hallucis, opposite the metatarso-phalangeal joint of the great toe; and occasionally one in the metatarso-phalangeal joint of the second toe, the little toe, and, still more rarely, the third and fourth toes.

Those found in the tendons which glide over certain bones occupy the following situations: one sometimes found in the tendon of the Biceps cubiti, opposite the tuberosity of the radius: one in the tendon of the Peroneus longus, where it glides through the groove in the cuboid bone; one appears late in life in the tendon of the Tibialis anticus, opposite the smooth facet of the internal cuneiform bone; one is found in the tendon of the Tibialis posticus, opposite the inner side of the head of the astragalus; one in the outer head of the Gastrocnemius, behind the outer condyle of the femur; and one in the conjoined tendon of the Psoas and Iliacus, where it glides over the os pubis. Sesamoid bones are found occasionally in the tendon of the Gluteus maximus, as it passes over the great trochanter, and in the tendons which wind round the inner and outer malleoli.

THE ARTICULATIONS.

THE various bones of which the Skeleton consists are connected together at different parts of their surfaces, and such a connection is designated by the name of *Joint* or *Articulation*. If the joint is *immovable*, as between the cranial and most of the facial bones, the adjacent margins of the bones are applied in almost close contact, a thin layer of fibrous membrane, the *sutural ligament*, and, at the base of the skull, in certain situations, a thin layer of cartilage, being interposed. Where slight movement is required, combined with great strength, the osseous surfaces are united by tough and elastic fibro-cartilages, as in the joints between the vertebral bodies and interpubic articulations; but in the *movable* joints the bones forming the articulation are generally expanded for greater convenience of mutual connection, covered by *cartilage*, held together by strong bands or capsules of fibrous tissue called *ligaments*, and partially lined by a membrane, the *synovial membrane*, which secretes a fluid to lubricate the various parts of which the joint is formed; so that the structures which enter into the formation of a joint are bone, cartilage, fibro-cartilage, ligament, and synovial membrane.

Bone constitutes the fundamental element of all the joints. In the long bones the extremities are the parts which form the articulations; they are generally somewhat enlarged, consisting of spongy cancellous tissue, with a thin coating of compact substance. In the flat bones the articulations usually take place at the edges, and, in the short bones at various parts of their surface. The layer of compact bone which forms the articular surface, and to which the cartilage is attached, is called the *articular lamella*. It is of a white color, extremely dense, and varies in thickness. Its structure differs from ordinary bone-tissue in this respect, that it contains no Haversian canals, and its lacunæ are much larger than in ordinary bone and have no canaliculi. The vessels of the cancellous tissue, as they approach the articular lamella, turn back in loops, and do not perforate it; this layer is consequently more dense and firmer than ordinary bone, and is evidently designed to form a firm and unyielding support for the articular cartilage.

The **cartilage,** which covers the articular surfaces of bone, and is called the *articular*, will be found described, with the other varieties of cartilage, in the section on General Anatomy.

Ligaments consist of bands of various forms, serving to connect together the articular extremities of bones, and composed mainly of bundles of *white fibrous tissue* placed parallel with, or closely interlaced with, one another, and presenting a white, shining, silvery aspect. A ligament is pliant and flexible, so as to allow of the most perfect freedom of movement, but strong, tough, and inextensile, so as not readily to yield under the most severely applied force; it is consequently well adapted to serve as the connecting medium between the bones. Some ligaments consist entirely of *yellow elastic tissue*, as the ligamenta subflava, which connect together the adjacent arches of the vertebræ and the ligamentum nuchæ in the lower animals. In these cases it will be observed that the elasticity of the ligament is intended to act as a substitute for muscular power.

Synovial membrane is a thin, delicate membrane of connective tissue, with branched connective-tissue corpuscles. Its secretion is thick, viscid, and glairy, like the white of egg, and is hence termed *synovia*. The synovial membranes found in the body admit of subdivision into three kinds—articular, bursal, and vaginal.

The *articular synovial membranes* are found in all the freely movable joints. In the fœtus this membrane is said, by Toynbee, to be continued over the surface

of the cartilages; but in the adult it is wanting, excepting at their circumference, upon which it encroaches for a short distance, and to which it is firmly attached; it then invests the inner surface of the capsular or other ligaments enclosing the joint, and is reflected over the surface of any tendons passing through its cavity, as the tendon of the Popliteus in the knee and the tendon of the Biceps in the shoulder. Hence the articular synovial membrane may be regarded as a short wide tube, attached by its open ends to the margins of the articular cartilages, and covering the inner surface of the various ligaments which connect the articular surfaces, so that along with the cartilages it completely encloses the joint-cavity. In some of the joints the synovial membrane is thrown into folds, which pass across the cavity. They are called *synovial ligaments*, and are especially distinct in the knee. In other joints there are flattened folds, subdivided at their margins into fringe-like processes, the vessels of which have a convoluted arrangement. These latter generally project from the synovial membrane near the margin of the cartilage and lie flat upon its surface. They consist of connective tissue covered with endothelium, and contain fat-cells in variable quantities, and, more rarely, isolated cartilage-cells. The larger folds often contain considerable quantities of fat. They were described by Clopton Havers as *mucilaginous glands*, and as the source of the synovial secretion. Under certain diseased conditions similar processes are found covering the entire surface of the synovial membrane, forming a mass of pedunculated fibro-fatty growths which project into the joint. Similar structures are also found in some of the bursal and vaginal synovial membranes.

The *bursal synovial membranes* are found interposed between surfaces which move upon each other, producing friction, as in the gliding of a tendon or of the integument over projecting bony surfaces. They admit of subdivision into two kinds, the *bursæ mucosæ* and the *bursæ synoviæ*. The *bursæ mucosæ* are large, simple, or irregular cavities in the subcutaneous areolar tissue, enclosing a clear viscid fluid. They are found in various situations, as between the integument and the front of the patella, over the olecranon, the malleoli, and other prominent parts. The *bursæ synoviæ* are found interposed between muscles or tendons as they play over projecting bony surfaces, as between the Glutei muscles and the surface of the great trochanter. They consist of a thin wall of connective tissue, partially covered by patches of cells, and contain a viscid fluid. Where one of these exists in the neighborhood of a joint, it may communicate with its cavity, as in the case of the bursa between the tendon of the Psoas and Iliacus and the capsular ligament of the hip, or the one interposed between the under surface of the Subscapularis and the neck of the scapula.

The *vaginal synovial membranes* (*synovial sheaths*) serve to facilitate the gliding of tendons in the osseo-fibrous canals through which they pass. The membrane is here arranged in the form of a sheath, one layer of which adheres to the wall of the canal, and the other is reflected upon the surface of the contained tendon, the space between the two free surfaces of the membrane containing synovia. These sheaths are chiefly found surrounding the tendons of the flexor and extensor muscles of the fingers and toes as they pass through the osseo-fibrous canals in the hand or foot.

Synovia is a transparent, yellowish-white or slightly reddish fluid, viscid like the white of egg, having an alkaline reaction and slightly saline taste. It consists, according to Frerichs, in the ox, of 94.85 water, 0.56 mucus and epithelium, 0.07 fat, 3.51 albumen and extractive matter, and 0.99 salts.

The articulations are divided into three classes: *synarthrosis*, or immovable; *amphiarthrosis*, or mixed; and *diarthrosis*, or movable joints.

1. Synarthrosis. Immovable Articulations.

Synarthrosis includes all those articulations in which the surfaces of the bones are in almost direct contact, fastened together by an intervening mass of connective tissue, and in which there is no appreciable motion, as the joints between the bones

of the cranium and face, excepting those of the lower jaw. The varieties of synarthrosis are four in number: Sutura, Schindylesis, Gomphosis, and Synchondrosis.

Sutura (a seam) is that form of articulation where the contiguous margins of flat bones are united by a thin layer of fibrous tissue. It is met with only in the skull. Where the articulating surfaces are connected by a series of processes and indentations interlocked together, it is termed *sutura vera*, of which there are three varieties: sutura dentata, serrata, and limbosa. The surfaces of the bones are not in direct contact, being separated by a layer of membrane continuous externally with the pericranium, internally with the dura mater. The *sutura dentata* (*dens*, a tooth) is so called from the tooth-like form of the projecting articular processes, as in the suture between the parietal bones. In the *sutura serrata* (*serra*, a saw) the edges of the two bones forming the articulation are serrated like the teeth of a fine saw, as between the two portions of the frontal bone. In the *sutura limbosa* (*limbus*, a selvage), besides the dentated processes, there is a certain degree of bevelling of the articular surfaces, so that the bones overlap one another, as in the suture between the parietal and frontal bones. When the articulation is formed by roughened surfaces placed in apposition with one another, it is termed the *false suture* (*sutura notha*), of which there are two kinds: the *sutura squamosa* (*squama*, a scale), formed by the overlapping of two contiguous bones by broad bevelled margins, as in the squamo-parietal (squamous) suture; and the *sutura harmonia* (ἁρμονία, a joining together), where there is simple apposition of two contiguous rough bony surfaces, as in the articulation between the two superior maxillary bones or of the horizontal plates of the palate bones.

Schindylesis (σχινδύλησις, a fissure) is that form of articulation in which a thin plate of bone is received into a cleft or fissure formed by the separation of two laminæ in another bone, as in the articulation of the rostrum of the sphenoid and perpendicular plate of the ethmoid with the vomer, or in the reception of the latter in the fissure between the superior maxillary and palate bones.

Gomphosis (γόμφος, a nail) is an articulation formed by the insertion of a conical process into a socket, as a nail is driven into a board; this is not illustrated by any articulation between bones, properly so called, but is seen in the articulation of the teeth with the alveoli of the maxillary bones.

Synchondrosis.—Where the connecting medium is cartilage the joint is termed a synchondrosis. This is a temporary form of joint, for the cartilage becomes converted into bone before adult life. Such a joint is found between the epiphyses and shafts of long bones.

2. Amphiarthrosis. Mixed Articulations.

In this form of articulation the contiguous osseous surfaces are either connected together by broad flattened disks of fibro-cartilage, of a more or less complex structure, which adhere to the end of each bone, as in the articulation between the bodies of the vertebræ and the pubic symphyses. This is termed **Symphysis.** Or, secondly, the bony surfaces are united by an interosseous ligament, as in the inferior tibio-fibular articulation. To this the term **Syndesmosis** is applied.

3. Diarthrosis. Movable Articulations.

This form of articulation includes the greater number of the joints in the body, mobility being their distinguishing character. They are formed by the approximation of two contiguous bony surfaces covered with cartilage, connected by ligaments and lined by synovial membrane. The varieties of joints in this class have been determined by the kind of motion permitted in each. There are two varieties in which the movement is uniaxial; that is to say, all movements take place around one axis. In one form, the Ginglymus, this axis is, practically speaking, transverse; in the other, the trochoid or pivot-joint, it is longitudinal. There are two varieties where the movement is biaxial, or around two horizontal

axes at right angles to each other or at any intervening axis between the two. These are the condyloid and saddle-joint. There is one form of joint where the movement is polyaxial, the enarthrosis or ball-and-socket joint. And finally there are the Arthrodia or Gliding joints.

Ginglymus or **Hinge-joint** (*γίγγλυμος*, a hinge).—In this form of joint the articular surfaces are moulded to each other in such a manner as to permit motion only in one plane, forward and backward; the extent of motion at the same time being considerable. The direction which the distal bone takes in this motion is never in the same plane as that of the axis of the proximal bone, but there is always a certain amount of alteration from the straight line during flexion. The articular surfaces are connected together by strong lateral ligaments, which form their chief bond of union. The most perfect forms of ginglymus are the interphalangeal joints and the joint between the humerus and ulna; the knee and ankle are less perfect, as they allow a slight degree of rotation or lateral movement in certain positions of the limb.

Trochoides (pivot-joint).—Where the movement is limited to rotation, the joint is formed by a pivot-like process turning within a ring, or the ring on the pivot, the ring being formed partly of bone, partly of ligament. In the superior radio-ulnar articulation the ring is formed partly by the lesser sigmoid cavity of the ulna; in the rest of its extent, by the orbicular ligament; here the head of the radius rotates within the ring. In the articulation of the odontoid process of the axis with the atlas the ring is formed in front by the anterior arch of the atlas; behind, by the transverse ligament; here the ring rotates round the odontoid process.

Condyloid Articulations.—In this form of joint an ovoid articular head, or condyle, is received into an elliptical cavity in such a manner as to permit of flexion and extension, adduction and abduction and circumduction, but no axial rotation. The articular surfaces are connected together by anterior, posterior, and lateral ligaments. An example of this form of joint is found in the wrist.

Articulations by Reciprocal Reception (saddle-joint).—In this variety the articular surfaces are concavo-convex; that is to say, they are inversely convex in one direction and concave in the other. The movements are the same as in the preceding form; that is to say, there is flexion, extension, adduction, abduction, and circumduction, but no axial rotation. The articular surfaces are connected by a capsular ligament. The best example of this form of joint is the carpo-metacarpal joint of the thumb.

Enarthrosis is that form of joint in which the distal bone is capable of motion around an indefinite number of axes which have one common centre. It is formed by the reception of a globular head into a deep cup-like cavity (hence the name "ball-and-socket"), the parts being kept in apposition by a capsular ligament strengthened by accessory ligamentous bands. **Examples** of this form of articulation are found in the hip and shoulder.

Arthrodia is that form of joint which admits of a gliding movement; it is formed by the approximation of plane surfaces or one slightly concave, the other slightly convex, the amount of motion between them being limited by the ligaments, or osseous processes, surrounding the articulation; as in the articular processes of the vertebræ, the carpal joints, except that of the os magnum with the scaphoid and semilunar bones, and the tarsal joints with the exception of the joint between the astragalus and the navicular.

On the next page, in a tabular form, are the names, distinctive characters, and examples of the different kinds of articulations.

The Kinds of Movement admitted in Joints.

The movements admissible in joints may be divided into four kinds: gliding, angular movement, circumduction, and rotation. These movements are often, however, more or less combined in the various joints, so as to produce an infinite variety, and it is seldom that we find only one kind of motion in any particular joint.

Synarthrosis, or Immovable Joint. Surfaces separated by fibrous membrane or by line of cartilage, without any intervening synovial cavity, and immovably connected with each other.

As in joints of cranium and face (except lower jaw).

- ***Sutura.*** Articulation by processes and indentations interlocked together.
  - ***Sutura vera*** (true), articulate by indented borders.
    - *Dentata*, having tooth-like processes. As in interparietal suture.
    - *Serrata*, having serrated edges like the teeth of a saw. As in interfrontal suture.
    - *Limbosa*, having bevelled margins and dentated processes. As in fronto-parietal suture.
  - ***Sutura notha*** (false), articulate by rough surfaces.
    - *Squamosa*, formed by thin bevelled margins, overlapping each other. As in squamo-parietal suture.
    - *Harmonia*, formed by the apposition of contiguous rough surfaces. As in intermaxillary suture.
- ***Schindylesis.***—Articulation formed by the reception of a thin plate of one bone into a fissure of another. As in articulation of rostrum of sphenoid with vomer.
- ***Gomphosis.***—Articulation formed by the insertion of a conical process into a socket: the teeth.

Amphiarthrosis, Mixed Articulation.

- ***Symphysis.***—Surfaces connected by fibro-cartilage, not separated by synovial membrane, and having limited motion. As in joints between bodies of vertebræ.
- ***Syndesmosis.***—Surfaces united by an interosseous ligament. As in the inferior tibio-fibular articulation.

Diarthrosis, Movable Joint.

- ***Ginglymus.***—Hinge-joint; motion limited to two directions, forward and backward. Articular surfaces fitted together so as to permit of movement in one plane. As in the interphalangeal joints and the joint between the humerus and the ulna.
- ***Trochoides, or Pivot-joint.***—Articulation by a pivot process turning within a ring or ring around a pivot. As in superior radio-ulnar articulation and atlanto-axial joint.
- ***Condyloid.***—Ovoid head received into elliptical cavity. Movements in every direction except axial rotation. As the wrist-joint.
- ***Reciprocal Reception*** (saddle-joint).—Articular surfaces inversely convex in one direction and concave in the other. Movement in every direction except axial rotation. As in the carpo-metacarpal joint of the thumb.
- ***Enarthrosis.***—Ball-and-socket joint; capable of motion in all directions. Articulations by a globular head received into a cup-like cavity. As in hip- and shoulder-joints.
- ***Arthrodia.***—Gliding joint; articulations by plane surfaces, which glide upon each other. As in carpal and tarsal articulations.

Gliding movement is the most simple kind of motion that can take place in a joint, one surface gliding or moving over another without any angular or rotatory movement. It is common to all movable joints, but in some, as in the articulations of the carpus and tarsus, it is the only motion permitted. This movement is not confined to plane surfaces, but may exist between any two contiguous surfaces, of whatever form, limited by the ligaments which enclose the articulation.

Angular movement occurs only between the long bones, and by it the angle between the two bones is increased or diminished. It may take place in four directions: forward and backward, constituting flexion and extension, or inward and outward, from the mesial line of the body (or in the fingers and toes from the middle line of the hand or foot), constituting adduction and abduction. The strictly ginglymoid or hinge-joints admit of flexion and extension only. Abduction and adduction, combined with flexion and extension, are met with in the more movable joints; as in the hip, shoulder, and metacarpal joint of the thumb, and partially in the wrist.

Circumduction is that limited degree of motion which takes place between the head of a bone and its articular cavity, whilst the extremity and sides of the limb are made to circumscribe a conical space, the base of which corresponds with the inferior extremity of the limb, the apex with the articular cavity; this kind of motion is best seen in the shoulder- and hip-joints.

Rotation is the movement of a bone upon an axis, which is the axis of the pivot on which the bone turns, as in the articulation between the atlas and axis, when the odontoid process serves as a pivot around which the atlas turns; or else is the axis of a pivot-like process which turns within a ring, as in the rotation of the radius upon the humerus.

Ligamentous Action of Muscles.—The movements of the different joints of a limb are combined by means of the long muscles which pass over more than one joint, and which, when relaxed and stretched to their greatest extent, act as elastic ligaments in restraining certain movements of one joint, except when combined with corresponding movements of the other, these latter movements being usually in the opposite direction. Thus the shortness of the hamstring muscles prevents complete flexion of the hip, unless the knee-joint is also flexed, so as to bring their attachments nearer together. The uses of this arrangement are threefold: 1. It co-ordinates the kinds of movement which are the most habitual and necessary, and enables them to be performed with the least expenditure of power. "Thus in the usual gesture of the arms, whether in grasping or rejecting, the shoulder and the elbow are flexed simultaneously, and simultaneously extended," in consequence of the passage of the Biceps and Triceps cubiti over both joints. 2. It enables the short muscles which pass over only one joint to act upon more than one. "Thus, if the Rectus femoris remain tonically of such length that, when stretched over the extended hip, it compels extension of the knee, then the Gluteus maximus becomes not only an extensor of the hip, but an extensor of the knee as well." 3. It provides the joints with ligaments which, while they are of very great power in resisting movements to an extent incompatible with the mechanism of the joint, at the same time spontaneously yield when necessary. "Taxed beyond its strength, a ligament will be ruptured, whereas a contracted muscle is easily relaxed; also, if neighboring joints be united by ligaments, the amount of flexion or extension of each must remain in constant proportion to that of the other; while, if the union be by muscles, the separation of the points of attachment of those muscles may vary considerably in different varieties of movement, the muscles adapting themselves tonically to the length required." The quotations are from a very interesting paper by Dr. Cleland in the *Journal of Anatomy and Physiology*, No. 1, 1866, p. 85; by whom I believe this important fact in the mechanism of joints was first clearly pointed out, though it has been independently observed afterward by other anatomists. Dr. W. W. Keen points out how important it is "that the surgeon should remember this ligamentous action of

muscles in making passive motion—for instance, at the wrist after Colles's fracture. If the fingers be extended, the wrist can be flexed to a right angle. If, however, they be first flexed, as in "making a fist," flexion at the wrist is quickly limited to from forty to fifty degrees in different persons, and is very painful beyond that point. Hence passive motion here should be made with the fingers extended. In the leg, when flexing the hip, the knee should be flexed." Dr. Keen further points out that "a beautiful illustration of this is seen in the perching of birds, whose toes are forced to clasp the perch by just such a passive ligamentous action so soon as they stoop. Hence they can go to sleep and not fall off the perch."

The articulations may be arranged into those of the trunk, those of the upper extremity, and those of the lower extremity.

ARTICULATIONS OF THE TRUNK.

These may be divided into the following groups, viz.:

I. Of the vertebral column.
II. Of the atlas with the axis.
III. Of the atlas with the occipital bone.
IV. Of the axis with the occipital bone.
V. Of the lower jaw.
VI. Of the ribs with the vertebræ.
VII. Of the cartilages of the ribs with the sternum and with each other.
VIII. Of the sternum.
IX. Of the vertebral column with the pelvis.
X. Of the pelvis.

I. Articulations of the Vertebral Column.

The different segments of the spine are connected together by ligaments, which may be divided into five sets: 1. Those connecting the *bodies* of the vertebræ. 2. Those connecting the *laminæ*. 3. Those connecting the *articular processes*. 4. Those connecting the *spinous processes*. 5. Those of the *transverse processes*.

The articulations of the *bodies* of the vertebræ with each other form a series of amphiarthrodial joints; those between the *articular processes* form a series of arthrodial joints.

1. The Ligaments of the Body.

Anterior Common Ligament. Posterior Common Ligament.
Intervertebral Substance.

The **Anterior Common Ligament** (Figs. 152, 153, 160, 164) is a broad and strong band of fibres which extends along the anterior surface of the bodies of the vertebræ from the axis to the sacrum. It is broader below than above, thicker in the dorsal than in the cervical or lumbar regions, and somewhat thicker opposite the front of the body of each vertebra than opposite the intervertebral substance. It is attached, above, to the body of the axis by a pointed process, where it is continuous with the anterior atlanto-axial ligament, and is connected with the tendon of insertion of the Longus colli muscle, and extends down as far as the upper bone of the sacrum. It consists of dense longitudinal fibres, which are intimately adherent to the intervertebral substance and the prominent margins of the vertebræ, but less closely to the middle of the bodies. In the latter situation the fibres are exceedingly thick, and serve to fill up the concavities on their front surface and to make the anterior surface of the spine more even. This ligament is composed of several layers of fibres, which vary in length, but are closely interlaced with each other. The most superficial or longest fibres extend between four or five vertebræ. A second subjacent set extend between two or three vertebræ, whilst a third set, the shortest and deepest, extend from one vertebra to the next. At the side of the bodies the ligament consists of a few short fibres, which pass from one vertebra to the next, separated from the median portion by large oval apertures for the passage of vessels.

The **Posterior Common Ligament** (Figs. 152, 156) is situated within the spinal

canal, and extends along the posterior surface of the bodies of the vertebræ from the body of the axis above, where it is continuous with the occipito-axial ligament, to the sacrum below. It is broader above than below, and thicker in the dorsal than in the cervical or lumbar regions. In the situation of the intervertebral substance and contiguous margins of the vertebræ, where the ligament is more intimately adherent, it is broad, and presents a series of dentations with intervening concave margins; but it is narrow and thick over the centre of the bodies, from which it is separated by the *venæ basis vertebræ*. This ligament is composed of smooth, shining, longitudinal fibres, denser and more compact than those of the anterior ligament, and composed of a superficial layer occupying the interval between three or four vertebræ, and of a deeper layer which extends between one vertebra and the next adjacent to it. It is separated from the dura mater of

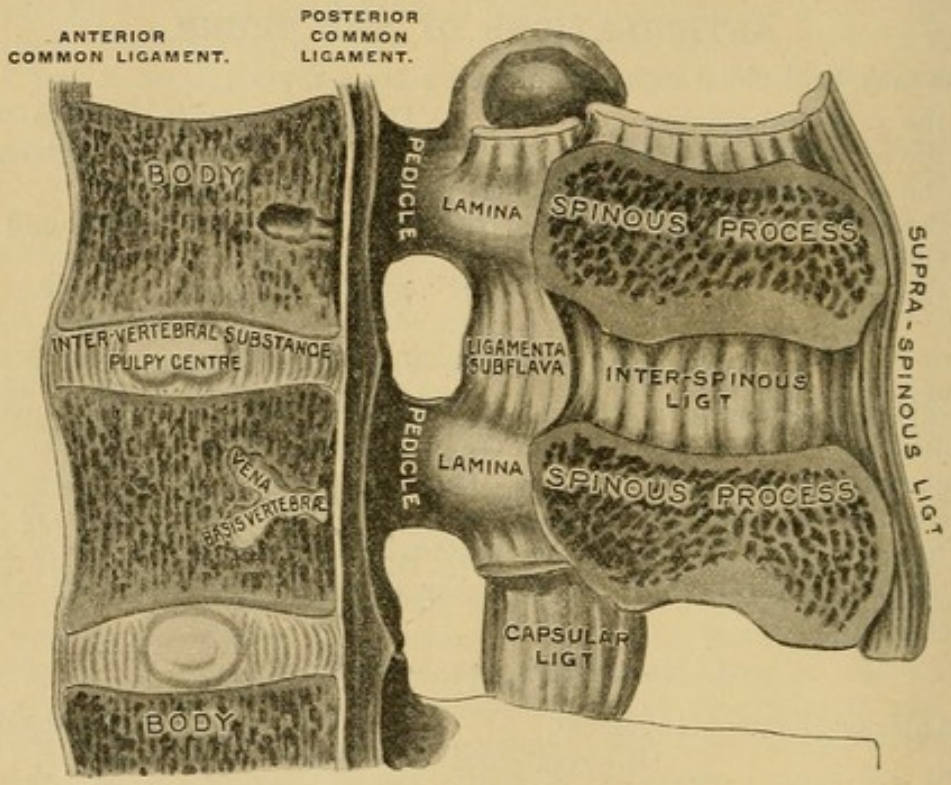

FIG. 152.—Vertical section of two vertebræ and their ligaments, from the lumbar region.

the spinal cord by some loose connective tissue which is very liable to serous infiltration.

The **Intervertebral Substance** (Figs. 152, 161) is a lenticular disk of composite structure interposed between the adjacent surfaces of the bodies of the vertebræ from the axis to the sacrum, and forming the chief bond of connection between those bones. These disks vary in shape, size, and thickness in different parts of the spine. In *shape* they accurately correspond with the surfaces of the bodies between which they are placed, being oval in the cervical and lumbar regions, and circular in the dorsal. Their *size* is greatest in the lumbar region. In *thickness* they vary not only in the different regions of the spine, but in different parts of the same disk: thus, they are thicker in front than behind in the cervical and lumbar regions, while they are uniformly thick in the dorsal region. The intervertebral disks form about one-fourth of the spinal column, exclusive of the first two vertebræ; they are not equally distributed, however, between the various bones; the dorsal portion of the spine having, in proportion to its length, a much smaller quantity than in the cervical and lumbar regions, which necessarily gives to the latter parts greater pliancy and freedom of movement. The intervertebral disks are adherent, by their surfaces, to a thin layer of hyaline cartilage which covers the upper and under surfaces of the bodies of the vertebræ, and in which, in early life, the epiphyseal plate develops, and by their circumference are closely connected in

front to the anterior, and behind to the posterior common ligament; whilst in the dorsal region they are connected laterally, by means of the interarticular ligament, to the heads of those ribs which articulate with two vertebræ; they, consequently, form part of the articular cavities in which the heads of these bones are received.

Structure of the Intervertebral Substance.—The intervertebral substance is composed, at its circumference, of laminæ of fibrous tissue and fibro-cartilage; and, at its centre, of a soft, pulpy, highly elastic substance, of a yellowish color, which rises up considerably above the surrounding level when the disk is divided horizontally. This pulpy substance, which is especially well developed in the lumbar region, is the remains of the chorda dorsalis, and, according to Luschka, contains a small synovial cavity in its centre. The laminæ are arranged concentrically one within the other, the outermost consisting of ordinary fibrous tissue, but the others and more numerous consisting of white fibro-cartilage. These plates are not quite vertical in their direction, those near the circumference being curved outward and closely approximated; whilst those nearest the centre curve in the opposite direction, and are somewhat more widely separated. The fibres of which each plate is composed are directed, for the most part, obliquely from above downward, the fibres of adjacent plates passing in opposite directions and varying in every layer; so that the fibres of one layer are directed across those of another, like the limbs of the letter X. This laminar arrangement belongs to about the outer half of each disk. The pulpy substance presents no concentric arrangement, and consists of a fine fibrous matrix, containing angular cells, united to form a reticular structure.

2. Ligaments connecting the Laminæ.

Ligamenta Subflava.

The **Ligamenta Subflava** (Fig. 152) are interposed between the laminæ of the vertebræ, from the axis to the sacrum. They are most distinct when seen from the interior of the spinal canal; when viewed from the outer surface they appear short, being overlapped by the laminæ. Each ligament consists of two lateral portions, which commence on each side at the root of either articular process, and pass backward to the point where the laminæ converge to form the spinous process, where their margins are in contact and to a certain extent united; slight intervals being left for the passage of small vessels. These ligaments consist of yellow elastic tissue, the fibres of which, almost perpendicular in direction, are attached to the anterior surface of the laminæ above, some distance from its inferior margin, and to the posterior surface, as well as to the margin of the lamina below. In the cervical region they are thin in texture, but very broad and long; they become thicker in the dorsal region, and in the lumbar acquire very considerable thickness. Their highly elastic property serves to preserve the upright posture and to assist in resuming it after the spine has been flexed. These ligaments do not exist between the occiput and atlas or between the atlas and axis.

3. Ligaments connecting the Articular Processes.

Capsular.

The **Capsular Ligaments** (Fig. 154) are thin and loose ligamentous sacs, attached to the contiguous margins of the articulating processes of each vertebra through the greater part of their circumference, and completed internally by the ligamenta subflava. They are longer and looser in the cervical than in the dorsal or lumbar regions. The capsular ligaments are lined on their inner surface by synovial membrane.

4. Ligaments connecting the Spinous Processes.

Supraspinous. Interspinous.

The **Supraspinous Ligament** (Fig. 152) is a strong fibrous cord, which connects

together the apices of the spinous processes from the seventh cervical to the spinous processes of the sacrum. It is thicker and broader in the lumbar than in the dorsal region, and intimately blended, in both situations, with the neighboring aponeurosis. The most superficial fibres of this ligament connect three or four vertebræ; those deeper-seated pass between two or three vertebræ; whilst the deepest connect the contiguous extremities of neighboring vertebræ. It is continued upward to the external occipital protuberance, as the ligamentum nuchæ, which, in the human subject, is thin and forms merely an intermuscular septum.

The **Interspinous Ligaments** (Fig. 152), thin and membranous, are interposed between the spinous processes. Each ligament extends from the root to the summit of each spinous process and connects together their adjacent margins. They meet the ligamenta subflava in front and the supra-spinous ligament behind. They are narrow and elongated in the dorsal region; broader, quadrilateral in form, and thicker in the lumbar region; and only slightly developed in the neck.

5. Ligaments connecting the Transverse Processes.

Intertransverse.

The **Intertransverse Ligaments** consist of bundles of fibres interposed between the transverse processes. In the cervical region they consist of a few irregular, scattered fibres; in the dorsal, they are rounded cords intimately connected with the deep muscles of the back; in the lumbar region they are thin and membranous.

Actions.—The movements permitted in the spinal column are, Flexion, Extension, Lateral Movement, Circumduction, and Rotation.

In *Flexion*, or movement of the spine forward, the anterior common ligament is relaxed, and the intervertebral substances are compressed in front, while the posterior common ligament, the ligamenta subflava, and the inter- and supra-spinous ligaments are stretched, as well as the posterior fibres of the intervertebral disks. The interspaces between the laminæ are widened, and the inferior articular processes of the vertebræ above glide upward upon the articular processes of the vertebræ below. Flexion is the most extensive of all the movements of the spine.

In *Extension*, or movement of the spine backward, an exactly opposite disposition of the parts takes place. This movement is not extensive, being limited by the anterior common ligament and by the approximation of the spinous processes.

Flexion and extension are free in the lower part of the lumbar region between the third and fourth and fourth and fifth lumbar vertebræ; above the third they are much diminished, and reach their minimum in the middle and upper part of the back. They increase again in the neck, the capability of motion backward from the upright position being in this region greater than that of the motion forward, whereas in the lumbar region the reverse is the case.

In *Lateral Movement*, the sides of the intervertebral disks are compressed, the extent of motion being limited by the resistance offered by the surrounding ligaments and by the approximation of the transverse processes. This movement may take place in any part of the spine, but is most free in the neck and loins.

Circumduction is very limited, and is produced merely by a succession of the preceding movements.

Rotation is produced by the twisting of the intervertebral substances; this, although only slight between any two vertebræ, produces a considerable extent of movement when it takes place in the whole length of the spine, the front of the upper part of the column being turned to one or the other side. This movement takes place only to a slight extent in the neck, but is freer in the upper part of the dorsal region, and is altogether absent in the lumbar region.

It is thus seen that the *cervical region* enjoys the greatest extent of each variety of movement, flexion and extension especially being very free. In the *dorsal region* the three movements of flexion, extension, and circumduction are permitted only to a slight extent, while rotation is very free in the upper part and

ceases below. In the lumbar region there is free flexion, extension, and lateral movement, but no rotation.

As Sir George Humphry has pointed out, the movements permitted are mainly due to the shape and position of the articulating processes. In the loins the inferior articulating processes are turned outward and embraced by the superior; this renders rotation in this region of the spine impossible, while there is nothing to prevent a sliding upward and downward of the surfaces on each other, so as to allow of flexion and extension. In the dorsal region, on the other hand, the articulating processes, by their direction and mutual adaptation, especially at the upper part of the series, permit of rotation, but prevent extension and flexion, while in the cervical region the greater obliquity and lateral slant of the articular processes allow not only flexion and extension, but also rotation.

The principal muscles which produce *flexion* are the Sterno-mastoid, Rectus capitis anticus major, and Longus colli; the Scaleni; the abdominal muscles and the Psoas magnus. *Extension* is produced by the fourth layer of the muscles of the back, assisted in the neck by the Splenius, Semispinalis dorsi et colli, and the Multifidus spinæ. *Lateral* motion is produced by the fourth layer of the muscles of the back, by the Splenius and the Scaleni, the muscles of one side only acting; and *rotation* by the action of the following muscles of one side only—viz. the Sterno-mastoid, the Rectus capitis anticus major, the Scaleni, the Multifidus spinæ, the Complexus, and the abdominal muscles.

II. Articulation of the Atlas with the Axis.

The articulation of the Atlas with the Axis is of a complicated nature, comprising no fewer than four distinct joints. There is a pivot articulation between the odontoid process of the axis and the ring formed between the anterior arch of the atlas and the transverse ligament (see Fig. 155). Here there are two joints: one in front between the posterior surface of the anterior arch of the atlas and the front of the odontoid process (the *atlanto-odontoid joint of Cruveilhier*); the other between the anterior surface of the transverse ligament and the back of the process (the *syndesmo-odontoid joint*). Between the articular processes of the two bones there is a double arthrodia or gliding joint. The ligaments which connect these bones are the

Anterior Atlanto-axial.	Transverse.
Posterior Atlanto-axial.	Two Capsular.

The **Anterior Atlanto-axial Ligament** (Fig. 153) is a strong, membranous layer, attached, above, to the lower border of the anterior arch of the atlas; below, to the base of the odontoid process and to the front of the body of the axis. It is strengthened in the middle line by a rounded cord, which is attached, above, to the tubercle on the anterior arch of the atlas, and below to the body of the axis, being a continuation upward of the anterior common ligament of the spine. These ligaments are in relation, in front, with the Recti antici majores.

The **Posterior Atlanto-axial Ligament** (Fig. 154) is a broad and thin membranous layer, attached, above, to the lower border of the posterior arch of the atlas; below, to the upper edge of the laminæ of the axis. This ligament supplies the place of the ligamenta subflava, and is in relation, behind, with the Inferior oblique muscles.

The **Transverse Ligament**[1] (Figs. 155, 156) is a thick, strong band, which arches across the ring of the atlas, and serves to retain the odontoid process in firm connection with its anterior arch. This ligament is flattened from before backward, broader and thicker in the middle than at either extremity, and firmly attached on

[1] It has been found necessary to describe the transverse ligament with those of the atlas and axis; but the student must remember that it is really a portion of the mechanism by which the movements of the head on the spine are regulated; so that the connections between the atlas and axis ought always to be studied together with those between the latter bones and the skull.

each side to a small tubercle on the inner surface of the lateral mass of the atlas. As it crosses the odontoid process, a small fasciculus is derived from its upper, and another from its lower, border; the former passing upward, to be inserted into the basilar process of the occipital bone; the latter, downward, to be attached to the posterior surface of the body of the axis; hence, the whole ligament has received the name of *cruciform*. The transverse ligament divides the ring of the atlas into two unequal parts: of these, the posterior and larger serves for the transmission of the cord and its membranes and the spinal accessory nerves; the anterior and smaller contains the odontoid process. Since the space between the anterior arch of the atlas and the transverse ligament is smaller at the lower

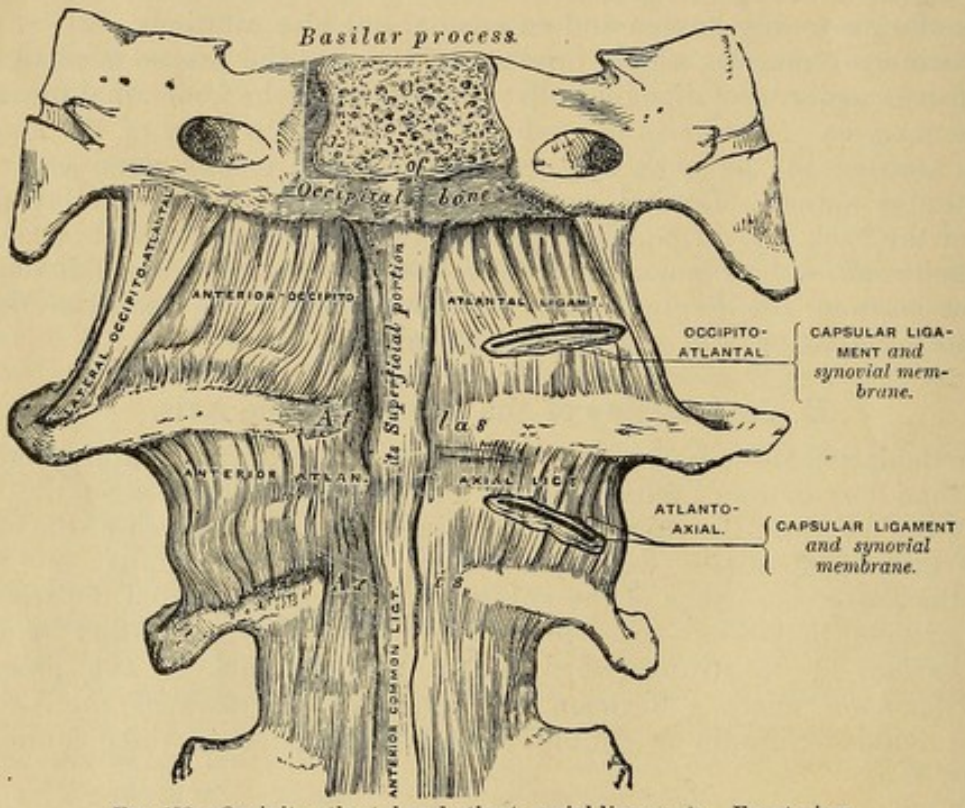

FIG. 153.—Occipito-atlantal and atlanto-axial ligaments. Front view.

part than the upper (because the transverse ligament embraces firmly the narrow neck of the odontoid process), this process is retained in firm connection with the atlas after all the other ligaments have been divided.

The **Capsular Ligaments** are two thin and loose capsules, connecting the lateral masses of the atlas with the superior articular surfaces of the axis, the fibres being strengthened at the posterior and inner part of the articulation by an *accessory ligament*, which is attached below to the body of the axis near the base of the odontoid process.

There are *four* **Synovial Membranes** in this articulation: one lining the inner surface of each of the capsular ligaments; one between the anterior surface of the odontoid process and the anterior arch of the atlas, the *atlanto-odontoid joint;* and one between the posterior surface of the odontoid process and the transverse ligament, the *syndesmo-odontoid joint.* The latter often communicates with those between the condyles of the occipital bone and the articular surfaces of the atlas.

Actions.—This joint allows the rotation of the atlas (and, with it, of the cranium) upon the axis, the extent of rotation being limited by the odontoid ligaments.

The principal muscles by which this action is produced are the Sterno-mastoid and Complexus of one side, acting with the Rectus capitis anticus major, Splenius, Trachelo-mastoid, Rectus capitis posticus major, and Inferior oblique of the other side.

ARTICULATIONS OF THE SPINE WITH THE CRANIUM.

The ligaments connecting the spine with the cranium may be divided into two sets—those connecting the occipital bone with the atlas, and those connecting the occipital bone with the axis.

III. Articulation of the Atlas with the Occipital Bone.

This articulation is a double condyloid joint. Its ligaments are the

Anterior Occipito-atlantal.	Two Lateral Occipito-atlantal.
Posterior Occipito-atlantal.	Two Capsular.

The **Anterior Occipito-atlantal Ligament** (Fig. 153) is a broad membranous layer, composed of densely woven fibres, which passes between the anterior

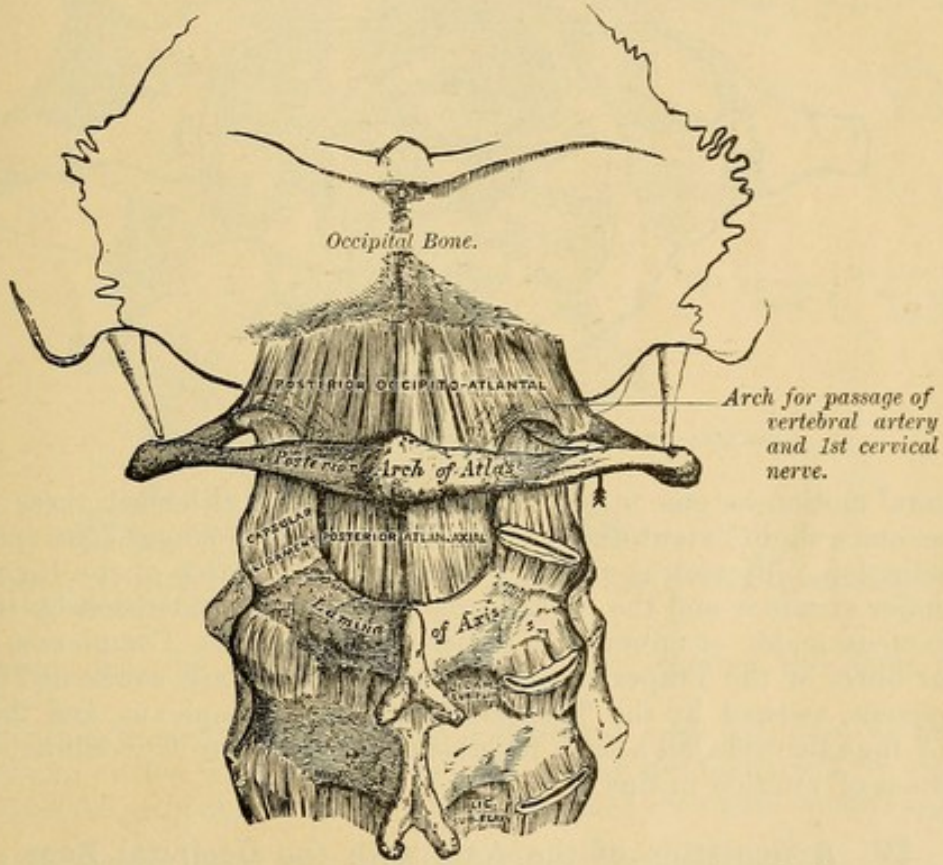

FIG. 154.—Occipito-atlantal and atlanto-axial ligaments. Posterior view.

margin of the foramen magnum above, and the whole length of the upper border of the anterior arch of the atlas below. Laterally, it is continuous with the capsular ligaments. In the middle line in front it is strengthened by a strong, narrow, rounded cord, which is attached, above, to the basilar process of the occiput, and, below, to the tubercle on the anterior arch of the atlas. This ligament is in relation, in front, with the Recti antici minores; behind, with the odontoid ligaments.

The **Posterior Occipito-atlantal Ligament** (Fig. 154) is a very broad but thin membranous lamina intimately blended with the dura mater. It is connected, above, to the posterior margin of the foramen magnum; below, to the upper border of the posterior arch of the atlas. This ligament is incomplete at each side, and forms, with the superior intervertebral notch, an opening for the passage of the vertebral artery and suboccipital nerve. The fibrous band which arches over the artery and nerve sometimes becomes ossified. It is in relation, behind, with the Recti postici minores and Obliqui superiores; in front, with the dura mater of the spinal canal, to which it is intimately adherent.

The **Lateral Ligaments** are strong fibrous bands, directed obliquely upward and

inward, attached above to the jugular process of the occipital bone; below, to the base of the transverse process of the atlas.

The **Capsular Ligaments** surround the condyles of the occipital bone, and connect them with the articular processes of the atlas; they consist of thin and loose capsules, which enclose the synovial membrane of the articulation.

Synovial Membranes.—There are two synovial membranes in this articulation, one lining the inner surface of each of the capsular ligaments. These occasionally communicate with that between the posterior surface of the odontoid process and the transverse ligament.

Actions.—The movements permitted in this joint are flexion and extension, which give rise to the ordinary forward and backward nodding of the head, besides

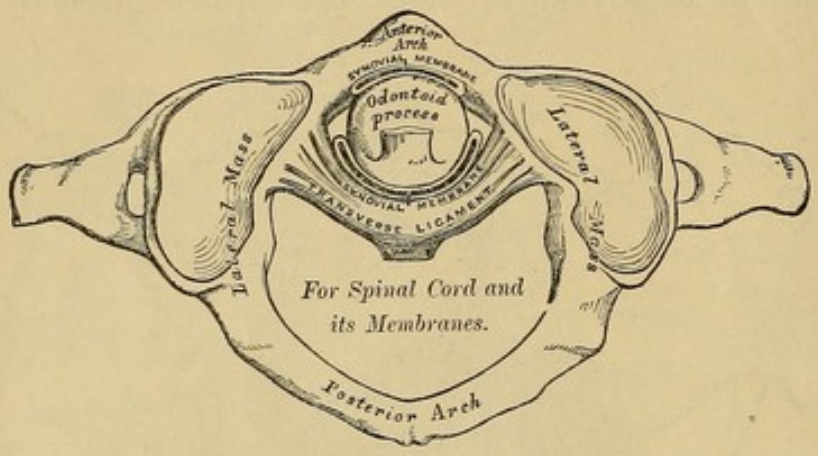

FIG. 155.—Articulation between odontoid process and atlas.

slight lateral motion to one or the other side. When either of these actions is carried beyond a slight extent, the whole of the cervical portion of the spine assists in its production. Flexion is mainly produced by the action of the Rectus capitis anticus major et minor and the Sterno-mastoid muscles; extension by the Rectus capitis posticus major et minor, the Superior oblique, the Complexus, Splenius, and upper fibres of the Trapezius. The Recti laterales are concerned in the lateral movement, assisted by the Trapezius, Splenius, Complexus, and the Sterno-mastoid of the same side, all acting together. According to Cruveilhier, there is a slight motion of rotation in this joint.

IV. Articulation of the Axis with the Occipital Bone.

Occipito-axial. Three Odontoid.

To expose these ligaments the spinal canal should be laid open by removing the posterior arch of the atlas, the laminæ and spinal process of the axis, and the portion of the occipital bone behind the foramen magnum, as seen in Fig. 156.

The **Occipito-axial Ligament** (*apparatus ligamentosus colli*) is situated within the spinal canal. It is a broad, strong band, which covers the odontoid process and its ligaments, and appears to be a prolongation upward of the posterior common ligament of the spine. It is attached, below, to the posterior surface of the body of the axis, and, becoming expanded as it ascends, is inserted into the basilar groove of the occipital bone, in front of the foramen magnum, where it becomes blended with the dura mater of the skull.

Relations.—By its anterior surface with the transverse ligament; by its posterior surface with the dura mater.

The **Odontoid** or **Check Ligaments** (*alar ligaments*) are strong, rounded, fibrous cords, which arise one on either side of the upper part of the odontoid process, and, passing obliquely upward and outward, are inserted into the rough depressions on the inner side of the condyles of the occipital bone. In the triangular interval left between these ligaments another strong fibrous cord (*ligamentum suspensorium*, or

middle odontoid ligament) may be seen, which passes almost perpendicularly from the apex of the odontoid process to the anterior margin of the foramen magnum, being intimately blended with the deep portion of the anterior occipito-atlantal ligament and upper fasciculus of the transverse ligament of the atlas.

Actions.—The odontoid ligaments serve to limit the extent to which rotation

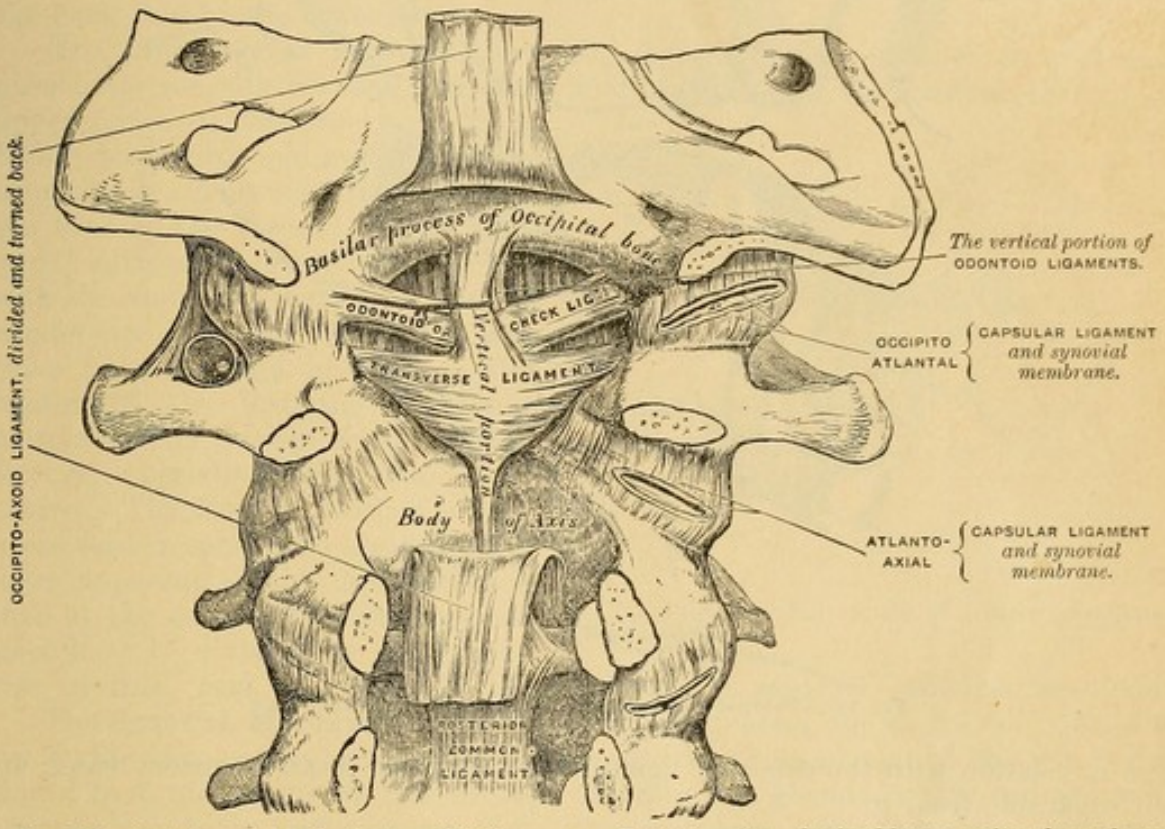

FIG. 156.—Occipito-axial and atlanto-axial ligaments. Posterior view, obtained by removing the arches of the vertebræ and the posterior part of the skull.

of the cranium may be carried; hence they have received the name of *check ligaments.*

In addition to these ligaments, which connect the atlas and axis to the skull, the ligamentum nuchæ must be regarded as one of the ligaments by which the spine is connected with the cranium. It is described on a subsequent page.

Surgical Anatomy.—The ligaments which unite the component parts of the vertebræ together are so strong, and these bones are so interlocked by the arrangement of their articulating processes, that dislocation is very uncommon, and, indeed, unless accompanied by fracture, rarely occurs, except in the upper part of the neck. Dislocation of the occiput from the atlas has only been recorded in one or two cases; but dislocation of the atlas from the axis, with rupture of the transverse ligament, is much more common: it is the mode in which death is produced in many cases of execution by hanging. In the lower part of the neck—that is, below the third cervical vertebra—dislocation unattended by fracture occasionally takes place.

V. Articulation of the Lower Jaw (Temporo-mandibular).

This is a ginglymo-arthrodial joint: the parts entering into its formation on each side are, above, the anterior part of the glenoid cavity of the temporal bone and the eminentia articularis; and, below, the condyle of the lower jaw. The ligaments are the following:

External Lateral.	Stylo-mandibular.
Internal Lateral.	Capsular.

Interarticular Fibro-cartilage.

The **External Lateral Ligament** (Fig. 157) is a short, thin, and narrow fasciculus, attached, above, to the outer surface of the zygoma and to the tubercle on its lower border; below, to the outer surface and posterior border of the neck of the lower jaw. It is broader above than below; its fibres are placed

parallel with one another, and directed obliquely downward and backward. Externally, it is covered by the parotid gland and by the integument. Internally,

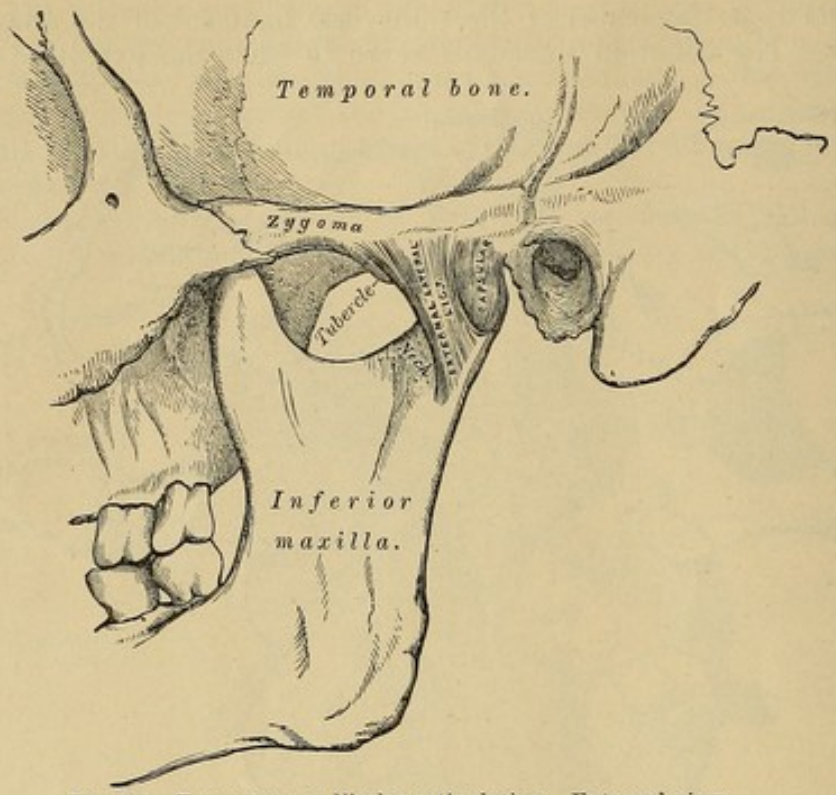

FIG. 157.—Temporo-mandibular articulation. External view.

it is in relation with the capsular ligament, of which it is an accessory band, and not separable from it.

The **Internal Lateral Ligament** (*Spheno-mandibular*) (Fig. 158) is a flat, thin band which is attached above to the spinous process of the sphenoid bone, and, becoming broader as it descends, is inserted into the lingula and margin of the dental foramen. Its outer surface is in relation, above, with the External pterygoid muscle; lower down it is separated from the neck of the condyle by the internal maxillary artery; and still more inferiorly, the inferior dental vessels and nerve separate it from the ramus of the jaw. The inner surface is in relation with the Internal pterygoid. It is really the fibrous covering of a part of Meckel's cartilage.

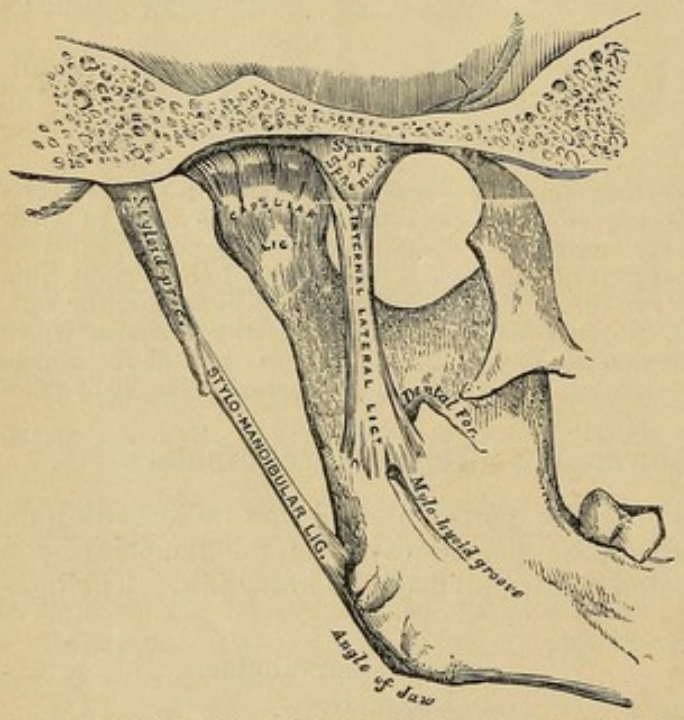

FIG. 158.—Temporo-mandibular articulation. Internal view.

The **Stylo-mandibular Ligament** is a specialized band of the cervical fascia, which extends from near the apex of the styloid process of the temporal bone to the angle and posterior border of the ramus of the lower jaw, between the Masseter and Internal pterygoid muscles. This ligament separates the parotid from the submaxillary gland, and has attached to its inner side part of the fibres of origin of the Stylo-glossus muscle. Although

usually classed among the ligaments of the jaw, it can be considered only as an accessory to the articulation.

The **Capsular Ligament** forms a thin and loose capsule, attached above to the circumference of the glenoid cavity and the articular surface immediately in front; below, to the neck of the condyle of the lower jaw. It consists of a few thin scattered fibres, and can hardly be considered as a distinct ligament; it is thickest at the back part of the articulation.[1]

The **Interarticular Fibro-cartilage** (Fig. 159) is a thin plate of an oval form, placed horizontally between the condyle of the jaw and the glenoid cavity. Its upper surface is concavo-convex from before backward, and a little convex transversely, to accommodate itself to the form of the glenoid cavity. Its under surface, where it is in contact with the condyle, is concave. Its circumference is connected to the capsular ligament, and in front to the tendon of the External pterygoid muscle. It is thicker at its circumference, especially behind, than at its centre. The fibres of which it is composed have a concentric arrangement, more apparent at the circumference than at the centre. Its surfaces are smooth. It divides the joint into two cavities, each of which is furnished with a separate synovial membrane.

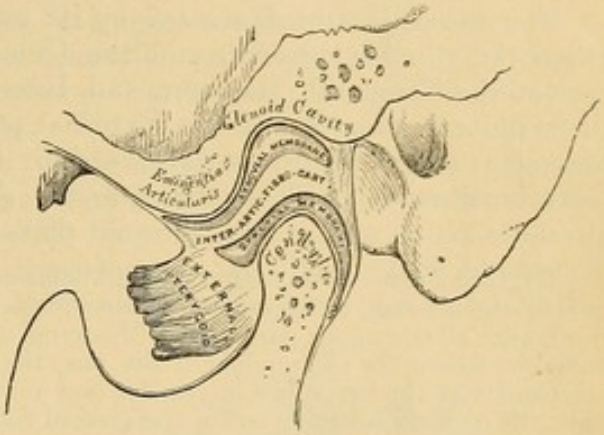

FIG. 159.—Vertical section of temporo-mandibular articulation.

The **Synovial Membranes**, two in number, are placed, one above, and the other below, the fibro-cartilage. The upper one, the larger and looser of the two, is continued from the margin of the cartilage covering the glenoid cavity and eminentia articularis on to the upper surface of the fibro-cartilage. The lower one passes from the under surface of the fibro-cartilage to the neck of the condyle of the jaw, being prolonged downward a little farther behind than in front. The interarticular cartilage is sometimes perforated in its centre; the two synovial sacs then communicate with each other.

The *nerves* of this joint are derived from the auriculo-temporal and masseteric branches of the inferior maxillary. The *arteries* are derived from the temporal branch of the external carotid.

Actions.—The movements permitted in this articulation are very extensive. Thus, the jaw may be depressed or elevated, or it may be carried forward or backward. It must be borne in mind that there are two distinct joints in this articulation—that is to say, one between the condyle of the jaw and the interarticular fibro-cartilage, and another between the fibro-cartilage and the glenoid fossa; when the jaw is depressed, as in opening the mouth, the movements which take place in these two joints are not the same. In the lower compartment, that between the condyle and the fibro-cartilage, the movement is of a ginglymoid or hinge-like character, the condyle rotating on a transverse axis on the fibro-cartilage; while in the upper compartment the movement is of a gliding character, the fibro-cartilage, together with the condyle, gliding forward on to the eminentia articularis. These two movements take place simultaneously—the condyle and fibro-cartilage move forward on the eminence, and at the same time the condyle revolves on the fibro-cartilage. In the opposite movement of shutting the mouth the reverse action takes place; the fibro-cartilage glides back, carrying the condyle with it, and this at the same time revolves back to its former position. When the jaw is carried horizontally forward, as in protruding the lower incisors in front of the upper, the move-

[1] Sir G. Humphry describes the internal portion of the capsular ligament separately as the short internal lateral ligament; and it certainly seems as deserving of a separate description as the external lateral ligament is.

ment takes place principally in the upper compartment of the joint: the fibro-cartilage, carrying with it the condyle, glides forward on the glenoid fossa. This is because this movement is mainly effected by the External pterygoid muscles, which are inserted into both condyle and interarticular fibro-cartilage. The grinding or chewing movement is produced by the alternate movement of one condyle, with its fibro-cartilage, forward and backward, while the other condyle moves simultaneously in the opposite direction; at the same time the condyle undergoes a vertical rotation on its own axis on the fibro-cartilage in the lower compartment. One condyle advances and rotates, the other condyle recedes and rotates, in alternate succession.

The lower jaw is *depressed* by its own weight, assisted by the Platysma, the Digastric, the Mylo-hyoid, and the Genio-hyoid. It is *elevated* by the anterior part of the Temporal, Masseter, and Internal pterygoid. It is drawn *forward* by the simultaneous action of the External pterygoid and the superficial fibres of the Masseter; and it is drawn *backward* by the deep fibres of the Masseter and the posterior fibres of the Temporal muscle. The grinding movement is caused by the alternate action of the two External pterygoids.

Surface Form.—The temporo-mandibular articulation is quite superficial, situated below the base of the zygoma, in front of the tragus and external auditory meatus, and behind the posterior border of the upper part of the Masseter muscle. Its exact position can be at once ascertained by feeling for the condyle of the jaw, the working of which can be distinctly felt in the movements of the lower jaw in opening and shutting the mouth. When the mouth is opened wide, the condyle advances out of the glenoid fossa on to the eminentia articularis, and a depression is felt in the situation of the joint.

Surgical Anatomy.—The lower jaw is dislocated only in one direction—viz. forward. The accident is caused by violence or muscular action. When the mouth is open, the condyle is situated on the eminentia articularis, and any sudden violence, or even a sudden muscular spasm, as during a convulsive yawn, may displace the condyle forward into the zygomatic fossa. The displacement may be unilateral or bilateral, according as one or both of the condyles are displaced. The latter of the two is the more common.

Sir Astley Cooper described a condition which he termed "subluxation." It occurs principally in delicate women, and is believed by some to be due to the relaxation of the ligaments, permitting too free movement of the bone, and possibly some displacement of the fibro-cartilage. Others have believed that it is due to gouty or rheumatic changes in the joint. In close relation to the condyle of the jaw is the external auditory meatus and the tympanum; any force, therefore, applied to the bone is liable to be attended with damage to these parts, or inflammation in the joint may extend to the ear, or on the other hand inflammation of the middle ear may involve the articulation and cause its destruction, thus leading to ankylosis of the joint. In children, arthritis of this joint may follow the exanthemata, and in adults it occurs as the result of some constitutional conditions, as rheumatism or gout. The temporo-mandibular joint is also occasionally the seat of osteo-arthritis, leading to great suffering during efforts of mastication. A peculiar affection sometimes attacks the neck and condyle of the lower jaw, consisting in hypertrophy and elongation of these parts and consequent protrusion of the chin to the opposite side.

VI. Articulations of the Ribs with the Vertebræ.

The articulations of the ribs with the vertebral column may be divided into two sets: 1. Those which connect the heads of the ribs with the bodies of the vertebræ, *costo-central*. 2. Those which connect the necks and tubercles of the ribs with the transverse processes, *costo-transverse*.

1. Articulations between the Heads of the Ribs and the Bodies of the Vertebræ (Fig. 160).

These constitute a series of arthrodial joints, formed by the articulation of the heads of the ribs with the cavities on the contiguous margins of the bodies of the dorsal vertebræ and the intervertebral substance between them, except in the case of the first, tenth, eleventh, and twelfth ribs, where the cavity is formed by a single vertebra. The bones are connected by the following ligaments:

Anterior Costo-vertebral or Stellate.

Capsular. Interarticular.

The **Anterior Costo-vertebral** or **Stellate Ligament** connects the anterior part of

the head of each rib with the sides of the bodies of two vertebræ and the intervertebral disk between them. It consists of three flat bundles of ligamentous fibres, which are attached to the anterior part of the head of the rib, just beyond the articular surface. The superior fibres pass upward to be connected with the body of the vertebra above; the inferior one descends to the body of the vertebra below; and the middle one, the smallest and least distinct, passes horizontally inward, to be attached to the intervertebral substance.

Relations.—In front, with the thoracic ganglia of the sympathetic, the pleura, and, on the right side, with the vena azygos major; behind, with the interarticular ligament and synovial membranes.

In the first rib, which articulates with a single vertebra, this ligament does not present a distinct division into three fasciculi; its fibres, however, radiate, and are attached to the body of the last cervical vertebra, as well as to the body of the vertebra with which the rib articulates. In the tenth, eleventh, and twelfth ribs also, which likewise articulate with a single vertebra, the division does not exist; but the fibres of the ligament in each case radiate and are connected with the vertebra above, as well as that with which the ribs articulate.

The **Capsular Ligament** is a thin and loose ligamentous bag, which surrounds the joint between the head of the rib and the articular cavity formed by the intervertebral disk and the adjacent vertebra. It is very thin, firmly connected with the anterior ligament, and most distinct at the upper and lower parts of the articulation. Behind, some of its fibres pass through the intervertebral foramen to the back of the intervertebral disk. This is the analogue of the *ligamentum conjugale* of some mammals, which unites the heads of opposite ribs across the back of the intervertebral disk.

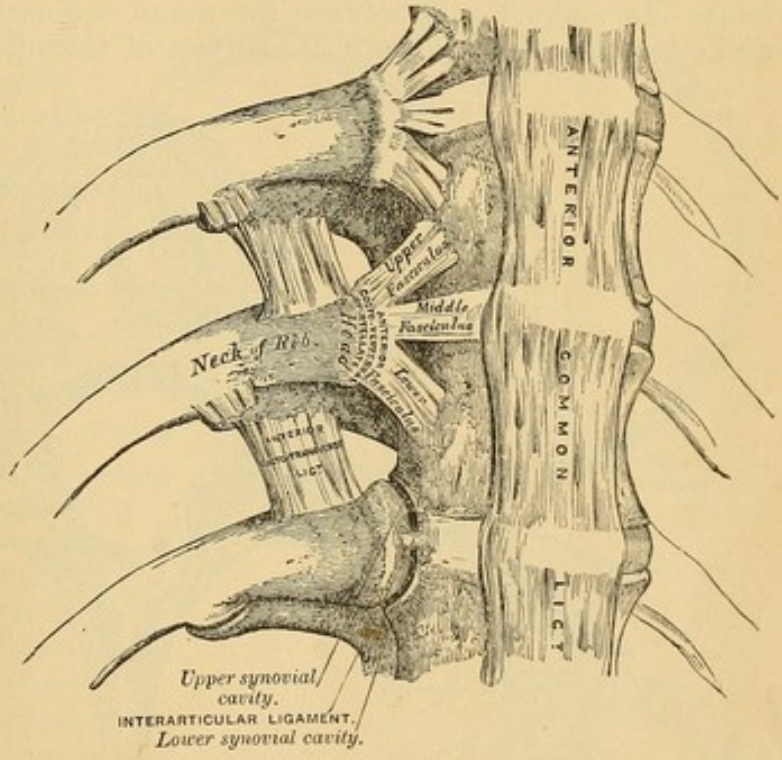

FIG. 160.—Costo-vertebral and costo-transverse articulations. Anterior view.

The **Interarticular Ligament** is situated in the interior of the joint. It consists of a short band of fibres, flattened from above downward, attached by one extremity to the sharp crest which separates the two articular facets on the head of the rib, and by the other to the intervertebral disk. It divides the joint into two cavities, which have no communication with each other. In the first, tenth, eleventh, and twelfth ribs the interarticular ligament does not exist; consequently there is but one synovial membrane.

The Synovial Membrane.—There are two synovial membranes in each of the articulations in which there is an interarticular ligament, one on each side of this structure.

2. Articulations of the Necks and Tubercles of the Ribs with the Transverse Processes (Fig. 161).

The articular portion of the tubercle of the rib and adjacent transverse process form an arthrodial joint.

In the *eleventh* and *twelfth ribs* this articulation is wanting.

The ligaments connecting these parts are the—

Anterior Costo-transverse.
Middle Costo-transverse (Interosseous).
Posterior Costo-transverse.
Capsular.

The **Anterior Costo-transverse Ligament** (*superior* or *long*) consists of two sets of fibres: the one (*anterior*) is attached below to the sharp crest on the upper border of the neck of each rib, and passes obliquely upward and outward to the lower border of the transverse process immediately above; the other (*posterior*) is attached below to the neck of the rib, and passes upward and inward to the base of the transverse process and outer border of the lower articular process of the vertebra above. This ligament is in relation, in front, with the intercostal vessels and nerves; behind, with the Longissimus dorsi. Its *internal border* is thickened and free, and bounds an aperture through which pass the posterior branches of the intercostal vessels and nerves. Its *external border* is continuous with a thin aponeurosis which covers the External intercostal muscle.

The *first rib* has no anterior costo-transverse ligament.

The **Middle Costo-transverse** or **Interosseous Ligament** consists of short but strong fibres which pass between the rough surface on the posterior part of the neck of each rib and the anterior surface of the adjacent transverse process. In

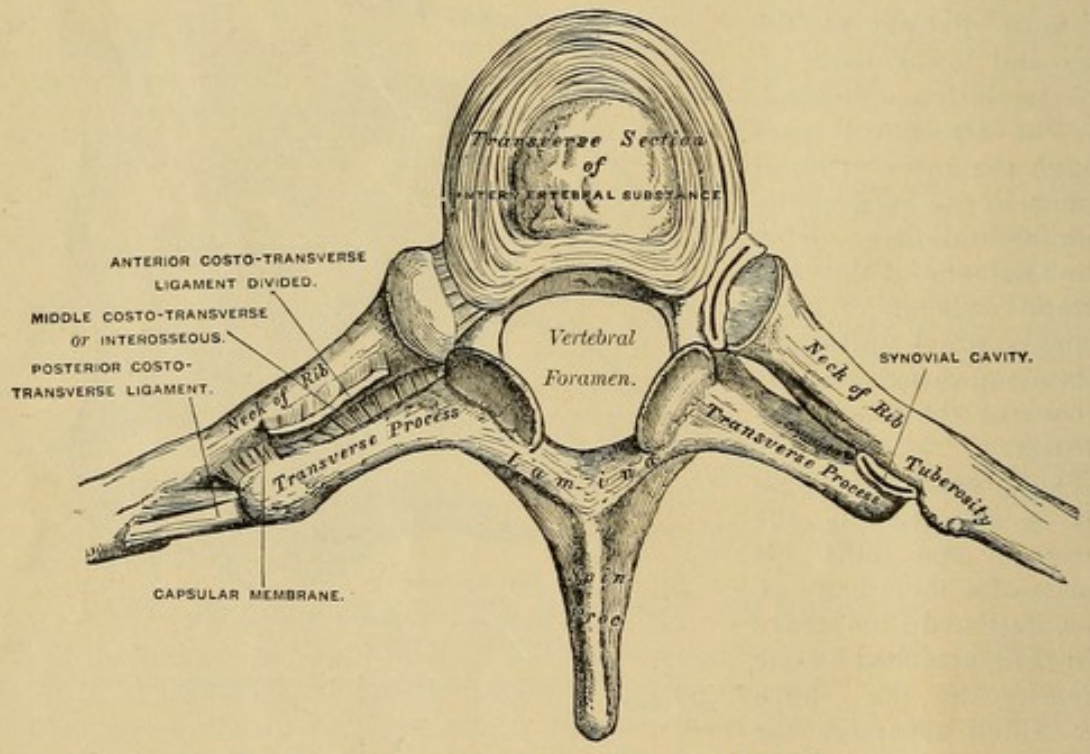

FIG. 161.—Costo-transverse articulation. Seen from above.

order fully to expose this ligament, a horizontal section should be made across the transverse process and corresponding part of the rib; or the rib may be forcibly separated from the transverse process and its fibres put on the stretch.

In the *eleventh* and *twelfth ribs* this ligament is quite rudimentary or wanting.

The **Posterior Costo-transverse Ligament** is a short but thick and strong fasciculus which passes obliquely from the summit of the transverse process to the rough non-articular portion of the tubercle of the rib. This ligament is shorter and more oblique in the upper than in the lower ribs. Those corresponding to the superior ribs ascend, while those of the inferior ribs descend slightly.

In the *eleventh* and *twelfth ribs* this ligament is wanting.

The **Capsular Ligament** is a thin, membranous sac attached to the circumference of the articular surfaces, and enclosing a small synovial membrane.

In the *eleventh* and *twelfth ribs* this ligament is absent.

Actions.—The heads of the ribs are so closely connected to the bodies of the vertebræ by the stellate and interarticular ligaments, and the necks and tubercles of the ribs to the transverse processes, that only a slight sliding movement of the articular surfaces on each other can take place in these articulations. The result of this gliding movement with respect to the six upper ribs consists in an elevation of the front and middle portion of the rib, the hinder part being prevented from performing any upward movement by its close connection with the spine. In this gliding movement the rib rotates on an axis corresponding with a line drawn through the two articulations, Costo-central and Costo-transverse, which the rib forms with the spine. With respect to the seventh, eighth, ninth, and tenth ribs, each one, besides rotating in a similar manner to the upper six, also rotates on an axis corresponding with a line drawn from the head of the rib to the sternum. By the first movement—that of rotation of the rib on an axis corresponding with a line drawn through the two articulations which this bone forms with the spine—an elevation of the anterior part of the rib takes place, and a consequent enlargement of the antero-posterior diameter of the chest. None of the ribs lie in a truly horizontal plane; they are all directed more or less obliquely, so that their anterior extremities lie on a lower level than their posterior, and this obliquity increases from the first to the seventh, and then again decreases. If we examine any one rib—say, that in which there is the greatest obliquity—we shall see that it is obvious that as its sternal extremity is carried upward, it must also be thrown forward; so that the rib may be regarded as a radius moving on the vertebral joint as a centre, and causing the sternal attachment to describe an arc of a circle in the vertical plane of the body. Since all the ribs are oblique and connected in front to the sternum by the elastic costal cartilages, they must have a tendency to thrust the sternum forward, and so increase the antero-posterior diameter of the chest. By the *second* movement—that of the rotation of the rib on an axis corresponding with a line drawn from the head of the rib to the sternum—an elevation of the middle portion of the rib takes place, and consequently an increase in the transverse diameter of the chest. For the ribs not only slant downward and forward from their vertebral attachment, but they are also oblique in relation to their transverse plane—that is to say, their middle is on a lower level than either their vertebral or

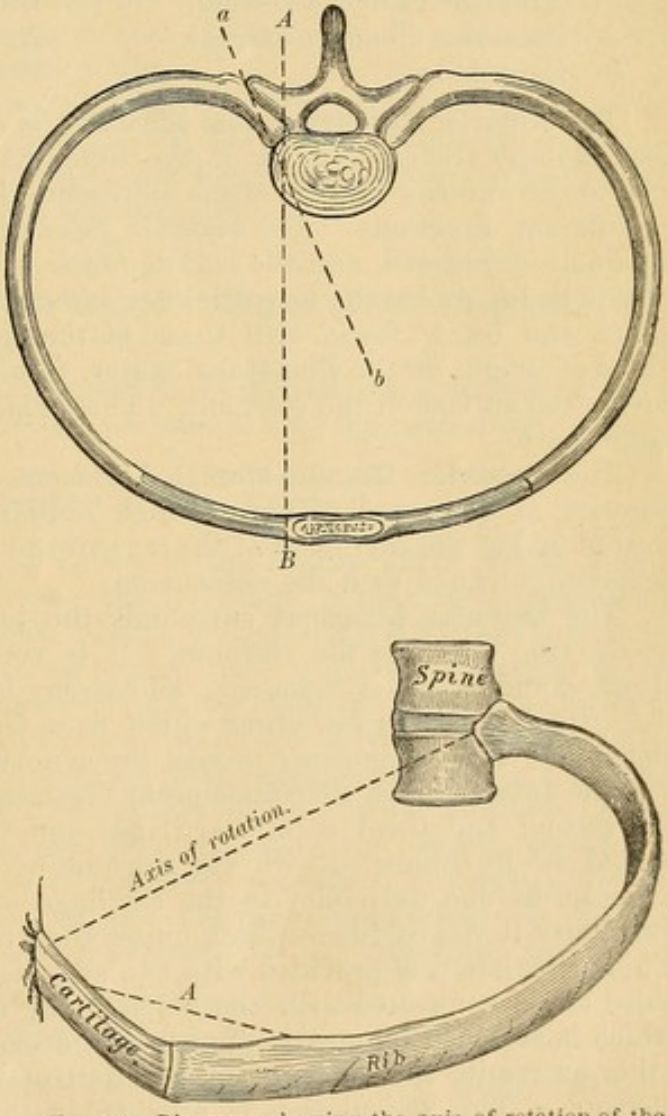

FIG. 162.—Diagrams showing the axis of rotation of the ribs in the movements of respiration. The one axis of rotation corresponds with a line drawn through the two articulations which the rib forms with the spine (*a*, *b*), and the other with a line drawn from the head of the rib to the sternum (A, B). (From Kirke's *Handbook of Physiology*.)

sternal extremities. It results from this that when the ribs are raised, the centre portion is thrust outward, somewhat after the fashion in which the handle of a bucket is thrust away from the side when raised to a horizontal position, and the lateral diameter of the chest is increased (see Fig. 162). The mobility of the different ribs varies very much. The first rib is more fixed than the others, on account of the weight of the upper extremity and the strain of the ribs beneath; but on the freshly dissected thorax it moves as freely as the others. From the same causes the movement of the second rib is also not very extensive. In the other ribs this mobility increases successively down to the last two, which are very movable. The ribs are generally more movable in the female than in the male.

VII. Articulation of the Cartilages of the Ribs with the Sternum, etc. (Fig. 163).

The articulations of the cartilages of the true ribs with the sternum are arthrodial joints, with the exception of the first, in which the cartilage is almost always directly united with the sternum, and which must therefore be regarded as a synarthrodial articulation. The ligaments connecting them are—

Anterior Chondro-sternal.	Interarticular Chondro-sternal.
Posterior Chondro-sternal.	Anterior Chondro-xiphoid.
Capsular.	Posterior Chondro-xiphoid.

The **Anterior Chondro-sternal Ligament** is a broad and thin membranous band that radiates from the front of the inner extremity of the cartilages of the true ribs to the anterior surface of the sternum. It is composed of fasciculi which pass in different directions. The *superior fasciculi* ascend obliquely, the *inferior* pass obliquely downward, and the *middle fasciculi* horizontally. The superficial fibres of this ligament are the longest: they intermingle with the fibres of the ligaments above and below them, with those of the opposite side, and with the tendinous fibres of origin of the Pectoralis major, forming a thick fibrous membrane which covers the surface of the sternum. This is more distinct at the lower than at the upper part.

The **Posterior Chondro-sternal Ligament,** less thick and distinct than the anterior, is composed of fibres which radiate from the posterior surface of the sternal end of the cartilages of the true ribs to the posterior surface of the sternum, becoming blended with the periosteum.

The **Capsular Ligament** surrounds the joints formed between the cartilages of the true ribs and the sternum. It is very thin, intimately blended with the anterior and posterior ligaments, and strengthened at the upper and lower part of the articulation by a few fibres which pass from the cartilage to the side of the sternum. These ligaments protect the synovial membranes.

The Interarticular Chondro-sternal Ligaments.—These are only found between the second and third costal cartilages and the sternum. The cartilage of the *second rib* is connected with the sternum by means of an *interarticular ligament* attached by one extremity to the cartilage of the second rib, and by the other extremity to the cartilage which unites the first and second pieces of the sternum. This articulation is provided with two synovial membranes. The cartilage of the third rib is connected with the sternum by means of an interarticular ligament which is attached by one extremity to the cartilage of the third rib, and by the other extremity to the point of junction of the second and third pieces of the sternum. This articulation is provided with two synovial membranes.

The Anterior Chondro-xiphoid.—This is a band of ligamentous fibres which connects the anterior surface of the seventh costal cartilage, and occasionally also that of the sixth, to the anterior surface of the ensiform appendix. It varies in length and breadth in different subjects.

The **Posterior Chondro-xiphoid** is a similar band of fibres on the internal or posterior surface, though less thick and distinct.

Synovial Membranes.—There is no synovial membrane between the first costal cartilage and the sternum, as this cartilage is directly continuous with the sternum. There are two synovial membranes, both in the articulation of the second and third costal cartilages to the sternum. There is generally one synovial membrane in each of the joints between the fourth, fifth, sixth, and seventh costal cartilages to the sternum; but it is sometimes absent in the sixth and seventh chondro-sternal joints. Thus there are *eight* synovial cavities on each side in the articulations between the costal cartilages of the true ribs and the sternum. After middle life the articular surfaces lose their polish, become roughened, and the synovial membranes appear to be wanting. In old age the articulations do not exist, the cartilages of most of the ribs becoming continuous with the sternum.

Actions.—The movements which are permitted in the chondro-sternal articulations are limited to elevation and depression, and these only to a slight extent.

Articulations of the Cartilages of the Ribs with each other (Interchondral) (Fig. 163).

The contiguous borders of the sixth, seventh, and eighth, and sometimes the ninth and tenth, costal cartilages articulate with each other by small, smooth, oblong-shaped facets. Each articulation is enclosed in a thin *capsular ligament* lined by *synovial membrane*, and strengthened externally and internally by ligamentous fibres (interchondral ligaments) which pass from one cartilage to the other. Sometimes the fifth costal cartilage, more rarely that of the ninth, articulates, by its lower border, with the adjoining cartilage by a small oval facet; more frequently they are connected together by a few ligamentous fibres. Occasionally the articular surfaces above mentioned are wanting.

Articulations of the Ribs with their Cartilages (Costo-chondral) (Fig. 163).

The outer extremity of each costal cartilage is received into a depression in the sternal end of the ribs, and the two are held together by the periosteum.

VIII. Articulations of the Sternum.

The first piece of the sternum is united to the second either by an amphiarthrodial joint—a single piece of true fibro-cartilage uniting the segments—or by a diarthrodial joint, in which each bone is clothed with a distinct lamina of cartilage, adherent on one side, free and lined with synovial membrane on the other. In the latter case the cartilage covering the gladiolus is continued without interruption on to the cartilages of the second ribs. Mr. Rivington has found the diarthrodial form of joint in about one-third of the specimens examined by him; Mr. Maisonneuve more frequently. It appears to be rare in childhood, and is formed, in Mr. Rivington's opinion, from the amphiarthrodial form by absorption. The diarthrodial joint seems to have no tendency to ossify at any age, while the amphiarthrodial is more liable to do so, and has been found ossified as early as thirty-four years of age. The two segments are further connected by an

Anterior Intersternal Ligament.
Posterior Intersternal Ligament.

The **Anterior Intersternal Ligament** consists of a layer of fibres, having a longitudinal direction; it blends with the fibres of the anterior chondro-sternal ligaments on both sides, and with the tendinous fibres of origin of the Pectoralis major. This ligament is rough, irregular, and much thicker below than above.

The **Posterior Intersternal Ligament** is disposed in a somewhat similar manner on the posterior surface of the articulation.

IX. Articulation of the Vertebral Column with the Pelvis.

The ligaments connecting the last lumbar vertebra with the sacrum are similar to those which connect the segments of the spine with each other—viz.: 1. The

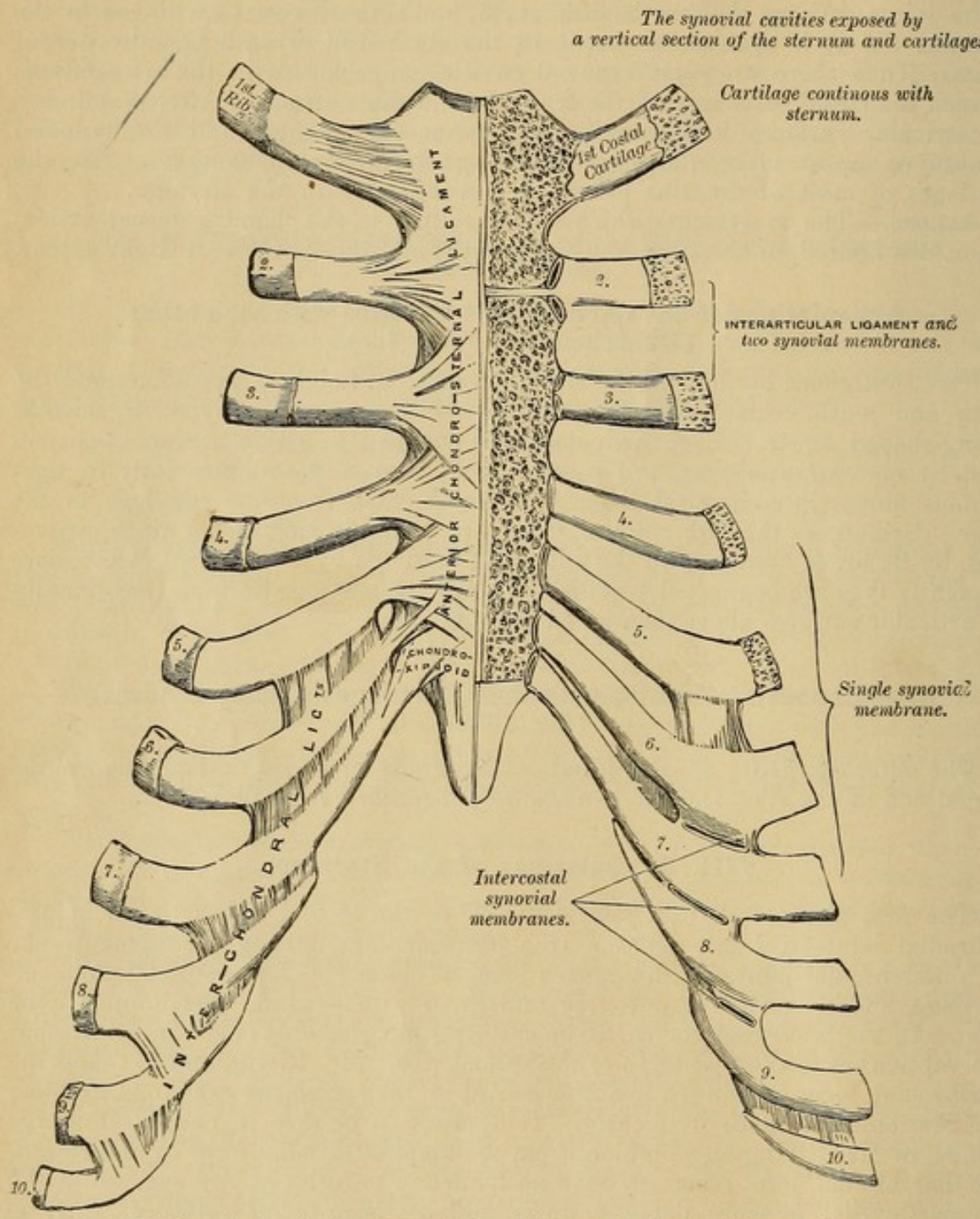

FIG. 163.—Chondro-sternal, chondro-xiphoid, and interchondral articulations. Anterior view.

continuation downward of the anterior and posterior common ligaments. 2. The intervertebral substance connecting the flattened oval surfaces of the two bones and forming an amphiarthrodial joint. 3. Ligamenta subflava, connecting the arch of the last lumbar vertebra with the posterior border of the sacral canal. 4. Capsular ligaments connecting the articulating processes and forming a double arthrodia. 5. Inter- and supraspinous ligaments.

The two proper ligaments connecting the pelvis with the spine are the lumbo-sacral and ilio-lumbar.

The **Lumbo-sacral Ligament** (Fig. 164) is a short, thick, triangular fasciculus, which is connected above to the lower and front part of the transverse process

of the last lumbar vertebra, passes obliquely outward, and is attached below to the lateral surface of the base of the sacrum, becoming blended with the anterior sacro-iliac ligament. This ligament is in relation, in front, with the Psoas muscle.

The **Ilio-lumbar Ligament** (Fig. 164) passes horizontally outward from the

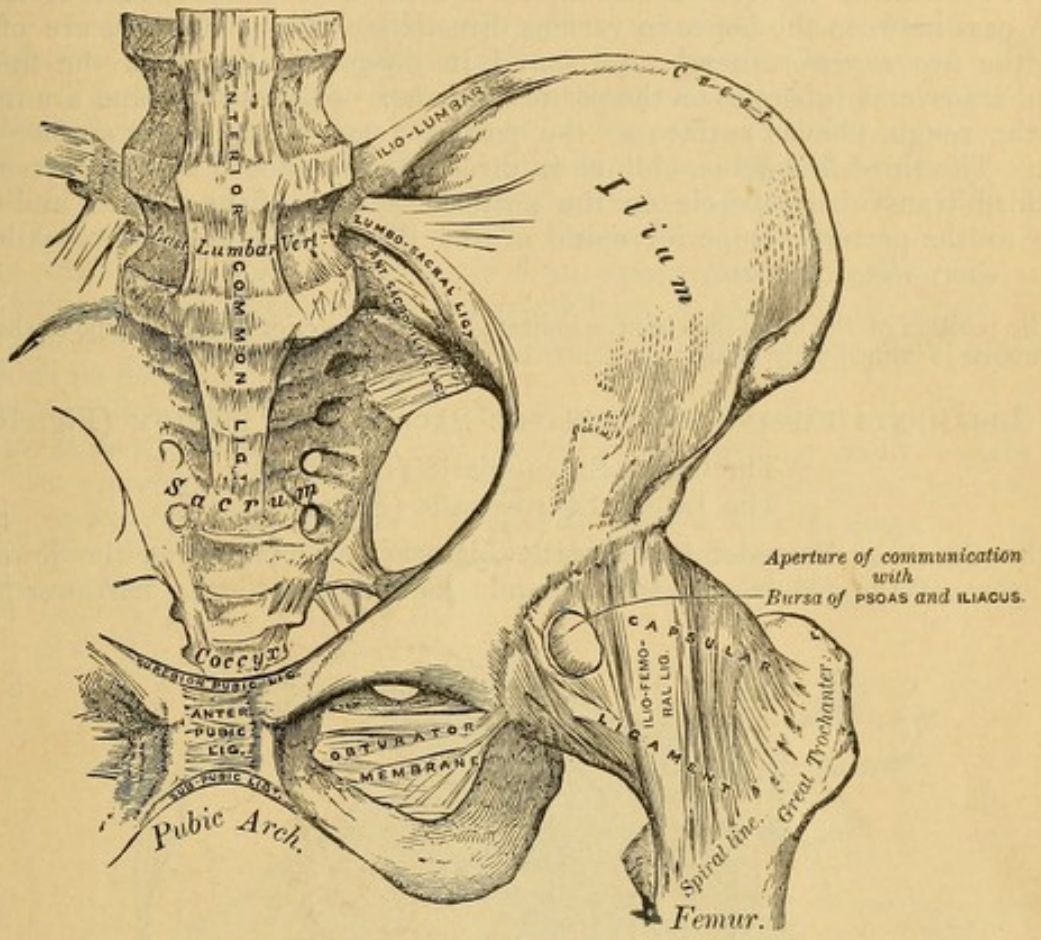

FIG. 164.—Articulations of pelvis and hip. Anterior view.

apex of the transverse process of the last lumbar vertebra to the crest of the ilium immediately in front of the sacro-iliac articulation. It is of a triangular form, thick and narrow internally, broad and thinner externally. It is in relation, in front, with the Psoas muscle; behind, with the muscles occupying the vertebral groove; above, with the Quadratus lumborum.

X. Articulations of the Pelvis.

The ligaments connecting the bones of the pelvis with each other may be divided into four groups: 1. Those connecting the sacrum and ilium. 2. Those passing between the sacrum and ischium. 3. Those connecting the sacrum and coccyx. 4. Those between the two pubic bones.

1. Articulations of the Sacrum and Ilium.

The sacro-iliac articulation is an amphiarthrodial joint, formed between the lateral surfaces of the sacrum and ilium. The anterior or auricular portion of each articular surface is covered with a thin plate of cartilage, thicker on the sacrum than on the ilium. These are in close contact with each other, and to a certain extent united together by irregular patches of softer fibro-cartilage, and at their upper and posterior part by fine fibres of interosseous fibrous tissue. In a considerable part of their extent, especially in advanced life, they are not connected together, but are separated by a space containing a synovial-like fluid, and hence the joint presents the characters of a diarthrosis.

The ligaments connecting these surfaces are the anterior and posterior sacro-iliac.

The **Anterior Sacro-iliac Ligament** (Fig. 164) consists of numerous thin bands which connect the anterior surfaces of the sacrum and ilium.

The **Posterior Sacro-iliac** (Fig. 165) is a strong interosseous ligament, situated in a deep depression between the sacrum and ilium behind, and forming the chief bond of connection between those bones. It consists of numerous strong fasciculi which pass between the bones in various directions. Three of these are of large size: the *two superior*, nearly horizontal in direction, arise from the first and second transverse tubercles on the posterior surface of the sacrum, and are inserted into the rough, uneven surface at the posterior part of the inner surface of the ilium. The third fasciculus, oblique in direction, is attached by one extremity to the third transverse tubercle on the posterior surface of the sacrum, and by the other to the posterior superior spine of the ilium; it is sometimes called the *oblique sacro-iliac ligament*.

The position of the sacro-iliac joint is indicated by the posterior superior spine of the ilium. This process is immediately behind the centre of the articulation.

2. Ligaments passing between the Sacrum and Ischium (Fig. 165).

The Great Sacro-sciatic (Posterior).
The Lesser Sacro-sciatic (Anterior).

The **Great** or **Posterior Sacro-sciatic Ligament** is situated at the lower and back part of the pelvis. It is flat, and triangular in form; narrower in the

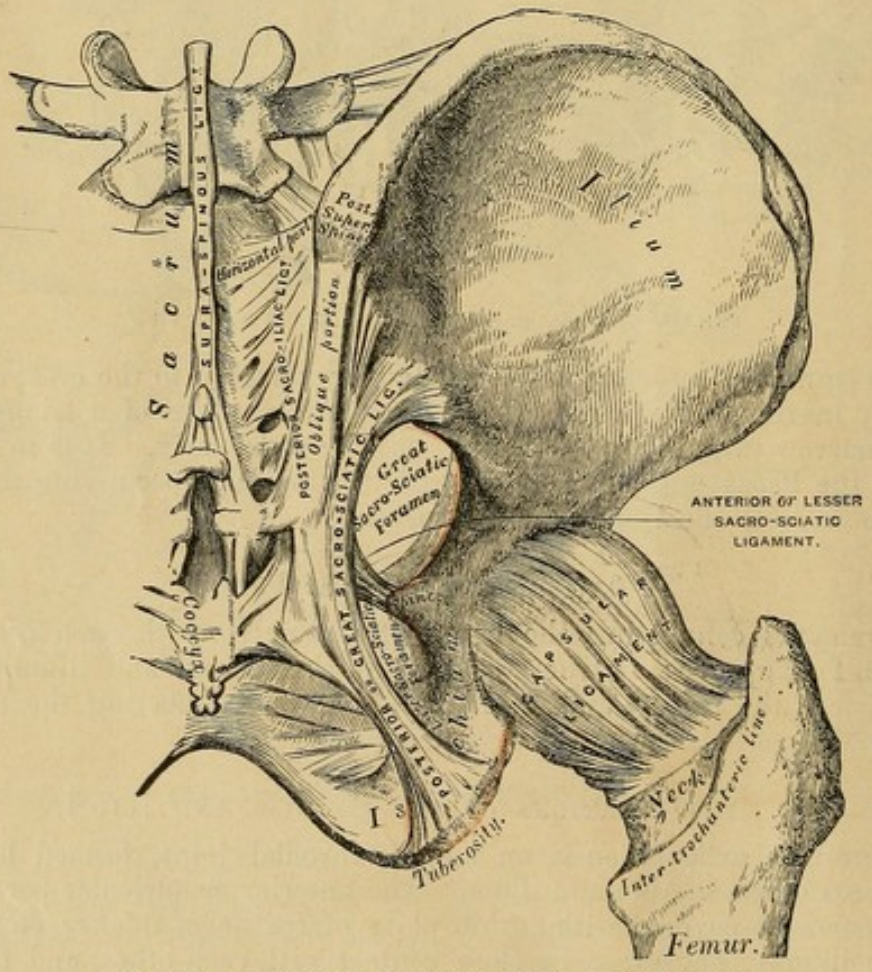

Fig. 165.—Articulations of pelvis and hip. Posterior view

middle than at the extremities; attached by its broad base to the posterior inferior spine of the ilium, to the fourth and fifth transverse tubercles of the sacrum, and to the lower part of the lateral margin of that bone and the coccyx. Passing obliquely downward, outward, and forward, it becomes narrow and thick, and at its insertion into the inner margin of the tuberosity of the ischium it increases

in breadth, and is prolonged forward along the inner margin of the ramus, forming what is known as the *falciform ligament*. The free concave edge of this prolongation has attached to it the obturator fascia, with which it forms a kind of groove, protecting the internal pudic vessels and nerve. One of its surfaces is turned toward the perinæum, the other toward the Obturator internus muscle.

The *posterior surface* of this ligament gives origin, by its whole extent, to fibres of the Gluteus maximus. Its *anterior surface* is united to the lesser sacro-sciatic ligament. Its *external border* forms, above, the posterior boundary of the great sacro-sciatic foramen, and, below, the posterior boundary of the lesser sacro-sciatic foramen. Its *lower border* forms part of the boundary of the perinæum. It is pierced by the coccygeal branch of the sciatic artery and coccygeal nerve.

The **Lesser** or **Anterior Sacro-sciatic Ligament,** much shorter and smaller than the preceding, is thin, triangular in form, attached by its apex to the spine of the ischium, and internally, by its broad base, to the lateral margin of the sacrum and coccyx, anterior to the attachment of the great sacro-sciatic ligament, with which its fibres are intermingled.

It is in relation, *anteriorly*, with the Coccygeus muscle; *posteriorly*, it is covered by the great sacro-sciatic ligament and crossed by the internal pudic vessels and nerve. Its *superior border* forms the lower boundary of the great sacro-sciatic foramen; its *inferior border*, part of the lesser sacro-sciatic foramen.

These two ligaments convert the sacro-sciatic notches into foramina. The *superior* or *great* sacro-sciatic foramen is bounded, in front and above, by the

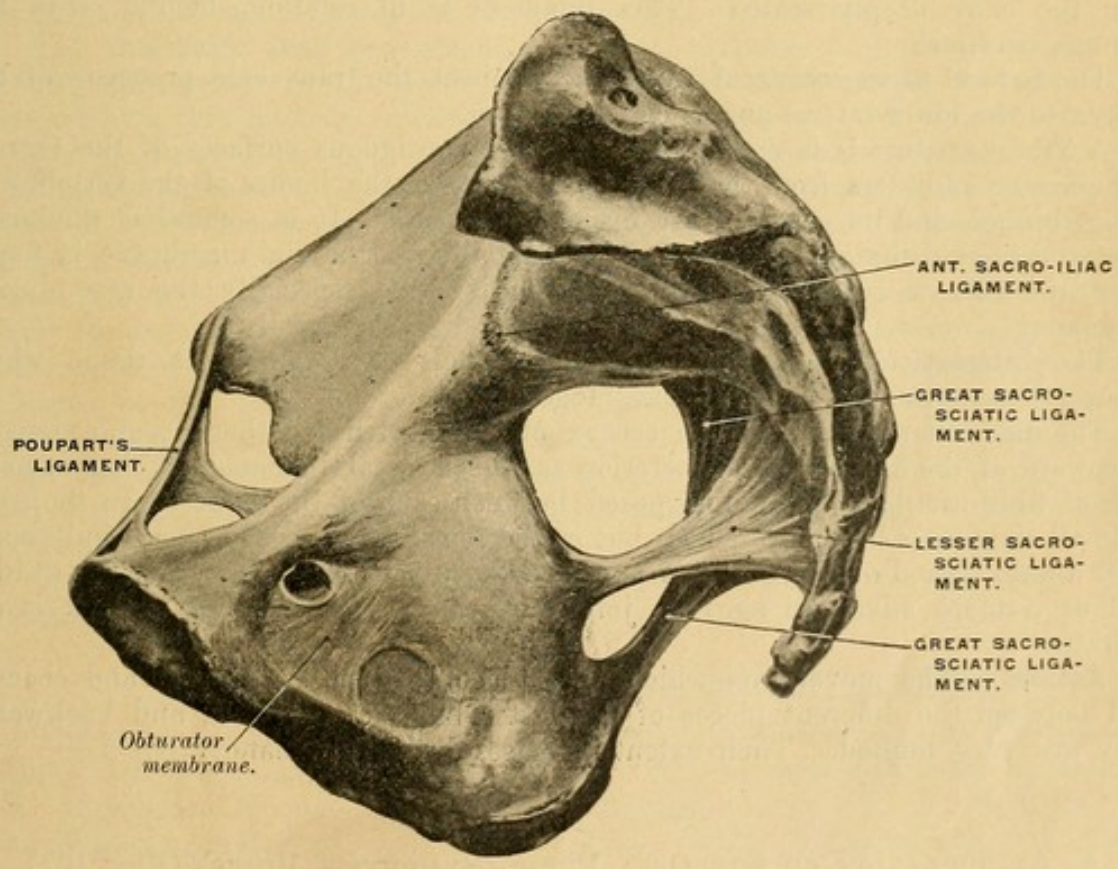

FIG. 166.—Side view of pelvis, showing the great and lesser sacro-sciatic ligaments.

posterior border of the os innominatum; behind, by the great sacro-sciatic ligament; and below, by the lesser sacro-sciatic ligament. It is partially filled up, in the recent state, by the Pyriformis muscle, which passes through it. Above this muscle the gluteal vessels and superior gluteal nerve emerge from the pelvis, and, below it, the sciatic vessels and nerves, the internal pudic vessels and nerve, the inferior gluteal nerve, and the nerves to the obturator internus and quadratus femoris. The *inferior* or *lesser* sacro-sciatic foramen is bounded, in front, by the tuber ischii; above, by the spine and lesser sacro-sciatic ligament; behind, by the greater sacro-

sciatic ligament. It transmits the tendon of the Obturator internus muscle, its nerve, and the internal pudic vessels and nerve.

3. Articulation of the Sacrum and Coccyx.

This articulation is an amphiarthrodial joint, formed between the oval surface at the apex of the sacrum and the base of the coccyx. It is analogous to the joints between the bodies of the vertebræ, and is connected by similar ligaments. They are the

Anterior Sacro-coccygeal.	Lateral Sacro-coccygeal.
Posterior Sacro-coccygeal.	Interposed Fibro-cartilage.

Interarticular.

The **Anterior Sacro-coccygeal Ligament** consists of a few irregular fibres which descend from the anterior surface of the sacrum to the front of the coccyx, becoming blended with the periosteum.

The **Posterior Sacro-coccygeal Ligament** is a flat band of a pearly tint, which arises from the margin of the lower orifice of the sacral canal, and descends to be inserted into the posterior surface of the coccyx. This ligament completes the lower and back part of the sacral canal. Its superficial fibres are much longer than the more deeply seated. This ligament is in relation, behind, with the Gluteus maximus.

The **Lateral Sacro-coccygeal Ligaments** connect the transverse processes of the coccyx to the lower lateral angles of the sacrum.

A **Fibro-cartilage** is interposed between the contiguous surfaces of the sacrum and coccyx; it differs from that interposed between the bodies of the vertebræ in being thinner, and its central part firmer in texture. It is somewhat thicker in front and behind than at the sides. Occasionally, a synovial membrane is found when the coccyx is freely movable, which is more especially the case during pregnancy.

The **Interarticular Ligaments** are thin bands of ligamentous tissue which connect the cornua of the two bones together.

The different segments of the coccyx are connected together by an extension downward of the anterior and posterior sacro-coccygeal ligaments, a thin annular disk of fibro-cartilage being interposed between each of the bones. In the adult male all the pieces become ossified, but in the female this does not commonly occur until a later period of life. The separate segments of the coccyx are first united, and at a more advanced age the joint between the sacrum and coccyx is obliterated.

Actions.—The movements which take place between the sacrum and coccyx, and between the different pieces of the latter bone, are forward and backward; they are very limited. Their extent increases during pregnancy.

4. Articulation of the Ossa Pubis (Symphysis Pubis) (Fig. 167).

The articulation between the pubic bones is an amphiarthrodial joint, formed by the junction of the two oval articular surfaces of the ossa pubis. The ligaments of this articulation are the

Anterior Pubic.	Posterior Pubic.
Superior Pubic.	Subpubic.

Interpubic Disk.

The **Anterior Pubic Ligament** consists of several superimposed layers which pass across the front of the articulation. The superficial fibres pass obliquely from one bone to the other, decussating and forming an interlacement with the fibres of the aponeurosis of the External oblique and the tendon of the Rectus muscles. The deep fibres pass transversely across the symphysis, and are blended with the fibro-cartilage.

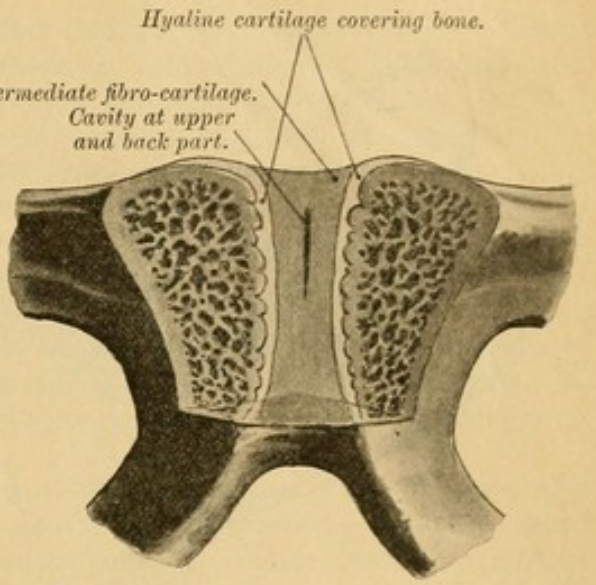

FIG. 167.—Vertical section of the symphysis pubis. Made near its posterior surface.

The **Posterior Pubic Ligament** consists of a few thin, scattered fibres which unite the two pubic bones posteriorly.

The **Superior Pubic Ligament** is a band of fibres which connects together the two pubic bones superiorly.

The **Subpubic Ligament** is a thick, triangular arch of ligamentous fibres, connecting together the two pubic bones below and forming the upper boundary of the pubic arch. Above, it is blended with the interarticular fibro-cartilage; laterally it is united with the descending rami of the os pubis. Its fibres are closely connected and have an arched direction.

The **Interpubic Disk** consists of a disk of cartilage and fibro-cartilage connecting the surfaces of the pubic bones in front. Each of the two surfaces is covered by a thin layer of hyaline cartilage which is firmly connected to the bone by a series of nipple-like processes which accurately fit within corresponding depressions on the osseous surfaces. These opposed cartilaginous surfaces are connected together by an intermediate stratum of fibrous tissue and fibro-cartilage which varies in thickness in different subjects. It often contains a cavity in its centre, probably formed by the softening and absorption of the fibro-cartilage, since it rarely appears before the tenth year of life, and is not lined by synovial membrane. It is larger in the female than in the male, but it is very questionable whether it enlarges, as was formerly supposed, during pregnancy. It is most frequently limited to the upper and back part of the joint, but it occasionally reaches to the front, and may extend the entire length of the cartilage. This cavity may be easily demonstrated by making a vertical section of the symphysis pubis near its posterior surface (Fig. 167).

The **Obturator Ligament** is more properly regarded as analogous to the muscular fasciæ, with which it will be described.

ARTICULATIONS OF THE UPPER EXTREMITY.

The articulations of the upper extremity may be arranged in the following groups: I. Sterno-clavicular articulation. II. Acromio-clavicular articulation. III. Ligaments of the Scapula. IV. Shoulder-joint. V. Elbow-joint. VI. Radio-ulnar articulations. VII. Wrist-joint. VIII. Articulations of the Carpal Bones. IX. Carpo-metacarpal articulations. X. Metacarpo-phalangeal articulations. XI. Articulations of the Phalanges.

I. Sterno-clavicular Articulation (Fig. 168).

The **Sterno-clavicular** is regarded by most anatomists as an arthrodial joint, but Cruveilhier considers it to be an articulation by reciprocal reception. Probably the former opinion is the correct one, the varied movement which the joint enjoys being due to the interposition of an interarticular fibro-cartilage between the joint surfaces. The parts entering into its formation are the sternal end of the

clavicle, the upper and lateral part of the first piece of the sternum, and the cartilage of the first rib. The articular surface of the clavicle is much larger than

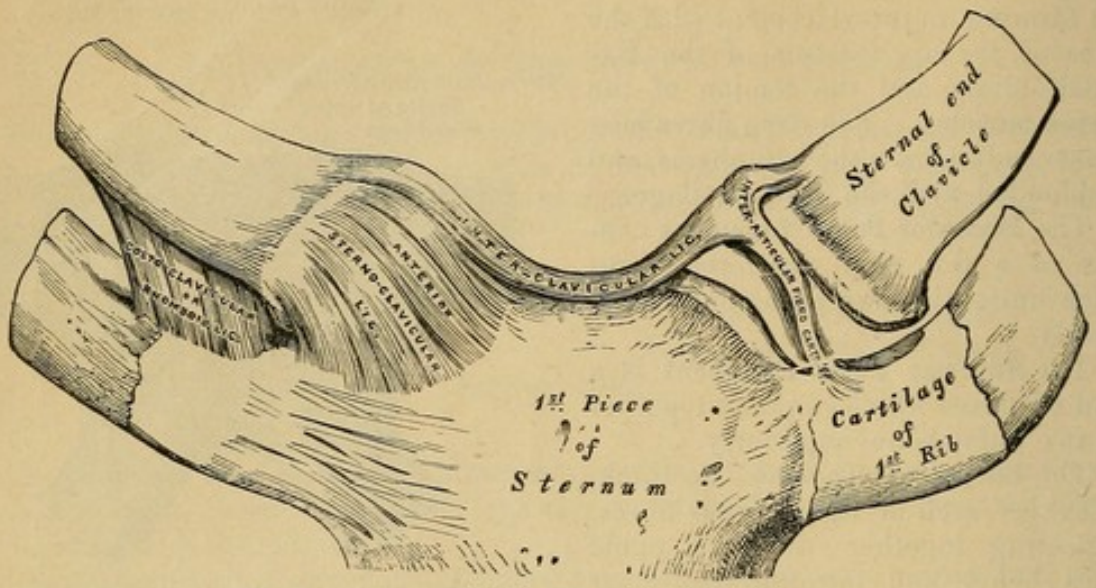

FIG. 168.—Sterno-clavicular articulation. Anterior view.

that of the sternum, and invested with a layer of cartilage [1] which is considerably thicker than that on the latter bone. The ligaments of this joint are the

Capsular.	Interclavicular.
Anterior Sterno-clavicular.	Costo-clavicular (rhomboid).
Posterior Sterno-clavicular.	Interarticular Fibro-cartilage.

The **Capsular Ligament** completely surrounds the articulation, consisting of fibres of varying degrees of thickness and strength. Those in front and behind are of considerable thickness, and form the anterior and posterior sterno-clavicular ligaments; but those above and below, especially in the latter situation, are thin and scanty, and partake more of the character of connective tissue than true fibrous tissue.

The **Anterior Sterno-clavicular Ligament** is a broad band of fibres which covers the anterior surface of the articulation, being attached, above, to the upper and front part of the inner extremity of the clavicle, and, passing obliquely downward and inward, is attached, below, to the upper and front part of the first piece of the sternum. This ligament is covered, in front, by the sternal portion of the Sterno-cleido-mastoid and the integument; behind, it is in relation with the interarticular fibro-cartilage and the two synovial membranes.

The **Posterior Sterno-clavicular Ligament** is a similar band of fibres which covers the posterior surface of the articulation, being attached, above, to the upper and back part of the inner extremity of the clavicle, and, passing obliquely downward and inward, is attached, below, to the upper and back part of the first piece of the sternum. It is in relation, in front, with the interarticular fibro-cartilage and synovial membranes; behind, with the Sterno-hyoid and Sterno-thyroid muscles.

The **Interclavicular Ligament** is a flattened band which varies considerably in form and size in different individuals; it passes in a curved direction from the upper part of the inner extremity of one clavicle to the other, and is also attached to the upper margin of the sternum. It is in relation, in front, with the integument; behind, with the Sterno-thyroid muscles.

The **Costo-clavicular Ligament** (**rhomboid**) is short, flat, and strong: it is of a rhomboid form, attached, below, to the upper and inner part of the cartilage of the first rib: it ascends obliquely backward and outward, and is attached, above,

[1] According to Bruch, the sternal end of the clavicle is covered by a tissue which is rather fibrous than cartilaginous in structure.

to the rhomboid depression on the under surface of the clavicle. It is in relation, in front, with the tendon of origin of the Subclavius; behind, with the subclavian vein.

The **Interarticular Fibro-cartilage** is a flat and nearly circular disk, interposed between the articulating surfaces of the sternum and clavicle. It is attached, above, to the upper and posterior border of the articular surface of the clavicle; below, to the cartilage of the first rib, at its junction with the sternum; and by its circumference, to the anterior and posterior sterno-clavicular and interclavicular ligaments. It is thicker at the circumference, especially its upper and back part, than at its centre or below. It divides the joint into two cavities, each of which is furnished with a separate synovial membrane.

Of the two **Synovial Membranes** found in this articulation, one is reflected from the sternal end of the clavicle over the adjacent surface of the fibro-cartilage and cartilage of the first rib; the other is placed between the articular surface of the sternum and adjacent surface of the fibro-cartilage; the latter is the larger of the two.

Actions.—This articulation is the centre of the movements of the shoulder, and admits of a limited amount of motion in nearly every direction—upward, downward, backward, forward—as well as circumduction. When these movements take place in the joint, the clavicle in its motion carries the scapula with it, this bone gliding on the outer surface of the chest. This joint therefore forms the centre from which all movements of the supporting arch of the shoulder originate, and is the only point of articulation of this part of the skeleton with the trunk. "The movements attendant on elevation and depression of the shoulder take place between the clavicle and the interarticular fibro-cartilage, the bone rotating upon the ligament on an axis drawn from before backward through its own articular facet. When the shoulder is moved forward and backward, the clavicle, with the interarticular fibro-cartilage, rolls to and fro on the articular surface of the sternum, revolving, with a sliding movement, round an axis drawn nearly vertically through the sternum. In the circumduction of the shoulder, which is compounded of these two movements, the clavicle revolves upon the interarticular fibro-cartilage, and the latter, with the clavicle, rolls upon the sternum."[1] Elevation of the clavicle is principally limited by the costo-clavicular ligament; depression, by the interclavicular. The muscles which *raise* the clavicle, as in shrugging the shoulders, are the upper fibres of the Trapezius, the Levator anguli scapulæ, the clavicular head of the Sterno-mastoid, assisted to a certain extent by the two Rhomboids, which pull the vertebral border of the Scapula backward and upward, and so raise the clavicle. The *depression* of the clavicle is principally effected by gravity, assisted by the Subclavius, Pectoralis minor, and lower fibres of the Trapezius. It is drawn *backward* by the Rhomboids and the middle and lower fibres of the Trapezius, and *forward* by the Serratus magnus and Pectoralis minor.

Surface Form.—The position of the sterno-clavicular joint may be easily ascertained by feeling the enlarged sternal end of the collar-bone just external to the long, cord-like, sternal origin of the Sterno-mastoid muscle. If this muscle is relaxed by bending the head forward, a depression just internal to the end of the clavicle, and between it and the sternum, can be felt, indicating the exact position of the joint, which is subcutaneous. When the arm hangs by the side, the cavity of the joint is V-shaped. If the arm is raised, the bones become more closely approximated, and the cavity becomes a mere slit.

Surgical Anatomy.—The strength of this joint mainly depends upon its ligaments, and it is to this, and to the fact that the force of the blow is generally transmitted along the long axis of the clavicle, that dislocation rarely occurs, and that the bone is generally broken rather than displaced. When dislocation does occur, the course which the displaced bone takes depends more upon the direction in which the violence is applied than upon the anatomical construction of the joint; it may be either forward, backward, or upward. The chief point worthy of note, as regards the construction of the joint, in regard to dislocations, is the fact that, owing to the shape of the articular surfaces being so little adapted to each other, and that the strength of the joint mainly depends upon the ligaments, the displacement when reduced is very liable to recur, and hence it is extremely difficult to keep the end of the bone in its proper place.

[1] Humphry, *On the Human Skeleton*, p. 402.

II. Acromio-clavicular Articulation (Fig. 169).

The **Acromio-clavicular** is an arthrodial joint formed between the outer extremity of the clavicle and the inner margin of the acromion process of the scapula. Its ligaments are the

Superior Acromio-clavicular.
Inferior Acromio-clavicular.
Interarticular Fibro-cartilage.
Coraco-clavicular { Trapezoid and Conoid.

The **Superior Acromio-clavicular Ligament** is a quadrilateral band which covers the superior part of the articulation, extending between the upper part of the outer end of the clavicle and the adjoining part of the upper surface of the acromion. It is composed of parallel fibres which interlace with the aponeurosis of the Trapezius and Deltoid muscles; below, it is in contact with the interarticular fibro-cartilage (when it exists) and the synovial membranes.

The **Inferior Acromio-clavicular Ligament,** somewhat thinner than the preceding, covers the under part of the articulation, and is attached to the adjoining surfaces of the two bones. It is in relation, above, with the synovial membranes, and in rare cases with the interarticular fibro-cartilage; below, with the tendon

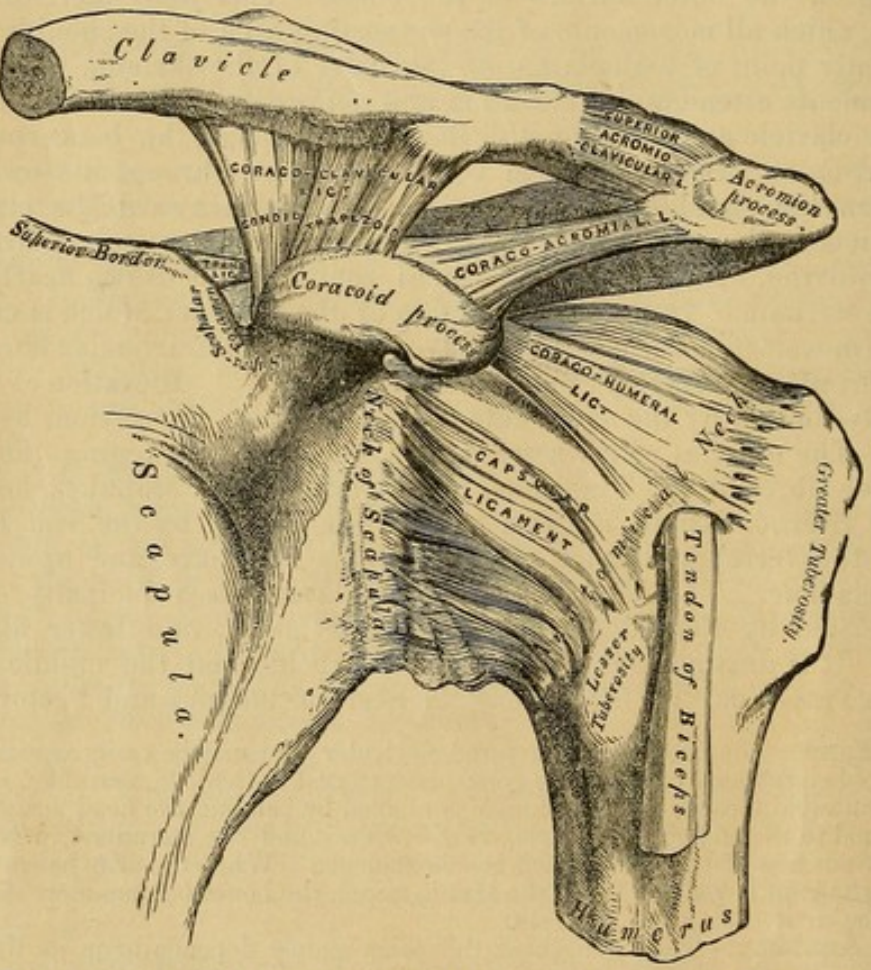

FIG. 169.—The left shoulder-joint, scapulo-clavicular articulations, and proper ligaments of scapula.

of the Supraspinatus. These two ligaments are continuous with each other in front and behind, and form a complete capsule round the joint.

The **Interarticular Fibro-cartilage** is frequently absent in this articulation. When it exists it generally only partially separates the articular surfaces, and occupies the upper part of the articulation. More rarely it completely separates the joint into two cavities.

The Synovial Membrane.—There is usually only one synovial membrane in

this articulation, but when a complete interarticular fibro-cartilage exists there are two synovial membranes.

The **Coraco-clavicular Ligament** serves to connect the clavicle with the coracoid process of the scapula. It does not properly belong to this articulation, but as it forms a most efficient means in retaining the clavicle in contact with the acromial process, it is usually described with it. It consists of two fasciculi, called the *trapezoid* and *conoid ligaments*.

The *Trapezoid Ligament*, the anterior and external fasciculus, is broad, thin, and quadrilateral; it is placed obliquely between the coracoid process and the clavicle. It is attached, below, to the upper surface of the coracoid process; above, to the oblique line on the under surface of the clavicle. Its anterior border is free; its posterior border is joined with the conoid ligament, the two forming by their junction a projecting angle.

The *Conoid Ligament*, the posterior and internal fasciculus, is a dense band of fibres, conical in form, the base being directed upward, the summit downward. It is attached by its apex to a rough impression at the base of the coracoid process, internal to the preceding; above, by its expanded base, to the conoid tubercle on the under surface of the clavicle, and to a line proceeding internally from it for half an inch. These ligaments are in relation, in front, with the Subclavius and Deltoid; behind, with the Trapezius. They serve to limit rotation of the scapula, the Trapezoid limiting rotation forward, and the Conoid backward.

Actions.—The movements of this articulation are of two kinds: 1. A gliding motion of the articular end of the clavicle on the acromion. 2. Rotation of the scapula forward and backward upon the clavicle, the extent of this rotation being limited by the two portions of the coraco-clavicular ligament.

The acromio-clavicular joint has important functions in the movements of the upper extremity. It has been well pointed out by Sir George Humphry that if there had been no joint between the clavicle and scapula the circular movement of the scapula on the ribs (as in throwing both shoulders backward or forward) would have been attended with a greater alteration in the direction of the shoulder than is consistent with the free use of the arm in such position, and it would have been impossible to give a blow straight forward with the full force of the arm; that is to say, with the combined force of the scapula, arm, and forearm. "This joint," as he happily says, "is so adjusted as to enable either bone to turn in a hinge-like manner upon a vertical axis drawn through the other, and it permits the surfaces of the scapula, like the baskets in a roundabout swing, to look the same way in every position or nearly so." Again, when the whole arch formed by the clavicle and scapula rises and falls (in elevation or depression of the shoulders), the joint between these two bones enables the scapula still to maintain its lower part in contact with the ribs.

Surface Form.—The position of the acromio-clavicular joint can generally be ascertained by the slightly enlarged extremity of the outer end of the clavicle, which causes it to project above the level of the acromion process of the scapula. Sometimes this enlargement is so considerable as to form a rounded eminence, which is easily to be felt. The joint lies in the plane of a vertical line passing up the middle of the front of the arm.

Surgical Anatomy.—Owing to the slanting shape of the articular surfaces of this joint, dislocation generally occurs downward; that is to say, the acromion process of the scapula is dislocated under the outer end of the clavicle; but dislocations in the opposite direction have been described. The displacement is often incomplete, on account of the strong coraco-clavicular ligaments, which remain untorn. The same difficulty exists, as in the sterno-clavicular dislocation, in maintaining the ends of the bone in position after reduction.

III. Proper Ligaments of the Scapula (Fig. 169).

The proper ligaments of the scapula are the

Coraco-acromial. Transverse.

The **Coraco-acromial Ligament** is a strong triangular band, extending between the coracoid and acromial processes. It is attached, by its apex, to the summit

of the acromion just in front of the articular surface for the clavicle, and by its broad base to the whole length of the outer border of the coracoid process. Its posterior fibres are directed inward, its anterior fibres forward and inward. This ligament completes the vault formed by the coracoid and acromion processes for the protection of the head of the humerus. It is in relation, above, with the clavicle and under surface of the Deltoid; below, with the tendon of the Supraspinatus muscle, a bursa being interposed. Its outer border is continuous with a dense lamina that passes beneath the Deltoid upon the tendons of the Supra- and Infraspinatus muscles. This ligament is sometimes described as consisting of two marginal bands and a thinner intervening portion, the two bands being attached respectively to the apex and base of the coracoid process, and joining together at their attachment into the acromion process. When the Pectoralis minor is inserted, as sometimes is the case, into the capsule of the shoulder-joint instead of into the coracoid process, it passes between these two bands, and the intervening portion is then deficient.

The **Transverse** or **Coracoid** (*suprascapular*) **Ligament** converts the suprascapular notch into a foramen. It is a thin and flat fasciculus, narrower at the middle than at the extremities, attached by one end to the base of the coracoid process, and by the other to the inner extremity of the scapular notch. The suprascapular nerve passes through the foramen; the suprascapular vessels pass over the ligament.

An additional ligament (the *spino-glenoid*) is sometimes found on the scapula, stretching from the outer border of the spine to the margin of the glenoid cavity. When present, it forms an arch under which the suprascapular vessels and nerve pass as they enter the infraspinous fossa.

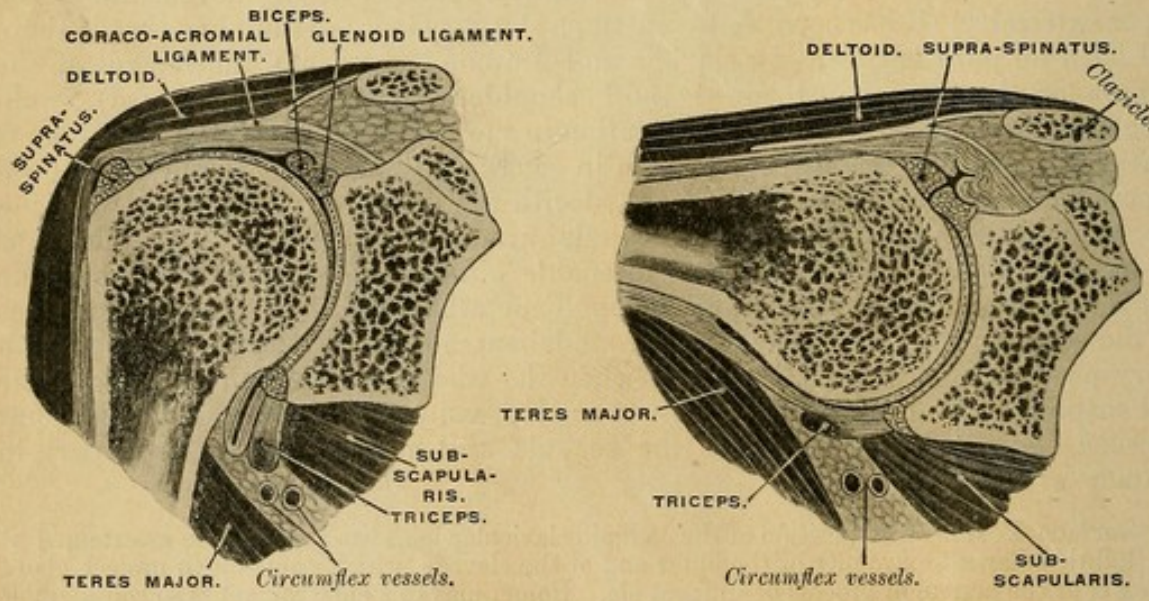

FIG. 170.—Vertical sections through the shoulder-joint, the arm being vertical and horizontal. (After Henle.)

Movements of Scapula.—The scapula is capable of being moved upward and downward, forward and backward, or, by a combination of these movements, circumducted on the wall of the chest. The muscles which *raise* the scapula are the upper fibres of the Trapezius, the Levator anguli scapulæ, and the two Rhomboids; those which *depress* it are the lower fibres of the Trapezius, the Pectoralis minor, and, through the clavicle, the Subclavius. The scapula is drawn *backward* by the Rhomboids and the middle and lower fibres of the Trapezius, and *forward* by the Serratus magnus and Pectoralis minor, assisted, when the arm is fixed, by the Pectoralis major. The mobility of the scapula is very considerable, and greatly assists the movements of the arm at the shoulder-joint. Thus, in raising the arm from the side the Deltoid and Supraspinatus can only lift it to a right

angle with the trunk, the further elevation of the limb being effected by the Trapezius and Serratus magnus moving the scapula on the wall of the chest. This mobility is of special importance in ankylosis of the shoulder-joint, the movements of this bone compensating to a very great extent for the immobility of the joint.

IV. Shoulder-joint (Fig. 169).

The **Shoulder** is an enarthrodial or ball-and-socket joint. The bones entering into its formation are the large globular head of the humerus, which is received into the shallow glenoid cavity of the scapula—an arrangement which permits of very considerable movement, whilst the joint itself is protected against displacement by the tendons which surround it and by atmospheric pressure. The ligaments do not maintain the joint surfaces in apposition, because when they alone remain the humerus can be separated to a considerable extent from the glenoid cavity; their use, therefore, is to limit the amount of movement. Above, the joint is protected by an arched vault, formed by the under surface of the coracoid and acromion processes, and the coraco-acromial ligament. The articular surfaces are covered by a layer of cartilage: that on the head of the humerus is thicker at the centre than at the circumference, the reverse being the case in the glenoid cavity. The ligaments of the shoulder are the

Capsular.	Transverse humeral.
Coraco-humeral.	Glenoid.[1]

The **Capsular Ligament** completely encircles the articulation, being attached, above, to the circumference of the glenoid cavity beyond the glenoid ligament; below, to the anatomical neck of the humerus, approaching nearer to the articular cartilage above than in the rest of its extent. It is thicker above and below than elsewhere, and is remarkably loose and lax, and much larger and longer than is necessary to keep the bones in contact, allowing them to be separated from each other more than an inch—an evident provision for that extreme freedom of movement which is peculiar to this articulation. Its superficial surface is strengthened, above, by the Supraspinatus; below, by the long head of the Triceps; behind, by the tendons of the Infraspinatus and Teres minor; and in front, by the tendon of the Subscapularis. The capsular ligament usually presents three openings; one anteriorly, below the coracoid process, establishes a communication between the synovial membrane of the joint and a bursa beneath the tendon of the Subscapularis muscle. The second, which is not constant, is at the posterior part, where a communication sometimes exists between the joint and a bursal sac belonging to the Infraspinatus muscle. The third is seen between the two tuberosities, for the passage of the long tendon of the Biceps muscle.

The **Coraco-humeral** is a broad band which strengthens the upper part of the capsular ligament. It arises from the outer border of the coracoid process, and passes obliquely downward and outward to the front of the great tuberosity of the humerus, being blended with the tendon of the Supraspinatus muscle. This ligament is intimately united to the capsular in the greater part of its extent.

Supplemental Bands of the Capsular Ligament.—In addition to the coraco-humeral ligament, the capsular ligament is strengthened by supplemental bands in the interior of the joint. One of these bands is situated on the inner side of the joint, and passes from the inner edge of the glenoid cavity to the lower part of the lesser tuberosity of the humerus. This is sometimes known as *Flood's ligament*, and is supposed to correspond with the ligamentum teres of the hip-joint. A second of these bands is situated at the lower part of the joint, and passes from the under edge of the glenoid cavity to the under part of the neck of the humerus, and is known as *Schlemm's ligament*. A third, called the *gleno-humeral ligament*, is situated at the upper part of the joint, and projects into its interior, so that it can

[1] The long tendon of origin of the Biceps muscle also acts as one of the ligaments of this joint. See the observations on p. 222 on the function of the muscles passing over more than one joint.

be seen only when the capsule is opened. It is attached above to the apex of the glenoid cavity, close to the root of the coracoid process, and, passing downward along the inner edge of the tendon of the Biceps, is attached below to the lesser tuberosity of the humerus, where it forms the inner boundary of the upper part of the bicipital groove. It is a thin, ribbon-like band, occasionally quite free from the capsule.

The Transverse Humeral Ligament.—This is a broad band of fibrous tissue passing from the lesser to the greater tuberosity of the humerus, and always limited to that portion of the bone which lies above the epiphyseal line. It converts the bicipital groove into an osseo-aponeurotic canal, and is the analogue of the strong process of bone which connects the summits of the two tuberosities in the musk ox.

The **Glenoid Ligament** is a fibro-cartilaginous rim, attached round the margin of the glenoid cavity. It is triangular on section, the thickest portion being fixed to the circumference of the cavity, the free edge being thin and sharp. It is continuous above with the long tendon of the Biceps muscle, which bifurcates at the upper part of the cavity into two fasciculi, and becomes continuous with the fibrous tissue of the glenoid ligament. This ligament deepens the cavity for articulation, and protects the edges of the bone. It is lined by the synovial membrane.

The **Synovial Membrane** is reflected from the margin of the glenoid cavity over the fibro-cartilaginous rim surrounding it: it is then reflected over the internal surface of the capsular ligament, covers the lower part and sides of the anatomical neck of the humerus as far as the cartilage covering the head of the bone. The long tendon of the Biceps muscle which passes through the capsular ligament is enclosed in a tubular sheath of synovial membrane, which is reflected upon it at the point where it perforates the capsule, and is continued around it as far as the summit of the glenoid cavity. The tendon of the Biceps is thus enabled to traverse the articulation, but it is not contained in the interior of the synovial cavity. The synovial membrane communicates with a large bursal sac beneath the tendon of the Subscapularis by an opening at the inner side of the capsular ligament; it also occasionally communicates with another bursal sac, beneath the tendon of the Infraspinatus, through an orifice at its posterior part. A third bursal sac, which does not communicate with the joint, is placed between the under surface of the Deltoid and the outer surface of the capsule.

The *Muscles* in relation with the joint are, above, the Supraspinatus; below, the long head of the Triceps; in front, the Subscapularis; behind, the Infraspinatus and Teres minor; within, the long tendon of the Biceps. The Deltoid is placed most externally, and covers the articulation on its outer side, as well as in front and behind.

The *Arteries* supplying the joint are articular branches of the anterior and posterior circumflex, and suprascapular.

The *Nerves* are derived from the circumflex and suprascapular.

Actions.—The shoulder-joint is capable of movement in every direction, forward, backward, abduction, adduction, circumduction, and rotation. The humerus is drawn *forward* by the Pectoralis major, anterior fibres of the Deltoid, Coracobrachialis, and by the Biceps when the forearm is flexed; *backward*, by the Latissimus dorsi, Teres major, posterior fibres of the Deltoid, and by the Triceps when the forearm is extended; it is *abducted* (elevated) by the Deltoid and Supraspinatus; it is *adducted* (depressed) by the Subscapularis, Pectoralis major, Latissimus dorsi, and Teres major; it is *rotated outward* by the Infraspinatus and Teres minor; and it is *rotated inward* by the Subscapularis, Latissimus dorsi, Teres major, and Pectoralis major.

The most striking peculiarities in this joint are: 1. The large size of the head of the humerus in comparison with the depth of the glenoid cavity, even when supplemented by the glenoid ligament. 2. The looseness of the capsule of the

joint. 3. The intimate connection of the capsule with the muscles attached to the head of the humerus. 4. The peculiar relation of the biceps tendon to the joint.

It is in consequence of the relative size of the two articular surfaces that the joint enjoys such free movement in every possible direction. When these movements of the arm are arrested in the shoulder-joint by the contact of the bony surfaces and by the tension of the corresponding fibres of the capsule, together with that of the muscles acting as accessory ligaments, they can be carried considerably farther by the movements of the scapula, involving, of course, motion at the acromio- and sterno-clavicular joints. These joints are therefore to be regarded as accessory structures to the shoulder-joint.[1] The extent of these movements of the scapula is very considerable, especially in extreme elevation of the arm, which movement is best accomplished when the arm is thrown somewhat forward and outward, because the margin of the head of the humerus is by no means a true circle; its greatest diameter is from the bicipital groove downward, inward, and backward, and the greatest elevation of the arm can be obtained by rolling its articular surface in the direction of the measurement. The great width of the central portion of the humeral head also allows of very free horizontal movement when the arm is raised to a right angle, in which movement the arch formed by the acromion, the coracoid process, and the coraco-acromial ligament constitutes a sort of supplemental articular cavity for the head of the bone.

The looseness of the capsule is so great that the arm will fall about an inch from the scapula when the muscles are dissected from the capsular ligament and an opening made in it to remove the atmospheric pressure. The movements of the joint, therefore, are not regulated by the capsule so much as by the surrounding muscles and by the pressure of the atmosphere—an arrangement which "renders the movements of the joint much more easy than they would otherwise have been, and permits a swinging, pendulum-like vibration of the limb when the muscles are at rest" (Humphry). The fact, also, that in all ordinary positions of the joint the capsule is not put on the stretch enables the arm to move freely in all directions. Extreme movements are checked by the tension of appropriate portions of the capsule, as [illegible] interlocking of the bones. Thus it is said that "abduction is [illegible] contact of the great tuberosity with the upper edge of the glenoid [illegible] by the tension of the coraco-humeral ligament" (Beaunis et [illegible] and[2] maintains that the limitations of movement at the shoulder-[illegible] he structure of the joint itself, the glenoid ligament fitting, in [illegible] f the elevated arm, into the anatomical neck of the humerus.

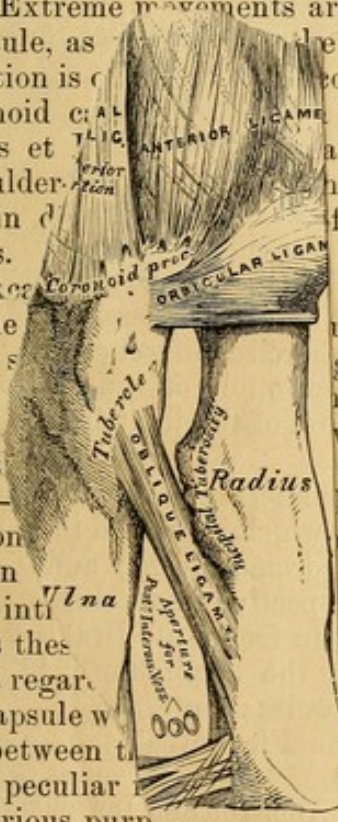

Cath[illegible] that in abducting the arm and raising it above the head, the [illegible] ughout the whole movement with the exception of a short s[illegible] g and at the end; that the humerus moves on the scapula [illegible] ging to the horizontal position, but also in passing upward [illegible] vertical above; that the clavicle moves not only during t[illegible] movement but in the first as well, though to a less extent—[illegible] lavicle are concerned in the first stage as well as in the secon[illegible] nerus is partly involved in the second as well as chiefly in [illegible]

The inti[illegible] endons of the four short muscles with the capsule converts thes[illegible] tic and spontaneously acting ligaments of the joint, and it is regar[illegible] ntended to prevent the folds into which all portions of the capsule w[illegible] fall in the varying positions of the joint from being driven between t[illegible] e pressure of the atmosphere.

The peculiar [illegible] Biceps tendon to the shoulder-joint appear to subserve various purp[illegible] first place, by its connection with both the shoulder and elbow the mu[illegible] zes the action of the two joints, and acts as an elastic ligament in [illegible] in the manner previously adverted to.[4] Next, it strengthens the upp[illegible] of the c[illegible] e articular cavity, and prevents the head of the on each [illegible]

[1] See p. 249. [2] *Journal* [illegible] *d Physiology*, vol. xviii., 1884. [3] *Ibid.* [4] See p. 222.

humerus from being pressed up against the acromion process, when the Deltoid contracts, instead of forming the centre of motion in the glenoid cavity. By its passage along the bicipital groove it assists in rendering the head of the humerus steady in the various movements of the arm. When the arm is raised from the side it assists the Supra- and Infraspinatus in rotating the head of the humerus in the glenoid cavity. It also holds the head of the bone firmly in contact with the glenoid cavity, and prevents its slipping over its lower edge, or being displaced by the action of the Latissimus dorsi and Pectoralis major, as in climbing and many other movements.

Surface Form.—The direction and position of the shoulder-joint may be indicated by a line drawn from the middle of the coraco-acromial ligament, in a curved direction, with its convexity inward, to the innermost part of that portion of the head of the humerus which can be felt in the axilla when the arm is forcibly abducted from the side. When the arm hangs by the side, not more than one-third of the head of the bone is in contact with the glenoid cavity, and three-quarters of its circumference is in front of a vertical line drawn from the anterior border of the acromion process.

Surgical Anatomy.—Owing to the construction of the shoulder-joint and the freedom of movement which it enjoys, as well as in consequence of its exposed situation, it is more frequently dislocated than any other joint in the body. Dislocation occurs when the arm is abducted, and when, therefore, the head of the humerus presses against the lower and front part of the capsule, which is the thinnest and least supported part of the ligament. The rent in the capsule almost invariably takes place in this situation, and through it the head of the bone escapes, so that the dislocation in most instances is primarily subglenoid. The head of the bone does not usually remain in this situation, but generally assumes some other position, which varies according to the direction and amount of force producing the dislocation and the relative strength of the muscles in front and behind the joint. In consequence of the muscles at the back being stronger than those in front, and especially on account of the long head of the Triceps preventing the bone passing backward, dislocation forward is much more common than backward. The most frequent position which the head of the humerus ultimately assumes is on the front of the neck of the scapula, beneath the coracoid process, and hence named subcoracoid dislocation. Occasionally, in consequence probably of a greater amount of force being brought to bear on the limb, the head is driven farther inward, and rests on the upper part of the front of the chest, beneath the clavicle (subclavicular). Sometimes it remains in the position in which it was primarily displaced, resting o[illegible]illary border of [illegible] scapula (subglenoid), and rarely it passes backward and remains well as by [illegible] inner sideath the spine (subspinous).

The shoulder-joint is sometimes the s[illegible]checked by the [illegible]other bursal s[illegible]s, both acute and chronic, which attack joints, though perh[illegible]vity, adduction its posterior [illegible]ints of equal size and importance. Acute synovitis may r[illegible]Bouchard). Clel[illegible]t, is placed betw[illegible]mia, or may follow secondarily on the so-called acute [illegible]joint are due to t[illegible]capsule. [illegible]th effusion into the joint, and when this occurs the [illegible]fferent positions o[illegible]ve, the Supraspin[illegible]r of the joint rounded. Special projections may o[illegible] scapularis; behind, [illegible]lar ligament. Thus a swelling may appear just in f[illegible]rt[3] has pointed out [illegible]of the Biceps. The [illegible]ty, from effusion into the bursa beneath the Sul[illegible] scapula rotates thro[illegible]n its outer side, as [illegible]is sometimes bilobed may be seen in the interval [illegible]pace at the beginnin[illegible] [illegible]s, from effusion into the diverticulum, which [illegible] not only from the ha[illegible] branches of the ant[illegible] the biceps. The effusion into the synovial me[illegible] as it approaches the [illegible] the axilla, where a soft, elastic, fluctuating s[illegible]

Tubercular arthritis not unf[illegible]he second half of the [illegible]l suprascapular. [illegible]o total destruction of the articulation, wh[illegible] *i. e.*, the scapula and c[illegible]ent in every direction. [illegible]ation may necessitate excision. This joint is [illegible]nd rotation. The h[illegible]t of osteoarthritis, and may also be affected; and that the hu[illegible] the first. [illegible]ky, when it becomes the seat of Charcot's disea[illegible] fibres of the Delto[illegible]ly the tubercular form) which have gone on to d[illegible]mate union of the [illegible]flexed; *backward*, [illegible]slocations and fractures, particularly those arising [illegible]e muscles into elas[illegible]eltoid, and by the [illegible]been extensive injury to the head of the bone; in som[illegible]led as being also [illegible] the Deltoid and [illegible]re there is much pain; and possibly in some few cases of [illegible]ould alternately [illegible]toralis major, [illegible]of the bone. The operation is best performed by making a[illegible]e bones by th[illegible]nfraspinatus a[illegible]raco-acromial ligament down the arm for about three inches [illegible]elations of th[illegible]issimus dorsi, [illegible]ove and the tendon of the Biceps, which may be either divide[illegible]oses. In the [illegible]ding as to whether it is implicated in the disease or not. The ca[illegible]scle harmon[illegible] the muscles attached to the greater and lesser tuberosities of [illegible]: 1. The la[illegible] head of the bone can then be thrust out of the wound and sa[illegible]all positions, the glenoi[illegible]rrow saw *in situ* and subsequently removed. The section should [illegible]r part of th[illegible] looseness [illegible]w the articular surface, so as to leave the bone as long as possible [illegible] then be examined, and gouged if carious.

of Anatomy an

V. Elbow-joint (Figs. 171, 172).

The **Elbow** is a *ginglymus* or hinge-joint. The bones entering into its formation are the trochlear of the humerus, which is received into the greater sigmoid cavity of the ulna, and admits of the movements peculiar to this joint—viz. flexion and extension; whilst the lesser, or radial, head of the humerus articulates with the cup-shaped depression on the head of the radius; the circumference of the head of the radius articulates with the lesser sigmoid cavity of the ulna, allowing of the movement of rotation of the radius on the ulna, the chief action of the superior radio-ulnar articulation. The articular surfaces are covered with a thin layer of cartilage, and connected together by a capsular ligament of unequal thickness, being especially thickened on its two sides and, to a less extent, in front and behind. These thickened portions are usually described as distinct ligaments under the following names:

Anterior.	Internal Lateral.
Posterior.	External Lateral.

The orbicular ligament of the upper radio-ulnar articulation must also be reckoned among the ligaments of the elbow.

The **Anterior Ligament** (Fig. 171) is a broad and thin fibrous layer which covers the anterior surface of the joint. It is attached to the front of the internal condyle and to the front of the humerus immediately above the coronoid and radial fossæ; below,

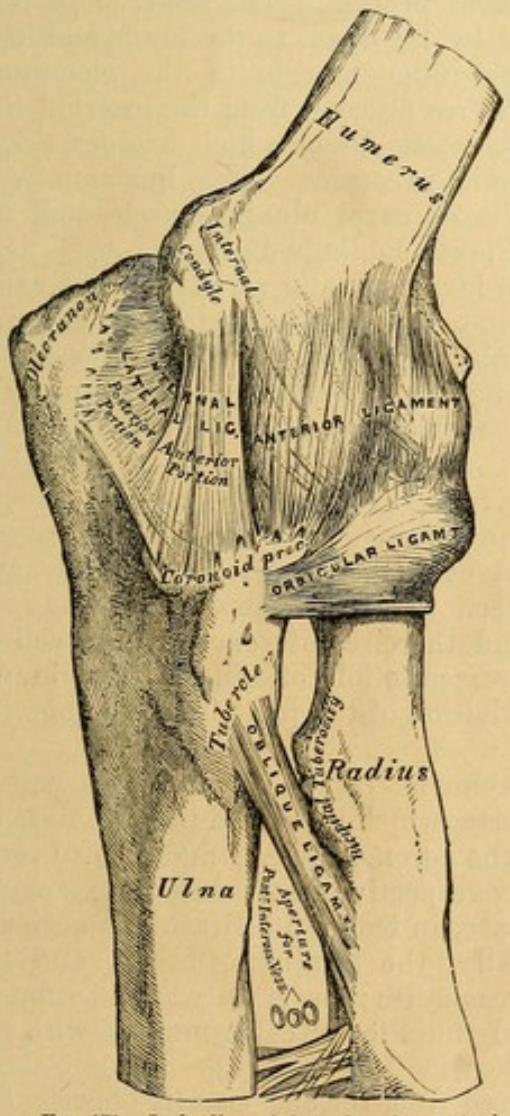

FIG. 171.—Left elbow-joint, showing anterior and internal ligaments.

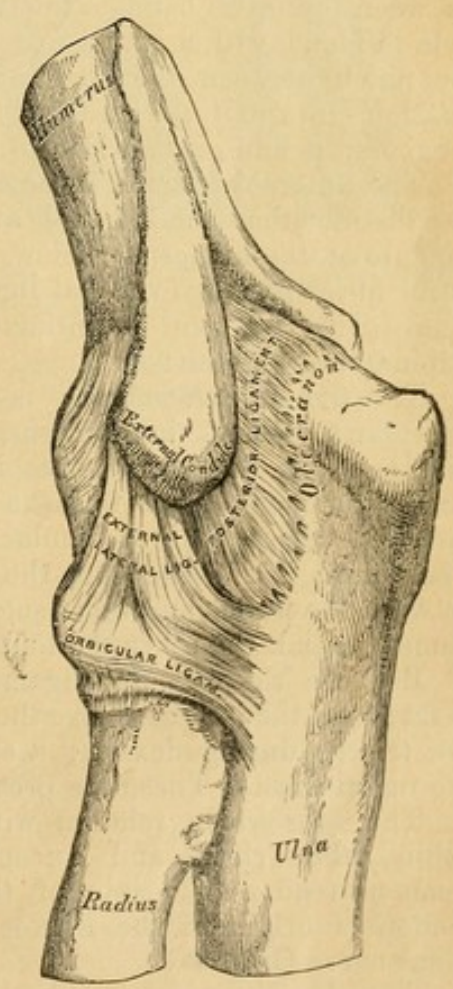

FIG. 172.—Left elbow-joint, showing posterior and external ligaments.

to the anterior surface of the coronoid process of the ulna and orbicular ligament, being continuous on each side with the lateral ligaments. Its superficial

fibres pass obliquely from the inner condyle of the humerus outward to the orbicular ligament. The middle fibres, vertical in direction, pass from the upper part of the coronoid depression and become partly blended with the preceding, but mainly inserted into the anterior surface of the coronoid process. The deep or transverse set intersects these at right angles. This ligament is in relation, in front, with the Brachialis anticus, except at its outermost part; behind, with the synovial membrane.

The **Posterior Ligament** (Fig. 172) is a thin and loose membranous fold, attached, above, to the lower end of the humerus, above and at the sides of the olecranon fossa; below, to the groove on the upper and outer surfaces of the olecranon. The superficial or transverse fibres pass between the adjacent margins of the olecranon fossa. The deeper portion consists of vertical fibres, some of which, thin and weak, pass from the upper part of the olecranon fossa to the margin of the olecranon; others, thicker and stronger, pass from the back of the capitellum of the humerus to the posterior border of the lesser sigmoid cavity of the ulna. This ligament is in relation, behind, with the tendon of the Triceps and the Anconeus; in front, with the synovial membrane.

The **Internal Lateral Ligament** (Fig. 171) is a thick triangular band consisting of two portions, an anterior and posterior, united by a thinner intermediate portion. The *anterior portion*, directed obliquely forward, is attached, above, by its apex, to the front part of the internal condyle of the humerus; and, below, by its broad base, to the inner margin of the coronoid process. The *posterior portion*, also of triangular form, is attached, above, by its apex, to the lower and back part of the internal condyle; below, to the inner margin of the olecranon. Between these two bands a few intermediate fibres descend from the internal condyle to blend with a transverse band of ligamentous tissue which bridges across the notch between the olecranon and coronoid processes. This ligament is in relation, internally, with the Triceps and Flexor carpi ulnaris muscles and the ulnar nerve, and gives origin to part of the Flexor sublimis digitorum.

The **External Lateral Ligament** (Fig. 172) is a short and narrow fibrous band less distinct than the internal, attached, above, to a depression below the external condyle of the humerus; below, to the orbicular ligament, some of its most posterior fibres passing over that ligament, to be inserted into the outer margin of the ulna. This ligament is intimately blended with the tendon of origin of the Supinator brevis muscle.

The **Synovial Membrane** is very extensive. It covers the margin of the articular surface of the humerus, and lines the coronoid and olecranon fossæ on that bone; from these points it is reflected over the anterior, posterior, and lateral ligaments, and forms a pouch between the lesser sigmoid cavity, the internal surface of the orbicular ligament, and the circumference of the head of the radius. Projecting into the cavity is a crescentic fold of synovial membrane, between the radius and ulna, suggesting the division of the joint into two: one the humero-radial, the other the humero-ulnar.

Between the capsular ligament and the synovial membrane are three masses of fat; one, the largest, above the olecranon fossa, which is pressed into the fossa by the triceps during flexion; a second, over the coronoid fossa; and a third, over the radial fossa. These are pressed into their respective fossæ during extension.

The *Muscles* in relation with the joint are, in front, the Brachialis anticus; behind, the Triceps and Anconeus; externally, the Supinator brevis and the common tendon of origin of the Extensor muscles; internally, the common tendon of origin of the Flexor muscles, and the Flexor carpi ulnaris, with the ulnar nerve (Fig. 173).

The *Arteries* supplying the joint are derived from the anastomosis between the superior profunda, inferior profunda, and anastomotica magna arteries, branches of the brachial, with the anterior, posterior, and interosseous recurrent branches of the ulnar and the recurrent branch of the radial. These vessels form a complete chain of inosculation around the joint.

The *Nerves* are derived from the ulnar as it passes between the internal condyle and the olecranon; a filament from the musculo-cutaneous (Rüdinger), and two from the median (Macalister).

Actions.—The elbow-joint comprises three different portions—viz., the joint between the ulna and humerus, that between the head of the radius and the humerus, and the superior radio-ulnar articulation, described below. All these articular surfaces are invested by a common synovial membrane, and the movements of the whole joint should be studied together. The combination of the movements of flexion and extension of the forearm with those of pronation and supination of the hand, which is ensured by the two being performed at the same joint, is essential to the accuracy of the various minute movements of the hand.

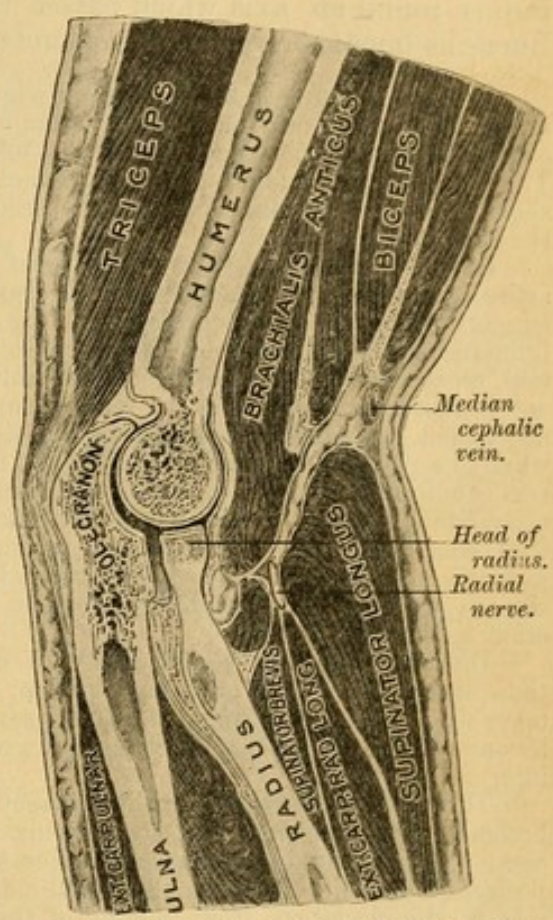

FIG. 173.—Sagittal section of the right elbow-joint, taken somewhat obliquely and seen from the radial aspect. (After Braune.)

The portion of the joint between the ulna and humerus is a simple hinge-joint, and allows of movements of flexion and extension only. Owing to the obliquity of the trochlear surface of the humerus, this movement does not take place in a straight line; so that when the forearm is extended and supinated the axis of the arm and forearm is not in the same line, but the one portion of the limb forms an angle with the others, and the hand, with the forearm, is directed outward. During flexion, on the other hand, the forearm and the hand tend to approach the middle line of the body, and thus enable the hand to be easily carried to the face. The shape of the articular surface of the humerus, with its prominences and depressions accurately adapted to the opposing surfaces of the olecranon, prevents any lateral movement. *Flexion* is produced by the action of the Biceps and Brachialis anticus, assisted by the muscles arising from the internal condyle of the humerus and the Supinator longus; *extension*, by the Triceps and Anconeus, assisted by the extensors of the wrist and by the Extensor communis digitorum and Extensor minimi digiti.

The joint between the head of the radius and the capitellum or radial head of the humerus is an arthrodial joint. The bony surfaces would of themselves constitute an enarthrosis, and allow of movement in all directions were it not for the orbicular ligament by which the head of the radius is bound down firmly to the sigmoid cavity of the ulna, and which prevents any separation of the two bones laterally. It is to the same ligament that the head of the radius owes its security from dislocation, which would otherwise constantly occur as a consequence of the shallowness of the cup-like surface on the head of the radius. In fact, but for this ligament the tendon of the biceps would be liable to pull the head of the radius out of the joint.[1] In complete extension the head of the radius glides so far back on the outer condyle that its edge is plainly felt at the back of the articulation. Flexion and extension of the elbow-joint are limited by the tension of the structures on the front and back of the joint, the limitation of flexion being also aided by the soft structures of the arm and forearm coming in contact.

In combination with any position of flexion or extension the head of the radius

[1] Humphry, *op. cit.*, p. 419.

can be rotated in the upper radio-ulnar joint, carrying the hand with it. The hand is directly articulated to the lower surface of the radius only, and the concave or sigmoid surface on the lower end of the radius travels round the lower end of the ulna. The latter bone is excluded from the wrist-joint (as will be seen in the sequel) by the interarticular fibro-cartilage. Thus, rotation of the head of the radius round an axis which passes through the centre of the radial head of the humerus imparts circular movement to the hand through a very considerable arc.

Surface Form.—If the forearm be slightly flexed on the arm, a curved crease or fold with its convexity downward may be seen running across the front of the elbow, extending from one condyle to the other. The centre of this fold is some slight distance above the line of the joint. The position of the radio-humeral portion of the joint can be at once ascertained by feeling for a slight groove or depression between the head of the radius and the capitellum of the humerus at the back of the articulation.

Surgical Anatomy.—From the great breadth of the joint, and the manner in which the articular surfaces are interlocked, and also on account of the strong lateral ligaments and the support which the joint derives from the mass of muscles attached to each condyle of the humerus, lateral displacement of the bones is very uncommon, whereas antero-posterior dislocation, on account of the shortness of the antero-posterior diameter, the weakness of the anterior and posterior ligaments, and the want of support of muscles, much more frequently takes place, dislocation backward taking place when the forearm is in a position of extension, and forward when in a position of flexion. For, in the former position, that of extension, the coronoid process is not interlocked into the coronoid fossa, and loses its grip to a certain extent, whereas the olecranon process is in the olecranon fossa, and entirely prevents displacement forward. On the other hand, during flexion, the coronoid process is in the coronoid fossa, and prevents dislocation backward, while the olecranon loses its grip and is not so efficient, as during extension, in preventing a forward displacement. When lateral dislocation does take place, it is generally incomplete.

Dislocation of the elbow-joint is of common occurrence in children, far more common than dislocation of any other articulation, for, as a rule, fracture of a bone more frequently takes place, under the application of any severe violence, in young persons than dislocation. In lesions of this joint there is often very great difficulty in ascertaining the exact nature of the injury.

The elbow-joint is occasionally the seat of acute synovitis. The synovial membrane then becomes distended with fluid, the bulging showing itself principally around the olecranon process; that is to say, on its inner and outer sides and above, in consequence of the laxness of the posterior ligament. Occasionally a well-marked, triangular projection may be seen on the outer side of the olecranon, from bulging of the synovial membrane beneath the Anconeus muscle. Again, there is often some swelling just above the head of the radius, in the line of the radio-humeral joint. There is generally not much swelling at the front of the joint, though sometimes deep-seated fulness beneath the Brachialis anticus may be noted. When suppuration occurs the abscess usually points at one or other border of the Triceps muscle; occasionally the pus discharges itself in front, near the insertion of the Brachialis anticus muscle. Chronic synovitis, usually of tubercular origin, is of common occurrence in the elbow-joint: under these circumstances the forearm tends to assume the position of semi-flexion which is that of greatest ease and relaxation of ligaments. It should be borne in mind that should ankylosis occur in this or the extended position, the limb will not be nearly so useful as if ankylosed in a position of rather less than a right angle. Loose cartilages are sometimes met with in the elbow-joint, not so commonly, however, as in the knee; nor do they, as a rule, give rise to such urgent symptoms, and rarely require operative interference. The elbow-joint is also sometimes affected with osteo-arthritis, but this affection is less common in this articulation than in some other of the larger joints.

Excision of the elbow is principally required for three conditions: viz. tubercular arthritis, injury and its results, and faulty ankylosis; but may be necessary for some other rarer conditions, such as disorganizing arthritis after pyæmia, unreduced dislocations, and osteo-arthritis. The results of the operation are, as a rule, more favorable than those of excision of any other joint, and it is one, therefore, that the surgeon should never hesitate to perform, especially in the first three of the conditions mentioned above. The operation is best performed by a single vertical incision down the back of the joint, a transverse incision, over the outer condyle, being added if the parts are much thickened and fixed. A straight incision is made about four inches long, the mid-point of which is on a level with and a little to the inner side of the tip of the olecranon. This incision is made down to the bone, through the substance of the Triceps muscle. The operator with the point of his knife, and guarding the soft parts with his thumb-nail, separates them from the bone. In doing this there are two structures which he should carefully avoid: the ulnar nerve, which lies parallel to his incision, but a little internal, as it courses down between the internal condyle and the olecranon process, and the prolongation of the Triceps into the deep fascia of the forearm over the Anconeus muscle. Having cleared the bones and divided the lateral and posterior ligaments, the forearm is strongly flexed and the ends of the bone turned out and sawn off. The section of the humerus should be through

the base of the condyles, that of the ulna and radius should be just below the level of the lesser sigmoid cavity of the ulna and the neck of the radius. In this operation the object is to obtain such union as shall allow free motion of the bones of the forearm; and, therefore, passive motion must be commenced early, that is to say, about the tenth day.

VI. Radio-ulnar Articulations.

The articulation of the radius with the ulna is effected by ligaments which connect together both extremities as well as the shafts of these bones. They may, consequently, be subdivided into three sets: 1, the superior radio-ulnar, which is a portion of the elbow-joint; 2, the middle radio-ulnar; and, 3, the inferior radio-ulnar articulations.

1. Superior Radio-ulnar Articulation.

This articulation is a trochoid or pivot-joint. The bones entering into its formation are the inner side of the circumference of the head of the radius rotating within the lesser sigmoid cavity of the ulna. Its only ligament is the *annular* or *orbicular*.

The **Orbicular Ligament** (Fig. 172) is a strong, flat band of ligamentous fibres, which surrounds the head of the radius, and retains it in firm connection with the lesser sigmoid cavity of the ulna. It forms about four-fifths of an osseo-fibrous ring, attached by each end to the extremities of the lesser sigmoid cavity, and is smaller at the lower part of its circumference than above, by which means the head of the radius is more securely held in its position. Its *outer surface*, is strengthened by the external lateral ligament of the elbow, and affords origin to part of the Supinator brevis muscle. Its *inner surface* is smooth, and lined by synovial membrane. The synovial membrane is continuous with that which lines the elbow-joint.

Actions.—The movement which takes place in this articulation is limited to rotation of the head of the radius within the orbicular ligament, and upon the lesser sigmoid cavity of the ulna, rotation forward being called *pronation;* rotation backward, *supination*. Supination is performed by the Biceps and Supinator brevis, assisted to a slight extent by the Extensor muscles of the thumb and, in certain positions, by the Supinator longus. Pronation is performed by the Pronator radii teres and the Pronator quadratus, assisted, in some positions, by the Supinator longus.

Surface Form.—The position of the superior radio-ulnar joint is marked on the surface of the body by the little dimple on the back of the elbow which indicates the position of the head of the radius.

Surgical Anatomy.—Dislocation of the head of the radius alone is not an uncommon accident, and occurs most frequently in young persons from falls on the hand when the forearm is extended and supinated, the head of the bone being displaced forward. It is attended by rupture of the orbicular ligament. Occasionally a peculiar injury, which is supposed to be a subluxation, occurs in young children in lifting them from the ground by the hand or forearm. It is believed that the head of the radius is displaced downward in the orbicular ligament, the upper border of which becomes folded over the head of the radius, between it and the capitellum of the humerus.

2. Middle Radio-ulnar Union.

The interval between the shafts of the radius and ulna is occupied by two ligaments.

Oblique. Interosseous.

The **Oblique** or **Round Ligament** (Fig. 171) is a small, flattened fibrous band which extends obliquely downward and outward from the tubercle of the ulna at the base of the coronoid process to the radius a little below the bicipital tuberosity. Its fibres run in the opposite direction to those of the interosseous ligament, and it appears to be placed as a substitute for it in the upper part of the interosseous interval. This ligament is sometimes wanting.

The **Interosseous Membrane** is a broad and thin plane of fibrous tissue descending obliquely downward and inward, from the interosseous ridge on the radius to that

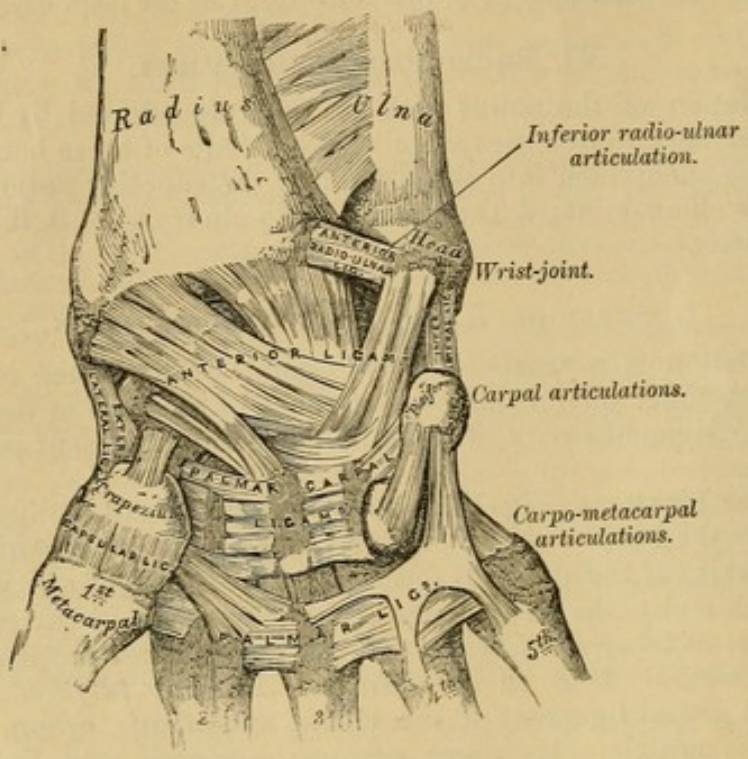

FIG. 174.—Ligaments of wrist and hand. Anterior view.

on the ulna. It is deficient above, commencing about an inch beneath the tubercle of the radius; is broader in the middle than at either extremity; and presents an oval aperture just above its lower margin for the passage of the anterior interosseous vessels to the back of the forearm. This ligament serves to connect the bones and to increase the extent of surface for the attachment of the deep muscles. Between its upper border and the oblique ligament an interval exists through which the posterior interosseous vessels pass. Two or three fibrous bands are occasionally found on the posterior surface of this membrane which descend obliquely from the ulna toward the radius, and which have consequently a direction contrary to that of the other fibres. It is in relation, *in front*, by its upper three-fourths with the Flexor longus pollicis on the outer side, and with the Flexor profundus digitorum on the inner, lying upon the interval between which are the anterior interosseous vessels and nerve; by its lower fourth, with the Pronator quadratus; *behind*, with the Supinator brevis, Extensor ossis metacarpi pollicis, Extensor brevis pollicis, Extensor longus pollicis, Extensor indicis; and, near the wrist, with the anterior interosseous artery and posterior interosseous nerve.

3. INFERIOR RADIO-ULNAR ARTICULATION.

This is a pivot-joint, formed by the head of the ulna received into the sigmoid cavity at the inner side of the lower end of the radius. The articular surfaces are covered by a thin layer of cartilage, and connected together by the following ligaments:

Anterior Radio-ulnar. Posterior Radio-ulnar.
Interarticular Fibro-cartilage.

The **Anterior Radio-ulnar Ligament** (Fig. 174) is a narrow band of fibres extending from the anterior margin of the sigmoid cavity of the radius to the anterior surface of the head of the ulna.

The **Posterior Radio-ulnar Ligament** (Fig. 175) extends between similar points on the posterior surface of the articulation.

The **Interarticular Fibro-cartilage** (Fig. 177) is triangular in shape, and is

placed transversely beneath the head of the ulna, binding the lower end of this bone and the radius firmly together. Its periphery is thicker than its centre, which is thin and occasionally perforated. It is attached by its apex to a depression which separates the styloid process of the ulna from the head of that bone; and by its base, which is thin, to the prominent edge of the radius, which separates the sigmoid cavity from the carpal articulating surface. Its margins are united to the ligaments of the wrist-joint. Its *upper surface*, smooth and concave, articulates with the head of the ulna, forming an arthrodial joint; its *under surface*, also concave and smooth, forms part of the wrist-joint and articulates with the cuneiform and inner part of the semilunar bone. Both surfaces are lined by a synovial membrane—the upper surface, by one peculiar to the radio-ulnar articulation; the under surface, by the synovial membrane of the wrist.

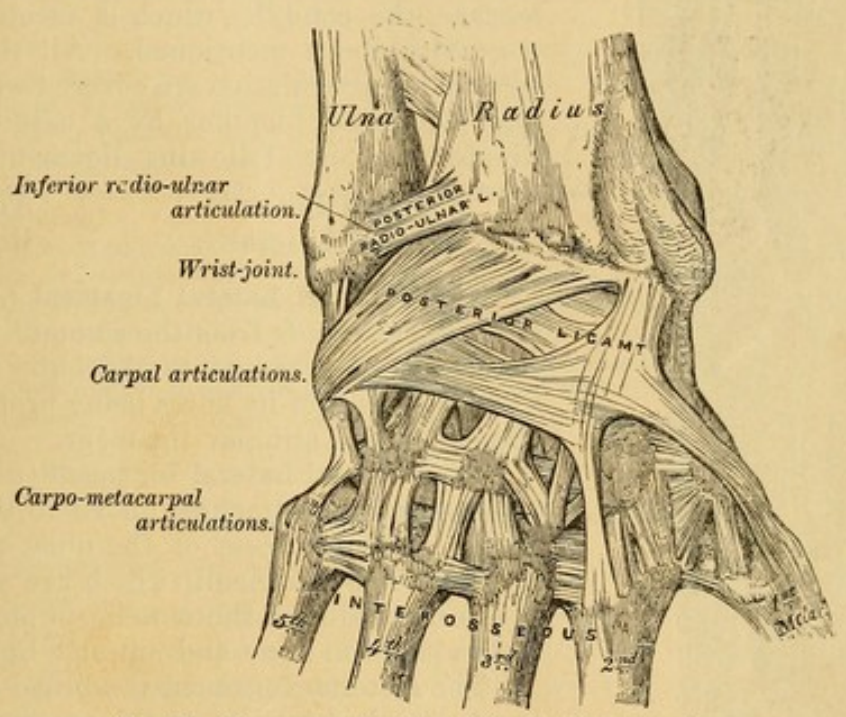

FIG. 175.—Ligaments of wrist and hand. Posterior view.

The **Synovial Membrane** (Fig. 177) of this articulation has been called, from its extreme looseness, the *membrana sacciformis;* it extends horizontally inward between the head of the ulna and the interarticular fibro-cartilage, and upward between the radius and the ulna, forming here a very loose *cul-de-sac*. The quantity of synovia which it contains is usually considerable.

Actions.—The movement in the inferior radio-ulnar articulation is just the reverse of that in the superior radio-ulnar joint. It consists of a movement of rotation of the lower end of the radius round an axis which corresponds to the centre of the head of the ulna. When the radius rotates forward, *pronation* of the forearm and hand is the result; and when backward, *supination*. It will thus be seen that in pronation and supination of the forearm and hand the radius describes a segment of a cone, the axis of which extends from the centre of the head of the radius to the middle of the head of the ulna. In this movement, however, the ulna is not quite stationary, but rotates a little in the opposite direction. So that it also describes the segment of a cone, though of smaller size than that described by the radius. The movement which causes this alteration in the position of the head of the ulna takes place principally at the shoulder-joint by a rotation of the humerus, but possibly also to a slight extent at the elbow-joint.[1]

Surface Form.—The position of the inferior radio-ulnar joint may be ascertained by feeling for a slight groove at the back of the wrist, between the prominent head of the ulna and the lower end of the radius, when the forearm is in a state of almost complete pronation.

[1] See *Journ. of Anat. and Phys.*, vol. xix., parts ii., iii., and iv.

VII. Radio-carpal or Wrist-joint.

The **Wrist** is a condyloid articulation. The parts entering into its formation are the lower end of the radius and under surface of the interarticular fibro-cartilage, which form together the receiving cavity, and the scaphoid, semilunar, and cuneiform bones, which form the condyle. The articular surface of the radius and the under surface of the inter-articular fibro-cartilage are the receiving cavity, forming together a transversely elliptical concave surface. The articular surfaces of the scaphoid, semilunar, and cuneiform bones form together a smooth, convex surface, the condyle, which is received into the concavity above mentioned. All the bony surfaces of the articulation are covered with cartilage, and connected together by a capsule, which is divided into the following ligaments:

External Lateral.	Anterior.
Internal Lateral.	Posterior.

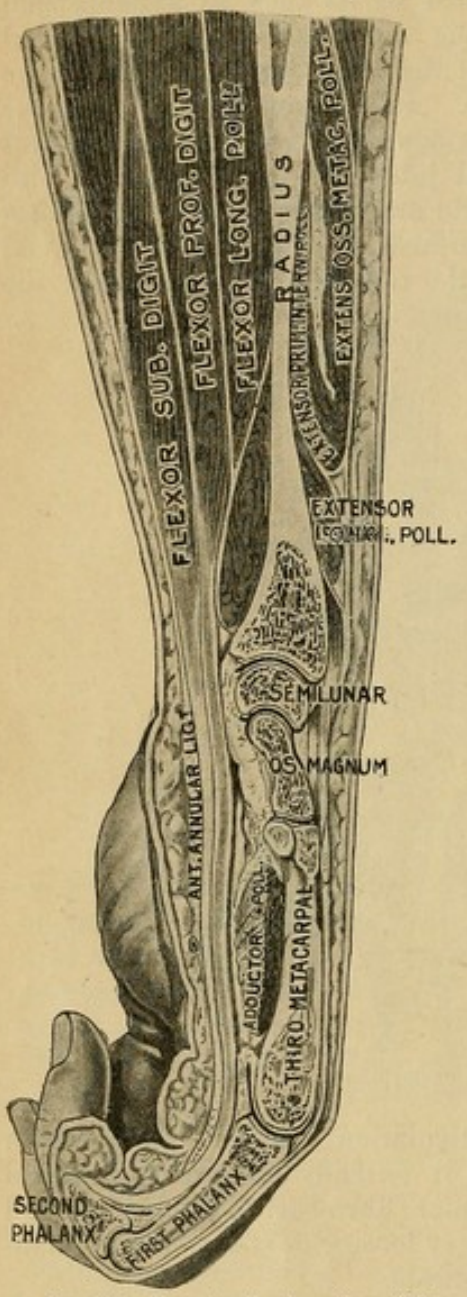

FIG. 176.—Longitudinal section of the right forearm, hand, and third finger, viewed from the ulnar aspect. (After Braune.)

The **External Lateral Ligament** (*radio-carpal*) (Fig. 174) extends from the summit of the styloid process of the radius to the outer side of the scaphoid, some of its fibres being prolonged to the trapezium and annular ligament.

The **Internal Lateral Ligament** (*ulno-carpal*) is a rounded cord, attached, above, to the extremity of the styloid process of the ulna, and dividing below into two fasciculi, which are attached, one to the inner side of the cuneiform bone, the other to the pisiform bone and annular ligament.

The **Anterior Ligament** is a broad membranous band, attached, above, to the anterior margin of the lower end of the radius, its styloid process and the ulna: its fibres pass downward and inward to be inserted into the palmar surface of the scaphoid, semilunar, and cuneiform bones, some of the fibres being continued to the os magnum. In addition to this broad membrane, there is a distinct rounded fasciculus, superficial to the rest, which passes from the base of the styloid process of the ulna to the semilunar and cuneiform bones. This ligament is perforated by numerous apertures for the passage of vessels, and is in relation, in front, with the tendons of the Flexor profundus digitorum and Flexor longus pollicis; behind, with the synovial membrane of the wrist-joint.

The **Posterior Ligament** (Fig. 175), less thick and strong than the anterior, is attached, above, to the posterior border of the lower end of the radius; its fibres pass obliquely downward and inward, to be attached to the dorsal surface of the scaphoid, semilunar, and cuneiform bones, being continuous with those of the dorsal carpal ligaments. This ligament is in relation, behind, with the extensor tendons of the fingers; in front, with the synovial membrane of the wrist.

The **Synovial Membrane** (Fig. 177) lines the inner surface of the ligaments above described, extending from the lower end of the radius and interarticular fibro-cartilage above to the articular surfaces of the carpal bones below. It is loose and lax, and presents numerous folds, especially behind.

Relations.—The wrist-joint is covered in front by the flexor and behind by the extensor tendons; it is also in relation with the radial and ulnar arteries.

The *Arteries* supplying the joint are the anterior and posterior carpal branches of the radial and ulnar, the anterior and posterior interosseous, and some ascending branches from the deep palmar arch.

The *Nerves* are derived from the ulnar and posterior interosseous.

Actions.—The movements permitted in this joint are flexion, extension, abduction, adduction, and circumduction. Its actions will be further studied with those of the carpus, with which they are combined.

Surface Form.—The line of the radio-carpal joint is on a level with the apex of the styloid process of the ulna.

Surgical Anatomy.—The wrist-joint is rarely dislocated, its strength depending mainly upon the numerous strong tendons which surround the articulation. Its security is further provided for by the number of small bones of which the carpus is made up, and which are united by very strong ligaments. The slight movement which takes place between the several bones serves to break the jars that result from falls or blows on the hand. Dislocation backward, which is the more common, simulates to a considerable extent Colles' fracture of the radius, and is liable to be mistaken for it. The diagnosis can be easily made out by observing the relative position of the styloid processes of the radius and the ulna. In the natural condition the styloid process of the radius is on a lower level—*i. e.* nearer the ground—when the arm hangs by the side, than that of the ulna, and the same would be the case in dislocation. In Colles' fracture, on the other hand, the styloid process of the radius is on the same, or even a higher level than that of the ulna.

The wrist-joint is occasionally the seat of acute synovitis, the result of traumatism or arising in the rheumatic or pyæmic state. When the synovial sac is distended with fluid, the swelling is greatest on the dorsal aspect of the wrist, showing a general fulness, with some bulging between the tendons. The inflammation is prone to extend to the intercarpal joints and to attack also the sheaths of the tendons in the neighborhood. Chronic inflammation of the wrist is generally tubercular, and often leads to similar disease in the synovial sheaths of adjacent tendons and of the intercarpal joints. The disease, therefore, when progressive, often leads to necrosis of the carpal bones, and the result is often unsatisfactory.

VIII. Articulations of the Carpus.

These articulations may be subdivided into three sets:

1. The Articulations of the First Row of Carpal Bones.
2. The Articulations of the Second Row of Carpal Bones
3. The Articulations of the Two Rows with each other.

1. Articulations of the First Row of Carpal Bones.

These are arthrodial joints. The ligaments connecting the scaphoid, semilunar, and cuneiform bones are—

Dorsal. Palmar.

Two Interosseous.

The **Dorsal Ligaments** are placed transversely behind the bones of the first row; they connect the scaphoid and semilunar and the semilunar and cuneiform.

The **Palmar Ligaments** connect the scaphoid and semilunar and the semilunar and cuneiform bones; they are less strong than the dorsal, and placed very deeply below the anterior ligament of the wrist.

The **Interosseous Ligaments** (Fig. 177) are two narrow bundles of fibrous tissue connecting the semilunar bone on one side with the scaphoid, and on the other with the cuneiform. They are on a level with the superior surfaces of these bones, and close the upper part of the spaces between them. Their upper surfaces are smooth, and form with the bones the convex articular surfaces of the wrist-joint.

The ligaments connecting the pisiform bone are—

Capsular. Two Palmar ligaments.

The **Capsular Ligament** is a thin membrane which connects the pisiform bone to the cuneiform. It is lined with a separate synovial membrane.

The **two Palmar Ligaments** are two strong fibrous bands which connect the

pisiform to the unciform, the *piso-uncinate*, and to the base of the fifth metacarpal bone, the *piso-metacarpal ligament* (Fig. 174).

2. Articulations of the Second Row of Carpal Bones.

These are also arthrodial joints. The articular surfaces are covered with cartilage, and connected by the following ligaments:

Dorsal. Palmar.
Three Interosseous.

The **Dorsal Ligaments** extend transversely from one bone to another on the dorsal surface, connecting the trapezium with the trapezoid, the trapezoid with the os magnum, and the os magnum with the unciform.

The **Palmar Ligaments** have a similar arrangement on the palmar surface.

The **three Interosseous Ligaments,** much thicker than those of the first row, are placed one between the os magnum and the unciform, a second between the os magnum and the trapezoid, and a third between the trapezium and trapezoid. The first of these is much the strongest, and the third is sometimes wanting.

3. Articulations of the Two Rows of Carpal Bones with each Other.

The joint between the scaphoid, semilunar, and cuneiform, and the second row of the carpus, or the *mid-carpal joint*, is made up of three distinct portions; in the centre the head of the os magnum and the superior surface of the unciform articulate with the deep, cup-shaped cavity formed by the scaphoid and semilunar bones, and constitute a sort of ball-and-socket joint. On the outer side the trapezium and trapezoid articulate with the scaphoid, and on the inner side the unciform articulates with the cuneiform, forming gliding joints.

The ligaments are—

Anterior or Palmar. External Lateral.
Posterior or Dorsal. Internal Lateral.

The **Anterior** or **Palmar Ligaments** consist of short fibres, which pass, for the most part, from the palmar surface of the bones of the first row to the front of the os magnum.

The **Posterior** or **Dorsal Ligaments** consist of short, irregular bundles of fibres passing between the bones of the first and second row on the dorsal surface of the carpus.

The **Lateral Ligaments** are very short: they are placed, one on the radial, the other on the ulnar side of the carpus; the former, the stronger and more distinct, connecting the scaphoid and trapezium bones, the latter the cuneiform and unciform; they are continuous with the lateral ligaments of the wrist-joint. In addition to these ligaments, a slender interosseous band sometimes connects the os magnum and the scaphoid.

The **Synovial Membrane of the Carpus** is very extensive: it passes from the under surface of the scaphoid, semilunar, and cuneiform bones to the upper surface of the bones of the second row, sending upward two prolongations—between the scaphoid and semilunar and the semilunar and cuneiform; sending downward three prolongations between the four bones of the second row, which are further continued onward into the carpo-metacarpal joints of the four inner metacarpal bones, and also for a short distance between the metacarpal bones. There is a separate synovial membrane between the pisiform and cuneiform bones.

Actions.—The articulation of the hand and wrist, considered as a whole, is divided into three parts: (1) the radius and the interarticular fibro-cartilage; (2) the meniscus, formed by the scaphoid, semilunar, and cuneiform, the pisiform bone having no essential part in the movements of the hand; (3) the hand proper, the metacarpal bones with the four carpal bones on which they are supported—viz. the trapezium, trapezoid, os magnum, and unciform. These three elements form

two joints: (1) the superior (wrist-joint proper), between the meniscus and bones of the forearm; (2) the inferior, between the hand and meniscus (transverse or mid-carpal joint).

(1) The articulation between the forearm and carpus is a true condyloid articulation, and therefore all movements but rotation are permitted. Flexion and extension are the most free, and of these a greater amount of extension than flexion is permitted on account of the articulating surfaces extending farther on the dorsal than on the palmar aspect of the carpal bones. In this movement the carpal bones rotate on a transverse axis drawn between the tips of the styloid processes of the radius and ulna. A certain amount of adduction (or ulnar flexion) and abduction (or radial flexion) is also permitted. Of these the former is considerably greater in extent than the latter. In this movement the carpus revolves upon an antero-posterior axis drawn through the centre of the wrist. Finally, circumduction is permitted by the consecutive movements of adduction, extension, abduction, and flexion, with intermediate movements between them. There is no rotation, but this is provided for by the supination and pronation of the radius on the ulna. The movement of *flexion* is performed by the Flexor carpi radialis, the Flexor carpi ulnaris, and the Palmaris longus; *extension*, by the Extensor carpi radialis longior et brevior and the Extensor carpi ulnaris; *adduction* (ulnar flexion), by the Flexor carpi ulnaris and the Extensor carpi ulnaris; and *abduction* (radial flexion), by the Extensors of the thumb and the Extensor carpi radialis longior et brevior and the Flexor carpi radialis.

(2) The chief movements permitted in the transverse or mid-carpal joint are flexion and extension and a slight amount of rotation. In flexion and extension, which is the movement most freely enjoyed, the trapezium and trapezoid on the radial side and the unciform on the ulnar side glide forward and backward on the scaphoid and cuneiform respectively, while the head of the os magnum and the superior surface of the unciform rotate in the cup-shaped cavity of the scaphoid and semilunar. Flexion at this joint is freer than extension. A very trifling amount of rotation is also permitted, the head of the os magnum rotating round a vertical axis drawn through its own centre, while at the same time a slight gliding movement takes place in the lateral portions of the joint.

IX. Carpo-metacarpal Articulations.

1. Articulation of the Metacarpal Bone of the Thumb with the Trapezium.

This is a joint of reciprocal reception, and enjoys great freedom of movement, on account of the configuration of its articular surfaces, which are saddle-shaped, so that, on section, each bone appears to be received into a cavity in the other, according to the direction in which they are cut. The joint is surrounded by a capsular ligament.

The **Capsular Ligament** is thick, but loose, and passes from the circumference of the upper extremity of the metacarpal bone to the rough edge bounding the articular surface of the trapezium; it is thickest externally and behind, and lined by a separate *synovial membrane*.

Movements.—In the articulation of the metacarpal bone of the thumb with the trapezium the movements permitted are flexion, extension, adduction, abduction, and circumduction. When the joint is flexed the metacarpal bone is brought in front of the palm and the thumb is gradually turned to the fingers. It is by this peculiar movement that the tip of the thumb is opposed to the other digits; for by slightly flexing the fingers the palmar surface of the thumb can be brought in contact with their palmar surfaces one after another.

2. Articulations of the Metacarpal Bones of the Four Inner Fingers with the Carpus.

The joints formed between the carpus and four inner metacarpal bones are arthrodial joints. The ligaments are—

Dorsal. Palmar.
Interosseous.

The **Dorsal Ligaments**, the strongest and most distinct, connect the carpal and metacarpal bones on their dorsal surface. The second metacarpal bone receives two fasciculi—one from the trapezium, the other from the trapezoid; the third metacarpal receives two—one from the trapezoid and one from the os magnum; the fourth two—one from the os magnum and one from the unciform; the fifth receives a single fasciculus from the unciform bone, which is continuous with a similar ligament on the palmar surface, forming an incomplete capsule.

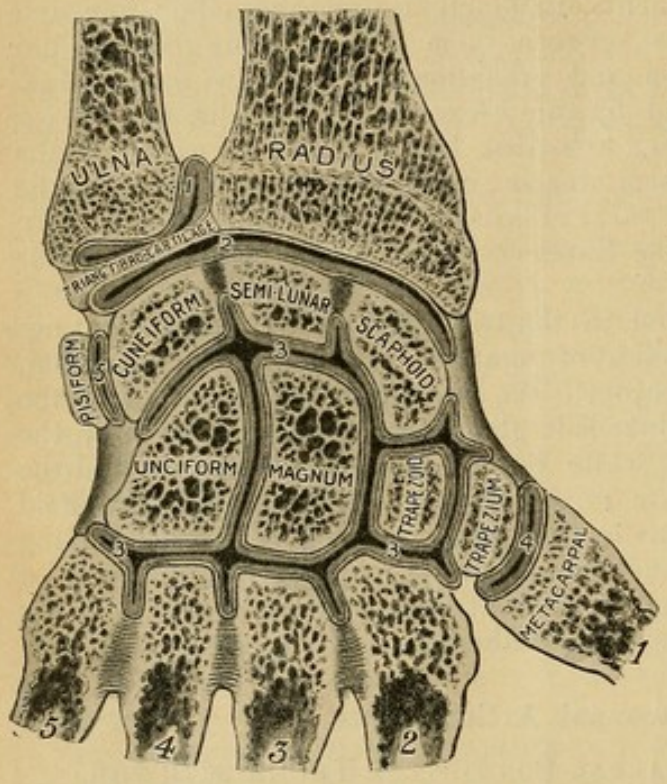

Fig. 177.—Vertical section through the articulations at the wrist, showing the five synovial membranes.

The **Palmar Ligaments** have a somewhat similar arrangement on the palmar surface, with the exception of the third metacarpal, which has three ligaments—an external one from the trapezium, situated above the sheath of the tendon of the Flexor carpi radialis; a middle one, from the os magnum; and an internal one, from the unciform.

The **Interosseous Ligaments** consist of short, thick fibres, which are limited to one part of the carpo-metacarpal articulation; they connect the contiguous inferior angles of the os magnum and unciform with the adjacent surfaces of the third and fourth metacarpal bones.

The **Synovial Membrane** is a continuation of that between the two rows of carpal bones. Occasionally, the articulation of the unciform with the fourth and fifth metacarpal bones has a separate synovial membrane.

The synovial membranes of the wrist and carpus (Fig. 177) are thus seen to be five in number. The *first*, the *membrana sacciformis*, passes from the lower end of the ulna to the sigmoid cavity of the radius, and lines the upper surface of the interarticular fibro-cartilage. The *second* passes from the lower end of the radius and interarticular fibro-cartilage above to the bones of the first row below. The *third*, the most extensive, passes between the contiguous margins of the two rows of carpal bones—between the bones of the second row to the carpal extremities of the four inner metacarpal bones. The *fourth*, from the margin of the trapezium to the metacarpal bone of the thumb. The *fifth*, between the adjacent margins of the cuneiform and pisiform bones.

Actions.—The movement permitted in the carpo-metacarpal articulations of the four inner fingers is limited to a slight gliding of the articular surfaces upon each other, the extent of which varies in the different joints. Thus the articulation of the metacarpal bone of the little finger is most movable, then that of the ring finger. The metacarpal bones of the index and middle fingers are almost immovable.

3. Articulations of the Metacarpal Bones with each other.

The carpal extremities of the four inner metacarpal bones articulate with one another at each side by small surfaces covered with cartilages, and connected together by dorsal, palmar, and interosseous ligaments.

The **Dorsal** and **Palmar Ligaments** pass transversely from one bone to another on the dorsal and palmar surfaces. The *Interosseous Ligaments* pass between their contiguous surfaces, just beneath their lateral articular facets.

The **Synovial Membrane** between the lateral facets is a reflection from that between the two rows of carpal bones.

The **Transverse Metacarpal Ligaments** (Fig. 178) is a narrow fibrous band which passes transversely across the anterior surfaces of the digital extremities of the four inner metacarpal bones, connecting them together. It is blended anteriorly with the anterior (glenoid) ligament of the metacarpal-phalangeal articulations. To its posterior border is connected the fascia which covers the Interossei muscles. Its anterior surface is concave where the flexor tendons pass over it. Behind it the tendons of the Interossei muscles pass to their insertion.

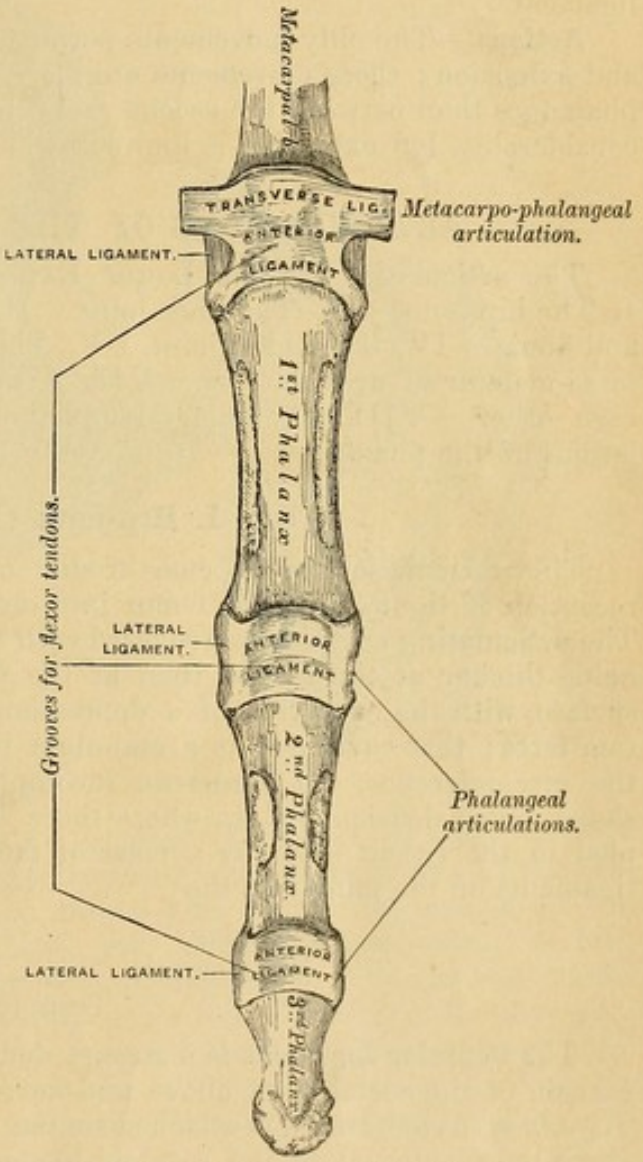

FIG. 178.—Articulations of the phalanges.

X. Metacarpo-phalangeal Articulations (Fig. 178).

These articulations are of the condyloid kind, formed by the reception of the rounded head of the metacarpal bone into a shallow cavity in the extremity of the first phalanx. The ligaments are—

Anterior.
Two Lateral.

The **Anterior Ligaments** (*Glenoid Ligaments* of Cruveilhier) are thick, dense, fibrous structures, placed on the palmar surface of the joints in the intervals between the lateral ligaments, to which they are connected; they are loosely united to the metacarpal bone, but very firmly to the base of the first phalanges. Their palmar surface is intimately blended with the transverse metacarpal ligament, and presents a groove for the passage of the flexor tendons, the sheath surrounding which is connected to each side of the groove. By their deep surface they form part of the articular surface for the head of the metacarpal bone, and are lined by a synovial membrane.

The **Lateral Ligaments** are strong, rounded cords placed one on each side of the joint, each being attached by one extremity to the posterior tubercle on the side of the head of the metacarpal bone, and by the other to the contiguous extremity of the phalanx.

Actions.—The movements which occur in these joints are flexion, extension, adduction, abduction, and circumduction; the lateral movements are very limited.

Surface Form.—The prominences of the knuckles do not correspond to the position of the joints either of the metacarpo-phalangeal or interphalangeal articulations. These prominences are invariably formed by the distal ends of the proximal bone of each joint, and the line indicating the position of the joint must be sought considerably in front of the middle of the knuckle. The usual rule for finding these joints is to flex the distal phalanx on the proximal one to a right angle; the position of the joint is then indicated by an imaginary line drawn along the middle of the lateral aspect of the proximal phalanx.

XI. Articulations of the Phalanges.

These are ginglymus joints. The ligaments are—

Anterior. Two Lateral.

The arrangement of these ligaments is similar to those in the metacarpo-phalangeal articulations; the extensor tendon supplies the place of a posterior ligament.

Actions.—The only movements permitted in the phalangeal joints are flexion and extension; these movements are more extensive between the first and second phalanges than between the second and third. The movement of flexion is very considerable, but extension is limited by the anterior and lateral ligaments.

ARTICULATIONS OF THE LOWER EXTREMITY.

The articulations of the Lower Extremity comprise the following groups: I. The hip-joint. II. The knee-joint. III. The articulations between the tibia and fibula. IV. The ankle-joint. V. The articulations of the tarsus. VI. The tarso-metatarsal articulations. VII. Articulations of the metatarsal bones with each other. VIII. The metatarso-phalangeal articulations. IX. The articulations of the phalanges.

I. Hip-joint (Fig. 179).

This articulation is an enarthrodial or ball-and-socket joint, formed by the reception of the head of the femur into the cup-shaped cavity of the acetabulum. The articulating surfaces are covered with cartilage, that on the head of the femur being thicker at the centre than at the circumference, and covering the entire surface, with the exception of a depression just below its centre for the ligamentum teres; that covering the acetabulum is much thinner at the centre than at the circumference. It forms an incomplete cartilaginous ring of a horseshoe shape, being deficient below, where there is a circular depression, which is occupied in the recent state by a mass of fat covered by synovial membrane. The ligaments of the joints are the

Capsular. Teres.
Ilio-femoral. Cotyloid.
Transverse.

The **Capsular Ligament** is a strong, dense, ligamentous capsule, embracing the margin of the acetabulum above and surrounding the neck of the femur below. Its *upper circumference* is attached to the acetabulum, above and behind, two or three lines external to the cotyloid ligament; but in front it is attached to the outer margin of this ligament, and opposite to the notch where the margin of this cavity is deficient, it is connected to the transverse ligament, and by a few fibres to the edge of the obturator foramen. Its *lower circumference* surrounds the neck of the femur, being attached, in front, to the spiral or anterior intertrochanteric line; above, to the base of the neck; behind, to the neck of the bone, about half an inch above the posterior intertrochanteric line. From this insertion the fibres are reflected upward over the neck of the femur, forming a sort of tubular sheath (the *cervical reflection*), which blends with the periosteum and can be traced as far as the articular cartilage. On the surface of the neck of the femur some of these reflected fibres are raised into longitudinal folds, termed *retinacula*. It is much thicker at the upper and fore part of the joint, where the greatest amount of

resistance is required, than below and internally, where it is thin, loose, and longer than in any other part. It consists of two sets of fibres, circular and longitudinal. The circular fibres (*zona orbicularis*) are most abundant at the lower and back part of the capsule, and form a sling or collar around the neck of the femur. Anteriorly they blend with the deep surface of the ilio-femoral ligament, and through its medium reach the anterior inferior spine of the ilium. The longitudinal fibres are greatest in amount at the upper and front part of the cap-

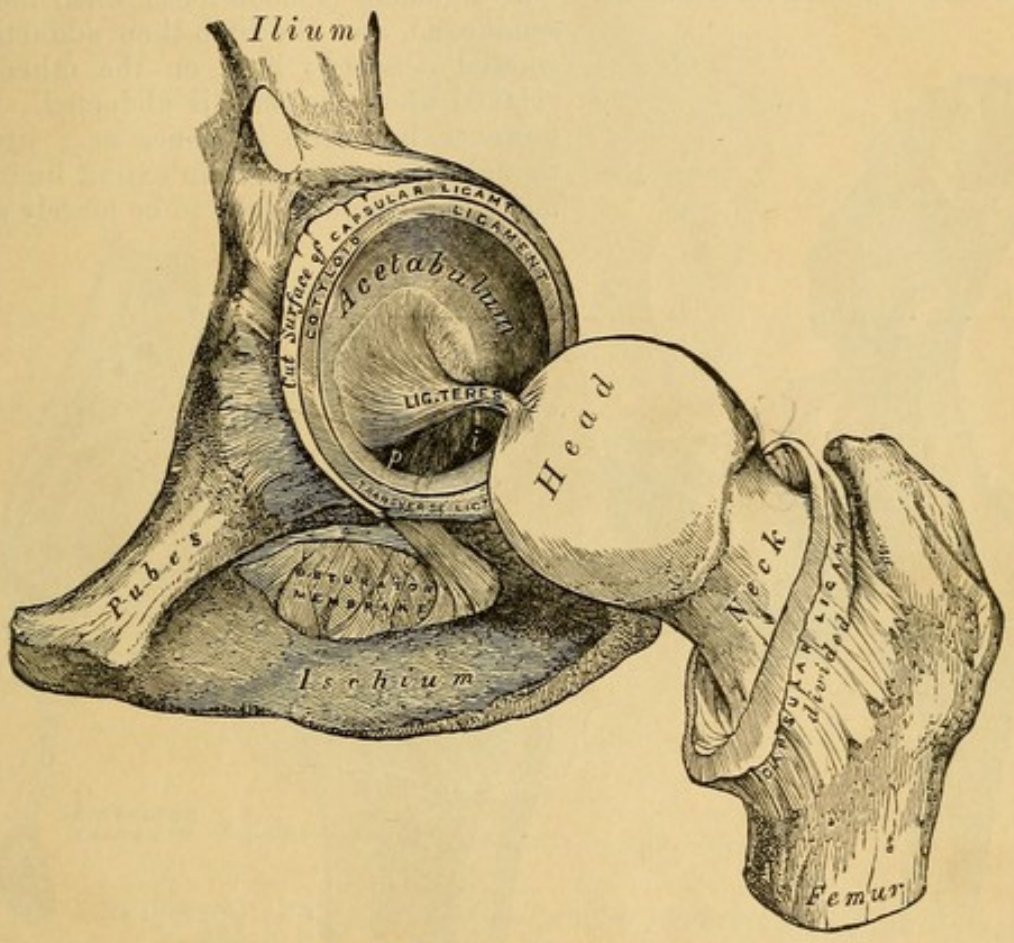

FIG. 179.—Left hip-joint laid open.

sule, where they form distinct bands or accessory ligaments, of which the most important is the *ilio-femoral*. The other accessory bands are known as the *pubo-femoral*, passing from the ilio-pectineal eminence to the front of the capsule; and *ischio-capsular*, passing from the ischium, just below the acetabulum, to blend with the circular fibres at the lower part of the joint. The external surface (Fig. 164, page 241) is rough, covered by numerous muscles, and separated in front from the Psoas and Iliacus by a synovial bursa, which not infrequently communicates, by a circular aperture, with the cavity of the joint. It differs from the capsular ligament of the shoulder in being much less loose and lax, and in not being perforated for the passage of a tendon.

The **Ilio-femoral Ligament** (Figs. 164 and 180) is an accessory band of fibres extending obliquely across the front of the joint; it is intimately connected with the capsular ligament, and serves to strengthen it in this situation. It is attached, above, to the lower part of the anterior inferior spine of the ilium; and, diverging below, forms two bands, of which one passes downward to be inserted into the lower part of the anterior intertrochanteric line; the other passes downward and outward to be inserted into the upper part of the same line and adjacent part of the neck of the femur. Between the two bands is a thinner part of the capsule. Sometimes there is no division, but the ligament spreads out into a flat, triangular band, which is attached below into the whole length of the anterior intertrochanteric line. This ligament is frequently called the Y-shaped ligament of Bigelow;

and the outer or upper of the two bands is sometimes described as a separate ligament, under the name of the *ilio-trochanteric ligament.*

The **Ligamentum Teres** is a triangular band implanted by its apex into the depression a little behind and below the centre of the head of the femur, and by its broad base into the margins of the cotyloid notch, becoming blended with the transverse ligament. It is formed of connective tissue, surrounded by a tubular sheath of synovial membrane. Sometimes only the synovial fold exists, or the ligament may be altogether absent. The ligament is made tense when the hip is semiflexed, and the limb then adducted and rotated outward; it is, on the other hand, relaxed when the limb is abducted. It has, however, but little influence as a ligament, though it may to a certain extent limit movement, and would appear to be merely a modification of the folds which in other joints fringe the margins of reflection of synovial membranes (see page 218).

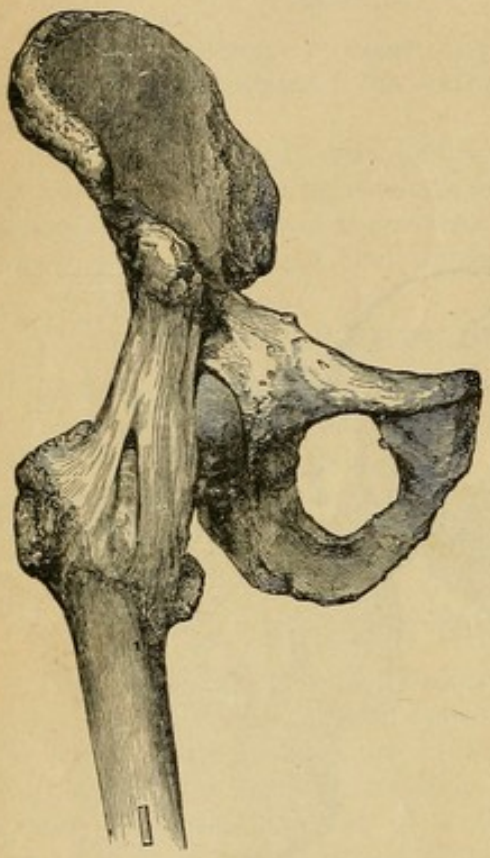

FIG. 180.—Hip-joint, showing the ilio-femoral ligament. (After Bigelow.)

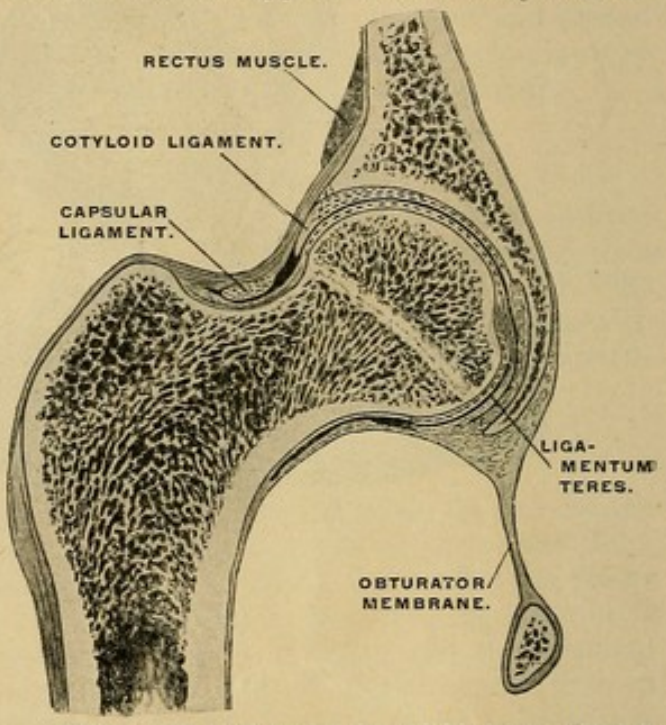

FIG. 181.—Vertical section through hip-joint. (Henle.)

The **Cotyloid Ligament** is a fibro-cartilaginous rim attached to the margin of the acetabulum, the cavity of which deepens; at the same time it protects the edges of the bone and fills up the inequalities on its surface. It bridges over the notch as the *transverse ligament*, and thus forms a complete circle, which closely surrounds the head of the femur, and assists in holding it in its place, acting as a sort of valve. It is prismoid on section, its base being attached to the margin of the acetabulum, and its opposite edge being free and sharp; whilst its two surfaces are invested by synovial membrane, the external one being in contact with the capsular ligament, the internal one being inclined inward, so as to narrow the acetabulum and embrace the cartilaginous surface of the head of the femur. It is much thicker above and behind than below and in front, and consists of close, compact fibres, which arise from different points of the circumference of the acetabulum and interlace with each other at very acute angles.

The **Transverse Ligament** is in reality a portion of the cotyloid ligament, though differing from it in having no cartilage-cells amongst its fibres. It consists of strong, flattened fibres, which cross the notch at the lower part of the acetabulum and convert it into a foramen. Thus an interval is left beneath the ligament for the passage of nutrient vessels to the joint.

The **Synovial Membrane** is very extensive. Commencing at the margin of the cartilaginous surface of the head of the femur, it covers all that portion of the neck which is contained within the joint; from the neck it is reflected on the internal surface of the capsular ligament, covers both surfaces of the cotyloid ligament and the mass of fat contained in the depression at the bottom of the acetab-

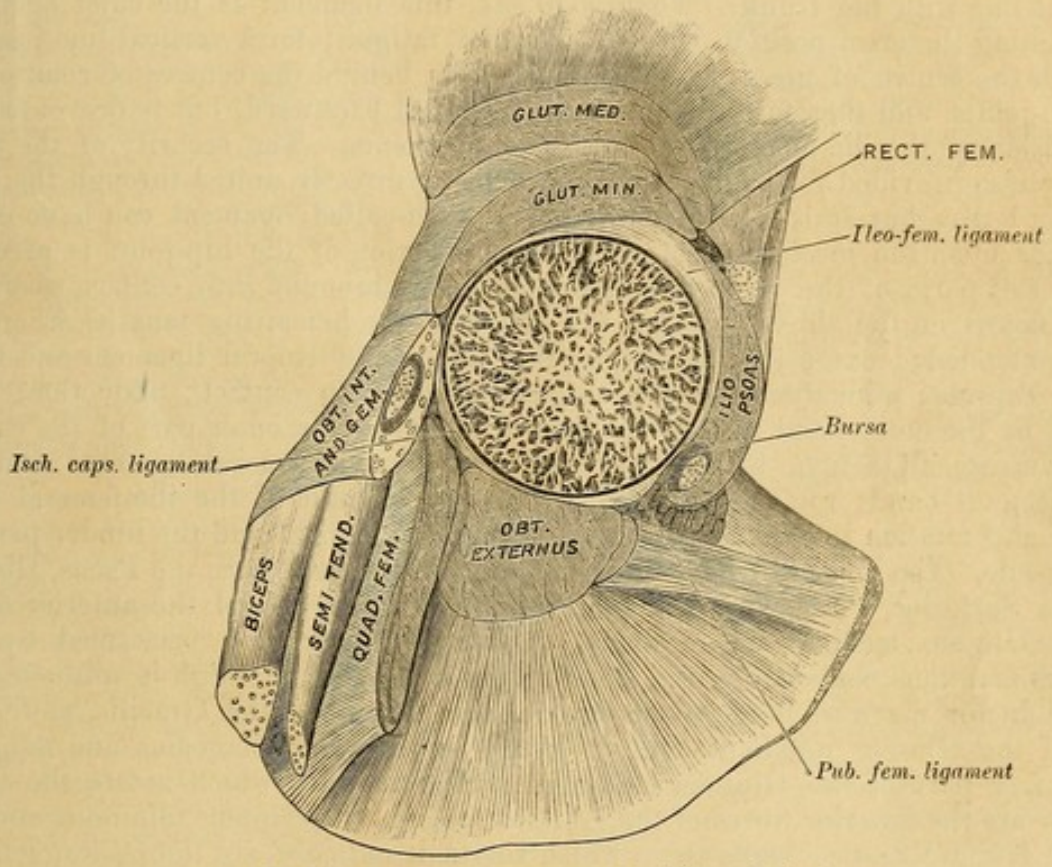

FIG. 182.—Relation of muscles to hip-joint. (Henle.)

ulum, and is prolonged in the form of a tubular sheath around the ligamentum teres, as far as the head of the femur. It sometimes communicates through a hole in the capsular ligament between the inner band of the Y-shaped ligament and the pubo-femoral ligament with a bursa situated on the under surface of the Ilio-psoas muscle.

The muscles in relation with the joint are, in front, the Psoas and Iliacus, separated from the capsular ligament by a synovial bursa; above, the reflected head of the Rectus and Gluteus minimus, the latter being closely adherent to the capsule; internally, the Obturator externus and Pectineus; behind, the Pyriformis, Gemellus superior, Obturator internus, Gemellus inferior, Obturator externus, and Quadratus femoris (Fig. 182).

The arteries supplying the joint are derived from the obturator, sciatic, internal circumflex, and gluteal.

The nerves are articular branches from the sacral plexus, great sciatic, obturator, accessory obturator, and a filament from the branch of the anterior crural supplying the Rectus.

Actions.—The movements of the hip are very extensive, and consist of flexion, extension, adduction, abduction, circumduction, and rotation.

The hip-joint presents a very striking contrast to the shoulder-joint in the much more complete mechanical arrangements for its security and for the limitation of its movements. In the shoulder, as we have seen, the head of the humerus is not adapted at all in size to the glenoid cavity, and is hardly restrained in any of its ordinary movements by the capsular ligament. In the hip-joint, on the contrary, the head of the femur is closely fitted to the acetabulum

for a distance extending over nearly half a sphere, and at the margin of the bony cup it is still more closely embraced by the cotyloid ligament, so that the head of the femur is held in its place by that ligament even when the fibres of the capsule have been quite divided (Humphry). The anterior portion of the capsule, described as the ilio-femoral ligament, is the strongest of all the ligaments in the body, and is put on the stretch by any attempt to extend the femur beyond a straight line with the trunk. That is to say, this ligament is the chief agent in maintaining the erect position without muscular fatigue; for a vertical line passing through the centre of gravity of the trunk falls behind the centres of rotation in the hip-joints, and therefore the pelvis tends to fall backward, but is prevented by the tension of the ilio-femoral and capsular ligaments. The security of the joint may be also provided for by the two bones being directly united through the ligamentum teres; but it is doubtful whether this so-called ligament can have much influence upon the mechanism of the joint. Flexion of the hip-joint is arrested by the soft parts of the thigh and abdomen being brought into contact when the leg is flexed on the thigh; and by the action of the hamstring muscles when the leg is extended;[1] extension, by the tension of the ilio-femoral ligament and front of the capsule; adduction, by the thighs coming into contact; adduction, with flexion by the outer band of the ilio-femoral ligament, the outer part of the capsular ligament; abduction, by the inner band of the ilio-femoral ligament and the pubo-femoral band; rotation outward, by the outer band of the ilio-femoral ligament; and rotation inward, by the ischio-capsular ligament and the hinder part of the capsule. The muscles which *flex* the femur on the pelvis are the Psoas, Iliacus, Rectus, Sartorius, Pectineus, Adductor longus and brevis, and the anterior fibres of the Gluteus medius and minimus. *Extension* is mainly performed by the Gluteus maximus, assisted by the hamstring muscles. The thigh is *adducted* by the Adductor magnus, longus, and brevis, the Pectineus, the Gracilis, and lower part of the Gluteus maximus, and *abducted* by the Gluteus medius and minimus and upper part of the Gluteus maximus. The muscles which *rotate* the thigh *inward* are the anterior fibres of the Gluteus medius, the Gluteus minimus, and the Tensor fasciæ femoris; while those which rotate it *outward* are the posterior fibres of the Gluteus medius, the Pyriformis, Obturator externus and internus, Gemellus superior and inferior, Quadratus femoris, Iliacus, Gluteus maximus, the three Adductors, the Pectineus, and the Sartorius.

Surface Form.—A line drawn from the anterior superior spinous process of the ilium to the most prominent part of the tuberosity of the ischium (Nélaton's line) runs through the centre of the acetabulum, and would, therefore, indicate the level of the hip-joint; or, in other words, the upper border of the great trochanter, which lies on Nélaton's line, is on a level with the centre of the hip-joint.

Surgical Anatomy.—In dislocation of the hip "the head of the thigh-bone may rest at any point around its socket" (Bryant); but whatever position the head ultimately assumes, the primary displacement is generally downward and inward, the capsule giving way at its weakest—that is, its lower and inner—part. The situation that the head of the bone subsequently assumes is determined by the degree of flexion or extension, and of outward or inward rotation of the thigh at the moment of luxation, influenced, no doubt, by the ilio-femoral ligament, which is not easily ruptured. When, for instance, the head is forced backward, this ligament forms a fixed axis, round which the head of the bone rotates, and is thus driven on to the dorsum of the ilium. The ilio-femoral ligament also influences the position of the thigh in the various dislocations: in the dislocations backward it is tense, and produces inversion of the limb; in the dislocation on to the pubes it is relaxed, and therefore allows the external rotators to evert the thigh; while in the thyroid dislocation it is tense and produces flexion. The muscles inserted into the upper part of the femur, with the exception of the Obturator internus, have very little direct influence in determining the position of the bone. But Bigelow has endeavored to show that the Obturator internus is the principal agent in determining whether, in the backward dislocations, the head of the bone shall be ultimately lodged on the dorsum of the ilium or in or near the sciatic notch. In both dislocations the head passes, in the first instance, in the same direction; but, as Bigelow asserts, in the displacement on to the dorsum, the head of the bone travels up behind the acetabulum, in front of the muscle; while in the dislocation into the

[1] The hip-joint cannot be completely flexed, in most persons, without at the same time flexing the knee, on account of the shortness of the hamstring muscles.—Cleland, *Journ. of Anat. and Phys.*, No. 1, Old Series, p. 87.

sciatic notch, the head passes behind the muscle, and is therefore prevented from reaching the dorsum, in consequence of the tendon of the muscle arching over the neck of the bone, and so remains in the neighborhood of the sciatic notch. Bigelow, therefore, distinguishes these two forms of dislocation by describing them as dislocations backward, "above and below," the Obturator internus.

The ilio-femoral ligament is rarely torn in dislocations of the hip, and this fact is taken advantage of by the surgeon in reducing these dislocations by manipulation. It is made to act as a fulcrum to a lever, of which the long arm is the shaft of the femur, and the short arm the neck of the bone.

The hip-joint is rarely the seat of acute synovitis from injury, on account of its deep position and its thick covering of soft parts. Acute inflammation may, and does, frequently occur as the result of constitutional conditions, as rheumatism, pyæmia, etc. When, in these cases, effusion takes place, and the joint becomes distended with fluid, the swelling is not very easy to detect on account of the thickness of the capsule and the depth of the articulation. It is principally to be found on the front of the joint, just internal to the ilio-femoral ligament; or behind, at the lower and back part. In these two places the capsule is thinner than elsewhere. Disease of the hip-joint is much more frequently of a chronic character and is usually of a tubercular origin. It begins either in the bones or in the synovial membrane, more frequently in the former, and probably, in most cases, at the growing, highly vascular tissue in the neighborhood of the epiphysial cartilage. In this respect it differs very materially from tubercular arthritis of the knee, where the disease usually commences in the synovial membrane. The reasons why the disease so frequently begins in this situation are twofold: first, this part being the centre of rapid growth, its nutrition is unstable and apt to pass into inflammatory action; and, secondly, great strain is thrown upon it, from the frequency of falls and blows upon the hip, which causes crushing of the epiphyseal cartilage or the cancellous tissue in its neighborhood, with the results likely to follow such an injury. In addition to these, the depth of the joint protects it from the causes of synovitis.

In chronic hip-disease the affected limb assumes an altered position, the cause of which it is important to understand. In the early stage of a typical case the limb is flexed, abducted, and rotated outward. In this position all the ligaments of the joint are relaxed: the front of the capsule by flexion; the outer band of the ilio-femoral ligament by abduction; and the inner band of this ligament and the back of the capsule by rotation outward. It is, therefore, the position of the greatest ease. The condition is not quite obvious at first upon examining a patient. If the patient is laid in the supine position, the affected limb will be found to be extended and parallel with the other. But it will be found that the pelvis is tilted downward on the diseased side and the limb apparently longer than its fellow, and that the lumbar spine is arched forward (lordosis). If now the thigh is abducted and flexed, the tilting downward and the arching forward of the pelvis disappears. The condition is thus explained. A limb which is flexed and abducted is obviously useless for progression, and, in order to overcome the difficulty, the patient depresses the affected side of his pelvis in order to produce parallelism of his limbs, and at the same time rotates his pelvis on its transverse horizontal axis, so as to direct the limb downward instead of forward. In the latter stages of the disease the limb becomes flexed and abducted and inverted. This position probably depends upon muscular action, at all events as regards the adduction. The Adductor muscles are supplied by the obturator nerve, which also largely supplies the joint. These muscles are therefore thrown into reflex action by the irritation of the peripheral terminations of this nerve in the inflamed articulation. Osteo-arthritis is not uncommon in the hip-joint, and it is said to be more common in the male than in the female, in whom the knee-joint is more frequently affected. It is a disease of middle age or more advanced period of life.

Congenital dislocation is more commonly met with in the hip-joint than in any other articulation. The displacement usually takes place on to the dorsum ilii. It gives rise to extreme lordosis, and a waddling gait is noticed as soon as the child commences to walk.

Excision of the hip may be required for disease or for injury, especially gunshot. It may be performed either by an anterior incision or a posterior one. The former one entails less interference with important structures, especially muscles, than the posterior one, but permits of less efficient drainage. In these days, however, when the surgeon aims at securing healing of his wound without suppuration, this second desideratum is not of so much importance. In the operation in front the surgeon makes an incision three to four inches in length, starting immediately below and external to the anterior superior spinous process of the ilium, downward and inward between the Sartorius and Tensor fasciæ femoris, to the neck of the bone, dividing the capsule at its upper part. A narrow-bladed saw now divides the neck of the femur, and the head of the bone is extracted with sequestrum forceps. All diseased tissue is carefully removed with a sharp spoon or scissors, and the cavity thoroughly flushed out with a hot antiseptic fluid.

The posterior method consists in making an incision three or four inches long, commencing midway between the top of the great trochanter and the anterior superior spine, and ending over the shaft, just below the trochanter. The muscles are detached from the great trochanter, and the capsule opened freely. The head and neck are freed from the soft parts and the bone sawn through just below the top of the trochanter with a narrow saw. The head of the bone is then levered out of the acetabulum. In both operations, if the acetabulum is eroded, it must be freely gouged.

II. Knee-joint.

The knee-joint was formerly described as a ginglymus or hinge-joint, but is really of a much more complicated character. It must be regarded as consisting of three articulations in one: one between each condyle of the femur and the corresponding tuberosity of the tibia, which are condyloid joints, and one between the patella and the femur, which is partly arthrodial, but not completely so, since the articular surfaces are not mutually adapted to each other, so that the movement is not a simple gliding one. This view of the construction of the knee-joint receives confirmation from the study of the articulation in some of the lower mammals, where three synovial membranes are sometimes found, corresponding to these three subdivisions, either entirely distinct or only connected together by small communications. This view is further rendered probable by the existence of the two crucial ligaments within the joint, which must be regarded as the external and internal lateral ligaments of the inner and outer joints respectively. The existence of the ligamentum mucosum would further indicate a tendency to separation of the synovial cavity into two minor sacs, one corresponding to each joint.

The bones entering into the formation of the knee-joint are the condyles of the femur above, the head of the tibia below, and the patella in front. The bones are connected together by ligaments, some of which are placed on the exterior of the joint, while others occupy its interior.

External Ligaments.	*Interior Ligaments.*
Anterior, or Ligamentum Patellæ.	Anterior, or External Crucial.
Posterior, or Ligamentum Posticum Winslowii.	Posterior, or Internal Crucial.
Internal Lateral.	Two Semilunar Fibro-cartilages.
Two External Lateral.	Transverse.
Capsular.	Coronary.
	Ligamentum mucosum. } Processes of Synovial Membrane.
	Ligamenta alaria. }

The **Anterior Ligament,** or **Ligamentum Patellæ** (Fig. 183), is the central portion of the common tendon of the Extensor muscles of the thigh which is continued from the patella to the tubercle of the tibia, supplying the place of an anterior ligament. It is a strong, flat, ligamentous band about three inches in length, attached, above, to the apex of the patella and the rough depression on its posterior surface; below, to the lower part of the tubercle of the tibia, its superficial fibres being continuous over the front of the patella with those of the tendon of the Quadriceps extensor. The lateral portions of the tendon of the Extensor muscles pass down on either side of the patella, attached to the borders of this bone and its ligament, to be inserted into the upper extremity of the tibia on each side of the tubercle; externally, these portions merge into the capsular ligament. They are termed *lateral patellar ligaments.* The posterior surface of the ligamentum patellæ can usually be easily separated from the front of the capsular ligament.

The **Posterior Ligament** (**Ligamentum Posticum Winslowii**) (Fig. 184) is a broad, flat, fibrous band, formed of fasciculi separated from one another by apertures for the passage of vessels and nerves. It is attached, above, to the upper margin of the intercondyloid notch of the femur, and below, to the posterior margin of the head of the tibia. Superficial to the main part of the ligament is a strong fasciculus derived from the tendon of the Semimembranosus, and passing from the back part of the inner tuberosity of the tibia obliquely upward and outward to the back part of the outer condyle of the femur. The posterior ligament forms part of the floor of the popliteal space, and the popliteal artery rests upon it.

The **Internal Lateral Ligament** is a broad, flat, membranous band, thicker behind than in front, and situated nearer to the back than the front of the joint. It is attached, above, to the inner tuberosity of the femur; below, to the inner tuberosity and inner surface of the shaft of the tibia to the extent of about two inches. It is crossed, at its lower part, by the tendons of the Sartorius, Gracilis,

and Semitendinosus muscles, a synovial bursa being interposed. Its *deep surface* covers the anterior portion of the tendon of the Semimembranosus, with which it is connected by a few fibres, the synovial membrane of the joint, and the inferior internal articular vessels and nerve; it is intimately adherent to the internal semilunar fibro-cartilage.

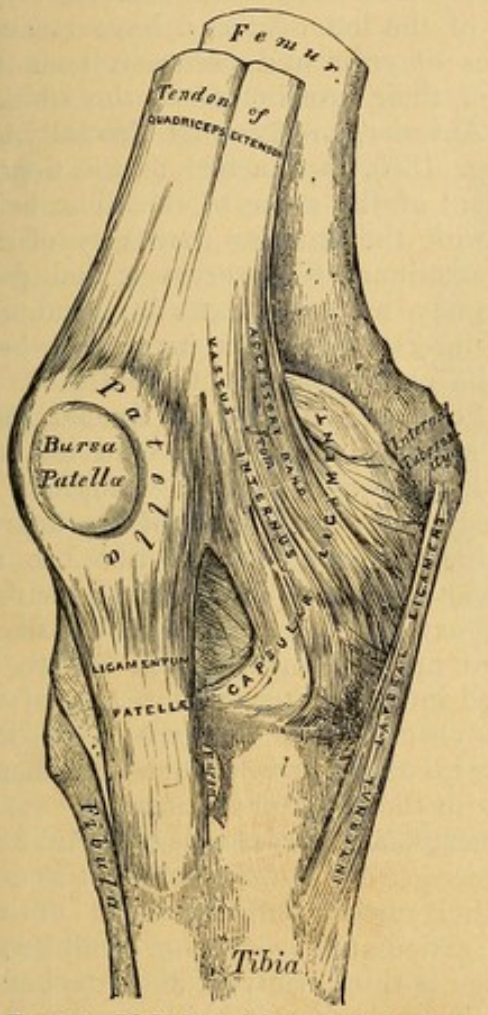

FIG. 183.—Right knee-joint. Anterior view.

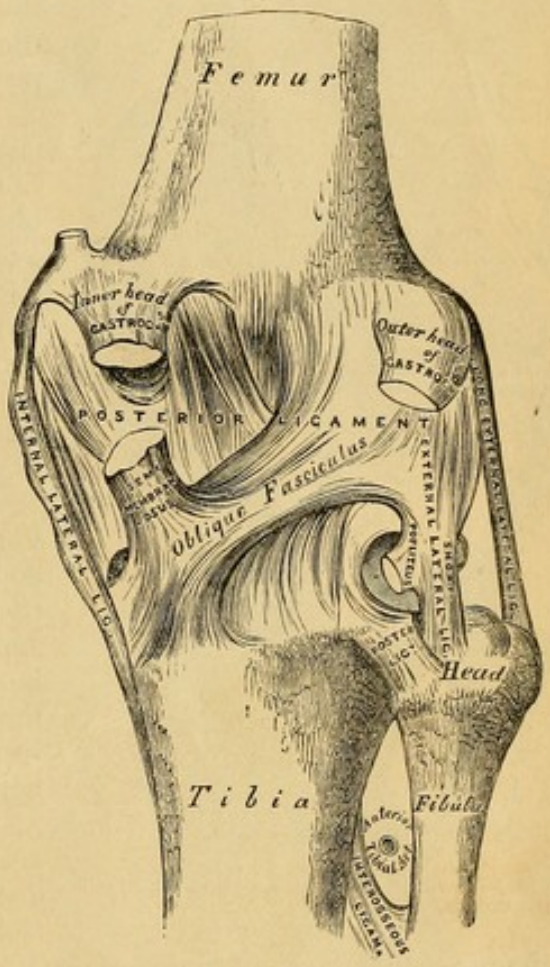

FIG. 184.—Right knee-joint. Posterior view.

The **Long External Lateral Ligament** is a strong, rounded, fibrous cord situated nearer to the back than the front of the joint. It is attached, above, to the back part of the outer tuberosity of the femur; below, to the outer part of the head of the fibula. Its *outer surface* is covered by the tendon of the Biceps, which divides at its insertion into two parts, separated by the ligament. The ligament has, passing beneath it, the tendon of the Popliteus muscle and the inferior external articular vessels and nerve.

The **Short External Lateral Ligament** is an accessory bundle of fibres placed behind and parallel with the preceding, attached, above, to the lower and back part of the outer tuberosity of the femur; below, to the summit of the styloid process of the fibula. This ligament is intimately connected with the capsular ligament, and has, passing beneath it, the tendon of the Popliteus muscle and the inferior external articular vessels and nerve.

The **Capsular Ligament** consists of an exceedingly thin but strong, fibrous membrane which fills in the intervals left between the stronger bands above described, and is inseparably connected with them. In front it blends with and forms part of the lateral patellar ligaments and fills in the interval between the anterior and lateral ligaments of the joint, with which latter structures it is closely connected. Behind, it is formed chiefly of vertical fibres, which arise above from the condyles and intercondyloid notch of the femur, and is connected below with the back part of the head of the tibia, being closely united with the origins of

the Gastrocnemius, Plantaris, and Popliteus muscles. It passes in front of, but is inseparably connected with, the posterior ligament.

The **Crucial** are two interosseous ligaments of considerable strength situated in the interior of the joint, nearer its posterior than its anterior part. They are called *crucial* because they cross each other somewhat like the lines of the letter X; and have received the names *anterior* and *posterior*, from the position of their attachment to the tibia.

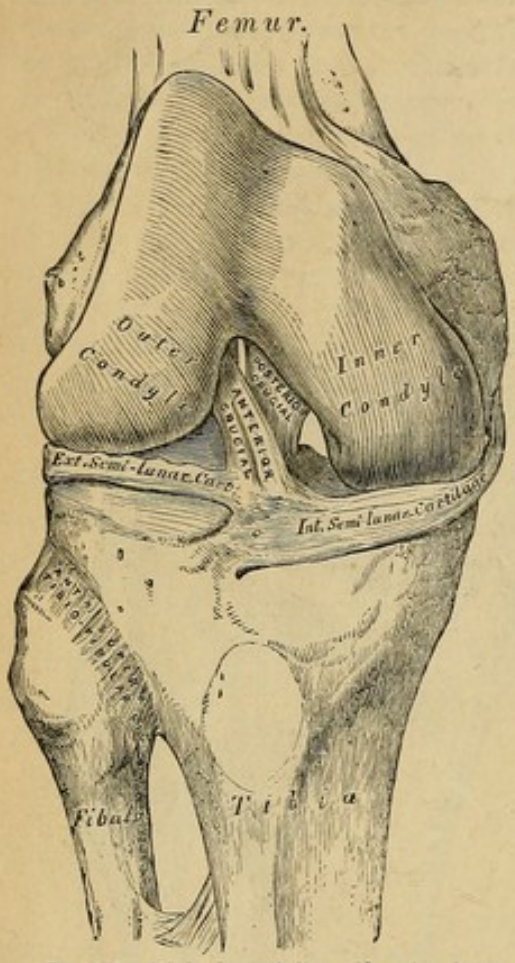

FIG. 185.—Right knee-joint. Showing internal ligaments.

The **Anterior, or External Crucial Ligament** (Fig. 185), is attached to the depression in front of the spine of the tibia, being blended with the anterior extremity of the external semilunar fibro-cartilage, and, passing obliquely upward, backward, and outward, is inserted into the inner and back part of the outer condyle of the femur.

The **Posterior, or Internal Crucial Ligament,** is stronger, but shorter and less oblique in its direction, than the anterior. It is attached to the back part of the depression behind the spine of the tibia, to the popliteal notch, and to the posterior extremity of the external semilunar fibro-cartilage; and passes upward, forward, and inward, to be inserted into the outer and fore part of the inner condyle of the femur. It is in relation, in front, with the anterior crucial ligament; behind, with the capsular ligament.

The **Semilunar Fibro-cartilages** (Fig. 186) are two crescentic lamellæ which serve to deepen the surface of the head of the tibia, for articulation with the condyles of the femur. The circumference of each cartilage is thick, convex, and attached to the inside of the capsule of the knee; the inner border is thin, concave and free. Their upper surfaces are concave, and in relation with the condyles of the femur; their lower surfaces are flat, and rest upon the head of the tibia. Each cartilage covers nearly the outer two-thirds of the corresponding articular surface of the tibia, leaving the inner third uncovered; both surfaces are smooth and invested by synovial membrane.

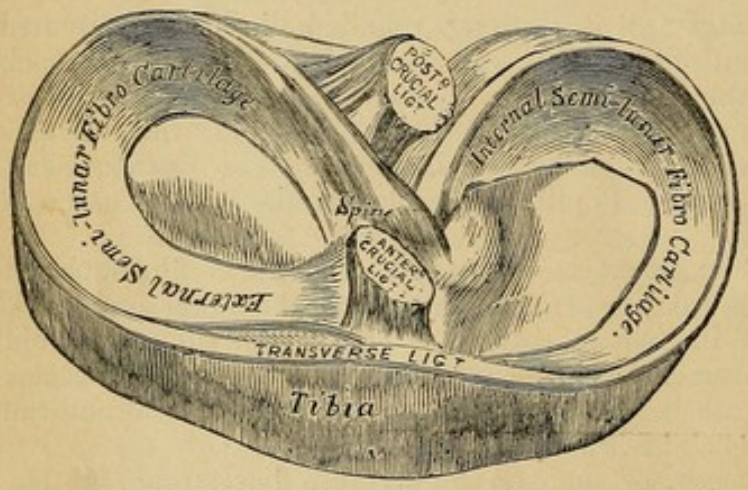

FIG. 186.—Head of tibia, with semilunar cartilages, etc. Seen from above. Right side.

The **Internal Semilunar Fibro-cartilage** is nearly semicircular in form, a little elongated from before backward, and broader behind than in front; its anterior extremity, thin and pointed, is attached to a depression on the anterior margin of the head of the tibia, in front of the anterior crucial ligament; its posterior extremity is attached to the depression behind the spine, between the attachments of the external semilunar fibro-cartilage and the posterior crucial ligaments.

The **External Semilunar Fibro-cartilage** forms nearly an entire circle, covering a larger portion of the articular surface than the internal one. It is grooved on its outer side for the tendon of the Popliteus muscle. Its extremities, at their insertion, are interposed between the two extremities of the internal semilunar fibro-cartilage; the anterior extremity being attached in front of the spine of the tibia to the outer side of, and behind, the anterior crucial ligament, with which it blends; the posterior extremity being attached behind the spine of the tibia, in front of the posterior extremity of the internal semilunar fibro-cartilage. Just before its insertion posteriorly it gives off a strong fasciculus, the *ligament of Wrisberg*, which passes obliquely upward and outward, to be inserted into the inner condyle of the femur, close to the attachment of the posterior crucial ligament. Occasionally a small fasciculus is given off which passes forward to be inserted into the back part of the anterior crucial ligament. The external semilunar fibro-cartilage gives off from its anterior convex margin a fasciculus which forms the transverse ligament.

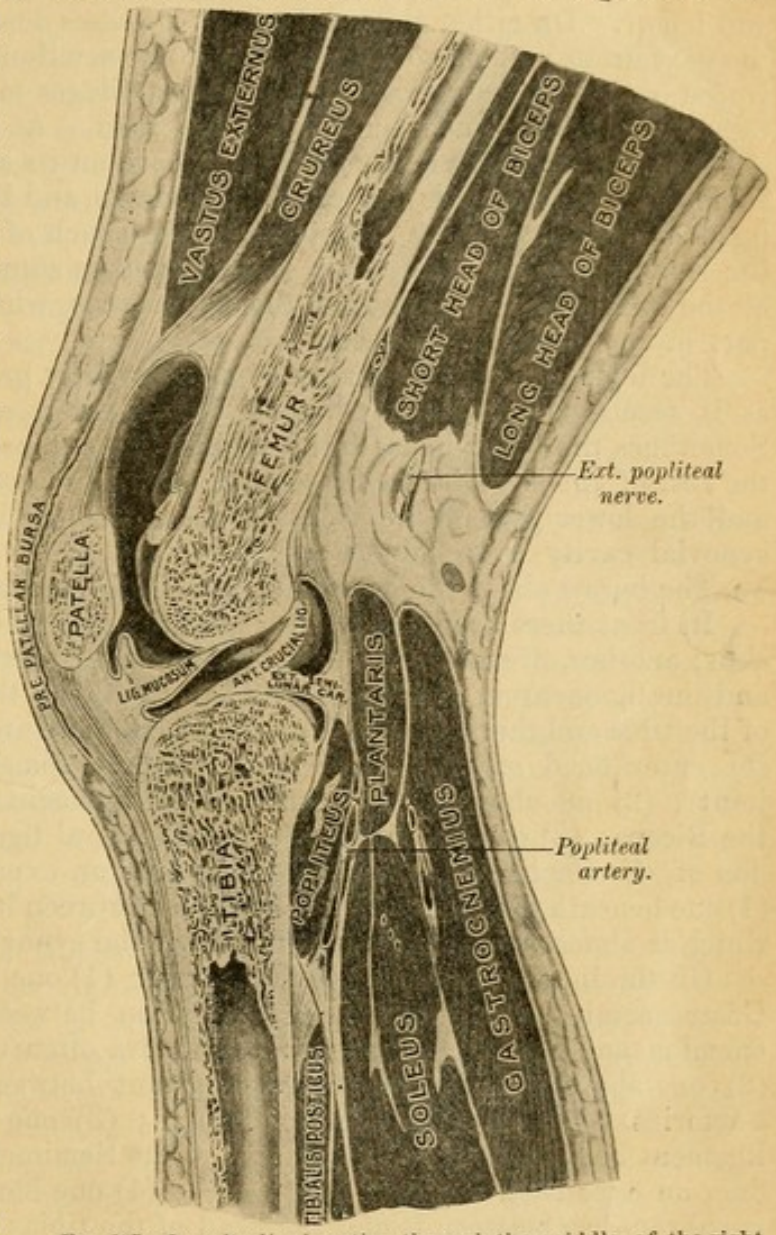

FIG. 187.—Longitudinal section through the middle of the right knee-joint. (After Braune.)

The **Transverse Ligament** is a band of fibres which passes transversely from the anterior convex margin of the external semilunar fibro-cartilage to the anterior convex margin of the internal semilunar fibro-cartilage; its thickness varies considerably in different subjects, and it is sometimes absent altogether.

The **Coronary Ligaments** are merely portions of the capsular ligament, which connect the circumference of each of the semilunar fibro-cartilages with the margin of the head of the tibia.

The **Synovial Membrane** of the knee-joint is the largest and most extensive in the body. Commencing at the upper border of the patella, it forms a short *cul-de-sac* beneath the Quadriceps extensor tendon of the thigh, on the lower part of the front of the shaft of the femur: this communicates with a synovial bursa interposed between the tendon and the front of the femur by an orifice of variable size. On each side of the patella the synovial membrane extends beneath the aponeurosis of the Vasti muscles, and more especially beneath that of the Vastus internus. Below the patella it is separated from the anterior ligament by the anterior part of the capsule and a considerable quantity of adipose tissue. In this situation it sends off a triangular prolongation, containing a few ligamentous fibres, which extends from the anterior part of the joint below the patella to the front of the intercondyloid notch. This fold has been termed the *ligamentum mucosum*. It

also sends off two fringe-like folds, called the *ligamenta alaria*, which extend from the sides of the ligamentum mucosum, upward and laterally between the patella and femur. On either side of the joint it passes downward from the femur, lining the capsule to its point of attachment to the semilunar cartilages; it may then be traced over the upper surfaces of these cartilages to their free borders, and from thence along their under surfaces to the tibia. At the back part of the external one it forms a *cul-de-sac* between the groove on its surface and the tendon of the Popliteus; it surrounds the crucial ligaments and lines the inner surface of the ligaments which enclose the joint. The pouch of synovial membrane between the Extensor tendon and front of the femur is supported, during the movements of the knee, by a small muscle, the Subcrureus, which is inserted into the upper part of the capsular ligament.

The folds of synovial membrane and the fatty processes contained in them act, as it seems, mainly as padding to fill up interspaces and obviate concussions. Sometimes the bursa beneath the Quadriceps extensor is completely shut off from the rest of the synovial cavity, thus forming a closed sac between the Quadriceps and the lower part of the front of the femur, or it may communicate with the synovial cavity by a minute aperture.

The bursæ about the knee-joint are the following:

In front there are three bursæ: one is interposed between the patella and the skin; another, of small size, between the upper part of the tuberosity of the tibia and the ligamentum patellæ; and a third between the lower part of the tuberosity of the tibia and the skin. On the outer side there are four bursæ: (1) one beneath the outer head of the Gastrocnemius (which sometimes communicates with the joint); (2) one above the external lateral ligament between it and the tendon of the Biceps; (3) one beneath the external lateral ligament between it and the tendon of the Popliteus (this is sometimes only an expansion from the next bursa); (4) one beneath the tendon of the Popliteus between it and the condyle of the femur, which is almost always an extension from the synovial membrane.

On the inner side there are five bursæ: (1) one beneath the inner head of the Gastrocnemius, which sends a prolongation between the tendons of the Gastrocnemius and Semimembranosus: this bursa often communicates with the joint; (2) one above the internal lateral ligament between it and the tendons of the Sartorius, Gracilis, and Semitendinosus; (3) one beneath the internal lateral ligament between it and the tendon of the Semimembranosus: this is sometimes only an expansion from the next bursa; (4) one beneath the tendon of the Semimembranosus, between it and the head of the tibia; (5) sometimes there is a bursa between the tendons of the Semimembranosus and of the Semitendinosus.

Structures around the Joint.—In front and at the sides, the Quadriceps extensor; on the outer side, the tendons of the Biceps and the Popliteus and the external popliteal nerve; on the inner side, the Sartorius, Gracilis, Semitendinosus, and Semimembranosus; behind, an expansion from the tendon of the Semimembranosus, the popliteal vessels, and the internal popliteal nerve, Popliteus, Plantaris, and inner and outer heads of the Gastrocnemius, some lymphatic glands, and fat.

The *Arteries* supplying the joint are derived from the anastomotica magna branch of the femoral, articular branches of the popliteal, anterior and posterior recurrent branches of the anterior tibial, and descending branch from the external circumflex of the Profunda.

The *Nerves* are derived from the obturator, anterior crural, and external and internal popliteal.

Actions.—The knee-joint permits of movements of flexion and extension, and, in certain positions, of slight rotation inward and outward. The movement of flexion and extension does not, however, take place in a simple, hinge-like manner, as in other joints, but is a complicated movement, consisting of a certain amount of gliding and rotation; so that the same part of one articular surface is not always applied to the same part of the other articular surface, and the axis

of motion is not a fixed one. If the joint is examined while in a condition of extreme flexion, the posterior part of the articular surfaces of the tibia will be found to be in contact with the posterior rounded extremities of the condyles of the femur; and if a simple hinge-like movement were to take place, the axis, round which the revolving movement of the tibia occurs, would be in the back part of the condyle. If the leg is now brought forward into a position of semiflexion, the upper surface of the tibia will be seen to glide over the condyles of the femur, so that the middle part of the articular facets are in contact, and the axis of rotation must therefore have shifted forward to nearer the centre of the condyles. If the leg is now brought into the extended position, a still further gliding takes place and a further shifting forward of the axis of rotation. This is not, however, a simple movement, but is accompanied by a certain amount of rotation outward round a vertical axis drawn through the centre of the head of the tibia. This rotation is due to the greater length of the internal condyle, and to the fact that the anterior portion of its articular surface is inclined obliquely outward. In consequence of this it will be seen that toward the close of the movement of extension—that is to say, just before complete extension is effected—the tibia glides obliquely upward and outward over this oblique surface on the inner condyle, and the leg is therefore necessarily rotated outward. In flexion of the joint the converse of these movements takes place: the tibia glides backward round the end of the femur, and at the commencement of the movement the tibia is directed downward and inward along the oblique curve of the inner condyle, thus causing an inward rotation to the leg.

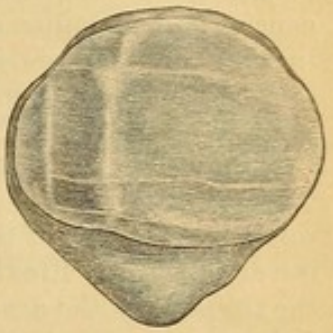

FIG. 188.—View of the posterior surface of the patella, showing diagrammatically the areas of contact with the femur in different positions of the knee.

During flexion and extension the patella moves on the lower end of the femur, but this movement is not a simple gliding one; for if the articular surface of this bone is examined, it will be found to present on each side of the central vertical ridge two less marked transverse ridges, which divide the surface, except a small portion along the inner border, which is cut off by a slight vertical ridge into six facets (see Fig. 188), and therefore does not present a uniform curved surface, as would be the case if a simple gliding movement took place. These six facets—three on each side of the median vertical ridge—correspond to and denote the parts of the bone respectively in contact with the condyles of the femur during flexion, semiflexion, and extension. In flexion only the upper facets on the patella are in contact with the condyles of the femur; the lower two-thirds of the bone rests upon the mass of fat which occupies the space between the femur and tibia. In the semiflexed position of the joint the middle facets on the patella rest upon the most prominent portion of the condyles, and thus afford greater leverage to the Quadriceps by increasing its distance from the centre of motion. In complete extension the patella is drawn up, so that only the lower facets are in contact with the articular surfaces of the condyles. The narrow strip along the inner border is in contact with the outer aspect of the internal condyle when the leg is fully flexed at the knee-joint. As in the elbow, so it is in the knee—the axis of rotation in flexion and extension is not precisely at right angles to the axis of the bone, but during flexion there is a certain amount of alteration of plane; so that, whereas in flexion the femur and tibia are in the same plane, in extension the one bone forms an angle of about ten degrees with the other. There is, however, this difference between the two extremities: that in the upper, during extension, the humeri are parallel and the bones of the forearm diverge; in the lower, the femora converge below and the tibia are parallel.

In addition to the slight rotation during flexion and extension, the tibia enjoys an independent rotation on the condyles of the femur in certain positions of the joint. This movement takes place between the interarticular fibro-cartilages and

the tibia, whereas the movement of flexion and extension takes place between the interarticular fibro-cartilages and the femur. So that the knee may be said to consist of two joints, separated by the fibro-cartilages: an upper (menisco-femoral), in which flexion and extension take place; and a lower (menisco-tibial), allowing of a certain amount of rotation. This latter movement can only take place in the semiflexed position of the limb, when all the ligaments are relaxed.

During *flexion* the ligamentum patellæ is put upon the stretch, as is also the posterior crucial ligament in extreme flexion. The other ligaments are all relaxed by flexion of the joint, though the relaxation of the anterior crucial ligament is very trifling. Flexion is only checked during life by the contact of the leg with the thigh. In the act of extending the leg upon the thigh the ligamentum patellæ is tightened by the Quadriceps extensor; but when the leg is fully extended, as in the erect posture, the ligament becomes relaxed, so as to allow free lateral movement to the patella, which then rests on the front of the lower end of the femur. The other ligaments, with the exception of the posterior crucial, which is partly relaxed, are all on the stretch. When the limb has been brought into a straight line, extension is checked mainly by the tension of all the ligaments except the posterior crucial and ligamentum patellæ. The movements of *rotation* of which the knee is capable are permitted in the semiflexed condition by the partial relaxation of both crucial ligaments, as well as the lateral ligaments. Rotation inward appears to be limited by the tension of the anterior crucial ligament, and by the interlocking of the two ligaments; but rotation outward does not appear to be checked by either crucial ligament, since they uncross during the execution of this movement, but by the lateral ligaments, especially the internal. The main function of the crucial ligaments is to act as a direct bond of union between the tibia and femur, preventing the former bone from being carried too far backward or forward. Thus the anterior crucial ligament prevents the tibia being carried too far forward by the extensor tendons, and the posterior crucial checks too great movement backward by the flexors. They also assist the lateral ligaments in resisting any lateral bending of the joint. The interarticular cartilages are intended, as it seems, to adapt the surface of the tibia to the shape of the femur to a certain extent, so as to fill up the intervals which would otherwise be left in the varying positions of the joint, and to interrupt the jars which would be so frequently transmitted up the limb in jumping or falls on the feet; also to permit of the two varieties of motion, flexion and extension, and rotation, as explained above. The patella is a great defence to the knee-joint from any injury inflicted in front, and it distributes upon a large and tolerably even surface during kneeling the pressure which would otherwise fall upon the prominent ridges of the condyles; it also affords leverage to the Quadriceps extensor muscle to act upon the tibia; and Mr. Ward has pointed out [1] how this leverage varies in the various positions of the joint, so that the action of the muscles produces velocity at the expense of force in the commencement of extension, and, on the contrary, at the close of extension tends to diminish velocity, and therefore the shock to the ligaments at the moment tension of the structures takes place.

Extension of the leg on the thigh is performed by the Quadriceps extensor; *flexion* by the hamstring muscles, assisted by the Gracilis and Sartorius, and, indirectly, by the Gastrocnemius, Popliteus, and Plantaris; *rotation outward*, by the Biceps; and *rotation inward* by the Popliteus, Semitendinosus, and, to a slight extent, the Semimembranosus, the Sartorius, and the Gracilis.

Surface Form.—The interval between the two bones entering into the formation of the knee-joint can always easily be felt. If the limb is extended, it is situated on a slightly higher level than the apex of the patella; but if the limb is slightly flexed, a knife carried horizontally backward immediately below the apex of the patella would pass directly into the joint. When the knee-joint is distended with fluid, the outline of the synovial membrane at the front of the knee may be fairly well mapped out.

Surgical Anatomy.—From a consideration of the construction of the knee-joint it would at first sight appear to be one of the least secure of any of the joints in the body. It is formed

[1] *Human Osteology*, p. 405.

between the two longest bones, and therefore the amount of leverage which can be brought to bear upon it is very considerable; the articular surfaces are but ill adapted to each other, and the range and variety of motion which it enjoys is great. All these circumstances tend to render the articulation very insecure; but, nevertheless, on account of the very powerful ligaments which bind the bones together, the joint is one of the strongest in the body, and dislocation from traumatism is of very rare occurrence. When, on the other hand, the ligaments have been softened or destroyed by disease, partial displacement is very liable to occur, and is frequently brought about by the mere action of the muscles displacing the articular surfaces from each other. The tibia may be dislocated in any direction from the femur—forward, backward, inward, or outward; or a combination of two of these dislocations may occur—that is, the tibia may be dislocated forward and laterally, or backward and laterally; and any of these dislocations may be complete or incomplete. As a rule, however, the antero-posterior dislocations are complete, the lateral ones incomplete.

One or other of the semilunar cartilages may become displaced and nipped between the femur and tibia. The accident is produced by a twist of the leg when the knee is flexed, and is accompanied by a sudden pain and fixation of the knee in a flexed position. The cartilage may be displaced either inward or outward: that is to say, either inward toward the tibial spine, so that the cartilage becomes lodged in the intercondyloid notch; or outward, so that the cartilage projects beyond the margin of the two articular surfaces. Acute synovitis, the result of traumatism or exposure to cold, is very common in the knee, on account of its superficial position. When distended with fluid, the swelling shows itself above and at the sides of the patella, reaching about an inch or more above the trochlear surface of the femur, and extending a little higher under the Vastus internus than the Vastus externus. Occasionally the swelling may extend two inches or more. At the sides of the patella the swelling extends lower at the inner side than it does on the outer side. The lower level of the synovial membrane is just above the level of the upper part of the head of the fibula. In the middle line it covers the upper third of the ligamentum patellæ, being separated from it, however, by the capsule and a pad of fat. Chronic synovitis principally shows itself in the form of pulpy degeneration of the synovial membrane, leading to tubercular arthritis. The reasons why tubercular disease of the knee usually commences in the synovial membrane appear to be the complex and extensive nature of this sac; the extensive vascular supply to it; and the fact that injuries are generally diffused and applied to the front of the joint rather than to the ends of the bones. Syphilitic disease not unfrequently attacks the knee-joint. In the hereditary form of the disease it is usually symmetrical, attacking both joints, which become filled with synovial effusion, and is very intractable and difficult of cure. In the tertiary form of the disease gummatous infiltration of the synovial membrane may take place. The knee is one of the joints most commonly affected with osteo-arthritis, and is said to be more frequently the seat of this disease in women than in men. The occurrence of the so-called loose cartilage is almost confined to the knee, though they are occasionally met with in the elbow, and, rarely, in some other joints. Many of them occur in cases of osteo-arthritis, in which calcareous or cartilaginous material is formed in one of the synovial fringes and constitutes the foreign body, and may or may not become detached, in the former case only meriting the usual term, "loose" cartilage. In other cases they have their origin in the exudation of inflammatory lymph, and possibly, in some rare instances, a portion of the articular cartilage or one of the semilunar cartilages becomes detached and constitutes the foreign body.

Genu valgum, or knock-knee, is a common deformity of childhood, in which, owing to changes in and about the joint, the angle between the outer border of the tibia and femur is diminished, so that as the patient stands the two internal condyles of the femora are in contact, but the two internal malleoli of the tibiæ are more or less widely separated from each other. When, however, the knees are flexed to a right angle, the two legs are practically parallel with each other. At the commencement of the disease there is a yielding of the internal lateral ligament and other fibrous structures on the inner side of the joint; as a result of this there is a constant undue pressure of the outer tuberosity of the tibia against the outer condyle of the femur. This extra pressure causes arrest of growth and, possibly, wasting of the outer condyle, and a consequent tendency for the tibia to become separated from the internal condyle. To prevent this the internal condyle becomes depressed; probably, as was first pointed out by Mikulicz, by an increased growth of the lower end of the diaphysis on its inner side, so that the line of the epiphysis becomes oblique instead of transverse to the axis of the bone, with a direction downward and inward.

Excision of the knee-joint is most frequently required for tubercular disease of this articulation, but is also practised in cases of disorganization of the knee after rheumatic fever, pyæmia, etc., in osteo-arthritis, and in ankylosis. It is also occasionally called for in cases of injury, gunshot or otherwise. The operation is best performed either by a horseshoe incision, starting from one condyle, descending as low as the tubercle of the tibia, where it crosses the leg, and is then carried upward to the other condyle; or by a transverse incision across the patella. In this latter incision the patella is either removed or sawn across, and the halves subsequently sutured together. The bones having been cleared, and in those cases where the operation is performed for tubercular disease all pulpy tissue having been carefully removed, the section of the femur is first made. This should never include, in children, more than, at the most, two-thirds of the articular surface, otherwise the epiphyseal cartilage will be involved, with disastrous results as regards the growth of the limb. Afterward a thin slice should be removed from the upper

end of the tibia, not more than half an inch. If any diseased tissue still appears to be left in the bones, it should be removed with the gouge rather than that a further section of the bones should be made.

III. Articulations between the Tibia and Fibula.

The articulations between the tibia and fibula are effected by ligaments which connect both extremities, as well as the shafts of the bones. They may, consequently, be subdivided into three sets: 1. The Superior Tibio-fibular articulation. 2. The Middle Tibio-fibular ligament or interosseous membrane. 3. The Inferior Tibio-fibular articulation.

1. Superior Tibio-fibular Articulation.

This articulation is an arthrodial joint. The contiguous surfaces of the bones present two flat, oval facets covered with cartilage, and connected together by the following ligaments:

Capsular.
Anterior Superior Tibio-fibular.
Posterior Superior Tibio-fibular.

The **Capsular Ligament** consists of a membranous bag which surrounds the articulation, being attached around the margins of the articular facets on the tibia and fibula, and is much thicker in front than behind.

The **Anterior Superior Ligament** (Fig. 185) consists of two or three broad and flat bands which pass obliquely upward and inward from the front of the head of the fibula to the front of the outer tuberosity of the tibia.

The **Posterior Superior Ligament** (Fig. 184) is a single thick and broad band which passes upward and inward from the back part of the head of the fibula to the back part of the outer tuberosity of the tibia. It is covered by the tendon of the Popliteus muscle.

A **Synovial Membrane** lines this articulation, which at its upper and back part is occasionally continuous with that of the knee-joint.

2. Middle Tibio-fibular Ligament or Interosseous Membrane.

An interosseous membrane extends between the contiguous margins of the tibia and fibula, and separates the muscles on the front from those on the back of the leg. It consists of a thin, aponeurotic lamina composed of oblique fibres which for the most part pass downward and outward between the interosseous ridges on the two bones; some few fibres, however, pass in the opposite direction, downward and inward. It is broader above than below. Its upper margin does not quite reach the superior tibio-fibular joint, but presents a free concave border, above which is a large, oval aperture for the passage of the anterior tibial vessels forward to the anterior aspect of the leg. At its lower part is an opening for the passage of the anterior peroneal vessels. It is continuous below with the inferior interosseous ligament, and is perforated in numerous parts for the passage of small vessels. It is in relation, in front, with the Tibialis anticus, Extensor longus digitorum, Extensor proprius hallucis, Peroneus tertius, and the anterior tibial vessels and nerve; behind, with the Tibialis posticus and Flexor longus hallucis.

3. Inferior Tibio-fibular Articulation.

This articulation is formed by the rough, convex surface of the inner side of the lower end of the fibula, connected with a concave rough surface on the outer side of the tibia. Below, to the extent of about two lines, these surfaces are smooth, and covered with cartilage, which is continuous with that of the ankle-joint. The ligaments of this joint are—

Anterior Inferior Tibio-fibular.
Posterior Inferior Tibio-fibular.
Transverse or Inferior.
Inferior Interosseous.

The **Anterior Inferior Ligament** (Fig. 190) is a flat, triangular band of fibres, broader below than above, which extends obliquely downward and outward between the adjacent margins of the tibia and fibula, on the front aspect of the articulation. It is in relation, in front, with the Peroneus tertius, the aponeurosis of the leg, and the integument; behind, with the inferior interosseous ligament; and lies in contact with the cartilage covering the astragalus.

The **Posterior Inferior Ligament,** smaller than the preceding, is disposed in a similar manner on the posterior surface of the articulation.

The **Transverse Ligament** or **Inferior Ligament** lies under cover of the posterior ligament, and is a strong, thick band of yellowish fibres which passes transversely across the back of the joint, from the external malleolus to the posterior border of the articular surface of the tibia, almost as far as its malleolar process. This ligament projects below the margin of the bones, and forms part of the articulating surface for the astragalus.

The **Inferior Interosseous Ligament** consists of numerous short, strong, fibrous bands which pass between the contiguous rough surfaces of the tibia and fibula, and constitute the chief bond of union between the bones. This ligament is continuous above with the interosseous membrane.

The **Synovial Membrane** lining the articular surface is derived from that of the ankle-joint.

Actions.—The movement permitted in these articulations is limited to a very slight gliding of the articular surfaces one upon another.

IV. Ankle-joint.

The **Ankle** is a ginglymus or hinge-joint. The bones entering into its formation are the lower extremity of the tibia and its malleolus and the external malleolus of the fibula, which forms a mortise to receive the upper convex surface of the astragalus and its two lateral facets. The bony surfaces are covered with carti-

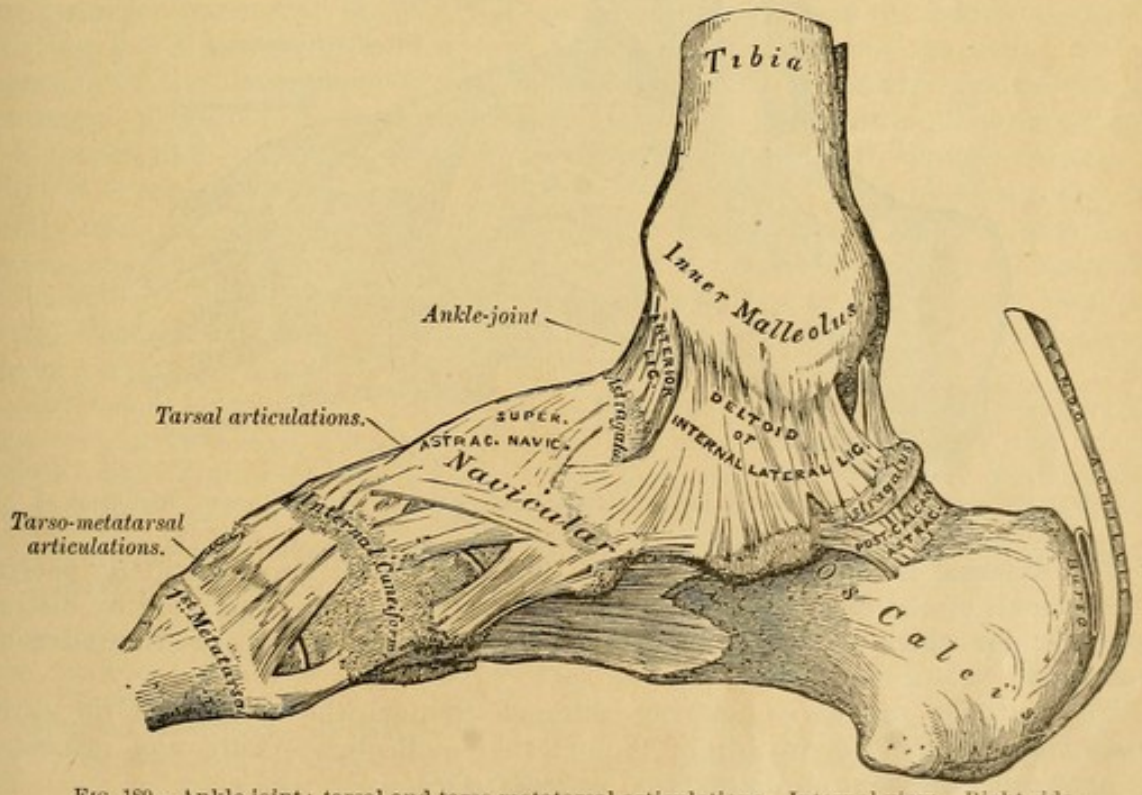

FIG. 189.—Ankle-joint: tarsal and tarso-metatarsal articulations. Internal view. Right side.

lage and connected together by a capsule, which in places forms thickened bands constituting the following ligaments:

Anterior.	Internal Lateral.
Posterior.	External Lateral.

The **Anterior Ligament** (Fig. 189) is a broad, thin, membranous layer, attached, above, to the anterior margin of the lower extremity of the tibia; below, to the margin of the astragalus, in front of its articular surface. It is in relation, in front, with the Extensor tendons of the toes, with the tendons of the Tibialis anticus and Peroneus tertius, and the anterior tibial vessels and nerve; behind, it lies in contact with the synovial membrane.

The **Posterior Ligament** is very thin, and consists principally of transverse fibres. It is attached, above, to the margin of the articular surface of the tibia, blending with the transverse tibio-fibular ligament; below, to the astragalus, behind its superior articular facet. Externally, where a somewhat thickened band of transverse fibres is attached to the hollow on the inner surface of the external malleolus, it is thicker than internally.

The **Internal Lateral** or **Deltoid Ligament** is a strong, flat, triangular band, attached, above, to the apex and anterior and posterior borders of the inner malleolus. The most anterior fibres pass forward to be inserted into the navicular bone and the inferior calcaneo-navicular ligament; the middle descend almost perpendicularly to be inserted into the sustentaculum tali of the os calcis; and the posterior fibres pass backward and outward to be attached to the inner side of the astragalus. This ligament is covered by the tendons of the Tibialis posticus and Flexor longus digitorum muscles.

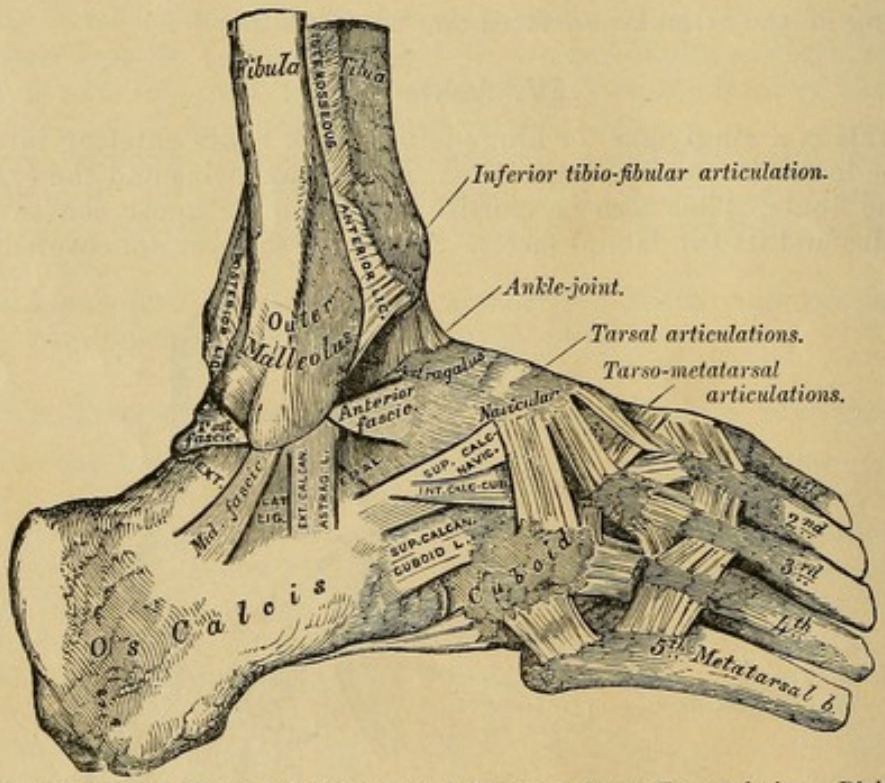

FIG. 190.—Ankle-joint: tarsal and tarso-metatarsal articulations. External view. Right side.

The **External Lateral Ligament** (Fig. 190) consists of three distinctly specialized fasciculi of the capsule, taking different directions and separated by distinct intervals; for which reason it is described by some anatomists as three distinct ligaments.[1]

The *anterior fasciculus* (anterior astragalo-fibular), the shortest of the three, passes from the anterior margin of the external malleolus forward and inward to the astragalus, in front of its external articular facet.

The *posterior fasciculus* (posterior astragalo-fibular), the most deeply seated, passes inward from the depression at the inner and back part of the external malleolus to a prominent tubercle on the posterior surface of the astragalus. Its fibres are almost horizontal in direction.

[1] Humphry, *On the Skeleton*, p. 559.

The *middle fasciculus* (calcaneo-fibular), the longest of the three, is a narrow, rounded cord passing from the apex of the external malleolus downward and slightly backward to a tubercle on the outer surface of the os calcis. It is covered by the tendons of the Peroneus longus and brevis.

The **Synovial Membrane** invests the inner surface of the ligaments, and sends a duplicature upward between the lower extremities of the tibia and fibula for a short distance.

Relations.—The tendons, vessels, and nerves in connection with the joint are, in front, from within outward, the Tibialis anticus, Extensor proprius hallucis, anterior tibial vessels, anterior tibial nerve, Extensor longus digitorum, and Peroneus tertius; behind, from within outward, the Tibialis posticus, Flexor longus digitorum, posterior tibial vessels, posterior tibial nerve, Flexor longus hallucis; and, in the groove behind the external malleolus, the tendons of the Peroneus longus and brevis.

The *Arteries* supplying the joint are derived from the malleolar branches of the anterior tibial and the peroneal.

The *Nerves* are derived from the anterior and posterior tibial.

Actions.—The movements of the joint are those of flexion and extension. Flexion consists in the approximation of the dorsum of the foot to the front of the leg, while in extension the heel is drawn up and the toes pointed downward. The malleoli tightly embrace the astragalus in all positions of the joint, so that any slight degree of lateral movement which may exist is simply due to stretching of the inferior tibio-fibular ligaments and slight bending of the shaft of the fibula. Of the ligaments, the internal, or deltoid, is of very great power—so much so that it usually resists a force which fractures the process of bone to which it is attached. Its middle portion, together with the middle fasciculus of the external lateral ligament, binds the bones of the leg firmly to the foot and resists displacement in every direction. Its anterior and posterior fibres limit extension and flexion of the foot respectively, and the anterior fibres also limit abduction. The posterior portion of the external lateral ligament assists the middle portion in resisting the displacement of the foot backward, and deepens the cavity for the reception of the astragalus. The anterior fasciculus is a security against the displacement of the foot forward, and limits extension of the joint. The movements of *inversion* and *eversion* of the foot, together with the minute changes in form by which it is applied to the ground or takes hold of an object in climbing, etc., are mainly effected in the tarsal joints, the one which enjoys the greatest amount of motion being that between the astragalus and os calcis behind and the navicular and cuboid in front. This is often called the *transverse* or *medio-tarsal joint*, and it can, with the subordinate joints of the tarsus, replace the ankle-joint in a great measure when the latter has become ankylosed.

Extension of the tarsal bones upon the tibia and fibula is produced by the Gastrocnemius, Soleus, Plantaris, Tibialis posticus, Peroneus longus and brevis, Flexor longus digitorum, and Flexor longus hallucis; *flexion*, by the Tibialis anticus, Peroneus tertius, Extensor longus digitorum, and Extensor proprius hallucis;[1] *inversion*, in the extended position, is produced by the Tibialis anticus and posticus; and *eversion* by the Peronei.

Surface Form.—The line of the ankle-joint may be indicated by a transverse line drawn across the front of the lower part of the leg, about half an inch above the level of the tip of the internal malleolus.

Surgical Anatomy.—Displacement of the trochlear surface of the astragalus from the tibio-fibular mortise is not of common occurrence, as the ankle-joint is a very strong and powerful articulation, and great force is required to produce it. Nevertheless, dislocation does occasionally occur, both in an antero-posterior and a lateral direction. In the latter, which is the most common, fracture is a necessary accompaniment of the injury. The dislocation in these cases is somewhat peculiar, and is not a displacement in a horizontally lateral direction, such as usually

[1] The student must bear in mind that the Extensor longus digitorum and Extensor proprius hallucis are *extensors* of the toes, but *flexors* of the ankle, and that the Flexor longus digitorum and Flexor longus hallucis are *flexors* of the toes, but *extensors* of the ankle.

occurs in lateral dislocations of ginglymoid joints, but the astragalus undergoes a partial rotation round an antero-posterior axis drawn through its own centre, so that the superior surface, instead of being directed upward, is inclined more or less inward or outward according to the variety of the displacement.

The ankle-joint is more frequently sprained than any joint in the body, and this may lead to acute synovitis. In these cases, when the synovial sac is distended with fluid, the bulging appears principally in the front of the joint, beneath the anterior tendons, and on either side, between the Tibialis anticus and the internal lateral ligament on the inner side, and between the Peroneus tertius and the external lateral ligament on the outer side. In addition to this, bulging frequently occurs posteriorly, and a fluctuating swelling may be detected on either side of the tendo Achillis.

Chronic synovitis may result from frequent sprains, and when once this joint has been sprained it is more liable to a recurrence of the injury than it was before; or it may be tuber-

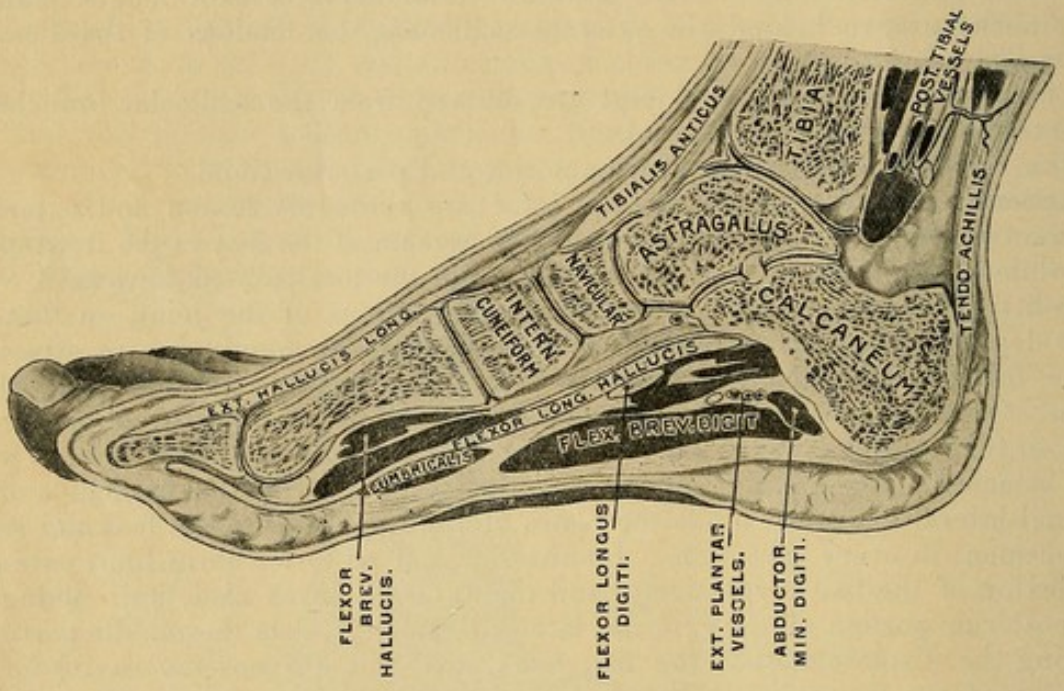

FIG. 191.—Section of the right foot near its inner border, dividing the tibia, astragalus, navicular, internal cuneiform, and first metatarsal bone, and the first phalanx of the great toe. (After Braune.)

cular in its origin, the disease usually commencing in the astragalus and extending to the joint, though it may commence as a synovitis the result probably of some slight strain in a tubercular subject.

Excision of the ankle-joint is not often performed for two reasons. In the first place, disease of the articulation for which this operation is indicated is frequently associated with disease of the tarsal bones, which prevents its performance; and, secondly, the foot after excision is frequently of very little use; far less, in fact, than after a Symes's amputation, which is often, therefore, a preferable operation in these cases. Excision may, however, be attempted in cases of tubercular arthritis, in a young and otherwise healthy subject, where the disease is limited to the bones forming the joint. It may also be required after injury where the vessels and nerves have not been damaged and the patient is young and free from visceral disease. The excision is best performed by two lateral incisions. One commencing two and a half inches above the external malleolus, carried down the posterior border of the fibula, round the end of the bone, and then forward and downward as far as the calcaneo-cuboid joint, midway between the tip of the external malleolus and the tuberosity on the fifth metatarsal bone. Through this incision the fibula is cleared, the external lateral ligament is divided, and the bone sawn through about half an inch above the level of the ankle-joint and removed. A similar curved incision is now made on the inner side of the foot, commencing two and a half inches above the lower end of the tibia, carried down the posterior border of the bone, round the internal malleolus, and forward and downward to the tuberosity of the navicular bone. Through this incision the tibia is cleared in front and behind, the internal lateral, the anterior and posterior ligaments divided, and the end of the tibia protruded through the wound by displacing the foot outward, and sawn off sufficiently high to secure a healthy section of bone. The articular surface of the astragalus is now to be sawn off or the whole bone removed. In cases where the operation is performed for tubercular arthritis the latter course is probably preferable, as the injury done by the saw is frequently the starting point of fresh caries; and after removal of the whole bone the shortening is not appreciably increased, and the result as regards union appears to be as good as when two sawn surfaces of bone are brought into apposition.

V. Articulations of the Tarsus.

1. Articulations of the Os Calcis and Astragalus.

The articulations between the os calcis and astragalus are two in number—anterior and posterior. They are arthrodial joints. The bones are connected together by four ligaments:

External Calcaneo-astragaloid.	Posterior Calcaneo-astragaloid.
Internal Calcaneo-astragaloid.	Interosseous.

The **External Calcaneo-astragaloid Ligament** (Fig. 190) is a short, strong, fasciculus passing from the outer surface of the astragalus, immediately beneath its external malleolar facet, to the outer surface of the os calcis. It is placed in front of the middle fasciculus of the external lateral ligament of the ankle-joint, with the fibres of which it is parallel.

The **Internal Calcaneo-astragaloid Ligament** is a band of fibres connecting the internal tubercle of the back of the astragalus with the back of the sustentaculum tali. Its fibres blend with those of the inferior calcaneo-navicular ligament.

The **Posterior Calcaneo-astragaloid Ligament** (Fig. 189) connects the external tubercle of the astragalus with the upper and inner part of the os calcis; it is a short band, the fibres of which radiate from their narrow attachment to the astragalus.

The **Interosseous Ligament** forms the chief bond of union between the bones. It consists of numerous vertical and oblique fibres attached by one extremity to the groove between the articulating facets on the under surface of the astragalus; by the other to a corresponding depression on the upper surface of the os calcis. It is very thick and strong, being at least an inch in breadth from side to side, and serves to unite the os calcis and astragalus solidly together.

The **Synovial Membranes** (Fig. 193) are two in number: one for the posterior calcaneo-astragaloid articulation; a second for the anterior calcaneo-astragaloid joint. The latter synovial membrane is continued forward between the contiguous surfaces of the astragalus and navicular bones.

Actions.—The movements permitted between the astragalus and os calcis are limited to a gliding of the one bone on the other in a direction from before backward, and from side to side.

2. Articulations of the Os Calcis with the Cuboid.

The ligaments connecting the os calcis with the cuboid are four in number:

Dorsal.	Superior Calcaneo-cuboid. Internal Calcaneo-cuboid (Interosseous).
Plantar.	Long Calcaneo-cuboid. Short Calcaneo-cuboid.

The **Superior Calcaneo-cuboid Ligament** (Fig. 190) is a thin and narrow fasciculus which passes between the contiguous surfaces of the os calcis and cuboid on the dorsal surface of the joint.

The **Internal Calcaneo-cuboid (Interosseous) Ligament** (Fig. 190) is a short but thick and strong band of fibres arising from the os calcis, in the deep hollow which intervenes between it and the astragalus, and closely blended, at its origin, with the superior calcaneo-navicular ligament. It is inserted into the inner side of the cuboid bone. This ligament forms one of the chief bonds of union between the first and second rows of the tarsus.

The **Long Calcaneo-cuboid (Long Plantar) Ligament** (Fig. 192), the more superficial of the two plantar ligaments, is the longest of all the ligaments of the tarsus: it is attached to the under surface of the os calcis, from near the tuberosities, as far forward as the anterior tubercle; its fibres pass forward to be attached to the ridge on the under surface of the cuboid bone, the more superficial fibres being

continued onward to the bases of the second, third, and fourth metatarsal bones. This ligament crosses the groove on the under surface of the cuboid bone, converting it into a canal for the passage of the tendon of the Peroneus longus.

The **Short Calcaneo-cuboid (Short Plantar) Ligament** lies nearer to the bones than the preceding, from which it is separated by a little areolar tissue. It is exceedingly broad, about an inch in length, and extends from the tubercle and the depression in front of it, on the fore part of the under surface of the os calcis, to the inferior surface of the cuboid bone behind the peroneal groove.

Synovial Membrane.—The synovial membrane in this joint is distinct. It lines the inner surface of the ligaments.

Actions.—The movements permitted between the os calcis and cuboid are limited to a slight gliding upon each other.

3. The Ligaments connecting the Os Calcis and Navicular.

Though these two bones do not directly articulate, they are connected together by two ligaments:

Superior or External Calcaneo-navicular.
Inferior or Internal Calcaneo-navicular.

The **Superior** or **External Calcaneo-navicular** (Fig. 190) arises, as already mentioned, with the internal calcaneo-cuboid in the deep hollow between the astragalus and os calcis; it passes forward from the upper surface of the anterior extremity of the os calcis to the outer side of the navicular bone. These two ligaments resemble the letter Y, being blended together behind, but separated in front.

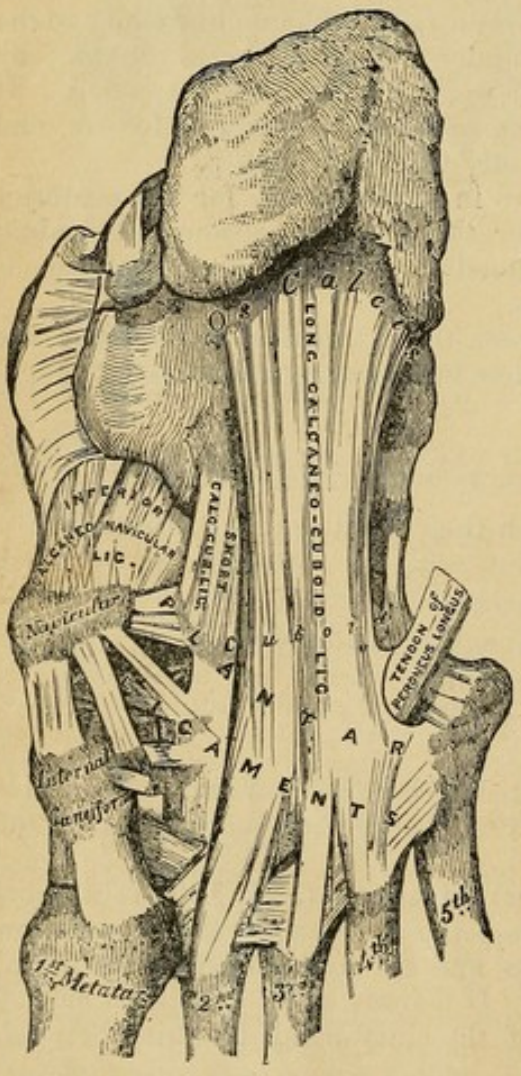

Fig. 192.—Ligaments of the plantar surface of the foot.

The **Inferior** or **Internal Calcaneo-navicular** (Fig. 192) is by far the larger and stronger of the two ligaments between these bones; it is a broad and thick band of fibres, which passes forward and inward from the anterior margin of the sustentaculum tali of the os calcis to the under surface of the navicular bone. This ligament not only serves to connect the os calcis and navicular, but supports the head of the astragalus, forming part of the articular cavity in which it is received. The *upper surface* presents a fibro-cartilaginous facet, lined by the synovial membrane continued from the anterior calcaneo-astragaloid articulation, upon which a portion of the head of the astragalus rests. Its *under surface* is in contact with the tendon of the Tibialis posticus muscle;[1] its inner border is blended with the fore part of the Deltoid ligament, thus completing the socket for the head of the astragalus.

Surgical Anatomy.—The inferior calcaneo-navicular ligament, by supporting the head of the astragalus, is principally concerned in maintaining the arch of the foot, and when it yields, the head of the astragalus is pressed downward, inward, and forward by the weight of the body, and the foot becomes flattened, expanded, and turned outward, constituting the disease known as *flat-foot*. This ligament contains a considerable amount of elastic fibre, so as to

[1] Mr. Hancock describes an extension of this ligament upward on the inner side of the foot, which completes the socket of the joint in that direction (*Lancet*, 1866 vol. i., p. 618).

give elasticity to the arch and spring to the foot; hence it is sometimes called the "spring" ligament. It is supported, on its under surface, by the tendon of the Tibialis posticus, which spreads out at its insertion into a number of fasciculi which are attached to most of the tarsal and metatarsal bones; this prevents undue stretching of the ligament and is a protection against the occurrence of flat-foot.

4. Articulation of the Astragalus with the Navicular Bone.

The articulation between the astragalus and navicular is an arthrodial joint: the rounded head of the astragalus being received into the concavity formed by the posterior surface of the navicular, the anterior articulating surface of the calcaneum, and the upper surface of the inferior calcaneo-navicular ligament, which fills up the triangular interval between these bones. The only ligament of this joint is the **superior astragalo-navicular.** It is a broad band, which passes obliquely forward from the neck of the astragalus to the superior surface of the navicular bone. It is thin, and weak in texture, and covered by the Extensor tendons. The inferior calcaneo-navicular supplies the place of an inferior ligament.

The **Synovial Membrane** which lines the joint is continued forward from the anterior calcaneo-astragaloid articulation.

Actions.—This articulation permits of considerable mobility, but its feebleness is such as to allow occasionally of dislocation of the other bones of the tarsus from the astragalus.

The *transverse tarsal* or *medio-tarsal joint* is formed by the articulation of the os calcis with the cuboid, and by the articulation of the astragalus with the navicular. The movement which takes place in this joint is more extensive than that in the other tarsal joints, and consists of a sort of rotation by means of which the sole of the foot may be slightly flexed and extended or carried inward (inverted) and outward (everted).

5. The Articulation of the Navicular with the Cuneiform Bones.

The navicular is connected to the three cuneiform bones by

Dorsal and Plantar ligaments.

The **Dorsal Ligaments** are small, longitudinal bands of fibrous tissue arranged as three bundles, one to each of the cuneiform bones. That bundle of fibres which connects the navicular with the internal cuneiform is continued round the inner side of the articulation to be continuous with the plantar ligament which connects these two bones.

The **Plantar Ligaments** have a similar arrangement to those on the dorsum. They are strengthened by processes given off from the tendon of the Tibialis posticus.

Actions.—The movements permitted between the navicular and cuneiform bones are limited to a slight gliding upon each other.

The **Synovial Membrane** of these joints is part of the great tarsal synovial membrane.

6. The Articulation of the Navicular with the Cuboid.

The navicular bone is connected with the cuboid by

Dorsal, Plantar, and Interosseous ligaments.

The **Dorsal Ligament** consists of a band of fibrous tissue which passes obliquely forward and outward from the navicular to the cuboid bone.

The **Plantar Ligament** consists of a band of fibrous tissue which passes nearly transversely between these two bones.

The **Interosseous Ligament** consists of strong transverse fibres which pass between the rough non-articular portions of the lateral surfaces of these two bones.

Actions.—The movements permitted between the navicular and cuboid bones are limited to a slight gliding upon each other.

The **Synovial Membrane** of this joint is part of the great tarsal synovial membrane.

7. The Articulation of the Cuneiform Bones with each other.

These bones are connected together by

Dorsal, Plantar, and Interosseous ligaments.

The **Dorsal Ligaments** consist of two bands of fibrous tissue which pass transversely, one connecting the internal with the middle cuneiform, and the other connecting the middle with the external cuneiform.

The **Plantar Ligaments** have a similar arrangement to those on the dorsum. They are strengthened by the processes given off from the tendon of the Tibialis posticus.

The **Interosseous Ligaments** consist of strong transverse fibres which pass between the rough non-articular portions of the lateral surfaces of the adjacent cuneiform bones.

The **Synovial Membrane** of these joints is part of the great tarsal synovial membrane.

Actions.—The movements permitted between the cuneiform bones are limited to a slight gliding upon each other.

8. The Articulation of the External Cuneiform Bone with the Cuboid.

These bones are connected together by

Dorsal, Plantar, and Interosseous ligaments.

The **Dorsal Ligament** consists of a band of fibrous tissue which passes transversely between these two bones.

The **Plantar Ligament** has a similar arrangement. It is strengthened by a process given off from the tendon of the Tibialis posticus.

The **Interosseous Ligament** consists of strong transverse fibres which pass between the rough non-articular portions of the lateral surfaces of the adjacent sides of these two bones.

The **Synovial Membrane** of this joint is part of the great tarsal synovial membrane.

Actions.—The movements permitted between the external cuneiform and cuboid are limited to a slight gliding upon each other.

Nerve-supply.—All the joints of the tarsus are supplied by the anterior tibial nerve.

Surgical Anatomy.—In spite of the great strength of the ligaments which connect the tarsal bones together, dislocation at some of the tarsal joints does occasionally occur; though, on account of the spongy character of the bones, they are more frequently broken than dislocated, as the result of violence. When dislocation does occur, it is most commonly in connection with the astragalus; for not only may this bone be dislocated from the tibia and fibula at the ankle-joint, but the other bones may be dislocated from it, the trochlear surface of the bone remaining *in situ* in the tibio-fibular mortise. This constitutes what is known as the *subastragaloid* dislocation. Or, again, the astragalus may be dislocated from all its connections—from the tibia and fibula above, the os calcis below, and the navicular in front—and may even undergo a rotation, either on a vertical or horizontal axis. In the former case the long axis of the bone becoming directed across the joint, so that the head faces the articular surface on one or other malleolus; or, in the latter, the lateral surfaces becoming directed upward and downward, so that the trochlear surface faces to one or the other side. Finally, dislocation may occur at the medio-tarsal joint, the anterior tarsal bones being luxated from the astragalus and calcaneum. The other tarsal bones are also, occasionally, though rarely, dislocated from their connections.

VI. Tarso-metatarsal Articulations.

These are arthrodial joints. The bones entering into their formation are four tarsal bones—viz. the internal, middle, and external cuneiform and the cuboid—which articulate with the metatarsal bones of the five toes. The metatarsal bone of the great toe articulates with the internal cuneiform; that of the second is deeply wedged in between the internal and external cuneiform, resting against the middle cuneiform, and being the most strongly articulated of all the metatarsal bones; the third metatarsal articulates with the extremity of the external cunei-

form; the fourth with the cuboid and external cuneiform; and the fifth, with the cuboid. The articular surfaces are covered with cartilage, lined by synovial membrane, and connected together by the following ligaments:

Dorsal. Plantar. Interosseous.

The **Dorsal Ligaments** consist of strong, flat, fibrous bands, which connect the tarsal with the metatarsal bones. The first metatarsal is connected to the internal cuneiform by a single broad, thin, fibrous band; the second has three dorsal ligaments, one from each cuneiform bone; the third has one from the external cuneiform; the fourth has two, one from the external cuneiform and one from the cuboid; and the fifth, one from the cuboid.

The **Plantar Ligaments** consist of longitudinal and oblique fibrous bands connecting the tarsal and metatarsal bones, but disposed with less regularity than on the dorsal surface. Those for the first and second metatarsal are the most strongly marked; the second and third metatarsal receive strong fibrous bands which pass obliquely across from the internal cuneiform; the plantar ligaments of the fourth and fifth metatarsal consist of a few scanty fibres derived from the cuboid.

The **Interosseous Ligaments** are three in number—internal, middle, and external. The *internal* one is the strongest of the three, and passes from the outer extremity of the internal cuneiform to the adjacent angle of the second metatarsal. The *middle* one, less strong than the preceding, connects the external cuneiform with the adjacent angle of the second metatarsal. The *external* interosseous ligament connects the outer angle of the external cuneiform with the adjacent side of the third metatarsal.

The **Synovial Membrane** between the internal cuneiform bone and the first metatarsal bone is a distinct sac. The synovial membrane between the middle and external cuneiform behind, and the second and third metatarsal bones in front, is part of the great tarsal synovial membrane. Two prolongations are sent forward from it—one between the adjacent sides of the second and third metatarsal bones, and one between the third and fourth metatarsal bones. The synovial membrane between the cuboid and the fourth and fifth metatarsal bones is a distinct sac. From it a prolongation is sent forward between the fourth and fifth metatarsal bones.

Actions.—The movements permitted between the tarsal and metatarsal bones are limited to a slight gliding upon each other.

VII. Articulations of the Metatarsal Bones with Each Other.

The base of the first metatarsal bone is not connected with the second metatarsal bone by any ligaments; in this respect it resembles the thumb.

The bases of the four outer metatarsal bones are connected together by dorsal, plantar, and interosseous ligaments.

The **Dorsal Ligaments** consist of bands of fibrous tissue which pass transversely between the adjacent metatarsal bones.

The **Plantar Ligaments** have a similar arrangement to those on the dorsum.

The **Interosseous Ligaments** consist of strong transverse fibres which pass between the rough non-articular portions of the lateral surfaces.

The **Synovial Membrane** between the second and third and the third and fourth metatarsal bones is part of the great tarsal synovial membrane.

The synovial membrane between the fourth and fifth metatarsal bones is a prolongation of the synovial membrane of the cubo-metatarsal joint.

Actions.—The movement permitted in the tarsal ends of the metatarsal bones is limited to a slight gliding of the articular surfaces upon one another.

The Synovial Membranes in the Tarsal and Metatarsal Joints.

The **Synovial Membranes** (Fig. 193) found in the articulations of the tarsus and metatarsus are six in number: one for the posterior calcaneo-astragaloid

articulation; a second for the anterior calcaneo-astragaloid and astragalo-navicular articulations; a third for the calcaneo-cuboid articulation; and a fourth for the articulations of the navicular with the three cuneiform, the three cuneiform with each other, the external cuneiform with the cuboid, and the middle and external cuneiform with the bases of the second and third metatarsal bones, and the lateral surfaces of the second, third, and fourth metatarsal bones with each other; a fifth for the internal cuneiform with the metatarsal bone of the great toe; and a sixth for the articulation of the cuboid with the fourth and fifth metatarsal bones. A small synovial membrane is sometimes found between the contiguous surfaces of the navicular and cuboid bones.

Nerve-supply.—The nerves supplying the tarso-metatarsal joints are derived from the anterior tibial.

The *digital extremities* of all the metatarsal bones are connected together by the *transverse metatarsal ligament.*

The **Transverse Metatarsal Ligament** is a narrow fibrous band which passes transversely across the anterior extremities of all the metatarsal bones, connecting

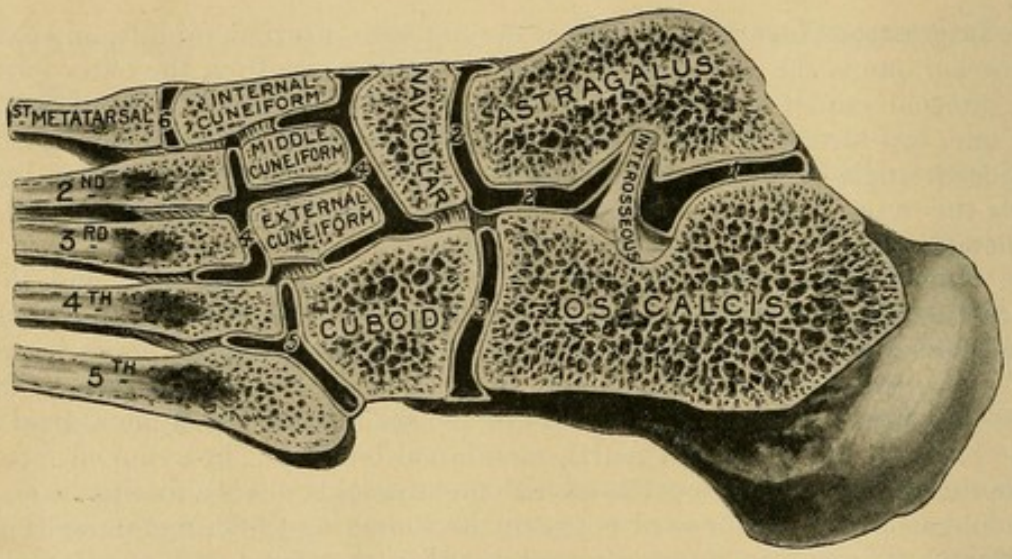

FIG. 193.—Oblique section of the articulations of the tarsus and metatarsus. Showing the six synovial membranes.

them together. It is blended anteriorly with the plantar (glenoid) ligament of the metatarso-phalangeal articulations. To its posterior border is connected the fascia covering the Interossei muscles. Its inferior surface is concave where the Flexor tendons pass over it. Above it the tendons of the Interossei muscles pass to their insertion. It differs from the transverse metacarpal ligament in that it connects the metatarsal bone of the great toe with the rest of the metatarsal bones.

VIII. Metatarso-phalangeal Articulations.

The metatarso-phalangeal articulations are of the condyloid kind, formed by the reception of the rounded head of the metatarsal bone into a superficial cavity in the extremity of the first phalanx.

The ligaments are—

Plantar. Two Lateral.

The **Plantar Ligaments** (Glenoid ligaments of Cruveilhier) are thick, dense, fibrous structures. Each is placed on the plantar surface of the joint in the interval between the lateral ligaments, to which they are connected; they are loosely united to the metatarsal bone, but very firmly to the base of the first phalanges. Their plantar surface is intimately blended with the transverse metatarsal ligament, and presents a groove for the passage of the Flexor tendons, the sheath surrounding which is connected to each side of the groove. By their deep

surface they form part of the articular surface for the head of the metatarsal bone, and are lined by a synovial membrane.

The **Lateral Ligaments** are strong, rounded cords, placed one on each side of the joint, each being attached, by one extremity, to the posterior tubercle on the side of the head of the metatarsal bone; and, by the other, to the contiguous extremity of the phalanx.

The **Posterior Ligament** is supplied by the extensor tendon placed over the back of the joint.

Actions.—The movements permitted in the metatarso-phalangeal articulations are flexion, extension, abduction, and adduction.

IX. Articulations of the Phalanges.

The articulations of the phalanges are ginglymus joints.

The ligaments are—

Plantar. Two Lateral.

The arrangement of these ligaments is similar to those in the metatarso-phalangeal articulations; the extensor tendon supplies the place of a posterior ligament.

Actions.—The only movements permitted in the phalangeal joints are flexion and extension; these movements are more extensive between the first and second phalanges than between the second and third. The movement of flexion is very considerable, but extension is limited by the plantar and lateral ligaments.

Surface Form.—The principal joints which it is necessary to distinguish, with regard to the surgery of the foot, are the medio-tarsal and the tarso-metatarsal joints. The joint between the astragalus and the navicular is best found by means of the tubercle of the navicular bone, for the line of the joint is immediately behind this process. If the foot is grasped and forcibly extended, a rounded prominence, the head of the astragalus, will appear on the inner side of the dorsum in front of the ankle-joint, and if a knife is carried downward, just in front of this prominence and behind the line of the navicular tubercle, it will enter the astragalo-navicular joint. The calcaneo-cuboid joint is situated midway between the external malleolus and the prominent end of the fifth metatarsal bone. The plane of the joint is in the same line as that of the astragalo-navicular. The position of the joint between the fifth metatarsal bone and the cuboid is easily found by the projection of the fifth metatarsal bone, which is the guide to it. The direction of the line of the joint is very oblique, so that, if continued onward, it would pass through the head of the first metatarsal bone. The joint between the fourth metatarsal bone and the cuboid and external cuneiform is the direct continuation inward of the previous joint, but its plane is less oblique; it would be represented by a line drawn from the outer side of the articulation to the middle of the first metatarsal bone. The plane of the joint between the third metatarsal bone and the external cuneiform is almost transverse. It would be represented by a line drawn from the outer side of the joint to the base of the first metatarsal bone. The tarso-metatarsal articulation of the great toe corresponds to a groove which can be felt by making firm pressure on the inner side of the foot one inch in front of the tubercle on the navicular bone; and the joint between the second metatarsal bone and the middle cuneiform is to be found on the dorsum of the foot, half an inch behind the level of the tarso-metatarsal joint of the great toe. The line of the joints between the metatarsal bones and the first phalanges is about an inch behind the webs of the corresponding toes.

THE MUSCLES AND FASCIÆ.[1]

THE Muscles are connected with the bones, cartilages, ligaments, and skin, either directly or through the intervention of fibrous structures called tendons or aponeuroses. Where a muscle is attached to bone or cartilage, the fibres terminate in blunt extremities upon the periosteum or perichondrium, and do not come into direct relation with the osseous or cartilaginous tissue. Where muscles are connected with the skin, they either lie as a flattened layer beneath it, or are connected with its areolar tissue by larger or smaller bundles of fibres, as in the muscles of the face.

The muscles vary extremely in their form. In the limbs, they are of considerable length, especially the more superficial ones, the deep ones being generally broad; they surround the bones and form an important protection to the various joints. In the trunk they are broad, flattened, and expanded, forming the parietes of the cavities which they enclose; hence the reason of the terms, *long*, *broad*, *short*, etc., used in the description of a muscle.

There is a considerable variation in the arrangement of the fibres of certain muscles with reference to the tendons to which they are attached. In some, the fibres are parallel and run directly from their origin to their insertion; these are quadrilateral muscles, such as the Thyro-hyoid. A modification of these is found in the fusiform muscles, in which the fibres are not quite parallel, but slightly curved, so that the muscle tapers at each end; in their action, however, they resemble the quadrilateral muscles. Secondly, in other muscles the fibres are convergent; arising by a broad origin, they converge to a narrow or pointed insertion. This arrangement of fibres is found in the triangular muscles—*e. g.* the Temporal. In some muscles, which otherwise would belong to the quadrilateral or triangular type, the origin and insertion are not in the same plane, but the plane of the line of origin intersects that of their insertion; such is the case in the Pectineus muscle. Thirdly, in some muscles the fibres are oblique and converge, like the plumes of a pen, to one side of a tendon, which runs the entire length of the muscle. Such a muscle is rhomboidal or penniform, as the Peronei. A modification of these rhomboidal muscles is found in those cases where oblique fibres converge to both sides of a central tendon which runs down the middle of the muscle; these are called bipenniform, and an example is afforded in the Rectus femoris. Finally, we have muscles in which the fibres are arranged in curved bundles in one or more planes, as in the Sphincter muscles. The arrangement of the muscular fibres is of considerable importance in respect to their relative strength and range of movement. Those muscles where the fibres are long and few in number have great range, but diminished strength; where, on the other hand, the fibres are short and more numerous, there is great power, but lessened range.

Muscles differ much in size: the Gastrocnemius forms the chief bulk of the back of the leg, and the fibres of the Sartorius are nearly two feet in length, whilst

[1] The Muscles and Fasciæ are described conjointly, in order that the student may consider the arrangement of the latter in his dissection of the former. It is rare for the student of anatomy in this country to have the opportunity of dissecting the fasciæ separately; and it is for this reason, as well as from the close connection that exists between the muscles and their investing sheaths, that they are considered together. Some general observations are first made on the anatomy of the muscles and fasciæ, the special description being given in connection with the different regions.

the Stapedius, a small muscle of the internal ear, weighs about a grain, and its fibres are not more than two lines in length.

The names applied to the various muscles have been derived—1, from their situation, as the Tibialis, Radialis, Ulnaris, Peroneus; 2, from their direction, as the Rectus abdominis, Obliqui capitis, Transversalis; 3, from their uses, as Flexors, Extensors, Abductors, etc.; 4, from their shape, as the Deltoid, Trapezius, Rhomboideus; 5, from the number of their divisions, as the Biceps, the Triceps; 6, from their points of attachment, as the Sterno-cleido-mastoid, Sterno-hyoid, Sterno-thyroid.

In the description of a muscle the term *origin* is meant to imply its more fixed or central attachment, and the term *insertion*, the movable point to which the force of the muscle is directed; but the origin is absolutely fixed in only a very small number of muscles, such as those of the face, which are attached by one extremity to the bone and by the other to the movable integument; in the greater number the muscle can be made to act from either extremity.

In the dissection of the muscles the student should pay especial attention to the exact *origin*, *insertion*, and *actions* of each, and its more important *relations* with surrounding parts. An accurate knowledge of the points of attachment of the muscles is of great importance in the determination of their action. By a knowledge of the action of the muscles the surgeon is able to explain the causes of displacement in various forms of fracture and the causes which produce distortion in various deformities, and, consequently, to adopt appropriate treatment in each case. The relations, also, of some of the muscles, especially those in immediate apposition with the larger blood-vessels, and the surface-markings they produce, should be especially remembered, as they form useful guides in the application of a ligature to those vessels.

Tendons are white, glistening, fibrous cords, varying in length and thickness, sometimes round, sometimes flattened, of considerable strength, and devoid of elasticity. They consist almost entirely of white fibrous tissue, the fibrils of which have an undulating course parallel with each other and are firmly united together. They are very sparingly supplied with blood-vessels, the smaller tendons presenting in their interior not a trace of them. Nerves also are not present in the smaller tendons, but the larger ones, as the tendo Achillis, receive nerves which accompany the nutrient vessels. The tendons consist principally of a substance which yields gelatin.

Aponeuroses are flattened or ribbon-shaped tendons, of a pearly-white color, iridescent, glistening, and similar in structure to the tendons. They are destitute of nerves, and the thicker ones only sparingly supplied with blood-vessels.

The tendons and aponeuroses are connected, on the one hand, with the muscles, and, on the other hand, with the movable structures, as the bones, cartilages, ligaments, fibrous membranes (for instance, the sclerotic). Where the muscular fibres are in a direct line with those of the tendon or aponeurosis, the two are directly continuous, the muscular fibre being distinguishable from that of the tendon only by its striation. But where the muscular fibre joins the tendon or aponeurosis at an oblique angle the former terminates, according to Kölliker, in rounded extremities, which are received into corresponding depressions on the surface of the latter, the connective tissue between the fibres being continuous with that of the tendon. The latter mode of attachment occurs in all the penniform and bipenniform muscles, and in those muscles the tendons of which commence in a membranous form, as the Gastrocnemius and Soleus.

The fasciæ (*fascia*, a bandage) are fibro-areolar or aponeurotic laminæ of variable thickness and strength, found in all regions of the body, investing the softer and more delicate organs. The fasciæ have been subdivided, from the situation in which they are found, into two groups, superficial and deep.

The *superficial fascia* is found immediately beneath the integument over almost the entire surface of the body. It connects the skin with the deep or aponeurotic

fascia, and consists of fibro-areolar tissue, containing in its meshes pellicles of fat in varying quantity. In the eyelids and scrotum, where adipose tissue is rarely deposited, this tissue is very liable to serous infiltration. The superficial fascia varies in thickness in different parts of the body: in the groin it is so thick as to be capable of being subdivided in several laminæ. Beneath the fatty layer of the superficial fascia, which is immediately subcutaneous, there is generally another layer of the same structure, comparatively devoid of adipose tissue, in which the trunks of the subcutaneous vessels and nerves are found, as the superficial epigastric vessels in the abdominal region, the radial and ulnar veins in the forearm, the saphenous veins in the leg and thigh, and the superficial lymphatic glands; certain cutaneous muscles also are situated in the superficial fascia, as the Platysma myoides in the neck, and the Orbicularis palpebrarum around the eyelids. This fascia is most distinct at the lower part of the abdomen, the scrotum, perinæum, and extremities; is very thin in those regions where muscular fibres are inserted into the integument, as on the side of the neck, the face, and around the margin of the anus. It is very dense in the scalp, in the palms of the hands and soles of the feet, forming a fibro-fatty layer which binds the integument firmly to the subjacent structure.

The superficial fascia connects the skin to the subjacent parts, facilitates the movement of the skin, serves as a soft medium for the passage of vessels and nerves to the integument, and retains the warmth of the body, since the fat contained in its areolæ is a bad conductor of heat.

The *deep fascia* is a dense, inelastic, unyielding fibrous membrane, forming sheaths for the muscles and affording them broad surfaces for attachment. It consists of shining tendinous fibres, placed parallel with one another, and connected together by other fibres disposed in a rectilinear manner. It is usually exposed on the removal of the superficial fascia, forming a strong investment, which not only binds down collectively the muscles in each region, but gives a separate sheath to each, as well as to the vessels and nerves. The fasciæ are thick in unprotected situations, as on the outer side of a limb, and thinner on the inner side. The deep fasciæ assist the muscles in their action by the degree of tension and pressure they make upon their surface; and in certain situations this is increased and regulated by muscular action; as, for instance, by the Tensor fasciæ femoris and Gluteus maximus in the thigh, by the Biceps in the upper and lower extremities, and Palmaris longus in the hand. In the limbs the fasciæ not only invest the entire limb, but give off septa which separate the various muscles, and are attached beneath to the periosteum: these prolongations of fasciæ are usually spoken of as intermuscular septa.

The Muscles and Fasciæ may be arranged, according to the general division of the body, into those of the cranium, face, and neck; those of the trunk; those of the upper extremity; and those of the lower extremity.

MUSCLES AND FASCIÆ OF THE CRANIUM AND FACE.

The muscles of the Cranium and Face consist of ten groups, arranged according to the region in which they are situated:

1. Cranial Region.
2. Auricular Region.
3. Palpebral Region.
4. Orbital Region.
5. Nasal Region.
6. Maxillary Region.
7. Mandibular Region.
8. Intermaxillary Region.
9. Temporo-mandibular Region.
10. Pterygo-mandibular Region.

The muscles contained in each of these groups are the following:

1. *Cranial Region.*

Occipito-frontalis.

2. *Auricular Region.*

Attrahens auriculam.
Attollens auriculam.
Retrahens auriculam.

3. *Palpebral Region.*

Orbicularis palpebrarum.
Corrugator supercilii.
Tensor tarsi.

4. *Orbital Region.*

Levator palpebræ.
Rectus superior.
Rectus inferior.
Rectus internus.
Rectus externus.
Obliquus superior.
Obliquus inferior.

5. *Nasal Region.*

Pyramidalis nasi.
Levator labii superioris alæque nasi.
Dilatator naris posterior.
Dilatator naris anterior.
Compressor nasi.
Compressor narium minor.
Depressor alæ nasi.

6. *Maxillary Region.*

Levator labii superioris.
Levator anguli oris.
Zygomaticus major.
Zygomaticus minor.

7. *Mandibular Region.*

Levator labii inferioris.
Depressor labii inferioris.
Depressor anguli oris.

8. *Intermaxillary Region.*

Buccinator.
Risorius.
Orbicularis oris.

9. *Temporo-mandibular Region.*

Masseter.
Temporal.

10. *Pterygo-mandibular Region.*

Pterygoideus externus.
Pterygoideus internus.

1. Cranial Region—Occipito-frontalis.

Dissection (Fig. 194).—The head being shaved, and a block placed beneath the back of the neck, make a vertical incision through the skin from before backward, commencing at the root of the nose in front, and terminating behind at the occipital protuberance; make

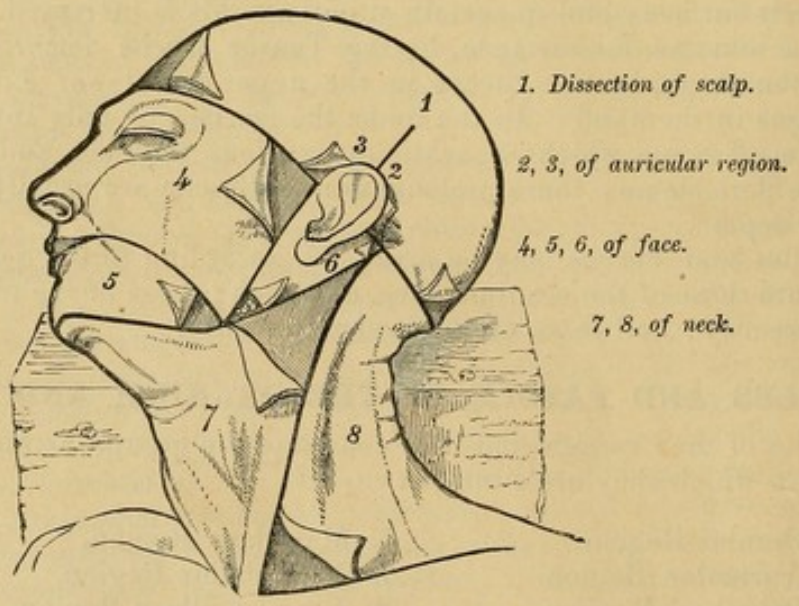

FIG. 194.—Dissection of the head, face, and neck.

a second incision in a horizontal direction along the forehead and round the side of the head, from the anterior to the posterior extremity of the preceding. Raise the skin in front, from the subjacent muscle, from below upward; this must be done with extreme care, removing the integument from the outer surface of the vessels and the nerves which lie immediately beneath the skin.

The Skin of the Scalp.—This is thicker than in any other part of the body. It is intimately adherent to the superficial fascia. The hair-follicles are very closely

set together, and extend throughout the whole thickness of the skin. It also contains a number of sebaceous glands.

The **superficial fascia** in the cranial region is a firm, dense, fibro-fatty layer, intimately adherent to the integument, and to the Occipito-frontalis and its tendi-

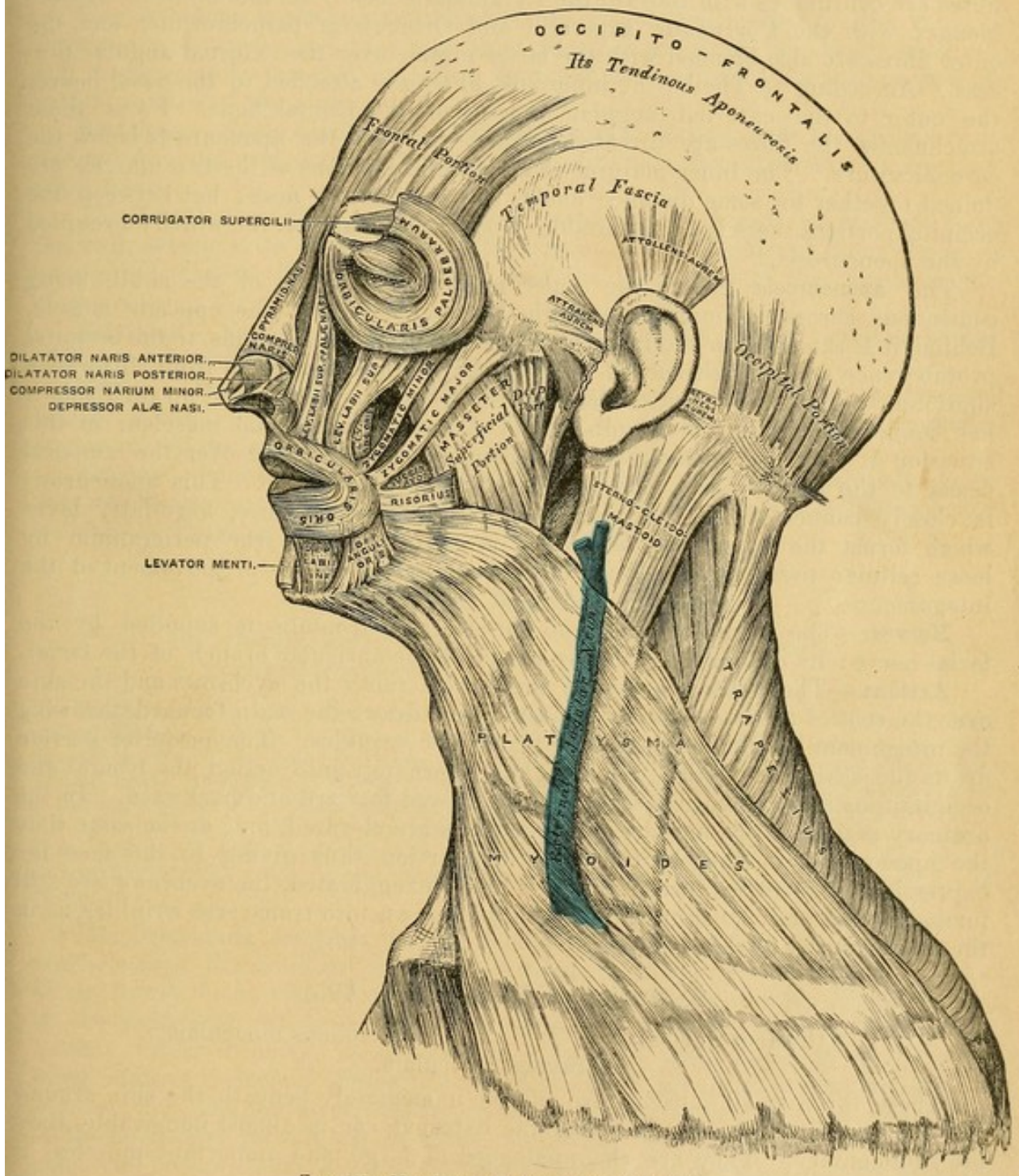

FIG. 195.—Muscles of the head, face, and neck.

nous aponeurosis; it is continuous, behind, with the superficial fascia at the back part of the neck; and, laterally, is continued over the temporal fascia. It contains between its layers the superficial vessels and nerves and much granular fat.

The **Occipito-frontalis** (Fig. 195) is a broad musculo-fibrous layer, which covers the whole of one side of the vertex of the skull, from the occiput to the eyebrow. It consists of two muscular slips, separated by an intervening tendinous aponeurosis. The *occipital portion* (sometimes called the *occipitalis* muscle) is thin, quadrilateral in form, and about an inch and a half in length; it arises from the outer two-thirds of the superior curved line of the occipital bone, and from the mastoid portion of the temporal. Its fibres of origin are tendinous, but they soon become

muscular, and ascend in a parallel direction to terminate in a tendinous aponeurosis. The *frontal portion* (sometimes called the *frontalis* muscle) is thin, of a quadrilateral form, and intimately adherent to the superficial fascia. It is broader, its fibres are longer, and their structure paler than the occipital portion. Its internal fibres are continuous with those of the Pyramidalis nasi. Its middle fibres become blended with the Corrugator supercilii and Orbicularis palpebrarum; and the outer fibres are also blended with the latter muscle over the external angular process. According to Theile, the innermost fibres are attached to the nasal bones, the outer to the external angular process of the frontal bone. From these attachments the fibres are directed upward, and join the aponeurosis below the coronal suture. The inner margins of the frontal portions of the two muscles are joined together for some distance above the root of the nose; but between the occipital portions there is a considerable, though variable, interval, which is occupied by the aponeurosis.

The **aponeurosis** covers the upper part of the vertex of the skull, being continuous across the middle line with the aponeurosis of the opposite muscle. Behind, it is attached, in the interval between the occipital origins, to the occipital protuberance and highest curved lines of the occipital bone; in front, it forms a short and narrow prolongation between the frontal portions; and on each side it has connected with it the Attollens and Attrahens auriculam muscles; in this situation it loses its aponeurotic character, and is continued over the temporal fascia to the zygoma as a layer of laminated areolar tissue. This aponeurosis is closely connected to the integument by the firm, dense, fibro-fatty layer which forms the superficial fascia; it is connected with the pericranium by loose cellular tissue, which allows of a considerable degree of movement of the integument.

Nerves.—The frontal portion of the Occipito-frontalis is supplied by the facial nerve; its occipital portion by the posterior auricular branch of the facial.

Actions.—The frontal portion of the muscle raises the eyebrows and the skin over the root of the nose, and at the same time draws the scalp forward, throwing the integument of the forehead into transverse wrinkles. The posterior portion draws the scalp backward. By bringing alternately into action the frontal and occipital portions the entire scalp may be moved forward and backward. In the ordinary action of the muscles, the eyebrows are elevated, and at the same time the aponeurosis is fixed by the posterior portion, thus giving to the face the expression of surprise: if the action is more exaggerated, the eyebrows are still further raised, and the skin of the forehead thrown into transverse wrinkles, as in the expression of fright or horror.

2. Auricular Region (Fig. 195).

Attrahens auriculam. Attollens auriculam.
Retrahens auriculam.

These three small muscles are placed immediately beneath the skin around the external ear. In man, in whom the external ear is almost immovable, they are rudimentary. They are the analogues of large and important muscles in some of the mammalia.

Dissection.—This requires considerable care, and should be performed in the following manner: To expose the Attollens auriculam, draw the pinna, or broad part of the ear, downward, when a tense band will be felt beneath the skin, passing from the side of the head to the upper part of the concha; by dividing the skin over this band in a direction from below upward, and then reflecting it on each side, the muscle is exposed. To bring into view the Attrahens auriculam, draw the helix backward by means of a hook, when the muscle will be made tense, and may be exposed in a similar manner to the preceding. To expose the Retrahens auriculam, draw the pinna forward, when the muscle, being made tense, may be felt beneath the skin at its insertion into the back part of the concha, and may be exposed in the same manner as the other muscles.

The **Attrahens auriculam** (*Auricularis anterior*), the smallest of the three, is thin, fan-shaped, and its fibres pale and indistinct: they arise from the lateral

edge of the aponeurosis of the Occipito-frontalis, and converge to be inserted into a projection on the front of the helix.

Relations.—*Superficially*, with the skin; *deeply*, with the areolar tissue derived from the aponeurosis of the Occipito-frontalis, beneath which are the temporal artery and vein and the temporal fascia.

The **Attollens auriculam** (*Auricularis superior*), the largest of the three, is thin and fan-shaped: its fibres arise from the aponeurosis of the Occipito-frontalis and converge to be inserted by a thin, flattened tendon into the upper part of the cranial surface of the pinna.

Relations.—*Superficially*, with the integument; *deeply*, with the areolar tissue derived from the aponeurosis of the Occipito-frontalis, beneath which is the temporal fascia.

The **Retrahens auriculam** (*Auricularis posterior*) consists of two or three fleshy fasciculi, which arise from the mastoid portion of the temporal bone by short aponeurotic fibres. They are inserted into the lower part of the cranial surface of the concha.

Relations.—*Superficially*, with the integument; *deeply*, with the mastoid portion of the temporal bone and the posterior auricular artery and nerve.

Nerves.—The Attrahens and Attollens auriculam are supplied by the temporal branch of the facial; the Retrahens auriculam is supplied by the posterior auricular branch of the same nerve.

Actions.—In man, these muscles possess very little action: the Attrahens auriculam draws the ear forward and upward; the Attollens auriculam slightly raises it; and the Retrahens auriculam draws it backward.

3. Palpebral Region (Fig. 195).

Orbicularis palpebrarum.	Levator palpebræ.
Corrugator supercilii.	Tensor tarsi.

Dissection (Fig. 194).—In order to expose the muscles of the face, continue the longitudinal incision made in the dissection of the Occipito-frontalis down the median line of the face to the tip of the nose, and from this point onward to the upper lip; and carry another incision along the margin of the lip to the angle of the mouth, and transversely across the face to the angle of the jaw. Then make an incision in front of the external ear, from the angle of the jaw upward, to join the transverse incision made in exposing the Occipito-frontalis. These incisions include a square-shaped flap, which should be removed in the direction marked in the figure, with care, as the muscles at some points are intimately adherent to the integument.

The **Orbicularis palpebrarum** is a sphincter muscle, which surrounds the circumference of the orbit and eyelids. It arises from the internal angular process of the frontal bone, from the nasal process of the superior maxillary bone in front of the lachrymal groove for the nasal duct, and from the anterior surface and borders of a short tendon, the *tendo oculi*, or *internal tarsal ligament*, placed at the inner angle of the orbit. From this origin the fibres are directed outward, forming a broad, thin, and flat layer, which covers the eyelids, surrounds the circumference of the orbit, and spreads out over the temple and downward on the cheek. The palpebral portion (ciliaris) of the Orbicularis is thin and pale; it arises from the bifurcation of the tendo palpebrarum, and forms a series of concentric curves, which are on the outer side of the eyelids inserted into the external tarsal ligament. The orbital portion (orbicularis latus) is thicker and of a reddish color: its fibres are well developed, and form complete ellipses. The upper fibres of this portion blend with the Occipito-frontalis and Corrugator supercilii.

Relations.—By its *superficial surface*, with the integument. By its *deep surface*, above, with the Occipito-frontalis and Corrugator supercilii, with which it is intimately blended, and with the supra-orbital vessels and nerve; below, it covers the lachrymal sac, and the origin of the Levator labii superioris alæque nasi, the Levator labii superioris, and the Zygomaticus minor muscles. *Internally*, it is occasionally blended with the Pyramidalis nasi. *Externally*, it lies on the temporal

fascia. On the eyelids it is separated from the conjunctiva by the Levator palpebræ, the tarsal ligaments, the tarsal plates, and the Meibomian glands.

The *tendo oculi* (internal tarsal ligament) is a short tendon, about two lines in length and one in breadth, attached to the nasal process of the superior maxillary bone in front of the lachrymal groove. Crossing the lachrymal sac, it divides into two parts, each division being attached to the inner extremity of the corresponding tarsal plate. As the tendon crosses the lachrymal sac, a strong aponeurotic lamina is given off from the posterior surface, which expands over the sac, and is attached to the ridge on the lachrymal bone. This is the reflected aponeurosis of the tendo oculi.

The *external tarsal ligament* is a much weaker structure than the tendo oculi. It is attached to the margin of the frontal process of the malar bone, and passes inward to the outer commissure of the eyelids; it connects together the outer extremities of the two tarsal cartilages.

Use of Tendo oculi.—Besides giving attachment to part of the Orbicularis palpebrarum and to the tarsal plates, it serves to suck the tears into the lachrymal sac, by its attachment to the sac. Thus, each time the eyelids are closed, the tendo oculi becomes tightened, through the action of the Orbicularis, and draws the wall of the lachrymal sac outward and forward, so that a vacuum is made in the sac, and the tears are sucked along the lachrymal canals into it.

The **Corrugator supercilii** is a small, narrow, pyramidal muscle, placed at the inner extremity of the eyebrow, beneath the Occipito-frontalis and Orbicularis palpebrarum muscles. It arises from the inner extremity of the superciliary ridge, from whence its fibres pass upward and outward, and, passing between the palpebral and orbital portions of the Orbicularis palpebrarum, are inserted into the deep surface of the skin, opposite the middle of the orbital arch.

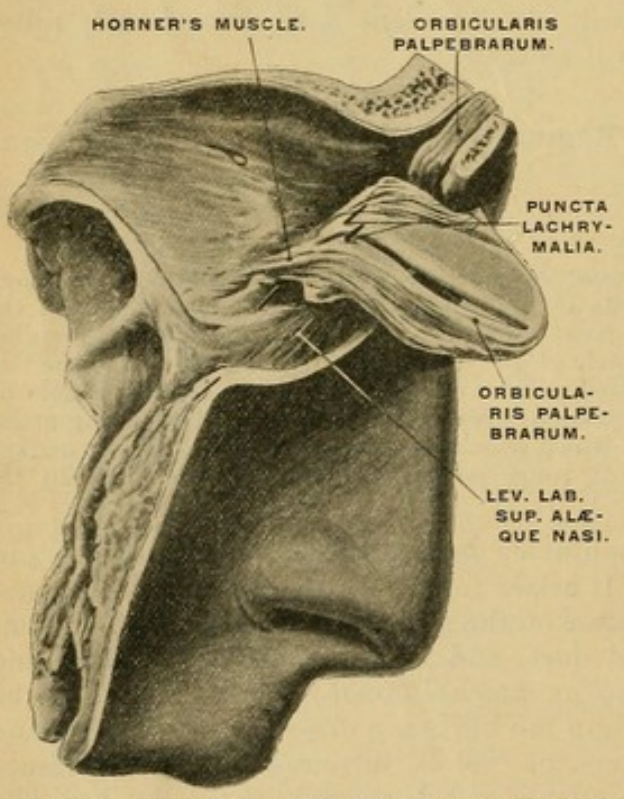

FIG. 196.—Horner's muscle. (From a preparation in the Museum of the Royal College of Surgeons of England.)

Relations.—By its *anterior surface* with the Occipito-frontalis and Orbicularis palpebrarum muscles; by its *posterior surface*, with the frontal bone and supratrochlear nerve.

The **Levator palpebræ** will be described with the muscles of the orbital region.

The **Tensor tarsi** (Horner's muscle) (Fig. 196) is a small thin muscle about three lines in breadth and six in length, situated at the inner side of the orbit, behind the tendo oculi. It arises from the crest and adjacent part of the orbital surface of the lachrymal bone, and, passing across the lachrymal sac, divides into two slips, which cover the lachrymal canals and are inserted into the tarsal plates internal to the puncta lachrymalia. Its fibres appear to be continuous with those of the palpebral portion of the Orbicularis palpebrarum; it is occasionally very indistinct.

Nerves.—The Orbicularis palpebrarum, Corrugator supercilii, and Tensor tarsi are supplied by the facial nerve. Recent investigations tend to show that the Orbicularis palpebrarum, Corrugator supercilii, and frontal part of the Occipito-frontalis are in reality supplied by fibres of the third nerve, which descend through the pons varolii to join the facial nerve.

Actions.—The Orbicularis palpebrarum is the sphincter muscle of the eyelids.

The palpebral portion acts involuntarily, closing the lids gently, as in sleep or in blinking; the orbicular portion is subject to the will. When the entire muscle is brought into action, the skin of the forehead, temple, and cheek is drawn inward toward the inner angle of the orbit, and the eyelids are firmly closed as in photophobia. When the skin of the forehead, temple, and cheek is thus drawn inward by the action of the muscle it is thrown into folds, especially radiating from the outer angle of the eyelids, which give rise in old age to the so-called "crow's feet." The Levator palpebræ is the direct antagonist of this muscle; it raises the upper eyelid and exposes the globe. The Corrugator supercilii draws the eyebrow downward and inward, producing the vertical wrinkles of the forehead. It is the "frowning" muscle, and may be regarded as the principal agent in the expression of suffering. The Tensor tarsi draws the eyelids and the extremities of the lachrymal canals inward and compresses them against the surface of the globe of the eye; thus placing them in the most favorable situation for receiving the tears. It serves, also, to compress the lachrymal sac.

4. Orbital Region (Fig. 197).

Levator palpebræ superioris.
Rectus superior.
Rectus inferior.
Rectus internus.
Rectus externus.
Obliquus oculi superior.
Obliquus oculi inferior.

Dissection.—To open the cavity of the orbit, remove the skull-cap and brain; then saw through the frontal bone at the inner extremity of the supraorbital ridge, and externally at its

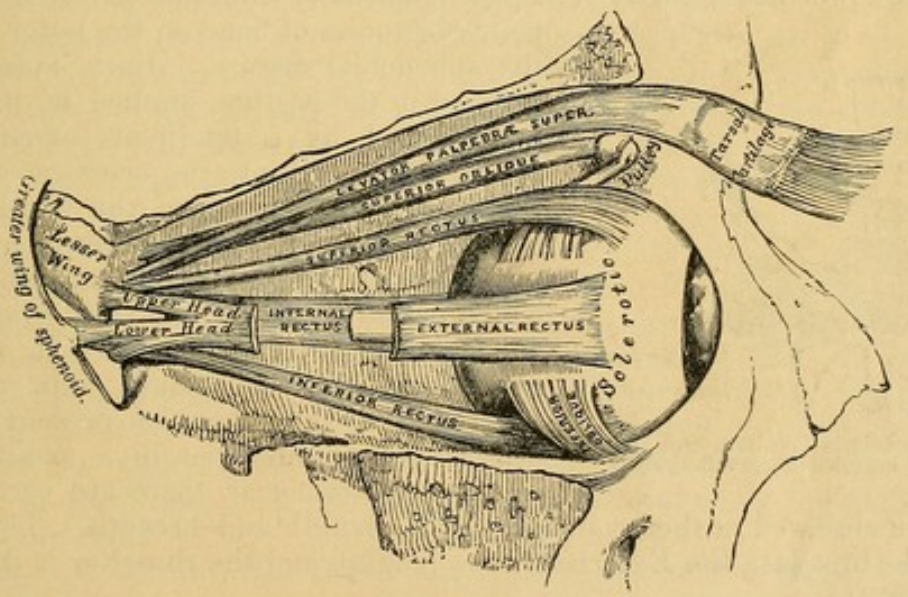

FIG. 197.—Muscles of the right orbit.

junction with the malar. Break in pieces the thin roof of the orbit by a few slight blows of the hammer, and take it away; drive forward the superciliary portion of the frontal bone by a smart stroke, but do not remove it, as that would destroy the pulley of the Obliquus superior. When the fragments are cleared away, the periosteum of the orbit will be exposed; this being removed, together with the fat which fills the cavity of the orbit, the several muscles of this region can be examined. The dissection will be facilitated by distending the globe of the eye. In order to effect this, puncture the optic nerve near the eyeball with a curved needle, and push the needle onward into the globe; insert the point of a blowpipe through this aperture, and force a little air into the cavity of the eyeball; then apply a ligature round the nerve so as to prevent the air escaping. The globe being now drawn forward, the muscles will be put upon the stretch.

The **Levator palpebræ superioris** is thin, flat, and triangular in shape. It arises from the under surface of the lesser wing of the sphenoid, above and in front of the optic foramen, from which it is separated by the origin of the Superior rectus. At its origin it is narrow and tendinous, but soon becomes broad and

fleshy, and finally terminates in a wide aponeurosis, which is inserted into the upper margin of the superior tarsal plate. From this aponeurosis a thin expansion is continued onward, passing between the fibres of the Orbicularis to be inserted into the skin of the lid, and some deeper fibres blend with an expansion from the sheath of the Superior rectus muscle, and are with it prolonged into the conjunctiva.

Relations.—By its *upper surface*, with the frontal nerve and supraorbital artery, the periosteum of the orbit and lachrymal gland; and, in the lid, with the inner surface of the tarsal ligament; by its *under surface*, with the Superior rectus, and, in the lid, with the conjunctiva. A small branch of the third nerve enters its under surface.

The **Superior rectus**, the thinnest and narrowest of the four Recti, arises from the upper margin of the optic foramen beneath the Levator palpebræ, and from the fibrous sheath of the optic nerve; and is inserted by a tendinous expansion into the sclerotic coat, about three or four lines from the margin of the cornea.

Relations.—By its *upper surface*, with the Levator palpebræ; by its *under surface*, with the optic nerve, the ophthalmic artery, the nasal nerve, and the branch of the third nerve which supplies it; and, in front, with the tendon of the Superior oblique and the globe of the eye.

The **Inferior** and **Internal Recti** arise by a common tendon (the *ligament of Zinn*),[1] which is attached round the circumference of the optic foramen, except at its upper and outer part. The **External rectus** has two heads: the upper one arises from the outer margin of the optic foramen immediately beneath the Superior rectus; the lower head, partly from the ligament of Zinn and partly from a small pointed process of bone on the lower margin of the sphenoidal fissure. Each muscle passes forward in the position implied by its name, to be inserted by a tendinous expansion (the *tunica albuginea*) into the sclerotic coat, about three or four lines from the margin of the cornea. Between the two heads of the External rectus is a narrow interval, through which passes the third, the nasal branch of the ophthalmic division of the fifth and sixth nerves, and the ophthalmic vein. Although nearly all of these muscles present a common origin and are inserted in a similar manner into the sclerotic coat, there are certain differences to be observed in them as regards their length and breadth. The Internal rectus is the broadest, the External is the longest, and the Superior is the thinnest and narrowest.

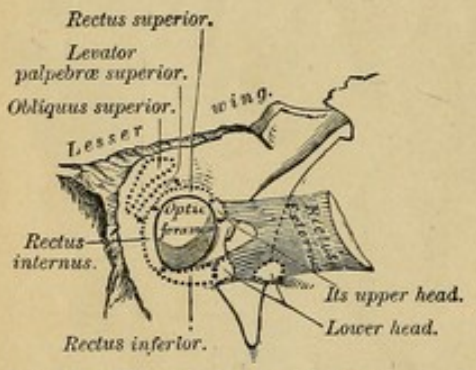

FIG. 198.—The relative position and attachment of the muscles of the left eyeball.

The **Superior oblique** is a fusiform muscle placed at the upper and inner side of the orbit, internal to the Levator palpebræ. It arises about a line above the inner margin of the optic foramen, and, passing forward to the inner angle of the orbit, terminates in a rounded tendon, which plays in a ring or pulley formed by cartilaginous tissue attached to a depression beneath the internal angular process of the frontal bone, the contiguous surfaces of the tendon and ring being lined by a delicate synovial membrane and enclosed in a thin fibrous investment. The tendon is reflected backward, outward, and downward beneath the Superior rectus to the outer part of the globe of the eye, and is inserted into the sclerotic coat,

[1] The ligament of Zinn ought, perhaps more appropriately, to be termed the *aponeurosis* or *tendon of Zinn*. Mr. C. B. Lockwood has described a somewhat similar structure on the under surface of the Superior rectus muscle, which is attached to the lesser wing of the sphenoid, forming the upper and outer margin of the optic foramen. This *superior tendon* gives origin to the Superior rectus, the superior head of the External rectus, and the upper part of the Internal rectus. (*Journal of Anatomy and Physiology*, vol. xx. part i. p. 1.)

behind the equator of the eyeball, the insertion of the muscle lying between the Superior and External recti.

Relations.—By its *upper surface*, with the periosteum covering the roof of the orbit and the fourth nerve: the tendon, where it lies on the globe of the eye, is covered by the Superior rectus; by its *under surface*, with the nasal nerve, ethmoidal arteries, and the upper border of the internal rectus.

The **Inferior oblique** is a thin, narrow muscle placed near the anterior margin of the orbit. It arises from a depression on the orbital plate of the superior maxillary bone, external to the lachrymal groove. Passing outward, backward, and upward between the Inferior rectus and the floor of the orbit, and then between the eyeball and the External rectus, it is inserted into the outer part of the sclerotic coat between the Superior and External recti, near to, but somewhat behind, the tendon of insertion of the Superior oblique.

Relations.—By its *ocular surface*, with the globe of the eye and with the Inferior rectus; by its *orbital surface*, with the periosteum covering the floor of the orbit, and with the External rectus. Its borders look forward and backward; the posterior one receives a branch of the third nerve.

Nerves.—The Levator palpebræ, Inferior oblique, and all the Recti excepting the External, are supplied by the third nerve; the Superior oblique, by the fourth; the External rectus, by the sixth.

Actions.—The Levator palpebræ raises the upper eyelid, and is the direct antagonist of the Orbicularis palpebrarum. The four Recti muscles are attached in such a manner to the globe of the eye that, acting singly, they will turn it either upward, downward, inward, or outward, as expressed by their names. The movement produced by the Superior or Inferior rectus is not quite a simple one, for, inasmuch as they pass obliquely outward and forward to the eyeball, the elevation or depression of the cornea must be accompanied by a certain deviation inward, with a slight amount of rotation, which, however, is corrected by the Oblique muscles, the Inferior oblique correcting the deviation inward of the Superior rectus, and the Superior oblique that of the Inferior rectus. The contraction of the External and Internal recti, on the other hand, produces a purely horizontal movement. If any two contiguous recti of one eye act together, they carry the globe of the eye in the diagonal of these directions—viz. upward and inward, upward and outward, downward and inward, or downward and outward. The movement of circumduction, as in looking round a room, is performed by the alternate action of the four Recti. The Oblique muscles rotate the eyeball on its *antero-posterior axis*, this kind of movement being required for the correct viewing of an object when the head is moved laterally, as from shoulder to shoulder, in order that the picture may fall in all respects on the same part of the retina of each eye.[1]

Fasciæ of the Orbit.—The connective tissue of the orbit is in various places condensed into thin membranous layers, which may be conveniently described as (1) the orbital fascia; (2) the sheath of the muscles; and (3) the covering of the eyeball.

(1) The *orbital fascia*. This forms the periosteum of the orbit. It is loosely connected to the bones, from which it can be readily separated. Behind, it is connected with the dura mater by processes which pass through the optic foramen and sphenoidal fissure, and with the sheath of the optic nerve. In front it is connected with the periosteum at the margin of the orbit, and sends off a process which assists in forming the palpebral fascia. From its internal surface two processes are given off—one to enclose the lachrymal gland, the other to hold the pulley of the Superior oblique muscle in position.

(2) The sheaths of the muscles give off expansions to the margins of the orbit which limit the action of the muscles.

[1] "On the Oblique Muscles of the Eye in Man and Vertebrate Animals," by John Struthers, M. D., in *Anatomical and Physiological Observations*. For a fuller account of the various co-ordinate actions of the muscles of a single eye and of both eyes than our space allows, the reader may be referred to Dr. M. Foster's *Text-book of Physiology*.

(3) The fascia covering the eyeball—Tenon's capsule—will be described in the sequel.

Surgical Anatomy.—The position and exact point of insertion of the tendons of the Internal and External recti muscles into the globe should be carefully examined from the front of the eyeball, as the surgeon is often required to divide the one or the other muscle for the cure of strabismus. In convergent strabismus, which is the more common form of the disease, the eye is turned inward, requiring the division of the Internal rectus. In the divergent form, which is more rare, the eye is turned outward, the External rectus being especially implicated. The deformity produced in either case is to be remedied by division of one or the other muscle. The operation is thus performed: The lids are to be well separated; the eyeball being rotated outward or inward, the conjunctiva should be raised by a pair of forceps and divided immediately beneath the lower border of the tendon of the muscle to be divided, a little behind its insertion into the sclerotic; the submucous areolar tissue is then divided, and into the small aperture thus made a blunt hook is passed upward between the muscle and the globe, and the tendon of the muscle and conjunctiva covering it divided by a pair of blunt-pointed scissors. Or the tendon may be divided by a subconjunctival incision, one blade of the scissors being passed upward between the tendon and the conjunctiva, and the other between the tendon and the sclerotic. The student, when dissecting these muscles, should remove on one side of the subject the conjunctiva from the front of the eye, in order to see more accurately the position of the tendons, while on the opposite side the operation may be performed.

5. Nasal Region (Fig. 195).

Pyramidalis nasi.
Levator labii superioris alæque nasi.
Dilatator naris posterior.
Dilatator naris anterior.
Compressor nasi.
Compressor narium minor.
Depressor alæ nasi.

The **Pyramidalis nasi** is a small pyramidal slip placed over the nasal bone. Its origin is by tendinous fibres from the fascia covering the lower part of the nasal bone and upper part of the cartilage, where it blends with the Compressor nasi, and it is inserted into the skin over the lower part of the forehead between the two eyebrows, its fibres decussating with those of the Occipito-frontalis.

Relations.—By its *upper surface*, with the skin; by its *under surface*, with the frontal and nasal bones.

The **Levator labii superioris alæque nasi** is a thin triangular muscle placed by the side of the nose, and extending between the inner margin of the orbit and upper lip. It arises by a pointed extremity from the upper part of the nasal process of the superior maxillary bone, and, passing obliquely downward and outward, divides into two slips, one of which is inserted into the cartilage of the ala of the nose; the other is prolonged into the upper lip, becoming blended with the Orbicularis oris and Levator labii superioris proprius.

Relations.—In front, with the integument, and with a small part of the Orbicularis palpebrarum above.

The **Dilatator naris posterior** is a small muscle which is placed partly beneath the elevator of the nose and lip. It arises from the margin of the nasal notch of the superior maxilla and from the sesamoid cartilages, and is inserted into the skin near the margin of the nostril.

The **Dilatator naris anterior** is a thin delicate fasciculus passing from the cartilage of the ala of the nose to the integument near its margin. This muscle is situated in front of the preceding.

The **Compressor nasi** is a small, thin, triangular muscle arising by its apex from the superior maxillary bone, above and a little external to the incisive fossa; its fibres proceed upward and inward, expanding into a thin aponeurosis which is attached to the fibro-cartilage of the nose and is continuous on the bridge of the nose with that of the muscle of the opposite side and with the aponeurosis of the Pyramidalis nasi.

The **Compressor narium minor** is a small muscle attached by one end to the alar cartilage, and by the other to the integument at the end of the nose.

The **Depressor alæ nasi** is a short radiated muscle arising from the incisive fossa of the superior maxilla; its fibres ascend to be inserted into the septum and

back part of the ala of the nose. This muscle lies between the mucous membrane and muscular structure of the lip.

Nerves.—All the muscles of this group are supplied by the facial nerve.

Actions.—The Pyramidalis nasi draws down the inner angle of the eyebrows and produces transverse wrinkles over the bridge of the nose. The Levator labii superioris alæque nasi draws upward the upper lip and ala of the nose: its most important action is upon the nose, which it dilates to a considerable extent. The action of this muscle produces a marked influence over the countenance, and it is the principal agent in the expression of contempt aud disdain. The two Dilatatores nasi enlarge the aperture of the nose. Their action in ordinary breathing is to resist the tendency of the nostrils to close from atmospheric pressure, but in difficult breathing they may be noticed to be in violent action, as well as in some emotions, as anger. The Depressor alæ nasi is a direct antagonist of the other muscles of the nose, drawing the ala of the nose downward, and thereby constricting the aperture of the nares. The Compressor nasi depresses the cartilaginous part of the nose and compresses the alæ together.

6. Superior Maxillary Region (Fig. 195).

Levator labii superioris.	Zygomaticus major.
Levator anguli oris.	Zygomaticus minor.

The **Levator labii superioris (proprius)** is a thin muscle of a quadrilateral form. It arises from the lower margin of the orbit immediately above the infraorbital foramen, some of its fibres being attached to the superior maxilla, others to the malar bone; its fibres converge to be inserted into the muscular substance of the upper lip.

Relations.—By its *superficial surface* above, with the lower segment of the Orbicularis palpebrarum; below, it is subcutaneous. By its *deep surface* it conceals the origin of the Compressor nasi and Levator anguli oris muscles, and the infraorbital vessels and nerve, as they escape from the infraorbital foramen.

The **Levator anguli oris** arises from the canine fossa immediately below the infraorbital foramen; its fibres incline downward and a little outward, to be inserted into the angle of the mouth, intermingling with those of the Zygomaticus major, the Depressor anguli oris, and the Orbicularis.

Relations.—By its *superficial surface*, with the Levator labii superioris and the infraorbital vessels and nerves; by its *deep surface*, with the superior maxilla, the Buccinator, and the mucous membrane.

The **Zygomaticus major** is a slender fasciculus which arises from the malar bone, in front of the zygomatic suture, and, descending obliquely downward and inward, is inserted into the angle of the mouth, where it blends with the fibres of the Levator anguli oris, the Orbicularis oris, and the Depressor anguli oris.

Relations.—By its *superficial surface*, with the subcutaneous adipose tissue; by its *deep surface*, with the Masseter and Buccinator muscles and the facial artery and vein.

The **Zygomaticus minor** arises from the malar bone immediately behind the maxillary suture, and, passing downward and inward, is continuous with the Orbicularis oris at the outer margin of the Levator labii superioris. It lies in front of the preceding.

Relations.—By its *superficial surface*, with the integument and the Orbicularis palpebrarum above; by its *deep surface*, with the Masseter, Buccinator, and Levator anguli oris, and the facial artery and vein.

Nerves.—This group of muscles is supplied by the facial nerve.

Actions.—The Levator labii superioris is the proper elevator of the upper lip, carrying it at the same time a little forward. It assists in forming the naso-labial ridge, which passes from the side of the nose to the upper lip and gives to the face an expression of sadness. The Levator anguli oris raises the angle of the mouth,

and assists the Levator labii superioris in producing the naso-labial ridge. The Zygomaticus major draws the angle of the mouth backward and upward, as in laughing; whilst the Zygomaticus minor, being inserted into the outer part of the upper lip and not into the angle of the mouth, draws it backward, upward, and outward, and thus gives to the face an expression of sadness.

7. Inferior Maxillary Region (Fig. 195).

Levator labii inferioris (Levator menti).
Depressor labii inferioris (Quadratus menti).
Depressor anguli oris (Triangularis menti).

Dissection.—The muscles in this region may be dissected by making a vertical incision through the integument from the margin of the lower lip to the chin: a second incision should then be carried along the margin of the lower jaw as far as the angle, and the integument carefully removed in the direction shown in Fig. 194.

The **Levator labii inferioris** (**Levator menti**) is to be dissected by everting the lower lip and raising the mucous membrane. It is a small conical fasciculus placed on the side of the frænum of the lower lip. It arises from the incisive fossa, external to the symphysis of the lower jaw; its fibres descend to be inserted into the integument of the chin.

Relation.—On its *inner surface*, with the mucous membrane; in the *median line*, it is blended with the muscle of the opposite side; and on its *outer side*, with the Depressor labii inferioris.

The **Depressor labii inferioris** (**Quadratus menti**) is a small quadrilateral muscle. It arises from the external oblique line of the lower jaw, between the symphysis and mental foramen, and passes obliquely upward and inward, to be inserted into the integument of the lower lip, its fibres blending with the Orbicularis oris and with those of its fellow of the opposite side. It is continuous with the fibres of the Platysma at its origin. This muscle contains much yellow fat intermingled with its fibres.

Relations.—By its *superficial surface*, with part of the Depressor anguli oris and with the integument, to which it is closely connected; by its *deep surface*, with the mental vessels and nerves, the mucous membrane of the lower lip, the labial glands, and the Levator menti, with which it is intimately united.

The **Depressor anguli oris** (**Triangularis menti**) is triangular in shape, arising, by its broad base, from the external oblique line of the lower jaw, from whence its fibres pass upward, to be inserted, by a narrow fasciculus, into the angle of the mouth. It is continuous with the Platysma at its origin and with the Orbicularis oris and Risorius at its insertion, and some of its fibres are directly continuous with those of the Levator anguli oris.

Relations.—By its *superficial surface*, with the integument; by its *deep surface*, with the Depressor labii inferioris and Buccinator.

Nerves.—This group of muscles is supplied by the facial nerve.

Actions.—The Levator labii inferioris raises the lower lip and protrudes it forward, and at the same time wrinkles the integument of the chin, expressing doubt or disdain. The Depressor labii inferioris draws the lower lip directly downward and a little outward, as in the expression of irony. The Depressor anguli oris depresses the angle of the mouth, being the antagonist to the Levator anguli oris and Zygomaticus major; acting with these muscles, it will draw the angle of the mouth directly backward.

8. Intermaxillary Region.

Orbicularis oris. Buccinator. Risorius.

Dissection.—The dissection of these muscles may be considerably facilitated by filling the cavity of the mouth with tow, so as to distend the cheeks and lips; the mouth should then be closed by a few stitches and the integument carefully removed from the surface.

The **Orbicularis oris** (Fig. 195) is not a sphincter muscle, like the Orbicularis

palpebrarum, but consists of numerous strata of muscular fibres, having different directions, which surround the orifice of the mouth. These fibres are partially derived from the other facial muscles which are inserted into the lips, and are partly fibres proper to the lips themselves. Of the former, a considerable number are derived from the Buccinator and form the deeper stratum of the Orbicularis. Some of them—namely, those near the middle of the muscle—decussate at the angle of the mouth, those arising from the upper jaw passing to the lower lip, and those from the lower jaw to the upper lip. Other fibres of the muscle, situated at its upper and lower part, pass across the lips from side to side without decussation. Superficial to this stratum is a second, formed by the Levator and Depressor anguli oris, which cross each other at the angle of the mouth, those from the Depressor passing to the upper lip, and those from the Levator to the lower lip, along which they run to be inserted into the skin near the median line. In addition to these there are fibres from the other muscles inserted into the lips—the Levator labii superioris, the Levator labii superioris alæque nasi, the Zygomatici, and the Depressor labii inferioris; these intermingle with the transverse fibres above described, and have principally an oblique direction. The proper fibres of the lips are oblique, and pass from the under surface of the skin to the mucous membrane through the thickness of the lip. And in addition to these are fibres by which the muscle is connected directly with the maxillary bones and the septum of the nose. These consist, in the upper lip, of four bands, two of which (*Musculus incisivus superior*) arise from the alveolar border of the superior maxilla, opposite the lateral incisor tooth, and, arching outward on each side, are continuous at the angles of the mouth with the other muscles inserted into this part. The two remaining muscular slips, called the *Naso-labialis*, connect the upper lip to the back of the septum of the nose: as they descend from the septum an interval is left between them. It is this interval which forms the depression seen on the surface of the skin beneath the septum of the nose. The additional fibres for the lower segment (*Musculus incisivus inferior*) arise from the inferior maxilla, externally to the Levator labii inferioris, and arch outward to the angles of the mouth, to join the Buccinator and the other muscles attached to this part.

Relations.—By its *superficial surface*, with the integument, to which it is closely connected; by its *deep surface*, with the buccal mucous membrane, the labial glands, and coronary vessels; by its *outer circumference* it is blended with the numerous muscles which converge to the mouth from various parts of the face. Its *inner circumference* is free, and covered by the mucous membrane.

The **Buccinator** (Fig. 208) is a broad, thin muscle, quadrilateral in form, which occupies the interval between the jaws at the side of the face. It arises from the outer surface of the alveolar processes of the upper and lower jaws, corresponding to the three molar teeth, and, behind, from the anterior border of the pterygo-maxillary ligament. The fibres converge toward the angle of the mouth, where the central fibres intersect each other, those from below being continuous with the upper segment of the Orbicularis oris, and those from above with the inferior segment; the highest and lowest fibres continue forward uninterruptedly into the corresponding segment of the lip, without decussation.

Relations.—By its *superficial surface*, behind, with a large mass of fat, which separates it from the ramus of the lower jaw, the Masseter, and a small portion of the Temporal muscle; anteriorly, with the Zygomatici, Risorius, Levator anguli oris, Depressor anguli oris, and Stenson's duct, which pierces it opposite the second molar tooth of the upper jaw; the facial artery and vein cross it from below upward; it is also crossed by the branches of the facial and buccal nerves; by its *internal surface*, with the buccal glands and mucous membrane of the mouth.

The *pterygo-maxillary ligament* separates the Buccinator muscle from the Superior constrictor of the pharynx. It is a tendinous band, attached by one extremity to the apex of the internal pterygoid plate, and by the other to the posterior extremity of the internal oblique line of the lower jaw. Its *inner surface*

corresponds to the cavity of the mouth, and is lined by mucous membrane. Its *outer surface* is separated from the ramus of the jaw by a quantity of adipose tissue. Its *posterior border* gives attachment to the Superior constrictor of the pharynx; its *anterior border*, to the fibres of the Buccinator (see Fig. 208).

The **Risorius (Santorini)** (Fig. 195) consists of a narrow bundle of fibres which arises in the fascia over the Masseter muscle, and, passing horizontally forward, is inserted into the skin at the angle of the mouth. It is placed superficial to the Platysma, and is broadest at its outer extremity. This muscle varies much in its size and form.

Nerves.—The muscles in this group are all supplied by the facial nerve. The buccal branch of the inferior maxillary nerve pierces the Buccinator muscle, and by some anatomists is regarded as partly supplying this muscle. Probably it merely pierces it on its way to the mucous membrane of the cheek.

Actions.—The Orbicularis oris in its ordinary action produces the direct closure of the lips; by its deep fibres, assisted by the oblique ones, it closely applies the lips to the alveolar arch. The superficial part, consisting principally of the decussating fibres, brings the lips together and also protrudes them forward. The Buccinators contract and compress the cheeks, so that, during the process of mastication, the food is kept under the immediate pressure of the teeth. When the cheeks have been previously distended with air, the Buccinator muscles expel it from between the lips, as in blowing a trumpet. Hence the name (*buccina*, a trumpet). The Risorius retracts the angles of the mouth, and produces the unpleasant expression which is sometimes seen in tetanus, and is known as "risus sardonicus."

9. Temporo-mandibular Region.

Masseter. Temporal.

Masseteric Fascia.—Covering the Masseter muscle, and firmly connected with it, is a strong layer of fascia derived from the deep cervical fascia. Above, this fascia is attached to the lower border of the zygoma, and, behind, it covers the parotid gland, constituting the *parotid fascia.*

The **Masseter** is exposed by the removal of this fascia (Fig. 195); it is a short, thick muscle, somewhat quadrilateral in form, consisting of two portions, superficial and deep. The *superficial portion*, the larger, arises by a thick, tendinous aponeurosis from the malar process of the superior maxilla, and from the anterior two-thirds of the lower border of the zygomatic arch: its fibres pass downward and backward, to be inserted into the angle and lower half of the outer surface of the ramus of the jaw. The *deep portion* is much smaller and more muscular in texture; it arises from the posterior third of the lower border and the whole of the inner surface of the zygomatic arch; its fibres pass downward and forward, to be inserted into the upper half of the ramus and outer surface of the coronoid process of the jaw. The deep portion of the muscle is partly concealed, in front by the superficial portion; behind, it is covered by the parotid gland. The fibres of the two portions are united at their insertion.

Relations.—By its *superficial surface*, with the Zygomatici, the parotid gland and Socia parotidis, and Stenson's duct; the branches of the facial nerve and the transverse facial vessels, which cross it; the masseteric fascia; the Risorius, Santorini, Platysma myoides, and the integument; by its *deep surface*, with the Temporal muscle at its insertion, the ramus of the jaw, the Buccinator and the long buccal nerve, from which it is separated by a mass of fat. The masseteric nerve and artery enter in on its under surface. Its *posterior margin* is overlapped by the parotid gland. Its *anterior margin* projects over the Buccinator muscle, and the facial vein lies on it below.

The *temporal fascia* is seen, at this stage of the dissection, covering in the Temporal muscle. It is a strong, fibrous investment, covered, on its outer surface, by the Attrahens and Attollens auriculam muscles, the aponeurosis of the Occipito-

frontalis, and by part of the Orbicularis palpebrarum. The temporal vessels and the auriculo-temporal nerve cross it from below upward. Above, it is a single layer, attached to the entire extent of the upper temporal ridge; but below, where it is attached to the zygoma, it consists of two layers, one of which is inserted into the outer, and the other into the inner, border of the zygomatic arch. A small quantity of fat, the orbital branch of the temporal artery, and a filament from the orbital, or temporo-malar, branch of the superior maxillary nerve, are contained between these two layers. It affords attachment by its inner surface to the superficial fibres of the Temporal muscle.

Dissection.—In order to expose the Temporal muscle, remove the temporal fascia, which may be effected by separating it at its attachment along the upper border of the zygoma, and dissecting it upward from the surface of the muscle. The zygomatic arch should then be divided in front at its junction with the malar bone, and behind near the external auditory meatus, and drawn downward with the Masseter, which should be detached from its insertion into the ramus and angle of the jaw. The whole extent of the Temporal muscle is then exposed.

The **Temporal** (Fig. 199) is a broad, radiating muscle situated at the side of the head and occupying the entire extent of the temporal fossa. It arises from the whole of the temporal fossa except that portion of it that is formed by the malar bone. Its attachment extends from the external angular process of the frontal in front to the mastoid portion of the temporal behind, and from the curved line on the frontal and parietal bones above to the pterygoid ridge on the great wing of the sphenoid below. It is also attached to the inner surface of the temporal fascia. Its fibres converge as they descend, and terminate in an aponeurosis, the fibres of

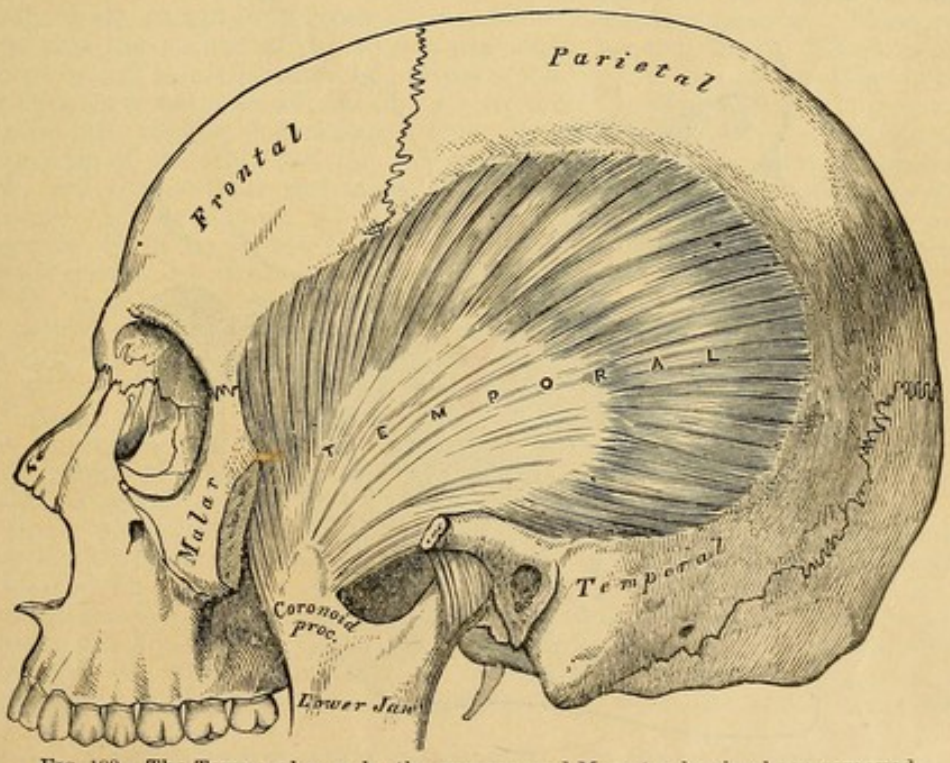

FIG. 199.—The Temporal muscle, the zygoma and Masseter having been removed.

which, radiated at its commencement, converge into a thick and flat tendon, which is inserted into the inner surface, apex, and anterior border of the coronoid process of the jaw, nearly as far forward as the last molar tooth.

Relations.—By its *superficial surface*, with the integument, the Attrahens and Attollens auriculam muscles, the temporal vessels and nerves, the aponeurosis of the Occipito-frontalis, the temporal fascia, the zygoma, and Masseter; by its *deep surface*, with the temporal fossa, the External pterygoid and part of the Buccinator muscles, the internal maxillary artery, its deep temporal branches, and the deep temporal nerves. Behind the tendon are the masseteric vessels and

nerve, and in front of it the buccal vessels and nerve. Its anterior border is separated from the malar bone by a mass of fat.

Nerves.—Both muscles are supplied by the inferior maxillary nerve.

10. Pterygo-mandibular Region (Fig. 200).

External Pterygoid. Internal Pterygoid.

Dissection.—The Temporal muscle having been examined, saw through the base of the coronoid process, and draw it upward, together with the Temporal muscle, which should be detached from the surface of the temporal fossa. Divide the ramus of the jaw just below the condyle, and also, by a transverse incision extending across the middle, just above the dental foramen; remove the fragment, and the Pterygoid muscles will be exposed.

The **External Pterygoid** is a short, thick muscle, somewhat conical in form, which extends almost horizontally between the zygomatic fossa and the condyle of the jaw. It arises by two heads, separated by a slight interval: the *upper* arises from the inferior surface of the greater wing of the sphenoid and from the pterygoid ridge, which separates the zygomatic from the temporal fossa; the *lower* from the outer surface of the external pterygoid plate. Its fibres pass horizontally backward and outward, to be inserted into a depression in front of the neck of the condyle of the lower jaw and into the corresponding part of the interarticular fibro-cartilage.

Relations.—By its *external surface*, with the ramus of the lower jaw, the internal maxillary artery, which crosses it,[1] the tendon of the Temporal muscle, and the Masseter; by its *internal surface* it rests against the upper part of the Internal pterygoid, the internal lateral ligament, the middle meningeal artery,

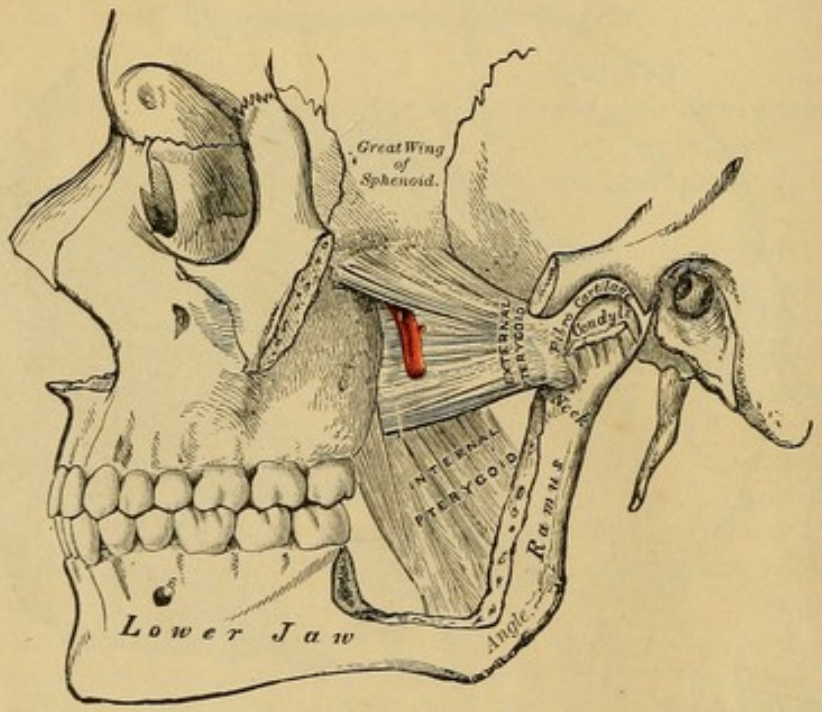

Fig. 200.—The Pterygoid muscles, the zygomatic arch and a portion of the ramus of the jaw having been removed.

and inferior maxillary nerve; by its *upper border* it is in relation with the temporal and masseteric branches of the inferior maxillary nerve; by its *lower border* it is in relation with the inferior dental and gustatory nerves. Through the interval between the two portions of the muscle, the buccal nerve emerges and the internal maxillary artery passes, when the trunk of this vessel lies on the muscle (see Fig. 200).

The **Internal Pterygoid** is a thick, quadrilateral muscle, and resembles the Masseter in form. It arises from the pterygoid fossa, being attached to the inner

[1] This is the usual relation, but in many cases the artery will be found below the muscle.

surface of the external pterygoid plate and to the grooved surface of the tuberosity of the palate bone, and by a second slip from the outer surface of the tuberosities of the palate and superior maxillary bones; its fibres pass downward, outward, and backward, to be inserted, by a strong, tendinous lamina, into the lower and back part of the inner side of the ramus and angle of the lower jaw, as high as the dental foramen.

Relations.—By its *external surface,* with the ramus of the lower jaw, from which it is separated, at its upper part, by the External pterygoid, the internal lateral ligament, the internal maxillary artery, the dental vessels and nerves, and the lingual nerve, and a process of the parotid gland. By its *internal surface,* with the Tensor palati, being separated from the Superior constrictor of the pharynx by a cellular interval.

Nerves.—These muscles are supplied by the inferior maxillary nerve.

Actions.—The Temporal and Masseter and Internal pterygoid raise the lower jaw against the upper with great force. The superficial portion of the Masseter assists the External pterygoid in drawing the lower jaw forward upon the upper, the jaw being drawn back again by the deep fibres of the Masseter and posterior fibres of the Temporal. The External pterygoid muscles are the direct agents in the trituration of the food, drawing the lower jaw directly forward, so as to make the lower teeth project beyond the upper. If the muscle of one side acts, the corresponding side of the jaw is drawn forward, and, the other condyle remaining fixed, the symphysis deviates to the opposite side. The alternation of these movements on the two sides produces trituration.

Surface Form.—The outline of the muscles of the head and face cannot be traced on the surface of the body, except in the case of two of the masticatory muscles. Those of the head are thin, so that the outline of the bone is perceptible beneath them. Those in the face are small, covered by soft skin, and often by a considerable layer of fat, so that their outline is concealed, but they serve to round off and smooth prominent borders and to fill up what would be otherwise unsightly angular depressions. Thus, the Orbicularis palpebrarum rounds off the prominent margin of the orbit, and the Pyramidalis nasi fills in the sharp depression beneath the glabella, and thus softens and tones down the abrupt depression which is seen on the unclothed bone. In like manner, the labial muscles, converging to the lips and assisted by the superimposed fat, fill in the sunken hollow of the lower part of the face. Although the muscles of the face are usually described as arising from the bones and inserted into the nose, lips, and corners of the mouth, they have fibres inserted into the skin of the face along their whole extent, so that almost every point of the skin of the face has its muscular fibre to move it; hence it is that when in action the facial muscles produce alterations in the skin-surface, giving rise to the formation of various folds or wrinkles, or otherwise altering the relative position of parts, so as to produce the varied expressions with which the face is endowed; hence these muscles are termed the "muscles of expression." The only two muscles in this region which greatly influence surface form are the Masseter and the Temporal. The Masseter is a quadrilateral muscle, which imparts fulness to the hinder part of the cheek. When the muscle is firmly contracted, as when the teeth are clenched, its outline is plainly visible; the anterior border forms a prominent vertical ridge, behind which is a considerable fulness, especially marked at the lower part of the muscle; this fulness is entirely lost when the mouth is opened and the muscle no longer in a state of contraction. The Temporal muscle is fan-shaped, and fills the Temporal fossa, substituting for it a somewhat convex form, the anterior part of which, on account of the absence of hair over the temple, is more marked than the posterior, and stands out in strong relief when the muscle is in a state of contraction.

MUSCLES AND FASCIÆ OF THE NECK.

The muscles of the neck may be arranged into groups corresponding with the region in which they are situated.

These groups are nine in number:

1. Superficial cervical region.
2. Depressors of the Os Hyoides and Larynx.
3. Elevators of the Os Hyoides and Larynx.
4. Muscles of the Tongue.
5. Muscles of the Pharynx.
6. Muscles of the Soft Palate.
7. Muscles of the Anterior Vertebral Region.
8. Muscles of the Lateral Vertebral Region.
9. Muscles of the Larynx.

The muscles contained in each of these groups are the following:

1. *Superficial Region.*
   - Platysma myoides.
   - Sterno-cleido-mastoid.

Infra-hyoid Region.

2. *Depressors of the Os hyoides and Larynx.*
   - Sterno-hyoid.
   - Sterno-thyroid.
   - Thyro-hyoid.
   - Omo-hyoid.

Supra-hyoid Region.

3. *Elevators of the Os hyoides and Larynx.*
   - Digastric.
   - Stylo-hyoid.
   - Mylo-hyoid.
   - Genio-hyoid.

Lingual Region.

4. *Muscles of the Tongue.*
   - Genio-hyo-glossus.
   - Hyo-glossus.
   - Chondro-glossus.
   - Stylo-glossus.
   - Palato-glossus.

5. *Muscles of the Pharynx.*
   - Inferior constrictor.
   - Middle constrictor.
   - Superior constrictor.
   - Stylo-pharyngeus.
   - Palato-pharyngeus.

6. *Muscles of the Soft Palate.*
   - Levator palati.
   - Tensor palati.
   - Azygos uvulæ.
   - Palato-glossus.
   - Palato-pharyngeus.
   - Salpingo-pharyngeus.

7. *Muscles of the Anterior Vertebral Region.*
   - Rectus capitis anticus major.
   - Rectus capitis anticus minor.
   - Rectus capitis lateralis.
   - Longus colli.

8. *Muscles of the Lateral Vertebral Region.*
   - Scalenus anticus.
   - Scalenus medius.
   - Scalenus posticus.

9. *Muscles of the Larynx.*
   - Included in the description of the Larynx.

1. Superficial Cervical Region.

Platysma myoides. Sterno-cleido-mastoid.

Dissection.—A block having been placed at the back of the neck, and the face turned to the side opposite that to be dissected, so as to place the parts upon the stretch, make two transverse incisions: one from the chin, along the margin of the lower jaw, to the mastoid process, and the other along the upper border of the clavicle. Connect these by an oblique incision made in the course of the Sterno-mastoid muscle, from the mastoid process to the sternum; the two flaps of integument having been removed in the direction shown in Fig. 194, the superficial fascia will be exposed.

The **Superficial Cervical Fascia** is a thin, aponeurotic lamina which is hardly demonstrable as a separate membrane. Beneath it is found the Platysma myoides muscle.

The **Platysma myoides** (Fig. 195) is a broad, thin plane of muscular fibres placed immediately beneath the superficial fascia on each side of the neck. It arises by thin, fibrous bands from the fascia covering the upper part of the Pectoral and Deltoid muscles; its fibres pass over the clavicle and proceed obliquely upward and inward along the side of the neck. The anterior fibres interlace, below and behind the symphysis menti, with the fibres of the muscle of the opposite side; the posterior fibres pass over the lower jaw, some of them being attached to the bone below the external oblique line, others passing on to be inserted into the skin and subcutaneous tissue of the lower part of the face, many of these fibres blending with the muscles about the angle and lower part of the mouth. Sometimes fibres can be traced to the Zygomatic muscles or to the margin of the Orbicularis oris. Beneath the Platysma the external jugular vein may be seen descending from the angle of the jaw to the clavicle.

Surgical Anatomy.—It is essential to remember the direction of the fibres of the Platysma in connection with the operation of bleeding from the external jugular vein; for if the point of the lancet is introduced in the direction of the muscular fibres, the orifice made will be filled up by the contraction of the muscle, and blood will not flow; but if the incision is made across the course of the fibres, they will retract and expose the orifice in the vein, and so allow the flow of blood.

Relations.—By its *external surface*, with the integument, to which it is united more closely below than above; by its *internal surface*, with the Pectoralis major and Deltoid, and with the clavicle. In the *neck*, with the external and anterior jugular veins, the deep cervical fascia, the superficial branches of the cervical plexus, the Sterno-mastoid, Sterno-hyoid, Omo-hyoid, and Digastric muscles; behind the Sterno-mastoid muscle it covers in the posterior triangle of the neck. On the *face* it is in relation with the parotid gland, the facial artery and vein, and the Masseter and Buccinator muscles.

Action.—The Platysma myoides produces a slight wrinkling of the surface of the skin of the neck, in an oblique direction, when the entire muscle is brought into action. Its anterior portion, the thickest part of the muscle, depresses the lower jaw; it also serves to draw down the lower lip and angle of the mouth on each side, being one of the chief agents in the expression of melancholy.

The **Deep cervical fascia** lies under cover of the Platysma myoides muscle and constitutes a complete investment for the neck. It also forms a sheath for the carotid vessels, and, in addition, is prolonged deeply in the shape of certain processes or lamellæ, which come into close relation with the structures situated in front of the vertebral column.

The investing portion of the fascia is attached behind to the ligamentum nuchæ and to the spine of the seventh cervical vertebra. Along this line it splits to enclose the Trapezius muscle, at the anterior border of which the two enclosing lamellæ unite and form a strong membrane, which extends forward so as to roof in the posterior triangle of the neck. Along the hinder edge of the Sterno-mastoid this membrane again divides to enclose this muscle, at the anterior edge of which it once more forms a single lamella, which roofs in the anterior triangle of the neck, and, reaching forward to the middle line, is continuous with the corresponding part from the opposite side of the neck. In the middle line of the neck it is attached to the symphysis menti and body of the hyoid bone.

Above, the fascia is attached to the superior curved line of the occiput, to the mastoid process of the temporal, and to the whole length of the body of the jaw. Opposite the angle of the jaw the fascia is very strong, and binds the anterior edge of the Sterno-mastoid firmly to that bone. Between the jaw and the mastoid process it ensheaths the parotid gland—the layer which covers the gland extending upward under the name of the parotid fascia to be fixed to the zygomatic arch. From the layer which passes under the parotid a strong band, *the stylo-mandibular ligament*, reaches from the styloid process to the angle of the jaw.

Below, the fascia is attached to the acromion process, the clavicle, and manubrium sterni. Some little distance above the last, however, it splits into two layers, superficial and deep. The former is attached to the anterior border of the manubrium, the latter to its posterior border and to the interclavicular ligament. Between these two layers is a slit-like interval, the *suprasternal space*, or *space of Burns*. It contains a small quantity of areolar tissue, and sometimes a lymphatic gland; the lower portions of the anterior jugular veins and their transverse connecting branch; and also the sternal heads of the Sterno-mastoid muscles.

The fascia which lines the deep aspect of the Sterno-mastoid gives off certain important processes, viz.: (1) A process to envelop the tendon of the Omo-hyoid, and bind it down to the sternum and first costal cartilage. (2) A strong sheath, the carotid sheath, for the large vessels of the neck, enclosed within which are the carotid artery, internal jugular vein, the vagus, and descendens hypoglossi nerves. (3) The prevertebral fascia, which extends inward behind the carotid vessels, where it assists in forming their sheath, and passes in front of the prevertebral muscles. It thus forms the posterior limit of a fibrous compartment which contains

the larynx and trachea, the thyroid gland, and the pharynx and œsophagus. The prevertebral fascia is fixed above to the base of the skull, while below it is continued into the thorax in front of the Longus colli muscles. Parallel to the carotid vessels and along their inner aspect it gives off a thin lamina, the *bucco-pharyngeal fascia*, which closely invests the constrictor muscles of the pharynx, and is continued forward from the Superior constrictor on to the Buccinator. It is attached to the prevertebral layer by loose connective tissue only, and thus an easily distended space, the *retro-pharyngeal space*, is found between them. This space is limited above by the base of the skull, while below it extends behind the

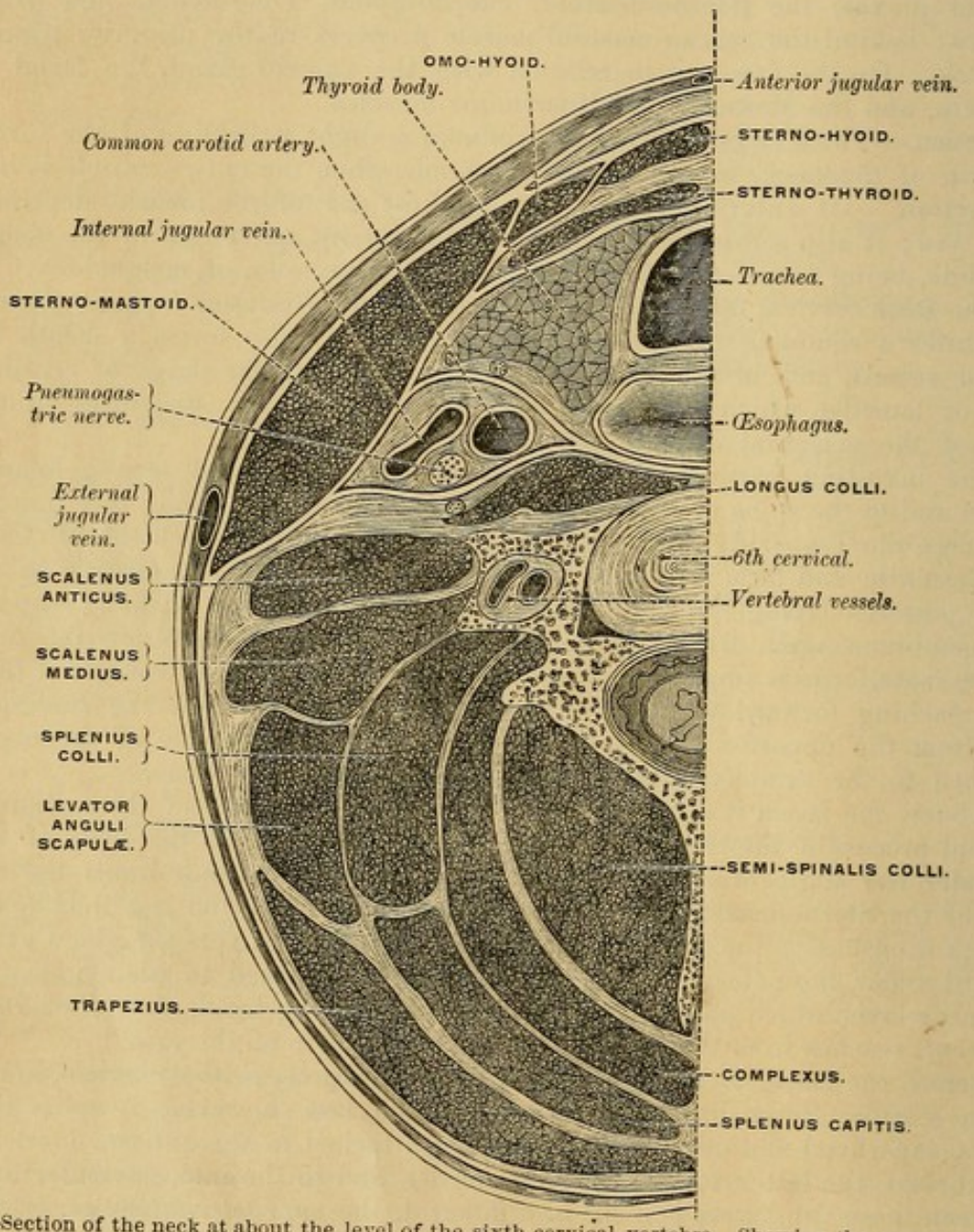

FIG. 201.—Section of the neck at about the level of the sixth cervical vertebra. Showing the arrangement of the deep cervical fascia.

œsophagus into the thorax, where it is continued into the posterior mediastinum. The prevertebral fascia is prolonged downward and outward behind the carotid vessels and in front of the Scaleni muscles, and forms a sheath for the brachial nerves and subclavian vessels in the posterior triangle of the neck, and, continued under the clavicle as the axillary sheath, is attached to the deep surface of the costo-coracoid membrane. Immediately above the clavicle an areolar space exists between the investing layer and the sheath of the subclavian vessels, and in it are found the lower part of the external jugular vein, the descending clavicular nerves, the suprascapular and transversalis colli vessels, and the posterior belly of the

Omo-hyoid muscle. This space extends downward behind the clavicle, and is limited below by the fusion of the costo-coracoid membrane with the anterior wall of the axillary sheath. (4) The pre-tracheal fascia, which extends inward in front of the carotid vessels, and assists in forming the carotid sheath. It is further continued behind the depressor muscles of the hyoid bone, and, after enveloping the thyroid body, is prolonged in front of the trachea to meet the corresponding layer of the opposite side. Above, it is fixed to the hyoid bone, while below it is carried downward in front of the trachea and large vessels at the root of the neck, and ultimately blends with the fibrous pericardium.

Surgical Anatomy.—The cervical fascia is of considerable importance from a surgical point of view. As will be seen from the foregoing description, it may be divided into three layers: (1) A superficial layer; (2) a layer passing in front of the trachea, and forming with the superficial layer a sheath for the depressors of the hyoid bone; (3) a prevertebral layer passing in front of the bodies of the cervical vertebræ, and forming with the second layer a space in which are contained the trachea, œsophagus, etc. The superficial layer forms a complete investment for the neck. It is attached behind to the ligamentum nuchæ and the spine of the seventh cervical vertebra; above it is attached to the external occipital protuberance, to the superior curved line of the occiput, to the mastoid process, to the zygoma and the lower jaw; below it is attached to the manubrium sterni, the clavicle, the acromion process, and the spine of the scapula; in front it blends with the fascia of the opposite side. This layer would oppose the extension of abscesses or new growths toward the surface, and pus forming beneath it would have a tendency to extend laterally. If it is in the posterior triangle, it might extend backward under the Trapezius, forward under the Sterno-mastoid, or downward under the clavicle for some distance, until stopped by the junction of the cervical fascia to the Costo-coracoid membrane. If the pus is contained in the anterior triangle, it might find its way into the anterior mediastinum, being situated in front of the layer of fascia which passes down into the thorax to become continuous with the pericardium; but owing to the lesser density and thickness of the fascia in this situation it more frequently finds its way through it and points above the sternum. The second layer of fascia is connected above with the hyoid bone. It passes down beneath the depressors and in front of the thyroid body and trachea to become continuous with the fibrous layer of the pericardium. Laterally it invests the great vessels of the neck and is connected with the superficial layer beneath the Sterno-mastoid. Pus forming beneath this layer would in all probability find its way into the posterior mediastinum. The third layer (the prevertebral fascia) is connected above to the base of the skull. Pus forming beneath this layer, in cases, for instance, of caries of the bodies of the cervical vertebræ, might extend toward the posterior and lateral part of the neck and point in this situation, or might perforate this layer of fascia and the pharyngeal fascia and point into the pharynx (retro-pharyngeal abscess).

In cases of cut throat the cervical fascia is of considerable importance. When the wound involves only the superficial layer the injury is usually trivial, the only special danger being injury to the external jugular vein, and the only special complication being diffuse cellulitis. But where the second of the two layers has been opened up, important structures may have been injured, which may lead to serious results.

It may be worth while mentioning that in Burns's space is contained the sternal head of origin of the Sterno-mastoid muscle, so that this space is opened in division of this tendon. The anterior jugular vein is also contained in the same space.

The **Sterno-mastoid** or **Sterno-cleido-mastoid** (Fig. 202) is a large, thick muscle, which passes obliquely across the side of the neck, being enclosed between the two layers of the deep cervical fascia. It is thick and narrow at its central part, but is broader and thinner at each extremity. It arises, by two heads, from the sternum and clavicle. The *sternal portion* is a rounded fasciculus, tendinous in front, fleshy behind, which arises from the upper and anterior part of the first piece of the sternum, and is directed upward, outward, and backward. The *clavicular portion* arises from the inner third of the superior border and anterior surface of the clavicle, being composed of fleshy and aponeurotic fibres; it is directed almost vertically upward. These two portions are separated from one another, at their origin, by a triangular cellular interval, but become gradually blended, below the middle of the neck, into a thick, rounded muscle, which is inserted, by a strong tendon, into the outer surface of the mastoid process, from its apex to its superior border, and by a thin aponeurosis into the outer half of the superior curved line of the occipital bone. The Sterno-mastoid varies much in its extent of attachment to the clavicle: in one case the clavicular may be as narrow as the sternal portion; in another, as much as three inches in breadth. When the clavicular

origin is broad, it is occasionally subdivided into numerous slips separated by narrow intervals. More rarely, the corresponding margins of the Sterno-mastoid and Trapezius have been found in contact. In the application of a ligature to the third part of the subclavian artery it will be necessary, where the muscles come close together, to divide a portion of one or of both.

This muscle divides the quadrilateral space at the side of the neck into two triangles, an anterior and a posterior. The boundaries of the *anterior triangle* are, in front, the median line of the neck; above, the lower border of the body of the jaw, and an imaginary line drawn from the angle of the jaw to the mastoid

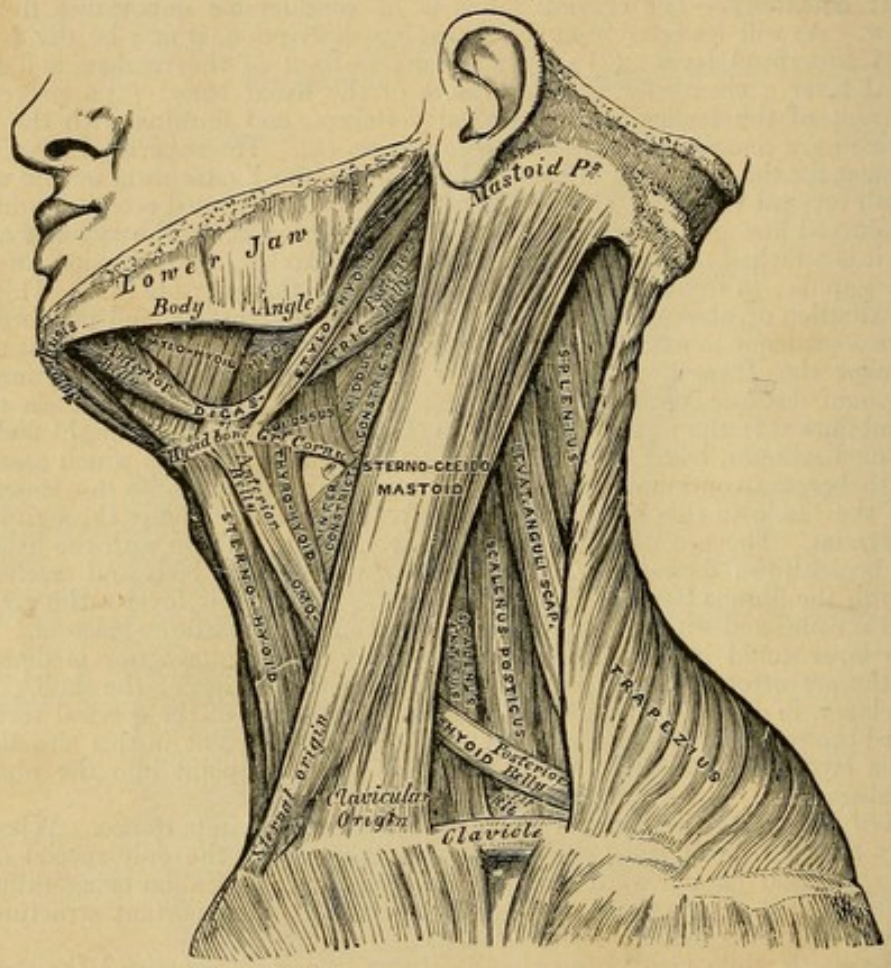

FIG. 202.—Muscles of the neck and boundaries of the triangles.

process; behind, the anterior border of the Sterno-mastoid muscle. The apex of the triangle is at the upper border of the sternum. The boundaries of the *posterior triangle* are, in front, the posterior border of the Sterno-mastoid; below, the middle third of the clavicle; behind, the anterior margin of the Trapezius.[1] The apex corresponds with the meeting of the Sterno-mastoid and Trapezius on the occipital bone.

Relations.—By its *superficial surface*, with the integument and Platysma, from which it is separated by the external jugular vein, the superficial branches of the cervical plexus, and the anterior layer of the deep cervical fascia. By its *deep surface* it is in relation with the Sterno-clavicular articulation; a process of the deep cervical fascia; the Sterno-hyoid, Sterno-thyroid, Omo-hyoid, posterior belly of the Digastric, Levator anguli scapulæ, Splenius and Scaleni muscles; common carotid artery, internal and anterior jugular veins, commencement of the internal and external carotid arteries, the occipital, subclavian, transversalis colli, and suprascapular arteries and veins; the phrenic, pneumogastric, hypoglossal, descendens and communicans hypoglossi nerves; the spinal accessory nerve, which

[1] The anatomy of these triangles will be more exactly described with that of the vessels of the neck.

pierces its upper third; the cervical plexus, parts of the thyroid and parotid glands, and deep lymphatic glands.

Nerves.—The Platysma myoides is supplied by the facial nerve; the Sterno-cleido-mastoid, by the spinal accessory and deep branches of the cervical plexus.

Actions.—When only one Sterno-mastoid muscle acts, it draws the head toward the shoulder of the same side, assisted by the Splenius and the Obliquus capitis inferior of the opposite side. At the same time it rotates the head so as to carry the face toward the opposite side. If the head is fixed, the two muscles assist in elevating the thorax in forced inspiration.

Surface Form.—The anterior edge of the muscle forms a very prominent ridge beneath the skin, which it is important to notice, as it forms a guide to the surgeon in making the necessary incisions for ligature of the common carotid artery and for œsophagotomy.

Surgical Anatomy.—The relations of the sternal and clavicular parts of the Sterno-mastoid should be carefully examined, as the surgeon is sometimes required to divide one or both portions of the muscles in *wry-neck*. One variety of this distortion is produced by spasmodic contraction or rigidity of the Sterno-mastoid; the head being carried down toward the shoulder of the same side, and the face turned to the opposite side and fixed in that position. When there is permanent shortening, subcutaneous division of the muscle is resorted to by some surgeons. This is performed by introducing a tenotomy knife beneath it, close to its origin, and dividing it from behind forward whilst the muscle is put well upon the stretch. There is seldom any difficulty in dividing the sternal portion by making a puncture on the inner side of the tendon, and then pushing a blunt tenotome behind it, and cutting forward. In dividing the clavicular portion care must be taken to avoid wounding the external jugular vein, which runs parallel with the posterior border of the muscle in this situation, or the anterior jugular vein, which crosses beneath it. If the external jugular vein lies near the muscle, it is safer to make the first puncture at the outer side of the tendon, and introduce a blunt tenotome from without inward. Many surgeons prefer dividing the muscle by the open method. An incision is made over either origin of the muscle, the tendon is exposed, a director is passed underneath it, and it is then divided. With care and attention to asepsis this plan of treatment is devoid of risk, and in this way the accidental division of the vessels can be avoided. Some of the fibres of the Sterno-mastoid muscle are occasionally torn during birth, especially in breech presentations; this is accompanied by hemorrhage and formation of a swelling within the substance of the muscle. This by some is believed to be one of the causes of wry-neck, the scar tissue which is formed contracting and shortening the muscle.

2. Infra-hyoid Region (Figs. 202, 203).

Depressors of the Os Hyoides and Larynx.

Sterno-hyoid.	Thyro-hyoid.
Sterno-thyroid.	Omo-hyoid.

Dissection.—The muscles in this region may be exposed by removing the deep fascia from the front of the neck. In order to see the entire extent of the Omo-hyoid it is necessary to divide the Sterno-mastoid at its centre, and turn its ends aside, and to detach the Trapezius from the clavicle and scapula. This, however, should not be done until the Trapezius has been dissected.

The **Sterno-hyoid** is a thin, narrow, ribbon-like muscle, which arises from the inner extremity of the clavicle, the posterior sterno-clavicular ligament, and the upper and posterior part of the first piece of the sternum; passing upward and inward, it is inserted, by short, tendinous fibres, into the lower border of the body of the os hyoides. This muscle is separated, below, from its fellow by a considerable interval; but the two muscles come into contact with one another in the middle of their course, and from this upward lie side by side.—It sometimes presents, immediately above its origin, a transverse tendinous intersection, like those in the Rectus abdominis.

Relations.—By its *superficial surface*, below, with the sternum, the sternal end of the clavicle, and the Sterno-mastoid; and above, with the Platysma and deep cervical fascia; by its *deep surface*, with the Sterno-thyroid, Crico-thyroid, and Thyro-hyoid muscles, the thyroid gland, the superior thyroid vessels, the thyroid cartilage, the crico-thyroid and thyro-hyoid membranes.

The **Sterno-thyroid** is situated beneath the preceding muscle, but is shorter and wider than it. It arises from the posterior surface of the first bone of the sternum,

below the origin of the Sterno-hyoid, and from the edge of the cartilage of the first rib, occasionally of the second rib also, and is inserted into the oblique line on the side of the ala of the thyroid cartilage. This muscle is in close contact with its fellow at the lower part of the neck, and is occasionally traversed by a transverse or oblique tendinous intersection, like those in the Rectus abdominis.

Relations.—By its *anterior surface*, with the Sterno-hyoid, Omo-hyoid, and Sterno-mastoid; by its *posterior surface*, from below upward, with the trachea, vena innominata, common carotid (and on the right side the arteria innominata), the thyroid gland and its vessels, and the lower part of the larynx and pharynx. The inferior thyroid vein lies along its inner border, a relation which it is important to remember in the operation of tracheotomy. On the left side the deep surface of the muscle is in relation to the œsophagus.

The **Thyro-hyoid** is a small, quadrilateral muscle appearing like a continuation of the Sterno-thyroid. It arises from the oblique line on the side of the thyroid cartilage, and passes vertically upward to be inserted into the lower border of the body and greater cornu of the hyoid bone.

Relations.—By its *external surface*, with the Sterno-hyoid and Omo-hyoid muscles; by its *internal surface*, with the thyroid cartilage, the thyro-hyoid membrane, and the superior laryngeal vessels and nerve.

The **Omo-hyoid** passes across the side of the neck, from the scapula to the

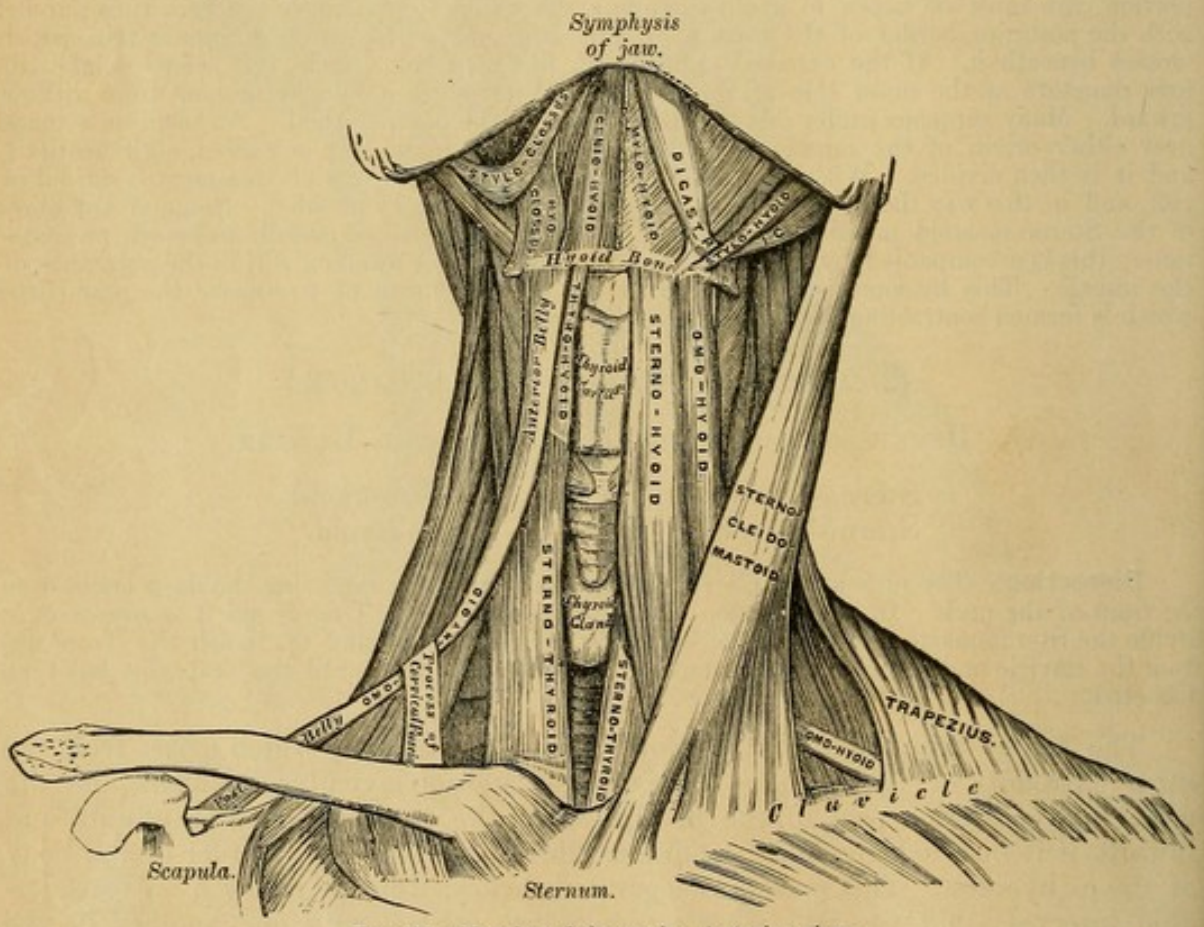

FIG. 203.—Muscles of the neck. Anterior view.

hyoid bone. It consists of two fleshy bellies, united by a central tendon. It arises from the upper border of the scapula, and occasionally from the transverse ligament which crosses the suprascapular notch, its extent of attachment to the scapula varying from a few lines to an inch. From this origin the posterior belly forms a flat, narrow fasciculus, which inclines forward and slightly upward across the lower part of the neck, behind the Sterno-mastoid muscle, where it becomes tendinous; it then changes its direction, forming an obtuse angle, and terminates in the anterior belly, which passes almost vertically upward, close to the outer border of the Sterno-hyoid, to be inserted into the lower border of the body of the

os hyoides, just external to the insertion of the Sterno-hyoid. The central tendon of this muscle, which varies much in length and form, is held in position by a process of the deep cervical fascia, which includes it in a sheath. This process is prolonged down, to be attached to the clavicle and first rib. It is by this means that the angular form of the muscle is maintained.

This muscle subdivides each of the two large triangles at the side of the neck into two smaller triangles; the two posterior ones being the *posterior superior* or *occipital*, and the *posterior inferior* or *subclavian;* the two anterior, the *anterior superior* or *superior carotid*, and the *anterior inferior* or *inferior carotid triangles.*

Relations.—By its *superficial surface*, with the Trapezius, the Sterno-mastoid, deep cervical fascia, Platysma, and integument; by its *deep surface*, with the Scaleni muscles, phrenic nerve, lower cervical nerves, which go to form the brachial plexus, the suprascapular vessels and nerve, sheath of the common carotid artery and internal jugular vein, the Sterno-thyroid and Thyro-hyoid muscles.

Nerves.—The Thyro-hyoid is supplied by the hypoglossal; the other muscles of this group by branches from the loop of communication between the descendens and communicans hypoglossi.

Actions.—These muscles depress the larynx and hyoid bone, after they have been drawn up with the pharynx in the act of deglutition. The Omo-hyoid muscles not only depress the hyoid bone, but carry it backward and to one or the other side. It is concerned especially in prolonged inspiratory efforts; for by tensing the lower part of the cervical fascia it lessens the inward suction of the soft parts, which would otherwise compress the great vessels and the apices of the lungs. The Thyro-hyoid may act as an elevator of the thyroid cartilage when the hyoid bone ascends, drawing upward the thyroid cartilage, behind the os hyoides. The Sterno-thyroid acts as a depressor of the thyroid cartilage.

3. Supra-hyoid Region (Figs. 202, 203).

ELEVATORS OF THE OS HYOIDES—DEPRESSORS OF THE LOWER JAW.

Digastric.	Mylo-hyoid.
Stylo-hyoid.	Genio-hyoid.

Dissection.—To dissect these muscles a block should be placed beneath the back of the neck, and the head drawn backward and retained in that position. On the removal of the deep fascia the muscles are at once exposed.

The **Digastric** consists of two fleshy bellies united by an intermediate, rounded tendon. It is a small muscle, situated below the side of the body of the lower jaw, and extending, in a curved form, from the side of the head to the symphysis of the jaw. The *posterior belly*, longer than the anterior, arises from the digastric groove on the inner side of the mastoid process of the temporal bone, and passes downward, forward, and inward. The *anterior belly* arises from a depression on the inner side of the lower border of the jaw, close to the symphysis, and passes downward and backward. The two bellies terminate in the central tendon which perforates the Stylo-hyoid, and is held in connection with the side of the body and the greater cornu of the hyoid bone by a fibrous loop, lined by a synovial membrane. A broad aponeurotic layer is given off from the tendon of the Digastric on each side, which is attached to the body and great cornu of the hyoid bone: this is termed the *supra-hyoid aponeurosis*. It forms a strong layer of fascia between the anterior portion of the two muscles, and a firm investment for the other muscles of the supra-hyoid region which lie deeper.

The Digastric muscle divides the anterior superior triangle of the neck into two smaller triangles; the upper, or *submaxillary*, being bounded, above, by the lower border of the body of the jaw, and a line drawn from its angle to the mastoid process; below, by the posterior belly of the Digastric and the Stylo-hyoid muscles; in front, by the middle line of the neck and the anterior belly of the Digastric, the lower or *superior carotid triangle* being bounded above by the posterior belly of the Digastric, behind by the Sterno-mastoid, below by the Omo-hyoid.

Relations.—By its *superficial surface* with the mastoid process, the Platysma, sterno-mastoid, part of the Splenius, Trachelo-mastoid, and Stylo-hyoid muscles, and the parotid gland. By its *deep surface*, the anterior belly lies on the Mylo-hyoid; the posterior belly on the Stylo-glossus, Stylo-pharyngeus, and Hyo-glossus muscles, the external carotid artery and its occipital, lingual, facial, and ascending pharyngeal branches, the internal carotid artery, internal jugular vein, and hypoglossal nerve.

The **Stylo-hyoid** is a small, slender muscle, lying in front of, and above, the posterior belly of the Digastric. It arises from the back and outer surface of the styloid process, near the base; and, passing downward and forward, is inserted into the body of the hyoid bone, just at its junction with the greater cornu, and immediately above the Omo-hyoid. This muscle is perforated, near its insertion, by the tendon of the Digastric.

Relations.—By its *superficial surface* above with the parotid gland and deep cervical fascia; below it is superficial, being situated immediately beneath the deep cervical fascia. By its *deep surface*, with the posterior belly of the Digastric, the external carotid artery, with its lingual and facial branches, the Hyo-glossus muscle, and the hypoglossal nerve.

The Stylo-hyoid Ligament.—In connection with the Stylo-hyoid muscle may be described a ligamentous band, the *Stylo-hyoid ligament*. It is a fibrous cord, often containing a little cartilage in its centre, which continues the styloid process down to the hyoid bone, being attached to the tip of the former and the small cornu of the latter. It is often more or less ossified, and in many animals forms a distinct bone, the *epihyal*.

The anterior belly of the Digastric should be removed, in order to expose the next muscle.

The **Mylo-hyoid** is a flat, triangular muscle, situated immediately beneath the anterior belly of the Digastric, and forming, with its fellow of the opposite side, a muscular floor for the cavity of the mouth. It arises from the whole length of the mylo-hyoid ridge of the lower jaw, extending from the symphysis in front to the last molar tooth behind. The posterior fibres pass inward and slightly downward, to be inserted into the body of the os hyoides. The middle and anterior fibres are inserted into a median fibrous raphé, extending from the symphysis of the lower jaw to the hyoid bone, where they join at an angle with the fibres of the opposite muscle. The median raphé is sometimes wanting; the muscular fibres of the two sides are then directly continuous with one another.

Relations.—By its *cutaneous* or *under surface*, with the Platysma, the anterior belly of the Digastric, the supra-hyoid aponeurosis, the submaxillary gland, submental vessels, and mylo-hyoid vessels and nerve; by its *deep* or *superior surface*, with the Genio-hyoid, part of the Hyo-glossus and Stylo-glossus muscles, the hypoglossal and lingual nerves, the submaxillary ganglion, the sublingual gland, the deep portion of the submaxillary gland, and Wharton's duct; the sublingual and ranine vessels, and the buccal mucous membrane.

Dissection.—The Mylo-hyoid should now be removed, in order to expose the muscles which lie beneath; this is effected by reflecting it from its attachments to the hyoid bone and jaw, and separating it by a vertical incision from its fellow of the opposite side.

The **Genio-hyoid** is a narrow, slender muscle, situated immediately beneath[1] the inner border of the preceding. It arises from the inferior genial tubercle on the inner side of the symphysis of the jaw, and passes downward and backward, to be inserted into the anterior surface of the body of the os hyoides. This muscle lies in close contact with its fellow of the opposite side, and increases slightly in breadth as it descends.

Relations.—It is covered by the Mylo-hyoid, and lies along the lower border of the Genio-hyo-glossus.

Nerves.—The Digastric is supplied: its anterior belly, by the mylo-hyoid branch

[1] This refers to the depth of the muscles from the skin in the order of dissection. In the erect position of the body each of these muscles lies above the preceding.

of the inferior dental; its posterior belly, by the facial; the Stylo-hyoid, by the facial; the Mylo-hyoid, by the mylo-hyoid branch of the inferior dental; the Genio-hyoid, by the hypoglossal.

Actions.—This group of muscles performs two very important actions. They raise the hyoid bone, and with it the base of the tongue, during the act of deglutition; or, when the hyoid bone is fixed by its depressors and those of the larynx, they depress the lower jaw. During the first act of deglutition, when the mass is being driven from the mouth into the pharynx, the hyoid bone, and with it the tongue, is carried upward and forward by the anterior belly of the Digastric, the Mylo-hyoid, and Genio-hyoid muscles. In the second act, when the mass is passing through the pharynx, the direct elevation of the hyoid bone takes place by the combined action of all the muscles; and after the food has passed the hyoid bone is carried upward and backward by the posterior belly of the Digastric and Stylo-hyoid muscles, which assist in preventing the return of the morsel into the mouth.

4. Lingual Region.

Genio-hyo-glossus. Stylo-glossus.
Hyo-glossus. Palato-glossus.
Chondro-glossus.

Dissection.—After completing the dissection of the preceding muscles, saw through the lower jaw just external to the symphysis. Then draw the tongue forward, and attach it, by a stitch, to the nose; when its muscles, which are thus put on the stretch, may be examined.

The **Genio-hyo-glossus** has received its name from its triple attachment to the jaw, hyoid bone, and tongue, but it would be better named the *Genio-glossus*,

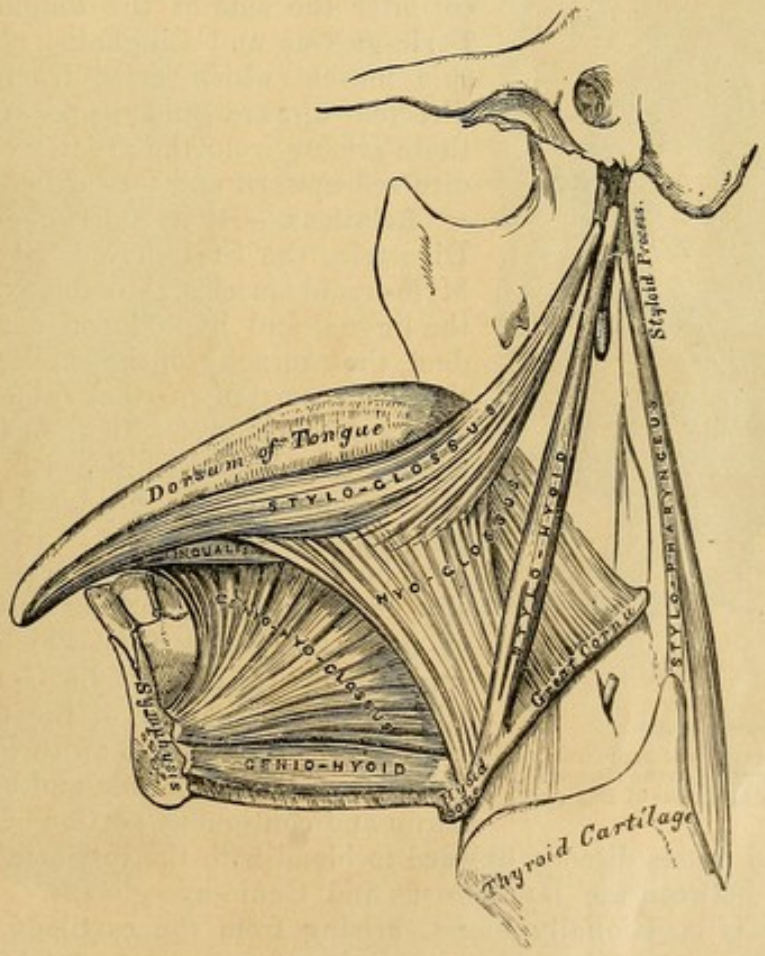

FIG. 204.—Muscles of the tongue. Left side.

since its attachment to the hyoid bone is very slight or altogether absent. It is a flat, triangular muscle, placed vertically on either side of the middle line, its apex

corresponding with its point of attachment to the lower jaw, its base with its insertion into the tongue and hyoid bone. It arises by a short tendon from the superior genial tubercle on the inner side of the symphysis of the jaw, immediately above the Genio-hyoid; from this point the muscle spreads out in a fan-like form, the lower of the inferior fibres passing downward, to be attached by a thin aponeurosis to the upper part of the body of the hyoid bone, a few fibres passing between the Hyo-glossus and Chondro-glossus to blend with the Constrictor muscles of the pharynx; the middle fibres passing backward, and the superior ones upward and forward, to enter the whole length of the under surface of the tongue, from the base to the apex. The two muscles lie on either side of the median plane; behind, they are quite distinct from each other, and are separated at their insertion into the under surface of the tongue by a tendinous raphé, which extends through the middle of the organ; in front, the two muscles are more or less blended: distinct fasciculi are to be seen passing off from one muscle, crossing the middle line, and intersecting with bundles of fibres derived from the muscle on the other side (Fig. 205).

Relations.—By its *internal surface* it is in contact with its fellow of the opposite side; by its *external surface*, with the Inferior lingualis, the Hyo-glossus, the lingual artery and hypoglossal nerve, the lingual nerve, and sublingual gland; by its *upper border*, with the mucous membrane of the floor of the mouth (frænum linguæ); by its *lower border*, with the Genio-hyoid.

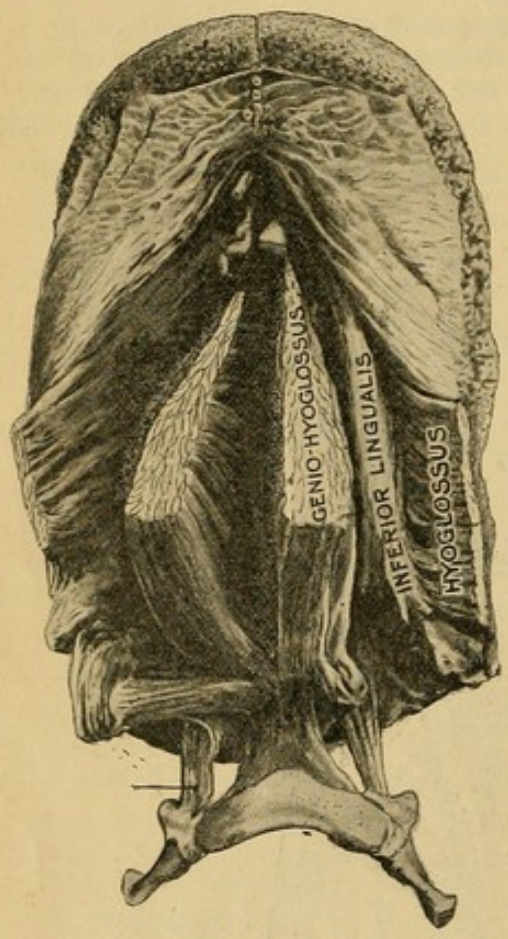

FIG. 205.—Muscles of the tongue from below. (From a preparation in the Museum of the Royal College of Surgeons of England.)

The **Hyo-glossus** is a thin, flat, quadrilateral muscle which arises from the side of the body and whole length of the greater cornu of the hyoid bone, and passes almost vertically upward to enter the side of the tongue, between the Stylo-glossus and Lingualis. Those fibres of this muscle which arise from the body are directed upward and backward, overlapping those arising from the greater cornu, which are directed upward and forward.

Relations.—By its *external surface*, with the Digastric, the Stylo-hyoid, Stylo-glossus, and Mylo-hyoid muscles, the submaxillary ganglion, the lingual and hypoglossal nerves, Wharton's duct, the ranine vein, the sublingual gland, and the deep portion of the submaxillary gland. By its *deep surface*, with the Stylo-hyoid ligament, the Genio-hyo-glossus, Lingualis, and Middle constrictor, the lingual vessels, and the glosso-pharyngeal nerve.

The **Chondro-glossus** is a distinct muscular slip, though it is sometimes described as a part of the Hyo-glossus, from which, however, it is separated by the fibres of the Genio-hyo-glossus, which pass to the side of the pharynx. It is about three-quarters to an inch in length, and arises from the inner side and base of the lesser cornu and contiguous portion of the body of the hyoid bone, and passes directly upward to blend with the intrinsic muscular fibres of the tongue, between the Hyo-glossus and Genio-hyo-glossus. A small slip of muscular fibre is occasionally found, arising from the cartilago triticia in the thyro-hyoid ligament, and passing upward and forward to enter the tongue with the hindermost fibres of the Hyo-glossus.

The **Stylo-glossus**, the shortest and smallest of the three styloid muscles, arises from the anterior and outer side of the styloid process, near its apex, and from the

stylo-mandibular ligament, to which its fibres, in most cases, are attached by a thin aponeurosis. Passing downward and forward between the internal and external carotid arteries, and becoming nearly horizontal in its direction, it divides upon the side of the tongue into two portions: one longitudinal, which enters the side of the tongue near its dorsal surface, blending with the fibres of the Lingualis in front of the Hyo-glossus; the other oblique, which overlaps the Hyo-glossus muscle and decussates with its fibres.

Relations.—By its *external surface*, from above downward, with the parotid gland, the Internal pterygoid muscle, the lingual nerve, and the mucous membrane of the mouth; by its *internal surface*, with the tonsil, the Superior constrictor, and the Hyo-glossus muscle.

The **Palato-glossus,** or **Constrictor isthmi faucium,** although it is one of the muscles of the tongue, serving to draw its base upward during the act of deglutition, is more nearly associated with the soft palate, both in its situation and function; it will consequently be described with that group of muscles.

Nerves.—The Palato-glossus is probably innervated by the spinal accessory nerve, through the pharyngeal plexus; the remaining muscles of this group, by the hypoglossal.

Muscular Substance of Tongue.—The muscular fibres of the tongue run in various directions. These fibres are divided into two sets—Extrinsic and Intrinsic. The extrinsic muscles of the tongue are those which have their origin external, and only their terminal fibres contained in the substance of the organ. They are: the Stylo-glossus, the Hyo-glossus, the Palato-glossus, the Genio-hyo-glossus, and part of the Superior constrictor of the pharynx (Pharyngeo-glossus). The intrinsic are those which are contained entirely within the tongue, and form the greater part of its muscular structure.

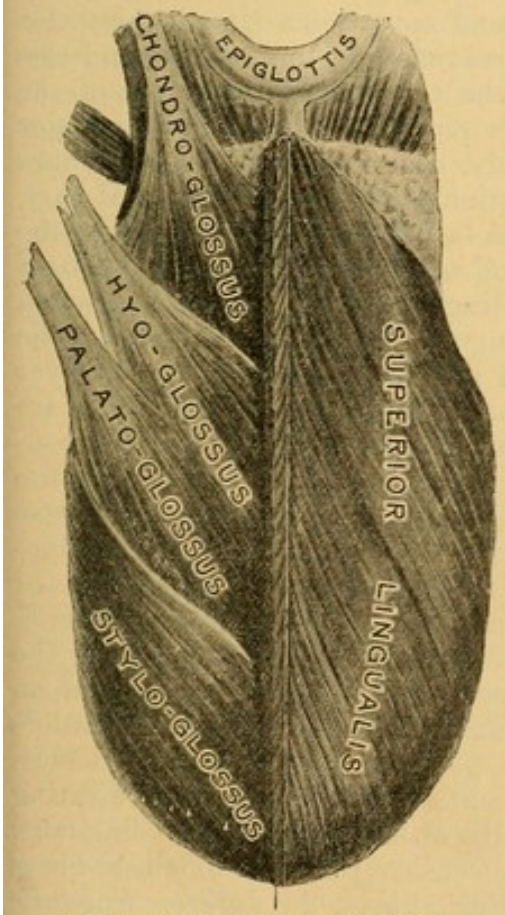

FIG. 206.—Muscles on the dorsum of the tongue.

The tongue consists of symmetrical halves separated from each other in the middle line by a fibrous septum. Each half is composed of muscular fibres arranged in various directions, containing much interposed fat, and supplied by vessels and nerves.

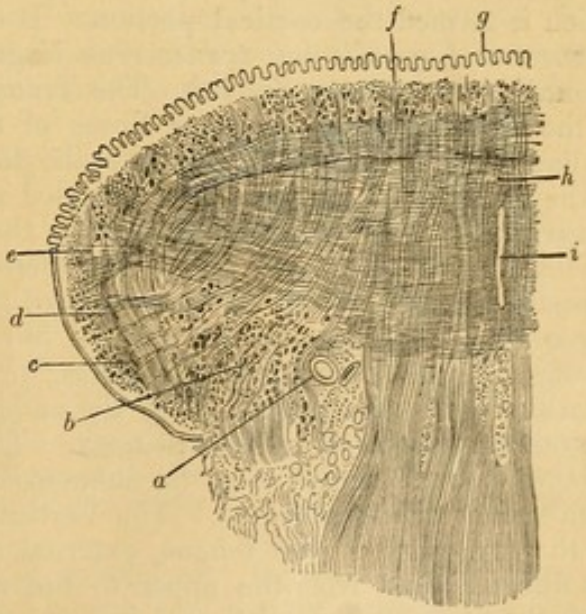

FIG. 207.—Coronal section of tongue. Showing intrinsic muscles. (Altered from Krause.) *a*, lingual artery; *b*, Inferior lingualis, cut through; *c*, fibres of Hyo-glossus; *d*, oblique fibres of Stylo-glossus; *e*, insertion of Transverse linguaiis; *f*, Superior lingualis; *g*, papillæ to tongue; *h*, vertical fibres of Genio-hyo-glossus intersecting Transverse lingualis; *i*, septum.

To demonstrate the various fibres of the tongue, the organ should be subjected to prolonged boiling, in order to soften the connective tissue; the dis-

section may then be commenced from the dorsum (Fig. 206). Immediately beneath the mucous membrane is a submucous, fibrous layer, into which the muscular fibres which terminate on the surface of the tongue are inserted. Upon removing this, with the mucous membrane, the first stratum of muscular fibres is exposed. This belongs to the group of intrinsic muscles, and has been named the *Superior lingualis* (*m. longitudinalis superior*). It consists of a thin layer of oblique and longitudinal fibres which arise from the submucous fibrous layer, close to the Epiglottis, and from the fibrous septum, and pass forward and outward to the edges of the tongue. Between its fibres pass some vertical fibres derived from the Genio-hyo-glossus and from the vertical intrinsic muscle, which will be described later on. Beneath this layer is the second stratum of muscular fibres, derived principally from the extrinsic muscles. In front it is formed by the fibres derived from the Stylo-glossus, running along the side of the tongue, and sending one set of fibres over the dorsum which runs obliquely forward and inward to the middle line, and another set of fibres, seen at a later period of the dissection, on to the under surface of the sides of the anterior part of the tongue, which run forward and inward, between the fibres of the Hyo-glossus, to the middle line. Behind this layer of fibres, derived from the Stylo-glossus, are fibres derived from the Hyo-glossus, assisted by some few fibres of the Palato-glossus. The Hyo-glossus, entering the side of the under surface of the tongue, between the Stylo-glossus and Inferior lingualis, passes round its margin and spreads out into a layer on the dorsum, which occupies the middle third of the organ, and runs almost transversely inward to the septum. It is reinforced by some fibres from the Palato-glossus; other fibres of this muscle pass more deeply and intermingle with the next layer. The posterior part of the second layer of the muscular fibres of the tongue is derived from those fibres of the Hyo-glossus which arise from the lesser cornu of the hyoid bone, and are here described as a separate muscle—the Chondro-glossus. The fibres of this muscle are arranged in a fan-shaped manner, and spread out over the posterior third of the tongue. Beneath this layer is the great mass of the intrinsic muscles of the tongue, intersected at right angles by the terminal fibres of one of the extrinsic muscles—the Genio-hyo-glossus. This portion of the tongue is paler in color and softer in texture than that already described, and is sometimes designated the medullary portion in contradistinction to the firmer superficial part, which is termed the cortical portion. It consists largely of transverse fibres, the *Transverse lingualis* (*m. transversus linguæ*), and of vertical fibres, the *Vertical lingualis* (*m. verticulis linguæ*). The Transverse lingualis forms the largest portion of the third layer of muscular fibres of the tongue. The fibres arise from the median septum, and pass outward to be inserted into the submucous fibrous layer at the sides of the tongue. Intermingled with these transverse intrinsic fibres are transverse extrinsic fibres derived from the Palato-glossus and the Superior constrictor of the pharynx. These transverse extrinsic fibres, however, run in the opposite direction, passing inward toward the septum. Intersecting the transverse fibres are a large number of vertical fibres derived partly from the Genio-hyo-glossus and partly from intrinsic fibres, the Vertical lingualis. The fibres derived from the Genio-hyo-glossus enter the under surface of the tongue on each side of the median septum from base to apex. They ascend in a radiating manner to the dorsum, being inserted into the submucous fibrous layer covering the tongue on each side of the middle line. The Vertical lingualis is found only at the borders of the fore part of the tongue, external to the fibres of the Genio-hyo-glossus. Its fibres extend from the upper to the under surface of the organ, decussating with the fibres of the other muscles, and especially with the Transverse lingualis. The fourth layer of muscular fibres of the tongue consists partly of extrinsic fibres derived from the Stylo-glossus, and partly of intrinsic fibres, the *Inferior lingualis* (*m. longitudinalis inferior*). At the sides of the under surface of the organ are some fibres derived from the Stylo-glossus, which, as it runs forward at the side of the tongue, gives off fibres which, passing forward and inward between the fibres of the Hyo-glossus, form an inferior oblique stratum which joins in front with the

anterior fibres of the Inferior lingualis. The Inferior lingualis is a longitudinal band, situated on the under surface of the tongue, and extending from the base to the apex of the organ. Behind, some of its fibres are connected with the body of the hyoid bone. It lies between the Hyo-glossus and the Genio-hyo-glossus, and in front of the Hyo-glossus it gets into relation with the Stylo-glossus, with the fibres of which it blends. It is in relation by its under surface with the ranine artery.

Surgical Anatomy.—The fibrous septum which exists between the two halves of the tongue is very complete, so that the anastomosis between the two lingual arteries is not very free, a fact often illustrated by injecting one-half of the tongue with colored size, while the other half is left uninjected or is injected with size of a different color.

This is a point of considerable importance in connection with removal of one-half of the tongue for cancer, an operation which is now frequently resorted to when the disease is strictly confined to one side of the tongue. If the mucous membrane is divided longitudinally exactly in the middle line, the tongue can be split into halves along the median raphe without any appreciable hæmorrhage, and the diseased half can then be removed.

Actions.—The movements of the tongue, although numerous and complicated, may be understood by carefully considering the direction of the fibres of its muscles. The *Genio-hyo-glossi* muscles, by means of their posterior fibres, draw the base of the tongue forward, so as to protrude the apex from the mouth. The anterior fibres draw the tongue back into the mouth. The whole length of these two muscles, acting along the middle line of the tongue, draw it downward, so as to make it concave from side to side, forming a channel along which fluids may pass toward the pharynx, as in sucking. The *Hyo-glossi* muscles depress the tongue and draw down its sides, so as to render it convex from side to side. The *Stylo-glossi* muscles draw the tongue upward and backward. The *Palato-glossi* muscles draw the base of the tongue upward. With regard to the intrinsic muscles, both the Superior and Inferior linguales tend to shorten the tongue, but the former, in addition, turn the tip and sides upward so as to render the dorsum concave, while the latter pull the tip downward and cause the dorsum to become convex. The Transverse lingualis narrows and elongates the tongue, and the Vertical lingualis flattens and broadens it. The complex arrangement of the muscular fibres of the tongue, and the various directions in which they run, give to this organ the power of assuming the various forms necessary for the enunciation of the different consonantal sounds; and Dr. Macalister states that "there is reason to believe that the musculature of the tongue varies in different races owing to the hereditary practice and habitual use of certain motions required for enunciating the several vernacular languages."

5. Pharyngeal Region.

Inferior constrictor.	Superior constrictor.
Middle constrictor.	Stylo-pharyngeus.
Palato-pharyngeus. } Salpingo-pharyngeus. }	(See next section.)

Dissection (Fig. 208).—In order to examine the muscles of the pharynx, cut through the trachea and œsophagus just above the sternum, and draw them upward by dividing the loose areolar tissue connecting the pharynx with the front of the vertebral column. The parts being drawn well forward, apply the edge of the saw immediately behind the styloid processes, and saw the base of the skull through from below upward. The pharynx and mouth should then be stuffed with tow, in order to distend its cavity and render the muscles tense and easier of dissection.

The **Inferior constrictor,** the most superficial and thickest of the three constrictors, arises from the sides of the cricoid and thyroid cartilages. To the cricoid cartilage it is attached in the interval between the Crico-thyroid muscle in front and the articular facet for the thyroid cartilage behind. To the thyroid cartilage it is attached to the oblique line on the side of the great ala, the cartilaginous surface behind it, nearly as far as its posterior border, and to the inferior cornu. From these attachments the fibres spread backward and inward, to be inserted into the fibrous raphe in the posterior median line of the pharynx.

The inferior fibres are horizontal, and continuous with the fibres of the œsophagus: the rest ascend, increasing in obliquity, and overlap the Middle constrictor.

Relations.—It is covered by a thin membrane which surrounds the entire pharynx (bucco-pharyngeal fascia). *Behind*, it is in relation with the vertebral column and the prevertebral fascia and muscles; *laterally*, with the thyroid gland, the common carotid artery, and the Sterno-thyroid muscle; by its *internal surface*, with the Middle constrictor, the Stylo-pharyngeus, Palato-pharyngeus, the fibrous coat and mucous membrane of the pharynx. The internal laryngeal nerve and the laryngeal branch of the Superior Thyroid artery pass near the upper border, and the inferior, or recurrent laryngeal nerve, and the laryngeal branch of the Inferior Thyroid artery, beneath the lower border of this muscle, previous to their entering the larynx.

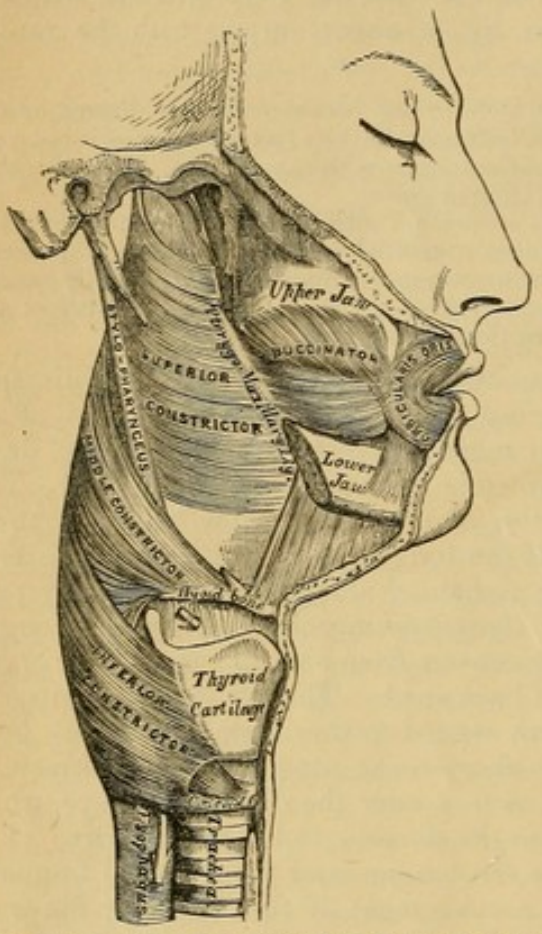

FIG. 208.—Muscles of the pharynx. External view.

The **Middle constrictor** is a flattened, fan-shaped muscle, smaller than the preceding. It arises from the whole length of the upper border of the greater cornu of the hyoid bone, from the lesser cornu, and from the stylo-hyoid ligament. The fibres diverge from their origin, the lower ones descending beneath the Inferior constrictor, the middle fibres passing transversely, and the upper fibres ascending and overlapping the Superior constrictor. The muscle is inserted into the posterior median fibrous raphé, blending in the middle line with the one of the opposite side.

Relations.—This muscle is separated from the Superior constrictor by the glosso-pharyngeal nerve and the Stylo-pharyngeus muscle and Stylo-hyoid ligament; and from the Inferior constrictor by the superior laryngeal nerve. *Behind*, it lies on the vertebral column, the Longus colli, and the Rectus capitis anticus major. *On each side* it is in relation with the carotid vessels, the pharyngeal plexus, and some lymphatic glands. Near its origin it is covered by the Hyo-glossus, from which it is separated by the lingual vessels. It lies upon the Superior constrictor, the Stylo-pharyngeus, the Palato-pharyngeus, the fibrous coat, and the mucous membrane of the pharynx.

The **Superior Constrictor** is a quadrilateral muscle, thinner and paler than the other constrictors, and situated at the upper part of the pharynx. It arises from the lower third of the posterior margin of the internal pterygoid plate and its hamular process, from the contiguous portion of the palate bone and the reflected tendon of the Tensor palati muscle, from the pterygo-maxillary ligament, from the alveolar process above the posterior extremity of the mylo-hyoid ridge, and by a few fibres from the side of the tongue. From these points the fibres curve backward, to be inserted into the median raphe, being also prolonged by means of a fibrous aponeurosis to the pharyngeal spine on the basilar process of the occipital bone. The superior fibres arch beneath the Levator palati and the Eustachian tube, the interval between the upper border of the muscle and the basilar process being deficient in muscular fibres and closed by the pharyngeal aponeurosis. This interval is known as the *sinus of Morgagni*.

Relations.—By its *outer surface*, with the prevertebral fascia and muscles, the vertebral column, the internal carotid and ascending pharyngeal arteries, the

internal jugular vein and pharyngeal venous plexus, the glosso-pharyngeal, pneumogastric, spinal accessory, hypoglossal, lingual, and sympathetic nerves, the Middle constrictor and Internal pterygoid muscles, the Styloid process, the Stylo-hyoid ligament, and the Stylo-pharyngeus. By its *internal surface*, with the Palato-pharyngeus, the tonsil, the fibrous coat and mucous membrane of the pharynx.

The **Stylo-pharyngeus** is a long, slender muscle, round above, broad and thin below. It arises from the inner side of the base of the styloid process, passes downward along the side of the pharynx between the Superior and Middle constrictors, and spreads out beneath the mucous membrane, where some of its fibres are lost in the Constrictor muscles; and others, joining with the Palato-pharyngeus, are inserted into the posterior border of the thyroid cartilage. The glosso-pharyngeal nerve runs on the outer side of this muscle, and crosses over it in passing forward to the tongue.

Relations.—*Externally*, with the Stylo-glossus muscle, the parotid gland, the external carotid artery, and the Middle constrictor; *internally*, with the internal carotid, the internal jugular vein, the Superior constrictor, Palato-pharyngeus, and mucous membrane.

Nerves.—The Constrictors are supplied by branches from the pharyngeal plexus, the Stylo-pharyngeus by the glosso-pharyngeal nerve, and the Inferior constrictor by an additional branch from the external laryngeal nerve and by the recurrent laryngeal.

Actions.—When deglutition is about to be performed, the pharynx is drawn upward and dilated in different directions, to receive the morsel propelled into it from the mouth. The Stylo-pharyngei, which are much farther removed from one another at their origin than at their insertion, draw the sides of the pharynx upward and outward, and so increase its transverse diameter, its breadth in the antero-posterior direction being increased by the larynx and tongue being carried forward in their ascent. As soon as the morsel is received in the pharynx, the Elevator muscles relax, the bag descends, and the Constrictors contract upon the morsel, and convey it gradually downward into the œsophagus. Besides its action in deglutition, the pharynx also exerts an important influence in the modulation of the voice, especially in the production of the higher tones.

6. Palatal Region.

Levator palati.	Palato-glossus.
Tensor palati.	Palato-pharyngeus.
Azygos uvulæ.	Salpingo-pharyngeus.

Dissection (Fig. 209).—Lay open the pharynx from behind by a vertical incision extending from its upper to its lower part, and partially divide the occipital attachment by a transverse incision on each side of the vertical one; the posterior surface of the soft palate is then exposed. Having fixed the uvula so as to make it tense, the mucous membrane and glands should be carefully removed from the posterior surface of the soft palate, and the muscles of this part are at once exposed.

The **Levator palati** is a long, thick, rounded muscle, placed on the outer side of the posterior nares. It arises from the under surface of the apex of the petrous portion of the temporal bone, and from the inner surface of the cartilaginous portion of the Eusatchian tube; after passing into the pharynx, above the upper concave margin of the Superior constrictor, it passes obliquely downward and inward, its fibres spreading out in the soft palate as far as the middle line, where they blend with those of the opposite side.

Relations.—*Externally*, with the Tensor palati and Superior constrictor and Eustachian tube; *internally*, with the mucous membrane of the pharynx; *posteriorly*, with the posterior fasciculus of the Palato-pharyngeus, the Azygos uvulæ, and the mucous lining of the soft palate.

The **Circumflexus** or **Tensor palati** is a broad, thin, ribbon-like muscle, placed on the outer side of the Levator palati, and consisting of a vertical and a horizontal

portion. The vertical portion arises by a flat lamella from the scaphoid fossa at the base of the internal pterygoid plate; from the spine of the sphenoid and the outer side of the cartilaginous portion of the Eustachian tube: descending vertically between the internal pterygoid plate and the inner surface of the Internal pterygoid muscle, it terminates in a tendon, which winds round the hamular process, being retained in this situation by some of the fibres of origin of the Internal pterygoid muscle. Between the hamular process and the tendon is a small bursa. The tendon or horizontal portion then passes horizontally inward, and is inserted into a broad aponeurosis, the *palatine aponeurosis*, and into the transverse ridge on the horizontal portion of the palate bone.

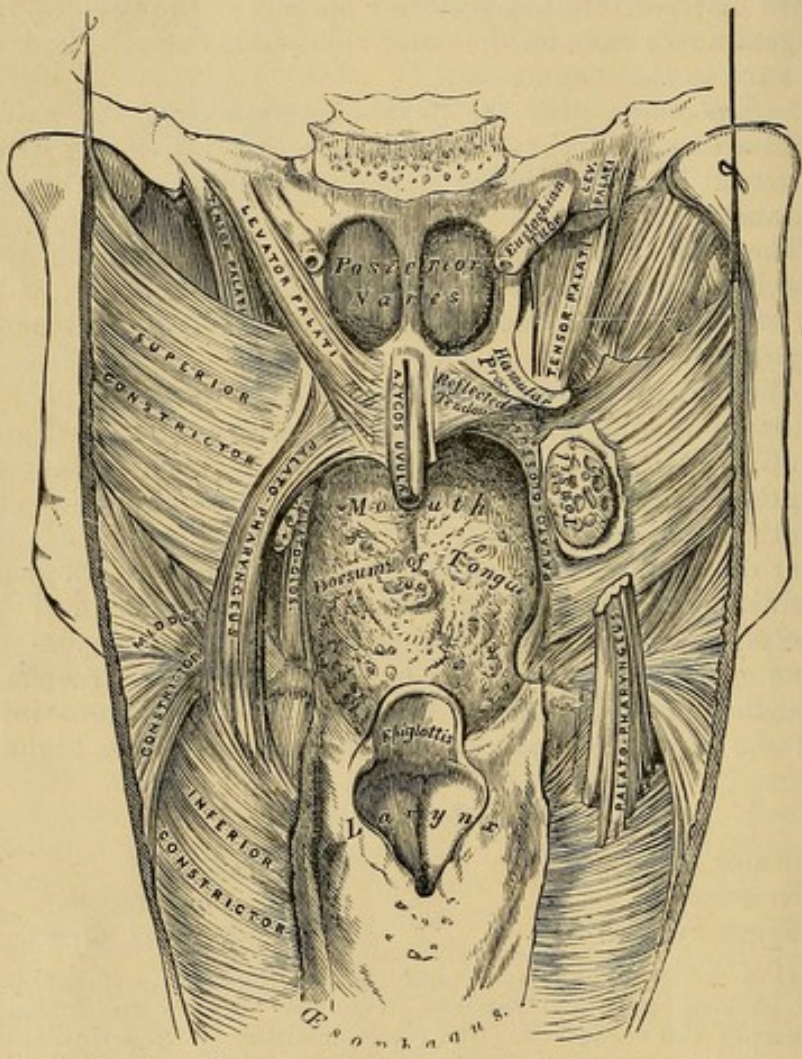

FIG. 209.—Muscles of the soft palate, the pharynx being laid open from behind.

Relations.—*Externally*, with the Internal pterygoid; *internally*, with the Levator palati, from which it is separated by the Eustachian tube and Superior constrictor, and with the internal pterygoid plate. In the soft palate its tendon and the palatine aponeurosis are anterior to those of the Levator palati, being covered by the Palato-glossus and the mucous membrane.

Palatine Aponeurosis.—Attached to the posterior border of the hard palate is a thin, firm, fibrous lamella which supports the muscles and gives strength to the soft palate. It is thicker above than below, where it becomes very thin and difficult to define. Laterally, it is continuous with the pharyngeal aponeurosis.

The **Azygos uvulæ** is not a single muscle, as would be inferred from its name, but a pair of narrow cylindrical fleshy fasciculi placed on either side of the median line of the soft palate. Each muscle arises from the posterior nasal spine of the palate bone and from the contiguous tendinous aponeurosis of the soft palate, and descends to be inserted into the uvula.

Relations.—*Anteriorly*, with the tendinous expansion of the Levatores palati; *behind*, with the posterior fasciculus of the Palato-pharyngeus and the mucous membrane.

The two next muscles are exposed by removing the mucous membrane from the pillars of the fauces throughout nearly their whole extent.

The **Palato-glossus** (**Constrictor isthmi faucium**) is a small fleshy fasciculus, narrower in the middle than at either extremity, forming, with the mucous membrane covering its surface, the anterior pillar of the soft palate. It arises from the anterior surface of the soft palate on each side of the uvula, and, passing downward, forward, and outward in front of the tonsil, is inserted into the side of the tongue, some of its fibres spreading over the dorsum, and others passing deeply into the substance of the organ to intermingle with the Transversus linguæ. In the soft palate the fibres of this muscle are continuous with those of the muscle of the opposite side.

The **Palato-pharyngeus** is a long, fleshy fasciculus, narrower in the middle than at either extremity, forming, with the mucous membrane covering its surface, the posterior pillar of the soft palate. It is separated from the Palato-glossus by an angular interval, in which the tonsil is lodged. It arises from the soft palate by an expanded fasciculus, which is divided into two parts by the Levator palati and Azygos uvulæ. The *posterior fasciculus* lies in contact with the mucous membrane, and also joins with the corresponding muscle in the middle line; the *anterior fasciculus*, the thicker, lies in the soft palate between the Levator and Tensor, and joins in the middle line the corresponding part of the opposite muscle. Passing outward and downward behind the tonsil, the Palato-pharyngeus joins the Stylo-pharyngeus, and is inserted with that muscle into the posterior border of the thyroid cartilage, some of its fibres being lost on the side of the pharynx, and others passing across the middle line posteriorly to decussate with the muscle of the opposite side.

Relations.—In the soft palate its *posterior surface* is covered by mucous membrane, from which it is separated by a layer of palatine glands. By its *anterior surface* it is in relation with the Tensor palati. Where it forms the posterior pillar of the fauces it is covered by mucous membrane, excepting on its outer surface. In the *pharynx* it lies between the mucous membrane and the Constrictor muscles.

The Salpingo-pharyngeus.—This muscle arises from the inferior part of the Eustachian tube near its orifice; it passes downward and blends with the posterior fasciculus of the Palato-pharyngeus.

In a dissection of the soft palate from its posterior or nasal surface to its anterior or oral surface, the muscles would be exposed in the following order: viz. the posterior fasciculus of the Palato-pharyngeus, covered over by the mucous membrane reflected from the floor of the nasal fossæ; the Azygos uvulæ; the Levator palati; the anterior fasciculus of the Palato-pharyngeus; the aponeurosis of the Tensor palati, and the Palato-glossus covered over by a reflection from the oral mucous membrane.

Nerves.—The Tensor palati is supplied by a branch from the otic ganglion; the remaining muscles of this group are in all probability supplied by the internal branch of the spinal accessory, whose fibres are distributed along with certain branches of the pneumogastric through the pharyngeal plexus.[1] It is possible, however, that the Levator palati may be supplied by the facial through the Petrosal branch of the Vidian.

Actions.—During the *first stage* of deglutition the morsel of food is driven back into the fauces by the pressure of the tongue against the hard palate, the base of the tongue being, at the same time, retracted, and the larynx raised with the pharynx, and carried forward under it. During the *second stage* the entrance to the larynx is closed, not, as was formerly supposed, by the folding backward

[1] *Journal of Anatomy and Physiology*, vol. xxiii., p. 523.

of the epiglottis over it, but, as Anderson Stuart has shown, by the drawing forward of the arytenoid cartilages toward the cushion of the epiglottis—a movement produced by the contraction of the external thyro-arytenoid, the arytenoid, and aryteno-epiglottidean muscles.

The morsel of food after leaving the tongue passes on to the posterior or laryngeal surface of the epiglottis, and glides along this for a certain distance;[1] then the Palato-glossi muscles, the constrictors of the fauces, contract behind the food; the soft palate is slightly raised by the Levator palati, and made tense by the Tensor palati; and the Palato-pharyngei, by their contraction, pull the pharynx upward over the morsel of food, and at the same time come nearly together, the uvula filling up the slight interval between them. By these means the food is prevented passing into the upper part of the pharynx or the posterior nares; at the same time the latter muscles form an inclined plane, directed obliquely downward and backward, along the under surface of which the morsel descends into the lower part of the pharynx. The Salpingo-pharyngeus raises the upper and lateral part of the pharynx—*i. e.* that part which is above the point where the Stylo-pharyngeus is attached to the pharynx.

Surgical Anatomy.—The muscles of the soft palate should be carefully dissected, the relations they bear to the surrounding parts especially examined, and their action attentively studied upon the dead subject, as the surgeon is required to divide one or more of these muscles in the operation of staphylorraphy. Sir W. Fergusson was the first to show that in the congenital deficiency called *cleft palate* the edges of the fissure are forcibly separated by the action of the Levatores palati and Palato-pharyngei muscles, producing very considerable impediment to the healing process after the performance of the operation for uniting their margins by adhesion; he, consequently, recommended the division of these muscles as one of the most important steps in the operation. This he effected by an incision made with a curved knife introduced behind the soft palate. The incision is to be halfway between the hamular process and Eustachian tube, and perpendicular to a line drawn between them. This incision perfectly accomplishes the division of the Levator palati. The Palato-pharyngeus may be divided by cutting across the posterior pillar of the soft palate, just below the tonsil, with a pair of blunt-pointed curved scissors; and the anterior pillar may be divided also. To divide the Levator palati the plan recommended by Mr. Pollock is to be greatly preferred. The soft palate being put upon the stretch, a double-edged knife is passed through it just on the inner side of the hamular process and above the line of the Levator palati. The handle being now alternately raised and depressed, a sweeping cut is made along the posterior surface of the soft palate, and the knife withdrawn, leaving only a small opening in the mucous membrane on the anterior surface. If this operation is performed on the dead body and the parts afterward dissected, the Levator palati will be found completely divided. In the present day, however, this division of the muscles, as part of the operation of staphylorraphy, is not so much insisted upon. All tension is prevented by making longitudinal incisions on either side, parallel to the cleft and just internal to the hamular process, in such a position as to avoid the posterior palatine artery.

7. Anterior Vertebral Region.

Rectus capitis anticus major.	Rectus capitis lateralis.
Rectus capitis anticus minor.	Longus colli.

The **Rectus capitis anticus major** (Fig. 210), broad and thick above, narrow below, appears like a continuation upward of the Scalenus anticus. It arises by four tendinous slips from the anterior tubercles of the transverse processes of the third, fourth, fifth, and sixth cervical vertebræ, and ascends, converging toward its fellow of the opposite side, to be inserted into the basilar process of the occipital bone.

Relations.—By its *anterior surface*, with the pharynx, the sympathetic nerve, and the sheath enclosing the internal and common carotid artery, internal jugular vein, and pneumogastric nerve; by its *posterior surface*, with the Longus colli, the Rectus capitis anticus minor, and the upper cervical vertebræ.

The **Rectus capitis anticus minor** is a short, flat muscle, situated immediately behind the upper part of the preceding. It arises from the anterior surface of the lateral mass of the atlas and from the root of its transverse process, and, passing

[1] Walton (quoted by A. Stuart) maintains that the epiglottis is not essential to the deglutition even of liquids.

obliquely upward and inward, is inserted into the basilar process immediately behind the preceding muscle.

Relations.—By its *anterior surface*, with the Rectus capitis anticus major; by its *posterior surface*, with the front of the occipito-atlantal articulation.

The **Rectus capitis lateralis** is a short, flat muscle, which arises from the upper surface of the transverse process of the atlas, and is inserted into the under surface of the jugular process of the occipital bone.

Relations.—By its *anterior surface*, with the internal jugular vein; by its *posterior surface*, with the vertebral artery. On its *outer side* lies the occipital artery; on its *inner side*, the suboccipital nerve.

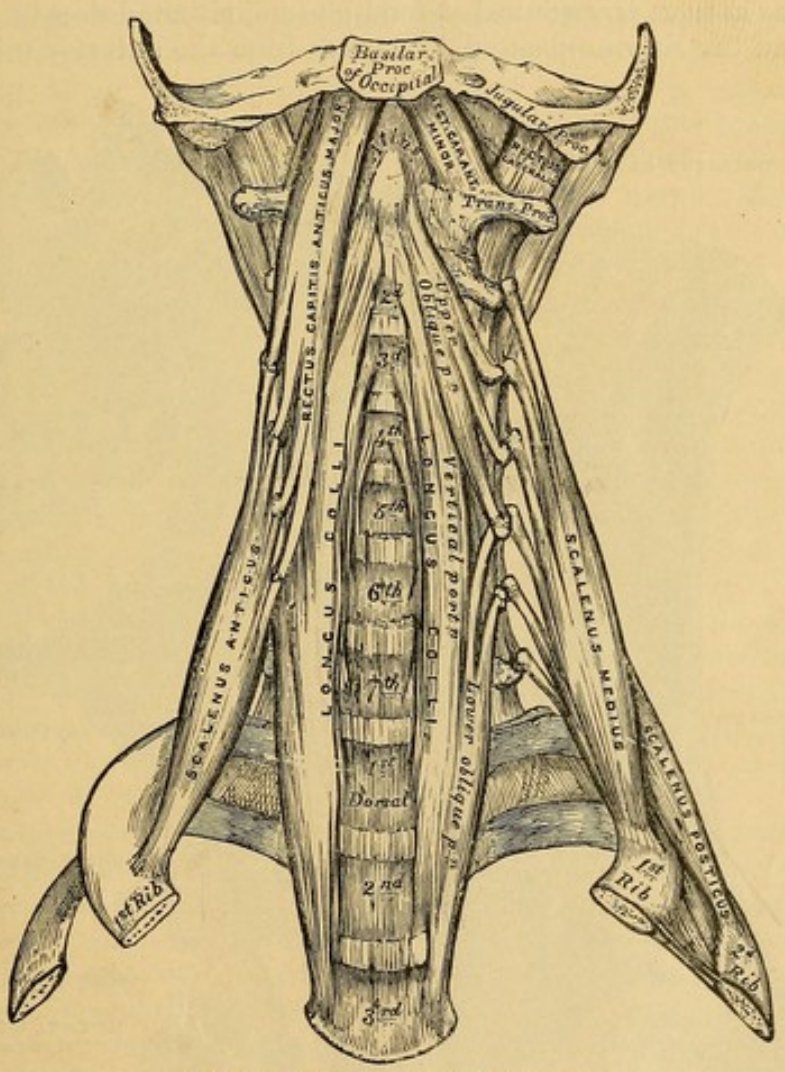

FIG. 210.—The prevertebral muscles.

The **Longus colli** is a long, flat muscle, situated on the anterior surface of the spine, between the atlas and the third dorsal vertebra. It is broad in the middle, narrow and pointed at each extremity, and consists of three portions: a superior oblique, an inferior oblique, and a vertical portion. The *superior oblique portion* arises from the anterior tubercles of the transverse processes of the third, fourth, and fifth cervical vertebræ, and, ascending obliquely inward, is inserted by a narrow tendon into the tubercle on the anterior arch of the atlas. The *inferior oblique portion*, the smallest part of the muscle, arises from the front of the bodies of the first two or three dorsal vertebræ, and, ascending obliquely outward, is inserted into the anterior tubercles of the transverse processes of the fifth and sixth cervical vertebræ. The *vertical portion* lies directly on the front of the spine; it arises, below, from the front of the bodies of the upper three dorsal and lower three cervical vertebræ, and is inserted above into the front of the bodies of the second, third, and fourth cervical vertebræ above.

Relations.—By its *anterior surface*, with the prevertebral fascia, the pharynx, the œsophagus, sympathetic nerve, the sheath of the great vessels of the neck, the inferior thyroid artery, and recurrent laryngeal nerve; by its *posterior surface*, with the cervical and dorsal portions of the spine. Its *inner border* is separated from the opposite muscle by a considerable interval below, but they approach each other above.

8. Lateral Vertebral Region.

Scalenus anticus. Scalenus medius.
Scalenus posticus.

The **Scalenus anticus** is a conical-shaped muscle, situated deeply at the side of the neck, behind the Sterno-mastoid. It arises from the anterior tubercles of the

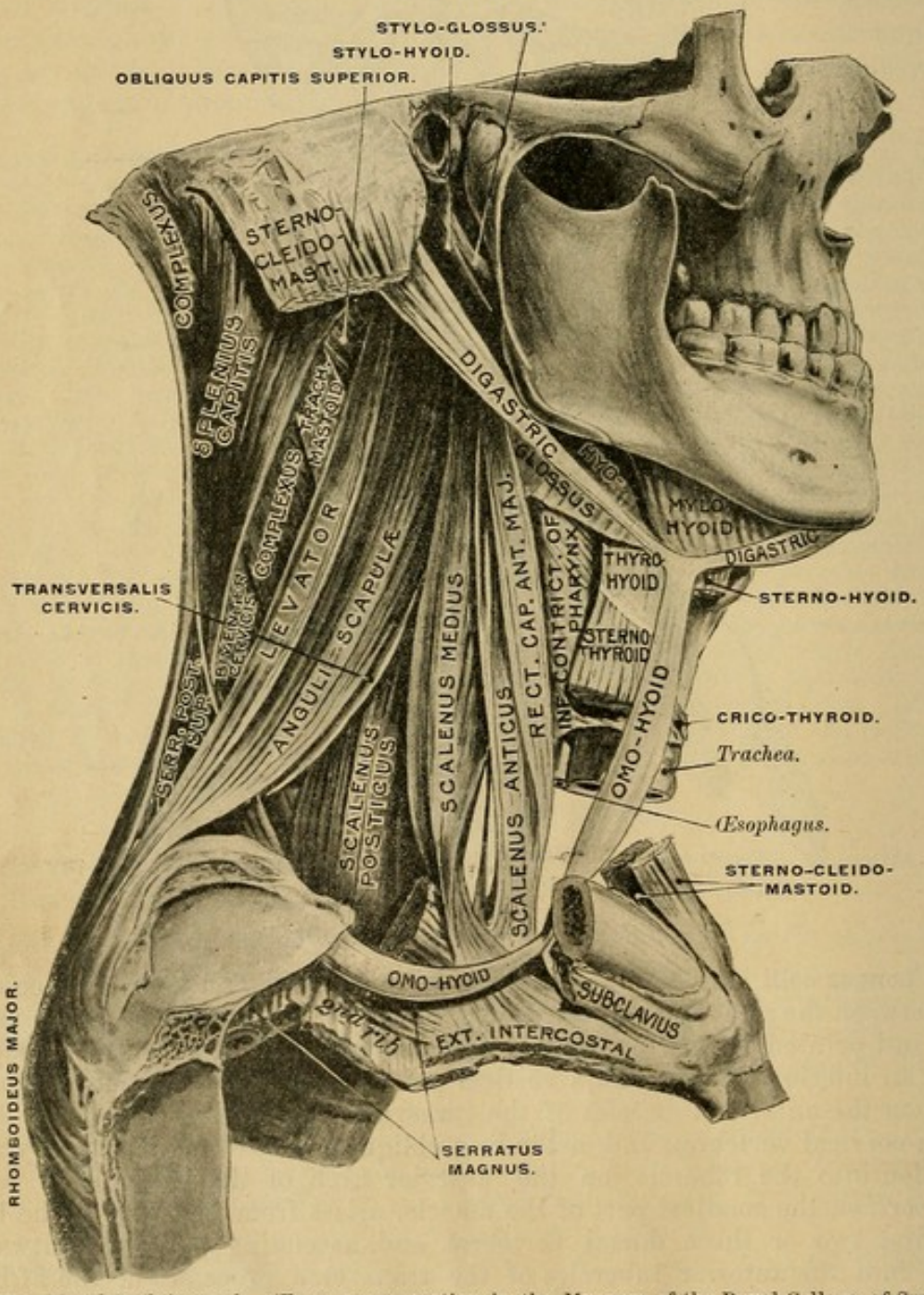

FIG. 211.—Muscles of the neck. (From a preparation in the Museum of the Royal College of Surgeons of England.)

transverse processes of the third, fourth, fifth, and sixth cervical vertebræ, and, descending almost vertically, is inserted by a narrow, flat tendon into the Scalene

tubercle on the inner border and upper surface of the first rib. The lower part of this muscle separates the subclavian artery and vein, the latter being in front, and the former, with the brachial plexus, behind.

Relations.—*In front*, with the clavicle, the Subclavius, Sterno-mastoid, and Omo-hyoid muscles, the transversalis colli, the suprascapular and ascending cervical arteries, the subclavian vein, and the phrenic nerve; by its *posterior surface*, with the Scalenus medius, pleura, the subclavian artery, and brachial plexus of nerves. It is separated from the Longus colli, on the inner side, by the vertebral artery. On the anterior tubercles of the transverse processes of the cervical vertebræ, between the attachments of the Scalenus anticus and Longus colli, lies the ascending cervical branch of the inferior thyroid artery.

The **Scalenus medius,** the largest and longest of the three Scaleni, arises from the posterior tubercles of the transverse processes of the lower six cervical vertebræ, and, descending along the side of the vertebral column, is inserted by a broad attachment into the upper surface of the first rib, behind the groove for the subclavian artery, as far back as the tubercle. It is separated from the Scalenus anticus by a subclavian artery below and the cervical nerves above. The posterior thoracic, or nerve of Bell, is formed in the substance of the Scalenus medius and emerges from it. The nerve to the Rhomboids also pierces it.

Relations.—By its *anterior surface*, with the Sterno-mastoid; it is crossed by the clavicle, the Omo-hyoid muscle, subclavian artery, and the cervical nerves. To its *outer side* is the Levator anguli scapulæ and the Scalenus posticus muscle.

The **Scalenus posticus,** the smallest of the three Scaleni, arises, by two or three separate tendons, from the posterior tubercles of the transverse processes of the lower two or three cervical vertebræ, and, diminishing as it descends, is inserted by a thin tendon into the outer surface of the second rib, behind the attachment of the Serratus magnus. This is the most deeply placed of the three Scaleni, and is occasionally blended with the Scalenus medius.

Nerves.—The Rectus capitis anticus major and minor and the Rectus lateralis are supplied by the first cervical nerve, and from the loop formed between it and the second; the Longus colli and Scaleni, by branches from the anterior divisions of the lower cervical nerves (fifth, sixth, seventh, and eighth) before they form the brachial plexus. The Scalenus medius also receives a filament from the deep external branches of the cervical plexus.

Actions.—The Rectus anticus major and minor are the direct antagonists of the muscles at the back of the neck, serving to restore the head to its natural position after it has been drawn backward. These muscles also serve to flex the head, and, from their obliquity, rotate it, so as to turn the face to one or the other side. The Longus colli flexes and slightly rotates the cervical portion of the spine. The Scaleni muscles, when they take their fixed point from above, elevate the first and second ribs, and are, therefore, inspiratory muscles. When they take their fixed point from below, they bend the spinal column to one or the other side. If the muscles of both sides act, lateral movement is prevented, but the spine is slightly flexed. The Rectus lateralis, acting on one side, bends the head laterally.

Surface Form.—The muscles in the neck, with the exception of the Platysma myoides, are invested by the deep cervical fascia, which softens down their form, and is of considerable importance in connection with deep cervical abscesses and tumors, modifying the direction of their growth and causing them to extend laterally instead of toward the surface. The *Platysma myoides* does not influence surface form except it is in action, when it produces wrinkling of the skin of the neck, which is thrown into oblique ridges parallel with the fasciculi of the muscle. Sometimes this contraction takes place suddenly and repeatedly as a sort of spasmodic twitching, the result of a nervous habit. The *Sterno-cleido-mastoid* is the most important muscle of the neck as regards its surface form. If the muscle is put into action by drawing the chin downward and to the opposite shoulder, its surface form will be plainly outlined. The sternal origin will stand out as a sharply-defined ridge, while the clavicular origin will present a flatter and not so prominent an outline. The fleshy middle portion will appear as an oblique roll or elevation, with a thick rounded anterior border gradually becoming less marked above. On the opposite side—*i. e.* on the side to which the head is turned—the outline is lost, its place being occupied by an oblique groove in the integument. When the muscle is at rest its anterior border is still

visible, forming an oblique rounded ridge, terminating below in the sharp outline of the sternal head. The posterior border of the muscle does not show above the clavicular head. The anterior border is defined by drawing a line from the tip of the mastoid process to the sterno-clavicular joint. It is an important surface-marking in the operation of ligature of the common carotid artery and some other operations. Between the sternal and clavicular heads is a slight depression, most marked when the muscle is in action. This is bounded below by the prominent sternal extremity of the clavicle. Between the sternal origins of the two muscles is a V-shaped space, the *suprasternal notch*, more pronounced below, and becoming toned down above, where the Sterno-hyoid and Sterno-thyroid muscles, lying upon the trachea, become more prominent. Above the hyoid bone, in the middle line, the anterior belly of the *Digastric* to a certain extent influences surface form. It corresponds to a line drawn from the symphysis of the lower jaw to the side of the body of the hyoid bone, and renders this part of the hyo-mental region convex. In the posterior triangle of the neck, the posterior belly of the *Omo-hyoid*, when in action, forms a conspicuous object, especially in thin necks, presenting a cord-like form running across this region, almost parallel with, and a little above, the clavicle.

MUSCLES AND FASCIÆ OF THE TRUNK.

The muscles of the Trunk may be arranged in four groups, corresponding with the region in which they are situated.

I. The Back.
II. The Thorax.
III. The Abdomen.
IV. The Perinæum.

I. MUSCLES OF THE BACK.

The muscles of the Back are very numerous, and may be subdivided into five layers:

First Layer.

Trapezius.
Latissimus dorsi.

Second Layer.

Levator anguli scapulæ.
Rhomboideus minor.
Rhomboideus major.

Third Layer.

Serratus posticus superior.
Serratus posticus inferior.
Splenius capitis.
Splenius colli.

Fourth Layer.

Sacral and Lumbar Regions.

Erector spinæ.

Dorsal Region.

Ilio-costalis.
Musculus accessorius ad ilio-costalem.
Longissimus dorsi.
Spinalis dorsi.

Cervical Region.

Cervicalis ascendens.
Transversalis cervicis.
Trachelo-mastoid.
Complexus.
Biventer cervicis.
Spinalis colli.

Fifth Layer.

Semispinalis dorsi.
Semispinalis colli.
Multifidus spinæ.
Rotatores spinæ.
Supraspinales.
Interspinales.
Extensor coccygis.
Intertransversales.
Rectus capitis posticus major.
Rectus capitis posticus minor.
Obliquus capitis inferior.
Obliquus capitis superior.

First Layer.

Trapezius. Latissimus dorsi.

Dissection (Fig. 212).—Place the body in a prone position, with the arms extended over the sides of the table, and the chest and abdomen supported by several blocks, so as to render the muscles tense. Then make an incision along the middle line of the back from the occipital protuberance to the coccyx. Make a transverse incision from the upper end of this to

the mastoid process, and a third incision from its lower end, along the crest of the ilium to about its middle. This large intervening space should, for convenience of dissection, be subdivided by a fourth incision, extending obliquely from the spinous process of the last dorsal vertebra, upward and outward, to the acromion process. This incision corresponds with the lower border of the Trapezius muscle. The flaps of integument are then to be removed in the direction shown in the figure.

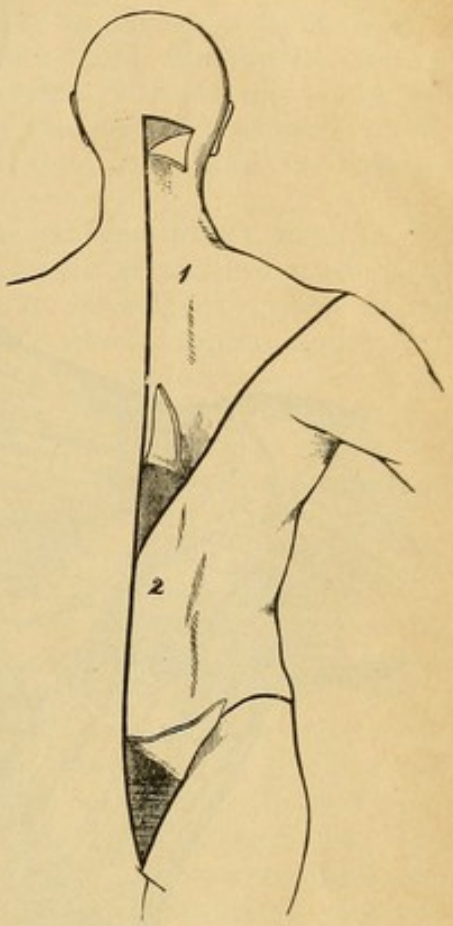

FIG. 212.—Dissection of the muscles of the back.

The **superficial fascia** is exposed upon removing the skin from the back. It forms a layer of considerable thickness and strength, in which a quantity of granular pinkish fat is contained. It is continuous with the superficial fascia in other parts of the body. The **deep fascia** is a dense fibrous layer attached to the occipital bone, the spines of the vertebræ, the crest of the ilium, and the spine of the scapula. It covers over the superficial muscles, forming sheaths for them, and in the neck forms the posterior part of the deep cervical fascia; in the thorax it is continuous with the deep fascia of the axilla and chest, and in the abdomen with that covering the abdominal muscles.

The **Trapezius** (Fig. 213) is a broad, flat, triangular muscle, placed immediately beneath the skin and fascia, and covering the upper and back part of the neck and shoulders. It arises from the external occipital protuberance and the inner third of the superior curved line of the occipital bone; from the ligamentum nuchæ, the spinous process of the seventh cervical, and those of all the dorsal vertebræ; and from the corresponding portion of the supraspinous ligament. From this origin the superior fibres proceed downward and outward, the inferior ones upward and outward, and the middle fibres horizontally, and are inserted, the superior ones into the outer third of the posterior border of the clavicle; the middle fibres into the inner margin of the acromion process, and into the superior lip of the posterior border or crest of the spine of the scapula; the inferior fibres converge near the scapula, and terminate in a triangular aponeurosis, which glides over a smooth surface at the inner extremity of the spine, to be inserted into a tubercle at the outer part of this smooth surface. The Trapezius is fleshy in the greater part of its extent, but tendinous at its origin and insertion. At its occipital origin it is connected to the bone by a thin fibrous lamina, firmly adherent to the skin, and wanting the lustrous, shining appearance of aponeuroses. At its origin from the spines of the vertebræ it is connected to the bones by means of a broad semi-elliptical aponeurosis, which occupies the space between the sixth cervical and the third dorsal vertebræ, and forms, with the aponeurosis of the opposite muscle, a tendinous ellipse. The rest of the muscle arises by numerous short tendinous fibres. If the Trapezius is dissected on both sides, the two muscles resemble a trapezium or diamond-shaped quadrangle; two angles corresponding to the shoulders; a third to the occipital protuberance; and the fourth to the spinous process of the last dorsal vertebra.

The clavicular insertion of this muscle varies as to the extent of its attachment; it sometimes advances as far as the middle of the clavicle, and may even become blended with the posterior edge of the Sterno-mastoid or overlap it. This should be borne in mind in the operation for tying the third part of the subclavian artery.

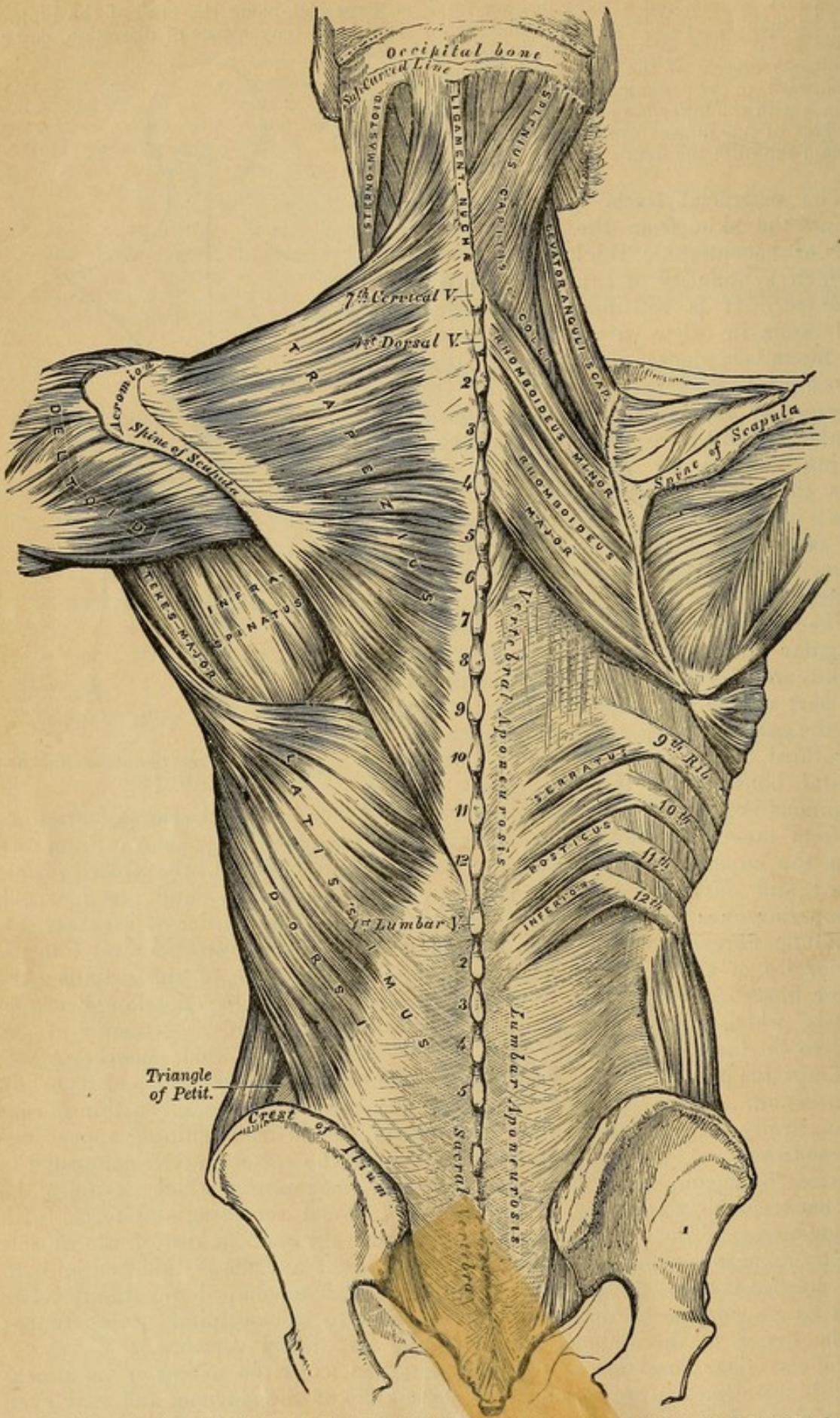

FIG. 213.—Muscles of the back. On the left side is exposed the first layer; on the right side, the second layer and part of the third.

Relations.—By its *superficial surface*, with the integument; by its *deep surface*, in the neck, with the Complexus, Splenius, Levator anguli scapulæ, and

Rhomboideus minor; in the back, with the Rhomboideus major, Supraspinatus, Infraspinatus, and Vertebral aponeurosis (which separates it from the prolongations of the Erector spinæ), and the Latissimus dorsi. The spinal accessory nerve and the superficial cervical artery and branches from the third and fourth cervical nerves pass beneath the anterior border of this muscle. The anterior margin of its cervical portion forms the posterior boundary of the posterior triangle of the neck, the other boundaries being the Sterno-mastoid in front and the clavicle below.

The **Ligamentum nuchæ** (Fig. 213) is a fibrous membrane, which, in the neck, represents the supraspinous and interspinous ligaments of the lower vertebræ. It extends from the external occipital protuberance to the spinous process of the seventh cervical vertebra. From its anterior border a fibrous lamina is given off, which is attached to the external occipital crest, the posterior tubercle of the atlas, and the spinous process of each of the cervical vertebræ, so as to form a septum between the muscles on each side of the neck. In man it is merely the rudiment of an important elastic ligament, which, in some of the lower animals, serves to sustain the weight of the head.

The **Latissimus dorsi** is a broad flat muscle which covers the lumbar and the lower half of the dorsal regions, and is gradually contracted into a narrow fasciculus at its insertion into the humerus. It arises by tendinous fibres from the spinous processes of the six inferior dorsal vertebræ and from the posterior layer of the lumbar fascia (see page 342), by which it is attached to the spines of the lumbar and sacral vertebræ and to the supraspinous ligament. It also arises from the external lip of the crest of the ilium, behind the origin of the External oblique, and by fleshy digitations from the three or four lower ribs, which are interposed between similar processes of the External oblique muscle (Fig. 218, page 358). From this extensive origin the fibres pass in different directions, the upper ones horizontally, the middle obliquely upward, and the lower vertically upward, so as to converge and form a thick fasciculus, which crosses the inferior angle of the scapula, and occasionally receives a few fibres from it. The muscle then curves around the lower border of the Teres major, and is twisted upon itself, so that the superior fibres become at first posterior and then inferior, and the vertical fibres at first anterior and then superior. It then terminates in a short quadrilateral tendon, about three inches in length, which, passing in front of the tendon of the Teres major, is inserted into the bottom of the bicipital groove of the humerus, its insertion extending higher on the humerus than that of the tendon of the Pectoralis major. The lower border of the tendon of this muscle is united with that of the Teres major, the surfaces of the two being separated by a bursa; another bursa is sometimes interposed between the muscle and the inferior angle of the scapula. This muscle at its insertion gives off an expansion to the deep fascia of the arm.

A muscular slip, *axillary arch*, varying from 3 to 4 inches in length, and from ¼ to ¾ of an inch in breadth, occasionally arises from the upper edge of the Latissimus dorsi about the middle of the posterior fold of the axilla, and crosses the axilla in front of the axillary vessels and nerves, to join the under surface of the tendon of the Pectoralis major, the Coraco-brachialis, or the fascia over the Biceps. The position of this abnormal slip is a point of interest in its relation to the axillary artery, as it crosses the vessel just above the spot usually selected for the application of a ligature, and may mislead the surgeon during the operation. It may be easily recognized by the transverse direction of its fibres. Dr. Struther found it, in 8 out of 105 subjects, occurring seven times on both sides.

There is usually a fibrous slip which passes from the lower border of the tendon of the Latissimus dorsi, near its insertion, to the long head of the Triceps. This is occasionally muscular, and is the representative of the *Dorso-epitrochlearis* muscle of apes.

Relations.—Its *superficial surface* is subcutaneous, excepting at its upper part, where it is covered by the Trapezius, and at its insertion, where its tendon is crossed by the axillary vessels and the brachial plexus of nerves. By its *deep surface* it is in relation with the Lumbar fascia, the Serratus posticus inferior, the lower external intercostal muscles and ribs, inferior angle of the scapula, Rhomboideus major, Infraspinatus, and Teres major. Its outer margin is

separated below from the External oblique by a small triangular interval, the triangle of Petit; and another triangular interval exists between its upper border and the margin of the Trapezius, in which the Rhomboideus major muscle is exposed.

Nerves.—The Trapezius is supplied by the spinal accessory, and by branches from the anterior divisions of the third and fourth cervical nerves: the Latissimus dorsi, by the middle or long subscapular nerve.

Second Layer.

Levator anguli scapulæ. Rhomboideus minor.
Rhomboideus major.

Dissection.—The Trapezius must be removed, in order to expose the next layer; to effect this, detach the muscle from its attachment to the clavicle and spine of the scapula, and turn it back toward the spine.

The **Levator anguli scapulæ** is situated at the back part and side of the neck. It arises by tendinous slips from the transverse process of the atlas, and from the posterior tubercles of the transverse process of the second, third, and fourth cervical vertebræ; these, becoming fleshy, are united so as to form a flat muscle, which, passing downward and backward, is inserted into the posterior border of the scapula, between the superior angle and the triangular smooth surface at the root of the spine.

Relations.—By its *superficial surface*, with the integument, Trapezius, and Sterno-mastoid; by its *deep surface*, with the Splenius colli, Transversalis cervicis, Cervicalis ascendens, and Serratus posticus superior muscles, and with the posterior scapular artery and the nerve to the Rhomboids.

The **Rhomboideus minor** arises from the ligamentum nuchæ and spinous processes of the seventh cervical and first dorsal vertebræ. Passing downward and outward, it is inserted into the margin of the triangular smooth surface at the root of the spine of the scapula. This small muscle is usually separated from the Rhomboideus major by a slight cellular interval.

Relations.—By its *superficial* (*posterior*) *surface*, with the Trapezius; by its *deep surface*, with the same structures as the Rhomboideus major.

The **Rhomboideus major** is situated immediately below the preceding, the adjacent margins of the two being occasionally united. It arises by tendinous fibres from the spinous processes of the four or five upper dorsal vertebræ and the supraspinous ligament, and is inserted into a narrow tendinous arch attached above to the lower part of the triangular surface at the root of the spine; below, to the inferior angle, the arch being connected to the border of the scapula by a thin membrane. When the arch extends, as it occasionally does, but a short distance, the muscular fibres are inserted into the scapula itself.

Relations.—By its *superficial* (*posterior*) *surface*, with the Latissimus dorsi; by its *deep* (*anterior*) *surface*, with the Serratus posticus superior, posterior scapular artery, the vertebral aponeurosis which separates it from the prolongations from the Erector spinæ, the Intercostal muscles, and ribs.

Nerves.—The Rhomboid muscles are supplied by branches from the anterior division of the fifth cervical nerve; the Levator anguli scapulæ, by the anterior division of the third and fourth cervical nerves, and frequently by a branch from the nerve to the Rhomboids.

Actions.—The movements effected by the preceding muscles are numerous, as may be conceived from their extensive attachment. The whole of the Trapezius when in action retracts the scapula and braces back the shoulder; if the head is fixed, the upper part of the *Trapezius* will elevate the point of the shoulder, as in supporting weights; when the lower fibres are brought into action, they assist in depressing the bone. The middle and lower fibres of the muscle rotate the scapula, causing elevation of the acromion process If the shoulders are fixed, both

Trapezii, acting together, will draw the head directly backward; or if only one acts, the head is drawn to the corresponding side.

The *Latissimus dorsi*, when it acts upon the humerus, depresses it, draws it backward, adducts, and at the same time rotates it inward. It is the muscle which is principally employed in giving a downward blow, as in felling a tree or in sabre practice. If the arm is fixed, the muscle may act in various ways upon the trunk; thus, it may raise the lower ribs and assist in forcible inspiration; or, if both arms are fixed, the two muscles may assist the Abdominal and great Pectoral muscles in suspending and drawing the whole trunk forward, as in climbing or walking on crutches.

The *Levator anguli scapulæ* raises the superior angle of the scapula, assisting the Trapezius in bearing weights or in shrugging the shoulders. If the shoulder be fixed, the Levator anguli scapulæ inclines the neck to the corresponding side and rotates it in the same direction. The Rhomboid muscles carry the inferior angle backward and upward, thus producing a slight rotation of the scapula upon the side of the chest, the Rhomboideus major acting especially on the lower angle of the scapula through the tendinous arch by which it is inserted. The Rhomboid muscles, acting together with the middle and inferior fibres of the Trapezius, will draw the scapula directly backward toward the spine.

Third Layer.

Serratus posticus superior. Serratus posticus inferior.

Splenius { Splenius capitis. / Splenius colli.

Dissection.—To bring into view the third layer of muscles, remove the whole of the second, together with the Latissimus dorsi, by cutting through the Levator anguli scapulæ and Rhomboid muscles near their origin, and reflecting them downward, and by dividing the Latissimus dorsi in the middle by a vertical incision carried from its upper to its lower part, and reflecting the two halves of the muscle.

The **Serratus posticus superior** is a thin, flat, quadrilateral muscle situated at the upper and back part of the thorax. It arises by a thin and broad aponeurosis from the ligamentum nuchæ, and from the spinous processes of the last cervical and two or three upper dorsal vertebræ and from the supraspinous ligament. Inclining downward and outward, it becomes muscular, and is inserted, by four fleshy digitations into the upper borders of the second, third, fourth, and fifth ribs, a little beyond their angles.

Relations.—By its *superficial surface*, with the Trapezius, Rhomboidei, and Levator anguli scapulæ; by its *deep surface*, with the Splenius and the vertebral aponeurosis, which separates it from the prolongations of the Erector spinæ, and with the Intercostal muscles and ribs.

The **Serratus posticus inferior** is situated at the junction of the dorsal and lumbar regions; it is of an irregularly quadrilateral form, broader than the preceding, and separated from it by a considerable interval. It arises by a thin aponeurosis from the spinous processes of the last two dorsal and two or three upper lumbar vertebræ, and from the supraspinous ligaments. Passing obliquely upward and outward, it becomes fleshy, and divides into four flat digitations, which are inserted into the lower borders of the four lower ribs, a little beyond their angles. The thin aponeurosis of origin is intimately blended with the lumbar fascia.

Relations.—By its *superficial surface*, with the Latissimus dorsi. By its *deep surface*, with the Erector spinæ, ribs, and Intercostal muscles. Its upper margin is continuous with the vertebral aponeurosis.

The *Vertebral aponeurosis* is a thin, fibrous lamina, extending along the whole length of the back part of the thoracic region, serving to bind down the long Extensor muscles of the back which support the spine and head, and separate them from those muscles which connect the spine to the upper extremity. It consists of longitudinal and transverse fibres blended together, forming a thin lamella, which is attached in the median line to the spinous processes of the dorsal vertebræ; ex-

ternally, to the angles of the ribs; and below, to the upper border of the Serratus posticus inferior and a portion of the lumbar fascia, which gives origin to the Latissimus dorsi; above, it passes beneath the Serratus posticus superior and the Splenius, and blends with the deep fascia of the neck.

The *Lumbar fascia* or *aponeurosis* (Fig. 213), which may be regarded as the posterior aponeurosis of the Transversalis abdominis muscle, consists of three laminæ, which are attached as follows: the posterior layer, to the spines of the lumbar and sacral vertebræ and their supraspinous ligaments; the middle, to the tips of the transverse processes of the lumbar vertebræ and their intertransverse ligaments; the anterior, to the roots of the lumbar transverse processes. The posterior layer is continued above as the vertebral aponeurosis, while inferiorily it is fixed to the outer lip of the iliac crest. With this layer are blended the aponeurotic origin of the Serratus posticus inferior and part of that of the Latissimus dorsi. The middle layer is attached above to the last rib, and below to the iliac crest; the anterior layer is fixed below to the ilio-lumbar ligament and iliac crest; while above it is thickened to form the external arcuate ligament of the diaphragm, and stretches from the tip of the last rib to the transverse process of the first or second lumbar vertebra. These three layers, together with the vertebral column, enclose two spaces, the posterior of which is occupied by the Erector spinæ muscle, and the anterior by the Quadratus lumborum.

Now detach the Serratus posticus superior from its origin, and turn it outward, when the Splenius muscle will be brought into view.

The **Splenius** is situated at the back of the neck and upper part of the dorsal region. At its origin it is a single muscle, narrow, and pointed in form; but it soon becomes broader, and divides into two portions, which have separate insertions. It arises, by tendinous fibres, from the lower half of the ligamentum nuchæ, from the spinous processes of the last cervical and of the six upper dorsal vertebræ, and from the supraspinous ligament. From this origin the fleshy fibres proceed obliquely upward and outward, forming a broad flat muscle, which divides as it ascends into two portions, the Splenius capitis and Splenius colli.

The **Splenius capitis** is inserted into the mastoid process of the temporal bone, and into the rough surface on the occipital bone just beneath the superior curved line.

The **Splenius colli** is inserted, by tendinous fasciculi, into the posterior tubercles of the transverse processes of the two or three upper cervical vertebræ.

The Splenius is separated from its fellow of the opposite side by a triangular interval, in which is seen the Complexus.

Relations.—By its *superficial surface*, with the Trapezius, from which it is separated below by the Rhomboidei and the Serratus posticus superior. It is covered at its insertion by the Sterno-mastoid, and at the lower and back part of the neck by the Levator anguli scapulæ; by its *deep surface*, with the Spinalis dorsi, Longissimus dorsi, Semispinalis colli, Complexus, Trachelo-mastoid, and Transversalis cervicis.

Nerves.—The Splenius is supplied from the external branches of the posterior divisions of the cervical nerves; the Serratus posticus superior is supplied by the external branches of the posterior divisions of the upper dorsal nerves; the Serratus posticus inferior by the external branches of the posterior divisions of the lower dorsal nerves.

Actions.—The Serrati are respiratory muscles. The Serratus posticus superior elevates the ribs; it is therefore an inspiratory muscle; while the Serratus inferior draws the lower ribs downward and backward, and thus elongates the thorax. It also fixes the lower ribs, thus aiding the downward action of the diaphragm and resisting the tendency which it has to draw the lower ribs upward and forward. It must therefore be regarded as a muscle of inspiration. This muscle is also probably a tensor of the vertebral aponeurosis. The Splenii muscles of the two sides, acting together, draw the head directly backward, assisting the Trapezius

and Complexus; acting separately, they draw the head to one or the other side, and slightly rotate it, turning the face to the same side. They also assist in supporting the head in the erect position.

Fourth Layer.

I. Erector spinæ.

a. Outer Column.	*b. Middle Column.*
Ilio-costalis.	Longissimus dorsi.
Musculus accessorius.	Transversalis cervicis.
Cervicalis ascendens.	Trachelo-mastoid.

c. Inner Column.

Spinalis dorsi.

II. Complexus.

Dissection.—To expose the muscles of the fourth layer, remove entirely the Serrati and the vertebral and lumbar fasciæ. Then detach the Splenius by separating its attachment to the spinous processes and reflecting it outward.

The **Erector spinæ** (Fig. 214) and its prolongations in the dorsal and cervical regions fill up the vertebral groove on each side of the spine. It is covered in the lumbar region by the lumbar fascia; in the dorsal region, by the Serrati muscles and the vertebral aponeurosis; and in the cervical region, by a layer of cervical fascia continued beneath the Trapezius and the Splenius. This large muscular and tendinous mass varies in size and structure at different parts of the spine. In the sacral region the Erector spinæ is narrow and pointed, and its origin chiefly tendinous in structure. In the lumbar region the muscle becomes enlarged, and forms a large fleshy mass. In the dorsal region it subdivides into two parts, which gradually diminish in size as they ascend to be inserted into the vertebræ and ribs.

The Erector spinæ arises from the anterior surface of a very broad and thick tendon, which is attached, internally, to the spines of the sacrum, to the spinous processes of the lumbar and the eleventh and twelfth dorsal vertebræ, and the supraspinous ligament; externally, to the back part of the inner lip of the crest of the ilium, and to the series of eminences on the posterior part of the sacrum, which represents the transverse processes, where it blends with the great sacro-sciatic and posterior sacro-iliac ligaments. Some of its fibres are continuous with the fibres of origin of the Gluteus maximus. The muscular fibres form a single large fleshy mass, bounded in front by the transverse processes of the lumbar vertebræ and by the middle lamella of the lumbar fascia. Opposite the last rib it divides into two parts, the Ilio-costalis and the Longissimus dorsi; the Spinalis dorsi is given off from the latter in the upper dorsal region.

The **Ilio-costalis** (*Sacro-lumbalis*), the external portion of the Erector spinæ, is inserted, generally, by six or seven flattened tendons into the inferior borders of the angles of the six or seven lower ribs. The number of the tendons of this muscle is, however, very variable, and therefore the number of ribs into which it is inserted. Frequently it is found to possess nine or ten tendons, and sometimes as many tendons as there are ribs, and is then inserted into the angles of all the ribs. If this muscle is reflected outward, it will be seen to be reinforced by a series of muscular slips which arise from the angles of the ribs; by means of these the Ilio-costalis is continued upward to the upper ribs and cervical portion of the spine. The accessory portions form two additional muscles, the Musculus accessorius and the Cervicalis ascendens.

The **Musculus accessorius ad ilio-costalem** arises, by separate flattened tendons, from the upper borders of the angles of the six lower ribs: these become muscular, and are finally inserted, by separate tendons, into the upper borders of the angles

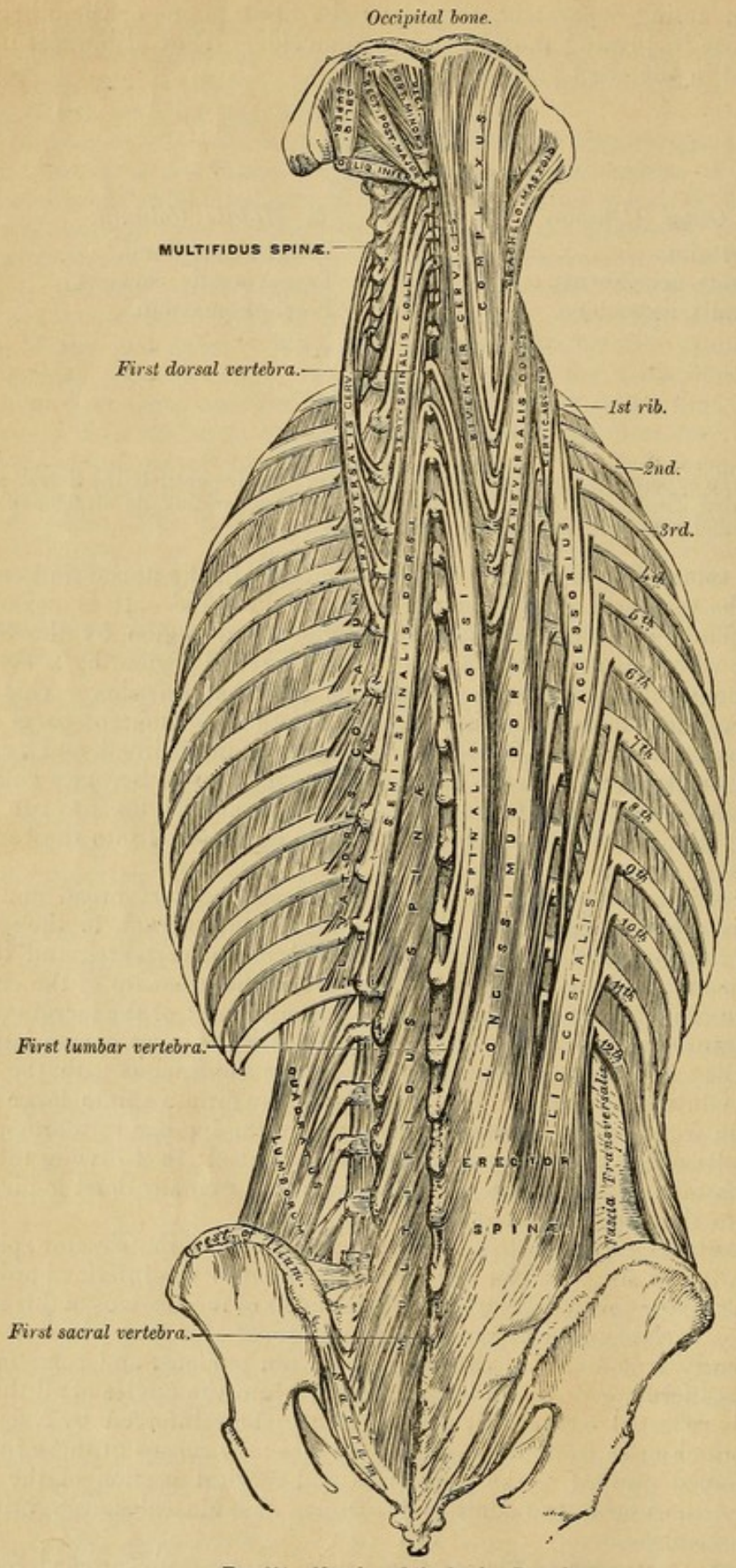

FIG. 214.—Muscles of the back. Deep layers.

of the six upper ribs and into the back of the transverse process of the seventh cervical vertebra.

The **Cervicalis ascendens**[1] is the continuation of the Accessorius upward into the neck; it is situated on the inner side of the tendons of the Accessorius, arising from the angles of the four or five upper ribs, and is inserted by a series of slender tendons into the posterior tubercles of the transverse processes of the fourth, fifth, and sixth cervical vertebræ.

The **Longissimus dorsi** is the middle and largest portion of the Erector spinæ. In the lumbar region, where it is as yet blended with the Ilio-costalis, some of the fibres are attached to the whole length of the posterior surface of the transverse processes and the accessory processes of the lumbar vertebræ, and to the middle layer of the lumbar fascia. In the dorsal region, the Longissimus dorsi is inserted, by long thin tendons, into the tips of the transverse processes of all the dorsal vertebræ, and into from seven to eleven of the lower ribs between their tubercles and angles. This muscle is continued upward to the cranium and cervical portion of the spine by means of two additional muscles, the Transversalis cervicis and Trachelo-mastoid.

The **Transversalis cervicis** or **colli,** placed on the inner side of the Longissimus dorsi, arises by long thin tendons from the summits of the transverse processes of the six upper dorsal vertebræ, and is inserted by similar tendons into the posterior tubercles of the transverse processes of the cervical vertebræ, from the second to the sixth inclusive.

The **Trachelo-mastoid** lies on the inner side of the preceding, between it and the Complexus muscle. It arises, by tendons, from the transverse processes of the five or six upper dorsal vertebræ, and the articular processes of the three or four lower cervical. The fibres form a small muscle, which ascends to be inserted into the posterior margin of the mastoid process, beneath the Splenius and Sterno-mastoid muscles. This small muscle is almost always crossed by a tendinous intersection near its insertion into the mastoid process.[2]

The **Spinalis dorsi** connects the spinous processes of the upper lumbar and the dorsal vertebræ together by a series of muscular and tendinous slips which are intimately blended with the Longissimus dorsi. It is situated at the inner side of the Longissimus dorsi, arising, by three or four tendons, from the spinous processes of the first two lumbar and the last two dorsal vertebræ: these, uniting, form a small muscle, which is inserted, by separate tendons, into the spinous processes of the dorsal vertebræ, the number varying from four to eight. It is intimately united with the Semispinalis dorsi, which lies beneath it.

The **Spinalis colli** is a small muscle, connecting together the spinous processes of the cervical vertebræ, and analogous to the Spinalis dorsi in the dorsal region. It varies considerably in its size and in its extent of attachment to the vertebræ, not only in different bodies, but on the two sides of the same body. It usually arises by fleshy or tendinous slips, varying from two to four in number, from the spinous processes of the fifth, sixth, and seventh cervical vertebræ, and occasionally from the first and second dorsal, and is inserted into the spinous process of the axis, and occasionally into the spinous processes of the two vertebræ below it. This muscle was found absent in five cases out of twenty-four.

Relations.—The Erector spinæ and its prolongations are bound down to the vertebræ and ribs in the lumbar and dorsal regions by the lumbar fascia and the vertebral aponeurosis. The inner part of these muscles covers the muscles of the fifth layer. In the neck they are in relation, by their *superficial surface*, with the Trapezius and Splenius; by their *deep surface*, with the Semispinalis dorsi et colli and the Recti and Obliqui.

The **Complexus** is a broad thick muscle, situated at the upper and back part of the neck, beneath the Splenius, and internal to the Transversalis cervicis and

[1] This muscle is sometimes called "Cervicalis descendens." The student should remember that these long muscles take their fixed point from above or from below, according to circumstances.

[2] These two muscles (Transversalis cervicis and Trachelo-mastoid) are sometimes described as one, having a common origin, but dividing above at their insertion. The Trachelo-mastoid is then termed the *Transversalis capitis*.

Trachelo-mastoid. It arises, by a series of tendons, from the tips of the transverse processes of the upper six or seven dorsal and the last cervical vertebræ, and from the articular processes of the three cervical above this. The tendons, uniting, form a broad muscle, which passes obliquely upward and inward, and is inserted into the innermost depression between the two curved lines of the occipital bone. This muscle, about its middle, is traversed by a transverse tendinous intersection. The *Biventer cervicis* is a small fasciculus, situated on the inner side of the preceding, and in the majority of cases blended with it; it has received its name from having a tendon intervening between two fleshy bellies. It is sometimes described as a part of the Complexus. It arises by from two to four tendinous slips, from the transverse processes of as many of the upper dorsal vertebræ, and is inserted, on the inner side of the Complexus, into the superior curved line of the occipital bone.

Relations.—The Complexus is covered by the Splenius and the Trapezius. It lies on the Rectus capitis posticus major and minor, the Obliquus capitis superior and inferior, and on the Semispinalis colli, from which it is separated by the profunda cervicis artery, the princeps cervicis artery, and branches of the posterior primary divisions of the cervical nerves. The Biventer cervicis is separated from its fellow of the opposite side by the ligamentum nuchæ.

Fifth Layer.

Semispinalis dorsi.	Extensor coccygis.
Semispinalis colli.	Intertransversales.
Multifidus spinæ.	Rectus capitis posticus major.
Rotatores spinæ.	Rectus capitis posticus minor.
Supraspinales.	Obliquus capitis inferior.
Interspinales.	Obliquus capitis superior.

Dissection.—Remove the muscles of the preceding layer by dividing and turning aside the Complexus; then detach the Spinalis and Longissimus dorsi from their attachments, divide the Erector spinæ at its connection below to the sacral and lumbar spines, and turn it outward. The muscles filling up the interval between the spinous and transverse processes are then exposed.

The **Semispinalis dorsi** (Fig. 214) consists of thin, narrow, fleshy fasciculi interposed between tendons of considerable length. It arises by a series of small tendons from the transverse processes of the lower dorsal vertebræ, from the tenth or eleventh to the fifth or sixth; and is inserted, by five or six tendons, into the spinous processes of the upper four dorsal and lower two cervical vertebræ.

The **Semispinalis colli**, thicker than the preceding, arises by a series of tendinous and fleshy fibres from the transverse processes of the upper five or six dorsal vertebræ, and is inserted into the spinous processes of four cervical vertebræ, from the axis to the fifth cervical. The fasciculus connected with the axis is the largest, and chiefly muscular in structure.

Relations.—By their *superficial surface*, from below upward, with the Spinalis dorsi, Longissimus dorsi, Splenius, Complexus, the profunda cervicis artery, the princeps cervicis artery, and the internal branches of the posterior divisions of the first, second, and third cervical nerves; by their *deep surface*, with the Multifidus spinæ.

The **Multifidus spinæ** consists of a number of fleshy and tendinous fasciculi which fill up the groove on either side of the spinous processes of the vertebræ, from the sacrum to the axis. In the sacral region these fasciculi arise from the back of the sacrum, as low as the fourth sacral foramen, and from the aponeurosis of origin of the Erector spinæ; from the inner surface of the posterior superior spine of the ilium and posterior sacro-iliac ligaments; in the lumbar regions, from the articular processes; in the dorsal region, from the transverse processes; and in the cervical region, from the articular processes of the three or four lower vertebræ. Each fasciculus, passing obliquely upward and inward, is inserted into the whole length of the spinous process of one of the vertebræ above. These fasciculi vary in length: the most superficial, the longest, pass from one vertebra to the

third or fourth above; those next in order pass from one vertebra to the second or third above; whilst the deepest connect two contiguous vertebræ.

Relations.—By its *superficial surface*, with the Longissimus dorsi, Spinalis dorsi, Semispinalis dorsi, and Semispinalis colli; by its *deep surface*, with the laminæ and spinous processes of the vertebræ, and with the Rotatores spinæ in the dorsal region.

The **Rotatores spinæ** are found only in the dorsal region of the spine, beneath the Multifidus spinæ; they are eleven in number on each side. Each muscle is small and somewhat quadrilateral in form; it arises from the upper and back part of the transverse process, and is inserted into the lower border and outer surface of the lamina of the vertebra above, the fibres extending as far inward as the root of the spinous process. The first is found between the first and second dorsal; the last, between the eleventh and twelfth. Sometimes the number of these muscles is diminished by the absence of one or more from the upper or lower end.

The **Supraspinales** consist of a series of fleshy bands which lie on the spinous processes in the cervical region of the spine.

The **Interspinales** are short muscular fasciculi, placed in pairs between the spinous processes of the contiguous vertebræ, one on each side of the interspinous ligament. In the *cervical region* they are most distinct, and consist of six pairs, the first being situated between the axis and third vertebra, and the last between the last cervical and the first dorsal. They are small narrow bundles, attached, above and below, to the apices of the spinous processes. In the *dorsal region* they are found between the first and second vertebræ, and occasionally between the second and third; and below, between the eleventh and twelfth. In the *lumbar region* there are four pairs of these muscles in the intervals between the five lumbar vertebræ. There is also occasionally one in the interspinous space, between the last dorsal and first lumbar, and between the fifth lumbar and the sacrum.

The **Extensor coccygis** is a slender muscular fasciculus, occasionally present, which extends over the lower part of the posterior surface of the sacrum and coccyx. It arises by tendinous fibres from the last bone of the sacrum or first piece of the coccyx, and passes downward to be inserted into the lower part of the coccyx. It is a rudiment of the Extensor muscle of the caudal vertebræ of the lower animals.

The **Intertransversales** are small muscles placed between the transverse processes of the vertebræ. In the *cervical region* they are most developed, consisting of rounded muscular and tendinous fasciculi, which are placed in pairs, passing between the anterior and the posterior tubercles of the transverse processes of two contiguous vertebræ, separated from one another by the anterior division of the cervical nerve, which lies in the groove between them. In this region there are seven pairs of these muscles, the first pair being between the atlas and axis, and the last pair between the seventh cervical and first dorsal vertebræ. In the *dorsal region* they are least developed, consisting chiefly of rounded tendinous cords in the intertransverse spaces of the upper dorsal vertebræ; but between the transverse processes of the lower three dorsal vertebræ, and between the transverse processes of the last dorsal and the first lumbar, they are muscular in structure. In the *lumbar region* they are arranged in pairs, on either side of the spine, one set occupying the entire interspace between the transverse processes of the lumbar vertebræ, the *intertransversales laterales*; the other set, *intertransversales mediales*, passing from the accessory process of one vertebra to the mammillary process of the next.

The **Rectus capitis posticus major** arises by a pointed tendinous origin from the spinous process of the axis, and, becoming broader as it ascends, is inserted into the inferior curved line of the occipital bone and the surface of bone immediately below it. As the muscles of the two sides pass upward and outward, they leave between them a triangular space, in which are seen the Recti capitis postici minores muscles.

Relations.—By its *superficial surface*, with the Complexus, and, at its insertion, with the Superior oblique ; by its *deep surface*, with part of the Rectus capitis posticus minor, the posterior arch of the atlas, the posterior occipito-atlantal ligament, and part of the occipital bone.

The **Rectus capitis posticus minor**, the smallest of the four muscles in this region, is of a triangular shape ; it arises by a narrow pointed tendon from the tubercle on the posterior arch of the atlas, and, becoming broader as it ascends, is inserted into the rough surface beneath the inferior curved line, nearly as far as the foramen magnum, nearer to the middle line than the preceding.

Relations.—By its *superficial surface*, with the Complexus and the Rectus capitis posticus major; by its *deep surface*, with the posterior occipito-atlantal ligament.

The **Obliquus capitis inferior**, the larger of the two Oblique muscles, arises from the apex of the spinous process of the axis, and passes outward and slightly upward, to be inserted into the lower and back part of the transverse process of the atlas.

Relations.—By its *superficial surface*, with the Complexus and with the posterior division of the second cervical nerve, which crosses it ; by its *deep surface*, with the vertebral artery and posterior atlanto-axial ligament.

The **Obliquus capitis superior**, narrow below, wide and expanded above, arises by tendinous fibres from the upper surface of the transverse process of the atlas, joining with the insertion of the preceding, and, passing obliquely upward and inward, is inserted into the occipital bone, between the two curved lines, external to the Complexus.

Relations.—By its *superficial surface*, with the Complexus and Trachelo-mastoid and occipital artery. By its *deep surface*, with the posterior occipito-atlantal ligament.

The Suboccipital Triangle.—Between the two oblique muscles and the Rectus capitis posticus major a triangular interval exists, the *suboccipital triangle*. This triangle is bounded, above and internally, by the Rectus capitis posticus major; above and externally, by the Obliquus capitis superior ; below and externally, by the Obliquus capitis inferior. It is covered in by a layer of dense fibro-fatty tissue, situated beneath the Complexus muscle. The floor is formed by the posterior occipito-atlantal ligament and the posterior arch of the atlas. It contains the vertebral artery, as it runs in a deep groove on the upper surface of the posterior arch of the atlas, and the posterior division of the suboccipital nerve.

Nerves.—The third, fourth, and fifth layers of the muscles of the back are supplied by the posterior primary divisions of the spinal nerves.

Actions.—When both the Spinales dorsi contract, they extend the dorsal region of the spine; when only one muscle contracts, it helps to bend the dorsal portion of the spine to one side. The Erector spinæ, comprising the Ilio-costalis and the Longissimus dorsi with their accessory muscles, serves, as its name implies, to maintain the spine in the erect posture; it also serves to bend the trunk backward when it is required to counterbalance the influence of any weight at the front of the body, as, for instance, when a heavy weight is suspended from the neck, or when there is any great abdominal distension, as in pregnancy or dropsy ; the peculiar gait under such circumstances depends upon the spine being drawn backward by the counterbalancing action of the Erector spinæ muscles. The muscles which form the continuation of the Erector spinæ upward steady the head and neck, and fix them in the upright position. If the Ilio-costalis and Longissimus dorsi of one side act, they serve to draw down the chest and spine to the corresponding side. The Cervicales ascendens, taking their fixed points from the cervical vertebræ, elevate those ribs to which they are attached; taking their fixed points from the ribs, both muscles help to extend the neck ; while one muscle bends the neck to its own side. The Transversalis cervicis, when both muscles act, taking their fixed point from below, bend the neck backward. The Trachelo-mastoid, when both muscles act, taking their fixed point from below, bend the head backward ; while, if only one muscle acts, the face is turned to the side on which the muscle is acting, and then the head is bent to the shoulder. The two Recti

muscles draw the head backward. The Rectus capitis posticus major, owing to its obliquity, rotates the cranium, with the atlas, round the odontoid process, turning the face to the same side. The Multifidus spinæ acts successively upon the different parts of the spine; thus, the sacrum furnishes a fixed point from which the fasciculi of this muscle act upon the lumbar region; these then become the fixed points for the fasciculi moving the dorsal region, and so on throughout the entire length of the spine; it is by the successive contraction and relaxation of the separate fasciculi of this and other muscles that the spine preserves the erect posture without the fatigue that would necessarily have been produced had this position been maintained by the action of a single muscle. The Multifidus spinæ, besides preserving the erect position of the spine, serves to rotate it, so that the front of the trunk is turned to the side opposite to that from which the muscle acts, this muscle being assisted in its action by the Obliquus externus abdominis. The Complexi draw the head directly backward: if one muscle acts, it draws the head to one side, and rotates it so that the face is turned to the opposite side. The Superior oblique draws the head backward, and, from the obliquity in the direction of its fibres, will slightly rotate the cranium, turning the face to the opposite side. The Obliquus capitis inferior rotates the atlas, and with it the cranium, round the odontoid process, turning the face to the same side. The Semispinales, when the muscles of the two sides act together, help to extend the spine; when the muscles of one side only act, they rotate the dorsal and cervical parts of the spine, turning the body to the opposite side. The Supraspinales and Interspinales by approximating the spinous processes help to extend the spine. The Intertransversales approximate the transverse processes, and help to bend the spine to one side. The Rotatores spinæ assist the Multifidus spinæ to rotate the spine, so that the front of the trunk is turned to the side opposite to that from which the muscle acts.

Surface Forms.—The surface forms produced by the muscles of the back are numerous and difficult to analyze unless they are considered in systematic order. The most superficial layer, consisting of large strata of muscular substance, influences to a certain extent the surface form, and at the same time reveals the forms of the layers beneath. The *Trapezius* at the upper part of the back, and in the neck, covers over and softens down the outline of the underlying muscles. Its anterior border forms the posterior boundary of the posterior triangle of the neck. It forms a slight undulating ridge which passes downward and forward from the occiput to the junction of the middle and outer third of the clavicle. The tendinous ellipse formed by a part of the origin of the two muscles at the back of the neck is always to be seen as an oval depression, more marked when the muscle is in action. A slight dimple on the skin opposite the interval between the spinous processes of the third and fourth dorsal vertebræ marks the triangular aponeurosis by which the inferior fibres are inserted into the root of the spine of the scapula. From this point the inferior border of the muscle may be traced as an undulating ridge to the spinous process of the twelfth dorsal vertebra. In like manner, the *Latissimus dorsi* softens down and modulates the underlying structures at the lower part of the back and lower part of the side of the chest. In this way it modulates the outline of the Erector spinæ; of the Serratus posticus inferior, which is sometimes to be discerned through it, and is sometimes entirely obscured by it; of part of the Serratus magnus and Superior oblique, which it covers; and of the convex oblique ridges formed by the ribs with the intervening intercostal spaces. The anterior border of the muscle is the only part which gives a distinct surface form. This border may be traced, when the muscle is in action, as a rounded edge, starting from the crest of the ilium, and passing obliquely forward and upward to the posterior border of the axilla, where it combines with the Teres major in forming a thick rounded fold, the posterior boundary of the axillary space. The muscles in the second layer influence to a very considerable extent the surface form of the back of the neck and upper part of the trunk. The *Levator anguli scapulæ* reveals itself as a prominent divergent line, running downward and outward, from the transverse processes of the upper cervical vertebræ to the angle of the scapula, covered over and toned down by the overlying Trapezius. The *Rhomboidei* produce, when in action, a vertical eminence between the vertebral border of the scapula and the spinal furrow, varying in intensity according to the condition of contraction or relaxation of the Trapezius muscle, by which they are for the most part covered. The lowermost part of the Rhomboideus major is uncovered by the Trapezius, and forms on the surface an oblique ridge running upward and inward from the inferior angle of the scapula. Of the muscles of the third layer of the back, the *Serratus posticus superior* does not in any way influence surface form. The *Serratus posticus inferior*, when in strong action, may occasionally be revealed as an elevation beneath the Latissimus dorsi. The *Splenii* by their divergence serve to broaden out the upper part of the back of the neck and produce a

local fulness in this situation, but do not otherwise influence surface form. Beneath all these muscles those of the fourth layer—the *Erector spinæ* and its continuations—influence the surface form in a decided manner. In the loins, the Erector spinæ, bound down by the lumbar fascia, forms a rounded vertical eminence, which determines the depth of the spinal furrow, and which below tapers to a point on the posterior surface of the sacrum and becomes lost there. In the back it forms a flattened plane which gradually becomes lost. In the neck the only part of this group of muscles which influences surface form is the *Trachelo-mastoid*, which produces a short convergent line across the upper part of the posterior triangle of the neck, appearing from under cover of the posterior border of the Sterno-mastoid and being lost below beneath the Trapezius.

2. MUSCLES AND FASCIÆ OF THE THORAX.

The muscles belonging exclusively to this region are few in number. They are the

Intercostales externi.	Triangularis sterni.
Intercostales interni.	Levatores costarum.
Infracostales.	Diaphragm.

Intercostal Fasciæ.—A thin but firm layer of fascia covers the outer surface of the External intercostal and the inner surface of the Internal intercostal muscles; and a third layer, the middle intercostal fascia, more delicate, is interposed between the two planes of muscular fibres. These are the intercostal fasciæ; they are best marked in those situations where the muscular fibres are deficient, as between the External intercostal muscles and sternum, in front, and between the Internal intercostals and spine, behind.

The **Intercostal muscles** (Fig. 230) are two thin planes of muscular and tendinous fibres, placed one over the other, filling up the intercostal spaces, and being directed obliquely between the margins of the adjacent ribs. They have received the name "external" and "internal" from the position they bear to one another. The tendinous fibres are longer and more numerous than the muscular; hence the walls of the intercostal spaces possess very considerable strength, to which the crossing of the muscular fibres materially contributes.

The **External Intercostals** are eleven in number on each side. They extend from the tubercles of the ribs, behind, to the commencement of the cartilages of the ribs, in front, where they terminate in a thin membrane, the anterior intercostal membrane, which is continued forward to the sternum. They arise from the lower border of each rib, and are inserted into the upper border of the rib below. In the two lowest spaces they extend to the end of the cartilages, and in the upper two or three spaces they do not quite extend to the ends of the ribs. Their fibres are directed obliquely downward and forward, in a similar direction with those of the External oblique muscle of the abdomen. They are thicker than the Internal intercostals.

Relations.—By their *outer surface*, with the muscles which immediately invest the chest—viz. the Pectoralis major and minor, Serratus magnus, and Rhomboideus major, Serratus posticus superior and inferior, Scalenus posticus, Ilio-costalis, Longissimus dorsi, Cervicalis ascendens, Transversalis cervicis, Levatores costarum, Obliquus externus abdominis, and the Latissimus dorsi; by their *internal surface*, with the middle intercostal fascia, which separates them from the intercostal vessels and nerve and the Internal intercostal muscles, and, behind, from the pleura.

The **Internal intercostals** are also eleven in number on each side. They commence anteriorly at the sternum, in the interspaces between the cartilages of the true ribs, and from the anterior extremities of the cartilages of the false ribs, and extend backward as far as the angles of the ribs, whence they are continued to the vertebral column by a thin aponeurosis, the posterior intercostal membrane. They arise from the ridge on the inner surface of each rib, as well as from the corresponding costal cartilage, and are inserted into the upper border of the rib below. Their fibres are directed obliquely downward and backward, passing in the opposite direction to the fibres of the External intercostal muscle.

Relations.—By their *external surface*, with the intercostal vessels and nerves and the External intercostal muscles; near the sternum, with the anterior inter-

costal membrane and the Pectoralis major. By their *internal surface*, with the pleura costalis, Triangularis sterni, and Diaphragm.

The **Infracostales** (**subcostales**) consist of muscular and aponeurotic fasciculi, which vary in number and length: they are placed on the inner surface of the ribs, where the Internal intercostal muscles cease; they arise from the inner surface of one rib, and are inserted into the inner surface of the first, second, or third rib below. Their direction is most usually oblique, like the Internal intercostals. They are most frequent between the lower ribs.

The **Triangularis sterni** (Fig. 215) is a thin plane of muscular and tendinous fibres, situated upon the inner wall of the front of the chest. It arises from the lower third of the posterior surface of the sternum, from the posterior surface of the ensiform cartilage, and from the sternal ends of the costal cartilages of the three

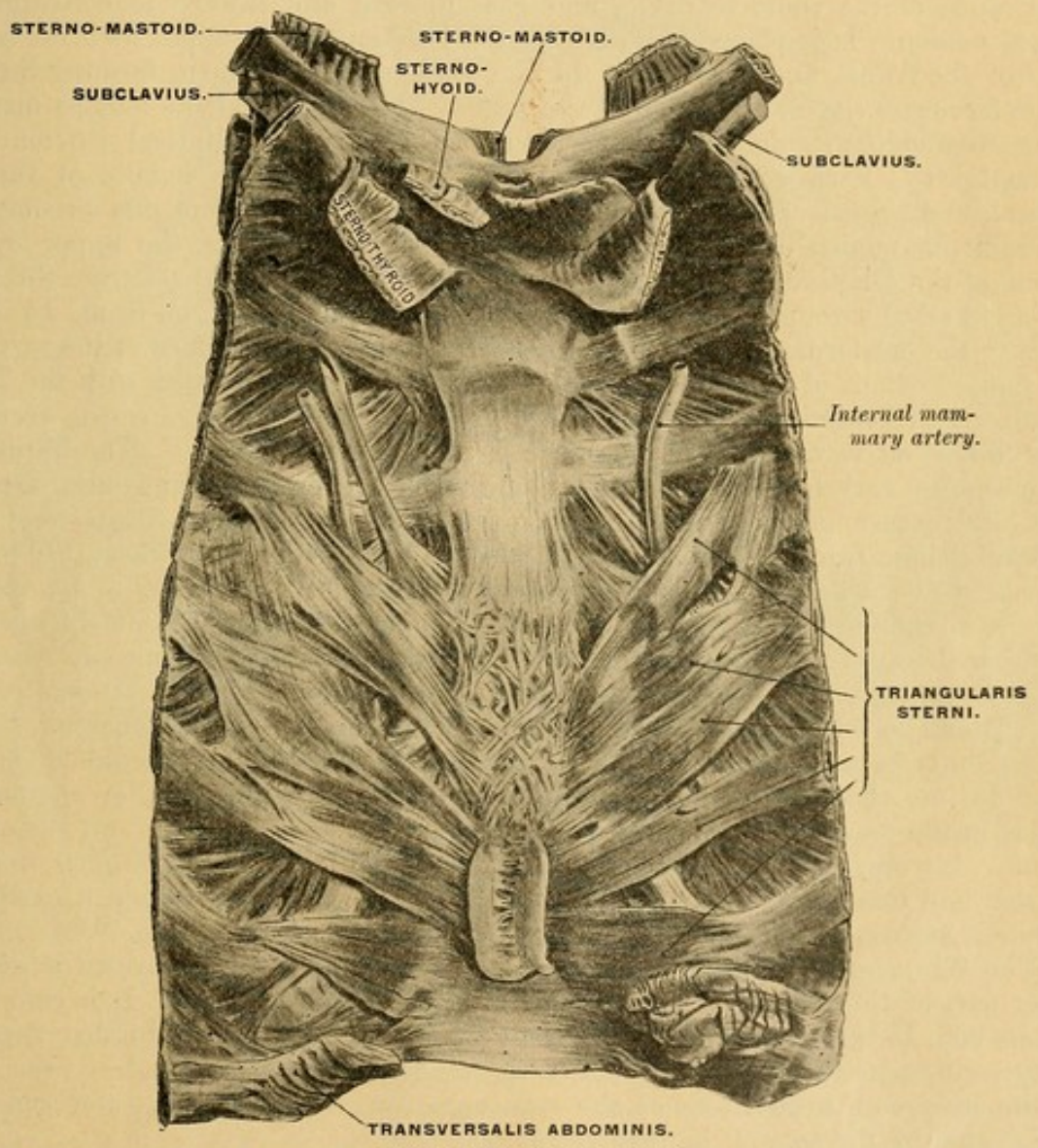

FIG. 215.—Posterior surface of sternum and costal cartilages, showing Triangularis sterni muscle. (From a preparation in the Museum of the Royal College of Surgeons of England.)

or four lower true ribs. Its fibres diverge upward and outward, to be inserted by digitations into the lower border and inner surfaces of the costal cartilages of the second, third, fourth, fifth, and sixth ribs. The lowest fibres of this muscle are horizontal in their direction, and are continuous with those of the Transversalis; those which succeed are oblique, whilst the superior fibres are almost vertical. This muscle varies much in its attachment, not only in different bodies, but on opposite sides of the same body.

Relations.—*In front*, with the sternum, ensiform cartilage, costal cartilages,

Internal intercostal muscles, and internal mammary vessels; *behind*, with the pleura, pericardium, and anterior mediastinum.

The **Levatores Costarum** (Fig. 214), twelve in number on each side, are small tendinous and fleshy bundles which arise from the extremities of the transverse processes of the seventh cervical and eleven upper dorsal vertebræ, and, passing obliquely downward and outward, are inserted into the upper border of the rib below them, between the tubercle and the angle. The Inferior levatores divide into two fasciculi, one of which is inserted as above described; the other fasciculus passes down to the second rib below its origin; thus, each of the lower ribs receives fibres from the transverse processes of two vertebræ.

Nerves.—The muscles of this group are supplied by the intercostal nerves.

The **Diaphragm** (*διάφραγμα, a partition wall*) (Fig. 216) is a thin, musculofibrous septum, consisting of muscular fibres externally, which arise from the circumference of the thoracic cavity and pass upward and inward to converge to a central tendon. It is placed obliquely at the junction of the upper with the middle third of the trunk, and, separating the thorax from the abdomen, forming the floor of the former cavity and the roof of the latter. It is elliptical, its longest diameter being from side to side, somewhat fan-shaped, the broad elliptical portion being horizontal, the narrow part, the *crura*, which represents the handle of the fan, vertical, and joined at right angles to the former. It is from this circumstance that some anatomists describe it as consisting of two portions, the upper or great muscle of the Diaphragm, and the lower or lesser muscle. It arises from the whole of the internal circumference of the thorax, being attached, in front, by fleshy fibres to the ensiform cartilage; on either side, to the inner surface of the cartilages and bony portions of the six or seven inferior ribs, interdigitating with the Transversalis; and behind, to two aponeurotic arches, named the *ligamentum arcuatum externum et internum*, and by the crura, to the lumbar vertebræ. The fibres from these sources vary in length: those arising from the ensiform appendix are very short and occasionally aponeurotic; those from the ligamenta arcuata, and more especially those from the cartilages of the ribs at the side of the chest, are longer, describe well-marked curves as they ascend, and finally converge to be inserted into the circumference of the central tendon. Between the sides of the muscular slip from the ensiform appendix and the cartilages of the adjoining ribs the fibres of the Diaphragm are deficient, the interval being filled by areolar tissue, covered on the thoracic side by the pleuræ; on the abdominal, by the peritoneum. This is, consequently, a weak point, and a portion of the contents of the abdomen may protrude into the chest, forming phrenic or diaphragmatic hernia, or a collection of pus in the mediastinum may descend through it, so as to point at the epigastrium. A triangular gap is sometimes seen between the fibres springing from the internal and those arising from the external arcuate ligament. When it exists, the kidney is separated from the pleura only by fatty and areolar tissue.

The *ligamentum arcuatum internum* is a tendinous arch, thrown across the upper part of the Psoas magnus muscle, on each side of the spine. It is connected, by one end, to the outer side of the body of the first or second lumbar vertebra, being continuous with the outer side of the tendon of the corresponding crus; and, by the other end, to the front of the transverse process of the first, and sometimes also to that of the second, lumbar vertebra.

The *ligamentum arcuatum externum* is the thickened upper margin of the anterior lamella of the lumbar fascia; it arches across the upper part of the Quadratus lumborum, being attached, by one extremity, to the front of the transverse process of the first lumbar vertebra, and, by the other, to the apex and lower margin of the last rib.

The Crura.—The Diaphragm is connected to the spine by two *crura* or *pillars*, which are situated on the bodies of the lumbar vertebræ, on each side of the aorta. The crura, at their origin, are tendinous in structure; the right crus, larger and longer than the left, arising from the anterior surface of the bodies and intervertebral substances of the three or four upper lumbar vertebræ; the left, from

the two upper; both blending with the anterior common ligament of the spine. These tendinous portions of the crura pass forward and inward, and gradually converge to meet in the middle line, forming an arch, beneath which passes the aorta, vena azygos major, and thoracic duct. From this tendinous arch muscular fibres arise, which diverge, the outermost portion being directed upward and outward to the central tendon; the innermost decussating in front of the aorta, and then diverging, so as to surround the œsophagus before ending in the central tendon. The fibres derived from the right crus are the most numerous and pass in front of those derived from the left.

The *Central* or *Cordiform Tendon* of the Diaphragm is a thin but strong tendinous aponeurosis, situated at the centre of the vault formed by the muscle,

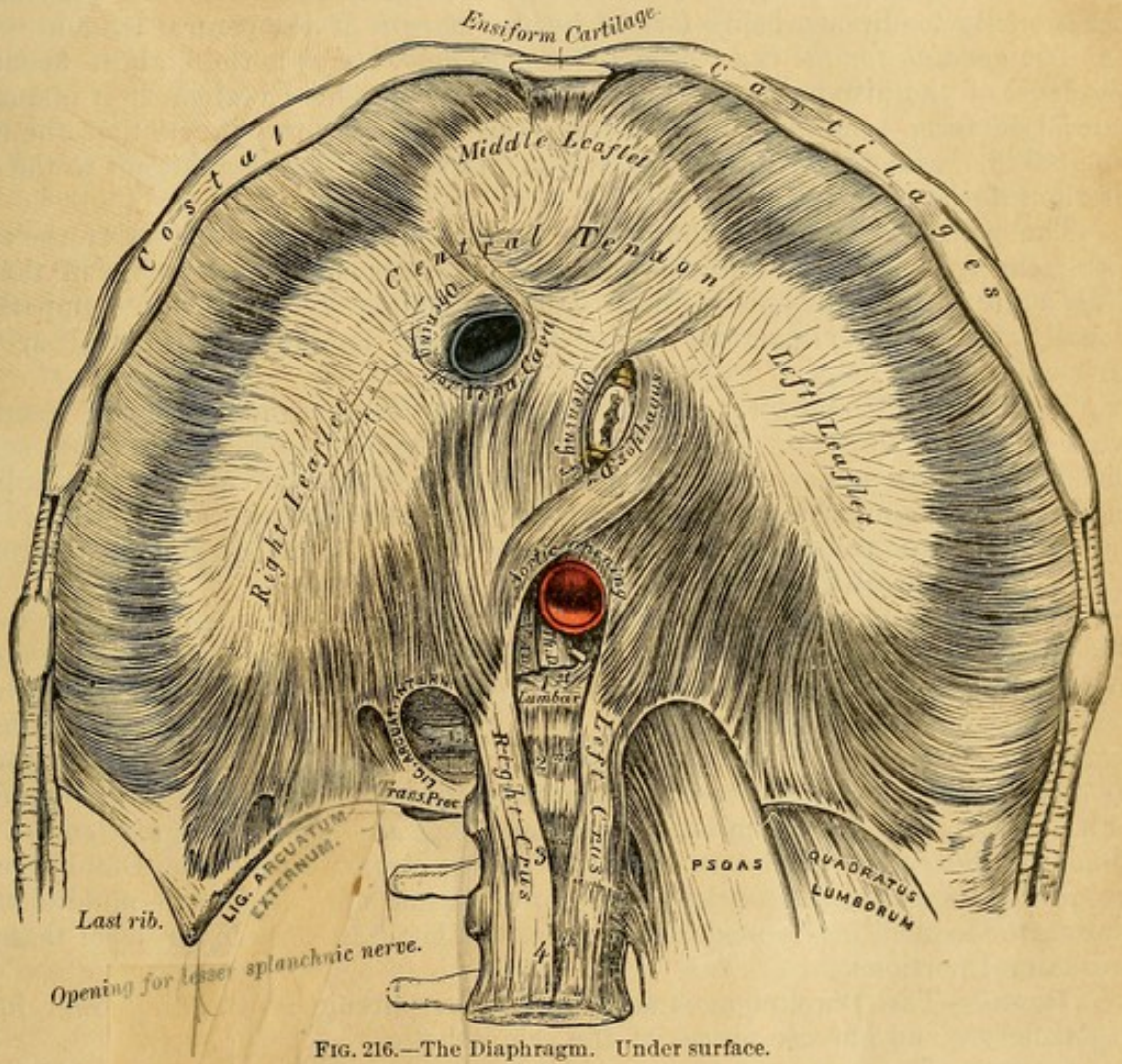

FIG. 216.—The Diaphragm. Under surface.

immediately below the pericardium, with which it is partly blended. It is shaped somewhat like a trefoil leaf, consisting of three divisions, or leaflets, separated from one another by slight indentations. The right leaflet is the largest; the middle one, directed toward the ensiform cartilage, the next in size; and the left, the smallest. In structure, the tendon is composed of several planes of fibres which intersect one another at various angles, and unite into straight or curved bundles—an arrangement which affords it additional strength.

The *Openings* connected with the Diaphragm are three large and several smaller apertures. The former are the aortic, the œsophageal, and the opening for the vena cava.

The *aortic opening* is the lowest and the most posterior of the three large apertures connected with this muscle, being at the level of the first lumbar vertebra. It is situated slightly to the left of the middle line, immediately in front of the bodies of the vertebræ; and is, therefore, *behind* the Diaphragm, not

in it. It is an osseo-aponeurotic aperture, formed by a tendinous arch thrown across the front of the bodies of the vertebræ, from the crus on one side to that on the other, and transmits the aorta, vena azygos major, and thoracic duct. Sometimes the vena azygos major is transmitted upward through the right crus. Occasionally some tendinous fibres are prolonged across the bodies of the vertebræ from the inner part of the lower end of the crura, passing behind the aorta, and thus converting the opening into a fibrous ring.

The *œsophageal opening* is situated at the level of the tenth dorsal vertebra; it is elliptical in form, muscular in structure, and, formed by the decussating fibres of the two crura, is placed above, and, at the same time, anterior, and a little to the left of the preceding. It transmits the œsophagus and pneumogastric nerves and some small œsophageal arteries. The anterior margin of this aperture is occasionally tendinous, being formed by the margin of the central tendon.

The *opening for the vena cava* (*foramen quadratum*) is the highest, about on the level of the disc between the eighth and ninth dorsal vertebræ; it is quadrilateral in form, tendinous in structure, and placed at the junction of the right and middle leaflets of the central tendon, its margins being adherent to the wall of the inferior vena cava.

The *right crus* transmits the greater and lesser splanchnic nerves of the right side; the *left crus* transmits the greater and lesser splanchnic nerves of the left side, and the vena azygos minor. The gangliated cords of the sympathetic usually enter the abdominal cavity by passing behind the internal arcuate ligaments.

The *Serous Membranes* in relation with the Diaphragm are four in number: three lining its upper or thoracic surface; one, its abdominal. The three serous membranes on its upper surface are the pleura on either side and the serous layer of the pericardium, which covers the middle portion of the tendinous centre. The serous membrane covering its under surface is a portion of the general peritoneal membrane of the abdominal cavity.

The Diaphragm is arched, being convex toward the chest and concave to the abdomen. The *right portion* forms a complete arch from before backward, being accurately moulded over the convex surface of the liver, and having resting upon it the concave base of the right lung. The *left portion* is arched from before backward in a similar manner; but the arch is narrower in front, being encroached upon by the pericardium, and lower than the right, at its summit, by about three-quarters of an inch. It supports the base of the left lung, and covers the great end of the stomach, the spleen, and left kidney. At its circumference the Diaphragm is higher in the mesial line of the body than at either side; but in the middle of the thorax the central portion, which supports the heart, is on a lower level than the two lateral portions.

Nerves.—The Diaphragm is supplied by the phrenic nerves and lower intercostal nerves and phrenic plexus of the sympathetic.

Actions.—The Intercostals are the chief agents in the movement of the ribs in ordinary respiration. When the first rib is elevated and fixed by the Scaleni, the External intercostals raise the other ribs, especially their fore part, and so increase the capacity of the chest from before backward; at the same time they evert their lower borders, and so enlarge the thoracic cavity transversely. The Internal intercostals, at the side of the thorax, depress the ribs and invert their lower borders, and so diminish the thoracic cavity; but at the fore part of the chest these muscles assist the External intercostals in raising the cartilages.[1] The Levatores

[1] The view of the action of the Intercostal muscles given in the text is that which is taught by Hutchinson (*Cycl. of Anat. and Phys.*, art. "Thorax"), and is usually adopted in our schools. It is, however, much disputed. Hamberger believed that the External intercostals act as elevators of the ribs, or muscles of inspiration, while the Internal act in expiration. Haller taught that both sets of muscles act in common—viz. as muscles of inspiration—and this view is adopted by many of the best anatomists of the Continent, and appears supported by many observations made on the human subject under various conditions of disease, and on living animals after the muscles have been exposed under chloroform. The reader may consult an interesting paper by Dr. Cleland in the *Journal of Anat. and*

costarum assist the External intercostals in raising the ribs. The Triangularis sterni draws down the costal cartilages; it is therefore an expiratory muscle.

The Diaphragm is the principal muscle of inspiration. When in a condition of rest the muscle presents a domed surface, concave toward the abdomen; and consists of a circumferential muscular and a central tendinous part. When the muscular fibres contract, they become less arched, or nearly straight, and thus cause the central tendon to descend, and in consequence the level of the chest-wall is lowered, the vertical diameter of the chest being proportionally increased. In this descent the different parts of the tendon move unequally. The left leaflet descends to the greatest extent; the right to a less extent, on account of the liver; and the central leaflet the least, because of its connection to the pericardium. In descending the diaphragm presses on the abdominal viscera, and so to a certain extent causes a projection of the abdominal wall; but in consequence of these viscera not yielding completely, the central tendon becomes a fixed point, and enables the circumferential muscular fibres to act *from* it, and so elevate the lower ribs and expand the lower part of the thoracic cavity; and Duchenne has shown that the Diaphragm has the power of elevating the ribs, to which it is attached, by its contraction, if the abdominal viscera are *in situ*, but that if these organs are removed, this power is lost. When at the end of inspiration the Diaphragm relaxes, the thoracic walls return to their natural position in consequence of their elastic reaction and of the elasticity and weight of the displaced viscera.[1]

In all expulsive acts the Diaphragm is called into action, to give additional power to each expulsive effort. Thus, before sneezing, coughing, laughing, and crying, before vomiting, previous to the expulsion of the urine and fæces, or of the fœtus from the womb, a deep inspiration takes place.

The height of the Diaphragm is constantly varying during respiration, the muscle being carried upward or downward from the average level; its height also varies according to the degree of distension of the stomach and intestines, and the size of the liver. After a forced expiration, the right arch is on a level, in front, with the fourth costal cartilage; at the side, with the fifth, sixth, and seventh ribs; and behind, with the eighth rib, the left arch being usually from one to two ribs' breadth below the level of the right one. In a forced inspiration, it descends from one to two inches; its slope would then be represented by a line drawn from the ensiform cartilage toward the tenth rib.

Muscles of Inspiration and Expiration.—The muscles which assist the action of the Diaphragm in ordinary tranquil inspiration are the Intercostals and the Levatores costarum, as above stated, and the Scaleni. When the need for more forcible action exists, the shoulders and the base of the scapula are fixed, and then the powerful muscles of forced inspiration come into play; the chief of these are the Trapezius, the Pectoralis minor, the Serratus posticus superior and inferior, and the Rhomboidei. The lower fibres of the Serratus magnus may possibly assist slightly in dilating the chest by raising and everting the ribs. The Sterno-mastoid also, when the head is fixed, assists in forced inspiration by drawing up the sternum and by fixing the clavicle, and thus affording a fixed point for the action of the muscles of the chest. The Ilio-costalis and Quadratus lumborum assist in forced inspiration by fixing the last rib (see page 367).

The ordinary action of expiration is hardly effected by muscular force, but results from a return of the walls of the thorax to a condition of rest, owing to their own elasticity and to that of the lungs. Forced expiratory actions are

Phys. No. II., May, 1867, p. 209, "On the Hutchinsonian Theory of the Action of the Intercostal Muscles," who refers also to Henle, Luschka, Budge, and Baumler, *Observations on the Action of the Intercostal Muscles*, Erlangen, 1860. (In *New Syd. Soc.'s Year-Book for* 1861, p. 69.) Dr. W. W. Keen has come to the conclusion, from experiments made upon a criminal executed by hanging, that the External intercostals are muscles of expiration, as they pulled the ribs down, while the Internal intercostals pulled the ribs up and are muscles of inspiration (*Trans. Coll. Phys. Philadelphia*, Third Series, vol. i., 1875, p. 97).

[1] For a detailed description of the general relations of the Diaphragm, and its action, refer to Dr. Sibson's *Medical Anatomy*.

performed mainly by the flat muscles (Obliqui and Transversalis) of the abdomen, assisted also by the Rectus. Other muscles of forced expiration are the Internal and Triangularis sterni (as above mentioned).

3. MUSCLES OF THE ABDOMEN.

The muscles of the abdomen may be divided into two groups: 1. The superficial muscles of the abdomen; 2. The deep muscles of the abdomen.

1. Superficial Muscles.

The Muscles in this region are, the

Obliquus Externus.	Transversalis.
Obliquus Internus.	Rectus.
	Pyramidalis.

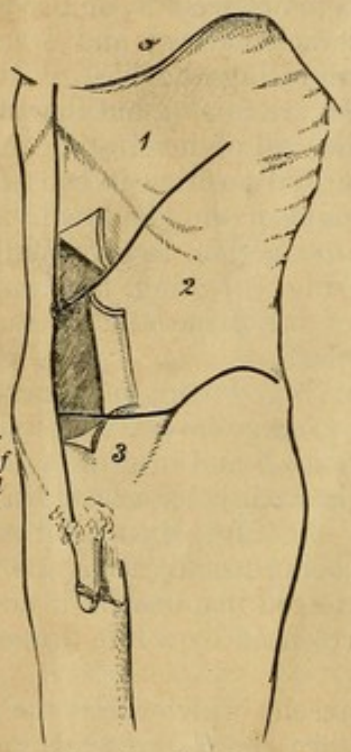

3. Dissection of inguinal hernia.

FIG. 217.—Dissection of abdomen.

Dissection (Fig. 217).—To dissect the abdominal muscles, make a vertical incision from the ensiform cartilage to the symphysis pubis; a second incision from the umbilicus obliquely upward and outward to the outer surface of the chest, as high as the lower border of the fifth or sixth rib; and a third, commencing midway between the umbilicus and pubes, transversely outward to the anterior superior iliac spine, and along the crest of the ilium as far as its posterior third. Then reflect the three flaps included between these incisions from within outward, in the lines of direction of the muscular fibres. If necessary, the abdominal muscles may be made tense by inflating the peritoneal cavity through the umbilicus.

The **Superficial fascia** of the abdomen consists, over the greater part of the abdominal wall, of a single layer of fascia, which contains a variable amount of fat; but as this layer approaches the groin it is easily divisible into two layers, between which are found the superficial vessels and nerves and the superficial inguinal lymphatic glands. The superficial layer (*fascia of Camper*) is thick, areolar in texture, containing adipose tissue in its meshes, the quantity of which varies in different subjects. Below it passes over Poupart's ligament, and is continuous with the outer layer of the superficial fascia of the thigh. In the male this fascia is continued over the penis and outer surface of the cord to the scrotum, where it helps to form the dartos. As it passes to the scrotum it changes its character, becoming thin, destitute of adipose tissue, and of a pale reddish color, and in the scrotum it acquires some involuntary muscular fibres. From the scrotum it may be traced backward to be continuous with the superficial fascia of the perinæum. In the female this fascia is continued into the labia majora. The deeper layer (*fascia of Scarpa*) is thinner and more membranous in character than the superficial layer. In the middle line it is intimately adherent to the linea alba and to the symphysis pubis, and is prolonged on to the dorsum of the penis, forming the suspensory ligament; above, it is continuous with the superficial fascia over the rest of the trunk; below, it blends with the fascia lata of the thigh a little below Poupart's ligament; and below and internally it is continued over the penis and spermatic cord to the scrotum, where it helps to form the dartos. From the scrotum it may be traced backward to be continuous with the deep layer of the superficial fascia of the perinæum. In the female it is continued into the labia majora.

The **External** or **Descending Oblique muscle** (Fig. 218) is situated on the side and fore part of the abdomen; being the largest and the most superficial of the three flat muscles in this region. It is broad, thin, and irregularly quadrilateral, its muscular portion occupying the side, its aponeurosis the anterior wall, of the

abdomen. It arises, by eight fleshy digitations, from the external surface and lower borders of the eight inferior ribs; these digitations are arranged in an oblique line running downward and backward; the upper ones being attached close to the cartilages of the corresponding ribs; the lowest, to the apex of the cartilage of the last rib; the intermediate ones, to the ribs at some distance from their cartilages. The five superior serrations increase in size from above downward, and are received between corresponding processes of the Serratus magnus; the three lower ones diminish in size from above downward, receiving between them corresponding processes from the Latissimus dorsi. From these attachments, the fleshy fibres proceed in various directions. Those from the lowest ribs pass nearly vertically downward, to be inserted into the anterior half of the outer lip of the crest of the ilium; the middle and upper fibres, directed downward and forward, terminate in an aponeurosis, opposite a line drawn from the prominence of the ninth costal cartilage to the anterior superior spinous process of the ilium.

The **Aponeurosis of the External Oblique** is a thin, but strong membranous aponeurosis, the fibres of which are directed obliquely downward and inward. It is joined with that of the opposite muscle along the median line, covers the whole of the front of the abdomen; above, it is connected with the lower border of the Pectoralis major; below, its fibres are closely aggregated together, and extend obliquely across from the anterior superior spine of the ilium to the spine of the os pubis and the linea ilio-pectinea. In the median line it interlaces with the aponeurosis of the opposite muscle, forming the linea alba, which extends from the ensiform cartilage to the symphysis pubis.

That portion of the aponeurosis which extends between the anterior superior spine of the ilium and the spine of the os pubis is a broad band, folded inward and continuous below with the fascia lata; it is able.
portion which is reflected from Poupart's line lower border of the aponeurosis of along the pectineal line is called *Gimbernat's* from the anterior superior spine of ment of the latter to the pectineal line, latter point it is reflected outward to be behind the inner pillar of the ring, to the li half an inch, forming Gimbernat's liga- and form a thin, triangular fibrous layer, downward toward the thigh, where it is *the abdomen.* half is rounded and oblique in direction.

In the aponeurosis of the External oblihment to the os pubis, is more horizontal os pubis, is a triangular opening, the *extern*tic cord.
tion of the fibres of the aponeurosis in thisuded between the crural arch and the

Relations.—By its *external surface*, wwhich descend from the abdomen into the epigastric and circumflex iliac vessels, and n a subsequent page.
surface, with the Internal oblique, the lowthe aponeurosis of the External oblique Intercostal muscles, the Cremaster, the sperward from the spine of the os pubis to be ment in the female. Its *posterior border*, eout half an inch in length, larger in the of the ilium, is fleshy throughout and free in direction in the erect posture, and of Latissimus dorsi, though generally a triangward. Its base, or outer margin, is con- muscles near the crest of the ilium, in wct with the crural sheath, forming the oblique. This triangle, *Petit's triangle*, i apex corresponds to the spine of the os External oblique, behind by the Latissimus o the pectineal line, and is continuous while its floor is formed by the Internal obli Its anterior margin is continuous with

The following parts of the aponeurosis oted upward and downward.
to be further described: viz., the external ab is a layer of tendinous fibres of a and fascia, Poupart's ligament, Gimbernat' apex to the pectineal line, where it is of the abdomen. t passes inward beneath the spermatic

The External Abdominal Ring.—Just abed fascia, lying behind the inner pillar of the os pubis an interval is seen in the of the conjoined tendon, and interlaces called the *External Abdominal Ring.* The nea alba.
what triangular in form, and corresponds ligamentous band, which was first de- aponeurosis. It usually measures from upward and backward from the base of transversely about half an inch. It is boal line, to which it is attached. It i pubis; above by a series of curved fibres, ty the pectineal aponeurosis, and by

the upper angle of the ring, so as to increase its strength; and on each side, by the margins of the opening in the aponeurosis, which are called the columns or pillars of the ring.

The external pillar, which is at the same time inferior from the obliquity of its direction, is the stronger: it is formed by that portion of Poupart's ligament which is inserted into the spine of the os pubis; it is curved so as to form a kind of groove, upon which the spermatic cord rests. The internal or superior pillar

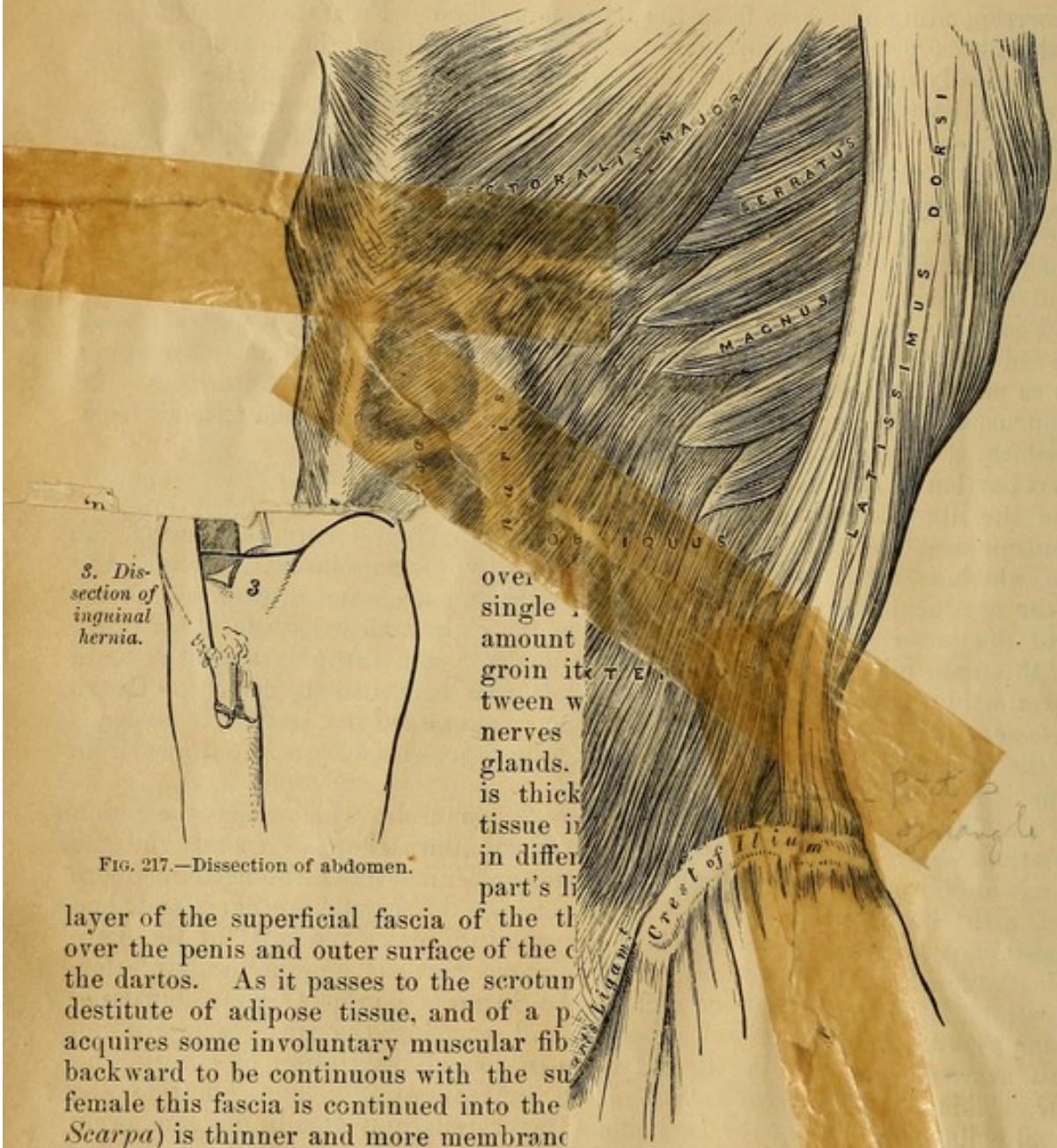

3. Dissection of inguinal hernia.

FIG. 217.—Dissection of abdomen.

over
single
amount
groin it
tween w
nerves
glands.
is thick
tissue i
in differ
part's li
layer of the superficial fascia of the th
over the penis and outer surface of the c
the dartos. As it passes to the scrotum
destitute of adipose tissue, and of a p
acquires some involuntary muscular fib
backward to be continuous with the su
female this fascia is continued into the
Scarpa) is thinner and more membranc
In the middle line it is intimately adhe
pubis, and is prolonged on to the do
ligament; above, it is continuous with
trunk; below, it blends with the fascia
ligament; and below and internally it
cord to the scrotum, where it helps to
be traced backward to be continuous w
of the perinæum. In the female it is

tached to the front of the symphysis pubis,
site side, that of the right side being super-
s passage to the spermatic cord in the male,
it is much larger in men than in women, on
atic cord, and hence the greater frequency

The **External** or **Descending Oblique**
and fore part of the abdomen; being
three flat muscles in this region. It i
its muscular portion occupying the si

eries of curved tendinous fibres, which arch

across the lower part of the aponeurosis of the External oblique. They have received their name from stretching across between the two pillars of the external ring, describing a curve with the convexity downward. They are much thicker and stronger at the outer margin of the external ring, where they are connected to the outer third of Poupart's ligament, than internally, where they are inserted into the linea alba. They are more strongly developed in the male than in the female. The intercolumnar fibres increase the strength of the lower part of the aponeurosis, and prevent the divergence of the pillars from one another.

These intercolumnar fibres as they pass across the external abdominal ring are themselves connected together by delicate fibrous tissue, thus forming a fascia, which as it is attached to the pillars of the ring covers it in, and is called the *intercolumnar fascia*. This **intercolumnar fascia** is continued down as a tubular prolongation around the outer surface of the cord and testis, and encloses them in a distinct sheath; hence it is also called the external spermatic fascia.

The sac of an inguinal hernia, in passing through the external abdominal ring, receives an investment from the intercolumnar fascia.

If the finger is introduced a short distance into the external abdominal ring and the limb is then extended and rotated outward, the aponeurosis of the External oblique, together with the iliac portion of the fascia lata, will be felt to become tense, and the external ring much contracted; if the limb is on the contrary flexed upon the pelvis and rotated inward, this aponeurosis will become lax and the external abdominal ring sufficiently enlarged to admit the finger with comparative ease: hence the patient should always be put in the latter position when the taxis is applied for the reduction of an inguinal hernia in order that the abdominal walls may be relaxed as much as possible.

Poupart's ligament, or the **crural arch,** is the lower border of the aponeurosis of the External oblique muscle, and extends from the anterior superior spine of the ilium to the pubic spine. From this latter point it is reflected outward to be attached to the pectineal line for about half an inch, forming Gimbernat's ligament. Its general direction is curved downward toward the thigh, where it is continuous with the fascia lata. Its outer half is rounded and oblique in direction. Its inner half gradually widens at its attachment to the os pubis, is more horizontal in direction, and lies beneath the spermatic cord.

Nearly the whole of the space included between the crural arch and the innominate bone is filled in by the parts which descend from the abdomen into the thigh. These will be referred to again on a subsequent page.

Gimbernat's ligament is that part of the aponeurosis of the External oblique muscle which is reflected upward and outward from the spine of the os pubis to be inserted into the pectineal line. It is about half an inch in length, larger in the male than in the female, almost horizontal in direction in the erect posture, and of a triangular form with the base directed outward. Its base, or outer margin, is concave, thin, and sharp, and lies in contact with the crural sheath, forming the inner boundary of the femoral ring. Its apex corresponds to the spine of the os pubis. Its posterior margin is attached to the pectineal line, and is continuous with the pubic portion of the fascia lata. Its anterior margin is continuous with Poupart's ligament. Its surfaces are directed upward and downward.

The **triangular fascia** of the abdomen is a layer of tendinous fibres of a triangular shape, which is attached by its apex to the pectineal line, where it is continuous with Gimbernat's ligament. It passes inward beneath the spermatic cord, and expands into a somewhat fan-shaped fascia, lying behind the inner pillar of the external abdominal ring, and in front of the conjoined tendon, and interlaces with the ligament [illegible] passe[illegible]de at the linea alba.

Ligament of C[illegible] this muscle [illegible] strong ligamentous band, which was first described by Sir A[illegible] the testicle and co[illegible]xtends upward and backward from the base of Gimbernat's lig[illegible] the C[illegible]remaster surro[illegible] pectineal line, to which it is attached. It i[illegible] strengthened by [illegible] salis, by the pectineal aponeurosis, and by [illegible]

lateral expansion from the lower attachment of the linea alba (adminiculum lineæ albæ).

Dissection.—Detach the External oblique by dividing it across, just in front of its attachment to the ribs, as far as its posterior border, and separate it below from the crest of the ilium as far as the anterior superior spine; then separate the muscle carefully from the Internal oblique, which lies beneath, and turn it toward the opposite side.

The **Internal** or **Ascending oblique muscle** (Fig. 219), thinner and smaller than the preceding, beneath which it lies, is of an irregularly quadrilateral form,

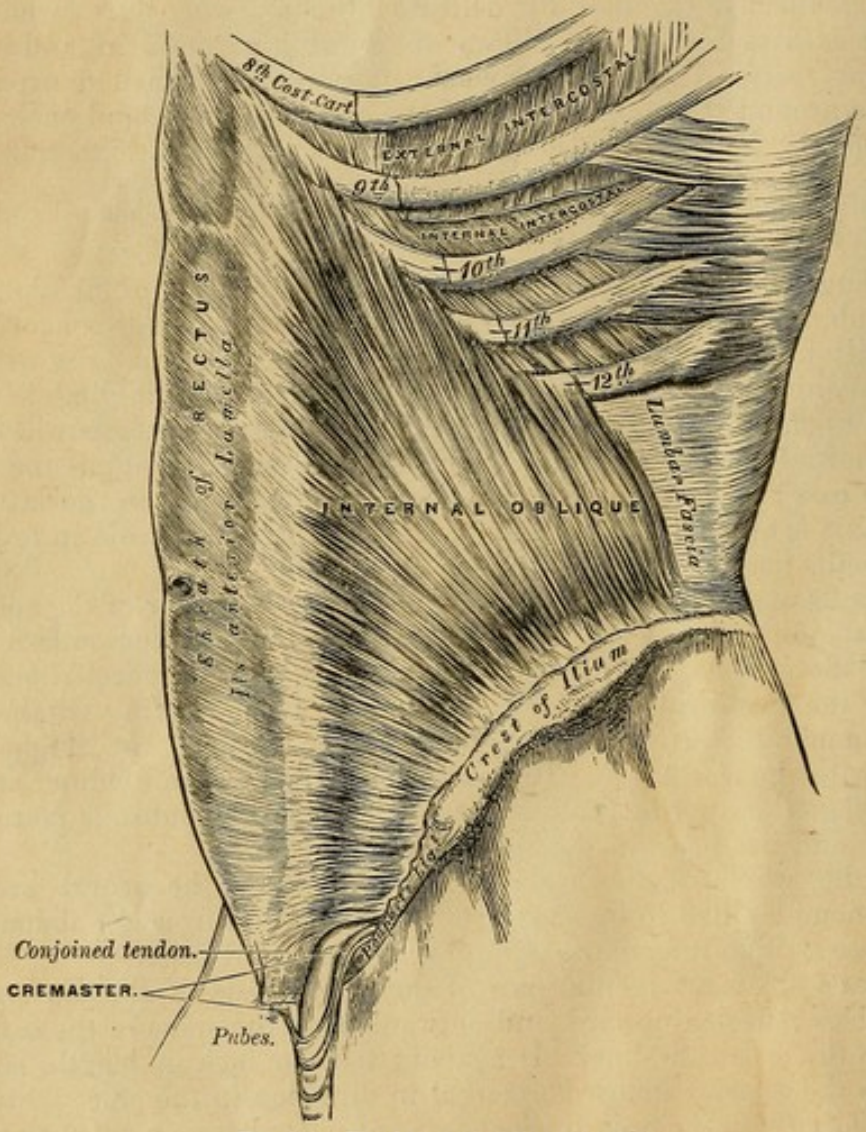

FIG. 219.—The internal oblique muscle.

and situated at the side and fore part of the abdomen. It arises, by fleshy fibres, from the outer half of Poupart's ligament, being attached to the groove on its upper surface; from the anterior two-thirds of the middle lip of the crest of the ilium, and from the posterior lamella of the lumbar fascia. From this origin the fibres diverge: those from Poupart's ligament, few in number and paler in color than the rest, arch downward and inward across the spermatic cord in the male and the round ligament in the female, and, becoming tendinous, are inserted, conjointly with those of the Transversalis, into the crest of the os pubis and pectineal line, to the extent of half an inch, forming what is known as the conjoined tendon of the Internal oblique and Transversalis; those from the [illegible] of the iliac origin are horizontal in their direction, and, becoming [illegible] larger in men [illegible] lower fourth of the linea semilunaris, pass in front of the Re[illegible]d, and hence the [illegible]nserted into the linea alba; those which arise from the middle [illegible] from the crest of its ilium pass obliquely upward and inwar[illegible] curved tendinous fi[illegible] an aponeurosis

which divides at the outer border of the Rectus muscle into two lamellæ, which are continued forward, in front and behind this muscle, to the linea alba, the posterior lamella being also connected to the cartilages of the seventh, eighth, and ninth ribs; the most posterior fibres pass almost vertically upward, to be inserted into the lower borders of the cartilages of the three lower ribs, being continuous with the Internal intercostal muscles.

The conjoined tendon of the Internal oblique and Transversalis is inserted into the crest of the os pubis and pectineal line, immediately behind the external abdominal ring, serving to protect what would otherwise be a weak point in the abdominal wall. Sometimes this tendon is insufficient to resist the pressure from within, and is carried forward in front of the protrusion through the external ring, forming one of the coverings of direct inguinal hernia; or the hernia forces its way through the fibres of the conjoined tendon. The conjoined tendon is sometimes divided into an outer and an inner portion—the former being termed the *ligament of Hesselbach;* the latter, the *ligament of Henle.*

The aponeurosis of the Internal oblique is continued forward to the middle line of the abdomen, where it joins with the aponeurosis of the opposite muscle at the linea alba, and extends from the margin of the thorax to the os pubis. At the outer margin of the Rectus muscle this aponeurosis, for the upper three-fourths of its extent, divides into two lamellæ, which pass, one in front and the other behind the muscle, enclosing it in a kind of sheath, and reuniting on its inner border at the linea alba; the anterior layer is blended with the aponeurosis of the External oblique muscle; the posterior layer with that of the Transversalis. Along the lower fourth the aponeurosis passes altogether in front of the Rectus without any separation. Where the aponeurosis ceases to split, and passes altogether in front of the Rectus muscle, a deficiency is left in the sheath of the muscle behind; this is marked above by a sharp lunated margin having its concavity downward. This is known as the *semilunar fold of Douglas.*

Relations.—By its *external surface*, with the External oblique, Latissimus dorsi, spermatic cord, and external ring; by its *internal surface*, with the Transversalis muscle, the lower intercostal vessels and nerves, the ilio-hypogastric and the ilio-inguinal nerves. Near Poupart's ligament it lies on the fascia transversalis, internal ring, and spermatic cord. Its lower border forms the upper boundary of the inguinal canal.

The **Cremaster muscle** is a thin, muscular layer, composed of a number of fasciculi which arise from the inner part of Poupart's ligament, where its fibres are continuous with those of the Internal oblique and also occasionally with the Transversalis. It passes along the outer side of the spermatic cord, descends with it through the external abdominal ring upon the front and sides of the cord, and forms a series of loops which differ in thickness and length in different subjects. Those at the upper part of the cord are exceedingly short, but they become in succession longer and longer, the longest reaching down as low as the testicle, where a few are inserted into the tunica vaginalis. These loops are united together by areolar tissue, and form a thin covering over the cord and testis, the *fascia cremasterica.* The fibres ascend along the inner side of the cord, and are inserted by a small pointed tendon into the crest of the os pubis and front of the sheath of the Rectus muscle.

It will be observed that the origin and insertion of the Cremaster is precisely similar to that of the lower fibres of the Internal oblique. This fact affords an easy explanation of the manner in which the testicle and cord are invested by this muscle. At an early period of fetal life the testis is placed at the lower and back part of the abdominal cavity, but during its descent toward the scrotum, which takes place before birth, it passes beneath the arched fibres of the Internal oblique. In its passage beneath this muscle some fibres are derived from its lower part which accompany the testicle and cord into the scrotum. It occasionally happens that the loops of the Cremaster surround the cord, some lying behind as well as in

front. It is probable that under these circumstances the testis, in its descent, passed through instead of beneath the fibres of the Internal oblique.

In the descent of an oblique inguinal hernia, which takes the same course as the spermatic cord, the Cremaster muscle forms one of its coverings. This muscle becomes largely developed in cases of hydrocele and large old scrotal hernia. The Cremaster muscle is found only in the male, but almost constantly in the female a few muscular fibres may be seen on the surface of the round ligament, which correspond to this muscle, and in cases of oblique inguinal hernia in the female a considerable amount of muscular fibre may be found covering the sac.

Dissection.—Detach the Internal oblique in order to expose the Transversalis beneath. This may be effected by dividing the muscle, above, at its attachment to the ribs; below, at its connection with Poupart's ligament and the crest of the ilium; and behind, by a vertical incision extending from the last rib to the crest of the ilium. The muscle should previously be made tense by drawing upon it with the fingers of the left hand, and if its division is carefully effected, the cellular interval between it and the Transversalis, as well as the direction of the fibres of the latter muscle, will afford a clear guide to their separation; along the crest of the ilium the circumflex iliac vessels are interposed between them, and form an important guide in separating them. The muscle should then be thrown inward toward the linea alba.

The **Transversalis muscle** (Fig. 220), so called from the direction of its fibres, is the most internal flat muscle of the abdomen, being placed immediately beneath the Internal oblique. It arises by fleshy fibres from the outer third of Poupart's ligament; from the inner lip of the crest of the ilium for its anterior three-fourths; from the inner surface of the cartilages of the six lower ribs, interdigitating with the Diaphragm; and from the lumbar fascia, which may be regarded as the posterior aponeurosis of the muscle. (See page 342.) The muscle terminates in front in a broad aponeurosis, the lower fibres of which curve downward and inward, and are inserted, together with those of the Internal oblique, into the lower part of the linea alba, the crest of the os pubis and pectineal line forming what is known as the conjoined tendon of the Internal oblique and Transversalis. Throughout the rest of its extent the aponeurosis passes horizontally inward, and is inserted into the linea alba, its upper three-fourths passing behind the Rectus muscle, blending with the posterior lamella of the Internal oblique; its lower fourth passing in front of the Rectus.

Relations.—By its *external surface*, with the Internal oblique, the lower intercostal nerves, and the inner surface of the cartilages of the lower ribs; by its *internal surface*, with the fascia transversalis, which separates it from the peritoneum. Its lower border forms the upper boundary of the inguinal canal.

Dissection.—To expose the Rectus muscle, open its sheath by a vertical incision extending from the margin of the thorax to the os pubis, and then reflect the two portions from the surface of the muscle, which is easily done, excepting at the lineæ transversæ, where so close an adhesion exists that the greatest care is requisite in separating them. Now raise the outer edge of the muscle, in order to examine the posterior layer of the sheath. By dividing the muscle in the centre, and turning its lower part downward, the point where the posterior wall of the sheath terminates in a thin curved margin will be seen.

The **Rectus abdominis** is a long flat muscle, which extends along the whole length of the front of the abdomen, being separated from its fellow of the opposite side by the linea alba. It is much broader, but thinner, above than below, and arises by two tendons, the external or larger being attached to the crest of the os pubis, the internal, smaller portion interlacing with its fellow of the opposite side, and being connected with the ligaments covering the front of the symphysis pubis. The fibres ascend, and the muscle is inserted by three portions of unequal size into the cartilages of the fifth, sixth, and seventh ribs. The upper portion, attached principally to the cartilage of the fifth rib, usually has some fibres of insertion into the anterior extremity of the rib itself. Some fibres are occasionally connected with the costo-xiphoid ligaments and side of the ensiform cartilage.

The Rectus muscle is traversed by tendinous intersections, three in number.

which have received the name of *lineæ transversæ*. One of these is usually situated opposite the umbilicus, and two above that point; of the latter, one corresponds to the extremity of the ensiform cartilage, and the other to the interval between the ensiform cartilage and the umbilicus. These intersections pass transversely or obliquely across the muscle in a zigzag course; they rarely extend completely through its substance, sometimes pass only halfway across

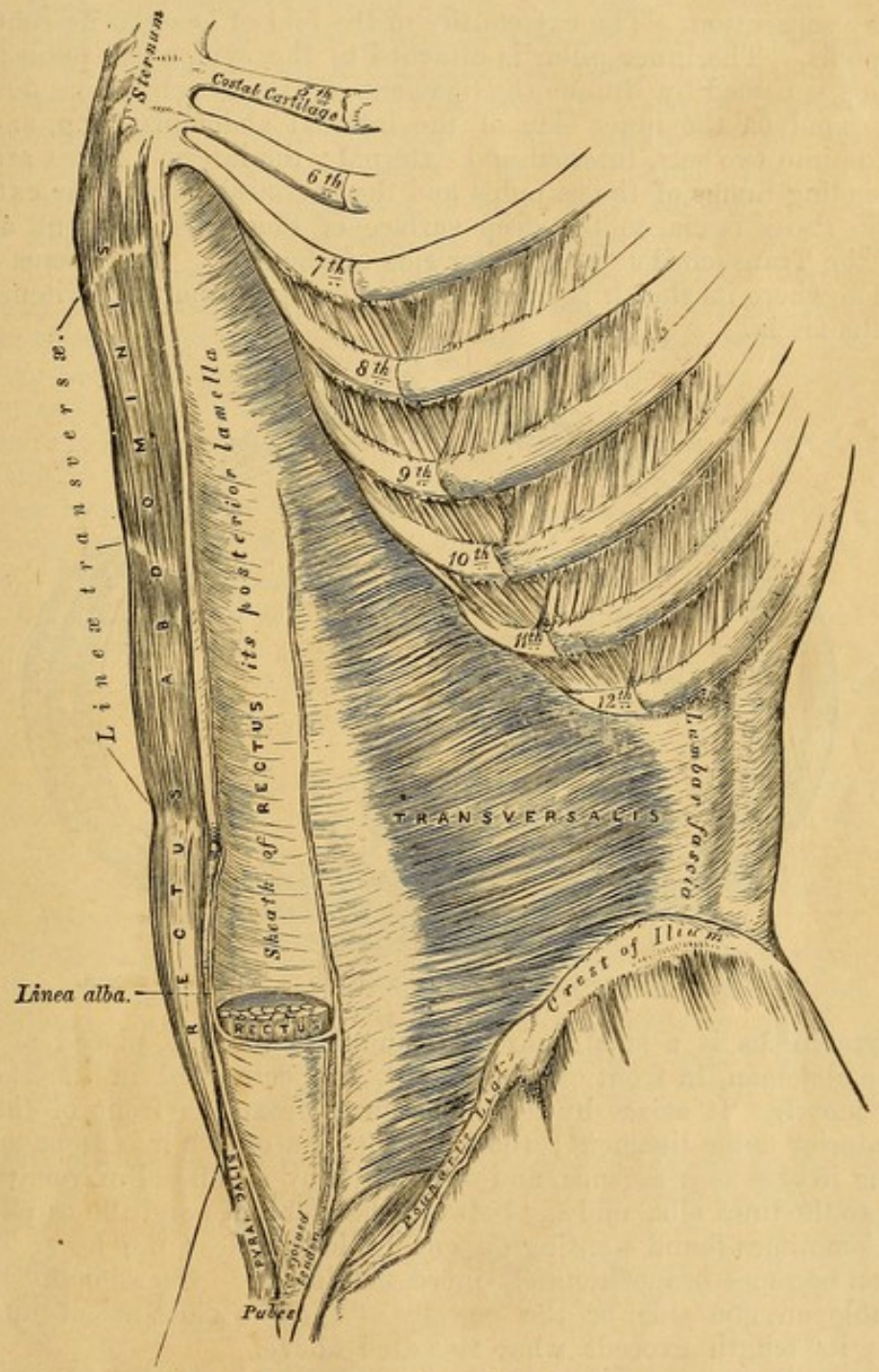

FIG. 220.—The Transversalis, Rectus, and Pyramidalis muscles.

it, and are intimately adherent in front to the sheath in which the muscle is enclosed. Sometimes one or two additional lines may be seen, one usually below the umbilicus; the position of the other, when it exists, is variable. These additional lines are for the most part incomplete.

The Rectus is enclosed in a sheath (Fig. 221) formed by the aponeuroses of the Oblique and Transversalis muscles, which are arranged in the following manner. When the aponeurosis of the Internal oblique arrives at the outer margin of the Rectus, it divides into two lamellæ, one of which passes in front of the Rectus.

blending with the aponeurosis of the External oblique; the other, behind it, blending with the aponeurosis of the Transversalis; and these, joining again at its inner border, are inserted into the linea alba. This arrangement of the aponeuroses exists along the upper three-fourths of the muscle: at the commencement of the lower fourth, the posterior wall of the sheath terminates in a thin curved margin, the *semilunar fold of Douglas*, the concavity of which looks downward toward the pubes; the aponeuroses of all three muscles passing in front of the Rectus without any separation. The extremities of the fold of Douglas descend as pillars to the os pubis. The inner pillar is attached to the symphysis pubis; the outer pillar, which is named by Braune the ligament of Hesselbach, passes downward as a distinct band on the inner side of the internal abdominal ring, and there its fibres divide into two sets, internal and external; the internal fibres are attached to the ascending ramus of the os pubis and the pectineal fascia; the external ones pass to the Psoas fascia, to the deep surface of Poupart's ligament, and to the tendon of the Transversalis on the outer side of the ring. The Rectus muscle, in the situation where its sheath is deficient, is separated from the peritoneum by the transversalis fascia.

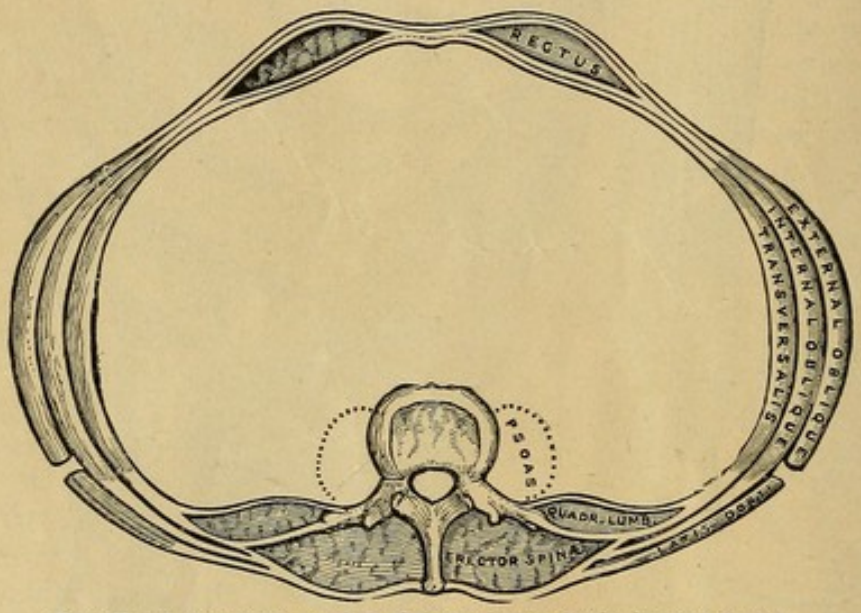

FIG. 221.—A transverse section of the abdomen in the lumbar region.

The **Pyramidalis** is a small muscle, triangular in shape, placed at the lower part of the abdomen, in front of the Rectus, and contained in the same sheath with that muscle. It arises by tendinous fibres from the front of the os pubis and the anterior pubic ligament; the fleshy portion of the muscle passes upward, diminishing in size as it ascends, and terminates by a pointed extremity, which is inserted into the linea alba, midway between the umbilicus and the os pubis. This muscle is sometimes found wanting on one or both sides; the lower end of the Rectus then becomes proportionately increased in size. Occasionally it has been found double on one side, or the muscles of the two sides are of unequal size. Sometimes its length exceeds what is stated above.

Besides the Rectus and Pyramidalis muscles, the sheath of the Rectus contains the superior and deep epigastric arteries, the terminations of the lumbar arteries and of the lower intercostal arteries and nerves.

Nerves.—The abdominal muscles are supplied by the lower intercostal nerves. The Transversalis and Internal oblique also receive filaments from the hypogastric branch of the ilio-hypogastric and sometimes from the ilio-inguinal. The Cremaster is supplied by the genital branch of the Genito-crural.

In the description of the abdominal muscles mention has frequently been made of the linea alba, lineæ semilunares, and lineæ transversæ; when the dissection of the muscles is completed these structures should be examined.

The **linea alba** is a tendinous raphé seen along the middle line of the abdomen, extending from the ensiform cartilage to the symphysis pubis, to which it is attached. It is placed between the inner borders of the Recti muscles, and is formed by the blending of the aponeuroses of the Obliqui and Transversales muscles. It is narrow below, corresponding to the narrow interval existing between the Recti; but broader above, as these muscles diverge from one another in their ascent, becoming of considerable breadth after great distension of the abdomen from pregnancy or ascites. It presents numerous apertures for the passage of vessels and nerves: the largest of these is the umbilicus, which in the fœtus transmits the umbilical vessels, but in the adult is obliterated, the cicatrix being stronger than the neighboring parts; hence umbilical hernia occurs in the adult *near* the umbilicus, whilst in the fœtus it occurs *at* the umbilicus. The linea alba is in relation, in front, with the integument, to which it is adherent, especially at the umbilicus; behind, it is separated from the peritoneum by the transversalis fascia; and below, by the urachus, and the bladder when that organ is distended.

The **lineæ semilunares** are two curved tendinous lines placed one on each side of the linea alba. Each corresponds with the outer border of the Rectus muscle, extends from the cartilage of the ninth rib to the pubic spine, and is formed by the aponeurosis of the Internal oblique at its point of division to enclose the Rectus, where it is reinforced in front by the External oblique and behind by the Transversalis.

The **lineæ transversæ** are narrow transverse lines which intersect the Recti muscles, as already mentioned; they connect the lineæ semilunares with the linea alba.

Actions.—The abdominal muscles perform a threefold action:

When the pelvis and thorax are fixed, they compress the abdominal viscera, by constricting the cavity of the abdomen, in which action they are materially assisted by the descent of the diaphragm. By these means the fœtus is expelled from the uterus, the fæces from the rectum, the urine from the bladder, and the contents of the stomach in vomiting.

If the pelvis and spine are fixed, these muscles compress the lower part of the thorax, materially assisting expiration. If the pelvis alone is fixed, the thorax is bent directly forward when the muscles of both sides act, or to either side when those of the two sides act alternately, rotation of the trunk at the same time taking place to the opposite side.

If the thorax is fixed, these muscles, acting together, draw the pelvis upward, as in climbing; or, acting singly, they draw the pelvis upward, and bend the vertebral column to one side or the other. The Recti muscles, acting from below, depress the thorax, and consequently flex the vertebral column; when acting from above, they flex the pelvis upon the vertebral column. The Pyramidales are tensors of the linea alba.

The **fascia transversalis** is a thin aponeurotic membrane which lies between the inner surface of the Transversalis muscle and the extra-peritoneal fat. It forms part of the general layer of fascia which lines the interior of the abdominal and pelvic cavities, and is directly continuous with the iliac and pelvic fasciæ. In the inguinal region the transversalis fascia is thick and dense in structure, and joined by fibres from the aponeurosis of the Transversalis muscle, but it becomes thin and cellular as it ascends to the Diaphragm, and blends with the fascia covering this muscle. In front, it unites across the middle line with the fascia on the opposite side of the body, and behind it becomes lost in the fat which covers the posterior surfaces of the kidneys. Below, it has the following attachments: posteriorly, it is connected to the whole length of the crest of the ilium, between the attachments of the Transversalis and Iliacus muscles; between the anterior superior spine of the ilium and the femoral vessels it is connected to the posterior margin of Poupart's ligament, and is there continuous with the iliac fascia. Internal to the femoral vessels it is thin and attached to the os pubis and pectineal line, behind the conjoined tendon, with which it is united; and, corresponding to the point where the femoral vessels pass into the thigh, this fascia descends in

front of them, forming the anterior wall of the crural sheath. Beneath Poupart's ligament it is strengthened by a band of fibrous tissue, which is only loosely connected to Poupart's ligament, and is specialized as the *deep crural arch*. The spermatic cord in the male and the round ligament in the female pass through this fascia; the point where they pass through is called the *internal abdominal ring*. This opening is not visible externally, owing to a prolongation of the transversalis fascia on these structures, forming the *infundibuliform fascia*.

The **internal** or **deep abdominal ring** is situated in the transversalis fascia, midway between the anterior superior spine of the ilium and the symphysis pubis, and about half an inch above Poupart's ligament. It is of an oval form, the extremities of the oval directed upward and downward, varies in size in different subjects, and is much larger in the male than in the female. It is bounded, above and externally, by the arched fibres of the Transversalis; below and internally, by the deep epigastric vessels. It transmits the spermatic cord in the male and the round ligament in the female. From its circumference a thin funnel-shaped membrane, the *infundibuliform fascia*, is continued round the cord and testis, enclosing them in a distinct pouch.

When the sac of an oblique inguinal hernia passes through the internal or deep abdominal ring, the infundibuliform process of the transversalis fascia forms one of its coverings.

The **inguinal** or **spermatic canal** contains the spermatic cord in the male and the round ligament in the female. It is an oblique canal about an inch and a half in length, directed downward and inward, and placed parallel to and a little above Poupart's ligament. It commences above at the internal or deep abdominal ring, which is the point where the cord enters the spermatic canal, and terminates below at the external ring. It is bounded in front by the integument and superficial fascia, by the aponeurosis of the External oblique throughout its whole length, and by the Internal oblique for its outer third; behind, by the triangular fascia, the conjoined tendon of the Internal oblique and Transversalis, transversalis fascia, and the subperitoneal fat and peritoneum; above, by the arched fibres of the Internal oblique and Transversalis; below, by Gimbernat's ligament, and by the union of the fascia transversalis with Poupart's ligament. The deep epigastric artery passes upward and inward behind the canal lying close to the inner side of the internal abdominal ring. The interval between this artery and the outer edge of the Rectus is named Hesselbach's triangle, the base of which is formed by Poupart's ligament.

That form of protrusion in which the intestine follows the course of the spermatic cord along the spermatic canal is called oblique inguinal hernia.

The Deep Crural Arch.—Curving over the vessels, just at the point where they become femoral, on the abdominal side of Poupart's ligament and loosely connected with it, is a thickened band of fibres called the deep crural arch. It is apparently a thickening of the fascia transversalis, joining externally to the centre of Poupart's ligament, and arching across the front of the crural sheath to be inserted by a broad attachment into the spine of the os pubis and ilio-pectineal line, behind the conjoined tendon. In some subjects this structure is not very prominently marked, and not infrequently it is altogether wanting.

Surface Form.—The only two muscles of this group which have any considerable influence on surface form are the External oblique and Rectus muscles of the abdomen. With regard to the External oblique, the upper digitations of its origin from the ribs are well marked, intermingled with the serrations of the Serratus magnus; the lower digitations are not visible, being covered by the thick border of the Latissimus dorsi. Its attachment to the crest of the ilium, in conjunction with the Internal oblique, forms a thick oblique roll, which determines the iliac furrow. Sometimes on the front of the lateral region of the abdomen an undulating outline marks the spot where the muscular fibres terminate and the aponeurosis commences. The outer border of the Rectus is defined by the *linea semilunaris*, which may be exactly defined by putting the muscle into action. It corresponds with a curved line, with its convexity outward, drawn from the end of the cartilage of the ninth rib to the spine of the os pubis, so that the centre of the line, at or near the umbilicus, is three inches from the median line. The

inner border of the Rectus corresponds to the *linea alba*, marked on the surface of the body by a groove, the *abdominal furrow*, which extends from the infrasternal fossa to, or to a little below, the umbilicus, where it gradually becomes lost. The surface of the Rectus presents three transverse furrows, the *lineæ transversæ*. The upper two of these, one opposite or a little below the tip of the ensiform cartilage, and another, midway between this point and the umbilicus, are usually well marked; the third, opposite the umbilicus, is not so distinct. The umbilicus, situated in the linea alba, varies very much in position as regards its height. It is always situated above a zone drawn round the body opposite the highest point of the crest of the ilium, generally being about three-quarters of an inch to an inch above this line. It generally corresponds, therefore, to the fibro-cartilage between the third and fourth lumbar vertebræ.

2. Deep Muscles of the Abdomen.

Psoas magnus.	Iliacus.
Psoas parvus.	Quadratus lumborum.

The Psoas magnus, the Psoas parvus, and the Iliacus muscles, with the fascia covering them, will be described with the Muscles of the Lower Extremity.

The Fascia covering the Quadratus Lumborum.—This is the most anterior of the three layers of the lumbar fascia. It is a thin layer of fascia, which, passing over the anterior surface of the Quadratus lumborum, is attached, internally, to the bases of the transverse processes of the lumbar vertebræ; below, to the ilio-lumbar ligament; and above, to the apex and lower border of the last rib.

The portion of this fascia which extends from the transverse process of the first lumbar vertebra to the apex and lower border of the last rib constitutes the ligamentum arcuatum externum.

The **Quadratus lumborum** (Fig. 214, page 344) is situated in the lumbar region. It is irregularly quadrilateral in shape, and broader below than above. It arises by aponeurotic fibres from the ilio-lumbar ligament and the adjacent portion of the crest of the ilium for about two inches, and is inserted into the lower border of the last rib for about half its length, and by four small tendons, into the apices of the transverse processes of the four upper lumbar vertebræ. Occasionally a second portion of this muscle is found situated in front of the preceding. This arises from the upper borders of the transverse processes of three or four of the lower lumbar vertebræ, and is inserted into the lower margin of the last rib. The Quadratus lumborum is contained in a sheath formed by the anterior and middle lamellæ of the lumbar fasciæ.

Relations.—Its *anterior surface* (or rather the fascia which covers its anterior surface) is in relation with the colon, the kidney, the Psoas muscle, and the Diaphragm. Between the fascia and the muscle are the last dorsal, ilio-hypogastric, and ilio-inguinal nerves. Its *posterior surface* is in relation with the middle lamella of the lumbar fascia, which separates it from the Erector spinæ. The Quadratus lumborum extends, however, beyond the outer border of the Erector spinæ.

Nerve-supply.—The anterior branches of the last dorsal and first lumbar nerves; sometimes also a branch from the second lumbar nerve.

Actions.—The Quadratus lumborum draws down the last rib, and acts as a muscle of inspiration by helping to fix the origin of the Diaphragm. If the thorax and spine are fixed, it may act upon the pelvis, raising it toward its own side when only one muscle is put in action; and when both muscles act together, either from below or above, they flex the trunk.

IV. MUSCLES OF THE PELVIC OUTLET.

The muscles of this region are situated at the pelvic outlet in the ischio-rectal region and the perinæum. They include the following:

I. Muscles of the ischio-rectal region.

II. Muscles of the perinæum: A. In the Male; B. In the Female.

I. Muscles of the Ischio-rectal Region.

Corrugator cutis ani. Internal sphincter ani.
External sphincter ani. Levator ani.
Coccygeus.

The Corrugator Cutis Ani.—Around the anus is a thin stratum of involuntary muscular fibre, which radiates from the orifice. Internally, the fibres fade off into the submucous tissue, while externally they blend with the true skin. By its contraction it raises the skin into ridges around the margin of the anus.

The **External sphincter ani** is a thin, flat plane of muscular fibres, elliptical in shape and intimately adherent to the integument surrounding the margin of the anus. It measures about three or four inches in length from its anterior to its posterior extremity, being about an inch in breadth opposite the anus. It arises from the tip and back of the coccyx by a narrow tendinous band, and from the superficial fascia in front of that bone; and is inserted into the central tendinous point of the perinæum, joining with the Transversus perinæi, the Levator ani, and the Accelerator urinæ. Like other sphincter muscles, it consists of two planes of muscular fibre, which surround the margin of the anus and join in a commissure in front and behind, some fibres crossing from side to side in front and behind the anus.

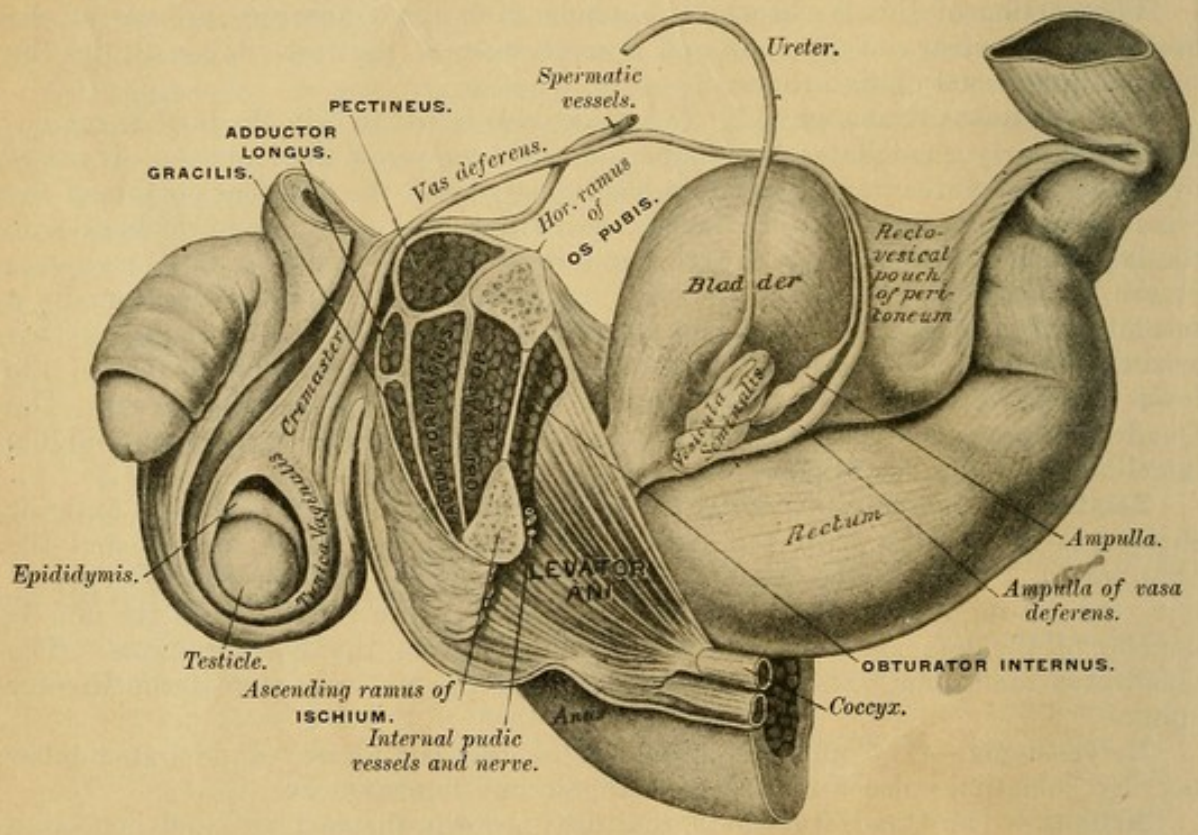

FIG. 222.—Side view of pelvis, showing Levator ani. (From a preparation in the Museum of the Royal College of Surgeons.)

Nerve-supply.—A branch from the anterior division of the fourth sacral and the inferior hæmorrhoidal branch of the internal pudic.

Actions.—The action of this muscle is peculiar: 1. It is, like other muscles, always in a state of tonic contraction, and having no antagonistic muscle, it keeps the anal orifice closed. 2. It can be put into a condition of greater contraction under the influence of the will, so as to occlude more firmly the anal aperture in expiratory efforts unconnected with defecation. 3. Taking its fixed point at the coccyx, it helps to fix the central point of the perinæum, so that the Accelerator urinæ may act from this fixed point.

The **Internal sphincter ani** is a muscular ring which surrounds the lower

extremity of the rectum for about an inch, its inferior border being contiguous to, but quite separate from, the External sphincter. This muscle is about two lines in thickness, and is formed by an aggregation of the involuntary circular fibres of the intestine. It is paler in color and less coarse in texture than the External sphincter.

Actions.—Its action is entirely involuntary. It helps the External sphincter to occlude the anal aperture.

The **Levator ani** (Fig. 222) is a broad, thin muscle, situated on each side of the pelvis. It is attached to the inner surface of the sides of the true pelvis, and descending, unites with its fellow of the opposite side to form the floor of the pelvic cavity. It supports the viscera in this cavity and surrounds the various structures which pass through it. It arises, in front, from the posterior surface of the body of the os pubis on the outer side of the symphysis; posteriorly, from the inner surface of the spine of the ischium; and between these two points, from the angle of division between the obturator and recto-vesical layers of the pelvic fascia at their under part. The fibres pass downward to the middle line of the floor of the pelvis, and are inserted, the most posterior into the sides of the apex of the coccyx; those placed more anteriorly unite with the muscles of the opposite side in a median fibrous raphé, which extends between the coccyx and the margin of the anus. The middle fibres, which form the larger portion of the muscle, are inserted into the side of the rectum, blending with the fibres of the Sphincter muscles; lastly, the anterior fibres, the longest, descend upon the side of the prostate gland to unite beneath it with the muscle of the opposite side, blending with the fibres of the External sphincter and Transversus perinæi muscles at the central tendinous point of the perinæum.

The anterior portion is occasionally separated from the rest of the muscle by connective tissue. From this circumstance, as well as from its peculiar relation with the prostate gland, descending by its side, and surrounding it as in a sling, it has been described by Santorini and others as a distinct muscle, under the name of Levator prostatæ. In the female, the anterior fibres of the Levator ani descend upon the side of the vagina.

Relations.—By its *inner* or *pelvic surface*, with the recto-vesical fascia, which separates it from the viscera of the pelvis and from the peritoneum. By its *outer* or *perineal surface*, it forms the inner boundary of the ischio-rectal fossa, and is covered by a thin layer of fascia, the *ischio-rectal* or *anal fascia*, given off from the obturator fascia. Its *posterior border* is free and separated from the Coccygeus muscle by a cellular interspace. Its *anterior border* is separated from the muscle of the opposite side by a triangular space, through which the urethra, and in the female the vagina, passes from the pelvis.

Nerve-supply.—A branch from the anterior division of the fourth sacral nerve and a branch from the pudic nerve, which is sometimes derived from the perineal, sometimes from the inferior hæmorrhoidal division.

Actions.—This muscle supports the lower end of the rectum and vagina, and also the bladder during the efforts of expulsion. It elevates and inverts the lower end of the rectum after it has been protruded and everted during the expulsion of the fæces. It is also a muscle of forced expiration.

The **Coccygeus** is situated behind and parallel with the preceding. It is a triangular plane of muscular and tendinous fibres, arising, by its apex, from the spine of the ischium and lesser sacro-sciatic ligament, and inserted, by its base, into the margin of the coccyx and into the side of the lower piece of the sacrum. It assists the Levator ani and Pyriformis in closing in the back part of the outlet of the pelvis.

Relations.—By its *inner* or *pelvic surface*, with the rectum. By its *external surface*, with the lesser sacro-sciatic ligament. The *lower border* is in relation with the posterior border of the Levator ani, but separated from it by a cellular interval: its *upper border* is in relation with the lower border of the Pyriformis, but separated from it by the sciatic and internal pudic vessels and nerve.

Nerve-supply.—A branch from the fourth and fifth sacral nerves.

Action.—The Coccygei muscles raise and support the coccyx, after it has been pressed backward during defecation or parturition.

II. A. Muscles and Fasciæ of the Perinæum in the Male.

Transversus perinæi.	Erector penis.
Accelerator urinæ.	Compressor urethræ.

Superficial Fascia.—The superficial fascia of the perinæum consists of two layers, superficial and deep, as in other regions of the body.

The *superficial layer* is thick, loose, areolar in texture, and contains much adipose tissue in its meshes, the amount of which varies in different subjects. In front, it is continuous with the dartos of the scrotum; behind, it is continuous with the subcutaneous areolar tissue surrounding the anus; and, on either side, with the same fascia on the inner side of the thighs. This layer should be carefully removed after it has been examined, when the deep layer will be exposed.

The *deep layer of superficial fascia* (Fascia of Colles) is thin, aponeurotic in structure, and of considerable strength, serving to bind down the muscles of the root of the penis. It is continuous, in front, with the dartos of the scrotum; on either side it is firmly attached to the margins of the rami of the os pubis and ischium, external to the crus penis, and as far back as the tuberosity of the ischium; posteriorly, it curves down behind the Transversus perinæi muscles to join

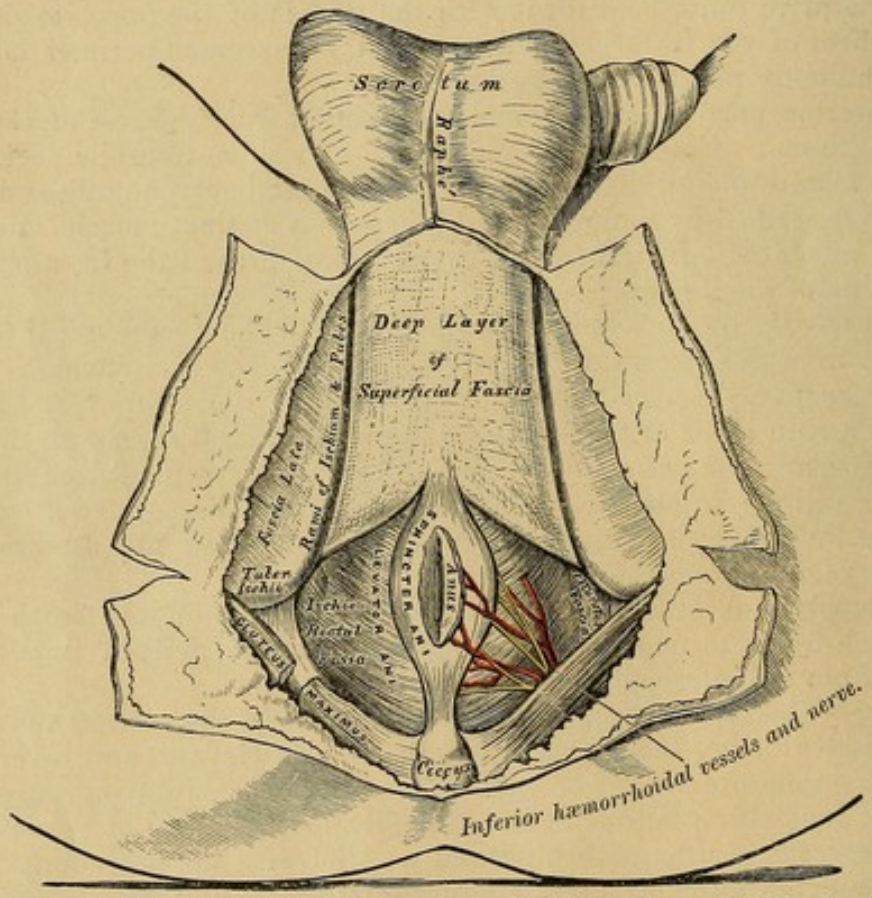

FIG. 223.—The perinæum. The integument and superficial layer of superficial fascia reflected.

the lower margin of the triangular ligament. This fascia not only covers the muscles in this region, but sends upward a vertical septum from its deep surface, which separates the back part of the subjacent space into two, the septum being incomplete in front.

The Central Tendinous Point of the Perinæum.—This is a fibrous point in the middle line of the perinæum, between the urethra and the rectum, being about half an inch in front of the anus. At this point four muscles converge and are attached: viz., the External sphincter ani, the Accelerator urinæ, and the two

Transversus perinæi; so that by the contraction of these muscles, which extend in opposite directions, it serves as a fixed point of support.

The **Transversus perinæi** is a narrow muscular slip, which passes more or less transversely across the back part of the perineal space. It arises by a small tendon from the inner and fore part of the tuberosity of the ischium, and, passing inward, is inserted into the central tendinous point of the perinæum, joining in this situation

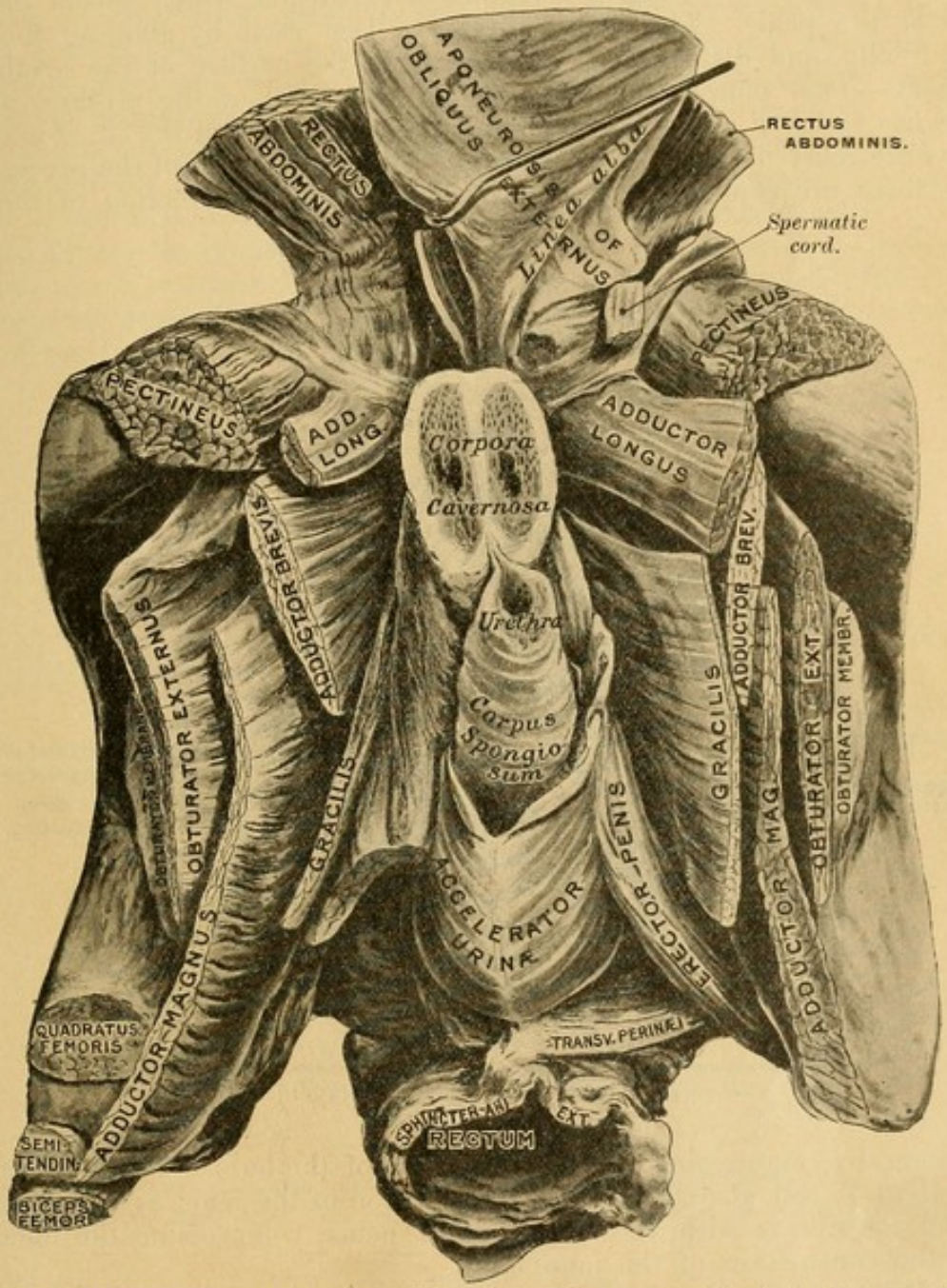

FIG. 224.—The muscles attached to the front of the pelvis. (From a preparation in the Museum of the Royal College of Surgeons of England.)

with the muscle of the opposite side, the External sphincter ani behind, and the Accelerator urinæ in front.

Nerve-supply.—The perineal branch of the internal pudic.

Actions.—By their contraction they serve to fix the central tendinous point of the perinæum.

The **Accelerator urinæ** (*Ejaculator seminis*, or *Bulbo-cavernosus*) is placed in the middle line of the perinæum, immediately in front of the anus. It consists of two symmetrical halves, united along the median line by a tendinous raphé. It arises from the central tendon of the perinæum, and from the median raphé in front. From this point its fibres diverge like the plumes of a pen; the most

posterior form a thin layer, which is lost on the anterior surface of the triangular ligament; the middle fibres encircle the bulb and adjacent parts of the corpus spongiosum, and join with the fibres of the opposite side, on the upper part of the corpus spongiosum, in a strong aponeurosis; the anterior fibres, the longest and most distinct, spread out over the sides of the corpus cavernosum, to be inserted partly into that body, anterior to the Erector penis, occasionally extending to the os pubis; partly terminating in a tendinous expansion, which covers the dorsal vessels of the penis. The latter fibres are best seen by dividing the muscle longitudinally, and dissecting it outward from the surface of the urethra.

Action.—This muscle serves to empty the canal of the urethra, after the bladder has expelled its contents; during the greater part of the act of micturition its fibres are relaxed, and it only comes into action at the end of the process. The middle fibres are supposed, by Krause, to assist in the erection of the corpus

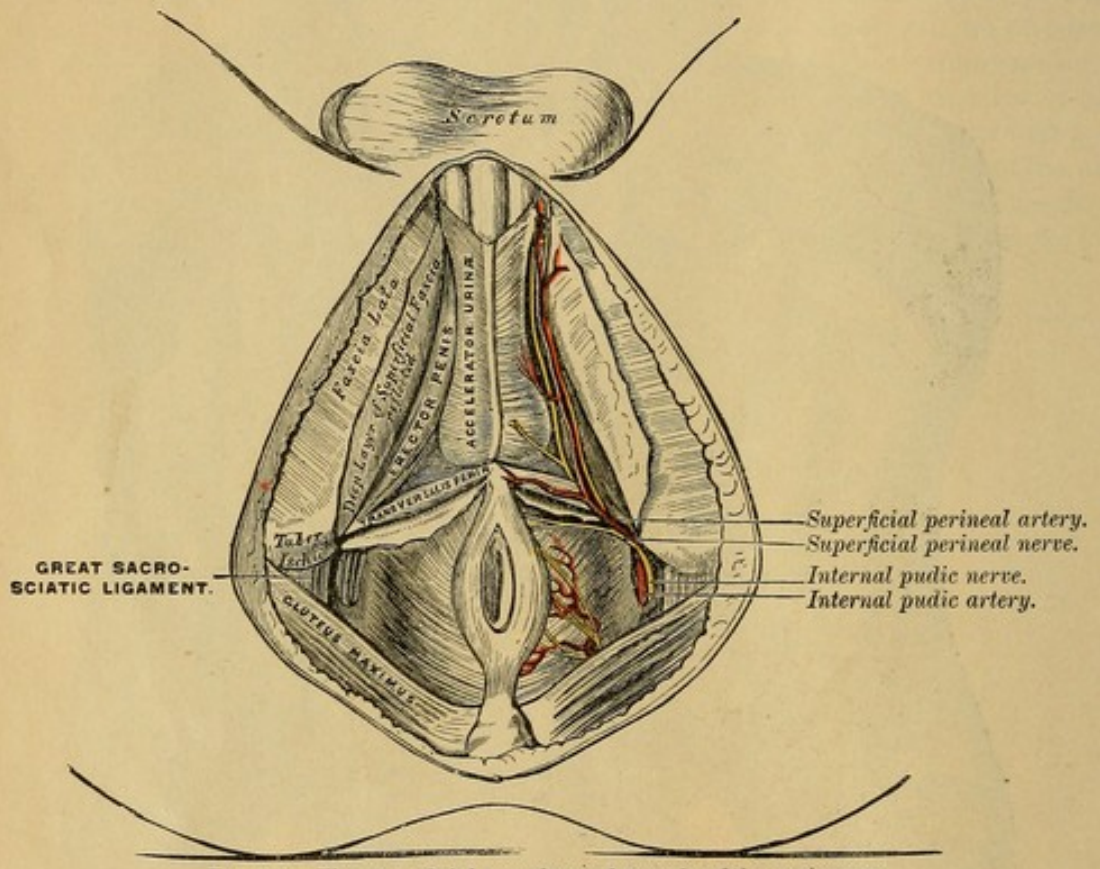

FIG. 225.—The superficial muscles and vessels of the perinæum.

spongiosum, by compressing the erectile tissue of the bulb. The anterior fibres, according to Tyrrel, also contribute to the erection of the penis, as they are inserted into, and continuous with, the fascia of the penis, compressing the dorsal vein during the contraction of the muscle.

The **Erector penis** (*Ischio-cavernous*) covers part of the crus penis. It is an elongated muscle, broader in the middle than at either extremity, and situated on either side of the lateral boundary of the perinæum. It arises by tendinous and fleshy fibres from the inner surface of the tuberosity of the ischium, behind the crus penis, from the surface of the crus, and from the adjacent portion of the ramus of the ischium. From these points fleshy fibres succeed, which end in an aponeurosis which is inserted into the sides and under surface of the crus penis.

Nerve-supply.—The perineal branch of the internal pudic.

Actions.—It compresses the crus penis and retards the return of the blood through the veins, and thus serves to maintain the organ erect.

Between the muscles just examined a triangular space exists, bounded internally by the Accelerator urinæ, externally by the Erector penis, and behind

by the Transversus perinæi. The floor of this space is formed by the triangular ligament of the urethra (deep perineal fascia), and running from behind forward in it are the superficial perineal vessels and nerves, the long pudendal nerve; the transverse perineal artery coursing along the posterior boundary of the space on the Transversus perinæi muscle.

The **Triangular Ligament** (*Deep perineal fascia*) is stretched almost horizontally across the pubic arch, so as to close in the front part of the outlet of the pelvis. It consists of two dense membranous laminæ, which are united along their posterior borders, but are separated in front by intervening structures. The superficial of these two layers, the *inferior layer of the triangular ligament*, is triangular in shape, about an inch and a half in depth. Its apex is directed forward, and is separated from the subpubic ligament by an oval opening for the transmission of the dorsal vein of the penis. Its lateral margins are attached on each side to the rami of the ischium and os pubis, above the crura penis. Its base is directed toward the rectum, and connected to the central tendinous point of the perinæum. It is continuous with the deep layer of the superficial fascia behind the Transversus perinæi muscle, and with a thin fascia which covers the cutaneous surface of the Levator ani muscle (*anal* or *ischio-rectal* fascia).

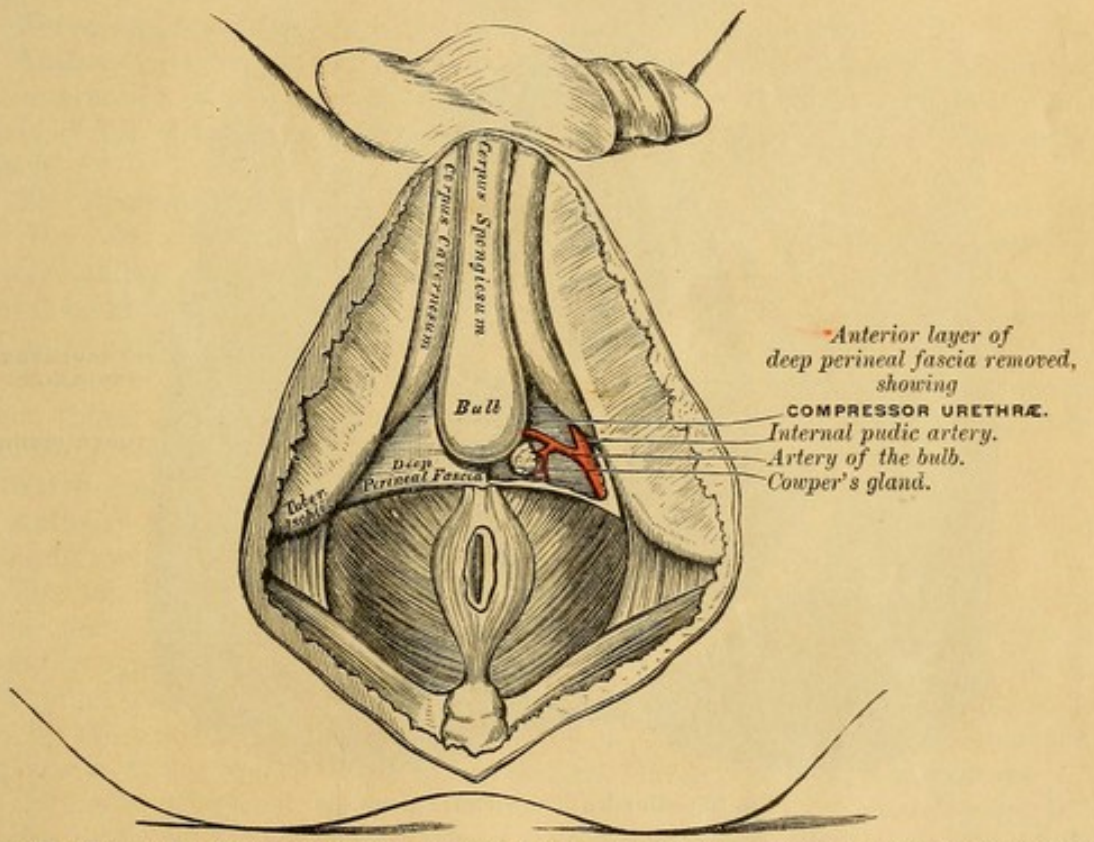

FIG. 226.—Triangular ligament or deep perineal fascia. On the left side the superficial layer has been removed.

This layer of the triangular ligament is perforated, about an inch below the symphysis pubis, by the urethra, the aperture for which is circular in form and about three or four lines in diameter; by the arteries to the bulb and the ducts of Cowper's glands close to the urethral orifice; by the arteries to the corpora cavernosa—one on each side, close to the pubic arch and about halfway along the attached margin of the ligament; by the dorsal arteries and nerves of the penis near the apex of the ligament. Its base is also perforated by the superficial perineal vessels and nerves, while between its apex and the subpubic ligament the dorsal vein of the penis passes upward into the pelvis.

If this superficial or inferior layer of the triangular ligament is detached on either side, the following structures will be seen between it and the deeper layer: the dorsal vein of the penis; the membranous portion of the urethra, and the

Compressor urethræ muscle; Cowper's glands and their ducts; the pudic vessels and dorsal nerve of the penis; the artery and nerve of the bulb, and a plexus of veins.

The deep layer of the ligament (*superior layer of the triangular ligament*) is derived from the obturator fascia and stretches across the pubic arch. If the obturator fascia is traced inward after covering the Obturator internus muscle, it will be found to be attached by some of its deeper or anterior fibres to the inner margin of the ischio-pubic ramus, while its superficial or posterior fibres pass over this attachment to become the superior layer of the triangular ligament. Behind, this layer of the fascia is continuous with the inferior layer and with the fascia of Colles, and in front it is separated from the apex of the prostate gland through the intervention of a prolongation of the recto-vesical fascia. It is pierced by the urethra, or rather consists of two halves which are separated in the middle line by the urethra passing between them.

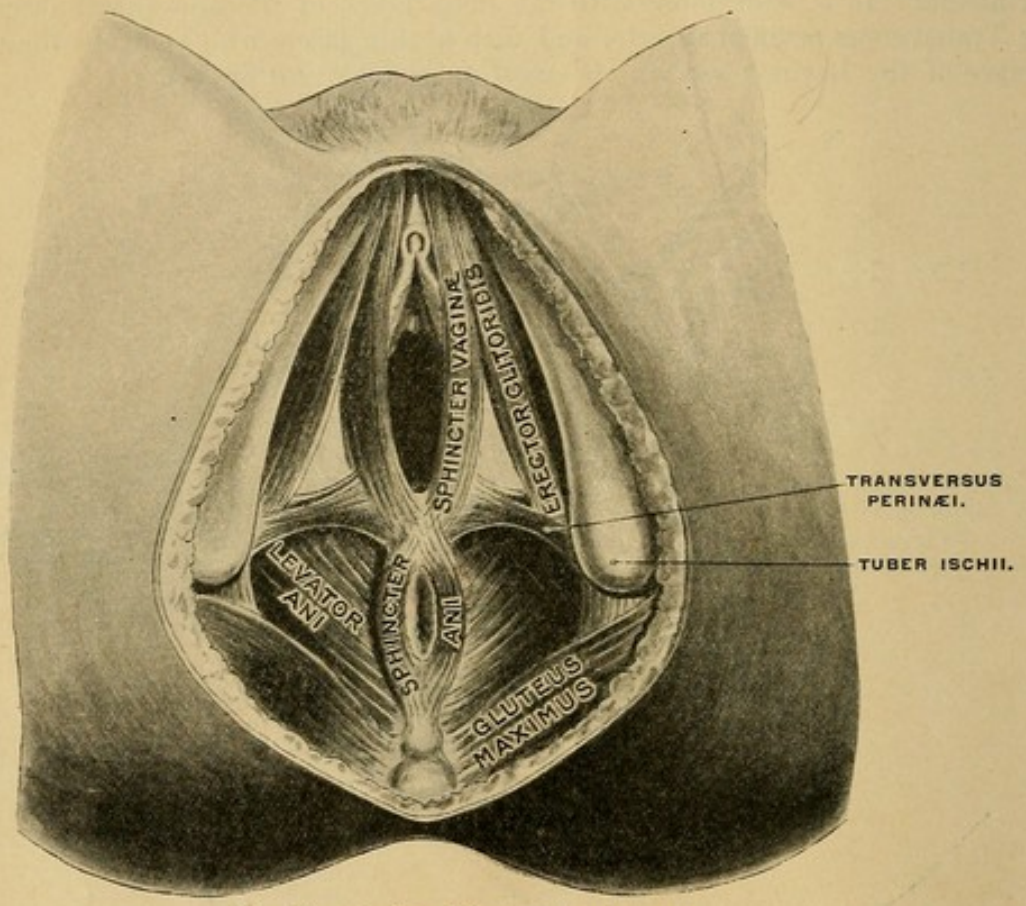

FIG. 227.—Muscles of the female perinæum.

The **Compressor urethræ** (*Constrictor urethræ*) surrounds the whole length of the membranous portion of the urethra, and is contained between the two layers of the triangular ligament. It arises, by aponeurotic fibres, from the junction of the rami of the os pubis and ischium, to the extent of half or three-quarters of an inch: each segment of the muscle passes inward, and divides into two fasciculi, which surround the urethra from the prostate gland behind to the bulbous portion of the urethra in front; and unite, at the upper and lower surfaces of this tube, with the muscle of the opposite side by means of a tendinous raphé.

Nerve-supply.—The perineal branch of the internal pudic.

Actions.—The muscles of both sides act together as a sphincter, compressing the membranous portion of the urethra. During the transmission of fluids they, like the Acceleratores urinæ, are relaxed, and come into action only at the end of the process, to eject the last drops of the fluid.

II. B. Muscles of the Perinæum in the Female (Fig. 227).

Transversus perinæi.	Erector clitoridis.
Sphincter vaginæ.	Compressor urethræ.

The **Transversus perinæi** in the **female** is a narrow muscular slip, which passes more or less transversely across the back part of the perineal space. It arises by a small tendon from the inner and fore part of the tuberosity of the ischium, and, passing inward, is inserted into the central point of the perinæum, joining in this situation with the muscle of the opposite side, the External sphincter ani behind, and the Sphincter vaginæ in front.

Nerve-supply.—The perineal branch of the internal pudic.

Actions.—By their contraction they serve to fix the central tendinous point of the perinæum.

The **Sphincter vaginæ** surrounds the orifice of the vagina, and is analogous to the Accelerator urinæ in the male. It is attached posteriorly to the central tendinous point of the perinæum, where it blends with the External sphincter ani. Its fibres pass forward on each side of the vagina, to be inserted into the corpora cavernosa of the clitoris, a fasciculus crossing over the body of the organ so as to compress the dorsal vein.

Nerve-supply.—The perineal branch of the internal pudic.

Actions.—It diminishes the orifice of the vagina. The anterior fibres contribute to the erection of the clitoris, as they are inserted into and are continuous with the fascia of the clitoris; compressing the dorsal vein during the contraction of the muscle.

The **Erector clitoridis** resembles the Erector penis in the male, but is smaller than it. It covers the unattached part of the crus clitoridis. It is an elongated muscle, broader at the middle than at either extremity, and situated on either side of the lateral boundary of the perinæum. It arises by tendinous and fleshy fibres from the inner surface of the tuberosity of the ischium, behind the crus clitoridis from the surface of the crus, and from the adjacent portion of the ramus of the ischium. From these points fleshy fibres succeed, which end in an aponeurosis, which is inserted into the sides and under surface of the crus clitoridis.

Nerve-supply.—The perineal branch of the internal pudic.

Actions.—It compresses the crus clitoridis and retards the return of blood through the veins, and thus serves to maintain the organ erect.

The **triangular ligament** (*deep perineal fascia*) in the female is not so strong as in the male. It is attached to the pubic arch, its apex being connected with the subpubic ligament. It is divided in the middle line by the aperture of the vagina, with the external coat of which it becomes blended, and in front of this is perforated by the urethra. Its posterior border is continuous, as in the male, with the deep layer of the superficial fascia around the Transversus perinæi muscle.

Like the triangular ligament in the male, it consists of two layers, between which are to be found the following structures: the dorsal vein of the clitoris, a portion of the urethra and the Compressor urethræ muscle, the glands of Bartholin and their ducts; the pudic vessels and the dorsal nerve of the clitoris; the arteries of the bulbi vestibuli, and a plexus of veins.

The **Compressor urethræ** (*Constrictor urethræ*) arises on each side from the margin of the descending ramus of the os pubis. The fibres, passing inward, divide into two sets: those of the fore part of the muscle are directed across the subpubic arch in front of the urethra to blend with the muscular fibres of the opposite side; while those of the hinder and larger part pass inward to blend with the wall of the vagina behind the urethra.

Nerve-supply.—The perineal branch of the internal pudic.

MUSCLES AND FASCIÆ OF THE UPPER EXTREMITY.

The Muscles of the Upper Extremity are divisible into groups, corresponding with the different regions of the limb.

I. Of the Thoracic Region.

1. *Anterior Thoracic Region.*

Pectoralis major. Pectoralis minor.
Subclavius.

2. *Lateral Thoracic Region.*

Serratus magnus.

II. Of the Shoulder and Arm.

3. *Acromial Region.*

Deltoid.

4. *Anterior Scapular Region.*

Subscapularis.

5. *Posterior Scapular Region.*

Supraspinatus. Teres minor.
Infraspinatus. Teres major.

6. *Anterior Humeral Region.*

Coraco-brachialis. Biceps.
Brachialis anticus.

7. *Posterior Humeral Region.*

Triceps. Subanconeus.

III. Of the Forearm.

8. *Anterior Radio-Ulnar Region.*

Superficial Layer.
- Pronator radii teres.
- Flexor carpi radialis.
- Palmaris longus.
- Flexor carpi ulnaris.
- Flexor sublimis digitorum.

Deep Layer.
- Flexor profundus digitorum.
- Flexor longus pollicis.
- Pronator quadratus.

9. *Radial Region.*

Supinator longus.
Extensor carpi radialis longior.
Extensor carpi radialis brevior.

10. *Posterior Radio-Ulnar Region.*

Superficial Layer.
- Extensor communis digitorum.
- Extensor minimi digiti.
- Extensor carpi ulnaris.
- Anconeus.

Deep Layer.
- Supinator brevis.
- Extensor ossis metacarpi pollicis.
- Extensor brevis pollicis.
- Extensor longus pollicis.
- Extensor indicis.

IV. Of the Hand.

11. *Radial Region.*

Abductor pollicis.
Flexor ossis metacarpi pollicis (Opponens pollicis).
Flexor brevis pollicis.
Adductor obliquus pollicis.
Adductor transversus pollicis.

12. *Ulnar Region.*

Palmaris brevis.
Abductor minimi digiti.
Flexor brevis minimi digiti.
Flexor ossis metacarpi minimi digiti (Opponens minimi digiti).

13. *Middle Palmar Region.*

Lumbricales.
Interossei palmares.
Interossei dorsales.

Dissection of Pectoral Region and Axilla (Fig. 228).—The arm being drawn away from the side nearly at right angles with the trunk and rotated outward, make a vertical incision through the integument in the median line of the chest, from the upper to the lower part of the sternum; a second incision along the lower border of the Pectoral muscle, from the ensiform cartilage to the inner side of the axilla; a third, from the sternum along the clavicle, as far as its centre; and a fourth, from the middle of the clavicle obliquely downward, along the interspace between the Pectoral and Deltoid muscles, as low as the fold of the armpit. The flap of integument is then to be dissected off in the direction indicated in the figure, but not entirely removed, as it should be replaced on completing the dissection. If a transverse incision is now made from the lower end of the sternum to the side of the chest, as far as the posterior fold of the armpit, and the integument reflected outward, the axillary space will be more completely exposed.

I. Muscles and Fasciæ of the Thoracic Region.

1. *Anterior Thoracic Region.*

Pectoralis major. Pectoralis minor.

Subclavius.

The **superficial fascia** of the thoracic region is a loose cellulo-fibrous layer enclosing masses of fat in its spaces. It is continuous with the superficial fascia of the neck and upper extremity above, and of the abdomen below. Opposite the mamma it divides into two layers, one of which passes in front, the other behind, that gland; and from both of these layers numerous septa pass into its substance, supporting its various lobes: from the anterior layer fibrous processes pass forward to the integument and nipple. These processes were called by Sir A. Cooper the *ligamenta suspensoria*, from the support they afford to the gland in this situation.

The **deep fascia** of the thoracic region is a thin aponeurotic lamina, covering the surface of the great Pectoral muscle, and sending numerous prolongations

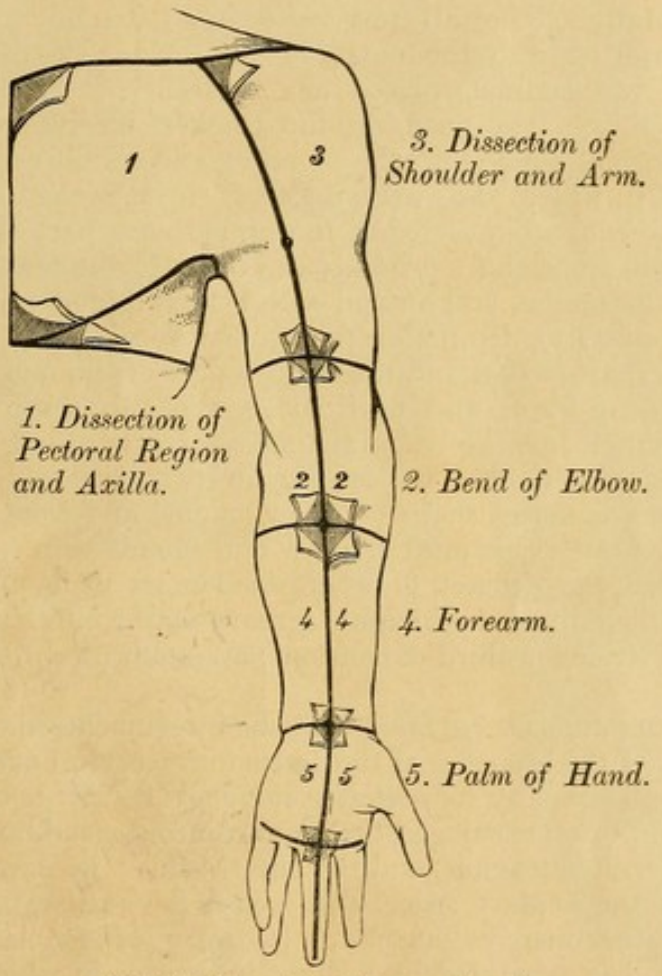

FIG. 228.—Dissection of upper extremity.

between its fasciculi: it is attached, in the middle line, to the front of the sternum, and above to the clavicle; externally and below it becomes continuous with the fascia over the shoulder, axilla, and thorax. It is very thin over the upper part of the muscle, thicker in the interval between the Pectoralis major and Latissimus dorsi, where it closes in the axillary space, and divides at the outer margin of the latter muscle into two layers, one of which passes in front and the other behind it; these proceed as far as the spinous processes of the dorsal vertebræ, to which they are attached. As the fascia leaves the lower edge of the Pectoralis major to pass across the floor of the axilla it sends a layer upward under cover of the muscle: this lamina splits to envelop the Pectoralis minor, at the upper edge of which it becomes continuous with the costo-coracoid membrane. The hollow of the armpit, seen when the arm is abducted, is mainly produced by the traction of this

fascia on the axillary floor, and hence it is sometimes named the *suspensory ligament* of the axilla. At the lower part of the thoracic region this fascia is well developed, and is continuous with the fibrous sheath of the Recti muscles.

The **Pectoralis major** (Fig. 229) is a broad, thick, triangular muscle, situated at the upper and fore part of the chest, in front of the axilla. It arises from the anterior surface of the sternal half of the clavicle; from half the breadth of the anterior surface of the sternum, as low down as the attachment of the cartilage of the sixth or seventh rib; this portion of its origin consists of aponeurotic fibres, which intersect with those of the opposite muscle; it also arises from the cartilages of all the true ribs, with the exception, frequently, of the first or of the seventh, or both; and from the aponeurosis of the External oblique muscle of the abdomen. The fibres from this extensive origin converge toward its insertion, giving to the muscle a radiated appearance. Those fibres which arise from the clavicle pass obliquely outward and downward, and are usually separated from the rest by a cellular interval: those from the lower part of the sternum, and the cartilages of the lower true ribs, pass upward and outward, whilst the middle fibres pass horizontally. They all terminate in a flat tendon, about two inches broad, which is inserted into the outer bicipital ridge of the humerus. This tendon consists of two laminæ, placed one in front of the other, and usually blended together below. The anterior, the thicker, receives the clavicular and upper half of the sternal portion of the muscle; and its fibres are inserted in the same order as that in which they arise; that is to say, the outermost fibres of origin from the clavicle are inserted at the uppermost part of the tendon; the upper fibres of origin from the sternum pass down to the lowermost part of this anterior lamina of the tendon and extend as low as the tendon of the Deltoid and join with it. The posterior lamina of the tendon receives the attachment of the lower half of the sternal portion and the deeper part of the muscle from the costal cartilages. These deep fibres, and particularly those from the lower costal cartilages, ascend the higher, turning backward successively behind the superficial and upper ones, so that the tendon appears to be twisted. The posterior lamina reaches higher on the humerus than the anterior one, and from it an expansion is given off which covers the bicipital groove and blends with the capsule of the shoulder-joint. From the deepest fibres of this lamina at its insertion an expansion is given off which lines the bicipital groove of the humerus, while from the lower border of the tendon a third expansion passes downward to the fascia of the arm.

Relations.—By its *anterior surface*, with the integument, the superficial fascia, the Platysma, some of the branches of the descending cervical nerves, the mammary gland, and the deep fascia; by its *posterior surface:* its *thoracic portion*, with the sternum, the ribs and costal cartilages, the costo-coracoid membrane, the Subclavius, Pectoralis minor, Serratus magnus, and the Intercostals; its *axillary portion* forms the anterior wall of the axillary space, and covers the axillary vessels and nerves, the Biceps and Coraco-brachialis muscles. Its *upper border* lies parallel with the Deltoid, from which it is separated by a slight interspace in which lie the cephalic vein and humeral branch of the acromial thoracic artery. Its *lower border* forms the anterior margin of the axilla, being at first separated from the Latissimus dorsi by a considerable interval; but both muscles gradually converge toward the outer part of the space.

Dissection.—Detach the Pectoralis major by dividing the muscle along its attachment to the clavicle, and by making a vertical incision through its substance a little external to its line of attachment to the sternum and costal cartilages. The muscle should then be reflected outward, and its tendon carefully examined. The Pectoralis minor is now exposed, and immediately above it, in the interval between its upper border and the clavicle, a strong fascia, the *costo-coracoid membrane.*

The **costo-coracoid membrane** is a strong fascia, situated under cover of the clavicular portion of the Pectoralis major muscle. It occupies the interval between the Pectoralis minor and Subclavius muscles, and protects the axillary vessels and

nerves. Traced upward, it splits to enclose the Subclavius muscle, and its two layers are attached to the clavicle, one in front of and the other behind the muscle; the latter layer fuses with the deep cervical fascia and with the sheath of the axillary vessels. Internally, it blends with the fascia covering the first two inter-

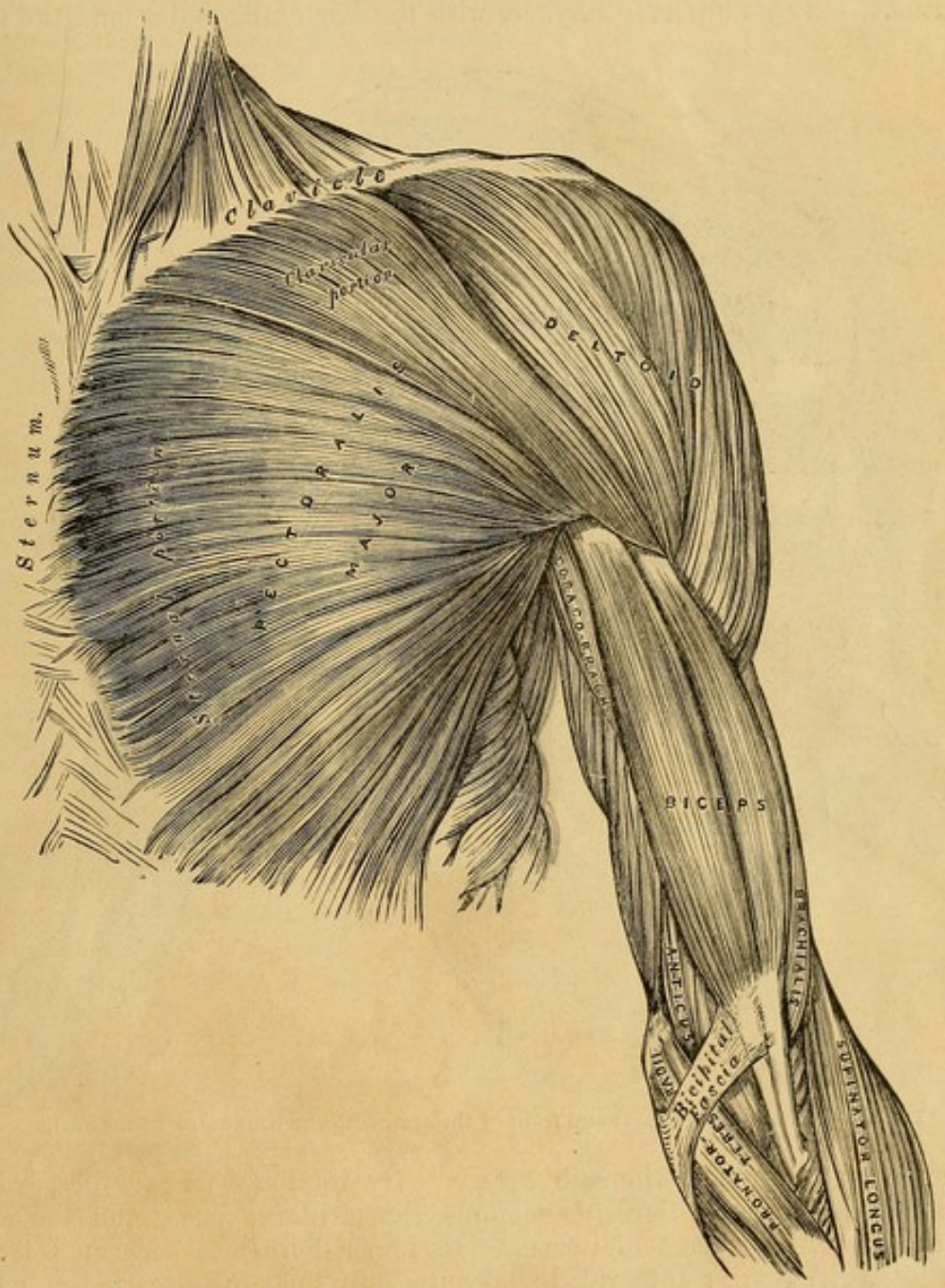

FIG. 229.—Muscles of the chest and front of the arm. Superficial view.

costal spaces, and is attached also to the first rib internal to the origin of the Subclavius muscle. Externally it is very thick and dense, and is attached to the coracoid process. The portion extending from its attachment to the first rib to the coracoid process is often whiter and denser than the rest; this is sometimes called the *costo-coracoid ligament*. Below, it is thin, and at the upper border of the Pectoralis minor it splits into two layers to invest the muscle; from the lower border of the Pectoralis minor it is continued downward to join the axillary fascia, and outward to join the fascia over the short head of the Biceps. The costo-coracoid membrane is pierced by the cephalic vein, the acromial thoracic artery and vein, superior thoracic artery, and anterior thoracic nerves.

The **Pectoralis minor** (Fig. 230) is a thin, flat, triangular muscle, situated at the upper part of the thorax, beneath the Pectoralis major. It arises by three

tendinous digitations from the upper margin and outer surface of the third, fourth, and fifth ribs, near their cartilages, and from the aponeurosis covering the Intercostal muscles; the fibres pass upward and outward, and converge to form a flat tendon, which is inserted into the inner border and upper surface of the coracoid process of the scapula.

Relations.—By its *anterior surface*, with the Pectoralis major and the thoracic

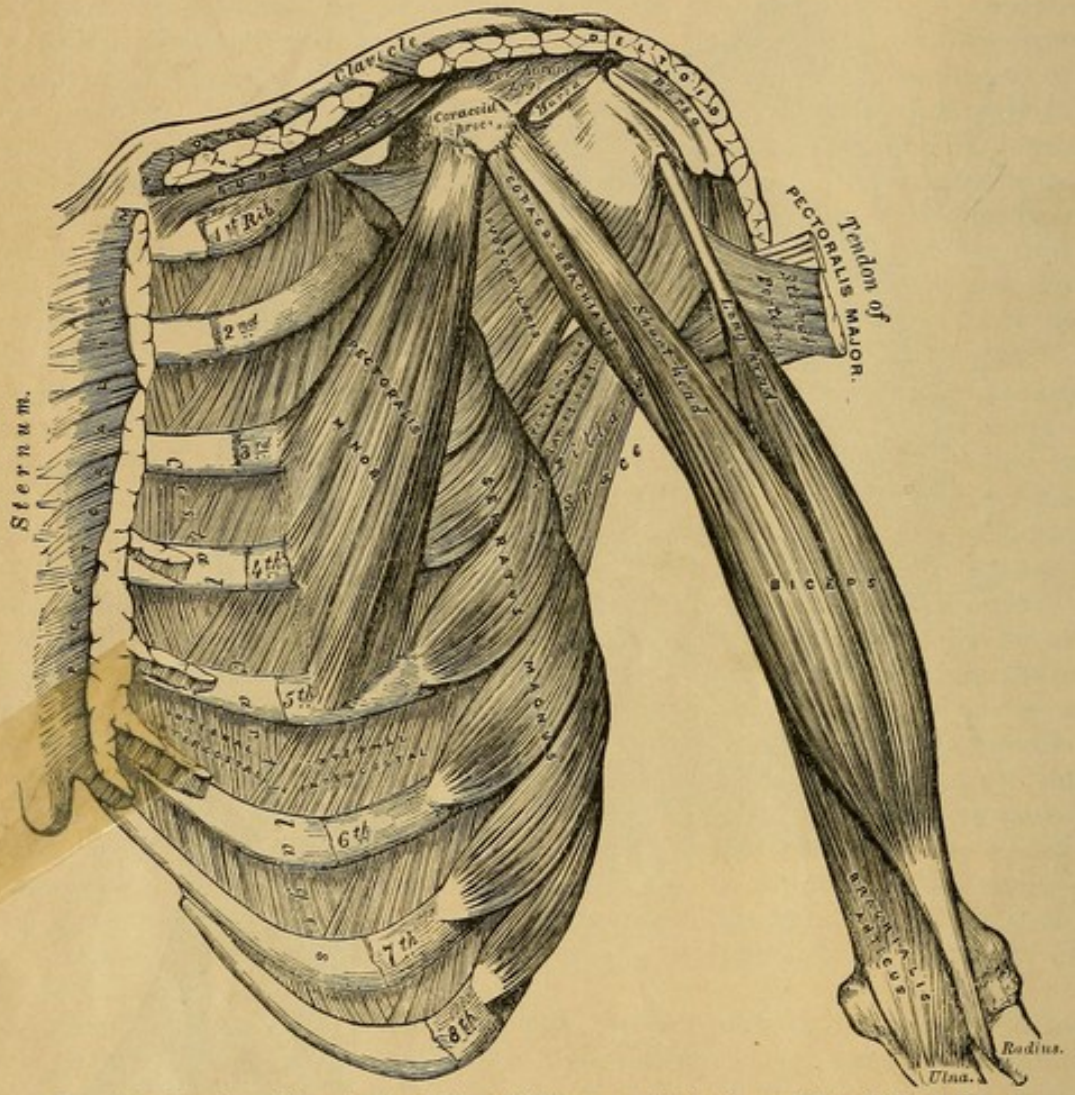

Fig. 230.—Muscles of the chest and front of the arm, with the boundaries of the axilla.

branches of the acromial thoracic artery. By its *posterior surface*, with the ribs, Intercostal muscles, Serratus magnus, the axillary space, and the axillary vessels and brachial plexus of nerves. Its upper border is separated from the clavicle by a triangular interval, broad internally, narrow externally, which is occupied by the costo-coracoid membrane. In this space is the first part of the axillary vessels and nerves. Running parallel to the lower border of the muscle is the long thoracic artery.

The costo-coracoid membrane should now be removed, when the Subclavius muscle will be seen.

The **Subclavius** is a small triangular muscle, placed in the interval between the clavicle and the first rib. It arises by a short, thick tendon from the first rib and its cartilage at their junction, in front of the rhomboid ligament; the fleshy fibres proceed obliquely upward and outward, to be inserted into a deep groove on the under surface of the clavicle.

Relations.—By its *upper surface*, with the clavicle. By its *deep surface* it is separated from the first rib by the subclavian vessels and brachial plexus of nerves. Its *anterior surface* is separated from the Pectoralis major by the costo-coracoid

membrane, which, with the clavicle, forms an osseo-fibrous sheath in which the muscle is enclosed.

If the costal attachment of the Pectoralis minor is divided across, and the muscle reflected outward, the axillary vessels and nerves are brought fully into view, and should be examined.

Nerves.—The Pectoral muscles are supplied by the anterior thoracic nerves; the Pectoralis major through these nerves receives filaments from all the spinal nerves entering into the formation of the brachial plexus; the Pectoralis minor receives its fibres from the eighth cervical and first dorsal nerves. The Subclavius is supplied by a filament from the fifth cervical nerve.

Actions.—If the arm has been raised by the Deltoid, the Pectoralis major will, conjointly with the Latissimus dorsi and Teres major, depress it to the side of the chest. If acting alone, it adducts and draws forward the arm, bringing it across the front of the chest, and at the same time rotates it inward. The Pectoralis minor depresses the point of the shoulder, drawing the scapula downward and inward to the thorax, and throwing the inferior angle backward. The Subclavius depresses the shoulder, drawing the clavicle downward and forward. When the arms are fixed, all three muscles act upon the ribs, drawing them upward and expanding the chest, and thus becoming very important agents in forced inspiration. Asthmatic patients always assume an attitude which fixes the shoulders, so that all these muscles may be brought into action to assist in dilating the cavity of the chest.

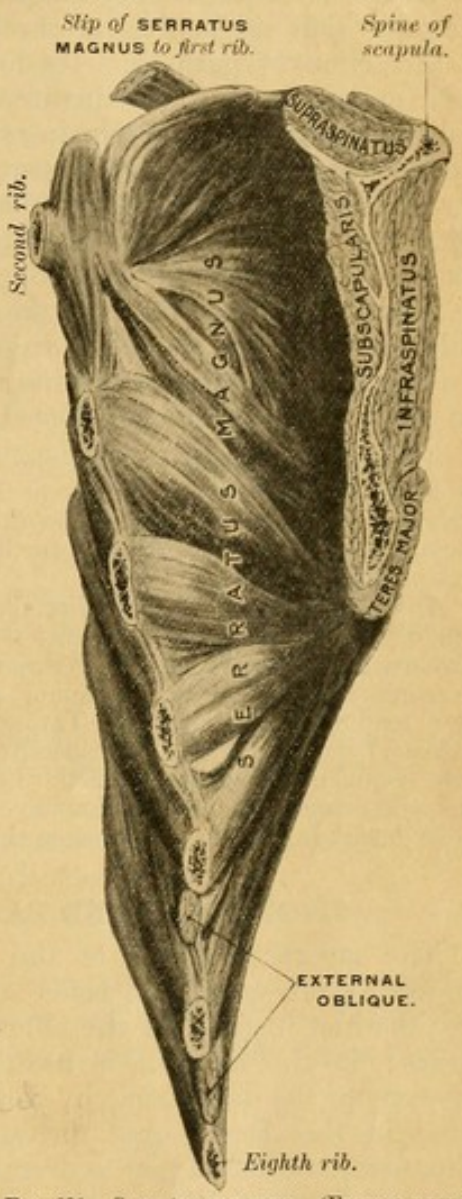

FIG. 231.—Serratus magnus. (From a preparation in the Museum of the Royal College of Surgeons of England.)

2. Lateral Thoracic Region.

Serratus magnus.

The **Serratus magnus** (Fig. 231) is a thin, irregularly quadrilateral muscle, situated between the ribs and the scapula at the upper and lateral part of the chest. It arises by nine digitations or slips from the outer surface and upper border of the eight upper ribs (the second rib giving origin to two slips), and from the aponeurosis covering the corresponding intercostal muscles. From this extensive attachment the fibres pass backward, closely applied to the chest-wall, and reach the vertebral border of the scapula, and are inserted into its ventral aspect in the following manner. The upper two digitations—*i. e.*, the one from the first rib and the higher, of the two from the second rib—converge to be inserted into a triangular area on the ventral aspect of the superior angle. The next two digitations spread out to form a thin triangular sheet, the base of which is directed backward and is inserted into nearly the whole length of the ventral aspect of the vertebral border. The lower five digitations converge, as they pass backward from the ribs, to form a fan-shaped structure, the apex of which is inserted, partly by muscular and partly by tendinous fibres, into a triangular impression on the ventral aspect of the inferior angle. The lower four slips interdigitate at their origin with the upper five slips of the External oblique muscle of the abdomen.

Relations.—This muscle is partly covered, in front, by the Pectoral muscles; behind, by the Subscapularis. The axillary vessels and nerves lie upon its upper part, while its *deep surface* rests upon the ribs and intercostal muscles.

Nerve.—The Serratus magnus is supplied by the posterior thoracic nerve, which is derived from the fifth, sixth, and generally the seventh cervical nerves.

Actions.—The Serratus magnus, as a whole, carries the scapula forward, and at the same time raises the vertebral border of the bone. It is therefore concerned in the action of pushing. Its lower and stronger fibres move forward the lower angle and assist the Trapezius in rotating the bone round an axis through its centre, and thus assists this muscle in raising the acromion and supporting weights upon the shoulder. It is also an assistant to the Deltoid in raising the arm, inasmuch as during the action of this latter muscle it fixes the scapula and so steadies the glenoid cavity on which the head of the humerus rotates. After the Deltoid has raised the arm to a right angle with the trunk, the Serratus magnus and the Trapezius, by rotating the scapula, raise the arm into an almost vertical position. It is possible that when the shoulders are fixed the lower fibres of the Serratus magnus may assist in raising and everting the ribs; but it is not the important inspiratory muscle which it was formerly believed to be.

Surgical Anatomy.—When the muscle is paralyzed, the vertebral border, and especially the lower angle of the scapula, leaves the ribs and stands out prominently on the surface, giving a peculiar "winged" appearance to the back. The patient is unable to raise the arm, and an attempt to do so is followed by a further projection of the lower angle of the scapula from the back of the thorax.

Dissection.—After completing the dissection of the axilla, if the muscles of the back have been dissected, the upper extremity should be separated from the trunk. Saw through the clavicle at its centre, and then cut through the muscles which connect the scapula and arm with the trunk, viz.: the Pectoralis minor in front, Serratus magnus at the side, and the Levator anguli scapulæ, the Rhomboids, Trapezius, and Latissimus dorsi behind. These muscles should be cleaned and traced to their respective insertions. Then make an incision through the integument, commencing at the outer third of the clavicle, and extending along the margin of that bone, the acromion process, and spine of the scapula; the integument should be dissected from above downward and outward, when the fascia covering the Deltoid is exposed (Fig. 228, No. 3).

II. MUSCLES AND FASCIÆ OF THE SHOULDER AND ARM

The **superficial fascia** of the upper extremity is a thin cellulo-fibrous layer, containing the superficial veins and lymphatics, and the cutaneous nerves. It is most distinct in front of the elbow, and contains very large superficial veins and nerves; in the hand it is hardly demonstrable, the integument being closely adherent to the deep fascia by dense fibrous bands. Small subcutaneous bursæ are found in this fascia over the acromion, the olecranon, and the knuckles. The deep fascia of the upper extremity comprises the aponeurosis of the shoulder, arm, and forearm, the anterior and posterior annular ligaments of the carpus, and the palmar fascia. These will be considered in the description of the muscles of the several regions.

3. Acromial Region.

Deltoid.

The **deep fascia** covering the Deltoid (deltoid aponeurosis) is a fibrous layer which covers the outer surface of the muscle, thick and strong behind, where it is continuous with the infraspinatus fascia, thinner over the rest of its extent. It sends down numerous prolongations between the fasciculi of the muscle. In front, it is continuous with the fascia covering the great Pectoral muscle; behind, with that covering the Infraspinatus; above, it is attached to the clavicle, the acromion, and spine of the scapula; below, it is continuous with the deep fascia of the arm.

The **Deltoid** (Fig. 229) is a large, thick, triangular muscle, which gives the rounded outline to the shoulder, and has received its name from its resemblance to the Greek letter Δ reversed. It surrounds the shoulder-joint in the greater part of its extent, covering it on its outer side, and in front and behind. It arises from

the outer third of the anterior border and upper surface of the clavicle; from the outer margin and upper surface of the acromion process, and from the lower lip of the posterior border of the spine of the scapula, as far back as the triangular surface at its inner end. From this extensive origin the fibres converge toward their insertion, the middle passing vertically, the anterior obliquely, backward, the posterior obliquely forward; they unite to form a thick tendon, which is inserted into a rough triangular prominence on the middle of the outer side of the shaft of the humerus. At its insertion the muscle gives off an expansion to the deep fascia of the arm. This muscle is remarkably coarse in texture, and the arrangement of its muscular fibres is somewhat peculiar; the central portion of the muscle—that is to say, the part arising from the acromion process—consists of oblique fibres, which arise in a bipenniform manner from the sides of tendinous intersections, generally four in number, which are attached above to the acromion process and pass downward parallel to one another in the substance of the muscle. The oblique muscular fibres thus formed are inserted into similar tendinous intersections, generally three in number, which pass upward from the insertion of the muscle into the humerus and alternate with the descending septa. The portions of the muscle which arise from the clavicle and spine of the scapula are not arranged in this manner, but pass from their origin above, to be inserted into the margins of the inferior tendon.

Relations.—By its *superficial surface*, with the integument, the superficial and deep fasciæ, Platysma, and supra-acromial nerves. Its *deep surface* is separated from the head of the humerus by a large sacculated synovial bursa, and covers the coracoid process, coraco-acromial ligament, Pectoralis minor, Coraco-brachialis, both heads of the Biceps, the tendon of the Pectoralis major, the insertions of the Supraspinatus, Infraspinatus, and Teres minor, the scapular and external heads of the Triceps, the circumflex vessels and nerve, and the humerus. Its *anterior border* is separated at its upper part from the Pectoralis major by a cellular interspace, which lodges the cephalic vein and humeral branch of the acromial thoracic artery: lower down the two muscles are in close contact. Its *posterior border* rests on the Infraspinatus and Triceps muscles.

Nerves.—The Deltoid is supplied by the fifth and sixth cervical through the circumflex nerve.

Actions.—The Deltoid raises the arm directly from the side, so as to bring it at right angles with the trunk. Its anterior fibres, assisted by the Pectoralis major, draw the arm forward; and its posterior fibres, aided by the Teres major and Latissimus dorsi, draw it backward.

Surgical Anatomy.—The Deltoid is very liable to atrophy, and when in this condition simulates dislocation of the shoulder-joint, as there is flattening of the shoulder and apparent prominence of the acromion process; upon examination, however, it will be found that the relative position of the great tuberosity of the humerus to the acromion and coracoid process is unchanged. Atrophy of the Deltoid may be due to disuse or loss of trophic influence, either from injury to the circumflex nerve or cord lesions, as in infantile paralysis.

Dissection.—Divide the Deltoid across, near its upper part, by an incision carried along the margin of the clavicle, the acromion process and spine of the scapula, and reflect it downward, when the structures under cover of it will be seen.

4. Anterior Scapular Region.

Subscapularis.

The **subscapular fascia** is a thin membrane attached to the entire circumference of the subscapular fossa, and affording attachment by its inner surface to some of the fibres of the Subscapularis muscle: when this is removed, the Subscapularis muscle is exposed.

The **Subscapularis** (Fig. 230) is a large triangular muscle which fills up the subscapular fossa, arising from its internal two-thirds, with the exception of a narrow margin along the posterior border, and the surfaces at the superior and inferior angles which afford attachment to the Serratus magnus: it also arises from

the lower two-thirds of the groove on the axillary border of the bone. Some fibres arise from tendinous laminæ, which intersect the muscle, and are attached to ridges on the bone; and others from an aponeurosis, which separates the muscle from the Teres major and the long head of the Triceps. The fibres pass outward, and, gradually converging, terminate in a tendon, which is inserted into the lesser tuberosity of the humerus. Those fibres which arise from the axillary border of the scapula are inserted into the neck of the humerus to the extent of an inch below the tuberosity. The tendon of the muscle is in close contact with the anterior part of the capsular ligament of the shoulder-joint, and glides over a large bursa, which separates it from the base of the coracoid process. This bursa communicates with the cavity of the joint by an aperture in the capsular ligament.

Relations.—Its *anterior surface* forms a considerable part of the posterior wall of the axilla, and is in relation with the Serratus magnus, Coraco-brachialis, and Biceps, the axillary vessels and brachial plexus of nerves, and the subscapular vessels and nerves. By its *posterior surface*, with the scapula and the capsular ligament of the shoulder-joint. Its *lower border* is contiguous with the Teres major and Latissimus dorsi.

Nerves.—It is supplied by the fifth and sixth cervical nerves through the upper and lower subscapular nerves.

Actions.—The Subscapularis rotates the head of the humerus inward; when the arm is raised, it draws the humerus forward and downward. It is a powerful defence to the front of the shoulder-joint, preventing displacement of the head of the bone.

5. Posterior Scapular Region (Fig. 232).

Supraspinatus.	Teres minor.
Infraspinatus.	Teres major.

Dissection.—To expose these muscles, and to examine their mode of insertion into the humerus, detach the Deltoid and Trapezius from their attachment to the spine of the scapula and acromion process. Remove the clavicle by dividing the ligaments connecting it with the coracoid process, and separate it at its articulation with the scapula: divide the acromion process near its root with a saw. The fragments being removed, the tendons of the posterior Scapular muscles will be fully exposed, and can be examined. A block should be placed beneath the shoulder-joint, so as to make the muscles tense.

The **Supraspinous fascia** is a thick and dense membranous layer, which completes the osseo-fibrous case in which the Supraspinatus muscle is contained, affording attachment, by its inner surface, to some of the fibres of the muscle. It is thick internally, but thinner externally under the coraco-acromial ligament. When this fascia is removed, the Supraspinatus muscle is exposed.

The **Supraspinatus muscle** occupies the whole of the supraspinous fossa, arising from its internal two-thirds and from the strong fascia which covers its surface. The muscular fibres converge to a tendon which passes across the upper part of the capsular ligament of the shoulder-joint, to which it is intimately adherent, and is inserted into the highest of the three facets on the great tuberosity of the humerus.

Relations.—By its *upper surface*, with the Trapezius, the clavicle, the acromion, the coraco-acromial ligament, and the Deltoid; by its *under surface*, with the scapula, the suprascapular vessels and nerve, and upper part of the shoulder-joint.

The **Infraspinous fascia** is a dense fibrous membrane, covering in the Infraspinatus muscle and attached to the circumference of the infraspinous fossa; it affords attachment, by its inner surface, to some fibres of that muscle. At the point where the Infraspinatus commences to be covered by the Deltoid, this fascia divides into two layers: one layer passes over the Deltoid muscle, helping to form the Deltoid fascia already described; the other passes beneath the Deltoid to the shoulder-joint.

The **Infraspinatus** is a thick, triangular muscle, which occupies the chief part of the infraspinous fossa, arising by fleshy fibres from its internal two-thirds, and

by tendinous fibres from the ridges on its surface: it also arises from a strong fascia which covers it externally, and separates it from the Teres major and minor. The fibres converge to a tendon which glides over the external border of the spine of the scapula, and, passing across the posterior part of the capsular ligament of the shoulder-joint, is inserted into the middle facet on the great tuberosity of the humerus. The tendon of this muscle is occasionally separated from the spine of the scapula by a synovial bursa which communicates with the synovial cavity of the shoulder-joint.

Relations.—By its *posterior surface*, with the Deltoid, the Trapezius, Latissimus dorsi, and the integument; by its *anterior surface*, with the scapula, from which

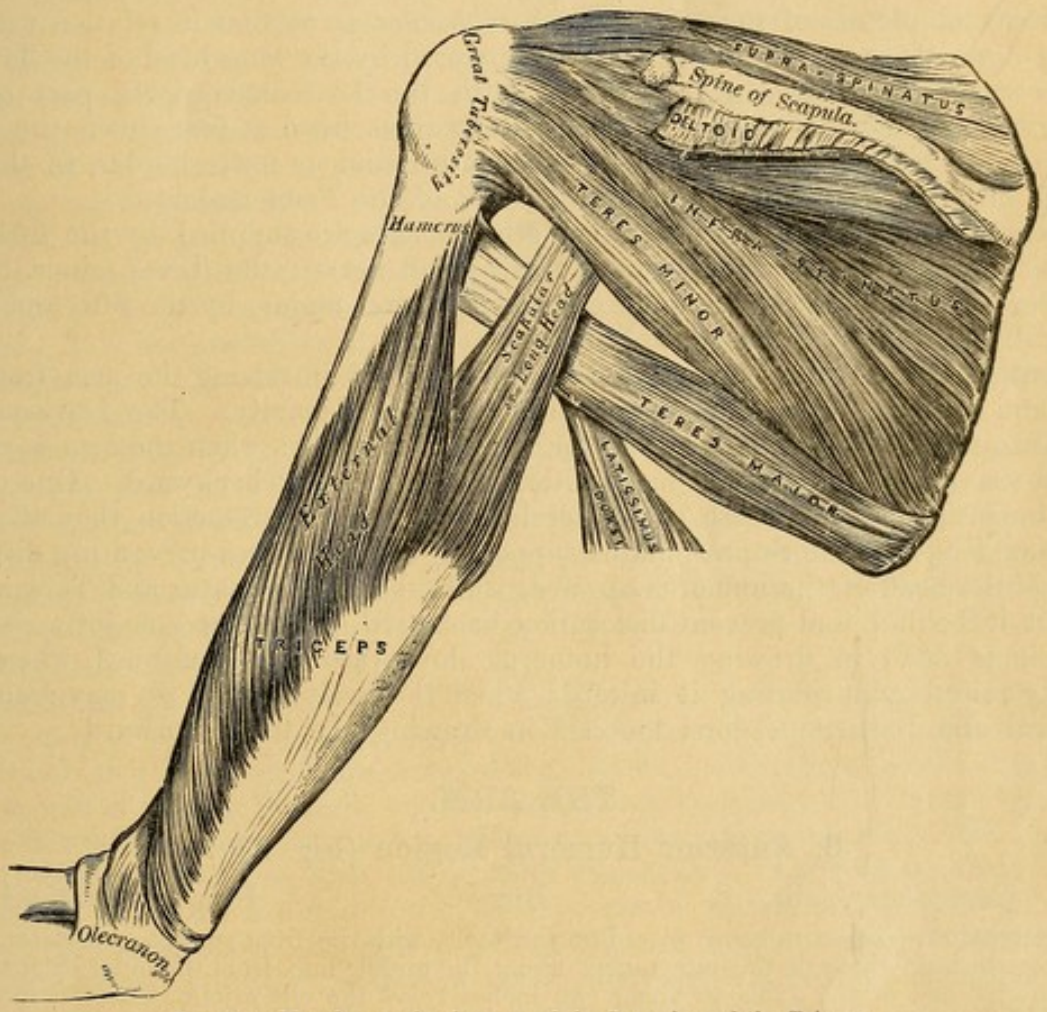

FIG. 232.—Muscles on the dorsum of the Scapula and the Triceps.

it is separated by the suprascapular and dorsalis scapulæ vessels, and with the capsular ligament of the shoulder-joint. Its *lower border* is in contact with the Teres minor, occasionally united with it, and with the Teres major.

The **Teres minor** is a narrow, elongated muscle, which arises from the dorsal surface of the axillary border of the scapula for the upper two-thirds of its extent, and from two aponeurotic laminæ, one of which separates this muscle from the Infraspinatus, the other from the Teres major; its fibres pass obliquely upward and outward, and terminate in a tendon which is inserted into the lowest of the three facets on the great tuberosity of the humerus, and, by fleshy fibres, into the humerus immediately below it. The tendon of this muscle passes across the posterior part of the capsular ligament of the shoulder-joint.

Relations.—By its *posterior surface*, with the Deltoid and the integument; by its *anterior surface*, with the scapula and dorsal branch of the subscapular artery, the long head of the Triceps, and the shoulder-joint; by its *upper border*, with the Infraspinatus; by its *lower border*, with the Teres major, from which it is separated anteriorly by the long head of the Triceps.

The **Teres major** is a thick but somewhat flattened muscle, which arises from the oval surface on the dorsal aspect of the inferior angle of the scapula, and from the fibrous septa interposed between it and the Teres minor and Infraspinatus; the fibres are directed upward and outward, and terminate in a flat tendon, about two inches in length, which is inserted into the inner bicipital ridge of the humerus. The tendon of this muscle, at its insertion into the humerus, lies behind that of the Latissimus dorsi, from which it is separated by a synovial bursa, the two tendons being, however, united along their lower borders for a short distance.

Relations.—By its *posterior surface*, with the Latissimus dorsi below, and the long head of the Triceps above. By its *anterior surface*, with the Subscapularis, Latissimus dorsi, Coraco-brachialis, short head of the Biceps, the axillary vessels, and brachial plexus of nerves. Its *upper border* is at first in relation with the Teres minor, from which it is afterward separated by the long head of the Triceps. Its *lower border* forms, in conjunction with the Latissimus dorsi, part of the posterior boundary of the axilla. The Latissimus dorsi at first covers the origin of the Teres major, then wraps itself obliquely round its lower border, so that its tendon ultimately comes to lie in front of that of the Teres major.

Nerves.—The Supra- and Infra-spinatus muscles are supplied by the fifth and sixth cervical nerves through the suprascapular nerve; the Teres minor, by the fifth cervical, through the circumflex; and the Teres major, by the fifth and sixth cervical, through the lower subscapular.

Actions.—The Supraspinatus assists the Deltoid in raising the arm from the side, and fixes the head of the humerus in the glenoid cavity. The Infraspinatus and Teres minor rotate the head of the humerus outward: when the arm is raised, they assist in retaining it in that position and carrying it backward. One of the most important uses of these three muscles is the great protection they afford to the shoulder-joint, the Supraspinatus supporting it above, and preventing displacement of the head of the humerus upward, while the Infraspinatus and Teres minor protect it behind, and prevent dislocation backward. The Teres major assists the Latissimus dorsi in drawing the humerus downward and backward, when previously raised, and rotating it inward; when the arm is fixed, it may assist the Pectoral and Latissimus dorsi muscles in drawing the trunk forward.

THE ARM.

6. Anterior Humeral Region (Fig. 230).

Coraco-brachialis. Biceps. Brachialis anticus.

Dissection.—The arm being placed on the table, with the front surface uppermost, make a vertical incision through the integument along the middle line, from the outer extremity of the anterior fold of the axilla to about two inches below the elbow-joint, where it should be joined by a transverse incision, extending from the inner to the outer side of the forearm; the two flaps being reflected on either side, the fascia should be examined (Fig. 228).

The **deep fascia** of the arm is continuous with that covering the Deltoid and the great Pectoral muscles, by means of which it is attached, above, to the clavicle, acromion, and spine of the scapula; it forms a thin, loose, membranous sheath investing the muscles of the arm, sending down septa between them, and composed of fibres disposed in a circular or spiral direction, and connected together by vertical and oblique fibres. It differs in thickness at different parts, being thin over the Biceps, but thicker where it covers the Triceps, and over the condyles of the humerus; it is strengthened by fibrous aponeuroses, derived from the Pectoralis major and Latissimus dorsi on the inner side, and from the Deltoid externally. On either side it gives off a strong *intermuscular septum*, which is attached to the supracondylar ridge and condyle of the humerus. These septa serve to separate the muscles of the anterior from those of the posterior brachial region. The external intermuscular septum extends from the lower part of the anterior bicipital ridge, along the external supracondylar ridge, to the outer condyle; it is blended with the tendon of the Deltoid, gives attachment to the Triceps behind, to the Brachialis anticus, Supinator longus, and Extensor carpi radialis longior, in front, and is

perforated by the musculo-spiral nerve and superior profunda artery. The internal intermuscular septum, thicker than the preceding, extends from the lower part of the posterior lip of the bicipital groove below the Teres major, along the internal supra-condylar ridge to the inner condyle; it is blended with the tendon of the Coraco-brachialis, and affords attachment to the Triceps behind, and the Brachialis anticus in front. It is perforated by the ulnar nerve and the inferior profunda and anastomotic arteries. At the elbow the deep fascia is attached to all the prominent points round the joint—viz. the condyles of the humerus and the olecranon process of the ulna—and is continuous with the deep fascia of the forearm. Just below the middle of the arm, on its inner side, in front of the internal intermuscular septum, is an oval opening in the deep fascia which transmits the basilic vein and some lymphatic vessels. On the removal of this fascia the muscles, vessels, and nerves of the anterior humeral region are exposed.

The **Coraco-brachialis,** the smallest of the three muscles in this region, is situated at the upper and inner part of the arm. It arises by fleshy fibres from the apex of the coracoid process, in common with the short head of the Biceps, and from the intermuscular septum between the two muscles; the fibres pass downward, backward, and a little outward, to be inserted by means of a flat tendon into an impression at the middle of the inner surface and internal border of the shaft of the humerus between the origins of the Triceps and Brachialis anticus. It is perforated by the musculo-cutaneous nerve. The inner border of the muscle forms a guide to the position of the brachial artery in tying the vessel in the upper part of its course.

Relations.—By its *anterior surface*, with the Pectoralis major above, and at its insertion with the brachial vessels and median nerve which cross it; by its *posterior surface*, with the tendons of the Subscapularis, Latissimus dorsi, and Teres major, the inner head of the Triceps, the humerus, and the anterior circumflex vessels; by its *inner border*, with the brachial artery, and the median and musculo-cutaneous nerves; by its *outer border*, with the short head of the Biceps and Brachialis anticus.

The **Biceps** (*Biceps flexor cubiti*) is a long fusiform muscle, occuping the whole of the anterior surface of the arm, and divided above into two portions or heads, from which circumstance it has received its name. The short head arises by a thick flattened tendon from the apex of the coracoid process, in common with the Coraco-brachialis. The long head arises from the upper margin of the glenoid cavity, and is continuous with the glenoid ligament. This tendon arches over the head of the humerus, being enclosed in a special sheath of the synovial membrane of the shoulder-joint; it then passes through an opening in the capsular ligament at its attachment to the humerus, and descends in the bicipital groove, in which it is retained by a fibrous prolongation from the tendon of the Pectoralis major. Each tendon is succeeded by an elongated muscular belly, and the two bellies, although closely applied to each other, can readily be separated until within about three inches of the elbow-joint. Here they end in a flattened tendon, which is inserted into the back part of the tuberosity of the radius, a synovial bursa being interposed between the tendon and the front of the tuberosity. As the tendon of the muscle approaches the radius it becomes twisted upon itself, so that its anterior surface becomes external and is applied to the tuberosity of the radius at its insertion: opposite the bend of the elbow the tendon gives off, from its inner side, a broad aponeurosis, the *bicipital fascia* (*semilunar fascia*), which passes obliquely downward and inward across the brachial artery, and is continuous with the deep fascia of the forearm (Fig. 229). The inner border of this muscle forms a guide to the position of the vessel in tying the brachial artery in the middle of the arm.[1]

[1] A third head to the Biceps is occasionally found (Theile says as often as once in eight or nine subjects), arising at the upper and inner part of the Brachialis anticus, with the fibres of which it is continuous, and inserted into the bicipital fascia and inner side of the tendon of the Biceps. In most cases this additional slip passes behind the brachial artery in its course down the arm. Occasionally the third head consists of two slips which pass down, one in front, the other behind the artery, concealing the vessel in the lower half of the arm.

Relations.—Its *anterior surface* is overlapped above by the Pectoralis major and Deltoid; in the rest of its extent it is covered by the superficial and deep fasciæ and the integument. Its *posterior surface* rests above on the shoulder-joint and upper part of the humerus; below it rests on the Brachialis anticus, with the musculo-cutaneous nerve intervening between the two, and on the Supinator brevis. Its *inner border* is in relation with the Coraco-brachialis, and overlaps the brachial vessels and median nerve; its *outer border*, with the Deltoid and Supinator longus.

The **Brachialis anticus** is a broad muscle, which covers the elbow-joint and the lower half of the front of the humerus. It is somewhat compressed from before backward, and is broader in the middle than at either extremity. It arises from the lower half of the outer and inner surfaces of the shaft of the humerus, and commences above at the insertion of the Deltoid, which it embraces by two angular processes. Its origin extends below, to within an inch of the margin of the articular surface, and is limited on each side by the external and internal borders of the shaft of the humerus. It also arises from the intermuscular septa on each side, but more extensively from the inner than the outer, from which it is separated below by the Supinator longus and Extensor carpi radialis longior. Its fibres converge to a thick tendon, which is inserted into a rough depression on the anterior surface of the coronoid process of the ulna, being received into an interval between two fleshy slips of the Flexor profundus digitorum.

Relations.—By its *anterior surface*, with the Biceps, the brachial vessels, musculo-cutaneous, and median nerves; by its *posterior surface*, with the humerus and front of the elbow-joint; by its *inner border*, with the Triceps, ulnar nerve, and Pronator radii teres, from which it is separated by the intermuscular septum; by its *outer border*, with the musculo-spiral nerve, radial recurrent artery, the Supinator longus, and Extensor carpi radialis longior.

Nerves.—The muscles of this group are supplied by the musculo-cutaneous nerve. The Brachialis anticus usually receives an additional filament from the musculo-spiral. The Coraco-brachialis receives its supply primarily from the seventh cervical, the Biceps and Brachialis anticus from the fifth and sixth cervical nerves.

Actions.—The Coraco-brachialis draws the humerus forward and inward, and at the same time assists in elevating it toward the scapula. The Biceps is a flexor of the forearm; it is also a powerful supinator, and serves to render tense the deep fascia of the forearm by means of the broad aponeurosis given off from its tendon. The Brachialis anticus is a flexor of the forearm, and forms an important defence to the elbow-joint. When the forearm is fixed, the Biceps and Brachialis anticus flex the arm upon the forearm, as is seen in efforts of climbing.

7. Posterior Humeral Region.

Triceps. Subanconeus.

The **Triceps** (*Triceps extensor cubiti*) (Fig. 232) is situated on the back of the arm, extending the entire length of the posterior surface of the humerus. It is of large size, and divided above into three parts; hence its name. These three portions have been named (1) the middle, scapular, or long head; (2) the external, or long humeral; and (3) the internal, or short humeral head.

The *middle* or *scapular head* arises, by a flattened tendon, from a rough triangular depression on the scapula, immediately below the glenoid cavity, being blended at its upper part with the capsular ligament; the muscular fibres pass downward between the two other portions of the muscle, and join with them in the common tendon of insertion.

The *external head* arises from the posterior surface of the shaft of the humerus, between the insertion of the Teres minor and the upper part of the musculo-spiral groove; from the external border of the humerus and the external intermuscular

septum: the fibres from this origin converge toward the common tendon of insertion.

The *internal head* arises from the posterior surface of the shaft of the humerus, below the groove for the musculo-spiral nerve; commencing above, narrow and pointed, below the insertion of the Teres major, and extending to within an inch of the trochlear surface: it also arises from the internal border of the humerus, and from the back of the whole length of the internal and lower part of the external intermuscular septa. The fibres of this portion of the muscle are directed, some downward to the olecranon, whilst others converge to the common tendon of insertion.

The *common tendon* of the Triceps commences about the middle of the back part of the muscle: it consists of two aponeurotic laminæ, one of which is subcutaneous and covers the posterior surface of the muscle for the lower half of its extent; the other is more deeply seated in the substance of the muscle: after receiving the attachment of the muscular fibres, they join together above the elbow, and are inserted, for the most part, into the back part of the upper surface of the olecranon process; a band of fibres is, however, continued downward, on the outer side, over the Anconeus, to blend with the deep fascia of the forearm. A small bursa, occasionally multilocular, is situated on the front part of this surface, beneath the tendon.

The long head of the Triceps descends between the Teres minor and Teres major, dividing the triangular space between these two muscles and the humerus into two smaller spaces, one triangular, the other quadrangular (Fig. 232). The triangular space contains the dorsalis scapulæ vessels; it is bounded by the Teres minor above, the Teres major below, and the scapular head of the Triceps externally: the quadrangular space transmits the posterior circumflex vessels and the circumflex nerve; it is bounded by the Teres minor above, the Teres major below, the scapular head of the Triceps internally, and the humerus externally.

Relations.—By its *posterior surface*, with the Deltoid above: in the rest of its extent it is subcutaneous; by its *anterior surface*, with the humerus, musculo-spiral nerve, superior profunda vessels, and back part of the elbow-joint. Its *middle* or *long head* is in relation, behind, with the Deltoid and Teres minor; in front, with the Subscapularis, Latissimus dorsi, and Teres major.

The **Subanconeus** is a name given to a few fibres from the under surface of the lower part of the Triceps muscle, which are inserted into the posterior ligament of the elbow-joint. By some authors it is regarded as the analogue of the Subcrureus in the lower limb, but it is not a separate muscle.

Nerves.—The Triceps is supplied by the seventh and eighth cervical nerves through the musculo-spiral nerve.

Actions.—The Triceps is the great extensor muscle of the forearm, serving, when the forearm is flexed, to extend the elbow-joint. It is the direct antagonist of the Biceps and Brachialis anticus. When the arm is extended the long head of the muscle may assist the Teres major and Latissimus dorsi in drawing the humerus backward and in adducting it to the thorax. The long head of the Triceps protects the under part of the shoulder-joint, and prevents displacement of the head of the humerus downward and backward. The Subanconeus draws up the posterior ligament during extension of the forearm.

Surgical Anatomy.—The existence of the band of fibres from the Triceps to the fascia of the forearm is of importance in excision of the elbow, and should always be carefully preserved from injury by the operator, as by means of these fibres the patient is enabled to extend the forearm, a movement which would otherwise mainly be accomplished by gravity; that is to say, allowing the forearm to drop from its own weight.

III. MUSCLES AND FASCIÆ OF THE FOREARM.

Dissection.—To dissect the forearm, place the limb in the position indicated in Fig. 228; make a vertical incision along the middle line from the elbow to the wrist, and a transverse incision at the extremity of this; the superficial structures being removed, the deep fascia of the forearm is exposed.

The **deep fascia** of the forearm, continuous above with that enclosing the arm, is a dense, highly glistening aponeurotic investment, which forms a general sheath enclosing the muscles in this region; it is attached, behind, to the olecranon and posterior border of the ulna, and gives off from its inner surface numerous intermuscular septa, which enclose each muscle separately. Below, it is continuous in front with the anterior annular ligament, and forms a sheath for the tendon of the Palmaris longus muscle, which passes over the annular ligament to be inserted into the palmar fascia. Behind, near the wrist-joint, it becomes much thickened by the addition of many transverse fibres, and forms the posterior annular ligament. It consists of circular and oblique fibres, connected together by numerous vertical fibres. It is much thicker on the dorsal than on the palmar surface, and at the lower than at the upper part of the forearm, and is strengthened above by tendinous fibres derived from the Brachialis anticus and Biceps in front, and from the Triceps behind. Its deep surface gives origin to muscular fibres, especially at the upper part of the inner and outer sides of the forearm, and forms the boundaries of a series of conical-shaped cavities, in which the muscles are contained. Besides the vertical septa separating each muscle, transverse septa are given off both on the anterior and posterior surfaces of the forearm, separating the deep from the superficial layer of muscles. Numerous apertures exist in the fascia for the passage of vessels and nerves; one of these, of large size, situated at the front of the elbow, serves for the passage of a communicating branch between the superficial and deep veins.

The muscles of the forearm may be subdivided into groups corresponding to the region they occupy. One group occupies the inner and anterior aspect of the forearm, and comprises the Flexor and Pronator muscles. Another group occupies its outer side, and a third its posterior aspect. The two latter groups include all the Extensor and Supinator muscles.

8. Anterior Radio-ulnar Region.

The muscles in this region are divided for convenience of description into two groups or layers, superficial and deep.

Superficial Layer.

Pronator radii teres.	Flexor carpi ulnaris.
Flexor carpi radialis.	Flexor sublimis digitorum.
Palmaris longus.	

These muscles take origin from the internal condyle of the humerus by a common tendon.

The **Pronator radii teres** arises by two heads. One, the larger and more superficial, arises from the humerus, immediately above the internal condyle, and from the tendon common to the origin of the other muscles; also from the fascia of the forearm and intermuscular septum between it and the Flexor carpi radialis. The other head is a thin fasciculus which arises from the inner side of the coronoid process of the ulna, joining the preceding at an acute angle. Between the two heads the median nerve enters the forearm. The muscle passes obliquely across the forearm from the inner to the outer side, and terminates in a flat tendon, which turns over the outer margin of the radius, and is inserted into a rough impression at the middle of the outer surface of the shaft of that bone.

Relations.—By its *anterior surface*, throughout the greater part of its extent, with the deep fascia; at its insertion it is crossed by the radial vessels and nerve, and covered by the Supinator longus; by its *posterior surface*, with the Brachialis anticus, Flexor sublimis digitorum, the median nerve, and ulnar artery, the small or deep head being interposed between the two latter structures. Its *outer border* forms the inner boundary of a triangular space in which are placed the brachial artery, median nerve, and tendon of the Biceps muscle. Its *inner border* is in contact with the Flexor carpi radialis.

Surgical Anatomy.—This muscle, when suddenly brought into very active use, as in the game of lawn tennis, is apt to be strained, producing slight swelling, tenderness, and pain on putting the muscle into action. This is known as "lawn-tennis arm."

The **Flexor carpi radialis** lies on the inner side of the preceding muscle. It arises from the internal condyle by the common tendon, from the fascia of the forearm, and from the intermuscular septa between it and the Pronator radii teres, on the outside, the Palmaris longus internally, and the Flexor sublimis digitorum beneath. Slender and aponeurotic in structure at its commencement, it increases in size, and terminates in a tendon which forms rather more than the lower half of its length. This tendon passes through a canal on the outer side of the annular ligament, runs through a groove in the os trapezium (which is converted into a canal by a fibrous sheath, and lined by a synovial membrane), and is inserted into the base of the metacarpal bone of the index finger, and by a slip into the base of the metacarpal bone of the middle finger. The radial artery lies between the tendon of this muscle and the Supinator longus, and may easily be tied in this situation.

Relations.—By its *superficial surface*, with the deep fascia and the integument; by its *deep surface*, with the Flexor sublimis digitorum, Flexor longus pollicis, and wrist-joint; by its *outer border*, with the Pronator radii teres and the radial vessels; by its *inner border*, with the palmaris longus above and the median nerve below.

The **Palmaris longus** is a slender, fusiform muscle lying on the inner side of the preceding. It arises from the inner condyle of the humerus by the common tendon, from the deep fascia, and the intermuscular septa between it and the adjacent muscles. It terminates in a slender flattened tendon, which passes over the upper part of the annular ligament, to end in the central part of the palmar fascia and lower part of the annular ligament, frequently sending a tendinous slip to the short muscles of the thumb. This muscle is often absent, and is subject to very considerable variations: it may be tendinous above and muscular below; or it may be muscular in the centre, with a tendon above and below; or it may present two muscular bundles with a central tendon; or finally it may consist simply of a mere tendinous band.

Relations.—By its *superficial surface*, with the deep fascia. By its *deep surface*, with the Flexor sublimis digitorum. *Internally*, with the Flexor carpi ulnaris. *Externally*, with the Flexor carpi radialis. The median nerve lies close to the tendon, just above the wrist, on its inner and posterior side.

The **Flexor carpi ulnaris** lies along the ulnar side of the forearm. It arises by two heads, connected by a tendinous arch, beneath which pass the ulnar nerve and posterior ulnar recurrent artery. One head arises from the inner condyle of the humerus by the common tendon; the other from the inner margin of the olecranon and from the upper two-thirds of the posterior border of the ulna by an aponeurosis, common

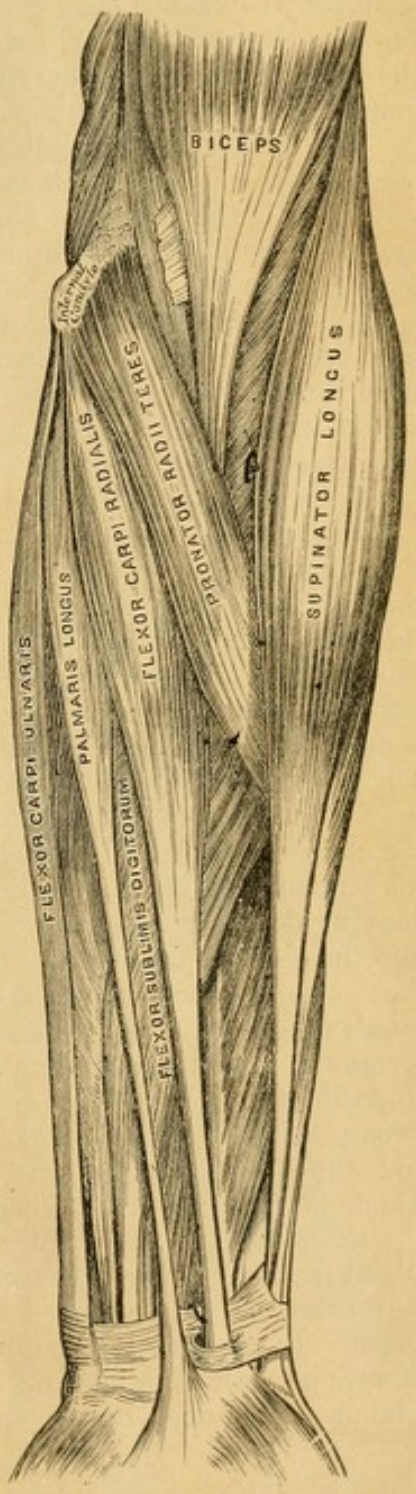

FIG. 233.—Front of the left forearm. Superficial muscles.

to it and the Extensor carpi ulnaris and Flexor profundus digitorum; and from the intermuscular septum between it and the Flexor sublimis digitorum. The fibres terminate in a tendon which occupies the anterior part of the lower half of the muscle, and is inserted into the pisiform bone, and is prolonged from this to the fifth metacarpal and unciform bones, by the piso-metacarpal and piso-uncinate ligaments: it is also attached by a few fibres to the annular ligament. The ulnar artery lies on the outer side of the tendon of this muscle, in the lower two-thirds of the forearm, the tendon forming a guide in tying the vessel in this situation.

Relations.—By its *superficial surface*, with the deep fascia, with which it is intimately connected for a considerable extent; by its *deep surface*, with the Flexor sublimis digitorum, the Flexor profundus digitorum, the Pronator quadratus, and the ulnar vessels and nerve; by its *outer* or *radial border*, with the Palmaris longus above and the ulnar vessels and nerve below.

The **Flexor sublimis digitorum (perforatus)** is placed beneath the preceding muscles, which therefore must be removed in order to bring its attachment into view. It is the largest of the muscles of the superficial layer, and arises by three heads. One head arises from the internal condyle of the humerus by the common tendon, from the internal lateral ligament of the elbow-joint, and from the intermuscular septum common to it and the preceding muscles. The second head arises from the inner side of the coronoid process of the ulna, above the ulnar origin of the Pronator radii teres (Fig. 100, p. 151). The third head arises from the oblique line of the radius, extending from the tubercle to the insertion of the Pronator radii teres. The fibres pass vertically downward, forming a broad and thick muscle, which speedily divides into two planes of muscular fibres, superficial and deep: the superficial plane divides into two parts which end in tendons for the middle and ring fingers; the deep plane also divides into two parts, which end in tendons for the index and little fingers, but previously to having done so, it gives off a muscular slip, which joins that part of the superficial plane which is intended for the ring finger. As the four tendons thus formed pass beneath the annular ligament into the palm of the hand, they are arranged in pairs, the superficial pair corresponding to the middle and ring fingers, the deep pair to the index and little fingers. The tendons diverge from one another as they pass onward. Opposite the bases of the first phalanges each tendon divides into two slips, to allow of the passage of the corresponding tendon of the Flexor profundus digitorum; the two portions of the tendon then unite and form a grooved channel for the reception of the accompanying deep flexor tendon. Finally they subdivide a second time, to be inserted into the sides of the second phalanges about their middle. After leaving the palm, these tendons, accompanied by the deep flexor tendons, lie in osseo-aponeurotic canals (Fig. 234). These canals are formed by strong fibrous bands, which arch across the tendons, and are attached on each side to the margins of the phalanges. Opposite the middle of the proximal and second phalanges the sheath is very strong, and the fibres pass transversely; but opposite the joints it is much thinner, and the fibres pass obliquely. Each sheath is lined by a synovial membrane, which is reflected on the contained tendons.

Relations.—In the forearm, by its *superficial surface*, with the deep fascia and all the preceding superficial muscles; by its *deep surface*, with the Flexor profundus digitorum, Flexor longus pollicis, the ulnar vessels and nerve, and the median nerve. In the hand its tendons are in relation, *in front*, with the palmar fascia, superficial palmar arch, and the branches of the median nerve; *behind*, with the tendons of the deep Flexor and the Lumbricales.

Deep Layer.

Flexor profundus digitorum. Flexor longus pollicis.
Pronator quadratus.

Dissection.—Divide each of the superficial muscles at its centre, and turn either end aside; the deep layer of muscles, together with the median nerve and ulnar vessels, will then be exposed.

The **Flexor profundus digitorum (perforans)** (Fig. 234) is situated on the ulnar side of the forearm, immediately beneath the superficial Flexors. It arises from the upper three-fourths of the anterior and inner surfaces of the shaft of the ulna, embracing the insertion of the Brachialis anticus above, and extending, below, to within a short distance of the Pronator quadratus. It also arises from a depression on the inner side of the coronoid process; by an aponeurosis from the upper three-fourths of the posterior border of the ulna, in common with the Flexor and Extensor carpi ulnaris; and from the ulnar half of the interosseous membrane. The fibres form a fleshy belly of considerable size, which divides into four tendons: these pass under the annular ligament beneath the tendons of the Flexor sublimis digitorum. Opposite the first phalanges the tendons pass through the openings in the two slips of the tendons of the Flexor sublimis digitorum, and are finally inserted into the bases of the last phalanges. The portion of the muscle for the index finger is usually distinct throughout, but the tendons for the three inner fingers are connected together by cellular tissue and tendinous slips as far as the palm of the hand. The tendons of this muscle and those of the Flexor sublimis digitorum, whilst contained in the osseo-aponeurotic canals of the fingers, are invested in a synovial sheath, and are connected to each other and to the phalanges by slender tendinous filaments, called *vincula accessoria tendinum*. One of these connects the deep tendon to the bone before it passes through the superficial tendon; a second connects the two tendons together, after the deep tendons have passed through; and a third connects the deep tendon to the head of the second phalanx. This last consists largely of yellow elastic tissue, and may assist in drawing down the tendon after flexion of the finger.[1]

Four small muscles, the Lumbricales, are connected with the tendons of the Flexor profundus in the palm. They will be described with the muscles in that region.

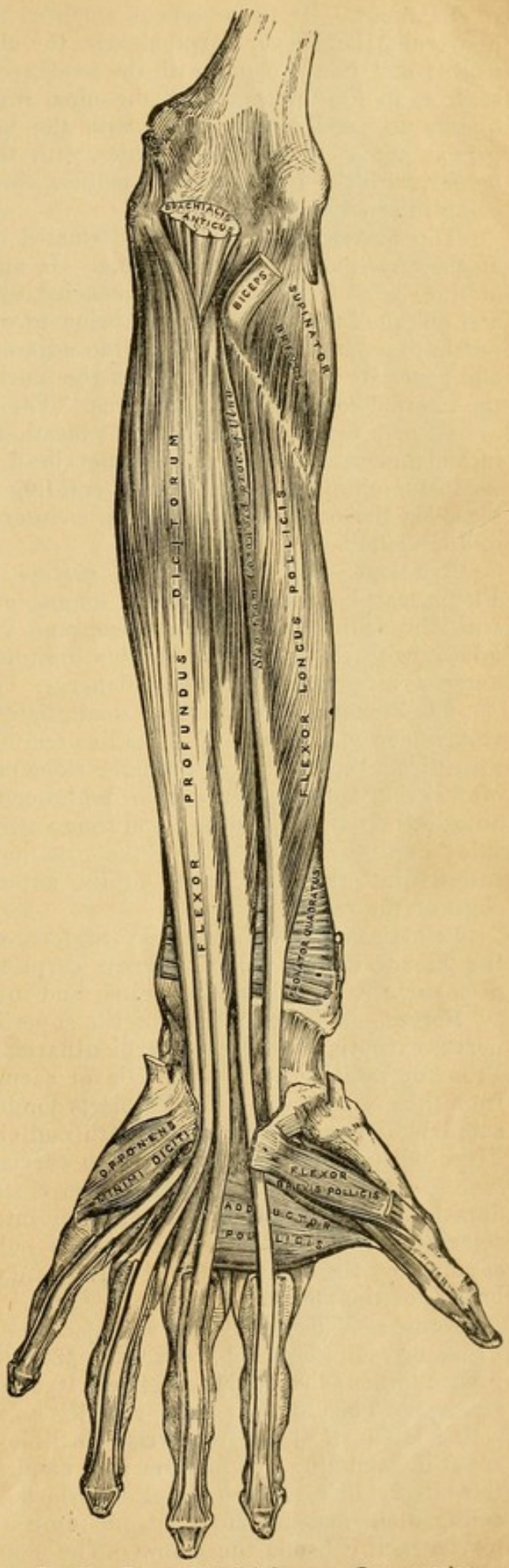

FIG. 234.—Front of the left forearm. Deep muscles.

[1] Marshall, *Brit. and For. Med.-Chir. Rev.*, 1853.

Relations.—By its *superficial surface*, in the forearm, with the Flexor sublimis digitorum, the Flexor carpi ulnaris, the ulnar vessels and nerve, and the median nerve; and in the hand, with the tendons of the superficial Flexor; by its *deep surface*, in the forearm, with the ulna, the interosseous membrane, the Pronator quadratus; and in the hand, with the interossei, Adductor pollicis, and deep palmar arch; by its *ulnar border*, with the Flexor carpi ulnaris; by its *radial border*, with the Flexor longus pollicis, the anterior interosseous vessels and nerve being interposed.

The **Flexor longus pollicis** is situated on the radial side of the forearm, lying on the same plane as the preceding. It arises from the grooved anterior surface of the shaft of the radius, commencing above, immediately below the tuberosity and oblique line, and extending below to within a short distance of the Pronator quadratus. It also arises from the adjacent part of the interosseous membrane, and generally by a fleshy slip from the inner border of the coronoid process or from the internal condyle of the humerus. The fibres pass downward, and terminate in a flattened tendon which passes beneath the annular ligament, is then lodged in the interspace between the outer head of the Flexor brevis pollicis and the Adductor obliquus pollicis, and, entering an osseo-aponeurotic canal similar to those for the other flexor tendons, is inserted into the base of the last phalanx of the thumb.

Relations.—By its *superficial surface*, with the Flexor sublimis digitorum, Flexor carpi radialis, Supinator longus, and radial vessels; by its *deep surface*, with the radius, interosseous membrane, and Pronator quadratus; by its *ulnar border*, with the Flexor profundus digitorum, from which it is separated by the anterior interosseous vessels and nerve.

The **Pronator quadratus** is a small, flat, quadrilateral muscle, extending transversely across the front of the radius and ulna, above their carpal extremities. It arises from the oblique or pronator ridge on the lower part of the anterior surface of the shaft of the ulna; from the lower fourth of the anterior surface and the anterior border of the ulna; and from a strong aponeurosis which covers the inner third of the muscle. The fibres pass outward and slightly downward, to be inserted into the lower fourth of the anterior surface and anterior border of the shaft of the radius.

Relations.—By its *superficial surface*, with the Flexor profundus digitorum, the Flexor longus pollicis, Flexor carpi radialis, and the radial vessels; by its *deep surface*, with the radius, ulna, and interosseous membrane.

Nerves.—All the muscles of the superficial layer are supplied by the median nerve, excepting the Flexor carpi ulnaris, which is supplied by the ulnar. The Pronator radii teres and the Flexor carpi radialis derive their supply primarily from the sixth cervical; the Palmaris longus from the eighth cervical; the Flexor sublimis digitorum from the seventh and eighth cervical and first dorsal, and the Flexor carpi ulnaris from the eighth cervical and first dorsal nerves. Of the deep layer, the Flexor profundus digitorum is supplied by the eighth cervical and first dorsal through the ulnar and anterior interosseous branch of the median. The remaining two muscles, Flexor longus pollicis and Pronator quadratus, are also supplied by the eighth cervical and first dorsal through the anterior interosseous branch of the median.

Actions.—These muscles act upon the forearm, the wrist, and hand. The Pronator radii teres helps to rotate the radius upon the ulna, rendering the hand prone: when the radius is fixed it assists the other muscles in flexing the forearm. The Flexor carpi radialis is one of the flexors of the wrist; when acting alone it flexes the wrist, inclining it to the radial side. It can also assist in pronating the forearm and hand, and, by continuing its action, to bend the elbow. The Flexor carpi ulnaris is one of the flexors of the wrist: when acting alone it flexes the wrist, inclining it to the ulnar side, and by continuing to contract, it bends the elbow. The Palmaris longus is a tensor of the palmar fascia. It also assists in flexing the wrist and elbow. The Flexor sublimis

digitorum flexes first the middle and then the approximal phalanx. It assists in flexing the wrist and elbow. The Flexor profundus digitorum is one of the flexors of the phalanges. After the Flexor sublimis has bent the second phalanx, the Flexor profundus flexes the terminal one, but it cannot do so until after the contraction of the superficial muscle. It also assists in flexing the wrist. The Flexor longus pollicis is a flexor of the phalanges of the thumb. When the thumb is fixed it also assists in flexing the wrist. The Pronator quadratus helps to rotate the radius upon the ulna, rendering the hand prone.

9. Radial Region (Fig. 235).

Supinator longus.
Extensor carpi radialis longior.
Extensor carpi radialis brevior.

Dissection.—Divide the integument in the same manner as in the dissection of the anterior brachial region, and, after having examined the cutaneous vessels and nerves and deep fascia, remove all those structures. The muscles will then be exposed. The removal of the fascia will be considerably facilitated by detaching it from below upward. Great care should be taken to avoid cutting across the tendons of the muscles of the thumb, which cross obliquely the larger tendons running down the back of the radius.

The **Supinator longus** (brachio-radialis) is the most superficial muscle on the radial side of the forearm; it is fleshy for the upper two-thirds of its extent, tendinous below. It arises from the upper two-thirds of the external supracondylar ridge of the humerus, and from the external intermuscular septum, being limited above by the musculo-spiral groove. The fibres terminate above the middle of the forearm in a flat tendon, which is inserted into the outer side of the base of the styloid process of the radius.

Relations.—By its *superficial surface*, with the integument and fascia for the greater part of its extent; near its insertion it is crossed by the Extensor ossis metacarpi pollicis and the Extensor brevis pollicis; by its *deep surface*, with the humerus, the Extensor carpi radialis longior and brevior, the insertion of the Pronator radii teres, and the Supinator brevis;

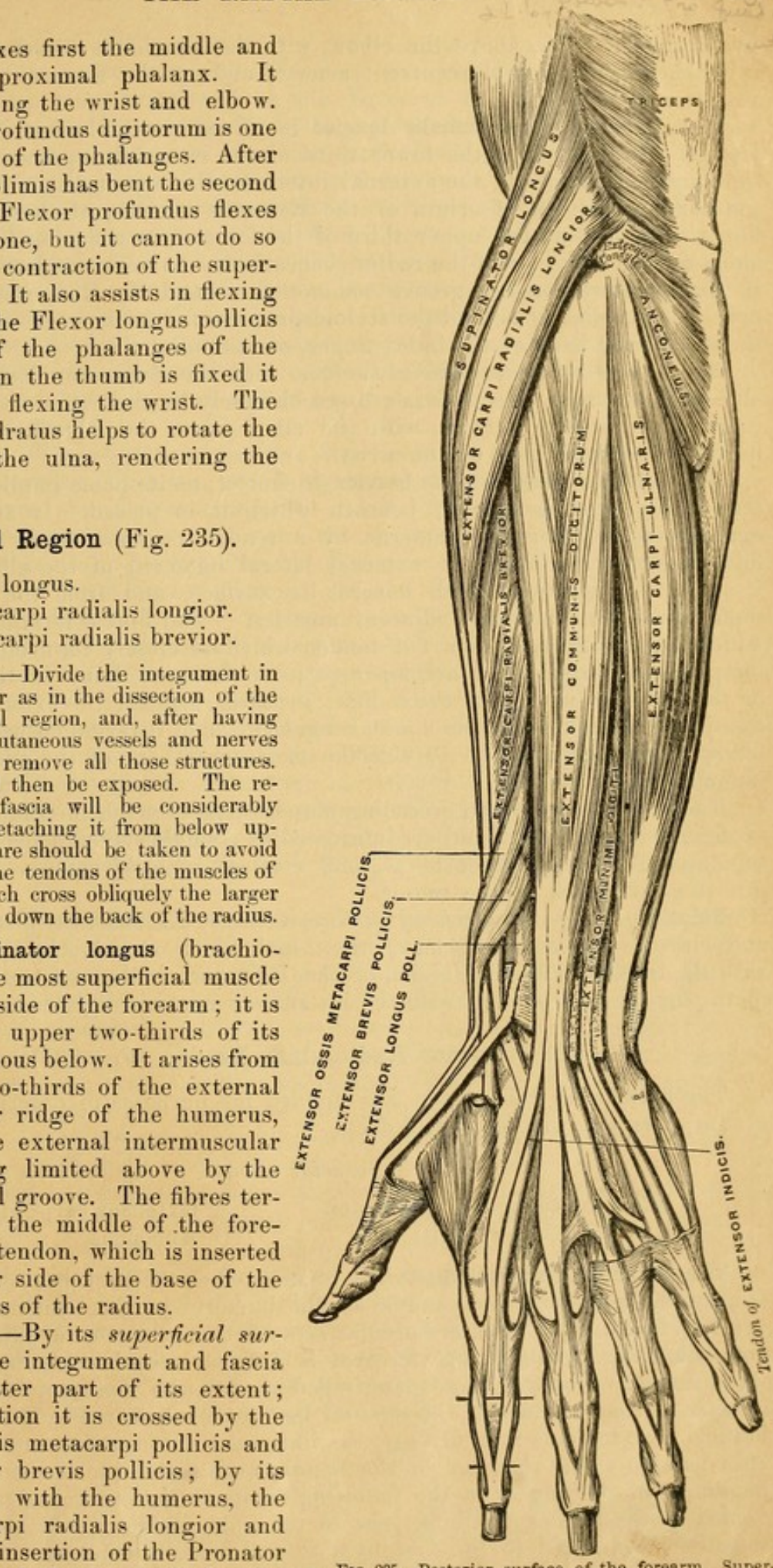

FIG. 235.—Posterior surface of the forearm. Superficial muscles.

by its *inner border*, above the elbow, with the Brachialis anticus, the musculo-spiral nerve, and radial recurrent artery; and in the forearm with the radial vessels and nerve.

The **Extensor carpi radialis longior** is placed partly beneath the preceding muscle. It arises from the lower third of the external supracondylar ridge of the humerus, and from the external intermuscular septum by a few fibres from the common tendon of origin of the Extensor muscles of the forearm. The fibres terminate at the upper third of the forearm in a flat tendon, which runs along the outer border of the radius, beneath the extensor tendons of the thumb; it then passes through a groove common to it and the Extensor carpi radialis brevior, immediately behind the styloid process, and is inserted into the base of the metacarpal bone of the index finger, on its radial side.

Relations.—By its *superficial surface*, with the Supinator longus and fascia of the forearm; its *outer side* is crossed obliquely by the extensor tendons of the thumb; by its *deep surface*, with the elbow-joint, the Extensor carpi radialis brevior, and back part of the wrist.

The **Extensor carpi radialis brevior** is shorter, as its name implies, and thicker than the preceding muscle, beneath which it is placed. It arises from the external condyle of the humerus by a tendon common to it and the three following muscles; from the external lateral ligament of the elbow-joint, from a strong aponeurosis which covers its surface, and from the intermuscular septa between it and the adjacent muscles. The fibres terminate about the middle of the forearm in a flat tendon which is closely connected with that of the preceding muscle, and accompanies it to the wrist, lying in the same groove on the posterior surface of the radius; it passes beneath the extensor tendons of the thumb, then beneath the annular ligament, and, diverging somewhat from its fellow, is inserted into the base of the metacarpal bone of the middle finger, on its radial side.

The tendons of the two preceding muscles pass through the same compartment of the annular ligament, and are lubricated by a single synovial membrane, but are separated from each other by a small vertical ridge of bone as they lie in the groove at the back of the radius.

Relations.—By its *superficial surface*, with the Extensor carpi radialis longior, and with the Extensor muscles of the thumb which cross it; by its *deep surface*, with the Supinator brevis, tendon of the Pronator radii teres, radius, and wrist-joint; by its *ulnar border*, with the Extensor communis digitorum.

10. Posterior Radio-ulnar Region (Fig. 235).

The muscles in this region are divided for purposes of description into two groups or layers, superficial and deep.

Superficial Layer.

Extensor communis digitorum.	Extensor carpi ulnaris.
Extensor minimi digiti.	Anconeus.

The **Extensor communis digitorum** is situated at the back part of the forearm. It arises from the external condyle of the humerus by the common tendon, from the deep fascia, and the intermuscular septa between it and the adjacent muscles. Just below the middle of the forearm it divides into three fleshy masses, from which tendons proceed; these pass, together with the Extensor indicis, through a separate compartment of the annular ligament, lubricated by a synovial membrane. The tendons then diverge, the innermost one dividing into two; and all, after passing across the back of the hand, are inserted into the second and third phalanges of the fingers in the following manner: the outermost tendon, accompanied by the Extensor indicis, goes to the index finger; the second tendon is sometimes connected to the first by a thin transverse band, and receives a slip from the third tendon; it goes to the middle finger; the third tendon gives off

the slip to the second, and receives a very considerable part of the fourth tendon; the fourth, or innermost tendon, divides into two parts: one goes to join the third tendon, the other, reinforced by the Extensor minimi digiti, goes to the little finger. Each tendon opposite the metacarpo-phalangeal articulation becomes narrow and thickened, and gives off a thin fasciculus upon each side of the joint, which blends with the lateral ligaments and serves as the posterior ligament; after having passed the joint it spreads out into a broad aponeurosis, which covers the whole of the dorsal surface of the first phalanx, being reinforced, in this situation, by the tendons of the Interossei and Lumbricales. Opposite the first phalangeal joint this aponeurosis divides into three slips, a middle and two lateral: the former is inserted into the base of the second phalanx; and the two lateral, which are continued onward along the sides of the second phalanx, unite by their contiguous margins, and are inserted into the dorsal surface of the last phalanx. As the tendons cross the phalangeal joints they furnish them with posterior ligaments.

Relations.—By its *superficial surface*, with the fascia of the forearm and hand, the posterior annular ligament, and integument; by its *deep surface*, with the Supinator brevis, the Extensor muscles of the thumb and index finger, the posterior interosseous vessels and nerve, the wrist-joint, carpus, metacarpus, and phalanges; by its *radial border*, with the Extensor carpi radialis brevior; by its *ulnar border*, with the Extensor minimi digiti and Extensor carpi ulnaris.

The **Extensor minimi digiti** is a slender muscle placed on the inner side of the Extensor communis, with which it is generally connected. It arises from the common tendon by a thin, tendinous slip, and from the intermuscular septa between it and the adjacent muscles. Its tendon runs through a separate compartment in the annular ligament behind the inferior radio-ulnar joint, then divides into two as it crosses the hand, the outermost division being joined by the slip from the innermost tendon of the common extensor. The two slips thus formed spread into a broad aponeurosis, which after receiving a slip from the Abductor minimi digiti is inserted into the second and third phalanges. The tendon is situated on the ulnar side of, and somewhat more superficial than, the common extensor.

The **Extensor carpi ulnaris** is the most superficial muscle on the ulnar side of the forearm. It arises from the external condyle of the humerus by the common tendon; by an aponeurosis from the posterior border of the ulna in common with the Flexor carpi ulnaris and the Flexor profundus digitorum; and from the deep fascia of the forearm. This muscle terminates in a tendon which runs through a groove behind the styloid process of the ulna, passes through a separate compartment in the annular ligament, and is inserted into the prominent tubercle on the ulnar side of the base of the metacarpal bone of the little finger.

Relations.—By its *superficial surface*, with the deep fascia of the forearm; by its *deep surface*, with the ulna and the muscles of the deep layer.

The **Anconeus** is a small triangular muscle placed behind and below the elbow-joint, and appears to be a continuation of the external portion of the Triceps. It arises by a separate tendon from the back part of the outer condyle of the humerus, and is inserted into the side of the olecranon and upper fourth of the posterior surface of the shaft of the ulna; its fibres diverge from their origin, the upper ones being directed transversely, the lower obliquely inward.

Relations.—By its *superficial surface*, with a strong fascia derived from the Triceps; by its *deep surface*, with the elbow-joint, the orbicular ligament, the ulna, and a small portion of the Supinator brevis.

Deep Layer (Fig. 237).

Supinator brevis.
Extensor ossis metacarpi pollicis.
Extensor brevis pollicis.
Extensor longus pollicis.
Extensor indicis.

The **Supinator brevis** (Fig. 236) is a broad muscle, of hollow cylindrical form, curved round the upper third of the radius. It consists of two distinct planes of muscular fibres, between which lies the posterior interosseous nerve. The two planes arise in common: the superficial one by tendinous, and the deeper by muscular, fibres from the external condyle of the humerus; from the external lateral ligament of the elbow-joint and the orbicular ligament of the radius; from the ridge on the ulna, which runs obliquely downward from the posterior extremity of the lesser sigmoid cavity; from the triangular depression in front of it; and from a tendinous expansion which covers the surface of the muscle. The superficial fibres surround the upper part of

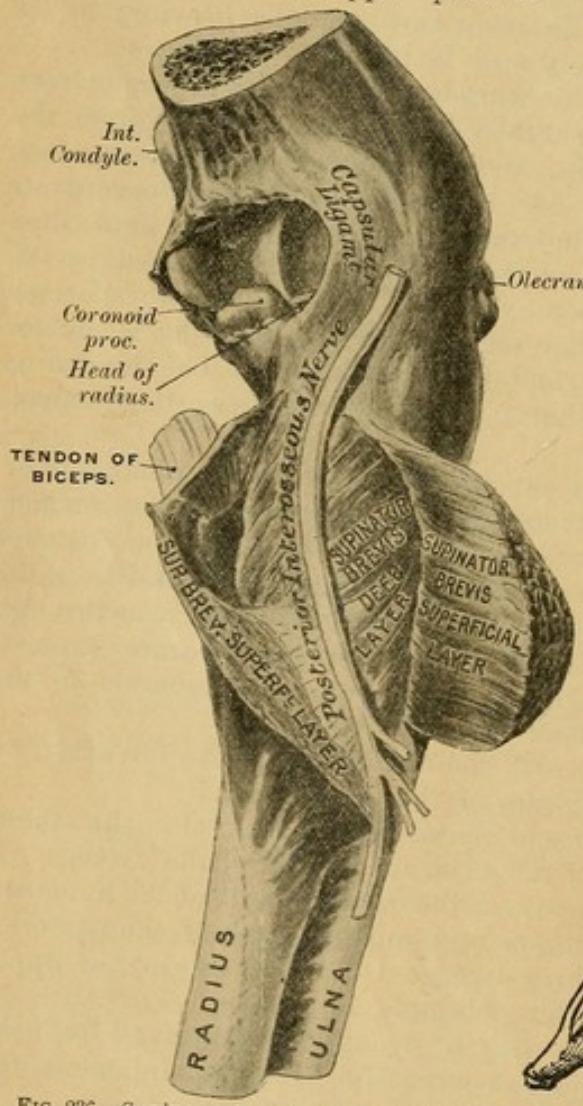

FIG. 236.—Supinator brevis. (From a preparation in the Museum of the Royal College of Surgeons of England.)

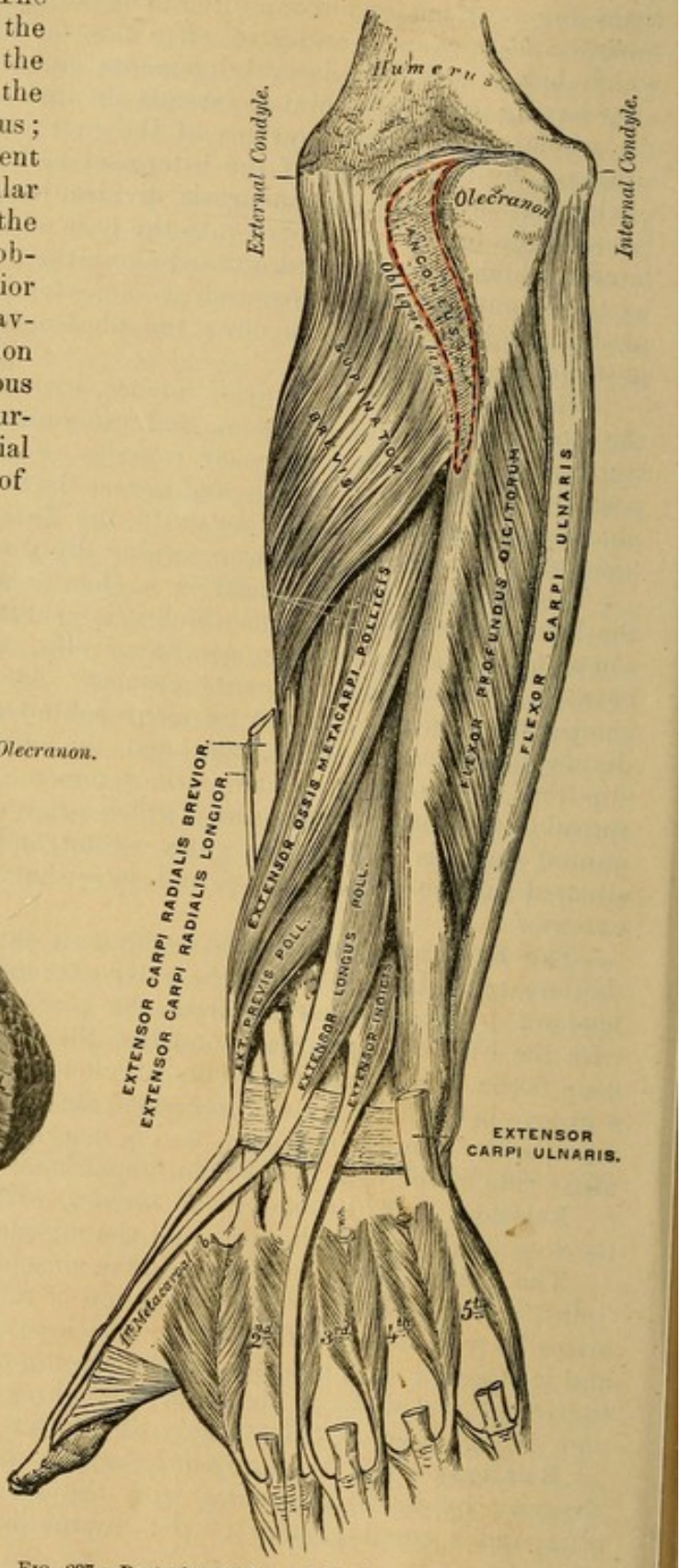

FIG. 237.—Posterior surface of the forearm. Deep muscles.

the radius, and are inserted into the outer edge of the bicipital tuberosity and to the oblique line of the radius, as low down as the insertion of the Pronator radii teres. The upper fibres of the deeper plane form a sling-like fasciculus, which encircles the neck of the radius above the tuberosity and is

attached to the back part of its inner surface: the greater part of this portion of the muscle is inserted into the posterior and external surface of the shaft, midway between the oblique line and the head of the bone. Between the insertion of the two planes the posterior interosseous nerve lies on the shaft of the bone.

Relations.—By its *superficial surface*, with the superficial Extensor and Supinator muscles, and the radial vessels and nerve; by its *deep surface*, with the elbow-joint, the interosseous membrane, and the radius.

The **Extensor ossis metacarpi pollicis** is the most external and the largest of the deep extensor muscles: it lies immediately below the Supinator brevis, with which it is sometimes united. It arises from the outer part of the posterior surface of the shaft of the ulna below the insertion of the Anconeus, from the interosseous membrane, and from the middle third of the posterior surface of the shaft of the radius. Passing obliquely downward and outward, it terminates in a tendon which runs through a groove on the outer side of the styloid process of the radius, accompanied by the tendon of the Extensor brevis pollicis, and is inserted into the base of the metacarpal bone of the thumb. It occasionally gives off two slips near its insertion—one to the Trapezium, and the other to blend with the origin of the Abductor pollicis.

Relations.—By its *superficial surface*, with the Extensor communis digitorum, Extensor minimi digiti, and fascia of the forearm, and with the branches of the posterior interosseous artery and nerve which cross it; by its *deep surface*, with the ulna, interosseous membrane, radius, the tendons of the Extensor carpi radialis longior and brevior, which it crosses obliquely, and, at the outer side of the wrist, with the radial vessels; by its *upper border*, with the Supinator brevis; by its *lower border*, with the Extensor brevis pollicis.

The **Extensor brevis pollicis** (*Extensor primi internodii pollicis*), the smallest muscle of this group, lies on the inner side of the preceding. It arises from the posterior surface of the shaft of the radius, below the Extensor ossis metacarpi pollicis, and from the interosseous membrane. Its direction is similar to that of the Extensor ossis metacarpi pollicis, its tendon passing through the same groove on the outer side of the styloid process, to be inserted into the base of the first phalanx of the thumb.

Relations.—The same as those of the Extensor ossis metacarpi pollicis.

The **Extensor longus pollicis** (*Extensor secundi internodii pollicis*) is much larger than the preceding muscle, the origin of which it partly covers in. It arises from the outer part of the posterior surface of the shaft of the ulna, below the origin of the Extensor ossis metacarpi pollicis, and from the interosseous membrane. It terminates in a tendon which passes through a separate compartment in the annular ligament, lying in a narrow, oblique groove at the back part of the lower end of the radius. It then crosses obliquely the tendons of the Extensor carpi radialis longior and brevior, being separated from the other extensor tendons of the thumb by a triangular interval, in which the radial artery is found, and is finally inserted into the base of the last phalanx of the thumb.

Relations.—By its *superficial surface*, with the same parts as the Extensor ossis metacarpi pollicis; by its *deep surface*, with the ulna, interosseous membrane, the posterior interosseous nerve, radius, the wrist, the radial vessels, and metacarpal bone of the thumb.

The **Extensor indicis** is a narrow, elongated muscle placed on the inner side of, and parallel with, the preceding. It arises from the posterior surface of the shaft of the ulna, below the origin of the Extensor longus pollicis and from the interosseous membrane. Its tendon passes with the Extensor communis digitorum through the same canal in the annular ligament, and subsequently joins the tendon of the Extensor communis which belongs to the index finger, opposite the lower end of the corresponding metacarpal bone, lying to the ulnar side of the tendon from the common Extensor.

Relations.—The relations are similar to those of the preceding muscles.

Nerves.—The Supinator longus is supplied by the sixth, the Extensor carpi

radialis longior by the sixth and seventh, and the Anconeus by the seventh and eighth cervical nerves, all through the musculo-spiral nerve; the remaining muscles of the radial and posterior brachial region are supplied through the posterior interosseous nerve, the Supinator brevis being supplied by the sixth cervical, the Extensor carpi radialis brevior by the sixth and seventh cervical, and all the other muscles by the seventh cervical.

Actions.—The muscles of the radial and posterior brachial regions, which comprise all the extensor and supinator muscles, act upon the forearm, wrist, and hand; they are the direct antagonists of the pronator and flexor muscles. The Anconeus assists the Triceps in extending the forearm. The chief action of the Supinator longus is that of a flexor of the elbow-joint, but in addition to this it may act both as a supinator or a pronator; that is to say, if the forearm is forcibly pronated it will act as a supinator, and bring the bones into a position midway between supination and pronation; and, *vice versâ*, if the arm is forcibly supinated, it will act as a pronator, and bring the bones into the same position, midway between supination and pronation. The action of the muscle is therefore to throw the forearm and hand into the position they naturally occupy when placed across the chest. The Supinator brevis is a supinator; that is to say, when the radius has been carried across the ulna in pronation and the back of the hand is directed forward, this muscle carries the radius back again to its normal position on the outer side of the ulna, and the palm of the hand is again directed forward. The Extensor carpi radialis longior extends the wrist and abducts the hand. It may also assist in bending the elbow-joint; at all events, it serves to fix or steady this articulation. The Extensor carpi radialis brevior assists the Extensor carpi radialis longior in extending the wrist, and may also act slightly as an abductor of the hand. The Extensor carpi ulnaris helps to extend the hand, but when acting alone inclines it toward the ulnar side; by its continued action it extends the elbow-joint. The Extensor communis digitorum extends the phalanges, then the wrist, and finally the elbow. It acts principally on the proximal phalanges, the middle and terminal phalanges being extended by the Interossei and Lumbricales. It has also a tendency to separate the fingers as it extends them. The Extensor minimi digiti extends similarly the little finger, and by its continued action it assists in extending the wrist. It is owing to this muscle that the little finger can be extended or pointed whilst the others are flexed. The chief action of the Extensor ossis metacarpi pollicis is to carry the thumb outward and backward from the palm of the hand, and hence it has been called the *abductor pollicis longus*. By its continued action it helps to extend and abduct the wrist. The Extensor brevis pollicis extends the proximal phalanx of the thumb. By its continued action it helps to extend and abduct the wrist. The Extensor longus pollicis extends the terminal phalanx of the thumb. By its continued action it helps to extend and abduct the wrist. The Extensor indicis extends the index finger, and by its continued action assists in extending the wrist. It is owing to this muscle that the index finger can be extended or pointed while the others are flexed.

Surgical Anatomy.—The tendons of the Extensor muscles of the thumb are liable to become strained and their sheaths inflamed after excessive exercise, producing a sausage-shaped swelling along the course of the tendon, and giving a peculiar creaking sensation to the finger when the muscle acts. In consequence of its often being caused by such movements as wringing clothes, it is known as "washerwoman's sprain."

IV. MUSCLES AND FASCIÆ OF THE HAND.

The **Muscles of the Hand** are subdivided into three groups: 1. Those of the thumb, which occupy the radial side and produce the *thenar* eminence; 2. Those of the little finger, which occupy the ulnar side and give rise to the *hypothenar* eminence; 3. Those in the middle of the palm and within the interosseous spaces.

Dissection (Fig. 228).—Make a transverse incision across the front of the wrist, and a second across the heads of the metacarpal bones: connect the two by a vertical incision in the middle line, and continue it through the centre of the middle finger. The anterior and posterior annular ligaments and the palmar fascia should then be dissected.

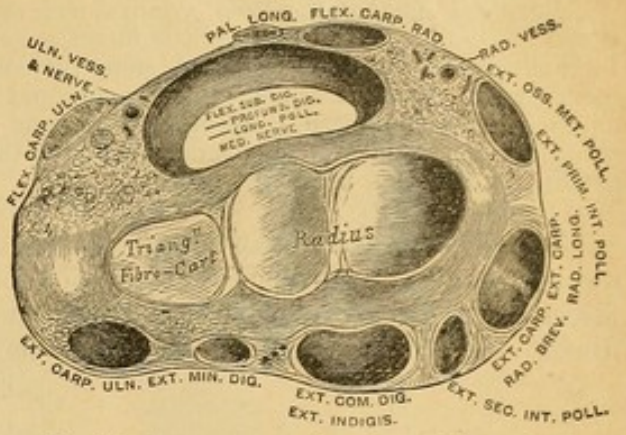

FIG. 238.—Transverse section through the wrist, showing the annular ligaments and the canals for the passage of the tendons.

The **Anterior Annular Ligament** is a strong, fibrous band which arches over the carpus, converting the deep groove on the front of the carpal bones into a canal, beneath which pass the flexor tendons of the fingers. It is attached, internally, to the pisiform bone and the hook of the unciform bone, and externally to the tuberosity of the scaphoid and to the inner part of the anterior surface and the ridge on the trapezium. It is continuous, above, with the deep fascia of the forearm, of which it may be regarded as a thickened portion, and, below, with the palmar fascia. It is crossed by the ulnar vessels and nerve and the cutaneous branches of the median and ulnar nerves. At its outer extremity is the tendon of the Flexor carpi radialis, which lies in the groove on the trapezium between the attachments of the annular ligament to the bone. It has inserted into its anterior surface a part of the tendon of the Palmaris longus and part of the tendon of the Flexor carpi ulnaris, and has arising from it, below, the small

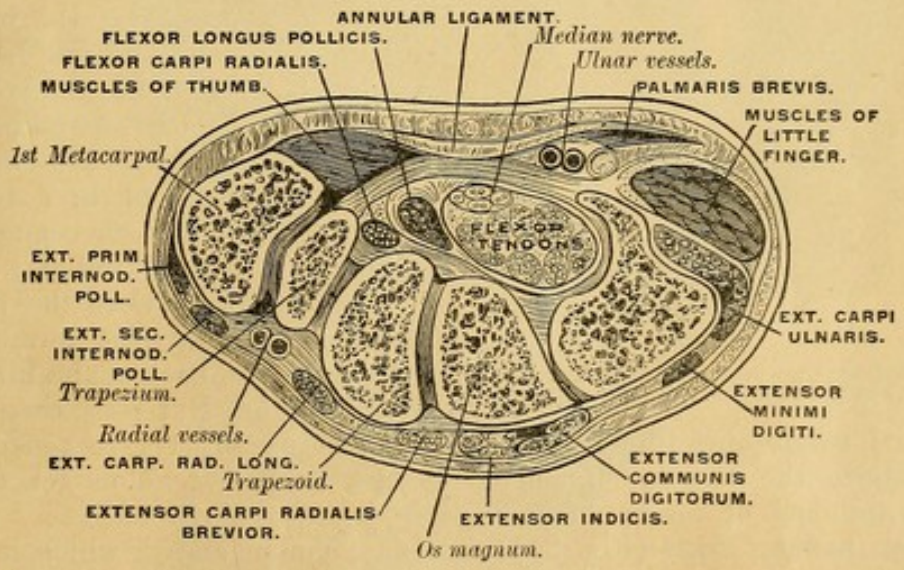

FIG. 239.—Transverse section through the carpus, showing the relative positions of the tendons, vessels, and nerves. (Henle.)

muscles of the thumb and little finger. Beneath it pass the tendons of the Flexor sublimis and profundus digitorum, the Flexor longus pollicis, and the median nerve.

The Synovial Membranes of the Flexor Tendons at the Wrist.—There are two synovial membranes which enclose all the tendons as they pass beneath this ligament—one for the Flexor sublimis and profundus digitorum, the other for the Flexor longus pollicis. They extend up into the forearm for about an inch above the annular ligament, and downward about halfway along the metacarpal bone, where they terminate in a blind diverticulum around each pair of tendons, with the exception of that of the thumb and those of the little finger—in these two digits the diverticulum is continued on, and communicates with the synovial sheath of the tendons in the fingers. In the other three fingers the synovial sheath of the

tendons begins as a blind pouch without communication with the large synovial sac (Fig. 240).

Surgical Anatomy.—This arrangement of the synovial sheaths explains the fact that thecal abscess in the thumb and little finger is liable to be followed by abscesses in the forearm, from extension of the inflammation along the continuous synovial sheaths. Ganglion is apt to occur in this situation, constituting "compound palmar ganglion"; it presents an hour-glass outline, with a swelling in front of the wrist and in the palm of the hand, and a constriction corresponding to the annular ligament between the two. The fluid can be forced from the one swelling to the other under the ligament.

The **Posterior Annular Ligament** is a strong fibrous band extending obliquely downward and inward across the back of the wrist, and consisting of the deep fascia of the back of the forearm, strengthened by the addition of some transverse fibres. It binds down the extensor tendons in their passage to the fingers, being attached, internally, to the styloid process of the ulna, the cuneiform and pisiform bones; externally, to the margin of the radius; and, in its passage across the wrist, to the elevated ridges on the posterior surface of the radius. It presents six compartments for the passage of tendons, each of which is lined by a separate synovial membrane. These are, from without inward—1. On the outer side of the styloid process, for the tendons of the Extensor ossis metacarpi and Extensor brevis pollicis; 2. Behind the styloid process, for the tendons of the Extensor carpi radialis longior and brevior; 3. About the middle of the posterior surface of the radius, for the tendon of the Extensor longus pollicis; 4. To the inner side of the latter, for the tendons of the Extensor communis digitorum and Extensor indicis; 5. Opposite the interval between the radius and ulna, for the Extensor minimi digiti; 6. Grooving the back of the ulna, for the tendon of the Extensor carpi ulnaris. The synovial membranes lining these sheaths are usually very extensive, reaching from above the annular ligament, down upon the tendons for a variable distance on the back of the hand.

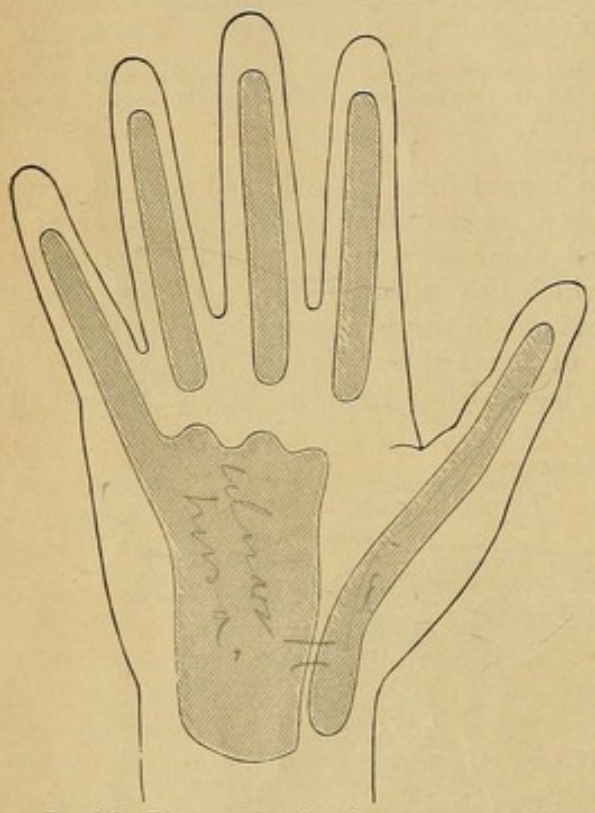

FIG. 240.—Diagram showing the arrangement of the synovial sheaths of the palm and fingers.

The **deep palmar fascia** (Fig. 241) forms a common sheath which invests the muscles of the hand. It consists of a central and two lateral portions.

The *central portion* occupies the middle of the palm, is triangular in shape, of great strength and thickness, and binds down the tendons and protects the vessels and nerves in this situation. It is narrow above, where it is attached to the lower margin of the annular ligament, and receives the expanded tendon of the Palmaris longus muscle. Below, it is broad and expanded, and divides into four slips for the four fingers. Each slip gives off superficial fibres, which are inserted into the skin of the palm and finger, those to the palm joining the skin at the furrow corresponding to the metacarpo-phalangeal articulation, and those to the fingers passing into the skin at the transverse fold at the base of the fingers. The deeper part of each slip subdivides into two processes, which are inserted into the lateral margins of the anterior (glenoid) ligament of the metacarpo-phalangeal joint. From the sides of these processes offsets are sent backward, to be attached to the borders of the lateral surfaces of

the metacarpal bones at their distal extremities. By this arrangement short channels are formed on the front of the lower ends of the metacarpal bones, through which the flexor tendons pass. Dr. W. W. Keen describes a fifth slip as frequently found passing to the thumb. The intervals left in the fascia between the four fibrous slips transmit the digital vessels and nerves and the tendons of the Lumbricales. At the points of division of the palmar fascia into the slips above mentioned numerous strong, transverse fibres bind the separate processes together. The palmar fascia is intimately adherent to the integument by dense fibro-areolar tissue, forming the superficial palmar fascia, and gives origin by its inner margin to the Palmaris brevis: it covers the superficial palmar arch, the

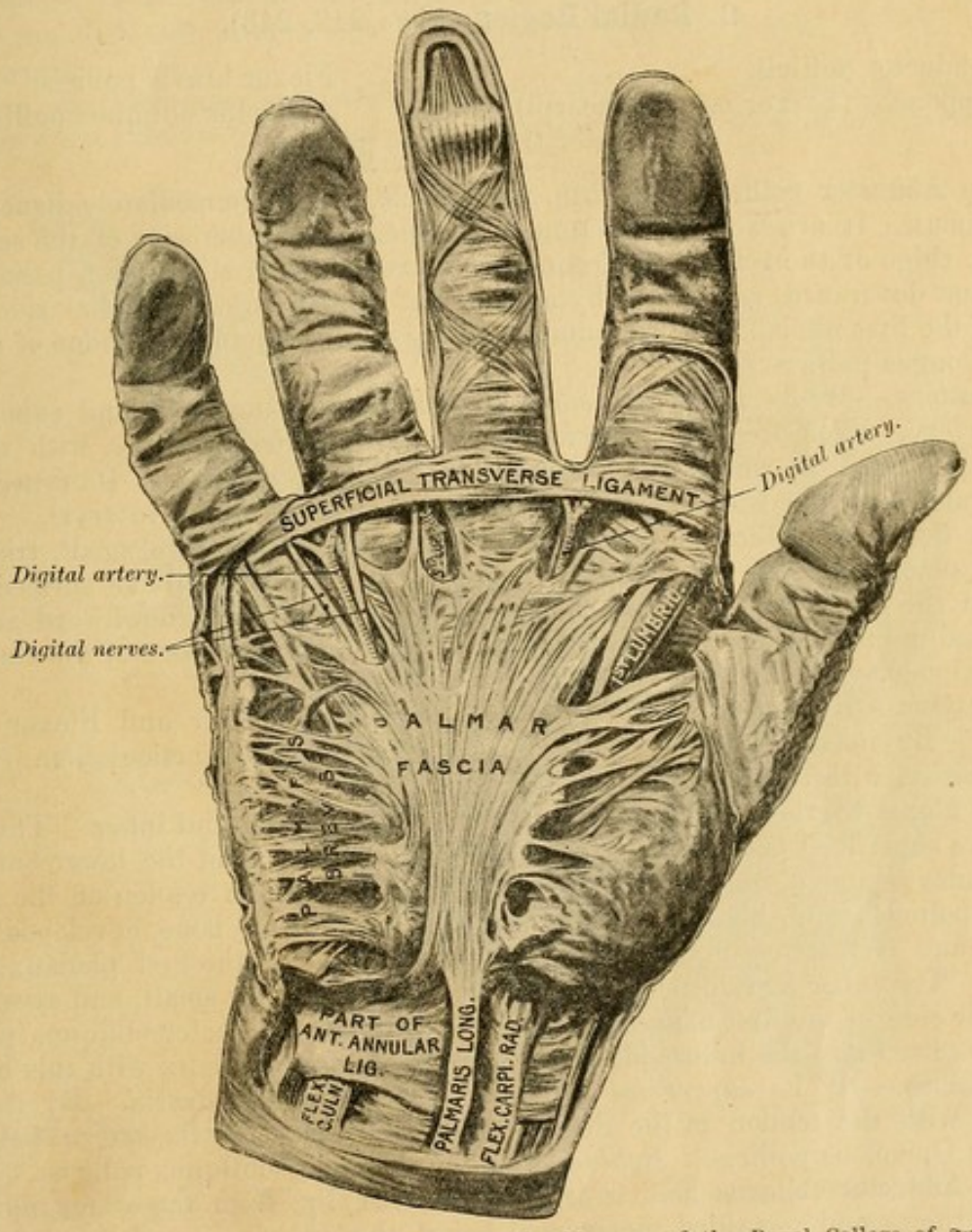

FIG. 241.—Palmar fascia. (From a preparation in the Museum of the Royal College of Surgeons of England.)

tendons of the flexor muscles, and the branches of the median and ulnar nerves, and on each side it gives off a vertical septum, which is continuous with the interosseous aponeurosis and separates the lateral from the middle palmar group of muscles.

The *lateral portions* of the palmar fascia are thin, fibrous layers, which cover, on the radial side, the muscles of the ball of the thumb, and, on the ulnar side, the muscles of the little finger; they are continuous with the dorsal fascia, and in the palm with the central portion of the palmar fascia.

The **Superficial Transverse Ligament of the Fingers** is a thin, fibrous band which stretches across the roots of the four fingers, and is closely attached to the skin of the clefts, and internally to the fifth metacarpal bone, forming a sort of rudimentary web. Beneath it the digital vessels and nerves pass onward to their destination.

Surgical Anatomy.—The palmar fascia is liable to undergo contraction, producing a very inconvenient deformity known as "Dupuytren's contraction." The ring and little fingers are most frequently implicated, but the middle, the index, and the thumb may be involved. The proximal phalanx is drawn down and cannot be straightened, and the two distal phalanges become similarly flexed as the disease advances.

2. Radial Region (Figs. 242, 243).

Abductor pollicis. Flexor brevis pollicis.
Opponens (Flexor ossis metacarpi) pollicis. Abductor obliquus pollicis.
Adductor transversus pollicis.

The **Abductor pollicis** is a thin, flat muscle, placed immediately beneath the integument. It arises from the annular ligament, the tuberosity of the scaphoid, and the ridge of the trapezium, frequently by two distinct slips; and, passing outward and downward, is inserted by a thin, flat tendon into the radial side of the base of the first phalanx of the thumb, sending a slip to join the tendon of the Extensor longus pollicis.

Relations.—By its *superficial surface*, with the palmar fascia and superficialis volæ artery, which frequently perforates it. By its *deep surface*, with the Opponens pollicis, from which it is separated by a thin aponeurosis. Its *inner border* is separated from the Flexor brevis pollicis by a narrow cellular interval.

The **Opponens pollicis** (*Flexor ossis metacarpi pollicis*) is a small, triangular muscle, placed beneath the preceding. It arises from the palmar surface of the ridge on the trapezium and from the annular ligament, passes downward and outward, and is inserted into the whole length of the metacarpal bone of the thumb on its radial side.

Relations.—By its *superficial surface*, with the Abductor and Flexor brevis pollicis. By its *deep surface*, with the trapezio-metacarpal articulation. By its *inner border*, with the Adductor obliquus pollicis.

The **Flexor brevis pollicis** consists of two portions, outer and inner. The outer and more superficial portion arises from the outer two-thirds of the lower border of the annular ligament, and passes along the outer side of the tendon of the Flexor longus pollicis; and, becoming tendinous, has a sesamoid bone developed in its tendon, and is inserted into the outer side of the base of the first phalanx of the thumb. The inner and deeper portion of the muscle is very small, and arises from the ulnar side of the first metacarpal bone beneath the Adductor obliquus pollicis, and is inserted into the inner side of the base of the first phalanx with this muscle.

Relations.—By its *superficial surface*, with the palmar fascia. By its *deep surface*, with the tendon of the Flexor longus pollicis. By its *external surface*, with the Opponens pollicis. *Behind*, with the Adductor obliquus pollicis.

The **Adductor obliquus pollicis** arises by several slips from the os magnum, the bases of the second and third metacarpal bones, the anterior carpal ligaments, and the sheath of the tendon of the Flexor carpi radialis. From this origin the greater number of fibres pass obliquely downward and converge to a tendon, which, uniting with the tendons of the deeper portion of the Flexor brevis pollicis and the Adductor transversus, is inserted into the inner side of the base of the first phalanx of the thumb, a sesamoid bone being developed in the tendon of insertion. A considerable fasciculus, however, passes more obliquely outward beneath the tendon of the long flexor to join the superficial portion of the short flexor and the Abductor pollicis.[1]

[1] This muscle was formerly described as the deep portion of the Flexor brevis pollicis.

Relations.—By its *superficial surface*, with the Flexor longus pollicis and the outer head of the Flexor brevis pollicis. Its *deep surface* is in relation with the deep palmar arch, which passes between the two adductors.

The **Adductor transversus pollicis** (Fig. 242) is the most deeply seated of this group of muscles. It is of a triangular form, arising, by its broad base, from the lower two-thirds of the metacarpal bone of the middle finger on its palmar surface; the fibres, proceeding outward, converge, to be inserted, with the inner part of the Flexor brevis pollicis, and the Adductor obliquus pollicis, into the ulnar side of the base of the first phalanx of the thumb. From the common tendon of insertion a slip is prolonged to the Extensor longus pollicis.

Relations.—By its *superficial surface*, with the Adductor obliquus pollicis, the tendons of the Flexor profundus, and the Lumbricales. Its *deep surface* covers the first two interosseous spaces, from which it is separated by a strong aponeurosis.

Three of these muscles of the thumb, the Abductor, the Adductor transversus, and the Flexor brevis pollicis, at their insertions give off fibrous expansions which

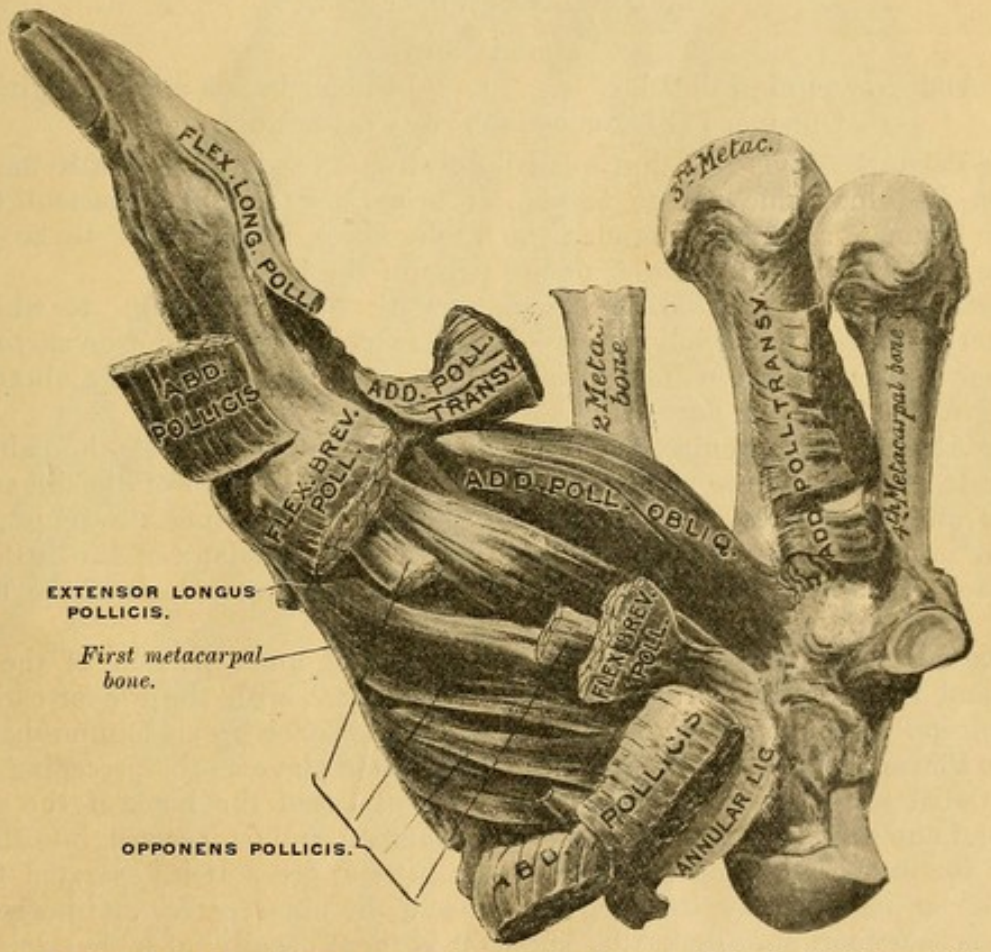

FIG. 242.—Muscles of thumb. (From a preparation in the Museum of the Royal College of Surgeons of England.)

join the tendon of the Extensor longus pollicis. This permits of flexion of the proximal phalanx and extension of the terminal phalanx at the same time. These expansions, originally figured by Albinus, have been more recently described by M. Duchenne (*Physiologie des Mouvements*).

Nerves.—The Abductor, Opponens, and outer head of the Flexor brevis pollicis are supplied by the sixth cervical through the median nerve; the inner head of the Flexor brevis, and the Adductors, by the eighth cervical through the ulnar nerve.

Actions.—The actions of the muscles of the thumb are almost sufficiently indicated by their names. This segment of the hand is provided with three extensors —an extensor of the metacarpal bone, an extensor of the first, and an extensor of the second phalanx; these occupy the dorsal surface of the forearm and hand.

There are also three flexors on the palmar surface—a flexor of the metacarpal bone, a flexor of the proximal, and a flexor of the terminal phalanx; there is also an Abductor and two Adductors. The Abductor pollicis moves the metacarpal bone of the thumb outward; that is, away from the index finger. The Flexor ossis metacarpi pollicis flexes the metacarpal bone—that is, draws it inward over the palm—and at the same time rotates the bone, so as to turn the ball of the thumb toward the fingers, thus producing the movement of opposition. The Flexor brevis pollicis flexes and adducts the proximal phalanx of the thumb. The Adductores pollicis move the metacarpal bone of the thumb inward; that is, toward the index finger. These muscles give to the thumb its extensive range of motion. It will be noticed, however, that in consequence of the position of the first metacarpal bone, these movements differ from the corresponding movements of the metacarpal bones of the other fingers. Thus extension of the thumb more nearly corresponds to the motion of abduction in the other fingers, and flexion to adduction.

12. Ulnar Region (Fig. 243).

Palmaris brevis.

Abductor minimi digiti. Flexor brevis minimi digiti.

Opponens (Flexor ossis metacarpi) minimi digiti.

The **Palmaris brevis** is a thin quadrilateral muscle placed beneath the integument on the ulnar side of the hand. It arises by tendinous fasciculi from the annular ligament and palmar fascia; the fleshy fibres pass inward, to be inserted into the skin on the inner border of the palm of the hand.

Relations.—By its *superficial surface*, with the integument, to which it is intimately adherent, especially by its inner extremity; by its *deep surface*, with the inner portion of the palmar fascia, which separates it from the ulnar vessels and nerve, and from the muscles of the ulnar side of the hand.

The **Abductor minimi digiti** is situated on the ulnar border of the palm of the hand. It arises from the pisiform bone and from the tendon of the Flexor carpi ulnaris, and terminates in a flat tendon, which divides into two slips; one is inserted into the ulnar side of the base of the first phalanx of the little finger. The other slip is inserted into the ulnar border of the aponeurosis of the Extensor minimi digiti.

Relations.—By its *superficial surface*, with the inner portion of the palmar fascia and the Palmaris brevis; by its *deep surface*, with the Flexor ossis metacarpi minimi digiti; by its *outer border*, with the Flexor brevis minimi digiti.

The **Flexor brevis minimi digiti** lies on the same plane as the preceding muscle, on its radial side. It arises from the convex aspect of the hook of the unciform bone and anterior surface of the annular ligament, and is inserted into the inner side of the base of the first phalanx of the little finger. It is separated from the Abductor at its origin by the deep branches of the ulnar artery and nerve. This muscle is sometimes wanting; the Abductor is then, usually, of large size.

Relations.—By its *superficial surface*, with the internal portion of the palmar fascia and the Palmaris brevis; by its *deep surface*, with the Opponens. The deep branch of the ulnar artery and the corresponding branch of the ulnar nerve pass between the Abductor and Flexor brevis minimi digiti muscles.

The **Opponens (Flexor ossis metacarpi) minimi digiti** (Fig. 234) is of a triangular form, and placed immediately beneath the preceding muscles. It arises from the convexity of the hook of the unciform bone and contiguous portion of the annular ligament; its fibres pass downward and inward, to be inserted into the whole length of the metacarpal bone of the little finger, along its ulnar margin.

Relations.—By its *superficial surface*, with the Flexor brevis and Abductor minimi digiti; by its *deep surface*, with the Interossei muscles in the fourth metacarpal space, the metacarpal bone, and the Flexor tendons of the little finger.

Nerves.—All the muscles of this group are supplied by the eighth cervical nerve through the ulnar nerve.

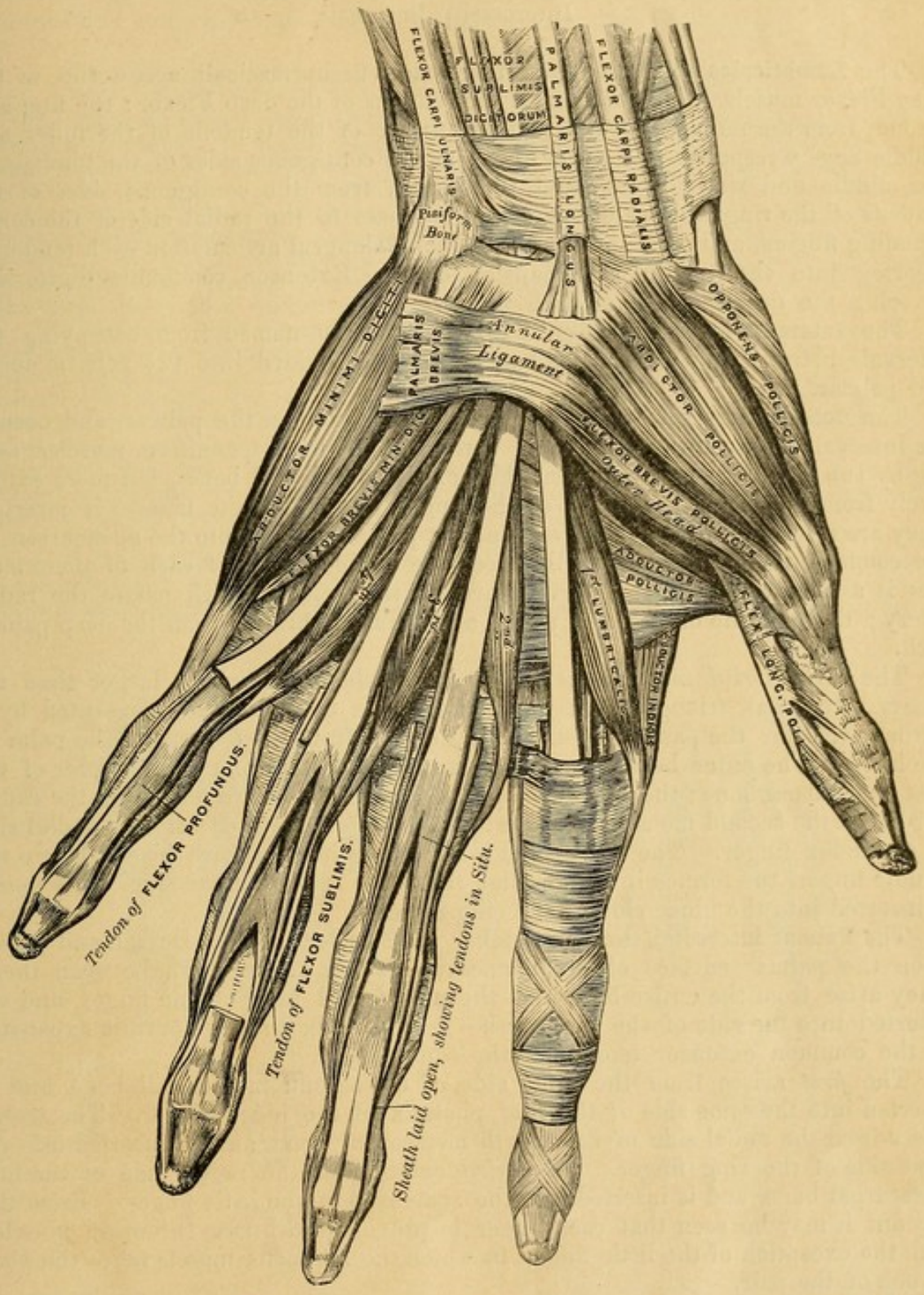

FIG. 243.—Muscles of the left hand. Palmar surface.

Actions.—The Abductor minimi digiti abducts the little finger from the middle line of the hand. It corresponds to a dorsal interosseous muscle. It also assists in flexing the proximal phalanx. The Flexor brevis minimi digiti abducts the little finger from the middle line of the hand. It also assists in flexing the proximal phalanx. The Opponens minimi digiti draws forward the fifth metacarpal bone, so as to deepen the hollow of the palm. The Palmaris brevis corrugates the skin on the inner side of the palm of the hand.

13. Middle Palmar Region.

Lumbricales. Interossei dorsales.
Interossei palmares.

The **Lumbricales** (Fig. 243) are four small fleshy fasciculi, accessories to the deep Flexor muscle. They arise from the tendons of the deep Flexor: the first and second, from the radial side and palmar surface of the tendons of the index and middle fingers respectively; the third, from the contiguous sides of the tendons of the middle and ring fingers; and the fourth, from the contiguous sides of the tendons of the ring and little fingers. They pass to the radial side of the corresponding fingers, and opposite the metacarpo-phalangeal articulation each tendon is inserted into the tendinous expansion of the Extensor communis digitorum, covering the dorsal aspect of each finger.

The **Interossei muscles** (Figs. 244, 245) are so named from occupying the intervals between the metacarpal bones, and are divided into two sets, a dorsal and palmar.

The **Dorsal interossei** are four in number, larger than the palmar, and occupy the intervals between the metacarpal bones. They are bipenniform muscles, arising by two heads from the adjacent sides of the metacarpal bones, but more extensively from the metacarpal bone of the finger into which the muscle is inserted. They are inserted into the bases of the first phalanges and into the aponeurosis of the common Extensor tendon. Between the double origin of each of these muscles is a narrow triangular interval, through the first of which passes the radial artery; through the other three passes a perforating branch from the deep palmar arch.

The *First dorsal interosseous muscle*, or *Abductor indicis*, is larger than the others. It is flat, triangular in form, and arises by two heads, separated by a fibrous arch, for the passage of the radial artery from the dorsum to the palm of the hand. The outer head arises from the upper half of the ulnar border of the first metacarpal bone; the inner head, from almost the entire length of the radial border of the second metacarpal bone; the tendon is inserted into the radial side of the index finger. The *second* and *third dorsal interossei* are inserted into the middle finger, the former into its radial, the latter into its ulnar side. The *fourth* is inserted into the ulnar side of the ring finger.

The **Palmar interossei**, three in number, are smaller than the Dorsal, and placed upon the palmar surface of the metacarpal bones, rather than between them. They arise from the entire length of the metacarpal bone of one finger, and are inserted into the side of the base of the first phalanx and aponeurotic expansion of the common extensor tendon of the same finger.

The *first* arises from the ulnar side of the second metacarpal bone, and is inserted into the same side of the first phalanx of the index finger. The *second* arises from the radial side of the fourth metacarpal bone, and is inserted into the same side of the ring finger. The *third* arises from the radial side of the fifth metacarpal bone, and is inserted into the same side of the little finger. From this account it may be seen that each finger is provided with two Interossei muscles, with the exception of the little finger, in which the Abductor muscle takes the place of one of the pair.

Nerves.—The two outer Lumbricales are supplied by the sixth cervical nerve, through the third and fourth digital branches of the median nerve: the two inner Lumbricales and all the Interossei are supplied by the eighth cervical nerve, through the deep palmar branch of the ulnar nerve. Brooks states that the third lumbrical received a twig from the median in twelve out of twenty-one cases.

Actions.—The Palmar interossei muscles adduct the fingers to an imaginary line drawn longitudinally through the centre of the middle finger; and the Dorsal interossei abduct the fingers from that line. In addition to this, the Interossei, in

conjunction with the Lumbricales, *flex the first phalanges* at the metacarpo-phalangeal joints, and extend the second and third phalanges in consequence of their insertion into the expansion of the extensor tendons. The Extensor communis digitorum is believed to act almost entirely on the first phalanges.

SURFACE FORM OF THE UPPER EXTREMITY.

The *Pectoralis major* largely influences surface form and conceals a considerable part of the thoracic wall in front. Its sternal origin presents a festooned border which bounds and determines the width of the sternal furrow. Its clavicular origin is somewhat depressed and flattened, and between the two portions of the muscle is often an oblique depression which differentiates the one from the other. The outer margin of the muscle is generally well marked above, and bounds the infraclavicular fossa, a triangular interval which separates the Pectoralis major from the Deltoid. It gradually becomes less marked as it approaches the tendon of insertion, and becomes more closely blended with the Deltoid muscle. The lower border of the Pectoralis major forms the rounded anterior axillary fold, and corresponds with the direction of the fifth rib. The *Pectoralis minor* influences surface form. When the arm is raised its lowest slip of origin produces a local fulness just below the border of the anterior fold of the axilla, and so serves to break the sharp line of the lower border of the Pectoralis major muscle, which is produced when the arm is in this position. The origin of the *Serratus magnus* produces a very characteristic surface marking. When the arm is raised from the side in a well-developed subject, the five or six lower serrations are plainly discernible, forming a zigzag line, caused by the series of digitations, which diminish in size from above downward, and have their apices arranged in the form of a curve. When the arm is lying by the side, the first serration to appear, at the lower margin of the Pectoralis major, is the one attached to the fifth rib. The *Deltoid*, with the prominence of the upper extremity of the humerus, produces the rounded outline of the shoulder. It is rounder and fuller in front than behind, where it presents a somewhat flattened form. Its anterior border, above, presents a rounded, slightly curved eminence, which bounds externally the infraclavicular fossa; below, it is closely united with the

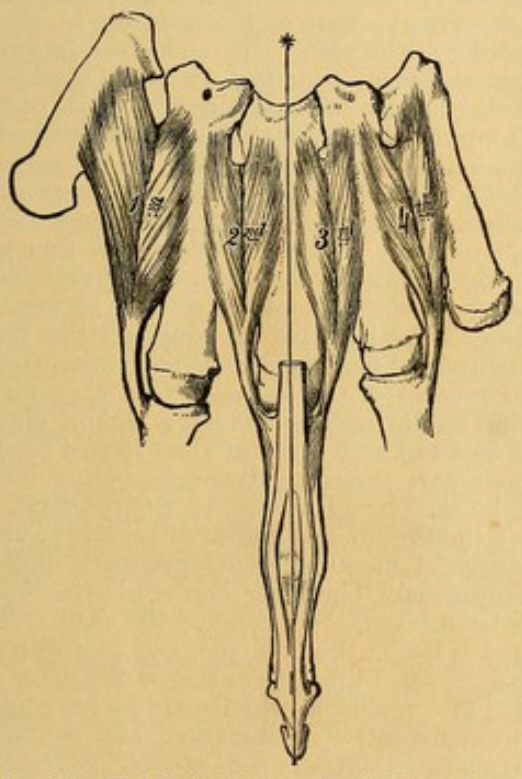

FIG. 244.—The Dorsal interossei of left hand.

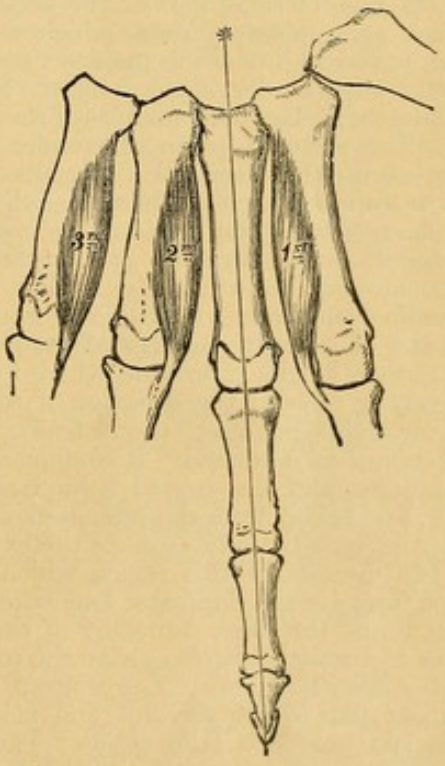

FIG. 245.—The Palmar interossei of left hand.

Pectoralis major. Its posterior border is thin, flattened, and scarcely marked above; below, it is thicker and more prominent. When the muscle is in action, the middle portion becomes irregular, presenting alternate longitudinal elevations and depressions, the elevations corresponding to the fleshy portions, the depressions to the tendinous intersections of the muscle. The insertion of the Deltoid is marked by a depression on the outer side of the middle of the arm. Of the scapular muscles, the only one which materially influences surface form is the *Teres major*, which assists the Latissimus dorsi in forming the thick, rounded fold of the posterior boundary of the axilla. When the arm is raised, the Coraco-brachialis reveals itself as a long, narrow elevation which emerges from under cover of the anterior fold of the axilla and runs downward, internal to the shaft of the humerus. When the arm is hanging by the side, its

front and inner part presents the prominence of the Biceps, bounded on either side by an intermuscular depression. This muscle determines the contour of the front of the arm, and extends from the anterior margin of the axilla to the bend of the elbow. Its upper tendons are concealed by the Pectoralis major and the Deltoid, and its lower tendon sinks into the space at the bend of the elbow. When the muscle is in a state of complete contraction—that is to say, when the forearm has been flexed and supinated—it presents a rounded convex form, bulged out laterally, and its length is diminished. On each side of the Biceps, at the lower part of the arm, the *Brachialis anticus* is discernible. On the outer side it forms a narrow eminence which extends some distance up the arm along the border of the Biceps. On the inner side it shows itself only as a little fulness just above the elbow. On the back of the arm the long head of the *Triceps* may be seen as a longitudinal eminence emerging from under cover of the Deltoid, and gradually merging into the longitudinal flattened plane of the tendon of the muscle on the lower part of the back of the arm. The tendon of insertion of the muscle extends about halfway up the back of the arm, where it forms an elongated flattened plane when the muscle is in action. Under similar conditions the surface forms produced by the three heads of the muscle are well seen. On the anterior aspect of the elbow are to be seen two muscular elevations, one on each side, separated above and converging below so as to form a triangular space. Of these, the inner elevation, consisting of the flexors and pronator, forms the prominence along the inner side and front of the forearm. It is a fusiform mass, pointed above at the internal condyle and gradually tapering off below. The *Pronator radii teres*, the innermost muscle of the group, forms the boundary of the triangular space at the bend of the elbow. It is shorter, less prominent, and more oblique than the outer boundary. The most prominent part of the eminence is produced by the *Flexor carpi radialis*, the muscle next in order on the inner side of the preceding one. It forms a rounded prominence above, and can be traced downward to its tendon, which can be felt lying on the front of the wrist, nearer to the radial than to the ulnar border, and to the inner side of the radial artery. The *Palmaris longus* presents no surface marking above, but below is the most prominent tendon on the front of the wrist, standing out, when the muscle is in action, as a sharp, tense cord beneath the skin. The *Flexor sublimis digitorum* does not directly influence surface form. The position of its four tendons on the front of the lower part of the forearm is indicated by an elongated depression between the tendons of the Palmaris longus and the Flexor carpi ulnaris. The *Flexor carpi ulnaris* occupies a small part of the posterior surface of the forearm, and is separated from the extensor and supinator group, which occupies the greater part of this surface, by the ulnar furrow, produced by the subcutaneous posterior border of the ulna. Its tendon can be perceived along the ulnar border of the front of the forearm, and is most marked when the hand is flexed and adducted. The deep muscles of the front of the forearm have no direct influence on surface form. The external group of muscles of the forearm, consisting of the extensors and supinators, occupy the outer and a considerable portion of the posterior surface of this region. It has a fusiform outline, which is altogether on a higher level than the pronato-flexor group. Its apex emerges from between the Triceps and Brachialis anticus muscles some distance above the elbow-joint, and acquires its greatest breadth opposite the external condyle, and thence gradually shades off into a flattened surface. About the middle of the forearm it divides into two longitudinal eminences which diverge from each other, leaving a triangular interval between them. The outer of these two groups of muscles consists of the Supinator longus and the Extensor carpi radialis longior et brevior, which form a longitudinal eminence descending from the external condylar ridge in the direction of the styloid process of the radius. The other and more posterior group consists of the Extensor communis digitorum, the Extensor minimi digiti, and the Extensor carpi ulnaris. It commences above as a tapering form at the external condyle of the humerus, and is separated behind at its upper part from the Anconeus by a well-marked furrow, and below, from the pronato-flexor mass, by the ulnar furrow. In the triangular interval left between these two groups the extensors of the thumb and index finger are seen. The only two muscles of this region which require special mention as independently influencing surface form are the Supinator longus and the Anconeus. The inner border of the *Supinator longus* forms the outer boundary of the triangular space at the bend of the elbow. It commences as a rounded border above the condyle, and is longer, less oblique, and more prominent than the inner boundary. Lower down, the muscle forms a full fleshy mass on the outer side of the upper part of the forearm, and below tapers into a tendon, which may be traced down to the styloid process of the radius. The *Anconeus* presents a well-marked and characteristic surface form in the shape of a triangular, slightly elevated surface, immediately external to the subcutaneous posterior surface of the olecranon, and differentiated from the common extensor group by a well-marked oblique longitudinal depression. The upper angle of the triangle corresponds to the external condyle, and is marked by a depression or dimple in this situation. In the interval caused by the divergence from each other of the two groups of muscles into which the extensor and supinator group is divided at the lower part of the forearm an oblique elongated eminence is seen, caused by the emergence of two of the extensors of the thumb from their deep origin at the back of the forearm. This eminence, full above and becoming flattened out and partially subdivided below, runs downward and outward over the back and outer surface of the radius to the outer side of the wrist-joint, where it forms a ridge, especially marked when the thumb is extended, which passes onward to the posterior aspect of the thumb. The tendons of most of the extensor muscles are to be seen and felt at the level of the wrist-joint. Most externally are the tendons of the Extensor ossis metacarpi pollicis and

the Extensor brevis pollicis, forming a vertical ridge over the outer side of the joint from the styloid process of the radius to the thumb. Internal to this is the oblique ridge produced by the tendon of the Extensor longus pollicis, very noticeable when the muscle is in action. The Extensor carpi radialis longior is scarcely to be felt, but the Extensor carpi radialis brevior can be distinctly perceived as a vertical ridge emerging from under the inner border of the tendon of the Extensor longus pollicis, when the hand is forcibly extended at the wrist. Internal to this, again, can be felt the tendons of the Extensor indicis, Extensor communis digitorum, and Extensor minimi digiti; the latter tendon being separated from those of the common extensor by a slight furrow. The muscles of the hand are principally concerned, as far as regards surface-form, in producing the thenar and hypothenar eminences, and individually are not to be distinguished, on the surface, from each other. The *Adductor transversus pollicis* is, however, an exception to this; its anterior border gives rise to a ridge across the web of skin connecting the thumb to the rest of the hand. The thenar eminence is much larger and rounder than the hypothenar one, which presents a longer and narrower eminence along the ulnar side of the hand. When the *Palmaris brevis* is in action it produces a wrinkling of the skin over the hypothenar eminence, and a deep dimple on the ulnar border of the hand. The anterior extremities of the *Lumbrical muscles* help to produce the soft eminences just behind the clefts of the fingers, separated from each other by depressions corresponding to the flexor tendons in their sheaths. Between the thenar and hypothenar eminences, at the wrist-joint, is a slight groove or depression, widening out as it approaches the fingers; beneath this we have the strong central part of the palmar fascia. Here we have some furrows, which are pretty constant in their arrangement, and bear some resemblance to the letter M. One of these furrows passes obliquely outward from the groove between the thenar and hypothenar regions near the wrist to the head of the metacarpal bone of the index finger. A second passes inward, with a slight inclination upward, from the termination of the first to the ulnar side of the hand. A third runs nearly parallel with the second and about three-quarters of an inch below it. Lastly, crossing these two latter furrows, is an oblique furrow parallel with the first. The skin of the palm of the hand differs considerably from that of the forearm. At the wrist it suddenly becomes hard and dense, and covered with a thick layer of cuticle. The skin in the thenar region presents these characteristics less than elsewhere. In spite of this hardness and density, the skin of the palm is exceedingly sensitive and very vascular. It is destitute of hair, and no sebaceous follicles have been found in this region. Over the fingers the skin again becomes thinner, especially at the flexures of the joints, and over the terminal phalanges it is thrown into numerous ridges in consequence of the arrangement of the papillæ in it. These ridges form, in different individuals, distinctive and permanent patterns, which may be used for purposes of identification. The superficial fascia in the palm is made up of dense fibro-fatty tissue. This tissue binds down the skin so firmly to the deep palmar fascia that very little movement is permitted between the two. On the back of the hand the *Dorsal interossei* produce elongated swellings between the metacarpal bones. The first dorsal interosseous (Abductor indicis), when the thumb is closely adducted to the hand, forms a prominent fusiform bulging; the other interossei are not so marked.

SURGICAL ANATOMY OF THE UPPER EXTREMITY.

The student, having completed the dissection of the muscles of the upper extremity, should consider the effects likely to be produced by the action of the various muscles in fracture of the bones.

In considering the actions of the various muscles upon fractures of the upper extremity, the most common forms of injury have been selected both for illustration and description.

Fracture of the *middle of the clavicle* (Fig. 246) is always attended with considerable displacement; the inner end of the outer fragment is displaced inward and backward, while the outer end of the same fragment is rotated forward. The whole outer fragment is somewhat depressed.

The displacement is produced as follows: *inward*, by the muscles passing from the chest to the outer fragment of the clavicle, to the scapula, and to the humerus, viz., the Subclavius and the Pectoralis minor, and, to a less extent, the Pectoralis major and the Latissimus dorsi; *backward*, in consequence of the rotation of the outer fragment. The Serratus magnus causes the scapula to rotate on the wall of the chest; this carries the acromion and outer end of the outer fragment of the clavicle forward and causes the piece of bone to rotate round a vertical axis through its centre, and so carries the inner end of the outer portion backward. The depression of the whole outer fragment is produced by the weight of the arm and by the contraction of the Deltoid. The outer end of the inner fragment appears to be elevated, the skin being drawn tensely over it; this is owing to the depression of the outer fragment, as the inner fragment is usually kept fixed by the costo-clavicular ligament and by the antagonism between the Sterno-mastoid and Pectoralis major muscles. But it may be raised by an unusually strong Sterno-mastoid, or by the inner end of the outer fragment getting below and behind it. The causes of displacement having been ascertained, it is easy to apply the appropriate treatment. The outer fragment is to be drawn outward, and, together with the scapula, raised upward to a level with the inner fragment, and retained in that position.

In fracture of the *acromial end of the clavicle*, between the conoid and trapezoid ligaments, only slight displacement occurs, as these ligaments, from their oblique insertion, serve to hold both portions of the bone in apposition. Fracture, also, of the *sternal end*, internal to the costo-clavicular ligament, is attended with only slight displacement, this ligament serving to retain the fragments in close apposition.

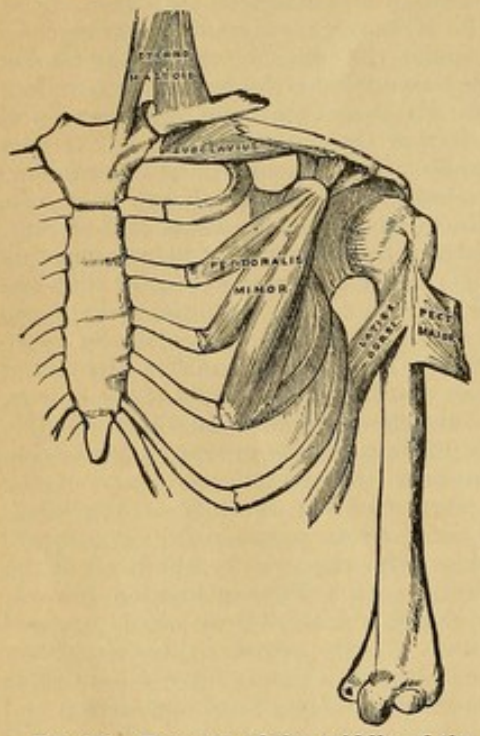

FIG. 246.—Fracture of the middle of the clavicle.

Fracture of the *acromion process* usually arises from violence applied to the upper and outer part of the shoulder; it is generally known by the rotundity of the shoulder being lost, from the Deltoid drawing the fractured portion downward and forward; and the displacement may easily be discovered by tracing the margin of the clavicle outward, when the fragment will be found resting on the front and upper part of the head of the humerus. In order to relax the anterior and outer fibres of the Deltoid (the opposing muscle), the arm should be drawn forward across the chest and the elbow well raised, so that the head of the bone may press the acromion process upward and retain it in its position.

Fracture of the *coracoid process* is an extremely rare accident, and is usually caused by a sharp blow on the point of the shoulder. Displacement is here produced by the combined actions of the Pectoralis minor, short head of the Biceps, and Coraco-brachialis, the former muscle drawing the fragment inward, and the latter directly downward, the amount of displacement being limited by the connection of this process to the acromion by means of the coraco-acromial ligament. In many cases there appears to have been little or no displacement, from the fact that the coraco-clavicular ligament has remained intact, and has kept the separated fragment from displacement. In order to relax these muscles and replace the fragments in close apposition, the forearm should be flexed so as to relax the Biceps, and the arm drawn forward and inward across the chest, so as to relax the Coraco-brachialis; the humerus should then be pushed upward against the coraco-acromial ligament, and the arm retained in that position.

Fracture of the *surgical neck of the humerus* (Fig. 247) is very common, is attended with considerable displacement, and its appearances correspond somewhat with those of dislocation of the head of the humerus into the axilla. The upper fragment is slightly elevated under the coraco-acromial ligament by the muscles attached to the greater and lesser tuberosities; the lower fragment is drawn inward by the Pectoralis major, Latissimus dorsi, and Teres major; and the humerus is thrown obliquely outward from the side by the Deltoid, and occasionally elevated so as to cause the upper end of the lower fragment to project beneath and in front of the coracoid process. The deformity is reduced by fixing the shoulder, and drawing the arm outward and downward. To counteract the opposing muscles, and to keep the fragments in position, a small conical-shaped pad should be placed in the axilla, and the arm bandaged to the side by a broad roller passed round the chest, in such a manner that the elbow is carried slightly forward, so as to throw the upper end of the lower fragment backward and outward toward the head of the bone. The whole is then covered with a carefully moulded gutta-percha or poroplastic shoulder cap.

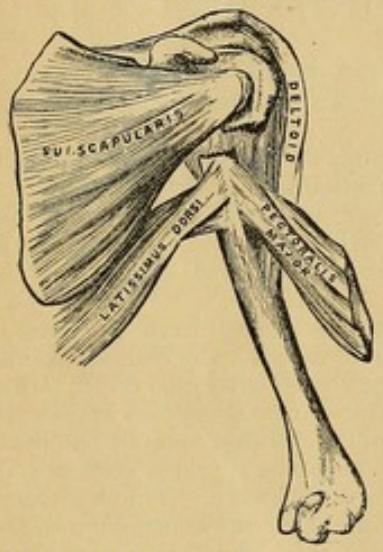

FIG. 247.—Fracture of the surgical neck of the humerus.

In fracture of the *shaft of the humerus* below the insertion of the Pectoralis major, Latissimus dorsi, and Teres major, and above the insertion of the Deltoid, there is also considerable deformity, the upper fragment being drawn inward by the first-mentioned muscles, and the lower fragment upward and outward by the Deltoid, producing shortening of the limb and a considerable prominence at the seat of fracture, from the fractured ends of the bone riding over one another, especially if the fracture takes place in an oblique direction. The fragments may be brought into apposition by extension from the elbow, and retained in that position by adopting the same means as in the preceding injury.

In fractures of the *shaft of the humerus* immediately below the insertion of the Deltoid, the amount of deformity depends greatly upon the direction of the fracture. If it occurs in a transverse direction, only slight displacement takes place, the upper fragment being drawn a little forward; but in oblique fracture the combined actions of the Biceps and Brachialis anticus muscles in front and the Triceps behind draw upward the lower fragment, causing it to glide over the upper fragment, either backward or forward, accord-

ing to the direction of the fracture. Simple extension reduces the deformity, and the application of a shoulder cap and splints to the arm will retain the fragments in apposition. Care should be taken not to raise the elbow, but the forearm and hand may be supported in a sling.

Fracture of the *humerus* (Fig. 248) immediately above the condyles deserves very attentive consideration, as the general appearances correspond somewhat with those produced by separation of the epiphysis of the humerus, and with those of dislocation of the radius and ulna backward. If the direction of the fracture is oblique from above, downward and forward, the lower fragment is drawn upward by the Brachialis anticus and Biceps in front and the Triceps behind; and at the same time is drawn backward behind the upper fragment of the Triceps. This injury may be diagnosed from dislocation by the increased mobility in fracture, the existence of crepitus, and the fact of the deformity being remedied by extension, on the discontinuance of which it is reproduced. The age of the patient is of importance in distinguishing this form of injury from separation of the epiphysis. If fracture occurs in the opposite direction to that shown in Fig. 248, the lower fragment is drawn upward and forward, causing a considerable prominence in front, and the upper fragment projects backward beneath the tendon of the Triceps muscle.

Fracture of the *olecranon process* (Fig. 249) is a frequent accident. The detached fragment is displaced upward, by the action of the Triceps muscle, from half an inch to two inches; the

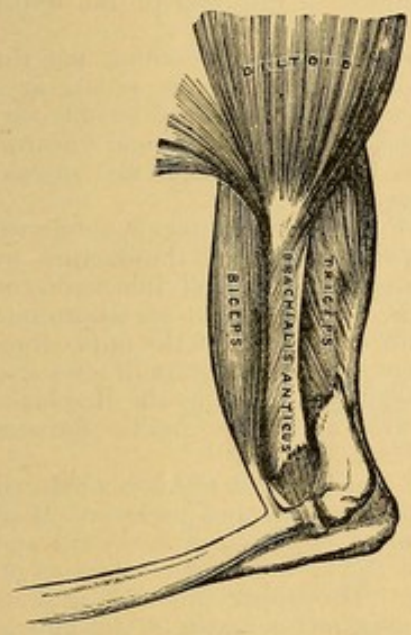

FIG. 248.—Fracture of the humerus above the condyles.

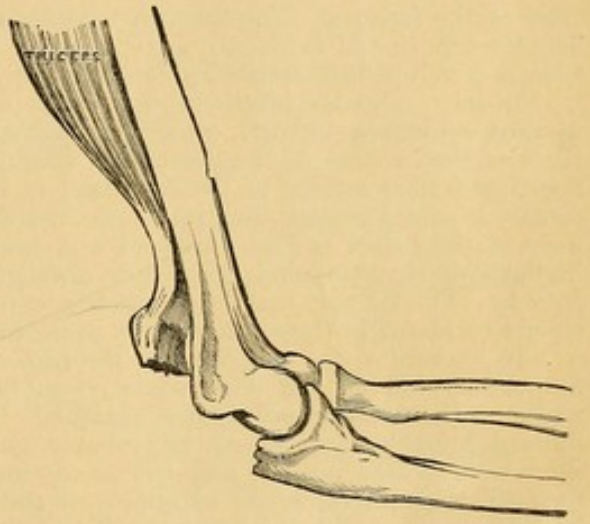

FIG. 249.—Fracture of the olecranon.

prominence of the elbow is consequently lost, and a deep hollow is felt at the back part of the joint, which is much increased on flexing the limb. The patient at the same time loses, more or less, the power of extending the forearm. The treatment consists in relaxing the Triceps by extending the limb, and retaining it in the extended position by means of a long straight splint applied to the front of the arm; the fragments are thus brought into close apposition, and may be further approximated by drawing down the upper fragment. Union is generally ligamentous.

Fracture of the *neck of the radius* is an exceedingly rare accident, and is generally caused by direct violence. Its diagnosis is somewhat obscure, on account of the slight deformity visible, the injured part being surrounded by a large number of muscles; but the movements of pronation and supination are entirely lost. The upper fragment is drawn outward by the Supinator brevis, its extent of displacement being limited by the attachment of the orbicular ligament. The lower fragment is drawn forward and slightly upward by the Biceps, and inward by the Pronator radii teres, its displacement forward and upward being counteracted in some degree by the Supinator brevis. The treatment essentially consists in relaxing the Biceps, Supinator brevis, and Pronator radii teres muscles by flexing the forearm, and placing it in a position midway between pronation and supination, extension having been previously made so as to bring the parts in apposition.

In fracture of the *radius* below the insertion of the Biceps, but above the insertion of the Pronator radii teres, the upper fragment is strongly supinated by the Biceps and Supinator brevis, and at the same time drawn forward and flexed by the Biceps; the lower fragment is pronated and drawn inward toward the ulna by the pronators. Thus there is extreme displacement with very little deformity. In treating such a fracture the arm must be put up in

a position of supination, otherwise union will take place with great impairment of the movements of the hand. In fractures of the radius below the insertion of the Pronator radii teres (Fig. 250), the upper fragment is drawn upward by the Biceps and inward by the Pronator radii teres, holding a position midway between pronation and supination, and a degree of fulness in the upper half of the forearm is thus produced: the lower fragment is drawn downward and inward toward the ulna by the Pronator quadratus, and thrown into a state of pronation by the same muscle; at the same time, the Supinator longus, by elevating the styloid process, into which it is inserted, will serve to depress the upper end of the lower fragment still more toward the ulna. In order to relax the opposing muscles the forearm should be bent, and the limb placed in a position midway between pronation and supination; the fracture is then easily reduced by extension from the wrist and elbow: well-padded splints should be applied on both sides of the forearm from the elbow to the wrist; the hand being allowed to fall, will, by its own weight, counteract the action of the Pronator quadratus and Supinator longus, and elevate the lower fragment to the level of the upper one.

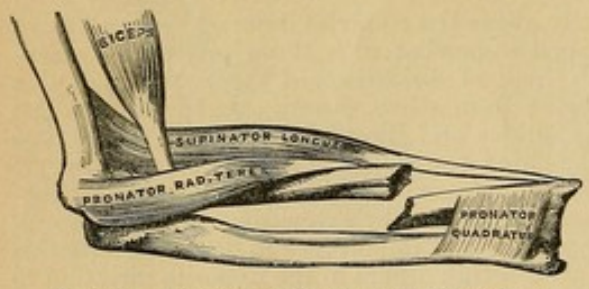

FIG. 250.—Fracture of the shaft of the radius.

In fracture of the *shaft of the ulna* the upper fragment retains its usual position, but the lower fragment is drawn outward toward the radius by the Pronator quadratus, producing a well-marked depression at the seat of fracture and some fulness on the dorsal and palmar surfaces of the forearm. The fracture is easily reduced by extension from the wrist and forearm. The forearm should be flexed, and placed in a position midway between pronation and supination, and well-padded splints applied from the elbow to the ends of the fingers.

In fracture of the *shafts of the radius and ulna together* the lower fragments are drawn upward, sometimes forward, sometimes backward, according to the direction of the fracture, by the combined actions of the Flexor and Extensor muscles, producing a degree of fulness on the dorsal or palmar surface of the forearm; at the same time the two fragments are drawn into contact by the Pronator quadratus, the radius being in a state of pronation: the upper fragment of the radius is drawn upward and inward by the Biceps and Pronator radii teres to a higher level than the ulna; the upper portion of the ulna is slightly elevated by the Brachialis anticus. The fracture may be reduced by extension from the wrist and elbow, and the forearm should be placed in the same position as in fracture of the ulna.

In fracture of the *lower end of the radius* (Fig. 251) the displacement which is produced is very considerable, and bears some resemblance to dislocation of the carpus backward, from which it should be carefully distinguished. The lower fragment is displaced backward and upward, but this displacement is probably due to the force of the blow driving the portion of the bone into this position and not to any muscular influence. The upper fragment projects forward, often lacerating the substance of the Pronator quadratus, and is drawn by this muscle into close contact with the lower end of the ulna, causing a projection on the anterior surface of

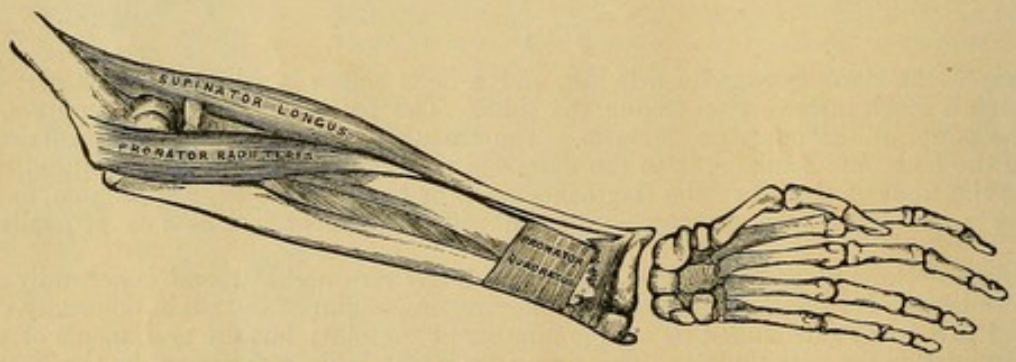

FIG. 251.—Fracture of the lower end of the radius.

the forearm, immediately above the carpus, from the flexor tendons being thrust forward. This fracture may be distinguished from dislocation by the deformity being removed on making sufficient extension, when crepitus may be occasionally detected; at the same time, on extension being discontinued, the parts immediately resume their deformed appearance (see also page 128). The age of the patient will also assist in determining whether the injury is fracture or separation of the epiphysis. The treatment consists in flexing the forearm, and making powerful extension from the wrist and elbow, depressing at the same time the radial side of the hand, and retaining the parts in that position by well-padded *pistol-shaped* splints.

MUSCLES AND FASCIÆ OF THE LOWER EXTREMITY.

The Muscles of the Lower Extremity are subdivided into groups corresponding with the different regions of the limb.

I. Iliac Region.

Psoas magnus.
Psoas parvus.
Iliacus.

II. Thigh.

1. *Anterior Femoral Region.*

Tensor fasciæ femoris.
Sartorius.
Quadriceps extensor: Rectus. Vastus externus. Vastus internus. Crureus.
Subcrureus.

2. *Internal Femoral Region.*

Gracilis.
Pectineus.
Adductor longus.
Adductor brevis.
Adductor magnus.

3. *Gluteal Region.*

Gluteus maximus.
Gluteus medius.
Gluteus minimus.
Pyriformis.
Obturator internus.
Gemellus superior.
Gemellus inferior.
Quadratus femoris.
Obturator externus.

4. *Posterior Femoral Region.*

Biceps.
Semitendinosus.
Semimembranosus.

III. Leg.

5. *Anterior Tibio-fibular Region.*

Tibialis anticus.
Extensor proprius hallucis.
Extensor longus digitorum.
Peroneus tertius.

6. *Posterior Tibio-fibular Region.*

Superficial Layer.

Gastrocnemius.
Soleus.
Plantaris.

Deep Layer.

Popliteus.
Flexor longus hallucis.
Flexor longus digitorum.
Tibialis posticus.

7. *Fibular Region.*

Peroneus longus.
Peroneus brevis.

IV. Foot.

8. *Dorsal Region.*

Extensor brevis digitorum.

9. *Plantar Region.*

First Layer.

Abductor hallucis.
Flexor brevis digitorum.
Abductor minimi digiti.

Second Layer.

Flexor accessorius.
Lumbricales.

Third Layer.

Flexor brevis hallucis.
Adductor obliquus hallucis.
Flexor brevis minimi digiti.
Adductor transversus hallucis.

Fourth Layer.

The Interossei.

I. MUSCLES AND FASCIÆ OF THE ILIAC REGION.

Psoas magnus. Psoas parvus. Iliacus.

Dissection.—No detailed description is required for the dissection of these muscles. On the removal of the viscera from the abdomen they are exposed, covered by the peritoneum and a thin layer of fascia, the iliac fascia.

The **iliac fascia**[1] is the aponeurotic layer which lines the back part of the abdominal cavity, and covers the Psoas and Iliacus muscles throughout their whole

[1] The student must not confound this fascia with the *iliac portion of the fascia lata* (see p. 420).

extent. It is thin above, and becomes gradually thicker below as it approaches the crural arch.

The *portion covering the Psoas* is attached, above, to the ligamentum arcuatum internum; internally, by a series of arched processes to the intervertebral substances and prominent margins of the bodies of the vertebræ, and to the upper part of the sacrum, the intervals so left, opposite the constricted portions of the bodies, transmitting the lumbar arteries and veins and filaments of the sympathetic cord. Externally, above the crest of the ilium, this portion of the iliac fascia is continuous with the anterior lamella of the lumbar fascia (see page 342), but below the crest of the ilium it is continuous with the fascia covering the Iliacus.

The *portion investing the Iliacus* is connected externally to the whole length of the inner border of the crest of the ilium, and internally to the brim of the true pelvis, where it is continuous with the periosteum; and at the ilio-pectineal eminence it receives the tendon of insertion of the Psoas parvus, when that muscle exists. External to the femoral vessels, this fascia is intimately connected to the posterior margin of Poupart's ligament, and is continuous with the fascia transversalis. Immediately to the outer side of the femoral vessels the fascia iliaca is prolonged backward and inward from Poupart's ligament as a band, the *ilio-pectineal ligament*, which is attached to the ilio-pectineal eminence. This ligament divides the space between Poupart's ligament and the innominate bone into two parts, the inner of which transmits the femoral vessels, the outer the ilio-psoas and the anterior crural nerve (Fig. 166). Internal to the vessels the iliac fascia is attached to the ilio-pectineal line behind the conjoined tendon, where it is again continuous with the transversalis fascia; and, corresponding to the point where the femoral vessels pass into the thigh, this fascia descends behind them, forming the posterior wall of the femoral sheath. This portion of the iliac fascia which passes behind the femoral vessels is also attached to the ilio-pectineal line beyond the limits of the attachment of the conjoined tendon; at this part it is continuous with the pubic portion of the fascia lata of the thigh. The external iliac vessels lie in front of the iliac fascia, but all the branches of the lumbar plexus behind it; it is separated from the peritoneum by a quantity of loose areolar tissue.

The **Psoas magnus** (Fig. 253) is a long fusiform muscle placed on the side of the lumbar region of the spine and margin of the pelvis. It arises from the front of the bases and lower borders of the transverse processes of the lumbar vertebræ by five fleshy slips; also from the sides of the bodies and the corresponding intervertebral substances of the last dorsal and all the lumbar vertebræ. The muscle is connected to the bodies of the vertebræ by five slips; each slip is attached to the upper and lower margins of two vertebræ, and to the intervertebral substance between them, the slips themselves being connected by the tendinous arches which extend across the constricted part of the bodies, and beneath which pass the lumbar arteries and veins and filaments of the sympathetic cord. These tendinous arches also give origin to muscular fibres, and protect the blood-vessels and nerves from pressure during the action of the muscle. The first slip is attached to the contiguous margins of the last dorsal and first lumbar vertebræ; the last to the contiguous margins of the fourth and fifth lumbar vertebræ, and to the intervertebral substance. From these points the muscle passes down across the brim of the pelvis, and, diminishing gradually in size, passes beneath Poupart's ligament, and terminates in a tendon which, after receiving nearly the whole of the fibres of the Iliacus, is inserted into the lesser trochanter of the femur.

Relations.—In the lumbar region: by its *anterior surface*, which is placed behind the peritoneum, with the iliac fascia, the ligamentum arcuatum internum, the kidney, Psoas parvus, renal vessels, ureter, spermatic vessels, genito-crural nerve, and the colon; by its *posterior surface*, with the transverse processes of the lumbar vertebræ and the Quadratus lumborum, from which it is separated by the anterior lamella of the lumbar fascia. The lumbar plexus is situated in the posterior part of the substance of the muscle. By its *inner side* the muscle is in relation with the bodies of the lumbar vertebræ, the lumbar arteries, the ganglia

of the sympathetic nerve, and their branches of communication with the spinal nerves; the lumbar glands; the vena cava inferior on the right and the aorta on the left side, and along the brim of the pelvis with the external iliac artery. In the thigh it is in relation, in front, with the fascia lata; behind, with the capsular ligament of the hip, from which it is separated by a synovial bursa, which frequently communicates with the cavity of the joint through an opening of variable size; by its *inner border*, with the Pectineus and internal circumflex artery, and also with the femoral artery, which slightly overlaps it: by its *outer border*, with the anterior crural nerve and Iliacus muscle.

The **Psoas parvus** is a long slender muscle placed in front of the Psoas magnus. It arises from the sides of the bodies of the last dorsal and first lumbar vertebræ and from the intervertebral substance between them. It forms a small flat muscular bundle, which terminates in a long flat tendon inserted into the ilio-pectineal eminence, and, by its outer border, into the iliac fascia. This muscle is often absent, and, according to Cruveilhier, sometimes double.

Relations.—It is covered by the peritoneum, and, at its origin, by the ligamentum arcuatum internum; it rests on the Psoas magnus.

The **Iliacus** is a flat, triangular muscle which fills up the whole of the iliac fossa. It arises from the upper two-thirds of this fossa and from the inner margin of the crest of the ilium; behind, from the ilio-lumbar ligament and base of the sacrum; in front, from the anterior superior and anterior inferior spinous processes of the ilium, from the notch between them, and by a few fibres from the capsule of the hip-joint. The fibres converge to be inserted into the outer side of the tendon of the Psoas, some of them being prolonged on to the shaft of the femur for about an inch below and in front of the lesser trochanter.[1]

Relations.— *Within the abdomen:* by its *anterior surface*, with the iliac fascia, which separates the muscle from the peritoneum, and with the external cutaneous nerve; on the right side, with the cæcum; on the left side, with the sigmoid flexure of the colon; by its *posterior surface*, with the iliac fossa; by its *inner border*, with the Psoas magnus and anterior crural nerve. In the thigh, it is in relation, by its *anterior surface*, with the fascia lata, Rectus, Sartorius, and profunda femoris artery; behind, with the capsule of the hip-joint, a synovial bursa common to it and the Psoas magnus being interposed.

Nerves.—The Psoas magnus is supplied by the anterior branches of the second and third lumbar nerves; the Psoas parvus, when it exists, is supplied by the anterior branch of the first lumbar nerve; and the Iliacus by the anterior branches of the second and third lumbar nerves through the anterior crural.

Actions.—The Psoas and Iliacus muscles, acting from above, flex the thigh upon the pelvis. Acting from below, the femur being fixed, the muscles of both sides bend the lumbar portion of the spine and pelvis forward. They also serve to maintain the erect position, by supporting the spine and pelvis upon the femur, and assist in raising the trunk when the body is in the recumbent posture.

The *Psoas parvus* is a tensor of the iliac fascia.

Surgical Anatomy.—In the iliac fascia there is no definite septum between the portions of fascia covering the Psoas and Iliacus respectively, and the fascia is only connected to the subjacent muscles by a quantity of loose connective tissue. When abscess forms beneath this fascia, as it is very apt to do, the matter is contained in an osseo-fibrous cavity which is closed on all sides within the abdomen, and is open only at its lower part, where the fascia is prolonged over the muscle into the thigh.

Abscess within the sheath of the Psoas muscle (*Psoas abscess*) is generally due to tubercular caries of the bodies of the lower dorsal and lumbar vertebræ. When the disease is in the dorsal region, the matter tracts down the posterior mediastinum, in front of the bodies of the vertebræ, and, passing beneath the ligamentum arcuatum internum, enters the sheath of the Psoas muscle, down which it passes as far as the pelvic brim; it then gets beneath the iliac portion of the fascia and fills up the iliac fossa. In consequence of the attachment of the fascia to the pelvic brim, it rarely finds its way into the pelvis, but passes by a narrow opening under Poupart's ligament

[1] The Psoas and Iliacus are sometimes regarded as a single muscle, the *Ilio-psoas*, having two heads of origin and a single insertion.

into the thigh, to the outer side of the femoral vessels. It thus follows that a Psoas abscess may be described as consisting of four parts: (1) a somewhat narrow channel at its upper part, in the Psoas sheath; (2) a dilated sac in the iliac fossa; (3) a constricted neck under Poupart's ligament; and (4) a dilated sac in the upper part of the thigh. When the lumbar vertebræ are the seat of the disease, the matter finds its way directly into the substance of the muscle. The muscular fibres are destroyed, and the nervous cords contained in the abscess are isolated and exposed in its interior; the femoral vessels which lie in front of the fascia remain intact, and the peritoneum seldom becomes implicated. All Psoas abscesses do not, however, pursue this course: the matter may leave the muscle above the crest of the ilium, and, tracking backward, may point in the loin (*lumbar abscess*); or it may point above Poupart's ligament in the inguinal region; or it may follow the course of the iliac vessels into the pelvis, and, passing through the great sacro-sciatic notch, discharge itself on the back of the thigh; or it may open into the bladder or find its way into the perinæum.

II. MUSCLES AND FASCIÆ OF THE THIGH.

1. Anterior Femoral Region.

Tensor fasciæ femoris.
Sartorius.
Quadriceps extensor { Rectus. Vastus externus. Vastus internus. Crureus.
Subcrureus.

Dissection.—To expose the muscles and fasciæ in this region, make an incision along Poupart's ligament, from the anterior superior spine of the ilium to the spine of the os pubis; a vertical incision from the centre of this, along the middle of the thigh to below the knee-joint; and a transverse incision from the inner to the outer side of the leg, at the lower end of the vertical incision. The flaps of integument having been removed, the superficial and deep fasciæ should be examined. The more advanced student should commence the study of this region by an examination of the anatomy of femoral hernia and Scarpa's triangle, the incisions for the dissection of which are marked out in the figure 252.

The **superficial fascia** forms a continuous layer over the whole of the thigh, consisting of areolar tissue, containing in its meshes much fat, and capable of being separated into two or more layers, between which are found the superficial vessels and nerves. It varies in thickness in different parts of the limb: in the groin it is thick, and the two layers are separated from one another by the superficial inguinal lymphatic glands, the internal saphenous vein, and several smaller vessels. One of these two layers, the superficial, is continuous above with the superficial fascia of the abdomen. The deep layer of the superficial fascia is a very thin, fibrous layer, best marked on the inner side of the long saphenous vein and below Poupart's ligament. It is placed beneath the subcutaneous vessels and nerves and upon the surface of the fascia lata. It is intimately adherent to the fascia lata a little below Poupart's ligament. It covers the saphenous opening in the fascia lata, being closely united to its circumference, and is connected to the sheath of the femoral vessels, corresponding to its under surface. The portion of fascia covering this aperture is perforated by the internal saphenous vein and by numerous blood- and lymphatic vessels; hence it has been termed the *cribriform fascia*, the openings for these vessels having been likened to the holes in a sieve. The cribriform fascia adheres closely both to the superficial fascia and to the fascia lata, so that it is described by some anatomists as part of the fascia lata, but is usually considered (as in this work) as belonging to the superficial fascia. It is not until the cribriform fascia has been cleared away that the saphenous opening is seen, so that this opening does not in ordinary cases exist naturally, but is the result of dissection. Mr. Callender, however, speaks of cases in which, probably as the result of pressure from enlarged inguinal lymphatic glands, the fascia has become atrophied, and a saphenous opening exists independent of dissection. A femoral hernia in passing through the saphenous opening receives the cribriform fascia as one of its coverings. A large subcutaneous bursa is found in the superficial fascia over the patella.

The **deep fascia** of the thigh is exposed on the removal of the superficial fascia,

and is named, from its great extent, the *fascia lata;* it forms a uniform investment for the whole of this region of the limb, but varies in thickness in different parts; thus, it is thicker in the upper and outer part of the thigh, where it receives a fibrous expansion from the Gluteus maximus muscle, and the Tensor fasciæ femoris is inserted between its layers: it is very thin behind, and at the upper and inner part where it covers the Adductor muscles, and again becomes stronger around the knee, receiving fibrous expansions from the tendon of the Biceps externally, and from the Sartorius internally, and Quadriceps extensor cruris in front. The fascia lata is attached, above and behind, to the back of the sacrum and coccyx; externally, to the crest of the ilium; in front, to Poupart's ligament and to the body of the os pubis; and internally, to the descending ramus of the os pubis, to the ramus and tuberosity of the ischium, and to the lower border of the great sacro-sciatic ligament. From its attachment to the crest of the ilium it passes down over the Gluteus medius muscle to the upper border of the Gluteus maximus, where it splits into two layers, one passing superficial to and the other beneath this muscle. At the lower border of the muscle the two layers reunite. Externally the fascia lata receives the greater part of the tendon of insertion of the Gluteus maximus, and becomes proportionately thickened. The portion of the fascia lata arising from the front part of the crest of the ilium, corresponding to the origin of the Tensor fasciæ femoris, passes down the outer side of the thigh as two layers, one superficial to and the other beneath this muscle; these at its lower end become blended together into a thick and strong band, having first received the insertion of the muscle. This band is continued downward, under the name of the *ilio-tibial band*, to be inserted into the external tuberosity of the tibia. Below, the fascia lata is attached to all the prominent points around the knee-joint—viz., the condyles of the femur, tuberosities of the tibia, and head of the fibula. On each side of the patella it is strengthened by transverse fibres given off from the lower part of the Vasti muscles, which are attached to and support this bone. Of these the outer is the stronger, and is continuous with the ilio-tibial band. From the inner surface of the fascia lata are given off two strong intermuscular septa, which are attached to the whole length of the linea aspera and its prolongations above and below: the external and stronger one, which extends from the insertion of the Gluteus maximus to the outer condyle, separates the Vastus externus in front from the short head of the Biceps behind, and gives partial origin to these muscles; the inner one, the thinner of the two, separates the Vastus internus from the Adductor and Pectineus muscles. Besides these there are numerous smaller septa, separating the individual muscles and enclosing each in a distinct sheath. At the upper and inner part of the thigh, a little below Poupart's ligament, a large oval-shaped aperture is observed after the superficial fascia has been cleared off: it transmits the internal saphenous vein and other smaller vessels, and is termed the *saphenous opening*. In order more correctly to consider the mode of formation of this aperture, the fascia lata in this

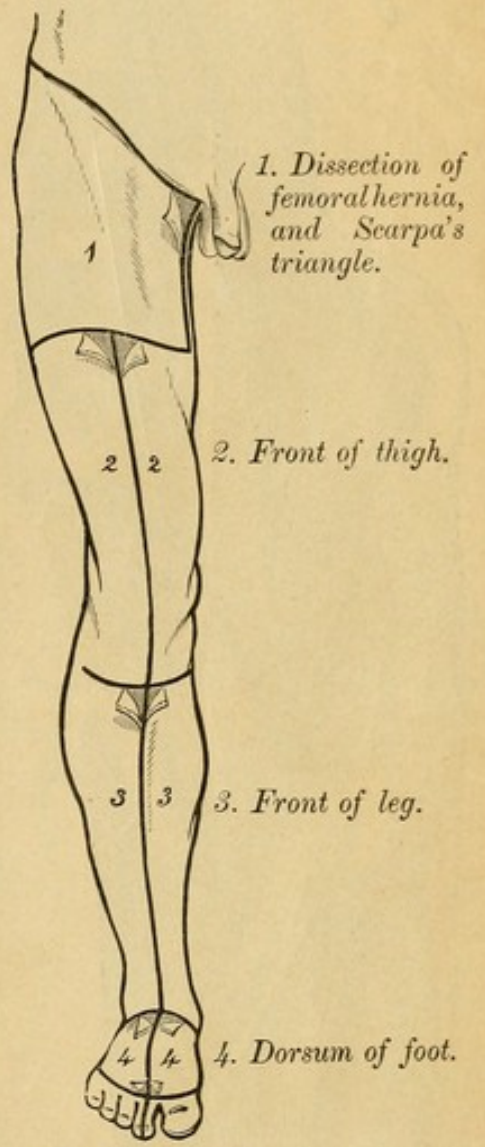

FIG. 252.—Dissection of lower extremity. Front view.

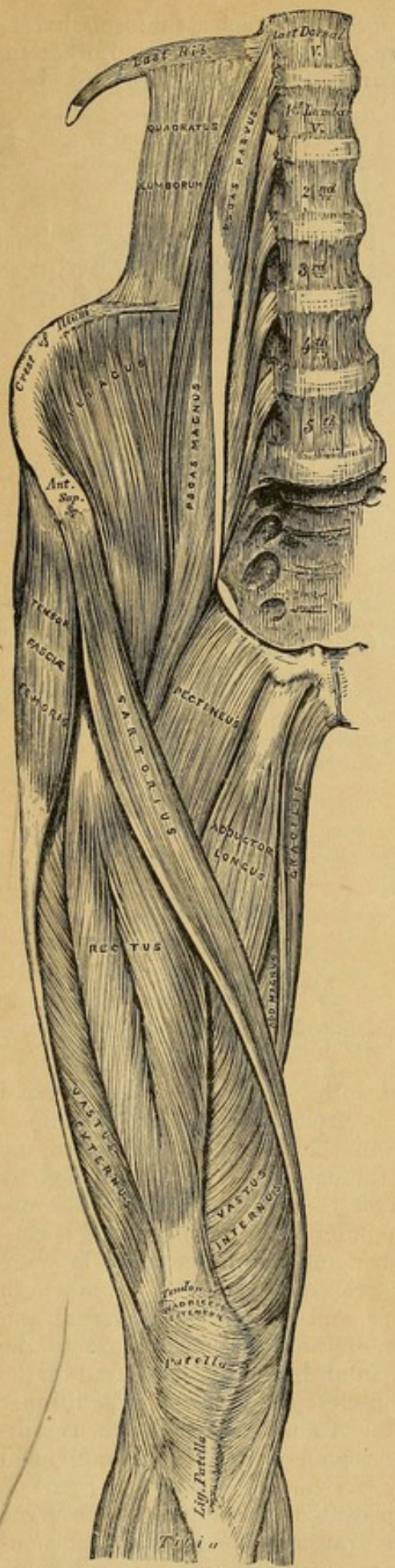

FIG. 253.—Muscles of the iliac and anterior femoral region.

part of the thigh is described as consisting of two portions—an iliac portion and a pubic portion.

The *iliac portion* is all that part of the fascia lata on the outer side of the saphenous opening. It is attached, externally, to the crest of the ilium and its anterior superior spine, to the whole length of Poupart's ligament as far internally as the spine of the os pubis, and to the pectineal line in conjunction with Gimbernat's ligament. From the spine of the os pubis it is reflected downward and outward, forming an arched margin, the *falciform process* or boundary (*superior cornu*) of the saphenous opening; this margin overlies and is adherent to the anterior layer of the sheath of the femoral vessels: to its edge is attached the cribriform fascia; and, below, it is continuous with the pubic portion of the fascia lata.

The *pubic portion* is situated at the inner side of the saphenous opening: at the lower margin of this aperture it is continuous with the iliac portion; traced upward, it covers the surface of the Pectineus, Adductor longus, and Gracilis muscles, and, passing behind the sheath of the femoral vessels, to which it is closely united, is continuous with the sheath of the Psoas and Iliacus muscles, and is attached above to the ilio-pectineal line, where it becomes continuous with the iliac fascia. From this description it may be observed that the iliac portion of the fascia lata passes in front of the femoral vessels, and the pubic portion behind them, so that an apparent aperture exists between the two, through which the internal saphenous joins the femoral vein.[1]

The fascia should now be removed from the surface of the muscles. This may be effected by pinching it up between the forceps, dividing it, and separating it from each muscle in the course of its fibres.

The **Tensor fasciæ femoris** arises from the anterior part of the outer lip of the crest of the ilium, and from the outer surface of the anterior superior spinous process, and part of the outer border of the notch below it, between the Gluteus medius and Sartorius, and from the surface of the fascia covering the Gluteus medius. It is inserted between two layers of the fascia lata, about one-fourth down the outer side of the thigh. From the point of insertion the fascia is continued downward to the external tuberosity of the tibia as a thickened band, the *ilio-tibial band*.

[1] These parts will be again more particularly described with the anatomy of Hernia.

Relations.—By its *superficial surface*, with the fascia lata and the integument; by its *deep surface*, with the Gluteus medius, Rectus femoris, Vastus externus, and the ascending branches of the external circumflex artery; by its *anterior border*, with the Sartorius, from which it is separated below by a triangular space, in which is seen the Rectus femoris; by its *posterior border*, with the Gluteus medius.

The **Sartorius**, the longest muscle in the body, is flat, narrow, and ribbon-like; it arises by tendinous fibres from the anterior superior spinous process of the ilium and the upper half of the notch below it, passes obliquely across the upper and anterior part of the thigh, from the outer to the inner side of the limb, then descends vertically, as far as the inner side of the knee, passing behind the inner condyle of the femur, and terminates in a tendon which, curving obliquely forward, expands into a broad aponeurosis, inserted, in front of the Gracilis and Semitendinosus, into the upper part of the inner surface of the shaft of the tibia, nearly as far forward as the crest. The upper part of the tendon is curved backward over the upper edge of the tendon of the Gracilis so as to be inserted behind it. An offset is derived from the upper margin of this aponeurosis, which blends with the fibrous capsule of the knee-joint, and another, given off from its lower border, blends with the fascia on the inner side of the leg.

The relations of this muscle to the femoral artery should be carefully examined, as it constitutes the chief guide in tying the vessel. In the upper third of the thigh it forms the outer side of a triangular space, *Scarpa's triangle*, the inner side of which is formed by the inner border of the Adductor longus, and the base, turned upward, by Poupart's ligament; the femoral artery passes perpendicularly through the middle of this space from its base to its apex. In the middle third of the thigh the femoral artery lies first along the inner border, and then behind the Sartorius.

Relations.—By its *superficial surface*, with the fascia lata and integument; by its *deep surface*, with the Rectus, Iliacus, Vastus internus, anterior crural nerve, sheath of the femoral vessels, Adductor longus, Adductor magnus, Gracilis, Semitendinosus, long saphenous nerve, and internal lateral ligament of the knee-joint.

The **Quadriceps extensor** includes the four remaining muscles on the front of the thigh. It is the great Extensor muscle of the leg, forming a large fleshy mass which covers the front and sides of the femur, being united below into a single tendon, attached to the patella, and above subdivided into separate portions, which have received distinct names. Of these, one occupying the middle of the thigh, connected above with the ilium, is called the *Rectus femoris*, from its straight course. The other divisions lie in immediate connection with the shaft of the femur, which they cover from the trochanters to the condyles. The portion on the outer side of the femur is termed the *Vastus externus;* that covering the inner side, the *Vastus internus;* and that covering the front of the femur, the *Crureus*.

The **Rectus femoris** is situated in the middle of the anterior region of the thigh; it is fusiform in shape, and its superficial fibres are arranged in a bipenniform manner, the deep fibres running straight down to the deep aponeurosis. It arises by two tendons: one, the anterior or straight, from the anterior inferior spinous process of the ilium; the other, the posterior or reflected tendon, from a groove above the brim of the acetabulum; the two unite at an acute angle and spread into an aponeurosis, which is prolonged downward on the anterior surface of the muscle and from which the muscular fibres arise.[1] The muscle terminates in a broad and thick aponeurosis, which occupies the lower two-thirds of its pos-

[1] Mr. W. R. Williams, in an interesting paper in the *Journ. of Anat. and Phys.*, vol. xiii. p. 204, points out that the reflected tendon is the real origin of the muscle, and is alone present in early fœtal life. The direct tendon is merely an accessory band of condensed fascia. The paper will well repay perusal, though in some particulars I think the description in the text more generally accurate.—Ed.

terior surface, and, gradually becoming narrowed into a flattened tendon, is inserted into the patella in common with the Vasti and Crureus.

Relations.—By its *superficial surface*, with the anterior fibres of the Gluteus minimus, the Tensor fasciæ femoris, the Sartorius, and the Iliacus; by its lower three-fourths, with the fascia lata. By its *posterior surface*, with the hip-joint, the external circumflex vessels, branches of the anterior crural nerve, and the Crureus and Vasti muscles.

The **Vastus externus** is the largest part of the Quadriceps extensor. It arises by a broad aponeurosis, which is attached to the upper half of the anterior intertrochanteric line, to the anterior and inferior borders of the root of the great trochanter, to the outer lip of the gluteal ridge, and to the upper half of the outer lip of the linea aspera: this aponeurosis covers the upper three-fourths of the muscle, and from its inner surface many fibres take origin. A few additional fibres arise from the tendon of the Gluteus maximus, and from the external intermuscular septum between the Vastus externus and short head of the Biceps. The fibres form a large fleshy mass, which is attached to a strong aponeurosis, placed on the under surface of the muscle at its lower part: this becomes contracted and thickened into a flat tendon, which is inserted into the outer border of the patella, blending with the great Extensor tendon, and giving an expansion to the capsule of the knee-joint.

Relations.—By its *superficial surface*, with the Rectus, the Tensor fasciæ femoris, the fascia lata, and the tendon of the Gluteus maximus, from which it is separated by a synovial bursa. By its *deep surface*, with the Crureus, some large branches of the external circumflex artery and anterior crural nerve being interposed.

The **Vastus internus** and **Crureus** appear to be inseparably united, but when the Rectus femoris has been reflected, a narrow interval will be observed extending upward from the inner border of the patella between the two muscles. Here they can be separated, and the separation should be continued upward as far as the lower part of the anterior intertrochanteric line, where, however, the two muscles are frequently continuous.

The **Vastus internus** arises from the lower half of the anterior intertrochanteric line, the spiral line, the inner lip of the linea aspera, the upper part of the internal supra-condylar line, and the tendon of the Adductor magnus and internal intermuscular septum. Its fibres are directed downward and forward, and are chiefly attached to an aponeurosis which lies on the deep surface of the muscle and is inserted into the inner border of the patella and the Quadriceps extensor tendon, an expansion being sent to the capsule of the knee-joint.

The **Crureus** arises from the front and outer aspect of the shaft of the femur in its upper two-thirds and from the lower part of the external intermuscular septum. Its fibres end in a superficial aponeurosis, which forms the deep part of the Quadriceps extensor tendon.

Relations.—The inner edge of the Crureus is in contact with the anterior edge of the Vastus internus, but when separated from each other, as directed above, the latter muscle is seen merely to overlap the inner aspect of the femoral shaft without taking any fibres of origin from it. The Vastus internus is partly covered by the Rectus and Sartorius, but where these separate near the knee it becomes superficial, and produces a well-marked prominence above the inner aspect of the knee. In the middle third of the thigh it forms the outer wall of Hunter's canal, which contains the femoral vessels and the long saphenous nerve—the roof of the canal being formed by a strong fascia which extends from the Vastus internus to the Adductores longus and magnus. The Crureus is almost completely hidden by the Rectus femoris and Vastus externus. The deep surface of the two muscles is in relation to the femur and Subcrureus muscle. A synovial bursa is situated between the femur and the portion of the Quadriceps extensor tendon above the patella; in the adult it communicates with the synovial cavity of the knee-joint.

The *tendons* of the different portions of the Quadriceps extensor unite at the

lower part of the thigh, so as to form a single strong tendon, which is inserted into the upper part of the patella, some few fibres passing over it to blend with the Ligamentum patellæ. More properly, the patella may be regarded as a sesamoid bone, developed in the tendon of the Quadriceps; and the Ligamentum patellæ, which is continued from the lower part of the patella to the tuberosity of the tibia, as the proper tendon of insertion of the muscle. A synovial bursa, the *post-patellar bursa*, is interposed between the tendon and the upper part of the tuberosity of the tibia; and another, the *pre-patellar bursa*, is placed over the patella itself. This latter bursa often becomes enlarged, constituting "house-maid's knee."

The **Subcrureus** is a small muscle, usually distinct from the Crureus, but occasionally blended with it, which arises from the anterior surface of the lower part of the shaft of the femur, and is inserted into the upper part of the *cul-de-sac* of the capsular ligament which projects upward beneath the Quadriceps for a variable distance. It sometimes consists of several separate muscular bundles.

Nerves.—The Tensor fasciæ femoris is supplied by the fourth and fifth lumbar and first sacral nerves through the superior gluteal nerve; the other muscles of this region, by the second, third, and fourth lumbar nerves, through branches of the anterior crural.

Actions.—The Tensor fasciæ femoris is a tensor of the fascia lata; continuing its action, the oblique direction of its fibres enables it to abduct and to rotate the thigh inward. In the erect posture, acting from below, it will serve to steady the pelvis upon the head of the femur, and by means of the ilio-tibial band it steadies the condyles of the femur on the articular surfaces of the tibia, and assists the Gluteus maximus in supporting the knee in the extended position. The Sartorius flexes the leg upon the thigh, and, continuing to act, flexes the thigh upon the pelvis; it next rotates the thigh outward. It was formerly supposed to adduct the thigh, so as to cross one leg over the other, and hence received its name of Sartorius, or tailor's muscle (*sartor*, a tailor), because it was supposed to assist in crossing the legs in the squatting position. When the knee is bent the Sartorius assists the Semitendinosus, Semimembranosus, and Popliteus in rotating the tibia inward. Taking its fixed point from the leg, it flexes the pelvis upon the thigh, and, if one muscle acts, assists in rotating the pelvis. The Quadriceps extensor extends the leg upon the thigh. The Rectus muscle assists the Psoas and Iliacus in supporting the pelvis and trunk upon the femur. It also assists in flexing the thigh on the pelvis, or if the thigh is fixed it will flex the pelvis. The Vastus internus draws the patella inward as well as upward.

Surgical Anatomy.—A few fibres of the Rectus muscle are liable to be ruptured from severe strain. This accident is especially liable to occur during the games of football and cricket, and is sometimes known as "cricket thigh." The patient experiences a sudden pain in the part, as if he had been struck, and the Rectus muscle stands out and is felt to be tense and rigid. The accident is often followed by considerable swelling from inflammatory effusion. Occasionally the Quadriceps extensor may be torn away from its insertion into the patella, or the tendon of the patella may be ruptured about an inch above the bone. This accident is caused in the same manner as fracture of the patella by muscular action is produced—viz. by a violent muscular effort to prevent falling whilst the knee is in a position of semiflexion. A distinct gap can be felt above the patella, and, owing to the retraction of the muscular fibres, union may fail to take place.

2. Internal Femoral Region.

Gracilis. Adductor longus.
Pectineus. Adductor brevis.
Adductor magnus.

Dissection.—These muscles are at once exposed by removing the fascia from the fore part and inner side of the thigh. The limb should be abducted, so as to render the muscles tense and easier of dissection.

The **Gracilis** (Figs. 253, 256) is the most superficial muscle on the inner side of the thigh. It is thin and flattened, broad above, narrowing and tapering below. It arises by a thin aponeurosis from the lower half of the margin of the symphysis and the anterior half of the pubic arch. The fibres pass vertically downward, and

terminate in a rounded tendon which passes behind the internal condyle of the femur, and, curving round the inner tuberosity of the tibia, becomes flattened, and is inserted into the upper part of the inner surface of the shaft of the tibia, below the tuberosity. A few of the fibres of the lower part of the tendon are prolonged into the deep fascia of the leg. The tendon of this muscle is situated immediately above that of the Semitendinosus, and its upper edge is overlapped by the tendon of the Sartorius, with which it is in part blended. As it passes across the internal lateral ligament of the knee-joint it is separated from it by a synovial bursa common to it and the Semitendinosus muscle.

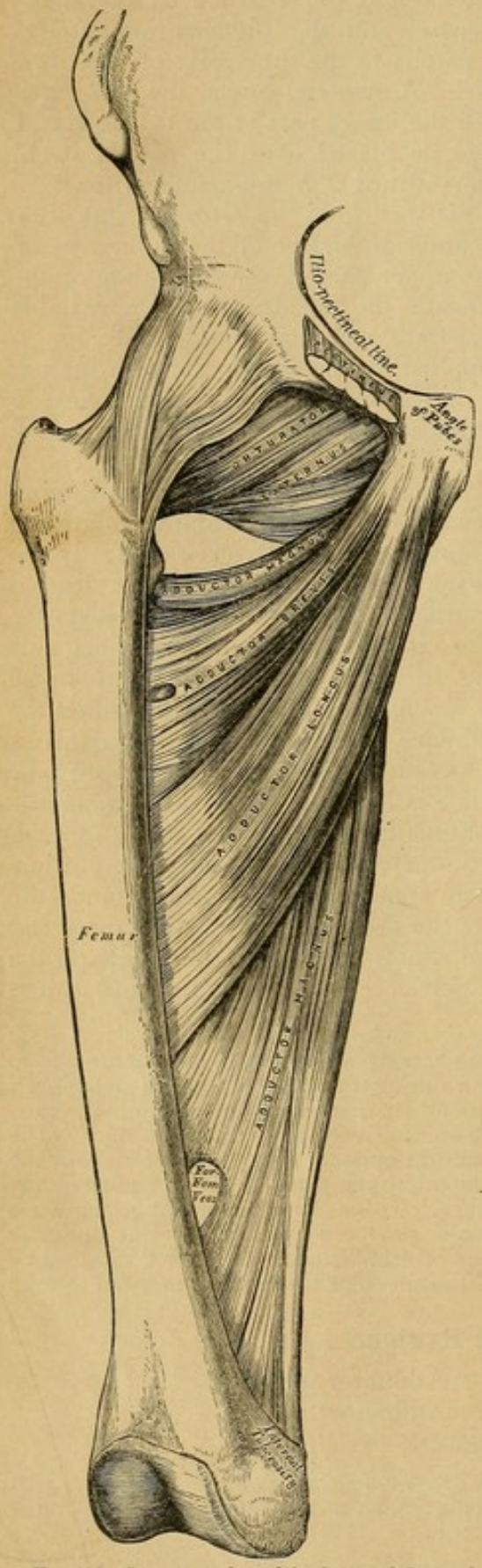

FIG. 254.—Deep muscles of the internal femoral region.

Relations.—By its *superficial surface*, with the fascia lata and the Sartorius below: the internal saphenous vein crosses it obliquely near its lower part, lying superficial to the fascia lata; the internal saphenous nerve emerges between its tendon and that of the Sartorius; by its *deep surface*, with the Adductor brevis and the Adductor magnus and the internal lateral ligament of the knee-joint.

The **Pectineus** (Fig. 253) is a flat, quadrangular muscle, situated at the anterior part of the upper and inner aspect of the thigh. It arises from the linea ilio-pectinea, and to a slight extent from the surface of the bone in front of it between the pectineal eminence and spine of the os pubis, and from the fascia covering the anterior surface of the muscle; the fibres pass downward, backward, and outward, to be inserted into a rough line leading from the lesser trochanter to the linea aspera.

Relations.—By its *anterior surface*, with the pubic portion of the fascia lata, which separates it from the femoral vessels and internal saphenous vein; by its *posterior surface*, with the capsular ligament of the hip-joint, the Adductor brevis and Obturator externus muscles, the obturator vessels and nerve being interposed; by its *outer border*, with the Psoas, a cellular interval separating them, through which pass the internal circumflex vessels; by its *inner border*, with the margin of the Adductor longus.

The **Adductor longus**, the most superficial of the three Adductors, is a flat triangular muscle lying on the same plane as the Pectineus. It arises, by a flat narrow tendon, from the front of the os pubis, at the angle of junction of the crest with the symphysis; and soon expands into a broad fleshy belly, which, passing downward, backward, and outward, is inserted by an aponeurosis, into the linea

aspera, between the Vastus internus and the Adductor magnus, with both of which it is usually blended.

Relations.—By its *anterior surface*, with the fascia lata, the Sartorius, and, near its insertion, with the femoral artery and vein; by its *posterior surface*, with the Adductor brevis and magnus, the anterior branches of the obturator nerve, and with the profunda artery and vein near its insertion; by its *outer border*, with the Pectineus; by its *inner border*, with the Gracilis.

The Pectineus and Adductor longus should now be divided near their origin, and turned downward, when the Adductor brevis and Obturator externus will be exposed.

The **Adductor brevis** is situated immediately behind the two preceding muscles. It is somewhat triangular in form, and arises by a narrow origin from the outer surface of the body and descending ramus of the os pubis, between the Gracilis and Obturator externus. Its fibres, passing backward, outward, and downward, are inserted, by an aponeurosis, into the lower part of the line leading from the lesser trochanter to the linea aspera and the upper part of the same line, immediately behind the Pectineus and upper part of the Adductor longus.

Relations.—By its *anterior surface*, with the Pectineus, Adductor longus, profunda femoris artery, and anterior branches of the obturator nerve; by its *posterior surface*, with the Adductor magnus and posterior branch of the obturator nerve; by its *outer border*, with the internal circumflex artery, the Obturator externus, and conjoined tendon of the Psoas and Iliacus; by its *inner border*, with the Gracilis and Adductor magnus. This muscle is pierced, near its insertion, by the second or first and second perforating branches of the profunda femoris artery.

The Adductor brevis should now be cut away near its origin, and turned outward, when the entire extent of the Adductor magnus will be exposed.

The **Adductor magnus** is a large triangular muscle forming a septum between the muscles on the inner and those on the back of the thigh. It arises from a small part of the descending ramus of the os pubis, from the ramus of the ischium, and from the outer margin of the inferior part of the tuberosity of the ischium. Those fibres which arise from the ramus of the os pubis are very short, horizontal in direction, and are inserted into the rough line leading from the great trochanter to the linea aspera, internal to the Gluteus maximus; those from the ramus of the ischium are directed downward and outward with different degrees of obliquity, to be inserted, by means of a broad aponeurosis, into the linea aspera and the upper part of its internal prolongation below. The internal portion of the muscle, consisting principally of those fibres which arise from the tuberosity of the ischium, forms a thick fleshy mass consisting of coarse bundles which descend almost vertically, and terminate about the lower third of the thigh in a rounded tendon, which is inserted into the Adductor tubercle on the inner condyle of the femur, being connected by a fibrous expansion to the line leading upward from the tubercle to the linea aspera. Between the two portions of the muscle an interval is left, tendinous in front, fleshy behind, for the passage of the femoral vessels into the popliteal space. The external portion of the muscle at its attachment to the femur presents three or four osseo-aponeurotic openings, formed by tendinous arches attached to the bone, from which muscular fibres arise. The three superior of these apertures are for the three perforating arteries, and the fourth, when it exists, for the terminal branch of the profunda.

Relations.—By its *anterior surface*, with the Pectineus, Adductor brevis, Adductor longus, and the femoral and profunda vessels and obturator nerve; by its *posterior surface*, with the great sciatic nerve, the Gluteus maximus, the Semitendinosus, and Semimembranosus. By its *superior* or *shortest* border, with the Obturator parallel with the Quadratus femoris, the internal circumflex artery, and the Gracilis overlapped by the two them; by its *internal* or *longest border*, with the Gracilis in front of it and form a lata; by its *external* or *attached border* it is inserted in Adductor brevis and Adductor longus, which separate it

and in front of the Gluteus maximus and short head of the Biceps, which separate it from the Vastus externus.

Nerves.—The three Adductor muscles and the Gracilis are supplied by the third and fourth lumbar nerves through the obturator nerve; the Adductor magnus receiving an additional branch from the sacral plexus through the great sciatic. The Pectineus is supplied by the second, third, and fourth lumbar nerves through the anterior crural, and by the accessory obturator, from the third lumbar, when it exists. Occasionally it receives a branch from the obturator nerve.[1]

Actions.—The Pectineus and three Adductors adduct the thigh powerfully; they are especially used in horse exercise, the flanks of the horse being grasped between the knees by the actions of these muscles. In consequence of the obliquity of their insertion into the linea aspera they rotate the thigh outward, assisting the external Rotators, and when the limb has been abducted they draw it inward, carrying the thigh across that of the opposite side. The Pectineus and Adductor brevis and longus assist the Psoas and Iliacus in flexing the thigh upon the pelvis. In progression, also, all these muscles assist in drawing forward the hinder limb. The Gracilis assists the Sartorius in flexing the leg and rotating it inward; it is also an adductor of the thigh. If the lower extremities are fixed, these muscles may take their fixed point from below and act upon the pelvis, serving to maintain the body in an erect posture, or, if their action is continued, to flex the pelvis forward upon the femur.

Surgical Anatomy.—The Adductor longus is liable to be severely strained in those who ride much on horseback, or its tendon to be ruptured by suddenly gripping the saddle. And, occasionally, especially in cavalry soldiers, the tendon may become ossified, constituting the "rider's bone."

THE HIP.

3. Gluteal Region.

Gluteus maximus.	Obturator internus.
Gluteus medius.	Gemellus superior.
Gluteus minimus.	Gemellus inferior.
Pyriformis.	Quadratus femoris.

Obturator externus.

Dissection (Fig. 255).—The subject should be turned on its face, a block placed beneath the pelvis to make the buttocks tense, and the limbs allowed to hang over the end of the table, with the foot inverted and the thigh abducted. Make an incision through the integument along the crest of the ilium to the middle of the sacrum, and thence downward to the tip of the coccyx, and carry a second incision from that point obliquely downward and outward to the outer side of the thigh, four inches below the great trochanter. The portion of integument included between these incisions is to be removed in the direction shown in the figure.

The **Gluteus maximus** (Fig. 256), the most superficial muscle in the gluteal region, is a very broad and thick, fleshy mass of a quadrilateral shape, which forms the prominence of the nates. Its large size is one of the most characteristic points in the muscular system in man, connected as it is with the power he has of maintaining the trunk in the erect posture. In structure the muscle is remarkably coarse, being made up of muscular fasciculi lying parallel with one another, and collected together into large bundles, separated by deep cellular intervals. It arises from the superior curved line of the ilium and the portion of bone, including the crest, immediately above and behind it; from the posterior surface of the lower part of the sacrum, the side of the coccyx, the aponeurosis of the Erector spinæ muscle, the great sacro-sciatic ligament, and the fascia covering the Gluteus medius. The fibres are directed obliquely downward and outward; those forming the upper [illegible] portion of the muscle, together with the *superficial* fibres of the lower

FIG. 254. -Deep muscle describes the Pectineus as consisting of two incompletely separated strata, of region. [illegible]atum, which is constant, is supplied by the anterior crural nerve, or in [illegible]urator, with which it is intimately related; while the inner or ven- symphysis; and soon [illegible]upplied by the obturator nerve.—*Journal of Anatomy and Physiology*, ward, backward, and o

ıter, behind, but often partly blended with, the tendon of the Obturator inter-
port and Gemelli muscles.

Relations.—By its *anterior surface, within the pelvis*, with the Rectum (espe-
fibr lly on the left side), the sacral plexus of nerves, and the branches of the internal
sert c vessels; *external to the pelvis*, with the posterior surface of the ischium and
troch sular ligament of the hip-joint; by its *posterior surface, within the pelvis*, with
tus sacrum, and *external to it*, with the Gluteus maximus; by its *upper border*,
h the Gluteus medius, from which it is separated by the gluteal vessels and
latio erior gluteal nerve; by its *lower border*, with the Gemellus superior and
size, ccygeus, the sciatic vessels and nerves, the internal pudic vessels and nerve, and
from scular branches from the sacral plexus, passing from the pelvis in the interval
want ween the two muscles.

ischi The **Obturator membrane** (Fig. 166) is a thin layer of interlacing fibres which
of th es the obturator foramen. It is attached, externally, to the margin of the
R men; internally, to the posterior surface of the ischio-pubic ramus, below and
a thi rnal to the margin of the foramen. It is occasionally incomplete, and presents
cutan ts upper and outer part a small canal, which is bounded below by a thickened
abov d of fibres, for the passage of the obturator vessels and nerve. Both obturator
and scles are connected with this membrane.

Glut **Dissection.**—The next muscle, as well as the origin of the Pyriformis, can only be seen
inter n the pelvis is divided and the viscera removed.
the is

Bicep The **Obturator internus,** like the preceding muscle, is situated partly within the
Addu ty of the pelvis, and partly at the back of the hip-joint. It arises from the
of the r surface of the anterior and external wall of the pelvis, where it surrounds
of the greater part of the obturator foramen, being attached to the descending ramus
and t he os pubis and the ramus of the ischium, and at the side to the inner surface
pudic e innominate bone below and behind the pelvic brim, reaching from the upper
from t of the great sacro-sciatic foramen above and behind to the thyroid foramen
low th w and in front. It also arises from the inner surface of the obturator mem-
and t e except at its posterior part, from the tendinous arch which completes the
cumfle l for the passage of the obturator vessels and nerve and to a slight extent from
muscl obturator layer of the pelvic fascia, which covers it. The fibres converge
with t lly, and are directed backward and downward, and terminate in four or five
lower inous bands, which are found on its deep surface; these bands are reflected at
ght angle over the inner surface of the tuberosity of the ischium, which is

Di ved for their reception; the groove is covered with cartilage, and lined by a
its orig vial bursa. The muscle leaves the pelvis by the lesser sacro-sciatic foramen;
to its the tendinous bands unite into a single flattened tendon, which passes horizon-
posed, outward, and, after receiving the attachment of the Gemelli, is inserted into
upper fore part of the inner surface of the great trochanter in front of the Obturator
ward; nus. A synovial bursa, narrow and elongated in form, is usually found
osity of een the tendon of this muscle and the capsular ligament of the hip: it
of this sionally communicates with the bursa between the tendon and the tuberosity
e ischium, the two forming a single sac.

Th n order to display the peculiar appearances presented by the tendon of this muscle, it
surfac be divided near its insertion and reflected inward.
anteri
arises

Relations.—*Within the pelvis* this muscle is in relation, by its *anterior surface*,
lines, the obturator membrane and inner surface of the anterior wall of the pelvis;
it also s *posterior surface*, with the pelvic and obturator fasciæ, which separate it
The fi the Levator ani; and it is crossed by the internal pudic vessels and nerve.
line w surface forms the outer boundary of the ischio-rectal fossa. *External to the*
separa *is* it is covered by the Gluteus maximus, crossed by the great sciatic nerve,
its ins rests on the back p of the joint. As the tendon of the Obturator
Re nus emerges from t When the femur is n amen it is overlapped by the two
Tenso elli, while nearer ne pelvis forward if it has ss in front of it and form a
teus m ve in which the on the head of the femur.
is ble
Pyrif

The **Gemelli** are two small muscular fasciculi, accessories to the tendon of the Obturator internus, which is received into a groove between them. They are called *superior* and *inferior*.

The **Gemellus superior**, the smaller of the two, arises from the outer surface of the spine of the ischium, and, passing horizontally outward, becomes blended with the upper part of the tendon of the Obturator internus, and is inserted with it into the inner surface of the great trochanter. This muscle is sometimes wanting.

Relations.—By its *superficial surface*, with the Gluteus maximus and the sciatic vessels and nerves; by its *deep surface*, with the capsule of the hip-joint; by its *upper border*, with the lower margin of the Pyriformis; by its *lower border*, with the tendon of the Obturator internus.

The **Gemellus inferior** arises from the upper part of the tuberosity of the ischium, where it forms the lower edge of the groove for the Obturator internus tendon, and, passing horizontally outward, is blended with the lower part of the tendon of the Obturator internus, and is inserted with it into the inner surface of the great trochanter.

Relations.—By its *superficial surface*, with the Gluteus maximus and the sciatic vessels and nerves; by its *deep surface*, with the capsular ligament of the hip-joint; by its *upper border*, with the tendon of the Obturator internus; by its *lower border*, with the tendon of the Obturator externus and Quadratus femoris.

The **Quadratus femoris** is a short, flat muscle, quadrilateral in shape (hence its name), situated between the Gemellus inferior and the upper margin of the Adductor magnus. It arises from the upper part of the external lip of the tuberosity of the ischium, and, proceeding horizontally outward, is inserted into the upper part of the linea quadrata; that is, the line which crosses the posterior intertrochanteric line. A synovial bursa is often found between the under surface of this muscle and the lesser trochanter, which it covers.

Relations.—By its *posterior surface*, with the Gluteus maximus and the sciatic vessels and nerves; by its *anterior surface*, with the tendon of the Obturator externus and trochanter minor and with the capsule of the hip-joint; by its *upper border*, with the Gemellus inferior. Its *lower border* is separated from the Adductor magnus by the terminal branches of the internal circumflex vessels.

Dissection.—In order to expose the next muscle (the Obturator externus), it is necessary to remove the Psoas, Iliacus, Pectineus, and Adductor brevis and longus muscles from the front and inner side of the thigh, and the Gluteus maximus and Quadratus femoris from the back part. Its dissection should, consequently, be postponed until the muscles of the anterior and internal femoral regions have been explained.

The **Obturator externus** (Fig. 257) is a flat, triangular muscle, which covers the outer surface of the anterior wall of the pelvis. It arises from the margin of bone immediately around the inner side of the obturator foramen, viz., from the body and ramus of the os pubis and the ramus of the ischium; it also arises from the inner two-thirds of the outer surface of the obturator membrane, and from the tendinous arch which completes the canal for the passage of the obturator vessels and nerves. The fibres from the pubic arch extend on to the inner surface of the bone, from which they obtain a narrow origin between the margin of the foramen and the attachment of the membrane. The fibres converging pass backward, outward, and upward, and terminate in a tendon which runs across the back part of the hip-joint, and is inserted into the digital fossa of the femur.

Relations.—By its *anterior surface*, with the Psoas, Iliacus, Pectineus, Adductor magnus, and Adductor brevis; and more externally, with the neck of the femur and capsule of the hip-joint. The obturator artery and vein lie between this muscle and the obturator membrane; the superficial part of the obturator nerve lies above the muscle, and the deep part, consisting of two in constant, is supplied by the muscle, and by its *posterior surface*, with the obturator membrane and with which it is intimately related;

Nerves.—The Gluteus m[illegible] by the obturator nerve.—*Journal of* [illegible]umbar and first and

second sacral nerves through the inferior gluteal nerve from the sacral plexus; the Gluteus medius and minimus, by the fourth and fifth lumbar and first sacral nerves through the superior gluteal; the Pyriformis is supplied by the first and second sacral nerves; the Gemellus inferior and Quadratus femoris by the last lumbar and first sacral nerve; the Gemellus superior and Obturator internus by the fifth lumbar and first and second sacral nerves, and the Obturator externus by the second, third, and fourth lumbar nerves through the obturator.

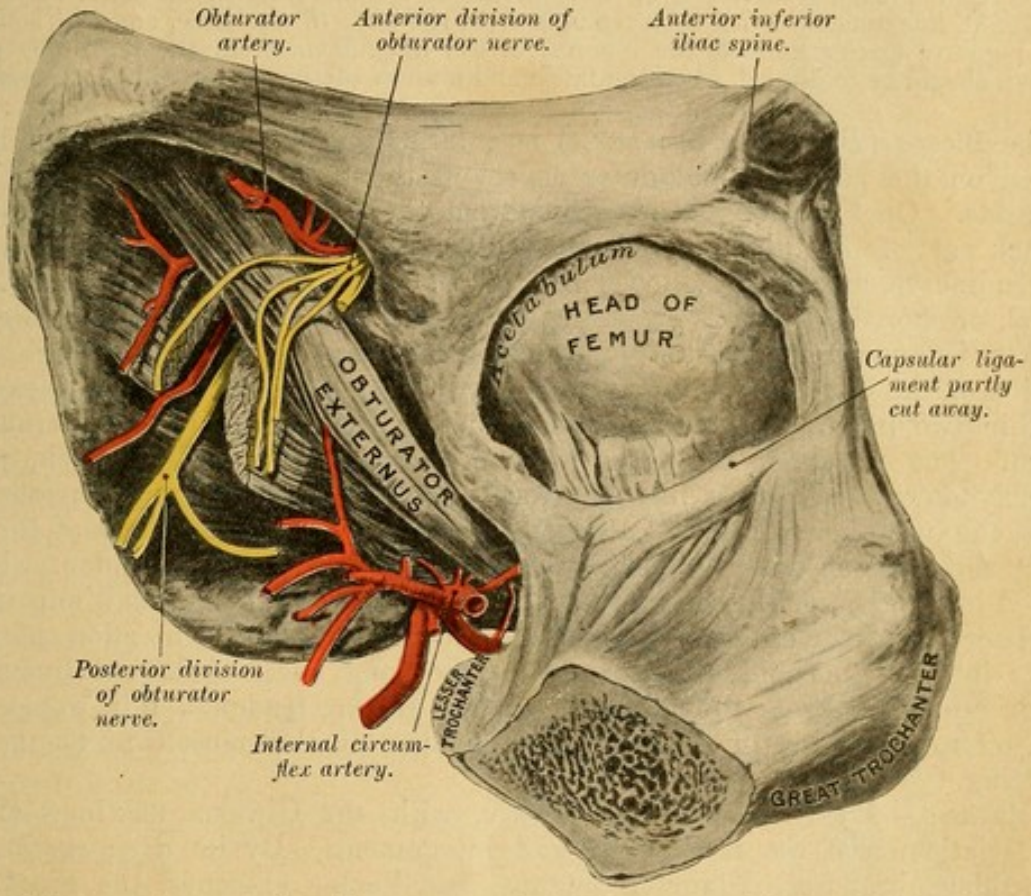

FIG. 257.—Obturator externus muscle. (From a preparation in the Museum of the Royal College of Surgeons of England.)

Actions.—The Gluteus maximus, when it takes its fixed point from the pelvis, extends the femur and brings the bent thigh into a line with the body. Taking its fixed point from below, it acts upon the pelvis, supporting it and the whole trunk upon the head of the femur, which is especially obvious in standing on one leg. Its most powerful action is to cause the body to regain the erect position after stooping by drawing the pelvis backward, being assisted in this action by the Biceps, Semitendinosus, and Semimembranosus. The Gluteus maximus is a tensor of the fascia lata, and by its connection with the ilio-tibial band it steadies the femur on the articular surface of the tibia during standing, when the extensor muscles are relaxed. The lower part of the muscle also acts as an adductor and external rotator of the limb. The Gluteus medius and minimus abduct the thigh when the limb is extended, and are principally called into action in supporting the body on one limb, in conjunction with the Tensor fasciæ femoris. Their anterior fibres, by drawing the great trochanter forward, rotate the thigh inward, in which action they are also assisted by the Tensor fasciæ femoris. The remaining muscles are powerful rotators of the thigh outward. In the sitting posture, when the thigh is flexed upon the pelvis, their action as rotator ceases, and they become abductors, with the exception of the Obturator externus, which still rotates the femur outward. When the femur is fixed, the Pyriformis and Obturator muscles serve to draw the pelvis forward if it has been inclined backward, and assist in steadying it upon the head of the femur.

4. Posterior Femoral Region.

Biceps. Semitendinosus. Semimembranosus.
(*Hamstring muscles.*)

Dissection (Fig. 255).—Make a vertical incision along the middle of the back of the thigh, from the lower fold of the nates to about three inches below the back of the knee-joint, and there connect it with a transverse incision, carried from the inner to the outer side of the leg. Make a third incision transversely at the junction of the middle with the lower third of the thigh. The integument having been removed from the back of the knee, and the boundaries of the popliteal space examined, the removal of the integument from the remaining part of the thigh should be continued, when the fascia and muscles of this region will be exposed.

The **Biceps** (*Biceps flexor cruris*) is a large muscle, of considerable length, situated on the posterior and outer aspect of the thigh (Fig. 256). It arises by two heads. One, the long head, arises from the lower and inner impression on the back part of the tuberosity of the ischium, by a tendon common to it and the Semitendinosus, and from the lower part of the great sacro-sciatic ligament. The femoral, or short head, arises from the outer lip of the linea aspera, between the Adductor magnus and Vastus externus, extending up almost as high as the insertion of the Gluteus maximus; from the outer prolongation of the linea aspera to within two inches of the outer condyle; and from the external intermuscular septum. The fibres of the long head form a fusiform belly, which, passing obliquely downward and a little outward, terminates in an aponeurosis which covers the posterior surface of the muscle, and receives the fibres of the short head: this aponeurosis becomes gradually contracted into a tendon, which is inserted into the outer side of the head of the fibula, and by a small slip into the lateral surface of the external tuberosity of the tibia. At its insertion the tendon divides into two portions, which embrace the long external lateral ligament of the knee-joint. From the posterior border of the tendon a thin expansion is given off to the fascia of the leg. The tendon of this muscle forms the outer hamstring.

Relations.—By its *superficial surface*, with the Gluteus maximus and the small sciatic nerve, the fascia lata, and integument. By its *deep surface*, with the Semimembranosus, Adductor magnus, and Vastus externus, the great sciatic nerve, and, near its insertion, with the external head of the Gastrocnemius, Plantaris, the superior external articular artery, and the external popliteal nerve.

The **Semitendinosus,** remarkable for the great length of its tendon, is situated at the posterior and inner aspect of the thigh. It arises from the lower and inner impression on the tuberosity of the ischium by a tendon common to it and the long head of the Biceps; it also arises from an aponeurosis which connects the adjacent surfaces of the two muscles to the extent of about three inches after their origin. It forms a fusiform muscle, which, passing downward and inward, terminates a little below the middle of the thigh in a long round tendon which lies along the inner side of the popliteal space, then curves around the inner tuberosity of the tibia, and is inserted into the upper part of the inner surface of the shaft of that bone nearly as far forward as its anterior border. At its insertion it gives off from its lower border a prolongation to the deep fascia of the leg. This tendon lies behind the tendon of the Sartorius, and below that of the Gracilis, to which it is united. A tendinous intersection is usually observed about the middle of the muscle.

Relations.—By its *superficial surface*, with the Gluteus maximus and fascia lata; by its *deep surface*, with the Semimembranosus, Adductor magnus, inner head of the Gastrocnemius, and internal lateral ligament of the knee-joint, the last being separated from the tendon by a bursa.

The **Semimembranosus,** so called from its membranous tendon of origin, is situated at the back part and inner side of the thigh. It arises by a thick tendon from the upper and outer impression on the back part of the tuberosity of the ischium, above and to the outer side of the Biceps and Semitendinosus, and is inserted into the groove on the inner and back part of the inner tuberosity of the tibia, be-

neath the internal lateral ligament. The tendon of the muscle at its origin expands into an aponeurosis which covers the upper part of its anterior surface: from this aponeurosis muscular fibres arise, and converge to another aponeurosis, which covers the lower part of its posterior surface and contracts into the tendon of insertion. The tendon of the muscle at its insertion gives off certain fibrous expansions; one of these, of considerable size, passes upward and outward to be inserted into the back part of the outer condyle of the femur, forming part of the posterior ligament of the knee-joint; a second is continued downward to the fascia which covers the Popliteus muscle. The tendon also sends a few fibres to join the internal lateral ligament of the joint.

The tendons of the two preceding muscles, with that of the Gracilis, form the inner hamstring.

Relations.—By its *superficial surface*, with the Gluteus maximus, Semitendinosus, Biceps, and fascia lata; by its *deep surface*, with the origin of the Quadratus femoris, popliteal vessels, Adductor magnus, and inner head of the Gastrocnemius, from which it is separated by a synovial bursa; by its *inner border*, with the Gracilis; by its *outer border*, with the great sciatic nerve, and its internal popliteal branch.

Nerves.—The muscles of this region are supplied by the first, second, and third sacral nerves through the great sciatic nerve.

Actions.—The hamstring muscles flex the leg upon the thigh. When the knee is semiflexed, the Biceps, in consequence of its oblique direction downward and outward, rotates the leg slightly outward; and the Semitendinosus, and to a slight extent the Semimembranosus, rotate the leg inward, assisting the Popliteus. Taking their fixed point from below, these muscles serve to support the pelvis upon the head of the femur and to draw the trunk directly backward, as in raising it from the stooping position or in feats of strength, when the body is thrown backward in the form of an arch. When the leg is extended upon the thigh, they limit the amount of flexion of the trunk on the lower limbs.

Surgical Anatomy.—The tendons of these muscles occasionally require subcutaneous division in some forms of spurious ankylosis of the knee-joint dependent upon permanent contraction and hereditary of the Flexor muscles, or from stiffening of the ligamentous and other tissues surrounding the joint, the result of disease. This is effected by putting the tendon upon the stretch, and inserting a narrow, sharp-pointed knife between it and the skin: the cutting edge being then turned toward the tendon, it should be divided, taking great care that the wound in the skin is not at the same time enlarged. The relation of the external popliteal nerve to the tendon of the Biceps must always be borne in mind in dividing this tendon.

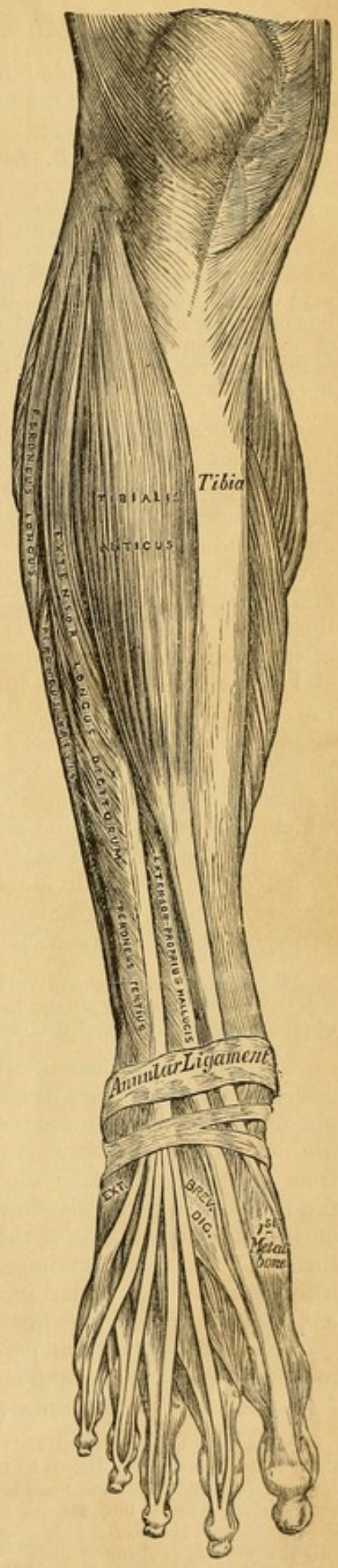

FIG. 258.—Muscles of the front of the leg.

III. MUSCLES AND FASCIÆ OF THE LEG.

These may be divided into three groups: those on the anterior, those on the posterior, and those on the outer side of the leg.

5. Anterior Tibio-fibular Region.

Tibialis anticus.	Extensor longus digitorum.
Extensor proprius hallucis.[1]	Peroneus tertius.

Dissection (Fig. 252).—The knee should be bent, a block placed beneath it, and the foot kept in an extended position; then make an incision through the integument in the middle line of the leg to the ankle, and continue it along the dorsum of the foot to the toes. Make a second incision transversely across the ankle, and a third in the same direction across the bases of the toes; remove the flaps of integument included between these incisions in order to examine the deep fascia of the leg.

The **Deep Fascia of the Leg** forms a complete investment to the muscles, but is not continued over the subcutaneous surfaces of the bones. It is continuous above with the fascia lata, receiving an expansion from the tendon of the Biceps on the outer side, and from the tendons of the Sartorius, Gracilis, and Semitendinosus on the inner side; in front it blends with the periosteum covering the subcutaneous surface of the tibia, and with that covering the head and external malleolus of the fibula; below it is continuous with the annular ligaments of the ankle. It is thick and dense in the upper and anterior part of the leg, and gives attachment, by its deep surface, to the Tibialis anticus and Extensor longus digitorum muscles, but thinner behind, where it covers the Gastrocnemius and Soleus muscles. Over the popliteal space it is much strengthened by transverse fibres which stretch across from the inner to the outer hamstring muscles, and it is here perforated by the external saphenous vein. Its deep surface gives off, on the outer side of the leg, two strong intermuscular septa which enclose the Peronei muscles, and separate them from the muscles on the anterior and posterior tibial regions and several smaller and more slender processes which enclose the individual muscles in each region; at the same time a broad transverse intermuscular septum, called the *deep transverse fascia of the leg*, intervenes between the superficial and deep muscles in the posterior tibio-fibular region.

Remove the fascia by dividing it in the same direction as the integument, excepting opposite the ankle, where it should be left entire. Commence the removal of the fascia from below, opposite the tendons, and detach it in the line of direction of the muscular fibres.

The **Tibialis anticus** is situated on the outer side of the tibia; it is thick and fleshy at its upper part, tendinous below. It arises from the outer tuberosity and upper two-thirds of the external surface of the shaft of the tibia; from the adjoining part of the interosseous membrane; from the deep surface of the fascia; and from the intermuscular septum between it and the Extensor longus digitorum: the fibres pass vertically downward, and terminate in a tendon which is apparent on the anterior surface of the muscle at the lower third of the leg. After passing through the innermost compartment of the anterior annular ligament, it is inserted into the inner and under surface of the internal cuneiform bone and base of the metatarsal bone of the great toe.

Relations.—By its *anterior surface*, with the fascia and the annular ligament; by its *posterior surface*, with the interosseous membrane, tibia, ankle-joint, and inner side of the tarsus: this surface also overlaps the Anterior tibial vessels

[1] There is no such word as "Hallux, -cis." It is the result of some ignorant blunder, copied until it has become established by usage; it has been thought better, therefore, to retain it. According to Lewis and Short the word is ALLEX, masculine; genitive, ALLICIS, the great toe, and the correct rendering would be Extensor proprius allĭcis. It is a rare word, and is sometimes spelt, but not so correctly, "Hallex." It is used by Plautus, in the "Pœnulus" V., v. 31, of a little man, as we might say "a hop-o'-my-thumb." "Tunc hic amator audes esse, *allex* viri" (To think of you daring to make up to her, you hop-o'-my-thumb!). The word "alex," sometimes spelt "allex," a fish sauce, is probably a different word altogether. It is used by Horace and Pliny.

and nerve in the upper part of the leg. By its *inner surface*, with the tibia; by its *outer surface*, with the Extensor longus digitorum and Extensor proprius hallucis, and the anterior tibial vessels and nerve.

The **Extensor proprius hallucis** is a thin, elongated, and flattened muscle situated between the Tibialis anticus and Extensor longus digitorum. It arises from the anterior surface of the fibula for about the middle two-fourths of its extent, its origin being internal to that of the Extensor longus digitorum; it also arises from the interosseous membrane to a similar extent. The fibres pass downward, and terminate in a tendon which occupies the anterior border of the muscle, passes through a distinct compartment in the lower portion of the annular ligament, crosses the anterior tibial vessels near the bend of the ankle, and is inserted into the base of the last phalanx of the great toe. Opposite the metatarso-phalangeal articulation the tendon gives off a thin prolongation on each side, which covers the surface of the joint. It usually sends an expansion from the inner side of the tendon, to be inserted into the base of the first phalanx.

Relations.—By its *anterior surface*, with the fascia and the anterior annular ligament; by its *posterior surface*, with the interosseous membrane, fibula, tibia, and ankle-joint; by its *outer side*, with the Extensor longus digitorum above, the dorsalis pedis vessels, anterior tibial nerve, and Extensor brevis digitorum below; by its *inner side*, with the Tibialis anticus and the anterior tibial vessels above. The muscle is external to the anterior tibial vessels in the upper part of the leg; but in the lower third its tendon crosses over them, so that it lies internal to them on the dorsum of the foot.

The **Extensor longus digitorum** is an elongated, flattened, penniform muscle situated the most externally of all the muscles on the fore part of the leg. It arises from the outer tuberosity of the tibia; from the upper three-fourths of the anterior surface of the shaft of the fibula; from the interosseous membrane; from the deep surface of the fascia; and from the intermuscular septa between it and the Tibialis anticus on the inner and the Peronei on the outer side. The tendon enters a canal in the annular ligament with the Peroneus tertius, and divides into four slips, which run across the dorsum of the foot and are inserted into the second and third phalanges of the four lesser toes. The mode in which the tendons are inserted is the following: The three inner tendons opposite the metatarso-phalangeal articulation are joined, on their outer side, by a tendon of the Extensor brevis digitorum. They all receive a fibrous expansion from the Interossei and Lumbricales, and then spread out into a broad aponeurosis, which covers the dorsal surface of the first phalanx: this aponeurosis, at the articulation of the first with the second phalanx, divides into three slips—a middle one, which is inserted into the base of the second phalanx, and two lateral slips, which, after uniting on the dorsal surface of the second phalanx, are continued onward, to be inserted into the base of the third.

Relations.—By its *anterior surface*, with the fascia and the annular ligament; by its *posterior surface*, with the fibula, interosseous membrane, ankle-joint, and Extensor brevis digitorum; by its *inner side*, with the Tibialis anticus, Extensor proprius hallucis, and anterior tibial vessels and nerve; by its *outer side*, with the Peroneus longus and brevis.

The **Peroneus tertius** is a part of the Extensor longus digitorum, and might be described as its fifth tendon. The fibres belonging to this tendon arise from the lower fourth of the anterior surface of the fibula, from the lower part of the interosseous membrane, and from an intermuscular septum between it and the Peroneus brevis. The tendon, after passing through the same canal in the annular ligament as the Extensor longus digitorum, is inserted into the dorsal surface of the base of the metatarsal bone of the little toe. This muscle is sometimes wanting.

Nerves.—These muscles are supplied by the fourth and fifth lumbar and first sacral nerves through the anterior tibial nerve.

Actions.—The Tibialis anticus and Peroneus tertius are the direct flexors of the

foot at the ankle-joint; the former muscle, when acting in conjunction with the Tibialis posticus, raises the inner border of the foot (*i. e.*, inverts the foot): and the latter, acting with the Peroneus brevis and longus, draws the outer border of the foot upward and the sole outward (*i. e.*, everts the foot). The Extensor longus digitorum and Extensor proprius hallucis extend the phalanges of the toes, and, continuing their action, flex the foot upon the leg. Taking their fixed point from below, in the erect posture, all these muscles serve to fix the bones of the leg in the perpendicular position, and give increased strength to the ankle-joint.

6. Posterior Tibio-fibular Region.

Dissection (Fig. 255).—Make a vertical incision along the middle line of the back of the leg, from the lower part of the popliteal space to the heel, connecting it below by a transverse incision extending between the two malleoli; the flaps of integument being removed, the fascia and muscles should be examined.

The muscles in this region of the leg are subdivided into two layers—superficial and deep. The superficial layer constitutes a powerful muscular mass, forming the calf of the leg. Their large size is one of the most characteristic features of the muscular apparatus in man, and bears a direct connection with his ordinary attitude and mode of progression.

Superficial Layer.

Gastrocnemius. Soleus. Plantaris.

The **Gastrocnemius** is the most superficial muscle, and forms the greater part of the calf. It arises by two heads, which are connected to the condyles of the femur by two strong flat tendons. The inner and larger head arises from a depression at the upper and back part of the inner condyle and from the adjacent part of the femur. The outer head arises from an impression on the outer side of the external condyle and from the posterior surface of the femur immediately above the condyle. Both heads, also, arise by a few tendinous and fleshy fibres from the ridges which are continued upward from the condyles to the linea aspera. Each tendon spreads out into an aponeurosis, which covers the posterior surface of that portion of the muscle to which it belongs; the muscular fibres of the inner head being thicker and extending lower than those of the outer. From the anterior surface of these tendinous expansions muscular fibres are given off. The fibres in the median line, which correspond to the accessory portions of the muscle derived from the bifurcations of the linea aspera, unite at an angle upon a median tendinous raphe below: the remaining fibres converge to an aponeurosis which covers the anterior surface of the muscle, and this, gradually contracting, unites with the tendon of the Soleus, and forms with it the tendo Achillis.

Relations.—By its *superfiical surface*, with the fascia of the leg, which separates it from the external saphenous vein and nerve; by its *deep surface*, with the posterior ligament of the knee-joint, the Popliteus, Soleus, Plantaris, popliteal vessels, and internal popliteal nerve. The tendon of the inner head corresponds with the back part of the inner condyle, from which it is separated by a synovial bursa, which, in some cases, communicates with the cavity of the knee-joint. The tendon of the outer head contains a sesamoid fibro-cartilage (rarely osseous) where it plays over the corresponding outer condyle; and one is occasionally found in the tendon of the inner head.

The Gastrocnemius should be divided across, just below its origin, and turned downward, in order to expose the next two muscles.

The **Soleus** is a broad flat muscle situated immediately beneath the Gastrocnemius. It has received its name from its resemblance in shape to a sole-fish. It arises by tendinous fibres from the back part of the head of the fibula and from the upper third of the posterior surface of its shaft; from the oblique line of the

tibia and from the middle third of its internal border; some fibres also arise from a tendinous arch placed between the tibial and fibular origins of the muscle, beneath which the popliteal vessels and internal popliteal nerve pass. The fibres pass backward to an aponeurosis which covers the posterior surface of the muscle, and this, gradually becoming thicker and narrower, joins with the tendon of the Gastrocnemius, and forms with it the tendo Achillis.

Relations.—By its *superficial surface*, with the Gastrocnemius and Plantaris; by its *deep surface*, with the Flexor longus digitorum, Flexor longus hallucis, Tibialis posticus, and posterior tibial vessels and nerve, from which it is separated by the transverse intermuscular septum or deep transverse fascia of the leg.

The **Tendo Achillis**, the common tendon of the Gastrocnemius and Soleus,[1] is the thickest and strongest tendon in the body. It is about six inches in length, and commences about the middle of the leg, but receives fleshy fibres on its anterior surface nearly to its lower end. Gradually becoming contracted below, it is inserted into the lower part of the posterior surface of the os calcis, a synovial bursa being interposed between the tendon and the upper part of this surface. The tendon spreads out somewhat at its lower end, so that its narrowest part is usually about an inch and a half above its insertion. The tendon is covered by the fascia and the integument, and is separated from the deep muscles and vessels by a considerable interval filled up with areolar and adipose tissue. Along its outer side, but superficial to it, is the external saphenous vein.

The **Plantaris** is an extremely diminutive muscle placed between the Gastrocnemius and Soleus, and remarkable for its long and delicate tendon. It arises from the lower part of the outer prolongation of the linea aspera and from the posterior ligament of the knee-joint. It forms a small fusiform belly, about three or four inches in length, terminating in a long slender tendon which crosses obliquely between the two muscles of the calf, and, running along the inner border of the tendo Achillis, is inserted with it into the posterior part of the os calcis. This muscle is occasionally double, and is sometimes wanting. Occasionally, its tendon is lost in the internal annular ligament or in the fascia of the leg.

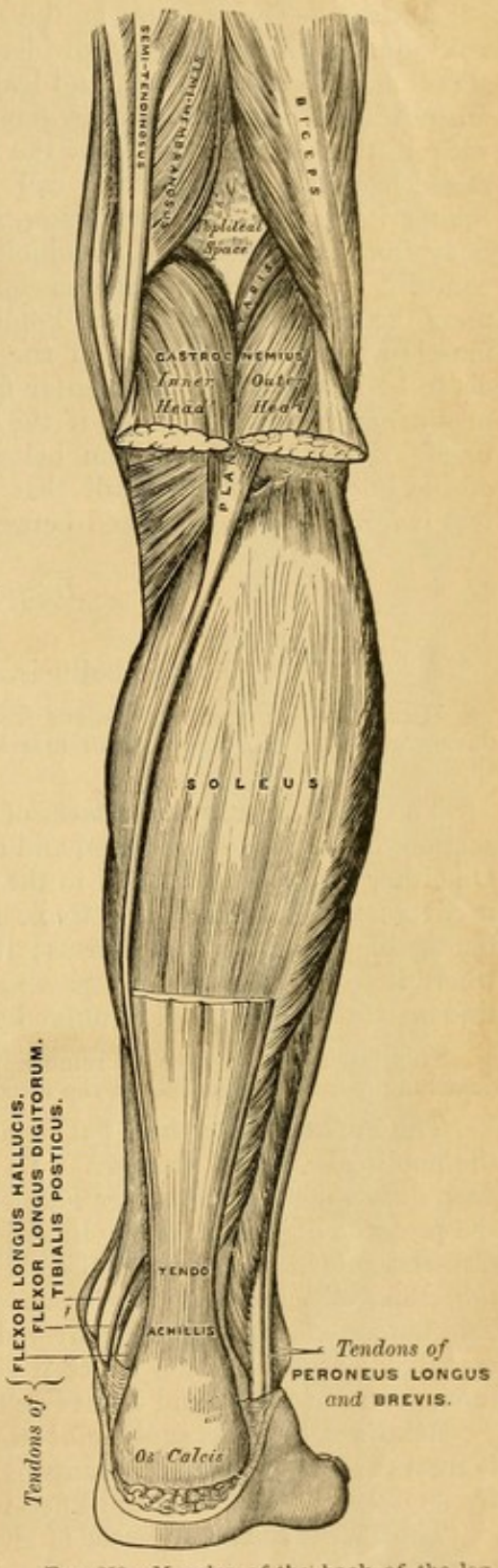

FIG. 259.—Muscles of the back of the leg. Superficial layer.

Nerves.—The Gastrocnemius is supplied by the first and second sacral nerves,

[1] These two muscles with a common tendon are by some anatomists classed together as one muscle, the *Triceps suræ*, the two heads of origin of the Gastrocnemius and the Soleus constituting the three heads of the Triceps, and the tendo Achillis the single tendon of insertion.

and the Plantaris by the fourth and fifth lumbar and first sacral nerves through the internal popliteal. The Soleus is supplied by the fifth lumbar and first and second sacral nerves through the internal popliteal and posterior tibial.

Actions.—The muscles of the calf are the chief extensors of the foot at the ankle-joint. They possess considerable power, and are constantly called into use in standing, walking, dancing, and leaping; hence the large size they usually present. In walking these muscles draw powerfully upon the os calcis, raising the heel, and with it the entire body, from the ground; the body being thus supported on the raised foot, the opposite limb can be carried forward. In standing, the Soleus, taking its fixed point from below, steadies the leg upon the foot, and prevents the body from falling forward, to which there is a constant tendency from the superincumbent weight. The Gastrocnemius, acting from below, serves to flex the femur upon the tibia, assisted by the Popliteus. The Plantaris is the rudiment of a large muscle which exists in some of the lower animals and is continued over the os calcis to be inserted into the plantar fascia. In man it is an accessory to the Gastrocnemius, extending the ankle if the foot is free, or bending the knee if the foot is fixed. Possibly, acting from below, by its attachment to the posterior ligament of the knee-joint, it may pull that ligament backward during flexion, and so protect it from being compressed between the two articular surfaces.

Deep Layer (Fig. 260).

Popliteus.	Flexor longus digitorum.
Flexor longus hallucis.	Tibialis posticus.

Dissection.—Detach the Soleus from its attachment to the fibula and tibia, and turn it downward, when the deep layer of muscles is exposed, covered by the deep transverse fascia of the leg.

The **Deep Transverse Fascia** of the leg is a transversely placed, intermuscular septum, between the superficial and deep muscles in the posterior tibio-fibular region. On either side it is connected to the margins of the tibia and fibula. Above, where it covers the Popliteus, it is thick and dense, and receives an expansion from the tendon of the Semimembranosus; it is thinner in the middle of the leg, but below, where it covers the tendons passing behind the malleoli, it is thickened and continuous with the internal annular ligament.

This fascia should now be removed, commencing from below opposite the tendons, and detaching it from the muscles in the direction of their fibres.

The **Popliteus** is a thin, flat, triangular muscle, which forms part of the floor of the popliteal space. It arises by a strong tendon, about an inch in length, from a deep depression on the outer side of the external condyle of the femur, and from the posterior ligament of the knee-joint, and is inserted into the inner two-thirds of the triangular surface above the oblique line on the posterior surface of the shaft of the tibia, and into the tendinous expansion covering the surface of the muscle. The tendon of the muscle is covered by that of the Biceps and by the external lateral ligament of the knee-joint; it grooves the posterior border of the external semilunar fibro-cartilage, and is invested by the synovial membrane of the knee-joint.

Relations.—By its *superficial surface*, with the fascia covering it, which separates it from the Gastrocnemius, Plantaris, popliteal vessels, and internal popliteal nerve; by its *deep surface*, with the knee-joint and back of the tibia.

The **Flexor longus hallucis** is situated on the fibular side of the leg, and is the most superficial and largest of the three next muscles. It arises from the lower two-thirds of the posterior surface of the shaft of the fibula, with the exception of an inch at its lowest part; from the lower part of the interosseous membrane; from an intermuscular septum between it and the Peronei, externally; and from the fascia covering the Tibialis posticus internally. The fibres pass obliquely downward and backward, and terminate in a tendon which occupies nearly the whole length of the posterior surface of the muscle. This tendon occupies a groove on the posterior surface of the lower end of the tibia; it then lies in a second groove

on the posterior surface of the astragalus, and finally in a third groove, beneath the sustentaculum tali of the os calcis, and passes into the sole of the foot, where it runs forward between the two heads of the Flexor brevis hallucis, and is inserted into the base of the last phalanx of the great toe. The grooves in the astragalus and os calcis, which contain the tendon of the muscle, are converted by tendinous fibres into distinct canals lined by synovial membrane; and as the tendon crosses the sole of the foot, it is connected to the common flexor by a tendinous slip.

Relations.—By its *superficial surface*, with the Soleus and tendo Achillis, from which it is separated by the deep transverse fascia; by its *deep surface*, with the fibula, Tibialis posticus, the peroneal vessels, the lower part of the interosseous membrane, and the ankle-joint; by its *outer border*, with the Peronei; by its *inner border*, with the Tibialis posticus and posterior tibial vessels and nerve. In the sole of the foot it lies above the Abductor hallucis and Flexor longus digitorum.

The **Flexor longus digitorum** (*perforans*) is situated on the tibial side of the leg. At its origin it is thin and pointed, but gradually increases in size as it descends. It arises from the posterior surface of the shaft of the tibia, immediately below the oblique line to within three inches of its extremity, internal to the tibial origin of the Tibialis posticus; some fibres also arise from the fascia covering the Tibialis posticus. The fibres terminate in a tendon which runs nearly the whole length of the posterior surface of the muscle. This tendon passes behind the internal malleolus in a groove, common to it and the Tibialis posticus, but separated from the latter by a fibrous septum, each tendon being contained in a special sheath lined by a separate synovial membrane. It then passes obliquely forward and outward, superficial to the internal lateral ligament into the sole of the foot (Fig. 262), where, crossing superficially to the tendon of the Flexor longus hallucis,[1] to which it is connected by a strong tendinous slip, it becomes expanded, is joined by the Flexor accessorius, and finally divides into four tendons which are inserted into the bases of the last phalanges of the four lesser toes, each tendon passing through a fissure in the tendon of the Flexor brevis digitorum opposite the base of the first phalanges.

Relations.—*In the leg:* by its *superficial surface*, with the posterior tibial vessels and nerve, and the deep transverse fascia, which separates it from the Soleus muscle; by its *deep surface*, with the Tibia and Tibialis posticus. *In the foot* it is covered by the Abductor hallucis and Flexor brevis digitorum, and crosses superficial to the Flexor longus hallucis.

The **Tibialis posticus** lies between the two preceding muscles, and is the most deeply seated of all the muscles in the leg. It commences above by two pointed processes, separated by an angular interval, through which the anterior tibial vessels pass forward to the front of the leg. It arises from the whole of the posterior surface of the interosseous membrane, excepting its lowest part, from the outer portion of the posterior surface of the shaft of the tibia, between the

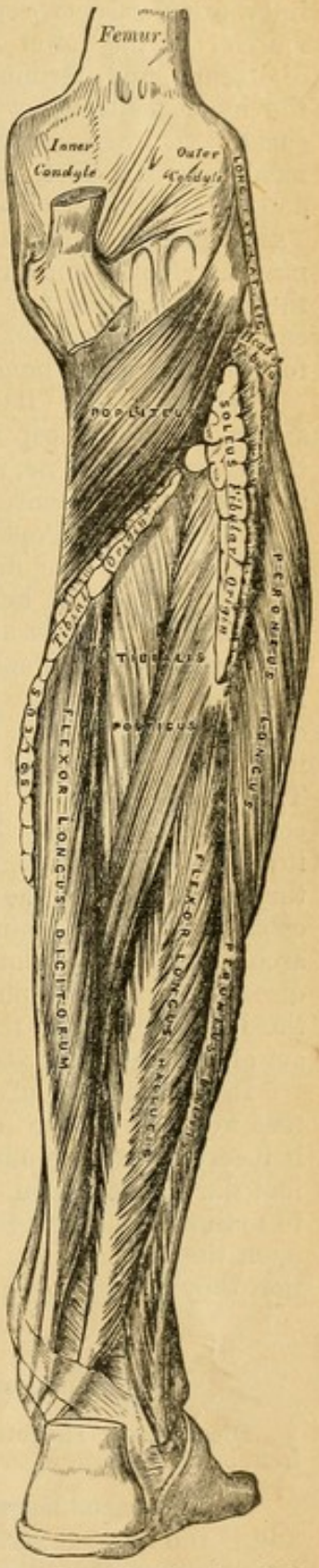

FIG. 260.—Muscles of the back of the leg. Deep layer.

[1] That is, in the order of dissection of the sole of the foot.

commencement of the oblique line above, and the junction of the middle and lower third of the shaft below; and from the upper two-thirds of the internal surface of the fibula; some fibres also arise from the deep transverse fascia and from the intermuscular septa, separating it from the adjacent muscles on each side. This muscle, in the lower fourth of the leg, passes in front of the Flexor longus digitorum, and terminates in a tendon which passes through a groove behind the inner malleolus with the tendon of that muscle, but enclosed in a separate sheath; it then passes through another sheath, over the internal lateral ligament into the foot, and then beneath the inferior calcaneo-navicular ligament, and is inserted into the tuberosity of the navicular and internal cuneiform bones. The tendon of this muscle contains a sesamoid fibro-cartilage as it passes over the navicular bone, and gives off fibrous expansions, one of which passes backward to the sustentaculum tali of the os calcis, others outward to the middle and external cuneiform and cuboid, and some forward to the bases of the second, third, and fourth metatarsal bones (Fig. 263).

Relations.—By its *superficial surface*, with the Soleus, from which it is separated by the deep transverse fascia, the Flexor longus digitorum, the posterior tibial vessels and nerve, and the peroneal vessels; by its *deep surface*, with the interosseous ligament, the tibia, fibula, and ankle-joint.

Nerves.—The Popliteus is supplied by the fourth and fifth lumbar and first sacral nerves, through the internal popliteal; the Flexor longus digitorum and Tibialis posticus by the fifth lumbar and first sacral; and the Flexor longus hallucis by the fifth lumbar and first and second sacral nerves through the posterior tibial.

Actions.—The Popliteus assists in flexing the leg upon the thigh; when the leg is flexed, it will rotate the tibia inward. It is especially called into action at the commencement of the act of bending the knee, inasmuch as it produces a slight inward rotation of the tibia, which is essential in the early stage of this movement. The Tibialis posticus is a direct extensor of the foot at the ankle-joint; acting in conjunction with the Tibialis anticus, it turns the sole of the foot inward (*i. e.*, inverts the foot), antagonizing the Peronei, which turn it outward (evert it). In the sole of the foot the tendon of the Tibialis posticus lies directly below the inferior calcaneo-scaphoid ligament, and is therefore an important factor in maintaining the arch of the foot. The Flexor longus digitorum and Flexor longus hallucis are the direct flexors of the phalanges, and, continuing their action, extend the foot upon the leg; they assist the Gastrocnemius and Soleus in extending the foot, as in the act of walking or in standing on tiptoe.

In consequence of the oblique direction of the tendon of the long flexor the toes would be drawn inward were it not for the Flexor accessorius muscle, which is inserted into the outer side of its tendon and draws it to the middle line of the foot during its action. Taking their fixed point from the foot, these muscles serve to maintain the upright posture by steadying the tibia and fibula perpendicularly upon the ankle-joint. They also serve to raise these bones from the oblique position they assume in the stooping posture.

7. Fibular Region.

Peroneus longus. Peroneus brevis.

Dissection.—The muscles are readily exposed by removing the fascia covering their surface, from below upward, in the line of direction of their fibres.

The **Peroneus longus** is situated at the upper part of the outer side of the leg, and is the more superficial of the two muscles. It arises from the head and upper two-thirds of the outer surface of the shaft of the fibula, from the deep surface of the fascia, and from the intermuscular septa between it and the muscles on the front, and those on the back of the leg, occasionally also by a few fibres from the outer tuberosity of the tibia. Between its attachment to the head and to the shaft of the fibula there is a small interval of bone from which no muscular fibres arise; through this gap the external popliteal nerve passes beneath the muscle.

It terminates in a long tendon, which passes behind the outer malleolus, in a groove common to it and the tendon of the Peroneus brevis, behind which it lies, the groove being converted into a canal by a fibrous band, and the tendons invested by a common synovial membrane; it is then reflected obliquely forward across the outer side of the os calcis, below its peroneal tubercle, being contained in a separate fibrous sheath, lined by a prolongation of the synovial membrane which lines the groove behind the malleolus. Having reached the outer side of the cuboid bone, it runs in a groove on the under surface of that bone, which is converted into a canal by the long calcaneo-cuboid ligament, and is lined by a synovial membrane: the tendon then crosses the sole of the foot obliquely, and is inserted into the outer side of the base of the metatarsal bone of the great toe and the internal cuneiform bone. Occasionally it sends a slip to the base of the second metatarsal bone. The tendon changes its direction at two points: first, behind the external malleolus; secondly, on the outer side of the cuboid bone; in both of these situations the tendon is thickened, and in the latter a sesamoid fibro-cartilage, or sometimes a bone, is usually developed in its substance.

Relations.—By its *superficial surface*, with the fascia and integument; by its *deep surface*, with the fibula, external popliteal nerve, the Peroneus brevis, os calcis, and cuboid bone; by its *anterior border*, with an intermuscular septum, which intervenes between it and the Extensor longus digitorum; by its *posterior border*, with an intermuscular septum, which separates it from the Soleus above and the Flexor longus hallucis below.

The **Peroneus brevis** lies beneath the Peroneus longus, and is shorter and smaller than it. It arises from the lower two-thirds of the external surface of the shaft of the fibula, internal to the Peroneus longus, and from the intermuscular septa separating it from the adjacent muscles on the front and back part of the leg. The fibres pass vertically downward, and terminate in a tendon which runs in front of that of the preceding muscle through the same groove, behind the external malleolus, being contained in the same fibrous sheath and lubricated by the same synovial membrane. It then passes through a separate sheath on the outer side of the os calcis, above that for the tendon of the Peroneus longus, the two tendons being here separated by the peroneal tubercle, and is finally inserted into the tuberosity at the base of the metatarsal bone of the little toe, on its outer side.

Relations.—By its *superficial surface*, with the Peroneus longus and the fascia of the leg and foot; by its *deep surface*, with the fibula and outer side of the os calcis.

Nerves.—The Peroneus longus and brevis are supplied by the fourth and fifth lumbar and first sacral nerves through the musculo-cutaneous branch of the external popliteal nerve.

Actions.—The Peroneus longus and brevis extend the foot upon the leg, in conjunction with the Tibialis posticus, antagonizing the Tibialis anticus and Peroneus tertius, which are flexors of the foot. The Peroneus longus also everts the sole of the foot; hence the extreme eversion occasionally observed in fracture of the lower end of the fibula, where that bone offers no resistance to the action of this muscle. From the oblique direction of the Peroneus longus tendon across the sole of the foot it is an important agent in the maintenance of the transverse arch of the foot. Taking their fixed point below, the Peronei serve to steady the leg upon the foot. This is especially the case in standing upon one leg, when the tendency of the superincumbent weight is to throw the leg inward: the Peroneus longus overcomes this tendency by drawing on the outer side of the leg, and thus maintains the perpendicular direction of the limb.

Surgical Anatomy.—The student should now consider the position of the tendons of the various muscles of the leg, their relation with the ankle-joint and surrounding blood-vessels, and especially their action upon the foot, as their rigidity and contraction give rise to one or other of the kinds of deformity known as *club-foot*. The most simple and common deformity, and one

that is rarely, if ever, congenital, is the *talipes equinus*, the heel being raised by rigidity and contraction of the Gastrocnemius muscle, and the patient walking upon the ball of the foot. In the *talipes varus* the foot is forcibly adducted and the inner side of the sole raised, sometimes to a right angle with the ground, by the action of the Tibialis anticus and posticus. In the *talipes valgus* the outer edge of the foot is raised by the Peronei muscles, and the patient walks on the inner ankle. In the *talipes calcaneus* the toes are raised by the extensor muscles, the heel is depressed, and the patient walks upon it. Other varieties of deformity are met with, as the *talipes equino-varus*, *equino-valgus*, and *calcaneo-valgus*, whose names sufficiently indicate their nature. Of these, the talipes equino-varus is the most common congenital form: the heel is raised by the tendo Achillis, the inner border of the foot drawn upward by the Tibialis anticus, the anterior two-thirds twisted inward by the Tibialis posticus, and the arch increased by the contraction of the plantar fascia, so that the patient walks on the middle of the outer border of the foot. Each of these deformities may sometimes be successfully relieved by division of the opposing tendons and fascia: by this means the foot regains its proper position, and the tendons heal by the organization of lymph thrown out between the divided ends. The operation is easily performed by putting the contracted tendon upon the stretch, and dividing it by means of a narrow, sharp-pointed knife inserted beneath it.

Rupture of a few of the fibres of the Gastrocnemius or rupture of the Plantaris tendon not uncommonly occurs, especially in men somewhat advanced in life, from some sudden exertion, and frequently occurs during the game of lawn tennis, and is hence known as "lawn-tennis leg." The accident is accompanied by a sudden pain, and produces a sensation as if the individual had been struck a violent blow on the part. The tendo Achillis is also sometimes ruptured. It is stated that John Hunter ruptured his tendo Achillis whilst dancing at the age of forty.

IV. MUSCLES AND FASCIÆ OF THE FOOT.

The fibrous bands, or thickened portions of the fascia of the leg, which bind down the tendons in front of and behind the ankle in their passage to the foot should now be examined; they are termed the *annular ligaments*, and are three in number—anterior, internal, and external.

The **Anterior Annular Ligament** consists of a superior or transverse portion, which binds down the Extensor tendons as they descend on the front of the tibia and fibula; and an inferior or Y-shaped portion, which retains them in connection with the tarsus, the two portions being connected by a thin intervening layer of fascia. The transverse portion is attached externally to the lower end of the fibula and internally to the tibia; above it is continuous with the fascia of the leg; it contains only one synovial sheath, for the tendon of the Tibialis anticus; the other tendons and the anterior tibial vessels and nerve passing beneath it, but without any distinct synovial sheath. The Y-shaped portion is placed in front of the ankle-joint, the stem of the Y being attached externally to the upper surface of the os calcis, in front of the depression for the interosseous ligament; it is directed inward, as a double layer, one lamina passing in front, and the other behind, the tendons of the Peroneus tertius and Extensor longus digitorum. At the inner border of the latter tendon these two layers join together, forming a sort of loop or sheath in which the tendons are enclosed, surrounded by a synovial membrane. From the inner extremity of this loop the two limbs of the Y diverge: one passes upward and inward, to be attached to the internal malleolus, passing over the Extensor proprius hallucis and the vessels and nerves, but enclosing the Tibialis anticus and its synovial sheath by a splitting of its fibres. The other limb extends downward and inward to be attached to the inner border of the plantar fascia, and passes over the tendons of the Extensor proprius hallucis and Tibialis anticus and also the vessels and nerves. These two tendons are contained in separate synovial sheaths situated beneath the ligament.

The **Internal Annular Ligament** is a strong fibrous band which extends from the inner malleolus above to the internal margin of the os calcis below, converting a series of grooves in this situation into canals for the passage of the tendons of the Flexor muscles and vessels into the sole of the foot. It is continuous by its upper border with the deep fascia of the leg, and by its lower border with the plantar fascia and the fibres of origin of the Abductor hallucis muscle. The four canals which it forms transmit, from within outward, first, the tendon of the Tibialis posticus; second, the tendon of the Flexor longus digitorum; third, the pos-

terior tibial vessels and nerve, which run through a broad space beneath the ligament; lastly, in a canal formed partly by the astragalus, the tendon of the Flexor longus hallucis. The canals for the tendons are lined by a separate synovial membrane.

The **External Annular Ligament** extends from the extremity of the outer malleolus to the outer surface of the os calcis: it binds down the tendons of the Peroneus longus and brevis muscles in their passage beneath the outer ankle. The two tendons are enclosed in one synovial sac.

Dissection of the Sole of the Foot.—The foot should be placed on a high block with the sole uppermost, and firmly secured in that position. Carry an incision round the heel and along the inner and outer borders of the foot to the great and little toes. This incision should divide the integument and thick layer of granular fat beneath until the fascia is visible; the skin and fat should then be removed from the fascia in a direction from behind forward, as seen in Fig. 255.

The **Plantar Fascia,** the densest of all the fibrous membranes, is of great strength, and consists of pearly-white glistening fibres, disposed, for the most part, longitudinally: it is divided into a central and two lateral portions.

The *central portion*, the thickest, is narrow behind and attached to the inner tubercle of the os calcis, posterior to the origin of the Flexor brevis digitorum, and, becoming broader and thinner in front, divides near the heads of the metatarsal bones into five processes, one for each of the toes. Each of these processes divides opposite the metatarso-phalangeal articulation into two strata, superficial and deep. The superficial stratum is inserted into the skin of the transverse sulcus which divides the toes from the sole. The deeper stratum divides into two slips which embrace the sides of the flexor tendons of the toes, and blend with the sheaths of the tendons, and laterally with the transverse metatarsal ligament, thus forming a series of arches through which the tendons of the short and long flexors pass to the toes. The intervals left between the five processes allow the digital vessels and nerves and the tendons of the Lumbricales muscles to become superficial. At the point of division of the fascia into processes and slips numerous transverse fibres are superadded, which serve to increase the strength of the fascia at this part by binding the processes together and connecting them with the integument. The central portion of the plantar fascia is continuous with the lateral portions at each side, and sends upward into the foot, at their point of junction, two strong vertical intermuscular septa, broader in front than behind, which separate the middle from the external and internal plantar group of muscles; from these, again, thinner transverse septa are derived, which separate the various layers of muscles in this region. The upper surface of this fascia gives attachment behind to the Flexor brevis digitorum muscle.

The *lateral portions* of the plantar fascia are thinner than the central piece, and cover the sides of the foot.

The *outer portion* covers the under surface of the Abductor minimi digiti; it is thick behind, thin in front, and extends from the os calcis, forward, to the base of the fifth metatarsal bone, into the outer side of which it is attached; it is continuous internally with the middle portion of the plantar fascia, and externally with the dorsal fascia.

The *inner portion* is very thin, and covers the Abductor hallucis muscle; it is attached behind to the internal annular ligament, and is continuous around the side of the foot with the dorsal fascia, and externally with the middle portion of the plantar fascia.

8. Dorsal Region.

Extensor brevis digitorum.

The **Fascia** on the dorsum of the foot is a thin membranous layer continuous above with the anterior margin of the annular ligament; it becomes gradually lost opposite the heads of the metatarsal bones, and on each side blends with the

lateral portions of the plantar fascia; it forms a sheath for the tendons placed on the dorsum of the foot. On the removal of this fascia the muscles and tendons of the dorsal region of the foot are exposed.

The **Extensor brevis digitorum** (Fig. 258) is a broad thin muscle which arises from the fore part of the upper and outer surfaces of the os calcis, in front of the groove for the Peroneus brevis, from the external calcaneo-astragaloid ligament, and from the common limb of the Y-shaped portion of the anterior annular ligament. It passes obliquely across the dorsum of the foot, and terminates in four tendons. The innermost, which is the largest, is inserted into the dorsal surface of the base of the first phalanx of the great toe, crossing the Dorsalis pedis artery; the other three, into the outer sides of the long extensor tendons of the second, third, and fourth toes.

Relations.—By its *superficial surface*, with the fascia of the foot, the tendons of the Extensor longus digitorum and Peroneus tertius; by its *deep surface*, with the tarsal and metatarsal arteries and bones and the Dorsal interossei muscles.

Nerves.—It is supplied by the anterior tibial nerve.

Actions.—The Extensor brevis digitorum is an accessory to the long Extensor, extending the phalanges of the four inner toes, but acting only on the first phalanx of the great toe. The obliquity of its direction counteracts the oblique movement given to the toes by the long Extensor, so that, both muscles acting together, the toes are evenly extended.

9. Plantar Region.

The muscles in the plantar region of the foot may be divided into three groups, in a similar manner to those in the hand. Those of the internal plantar region are connected with the great toe, and correspond with those of the thumb; those of the external plantar region are connected with the little toe, and correspond with those of the little finger; and those of the middle plantar region are connected with the tendons intervening between the two former groups. But in order to facilitate the dissection of these muscles it will be found more convenient to divide them into four layers, as they present themselves, in the order in which they are successively exposed.

First Layer.

Abductor hallucis. Flexor brevis digitorum.
Abductor minimi digiti.

Dissection.—Remove the fascia on the inner and outer sides of the foot, commencing in front over the tendons and proceeding backward. The central portion should be divided transversely in the middle of the foot, and the two flaps dissected forward and backward.

The **Abductor hallucis** lies along the inner border of the foot. It arises from the inner tubercle on the under surface of the os calcis; from the internal annular ligament; from the plantar fascia; and from the intermuscular septum between it and the Flexor brevis digitorum. The fibres terminate in a tendon which is inserted, together with the innermost tendon of the Flexor brevis hallucis, into the inner side of the base of the first phalanx of the great toe.

Relations.—By its *superficial surface*, with the plantar fascia; by its *deep surface*, with the Flexor brevis hallucis, the Flexor accessorius, and the tendons of the Flexor longus digitorum and Flexor longus hallucis, the Tibialis anticus and posticus, the plantar vessels and nerves. Its outer border is in relation to the Flexor brevis digitorum.

The **Flexor brevis digitorum** (*perforatus*) lies in the middle of the sole of the foot, immediately beneath[1] the plantar fascia, with which it is firmly united. It arises by a narrow tendinous process, from the inner tubercle

[1] That is, in order of dissection of the sole of the foot.

of the os calcis, from the central part of the plantar fascia, and from the intermuscular septa between it and the adjacent muscles. It passes forward, and divides into four tendons, one for each of the four outer toes. Opposite the bases of the first phalanges each tendon divides into two slips, to allow of the passage of the corresponding tendon of the Flexor longus digitorum; the two portions of the tendon then unite and form a grooved channel for the reception of the accompanying long flexor tendon. Finally, they divide a second time, to be inserted into the sides of the second phalanges about their middle. The mode of division of the tendons of the Flexor brevis digitorum and their insertion into the phalanges is analogous to the Flexor sublimis digitorum in the hand.

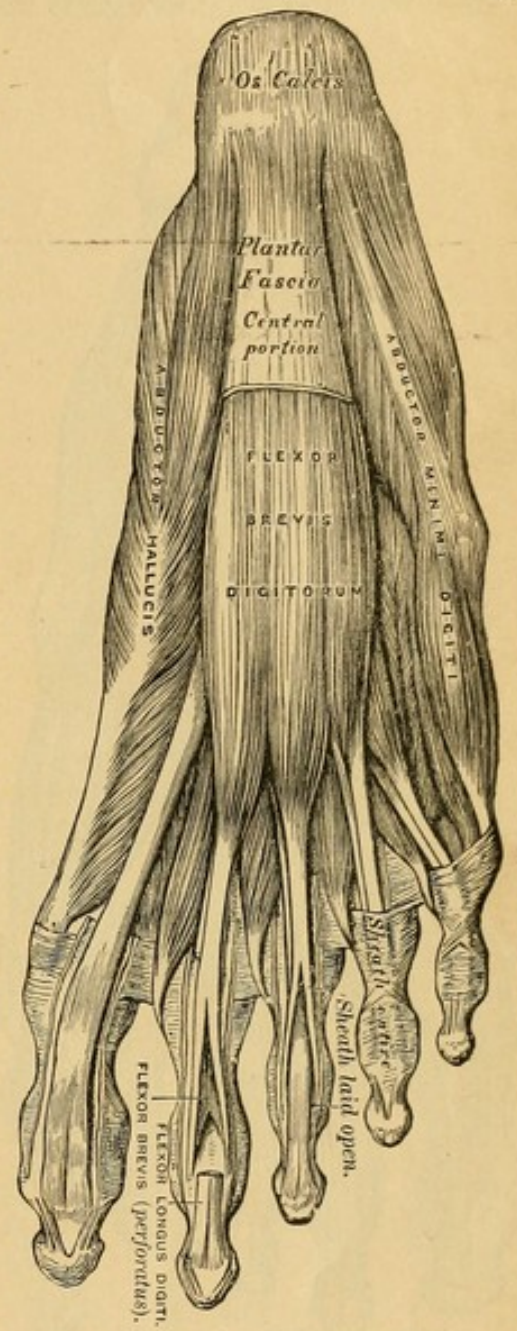

FIG. 261.—Muscles of the sole of the foot. First Layer.

Relations.—By its *superficial surface*, with the plantar fascia; by its *deep surface*, with the Flexor accessorius, the Lumbricales, the tendons of the Flexor longus digitorum, and the external plantar vessels and nerve, from which it is separated by a thin layer of fascia. The *outer* and *inner borders* are separated from the adjacent muscles by means of vertical prolongations of the plantar fascia.

Fibrous Sheaths of the Flexor Tendons.—These are not so well marked as in the fingers. The flexor tendons of the toes as they run along the phalanges are retained against the bones by a fibrous sheath, forming osseo-aponeurotic canals. These sheaths are formed by strong fibrous bands which arch across the tendons and are attached on each side to the margins of the phalanges. Opposite the middle of the proximal and second phalanges the sheath is very strong, and the fibres pass transversely, but opposite the joints it is much thinner, and the fibres pass obliquely. Each sheath is lined by a synovial membrane which is reflected on the contained tendon.

The **Abductor minimi digiti** lies along the outer border of the foot. It arises, by a very broad origin, from the outer tubercle of the os calcis, from the under surface of the os calcis between the two tubercles, from the fore part of the inner tubercle, from the plantar fascia and the intermuscular septum, between it and the Flexor brevis digitorum. Its tendon, after gliding over a smooth facet on the under surface of the base of the fifth metatarsal bone, is inserted with the short Flexor of the little toe into the outer side of the base of the first phalanx of this toe.

Relations.—By its *superficial surface*, with the plantar fascia; by its *deep surface*, with the Flexor accessorius, the Flexor brevis minimi digiti, the long plantar ligament, and the tendon of the Peroneus longus. On its *inner side* are the external plantar vessels and nerve, and it is separated from the Flexor brevis digitorum by a vertical septum of fascia.

Dissection.—The muscles of the superficial layer should be divided at their origin by inserting the knife beneath each, and cutting obliquely backward, so as to detach them from the bone; they should then be drawn forward, in order to expose the second layer, but not cut

away at their insertion. The two layers are separated by a thin membrane, the *deep plantar fascia*, on the removal of which is seen the tendon of the Flexor longus digitorum, the Flexor accessorius, the tendon of the Flexor longus hallucis, and the Lumbricales. The long flexor tendons diverge from each other at an acute angle; the Flexor longus hallucis runs along the inner side of the foot, on a plane superior to that of the Flexor longus digitorum, the direction of which is obliquely outward.

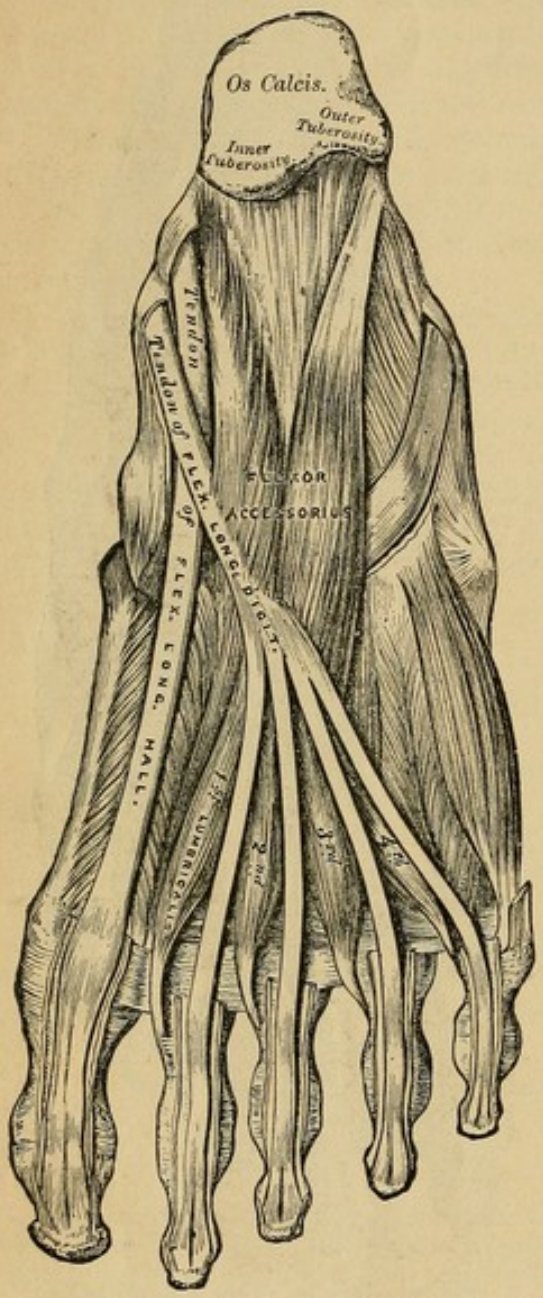

FIG. 262.—Muscles of the sole of the foot. Second layer.

Second Layer.

Flexor accessorius. Lumbricales.

The **Flexor accessorius** arises by two heads, which are separated from each other by the long plantar ligament: the inner or larger, which is muscular, being attached to the inner concave surface of the os calcis below the groove which lodges the tendon of the Flexor longus hallucis; the outer head, flat and tendinous, to the outer surface of the os calcis, in front of its lesser tubercle, and to the long plantar ligament; the two portions join at an acute angle, and are inserted into the outer margin and upper and under surfaces of the tendon of the Flexor longus digitorum, forming a kind of groove in which the tendon is lodged.[1]

Relations.—By its *superficial surface*, with the muscles of the superficial layer, from which it is separated by the external plantar vessels and nerves; by its *deep surface*, with the os calcis and long calcaneo-cuboid ligament.

The **Lumbricales** are four small muscles accessory to the tendons of the Flexor longus digitorum: they arise from the tendons of the long Flexor, as far back as their angle of division, each arising from two tendons, except the internal one. Each muscle terminates in a tendon, which passes forward on the inner side of the four lesser toes, and is inserted into the expansion of the long Extensor tendon on the dorsum of the first phalanx of the corresponding toe.

Dissection.—The flexor tendons should be divided at the back part of the foot, and the Flexor accessorius at its origin, and drawn forward, in order to expose the third layer.

Third Layer.

Flexor brevis hallucis.
Adductor obliquus hallucis.
Flexor brevis minimi digiti.
Adductor transversus hallucis.

The **Flexor brevis hallucis** arises, by a pointed tendinous process, from the inner part of the under surface of the cuboid bone, from the contiguous portion of the external cuneiform, and from the prolongation of the tendon of the Tibialis

[1] According to Turner, the fibres of the Flexor accessorius end in aponeurotic bands, which contribute slips to the second, third, and fourth digits.

posticus, which is attached to that bone. The muscle divides, in front, into two portions, which are inserted into the inner and outer sides of the base of the first phalanx of the great toe, a sesamoid bone being developed in each tendon at its insertion. The inner portion of this muscle is blended with the Abductor hallucis previous to its insertion, the outer with the Adductor obliquus hallucis, and the tendon of the Flexor longus hallucis lies in a groove between them.

Relations.—By its *superficial surface*, with the Abductor hallucis and the tendon of the Flexor longus hallucis; by its *deep surface*, with the tendon of the Peroneus longus and metatarsal bone of the great toe; by its *inner border*, with the Abductor hallucis; by its *outer border*, with the Adductor obliquus hallucis.

The **Adductor obliquus hallucis** is a large, thick, fleshy mass passing obliquely across the foot and occupying the hollow space between the four inner metatarsal bones. It arises from the tarsal extremities of the second, third and fourth metatarsal bones, and from the sheath of the tendon of the Peroneus longus, and is inserted, together with the outer portion of the Flexor brevis hallucis, into the outer side of the base of the first phalanx of the great toe.

The small muscles of the great toe, the Abductor, Flexor brevis, Adductor obliquus, and Adductor transversus, like the similar muscles of the thumb, give off fibrous expansions, at their insertions, to blend with the long Extensor tendon.

The **Flexor brevis minimi digiti** lies on the metatarsal bone of the little toe, and much resembles one of the Interossei. It arises from the base of the metatarsal bone of the little toe, and from the sheath of the Peroneus longus; its tendon is inserted into the base of the first phalanx of the little toe on its outer side. Occasionally some of the deeper fibres of the muscle are inserted into the outer part of the distal half of the fifth metatarsal bone; these are described by some as a distinct muscle, the Opponens minimi digiti.

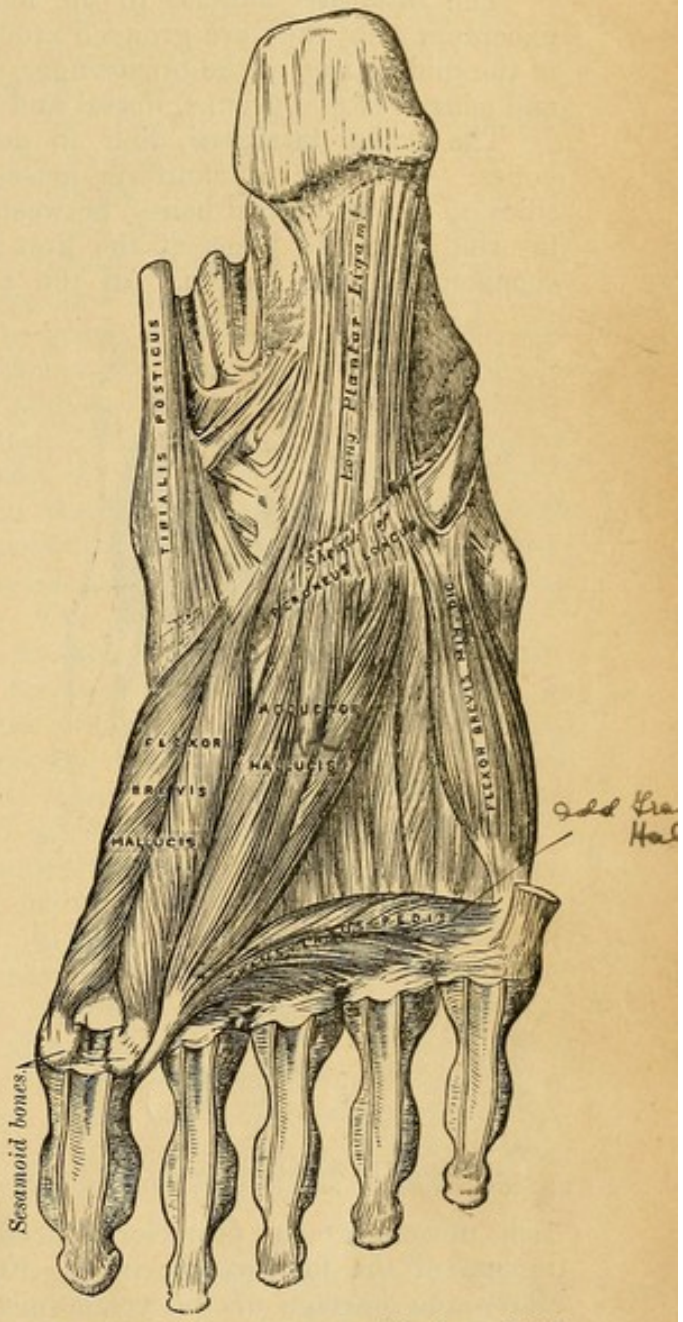

FIG. 263.—Muscles of the sole of the foot. Third layer.

Relations.—By its *superficial surface*, with the plantar fascia and tendon of the Abductor minimi digiti; by its *deep surface*, with the fifth metatarsal bone.

The **Adductor transversus hallucis** (*Transversus pedis*) is a narrow, flat, muscular fasciculus, stretched transversely across the heads of the metatarsal bones, between them and the flexor tendons. It arises from the inferior metatarso-phalangeal ligaments of the three outer toes, sometimes only from the third and fourth and from the transverse ligament of the metatarsus; and is inserted into the outer side of the first phalanx of the great toe, its fibres being blended with the tendon of insertion of the Adductor obliquus hallucis.

Relations.—By its *superficial surface*, with the tendons of the long and short Flexors and Lumbricales; by its *deep surface*, with the Interossei.

Fourth Layer.

The Interossei.

The **Interossei muscles** in the foot are similar to those in the hand, with this exception, that they are grouped around the middle line of the *second* toe, instead of the middle line of the *third* finger, as in the hand. They are seven in number, and consist of two groups, dorsal and plantar.

The **Dorsal interossei,** four in number, are situated between the metatarsal bones. They are bipenniform muscles, arising by two heads from the adjacent sides of the metatarsal bones, between which they are placed; their tendons are inserted into the bases of the first phalanges, and into the aponeurosis of the common extensor tendon. In the angular interval left between the heads of

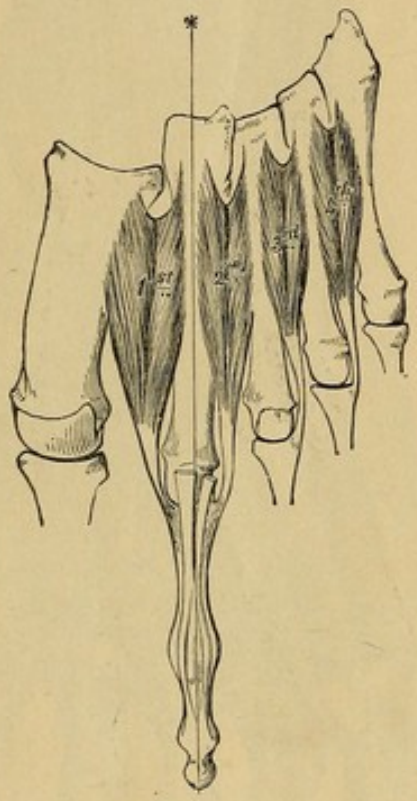

FIG. 264.—The Dorsal interossei. Left foot.

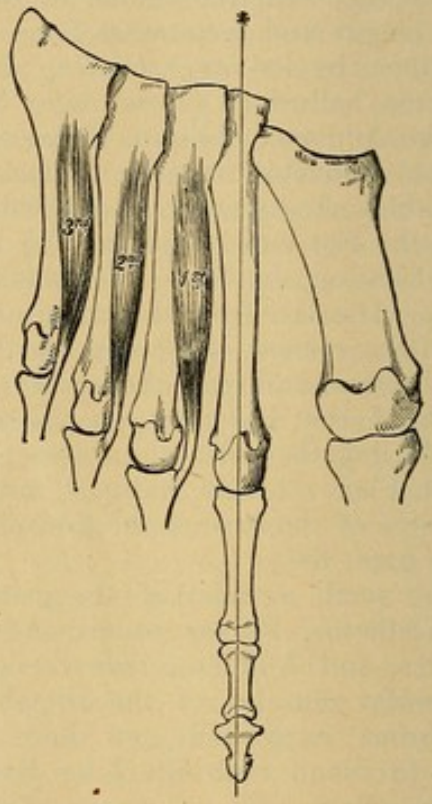

FIG. 265.—The Plantar interossei. Left foot.

each muscle at its posterior extremity the perforating arteries pass to the dorsum of the foot, except in the First interosseous muscle, where the interval allows the passage of the communicating branch of the dorsalis pedis artery. The First dorsal interosseous muscle is inserted into the inner side of the second toe; the other three are inserted into the outer sides of the second, third, and fourth toes.

The **Plantar interossei,** three in number, lie beneath, rather than between, the metatarsal bones. They are single muscles, and are each connected with but one metatarsal bone. They arise from the base and inner sides of the shaft of the third, fourth, and fifth metatarsal bones, and are inserted into the inner sides of the bases of the first phalanges of the same toes, and into the aponeurosis of the common extensor tendon.

Nerves.—The Flexor brevis digitorum, the Flexor brevis and Abductor hallucis, and the innermost Lumbrical[1] are supplied by the internal plantar nerve. All

[1] Formerly the two inner Lumbricales were described as being supplied by the internal plantar nerve. Brooks, however (*Journal of Anatomy*, vol. xxi., p. 575), in ten dissections found that in nine of them only the inner Lumbrical obtained its nerve supply from this source. In the tenth instance the first and second Lumbricales were supplied by both external and internal plantar.

the other muscles in the sole of the foot by the external plantar. The first dorsal interosseous muscle frequently receives an extra filament from the internal branch of the anterior tibial nerve on the dorsum of the foot, and the second dorsal interosseous a twig from the external branch of the same nerve.

Actions.—All the muscles of the foot act upon the toes, and for purposes of description as regards their action may be grouped as Abductors, Adductors, Flexors, or Extensors. The *Abductors* are the Dorsal interossei, the Abductor hallucis, and the Abductor minimi digiti. The Dorsal interossei are abductors from an imaginary line passing through the axis of the second toe, so that the first muscle draws the second toe inward, toward the great toe; the second muscle draws the same toe, outward; the third draws the third toe, and the fourth draws the fourth toe, in the same direction. Like the interossei in the hand, they also flex the proximal phalanges and extend the two terminal phalanges. The Abductor hallucis abducts the great toe from the others, and also flexes the proximal phalanx of this toe. And in the same way the action of the Abductor minimi digiti is twofold—as an abductor of this toe from the others, and also as a flexor of the proximal phalanx. The *Adductors* are the Plantar interossei, the Adductor obliquus hallucis, and the Adductor transversus hallucis. The plantar interosseous muscles adduct the third, fourth, and fifth toes toward the imaginary line passing through the second toe, and by means of their insertion into the aponeurosis of the extensor tendon they flex the proximal phalanges and extend the two terminal phalanges. The Adductor obliquus hallucis is chiefly concerned in adducting the great toe toward the second one, but also assists in flexing this toe. The Adductor transversus hallucis approximates all the toes, and thus increases the curve of the transverse arch of the metatarsus. The *Flexors* are the Flexor brevis digitorum, the Flexor accessorius, the Flexor brevis hallucis, the Flexor brevis minimi digiti, and the Lumbricales. The Flexor brevis digitorum flexes the second phalanges upon the first, and, continuing its action, may flex the first phalanges also and bring the toes together. The Flexor accessorius assists the Long flexor of the toes, and converts the oblique pull of the tendons of that muscle into a direct backward pull upon the toes. The Flexor brevis minimi digiti flexes the little toe and draws its metatarsal bone downward and inward. The Lumbricales, like the corresponding muscles in the hand, assist in flexing the proximal phalanx, and by their insertion into the long Extensor tendon aid in straightening the two terminal phalanges. The only muscle in the *Extensor* group is the Extensor brevis digitorum. It extends the first phalanx of the great toe, and assists the long Extensor in extending the next three toes, and at the same time gives to the toes an outward direction when they are extended.

Surface Form.—Of the muscles of the thigh, those of the iliac region have no influence on surface form, while those of the anterior femoral region, being to a great extent superficial, largely contribute to the surface form of this part of the body. The *Tensor fasciæ femoris* produces a broad elevation immediately below the anterior portion of the crest of the ilium and behind the anterior superior spinous process. From its lower border a longitudinal groove, corresponding to the ilio-tibial band, may be seen running down the outer side of the thigh to the outer side of the knee-joint. The *Sartorius* muscle, when it is brought into action by flexing the leg on the thigh and the thigh on the pelvis, and rotating the thigh outward, presents a well-marked surface form. At its upper part, where it constitutes the outer boundary of Scarpa's triangle, it forms a prominent oblique ridge, which becomes changed into a flattened plane below, and this gradually merges in a general fulness on the inner side of the knee-joint. When the Sartorius is not in action, a depression exists between the Extensor quadriceps and the Adductor muscles, running obliquely downward and inward from the apex of Scarpa's triangle to the inner side of the knee, which corresponds to this muscle. In the depressed angle formed by the divergence of the Sartorius and Tensor fasciæ femoris muscles, just below the anterior superior spinous process of the ilium, the *Rectus femoris muscle* appears, and, below this, determines to a great extent the convex form of the front of the thigh. In a well-developed subject the borders of the muscle, when in action, are clearly to be defined. The *Vastus externus* forms a long flattened plane on the outer side of the thigh, traversed by the longitudinal groove formed by the ilio-tibial band. The *Vastus internus*, on the inner side of the lower half of the thigh, gives rise to a considerable prominence, which increases toward

the knee and terminates somewhat abruptly in this situation with a full, curved outline. The *Crureus* and *Subcrureus* are completely hidden, and do not directly influence surface form. The *Adductor muscles*, constituting the internal femoral group, are not to be individually distinguished from each other, with the exception of the upper tendon of the Adductor longus and the lower tendon of the Adductor magnus. The upper tendon of the *Adductor longus*, when the muscle is in action, stands out as a prominent ridge, which runs obliquely downward and outward from the neighborhood of the pubic spine, and forms the inner boundary of a flattened triangular space on the upper part of the front of the thigh, known as Scarpa's triangle. The lower tendon of the *Adductor magnus* can be distinctly felt as a short ridge extending down to the Adductor tubercle on the internal condyle, between the Sartorius and Vastus internus. The Adductor group of muscles fills in the triangular space at the upper part of the thigh, formed between the oblique femur and the pelvic wall, and to them is due the contour of the inner border of the thigh, the *Gracilis* largely contributing to the smoothness of the outline. These muscles are not marked off on the surface from those of the posterior femoral region by any intermuscular marking; but on the outer side of the thigh these latter muscles are defined from the Vastus externus by a distinct marking, corresponding to the external intermuscular septum. The *Gluteus maximus* and a part of the *Gluteus medius* are the only muscles of the buttock which influence surface form. The other part of the Gluteus medius, the Gluteus minimus, and the External rotators are completely hidden. The *Gluteus maximus* forms the full rounded outline of the buttock; it is more prominent behind, compressed in front, and terminates at its tendinous insertion in a depression immediately behind the great trochanter. Its lower border does not correspond to the gluteal fold, but is much more oblique, being marked by a line drawn from the side of the coccyx to the junction of the upper with the lower two-thirds of the thigh on the outer side. From beneath the lower margin of this muscle the *hamstring muscles* appear, at first narrow and not well marked, but as they descend becoming more prominent and widened out, and eventually dividing into two well-marked ridges, which constitute the upper boundaries of the popliteal space, and are formed by the tendons of the inner and outer hamstring muscles respectively. In the upper part of the thigh these muscles are not to be individually distinguished from each other, but lower down the separation between the Semitendinosus and Semimembranosus is denoted by a slight intermuscular marking. The external hamstring tendon formed by the *Biceps* is seen as a thick cord running down to the head of the fibula. The inner hamstring tendons comprise the Semitendinosus, the Semimembranosus, and the Gracilis. The *Semitendinosus* is the most internal of these, and can be felt, in certain positions of the limb, as a sharp cord; the *Semimembranosus* is thick, and the *Gracilis* is situated a little farther forward than the other two. All the muscles on the front of the leg appear to a certain extent somewhere on the surface, but the form of this region is mainly dependent upon the Tibialis anticus and the Extensor longus digitorum. The *Tibialis anticus* is well marked, and presents a fusiform enlargement at the outer side of the tibia, and projects beyond the crest of the shin-bone. From the muscular mass its tendon may be traced downward, standing out boldly, when the muscle is in action, on the front of the tibia and ankle-joint, and coursing down to its insertion along the inner border of the foot. A well-marked groove separates this muscle externally from the *Extensor longus digitorum*, which fills up the rest of the space between the upper part of the shaft of the tibia and fibula. It does not present so bold an outline as the Tibialis anticus, and its tendon below, diverging from the tendon of the Tibialis anticus, forms with the latter a sort of plane, in which may be seen the tendon of the Extensor proprius hallucis. A groove on the outer side of the Extensor longus digitorum, seen most plainly when the muscle is in action, separates the tendon from a slight eminence corresponding to the *Peroneus tertius*. The fleshy fibres of the *Peroneus longus* are strongly marked at the upper part of the outer side of the leg, especially when the muscle is in action. It forms a bold swelling, separated by furrows from the Extensor longus digitorum in front and the Soleus behind. Below, the fleshy fibres terminate abruptly in a tendon which overlaps the more flattened form of the *Peroneus brevis*. At the external malleolus the tendon of the Peroneus brevis is more marked than that of the Peroneus longus. On the dorsum of the foot the tendons of the Extensor muscles, emerging from beneath the anterior annular ligament, spread out and can be distinguished in the following order: The most internal and largest is the Tibialis anticus, then the Extensor proprius hallucis: next comes the Extensor longus digitorum, dividing into four tendons to the four outer toes; and lastly, most externally, is the Peroneus tertius. The flattened form of the dorsum of the foot is relieved by the rounded outline of the fleshy belly of the *Extensor brevis digitorum*, which forms a soft fulness on the outer side of the tarsus in front of the external malleolus, and by the Dorsal interossei, which bulge between the metatarsal bones. At the back of the knee is the popliteal space, bounded above by the tendons of the hamstring muscle; below, by the two heads of the Gastrocnemius. Below this space is the prominent fleshy mass of the calf of the leg, produced by the *Gastrocnemius* and *Soleus*. When these muscles are in action, as in standing on tiptoe, the borders of the Gastrocnemius are well defined, presenting two curved lines, which converge to the tendon of insertion. Of these borders, the inner is more prominent than the outer. The fleshy mass of the calf terminates somewhat abruptly below in the tendo Achillis, which stands out prominently on the lower part of the back of the leg. It presents a somewhat tapering form in the upper three-fourths of its extent, but widens out slightly below. When the muscles of the calf are in action, the lateral portions of the *Soleus* may be seen, forming

curved eminences, of which the outer is the longer, on either side of the Gastrocnemius. Behind the inner border of the lower part of the shaft of the tibia a well-marked ridge, produced by the tendon of the Tibialis posticus, is visible when this muscle is in a state of contraction.

On the sole of the foot the superficial layer of muscles influences surface form; the *Abductor minimi digiti* most markedly. This muscle forms a narrow rounded elevation along the outer border of the foot, while the *Abductor hallucis* does the same, though to a less extent, on the inner side. The *Flexor brevis digitorum*, bound down by the plantar fascia, is not very apparent; it produces a flattened form, covered by the thickened skin of the sole, which is here thrown into numerous wrinkles.

SURGICAL ANATOMY OF THE LOWER EXTREMITY.

The student should now consider the effects produced by the action of the various muscles in fractures of the bones of the lower extremity. The more common forms of fractures are selected for illustration and description.

In fracture of the *neck of the femur internal to the capsular ligament* (Fig. 266) the characteristic marks are slight shortening of the limb and eversion of the foot, neither of which symptoms occurs, however, in some cases until some time after

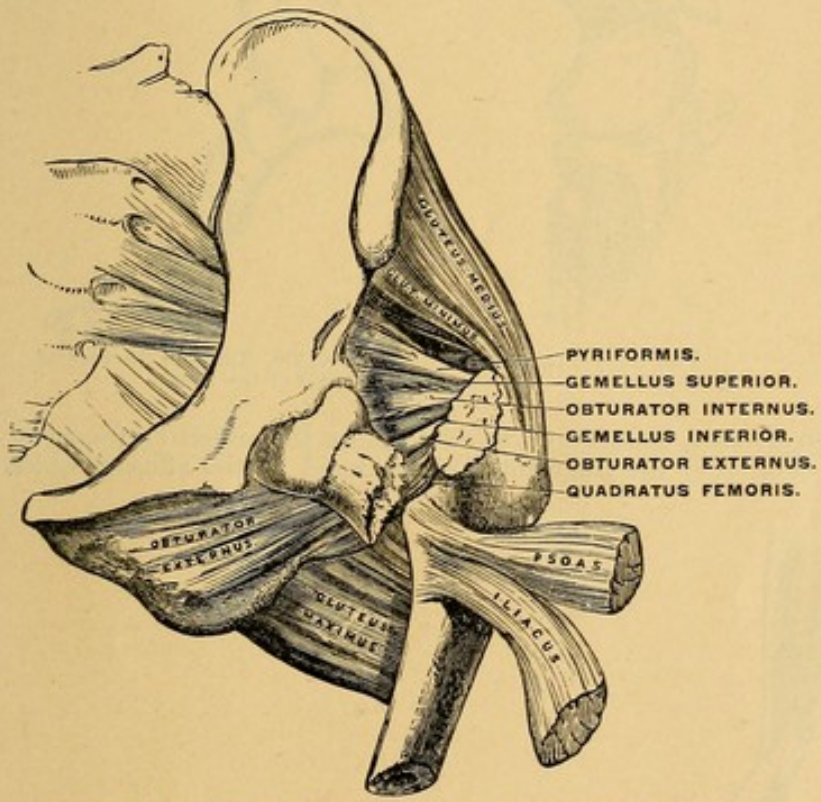

FIG. 266.—Fracture of the neck of the femur within the capsular ligament.

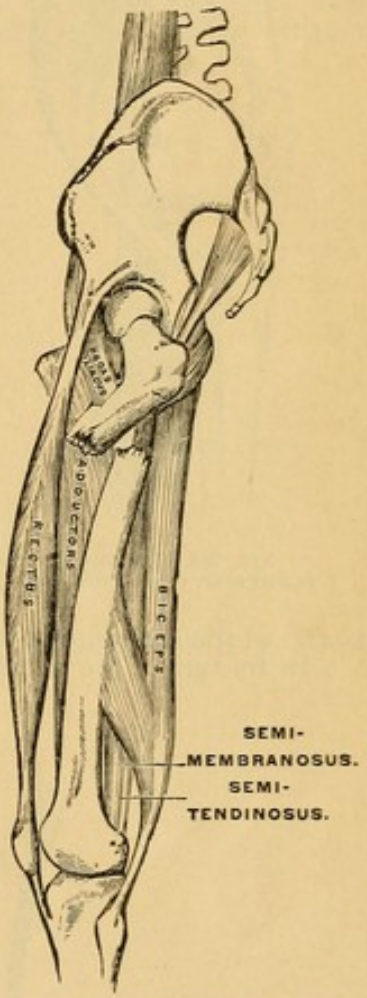

FIG. 267.—Fracture of the femur below the trochanters.

the injury. The eversion is caused by the weight of the limb rotating it outward. The shortening is produced by the action of the Glutei, and by the Rectus femoris in front and the Biceps, Semitendinosus, and Semimembranosus behind.

In fracture of the *femur just below the trochanters* (Fig. 267), the upper fragment, the portion chiefly displaced, is tilted forward almost at right angles with the pelvis by the combined action of the Psoas and Iliacus, and, at the same time, everted and drawn outward by the External rotator and Glutei muscles, causing a marked prominence at the upper and outer side of the thigh, and much pain from the bruising and laceration of the muscles. The limb is shortened, in consequence of the lower fragment being drawn upward by the Rectus in front, and the Biceps, Semimembranosus, and Semitendinosus behind, and is at the same time everted. This fracture may be reduced in two different methods: either by direct relaxation of all the opposing muscles, to effect which the limb should be put up in such a manner that the thigh is flexed on the pelvis and the leg on the thigh; or by overcoming the contraction of the muscles by continued extension, which may be effected by means of the long splint.

Oblique fracture of the femur *immediately above the condyles* (Fig. 268) is a formidable

injury, and attended with considerable displacement. On examination of the limb the lower fragment may be felt deep in the popliteal space, being drawn backward by the Gastrocnemius and Plantaris muscles, and upward by the Hamstring and Rectus muscles. The pointed end of the upper fragment is drawn inward by the Pectineus and Adductor muscles, and tilted forward by the Psoas and Iliacus, piercing the Rectus muscle and occasionally the integument. Relaxation of these muscles and direct approximation of the broken fragments are effected by placing the limb on a double inclined plane. The greatest care is requisite in keeping the pointed extremity of the upper fragment in proper position; otherwise, after union of the fracture, the power of extension of the limb is partially destroyed, from the Rectus muscle being held down by the fractured end of the

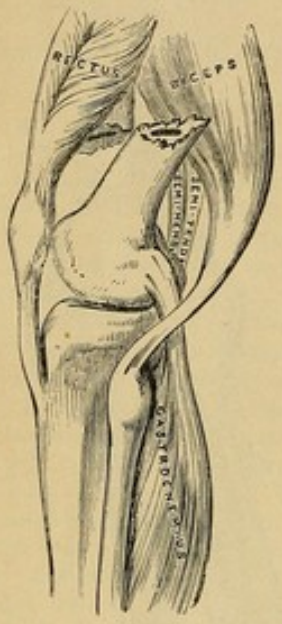

FIG. 268.—Fracture of the femur above the condyles.



FIG. 269.—Fracture of the patella.

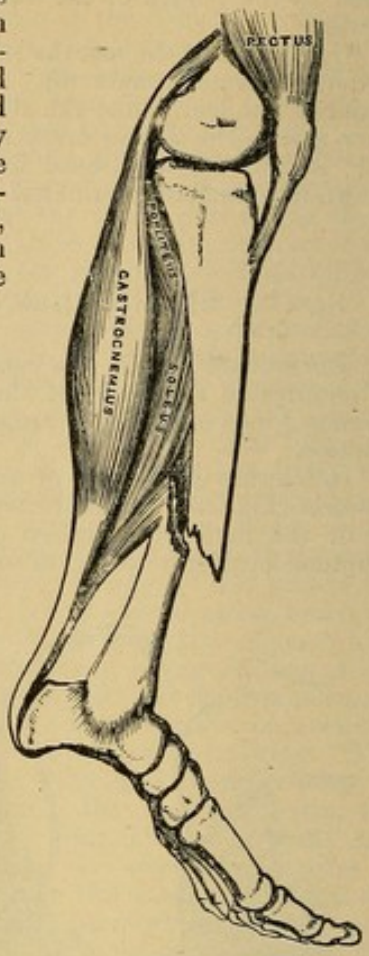

FIG. 270.—Oblique fracture of the shaft of the tibia.

bone, and from the patella, when elevated, being drawn upward against the projecting fragment.

In fracture of the *patella* (Fig. 269) the fragments are separated by the effusion which

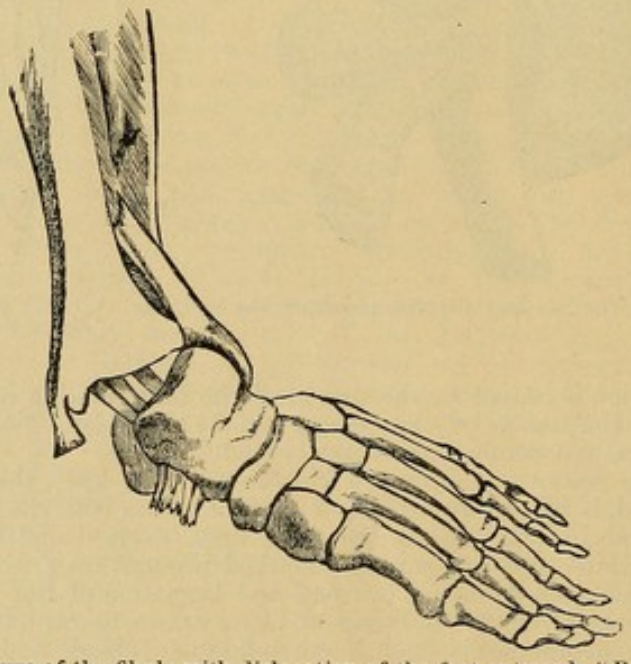

FIG. 271.—Fracture of the fibula with dislocation of the foot outward—"Pott's fracture."

takes place into the joint, and possibly by the action of the Quadriceps extensor; the extent of separation of the two fragments depending upon the degree of laceration of the ligamentous structures around the bone.

In oblique fracture of the *shaft of the tibia* (Fig. 270), if the fracture has taken place obliquely from above, downward and forward, the fragments ride over one another, the lower fragments being drawn backward and upward by the powerful action of the muscles of the calf; the pointed extremity of the upper fragment projects forward immediately beneath the integument, often protruding through it and rendering the fracture a compound one. If the direction of the fracture is the reverse of that shown in the figure, the pointed extremity of the lower fragment projects forward, riding upon the lower end of the upper one. By bending the knee, which relaxes the opposing muscles, and making extension from the ankle and counter-extension at the knee, the fragments may be brought into apposition. It is often necessary, however, in compound fracture, to remove a portion of the projecting bone with the saw before complete adaptation can be effected.

Fracture of the *fibula with dislocation of the foot outward* (Fig. 271), commonly known as "Pott's fracture," is one of the most frequent injuries of the ankle-joint. The fibula is fractured about three inches above the ankle; in addition to this the internal malleolus is broken off, or the deltoid ligament torn through, and the end of the tibia displaced from the corresponding surface of the astragalus. The foot is markedly everted, and the sharp edge of the upper end of the fractured malleolus presses strongly against the skin; at the same time, the heel is drawn up by the muscles of the calf. This injury can generally be reduced by flexing the leg at right angles with the thigh, which relaxes all the opposing muscles, and by making extension from the ankle and counter-extension at the knee.

THE BLOOD-VASCULAR SYSTEM.

THE blood-vascular system comprises the heart and blood-vessels with their contained fluid, the blood. The composition of the blood and the minute anatomy of the blood-vessels will be considered in the section on Histology.

The Heart is the central organ of the entire system, and consists of a hollow muscle; by its contraction the blood is pumped to all parts of the body through a complicated series of tubes, termed *arteries*. The arteries undergo enormous ramification in their course throughout the body, and end in very minute vessels, called *arterioles*, which in their turn open into a close-meshed network of microscopic vessels, termed *capillaries*. After the blood has passed through the capillaries it is collected into a series of larger vessels, called *veins*, by which it is again returned to the heart. The passage of the blood through the heart and blood-vessels constitutes what is termed the *circulation* of the blood, of which the following is an outline.

The human heart is divided by a septum into two halves, right and left, each half being further constricted into two cavities, the upper of the two being termed the *auricle* and the lower the *ventricle*. The heart therefore consists of four chambers or cavities, two forming the right half, the right auricle and right ventricle, and two the left half, the left auricle and left ventricle. The right half of the heart contains venous or impure blood; the left, arterial or pure blood. From the cavity of the left ventricle the pure blood is carried into a large artery, the *aorta*, through the numerous branches of which it is distributed to all parts of the body, with the exception of the lungs. In its passage through the capillaries of the body the blood gives up to the tissues the materials necessary for their growth and nourishment, and at the same time receives from the tissues the waste products resulting from their metabolism, and in doing so becomes changed from arterial or pure blood into venous or impure blood, which is collected by the veins and through them returned to the right auricle of the heart. From this cavity the impure blood passes into the right ventricle, from which it is conveyed through the *pulmonary arteries* to the lungs. In the capillaries of the lungs it again becomes arterialized, and is then carried to the left auricle by the *pulmonary veins*. From this cavity it passes into that of the left ventricle, from which the cycle once more begins.

The course of the blood from the left ventricle through the body generally to the right side of the heart constitutes the greater or *systemic* circulation, while its passage from the right ventricle through the lungs to the left side of the heart is termed the lesser or *pulmonary* circulation.

It is necessary, however, to state that the blood which circulates through the spleen, pancreas, stomach, small intestine, and the greater part of the large intestine is not returned directly from these organs to the heart, but is collected into a large vein, termed the *portal vein*, by which it is carried to the liver. In the liver this vein divides, after the manner of an artery, and ultimately ends in capillary vessels, from which the rootlets of a series of veins, called the *hepatic veins*, arise; these carry the blood into the inferior vena cava, which conveys it to the right auricle.

From this it will be seen that the blood contained in the portal vein passes through two sets of capillary vessels: (1) those in the spleen, pancreas, stomach, etc., and (2) those in the liver.

Speaking generally, the arteries may be said to contain pure, and the veins impure, blood. This is true of the systemic, but not of the pulmonary, vessels, since it has been seen that the impure blood is conveyed from the heart to the lungs by the pulmonary arteries, and the pure blood returned from the lungs to the heart by the pulmonary veins. Arteries, therefore, must be defined as vessels which convey blood *from* the heart, and veins as vessels which return blood *to* the heart.

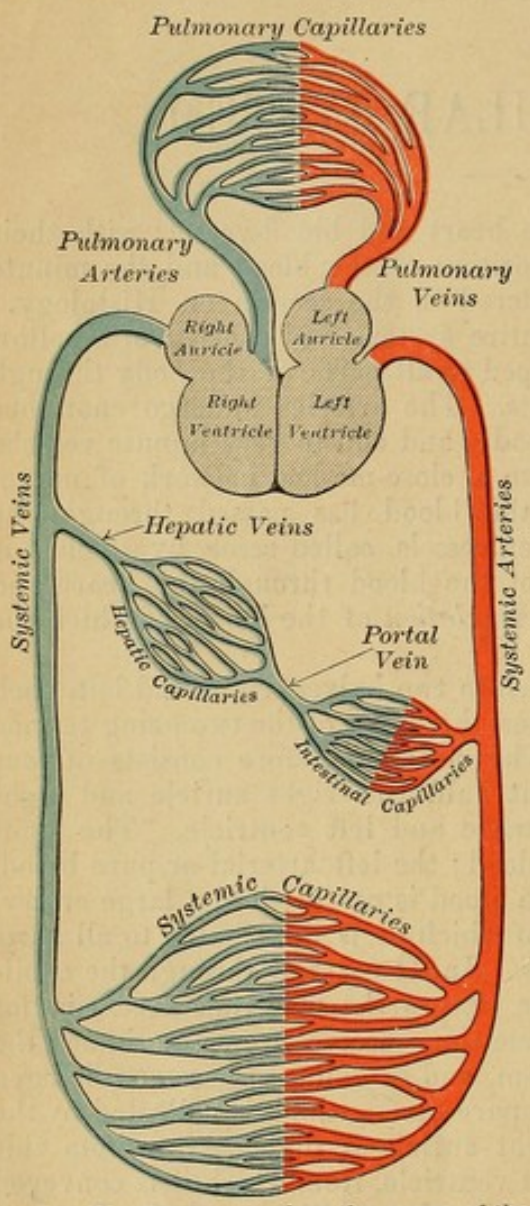

FIG. 272.—Diagram to show the course of the circulation of the blood.

The heart and lungs are contained within the cavity of the thorax, the walls of which afford them protection. The heart lies between the two lungs, and is there enclosed within a membranous bag, the *pericardium*, while each lung is invested by a serous membrane, the *pleura*. The skeleton of the thorax and the shape and boundaries of the cavity will be described in the section on General Anatomy.

The Cavity of the Thorax.—The capacity of the cavity of the thorax does not correspond with its apparent size externally, because (1) the space enclosed by the lower ribs is occupied by some of the abdominal viscera; and (2) the cavity extends above the first rib into the neck. The size of the cavity of the thorax is constantly varying during life with the movements of the ribs and Diaphragm, and with the degree of distention of the abdominal viscera. From the collapsed state of the lungs, as seen when the thorax is opened, in the dead body, it would appear as if the viscera only partly filled the cavity of the thorax, but during life there is no vacant space, that which is seen after death being filled up by the expanded lungs.

The Upper Opening of the Thorax.—The parts which pass through the upper opening of the thorax are, from before backward in or near the middle line, the Sterno-hyoid and Sterno-thyroid muscles, the remains of the thymus gland, the trachea, œsophagus, thoracic duct, the inferior thyroid veins, and the Longus colli muscle of each side; at the sides, the innominate artery, the left common carotid and left subclavian arteries, the internal mammary and superior intercostal arteries, the right and left innominate veins, the pneumogastric, cardiac, phrenic, and sympathetic nerves, the anterior branch of the first dorsal nerve, and the recurrent laryngeal nerve of the left side. The apex of each lung, covered by the pleura, also projects through this aperture, a little above the margin of the first rib.

The **Lower Opening of the Thorax** is wider transversely than from before backward. It slopes obliquely downward and backward, so that the cavity of the thorax is much deeper behind than in front. The Diaphragm (see page 325) closes in the opening, forming the floor of the thorax. The floor is flatter at the centre than at the sides, and is higher on the right side than on the left, corresponding in the dead body to the upper border of the fifth costal cartilage on the former, and to the corresponding part of the sixth costal cartilage on the latter. From the highest point on each side the floor slopes suddenly downward to the attachment

of the Diaphragm to the ribs; this is more marked behind than in front, so that only a narrow space is left between it and the wall of the thorax.

THE PERICARDIUM.

The **Pericardium** (Figs. 273, 274) is a conical membranous sac in which the heart and the commencement of the great vessels are contained. It is placed behind the sternum and the cartilages of the third, fourth, fifth, sixth, and seventh ribs of the left side, in the interval between the pleuræ.

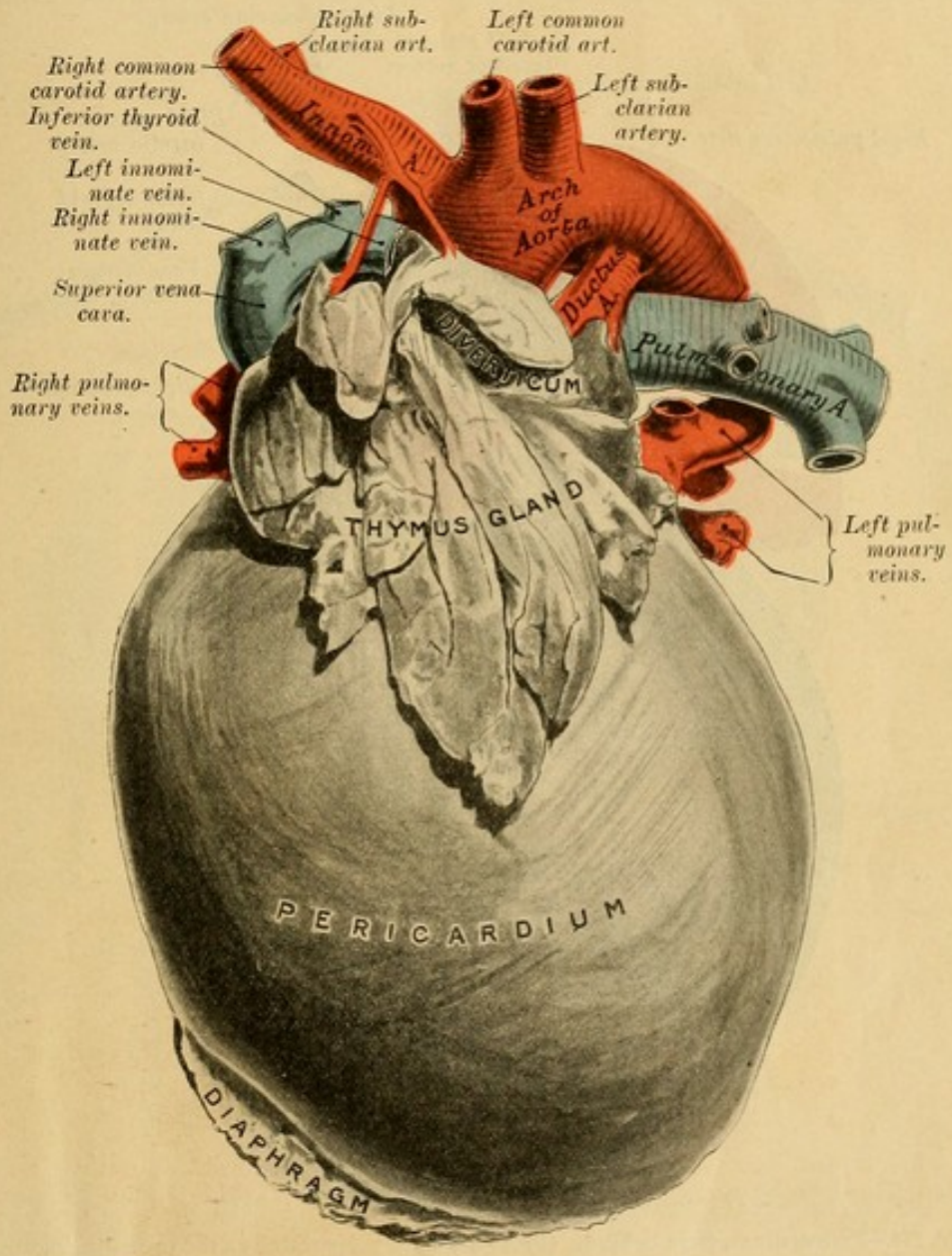

FIG. 273.—Pericardium, from in front. The sac has been distended with plaster. (From a preparation in the Museum of the Royal College of Surgeons of England.)

Its *apex* is directed upward, and surrounds the great vessels about two inches above their origin from the base of the heart. Its *base* is attached to the central tendon and to the left part of the adjoining muscular structure of the Diaphragm. *In front* it is separated from the sternum by the remains of the thymus gland above and a little loose areolar tissue below, and is covered by the margins of the lungs, especially the left. *Behind*, it rests upon the bronchi, the œsophagus, and the descending aorta. *Laterally*, it is covered by the pleuræ, and is in relation to the inner surface of the lungs; the phrenic nerve with its accompanying vessels descends between the pericardium and pleura on either side.

Structure of the Pericardium.—The pericardium is a fibro-serous membrane, and consists, therefore, of two layers, an external fibrous and an internal serous.

The *fibrous layer* is a strong, dense membrane. Above, it surrounds the great vessels arising from the base of the heart, on which it is continued in the form of tubular prolongations which are gradually lost upon their external coat, the strongest being that which encloses the aorta. The pericardium may be traced over these vessels, to become continuous with the deep layer of the cervical fascia. In front the pericardium is connected to the posterior surface of the sternum by two fibrous bands, the *superior* and *inferior sterno-pericardiac ligaments*, the upper

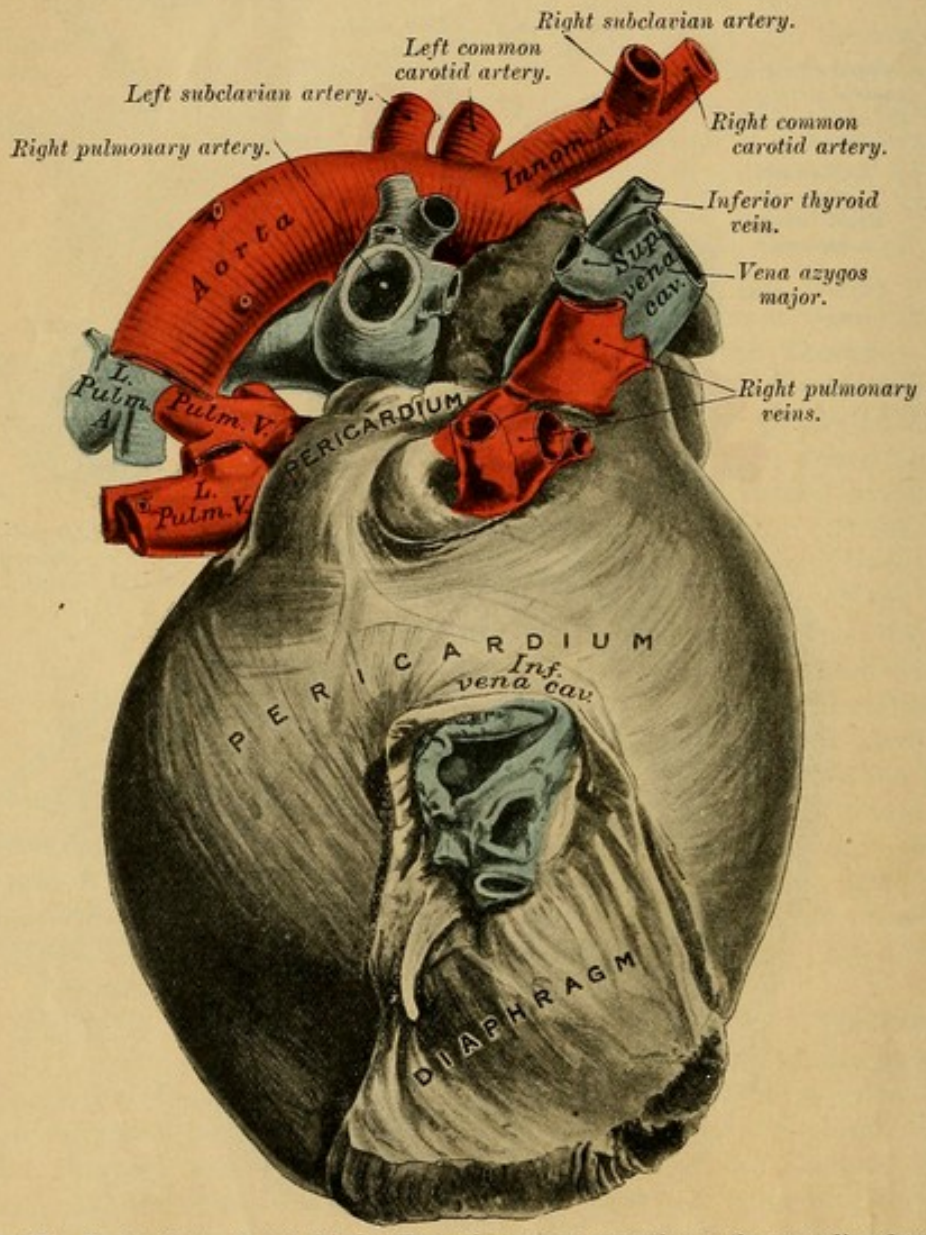

FIG. 274.—Pericardium, from behind. (From the same preparation as the preceding figure.)

passing to the manubrium, and the lower to the ensiform cartilage. On each side of the ascending aorta it sends upward a diverticulum: the one on the left side, somewhat conical in shape, passes upward and outward, between the arch of the aorta and the pulmonary artery, as far as the ductus arteriosus, where it terminates in a cæcal extremity, which is attached by loose connective tissue to the obliterated duct (Fig. 273). The one on the right side passes upward and to the right, between the ascending aorta and vena cava superior, and also terminates in a cæcal extremity. Below, the fibrous layer is attached to the central tendon of the Diaphragm, and on the left side to its muscular fibres.

The vessels receiving fibrous prolongations from this membrane are the aorta, the superior vena cava, the right and left pulmonary arteries, and the four pulmo-

nary veins. As the inferior vena cava enters the pericardium through the central tendon of the Diaphragm, it receives no covering from the *fibrous* layer.

The *serous layer* invests the heart, and is then reflected on the inner surface of the pericardium. It consists, therefore, of a visceral and parietal portion. The former invests the surface of the heart, and the commencement of the great vessels, to the extent of an inch and a half from their origin; from these it is reflected upon the inner surface of the fibrous layer, lining, below, the upper surface of the central tendon of the Diaphragm. The serous membrane encloses the aorta and pulmonary artery in a single tube, so that a passage, termed the *transverse sinus* of the pericardium, exists between these vessels in front and the auricles behind.

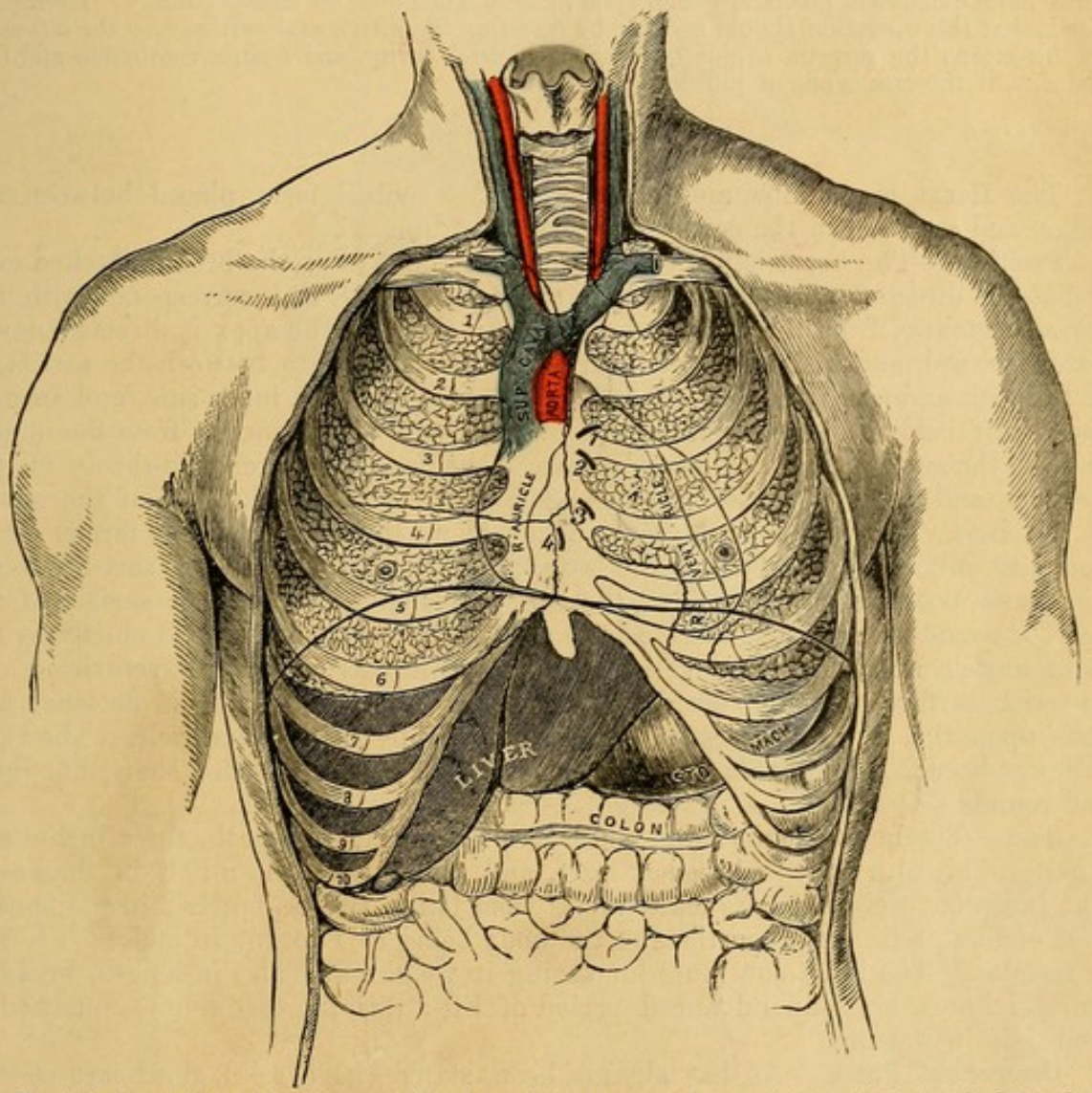

FIG. 275.—Front view of the thorax. The ribs and sternum are represented in relation to the lungs, heart, and other internal organs. 1. Pulmonary orifice. 2. Aortic orifice. 3. Left auriculo-ventricular orifice. 4. Right auriculo-ventricular orifice.

The membrane only partially covers the superior vena cava and the four pulmonary veins, and scarcely covers the inferior cava, as this vessel enters the heart almost directly after it has passed through the Diaphragm. Its inner surface is smooth and glistening, and secretes a serous fluid, which serves to facilitate the movements of the heart.

Arteries of the Pericardium.—These are derived from the internal mammary and its musculo-phrenic branch, and from the descending thoracic aorta.

Nerves of the Pericardium.—These are branches from the vagus, the phrenic, and the sympathetic.

The Vestigial Fold of the Pericardium.—Between the left pulmonary artery and subjacent pulmonary vein is a triangular fold of the serous pericardium; it is known

as the *vestigial fold of Marshall.* It is formed by the duplicature of the serous layer over the remnant of the lower part of the left superior cava (duct of Cuvier), which, after birth, becomes obliterated, and remains as a fibrous band stretching from the left superior intercostal vein to the left auricle, where it is continuous with a small vein, the oblique vein of Marshall, which opens into the coronary sinus.

Surgical Anatomy.—Paracentesis of the pericardium is sometimes required in cases of effusion into its cavity. The operation is best performed in the fifth intercostal space, one inch to the left of the sternum. The operation has been performed, however, in the fourth, sixth, and seventh spaces, and also on the right side of the sternum. Porter considers that by "reason of the uncertain and varying relations of the pleura, and also of the anterior position of the heart, whenever the pericardial sac is distended with fluid, aspiration of the pericardium is a much more dangerous procedure than open incision when done by skilled hands." He recommends that the operation should be done by resecting the fifth costal cartilage on the left side. By this means the surgeon avoids opening the pleural cavity, and secures continuous and free drainage, if the case is one of purulent pericarditis.

THE HEART.

The **Heart** is a hollow muscular organ of a conical form, placed between the lungs, and enclosed in the cavity of the pericardium.

Position.—The heart is placed obliquely in the chest: the broad attached end, or base, is directed upward, backward, and to the right, and corresponds with the dorsal vertebræ, from the fifth to the eighth inclusive; the apex is directed downward, forward, and to the left, and corresponds to the space between the cartilages of the fifth and sixth ribs, three-quarters of an inch to the inner side, and an inch and a half below the left nipple, or about three and a half inches from the middle line of the sternum. The heart is placed behind the lower two-thirds of the sternum, and projects farther into the left than into the right half of the cavity of the chest, extending from the median line about three inches in the former direction, and only one and a half in the latter; about one-third of the heart lies to the right and two-thirds to the left of the mesial plane. The anterior surface of the heart is round and convex, directed upward and forward, and formed chiefly by the right auricle and ventricle, together with a small part of the left ventricle. Its posterior surface, which looks downward rather than backward, is flattened and rests upon the Diaphragm, and is formed chiefly by the left ventricle. The right or lower border is long, thin, and sharp; the left or upper border short, but thick and round.

Size.—The heart, in the adult, measures five inches in length, three inches and a half in breadth in the broadest part, and two inches and a half in thickness. The prevalent weight, in the male, varies from ten to twelve ounces; in the female, from eight to ten: its proportions to the body being as 1 to 169 in males; 1 to 149 in females. The heart continues increasing in weight, and also in length, breadth, and thickness, up to an advanced period of life: this increase is more marked in men than in women.

Component Parts.—As has already been stated (page 455), the heart is subdivided by a muscular septum into two lateral halves, which are named respectively right and left; and a transverse constriction subdivides each half of the organ into two cavities, the upper cavity on each side being called the *auricle*, the lower the *ventricle*. The course of the blood through the heart cavities and blood-vessels has already been described (page 455).

The division of the heart into four cavities is indicated by grooves upon its surface. The groove separating the auricles from the ventricles is called the *auriculo-ventricular groove*. It is deficient, in front, where it is crossed by the root of the pulmonary artery. It contains the trunks of the nutrient vessels of the heart. The auricular portion occupies the base of the heart, and is subdivided into two cavities by a median septum. The two ventricles are also separated into a right and left by two furrows, the *interventricular grooves*, which are situated one on the anterior, the other on the posterior, surface; these extend from the base of the ventricular portion to near the apex of the organ; the former being situated

nearer to the left border of the heart, and the latter to the right. It follows, therefore, that the right ventricle forms the greater portion of the anterior surface of the heart, and the left ventricle more of its posterior surface.

Each of these cavities should now be separately examined.

The **Right Auricle** is a little larger than the left, its walls somewhat thinner, measuring about one line; and its cavity is capable of containing about two ounces. It consists of two parts: a principal cavity, the *sinus venosus*, or *atrium*, situated posteriorly, and an anterior, smaller portion, the *appendix auriculæ*.

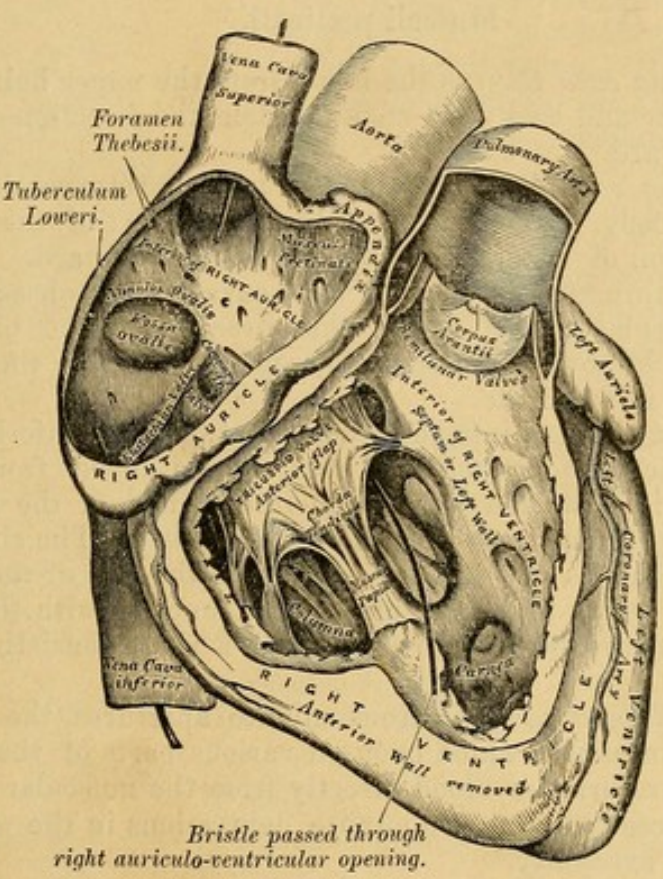

FIG. 276.—The right auricle and ventricle laid open, the anterior walls of both being removed.

The *sinus* is the large quadrangular cavity, placed between the two venæ cavæ; its walls are extremely thin; it is connected below with the right ventricle, and internally with the left auricle, being free in the rest of its extent.

The *appendix auriculæ*, so called from its fancied resemblance to a dog's ear, is a small conical muscular pouch, the margins of which present a dentated edge. It projects from the sinus forward and to the left side, overlapping the root of the aorta.

To examine the interior of the right auricle, an incision should be made along its right border, from the entrance of the superior vena cava to that of the inferior. A second cut is to be made from the centre of this first incision to the tip of the auricular appendix, and the flaps raised.

The internal surface of the right auricle is smooth, except in the appendix and adjacent part of the anterior wall of the sinus venosus, where the muscular wall is thrown into parallel ridges resembling the teeth of a comb and hence named the *musculi pectinati*. These end behind on a vertical smooth ridge, the *crista terminalis* of His, the position of which is indicated on the surface of the distended auricle by a furrow, the *sulcus terminalis* (His); this represents the line of fusion of the sinus venosus of the embryo with the primitive auricle proper.

It presents the following parts for examination:

Openings { Superior cava. / Inferior cava. / Coronary sinus. / Foramina Thebesii. / Auriculo-ventricular. } Valves { Eustachian. / Coronary. }

Fossa ovalis.
Annulus ovalis.
Tuberculum Loweri.
Musculi pectinati.

The *superior vena cava* returns the blood from the upper half of the body, and opens into the upper and back part of the auricle, the direction of its orifice being downward and forward.

The *inferior vena cava*, larger than the superior, returns the blood from the lower half of the body, and opens into the lowest part of the auricle near the septum, the direction of its orifice being upward and inward. The direction of a current of blood through the superior vena cava would consequently be toward the auriculo-ventricular orifice, whilst the direction of the blood through the inferior cava would be toward the auricular septum. This is the normal direction of the two currents in fœtal life.

The *coronary sinus* opens into the auricle, between the inferior vena cava and the auriculo-ventricular opening. It returns the blood from the substance of the heart, and is protected by a semicircular fold of the lining membrane of the auricle, the *coronary valve* (*valve of Thebesius*). The sinus, before entering the auricle, is considerably dilated—nearly to the size of the end of the little finger. Its wall is partly muscular, and at its junction with the great coronary vein is somewhat constricted and furnished with a valve consisting of two unequal segments.

The *foramini Thebesii* are numerous minute apertures, the mouths of small veins (*venæ cordis minimæ*), which open on various parts of the inner surface of the auricle. They return the blood directly from the muscular substance of the heart. Some of these foramina are minute depressions in the walls of the heart, presenting a closed extremity.

The *auriculo-ventricular opening* is the large oval aperture of communication between the auricle and the ventricle, to be presently described.

The *Eustachian valve* is situated between the anterior margin of the inferior vena cava and the auriculo-ventricular orifice. It is semilunar in form, its convex margin being attached to the wall of the vein; its concave margin, which is free, terminating in two cornua, of which the left is attached to the anterior edge of the annulus ovalis, the right being lost on the wall of the auricle. The valve is formed by a duplicature of the lining membrane of the auricle containing a few muscular fibres.

In the fœtus this valve is of large size, and serves to direct the blood from the inferior vena cava, through the foramen ovale, into the left auricle.

In the adult it is occasionally persistent, and may assist in preventing the reflux of blood into the inferior vena cava; more commonly it is small, and its free margin presents a cribriform or filamentous appearance; occasionally it is altogether wanting.

The *coronary valve* (valve of Thebesius) is a semicircular fold of the lining membrane of the auricle, protecting the orifice of the coronary sinus. It prevents the regurgitation of blood into the sinus during the contraction of the auricle. This valve is occasionally double.

The *fossa ovalis* is an oval depression corresponding to the situation of the foramen ovale in the fœtus. It is situated at the lower part of the septum auricularum, above and to the left of the orifice of the inferior vena cava.

The *annulus ovalis* is the prominent oval margin of the foramen ovale. It is

most distinct above and at the sides; below, it is deficient. A small slit-like valvular opening is occasionally found, at the upper margin of the fossa ovalis, which leads upward beneath the annulus into the left auricle, and is the remains of the aperture between the two auricles in the fœtus.

The *tuberculum Loweri* is a small projection on the right wall of the auricle, between the two venæ cavæ. It is most distinct in the hearts of quadrupeds; in man it is scarcely visible. It was supposed by Lower to direct the blood from the superior cava toward the auriculo-ventricular opening.

The **Right Ventricle** is triangular in form, and extends from the right auricle to near the apex of the heart. Its anterior or upper surface is rounded and convex, and forms the larger part of the front of the heart. Its under surface is flattened, rests upon the Diaphragm, and forms only a small part of the back of the heart. Its posterior wall is formed by the partition between the two ventricles, the *septum ventriculorum*, so that a transverse section of the cavity presents a semilunar outline. The surface of the septum is convex and bulges into the cavity of the right ventricle. Its upper and inner angle is prolonged into a conical pouch, the *infundibulum*, or *conus arteriosus*, from which the pulmonary artery arises. The walls of the right ventricle are thinner than those of the left, the proportion between them being as 1 to 3. The wall is thickest at the base, and gradually becomes thinner toward the apex. The cavity equals in size that of the left ventricle, and is capable of containing about three fluidounces.[1]

To examine the interior of the right ventricle, its anterior wall should be turned downward and to the right in the form of a triangular flap. This is accomplished by making two incisions: (1) from the pulmonary artery to the apex of the ventricle parallel to, but a little to the right of, the anterior interventricular furrow; (2) another, starting from the upper extremity of the first and carried outward parallel to, but a little below, the auriculo-ventricular furrow, care being taken not to injure the auriculo-ventricular valve.

The following parts present themselves for examination:

Openings { Auriculo-ventricular. / Opening of the pulmonary artery.
Valves { Tricuspid. / Semilunar.

And a muscular and tendinous apparatus connected with the tricuspid valve:

Columnæ carneæ. Chordæ tendineæ.

The *auriculo-ventricular orifice* is the large oval aperture of communication between the auricle and ventricle. It is situated at the base of the ventricle, near the right border of the heart. It is about an inch and a half in diameter,[2] oval from side to side, surrounded by a fibrous ring, covered by the lining membrane of the heart; it is considerably larger than the corresponding aperture on the left side, being sufficient to admit the ends of four fingers. It is guarded by the tricuspid valve.

The *opening of the pulmonary artery* is circular in form, and situated at the summit of the conus arteriosus, close to the septum ventriculorum. It is pla[illegible]on above and on the left side of the auriculo-ventricular opening, upon the a[illegible]onding aspect of the heart. Its orifice is guarded by the pulmonary semilunar v[illegible]

The *tricuspid valve* consists of three segments of a triangular or [illegible] right side; shape, formed by a duplicature of the lining membrane of the heart, by a layer of fibrous tissue, which contains, according to Kürschn[illegible] seen a lunated which is turned

[1] Morrant Baker says that "taking the mean of various estimates, it may b[illegible]ght auricle. ventricle is able to contain four to six ounces of blood" (Kirke's *Physiology*, 10[illegible]

[2] In the *Pathological Transactions*, vol. vi., p. 119, Dr. Peacock has given [illegible] little to the left of the upon the weight and dimensions of the heart in health and disease. He st[illegible]rt, and carry it up from investigations, that, in the healthy adult heart, the right auriculo-ventricul[illegible]ly as far as the auriculo- circumference of 54.4 lines, or 4$\frac{2}{4}$ inches; the left auriculo-ventricular ape[illegible] ence of 44.3 lines, or 3$\frac{3}{4}$ inches; the pulmonic orifice of 40 lines, or 3$\frac{1}{4}$ in[illegible] of 35.5 lines, or 3$\frac{1}{4}$ inches; but the dimensions of the orifices [illegible] shape than the right ventricle, right auriculo-ventricular aperture having a range of from 40 [illegible]val or nearly circular outline. It proportion. [illegible] heart, and a considerable part of

muscular fibres. These segments are connected by their bases to the fibrous ring surrounding the auriculo-ventricular orifice, and by their sides with one another, so as to form a continuous annular membrane, which is attached round the margin of the auriculo-ventricular opening, their free margins and ventricular surfaces affording attachment to a number of delicate tendinous cords, the *chordæ tendineæ*. The largest and most movable segment is placed toward the left side of the auriculo-ventricular opening, interposed between that opening and the infundibulum; hence it is called the *left* or *infundibular cusp*. Another segment corresponds to the right part of the front of the ventricle, the *right* or *marginal cusp;* and a third to its posterior wall, the *posterior* or *septal cusp*. The central part of each segment is thick and strong: the lateral margins are thin and translucent. The chordæ tendineæ are connected with the adjacent margins of the principal segments of the valve, and are further attached to each segment in the following manner: 1. Three or four reach the attached margin of each segment, where they are continuous with the auriculo-ventricular tendinous ring. 2. Others, four to six in number, are attached to the central thickened part of each segment. 3. The most numerous and finest are connected with the marginal portion of each segment.

The *columnæ carneæ* are the rounded muscular columns which project from nearly the whole of the inner surface of the ventricle, excepting near the opening of the pulmonary artery, where the wall is smooth. They may be classified, according to their mode of connection with the ventricle, into three sets. The first set merely form prominent ridges on the inner surface of the ventricle, being attached by their entire length on one side, as well as by their extremities. The second set are attached by their two extremities, but are free in the rest of their extent; while the third set (*musculi papillares*) are attached by one extremity to the wall of the heart, the opposite extremity giving attachment to the *chordæ tendineæ*. There are two papillary muscles, anterior and posterior: of these, the anterior is the larger; its chordæ tendineæ are connected with the right and left segments of the valve. The posterior is not always single, but sometimes consists of two or three muscular columns; its chordæ tendineæ are connected with the posterior and the right segments. In addition to these, some few chordæ may be seen springing directly from the ventricular septum, or from small eminences on it, and passing to the left and posterior segments. A fleshy band, well marked in the ox and some other animals, is frequently seen passing from the base of the anterior papillary muscle to the interventricular septum. From its attachments it may assist in preventing over-distention of the auricle, and so has been named the *moderator band*.

The right auriculo-ventricular orifice allows the blood to pass freely from the right auricle into the right ventricle, and it will be noted that the surface of the tricuspid valve next the blood-current is quite smooth. When the right ventricle contracts to force the blood into the pulmonary artery, the segments of the tricuspid valve come together and close the auriculo-ventricular opening, and so prevent the blood from passing back into the auricle. The papillary muscles and chordæ tendineæ moor the segments of the valve, and prevent their being forced through into

In auricle by the weight of blood behind them.

inferior *semilunar valves*, three in number,[1] guard the orifice of the pulmonary

In the They consist of three semicircular folds, two anterior (right and left) and

reflux of blo r, formed by a duplicature of the lining membrane, strengthened by

free margin p They are attached, by their convex margins, to the wall of the

altogether wanti unction with the ventricle, the straight border being free, and

The *coronary* in the lumen of the vessel. The free margin of each is some-

membrane of the au the rest of the valve, is strengthened by a bundle of tendinous

the regurgitation of , at its middle, a small projecting thickened nodule, called *cor-*

This valve is occasio nsisting of bundles of interlacing connective-tissue fibres with

The *fossa ovalis* -tissue cells and some few elastic fibres. From this nodule

foramen ovale in the fœtus. es have been found to be two in number instead of three (Dr.

larum, above and to the left of t stern Med. and Surg. Journ., July, 1873), and the same variety

The *annulus ovalis* is the pro semilunar valves.

tendinous fibres radiate through the valve to its attached margin, and these fibres form a constituent part of its substance throughout its whole extent, excepting two narrow lunated portions, the *lunulæ*, placed one on each side of the nodule immediately adjoining the free margin; here the valve is thin, and formed merely by the lining membrane. During the passage of the blood along the pulmonary artery these valves are opened, and the course of the blood along the tube is uninterrupted; but during the ventricular diastole, when the current of blood along the pulmonary artery is checked and partly thrown back by its elastic walls, these valves become immediately expanded, and effectually close the entrance of the tube. When the valves are closed, the lunated portions of each are brought into contact with one another by their opposed surfaces, the three corpora Arantii filling up the small triangular space that would be otherwise left by the approximation of the three semilunar valves.

Between the semilunar valves and the commencement of the pulmonary artery are three pouches or dilatations, one behind each valve. These are the pulmonary sinuses (*sinuses of Valsalva*). Similar sinuses exist between the semilunar valves and the commencement of the aorta; they are larger than the pulmonary sinuses. The blood, in its regurgitation toward the heart, finds its way into these sinuses, and so shuts down the valve-flaps.

In order to examine the interior of the left auricle, make an incision on the posterior surface of the auricle from the pulmonary veins on one side to those on the other, the incision being carried a little way into the vessels. Make another incision from the middle of the horizontal one to the appendix.

The **Left Auricle** is rather smaller than the right; its walls thicker, measuring about one line and a half; it consists, like the right, of two parts, a principal cavity, or *sinus*, and an *appendix auriculæ*.

The *sinus* is cuboidal in form, and concealed in front by the pulmonary artery and aorta: internally, it is separated from the right auricle by the septum auricularum; behind, it receives on each side two pulmonary veins, being free in the rest of its extent.

The *appendix auriculæ* is somewhat constricted at its junction with the auricle; it is longer, narrower, and more curved than that of the right side, and its margins are more deeply indented, presenting a kind of foliated appearance. Its direction is forward and toward the right side, overlapping the root of the pulmonary artery.

Within the auricle the following parts present themselves for examination:

The openings of the four pulmonary veins.
Auriculo-ventricular opening.
Musculi pectinati.

The *pulmonary veins*, four in number, open, two into the right, and two into the left side of the auricle. The two left veins frequently terminate by a common opening. They are not provided with valves.

The *auriculo-ventricular opening* is the large oval aperture of communication between the auricle and ventricle. It is rather smaller than the corresponding opening on the opposite side (see note, page 463).

The *musculi pectinati* are fewer in number and smaller than on the right side; they are confined to the inner surface of the appendix.

On the inner surface of the septum auricularum may be seen a lunated impression bounded below by a crescentic ridge the concavity of which is turned upward. The depression is just above the fossa ovalis in the right auricle.

To examine the interior of the left ventricle, make an incision a little to the left of the anterior interventricular groove from the base to the apex of the heart, and carry it up from thence, a little to the left of the posterior interventricular groove, nearly as far as the auriculo-ventricular groove.

The **Left Ventricle** is longer and more conical in shape than the right ventricle, and on transverse section its cavity presents an oval or nearly circular outline. It forms a small part of the anterior surface of the heart, and a considerable part of

its posterior surface. It also forms the apex of the heart by its projection beyond the right ventricle. Its walls are much thicker than those of the right side, the proportion being as 3 to 1. They are thickest opposite the widest part of the ventricle, becoming gradually thinner toward the base, and also toward the apex, which is the thinnest part.

The following parts present themselves for examination :

Openings	Auriculo-ventricular.	Valves	Mitral.
	Aortic.		Semilunar.
	Chordæ tendineæ.		Columnæ carneæ.

The *auriculo-ventricular opening* is placed below and to the left of the aortic orifice. It is a little smaller than the corresponding aperture of the opposite side,

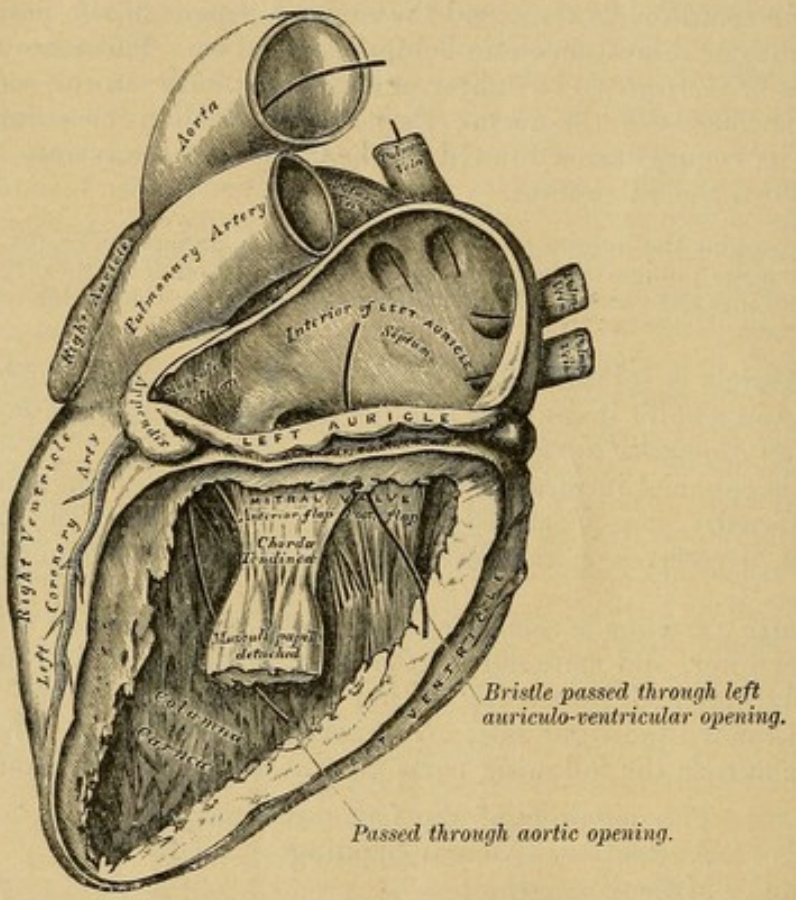

FIG. 277.—The left auricle and ventricle laid open, the posterior walls of both being removed.

admitting only two fingers; but, like it, is broader in the transverse than in the antero-posterior diameter. It is surrounded by a dense fibrous ring, covered by the lining membrane of the heart, and guarded by the mitral valves.

The *aortic opening* is a circular aperture, in front and to the right side of the auriculo-ventricular, from which it is separated by one of the segments of the mitral valve. Its orifice is guarded by the semilunar valves. The portion of the ventricle immediately below the aortic orifice is often termed the *aortic vestibule* of Sibson. It possesses fibrous instead of muscular walls, and so does not collapse during the ventricular diastole; it thus gives space for the segments of the aortic valve during its closure.

The *mitral valve* is attached to the circumference of the auriculo-ventricular orifice in the same way that the tricuspid valve is on the opposite side. It is formed by a duplicature of the lining membrane, strengthened by fibrous tissue, and contains a few muscular fibres. It is larger in size, thicker, and altogether stronger than the tricuspid, and consists of two segments of unequal size. The larger segment is placed in front and to the right between the auriculo-ventricular

and aortic orifices, the smaller to the left and behind the opening, close to the wall of the ventricle. Two smaller segments are usually found at the angles of junction of the larger. The mitral valve-flaps are furnished with chordæ tendineæ, the mode of attachment of which is precisely similar to those on the right side; but they are thicker, stronger, and less numerous.

The *semilunar valves* surround the orifice of the aorta; two are posterior (right and left) and one anterior: they are similar in structure and in their mode of attachment to those of the pulmonary artery. They are, however, larger, thicker, and stronger than those of the right side; the lunulæ are more distinct, and the corpora Arantii larger and more prominent. Opposite each segment the wall of the aorta presents a slight dilatation or bulging (sinus of Valsalva). They are larger than those at the commencement of the pulmonary artery.

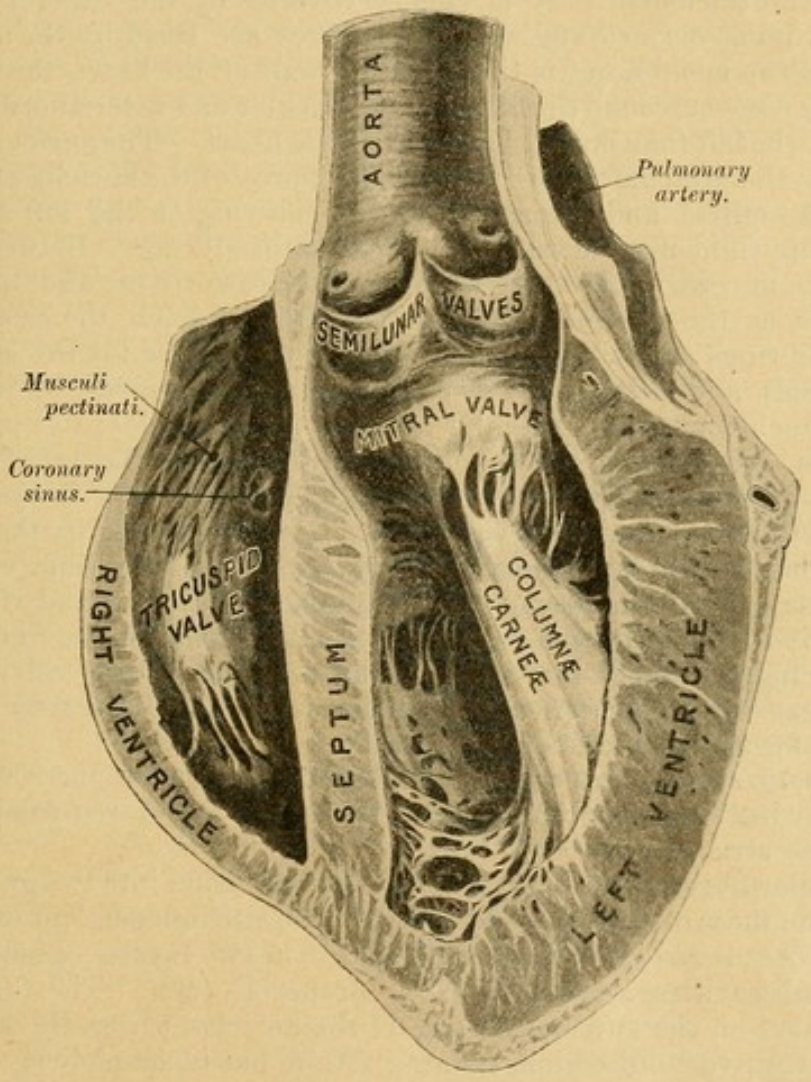

FIG. 278.—Section of the heart, showing the interventricular septum.

The *columnæ carneæ* admit of a subdivision into three sets, like those upon the right side; but they are smaller, more numerous, and present a dense interlacement, especially at the apex, and upon the posterior wall. Those attached by one extremity only, the *musculi papillares*, are two in number, being connected one to the anterior, the other to the posterior wall; they are of large size, and terminate by free rounded extremities, from which the chordæ tendineæ arise.

The septum between the two ventricles is thick, especially below (Fig. 278). At its upper part it suddenly tapers off and becomes destitute of muscular fibres, consisting only of fibrous tissue, covered by two layers of endocardium; and on the right side also covered, during diastole, by one of the flaps of the tricuspid valve. This upper portion is termed the *membranous part* of the septum, and is continued upward and forms the septum between the aortic vestibule and the right

auricle. It is derived from the lower part of the aortic septum of the fœtus, and an abnormal communication may exist at this part, owing to defective development of this septum.

The *Endocardium* is a thin membrane which lines the internal surface of the heart; it assists in forming the valves by its reduplications, and is continuous with the lining membrane of the great blood-vessels. It is a smooth, transparent membrane, giving to the inner surface of the heart its glistening appearance. It is more opaque on the left than on the right side of the heart, thicker in the auricles than in the ventricles, and thickest in the left auricle. It is thin on the musculi pectinati and on the columnæ carneæ, but thicker on the smooth part of the auricular and ventricular walls and on the tips of the musculi papillares.

Structure.—The heart consists of muscular fibres, and of fibrous rings which serve for their attachment. It is closely covered by the visceral layer of the serous pericardium (*epicardium*), and its cavities are lined by the *endocardium*. Between these two membranes is the muscular wall of the heart, the *myocardium*.

The *fibrous rings* surround the auriculo-ventricular and arterial orifices; they are stronger upon the left than on the right side of the heart. The auriculo-ventricular rings serve for the attachment of the muscular fibres of the auricles and ventricles, and also for the mitral and tricuspid valves; the ring on the left side is closely connected by its right margin with the aortic arterial ring. Between these and the right auriculo-ventricular ring is a mass of fibrous tissue, and in some of the larger animals, as the ox and elephant, a nodule of bone, the *os cordis*.

The fibrous rings surrounding the arterial orifices serve for the attachment of the great vessels and semilunar valves. Each ring receives, by its ventricular margin, the attachment of the muscular fibres of the ventricles; its opposite margin presents three deep semicircular notches, within which the middle coat of the artery (which presents three convex semicircular segments) is firmly fixed, the attachment of the artery to its fibrous ring being strengthened by the thin cellular coat and serous membrane externally and by the endocardium within. It is opposite the margins of these semicircular notches, in the arterial rings, that the endocardium by its reduplication, forms the semilunar valves, the fibrous structure of the ring being continued into each of the segments of the valve at this part. The middle coat of the artery in this situation is thin, and the sides of the vessel are dilated to form the sinuses of Valsalva.

The *muscular structure of the heart* consists of bands of fibres which present an exceedingly intricate interlacement. They are of a deep red color and marked with transverse striæ.

The muscular fibres of the heart admit of a subdivision into two groups, those of the auricles and those of the ventricles, which are quite independent of one another.

Fibres of the Auricles.—These are disposed in two layers—a superficial layer common to both cavities, and a deep layer proper to each. The *superficial fibres* are more distinct on the anterior surface of the auricles, across the bases of which they run in a transverse direction, forming a thin, but incomplete layer. Some of these fibres pass into the septum auricularum. The *internal* or *deep fibres* proper to each auricle consist of two sets, looped and annular fibres. The *looped fibres* pass upward over each auricle, being attached by two extremities to the corresponding auriculo-ventricular rings in front and behind. The *annular fibres* surround the whole extent of the appendices auricularum, and are continued upon the walls of the venæ cavæ and coronary sinus on the right side, and upon the pulmonary veins on the left side, at their connection with the heart. In the appendices they interlace with the longitudinal fibres.

Fibres of the Ventricles.—These are arranged in an exceedingly complex manner, and the accounts given by various anatomists differ considerably. This is probably due partly to the fact that the various layers of muscular fibres of which the heart is said to be composed are not independent, but their fibres are interlaced to a considerable extent, and therefore any separation into layers must be to a great extent artificial; and also partly to the fact, pointed out by Henle, that

there are varieties in the arrangement due to individual differences. If the *epicardium* and the subjacent fat are removed from a heart which has been subjected to prolonged boiling, so as to dissolve the connective tissues, the superficial fibres of the ventricles will be exposed. They will be seen to commence at the base of the heart, where they are attached to the tendinous rings around the orifices, and to pass obliquely downward toward the apex, with a direction from right to left. At the apex the fibres turn suddenly inward into the interior of the ventricle, forming what is called the *vortex*. On the back of the heart it will be seen that the fibres pass continuously from one ventricle to the other over the interventricular groove; and the same thing will be noticed on the front of the heart at the upper and lower end of the anterior interventricular groove, but in the middle portion of this groove the fibres passing from one ventricle to the other are interrupted by fibres emerging from the septum along the groove; many of the superficial fibres pass in also at this groove to the septum. The vortex is produced, as stated above, by the sudden turning inward of the superficial fibres in a peculiar spiral manner into the interior of the ventricle. Those fibres which descended on the posterior surface of the heart enter the left ventricle at the vortex, and, ascending, form the posterior part of the inner layer of muscular fibres lining this cavity and the right (posterior) musculus papillaris; those fibres which descend on the front of the heart to reach the apex also pass, at the vortex, into the interior of the ventricle, where they form the remainder of the innermost layer of the ventricle and the left (anterior) musculus papillaris. The fibres forming the inner layer of the wall of the ventricle ascend to be attached to the fibrous rings around the orifices.

By dissection these superficial fibres may be removed as a thin stratum, and it will then be found that the ventricles are made up of oblique fibres superimposed in layers one on the top of another, and assuming gradually a less oblique direction as they pass to the middle of the thickness of the ventricular wall, so that in the centre of the wall the fibres are transverse. Internal to this central transverse layer the fibres become oblique again, but in the opposite direction to the external ones. This division into distinct layers is, however, to a great extent artificial, as the fibres pass across from one layer to another, and have therefore to be divided in the dissection, and the change in the direction of the fibres is very gradual. These oblique fibres commence above at the fibrous rings at the base of the heart, and, descending toward the apex, they enter the septum near its lower end. In the septum the fibres which form the left ventricle may be traced in three directions: 1. Some pass upward to be attached to the central mass of fibrous tissue. 2. Others pass through the septum to become continuous with the fibres of the right ventricle. 3. The remainder pass through the septum to encircle the ventricle as annular fibres. Of the fibres of the right ventricle, some on entering the septum pass upward to be attached to the central mass of fibrous tissue; some, entering the septum from behind, pass forward to become continuous with the fibres on the anterior surface of the left ventricle; and others, entering in front, pass backward to join the fibres on the posterior wall of the left ventricle. The septum therefore consists of three varieties of fibres—viz., annular fibres, special to the left ventricle; ascending fibres, derived from both ventricles and ascending through the septum to the central fibro-cartilage; and decussating fibres, derived from the anterior wall of one ventricle and passing to the posterior wall of the other ventricle, or from the posterior wall of the right ventricle and passing to the anterior wall of the left. In addition to these fibres there are a considerable number which appear to encircle both ventricles and which pass across the septum without turning into it.

Vessels and Nerves.—The *arteries* supplying the heart are the right and left coronary from the aorta.

The *veins* accompany the arteries, and terminate in the right auricle. They are, the anterior or great, posterior, left and anterior cardiac veins, the right or small, and the left or great, coronary sinuses and the venæ Thebesii (*venæ cordis minimæ*).

The *lymphatics* terminate in the thoracic and right lymphatic ducts.

The *nerves* are derived from the cardiac plexuses, which are formed partly from the cranial nerves and partly from the sympathetic. They are freely distributed both on the surface and in the substance of the heart, the separate filaments being furnished with small ganglia.

Surface Form.—In order to show the extent of the heart in relation to the front of the chest, draw a line from the lower border of the second left costal cartilage, one inch from the sternum, to the upper border of the third right costal cartilage, half an inch from the sternum. This represents the base-line or upper limit of the organ. Take a point an inch and a half below and three-quarters of an inch internal to the left nipple—that is, about three and a half inches to the left of the median line of the body. This represents the apex of the heart. Draw a line from this apex-point, with a slight convexity downward, to the junction of the seventh right costal cartilage to the sternum. This represents the lower limit of the heart. Join the right extremity of the first line—that is, the base-line—with the right extremity of this line—that is, to the seventh right chondro-sternal joint—with a slight curve outward, so that it projects about an inch and a half from the middle line of the sternum. Lastly, join the left extremity of the base-line and the apex-point by a line curved slightly to the left.

The position of the various orifices is as follows: viz. the pulmonary orifice is situated in the upper angle formed by the articulation of the third left costal cartilage with the sternum; the aortic orifice is a little below and internal to this, behind the left border of the sternum, close to the articulation of the third left costal cartilage to this bone. The left auriculo-ventricular opening is behind the sternum, rather to the left of the median line, and opposite the fourth costal cartilages. The right auriculo-ventricular opening is a little lower, opposite the fourth interspace and in the middle line of the body (Fig. 275).

A portion of the area of the heart thus mapped out is uncovered by lung, and therefore gives a dull note on percussion; the remainder, being overlapped by the lung, gives a more or less resonant note. The former is known as the area of superficial cardiac dulness; the latter as the area of deep cardiac dulness. The area of superficial cardiac dulness is included between a line drawn from the centre of the sternum, on a level with the fourth costal cartilages, to the apex of the heart and a line drawn from the same point down the lower third of the middle line of the sternum. Below, this area merges into the dulness which corresponds to the liver. Dr. Latham lays down the following rule as a sufficient practical guide for the definition of the portion of the heart which is uncovered by lung or pleura: "Make a circle of two inches in diameter round a point midway between the nipple and the end of the sternum."

Surgical Anatomy.—Wounds of the heart are often immediately fatal, but not necessarily so. They may be non-penetrating, when death may occur from hemorrhage, if one of the coronary vessels has been wounded, or subsequently from pericarditis; or, on the other hand, the patient may recover. Even a penetrating wound is not necessarily fatal, if the wound is a small one. A flap comprising the whole thickness of the thoracic wall may be made, the cavity of the pericardium opened, and the wound in the heart sutured. This has been done successfully.

Peculiarities in the Vascular System of the Fœtus.

The chief peculiarities in the heart of the fœtus are the direct communication between the two auricles through the foramen ovale and the large size of the Eustachian valve. There are also several minor peculiarities. Thus, the position of the heart is vertical until the fourth month, when it commences to assume an oblique direction. Its size is also very considerable as compared with the body, the proportion at the second month being 1 to 50; at birth it is as 1 to 120; whilst in the adult the average is about 1 to 160. At an early period of fœtal life the auricular portion of the heart is larger than the ventricular, the right auricle being more capacious than the left; but toward birth the ventricular portion becomes the larger. The thickness of both ventricles is at first about equal, but toward birth the left becomes much the thicker of the two.

The *foramen ovale* is situated at the lower and back part of the septum auricularum, forming a communication between the auricles. It remains as a free oval opening until the middle period of fœtal life. About this period a fold grows up from the posterior wall of the auricle to the left of the foramen ovale, and advances over the opening so as to form a sort of valve, which allows the blood to pass only from the right to the left auricle, and not in the opposite direction.

The *Eustachian valve* is directed upward on the left side of the opening of the inferior vena cava, and serves to direct the blood from this vessel through the foramen ovale into the left auricle.

The peculiarities in the arterial system of the fœtus are the communication between the pulmonary artery and the descending aorta by means of the *ductus*

arteriosus, and the communication between the internal iliac arteries and the placenta by means of the umbilical arteries.

The *ductus arteriosus* is a short tube, about half an inch in length at birth, and of the diameter of a goosequill. In the early condition it forms the continuation of the pulmonary artery, and opens into the descending aorta just below the origin of the left subclavian artery, and so conducts the chief part of the blood from the right ventricle into this vessel. When the branches of the pulmonary artery have become larger relatively to the ductus arteriosus, the latter is chiefly connected to the left pulmonary artery; and the fibrous cord, which is all that remains of the ductus arteriosus in later life, will be found to be attached to the root of that vessel.

The *umbilical* or *hypogastric arteries* arise from the internal iliacs, in addition to the branches given off from those vessels in the adult. Ascending along the sides of the bladder to its apex, they pass out of the abdomen at the umbilicus and are continued along the umbilical cord to the placenta, coiling round the umbilical vein. They carry to the placenta the blood which has circulated in the system of the fœtus.

The peculiarity in the venous system of the fœtus is the communication established between the placenta and the liver and portal vein through the umbilical vein, and the inferior vena cava through the ductus venosus.

Fœtal Circulation.

The blood destined for the nutrition of the fœtus is returned from the placenta to the fœtus by the umbilical vein. This vein enters the abdomen at the umbilicus, and passes upward along the free margin of the suspensory ligament of the liver to the under surface of that organ, where it gives off two or three branches to the left lobe, one of which is of large size, and others to the lobus quadratus and lobulus Spigelii. At the transverse fissure it divides into two branches: of these, the larger is joined by the portal vein and enters the right lobe; the smaller branch continues outward, under the name of the ductus venosus, and joins the left hepatic vein at the point of junction of that vessel with the inferior vena cava. The blood, therefore, which traverses the umbilical vein reaches the inferior vena cava in three different ways: the greater quantity circulates through the liver with the portal venous blood before entering the vena cava by the hepatic veins; some enters the liver directly, and is also returned to the inferior cava by the hepatic veins; the smaller quantity passes directly into the vena cava by the junction of the ductus venosus with the left hepatic vein.

In the inferior cava the blood carried by the ductus venosus and hepatic veins becomes mixed with that returning from the lower extremities and wall of the abdomen. It enters the right auricle, and, guided by the Eustachian valve, passes through the foramen ovale into the left auricle, where it becomes mixed with a small quantity of blood returned from the lungs by the pulmonary veins. From the left auricle it passes into the left ventricle, and from the left ventricle into the aorta, by means of which it is distributed almost entirely to the head and upper extremities, a small quantity being probably carried into the descending aorta. From the head and upper extremities the blood is returned by the tributaries of the superior vena cava to the right auricle, where it becomes mixed with a small portion of the blood from the inferior cava. From the right auricle it descends over the Eustachian valve into the right ventricle, and from the right ventricle passes into the pulmonary artery. The lungs of the fœtus being inactive, only a small quantity of the blood of the pulmonary artery is distributed to them by the right and left pulmonary arteries, and is returned by the pulmonary veins to the left auricle; the greater part passes through the ductus arteriosus into the commencement of the descending aorta, where it becomes mixed with a small quantity of blood transmitted by the left ventricle into the aorta. Through

this vessel it descends to supply the lower extremities and viscera of the abdomen and pelvis, the chief portion being, however, conveyed by the umbilical arteries to the placenta.

From the preceding account of the circulation of the blood in the fœtus it will be seen—

1. That the placenta serves the purposes of nutrition and excretion, receiving

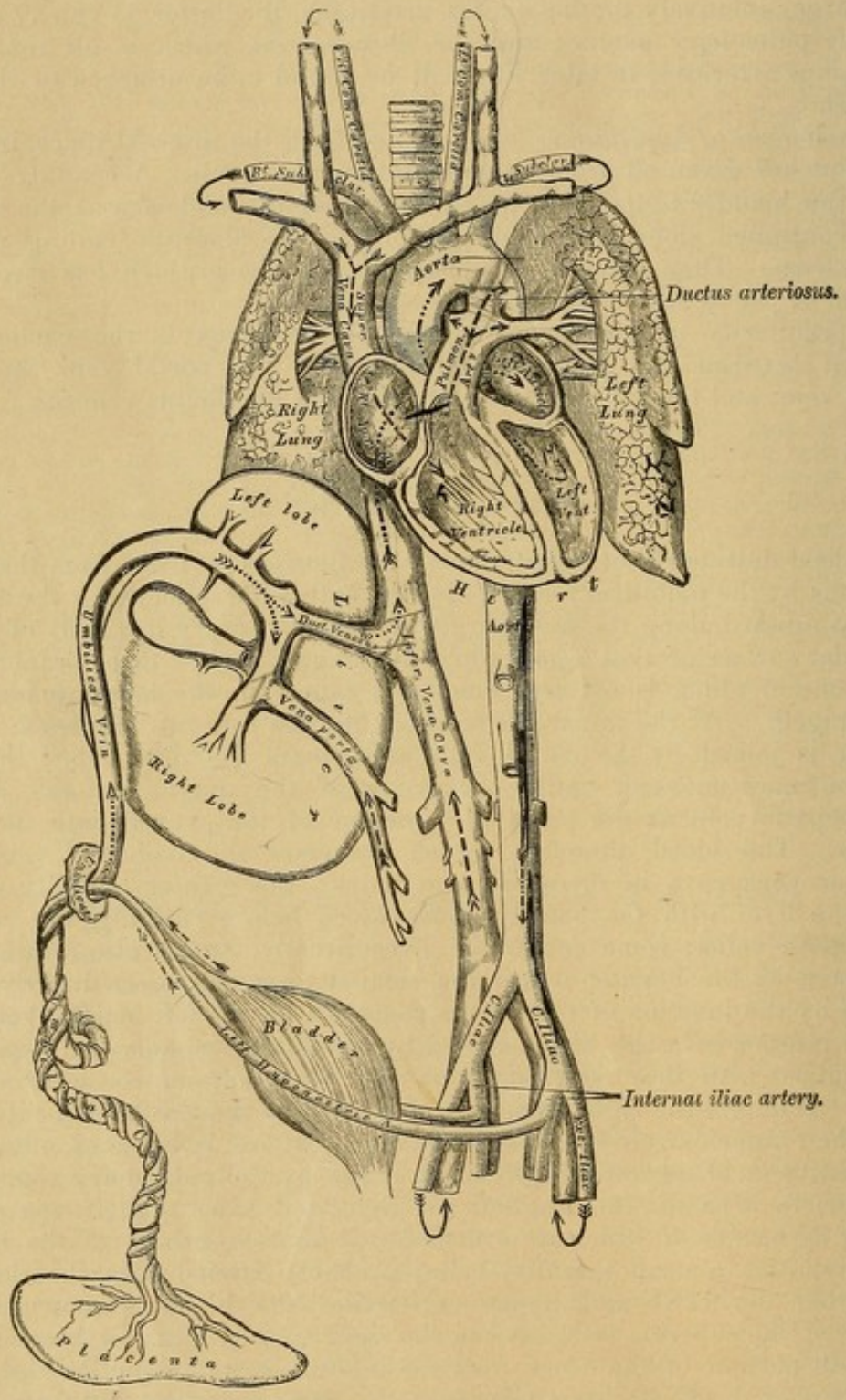

Fig. 279.—Plan of the fœtal circulation. In this plan the figured arrows represent the kind of blood, as well as the direction which it takes in the vessels. Thus, arterial blood is figured ≫—·····—>; venous blood, ≫— — — —>; mixed (arterial and venous) blood, ≫·— ·· —>.

the impure blood from the fœtus, and returning it charged with additional nutritive material.

2. That nearly the whole of the blood of the umbilical vein traverses the liver

before entering the inferior cava; hence the large size of this organ, especially at an early period of fœtal life.

3. That the right auricle is the point of meeting of a double current, the blood in the inferior cava being guided by the Eustachian valve into the left auricle, whilst that in the superior cava descends into the right ventricle. At an early period of fœtal life it is highly probable that the two streams are quite distinct, for the inferior cava opens almost directly into the left auricle, and the Eustachian valve would exclude the current along the vein from entering the right ventricle. At a later period, as the separation between the two auricles becomes more distinct, it seems probable that some mixture of the two streams must take place.

4. The pure blood carried from the placenta to the fœtus by the umbilical vein, mixed with the blood from the portal vein and inferior cava, passes almost directly to the arch of the aorta, and is distributed by the branches of that vessel to the head and upper extremities; hence the large size and perfect development of those parts at birth.

5. The blood contained in the descending aorta, chiefly derived from that which has already circulated through the head and upper limbs, together with a small quantity from the left ventricle, is distributed to the lower extremities; hence the small size and imperfect development of these parts at birth.

Changes in the Vascular System at Birth.

At birth, when respiration is established, an increased amount of blood from the pulmonary artery passes through the lungs, which now perform their office as respiratory organs, and at the same time the placental circulation is cut off. The foramen ovale becomes gradually closed by about the tenth day after birth; the valvular fold above mentioned becomes adherent to the margins of the foramen for the greater part of its circumference, but above a slit-like opening is left between the two auricles which sometimes remains persistent.

The *ductus arteriosus* begins to contract immediately after respiration is established, becomes completely closed from the fourth to the tenth day, and ultimately degenerates into an impervious cord which serves to connect the left pulmonary artery to the descending aorta.

Of the *umbilical* or *hypogastric arteries*, the portion continued on to the bladder from the trunk of the corresponding internal iliac remains pervious as the superior vesical artery, and the part extending from the side of the bladder to the umbilicus becomes obliterated between the second and fifth days after birth, and projects as a fibrous cord toward the abdominal cavity, carrying on it a fold of peritoneum and separating two of the fossæ of the peritoneum spoken of in the section on the surgical anatomy of direct inguinal hernia.

The *umbilical vein* and *ductus venosus* become completely obliterated between the second and fifth days after birth, and ultimately dwindle to fibrous cords, the former becoming the round ligament of the liver, the latter the fibrous cord, which in the adult may be traced along the fissure of the ductus venosus.

THE ARTERIES.

THE Arteries are cylindrical tubular vessels which serve to convey blood from both ventricles of the heart to every part of the body. These vessels were named arteries (*ἀήρ*, air; *τηρεῖν*, to contain) from the belief entertained by the ancients that they contained air. To Galen is due the honor of refuting this opinion; he showed that these vessels, though for the most part empty after death, contain blood in the living body.

The distribution of the systemic arteries is like a highly ramified tree, the common trunk of which, formed by the aorta, commences at the left ventricle of the heart, the smallest ramifications corresponding to the circumference of the body and the contained organs. The arteries are found in nearly every part of the body, with the exception of the hairs, nails, epidermis, cartilages, and cornea; and the larger trunks usually occupy the most protected situations, running, in the limbs, along the flexor side, where they are less exposed to injury.

There is considerable variation in the mode of division of the arteries: occasionally a short trunk subdivides into several branches at the same point, as we observe in the cœliac and thyroid axes; or the vessel may give off several branches in succession, and still continue as the main trunk, as is seen in the arteries of the limbs; but the usual division is dichotomous; as, for instance, the aorta dividing into the two common iliacs, and the common carotid into the external and internal.

The branches of arteries arise at very variable angles: some, as the superior intercostal arteries from the aorta, arise at an obtuse angle: others, as the lumbar arteries, at a right angle; or, as the spermatic, at an acute angle. An artery from which a branch is given off is smaller in size, but retains a uniform diameter until a second branch is derived from it. A branch of an artery is smaller than the trunk from which it arises; but if an artery divides into two branches, the combined area of the two vessels is, in nearly every instance, somewhat greater than that of the trunk; and the combined area of all the arterial branches greatly exceeds the area of the aorta; so that the arteries collectively may be regarded as a cone, the apex of which corresponds to the aorta, the base to the capillary system.

The arteries, in their distribution, communicate with one another, forming what is called an *anastomosis* (*ἀνά*, between; *στόμα*, mouth), or inosculation; and this communication is very free between the large as well as between the smaller branches. The anastomosis between trunks of equal size is found where great activity of the circulation is requisite, as in the brain; here the two vertebral arteries unite to form the basilar, and the two internal carotid arteries are connected by a short communicating trunk; it is also found in the abdomen, the intestinal arteries having very ample anastomoses between their larger branches. In the limbs the anastomoses are most numerous and of largest size around the joints, the branches of an artery above inosculating with branches from the vessels below; these anastomoses are of considerable interest to the surgeon, as it is by their enlargement that a *collateral circulation* is established after the application of a ligature to an artery for the cure of aneurism. The smaller branches of arteries anastomose more frequently than the larger, and between the smallest twigs these inosculations become so numerous as to constitute a close network that pervades nearly every tissue of the body.

Throughout the body generally the larger arterial branches pursue a perfectly straight course, but in certain situations they are tortuous; thus, the facial artery in its course over the face, and the arteries of the lips, are extremely tortuous in their course, to accommodate themselves to the movements of the parts. The

uterine arteries are also tortuous, to accommodate themselves to the increase of size which the organ undergoes during pregnancy. Again, the internal carotid and vertebral arteries, previous to their entering the cavity of the skull, describe a series of curves, which are evidently intended to diminish the velocity of the current of blood by increasing the extent of surface over which it moves and adding to the amount of impediment which is produced by friction.

The arteries are dense in structure, of considerable strength, highly elastic, and, when divided, they preserve, although empty, their cylindrical form.

The minute structure of these vessels has been described in the chapter on General Anatomy.

In the description of the arteries we shall first consider the efferent trunk of the pulmonic circulation, the pulmonary artery, and then the efferent trunk of the systemic circulation, the aorta and its branches.

PULMONARY ARTERY (Fig. 280).

The Pulmonary Artery conveys the venous blood from the right side of the heart to the lungs. It is a short, wide vessel, about 2 inches in length and 1¼ inches (30 mm.) in diameter, arising from the left side of the base (conus arteriosus) of the right ventricle, in front of the aorta. It extends obliquely upward and backward, passing at first in front of and then to the left of the ascending aorta, as far as the under surface of the arch, where it divides, about on a level with the intervertebral substance between the fifth and sixth dorsal vertebræ, into two branches of nearly equal size, the *right* and *left pulmonary arteries.*

Relations.—The whole of this vessel is contained, together with the ascending aorta, in the pericardium. It is enclosed with the aorta in a single tube of the serous pericardium, which is continued upward upon them from the base of the heart and connects them together. The fibrous layer of the pericardium becomes gradually lost upon the external coat of its two branches. In front, the pulmonary artery is separated from the anterior extremity of the second left intercostal space by the pleura and left lung, in addition to the pericardium; it rests at first upon the ascending aorta, and higher up lies in front of the left auricle on a plane posterior to the ascending aorta. On each side of its origin is the appendix of the corresponding auricle and a coronary artery, the left coronary artery passing, in the first part of its course, behind the vessel.

The right pulmonary artery, longer and larger than the left, runs horizontally outward, behind the ascending aorta and superior vena cava, to the root of the right lung, where it divides into two branches, of which the lower and larger supplies the middle and lower lobes; the upper and smaller is distributed to the upper lobe.

The left pulmonary artery, shorter and somewhat smaller than the right, passes horizontally in front of the descending aorta and left bronchus to the root of the left lung, where it divides into two branches for the two lobes.

The root of the left pulmonary artery is connected to the under surface of the arch of the aorta by a short fibrous cord, the *ligamentum arteriosum;* this is the remains of a vessel peculiar to fœtal life, the *ductus arteriosus.*

The terminal branches of the pulmonary artery will be described with the anatomy of the lung.

THE AORTA.

The aorta (*ἀορτή*, arteria magna) is the main trunk of a series of vessels which convey the oxygenated blood to the tissues of the body for their nutrition. This vessel commences at the upper part of the left ventricle, where it is about one and one-eighth inches in diameter, and, after ascending for a short distance, arches backward and to the left side, over the root of the left lung, then descends within the thorax on the left side of the vertebral column, passes through the aortic opening in the Diaphragm, and, entering the abdominal cavity, terminates, considerably diminished in size (about seven-tenths of an inch in diameter), opposite the lower border of the fourth lumbar vertebra, where it divides into the right and left common iliac arteries. Hence it is divided into the *ascending aorta*, the *arch* of

the aorta, and the *descending aorta*, which last is again divided into *thoracic aorta* and *abdominal aorta*, from the position of these parts.

THE ASCENDING AORTA.

The **ascending aorta** is about two inches in length. It commences at the upper part of the left ventricle, on a level with the lower border of the third costal cartilage, behind the left half of the sternum; it passes obliquely upward, forward, and to the right, in the direction of the heart's axis, as high as the upper border of the

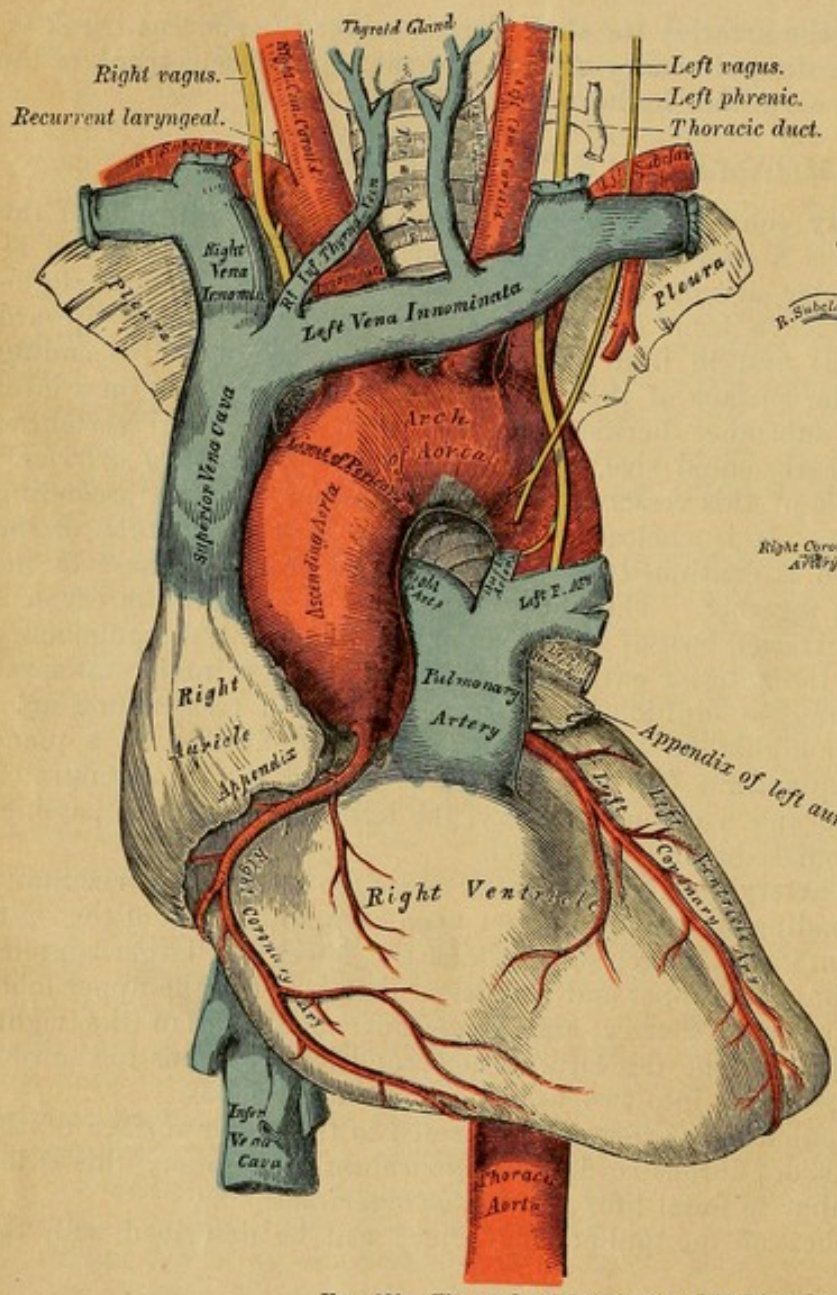

FIG. 280.—The arch of the aorta and its branches.

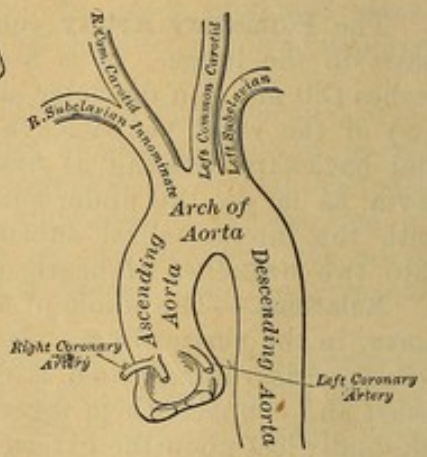

FIG. 281.—Plan of the branches.

second right costal cartilage, describing a slight curve in its course, and being situated, when distended, about a quarter of an inch behind the posterior surface of the sternum. A little above its commencement it is somewhat enlarged, and presents three small dilatations, called the sinuses of Valsalva, opposite to which are attached the three semilunar valves, which serve the purpose of preventing any regurgitation of blood into the cavity of the ventricle. These valves are placed one in front and two behind. At the union of the ascending with the transverse part of the aorta the calibre of the vessel is increased, owing to a bulging outward of its right wall. This dilatation is termed the *great sinus of the aorta*. A section of the aorta

opposite this part has a somewhat oval figure; but below the attachment of the valves it is circular. This portion of the aorta is contained in the cavity of the pericardium, and, together with the pulmonary artery, is invested in a tube of serous membrane, continued on to them from the surface of the heart.

Relations.—The ascending aorta is covered at its commencement by the trunk of the pulmonary artery and the right auricular appendix, and, higher up, is separated from the sternum by the pericardium, the right pleura, and anterior margin of right lung, some loose areolar tissue, and the remains of the thymus gland; *behind*, it rests upon the right pulmonary artery and left auricle. On the *right side* it is in relation with the superior vena cava and right auricle; on the *left side*, with the pulmonary artery.

PLAN OF THE RELATIONS OF THE ASCENDING AORTA.

In front.
Pulmonary artery.
Right auricular appendix.
Pericardium.
Right pleura and lung.
Remains of thymus gland.

Right side.
Superior vena cava.
Right auricle.



Left side.
Pulmonary artery.

Behind.
Right pulmonary artery.
Left auricle.

BRANCHES OF THE ASCENDING AORTA.

The only branches of the ascending aorta are the coronary arteries. They supply the heart, and are two in number, right and left, arising near the commencement of the aorta, immediately above the free margin of the semilunar valves.

THE CORONARY ARTERIES.

The **Right Coronary Artery**, about the size of a crow's quill, arises from the anterior sinus of Valsalva. It passes forward between the pulmonary artery and the right auricular appendix, then runs obliquely to the right side, in the groove between the right auricle and ventricle, and, curving around the right border of the heart, runs along its posterior surface as far as the posterior interventricular groove, where its divides into two branches, one of which (*transverse*) continues onward in the groove between the left auricle and ventricle, and anastomoses with the left coronary; the other (*descending*) courses along the posterior interventricular furrow, supplying branches to both ventricles and to the septum, and anastomosing at the apex of the heart with the descending branches of the left coronary.

This vessel sends a large branch (*marginal*) along the thin margin of the right ventricle to the apex, which in its course gives off numerous small branches to the anterior and posterior surfaces of the ventricle. It also gives off a branch (*infundibular*) which ramifies over the front part of the conus arteriosus of the right ventricle.

The **Left Coronary**, larger than the former, arises from the left posterior sinus of Valsalva; it passes forward between the pulmonary artery and the left auricular appendix, and divides into two branches. Of these, one (*transverse*) passes transversely outward in the left auriculo-ventricular groove, and winds around the left border of the heart to its posterior surface, where it anastomoses with the trans-

verse branch of the right coronary; the other (*descending*) passes along the anterior interventricular groove to the apex of the heart, where it anastomoses with the descending branches of the right coronary. The left coronary supplies the left auricle and its appendix, gives branches to both ventricles, and numerous small branches to the pulmonary artery and commencement of the aorta.[1]

Peculiarities.—These vessels occasionally arise by a common trunk, or their number may be increased to three, the additional branch being of small size. More rarely there are two additional branches.

THE ARCH OF THE AORTA.

The **arch**, or **transverse aorta**, commences at the upper border of the second chondro-sternal articulation of the right side, and passes at first upward and backward and from right to left, and then from before backward, to the left side of the lower border of the fourth dorsal vertebra behind. Its upper border is usually about an inch below the upper margin of the sternum.

Between the origin of the left subclavian artery and the attachment of the ductus arteriosus the lumen of the fœtal aorta is considerably narrowed, forming what is termed the *aortic isthmus*, while immediately beyond the ductus arteriosus the vessel presents a fusiform dilatation which His has named the *aortic spindle*—the point of junction of the two parts being marked in the concavity of the arch by an indentation or angle. These conditions persist, to some extent, in the adult, where His found that the average diameter of the spindle exceeded that of the isthmus by 3 mm. (about one-eighth of an inch).

Relations.—Its *anterior surface* is covered by the pleuræ and lungs and the remains of the thymus gland, and crossed toward the left side by the left pneumogastric and phrenic nerves and superficial cardiac branches of the left sympathetic and vagus, and by the left superior intercostal vein. Its *posterior surface* lies on the trachea, just above its bifurcation, on the great, or deep, cardiac plexus, the œsophagus, thoracic duct, and left recurrent laryngeal nerve. Its *upper border* is in relation with the left innominate vein, and from its upper part are given off the innominate, left common carotid and left subclavian arteries. Its *lower border* is in relation with the bifurcation of the pulmonary artery, the remains of the ductus arteriosus, which is connected with the left division of that vessel, and the superficial cardiac plexus; the left recurrent laryngeal nerve winds round it from before backward, whilst the left bronchus passes below it.

PLAN OF THE RELATIONS OF THE ARCH OF THE AORTA.

Above.
Left innominate vein.
Innominate artery.
Left carotid.
Left subclavian.

In Front.
Pleuræ and lungs.
Remains of thymus gland.
Left pneumogastric nerve.
Left phrenic nerve.
Superficial cardiac nerves.
Left superior intercostal vein.



Behind.
Trachea.
Deep cardiac plexus.
Œsophagus.
Thoracic duct.
Left recurrent nerve.

Below.
Bifurcation of pulmonary artery.
Remains of ductus arteriosus.
Superficial cardiac plexus.
Left recurrent nerve.
Left bronchus.

[1] According to Dr. Samuel West, there is a very free and complete anastomosis between the two coronary arteries (*Lancet*, June 2, 1883, p. 945). This, however, is not the view generally held by anatomists, for, with the exception of the anastomosis mentioned above in the auriculo-ventricular and interventricular grooves, it is believed that the two arteries only communicate by very small vessels in the substance of the heart.

Peculiarities.—The height to which the aorta rises in the chest is usually about an inch below the upper border of the sternum; but it may ascend nearly to the top of that bone. Occasionally it is found an inch and a half, more rarely two or even three inches, below this point.

In Direction.—Sometimes the aorta arches over the root of the right instead of the left lung, as in birds, and passes down on the right side of the spine. In such cases all of the viscera of the thoracic and abdominal cavities are transposed. Less frequently, the aorta, after arching over the root of the right lung, is directed to its usual position on the left side of the spine, this peculiarity not being accompanied by any transposition of the viscera.

In Conformation.—The aorta occasionally divides, as in some quadrupeds, into an ascending and descending trunk, the former of which is directed vertically upward, and subdivides into three branches, to supply the head and upper extremities. Sometimes the aorta subdivides soon after its origin into two branches, which soon reunite. In one of these cases the œsophagus and trachea were found to pass through the interval left by their division; this is the normal condition of the vessel in the reptilia.

Surgical Anatomy.—Of all the vessels of the arterial system, the aorta, and more especially its arch, is most frequently the seat of disease; hence it is important to consider some of the consequences that may ensue from aneurism of this part.

It will be remembered that the ascending aorta is contained in the pericardium, just behind the sternum, being crossed at its commencement by the pulmonary artery and right auricular appendix, and having the right pulmonary artery behind, the vena cava on the right side, and the pulmonary artery and left auricle on the left side.

Aneurism of the ascending aorta, in the situation of the sinuses of Valsalva, in the great majority of cases, affects the anterior sinus; this is mainly owing to the fact that the regurgita-

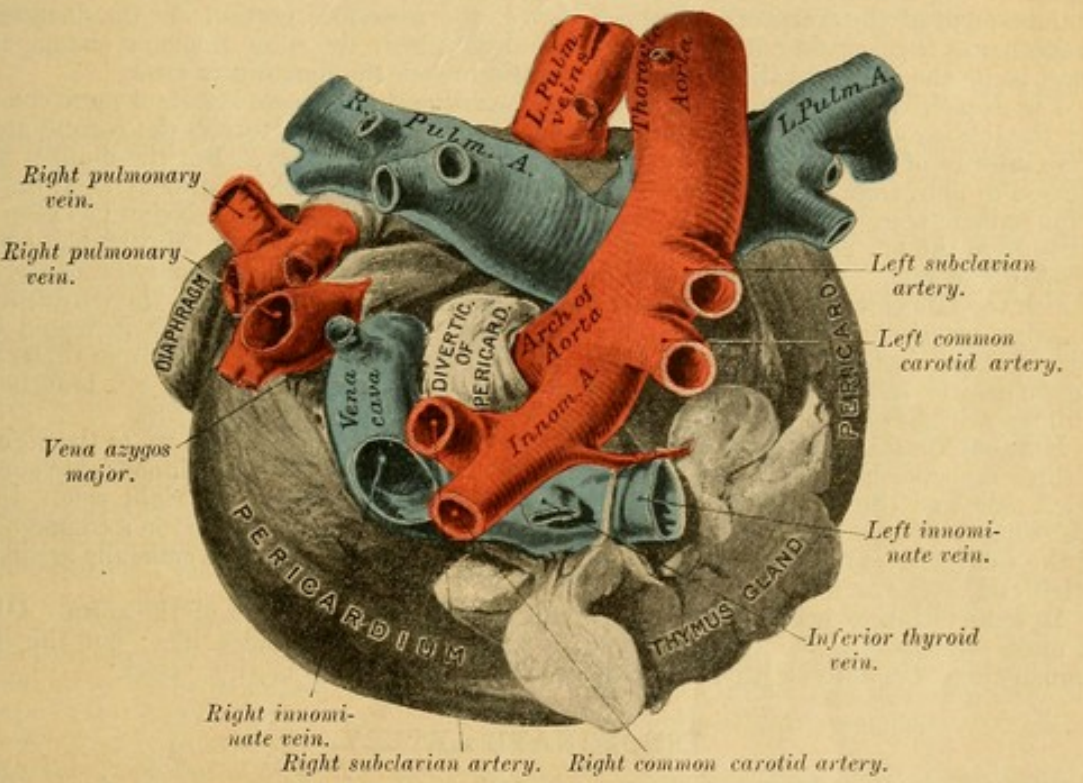

FIG. 282.—Relation of great vessels at base of heart, seen from above. (From a preparation in the Museum of the Royal College of Surgeons of England.)

tion of blood upon the sinuses takes place chiefly on the anterior aspect of the vessel. As the aneurismal sac enlarges it may compress any or all of the structures in immediate proximity with it, but chiefly projects toward the right anterior side, and, consequently, interferes mainly with those structures that have a corresponding relation with the vessel. In the majority of cases it bursts into the cavity of the pericardium, the patient suddenly drops down dead, and, upon a post-mortem examination, the pericardial sac is found full of blood; or it may compress the right auricle, or the pulmonary artery and adjoining part of the right ventricle, and open into one or the other of these parts, or may press upon the superior vena cava.

Aneurism of the ascending aorta, originating above the sinuses, most frequently implicates the right anterior wall of the vessel, where, as has been explained, there exists a normal dilatation, the great sinus of the aorta; this is probably mainly owing to the blood being impelled against this part. The direction of the aneurism is also chiefly toward the right of the median line. If it attains a large size and projects forward, it may absorb the sternum and the cartilages of the ribs, usually on the right side, and appear as a pulsating tumor on the front of the chest, just below the manubrium; or it may burst into the pericardium, or may compress or open into the right lung, the trachea, bronchi, or œsophagus.

Regarding the transverse aorta, the student is reminded that the vessel lies on the trachea, the œsophagus, and thoracic duct; that the recurrent laryngeal nerve winds around it; and that from its upper part are given off three large trunks, which supply the head, neck, and upper extremities. Now, an aneurismal tumor, taking origin from the posterior part of the vessel, its most usual site, may press upon the trachea, impede the breathing, or produce cough, hæmoptysis, or stridulous breathing, or it may ultimately burst into that tube, producing fatal hemorrhage. Again, its pressure on the laryngeal nerves may give rise to symptoms which so accurately resemble those of laryngitis that the operation of tracheotomy has in some cases been resorted to, from the supposition that disease existed in the larynx; or it may press upon the thoracic duct and destroy life by inanition; or it may involve the œsophagus, producing dysphagia; or may burst into the œsophagus, when fatal hæmorrhage will occur. Again, the innominate artery, or the subclavian, or left carotid, may be so obstructed by clots as to produce a weakness, or even a disappearance, of the pulse in one or the other wrist or in the left temporal artery; or the tumor may present itself at or above the manubrium, generally either in the median line or to the right of the sternum, and may simulate an aneurism of one of the arteries of the neck.

Branches of the Arch of the Aorta (Figs. 280, 281).

The branches given off from the arch of the aorta are three in number: the innominate artery, the left common carotid, and the left subclavian.

Peculiarities.—Position of the Branches.—The branches, instead of arising from the highest part of the arch (their usual position), may be moved more to the right, arising from the commencement of the transverse or upper part of the ascending portion: or the distance from one another at their origin may be increased or diminished, the most frequent change in this respect being the approximation of the left carotid toward the innominate artery.

The Number of the primary branches may be reduced to a single vessel, or more commonly two: the left carotid arising from the innominate artery, or (more rarely) the carotid and subclavian arteries of the left side arising from a left innominate artery. But the number may be increased to four, from the right carotid and subclavian arteries arising directly from the aorta, the innominate being absent. In most of these latter cases the right subclavian has been found to arise from the left end of the arch; in other cases it was the second or third branch given off instead of the first. Another common form in which there are four primary branches is that in which the left vertebral artery arises from the arch of the aorta between the left carotid and subclavian arteries. Lastly, the number of trunks from the arch may be increased to five or six; in these instances, the external and internal carotids arise separately from the arch, the common carotid being absent on one or both sides. In some cases, where six branches have been found, it has been due to a separate origin of the vertebral on both sides.

Number Usual, Arrangement Different.—When the aorta arches over to the right side, the three branches have an arrangement the reverse of what is usual, the innominate supplying the left side, and the carotid and subclavian (which arise separately) the right side. In other cases, where the aorta takes its usual course, the two carotids may be joined in a common trunk, and the subclavians arise separately from the arch, the right subclavian generally arising from the left end of the arch.[1]

In some instances other arteries are found to arise from the arch of the aorta. Of these the most common are the bronchial, one or both, and the thyroidea ima; but the internal mammary and the inferior thyroid have been seen to arise from this vessel.

INNOMINATE ARTERY.

The **innominate artery** (**brachio-cephalic**) is the largest branch given off from the arch of the aorta. It arises, on a level with the upper border of the second right costal cartilage, from the commencement of the arch of the aorta in front of the left carotid, and, ascending obliquely to the upper border of the right sterno-clavicular articulation, divides into the right common carotid and right subclavian arteries. This vessel varies from an inch and a half to two inches in length.

Relations.—*In front*, it is separated from the first piece of the sternum by the Sterno-hyoid and Sterno-thyroid muscles, the remains of the thymus gland, the left innominate and right inferior thyroid veins which cross its root, and sometimes the inferior cervical cardiac branch of the right pneumogastric. *Behind*, it lies upon the trachea, which it crosses obliquely. On the *right side* is the right innominate vein, right pneumogastric nerve, and the pleura; and on the *left side*,

[1] The anomalies of the aorta and its branches are minutely described by Krause in Henle's *Anatomy* (Brunswick, 1868), vol. iii., p. 203 *et seq.*

he remains of the thymus gland, the origin of the left carotid artery, the left nferior thyroid vein, and the trachea.

Branches.—The innominate usually gives off no branches, but occasionally a mall branch, the *thyroidea ima*, is given off from this vessel. It also sometimes ives off a *thymic* or *bronchial branch*. The **Thyroidea ima** ascends in front of he trachea to the lower part of the thyroid body, which it supplies. It varies reatly in size, and appears to compensate for deficiency or absence of one of the ther thyroid vessels. It occasionally is found to arise from the right common arotid or from the aorta, the subclavian, or internal mammary vessels.

PLAN OF THE RELATIONS OF THE INNOMINATE ARTERY.

In front.

Sternum.
Sterno-hyoid and Sterno-thyroid muscles.
Remains of thymus gland.
Left innominate and right inferior thyroid veins.
Inferior cervical cardiac branch from right pneumogastric nerve.

Right side.

Right innominate vein.
Right pneumogastric nerve.
Pleura.



Left side.

Remains of thymus.
Left carotid.
Left inferior thyroid vein.
Trachea.

Behind.

Trachea.

Peculiarities in Point of Division.—When the bifurcation of the innominate artery varies rom the point above mentioned, it sometimes ascends a considerable distance above the sternal nd of the clavicle; less frequently it divides below it. In the former class of cases its length ay exceed two inches, and in the latter be reduced to an inch or less. These are points of conderable interest for the surgeon to remember in connection with the operation of tying this vessel.

Position.—When the aorta arches over to the right side, the innominate is directed to the ft side of the neck instead of the right.

Collateral Circulation.—Allan Burns demonstrated, on the dead subject, the possibility of he establishment of the collateral circulation after ligature of the innominate artery, by tying nd dividing that artery, after which, he says, "Even coarse injection, impelled into the aorta, assing freely by the anastomosing branches into the arteries of the right arm, filling them and ll the vessels of the head completely" (*Surgical Anatomy of the Head and Neck*, p. 62). he branches by which this circulation would be carried on are very numerous; thus, all the ommunications across the middle line between the branches of the carotid arteries of opposite ides would be available for the supply of blood to the right side of the head and neck; while he anastomosis between the superior intercostal of the subclavian and the first aortic intercostal see *infra* on the collateral circulation after obliteration of the thoracic aorta) would bring the lood, by a free and direct course, into the right subclavian: the numerous connections, also, etween the intercostal arteries and the branches of the axillary and internal mammary arteries ould, doubtless, assist in the supply of blood to the right arm, while the deep epigastric, from he external iliac, would, by means of its anastomosis with the internal mammary, compensate or any deficiency in the vascularity of the wall of the chest.

Surgical Anatomy.—Although the operation of tying the innominate artery has been erformed by several surgeons for aneurism of the right subclavian extending inward as far as he Scalenus, in only five instances, according to Mr. Jacobson, has the patient survived. Iott's patient, however, on whom the operation was first performed, lived nearly four weeks, nd Graefe's more than two months. The chief danger of the operation appears to be the frequency of secondary hemorrhage; but in the present day, with the practice of aseptic surgery nd our greater knowledge of the use of the ligature, more favorable results may be anticipated. Other causes of death after operation are pleurisy, pericarditis, and suppurative cellulitis. The nain obstacles to the operation are, as the student will perceive from his dissection of this essel, the deep situation of the artery behind and beneath the sternum, and the number of mportant structures which surround it in every part.

In order to apply a ligature to this vessel, the patient is to be placed upon his back, with the horax slightly raised, the head bent a little backward, and the shoulder on the side of the aneuism strongly depressed, so as to draw out the artery from behind the sternum into the neck. An incision three or more inches long is then made along the anterior border of the Sterno-mastoid muscle, terminating at the sternal end of the clavicle. From this point a second incision is carried about the same length along the upper border of the clavicle. The skin is then dissected back, and the Platysma divided on a director: the sternal end of the Sterno-mastoid is now brought into view, and, a director being passed beneath it and close to its under surface, so as to avoid any small vessels, it is to be divided; in like manner the clavicular origin is to be divided

throughout the whole or greater part of its attachment. By pressing aside any loose cellular tissue or vessels that may now appear the Sterno-hyoid and Sterno-thyroid muscles will be exposed, and must be divided, a director being previously passed beneath them. The inferior thyroid veins may come into view, and must be carefully drawn, either upward or downward, by means of a blunt hook, or tied with double ligatures and divided. After tearing through a strong fibro-cellular lamina, the right carotid is brought into view, and, being traced downward, the arteria innominata is arrived at. The left innominate vein should now be depressed; the right innominate vein, the internal jugular vein, and the pneumogastric nerve drawn to the right side; and a curved aneurism needle may then be passed around the vessel, close to its surface, and in a direction from below upward and inward, care being taken to avoid the right pleural sac, the trachea, and cardiac nerves. The ligature should be applied to the artery as high as possible, in order to allow room between it and the aorta for the formation of the coagulum. The importance of avoiding the thyroid plexus of veins during the primary steps of the operation, and the pleural sac whilst including the vessel in the ligature, should be most carefully borne in mind. After the artery has been secured, the common carotid should be tied about half an inch above its origin, and also the thyroidea ima if the vessel is of any size. The several muscles are united by buried sutures.

ARTERIES OF THE HEAD AND NECK.

The artery which supplies the head and neck is the Common Carotid: it ascends in the neck and divides into two branches: the External Carotid, supplying the superficial parts of the head and face and the greater part of the neck; and the Internal Carotid, supplying to a great extent the parts within the cranial cavity.

The Common Carotid Arteries.

The **common carotid arteries,** although occupying a nearly similar position in the neck, differ in position, and, consequently, in their relation at their origin. The right carotid arises from the innominate artery, behind the right sterno-clavicular articulation; the left from the highest part of the arch of the aorta. The left carotid is, consequently, longer, and at its origin is contained within the thorax. The course and relations of that portion of the left carotid which intervenes between the arch of the aorta and the left sterno-clavicular articulation will first be described (see Fig. 280).

The left carotid within the thorax ascends obliquely outward from the arch of the aorta to the root of the neck. *In front*, it is separated from the first piece of the sternum by the Sterno-hyoid and Sterno-thyroid muscles, the left innominate vein, and the remains of the thymus gland; *behind*, it lies on the trachea, œsophagus, and thoracic duct. *Internally*, it is in relation with the innominate artery, inferior thyroid veins and remains of thymus gland; *externally*, with the left pneumogastric nerve, left pleura, and lung. The left subclavian artery is posterior and slightly external to it.

PLAN OF THE RELATIONS OF THE LEFT COMMON CAROTID.
THORACIC PORTION.

In front.
Sternum.
Sterno-hyoid and Sterno-thyroid muscles.
Left innominate vein.
Remains of thymus gland.

Internally.
Innominate artery.
Inferior thyroid veins.
Remains of thymus gland.



Externally.
Left pneumogastric nerve.
Left pleura and lung.
Left subclavian artery.

Behind.
Trachea.
Œsophagus.
Thoracic duct.
Left subclavian artery.

In the neck the two common carotids resemble each other so closely that one description will apply to both. Each vessel passes obliquely upward from behind the sterno-clavicular articulation to a level with the upper border of the thyroid cartilage, opposite the fourth cervical vertebra, where it divides into the external

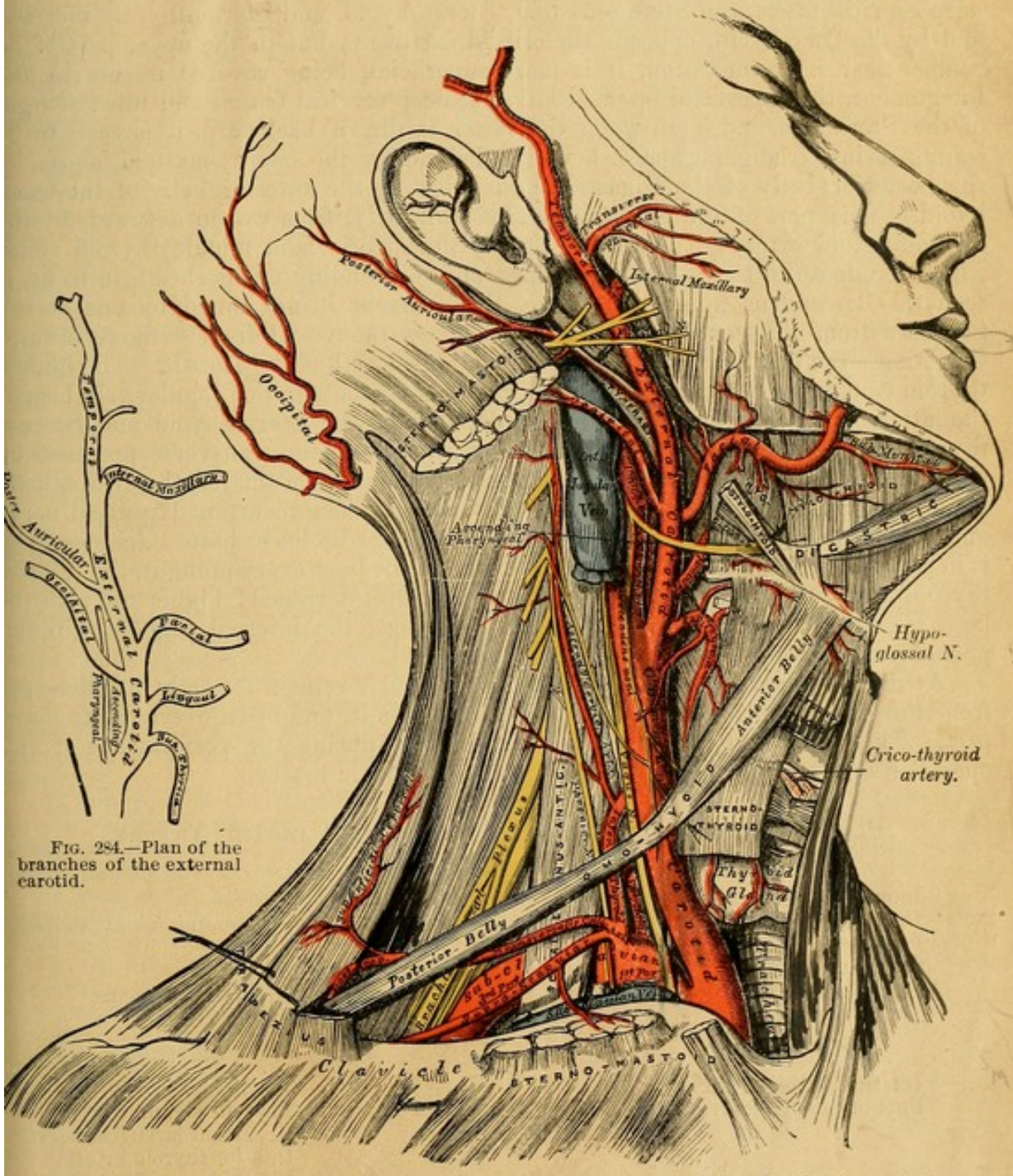

FIG. 284.—Plan of the branches of the external carotid.

FIG. 283.—Surgical anatomy of the arteries of the neck, showing the carotid and subclavian arteries.

and internal carotid; these names being derived from the distribution of the arteries to the external parts of the head and face and to the internal parts of the cranium and orbit respectively.

At the lower part of the neck the two common carotid arteries are separated from each other by a small interval, which contains the trachea; but at the upper part, the thyroid body, the larynx and pharynx project forward between the two vessels, and give the appearance of their being placed farther back in this situation. The common carotid artery is contained in a sheath derived from the deep cervical fascia, which also encloses the internal jugular vein and pneumogastric nerve, the vein lying on the outer side of the artery, and the nerve between

the artery and vein, on a plane posterior to both. On opening the sheath these three structures are seen to be separated from one another, each being enclosed in a separate fibrous investment.

Relations.—At the lower part of the neck the common carotid artery is very deeply seated, being covered by the integument, superficial fascia, Platysma, and deep cervical fascia, the Sterno-mastoid, Sterno-hyoid, and Sterno-thyroid muscles, and by the Omo-hyoid, opposite the cricoid cartilage; but in the upper part of its course, near its termination, it is more superficial, being covered merely by the integument, the superficial fascia, Platysma, deep cervical fascia, and inner margin of the Sterno-mastoid, and, when the latter is drawn backward, it is seen to be contained in a triangular space, bounded behind by the Sterno-mastoid, above by the posterior belly of the Digastric, and below by the anterior belly of the Omo-hyoid. This part of the artery is crossed obliquely, from within outward, by the sterno-mastoid artery; it is crossed also by the superior and middle thyroid veins, which terminate in the internal jugular; and, descending on its sheath in front, is seen the descendens hypoglossi nerve, this filament being joined by one or two branches from the cervical nerves, which cross the vessel from without inward. Sometimes the descendens hypoglossi is contained within the sheath. The middle thyroid vein crosses the artery about its middle, and the anterior jugular vein below; the latter, however, is separated from the artery by the Sterno-hyoid and Sterno-thyroid muscles. *Behind*, the artery is separated from the transverse processes of the vertebræ by the Longus colli and Rectus capitis anticus major, the sympathetic nerve being interposed between it and the muscles. The recurrent laryngeal nerve and inferior thyroid artery cross behind the vessel at its lower part. *Internally*, it is in relation with the trachea and thyroid gland, the later overlapping it, the inferior thyroid artery and recurrent laryngeal nerve being interposed: higher up, with the larynx and pharynx. On its *outer side* are placed the internal jugular vein and pneumogastric nerve.

At the lower part of the neck the internal jugular vein on the right side diverges from the artery, but on the left side it approaches it, and often overlaps its lower part. This is an important fact to bear in mind during the performance of any operation on the lower part of the left common carotid artery.

PLAN OF THE RELATIONS OF THE COMMON CAROTID ARTERY.

In front.

Integument and superficial fascia.
Deep cervical fascia.
Platysma.
Sterno-mastoid.
Sterno-hyoid.
Sterno-thyroid.
Omo-hyoid.
Descendens and Communicans hypoglossi nerves.
Sterno-mastoid artery.
Superior and middle thyroid veins.
Anterior jugular vein.

Externally.

Internal jugular vein.
Pneumogastric nerve.

Common Carotid.

Internally.

Trachea.
Thyroid gland.
Recurrent laryngeal nerve.
Inferior thyroid artery.
Larynx.
Pharynx.

Behind.

Longus colli.
Rectus capitis anticus major.
Sympathetic nerve.
Inferior thyroid artery.
Recurrent laryngeal nerve.

Peculiarities as to Origin.—The *right common carotid* may arise above or below the upper border of the sterno-clavicular articulation. This variation occurs in one out of about eight cases and a half, and the origin is more frequently below than above; or the artery may arise as a separate branch from the arch of the aorta or in conjunction with the left carotid. The *left common carotid* varies more frequently in its origin than the right. In the majority of abnormal cases it arises with the innominate artery, or, if the innominate artery is absent, the two carotids arise usually by a single trunk. It rarely joins with the left subclavian, except in cases of transposition of the arch.

Peculiarities as to Point of Division.—The most important peculiarities of this vessel, in a surgical point of view, relate to its place of division in the neck. In the majority of abnormal cases this occurs higher than usual, the artery dividing into two branches opposite the hyoid bone, or even higher; more rarely it occurs below, opposite the middle of the larynx or the lower border of the cricoid cartilage; and one case is related by Morgagni where the common carotid, only an inch and a half in length, divided at the root of the neck. Very rarely the common carotid ascends in the neck without any subdivision, the internal carotid being wanting; and in a few cases the common carotid has been found to be absent, the external and internal carotids arising directly from the arch of the aorta. This peculiarity existed on both sides in some instances, on one side in others.

Occasional Branches.—The common carotid usually gives off no branch previous to its bifurcation; but it occasionally gives origin to the superior thyroid or its laryngeal branch, the ascending pharyngeal, the inferior thyroid, or, more rarely, the vertebral artery.

Surface Marking.—The carotid arteries are covered throughout their entire extent by the Sterno-mastoid muscle, but their course does not correspond to the anterior border of the muscle, which passes in a somewhat curved direction from the mastoid process to the sterno-clavicular joint. The course of the artery is indicated more exactly by a line drawn from the sternal end of the clavicle below, to a point midway between the angle of the jaw and the mastoid process above. That portion of the line below the level of the upper border of the thyroid cartilage would represent the course of the vessel.

Surgical Anatomy.—The operation of tying the common carotid artery may be necessary in a case of wound of that vessel or its branches, in aneurism, or in a case of pulsating tumor of the orbit or skull. If the wound involves the trunk of the common carotid, it will be necessary to tie the artery above and below the wounded part. But in cases of aneurism, or where one of the branches of the common carotid is wounded in an inaccessible situation, it may be judged necessary to tie the trunk. In such cases the whole of the artery is accessible, and any part may be tied except close to either end. When the case is such as to allow of a choice being made, the lower part of the carotid should never be selected as the spot upon which to place a ligature, for not only is the artery in this situation placed very deeply in the neck, but it is covered by three layers of muscles, and, on the left side, the internal jugular vein, in the great majority of cases, passes obliquely in front of it. Neither should the upper end be selected, for here the superior thyroid vein and its tributaries would give rise to very considerable difficulty in the application of a ligature. The point most favorable for the operation is that part of the vessel which is at the level of the cricoid cartilage. It occasionally happens that the carotid artery bifurcates below its usual position: if the artery be exposed at its point of bifurcation, both divisions of the vessel should be tied near their origin, in preference to tying the trunk of the artery near its termination; and if, in consequence of the entire absence of the common carotid or from its early division, two arteries, the external and internal carotids, are met with, the ligature should be placed on that vessel which is found on compression to be connected with the disease.

In this operation the direction of the vessel and the inner margin of the Sterno-mastoid are the chief guides to its performance. The patient should be placed on his back with the head thrown back and turned slightly to the opposite side: an incision is to be made, three inches long, in the direction of the anterior border of the Sterno-mastoid, so that the centre corresponds to the level of the cricoid cartilage: after dividing the integument, superficial fascia, and Platysma, the deep fascia must be cut through on a director, so as to avoid wounding numerous small veins that are usually found beneath. The head may now be brought forward so as to relax the parts somewhat, and the margins of the wound held asunder by retractors. The descendens hypoglossi nerve may now be exposed, and must be avoided, and, the sheath of the vessel having been raised by forceps, is to be opened to a small extent over the artery at its inner side. The internal jugular vein may present itself alternately distended and relaxed; this should be compressed both above and below, and drawn outward, in order to facilitate the operation. The aneurism needle is passed from the outside, care being taken to keep the needle in close contact with the artery, and thus avoid the risk of injuring the internal jugular vein or including the vagus nerve. Before the ligature is tied it should be ascertained that nothing but the artery is included in it.

Ligature of the Common Carotid at the Lower Part of the Neck.—This operation is sometimes required in cases of aneurism of the upper part of the carotid, especially if the sac is of large size. It is best performed by dividing the sternal origin of the Sterno-mastoid muscle, but may be done in some cases, if the aneurism is not of very large size, by an incision along the anterior border of the Sterno-mastoid, extending down to the sterno-clavicular articulation, and by then retracting the muscle. The easiest and best plan, however, is to make an incision two or three inches long down the lower part of the anterior border of the Sterno-mastoid muscle to the sterno-clavicular joint, and a second incision, starting from the termination of the first, along the upper border of the clavicle for about two inches. This incision is made through the superficial and deep fascia, and the sternal origin of the muscle exposed. This is to be divided on a director, and turned up, with the superficial structures, as a triangular flap. Some loose connective tissue is to be divided or torn through, and the o er border of the Sterno-hyoid muscle exposed. In doing this care must be taken not to wound the anterior jugular vein, which crosses the muscle to reach the external jugular or subclavian vein. The Sterno-hyoid, and with it the Sterno-thyroid, are to be drawn inward by means of a retractor.

and the sheath of the vessel is exposed. This must be opened with great care on its inner or tracheal side, so as to avoid the internal jugular vein. This is especially necessary on the left side, where the artery is commonly overlapped by the vein. On the right side there is usually an interval between the artery and the vein, and not the same risk of wounding the latter.

The common carotid artery, being a long vessel without any branches, is particularly suitable for the performance of Brasdor's operation for the cure of an aneurism of the lower part of the vessel. Brasdor's procedure consists in ligaturing the artery on the distal side of the aneurism, and in the case of the common carotid there are no branches given off from the vessel between the aneurism and the site of the ligature; hence the flow of blood through the sac of the aneurism is diminished and cure takes place in the usual way, by the deposit of laminated fibrin.

Collateral Circulation.—After ligature of the common carotid the collateral circulation can be perfectly established, by the free communication which exists between the carotid arteries of opposite sides, both without and within the cranium, and by enlargement of the branches of the subclavian artery on the side corresponding to that on which the vessel has been tied—the chief communication outside the skull taking place between the superior and inferior thyroid arteries, and the profunda cervicis and arteria princeps cervicis of the occipital; the vertebral taking the place of the internal carotid within the cranium.

Sir A. Cooper had an opportunity of dissecting, thirteen years after the operation, the case in which he first successfully tied the common carotid (the second case in which he performed the operation).[1] The injection, however, does not seem to have been a successful one. It showed merely that the arteries at the base of the brain (circle of Willis) were much enlarged on the side of the tied artery, and that the anastomosis between the branches of the external carotid on the affected side and those of the same artery on the sound side was free, so that the external carotid was pervious throughout.

The External Carotid Artery.

The **external carotid artery** (Fig. 283) commences opposite the upper border of the thyroid cartilage, and, taking a slightly curved course, passes upward and forward, and then inclines backward to the space between the neck of the condyle of the lower jaw and the external meatus, where it divides into the temporal and internal maxillary arteries. It rapidly diminishes in size in its course up the neck, owing to the number and large size of the branches given off from it. In the child it is somewhat smaller than the internal carotid, but in the adult the two vessels are of nearly equal size. At its commencement this artery is more superficial, and placed nearer the middle line than the internal carotid, and is contained in the triangular space bounded by the Sterno-mastoid behind, the Omo-hyoid below, and the posterior belly of the Digastric and Stylo-hyoid above.

Relations.—It is covered by the skin, superficial fascia, Platysma, deep fascia, and anterior margin of the Sterno-mastoid, crossed by the hypoglossal nerve, and by the lingual and facial veins; it is afterward crossed by the Digastric and Stylo-hyoid muscles, and higher up passes deeply into the substance of the parotid gland, where it lies beneath the facial nerve and the junction of the temporal and internal maxillary veins. *Internally* is the hyoid bone, wall of the pharynx, the superior laryngeal nerve, and the ramus of the jaw, from which it is separated by a portion of the parotid gland. *Externally*, in the lower part of its course, is the internal carotid artery. *Behind* it, near its origin, is the superior laryngeal nerve; and higher up, it is separated from the internal carotid by the Stylo-glossus and Stylo-pharyngeus muscles, the glosso-pharyngeal nerve, and part of the parotid gland.

Plan of the Relations of the External Carotid.

In front.

Skin, superficial fascia.
Platysma and deep fascia.
Anterior border of Sterno-mastoid.
Hypoglossal nerve.
Lingual and facial veins.
Digastric and Stylo-hyoid muscles.
Parotid gland with facial nerve and temporo-maxillary vein in its substance.

[1] *Guy's Hospital Reports*, i., 56.

Internally.
Hyoid bone.
Pharynx.
Superior laryngeal nerve.
Parotid gland.
Ramus of jaw.



Externally.
Internal carotid artery.

Behind.
Superior laryngeal nerve.
Stylo-glossus.
Stylo-pharyngeus.
Glosso-pharyngeal nerve.
Parotid gland.

Surface Marking.—The position of the external carotid artery may be marked out with sufficient accuracy by a line drawn from the front of the meatus of the external ear to the side of the cricoid cartilage, slightly arching the line forward.

Surgical Anatomy.—The application of a ligature to the external carotid may be required in case of wounds of this vessel, or of its branches when these cannot be tied, and in some cases of pulsating tumor of the scalp or face. The operation has not received the attention which it deserves, owing to the fear which surgeons have entertained of secondary hæmorrhage, on account of the number of branches given off from the vessel. This fear, however, has been shown by Mr. Cripps not to be well founded.[1] To tie this vessel near its origin, below the point where it is crossed by the Digastric, an incision about three inches in length should be made along the margin of the Sterno-mastoid, from the angle of the jaw to the upper border of the thyroid cartilage. The ligature should be applied between the lingual and superior thyroid branches. To tie the vessel above the Digastric, between it and the parotid gland, an incision should be made, from the lobe of the ear to the great cornu of the os hyoides, dividing successively the skin, Platysma, and fascia. By drawing the Sterno-mastoid outward, and the posterior belly of the Digastric and Stylo-hyoid muscles downward, and separating them from the parotid gland, the vessel will be exposed, and a ligature may be applied to it. The circulation is at once re-established by the free communication between most of the large branches of the artery (facial, lingual, superior thyroid, occipital) and the corresponding arteries of the opposite side, and by the anastomosis of its branches with those of the internal carotid, and of the occipital with the branches of the subclavian, etc.

Branches.—The external carotid artery gives off eight branches, which, for convenience of description, may be divided into four sets. (See Fig. 284, Plan of the Branches).

Anterior.	*Posterior.*	*Ascending.*	*Terminal.*
Superior Thyroid.	Occipital.	Ascending Pharyngeal.	Superficial Temporal.
Lingual.	Posterior Auricular.		Internal Maxillary.
Facial.			

The student is here reminded that many variations are met with in the number, origin, and course of these branches in different subjects; but the above arrangement is that which is found in the great majority of cases.

The **Superior Thyroid Artery** (Figs. 283 and 288) is the first branch given off from the external carotid, being derived from that vessel just below the great cornu of the hyoid bone. At its commencement it is quite superficial, being covered by the integument, fascia, and Platysma, and is contained in the triangular space bounded by the Sterno-mastoid, Digastric, and Omo-hyoid muscles. After running upward and inward for a short distance, it curves downward and forward, in an arched and tortuous manner, to the upper part of the thyroid gland, passing beneath the Omo-hyoid, Sterno-hyoid, and Sterno-thyroid muscles, and supplying them. It distributes numerous branches to the upper part of the gland, anastomosing with its fellow of the opposite side and with the inferior thyroid arteries. The branches supplying the gland are generally three in number: one, the largest, supplies principally the anterior surface of the gland; it courses along the inner border of the lobe as far as the upper border of the isthmus, and then passes in the substance of the isthmus to the middle line of the neck, where it anastomoses with the corresponding artery of the opposite side: a second branch courses along the external border of the lobe, and supplies this portion of the gland, and the third passes to the posterior surface, the upper part of which it supplies.

[1] *Med.-Chir. Trans.*, lxi., 229.

Besides the arteries distributed to the muscles by which it is covered and to the substance of the gland, the branches of the superior thyroid are the following:

Hyoid.	Superior laryngeal.
Superficial descending branch (Sterno-mastoid).	Crico-thyroid.

The **hyoid** (**infra-hyoid**) is a small branch which runs along the lower border of the os hyoides beneath the Thyro-hyoid muscle; after supplying the muscles connected to that bone, it forms an arch, by anastomosing with the vessel of the opposite side.

The **superficial descending** or **Sterno-mastoid branch** runs downward and outward across the sheath of the common carotid artery, and supplies the Sterno-mastoid and neighboring muscles and integument. There is frequently a separate branch from the external carotid distributed to the Sterno-mastoid muscle.

The **superior laryngeal,** larger than either of the preceding, accompanies the internal laryngeal nerve, beneath the Thyro-hyoid muscle: it pierces the thyro-hyoid membrane, and supplies the muscles, mucous membrane, and glands of the larynx, anastomosing with the branch from the opposite side.

The **crico-thyroid** is a small branch which runs transversely across the crico-thyroid membrane, communicating with the artery of the opposite side.

Surgical Anatomy.—The superior thyroid, or one of its branches, is often divided in cases of cut throat, giving rise to considerable hemorrhage. In such cases the artery should be secured, the wound being enlarged for that purpose, if necessary. The operation may be easily performed, the position of the artery being very superficial, and the only structures of importance covering it being a few small veins. The operation of tying the superior thyroid artery in bronchocele has been performed in numerous instances with partial or temporary success. When, however, the collateral circulation between this vessel and the artery of the opposite side, and the inferior thyroid, is completely re-established, the tumor usually regains its former size, and hence the operation has been given up, especially as better results are obtained by other means. Both thyroid arteries on the same side, and indeed all the four thyroid arteries, have been tied in enlarged thyroid.

The position of the superficial descending branch is of importance in connection with the operation of ligation of the common carotid artery. It crosses and lies on the sheath of this vessel, and may chance to be wounded in opening the sheath. The position of the crico-thyroid branch should be remembered, as it may prove the source of troublesome hemorrhage during the operation of laryngotomy.

The **Lingual Artery** (Fig. 288) arises from the external carotid between the superior thyroid and facial; it first runs obliquely upward and inward to the great cornu of the hyoid bone; it then curves downward and forward, forming a loop which is crossed by the hypoglossal nerve, and, passing beneath the Digastric and Stylo-hyoid muscles, it runs horizontally forward, beneath the Hyo-glossus, and finally, ascending almost perpendicularly to the tongue, turns forward on its under surface as far as the tip, under the name of the *ranine artery.*

Relations.—Its first, or oblique, portion is superficial, being contained in the same triangular space as the superior thyroid artery, resting upon the middle constrictor of the pharynx, and covered by the Platysma and fascia of the neck. Its second, or curved, portion also lies upon the middle constrictor, being covered at first by the tendon of the Digastric and the Stylo-hyoid muscle, and afterward by the Hyo-glossus, the latter muscle separating it from the hypoglossal nerve. Its third, or horizontal, portion lies between the Hyo-glossus and Genio-hyo-glossus muscles. The fourth, or terminal, part, under the name of the *ranine*, runs along the under surface of the tongue to its tip: it is very superficial, being covered only by the mucous membrane, and rests on the Lingualis on the outer side of the Genio-hyo-glossus. The hypoglossal nerve crosses the lingual artery, and then becomes separated from it, in the second part of its course, by the Hyo-glossus muscle.

The branches of the lingual artery are—the

Hyoid.	Sublingual.
Dorsalis Linguæ.	Ranine.

The **hyoid branch** (**supra-hyoid**) runs along the upper border of the hyoid bone, supplying the muscles attached to it and anastomosing with its fellow of the opposite side.

The **dorsalis linguæ** (Fig. 288) arises from the lingual artery beneath the Hyo-glossus muscle (which, in the figure, has been partly cut away, to show the vessel); it ascends to the dorsum of the tongue, and supplies the mucous membrane, the tonsil, soft palate, and epiglottis, anastomosing with its fellow from the opposite side. This artery is frequently represented by two or three small branches.

The **sublingual,** which may be described as a branch of bifurcation of the lingual artery, arises at the anterior margin of the Hyo-glossus muscle, and runs forward between the Genio-hyo-glossus and the sublingual gland. It supplies the substance of the gland, giving branches to the Mylo-hyoid and neighboring muscles, the mucous membrane of the mouth and gums. One branch runs behind the alveolar process of the lower jaw in the substance of the gum to anastomose with a similar artery from the other side.

The **ranine** may be regarded as the other branch of bifurcation, or, as is more usual, as the continuation of the lingual artery; it runs along the under surface of the tongue, resting on the Inferior lingualis, and covered by the mucous membrane of the mouth; it lies on the outer side of the Genio-hyo-glossus, accompanied by the lingual nerve. On arriving at the tip of the tongue it has been said to anastomose with the artery of the opposite side, but this is denied by Hyrtl. These vessels in the mouth are placed one on each side of the frænum.

Surgical Anatomy.—The lingual artery may be divided near its origin in cases of cut throat, a complication that not unfrequently happens in this class of wounds; or severe hæmorrhage which cannot be restrained by ordinary means may ensue from a wound or deep ulcer of the tongue. In the former case the primary wound may be enlarged if necessary, and the bleeding vessels secured. In the latter case it has been suggested that the lingual artery should be tied near its origin. Ligature of the lingual artery is also occasionally practised, as a palliative measure, in cases of cancer of the tongue, in order to check the progress of the disease by starving the growth, and it is sometimes tied as a preliminary measure to removal of the tongue. The operation is a difficult one, on account of the depth of the artery, the number of important parts by which it is surrounded, the loose and yielding nature of the parts upon which it is supported, and its occasional irregularity of origin. An incision is to be made in a curved direction from a finger's breadth external to the symphysis of the jaw downward to the cornu of the hyoid bone, and then upward to near the angle of the jaw. Care must be taken not to carry this incision too far backward, for fear of endangering the facial vein. In the first incision the skin, superficial fascia, and Platysma will be divided, and the deep fascia exposed. This is then to be incised and the submaxillary gland exposed and pulled upward by retractors. A triangular space is now exposed, bounded internally by the posterior border of the Mylo-hyoid muscle: below and externally, by the tendon of the Digastric; and above, by the hypo-glossal nerve. The floor of the space is formed by the Hyo-glossus muscle, beneath which the artery lies. The fibres of this muscle are now to be cut through horizontally and the vessel exposed, care being taken, while near the vessel, not to open the pharynx.

Troublesome hæmorrhage may occur in the division of the frænum in children if the ranine artery, which lies on each side of it, is wounded. The student should remember that the operation is always to be performed with a pair of blunt-pointed scissors, and the mucous membrane only is to be divided by a very superficial cut, which cannot endanger any vessel. The scissors, also, should be directed away from the tongue. Any further liberation of the tongue which may be necessary can be effected by tearing.

The **Facial Artery** (Fig. 285) arises a little above the lingual, and passes obliquely upward, beneath the Digastric and Stylo-hyoid muscles, and frequently beneath the hypoglossal nerve; it now runs forward under cover of the body of the lower jaw, lodged in a groove on the posterior surface of the submaxillary gland; this may be called the cervical part of the artery. It then curves upward over the body of the jaw at the anterior inferior angle of the Masseter muscle; passes forward and upward across the cheek to the angle of the mouth, then upward along the side of the nose, and terminates at the inner canthus of the eye, under the name of the *angular artery*. This vessel, both in the neck and on the face, is remarkably tortuous: in the former situation, to accommodate itself to the movements of the pharynx in deglutition, and in the latter to the movements of the jaw and the lips and cheeks.

Relations.—*In the neck* its origin is superficial, being covered by the integument, Platysma, and fascia; it then passes beneath the Digastric and Stylo-hyoid muscles and part of the submaxillary gland. It lies upon the middle constrictor of the pharynx, and is separated from the Stylo-glossus and Hyo-glossus muscles by a portion of the submaxillary gland. *On the face*, where it passes over the body of the lower jaw, it is comparatively superficial, lying immediately beneath the Platysma. In this situation its pulsation may be distinctly felt, and compression of the vessel against the bone can be effectually made. In its course over the

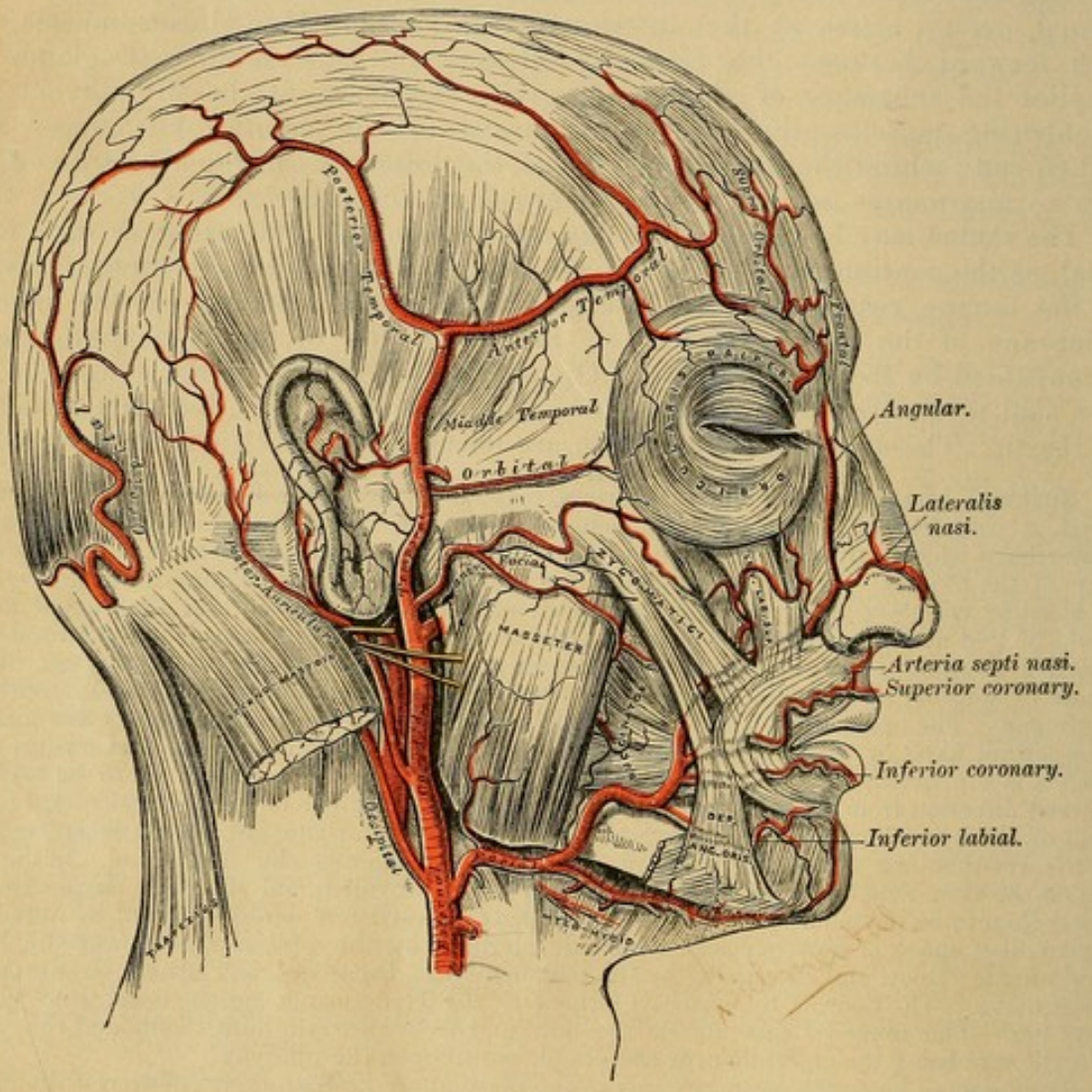

FIG. 285.—The arteries of the face and scalp.[1]

face it is covered by the integument, the fat of the cheek, and, near the angle of the mouth, by the Platysma, Risorius, and Zygomatici muscles. It rests on the Buccinator, the Levator anguli oris, and the Levator labii superioris (sometimes piercing or else passing under this last muscle). The facial vein lies to the outer side of the artery, and takes a more direct course across the face, where it is separated from the artery by a considerable interval. In the neck it lies superficial to the artery. The branches of the facial nerve cross the artery, and the infra-orbital nerve lies beneath it.

The branches of this vessel may be divided into two sets: those given off below the jaw (cervical), and those on the face (facial).

[1] The muscular tissue of the lips must be supposed to have been cut away, in order to show the course of the coronary arteries.

Cervical Branches.	*Facial Branches.*
Inferior or Ascending Palatine.	Muscular.
Tonsillar.	Inferior Labial.
Submaxillary.	Inferior Coronary.
Submental.	Superior Coronary.
Muscular.	Lateral Nasal.
	Angular.

The **inferior** or **ascending palatine** (Fig. 289) passes up between the Stylo-glossus and Stylo-pharyngeus to the outer side of the pharynx, along which it is continued between the Superior constrictor and the Internal pterygoid to near the base of the skull. It supplies the neighboring muscles, the tonsil, and Eustachian tube, and divides, near the Levator palati, into two branches: one follows the course of the Levator palati, and, winding over the upper border of the Superior constrictor, supplies the soft palate and the palatine glands, anastomosing with its fellow of the opposite side and with the posterior palatine branch of the internal maxillary artery; the other pierces the Superior constrictor and supplies the tonsil, anastomosing with the tonsillar and ascending pharyngeal arteries.

The **tonsillar branch** (Fig. 289) passes up between the Internal pterygoid and Stylo-glossus, and then ascends along the side of the pharynx, perforating the Superior constrictor, to ramify in the substance of the tonsil and root of the tongue.

The **submaxillary or glandular branches** consist of three or four large vessels, which supply the submaxillary gland, some being prolonged to the neighboring muscles, lymphatic glands, and integument.

The **submental,** the largest of the cervical branches, is given off from the facial artery just as that vessel quits the submaxillary gland: it runs forward upon the Mylo-hyoid muscle, just below the body of the jaw and beneath the Digastric; after supplying the surrounding muscles, and anastomosing with the sublingual artery by branches which perforate the Mylo-hyoid muscle, it arrives at the symphysis of the chin, where it turns over the border of the jaw and divides into a superficial and a deep branch; the former passes between the integument and Depressor labii inferioris, supplies both, and anastomoses with the inferior labial. The deep branch passes between the latter muscle and the bone, supplies the lip, and anastomoses with the inferior labial and mental arteries.

The **muscular branches** are distributed to the Internal pterygoid and Stylo-hyoid in the neck, and to the Masseter and Buccinator on the face.

The **inferior labial** passes beneath the Depressor anguli oris, to supply the muscles and integument of the lower lip, anastomosing with the inferior coronary and submental branches of the facial, and with the mental branch of the inferior dental artery.

The **inferior coronary** is derived from the facial artery, near the angle of the mouth: it passes upward and inward beneath the depressor anguli oris, and, penetrating the Orbicularis oris muscle, runs in a tortuous course along the edge of the lower lip between this muscle and the mucous membrane, inosculating with the artery of the opposite side. This artery supplies the labial glands, the mucous membrane, and muscles of the lower lip, and anastomoses with the inferior labial and the mental branch of the inferior dental artery.

The **superior coronary** is larger and more tortuous in its course than the preceding. It follows the same course along the edge of the upper lip, lying between the mucous membrane and the Orbicularis oris, and anastomoses with the artery of the opposite side. It supplies the textures of the upper lip, and gives off in its course two or three vessels which ascend to the nose. One, named the *inferior artery of the septum*, ramifies on the septum of the nares as far as the point of the nose; another, the *artery of the ala*, supplies the ala of the nose.

The **lateralis nasi** is derived from the facial, as that vessel is ascending along the side of the nose; it supplies the ala and dorsum of the nose, anastomosing

with its fellow, the nasal branch of the ophthalmic, the inferior artery of the septum, the artery of the ala, and the infra-orbital.

The **angular artery** is the termination of the trunk of the facial; it ascends to the inner angle of the orbit, imbedded in the fibres of the Levator labii superioris alæque nasi, and accompanied by a large vein, the *angular;* it distributes some branches on the cheek which anastomose with the infra-orbital, and after supplying the lachrymal sac and Orbicularis palpebrarum muscle, terminates by anastomosing with the nasal branch of the ophthalmic artery.

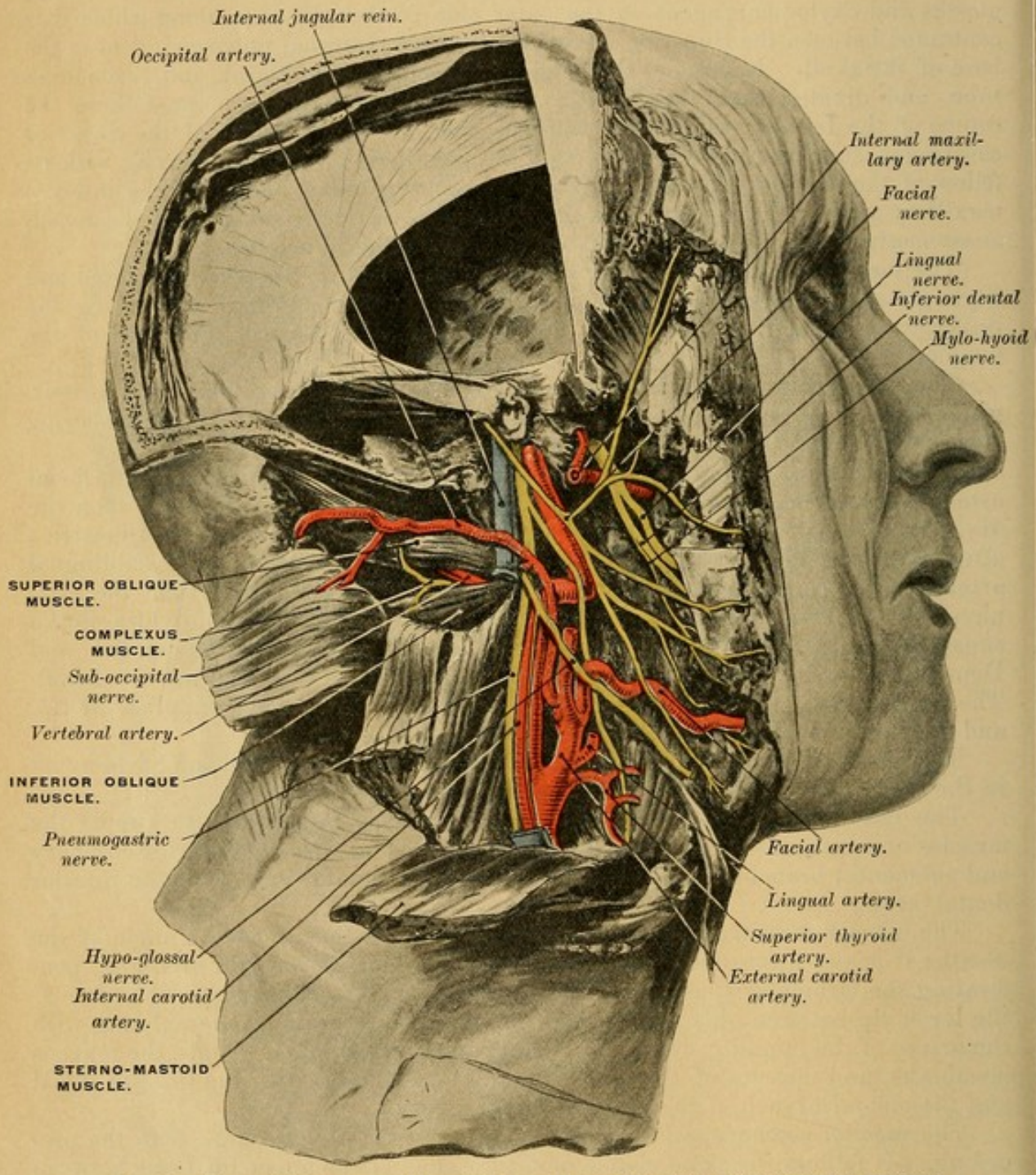

FIG. 286.—The occipital artery and its relations. (From a dissection by Mr. Gerald S. Hughes.)

The anastomoses of the facial artery are very numerous, not only with the vessel of the opposite side, but, in the neck, with the sublingual branch of the lingual; with the ascending pharyngeal; with the posterior palatine, a branch of the internal maxillary, by its inferior or ascending palatine and tonsillar branches; on the face, with the mental branch of the inferior dental as it emerges from the mental

foramen, with the transverse facial, a branch of the temporal; with the infra-orbital, a branch of the internal maxillary, and with the nasal branch of the ophthalmic.

Peculiarities.—The facial artery not unfrequently arises by a common trunk with the lingual. This vessel is also subject to some variations in its size and in the extent to which it supplies the face. It occasionally terminates as the submental, and not unfrequently supplies the face only as high as the angle of the mouth or nose. The deficiency is then supplied by enlargement of one of the neighboring arteries.

Surgical Anatomy.—The passage of the facial artery over the body of the jaw would appear to afford a favorable position for the application of pressure in case of hæmorrhage from the lips, the result either of an accidental wound or during an operation; but its application is useless, except for a very short time, on account of the free communication of this vessel with its fellow and with numerous branches from different sources. In a wound involving the lip it is better to seize the part between the fingers, and evert it, when the bleeding vessel may be at once secured with pressure-forceps. In order to prevent hæmorrhage in cases of removal of diseased growths from the part, the lip should be compressed on each side between the fingers and thumb or by a pair of specially devised clamp-forceps, whilst the surgeon excises the diseased part. In order to stop hæmorrhage where the lip has been divided in an operation, it is necessary, in uniting the edges of the wound, to pass the sutures through the cut edges, almost as deep as its mucous surface; by these means not only are the cut surfaces more neatly and securely adapted to each other, but the possibility of hæmorrhage is prevented by including in the suture the divided artery. If the suture is, on the contrary, passed through merely the cutaneous portion of the wound, hæmorrhage occurs into the cavity of the mouth. The student should, lastly, observe the relation of the angular artery to the lachrymal sac, and it will be seen that, as the vessel passes up along the inner margin of the orbit, it ascends on its nasal side. In operating for fistula lachrymalis the sac should always be opened on its outer side, in order that this vessel may be avoided.

The **Occipital Artery** (Figs. 285, 286) arises from the posterior part of the external carotid, opposite the facial, near the lower margin of the Digastric muscle. At its origin it is covered by the posterior belly of the Digastric and Stylo-hyoid muscles, and the hypoglossal nerve winds around it from behind forward; higher up, it passes across the internal carotid artery, the internal jugular vein, and the pneumogastric and spinal accessory nerves; it then ascends to the interval between the transverse process of the atlas and the mastoid process of the temporal bone, and passes horizontally backward, grooving the surface of the latter bone, being covered by the Sterno-mastoid, Splenius, Trachelo-mastoid, and Digastric muscles, and resting upon the Rectus lateralis, the Superior oblique, and Complexus muscles; it then changes its course and passes vertically upward, pierces the fascia which connects the cranial attachment of the Trapezius with the Sterno-mastoid, and ascends in a tortuous course over the occiput, as high as the vertex, where it divides into numerous branches. It is accompanied in the latter part of its course by the great occipital, and occasionally by a cutaneous filament from the suboccipital nerve.

The branches given off from this vessel are—

Muscular.	Auricular.
Sterno-mastoid.	Meningeal.

Arteria Princeps Cervicis.

The **muscular branches** supply the Digastric, Stylo-hyoid, Splenius, and Trachelo-mastoid muscles.

The **sterno-mastoid** is a large and constant branch, generally arising from the artery close to its commencement, but sometimes springing directly from the external carotid. It first passes downward and backward over the hypoglossal nerve, and enters the substance of the muscle in company with the spinal accessory nerve.

The **auricular branch** supplies the back part of the concha. It frequently gives off a branch, which enters the skull through the mastoid foramen and supplies the dura mater, the diploë, and the mastoid cells.

The **meningeal branch** ascends with the internal jugular vein, and enters the skull through the foramen lacerum posterius, to supply the dura mater in the posterior fossa.

The **arteria princeps cervicis** (Fig. 289), the largest branch of the occipital, descends along the back part of the neck and divides into a superficial and a deep

portion. The former runs beneath the Splenius, giving off branches which perforate that muscle to supply the Trapezius, which anastomose with the superficial cervical artery, a branch of the transversalis colli: the latter passes beneath the Complexus between it and the Semispinalis colli, and anastomoses with branches from the vertebral and with the deep cervical artery, a branch of the superior intercostal. The anastomosis between these vessels serves mainly to establish the collateral circulation after ligation of the carotid or subclavian artery.

The cranial branches of the occipital artery are distributed upon the occiput; they are very tortuous, and lie between the integument and Occipito-frontalis, anastomosing with the artery of the opposite side, the posterior auricular and temporal arteries. They supply the back part of the Occipito-frontalis muscle, the integument, and pericranium.

The **Posterior Auricular Artery** (Fig. 285) is a small vessel which arises from the external carotid, above the Digastric and Stylo-hyoid muscles, opposite the apex of the styloid process. It ascends, under cover of the parotid gland, on the styloid process of the temporal bone, to the groove between the cartilage of the ear and the mastoid process, immediately above which it divides into its two terminal branches, the auricular and mastoid. Just before arriving at the mastoid process, this artery is crossed by the portio dura, and has beneath it the spinal accessory nerve.

Besides several small branches to the Digastric, Stylo-hyoid, and Sterno-mastoid muscles and to the parotid gland, this vessel gives off three branches:

Stylo-mastoid. Auricular. Mastoid.

The **stylo-mastoid branch** enters the stylo-mastoid foramen, and supplies the tympanum, mastoid cells, and semicircular canals. In the young subject a branch from this vessel forms, with the tympanic branch from the internal maxillary, a vascular circle, which surrounds the membrana tympani, and from which delicate vessels ramify on that membrane. It anastomoses with the petrosal branch of the middle meningeal artery by a twig which enters the hiatus Fallopii.

The **auricular branch,** one of the terminal branches, ascends behind the ear, beneath the Retrahens auriculam muscle, and is distributed to the back part of the cartilage of the ear, upon which it ramifies minutely, some branches curving round the margin of the fibro-cartilage, others perforating it, to supply its anterior surface. It anastomoses with the posterior branch of the superficial temporal and also with its anterior auricular branches.

The **mastoid branch** passes backward, over the Sterno-mastoid muscle, to the scalp above and behind the ear. It supplies the posterior belly of the Occipito-frontalis muscle and the scalp in this situation. It anastomoses with the occipital artery.

The **Ascending Pharyngeal Artery** (Fig. 289), the smallest branch of the external carotid, is a long, slender vessel, deeply seated in the neck, beneath the other branches of the external carotid and the Stylo-pharyngeus muscle. It arises from the back part of the external carotid, near the commencement of that vessel, and ascends vertically between the internal carotid and the side of the pharynx, to the under surface of the base of the skull, lying on the Rectus capitis anticus major. Its branches may be subdivided into four sets:

Prevertebral. Pharyngeal. Tympanic. Meningeal.

The **prevertebral branches** are numerous small vessels which supply the Recti capitis antici and Longus colli muscles, the sympathetic, hypoglossal, and pneumogastric nerves, and the lymphatic glands, anastomosing with the ascending cervical artery.

The **pharyngeal branches** are three or four in number. Two of these descend to supply the middle and inferior Constrictors and the Stylo-pharyngeus, ramifying in their substance and in the mucous membrane lining them. The largest of the pharyngeal branches passes inward, running upon the Superior constrictor, and sends ramifications to the soft palate and tonsil, which take the place of the

ascending palatine branch of the facial artery when that vessel is of small size. A twig from this branch supplies the Eustachian tube.

The **tympanic branch** is a small artery which passes through a minute foramen in the petrous portion of the temporal bone, in company with the tympanic branch of the Glosso-pharyngeal nerve to supply the inner wall of the tympanum and anastomose with the other tympanic arteries.

The **meningeal branches** consist of several small vessels, which pass through foramina in the base of the skull, to supply the dura mater. One, the posterior meningeal, enters the cranium through the foramen lacerum posterius; a second passes through the foramen lacerum medium; and occasionally a third through the anterior condyloid foramen. They are all distributed to the dura mater.

Surgical Anatomy.—The ascending pharyngeal artery has been wounded from the throat, as in the case in which the stem of a tobacco-pipe was driven into the vessel, causing fatal hemorrhage.

The **Superficial Temporal Artery** (Fig. 285), the smaller of the two terminal branches of the external carotid, appears, from its direction, to be the continuation of that vessel. It commences in the substance of the parotid gland, in the interspace between the neck of the lower jaw and the external auditory meatus, crosses over the posterior root of the zygoma, passes beneath the Attrahens auriculam muscle, lying on the temporal fascia, and divides, about two inches above the zygomatic arch, into two branches, an anterior and a posterior.

The **anterior temporal** runs tortuously upward and forward to the forehead, supplying the muscles, integument, and pericranium in this region, and anastomoses with the supra-orbital and frontal arteries.

The **posterior temporal,** larger than the anterior, curves upward and backward along the side of the head, lying superficial to the temporal fascia, and inosculates with its fellow of the opposite side, and with the posterior auricular and occipital arteries.

The superficial temporal artery, as it crosses the zygoma, is covered by the Attrahens auriculam muscle, and by a dense fascia given off from the parotid gland: it is crossed by the temporo-facial division of the facial nerve and one or two veins, and is accompanied by the auriculo-temporal nerve, which lies behind it. Besides some twigs to the parotid gland, the articulation of the jaw, and the Masseter muscle, its branches are, the

Transverse Facial. Middle Temporal.
Anterior Auricular.

The **transverse facial** is given off from the temporal before that vessel quits the parotid gland; running forward through its substance, it passes transversely across the face, between Stenson's duct and the lower border of the zygoma, and divides on the side of the face into numerous branches, which supply the parotid gland, the Masseter muscle, and the integument, anastomosing with the facial, masseteric, and infra-orbital arteries. This vessel rests on the Masseter, and is accompanied by one or two branches of the facial nerve. It is sometimes a branch of the external carotid.

The **middle temporal artery** arises immediately above the zygomatic arch, and, perforating the temporal fascia, gives branches to the Temporal muscle, anastomosing with the deep temporal branches of the internal maxillary. It occasionally gives off an **orbital** branch, which runs along the upper border of the zygoma, between the two layers of the temporal fascia, to the outer angle of the orbit. This branch, which may arise directly from the superficial temporal artery, supplies the Orbicularis palpebrarum, and anastomoses with the lachrymal and palpebral branches of the ophthalmic artery.

The **anterior auricular branches** are distributed to the anterior portion of the pinna, the lobule, and part of the external meatus, anastomosing with branches of the posterior auricular.

Surgical Anatomy.—Formerly the operation of arteriotomy was performed upon this vessel in cases of inflammation of the eye or brain, but now the operation is probably never performed. If the student will consider the relations of the trunk of the vessel as it crosses the zygomatic arch, with the surrounding structures, he will observe that it is covered by a thick and dense fascia, crossed by one of the main divisions of the facial nerve and one or two veins, and accompanied by the auriculo-temporal nerve. Bleeding should not be performed in this situation, as much difficulty may arise from the dense fascia over the vessel preventing a free flow of blood, and considerable pressure is requisite afterward to arrest the hemorrhage. Again, a varicose aneurism may be formed by the accidental opening of one of the veins in front of the artery; or severe neuralgic pain may arise from the operation implicating one of the nervous filaments in the neighborhood. The anterior branch, on the contrary, is subcutaneous, is a large vessel, and is readily compressed; it is consequently more suitable for the operation.

The **Internal Maxillary** (Fig. 287), the larger of the two terminal branches of the external carotid, arises from that vessel opposite the neck of the condyle of the lower jaw, and is at first embedded in the substance of the parotid gland; it passes inward between the ramus of the jaw and the internal lateral ligament, and then upon the outer surface of the External pterygoid muscle to the spheno-maxillary fossa, to supply the deep structures of the face. For convenience of description it is divided into three portions: a maxillary, a pterygoid, and a spheno-maxillary.

In the first part of its course (*maxillary portion*) the artery passes horizontally forward and inward, between the ramus of the jaw and the internal lateral ligament. The artery here lies parallel to and a little below the auriculo-temporal nerve; it crosses the inferior dental nerve, and lies along the lower border of the External pterygoid muscle.

In the second part of its course (*pterygoid portion*) it runs obliquely forward and upward upon the outer surface of the External pterygoid muscle, being covered by the ramus of the lower jaw and lower part of the Temporal muscle; or it may pass on the inner surface of the External pterygoid muscle to reach the interval between its two heads, between which it passes to reach the spheno-maxillary fossa.

In the third part of its course (*spheno-maxillary portion*) it approaches the superior maxillary bone, and enters the spheno-maxillary fossa in the interval between the two heads of the External pterygoid, where it lies in relation with Meckel's ganglion, and gives off its terminal branches.

The branches of this vessel may be divided into three groups, corresponding with its three divisions.

Branches of the First or Maxillary Portion (Fig. 288).

Tympanic (anterior).
Deep auricular.
Middle meningeal.
Small meningeal.
Inferior dental.

The **tympanic branch** passes upward behind the articulation of the lower jaw, enters the tympanum through the Glaserian fissure, and ramifies upon the membrana tympani, forming a vascular circle around the membrane with the stylo-mastoid artery, and anastomosing with the Vidian and the tympanic branch from the internal carotid.

The **deep auricular branch** often arises in common with the preceding. It passes upward in the substance of the parotid gland, behind the temporo-maxillary articulation, pierces the cartilaginous or bony wall of the external auditory meatus, and supplies its cuticular lining and the outer surface of the membrana tympani.

The **middle meningeal** is the largest of the branches which supply the dura mater. It arises from the internal maxillary, between the internal lateral ligament and the neck of the jaw, and passes vertically upward between the two roots of the auriculo-temporal nerve to the foramen spinosum of the sphenoid bone. On entering the cranium it divides into two branches, anterior and posterior. The *anterior branch*, the larger, crosses the great ala of the sphenoid, and

reaches the groove, or canal, in the anterior inferior angle of the parietal bone: it then divides into branches which spread out between the dura mater and internal surface of the cranium, some passing upward over the parietal bone as far as the vertex, and others backward to the occipital bone. The *posterior branch* crosses the squamous portion of the temporal, and on the inner surface of the parietal

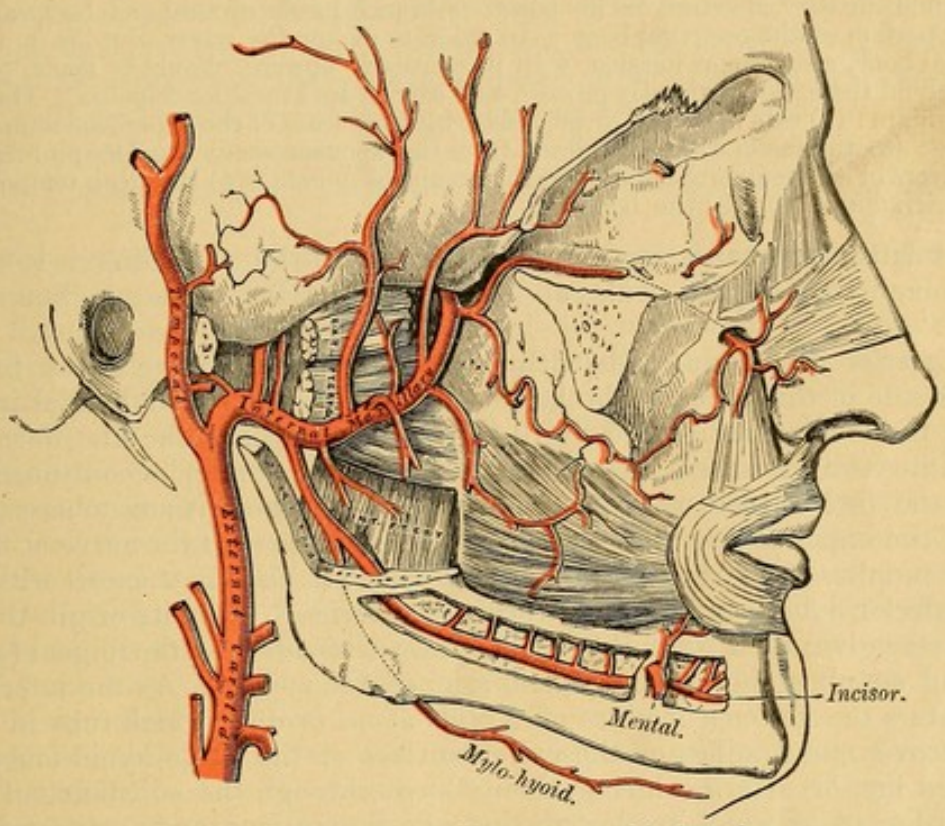

FIG. 287.—The internal maxillary artery and its branches.

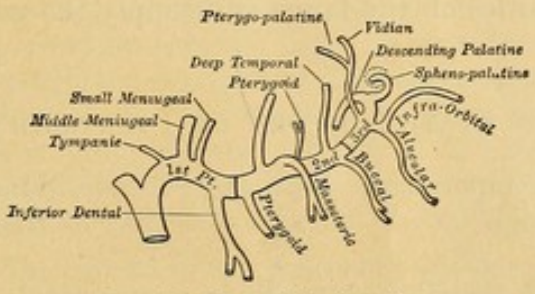

FIG. 288.—Plan of the branches.

bone divides into branches which supply the posterior part of the dura mater and cranium. The branches of this vessel are distributed partly to the dura mater, but chiefly to the bones; they anastomose with the arteries of the opposite side, and with the anterior and posterior meningeal.

The middle meningeal on entering the cranium gives off the following collateral branches: 1. Numerous small vessels to the Gasserian ganglion, and to the dura mater in this situation. 2. A branch (*petrosal branch*), which enters the hiatus Fallopii, supplies the facial nerve, and anastomoses with the stylo-mastoid branch of the posterior auricular artery. 3. A minute *tympanic* branch, which runs in the canal for the Tensor tympani muscle, and supplies this muscle and the lining membrane of the canal. 4. Orbital branches, which pass through the sphenoidal fissure, or through separate canals in the great wing of the sphenoid to anastomose with the lachrymal or other branches of the ophthalmic artery. 5. Temporal or anastomotic branches, which pass through foramina in the great wing of the sphenoid, and anastomose in the temporal fossa with the deep temporal arteries.

Surgical Anatomy.—The middle meningeal is an artery of considerable surgical importance, as it may be injured in fractures of the temporal region of the skull, and the injury may be followed by considerable hæmorrhage between the bone and dura mater, which may cause compression of the brain and require the operation of trephining for its relief. This artery crosses the anterior inferior angle of the parietal bone at a point 1½ inches behind the external angular process of the frontal bone, and 1¾ inches above the zygoma. From this point the anterior branch passes upward and slightly backward to the sagittal suture, lying about ½ inch to ¾ inch behind the coronal suture. The posterior branch passes upward and backward over the squamous portion of the temporal bone. In order to expose the artery as it lies in the canal in the parietal bone, a semilunar incision, with its convexity upward, should be made, commencing an inch behind the external angular process, and carried backward for 2 inches. The structures cut through are: (1) skin; (2) superficial fascia, with branches of the superficial temporal vessels and nerves; (3) the fascia continued down from the aponeurosis of the Occipito-frontalis; (4) the two layers of the temporal fascia; (5) the temporal muscle; (6) the deep temporal vessels; (7) the pericranium; and (8) the bone.

The **small meningeal** is sometimes derived from the preceding. It enters the skull through the foramen ovale, and supplies the Gasserian ganglion and dura mater.

The **inferior dental** descends with the inferior dental nerve to the foramen on the inner side of the ramus of the jaw. It runs along the dental canal in the substance of the bone, accompanied by the nerve, and opposite the first bicuspid tooth divides into two branches, incisor and mental; the former is continued forward beneath the incisor teeth as far as the symphysis, where it anastomoses with the artery of the opposite side; the mental branch escapes with the nerve at the mental foramen, supplies the structures composing the chin, and anastomoses with the submental inferior labial and inferior coronary arteries. Near its origin the inferior dental artery gives off a *lingual* branch, which descends with the lingual (gustatory) nerve and supplies the mucous membrane of the mouth. As the inferior dental artery enters the foramen it gives off a *mylo-hyoid branch*, which runs in the mylo-hyoid groove, and ramifies on the under surface of the Mylo-hyoid muscle. The dental and incisor arteries during their course through the substance of the bone give off a few twigs which are lost in the cancellous tissue, and a series of branches which correspond in number to the roots of the teeth: these enter the minute apertures at the extremities of the fangs and supply the pulp of the teeth.

Branches of the Second or Pterygoid Portion.

Deep Temporal.	Masseteric.
Pterygoid.	Buccal.

These branches are distributed, as their names imply, to the muscles in the maxillary region.

The **deep temporal branches,** two in number, anterior and posterior, each occupy that part of the temporal fossa indicated by its name. Ascending between the Temporal muscle and pericranium, they supply that muscle and anastomose with the middle temporal artery, the anterior branch communicating with the lachrymal through small branches which perforate the malar bone and great wing of the sphenoid.

The **pterygoid branches,** irregular in their number and origin, supply the Pterygoid muscles.

The **masseteric** is a small branch which passes outward, above the sigmoid notch of the lower jaw, to the deep surface of the Masseter. It supplies that muscle, and anastomoses with the masseteric branches of the facial and with the transverse facial artery.

The **buccal** is a small branch which runs obliquely forward between the Internal pterygoid and the ramus of the jaw, to the outer surface of the Buccinator, to which it is distributed, anastomosing with branches of the facial artery.

BRANCHES OF THE THIRD OR SPHENO-MAXILLARY PORTION.

Alveolar.	Vidian.
Infra-orbital.	Pterygo-palatine.
Posterior or Descending Palatine.	Naso- or Spheno-palatine.

The **alveolar** or **posterior dental branch** is given off from the internal maxillary by a common branch with the infra-orbital, and just as the trunk of the vessel is passing into the spheno-maxillary fossa. Descending upon the tuberosity of the superior maxillary bone, it divides into numerous branches, some of which enter the posterior dental canals, to supply the molar and bicuspid teeth and the lining of the antrum, and others are continued forward on the alveolar process to supply the gums.

The **infra-orbital** appears, from its direction, to be the continuation of the trunk of the internal maxillary. It arises from that vessel by a common trunk with the preceding branch, and runs along the infra-orbital canal with the superior maxillary nerve, emerging upon the face at the infra-orbital foramen, beneath the Levator labii superioris. Whilst contained in the canal, it gives off branches which ascend into the orbit, and assist in supplying the Inferior rectus and Inferior oblique muscles and the lachrymal gland. Other branches (*anterior dental*) descend through the anterior dental canals in the bone, to supply the mucous membrane of the antrum and the front teeth of the upper jaw. On the face, some branches pass upward to the inner angle of the orbit and the lachrymal sac, anastomosing with the angular branch of the facial artery; other branches pass inward toward the nose, anastomosing with the nasal branch of the ophthalmic; and other branches descend beneath the Levator labii superioris, and anastomose with the transverse facial and buccal arteries.

The four remaining branches arise from that portion of the internal maxillary which is contained in the spheno-maxillary fossa.

The **descending palatine** descends through the posterior palatine canal with the anterior palatine branch of Meckel's ganglion, and, emerging from the posterior palatine foramen, runs forward in a groove on the inner side of the alveolar border of the hard palate to the anterior palatine canal, where the terminal branch of the artery passes upward through the foramen of Stenson to anastomose with the naso-palatine artery. Its branches are distributed to the gums, the mucous membrane of the hard palate, and the palatine glands. Whilst it is contained in the palatine canal it gives off branches which descend in the accessory palatine canals to supply the soft palate and tonsil, anastomosing with the ascending palatine artery.

Surgical Anatomy.—The position of the descending palatine artery on the hard palate should be borne in mind in performing an operation for the closure of a cleft in the hard palate, as it is in danger of being wounded, and may give rise to formidable hemorrhage. In one case in which it was wounded it was necessary to plug the posterior palatine canal in order to arrest the bleeding.

The **Vidian branch** passes backward along the Vidian canal with the Vidian nerve. It is distributed to the upper part of the pharynx and Eustachian tube, sending a small branch into the tympanum, which anastomoses with the other tympanic arteries.

The **pterygo-palatine** is a very small branch, which passes backward through the pterygo-palatine canal with the pharyngeal nerve, and is distributed to the upper part of the pharynx and Eustachian tube.

The **spheno-palatine** passes through the spheno-palatine foramen into the cavity of the nose, at the back part of the superior meatus, and divides into two branches: one internal, the *naso-palatine* or *artery of the septum*, passes obliquely downward and forward along the septum nasi, supplies the mucous membrane, and anastomoses in front with the terminal branch of the descending palatine. The external branches, two or three in number, supply the mucous membrane covering the lateral wall of the nose, the antrum, and the ethmoid and sphenoid cells.

SURGICAL ANATOMY OF THE TRIANGLES OF THE NECK.

The student having considered the relative anatomy of the large arteries of the neck and their branches, and the relations they bear to the veins and nerves, should now examine these structures collectively, as they present themselves in certain regions of the neck, in each of which important operations are constantly being performed.

The side of the neck presents a somewhat quadrilateral outline, limited, above, by the lower border of the body of the jaw, and an imaginary line extending from the angle of the jaw to the mastoid process; below, by the prominent upper border of the clavicle; in front, by the median line of the neck; behind, by the anterior margin of the Trapezius muscle. This space is subdivided into two large triangles by the Sterno-mastoid muscle, which passes obliquely across the neck, from the sternum and clavicle below to the mastoid process above. The triangular space in front of this muscle is called the *anterior triangle;* and that behind it, the *posterior triangle.*

Anterior Triangle of the Neck.

The **anterior triangle** is bounded, in front, by a line extending from the chin to the sternum; behind, by the anterior margin of the Sterno-mastoid; its base, directed upward, is formed by the lower border of the body of the jaw and a line extending from the angle of the jaw to the mastoid process; its apex is below, at the sternum. This space is subdivided into three smaller triangles by the Digastric muscle above and the anterior belly of the Omo-hyoid below. These smaller triangles are named, from below upward, the inferior carotid, the superior carotid, and the submaxillary triangle.

The **Inferior Carotid Triangle** is bounded, in front, by the median line of the neck; behind, by the anterior margin of the Sterno-mastoid; above, by the anterior belly of the Omo-hyoid; and is covered by the integument, superficial fascia, Platysma, and deep fascia, ramifying between which are some of the descending branches of the superficial cervical plexus. Beneath these superficial structures are the Sterno-hyoid and Sterno-thyroid muscles, which, together with the anterior margin of the Sterno-mastoid, conceal the lower part of the common carotid artery.[1]

This vessel is enclosed within its sheath, together with the internal jugular vein and pneumogastric nerve; the vein lying on the outer side of the artery on the right side of the neck, but overlapping it below on the left side; the nerve lying between the artery and vein, on a plane posterior to both. In front of the sheath are a few filaments descending from the loop of communication between the descendens and communicans hypoglossi; behind the sheath are seen the inferior thyroid artery, the recurrent laryngeal nerve, and the sympathetic nerve; and on its inner side, the trachea, the thyroid gland—much more prominent in the female than in the male—and the lower part of the larynx. By cutting into the upper part of this space and slightly displacing the Sterno-mastoid muscle the common carotid artery may be tied below the Omo-hyoid muscle.

The **Superior Carotid Triangle** is bounded, behind, by the Sterno-mastoid; below, by the anterior belly of the Omo-hyoid; and above, by the Posterior belly of the Digastric muscle. It is covered by the integument, superficial fascia, Platysma, and deep fascia, ramifying between which are branches of the facial and superficial cervical nerves. Its floor is formed by parts of the Thyro-hyoid, Hyo-glossus, and the inferior and middle Constrictor muscles of the pharynx. This space, when dissected, is seen to contain the upper part of the common carotid

[1] Therefore the common carotid artery and internal jugular vein are not, strictly speaking, contained in this triangle, since they are covered by the Sterno-mastoid muscle; that is to say, lie behind the anterior border of that muscle, which forms the posterior border of the triangle. But as they lie very close to the structures which are really contained in the triangle, and whose position it is essential to remember in operating on this part of the artery, it has seemed expedient to study the relations of all these parts together.

artery, which bifurcates opposite the upper border of the thyroid cartilage into the external and internal carotid. These vessels are occasionally somewhat concealed from view by the anterior margin of the Sterno-mastoid muscle, which overlaps them. The external and internal carotids lie side by side, the external being the more anterior of the two. The following branches of the external carotid are also met with in this space: the superior thyroid, running forward and downward; the lingual, directly forward; the facial, forward and upward; the occipital, backward; and the ascending pharyngeal directly upward on the inner side of the internal carotid. The veins met with are: the internal jugular, which lies on the outer side of the common and internal carotid arteries, and veins corresponding to the above-mentioned branches of the external carotid—viz., the superior thyroid, the lingual, facial, ascending pharyngeal, and sometimes the occipital, all of which accompany their corresponding arteries and terminate in the internal jugular. The nerves in this space are the following: In front of the sheath of the common carotid is the descendens hypoglossi. The hypoglossal nerve crosses both the internal and external carotids above, curving round the occipital artery at its origin. Within the sheath, between the artery and vein, and behind both, is the pneumogastric nerve; behind the sheath, the sympathetic. On the outer side of the vessels the spinal accessory nerve runs for a short distance before it pierces the Sterno-mastoid muscle; and on the inner side of the external carotid, just below the hyoid bone, may be seen the internal laryngeal nerve; and, still more inferiorly, the external laryngeal nerve. The upper part of the larynx and lower part of the pharynx are also found in the front part of this space.

The **Submaxillary Triangle** corresponds to the part of the neck immediately beneath the body of the jaw. It is bounded, above, by the lower border of the body of the jaw and a line drawn from its angle to the mastoid process; below, by the posterior belly of the Digastric and Stylo-hyoid muscles; in front, by the anterior belly of the Digastric. It is covered by the integument, superficial fascia, Platysma, and deep fascia, ramifying between which are branches of the facial and ascending filaments of the superficial cervical nerves. Its floor is formed by the Mylo-hyoid and Hyo-glossus muscles. This space contains, in front, the subma illary gland, superficial to which is the facial vein, while imbedded in it facial artery and its glandular branches; beneath this gland, on the surf Mylo-hyoid muscle, are the submental artery and the mylo-hyoid artery nal in the

The posterior part of this triangle is separated from the anterior pare, then curves maxillary ligament: it contains the external carotid artery, enter the cavity of the substance of the parotid gland: this vessel hss. In this canal the artery lies to, the internal carotid, being crossed by ; from the latter cavity it is separated course the posterior auricular, temporal, m in the young subject, and often ab- deeply are the internal carotid, the in is separated from the Gasserian ganglion nerve, separated from the externals the floor of the fossa for the ganglion and the geus muscles and the glosso-phar the canal. Frequently this bony plate is more ganglion is separated from the artery by fibrous rated from the bony wall of the carotid canal by a

POSTERI d is surrounded by filaments of the carotid plexus, nch of the superior cervical ganglion of the sympa- veins.

The **posterior triangle** is internal carotid artery in this part of its course is behind, by the anterior m of the dura mater forming the cavernous sinus, but middle third of the clavi rane of the sinus. It at first ascends to the posterior about an inch above the forward by the side of the body of the sphenoid bone, divides it unequally into on the inner side of the anterior clinoid process, and triangle. forming the roof of the sinus. In this part of its course

The Occipital, the l nts of the sympathetic nerve, and has in relation with it aving perforated the dura mater, on the inner side of the the internal carotid passes between the second and third

' The same remark will The structures enumerated ase. the muscles which form the mind their close relation to gical or erations on this gla

front, by the Sterno-mastoid; behind, by the Trapezius; below, by the Omo-hyoid. Its floor is formed from above downward by the Splenius, Levator anguli scapulæ, and the middle and posterior Scaleni muscles. It is covered by the integument, the Platysma below, the superficial and deep fasciæ; the spinal accessory nerve is directed obliquely across the space from the Sterno-mastoid, which it pierces, to the under surface of the Trapezius; below, the descending branches of the cervical plexus and the transversalis colli artery and vein cross the space. A chain of lymphatic glands is also found running along the posterior border of the Sterno-mastoid, from the mastoid process to the root of the neck.

The **Subclavian,** the smaller of the two posterior triangles, is bounded, above, by the posterior belly of the Omo-hyoid; below, by the clavicle, its base, directed forward, being formed by the Sterno-mastoid. The size of the subclavian triangle varies according to the extent of attachment of the clavicular portion of the Sterno-mastoid and Trapezius muscles, and also according to the height at which the Omo-hyoid crosses the neck above the clavicle. Its height also varies much according to the position of the arm, being much diminished by raising the limb, on account of the ascent of the clavicle, and increased by drawing the arm downward, when that bone is depressed. This space is covered by the integument, the Platysma, the superficial and deep fasciæ, and crossed by the descending branches of the cervical plexus. Just above the level of the clavicle the third portion of the subclavian artery curves outward and downward from the outer margin of the Scalenus anticus, across the first rib, to the axilla. Sometimes this vessel rises as high as an inch and a half above the clavicle, or to any point intermediate between this and its usual level. Occasionally it passes in front of the Scalenus anticus or pierces the fibres of that muscle. The subclavian vein lies behind the clavicle, and is usually not seen in this space; but it occasionally rises as high up as the artery, and has even been seen to pass with that vessel behind the Scalenus anticus. The brachial plexus of nerves lies above the artery, and in close contact with it. Passing transversely behind the clavicle are the brachial vessels, and traversing its upper angle in the same direction, the are the salis colli artery and vein. The external jugular vein runs vertically ior margi behind the posterior border of the Sterno-mastoid, to terminate in the artery.[1] ein; it receives the transverse cervical and suprascapular veins, which

This vesse m a plexus in front of the artery, and a small vein which crosses vein and pneumoga the cephalic. The small nerve to the Subclavius muscle also the right side of the neck, but iddle. A lymphatic gland is also found in the lying between the artery and vein, of rib with the first digitation of the Serratus sheath are a few filaments descending fr

descendens and communicans hypoglossi; id Artery.

thyroid artery, the recurrent laryngeal nerve, an erior part of the brain, the eye, its inner side, the trachea, the thyroid gland—mu orehead and nose. Its size in than in the male—and the lower part of the lary hough in the child it is larger part of this space and slightly displacing the Ster of curvatures that it presents carotid artery may be tied below the Omo-hyoid mu one or two flexures near the

The **Superior Carotid Triangle** is bounded, beh otid canal and along the side below, by the anterior belly of the Omo-hyoid; and curvature which resembles of the Digastric muscle. It is covered by the int most probably diminish the Platysma, and deep fascia, ramifying between which t of surface over which it and superficial cervical nerves. Its floor is formed by l from friction. Hyo-glossus, and the inferior and middle Constrictor l it may be conveniently This space, when dissected, is seen to contain the upper p , and cerebral.

[1] Therefore the common carotid artery and internal jugular vein commences at the bifur-
tained in this triangle, since they are covered by the Sterno-mastoid m f the thyroid cartilage,
the anterior border of that muscle, which forms the posterior border of processes of the three
very close to the structures which are really contained in the triar portion of the temporal
essential to remember in operating on this part of the artery, it has
relations of all these parts together. ined in the superior

carotid triangle, and lying on the same level as the external carotid, but behind that artery overlapped by the Sterno-mastoid and covered by the deep fascia, Platysma, and integument: it then passes beneath the parotid gland, being crossed by the hypoglossal nerve, the Digastric and Stylo-hyoid muscles, and the occipital and posterior auricular arteries. Higher up, it is separated from the external carotid by the Stylo-glossus and Stylo-pharyngeus muscles, the glosso-pharyngeal nerve, and pharyngeal branch of the pneumogastric. It is in relation, *behind*, with the Rectus capitis anticus major, the superior cervical ganglion of the sympathetic, and superior laryngeal nerve; *externally*, with the internal jugular vein and pneumogastric nerve, the nerve lying on a plane posterior to the artery; *internally*, with the pharynx, tonsil, the superior laryngeal nerve, and ascending pharyngeal artery. At the base of the skull the glosso-pharyngeal, vagus, spinal accessory, and hypoglossal nerves lie between the artery and the internal jugular vein.

PLAN OF THE RELATIONS OF THE INTERNAL CAROTID ARTERY IN THE NECK.

In front.
Skin, superficial and deep fasciæ.
Platysma.
Sterno-mastoid.
Occipital and posterior auricular arteries.
Hypoglossal nerve.
Parotid gland.
Stylo-glossus and Stylo-pharyngeus muscles.
Glosso-pharyngeal nerve.
Pharyngeal branch of the pneumogastric.

Externally.
Internal jugular vein.
Pneumogastric nerve.

Interna Carotid Artery.

Internally.
Pharynx.
Superior laryngeal nerve.
Ascending pharyngeal artery.
Tonsil.

Behind.
Rectus capitis anticus major.
Sympathetic.
Superior laryngeal nerve.

Petrous Portion.—When the internal carotid artery enters the canal in the petrous portion of the temporal bone, it first ascends a short distance, then curves forward and inward, and again ascends as it leaves the canal to enter the cavity of the skull between the lingula and petrosal process. In this canal the artery lies at first in front of the cochlea and tympanum; from the latter cavity it is separated by a thin, bony lamella, which is cribriform in the young subject, and often absorbed in old age. Farther forward it is separated from the Gasserian ganglion by a thin plate of bone, which forms the floor of the fossa for the ganglion and the roof of the horizontal portion of the canal. Frequently this bony plate is more or less deficient, and then the ganglion is separated from the artery by fibrous membrane. The artery is separated from the bony wall of the carotid canal by a prolongation of dura mater, and is surrounded by filaments of the carotid plexus, derived from the ascending branch of the superior cervical ganglion of the sympathetic, and a number of small veins.

Cavernous Portion.—The internal carotid artery in this part of its course is situated between the layers of the dura mater forming the cavernous sinus, but covered by the lining membrane of the sinus. It at first ascends to the posterior clinoid process, then passes forward by the side of the body of the sphenoid bone, and again curves upward on the inner side of the anterior clinoid process, and perforates the dura mater, forming the roof of the sinus. In this part of its course it is surrounded by filaments of the sympathetic nerve, and has in relation with it externally the sixth nerve.

Cerebral Portion.—Having perforated the dura mater, on the inner side of the anterior clinoid process, the internal carotid passes between the second and third

cranial nerves to the anterior perforated spot at the inner extremity of the fissure of Sylvius, where it gives off its terminal or cerebral branches. This portion of the artery has the optic nerve on its inner side, and the third nerve externally.

Peculiarities.—The length of the internal carotid varies according to the length of the neck, and also according to the point of bifurcation of the common carotid. Its origin some-

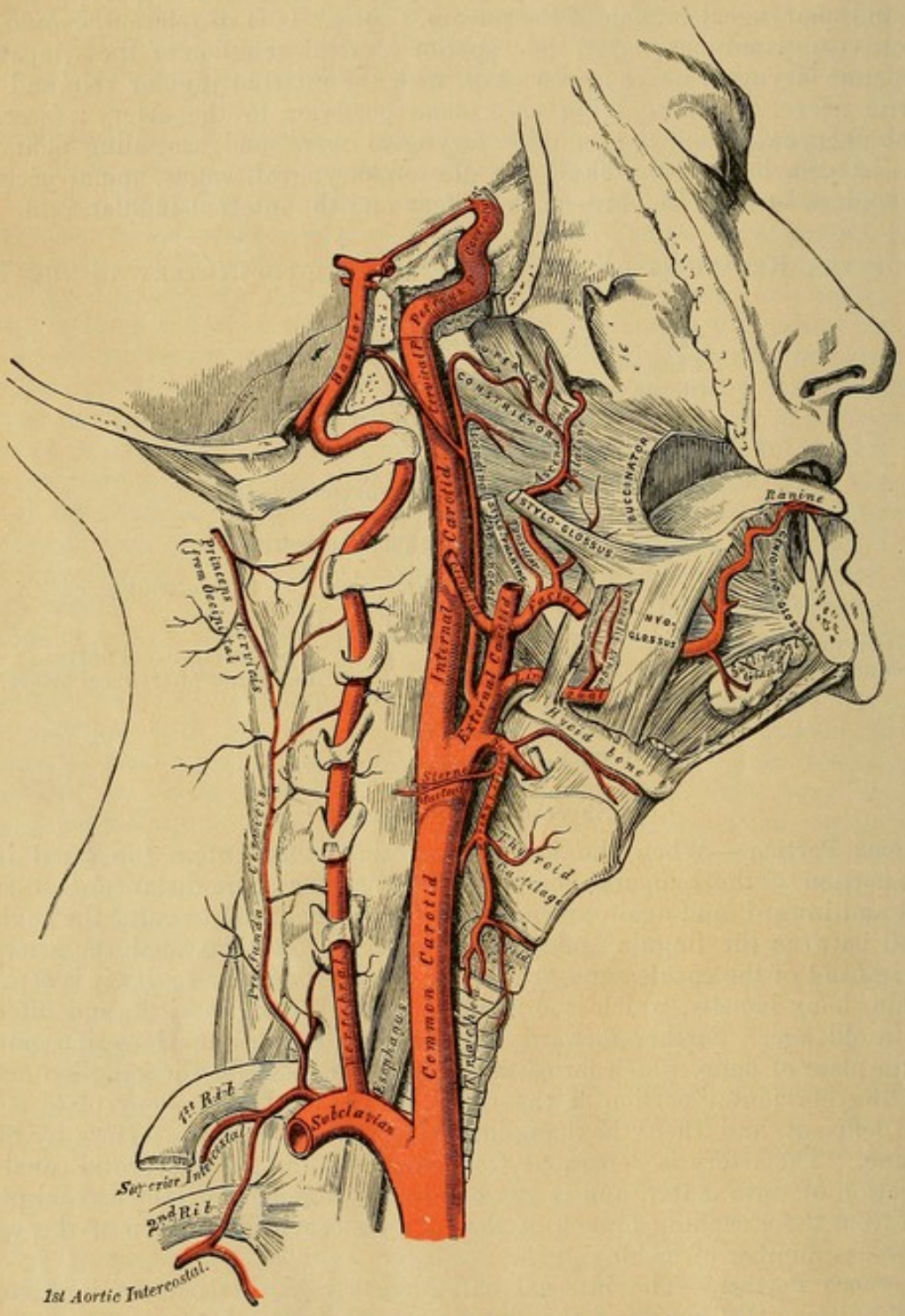

FIG. 289.—The internal carotid and vertebral arteries. Right side.

times takes place from the arch of the aorta; in such rare instances this vessel has been found to be placed nearer the middle line of the neck than the external carotid, as far upward as the larynx, when the latter vessel crossed the internal carotid. The course of the vessel, instead of being straight, may be very tortuous. A few instances are recorded in which this vessel was altogether absent: in one of these the common carotid passed up the neck, and gave off the usual branches of the external carotid, the cranial portion of the internal carotid being replaced by two branches of the internal maxillary, which entered the skull through the foramen rotundum and ovale and joined to form a single vessel.

Surgical Anatomy.—The cervical part of the internal carotid is very rarely wounded. Mr. Cripps, in an interesting paper in the *Medico-Chirurgical Transactions*, compares the rareness of a wound of the internal carotid with one of the external or its branches. It is, however, sometimes injured by a stab or gunshot wound in the neck, or even occasionally by a stab from within the mouth, as when a person receives a thrust from the end of a parasol or falls down with a tobacco-pipe in his mouth. The relation of the internal carotid with the tonsil should be especially remembered, as instances have occurred in which the artery has been wounded during the operation of scarifying the tonsil, and fatal hæmorrhage has supervened. The indications for ligature are wounds, when the vessel should be exposed by a careful dissection and tied above and below the bleeding point; and aneurism, which if non-traumatic may be treated by ligature of the common carotid, but if traumatic in origin by exposing the sac and tying the vessel above and below. The incision for ligature of the cervical portion of the internal carotid should be made along the anterior border of the Sterno-mastoid, from the angle of the jaw to the upper border of the thyroid cartilage. The superficial structures being divided and the Sterno-mastoid defined and drawn outward, the cellular tissue must be carefully separated and the posterior belly of the Digastric and hypoglossal nerve sought for as guides to the vessel. When the artery is found the external carotid should be drawn inward and the Digastric muscles upward, and the aneurism needle passed from without inward.

The branches given off from the internal carotid are—

From the Petrous portion	Tympanic (internal or deep).
From the Cavernous portion	Arteriæ Receptaculi. Anterior Meningeal. Ophthalmic.
From the Cerebral portion	Anterior Cerebral. Middle Cerebral. Posterior Communicating. Anterior Choroid.

The cervical portion of the internal carotid gives off no branches.

The **tympanic** is a small branch which enters the cavity of the tympanum through a minute foramen in the carotid canal, and anastomoses with the tympanic branch of the internal maxillary, and with the stylo-mastoid artery.

The **arteriæ receptaculi** are numerous small vessels, derived from the internal carotid in the cavernous sinus; they supply the pituitary body, the Gasserian ganglion, and the walls of the cavernous and inferior petrosal sinuses. Some of these branches anastomose with branches of the middle meningeal.

The **anterior meningeal** is a small branch which passes over the lesser wing of the sphenoid to supply the dura mater of the anterior fossa; it anastomoses with the meningeal branch from the posterior ethmoidal artery.

The **Ophthalmic Artery** arises from the internal carotid, just as that vessel is emerging from the cavernous sinus, on the inner side of the anterior clinoid process, and enters the orbit through the optic foramen, below and on the outer side of the optic nerve. It then passes over the nerve to the inner wall of the orbit, and thence horizontally forward, beneath the lower border of the Superior oblique muscle, to a point behind the internal angular process of the frontal bone, where it divides into two terminal branches, the *frontal* and *nasal*. As the artery crosses the optic nerve it is accompanied by the nasal nerve, and is separated from the frontal nerve by the Rectus superior and Levator palpebræ superioris muscles.

Branches.—The branches of this vessel may be divided into an *orbital group*, which are distributed to the orbit and surrounding parts, and an *ocular group*, which supply the muscles and globe of the eye:

Orbital Group.	*Ocular Group.*
Lachrymal.	Short Ciliary.
Supra-orbital.	Long Ciliary.
Posterior Ethmoidal.	Anterior Ciliary.
Anterior Ethmoidal.	Arteria Centralis Retinæ.
Internal Palpebral.	Muscular.
Frontal.	
Nasal.	

The **lachrymal** is one of the largest branches derived from the ophthalmic, arising close to the optic foramen; not infrequently it is given off from the artery before it enters the orbit. It accompanies the lachrymal nerve along the upper border of the External rectus muscle, and is distributed to the lachrymal gland. Its terminal branches, escaping from the gland, are distributed to the eyelids and conjunctiva: of those supplying the eyelids, two are of considerable size and are named the *external palpebral;* they run inward in the upper and lower lids

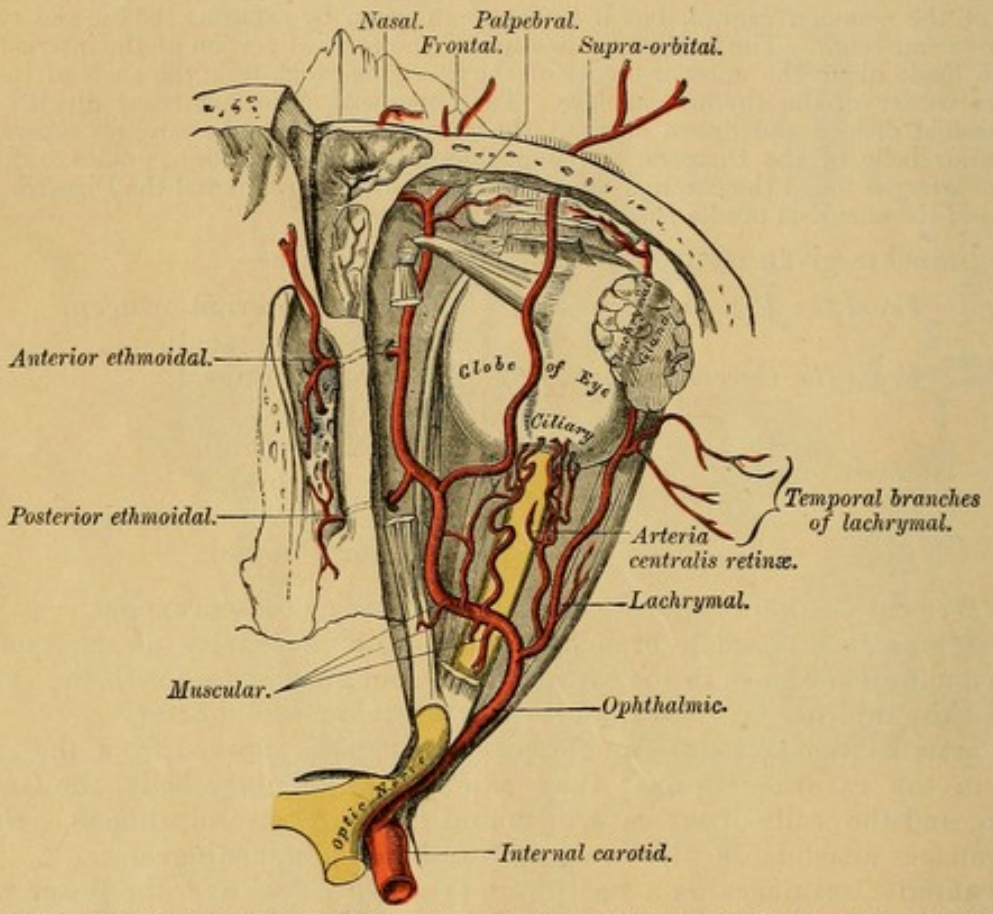

FIG. 290.—The ophthalmic artery and its branches, the roof of the orbit having been removed.

respectively, and anastomose with the internal palpebral arteries, forming an arterial circle in this situation. The lachrymal artery gives off one or two *malar branches*, one of which passes through a foramen in the malar bone, to reach the temporal fossa, and anastomoses with the deep temporal arteries; the other appears on the cheek through the malar foramen, and anastomoses with the transverse facial. A branch is also sent backward through the sphenoidal fissure to the dura mater, which anastomoses with a branch of the middle meningeal artery.

Peculiarities.—The lachrymal artery is sometimes derived from one of the anterior branches of the middle meningeal artery.

The **supra-orbital artery** arises from the ophthalmic as that vessel is crossing over the optic nerve. Ascending so as to arise above all the muscles of the orbit, it passes forward, with the supra-orbital nerve, between the periosteum and Levator palpebræ; and, passing through the supra-orbital foramen, divides into a superficial and deep branch, which supply the integument, the muscles, and the pericranium of the forehead, anastomosing with the frontal, the anterior branch of the temporal, and the artery of the opposite side. This artery in the orbit supplies the Superior rectus and the Levator palpebræ, and sends a branch inward, across the pulley of the Superior oblique muscle, to supply the parts at the inner canthus. At the supra-orbital foramen it frequently transmits a branch to the diploë.

The **ethmoidal branches** are two in number—posterior and anterior. The

former, which is the smaller, passes through the posterior ethmoidal foramen, supplies the posterior ethmoidal cells, and, entering the cranium, gives off a meningeal branch, which supplies the adjacent dura mater, and nasal branches which descend into the nose through apertures in the cribriform plate, anastomosing with branches of the spheno-palatine. The anterior ethmoidal artery accompanies the nasal nerve through the anterior ethmoidal foramen, supplies the

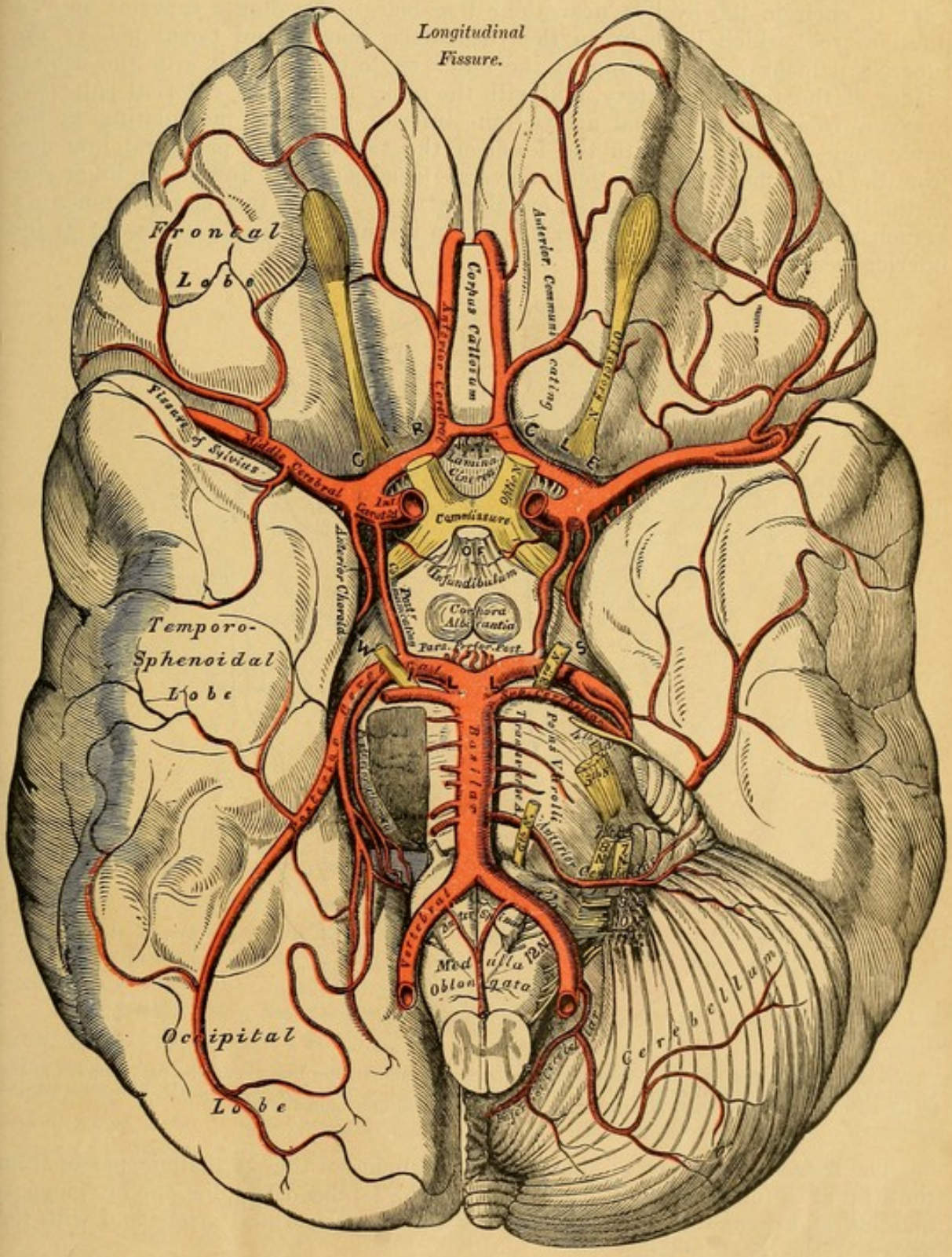

FIG. 291.—The arteries of the base of the brain. The right half of the cerebellum and pons have been removed.

N.B.—It will be noticed that in the illustration the two anterior cerebral arteries have been drawn at a considerable distance from each other: this makes the anterior communicating artery appear very much longer than it really is.

anterior ethmoidal cells and frontal sinuses, and, entering the cranium, gives off a meningeal branch, which supplies the adjacent dura mater and nasal branches, which descend into the nose, through the slit by the side of the crista galli, and, running along the groove on the under surface of the nasal bone, supply the skin of the nose.

The **palpebral arteries,** two in number, superior and inferior, arise from the ophthalmic, opposite the pulley of the Superior oblique muscle; they leave the orbit to encircle the eyelids near their free margin, forming a superior and an inferior arch, which lie between the Orbicularis muscle and tarsal plates; the superior palpebral inosculating at the outer angle of the orbit with the orbital branch of the temporal artery, and with the upper of the two external palpebral branches from the lachrymal artery—the inferior palpebral inosculating, at the outer angle of the orbit, with the lower of the two external palpebral branches from the lachrymal and with the transverse facial arteries, and at the inner side of the lid with a branch from the angular artery. From this last anastomosis a branch passes to the nasal duct, ramifying in its mucous membrane, as far as the inferior meatus.

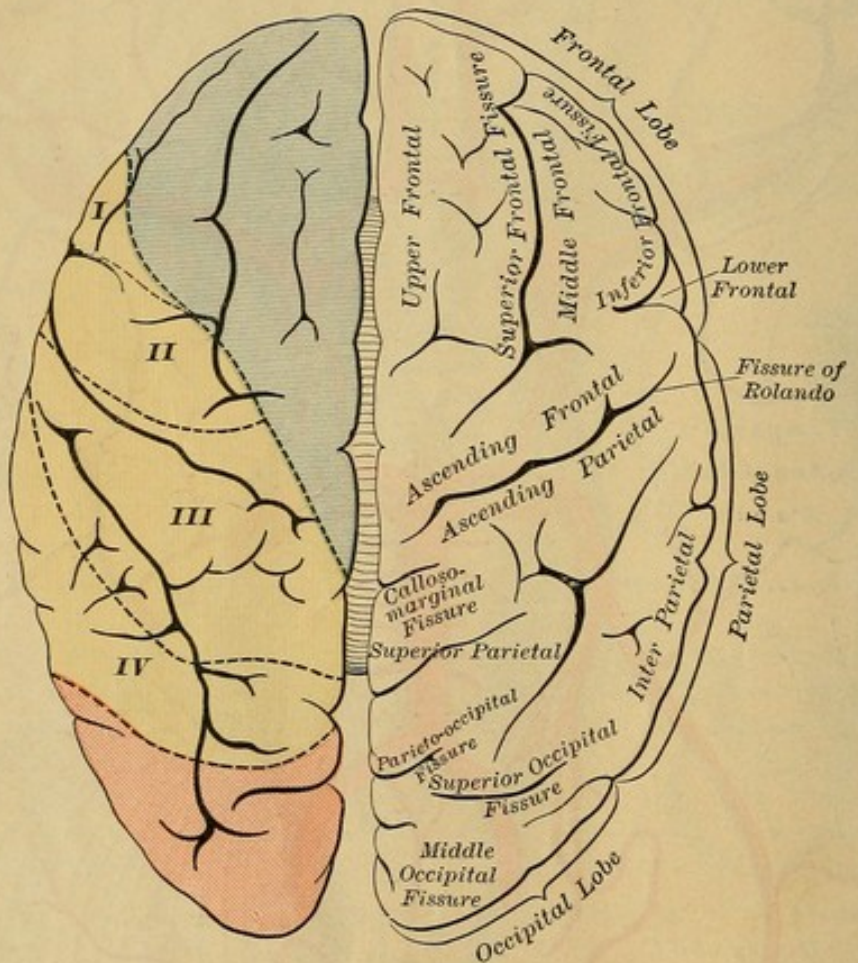

FIG. 292.—Vascular area of the upper surface of the cerebrum. (After Duret.) I. The part supplied by the external and inferior frontal artery. II. The part supplied by the ascending frontal. III. The part supplied by the ascending parietal. IV. The part supplied by the parieto-sphenoidal artery.

The **frontal artery,** one of the terminal branches of the ophthalmic, passes from the orbit at its inner angle, and, ascending on the forehead, supplies the integument, muscles, and pericranium, anastomosing with the supraorbital artery and with the artery of the opposite side.

The **nasal artery,** the other terminal branch of the ophthalmic, emerges from the orbit above the tendo oculi, and, after giving a branch to the upper part of the lachrymal sac, divides into two branches, one of which crosses the root of the nose, the *transverse nasal*, and anastomoses with the angular artery; the

other, the *dorsalis nasi*, runs along the dorsum of the nose, supplies its outer surface, and anastomoses with the artery of the opposite side and with the lateral nasal branch of the facial.

The **ciliary arteries** are divisible into three groups, the short, long, and anterior. The *short ciliary arteries*, from six to twelve in number, arise from the ophthalmic or some of its branches; they surround the optic nerve as they pass forward to the posterior part of the eyeball, pierce the sclerotic coat around the entrance of the nerve, and supply the choroid coat and ciliary processes. The *long ciliary arteries*, two in number, pierce the posterior part of the sclerotic at some little distance from the optic nerve, and run forward, along each side of the eyeball, between the sclerotic and choroid, to the ciliary muscle, where they divide into two branches; these form an arterial circle, the *circulus major*, around the circumference of the iris, from which numerous radiating branches pass forward, in its substance, to its free margin, where they form a second arterial circle, the *circulus minor*, around its pupillary margin. The *anterior ciliary arteries* are derived from the muscular branches; they pass to the front of the

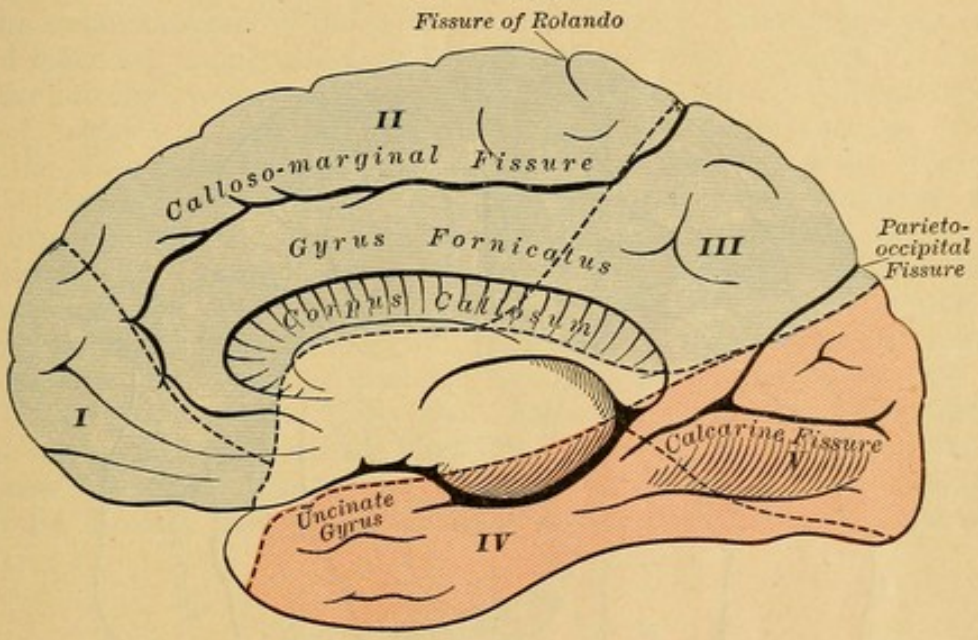

FIG. 293.—Vascular area of the internal surface of the cerebrum. (After Duret.) I. The part supplied by the anterior and internal frontal. II. The part supplied by the middle and internal frontal. III. The part supplied by the posterior and internal frontal. IV. The part supplied by the posterior temporal; and V. The part supplied by the occipital, both terminal branches of the posterior cerebral.

eyeball in company with the tendons of the Recti muscles, form a vascular zone beneath the conjunctiva, and then pierce the sclerotic a short distance from the cornea and terminate in the circulus major of the iris.

The **arteria centralis retinæ** is the first and one of the smallest branches of the ophthalmic artery. It runs for a short distance within the dural sheath of the nerve, but about half an inch behind the eyeball it pierces the optic nerve obliquely, and runs forward in the centre of its substance, and enters the globe of the eye through the porus opticus. Its mode of distribution will be described in the account of the anatomy of the eye.

The **muscular branches**, two in number, superior and inferior, frequently spring from a common trunk. The superior, the smaller, often wanting, supplies the Levator palpebræ, Superior rectus, and Superior oblique. The inferior, more constant in its existence, passes forward, between the optic nerve and Inferior rectus, and is distributed to the External, Internal, and Inferior recti, and Inferior oblique. This vessel gives off most of the anterior ciliary arteries. Additional muscular branches are given off from the lachrymal and supra-orbital arteries or from the ophthalmic itself.

The **anterior cerebral** arises from the internal carotid at the inner extremity of the fissure of Sylvius. It passes forward and inward across the anterior perforated space, above the optic nerve, to the commencement of the great longitudinal fissure. Here it comes into close relationship with the artery of the opposite side, and the two vessels are connected together by a short anastomosing trunk, about two lines in length, the *anterior communicating* artery. From this point the two vessels run side by side in the longitudinal fissure, curve round the genu of the corpus callosum, and, turning backward, continue along its upper surface to its posterior part, where they terminate by anastomosing with the posterior cerebral arteries. In their course they give off the following branches:

Antero-median ganglionic. Anterior internal frontal.
Inferior internal frontal. Middle internal frontal.
Posterior internal frontal.

The *antero-median ganglionic* is a group of small arteries which arise at the commencement of the anterior cerebral artery; they pierce the anterior perforated space and lamina cinerea, and supply the head of the caudate nucleus.

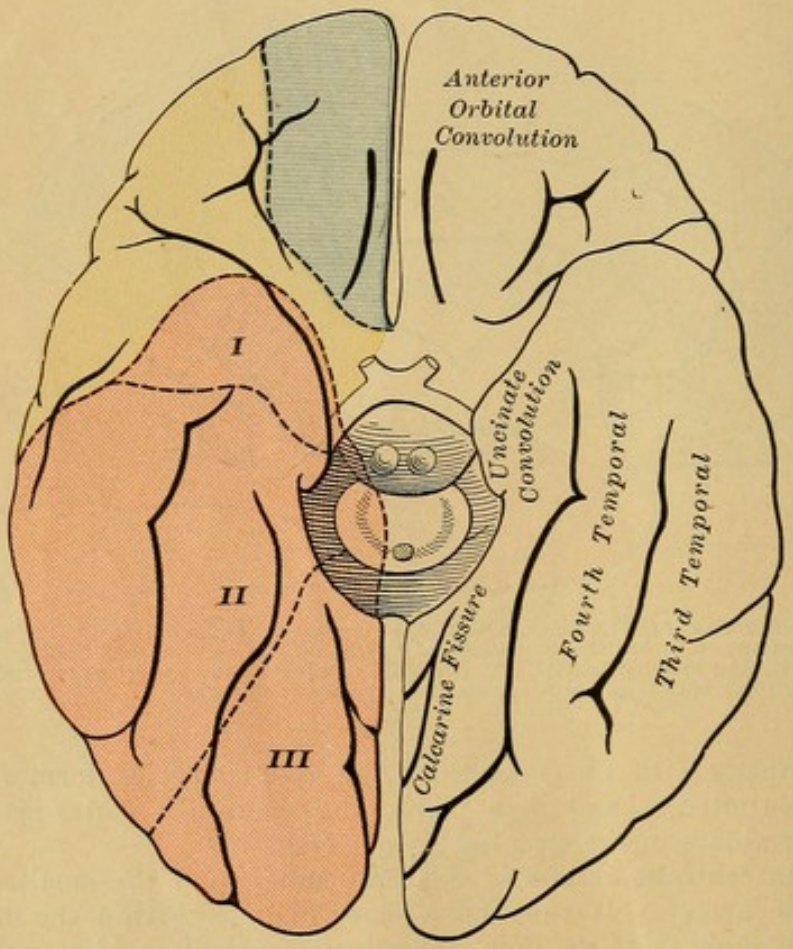

FIG. 294.—Vascular area of the inferior surface of the cerebrum. (After Duret.) I. The part supplied by the anterior temporal artery. II. The part supplied by the posterior temporal artery. III. The part supplied by the occipital artery.

The *inferior internal frontal*, two or three in number, are distributed to the orbital surface of the frontal lobe, where they supply the olfactory lobe, gyrus rectus, and internal orbital convolution.

The *anterior internal frontal branches* supply a part of the marginal convolution, and send branches over the edge of the hemisphere to the superior and middle frontal convolutions and upper part of the ascending frontal convolution. The *middle internal frontal branches* supply the corpus callosum, the convolution of the corpus callosum, the inner surface of the first frontal convolution, and the

upper part of the ascending frontal convolution. The *posterior internal frontal branches* supply the lobus quadratus and adjacent outer surface of the hemisphere.

The **anterior communicating artery** is a short branch, about two lines in length, but of moderate size, connecting together the two anterior cerebral arteries across the longitudinal fissure. Sometimes this vessel is wanting, the two arteries joining together to form a single trunk, which afterward divides. Or the vessel may be wholly or partially divided into two; frequently it is longer and smaller than usual. It gives off some of the antero-median ganglionic group of vessels, which are, however, principally derived from the anterior cerebral.

The **middle cerebral artery** (Fig. 295), the largest branch of the internal carotid, passes obliquely outward along the fissure of Sylvius, and opposite the island of Reil divides into its terminal branches. The branches of the middle cerebral artery are—

Antero-lateral ganglionic.	Ascending frontal.
Inferior external frontal.	Ascending parietal.
Parieto-temporal.	

The *antero-lateral ganglionic branches* are a group of small arteries which arise at the commencement of the middle cerebral artery; they pierce the anterior perforated space and supply the greater part of the caudate nucleus, the lenticular nucleus, the internal capsule, and a part of the optic thalamus. One artery of this group is of larger size than the rest, and is of special importance, as being the artery in the brain most frequently ruptured; it has been termed by Charcot the "*artery of cerebral hemorrhage.*" It passes up between the lenticular nucleus and the external capsule, and ultimately ends in the caudate nucleus. The *inferior external frontal* supplies the third or inferior frontal convolution (Broca's convolution) and the outer part of the orbital surface of the frontal lobe. The *ascending frontal* supplies the ascending frontal convolution. The *ascending parietal* supplies the ascending parietal convolution and the lower part of the superior parietal convolution. The *parieto-temporal* supplies the supra-marginal, the superior, and part of the middle temporal convolutions, and the angular gyrus.

The **posterior communicating artery** arises from the back part of the internal carotid, runs directly backward, and anastomoses with the posterior cerebral, a

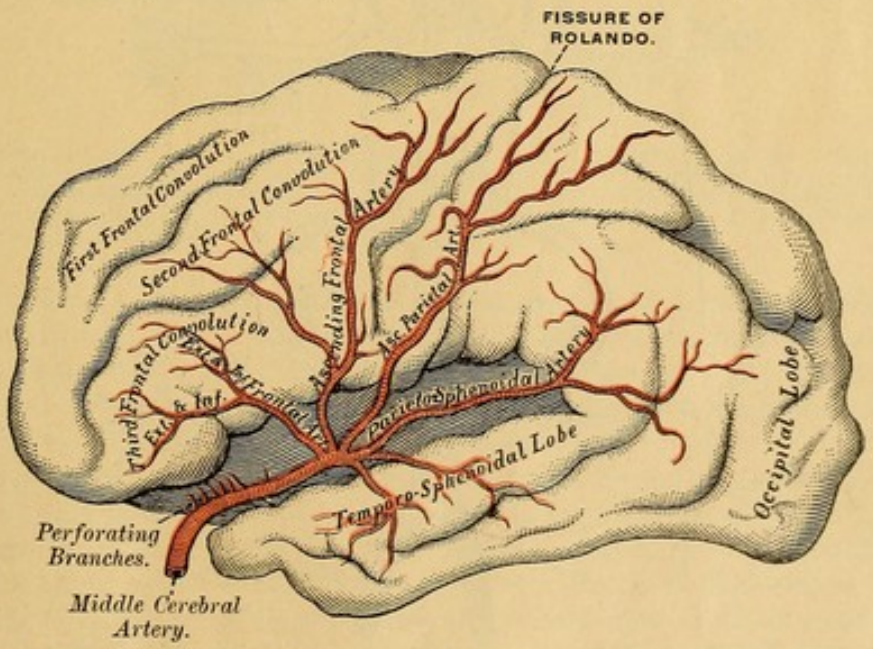

FIG. 295.—The distribution of the middle cerebral artery. (After Charcot.)

branch of the basilar. This artery varies considerably in size, being sometimes small, and occasionally so large that the posterior cerebral may be considered as arising from the internal carotid rather than from the basilar. It is frequently

larger on one side than on the other side. From the posterior half of this vessel are given off a number of small branches, the *postero-median ganglionic branches*, which, with similar vessels from the posterior cerebral, pierce the posterior perforated space and supply the internal surfaces of the optic thalami and the walls of the third ventricle.

The **anterior choroid** is a small but constant branch which arises from the back part of the internal carotid, near the posterior communicating artery. Passing backward and outward between the temporal lobe and the crus cerebri, it enters the descending horn of the lateral ventricle through the transverse fissure and ends in the choroid plexus. It is distributed to the hippocampus major, corpus fimbriatum, velum interpositum, and choroid plexus.

The Blood-vessels of the Brain.

Recent investigations have tended to show that the mode of distribution of the vessels of the brain has an important bearing upon a considerable number of the anatomical lesions of which this part of the nervous system may be the seat; it therefore becomes important to consider a little more in detail the way in which the cerebral vessels are distributed.

The cerebral arteries are derived from the internal carotid and the vertebral, which at the base of the brain form a remarkable anastomosis known as the *circle of Willis*. It is formed in front by the anterior cerebral arteries, branches of the internal carotid, which are connected together by the anterior communicating; behind by the two posterior cerebrals, branches of the basilar which are connected on each side with the internal carotid by the posterior communicating (Fig. 291, p. 507). The parts of the brain included within this arterial circle are the lamina cinerea, the commissure of the optic nerves, the infundibulum, the tuber cinereum, the corpora albicantia, and the posterior perforated space.

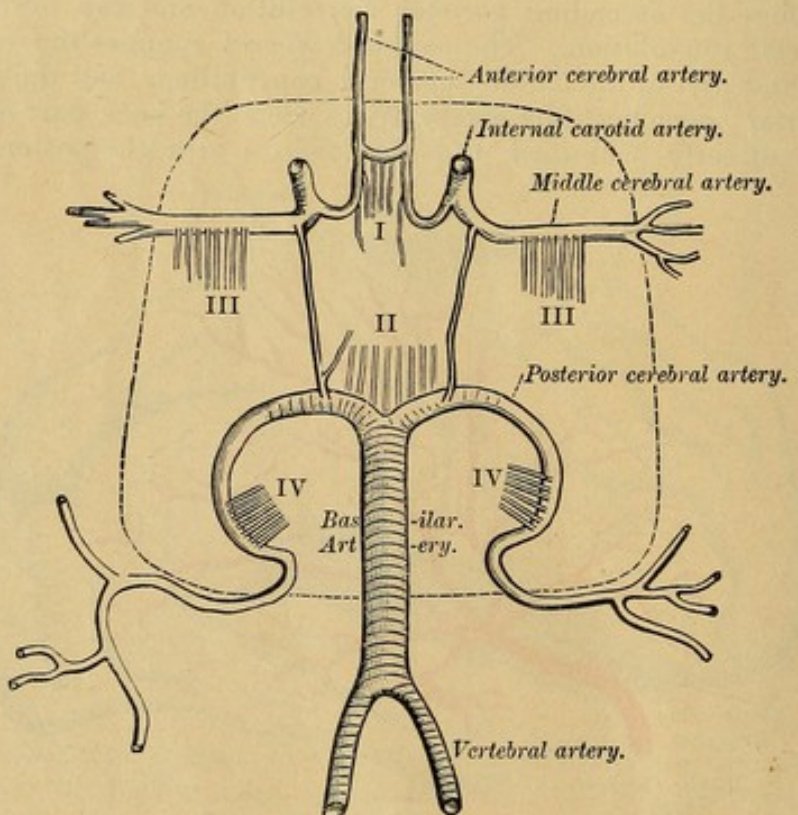

FIG. 296.—Diagram of the arterial circulation at the base of the brain. (After Charcot.) I. Antero-median group of ganglionic branches. II. Postero-median group. III. Right and left antero-lateral group. IV. Right and left postero-lateral group. The dotted line shows the limit of the ganglionic circle.

From the circle of Willis arise the three trunks which together supply each cerebral hemisphere. From its anterior part proceed the two anterior cerebrals, from its antero-lateral part the middle cerebrals, and from its posterior part the

posterior cerebrals. Each of these principal arteries gives origin to two very different systems of secondary vessels. One of these systems has been named the *central ganglionic system*, and the vessels belonging to it supply the central ganglia of the brain; the other has been named the *cortical arterial system*, and its vessels ramify in the pia mater and supply the cortex and subjacent medullary matter. These two systems, though they have a common origin, do not communicate at any point of their peripheral distribution, and are entirely independent of each other. Though some of the arteries of the cortical system approach, at their terminations, the regions supplied by the central ganglionic system, no communication between the two sets of vessels takes place, and there is between the parts supplied by the two systems a borderland of diminished nutritive activity, where, it is said, softening is especially liable to occur in the brains of old people.

The Central Ganglionic System.—All the vessels belonging to this system are given off from the circle of Willis or from the vessels immediately after their origin

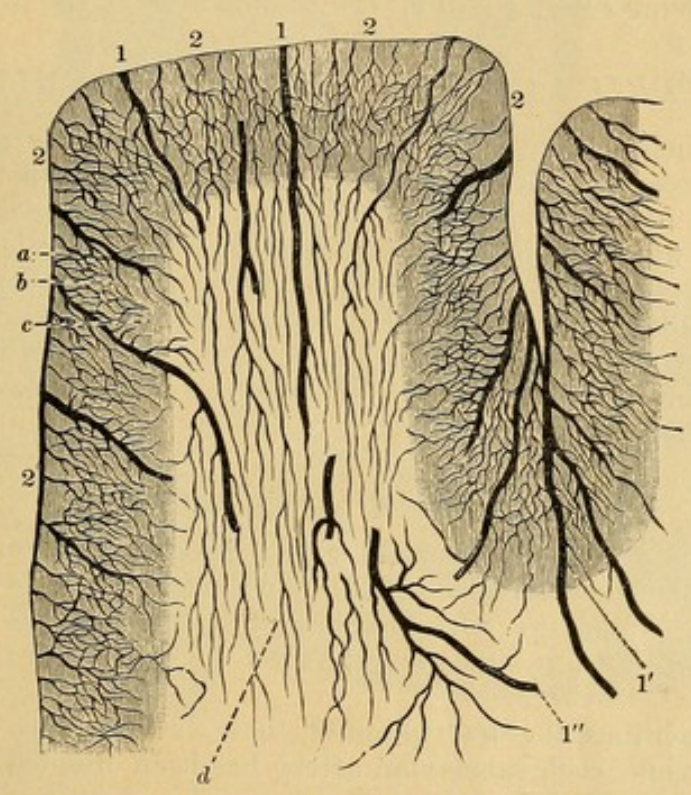

FIG. 297.—Distribution of the cortical arteries. (After Charcot.) 1. Medullary arteries. 1'. Group of medullary arteries in the sulcus between two adjacent convolutions. 1''. Arteries situated among the short association fibres. 2, 2. Cortical arteries. *a*. Capillary network with fairly wide meshes, situated beneath the pia mater. *b*. Network with more compact, polygonal meshes, situated in the cortex. *c*. Transitional network with wider meshes. *d*. Capillary network in the white matter.

from it, so that if a circle is drawn at a distance of about an inch from the circle of Willis, it will include the origin of all the arteries belonging to this system (Fig. 296). The vessels of this system form six principal groups: (I.) the *antero-median group*, derived from the anterior cerebrals and anterior communicating; (II.) the *postero-median group*, from the posterior cerebrals and posterior communicating; (III.) the right and left *antero-lateral group*, from the middle cerebrals: and (IV.) the right and left *postero-lateral group*, from the posterior cerebrals, after they have wound round the crura cerebri. The vessels belonging to this system are larger than those of the cortical system, and are what Cohnheim has termed "terminal" arteries; that is to say, vessels which from their origin to their termination neither supply nor receive any anastomotic branch, so that by one of the small vessels only a limited area of the central ganglia can be injected; and the injection cannot be driven beyond the area of the part supplied by the particular vessel which is the subject of the experiment.

The Cortical Arterial System.—The vessels forming this system are the terminal branches of the anterior, middle, and posterior cerebral arteries, described above.

These vessels divide and ramify in the substance of the pia mater, and give off nutrient arteries which penetrate the cortex perpendicularly. These nutrient vessels are divisible into two classes—the long and short. The *long*—or, as they are sometimes called, the *medullary—arteries* pass through the gray matter to penetrate the centrum ovale to the depth of about an inch and a half, without intercommunicating otherwise than by very fine capillaries, and thus constitute so many independent small systems. The *short vessels* are confined to the cortex, where they form with the long vessels a compact network in the middle zone of the gray matter, the outer and inner zones being sparingly supplied with blood (Fig. 297). The vessels of the cortical arterial system are not so strictly "terminal" as those of the central ganglionic system, but they approach this type very closely, so that injection of one area from the vessel of another area, though it may be possible, is frequently very difficult, and is only effected through vessels of small calibre. As a result of this, obstruction of one of the main branches or its divisions may have the effect of producing softening in a very limited area of the cortex.[1]

ARTERIES OF THE UPPER EXTREMITY.

The artery which supplies the upper extremity continues as a single trunk from its commencement down to the elbow, but different portions of it have received different names according to the region through which it passes. That part of the vessel which extends from its origin to the outer border of the first rib is termed the subclavian; beyond this point to the lower border of the axilla it is termed the axillary; and from the lower margin of the axillary space to the bend of the elbow it is termed brachial; here the single trunk terminates by dividing into two branches, the radial and ulnar—an arrangement precisely similar to what occurs in the lower limb.

THE SUBCLAVIAN ARTERIES (Fig. 298).

The **subclavian artery** on the right side arises from the innominate artery opposite the right sterno-clavicular articulation; on the left side it arises from the arch of the aorta. It follows, therefore, that these two vessels must, in the first part of their course, differ in their length, their direction, and their relation with neighboring parts.

In order to facilitate the description of these vessels, more especially from a surgical point of view, each subclavian artery has been divided into three parts. The first portion, on the right side, passes upward and outward from the origin of the vessel to the inner border of the Scalenus anticus. On the left side it ascends nearly vertically, to gain the inner border of that muscle. The second part passes outward, behind the Scalenus anticus; and the third part passes from the outer margin of that muscle, beneath the clavicle, to the outer border of the first rib, where it becomes the axillary artery. The first portion of these two vessels differs so much in its course and in its relation with neighboring parts that it will be described separately. The second and third parts are alike on the two sides.

First Part of the Right Subclavian Artery (Figs. 280, 283, 298).

The **right subclavian artery** arises from the arteria innominata, opposite the upper part of the right sterno-clavicular articulation, and passes upward and outward to the inner margin of the Scalenus anticus muscle. In this part of its course it ascends a little above the clavicle, the extent to which it does so varying in different cases. It is covered, *in front*, by the integument, superficial fascia, Platysma, deep fascia, the clavicular origin of the Sterno-mastoid, the Sterno-

[1] The student who desires further information on this subject is referred to Charcot's *Localization of Cerebral and Spinal Diseases*, p. 42 *et seq.*, whence the facts above given have been principally derived.

hyoid, and Sterno-thyroid muscles, and another layer of the deep fascia. It is crossed by the internal jugular and vertebral veins, and by the pneumogastric and the cardiac branches of the sympathetic. A loop of the sympathetic nerve itself also crosses the artery, forming a ring around the vessels. The anterior jugular vein passes outward in front of the artery but is not in contact with it, being separated from it by the Sterno-hyoid and Sterno-thyroid muscles. Below and behind the artery is the pleura, which separates it from the apex of the lung; *behind* is the cord of the sympathetic nerve; the recurrent laryngeal nerve winds round the lower and back part of the vessel.

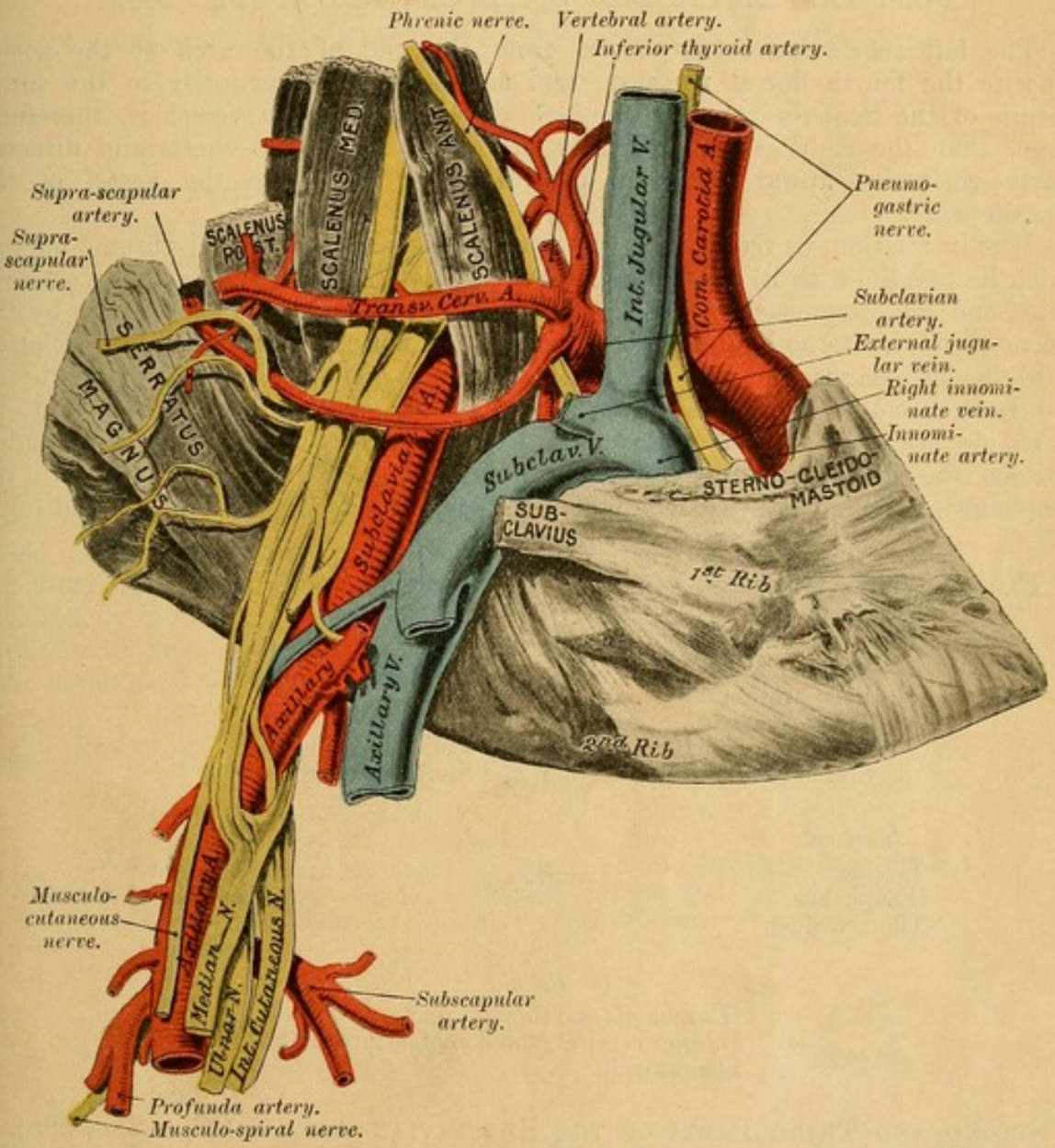

FIG. 298.—The subclavian artery, showing its relations. (From a preparation in the Museum of the Royal College of Surgeons of England.)

PLAN OF RELATIONS OF FIRST PORTION OF THE RIGHT SUBCLAV ..d the ..V.

In front.

Skin, superficial fascia.
Platysma, deep fascia.
Clavicular origin of Sterno-masto
Sterno-hyoid and Sterno-thy
Anterior jugular, Interna
Pneumogastric and card
Loop from the sympath

e takes place, in some cases
frequently, in the cavity of
ate trunk from the arch of the
even the last branch derived fr
rely the second or third. When
the innominate artery; when the secon
he right carotid; and when the last bra
upper or back part, and passes obliqu

ations.—
rvical fascia, Ste
e the phrenic nerv
scalene muscle, w
y immediately to th
pleura and the
Below, with the p
, separated from



Beneath.
Pleura.
Recurrent laryngeal nerve.

Behind.
Recurrent laryngeal nerve.
Sympathetic.
Pleura and apex of lung.

First Part of the Left Subclavian Artery (Fig. 280).

The **left subclavian artery** arises from the end of the arch of the aorta, opposite the fourth dorsal vertebra, and ascends nearly vertically to the inner margin of the Scalenus anticus muscle. This part of the vessel is, therefore, longer than the right, situated deeply in the cavity of the chest, and directed nearly vertically upward, instead of arching outward like the vessel of the opposite side.

It is in relation, *in front*, with the pneumogastric, cardiac, and phrenic nerves, which lie parallel with it, the left carotid artery, left internal jugular and vertebral veins, and the commencement of the left innominate vein, and is covered by the Sterno-thyroid, Sterno-hyoid, and Sterno-mastoid muscles; *behind*, it is in relation with the œsophagus, thoracic duct, inferior cervical ganglion of the sympathetic, and Longus colli; higher up, however, the œsophagus and thoracic duct lie to its right side; the latter ultimately arching over the vessel to join the angle of union between the subclavian and internal jugular veins. To its *inner side* are the œsophagus, trachea, and thoracic duct; to its *outer side*, the left pleura and lung.

Plan of Relations of First Portion of Left Subclavian Artery.

In front.
Pneumogastric, cardiac, and phrenic nerves.
Left carotid artery.
Thoracic duct.
Left internal jugular, vertebral, and innominate veins.
Sterno-thyroid, Sterno-hyoid, and Sterno-mastoid muscles.

Inner side.
Trachea.
Œsophagus.
Thoracic duct.



Outer side.
Pleura and left lung.

Behind.
Œsophagus and thoracic duct.
Inferior cervical ganglion of sympathetic.
Longus colli.

Second and Third Parts of the Subclavian Artery (Figs. 283, 298).

The **Second Portion of the Subclavian Artery** lies behind the Scalenus anticus muscle: it is very short, and forms the highest part of the arch described by that vessel. rig.

Relrt of t... is covered, *in front*, by the skin, superficial fascia, Platysma, deep c the inner margin of t astoid, and the Scalenus anticus muscle. On the right si ascends a little above the rated from the second part of the artery by the Anterio nt cases. It is covered, i he left side the nerve crosses the first part of the arter deep fascia, the clavicula of the muscle. *Behind*, it is in relation with the ndent who desires further information on *Above*, with the brachial plexus of nerves. nd Spinal Diseases, p. 42 *et seq.*, whence lavian vein lies below and in front of the artery s anticus.

PLAN OF RELATIONS OF SECOND PORTION OF SUBCLAVIAN ARTERY.

In front.
Skin and superficial fascia.
Platysma and deep cervical fascia.
Sterno-mastoid.
Phrenic nerve.
Scalenus anticus.
Subclavian vein.

Above. Brachial plexus.

Subclavian Artery. Second Portion.

Below. Pleura.

Behind.
Pleura and Middle Scalenus.

The **Third Portion of the Subclavian Artery** passes downward and outward from the outer margin of the Scalenus anticus to the outer border of the first rib, where it becomes the axillary artery. This portion of the vessel is the most superficial, and is contained in a subclavian triangle (see page 502).

Relations.—It is covered, in *front*, by the skin, the superficial fascia, the Platysma, the descending clavicular branches of the cervical plexus, and the deep cervical fascia; by the clavicle, the Subclavius muscle, and the suprascapular artery and vein, and the transverse cervical vein; the nerve to the Subclavius muscle passes vertically downward in front of the artery. The external jugular vein crosses it at its inner side, and receives the suprascapular and transverse cervical veins, which frequently form a plexus in front of it. The subclavian vien is below and in front of the artery, lying close behind the clavicle. *Behind*, it lies on the Middle scalene muscle and the lowest cord of the brachial plexus, formed by the union of the last cervical and first dorsal nerves. *Above* it, and to its outer side, is the brachial plexus and Omo-hyoid muscle. *Below*, it rests on the upper surface of the first rib.

PLAN OF RELATIONS OF THIRD PORTION OF SUBCLAVIAN ARTERY.

In front.
Skin and superficial fascia.
Platysma and deep cervical fascia.
Descending branches of cervical plexus. Nerve to Subclavius muscle.
Subclavius muscle, suprascapular artery, and vein.
The external jugular and transverse cervical veins.
The clavicle.

Above.
Brachial plexus.
Omo-hyoid.

Subclavian Artery. Third Portion.

Below. First rib.

Behind.
Scalenus medius.
Lower cord of brachial plexus.

Peculiarities.—The subclavian arteries vary in their origin, their course, and the height to which they rise in the neck.

The origin of the right subclavian from the innominate takes place, in some cases, above the sterno-clavicular articulation, and occasionally, but less frequently, in the cavity of the thorax, below that joint. Or the artery may arise as a separate trunk from the arch of the aorta. In such cases it may be either the first, second, third, or even the last branch derived from that vessel; in the majority of cases it is the first or last, rarely the second or third. When it is the first branch, it occupies the ordinary position of the innominate artery; when the second or third, it gains its usual position by passing behind the right carotid; and when the last branch, it arises from the left extremity of the arch, at its upper or back part, and passes obliquely toward the

right side, usually behind the trachea, œsophagus, and right carotid, sometimes between the œsophagus and trachea to the upper border of the first rib, whence it follows its ordinary course. In very rare instances this vessel arises from the thoracic aorta, as low down as the fourth dorsal vertebra. Occasionally it perforates the anterior Scalenus; more rarely it passes in front of that muscle. Sometimes the subclavian vein passes with the artery behind the Anterior Scalene. The artery may ascend as high as an inch and a half above the clavicle or any intermediate point between this and the upper border of the bone, the right subclavian usually ascending higher than the left.

The left subclavian is occasionally joined at its origin with the left carotid.

Surface Marking.—The course of the subclavian artery in the neck may be mapped out by describing a curve, with its convexity upward at the base of the posterior triangle. The inner end of this curve corresponds to the sterno-clavicular joint, the outer end to the centre of the lower border of the clavicle. The curve is to be drawn with such an amount of convexity that its mid-point reaches half an inch above the upper border of the clavicle. The left subclavian artery is more deeply placed than the right in the first part of its course, and, as a rule, does not reach quite as high a level in the neck. It should be borne in mind that the posterior border of the Sterno-mastoid muscle corresponds to the outer border of the Scalenus anticus, so that the third portion of the artery, that part most accessible for operation, lies immediately external to the posterior border of the Sterno-mastoid.

Surgical Anatomy.—The relations of the subclavian arteries of the two sides having been examined, the student should direct his attention to a consideration of the best position in which compression of the vessel may be effected, or in what situation a ligature may be best applied in cases of aneurism or wound.

Compression of the subclavian artery is required in cases of operations about the shoulder, in the axilla, or at the upper part of the arm; and the student will observe that there is only one situation in which it can be effectually applied—viz. where the artery passes across the upper surface of the first rib. In order to compress the vessel in this situation, the shoulder should be depressed, and the surgeon, grasping the side of the neck, should press with his thumb in the angle formed by the posterior border of the Sterno-mastoid with the upper border of the clavicle, downward, backward, and inward against the rib; if from any cause the shoulder cannot be sufficiently depressed, pressure may be made from before backward, so as to compress the artery against the middle Scalenus and transverse process of the seventh cervical vertebra. In appropriate cases, a preliminary incision may be made through the cervical fascia, and the finger may be pressed down directly upon the artery.

Ligature of the subclavian artery may be required in cases of wounds or of aneurism in the axilla, or in cases of aneurism on the cardiac side of the point of ligature; and the third part of the artery is that which is most favorable for an operation, on account of its being comparatively superficial and most remote from the origin of the large branches. In those cases where the clavicle is not displaced, this operation may be performed with comparative facility; but where the clavicle is pushed up by a large aneurismal tumor in the axilla the artery is placed at a great depth from the surface, which materially increases the difficulty of the operation. Under these circumstances it becomes a matter of importance to consider the height to which this vessel reaches above the bone. In ordinary cases its arch is about half an inch above the clavicle, occasionally as high as an inch and a half, and sometimes so low as to be on a level with its upper border. If the clavicle is displaced, these variations will necessarily make the operation more or less difficult according as the vessel is more or less accessible.

The chief points in the operation of tying the third portion of the subclavian artery are as follows: The patient being placed on a table in the supine position, with the head drawn over to the opposite side and the shoulder depressed as much as possible, the integument should be drawn downward over the clavicle, and an incision made through it, upon that bone, from the anterior border of the Trapezius to the posterior border of the Sterno-mastoid, to which may be added a short vertical incision meeting the inner end of the preceding. The object in drawing the skin downward is to avoid any risk of wounding the external jugular vein, for as it perforates the deep fascia above the clavicle, it cannot be drawn downward with the skin. The soft parts should now be allowed to glide up, and the cervical fascia should be divided upon a director, and if the interval between the Trapezius and Sterno-mastoid muscles be insufficient for the performance of the operation, a portion of one or both may be divided. The external jugular vein will now be seen toward the inner side of the wound: this and the suprascapular and transverse cervical veins, which terminate in it, should be held aside. If the external jugular vein is at all in the way and exposed to injury, it should be tied in two places and divided. The suprascapular artery should be avoided, and the Omo-hyoid muscle held aside if necessary. In the space beneath this muscle careful search must be made for the vessel: a deep layer of fascia and some connective tissue having been divided carefully, the outer margin of the Scalenus anticus muscle must be felt for, and, the finger being guided by it to the first rib, the pulsation of the subclavian artery will be felt as it passes over the rib. The sheath of the vessels having been opened, the aneurism needle may then be passed around the artery from above downward and inward, so as to avoid including any of the branches of the brachial plexus. If the clavicle is so raised by the tumor that the application of the ligature cannot be effected in this situation, the artery may be tied above the first rib, or even behind the Scalenus anticus muscle: the difficulties of the operation in such a case will be materially increased, on account of the greater depth of the artery and the alteration in position of the surrounding parts.

The second part of the subclavian artery, from being that portion which rises highest in the neck, has been considered favorable for the application of the ligature when it is difficult to tie the artery in the third part of its course. There are, however, many objections to the operation in this situation. It is necessary to divide the Scalenus anticus muscle, upon which lies the phrenic nerve, and at the inner side of which is situated the internal jugular vein; and a wound of either of these structures might lead to the most dangerous consequences. Again, the artery is in contact, below, with the pleura, which must also be avoided; and, lastly, the proximity of so many of its large branches arising internal to this point must be a still further objection to the operation. In cases, however, where the sac of an axillary aneurism encroaches on the neck, it may be necessary to divide the outer half or two-thirds of the Scalenus anticus muscle, so as to place the ligature on the vessel at a greater distance from the sac. The operation is performed exactly in the same way as ligature of the third portion, until the Scalenus anticus is exposed, when it is to be divided on a director (never to a greater extent than its outer two-thirds), and it immediately retracts. The operation is therefore merely an extension of ligature of the third portion of the vessel.

In those cases of aneurism of the axillary or subclavian artery which encroach upon the outer portion of the Scalenus muscle to such an extent that a ligature cannot be applied in that situation, it may be deemed advisable, as a last resource, to tie the first portion of the subclavian artery. On the left side this operation is almost impracticable; the great depth of the artery from the surface, its intimate relation with the pleura, and its close proximity to the thoracic duct and to so many important veins and nerves, present a series of difficulties which it is next to impossible to overcome.[1] On the right side the operation is practicable, and has been performed, though never with success. The main objection to the operation in this situation is the smallness of the interval which usually exists between the commencement of the vessel and the origin of the nearest branch. The operation may be performed in the following manner: The patient being placed on the table in the supine position with the neck extended, an incision should be made along the upper border of the inner part of the clavicle, and a second along the inner border of the Sterno-mastoid, meeting the former at an angle. The attachment of both heads of the Sterno-mastoid must be divided on a director and turned outward; a few small arteries and veins, and occasionally the anterior jugular, must be avoided, or, if necessary, ligatured in two places and divided, and the Sterno-hyoid and Sterno-thyroid muscles divided in the same manner as the preceding muscle. After tearing through the deep fascia with the finger-nail, the internal jugular vein will be seen crossing the subclavian artery; this should be pressed aside and the artery secured by passing the needle from below upward, by which the pleura is more effectually avoided. The exact position of the vagus nerve, the recurrent laryngeal, the phrenic and sympathetic nerves should be remembered, and the ligature should be applied near the origin of the vertebral, in order to afford as much room as possible for the formation of a coagulum between the ligature and the origin of the vessel. It should be remembered that the right subclavian artery is occasionally deeply placed in the first part of its course when it arises from the left side of the aortic arch, and passes in such cases behind the œsophagus or between it and the trachea.

Collateral Circulation.—After ligature of the third part of the subclavian artery the collateral circulation is mainly established by three sets of vessels, thus described in a dissection:

"1. A posterior set, consisting of the suprascapular and posterior scapular branches of the subclavian, anastomosing with the subscapular from the axillary.

"2. An internal set produced by the connection of the internal mammary on the one hand, with the superior and long thoracic arteries, and the branches from the subscapular on the other.

"3. A middle or axillary set, which consisted of a number of small vessels derived from branches of the subclavian, above, and, passing through the axilla, terminated either in the main trunk or some of the branches of the axillary below. This last set presented most conspicuously the peculiar character of newly-formed or, rather, dilated arteries, being excessively tortuous, and forming a complete plexus.

"The chief agent in the restoration of the axillary artery below the tumor was the subscapular artery, which communicated most freely with the internal mammary, suprascapular, and posterior scapular branches of the subclavian, from all of which it received so great an influx of blood as to dilate it to three times its natural size."[2]

When a ligature is applied to the first part of the subclavian artery, the collateral circulation is carried on by—1, the anastomosis between the superior and inferior thyroid; 2, the anastomosis of the two vertebrals; 3, the anastomosis of the internal mammary with the deep epigastric and the aortic intercostals; 4, the superior intercostal anastomosing with the aortic intercostals; 5, the profunda cervicis anastomosing with the princeps cervicis; 6, the scapular branches of the thyroid axis anastomosing with the branches of the axillary; and 7, the thoracic branches of the axillary anastomosing with the aortic intercostals.

[1] The operation was, however, performed in New York by Dr. J. K. Rodgers, and the case is related in *A System of Surgery*, edited by T. Holmes, 2d ed., vol. iii., pp. 620, etc.

[2] *Guy's Hospital Reports*, vol. i., 1836: case of axillary aneurism, in which Mr. Aston Key had tied the subclavian artery on the outer edge of the Scalenus muscle twelve years previously.

Branches.—The branches given off from the subclavian artery are:

Vertebral.	Thyroid axis.
Internal mammary.	Superior intercostal.

On the left side all four branches generally arise from the first portion of the vessel; but on the right side, the superior intercostal usually arises from the second portion of the vessel. On both sides of the body the first three branches arise close together at the inner margin of the Scalenus anticus; in the majority of cases, a free interval of from half an inch to an inch exists between the commencement of the artery and the origin of the nearest branch; in a samller number of cases, an interval of more than an inch exists, but it never exceeds an inch and three-quarters. In a very few instances, the interval has been found to be less than half an inch. The vertebral artery arises from the upper and posterior part of the artery, the internal mammary from the lower part of the artery; the thyroid axis from in front, and the superior intercostal from behind.

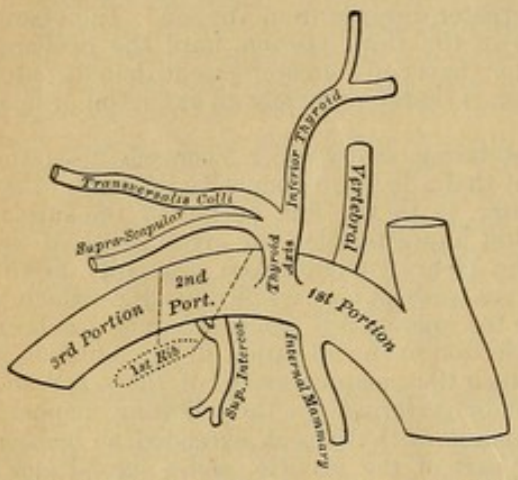

FIG. 299.—Plan of the branches of the right subclavian artery.

The **Vertebral Artery** (Fig. 289) is generally the first and largest branch of the subclavian; it arises from the upper and back part of the first portion of the vessel, and, passing upward, enters the foramen in the transverse process of the sixth cervical vertebra,[1] and ascends through the foramina in the transverse processes of all the vertebræ above this. Above the upper border of the axis it inclines outward and upward to the foramen in the transverse process of the atlas, through which it passes; it then winds backward behind its articular process, runs in a deep groove on the upper surface of the posterior arch of this bone, and, passing beneath the posterior occipito-atlantal ligament, pierces the dura mater and arachnoid, and enters the skull through the foramen magnum. It then passes forward and upward, inclining from the lateral aspect to the front of the medulla oblongata. It unites in the middle line with the vessel of the opposite side at the lower border of the pons Varolii to form the *basilar artery*.

Relations.—At its origin, it is situated behind the internal jugular and vertebral veins, and is crossed by the inferior thyroid artery: it lies between the Longus colli and Scalenus anticus muscles, having the thoracic duct in front of it on the left side. It rests on the transverse process of the seventh cervical vertebra and the sympathetic nerve. Within the foramina formed by the transverse processes of the vertebræ it is accompanied by a plexus of nerves from the inferior cervical ganglion of the sympathetic, and is surrounded by a dense plexus of veins which unite to form the vertebral vein at the lower part of the neck. It is situated in front of the cervical nerves, as they issue from the intervertebral foramina. While winding round the articular process of the atlas, it is contained in a triangular space (*suboccipital triangle*) formed by the Rectus capitis posticus major, the Superior and Inferior oblique muscles; and at this point is covered by the Complexus muscle. The suboccipital nerve here lies between the artery and the bone. Within the skull, as it winds round the medulla oblongata, it is placed between the hypoglossal nerve and the anterior root of the suboccipital nerve, beneath the first digitation of the ligamentum denticulatum, and finally ascends between the basilar process of the occipital bone and the anterior surface of the medulla oblongata.

[1] The vertebral artery sometimes enters the foramen in the transverse process of the fifth vertebra. Dr. Smyth, who tied this artery in the living subject, found it, in one of his dissections, passing into the foramen in the seventh vertebra.

Branches.—These may be divided into two sets—those given off in the neck and those within the cranium.

Cervical Branches.	*Cranial Branches.*
Lateral Spinal.	Posterior Meningeal.
Muscular.	Anterior Spinal.
	Posterior Spinal.
	Posterior Inferior Cerebellar.
	Bulbar.

The **lateral spinal branches** enter the spinal canal through the intervertebral foramina and divide into two branches. Of these, one passes along the roots of the nerves to supply the spinal cord and its membranes, anastomosing with the other arteries of the spinal cord; the other divides into an ascending and a descending branch, which unite with similar branches from the artery above and below, so that two lateral anastomotic chains are formed on the posterior surface of the bodies of the vertebræ near the attachment of the pedicles. From these anastomotic chains branches are given off to supply the periosteum and the bodies of the vertebræ, and to communicate with similar branches from the opposite side; from these latter small branches are given off which join similar branches above and below, so that a central anastomotic chain is formed on the posterior surface of the bodies of the vertebræ.

Muscular branches are given off to the deep muscles of the neck, where the vertebral artery curves round the articular process of the atlas. They anastomose with the occipital and with the ascending and deep cervical arteries.

The **posterior meningeal** are one or two small branches given off from the vertebral opposite the foramen magnum. They ramify between the bone and dura mater in the cerebellar fossæ, and supply the falx cerebelli.

The **anterior spinal** is a small branch which arises near the termination of the vertebral, and, descending in front of the medulla oblongata, unites with its fellow of the opposite side at about the level of the foramen magnum. One of these vessels is usually larger than the other, but occasionally they are about equal in size. The single trunk thus formed descends on the front of the spinal cord, and is reinforced by a succession of small branches which enter the spinal canal through the intervertebral foramina; these branches are derived from the vertebral and ascending cervical of the inferior thyroid in the neck; from the intercostal in the dorsal region; and from the lumbar, ilio-lumbar, and lateral sacral arteries in the lower part of the spine. They unite, by means of ascending and descending branches, to form a single anterior median artery, which extends as far as the lower part of the spinal cord. This vessel is placed in the pia mater along the anterior median fissure; it supplies that membrane and the substance of the cord, and sends off branches at its lower part to be distributed to the cauda equina, and ends on the central fibrous prolongation of the cord.

The **posterior spinal** arises from the vertebral at the side of the medulla oblongata: passing backward to the posterior aspect of the spinal cord, it descends on each side, lying behind the posterior roots of the spinal nerves, and is reinforced by a succession of small branches which enter the spinal canal through the intervertebral foramina, and by which it is continued to the lower part of the cord and to the cauda equina. Branches from these vessels form a free anastomosis round the posterior roots of the spinal nerves, and communicate, by means of very tortuous transverse branches, with the vessel of the opposite side. At its commencement it gives off an ascending branch, which terminates on the side of the fourth ventricle.

The **posterior inferior cerebellar artery** (Fig. 291), the largest branch of the vertebral, winds backward round the upper part of the medulla oblongata, passing between the origin of the pneumogastric and spinal accessory nerves, over the restiform body to the under surface of the cerebellum, where it divides into two

branches—an internal one, which is continued backward to the notch between the two hemispheres of the cerebellum; and an external one, which supplies the under surface of the cerebellum as far as its outer border, where it anastomoses with the anterior inferior cerebellar and the superior cerebellar branches of the basilar artery. Branches from this artery supply the choroid plexus of the fourth ventricle.

The **bulbar arteries** comprise several minute vessels which spring from the vertebral and its branches and are distributed to the medulla oblongata.

Surgical Anatomy.—The vertebral artery has been tied in several instances: 1, for wounds or traumatic aneurism; 2, after ligation of the innominate, either at the same time to prevent hemorrhage, or later on to arrest bleeding where it has occurred at the seat of ligature; and 3, in epilepsy. In these latter cases the treatment has been recommended by Dr. Alexander, of Liverpool, in the hope that by diminishing the supply of blood to the posterior part of the brain and the spinal cord a diminution or cessation of the epileptic fits would result. But, on account of the uncertainty as to what cases, if any, derived benefit from the operation, it has now been abandoned. The operation of ligation of the vertebral is performed by making an incision along the posterior border of the Sterno-mastoid muscle, just above the clavicle. The muscle is pulled to the inner side, and the anterior tubercle of the transverse process of the sixth cervical vertebra sought for. A deep layer of fascia being now divided, the interval between the Scalenus anticus and the Longus colli just below their attachment to the tubercle is defined, and the artery and vein found in the interspace. The vein is to be drawn to the outer side, and the aneurism needle passed from without inward. Drs. Ramskill and Bright have pointed out that severe pain at the back of the head may be symptomatic of disease of the vertebral artery just before it enters the skull. This is explained by the close connection of the artery with the suboccipital nerve in the groove on the posterior arch of the atlas. Disease of the same artery has been also said to affect speech, from pressure on the hypoglossal where it is in relation with the vessel, leading to paralysis of the muscles of the tongue.

The **Basilar Artery** (Fig. 291), so named from its position at the base of the skull, is a single trunk formed by the junction of the two vertebral arteries; it extends from the posterior to the anterior border of the pons Varolii, lying in its median groove, under cover of the arachnoid. It ends by dividing into the two *posterior cerebral arteries*. Its branches are, on each side, the following:

Transverse.	Superior Cerebellar.
Anterior Inferior Cerebellar.	Posterior Cerebral.

The **transverse branches** supply the pons Varolii and adjacent parts of the brain; one branch, the *internal auditory*, accompanies the auditory nerve into the internal auditory meatus.

The **anterior inferior cerebellar artery** passes backward across the crus cerebelli, to be distributed to the anterior border of the under surface of the cerebellum, anastomosing with the posterior inferior cerebellar branch of the vertebral.

The **superior cerebellar arteries** arise near the termination of the basilar. They pass outward, immediately behind the third nerves, which separate them from the posterior cerebral, wind round the crura cerebri, close to the fourth nerve, and, arriving at the upper surface of the cerebellum, divide into branches which ramify in the pia mater and, reaching the circumference of the cerebellum, anastomose with the branches of the inferior cerebellar arteries. Several branches are given to the pineal gland, the valve of Vieussens, and the velum interpositum.

The **posterior cerebral arteries,** the two terminal branches of the basilar, are larger than the preceding, from which they are separated near their origin by the third nerves. Passing outward, parallel to the superior cerebellar artery, and receiving the posterior communicating from the internal carotid, they wind round the crura cerebri, and pass to the under surface of the occipital lobes of the cerebrum, and break up into branches for the supply of the temporal and occipital lobes. The branches of the posterior cerebral artery are:

Postero-median ganglionic.		Anterior temporal.
Posterior choroid.	Three terminal.	Posterior temporal.
Postero-lateral ganglionic.		Occipital.

The *postero-median ganglionic branches* (Fig. 296) are a group of sm nerve, Sca- which arise at the commencement of the posterior cerebral artery; these, sometimes lar branches from the posterior communicating, pierce the posterior Trapezius space, and supply the internal surfaces of the optic thalami and the wal third ventricle. The *posterior choroid* enters the interior of the brain be splenium of the corpus callosum, and supplies the velum interpositum choroid plexus. The *postero-lateral ganglionic branches* are a group of arteries which arise from the posterior cerebral artery, after it has turned roun crus cerebri; they supply a considerable portion of the optic thalamus. *terminal branches* are distributed as follows: the first (*anterior temporal*) to uncinate gyrus; the second (*posterior temporal*) to the external occipital and third temporal convolutions; and the third (*occipital*) to the inner and out surfaces of the occipital lobe.

Circle of Willis.—The remarkable anastomosis which exists between the branches of the internal carotid and vertebral arteries at the base of the brain constitutes the *circle of Willis*. It is formed, in front, by the anterior cerebral arteries, branches of the internal carotid, which are connected together by the anterior communicating; behind, by the two posterior cerebrals, branches of the basilar, which are connected on each side with the internal carotid by the posterior communicating arteries (Fig. 291). It is by this anastomosis that the cerebral circulation is equalized, and provision made for effectually carrying it on if one or more of the branches are obliterated. The parts of the brain included within this arterial circle are—the lamina cinerea, the commissure of the optic nerves, the infundibulum, the tuber cinereum, the corpora albicantia, and the posterior perforated space.

The **Thyroid Axis** (Fig. 283) is a short thick trunk which arises from the fore part of the first portion of the subclavian artery, close to the inner border of the Scalenus anticus muscle, and divides, almost immediately after its origin, into three branches—the *inferior thyroid*, *suprascapular*, and *transversalis colli*.

The **Inferior thyroid artery** passes upward, in front of the vertebral artery and Longus colli muscle: then turns inward behind the sheath of the common carotid artery and internal jugular vein, and also behind the sympathetic nerve, the middle cervical ganglion resting upon the vessel, and, reaching the lower border of the lateral lobe of the thyroid gland, it divides into two branches, which supply the posterior and under part of the organ, and anastomose in its substance with the superior thyroid and with the corresponding artery of the opposite side. The recurrent laryngeal nerve passes upward, generally behind but occasionally in front of the artery. Its branches are: the

Inferior Laryngeal.	Œsophageal.
Tracheal.	Ascending Cervical.
Muscular.	

The **inferior laryngeal branch** ascends upon the trachea to the back part of the larynx, in company with the recurrent laryngeal nerve, and supplies the muscles and mucous membrane of this part, anastomosing with the branch from the opposite side and with the laryngeal branch from the superior thyroid artery.

The **tracheal branches** are distributed upon the trachea, anastomosing below with the bronchial arteries.

The **œsophageal branches** are distributed to the œsophagus, and anastomose with the œsophageal branches of the aorta.

The **ascending cervical** is a small branch which arises from the inferior thyroid just where that vessel is passing behind the common carotid artery, and runs up on the anterior tubercles of the transverse processes of the cervical vertebræ in the interval between the Scalenus anticus and Rectus capitis anticus major. It gives branches to the muscles of the neck, which anastomose with branches of the vertebral, and sends one or two branches into the spinal canal through the intervertebral foramina to be distributed to the spinal cord and its membranes, and to

The **posterior scapular** passes beneath the Levator anguli scapulæ to the superior angle of the scapula, and then descends along the posterior border of that bone as far as the inferior angle. In its course it is covered by the Rhomboid muscles, supplying them and the Latissimus dorsi and Trapezius, and anastomosing with the suprascapular and subscapular arteries, and with the posterior branches of some of the intercostal arteries.

Peculiarities.—The *superficial cervical* frequently arises as a separate branch from the thyroid axis; and the posterior scapular, from the third, more rarely from the second, part of the subclavian.

The **Internal mammary** (Fig. 301) arises from the under surface of the first portion of the subclavian artery, opposite the thyroid axis. It passes downward and inward behind the costal cartilage of the first rib to the inner surface of the anterior wall of the chest, resting against the costal cartilages about half an inch from the margin of the sternum; and, at the interval between the sixth and seventh cartilages, divides into two branches, the *musculo-phrenic* and *superior epigastric*.

Relations.—At its origin it is covered by the internal jugular and subclavian veins, and as it enters the thorax is crossed from without inward by the phrenic nerve, and then passes forward close to the outer side of the innominate vein. In the upper part of the thorax it lies behind the costal cartilages and Internal intercostal muscles, and is crossed by the terminations of the upper six intercostal nerves. At first it lies upon the pleura, but at the lower part of the thorax the Triangularis sterni separates the artery from this membrane. It has two venæ comites; these unite into a single vein, which joins the innominate vein of its own side.

The branches of the internal mammary are—

Comes Nervi Phrenici (Superior Phrenic).	Anterior Intercostal.
Mediastinal.	Perforating.
Pericardiac.	Musculo-phrenic.
Sternal.	Superior Epigastric.

The **comes nervi phrenici (superior phrenic)**, is a long slender branch which accompanies the phrenic nerve, between the pleura and pericardium, to the Diaphragm, to which it is distributed, anastomosing with the other phrenic arteries from the internal mammary and abdominal aorta.

The **mediastinal branches** are small vessels which are distributed to the areolar tissue and lymphatic glands in the anterior mediastinum and the remains of the thymus gland.

The **pericardiac branches** supply the upper part of the anterior surface of the pericardium, the lower part receiving branches from the musculo-phrenic artery.

The **sternal branches** are distributed to the Triangularis sterni and to the posterior surface of the sternum.

The mediastinal, pericardiac, and sternal branches, together with some twigs from the comes nervi phrenici, anastomose with branches from the intercostal and bronchial arteries, and form a minute plexus beneath the pleura, which has been named by Turner the *subpleural mediastinal plexus*.

The **anterior intercostal arteries** supply the five or six upper intercostal spaces. The branch corresponding to each space soon divides into two, or the two branches may come off separately from the parent trunk. The small vessels pass outward in the intercostal spaces, one lying near the lower margin of the rib above, and the other near the upper margin of the rib below, and anastomose with the intercostal arteries from the aorta. They are at first situated between the pleura and the Internal intercostal muscles, and then between the Internal and External intercostal muscles. They supply the Intercostal muscles, and, by branches which perforate the External intercostal muscle, the Pectoral muscles and the mammary gland.

The **perforating arteries** correspond to the five or six upper intercostal spaces. They arise from the internal mammary, pass forward through the intercostal spaces, and, curving outward, supply the Pectoralis major and the integument.

Those which correspond to the second, third, and fourth spaces are distributed to the mammary gland. In females, during lactation, these branches are of large size.

The **musculo-phrenic artery** is directed obliquely downward and outward, behind the cartilages of the false ribs, perforating the Diaphragm at the eighth or ninth rib, and terminating, considerably reduced in size, opposite the last intercostal space. It gives off anterior intercostal arteries to each of the intercostal spaces across which it passes; these diminish in size as the spaces decrease in length, and are distributed in a manner precisely similar to the anterior intercostals from the internal mammary. The musculo-phrenic also gives branches to the lower part of the pericardium, and others which run backward to the Diaphragm and downward to the abdominal muscles.

The **superior epigastric** continues in the original direction of the internal mammary; it descends through the cellular interval between the costal and sternal attachments of the Diaphragm, and enters the sheath of the Rectus abdominis muscle, at first lying behind the muscle, and then perforating it and supplying it, and anastomosing with the deep epigastric artery from the external iliac. Some vessels perforate the sheath of the Rectus, and supply the muscles of the abdomen and the integument, and a small branch, which passes inward upon the side of the ensiform appendix, anastomoses in front of that cartilage with the artery of the opposite side. It also gives some twigs to the Diaphragm, while from the artery of the right side small branches extend into the falciform ligament of the liver and anastomose with the hepatic artery.

Surgical Anatomy.—The course of the internal mammary artery may be defined by drawing a line across the six upper intercostal spaces half an inch from and parallel with the sternum. The position of the vessel must be remembered, as it is liable to be wounded in stabs of the chest-wall. It is most easily reached by a transverse incision in the second intercostal space.

The **Superior Intercostal** (Fig. 289) arises from the upper and back part of the subclavian artery, behind the Anterior scalenus muscle on the right side, and to the inner side of that muscle on the left side. Passing backward, it gives off the *deep cervical branch*, and then descends behind the pleura in front of the necks of the first two ribs, and inosculates with the first aortic intercostal. As it crosses the neck of the first rib it lies to the inner side of the anterior division of the first dorsal nerve and to the outer side of the first thoracic ganglion of the sympathetic. In the first intercostal space it gives off a branch which is distributed in a manner similar to the distribution of the aortic intercostals. The branch for the second intercostal space usually joins with one from the highest aortic intercostal. Each intercostal gives off a branch to the posterior spinal muscles, and a small one which passes through the corresponding intervertebral foramen to the spinal cord and its membranes.

The *deep cervical branch* (*profunda cervicis*) arises, in most cases, from the superior intercostal, and is analogous to the posterior branch of an aortic intercostal artery; occasionally it arises as a separate branch from the subclavian artery. Passing backward, above the eighth cervical nerve and between the transverse process of the seventh cervical vertebra and the first rib, it runs up the back part of the neck, between the Complexus and Semispinalis colli muscles, as high as the axis, supplying these and adjacent muscles, and anastomosing with the deep branch of the arteria princeps cervicis of the occipital, and with branches which pass outward from the vertebral. It gives off a special branch which enters the spinal canal through the intervertebral foramen between the seventh cervical and first dorsal vertebræ.

SURGICAL ANATOMY OF THE AXILLA.

The **Axilla** is a pyramidal space, situated between the upper and lateral part of the chest and the inner side of the arm.

Boundaries.—Its *apex*, which is directed upward toward the root of the neck, corresponds to the interval between the first rib, the upper edge of the scapula,

and the clavicle, through which the axillary vessels and nerves pass. The *base*, directed downward, is formed by the integument and a thick layer of fascia, the *axillary fascia*, extending between the lower border of the Pectoralis major in front and the lower border of the Latissimus dorsi behind; it is broad internally at the chest, but narrow and pointed externally at the arm. The *anterior boundary* is formed by the Pectoralis major and minor muscles, the former covering the whole of the anterior wall of the axilla, the latter covering only its central part. The space between the inner border of the Pectoralis minor and the clavicle is occupied by the costo-coracoid membrane. The *posterior boundary*, which extends somewhat lower than the anterior, is formed by the Subscapularis above, the Teres major and Latissimus dorsi below. On the *inner side* are the first four ribs with their corresponding Intercostal muscles, and part of the Serratus magnus. On the *outer side*, where the anterior and posterior boundaries converge, the space is narrow, and bounded by the humerus, the Coraco-brachialis and Biceps muscles.

Contents.—This space contains the axillary vessels and brachial plexus of nerves, with their branches, some branches of the intercostal nerves, and a large number of lymphatic glands, all connected together by a quantity of fat and loose areolar tissue.

Their Position.—The axillary artery and vein, with the brachial plexus of nerves, extend obliquely along the outer boundary of the axillary space, from its apex to its base, and are placed much nearer the anterior than the posterior wall, the vein lying to the inner or thoracic side of the artery and partially concealing it. At the fore part of the axillary space, in contact with the Pectoral muscles, are the thoracic branches of the axillary artery, and along the anterior margin

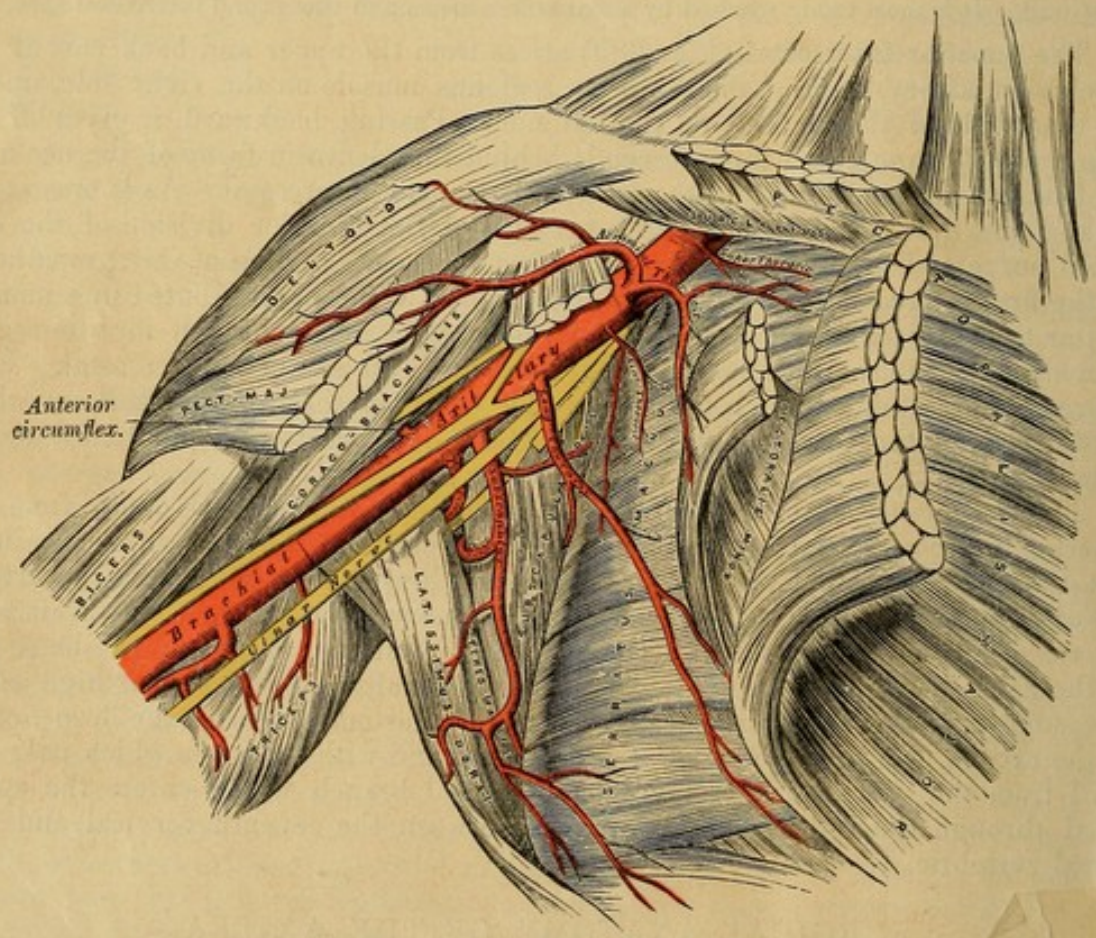

FIG. 302.—The axillary artery and its branches.

are the thoracic branches of the axillary artery, and along the lower margin of the Pectoralis minor the long thoracic artery extends to the side of the chest. At the back part, in contact with the lower margin of the Subscapularis muscle, are the subscapular vessels and nerves; winding around the outer border of this muscle is

the dorsalis scapulæ artery and veins; and, close to the neck of the humerus, the posterior circumflex vessels and the circumflex nerve are seen curving backward to the shoulder.

Along the inner or thoracic side no vessel of any importance exists, the upper part of the space being crossed merely by a few small branches from the superior thoracic artery. There are some important nerves, however, in this situation—viz. the posterior thoracic or external respiratory nerve, descending on the surface of the Serratus magnus, to which it is distributed; and perforating the upper and anterior part of this wall, the intercosto-humeral nerve or nerves, passing across the axilla to the inner side of the arm.

The cavity of the axilla is filled by a quantity of loose areolar tissue and a large number of small arteries and veins, all of which are, however, of inconsiderable size, and numerous lymphatic glands, the position and arrangement of which are described on a subsequent page.

Surgical Anatomy.—The axilla is a space of considerable surgical importance. It transmits the large vessels and nerves to the upper extremity, and these may be the seat of injury or disease: it contains numerous lymphatic glands which may require removal when diseased; in it is a quantity of loose connective and adipose tissue which may be readily infiltrated with blood or inflammatory exudation, and it may be the seat of rapidly-growing tumors. Moreover, it is covered at its base by thin skin, largely supplied with sebaceous and sweat glands, which is frequently the seat of small cutaneous abscesses and boils, and of eruptions due to irritation.

In suppuration in the axilla the arrangement of the fasciæ plays a very important part in the direction which the pus takes. As described on page 379, the costo-coracoid membrane, after covering in the space between the clavicle and the upper border of the Pectoralis minor, splits to enclose this muscle, and, reblending at its lower border, becomes incorporated with the axillary fascia at the anterior fold of the axilla. This is known as the clavi-pectoral fascia. Suppuration may take place either superficial to or beneath this layer of fascia; that is, either between the Pectorals or below the Pectoralis minor: in the former case, it would point either at the anterior border of the axillary fold or in the groove between the Deltoid and the Pectoralis major; in the latter, the pus would have a tendency to surround the vessels and nerves and ascend into the neck, that being the direction in which there is least resistance. Its progress toward the skin is prevented by the axillary fascia; its progress backward, by the Serratus magnus; forward, by the clavi-pectoral fascia; inward, by the wall of the thorax; and outward, by the upper limb. The pus in these cases, after extending into the neck, has been known to spread through the superior opening of the thorax into the mediastinum.

In opening an axillary abscess the knife should be entered in the floor of the axilla, midway between the anterior and posterior margins and near the thoracic side of the space. It is well to use a director and dressing forceps after an incision has been made through the skin and fascia in the manner directed by the late Mr. Hilton.

The student should attentively consider the relation of the vessels and nerves in the several parts of the axilla, for it is the almost universal plan, in the present day, to remove the glands from the axilla in operating for cancer of the breast. In performing such an operation it will be necessary to proceed with much caution in the direction of the outer wall and apex of the space, as here the axillary vessels will be in danger of being wounded. Toward the posterior wall it will be necessary to avoid the subscapular, dorsalis scapulæ, and posterior circumflex vessels. Along the anterior wall it will be necessary to avoid the thoracic branches. In clearing out the axilla the axillary vein should be first defined and cleared by the fingers and an elevator up to the apex of the axilla, the Pectoralis major being pulled up by an assistant with a retractor. When the apex of the space is reached, all fat and glands must be carefully removed and the whole axilla cleared by separating the tissues along the inner and posterior walls, so that when the proceeding is completed, the axilla is cleared of all its contents except the main vessels and nerves.

THE AXILLARY ARTERY.

The **Axillary Artery**, the continuation of the subclavian, commences at the outer border of the first rib, and terminates at the lower border of the tendon of the Teres major muscle, where it takes the name of brachial. Its direction varies with the position of the limb: when the arm lies by the side of the chest, the vessel forms a gentle curve, the convexity being upward and outward; when it is directed at right angles with the trunk, the vessel is nearly straight; and when it is elevated still higher, the artery describes a curve the concavity of which is directed upward. At its commencement the artery is very deeply situated, but near its termination is superficial, being covered only by the skin and fascia. The description of the relations of this vessel is facilitated by its division into three

portions, the first portion being that above the Pectoralis minor; the second portion, behind; and the third below, that muscle.

The **first portion of the axillary artery** is in relation, *in front*, with the clavicular portion of the Pectoralis major, the costo-coracoid membrane, the external anterior thoracic nerve, and the acromio-thoracic and cephalic veins; *behind*, with the first intercostal space, the corresponding Intercostal muscle, the second and a portion of the third digitations of the Serratus magnus, and the posterior thoracic and internal anterior thoracic nerves; on its *outer side*, with the brachial plexus, from which it is separated by a little cellular interval; on its *inner* or thoracic side, with the axillary vein, which overlaps the artery.

Relations of the First Portion of the Axillary Artery.

In front.
Pectoralis major.
Costo-coracoid membrane.
External anterior thoracic nerve.
Acromio-thoracic and Cephalic veins.

Outer side.
Brachial plexus.



Inner side.
Axillary vein.

Behind.
First Intercostal space and Intercostal muscle.
Second and third digitations of Serratus magnus.
Posterior thoracic and Internal anterior thoracic nerves.

The **second portion of the axillary artery** lies behind the Pectoralis minor. It is covered, *in front*, by the Pectoralis major and minor muscles; *behind*, it is separated from the Subscapularis by a cellular interval; on the *inner side* is the axillary vein, separated from the artery by the inner cord of the plexus and the internal anterior thoracic nerve. The brachial plexus of nerves surrounds the artery on three sides, and separates it from direct contact with the vein and adjacent muscles.

Relations of the Second Portion of the Axillary Artery.

In front.
Pectoralis major [illegible]or.

Outer side.
Outer cord of plexus.



Inner side.
Axillary vein.
Inner cord of plexus.
Internal anterior thoracic nerve.

Behind.
Subscapularis.
Posterior cord of plexus.

The **third portion of the axillary artery** lies below the Pectoralis minor. It is in relation, *in front*, with the lower part of the Pectoralis major above, being covered only by the integument and fascia below, where it is crossed by the inner head of the median nerve; *behind*, with the lower part of the Subscapularis and the tendons of the Latissimus dorsi and Teres major; on its *outer side*, with the Coraco-brachialis; on its *inner* or thoracic side, with the axillary vein. The nerves of the brachial plexus bear the following relation to the artery in this part of its course: on the *outer side* is the median nerve, and the musculo-cutaneous for a short distance; on the *inner side*, the ulnar (between the vein and artery) and lesser internal cutaneous nerves (to the inner side of the vein); in *front*, is the

internal cutaneous nerve, and *behind*, the musculo-spiral and circumflex, the latter extending only to the lower border of the Subscapularis muscle.

Relations of the Third Portion of the Axillary Artery.

In front.
Integument and fascia.
Pectoralis major.
Inner head of median nerve.
Internal cutaneous nerve.

Outer side.
Coraco-brachialis.
Median nerve.
Musculo-cutaneous nerve.

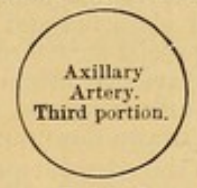

Inner side.
Ulnar nerve.
Axillary vein.
Lesser internal cutaneous nerve.

Behind.
Subscapularis.
Tendons of Latissimus dorsi and Teres major.
Musculo-spiral and circumflex nerves.

Peculiarities.—The axillary artery, in about one case out of every ten, gives off a large branch, which forms either one of the arteries of the forearm or a large muscular trunk. In the first set of cases this artery is most frequently the radial (1 in 33), sometimes the ulnar (1 in 72), and, very rarely, the interosseous (1 in 506). In the second set of cases the trunk has been found to give origin to the subscapular, circumflex, and profunda arteries of the arm. Sometimes only one of the circumflex, or one of the profunda arteries, arose from the trunk. In these cases the brachial plexus surrounded the trunk of the branches and not the main vessel.

Surface Marking.—The course of the axillary artery may be marked out by raising the arm to a right angle and drawing a line from the middle of the clavicle to the point where the tendon of the Pectoralis major crosses the prominence caused by the Coraco-brachialis as it emerges from under cover of the anterior fold of the axilla. The third portion of the artery can be felt pulsating beneath the skin and fascia, at the junction of the anterior with the middle third of the space between the anterior and posterior folds of the axilla, close to the inner border of the Coraco-brachialis.

Surgical Anatomy.—The student, having carefully examined the relations of the axillary artery in its various parts, should now consider in what situation compression of this vessel may be most easily effected, and the best position for the application of a ligature to it when necessary.

Compression of the vessel may be required in the removal of tumors or in amputation of the upper part of the arm; and the only situation in which this can be effectually made is in the lower part of its course; by pressing on it in this situation from within outward against the humerus the circulation may be effectually arrested.

The axillary artery is perhaps more frequently lacerated than any other artery in the body, with the exception of the popliteal, by violent movements of the upper extremity, especially in those cases where its coats are diseased. It has occasionally been ruptured in attempts to reduce old dislocations of the shoulder-joint. This lesion is most likely to occur during the preliminary breaking down of adhesions, in consequence of the artery having become fixed to the capsule of the joint. Aneurism of the axillary artery is of frequent occurrence, a large percentage of the cases being traumatic in their origin, due to the violence to which it is exposed in the varied, extensive, and often violent movement of the limb.

The **application of a ligature to the axillary artery** may be required in cases of aneurism of the upper part of the brachial or as a distal operation for aneurism of the subclavian; and there are only two situations in which it can be secured—viz. in the first and in the third parts of its course; for the axillary artery at its central part is so deeply seated, and, at the same time, so closely surrounded with large nervous trunks, that the application of a ligature to it in that situation would be almost impracticable.

In the **third part** of its course the operation is most simple, and may be performed in the following manner: The patient being placed on a bed and the arm separated from the side, with the hand supinated, an incision is made through the integument forming the floor of the axilla about two inches in length, a little nearer to the anterior than the posterior fold of the axilla. After carefully dissecting through the areolar tissue and fascia, the median nerve and axillary vein are exposed; the former having been displaced to the outer and the latter to the inner side of the arm, the elbow being at the same time bent, so as to relax the structures and facilitate their separation, the ligature may be passed round the artery from the ulnar to the radial side.

This portion of the artery is occasionally crossed by a muscular slip, the *axillary arch*, derived from the Latissimus dorsi, which may mislead the surgeon during an operation. The occasional existence of this muscular fasciculus was spoken of in the description of the muscles. It may easily be recognized by the transverse direction of its fibres.

The **first portion** of the axillary artery may be tied in cases of aneurism encroaching so far upward that a ligature cannot be applied in the lower part of its course. Notwithstanding that this operation has been performed in some few cases, and with success, its performance is attended with much difficulty and danger. The student will remark that in this situation it would be necessary to divide a thick muscle, and, after incising the costo-coracoid membrane, the artery would be exposed at the bottom of a more or less deep space, with the cephalic and axillary veins in such relation with it as must render the application of a ligature to this part of the vessel particularly hazardous. Under such circumstances it is an easier, and at the same time more advisable, operation to tie the subclavian artery in the third part of its course.

The vessel can be best secured by a curved incision with the convexity downward from a point half an inch external to the Sterno-clavicular joint to a point half an inch internal to the coracoid process. The limb is to be well abducted and the head inclined to the opposite side, and this incision carried through the superficial structures, care being taken of the cephalic vein at the outer angle of the incision. The clavicular origin of the Pectoralis major is then divided in the whole extent of the wound. The arm is now to be brought to the side, and the upper edge of the Pectoralis minor defined and drawn downward. The costo-coracoid membrane is to be carefully divided on a director close to the coracoid process, and the axillary sheath exposed; this is to be opened with especial care on account of the vein overlapping the artery. The needle should be passed from below, so as to avoid wounding the vein.

In a case of wound of the vessel the general practice of cutting down upon, and tying it above and below the wounded point should be adopted in all cases.

Collateral Circulation after Ligature of the Axillary Artery.—If the artery be tied above the origin of the acromial thoracic, the collateral circulation will be carried on by the same branches as after the ligature of the subclavian; if at a lower point, between the acromial thoracic and subscapular arteries, the latter vessel, by its free anastomoses with the other scapular arteries, branches of the subclavian, will become the chief agent in carrying on the circulation, to which the long thoracic, if it be below the ligature, will materially contribute by its anastomoses with the intercostal and internal mammary arteries. If the point included in the ligature be below the origin of the subscapular artery, it will most probably also be below the origins of the two circumflex arteries. The chief agents in restoring the circulation will then be the subscapular and the two circumflex arteries anastomosing with the superior profunda from the brachial, which will be afterward referred to as performing the same office after ligation of the brachial. The cases in which the operation has been performed are few in number, and no published account of dissections of the collateral circulation appears to exist.

Branches of the Axillary Artery.

The branches of the axillary artery are—

From first part { Superior Thoracic. / Acromial Thoracic. }

From second part { Long Thoracic. / Alar Thoracic. }

From third part { Subscapular. / Posterior Circumflex. / Anterior Circumflex. }

The **superior thoracic** is a small artery which arises from the axillary separately or by a common trunk with the acromial thoracic. Running forward and inward along the upper border of the Pectoralis minor, it passes between it and the Pectoralis major to the side of the chest. It supplies these muscles and the parietes of the thorax, anastomosing with the internal mammary and intercostal arteries.

The **acromial thoracic** is a short trunk which arises from the fore part of the axillary artery, its origin being generally overlapped by the upper edge of the Pectoralis minor. Projecting forward to the upper border of the Pectoralis minor, it divides into three sets of branches—*thoracic*, *acromial*, and *descending*. The *thoracic branches*, two or three in number, are distributed to the Serratus magnus and Pectoral muscles, anastomosing with the intercostal branches of the internal mammary. The *acromial branches* are directed outward toward the acromion, supplying the Deltoid muscle, and anastomosing, on the surface of the acromion, with the suprascapular and posterior circumflex arteries. The *descending* or *humeral branch* passes in the space between the Pectoralis major and Deltoid in the same groove as the cephalic vein, and supplies both muscles. The artery also gives off a very small branch, the *clavicular*, which passes upward to the Subclavius muscle.

The **long thoracic** passes downward and inward along the lower border of the Pectoralis minor to the side of the chest, supplying the Serratus magnus, the

Pectoral muscles, and mammary gland, and sending branches across the axilla to the axillary glands and Subscapularis; it anastomoses with the internal mammary and intercostal arteries.

The **alar thoracic** is a small branch which supplies the glands and areolar tissue of the axilla. Its place is frequently supplied by branches from some of the other thoracic arteries.

The **subscapular,** the largest branch of the axillary artery, arises opposite the lower border of the Subscapularis muscle, and passes downward and backward along its lower margin to the inferior angle of the scapula, where it anastomoses with the long thoracic and intercostal arteries and with the posterior scapular, a branch of the transversalis colli, from the thyroid axis of the subclavian. About an inch and a half from its origin it gives off a large branch, the *dorsalis scapulæ*, and terminates by supplying branches to the muscles in the neighborhood.

The **dorsalis scapulæ** is given off from the subscapular about an inch and a half from its origin, and is generally larger than the continuation of the vessel. It curves round the axillary border of the scapula, leaving the axilla through the space between the Teres minor above, the Teres major below, and the long head of the Triceps externally (Fig. 300), and enters the infraspinous fossa by passing under cover of the Teres minor, where it anastomoses with the posterior scapular and suprascapular arteries. In its course it gives off two sets of branches: one enters the subscapular fossa beneath the Subscapularis, which it supplies, anastomosing with the posterior scapular and suprascapular arteries; the other is continued along the axillary border of the scapula, between the Teres major and minor, and, at the dorsal surface of the inferior angle of the bone, anastomoses with the posterior scapular. In addition to these, small branches are distributed to the back part of the Deltoid muscle and the long head of the Triceps, anastomosing with an ascending branch of the superior profunda of the brachial.

The **circumflex arteries** wind round the neck of the humerus. The *posterior circumflex* (Fig. 300), the larger of the two, arises from the back part of the axillary opposite the lower border of the Subscapularis muscle, and, passing backward with the circumflex veins and nerve through the quadrangular space bounded by the Teres major and minor, the scapular head of the Triceps and the humerus, winds round the neck of that bone and is distributed to the Deltoid muscle and shoulder-joint, anastomosing with the anterior circumflex and acromial thoracic arteries, and with the superior profunda branch of the brachial artery. The *anterior circumflex* Figs. 300, 302), considerably smaller than the preceding, arises nearly opposite that vessel from the outer side of the axillary artery. It passes horizontally outward beneath the Coraco-brachialis and short head of the Biceps, lying upon the fore part of the neck of the humerus, and, on reaching the bicipital groove, gives off an ascending branch which passes upward along the groove to supply the head of the bone and the shoulder-joint. The trunk of the vessel is then continued outward beneath the Deltoid, which it supplies, and anastomoses with the posterior circumflex artery.

THE BRACHIAL ARTERY (Fig. 303).

The **Brachial Artery** commences at the lower margin of the tendon of the Teres major, and, passing down the inner and anterior aspect of the arm, terminates about half an inch below the bend of the elbow, where it divides into the *radial* and *ulnar arteries*. At first the brachial artery lies internal to the humerus; but as it passes down the arm it gradually gets in front of the bone, and at the bend of the elbow it lies midway between the two condyles.

Relations.—This artery is superficial throughout its entire extent, being covered, *in front*, by the integument, the superficial and deep fasciæ; the bicipital fascia separates it opposite the elbow from the median basilic vein; the median nerve crosses it at its middle; *behind*, it is separated from the long head of the Triceps by the musculo-spiral nerve and superior profunda artery. It then lies upon the

inner head of the Triceps, next upon the insertion of the Coraco-brachialis, and lastly on the Brachialis anticus; by its *outer side*, it is in relation with the commencement of the median nerve and the Coraco-brachialis and Biceps muscles, which overlap the artery to a considerable extent; by its *inner side*, its upper half is in relation with the internal cutaneous and ulnar nerves, its lower half with the median nerve. The basilic vein lies on the inner side of the artery, but is separated from it in the lower part of the arm by the deep fascia. It is accompanied by two venæ comites, which lie in close contact with the artery, being connected together at intervals by short transverse communicating branches.

PLAN OF THE RELATIONS OF THE BRACHIAL ARTERY.

In front.

Integument and fasciæ.
Bicipital fascia, median basilic vein.
Median nerve.
Overlapped by Coraco-brachialis and Biceps.

Outer side.

Median nerve (above).
Coraco-brachialis.
Biceps.



Inner side.

Internal cutaneous and Ulnar nerves.
Median nerve (below).
Basilic vein.

Behind.

Triceps (long and inner heads).
Musculo-spiral nerve.
Superior profunda artery.
Coraco-brachialis.
Brachialis anticus.

SURGICAL ANATOMY OF THE BEND OF THE ELBOW.

At the bend of the elbow the brachial artery sinks deeply into a triangular interval, the base of which is directed upward, and may be represented by a line connecting the two condyles of the humerus; the sides are bounded, externally, by the inner edge of the Supinator longus; internally, by the outer margin of the Pronator radii teres; its floor is formed by the Brachialis anticus and Supinator brevis. This space contains the brachial artery with its accompanying veins, the radial and ulnar arteries, the median and musculo-spiral nerves, and the tendon of the Biceps. The brachial artery occupies the middle line of this space, and divides opposite the neck of the radius into the radial and ulnar arteries; it is covered, *in front*, by the integument, the superficial fascia, and the median basilic vein, the vein being separated from direct contact with the artery by the bicipital fascia. *Behind*, it lies on the Brachialis anticus, which separates it from the elbow-joint. The median nerve lies on the inner side of the artery, close to it above, but separated from it below by the coronoid origin of the Pronator radii teres. The tendon of the Biceps lies to the outer side of the space, and the musculo-spiral nerve still more externally, situated upon the Supinator brevis and partly concealed by the Supinator longus.

Peculiarities of the Brachial Artery as regards its Course.—The brachial artery, accompanied by the median nerve, may leave the inner border of the Biceps and descend toward the inner condyle of the humerus, where it usually curves round a prominence of bone, the *supra-condylar process*, from which a fibrous arch is usually thrown over the artery; it then inclines outward, beneath or through the substance of the Pronator radii teres muscle, to the bend of the elbow. The variation bears considerable analogy to the normal condition of the artery in some of the carnivora: it has been referred to in the description of the humerus (page 146).

As regards its Division.—Occasionally, the artery is divided for a short distance at its upper part into two trunks, which are united above and below. A similar peculiarity occurs in the main vessel of the lower limb.

The point of bifurcation may be above or below the usual point, the former condition being by far the more frequent. Out of 481 examinations recorded by Mr. Quain, some made on the right and some on the left side of the body, in 386 the artery bifurcated in its normal position. In one case only was the place of division lower than usual, being two or three inches below the elbow-joint. "In 94 cases out of 481, or about 1 in $5\frac{1}{3}$, there were two arteries instead of one in some part or in the whole of the arm."

There appears, however, to be no correspondence between the arteries of the two arms with respect to their irregular division; for in 61 bodies it occurred on one side only in 43; on both sides, in different positions, in 13; on both sides, in the same position, in 5.

The point of bifurcation takes place at different parts of the arm, being most frequent in the upper part, less so in the lower part, and least so in the middle, the most usual point for the application of a ligature; under any of these circumstances two large arteries would be found in the arm instead of one. The most frequent (in three out of four) of these peculiarities is the high division of the radial. That artery often arises from the inner side of the brachial, and runs parallel with the main trunk to the elbow, where it crosses it, lying beneath the fascia; or it may perforate the fascia and pass over the artery immediately beneath the integument.

The ulnar sometimes arises from the brachial high up, and accompanies that vessel to the lower part of the arm, and descends toward the inner condyle. In the forearm it generally lies beneath the deep fascia, superficial to the flexor muscles; occasionally between the integument and deep fascia, and very rarely beneath the flexor muscles.

The interosseous artery sometimes arises from the upper part of the brachial or axillary; as it passes down the arm it lies behind the main trunk, and at the bend of the elbow regains its usual position.

In some cases of high division of the radial the remaining trunk (ulnar interosseous) occasionally passes, together with the median nerve, along the inner margin of the arm to the inner condyle, and then passing from within outward, beneath or through the Pronator radii teres, regains its usual position at the bend of the elbow.

Occasionally the two arteries representing the brachial are connected at the bend of the elbow by a short transverse branch, and are even sometimes reunited.

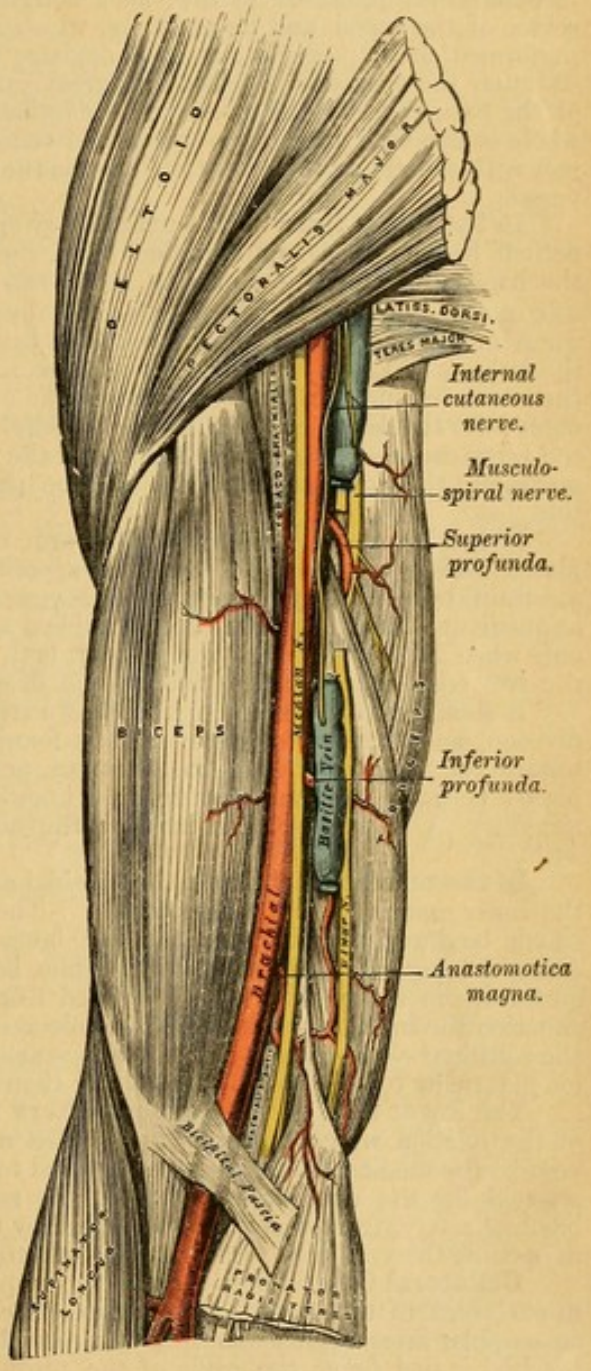

FIG. 303.—The brachial artery.

Sometimes, long slender vessels, *vasa aberrantia*, connect the brachial or axillary arteries with one of the arteries of the forearm or a branch from them. These vessels usually join the radial.

Varieties in Muscular Relations.[1]—The brachial artery is occasionally concealed in some part of its course by muscular or tendinous slips derived from the Coraco-brachialis, Biceps, Brachialis anticus, and Pronator radii teres muscles.

Surface Marking.—The direction of the brachial artery is marked by a line drawn along the inner edge of the Biceps from the insertion of the Teres major muscle to the point midway between the condyles of the humerus.

Surgical Anatomy.—Compression of the brachial artery is required in cases of amputation and some other operations in the arm and forearm; and it will be observed that it may be effected in almost any part of the course of the artery. If pressure is made in the upper part of the limb, it should be directed from within outward; and if in the lower part, from before backward, as the artery lies on the inner side of the humerus above and in front below. The most favorable situation is about the middle of the arm, where it lies on the tendon of the Coraco-brachialis on the inner flat side of the humerus.

[1] See Struther's *Anatomical and Physiological Observations.*

The application of a ligature to the brachial artery may be required in case of wound of the vessel and in some cases of wound of the palmar arch. It is also sometimes necessary in cases of aneurism of the brachial, the radial, ulnar, or interosseous arteries. The artery may be secured in any part of its course. The chief guides in determining its position are the surface markings produced by the inner margin of the Coraco-brachialis and Biceps, the known course of the vessel, and its pulsation, which should be carefully felt for before any operation is performed, as the vessel occasionally deviates from its usual position in the arm. In whatever situation the operation is performed, great care is necessary, on account of the extreme thinness of the parts covering the artery and the intimate connection which the vessel has throughout its whole course with important nerves and veins. Sometimes a thin layer of muscular fibre is met with concealing the artery; if such is the case, it must be cut across in order to expose the vessel.

In the upper third of the arm the artery may be exposed in the following manner: The patient being placed supine upon a table, the affected limb should be raised from the side and the hand supinated. An incision about two inches in length should be made on the inner side of the Coraco-brachialis muscle, and the subjacent fascia cautiously divided, so as to avoid wounding the internal cutaneous nerve or basilic vein, which sometimes runs on the surface of the artery as high as the axilla. The fascia having been divided, it should be remembered that the ulnar and internal cutaneous nerves lie on the inner side of the artery, the median on the outer side, the latter nerve being occasionally superficial to the artery in this situation, and that the venæ comites are also in relation with the vessel, one on either side. These being carefully separated, the aneurism needle should be passed round the artery from the inner to the outer side.

If two arteries are present in the arm in consequence of a high division, they are usually placed side by side: and if they are exposed in an operation, the surgeon should endeavor to ascertain, by alternately pressing on each vessel, which of the two communicates with the wound or aneurism, when a ligature may be applied accordingly; or if pulsation or hæmorrhage ceases only when both vessels are compressed, both vessels may be tied, as it may be concluded that the two communicate above the seat of disease or are reunited.

It should also be remembered that two arteries may be present in the arm in a case of high division, and that one of these may be found along the inner intermuscular septum, in a line toward the inner condyle of the humerus, or in the usual position of the brachial, but deeply placed beneath the common trunk: a knowledge of these facts will suggest the precautions necessary in every case, and indicate the measures to be adopted when anomalies are met with.

In the middle of the arm the brachial artery may be exposed by making an incision along the inner margin of the Biceps muscle. The forearm being bent so as to relax the muscle, it should be drawn slightly aside, and, the fascia being carefully divided, the median nerve will be exposed lying upon the artery (sometimes beneath); this being drawn inward and the muscle outward, the artery should be separated from its accompanying veins and secured. In this situation the inferior profunda may be mistaken for the main trunk, especially if enlarged, from the collateral circulation having become established; this may be avoided by directing the incision externally toward the Biceps, rather than inward or backward toward the Triceps.

The lower part of the brachial artery is of interest in a surgical point of view, on account of the relation which it bears to the veins most commonly opened in venesection. Of these vessels, the median basilic is the largest and most prominent, and, consequently, the one usually selected for the operation. It should be remembered that this vein runs parallel with the brachial artery, from which it is separated by the bicipital fascia, and that care should be taken in opening the vein not to carry the incision too deeply, so as to endanger the artery.

Collateral Circulation.—After the application of a ligature to the brachial artery in the upper third of the arm, the circulation is carried on by branches from the circumflex and subscapular arteries, anastomosing with ascending branches from the superior profunda. If the brachial is tied *below* the origin of the profunda arteries, the circulation is maintained by the branches of the profundæ, anastomosing with the recurrent radial, ulnar, and interosseous arteries. In two cases described by Mr. South,[1] in which the brachial artery had been tied some time previously, in one "a long portion of the artery had been obliterated, and sets of vessels are descending on either side from above the obliteration, to be received into others which ascend in a similar manner from below it. In the other the obliteration is less extensive, and a single curved artery about as big as a crow-quill passes from the upper to the lower open part of the artery."

The branches of the brachial artery are—the

Superior Profunda.	Inferior Profunda.
Nutrient.	Anastomotica Magna.

Muscular.

[1] Chelius's *Surgery*, vol. ii. p. 254. See also White's engraving, referred to by Mr. South, of the anastomosing branches after ligature of the brachial, in White's *Cases in Surgery*. Porta also gives a case (with drawings) of the circulation after ligature of both brachial and radial (*Alterazioni Patoligiche delle Arterie*).

The **superior profunda** arises from the inner and back part of the brachial, just below the lower border of the Teres major, and passes backward to the interval between the outer and inner heads of the Triceps muscle, accompanied by the musculo-spiral nerve; it winds around the back part of the shaft of the humerus in the spiral groove, between the outer head of the Triceps and the bone, to the outer side of the humerus, where it reaches the external intermuscular septum and divides into two terminal branches. One of these pierces the external intermuscular septum, and descends, in company with the musculo-spiral nerve, to the space between the Brachialis anticus and Supinator longus, where it anastomoses with the recurrent branch of the radial artery; while the other, much the larger of the two, descends along the back of the external intermuscular septum to the back of the elbow-joint, where it anastomoses with the posterior interosseous recurrent, and across the back of the humerus with the posterior ulnar recurrent, the anastomotica magna, and inferior profunda (Fig. 306). The superior profunda supplies the Triceps muscle and gives off a nutrient artery which enters the bone at the upper end of the musculo-spiral groove. Near its commencement it sends off a branch which passes upward between the external and long heads of the Triceps muscle to anastomose with the posterior circumflex artery, and, while in the groove, a small branch which accompanies a branch of the musculo-spiral nerve through the substance of the Triceps muscle and ends in the Anconeus below the outer condyle of the humerus.

The **nutrient artery** of the shaft of the humerus arises from the brachial, about the middle of the arm. Passing downward it enters the nutrient canal of that bone near the insertion of the Coraco-brachialis muscle.

The **inferior profunda,** of small size, arises from the brachial, a little below the middle of the arm; piercing the internal intermuscular septum, it descends on the surface of the inner head of the Triceps muscle to the space between the inner condyle and olecranon, accompanied by the ulnar nerve, and terminates by anastomosing with the posterior ulnar recurrent and anastomotica magna. It sometimes supplies a branch to the front of the internal condyle, which anastomoses with the anterior ulnar recurrent.

The **anastomotica magna** arises from the brachial about two inches above the elbow-joint. It passes transversely inward upon the Brachialis anticus, and, piercing the internal intermuscular septum, winds round the back part of the humerus between the Triceps and the bone, forming an arch above the olecranon fossa by its junction with the posterior articular branch of the superior profunda. As this vessel lies on the Brachialis anticus, branches ascend to join the inferior profunda, and others descend in front of the inner condyle to anastomose with the anterior ulnar recurrent. Behind the internal condyle an offset is given off which anastomoses with the inferior profunda and posterior ulnar recurrent arteries and supplies the Triceps.

The **muscular** are three or four large branches, which are distributed to the muscles in the course of the artery. They supply the Coraco-brachialis, Biceps, and Brachialis anticus muscles.

The Anastomosis around the Elbow-joint (Fig. 306).—The vessels engaged in this anastomosis may be conveniently divided into those situated *in front* and *behind* the internal and external condyles. The branches anastomo[illegible] of the internal condyle are the anastomotica magna, the anterior [illegible] and the anterior terminal branch of the inferior profunda. Those [illegible] condyle are the anastomotica magna, the posterior ulna[illegible] posterior terminal branch of the inferior profunda. The [illegible] *front* of the external condyle are the radial recurren[illegible] branch of the superior profunda. Those [illegible]orward upon the Interossei muscles, more properly described as being situate[illegible]ngers with the digital branches of the olecranon) are the anastomotica ma[illegible] terminal branch of the superio[illegible]ches arise from the concavity of the deep palmar mosis above the olecranon, fo[illegible]ront of the wrist, supplying the carpal articulations anastomotica magna and poste[illegible]terior carpal arch.



[illegible]adial arteries. Deep view.

From this description it will be observed that the anastomotica magna is the vessel most engaged, the only part of the anastomosis in which it is not employed being that *in front* of the external condyle.

Radial Artery (Fig. 304).

The **Radial Artery** appears, from its direction, to be the continuation of the brachial, but in size it is smaller than the ulnar. It commences at the bifurcation of the brachial, just below the bend of the elbow, and passes along the radial side of the forearm to the wrist; it then winds backward, round the outer side of the carpus, beneath the extensor tendons of the thumb, to the upper end of the space between the metacarpal bones of the thumb and index finger, and, finally, passes forward, between the two heads of the First dorsal interosseous muscle, into the palm of the hand, where it crosses the metacarpal bones to the ulnar border of the hand, to form the deep palmar arch. At its termination it inosculates with the deep branch of the ulnar artery. The relations of this vessel may thus be conveniently divided into three parts—viz., in the forearm, at the back of the wrist, and in the hand.

Relations.—*In the forearm* this vessel extends from opposite the neck of the radius to the fore part of the styloid process, being placed to the inner side of the shaft of the bone above and in front of it below. It is overlapped in the upper part of its course by the fleshy belly of the Supinator longus muscle; throughout the rest of its course it is superficial, being covered by the integument, the superficial and deep fasciæ. In its course downward it lies upon the tendon of the Biceps, the Supinator brevis, the Pronator radii teres, the radial origin of the Flexor sublimis digitorum, the Flexor longus pollicis, the Pronator quadratus, and the lower extremity of the radius. In the upper third of its course it lies between the Supinator longus and the Pronator radii teres; in its lower two-thirds, between the tendons of the Supinator longus and the Flexor carpi radialis. The radial nerve lies close to the outer side of the artery in the middle third of its course, and some filaments of the musculo-cutaneous nerve, after piercing the deep fascia, run along the lower part of the artery as it winds round the wrist. The vessel is accompanied by venæ comites throughout its whole course.

Plan of the Relations of the Radial Artery in the Forearm.

In front.
Skin, superficial and deep fasciæ.
Supinator longus.

Inner side.
Pronator radii teres.
Flexor carpi radialis.

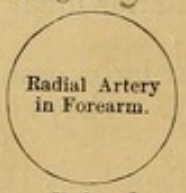

Outer side.
Supinator longus.
Radial nerve (middle third).

Behind.
Tendon of Biceps.
Supinator brevis.
Pronator radii teres.
Flexor sublimis digitorum.
Flexor longus pollicis.
Pronator quadratus.
Radius.

are descending
in a similar manne.
curved artery about .
artery."

The branches of the

Superior Pro.
Nutrient.

he outer side of the carpus from the styloid
Muse lies upon the external lateral ligament,
ium, being covered by the extensor
laments of the radial nerve, and
bend a filament of the musculo-

[1] Chelius's *Surgery*, vol. ii. p. 254. See also White's en... anastomosing branches after ligature of the brachial, in White... case (with drawings) of the circulation after ligature of ... *Patoligiche delle Arterie*).

In the hand it passes from the upper end of the first interosseous space, between the heads of the Abductor indicis or First dorsal interosseous muscle, transversely across the palm, to the base of the metacarpal bone of the little finger, where it inosculates with the communicating branch from the ulnar artery, forming the deep palmar arch. It lies upon the carpal extremities of the metacarpal bones and the Interossei muscles, being covered by the Adductor obliquus pollicis, the flexor tendons of the fingers, the Lumbricales, the Opponens, and Flexor brevis minimi digiti. Alongside of it is the deep branch of the ulnar nerve, but running in the opposite direction; that is to say, from within outward.

Peculiarities.—The origin of the radial artery, according to Quain, is, in nearly one case in eight, higher than usual; more frequently arising from the axillary or upper part of the brachial than from the lower part of this vessel. The variations in the position of this vessel in the arm and at the bend of the elbow have been already mentioned. In the forearm it deviates less frequently from its position than the ulnar. It has been found lying over the fascia instead of beneath it. It has also been observed on the surface of the Supinator longus, instead of under its inner border; and in turning round the wrist it has been seen lying over, instead of beneath, the extensor tendons of the thumb.

Surface Marking.—The position of the radial artery in the forearm is represented by a line drawn from the outer border of the tendon of the Biceps in the centre of the hollow in front of the elbow-joint with a straight course to the inner side of the fore part of the styloid process of the radius.

Surgical Anatomy.—The radial artery is much exposed to injury in its lower third, and is frequently wounded by the hand being driven through a pane of glass, by the slipping of a knife or chisel held in the other hand, and such-like accidents. The injury is often followed by a traumatic aneurism, for which the old operation of laying open the sac and securing the vessel above and below is required.

The operation of tying the radial artery is required in cases of wounds either of its trunk or of some of its branches, or for aneurism; and it will be observed that the vessel may be exposed in any part of its course through the forearm without the division of any muscular fibres. The operation in the middle or inferior third of the forearm is easily performed, but in the upper third, near the elbow, it is attended with some difficulty, from the greater depth of the vessel and from its being overlapped by the Supinator longus muscle.

To tie the artery in the upper third an incision three inches in length should be made through the integument, in a line drawn from the centre of the bend of the elbow to the front of the styloid process of the radius, avoiding the branches of the median vein; the fascia of the arm being divided and the Supinator longus drawn a little outward, the artery will be exposed. The venæ comites should be carefully separated from the vessel, and the ligature passed from the radial to the ulnar side.

In the middle third of the forearm the artery may be exposed by making an incision of similar length on the inner margin of the Supinator longus. In this situation the radial nerve lies in close relation with the outer side of the artery, and should, as well as the veins, be carefully avoided.

In the lower third the artery is easily secured by dividing the integument and fascia in the interval between the tendons of the Supinator longus and Flexor carpi radialis muscles.

The branches of the radial artery may be divided into three groups, corresponding with the three regions in which the vessel is situated.

In the Forearm.
- Radial Rec... ...ting branch
- Muscular. ...r arch.
- Anterior ...eries, three in
- Superfic... ...ard from the ...veen the heads ...orsal interossei ...with the dorsal

...rpal.

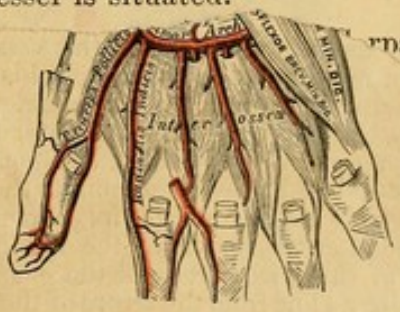

FIG. 305.—Ulnar and radial arteries. Deep view.

...osseous, three or

The radial recurren... from the con-
between the branches o...lmar arch; they run forward upon the Interossei muscles, and then between the ...the clefts of the fingers with the digital branches of the muscles and the elbow
superior profunda. ...ent branches arise from the concavity of the deep palmar

The muscular branche...d in front of the wrist, supplying the carpal articulations the forearm. ...nterior carpal arch.

The **anterior carpal** is a small vessel which arises from the radial artery near the lower border of the Pronator quadratus, and, running inward in front of the radius, anastomoses with the anterior carpal branch of the ulnar artery. In this way an arterial anastomosis, *anterior carpal arch*, is formed in front of the wrist; it is joined by branches from the anterior interosseous above, and by recurrent branches from the deep palmar arch below, and gives off branches which descend to supply the articulations of the wrist and carpus.

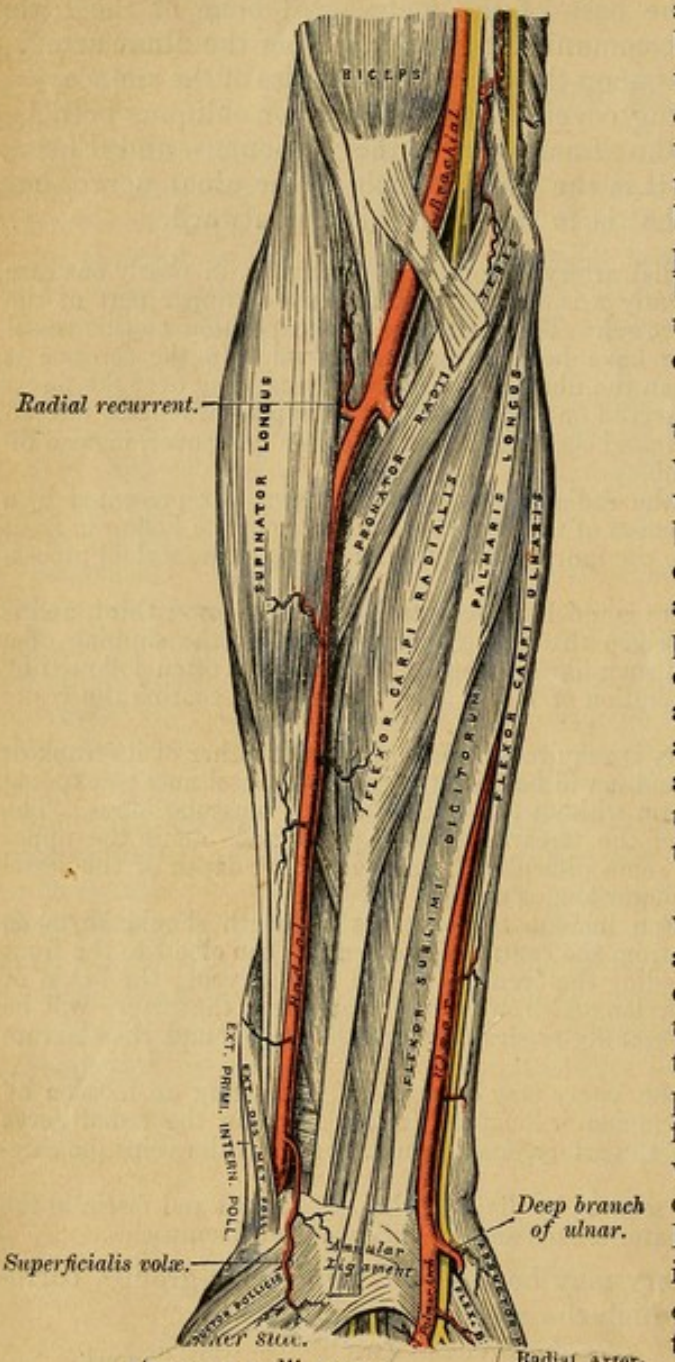

Pronator radii teres.
Flexor carpi radialis.

Behind.
Tendon of Biceps.
Supinator brevis.
Pronator radii teres.
Flexor sublimis digitorum.
Flexor longus pollicis.
Pronator quadratus.
Radius.

The **superficialis volæ** arises from the radial artery, just where this vessel is about to wind round the wrist. Running forward, it passes between, occasionally over, the muscles of the thumb, which it supplies, and sometimes anastomoses with the palmar portion of the ulnar artery, completing the superficial palmar arch. This vessel varies considerably in size: usually it is very small, and terminates in the muscles of the thumb; sometimes it is as large as the continuation of the radial.

The **posterior carpal** is a small vessel which arises from the radial artery beneath the extensor tendons of the thumb; crossing the carpus transversely to the inner border of the hand, it anastomoses with the posterior carpal branch of the ulnar, forming the *posterior carpal arch*, which is joined by the termination of the anterior interosseous artery. From this arch are given off descending branches, the *dorsal interosseous arteries* for the third and fourth interosseous spaces, which run forward ... hird and Fourth dorsal in- ... uscles, and divide into ... al branches which supply ... t sides of the middle, ... tle fingers respectively, ... ng with the digital ... he superficial palmar ... eir origin they anasto- ... e perforating branches ... p palmar arch.

... he outer side of the **acarpal (first dorsal inter-** ... Musc lies upon the exte) arises beneath the ex- ... um, being cons of the thumb, some- ... laments o the posterior carpal ... end a is muscle, it communicates, ... the deep palmar arch; and

... are descending ... in a similar manne... curved artery about ... artery."

The branches of th...

Superior Pr...
Nutrient.

[1] Chelius's *Surgery*, vol. ii. p. 254. See also White's en... anastomosing branches after ligature of the brachial, in White ... case (with drawings) of the circulation after ligature of b... *Patoligiche delle Arterie*).

in front it divides into two *dorsal digital branches*, which supply the adjoining sides of the index and middle fingers, inosculating with the digital branch of the superficial palmar arch.

The **dorsales pollicis** are two vessels which run along the sides of the dorsal aspect of the thumb. They arise separately, or occasionally by a common trunk, near the base of the first metacarpal bone.

The **dorsalis indicis,** also a small branch, runs along the radial side of the back of the index finger, sending a few branches to the Abductor indicis.

The **princeps pollicis** arises from the radial just as it turns inward to the deep part of the hand; it descends between the Abductor indicis and Adductor obliquus pollicis, then between the Adductor transversus pollicis and Adductor obliquus pollicis, along the ulnar side of the metacarpal bone of the thumb, to the base of the first phalanx, where it divides into two branches, which run along the sides of the palmar aspect of the thumb, and form an arch on the palmar surface of the last phalanx, from which branches are distributed to the integument and pulp of the thumb.

The **radialis indicis** arises close to the preceding, descends between the Abductor indicis and Adductor transversus pollicis, and runs along the radial side of the index finger to its extremity, where it anastomoses with the collateral digital artery from the superficial palmar arch. At the lower border of the Adductor transversus pollicis this vessel anastomoses with the princeps pollicis, and gives a communicating branch to the superficial palmar arch.

The **perforating arteries,** three in number, pass backward from the deep palmar arch between the heads of the last three Dorsal interossei muscles, to inosculate with the dorsal interosseous arteries.

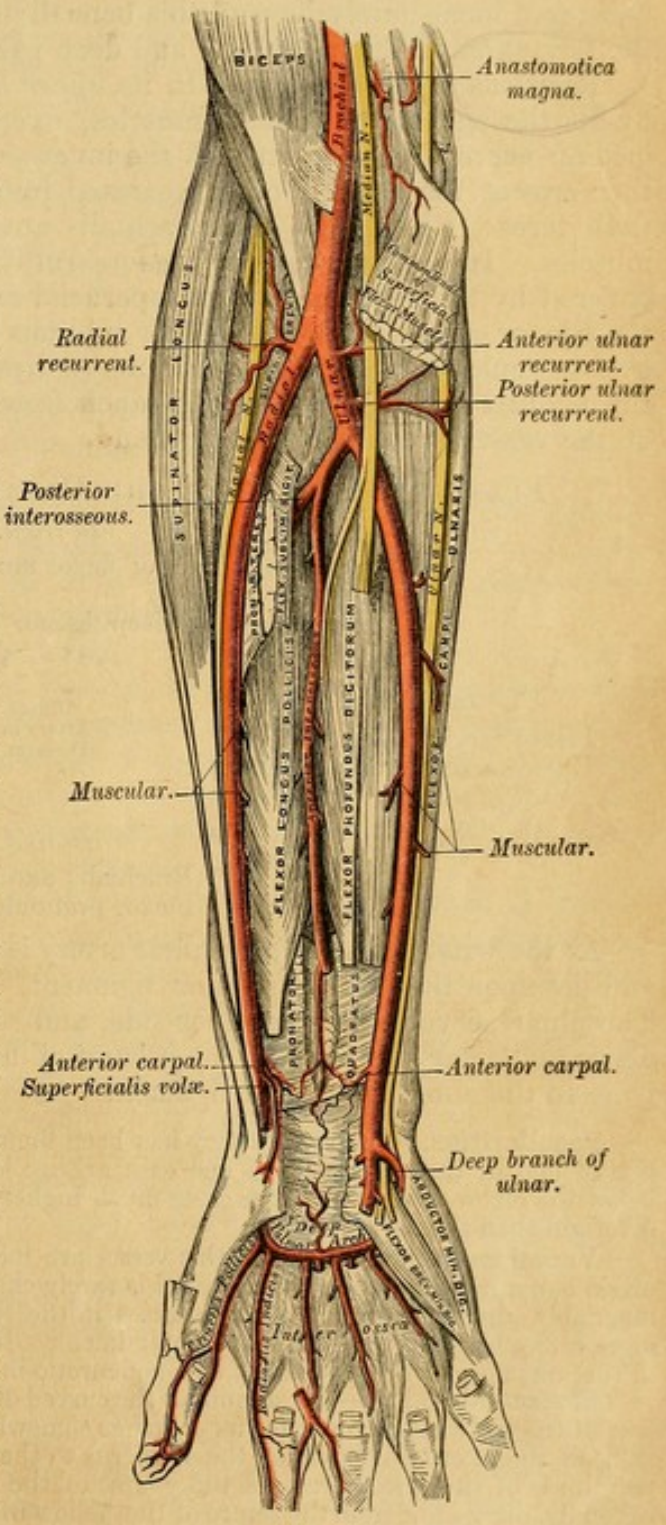

FIG. 305.—Ulnar and radial arteries. Deep view.

The **palmar interosseous,** three or four in number, arise from the convexity of the deep palmar arch; they run forward upon the Interossei muscles, and anastomose at the clefts of the fingers with the digital branches of the superficial arch.

The **palmar recurrent branches** arise from the concavity of the deep palmar arch. They pass upward in front of the wrist, supplying the carpal articulations and anastomosing with the anterior carpal arch.

joins the posterior carpal branch of the ulnar artery. This artery gives off, near its origin, the *interosseous recurrent branch.*

The **interosseous recurrent artery** is a large vessel which ascends to the interval between the external condyle and olecranon, on or through the fibres of the Supinator brevis, but beneath the Anconeus, anastomosing with a branch from the superior profunda, and with the posterior ulnar recurrent and anastomotica magna.

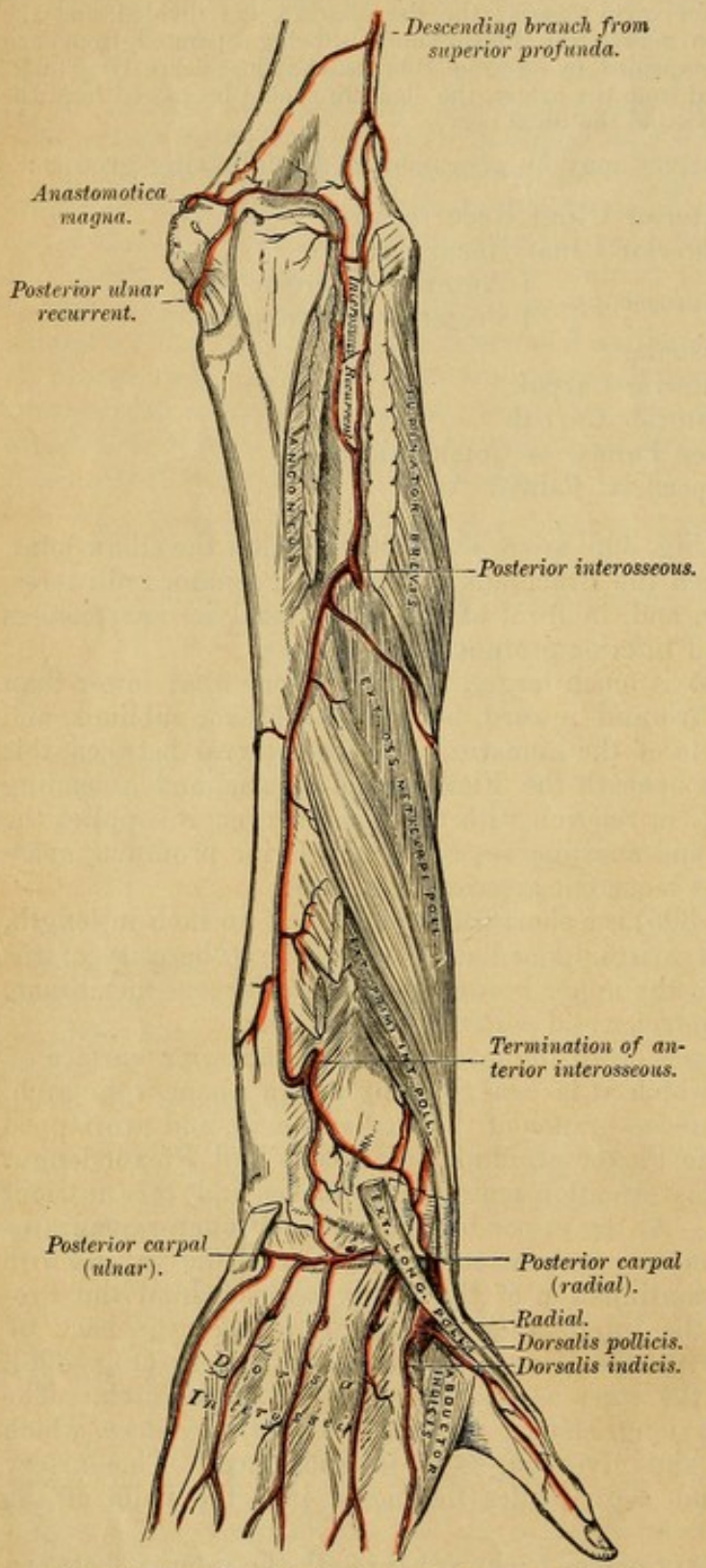

FIG. 306.—Arteries of the back of the forearm and hand.

The **muscular branches** are distributed to the muscles along the ulnar side of the forearm.

The **anterior carpal** is a small vessel which crosses the front of the carpus beneath the tendons of the Flexor profundus, and inosculates with a corresponding branch of the radial artery.

The **posterior carpal** arises immediately above the pisiform bone, and winds backward beneath the tendon of the Flexor carpi ulnaris: it passes across the dorsal surface of the carpus beneath the extensor tendons, anastomosing with a corresponding branch of the radial artery, and forming the *posterior carpal arch.* Immediately after its origin it gives off a small branch which runs along the ulnar side of the metacarpal bone of the little finger, forming one of the *metacarpal arteries*, and supplies the ulnar side of the dorsal surface of the little finger.

The **branch to the deep palmar arch** (**deep** or **communicating branch**) (Fig. 305) passes deeply inward between the Abductor minimi digiti and Flexor brevis minimi digiti, near their origins; it anastomoses with the termination of the radial artery, completing the deep palmar arch.

The continuation of the trunk of the ulnar artery in the hand forms the greater part of the superficial palmar arch.

The Superficial Palmar Arch (Fig. 304).

The **Superficial Palmar Arch** is formed by the ulnar artery in the hand, and is completed on the outer side by this vessel anastomosing with a branch from the radialis indicis, though sometimes the arch is completed by the ulnar anastomosing

with the superficialis volæ or princeps pollicis of the radial artery. The arch passes across the palm, describing a curve, with its convexity forward, to the space between the ball of the thumb and the index finger, where the above-mentioned anastomosis takes place.

Relations.—The superficial palmar arch is covered by the skin, the Palmaris brevis, and the palmar fascia. It lies upon the annular ligament, the Flexor brevis of the little finger, the tendons of the superficial flexor of the fingers, and the divisions of the median and ulnar nerves.

Plan of the Relations of the Superficial Palmar Arch.

In front.

Skin.
Palmaris brevis.
Palmar fascia.



Behind.

Annular ligament.
Flexor brevis of little finger.
Superficial flexor tendons.
Divisions of median and ulnar nerves.

Branches of the Superficial Palmar Arch.

Digital.

The **digital branches** (Fig. 304), four in number, are given off from the convexity of the superficial palmar arch. They supply the ulnar side of the little finger and the adjoining sides of the little, ring, middle, and index fingers, the radial side of the index finger and thumb being supplied from the radial artery. The digital arteries at first lie superficial to the flexor tendons, but as they pass forward with the digital nerves to the clefts between the fingers they lie between them, and are there joined by the interosseous branches from the deep palmar arch. The digital arteries on the sides of the fingers lie beneath the digital nerves; and about the middle of the last phalanx the two branches for each finger form an arch, from the convexity of which branches pass to supply the pulp of the finger.

Surface Marking.—The superficial palmar arch is represented by a curved line, starting from the outer side of the pisiform bone and carried downward as far as the middle third of the palm, and then curved outward on a level with the upper end of the cleft between the thumb and index finger.

The deep palmar arch is situated about half an inch nearer to the carpus.

Surgical Anatomy.—Wounds of the palmar arches are of special interest, and are always difficult to deal with. When the superficial arch is wounded it is generally possible, by enlarging the wound if necessary, to secure the vessel and tie it; or in cases where it is found impossible to encircle the vessel with a ligature, a pair of Wells's artery clips may be applied and left on for twenty-four or forty-eight hours. Wounds of the deep arch are not so easily dealt with. It may be possible to secure the vessel by forcipressure forceps, which may be left on; or, failing this, the wound may be carefully plugged with gauze and an outside dressing carefully bandaged on. The plug should be allowed to remain untouched for three or four days. In wounds of the deep palmar arch a ligature may be applied to the bleeding points from the dorsum of the hand by resection of the upper part of the third metacarpal bone. It is useless in these cases to ligate one of the arteries of the forearm alone, and indeed simultaneous ligation of both radial and ulnar arteries above the wrist is often unsuccessful, on account of the anastomosis carried on by the carpal arches. Therefore, upon the failure of pressure to arrest hemorrhage, it is expedient to apply a ligature to the brachial artery.

ARTERIES OF THE TRUNK.

THE DESCENDING AORTA.

The **Descending Aorta** is divided into two portions, the *thoracic* and *abdominal*, in correspondence with the two great cavities of the trunk in which it is situated.

THE THORACIC AORTA.

The **Thoracic Aorta** commences at the lower border of the fourth dorsal vertebra, on the left side, and terminates at the aortic opening in the Diaphragm, in front of the lower border of the last dorsal vertebra. At its commencement it is situated on the left side of the spine; it approaches the median line as it descends, and at its termination lies directly in front of the column. The direction of this vessel being influenced by the spine, upon which it rests, it describes a curve which is concave forward in the dorsal region. As the branches given off from it are small, the diminution in the size of the vessel is inconsiderable. It is contained in the back part of the posterior mediastinum.

Relations.—It is in relation, *in front*, from above downward, with the root of the left lung, the pericardium, the œsophagus, and the Diaphragm: *behind*, with the vertebral column and the vena azygos minor; on the *right side*, with the vena azygos major and thoracic duct; on the *left side*, with the left pleura and lung. The œsophagus, with its accompanying nerves, lies on the right side of the aorta *above;* but at the lower part of the thorax it gets in front of the aorta, and close to the Diaphragm is situated to its left side.

PLAN OF THE RELATIONS OF THE THORACIC AORTA.

In front.
Root of left lung.
Pericardium.
Œsophagus.
Diaphragm.

Right side.
Œsophagus (above).
Vena azygos major.
Thoracic duct.



Left side.
Pleura.
Left lung.
Œsophagus (below).

Behind.
Vertebral column.
Superior and inferior azygos minor veins.

The aorta is occasionally found to be obliterated at a particular spot—viz., at the junction of the arch with the thoracic aorta, just below the ductus arteriosus. Whether this is the result of disease or of congenital malformation is immaterial to our present purpose; it affords an interesting opportunity of observing the resources of the collateral circulation. The course of the anastomosing vessels, by which the blood is brought from the upper to the lower part of the artery, will be found well described in an account of two cases in the *Pathological Transactions*, vols. viii. and x. In the former (p. 162) Mr. Sydney Jones thus sums up the detailed description of the anastomosing vessels: "The principal communications by which the circulation was carried on, were—Firstly, the internal mammary, anastomosing with the intercostal arteries, with the phrenic of the abdominal aorta by means of the musculo-phrenic and comes nervi phrenici, and largely with the deep epigastric. Secondly, the superior intercostal, anastomosing anteriorly by means of a large branch with the first aortic intercostal, and posteriorly with the posterior branch of the same artery. Thirdly, the inferior thyroid, by means of a branch about the size of an ordinary radial, formed a communication with the first aortic intercostal. Fourthly, the transversalis colli, by means of very large communications with the posterior branches of the intercostals. Fifthly, the branches (of the subclavian and axillary) going to the side of the chest were large, and anastomosed freely with the lateral branches of the intercostals." In the second case also (vol. x. p. 97) Mr. Wood describes the anastomoses in a somewhat similar manner, adding the remark that "the blood which was brought into the aorta through the anastomoses of the intercostal arteries appeared to be expended principally in supplying the abdomen and pelvis, while the supply to the lower extremities had passed through the internal mammary and epigastrics."

Surgical Anatomy.—The student should now consider the effects likely to be produced by aneurism of the thoracic aorta, a disease of common occurrence. When we consider the great depth of the vessel from the surface and the number of important structures which surround it on every side, it may easily be conceived what a variety of obscure symptoms may arise from disease of this part of the arterial system, and how they may be liable to be mistaken for those of other affections. Aneurism of the thoracic aorta most usually extends backward along the left side of the spine, producing absorption of the bodies of the vertebræ, with curvature of the spine, whilst the irritation or pressure on the cord will give rise to pain, either in the chest, back, or loins, with radiating pain in the left upper intercostal spaces, from pressure on the intercostal nerves; at the same time the tumor may project backward on each side of the spine, beneath the integument, as a pulsating swelling, simulating abscess connected with diseased bone, or it may displace the œsophagus and compress the lung on one or the other side. If the tumor extend forward, it may press upon and displace the heart, giving rise to palpitation and other symptoms of disease of that organ; or it may displace, or even compress, the œsophagus, causing pain and difficulty of swallowing, as in stricture of that tube; and ultimately even open into it by ulceration, producing fatal hæmorrhage. If the disease extends to the right side, it may press upon the thoracic duct; or it may burst into the pleural cavity or into the trachea or lung; and lastly, it may open into the posterior mediastinum.

Branches of the Thoracic Aorta.

Pericardiac.	Œsophageal.
Bronchial.	Posterior Mediastinal.
Intercostal.	

The **pericardiac** are a few small vessels, irregular in their origin, distributed to the pericardium.

The **bronchial arteries** are the nutrient vessels of the lungs, and vary in number, size, and origin. That of the right side arises from the first aortic intercostal, or by a common trunk with the left bronchial from the front of the thoracic aorta. Those of the left side, usually two in number, arise from the thoracic aorta, one a little lower than the other. Each vessel is directed to the back part of the corresponding bronchus along which it runs, dividing and subdividing along the bronchial tube, supplying them, the cellular tissue of the lungs, the bronchial glands, and the œsophagus.

The **œsophageal arteries**, usually four or five in number, arise from the front of the aorta, and pass obliquely downward to the œsophagus, forming a chain of anastomoses along that tube, anastomosing with the œsophageal branches of the inferior thyroid arteries above, and with ascending branches from the phrenic and gastric arteries below.

The **posterior mediastinal arteries** are numerous small vessels which supply the glands and loose areolar tissue in the mediastinum.

The **Intercostal arteries** arise from the back of the aorta. They are usually nine in number on each side, the two superior intercostal spaces being supplied by the superior intercostal, a branch of the subclavian. The second space usually receives a considerable branch from the first aortic intercostal, which joins with the branch from the superior intercostal of the subclavian. The branch which runs along the lower border of the last rib is named the *subcostal artery*. The right intercostals are longer than the left, on account of the position of the aorta on the left side of the spine: they pass outward, across the bodies of the vertebræ, to the intercostal spaces, being covered by the pleura, the œsophagus, thoracic duct, sympathetic nerve, and the vena azygos major; the left, passing outward, are crossed by the sympathetic; the upper two are also crossed by the superior intercostal vein, the lower by the azygos minor veins. In each intercostal space the artery passes outward, at first lying upon the External intercostal muscle, covered in front by the pleura and a thin fascia. It then passes between the two layers of Intercostal muscles, and, having ascended obliquely to the lower border of the rib above it, is continued forward in the groove on its lower border and anastomoses with the anterior intercostal branches of the internal mammary. The first aortic intercostal [illegible] anastomoses with the superior intercostal, and the last three pass between the [illegible] (p. 652). [illegible] cles, inosculating with the epigastric in front

and with the phrenic and lumbar arteries. Each intercostal artery is accompanied ... vein and nerve, the former being above, and the latter below, except in the ... intercostal spaces, where the nerve is at first above the artery. The arteries ... rotected from pressure during the action of the Intercostal muscles by fibrous ...ches thrown across, and attached by each extremity to the bone. The lower ... in costal arteries are continued anteriorly from the intercostal spaces into the ...

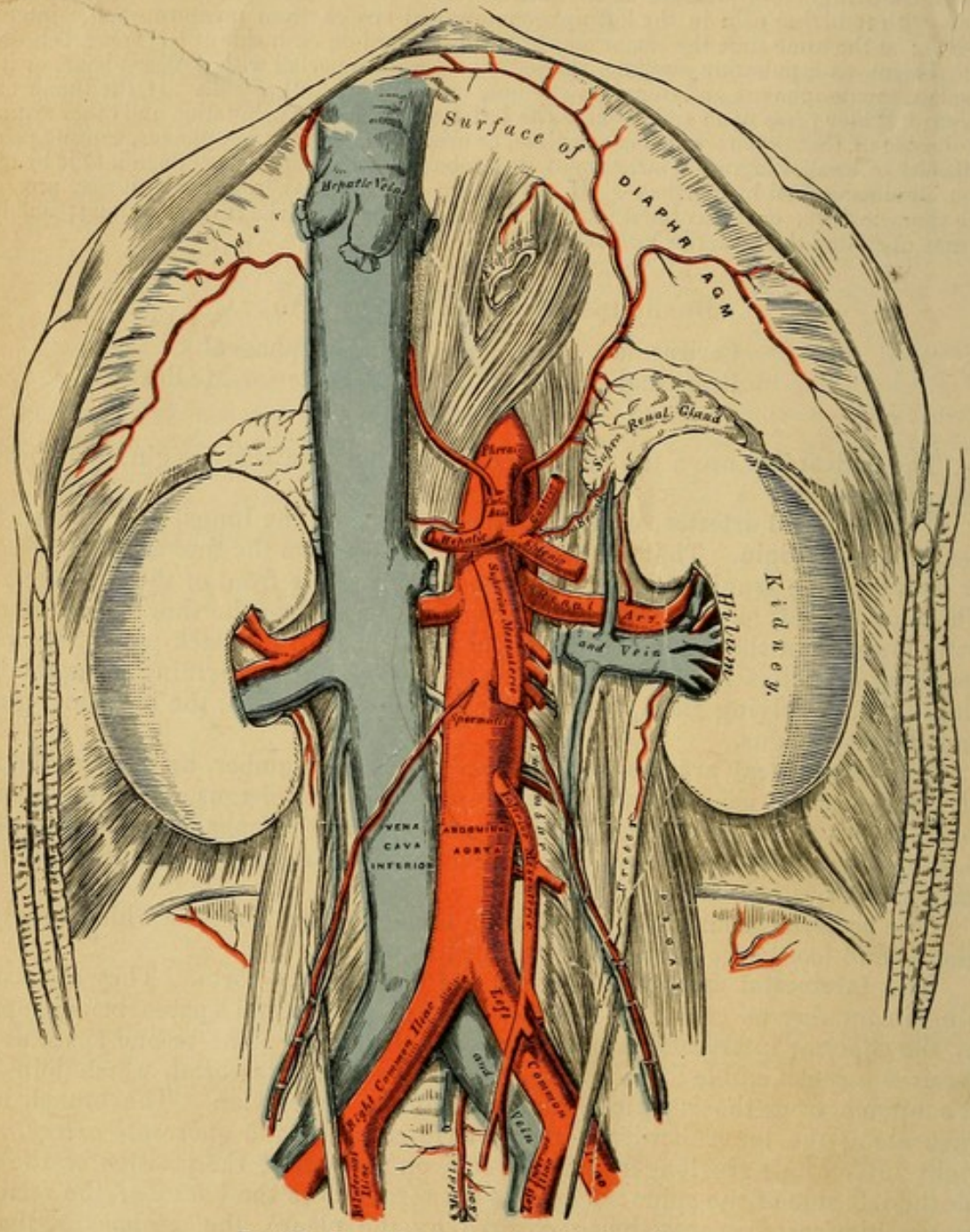

FIG. 307.—The abdominal aorta and its branches.

abdominal wall, except the *subcostal*, which lies throughout its whole course in the abdominal wall, since it is placed below the last rib. They pass behind the costal cartilages between the internal oblique and Transversalis muscle to the sheath of the Rectus, where they anastomose with the internal mammary and the deep epigastric arteries. Behind, the subcostal artery anastomoses with the first lumbar artery.

Each intercostal artery gives off the following branches:

Posterior or dorsal branch. ... internal mam. Spinal.

Collateral ...

The **posterior** or **dorsal branch** of each intercostal artery passes backward to the inner side of the anterior costo-transverse ligament, and divides into an external and internal branch, which are distributed to the muscles and integument of the back.

The **spinal branch,** which enters the spinal canal through the intervertebral foramen, is distributed to the spinal cord and its membranes, and to the bodies of the vertebræ in the same manner as the lateral spinal branches from the vertebral.

The **collateral intercostal branch** comes off from the intercostal artery near the angle of the rib, and descends to the upper border of the rib below, along which it courses to anastomose with the anterior intercostal branch of the internal mammary.

Surgical Anatomy.—The position of the intercostal vessels should be borne in mind in performing the operation of paracentesis thoracis. The puncture should never be made nearer the middle line posteriorly than the angle of the rib, as the artery crosses the space internal to this point. In the lateral portion of the chest, where the puncture is usually made, the artery lies at the upper part of the intercostal space, and therefore the puncture should be made just above the upper border of the rib forming the lower boundary of the space.

THE ABDOMINAL AORTA (Fig. 307).

The **Abdominal Aorta** commences at the aortic opening of the Diaphragm, in front of the lower border of the body of the last dorsal vertebra, and, descending a little to the left side of the vertebral column, terminates on the body of the fourth lumbar vertebra, commonly a little to the left of the middle line,[1] where it divides into the two common iliac arteries. It diminishes rapidly in size, in consequence of the many large branches which it gives off. As it lies upon the bodies of the vertebræ, the curve which it describes is convex forward, the greatest convexity corresponding to the third lumbar vertebra, which is a little above and to the left side of the umbilicus.

Relations.—It is covered, *in front*, by the lesser omentum and stomach, behind which are the branches of the cœliac axis and the solar plexus; below these, by the splenic vein, the pancreas, the left renal vein, the transverse portion of the duodenum, the mesentery, and aortic plexus. *Behind*, it is separated from the lumbar vertebræ and intervening discs by the anterior common ligament and left lumbar veins. On the *right side* it is in relation with the inferior vena cava (the right crus of the Diaphragm being interposed above), the vena azygos major, thoracic duct, and right semilunar ganglion; on the *left side*, with the sympathetic nerve and left semilunar ganglion.

Plan of the Relations of the Abdominal Aorta.

In front.

Lesser omentum and stomach.
Branches of the cœliac axis and solar plexus.
Splenic vein.
Pancreas.
Left renal vein.
Transverse duodenum.
Mesentery.
Aortic plexus.

Right side.

Right crus of Diaphragm.
Inferior vena cava.
Vena azygos major.
Thoracic duct.
Right semilunar ganglion.



Left side.

Sympathetic nerve.
Left semilunar ganglion.

Behind.

Left lumbar veins.
Vertebral column.

[1] Lord Lister, having accurately examined 30 bodies in order to ascertain the exact point of termination of this vessel, found it "either absolutely, or almost absolutely, mesial in 15, while in 13 it deviated more or less to the left, and in 2 was slightly to the right" (*System of Surgery*, edited by T. Holmes, 2d ed., vol. v., p. 652).

Surface Marking.—In order to map out the abdominal aorta on the surface of the abdomen, a line must be drawn from the middle line of the body, on a level with the distal extremity of the seventh costal cartilage, downward and slightly to the left, so that it just skirts the umbilicus, to a zone drawn round the body opposite the highest point of the crest of the ilium. This point is generally half an inch below and to the left of the umbilicus, but as the position of this structure varies with the obesity of the individual, it is not a reliable landmark as to the situation of the bifurcation of the aorta.

Surgical Anatomy.—Aneurisms of the abdominal aorta near the cœliac axis communicate in nearly equal proportion with the anterior and posterior parts of the artery.

When an aneurismal sac is connected with the back part of the abdominal aorta, it usually produces absorption of the bodies of the vertebræ, and forms a pulsating tumor that presents itself in the left hypochondriac or epigastric regions, and is accompanied by symptoms of disturbance in the alimentary canal. Pain is invariably present, and is usually of two kinds—a fixed and constant pain in the back, caused by the tumor pressing on or displacing the branches of the solar plexus and splanchnic nerves; and a sharp lancinating pain, radiating along those branches of the lumbar nerves which are pressed on by the tumor; hence the pain in the loins, the testes, the hypogastrium, and in the lower limb (usually of the left side). This form of aneurism usually bursts into the peritoneal cavity or behind the peritoneum in the left hypochondriac region; or it may form a large aneurismal sac, extending down as low as Poupart's ligament; hæmorrhage in these cases being generally very extensive, but slowly produced, and not rapidly fatal.

When an aneurismal sac is connected with the front of the aorta near the cœliac axis, it forms a pulsating tumor in the left hypochondriac or epigastric regions, usually attended with symptoms of disturbance of the alimentary canal, as sickness, dyspepsia, or constipation, and accompanied by pain, which is constant, but nearly always fixed in the loins, epigastrium, or some part of the abdomen; the radiating pain being rare, as the lumbar nerves are seldom implicated. This form of aneurism may burst into the peritoneal cavity or behind the peritoneum, between the layers of the mesentery, or, more rarely, into the duodenum; it rarely extends backward so as to affect the spine.

The abdominal aorta has been tied several times, and although none of the patients permanently recovered, still, as one of them lived as long as ten days, the possibility of the re-establishment of the circulation may be considered to be proved. In the lower animals this artery has been often successfully tied. The vessel may be reached in several ways. In the original operation, performed by Sir A. Cooper, an incision was made in the linea alba, the peritoneum opened in front, the finger carried down amongst the intestines toward the spine, the peritoneum again opened behind by scratching through the mesentery, and the vessel thus reached. Or either of the operations described below for securing the common iliac artery may, by extending the dissection a sufficient distance upward, be made use of to expose the aorta. The chief difficulty in the dead subject consists in isolating the artery in consequence of its great depth; but in the living subject the embarrassment resulting from the proximity of the aneurismal tumor, and the great probability of disease in the vessel itself, add to the dangers and difficulties of this formidable operation so greatly that it is very doubtful whether it ought ever to be performed.

The collateral circulation would be carried on by the anastomosis between the internal mammary and the deep epigastric; by the free communication between the superior and inferior mesenterics if the ligature were placed above the latter vessel; or by the anastomosis between the inferior mesenteric and the internal pudic when (as is more common) the point of ligature is below the origin of the inferior mesenteric; and possibly by the anastomoses of the lumbar arteries with the branches of the internal iliac.

The circulation through the abdominal aorta may be commanded, in thin persons, by firm pressure with the fingers. A tourniquet has been invented for this purpose which is sometimes used in amputation at the hip-joint and some other operations.

Branches of the Abdominal Aorta.

Phrenic.		Superior Mesenteric.	Ovarian in female.
Cœliac Axis.	Gastric.	Suprarenal.	Inferior Mesenteric.
	Hepatic.	Renal.	Lumbar.
	Splenic.	Spermatic in male.	Sacra Media.

The branches may be divided into two sets: 1. Those supplying the viscera. 2. Those distributed to the walls of the abdomen.

Visceral Branches.

Cœliac Axis: Gastric, Hepatic, Splenic.
Superior Mesenteric.
Inferior Mesenteric.
Suprarenal.
Renal.
Spermatic or Ovarian.

Parietal Branches.

Phrenic.
Lumbar.
Sacra Media.

The Cœliac Axis (Fig. 308).

To expose this artery raise the liver, draw down the stomach, and then tear through the layers of the lesser omentum.

The **Cœliac Axis** is a short thick trunk, about half an inch in length, which

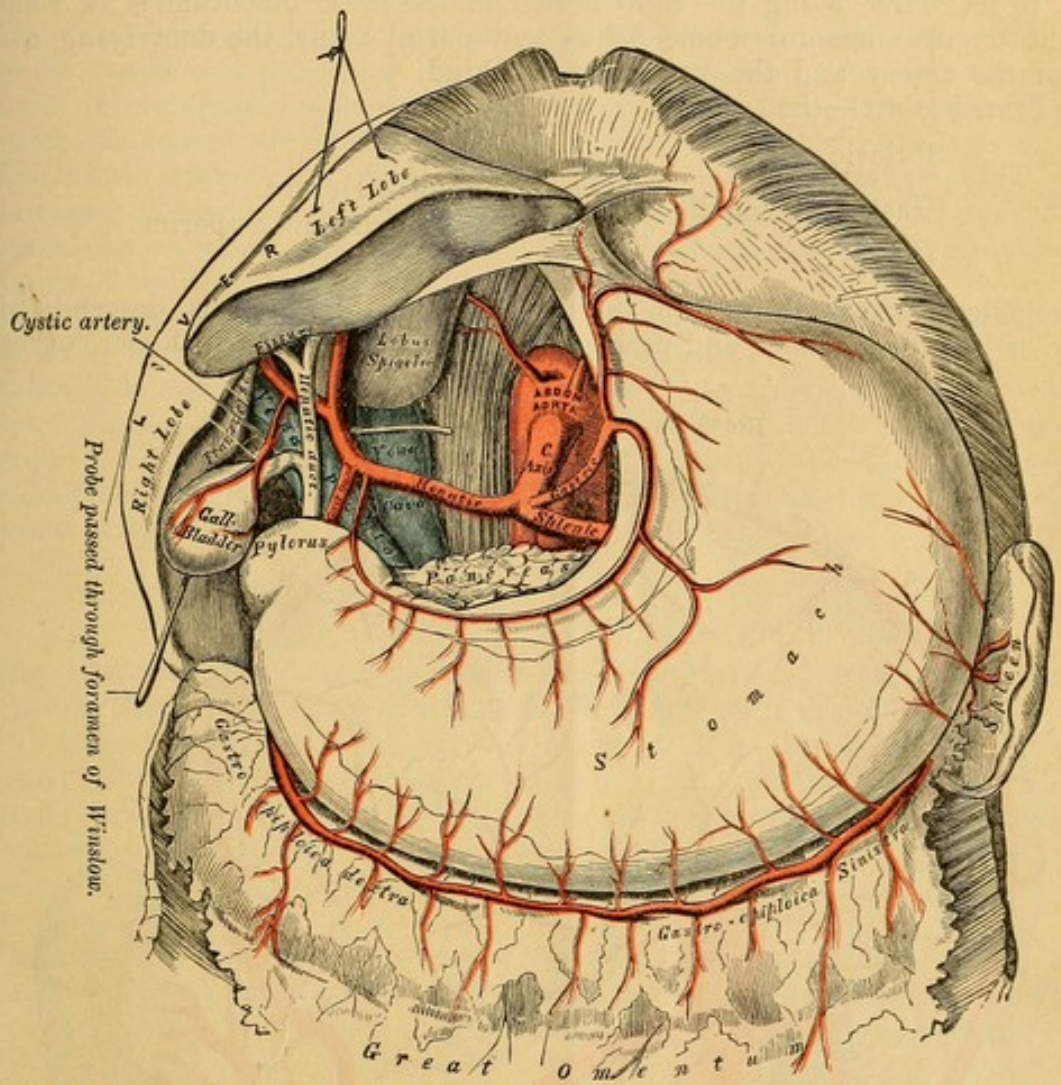

FIG. 308.—The cœliac axis and its branches, the liver having been raised and the lesser omentum removed.

arises from the aorta, close to the margin of the opening in the Diaphragm, and, passing nearly horizontally forward (in the erect posture), divides into three large branches, the *gastric*, *hepatic*, and *splenic*, occasionally giving off one of the phrenic arteries.

Relations.—It is covered by the lesser omentum. On the *right side* it is in relation with the right semilunar ganglion and the lobus Spigelii; on the *left side*, with the left semilunar ganglion and cardiac end of the stomach. *Below*, it rests upon the upper border of the pancreas.

The **Gastric** or **Coronary Artery**, the smallest of the three branches of the cœliac axis, passes upward and to the left side, to the cardiac orifice of the stomach, distributing branches to the œsophagus which anastomose with the aortic œsophageal arteries; others supply the cardiac end of the stomach, inosculating with branches of the splenic artery; it then passes from left to right, along the lesser curvature of the stomach to the pylorus, lying in its course between the layers of the lesser omentum, and giving branches to both surfaces of the organ: at its termination it anastomoses with the pyloric branch of the hepatic.

The **Hepatic Artery** in the adult is intermediate in size between the gastric and splenic; in the fœtus it is the largest of the three branches of the cœliac axis. It is first directed forward and to the right, to the upper margin of the pyloric end

of the stomach, forming the lower boundary of the foramen of Winslow. It then passes upward between the layers of the lesser omentum, and in front of the foramen of Winslow, to the transverse fissure of the liver, where it divides into two branches, right and left, which supply the corresponding lobes of that organ, accompanying the ramifications of the vena portæ and hepatic duct. The hepatic artery, in its course along the right border of the lesser omentum, is in relation with the ductus communis choledochus and portal veins, the duct lying to the right of the artery and the vena portæ behind.

Its branches are—the

Pyloric.
Gastro-duodenalis { Gastro-epiploica Dextra. / Pancreatico-duodenalis Superior.
Cystic.

The **pyloric branch** arises from the hepatic, above the pylorus, descends to the pyloric end of the stomach, and passes from right to left along its lesser curvature,

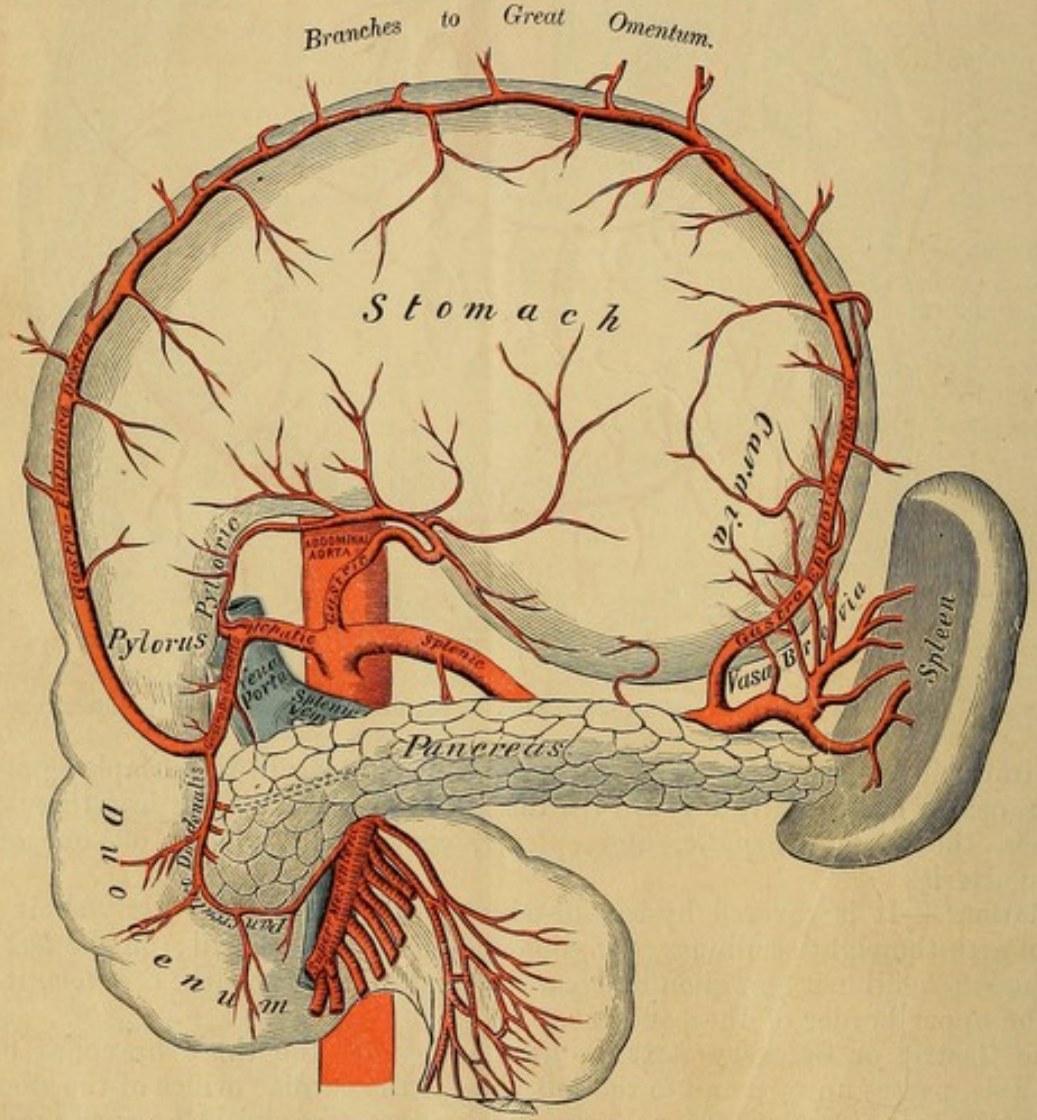

FIG. 309.—The cœliac axis and its branches, the stomach having been raised and the transverse meso-colon removed (semi-diagrammatic).

supplying it with branches and inosculating with the gastric branches of the coronary artery.

The **gastro-duodenalis** (Fig. 309) is a short but large branch, which descends, near the pylorus, behind the first portion of the duodenum, and divides at the lower border of this viscus into two branches, the *gastro-epiploica dextra* and the *pancreatico-duodenalis superior*. Previous to its division, it gives off two or three small inferior pyloric branches to the pyloric end of the stomach and pancreas.

The **gastro-epiploica dextra** runs from right to left along the greater curvature of the stomach, between the layers of the great omentum, anastomosing about the middle of the lower border of the stomach with the gastro-epiploica sinistra from the splenic artery. This vessel gives off numerous branches, some of which ascend to supply both surfaces of the stomach, whilst others descend to supply the great omentum.

The **pancreatico-duodenalis superior** descends between the contiguous margins of the duodenum and pancreas. It supplies both these organs, and anastomoses with the inferior pancreatico-duodenal branch of the superior mesenteric artery and with the pancreatic branches of the splenic.

The **cystic artery** (Fig. 308), usually a branch of the right hepatic, passes upward and forward along the neck of the gall-bladder, and divides into two branches, one of which ramifies on its free surface, the other between it and the substance of the liver.

The **Splenic Artery,** in the adult, is the largest of the three branches of the cœliac axis, and is remarkable for the extreme tortuosity of its course. It passes horizontally to the left side, behind the peritoneum and along the upper border of the pancreas, accompanied by the splenic vein, which lies below it, and on arriving near the spleen divides into branches, some of which enter the hilum of that organ to be distributed to its structure, whilst others are distributed to the pancreas and great end of the stomach. Its branches are—the

Pancreaticæ Parvæ.	Gastric (Vasa Brevia).
Pancreatica Magna.	Gastro-epiploica Sinistra.

The **pancreatic** are numerous small branches derived from the splenic as it runs behind the upper border of the pancreas, supplying its middle and left parts. One of these, larger than the rest, is given off from the splenic near the left extremity of the pancreas; it runs from left to right near the posterior surface of the gland, following the course of the pancreatic duct, and is called the *pancreatica magna.* These vessels anastomose with the pancreatic branches of the pancreatico-duodenal arteries, derived from the hepatic on the one hand and superior mesenteric on the other.

The **gastric** (**vasa brevia**) consists of from five to seven small branches, which arise either from the termination of the splenic artery or from its terminal branches, and, passing from left to right, between the layers of the gastro-splenic omentum, are distributed to the great curvature of the stomach, anastomosing with branches of the gastric and gastro-epiploica sinistra arteries.

The **gastro-epiploica sinistra,** the largest branch of the splenic, runs from left to right along the great curvature of the stomach, between the layers of the great omentum, and anastomoses with the gastro-epiploica dextra. In its course it distributes several branches to the stomach, which ascend upon both surfaces; others descend to supply the omentum.

The Superior Mesenteric Artery (Fig. 310).

In order to expose this vessel raise the great omentum and transverse colon, draw down the small intestines, and cut through the peritoneum where the transverse meso-colon and mesentery join: the artery will then be exposed just as it issues from beneath the lower border of the pancreas.

The **Superior Mesenteric Artery** supplies the whole length of the small intestine, except the first part of the duodenum; it also supplies the cæcum, ascending and transverse colon; it is a vessel of large size, arising from the fore part of the aorta about a quarter of an inch below the cœliac axis; being covered at its origin by the splenic vein and pancreas. It passes forward, between the pancreas and transverse portion of the duodenum, crosses in front of this portion of the intestine, and descends between the layers of the mesentery to the right iliac fossa, where, considerably diminished in size, it anastomoses with one of its own branches —viz., ileo-colic. In its course it forms an arch, the convexity of which is directed

forward and downward to the left side, the concavity backward and upward to the right. It is accompanied by the superior mesenteric vein, and is surrounded by the superior mesenteric plexus of nerves. Its branches are—the

Inferior Pancreatico-duodenal.
Vasa Intestini Tenuis.
Ileo-colic.
Colica Dextra.
Colica Media.

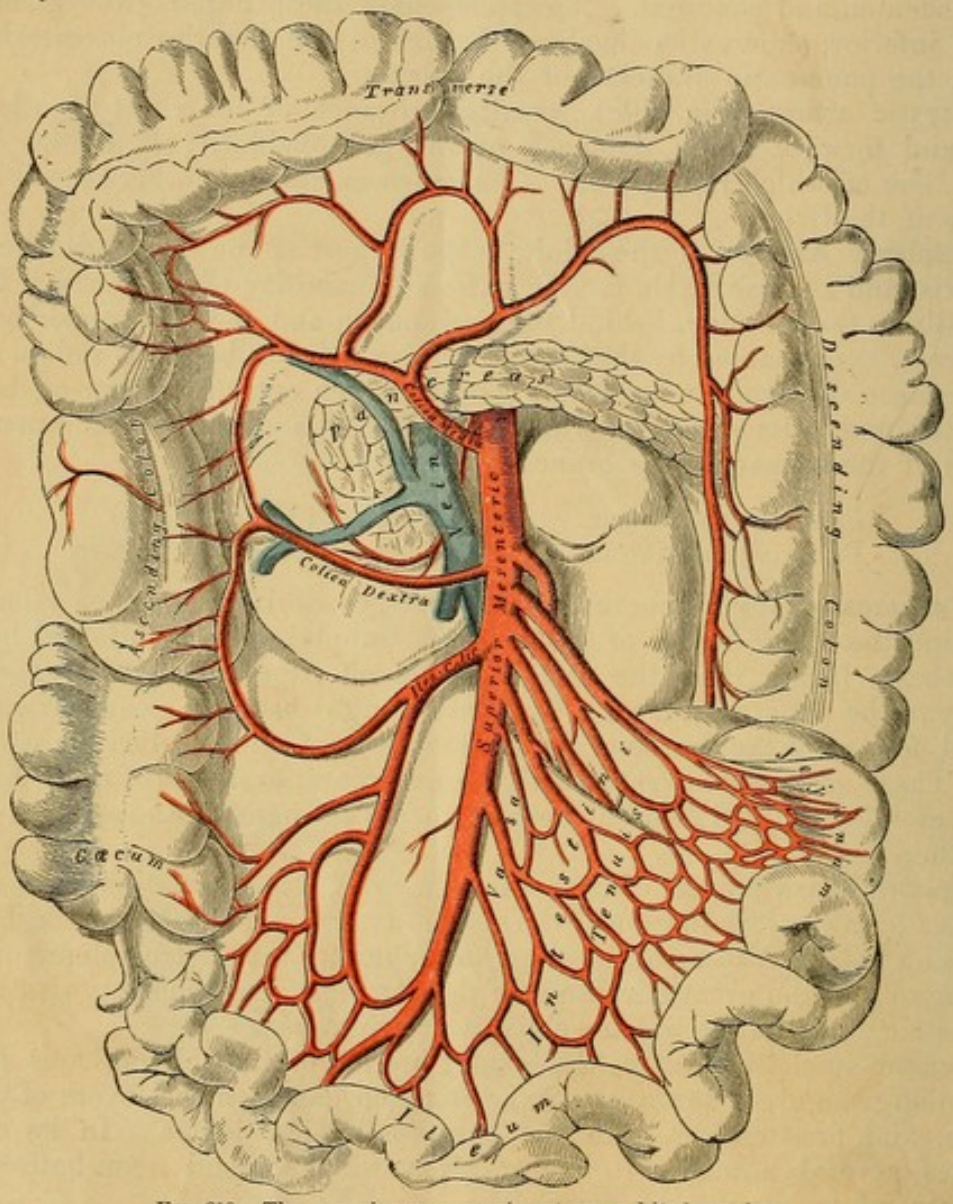

FIG. 310.—The superior mesenteric artery and its branches.

The **inferior pancreatico-duodenal** is given off from the superior mesenteric, or from its first intestinal branch behind the pancreas. It courses to the right between the head of the pancreas and duodenum, and then ascends to anastomose with the superior pancreatico-duodenal artery. It distributes branches to the head of the pancreas and to the transverse and descending portions of the duodenum.

The **vasa intestini tenuis** arise from the convex side of the superior mesenteric artery. They are usually from twelve to fifteen in number, and are distributed to the jejunum and ileum. They run parallel with one another between the layers of the mesentery, each vessel dividing into two branches, which unite with a similar branch on each side, forming a series of arches the convexities of which are directed toward the intestine. From this first set of arches branches arise, which again unite with similar branches from either side, and thus a second series of arches is formed; and from these latter, a third, and a fourth, or even fifth, series of arches is constituted, diminishing in size the nearer they approach the

intestine. From the terminal arches numerous small straight vessels arise which encircle the intestine, upon which they are distributed, ramifying between its coats. Throughout their course small branches are given off to the glands and other structures between the layers of the mesentery.

The **ileo-colic artery** is the lowest branch given off from the concavity of the superior mesenteric artery. It descends between the layers of the mesentery to the right iliac fossa, where it divides into two branches. Of these, the inferior division inosculates with the termination of the superior mesenteric artery, forming with it an arch, from the convexity of which branches proceed to supply the termination of the ileum, the cæcum and appendix cæci, and the ileo-cæcal valve. The superior division inosculates with the colica dextra and supplies the commencement of the colon.

The **colica dextra** arises from about the middle of the concavity of the superior mesenteric artery, and, passing behind the peritoneum to the middle of the ascending colon, divides into two branches—a descending branch, which inosculates with the ileo-colic; and the ascending branch, which anastomoses with the colica media. These branches form arches, from the convexity of which vessels are distributed to the ascending colon. The branches of this vessel are covered with peritoneum only on their anterior aspect.

The **colica media** arises from the upper part of the concavity of the superior mesenteric, and, passing forward between the layers of the transverse meso-colon, divides into two branches, the one on the right side inosculating with the colica dextra; that on the left side, with the colica sinistra, a branch of the inferior mesenteric. From the arches formed by their inosculation branches are distributed to the transverse colon. The branches of this vessel lie between two layers of the transverse meso-colon.

The Inferior Mesenteric Artery (Fig. 311).

In order to expose this vessel draw the small intestines and mesentery over to the right side of the abdomen, raise the transverse colon toward the thorax, and divide the peritoneum covering the front side of the aorta.

The **Inferior Mesenteric Artery** supplies the descending and sigmoid flexure of the colon and the greater part of the rectum. It is smaller than the superior mesenteric, and arises from the left side of the aorta, between one and two inches above its division into the common iliacs. It passes downward to the left iliac fossa, and then descends, between the layers of the meso-rectum, into the pelvis, under the name of the *superior hæmorrhoidal artery.* It lies at first in close relation with the left side of the aorta, and then passes as the superior hæmorrhoidal in front of the left common iliac artery. Its branches are—the

Colica Sinistra. Sigmoid.
Superior Hæmorrhoidal.

The **colica sinistra** passes behind the peritoneum, in front of the left kidney, to reach the descending colon, and divides into two branches—an ascending branch, which inosculates with the colica media; and a descending branch, which anastomoses with the sigmoid artery. From the arches formed by these inosculations branches are distributed to the descending colon.

The **sigmoid artery** runs obliquely downward across the Psoas muscle to the sigmoid flexure of the colon, and divides into branches which supply that part of the intestine, anastomosing above with the colica sinistra, and below with the superior hæmorrhoidal artery. This vessel is sometimes replaced by three or four small branches.

The **superior hæmorrhoidal artery,** the continuation of the inferior mesenteric, descends into the pelvis between the layers of the meso-rectum, crossing, in its course, the ureter and left common iliac vessels. It divides into two branches, which descend one on each side of the rectum, and about five inches from the anus break up into several small branches, which pierce the muscular coat of the bowel

and run downward, as straight vessels, placed at regular intervals from each other in the wall of the gut between its muscular and mucous coat, to the level of the internal sphincter; here they form a series of loops around the lower end of the rectum, and communicate with the middle hæmorrhoidal arteries, branches of the internal iliac, with the inferior hæmorrhoidal branches of the internal pudic.

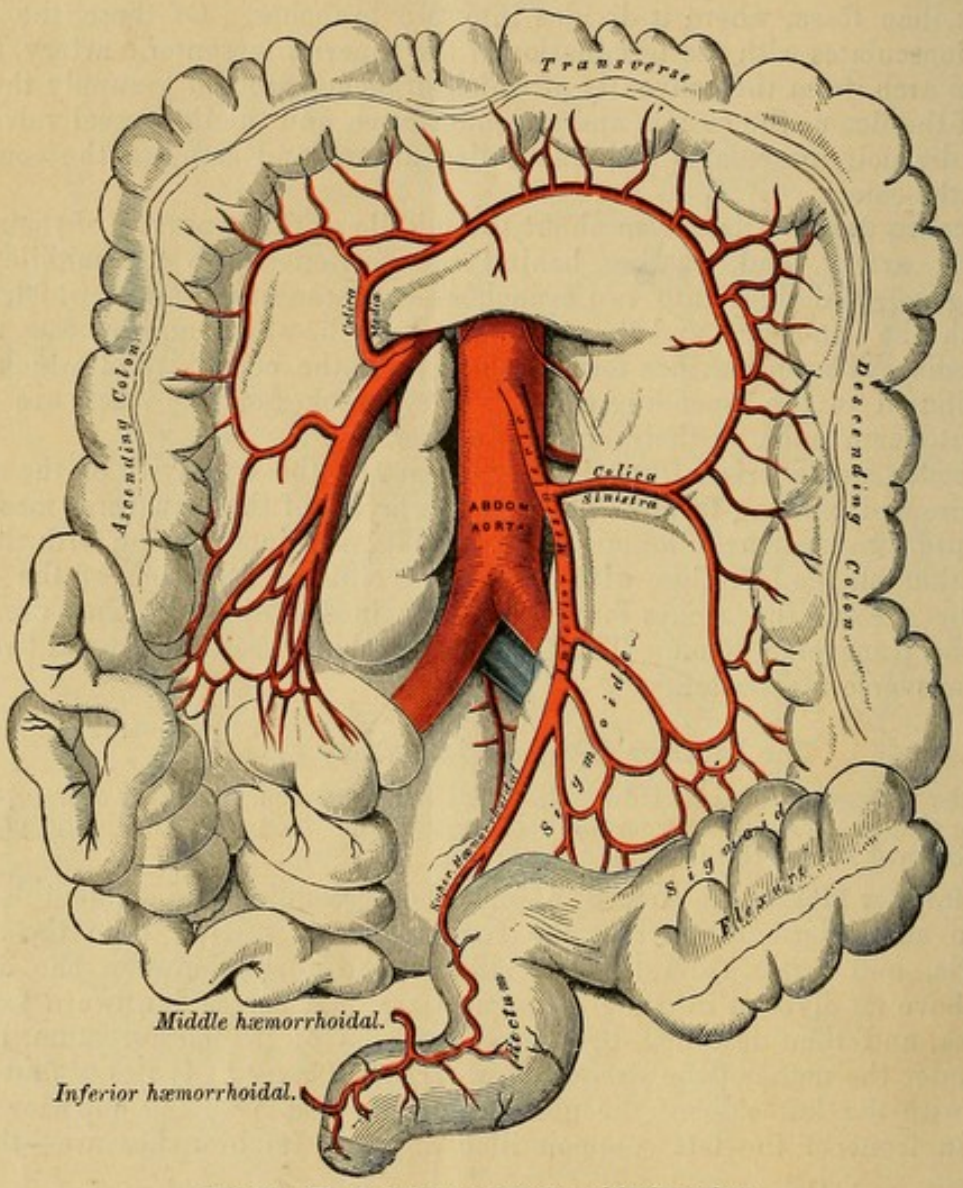

FIG. 311.—The inferior mesenteric and its branches.

The Suprarenal Arteries (Fig. 307).

The **suprarenal arteries** are two small vessels which arise, one on each side of the aorta, opposite the superior mesenteric artery. They pass obliquely upward and outward, over the crura of the Diaphragm, to the under surface of the suprarenal capsules, to which they are distributed, anastomosing with capsular branches from the phrenic and renal arteries. In the adult these arteries are of small size; in the fœtus they are as large as the renal arteries.

The Renal Arteries (Fig. 307).

The **renal arteries** are two large trunks which arise from the sides of the aorta immediately below the superior mesenteric artery. Each is directed outward across the crus of the Diaphragm, so as to form nearly a right angle with the aorta. The right is longer than the left, on account of the position of the aorta; it passes behind the inferior vena cava. The left is somewhat higher than the

right. Before reaching the hilum of the kidney, each artery divides into four or five branches; the greater number of which generally lie between the renal vein and ureter, the vein being in front, the ureter behind. Each vessel gives off some small branches to the suprarenal capsule, the ureter, and the surrounding cellular tissue and muscles. Frequently there is a second renal artery, which is given off from the abdominal aorta either above or below the renal artery proper, the former being the more common position. Instead of entering the kidney at the hilum, these accessory renal arteries usually pierce the upper or lower part of the gland.

The Spermatic Arteries.

The **spermatic arteries** are distributed to the testes. They are two slender vessels of considerable length, which arise from the front of the aorta a little below the renal arteries. Each artery passes obliquely outward and downward behind the peritoneum, resting on the Psoas muscle, the right spermatic lying in front of the inferior vena cava, the left behind the sigmoid flexure of the colon. It then crosses obliquely over the ureter and the lower part of the external iliac artery to reach the internal abdominal ring, through which it passes, and accompanies the other constituents of the spermatic cord along the inguinal canal to the scrotum, where it becomes tortuous, and divides into several branches, two or three of which accompany the vas deferens and supply the epididymis, anastomosing with the artery of the vas deferens; others pierce the back part of the tunica albuginea, and supply the substance of the testis.

The Ovarian Arteries.

The **ovarian arteries** (Fig. 313) are the corresponding arteries in the female to the spermatic in the male. They supply the ovaries, are shorter than the spermatic, and do not pass out of the abdominal cavity. The origin and course of the first part of the artery are the same as the spermatic in the male, but on arriving at the margin of the pelvis the ovarian artery passes inward, between the two layers of the broad ligament of the uterus, to be distributed to the ovary. One or two small branches supply the Fallopian tube; another passes on to the side of the uterus and anastomoses with the uterine arteries. Other offsets are continued along the round ligament through the inguinal canal, to the integument of the labium and groin.

At an early period of fœtal life, when the testes or ovaries lie by the side of the spine below the kidneys, the spermatic or ovarian arteries are short; but as these organs descend from the abdomen into the scrotum or pelvis, the arteries become gradually lengthened.

The Phrenic Arteries.

The **phrenic arteries** are two small vessels which present much variety in their origin. They may arise separately from the front of the aorta, immediately above the cœliac axis, or by a common trunk, which may spring either from the aorta or from the cœliac axis. Sometimes one is derived from the aorta, and the other from one of the renal arteries. In only one out of thirty-six cases examined did these arteries arise as two separate vessels from the aorta. They diverge from one another across the crura of the Diaphragm, and then pass obliquely upward and outward upon its under surface. The left phrenic passes behind the œsophagus and runs forward on the left side of the œsophageal opening. The right phrenic passes behind the inferior vena cava, and ascends along the right side of the aperture for transmitting that vein. Near the back part of the central tendon each vessel divides into two branches. The internal branch runs forward to the front of the thorax, supplying the Diaphragm and anastomosing with its fellow of

the opposite side, and with the musculo-phrenic and comes nervi phrenici, branches of the internal mammary. The external branch passes toward the side of the thorax and inosculates with the intercostal arteries. The internal branch of the right phrenic gives off a few vessels to the inferior vena cava, and the left one some branches to the œsophagus. Each vessel also sends capsular branches to the suprarenal capsule of its own side. The spleen on the left side and the liver on the right also receive a few branches from these vessels.

The Lumbar Arteries.

The **lumbar arteries** are analogous to the intercostal. They are usually four in number on each side, and arise from the back part of the aorta, nearly at right angles with that vessel. They pass outward and backward, around the sides of the body of the lumbar vertebra, behind the sympathetic nerve and the Psoas magnus muscle, those on the right side being covered by the inferior vena cava, and the two upper ones on each side by the crura of the Diaphragm. In the interval between the transverse processes of the vertebræ each artery divides into a *dorsal* and an *abdominal branch*.

The **dorsal branch** gives off, immediately after its origin, a spinal branch, which enters the spinal canal; it then continues its course backward between the transverse processes, and is distributed to the muscles and integument of the back, anastomosing with the similar branches of the adjacent lumbar arteries and with the posterior branches of the intercostal arteries.

The **spinal branch** enters the spinal canal through the intervertebral foramen, to be distributed to the spinal cord and its membranes and to the bodies of the vertebræ in the same manner as the lateral spinal branches from the vertebral (see page 521).

The **abdominal branches** pass outward, having a variable relation to the Quadratus lumborum muscle. Most frequently the first branch passes in front of the muscle and the others behind it; sometimes the order is reversed and the lowest branch passes in front of the muscle. At the outer border of the Quadratus they are continued between the abdominal muscles, anastomose with branches of the epigastric and internal mammary *in front*, the intercostals *above*, and those of the ilio-lumbar and circumflex iliac *below*.

The Middle Sacral Artery.

The **Middle Sacral Artery** is a small vessel, which arises from the back part of the aorta just at its bifurcation. It descends upon the last lumbar vertebra, and along the middle line of the front of the sacrum, to the upper part of the coccyx where it anastomoses with the lateral sacral arteries, and terminates in a minute branch, which runs down to the situation of the body immediately to be described as "Luschka's gland." From it branches arise which run through the meso-rectum to supply the posterior surface of the rectum. Other branches are given off on each side, which anastomose with the lateral sacral arteries, and send off small offsets which enter the anterior sacral foramina.

The artery is the representative of the caudal prolongation of the aorta of animals, and its lateral branches correspond to the intercostal and lumbar arteries in the dorsal and lumbar regions.

Coccygeal Gland, or Luschka's Gland.—Lying near the tip of the coccyx in a small tendinous interval formed by the union of the Levator ani muscles of each side, and just above the coccygeal attachment of the Sphincter ani, is a small conglobate body about as large as a lentil or a pea, first described by Luschka[1] and named by him the *coccygeal gland*. Its most obvious connections are with the arteries of the part.

Structure.—It consists of a congeries of small arteries with little aneurismal dilatations derived from the middle sacral and freely communicating with each

[1] *Der Hirnanhang und die Steissdrüse des Menschen*, Berlin, 1860; *Anatomie des Menschen*, Tübingen, 1864, vol. ii. pt. 2, p. 187.

other. These vessels are enclosed in one or more layers of polyhedral granular cells, and the whole structure is invested in a capsule of connective tissue which sends in trabeculæ, dividing the interior into a number of spaces in which the vessels and cells are contained. Nerves pass into this little body from the sympathetic, but their mode of termination is unknown. Macalister believes the glomerulus of vessels "consists of the condensed and convoluted metameric dorsal arteries of the caudal segments imbedded in tissue which is possibly a small persisting fragment of the neurenteric canal."

THE COMMON ILIAC ARTERIES.

The abdominal aorta divides into the two **common iliac arteries.** The bifurcation usually takes place on the left side of the body of the fourth lumbar vertebra. The common iliac arteries are about two inches in length; diverging from the termination of the aorta, they pass downward and outward to the margin of the pelvis, and divide opposite the intervertebral substance, between the last lumbar vertebra and the sacrum, into two branches, the *external* and *internal iliac arteries*, the former supplying the lower extremity; the latter, the viscera and parietes of the pelvis.

The **right common iliac** is somewhat longer than the left, and passes more obliquely across the body of the last lumbar vertebra. In front of it are the peritoneum, the small intestines, branches of the sympathetic nerve, and, at its point of division, the ureter. *Behind*, it is separated from the fourth and fifth lumbar vertebræ, with the intervening intervertebral disc, by the two common iliac veins. On its *outer side*, it is in relation with the inferior vena cava and the right common iliac vein, above, and the Psoas magnus muscle below.

The **left common iliac** is in relation, in front, with the peritoneum, branches of the sympathetic nerve, and the superior hæmorrhoidal artery; and is crossed at its point of bifurcation by the ureter. It rests on the bodies of the fourth and fifth lumbar vertebræ, with the intervening intervertebral disc. The left common iliac vein lies partly on the inner side, and partly beneath the artery; on its outer side, the artery is in relation with the Psoas magnus muscle.

PLAN OF THE RELATIONS OF THE COMMON ILIAC ARTERIES.

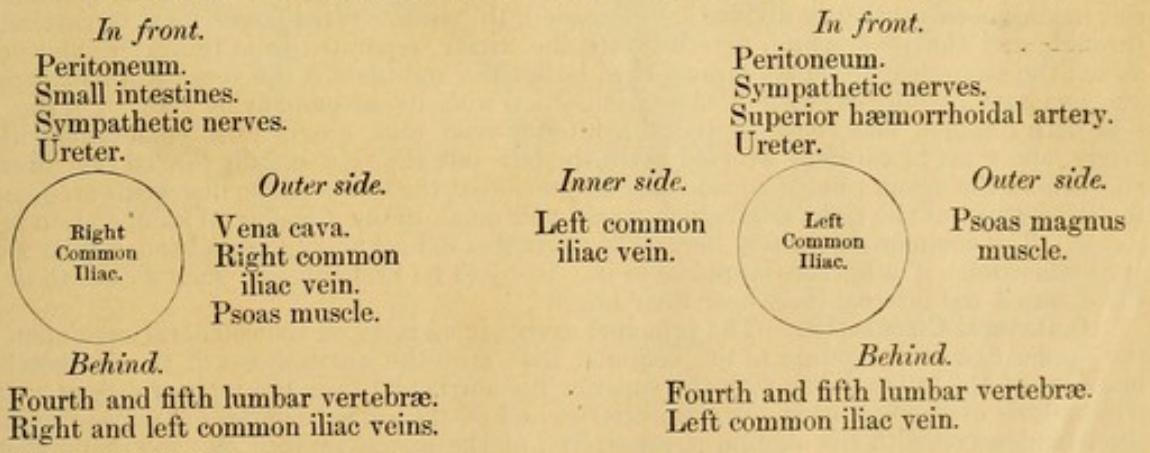

Branches.—The common iliac arteries give off small branches to the peritoneum Psoas magnus, ureters, and the surrounding cellular tissue, and occasionally give origin to the ilio-lumbar or renal arteries.

Peculiarities.—The *point of origin* varies according to the bifurcation of the aorta. In three-fourths of a large number of cases the aorta bifurcated either upon the fourth lumbar vertebra or upon the intervertebral disk between it and the fifth, the bifurcation being, in one case out of nine below, and in one out of eleven above, this point. In ten out of every thirteen cases the vessel bifurcated within half an inch above or below the level of the crest of the ilium more frequently below than above.

The point of division is subject to great variety. In two-thirds of a large number of cases it was between the last lumbar vertebra and the upper border of the sacrum being above that

point in one case out of eight; and below it in one case out of six. The left common iliac artery divides lower down more frequently than the right.

The *relative length*, also, of the two common iliac arteries varies. The right common iliac was the longer in sixty-three cases, the left in fifty-two, whilst they were both equal in fifty-three. The length of the arteries varied in five-sevenths of the cases examined from an inch and a half to three inches; in about half of the remaining cases the artery was longer and in the other half shorter, the minimum length being less than half an inch, the maximum four and a half inches. In two instances the right common iliac has been found wanting, the external and internal iliacs arising directly from the aorta.

Surface Marking.—Draw a zone round the body opposite the highest part of the crest of the ilium; in this line take a point half an inch to the left of the middle line. From this draw two lines to points midway between the anterior superior spines of the ilium and the symphysis pubis. These two diverging lines will represent the course of the common and external iliac arteries. Draw a second zone round the body corresponding to the level of the anterior superior spines of the ilium: the portion of the diverging lines between the two zones will represent the course of the common iliac artery; the portion below the lower zone, that of the external iliac artery.

Surgical Anatomy.—The application of a ligature to the common iliac artery may be required on account of aneurism or hæmorrhage implicating the external or internal iliacs. Now that the surgeon no longer dreads opening the peritoneal cavity, there can be no question that the easiest and best method of tying the artery is by a transperitoneal route. The abdomen is opened by an incision in either the semilunar line or the linea alba; the intestines are drawn to one side and the peritoneum covering the artery divided. The sheath is then opened, and the needle passed from within outward. On the right side great care must be exercised in passing the needle, since both the common iliac veins lie behind the artery. After the vessel has been tied the incision in the peritoneum over the artery should be sutured. Formerly there were two different methods by which the common iliac artery was tied, without opening the peritoneal cavity: 1, an anterior or iliac incision, by which the vessel is approached more directly from the front; and 2, a posterior abdominal or lumbar incision, by which the vessel is reached from behind. If the surgeon select the iliac region, a curved incision, from five to eight inches in length according to the amount of fat, is made, commencing just outside the middle of Poupart's ligament and a finger's breadth above it, and carried outward toward the anterior superior iliac spine, then upward toward the ribs, and finally curving inward toward the umbilicus. The abdominal muscles and transversalis fascia are divided, and the peritoneum raised upward and inward until the Psoas is reached. The artery will be found on the inner side of this muscle, and is to be cleared with a director, especial care being taken on the right side, as here the common iliac veins lie behind the artery. The aneurism needle is to be passed from within outward. But if the aneurismal tumor should extend high up in the abdomen, along the external iliac, it is better to select the posterior or lumbar, by making an incision partly in the abdomen, partly in the loin. The incision is commenced at the anterior extremity of the last rib, proceeding directly downward to the ilium; it is then curved forward along the crest of the ilium and a little above it to the anterior superior spine of that bone. The abdominal muscles having been cautiously divided in succession, the transversalis fascia must be carefully cut through, and the peritoneum, together with the ureter, separated from the artery and pushed aside; the sacro-iliac articulation must then be felt for, and upon it the vessel will be felt pulsating, and may be fully exposed in close connection with its accompanying vein. On the right side both common iliac veins, as well the inferior vena cava, are in close connection with the artery, and must be carefully avoided. On the left side the vein usually lies on the inner side and behind the artery; but it occasionally happens that the two common iliac veins are joined on the left instead of the right side, which would add much to the difficulty of an operation in such a case. The common iliac artery may be so short that danger may be apprehended from secondary hæmorrhage if a ligature is applied to it. It would be preferable, in such a case, to tie both the external and internal iliacs near their origin.

Collateral Circulation.—The principal agents in carrying on the collateral circulation after the application of a ligature to the common iliac are—the anastomoses of the hæmorrhoidal branches of the internal iliac with the superior hæmorrhoidal from the inferior mesenteric; the anastomoses of the uterine and ovarian arteries and of the vesical arteries of opposite sides; of the lateral sacral with the middle sacral artery; of the epigastric with the internal mammary, inferior intercostal, and lumbar arteries; of the circumflex iliac with the lumbar arteries; of the ilio-lumbar with the last lumbar artery; of the obturator artery, by means of its pubic branch, with the vessel of the opposite side and with the deep epigastric.

Compression of the Common Iliac Arteries.—The common iliac arteries are most efficiently compressed by Davy's lever. The instrument consists of a gum-elastic tube about two feet long, in which fits a round wooden "lever" considerably longer than the tube. A small quantity of olive oil having been injected into the rectum, the gum-elastic tube, softened in hot water, is passed into the bowel sufficiently far to permit its pressing upon the common iliac artery as it lies in the groove between the last lumbar vertebra and the Psoas muscle. The wooden lever is then inserted into the tube, and the projecting end carried toward the opposite thigh and raised, when it acts as a lever of the first order, the anus being the fulcrum. In cases

where the meso-rectum is abnormally short it may be impossible, without unjustifiable force, to compress the artery on the right side.

Internal Iliac Artery (Fig. 312).

The **internal iliac artery** supplies the walls and viscera of the pelvis, the generative organs, and inner side of the thigh. It is a short thick vessel, smaller in the adult than the external iliac, and about an inch and a half

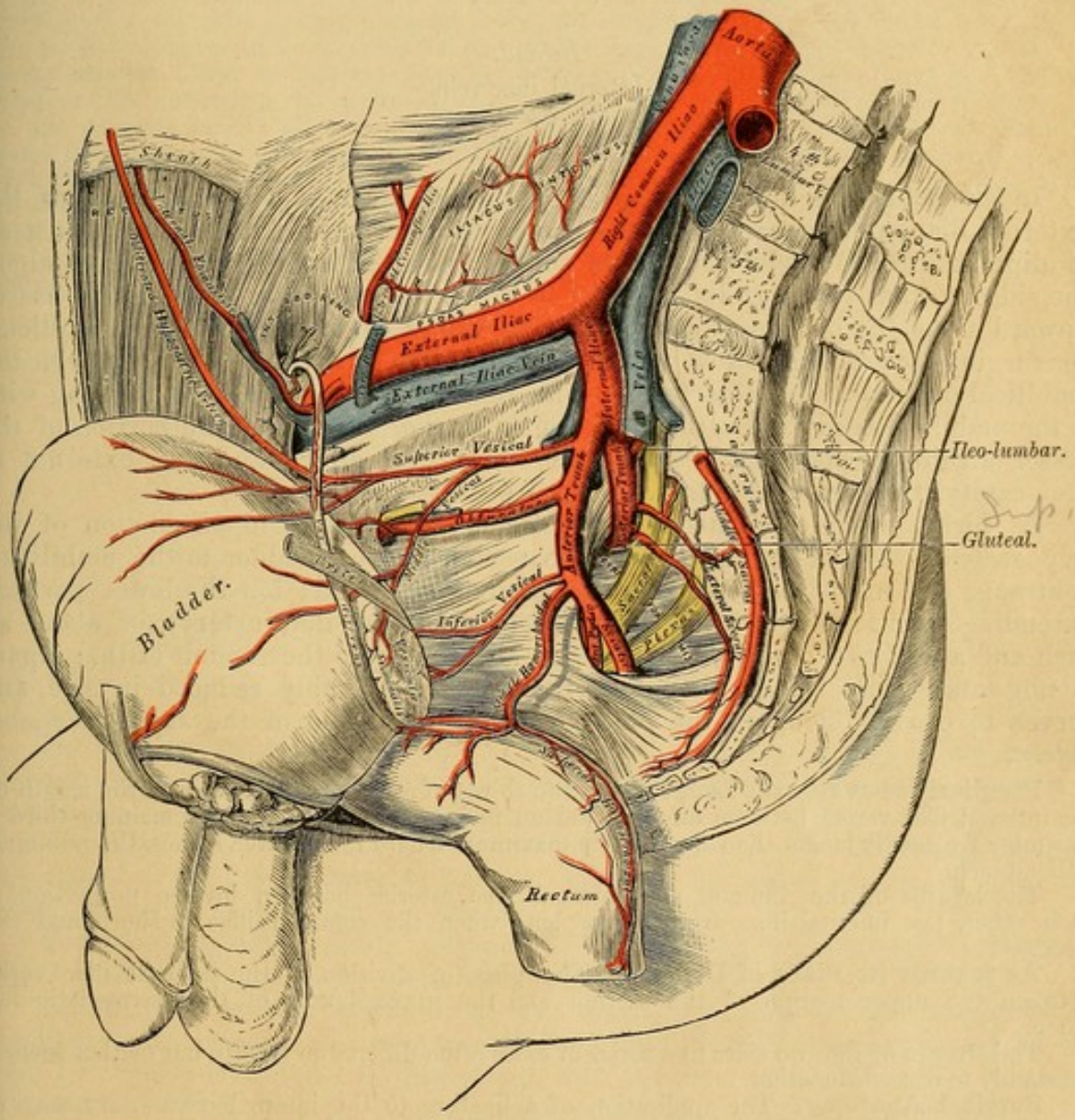

FIG. 312.—Arteries of the pelvis.

in length. It arises at the point of bifurcation of the common iliac, and, passing downward to the upper margin of the great sacro-sciatic foramen, divides into two large trunks, an *anterior* and *posterior;* from its anterior division a partially obliterated cord, the *hypogastric artery*, extends forward to the bladder.

Relations.—*In front*, with the ureter, which separates it from the peritoneum. *Behind*, with the internal iliac vein, the lumbo-sacral cord, and Pyriformis muscle. By its *outer side*, near its origin, with the Psoas magnus muscle.

PLAN OF THE RELATIONS OF THE INTERNAL ILIAC ARTERY.

In front.

Peritoneum.
Ureter.

Outer side.

Psoas magnus.



Behind.

Internal iliac vein.
Lumbo-sacral cord.
Pyriformis muscle.

In the fœtus the internal iliac artery (*hypogastric*) is twice as large as the external iliac, and appears to be the continuation of the common iliac. Instead of dipping into the pelvis, it passes forward to the bladder, and ascends along the sides of that viscus to its summit, to which it gives branches; it then passes upward along the back part of the anterior wall of the abdomen to the umbilicus, converging toward its fellow of the opposite side. Having passed through the umbilical opening, the two arteries twine round the umbilical vein, forming with it the umbilical cord, and ultimately ramify in the placenta. The portion of the vessel within the abdomen is called the *hypogastric artery*, and that external to that cavity, the *umbilical artery*.

At birth, when the placental circulation ceases, the upper portion of the hypogastric artery, extending from the summit of the bladder to the umbilicus, contracts, and ultimately dwindles to a solid fibrous cord; but the lower portion, extending from its origin (in what is now the internal iliac artery) for about an inch and a half to the wall of the bladder, and thence to the summit of that organ, is not totally impervious, though it becomes considerably reduced in size, and serves to convey blood to the bladder under the name of the *superior vesical artery*.

Peculiarities as regards Length.—In two-thirds of a large number of cases the length of the internal iliac varied between an inch and an inch and a half; in the remaining third it was more frequently longer than shorter, the maximum length being three inches, the minimum half an inch.

The lengths of the common and internal iliac arteries bear an inverse proportion to each other, the internal iliac artery being long when the common iliac is short, and *vice versâ*.

As regards its Place of Division.—The place of division of the internal iliac varies between the upper margin of the sacrum and the upper border of the sacro-sciatic foramen.

The arteries of the two sides in a series of cases often differed in length, but neither seemed constantly to exceed the other.

Surgical Anatomy.—The application of a ligature to the internal iliac artery may be required in cases of aneurism or hæmorrhage affecting one of its branches. The vessel may be secured by making an incision through the abdominal parietes in the iliac region in a direction and to an extent similar to that for securing the common iliac; the transversalis fascia having been cautiously divided, and the peritoneum pushed inward from the iliac fossa toward the pelvis, the finger may feel the pulsation of the external iliac at the bottom of the wound, and by tracing this vessel upward the internal iliac is arrived at, opposite the sacro-iliac articulation. It should be remembered that the vein lies behind and on the right side, a little external to the artery, and in close contact with it; the ureter and peritoneum, which lie in front, must also be avoided. The degree of facility in applying a ligature to this vessel will mainly depend upon its length. It has been seen that in the great majority of the cases examined the artery was short, varying from an inch to an inch and a half; in these cases the artery is deeply seated in the pelvis; when, on the contrary, the vessel is longer, it is found partly above that cavity. If the artery is very short, as occasionally happens, it would be preferable to apply a ligature to the common iliac or upon the external and internal iliacs at their origin.

Probably a better method of tying the internal iliac artery is by an abdominal section in the median line and reaching the vessel through the peritoneal cavity. This plan has been advocated by Dennis of New York on the following grounds: (1) It no way increases the danger of the operation; (2) it prevents a series of accidents which have occurred during ligature of the artery by the older methods; (3) it enables the surgeon to ascertain the exact extent of disease

in the main arterial trunk, and select his spot for the application of the ligature; and (4) it occupies much less time.

Collateral Circulation.—In Professor Owen's dissection of a case in which the internal iliac artery had been tied by Stevens ten years before death for aneurism of the sciatic artery, the internal iliac was found impervious for about an inch above the point where the ligature had been applied, but the obliteration did not extend to the origin of the external iliac, as the ilio-lumbar artery arose just above this point. Below the point of obliteration the artery resumed its natural diameter, and continued so for half an inch, the obturator, lateral sacral, and gluteal arising in succession from the latter portion. The obturator artery was entirely obliterated. The lateral sacral artery was as large as a crow's quill, and had a very free anastomosis with the artery of the opposite side and with the middle sacral artery. The sciatic artery was entirely obliterated as far as its point of connection with the aneurismal tumor, but on the distal side of the sac it was continued down along the back of the thigh nearly as large in size as the femoral, being pervious about an inch below the sac by receiving an anastomosing vessel from the profunda.[1] The circulation was carried on by the anastomoses of the uterine and ovarian arteries; of the opposite vesical arteries; of the hæmorrhoidal branches of the internal iliac with those from the inferior mesenteric; of the obturator artery, by means of its pubic branch, with the vessel of the opposite side and with the epigastric and internal circumflex; of the circumflex and perforating branches of the profunda femoris with the sciatic; of the gluteal with the posterior branches of the sacral arteries; of the ilio-lumbar with the last lumbar; of the lateral sacral with the middle sacral; and of the circumflex iliac with the ilio-lumbar and gluteal.

Branches of the Internal Iliac.

From the Anterior Trunk.	*From the Posterior Trunk.*
Superior Vesical.	Ilio-lumbar.
Middle Vesical.	Lateral Sacral.
Inferior Vesical.	Gluteal.
Middle Hæmorrhoidal.	
Obturator.	
Internal Pudic.	
Sciatic.	
In female { Uterine.	
In female { Vaginal.	

The **superior vesical** is that part of the fœtal hypogastric artery which remains pervious after birth. It extends to the side of the bladder, distributing numerous branches to the apex and body of the organ. From one of these a slender vessel is derived which accompanies the vas deferens in its course to the testis, where it anastomoses with the spermatic artery. This is the *artery of the vas deferens.* Other branches supply the ureter.

The **middle vesical,** usually a branch of the superior, is distributed to the base of the bladder and under surface of the vesiculæ seminales.

The **inferior vesical** arises from the anterior division of the internal iliac, frequently in common with the middle hæmorrhoidal, and is distributed to the base of the bladder, the prostate gland, and vesiculæ seminales. The branches distributed to the prostate communicate with the corresponding vessel of the opposite side.

The **middle hæmorrhoidal artery** usually arises together with the preceding vessel. It supplies the anus and parts outside the rectum, anastomosing with the other hæmorrhoidal arteries.

The **uterine artery** (Fig. 313) passes inward from the anterior trunk of the internal iliac to the neck of the uterus. Ascending in a tortuous course on the side of this viscus, between the layers of the broad ligament, it distributes branches to its substance, anastomosing, near its termination, with a branch from the ovarian artery. It gives off branches to the cervix uteri (*cervical*), and branches which descend on the vagina, and, joining with branches from the vaginal arteries, form a median longitudinal vessel both in front and behind; these descend on the anterior and posterior surfaces of the vagina, and are named the *azygos arteries of the vagina.*

[1] *Medico-Chirurgical Trans.*, vol. xvi.

The **vaginal artery** is analogous to the inferior vesical in the male; it descends upon the vagina, supplying its mucous membrane, and sending branches to the neck of the bladder and contiguous part of the rectum. It assists in forming the azygos arteries of the vagina.

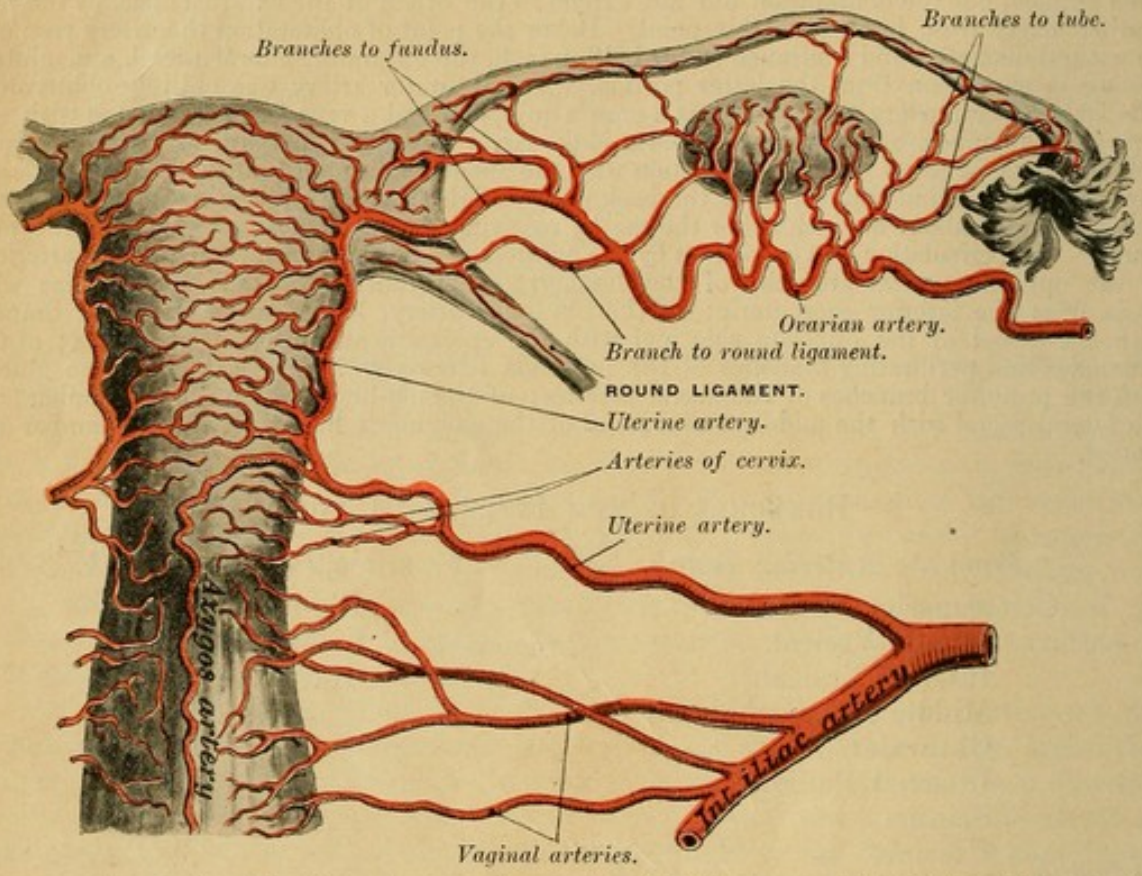

FIG. 313.—The arteries of the internal organs of generation of the female, seen from behind. (After Hyrtl.)

The **Obturator Artery** usually arises from the anterior trunk of the internal iliac; frequently from the posterior. It passes forward, below the brim of the pelvis, to the upper part of the obturator foramen, and, escaping from the pelvic cavity through a short canal formed by a groove on the under surface of the ascending ramus of the os pubis and the arched border of the obturator membrane, it divides into an internal and external branch. In the pelvic cavity this vessel lies upon the pelvic fascia, beneath the peritoneum, and a little below the obturator nerve.

Branches.— *Within the pelvis*, the obturator artery gives off an *iliac branch* to the iliac fossa, which supplies the bone and the Iliacus muscle, and anastomoses with the ilio-lumbar artery; a *vesical branch*, which runs backward to supply the bladder; and a *pubic branch*, which is given off from the vessel just before it leaves the pelvic cavity. This branch ascends upon the back of the os pubis, communicating with offsets from the deep epigastric artery and with the corresponding vessel of the opposite side. It is placed on the inner side of the femoral ring. *External to the pelvis*, the obturator artery divides into an *internal* and an *external branch*, which are deeply situated beneath the Obturator externus muscle.

The **internal branch** curves downward along the inner margin of the obturator foramen, lying beneath the Obturator externus muscle; it distributes branches to the Obturator externus, Pectineus, Adductors, and Gracilis, and anastomoses with the external branch and with the internal circumflex artery.

The **external branch** curves round the outer margin of the foramen, also lying beneath the Obturator externus muscle, to the space between the Gemellus inferior and Quadratus femoris, where it divides into two branches: one, the smaller, courses inward around the lower margin of the foramen and anastomoses with the internal branch and with the internal circumflex; the other inclines outward in the groove

below the acetabulum, and supplies the muscles attached to the tuberosity of the ischium and anastomoses with the sciatic artery. It sends a branch to the hip-joint through the cotyloid notch, which ramifies on the round ligament as far as the head of the femur.

Peculiarities.—In two out of every three cases the obturator arises from the internal iliac; in one case in three and a half from the epigastric; and in about one in seventy-two cases by two roots from both vessels. It arises in about the same proportion from the external iliac artery. The origin of the obturator from the epigastric is not commonly found on both sides of the same body.

When the obturator artery arises at the front of the pelvis from the epigastric, it descends almost vertically to the upper part of the obturator foramen. The artery in this course usually lies in contact with the external iliac vein and on the outer side of the femoral ring (Fig. 314, A); in such cases it would not be endangered in the operation for femoral hernia. Occasionally, however, it curves inward along the free margin of Gimbernat's ligament (Fig. 314, B), and



FIG. 314.—Variations in origin and course of obturator artery.

under such circumstances would almost completely encircle the neck of a hernial sac (supposing a hernia to exist in such a case), and would be in great danger of being wounded if an operation was performed.

The **internal pudic** is the smaller of the two terminal branches of the anterior trunk of the internal iliac, and supplies the external organs of generation. Though the course of the artery is the same in the two sexes, the vessel is much smaller in the female than in the male, and the distribution of its branches somewhat different. The description of its arrangement in the male will first be given, and subsequently the differences which it presents in the female will be mentioned.

The **Internal Pudic Artery in the Male** passes downward and outward to the lower border of the great sacro-sciatic foramen, and emerges from the pelvis between the Pyriformis and Coccygeus muscles: it then crosses the spine of the ischium and re-enters the pelvis through the lesser sacro-sciatic foramen. The artery now crosses the Obturator internus muscle along the outer wall of the ischio-rectal fossa, being situated about an inch and a half above the lower margin of the ischial tuberosity. It is here contained in a sheath of the obturator fascia, and gradually approaches the margin of the ramus of the ischium, along which it passes forward and upward, pierces the base of the superficial layer of the triangular ligament of the urethra, and runs forward along the inner margin of the ramus of the os pubis, and divides into its two terminal branches, the *dorsal artery of the penis* and the *artery of the corpus cavernosum*.

Relations.—In the first part of its course, within the pelvis, it lies in front of the Pyriformis muscle and sacral plexus of nerves, and the sciatic artery, and on the outer side of the rectum (on the left side). As it crosses the spine of the ischium it is covered by the Gluteus maximus and overlapped by the great sacro-sciatic ligament. Here the obturator nerve lies to the inner side and the nerve to the Obturator internus to the outer side of the vessel. In the pelvis it lies on the outer side of the ischio-rectal fossa, upon the surface of the Obturator internus muscle, contained in a fibrous canal (canal of Alcock) formed by the splitting of the obturator fascia. It is accompanied by the pudic veins and the pudic nerve.

Peculiarities.—The internal pudic is sometimes smaller than usual, or fails to give off one or two of its usual branches; in such cases the deficiency is supplied by branches derived from an additional vessel, the *accessory pudic*, which generally arises from the internal pudic artery before its exit from the great sacro-sciatic foramen. It passes forward along the lower part of the bladder and across the side of the prostate gland to the root of the penis, where it perforates the triangular ligament and gives off the branches usually derived from the pudic artery. The deficiency most frequently met with is that in which the internal pudic ends as the artery of the bulb, the artery of the corpus cavernosum and arteria dorsalis penis being derived from the accessory pudic. Or the pudic may terminate as the superficial perineal, the artery of the bulb being derived, with the other two branches, from the accessory vessel. Occasionally the accessory pudic artery is derived from one of the other branches of the internal iliac, most frequently the inferior vesical or the obturator.

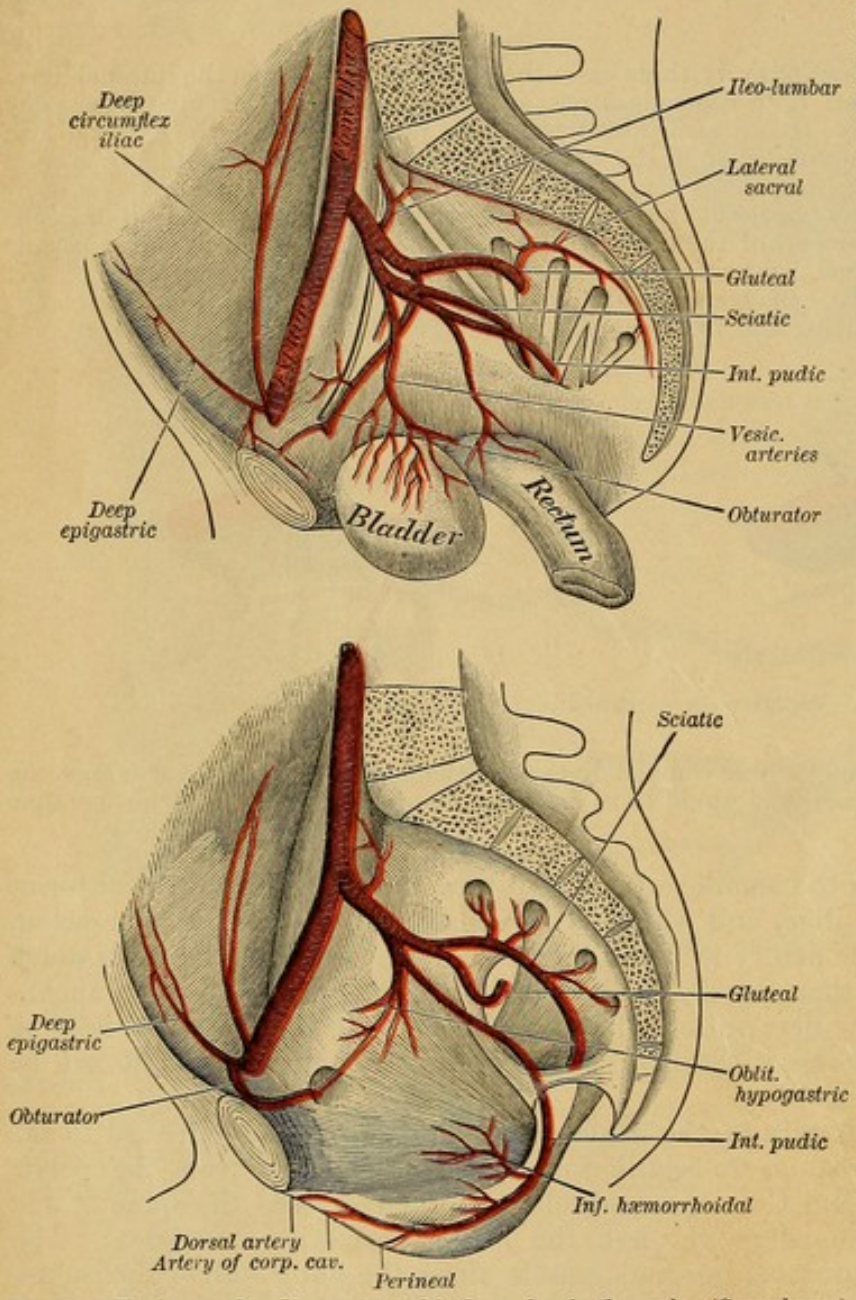

FIG. 315.—The internal pudic artery and its branches in the male. (Gegenbaur.)

Surgical Anatomy.—The relation of the accessory pudic to the prostate gland and urethra is of the greatest interest in a surgical point of view, as this vessel is in danger of being wounded in the lateral operation of lithotomy. The student should also study the position of the internal pudic artery and its branches, when running a normal course with regard to the same operation. The superficial and the transverse perineal arteries are, of necessity, divided in this operation, but the hemorrhage from these vessels is seldom excessive; should a ligature be required, it can readily be applied on account of their superficial position. The artery of the bulb may be divided if the incision be carried too far forward, and injury of this vessel may be attended with serious or even fatal consequences. The main trunk of the internal pudic artery may be wounded if the incision be carried too far outward; but, being bound down by the strong obturator fascia and under cover of the ramus of the ischium, the accident is not very likely to occur unless the vessel runs an anomalous course.

Branches.—The branches of the internal pudic artery are—

Muscular.	Transverse Perineal.
Inferior Hæmorrhoidal.	Artery of the Bulb.
Superficial Perineal.	Artery of the Corpus Cavernosum.

Dorsal Artery of the Penis.

The **muscular branches** consist of two sets—one given off in the pelvis, the other as the vessel crosses the ischial spine. The former are several small offsets which supply the Levator ani, the Obturator internus, the Pyriformis, and the

Coccygeus muscles. The branches given off outside the pelvis are distributed to the adjacent part of the Gluteus maximus and External rotator muscles. They anastomose with branches of the sciatic artery.

The **inferior hæmorrhoidal** are two or three small arteries which arise from the internal pudic as it passes above the tuberosity of the ischium. Crossing the ischio-rectal fossa, they are distributed to the muscles and integument of the anal region.

The **superficial perineal artery** supplies the scrotum and muscles and integument of the perinæum. It arises from the internal pudic in front of the preceding branches, and turns upward, crossing either over or under the Transversus perinæi muscle, and runs forward, parallel to the pubic arch, in the interspace between the Accelerator urinæ and Erector penis muscles, both of which it supplies, and is finally distributed to the skin and dartos of the scrotum. In its passage through the perinæum it lies beneath the superficial perineal fascia.

The **transverse perineal** is a small branch which arises either from the internal pudic or from the superficial perineal artery as it crosses the Transversus perinæi muscle. It runs transversely inward along the cutaneous surface of the Transversus perinæi muscle, which it supplies, as well as the structures between the anus and bulb of the urethra, and anastomoses with the one of the opposite side.

The **artery of the bulb** is a large but very short vessel which arises from the internal pudic between the two layers of the triangular ligament, and, passing nearly transversely inward, between the fibres of the Compressor urethræ muscle, it pierces the bulb of the urethra, in which it ramifies. It gives off a small branch which descends to supply Cowper's gland.

Surgical Anatomy.—This artery is of considerable importance in a surgical point of view, as it is in danger of being wounded in the lateral operation of lithotomy—an accident usually attended in the adult with alarming hemorrhage. The vessel is sometimes very small, occasionally wanting, or even double. It sometimes arises from the internal pudic earlier than usual, and crosses the perinæum to reach the back part of the bulb. In such a case the vessel could hardly fail to be wounded in the performance of the lateral operation of lithotomy. If, on the contrary, it should arise from an accessory pudic, it lies more forward than usual and is out of danger in the operation.

The **artery of the corpus cavernosum**, one of the terminal branches of the internal pudic, arises from that vessel while it is situated between the two layers of the triangular ligament; it pierces the superficial layer, and, entering the crus penis obliquely, it runs forward in the centre of the corpus cavernosum, to which its branches are distributed.

The **dorsal artery of the penis** ascends between the crus and pubic symphysis, and, piercing the triangular ligament, passes between the two layers of the suspensory ligament of the penis, and runs forward on the dorsum of the penis to the glans, where it divides into two branches, which supply the glans and prepuce. On the dorsum of the penis it lies immediately beneath the integument, parallel with the dorsal vein and the corresponding artery of the opposite side. It supplies the integument and fibrous sheath of the corpus cavernosum, sending branches through the sheath to anastomose with the preceding vessel.

The **Internal Pudic Artery in the Female** is smaller than in the male. Its origin and course are similar, and there is considerable analogy in the distribution of its branches. The superficial perineal artery supplies the labia pudendi; the artery of the bulb supplies the bulbi vestibuli and the erectile tissue of the vagina; the artery of the corpus cavernosum supplies the cavernous body of the clitoris; and the arteria dorsalis clitoridis supplies the dorsum of that organ, and terminates in the glans and in the membranous fold corresponding to the prepuce of the male.

The **Sciatic Artery** (Fig. 316), the larger of the two terminal branches of the anterior trunk of the internal iliac, is distributed to the muscles at the back of the pelvis. It passes down to the lower part of the great sacro-sciatic foramen behind the internal pudic artery, resting on the sacral plexus of nerves and Pyriformis

:cle, and escapes from the pelvis through this foramen between the Pyriformis or an Coccygeus. It then descends in the interval between the trochanter major and tuberosity of the ischium, accompanied by the sciatic nerves, and covered by the Gluteus maximus, and is continued down the back of the thigh supplying the skin, and anastomosing with branches of the perforating arteries.

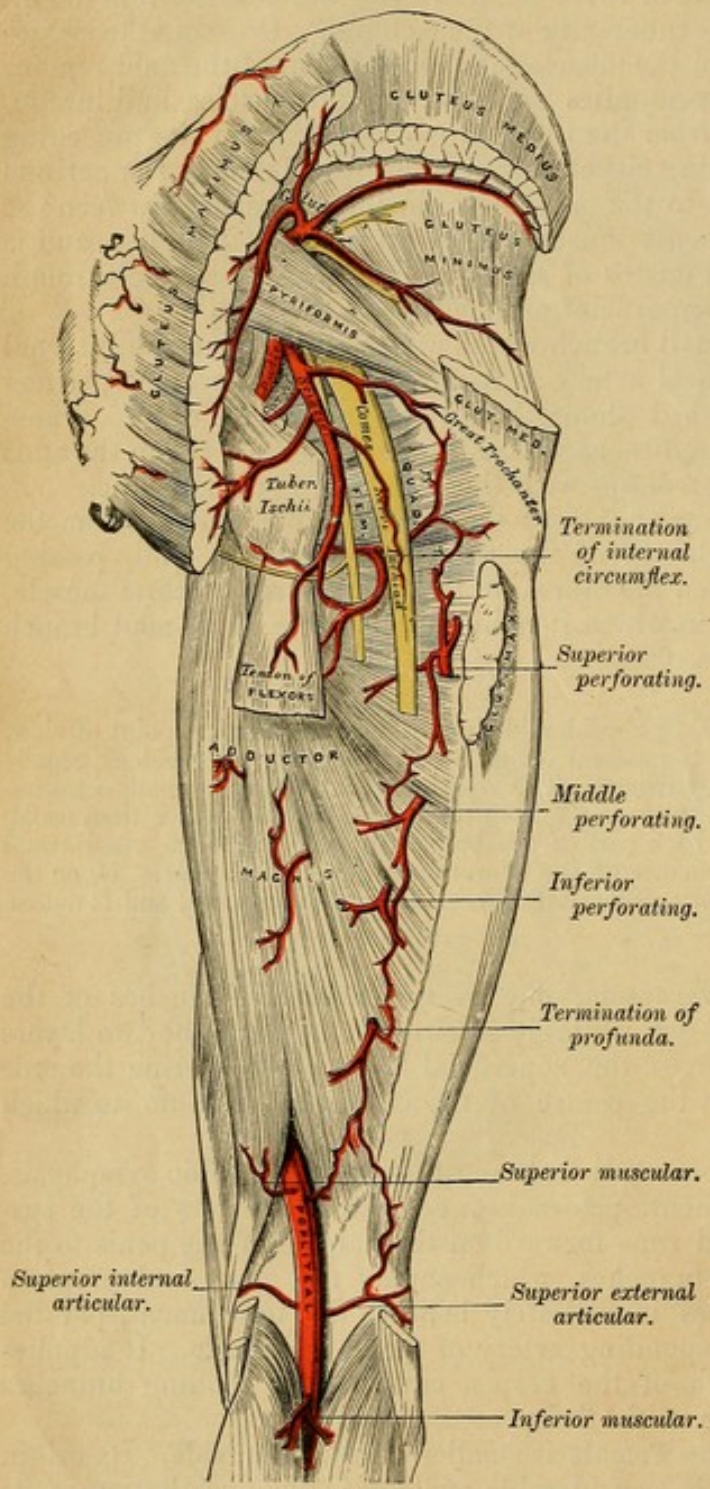

FIG. 316.—The arteries of the gluteal and posterior femoral regions.

Within the pelvis it distributes branches to the Pyriformis, Coccygeus, and Levator ani muscles; some hæmorrhoidal branches, which supply the rectum, and occasionally take the place of the middle hæmorrhoidal artery; and vesical branches to the base and neck of the bladder, vesiculæ seminales, and prostate gland. *External to the pelvis* it gives off the following branches:

Coccygeal.
Inferior Gluteal.
Comes Nervi Ischiadici.
Muscular.
Anastomotic.
Articular.

The **coccygeal branch** runs inward, pierces the great sacrosciatic ligament, and supplies the Gluteus maximus, the integument, and other structures on the back of the coccyx.

The **inferior gluteal branches,** three or four in number, supply the Gluteus maximus muscle, anastomosing with the gluteal artery in the substance of the muscle.

The **comes nervi ischiadici** is a long, slender vessel which accompanies the great sciatic nerve for a short distance; it then penetrates it and runs in its substance to the lower part of the thigh.

The **muscular branches** supply the Gluteus maximus, anastomosing with the gluteal artery in the substance of the muscle: the external rotators, anastomosing with the internal pudic artery; and the muscles attached to the tuberosity of the ischium, anastomosing with the external branch of the obturator and the internal circumflex arteries.

The **anastomotic artery** is directed downward across the external rotators, and assists in forming the so-called *crucial anastomosis* by anastomosing with the superior perforating and the internal and external circumflex.

The **articular branch,** generally derived from the anastomotic, is distributed to the capsule of the hip-joint.

The **Ilio-lumbar Artery,** given off from the posterior trunk of the internal iliac, turns upward and outward between the obturator nerve and lumbo-sacral cord, to the inner margin of the Psoas muscle, behind which it divides into a lumbar and an iliac branch.

The **lumbar branch** supplies the Psoas and Quadratus lumborum muscles, anastomosing with the last lumbar artery, and sends a small spinal branch through the intervertebral foramen, between the last lumbar vertebra and the sacrum, into the spinal canal, to supply the cauda equina.

The **iliac branch** descends to supply the Iliacus muscle; some offsets, running between the muscle and the bone, anastomose with the iliac branch of the obturator; one of these enters an oblique canal to supply the diploë, whilst others run along the crest of the ilium, distributing branches to the Gluteal and Abdominal muscles, and anastomose in their course with the gluteal, circumflex iliac, and external circumflex arteries.

The **Lateral Sacral Arteries** (Fig. 312) are usually two in number on each side, superior and inferior.

The **superior,** which is of large size, passes inward, and, after anastomosing with branches from the middle sacral, enters the first or second anterior sacral foramen, is distributed to the contents of the sacral canal, and, escaping by the corresponding posterior sacral foramen, supplies the skin and muscles on the dorsum of the sacrum, anastomosing with the gluteal.

The **inferior** passes obliquely across the front of the Pyriformis muscle and sacral nerves to the inner side of the anterior sacral foramina, descends on the front of the sacrum, and anastomoses over the coccyx with the sacra media and opposite lateral sacral arteries. In its course it gives off branches which enter the anterior sacral foramina; these, after supplying the contents of the sacral canal, escape by the posterior sacral foramina, and are distributed to the muscles and skin on the dorsal surface of the sacrum, anastomosing with the gluteal.

The **Gluteal Artery** is the largest branch of the internal iliac, and appears to be the continuation of the posterior division of that vessel. It is a short, thick trunk, which passes out of the pelvis above the upper border of the Pyriformis muscle, and immediately divides into a *superficial* and *deep branch.* Within the pelvis it gives off a few muscular branches to the Iliacus, Pyriformis, and Obturator internus, and, just previous to quitting that cavity, a nutrient artery, which enters the ilium.

The **superficial branch** passes beneath the Gluteus maximus and divides into numerous branches, some of which supply that muscle, whilst others perforate its tendinous origin, and supply the integument covering the posterior surface of the sacrum, anastomosing with the posterior branches of the sacral arteries.

The **deep branch** runs between the Gluteus medius and minimus, and subdivides into two. Of these, the superior division, continuing the original course of the vessel, passes along the upper border of the Gluteus minimus to the anterior superior spine of the ilium, anastomosing with the circumflex iliac and ascending branches of the external circumflex artery. The inferior division crosses the Gluteus minimus obliquely to the trochanter major, distributing branches to the Glutei muscles, and inosculates with the external circumflex artery. Some branches pierce the Gluteus minimus to supply the hip-joint.

Surface Marking.—The position of the three main branches of the internal iliac, the sciatic, internal pudic, and gluteal, which may occasionally be the object of surgical interference, is indicated on the surface in the following way: A line is to be drawn from the posterior superior iliac spine to the posterior superior angle of the great trochanter, with the limb slightly flexed and rotated inward: the point of emergence of the *gluteal artery* from the upper part of the sciatic notch will correspond with the junction of the upper with the middle third of this line. A second line is to be drawn from the same point to the outer part of the tuberosity of the ischium; the junction of the lower with the middle third marks the point of emergence of the *sciatic* and *pudic arteries* from the great sciatic notch.

Surgical Anatomy.—Any of these three vessels may require ligating for a wound or for aneurism, which is generally traumatic. The *gluteal* artery is ligated by turning the patient two-thirds over on his face and making an incision from the posterior superior spine of the ilium to the upper and posterior angle of the great trochanter. This must expose the Gluteus maximus muscle, and its fibres are to be separated through the whole thickness of the muscle and pulled apart with retractors. The contiguous margins of the Gluteus medius and Pyriformis are now to be separated from each other, and the artery will be exposed emerging from the sciatic notch. In ligation of the *sciatic* artery, the incision should be made parallel with that for ligation of the gluteal, but one inch and a half lower down. After the fibres of the Gluteus maximus have been separated, the vessel is to be sought for at the lower border of the Pyriformis; the great sciatic nerve, which lies just above it, forming the chief guide to the artery.

The External Iliac Artery (Fig. 312).

The **external iliac artery** is larger in the adult than the internal iliac, and passes obliquely downward and outward along the inner border of the Psoas muscle, from the bifurcation of the common iliac to Poupart's ligament, where it enters the thigh and becomes the femoral artery.

Relations.—*In front*, with the peritoneum, subperitoneal areolar tissue, the termination of the ileum on the right side, and the sigmoid flexure on the left, and a thin layer of fascia derived from the iliac fascia, which surrounds the artery and vein. At its origin it is occasionally crossed by the ureter. The spermatic vessels descend for some distance upon it near its termination, and it is crossed in this situation by the genital branch of the genito-crural nerve and the deep circumflex iliac vein; the vas deferens curves down along its inner side. *Behind*, it is in relation with the external iliac vein, which, at Poupart's ligament, lies at its inner side; on the left side the vein is altogether internal to the artery. *Externally*, it rests against the Psoas muscle, from which it is separated by the iliac fascia. The artery rests upon this muscle, near Poupart's ligament. Numerous lymphatic vessels and glands are found lying on the front and inner side of the vessel.

PLAN OF THE RELATIONS OF THE EXTERNAL ILIAC ARTERY.

In front.

Peritoneum, intestines, and fascia.

Near Poupart's Ligament:
- Lymphatic vessels and glands.
- Spermatic vessels.
- Genito-crural nerve (genital branch).
- Deep circumflex iliac vein.

Outer side.
Psoas magnus.
Iliac fascia.

External Iliac.

Inner side.
External iliac vein and vas deferens near Poupart's ligament.

Behind.
External iliac vein.
Psoas magnus.

Surface Marking.—The surface line indicating the course of the external iliac artery has been already given (see page 560).

Surgical Anatomy.—The application of a ligature to the external iliac may be required in cases of aneurism of the femoral artery or for a wound of the artery. This vessel may be secured in any part of its course, excepting near its upper end, which is to be avoided on account of the proximity of the great stream of blood in the internal iliac, and near its lower end, which should also be avoided, on account of the proximity of the deep epigastric and circumflex iliac vessels. The patient having been placed in the supine position, an incision should be made, commencing below at a point about three-quarters of an inch above Poupart's ligament, and a little external to its middle, and running upward and outward, parallel to Poupart's ligament, to a point one inch internal and one inch above the anterior superior spine of the ilium. When the artery is deeply seated, more room will be required, and may be obtained by curving the incision from the point last named inward toward the umbilicus for a short distance. Another mode of ligating the vessel is the plan advocated by Sir Astley Cooper, by making an incision close to Poupart's ligament from about half an inch outside of the external abdominal ring to one inch internal to the anterior superior spine of the ilium. This incision, being

made in the course of the fibres of the aponeurosis of the external oblique, is less likely to be followed by a ventral hernia, but there is danger of wounding the epigastric artery, and only the lower end of the vessel can be ligated. Abernethy, who first tied this artery, made his incision in the course of the vessel. The abdominal muscles and transversalis fascia having been cautiously divided, the peritoneum should be separated from the iliac fossa and raised toward the pelvis; and on introducing the finger to the bottom of the wound, the artery may be felt pulsating along the inner border of the Psoas muscle. The external iliac vein is generally found on the inner side of the artery, and must be cautiously separated from it by the finger-nail or handle of the knife, and the aneurism needle should be introduced on the inner side, between the artery and the vein.

Ligation of the external iliac artery has recently been performed by a transperitoneal method. An incision four inches in length is made in the semilunar line, commencing about an inch below the umbilicus and carried through the abdominal wall into the peritoneal cavity. The intestines are then pushed upward and held out of the way by a broad abdominal retractor, and an incision made through the peritoneum at the margin of the pelvis in the course of the artery, and the vessel secured in any part of its course which may seem desirable to the operator. The advantages of this operation appear to be that if it is found necessary, the common iliac artery can be ligated instead of the external iliac without extension or modification of the incision; and secondly, that the vessel can be ligated without in any way interfering with the coverings of the sac. Possibly a disadvantage may exist in the greater risk of hernia after this method.

Collateral Circulation.—The principal anastomoses in carrying on the collateral circulation, after the application of a ligature to the external iliac, are—the ilio-lumbar with the circumflex iliac; the gluteal with the external circumflex; the obturator with the internal circumflex; the sciatic with the superior perforating and circumflex branches of the profunda artery; and the internal pudic with the external pudic. When the obturator arises from the epigastric, it is supplied with blood by branches, either from the internal iliac, the lateral sacral, or the internal pudic. The epigastric receives its supply from the internal mammary and inferior intercostal arteries, and from the internal iliac by the anastomoses of its branches with the obturator.

In the dissection of a limb eighteen years after the successful ligature of the external iliac artery by Sir A. Cooper, which is to be found in *Guy's Hospital Reports*, vol. i. p. 50, the anastomosing branches are described in three sets: *An anterior set.*—1, a very large branch from the ilio-lumbar artery to the circumflex iliac; 2, another branch from the ilio-lumbar, joined by one from the obturator, and breaking up into numerous tortuous branches to anastomose with the external circumflex; 3, two other branches from the obturator, which passed over the brim of the pelvis, communicated with the epigastric, and then broke up into a plexus to anastomose with the internal circumflex. *An internal set.*—Branches given off from the obturator, after quitting the pelvis, which ramified among the adductor muscles on the inner side of the hip-joint, and joined most freely with branches of the internal circumflex. *A posterior set.*—1, three large branches from the gluteal to the external circumflex; 2, several branches from the sciatic around the great sciatic notch to the internal and external circumflex, and the perforating branches of the profunda.

Branches.—Besides several small branches to the Psoas muscle and the neighboring lymphatic glands, the external iliac gives off two branches of considerable size—the

Deep Epigastric and Deep Circumflex Iliac.

The **Deep Epigastric Artery** arises from the external iliac a few lines above Poupart's ligament. It at first descends to reach this ligament, and then ascends obliquely along the inner margin of the internal abdominal ring, lying between the transversalis fascia and peritoneum, and, continuing its course upward, it pierces the transversalis fascia, and, passing over the semilunar fold of Douglas, enters the sheath of the Rectus muscle. It then ascends on the posterior surface of the muscle, and finally divides into numerous branches, which anastomose, above the umbilicus, with the superior epigastric branch of the internal mammary and with the inferior intercostal arteries (Fig. 301). The deep epigastric artery bears a very important relation to the internal abdominal ring as it passes obliquely upward and inward from its origin from the external iliac. In this part of its course it lies along the lower and inner margin of the ring and beneath the commencement of the spermatic cord. As it passes to the inner side of the internal abdominal ring it is crossed by the vas deferens in the male and the round ligament in the female.

Branches.—The branches of this vessel are the following: The *cremasteric*, which accompanies the spermatic cord, and supplies the Cremaster muscle and

other coverings of the cord, anastomosing with the spermatic artery; a *pubic branch*, which runs along Poupart's ligament, and then descends behind the os pubis to the inner side of the femoral ring, and anastomoses with offsets from the obturator artery; *muscular branches*, some of which are distributed to the abdominal muscles and peritoneum, anastomosing with the lumbar and circumflex iliac arteries; others perforate the tendon of the External oblique, and supply the integument, anastomosing with branches of the superficial epigastric.

Peculiarities.—The origin of the epigastric may take place from any part of the external iliac between Poupart's ligament and two inches and a half above it, or it may arise below this ligament, from the common femoral or from the deep femoral.

Union with Branches.—It frequently arises from the external iliac by a common trunk with the obturator. Sometimes the epigastric arises from the obturator, the latter vessel being furnished by the internal iliac, or the epigastric may be formed of two branches, one derived from the external iliac, the other from the internal iliac.

Surgical Anatomy.—The deep epigastric artery follows a line drawn from the middle of Poupart's ligament toward the umbilicus; but shortly after this line crosses the linea semilunaris the direction changes, and the course of the vessel is directly upward in the line of junction of the inner third with the outer two-thirds of the Rectus muscle. It has important surgical relations, in addition to the fact that it is one of the principal means, through its anastomosis with the internal mammary, in establishing the collateral circulation after ligature of either the common or external iliac arteries. It lies close to the internal abdominal ring, and is therefore *internal* to an oblique inguinal hernia, but *external* to a direct inguinal hernia, as it emerges from the abdomen. It forms the outer boundary of Hesselbach's triangle. It is in close relationship with the spermatic cord, which lies in front of it in the inguinal canal, separated only by the transversalis fascia. The vas deferens hooks round its outer side.

The **Deep Circumflex Iliac Artery** arises from the outer side of the external iliac nearly opposite the epigastric artery. It ascends obliquely outward behind Poupart's ligament, contained in a fibrous sheath formed by the junction of the transversalis and iliac fasciæ, to the anterior superior spinous process of the ilium. It then runs along the inner surface of the crest of the ilium to about its middle, where it pierces the Transversalis, and runs backward between that muscle and the Internal oblique, to anastomose with the ilio-lumbar and gluteal arteries. Opposite the anterior superior spine of the ilium it gives off a large branch, which ascends between the Internal oblique and Transversalis muscles, supplying them, and anastomosing with the lumbar and epigastric arteries.

ARTERIES OF THE LOWER EXTREMITY.

The artery which supplies the greater part of the lower extremity is the direct continuation of the external iliac. It continues as a single trunk from Poupart's ligament to the lower border of the Popliteus muscle, and here divides into two branches, the anterior and posterior tibial, an arrangement exactly similar to what occurs in the upper limb. For convenience of description, the upper part of the main trunk is named femoral, the lower part, popliteal.

The Femoral Artery (Fig. 317).

The **femoral artery** commences immediately behind Poupart's ligament, midway between the anterior superior spine of the ilium and the symphysis pubis, and, passing down the fore part and inner side of the thigh, terminates at the opening in the Adductor magnus, at the junction of the middle with the lower third of the thigh, where it becomes the popliteal artery. The vessel, at the upper part of the thigh, lies in front of the hip-joint, just on a line with the innermost part of the head of the femur; in the lower part of its course it is in close relation with the inner side of the shaft of the bone, and between these two parts the vessel is some distance from the bone. In the upper third of the thigh it is contained in a triangular space called *Scarpa's triangle*. In the middle third of the thigh it is contained in an aponeurotic canal called *Hunter's canal*.

Scarpa's Triangle.—Scarpa's triangle corresponds to the depression seen immediately below the fold of the groin. It is a triangular space, the apex of which is directed downward, and the sides formed externally by the Sartorius, internally by the inner margin of the Adductor longus, and above by Poupart's

ligament. The floor of the space is formed from without inward by the Iliacus, Psoas, Pectineus (in some cases a small part of the Adductor brevis), and the Adductor longus muscles; and it is divided into two nearly equal parts by the femoral vessels, which extend from the middle of its base to its apex, the artery giving off in this situation its cutaneous and profunda branches, the vein receiving the deep femoral and internal saphenous. On the outer side of the femoral artery is the anterior crural nerve dividing into its branches. Besides the vessels and nerves, this space contains some fat and lymphatics.

Hunter's Canal.—This is the aponeurotic space in the middle third of the thigh, extending from the apex of Scarpa's triangle to the femoral opening in the Adductor magnus muscle. It is bounded, externally, by the Vastus internus; internally by the Adductors longus and magnus muscles; and covered in by a strong aponeurosis which extends transversely from the Vastus internus across the femoral vessels to the Adductor longus and magnus; lying on which aponeurosis is the Sartorius muscle. It contains the femoral artery and vein enclosed in their own sheath of areolar tissue, the vein being behind and on the outer side of the artery, and the internal or long saphenous nerve lying at first on the outer side and then in front of the vessels.

For convenience of description, and also in reference to its surgical anatomy, the femoral artery is divided into a short trunk, about an inch and a half or two inches long, which is known as the *common femoral artery*, while the remainder of the vessel is termed the *superficial femoral artery*, to distinguish it from the deep femoral (profunda femoris), a large branch given off from the common femoral at its termination, and which, by its derivation from the parent trunk, marks the commencement of the superficial femoral artery.

The **common femoral artery** is very superficial, being covered by the skin and superficial fascia, the superficial inguinal lymphatic glands, the iliac portion and the expansion downward of the Transversalis fascia forming the anterior wall of the sheath of the vessels. It has in front of it the genito-crural nerve, the superficial circu-

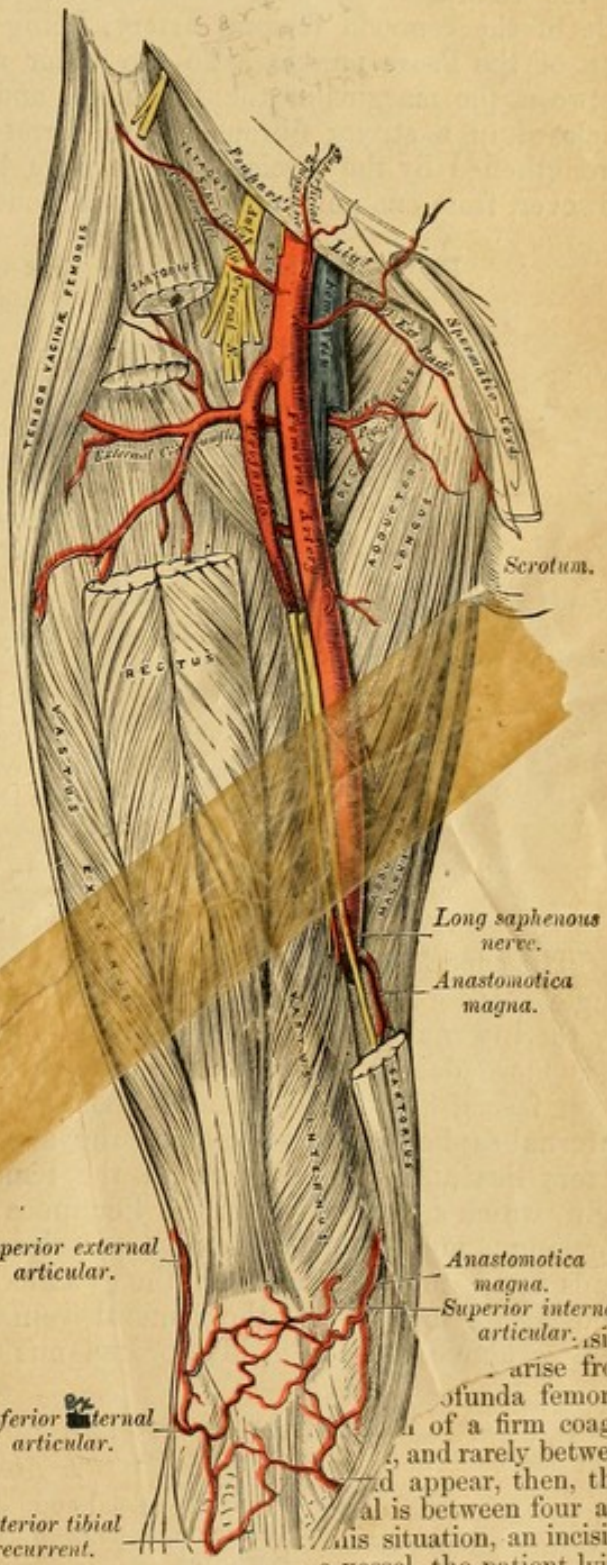

FIG. 317.—The [illegible], and rotated outward. A [illegible] to join the internal saphe-[illegible] cautiously divided and the [illegible] expose fully the sheath of [illegible] formed for elephantiasis of [illegible], vol. ii., p. 37).

[illegible] arise from [illegible] ofunda femoris, [illegible] of a firm coagu-[illegible], and rarely between [illegible] appear, then, that [illegible] is between four and [illegible] this situation, an incision [illegible] vessel, the patient lying

[illegible] Ligation of [illegible] leg and acute [illegible]

occasionally the superficial epigastric vein. It rests on the inner margin of the Psoas muscle, which separates it from the capsular ligament of the hip-joint, and a little lower on the Pectineus muscle; and crossing behind it is the branch to the Pectineus from the anterior crural nerve. Separating the artery from the Pectineus muscles in the pubic portion of the fascia lata and the prolongation from the fascia covering the Iliacus muscle, which forms the posterior layer of the sheath of the vessels. The anterior crural nerve lies about half an inch to the outer side of the common femoral artery, being separated from the artery by a small part of the Psoas muscle. To the inner side of the artery is the femoral vein, between the margins of the Pectineus and Psoas muscles. The two vessels are enclosed in a strong fibrous sheath formed by the proper sheath of the vessels, strengthened by the fascia lata (see page 419); the artery and vein are separated, however, from one another by a thin fibrous partition.

PLAN OF RELATIONS OF THE COMMON FEMORAL ARTERY.

In front.

Skin and superficial fascia.
Superficial inguinal glands.
Iliac portion of fascia lata.
Prolongation of transversalis fascia.
Crural branch of genito-crural nerve.
Superficial circumflex iliac vein.
Superficial epigastric vein.

Inner side.
Femoral vein.

Common Femoral Artery.

Outer side.
Small part of Psoas muscle, separating the artery from the anterior crural nerve.

Behind.

Prolongation of fascia covering Iliacus muscle.
Iliac portion of fascia lata.
Nerve to Pectineus.
Psoas muscle.
Pectineus muscle.
Capsule of hip-joint.

The **superficial femoral artery** is entirely superficial where it lies in Scarpa's triangle. Here it is covered by the skin, superficial and deep fascia, and crossed by the internal cutaneous branch of the anterior crural nerve. In Hunter's canal it is more deeply seated, being covered by the integument, the superficial and deep fascia, the Sartorius and aponeurotic covering of Hunter's canal. The internal saphenous nerve crosses the artery from without inward. Behind, the artery lies at its upper part on the femoral vein and the profunda artery and vein, which separate it from the Pectineus muscle, and lower down on the Adductor longus and Adductor magnus muscles. To the outer side is the long saphenous nerve and the nerve to the Vastus internus, the Vastus internus muscle, and, at its lower part, the femoral vein. To the inner side is the Adductor longus above and the Adductor magnus and Sartorius below.

Adductor m
where it become
lies in front of th
the femur; in the
of the shaft of the b
from the bone. In the
called *Scarpa's triangle*
aponeurotic canal called

PF RELATIONS OF THE SUPERFICIAL FEMORAL ARTERY.

In front.

Skin, superficial and deep fasciæ.
Internal cutaneous nerve.
Sartorius.
Aponeurotic covering of Hunter's canal.
Internal saphenous nerve.

Scarpa's Triangle.—
immediately below the f
which is directed dow
internally by the inne

us.
gnus.

Superficial Femoral Artery.

Outer si
Long saphenou
Nerve to vastu
Vastus interm
Femoral vein

ression
the apex
the Sartori
by Poupart

Behind.

Femoral vein.
Profunda artery and vein.
Pectineus muscle.
Adductor longus.
Adductor magnus.

The *femoral vein*, at Poupart's ligament, lies close to the inner side of the artery, separated from it by a thin fibrous partition; but lower down it is behind it, and then to its outer side.

The *internal saphenous nerve* is situated on the outer side of the artery, in the middle third of the thigh, beneath the aponeurotic covering of Hunter's canal, but not usually within the sheath of the vessels. The internal cutaneous nerve passes obliquely across the upper part of the sheath of the femoral artery.

Peculiarities.—Double Femoral reunited.—Several cases are recorded in which the femoral artery divided into two trunks below the origin of the profunda, and became reunited near the opening in the Adductor magnus so as to form a single popliteal artery. One of them occurred in a patient operated upon for popliteal aneurism.

Change of Position.—A few cases have been recorded in which the femoral artery was situated at the back of the thigh, the vessel being continuous above with the internal iliac, escaping from the pelvis through the great sacro-sciatic foramen, and accompanying the great sciatic nerve to the popliteal space, where its division occurred in the usual manner. The external iliac in these cases was small, and terminated in the profunda.

Position of the Vein.—The femoral vein is occasionally placed along the inner side of the artery, throughout the entire extent of Scarpa's triangle, or it may be slit so that a large vein is placed on each side of the artery for a greater or less extent.

Origin of the Profunda.—This vessel occasionally arises from the inner side, and, more rarely, from the back of the common trunk; but the more important peculiarity, in a surgical point of view, is that which relates to the height at which the vessel arises from the femoral. In three-fourths of a large number of cases it arose between one or two inches below Poupart's ligament; in a few cases the distance was less than an inch; more rarely, opposite the ligament; and in one case, above Poupart's ligament, from the external iliac. Occasionally, the distance between the origin of the vessel and Poupart's ligament exceeds two inches, and in one case it was found to be as much as four inches.

Surface Marking.—The upper two-thirds of a line drawn from a point midway between the anterior superior spine of the ilium and the symphysis pubis to the prominent tuberosity on the inner condyle of the femur, with the thigh abducted and rotated outward, will indicate the course of the femoral artery.

Surgical Anatomy.—*Compression* of the femoral artery, which is constantly requisite in amputations and other operations on the lower limb, and also for the cure of popliteal aneurisms, is most effectually made immediately below Poupart's ligament. In this situation the artery is very superficial, and is merely separated from the ascending ramus of the os pubis by the Psoas muscle; so that the surgeon, by means of his thumb or a compressor, may effectually control the circulation through it. This vessel may also be compressed in the middle third of the thigh by placing a compress over the artery, beneath the tourniquet, and directing the pressure from within outward, so as to compress the vessel against the inner side of the shaft of the femur.

The **application of a ligature** to the femoral artery may be required in the cases of wound or aneurism of the arteries of the leg, of the popliteal or femoral;[1] and the vessel may be exposed and tied in any part of its course. The great depth of this vessel at its lower part, its close connection with important structures, and the density of its sheath render the operation in this situation one of much greater difficulty than the application of a ligature at its upper part, where it is more superficial.

Ligature of the common femoral artery is usually considered unsafe, on account of the connection of large branches with it—viz. the deep epigastric and the deep circumflex iliac arising just above Poupart's ligament; on account of the number of small branches which arise from it in its short course; and on account of the uncertainty of the origin of the profunda femoris, which, if it arise high up, would be too close to the ligature for the formation of a firm coagulum. The profunda sometimes arises higher than the point above mentioned, and rarely between two or three inches (in one case four) below Poupart's ligament. It would appear, then, that the most favorable situation for the application of a ligature to the femoral is between four and five inches from its point of origin. In order to expose the artery in this situation, an incision between three and four inches long should be made in the course of the vessel, the patient lying in the recumbent position, with the limb slightly flexed and abducted, and rotated outward. A large vein is frequently met with, passing in the course of the artery to join the internal saphenous vein; this must be avoided, and, the fascia lata having been cautiously divided and the Sartorius exposed, that muscle must be drawn outward in order to expose fully the sheath of

[1] Ligation of the femoral artery has been also recommended and performed for elephantiasis of the leg and acute inflammation of the knee-joint (Maunder, *Clin. Soc. Trans.*, vol. ii., p. 37).

the vessels. The finger being introduced into the wound and the pulsation of the artery felt, the sheath should be opened on the outer side of the vessel to a sufficient extent to allow of the introduction of the ligature, but no farther; otherwise the nutrition of the coats of the vessel may be interfered with, or muscular branches which arise from the vessel at irregular intervals may be divided. In this part of the operation the long saphenous nerve and the nerve to the Vastus internus, which is in close relation with the sheath, should be avoided. The aneurism needle must be carefully introduced and kept close to the artery, to avoid the femoral vein, which lies behind the vessel in this part of its course.

To expose the artery in Hunter's canal, an incision should be made through the integument, between three and four inches in length, a finger's breadth internal to the line of the artery, in the middle of the thigh—*i. e.*, midway between the groin and the knee. The fascia lata having been divided, and the outer border of the Sartorius muscle exposed, it should be drawn inward, when the strong fascia which is stretched across from the Adductors to the Vastus internus will be exposed, and must be freely divided; the sheath of the vessels is now seen, and must be opened, and the artery secured by passing the aneurism needle between the vein and artery in the direction from without inward. The femoral vein in this situation lies on the outer side of the artery, the long saphenous nerve on its anterior and outer side.

It has been seen that the femoral artery occasionally divides into two trunks below the origin of the profunda. If in the operation for tying the femoral two vessels are met with, the surgeon should alternately compress each, in order to ascertain which vessel is connected with the aneurismal tumor or with the bleeding from the wound, and that one only should be tied which controls the pulsation or hæmorrhage. If, however, it is necessary to compress both vessels before the circulation in the tumor is controlled, both should be tied, as it would be probable that they became reunited, as in the instances referred to above.

In wounds of the femoral artery the question of the mode of treatment is of considerable importance. If the wound in the superficial structures is a large one, the injured vessel must be exposed and tied; but if the wound is a punctured one and the bleeding has ceased, the question will arise whether to cut down upon the artery or to trust to pressure. Mr. Cripps[1] advises that if the wound is in the "upper part of the thigh—that is to say, in a position where the femoral artery is comparatively superficial—the surgeon may enlarge the opening with a good prospect of finding the wounded vessel without an extensive or prolonged operation. If the wound be in the lower half of the thigh, owing to the greater depth of the artery and the possibility of its being the popliteal that is wounded, the search is rendered a far more severe and hazardous operation, and it should not be undertaken until a thorough trial of pressure has proved ineffectual."

Great care and attention are necessary for the successful application of pressure. The limb should be carefully bandaged from the foot upward to the wound, which is not covered, and then onward to the groin. The wound is then dusted with iodoform or boracic powder and a conical pad applied over the wound. Rollers the thickness of the index finger are then placed along the course of the vessel above and below the wound, and the whole carefully bandaged to a back splint with a foot-piece.

Collateral Circulation.—When the common femoral is tied the main channels for carrying on the circulation are the anastomoses of the gluteal and circumflex iliac arteries above with the external circumflex below; of the obturator and sciatic above with the internal circumflex below; and of the comes nervi ischiadici with the arteries in the ham.

The principal agents in carrying on the collateral circulation after ligature of the superficial femoral artery are, according to Sir A. Cooper, as follows:

"The arteria profunda formed the new channel for the blood." "The first artery sent off passed down close to the back of the thigh-bone, and entered the two superior articular branches of the popliteal artery."

"The second new large vessel, arising from the profunda at the same part with the former, passed down by the inner side of the Biceps muscle to a branch of the popliteal which was distributed to the Gastrocnemius muscle; whilst a third artery, dividing into several branches, passed down with the sciatic nerve behind the knee-joint, and some of its branches united themselves with the inferior articular arteries of the popliteal, with some recurrent branches of those arteries, with arteries passing to the Gastrocnemii, and, lastly, with the origin of the anterior and posterior tibial arteries."

"It appears, then, that it is those branches of the profunda which accompany the sciatic nerve that are the principal supporters of the new circulation."[2]

In Porta's work[3] (tab. xii., xiii.) is a good representation of the collateral circulation after the ligature of the femoral artery. The patient had survived the operation three years. The lower part of the artery is at least as large as the upper; about two inches of the vessel appear to have been obliterated. The external and internal circumflex arteries are seen anastomosing by a great number of branches with the lower branches of the femoral (muscular and anastomotica magna) and with the articular branches of the popliteal. The branches from the external circumflex are extremely large and numerous. One very distinct anastomosis can be traced between this artery on the outside and the anastomotica magna on the inside through the intervention of the superior external articular artery, with which they both anastomose; and

[1] Heath's *Dictionary of Practical Surgery*, vol. i. p. 525.
[2] *Med.-Chir. Trans.*, vol. ii. 1811.
[3] *Alterazioni patologiche delle Arterie.*

blood reaches even the anterior tibial recurrent from the external circumflex by means of anastomosis with the same external articular artery. The perforating branches of the profunda are also seen bringing blood round the obliterated portion of the artery into long branches (muscular) which have been given off just below that portion. The termination of the profunda itself anastomoses most freely with the superior external articular. A long branch of anastomosis is also traced down from the internal iliac by means of the comes nervi ischiadici of the sciatic, which anastomoses on the popliteal nerves with branches from the popliteal and posterior tibial arteries. In this case the anastomosis had been too free, since the pulsation and growth of the aneurism recurred, and the patient died after ligature of the external iliac.

There is an interesting preparation in the Museum of the Royal College of Surgeons of a limb on which John Hunter had tied the femoral artery fifty years before the patient's death. The whole of the superficial femoral and popliteal artery seems to have been obliterated. The

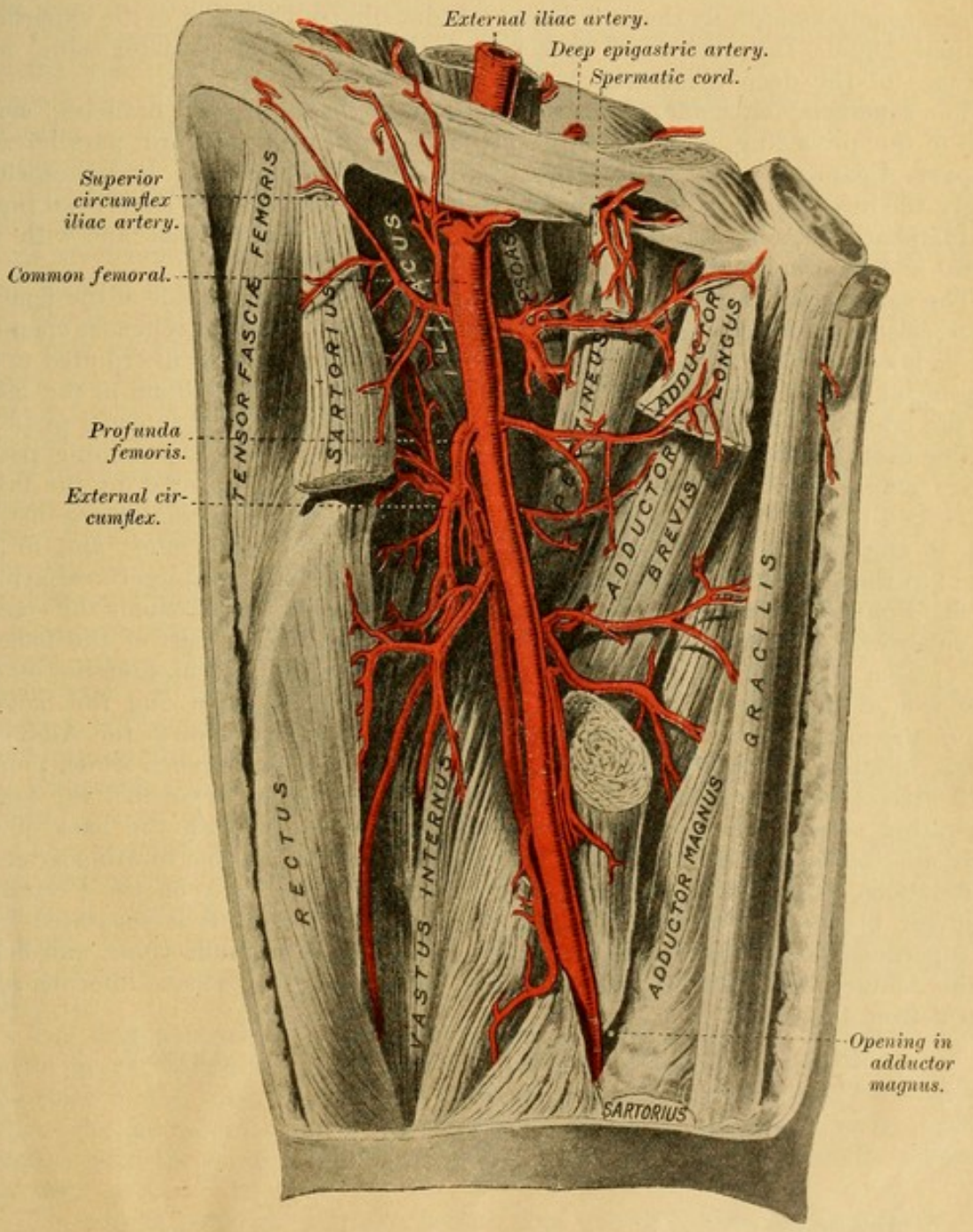

FIG. 318.—Femoral artery and its branches. (From a preparation in the Museum of the Royal College of Surgeons of England.)

anastomosis by means of the comes nervi ischiadici, which is shown in Porta's plate, is distinctly seen: the external circumflex and the termination of the profunda artery seem to have been the chief channels of anastomoses; but the injection has not been a very successful one.

Branches.—The branches of the femoral artery are—the

Superficial Epigastric.		External Circumflex.
Superficial Circumflex Iliac.	Profunda	Internal Circumflex.
Superficial External Pudic.		Three Perforating.
Deep External Pudic.	Muscular.	
	Anastomotica Magna.	

The **superficial epigastric** arises from the femoral about half an inch below Poupart's ligament, and, passing through the saphenous opening in the fascia lata, ascends on the abdomen, in the superficial fascia covering the External oblique muscle, nearly as high as the umbilicus. It distributes branches to the superficial inguinal glands, the superficial fascia, and the integument, anastomosing with branches of the deep epigastric.

The **superficial circumflex iliac**, the smallest of the cutaneous branches, arises close to the preceding, and, piercing the fascia lata, runs outward, parallel with Poupart's ligament, as far as the crest of the ilium, dividing into branches which supply the integument of the groin, the superficial fascia, and the superficial inguinal lymphatic glands, anastomosing with the deep circumflex iliac and with the gluteal and external circumflex arteries.

The **superficial external pudic** (superior) arises from the inner side of the femoral artery, close to the preceding vessels, and, after passing through the saphenous opening, courses inward, across the spermatic cord or round ligament, to be distributed to the integument on the lower part of the abdomen, the penis and scrotum in the male, and the labium in the female, anastomosing with branches of the internal pudic.

The **deep external pudic** (inferior), more deeply seated than the preceding, passes inward across the Pectineus and Adductor longus muscles, covered by the fascia lata, which it pierces at the inner border of the thigh, its branches being distributed, in the male, to the integument of the scrotum and perinæum; and in the female to the labium, anastomosing with branches of the superficial perineal artery.

The **Profunda Femoris** (*deep femoral artery*) (Fig. 318) nearly equals the size of the superficial femoral. It arises from the outer and back part of the femoral artery, from one to two inches below Poupart's ligament. It at first lies on the outer side of the superficial femoral, and then passes behind it and the femoral vein to the inner side of the femur, and, passing downward beneath the Adductor longus, terminates at the lower third of the thigh in a small branch which pierces the Adductor magnus (and from this circumstance is sometimes called the fourth perforating artery), and is distributed to the flexor muscles on the back of the thigh, anastomosing with branches of the popliteal and inferior perforating arteries.

Relations.—*Behind*, it lies first upon the Iliacus, and then on the Pectineus, Adductor brevis, and Adductor magnus muscles. *In front*, it is separated from the superficial femoral artery, above by the femoral and profunda veins, and below by the Adductor longus. On its *outer side* the origin of the Vastus internus separates it from the femur.

PLAN OF THE RELATIONS OF THE PROFUNDA ARTERY.

In front.
Superficial femoral artery.
Femoral and Profunda veins.
Adductor longus.

Outer side.
Vastus internus.



Behind.
Iliacus.
Pectineus.
Adductor brevis.
Adductor magnus.

The profunda gives off the following named branches:

External circumflex. Internal circumflex. Four perforating.

The **External Circumflex Artery** supplies the muscles on the front of the thigh. It arises from the outer side of the profunda, passes horizontally outward, between the divisions of the anterior crural nerve and behind the Sartorius and Rectus muscles, and divides into three sets of branches—ascending, transverse, and descending.

The **ascending branches** pass upward, beneath the Tensor fasciæ femoris muscle, to the outer side of the hip, anastomosing with the terminal branches of the gluteal and deep circumflex iliac arteries.

The **descending branches,** three or four in number, pass downward, behind the Rectus, upon the Vasti muscles, to which they are distributed, one or two passing beneath the Vastus externus as far as the knee, anastomosing with the superior articular branches of the popliteal artery. These are accompanied by the branch of the anterior crural nerve to the Vastus externus.

The **transverse branch,** the smallest, passes outward over the Crureus, pierces the Vastus externus, and winds round the femur to its back part, just below the great trochanter, anastomosing at the back of the thigh with the internal circumflex, sciatic, and superior perforating arteries.

The **Internal Circumflex Artery,** smaller than the external, arises from the inner and back part of the profunda, and winds round the inner side of the femur, between the Pectineus and Psoas muscles. On reaching the upper border of the Adductor brevis it gives off two branches, one of which passes inward to be distributed to the Adductor muscles, the Gracilis, and Obturator externus, anastomosing with the obturator artery; the other descends, and passes beneath the Adductor brevis, to supply it and the great Adductor; while the continuation of the vessel passes backward and divides into an ascending and a transverse branch (Fig. 257). The *ascending branch* passes obliquely upward upon the tendon of the Obturator externus and under cover of the Quadratus femoris toward the digital fossa, where it anastomoses with twigs from the gluteal and sciatic arteries. The *transverse branch*, larger than the ascending, appears between the Quadratus femoris and upper border of the Adductor magnus, anastomosing with the sciatic, external circumflex, and superior perforating arteries ("the *crucial anastomosis*"). Opposite the hip-joint, the artery gives off an articular vessel, which enters the joint beneath the transverse ligament; and, after supplying the adipose tissue, passes along the round ligament to the head of the bone.

The **perforating arteries** (Fig. 316), usually four in number, are so called from their perforating the tendon of the Adductor magnus muscle to reach the back of the thigh. They pass backward close to the linea aspera of the femur, under cover of small tendinous arches in the Adductor magnus. The first is given off above the Adductor brevis, the second in front of that muscle, and the third immediately below it.

The **first perforating artery** passes backward between the Pectineus and Adductor brevis (sometimes perforates the latter); it then pierces the Adductor magnus close to the linea aspera. It gives off branches which supply the Adductor brevis, the Adductor magnus, the Biceps, and Gluteus maximus muscles, and anastomoses with the sciatic, internal and external circumflex, and middle perforating arteries.

The **second perforating artery,** larger than the first, pierces the tendons of the Adductor brevis and Adductor magnus muscles, and divides into ascending and descending branches, which supply the flexor muscles of the thigh, anastomosing with the first and third perforating. The second artery frequently arises in common with the first. The nutrient artery of the femur is usually given off from this branch.

The **third perforating artery** is given off below the Adductor brevis; it pierces the Adductor magnus, and divides into branches which supply the flexor muscles

of the thigh; anastomosing above with the higher perforating arteries, and below with the terminal branches of the profunda and the muscular branches of the popliteal.

The **fourth perforating artery** is represented by the termination of the profunda femoris artery.

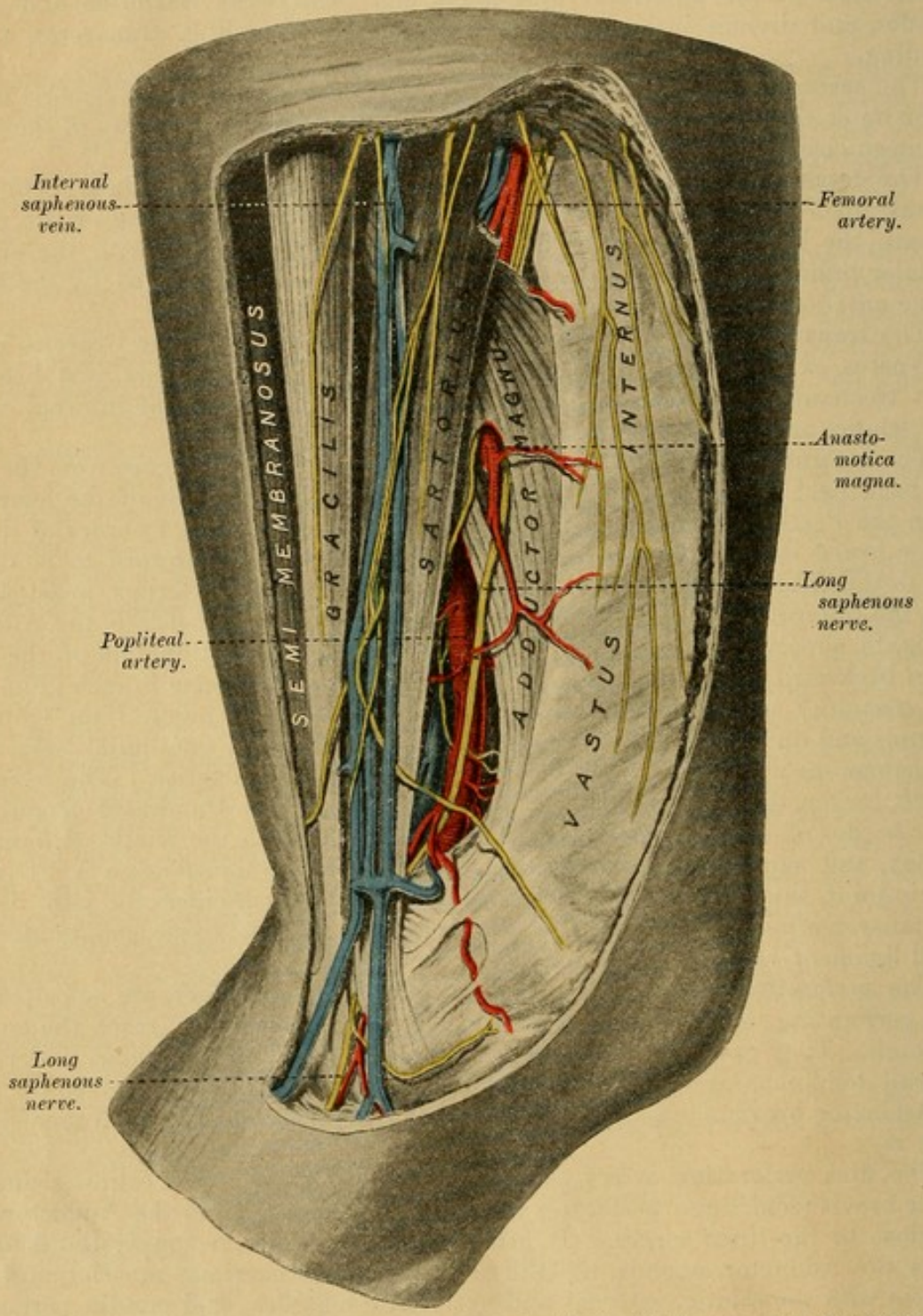

FIG. 319.—Side view of the popliteal artery. (From a preparation in the Museum of the Royal College of Surgeons of England.)

Muscular branches are given off from the superficial femoral throughout its entire course. They vary from two to seven in number, and supply chiefly the Sartorius and Vastus internus.

The **anastomotica magna** (Fig. 319) arises from the femoral artery just before it passes through the tendinous opening in the Adductor magnus muscle, and immediately divides into a superficial and deep branch.

The *superficial branch* pierces the aponeurotic covering of Hunter's canal, and

accompanies the long saphenous nerve to the inner side of the thigh. It passes between the Sartorius and Gracilis muscles, and, piercing the fascia lata, is distributed to the integument of the upper and inner part of the leg, anastomosing with the inferior internal articular.

The **deep branch** descends in the substance of the Vastus internus, lying in front of the tendon of the Adductor magnus, to the inner side of the knee, where it anastomoses with the superior internal articular artery and anterior recurrent branch of the anterior tibial. A branch from this vessel crosses outward above the articular surface of the femur, forming an anastomotic arch with the superior external articular artery, and supplies branches to the knee-joint.

Popliteal Artery.

The **popliteal artery** commences at the termination of the femoral at the opening in the Adductor magnus, and, passing obliquely downward and outward behind the knee-joint to the lower border of the Popliteus muscle, divides into the *anterior* and *posterior tibial arteries.* A portion of the artery lies in the popliteal space; but above and below, to a considerable extent, it is covered by the muscles which form the boundaries of the space, and is therefore beyond the confines of the hollow.

THE POPLITEAL SPACE (Fig. 320).

Dissection.—A vertical incision about eight inches in length should be made along the back part of the knee-joint, connected above and below by a transverse incision from the inner to the outer side of the limb. The flaps of integument included between these incisions should be reflected in the direction shown in Fig. 255, page 427.

Boundaries.—The **popliteal space,** or the **ham,** is a lozenge-shaped space, widest at the back part of the knee-joint, and deepest above the articular end of the femur. It is bounded externally, above the joint, by the Biceps, and, below the joint, by the Plantaris and external head of the Gastrocnemius. Internally, above the joint, by the Semimembranosus, Semitendinosus, Gracilis, and Sartorius; below the joint, by the inner head of the Gastrocnemius.

Above, it is limited by the apposition of the inner and outer hamstring muscles; below, by the junction of the two heads of the Gastrocnemius. The floor is formed by the lower part of the posterior surface of the shaft of the femur, the posterior ligament of the knee-joint, the upper end of the tibia, and the fascia covering the Popliteus muscle, and the space is covered in by the fascia lata.

Contents.—It contains the popliteal vessels and their branches, together with the termination of the external saphenous vein, the internal and external popliteal nerves and some of their branches, the lower extremity of the small sciatic nerve, the articular branch from the obturator nerve, a few small lymphatic glands, and a considerable quantity of loose adipose tissue.

Position of Contained Parts.—The internal popliteal nerve descends in the middle line of the space, lying superficial and crossing the artery from without inward. The external popliteal nerve descends on the outer side of the upper part of the space, lying close to the tendon of the Biceps muscle. More deeply at the bottom of the space are the popliteal vessels, the vein lying superficial to the artery, to which it is closely united by dense areolar tissue; it is a thick-walled vessel, and lies at first to the outer side of the artery, and then crosses it to gain the inner side below; sometimes the vein is double, the artery lying between the two venæ comites, which are usually connected by short transverse branches. More deeply, and, at its upper part, close to the surface of the bone, is the popliteal artery, and passing off from it at right angles are its articular branches. The articular branch from the obturator nerve descends upon the popliteal artery to supply the knee, and occasionally there is found deep in the space an articular filament from the great sciatic nerve. The popliteal lymphatic

glands, four or five in number, are found surrounding the artery; one usually lies superficial to the vessel; another is situated between it and the bone, and the rest are placed on either side of it.

The **Popliteal Artery,** in its course downward from the aperture in the Adductor magnus to the lower border of the Popliteus muscle, rests first on the inner surface of the femur, and is then separated by a little fat from the hollowed popliteal surface of the bone; in the middle of its course it rests on the posterior ligament of the knee-joint, and below on the fascia covering the Popliteus muscle. *Superficially*, it is covered above by the Semimembranosus; in the middle of its course, by a quantity of fat, which separates it from the deep fascia and integument; and below it is overlapped by the Gastrocnemius, Plantaris, and Soleus muscles, the popliteal vein, and the internal popliteal nerve. The popliteal vein, which is intimately attached to the artery, lies superficial and external to it above; it then crosses it and lies to its inner side. The internal popliteal nerve is still more superficial and external above, but below the joint it crosses the artery and lies on its inner side. *Laterally*, the artery is bounded by the muscles which are situated on either side of the popliteal space.

Plan of Relations of Popliteal Artery.

In front.
Femur.
Ligamentum posticum.
Popliteus.

Inner side.
Semimembranosus.
Internal condyle.
Gastrocnemius (inner head).

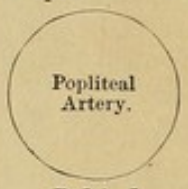

Outer side.
Biceps.
Outer condyle.
Gastrocnemius (outer head).
Plantaris.

Behind.
Semimembranosus.
Fascia.
Popliteal vein.
Internal popliteal nerve.
Gastrocnemius.
Plantaris.
Soleus.

Peculiarities in Point of Division.—Occasionally the popliteal artery divides prematurely into its terminal branches; this unusual division occurs most frequently opposite the knee-joint. The anterior tibial under these circumstances may pass in front of the Popliteus muscle.

Unusual Branches.—The artery sometimes divides into the anterior tibial and peroneal, the posterior tibial being wanting or very small. Occasionally the popliteal is found to divide into three branches, the anterior and posterior tibial and peroneal.

Surface Marking.—The course of the upper part of the popliteal artery is indicated by a line drawn from the outer border of the Semimembranosus muscle at the junction of the middle and lower third of the thigh obliquely downward to the middle of the popliteal space, exactly behind the knee-joint. From this point it passes vertically downward to the level of a line drawn through the lower part of the tubercle of the tibia.

Surgical Anatomy.—The popliteal artery is not infrequently the seat of injury. It may be torn by direct violence, as by the passage of a cart-wheel over the knee or by hyper-extension of the knee; and in the dead body, at all events, the middle and internal coats may be ruptured by extreme flexion. It may also be lacerated by fracture of the lower part of the shaft of the femur or by antero-posterior dislocation of the knee-joint. It has been torn in breaking down adhesions in cases of fibrous ankylosis of the knee, and is in danger of being wounded, and in fact has been wounded, in performing Macewen's operation of osteotomy of the lower end of the femur for genu valgum. In addition, Spencer records a case in which the popliteal artery was wounded from in front by a stab just below the knee, the knife passing through the interosseous space. The popliteal artery is more frequently the seat of aneurism than is any other artery in the body, with the exception of the thoracic aorta. This is due no doubt, in a great measure to the amount of movement to which it is subjected, and to the fact that it is supported by loose and lax tissue only, and not by muscles, as is the case with most arteries.

Ligature of the popliteal artery is required in cases of wound of that vessel, but for aneurism of the posterior tibial it is preferable to tie the superficial femoral. The popliteal may be tied in the upper or lower part of its course; but in the middle of the ham the operation is attended

with considerable difficulty, from the great depth of the artery and from the extreme degree of tension of the lateral boundaries of the space.

In order to expose the vessel in the upper part of its course, the patient should be placed in the supine position, with the knee flexed and the thigh rotated outward, so that it rests on its outer surface; an incision three inches in length, beginning at the junction of the middle and lower third of the thigh, is to be made parallel to and immediately behind the tendon of the Adductor magnus, and the skin, superficial and deep fasciæ divided. The tendon of the muscle is thus exposed, and is to be drawn forward and the hamstring tendons backward. A quantity of fatty tissue will now be opened up, in which the artery will be felt pulsating. This is to be separated with the point of a director until the artery is exposed. The vein and nerve will not be seen, as they lie to the outer side of the artery. The sheath is to be opened and the aneurism needle passed from before backward, keeping its point close to the artery for fear of injuring the vein. The only structure to avoid is the long saphenous vein in the superficial incision. The upper part of the popliteal artery may also be tied by an incision on the back of the limb, along the outer margin of the Semimembranosus, but the operation is a more difficult one, as the internal popliteal nerve and the popliteal vein are first exposed, and great care has to be exercised in separating them from the artery.

To expose the vessel in the lower part of its course, where the artery lies between the two heads of the Gastrocnemius, the patient should be placed in the prone position with the limb extended. An incision should then be made through the integument in the middle line, commencing opposite the bend of the knee-joint, care being taken to avoid the external saphenous vein and nerve. After dividing the deep fascia and separating some dense cellular membrane, the artery, vein, and nerve will be exposed, descending between the two heads of the Gastrocnemius. Some muscular branches of the popliteal should be avoided if possible, or, if divided, tied immediately. The leg being now flexed, in order the more effectually to separate the two heads of the Gastrocnemius, the nerve should be drawn inward and the vein outward, and the aneurism needle passed between the artery and vein from without inward.

Branches.—The branches of the popliteal artery are—the

Muscular {	Superior.	Superior External Articular.
	Inferior or Sural.	Azygos Articular.
Cutaneous.		Inferior Internal Articular.
Superior Internal Articular.		Inferior External Articular.

The **superior muscular branches,** two or three in number, arise from the upper part of the popliteal artery, and are distributed to the lower part of the Adductor magnus and flexor muscles of the thigh, anastomosing with the fourth perforating branch of the profunda.

The **inferior muscular (sural)** are two large branches which are distributed to the two heads of the Gastrocnemius and to the Plantaris muscle. They arise from the popliteal artery opposite the knee-joint.

The **cutaneous branches** arise separately from the popliteal artery or from some of its branches; they descend between the two heads of the Gastrocnemius muscle, and, piercing the deep fascia, are distributed to the integument of the calf. One branch usually accompanies the short, or external, saphenous vein.

The **superior articular arteries,** two in number, arise one on each side of the popliteal, and wind round the femur immediately above its condyles to the front of the knee-joint. The *internal branch* winds inward beneath the hamstring muscles, to which it supplies branches, above the inner head of the Gastrocnemius, and, passing beneath the tendon of the Adductor magnus, divides into two branches, one of which supplies the Vastus internus, inosculating with the anastomotica magna and inferior internal articular; the other ramifies close to the surface of the femur, supplying it and the knee-joint, and anastomosing with the superior external articular artery. This branch is frequently of small size, a condition which is associated with an increase in the size of the anastomotica magna. The *external branch* passes above the outer condyle, beneath the tendon of the Biceps, and divides into a superficial and deep branch: the superficial branch supplies the Vastus externus, and anastomoses with the descending branch of the external circumflex and the inferior external articular arteries; the deep branch supplies the lower part of the femur and knee-joint, and forms an anastomotic arch across the bone with the anastomotica magna and the inferior internal articular arteries.

The **azygos articular** is a small branch arising from the popliteal artery oppo-

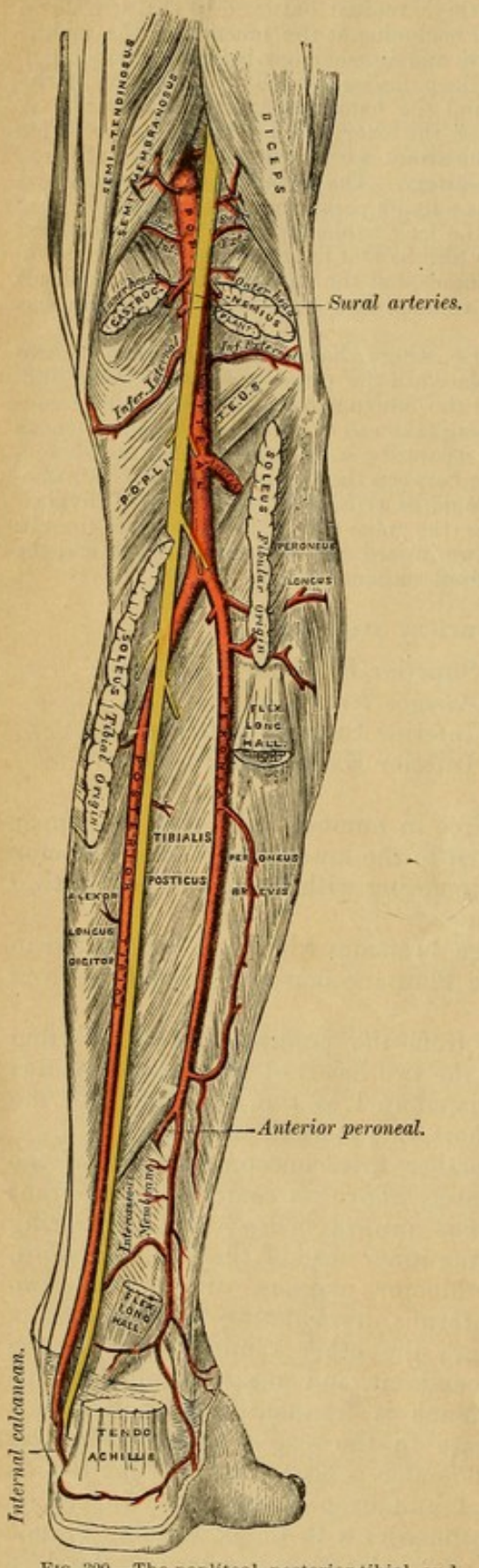

FIG. 320.—The popliteal, posterior tibial, and peroneal arteries.

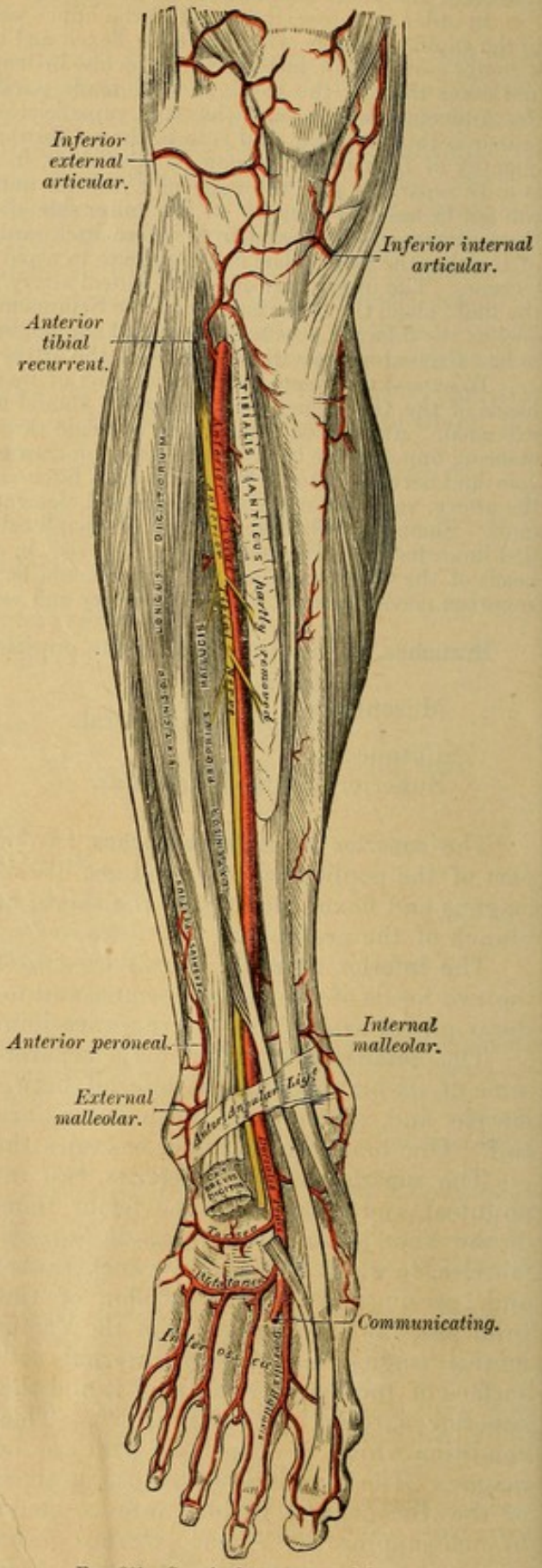

FIG. 321.—Surgical anatomy of the anterior tibial and dorsalis pedis arteries.

site the bend of the knee-joint. It pierces the posterior ligament, and supplies the ligaments and synovial membrane in the interior of the articulation.

The **inferior articular arteries,** two in number, arise from the popliteal beneath the Gastrocnemius, and wind round the head of the tibia below the joint. The *internal* one first descends along the upper margin of the Popliteus muscle, to which it gives branches; it then passes below the inner tuberosity, beneath the internal lateral ligament, at the anterior border of which it ascends to the front and inner side of the joint, to supply the head of the tibia and the articulation of the knee, anastomosing with the inferior external articular and superior internal articular arteries. The *external* one passes outward above the head of the fibula, to the front of the knee-joint, passing in its course beneath the outer head of the Gastrocnemius, the external lateral ligament, and the tendon of the Biceps muscle, and divides into branches which anastomose with the inferior internal articular artery, the superior external articular artery, and the anterior recurrent branch of the anterior tibial.

Circumpatellar Anastomosis.—Around and above the patella, and on the contiguous ends of the femur and tibia, is a large network of vessels, forming a superficial and deep plexus. The superficial plexus is situated between the fascia and skin round about the patella; the deep plexus, which forms a close network of vessels, lies on the surface of the lower end of the femur and upper end of the tibia around their articular surfaces, and sends numerous offsets into the interior of the joint. The arteries from which this plexus is formed are the two internal and two external articular branches of the popliteal, the anastomotica magna, the terminal branch of the profunda, the descending branch from the external circumflex, and the anterior recurrent branch of the anterior tibial.

The Anterior Tibial Artery (Fig. 321).

The **anterior tibial artery** commences at the bifurcation of the popliteal at the lower border of the Popliteus muscle, passes forward between the two heads of the Tibialis posticus, and through the large oval aperture above the upper border of the interosseous membrane to the deep part of the front of the leg: it here lies close to the inner side of the neck of the fibula; it then descends on the anterior surface of the interosseous membrane, gradually approaching the tibia; and at the lower part of the leg lies on this bone, and then on the anterior ligament of the ankle to the bend of the ankle-joint, where it lies more superficially, and becomes the *dorsalis pedis*.

Relations.—In the upper two-thirds of its extent it rests upon the interosseous membrane, to which it is connected by delicate fibrous arches thrown across it; in the lower third, upon the front of the tibia and the anterior ligament of the ankle-joint. In the upper third of its course it lies between the Tibialis anticus and Extensor longus digitorum; in the middle third, between the Tibialis anticus and Extensor proprius hallucis. At the bend of the ankle it is crossed by the tendon of the Extensor proprius hallucis, and lies between it and the innermost tendon of the Extensor longus digitorum. It is covered, in the upper two-thirds of its course, by the muscles which lie on either side of it and by the deep fascia; in the lower third, by the integument, anterior annular ligament, and fascia.

The anterior tibial artery is accompanied by two veins (venæ comites), which lie one on each side of the artery; the anterior tibial nerve, coursing round the outer side of the neck of the fibula, comes into relation with the outer side of the artery shortly after it has passed through the opening in the interosseous membrane; about the middle of the leg it is placed superficial to it; at the lower part of the artery the nerve is generally again on the outer side.

PLAN OF THE RELATIONS OF THE ANTERIOR TIBIAL ARTERY.

In front.

Integument, superficial and deep fasciæ.
Anterior tibial nerve.
Tibialis anticus (overlaps it in the upper part of the leg).
Extensor longus digitorum } (overlap it slightly).
Extensor proprius hallucis }
Anterior annular ligament.

Inner side.

Tibialis anticus.
Extensor proprius hallucis (crosses it at its lower part).



Outer side.

Anterior tibial nerve.
Extensor longus digitorum.
Extensor proprius hallucis.

Behind.

Interosseous membrane.
Tibia.
Anterior ligament of ankle-joint.

Peculiarities in Size.—This vessel may be diminished in size, may be deficient to a greater or less extent, or may be entirely wanting, its place being supplied by perforating branches from the posterior tibial or by the anterior division of the peroneal artery.

Course.—The artery occasionally deviates in its course toward the fibular side of the leg, regaining its usual position beneath the annular ligament at the front of the ankle. In two instances the vessel has been found to approach the surface in the middle of the leg, being covered merely by the integument and fascia below that point.

Surface Marking.—Draw a line from the inner side of the head of the fibula to midway between the two malleoli. In this line take a point one inch and a quarter below the head of the fibula, and the portion of the line below this point will mark the course of the artery.

Surgical Anatomy.—The anterior tibial artery may be tied in the upper or lower part of the leg. In the upper part the operation is attended with great difficulty, on account of the depth of the vessel from the surface. An incision, about four inches in length, should be made through the integument, midway between the spine of the tibia and the outer margin of the fibula, and the deep fascia exposed. The wound must now be carefully dried, its edges retracted, and the white line separating the Tibialis anticus from the Extensor longus digitorum sought for. When this has been clearly defined, the deep fascia is to be divided in this line, and the Tibialis anticus separated from adjacent muscles with the handle of the scalpel or a director until the interosseous membrane is reached. The foot is to be flexed in order to relax the muscles, and upon drawing them apart, the artery will be found lying on the interosseous membrane with the nerve on its outer side or on the top of the artery. The nerve should be drawn outward, and the venæ comites separated from the artery and the needle passed around it.

To tie the vessel in the lower third of the leg above the ankle-joint an incision about three inches in length should be made through the integument between the tendons of the Tibialis anticus and Extensor proprius hallucis muscles, the deep fascia being divided to the same extent. The tendon on either side should be held aside, when the vessel will be seen lying upon the tibia, with the nerve on the outer side and one of the venæ comites on either side.

The branches of the anterior tibial artery are—the

Posterior Recurrent Tibial.	Muscular.
Superior Fibular.	Internal Malleolar.
Anterior Recurrent Tibial.	External Malleolar.

The **posterior recurrent tibial** is not a constant branch, and is given off from the anterior tibial before that vessel passes through the interosseous space. It ascends beneath the Popliteus muscle, which it supplies, and anastomoses with the lower articular branches of the popliteal artery, giving off an offset to the superior tibio-fibular joint.

The **superior fibular** is sometimes given off from the anterior tibial, sometimes from the posterior tibial. It passes outward, round the neck of the fibula, through the Soleus, which it supplies, and ends in the substance of the Peroneus longus muscle.

The **anterior recurrent tibial branch** arises from the anterior tibial as soon as that vessel has passed through the interosseous space; it ascends in the Tibialis anticus muscle, and ramifies on the front and sides of the knee-joint, anastomos-

ing with the articular branches of the popliteal and with the anastomotica magna, assisting in the formation of the circumpatellar plexus.

The **muscular branches** are numerous; they are distributed to the muscles which lie on each side of the vessel, some piercing the deep fascia to supply the integument, others passing through the interosseous membrane, and anastomosing with branches of the posterior tibial and peroneal arteries.

The **malleolar arteries** supply the ankle-joint. The *internal* arises about two inches above the articulation, and passes beneath the tendons of the Extensor proprius hallucis and Tibialis anticus to the inner ankle, upon which it ramifies, anastomosing with branches of the posterior tibial and internal plantar arteries and with the internal calcanean from the posterior tibial. The *external* passes beneath the tendons of the Extensor longus digitorum and Peroneus tertius, and supplies the outer ankle, anastomosing with the anterior peroneal artery and with ascending branches from the tarsal branch of the dorsalis pedis.

The Dorsalis Pedis Artery (Fig. 321).

The **dorsalis pedis,** the continuation of the anterior tibial, passes forward from the bend of the ankle along the tibial side of the foot to the back part of the first intermetatarsal space, where it divides into two branches, the *dorsalis hallucis*, and *communicating*.

Relations.—This vessel, in its course forward, rests upon the astragalus, navicular, and middle cuneiform bones and the ligaments connecting them, being covered by the integument and fascia, anterior annular ligament, and crossed near its termination by the innermost tendon of the Extensor brevis digitorum. On its *tibial side* is the tendon of the Extensor proprius hallucis; on its *fibular side*, the innermost tendon of the Extensor longus digitorum, and the termination of the anterior tibial nerve. It is accompanied by two veins.

PLAN OF THE RELATIONS OF THE DORSALIS PEDIS ARTERY.

In front.
Integument and fascia.
Anterior annular ligament.
Innermost tendon of Extensor brevis digitorum.

Tibial side.
Extensor proprius hallucis.

Dorsalis Pedis.

Fibular side.
Extensor longus digitorum.
Anterior tibial nerve.

Behind.
Astragalus.
Navicular.
Middle cuneiform.
and their ligaments.

Peculiarities in Size.—The dorsal artery of the foot may be larger than usual, to compensate for a deficient plantar artery; or it may be deficient in its terminal branches to the toes, which are then derived from the internal plantar; or its place may be supplied altogether by a large anterior peroneal artery.

Position.—This artery frequently curves outward, lying external to the line between the middle of the ankle and the back part of the first interosseous space.

Surface Marking.—The dorsalis pedis artery is indicated on the surface of the dorsum of the foot by a line drawn from the centre of the space between the two malleoli to the back of the first intermetatarsal space.

Surgical Anatomy.—This artery may be tied, by making an incision through the integument between two and three inches in length, on the fibular side of the tendon of the Extensor proprius hallucis, in the interval between it and the inner border of the short Extensor muscle. The incision should not extend farther forward than the back part of the first intermetatarsal

space, as the artery divides in that situation. The deep fascia being divided to the same extent, the artery will be exposed, the nerve lying upon its outer side.

Branches.—The branches of the dorsalis pedis are—the

Tarsal.	Dorsalis Hallucis.
Metatarsal—Interosseous.	Communicating.

The **tarsal artery** arises from the dorsalis pedis, as that vessel crosses the navicular bone; it passes in an arched direction outward, lying upon the tarsal bones, and covered by the Extensor brevis digitorum; it supplies that muscle and the articulations of the tarsus, and anastomoses with branches from the metatarsal, external malleolar, peroneal, and external plantar arteries.

The **metatarsal** arises a little anterior to the preceding; it passes outward to the outer part of the foot, over the bases of the metatarsal bones, beneath the tendons of the short Extensor, its direction being influenced by its point of origin; and it anastomoses with the tarsal and external plantar arteries. This vessel gives off three branches, the *interosseous arteries*, which pass forward upon the three outer Dorsal interossei muscles, and, in the clefts between the toes, divide into two dorsal collateral branches for the adjoining toes. At the back part of each interosseous space these vessels receive the posterior perforating branches from the plantar arch, and at the fore part of each interosseous space they are joined by the anterior perforating branches from the digital arteries. The outermost interosseous artery gives off a branch which supplies the outer side of the little toe.

The **dorsalis hallucis** (*first dorsal interosseous*) runs forward along the outer border of the first metatarsal bone, and at the cleft between the first and second toes divides into two branches, one of which passes inward, beneath the tendon of the Extensor proprius hallucis, and is distributed to the inner border of the great toe; the outer branch bifurcates, to supply the adjoining sides of the great and second toes.

The **communicating artery** dips down into the sole of the foot, between the two heads of the First dorsal interosseous muscle, and inosculates with the termination of the external plantar artery, to complete the plantar arch. It here gives off its plantar digital branch, which is named the *arteria magna hallucis*. This artery passes forward along the first interosseous space, and, after sending a branch along the inner side of the great toe, bifurcates for the supply of the adjacent sides of the great and second toes.

The Posterior Tibial Artery.

The **posterior tibial** is an artery of large size, which extends obliquely downward from the lower border of the Popliteus muscle, along the tibial side of the leg, to the fossa between the inner ankle and the heel, where it divides beneath the origin of the Abductor hallucis, on a level with a line drawn from the point of the internal malleolus to the centre of the convexity of the heel, into the *internal* and *external plantar arteries*. At its origin it lies opposite the interval between the tibia and fibula; as it descends, it approaches the inner side of the leg, lying behind the tibia, and, in the lower part of its course, is situated midway between the inner malleolus and the tuberosity of the os calcis.

Relations.—It lies successively upon the Tibialis posticus, the Flexor longus digitorum, the tibia, and the back part of the ankle-joint. It is *covered* by the deep transverse fascia, which separates it above from the Gastrocnemius and Soleus muscles: at its termination it is covered by the Abductor hallucis muscle. In the lower third, where it is more superficial, it is covered only by the integument and fascia, and runs parallel with the inner border of the tendo Achillis. It is accompanied by two veins and by the posterior tibial nerve, which lies at first to the inner side of the artery, but soon crosses it, and is, in the greater part of its course, on its outer side.

PLAN OF THE RELATIONS OF THE POSTERIOR TIBIAL ARTERY.

In front.
Tibialis posticus.
Flexor longus digitorum.
Tibia.
Ankle-joint.

Inner side.
Posterior tibial nerve, upper third.



Outer side.
Posterior tibial nerve, lower two-thirds.

Behind.
Integument and fascia.
Gastrocnemius.
Soleus.
Deep transverse fascia.
Posterior tibial nerve.
Abductor hallucis.

Behind the Inner ankle the tendons and blood-vessels are arranged, under cover of the internal annular ligament, in the following order, from within outward: First, the tendons of the Tibialis posticus and Flexor longus digitorum, lying in the same groove, behind the inner malleolus, the former being the most internal. External to these is the posterior tibial artery, having a vein on either side: and, still more externally, the posterior tibial nerve. About half an inch nearer the heel is the tendon of the Flexor longus hallucis.

Peculiarities in Size.—The posterior tibial is not unfrequently smaller than usual, or absent, its place being supplied by a large peroneal artery which passes inward at the lower end of the tibia, and either joins the small tibial artery or continues alone to the sole of the foot.

Surface Marking.—The course of the posterior tibial artery is indicated by a line drawn from a point one inch below the centre of the popliteal space to midway between the tip of the internal malleolus and the centre of the convexity of the heel.

Surgical Anatomy.—The *application of a ligature* to the posterior tibial may be required in cases of wound of the sole of the foot attended with great hæmorrhage, when the vessel should be tied at the inner ankle. In cases of wound of the posterior tibial it will be necessary to enlarge the opening so as to expose the vessel at the wounded point, excepting where the vessel is injured by a punctured wound from the front of the leg. In cases of aneurism from wound of the artery low down, the vessel should be tied in the middle of the leg. But in aneurism of the posterior tibial high up it would be better to tie the femoral artery.

To tie the posterior tibial artery at the ankle, a semilunar incision, convex backward, should be made through the integument, about two inches and a half in length, midway between the heel and inner ankle or a little nearer the latter. The subcutaneous cellular tissue having been divided, a strong and dense fascia, the internal annular ligament, is exposed. This ligament is continuous above with the deep fascia of the leg, covers the vessels and nerves, and is intimately adherent to the sheaths of the tendons. This having been cautiously divided upon a director, the sheath of the vessels is exposed, and, being opened, the artery is seen with one of the venæ comites on each side. The aneurism needle should be passed round the vessel from the heel toward the ankle, in order to avoid the posterior tibial nerve, care being at the same time taken not to include the venæ comites.

The vessel may also be tied in the lower third of the leg by making an incision, about three inches in length, parallel with the inner margin of the tendo Achillis. The internal saphenous vein being carefully avoided, the two layers of fascia must be divided upon a director, when the artery is exposed along the outer margin of the Flexor longus digitorum, with one of its venæ comites on either side and the nerve lying external to it.

To tie the posterior tibial in the middle of the leg is a very difficult operation, on account of the great depth of the vessel from the surface. The patient being placed in the recumbent position, the injured limb should rest on its outer side, the knee being partially bent and the foot extended, so as to relax the muscles of the calf. An incision about four inches in length should then be made through the integument a finger's breadth behind the inner margin of the tibia, taking care to avoid the internal saphenous vein. The deep fascia having been divided, the margin of the Gastrocnemius is exposed, and must be drawn aside, and the tibial attachment of the Soleus divided, a director being previously passed beneath it. The artery may now be felt pulsating beneath the deep fascia about an inch from the margin of the tibia. The fascia having been divided, and the limb placed in such a position as to relax the muscles of the calf as much as possible, the veins should be separated from the artery, and the aneurism needle passed round the vessel from without inward, so as to avoid wounding the posterior tibial nerve.

The branches of the posterior tibial artery are—the

Peroneal.	Nutrient.
Muscular.	Communicating.

Internal Calcanean.

The **Peroneal Artery** lies, deeply seated, along the back part of the fibular side of the leg. It arises from the posterior tibial about an inch below the lower border of the Popliteus muscle, passes obliquely outward to the fibula, and then descends along the inner border of that bone, contained in a fibrous canal between the Tibialis posticus and the Flexor longus hallucis, or in the substance of the latter muscle to the lower third of the leg, where it gives off the *anterior peroneal*. It then passes across the articulation between the tibia and fibula to the outer side of the os calcis, where it gives off its terminal branches, the *external calcanean*.

Relations.—This vessel rests at first upon the Tibialis posticus, and then, for the greater part of its course, in a fibrous canal between the origins of the Flexor longus hallucis and Tibialis posticus, covered or surrounded by the fibres of the Flexor longus hallucis. It is *covered*, in the upper part of its course, by the Soleus and deep transverse fascia; *below*, by the Flexor longus hallucis.

PLAN OF THE RELATIONS OF THE PERONEAL ARTERY.

In front.
Tibialis posticus.
Flexor longus hallucis.

Outer side.
Fibula.
Flexor longus hallucis.



Inner side.
Flexor longus hallucis.

Behind.
Soleus.
Deep transverse fascia.
Flexor longus hallucis.

Peculiarities in Origin.—The peroneal artery may arise three inches below the Popliteus, or from the posterior tibial high up, or even from the popliteal.

Its size is more frequently increased than diminished; and then it either reinforces the posterior tibial by its junction with it, or altogether takes the place of the posterior tibial in the lower part of the leg and foot, the latter vessel only existing as a short muscular branch. In those rare cases where the peroneal artery is smaller than usual a branch from the posterior tibial supplies its place, and a branch from the anterior tibial compensates for the diminished anterior peroneal artery. In one case the peroneal artery has been found entirely wanting.

The anterior peroneal is sometimes enlarged, and takes the place of the dorsal artery of the foot.

The branches of the peroneal are—the

Muscular.	Communicating.
Nutrient.	Posterior Peroneal.
Anterior Peroneal.	External Calcanean.

Muscular Branches.—The **peroneal artery** in its course gives off branches to the Soleus, Tibialis posticus, Flexor longus hallucis, and Peronei muscles.

The *nutrient artery* supplies the fibula.

The *Anterior peroneal* pierces the interosseous membrane, about two inches above the outer malleolus, to reach the fore part of the leg, and, passing down beneath the Peroneus tertius to the outer ankle, ramifies on the front and outer side of the tarsus, anastomosing with the external malleolar and tarsal arteries.

The *communicating* is given off from the peroneal about an inch from its lower end, and, passing inward, joins the communicating branch of the posterior tibial.

The *Posterior peroneal* passes down behind the outer ankle to the back of the external malleolus, to terminate in branches which ramify on the outer surface and back of the os calcis.

The *External calcanean* are the terminal branches of the peroneal artery; they pass to the outer side of the heel, and communicate with the external malleolar, and, on the back of the heel, with the internal calcanean arteries.

The **nutrient artery** of the tibia arises from the posterior tibial near its origin, and, after supplying a few muscular branches, enters the nutrient canal of that bone, which it traverses obliquely from above downward. This is the largest nutrient artery of bone in the body.

The **muscular branches** of the posterior tibial are distributed to the Soleus and deep muscles along the back of the leg.

The **communicating branch,** to join a similar branch of the peroneal, runs transversely across the back of the tibia, about two inches above its lower end, passing beneath the Flexor longus hallucis.

The **internal calcanean** are several large arteries which arise from the posterior

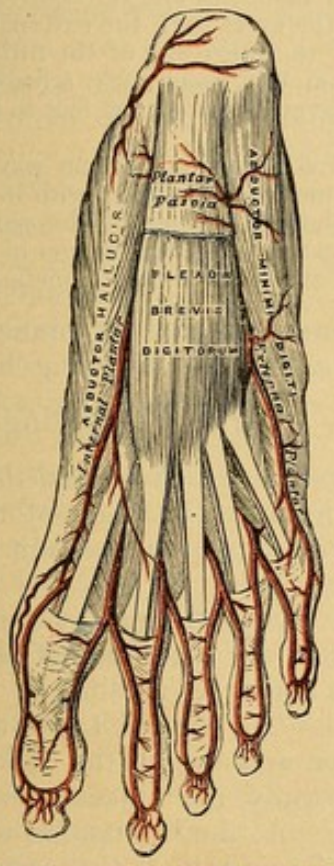

FIG. 322.—The plantar arteries. Superficial view.

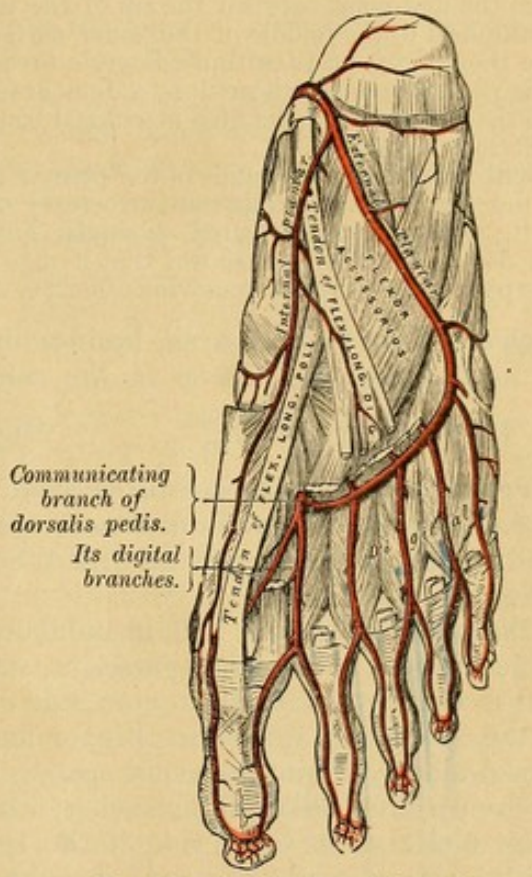

FIG. 323.—The plantar arteries. Deep view.

tibial just before its division: they are distributed to the fat and integument behind the tendo Achillis and about the heel, and to the muscles on the inner side of the sole, anastomosing with the peroneal and internal malleolar, and, on the back of the heel, with the external calcanean arteries.

The **Internal Plantar Artery** (Figs. 322, 323), much smaller than the external, passes forward along the inner side of the foot. It is at first situated above[1] the Abductor hallucis, and then between it and the Flexor brevis digitorum, both of which it supplies. At the base of the first metatarsal bone, where it has become much diminished in size, it passes along the inner border of the great toe, inosculating with its digital branch. Small superficial digital branches accompany the digital branches of the internal plantar nerve and join the plantar digital arteries of the three inner spaces.

The **External Plantar Artery,** much larger than the internal, passes obliquely outward and forward to the base of the fifth metatarsal bone. It then turns obliquely inward to the interval between the bases of the first and second

[1] This refers to the erect position of the body. In the ordinary position for dissection the artery is deeper than the muscle.

metatarsal bones, where it anastomoses with the communicating branch from the dorsalis pedis artery, thus completing the *plantar arch*. As this artery passes outward, it is first placed between the os calcis and Abductor hallucis, and then between the Flexor brevis digitorum and Flexor accessorius, and as it passes forward to the base of the little toe, it lies more superficially between the Flexor brevis digitorum and Abductor minimi digiti, covered by the deep fascia and integument. The remaining portion of the vessel is deeply situated: it extends from the base of the metatarsal bone of the little toe to the back part of the first interosseous space, and forms the plantar arch; it is convex forward, lies upon the Interossei muscles opposite the tarsal ends of the metatarsal bones, and is covered by the Adductor obliquus hallucis, the flexor tendons of the toes, and the Lumbricales.

Surface Marking.—The course of the internal plantar artery is represented by a line drawn from the mid-point between the tip of the internal malleolus and the centre of the convexity of the heel to the middle of the under surface of the great toe; the external plantar by a line from the same point to within a finger's breadth of the tuberosity of the fifth metatarsal bone. The plantar arch is indicated by a line drawn from this point; *i. e.* a finger's breadth internal to the tuberosity of the fifth metatarsal bone transversely across the foot to the back of the first interosseous space.

Surgical Anatomy.—Wounds of the plantar arch are always serious, on account of the depth of the vessel and the important structures which must be interfered with in an attempt to ligate it. They must be treated on similar lines to those of wounds of the palmar arches (see page 545). Delorme has shown that it may be ligated from the dorsum of the foot in almost any part of its course by removing a portion of one of the three middle metatarsal bones.

Branches.—The plantar arch, besides distributing numerous branches to the muscles, integument, and fasciæ in the sole, gives off the following branches:

Posterior Perforating. Digital—Anterior Perforating.

The **Posterior Perforating** are three small branches which ascend through the back part of the three outer interosseous spaces, between the heads of the Dorsal interossei muscles, and anastomose with the interosseous branches from the metatarsal artery.

The **Digital Branches** are four in number, and supply the three outer toes and half the second toe. The *first* passes outward from the outer side of the plantar arch, and is distributed to the outer side of the little toe, passing in its course beneath the Abductor and short Flexor muscles. The *second*, *third*, and *fourth* run forward along the interosseous spaces, and on arriving at the clefts between the toes divide into collateral branches, which supply the adjacent sides of the three outer toes and the outer side of the second. At the bifurcation of the toes each digital artery sends upward, through the fore part of the corresponding interosseous space, a small branch, which inosculates with the interosseous branches of the metatarsal artery. These are the *anterior perforating branches*.

From the arrangement already described of the distribution of the vessels to the toes it will be seen that both sides of the three outer toes and the outer side of the second toe are supplied by branches from the plantar arch; both sides of the great toe and the inner side of the second are supplied by the communicating branch of the dorsalis pedis.

THE VEINS.

The Veins are the vessels which serve to return the blood from the capillaries of the different parts of the body to the heart. They consist of two distinct sets of vessels, the *pulmonary* and *systemic*.

The **Pulmonary Veins** are concerned in the circulation in the lungs. Unlike other vessels of this kind, they contain arterial blood, which they return from the lungs to the left auricle of the heart.

The **Systemic Veins** are concerned in the general circulation; they return the venous blood from the body generally to the right auricle of the heart.

The **Portal Vein,** an appendage to the systemic venous system, is confined to the abdominal cavity, returning the venous blood from the viscera of digestion, and carrying it to the liver by a single trunk of large size, the *vena portæ*. This vessel ramifies in the substance of the liver and breaks up into a minute network of capillaries. These capillaries then re-collect to form the hepatic veins, by which the blood is conveyed to the inferior vena cava.

The veins, like the arteries, are found in nearly every tissue of the body. They commence by minute plexuses which receive the blood from the capillaries. The branches which have their commencement in these plexuses unite together into trunks, and these, in their passage toward the heart, constantly increase in size as they receive tributaries or join other veins. The veins are larger and altogether more numerous than the arteries; hence the entire capacity of the venous system is much greater than that of the arterial, the pulmonary veins excepted, which only slightly exceed in capacity the pulmonary arteries. From the combined area of the smaller venous branches being greater than the main trunks, it results that the venous system represents a cone, the summit of which corresponds to the heart, its base to the circumference of the body. In form the veins are perfectly cylindrical, like the arteries, their walls being collapsed when empty, and the uniformity of their surface being interrupted at intervals by slight constrictions, which indicate the existence of valves in their interior. They usually retain, however, the same calibre as long as they receive no branches.

The veins communicate very freely with one another, especially in certain regions of the body, and this communication exists between the larger trunks as well as between the smaller branches. Thus, in the cavity of the cranium and between the veins of the neck, where obstruction would be attended with imminent danger to the cerebral venous system, we find that the sinuses and larger veins have large and very frequent anastomoses. The same free communication exists between the veins throughout the whole extent of the spinal canal, and between the veins composing the various venous plexuses in the abdomen and pelvis, as the spermatic, uterine, vesical, and prostatic.

Veins have thinner walls than arteries, the difference in thickness being due to the small amount of elastic and muscular tissues which the veins contain. The superficial veins usually have thicker coats than the deep veins, and the veins of the lower limb are thicker than those of the upper.

The minute structure of these vessels will be described in the section on General Anatomy.

The systemic veins are subdivided into three sets: superficial, deep, and sinuses.

The **Superficial** or **Cutaneous Veins** are found between the layers of the superficial fascia, immediately beneath the integument; they return the blood from these structures, and communicate with the deep veins by perforating the deep fascia.

The **Deep Veins** accompany the arteries, and are usually enclosed in the same sheath with those vessels. With the smaller arteries—as the radial, ulnar, brachial, tibial, peroneal—they exist generally in pairs, one lying on each side of the vessel, and are called *venæ comites*. The larger arteries—as the axillary, subclavian, popliteal, and femoral—have usually only one accompanying vein. In certain organs of the body, however, the deep veins do not accompany the arteries; for instance, the veins in the skull and spinal canal, the hepatic veins in the liver, and the larger veins returning blood from the osseous tissue.

Sinuses are venous channels which, in their structure and mode of distribution, differ altogether from the veins. They are found only in the interior of the skull, and consist of channels formed by a separation of the two layers of the dura mater, their outer coat consisting of fibrous tissue, their inner of an endothelial layer continuous with the lining membrane of the veins.

THE PULMONARY VEINS.

The *Pulmonary Veins* return the arterial blood from the lungs to the left auricle of the heart. They are four in number, two for each lung. The pulmonary differ from other veins in several respects: 1. They carry arterial instead of venous blood. 2. They are destitute of valves. 3. They are only slightly larger than the arteries they accompany. 4. They accompany those vessels singly. They commence in a capillary network upon the walls of the air-cells, where they are continuous with the capillary ramifications of the pulmonary artery, and, uniting together, form one vessel for each lobule. These vessels, uniting successively, form a single trunk for each lobe, three for the right and two for the left lung. The vein from the middle lobe of the right lung generally unites with that from the upper lobe, forming two trunks on each side, which open separately into the left auricle. Occasionally they remain separate; there are then three veins on the right side. Not unfrequently the two left pulmonary veins terminate by a common opening.

Within the lung, the branches of the pulmonary artery are *in front*, the veins *behind*, and the bronchi *between* the two.

At the root of the lung, the veins are *in front*, the artery *in the middle*, and the bronchus *behind*.

Within the pericardium, their anterior surface is invested by the serous layer of this membrane. The right pulmonary veins pass behind the right auricle and ascending aorta and superior vena cava; the left pass in front of the thoracic aorta with the left pulmonary artery.

THE SYSTEMIC VEINS.

The systemic veins may be arranged into three groups: 1. Those of the head and neck, upper extremity, and thorax, which terminate in the superior vena cava. 2. Those of the lower extremity, abdomen, and pelvis, which terminate in the inferior vena cava. 3. The cardiac veins, which open directly into the right auricle of the heart.

VEINS OF THE HEAD AND NECK.

The veins of the head and neck may be subdivided into three groups: 1. The veins of the exterior of the head and face. 2. The veins of the neck. 3. The veins of the diploë and interior of the cranium.

Veins of the Exterior of the Head and Face.

The veins of the exterior of the head and face are—the

Frontal.
Supra-orbital.
Angular.
Facial.
Temporal.
Internal Maxillary.
Temporo-maxillary.
Posterior Auricular.
Occipital.

The **frontal vein** commences on the anterior part of the skull by a venous plexus which communicates with the anterior tributaries of the temporal vein. The veins converge to form a single trunk, which runs downward near the middle line of the forehead parallel with the vein of the opposite side, and unites with it at the root of the nose by a transverse branch called the *nasal arch.* Occasionally the frontal veins join to form a single trunk, which bifurcates at the

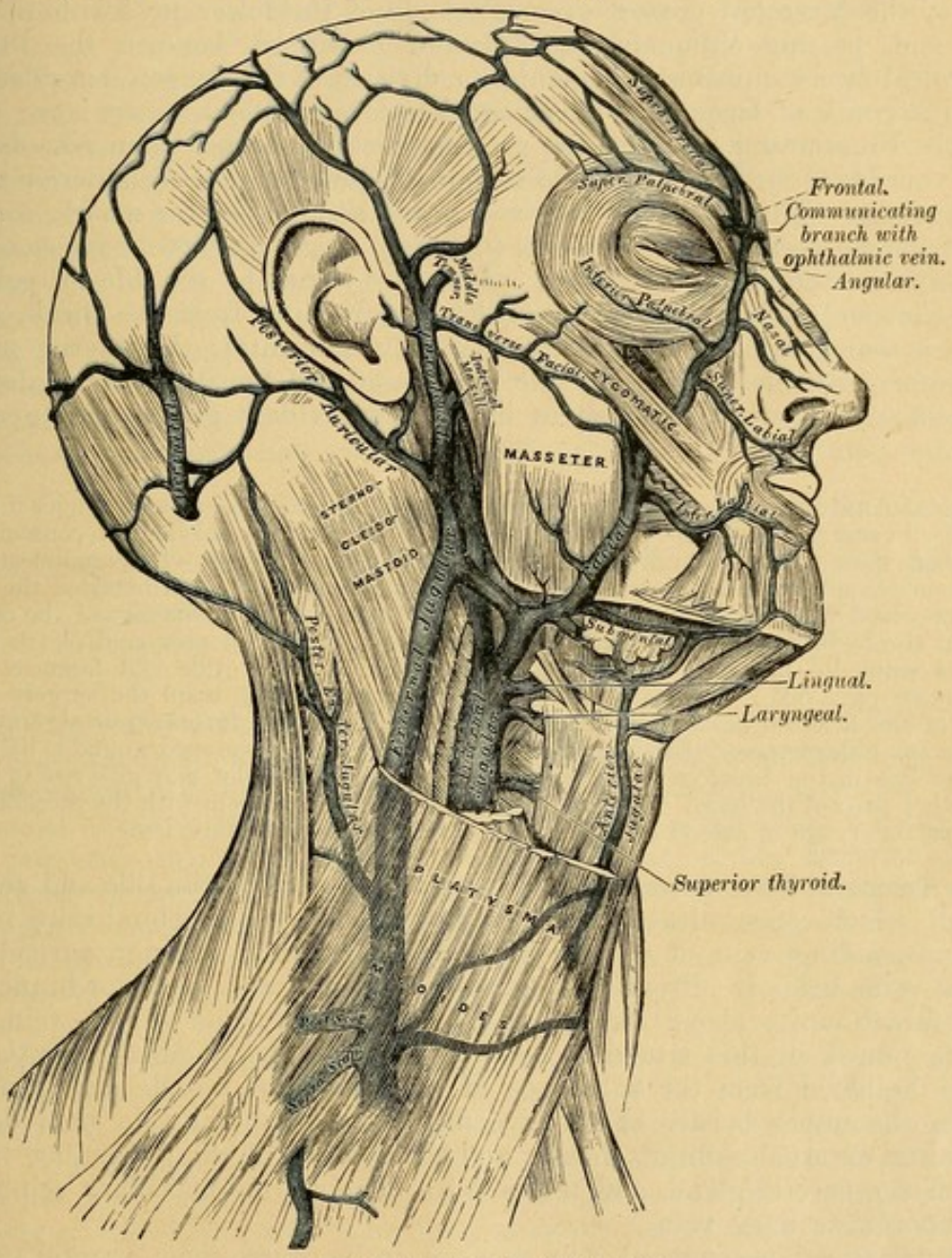

FIG. 324.—Veins of the head and neck.

root of the nose into the two angular veins. At the root of the nose the veins diverge and join the *supra-orbital vein*, at the inner angle of the orbit, to form the *angular vein.*

The **supra-orbital vein** commences on the forehead, communicating with the anterior temporal vein, and runs downward and inward, superficial to the Occipito-frontalis muscle, receiving tributaries from the neighboring structures, and joins the frontal vein at the inner angle of the orbit to form the *angular vein.*

The **angular vein,** formed by the junction of the frontal and supra-orbital veins, runs obliquely downward and outward on the side of the root of the nose, and receives the veins of the ala nasi on its inner side and the superior palpebral veins on its outer side; it moreover communicates with the ophthalmic vein, thus

establishing an important anastomosis between this vessel and the cavernous sinus. Some small veins from the dorsum of the nose terminate in the nasal arch.

The **Facial Vein** commences at the side of the root of the nose, being a direct continuation of the angular vein. It lies behind and follows a less tortuous course than the facial artery. It passes obliquely downward and outward, beneath the Zygomaticus major and minor muscles, descends along the anterior border of the Masseter, crosses over the body of the lower jaw, with the facial artery, and, passing obliquely outward and backward, beneath the Platysma and cervical fascia, unites with the anterior division of the temporo-maxillary vein, to form a trunk of large size (*common facial vein*), which enters the internal jugular. From near its termination a communicating branch often runs down the anterior border of the Sterno-mastoid to join the lower part of the anterior jugular.

Tributaries.—The facial vein receives, near the angle of the mouth, communicating tributaries of considerable size (the *deep facial* or *anterior internal maxillary vein*) from the pterygoid plexus. It is also joined by the inferior palpebral, the superior and inferior labial veins, the buccal veins from the cheek, and the masseteric veins. Below the jaw it receives the submental; the inferior palatine, which returns the blood from the plexus around the tonsil and soft palate; the submaxillary vein, which commences in the submaxillary gland; and, generally, the ranine vein.

Surgical Anatomy.—There are some points about the facial vein which render it of great importance in surgery. It is not so flaccid as are most superficial veins, and, in consequence of this, remains more patent when divided. It has, moreover, no valves. It communicates freely with the intracranial circulation, not only at its commencement by its tributaries, the angular and supra-orbital veins, communicating with the ophthalmic vein, a tributary of the cavernous sinus, but also by its deep branch, which communicates through the pterygoid plexus with the cavernous sinus by branches which pass through the foramen ovale and foramen lacerum medium (see page 606). These facts have an important bearing upon the surgery of some diseases of the face, for on account of its patency the facial vein favors septic absorption, and therefore any phlegmonous inflammation of the face following a poisoned wound is liable to set up thrombosis in the facial vein, and detached portions of the clot may give rise to purulent foci in other parts of the body. And on account of its communications with the cerebral sinuses these thrombi are apt to extend upward into them and so induce a false issue.

The **Temporal Vein** commences by a minute plexus on the side and vertex of the skull, which communicates with the frontal and supra-orbital veins in front, the corresponding vein of the opposite side, and the posterior auricular and occipital veins behind. From this network anterior and posterior branches are formed which unite above the zygoma, forming the trunk of the vein. This trunk is joined in this situation by a large vein, the *middle temporal*, which receives the blood from the substance of the Temporal muscle and pierces the fascia at the upper border of the zygoma. The temporal vein then descends between the external auditory meatus and the condyle of the jaw, enters the substance of the parotid gland, and unites with the internal maxillary vein to form the temporo-maxillary vein.

Tributaries.—The temporal vein receives in its course some parotid veins, an articular branch from the articulation of the jaw, anterior auricular veins from the external ear, and a vein of large size, the *transverse facial*, from the side of the face. The middle temporal vein, previous to its junction with the temporal vein, receives a branch, the *orbital vein*, which is formed by some external palpebral branches, and passes backward between the layers of the temporal fascia.

The **Internal Maxillary Vein** is a vessel of considerable size, receiving branches which correspond with those of the internal maxillary artery. Thus it receives the middle meningeal veins, the deep temporal, the pterygoid, masseteric, buccal, alveolar, some palatine veins, and the inferior dental. These branches form a large plexus, the *pterygoid*, which is placed between the Temporal and External pterygoid and partly between the Pterygoid muscles. This plexus communicates very freely with the facial vein and with the cavernous sinus by branches through the foramen Vesalii, foramen ovale, and foramen lacerum medium, at the base of

the skull. The trunk of the vein then passes backward behind the neck of the lower jaw, and unites with the temporal vein, forming the temporo-maxillary vein.

The **Temporo-maxillary Vein**, formed by the union of the temporal and internal maxillary veins, descends in the substance of the parotid gland on the outer surface of the external carotid artery, between the ramus of the jaw and the Sterno-mastoid muscle, and divides into two branches, an anterior, which passes inward to join the facial vein, and a posterior, which is joined by the posterior auricular vein and becomes the external jugular.

The **Posterior Auricular Vein** commences upon the side of the head by a plexus which communicates with the tributaries of the temporal and occipital veins. The vein descends behind the external ear and joins the posterior division of the temporo-maxillary vein, forming the external jugular. This vessel receives the stylo-mastoid vein and some tributaries from the back part of the external ear.

The **Occipital Veins** commence at the back part of the vertex of the skull by a plexus in a similar manner to the other veins. These unite and form one or two veins, which follow the course of the occipital artery, passing deeply beneath the muscles of the back part of the neck, and terminate in the internal jugular, occasionally in the external jugular vein. As these veins pass across the mastoid portion of the temporal bone, one of them receives the mastoid vein, which thus establishes a communication with the lateral sinus.

The Veins of the Neck.

The veins of the neck, which return the blood from the head and face, are—the

External Jugular.	Anterior Jugular.
Posterior External Jugular.	Internal Jugular.
Vertebral.	

The **External Jugular Vein** receives the greater part of the blood from the exterior of the cranium and deep parts of the face, being formed by the junction of the posterior division of the temporo-maxillary and posterior auricular veins. It commences in the substance of the parotid gland, on a level with the angle of the lower jaw, and runs perpendicularly down the neck in the direction of a line drawn from the angle of the jaw to the middle of the clavicle. In its course it crosses the Sterno-mastoid muscle, and runs parallel with its posterior border as far as its attachment to the clavicle, where it perforates the deep fascia, and terminates in the subclavian vein, on the outer side of or in front of the Scalenus anticus muscle. In the neck it is separated from the Sterno-mastoid by the investing layer of the deep cervical fascia, and is covered by the Platysma, the superficial fascia, and the integument. This vein is crossed about its middle by the superficialis colli nerve, and its upper half is accompanied by the auricularis magnus nerve. The external jugular vein varies in size, bearing an inverse proportion to that of the other veins of the neck; it is occasionally double. It is provided with two pairs of valves, the lower pair being placed at its entrance into the subclavian vein, the upper pair in most cases about an inch and a half above the clavicle. The portion of vein between the two sets of valves is often dilated, and is termed the *sinus*. These valves do not prevent the regurgitation of the blood or the passage of injection from below upward.[1]

Surgical Anatomy.—Venesection used formerly to be performed on the external jugular vein, but is now probably never resorted to. The anatomical point to be remembered in performing this operation is to cut across the fibres of the Platysma myoides in opening the vein, so that by their contraction they will expose the orifice in the vein and so allow the flow of blood.

Tributaries.—This vein receives the occipital occasionally, the posterior external jugular, and near its termination, the suprascapular and transverse cervical veins.

[1] The student may refer to an interesting paper by Dr. Struthers, "On Jugular Venesection in Asphyxia, anatomically and experimentally considered, including the Demonstration of Valves in the Veins of the Neck," in the *Edinburgh Medical Journal* for November, 1856.

It communicates with the anterior jugular, and, in the substance of the parotid, receives a large branch of communication from the internal jugular.

The **Posterior External Jugular Vein** commences in the occipital region, and returns the blood from the integument and superficial muscles in the upper and back part of the neck, lying between the Splenius and Trapezius muscles. It runs down the back part of the neck, and opens into the external jugular just below the middle of its course.

The **Anterior Jugular Vein** commences near the hyoid bone from the convergence of several superficial veins from the submaxillary region. It passes down between the median line and the anterior border of the Sterno-mastoid, and at the lower part of the neck passes beneath that muscle to open into the termination of the external jugular or into the subclavian vein (Fig. 331). This vein varies considerably in size, bearing almost always an inverse proportion to the external jugular. Most frequently there are two anterior jugulars, a right and left, but occasionally only one. This vein receives some laryngeal veins, and occasionally a small thyroid vein. Just above the sternum the two anterior jugular veins communicate by a transverse trunk, which receives tributaries from the inferior thyroid veins. It also communicates with the internal jugular. There are no valves in this vein.

The **Internal Jugular Vein** collects the blood from the interior of the cranium, from the superficial parts of the face, and from the neck. It commences just external to the jugular foramen, at the base of the skull, being formed by the coalescence of the lateral and inferior petrosal sinuses (Fig. 329). At its origin it is somewhat dilated, and this dilatation is called the *sinus*, or *gulf*, of the internal jugular vein. It runs down the side of the neck in a vertical direction, lying at first on the outer side of the internal carotid, and then on the outer side of the common carotid, and at the root of the neck unites with the subclavian vein to form the innominate vein. The internal jugular vein, at its commencement, lies upon the Rectus capitis lateralis, and behind the internal carotid artery and the nerves passing through the jugular foramen; lower down, the vein and artery lie upon the same plane, the glosso-pharyngeal and hypoglossal nerves passing forward between them; the pneumogastric descends between and behind them in the same sheath, and the spinal accessory passes obliquely outward, behind or in front of, the vein. At the root of the neck the vein of the right side is placed at a little distance from the artery; on the left side it usually lies over the artery at its lower part. The right internal jugular vein crosses the first part of the subclavian artery. The vein is of considerable size, but varies in different individuals, the left one being usually the smaller. It is provided with a pair of valves, which are placed at its point of termination or from half to three-quarters of an inch above it.

Tributaries.—This vein receives in its course the facial, lingual, pharyngeal, superior and middle thyroid veins, and sometimes the occipital. At its point of junction with the common facial vein it becomes greatly increased in size.

The **lingual veins** commence on the dorsum, sides, and under surface of the tongue, and, passing backward, following the course of the lingual artery and its branches, terminate in the internal jugular. Sometimes the ranine vein, which is a branch of considerable size commencing below the tip of the tongue, joins the lingual. Generally, however, it passes backward, crosses the Hyo-glossus muscle in company with the hypoglossal nerve, and joins the facial.

The **pharyngeal vein** commences in a minute plexus, the *pharyngeal*, at the back part and sides of the pharynx, and, after receiving meningeal tributaries and the Vidian and spheno-palatine veins, terminates in the internal jugular. It occasionally opens into the facial, lingual, or superior thyroid vein.

The **superior thyroid vein** commences in the substance and on the surface of the thyroid gland by tributaries corresponding with the branches of the superior thyroid artery, and terminates in the upper part of the internal jugular vein. It receives the superior laryngeal and crico-thyroid veins.

The **middle thyroid vein** collects the blood from the lower part of the lateral lobe of the thyroid gland, and, being joined by some veins from the larynx and trachea, terminates in the lower part of the internal jugular vein.

The facial and **occipital veins** have been described above.

Surgical Anatomy.—The internal jugular vein occasionally requires ligature in cases of septic thrombosis of the lateral sinus from suppuration in the middle ear, in order to prevent septic emboli being carried into the general circulation. This operation has been performed recently in several cases, with the most satisfactory results. The cases are generally those of chronic disease of the middle ear, with discharge of pus which perhaps has existed for many years. The patient is seized with acute septic inflammation, spreading to the mastoid cells, and consequent on this, septic thrombosis of the lateral sinus extending to the internal jugular vein. Such cases are always extremely grave, for there is a danger of a portion of the septic clot being detached and causing septic embolism in the thoracic viscera. If the condition is suspected, the sinus should be at once explored by trephining at a point an inch behind the centre of the external auditory meatus and a quarter of an inch above Reid's base line. The condition of the sinus is then investigated, and if it is found to be thrombosed, the surgeon should at once proceed to ligate the internal jugular vein, by an incision along the anterior border of the sterno-mastoid, the centre of which is on a level with the greater cornu of the hyoid bone. The vein should be ligated in two places and divided between. After the vessel has been secured and divided, the lateral sinus is to be thoroughly cleared out, and by removing the ligature from the upper end of the divided vein, all septic clots removed by syringing from the sinus through the vein. If hemorrhage occurs from the distal end of the sinus, it can be arrested by careful plugging with antiseptic gauze.

The **Vertebral Vein** commences in the occipital region by numerous small tributaries from the deep muscles at the upper and back part of the neck; these pass outward and enter the foramen in the transverse process of the atlas, and descend, forming a dense plexus around the vertebral artery in the canal formed by the foramina in the transverse processes of the cervical vertebræ. This plexus unites at the lower part of the neck into two main trunks, one of which emerges from the foramen in the transverse process of the sixth cervical vertebra, and the other through that of the seventh, and, uniting, form a single vessel, which terminates at the root of the neck in the back part of the innominate vein near its origin, its mouth being guarded by a pair of valves. On the right side it crosses the first part of the subclavian artery.

Tributaries.—The vertebral vein receives in its course a vein from the inside of the skull through the posterior condyloid foramen; muscular veins from the muscles in the prevertebral region; dorsi-spinal veins, from the back part of the cervical portion of the spine; meningo-rachidian veins, from the interior of the spinal canal; the anterior and posterior vertebral veins; and close to its termination it is joined by a *small vein* from the *first intercostal space* which accompanies the superior intercostal artery.

The **anterior vertebral vein** commences in a plexus around the transverse processes of the upper cervical vertebræ, descends in company with the ascending cervical artery between the Scalenus anticus and Rectus capitis anticus major muscles, and opens into the vertebral vein just before its termination.

The **posterior vertebral vein** (the **deep cervical**) accompanies the profunda cervicis artery, lying between the Complexus and Semispinalis colli. It commences in the suboccipital region by communicating branches from the occipital vein and tributaries from the deep muscles at the back of the neck. It receives tributaries from the plexuses around the spinous processes of the cervical vertebræ, and terminates in the lower end of the vertebral vein.

The Veins of the Diploë.

The diploë of the cranial bones is channelled in the adult by a number of tortuous canals, which are lined by a more or less complete layer of compact tissue.

The veins they contain are large and capacious, their walls being thin, and formed only of endothelium resting upon a layer of elastic tissue, and they present at irregular intervals pouch-like dilatations, or *culs-de-sac*, which serve as

reservoirs for the blood. These are the veins of the diploë; they can only be displayed by removing the outer table of the skull.

In adult life, as long as the cranial bones are distinct and separable, these veins are confined to the particular bones; but in old age, when the sutures are united, they communicate with each other and increase in size. These vessels communicate, in the interior of the cranium, with the meningeal veins and with the sinuses of the dura mater, and on the exterior of the skull with the veins of the pericranium. They are divided into the *frontal*, which opens into the supra-orbital vein by an aperture in the supra-orbital notch; the *anterior temporal*, which is confined chiefly to the frontal bone, and opens into one of the deep temporal veins, after escaping by an aperture in the great wing of the sphenoid;

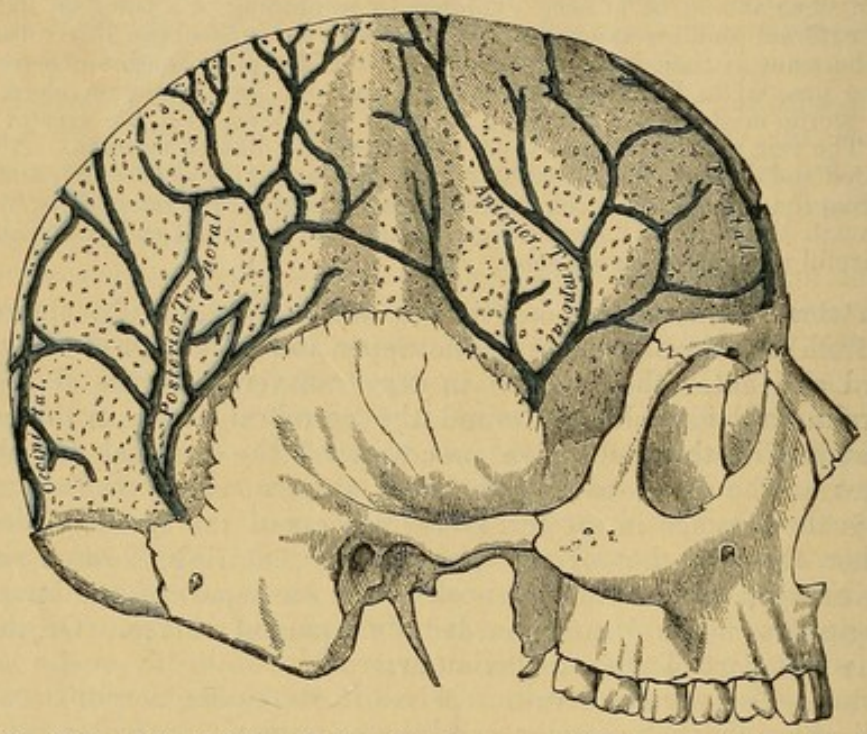

FIG. 325.—Veins of the Diploë as displayed by the removal of the outer table of the skull.

the *posterior temporal*, which is confined to the parietal bone, and terminates in the lateral sinus by an aperture at the posterior inferior angle of the parietal bone; and the *occipital*, the largest of the four, which is confined to the occipital bone, and opens either into the occipital vein or internally into the lateral sinus or torcular Herophili.

The Cerebral Veins.

The **Cerebral Veins** are remarkable for the extreme thinness of their coats in consequence of the muscular tissue in them being wanting, and for the absence of valves. They may be divided into two sets: the superficial, which are placed on the surface, and the deep veins, which occupy the interior of the organ.

The **Superficial Cerebral Veins** ramify upon the surface of the brain, being lodged in the sulci between the convolutions, a few running across the convolutions. They receive branches from the substance of the brain and terminate in the sinuses. They are named, from the position they occupy, superior, median, and inferior cerebral veins.

The **Superior Cerebral Veins**, eight to twelve in number on each side, return the blood from the convolutions on the superior surface of the hemisphere; they pass forward and inward toward the great longitudinal fissure, where they receive the *median cerebral veins;* near their termination they become invested with a tubular sheath of the arachnoid membrane, and open into the superior longitudinal sinus in the opposite direction to the course of the current of the blood.

The Median Cerebral Veins return the blood from the convolutions of the mesial

surface of the corresponding hemisphere; they open into the superior cerebral veins, or occasionally into the inferior longitudinal sinus.

The **Inferior Cerebral Veins** ramify on the lower part of the outer and on the under surface of the cerebral hemisphere. Some, collecting tributaries from the under surface of the anterior lobes of the brain, terminate in the cavernous sinus. One vein of large size, the *middle cerebral vein*, commences on the under surface of the temporal lobe, and, running along the fissure of Sylvius, opens into the cavernous sinus. Another large vein, the *great anastomotic vein of Trolard*, commences on the parietal lobe, runs along the horizontal limb of the fissure of Sylvius, and opens into the anterior part of the cavernous sinus under the lesser wing of the sphenoid. Others commence on the under surface of the base of the brain, and unite to form from three to five veins, which open into the superior petrosal and lateral sinuses from before backward.

The **Deep Cerebral,** or **Ventricular Veins** (*venæ Galeni*), are two in number. They are formed by the union of two veins, the *vena corporis striati*, and the *choroid vein*, on either side. They run backward, parallel with one another, between the layers of the velum interpositum, and pass out of the brain at the great transverse fissure, between the posterior extremity, or *splenium*, of the corpus callosum and the tubercula quadrigemina, to enter the straight sinus. The two veins usually unite to form one, *the vena magna Galeni*, before opening into the straight sinus, just before their union they receive the basilar vein.

The **vena corporis striati** commences in the groove between the corpus striatum and thalamus opticus, receives numerous veins from both of these parts, and unites behind the anterior pillar of the fornix with the choroid vein to form one of the venæ Galeni.

The **choroid vein** runs along the whole length of the outer border of the choroid plexus, receiving veins from the hippocampus major, the fornix and corpus callosum, and unites, at the anterior extremity of the choroid plexus, with the vein of the corpus striatum.

The **Basilar vein** commences at the anterior perforated space at the base of the brain by the union of a small anterior cerebral vein, which courses backward between the anterior lobes of the cerebrum, with the deep Sylvian vein, which descends through the lower part of the Sylvian fissure. It passes backward round the crus cerebri, receiving the inferior striate vein from the corpus striatum, interpeduncular veins from the interpeduncular space, ventricular veins from the middle cornu of the lateral ventricles, and tributaries from the uncinate convolution, and enters the vein of Galen just before its junction with the vein of the opposite side.

The **Cerebellar veins** occupy the surface of the cerebellum, and are disposed in three sets, superior, inferior, and lateral. The *superior* pass partly forward and inward, across the superior vermiform process, to terminate in the straight sinus and the venæ Galeni, partly outward to the lateral and superior petrosal sinuses. The *inferior cerebellar veins*, of large size, terminate in the lateral, superior petrosal, and occipital sinuses.

The perivascular lymphatics alluded to in the section on General Anatomy are especially found in connection with the vessels of the brain. These vessels are enclosed in a sheath, which acts as a lymphatic channel, through which the lymph is carried to the subarachnoid and subdural spaces, from which it is returned into the general circulation.

The Sinuses of the Dura Mater.

The sinuses of the dura mater are venous channels, analogous to the veins, their outer coat being formed by the dura mater; their inner, by a continuation of the lining membrane of the veins. They are fourteen in number, and are divided into two sets: 1, those situated at the upper and back part of the skull; 2, those at the base of the skull. The former are—the

Superior Longitudinal Sinus.
Inferior Longitudinal Sinus.
Straight Sinus.
Lateral Sinuses.
Occipital Sinus.

The **Superior Longitudinal Sinus** occupies the attached margin of the falx cerebri. Commencing at the foramen cæcum, through which, in the child, it constantly communicates by a small branch with the veins of the nasal fossæ, it runs from before backward, grooving the inner surface of the frontal, the adjacent margins of the two parietal, and the superior division of the crucial ridge of the occipital bone, and terminates by opening into the torcular Herophili. The sinus is triangular in form, narrow in front, and gradually increases in size as it passes backward. On examining its inner surface it presents the internal openings of the superior cerebral veins, which run, for the most part, from behind forward, and open chiefly at the back part of the sinus, their orifices being concealed by fibrous folds; numerous fibrous bands (*chordæ Willisii*) are also seen, extending transversely across the inferior angle of the sinus: and, lastly, some small, white, projecting bodies, the *glandulæ Pacchioni*. This sinus receives the superior cerebral veins, numerous veins from the diploë and dura mater, and, at the posterior extremity of the sagittal suture, veins from the pericranium, which pass through the parietal foramina.

The *torcular Herophili*, or *confluence of the sinuses*, is the dilated extremity of the superior longitudinal sinus. It is of irregular form, and is lodged on one side (generally the right) of the internal occipital protuberance. From it the lateral sinus of the side to which it is deflected is derived. It receives also the blood from the occipital sinus.

The **Inferior Longitudinal Sinus**, more correctly described as the *inferior longitudinal vein*, is contained in the posterior part of the free margin of the falx cerebri. It is of a cylindrical form, increases in size as it passes backward, and terminates in the straight sinus. It receives several veins from the falx cerebri, and occasionally a few from the mesial surface of the hemispheres.

The **Straight Sinus** is situated at the line of junction of the falx cerebri with the tentorium. It is triangular in form, increases in size as it proceeds backward, and runs obliquely downward and backward from the termination of the inferior longitudinal sinus to the lateral sinus of the opposite side to that into which the superior longitudinal sinus is prolonged. It communicates by a cross branch

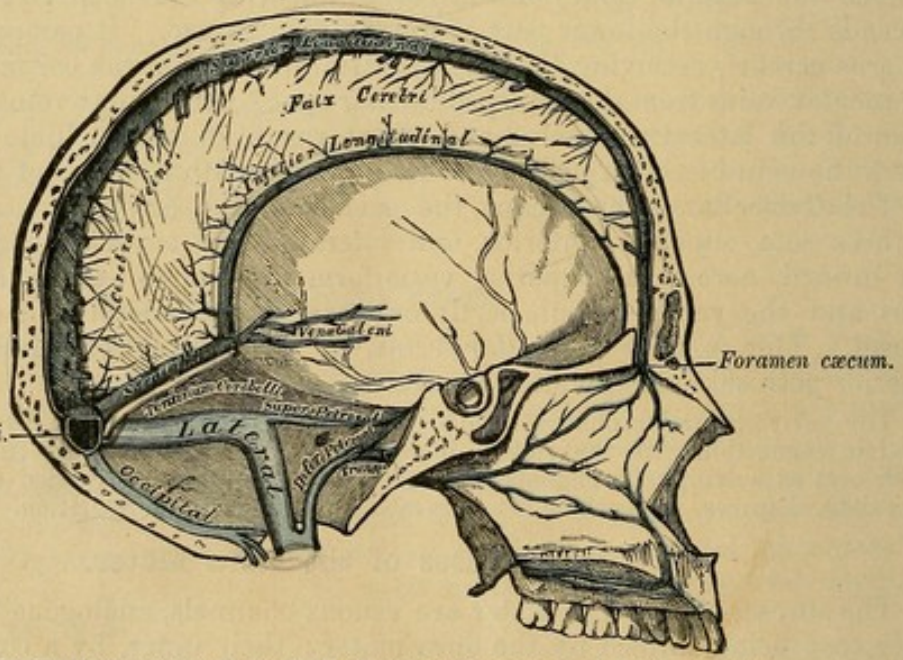

FIG. 326.—Vertical section of the skull, showing the sinuses of the dura mater.

with the torcular Herophili. Beside the inferior longitudinal sinus, it receives the venæ Galeni and the superior cerebellar veins. A few transverse bands cross its interior.

The **Lateral Sinuses** are of large size, and are situated in the attached margin of the tentorium cerebelli. They commence at the internal occipital protuberance,

one, generally the right, being the direct continuation of the superior longitudinal sinus, the other of the straight sinus. They pass outward and forward, describing a slight curve with its convexity upward, to the base of the petrous portion of the temporal bone, then curve downward and inward on each side to reach the jugular foramen, where they terminate in the internal jugular vein. Each sinus rests, in its course, upon the inner surface of the occipital, the posterior inferior angle of the parietal, the mastoid portion of the temporal, and on the occipital again just before its termination. These sinuses are frequently of unequal size, that formed by the superior longitudinal sinus being the larger, and they increase in size as they proceed from behind forward. The horizontal portion is of a triangular form, the curved portion semicylindrical. Their inner surface is smooth, and not crossed by the fibrous bands found in the other sinuses. These sinuses receive the blood from the superior petrosal sinuses at the base of the petrous portion of the temporal bone, and they unite with the inferior petrosal sinus, just external to the jugular foramen, to form the internal jugular vein (Fig. 329). They communicate with the veins of the pericranium by means of the mastoid and posterior condyloid veins, and they receive some of the inferior cerebral and inferior cerebellar veins and some veins from the diploë. The *petro-squamous sinus*, when present, runs backward along the junction of the petrous and squamous-temporal, and opens into the lateral sinus.

The **Occipital** is the smallest of the cranial sinuses. It is generally single, but occasionally there are two. It is situated in the attached margin of the falx cerebelli. It commences by several small veins around the margin of the foramen magnum, one of which joins the termination of the lateral sinus; it communicates with the posterior spinal veins and terminates in the torcular Herophili.

The sinuses at the base of the skull are—the

Cavernous sinuses. Superior Petrosal sinuses.
Circular sinus. Inferior Petrosal sinuses.
Transverse sinus.

The **Cavernous Sinuses** are named from their presenting a reticulated structure, due to their being traversed by numerous interlacing filaments. They are two in number, of irregular form, larger behind than in front, and are placed one on each side

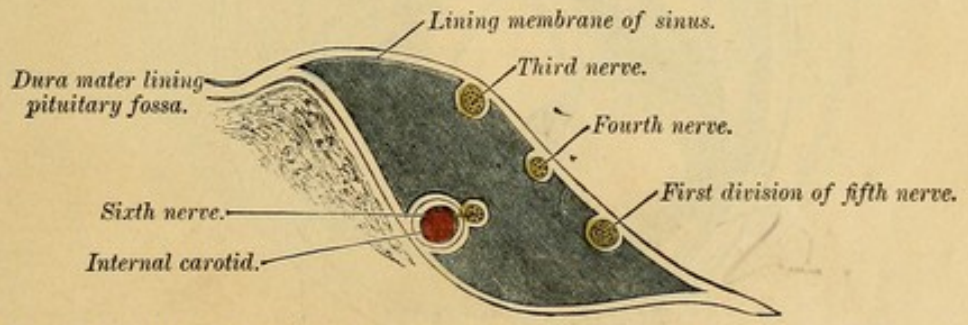

FIG. 327.—Plan showing the relative position of the structures in the right cavernous sinus, viewed from behind.

of the sella turcica, extending from the sphenoidal fissure to the apex of the petrous portion of the temporal bone; they receive anteriorly the ophthalmic vein through the sphenoidal fissure, and open behind into the petrosal sinuses. On the inner wall of each sinus is found the internal carotid artery, accompanied by filaments of the carotid plexus and by the sixth nerve; and on its outer wall, the third, fourth, and ophthalmic division of the fifth nerve. These parts are separated from the blood flowing along the sinus by the lining membrane, which is continuous with the inner coat of the veins. The cavernous sinuses receive some of the cerebral veins, and also a small sinus, the *spheno-parietal*, which extends inward on the under aspect of the lesser wing of the sphenoid; they communicate with the lateral sinuses by means of the superior and inferior petrosal sinuses, and with the facial vein through the ophthalmic vein. They also communicate with each other by means of the circular sinus.

Surgical Anatomy.—An arterio-venous communication may be established between the cavernous sinus and the carotid artery, as it lies in it, giving rise to a pulsating tumor in the orbit. These communications may be the result of injury, such as a bullet wound, a stab, or a blow or fall sufficiently severe to cause a fracture of the base of the skull in this situation, or they may occur idiopathically from the rupture of an aneurism or a diseased condition of the internal carotid artery. The disease begins with sudden noise and pain in the head, followed by exophthalmos, swelling, and congestion of the lids and conjunctivæ, and development of a pulsating tumor at the margin of the orbit, with thrill and the characteristic bruit; accompanying these symptoms there may be impairment of sight, paralysis of the iris and orbital muscles, and pain of varying intensity. In some cases the opposite orbit becomes affected by the passage of the arterial blood into the opposite sinus by means of the circular sinus. Or the arterial blood may find its way through the emissary veins (see page 605) into the pterygoid plexus, and thence into the veins of the face. Pulsating tumors of the orbit may also be due to traumatic aneurism of one of the orbital arteries, and symptoms resembling those of pulsating tumor may be produced by pressure on the ophthalmic vein, as it enters the sinus, by an aneurism of the internal carotid artery.

The **Ophthalmic Veins** are two in number, superior and inferior.

The *superior ophthalmic vein* connects the angular vein at the inner angle of the orbit with the cavernous sinus; it pursues the same course as the ophthalmic artery, and receives tributaries corresponding to the branches derived from that vessel. Forming a short single trunk, it passes through the inner extremity of the sphenoidal fissure, and terminates in the cavernous sinus.

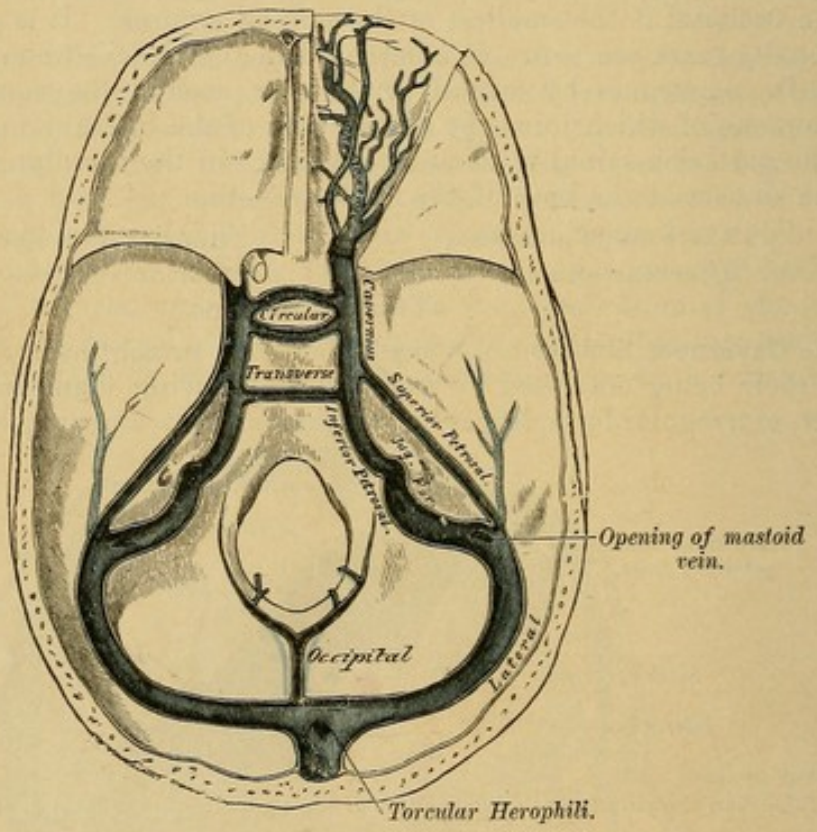

FIG. 328.—The sinuses at the base of the skull.

The *inferior ophthalmic vein* receives the veins from the floor of the orbit, and either passes out of the orbit through the spheno-maxillary fissure to join the pterygoid plexus of veins, or else, passing backward through the sphenoidal fissure, it enters the cavernous sinus, either by a separate opening, or, more frequently, in common with the superior ophthalmic vein.

The **Circular sinus** is formed by two transverse vessels, the *anterior* and *posterior intercavernous sinuses*, which connect together the two cavernous sinuses; the one passing in front and the other behind the pituitary body, and thus forming with the cavernous sinuses a venous circle around that body. The anterior one is usually the larger of the two, and one or other is occasionally found to be absent.

The **Superior petrosal sinus** is situated along the superior border of the petrous portion of the temporal bone, in the front part of the attached margin of the

tentorium. It is small and narrow, and connects together the cavernous and lateral sinuses at each side. It receives some cerebellar and inferior cerebral veins, and veins from the tympanic cavity.

The **Inferior petrosal sinus** is situated in the groove formed by the junction of the posterior border of the petrous portion of the temporal with the basilar process of the occipital. It commences in front at the termination of the cavernous sinus, and behind joins the lateral sinus after it has passed through the jugular foramen; the junction of these two sinuses forming the commencement of the internal jugular vein. The inferior petrosal sinus receives the veins from the internal ear and also veins from the medulla, pons, and under surface of the cerebellum.

The junction of the two sinuses takes place at the lower border of, or just external to, the jugular foramen. The exact relation of the parts to one another in the foramen is as follows: The inferior petrosal sinus is in front, with the meningeal branch of the ascending pharyngeal artery, and is directed obliquely downward and backward; the lateral sinus is situated at the back part of the fora-

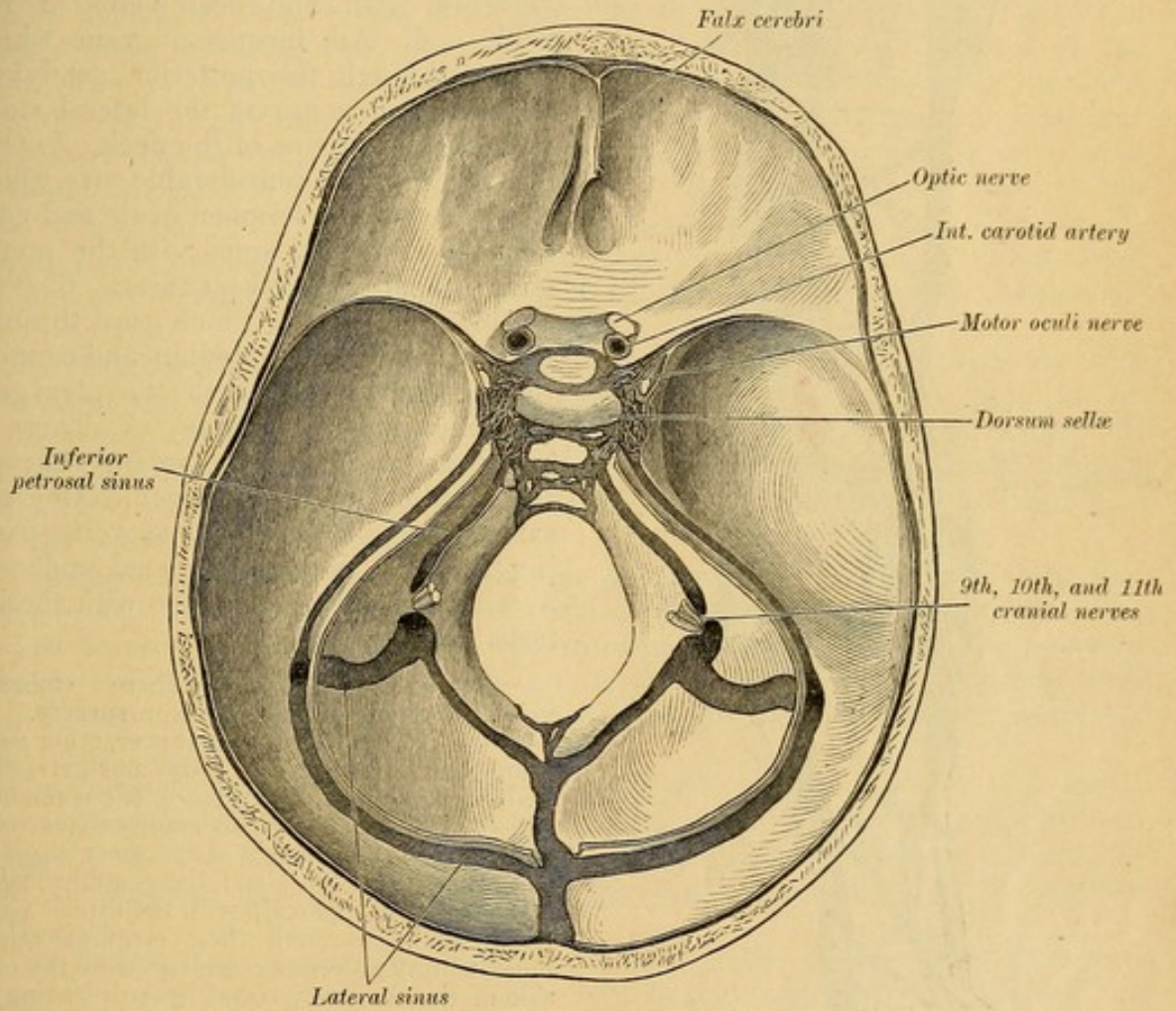

FIG. 329.—Relation of nerves to sinuses in jugular foramen. (Henle.)

men with a meningeal branch of the occipital artery, and between the two are the glosso-pharyngeal, pneumogastric, and spinal accessory nerves. These three sets of structures are divided from each other by two processes of fibrous tissue. The junction of the sinuses takes place superficial to the nerves, so that these latter lie a little internal to the venous channels in the foramen (see Fig. 329). These sinuses are semicylindrical in form.

The **Transverse Sinus**, or **basilar sinus**, consists of several interlacing veins between the layers of the dura mater over the basilar process of the occipital bone, which serve to connect the two inferior petrosal sinuses. With them the anterior spinal veins communicate.

Emissary Veins.—The emissary veins are vessels which pass through apertures

in the cranial wall and establish communications between the sinuses inside the skull and the veins external to it. Some of these are always present, others only occasionally so. They vary much in size in different individuals. The principal emissary veins are the following: 1. A vein, almost always present, which passes through the mastoid foramen and connects the lateral sinus with the posterior auricular or with an occipital vein. 2. A vein which passes through the parietal foramen and connects the superior longitudinal sinus with the veins of the scalp. 3. A plexus of minute veins which pass through the anterior condyloid foramen and connect the occipital sinus with the vertebral vein and deep veins of the neck. 4. An inconstant vein which passes through the posterior condyloid foramen and connects the lateral sinus with the deep veins of the neck. 5. One or two veins of considerable size which pass through the foramen ovale and connect the cavernous sinus with the pterygoid and pharyngeal plexuses. 6. Two or three small veins which pass through the foramen lacerum medium and connect the cavernous sinus with the pterygoid and pharyngeal plexuses. 7. There is sometimes a small vein passing through the foramen of Vesalius connecting the same parts. 8. A plexus of veins passing through the carotid canal and connecting the cavernous sinus with the internal jugular vein.

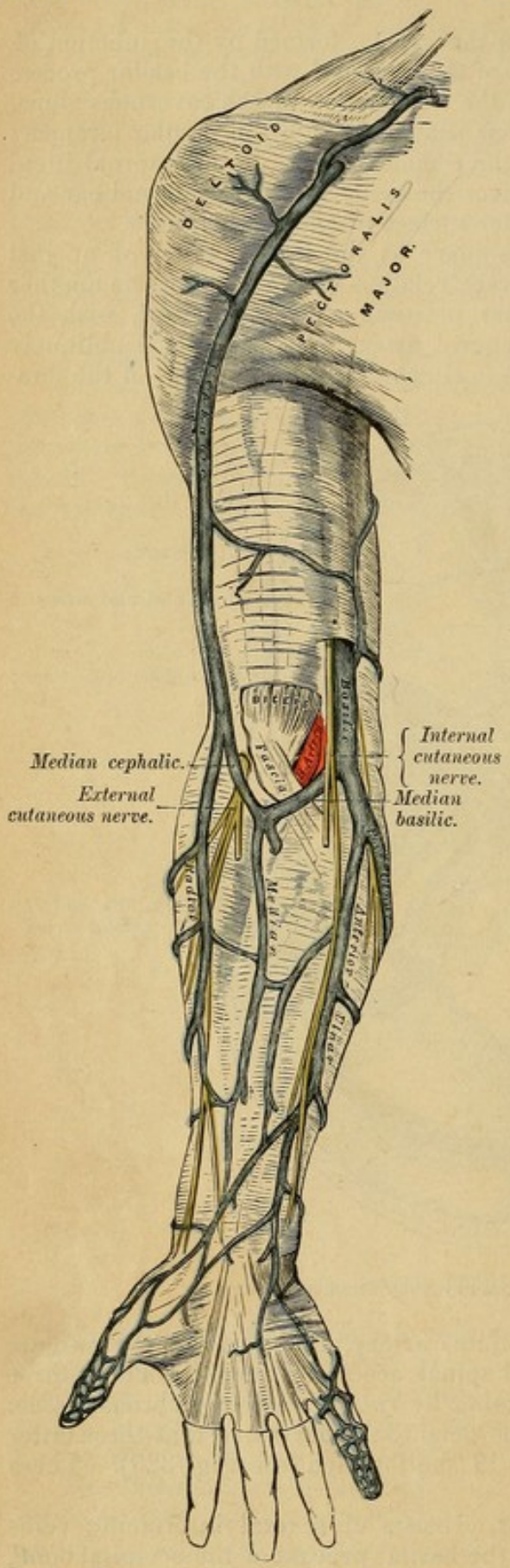

FIG. 330.—The superficial veins of the upper extremity.

Surgical Anatomy.—These emissary veins are of great importance in surgery. In addition to them there are, however, other communications between the intra- and extra-cranial circulation, as, for instance, the communication of the angular and supra-orbital veins with the ophthalmic vein at the inner angle of the orbit (page 595), and the communication of the veins of the scalp with the diploic veins (page 599). Through these communications inflammatory processes commencing on the outside of the skull may travel inward, leading to osteo-phlebitis of the diploë and inflammation of the membranes of the brain. To this in former days was to be attributed one of the principal dangers of scalp wounds and other injuries of the scalp.

By means of these emissary veins blood may be abstracted almost directly from the intracranial circulation. For instance, leeches applied behind the ear abstract blood almost directly from the lateral sinus by means of the vein passing through the mastoid foramen. Again, epistaxis in children will frequently relieve severe headache, the blood which flows from the nose being derived from the longitudinal sinus by means of the vein which passes through the foramen cæcum, which is another communication between the intracranial and extracranial circulation which is constantly found in children.

VEINS OF THE UPPER EXTREMITY AND THORAX.

The veins of the Upper Extremity are divided into two sets, *superficial* and *deep*.

The **Superficial Veins** are placed immediately beneath the integument between the two layers of superficial fascia.

The **Deep Veins** accompany the arteries, and constitute the venæ comites of those vessels.

Both sets of vessels are provided with valves, which are more numerous in the deep than in the superficial.

The superficial veins of the upper extremity are—the

Superficial veins of the Hand.	Median.
Anterior Ulnar.	Median Cephalic.
Posterior Ulnar.	Median Basilic.
Common Ulnar.	Basilic.
Radial.	Cephalic.

The **Superficial Veins of the Hand and Fingers** are principally situated on the dorsal surface, and form two plexuses, an inner and outer, on the back of the hand. The inner plexus is formed by the veins from the little finger (*vena salvatella*), the ring finger, and the ulnar side of the middle finger; from it the anterior and posterior ulnar veins are derived. The outer plexus is formed by veins from the thumb, the index finger, and radial side of the middle finger; from it the radial vein is derived. These two plexuses communicate on the back of the hand, forming the superficial arch of veins in this situation. The superficial veins from the palm of the hand form a plexus in front of the wrist, from which the median vein is derived.

The **Anterior Ulnar Vein** commences on the anterior surface of the ulnar side of the hand and wrist, and ascends along the anterior surface of the ulnar side of the forearm to the bend of the elbow, where it joins with the posterior ulnar vein to form the common ulnar. Occasionally it opens separately into the median basilic vein. It communicates with branches of the median vein in front and with the posterior ulnar behind.

The **Posterior Ulnar Vein** commences on the posterior surface of the ulnar side of the wrist. It runs on the posterior surface of the ulnar side of the forearm, and just below the elbow unites with the anterior ulnar vein to form the common ulnar, or else joins the median basilic to form the basilic. It communicates with the deep veins of the palm by a branch which emerges from beneath the Abductor minimi digiti muscle.

The **Common Ulnar** is a short trunk which is not constant. When it exists it is formed by the junction of the two preceding veins, and, passing upward and outward, joins the median basilic to form the basilic vein. When it does not exist the anterior and posterior ulnar veins open separately into the median basilic vein.

The **Radial Vein** commences from the dorsal surface of the wrist, communicating with the deep veins of the palm by a branch which passes through the first interosseous space. It forms a large vessel, which ascends along the radial side of the forearm and receives numerous veins from both its surfaces. At the bend of the elbow it unites with the median cephalic to form the cephalic vein.

The **Median Vein** ascends on the front of the forearm, and communicates with the anterior ulnar and radial veins. At the bend of the elbow it receives a branch of communication from the deep veins, and divides into two branches, the median cephalic and median basilic, which diverge from each other as they ascend.

The **Median Cephalic**, usually the smaller of the two, passes outward in the groove between the Supinator longus and Biceps muscles, and joins with the radial to form the cephalic vein. The branches of the external cutaneous nerve pass beneath this vessel.

The **Median Basilic Vein** passes obliquely inward, in the groove between the Biceps and Pronator radii teres, and joins the common ulnar to form the basilic. This vein passes in front of the brachial artery, from which it is separated by a fibrous expansion (the *bicipital fascia*) which is given off from the tendon of the Biceps to the fascia covering the Flexor muscles of the forearm. Filaments of the internal cutaneous nerve pass in front as well as behind this vessel.[1]

Venesection is usually performed at the bend of the elbow, and as a matter of practice the largest vein in this situation is commonly selected. This is usually the median basilic, and there are anatomical advantages and disadvantages in selecting this vein. The advantages are, that in addition to its being the largest, and therefore yielding a greater supply of blood, it is the least movable and can be easily steadied on the bicipital fascia on which it rests. The disadvantages are, that it is in close relationship with the brachial artery, separated only by the bicipital fascia; and formerly, when venesection was frequently practised, arterio-venous aneurism was no uncommon result of this practice. Another disadvantage is, that the median basilic is crossed by some of the branches of the internal cutaneous nerve, and these may be divided in the operation, giving rise to "traumatic neuralgia of extreme intensity" (Tillaux).

The **Basilic Vein** is of considerable size, formed by the coalescence of the common ulnar vein with the median basilic. It passes upward along the inner side of the Biceps muscle, pierces the deep fascia a little below the middle of the arm, and, ascending in the course of the brachial artery to the lower border of the tendons of the Latissimus dorsi and Teres major muscles, it is continued onward as the axillary vein.

The **Cephalic Vein** courses along the outer border of the Biceps muscle, lying in the same groove with the upper external cutaneous branch of the musculo-spiral nerve, to the upper third of the arm; it then passes in the interval between the Pectoralis major and Deltoid muscles, lying in the same groove with the descending or humeral branch of the acromial-thoracic artery. It pierces the costo-coracoid membrane, and crossing the axillary artery, it terminates in the axillary vein just below the clavicle. This vein is occasionally connected with the external jugular or subclavian by a branch which passes from it upward in front of the clavicle.

The **Deep Veins of the Upper Extremity** follow the course of the arteries, forming their venæ comites. They are generally two in number, one lying on each side of the corresponding artery, and they are connected at intervals by short transverse branches.

There are two digital veins accompanying each artery along the sides of the fingers: these, uniting at their base, pass along the interosseous spaces in the palm, and terminate in the two venæ comites which accompany the superficial palmar arch. Branches from these vessels on the radial side of the hand accompany the superficialis volæ, and on the ulnar side terminate in the deep ulnar veins. The deep ulnar veins, as they pass in front of the wrist, communicate with the interosseous and superficial veins, and at the elbow unite with the deep radial veins to form the venæ comites of the brachial artery.

The **Interosseous Veins** accompany the anterior and posterior interosseous arteries. The anterior interosseous veins commence in front of the wrist, where they communicate with the deep radial and ulnar veins; at the upper part of the forearm they receive the posterior interosseous veins, and terminate in the venæ comites of the ulnar artery.

The **Deep Palmar Veins** accompany the deep palmar arch, being formed by tributaries which accompany the ramifications of that vessel. They communicate with the deep ulnar veins at the inner side of the hand, and on the outer side terminate in the venæ comites of the radial artery. At the wrist they receive a dorsal and a palmar tributary from the thumb, and unite with the deep radial veins. Accompanying the radial artery, these vessels terminate in the venæ comites of the brachial artery.

[1] Cruveilhier says: "Numerous varieties are observed in the disposition of the veins of the elbow; sometimes the common median vein is wanting; but in those cases its two branches are furnished by the radial vein, and the cephalic is almost always in a rudimentary condition. In other cases only two veins are found at the bend of the elbow, the radial and ulnar, which are continuous, without any demarcation, with the cephalic and basilic."

The **Brachial Veins** are placed one on each side of the brachial artery, rec.. tributaries corresponding with the branches given off from that vessel; at ends lower margin of the Subscapularis, they join the axillary vein. rd

These deep veins have numerous anastomoses, not only with each other, but also with the superficial veins.

The **Axillary Vein** is of large size, and is the continuation upward of the basilic vein. It commences at the lower border of the tendons of the Teres major and Latissimus dorsi, increases in size as it ascends, by receiving tributaries corresponding with the branches of the axillary artery, and terminates immediately beneath the clavicle at the outer border of the first rib, where it becomes the subclavian vein. This vessel is covered in front by the Pectoral muscles and costo-coracoid membrane, and lies on the thoracic side of the axillary artery, which it partially overlaps. Near its termination it receives the cephalic vein. This vein is provided with a pair of valves opposite the lower border of the Subscapularis muscle; valves are also found at the termination of the cephalic and subscapular veins.

Surgical Anatomy.—There are several points of surgical interest in connection with the axillary vein. Being more superficial, larger, and slightly overlapping the axillary artery, it is more liable to be wounded in the operation of extirpation of the axillary glands, especially as these glands, when diseased, are apt to become adherent to the vessel. When wounded there is always a danger of air being drawn into its interior, and death resulting. This is due not only to the fact that it is near the thorax, and therefore liable to be influenced by the respiratory movements, but also because it is adherent by its anterior surface to the costo-coracoid membrane, and therefore if wounded is likely to remain patulous and favor the chance of air being sucked in. This adhesion of the vein to the fascia prevents its collapsing, and therefore favors the furious bleeding which takes place in these cases.

To avoid wounding the axillary vein in the extirpation of glands from the axilla, no sharp cutting instruments should be used after the axillary cavity has been freely exposed, and care should be taken to use no undue force in isolating the glands. Should the vein be so embedded in the malignant deposit that the latter cannot be removed without taking away a part of the vein, this must be done, the vessel having been first ligated above and below.

The **Subclavian Vein,** the continuation of the axillary, extends from the outer border of the first rib to the inner end of the clavicle, where it unites with the internal jugular to form the innominate vein. It is in relation, in front, with the clavicle and Subclavius muscle; behind and above, with the subclavian artery, from which it is separated internally by the Scalenus anticus muscle and phrenic nerve. Below, it rests in a depression on the first rib and upon the pleura. Above, it is covered by the cervical fascia and integument.

The subclavian vein occasionally rises in the neck to a level with the third part of the subclavian artery, and in two instances has been seen passing with this vessel behind the Scalenus anticus. This vessel is usually provided with valves about an inch from its termination in the innominate, just external to the entrance of the external jugular vein.

Tributaries.—It receives the external and anterior jugular veins and a small branch from the cephalic, outside the Scalenus, and on the inner side of that muscle the internal jugular vein. At the angle of junction with the internal jugular the left subclavian vein receives the thoracic duct, while the right subclavian vein receives the right lymphatic duct.

The **Innominate** or **Brachio-cephalic Veins** (Fig. 331) are two large trunks, placed one on each side of the root of the neck, and formed by the union of the internal jugular and subclavian veins of the corresponding side.

The **Right Innominate Vein** is a short vessel, an inch in length, which commences at the inner end of the clavicle, and, passing almost vertically downward, joins with the left innominate vein just below the cartilage of the first rib, close to the right border of the sternum, to form the superior vena cava. It lies superficial and external to the innominate artery; on its right side is the phrenic nerve, and the pleura is here interposed between it and the apex of the lung. This vein, at the angle of junction of the internal jugular with the subclavian, receives the right vertebral vein, and, lower down, the right internal mammary, right inferior thyroid, and sometimes the right superior intercostal veins.

The **Left Innominate Vein**, about two and a half inches in length, and larger than the right, passes from left to right across the upper and front part of the chest, at the same time inclining downward, to unite with its fellow of the opposite side, forming the *superior vena cava*. It is in relation, in front, with the first piece of the sternum, from which it is separated by the Sterno-hyoid and Sterno-thyroid muscles, the thymus gland or its remains, and some loose areolar tissue. Behind, it lies across the roots of the three large arteries arising from the arch of the aorta. This vessel is joined by the left vertebral, left internal mammary, left inferior thyroid, and the left superior intercostal veins, and occasionally some thymic and pericardiac veins. There are no valves in the innominate veins.

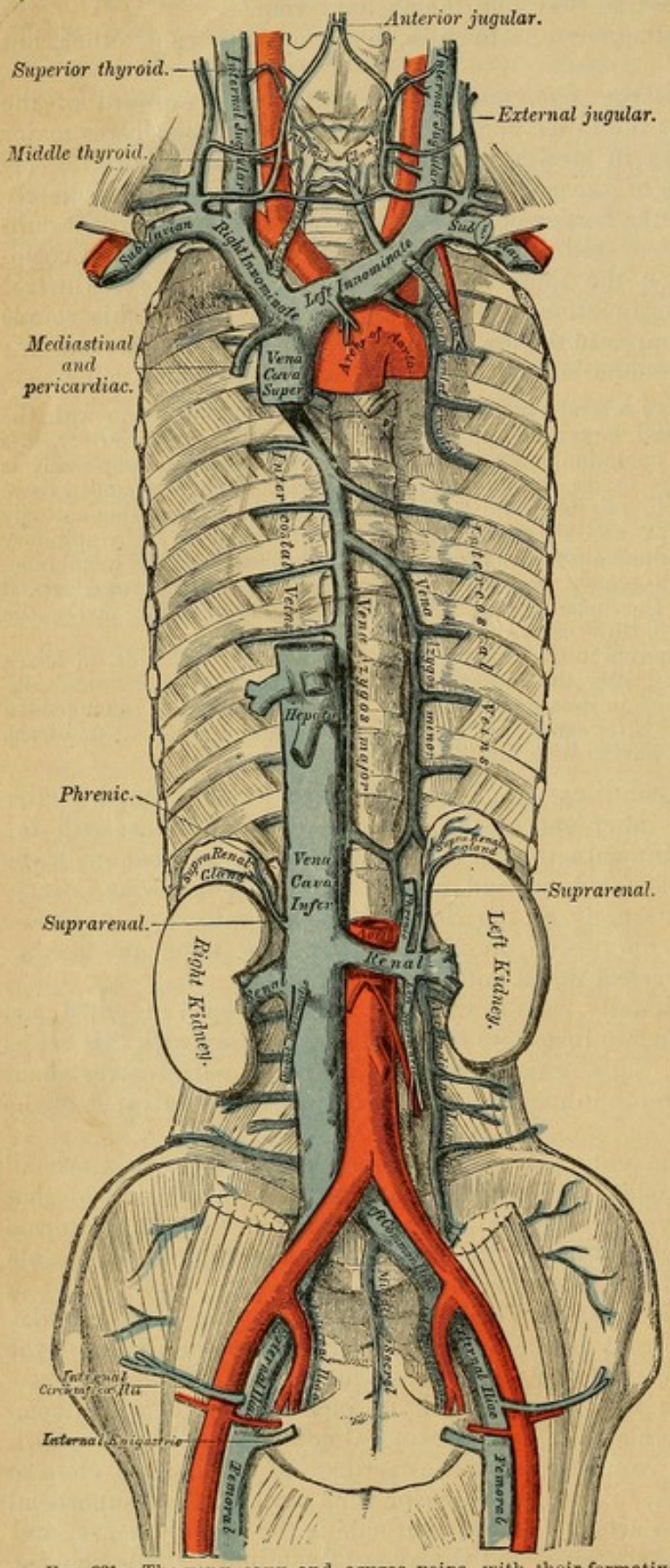

FIG. 331.—The venæ cavæ and azygos veins, with their formative branches.

Peculiarities.—Sometimes the innominate veins open separately into the right auricle; in such cases the right vein takes the ordinary course of the superior vena cava; but the left vein —*left superior vena cava*, as it is termed—after communicating by a small branch with the right one, passes in front of the root of the left lung, and, turning to the back of the heart, receives the cardiac veins, and terminates in the back of the right auricle. This occasional condition in the adult is due to the persistence of the early fœtal condition, and is the normal state of things in birds and some mammalia.

The **internal mammary veins**, two in number to each artery, follow the course of that vessel, and receive branches corresponding with those derived from it. The two veins of each side unite into a single trunk, which terminates in the innominate vein.

The **inferior thyroid veins**, two, frequently three or four, in number, arise in the venous plexus on the thyroid body, communicating with the middle and superior thyroid veins. They form a plexus in front of the

trachea, behind the Sterno-thyroid muscles. From this plexus a left vein descends and joins the left innominate trunk, and a right vein passes obliquely downward and outward across the innominate artery to open into the right innominate vein, just at its junction with the superior vena cava. These veins receive œsophageal, tracheal, and inferior laryngeal veins, and are provided with valves at their termination in the innominate veins.

The **Superior intercostal veins** (right and left) drain the blood from two or three intercostal spaces below the first. The *right* vein passes downward and inward and opens into the vena azygos major; the *left* runs across the transverse aorta and opens into the left innominate vein. It usually receives the left bronchial and left superior phrenic vein, and communicates below with the vena azygos minor superior. The *highest intercostal vein, i. e.*, from the first space, opens directly into the corresponding vertebral or innominate vein.

The **Superior Vena Cava** receives the blood which is conveyed to the heart from the whole of the upper half of the body. It is a short trunk, varying from two inches and a half to three inches in length, formed by the junction of the two innominate veins. It commences immediately below the cartilage of the first rib close to the sternum on the right side, and, descending vertically, enters the pericardium about an inch and a half above the heart, and terminates in the upper part of the right auricle opposite the upper border of the third right costal cartilage. In its course it describes a slight curve, the convexity of which is turned to the right side.

Relations.—*In front*, with the pericardium and process of cervical fascia which is continuous with it: this separates it from the thymus gland and from the sternum; *behind*, with the root of the right lung; on its *right side*, with the phrenic nerve and right pleura; on its *left side*, with the commencement of the innominate artery and ascending part of the aorta. The portion contained within the pericardium is covered by the serous layer of that membrane in its anterior three-fourths. It receives the vena azygos major just before it enters the pericardium, and several small veins from the pericardium and parts in the mediastinum. The superior vena cava has no valves.

The **Azygos Veins** connect together the superior and inferior venæ cavæ, taking the place of those vessels in that part of the chest occupied by the heart.

The larger, or *right azygos vein* (vena azygos major), commences opposite the first or second lumbar vertebra by a branch from the right lumbar veins (the *ascending lumbar*); sometimes by a branch from the right renal vein or from the inferior vena cava. It enters the thorax through the aortic opening in the Diaphragm, and passes along the right side of the vertebral column to the fourth dorsal vertebra, where it arches forward over the root of the right lung, and terminates in the superior vena cava just before that vessel enters the pericardium. Whilst passing through the aortic opening of the Diaphragm it lies with the thoracic duct on the right side of the aorta, and in the thorax it lies upon the intercostal arteries on the right side of the aorta and thoracic duct, and is partly covered by pleura.

Tributaries.—It receives the lower ten intercostal veins of the right side, the upper two or three of these opening first of all into the right superior intercostal vein. It receives the azygos minor veins, several œsophageal, mediastinal, and pericardial veins; near its termination, the right bronchial vein; and generally the right superior intercostal vein. A few imperfect valves are found in this vein; but its tributaries are provided with complete valves.

The intercostal veins on the left side, below the three upper intercostal spaces, usually form two trunks, named the left lower and the left upper azygos veins.

The *left lower*, or *smaller azygos vein* (vena azygos minor), commences in the lumbar region by a branch from one of the lumbar veins (*ascending lumbar*) or from the left renal. It passes into the thorax through the left crus of the Diaphragm, and, ascending on the left side of the spine as high as the ninth dorsal vertebra, passes across the column, behind the aorta and thoracic duct, to terminate

in the right azygos vein. It receives the four or five lower intercostal veins of the left side, and some œsophageal and mediastinal veins.

The *left upper azygos vein* varies inversely with the size of the left superior intercostal. It receives veins from the intercostal spaces between the left superior intercostal vein and highest tributary of the left lower azygos. They are usually three or four in number, and join to form a trunk which ends in the right azygos vein or in the left lower azygos. It sometimes receives the left bronchial vein. When this vein is small or altogether wanting, the left superior intercostal vein will extend as low as the fifth or six intercostal space.

Surgical Anatomy.—In obstruction of the inferior vena cava the azygos veins are one of the principal means by which the venous circulation is carried on, connecting as they do the superior and inferior venæ cavæ, and communicating with the common iliac veins by the ascending lumbar veins, and with many of the tributaries of the inferior vena cava.

The *bronchial veins* return the blood from the substance of the lungs; that of the right side opens into the vena azygos major near its termination; that of the left side, into the left superior intercostal vein or left upper azygos vein.

THE SPINAL VEINS.

The numerous venous plexuses placed upon and within the spine may be arranged into four sets:

1. Those placed on the exterior of the spinal column (the *dorsi-spinal veins*).
2. Those situated in the interior of the spinal canal, between the vertebræ and the theca vertebralis (*meningo-rachidian veins*).
3. The veins of the bodies of the vertebræ (*venæ basis vertebrarum*).
4. The veins of the spinal cord (*medulli-spinal*).

1. The **Dorsi-spinal Veins** commence by small branches which receive their

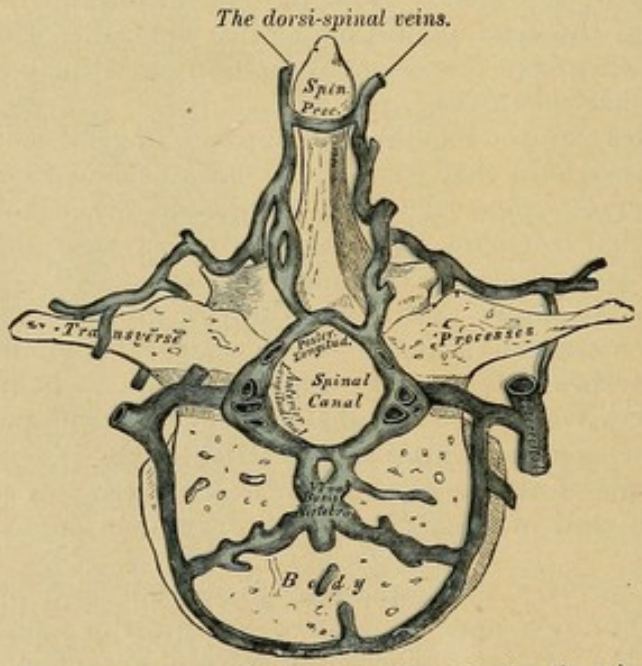

FIG. 332.—Transverse section of a dorsal vertebra, showing the spinal veins.

blood from the integument of the back of the spine and from the muscles in the vertebral grooves. They form a complicated network, which surrounds the spinous processes, the laminæ, and the transverse and articular processes of all the vertebræ. At the bases of the transverse processes they communicate, by means of ascending and descending branches, with the veins surrounding the contiguous vertebræ, and they join with the veins in the spinal canal by branches which perforate the ligamenta subflava. Other branches pass obliquely forward, between the transverse processes, and communicate with the intraspinal veins through the intervertebral foramina. They terminate by joining the vertebral

veins in the neck, the intercostal veins in the thorax, and the lumbar and sacral veins in the loins and pelvis.

2. **The Meningo-rachidian Veins.**—The principal veins contained in the spinal canal are situated between the theca vertebralis and the vertebræ. They consist of two longitudinal plexuses, one of which runs along the posterior surface of the bodies of the vertebræ (*anterior longitudinal spinal veins*). The other plexus (*posterior longitudinal spinal veins*) is placed on the inner or anterior surface of the laminæ of the vertebræ.

The *Anterior Longitudinal Spinal Veins* consist of two large, tortuous veins which extend along the whole length of the vertebral column, from the foramen magnum, where they communicate by a venous ring around that opening, to the base of the coccyx, being placed one on each side of the posterior surface of the bodies of the vertebræ along the margin of the posterior common ligament. These veins communicate together opposite each vertebra by transverse trunks which pass beneath the ligament, and receive the large *venæ basis vertebrarum* from the interior of the body of each vertebra. The anterior longitudinal spinal veins are least developed in the cervical and sacral regions. They are not of

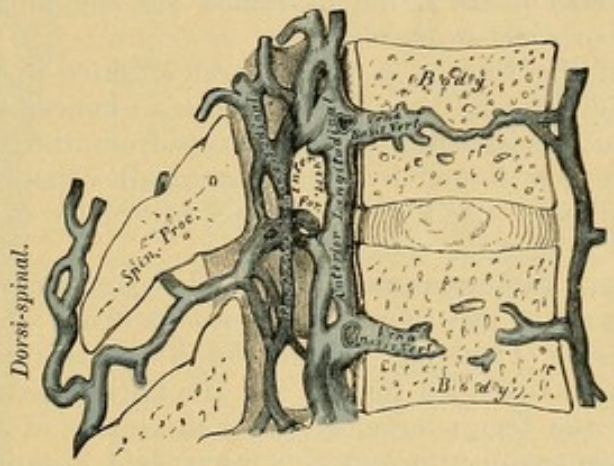

FIG. 333.—Vertical section of two dorsal vertebræ, showing the spinal veins.

uniform size throughout, being alternately enlarged and constricted. At the intervertebral foramina they communicate with the dorsi-spinal veins, and with the vertebral veins in the neck, with the intercostal veins in the dorsal region, and with the lumbar and sacral veins in the corresponding regions.

The *Posterior Longitudinal Spinal Veins*, smaller than the anterior, are situated one on each side, between the inner surface of the laminæ and the theca vertebralis. They communicate (like the anterior) opposite each vertebra by transverse trunks, and with the anterior longitudinal veins by lateral transverse branches which pass from behind forward. These veins, by branches which perforate the ligamenta subflava, join with the dorsi-spinal veins. From them branches are given off which pass through the intervertebral foramina and join the vertebral, intercostal, lumbar, and sacral veins.

3. The **Veins of the Bodies of the Vertebræ** (*venæ basis vertebrarum*) emerge from the foramina on their posterior surface, and join the transverse trunk connecting the anterior longitudinal spinal veins. They are contained in large, tortuous channels in the substance of the bones, similar in every respect to those found in the diploë of the cranial bones. These canals lie parallel to the upper and lower surface of the bones. They commence by small openings on the front and sides of the bodies of the vertebræ, through which communicating branches from the veins external to the bone pass into its substance, and converge to the principal canal, which is sometimes double toward its posterior part, and open into the corresponding transverse branch uniting the anterior longitudinal veins. They become greatly developed in advanced age.

4. The **Veins of the Spinal Cord** (*medulli-spinal*) consist of a minute, tortuous,

venous plexus which covers the entire surface of the cord, being situated between the pia mater and arachnoid. These vessels emerge chiefly from the median furrows, and are largest in the lumbar region. Near the base of the skull they unite and form two or three small trunks, which communicate with the vertebral veins, and then terminate in the inferior cerebellar veins or in the inferior petrosal sinuses. Each of the spinal nerves is accompanied by a branch as far as the intervertebral foramina, where it joins the other veins from the spinal canal.

There are no valves in the spinal veins.

VEINS OF THE LOWER EXTREMITY, ABDOMEN, AND PELVIS.

The Veins of the Lower Extremity are subdivided, like those of the upper, into two sets, superficial and deep, the superficial veins being placed beneath the integument, between the two layers of superficial fascia, the deep veins accompanying the arteries and forming the venæ comites of those vessels. Both sets of veins are provided with valves, which are more numerous in the deep than in the superficial set. These valves are also more numerous in the lower than in the upper limb.

The **Superficial Veins of the Lower Extremity** are the *internal* or *long saphenous* and the *external* or *short saphenous*.

On the dorsum of the foot is a venous arch situated in the superficial structures over the anterior extremities of the metatarsal bones. It has its convexity directed forward, and receives digital tributaries from the upper surface of the toes; at its concavity it is joined by numerous small veins which form a plexus on the dorsum of the foot. The arch terminates internally in the long saphenous, externally in a short saphenous vein.

The **internal** or **long saphenous vein** (Fig. 334) commences at the inner side of the arch on the dorsum of the foot; it ascends in front of the inner malleolus and along the inner side of the leg, behind the inner margin of the tibia, accompanied by the internal saphenous nerve. At the knee it passes backward behind the inner condyle of the femur, ascends along the inside of the thigh, and, passing through the saphenous opening in the fascia lata, terminates in the femoral vein about an inch and a half below Poupart's ligament. This vein receives in its course cutaneous tributaries from the leg and thigh, and at the saphenous opening the superficial epigastric, superficial circumflex iliac, and external pudic veins. The veins from the inner and back part of the thigh frequently unite to form a large vessel, which enters the main trunk near the saphenous opening; and sometimes those on the outer side of the thigh join to form another large vessel; so that occasionally three large veins are seen converging from different parts of the thigh toward the saphenous opening. The internal saphenous vein communicates in the foot with the internal plantar vein; in the leg, with the posterior tibial veins by branches which perforate the tibial origin of the Soleus muscle, and also with the anterior tibial veins; at the knee, with the articular veins; in the thigh, with the femoral vein by one or more branches. The valves in this vein vary from two to six in number; they are more numerous in the thigh than in the leg.

The **external** or **short saphenous vein** (Fig. 335) commences at the outer side of the arch on the dorsum of the foot; it ascends behind the outer malleolus, and along the outer border of the tendo Achillis, across which it passes at an acute angle to reach the middle line of the posterior aspect of the leg. Passing directly upward, it perforates the deep fascia in the lower part of the popliteal space, and terminates in the popliteal vein, between the heads of the Gastrocnemius muscle.[1] It receives numerous large tributaries from the back part of

[1] Mr. Gay calls attention to the fact that the external saphenous vein often (he says invariably) penetrates the fascia at or about the point where the tendon of the Gastrocnemius commences, and runs below the fascia in the rest of its course, or sometimes among the muscular fibres, to join the popliteal vein. (See Gay on *Varicose Disease of the Lower Extremities*, p. 24, where there is also a careful and elaborate description of the branches of the saphena veins.)

the leg, and communicates with the deep veins on the dorsum of the foot and behind the outer malleolus. Before it perforates the deep fascia it gives off a communicating branch, which passes upward and inward to join the internal saphenous vein. This vein has a variable number of valves, from three to nine (Gay), one of which is always found near its termination in the popliteal vein. The external saphenous nerve lies close beside this vein.

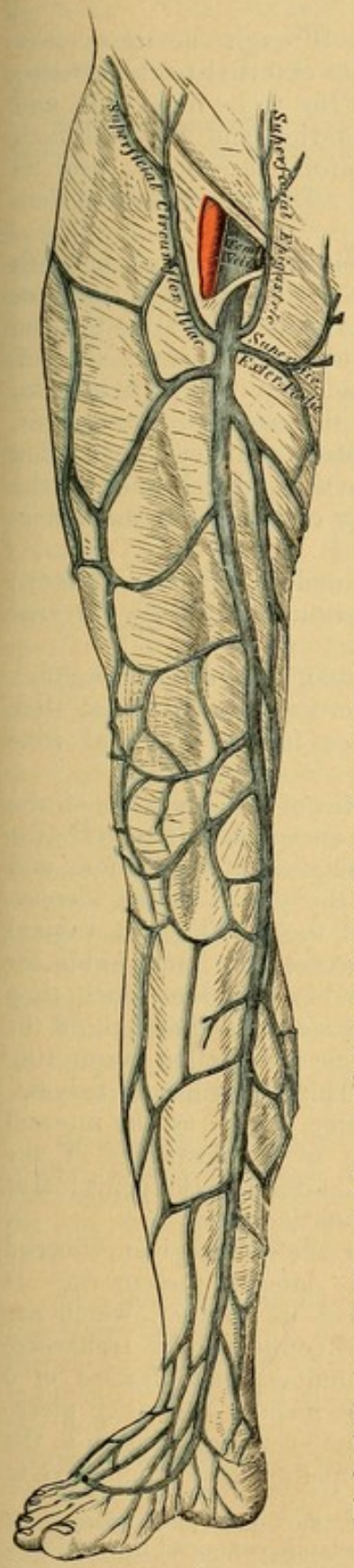

FIG. 334.—The internal or long saphenous vein and its branches.

Surgical Anatomy.—The saphena veins are of considerable surgical importance, since a varicose condition of these vessels is more frequently met with than of those in other parts of the body, except perhaps the spermatic and hæmorrhoidal veins. The course of the internal saphenous is in front of the tip of the malleolus, over the subcutaneous surface of the lower end of the tibia, and then along the internal border of this bone to the back part of the internal condyle of the femur, whence it follows the course of the Sartorius muscle, and is represented on the surface by a line drawn from the posterior border of the Sartorius on a level with the internal condyle to the saphenous opening. The short saphenous lies behind the external malleolus, and from this follows the middle line of the calf to just below the ham. It is not generally so apparent beneath the skin as the internal saphenous. Both these veins in the leg are accompanied by nerves, the internal saphenous being joined by its companion nerve just below the level of the knee-joint. No doubt much of the pain of varicose veins in the leg is due to this fact. On the Continent the internal saphenous vein as it rests on the tibia just above the malleolus is sometimes selected for venesection.

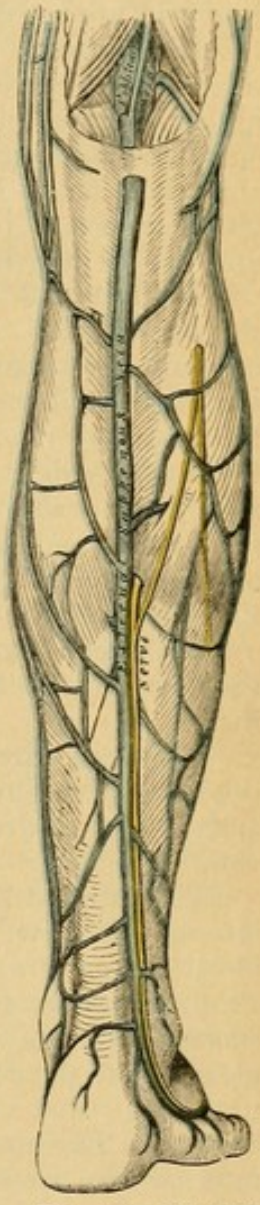

FIG. 335.—External or short saphenous vein.

The **Deep Veins of the Lower Extremity** accompany the arteries and their branches, and are called the *venæ comites* of those vessels.

The **external** and **internal plantar veins** unite to form the **posterior tibial.** They accompany the posterior tibial artery and are joined by the *peroneal veins.*

The **anterior tibial veins** are formed by a continuation upward of the venæ comites of the dorsalis pedis artery. They pass between the tibia and fibula, through the large oval aperture above the interosseous membrane, and form, by their junction with the posterior tibial, the popliteal vein.

The valves in the deep veins are very numerous.

The **Popliteal Vein** is formed by the junction of the venæ comites of the anterior and posterior tibial vessels; it ascends through the popliteal space to the tendinous aperture in the Adductor magnus, where it becomes the femoral vein. In the lower part of its course it is placed internal to the artery; between the

heads of the Gastrocnemius it is superficial to that vessel; but above the knee-joint it is close to its outer side. It receives the sural veins from the Gastrocnemius muscle, the articular veins, and the external saphenous. The valves in this vein are usually four in number.

The **Femoral Vein** accompanies the femoral artery through the upper two-thirds of the thigh. In the lower part of its course it lies external to the artery; higher up it is behind it; and at Poupart's ligament it lies to its inner side and on the same plane. It receives numerous muscular tributaries, and about an inch and a half below Poupart's ligament it is joined by the profunda femoris; near its termination it is joined by the internal saphenous vein. The valves in this vein are four or five in number.

The **External Iliac Vein** commences at the termination of the femoral, beneath the crural arch, and, passing upward along the brim of the pelvis, terminates opposite the sacro-iliac synchondrosis by uniting with the internal iliac to form the common iliac vein. On the right side it lies at first along the inner side of the external iliac artery, but as it passes upward gradually inclines behind it. On the left side it lies altogether on the inner side of the artery. It receives, immediately above Poupart's ligament, the deep epigastric and deep circumflex iliac veins and a small pubic vein, corresponding to the pubic branch of the obturator artery. According to Friedreich, it frequently contains one, and sometimes two valves.

The Deep Epigastric Veins.—Two veins accompany the deep epigastric artery; they usually unite into a single trunk before their termination in the external iliac vein.

The Deep Circumflex Iliac Veins.—Two veins accompany the deep circumflex iliac artery. These unite into a single trunk which crosses the external iliac artery just above Poupart's ligament and terminates in the external iliac vein.

The **Internal Iliac Vein** is formed by the venæ comites of the branches of the internal iliac artery, the umbilical arteries of the fœtus excepted. It receives the blood from the exterior of the pelvis by the gluteal, sciatic, internal pudic, and obturator veins, and from the organs in the cavity of the pelvis by the hæmorrhoidal and vesico-prostatic plexuses in the male, and the uterine and vaginal plexuses in the female. The vessels forming these plexuses are remarkable for their large size, their frequent anastomoses, and the number of valves which they contain. The internal iliac vein lies at first on the inner side, and then behind the internal iliac artery, and terminates opposite the sacro-iliac articulation by uniting with the external iliac to form the common iliac vein. This vessel has no valves.

The **internal pudic veins** (*venæ comites*) have the same course as the internal pudic artery. They receive tributaries corresponding to the branches of the artery, except the tributary corresponding to the dorsal artery of the penis; that is, the dorsal vein of the penis, which opens into the prostatic plexus.

The **hæmorrhoidal plexus** surrounds the lower end of the rectum, being formed by the superior hæmorrhoidal veins, tributaries of the inferior mesenteric. It commences as a series of dilated pouches, about twelve in number, which are arranged circularly at the verge of the anus and are connected by transverse branches. From these pouches veins, about six in number, pass upward in a straight direction in the submucous tissue for about three inches; they then pierce the muscular coat and become arranged in a circular manner at right angles to the long axis of the gut, and eventually unite to form the superior hæmorrhoidal vein.

Surgical Anatomy.—The veins of this plexus are apt to become dilated and varicose, and form piles. This is due to several anatomical reasons: the vessels are contained in very loose, lax connective tissue, so that they get less support from surrounding structures than most other veins, and are less capable of resisting increased blood pressure: the condition is favored by gravitation, being influenced by the erect posture, either sitting or standing, and by the fact that the superior hæmorrhoidal and portal veins have no valves: the veins pass through muscular tissue and are liable to be compressed by its contraction, especially during the act of defecation: they are affected by every form of portal obstruction.

The **vesico-prostatic plexus** surrounds the neck and base of the bladder and prostate gland. It communicates with the hæmorrhoidal plexus behind, and receives the dorsal vein of the penis, which enters the pelvis beneath the subpubic ligament. This plexus is supported upon the sides of the bladder by a reflection of the pelvic fascia. The veins composing it are very liable to become varicose, and often contain hard, earthy concretions, called *phleboliths.*

Surgical Anatomy.—This plexus is wounded in the lateral operation of lithotomy, and it is through it that septic matter finds its way into the general circulation after this operation.

The **dorsal vein of the penis** is a vessel of large size which returns the blood from the body of that organ. At first it consists of two branches, which are contained in the groove on the dorsum of the penis, and it receives veins from the glans penis, the corpus spongiosum, and numerous superficial veins; these unite into a single trunk, which passes between the two parts of the suspensory ligament of the penis, and through an aperture below the subpubic ligament, and divides into two branches, which enter the prostatic plexus.

The **vaginal plexus** surrounds the vagina, being especially developed at the orifice of the canal; it communicates with the vesical plexus in front, and with the hæmorrhoidal plexus behind.

The **uterine plexus** is situated along the sides and superior angles of the uterus, between the layers of the broad ligament, receiving, during pregnancy, large venous canals (the *uterine sinuses*) from the substance of the placenta. The veins composing this plexus anastomose frequently with each other and with the ovarian veins. They are not tortuous like the arteries.

The **Common Iliac Veins** are formed by the union of the external and internal iliac veins in front of the sacro-iliac articulation: passing obliquely upward toward the right side, they terminate upon the intervertebral substance between the fourth and fifth lumbar vertebræ, where the veins of the two sides unite at an acute angle to form the inferior vena cava. The *right common iliac* is shorter than the left, nearly vertical in its direction, and ascends behind and then to the outer side of its corresponding artery. The *left common iliac*, longer and more oblique in its course, is at first situated on the inner side of the corresponding artery, and then behind the right common iliac. Each common iliac receives the ilio-lumbar, and sometimes the lateral sacral, veins. The left receives, in addition, the middle sacral vein. No valves are found in these veins.

The **middle sacral veins** accompany the corresponding artery along the front of the sacrum, and join to form a single vein which terminates in the left common iliac vein; occasionally in the angle of junction of the two iliac veins.

Peculiarities.—The left common iliac vein, instead of joining with the right in its usual position, occasionally ascends on the left side of the aorta as high as the kidney, where, after receiving the left renal vein, it crosses over the aorta, and then joins with the right vein to form the vena cava. In these cases the two common iliacs are connected by a small communicating branch at the spot where they are usually united.[1]

The **Inferior Vena Cava** returns to the heart the blood from all the parts below the Diaphragm. It is formed by the junction of the two common iliac veins on the right side of the fifth lumbar vertebra. It passes upward along the front of the spine on the right side of the aorta, and, having reached the under surface of the liver, is contained in a groove on its posterior surface. It then perforates the central tendon of the Diaphragm, enters the pericardium, where it is covered for a very short distance by its serous layer, and terminates in the lower and back part of the right auricle. At its termination in the auricle it is provided with a valve, the *Eustachian*, which is of large size during fœtal life.

Relations.—*In front*, from below upward, with the mesentery, right spermatic artery, transverse portion of the duodenum, the pancreas, portal vein, and the

[1] See two cases which have been described by Mr. Walsham in the *St. Bartholomew's Hospital Reports*, vols. xvi. and xvii.

posterior surface of the liver, which partly and occasionally completely surrounds it; *behind*, with the vertebral column, the right crus of the Diaphragm, the right renal and lumbar arteries, right semilunar ganglion; on the *left side*, with the aorta.

Peculiarities.—*In Position.*—This vessel is sometimes placed on the left side of the aorta, as high as the left renal veins, after receiving which it crosses over to its usual position on the right side; or it may be placed altogether on the left side of the aorta, as far upward as its termination in the heart: in such cases the abdominal and thoracic viscera, together with the great vessels, are all transposed.

Point of Termination.—Occasionally the inferior vena cava joins the right azygos vein, which is then of large size. In such cases the superior cava receives the whole of the blood from the body before transmitting it to the right auricle, except the blood from the hepatic veins, which passes directly into the right auricle.

Tributaries.—It receives in its course the following veins:

Lumbar.	Suprarenal.
Right Spermatic.	Phrenic.
Renal.	Hepatic.

The **lumbar veins**, four in number on each side, collect the blood by dorsal tributaries from the muscles and integument of the loins and by abdominal tributaries from the walls of the abdomen, where they communicate with the epigastric veins. At the spine they receive veins from the spinal plexuses, and then pass forward, round the sides of the bodies of the vertebræ beneath the Psoas magnus, and terminate at the back part of the inferior cava. The left lumbar veins are longer than the right, and pass behind the aorta. The lumbar veins are connected together by a longitudinal vein which passes in front of the transverse processes of the lumbar vertebræ, and is called the *ascending lumbar*. It forms the most frequent origin of the corresponding vena azygos, and serves to connect the common iliac, ilio-lumbar, lumbar, and azygos veins of the corresponding side of the body.

The **spermatic veins** emerge from the back of the testis, and receive tributaries from the epididymis; they unite and form a convoluted plexus called the *spermatic plexus* (*plexus pampiniformis*), which forms the chief mass of the cord: the vessels composing this plexus are very numerous, and ascend along the cord in front of the vas deferens; below the external abdominal ring they unite to form three or four veins, which pass along the inguinal canal, and, entering the abdomen through the internal abdominal ring, coalesce to form two veins, which ascend on the Psoas muscle behind the peritoneum, lying one on each side of the spermatic artery, and unite to form a single vein, which opens on the right side into the inferior vena cava at an acute angle; on the left side into the left renal vein at a right angle. The spermatic veins are provided with valves.[1] The left spermatic vein passes behind the sigmoid flexure of the colon, and is thus exposed to pressure from the contents of that bowel.

Surgical Anatomy.—The spermatic veins are very frequently varicose, constituting the disease known as varicocele. Though it is quite possible that the originating cause of this affection may be a congenital abnormality either in the size or number of the veins of the pampiniform plexus, still it must be admitted that there are many anatomical reasons why these veins should become varicose—viz. the imperfect support afforded to them by the loose tissue of the scrotum; their great length; their vertical course; their dependent position; their plexiform arrangement in the scrotum, with their termination in one small vein in the abdomen; their few and imperfect valves; and the fact that they may be subjected to pressure in their passage through the abdominal wall.

The **ovarian veins** are analogous to the spermatic in the male; they form a plexus near the ovary and in the broad ligament and Fallopian tube, communicating with the uterine plexus. They terminate in the same way as the spermatic veins in the male. Valves are occasionally found in these veins. These vessels, like the uterine veins, become much enlarged during pregnancy.

[1] Rivington has pointed out that a valve is usually found at the orifices of both the right and left spermatic veins. When no valves exist at the opening of the left spermatic vein into the left renal vein, valves are generally present in the left renal vein within a quarter of an inch from the orifice of the spermatic vein (*Journal of Anatomy and Physiology*, vol. vii. p. 163).

The **renal veins** are of large size, and placed in front of the renal arteries.[1] The left is longer than the right, and passes in front of the aorta, just below the origin of the superior mesenteric artery. It receives the left spermatic, the left inferior phrenic, and, generally, the left suprarenal veins. It opens into the vena cava a little higher than the right.

The **suprarenal veins** are two in number: that on the right side terminates in the vena cava; that on the left side, in the left renal or phrenic vein.

The **phrenic veins** follow the course of the phrenic arteries. The *two superior*, of small size, accompany the phrenic nerve and comes nervi phrenici artery, and join the internal mammary. The *two inferior phrenic veins* follow the course of the phrenic arteries, and terminate, the right in the inferior vena cava, the left in the left renal vein.

The **hepatic veins** commence in the substance of the liver, in the capillary terminations of the portal vein and hepatic artery: these tributaries, gradually uniting, usually form three large veins, which converge toward the posterior surface of the liver and open into the inferior vena cava, whilst that vessel is situated in the groove at the back part of this organ. Of these three veins, one from the right, and another from the left lobe, open obliquely into the inferior vena cava, that from the middle of the organ and lobulus Spigelii having a straight course. The hepatic veins run singly, and are in direct contact with the hepatic tissue. They are destitute of valves.

The Portal System of Veins.

The portal venous system is composed of four large veins which collect the venous blood from the viscera of digestion (stomach, intestine, and pancreas) and from the spleen. The trunk formed by their union (*vena portæ*) enters the liver and ramifies throughout its substance after the manner of an artery and ends in capillaries, from which the blood is collected into the hepatic veins, which terminate in the inferior vena cava. The branches in this vein are in all cases single, and destitute of valves.

The veins forming the portal system are: the

Superior mesenteric.	Inferior mesenteric.
Splenic.	Gastric.
Cystic.	

The **superior mesenteric vein** returns the blood from the small intestines and from the cæcum and ascending and transverse portions of the colon, corresponding with the distribution of the branches of the superior mesenteric artery. The large trunk formed by the union of these branches ascends along the right side and in front of the corresponding artery, passes in front of the transverse portion of the duodenum, and unites, behind the upper border of the pancreas, with the splenic vein to form the vena portæ. It receives the right gastro-epiploic vein.

The **splenic vein** commences by five or six large branches which return the blood from the substance of the spleen. These, uniting, form a single vessel, which passes from left to right, grooving the upper and back part of the pancreas below the artery, and terminates at its greater end by uniting at a right angle with the superior mesenteric to form the vena portæ. The splenic vein is of large size, and not tortuous like the artery. It receives the vasa brevia from the left extremity of the stomach, the left gastro-epiploic vein, pancreatic branches from the pancreas, the pancreatico-duodenal vein, and the inferior mesenteric vein.

The **inferior mesenteric vein** returns the blood from the rectum, sigmoid flexure, and descending colon, corresponding with the ramifications of the branches of the inferior mesenteric artery. It lies to the left of the artery, and ascends beneath the peritoneum in the lumbar region; it passes behind the transverse portion

[1] The student may observe that all veins above the Diaphragm, which do not lie on the same plane as the arteries which they accompany, lie in front of them, and that all veins below the Diaphragm, which do not lie on the same plane as the arteries which they accompany, lie behind them, except the renal and profunda femoris vein.

of the duodenum and pancreas, and terminates in the splenic vein. Its hæmorrhoidal branches inosculate with those of the internal iliac, and thus establish a communication between the portal and the general venous system.[1]

The **gastric veins** are two in number: one, a small vein, corresponds to the pyloric branch of the hepatic artery; the other, considerably larger, corresponds to the gastric artery. The former (*pyloric*, Walsham) runs along the lesser cur-

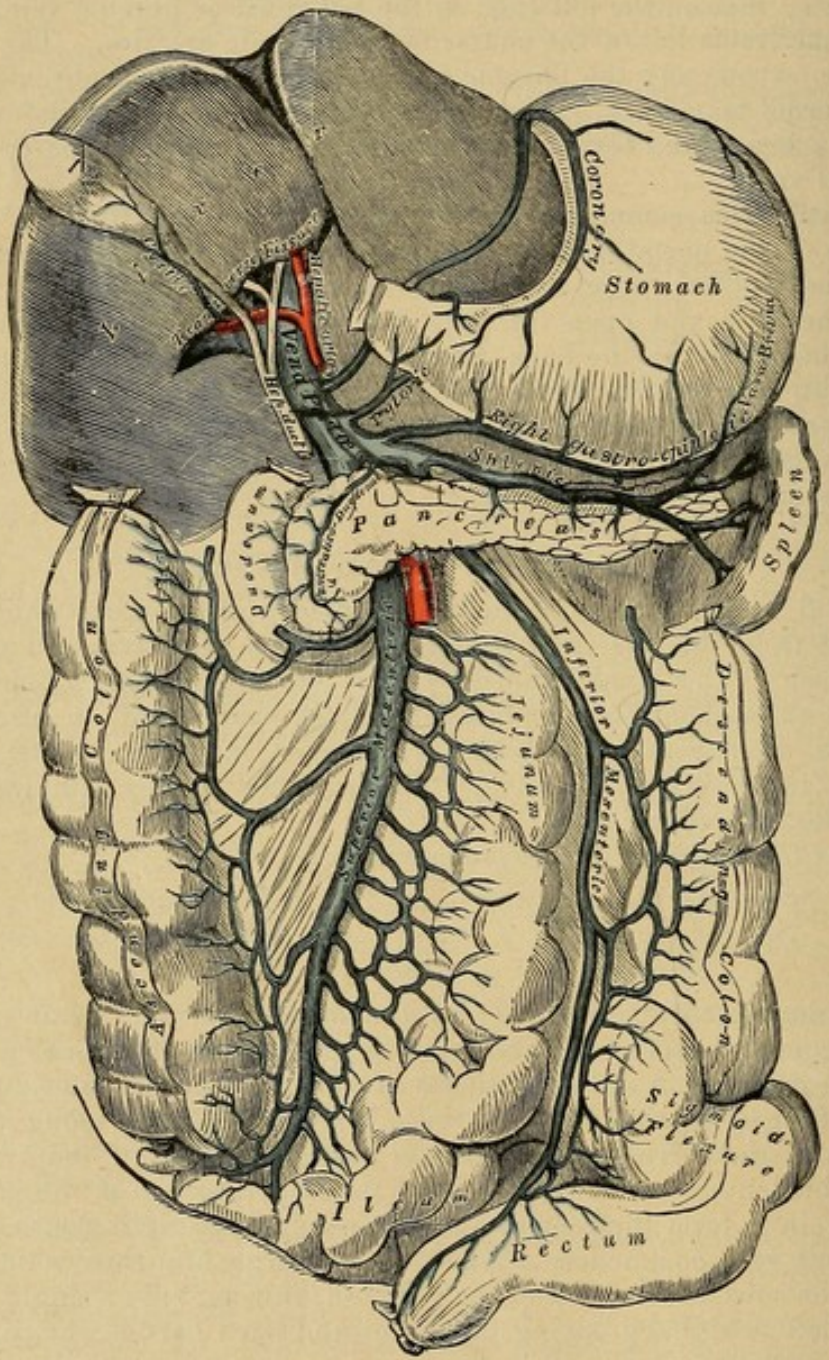

Fig. 336.—Portal vein and its branches.

Note.—In this diagram the right gastro-epiploic vein opens into the splenic vein; generally it empties itself into the superior mesenteric, close to its termination.

vature of the stomach toward the pyloric end, receives branches from the pylorus and duodenum, and ends in the vena portæ. The latter (*coronary*, Walsham) begins near the pylorus, runs along the lesser curvature of the stomach toward the

[1] Besides this anastomosis between the portal vein and the branches of the vena cava, other anastomoses between the portal and systemic veins are formed by the communication between the gastric veins and the œsophageal veins, which empty themselves into the vena azygos minor; between the left renal vein and the veins of the intestines, especially of the colon and duodenum; between the veins of the round ligament of the liver and the portal veins; and between the superficial branches of the portal veins of the liver and the phrenic veins, as pointed out by Mr. Kiernan. (See *Physiological Anatomy*, by Todd and Bowman, 1859, vol. ii. p. 348.)

œsophageal opening, and then passes across the front of the spine from left to right to end in the vena portæ, at a point a little above the junction of the pyloric vein.

The **Portal Vein** is formed by the junction of the superior mesenteric and splenic veins, their union taking place in front of the vena cava and behind the upper border of the head of the pancreas. Passing upward through the right border of the lesser omentum to the under surface of the liver, it enters the transverse fissure, where it is somewhat enlarged, forming the *sinus* of the portal vein, and divides into two branches which accompany the ramifications of the hepatic artery and hepatic duct throughout the substance of the liver. Of these two branches, the right is the larger, but the shorter, of the two. The portal vein is about three or four inches in length, and, whilst contained in the lesser omentum, lies behind and between the common bile duct and the hepatic artery, the former being to the right, the latter to the left. These structures are accompanied by filaments of the hepatic plexus of nerves and numerous lymphatics, surrounded by a quantity of loose areolar tissue (*capsule of Glisson*), and placed between the layers of the lesser omentum.

The Cystic Vein.—The vena portæ generally receives the cystic vein, although it sometimes terminates in the right branch of the vena portæ.

The portal vein divides, in the substance of the liver, like an artery, and its minute ramifications end in capillaries, from which the blood is carried to the inferior vena cava by the hepatic veins; these veins also collect the blood which has been brought to the liver by the hepatic artery. It will therefore be seen that the blood which is carried to the liver by the portal vein passes through two sets of capillary vessels, viz.: (1) the capillaries in the stomach, intestine, pancreas, and spleen, and (2) the capillaries of the portal vein in the liver.

THE CARDIAC VEINS.

The veins which return the blood from the substance of the heart are: the

Great cardiac vein.	Anterior cardiac veins.
Posterior cardiac vein.	Right or small coronary vein.
Left cardiac veins.	Coronary sinus.

Venæ Thebesii.

The **Great Cardiac Vein** (sometimes called the *Coronary vein*) is a vessel of considerable size, which commences at the apex of the heart, and ascends along the anterior interventricular groove to the base of the ventricles. It then curves to the left side, around the auriculo-ventricular groove, between the left auricle and ventricle, to the back part of the heart, and opens into the left extremity of the coronary sinus, its aperture being guarded by two valves. It receives, in its course, tributaries from both ventricles, but especially the left, and also from the left auricle; one of these, ascending along the thick margin of the left ventricle, is of considerable size. The vessels joining it are provided with valves.

The **Posterior Cardiac Vein** (sometimes called the *Middle cardiac vein*) commences by small tributaries, at the apex of the heart, communicating with those of the preceding. It ascends along the posterior interventricular groove to the base of the heart, and terminates in the coronary sinus, its orifice being guarded by a valve. It receives the veins from the posterior surface of both ventricles.

The **Left Cardiac Veins** are three or four small vessels, which collect the blood from the posterior surface of the left ventricle, and open into the lower border of the coronary sinus.

The **Anterior Cardiac Veins** are three or four small vessels, which collect the blood from the anterior surface of the right ventricle. One of these (the *vein of Galen*), larger than the rest, runs along the right border of the heart. They open separately into the lower part of the right auricle.

The **Right** or **Small Coronary Vein** runs along the groove between the right auricle and ventricle, to open into the right extremity of the coronary sinus. It receives blood from the back part of the right auricle and ventricle.

The **Coronary Sinus** is that portion of the anterior or great cardiac vein which is situated in the posterior part of the left auriculo-ventricular groove. It is about an inch in length, presents a considerable dilatation, and is covered by the muscular fibres of the left auricle. It receives the veins enumerated above, and an *oblique vein* from the back part of the left auricle, the remnant of the obliterated left Cuvierian duct of the fœtus, described by Mr. Marshall. The great coronary sinus terminates in the right auricle, between the inferior vena cava and the auriculo-ventricular aperture, its orifice being guarded by a semilunar fold of the lining membrane of the heart, the *Thebesian valve*. All the veins joining this vessel, excepting the oblique vein above mentioned, are provided with valves.

The **Venæ Thebesii** (*venæ cordis minimæ*) are numerous minute veins, which return the blood directly from the muscular substance, without entering the venous current. They open by minute orifices (*foramina Thebesii*) on the inner surface of the right auricle.

THE LYMPHATIC SYSTEM.

THE Lymphatic System includes not only the lymphatic vessels and the glands through which they pass, but also the *lacteal* or *chyliferous vessels*. The lacteals are the lymphatic vessels of the small intestine, and differ in no respect from the lymphatics generally, excepting that they contain a milk-white fluid, the *chyle*, during the process of digestion, and convey it into the blood through the thoracic duct.

The lymphatics have derived their name from the appearance of the fluid contained in their interior (*lympha*, water). They are also called *absorbents*, from the property they possess of absorbing certain materials from the tissues and conveying them into the circulation.

The lymphatics are exceedingly delicate vessels, the coats of which are so transparent that the fluid they contain is readily seen through them. They retain a nearly uniform size, being interrupted at intervals by constrictions, which give them a knotted or beaded appearance. These constrictions are due to the presence of valves in their interior. Lymphatics have been found in nearly every texture and organ of the body which contain blood-vessels. Such non-vascular structures as cartilage, the nails, cuticle, and hair have none, but with these exceptions it is probable that eventually all parts will be found to be permeated by these vessels.

The lymphatics are arranged into a superficial and deep set. The superficial lymphatics, on the surface of the body, are placed immediately beneath the integument, accompanying the superficial veins; they join the deep lymphatics in certain situations by perforating the deep fascia. In the interior of the body they lie in the submucous areolar tissue throughout the whole length of the gastro-pulmonary and genito-urinary tracts, and in the subserous tissue in the cranial, thoracic, and abdominal cavities. The method of their origin will be described later, along with the other details of their minute anatomy. Here it will be sufficient to say that a plexiform network of minute lymphatics may be found interspersed among the proper elements and blood-vessels of the several tissues, the vessels composing which, as well as the meshes between them, are much larger than those of the capillary plexus. From these networks small vessels emerge, which pass either to a neighboring gland or to join some larger lymphatic trunk. The deep lymphatics, fewer in number and larger than the superficial, accompany the deep blood-vessels. Their mode of origin is probably similar to that of the superficial vessels. The lymphatics of any part or organ exceed the veins in number, but in size they are much smaller. Their anastomoses also, especially those of the large trunks, are more frequent, and are effected by vessels equal in diameter to those which they connect, the continuous trunks retaining the same diameter.

The **lymphatic** or **absorbent glands**, named also *conglobate glands*, are small, solid, glandular bodies situated in the course of the lymphatic and lacteal vessels. In size they vary from a hemp-seed to an almond, and their color, on section, is of a pinkish-gray tint, excepting the bronchial glands, which in the adult are mottled with black. Each gland has a layer or capsule of cellular tissue investing it, from which prolongations dip into its substance, forming partitions. The lymphatic and lacteal vessels pass through these bodies in their passage to the thoracic and lymphatic ducts. A lymphatic or lacteal vessel, previous to

entering a gland, divides into several small branches, which are named *afferent vessels.* As they enter their external coat becomes continuous with the capsule of the gland, and the vessels, much thinned, and consisting only of their internal or endothelial coat, pass into the gland, and branch out upon and in the tissue of the capsule, these branches opening into the lymph-sinuses of the gland. From these sinuses fine branches proceed to form a plexus, the vessels of which unite to form a single *efferent vessel*, which, on emerging from the gland, is again invested with an external coat. (Further details on the minute anatomy of the lymphatic vessels and glands will be found in the section on General Anatomy.)

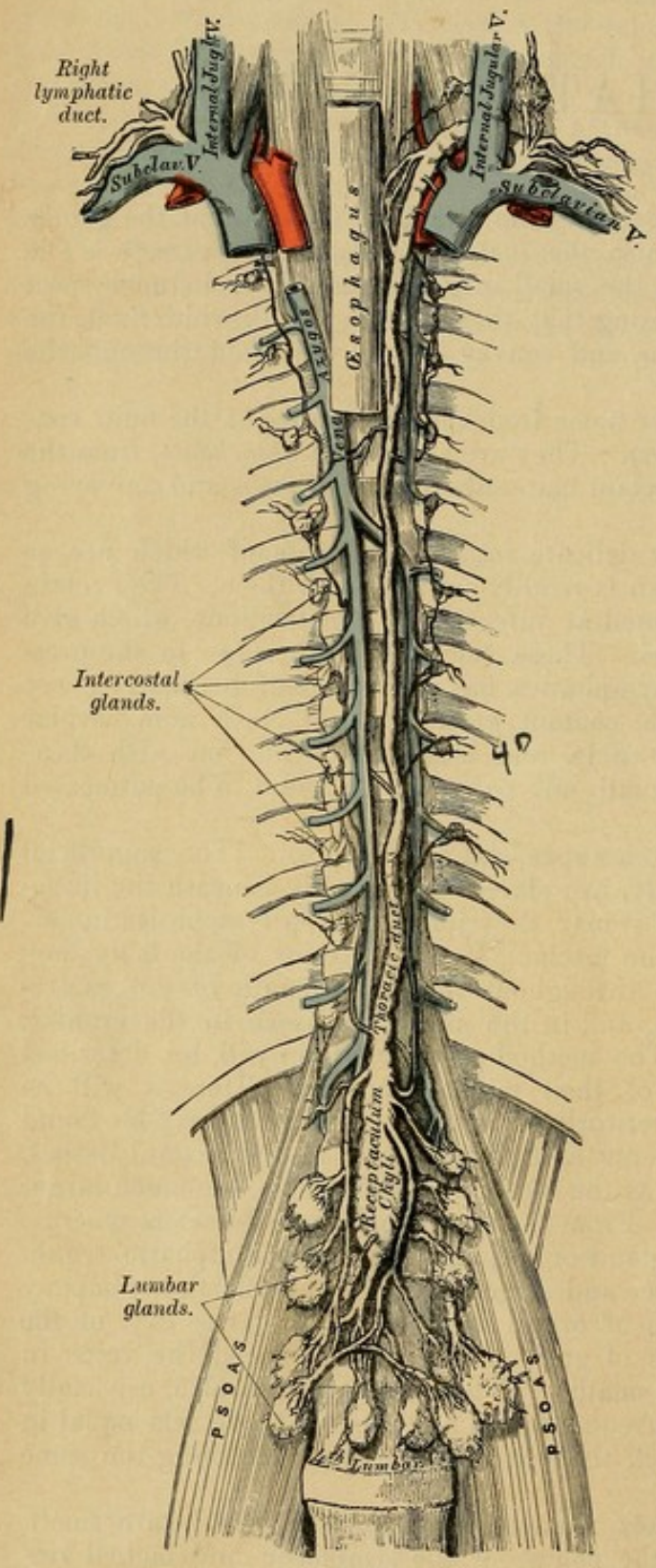

FIG. 337.—The thoracic and right lymphatic duct.

THE THORACIC DUCT.

The **thoracic duct** (Fig. 337) conveys the great mass of lymph and chyle into the blood. It is the common trunk of all the lymphatic vessels of the body, excepting those of the right side of the head, neck, and thorax, and right upper extremity, the right lung, right side of the heart, and the convex surface of the liver. It varies in length from fifteen to eighteen inches in the adult, and extends from the second lumbar vertebra to the root of the neck. It commences in the abdomen by a triangular dilatation, the *receptaculum chyli* (*reservoir* or *cistern of Pecquet*), which is situated upon the front of the body of the second lumbar vertebra, to the right side and behind the aorta, by the side of the right crus of the Diaphragm. It ascends into the thorax through the aortic opening in the Diaphragm, lying to the right of the aorta, and is placed in the posterior mediastinum in front of the vertebral column, lying between the aorta and vena azygos major. Opposite the fourth dorsal vertebra it inclines toward the left side, and ascends behind the arch of the aorta on the left side of the œsophagus, and behind the first portion of the left subclavian artery, to the upper orifice of the thorax. Opposite the seventh cervical vertebra it turns outward and then curves downward over the subclavian artery and in front of the Scalenus anticus muscle, so as to form an arch, and terminates in the left

subclavian vein at its angle of junction with the left internal jugular vein. The thoracic duct, at its commencement, is about equal in size to the diameter of a goosequill, diminishes considerably in its calibre in the middle of the thorax, and is again dilated just before its termination. It is generally flexuous in its course, and constricted at intervals so as to present a varicose appearance. The thoracic duct not unfrequently divides in the middle of its course into two branches of unequal size, which soon reunite, or into several branches, which form a plexiform interlacement. It occasionally divides, at its upper part, into two branches, of which the one on the left side terminates in the usual manner, while that on the right opens into the right subclavian vein, in connection with the right lymphatic duct. The thoracic duct has numerous valves throughout its whole course, but they are more numerous in the upper than in the lower part: at its termination it is provided with a pair of valves, the free borders of which are turned toward the vein, so as to prevent the passage of venous blood into the duct.

Tributaries.—The thoracic duct, at its commencement, receives four or five large trunks from the abdominal lymphatic glands, and also the trunk of the lacteal vessels. Within the thorax it is joined by the lymphatic vessels from the left half of the wall of the thoracic cavity, the lymphatics from the sternal and intercostal glands, those of the left lung, left side of the heart, trachea, and œsophagus; and, just before its termination, it receives the lymphatics of the left side of the head and neck and left upper extremity.

Structure.—The thoracic duct is composed of three coats, which differ in some respects from those of the lymphatic vessels. The *internal coat* consists of a single layer of flattened lanceolate-shaped endothelial cells with serrated borders; of a subendothelial layer, similar to that found in the arteries; and an elastic fibrous coat, the fibres of which run in a longitudinal direction. The *middle coat* consists of a longitudinal layer of white connective tissue with elastic fibres, external to which are several laminæ of muscular tissue, the fibres of which are for the most part disposed transversely, but some are oblique or longitudinal and intermixed with elastic fibres. The *external coat* is composed of areolar tissue, with elastic fibres and isolated fasciculi of muscular fibres.

The **Right Lymphatic Duct** is a short trunk, about half an inch in length and a line or a line and a half in diameter. It terminates in the right subclavian vein at its angle of junction with the right internal jugular vein. Its orifice is guarded by two semilunar valves, which prevent the passage of venous blood into the duct.

Tributaries.—It receives the lymph from the right side of the head and neck, the right upper extremity, the right side of the thorax, the right lung and right side of the heart, and from part of the convex surface of the liver.

LYMPHATICS OF THE HEAD, FACE, AND NECK.

The **Lymphatic Glands of the Head** (Fig. 338) are arranged in the following groups: (1) The *occipital*, one or two in number, placed at the back of the head, close to the occipital artery. (2) The *posterior auricular* or *mastoid*, usually two in number, situated on the insertion of the Sterno-mastoid to the mastoid process. Both these sets of glands are affected in cutaneous eruptions and other diseases of the scalp. (3) The *parotid* or *pre-auricular*, some of which are superficial to, and others are imbedded in, the substance of the parotid gland. (4) The *buccal*, one or more, placed on the surface of the Buccinator muscle. (5) The *internal maxillary*, beneath the ramus of the jaw. (6) The *lingual*, two or three in number, lying on the Hyo-glossus and Genio-hyo-glossus. (7) The *retro-pharyngeal*, lying one on each side of the middle line in front of the Rectus capitis anticus major.

The **lymphatic vessels of the scalp** are divided into an *anterior* and a *posterior set*, which follow the course of the temporal and occipital vessels. The *temporal* accompany the temporal artery in front of the ear, to the parotid lymphatic glands, from which they proceed to the lymphatic glands of the neck. The *occipital* follow the course of the occipital artery, descend to

the occipital and posterior auricular lymphatic glands, and finally join the cervical glands.

The **Lymphatic Vessels of the Face** are divided into two sets, *superficial* and *deep*.

The **superficial lymphatic vessels of the face** are more numerous than those of the head, and commence over its entire surface. Those from the frontal region accompany the frontal vessels; they then pass obliquely across the face, running

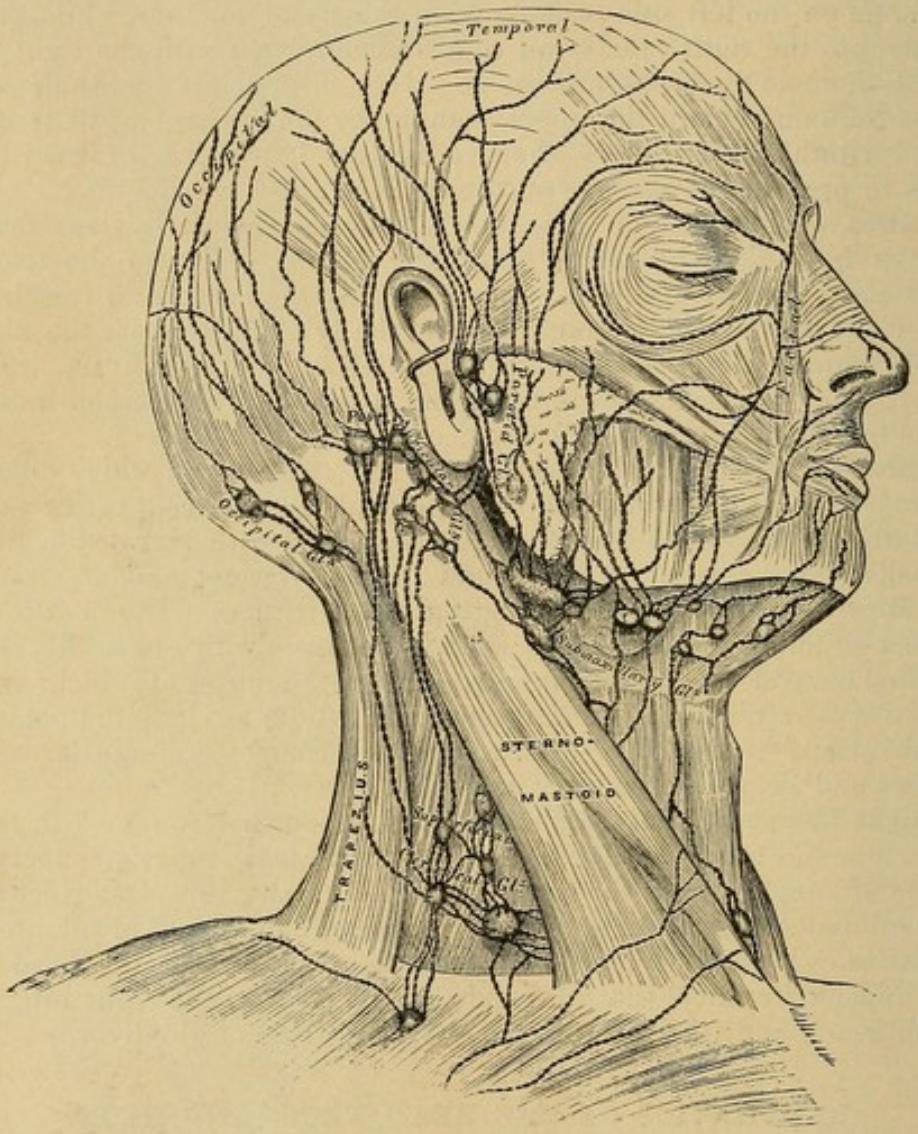

FIG. 338.—The superficial lymphatics and glands of the head, face, and neck.

with the facial vein, pass through the buccal glands on the surface of the Buccinator muscle, and join the submaxillary lymphatic glands. The latter receive the lymphatic vessels from the lips, and are often found enlarged in cases of malignant disease of those parts.

The **lymphatic vessels of the cranium** consist of two sets, the *meningeal* and *cerebral*. The *meningeal lymphatics* accompany the meningeal vessels, escape through foramina at the base of the skull, and join the deep cervical lymphatic glands. The *cerebral lymphatics* are described by Eshmann as being situated between the arachnoid and pia mater, as well as in the choroid plexuses of the lateral ventricles; they accompany the trunks of the carotid and vertebral arteries, and probably pass through foramina at the base of the skull to terminate in the deep cervical glands. They have not at present been demonstrated in the dura mater or in the substance of the brain.

The lymphatics of the orbit and of the temporal and zygomatic fossæ run with

the branches of the internal maxillary artery to the maxillary glands, and afterward to the deep cervical.

The lymphatics of the nose can be injected from the subdural and subarachnoid spaces. They terminate in the retro-pharyngeal and supra-hyoid glands. The lymphatics of the tongue chiefly accompany the ranine vein first to the lingual glands and from these to the deep cervical. Those from the anterior part of the tongue and floor of the mouth pierce the Mylo-hyoid muscles and so reach the submaxillary glands. From the upper part of the pharynx the lymphatics pass to the retro-pharyngeal glands; from the lower part, to the deep cervical glands. From the larynx two sets of vessels arise: an upper, piercing the thyro-hyoid

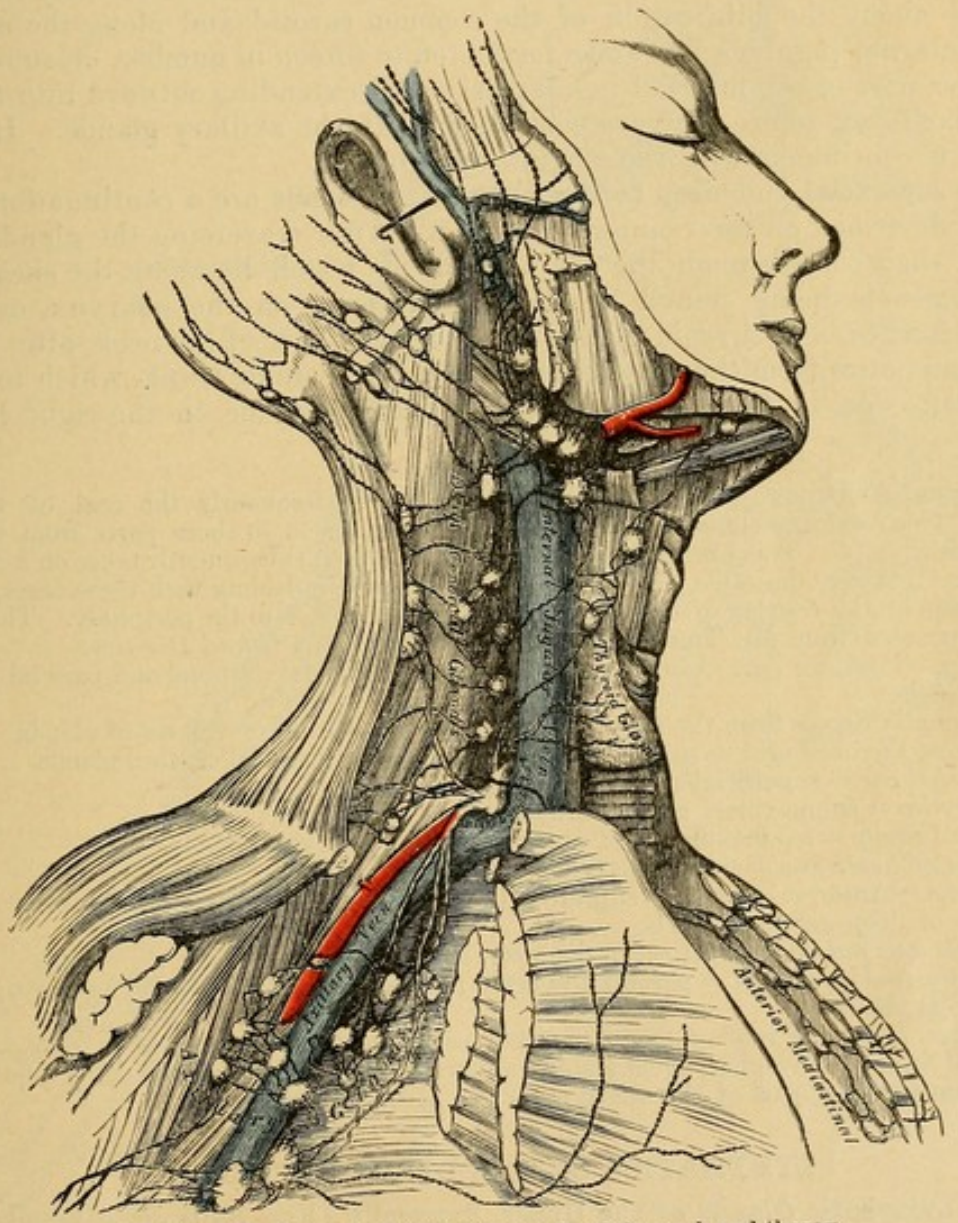

FIG. 339.—The deep lymphatics and glands of the neck and thorax.

membrane and joining the superior set of deep glands; and a lower, perforating the crico-thyroid membrane to join the lower set of deep cervical glands. The lymphatics of the thyroid body accompany the superior and inferior thyroid arteries, and open partly into the upper and partly into the lower set of deep cervical glands.

The **Lymphatic Glands of the Neck** are divided into two sets, *superficial* and *deep*.

The **superficial cervical glands** may be arranged in three sets: (1) The *submaxillary*, eight to ten in number, situated beneath the body of the lower jaw in the submaxillary triangle; (2) *suprahyoid*, one or two in number, situated

in the middle line of the neck, between the anterior bellies of the two digastric muscles; and (3) *cervical*, placed in the course of the external jugular vein between the Platysma and deep fascia. They are most numerous at the root of the neck, in the triangular interval between the clavicle, the Sterno-mastoid, and the Trapezius, where they are continuous with the axillary glands. A few small glands are also found on the front and sides of the larynx.

The **deep cervical glands** (Fig. 339) are numerous and of large size; they form a chain along the sheath of the carotid artery and internal jugular vein, lying by the side of the pharynx, œsophagus, and trachea, and extending from the base of the skull to the thorax, where they communicate with the lymphatic glands in that cavity. They are subdivided into two sets: an *upper*, ten to twenty in number. situated about the bifurcation of the common carotid and along the upper part of the internal jugular vein; and a *lower*, ten to fifteen in number, clustered around the lower part of the internal jugular vein, and extending outward into the supraclavicular fossa, where they are continuous with the axillary glands. Internally, this set is continuous with the mediastinal glands.

The **superficial** and **deep cervical lymphatic vessels** are a continuation of those already described on the cranium and face. After traversing the glands in those regions, they pass through the chain of glands which lie along the sheath of the carotid vessels, being joined by the lymphatics from the pharynx, œsophagus, larynx, trachea, and thyroid gland. At the lower part of the neck, after receiving some lymphatics from the thorax, they unite into a single trunk, which terminates, on the left side, in the thoracic duct; on the right side, in the right lymphatic duct.

Surgical Anatomy.—The cervical glands are very frequently the seat of tuberculous disease. This condition is most usually set up by some lesion in those parts from which they receive their lymph. This excites some inflammation, which subsequently takes on a tuberculous character. It is very desirable, therefore, for the surgeon, in dealing with these cases, to possess a knowledge of the relation of the respective groups of glands to the periphery. The following table is extracted from Mr. Treves's work on *Scrofula and its Gland Diseases:*

Scalp.—Posterior part = suboccipital and mastoid glands. Frontal and parietal portions = parotid glands.

Lymphatic vessels from the scalp also enter the superficial cervical set of glands.

Skin of face and neck = submaxillary, parotid, and superficial cervical glands.

External ear = superficial cervical glands.

Lower lip = submaxillary and suprahyoid glands.

Buccal cavity = submaxillary and upper set of deep cervical glands.

Gums of lower jaw = submaxillary glands.

Tongue.—Anterior portion = suprahyoid and submaxillary glands. Posterior portion = upper set of deep cervical glands.

Tonsils and palate = upper set of deep cervical glands.

Pharynx.—Upper part = parotid and retro-pharyngeal glands. Lower part = upper set of deep cervical glands.

Larynx, orbit, and roof of mouth = upper set of deep cervical glands.

Nasal fossæ = retro-pharyngeal glands, upper set of deep cervical glands. Some lymphatic vessels from posterior part of the fossæ enter the parotid glands.

LYMPHATICS OF THE UPPER EXTREMITY.

The **Lymphatic Glands of the Upper Extremity** (Fig. 340) are divided into two sets, *superficial* and *deep*.

The **superficial lymphatic glands** are few and of small size. There are occasionally two or three in front of the elbow, and one or two above the internal condyle of the humerus, near the basilic vein, while one or two may be found lying beside the cephalic vein between the Pectoralis major and Deltoid muscles.

The **deep lymphatic glands** are few in number, and are subdivided into those in the forearm, the arm, and the axilla. In the *forearm* a few small ones are occasionally found in the course of the radial and ulnar vessels. In the *arm* there is a chain of small glands along the inner side of the brachial artery. One, sometimes two, fairly constant glands are situated a little above and in front of the inner condyle of the humerus. In the *axilla* they are of large size, and

usually ten or twelve in number. A chain of these glands surrounds the axillary vessels, imbedded in a quantity of loose areolar tissue; they receive the lymphatic vessels from the arm; others are dispersed in the areolar tissue of the axilla; the remainder are arranged in two series, a small chain running along the lower border of the Pectoralis major, receiving the lymphatics from the front of the chest and mamma; and others are placed along the lower margin of the posterior wall of the axilla, which receive the lymphatics from the integument of the back.

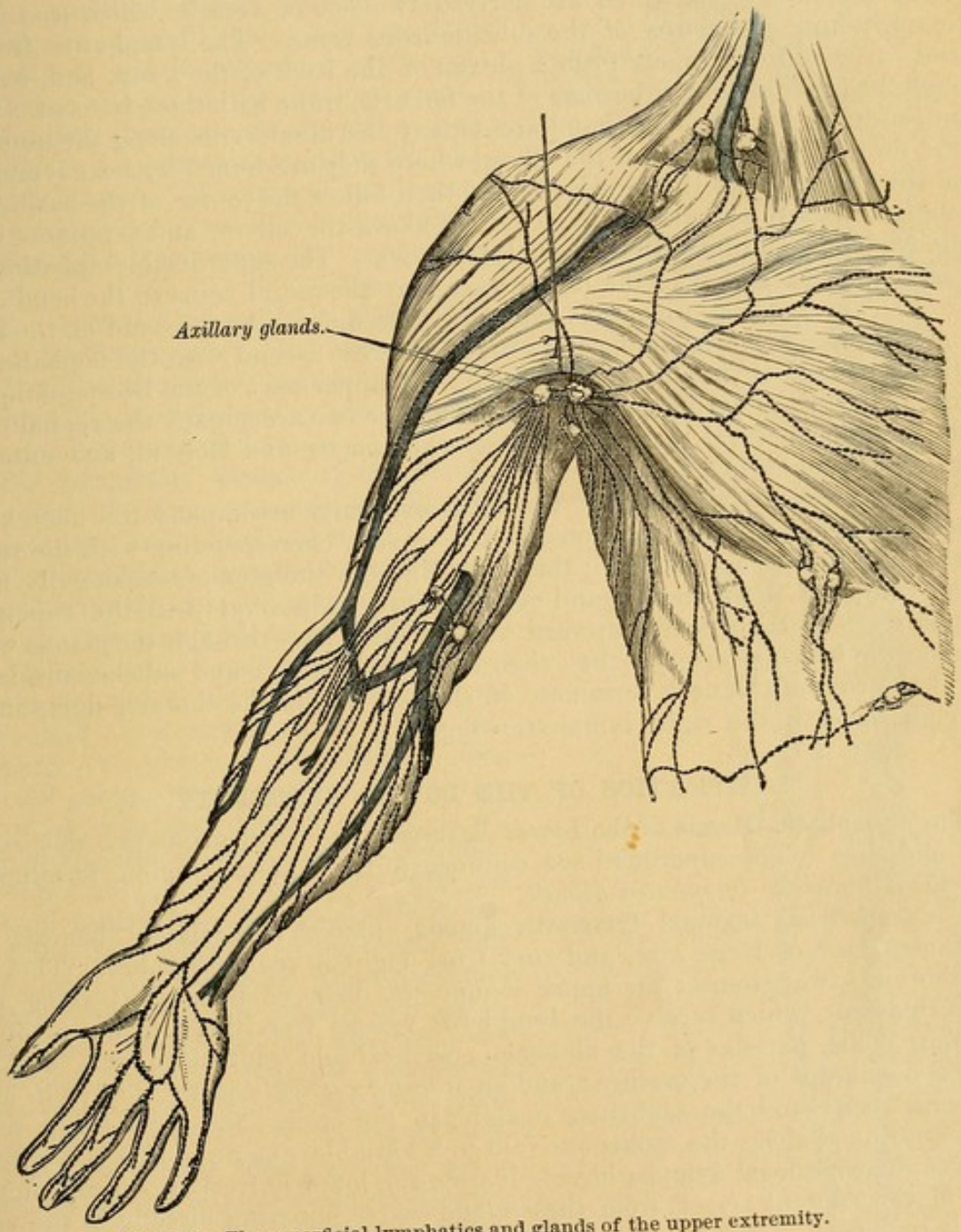

FIG. 340.—The superficial lymphatics and glands of the upper extremity.

Two or three subclavian or infra-clavicular lymphatic glands are placed immediately beneath the clavicle; it is through these that the axillary and deep cervical glands communicate with each other. The efferent vessels from the axillary glands may be from one to three or four in number. They accompany the subclavian vein into the neck, and end, on the right side, by joining the right lymphatic duct, on the left side by opening into the thoracic duct.

Surgical Anatomy.—In malignant diseases, tumors, or other affections implicating the upper part of the back and shoulder, the front of the chest and mamma, the upper part of the

front and side of the abdomen, or the hand, forearm, and arm, the axillary glands are liable to be found enlarged.

The **lymphatic vessels of the upper extremity** are divided into two sets, *superficial* and *deep*.

The **superficial lymphatic vessels of the upper extremity** commence on the fingers, two vessels running along either side of each finger, one on the palmar and the other on the dorsal surface. Those on the palmar surface form an arch in the palm of the hand, from which are derived two sets of vessels, which pass up the forearm, taking the course of the subcutaneous veins. The lymphatics from the dorsal surface of the fingers form a plexus on the back of the hand, and, winding around the inner and outer borders of the forearm, unite with those in front. Those from the inner border of the hand accompany the ulnar veins along the inner side of the forearm to the bend of the elbow, where they are joined by some lymphatics from the outer side of the forearm: they then follow the course of the basilic vein, communicate with the glands immediately above the elbow, and terminate in the axillary glands, joining with the deep lymphatics. The superficial lymphatics from the outer and back part of the hand accompany the radial veins to the bend of the elbow. They are less numerous than the preceding. At the bend of the elbow the greater number join the basilic group; the rest ascend with the cephalic vein on the outer side of the arm, some crossing the upper part of the Biceps obliquely, to terminate in the axillary glands, whilst one or two accompany the cephalic vein in the cellular interval between the Pectoralis major and Deltoid, and enter the subclavian lymphatic glands.

The **deep lymphatic vessels of the upper extremity** accompany the deep blood-vessels. In the forearm they consist of four sets, corresponding with the radial, ulnar, and interosseous arteries; they pass through the glands occasionally found in the course of those vessels, and communicate at intervals with the superficial lymphatics. In their course upward some of them pass through the glands which lie upon the brachial artery; they then enter the axillary and subclavian glands, and at the root of the neck terminate on the left side in the thoracic duct, and on the right side in the right lymphatic duct.

LYMPHATICS OF THE LOWER EXTREMITY.

The **Lymphatic Glands of the Lower Extremity** are divided into two sets, *superficial* and *deep*. The superficial are confined to the inguinal region, forming the *superficial inguinal lymphatic glands*.

The **superficial inguinal lymphatic glands**, placed immediately beneath the integument, are of large size, and vary from eight to ten in number. They are divisible into two groups: an upper *oblique* set, disposed irregularly along Poupart's ligament, which receive the lymphatic vessels from the integument of the scrotum, penis, parietes of the abdomen, perineal and gluteal regions, and the mucous membrane of the urethra; and an inferior *vertical* set, two to five in number, which surround the saphenous opening in the fascia lata, a few being sometimes continued along the saphenous vein to a variable extent. This latter group receives the superficial lymphatic vessels from the lower extremity. Leaf[1] figures some of the efferent vessels from these glands as terminating directly in the veins of this region.

Surgical Anatomy.—These glands frequently become enlarged in diseases implicating the parts from which their lymphatics originate. Thus in malignant or syphilitic affections of the prepuce and penis, or of the labia majora in the female, in cancer scroti, in abscess in the perinæum, or in any other diseases affecting the integument and superficial structures in those parts, or the subumbilical part of the abdominal wall or the gluteal region, the upper chain of glands is almost invariably enlarged, the lower chain being implicated in diseases affecting the lower limb.

The **deep lymphatic glands** are the anterior tibial, popliteal, deep inguinal, gluteal, and ischiatic.

[1] *The Surgical Anatomy of the Lymphatic Glands*, 1898.

The **anterior tibial gland** is not constant in its existence. It is generally found by the side of the anterior tibial artery, upon the interosseous membrane at the upper part of the leg. Occasionally, two glands are found in this situation.

The **popliteal glands,** four or five in number, are of small size; they surround the popliteal vessels, imbedded in the cellular tissue and fat of the popliteal space.

The **deep inguinal glands** are placed beneath the deep fascia around the femoral artery and vein. They are of small size, and communicate with the superficial inguinal glands through the saphenous opening.

The **gluteal** and **ischiatic glands** are placed, the former above, the latter below, the Pyriformis muscle, resting on their corresponding vessels as they pass through the great sacro-sciatic foramen.

The **Lymphatic Vessels of the Lower Extremity,** like the veins, may be divided into two sets, *superficial* and *deep*.

The **superficial lymphatic vessels** are placed beneath the integument in the superficial fascia, and are divisible into two groups: an internal group, which follow the course of the internal saphenous vein; and an external group, which accompany the external saphenous. The *internal group*, the larger, commence on the inner side and dorsum of the foot; they pass, some in front and some behind, the inner ankle, run up the leg with the internal saphenous vein, pass with it behind the inner condyle of the femur, and accompany it to the groin, where they terminate in the group of superficial inguinal lymphatic glands which surround the saphenous opening. Some of the efferent vessels from these glands pierce the cribriform fascia and sheath of the femoral vessels, and terminate in a lymphatic gland contained in the femoral canal, thus establishing a communication between the lymphatics of the lower extremity and those of the trunk; others pierce the fascia lata and join the deep inguinal glands. The *external group* arise from the outer side of the foot, ascend in front of the leg, and, just below the knee, cross the tibia from without inward, to join the lymphatics on the inner side of the thigh. Others commence on the outer side of the foot, pass behind the outer malleolus,

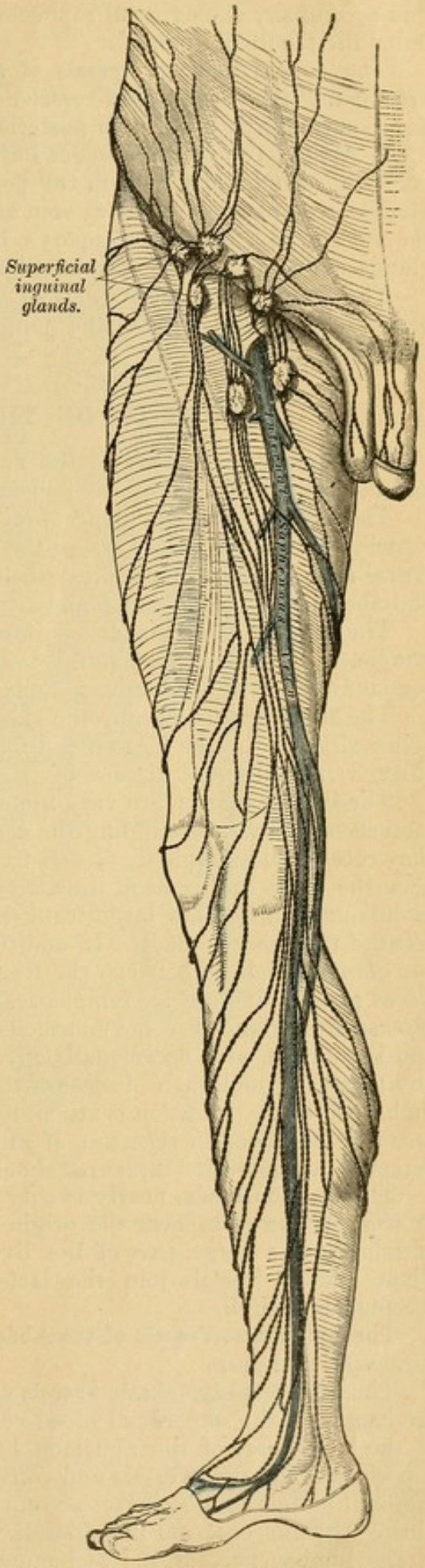

FIG. 341.—The superficial lymphatics and glands of the lower extremity.

and accompany the external saphenous vein along the back of the leg, where they enter the popliteal glands.

The **deep lymphatic vessels of the lower extremity** are few in number and accompany the deep blood-vessels. In the leg they consist of three sets, the anterior tibial, peroneal, and posterior tibial, which accompany the corresponding blood-vessels, two or three to each artery; they ascend with the blood-vessels and enter the lymphatic glands in the popliteal space; the efferent vessels from these glands accompany the femoral vein and join the deep inguinal glands; from these, the vessels pass beneath Poupart's ligament and communicate with the chain of glands surrounding the external iliac vessels.

The deep lymphatic vessels of the gluteal and ischiatic regions follow the course of the blood-vessels, and join the gluteal and ischiatic glands at the great sacro-sciatic foramen.

LYMPHATICS OF THE PELVIS AND ABDOMEN.

The **Lymphatic Glands in the Pelvis** are the external iliac, the internal iliac, and the sacral. Those of the abdomen are the lumbar and cœliac glands.

The **external iliac glands** form an uninterrupted chain round the external iliac vessels, three being placed round the commencement of the vessels just behind the crural arch. They communicate below with the deep inguinal lymphatic glands, and above with the lumbar glands.

The **internal iliac glands** surround the internal iliac vessels; they receive the lymphatic vessels corresponding to the branches of the internal iliac artery, and communicate with the lumbar glands.

The **sacral glands** occupy the sides of the anterior surface of the sacrum, some being situated in the meso-rectal fold. These and the internal iliac glands are affected in malignant disease of the bladder, rectum, or uterus.

The **lumbar glands** are very numerous; they are situated on the front of the lumbar vertebræ, surrounding the common iliac vessels, the aorta, and vena cava; they receive the lymphatic vessels from the lower extremities and pelvis, as well as from the testes and some of the abdominal viscera: the efferent vessels from these glands unite into a few large trunks, which, with the lacteals, form the commencement of the thoracic duct. In addition to these there are a few small *lateral lumbar glands* which lie between the transverse processes of the vertebræ, behind the Psoas muscle, and receive lymphatics from the back. In some cases of malignant disease these glands become enormously enlarged, completely surrounding the aorta and vena cava, and occasionally greatly contracting the calibre of those vessels. In all cases of malignant disease of the testes and in malignant disease of the lower limb, before any operation is attempted, careful examination of the abdomen should be made, in order to ascertain if any enlargement exists; and if any should be detected, all operative measures should be avoided as fruitless.

The **Cœliac Glands,** nearly twenty in number, surround the cœliac axis and lie in front of the aorta near the origin of that vessel. They receive the lymphatic vessels from a large part of the liver, from the spleen, pancreas, and stomach. Their efferent vessels join the lacteals from the intestine and open into the receptaculum chyli.

The **Lymphatic Vessels of the Abdomen and Pelvis** may be divided into two sets, *superficial* and *deep*.

The **superficial lymphatic vessels of the walls of the abdomen and pelvis** follow the course of the superficial blood-vessels. Those derived from the integument of the lower part of the abdomen below the umbilicus follow the course of the superficial epigastric vessels and converge to the superior group of the superficial inguinal glands; a deeper set accompany the deep epigastric vessels, and communicate with the external iliac glands. The superficial lymphatics from the sides of the lumbar part of the abdominal wall wind round the crest of the ilium, accompanying the superficial circumflex iliac vessels, to join the superior group

of the superficial inguinal glands; the greater number, however, run backward along with the ilio-lumbar and lumbar vessels, to join the lateral lumbar glands.

The **superficial lymphatic vessels of the gluteal region** turn horizontally round the outer side of the nates, and join the superficial inguinal glands.

The **superficial lymphatic vessels of the scrotum and perinæum** follow the course of the external pudic vessels, and terminate in the superficial inguinal glands.

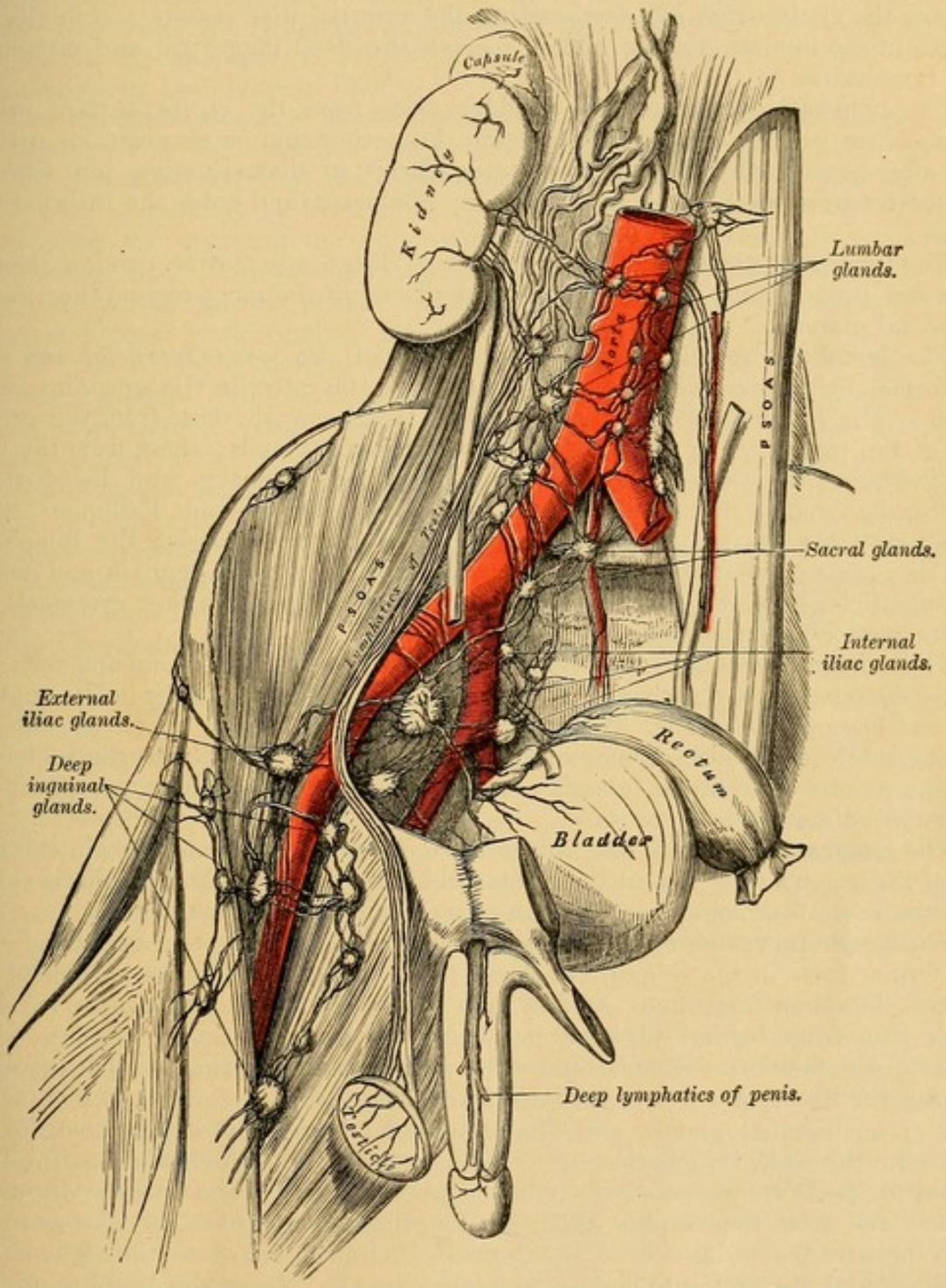

FIG. 342.—The deep lymphatic vessels and glands of the abdomen and pelvis.

The **superficial lymphatic vessels of the penis** occupy the sides and dorsum of the organ, the latter receiving the lymphatics from the skin covering the glans penis; they all converge to the upper chain of the superficial inguinal glans. The **deep lymphatic vessels of the penis** follow the course of the internal pudic vessels, and join the internal iliac glands.

In the female the lymphatic vessels of the mucous membrane of the labia, nymphæ, and clitoris terminate in the upper chain of the inguinal glands.

The **deep lymphatic vessels of the abdomen and pelvis** take the course of the principal blood-vessels. Those of the parietes of the pelvis, which accompany the gluteal, ischiatic, and obturator vessels, follow the course of the internal iliac artery, and ultimately join the lumbar lymphatics.

The efferent vessels from the inguinal glands enter the pelvis beneath Poupart's ligament, where they lie in close relation with the femoral vein; they then pass through the chain of glands surrounding the external iliac vessels, and finally terminate in the lumbar glands. They receive the deep epigastric and circumflex iliac lymphatics.

The **lymphatic vessels of the bladder** arise from the entire surface of the organ;[1] the greater number run beneath the peritoneum on its posterior surface, and, after passing through the lymphatic glands in that situation, join with the lymphatics from the prostate and vesiculæ seminales, and enter the internal iliac glands.

The **lymphatic vessels of the rectum** are of large size; after passing through some small glands that lie upon its outer wall and in the meso-rectum they pass to the sacral glands.

The **lymphatic vessels of the uterus** consist of two sets, *superficial* and *deep*, the former being placed beneath the peritoneum, the latter in the substance of the organ. The lymphatics of the cervix uteri, together with those from the greater part of the vagina, enter the internal iliac and sacral glands; those from the body and fundus of the uterus pass outward in the broad ligaments, and, being joined by the lymphatics from the ovaries, broad ligaments, and Fallopian tubes, ascend with the ovarian vessels to open into the lumbar glands; the lymphatics from the lower part of the vagina join those of the external genitals and pass to the superficial inguinal glands. In the unimpregnated uterus they are small, but during gestation they become very greatly enlarged.

The **lymphatic vessels of the testicle** consist of two sets, *superficial* and *deep:* the former commence on the surface of the tunica vaginalis, the latter in the epididymis and body of the testis. They form several large trunks which ascend with the spermatic cord, and, accompanying the spermatic vessels into the abdomen, terminate into the lumbar glands; hence the enlargement of these glands in malignant disease of the testis.

The **lymphatic vessels of the kidney** arise on the surface, and also in the interior of the organ; they join at the hilum, and, after receiving the lymphatic vessels from the ureter and suprarenal capsules, open into the lumbar glands.

The **lymphatic vessels of the liver** are divisible into two sets, *superficial* and *deep*. The former arise in the subperitoneal areolar tissue over the entire surface of the organ. Those on the convex surface may be divided into four groups: 1. Those which pass from behind forward, consisting of three or four branches, which ascend in the falciform ligament and unite to form a single trunk, which passes up between the fibres of the Diaphragm, behind the ensiform cartilage, to enter the anterior mediastinal glands, and finally ascends to the root of the neck, to terminate in the right lymphatic duct. 2. Another group, which also incline from behind forward, are reflected over the anterior margin of the liver to its under surface, and from thence pass along the longitudinal fissure to the glands in the gastro-hepatic omentum. 3. A third group incline outward to the right lateral ligament, and, uniting into one or two large trunks, pierce the Diaphragm, and run along its upper surface to enter the anterior mediastinal glands, or, instead of entering the thorax, turn inward across the crus of the Diaphragm and open into the commencement of the thoracic duct. 4. The fourth group incline outward from the surface of the left lobe of the liver to the left lateral ligament, pierce the Diaphragm, and, passing forward, terminate in the glands in the anterior mediastinum.

[1] Curnow states that they are confined to the base of the organ.

The *superficial lymphatics on the under surface of the liver* are divided into three sets: 1. Those on the right side of the gall-bladder enter the lumbar glands. 2. Those surrounding the gall-bladder form a remarkable plexus; they accompany the hepatic vessels, and open into the glands in the gastro-hepatic omentum. 3. Those on the left of the gall-bladder pass to the œsophageal glands and to the glands which are situated along the lesser curvature of the stomach.

The *deep lymphatics* accompany the branches of the portal vein and the hepatic artery and duct through the substance of the liver; passing out at the transverse fissure, they enter the lymphatic glands along the lesser curvature of the stomach and behind the pancreas, or join with one of the lacteal vessels previous to its termination in the thoracic duct.

The **lymphatic glands of the stomach** are of small size; they are placed along the upper part of the lesser and toward the pyloric end of the greater curvature.

The **lymphatic vessels of the stomach** consist of two sets, *superficial* and *deep*; the former originating in the subserous, and the latter in the submucous coat. They follow the course of the blood-vessels, and may consequently be arranged into three groups. The *first group* accompany the gastric vessels along the lesser curvature to the cardiac orifice, receiving branches from both surfaces of the organ, and pass to the cœliac glands. The *second group* pass from the great end of the stomach, accompanying the vasa brevia, and enter the splenic lymphatic glands. The *third group* run along the greater curvature with the right gastro-epiploic vessels toward the pylorus, and, receiving the lymphatics from the upper part of the duodenum, terminate in the cœliac glands.

The **lymphatic glands of the spleen** occupy the hilum. Its *lymphatic vessels* consist of two sets, superficial and deep; the former are placed beneath its peritoneal covering, the latter in the substance of the organ; they accompany the blood-vessels, passing through a series of small glands, and, after receiving the lymphatics from the pancreas, ultimately pass into the cœliac glands.

The *lymphatics of the pancreas* also enter the cœliac glands.

THE LYMPHATIC SYSTEM OF THE INTESTINES.

The **lymphatic glands of the small intestine** are placed between the layers of the mesentery, occupying the meshes formed by the superior mesenteric vessels, and hence called *mesenteric glands*. They vary in number from a hundred to a hundred and fifty, and in size from that of a pea to that of a small almond.[1] These glands are most numerous and largest above, the glands of the jejunum, being more numerous than those of the ileum. This latter group becomes enlarged and infiltrated with deposit in cases of fever accompanied with ulceration of the intestines.

The **lymphatic glands of the large intestine** are much less numerous than the mesenteric glands; they are situated along the vascular arches formed by the arteries previous to their distribution, and even sometimes upon the intestine itself. They are fewest in number along the transverse colon, where they form an uninterrupted chain with the mesenteric glands.

The **lymphatic vessels of the small intestine** are called **lacteals,** from the milk-white fluid they usually contain: they consist of two sets, superficial and deep, the former lie between the layers of the muscular coat and between the muscular and peritoneal coats, taking a longitudinal course along the outer side of the intestine; the latter occupy the submucous tissue, and course transversely round the intestine, accompanied by the branches of the mesenteric vessels; they pass between the layers of the mesentery, enter the mesenteric glands, and finally unite to form two or three large trunks which terminate separately in the receptaculum chyli; frequently, however, they first unite to form a single large trunk, termed the *intestinal lymphatic trunk.*

The **lymphatic vessels of the large intestine** consist of two sets: those of the

[1] Leaf (*op. cit.*) says it is very common to find not more than forty or fifty.

cæcum, ascending and transverse colon, which, after passing through their proper glands, enter the mesenteric glands; and those of the descending colon, sigmoid flexure, and rectum, which pass to the lumbar glands.

THE LYMPHATICS OF THE THORAX.

The **Lymphatic Glands of the Thoracic Wall** are the intercostal, internal mammary, anterior mediastinal, and posterior mediastinal.

The **intercostal glands** are small, and situated on each side of the spine, near the costo-vertebral articulations; they vary from one to three in each space.

The **sternal** or **internal mammary glands** are placed at the anterior extremity of each intercostal space, by the side of the internal mammary vessels.

The **anterior mediastinal glands** are placed in the loose areolar tissue of the anterior mediastinum, some lying upon the Diaphragm in front of the pericardium, and others round the great vessels at the base of the heart.

The **posterior mediastinal glands** are situated in the areolar tissue in the posterior mediastinum, forming a continuous chain by the side of the aorta and œsophagus; they communicate on each side with the intercostal, below with the lumbar, and above with the deep cervical glands.

The **Superficial Lymphatic Vessels of the Front of the Thorax** run across the great Pectoral muscle, and those on the back part of this cavity lie upon the Trapezius and Latissimus dorsi; they all converge to the axillary glands. The lymphatics from the greater part of the mammary gland pass outward to the lower border of the Pectoralis major muscle, where they enter a chain of small glands situated in the axillary space along the lower border of its anterior boundary. Some few lymphatics from the inner side of the mammary gland pass through the intercostal spaces to reach the anterior mediastinal glands.

The **Deep Lymphatic Vessels of the Thoracic Wall** are the intercostal, internal mammary, and diaphragmatic.

The **intercostal lymphatic vessels** follow the course of the intercostal vessels, receiving lymphatics from the intercostal muscles and pleura; they pass backward to the spine, and unite with lymphatics from the back part of the thorax and spinal canal. After traversing the intercostal glands, they pass down the spine and terminate in the thoracic duct.

The **internal mammary lymphatic vessels** follow the course of the internal mammary vessels; they commence in the muscles of the abdomen above the umbilicus, communicating with the epigastric lymphatics, ascend between the fibres of the Diaphragm at its attachment to the ensiform appendix, and in their course behind the costal cartilages are joined by the intercostal lymphatics; they terminate on the right side in the right lymphatic duct, on the left side in the thoracic duct.

The **lymphatic vessels of the Diaphragm** follow the course of their corresponding vessels, and terminate, some in front in the anterior mediastinal and internal mammary glands, some behind, in the intercostal and posterior mediastinal lymphatics.

The **Lymphatic Glands of the Viscera of the Thorax** are the bronchial glands.

The **bronchial glands** are situated round the bifurcation of the trachea and roots of the lungs. They are ten or twelve in number, the largest being placed opposite the bifurcation of the trachea, the smallest round the bronchi and their primary divisions for some little distance within the substance of the lungs. In infancy they present the same appearance as lymphatic glands in other situations; in the adult they assume a brownish tinge, and in old age a deep black color. Occasionally they become sufficiently enlarged to compress and narrow the canal of the bronchi, and they are often the seat of tuberculous deposits.

The **superior mediastinal** or **cardiac glands** lie in front of the transverse aorta

and left innominate vein; this group consists of numerous large glands. They receive the lymph from the pericardium, heart, and thymus gland.

The **lymphatic vessels of the lung** consist of two sets, *superficial* and *deep:* the former are placed beneath the pleura, forming a minute plexus which covers the outer surface of the lung; the latter accompany the blood-vessels and run along the bronchi: they both terminate at the root of the lungs in the bronchial glands. The efferent vessels from these glands, two or three in number, ascend upon the trachea to the root of the neck, traverse the tracheal and œsophageal glands, and terminate on the left side in the thoracic duct and on the right side in the right lymphatic duct.

The **cardiac lymphatic vessels** consist of two sets, *superficial* and *deep:* the former arise in the subserous areolar tissue of the surface, and the latter in the deeper tissues of the heart. They follow the course of the coronary vessels: those of the right side unite into a trunk at the root of the aorta, which, ascending across the arch of that vessel, communicates with one or more of the cardiac glands, and passes backward to the trachea, upon which it ascends, to terminate at the root of the neck in the right lymphatic duct. Those of the left side unite into a single vessel at the base of the heart, which, passing along the pulmonary artery and traversing some glands at the root of the aorta, ascends on the trachea to terminate in the thoracic duct.

The **thymic lymphatic vessels** arise from the under surface of the thymus gland, and enter the superior mediastinal glands, from which they emerge as two vessels: these terminate, one on each side, in the corresponding internal jugular vein.

The **lymphatic vessels of the œsophagus** form a plexus round that tube, traverse the glands in the posterior mediastinum, and, after communicating with the pulmonary lymphatic vessels near the roots of the lungs, terminate in the thoracic duct.

THE NERVOUS SYSTEM.

THE Nervous System is composed · 1. Of a series of large centres of nerve-matter, called, collectively, the *cerebro-spinal centres* or *cerebro-spinal axis.* 2. Of smaller centres, termed *ganglia.* 3. Of nerves connected either with the cerebro-spinal axis or the ganglia. And 4. Of certain modifications of the peripheral terminations of the nerves forming the organs of the external senses.

The **Cerebro-spinal axis** consists of the brain or encephalon and the spinal cord, which are contained within the skull and spinal canal. The brain and its membranes will be first considered, and then the spinal cord and its coverings.

THE MEMBRANES OF THE BRAIN.

Dissection.—To examine the brain with its membranes, the skull-cap must be removed. In order to effect this, saw through the external table, the section commencing, in front, about an inch above the margin of the orbit, and extending, behind, to a little above the level with the occipital protuberance. Then break the internal table with the chisel and hammer, to avoid injuring the investing membranes or brain; loosen and forcibly detach the skull-cap, when the dura mater will be exposed. The adhesion between the bone and the dura mater is very intimate, and much more so in the young subject than in the adult.

The membranes of the brain are: the dura mater, arachnoid membrane, and pia mater.

The Dura Mater.

The **Dura Mater** is a thick and dense inelastic fibrous membrane which lines the interior of the skull. Its outer surface is rough and fibrillated, and adheres closely to the inner surface of the bones, forming their internal periosteum, this adhesion being most marked opposite the sutures and at the base of the skull. Its inner surface is smooth and lined by a layer of endothelium. It sends four processes inward, into the cavity of the skull, for the support and protection of the different parts of the brain, and is prolonged to the outer surface of the skull through the various foramina which exist at the base, and thus becomes continuous with the pericranium; its fibrous layer forms sheaths for the nerves which pass through these apertures. At the base of the skull it sends a fibrous prolongation into the foramen cæcum; it sends a series of tubular prolongations round the filaments of the olfactory nerves as they pass through the cribriform plate, and also round the nasal nerve as it passes through the nasal slit; a prolongation is also continued through the sphenoidal fissure into the orbit, and another is continued into the same cavity through the optic foramen, forming a sheath for the optic nerve, which is continued as far as the eyeball. In the posterior fossa it sends a process into the internal auditory meatus, ensheathing the facial and auditory nerves; another through the jugular foramen, forming a sheath for the structures which pass through this opening; and a third through the anterior condyloid foramen. Around the margin of the foramen magnum it is closely adherent to the bone, and is continuous with the dura mater lining the spinal canal. In certain situations, as already mentioned (page 594), the fibrous layers of this membrane separate, to form sinuses for the passage of venous blood. Upon the outer surface of the dura mater, in the situation of the longitudinal sinus, may be seen numerous small whitish bodies, the *glandulæ Pacchioni.*

Structure.—The dura mater consists of white fibrous tissue with connective-tissue cells and elastic fibres arranged in flattened laminæ which are imperfectly separated by lacunar spaces and blood-vessels into two layers, *endosteal* and *meningeal.* The endosteal layer is the internal periosteum for the cranial bones,

and contains the blood-vessels for their supply. At the margin of the foramen magnum it becomes continuous with the periosteum lining the spinal canal. The meningeal or supporting layer is lined on its inner surface by a layer of nucleated endothelium, similar to that found on serous membranes: these cells were formerly regarded as belonging to the arachnoid membrane. By its reduplication the meningeal layer forms the falx cerebri, the tentorium and falx cerebelli, and the diaphragma sellæ. The two layers are connected by fibres which intersect each other obliquely.

Its *arteries* are very numerous, but are chiefly distributed to the bones. Those found in the anterior fossa are the anterior meningeal branches of the anterior and posterior ethmoidal and internal carotid, and a branch from the middle meningeal. In the middle fossa are the middle and small meningeal branches of the internal maxillary, a branch from the ascending pharyngeal, which enters the skull through the foramen lacerum medium basis cranii, branches from the internal carotid, and a recurrent branch from the lachrymal. In the posterior fossa are meningeal branches from the occipital, one of which enters the skull through the jugular foramen, and the other through the mastoid foramen; the posterior meningeal, from the vertebral; occasionally meningeal branches from the ascending pharyngeal, which enter the skull, one at the jugular foramen, the other at the anterior condyloid foramen, and a branch from the middle meningeal.

The *veins*, which return the blood from the dura mater, and partly from the bones, anastomose with the diploic veins. These vessels terminate in the various sinuses, with the exception of two which accompany the middle meningeal artery, and pass out of the skull at the foramen spinosum to join the internal maxillary vein; above they communicate with the superior longitudinal sinus. Many of the meningeal veins do not open directly into the sinuses, but indirectly through a series of ampullæ termed *venous lacunæ*. These are found on each side of the superior longitudinal sinus, especially near its middle portion, and are often invaginated by Pacchionian bodies; they also exist near the lateral and straight sinuses. They communicate with the underlying cerebral veins, and also with the diploic and emissary veins.

The *nerves* of the dura mater are filaments from the Gasserian ganglion, from the ophthalmic, superior maxillary, inferior maxillary, vagus, and hypoglossal nerves, and from the sympathetic.

Processes of the Dura Mater.—The processes of the dura mater, sent inward into the cavity of the skull, are four in number: the falx cerebri, the tentorium cerebelli, the falx cerebelli, and the diaphragma sellæ.

The *falx cerebri*, so named from its sickle-like form, is a strong arched process of the dura mater, which descends vertically in the longitudinal fissure between the two hemispheres of the brain. It is narrow in front, where it is attached to the crista galli of the ethmoid bone, and broad behind, where it is connected with the upper surface of the tentorium. Its upper margin is convex, and attached to the inner surface of the skull, in the middle line, as far back as the internal occipital protuberance; it contains the superior longitudinal sinus. Its lower margin is free, concave, and presents a sharp curved edge, which contains the inferior longitudinal sinus.

The *tentorium cerebelli* is an arched lamina of dura mater, elevated in the middle and inclining downward toward the circumference. It covers the upper surface of the cerebellum, and supports the occipital lobes of the brain, and prevents them pressing upon the cerebellum. It is attached, behind, by its convex border to the transverse ridges upon the inner surface of the occipital bone, and there encloses the lateral sinuses; in front, to the superior margin of the petrous portion of the temporal bone on either side, enclosing the superior petrosal sinuses; and at the apex of this bone the free or internal border and the attached or external border meet, and, crossing one another, are continued forward, to be attached to the anterior and posterior clinoid processes respectively. Along the middle line of its upper surface the posterior border of the falx cerebri is

attached, the straight sinus being placed at their point of junction. Its anterior border is free and concave, and bounds a large oval opening for the transmission of the crura cerebri.

The *falx cerebelli* is a small triangular process of dura mater received into the indentation between the two lateral lobes of the cerebellum behind. Its base is attached, above, to the under and back part of the tentorium; its posterior margin, to the lower division of the vertical crest on the inner surface of the occipital bone. As it descends it sometimes divides into two smaller folds, which are lost on the sides of the foramen magnum.

The *diaphragma sellæ* is a horizontal process formed by a reduplication of the meningeal layer of the dura mater. It forms a small circular fold, which constitutes a roof for the sella turcica. This almost completely covers the pituitary body, presenting merely a small central opening for the infundibulum to pass through.

The Arachnoid Membrane.

The arachnoid (*ἀράχνη εἶδος*, like a spider's web), so named for its extreme thinness, is a delicate membrane which envelops the brain, lying between the pia mater internally and the dura mater externally; from this latter membrane it is separated by a space, the *subdural space*.

It invests the brain loosely, being separated from direct contact with the cerebral substance by the pia mater, and a quantity of loose areolar tissue, the *subarachnoidean*. On the upper surface of the cerebrum the arachnoid is thin and transparent, and may be easily demonstrated by injecting a stream of air beneath it by means of a blowpipe; it passes over the convolutions without dipping down into the sulci between them. At the base of the brain the arachnoid is thicker, and slightly opaque toward the central part; it covers the anterior lobes, and extends across between the two temporal lobes so as to leave a considerable interval between it and the brain, the *anterior subarachnoidean space* (Cisterna pontis); it is in contact with the pons and under surface of the cerebellum; but between the hemispheres of the cerebellum and the medulla oblongata another considerable interval is left between it and the brain, called the *posterior subarachnoidean space* (Cisterna magna). These two spaces communicate together across the crura cerebelli. Other smaller cisternæ are found in various positions; and all communicate freely with one another. The arachnoid membrane surrounds the nerves which arise from the brain, and encloses them in loose sheaths as far as their point of exit from the skull.

The *subarachnoid space* is the interval between the arachnoid and pia mater. It is not, properly speaking, a *space*, for it is occupied everywhere by a spongy tissue consisting of trabeculæ of delicate connective tissue, which pass from the pia mater to the arachnoid, and in the meshes of which the subarachnoid fluid is contained. This so-called space is small on the surface of the hemispheres; but at the base of the brain the subarachnoid tissue is less abundant and its meshes larger, where it forms the Cisternæ pontis et magna mentioned above. In addition to these two large spaces, a third is formed on the upper surface of the corpus callosum, for the arachnoid stretches across from one cerebral hemisphere to the other immediately beneath the free border of the falx cerebri, and thus leaves a space in which the anterior cerebral arteries are contained. Another space is found in the fissure of Sylvius, for the arachnoid stretches across from the anterior to the middle lobe of the brain, without dipping down to the bottom of the fissure, and in this space the middle cerebral artery ramifies. The subarachnoid space communicates with the general ventricular cavity of the brain by means of three openings: one of these is in the middle line at the inferior boundary of the fourth ventricle, where an opening in the pia-matral covering of this cavity, the *foramen of Magendie*, exists and permits the passage of fluid from the one space to the other. The other two communications are at the extremities of the lateral recesses of the fourth ventricle, behind the upper roots of the glosso-pharyngeal nerves; they are named

the *foramina of Key and Retzius*. It is stated by Merkel that the lateral ventricles also communicate with the subarachnoid space at the apices of their descending horns.

The subdural space also contains fluid; this is, however, small in quantity compared with the cerebro-spinal fluid and is probably of the nature of lymph.

The *cerebro-spinal fluid* fills up the subarachnoid space. It is a clear, limpid fluid, having a saltish taste and a slightly alkaline reaction. According to Lassaigne, it consists of 98.5 parts of water, the remaining 1.5 per cent. being solid matters, animal and saline. It varies in quantity, being most abundant in old persons, and is quickly reproduced. Its chief use is probably to afford mechanical protection to the nervous centres, and to prevent the effects of concussions communicated from without.

Structure.—The arachnoid consists of bundles of white fibrous and elastic tissue intimately blended together. Its outer surface is covered with a layer of endothelium. Vessels of considerable size, but few in number, and, according to Bochdalek, a rich plexus of nerves derived from the motor division of the fifth, the facial, and the spinal accessory nerves, are found in the arachnoid.

Glandulæ Pacchioni or Arachnoid Villi.

The **glandulæ Pacchioni** are numerous small whitish granulations usually collected into clusters of variable size, which are found in the following situations: 1. Upon the outer surface of the dura mater, in the vicinity of the superior longitudinal sinus, being received into little depressions on the inner surface of the calvarium. 2. On the inner surface of the dura mater. 3. In the superior longitudinal sinus. 4. On the pia mater, near the margin of the hemispheres.

These bodies are not glandular in structure, but simply enlarged normal villi of the arachnoid. In their growth they appear to perforate the dura mater, and when of large size they cause absorption of the bone, and come to be lodged in pits or depressions on the inner table of the skull. Their manner of growth is as follows: at an early period they project through minute holes in the inner layer of the dura mater, which open into large venous spaces situated in the tissues of the membrane, on either side of the longitudinal sinus and communicating with it. In their onward growth the villi push the outer layer of the dura mater before them, and this forms over them a delicate membranous sheath. In structure they consist of spongy trabecular tissue, covered over by a membrane, which is continuous with the arachnoid. The space between these two coverings, derived from the dura mater and arachnoid respectively, corresponds to and is continuous with the subdural space. The spongy tissue of which they are composed is continuous with the trabecular tissue of the subarachnoid space; so that fluid injected into the subarachnoid space finds its way into the Pacchionian bodies; and through their coverings filters into the superior longitudinal sinus. They are supposed to be the means by which excess of cerebro-spinal fluid is got rid of, when its quantity is increased above normal.

These bodies are not found in infancy, and very rarely until the third year. They are usually found after the seventh year; and from this period they increase in number as age advances. Occasionally they are wanting.

The Pia Mater.

The pia mater is a vascular membrane, and derives its blood from the internal carotid and vertebral arteries. It consists of a minute plexus of blood-vessels, held together by an extremely fine areolar tissue. It invests the entire surface of the brain, dipping down between the convolutions and laminæ, and is prolonged into the interior, forming the velum interpositum and choroid plexuses of the lateral and fourth ventricles. Upon the surfaces of the hemispheres, where it covers the gray matter of the convolutions, it is very vascular, and gives off from its inner surface a multitude of minute vessels, which extend perpendicularly for some distance into the cerebral

substance. At the base of the brain, in the situation of the anterior and posterior perforated spaces, a number of long straight vessels are given off, which pass through the white matter to reach the gray substance in the interior. On the cerebellum the membrane is more delicate, and the vessels from its inner surface are shorter. The pia mater of the spinal cord is thicker, firmer, and less vascular than that of the brain, and as it is traced upward over the medulla it is seen to preserve these characters. At the upper border of the medulla it is prolonged over the lower half of the fourth ventricle, forming a covering for it (tela choroidea inferior) before it is reflected on to the under surface of the cerebellum.

According to Fohmann and Arnold, this membrane contains numerous lymphatic vessels. Its nerves are derived from the sympathetic, and also from the third, fifth, sixth, facial, glosso-pharyngeal, pneumogastric, and spinal accessory. They accompany the branches of the arteries.

THE BRAIN.

GENERAL CONSIDERATIONS AND DIVISIONS.

The **encephalon** or **brain** is that portion of the cerebro-spinal axis which is contained in the cavity of the cranium. For purposes of description it may be divided into five parts, as follows: (1) the two cerebral hemispheres; (2) the inter-brain; (3) the mid-brain; (4) the pons Varolii and cerebellum; and (5) the medulla oblongata. If the student will refer to the section on the Development of the Brain he will find that these five portions correspond fairly accurately to the five secondary cerebral vesicles, of which the brain at an early period of embryonal life consisted: the prosencephalon, or *first* vesicle, by means of a protrusion from its front part on either side, forms the cerebral hemispheres and the lateral ventricles; the remainder of the prosencephalon, together with the *second* vesicle, the thalamencephalon, form the inter-brain and third ventricle; the *third* vesicle, the mesencephalon, forms the mid-brain, or that portion which connects the inter-brain and hemispheres above with the pons Varolii below, and the cavity of the vesicle forms the aqueduct of Sylvius, or iter a tertio ad quartum ventriculum; the *fourth* vesicle, the epencephalon, becomes the future pons Varolii and cerebellum, and its cavity forms the upper half of the fourth ventricle; and, finally, the *fifth* vesicle, the melencephalon, develops into the medulla oblongata, and its cavity forms the lower half of the fourth ventricle. It will thus be seen that the five divisions of the encephalon mentioned above correspond to the five secondary cerebral vesicles, with the exception of the first two, which together form the cerebral hemispheres and the inter-brain. In consequence of this these two portions of the brain are sometimes grouped together as the *cerebrum*.

I. The Hemispheres of the Brain.

General Considerations.—The two hemispheres constitute the largest portion of the encephalon, and, together with the parts derived from the thalamencephalon, form what is called by some writers the *fore-brain*. They occupy the whole of the vault of the skull, and consist of a central cavity, in either hemisphere, surrounded by exceedingly thick and convoluted walls of nervous tissue. The under surface or base of the cerebrum is of an irregular form, resting in front on the anterior and middle fossæ of the skull and behind upon the tentorium cerebelli. The upper surface is of an ovoid form, broader behind than in front, convex in general outline, and divided into two lateral halves or hemispheres, right and left, by the *great longitudinal fissure*, which extends throughout the entire length of the cerebrum in the middle line, reaching down to the base of the brain in front and behind, but interrupted in the middle by a broad transverse commissure of white matter, the *corpus callosum*, which connects the two hemispheres together.

The Surface of the Cerebrum.—Each hemisphere presents an outer convex surface, filling the concavity of the corresponding half of the vault of the cranium;

an inner, flattened surface, which is vertical and directed toward the corresponding surface of the opposite hemisphere (the two forming the sides of the longitudinal fissure); and an under surface or base, of an irregular form, which rests in front on the anterior and middle fossæ of the base of the skull, and behind upon the tentorium cerebelli. The hemispheres are composed of an outer stratum of gray matter, called the *cortical substance*. It is thrown into a number of creases or infoldings, which are termed *fissures* and *sulci*, and these separate the surface into a number of irregular eminences, named *convolutions* or *gyri*.

The infoldings or creases are of two kinds, *fissures* and *sulci*. The fissures are of large size, and appear early in fœtal life; they are few in number, nearly constant in their arrangement, and are produced by infoldings of the entire thickness

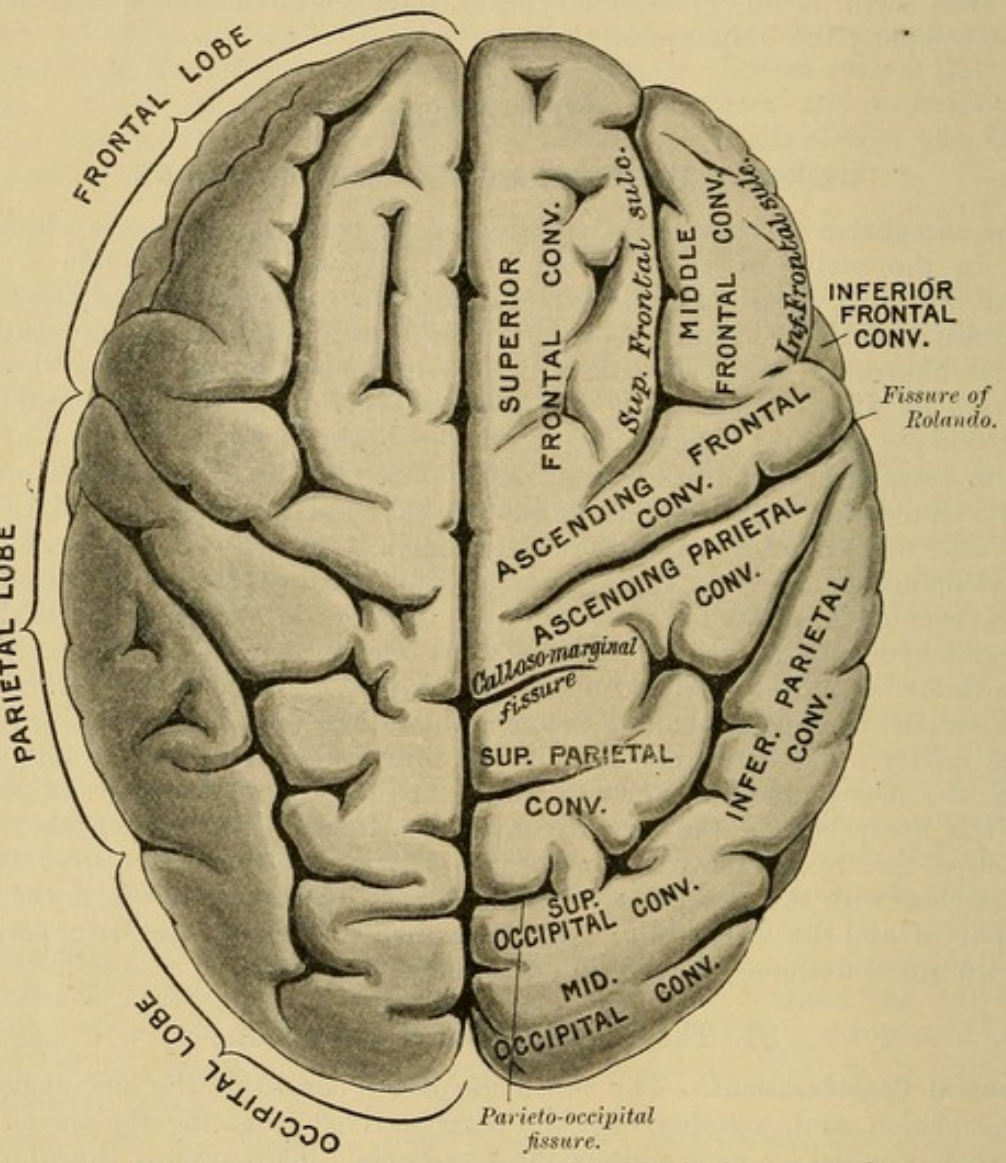

FIG. 343.—Upper surface of the brain, the arachnoid having been removed.

of the wall of the prosencephalon, producing corresponding elevations in the interior of the ventricle, and hence are termed *complete fissures*. They comprise (*a*) the hippocampal, or dentate fissure; (*b*) the anterior part of the calcarine fissure; (*c*) the collateral fissure. The *sulci* are more numerous; they are superficial depressions of the gray matter, which is folded inward and only indents the central white substance. They produce no corresponding elevations in the interior of the ventricle, and are therefore spoken of as *incomplete fissures*. They are fairly constant in their arrangement, and have received names indicative of their position and direction, but at the same time vary, within certain limits, in different individuals. They are similar, without being absolutely identical, on the two sides of the brain. It therefore follows that the gyri or convolutions which lie between these sulci are fairly constant in their general arrangement.

The number and extent of the convolutions, as well as the depth of the intervening sulci, appear to bear a close relation to the intellectual power of the individual, as is shown in their increasing complexity of arrangement as one ascends from the lowest mammalia up to man, where they present a most complex arrangement. Again, in the child, at birth, before the intellectual faculties are exercised, the convolutions are simpler, and the sulci between them shallower, than in the adult. In old age, when the mental faculties have diminished in activity, they become less prominently marked. By their arrangement the convolutions are adapted to increase the amount of gray matter without occupying much additional space, while they also afford a greater extent of surface for the termination of white fibres in gray matter.

It will be convenient, in the first instance, to describe the fissure which separates the two hemispheres from each other, and those which divide each hemisphere into its larger divisions.

The Longitudinal Fissure (Fig. 343).—This great fissure separates the cerebrum into two hemispheres, and reaches from the front to the back of the organ : it contains a vertical process of the dura mater, the falx cerebri (page 640). In front and behind it extends from the top to the bottom of the cerebrum, and completely sepa-

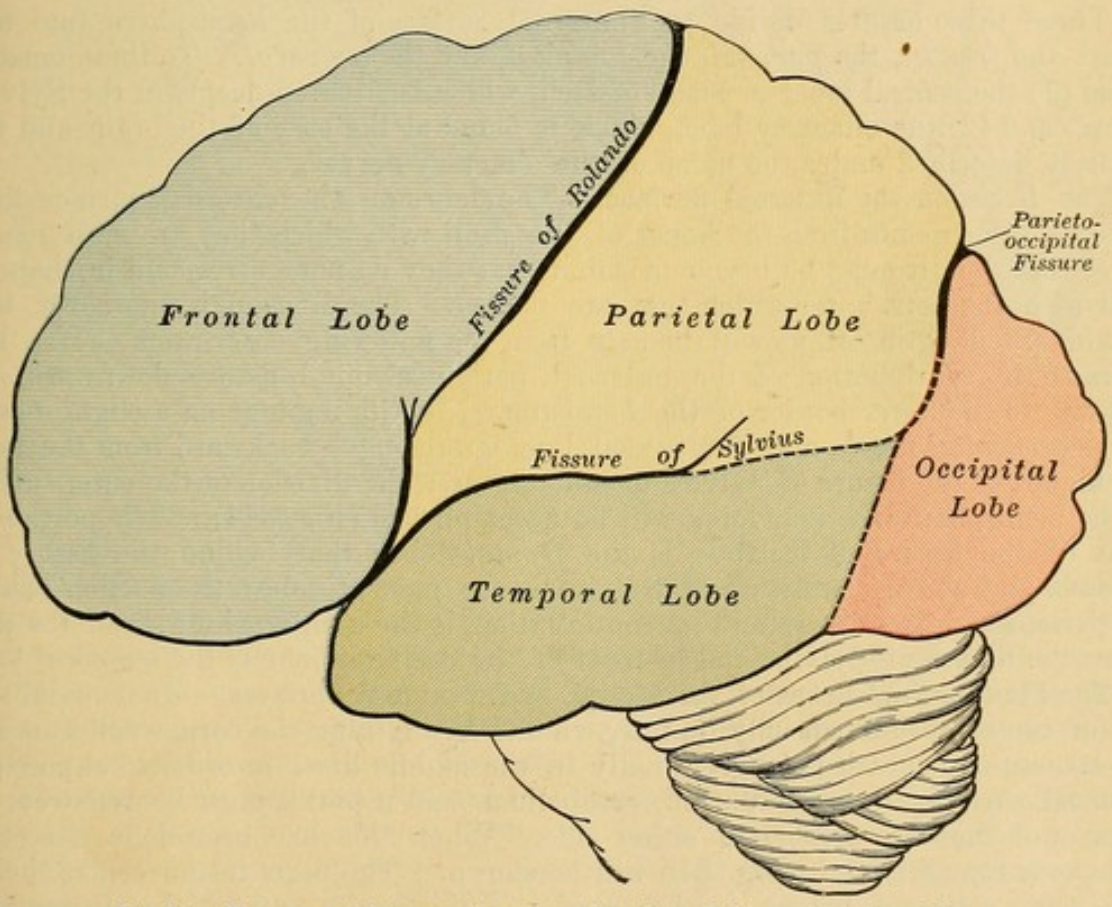

FIG. 344.—Fissures and lobes on the external surface of the cerebral hemispheres.

rates the two hemispheres, but its middle portion only separates the hemispheres for about half their vertical extent, the floor of this part of the fissure being formed by the great central white commissure, the *corpus callosum*, which connects the two hemispheres together.

The remaining fissures are situated in one or other of the two hemispheres, with the exception of the transverse fissure, one-half of which is contained in each hemisphere.

Sylvian Fissure (Fig. 344).—This fissure is a well-marked cleft on the base and side of the hemisphere. Starting at the base of the brain in a depression, the *vallecula Sylvii*, in which is situated the anterior perforated space, it passes outward to the external surface of the hemisphere. It here gives off a short *anterior*

limb, which passes forward, and a short *ascending limb*, which passes upward into the inferior frontal convolution. It is then continued backward as the *horizontal limb*, which terminates by an upward inflexion in the parietal lobe. It occupies the middle third of the lateral surface of the hemisphere.

The **Fissure of Rolando** is situated about the middle of the outer surface of the hemisphere, and, coursing obliquely downward and forward, divides the surface of the hemisphere into approximately equal parts. It commences at or near the longitudinal fissure, a little behind its mid-point, and runs sinuously downward and forward, to terminate a little above the horizontal limb of the fissure of Sylvius, and about half an inch behind the ascending limb of the same fissure. It forms two chief curves: the upper or *superior genu* is concave forward and upward, while the lower or *inferior genu* has its concavity directed backward.

The **parieto-occipital fissure** is only seen to a slight extent on the outer surface of the hemisphere, being situated for the most part on its mesial aspect. The portion on the outer surface is called the *external parieto-occipital fissure*, to distinguish it from the part continued on to the internal surface, which is termed the *internal parieto-occipital fissure*. The external parieto-occipital fissure commences about midway between the posterior extremity or occipital pole of the brain and the fissure of Rolando, and runs downward and outward for about an inch.

These three fissures divide the external surface of the hemisphere into four lobes: the *frontal*, the *parietal*, the *occipital*, and the *temporal*. To these must be added (1) the central lobe, or island of Reil, which is situated deeply in the Sylvian fissure, and (2) the olfactory lobe, which is found at the base of the brain and was formerly described under the name of the olfactory nerve.

The Lobes on the External Surface.—The lobes on the external surface have received their names from the bones of the skull with which they are most nearly in relation, but it must be borne in mind that they do not correspond in shape or limit with the bone after which they are named. The division is, moreover, to a certain extent artificial, as will be seen from the following description. If a line is drawn in continuation of the external parieto-occipital fissure downward and outward to the lower border of the hemisphere, it will impinge on a slight notch, the *pre-occipital notch*, and if a second line is prolonged backward from the horizontal part of the fissure of Sylvius to join the first, the division of the outer surface of the hemisphere into four lobes will be accomplished (Fig. 344). The portion in front of the fissure of Rolando is the *frontal* lobe; that behind the fissure of Rolando and above the fissure of Sylvius is the *parietal* lobe; the portion behind the parieto-occipital fissure and its continuation is the *occipital* lobe; and the part below the fissure of Sylvius and in front of the occipital lobe is the *temporal* lobe.

The Fissures and Lobes of the Mesial and Tentorial Surfaces.—The mesial surface of the cerebrum can only be fully viewed by dividing the corpus callosum and the structures beneath it longitudinally in the middle line; in order to expose the tentorial surface, the pons Varolii, cerebellum, and medulla must be removed, by division of the crus cerebri on either side. When this has been done, a section such as is represented in Fig. 345 will be shown. The parts in the centre, below the corpus callosum, belong to the interior of the brain, and will be disregarded for the present, while the lobes and fissures of the remaining portion of the hemisphere are considered. The fissures are five in number, in addition to a small part of the fissure of Sylvius, the commencement of which is seen, separating the frontal and temporal lobes. These fissures are named the *calloso-marginal*, the *internal parieto-occipital*, the *calcarine*, the *collateral*, and the *dentate* or *hippocampal*.

The **calloso-marginal fissure** commences below the anterior extremity of the corpus callosum; it at first runs forward and upward, parallel with the rostrum of the corpus callosum, and, winding round in front of the genu of that body, it continues from before backward, between the upper margin of the hemisphere and the convolution of the corpus callosum, to about midway between the anterior and posterior extremities of the brain, where it ascends to reach the upper margin

of the hemisphere, a short distance behind the superior extremity of the fissure of Rolando.

The **internal parieto-occipital** extends in an oblique direction downward and forward to join the calcarine fissure, on a level with the hinder end of the corpus callosum.

The **calcarine fissure** commences, usually by two branches, close to the posterior extremity of the hemisphere. These soon unite, and the fissure runs nearly horizontally forward, and is joined by the parieto-occipital fissure, and continues as far as the posterior extremity of the corpus callosum, a little below the level of which it terminates. Its anterior part causes the prominence in the interior of the brain, known as the hippocampus minor or calcar avis.

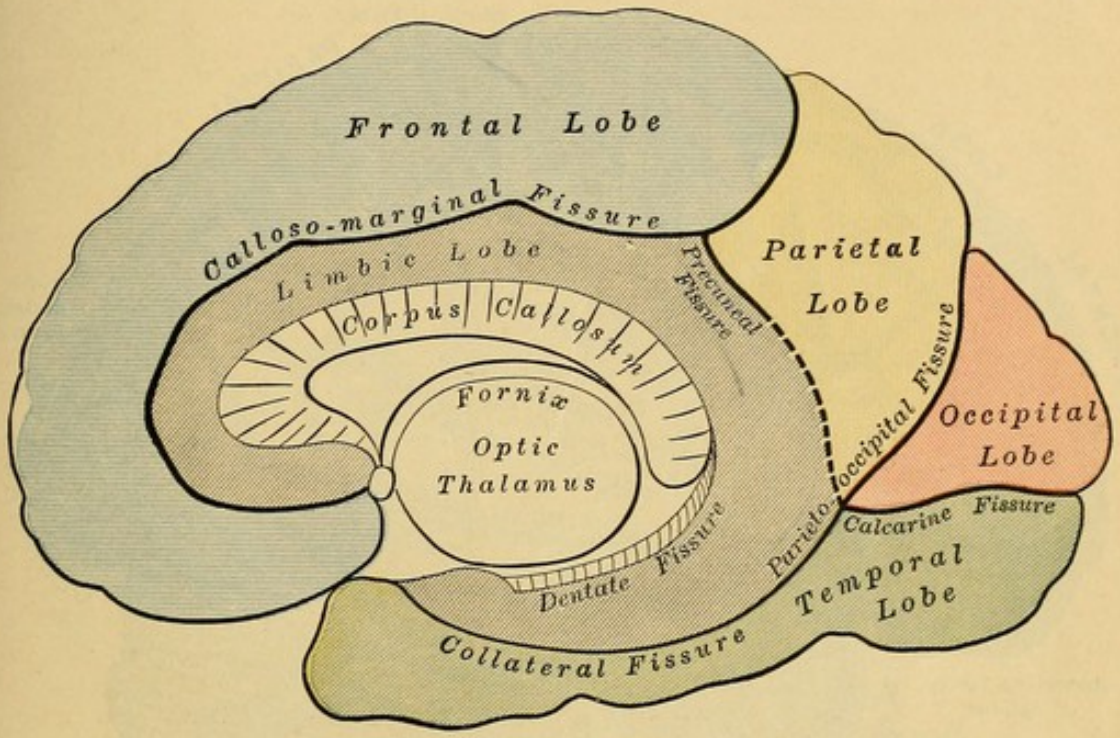

FIG. 345.—Fissures and lobes on the internal surface of the cerebral hemispheres.

The **collateral fissure** is situated on the tentorial surface, below and external to the preceding, being separated from it by the sub-collateral or uncinate gyrus. It runs forward, from the posterior extremity of the brain, nearly as far as the tip of the temporal lobe. It lies below the posterior and descending horns of the lateral ventricle, and its middle part causes the prominence in the interior of the brain, known as the eminentia collateralis.

The **dentate** or **hippocampal fissure** commences immediately behind the posterior extremity of the corpus callosum, and runs forward to terminate at the recurved part of the hippocampal gyrus. It causes the prominence of the hippocampus major in the descending horn of the lateral ventricle. In addition to these fissures, which are constant, there is frequently an irregular broken fissure, which appears to be a continuation backward of the posterior part of the calloso-marginal fissure, before it ascends to reach the upper edge of the hemisphere. This has been termed the *post-limbic fissure.* These fissures map off portions of the internal and tentorial surfaces of the hemispheres, which form parts of the lobes found on the external surface. That portion which lies in front and above the calloso-marginal fissure belongs almost entirely to the frontal lobe; its posterior extremity, which extends for a short distance behind the upper end of the fissure of Rolando, forms a small part of the parietal lobe; that portion which lies above the internal parieto-occipital fissure and behind the calloso-marginal fissure forms a part of the parietal lobe; that between the parieto-occipital fissure above and the calcarine fissure below is a portion of the occipital lobe; and all the region below the calcarine

fissure behind and the collateral fissure in front belongs to the temporal lobe. The remainder of the mesial and tentorial surfaces of the hemisphere constitute what Broca termed the *limbic lobe*, which is subsequently referred to (page 652).

The surface of the hemisphere has thus been divided into its different parts, viz.: the frontal, the parietal, the occipital, the temporal, the limbic, the olfactory lobes, and the island of Reil. Each of these lobes is further subdivided into convolutions or gyri by smaller fissures, which, though less constant in their arrangement than the fissures already described, have a fairly definite course.

1. The Frontal Lobe.—On its *external* surface the frontal lobe presents three sulci, which divide it into four convolutions (Fig. 346). The *precentral sulcus* runs upward through this lobe, parallel to the lower half of the fissure of

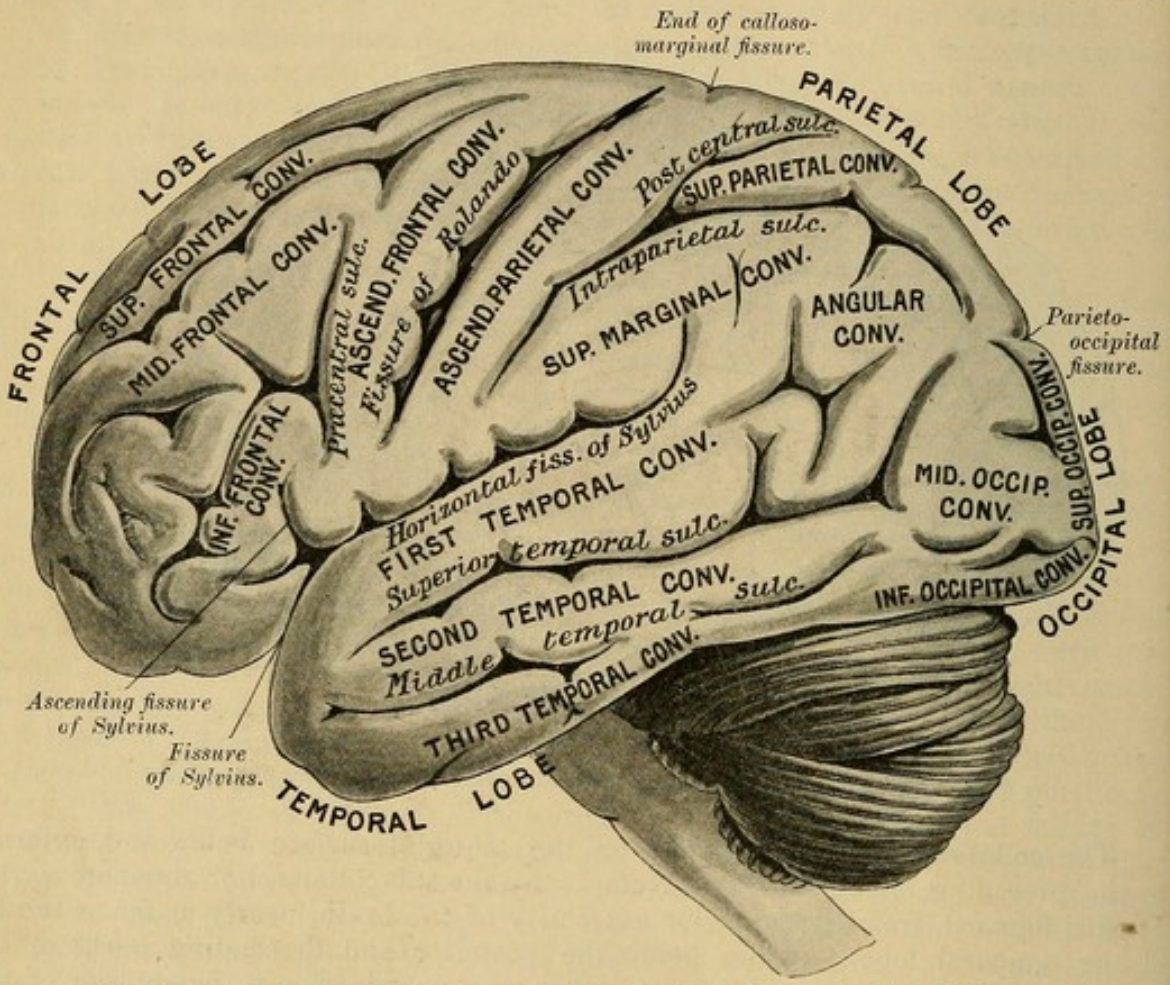

FIG. 346.—Convolutions and sulci on the external surface of the cerebral hemisphere.

Rolando. It is frequently broken or interrupted by annectant gyri. It limits a convolution, which lies between it and the fissure of Rolando, and which is called the *ascending frontal convolution*. From it two sulci, the *superior* and *inferior frontal*, run forward and downward, and divide the remainder of the outer surface of the lobe into three parallel principal convolutions, named respectively the *superior*, *middle*, and *inferior frontal convolutions*.

The *ascending frontal convolution* is a simple convolution, bounded in front by the precentral sulcus, behind by the fissure of Rolando, and extending from the upper margin of the hemisphere above to a little behind the bifurcation of the fissure of Sylvius below.

The *superior frontal convolution* is situated between the margin of the longitudinal fissure and the superior frontal sulcus. It extends above on to the inner aspect of the hemisphere, forming the greater part of the marginal convolution, and in front on to the orbital surface, forming the internal orbital convolution. It is usually more or less completely subdivided into two by an antero-posterior

sulcus, the *sulcus frontalis mesialis* of Cunningham, which, however, is frequently interrupted and broken into several parts by bridging convolutions.

The *middle frontal convolution* is situated between the superior and inferior frontal sulci, and extends from the precentral sulcus on to the orbital surface of the lobe, where it forms the anterior orbital convolution. The middle frontal convolution is frequently subdivided into two by a sagittally directed sulcus, the *sulcus frontalis medius* of Eberstaller.

The *inferior frontal convolution* is situated below the inferior frontal sulcus, and extends forward from the lower part of the precentral sulcus, on to the under surface of the lobe, where it forms the posterior orbital convolution. The inferior frontal convolution is subdivided by the anterior and ascending limbs of the fissure of Sylvius into three parts, viz.: (1) *anterior* or *pars orbitalis*, below the

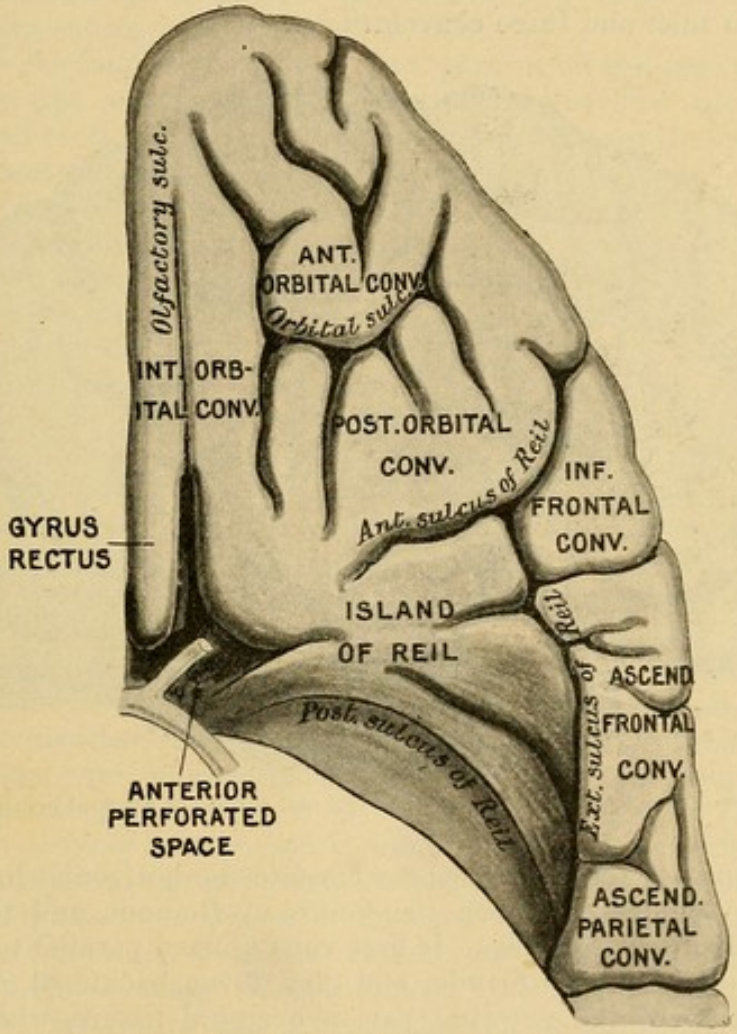

FIG. 347.—Convolutions and sulci on the under surface of the anterior lobe.

anterior limb of the fissure; (2) *middle* or *pars triangularis* ("cap" of Broca), between the two limbs; and (3) *posterior* or *pars basalis*, behind the ascending limb.

The left inferior frontal convolution is, as a rule, more highly developed than the right, and is named the *convolution of Broca*, from the fact that in 1861 Broca discovered that it was the centre for language.

The *under surface* of the frontal lobe rests on the orbital plate of the frontal bone, and is sometimes named the *orbital lobe* (Fig. 347). It is divided into three convolutions by a well-marked sulcus, the *orbital* or *tri-radiate sulcus*. These are named, from their position, the *internal*, *anterior*, and *posterior orbital convolutions*, and are the continuations respectively of the superior, middle, and inferior frontal convolutions of the external surface. The internal orbital convolution presents a well-marked antero-posterior groove or sulcus, the *olfactory sulcus*, for the olfactory

tract; and the portion internal to this is named the *gyrus rectus*, and is continuous with the marginal gyrus, presently to be described. The *mesial* or *internal surface* of the frontal lobe is occupied by a single curved convolution, which from its situation is termed the *marginal gyrus* (Fig. 348). It commences in front of the anterior perforated space, runs along the margin of the longitudinal fissure on the mesial surface of the orbital lobe, where it is continuous with the internal orbital convolution; it then ascends, and runs backward to the point where the callosomarginal fissure turns upward to reach the superior border of the hemisphere. An oval portion at the posterior part of this convolution is sometimes marked off by a vertical fissure, and is distinguished as the *paracentral gyrus*, because it is continuous with the convolutions in front and behind the central fissure or fissure of Rolando.

2. **The Parietal Lobe.**—On its external surface the parietal lobe presents for examination two sulci and three convolutions.

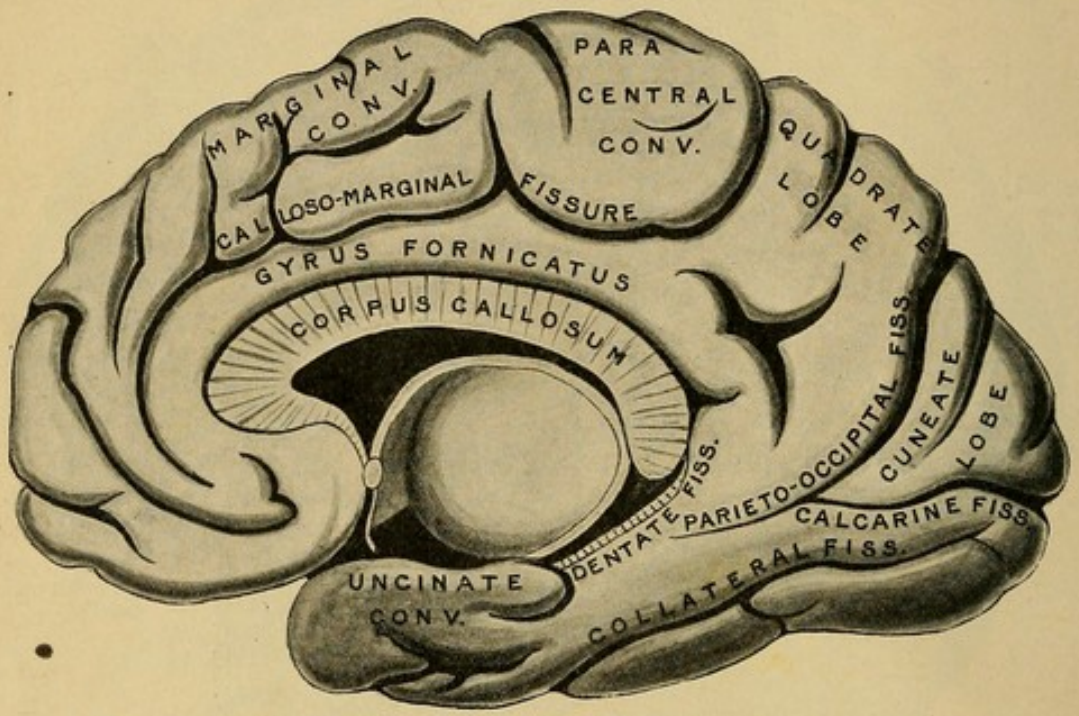

FIG. 348.—Convolutions and sulci on the internal surface of cerebral hemispheres.

The *intra-parietal sulcus* commences close to the horizontal limb of the fissure of Sylvius, about midway between the fissure of Rolando and the upturned extremity of the fissure of Sylvius. It first runs upward parallel to and behind the lower half of the fissure of Rolando, and then turns backward, extending nearly to the termination of the external parieto-occipital fissure, where it sometimes becomes continuous with the superior occipital sulcus. The ascending portion of this sulcus separates off a convolution, the *ascending parietal*, which lies between it and the fissure of Rolando, while the horizontal portion divides the remainder of the external surface of the parietal lobe into two other convolutions, the *superior* and *inferior parietal*.

The *post-central sulcus* is a slightly marked groove, which is sometimes a branch of the intra-parietal sulcus, being given off where the ascending portion of this sulcus turns backward. It lies parallel to and behind the upper part of the fissure of Rolando, and separates the ascending from the superior parietal convolution.[1]

[1] Professor Cunningham describes these two sulci, the intra-parietal and post-central, somewhat differently. He regards them as both belonging to the intra-parietal sulcus, which he divides into three parts: the ascending portion of the intra-parietal, as described above, he terms the *ramus verticalis inferior;* the horizontal portion as the *ramus horizontalis;* while the post-central sulcus he denominates the *ramus verticalis superior*. He states that considerable variability is exhibited in the relation to each other of these different parts of the intra-parietal sulcus, but that the one in which the three parts of the sulcus are confluent is by far the most constant condition. Sometimes, however,

The *ascending parietal convolution* is bounded in front by the fissure of Rolando, behind by the ascending portion of the intra-parietal sulcus and by the post-central sulcus. It extends from the great longitudinal fissure above to the horizontal limb of the fissure of Sylvius below. It lies parallel with the ascending frontal convolution, with which it is connected below, and also, sometimes, above the termination of the fissure of Rolando.

The *superior parietal convolution* is bounded in front by the post-central sulcus, which lies between it and the previous convolution, but with which it is usually connected above the upper extremity of the sulcus; behind, it is bounded by the external parieto-occipital fissure, below the termination of which it is joined to the occipital lobe by a narrow convolution, the *first annectant gyrus;* below, it is separated from the inferior parietal convolution by the horizontal portion of the intra-parietal sulcus; and above, it is continuous on the inner surface of the hemisphere with the quadrate lobe.

The *inferior parietal convolution* is that portion of the parietal lobe which is situated between the ascending portion of the intra-parietal sulcus in front, the horizontal portion of the same sulcus above, the horizontal limb of the fissure of Sylvius below, and the posterior boundary of the parietal lobe behind. It is divided into two convolutions by an indistinct groove. One, the *supra-marginal*, lies behind the ascending part of the intra-parietal sulcus and above the horizontal limb of the fissure of Sylvius, over the extremity of which it arches. It is connected in front with the ascending parietal convolution below the intra-parietal sulcus, and behind with the superior temporal convolution round the posterior extremity of the fissure of Sylvius. The other, the *angular*, is united anteriorly with the foregoing, while posteriorly it is continuous with the middle temporal convolution by a process which curves round the superior temporal or parallel sulcus. It is connected with the occipital lobe by the *second annectant gyrus.*

The *internal* or *mesial* surface of the parietal lobe is continuous with the external surface over the upper edge of the hemisphere. It is of small size, and forms one square-shaped convolution, which from its shape is termed the *quadrate lobe.* From its situation above the cuneate lobe it is sometimes named *precuneus.*

3. **The Occipital Lobe.**—The occipital lobe is divided on its *external* surface into three convolutions by two indistinct sulci, the *superior* and *middle occipital sulci.* They are directed backward across the lobe, being frequently small and ill marked; the superior is sometimes continuous with the horizontal portion of the intra-parietal sulcus.

The *superior occipital convolution* is situated above the superior sulcus, and is connected to the superior parietal convolution by the *first annectant gyrus.*

The *middle occipital convolution* is situated between the superior and middle occipital sulci, and is connected to the angular convolution by the *second annectant gyrus*, and to the middle temporal convolution by the *third annectant gyrus.*

The *inferior occipital convolution* is situated below the middle occipital sulcus, and is sometimes separated from the external occipito-temporal convolution on the under surface of the hemisphere by an inconstant sulcus, the *inferior occipital sulcus.* It is connected to the inferior temporal convolution by the *fourth annectant gyrus.*

The *internal* or *mesial* surface of the occipital lobe presents a triangular convolution, which is known as the *cuneus* or *cuneate lobule.* It is situated between the internal parieto-occipital and calcarine fissures, which, as already mentioned, meet some distance behind the posterior extremity of the corpus callosum.

the three parts of the sulcus may be separate, or the ramus horizontalis confluent with the ramus verticalis inferior, the ramus verticalis superior remaining separate; or, again, the vertical limbs may be confluent and the horizontal limb separate; or, finally, the ramus horizontalis may be joined to the lower end of the ramus verticalis superior, while the lower vertical ramus is separate. The prolongation of the intra-parietal sulcus into the occipital lobe, which sometimes exists, he calls the *ramus occipitalis.* In the majority of cases, however, the occipital ramus is separated from the main portion of the intra-parietal sulcus by a superficial or deep bridging convolution. (*Journal of Anatomy and Physiology,* vol. xxiv., part ii., p. 135.)

4. The **temporal lobe,** sometimes called the temporo-sphenoidal lobe, presents an outer and an inferior surface. The *outer surface* is subdivided by two fissures, named respectively the first and second temporal sulci. The *first temporal sulcus* is well marked, and runs from before backward through the temporal lobe parallel with, but some little distance below, the horizontal limb of the fissure of Sylvius, and hence is often termed the *parallel sulcus*. The *second temporal sulcus* takes the same direction as the first, but is situated at a lower level, and is often interrupted by one or more bridging convolutions. These two sulci subdivide this surface of the temporal lobe into three convolutions. The *first* or *superior temporal convolution* is situated between the horizontal limb of the fissure of Sylvius and the first temporal sulcus, and is continuous behind with the supra-marginal convolution. The *second* or *middle temporal convolution* lies between the first and second temporal sulci, and is continued behind into the angular and middle occipital convolutions. The *third* or *inferior temporal convolution* is placed below the second temporal sulcus: it is connected posteriorly with the inferior occipital convolution, and is also prolonged on to the under or tentorial surface of the temporal lobe, where it is limited internally by the third temporal sulcus, about to be described.

The inferior or tentorial surface presents two fissures, viz.: the third temporal sulcus and the collateral fissure—the latter of which has already been described (page 647). The *third temporal sulcus* extends from near the occipital pole behind, to near the anterior extremity of the temporal lobe in front, but is, however, frequently subdivided by bridging gyri. The convolutions on the inferior surface are (1) the *fourth temporal* or *subcollateral convolution* (sometimes called the *external occipito-temporal*), situated between the third temporal sulcus and the collateral fissure; and (2) the *subcalcarine convolution* or *lingual lobule*, lying between the calcarine fissure above and the posterior part of the collateral fissure below and continuous in front with the hippocampal convolution, the latter forming part of the limbic lobe.[1]

The **central lobe or island of Reil** (Fig. 349) lies deeply in the Sylvian fissure, and can only be seen when the lips of that fissure are widely separated, since it is overlapped and hidden by the convolutions which bound the fissure. These convolutions are termed the *opercula of the insula;* they are separated from each other by the three limbs of the Sylvian fissure, and named the orbital, frontal, fronto-parietal, and temporal opercula. It is almost surrounded by a deep *limiting sulcus*, which separates it from the frontal, parietal, and temporal lobes. When the opercula have been removed, the insula presents the form of a triangular eminence; its apex is directed downward and inward toward the anterior perforated space, and is continuous in front with the posterior orbital convolution and behind with the hippocampal convolution. It is divided into a *pre-central* and a *post-central* lobe by the *sulcus centralis*, which runs backward and upward from the apex of the insula. The pre-central lobe is further subdivided by shallow sulci into three or four short convolutions, the *gyri breves*, while the post-central lobe is named the *gyrus longus* and is often bifurcated at its upper extremity. The gray matter of the insula is continuous with that of the different opercula, while its mesial surface corresponds with the lenticular nucleus of the corpus striatum.

Limbic Lobe.—The term limbic lobe (*grande lobe limbique*) was introduced by Broca in 1878, and under it he included two convolutions, viz., the callosal and hippocampal, which together arch round the corpus callosum and the hippocampal fissure. These he separated on the morphological ground that they are well developed in animals possessing a keen sense of smell (osmatic

[1] It will be seen from this description that the tentorial surface of the occipital lobe is regarded as forming part of the same surface as the temporal lobe. The boundary between the occipital and temporal lobes on the tentorial surface is purely artificial, and if represented by a line drawn upward and inward from the pre-occipital notch, would cut both the subcollateral and subcalcarine gyri.

animals), such as the dog and fox. To the lobe thus defined the following parts must be added, viz.: the laminæ of the septum lucidum, together with the fornix and its fimbriæ, which may be regarded as forming an inner or deep arch; the peduncles and longitudinal striæ of the corpus callosum, together with the gyrus dentatus, which form a middle arch, while the outer arch is constituted by the callosal and hippocampal convolutions: the first two arches are separated from each other by the corpus callosum.

Convolutions of the Limbic Lobe.—(1) The *callosal convolution*, *gyrus fornicatus*, or *gyrus cinguli* is an arch-shaped convolution, lying in close relation to the superficial surface of the corpus callosum, from which it is separated by a slit-like fissure, the *callosal fissure*. It commences below the rostrum of the corpus callosum, curves round in front of the genu, extends along the upper surface of the body, and finally turns downward behind the splenium, where it is connected by a narrow isthmus with the gyrus hippocampi. It is separated from the marginal convolution by the calloso-marginal sulcus, from the quadrate lobe by the post-limbic sulcus, and from the subcalcarine convolution by the calcarine fissure.

(2) The *hippocampal convolution* (gyrus hippocampi) is bounded above by the hippocampal or dentate fissure, and below by the anterior part of the collateral

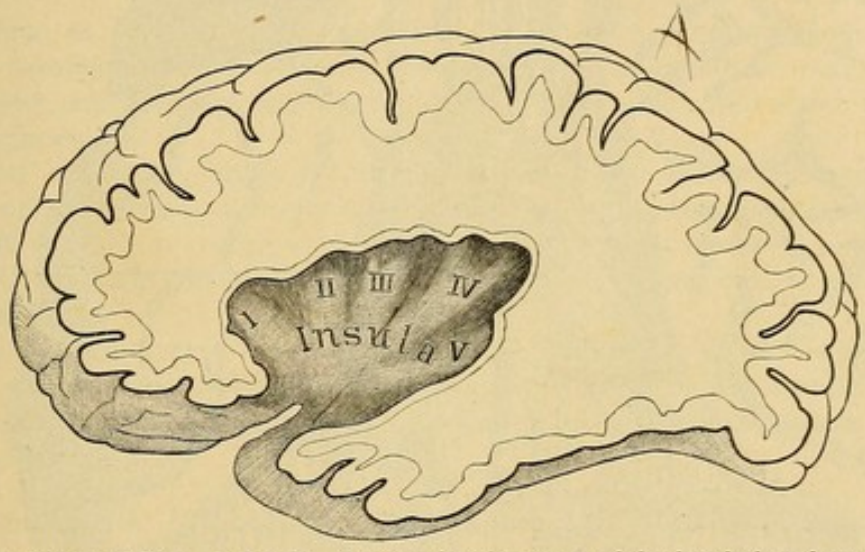

FIG. 349.—The Island of Reil. Left side. The overlapping parts of the hemisphere have been removed. (Dalton.) 1, 2, 3, gyri breves; 4, 5, gyrus longus, bifurcated at its upper extremity.

fissure. Behind, it is continuous superiorly, through the isthmus, with the callosal convolution, and inferiorly with the subcalcarine or lingual convolution. Its anterior extremity is recurved in the form of a hook, and is named the *uncus*. Running in the substance of the callosal and hippocampal convolutions, and connecting them together, is a tract of arched fibres, named the *cingulum*. The outer root of the olfactory tract passes into the anterior extremity of the hippocampal convolution, and the inner root into the commencement of the callosal convolution, so that these two convolutions, with the addition of the olfactory tract, present a racquet-like appearance—the olfactory tract constituting the handle and the two convolutions the circumference of the blade.

(3) The *dentate convolution* (formerly named the *dentate fascia*) is situated above the gyrus hippocampi, from which it is separated by the hippocampal or dentate fissure. It is covered by the fimbria, and is a narrow, elongated convolution, the free surface of which presents a notched or toothed appearance, hence its name. Posteriorly it is prolonged as a delicate lamina, the *fasciola cinerea*, around the splenium of the corpus callosum, and becomes continuous on the upper surface of that body with its mesial and lateral longitudinal striæ. Anteriorly it is prolonged into the notch produced by the recurving of the uncus, where it forms a sharp curve; from here it can be traced as a delicate band (*band of Giacomini*) over the uncus, on the outer surface of which it is lost.

The remaining structures which contribute to the formation of the limbic lobe will be subsequently described.

The **olfactory lobe** is situated on the under surface of the frontal lobe. It is rudimentary in man and some other mammals, but in vertebrates generally it is well developed, and consists of a distinct extension of the cerebral hemisphere, enclosing a portion of the anterior horn of the lateral ventricle. In man it is long and slender, and may be described as consisting of two parts, the *anterior* and *posterior olfactory lobules*.

The *anterior olfactory lobule* is made up of: (1) the olfactory bulb; (2) the olfactory tract; (3) the trigonum olfactorium; and (4) the area of Broca.

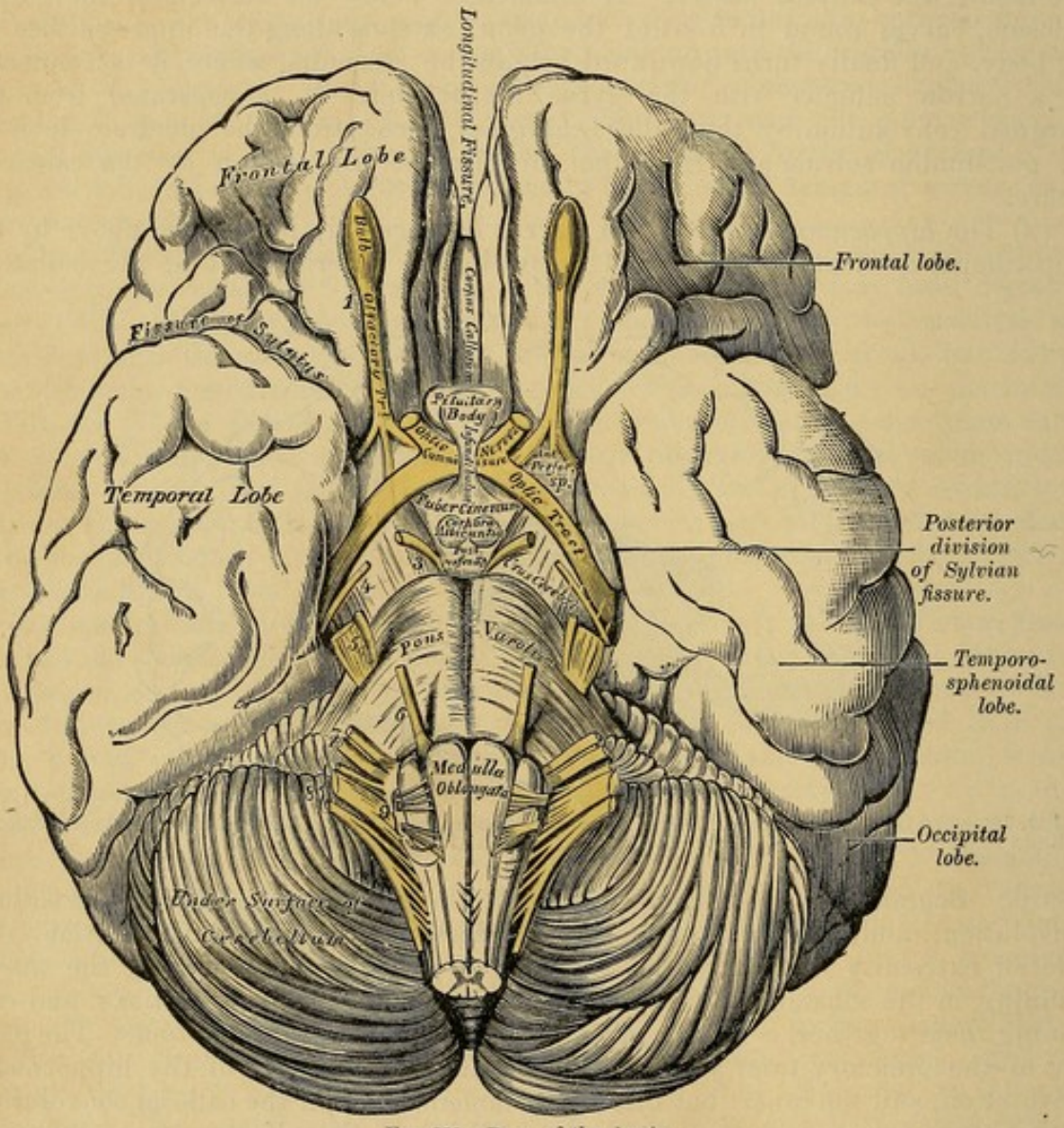

FIG. 350.—Base of the brain.

(1) The *olfactory bulb* is an oval mass of a reddish-gray color, which rests on the cribriform plate of the ethmoid bone, and forms the anterior expanded extremity of the olfactory tract. Its under surface receives the olfactory nerves, which pass upward through the cribriform plate from the olfactory region of the nose. Its minute structure will be subsequently described.

(2) The *olfactory tract* is a band of white matter, triangular on section, the apex being directed upward. It lies in the olfactory sulcus on the under surface of the frontal lobe. Traced backward, it is seen to divide into two roots, an outer and an inner. The *outer root* passes across the outer part of the anterior perforated space to the nucleus amygdalæ and the anterior part of the gyrus hippocampi. The *inner root* turns sharply inward, and ends partly in Broca's area and partly in

the callosal convolution; in other words, the inner root is continuous with one extremity and the outer root with the other extremity of the limbic lobe.

(3) The *trigonum olfactorium* is situated between the diverging roots of the olfactory tract, and is sometimes described at the *middle* or *gray root* of the tract. It is part of an area of gray matter, which forms the base of the anterior olfactory lobule; another portion of it is termed (4) the *area of Broca;* and a third portion, of no special significance, is situated external to the outer root of the olfactory tract. This area of gray matter is bounded internally and posteriorly by a fissure (*fissura prima*) which separates it from the peduncle of the corpus callosum and from the posterior olfactory lobule. The area of Broca is continuous with the gyrus fornicatus.

The *posterior olfactory lobule* or *anterior perforated space* is marked off from the anterior lobule by the fissura prima, and is situated at the commencement of the fissure of Sylvius. Internally, it is bounded by the peduncle of the corpus callosum, and is continuous with the lamina cinerea. Posteriorly it is bounded by the optic tract, and it is partially concealed by the temporal lobe which overlaps it. It has received the name of anterior perforated space from its being perforated by numerous openings, which transmit blood-vessels to the interior of the brain, and it corresponds to the under surface of the lenticular nucleus and part of the claustrum.

Under Surface or Base of the Encephalon (Fig. 350).—Having considered the surface of the hemispheres, the student should direct his attention to the base of the brain, before commencing the study of the component parts which make up the two hemispheres.

The base of the brain presents for examination the under surfaces of the frontal and temporal lobes; the structures contained in the interpeduncular space, with the crura cerebri or cerebral peduncles; the under surfaces of the pons Varolii, cerebellum, and medulla oblongata; and the superficial origins of the cranial nerves.

The various objects exposed to view (with the exception of the origins of the cranial nerves, which will be considered in another section) in the middle line and on either side of the middle line, are here arranged in the order they are met with from before backward.

In the Middle Line.	*On Each Side of the Middle Line.*
Longitudinal fissure.	Frontal lobe.
Rostrum and peduncles of corpus callosum.	Olfactory lobe.
Lamina cinerea.	Fissure of Sylvius.
Optic commissure.	Optic tracts.
Tuber cinereum.	Crus cerebri.
Infundibulum.	Temporal lobe.
Pituitary body.	Hemisphere of cerebellum.
Corpora albicantia.	
Posterior perforated space.	
Pons Varolii.	
Medulla oblongata.	

The **longitudinal fissure** partially separates the two hemispheres from each other. It divides completely the anterior portions of the two frontal lobes; and on raising the cerebellum and pons, it will be seen to separate completely the two occipital lobes: of these two portions of the longitudinal fissure, that which separates the occipital lobes is the longer. The intermediate part of the fissure is filled up by the great transverse band of white matter, the *corpus callosum.* In the fissure between the two frontal lobes the anterior cerebral arteries ascend on the corpus callosum.

The **corpus callosum** terminates at the base of the brain by a concave margin,

which is connected with the tuber cinereum through the intervention of a thin layer of gray substance, the *lamina cinerea*. This may be exposed by gently raising and drawing back the optic commissure. A white band may be observed on each side, passing backward from the under surface of the corpus callosum, across the posterior margin of the anterior perforated space to the hippocampal gyrus, where each meets the corresponding outer root of the olfactory tract: these bands are called the *peduncles of the corpus callosum*. They may be traced upward around the genu to become continuous with the *striæ longitudinales* on its upper surface. Laterally, this portion of the corpus callosum extends into the frontal lobe.

The **lamina cinerea** is a thin layer of gray substance, extending backward from the termination of the corpus callosum above the optic commissure to the tuber cinereum; it is continuous on each side with the gray matter of the anterior perforated space, and forms the anterior part of the inferior boundary of the third ventricle.

The **optic commissure** is situated in the middle line, immediately in front of the tuber cinereum and below the lamina cinerea; that is to say, the commissure is superficial to the lamina in the order of dissection when the base is uppermost. It is the point of junction between the two optic tracts, and will be described with the cranial nerves. Immediately behind the diverging optic tracts, and between them and the peduncles of the cerebrum (*crura cerebri*), is a lozenge-shaped interval, the *interpeduncular space*, which is bounded behind by the pons Varolii, and in which are found the following parts: the tuber cinereum, infundibulum, pituitary body, corpora albicantia, and the posterior perforated space.

The **tuber cinereum** is an eminence of gray matter, situated between the optic tracts, and extending from the corpora albicantia to the optic commissure, to which it is attached; it is connected with the surrounding parts of the cerebrum, forms part of the floor of the third ventricle, and is continuous with the gray substance in that cavity. From the middle of its under surface a conical tubular process of gray matter, about two lines in length, is continued downward and forward to be attached to the posterior lobe of the pituitary body. This is the **infundibulum**, and its canal, which is funnel-shaped, communicates with the third ventricle.

The **pituitary body** (*hypophysis cerebri*) is a small, reddish-gray, vascular mass, weighing from five to ten grains, and of an oval form, situated in the sella turcica, where it is retained by a process of dura mater, named the diaphragma sellæ. This process covers in the sella turcica, and has a small hole in its centre through which the infundibulum passes.

Structure.—The pituitary body is very vascular, and consists of two lobes, separated from one another by a fibrous lamina. Of these, the anterior is the larger, of an oblong form, and somewhat concave behind, where it receives the posterior lobe, which is round. The two lobes differ both in development and structure. The *anterior lobe*, of a dark, reddish-brown color, is developed from the epiblast of the buccal cavity, and resembles to a considerable extent, in microscopic structure, the thyroid body. It consists of a number of isolated vesicles and slightly convoluted tubules, lined by epithelium and united together by a very vascular connective tissue. The epithelium is columnar and occasionally ciliated. The alveoli sometimes contain a colloid material, similar to that found in the thyroid body, and their walls are surrounded by a close network of lymphatic and capillary blood-vessels. The *posterior lobe* is developed as an outgrowth from the embryonic brain, and during fœtal life contains a cavity which communicates through the infundibulum with the cavity of the third ventricle. In the adult it becomes firmer and more solid, and consists of a sponge-like connective tissue arranged in the form of reticulating bundles, between which are branched cells, some of them containing pigment. In the lower animals the two lobes are quite distinct, and it is only in the mammalia that they become fused together.

The **corpora albicantia** or **mammillaria** are two small, round, white masses, each about the size of a pea, placed side by side immediately behind the tuber

cinereum, and connected with each other across the mesial plane. They are mainly formed by the anterior crura of the fornix, which, after descending to the base of the brain, are twisted upon themselves to form loops, and constitute the white covering of the corpora albicantia. A second fasciculus, the *bundle of Vicq d'Azyr*, converges from the optic thalamus, and enters the anterior part of each body on its dorso-mesial surface. They are composed externally of white substance, and internally of gray matter; the nerve-cells of the gray matter are arranged in two sets, inner and outer, the cells of the former set being the smaller. They are also connected to the tegmentum by a small bundle of fibres, the peduncle of the mammillary body. At an early period of fœtal life they are blended together into one large mass, but become separated about the seventh month. In most vertebrates there is only one median corpus albicans.

The **posterior perforated space** (*pons Tarini*) corresponds to a whitish-gray fossa placed between the corpora albicantia in front, the pons Varolii behind, and the crus cerebri on either side. It forms the posterior part of the floor of the third ventricle, and is perforated by numerous small orifices for the passage of the postero-median ganglionic branches of the posterior cerebral and posterior communicating arteries.

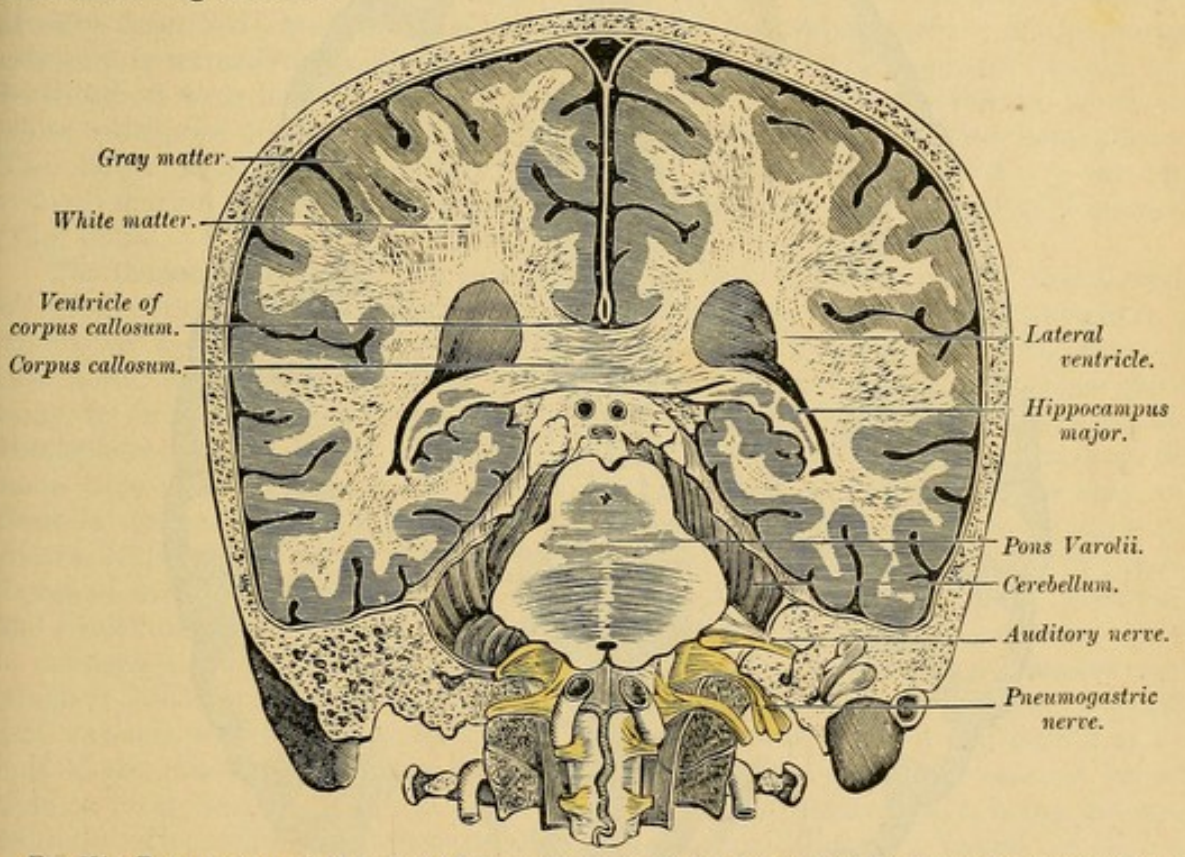

FIG. 351.—Transverse vertical section of the brain, through the fore part of the foramen magnum, looked at from the front. (After Hirschfield and Leveillé.)

The **pons Varolii** is situated immediately behind the two crura of the cerebrum. It consists of a broad band of white fibres, which pass transversely from one cerebellar hemisphere to the other; the band becoming narrower as it enters the cerebellum. In the middle line on its under surface a narrow groove runs from before backward and accommodates the basilar artery.

The **medulla oblongata** emerges from the posterior border of the pons Varolii; it is pyramidal in form, and is continuous below with the cervical portion of the spinal cord. It is marked on its ventral surface by a median fissure, continuous below with the anterior median fissure of the cord, and on either side by secondary fissures and columns, which will be described in the sequel.

The Frontal Lobe.—The under surface of the frontal lobe, sometimes named the orbital lobe, is seen on the anterior part of the base of the brain on either side of the median line. It has already been described (page 649).

The **fissure of Sylvius** at the base of the brain separates the frontal from the temporal lobe, and lodges the middle cerebral artery. It has also been described (page 645).

The **optic tracts** are well-marked flattened bands of fibres, which run obliquely across the crus cerebri on either side, and unite anteriorly to form the optic commissure. They will be described in connection with the cranial nerves.

The **crura cerebri** (*peduncles of the cerebrum*) are two thick cylindrical bundles of white matter, which appear in front of the anterior border of the pons, and diverge as they pass forward and outward to enter the under surface of each hemisphere. Each crus is about three-quarters of an inch in length, and is about the same in breadth anteriorly, but somewhat less posteriorly. They are marked upon their surface with longitudinal striæ, and each is crossed, just before entering the hemisphere, by the fourth nerve and the optic tract, the latter of which is adherent by its upper surface to the peduncle.

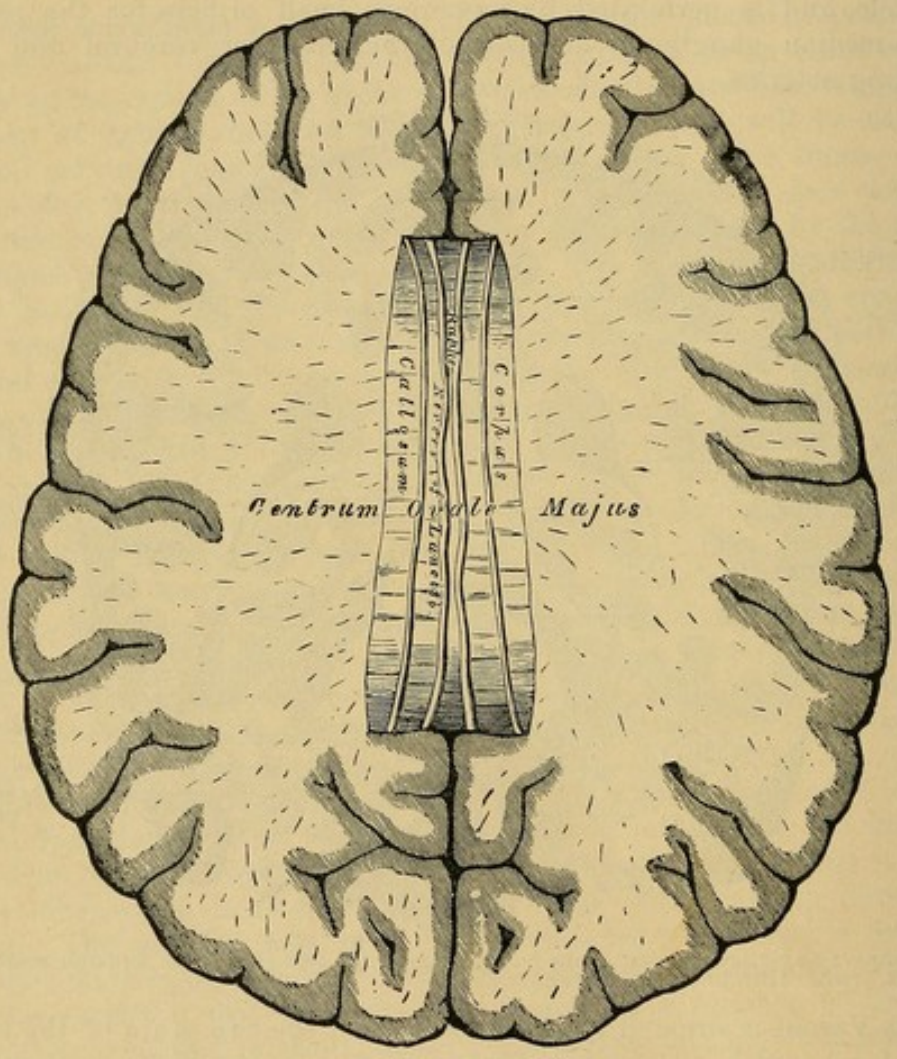

FIG. 352.—Section of the brain. Made on a level with the corpus callosum.

The Temporal Lobe.—The under surface of the temporal lobe is visible at the base of the brain, on either side of the crura and the structures contained in the interpeduncular space. It is separated anteriorly from the frontal lobe by the fissure of Sylvius, and behind is limited by the anterior border of the lateral hemispheres of the cerebellum. The fissures and lobes on its surface have already been described (page 652).

The **hemispheres of the cerebellum** are situated on either side of the middle line, and cover the occipital lobes of the cerebrum, when viewed from the base. The cerebellum differs much in appearance from the rest of the encephalon, being

of a darker color, while its convolutions are smaller and narrower, and arranged like the leaves of a book, and hence called *folia*.

General Arrangement of the Parts Composing the Cerebrum.—Each hemisphere, as already stated, consists of a central cavity, the *lateral ventricle*, surrounded by thick and convoluted walls of nervous tissue.

Interior of the Cerebrum.—If the upper part of either hemisphere is removed with a knife, about half an inch above the level of the corpus callosum, its internal white matter will be exposed. It is an oval-shaped centre, of white substance, surrounded on all sides by a narrow convoluted margin of gray matter, which presents an equal thickness in nearly every part. This white central mass has been called the *centrum ovale minus*. Its surface is studded with numerous minute red dots (*puncta vasculosa*), produced by the escape of blood from divided blood-vessels. In inflammation or great congestion of the brain these are very numerous and of a dark color. If the remaining portion of one hemisphere is slightly separated from the other, a broad band of white substance will be observed, connecting them at the bottom of the longitudinal fissure; this is the *corpus callosum*. The margins of the hemispheres which overlap this portion of the brain are called the *labii cerebri*. Each labium is part of the callosal convolution already described; and the space between it and the upper surface of the corpus callosum is termed the *callosal fissure* (Fig. 348). The hemispheres should now be sliced off to a level with the upper surface of the corpus callosum, when the white substance of that structure will be seen connecting the two hemispheres. The large expanse of medullary matter now exposed, surrounded by the convoluted margin of gray substance, is called the *centrum ovale majus of Vieussens* (Fig. 352).

The Corpus Callosum.—The corpus callosum is a thick stratum of transversely directed nerve-fibres, by which probably almost every part of one hemisphere is connected with the corresponding part of the other hemisphere. The fibres of this body, when they pass from it into the hemispheres radiate in various directions, to terminate in the gray matter of the periphery. It thus connects the two hemispheres of the brain, forming their great transverse commissure, and at the same time roofs in the lateral ventricles. The best conception of its size and form is obtained by making an anterior posterior vertical section through the centre of the brain (Fig. 353). It is then seen to be a long, thick, irregularly flattened arch; in front taking a sharp bend, the *genu*, and dipping downward and backward to the base of the brain by a reflected portion, the *rostrum*, which is connected with the lamina cinerea; behind it terminates by a rounded end, which is folded over and is named the *splenium*. It is about four inches in length, and extends to within an inch and a half of the anterior, and two inches and a half of the posterior extremity of the cerebrum. It is somewhat broader behind than in front, and is thicker at either end than in its central part, being thickest behind. The reflected anterior portion of the corpus callosum is called the *beak* or *rostrum;* it becomes gradually thinner as it descends, and is attached by its lateral margins to the frontal lobes. At its termination, in addition to joining the lamina cinerea, the corpus callosum gives off two bands of white substance, the peduncles of the corpus callosum, already described (page 656).

Posteriorly, the corpus callosum forms a thick rounded fold, called the *splenium* or *pad*, which is free for a little distance as it curves forward, and is then continuous by its under surface with the fornix. The splenium overlaps the mesencephalon, but is separated from it by the pia mater, which is prolonged forward to form the velum interpositum. On its upper surface, the structure of the corpus callosum is very apparent, being collected into coarse transverse bundles. Along the middle line is a longitudinal depression, the so-called *raphé*, bounded laterally by two or more slightly elevated longitudinal bands, called the *striæ longitudinales* or *nerves of Lancisi;* and, still more externally, other longitudinal striæ are seen, beneath the callosal convolutions. These are the *striæ longitudinales laterales*, or *tænia tectæ*. On each side of the middle line the under surface of the corpus cal-

losum forms the roof of the lateral ventricles, while in the mesial plane it is continuous behind with the fornix, being separated from it in front by the septum lucidum, which forms a vertical partition between the two ventricles. On each side the fibres of the corpus callosum extend into the substance of the hemispheres, connecting them together. The greater thickness of the two extremities of this commissure is explained by the fact that the fibres from the anterior and posterior parts of each hemisphere cannot pass directly across, but have to take a curved direction.

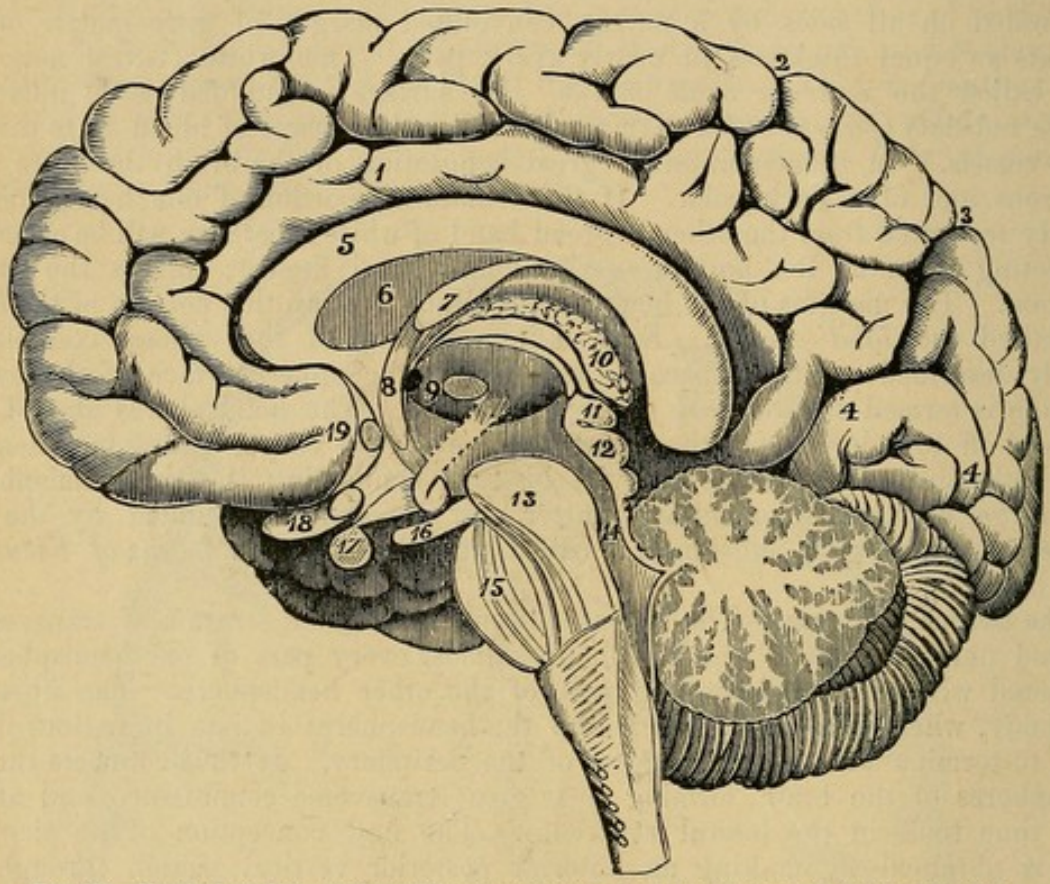

FIG. 353.—Vertical median section of the encephalon, showing the parts in the middle line.

1. Convolution of the corpus callosum. Above it is the calloso-marginal fissure.
2. Fissure of Rolando.
3. The parieto-occipital fissure.
4, 4, point to the calcarine fissure, which is just above the numbers. Between 2 and 3 are the convolutions of the quadrate lobe. Between 3 and 4 is the cuneate lobe.
5. The corpus callosum.
6. The septum lucidum.
7. The fornix.
8. Anterior crus of the fornix, descending to the base of the brain, and turning on itself to form the corpus albicans. The bundle of Vicq d'Azyr is indicated by a dotted line.
9. The optic thalamus. Behind the anterior crus of the fornix a shaded part indicates the foramen of Monro; in front of the number an oval mark shows the position of the gray or middle commissure.
10. The velum interpositum.
11. The pineal gland.
12. The corpora quadrigemina.
13. The crus cerebri.
14. The valve of Vieussens (to the right of the number).
15. The pons Varolii.
16. The third nerve.
17. The pituitary body.
18. The optic nerve.
19 points to the anterior commissure, indicated by the oval outline behind the number.

The part of the corpus callosum which curves forward on each side from the genu into the frontal lobe and covers the front part of the anterior cornu of the lateral ventricle is called the *forceps anterior* or *minor*. The part which curves backward from each side of the splenium into the occipital lobe is known as the *forceps posterior* or *major*. Between these two parts on each side is the main body of the fibres, which extend laterally into the temporal lobe and cover in the body of the lateral ventricle. These are known as the *tapetum* or *mat*.

An incision should now be made through the corpus callosum, on either side of the raphé, when two large irregular cavities will be exposed, which extend through a great part of the length of each hemisphere. These are the lateral ventricles.

The Lateral Ventricles (Fig. 354).—The lateral ventricles, two in number, right and left, are irregular cavities situated in the lower and inner parts of the cerebral

hemisphere, one on either side of the middle line. They are separated from each other by a mesial vertical partition, the *septum lucidum*, but communicate with the third ventricle and indirectly with each other through the *foramen of Monro*. They are lined by a thin, diaphanous membrane, the *ependyma*, which is covered by ciliated epithelium, and are moistened by a serous fluid, which, even in health, may be secreted in considerable amount. Each lateral ventricle consists of a central cavity or *body*, and three prolongations from it, termed *cornua*. The *anterior* cornu curves forward and outward into the frontal lobe; the *posterior* backward and inward into the occipital lobe; and the *middle* descends into the *temporal* lobe.

The **central cavity** or **body** of the lateral ventricle is situated in the lower part of the parietal lobe. It is an irregularly curved cavity, triangular in shape on

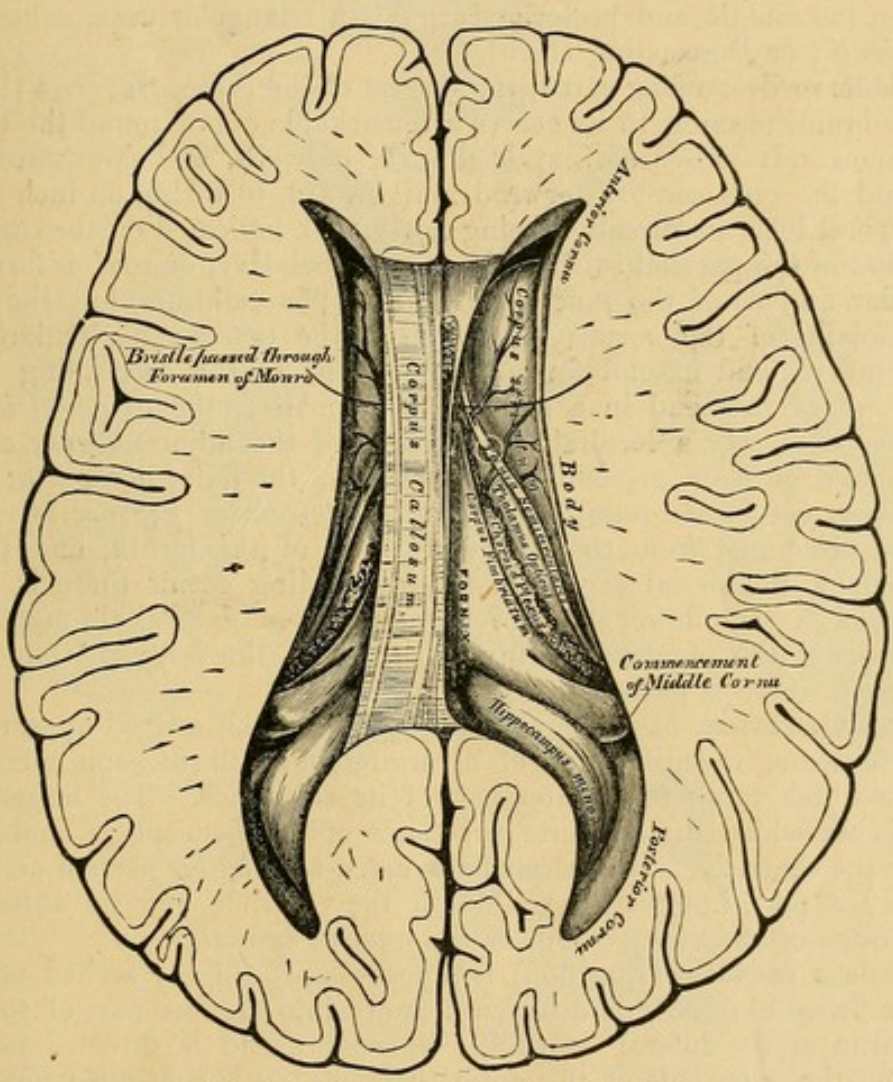

FIG. 354.—The lateral ventricles of the brain.

transverse section, and presents a roof, a floor, and an inner wall. Its *roof* is formed by the under surface of the corpus callosum; its *inner wall* is the septum lucidum, which separates it from the opposite ventricle and connects the under surface of the corpus callosum with the fornix; its *floor* is formed by the following parts, enumerated in their order of position, from before backward: the *caudate nucleus* of the *corpus striatum*, *tænia semicircularis*, *optic thalamus*, *choroid plexus*, one-half of the *fornix* and its *posterior pillar*.

The **anterior cornu** passes forward and outward, with a slight inclination downward, from the foramen of Monro into the frontal lobe, curving round the anterior extremity of the caudate nucleus. It is bounded above by the corpus callosum, and below by the upper surface of its reflected portion, the rostrum. It is bounded internally by the anterior portion of the septum lucidum, and externally by the

head of the caudate nucleus of the corpus striatum. Its apex reaches the posterior surface of the genu of the corpus callosum.

The **posterior cornu** curves backward into the substance of the occipital lobe, its direction being backward and outward, and then inward; its concavity is therefore directed inward. Its roof is formed by the fibres of the corpus callosum passing to the temporal and occipital lobes. On its inner wall is seen a longitudinal eminence, which is in an involution of the ventricular wall produced by the calcarine sulcus; this is called the *hippocampus minor*, or *calcar avis*. Just above this the forceps major of the corpus callosum, sweeping round to enter the occipital lobe, causes another projection, which is known as the *bulb of the posterior horn*. The hippocampus minor and bulb of the posterior horn are extremely variable in their degree of development, being in some cases ill defined, while in others they are unusually prominent.

Between the middle and posterior cornu is a triangular area, called the *trigonum ventriculi* (see Descending Horn).

The **middle** or **descending cornu**, the largest of the three, traverses the temporal lobe of the brain, forming in its course a remarkable curve round the back of the optic thalamus. It passes at first backward, outward, and downward, and then curves round the crus cerebri, forward and inward, to within an inch of the apex of the temporal lobe, its direction being fairly well indicated on the surface of the brain by that of the parallel sulcus. Its upper boundary, or roof, is formed chiefly by the under surface of the tapetum of the corpus callosum, but the tail of the nucleus caudatus of the corpus striatum and the tænia semicircularis are also prolonged into it, and extend forward in the roof of the descending horn to its extremity, where they end in a mass of gray matter, the *amygdaloid nucleus*; this nucleus is merely a localized thickening of the adjacent gray cortex. Its lower boundary, or floor, presents for examination the following parts: the *hippocampus major*, *pes hippocampi*, *eminentia collateralis* or *pes accessorius*, *corpus fimbriatum*, prolonged from the posterior pillar of the fornix, and the *choroid plexus*. Along the mesial aspect of the descending cornu there is a cleft-like opening, which is the lower part of the *transverse fissure*, through which the choroid plexus of the pia mater is invaginated into the ventricle, but covered by the ependyma, which is pushed in before it.

The **corpus striatum** has received its name from the striped appearance which its section presents, in consequence of diverging white fibres being mixed with the gray matter which forms the greater part of its substance. The larger portion of this body is embedded in the white substance of the hemisphere, and is therefore external to the ventricle. It is termed the *extra-ventricular portion* or the *nucleus lenticularis*; a part, however, is visible in the ventricle and its anterior cornu: this is the *intra-ventricular portion*, or the *nucleus caudatus*.

The **nucleus caudatus** (Fig. 355) is a pear-shaped, highly arched mass of gray matter; its broad extremity is directed forward into the fore part of the body and anterior cornu of the lateral ventricle; its narrow end is directed outward and backward on the outer side of the optic thalamus; it is continued downward into the roof of the descending cornu, where it terminates in the *nucleus amygdalæ*, a collection of gray matter in the apex of the temporal lobe. It is covered by the lining of the ventricle, and crossed by some veins of considerable size. It is separated from the extra-ventricular portion, in the greater part of its extent, by a lamina of white matter, which is called the *internal capsule*, but the two portions of the corpus striatum are united in front.

The **nucleus lenticularis**, or extra-ventricular portion of the corpus striatum, is only seen in sections of the hemisphere. When divided horizontally, it presents, to some extent, the appearance of a biconvex lens, while a vertical transverse section of it gives a somewhat triangular outline. It does not extend as far forward or backward as the nucleus caudatus. It is bounded externally by a lamina of white matter called the *external capsule*, on the outer surface of which is a thin layer of gray matter termed the *claustrum*. The claustrum presents ridges and furrows on

its outer surface, corresponding to the convolutions and sulci of the island of Reil, from which it is separated by a thin white lamina.

Upon making a transverse vertical section through the middle of the nucleus lenticularis it is seen to present two white lines, parallel with its lateral border, which divide it up into three zones, of which the outer and largest is of a reddish color, and is known as the *putamen*, while the two inner are paler and of a yellowish tint, and are termed the *globus pallidus*. All three zones are marked by fine radiating white fibres, which are most distinct in the putamen. The gray matter of the corpus striatum is traversed by nerve-fibres, some of which are believed to originate in it. The cells are multipolar, both large and small; those of the lenticular nucleus containing yellow pigment.

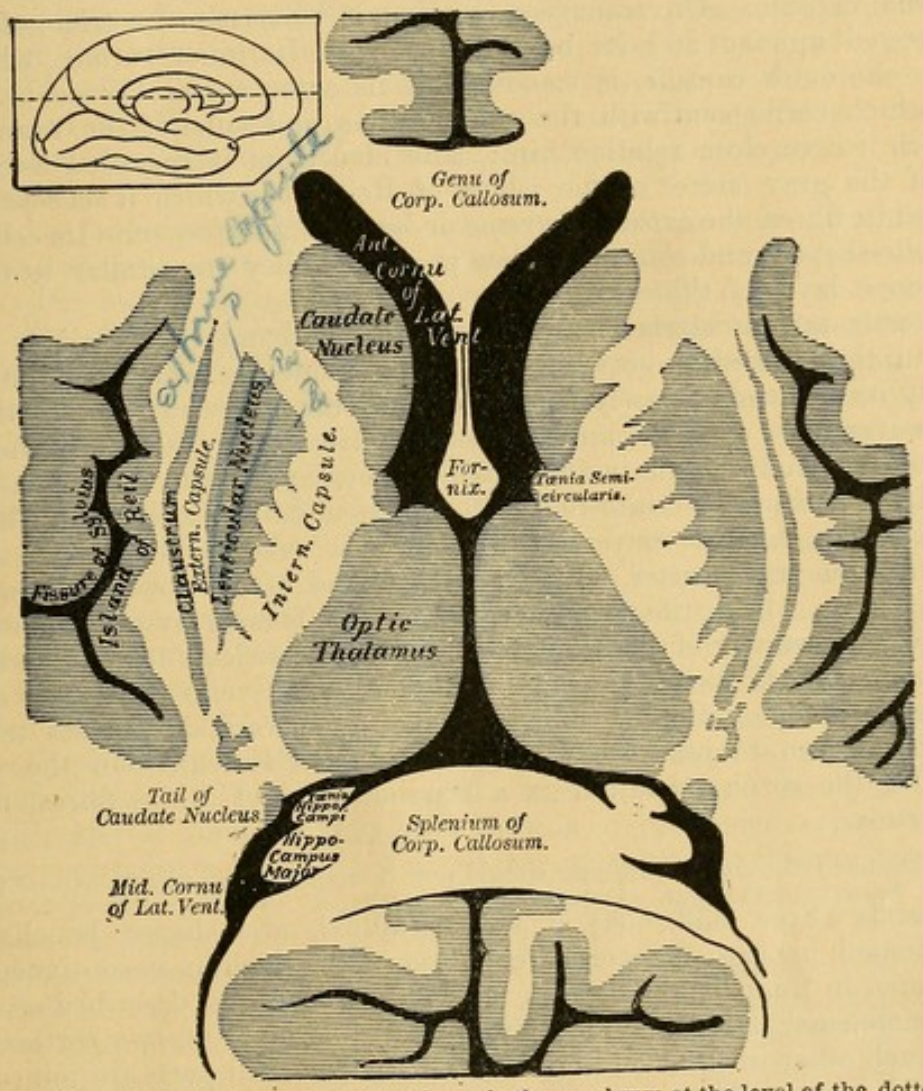

FIG. 355.—Middle part of a horizontal section through the cerebrum at the level of the dotted line in the small figure of one hemisphere. (From Ellis, after Dalton.)

The **internal capsule** is formed by fibres of the crusta of the crus cerebri, supplemented by fibres derived from the corpus striatum and optic thalamus on each side. In horizontal section (Fig. 355) it is seen to be somewhat abruptly curved, with its convexity inward; the prominence of the curve is called the *genu*, and projects between the caudate nucleus and the optic thalamus. The portion in front of the genu is termed the *anterior limb*, and separates the lenticular from the caudate nucleus; the portion behind the genu is the *posterior limb*, and separates the lenticular nucleus from the optic thalamus. The internal capsule is composed largely of fibres, which, derived from the crusta of the crus cerebri, are continued through it to the cortex of the cerebral hemispheres, the fibres of the anterior limb passing to the frontal region; those from the genu and the anterior two-thirds of the posterior limb pass to the Rolandic area of the cortex, while those in the

hindermost third of the same limb pass to the temporo-occipital region. In addition to these, there are fibres which terminate in the corpus striatum and the optic thalamus; and other fibres derived from the gray matter of these two bodies, from the subthalamic region,[1] and from the hemisphere of the opposite side through the corpus callosum, which pass through the internal capsule to the cerebral cortex.

The **external capsule** is a lamina of white matter, situated on the outer side of the lenticular nucleus, between it and the claustrum, and is continuous with the internal capsule below and behind the lenticular nucleus. It is made up of fibres derived partly from the anterior white commissure and partly from the subthalamic region.

The **claustrum** is a thin layer of gray matter, situated on the outer surface of the external capsule. On transverse section it is seen to be triangular, with its apex directed upward and its base downward. Its inner surface, which is contiguous to the outer capsule, is smooth, but its outer surface presents ridges and furrows which correspond with the convolutions and sulci of the island of Reil, with which it is in close relationship. The claustrum is regarded as a detached portion of the gray matter of the island of Reil, from which it is separated by a layer of white fibres, the *capsula extrema* or *band of Baillarger*. Its cells are small and spindle-shaped, and contain yellow pigment; they are similar to those found in the deepest layer of the cortex.

The **tænia semicircularis** is a narrow, whitish band of medullary substance, situated in the depression between the caudate nucleus and the optic thalamus. Anteriorly its fibres are partly continued into the anterior pillar of the fornix; some, however, pass over the anterior commissure to the gray matter between the caudate nucleus and septum lucidum, while others penetrate the caudate nucleus. Posteriorly it is continued into the roof of the middle or descending horn of the lateral ventricle, at the extremity of which it enters the *nucleus amygdalæ*, an oval mass of gray matter, situated in the roof of the lower extremity of the descending horn. Like the corpus striatum, it is formed by a localized thickening of the gray matter of the cortex cerebri. Superficial to it is a large vein, *vena corporis striati*, which receives numerous small veins from the surface of the corpus striatum and optic thalamus; it runs forward and passes through the foramen of Monro to join the corresponding vena Galeni. On the surface of the vein of the corpus striatum is a narrow band of white fibres, named the *lamina cornea*.

The remains of the corpus callosum should now be removed in order to expose the fornix.

The **fornix** (Figs. 353, 354) is a longitudinal, arch-shaped lamella of white matter, situated beneath the corpus callosum, with which it is continuous behind, but separated in front by the septum lucidum. It may be described as consisting of two symmetrical halves, one for either hemisphere. The two portions are not united to each other in front and behind, but their central parts are joined together in the middle line. The two anterior, separated parts are called the *anterior pillars* (*columnæ fornicis*); the intermediate united portions constitute the *body of the fornix*; and the posterior parts, which are also separated from each other, are called the *posterior pillars* (*crura fornicis*).

The *body of the fornix* is triangular, narrow in front, broad behind. Its upper surface is connected, in the median line, to the septum lucidum in front, and the corpus callosum behind; laterally this surface forms part of the floor of each lateral ventricle. Its under surface rests upon the velum interpositum, which separates it from the third ventricle and the inner portion of the upper surface of the optic thalami. Its outer edge, on each side, is free, and is connected with the choroid plexuses.

The *anterior pillars* arch downward toward the base of the brain, separated

[1] The *subthalamic region* is the mass upon which the optic thalamus rests, and is an extension forward of the tegmentum of the mesencephalon (see page 674).

from each other by a narrow interval. They are composed of white fibres, which descend through the gray matter in the lateral wall of the third ventricle, and are placed immediately behind the anterior commissure. At the base of the brain, each pillar becomes twisted upon itself to form a loop, somewhat resembling the figure of 8. The lowest part of the loop constitutes the white matter of the corresponding *corpus albicans*, from which the fibres can apparently be traced upward and backward, as the *bundle of Vicq d'Azyr*, into the substance of the corresponding optic thalamus (Fig. 353). It must be stated, however, that there is probably no direct continuity between this bundle and the anterior pillar of the fornix—the latter possibly ending in the gray matter of the corpus albicans. The anterior crura of the fornix are joined in their course by the peduncles of the pineal gland and the superficial fibres of the tænia semicircularis, and receive fibres from the septum lucidum. Zuckerkandl describes an *olfactory fasciculus*, which becomes detached from the main portion of the anterior pillar of the fornix, and passes downward, in front of the anterior commissure, to the base of the brain, where it divides into two bundles, one joining the inner root of the olfactory tract; the other, the peduncle of the corpus callosum, and through it reaching the hippocampal convolution.

Between the anterior pillars of the fornix and the anterior extremity of the optic thalamus, an oval aperture is seen on each side; this is the foramen of Monro (Fig. 359). The two openings descend toward the middle line, and lead into the upper part of the third ventricle. Through this foramen the lateral ventricles communicate with the third ventricle, and consequently with each other; through it also the two choroid plexuses become joined with each other across the middle line. The boundaries of the opening are, above and in front, the anterior pillars of the fornix; behind, the anterior extremity of the optic thalamus.

The *posterior pillars* are the backward prolongations of the two halves of the body of the fornix. They are flattened bands, and, at their commencement, are intimately connected by their upper surfaces with the corpus callosum. Diverging from one another, each curves round the posterior extremity of the optic thalamus, and then passes downward and forward into the descending horn of the lateral ventricle. Here it lies along the concavity of the hippocampus major, on the surface of which some of its fibres are spread out, while the remainder are continued, as the *corpus fimbriatum* or *tænia hippocampi*, into the hook or uncus of the hippocampal convolution. Upon examining the under surface of the fornix, between its diverging posterior pillars, a triangular portion of the under surface of the corpus callosum may be seen. On it are a number of curved or oblique lines passing between the two pillars of the fornix. This portion has been termed the *lyra*, from the fancied resemblance it bears to a harp.

The **anterior commissure** is a bundle of white fibres, placed in front of the anterior pillars of the fornix, and appears to connect together the corpora striata. On transverse section it is seen to be oval in shape, its long diameter being vertical in direction and measuring about one-fifth of an inch. Its fibres can be traced backward and downward through the globus pallidus and below the putamen on each side into the substance of the temporal lobe. It serves in this way to connect the two temporal lobes, but it also contains fibres from the olfactory tract of the opposite side, the decussation of which in the anterior commissure may serve to explain the condition of crossed anosmia, *e. g.*, where there is a lesion in one temporal lobe with a loss of smell in the olfactory area of the opposite side of the nose.

The **septum lucidum** is a thin, double, vertically placed partition, which forms the internal boundary of the body and anterior horn of the lateral ventricle. It consists of two distinct laminæ, separated in part of their extent by a narrow chink or interval, called the *fifth ventricle*. It is a thin, semitransparent septum, attached, above, to the under surface of the corpus callosum; below, to the anterior part of the fornix behind, and the reflected portion of the corpus callosum in front. It is triangular in form, broad in front and narrow behind; its inferior angle cor-

responds with the upper part of the anterior commissure. The outer surface of each lamina is directed toward the lateral ventricle, and is covered by the ependyma of that cavity, while its mesial surface bounds the cavity of the fifth ventricle.

Fifth Ventricle.—The fifth ventricle was originally a part of the great longitudinal fissure, which has become shut off by the union of the hemispheres in the formation of the corpus callosum above and the fornix below. Each half of the septum is therefore formed by the median wall of the hemisphere, and consists of an internal layer of gray matter, derived from the gray matter of the cortex, and an external layer of white substance continuous with the white matter of the cerebral hemispheres. The fifth ventricle differs from the other ventricles of the brain, inasmuch as it is not developed from the cavity of the cerebral vesicles, it is not lined by ciliated epithelium but by altered pia mater, and it does not communicate with the general ventricular cavity; further, the fluid it contains is of the nature of lymph.

The structures on the floor of the descending horn of the lateral ventricle will now be described.

The **hippocampus major,** or **cornu Ammonis** (Fig. 356), is a white eminence, about two inches in length, of a curved elongated form, extending throughout the

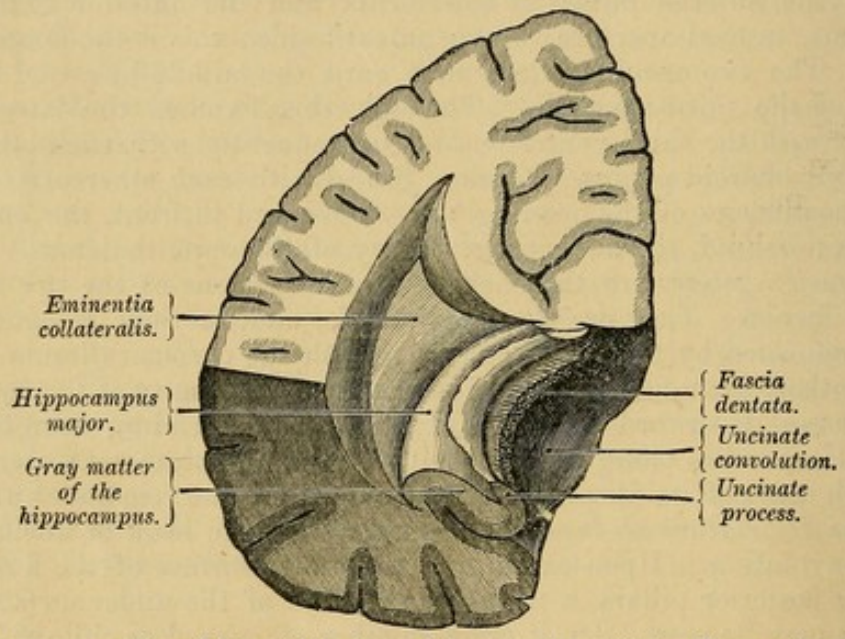

FIG. 356.—Transverse section of the middle horn of the lateral ventricle. (From a drawing by Mr. F. A. Barton.)

entire length of the floor of the descending horn of the lateral ventricle. At its lower extremity it becomes enlarged, and presenting two or three rounded elevations with intervening depressions, it resembles the paw of an animal, and is called the *pes hippocampi*. If a transverse section is made through the hippocampus major, it will be seen that this eminence is produced by the folding of the cortex of the brain to form the dentate (hippocampal) sulcus. To the outer side and parallel with the hippocampus major an elongated eminence, the *eminentia collateralis*, is frequently recognized. It corresponds with the middle part of the collateral fissure, and its size depends on the direction and depth of this fissure. The main mass of the hippocampus major consists of gray matter, but on its ventricular surface is a thin layer of white matter, known as the *alveus*, which is continuous with the corpus fimbriatum of the fornix and is covered by the ependyma of the ventricle. Dr. J. G. Macarthy, of McGill University, Montreal, has shown[1] that, if the alveus and superficial strata of gray matter be reflected from the surface of the hippocampus by an incision carried along its convexity, the "core" of the hippocampus, as he terms it, presents in many cases a corrugated or crimped appearance.

[1] *Journal of Anat. and Phys.*, vol. xxiii., 1899.

The **corpus fimbriatum** or **fimbria** (*tænia hippocampi*) has already been mentioned as a part of the posterior pillar of the fornix. It consists of a narrow white band, which is placed immediately below the choroid plexus, and is attached by its deep surface to the white matter (alveus) of the hippocampus major as it courses through the descending cornu of the lateral ventricle. It can be traced as far as the uncus or hook of the hippocampal gyrus. Its inner margin is free, and rests upon the dentate convolution, from which it is separated by a slit-like fissure, the *fimbrio-dentate fissure*. Its outer margin is attenuated and irregular, and forms the line along which the ependyma is reflected over the choroid plexus as the latter is invaginated through the inferior part of the transverse fissure. When the choroid plexus is pulled away it carries the ependyma with it, and the descending horn opens on to the surface of the brain through the transverse fissure. If now the inner border of the corpus fimbriatum be raised, a notched band of gray matter, the gyrus dentatus, will be exposed; this has already been described as forming part of the limbic lobe (page 653).

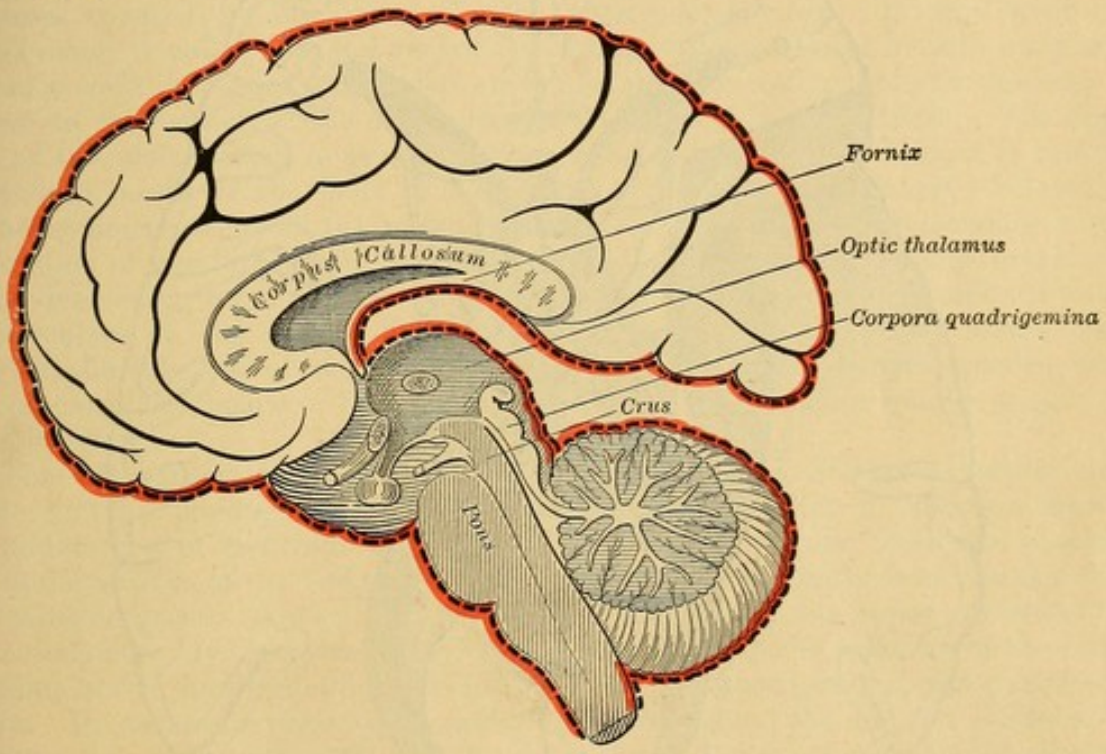

FIG. 357.—Diagram showing the mode of formation of the velum interpositum.

The **choroid plexus** is a highly vascular, fringe-like structure, which is situated partly in the body and partly in the descending cornu of the lateral ventricle. It will be desirable to consider these two portions separately, in order to get a just conception of how they are formed.

The portion in the body of the ventricle is the vascular, fringed border of a triangular fold of pia mater, the *velum interpositum*, which lies on the under surface of the fornix and forms the roof of the third ventricle. It will be remembered that the developing brain vesicles are covered by pia mater. As the prolongation from the first vesicle, which is to form the cerebral hemispheres, increases in size, it grows backward and downward and covers the other vesicles, with the result that the pia mater covering the hemisphere comes in contact with that covering the upper surface of the second vesicle (Fig. 357).[1] A portion of the two layers which are in contact forms the velum interpositum. Immediately above is the body of the fornix, which is formed by the fusion of the cerebral hemispheres [illegible] the middle line and below is the cavity of the second vesicle (the third ven[illegible] with the optic thalamus on either side (Fig. 359). Just beyond the [illegible] border of the fornix, between it and the tænia semicircularis, is a [illegible]

[1] In the diagram the two layers are represented as being separated from each [illegible] of clearness.

first cerebral vesicle, which is not developed into nervous matter but is made up only of ependyma covered by pia mater. The vessels of this portion of the highly vascular pia mater become dilated and prolonged, and grow into the ventricle, pushing the ependyma before them, and forming an irregular congeries of vessels, apparently encroaching on the cavity of the lateral ventricle, but in reality being external to it, because they are separated from it by the lining membrane of the cavity, the ependyma. This vascular structure is the choroid plexus of the body of the ventricle.

The part of the choroid plexus seen in the descending cornu is formed in exactly the same way, viz., by an ingrowth of the vessels of the pia mater into the cavity, pushing the ependyma before it, at a part of the wall of the horn where

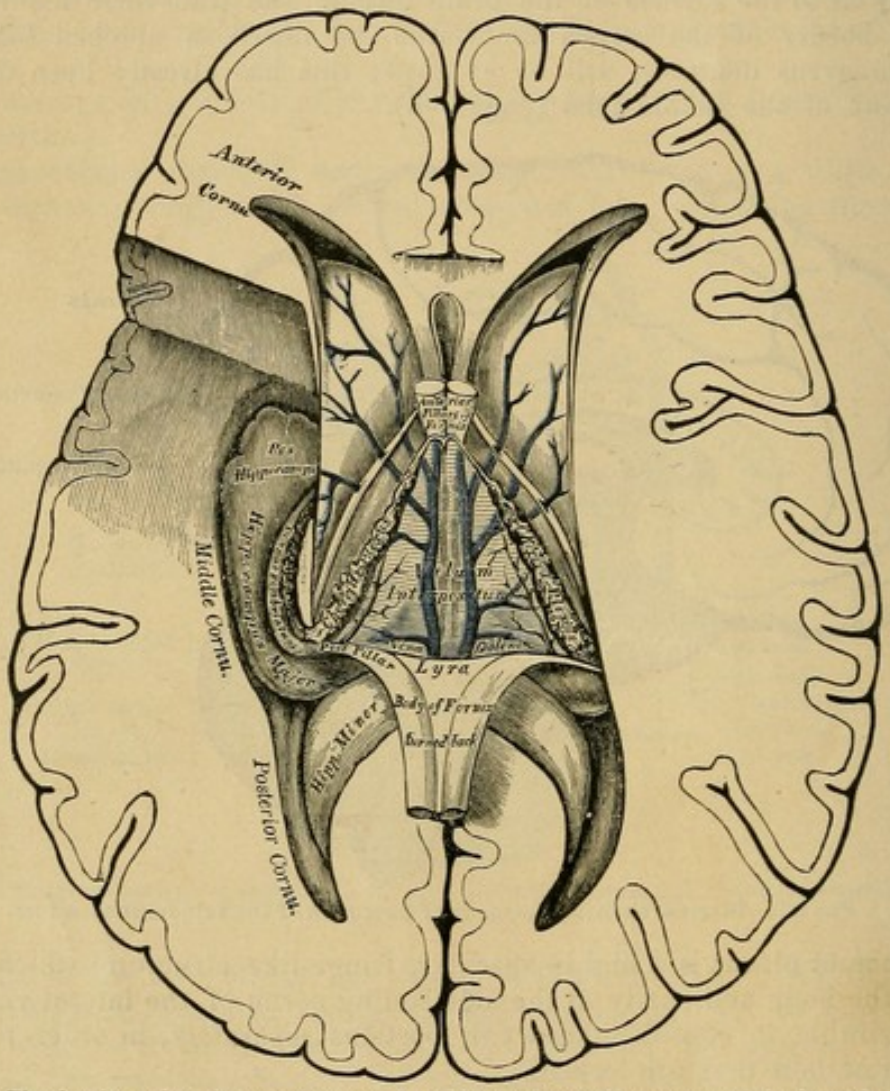

FIG. 358.—The fornix, velum interpositum, and middle or descending cornu of the lateral ventricle.

there is a similar absence of nervous tissue and where it consists simply of pia mater and ependyma in close contact. This portion lies between the corpus fimbriatum in the floor and the tænia semicircularis in the roof of the descending horn. This area, destitute of nervous matter, is continuous with the area in the body of the ventricle, from which the choroid plexus of this region originated, and in it the vessels of its pia mater increase, and, invaginating the ependyma, appear in the descending horn as its choroid plexus. In the body of the ventricle the choroid plexus is really the vascular fringed margin of the velum; beyond the posterior margin of the velum the plexus of the descending horn is continuous with the pia mater on the surface of the gyrus hippocampi; the two portions of the [illegible] are, however, directly continuous with each other. The gap or cleft which the invagination of the pia mater takes place is called the *transverse*.

In front, the choroid plexus of the lateral ventricle is small and tapering, and communicates with that of the opposite side through the *foramen of Monro*. In structure it consists of minute and highly vascular villous processes, containing an afferent and efferent vessel, and covered by a single layer of flattened epithelium, the cells of which often contain a yellowish fat molecule. The anterior choroidal artery is derived from the internal carotid, and enters the ventricle at the extremity of the descending cornu, and, after ramifying in the plexus, sends branches into the adjacent parts of the brain. The posterior choroidal arteries, one or two in number, are derived from the posterior cerebral artery, and reach the plexus by passing forward under the splenium of the corpus callosum. The veins of the choroid plexus unite to form a prominent vein, which courses from behind forward to the foramen of Monro, and joins with the vein of the corpus striatum to form the corresponding vein of Galen.

The **transverse fissure** is not a real fissure or cleft, because it is filled by the invagination of the pia mater, forming the velum interpositum and the choroid plexuses, covered by the lining of the ventricular cavities. If this involution of pia mater is pulled out, the ventricular lining will necessarily be torn away with it, and a cleft-like space will be left on either side, extending from the foramen of Monro to the bottom of the descending horn of the lateral ventricle. The upper part of this cleft, that is to say, the part nearest the foramen of Monro, is between the lateral border of the body of the fornix and the optic thalamus; below this, at the commencement of the middle horn, it is between the commencing corpus fimbriatum of the fornix and the pulvinar of the optic thalamus; and lower still, in the descending horn, between the corpus fimbriatum on the floor and the tænia semicircularis in the roof of the cornu. Posteriorly the transverse fissure opens between the splenium of the corpus callosum above, and the corpora quadrigemina and pineal gland below. Through the fissure the venæ Galeni emerge to join the straight sinus.

The **velum interpositum** or **tela choroidea superior** (Fig. 358) is a vascular membrane, and is a prolongation of the pia mater into the interior of the brain through the middle part of the transverse fissure. It is of a triangular form, and separates the under surface of the body and posterior pillars of the fornix from the cavity of the third ventricle. Laterally it covers the inner part of the upper surface of the optic thalamus. Its posterior border or base lies beneath the splenium of the corpus callosum above, and the optic thalamus, the corpora quadrigemina, and pineal body below. Its anterior extremity, or apex, ends just behind the anterior pillars of the fornix, where it is connected with the anterior extremities of the choroid plexuses, which are here united through the foramen of Monro, and are then prolonged backward on the under surface of the velum as the *choroid plexuses of the third ventricle*; in front, these plexuses of the third ventricle lie close to the middle line, but diverge from each other behind. The lateral margins of the velum interpositum form the choroid plexuses of the lateral ventricles. It is supplied by the anterior and posterior choroidal arteries, already described. The veins of the velum interpositum, the *venæ Galeni*, two in number, run between its layers, each being formed by the union of the vein of the corpus striatum with the choroid vein. The venæ Galeni unite posteriorly into a single trunk, the *vena magna Galeni*, which terminates in the straight sinus (Fig. 326).

II. The Inter-brain.

The **inter-brain** (thalamencephalon) is the region of the third ventricle, and comprises the parts developed from the second cerebral vesicle, together with that portion of the first vesicle which is not concerned in the formation of the cerebral hemispheres.

The inter-brain is connected above and in front with the cerebral hemispheres; behind, with the mid-brain or mesencephalon. On its upper surface it is entirely concealed from view, as it is covered by those portions of the internal surfaces of

the cerebral hemispheres which have fused together to form the corpus callosum and the fornix, and is separated from the latter by the two layers of pia mater which form the velum interpositum. Inferiorly it reaches the base of the brain, forming the structures contained in the interpeduncular space.

The third ventricle is the cavity of the inter-brain (Fig. 359). It is a narrow median crevice between the two optic thalami, which constitute the side walls of the inter-brain. Its roof is formed by the velum interpositum, from which are suspended the choroid plexuses of the third ventricle. Its floor, somewhat oblique in its direction, is formed, from before backward, by the tuber cinereum, with its infundibulum and pituitary body; the corpora albicantia; the posterior perforated space; and the tegmenta of the crura cerebri. Its sides are formed by the optic thalami, and are limited above by a delicate band of white fibres, the *stria pinealis*,

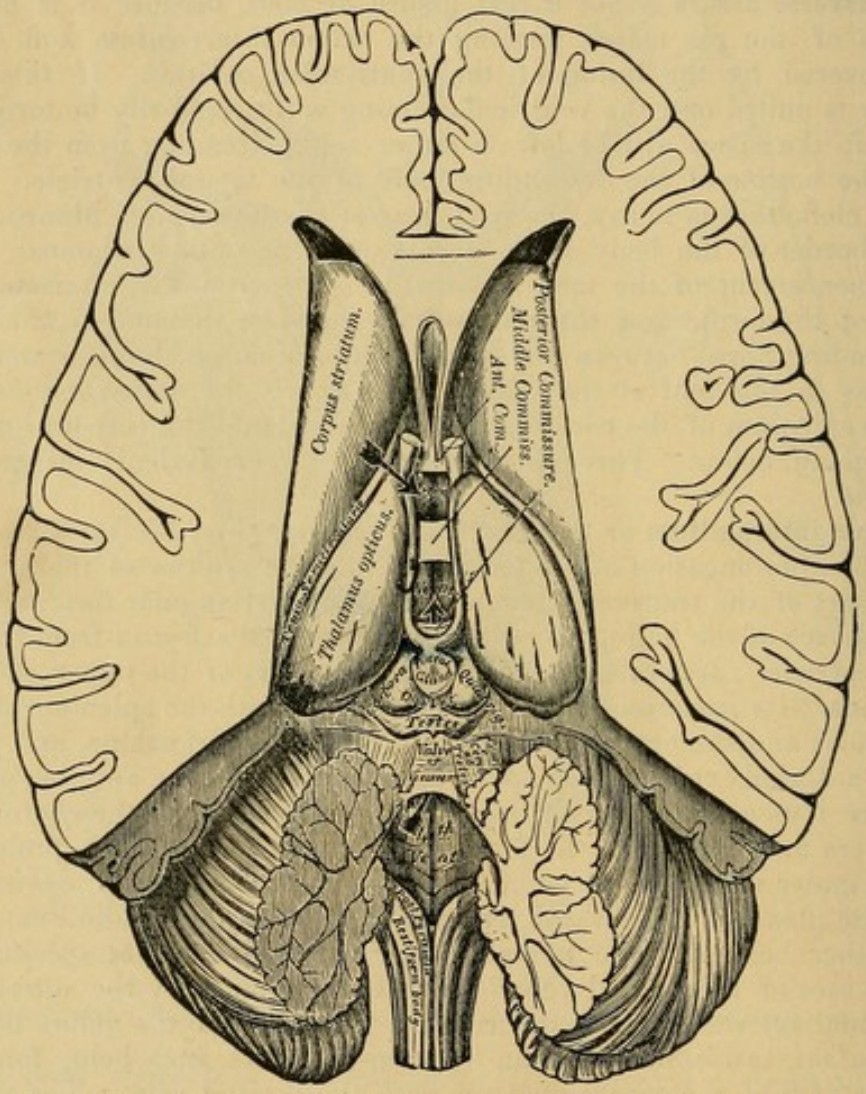

FIG. 359.—The third and fourth ventricles. An arrow has been placed in the position of the foramen of Monro.

which runs along the junction of the mesial and upper surfaces of the optic thalamus to join the anterior pillars of the fornix. Its sides are somewhat convex, so that in the middle of the ventricle the two lateral walls are almost in contact, and are here united across the middle line by a band of gray nervous matter, the *middle*, *gray*, or *soft* commissure. The ventricle is bounded in front by the anterior pillars of the fornix and the lamina cinerea; behind by the pineal gland, the posterior commissure, and the upper end of the iter a tertio ad quartum ventriculum. The cavity is much deeper in front than behind, and presents a recess at its anterior part, which lies over the optic commissure and is therefore termed the *optic recess*. Behind and below this is the conical depression of the infundibulum, passing downward and forward to the pituitary body. At its posterior extremity the cavity

forms another and smaller recess, which extends into the stalk of the pineal gland, and is termed the *pineal recess.* At its upper and anterior part, immediately behind the anterior pillars of the fornix and in front of the optic thalamus, is an opening, the *foramen of Monro*, by which this ventricle communicates with the lateral ventricle on either side. The roof of the cavity is limited in front and behind by transverse bands of white matter, known respectively as the *anterior* and *posterior commissures.* The former has already been described in connection with the corpus striatum (page 665).

The *middle* or *soft commissure* consists almost entirely of gray matter. It connects the two optic thalami, and is continuous with the gray matter lining the anterior part of the third ventricle. It is frequently broken in examining the brain, and might then be supposed to be wanting; it is sometimes double.

The *posterior commissure* is a rounded band of white fibres, which stretches across from one optic thalamus to the other, overlying the upper end of the aqueduct of Sylvius, or iter a tertio ad quartum ventriculum. It is usually described as belonging to the inter-brain, but would appear to belong in part to the mid-brain, since some of its fibres are commissural and connect the anterior corpora quadrigemina to the fillet of the opposite side (see below). In addition there are other decussating fibres, which come from the tegmentum of the crus cerebri on one side and decussate with those of the opposite side in the posterior commissure, and passing through the optic thalamus reach the cerebral hemispheres. Fibres have also been described as taking their origin in the pineal body and ganglion habenulæ, and passing across to the posterior longitudinal bundle and oculomotor nucleus of the opposite side; these fibres occupy the ventral part of the commissure, and receive their myelin sheath before those in its dorsal part. But to a certain extent the posterior commissure belongs to the inter-brain, since it contains fibres which serve as commissural fibres between the two optic thalami.

The **optic thalami** are two large oblong masses, situated on either side of the third ventricle, and lying between the diverging portions of the corpora striata. They are composed mainly of gray matter, but their free surfaces are coated with a thin layer of white nervous tissue. They present outer and under surfaces, which are not free, but are blended with contiguous parts of the brain, and upper, inner, and posterior surfaces, which are free. The anterior extremity is narrow, and forms the posterior boundary of the foramen of Monro. The outer surface is in contact with the posterior limb of the internal capsule, which separates it from the lenticular nucleus. The *inferior* surface rests upon and is continuous with the tegmentum of the crus cerebri. Its upper surface is free, and is separated from the caudate nucleus by a furrow which lodges the lamina cornea, the vein of the corpus striatum, and the tænia semicircularis. It is divided into an outer and an inner part by a groove which runs from behind, forward and inward. The outer part forms a portion of the floor of the lateral ventricle, and is covered by the ependyma of that cavity; it terminates in front in a tubercle, the *anterior tubercle* of the optic thalamus. The inner part is covered by the velum interpositum, which separates it from the fornix, and is excluded from both the lateral and third ventricles by the reflection of the lining of these cavities, and is therefore destitute of an ependymal covering.

The *internal* surface forms the lateral wall of the third ventricle, and running along its upper border is the peduncle of the pineal gland, from which the ependyma of the third ventricle is reflected on to the under surface of the velum interpositum. The *posterior* surface projects beyond the level of the corpora quadrigemina, and forms a well-marked rounded prominence, the *posterior tubercle* or *pulvinar.* The pulvinar is continued externally into a second eminence, the *external geniculate body*, which is placed above and to the outer side of the *internal geniculate body*, and from which it is separated by the superior brachium, one of the roots of the optic tract.

The optic thalamus is formed chiefly of gray matter, which is arranged in two masses, the *outer* and *inner nuclei*, and these are partially separated from each

other by an S-shaped vertical lamina of white matter, called the *internal medullary lamina*. This is named internal in contradistinction to a second or *external medullary lamina* of white matter, which coats the outer surface of the optic thalamus and connects it with the internal capsule. The inner nucleus is connected with the corresponding nucleus of the opposite side through the middle commissure of the third ventricle. The external nucleus, which is the larger of the two, extends backward into the pulvinar. The gray matter of the optic thalamus contains large multipolar and fusiform cells, and is traversed in every direction by numerous nerve-fibres.

The optic thalamus is intimately connected with the following structures:

1. It constitutes a relay for the greater number of the fibres of the tegmentum of the crus cerebri.

2. The pulvinar receives many of the fibres of the optic tract.

3. It is connected with the cerebral cortex, (*a*) through the *anterior stalk of the optic thalamus*, which passes from the anterior extremity of the thalamus through the anterior limb of the internal capsule to the frontal lobe; (*b*) through the *posterior stalk* or *optic radiations*, consisting of fibres which take their origin in the pulvinar and are transmitted through the extreme posterior part of the internal capsule to the occipital lobe; (*c*) through the *inferior stalk* or *ansa peduncularis*, made up of fibres which leave the inferior surface of the thalamus and end in the temporal lobe; (*d*) through fibres which pass from the external surface of the thalamus to the parietal lobe.

4. With the corpus striatum. The fibres destined for the caudate nucleus leave the external surface; those for the lenticular nucleus, the inferior aspect of the thalamus.

5. With the corpus albicans through the bundle of Vicq d'Azyr.

In connection with the optic thalamus two small nuclei of gray matter require consideration: (1) One of these, the *anterior nucleus*, is situated in the *anterior tubercle* of the optic thalamus. This nucleus receives the fibres (bundle of Vicq d'Azyr) which take origin in the cells of the corpus albicans (see page 657). Though this bundle of fibres appears to be the direct continuation of the anterior pillar of the fornix through the corpus albicans to the optic thalamus, it is believed to have no histological continuity with it. The fibres of the anterior pillar of the fornix form synapses in the corpus albicans around the cells which give origin to the bundle of Vicq d'Azyr, and thus an indirect communication only is established between the fornix and the optic thalamus. (2) The second gray nucleus lies in a depressed space, the *trigonum habenulæ*, situated between the pulvinar and the posterior part of the peduncle of the pineal gland. It is termed the *ganglion of the habenula*. It receives fibres from the peduncles of the pineal body, and sends off others which pass to a small collection of gray matter, situated between the diverging crura cerebri, and named the *ganglion interpedunculare*.

The **pineal gland** (*epiphysis cerebri*), so named from its peculiar shape (pinus, a *fir-cone*), is a small reddish gray body, conical in shape (hence its synonym, *conarium*), placed immediately above and behind the posterior commissure and between the anterior corpora quadrigemina, on which it rests. It is covered by the velum interpositum, which intervenes between it and the splenium of the corpus callosum. It is an upgrowth from the second cerebral vesicle (hence the name epiphysis), and is at first hollow, but soon becomes solid and loses its connection with the ventricular cavity. It is retained in its position by a duplicature of pia mater, derived from the under surface of the velum interpositum, which almost completely invests it. The pineal gland is about four lines in length and from two to three in width at its base, and is said to be larger in the child than in the adult, and in the female than in the male. It is attached on either side by a flattened stalk of white matter, the *pedunculus conarii*. This stalk consists of two laminæ, upper and lower, separated by a little recess, the *pineal recess* (see page 671). The lower lamina is prolonged into the posterior commissure. The upper

divides into two strands, the *peduncles of the pineal gland*, or *striæ pinealis;* these extend on either side along the optic thalamus at the junction of its mesial and upper surfaces (see page 671) to the anterior pillars of the fornix, with which they blend. The two stalks join together at their posterior extremity, in front of the pineal gland, forming a sort of festoon, and the base of the gland is connected to their posterior margin at the point of junction.

Structure.—The pineal gland consists of a number of follicles, lined by epithelium, and connected together by ingrowths of connective tissue. The follicles contain a transparent viscid fluid and a quantity of sabulous matter named *acervulus cerebri*, composed of phosphate and carbonate of lime, phosphate of magnesia and ammonia, with a little animal matter. These concretions are almost constant in their existence, and are present at all periods of life. They are found upon the surface of the pineal body and occasionally upon its peduncles.

Morphologically the pineal gland is regarded as the homologue of the structure termed the *pineal eye* of the lizards. In these reptiles the epiphysis cerebri is attached by an elongated stalk and projects through the parietal foramen. Its extremity lies immediately under the epidermis, and on microscopic examination presents, in a rudimentary fashion, structures similar to those found in the eyeball.

III. The Mid-Brain.

The **mid-brain,** or **mesencephalon,** is the constricted portion of the brain which connects the pons Varolii with the inter-brain and hemispheres, and hence it is frequently called the *isthmus cerebri*. It is developed from the third cerebral vesicle, the cavity of which becomes the aqueduct of Sylvius. It comprises the crura cerebri, the corpora quadrigemina, the geniculate bodies, and the Sylvian aqueduct. Its direction is from before backward and downward. In front and above it is continuous with the inter-brain; below with the pons. Its two surfaces are ventral and dorsal. They are free, but concealed: the ventral surface by the apices of the temporal lobes which overlap it; the dorsal, by the overhanging cerebral hemispheres. The *ventral* surface when exposed by drawing aside the temporal lobes, is seen to consist of two cylindrical bundles of white matter which emerge from the pons and diverge as they pass forward and outward to enter the inner and under part of either hemisphere. They are the *crura cerebri* or *cerebral peduncles*, and between them is a triangular area, already described as part of the interpeduncular space (see page 656); near the point of divergence of the crura the roots of the third nerve are seen to emerge in several bundles from a groove, the *sulcus oculomotorius*. The *dorsal* surface is not visible until a considerable portion of the cerebral hemispheres and other overlying structures have been removed. It then presents four rounded eminences placed in pairs, two in front and two behind, and separated from one another by a crucial depression. These are termed the *corpora* or *tubercula quadrigemina*. The ventral and dorsal surfaces meet on the side of the mid-brain, and are separated from each other by a furrow, the *lateral groove*, which runs from below upward and forward (Fig. 359).

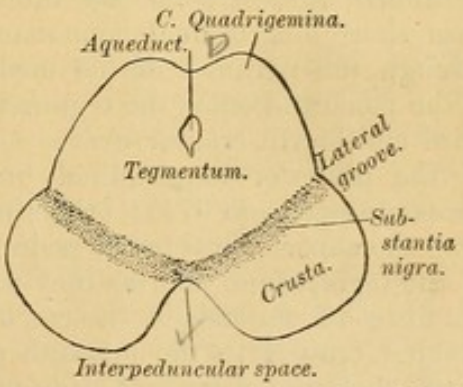

FIG. 360.—Transverse section of the mid-brain.

If a cross section be made through the mesencephalon (Fig. 360) it will be seen that each lateral half is divided into two unequal portions by a lamina of deeply pigmented gray matter, named the *substantia nigra;* of these the postero-superior portion is named the *tegmentum*, and the antero-inferior the *crusta* or *pes*. The substantia nigra is curved on section with its concavity upward, and extends from the lateral groove externally to the oculomotor sulcus internally. The two crustæ are quite separate from one another, but the two halves of the tegmentum are joined

to each other in the mesial plane by a prolongation forward of the raphé or median septum of the pons. Laterally the tegmenta are free, but dorsally they blend with the corpora quadrigemina.

Crustæ.—The crustæ, which are two in number, separated by the interpeduncular space, are semilunar in section, and consist of longitudinal bundles of white fibres, which may be divided into three principal sets: (1) Those occupying the outer third of the crusta are believed to arise from the cells of the nuclei pontis, gray nuclei in the pons Varolii, and pass through the posterior part of the internal capsule to the cerebral cortex of the occipital and temporal lobes. (2) The fibres occupying the middle third of the crusta take their origin in the cells of the Rolandic area of the cortex, and, converging to the internal capsule, pass down through its genu and through the anterior two-thirds of its posterior limb to the crusta, from which they are prolonged through the pons into the anterior pyramid of the medulla oblongata. (3) The origin, from below, of the fibres occupying the inner third of the crusta is uncertain, though by some they are believed to arise in the crusta itself, from the cells of the locus niger. Above, they pass through the anterior part of the internal capsule to the cerebral cortex of the frontal lobe. In addition to these three sets of longitudinal fibres, a well-marked bundle, defined by having an oblique direction, must be noted. This is named the *mesial fillet*. It arises from the fillet (see below), and at the lower part of the crusta is situated at its mesial border; as it ascends it courses obliquely outward to reach the lateral border of the middle group of fibres (pyramidal tract) and becomes lost in the subthalamic region.

The **tegmentum,** or that portion of the mid-brain which is superior to the substantia nigra, consists of longitudinally directed strands of white fibres, which are separated from each other by transversely arched fibres. There is also a considerable quantity of gray matter. It thus forms a peculiar reticulated structure, which has been named *formatio reticularis*, and is similar to a like structure in the pons and medulla, with which it is continuous. In some parts of the tegmentum the longitudinal fibres are arranged in fairly well-defined tracts, which are as follows: 1. The *posterior longitudinal bundle*, which is composed of large nerve-fibres, and lies on either side of the median line, just below the aqueduct. These fibres are continued upward from the anterior column of the cord, in which they probably form short longitudinal commissures between its different segments. They pass through the pyramid of the medulla, then form the posterior longitudinal bundle of the pons, and enter the tegmentum; here they give off fibres to the nuclei of the third and fourth cranial nerves. At the front of the mid-brain some of the fibres of the posterior longitudinal bundle enter the posterior commissure and there decussate (see page 671); others pass upward to the subthalamic region. 2. Fibres from the superior cerebellar peduncle. These lie on either side of the middle line of the tegmentum, and, as they pass through it, decussate with each other, so that the fibres of one half of the cerebellum pass to the opposite half of the cerebrum. Having crossed to the opposite side, the bundle of fibres passes upward and forward, enclosing a mass of gray matter, the *red nucleus*, or *nucleus of the tegmentum*, from which it probably receives fibres, and eventually passes into the optic thalamus. 3. The *fillet*. This takes its chief origin in the medulla, and passes through the pons to the mid-brain, as will be described in the sequel. It forms a considerable bundle of longitudinal fibres in the ventral part of the tegmentum, and divides into three parts—the *upper*, *mesial*, and *lower fillet*. The *upper* fillet passes to the upper pair of corpora quadrigemina and the occipital region of the cerebral hemisphere. The *mesial* fillet has already been alluded to in the description of the crusta. After separating from the rest of the fillet its fibres assume an oblique direction, and are eventually lost in the subthalamic region. The *lower* fillet, also called *lemniscus*, is situated in the ventral part of the tegmentum, through which it passes obliquely and emerges at its side, and after crossing the superior peduncle of the cerebellum, passes to the inferior quadrigeminal bodies. It is reinforced by some fibres from the superior medullary velum. 4. Fibres from

the olivary nucleus, which pass in a longitudinal direction through the reticular formation of the tegmentum and are continued onward into the internal capsule.

The *red nucleus* or *nucleus of the tegmentum*, is a tract of gray matter situated on either side of the middle line, and is composed of numerous large cells, which are deeply pigmented. It is pierced by the fibres of the third nerve, and prolonged above into the posterior part of the subthalamic region.

The Substantia Nigra.—This, as already stated, is a layer of deeply pigmented gray matter, which separates the crusta from the tegmentum. It is thicker internally than externally, where it is partially divided up by the mesial fillet passing from the tegmentum to the crusta. It is traversed at its inner part by some of the fibres of origin of the third cranial nerve. The cells are small and multipolar, and are characterized by containing a large amount of dark pigment granules.

The **corpora** or **tubercula quadrigemina** are four rounded eminences placed in pairs, two in front and two behind, and separated from one another by a crucial depression. They are situated on the dorsal surface of the mid-brain, immediately behind the third ventricle and posterior commissure, and beneath the splenium of the corpus callosum. The *anterior* or *upper* pair, sometimes called the *nates*, are the larger. They are oval, their long diameter being directed forward and outward, and are of a gray color. The *posterior* or *lower* pair, called the *testes*, are hemispherical in form, and lighter in color than the preceding. From the outer side of each of these eminences, a prominent white band, termed *brachium*, is continued forward and outward. Those from the nates (*brachia anteriora*) pass obliquely outward between the pulvinar and the inner geniculate bodies into the external geniculate bodies. Those from the testes (*brachia posteriora*) lose themselves beneath an oval prominence on either side of the corpora quadrigemina, called the *internal geniculate body*. The corpora quadrigemina are larger in the lower animals than in man. In fishes, reptiles, and birds they are hollow, and only two in number (*corpora bigemina*); they represent the anterior quadrigeminals of mammals. In these lower animals the corpora bigemina are frequently termed the *optic lobes*, because of their connection with the optic tracts. In the mammalia they are four in number, and solid. In the human fœtus all four bodies are differentiated by the fifth month, and form at this time a considerable proportion of the brain.

The corpora quadrigemina are composed of white matter externally, and gray matter within. The *posterior* pair consist almost entirely of gray matter, covered over by a very thin stratum of white substance. Beneath the gray matter is a thin layer of white fibres, forming a part of the lower fillet. This separates the gray matter of the posterior corpora quadrigemina from the central gray matter of the aqueduct. The *anterior* pair are covered superficially by a thin stratum of white matter, the *stratum zonale*, the fibres of which are fine and arranged transversely. Beneath this is the *stratum cinereum*, a layer of gray matter which resembles a cup, semilunar in shape, thicker in the centre, and thinning off toward the margins, and consisting of numerous multipolar cells, for the most part of small size, embedded in a fine network of nerve-fibres. Below this again is the *stratum opticum*, or *upper gray-white layer*, characterized by the large amount of fine nerve-fibres which intersect the gray matter. These fibres vary in size in different parts of the layer, but have for the most part a longitudinal direction. The nerve-cells between the fibres are larger, and send their axis-cylinder processes into the next stratum. Finally there is the *stratum lemnisci*, or *deep gray-white layer*, which separates the rest of the body from the gray matter around the aqueduct. It consists of fibres partly derived from the upper fillet and partly from the cells of the preceding layer. Interspersed among these fibres are nerve-cells of large size.

In close relationship with the corpora quadrigemina are the **superior peduncles of the cerebellum.** They emerge from the upper and mesial part of the hemispheres of the cerebellum, and run upward and forward to the corpora quadri-

gemina, with which they come in close contact. They then pass under these bodies, through the tegmentum (*vide* supra), and enter the optic thalamus.

The **corpora geniculata** are two small, oblong masses on each side, situated behind and beneath the posterior end of the optic thalamus, and named, from their position, *corpus geniculatum externum* and *internum*. These two bodies are separated from each other by the brachium anterius of the anterior quadrigeminal body. It is convenient and customary to describe these two bodies together, but the student should bear in mind that the corpus geniculatum externum belongs in reality to the optic thalamus; the corpus geniculatum internum alone being a part of the mid-brain. The *external* geniculate body is of a dark color, and presents a laminated arrangement, consisting of alternate layers of gray and white matter. Its cells are large, multipolar, and pigmented; their processes are intimately related with the visual area in the cerebral cortex of the occipital region. It is believed that the intercellular gray matter of these bodies is composed, to a considerable extent, of the terminations of the optic nerve, which form synapses around the cells. The *internal* geniculate body is smaller in size, lighter in color, and does not present a laminated arrangement. It receives the posterior brachium from the inferior quadrigeminal body, and some of the fibres of the optic tract appear to enter it. The internal geniculate bodies are connected with each other through the optic commissure by a band of fibres named *Gudden's commissure* (see page 721). The anterior quadrigeminal body, the pulvinar, and the external geniculate body are intimately concerned with vision. They constitute the lower cerebral centre for the optic nerve-fibres which end in them. Extirpation of the eyes in newly born animals entails an arrest of their development, but has no effect on the posterior quadrigeminal body or the internal geniculate body. These latter also are well developed in the mole, where the superior quadrigeminal body is rudimentary.

The Aqueduct of Sylvius, or Iter a Tertio ad Quartum Ventriculum.—This is a narrow canal, about half an inch in length, situated between the corpora quadrigemina and the tegmentum, and connecting the third with the fourth ventricle. Its shape on transverse section varies, being T-shaped below, triangular above, and oval about the middle of its course. It is lined by columnar ciliated epithelium, and surrounded by a layer of gray matter, called the *central gray matter of the aqueduct*, which is continuous with the gray matter of the third and fourth ventricles. This gray matter is separated above from that of the corpora quadrigemina by the stratum lemnisci; below it, is the posterior longitudinal bundle and the formatio reticularis of the tegmentum. The central gray matter is more abundant below the canal than above it. Here are certain defined group of cells, which are connected with the roots of the third, fourth, and fifth cranial nerves.

Subthalamic Region.—One other structure, to which allusion has already been made, requires mention in this connection; it is the *subthalamic region*. It is a prolongation forward of the tegmentum of the crus cerebri, which becomes continuous with the lower surface of the optic thalamus. Toward the anterior part of the crus cerebri the tegmentum becomes thinned out, and is blended with the superjacent portion of the optic thalamus. To this region, the name *subthalamic tegmental region* has been given. In front it is lost at the base of the brain in the gray matter of the anterior perforated space, and is continuous with the gray matter of the floor of the third ventricle. The subthalamic tegmental region contains a forward prolongation of the red nucleus, and consists from above downward of three layers: (1) *stratum dorsale*, which is directly applied to the under surface of the optic thalamus, and consists of fine longitudinal fibres; (2) *zona incerta*, a continuation forward of the formatio reticularis of the tegmentum; and (3) the *corpus subthalamicum*, a mass of gray matter which on section presents a lenticular shape, and lies immediately above the substantia nigra.

STRUCTURE OF THE CEREBRUM.

The **cerebrum**, like the other parts of the great nerve centre, is composed of gray and white matter. In order to give some general idea of its construction, at all events in part, it may be compared, for the sake of illustration, to a tree, the trunk of which divides into two main divisions, and these break up into smaller branches, which finally end in twigs, to which are attached the leaves, forming an investment to the branches and covering the whole tree. The trunk is represented by the medulla oblongata as it passes through the foramen magnum; the two main divisions by the crura cerebri, which break up into smaller branches; these diverge from each other, dividing and subdividing, until they reach the surface of the hemispheres, where they terminate in single nerve-fibres, which are continuous with the basal axial cylinder processes of the nerve-cells, the representatives of the leaves. These cells are arranged on the surface, resembling a cap, covering the hemispheres, and constitute the cerebral cortex. But here the analogy ends, for in the cerebrum there are, in addition to this cortex, other masses of gray matter situated in the middle of the brain; and other white fibres besides the diverging ones that have been mentioned, and which serve either to connect the two cerebral hemispheres, or to unite different structures in the same hemisphere.

The **white matter of the cerebrum** consists of medullated fibres, varying in size and arranged in bundles, separated by neuroglia. They may be divided into three distinct systems, according to the course they take. 1. Projection or peduncular fibres, which connect the hemisphere with the medulla oblongata and cord. 2. Transverse or commissural fibres, which unite together the two hemispheres. 3. Association fibres, which connect different structures in the same hemisphere. These are, in many instances, collateral branches of the projection fibres, but others are the axons of independent cells.

1. The **projection** or **peduncular fibres** consist of fibres which pass either to or from the cord. They form the longitudinal fibres of the pons, and at its upper border divide into two main groups, which, diverging from each other, constitute the *crura cerebri* or *cerebral peduncles*. In the crura cerebri, as has been before described, the diverging fibres are arranged in two strata, which are separated by the substantia nigra; the ventral or superficial stratum forming the *crusta* of these bodies, and the dorsal or deeper stratum, the *tegmentum*. The fibres derived from these two sources take a different course, and will have to be separately considered.

The fibres of the *crusta* are derived from the pyramid of the medulla, and are continued upward through the pons; they are reinforced in their passage through the crus by accessory fibres, derived from the central gray nucleus around the Sylvian aqueduct and from the substantia nigra. When they emerge from the crus, most of the fibres pass through the internal capsule, and when they leave it, spread out forward, upward, and backward, forming a series of radiating fibres, the *corona radiata*, which proceed to the cortex. As the fibres pass through the internal capsule they give off branches to the optic thalamus and to the caudate and lenticular nuclei of the striate body, and other fibres, derived especially from the first of these ganglia, form a part of the corona radiata, and pass to the cortex of the cerebral hemispheres. The fibres of the *tegmentum* are continuous with those longitudinal fibres of the pons which are derived from the nucleus gracilis and nucleus cuneatus, and from the formatio reticularis of the medulla. They are reinforced by fibres from the corpora quadrigemina and the corpora geniculata, and from the superior peduncle of the cerebellum. Some of the fibres are continued directly to the cerebral cortex, but the majority pass to the subthalamic region, and either end there or in the substance of the optic thalamus—the connection with the cortex being effected by means of fibres which arise in the optic thalamus. They spread out to form part of the corona radiata, and are distributed especially to the cortex of the temporal and occipital lobes.

2. The **transverse** or **commissural fibres** connect the two hemispheres. They

include: (*a*) the transverse fibres of the corpus callosum; (*b*) the anterior commissure; (*c*) the posterior commissure, and have already been described.

3. **Association Fibres.**—These connect different structures in the same hemisphere, and are of two kinds: (1) Those which unite adjacent convolutions, *short association fibres;* (2) those which pass between more distant parts in the same hemisphere, *long association fibres.*

The *short association fibres* are situated immediately beneath the gray substance of the cortex of the hemispheres, and connect together adjacent convolutions.

The *long association fibres* include the following: (*a*) the uncinate fasciculus; (*b*) the cingulum; (*c*) the superior longitudinal fasciculus; (*d*) the inferior longitudinal fasciculus; (*e*) the perpendicular fasciculus; and (*f*) the fornix.

(*a*) The *uncinate fasciculus* passes across the bottom of the Sylvian fissure, and connects the convolutions of the frontal lobe with the anterior end of the temporal lobe.

(*b*) The *cingulum* is a band of white matter which encircles the hemisphere in an antero-posterior direction, lying in the substance of the convolution of the corpus callosum. Commencing in front at the anterior perforated space, it passes forward and upward parallel with the rostrum, winds round the genu, runs in the convolution from before backward, immediately above the corpus callosum, turns round its posterior extremity, and passes into the hippocampus major, through which it courses to its anterior extremity.

(*c*) The *superior longitudinal fasciculus* runs along the convex surface of the hemisphere, and connects the frontal and occipital and the frontal and temporal lobes.

(*d*) The *inferior longitudinal fasciculus* is a collection of fibres which connects the temporal and occipital lobes, running along the outer wall of the descending and posterior cornua of the lateral ventricle.

(*e*) The *perpendicular fasciculus* runs vertically through the front part of the occipital lobe, and connects the inferior parietal lobule with the fourth temporal convolution.

(*f*) The *fornix* connects the hippocampal convolution with the corpus albicans, and, by means of the bundle of Vicq d'Azyr, with the optic thalamus (see page 672). Through the fibres of the lyra it probably also unites the opposite hippocampal convolutions.

The **gray matter of the cerebrum** is disposed in two great groups: (1) The gray matter of the cerebral cortex. (2) The gray matter of the basal ganglia, the nucleus caudatus and the nucleus lenticularis of the corpus striatum; the claustrum and the amygdaloid nucleus. They are, with the exception of the amygdaloid nucleus, situated to the inner side of the island of Reil, and form with this convolution the oldest part of the hemisphere, for they are the first parts of the encephalon to be differentiated in the development of the individual. They are simply semi-detached local thickenings of the gray cortex. The optic thalamus is not reckoned as a basal ganglion, but as belonging to the thalamencephalon.

GRAY MATTER OF THE CORTEX.

On examining a section through one of the convolutions of the Rolandic area with a lens, it is seen to consist of alternating white and gray layers thus disposed from the surface inward: (1) a thin layer of white substance; (2) a layer of gray substance; (3) a second layer of white substance (outer band of Baillarger or band of Gennari); (4) a second gray layer; (5) a third white layer (inner band of Baillarger); (6) a third gray layer, which rests on the medullary substance of the convolution.

The cortex is made up of nerve-cells which vary in size and shape, and of nerve-fibres, which are either medullated or naked axis-cylinders, embedded in a matrix of neuroglia.

Nerve-cells.—According to Cajal, whose description is now generally accepted, the **nerve-cells** are arranged in four layers, named from the surface inward as follows: (1) the molecular layer; (2) the layer of small pyramidal cells; (3) the layer of large pyramidal cells; (4) the layer of polymorphous cells.

The Molecular Layer.—In this layer the cells are polygonal, triangular, or fusiform in shape. Each polygonal cell gives off some four or five dendrites, while its axon may arise directly from the cell or from one of its dendrites. The axons and dendrites of these cells ramify in the molecular layer. Each triangular cell gives off two or three dendrites, from one of which the axon arises, the dendrites and the axon ramifying in the molecular layer. The fusiform cells are placed with their long axes parallel to the surface and are mostly bipolar, each pole being prolonged into a dendrite, which runs horizontally for some distance and furnishes ascending branches. Their axons, two or three in number, arise from the dendrites, and, like them, take a horizontal course, giving off numerous ascending collaterals. The distribution of the axons and dendrites of all three sets of cells is limited to the molecular layer.

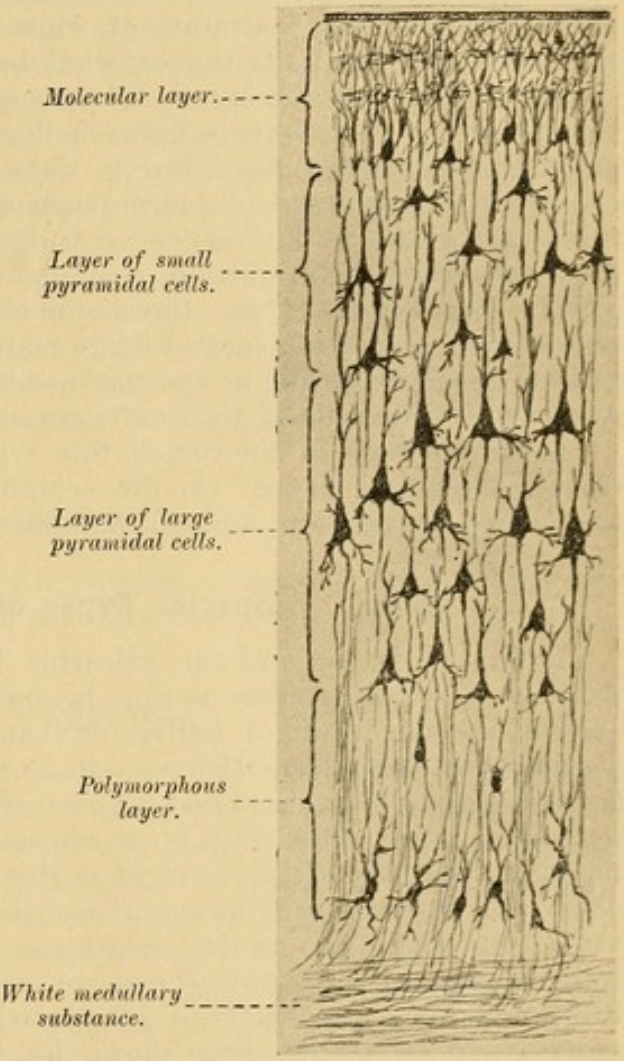

FIG. 361.—The four layers of cells in the cerebral cortex. (After Cajal.) Modified from Testut.

The Layer of Small and the Layer of Large Pyramidal Cells.—The cells in these two layers may be studied together, since, with the exception of the difference in size and the more superficial position of the smaller cells, they resemble each other. The body of each cell is pyramidal in shape, its base being directed to the deeper parts and its apex toward the surface. It contains granular pigment, and stains deeply with ordinary reagents. The nucleus is nucleolated, of large size, and round or oval in shape. The base of the cell gives off the axis-cylinder, and this passes into the central white substance, giving off collaterals in its course, and is distributed as a projection, commissural, or association fibre. Both the apical and basal parts of the cell give off dendrites. The apical dendrite is directed toward the surface, and ends in the molecular layer by dividing into numerous branches, all of which may be seen, when prepared by the silver or methylene-blue method, to be studied with projecting bristle-like processes. The larger pyramidal cells, especially in the Rolandic area, may exceed 50 μ in length and 40 μ in breadth, and are termed *giant cells.*

Layer of Polymorphous Cells.—The cells in this layer, as their name implies, are very irregular in contour, the commonest varieties being of a spindle, star, oval, or triangular shape. Their dendrites are directed outward, toward, but do not reach, the molecular layer; their axons pass into the subjacent white matter.

There are two other kinds of cells in the cerebral cortex, but their axons pass in a direction opposite to that of the pyramidal and polymorphous cells, among which they lie. They are: (*a*) the cells of Golgi, the axons of which do not become medullated, but divide immediately after their origin into a large number

of branches, which are directed toward the surface of the cortex; (*b*) the cells of Martinotti, which are chiefly found in the polymorphous layer. Their dendrites are short, and may have an ascending or descending course, while their axons pass out into the molecular layer and form an extensive horizontal arborization.

Nerve-fibres.—These fill up a large part of the intervals between the cells, and may be medullated or non-medullated—the latter comprising the axons of the smallest pyramidal cells and the cells of Golgi. In their direction the fibres may be either transverse (tangential or horizontal) or vertical (radial). The *transverse fibres* run parallel to the surface of the hemisphere, intersecting the vertical fibres at a right angle. They consist of several strata, of which the following are the most important: (1) a stratum of white fibres covering the superficial aspect of the molecular layer; (2) the external band of Baillarger, or band of Gennari, which runs through the layer of large pyramidal cells; (3) the internal band of Baillarger, which intervenes between the layer of large pyramidal cells and the polymorphous layer. According to Cajal, the transverse fibres consist of (*a*) the collaterals of the pyramidal and polymorphous cells and of the cells of Martinotti; (*b*) the arborizations of the axons of Golgi's cells; (*c*) the collaterals and terminal arborizations of the projection, commissural, or association fibres. The *vertical fibres*.—Some of these, viz., the axons of the pyramidal and polymorphous cells, are directed toward the central white matter, while others, the terminations of the commissural, projection, or association fibres, pass outward to end in the cortex. The axons of the cells of Martinotti are also ascending fibres.

In certain parts of the cortex this typical structure is departed from. The chief of these regions are: (1) the occipital lobe, (2) the hippocampus major, (3) the dentate convolution, and (4) the olfactory bulb.

Special Types of Gray Matter.

1. In the cuneus and the calcarine fissure of the occipital lobe, Cajal has recently described as many as nine layers. Here the inner band of Baillarger is absent; the outer band of Baillarger (band of Gennari) is, on the other hand, of considerable thickness. If a section be examined microscopically, an additional layer is seen to be interpolated between the molecular layer and the layer of small pyramidal cells. This extra layer consists of two or three strata of fusiform cells, the long axes of which are at right angles to the surface. Each cell gives off two dendrites, external and internal, from the latter of which the axon arises and passes into the white central substance. In the layer of small pyramidal cells, fusiform cells, identical with the above, are seen, as well as ovoid or star-like cells with ascending axons (cells of Martinotti). This area of the cortex forms the visual centre, and it has been shown by Dr. J. S. Bolton[1] that in old standing cases of optic atrophy the thickness of Gennari's band is reduced by nearly 50 per cent.

2. In the hippocampus major the molecular layer is very thick and contains a large number of Golgi cells. It has been divided into three strata: (*a*) S. convolutum or S. granulosum, containing many tangential fibres; (*b*) S. lacunosum, presenting numerous lymphatic or vascular spaces; (*c*) S. radiatum, exhibiting a rich plexus of fibrils. The two layers of pyramidal cells are condensed into one, and the cells are mostly of large size. The axons of the cells in the polymorphous layer may run in an ascending, descending, or horizontal direction. Between the polymorphous layer and the ventricular ependyma is the white substance of the alveus.

3. In the rudimentary dentate convolution the molecular layer contains some pyramidal cells, while the layer of pyramidal cells is almost entirely represented by small ovoid cells.

4. **The Olfactory Bulb.**—In many of the lower animals this contains a cavity which communicates through the hollow olfactory stalk with the cavity of the

[1] *Phil. Trans. of Royal Society*, Series B, vol. cxciii, p. 165.

lateral ventricle. In man the original cavity is filled up by neuroglia and its wall becomes thickened, but much more so on its ventral than on its dorsal aspect. Its dorsal part contains a small amount of gray and white matter, but it is scanty and ill defined. A section through the ventral part shows it to consist of the following layers from without inward. (1) A layer of olfactory nerve-fibres, which are the non-medullated axons prolonged from the olfactory cells of the nose, and which reach the bulb by passing through the cribriform plate of the ethmoid bone. At first they cover the bulb, and then penetrate it to end by forming synapses with the dendrons of the mitral cells, presently to be described. (2) *Glomerular layer.*—This contains numerous spheroidal reticulated enlargements, termed *glomeruli*, which are produced by the branching and arborization of the processes of the olfactory nerve-fibres with the descending dendrite of the mitral cells. (3) *Molecular layer.*—This is formed of a matrix of neuroglia, embedded in which are the *mitral cells*. These cells are pyramidal in shape, and the basal part of each gives off a thick dendron which descends into the glomerular layer, where it arborizes as indicated above, and others which interlace with similar dendrites of neighboring mitral cells. The axons pass through the next layer into the white matter of the bulb, from which, after becoming bent on themselves at a right angle, they are continued into the olfactory tract. (4) *Nerve-fibre layer.*—This lies next the central core of neuroglia, and its fibres consist of the axons or afferent processes of the mitral cells which are passing to the brain; some efferent fibres are, however, also present, and terminate in the molecular layer, but nothing is known as to their exact origin.

IV. The Hind-Brain.

The **hind-brain**, or **epencephalon**, comprises those parts which are developed from the fourth cerebral vesicle; namely, the pons, the cerebellum, and the upper half of the fourth ventricle.

PONS VAROLII.

The **pons Varolii** (*tuber annulare*) is the bond of union of the various segments of the encephalon, connecting the cerebrum above, the medulla oblongata below, and the cerebellum behind. It is situated above the medulla oblongata, below the crura cerebri, and between the hemispheres of the cerebellum. It is about an inch in length and in thickness, and about an inch and a half in width. It presents four surfaces: *superior*, which is attached, by direct continuation of fibres, to the mid-brain; *inferior*, which is continuous with the medulla oblongata; while the *anterior* or *ventral* and the *posterior* or *dorsal* surfaces are free.

The *anterior* or *ventral* surface is very prominent, markedly convex from side to side, and less so from before backward. It consists of transverse white fibres, which arch like a bridge across the middle line, and on either side are gathered together into a compact mass, forming the *middle peduncle of the cerebellum*. Above and below it presents a well-defined border; below, its transverse fibres slightly overlap the pyramidal bodies of the medulla, which disappear into its substance; above, the transverse fibres slightly overlap the crura cerebri which emerge from it. This surface rests upon the clivus of the sphenoid bone, and presents in the middle line a longitudinal groove, wider in front than behind, in which rests the basilar artery.

The *posterior* or *dorsal* surface of the pons is free, but is concealed from view by the cerebellum. It forms the upper part of the floor of the fourth ventricle, and will be described with this cavity.

Structure.—Transverse sections of the pons Varolii show that it consists of two parts, which differ in appearance and structure from each other: the anterior or *ventral* portion consists for the most part of fibres arranged in transverse and longitudinal bundles with a small amount of gray matter; the posterior or dorsal portion is a continuation of the reticular formation of the medulla, and is called

the *tegmental* portion, as most of its constituents are continued into the tegmentum of the crus cerebri.

The anterior or ventral part consists of three layers of fibres: 1. superficial transverse fibres; 2. longitudinal fibres; 3. deep transverse fibres. These three layers are not, however, completely differentiated from each other, for some transverse fibres may be seen between the bundles of the longitudinal fibres (Fig. 362).

1. The *superficial transverse fibres*, consisting of a rather thick layer on the ventral surface of the pons, cross the middle line, and proceeding laterally are collected into a large rounded bundle of fibres on each side. This bundle, with the addition of some transverse fibres from the deeper part of the pons, forms the *middle peduncle* of the cerebellum of the corresponding side.

2. The *longitudinal fibres* enter the pons below as a single mass, which forms the continuation upward of the fibres of the pyramids of the medulla; as they ascend they become broken up into bundles by some of the transverse fibres, and

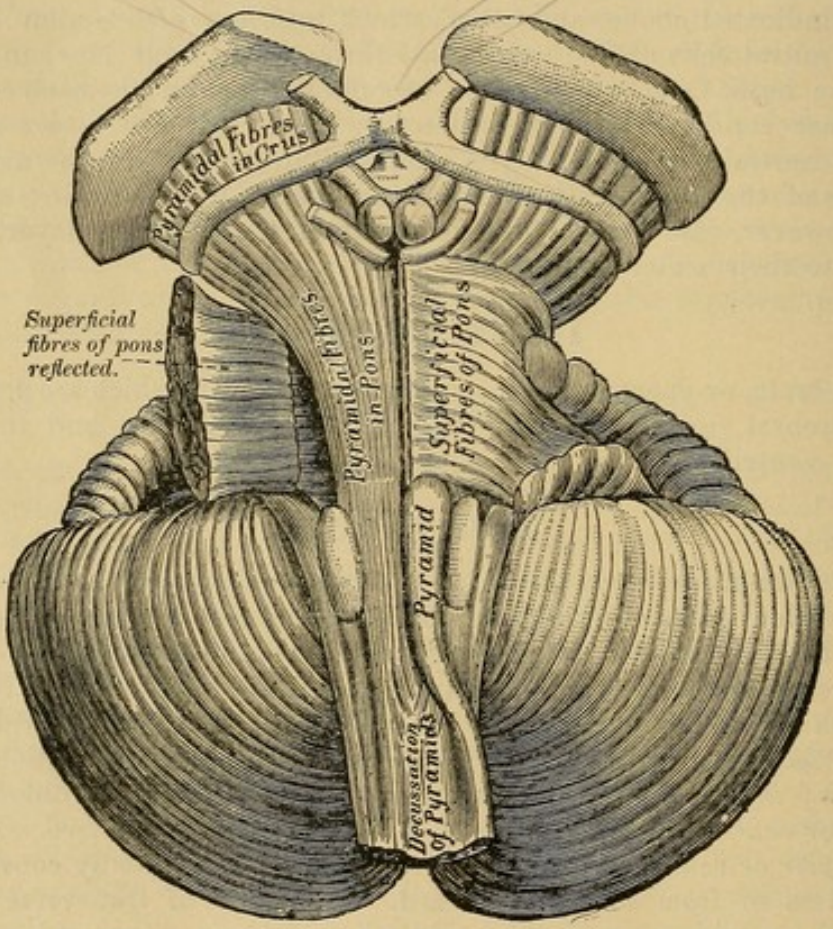

FIG. 362.—Superficial dissection of the medulla oblongata and pons. (Ellis.)

are continued into the crusta of the mid-brain. They lie on either side of the middle line, and cause a bulging of the superficial transverse fibres on the ventral surface of the pons, with a longitudinal mesial groove between them. This is the groove, mentioned above, in which the basilar artery is received. As the fibres ascend they are increased in number, being reinforced by others derived from the nerve-cells in the deep transverse strata.

3. The *deep transverse fibres* form a thicker layer than the superficial set, and there is much gray matter between them. The fibres pass from the middle line, where they interlace with those from the opposite side, and, coursing to the lateral borders of the pons, they, for the most part, curve dorsally, and assist the superficial transverse fibres in forming the middle peduncle of the cerebellum. Some of the fibres join the nerve-cells which are situated in the gray matter of this layer, and in addition nerve-fibres derived from others of these cells pass off to join the longitudinal fibres (see above).

The *tegmental* or *dorsal portion* of the pons is chiefly constituted by a continuation upward of the reticular formation and gray matter of the medulla. It is subdivided into lateral halves by a median raphé continuous with that of the medulla, but this does not extend into the ventral half of the pons, being here obliterated by the transverse fibres.

The dorsal portion of the pons, like the ventral, contains both transverse and longitudinal fibres. The transverse fibres are collected into a distinct bundle, which, from its shape, is sometimes termed the *trapezium* or *corpus trapezoides*. It consists of fibres which proceed laterally to become connected with the cells of the accessory auditory nucleus. The longitudinal fibres, which are continuous with those of the medulla, are mostly collected into two bundles on either side. One of these lies between the corpus trapezoides and the formatio reticularis of the pons, and is a continuation upward of the sensory tracts; it is termed the *fillet*. The other bundle is situated more dorsally, near the floor of the fourth ventricle; it is the *posterior longitudinal bundle*, and contains both ascending and descending fibres. Other longitudinal fibres, which are more diffusely distributed, arise from the cells of the gray matter of the pons itself. The greater part of the dorsal portion of the pons is, as stated above, a continuation upward of the formatio reticularis of the medulla, and, like it, presents, on transverse section, viewed under a moderate magnifying power, a reticular appearance. In addition to the gray matter, which presents a number of small reticularly arranged masses, with nerve-cells, there are some important collections of nerve-cells which require mention.

1. The **superior olivary nucleus** is a small isolated collection of gray matter, situated on the dorsal surface of the outer part of the trapezium. In structure it resembles the inferior olivary nucleus of the medulla, presently to be described, and is situated immediately above it. The nerve-fibres derived from its cells pass into the trapezium, and, as stated above, cross the middle line and enter the accessory auditory nucleus of the other side. The other collections of nerve-cells in the formatio reticularis of the pons are nuclei from which some of the cranial nerves arise.

2. **Nuclei of the Fifth Nerve.**—The nuclei of the fifth nerve in the pons are two in number: one for the motor root and the other for the sensory. The *motor* nucleus is situated in the higher portion of the pons, close under the dorsal surface and along the line of the lateral margin of the fourth ventricle. The *sensory* nucleus lies external to the motor one, beneath the superior peduncle of the cerebellum, which forms the lateral boundary of the upper half of the fourth ventricle. Some of the fibres from these nuclei pass to the raphé of the pons, and thence probably to the higher parts of the brain; the rest form the nerve-roots of the motor and sensory parts of the fifth nerve respectively. They pass through the pons to emerge on its ventral surface at its lateral and constricted portion, nearer its superior than its inferior margin. It must be mentioned that the whole of the roots of the fifth nerve are not formed from these nuclei. The sensory root is partly formed by a long tract of fibres, known as the *ascending* root, which can be traced through the pons and medulla to the upper part of the spinal cord. The motor root, in like manner, is partly formed by a long tract of fibres, which passes downward from the gray matter in the floor of the Sylvian aqueduct and which is termed the *descending* root.

3. The **nucleus of the sixth nerve** is situated beneath the floor of the fourth ventricle, on either side of the middle line. It lies close to the root of the facial nerve, immediately to be described, being a little external to and beneath it, and corresponds to the upper half of the fasciculus teres of the floor of the fourth ventricle (Fig. 371). The fibres pass through the substance of the pons, and emerge at the lower margin of this structure, between it and the upper end of the medulla.

4. The **nucleus of the facial nerve** is of elongated form, and is situated deeply in the reticular formation below the floor of the fourth ventricle and dorsal to

the superior olivary nucleus. The roots of the nerve derived from it pursue a remarkably tortuous course in the substance of the pons. At first they pass backward and inward till they reach the floor of the fourth ventricle, close to the median groove, where they are collected into a rounded bundle. This passes upward and forward, producing an elevation (*fasciculus teres*) in the floor of the ventricle, and then takes a sharp bend and arches outward through the substance of the pons to emerge at its lower border in the interval between the olivary and restiform bodies of the medulla.

5. The **nuclei of the auditory nerve** are two in number, dorsal and ventral. The *dorsal* nucleus is principally situated in the medulla, but is prolonged upward into the pons, where it lies beneath the upper half of the floor of the fourth ventricle. The *ventral* or accessory nucleus is also partly contained in the medulla and partly in the pons. In the medulla it is situated on the antero-external surface of the restiform body, lying between the vestibular and cochlear divisions of the auditory nerve, the latter being to its outer side. In the pons it is seen to lie beyond the boundary of the fourth ventricle on the outer and ventral aspect of the restiform body. A third nucleus (*nucleus of Deiters*) is sometimes termed the outer nucleus of the auditory nerve. It is situated below the outer angle of the fourth ventricle, and contains multipolar nerve-cells of large size. The root of the auditory nerve consists of two portions, lateral and mesial, which pass, one to the outer and the other to the inner side of the restiform body, those from the lateral part arising mainly from the ventral nucleus, those from the mesial part arising from the dorsal auditory nucleus. They emerge at the lower border of the pons, in the groove between the olivary and restiform bodies.

The Nuclei Pontis.—In addition to these nuclei of gray matter, which have been described as being situated in the tegmental or dorsal portion of the pons, there are small masses of gray matter, as mentioned above, in the anterior or ventral portion. These are known as the *nuclei pontis*, and consist of small multipolar nerve-cells, scattered between the bundles of transverse fibres.

THE CEREBELLUM.

The **Cerebellum** is contained in the inferior occipital fossæ, and is situated beneath the occipital lobes of the cerebrum, from which it is separated by the tentorium cerebelli. In form, it is oblong and flattened from above downward, its great diameter being from side to side. It measures from three and a half to four inches transversely, two to two and a half inches from before backward, and is about two inches thick in the centre, and about six lines at the circumference. It consists of gray and white matter: the former, darker than that of the cerebrum, occupies the surface; the latter, the interior. The surface of the cerebellum is not convoluted like that of the cerebrum, but is traversed by numerous curved furrows or sulci, which vary in depth at different parts, and separate the laminæ of which it is composed.

Lobes of the Cerebellum.—The cerebellum consists of three parts or lobes, a median and two lateral. They are all continuous with each other, and are substantially the same in structure. The median portion is called the *worm* or *vermiform process*, from the annulated appearance which it presents, owing to transverse ridges and furrows upon it. On the upper surface of the cerebellum, the worm is only slightly elevated above the level of the lateral portions, but on the under surface it is sunk almost out of sight in a deep depression, which is called the *vallecula*. The lateral parts are called *hemispheres;* they attain a considerable size, overlapping and obscuring the inferior part of the worm. Below and behind they are separated by a deep notch (*posterior cerebellar notch, incisura marsupialis*), and in front by a broader, shallower notch (*anterior cerebellar notch, incisura semilunaris*). The *anterior* notch lies close to the pons and upper part of the medulla, and its upper edge encircles the posterior corpora quadrigemina. The *posterior* notch is free, and contains, in the recent state, the upper part of the falx cerebelli.

The sides of the notches are formed by the margins of the hemispheres, while the bottom of the notches is formed by the anterior and posterior extremities of the worm respectively. The cerebellum is characterized by its laminated or foliated appearance; it is everywhere marked by deep, transverse, somewhat curved fissures, which lie close together, and extend for a considerable depth into the substance of the cerebellum, dividing it into a series of layers or leaves. Upon making sections across the laminæ it will be seen that the folia, though differing in appearance from the convolutions of the cerebrum, are homologous with them, inasmuch as they consist of a central white substance, with a covering or cortex of gray matter.

The largest and deepest fissure is the *great horizontal fissure*. It commences in front at the pons, and passes horizontally round the free margin of the hemisphere to the middle line behind, and divides the cerebellum into an upper and

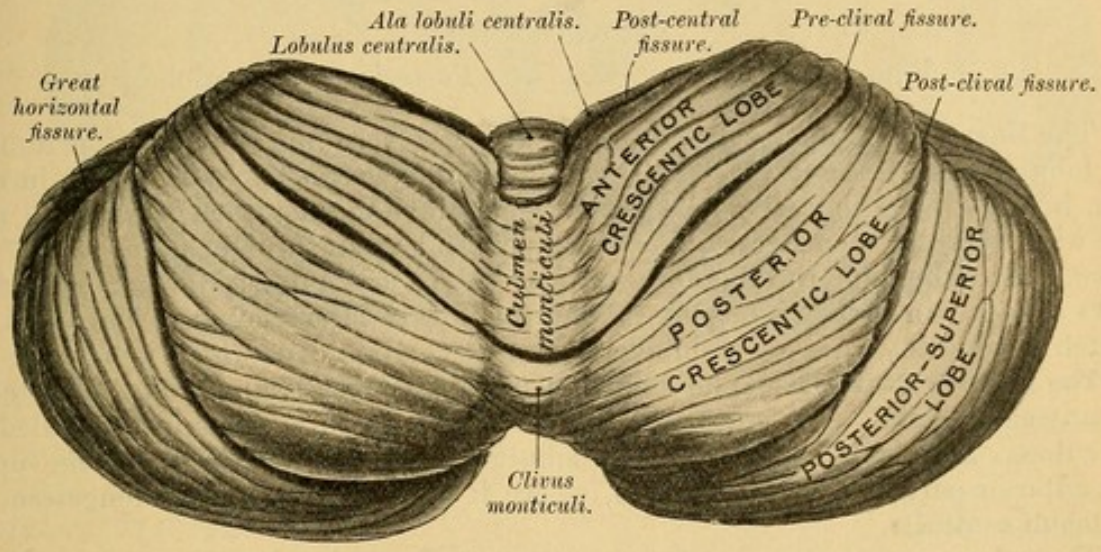

FIG. 363.—Upper surface of the cerebellum. (Schäfer.)

lower portion. Several secondary but deep fissures separate the cerebellum into lobes, and these are further subdivided by shallower sulci, which separate the individual folia or laminæ from each other.

The cerebellum is connected to the cerebrum, pons, and medulla by three pairs of peduncles; which will be described in the sequel; a *superior* pair, connect it with the cerebrum; a *middle* pair, with the pons; and an *inferior* pair, with the medulla.

Upper Surface of Cerebellum (Fig. 363).—The superior surface of the cerebellum is somewhat elevated in the middle line and sloped toward its circumference, its hemispheres being connected together by an elevated median portion or lobe, the *superior worm* or *superior vermiform process*. The surface is traversed by four curved fissures, which are named from their situation, in front or behind two prominent lobes of the worm, the central lobe and the clivus. (1) the pre-central fissure, (2) the post-central fissure, (3) the pre-clival fissure, and (4) the post-clival fissure. These four fissures divide the entire upper surface of the cerebellum into five lobes, but the portion of the lobe in the worm has received a different name from that in the hemisphere, though the two are continuous with each other. The five lobes in the worm are named from before backward: (1) the *lingula*, (2) the *lobulus centralis*, (3) the *culmen monticuli*, (4) the *clivus monticuli*, and (5) the *folium cacuminis*. The five lobes in the hemispheres are named from before backward: (1) the *frænulum*, (2) the *ala lobuli centralis*, (3) *anterior crescentic*, (4) *posterior crescentic*, and (5) *posterior superior*. The arrangement of these fissures and lobules will be understood by reference to the accompanying schematic arrangement, in which the lobules are named in order from before backward with the fissures which separate them:

UPPER SURFACE OF THE CEREBELLUM.

Worm.	*Hemisphere.*
Lingula.	Frænulum.
Pre-central fissure.	
Lobulus centralis.	Ala lobuli centralis.
Post-central fissure.	
Culmen monticuli.	Anterior crescentic lobe.
Pre-clival fissure.	
Clivus monticuli.	Posterior crescentic lobe.
Post-clival fissure.	
Folium cacuminis.	Posterior superior lobe.

The **lingula** is a tongue-shaped process of the cerebellum, which lies in front of the lobulus centralis and is partially or completely concealed by it. It is in relation, in front, with the valve of Vieussens, on the dorsal surface of which it rests and with which it is connected; its white matter being continuous with that of the valve. At either side the lingula gradually shades off, and is prolonged only for a short distance into the hemispheres, where it forms the **frænulum.** This does not stretch beyond the superior peduncle of the cerebellum over which it lies.

The Lobulus Centralis.—The lobulus centralis is a small square lobe, situated in the anterior notch. It overlaps the lingula and is in turn partially concealed by the culmen monticuli. Laterally the lobulus centralis extends along the upper and anterior part of each hemisphere, where it forms a wing-like prolongation, the **ala lobuli centralis.**

The **culmen monticuli** is much larger than the two lobes just described, and constitutes, with the succeeding lobe, the clivus, the bulk of the upper worm. In front it partially overlaps and obscures the lobulus centralis, and behind it is separated from the clivus by the *pre-clival fissure.* It forms the most prominent part of the upper worm, and is marked on its surface by three or four secondary fissures, dividing it up into smaller lobules. Laterally it is continuous with the **anterior crescentic lobe** of the hemispheres, which is distinctly differentiated from the posterior crescentic lobe by the pre-clival fissure, though the two were formerly classed together as the quadrate lobe of the lateral hemisphere.

The **clivus monticuli** is of considerable size, and, as stated above, forms with the culmen the major part of the superior worm. It consists of a group of laminæ, which in front are separated from the culmen by the pre-clival fissure and behind appear to be almost continuous with the folium cacuminis, especially in the median line; but it will be found, on careful examination, to be separated from it by a well-defined fissure, the *post-clival* fissure. Laterally this lobe is continued into the hemispheres as the **posterior crescentic lobe,** which is somewhat semilunar in shape, and, with the anterior crescentic lobe, constitutes the greater part of the upper surface of the hemispheres.

The **folium cacuminis** is a short and narrow, concealed band at the posterior extremity of the worm, consisting apparently of a single folium, but in reality marked on its upper and under surfaces by secondary fissures. Laterally it expands in either hemisphere into a considerable lobe, which is semilunar in shape, and is situated at the postero-superior part of the hemisphere and bounded below by the great horizontal fissure. It is named the **posterior superior lobe** and occupies the posterior third of the upper surface of the hemisphere, forming its rounded postero-lateral border.

The **Under Surface of the Cerebellum** (Fig. 364) presents in the middle line the *inferior worm,* buried in the vallecula, and separated from the hemispheres by

latera. grooves. Here, as on the upper surface, there are deep fissures, dividing it into separate segments or lobes, but the arrangement is more complicated, and the relation of the segments of the worm to those of the hemisphere is less clearly marked. The fissures are three in number, but are not so regularly disposed as

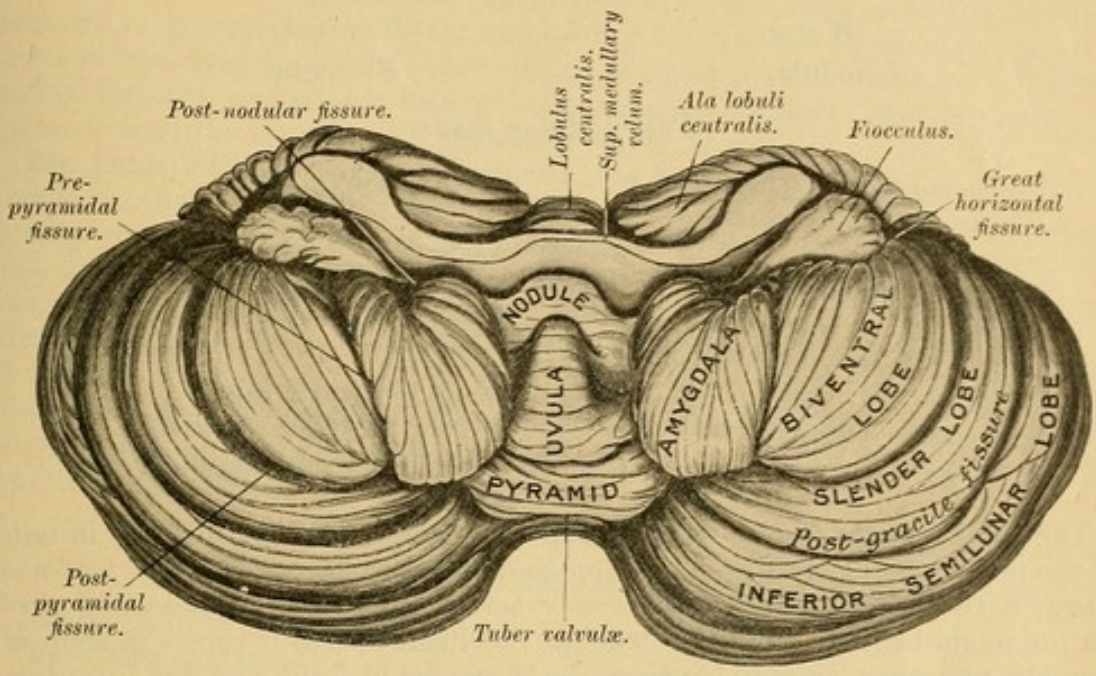

FIG. 364.—Under surface of the cerebellum. (Schäfer.)

those on the upper surface (Fig. 365). They are named, from their relation to the pyramid and nodule, two of the lobes on the under surface of the worm, (1) *post-nodular*, (2) *pre-pyramidal*, and (3) *post-pyramidal fissures*. The part of the worm in front of the post-nodular fissure is termed the *nodule*, and the lobule in the hemisphere corresponding with this is the *flocculus*. The next lobe is situated between

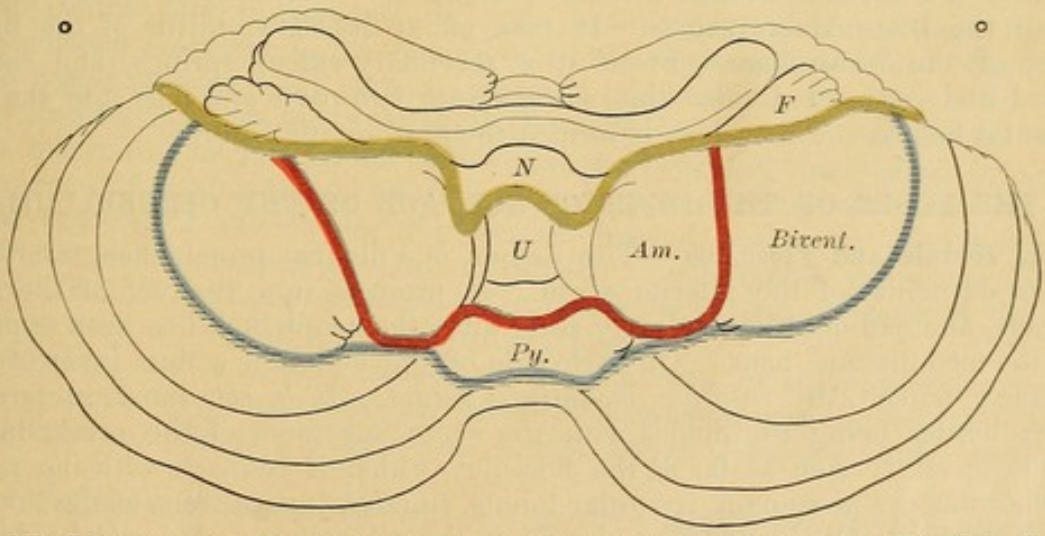

FIG. 365.—Diagram showing fissures on under surface of the cerebellum: F., flocculus; N., nodule; U, uvula; Py., pyramid; Am., amygdala; Bivent., biventral lobe.

the post-nodular and pre-pyramidal fissures. In the vermiform process it is known as the *uvula*, and its lateral expansion in the hemisphere is named the *amygdala* or *tonsil*. The lobule of the worm between the pre- and post-pyramidal fissures is the *pyramid*, and its corresponding part in the hemisphere is the *biventral* or *digastric* lobe. Finally, behind the post-pyramidal fissure in the worm is a small lobe, the *tuber valvulæ* or *tuber posticum*; this, in the hemispheres, expands into a large lobe, which occupies at least two-thirds of the inferior surface of the cerebellum, and is subdivided into two by a secondary fissure, named the *post-gracile*

fissure. The anterior of the two subdivisions is named the *slender* lobe; and the posterior, the *inferior semilunar* or *posterior inferior lobe*. These fissures and lobes are here arranged, from before backward, in a schematic form:

UNDER SURFACE OF THE CEREBELLUM.

Worm.	*Hemisphere.*
Nodule.	Flocculus.
Post-nodular fissure.	
Uvula.	Amygdala.
Pre-pyramidal fissure.	
Pyramid.	Biventral lobe.
Post-pyramidal fissure.	
Tuber valvulæ.	Slender lobe. *Post-gracile fissure.* Inferior semilunar lobe.

The **chief fissures of the under surface,** as stated above, are three in number, and are not so regularly disposed as on the upper surface. (1) The *post-nodular fissure* in the worm courses transversely across it, separating the nodule in front from the uvula behind. When it reaches the hemispheres it passes in front of the amygdala, and then crosses between the flocculus in front and the biventral lobe behind, and joins the anterior end of the great horizontal fissure. (2) The *pre-pyramidal fissure* crosses the worm between the uvula in front and the pyramid behind, then curves laterally behind the amygdala, and passes forward along the outer border of this lobe, between it and the biventral lobe, to join the post-nodular sulcus. (3) The *post-pyramidal fissure* passes across the worm behind the pyramid and in front of the tuber valvulæ, and in the hemispheres courses behind the amygdala and biventral lobes, and then along the outer border of the biventral lobe to the post-nodular sulcus. It cuts off at least two-thirds of the inferior surface of the hemisphere. From it a secondary sulcus springs, and coursing forward and outward divides this surface into two parts and falls into the great horizontal fissure. This sulcus is termed the *post-gracile fissure*.

THE LOBES OF THE INFERIOR SURFACE OF THE CEREBELLUM.

The Nodule and Flocculus.—The nodule is a distinct prominence, forming the anterior extremity of the inferior worm. It projects into the roof of the fourth ventricle, and can only be distinctly seen after the cerebellum has been separated from the medulla and pons. On each side of the nodule is a thin layer of white substance, named the *inferior medullary velum*. It is semilunar in form, its convex border being continuous with the white substance of the cerebellum; it extends on either side as far as the flocculus, which it connects with the nodule. The flocculus is a prominent, irregular lobule, situated just in front of the biventral lobe, between it and the middle peduncle of the cerebellum. It is subdivided into a few small laminæ, and is connected to the inferior medullary velum by its central white core.

The Uvula and Amygdalæ.—The uvula occupies a considerable portion of the inferior worm; it is separated on either side from the amygdala by a deep groove, the *sulcus valleculæ*, at the bottom of which it is connected to the amygdala by a commissure of gray matter, indented on its surface, and called the *furrowed band*. It is marked on its surface by three or four transverse fissures. The amygdalæ, or tonsils, are rounded masses, situated in the lateral hemispheres. Each lies in a deep fossa between the uvula and the biventral lobe; this fossa is known by the name of the *bird's nest* (*nidis avis*).

The Pyramid and Biventral Lobes.—The pyramid is a conical projection, forming the largest prominence of the lower worm. It is separated from the hemispheres by the sulcus valleculæ, across which it is connected to the biventral lobe by an indistinct band of gray matter, analogous to the furrowed band already described. The biventral lobe is triangular in shape, with the apex pointing inward and backward to become joined by the connecting band to the pyramid. The external border is separated from the slender lobe by the post-pyramidal fissure. The base is directed forward, and is on a line with the anterior border of the amygdala, and is separated from the flocculus by the post-nodular fissure.

The Tuber Valvulæ or Tuber Posticum, and Posterior Inferior Lobes.—The tuber valvulæ is the posterior division of the inferior worm. It is of small size, and laterally spreads out into the large posterior inferior lobes of the hemispheres. These lobes, which, as stated above, comprise at least two-thirds of the inferior surface of the hemisphere, are divided into two by the post-gracile fissure. The anterior lobe is named the *slender lobe*, and the posterior, the *inferior semilunar lobe*. Both these lobes show a tendency to subdivision into two; that of the slender lobe is well marked, and its subdivisions are sometimes described as distinct lobes and named the *anterior* and *posterior slender lobes*, the fissure between them being termed the *intra-gracile fissure*.

INTERNAL STRUCTURE OF THE CEREBELLUM.

The cerebellum consists of white and gray matter.

The White Matter.—If a sagittal section (Fig. 366) is made through either hemisphere of the cerebellum, the interior will be found to consist of a central stem of white matter, which contains in its interior a gray mass, the *corpus dentatum*. From the surface of this central stem a series of plates of medullary matter are detached, which, covered with gray matter, form the laminæ. In consequence of the main branches from the central stem dividing and subdividing, the section presents a characteristic appearance, which is named the *arbor vitæ*. If a vertical section is made in the median plane of the cerebellum it will be found that the central stem divides into two main branches, which, from their direction, may be named respectively the vertical and the horizontal branch. The *vertical* branch passes upward to the culmen, where it subdivides freely, some of its ramifications passing forward and upward to the central lobe. The *horizontal* branch passes backward to the folium cacuminis, considerably diminished in size in consequence of having given off large secondary branches: one, from its upper surface, ascends to the clivus; the others descend, and enter the lobes in the inferior vermiform process, the tuber valvulæ, the pyramid, the uvula, and the nodule. It is not necessary to describe in detail the various divisions of the white matter, as they correspond to the lobes on the surface.

The white matter of the cerebellum includes two varieties of nerve matter: (1) the *peduncular fibres*, which are directly continuous with those of the peduncles of the cerebellum; (2) the fibres proper (*fibræ propriæ*) of the cerebellum itself.

The Peduncles of the Cerebellum.—From the anterior part of each hemisphere arise three large processes or peduncles—superior, middle, and inferior—by which the cerebellum is connected with the rest of the encephalon.

The **superior peduncles** form the upper lateral boundaries of the floor of the fourth ventricle. As they extend forward and upward they converge on the dorsal aspect of the ventricle, and thus assist to roof it in. They may be traced as far as the corpora quadrigemina, under which they pass. They enter the upper and mesial part of the medullary substance of the hemispheres, beneath the ala lobuli centralis and the frænulum, and pass to a great extent into the interior of the corpus dentatum, though some of their fibres wind round it and reach the gray cortical matter, especially of the inferior surface.

The fibres of the superior peduncles mainly emerge from the hilum of the corpus

dentatum; others come from the cortex and probably also from the smaller nuclei in the central white substance. The majority of the fibres decussate with those of the opposite peduncle below the corpora quadrigemina, and pass to the red nucleus of the tegmentum, from which a relay is prolonged through the optic thalamus to the cerebral cortex. Fibres also connect the spinal cord with the cerebellum through its superior peduncles; these are chiefly derived from the antero-lateral ascending cerebellar tract of Gowers.

The Valve of Vieussens or Superior Medullary Velum.—Stretched across from one superior peduncle to the other is a thin, transparent lamina of white matter, the *valve of Vieussens;* on to the dorsal surface of its lower half the folia of the lingula are prolonged. It forms with the superior peduncles the roof of the upper part of the fourth ventricle, and is continuous with the central white stem of the cerebellum. It is narrow above, where it passes beneath the corpora quadrigemina, and broader below, at its connection with the white substance of the superior worm of the cerebellum. A slight elevated ridge descends upon the upper part of the valve from between the lower corpora quadrigemina, and on either side of this may be seen the fourth nerve.

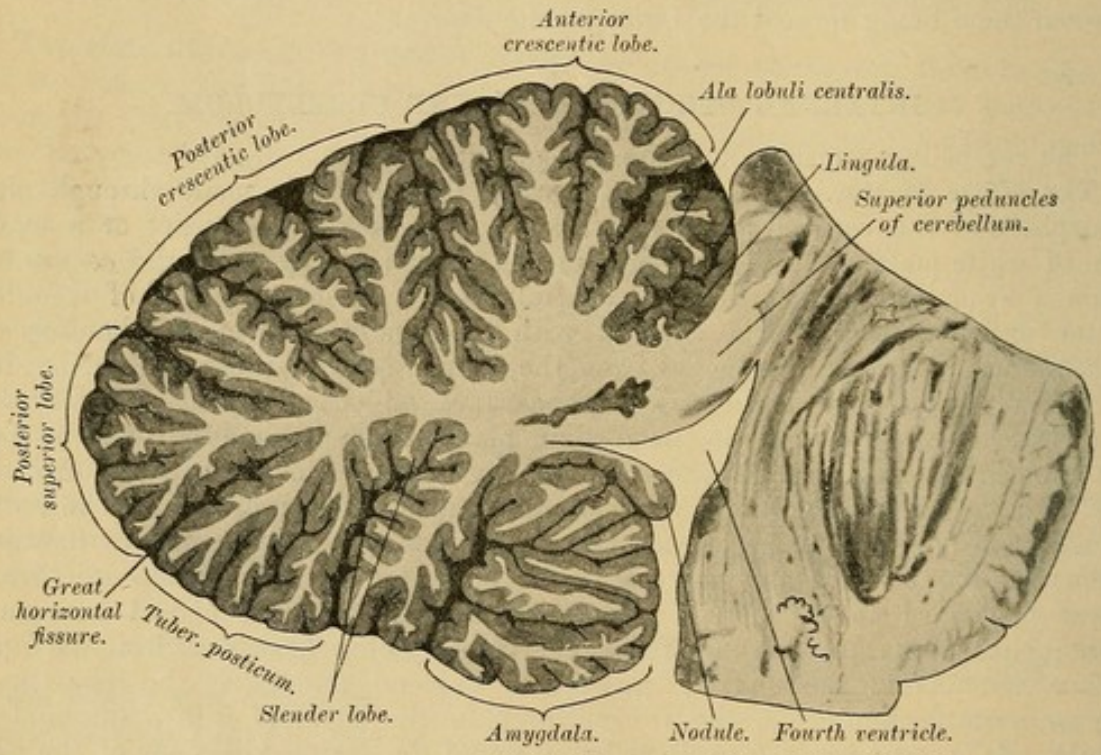

FIG. 366.—Sagittal section of the cerebellum, near the point of junction of the worm with the hemisphere. (Schäfer.)

The **middle peduncles** are the largest of the three pairs. They consist of a mass of curved fibres, which, as already described, comprises most of the transverse fibres of the pons. They enter the cerebellum between the margins of the great horizontal fissure at the anterior notch, and the fibres spread out in all directions: some passing to the upper part, and some to the lower part of the hemisphere, while others pass to its middle region. Of the fibres contained in the middle peduncles many are commissural between the two hemispheres of the cerebellum; others apparently end in the gray matter; others have been described as giving fibres to the posterior longitudinal bundle, and through it to the nuclei of the third, fourth, and six nerves. Cajal describes still another set, which have their origin in the gray reticular formation of the pons, and which pass partly into the peduncle of the same side and partly into that of the opposite side.

The **inferior peduncles** connect the cerebellum with the medulla oblongata. As the restiform bodies of the latter, they will be described in the sequel. They pass upward and outward, forming part of the lateral wall of the fourth ventricle, and

enter the cerebellum beneath the middle peduncle; passing upward they end in the gray cortex of the upper surface of the hemisphere, some being prolonged into the white matter of the superior vermiform process. The following are the chief sets of fibres in the inferior peduncles: (1) from the direct cerebellar tract of the spinal cord; (2) from the gracile and cuneate nuclei (crossed and uncrossed fibres); (3) from the opposite olivary body of the medulla; (4) fibres to the nuclei of the fifth, eighth, ninth, and tenth nerves; (5) descending cerebellar fibres which pass down the restiform body and antero-lateral column of the cord to terminate around the cells in the anterior horn of the cord.

The **fibræ propriæ of the cerebellum** are of two kinds: (1) *commissural fibres*, which cross the middle line to connect the opposite halves of the cerebellum, some at the anterior part, and others at the posterior part of the vermiform process; (2) *arcuate* or *association fibres*, which connect adjacent laminæ with each other.

The **gray matter** of the cerebellum is found in two situations: (1) on the surface, forming the cortex; (2) as independent masses in the interior.

1. The **gray matter of the cortex** presents a characteristic foliated appearance, due to the series of laminæ which are given off from the central white matter; these in their turn give off secondary laminæ, which are covered with gray matter. This

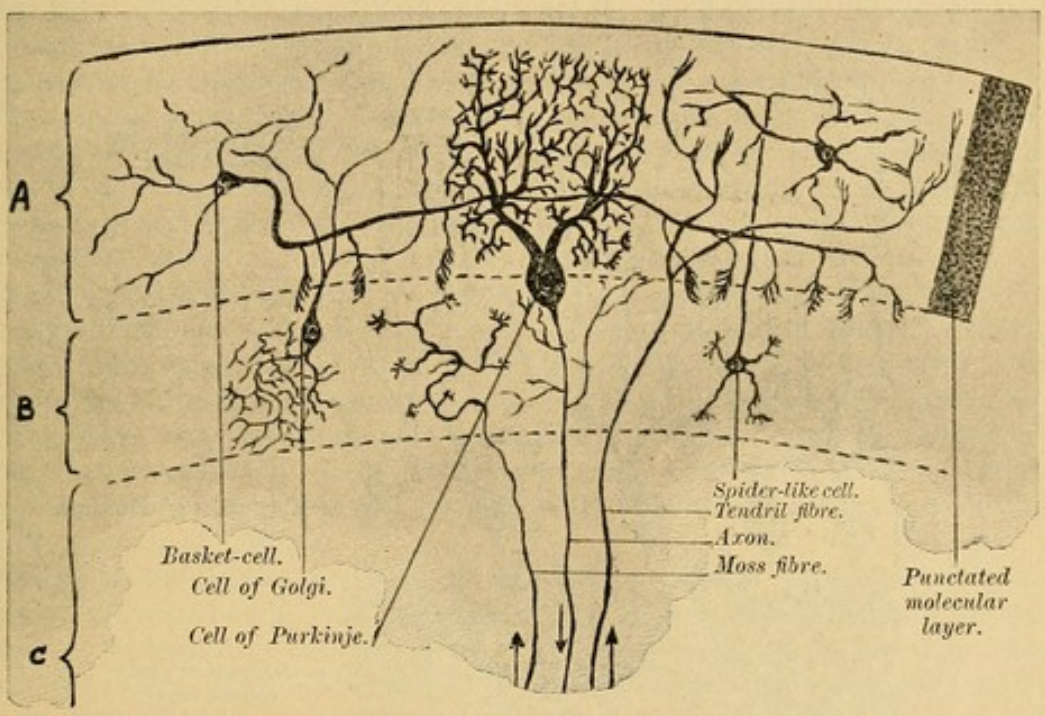

FIG. 367.—Diagrammatic representation of the cells of the cerebellum. (Modified from Foster's "Physiology.") A, molecular layer; B, nuclear layer; C, white matter.

arrangement gives to the cut surface of the organ a foliated appearance (Fig. 366). Externally, the cortex is covered by pia mater; internally, is the medullary centre, consisting mainly of nerve-fibres.

Microscopic Appearance of the Cortex.—The cortex presents a remarkable structure, consisting of two distinct layers, viz., an external gray molecular layer, and an internal, rust-colored, granular layer. Between the two layers is an incomplete stratum of the characteristic cells of the cerebellum, the *corpuscles of Purkinje*.

The *external gray* or *molecular layer* (Figs. 367, 368) consists of fibres and cells. The nerve-fibres are delicate fibrillæ, and are derived from the following sources: (*a*) the dendrites and axon collaterals of Purkinje's cells; (*b*) fibres from cells in the granular layer; (*c*) fibres from the central white substance of the cerebellum; (*d*) fibres derived from cells in the molecular layer itself. In addition to these are other fibres, which have a vertical direction. These are the processes of large glia-cells, situated in the granular layer. They pass outward to the periphery of the gray matter, where they expand into little conical enlargements, which form

a sort of limiting membrane beneath the pia mater, analogous to the membrana limitans interna in the retina, formed by the fibres of Müller.

The *cells* of the molecular layer are small, and are arranged in two strata, an outer and an inner. They all possess branching axis-cylinder processes; those of the inner layer run for some distance horizontally, *i. e.*, parallel with the surface of the folia, giving off at intervals collaterals, which pass in a vertical direction toward the cell-bodies of Purkinje's corpuscles, around which they become enlarged, and ramify like a basket. Hence these cells of the inner layer are named *basket-cells.*

The *corpuscles of Purkinje* (Fig. 368) are flask-shaped cells, situated at the junction of the molecular and granular layers, their bases resting against the latter.

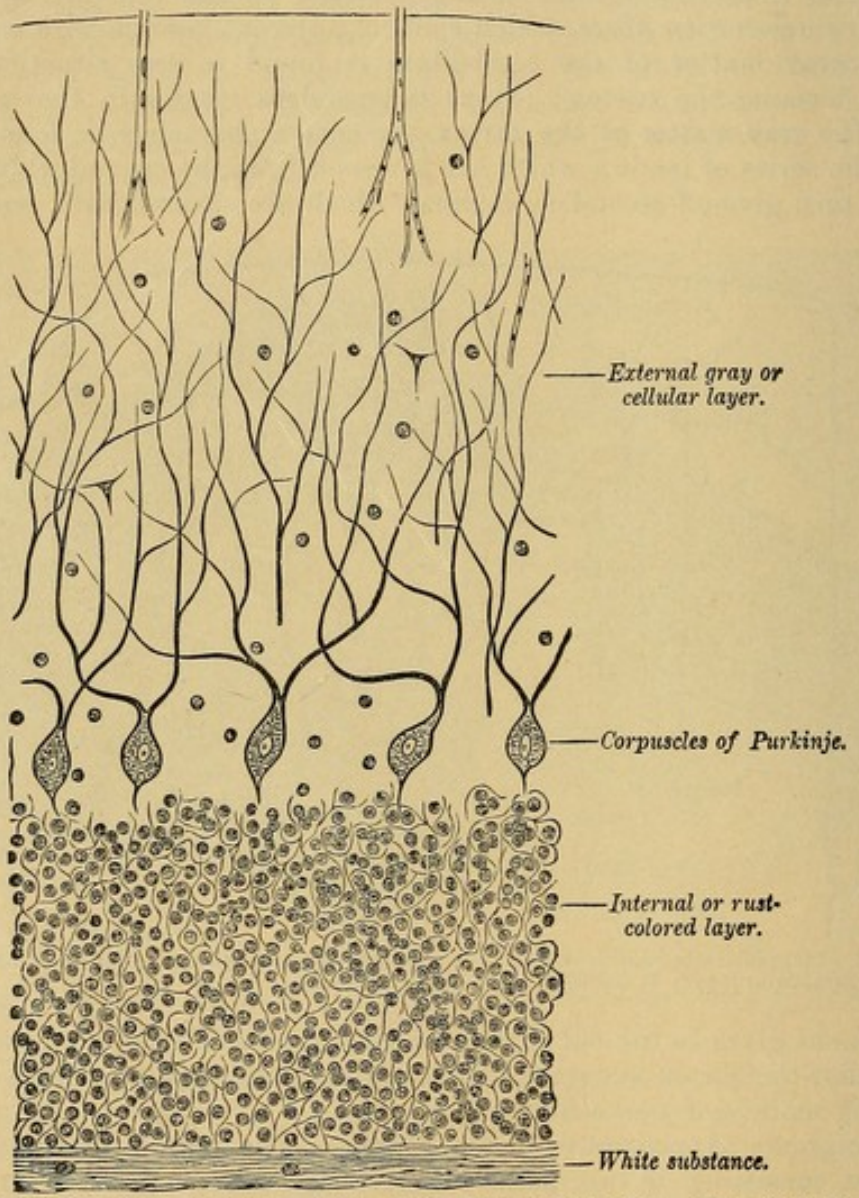

FIG. 368.—Vertical section through the gray matter of the human cerebellum. Magnified about 100 diameters. (Klein and Noble Smith.)

From the bottom of the flask the axis-cylinder process arises; this passes through the granular layer, and, becoming medullated, is continued as a nerve-fibre in the medullary substance beneath. This axon gives off fine collaterals as it passes through the granular layer, some of which run back into the molecular layer. From the neck of the flask numerous dendrites are given off, which branch in an antler-like manner in the molecular layer and terminate in free extremities.

The *internal rust-colored* or *granular layer* (Fig. 368) is characterized by containing numerous small nerve-cells or granules of a reddish-brown color, together with many nerve-fibrils. Most of the cells are nearly spherical and provided with

short dendrites, which spread out in a spider-like manner in the granular layer. Their axons pass outward into the molecular layer, and, bifurcating at right angles, run horizontally for some distance. In the outer part of the granular layer are also to be observed some larger cells, of the type termed *Golgi cells* (Fig. 367). Their axons undergo frequent division as soon as they leave the nerve-cells, and pass into the granular layer, while their dendrites ramify chiefly in the molecular layer.

Finally, in the gray matter of the cerebellar cortex fibres are to be seen which come from the white centre and penetrate the cortex. The cell origin of these fibres is unknown, though it is believed that it is probably in the gray matter of the spinal cord. Some of these fibres end in the granular layer, by dividing into numerous branches, on which are to be seen peculiar moss-like appendages; hence they have been termed by Ramón y Cajal the "moss fibres"; they form an arborescence around the cells of the granular layer. Other fibres derived from the medullary centre can be traced into the molecular layer, where their branches cling around the dendrites of Purkinje's cells, and hence they have been named the *clinging* or *tendril fibres*.

2. The **independent centres of gray matter in the cerebellum** are four in number on each side: one is of large size, and is known as the corpus dentatum; the other three, much smaller, are situated near the middle of the cerebellum, and are known as the nucleus emboliformis, nucleus globosus, and nucleus fastigii.

The *corpus dentatum* or *ganglion of the cerebellum* is situated a little to the inner side of the centre of the stem of the white matter of the hemisphere. It consists of an irregularly folded lamina of a grayish-yellow color, containing white fibres, and presenting on its antero-internal aspect an opening, the hilum, from which most of the fibres of the superior cerebellar peduncle emerge.

The *nucleus emboliformis* is a mass of gray matter placed immediately to the inner side of the corpus dentatum, and partly covering its hilum. The *nucleus globosus* is an elongated mass of gray matter, directed antero-posteriorly, and placed to the inner side of the preceding. The *nucleus fastigii* is somewhat larger than the other two, and is situated close to the middle line at the anterior end of the superior vermiform process, and immediately over the roof of the fourth ventricle, from which it is separated by a thin layer of white matter. It is known as the *roof nucleus of Stilling*.

Weight of the Cerebellum.—Its average weight in the male is about 5 oz., 4 drs. It attains its maximum weight between the twenty-fifth and fortieth years, its increase in weight after the fourteenth year being relatively greater in the female than in the male. The proportion between the cerebellum and cerebrum is, in the male, as 1 to $8\frac{1}{5}$, and in the female as 1 to 8. In the infant the cerebellum is proportionately much smaller than in the adult, the relation between it and the cerebrum being, according to Chaussier, between 1 to 13, and 1 to 26; by Cruveilhier the proportion was found to be 1 to 20.

V. The Medulla Oblongata (Fig. 370).

The **medulla oblongata** or **metencephalon**, known also as the **spinal bulb**, is the lowest division of the encephalon, and is continuous with the spinal cord. It is developed from the fifth cerebral vesicle, the cavity of which forms the lower half of the fourth ventricle. It extends from the lower margin of the pons Varolii to a plane passing transversely just below the decussation of the pyramids, at which level the spinal cord commences. This plane corresponds to the lower margin of the foramen magnum. The upper limit of the medulla is marked off from the pons Varolii on its ventral aspect by the abrupt lower margin of the latter.

The medulla oblongata is directed from above obliquely downward and backward; its ventral surface rests on the basilar groove of the occipital bone, while its dorsal surface is received into the fossa between the hemispheres of the cerebellum, and forms the lower part of the floor of the fourth ventricle. It is pyramidal

in shape, its broad extremity directed upward, its lower end being narrow at its point of connection with the cord. It measures an inch in length, three-quarters of an inch in breadth at its widest part, and half an inch in thickness. Its surface is marked, in the median line, in front and behind, by an *anterior* and a *posterior median fissure*, which are continuous with similar fissures on the anterior and posterior surfaces of the cord. The anterior fissure contains a fold of pia mater, and terminates just below the pons in a *cul-de-sac*, the *foramen cæcum* of Vicq d'Azyr. It is interrupted at its lower part by some bundles of fibres, which cross obliquely from one side to the other, forming the *decussation of the pyramids*. The posterior is a deep but narrow fissure, continued upward to about the middle of the medulla, where it expands into the fourth ventricle.

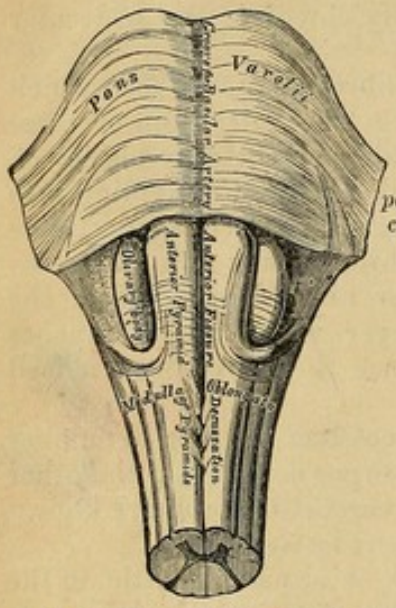

FIG. 369.—Medulla oblongata and pons Varolii. Anterior surface.

These two fissures divide the medulla into two symmetrical halves, each half presenting elongated eminences, which are continuous with the columns of the cord. By taking the lines along which some of the cranial nerves emerge from the medulla, as landmarks, the surface of this portion of the nervous system may be divided into three columns, in the same way as the spinal cord is divided into three columns by the lines corresponding to the points of exit of the anterior and posterior roots of the spinal nerves. The anterior column comprises that portion which is situated between the anterior median fissure and the fibres of origin of the hypoglossal nerve: this column is called the *pyramid*. The lateral column comprises that portion which is situated between the fibres of origin of the hypoglossal nerve and the fibres of origin of the glosso-pharyngeal, pneumogastric, and spinal accessory nerves. In the lower part of the medulla this column is single, and is called the *lateral tract:* but in the upper part an oval-shaped body comes forward between it and the pyramid, and pushes aside the lateral tract. This is called the *olivary body*. The posterior column comprises that portion which is situated between the fibres of the origin of the glosso-pharyngeal, pneumogastric, and spinal accessory nerves and the posterior median fissure. It is marked by slight furrows dividing it into smaller columns, and these in the lower part of the medulla are named, from without inward, the *funiculus of Rolando*, the *funiculus cuneatus*, and the *funiculus gracilis;* in the upper part of the medulla, the funiculus of Rolando and the funiculus cuneatus appear to become fused together, forming a single body, called the *restiform body* (Fig. 370).

The **pyramids** are two pyramidal bundles of white matter, placed one on either side of the anterior median fissure, and separated from the olivary body by a slight depression, from which the roots of the hypoglossal nerve emerge. At the lower border of the pons these bodies are somewhat constricted and are here crossed by a band of arched fibres, the *ponticulus* of Arnold; below this they become enlarged, and then taper as they descend to their lower extremity. The fibres of which these pyramids are composed may be arranged in two bundles: an outer, continuous below with the direct pyramidal tract of the anterior column of the same side of the spinal cord, and an inner, continuous with the crossed pyramidal tract of the lateral column of the opposite side of the cord. As will be subsequently mentioned, the direct pyramidal tract in the cord lies next to the anterior median fissure, but as the crossed pyramidal tract of the cord ascends to the medulla it decussates with its fellow of the opposite side across the anterior median fissure, and so displaces laterally the direct pyramidal tract, and ascends, after decus-

sation, through the medulla to its inner or mesial side. This decussation is usually spoken of as the *decussation of the pyramids*, but it must be borne in mind that it is only a portion of the fibres of the pyramid which decussate; namely, those derived from the crossed pyramidal tract of the cord; the outermost fibres, derived from the anterior column of the cord, do not decussate. Each pyramid enters the substance of the pons in one bundle, and may be traced through it, after breaking up into several smaller fasciculi, into the corresponding crus cerebri.

The **lateral column**, in the lower part of the medulla, is of the same width as the lateral column of the cord, and appears on the surface to be a direct continuation of it. As a matter of fact it is only a part of the lateral column of the spinal cord which is continued upward into this column; for the crossed pyramidal tract passes into the pyramid of the opposite side, and the direct cerebellar tract of the lateral column of the cord passes into the restiform body. The rest of the lateral column of the cord, that is to say, the antero-lateral ground bundle and the antero-lateral cerebellar tract, can be traced upward into this area. In the upper part of the medulla, the lateral tract, on account of the interpolation of the olivary body, becomes almost concealed by this body.

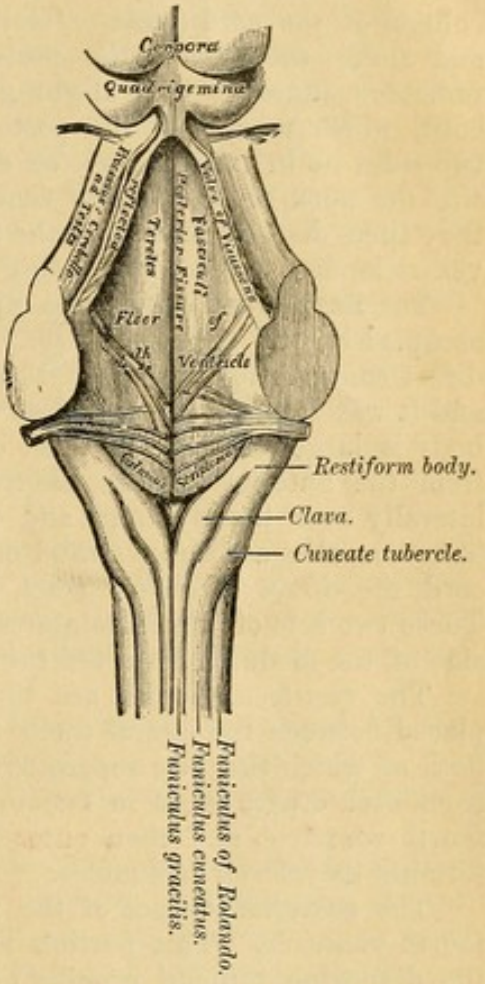

FIG. 370.—Posterior surface of the medulla oblongata.

The **olivary body** is a prominent oval mass, situated on the outer side of the pyramid, from which it is separated by a slight groove, along which the fibres of the hypoglossal nerve emerge. It is separated externally from the restiform body by a longitudinal, narrow band of fibres, prolonged upward from the lateral tract, and by a groove, from which the glosso-pharyngeal, pneumogastric, and spinal accessory nerves arise. It is equal in breadth to the pyramid; it is broader above than below, and is about half an inch in length, being separated above from the pons Varolii by a slight depression, in which a band of arched fibres is sometimes to be seen. Numerous white fibres (*superficial arciform fibres*) are seen winding across the lower half of the pyramid and the olivary body to enter the restiform body.

The **funiculus of Rolando** is a longitudinal prominence on the outer side of the lateral tract. It begins at the lower end of the medulla by a tapering extremity, and has, apparently, no corresponding column in the cord. It gradually enlarges as it ascends, and forms, at a level with the lower border of the olivary body, a considerable prominence, known as the *tubercle of Rolando*. This is caused by the substantia gelatinosa of Rolando of the cord gradually finding its way to the surface, so as to form a prominence there. About half an inch below the pons the funiculus of Rolando appears to blend with the funiculus cuneatus. In front, it is separated from the lateral tract by a distinct groove, the continuation upward of the postero-lateral groove of the cord; behind, the separation from the funiculus cuneatus is much less distinct.

The **funiculus cuneatus** is the direct continuation upward of the postero-lateral column (tract of Burdach) of the cord. It is situated between the funiculus of Rolando and the funiculus gracilis. It enlarges as it ascends, and forms, opposite the lower extremity of the fourth ventricle, a slight eminence or enlargement, the

cuneate tubercle, which is best marked in children. Above this point it disappears from the surface.

The **funiculus gracilis** is the direct continuation upward of the postero-median column of the cord (tract of Goll). It is a narrow white band, placed parallel to and along the side of the posterior median fissure. It is separated from the funiculus cuneatus by a slight groove, continuous with that on the surface of the cord, which marks off the postero-median column. At first the funiculi of the two sides lie in close contact on either side of the posterior median fissure. Opposite the apex of the fourth ventricle each presents an enlargement, the *clava;* they then diverge and form the lateral boundaries of the lower part of the fourth ventricle, and gradually tapering off become no longer traceable.

The Restiform Body.—The upper part of the posterior area of the medulla is occupied by the *restiform body*. It appears, at first sight, as if this body were the direct continuation upward of the funiculus cuneatus and the funiculus of Rolando, and it was formerly described as such. This, however, is not so, for the restiform body is largely formed by a set of fibres, the *external arcuate fibres*, which issue from the anterior median fissure and will presently be described. They pass laterally over the pyramid and olive, and assist in forming the restiform body. There is also a narrow strand of fibres, derived from the lateral column of the cord, the *direct cerebellar tract*, which joins the above-mentioned arcuate fibres. These two sets of fibres, reinforced by the *internal arcuate fibres* from the opposite side of the medulla, form the restiform body.

The restiform bodies are the largest prominences of the medulla, and are placed between the lateral tracts in front and the funiculus cuneatus behind, from both of which they are separated by slight grooves. As they ascend they diverge from each other, assist in forming the lower part of the lateral boundaries of the fourth ventricle, and then enter the corresponding hemisphere of the cerebellum, forming its inferior peduncles.

The **posterior surface of the medulla oblongata** forms part of the floor of the fourth ventricle. This portion is of a triangular form, bounded on each side by the diverging funiculi graciles and cuneati and restiform bodies. The divergence of these two funiculi and of the restiform bodies, together with the opening out of the posterior fissure and central canal of the spinal cord, displays in the floor of the ventricle the gray matter of the medulla, which is continuous below with the gray matter of the cord. In the middle line is seen a longitudinal furrow, which divides this part of the ventricle into right and left halves, and is continuous below with the central canal of the cord.

The **arciform** or **arcuate** fibres, which have been mentioned as forming part of the restiform body, are found in the upper half of the medulla, crossing its surface and also traversing its substance. They are divided for purposes of description into two sets—external and internal. The *external* or *superficial arciform fibres* have already been alluded to as crossing the pyramid and olivary body on each side. They emerge from the anterior median fissure, and if traced into it are found to enter the raphé and cross to the opposite side, after which their further course is a matter of some doubt. After emerging from the anterior median fissure they cross the pyramid and olivary body, often concealing from view the upper part of the cuneate and Rolandic funiculi, and enter the restiform body. As they cross the olivary body they are reinforced by some of the internal arciform fibres, which come to the surface on the inner side of, or through, this structure. The *internal arciform fibres* are described with the microscopic anatomy of the medulla.

It is advisable, at this stage, to take up the consideration of the cavity of the fourth ventricle, an acquaintance with which will render the description of the internal structure of the medulla oblongata more intelligible.

The Fourth Ventricle (Fig. 371).

The fourth ventricle is lozenge- or diamond-shaped; that is to say, it is composed of two triangles, with their bases in contact. The sides of the lower triangle are formed by the divergence of the funiculi graciles, funiculi cuneati, and restiform bodies of the medulla on either side. As these columns pass upward in the medulla they turn outward from the median line, and, diverging from each other, form the lateral boundaries of the lower half of the fourth ventricle. In like manner the sides of the upper triangle are formed by the convergence of the superior peduncles of the cerebellum. These peduncles are separated below by a somewhat wide interval, but as they pass upward and forward toward the corpora quadrigemina they gradually converge and ultimately come into contact with each other. This cavity is therefore bounded laterally by the superior peduncles of the cerebellum in its upper half, and by the funiculi graciles, the funiculi cuneati, and the restiform bodies in its lower half. It presents four angles. The upper angle reaches as high as the upper border of the pons, and corresponds with the lower opening of the aqueduct of Sylvius, by which this ventricle communicates with the third ventricle. The lower angle is on a level with the lower border of the olivary body, and is continuous with the central canal of the spinal cord. From the resemblance that it bears to the point of a writing pen it has been named the *calamus scriptorius*. Its lateral angles extend for some distance between the medulla and the cerebellum, each forming a pointed *lateral recess*.

The *roof* of the fourth ventricle is formed from above downward by the following structures: a part of the superior peduncles of the cerebellum, the superior medullary velum, the inferior medullary velum, the tela choroidea inferior, the obex, and the ligula.

The **superior peduncles of the cerebellum**, when they emerge from the medullary substance of its hemispheres, pass upward and forward, forming the lateral boundaries of the upper half of the fourth ventricle, but, converging as they approach the corpora quadrigemina, the mesial portions of the peduncles form a part of the roof of the cavity, in consequence of the ventricle extending to a slight extent underneath the peduncles.

The Superior Medullary Velum (Valve of Vieussens).—In the angular interval left between the two superior peduncles is a thin lamina of white matter, continuous with the white centre of the cerebellum, which bridges across from one peduncle to the other, and so completes the roof of the superior part of the ventricle. This is the *superior medullary velum*, or *valve of Vieussens*. Its dorsal surface is covered by the folia of the lingula, already described (page 686).

The **inferior medullary velum** is a thin layer of white substance, prolonged from the white centre of the medulla on either side of the nodule, which assists in forming a part of the roof of the fourth ventricle, stretching over it toward its lateral angles. It is continuous with the white substance of the cerebellum by its convex edge, while its thin concave margin is apparently free. In reality, however, it is continuous with the epithelium of the ventricle, which is prolonged downward from the velum to the edge of the ligula.

The **tela choroidea inferior** is a layer of pia mater, which covers in the lower part of the fourth ventricle below the inferior medullary velum. Superiorly it is reflected on to the under surface of the cerebellum, while inferiorly it is continued on to the restiform bodies and lower part of the medulla. This part of the roof of the ventricle contains no nervous matter, but consists merely of the ventricular epithelium covered by pia mater. The tela choroidea inferior, like the superior, really consists of two layers, which become more or less adherent, viz., that covering the under surface of the cerebellum and that covering the epithelium. It also possesses a pair of choroid plexuses, which project into the ventricular cavity invaginating before them the epithelial lining. Each plexus consists of a *vertical* portion which extends forward, near the middle line, from the

foramen of Majendie, and of a *transverse* part, which passes outward into the lateral recess of the ventricle as far as the foramina of Key and Retzius. The two plexuses present the form of a T, the vertical limb of which is, however, double, ⊤⊤. The tela does not form a complete membrane, for in it there are three openings, one in the middle line at the inferior angle of the ventricle, just above the position of the opening of the central canal of the cord; this is the *foramen of Majendie:* the other two are at the extremities of the lateral recesses of the ventricle, and are named the *foramina of Key and Retzius* (see page 642). Through these foramina the ventricles of the brain communicate with the subarachnoid space.

The **obex** is a thin triangular lamina of gray matter, continuous below with the anterior gray commissure of the cord, which fills in the angle between the two diverging funiculi graciles for a short distance.

The **ligula** (*tæniæ*) are narrow bands of white matter, which project from the internal border of the funiculi graciles. They at first run upward and forward,

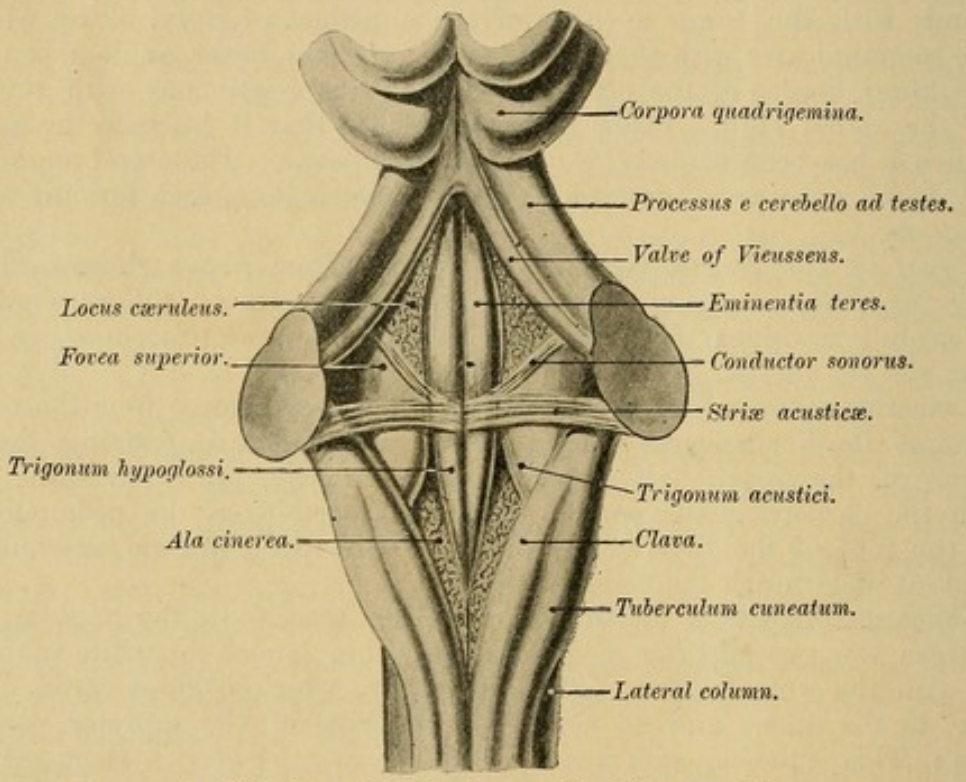

FIG. 371.—Floor of the fourth ventricle. Diagrammatic.

and then turn outward over the restiform bodies, as far as the latera recesses of the ventricle. Their inner borders are continuous with the epithelial roof of the ventricle.

The **floor of the fourth ventricle** (Fig. 371) is rhomboidal in shape, and is traversed by a vertical median fissure, the *sulcus longitudinalis medianus.* At its widest part, opposite the level of the lateral recesses, it is marked by some transverse white lines, the *striæ medullaris* or *striæ acusticæ.* These consist of white fibres, which emerge from the longitudinal sulcus, and pass outward across the floor of the ventricle.

These striæ divide the floor of the ventricle into two triangles, inferior and superior. The *inferior triangle*, or lower half of the floor, presents above an angular groove, the *fovea inferior*, the apex of which is at the striæ, while the two limbs diverge below, and form the sides of a triangular, dark area, termed the *ala cinerea*, which becomes elevated into a prominence below (*eminentia cinerea*). This area corresponds with the nuclei of the vagus and glosso-pharyngeal nerves, and is therefore termed the *trigonum vagi.* A second triangular area lies between the inner limb of the fovea and the median sulcus; its base is directed

upward, and limited by the striæ medullaris. It is termed the *trigonum hypoglossi*, because it corresponds in position to the tract of nerve-cells from which the hypoglossal nerve takes origin. A third triangular area to the outer side of the fovea inferior, is named the *trigonum acustici*. It lies between the groove forming the outer boundary of the fovea inferior and the lateral wall of the ventricle, and, like the trigonum hypoglossi, has its base directed upward. Here it is continuous with a prominence, the *tuberculum acusticum*, which extends into the anterior part of the floor of the ventricle.

The *superior triangle*, or upper half of the floor of the fourth ventricle, *i. e.*, the part above the striæ medullaris, presents in the middle line the continuation of the median longitudinal sulcus. On either side of this is a spindle-shaped longitudinal eminence, prominent in its centre, but less so above and below. This is the *eminentia teres*, and is produced by an underlying bundle of white fibres, the *funiculus teres*, formed, in part at all events, by the fibres of the facial nerve. Immediately above and to the outer side of the eminentia teres is an angular depression, the *fovea superior;* this is sometimes crossed by a whitish band of fibres, the *conductor sonorus*, which is connected below with the striæ medullaris. Above the fovea is a bluish depressed area, the *locus cæruleus*. Its color is due to some pigmented nerve-cells, showing through the white covering of the floor. These pigmented cells are named the *substantia ferruginosa*, and in them one of the roots of the fifth nerve terminates.

The **lining membrane** of the fourth ventricle is continuous above with that of the third, through the aqueduct of Sylvius, and below with that of the central canal of the spinal cord. The cavity of the ventricle communicates below with the subarachnoidean space by means of the foramen of Majendie and the foramina of Key and Retzius, already described.

Internal Structure of the Medulla Oblongata (Fig. 372).

If the cranial nerves emerging from the medulla are traced into its substance, it will be seen that they divide each half into three wedge-shaped areas, which are named the anterior, lateral, and posterior areas of the medulla, and each of which corresponds to one of the subdivisions already described on the surface of this portion of the encephalon.

The **anterior area** comprises that portion which is situated between the anterior median fissure and the fibres of origin of the hypoglossal nerve. On the surface of the medulla this area corresponds to the pyramid.

The **lateral area** is situated between the fibres of origin of the hypoglossal nerve on the one hand, and the fibres of the glosso-pharyngeal, pneumogastric, and spinal accessory nerves on the other. On the surface of the medulla, in its lower part, this area is single, and is called the *lateral tract;* but in the upper part an oval-shaped body, the *olivary body*, comes forward between it and the pyramid, pushing aside the lateral tract.

The **posterior area** comprises that portion which is situated between the fibres of origin of the glosso-pharyngeal, pneumogastric, and spinal accessory nerves, and the posterior median fissure. On the surface of the medulla this area is marked by slight furrows, splitting it up into smaller columns; those in the lower part of the medulla are named, from without inward, the funiculus of Rolando, the funiculus cuneatus, and the funiculus gracilis; in the upper part of the medulla they are replaced by the restiform body. Finally, the halves of the medulla are separated from each other by a median septum or raphé.

Each of these three areas is made up of gray and white matter, the former being derived for the most part from that of the cord. In like manner the white matter is partly made up of longitudinal fibres continuous with those of the cord, and partly of transverse fibres which intersect them.

In order to understand the internal structure of the medulla, it is necessary to

describe the appearances as they are seen in the upper and lower portions of the medulla, since they differ considerably in these two parts.

The Lower Part of the Medulla.—The first change in the internal structure is caused by the passage of the fibres of the crossed pyramidal tract obliquely through the gray matter of the anterior horn. As stated above, the pyramid is composed of fibres derived from the direct pyramidal tract of the anterior column of the cord of the same side, and from the crossed pyramidal tract of the lateral column of the opposite half of the cord. Those fibres which are derived from the direct pyramidal tract and which in the cord lie close to the median fissure are in the medulla placed to the outer side of the pyramid, being pushed aside, as it were, by the interpolation of the fibres derived from the crossed pyramidal tract, which are much more numerous. The crossed pyramidal fibres ascend from the lateral column of the spinal cord, and, passing through the anterior gray cornu and across the middle line, form the inner part of the pyramid. In consequence of this passage of white fibres through its substance the anterior gray cornu is

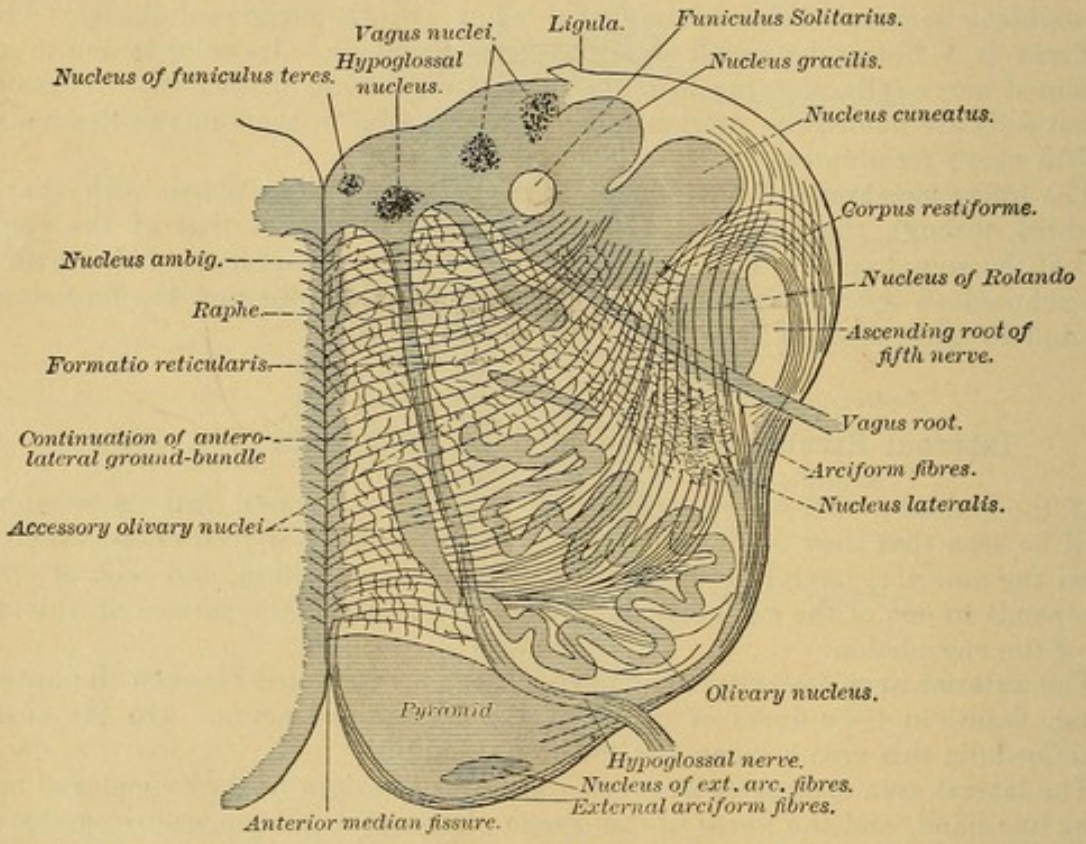

FIG. 372.—Section of the medulla oblongata at about the middle of the olivary body. (Schwalbe.)

broken up into a coarse network, while one portion of it, the caput cornu, is entirely separated from the rest; only the base of the cornu remains intact, close to the ventro-lateral aspect of the central canal. The caput cornu, thus separated, is displaced laterally, and comes to lie close to the caput cornu posterioris, which has also shifted its position. In consequence of this breaking up of the greater part of the anterior gray cornu by white fibres a coarse network is formed in the anterior and lateral areas of the medulla, which is named the *formatio reticularis.*

The posterior cornu also undergoes somewhat similar changes. It becomes subdivided by the passage through it of the sensory fibres of the columns of Goll and Burdach. These pass across to the opposite anterior area of the medulla, where they are seen to lie immediately on the dorsal aspect of the pyramids. In their passage through the posterior horns of gray matter the latter become subdivided, in a manner somewhat similar to what has been seen to occur in the anterior horns. This crossing of the sensory fibres is termed the *superior pyram-*

idal or *sensory decussation*. The caput cornu is displaced outward, so as almost to reach the surface, where it forms a projection, the *funiculus Rolando*, which enlarges above into a distinct prominence, the *tubercle of Rolando*. Above the level of the tubercle of Rolando the caput cornu is separated from the surface by a band of fibres, termed the *ascending root of the fifth nerve*, and by the external arcuate fibres. The neck of the cornu becomes broken up into a reticular formation by the decussation of the columns of Goll and Burdach, and by this means the caput is separated from the rest of the gray matter. The base of the cornu increases in size, and, as the central canal expands into the fourth ventricle, becomes pushed outward, and portions of it extend into the funiculi graciles and cuneati, and produce externally the eminences of the clava and cuneate tubercle. A third portion of the base becomes separated from the rest, and is placed outside the nucleus of the funiculus cuneatus. This is called the *accessory cuneate nucleus*, and is supposed to be a continuation upward of Clarke's vesicular column of the cord.

The Upper Part of the Medulla.—The upper part of the medulla comprises the portion which enters into the formation of the floor of the fourth ventricle, where, in fact, the upper end of the central canal has opened out into this cavity. In this region the formatio reticularis is confined chiefly to the anterior and lateral areas. In the ventral portion of the posterior area there is only a small amount of reticular formation, but in addition to this there are individual masses of cells scattered among the longitudinal fibres.

The **formatio reticularis** is situated in the medulla, behind the pyramid and olivary body, extending laterally as far as the restiform bodies, and dorsally to within a short distance of the floor of the fourth ventricle. It presents a peculiar reticulated appearance, from which it derives its name, and which is due to the intersection of bundles of fibres running at right angles to each other, some being longitudinal, others transverse. The formatio reticularis presents a different appearance in the anterior area from what it does in the lateral area. In the former there is almost an entire absence of nerve-cells in the reticulated network, and hence it is known as the *formatio reticularis alba;* whereas, in the lateral area, the nerve-cells are numerous, and, as a consequence, this part is known as the *formatio reticularis grisea*. In the substance of the formatio reticularis is a small nucleus of gray matter. It is situated near the dorsal aspect of the hilum of the olivary nucleus, and has been named the *inferior central nucleus*. The fibres of the formatio reticularis are longitudinal and transverse. In the anterior area the longitudinal fibres may be arranged in two well-defined sets: (1) one set lies immediately behind the pyramid, and is named the *fillet* or *lemniscus*. The fibres of the fillet are chiefly derived from the cells of the gracile and cuneate nuclei, and may therefore be regarded as relay fibres of the columns of Goll and Burdach of the spinal cord, which terminate in synapses around the cells of the gracile and cuneate nuclei. They are prolonged inward and forward across the middle line forming the superior pyramidal or sensory decussation (decussation of the fillet); (2) the other set is continued from the antero-lateral ground bundle of the cord, and a portion of these fibres forms the *posterior longitudinal bundle* already referred to (page 695). Both these sets of fibres are continued upward into the pons and mid-brain. The longitudinal fibres of the reticular formation in the lateral area are not arranged in distinct bundles. They are derived from the lateral column of the cord, after the crossed pyramidal tract has passed over to the opposite side. The longitudinal fibres of the posterior area are merely indeterminate fibres of the formatio reticularis, with the exception of two distinct bundles, which may be regarded as ascending roots of the fifth and vago-glosso-pharyngeal nerves; the latter is termed the *funiculus solitarius*.

The *transverse* fibres of the reticular formation are the arched or arcuate fibres. The *external arciform fibres* have already been described. The *internal arciform fibres* are more numerous than the superficial set; they traverse nearly the whole area of the upper half of the medulla, except the pyramid. They pass from the

raphé; some become superficial and join the external arciform fibres, while others remain deep and pass to the olivary body, the restiform body, and to the nuclei of the funiculus cuneatus and funiculus gracilis.

Independent Nuclei.—In the upper part of the medulla are several independent nuclei of gray matter, which may be divided into two sets: (1) those which are traceable from the gray matter of the spinal cord; and (2) those which are not represented in the cord. The former are the hypoglossal nucleus, the nucleus of the funiculus teres, and those of the auditory, glosso-pharyngeal, vagus, and spinal accessory nerves. The latter are the nucleus of the olivary body and the accessory olivary nuclei. In addition to these, small collections of gray matter are to be found in the median septum or raphé.

The Hypoglossal Nucleus.—The base of the anterior horn, which in the lower part of the medulla was situated on the ventro-lateral aspect of the central canal, now approaches the floor of the ventricle, where it lies close to the median sulcus under the funiculus teres. In it is a column of large nerve-cells, from which the roots of the hypoglossal nerve are derived. It is accordingly designated the *hypoglossal nucleus.*

The Auditory Nuclei.—Toward the upper part of the medulla, a considerable tract of gray matter may be found lying immediately beneath that portion of the floor of the fourth ventricle which is known as the trigonum acustici. This is the *dorsal* or *inner auditory nucleus*, and it lies just external to the vago-glosso-pharyngeal nucleus. In addition to this, there is a small collection of nerve-cells on the ventral surface of the restiform body, between the two roots of the auditory nerve, which is known as the *accessory* or *ventral auditory nucleus.* On the outer side of the restiform body is a mass of cells associated with the cochlear root of the auditory nerve. This mass is termed the *lateral acoustic tubercle* or *ganglion radicis cochlearis.*

Nuclei of the Glosso-pharyngeal and Vagus Nerves.—These are two in number, *principal* and *accessory.* The *principal* nucleus of the two nerves lies beneath that portion of the floor of the fourth ventricle, which is known as the ala cinerea and fovea inferior. They form an oblong mass of gray matter, above the nucleus of the spinal accessory and lateral to the hypoglossal nucleus. The *accessory* nuclei are situated in the reticular formation of the posterior area, some distance from the floor of the fourth ventricle. They consist of a pear-shaped mass of cells, which is connected with the rest of the gray matter by a sort of stalk or peduncle, and was formerly known as the *nucleus ambiguus.*

Nucleus of the Spinal Accessory Nerve.—This nucleus consists of a group of cells, which is situated partly in the lower part of the medulla at the base of the posterior horn and close to the central canal. It extends upward, lying beneath the lower part of the floor of the fourth ventricle and on the outer side of the hypoglossal nucleus.

The Nucleus of the Olivary Body.—When the olivary body is cut across, it is seen to be covered externally by white fibres, and internally to consist of a gray layer. This gray layer is the *nucleus of the olivary body*, or, as it is sometimes called, the *corpus dentatum of the olive.* It is composed of a thin, wavy lamina, which is arranged in the form of a hollow capsule, open at its upper and inner part, and presenting a zigzag or dentated outline. Microscopically examined, the olivary nucleus is seen to consist of small rounded yellowish nerve-cells embedded in a matrix of neuroglia and fine nerve-fibres. White fibres, which can be traced from the raphé, and are probably derived from the opposite olive, enter the interior of the capsule by the aperture at its upper or inner part, constituting the olivary peduncle.

The fibres of the olivary peduncle as they enter the body diverge, and some are lost in the gray matter of the olivary nucleus; others pass through it, and of these some turn backward to join the restiform body, and pass to the cerebellum as internal arcuate fibres; while others pierce the white matter of the olivary body and, reaching the surface, are continued to the restiform body as external arcuate

fibres. The fibres of the olivary peduncle connect the olivary nucleus with the cerebral hemisphere of the same side. The nucleus is also connected to the anterior horn of the same side of the cord; and with the opposite cerebellar hemisphere through the internal arcuate fibres. Removal of one cerebellar hemisphere is followed by atrophy of the opposite olivary nucleus.

Accessory Olivary Nuclei.—Two small isolated masses of gray matter are to be found, one on the mesial and the other on the dorsal aspect of the corpus dentatum. These are the *mesial* and *lateral accessory olivary nuclei.* They are connected with the restiform body by some of the internal arcuate fibres. The fibres of the hypoglossal nerve, as they traverse the bulb, pass between the mesial accessory nucleus and the chief olivary nucleus.

The Raphe.—The raphé is situated in the middle line of the medulla, above the decussation of the pyramids. It consists of nerve-fibres intermingled with nerve-cells. The fibres have different directions, which can only be seen in suitable microscopic sections, thus: 1. Some are antero-posterior; these in front are continuous with the superficial arciform fibres. 2. Some are longitudinal; these are derived from the arciform fibres, which on entering the raphé change their direction and become longitudinal. 3. Some are oblique; these are continuous with the deep arciform fibres which pass from the raphé.

The nerve-cells of the raphé are multipolar; some are connected with the antero-posterior fibres, others with the superficial arcuate fibres.

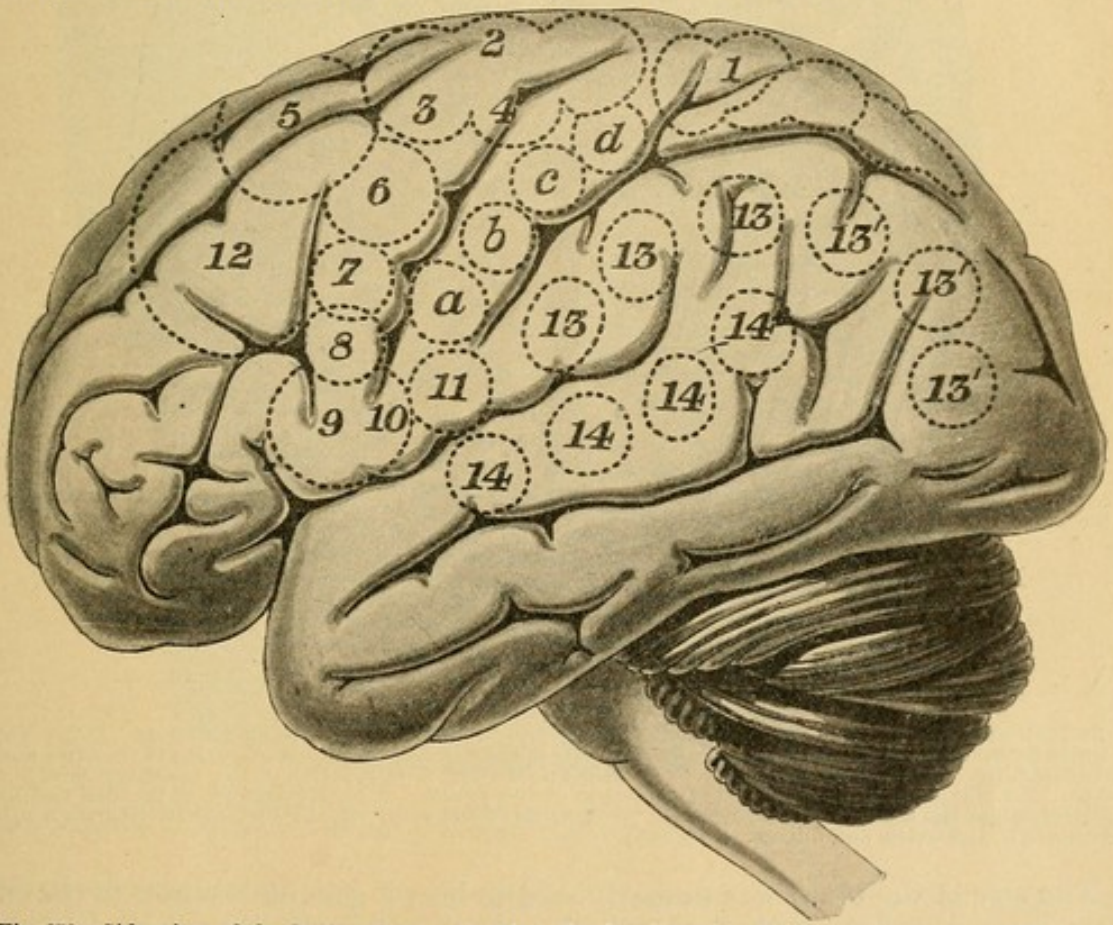

Fig. 373.—Side view of the brain of man, showing the localization of various functions. (After Ferrier.) 1. Centre for movements of opposite leg and foot. 2, 3, 4. Centres for complex movements of the arms and legs, as in swimming. 5. Extension forward of the arm and hand. 6. Supination of the hand and flexion of the forearm. 7, 8. Elevators and depressors of the angle of the mouth. 9, 10. Movements of the lips and tongue. 11. Retraction of the angle of the mouth. 12. Movements of the eyes. 13, 13'. Vision. 14. Hearing. *a, b, c, d.* Movements of the wrists and fingers.

Weight of the Encephalon.—The average weight of the brain in the adult male is 49½ oz., or a little more than 3 lbs. avoirdupois; that of the female 44 oz.; the average difference between the two being from 5 to 6 oz. The prevailing weight of the brain in the male ranges between 46 oz. and 53 oz., and in the female between 41 oz. and 47 oz. In the male the maximum weight out of 278 cases was 65 oz., and the minimum weight 34 oz. The maximum weight of the adult female

brain, out of 191 cases, was 56 oz., and the minimum weight 31 oz. According to Luschka, the average weight of a man's brain is 1424 grammes (about 45 oz.), of a woman's 1272 grammes (about 41 oz.), and, according to Krause, 1570 grammes (about 48½ oz.) for the male, and 1350 (about 43 oz.) for the female. It appears that the weight of the brain increases rapidly up to the seventh year, more slowly to between sixteen and twenty, and still more slowly to between thirty and forty, when it reaches its maximum. Beyond this period, as age advances and the mental faculties decline, the brain diminishes slowly in weight, about an ounce for each subsequent decennial period. These results apply alike to both sexes.

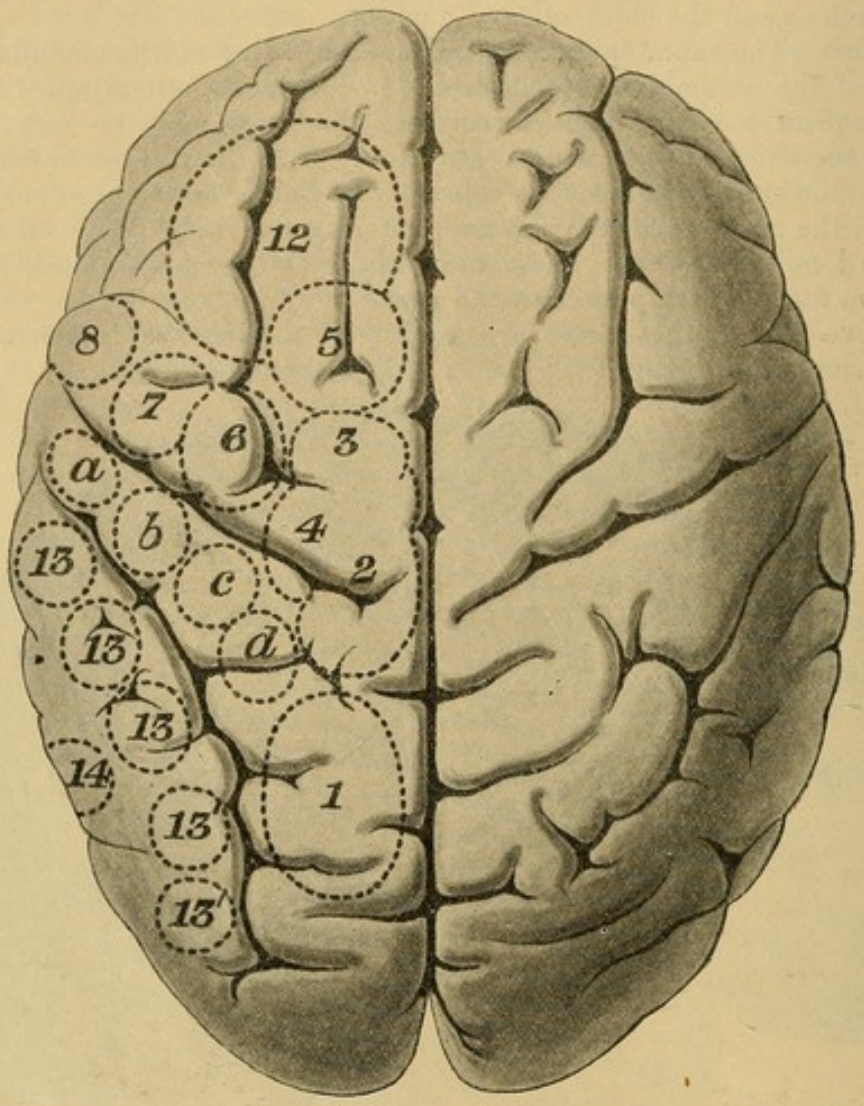

FIG. 374.—Top view of the brain of man, showing the localization of various functions. (After Ferrier.) 1. Centre for movements of opposite leg and foot. 2, 3, 4. Centres for complex movements of the arms and legs, as in swimming. 5. Extension forward of the arm and hand. 6. Supination of the hand and flexion of the forearm. 7, 8. Elevators and depressors of the angle of the mouth. 9, 10. Movements of the lips and tongue. 11. Retraction of the angle of the mouth. 12. Movements of the eyes. 13, 13'. Vision. 14. Hearing. *a*, *b*, *c*, *d*. Movements of the wrists and fingers.

The size of the brain was formerly said to bear a general relation to the intellectual capacity of the individual. Cuvier's brain weighed rather more than 64 oz., that of the late Dr. Abercrombie 63 oz., and that of Dupuytren 62⅓ oz. On the other hand, the brain of an idiot seldom weighs more than 23 oz. But these facts are by no means conclusive, and it is well known that these weights have been equalled by the brains of persons who never displayed any remarkable intellect. Dr. Haldennan of Cincinnati has recorded the case of a mulatto, aged forty-five, whose brain weighed 68⅜ oz.; he had been a slave, and was never regarded as particularly intelligent; he was illiterate, but is said to have been reserved, meditative, and economical. Dr. Ensor, district medical officer at Port Elizabeth, reports that the brain of Carey, the Irish informer, weighed 61 oz. M. Nikiforoff

has published an article on the subject of the weight of brains in the *Novosti*. According to him, the weight of the brain has no influence whatever on the mental faculties. It ought to be remembered that the significance of the weight of the brain should depend upon the proportion it bears to the dimensions of the whole body and to the age of the individual. It is equally important to know what was the cause of death, for long illness or old age exhausts the brain. To define the real degree of development of the brain it is therefore necessary to have a knowledge of the condition of the whole body, and, as this is usually lacking, the mere record of weight possesses little significance.

The human brain is heavier than that of all the lower animals, excepting the elephant and whale. The brain of the former weighs from eight to ten pounds; and that of a whale, in a specimen seventy-five feet long, weighed rather more than five pounds.

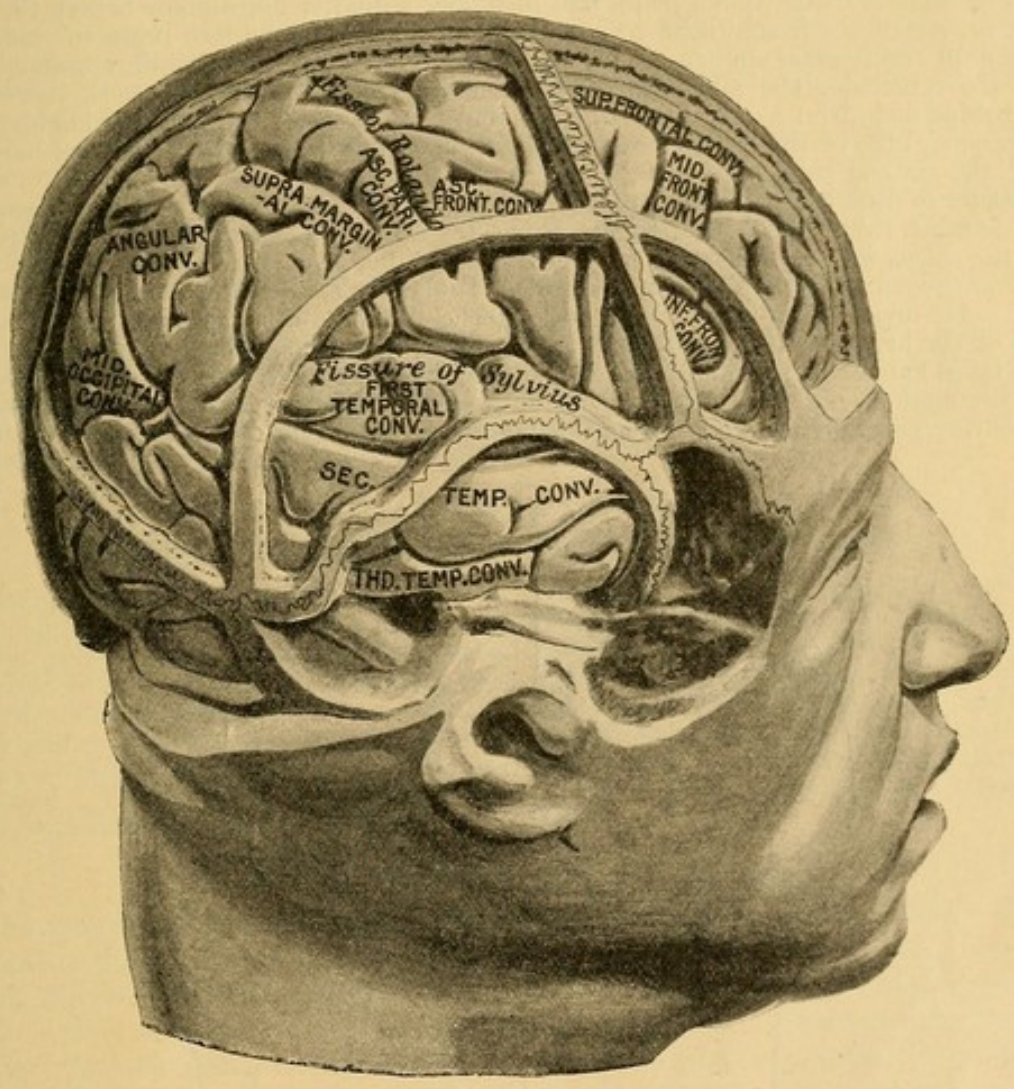

FIG. 375.—Drawing to illustrate cranio-cerebral topography. (Taken from a cast in the Museum of the Royal College of Surgeons of England, prepared by Professor Cunningham.)

Cerebral Localization and Topography.—Physiological and pathological research have now gone far to prove that the surface of the brain may be mapped out into series of definite areas, each one of which is intimately connected with some well-defined function. And this is especially true with regard to the convolutions on either side of the fissure of Rolando, which are believed by most physiologists of the present day to be concerned in motion, those grouped around the fissure being associated with movements of the extremities of the opposite side of the body, and those around the lower end of the fissure being related to movements of the mouth and tongue.

This is not the place, nor can space be given, to describe these localities. But the two accompanying cuts from Ferrier (Figs. 373, 374) have been introduced, and will serve to indicate the position of the more important areas.

The relation of the principal fissures and convolutions of the cerebrum to the outer surface of the scalp has been the subject of much investigation, and many systems have been

devised by which one may localize these parts from an examination of the external surface of the head.

These plans can only be regarded as approximately correct for several reasons: in the first place, because the relations of the convolutions and sulci to the surface are found to be very variable in different individuals; secondly, because the surface area of the scalp is greater than the surface area of the brain, so that lines drawn on the one cannot correspond exactly to sulci or convolutions on the other; and thirdly, because the sulci and convolutions in two individuals are never precisely alike. Nevertheless, the principal fissures and convolutions can be mapped out with sufficient accuracy for all practical purposes, so that any particular convolution can be generally exposed by removing with the trephine a certain portion of the skull's area.

The various landmarks on the outside of the skull, which can be easily felt, and which serve as indications of the position of the parts beneath, have been already referred to (see page 222), and the relation of the fissures and convolutions to these landmarks is as follows:

Longitudinal Fissure.—This corresponds to a line drawn from the glabella at the root of the nose to the external occipital protuberance.

The Fissure of Sylvius.—The position of the fissure of Sylvius and its horizontal limb is marked by a line starting from a point one inch and a quarter horizontally behind the external angular process of the frontal bone to a point three-quarters of an inch below the most prominent point of the parietal eminence. The first three-quarters of an inch will represent the main fissure, the remainder the horizontal limb. The bifurcation of the fissure is, therefore, two inches behind and about a quarter of an inch above the level of the external angular process. The ascending limb of the fissure passes upward from this point parallel to, and immediately behind, the coronal suture.

Fissure of Rolando.—To find the upper end of the fissure of Rolando, a measurement should be taken from the glabella to the external occipital protuberance. The position of the top of the sulcus will be, measuring from in front, 55.6 per cent. of the whole distance from the glabella to the external occipital protuberance. Professor Thane adopts a somewhat simpler method. He divides the distance from the glabella to the external occipital protuberance over the top of the head into two equal parts, and, having thus defined the middle point of the vertex, he takes half an inch behind it as the top of the sulcus. This is not quite so accurate as the former method, but it is sufficiently so for all practical purposes, and on account of its simplicity is very generally adopted. From this point the fissure runs downward and forward for $3\frac{3}{4}$

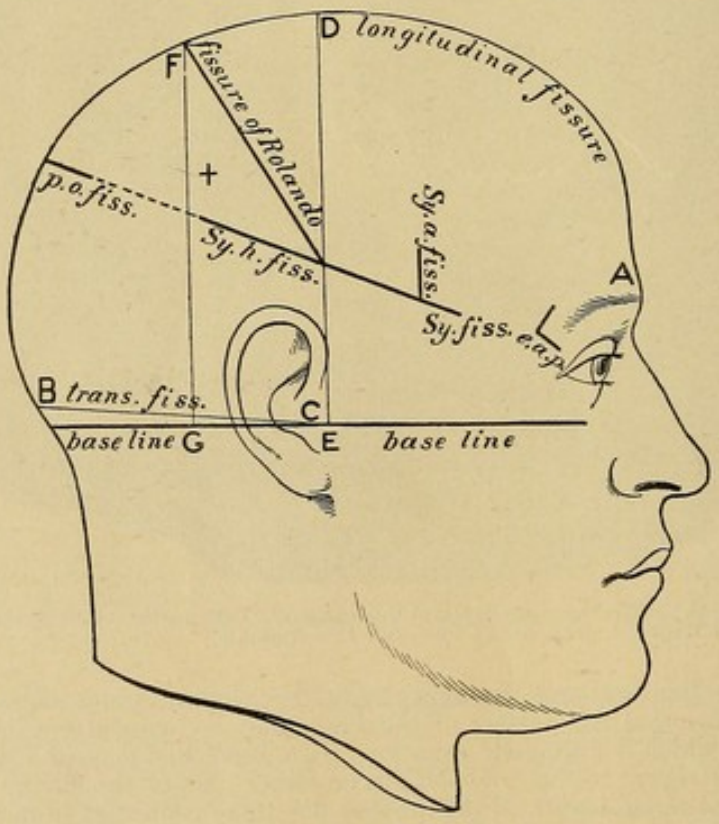

FIG. 376.—Relations of the principal fissures and convolutions of the cerebrum to the outer surface of the scalp. (Reid.)

inches, its axis making an angle of 67° with the middle line. Cunningham states that this angle more nearly averages 71.5°. In order to mark this groove, two strips of metal may be employed —one, the shorter, being fixed to the middle of the other at the angle mentioned. If the longer strip is now placed along the sagittal suture so that the junction of the two strips is over the point corresponding to the top of the furrow, the shorter, oblique strip will indicate the direction

and 3¾ inches will mark the length of the furrow. Dr. Wilson has devised an instrument, called a cyrtometer, which combines the scale of measurements for localizing the fissure with data for representing its length and direction.[1] Professor Thane gives the lower end of the furrow as "close to the posterior limb, and about half an inch behind the bifurcation of the fissure of Sylvius." So that, according to this anatomist, a line drawn from a point half an inch behind the mid-point between the glabella and external occipital protuberance to this spot would mark out the fissure of Rolando. Dr. Reid adopts a different method (Fig. 376). He first indicates on the surface the longitudinal fissure and the horizontal limb of the fissure of Sylvius (as above). He then draws two perpendicular lines from his "base-line" (that is, a line from the lowest part of the infra-orbital margin through the middle of the external auditory meatus to the back of the head) to the top of the cranium, one (D E, Fig. 376) from the depression in front of the external auditory meatus, and the other (F G, Fig. 376) from the posterior border of the mastoid process at its root. He has thus described on the surface of the head a four-sided figure (F D G E, Fig. 376), and a diagonal line from the posterior superior angle to the anterior perpendicular line where it is crossed by the fissure of Sylvius will represent the furrow.

The *parieto-occipital fissure* on the upper surface of the cerebrum runs outward at right angles to the great longitudinal fissure for about an inch, from a point one-fifth of an inch in front of the lambda (posterior fontanelle). Reid states that if the horizontal limb of the fissure of Sylvius be continued onward to the sagittal suture, the last inch of this line will indicate the position of the sulcus.

The *precentral sulcus* begins four-fifths of an inch in front of the middle of the fissure of Rolando, and extends nearly, but not quite, to the horizontal limb of the fissure of Sylvius.

The *superior frontal fissure* runs backward from the supra-orbital notch, parallel with the line of the longitudinal fissure to two-fifths of an inch in front of the line indicating the position of the fissure of Rolando.

The *inferior frontal fissure* follows the course of the superior temporal ridge on the frontal bone.

The *intraparietal fissure* begins on a level with the junction of the middle and lower third of the fissure of Rolando, on a line carried across the head from the back of the root of one auricle to that of the other. After passing upward it curves backward, lying parallel to the longitudinal fissure, midway between it and the parietal eminence; it then curves downward to end midway between the posterior fontanelle and the parietal eminence.

THE SPINAL CORD AND ITS MEMBRANES.

Dissection.—To dissect the cord and its membranes it will be necessary to lay open the whole length of the spinal canal. For this purpose the muscles must be separated from the vertebral grooves, so as to expose the spinous processes and laminæ of the vertebræ; and the latter must be sawn through on each side, close to the roots of the transverse processes, from the third or fourth cervical vertebra above to the sacrum below. The vertebral arches having been displaced by means of a chisel and the separate fragments removed, the dura mater will be exposed, covered by a plexus of veins and a quantity of loose areolar tissue, often infiltrated with serous fluid. The arches of the upper vertebræ are best divided by means of a strong pair of cutting bone-forceps.

MEMBRANES OF THE CORD.

The membranes which envelop the spinal cord are three in number. The most external is the *dura mater*, a strong fibrous membrane which forms a loose sheath around the cord. The most internal is the *pia mater*, a cellulo-vascular membrane which closely invests the entire surface of the cord. Between the two is the *arachnoid membrane*, a non-vascular membrane which envelops the cord and is connected to the pia mater by slender filaments of connective tissue.

The **Dura Mater** of the cord represents only the meningeal or supporting layer of the cranial dura mater. The endocranial or endosteal layer ceases at the foramen magnum posteriorly, but reaches as low as the third cervical vertebra in front; below these levels its place is taken by the periosteum. It forms a loose sheath which surrounds the cord, and is separated from the bony walls of the spinal canal by a quantity of loose areolar tissue and a plexus of veins. The situation of the veins between the dura mater of the cord and the periosteum of the vertebræ corresponds therefore to that of the cranial sinuses between the endocranial and supporting layers. It is attached to the circumference of the foramen magnum, and to the axis and third cervical vertebra; it is also fixed to the posterior common ligament, especially near the lower end of the spinal canal, by fibrous slips; it extends below as far as the second or third piece of the sacrum; here it becomes

[1] *Lancet*, 1888, vol. i., p. 408.

impervious, and, ensheathing the filum terminale, descends to the back of the coccyx, where it blends with the periosteum. The dura mater is much larger than is necessary for its contents, and its size is greater in the cervical and lumbar regions than in the dorsal. Its inner surface is smooth. On each side may be seen the double openings which transmit the two roots of the corresponding spinal nerve, the fibrous layer of the dura mater being continued in the form of a tubular prolongation on them as they pass through these apertures. These prolongations of the dura mater are short in the upper part of the spine, but become gradually longer below, forming a number of tubes of fibrous membrane, which enclose the sacral nerves, and are contained in the spinal canal.

The chief peculiarities of the dura mater of the cord, as compared with that investing the brain, are the following:

The dura mater of the cord is not adherent to the bones of the spinal canal, which have an independent periosteum.

It does not send partitions into the fissures of the cord, as in the brain.

Its fibrous laminæ do not separate to form venous sinuses, as in the brain.

Structure.—The dura mater consists of white fibrous and elastic tissue arranged in bands or lamellæ, which, for the most part, are parallel with one another and have a longitudinal arrangement. Its internal surface is covered by a layer of endothelial cells which gives this surface its smooth appearance. It is sparingly supplied with vessels, and some few nerves have been traced into it.

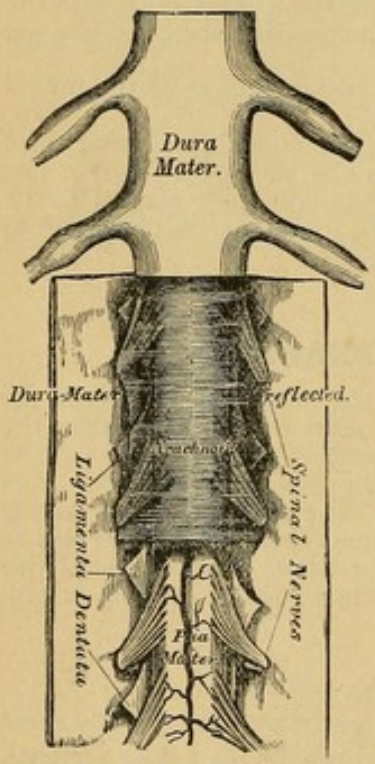

FIG. 377.—The spinal cord and its membranes.

The **Arachnoid** is exposed by slitting up the dura mater and reflecting that membrane to either side (Fig. 377). It is a thin, delicate, tubular membrane which invests the surface of the cord, and is connected to the pia mater by slender filaments of connective tissue. Above, it is continuous with the cerebral arachnoid, on each side it is continued on the various nerves, so as to form a sheath for them as they pass outward to the intervertebral foramina. The outer surface of the arachnoid is in contact with the inner surface of the dura mater, and the two are, here and there, joined together by isolated connective-tissue trabeculæ, especially on the posterior surface of the cord. For the most part, however, the membranes are not connected together, and the interval between them is named the *subdural space*. The inner surface of the arachnoid is separated from the pia mater by a considerable interval, which is called the *subarachnoidean space*. The space is the largest at the lower part of the spinal canal, and encloses the mass of nerves which form the cauda equina. Superiorly it is continuous with the cranial subarachnoid space, and communicates with the general ventricular cavity of the brain by means of an opening in the pia mater, in the roof of the fourth ventricle (*foramen of Majendie* and *foramina of Key and Retzius*). It contains an abundant serous secretion, the *cerebro-spinal fluid*. This secretion is sufficient in amount to expand the arachnoid membrane, so as to fill up completely the whole of the space included in the dura mater. The subarachnoidean space is occupied by trabeculæ of delicate connective tissue, connecting the pia mater on the one hand with the arachnoid membrane on the other. This is named *subarachnoid tissue*. In addition to this it is partially subdivided by a longitudinal membranous partition, the *septum posticum*, which serves to connect the arachnoid with the pia mater, opposite the posterior median fissure of the spinal cord, a partition which is incomplete and cribriform in structure, consisting of bundles of white fibrous tissue interlacing with each other. This space is to be regarded as, in reality, a great lymph space, from which the

lymph carried to it by the perivascular lymphatics is conveyed back into the circulation.

Structure.—The arachnoid is a delicate membrane made up of closely arranged interlacing bundles of connective tissue in several layers.

The **Pia Mater** of the cord is exposed on the removal of the arachnoid (Fig. 377). It covers the entire surface of the cord, to which it is very intimately adherent, forming its neurilemma, and sending a process downward into its anterior fissure. It also forms a sheath for each of the filaments of the spinal nerves, and invests the nerves themselves. A longitudinal fibrous band extends along the middle line on its anterior surface, called by Haller the *linea splendens;* and a somewhat similar band, the *ligamentum denticulatum*, is situated on each side. At the point where the cord terminates the pia mater becomes contracted, and is continued down as a long, slender filament (*filum terminale*), which descends through the centre of the mass of nerves forming the cauda equina. It perforates the dura about the level of the second or third lumbar vertebræ, receiving a sheath from it, and extends downward as far as the base of the coccyx, where it blends with the periosteum. It assists in maintaining the cord in its position during the movements of the trunk, and is from this circumstance called the *central ligament* of the spinal cord. It contains a little gray nervous substance, which may be traced for some distance into its upper part, and is accompanied by a small artery and vein. At the upper part of the cord the pia mater presents a grayish, mottled tint, which is owing to yellow or brown pigment-cells scattered among the elastic fibres.

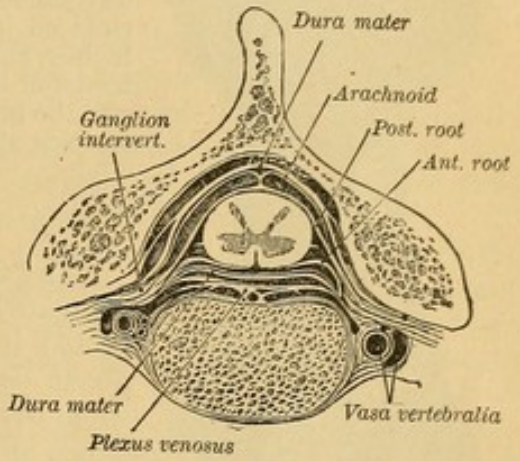

FIG. 378.—Transverse section of the spinal cord and its membranes. (Gegenbaur.)

Structure.—The pia mater of the cord is less vascular in structure, but thicker and denser, than the pia mater of the brain, with which it is continuous. It consists of two layers: an outer composed of bundles of connective-tissue fibres, arranged for the most part longitudinally; and an inner, consisting of stiff bundles of the same tissue, which present peculiar angular bends, and is covered on both surfaces by a layer of endothelium. Between the two layers are a number of cleftlike lymphatic spaces which communicate with the subarachnoid cavity, and a number of blood-vessels which are enclosed in a perivascular sheath, derived from the inner layer of the pia mater, into which the lymphatic spaces open. It is also supplied with nerves, which are derived from the sympathetic.

The **Ligamentum Denticulatum** (Fig. 377) is a narrow fibrous band, situated on each side of the spinal cord, throughout its entire length, and separating the anterior from the posterior roots of the spinal nerves. It has received its name from the serrated appearance which it presents. Its inner border is continuous with the pia mater at the side of the cord. Its outer border presents a series of triangular, dentated serrations, the points of which are fixed at intervals to the dura mater. These serrations are twenty-one in number on each side, the first being attached to the dura mater, opposite the margin of the foramen magnum between the vertebral artery and the hypoglossal nerve, and the last near the lower end of the cord. Its use is to support the cord in the fluid by which it is surrounded.

Surgical Anatomy.—Evidence of great value in the diagnosis of meningitis may be obtained by puncturing the theca of the cord and withdrawing some of the cerebrospinal fluid, and the operation is regarded by some as curative, under the supposition that the draining away of the cerebrospinal fluid relieves the patient by diminishing the intracranial pressure. The

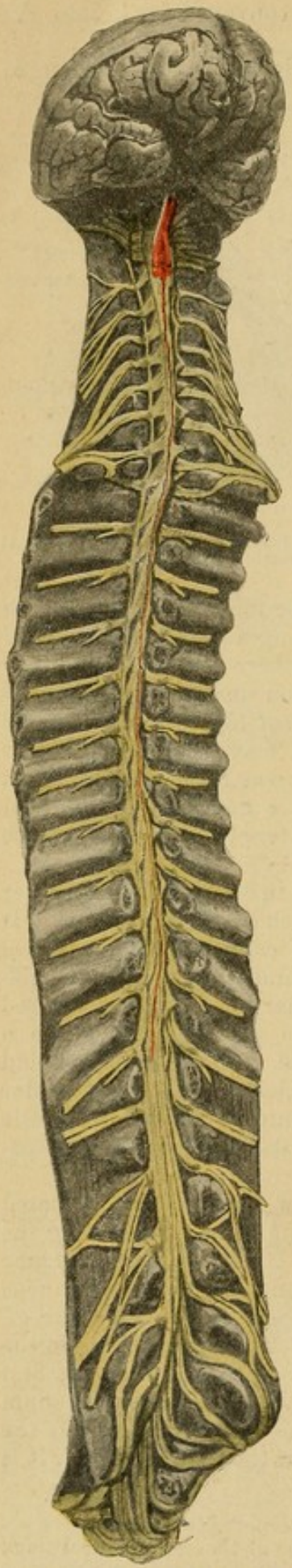

FIG. 379.—Posterior view of the spinal cord *in situ*.

operation is performed by inserting a trocar, of the smallest size, between the lamina of the third and fourth or the fourth and fifth lumbar vertebræ through the ligamenta subflava. The spinal cord even of a child at birth does not reach below the third lumbar vertebra, and therefore the canal may be punctured between the third and fourth vertebra without any risk of injuring its contents. The point of puncture is indicated by laying the child on its side and dropping a perpendicular line from the highest point of the crest of the ilium; this will cross the upper border of the spine of the fourth lumbar vertebra, and will indicate the level at which the trocar should be inserted a little to one side of the median line.

THE SPINAL CORD (Fig. 379).

The **Spinal Cord** (*medulla spinalis*) is the cylindrical, elongated part of the cerebro-spinal axis which is contained in the vertebral canal. Its length is usually about seventeen or eighteen inches, and its weight, when divested of its membranes and nerves, about one ounce and a half, its proportion to the encephalon being about 1 to 33. It does not nearly fill the canal in which it is contained, its investing membranes being separated from the surrounding walls by areolar tissue and a plexus of veins. It occupies, in the adult, the upper two-thirds of the vertebral canal, extending from the upper border of the atlas to the lower border of the body of the first lumbar vertebra, where it terminates in a slender filament of gray substance, which

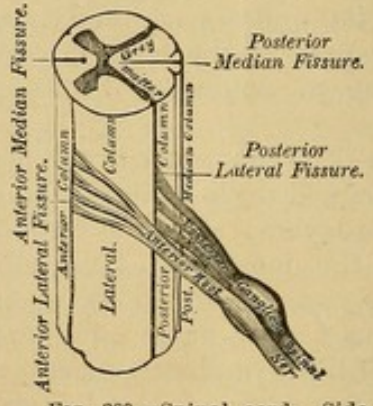

FIG. 380.—Spinal cord. Side view. Plan of the fissures and columns.

is continued for some distance into the *filum terminale*. In the fœtus, before the third month, it extends to the bottom of the sacral canal, but after this period it gradually recedes from below, as the growth of the bones composing the canal is more rapid in proportion than that of the cord, so that in the child at birth the cord extends as far as the third lumbar vertebra. Its position varies also according to the degree of curvature of the spinal column, being raised somewhat in flexion of the spine. On examining its surface it presents a difference in its diameter in different parts, being marked by two enlargements, an upper or cervical, and a lower or lumbar. The cervical enlargement extends from about the third cervical to the first or second dorsal vertebra: its greatest diameter is in the transverse direction (13 mm.), and it corresponds with the origin of the nerves

which supply the upper extremities. The lumbar enlargement is situated opposite the last two or three dorsal vertebræ, and corresponds with the origin of the nerves which supply the lower extremities. Below the lumbar enlargement the cord gradually tapers to form a cone, the *conus medullaris*, the apex of which is continuous with the filum terminale. In form, the spinal cord is a cylinder, flattened before and behind.

Fissures.—It presents on its anterior surface, along the middle line, a longitudinal fissure, the *anterior median fissure*, and on its posterior surface another fissure, which also extends along the entire length of the cord, the *posterior median fissure*. These fissures penetrate through the greater part of the thickness of the cord, and incompletely divide the cord into symmetrical halves, united in the middle line by a transverse band of nervous substance, the *commissure*.

The **Anterior Median Fissure** is wider, but of less depth, than the posterior, extending into the cord for about one-third of its thickness, and is deepest at the lower part of the cord. It contains a prolongation from the pia mater, and its floor is formed by the *anterior white commissure*, which is perforated by numerous blood-vessels passing to the centre of the cord.

The **Posterior Median Fissure** is not an actual fissure, as the space between the lateral halves of the posterior part of the cord is crossed by connective tissue and numerous blood-vessels, so that no actual hiatus exists, and there is consequently no prolongation of the pia mater into it. It extends into the cord to about one-half its depth, and its floor is formed by the *posterior gray commissure*.



Opposite middle of cervical region.



Opposite middle of dorsal region.



Opposite lumbar region.

FIG. 381.—Transverse sections of the cord.

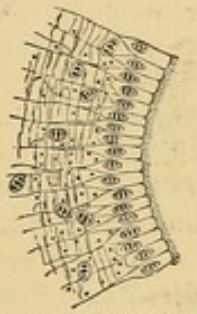

FIG. 382.—From a transverse section through the spinal cord of a calf. Magnified about 180 diameters, showing part of the central canal and the tissue immediately around it, viz., the central gray matter. (Klein and Noble Smith.) The canal is lined with epithelium, composed of ciliated, more or less conical, cells; in most instances a filamentous process passes from the cell into the tissue underneath. This tissue contains, in a hyaline matrix, a network of fibrils; most of these run horizontally; others have a longitudinal course, and appear therefore here cut transversely —*i. e.*, as small dots. The nuclei correspond to the cells of the neuroglia, the cell-substance not being shown. Both the nuclei of the neuroglia-cells and those of the epithelium contain three or more large disc-shaped particles.

Lateral Fissures.—On each side of the posterior median fissure, along the line of attachment of the posterior roots of the nerves, a delicate fissure may be seen, leading down to the gray matter which approaches the surface in this situation; this is called the *postero-lateral fissure* of the spinal cord. On the posterior surface of the spinal cord, between the posterior median fissure and the postero-lateral fissure on each side, is a slight longitudinal furrow (*posterior intermediate furrow*), marking off two slender tracts, the *postero-median and postero-lateral columns*. These are most distinct in the cervical region, but are stated by Foville to exist throughout the whole length of the cord. On each side of the anterior median fissure the anterior roots of the spinal nerves emerge from the cord, not in one vertical line, but by separate bundles which occupy an area of some width. This is called, by some anatomists, the *antero-lateral fissure* of the cord, although no actual fissure exists in this situation.

Columns of the Cord.—Each half of the spinal cord is thus divided into four columns: an anterior column, a lateral column, a posterior column, and a postero-median column. This division, however, is very imperfect, since the limit between

the so-called anterior and lateral columns cannot be defined on account of the bundles of the anterior roots being spread over a considerable area. It is therefore customary to divide each half of the spinal cord into two columns, separated by the postero-lateral groove: (1) a small *posterior column*, which is bounded internally by the posterior median fissure, and externally by the postero-lateral fissure, and (2) a large *antero-lateral column*, which comprises the rest of the cord. The posterior column is further divided, at all events at its upper part, by the posterior intermediate septum, into a postero-median column and a postero-lateral column.

Structure of the Cord.—If a transverse section of the spinal cord be made, it will be seen to consist of white and gray nervous substance. The white matter is situated externally, and constitutes the greater part. The gray substance occupies the centre, and is so arranged as to present on the surface of the section two crescentic masses, placed one in each lateral half of the cord, united together by a transverse band of gray matter, the *gray commissure*. Each crescentic mass has an anterior (ventral) and a posterior (dorsal) horn. The posterior horn is long and narrow, and approaches the surface of the postero-lateral fissure, near which it presents a slight enlargement, the *caput cornu:* from this it tapers to form the *apex cornu*, which at the surface of the cord becomes continuous with some of the fibres of the posterior roots of the spinal nerves. The anterior horn is short and thick, and does not quite reach the surface, but extends toward the point of attachment of the anterior roots of the nerves. Its margin presents a dentate or stellate appearance. Owing to the projections toward the surface of the anterior and posterior horns of the gray matter, each half of the cord is divided, more or less completely, into three columns, anterior, middle, and posterior, the anterior and middle being joined to form the antero-lateral column, as the anterior horn does not quite reach the surface.

The **commissure of the spinal cord** is composed of white and gray matter, and is therefore divided into the white and gray commissures. The *white commissure* is situated at the bottom of the anterior median fissure, and is formed of medullated nerve-fibres, which pass between the gray matter of the anterior horn and the anterior white column of the one side into similar parts on the other. The fibres are oblique in direction; many which enter at the posterior part of the commissure on the one side leave it at the anterior part of the commissure on the other, and *vice versâ*, a decussation taking place in the middle line.

The *gray commissure*, which connects the two crescentic masses of gray matter, is separated from the bottom of the anterior median fissure by the anterior white commissure. It consists of transverse medullated nerve-fibres, with a considerable quantity of neuroglia between them. The fibres when they reach the lateral crescents diverge: some pass backward to the posterior roots; others spread out, at various angles, into the crescent.

Running through the gray commissure of the whole length of the cord is a minute canal, which is barely visible to the naked eye in the human cord, but is proportionately larger in some of the lower vertebrata. It is called the *central canal;* it opens above into the fourth ventricle, and terminates below in a somewhat dilated extremity. It is surrounded by an area of neuroglia, which, in the recent state, has a gelatinous appearance, and in which there are no nerve-fibres. This is sometimes called the *substantia gelatinosa centralis.* When hardened in alcohol or chromic salts it has a finely reticulated appearance. The canal is lined in the fœtus by columnar ciliated epithelium, but in the adult the cilia have disappeared, and the canal is filled with their remains.

The mode of arrangement of the gray matter, and its amount in proportion to the white, vary in different parts of the cord. Thus, the posterior horns are long and narrow in the cervical region; short and narrower in the dorsal; short, but wider, in the lumbar region. In the cervical region the crescentic portions are small, and the white matter more abundant than in any other region of the cord. In the dorsal region the gray matter is least developed, the white matter being also small in quantity. In the lumbar region the gray matter is more abundant

than in any other region of the cord. Toward the lower end of the cord the white matter gradually ceases. The crescentic portions of the gray matter soon blend into a single mass, which forms the only constituent of the extreme point of the cord.

Minute Anatomy of the Cord.—The cord consists of an outer part, composed of medullated nerve-fibres, which is the *white substance;* and of a central part, the *gray matter*, both supported in a peculiar kind of tissue, called *neuroglia.*

The **neuroglia** consists of a homogeneous transparent matrix, of a network of very delicate fibrillæ, and of small stellate or branched cells, the *neuroglia-cells.*

In addition to forming a ground substance, in which the nerve-fibres, nerve-cells, and blood-vessels are imbedded, a considerable accumulation of neuroglia takes place in three situations—(1) on the surface of the cord, beneath the pia mater; (2) around the central canal, the *substantia gelatinosa centralis;* and (3) as a cap over the extremity of the posterior horn, forming the *substantia cinerea gelatinosa.*

The **white substance of the cord** consists of medullated nerve-fibres, mostly disposed longitudinally, with blood-vessels and neuroglia. When stained with carmine it presents a very striking appearance on transverse section. It is seen to be studded all over with minute dots, surrounded by a white area (Fig. 387). This is due to the longitudinal medullated fibres seen on section. The dot is the axis-cylinder, the white area the substance of Schwann. Externally, the neuroglia forms a sheath closely investing the outer surface of the cord immediately beneath the pia mater; from it numerous septa pass inward and separate the respective bundles of fibres and extend between the individual nerve-fibres, acting as a supporting medium, in which they are imbedded.

There are, however, also oblique and transverse fibres in the white substance. These principally consist of (1) the fibres of the white commissure; (2) horizontal or oblique fibres passing from the roots of the nerves into the gray matter; and (3) fibres leaving the gray matter and pursuing a longer or shorter horizontal course.

Conducting Tracts.—It is impossible to trace the course of the nerve-fibres in their passage through the cord; but the investigation of pathological lesions has shown that the white matter of the cord consists of certain columns or tracts of fibres; for it has been found that certain lesions are strictly limited to certain well-determined parts of the cord without involving neighboring regions. That these parts or fasciculi correspond to so many distinct anatomical systems, each endowed with special functions, seems abundantly proved by the researches of Flechsig and others on the development of the spinal cord during the later periods of utero-gestation and in the newly born infant. By these researches several tracts can be traced along the greater part of the cord and into or from the encephalon. Thus (1) in the antero-lateral column of the cord, on either side of the anterior median fissure, a portion of the column may be divided off as the *direct pyramidal tract* (*fasciculus of Türck*). This tract

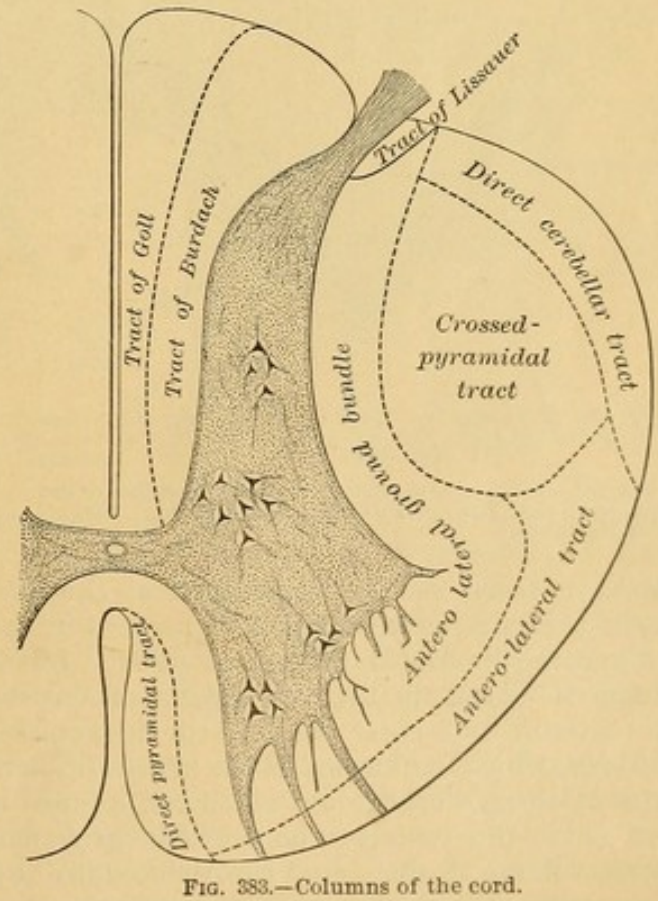

FIG. 383.—Columns of the cord.

is only found in the upper part of the cord; it gradually diminishes as it is traced downward, and disappears about the middle of the dorsal region. It consists of centrifugal or descending fibres which can be traced downward from the pyramid of the medulla of the same side, and are derived from the motor area of the cerebral cortex. The fibres of this tract decussate in their course down the cord, passing across the middle line through the anterior white commissure; this explains the gradual diminution and eventual disappearance of the tract. (2) In the hinder part of the antero-lateral column is a somewhat triangular area, larger than the preceding, which is named the *crossed pyramidal tract.* This also consists of descending fibres, which are derived from the pyramid of the medulla of the opposite side, and which have crossed in the decussation of the pyramids. The fibres are derived from the motor area of the cerebral cortex of the opposite side. Thus it will be seen that all the fibres from the motor area, which descend through the internal capsule, the crus cerebri, and the pons Varolii to the pyramidal body of the medulla, decussate; some at the upper part of the cord, and these descend through it as the crossed pyramidal tract; and others, which descend as the direct pyramidal tract and cross through the anterior commissure of the cord to reach the crossed pyramidal tract of the opposite side. Although this is the usual method of describing the crossing of the direct pyramidal tract in the cord, it seems probable that its fibres cross in the anterior commissure and pass directly to the anterior horn of gray matter, to end by forming synapses around its cells. (3) The *antero-lateral ascending tract* (Gower's tract) is an extensive crescent-shaped strand which skirts the circumference of the anterior three-quarters of the antero-lateral column of the cord. Behind, where it is thickest, it lies in the angle formed by the direct cerebellar and crossed pyramidal tracts, becoming narrower as it passes forward toward the direct pyramidal tract. It consists of centripetal or ascending fibres, which arise from cells situated at the base of the posterior horn and which cross to the opposite side of the cord in the anterior gray commissure. They can be traced upward through the medulla and pons to the cerebellum, reaching the latter through its superior peduncles. If the spinal cord is divided in the cervical region, some scattered fibres in this column degenerate in a downward direction. This would seem to prove therefore that it contains some descending fibres, which are believed to be derived from the same side of the cerebellum. (4) The *direct cerebellar tract* is situated at the circumference of the cord behind the preceding and external to the crossed pyramidal tract, occupying a narrow area which extends backward as far as the postero-lateral fissure or nearly so. It commences at the level of the upper lumbar region, and increases in size as it ascends and passes through the restiform body of the medulla to the cerebellum. Its fibres are derived from the cells of the posterior vesicular column of Clarke in the gray matter of the cord. (5) Close to the point where the posterior roots enter the cord, in the antero-lateral column, is a small collection of fibres, which is known as the *tract of Lissauer;* it is formed by some of the fibres of the posterior roots which run upward in the tract for a short distance, and then enter the posterior horn of the gray matter. (6) The rest of the antero-lateral column of the spinal cord is occupied by the *antero-lateral ground bundle.* It surrounds the anterior cornu and separates the antero-lateral tract and the crossed pyramidal tract from the gray matter of the cord. It consists of (*a*) longitudinal

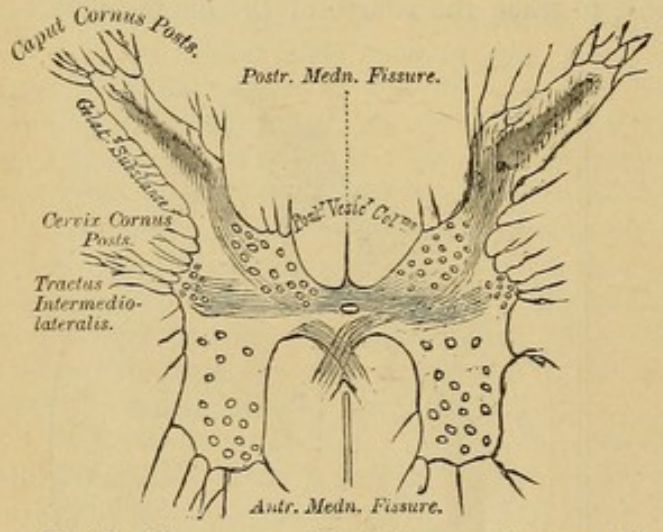

FIG. 384.—Transverse section of the gray substance of the spinal cord, near the middle of the dorsal region. Magnified 13 diameters.

commissural fibres, which unite the groups of cells in the gray matter with one another; (*b*) of fibres which pass across the anterior commissure from the gray matter of the opposite side; and (*c*) horizontal fibres belonging to the anterior roots of the nerves, which pass through it before leaving the cord.

In the posterior column of the cord there are two tracts. They are marked off from each other by the posterior intermediate furrow on the surface of the cord. The part which has been described previously as the posterior median column pretty nearly corresponds to the one tract, the *tract of Goll*, and the remainder of the posterior column corresponds to the other, the *tract of Burdach*. (7) The *tract of Goll* increases as it ascends, and consists of long, but small, fibres derived from the posterior roots of the spinal nerves, which ascend to the medulla oblongata, where they end in the nucleus gracilis. (8) The *tract of Burdach* consists of shorter, but larger, fibres than the preceding; they are, however, derived from the same source, the posterior roots; some ascend only for a short distance in the tract and then enter the gray matter and come into close relationship with the cells of the posterior vesicular column of Clarke; others incline toward the mesial plane, and, entering Goll's column, can be traced as far as the medulla. In the cervical

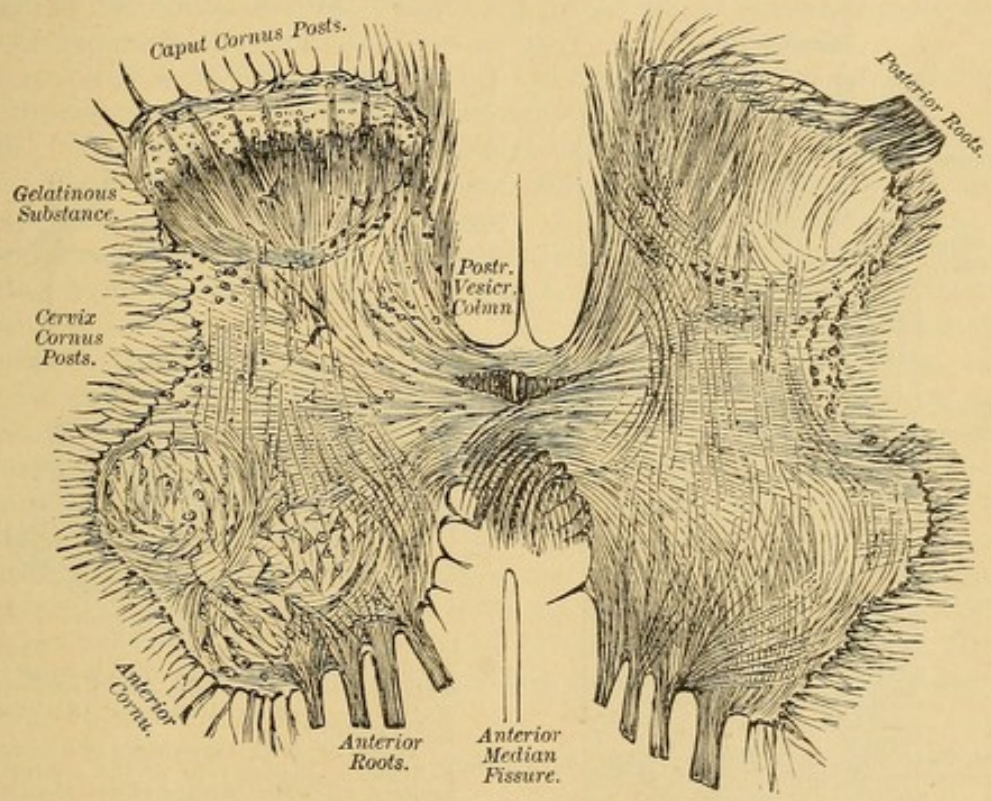

FIG. 385.—Transverse section of the gray substance of the spinal cord through the middle of the lumbar enlargement. On the left side of the figure groups of large cells are seen; on the right side, the course of the fibres is shown without the cells. Magnified 13 diameters.

and upper dorsal regions there is contained in the substance of Burdach's column a small strand of fibres, called the *descending comma tract*. It presents, on transverse section, the appearance of a comma, the blunt extremity of which is directed forward. The fibres forming it probably represent in part descending portions of the dorsal nerve-roots, together with descending commissural fibres within the cord itself. A small strand of similar descending fibres is seen, in the lower part of the cord, lying in the inner part of Goll's column.

The **gray substance of the cord** occupies its central part in the shape of two crescentic horns, joined together by the gray commissure. Each of these crescents has an anterior or ventral and a posterior or dorsal cornu.

The *posterior horn* consists of a slightly narrowed portion, at its base, where it is connected with the rest of the gray substance—this is the *cervix cornu;* from this it gradually expands into the main part of the horn, the *caput cornu*; around

its extremity is a lamina or layer of gelatinous material, which covers the head like a cap, and from this it tapers almost to a point, which approaches the surface of the cord at the postero-lateral groove.

The gelatinous substance is a peculiar accumulation of neuroglia (Klein) similar to that found around the central canal (page 713), and has been named by Rolando the *substantia cinerea gelatinosa*. It probably takes its origin from the columnar cells which line the posterior part of the embryonic spinal canal.

The *anterior horn of the gray substance* in the cervical and lumbar swellings, where it gives origin to the motor nerves of the extremities, is much larger than in any other region, and contains several distinct groups of large and variously shaped cells.

In addition to this, a *lateral horn* is found projecting outward from the lateral region of the gray matter on a level with the gray commissure in the upper part of the dorsal region of the cord; in the cervical and lumbar regions this lateral horn blends with the anterior horn, which thus becomes broad and expanded. From the concavity of the crescent, between the anterior and posterior horns, processes of gray matter extend into the white substance, where they divide and anastomose to form a network, termed the *formatio reticularis*.

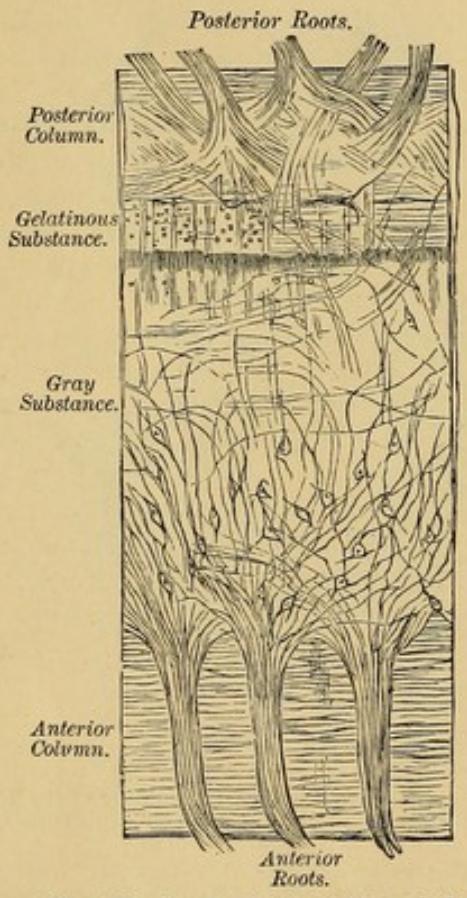

FIG. 386.—Longitudinal section of the white and gray substance of the spinal cord, through the middle of the lumbar enlargement. Magnified 14 diameters.

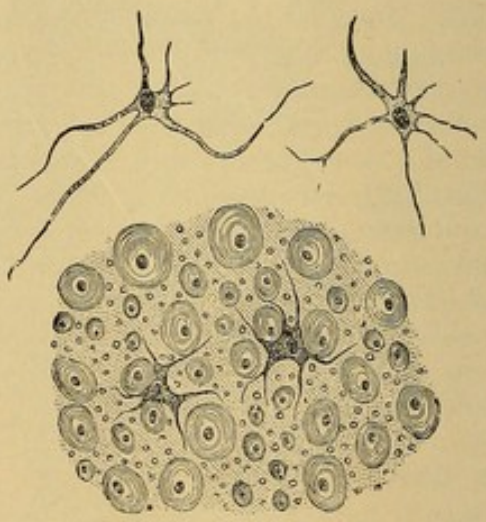

FIG. 387.—Transverse section through the white matter of the spinal cord of a calf. Magnified about 300 diameters. (Klein and Noble Smith.)

In the upper part are shown two isolated flattened nucleated cells of the neuroglia, under a somewhat higher power than the rest. In the bulk of the figure the nerve-fibres are seen in transverse section. They are of different sizes, and possess a laminated medullary sheath surrounding the axis-cylinder, which was deeply stained in the preparation, and is here represented by a black dot. The nerve-fibres are embedded in the neuroglia. Among the neuroglia are also seen two branched connective-tissue cells—neuroglia-cells.

The gray commissure contains the central canal, and is situated behind the white commissure, which separates it from the bottom of the anterior median fissure.

The **gray substance of the cord** consists of—(1) nerve-fibres of variable but smaller average diameter than those of the white columns; (2) nerve-cells of various shapes and sizes, with from two to eight processes; (3) blood-vessels and connective tissue.

The *nerve-fibres* of the gray matter of the posterior horn are for the most part composed of a dense interlacement of minute fibrils, intermingled with nerves

of a larger size. This interlacement is formed partly by the axons and dendrites of the cells of the gray matter, and partly by fibres which enter the gray matter and which come from various sources.

The *nerve-cells* of the gray matter are collected into groups as seen on transverse section, but they really form columns of cells placed longitudinally; or else they are found scattered throughout the whole of the gray matter.

In the anterior horn the cells consist of two chief groups: one mesial, the more constant, near the anterior column; the other lateral, near the lateral column. A second lateral group is present in the cervical and lumbar enlargements. At the base of the posterior horn on its inner side, adjoining the gray commissure, is a group of nerve-cells, called *Clarke's posterior vesicular column*, which extends from the eighth cervical to the second lumbar nerve.

At the junction of the anterior and posterior cornu, in the outer portion of the gray matter, is a third group of cells, the *lateral cell column;* this is best seen in the dorsal region. In certain regions of the cord these cells extend in among the fibres of the white matter of the lateral column, and give rise to the lateral horn. In addition to these groups a few large scattered cells are found in the posterior horn and in the substantia gelatinosa of Rolando.

Origin of the Spinal Nerves.—The roots of the spinal nerves are attached to the surface of the cord, opposite the horns of gray matter.

The *posterior nerve-root* enters the cord in two bundles, *mesial* and *lateral*. The mesial strand consists of coarse fibres which enter the outer part of the column of Burdach. The lateral strand is sometimes divided into a middle and an external bundle. The former contains large fibres, and passes through the gelatinous substance of Rolando into the posterior horn. The external bundle consists of fine fibres which assume a longitudinal direction in Lissauer's tract. All the posterior root-fibres divide into ascending and descending branches on entering the cord, and these in their turn give off collaterals. The fibres and their collaterals terminate by forming arborescences, some around the cells in the posterior horn, and others around the cells of Clarke's column, while the long ascending branches pass up in the columns of Goll and Burdach, and end by arborizing around the cells in the gracile and cuneate nuclei. Some of the fibres, however, pass to the gray matter of the opposite horn, and others to the anterior horn of the same side of the cord.

Anterior Nerve-roots.—The majority of the fibres of the anterior nerve-roots are the continuations outward of the axons of the large or small multipolar cells in the anterior horn of gray matter. Some, however, appear to pass across in the anterior white commissure to the cells in the anterior horn of the opposite side, while others extend backward to the posterior horn and outward to the lateral column of the same side.

The Nerve-tracts.

The anatomy of the various parts of the central nervous system having been described, a short account will now be given of the course taken by its more important nerve-tracts, and of the direction in which impulses pass along them. Before doing so, however, it is necessary to refer to the methods employed in elucidating this complex subject. All nerve fibres may be regarded as outgrowths from nerve-cells, and it is found that if a nerve-fibre be cut, the portion of it which is severed from the cell undergoes degeneration and becomes atrophied. Until recent years it was believed that the cell itself showed no change under such circumstances. This, however, is not the case, for if a nerve, the sciatic for instance, be divided in an animal, and after an interval of some weeks the animal be injected with methylene-blue and killed, it will be seen, on examining sections of the lumbar region of the spinal cord, that the cells are stained imperfectly or not at all, owing to a diminution, or, it may be, an entire disappearance of the chromatin, a substance which, in a normal cell, shows marked affinity for staining reagents. Further, the body of the cell is swollen, the nucleus displaced toward the periphery, and the part of the axon still attached to the altered cell is diminished in size and some-

what atrophied. Under favorable conditions the cell is capable of reassuming its normal appearance, and the axon may commence to grow. This method of injecting methylene-blue is of great value in determining the origin of nerve-fibres from their cells. Again, stimulation of certain localized areas of the brain or of the tracts arising from them is followed by the contraction of the muscles of the body. These cortical centres of the motor tracts are situated in the convolutions adjacent to the fissure of Rolando. When the stimulus is applied to one part the muscles of the hind limb contract, while other portions control the movements of the fore limb, etc. Destruction of these parts entails loss of function, paralysis of muscles, and degeneration of the tracts below the seat of injury. During life injury and disease may give rise to symptoms resembling either the effects of stimulation or those of destruction; and after death the tracts, or the centres of the tracts, are seen to be degenerated or otherwise altered. Further, by observing the development of the nervous system during the growth of the embryo, the fact is disclosed that all axis-cylinders do not acquire a medullary sheath at one and the same time. Speaking generally, it may be said that afferent fibres become medullated before efferent, and that in the case of the latter myelination occurs earlier in the brain than in the cord. By watching the effects of these different processes the functions of a considerable part of the brain and of the nerves leading from or to it have been determined.

The Motor, Efferent, or Descending Tract.

The constituent fibres of this tract are the axis-cylinder processes of cells situated in the cortex of the convolutions around the fissure of Rolando. At first they are somewhat widely diffused, but as they descend through the corona radiata they gradually approach each other and pass between the lenticular nucleus and optic thalamus in the genu and anterior two-thirds of the posterior limb of the internal capsule. Proceeding downward they next occupy the middle of the pes or crusta of the crus cerebri, and enter the pons Varolii, where the transverse fibres of this body not only conceal them, but divide them up into irregular bundles. Eventually they reach the medulla, and here the motor tracts form the anterior pyramids which lie one on each side of the median fissure. The transit of the fibres from the medulla is effected by two paths. The fibres nearest to the anterior median fissure cross the middle line, forming the *decussation of the pyramids*, and descend in the opposite side of the cord as the indirect or crossed pyramidal tract. Throughout the length of the spinal cord fibres from this column pass into the gray matter, to terminate by ramifying around the cells of the anterior horn. The more laterally placed portion of the motor tract does not decussate in the medulla, but descends as the direct or uncrossed pyramidal tract; these fibres, however, end in the anterior gray horn of the opposite side of the spinal cord by passing across in the

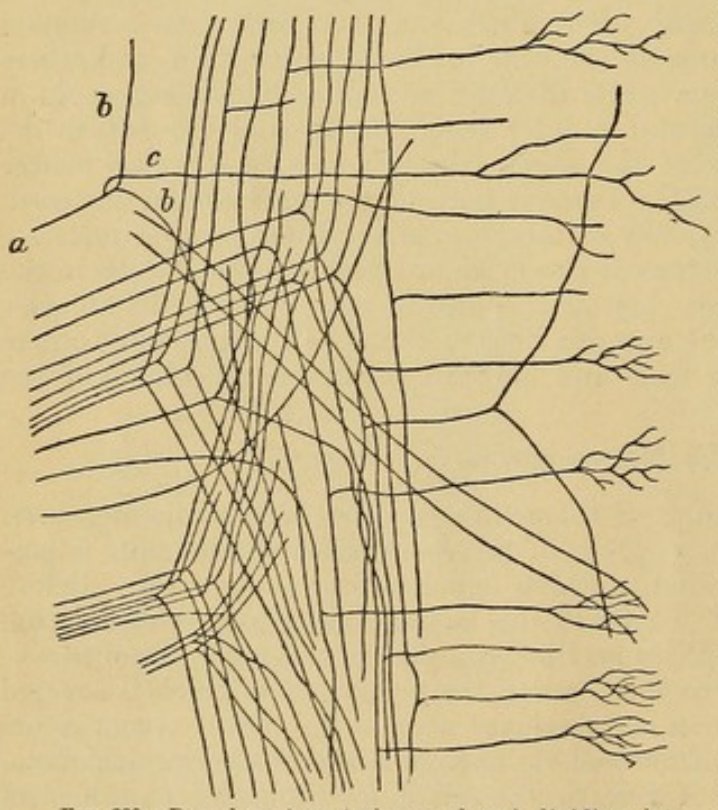

FIG. 388.—Dorsal roots entering cord and dividing into ascending and descending branches. (Van Gehuchten.) *a*, Stem-fibre; *b*, *b*, ascending and descending limbs of bifurcation; *c*, collateral arising from stem-fibre.

anterior white commissure. Further, it must be remembered that many fibres which descend in and constitute part of the motor tract decussate before reaching the medulla, and terminate by forming synapses with the nuclei of the cranial nerves situated near the aqueduct of Sylvius, in the pons or in the medulla itself. There is considerable variation in the extent to which decussation takes place in the medulla, the commonest condition being that in which about three-fourths of the fibres decussate in the medulla and the remainder in the cord.

Other Descending Tracts.

1. From the cortex of the frontal lobe, anterior to the Rolandic area, fibres arise which descend through the anterior limb of the internal capsule and enter the crusta, where they lie to the inner side of the pyramidal tract; finally they enter, and end in, the pons.

2. Descending fibres also take origin in the temporo-occipital cortex and pass through the posterior limb of the internal capsule behind the fibres from the Rolandic area. They pass through the crusta, where they lie to the outer side of the same tract, and end in the pons.

3. A small tract arises from the cells of the caudate nucleus and descends to end in the substantia nigra or pons. In the crus cerebri it lies immediately above the motor tract, which is on its ventral aspect.

The Sensory, Afferent, Ascending Tract.

The course taken by those fibres of the posterior nerve-roots which ascend has been arrived at by dividing the nerve-roots between their ganglia and their entrance into the spinal cord and subsequently examining the degenerated areas. It has been found that the fibres pursue an oblique course, being situated at first in the outer part of Burdach's column; higher up they occupy the middle of this column, being displaced inward by the accession of other entering fibres, while still higher they enter and are continued upward in the column of Goll. The upper cervical fibres do not reach the column of Goll, but are entirely confined to that of Burdach. The degeneration method proves that the localization of these fibres is very precise: the sacral nerves lying to the inner side of Goll's column and near its periphery; the lumbar nerves to their outer side; the dorsal nerves still more laterally: while the cervical nerves are confined to the outer part of Burdach's column.

On reaching the medulla these ascending fibres end by arborizing around the cells in the gracile and cuneate nuclei, and the further upward course of the tract is effected by the axis-cylinder processes of these cells. These new fibres decussate in the medulla, dorsal to the crossing of the motor tract, in what is termed the *superior pyramidal decussation*, the *sensory decussation*, or *decussation of the fillet;* terms which are synonymous. Having crossed the middle line they ascend through the pons and tegmentum of the crus cerebri, and, reaching the ventral surface of the optic thalamus, the majority end either in the subthalamic region or in the optic thalamus, but a small proportion is continued directly into the brain cortex. From the gray matter of the optic thalamus the fibres of the third link in the chain arise. They pass through the internal capsule and end in the cerebral cortex: those which go to the fronto-parietal cortex being situated in the extreme front part of the anterior limb of the internal capsule, while in the hinder extremity of the posterior limb other fibres pass to their distribution in the temporal and occipital cortex.

Other Ascending Tracts.

The direct cerebellar tract begins about the level of the second lumbar vertebra, and is the continuation upward of the axis-cylinders of Clarke's column. At the upper end of the cord it passes into the restiform body and through this reaches

the cerebellum. This tract seems to lose some of its fibres in the cord, since the area of its degeneration resulting from a section of the lower part of the cord diminishes from below upward; only some of its fibres therefore pass directly to the cerebellum. On the other hand, the tract is reinforced by an accession of fibres from the cord itself, so that its transverse area is greater above than below.

The antero-lateral ascending tract of Gower arises in the cord, probably as the axis-cylinders of cells situated in the posterior horn. Passing across the middle line through the anterior gray commissure the fibres ascend in the antero-lateral column of the cord, and ultimately reach the cerebellum through its superior peduncles.[1]

THE CRANIAL NERVES.

The cranial nerves arise from some part of the cerebrospinal centre, and are transmitted through foramina in the base of the cranium. They have been named numerically, according to the order in which they pass through the dura mater lining the base of the skull. Other names are also given to them, derived from the parts to which they are distributed or from their functions. Taken in their order, from before backward, they are as follows:

1st. Olfactory.
2d. Optic.
3d. Motor oculi.
4th. Trochlear (Pathetic).
5th. Trifacial (Trigeminus).
6th. Abducent.
7th. Facial (Portio dura).
8th. Auditory (Portio mollis).
9th. Glosso-pharyngeal.
10th. Pneumogastric (or Vagus).
11th. Spinal accessory.
12th. Hypoglossal.

All the cranial nerves are connected to some part of the surface of the brain. This is termed their *superficial* or *apparent origin*. But their fibres may, in all cases, be traced deeply into the substance of the brain to some special centre of gray matter, termed a *nucleus*. This is called their *deep* or *real origin*. The nerves, after emerging from the brain at their apparent origin, pass through foramina or tubular prolongations in the dura mater, leave the skull through foramina in its base, and pass to their final distribution.

The First Nerve (Fig. 350, page 654).

The **First cranial** or the **Olfactory nerves** (*nn. olfactorii*), the special nerves of the sense of smell, are about twenty in number. They are given off from the under surface of the olfactory bulb, an oval mass of a grayish color, which rests on the cribriform plate of the ethmoid bone, and forms the anterior expanded extremity of a slender process of brain-substance, named the *olfactory tract*. The olfactory tract and bulb have already been described (page 654).

Each nerve is surrounded by a tubular prolongation from the dura mater and pia mater, the former being lost on the periosteum lining the nose, the latter in the neurilemma of the nerve. The nerves, as they enter the nares, are divisible into two groups: an inner group, larger than those on the outer wall, spread out over the upper third of the septum; and an outer set, which is distributed over the superior turbinated bone, and the surface of the ethmoid in front of it. As the filaments descend, they unite in a plexiform network, and are believed by most observers to terminate by becoming continuous with the deep extremities of the olfactory cells.

The olfactory differs in structure from other nerves in being composed exclusively of non-medullated fibres. They are deficient in the white substance of Schwann, and consist of axis-cylinders, with a distinct nucleated sheath, in which there are, however, fewer nuclei than in ordinary non-medullated fibres. The olfactory centre in the cortex is not definitely known. It is generally asso-

[1] Testut describes the ascending column of Gower as joining with the fillet, and through it being carried to the cerebral cortex.

ciated with the temporal lobe, where it probably includes the gyrus hippocampi, uncus, and hippocampus major. It is further described as comprising the part of the callosal convolution which lies below the genu and rostrum of the corpus callosum, and also the posterior part of the orbital surface of the frontal lobe.

Surgical Anatomy.—In severe injuries to the head the olfactory bulb may become separated from the olfactory nerves, thus producing loss of the sense of smelling (*anosmia*), and with this a considerable loss in the sense of taste, as much of the perfection of the sense of taste is due to the sapid substances being also odorous and simultaneously exciting the sense of smell.

The Second Nerve (Fig. 389).

The **Second** or **Optic nerve** (*n. opticus*), the special nerve of the sense of sight, is distributed exclusively to the eyeball. The nerves of opposite sides are connected together at the commissure, and from the back of the commissure they may be traced to the brain, under the name of the *optic tracts*.

The *optic tract*, at its connection with the brain, is divided into two bands, external and internal. The *external* band is the larger; it arises from the external geniculate body and from the under part of the pulvinar of the optic thalamus, and is partly continuous with the brachium of the anterior or upper quadrigeminal body. The *internal* band curves round the crusta, and passes beneath the internal geniculate body, with which it is connected, and then appears to lose itself in the brachium of the posterior or inferior quadrigeminal body. The fibres by which it is connected to the internal geniculate body are merely commissural, forming part of Gudden's commissure. From this origin the tract winds obliquely across the under surface of the crus cerebri, in the form of a flattened band, and is attached to the crus by its anterior margin. It then assumes a cylindrical form, and, as it passes forward, is connected with the tuber cinereum and lamina cinerea. It finally joins with the tract of the opposite side to form the *optic commissure*.

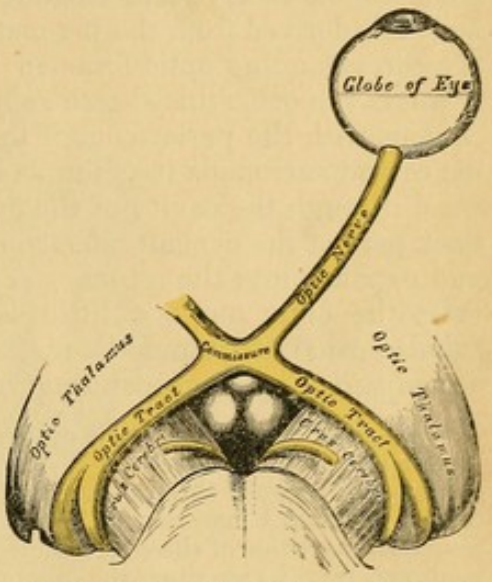

FIG. 389.—The left optic nerve and optic tracts.

The *commissure* or *chiasma*, somewhat quadrilateral in form, rests upon the olivary eminence and on the anterior part of the diaphragma sellæ, being bounded, above, by the lamina cinerea; behind by the tuber cinereum; on either side by the anterior perforated space. Within the commissure, the optic nerves of the two sides undergo a partial decussation. The fibres which form the inner margin of each tract and posterior part of the commissure have no connection with the optic nerves. They simply pass across the commissure from one hemisphere of the brain to the other, and connect the internal geniculate bodies of the two sides. They are known as the *commissure of Gudden*. The remainder and principal part of the commissure consists of two sets of fibres, crossed and uncrossed. The *crossed*, which are the more numerous, occupy the central part of the chiasma, and pass from the optic tract of one side to the optic nerve of the other, decussating in the commissure with similar fibres of the opposite tract. The uncrossed fibres occupy the outer part of the chiasma, and pass from the tract of one side to the nerve of the same side.[1]

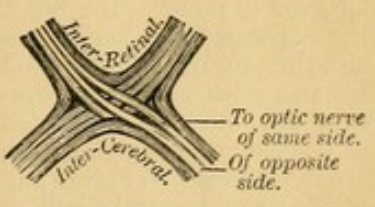

FIG. 390.—Course of the fibres in the optic commissure.

[1] A specimen of congenital absence of the optic commissure is to be found in the Museum of the Westminster Hospital. See also Henle, *Nervenlehre*, p. 393, ed. 2.

The great majority of the fibres of the optic nerve consist of the afferent axons of nerve-cells in the retina. Some few, however, are efferent fibres, and grow out from the brain. The afferent fibres end in arborizations around the cells in the external geniculate body, pulvinar, and upper quadrigeminal body, which are sometimes termed the *lower visual centres*. From these nuclei other fibres are prolonged to the *cortical visual centre*, which, according to most observers, is situated in the cuneus, and probably also in the lingual lobule of the occipital lobe.

It should be stated that some fibres are detached from the optic tract, and pass through the crus cerebri to the nucleus of the third nerve. These fibres are small, and may be regarded as afferent branches for the sphincter pupillæ and ciliary muscles. Other fibres pass to the cerebellum through its superior peduncles, while others, again, are lost in the pons.

The *optic nerves* arise from the fore part of the commissure, and, diverging from one another, become rounded in form and firm in texture, and are enclosed in a sheath derived from the pia mater and arachnoid. As each nerve passes through the corresponding optic foramen it receives a sheath from the dura mater; and as it enters the orbit this sheath subdivides into two layers, one of which becomes continuous with the periosteum of the orbit; the other forms the proper sheath of the nerve and surrounds it as far as the sclerotic. The nerve passes forward and outward through the cavity of the orbit, pierces the sclerotic and choroid coats at the back part of the eyeball, about one-eighth of an inch to the nasal side of its centre, and expands into the retina. A small artery, the *arteria centralis retinæ*, perforates the optic nerve a little behind the globe, and runs along its interior in a tubular canal of fibrous tissue. It supplies the inner surface of the retina, and is accompanied by corresponding veins.

Surgical Anatomy.—The optic nerve is peculiarly liable to become the seat of neuritis or undergo atrophy in affections of the central nervous system, and, as a rule, the pathological relationship between the two affections is exceedingly difficult to trace. There are, however, certain points in connection with the anatomy of this nerve which tend to throw light upon the frequent association of these affections with intracranial disease: (1) From its mode of development and from its structure the optic nerve must be regarded as a prolongation of the brain-substance, rather than as an ordinary cerebrospinal nerve. (2) As it passes from the brain it receives sheaths from the three cerebral membranes—a perineural sheath from the pia mater, an intermediate sheath from the arachnoid, and an outer sheath from the dura mater, which is also connected with the periosteum as it passes through the optic foramen. These sheaths are separated from each other by spaces which communicate with the subdural and subarachnoid spaces respectively. The innermost or perineural sheath sends a process around the arteria centralis retinæ into the interior of the nerve, and enters intimately into its structure. Thus inflammatory affections of the meninges or of the brain may readily extend themselves along these spaces or along the interstitial connective tissue in the nerve.

The course of the fibres in the optic commissure has an important pathological bearing, and has been the subject of much controversy. Microscopic examination, experiments, and pathology all seem to point to the fact that there is a partial decussation of the fibres, each tract supplying the corresponding half of each eye, so that the right tract supplies the right half of each eye, and the left tract the left half of each eye. At the same time, Charcot believes—and his view has met with general acceptation—that the fibres which do not decussate at the optic commissure have already decussated in the corpora quadrigemina, so that lesion of the cerebral centre of one side causes complete blindness of the opposite eye, because both sets of decussating fibres are destroyed. Whereas should one tract—say the right—be destroyed by disease, there will be blindness of the right half of both retinæ.

An antero-posterior section through the commissure would divide the decussating fibres, and would therefore produce blindness of the inner half of each eye; while a section at the margin of the side of the optic commissure would produce blindness of the external half of the retina of the same side.

The optic nerve may also be affected in injuries or diseases involving the orbit, in fractures of the anterior fossa of the base of the skull, in tumors of the orbit itself, or those invading this cavity from neighboring parts.

The Third Nerve (Figs. 391, 392, 393).

The **Third** or **Motor oculi nerve** (*n. oculo-motorius*) supplies all the muscles of the orbit except the Superior oblique and External rectus; it also supplies, through its connection with the ciliary ganglion, the Sphincter muscle of the iris

and the Ciliary muscle. It is rather a large nerve, of rounded form and firm texture.

Its aparent origin is from the inner surface of the crus cerebri, immediately in front of the pons Varolii. The *deep origin* may be traced through the substantia nigra and tegmentum of the crus to a nucleus situated on either side of the median line beneath the floor of the aqueduct of Sylvius. The nucleus of the third nerve also receives fibres from the sixth nerve of the opposite side. These will be referred to again in the description of the latter nerve. The nucleus of the third nerve, considered from a physiological standpoint, can be subdivided into several smaller groups of cells, each group controlling a particular muscle. The nerves to the different muscles appear to take their origin from before backward, as follows: Inferior oblique, Inferior rectus, Superior rectus and Levator palpebræ, Internal rectus; while from the anterior end of the nucleus the fibres for accommodation and for the Sphincter pupillæ take their origin.

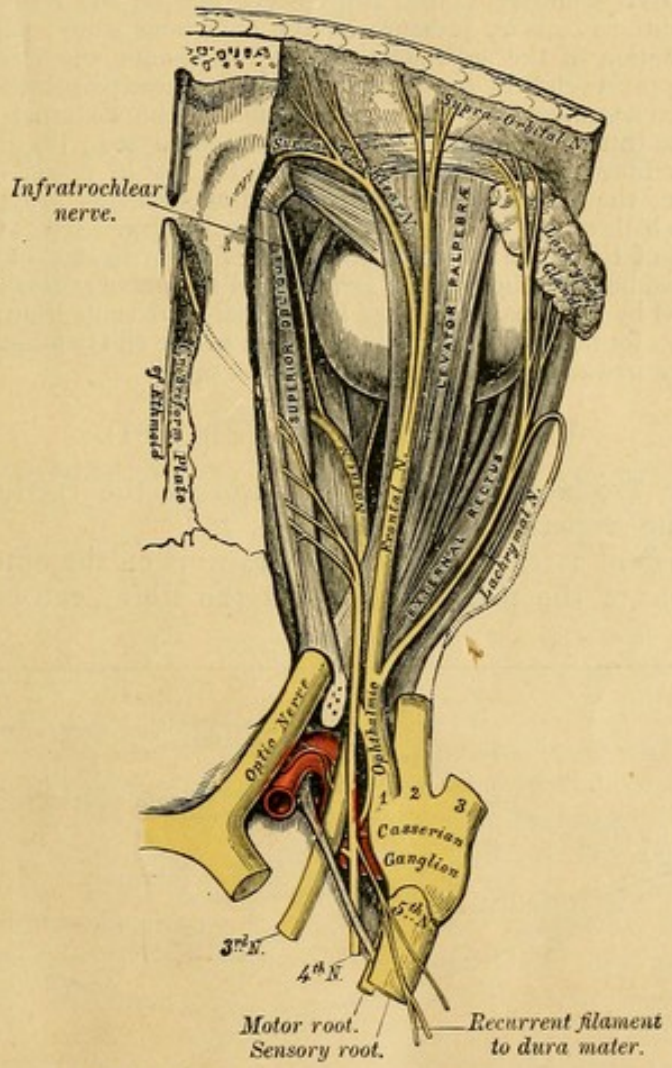

FIG. 391.—Nerves of the orbit. Seen from above.

On emerging from the brain, the nerve is invested with a sheath of pia mater, and enclosed in a prolongation from the arachnoid. It passes between the superior cerebellar and posterior cerebral arteries, and then pierces the dura mater in front of and external to the posterior clinoid process, passing between the two processes from the free and attached borders of the tentorium, which are prolonged forward to be connected with the anterior and posterior clinoid processes of the sphenoid bone. It passes along the outer wall of the cavernous sinus, above the other orbital nerves, receiving in its course one or two filaments from the cavernous plexus of the sympathetic, and a communicating branch from the first division of the fifth. It then divides into two branches, which enter the

orbit through the sphenoidal fissure, between the two heads of the External rectus muscle. On passing through the fissure, the nerve is placed below the fourth and the frontal and lachrymal branches of the ophthalmic nerve, and has passing between its two divisions the nasal nerve.

The *superior division*, the smaller, passes inward over the optic nerve, and supplies the Superior rectus and Levator palpebræ.

The *inferior division*, the larger, divides into three branches. One passes beneath the optic nerve to the Internal rectus; another, to the Inferior rectus; and the third, the longest of the three, passes forward between the Inferior and External recti to the Inferior oblique. From this latter a short, thick branch is given off to the lower part of the lenticular ganglion, which forms its inferior root. It also gives off one or two filaments to the Inferior rectus. All these branches enter the muscles on their ocular surface, except that to the Inferior oblique, which enters its posterior border.

Surgical Anatomy.—Paralysis of the third nerve may be the result of many causes: as cerebral disease; conditions causing pressure on the cavernous sinus; periostitis of the bones entering into the formation of the sphenoidal fissure. It results, when complete, in (1) ptosis, or drooping of the upper eyelid, in consequence of the Levator palpebræ being paralyzed; (2) external strabismus, on account of the unopposed action of the External rectus muscle, which is not supplied by the third nerve, and is not therefore paralyzed; (3) dilatation of the pupil, because the sphincter fibres of the iris are paralyzed; (4) loss of power of accommodation, as the sphincter pupillæ, the ciliary muscle, and the Internal rectus are paralyzed; (5) slight prominence of the eyeball, owing to most of its muscles being relaxed. Occasionally paralysis may affect only a part of the nerve; that is to say, there may be, for example, a dilated and fixed pupil, with ptosis, but no other signs. Irritation of the nerve causes spasm of one or other of the muscles supplied by it; thus, there may be internal strabismus from spasm of the Internal rectus; accommodation for near objects only from spasm of the ciliary muscle, or myosis, contraction of the pupil, from irritation of the sphincter of the pupil.

The Fourth Nerve (Fig. 391).

The **Fourth** or **Trochlear nerve** (*n. trochlearis*), the smallest of the cranial nerves, supplies the Superior oblique muscle.

Its *apparent origin*, at the base of the brain, is on the outer side of the crus cerebri, just in front of the pons Varolii, but the fibres can be traced backward

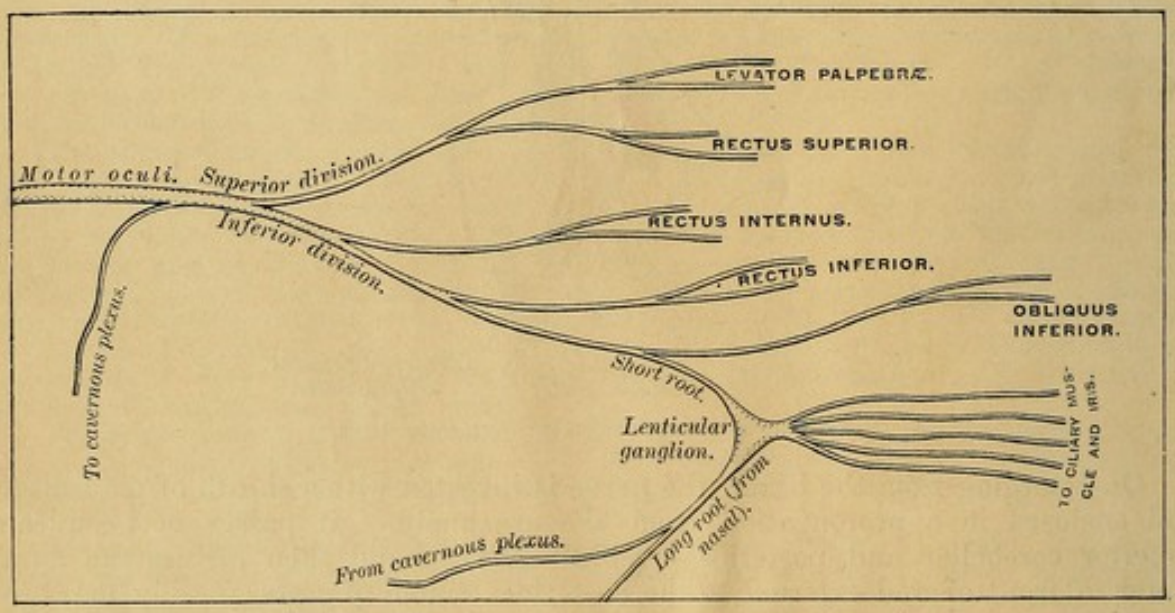

FIG. 392.—Plan of the motor oculi nerve. (After Flower.)

behind the corpora quadrigemina to the valve of Vieussens, on the upper surface of which the two nerves decussate. Its *deep origin* may be traced to a nucleus in the floor of the aqueduct of Sylvius immediately below that of the third nerve, with which it is continuous.

Emerging from the upper end of the valve of Vieussens, the nerve is directed outward across the superior peduncle of the cerebellum, and then winds forward round the outer side of the crus cerebri, immediately above the pons Varolii, pierces the dura mater in the free border of the tentorium cerebelli, just behind, and external to, the posterior clinoid process, and passes forward in the outer wall of the cavernous sinus, between the third nerve and the ophthalmic division of the fifth. It crosses the third nerve and enters the orbit through the sphenoidal fissure. It now becomes the highest of all the nerves, lying at the inner extremity of the fissure internal to the frontal nerve. In the orbit it passes inward, above the origin of the Levator palpebræ, and finally enters the orbital surface of the Superior oblique muscle. In the outer wall of the cavernous sinus this nerve is not infrequently blended with the ophthalmic division of the fifth.

Branches of Communication.—In the outer wall of the cavernous sinus it receives some filaments from the cavernous plexus of the sympathetic. In the sphenoidal fissure it occasionally gives off a branch to assist in the formation of the lachrymal nerve.

Branches of Distribution.—It gives off a recurrent branch, which passes backward between the layers of the tentorium, dividing into two or three filaments which may be traced as far back as the wall of the lateral sinus.

Surgical Anatomy.—The fourth nerve when paralyzed causes loss of function in the Superior oblique, so that the patient is unable to turn his eye downward and outward. Should the patient attempt to do this, the eye on the affected side is twisted inward, producing diplopia or double vision. Accordingly, it is said that the first symptom of this disease which presents itself is giddiness when going down hill or in descending stairs, owing to the double vision induced by the patient looking at his steps while descending.

The Fifth Nerve.

The **Fifth** or **Trifacial Nerve** (*n. trigeminus*) is the largest cranial nerve. It resembles a spinal nerve (1) in arising by two roots; (2) in having a ganglion developed on its posterior root; and (3) in its function, since it is a compound nerve. It is the great sensory nerve of the head and face and the motor nerve of the muscles of mastication. Its upper two divisions are entirely sensory; the third division is partly sensory and partly motor. It arises by two roots: of these the anterior is the smaller, and is the motor root; the posterior, the larger and sensory. Its *superficial origin* is from the side of the pons Varolii, nearer to the upper than the lower border. The smaller root consists of three or four bundles; the larger root consists of numerous bundles of fibres, varying in number from seventy to a hundred. The two roots are separated from one another by a few of the transverse fibres of the pons. The *deep origin* of the larger or sensory root is chiefly from a long tract in the medulla, the *lower sensory nucleus*, which is continuous below with the substantia gelatinosa of Rolando. The fibres from this nucleus form the so-called *ascending root of the fifth*; they pass upward through the pons and join with fibres from the locus cæruleus or *upper sensory nucleus*, which is situated to the outer side of the nucleus, from which the lower part of the motor root takes origin. The *deep origin* of the smaller or motor root is derived partly from a nucleus embedded in the gray matter of the upper part of the floor of the fourth ventricle and partly from a collection of nerve-cells situated at the side of the aqueduct of Sylvius, from which the fibres pass downward under the name of the *descending root of the fifth*. The real origin of the sensory root is from the Gasserian ganglion, which corresponds with the ganglion on a spinal nerve (see Development of Spinal Nerves in section on Embryology).

The two roots of the nerve pass forward below the tentorium cerebelli as it bridges over the notch on the inner part of the superior border of the petrous portion of the temporal bone; they then run between the bone and the dura mater to the apex of the petrous portion of the temporal bone, where the fibres of the sensory root form a large semilunar ganglion (*Gasserian*), while the motor

root passes beneath the ganglion without having any connection with it, and joins outside the cranium with one of the trunks derived from it.

The **Gasserian** or **semilunar ganglion**[1] is lodged in an osteo-fibrous space, the *cavum Meckelii*, near the apex of the petrous portion of the temporal bone. It is of somewhat crescentic form, with its convexity turned forward. Its upper surface is intimately adherent to the dura mater. Besides the small or motor root, the large superficial petrosal nerve lies underneath the ganglion.

Branches of Communication.—This ganglion receives, on its *inner side*, filaments from the carotid plexus of the sympathetic. *Branches of Distribution.*—It gives off minute branches to the tentorium cerebelli and the dura mater in the middle fossa of the cranium. From its *anterior border*, which is directed forward and outward, three large branches proceed—the *ophthalmic*, *superior maxillary*, and *inferior maxillary*. The ophthalmic and superior maxillary consist exclusively of fibres derived from the larger root and ganglion, and are solely nerves of common sensation. The third division, or inferior maxillary, is joined outside the cranium by the motor root. This, therefore, strictly speaking, is the only portion of the fifth nerve which can be said to resemble a spinal nerve.

Ophthalmic Nerve (Figs. 391, 393, 394).

The **Ophthalmic** (*n. ophthalmicus*), or first division of the fifth, is a sensory nerve. It supplies the eyeball, the lachrymal gland, the mucous lining of the eye and nasal fossæ, and the integument of the eyebrow, forehead, and nose. It is the smallest of the three divisions of the fifth, arising from the upper part of the Gasserian ganglion. It is a short, flattened band, about an inch in length, which passes forward along the outer wall of the cavernous sinus, below the other nerves, and just before entering the orbit, through the sphenoidal fissure, divides into three branches—*lachrymal*, *frontal*, and *nasal*.

Branches of Communication.—The ophthalmic nerve is joined by filaments from the cavernous plexus of the sympathetic, communicates with the third and sixth nerves, and is not infrequently joined with the fourth.

Branches of Distribution.—It gives off recurrent filaments which pass between the layers of the tentorium, and then divides into

Lachrymal. Frontal. Nasal.

The **lachrymal** is the smallest of the three branches of the ophthalmic. It sometimes receives a filament from the fourth nerve, but this is possibly derived from the branch of communication which passes from the ophthalmic to the fourth. It passes forward in a separate tube of dura mater and enters the orbit through the narrowest part of the sphenoidal fissure. In the orbit it runs along the upper border of the External rectus muscle, with the lachrymal artery, and communicates with the temporo-malar branch of the superior maxillary. It enters the lachrymal gland and gives off several filaments which supply the gland and the conjunctiva. Finally, it pierces the superior palpebral ligament, and terminates in the integument of the upper eyelid, joining with filaments of the facial nerve. The lachrymal nerve is occasionally absent, when its place is taken by the temporal branch of the superior maxillary. Sometimes the latter branch is absent, and a continuation of the lachrymal is substituted for it.

The **frontal** is the largest division of the ophthalmic, and may be regarded, both from its size and direction, as the continuation of the nerve. It enters the orbit above the muscles, through the sphenoidal fissure, and runs forward along the middle line, between the Levator palpebræ and the periosteum. Midway between

[1] A Viennese anatomist, Raimund Balthasar Hirsch (1765), was the first who recognized the ganglionic nature of the swelling on the sensory root of the fifth nerve, and called it, in honor of his otherwise unknown teacher, Jon. Laur. Gasser, the "Ganglion Gasseri." Julius Casserius, whose name is given to the musculo-cutaneous nerve of the arm, was professor at Padua, 1545–1605. (See Hyrtl, *Lehrbuch der Anatomie*, p. 895 and p. 55.)

the apex and the base of the orbit it divides into two branches, supratrochlear and supra-orbital.

The *supratrochlear branch*, the smaller of the two, passes inward, above the pulley of the superior oblique muscle, and gives off a descending filament, which joins with the infratrochlear branch of the nasal nerve. It then escapes from the orbit between the pulley of the Superior oblique and the supra-orbital foramen, curves up on to the forehead close to the bone, ascends beneath the Corrugator supercilii and Occipito-frontalis muscles, and, dividing into branches which pierce these muscles, it supplies the integument of the lower part of the forehead on either side of the middle line and sends filaments to the conjunctiva and skin of the upper lid.

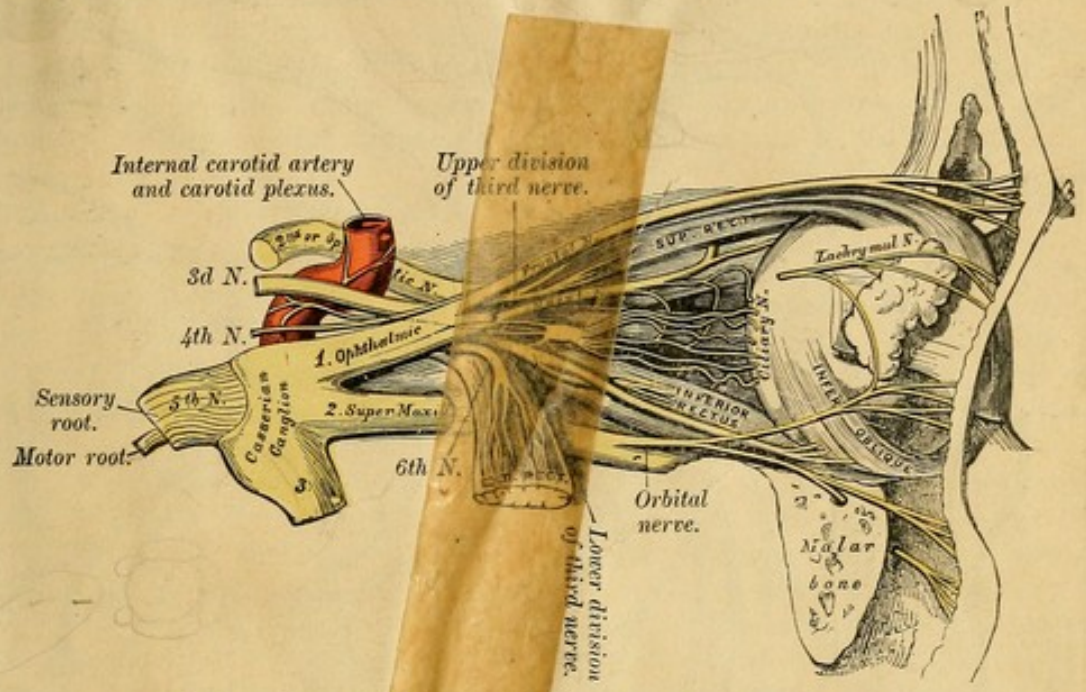

FIG. 393.—Nerves of the orbit and ophthalmic ganglion. Side view.

The *supra-orbital branch* passes forward through the supra-orbital foramen, and gives off, in this situation, palpebral filaments to the upper eyelid. It then ascends upon the forehead, and terminates in cutaneous and pericranial branches. The *cutaneous branches*, tw[illegible] number, an inner and an outer, supply the integument of the cranium [illegible] far back as the occiput. They are [illegible] separately. beneath the Occipito-fronta[illegible], the inner branch perforating [illegible]mmunication from the muscle, the outer branch its t[illegible]ous aponeurosis. [illegible] are distributed to the pericraniu[illegible] short [illegible]al a[illegible]erves. These are delicate

The **Nasal nerve** is interme[illegible]ber, which arise from the fore part of the ganglion more deeply placed than the [illegible]ts superior and inferior angles; the lower bundle between the two heads of th[illegible]rd [illegible]th the ciliary arteries in a wavy course, one the optic nerve, beneath the [illegible] the optic nerve, and are accompanied by the long inner wall of the orbit, wher[illegible] They pierce the sclerotic at the back part of the and, entering the cavity of [illegible] grooves on its inner surface, and are distributed to the cribriform plate of the [illegible]ornea. Tiedemann has described [illegible]mall branch side of the crista galli, in[illegible] [illegible]ith the arteria centralis retinæ.

nal and an external. The [illegible]rior **Maxillary Nerve** (Fig. 395).

the fore part of the septum [illegible]

on the inner surface of the [illegible] *maxillaris*), or second division of the fifth, is a sensory membrane covering the fore[illegible]om in position and size, between the ophthalmic rior spongy bone; it then le[illegible]mmences at the middle of the Gasserian ganglion as of the nasal bo[illegible]e and the u[illegible]d, passing horizontally forward, it leaves the skull beneath the Compressor nasi[illegible]n, where it becomes more cylindrical in form and nose, joining with the facial n[illegible]

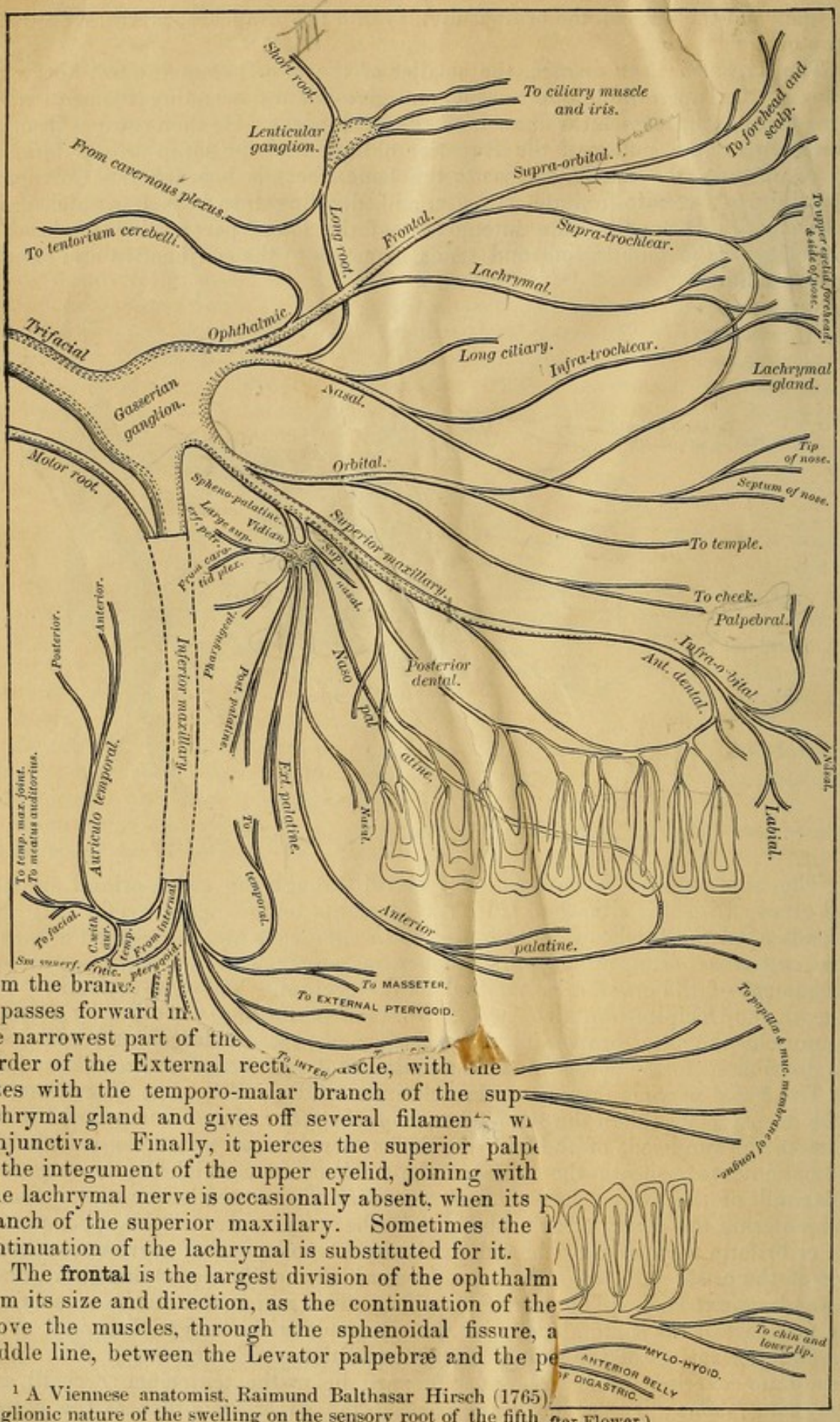

from the brane
It passes forward in
the narrowest part of the
border of the External rectu
cates with the temporo-malar branch of the sup
lachrymal gland and gives off several filamen
conjunctiva. Finally, it pierces the superior palp
in the integument of the upper eyelid, joining with
The lachrymal nerve is occasionally absent, when its
branch of the superior maxillary. Sometimes the
continuation of the lachrymal is substituted for it.

The **frontal** is the largest division of the ophthalm
from its size and direction, as the continuation of the
above the muscles, through the sphenoidal fissure, a
middle line, between the Levator palpebræ and the pe

[1] A Viennese anatomist, Raimund Balthasar Hirsch (1765)
ganglionic nature of the swelling on the sensory root of the fifth
otherwise unknown teacher, Jon. Laur. Gasser, the "Ganglion
name is given to the musculo-cutaneous nerve of the arm, was
Hyrtl, *Lehrbuch der Anatomie*, p. 895 and p. 55.)

fter Flower.)

anglionic, *ciliary*, and *infra-*

The *ganglionic* is a slender branch, about half an inch in length, which usually arises from the nasal, between the two heads of the External rectus. It passes forward on the outer side of the optic nerve, and enters the postero-superior angle of the ciliary ganglion, forming its superior or long root. It is sometimes joined by a filament from the cavernous plexus of the sympathetic or from the superior division of the third nerve.

The *long ciliary nerves*, two or three in number, are given off from the nasal as it crosses the optic nerve. They join the short ciliary nerves from the ciliary ganglion, pierce the posterior part of the sclerotic, and, running forward between it and the choroid, are distributed to the ciliary muscles, iris, and cornea.

The *infratrochlear branch* is given off just before the nasal nerve passes through the anterior ethmoidal foramen. It runs forward along the upper border of the Internal rectus, and is joined, beneath the pulley of the Superior oblique, by a filament from the supratrochlear nerve. It then passes to the inner angle of the eye, and supplies the integument of the eyelids and side of the nose, the conjunctiva, lachrymal sac, and caruncula lachrymalis.

The Ophthalmic Ganglion (Figs. 391, 394).

Connected with the three divisions of the fifth nerve are four small ganglia. With the first division is connected the *ophthalmic ganglion;* with the second division, the *spheno-palatine* or *Meckel's ganglion;* and with the third, the *otic* and *submaxillary ganglia.* All the four receive sensory filaments from the fifth, and motor and sympathetic filaments from various sources; these filaments are called the *roots of the ganglia.*

The **Ophthalmic, Lenticular,** or **Ciliary Ganglion** is a small, quadrangular, flattened ganglion, of a reddish-gray color, and about the size of a pin's head, situated at the back part of the orbit between the optic nerve and the External rectus muscle, lying generally on the outer side of the ophthalmic artery. It is enclosed in a quantity of loose fat, which makes its dissection somewhat difficult.

Its *branches of communication*, or *roots*, are three, all of which enter its posterior border. One, the long or sensory root, is derived from the nasal branch of the ophthalmic and joins its superior angle. The second, the short or motor root, is a short, thick nerve, occasionally divided into two parts, which is derived from the branch of the third nerve to the Inferior oblique muscle, and is connected with the inferior angle of the ganglion. The third, the sympathetic root, is a slender filament from the cavernous plexus of the sympathetic. This is frequently blended with the long root, though it sometimes passes to the ganglion separately. According to Tiedemann, this ganglion receives a filament of communication from the spheno-palatine ganglion.

Its *branches of distribution* are the short ciliary nerves. These are delicate filaments, from six to ten in number, which arise from the fore part of the ganglion in two bundles, connected with its superior and inferior angles; the lower bundle is the larger. They run forward with the ciliary arteries in a wavy course, one set above and the other below the optic nerve, and are accompanied by the long ciliary nerves from the nasal. They pierce the sclerotic at the back part of the globe, pass forward in delicate grooves on its inner surface, and are distributed to the Ciliary muscle, iris, and cornea. Tiedemann has described a small branch as penetrating the optic nerve with the arteria centralis retinæ.

The Superior Maxillary Nerve (Fig. 395).

The **Superior Maxillary** (*n. maxillaris*), or second division of the fifth, is a sensory nerve. It is intermediate, both in position and size, between the ophthalmic and inferior maxillary. It commences at the middle of the Gasserian ganglion as a flattened plexiform band, and, passing horizontally forward, it leaves the skull through the foramen rotundum, where it becomes more cylindrical in form and

firmer in texture. It then crosses the spheno-maxillary fossa, enters the orbit through the spheno-maxillary fissure, traverses the infra-orbital canal in the floor of the orbit, and appears upon the face at the infra-orbital foramen.[1] At its termination the nerve lies beneath the Levator labii superioris muscle, and divides into a leash of branches, which spread out upon the side of the nose, the lower eyelid, and upper lip, joining with filaments of the facial nerve.

Branches of Distribution.—The branches of this nerve may be divided into four groups: 1. Those given off in the cranium. 2. Those given off in the spheno-maxillary fossa. 3. Those in the infra-orbital canal. 4. Those on the face.

In the cranium . . .	Meningeal.
Spheno-maxillary fossa	Orbital or temporo-malar.
	Spheno-palatine.
	Posterior superior dental.
Infra-orbital canal .	Middle superior dental.
	Anterior superior dental.
On the face . .	Palpebral.
	Nasal.
	Labial.

The **meningeal branch** is given off directly after its origin from the Gasserian ganglion; it accompanies the middle meningeal artery and supplies the dura mater.

The **orbital** or **temporo-malar branch** arises in the spheno-maxillary fossa, enters the orbit by the spheno-maxillary fissure, and divides at the back of that cavity into two branches, temporal and malar.

The *temporal branch* runs in a groove along the outer wall of the orbit (in the malar bone), receives a branch of communication from the lachrymal, and, passing through a foramen in the malar bone, enters the temporal fossa. It ascends between the bone and substance of the Temporal muscle, pierces this muscle and the temporal fascia about an inch above the zygoma, and is distributed to the integument covering the temple and side of the forehead, communicating with the facial and auriculo-temporal branch of the inferior maxillary nerve. As it pierces the temporal fascia it gives off a slender twig, which runs between the two layers of the fascia to the outer angle of the orbit.

The *malar branch* passes along the external inferior angle of the orbit, emerges upon the face through a foramen in the malar bone, and, perforating the Orbicularis palpebrarum muscle, supplies the skin on the prominence of the cheek, and is named *subcutaneus malæ*. It joins with the facial and the palpebral branches of the superior maxillary.

The **spheno-palatine branches,** two in number, descend to the spheno-palatine ganglion.

The **posterior superior dental branches** arise from the trunk of the nerve just as it is about to enter the infra-orbital canal; they are generally two in number, but sometimes arise by a single trunk, and immediately divide and pass downward on the tuberosity of the superior maxillary bone. They give off several twigs to the gums and neighboring parts of the mucous membrane of the cheek (*superior gingival branches*). They then enter the posterior dental canals on the zygomatic surface of the superior maxillary bone, and, passing from behind forward in the substance of the bone, communicate with the middle dental nerve, and give off branches to the lining membrane of the antrum and three twigs to each of the molar teeth. These twigs enter the foramina at the apices of the fangs and supply the pulp.

The **middle superior dental branch** is given off from the superior maxillary nerve in the back part of the infra-orbital canal, and runs downward and forward in a special canal in the outer wall of the antrum to supply the two bicuspid teeth. It communicates with the posterior and anterior dental branches. At its point of

[1] After it enters the infra-orbital canal, the nerve is frequently called the *infra-orbital.*

communication with the posterior branch is a slight thickening which has received the name of the *ganglion of Valentin;* and at its point of communication with the anterior branch is a second enlargement, which is called the *ganglion of Bochdalek.* Neither of these is probably a true ganglion.

The **anterior superior dental branch,** of large size, is given off from the superior maxillary nerve just before its exit from the infra-orbital foramen; it enters a special canal in the anterior wall of the antrum, and divides into a series of branches which supply the incisor and canine teeth. It communicates with the middle dental nerve, and gives off a *nasal branch,* which passes through a minute canal into the nasal fossa, and supplies the mucous membrane of the fore part of the inferior meatus and the floor of this cavity, communicating with the nasal branches from Meckel's ganglion.

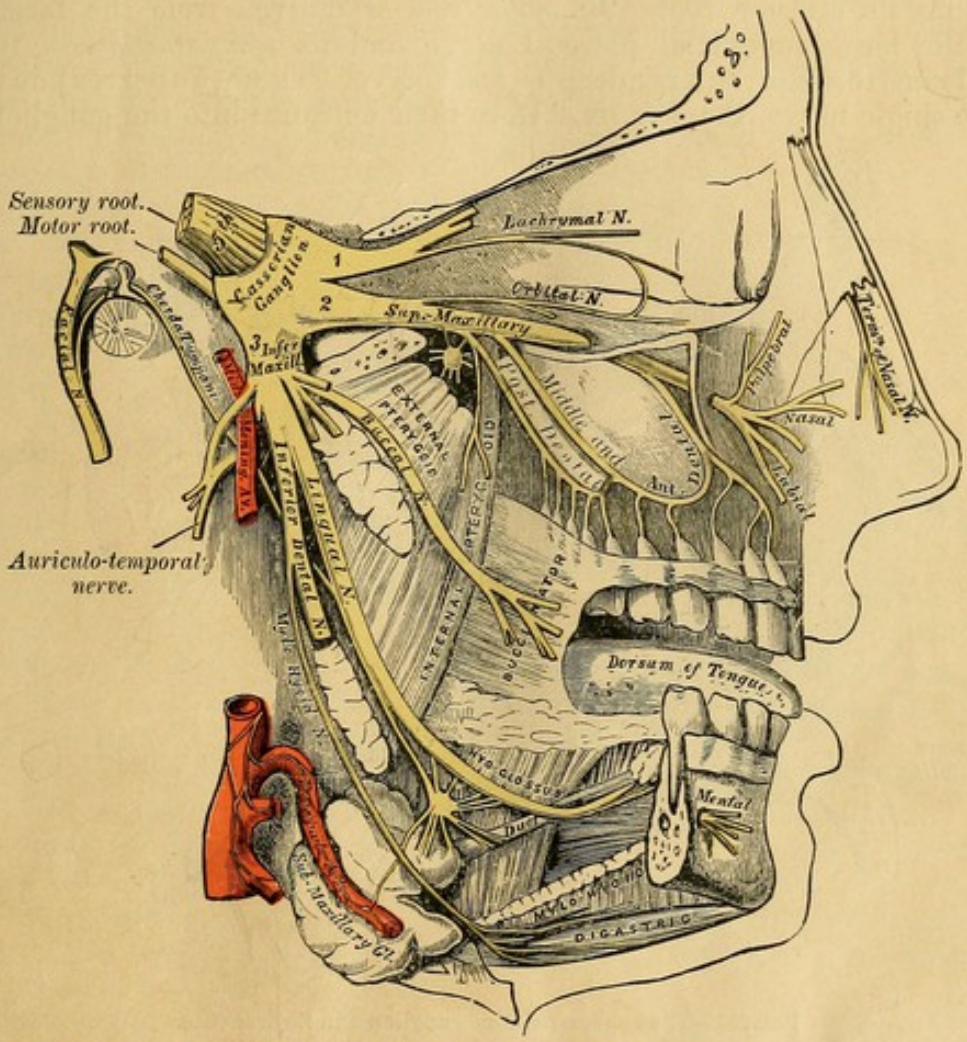

FIG. 395.—Distribution of the second and third divisions of the fifth nerve and submaxillary ganglion.

The **palpebral branches** pass upward beneath the Orbicularis palpebrarum. They supply the integument and conjunctiva of the lower eyelid with sensation, joining at the outer angle of the orbit with the facial nerve and malar branch of the orbital.

The **nasal branches** pass inward; they supply the integument of the side of the nose and join with the nasal branch of the ophthalmic.

The **labial branches,** the largest and most numerous, descend beneath the Levator labii superioris, and are distributed to the integument of the upper lip, the mucous membrane of the mouth, and labial glands.

All these branches are joined, immediately beneath the orbit, by filaments from the facial nerve, forming an intricate plexus, the *infra-orbital.*

The Spheno-palatine Ganglion (Fig. 396).

The **spheno-palatine ganglion** (*Meckel's*), the largest of the cranial ganglia, is deeply placed in the spheno-maxillary fossa, close to the spheno-palatine foramen. It is triangular or heart-shaped, of a reddish-gray color, and is situated just below the superior maxillary nerve as it crosses the fossa.

Its Branches of Communication.—Like the other ganglia of the fifth nerve, it possesses a motor, a sensory, and a sympathetic root. Its *sensory root* is derived from the superior maxillary nerve through its two spheno-palatine branches. These branches of the nerve, given off in the spheno-maxillary fossa, descend to the ganglion. Their fibres, for the most part, pass in front of the ganglion, as they proceed to their destination, in the palate and nasal fossa, and are not incorporated in the ganglionic mass; some few of the fibres, however, enter the ganglion, constituting its sensory root. Its *motor root* is derived from the facial nerve through the large superficial petrosal nerve, and its *sympathetic root* from the carotid plexus, through the large deep petrosal nerve. These two nerves join together to form a single nerve, the *Vidian*, before their entrance into the ganglion.

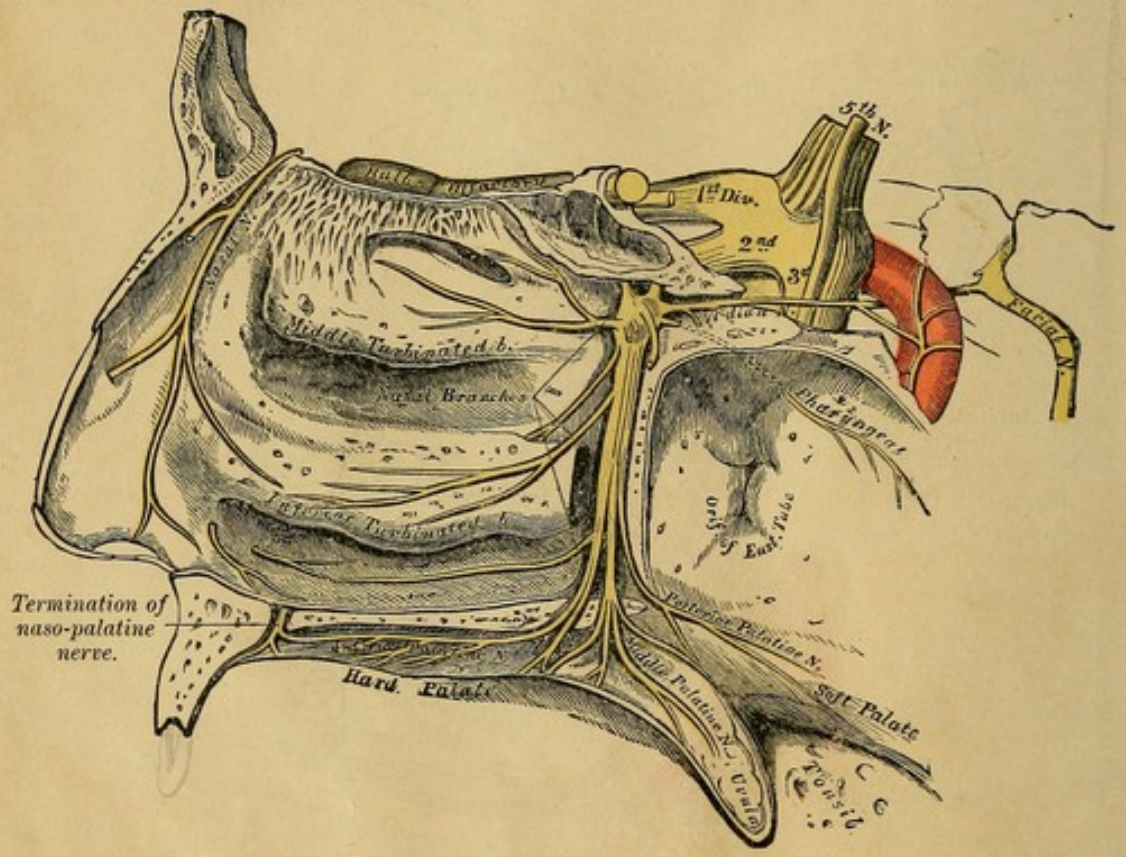

FIG. 396.—The spheno-palatine ganglion and its branches.

The *large superficial petrosal branch* (*nervus petrosus superficialis major*) is given off from the geniculate ganglion of the facial nerve in the aqueductus Fallopii; it passes through the hiatus Fallopii; enters the cranial cavity, and runs forward contained in a groove on the anterior surface of the petrous portion of the temporal bone, lying beneath the dura mater. It then enters the cartilaginous substance which fills in the foramen lacerum medium basis cranii, and, joining with the large deep petrosal branch, forms the Vidian nerve.

The *large deep petrosal branch* (*nervus petrosus profundus*) is given off from the carotid plexus, and runs through the carotid canal on the outer side of the internal carotid artery. It then enters the cartilaginous substance which fills in the foramen lacerum medium, and joins with the large superficial petrosal nerve to form the Vidian.

The *Vidian nerve*, formed in the cartilaginous substance which fills in the middle lacerated foramen by the junction of the two preceding nerves, passes

forward, through the Vidian canal, with the artery of the same name, and is joined by a small ascending branch, the *sphenoidal branch*, from the otic ganglion. Finally, it enters the spheno-maxillary fossa, and joins the posterior angle of Meckel's ganglion.

Its *branches of distribution* are divisible into four groups: *ascending*, which pass to the orbit; *descending*, to the palate; *internal*, to the nose; and *posterior branches*, to the pharynx and nasal fossæ.

The *ascending branches* are two or three delicate filaments, which enter the orbit by the spheno-maxillary fissure, and supply the periosteum. According to Luschka, some filaments pass through foramina in the suture between the os planum of the ethmoid and frontal bones to supply the mucous membrane of the posterior ethmoidal and sphenoidal sinuses.

The *descending* or *palatine branches* are distributed to the roof of the mouth, the soft palate, tonsil, and lining membrane of the nose. They are almost a direct continuation of the spheno-palatine branches of the superior maxillary nerve, and are three in number—anterior, middle, and posterior.

The *anterior* or *large palatine nerve* descends through the posterior palatine canal, emerges upon the hard palate at the posterior palatine foramen, and passes forward through a groove in the hard palate nearly as far as the incisor teeth. It supplies the gums, the mucous membrane and glands of the hard palate, and communicates in front with the termination of the naso-palatine nerve. While in the posterior palatine canal it gives off *inferior nasal branches*, which enter the nose through openings in the palate bone, and ramify over the inferior turbinated bone and middle and inferior meatuses; and at its exit from the canal a palatine branch is distributed to both surfaces of the soft palate.

The *middle* or *external palatine nerve* descends through one of the accessory palatine canals, distributing branches to the uvula, tonsil, and soft palate. It is occasionally wanting.

The *posterior* or *small palatine nerve* descends with a minute artery through the small posterior palatine canal, emerging by a separate opening behind the posterior palatine foramen. It supplies the Levator palati and Azygos uvulæ muscles,[1] the soft palate, tonsil, and uvula. The middle and posterior palatine join with the tonsillar branches of the glosso-pharyngeal to form the plexus around the tonsil (*circulus tonsillaris*).

The *internal branches* are distributed to the septum and outer wall of the nasal fossæ. They are the superior nasal (anterior) and the naso-palatine.

The *superior nasal branches* (*anterior*), four or five in number, enter the back part of the nasal fossa by the spheno-palatine foramen. They supply the mucous membrane covering the superior and middle spongy bones, and that lining the posterior ethmoidal cells, a few being prolonged to the upper and back part of the septum.

The *naso-palatine nerve* (*Cotunnius*) also enters the nasal fossa through the spheno-palatine foramen, and passes inward across the roof of the nose, below the orifice of the sphenoidal sinus, to reach the septum; it then runs obliquely downward and forward along the lower part of the septum, to the anterior palatine foramen, lying between the periosteum and mucous membrane. It descends to the roof of the mouth through the anterior palatine canal. The two nerves are here contained in separate and distinct canals, situated in the intermaxillary suture, and termed the foramina of Scarpa, the left nerve being usually anterior to the right one. In the mouth they become united, supply the mucous membrane behind the incisor teeth, and join with the anterior palatine nerve. The naso-palatine nerve furnishes a few small filaments to the mucous membrane of the septum.

The *posterior branches* are the pharyngeal (pterygo-palatine) and the upper posterior nasal branches.

The *pharyngeal nerve* (*pterygo-palatine*) is a small branch arising from the

[1] It is probable that this is not the true motor supply to these muscles, but that they are supplied by the spinal accessory through the pharyngeal plexus.

back part of the ganglion, being generally blended with the Vidian nerve. It passes through the pterygo-palatine canal with the pterygo-palatine artery, and is distributed to the mucous membrane of the upper part of the pharynx, behind the Eustachian tube.

The *upper posterior nasal branches* are a few twigs given off from the posterior part of the ganglion, which run backward in the sheath of the Vidian nerve to the mucous membrane at the back part of the roof, septum, and superior meatus of the nose and that covering the end of the Eustachian tube.

The Inferior Maxillary Nerve (Fig. 395).

The **Inferior Maxillary Nerve** (*n. mandibularis*) distributes branches to the teeth and gums of the lower jaw, the integument of the temple and external ear, the lower part of the face and lower lip, and the muscles of mastication; it also supplies the tongue with a large branch. It is the largest of the three divisions of the fifth, and is made up of two roots: a large or sensory root proceeding from the inferior angle of the Gasserian ganglion; and a small or motor root, which passes beneath the ganglion, and unites with the sensory root just after its exit from the skull through the foramen ovale. Immediately beneath the base of the skull this nerve divides into two trunks, anterior and posterior. Previous to its division the primary trunk gives off from its inner side a recurrent (meningeal) branch and the nerve to the Internal pterygoid muscle.

The **recurrent branch** is given off directly after its exit from the foramen ovale. It passes backward into the skull through the foramen spinosum with the middle meningeal artery. It divides into two branches, anterior and posterior, which accompany the main divisions of the artery and supply the dura mater. The posterior branch also supplies the mucous lining of the mastoid cells. The anterior branch communicates with the meningeal branch of the superior maxillary nerve.

The **Internal Pterygoid Nerve,** given off from the inferior maxillary previous to its division, is intimately connected at its origin with the otic ganglion. It is a long and slender branch, which passes inward to enter the deep surface of the Internal pterygoid muscle.

The *anterior* and smaller division, which receives nearly the whole of the motor root, divides into branches which supply the muscles of mastication. They are the masseteric, deep temporal, buccal, and external pterygoid.

The **masseteric branch** passes outward, above the External pterygoid muscle, in front of the temporo-mandibular articulation and behind the tendon of the temporal muscle; it crosses the sigmoid notch with the masseteric artery, to the deep surface of the Masseter muscle, in which it ramifies nearly as far as its anterior border. It occasionally gives a branch to the Temporal muscle, and a filament to the articulation of the jaw.

The **deep temporal branches,** two in number, anterior and posterior, supply the deep surface of the Temporal muscle. The *posterior branch*, of small size, is placed at the back of the temporal fossa. It is sometimes joined with the masseteric branch. The *anterior branch* is frequently given off from the buccal nerve; it is reflected upward, at the pterygoid ridge of the sphenoid, to the front of the temporal fossa. Sometimes there are three deep temporal branches; the third branch (*middle deep temporal*) passes outward above the External pterygoid muscle, and runs upward on the bone to enter the deep surface of the Temporal muscle.

The **buccal branch** passes forward between the two heads of the External pterygoid, and downward beneath the inner surface of the coronoid process of the lower jaw, or through the fibres of the Temporal muscle, to reach the surface of the Buccinator, upon which it divides into a superior and an inferior branch. It gives a branch to the External pterygoid during its passage through that muscle, and a few ascending filaments to the Temporal muscle, one of which occasionally joins with the anterior branch of the deep temporal nerve. The *upper branch* supplies the integument and upper part of the Buccinator muscle, joining with

the facial nerve round the facial vein. The *lower branch* passes forward to the angle of the mouth: it supplies the integument and Buccinator muscle, as well as the mucous membrane lining the inner surface of that muscle, and joins the facial nerve.[1]

The **External Pterygoid Nerve** is most frequently derived from the buccal, but it may be given off separately from the anterior trunk of the nerve. It enters the muscle on its inner surface.

The *posterior* and larger division of the inferior maxillary nerve is for the most part sensory, but receives a few filaments from the motor root. It divides into three branches: auriculo-temporal, lingual (gustatory), and inferior dental.

The **auriculo-temporal nerve** generally arises by two roots, between which the middle meningeal artery passes. It runs backward beneath the External pterygoid muscle to the inner side of the neck of the lower jaw. It then turns upward with the temporal artery, between the external ear and condyle of the jaw, under cover of the parotid gland, and, escaping from beneath this structure, ascends over the zygoma and divides into two temporal branches.

The *branches of communication* are with the facial and with the otic ganglion. The branches of communication with the facial, usually two in number, pass forward from behind the neck of the condyle of the jaw, to join this nerve at the posterior border of the Masseter muscle. They form one of the principal branches of communication between the facial and the fifth nerve. The filaments of communication with the otic ganglion are derived from the commencement of the auriculo-temporal nerve.

The *branches of distribution* are—

Anterior auricular.
Branches to the meatus auditorius.
Superficial temporal.
Articular.
Parotid.

The *anterior auricular branches* are usually two in number. They supply the front of the upper part of the pinna, being distributed principally to the skin covering the front of the helix and tragus.

Branches to the meatus auditorius, two in number, enter the canal between the bony and cartilaginous portion of the meatus. They supply the skin lining the meatus; the upper one sending a filament to the membrana tympani.

A *branch to the temporo-mandibular articulation* is usually derived from the auriculo-temporal nerve.

The *parotid branches* supply the parotid gland.

The *superficial temporal* accompanies the temporal artery to the vertex of the skull, and supplies the integument of the temporal region, communicating with the facial nerve, and the temporal branch of the temporo-malar, from the superior maxillary.

The **lingual nerve (gustatory)** supplies the papillæ and mucous membrane of the anterior two-thirds of the tongue. It is deeply placed throughout the whole of its course. It lies at first beneath the External pterygoid muscle, together with the inferior dental nerve, being placed to the inner side of this nerve, and is occasionally joined to it by a branch which may cross the internal maxillary artery. The chorda tympani also joins it at an acute angle in this situation. The nerve then passes between the Internal pterygoid muscle and the inner side of the ramus of the jaw, and crosses obliquely to the side of the tongue over the Superior constrictor and Stylo-glossus muscles, and then between the Hyo-glossus muscle and deep part of the submaxillary gland; the nerve finally runs across Wharton's duct, and along the side of the tongue to its apex, lying immediately beneath the mucous membrane.

The *branches of communication* are with the facial through the chorda tympani, the inferior dental and hypoglossal nerves, and the submaxillary ganglion.

[1] There seems to be no reason to doubt that the branch supplying the Buccinator muscle is entirely a nerve of ordinary sensation, and that the true motor supply of this muscle is from the facial.

The branches to the submaxillary ganglion are two or three in number; those connected with the hypoglossal nerve form a plexus at the anterior margin of the Hyo-glossus muscle.

The *branches of distribution* supply the mucous membrane of the mouth, the gums, the sublingual gland, the filiform and fungiform papillæ and mucous membrane of the tongue; the terminal filaments communicate, at the tip of the tongue, with the hypoglossal nerve.

The **Inferior Dental** is the largest of the three branches of the inferior maxillary nerve. It passes downward with the inferior dental artery, at first beneath the External pterygoid muscle, and then between the internal lateral ligament and the ramus of the jaw to the dental foramen. It then passes forward in the dental canal of the inferior maxillary bone, lying beneath the teeth, as far as the mental foramen, where it divides into two terminal branches, incisor and mental.

The branches of the inferior dental are, the mylo-hyoid, dental, incisive, and mental.

The *mylo-hyoid* is derived from the inferior dental just as that nerve is about to enter the dental foramen. It descends in a groove on the inner surface of the ramus of the jaw, in which it is retained by a process of fibrous membrane. It reaches the under surface of the Mylo-hyoid muscle, and supplies it and the anterior belly of the Digastric.

The *dental branches* supply the molar and bicuspid teeth. They correspond in number to the fangs of those teeth: each nerve entering the orifice at the point of the fang and supplying the pulp of the tooth.

The *incisive branch* is continued onward within the bone to the middle line, and supplies the canine and incisor teeth.

The *mental branch* emerges from the bone at the mental foramen, and divides beneath the Depressor anguli oris into two or three branches; one descends to supply the skin of the chin, and another (sometimes two) ascends to supply the skin and mucous membrane of the lower lip. These branches communicate freely with the facial nerve.

Two small ganglia are connected with the inferior maxillary nerve—the otic with the trunk of the nerve, and the submaxillary with its lingual branch.

Otic Ganglion (Fig. 397).

The **Otic Ganglion** (*Arnold's*) is a small, oval-shaped, flattened ganglion of a reddish-gray color, situated immediately below the foramen ovale, on the inner surface of the inferior maxillary nerve, and round the origin of the internal pterygoid nerve. It is in relation, *externally*, with the trunk of the inferior maxillary nerve, at the point where the motor root joins the sensory portion; *internally*, with the cartilaginous part of the Eustachian tube, and the origin of the Tensor palati muscle; *behind* it is the middle meningeal artery.

Branches of Communication.—This ganglion is connected with the internal pterygoid branch of the inferior maxillary nerve by two or three short, delicate filaments. From this it may obtain a motor root, and possibly also a sensory root, as these filaments from the nerve to the Internal pterygoid may contain sensory fibres. It communicates with the glosso-pharyngeal and facial nerves through the small superficial petrosal nerve continued from the tympanic plexus, and through this communication it probably receives its sensory root from the glosso-pharyngeal and its motor root from the facial; its communication with the sympathetic is effected by a filament from the plexus surrounding the middle meningeal artery. The ganglion also communicates with the auriculo-temporal nerve. This is probably a branch from the glosso-pharyngeal which passes to the ganglion, and through it and the auriculo-temporal nerve to the parotid gland. A slender filament (*sphenoidal*) ascends from it to the Vidian nerve.

Its *branches of distribution* are a filament to the Tensor tympani and one to the Tensor palati. The former passes backward on the outer side of the Eustachian

tube; the latter arises from the ganglion, near the origin of the internal pterygoid nerve, and passes forward. The fibres of these nerves are, however, mainly derived

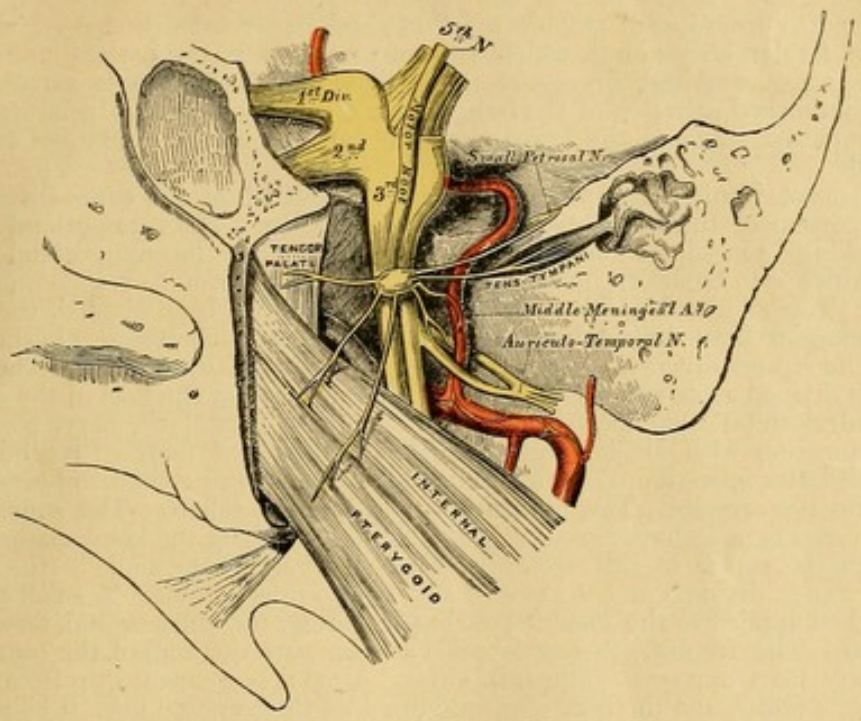

FIG. 397.—The otic ganglion and its branches.

from the nerve to the Internal pterygoid muscle. It also gives off a small communicating branch to the chorda tympani.

The Submaxillary Ganglion (Fig. 395).

The **submaxillary ganglion** is of small size, fusiform in shape, and situated above the deep portion of the submaxillary gland, near the posterior border of the Mylo-hyoid muscle, being connected by filaments with the lower border of the lingual (gustatory) nerve.

Branches of Communication.—This ganglion is connected with the lingual (gustatory) nerve by a few filaments which join it separately at its fore and back part. It also receives a branch from the chorda tympani, by which it communicates with the facial, and communicates with the sympathetic by filaments from the sympathetic plexus around the facial artery.

Branches of Distribution.—These are five or six in number: they arise from the lower part of the ganglion, and supply the mucous membrane of the mouth and Wharton's duct, some being lost in the submaxillary gland. The branch of communication from the lingual to the fore part of the ganglion is by some regarded as a branch of distribution, by which filaments of the chorda tympani pass from the ganglion to the nerve, and by it are conveyed to the sublingual gland and the tongue.

Surface Marking.—It will be seen from the above description that the three terminal branches of the three divisions of the fifth nerve emerge from foramina in the bones of the skull and face on to the face: the terminal branch of the first division emerging through the supra-orbital foramen; that of the second through the infra-orbital foramen; and the third through the mental foramen. The supra-orbital foramen is situated at the junction of the internal and middle third of the supra-orbital arch. If a straight line is drawn from this point to the lower border of the inferior maxillary bone, so that it passes between the two bicuspid teeth of the lower jaw, it will pass over the infra-orbital and mental foramina, the former being situated about one centimetre (two-fifths of an inch) below the margin of the orbit, and the latter varying in position according to the age of the individual. In the adult it is midway between the upper and lower borders of the inferior maxillary bone; in the child it is nearer the lower border; and in the edentulous jaw of old age it is close to the upper margin.

Surgical Anatomy.—The fifth nerve may be affected in its entirety, or its sensory or motor root may be affected, or one of its primary main divisions. In injury to the sensory root there is anæsthesia of the half of the face on the side of the lesion, with the exception of the skin over the parotid gland; insensibility of the conjunctiva, followed by destructive inflammation of the cornea, partly from loss of trophic influence, and partly from the irritation produced by the presence of foreign bodies on it, which are not perceived by the patient, and therefore not expelled by the act of winking; dryness of the nose, loss to a considerable extent of the sense of taste, and diminished secretion of the lachrymal and salivary glands. In injury to the motor root there is impaired action of the lower jaw from paralysis of the muscles of mastication on the affected side.

The fifth nerve is often the seat of neuralgia, and each of the three divisions has been divided or a portion of the nerve excised for this affection. The supra-orbital nerve may be exposed by making an incision an inch and a half in length along the supra-orbital margin below the eyebrow, which is to be drawn upward, the centre of the incision corresponding to the supra-orbital notch. The skin and Orbicularis palpebrarum having been divided, the nerve can be easily found emerging from the notch and lying in some loose cellular tissue. It should be drawn up by a blunt hook and divided, or, what is better, a portion of it removed. The infra-orbital nerve has been divided at its exit by an incision on the cheek; or the floor of the orbit has been exposed, the infra-orbital canal opened up, and the anterior part of the nerve resected; or the whole nerve, together with Meckel's ganglion as far back as the foramen rotundum, has been removed. This latter operation, though undoubtedly a severe proceeding, appears to have been followed by the best results. The operation is performed as follows: The superior maxillary bone is first exposed by a T-shaped incision, one limb passing along the lower margin of the orbit, the other from the centre of this vertically down the cheek to the angle of the mouth. The nerve is then found, divided, and a piece of silk tied to it as a guide. A small trephine (one-half inch) is then applied to the bone below, but including, the infra-orbital foramen, and the antrum opened. The trephine is now applied to the posterior wall of the antrum, and the spheno-maxillary fossa exposed. The infra-orbital canal is now opened up from below by fine cutting-pliers or a chisel, and the nerve drawn down into the trephine hole, it being held on the stretch by means of the piece of silk; it is severed with fine curved scissors as near the foramen rotundum as possible, any branches coming off from the ganglion being also divided.[1] The mental branch of the inferior dental nerve has been divided at its exit from the foramen by an incision made through the mucous membrane where it is reflected from the alveolar process on to the lower lip; or a portion of the trunk of the inferior dental nerve has been resected by an incision on the cheek through the Masseter muscle, exposing the outer surface of the ramus of the jaw. A trephine was then applied over the position of the inferior dental foramen and the outer table removed, so as to expose the inferior dental canal. The nerve was dissected out of the portion of the canal exposed, and, having been divided after its exit from the mental foramen, it was by traction on the end exposed in the trephine hole, drawn out entire, and cut off as high up as possible.[2] The inferior dental nerve has also been divided by an incision within the mouth, the bony point guarding the inferior dental foramen forming the guide to the nerve. The buccal nerve may be divided by an incision through the mucous membrane of the mouth and the Buccinator just in front of the anterior border of the ramus of the lower jaw (Stimson).

The lingual (gustatory) nerve is occasionally divided with the view of relieving the pain in cancerous disease of the tongue. This may be done in that part of its course where it lies below and behind the last molar tooth. If a line is drawn from the middle of the crown of the last molar tooth to the angle of the jaw, it will cross the nerve, which lies about half an inch behind the tooth, parallel to the bulging alveolar ridge on the inner side of the body of the bone. If the knife is entered three-quarters of an inch behind and below the last molar tooth and carried down to the bone, the nerve will be divided. Hilton divided it opposite the second molar tooth, where it is covered only by the mucous membrane, and Lucas pulls the tongue forward and over to the opposite side, when the nerve can be seen standing out as a firm cord under the mucous membrane by the side of the tongue and can be easily seized with a sharp hook and divided or a portion excised. This is a simple enough operation on the cadaver, but when the disease is extensive and has extended to the floor of the mouth, as is generally the case when division of the nerve is required, the operation is not practicable.

The Sixth Nerve (Fig. 393).

The **Sixth** or **Abducent Nerve** supplies the External rectus muscle.

Its *superficial origin* is by several filaments from the constricted part of the pyramid, close to the pons, or from the lower border of the pons itself, in the groove between this body and the medulla. Its *deep origin* is from the upper part of the floor of the fourth ventricle, close to the median line, beneath the eminentia teres.

From the nucleus of the sixth nerve fibres pass through the posterior longi-

[1] Camochan, *Amer. Journ. Med. Science*, 1858, p. 136.
[2] Mears, *Trans. Amer. Surg. Assoc.*, vol. ii. p. 469.

tudinal bundle to the oculo-motor nucleus of the opposite side and into the third nerve, along which they are carried to the Internal rectus muscle. The External rectus of one eye and the Internal rectus of the other may therefore be said to receive their nerves from the same nucleus—a factor of great importance in connection with the conjugate movements of the eyeball, and one that may explain certain paralytic phenomena of the Recti muscles, which are often associated with lesions in the pons.

The nerve pierces the dura mater on the basilar surface of the sphenoid bone, runs through a notch immediately below the posterior clinoid process, and enters the cavernous sinus. It passes forward through the sinus, lying on the outer side of the internal carotid artery. It enters the orbit through the sphenoidal fissure, and lies above the ophthalmic vein, from which it is separated by a lamina of dura mater. It then passes between the two heads of the External rectus, and is distributed to that muscle on its ocular surface.

Branches of Communication.—It is joined by several filaments from the carotid and cavernous plexus, and by one from the ophthalmic nerve.

The above-mentioned nerve, as well as the third, fourth, and the ophthalmic division of the fifth, as they pass to the orbit, bear a certain relation to each other in the cavernous sinus, at the sphenoidal fissure, and in the cavity of the orbit, which will now be described.

In the *cavernous sinus* (Fig. 327) the third, fourth, and ophthalmic division of the fifth are placed on the outer wall of the sinus, in their numerical order both from above downward and from within outward. The sixth nerve lies at the outer side of the internal carotid artery. As these nerves pass forward to the sphenoidal fissure, the third and fifth nerves become divided into branches, and the sixth approaches the rest, so that their relative position becomes considerably changed.

In the *sphenoidal fissure* (Fig. 398) the fourth and the frontal and lachrymal divisions of the ophthalmic lie upon the same plane, the former being most

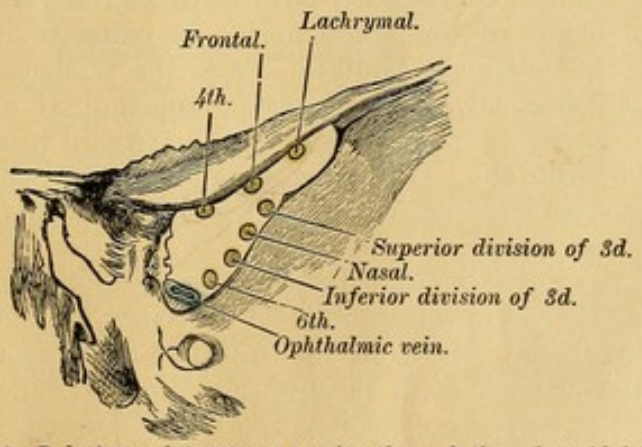

FIG. 398.—Relations of structures passing through the sphenoidal fissure.

internal, the latter external, and they enter the cavity of the orbit above the muscles. The remaining nerves enter the orbit between the two heads of the External rectus. The superior division of the third is the highest of these; beneath this lies the nasal branch of the ophthalmic; then the inferior division of the third; and the sixth lowest of all.

In the *orbit* the fourth and the frontal and lachrymal divisions of the ophthalmic lie on the same plane immediately beneath the periosteum, the fourth nerve being internal and resting on the Superior oblique, the frontal resting on the Levator palpebræ, and the lachrymal on the External rectus. Next in order comes the superior division of the third nerve, lying immediately beneath the Superior rectus, and then the nasal branch of the ophthalmic, crossing the optic nerve from the outer to the inner side of the orbit. Beneath these is found the optic nerve, surrounded in front by the ciliary nerves, and having the lenticular

ganglion on its outer side, between it and the External rectus. Below the optic is the inferior division of the third and the sixth, which lies on the outer side of the orbit.

Surgical Anatomy.—The sixth nerve is more frequently involved in fractures of the base of the skull than any other of the cranial nerves. The result of paralysis of this nerve is internal or convergent squint. When injured so that its function is destroyed, there is, in addition to the paralysis of the External rectus muscle, often a certain amount of contraction of the pupil, because some of the sympathetic fibres to the radiating muscle of the iris pass along with this nerve.

The Seventh Nerve (Figs. 399, 400, 401).

The **Seventh** or **Facial Nerve** (*portio dura*) is the motor nerve of all the muscles of expression in the face, and of the Platysma and Buccinator; the muscles of the External ear; the posterior belly of the Digastric, and the Stylo-hyoid. Its chorda tympani branch is the nerve of taste for the anterior two-thirds of the tongue and the vaso-dilator nerve of the submaxillary and sublingual glands; its tympanic branch supplies the Stapedius.

Its *superficial origin* is from the upper end of the medulla oblongata, in the groove between the olivary and restiform bodies. Its *deep origin* is from a nucleus situated in the reticular formation of the lower part of the pons, a little external and ventral to the nucleus of the sixth nerve. From this origin the fibres pursue a curved course in the substance of the pons. They first pass backward and inward, and then turn upward and forward forming the funiculus teres, which produces an eminence (eminentia teres) on the floor of the fourth ventricle, and finally bend sharply downward and outward round the upper end of the nucleus of origin of the sixth nerve, to reach their superficial origin between the olivary and restiform bodies. From the nucleus of the third nerve some fibres arise which descend in the posterior longitudinal bundle and join the facial just before it leaves the pons; these fibres are said to supply the anterior belly of the Occipito-frontalis, Orbicularis palpebrarum, and the Corrugator supercilii, as these muscles have been observed to escape paralysis in lesions of the nucleus of the facial nerve.

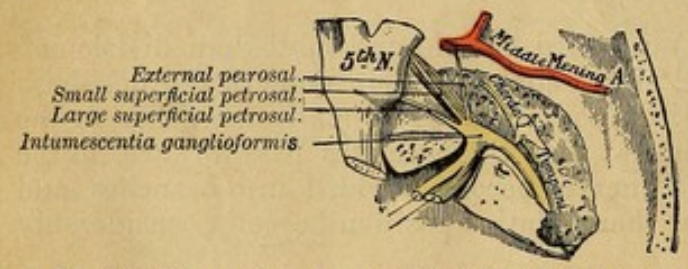

FIG. 399.—The course and connections of the facial nerve in the temporal bone.

The auditory nerve (*portio mollis*) lies to its outer side; and between the two is a small fasciculus, the *pars intermedia* of Wrisberg, which arises from the medulla and joins the facial nerve in the internal auditory meatus. The deep origin of the pars intermedia is from the upper end of the nucleus of the glosso-pharyngeal nerve, and at its emergence it is frequently connected with both nerves.

The pars intermedia may be regarded as the sensory root of the facial nerve, analogous to the sensory root of the fifth, and its real nucleus of origin would then consist of the geniculate ganglion.

The facial nerve, firmer, rounder, and smaller than the auditory, passes forward and outward upon the middle peduncle of the cerebellum, and enters the internal auditory meatus with the auditory nerve. Within the meatus the facial nerve lies in a groove along the upper and anterior part of the auditory nerve, and the pars intermedia is placed between the two, and joins the inner angle of the geniculate ganglion. Occasionally a few of its fibres pass into the auditory nerve. Beyond the ganglion its fibres are generally regarded as forming the chorda tympani.

At the bottom of the meatus, the facial nerve enters the aquæductus Fallopii, and follows the course of that canal through the petrous portion of the temporal bone, from its commencement at the internal meatus, to its termination at the stylo-mastoid foramen. It is at first directed outward between the cochlea and vestibule toward the inner wall of the tympanum; it then bends suddenly backward and arches downward behind the tympanum to the stylo-mastoid foramen.

At the point where it changes its direction, it presents a reddish gangliform swelling (*intumescentia ganglioformis*, or *geniculate ganglion*). On emerging from the stylo-mastoid foramen it runs forward in the substance of the parotid gland, crosses the external carotid artery, and divides behind the ramus of the lower jaw into two primary branches, *temporo-facial* and *cervico-facial*, from which numerous offsets are distributed over the side of the head, face, and upper part of the neck, supplying the superficial muscles in these regions. As the primary branches and their offsets diverge from each other, they present somewhat the appearance of a bird's claw; hence the name of *pes anserinus* is given to the divisions of the facial nerve in and near the parotid gland.

The communications of the facial nerve may be thus arranged:

In the internal auditory meatus .	With the auditory nerve.
From the geniculate ganglion .	With Meckel's ganglion by the large superficial petrosal nerve.
	With the otic ganglion by the small superficial petrosal nerve.
	With the sympathetic on the middle meningeal by the external superficial petrosal nerve.
In the Fallopian aqueduct . .	With the auricular branch of the pneumogastric.
At its exit from the stylo-mastoid foramen	With the glosso-pharyngeal.
	With the pneumogastric.
	With the auricularis magnus.
	With the auriculo-temporal.
Behind the ear	With the small occipital.
On the face	With the three divisions of the fifth.
In the neck	With the superficial cervical.

In the internal auditory meatus some minute filaments pass between the facial and auditory nerves.

Opposite the hiatus Fallopii, the gangliform enlargement on the facial nerve communicates with Meckel's ganglion by means of the large superficial petrosal nerve, which forms its motor root; with the otic ganglion, by the small superficial petrosal nerve; and with the sympathetic filaments accompanying the middle meningeal artery, by the external petrosal (Bidder). From the gangliform enlargement, according to Arnold, a twig is sent back to the auditory nerve. Just before the facial nerve emerges from the stylo-mastoid foramen it generally receives a twig of communication from the auricular branch of the pneumogastric.

After its exit from the stylo-mastoid foramen, it sends a twig to the glosso-pharyngeal, another to the pneumogastric nerve, and communicates with the great auricular branch of the cervical plexus, with the auriculo-temporal branch of the inferior maxillary nerve in the parotid gland, with the small occipital behind the ear, on the face with the terminal branches of the three divisions of the fifth, and in the neck with the transverse cervical.

Branches of Distribution.

Within the aquæductus Fallopii .	Tympanic, to the Stapedius muscle.
	Chorda tympani.
At its exit from the stylo-mastoid foramen	Posterior Auricular.
	Digastric.
	Stylo-hyoid.
On the face	Temporo-facial: Temporal.
	Malar.
	Infra-orbital.
	Cervico-facial: Buccal.
	Supramaxillary.
	Inframaxillary.

The **tympanic branch** arises from the nerve opposite the pyramid; it passes through a small canal in the pyramid and supplies the Stapedius muscle.

The **chorda tympani** is given off from the facial as it passes vertically downward at the back of the tympanum, about a quarter of an inch before its exit from the stylo-mastoid foramen. It passes from below upward and forward in a

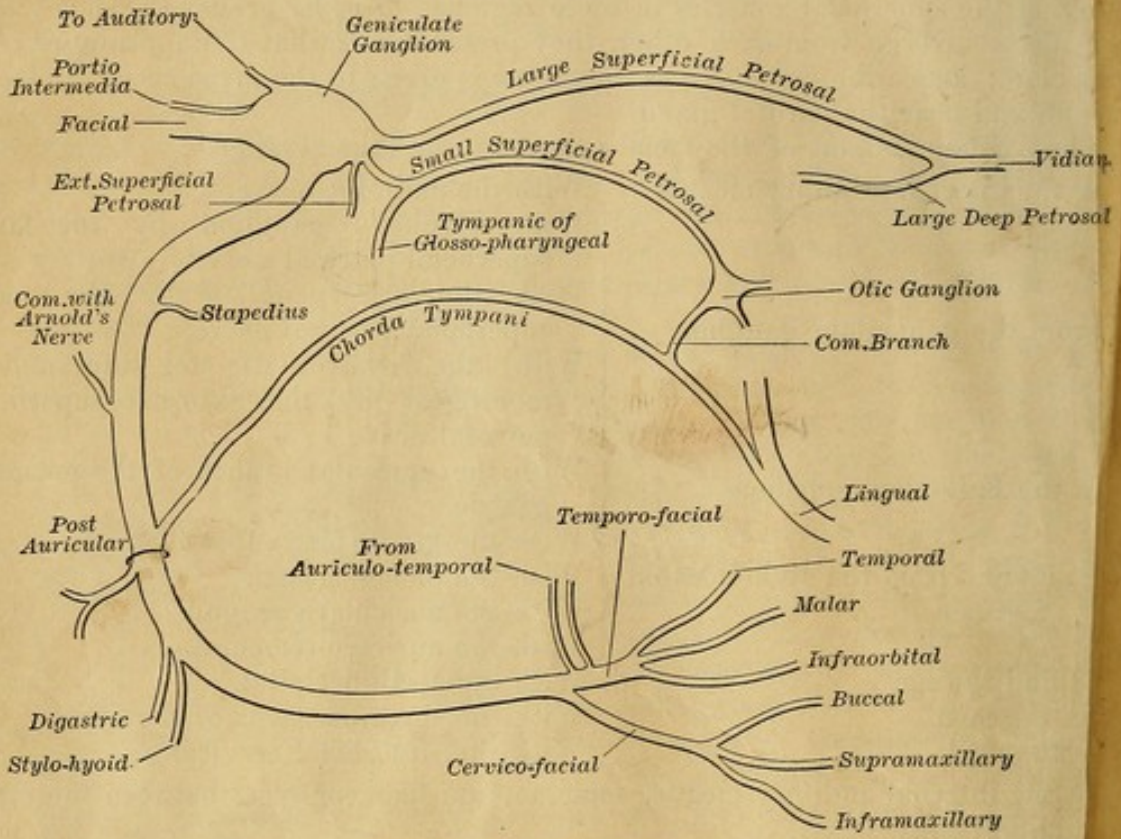

FIG. 400.—Plan of the facial nerve.

distinct canal, and enters the cavity of the tympanum through an aperture (*iter chordæ posterius*) on its posterior wall between the opening of the mastoid cells and the attachment of the membrana tympani, and becomes invested with mucous membrane. It passes forward through the cavity of the tympanum, between the fibrous and mucous layers of the membrana tympani, and over the handle of the malleus, emerging from that cavity through a foramen at the inner end of the Glaserian fissure, which is called the *iter chordæ anterius*, or *canal of Huguier*. It then descends between the two Pterygoid muscles, meets the lingual nerve at an acute angle, and accompanies it to the submaxillary gland; part of it then joins the submaxillary ganglion; the rest is continued onward through the muscular substance of the tongue to the mucous membrane covering its anterior two-thirds. A few of its fibres probably pass through the submaxillary ganglion to the sublingual gland. Before joining the lingual nerve it receives a small communicating branch from the otic ganglion. As already stated, the chorda tympani nerve is by many regarded as the continuation of the pars intermedia of Wrisberg.

The **Posterior auricular nerve** arises close to the stylo-mastoid foramen, and passes upward in front of the mastoid process, where it is joined by a filament from the auricular branch of the pneumogastric, and communicates with the mastoid branch of the great auricular and with the small occipital. As it ascends between the meatus and mastoid process it divides into two branches. The *auricular branch* supplies the Retrahens auriculum and the small muscles on the cranial surface of the pinna. The *occipital branch*, the larger, passes backward along the superior curved line of the occipital bone, and supplies the occipital portion of the Occipito-frontalis.

The **digastric branch** usually arises by a common trunk with the Stylo-hyoid branch: it divides into several filaments, which supply the posterior belly of the Digastric; one of these perforates that muscle to join the glosso-pharyngeal nerve.

The **stylo-hyoid** is a long, slender branch, which passes inward, entering the Stylo-hyoid muscle about its middle.

The **Temporo-facial**, the larger of the two terminal branches, passes upward and forward through the parotid glands, crosses the external carotid artery and temporo-maxillary vein, and passes over the neck of the condyle of the jaw, being connected in this situation with the auriculo-temporal branch of the inferior maxillary nerve, and divides into branches which are distributed over the temple and upper part of the face; these are divided into three sets—temporal, malar, and infra-orbital.

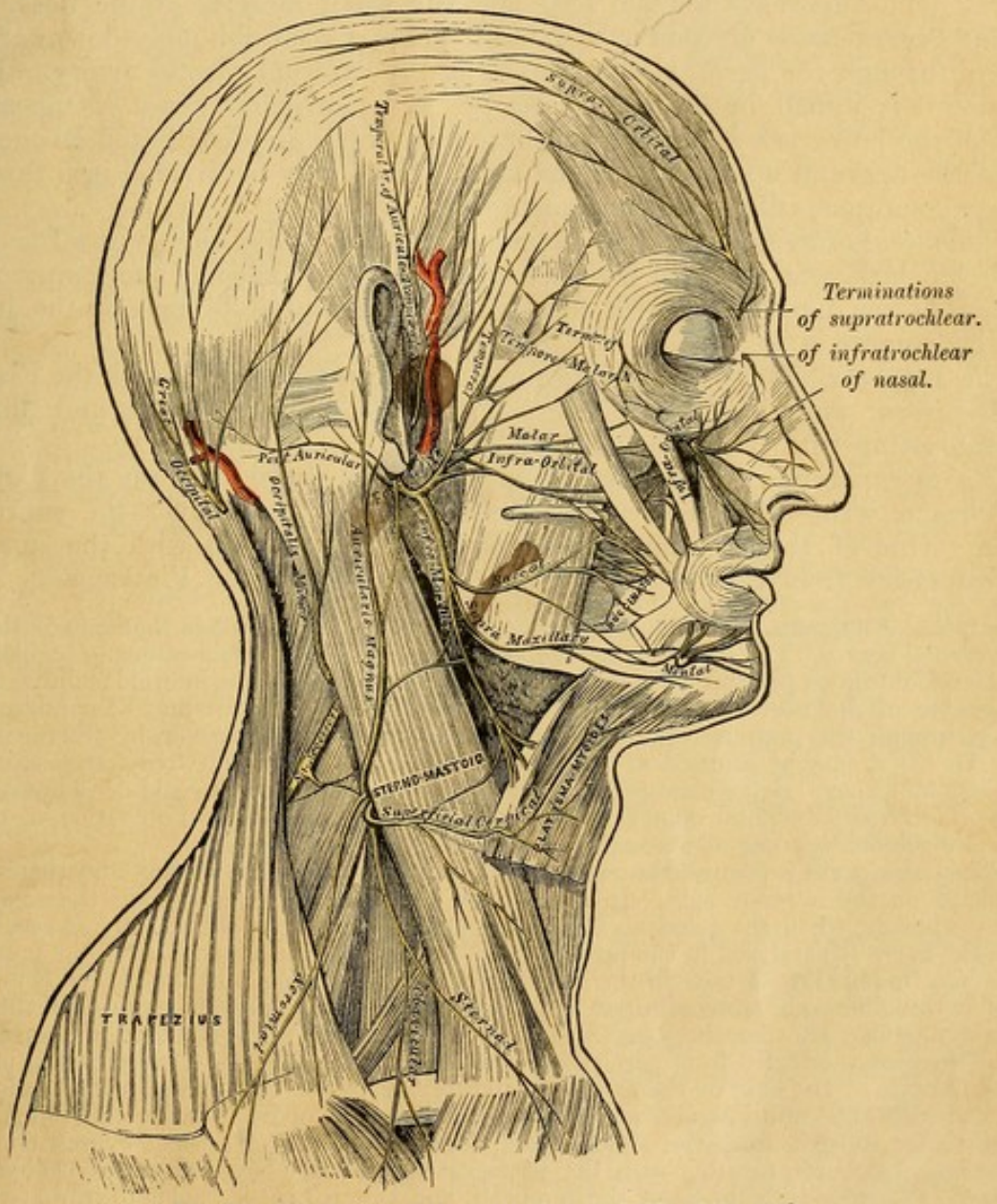

FIG. 401.—The nerves of the scalp, face, and side of the neck.

The *temporal branches* cross the zygoma to the temporal region, supplying the Attrahens and Attollens auriculam muscles, and join with the temporal branch of the temporo-malar, a branch of the superior maxillary, and with the auriculo-temporal branch of the inferior maxillary. The more anterior branches supply the frontal portion of the Occipito-frontalis, the Orbicularis palpebrarum, and Corrugator supercilii muscles, joining with the supra-orbital and lachrymal branches of the ophthalmic.

The *malar branches* pass across the malar bone to the outer angle of the orbit,

where they supply the Orbicularis palpebrarum muscle, joining with filaments from the lachrymal nerve; others supply the lower eyelid, joining with filaments of the malar branch (*subcutaneus malæ*) of the superior maxillary nerve.

The *infra-orbital*, of larger size than the rest, pass horizontally forward to be distributed between the lower margin of the orbit and the mouth. The *superficial branches* run beneath the skin and above the superficial muscles of the face, which they supply: some branches are distributed to the Pyramidalis nasi, joining at the inner angle of the orbit with the infratrochlear and nasal branches of the ophthalmic. The *deep branches* pass beneath the Zygomatici and the Levator labii superioris, supplying them and the Levator anguli oris, and form a plexus (*infra-orbital*) by joining with the infra-orbital branch of the superior maxillary nerve and the buccal branches of the cervico-facial. This branch also supplies the Levator labii superioris alæque nasi and the small muscles of the nose.

The **Cervico-facial division of the facial nerve** passes obliquely downward and forward through the parotid gland, crossing the external carotid artery. In this situation it is joined by branches from the great auricular nerve. Opposite the angle of the lower jaw it divides into branches which are distributed on the lower half of the face and upper part of the neck. These may be divided into three sets —buccal, supramaxillary, and inframaxillary.

The *buccal branches* cross the Masseter muscle. They supply the Buccinator and Orbicularis oris, and join with the infra-orbital branches of the temporo-facial division of the nerve, and with filaments of the buccal branch of the inferior maxillary nerve.

The *supramaxillary* or *mandibular branches* pass forward beneath the Platysma and Depressor anguli oris, supplying the muscles of the lower lip and chin, and communicating with the mental branch of the inferior dental nerve.

The *inframaxillary* or *cervical branches* run forward beneath the Platysma, and form a series of arches across the side of the neck over the suprahyoid region. One of these branches descends vertically to join with the superficial cervical nerve from the cervical plexus; others supply the Platysma.

Surgical Anatomy.—The facial nerve is more frequently paralyzed than any of the other of the cranial nerves. The paralysis may depend either upon (1) central causes—*i. e.* blood-clots or intracranial tumors pressing on the nerve before its entrance into the internal auditory meatus. It is also one of the nerves involved in "bulbar paralysis." Or (2) it may be paralyzed in its passage through the petrous bone by damage due to middle-ear disease or by fractures of the base. Or (3) it may be affected at or after its exit from the stylo-mastoid foramen. This is commonly known as "Bell's paralysis." It may be due to exposure to cold or to injury of the nerve, either from accidental wounds of the face or during some surgical operation, as removal of parotid tumors, opening of abscesses, or operations on the lower jaw.

When the cause is central, the sixth nerve is usually paralyzed as well, and there is also hemiplegia on the opposite side. In these cases the electrical reactions are the same as in health; whereas, when the paralysis is in the course of the nerve, the reaction is usually lost. When the nerve is paralyzed in the petrous bone, in addition to the paralysis of the muscles of expression, there is loss of taste in the anterior part of the tongue, and the patient is unable to recognize the difference between bitters and sweets, acids and salines, from involvement of the chorda tympani. The mouth is dry, because the salivary glands are not secreting; and the sense of hearing is affected from paralysis of the Stapedius. When the cause of the paralysis is from fracture of the base of the skull, the auditory nerve and the petrosal nerves, which are connected with the intumescentia ganglioformis, are also involved. When the injury to the nerve is after its exit from the stylo-mastoid foramen, all the muscles of expression, except the Levator palpebræ, together with the posterior belly of the Digastric and Stylo-hyoid, are paralyzed. There is smoothness of the forehead, and the patient is unable to frown; the eyelids cannot be closed, and the lower lid droops, so that the punctum is no longer in contact with the globe, and the tears run down the cheek; there is smoothness of the cheek and loss of the naso-labial furrow; the nostril cannot be dilated; the mouth is drawn to the sound side, and there is inability to whistle; food collects between the cheek and gum from paralysis of the Buccinator.

The facial nerve is at fault in cases of so-called "histrionic spasm," which consists in an almost constant and uncontrollable twitching of the muscles of the face. This twitching is sometimes so severe as to cause great discomfort and annoyance to the patient and to interfere with sleep, and for its relief the facial nerve has been stretched. The operation is performed by making an incision behind the ear from the root of the mastoid process to the angle of the jaw. The parotid is turned forward, and the dissection carried along the anterior border of the

Sterno-mastoid muscle and mastoid process until the upper border of the posterior belly of the Digastric is found. The nerve is parallel to this on about a level of the middle of the mastoid process. When found, the nerve must be stretched by passing a blunt hook beneath it and pulling it forward and outward. Too great force must not be used, for fear of permanent injury to the nerve.

Eighth Nerve.

The **Eighth** or **Auditory Nerve** (*portio mollis*) is the special nerve of the sense of hearing, being distributed exclusively to the internal ear.

Origin of the Eighth Nerve.—The eighth nerve consists of two sets of fibres, which, although differing in their central connections, are both concerned in the transmission of afferent impulses from the internal ear to the medulla and pons, and from there, by means of new fibres which arise from collections of gray matter in these structures, to the cerebrum and cerebellum. One set of fibres forms the vestibular root of the nerve, and arises from the cells in the ganglion of Scarpa; the other set constitutes the cochlear root, and takes origin from the cells in the ganglion spirale or ganglion of Corti. At its connection with the brain the eighth nerve occupies the groove between the pons and medulla, where it is situated between the restiform body, which is behind, and the seventh nerve, which is in front.

Vestibular or Ventral Root.—The fibres of this root enter the medulla to the inner side of those of the cochlear root, and pass between the restiform body, which is to their outer side, and the inferior root of the fifth, which lies to their inner side. They then divide into an ascending and a descending set. The fibres of the latter end by arborizing round the cells of the internal nucleus, which is situated in the *trigonum acustici* in the floor of the fourth ventricle. The ascending fibres either end in the same manner or in the *external nucleus*, which is situated to the outer side of the trigonum acustici and farther from the ventricular floor. It is described as consisting of two parts, an inner, the *nucleus of Deiters*, and an outer, the *nucleus of Bechteren*. Some of the axons of the cells of the external nucleus, and possibly also of the internal nucleus, are continued upward through the restiform body to the roof nuclei of the opposite side of the cerebellum, to which also are prolonged other fibres of the vestibular root without undergoing a relay in the nuclei of the medulla. A second set of fibres from the internal and external nuclei end partly in the tegmentum, while the remainder ascend in the posterior longitudinal bundle to arborize around the nuclei of the oculo-motor nerve.

Cochlear or Dorsal Root.—This part of the nerve is placed externally to the vestibular root. Its fibres end in two nuclei, one of which, the *accessory nucleus*, lies immediately in front of the restiform body; the other, the *tuberculum acusticum*, somewhat to its outer side.

The striæ acusticæ or medullary striæ are the axons of the cells of the tuberculum acusticum. They pass backward and inward over the restiform body, and across the floor of the fourth ventricle toward the middle line. Here they dip into the substance of the pons, to end around the cells of the *superior olive* of the same or opposite side. There are, however, other fibres, and these are both direct and crossed, which do not arborize around the tegmental nuclei, but pass into the lateral fillet. The cells of the accessory nucleus give origin to fibres which pass transversely in the pons and constitute the trapezium. The description given as to the mode of ending of the striæ acusticæ is applicable to that of the trapezoid fibres, viz., around the cells of the superior olive or of the *trapezoid nucleus* (which lies ventral to the olive) of the same or opposite side, while others, crossed or uncrossed, pass directly into the lateral fillet.

If the further connections of the cochlear nerve of one side, say the left, are considered, it is found that they lie to the outer side of the main sensory tract, the fillet, and are therefore termed the *lateral fillet*. The fibres comprising the left lateral fillet arise in the superior olive or trapezoid nucleus of the same or opposite side, while others are the uninterrupted fibres already alluded to, and these are

either crossed or uncrossed, the former being the axons of the cells of the right accessory nucleus or of the cells of the right tuberculum acusticum, while the latter are derived from the same cells of the left side. In the upper part of the fillet there is a collection of nerve-cells, the *nucleus of the fillet*, around the cells of which some of the fibres arborize, and from the cells of which axons originate to continue upward the tract of the lateral fillet. The ultimate ending of the left lateral fillet is partly in the quadrigeminal bodies of the same or opposite side, while the remainder of the fibres ascend in the posterior limb of the internal capsule to reach the first and perhaps the second left temporal convolution.

The auditory nerve contains a few afferent fibres which arise in the quadrigeminal bodies, the nucleus of the lateral fillet, trapezoid nucleus, and superior olive.

The auditory nerve after leaving the medulla passes forward across the posterior border of the middle peduncle of the cerebellum, in company with the facial nerve, from which it is partially separated by a small artery (auditory). It then enters the internal auditory meatus with the facial nerve. At the bottom of the meatus it receives one or two filaments from the facial nerve, and then divides into its two branches, *cochlear* and *vestibular*. The auditory nerve is soft in texture (hence the name, *portio mollis*), and is destitute of neurilemma. The distribution of the auditory nerve in the internal ear will be found described along with the anatomy of that organ in a subsequent page.

Surgical Anatomy.—The auditory nerve is frequently injured, together with the facial nerve, in fractures of the middle fossa of the base of the skull implicating the internal auditory meatus. The nerve may be either torn across, producing permanent deafness, or it may be bruised or pressed upon by extravasated blood or inflammatory exudation, when the deafness will in all probability be temporary. The nerve may also be injured by violent blows on the head without fracture, and deafness may arise from loud explosions from dynamite, etc., probably from some lesion of this nerve, which is more liable to be injured than the other cranial nerves on account of its structure. The test that the nerve is destroyed and that the deafness is not due to some lesion of the auditory apparatus is obtained by placing a vibrating tuning-fork on the head. The vibrations will be heard in cases where the auditory apparatus is at fault, but not in cases of destruction of the auditory nerve.

The Ninth Pair (Figs. 402, 403, 404).

The **Ninth** or **Glosso-pharyngeal Nerve** is distributed, as its name implies, to the tongue and pharynx, being the nerve of ordinary sensation to the mucous membrane of the pharynx, fauces, and tonsil; and the nerve of taste to all parts of the tongue to which it is distributed.

Its *superficial origin* is by three or four filaments, closely connected together, from the upper part of the medulla oblongata, in the groove between the olivary and restiform body.

Its *deep origin* may be traced through the fasciculi of the lateral tract, to three different sources: (1) some of the fibres may be traced to a nucleus of gray matter at the lower part of the floor of the fourth ventricle beneath the inferior fovea; (2) others may be traced downward into the *funiculus solitarius*, a rounded bundle of fibres in the lower part of the medulla, commencing immediately above the decussation of the pyramids (these fibres have not been distinctly traced to cells); (3) a third set of fibres take origin from the cells of the *nucleus ambiguus*. This nucleus is situated some distance from the floor of the fourth ventricle and lies slightly internal to the inferior fovea. It gives origin to the motor branches of the glosso-pharyngeal and vagus, and to the bulbar part of the spinal accessory. The real origin of the sensory fibres of the glosso-pharyngeal must be looked for in the jugular and petrosal ganglia which are developed from the neural crest.

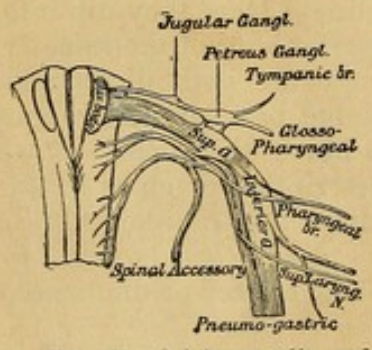

FIG. 402.—Origin, ganglia, and communications of the ninth, tenth, and eleventh cranial nerves.

From its superficial origin it passes outward across the flocculus, and leaves the

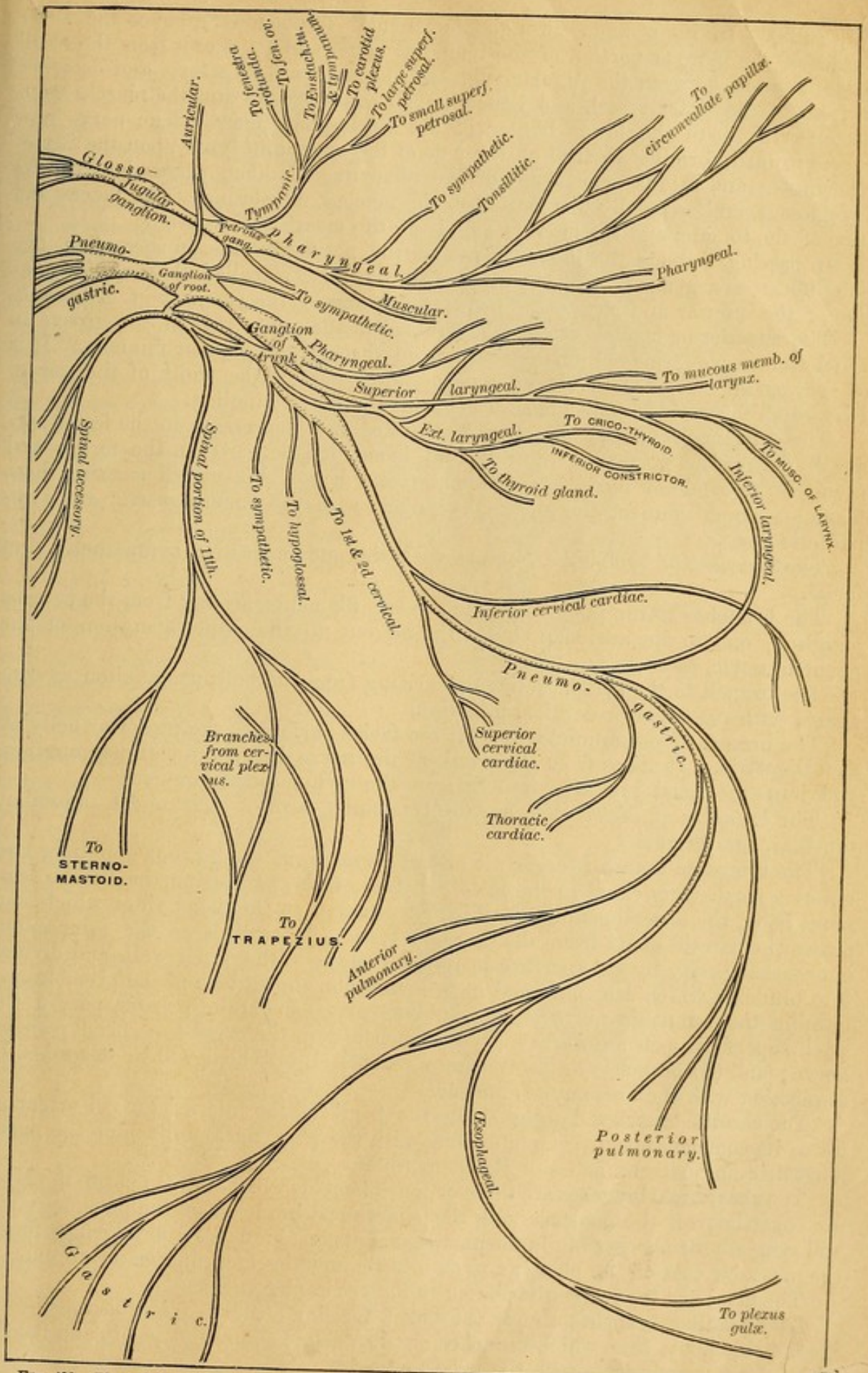

FIG. 403.—Plan of the glosso-pharyngeal, pneumogastric, and spinal accessory nerves. (After Fl-, and

skull at the central part of the jugular foramen, in a separate sheath to a second mater, external to and in front of the pneumogastric and spinal acce*the trunk of*

(Fig. 329). In its passage through the jugular foramen it grooves the lower border of the petrous portion of the temporal bone, and at its exit from the skull passes forward between the jugular vein and internal carotid artery, and descends in front of the latter vessel, and beneath the styloid process and the muscles connected with it, to the lower border of the Stylo-pharyngeus. The nerve now curves inward, forming an arch on the side of the neck, and lying upon the Stylo-pharyngeus and Middle constrictor of the pharynx. It then passes beneath the Hyoglossus, and is finally distributed to the mucous membrane of the fauces and base of the tongue, and the mucous glands of the mouth and tonsil.

In passing through the jugular foramen the nerve presents, in succession, two gangliform enlargements. The superior, the smaller, is called the *jugular ganglion;* the inferior and larger, the *petrous ganglion*, or the *ganglion of Andersch.*

The **superior** or **jugular ganglion** is situated in the upper part of the groove in which the nerve is lodged during its passage through the jugular foramen. It is of very small size, and involves only the lower part of the trunk of the nerve. It is usually regarded as a segmentation from the lower ganglion.

The **inferior,** or **petrous, ganglion** is situated in a depression in the lower border of the petrous portion of the temporal bone; it is larger than the former and involves the whole of the fibres of the nerve. From this ganglion arise those filaments which connect the glosso-pharyngeal with the pneumogastric and sympathetic nerves.

The *branches of communication* are with the pneumogastric, sympathetic, and facial.

The branches to the pneumogastric are two filaments, arising from the petrous ganglion, one to its auricular branch, and one to the upper ganglion of the pneumogastric.

The branch to the sympathetic, also arising from the petrous ganglion, is connected with the superior cervical ganglion.

The branch of communication with the facial perforates the posterior belly of the Digastric. It arises from the trunk of the nerve below the petrous ganglion, and joins the facial just after its exit from the stylo-mastoid foramen.

The *branches of distribution* are the tympanic, carotid, pharyngeal, muscular, tonsillar, and lingual.

The **tympanic branch** (*Jacobson's nerve*) arises from the petrous ganglion, and enters a small bony canal in the lower surface of the petrous portion of the temporal bone, the lower opening of which is situated on the bony ridge which separates the carotid canal from the jugular fossa. It ascends to the tympanum, enters that cavity by an aperture in its floor close to the inner wall, and divides into branches which are contained in grooves upon the surface of the promontory, forming the tympanic plexus. This plexus gives off (1) the greater part of the small superficial petrosal nerve; (2) a branch to join the great superficial petrosal nerve; and (3) branches to the tympanic cavity, all of which will be described in connection with the anatomy of the ear.

The **carotid branches** descend along the trunk of the internal carotid artery as far as its commencement, communicating with the pharyngeal branch of the pneumogastric and with branches of the sympathetic.

The **pharyngeal branches** are three or four filaments which unite opposite the Middle constrictor of the pharynx with the pharyngeal branches of the pneumogastric and sympathetic nerves to form the pharyngeal plexus, branches from which perforate the muscular coat of the pharynx to supply the muscles and mucous membrane.

The **muscular branch** is distributed to the Stylo-pharyngeus.

The **tonsillar branches** supply the tonsil, forming a plexus (*circulus tonsillaris*) around this body, from which branches are distributed to the soft palate and fauces, [illegible] they communicate with the palatine nerves.

[illegible] **lingual branches** are two in number: one supplies the circumvallate papillæ [illegible]trosal gan[illegible]cous membrane covering the surface of the base of the tongue; the other From i[illegible]s substance, and supplies the mucous membrane and follicular glands of half of the tongue and communicates with the lingual nerve.

The Tenth Pair (Figs. 403, 404).

The **Tenth** or **Pneumogastric Nerve** (*nervus vagus* or *par vagum*) has a more extensive distribution than any of the other cranial nerves, passing through the neck and thorax to the upper part of the abdomen. It is composed of both motor and sensory fibres. It supplies the organs of voice and respiration with motor and sensory fibres, and the pharynx, œsophagus, stomach, and heart with motor fibres. Its *superficial origin* is by eight or ten filaments from the groove between the olivary and the restiform body below the glosso-pharyngeal; its *deep origin* may be traced through the fasciculi of the medulla to terminate in a nucleus of gray matter, the *nucleus vagi*, at the lower part of the floor of the fourth ventricle beneath the ala cinerea below and continuous with the nucleus of origin of the glosso-pharyngeal. In addition to this a few fibres pass into the funiculus solitarius, and others into the nucleus ambiguus or accessory vagal nucleus. The real origin of the sensory fibres of the vagus is to be found in the cells of the ganglia on the nerve, viz., the ganglion of the root and the ganglion of the trunk. The filaments become united and form a flat cord, which passes outward beneath the flocculus to the jugular foramen, through which it emerges from the cranium. In passing through this opening the pneumogastric accompanies the spinal accessory, being contained in the same sheath of dura mater with it, a membranous septum separating them from the glosso-pharyngeal, which lies in front (Fig. 329). The nerve in this situation presents a well-marked ganglionic enlargement, which is called the *jugular ganglion*, or the *ganglion of the root of the pneumogastric*: to it the accessory part of the spinal accessory nerve is connected by one or two filaments. After the exit of the nerve from the jugular foramen the nerve is joined by the accessory portion of the spinal accessory, and enlarges into a second gangliform swelling, called the *ganglion inferius*, or the *ganglion of the trunk of*

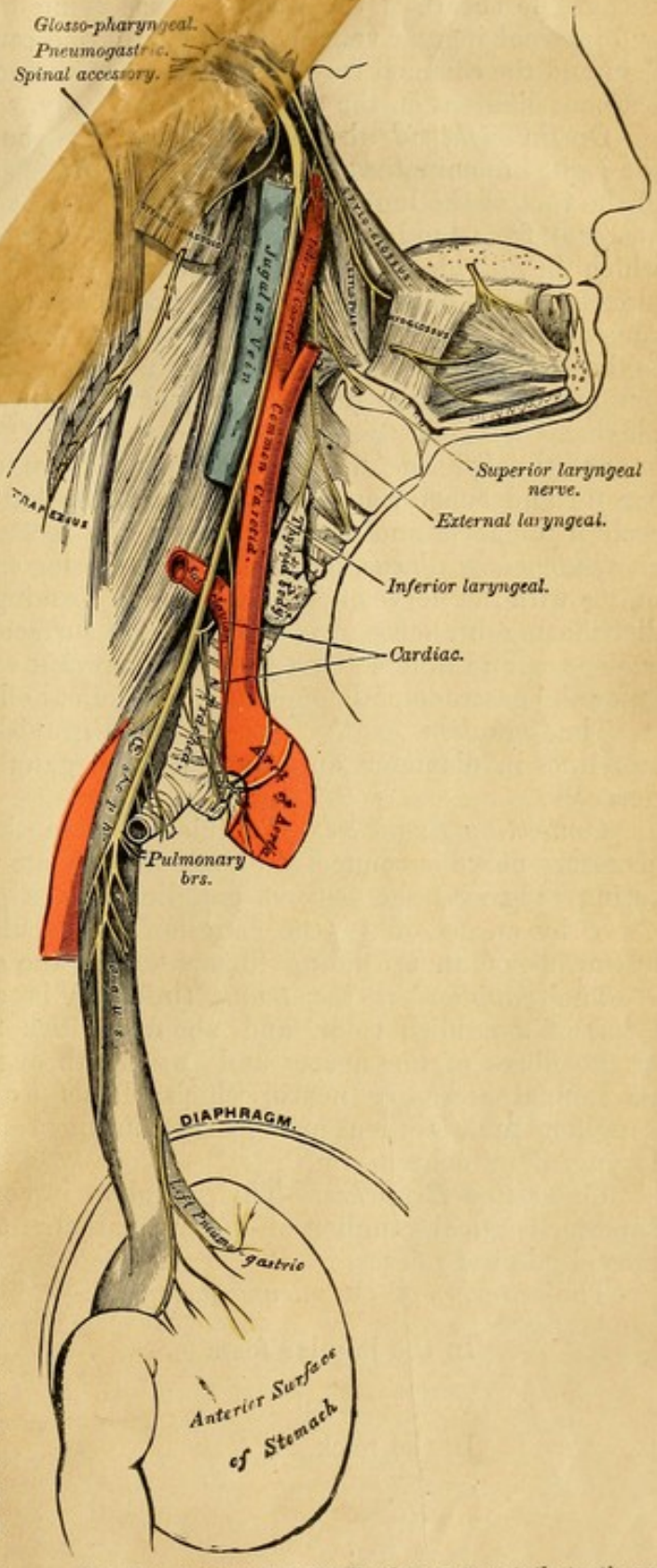

FIG. 404.—Course and distribution of the ninth, tenth, and eleventh nerves.

the nerve, through which the fibres of the spinal accessory pass unchanged, being principally distributed to the pharyngeal and superior laryngeal branches of the vagus; but some of the filaments from it are continued into the trunk of the vagus below the ganglion, to be distributed with the recurrent laryngeal nerve, and probably also with the cardiac nerves. The nerve passes vertically down the neck within the sheath of the carotid vessels lying between the internal carotid artery and internal jugular vein as far as the thyroid cartilage, and then between the same vein and the common carotid to the root of the neck. Here the course of the nerve becomes different on the two sides of the body.

On the *right side* the nerve passes across the subclavian artery between it and the right innominate vein, and descends by the side of the trachea to the back part of the root of the lung, where it spreads out in a plexiform network (*posterior pulmonary*), from the lower part of which two cords descend upon the œsophagus, on which they divide, forming, with branches from the opposite nerve, the œsophageal plexus (*plexus gulæ*); below, these branches are collected into a single cord, which runs along the back part of the œsophagus, enters the abdomen, and is distributed to the posterior surface of the stomach, joining the left side of the solar plexus, and sending filaments to the splenic plexus and a considerable branch to the cœliac plexus.

On the *left side* the pneumogastric nerve enters the chest between the left carotid and subclavian arteries, behind the left innominate vein. It crosses the arch of the aorta and descends behind the root of the left lung, forming the *posterior pulmonary plexus*, and along the anterior surface of the œsophagus, where it unites with the nerve of the right side in forming the plexus gulæ, to the stomach, distributing branches over its anterior surface, some extending over the great *cul-de-sac*, and others along the lesser curvature. Filaments from these branches enter the gastro-hepatic omentum and join the hepatic plexus.

The *ganglion of the root* is of a grayish color, circular in form, about two lines in diameter, and resembles the ganglion on the large root of the fifth nerve.

Connecting Branches.—To this ganglion the accessory portion of the spinal accessory nerve is connected by several delicate filaments; it also has a communicating twig with the petrous ganglion of the glosso-pharyngeal, with the facial nerve by means of its (the ganglion's) auricular branch, and with sympathetic by means of an ascending filament from the superior cervical ganglion.

The *ganglion of the trunk* (inferior) is a plexiform cord, cylindrical in form, of a reddish color, and about an inch in length; it involves the whole of the fibres of the nerve, and passing through it is the accessory portion of the spinal accessory nerve, which blends with the pneumogastric below the ganglion, and is then principally continued into its pharyngeal and superior laryngeal branches.

Connecting Branches.—This ganglion is connected with the hypoglossal, the superior cervical ganglion of the sympathetic, and the loop between the first and second cervical nerves.

The *branches of the pneumogastric* are—

In the jugular fossa . . .	Meningeal. Auricular.
In the neck	Pharyngeal. Superior laryngeal. Recurrent laryngeal. Cervical cardiac.
In the thorax	Thoracic cardiac. Anterior pulmonary. Posterior pulmonary. Œsophageal.
In the abdomen	Gastric.

The **meningeal branch** is a recurrent filament given off from the ganglion of the root in the jugular foramen. It passes backward, and is distributed to the dura mater covering the posterior fossa of the base of the skull.

The **auricular branch** (*Arnold's*) arises from the ganglion of the root, and is joined soon after its origin by a filament from the petrous ganglion of the glosso-pharyngeal; it passes outward behind the jugular vein, and enters a small canal on the outer wall of the jugular fossa. Traversing the substance of the temporal bone, it crosses the aqueductus Fallopii about two lines above its termination at the stylo-mastoid foramen; here it gives off an ascending branch, which joins the facial: the continuation of the nerve reaches the surface by passing through the auricular fissure between the mastoid process and the external auditory meatus, and divides into two branches, one of which communicates with the posterior auricular nerve, while the other supplies the integument at the back part of the pinna and the posterior part of the external auditory meatus.

The **pharyngeal branch**, the principal motor nerve of the pharynx, arises from the upper part of the inferior ganglion of the pneumogastric. It consists principally of filaments from the accessory portion of the spinal accessory: it passes across the internal carotid artery to the upper border of the Middle constrictor, where it divides into numerous filaments which join with those from the glosso-pharyngeal, superior laryngeal (its external branch), and sympathetic, to form the pharyngeal plexus, from which branches are distributed to the muscles and mucous membrane of the pharynx and the muscles of the soft palate. From the pharyngeal plexus a minute filament is given off, which descends and joins the hypoglossal nerve as it winds round the occipital artery.

The **superior laryngeal** is the nerve of sensation to the larynx. It is larger than the preceding, and arises from the middle of the inferior ganglion of the pneumogastric. It consists principally of filaments from the accessory portion of the spinal accessory. In its course it receives a branch from the superior cervical ganglion of the sympathetic. It descends by the side of the pharynx behind the internal carotid, where it divides into two branches, the external and internal laryngeal.

The *external laryngeal branch*, the smaller, descends by the side of the larynx, beneath the Sterno-thyroid, to supply the Crico-thyroid muscle. It gives branches to the pharyngeal plexus and the Inferior constrictor, and communicates with the superior cardiac nerve, behind the common carotid.

The *internal laryngeal branch* descends to the opening in the thyro-hyoid membrane, through which it passes with the superior laryngeal artery, and is distributed to the mucous membrane of the larynx. A small branch communicates with the recurrent laryngeal nerve. The branches to the mucous membrane are distributed, some in front to the epiglottis, the base of the tongue, and the epiglottidean glands; while others pass backward, in the aryteno-epiglottidean fold, to supply the mucous membrane surrounding the superior orifice of the larynx, as well as the membrane which lines the cavity of the larynx as low down as the vocal cord. The filament which joins with the recurrent laryngeal descends beneath the mucous membrane on the inner surface of the thyroid cartilage, where the two nerves become united.

The **inferior or recurrent laryngeal**, so called from its reflected course, is the motor nerve of the larynx. It arises on the right side, in front of the subclavian artery; winds from before backward round that vessel, and ascends obliquely to the side of the trachea, behind the common carotid and behind or in front of the inferior thyroid artery. On the left side it arises in front of the arch of the aorta, and winds from before backward round the aorta at the point where the remains of the ductus arteriosus are connected with it, and then ascends to the side of the trachea. The nerves on both sides ascend in the groove between the trachea and œsophagus, and, passing under the lower border of the Inferior constrictor muscle, enter the larynx behind the articulation of the inferior cornu of the thyroid cartilage with the cricoid, being distributed to all the muscles of the larynx except the Crico-thyroid. It communicates with the superior laryngeal

nerve and gives off a few filaments to the mucous membrane of the lower part of the larynx.

The recurrent laryngeal, as it winds round the subclavian artery and aorta, gives off several cardiac filaments, which unite with the cardiac branches from the pneumogastric and sympathetic. As it ascends in the neck it gives off œsophageal branches, more numerous on the left than on the right side, which supply the mucous membrane and muscular coat of the œsophagus; tracheal branches to the mucous membrane and muscular fibres of the trachea: and some pharyngeal filaments to the Inferior constrictor of the pharynx.

The **cervical cardiac branches,** two or three in number, arise from the pneumogastric, at the upper and lower part of the neck.

The *superior branches* are small, and communicate with the cardiac branches of the sympathetic. They can be traced to the great or deep cardiac plexus.

The *inferior branches*, one on each side, arise at the lower part of the neck, just above the first rib. On the right side this branch passes in front or by the side of the arteria innominata, and communicates with one of the cardiac nerves proceeding to the great or deep cardiac plexus. On the left side it passes in front of the arch of the aorta and joins the superficial cardiac plexus.

The **thoracic cardiac branches,** on the right side, arise from the trunk of the pneumogastric as it lies by the side of the trachea, and from its recurrent laryngeal branch, but on the left side from the recurrent nerve only; passing inward, they terminate in the deep cardiac plexus.

The **anterior pulmonary branches,** two or three in number, and of small size, are distributed on the anterior aspect of the root of the lungs. They join with filaments from the sympathetic, and form the *anterior pulmonary plexus.*

The **posterior pulmonary branches,** more numerous and larger than the anterior, are distributed on the posterior aspect of the root of the lung: they are joined by filaments from the third and fourth (sometimes also first and second) thoracic ganglia of the sympathetic, and form the *posterior pulmonary plexus.* Branches from both plexuses accompany the ramification of the air-tubes through the substance of the lungs.

The **œsophageal branches** are given off from the pneumogastric both above and below the pulmonary branches. The lower are more numerous and larger than the upper. They form, together with branches from the opposite nerve, the *œsophageal plexus* or *plexus gulæ.* From this plexus branches are distributed to the back of the pericardium.

The **gastric branches** are the terminal filaments of the pneumogastric nerve. The nerve on the right side is distributed to the posterior surface of the stomach, and joins the left side of the cœliac plexus and the splenic plexus. The nerve on the left side is distributed over the anterior surface of the stomach, some filaments passing across the great *cul-de-sac*, and others along the lesser curvature. They unite with branches of the right nerve and with the sympathetic, some filaments passing through the lesser omentum to the hepatic plexus.

Surgical Anatomy.—The laryngeal nerves are of considerable importance in considering some of the morbid conditions of the larynx. When the peripheral terminations of the superior laryngeal nerve are irritated by some foreign body passing over them, reflex spasm of the glottis is the result. When the trunk of this same nerve is pressed upon by, for instance, a goitre or an aneurism of the upper part of the carotid, we have a peculiar dry, brassy cough. When the nerve is paralyzed, we have anæsthesia of the mucous membrane of the larynx, so that foreign bodies can readily enter the cavity, and, in consequence of its supplying the crico-thyroid muscle, the vocal cords cannot be made tense, and the voice is deep and hoarse. Paralysis of the superior laryngeal nerves may be the result of bulbar paralysis, may be a sequel to diphtheria, when both nerves are usually involved, or it may, though less commonly, be caused by the pressure of tumors or aneurisms, when the paralysis is generally unilateral. Irritation of the inferior laryngeal nerves produces spasm of the muscles of the larynx. When both these recurrent nerves are paralyzed, the vocal cords are motionless, in the so-called "cadaveric position"—that is to say, in the position in which they are found in ordinary tranquil respiration—neither closed as in phonation, nor open as in deep inspiratory efforts. When one recurrent nerve is paralyzed, the cord of the same side is motionless, while the opposite one crosses the middle line to accommodate itself to the affected one; hence phonation is present, but the voice

is altered and weak in timbre. The recurrent laryngeal nerves may be paralyzed in bulbar paralysis or after diphtheria, when it usually affects both sides; or they may be affected by the pressure of aneurisms of the aorta, innominate or subclavian arteries; by mediastinal tumors; by bronchocele; or by cancer of the upper part of the œsophagus, when the paralysis is often unilateral.

The Eleventh Pair (Figs. 403, 404).

The **Eleventh** or **Spinal Accessory Nerve** consists of two parts: one, the accessory part to the vagus, and the other the spinal portion.

The **bulbar** or **accessory part** is the smaller of the two. Its *superficial origin* is by four or five delicate filaments from the side of the medulla, below the roots of the vagus. Its *deep origin* may be traced to a nucleus of gray matter at the back of the medulla, dorso-lateral to the hypoglossal nucleus, and extending as far down as the intermedio-lateral tract of the spinal cord. It passes outward to the jugular foramen, where it interchanges fibres with the spinal portion or becomes united to it for a short distance; it is also connected, in the foramen, with the upper ganglion of the vagus by one or two filaments. It then passes through the foramen, and becoming again separated from the spinal portion it is continued over the surface of the ganglion of the trunk of the vagus, being adherent to its surface, and is distributed principally to the pharyngeal and superior laryngeal branches of the pneumogastric. Through the pharyngeal branch it probably supplies the muscles of the soft palate (see page 331). Some few filaments from it are continued into the trunk of the vagus below the ganglion, to be distributed with the recurrent laryngeal nerve, and probably also with the cardiac nerves.

The **spinal portion** is firm in texture. Its *superficial origin* is by several filaments from the lateral tract of the cord, as low down as the sixth cervical nerve. Its *deep origin* may be traced to the intermedio-lateral tract of the gray matter of the cord. This portion of the nerve ascends between the ligamentum denticulatum and the posterior roots of the spinal nerves, enters the skull through the foramen magnum, and is then directed outward to the jugular foramen, through which it passes, lying in the same sheath as the pneumogastric, but separated from it by a fold of the arachnoid. In the jugular foramen it receives one or two filaments from the accessory portion. At its exit from the jugular foramen it passes backward, either in front of or behind the internal jugular vein, and descends obliquely behind the Digastric and Stylo-hyoid muscles to the upper part of the Sterno-mastoid. It pierces that muscle, and passes obliquely across the posterior triangle, to terminate in the deep surface of the Trapezius. This nerve gives several branches to the Sterno-mastoid during its passage through it, and joins in its substance with branches from the second cervical, which supply the muscle. In the posterior triangle it joins with the second and third cervical nerves, while beneath the Trapezius it forms a sort of plexus with the third and fourth cervical nerves, and from this plexus fibres are distributed to the muscle.

Surgical Anatomy.—In cases of spasmodic torticollis in which all palliative treatment has failed, division or excision of a portion of the spinal accessory nerve has been resorted to. This may be done either along the anterior or posterior border of the Sterno-mastoid muscle. The former operation is performed by making an incision from the apex of the mastoid process, three inches in length, along the anterior border of the Sterno-mastoid muscle. The anterior border of the muscle is defined and pulled backward, so as to stretch the nerve, which is then to be sought for beneath the Digastric muscle, about two inches below the apex of the mastoid process. The other operation consists in making an incision along the posterior border of the muscle, so that the centre of the incision corresponds to the middle of this border of the muscle. The superficial structures having been divided and the border of the muscle defined, the nerve is to be sought for as it emerges from the muscle to cross the occipital triangle. When found, it is to be traced upward through the muscle, and a portion of it excised above the point where it gives off its branches to the Sterno-mastoid. In this operation one of the descending branches of the superficial cervical plexus is liable to be mistaken for the nerve.

The Twelfth Pair (Figs. 405, 406).

The **Twelfth** or **Hypoglossal Nerve** is the motor nerve of the tongue.

Its *superficial origin* is by several filaments, from ten to fifteen in number, from the groove between the pyramidal and olivary bodies of the medulla, in a continuous line with the anterior roots of the spinal nerves. Its *deep origin* can be traced to a nucleus of gray matter (*trigonum hypoglossi*) on the floor of the fourth ventricle.

The filaments of this nerve are collected into two bundles, which perforate the dura mater separately, opposite the anterior condyloid foramen, and unite together after their passage through it. In those cases in which the anterior condyloid foramen in the occipital bone is double, these two portions of the nerve are separated by the small piece of bone which divides the foramen. The nerve descends almost vertically to a point corresponding with the angle of the jaw. It is at first deeply seated beneath the internal carotid artery and internal jugular vein, and intimately connected with the pneumogastric nerve; it then passes forward

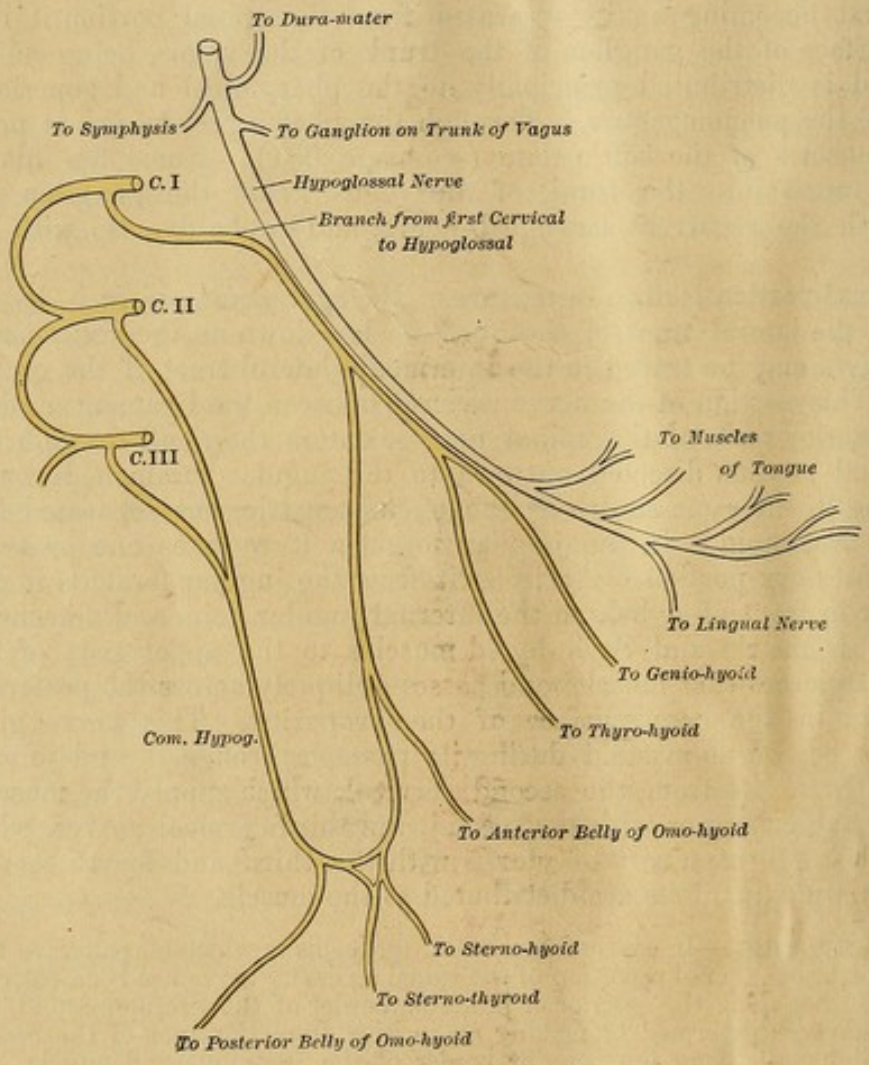

FIG. 405.—Plan of the hypoglossal nerve.

between the vein and artery, and lower down in the neck becomes superficial below the Digastric muscle. The nerve then loops round the occipital artery, and crosses the external carotid and its lingual branch below the tendon of the Digastric muscle. It passes beneath the tendon of the Digastric, the Stylo-hyoid, and the Mylo-hyoid muscles, lying between the last-named muscle and the Hyo-glossus, and communicates at the anterior border of the Hyo-glossus with the lingual (gustatory) nerve; it is then continued forward in the fibres of the Genio-hyo-glossus muscle as far as the tip of the tongue, distributing branches to its muscular substance.

The *branches of communication* are—with the

Pneumogastric.	First and Second Cervical Nerves.
Sympathetic.	Lingual (gustatory).

The first mentioned takes place close to the exit of the nerve from the skull, numerous filaments passing between the hypoglossal and lower ganglion of the pneumogastric through the mass of connective tissue which here unites the two nerves. It also communicates with the pharyngeal plexus by a minute filament as it winds round the occipital artery.

The communication with the sympathetic takes place opposite the atlas by branches derived from the superior cervical ganglion, and in the same situation the nerve is joined by filaments derived from the loop connecting the first two cervical nerves.

The communication with the lingual (gustatory) takes place near the anterior border of the Hyo-glossus muscle by numerous filaments which ascend upon it.

The *branches of distribution* are—the

Meningeal.	Thyro-hyoid.
Descendens hypoglossi.	Muscular.

Meningeal Branches.—As the hypoglossal nerve passes through the anterior

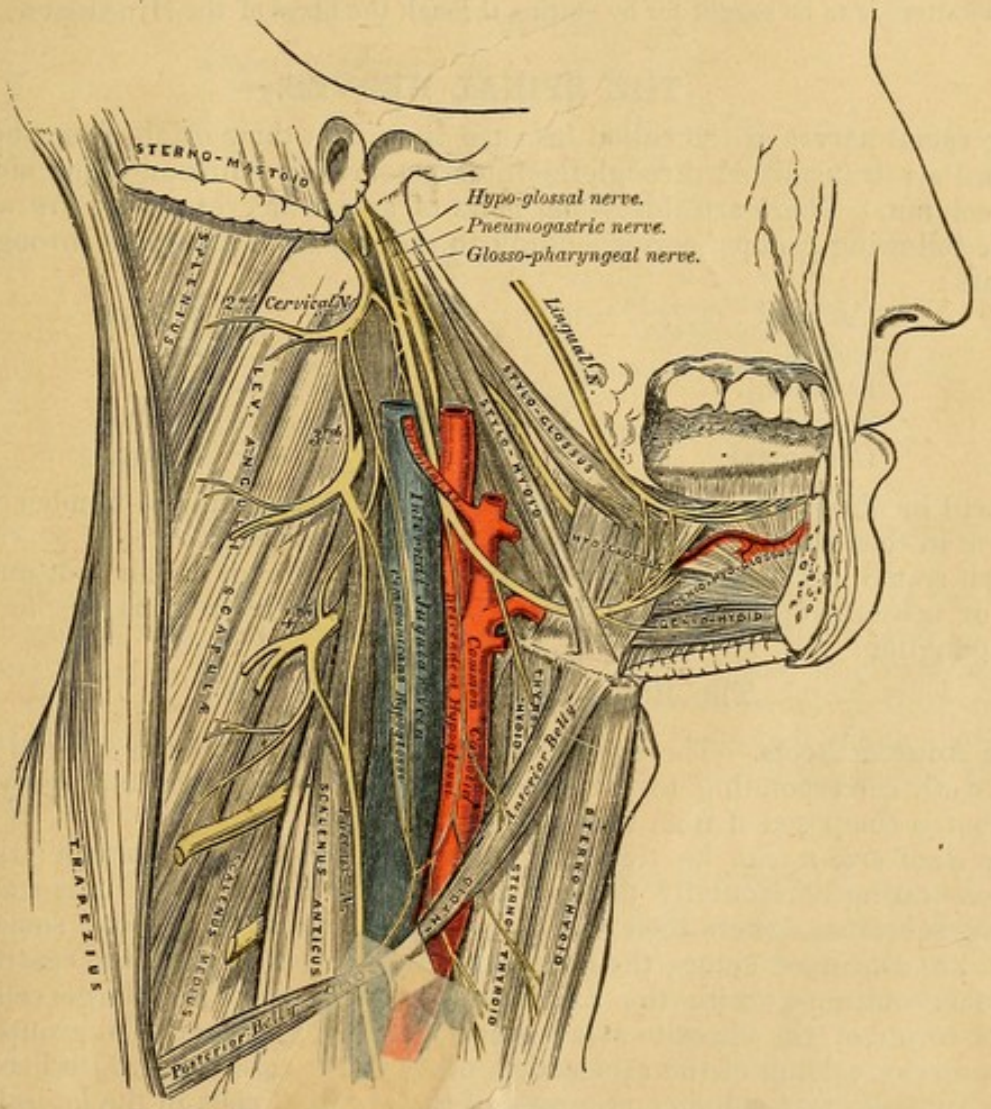

FIG. 406.—Hypoglossal nerve, cervical plexus, and their branches.

condyloid foramen it gives off, according to Luschka, several filaments to the dura mater in the posterior fossa of the base of the skull; these filaments are probably

derived from a branch which passes from the first cervical nerve to the hypoglossal nerve.

The **descendens hypoglossi** is a long slender branch, which quits the hypoglossal where it turns round the occipital artery. It consists mainly of fibres which pass to the hypoglossal from the first and second cervical nerves in the above-mentioned communication. It descends in front of or within the sheath of the carotid vessels, giving off a branch to the anterior belly of the Omo-hyoid, and then joins the communicating branches from the second and third cervical nerves, just below the middle of the neck, to form a loop, the *ansa hypoglossi*. From the convexity of this loop branches pass to supply the Sterno-hyoid, Sterno-thyroid, and the posterior belly of the Omo-hyoid. According to Arnold, another filament descends in front of the vessels into the chest, and joins the cardiac and phrenic nerves.

The **thyro-hyoid** is a small branch arising from the hypoglossal near the posterior border of the Hyo-glossus; it passes obliquely across the great cornu of the hyoid bone and supplies the Thyro-hyoid muscle.

The **muscular branches** are distributed to the Stylo-glossus, Hyoglossus, Genio-hyoid, and Genio-hyo-glossus muscles. At the under surface of the tongue numerous slender branches pass upward into the substance of the organ to supply its intrinsic muscles.

Surgical Anatomy.—The hypoglossal nerve is an important guide in the operation of ligation of the lingual artery (see page 489). It runs forward on the Hyo-glossus just above the great cornu of the hyoid bone, and forms the upper boundary of the triangular space in which the artery is to be sought for by cutting through the fibres of the Hyo-glossus.

THE SPINAL NERVES.

The **spinal nerves** are so called because they take their origin from the spinal cord, and are transmitted through the intervertebral foramina on either side of the spinal column. There are thirty-one pairs of spinal nerves, which are arranged into the following groups, corresponding to the region of the spine through which they pass:

Cervical	8 pairs.
Dorsal	12 "
Lumbar	5 "
Sacral	5 "
Coccygeal	1 pair.

It will be observed that each group of nerves corresponds in number with the vertebræ in that region, except the cervical and coccygeal.

Each spinal nerve arises by two roots, an anterior or motor root and a posterior or sensory root, the latter being distinguished by a ganglion, termed the *spinal* ganglion.

The Roots of the Spinal Nerves.

The Anterior Roots.—The *superficial origin* is from the antero-lateral columns of the cord, corresponding to the situation of the anterior cornu of gray matter. Each root is composed of from four to eight filaments.

The *deep origin* can be traced through the antero-lateral column; the roots, after penetrating horizontally through the longitudinal fibres of this tract, enter the gray substance, where their fibrils diverge in several directions: some passing inward, are continued across the anterior commissure in front of the central canal, to become continuous with the axis-cylinder processes of the large cells of the anterior cornu of the opposite side; others terminate in the mesial group of cells of the anterior column of the same side; other fibrils pass outward, to become continuous with the axis-cylinder processes of the group of cells in the lateral part of the anterior column.

The Posterior Roots.—The *superficial origin* is from the postero-lateral fissure of the cord. The *real origin* of these fibres is from the nerve-cells in the posterior

root ganglion, from which they can be traced into the cord in two main bundles, the course of which has already been studied (page 697).

The *anterior roots* are smaller than the posterior, devoid of ganglionic enlargement, and their component fibrils are collected into two bundles near the intervertebral foramina.

The *posterior roots* of the nerves are larger, but the individual filaments are finer and more delicate than those of the anterior. As their component fibrils pass outward toward the aperture in the dura mater, they coalesce into two bundles, receive a tubular sheath from that membrane, and enter the ganglion which is developed upon each root.

The posterior root of the first cervical nerve forms an exception to these characters. It is smaller than the anterior, has occasionally no ganglion developed upon it, and when the ganglion exists, it is often situated within the dura mater.

The Ganglia of the Spinal Nerves.

A **ganglion** is developed upon the posterior root of each of the spinal nerves. These ganglia are of an oval form and of a reddish color; they bear a proportion in size to the nerves upon which they are formed, and are placed in the intervertebral foramina, external to the point where the nerves perforate the dura

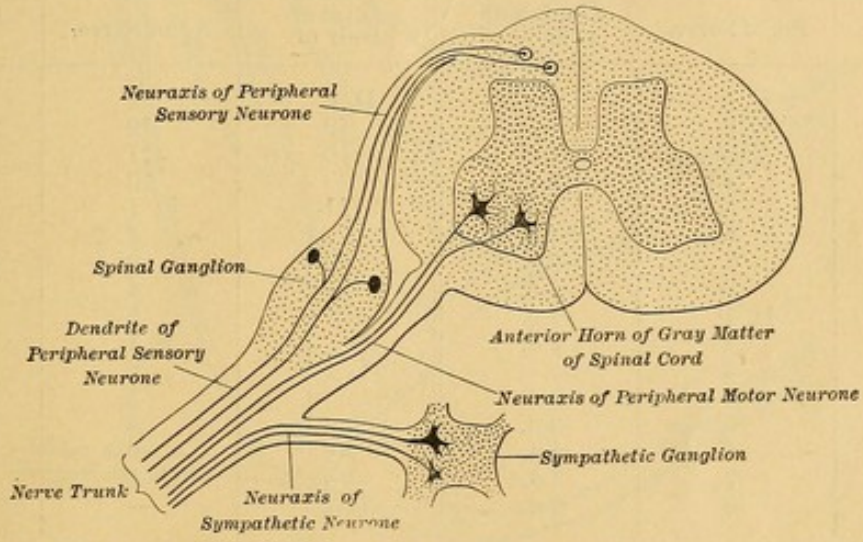

FIG. 407.—Diagram to show the composition of a peripheral nerve-trunk. (Böhm and Davidoff.)

mater. Each ganglion is bifid internally, where it is joined by the two bundles of the posterior root, the two portions being united into a single mass externally. The ganglion upon the first and second cervical nerves forms an exception to these characters, being placed on the arches of the vertebræ over which the nerves pass. The ganglia of the sacral nerves are placed within the spinal canal; and that on the coccygeal nerve, also in the canal, is situated at some distance from the origin of the posterior root.

DISTRIBUTION OF THE SPINAL NERVES.

Immediately beyond the ganglion the two roots coalesce, their fibres intermingle, and the trunk thus formed constitutes the *spinal nerve;* it passes out of the intervertebral foramen, and divides into a posterior division for the supply of the posterior part of the body, and an anterior division for the supply of the anterior part of the body, each containing fibres from both roots.

Before dividing, each spinal nerve gives off a small *recurrent* or *meningeal* branch, which is joined by a filament from the communicating branch of the sympathetic, which connects the ganglion with the anterior division. It passes inward through the intervertebral foramen and supplies the dura mater, sending branches to the bones and ligaments.

The **posterior divisions of the spinal nerves** are generally smaller than the anterior; they arise from the trunk resulting from the union of the roots, in the intervertebral foramina; and, passing backward, divide into internal and external branches, which are distributed to the muscles and integument behind the spine. The first cervical, the fourth and fifth sacral, and the coccygeal, do not divide into external and internal branches.

The **anterior divisions of the spinal nerves** supply the parts of the body in front of the spine, including the limbs. They are for the most part larger than the posterior divisions. Each division is connected by a slender filament with the sympathetic. In the dorsal region the anterior divisions of the spinal nerves are quite separate from each other, and are uniform in their distribution; but in the cervical, lumbar, and sacral regions they form intricate plexuses previous to their distribution.

Points of Emergence of the Spinal Nerves.

The roots of the spinal nerves from their origin in the cord run obliquely downward to their point of exit from the intervertebral foramina, the amount of obliquity varying in different regions of the spine, and being greater in the lower than the upper part. The level of their emergence from the cord is within certain

Level of Body of	No. of Nerve.	Level of tip of Spine of	Level of Body of	No. of Nerve.	Level of tip of Spine of
C. 1	C. 1	—	D. 8	9	7 d.
2	2	—	9	10	8 d.
	3	1 c.	10	11	9 d.
3	4	2 c.	—	12	10 d.
4	5	3 c.	11	L. 1	11 d.
5	6	4 c.	12	2	—
6	7	5 c.		3	12 d.
—	8	6 c.		4	
7	D. 1	7 c.		5	—
D. 1	2	1 d.		S. 1	
2	3	—	L. 1	2	
3	4	2 d.		3	
4	5	3 d.		4	1 L.
5	6	4 d.	—	5	
6	7	5 d.	—	C. 1	
7	8	6 d.	L. 2	—	—

limits variable, and of course does not correspond to the point of emergence of the nerve from the intervertebral foramina. The preceding table, from Macalister, shows as accurately as can be shown the relation of these points of origin from the spinal cord to the bodies and spinous processes of the vertebræ.

THE CERVICAL NERVES.

The **roots of the cervical nerves** increase in size from the first to the fifth, and then remain the same size to the eighth. The posterior roots bear a proportion to the anterior as 3 to 1, which is much greater than in any other region, the individual filaments being also much larger than those of the anterior roots. The posterior root of the first cervical is an exception to this rule: it is smaller than the anterior root. In direction the roots of the cervical are less oblique than those of the other spinal nerves. The first cervical nerve is directed a little upward and outward; the second is horizontal; the others are directed obliquely downward and outward, the lowest being the most oblique, and consequently longer than the upper, the distance between their place of origin and their point of exit from the spinal canal never exceeding the depth of one vertebra.

The *trunk of the first cervical nerve* (*suboccipital*) leaves the spinal canal between the occipital bone and the posterior arch of the atlas; the second, between the

posterior arch of the atlas and the lamina of the axis; and the eighth (the last), between the last cervical and first dorsal vertebræ.

Each nerve, at its exit from the intervertebral foramen, divides into a posterior and an anterior division. The anterior divisions of the four upper cervical nerves form the cervical plexus. The anterior divisions of the four lower cervical nerves, together with the first dorsal, form the brachial plexus.

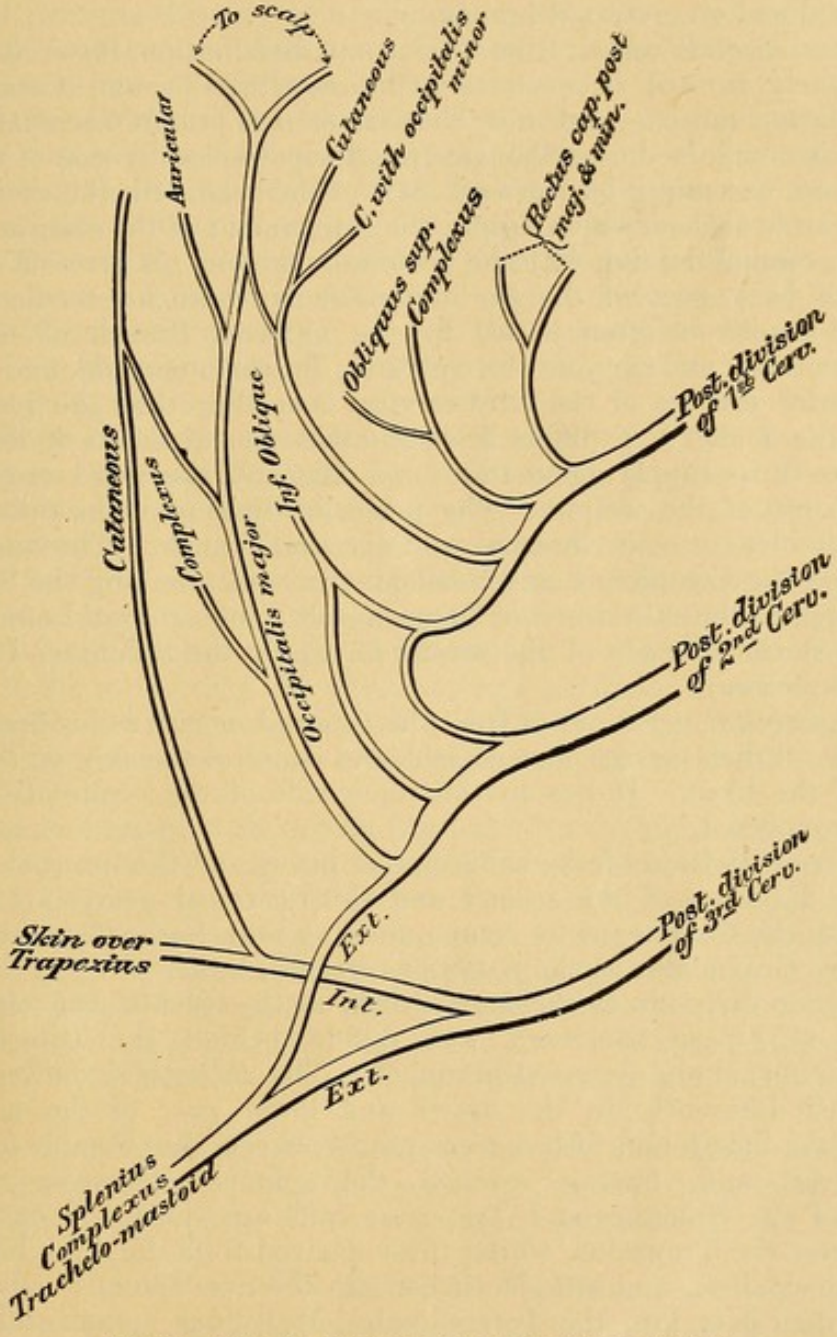

FIG. 408.—Posterior divisions of the upper cervical nerves.

Posterior Divisions of the Cervical Nerves (Fig. 408).

The **posterior division of the first cervical** (*suboccipital*) **nerve** differs from the posterior divisions of the other cervical nerves in not dividing into an internal and external branch. It is larger than the anterior division, and escapes from the spinal canal between the occipital bone and the posterior arch of the atlas, lying beneath the vertebral artery. It enters the suboccipital triangle formed by the Rectus capitis posticus major, the Obliquus superior, and Obliquus inferior, and supplies the Recti and Obliqui muscles, and the Complexus. From the branch which supplies the Inferior oblique a filament is given off which joins the second cervical nerve. This nerve also occasionally gives off a cutaneous filament, which

accompanies the occipital artery and communicates with the occipitalis major and minor nerves.

The **posterior division of the second cervical nerve** is three or four times greater than the anterior division, and the largest of all the posterior cervical divisions. It emerges from the spinal canal between the posterior arch of the atlas and lamina of the axis, below the Inferior oblique. It supplies a twig to this muscle, and receives a communicating filament from the first cervical. It then divides into an internal and an external branch.

The *internal branch*, called, from its size and distribution, the *occipitalis major*, ascends obliquely inward between the Obliquus inferior and Complexus, and pierces the latter muscle and the Trapezius near their attachments to the cranium. It is now joined by a filament from the posterior division of the third cervical nerve, and, ascending on the back part of the head with the occipital artery, divides into two branches, which supply the integument of the scalp as far forward as the vertex, communicating with the occipitalis minor. It gives off an auricular branch to the back part of the ear and muscular branches to the Complexus. The *external branch* is often joined by the external branch of the posterior division of the third, and supplies the Splenius, Trachelo-mastoid, and Complexus.

The **posterior division of the third cervical** is smaller than the preceding, but larger than the fourth; it differs from the posterior divisions of the remaining cervical nerves in its supplying an additional filament, the third occipital nerve, to the integument of the occiput. The posterior division of the third nerve, like the others, divides into an internal and external branch. The *internal branch* passes between the Complexus and Semispinalis, and, piercing the Splenius and Trapezius, supplies the skin over the latter muscle; the *external branch* joins with that of the posterior division of the second to supply the Splenius, Trachelo-mastoid, and Complexus.

The *third occipital nerve* arises from the internal or cutaneous branch beneath the Trapezius; it then pierces that muscle, and supplies the skin on the lower and back part of the head. It lies to the inner side of the occipitalis major, with which it is connected.

The posterior division of the suboccipital nerve and the internal branches of the posterior divisions of the second and third cervical nerves are occasionally joined beneath the Complexus by communicating branches. This communication is described by Cruveilhier as the *posterior cervical plexus*.

The **posterior divisions of the fourth, fifth, sixth, seventh, and eighth cervical nerves** (Fig. 415) pass backward, and divide, behind the Intertransversales muscles, into internal and external branches. The *internal branches*, the larger, are distributed differently in the upper and lower part of the neck. Those derived from the fourth and fifth nerves pass between the Complexus and Semispinalis muscles, and, having reached the spinous processes, perforate the aponeurosis of the Splenius and Trapezius, and are continued outward to the integument over the Trapezius, whilst those derived from the three lowest cervical nerves are the smallest, and are placed beneath the Semispinalis colli, which they supply, and then pass into the Interspinales, Multifidus spinæ, and Complexus, and send twigs through this latter muscle to supply the integument near the spinous processes (Hirschfeld). The *external branches* supply the muscles at the side of the neck—viz. the Cervicalis ascendens, Transversalis colli, and Trachelo-mastoid.

Anterior Divisions of the Cervical Nerves.

The **anterior division of the first** or **suboccipital nerve** is of small size. It escapes from the spinal canal through a groove upon the posterior arch of the atlas. In this groove it lies beneath the vertebral artery, to the inner side of the Rectus capitis lateralis. As it crosses the foramen in the transverse process

of the atlas it receives a filament from the sympathetic. It then descends in front of this process, to communicate with an ascending branch from the second cervical nerve.

Communicating filaments from the loop between this nerve and the second join the pneumogastric, the hypoglossal, and sympathetic and some branches are distributed to the Rectus lateralis and the two Anterior recti. The fibres which communicate with the hypoglossal simply pass through the latter nerve to become for the most part the descendens hypoglossi. According to Valentin, the anterior division of the suboccipital distributes filaments to the occipito-atlantal articulation and mastoid process of the temporal bone.

The **anterior division of the second cervical nerve** escapes from the spinal canal, between the posterior arch of the atlas and the lamina of the axis, and, passing forward on the outer side of the vertebral artery, divides in front of the Intertransverse muscle into an ascending branch, which joins the first cervical; and one or two descending branches, which join the third. It gives off the small occipital; a branch to assist in forming the great auricular; another to assist in forming the superficial cervical; one of the communicantes hypoglossi, and a filament to the Sterno-mastoid, which communicates in the substance of the muscle with the spinal accessory.

The **anterior division of the third cervical nerve** is double the size of the preceding. At its exit from the intervertebral foramen it passes downward and outward beneath the Sterno-mastoid, and divides into two branches. The ascending branch joins the anterior division of the second cervical; the descending branch passes down in front of the Scalenus anticus and communicates with the fourth. It gives off the larger part of the great auricular and superficial cervical nerves; one of the communicantes hypoglossi; a branch to the supraclavicular nerves; a filament to assist in forming the phrenic; and muscular branches to the Levator anguli scapulæ and Trapezius; this latter nerve communicates beneath the muscle with the spinal accessory. Sometimes the nerve to the Scalenus medius is derived from this source.

The **anterior division of the fourth cervical** is of the same size as the preceding. It receives a branch from the third, sends a communicating branch to the fifth cervical, and, passing downward and outward, divides into numerous filaments, which cross the posterior triangle of the neck, forming the supraclavicular nerves. It gives a branch to the phrenic nerve, while it is contained in the intertransverse space, and sometimes a branch to the Scalenus medius muscle. It also gives a branch to the Levator anguli scapulæ and to the Trapezius, which unites with the branch given off from the third nerve, and communicates beneath the muscle with the spinal accessory.

The **anterior divisions of the fifth, sixth, seventh,** and **eighth cervical nerves** are remarkable for their size. They are much larger than the preceding nerves, and are all of equal dimensions. They assist in the formation of the brachial plexus.

The Cervical Plexus.

The cervical plexus (Fig. 409) is formed by the anterior divisions of the four upper cervical nerves. It is situated opposite the four upper cervical vertebræ, resting upon the Levator anguli scapulæ and Scalenus medius muscles, and covered in by the Sterno-mastoid.

Its branches may be divided into two groups, *superficial* and *deep*, which may be thus arranged:

- *Superficial*
  - Ascending
    - Occipitalis minor.
    - Auricularis magnus.
    - Superficialis colli.
  - Descending
    - Supraclavicular
      - Suprasternal.
      - Supraclavicular.
      - Supra-acromial.

Deep . . .
- Internal . .
  - Communicating.
  - Muscular.
  - Communicantes hypoglossi.
  - Phrenic.
- External . .
  - Communicating.
  - Muscular.

Superficial Branches of the Cervical Plexus.

The **Occipitalis minor** (Fig. 415) arises from the second cervical nerve, sometimes also from the third; it curves round the posterior border of the Sterno-mastoid, and ascends, running parallel to the posterior border of the muscle, to the back part of the side of the head. Near the cranium it perforates the deep fascia, and is continued upward along the side of the head behind the ear, supplying the integument, and communicating with the occipitalis major, the auricularis magnus, and with the posterior auricular branch of the facial.

This nerve gives off an *auricular branch*, which supplies the integument of the upper and back part of the auricle, communicating with the mastoid branch of the auricularis magnus. This branch is occasionally derived from the great occipital nerve. The occipitalis minor varies in size; it is occasionally double.

The **Auricularis Magnus** is the largest of the ascending branches. It arises from the second and third cervical nerves, winds round the posterior border of the Sterno-mastoid, and, after perforating the deep fascia, ascends upon that muscle beneath the Platysma to the parotid gland, where it divides into facial, auricular, and mastoid branches.

The *facial branches* pass across the parotid, and are distributed to the integument of the face over the parotid gland; others penetrate the substance of the gland and communicate with the facial nerve.

The *auricular branches* ascend to supply the integument of the back of the pinna, except at its upper part, communicating with the auricular branches of the facial and pneumogastric nerves. A filament pierces the pinna to reach its outer surface, where it is distributed to the lobule and lower part of the concha.

The *mastoid branch* communicates with the occipitalis minor and the posterior auricular branch of the facial, and is distributed to the integument behind the ear.

The **Superficialis Colli** arises from the second and third cervical nerves, turns round the posterior border of the Sterno-mastoid about its middle, and, passing obliquely forward beneath the external jugular vein to the anterior border of the muscle, perforates the deep cervical fascia, and divides beneath the Platysma into two branches which are distributed to the antero-lateral parts of the neck.

The *ascending branch* gives a filament which accompanies the external jugular vein; it then passes upward to the submaxillary region, and divides into branches, some of which form a plexus with the cervical branches of the facial nerve beneath the Platysma; others pierce that muscle and are distributed to the integument of the upper half of the neck, at its fore part, as high as the chin.

The *descending branch* (occasionally represented by two or more filaments) pierces the Platysma, and is distributed to the integument of the side and front of the neck, as low as the sternum.

The **Descending** or **supraclavicular branches** arise from the third and fourth cervical nerves: emerging beneath the posterior border of the Sterno-mastoid, they descend in the posterior triangle of the neck beneath the Platysma and deep cervical fascia. Near the clavicle they perforate the fascia and Platysma to become cutaneous, and are arranged, according to their position, into three groups.

The *inner* or *suprasternal branches* cross obliquely over the external jugular vein and the clavicular and sternal attachments of the Sterno-mastoid, and supply the integument as far as the median line. They furnish one or two filaments to the sterno-clavicular joint.

The *middle* or *supraclavicular branches* cross the clavicle, and supply the integument over the Pectoral and Deltoid muscles, communicating with the cutaneous branches of the upper intercostal nerves.

The *external* or *supra-acromial branches* pass obliquely across the outer surface of the Trapezius and the acromion, and supply the integument of the upper and back part of the shoulder.

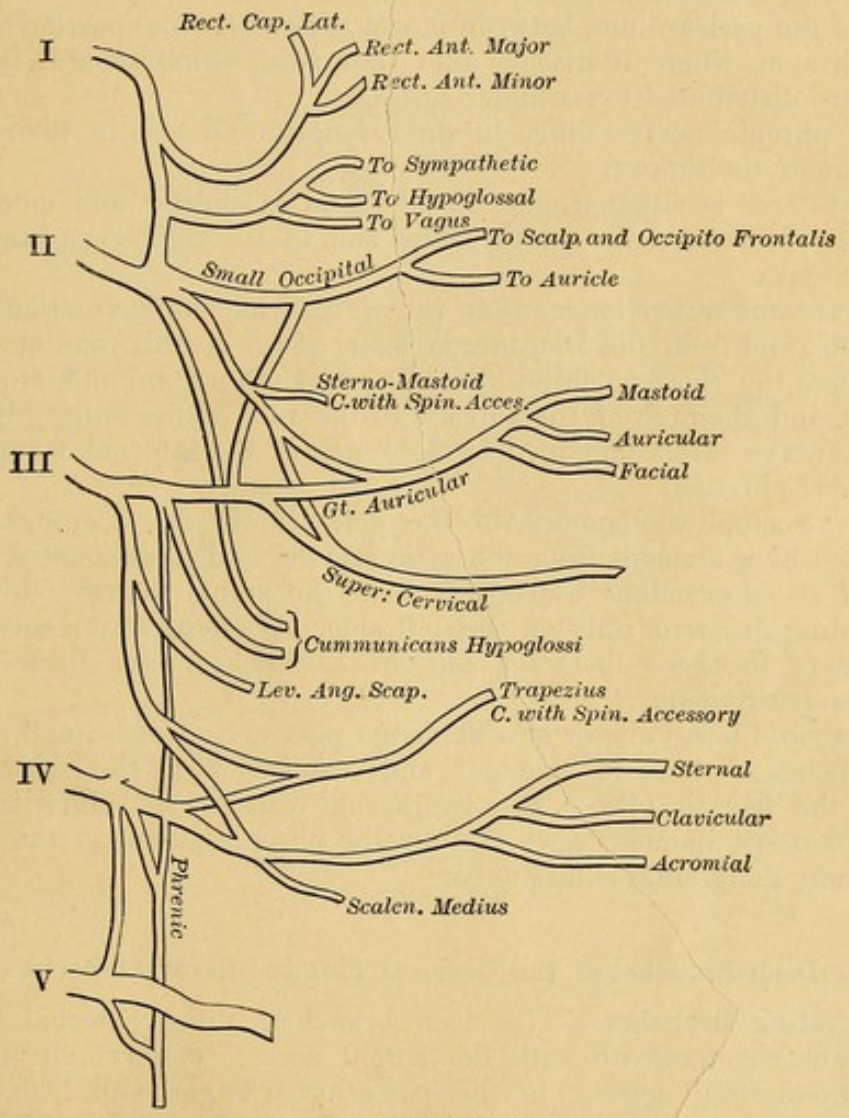

FIG. 409.—Plan of the cervical plexus.

Deep Branches of the Cervical Plexus. Internal Series.

The **communicating branches** consist of several filaments, which pass from the loop between the first and second cervical nerves in front of the atlas to the pneumogastric, hypoglossal, and sympathetic; of branches from all four cervical nerves to the superior cervical ganglion of the sympathetic, together with a branch from the fourth to the fifth cervical.

Muscular branches supply the Anterior recti and Rectus lateralis muscles; they proceed from the first cervical nerve, and from the loop formed between it and the second.

The **Communicans Hypoglossi** (Fig. 406) consists usually of two filaments, one being derived from the second, and the other from the third, cervical. These filaments pass downward on the outer side of the internal jugular vein, cross in front of the vein a little below the middle of the neck, and form a loop with the descendens hypoglossi in front of the sheath of the carotid vessels (see page 756). Occasionally, the junction of these nerves takes place within the sheath.

The **Phrenic Nerve** (*internal respiratory of Bell*) arises chiefly from the fourth

cervical nerve, with a few filaments from the third and a communicating branch from the fifth. It descends to the root of the neck, running obliquely across the front of the Scalenus anticus, and beneath the Sterno-mastoid, the posterior belly of the Omo-hyoid, and the Transversalis colli and suprascapular vessels. It next passes over the first part of the subclavian artery, between it and the subclavian vein, and, as it enters the chest, crosses the internal mammary artery near its origin. Within the chest it descends nearly vertically in front of the root of the lung and by the side of the pericardium, between it and the mediastinal portion of the pleura, to the Diaphragm, where it divides into branches, which separately pierce that muscle and are distributed to its under surface.

The two phrenic nerves differ in their length, and also in their relations at the upper part of the thorax.

The *right nerve* is situated more deeply, and is shorter and more vertical in direction than the left; it lies on the outer side of the right vena innominata and superior vena cava.

The *left nerve* is rather longer than the right, from the inclination of the heart to the left side, and from the Diaphragm being lower on this than on the opposite side. It enters the thorax behind the left innominate vein, and crosses in front of the vagus and the arch of the aorta and the root of the lung. In the thorax each phrenic nerve is accompanied by a branch of the internal mammary artery, the comes nervi phrenici.

Each nerve supplies filaments to the pericardium and pleura, and near the chest is joined by a filament from the sympathetic, and, occasionally, by one from the union of the descendens hypoglossi with the spinal nerves: this filament is found, according to Swan, only on the left side. It frequently receives a filament from the nerve to the Subclavius muscle. Branches have been described as passing to the peritoneum.

From the *right nerve* one or two filaments pass to join in a small ganglion with phrenic branches of the solar plexus; and branches from this ganglion are distributed to the hepatic plexus, the suprarenal capsule, and inferior vena cava. From the *left nerve* filaments pass to join the phrenic plexus of the sympathetic, but without any ganglionic enlargement.

Deep Branches of the Cervical Plexus. External Series.

Communicating Branches.—The deep branches of the external series of the cervical plexus communicate with the spinal accessory nerve, in the substance of the Sterno-mastoid muscle, in the posterior triangle, and beneath the Trapezius.

Muscular branches are distributed to the Sterno-mastoid, Trapezius, Levator anguli scapulæ, and Scalenus medius.

The branch for the Sterno-mastoid is derived from the second cervical; the Trapezius and Levator anguli scapulæ receive branches from the third and fourth. The Scalenus medius is derived sometimes from the third, sometimes the fourth, and occasionally from both nerves.

The Brachial Plexus (Fig. 410).

The **Brachial Plexus** is formed by the union of the anterior divisions of the four lower cervical and the greater part of the first dorsal nerves, receiving usually a fasciculus from the fourth cervical nerve, and frequently one from the second dorsal nerve. It extends from the lower part of the side of the neck to the axilla. It is very broad, and presents little of a plexiform arrangement at its commencement. It is narrow opposite the clavicle, becomes broad and forms a more dense interlacement in the axilla, and divides opposite the coracoid process into numerous branches for the supply of the upper limb. The nerves which form the plexus are all similar in size, and their mode of communica-

tion is subject to considerable variation, so that no one plan can be given as applying to every case. The following appears, however, to be the most constant arrangement: the fifth and sixth cervical unite together soon after their exit from the intervertebral foramina to form a common trunk. The eighth cervical and first dorsal also unite to form one trunk. So that the nerves forming the plexus, as they lie on the Scalenus medius external to the outer border of the

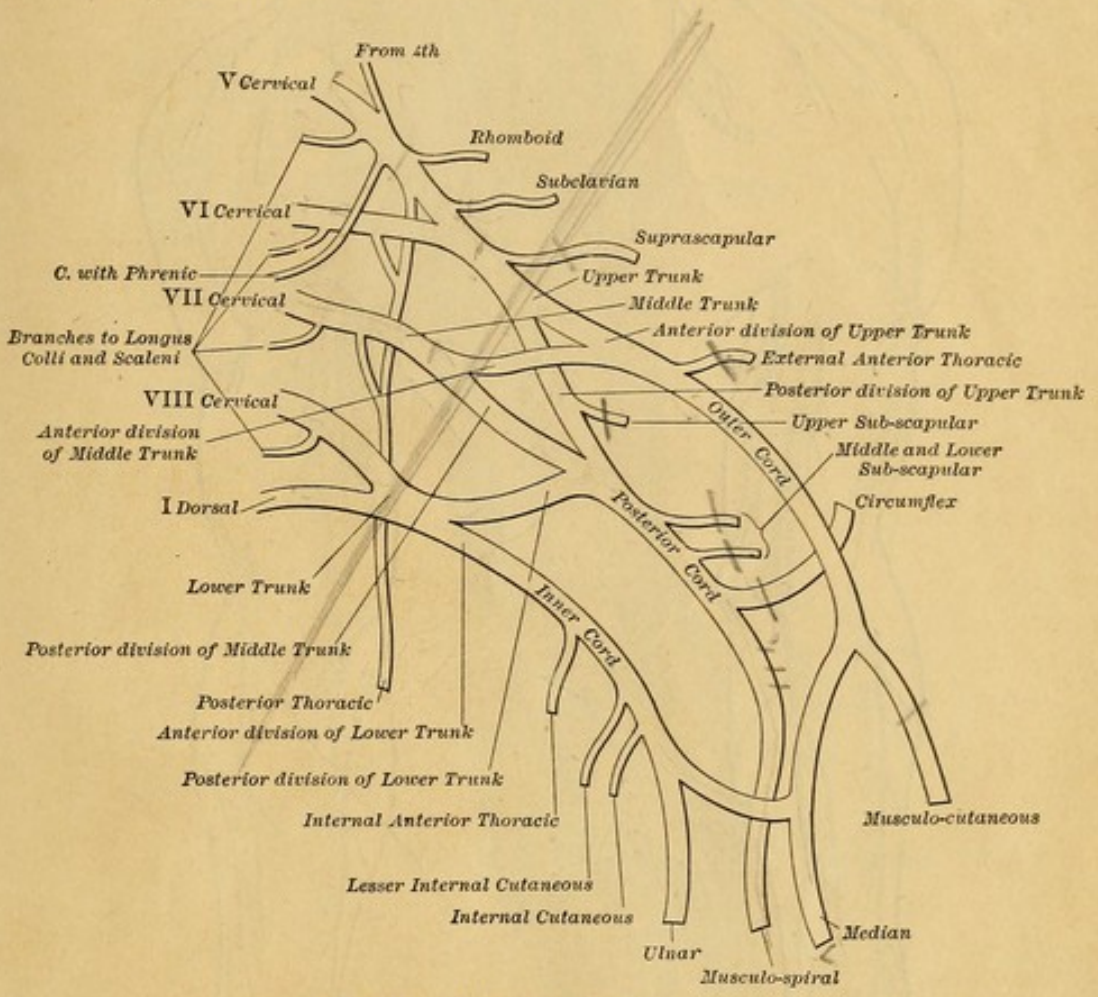

FIG. 410.—Plan of the brachial plexus.

Scalenus anticus, are blended into three trunks—an upper one, formed by the junction of the fifth and sixth cervical nerves; a middle one, consisting of the seventh cervical nerve; and a lower one, formed by the junction of the eighth cervical and first dorsal nerves. As they pass beneath the clavicle, each of these three trunks divides into two branches, an *anterior* and a *posterior*.[1] The anterior divisions of the upper and middle trunks then unite to form a common cord, which is situated on the outer side of the middle part of the axillary artery, and is called the *outer cord* of the brachial plexus. The anterior division of the lower trunk passes down on the inner side of the axillary artery in the middle of the axilla, and forms the *inner cord* of the brachial plexus. The posterior divisions of all three trunks unite to form the *posterior cord* of the brachial plexus, which is situated behind the second portion of the axillary artery. From this posterior cord are given off the two lower subscapular nerves, the upper subscapular nerve being given off from the posterior division of the upper trunk prior to its junction with the posterior division of the lower and middle trunks. The posterior cord divides into the circumflex and musculo-spiral nerves.

The brachial plexus communicates with the cervical plexus by a branch from the fourth to the fifth nerve, and with the phrenic nerve by a branch from the

[1] The posterior division of the lower trunk is very much smaller than the others, and is frequently derived entirely from the eighth cervical nerve.

fifth cervical, which joins that nerve on the Anterior scalenus muscle: the fifth and sixth cervical nerves are joined by filaments to the middle cervical ganglion of the sympathetic, the seventh and eighth cervical to its inferior ganglion, and

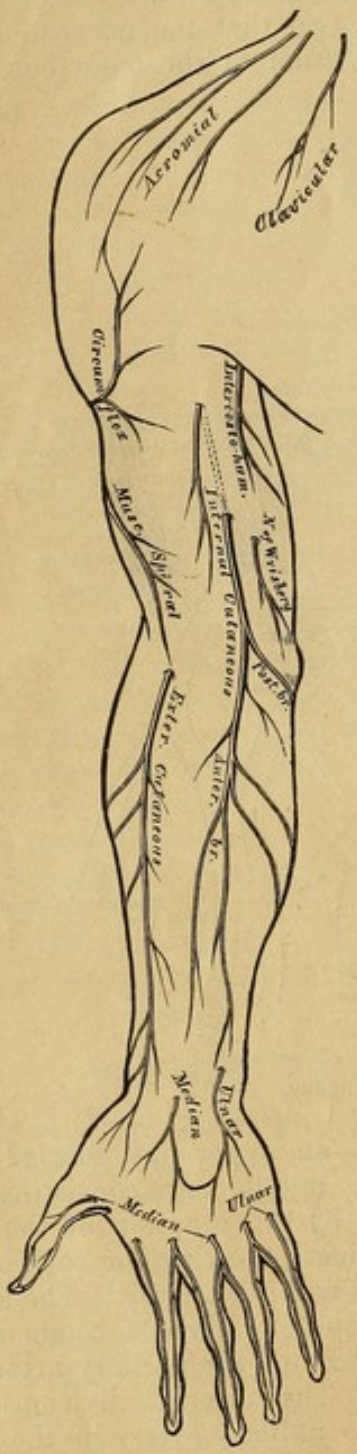

FIG. 411.—Cutaneous nerves of right upper extremity. Anterior view.

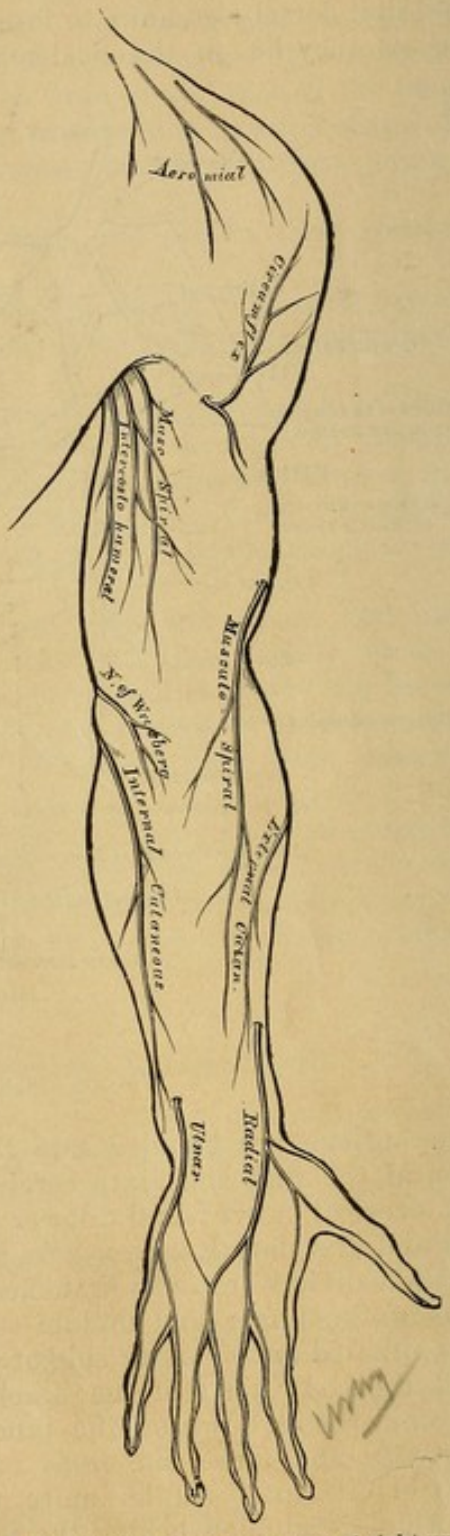

FIG. 412.—Cutaneous nerves of right upper extremity. Posterior view.

the first dorsal nerve to its first thoracic ganglion, close to their exit from the intervertebral foramina.

Relations.—*In the neck*, the brachial plexus lies in the posterior triangle, being covered by the skin, Platysma, and deep fascia: it is crossed by the posterior belly of the Omo-hyoid and by the Transversalis colli artery. When the posterior scapular artery arises from the third part of the subclavian, it usually passes between the roots of the plexus. It lies at first between the Anterior and Middle

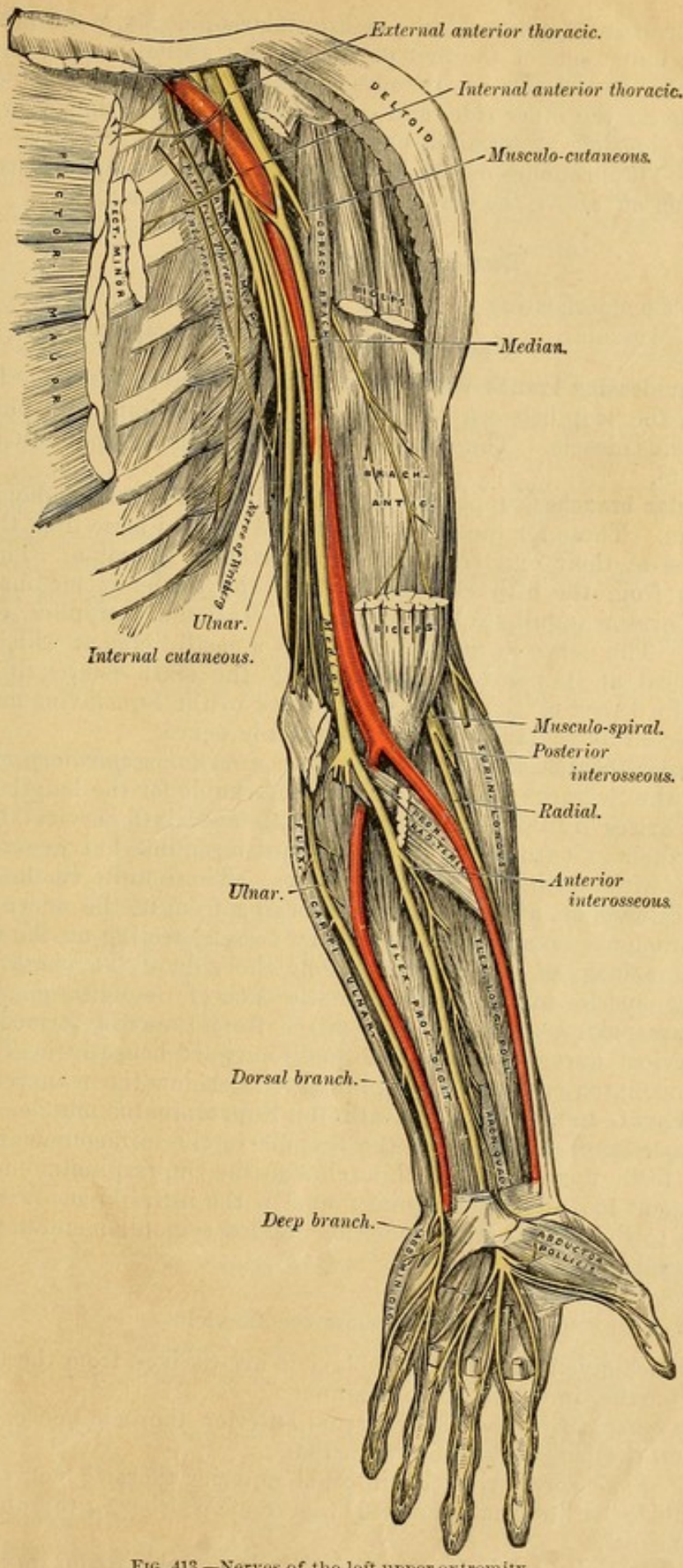

FIG. 413.—Nerves of the left upper extremity.

scaleni muscles, and then above and to the outer side of the subclavian artery: it next passes behind the clavicle and Subclavius muscle, lying upon the first serra-

tion of the Serratus magnus, and the Subscapularis muscles. *In the axilla*, it is placed on the outer side of the first portion of the axillary artery; it surrounds the artery in the second part of its course, one cord lying upon the outer side of that vessel, one on the inner side, and one behind it, and at the lower part of the axillary space gives off its terminal branches to the upper extremity.

Branches.—The branches of the brachial plexus are arranged in two groups—viz., those given off above the clavicle, and those below that bone.

Branches above the Clavicle.

Communicating.	Posterior thoracic.
Muscular.	Suprascapular.

The **communicating branch** with the phrenic is derived from the fifth cervical nerve or from the loop between the fifth and sixth; it joins the phrenic on the Anterior scalenus muscle. The communications with the sympathetic have already been referred to.

The **muscular branches** supply the Longus colli, Scaleni, Rhomboidei, and Subclavius muscles. Those for the Longus colli and Scaleni arise from the four lower cervical nerves at their exit from the intervertebral foramina. The Rhomboid branch arises from the fifth cervical, pierces the Scalenus medius, and passes beneath the Levator anguli scapulæ, which it occasionally supplies, to the Rhomboid muscles. The nerve to the Subclavius is a small filament which arises from the fifth cervical at its point of junction with the sixth nerve; it descends in front of the third part of the subclavian artery to the Subclavius muscle, and is usually connected by a filament with the phrenic nerve.

The **posterior thoracic nerve** (*long thoracic, external respiratory of Bell*) (Fig. 413) supplies the Serratus magnus, and is remarkable for the length of its course. It sometimes arises by two roots from the fifth and sixth cervical nerves immediately after their exit from the intervertebral foramina, but generally by three roots from the fifth, sixth, and seventh nerves. These unite in the substance of the Middle scalenus muscle, and, after emerging from it, the nerve passes down behind the brachial plexus and the axillary vessels, resting on the outer surface of the Serratus magnus. It extends along the side of the chest to the lower border of that muscle, supplying filaments to each of its digitations.

The **suprascapular nerve** (Fig. 414) arises from the cord formed by the fifth and sixth cervical nerves; passing obliquely outward beneath the Trapezius and the Omo-hyoid, it enters the supraspinous fossa below the transverse or suprascapular ligament, and, passing beneath the Supraspinatus muscle, curves round the external border of the spine of the scapula to the infraspinous fossa. In the supraspinous fossa it gives off two branches to the Supraspinatus muscle, and an articular filament to the shoulder-joint; and in the infraspinous fossa it gives off two branches to the Infraspinatus muscle, besides some filaments to the shoulder-joint and scapula.

Branches below the Clavicle.

The branches given off below the clavicle are derived from the three cords of the brachial plexus, in the following manner:

From the outer cord arise the external anterior thoracic nerve, the musculo-cutaneous, and the outer head of the median.

From the inner cord arise the internal anterior thoracic nerve, the internal cutaneous, the lesser internal cutaneous (nerve of Wrisberg), the ulnar, and inner head of the median.

From the posterior cord arise two of the three subscapular nerves, the third taking origin from the posterior division of the trunk formed by the fifth and sixth cervical nerves; the cord then divides into the musculo-spiral and circumflex nerves.

These may be arranged according to the parts they supply:

To the chest	Anterior thoracic.
To the shoulder	Subscapular. Circumflex.
To the arm, forearm, and hand .	Musculo-cutaneous. Internal cutaneous. Lesser internal cutaneous. Median. Ulnar. Musculo-spiral.

The fasciculi of which these nerves are composed may be traced through the plexus to the spinal nerves from which they originate. They are as follows:

External anterior thoracic	from	5th, 6th, and 7th cervical.
Internal anterior thoracic	"	8th cervical and 1st dorsal.
Subscapular	"	5th, 6th, 7th, and 8th cervical.
Circumflex	"	5th and 6th cervical.
Musculo-cutaneous	"	5th and 6th cervical.
Internal cutaneous	"	8th cervical and 1st dorsal.
Lesser internal cutaneous	"	1st dorsal.
Median	"	6th, 7th, and 8th cervical, and 1st dorsal.
Ulnar	"	8th cervical and 1st dorsal.
Musculo-spiral	"	6th, 7th, and 8th cervical, sometimes also from the 5th.

The **Anterior Thoracic Nerves** (Fig. 413), two in number, supply the Pectoral muscles.

The *external* or superficial nerve, the larger of the two, arises from the outer cord of the brachial plexus, through which its fibres may be traced to the fifth, sixth, and seventh cervical nerves. It passes inward, across the axillary artery and vein, pierces the costo-coracoid membrane, and is distributed to the under surface of the Pectoralis major. It sends down a communicating filament to join the internal nerve, which forms a loop round the inner side of the axillary artery.

The *internal* or deep nerve arises from the inner cord, and through it from the eighth cervical and first dorsal. It passes behind the first part of the axillary artery, then curves forward between the axillary artery and vein, and joins with the filament from the anterior nerve. It then passes to the under surface of the Pectoralis minor muscle, where it divides into a number of branches, which supply the muscle on its under surface. Some two or three branches pass through the muscle to supply the Pectoralis major.

The **Subscapular Nerves**, three in number, supply the Subscapularis, Teres major, and Latissimus dorsi muscles. The fasciculi of which they are composed may be traced to the fifth, sixth, seventh, and eighth cervical nerves.

The *upper subscapular nerve*, the smallest, enters the upper part of the Subscapularis muscle; this nerve is frequently represented by two branches.

The *lower subscapular nerve* enters the axillary border of the Subscapularis and terminates in the Teres major. The latter muscle is sometimes supplied by a separate branch.

The *middle* or *long subscapular*, the largest of the three, follows the course of the subscapular artery, along the posterior wall of the axilla to the Latissimus dorsi, through which it may be traced as far as its lower border.

The **Circumflex Nerve** (Fig. 414) supplies some of the muscles and the integument of the shoulder and the shoulder-joint. It arises from the posterior cord of the brachial plexus, in common with the musculo-spiral nerve, and its fibres may be traced through the posterior cord to the fifth and sixth cervical nerves. It is at first placed behind the axillary artery, between it and the Subscapularis muscle,

and passes downward and outward to the lower border of that muscle. It then winds backward in company with the posterior circumflex artery, through a quadrilateral space bounded above by the Teres minor, below by the Teres major, internally by the long head of the Triceps, and externally by the neck of the humerus, and divides into two branches.

The *upper branch* winds round the surgical neck of the humerus, beneath the Deltoid, with the posterior circumflex vessels, as far as the anterior border of that muscle, supplying it, and giving off cutaneous branches, which pierce the muscle and ramify in the integument covering its lower part.

The *lower branch*, at its origin, distributes filaments to the Teres minor and back part of the Deltoid muscles. Upon the filament to the former muscle an oval enlargement usually exists. The nerve then pierces the deep fascia, and supplies the integument over the lower two-thirds of the posterior surface of the Deltoid, as well as that covering the long head of the Triceps.

The circumflex nerve, before its division, gives off an articular filament, which enters the shoulder-joint below the Subscapularis.

The **Musculo-cutaneous Nerve** (Fig. 413) (*external cutaneous* or *perforans Casserii*)[1] supplies some of the muscles of the arm and the integument of the forearm. It arises from the outer cord of the brachial plexus, opposite the lower border of the Pectoralis minor, receiving filaments from the fifth, sixth, and seventh cervical nerves. It perforates the Coraco-brachialis muscle, passes obliquely between the Biceps and Brachialis anticus to the outer side of the arm, and, a little above the elbow, winds round the outer border of the tendon of the Biceps, and, perforating the deep fascia, becomes cutaneous. This nerve, in its course through the arm, supplies the Coraco-brachialis, Biceps, and the greater part of the Brachialis anticus muscles. The branch to the Coraco-brachialis is given off from the nerve close to its origin, and in some instances, especially in early life, as a separate filament from the outer cord of the plexus. The branches to the Biceps and Brachialis anticus are given off after the nerve has pierced the Coraco-brachialis. The nerve also sends a small branch to the bone, which enters the nutrient foramen with the accompanying artery, and a filament, from the branch supplying the Brachialis anticus, to the elbow-joint.

The cutaneous portion of the nerve passes behind the median cephalic vein, and divides, opposite the elbow-joint, into an anterior and a posterior branch.

The *anterior branch* descends along the radial border of the forearm to the wrist, and supplies the integument over the outer half of the anterior surface. At the wrist-joint it is placed in front of the radial artery, and some filaments, piercing the deep fascia, accompany that vessel to the back of the wrist, supplying the carpus. The nerve then passes downward to the ball of the thumb, where it terminates in cutaneous filaments. It communicates with a branch from the radial nerve and the palmar cutaneous branch of the median.

The *posterior branch* passes downward along the back part of the radial side of the forearm to the wrist. It supplies the integument of the lower third of the forearm, communicating with the radial nerve and the external cutaneous branch of the musculo-spiral.

The musculo-cutaneous nerve presents frequent irregularities. It may adhere for some distance to the median and then pass outward, beneath the Biceps, instead of through the Coraco-brachialis. Frequently some of the fibres of the median run for some distance in the musculo-cutaneous and then leave it to join their proper trunk. Less frequently the reverse is the case, and the median sends a branch to join the musculo-cutaneous. Instead of piercing the Coraco-brachialis, the nerve may pass under it or through the Biceps. Occasionally it gives a filament to the Pronator teres, and it has been seen to supply the back of the thumb when the radial nerve was absent.

The **Internal Cutaneous Nerve** (Fig. 413) is one of the smallest branches of the brachial plexus. It arises from the inner cord in common with the ulnar and

[1] See foot-note, page 726.

internal head of the median, and, at its commencement, is placed on the inner side of the axillary, and afterward of the brachial artery. It derives its fibres from the eighth cervical and first dorsal nerves. It passes down the inner side of the arm, pierces the deep fascia with the basilic vein, about the middle of the limb, and, becoming cutaneous, divides into two branches, anterior and posterior.

This nerve gives off, near the axilla, a cutaneous filament, which pierces the fascia and supplies the integument covering the Biceps muscle nearly as far as the elbow. This filament lies a little external to the common trunk, from which it arises.

The *anterior branch*, the larger of the two, passes usually in front of, but occasionally behind, the median basilic vein. It then descends on the anterior surface of the ulnar side of the forearm, distributing filaments to the integument as far as the wrist, and communicating with a cutaneous branch of the ulnar nerve.

The *posterior branch* passes obliquely downward on the inner side of the basilic vein, passes in front of, or over, the internal condyle of the humerus to the back of the forearm, and descends on the posterior surface of its ulnar side as far as the wrist, distributing filaments to the integument. It communicates, above the elbow, with the lesser internal cutaneous, and above the wrist with the dorsal cutaneous branch of the ulnar nerve (Swan).

The **Lesser Internal Cutaneous Nerve** (*nerve of Wrisberg*) (Fig. 413) is distributed to the integument on the inner side of the arm. It is the smallest of the branches of the brachial plexus, and, arising from the inner cord with the internal cutaneous and ulnar nerves, receives its fibres from the first dorsal nerve. It passes through the axillary space, at first lying behind, and then on the inner side of, the axillary vein, and communicates with the intercosto-humeral nerve. It descends along the inner side of the brachial artery to the middle of the arm, where it pierces the deep fascia, and is distributed to the integument of the back part of the lower third of the arm, extending as far as the elbow, where some filaments are lost in the integument in front of the inner condyle, and others over the olecranon. It communicates with the posterior branch of the internal cutaneous nerve.

In some cases the nerve of Wrisberg and intercosto-humeral are connected by two or three filaments which form a plexus at the back part of the axilla. In other cases the intercosto-humeral is of large size, and takes the place of the nerve of Wrisberg, receiving merely a filament of communication from the brachial plexus, which represents the latter nerve. In other cases this filament is wanting, the place of the nerve of Wrisberg being supplied entirely from the intercosto-humeral.

The **Median Nerve** (Fig. 413) has received its name from the course it takes along the middle of the arm and forearm to the hand, lying between the ulnar and the musculo-spiral and radial nerves. It arises by two roots, one from the outer, and one from the inner, cord of the brachial plexus; these embrace the lower part of the axillary artery, uniting either in front or on the outer side of that vessel. It receives filaments from the sixth, seventh, and eighth cervical and the first dorsal. As it descends through the arm, it lies at first on the outer side of the brachial artery, crosses that vessel in the middle of its course, usually in front, but occasionally behind it, and lies on its inner side to the bend of the elbow, where it is placed beneath the bicipital fascia, and is separated from the elbow-joint by the Brachialis anticus. *In the forearm* it passes between the two heads of the Pronator radii teres, and descends beneath the Flexor sublimis, lying on the Flexor profundus, to within two inches above the annular ligament, where it becomes more superficial, lying between the tendons of the Flexor sublimis and Flexor carpi radialis, beneath, and rather to the radial side of, the tendon of the Palmaris longus, covered by the integument and fascia. It then passes beneath the annular ligament into the hand. In its course through the forearm it is accompanied by a branch of the anterior interosseous artery.

Branches.—With the exception of the nerve to the Pronator teres, which sometimes arises above the elbow-joint, the median nerve gives off no branches in the arm. *In the forearm* its branches are muscular, anterior interosseous, and palmar cutaneous, and, according to Rüdinger and Macalister, two articular twigs to the elbow-joint.

The *muscular branches* supply all the superficial muscles on the front of the forearm except the Flexor carpi ulnaris. These branches are derived from the nerve near the elbow.

The *anterior interosseous* supplies the deep muscles on the front of the forearm, except the inner half of the Flexor profundus digitorum. It accompanies the anterior interosseous artery along the interosseous membrane, in the interval between the Flexor longus pollicis and Flexor profundus digitorum muscles, both of which it supplies, and terminates below in the Pronator quadratus and wrist-joint.

The *palmar cutaneous branch* arises from the median nerve at the lower part of the forearm. It pierces the fascia above the annular ligament, and, descending over that ligament, divides into two branches; of which the *outer* supplies the skin over the ball of the thumb, and communicates with the anterior cutaneous branch of the musculo-cutaneous nerve; and the *inner* supplies the integument of the palm of the hand, communicating with the cutaneous branch of the ulnar.

In the palm of the hand the median nerve is covered by the integument and palmar fascia and crossed by the superficial palmar arch. It rests upon the tendons of the flexor muscles. In this situation it becomes enlarged, somewhat flattened, of a reddish color, and divides into two branches. Of these, the *external* supplies a muscular branch to some of the muscles of the thumb and digital branches to the thumb and index finger; the *internal* supplies digital branches to the contiguous sides of the index and middle and of the middle and ring fingers.

The *branch to the muscles of the thumb* is a short nerve which divides to supply the Abductor, Opponens, and the superficial head of the Flexor brevis pollicis muscles, the remaining muscles of this group being supplied by the ulnar nerve.

The *digital branches* are five in number. The *first* and *second* pass along the borders of the thumb, the external branch communicating with branches of the radial nerve. The *third* passes along the radial side of the index finger, and supplies the First lumbricalis muscle. The *fourth* subdivides to supply the adjacent sides of the index and middle fingers, and sends a branch to the Second lumbrical muscle. The *fifth* supplies the adjacent sides of the middle and ring fingers, and communicates with a branch from the ulnar nerve.

Each digital nerve, opposite the base of the first phalanx, gives off a dorsal branch, which joins the dorsal digital nerve from the radial and runs along the side of the dorsum of the finger, to end in the integument over the last phalanx. At the end of the finger the digital nerve divides into a palmar and a dorsal branch, the former of which supplies the extremity of the finger, and the latter ramifies round and beneath the nail. The digital nerves, as they run along the fingers, are placed superficial to the digital arteries.

The **Ulnar Nerve** (Fig. 413) is placed along the inner or ulnar side of the upper limb, and is distributed to the muscles and integument of the forearm and hand. It is smaller than the median, behind which it is placed, diverging from it in its course down the arm. It arises from the inner cord of the brachial plexus, in common with the inner head of the median and the internal cutaneous nerve, and derives its fibres from the eighth cervical and first dorsal nerves. At its commencement it lies to the inner side of the axillary artery, and holds the same relation with the brachial artery to the middle of the arm. From this point it runs obliquely across the internal head of the Triceps, pierces the internal intermuscular septum, and descends to the groove between the internal condyle and the olecranon, accompanied by the inferior profunda artery. *At the elbow* it rests upon the back of the

inner condyle, and passes into the forearm between the two heads of the Flexor carpi ulnaris. *In the forearm* it descends in a perfectly straight course along its ulnar side, lying upon the Flexor profundus digitorum, its upper half being covered by the Flexor carpi ulnaris, its lower half lying on the outer side of the muscle, covered by the integument and fascia. The ulnar artery, in the upper third of its course, is separated from the ulnar nerve by a considerable interval, but in the rest of its extent the nerve lies to its inner side. *At the wrist* the ulnar nerve crosses the annular ligament on the outer side of the pisiform bone, to the inner side of and a little behind the ulnar artery, and immediately beyond this bone divides into two branches, superficial and deep palmar.

The branches of the ulnar nerve are—

In the forearm: Articular (elbow). Muscular. Cutaneous. Dorsal cutaneous. Articular (wrist).

In the hand: Superficial palmar. Deep palmar.

The *articular branches* distributed to the elbow-joint consist of several small filaments. They arise from the nerve as it lies in the groove between the inner condyle and olecranon.

The *muscular branches* are two in number—one supplying the Flexor carpi ulnaris; the other, the inner half of the Flexor profundus digitorum. They arise from the trunk of the nerve near the elbow.

The *cutaneous branch* arises from the ulnar nerve about the middle of the forearm, and divides into two branches.

One branch (frequently absent) pierces the deep fascia near the wrist, and is distributed to the integument, communicating with a branch of the internal cutaneous nerve.

The second branch (*palmar cutaneous*) lies on the ulnar artery, which it accompanies to the hand, some filaments entwining round the vessel; it ends in the integument of the palm, communicating with branches of the median nerve.

The *dorsal cutaneous branch* arises about two inches above the wrist; it passes backwards beneath the Flexor carpi ulnaris, perforates the deep fascia, and, running along the ulnar side of the back of the wrist and hand, divides into five branches; one of these supplies the inner side of the little finger; a second supplies the adjacent sides of the little and ring fingers; a third joins the branch of the radial nerve which supplies the adjoining sides of the middle and ring fingers, and assists in supplying them; a fourth is distributed to the metacarpal region of the hand, communicating with a branch of the radial nerve.

On the little finger the dorsal digital branches extend only as far as the base of the terminal phalanx, and on the ring finger as far as the base of the second phalanx; the more distal parts of these digits are supplied by dorsal branches derived from the palmar digital branches of the ulnar.

The *superficial palmar branch* supplies the Palmaris brevis and the integument on the inner side of the hand, and terminates in two digital branches, which are distributed one to the ulnar side of the little finger, the other to the adjoining sides of the little and ring fingers, the latter communicating with a branch from the median. The digital branches are distributed to the fingers in the same manner as the digital branches of the median.

The *deep palmar branch*, accompanied by the deep branch of the ulnar artery, passes between the Abductor and Flexor brevis minimi digiti muscles; it then perforates the Opponens minimi digiti and follows the course of the deep palmar arch beneath the flexor tendons. At its origin it supplies the muscles of the little finger. As it crosses the deep part of the hand it sends two branches to each interosseous space, one for the Dorsal and one for the Palmar interosseous muscle, the branches to the Second and Third palmar interossei supplying filaments to the two innermost lumbrical muscles. At its termination between the thumb and index

finger, it supplies the Adductores transversus et obliquus pollicis and the inner head of the Flexor brevis pollicis. It also sends articular filaments to the wrist-joint.

It will be remembered that the inner part of the Flexor profundus digitorum is supplied by the ulnar nerve; the two inner Lumbricales, which are connected with the tendons of this part of the muscle, are therefore supplied by the same nerve. The outer part of the Flexor profundus is supplied by the median nerve; the two outer Lumbricales, which are connected with the tendons of this part of the muscle, are therefore supplied by the same nerve. Brooks states that in twelve instances out of twenty-one he found that the third lumbrical received a twig from the median nerve, in addition to its branch from the ulnar.

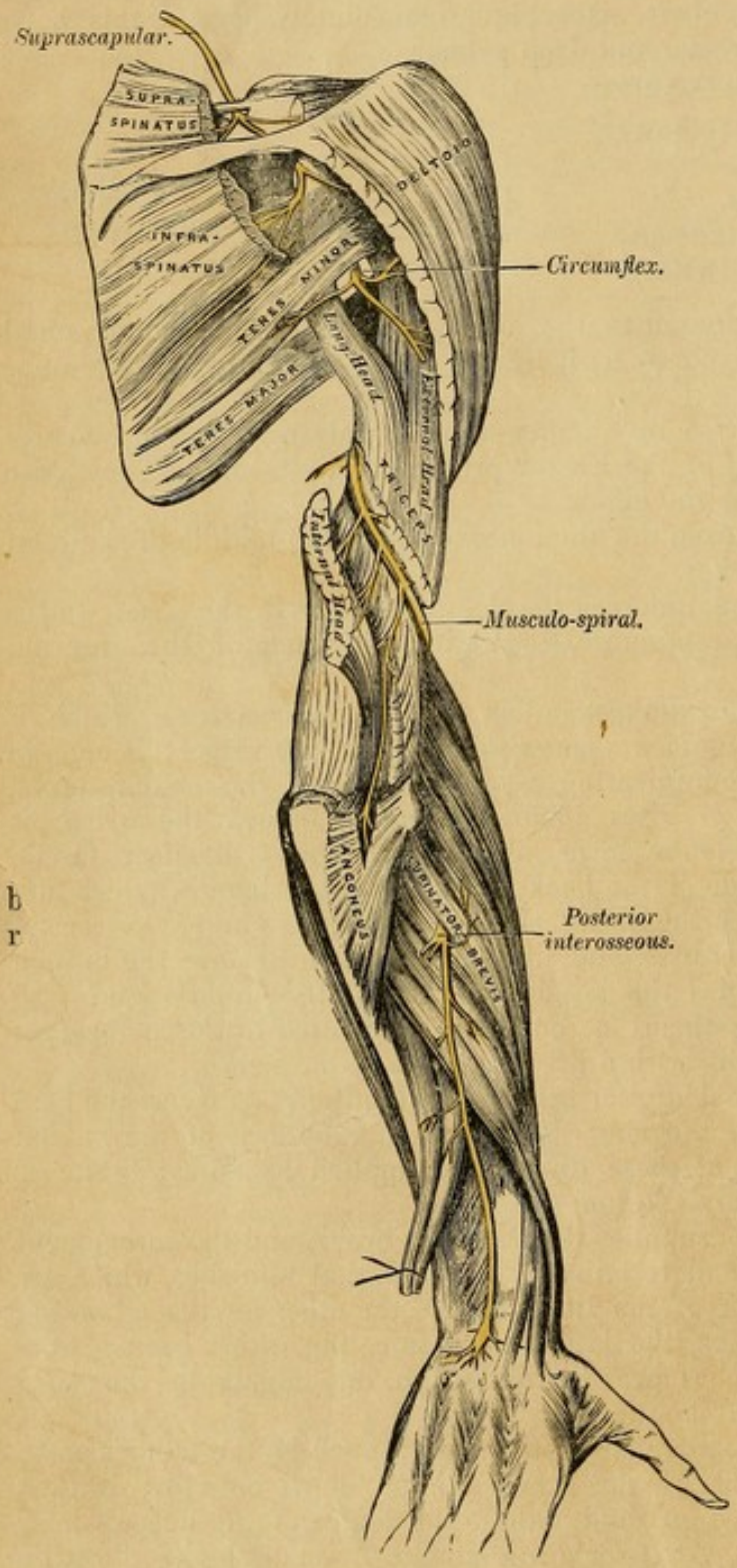

FIG. 414.—The suprascapular, circumflex, and musculo-spiral nerves.

The **Musculo-spiral Nerve** (Fig. 414), the largest branch of the brachial plexus, supplies the muscles of the back part of the arm and forearm, and the integument of the same parts, as well as that of the back of the hand. It arises from the posterior cord of the brachial plexus, of which it may be regarded as the continuation. It receives filaments from the sixth, seventh, and eighth, and sometimes also from the fifth cervical nerves. At its commencement it is placed behind the axillary and upper part of the brachial arteries, passing down in front of the tendons of the Latissimus dorsi and Teres major. It winds round the humerus in the musculo-spiral groove with the superior profunda artery, passing from the inner to the outer side of the bone, between the internal and external heads of the Triceps muscle. It pierces the external intermuscular septum, and descends between the Brachialis anticus and Supinator longus to the front of the external condyle, where it divides into the radial and posterior interosseous nerves.

The branches of the musculo-spiral nerve are—

Muscular.
Cutaneous.
Radial.
Posterior interosseous.

The *muscular branches* are divided into internal, posterior and external;

they supply the Triceps, Anconeus, Supinator longus, Extensor s only slightly longior, and Brachialis anticus. These branches are derived fron length from the inner side, back part, and outer side of the arm. wn in contact

The internal muscular branches supply the inner and middle vo vertebræ, Triceps muscle. That to the inner head of the Triceps is a long, slenervertebral which lies close to the ulnar nerve, as far as the lower third of tlerior (dorsal) therefore frequently spoken of as the *ulnar collateral.*

The posterior muscular branch, of large size, arises from the nerv me respects. between the Triceps and the humerus. It divides into branches w outer and inner head of the Triceps and Anconeus muscles. The branch latter muscle is a long, slender filament which descends in the substance of Triceps to the Anconeus.

The external muscular branches supply the Supinator longus, Extensor carpi radialis longior, and (usually) the outer part of the Brachialis anticus.

The *cutaneous branches* are three in number, one internal and two external.

The internal cutaneous branch arises in the axillary space with the inner muscular branch. It is of small size, and passes through the axilla to the inner side of the arm, supplying the integument on its posterior aspect nearly as far as the olecranon. In its course it crosses beneath the intercosto-humeral, with which it communicates.

The two external cutaneous branches perforate the outer head of the Triceps at its attachment to the humerus. The upper and smaller one passes to the front of the elbow, lying close to the cephalic vein, and supplies the integument of the lower half of the arm on its anterior aspect. The lower branch pierces the deep fascia below the insertion of the Deltoid, and passes down along the outer side of the arm and elbow, and then along the back part of the radial side of the forearm to the wrist, supplying the integument in its course, and joining, near its termination, with the posterior cutaneous branch of the musculo-cutaneous nerve.

The **radial nerve** passes along the front of the radial side of the forearm to the commencement of its lower third. It lies at first a little to the outer side of the radial artery, concealed beneath the Supinator longus. In the middle third of the forearm it lies beneath the same muscle, in close relation with the outer side of the artery. It quits the artery about three inches above the wrist, passes beneath the tendon of the Supinator longus, and, piercing the deep fascia at the outer border of the forearm, divides into two branches.

The external branch, the smaller of the two, supplies the integument of the radial side and ball of the thumb, joining with the anterior branch of the musculo-cutaneous nerve.

The internal branch communicates, above the wrist, with the posterior cutaneous branch from the musculo-cutaneous, and on the back of the hand forms an arch with the dorsal cutaneous branch of the ulnar nerve. It then divides into four digital nerves, which are distributed as follows: The first supplies the ulnar side of the thumb; the second, the radial side of the index finger; the third, the adjoining sides of the index and middle fingers; and the fourth, the adjacent borders of the middle and ring fingers.[1] The latter nerve communicates with a filament from the dorsal branch of the ulnar nerve.

The **Posterior Interosseous Nerve** winds to the back of the forearm round the outer side of the radius, passes between the two planes of fibres of the Supinator brevis, and is prolonged downward between the superficial and deep layer of muscles, to the middle of the forearm. Considerably diminished in size, it descends on the interosseous membrane, beneath the Extensor longus pollicis, to the back of the carpus, where it presents a gangliform enlargement from which filaments are distributed to the ligaments and articulations of the carpus. It supplies

[1] According to Hutchinson, the digital nerve to the thumb reaches only as high as the root of the nail; the one to the forefinger as high as the middle of the second phalanx, and the one to the middle and ring fingers not higher than the first phalangeal joint (*London Hosp. Gaz.*, vol. iii., p. 319).

finger, it suppli of the radial and posterior brachial regions, excepting the Anco-
of the Flexor l r longus, and Extensor carpi radialis longior.

It will be

is supplied b**natomy.**—The brachial plexus may be ruptured by traction on the limb, leading
with the ten alysis. In these cases the lesion would appear to be rather a tearing away of the
spinal cord than a solution of continuity of the nerve-fibres themselves. In the
nerve. The c nerves forming the brachial plexus may be injured in a wound of this part, the
the two outer e one which is most frequently damaged from its exposed position, and the
n account of its sheltered and deep position, being the least often wounded.
vus in the axilla is often damaged from the pressure of a crutch, producing the
Suprascapular. as "crutch paralysis." In these cases the musculo-spiral appears most fre-
be the nerve which is chiefly implicated; the ulnar nerve being the one that appears
uffer next in frequency.

The *circumflex nerve* is of particular surgical interest. On account of its course round the surgical neck of the humerus, it is liable to be torn in fractures of this part of the bone, and in dislocations of the shoulder-joint, leading to paralysis of the deltoid, and, according to Erb, inflammation of the shoulder-joint is liable to be followed by a neuritis of this nerve from extension of the inflammation to it.

Mr. Hilton takes the circumflex nerve as an illustration of a law which he lays down, that "the same trunks of nerves whose branches supply the groups of muscles moving a joint furnish also a distribution of nerves to the skin over the insertions of the same muscles, and the interior of the joint receives its nerves from the same source." In this way he explains the fact that an inflamed joint becomes rigid, because the same nerves which supply the interior of the joint supply the muscles also which move that joint.

The *median nerve* is liable to injury in wounds of the forearm. When paralyzed, there is loss of flexion of the second phalanges of all the fingers and of the terminal phalanges of the index and middle fingers. Flexion of the terminal phalanges of the ring and middle fingers is effected by that portion of the Flexor profundus digitorum which is supplied by the ulnar nerve. There is power to flex the proximal phalanges through the Interossei. The thumb cannot be flexed or opposed, and is maintained in a position of extension and adduction. All power of pronation is lost. The wrist can be flexed, if the hand is first adducted, by the action of the Flexor carpi ulnaris. There is loss or impairment of sensation on the palmar surface of the thumb, index, middle, and outer half of the ring fingers, and on the dorsal surface of the same fingers over the last two phalanges; except in the thumb, where the loss of sensation would be limited to the back of the last phalanx. In order to expose the median nerve for the purpose of stretching an incision should be made along the radial side of the tendon of the Palmaris longus, which serves as a guide to the nerve.

The *ulnar nerve* is also liable to be injured in wounds of the forearm. When paralyzed, there is loss of power of flexion in the ring and little fingers; there is impaired power of ulnar flexion and adduction; there is inability to spread out the fingers from paralysis of the Interossei; and there is inability to adduct the thumb. Sensation is lost or impaired in the skin supplied by the nerve. In order to expose the nerve in the lower part of the forearm, an incision should be made along the outer border of the tendon of the Flexor carpi ulnaris, and the nerve will be found lying on the ulnar side of the ulnar artery.

The *musculo-spiral nerve* is probably more frequently injured than any other nerve of the upper extremity. In consequence of its close relationship to the humerus as it lies in the musculo-spiral groove, it is frequently torn or injured in fractures of this bone, or subsequently involved in the callus that may be thrown out around a fracture, and thus pressed upon and its functions interfered with. It is also liable to be contused against the bone by kicks or blows or to be divided by wounds of the arm. When paralyzed, the hand is flexed at the wrist and lies flaccid. This is known as "drop-wrist." The fingers are also flexed, and on an attempt being made to extend them the last two phalanges only will be extended through the action of the Interossei, the first phalanges remaining flexed. There is no power of extending the wrist. Supination is completely lost when the forearm is extended on the arm, but it is possible to a certain extent if the forearm is flexed so as to allow of the action of the Biceps. The power of extension of the forearm is lost on account of paralysis of the Triceps. The best position in which to expose the nerve for the purpose of stretching is to make an incision along the inner border of the Supinator longus, just above the level of the elbow-joint. The skin and superficial structures are to be divided and the deep fascia exposed. The white line in this structure indicating the border of the muscle is to be defined, and the deep fascia divided in this line. By now raising the Supinator longus the nerve will be found lying beneath it, on the Brachialis anticus.

THE DORSAL NERVES (Fig. 415).

The **Dorsal Nerves** are twelve in number on each side. The first appears between the first and second dorsal vertebræ, and the last between the last dorsal and first lumbar.

The *roots of the dorsal nerves* are of small size, and vary but slightly from the

second to the last. Both roots are very slender, the posterior roots only slightly exceeding the anterior in thickness. They gradually increase in length from above downward, and in the lower part of the dorsal region pass down in contact with the spinal cord for a distance equal to the height of at least two vertebræ, before they emerge from the spinal canal. They then join in the intervertebral foramen, and at their exit divide into two primary divisions, a posterior (dorsal) and an anterior (intercostal).

The first, the second, and the last dorsal nerves are peculiar in some respects.

Posterior Divisions of the Dorsal Nerves.

The **posterior divisions of the dorsal nerves**, which are smaller than the anterior, pass backward between the transverse processes, and divide into internal and external branches.

The *internal branches of the six upper nerves* pass inward between the Semispinalis dorsi and Multifidus spinæ muscles, which they supply, and then, piercing the origins of the Rhomboidei and Trapezius muscles, become cutaneous by the side of the spinous processes and ramify in the integument. The internal branches of the six lower nerves are distributed to the Multifidus spinæ, without giving off any cutaneous filaments.

The *external branches* increase in size from above downward. They pass through the Longissimus dorsi to the cellular interval between it and the Iliocostalis, and supply those muscles, as well as their continuations upward to the head, and the Levatores costarum; the five or six lower nerves also give off cutaneous filaments, which pierce the Serratus posticus inferior and Latissimus dorsi in a line with the angles of the ribs, and then ramify in the integument.

The *cutaneous branches of the posterior primary divisions of the dorsal nerves* are twelve in number. The six upper cutaneous nerves are derived from the internal branches of the posterior divisions of the dorsal nerves. They pierce the origins of the Rhomboidei and Trapezius muscles, and become cutaneous by the side of the spinous processes, and then ramify in the integument. They are frequently furnished with gangliform enlargements. The six lower cutaneous nerves are derived from the external branches of the posterior divisions of the dorsal nerves. They pierce the Serratus posticus inferior and Latissimus dorsi in a line with the angles of the ribs, and then ramify in the integument.

Anterior Divisions of the Dorsal Nerves.

The **anterior divisions of the dorsal nerves** (*intercostal nerves*) are twelve in number on each side. They are, for the most part, distributed to the parietes of the thorax and abdomen, separately from each other, without being joined in a plexus; in which respect they differ from the other spinal nerves. Each nerve is connected with the adjoining ganglia of the sympathetic by one or two filaments. The intercostal nerves may be divided into two sets, from the difference they present in their distribution. The six upper, with the exception of the first and the intercosto-humeral branch of the second, are limited in their distribution to the parietes of the chest. The six lower supply the parietes of the chest and abdomen, the last one sending a cutaneous filament to the buttock.

The First Dorsal Nerve.—The anterior division of the first dorsal nerve divides into two branches: one, the larger, leaves the thorax in front of the neck of the first rib, and enters into the formation of the brachial plexus; the other and smaller branch runs along the first intercostal space, forming the *first intercostal nerve*, and terminates on the front of the chest by forming the first anterior cutaneous nerve of the thorax. Occasionally this anterior cutaneous branch is wanting. The first intercostal nerve, as a rule, gives off no lateral cutaneous branch, but sometimes a small branch is given off which communicates with the intercosto-humeral. It frequently receives a connecting twig from the second dorsal nerve, which passes upward over the neck of the second rib.

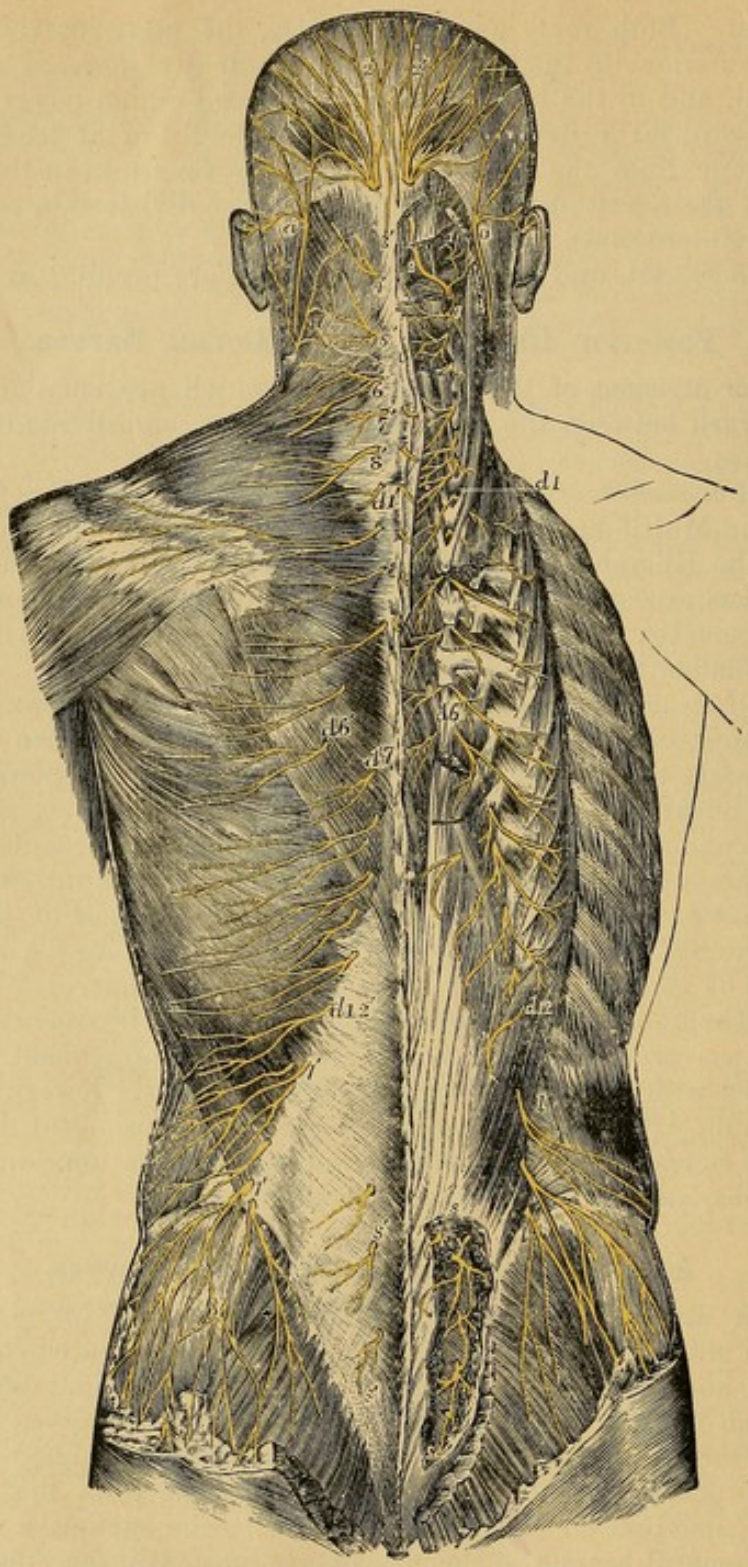

FIG. 415.—Superficial and deep distribution of the posterior divisions of the spinal nerves (after Hirschfeld and Leveillé). On the left side the cutaneous branches are represented lying on the superficial layer of muscles. On the right side the superficial muscles have been removed, the Splenius capitis and Complexus divided in the neck, and the Erector spinæ divided and partly removed in the back, so as to expose the posterior divisions of the spinal nerves near their origin. *a a.* Lesser occipital nerve from the cervical plexus. 1. External muscular branches of the first cervical nerve, and union by a loop with the second. 2, placed on the Rectus capitis posticus major muscle, marks the great occipital nerve, passing round the short muscles and piercing the Complexus: the external branch is seen to the outside. 3. External branch from the posterior division of the third nerve. 3'. Its internal branch, sometimes called the third occipital. 4' to 8'. The internal branches of the several corresponding nerves on the left side. The external branches of these nerves, proceeding to muscles, are displayed on the right side, *d* 1 to *d* 6, and thence to *d* 12. External muscular branches of the posterior divisions of the twelve dorsal nerves on the right side, *d* 1' to *d* 6'. The internal cutaneous branches of the six upper dorsal nerves on the left side, *d* 7' to *d* 12'. Cutaneous twigs from the external branches of the six lower dorsal nerves. *l l.* External branches from the posterior divisions of several lumbar nerves on the right side, piercing the muscles, the lower descending over the gluteal region. *l' l'.* The same, more superficially, on the left side. *s s.* The issue and union by loops of the posterior divisions of four sacral nerves on the right side. *s' s'.* Some of those distributed to the skin on the left side.

The Upper Dorsal Nerves.—The anterior divisions of the second, third, fourth, fifth, and sixth dorsal nerves and the small branch from the first dorsal are

confined to the parietes of the thorax, and are named *upper* or *pectoral intercostal nerves*. They pass forward in the intercostal spaces with the intercostal vessels, being situated below them. At the back of the chest they lie between the pleura and the External intercostal muscle, but are soon placed between the two planes of Intercostal muscles as far as the middle of the rib. They then enter the substance of the Internal intercostal muscles, and, running amidst their fibres as far as the costal cartilages, they gain the inner surface of the muscles and lie between them and the pleura. Near the sternum, they cross in front of the internal mammary artery and Triangularis sterni muscle, pierce the Internal intercostal muscles, the anterior intercostal membrane, and Pectoralis major muscle, and supply the integument of the front of the chest and over the mammary gland, forming the anterior cutaneous nerves of the thorax; the branch from the second nerve is joined with the supraclavicular nerves of the cervical plexus.

Branches.—Numerous slender muscular filaments supply the Intercostals, the Infracostales, the Levatores costarum, Serratus posticus superior, and Triangularis sterni muscles. Some of these branches, at the front of the chest, cross the costal cartilages from one to another intercostal space.

Lateral Cutaneous Nerves.—These are derived from the intercostal nerves, midway between the vertebræ and sternum; they pierce the External intercostal and Serratus magnus muscles, and divide into two branches, anterior and posterior.

The *anterior branches* are reflected forward to the side and the fore part of the chest, supplying the integument of the chest and mamma; those of the fifth and sixth nerves supply the upper digitations of the External oblique.

The *posterior branches* are reflected backward to supply the integument over the scapula and over the Latissimus dorsi.

The lateral cutaneous branch of the second intercostal nerve is of large size, and does not divide, like the other nerves, into an anterior and posterior branch. It is named, from its origin and distribution, the *intercosto-humeral nerve* (Fig. 413). It pierces the External intercostal muscle, crosses the axilla to the inner side of the arm, and joins with a filament from the nerve of Wrisberg. It then pierces the fascia, and supplies the skin of the upper half of the inner and back part of the arm, communicating with the internal cutaneous branch of the musculo-spiral nerve. The size of this nerve is in inverse proportion to the size of the other cutaneous nerves, especially the nerve of Wrisberg. A second intercosto-humeral nerve is frequently given off from the third intercostal. It supplies filaments to the armpit and inner side of the arm.

The Lower Dorsal Nerves.—The anterior divisions of the seventh, eighth, ninth, tenth, and eleventh dorsal nerves are continued anteriorly from the intercostal spaces into the abdominal wall, and the twelfth dorsal is continued throughout its whole course in the abdominal wall, since it is placed below the last rib; hence these nerves are named *lower* or *abdominal intercostal nerves*. They have (with the exception of the last) the same arrangement as the upper ones as far as the anterior extremities of the intercostal spaces, where they pass behind the costal cartilages, and between the Internal oblique and Transversalis muscles, to the sheath of the Rectus, which they perforate. They supply the Rectus muscle, and terminate in branches which become subcutaneous near the linea alba. These branches are named the anterior cutaneous nerves of the abdomen. They are directed outward as far as the lateral cutaneous nerves, supplying the integument of the front of the belly. The lower intercostal nerves supply the Intercostals, Serratus posticus inferior, and Abdominal muscles, and, about the middle of their course, give off lateral cutaneous branches which pierce the External intercostal and External oblique muscles, in the same line as the lateral cutaneous nerves of the thorax, and divide into anterior and posterior branches, which are distributed to the integument of the abdomen and back; the anterior branches supply the digitations of the External oblique muscle and extend downward and forward nearly as far as the margin of the Rectus; the posterior branches pass backward to supply the skin over the Latissimus dorsi.

The **last dorsal** is larger than the other dorsal nerves. Its anterior division runs along the lower border of the last rib, and passes under the external arcuate ligament of the Diaphragm. It then runs in front of the Quadratus lumborum, perforates the Transversalis, and passes forward between it and the Internal oblique, to be distributed in the same manner as the lower intercostal nerves. It communicates with the ilio-hypogastric branch of the lumbar plexus, and is frequently connected with the first lumbar nerve by a slender branch, the *dorsi-lumbar nerve*, which descends in the substance of the Quadratus lumborum. It gives a branch to the Pyramidalis muscle.

The *lateral cutaneous branch of the last dorsal* is remarkable for its large size; it perforates the Internal and External oblique muscles, passes downward over the crest of the ilium in front of the iliac branch of the ilio-hypogastric (Fig. 422), and is distributed to the integument of the front part of the gluteal region, some of its filaments extending as low down as the trochanter major. It does not divide into an anterior and a posterior branch, like the other lateral cutaneous branches of the intercostal nerves.

Surgical Anatomy.—The lower seven intercostal nerves and the ilio-hypogastric from the first lumbar nerve supply the skin of the abdominal wall. They run downward and inward fairly equidistant from each other. The sixth and seventh supply the skin over the "pit of the stomach;" the eighth corresponds to about the position of the middle linea transversa; the tenth to the umbilicus; and the ilio-hypogastric supplies the skin over the pubes and external abdominal ring. There are several points of surgical importance about the distribution of these nerves, and it is important to remember their origin and course, for in many diseases affecting the nerve-trunks at or near the origin the pain is referred to their peripheral terminations. Thus in Pott's disease of the spine children will often be brought to the surgeon suffering from pain in the belly. This is due to the fact that the nerves are irritated at the seat of disease as they issue from the spinal canal. When the irritation is confined to a single pair of nerves, the sensation complained of is often a feeling of constriction, as if a cord were tied round the abdomen; and in these cases the situation of the sense of constriction may serve to localize the disease in the spinal column. In other cases, where the bone disease is more extensive and two or more nerves are involved, a more general diffused pain in the abdomen is complained of. A similar condition is sometimes present in affections of the cord itself, as in tabes dorsalis.

Again, it must be borne in mind that the same nerves which supply the skin of the abdomen supply also the planes of muscle which constitute the greater part of the abdominal wall. Hence it follows that any irritation applied to the peripheral terminations of the cutaneous branches in the skin of the abdomen is immediately followed by reflex contraction of the abdominal muscles. A good practical illustration of this may sometimes be seen in watching two surgeons examine the abdomen of the same patient. One, whose hand is cold, causes the muscles of the abdominal wall to at once contract and the belly to become rigid, and thus not nearly so suitable for examination; the other, who has taken the precaution to warm his hand, examines the abdomen without exciting any reflex contraction. The supply of both muscles and skin from the same source is of importance in protecting the abdominal viscera from injury. A blow on the abdomen, even of a severe character, will do no injury to the viscera if the muscles are in a condition of firm contraction; whereas in cases where the muscles have been taken unawares, and the blow has been struck while they were in a state of rest, an injury insufficient to produce any lesion of the abdominal wall has been attended with rupture of some of the abdominal contents. The importance, therefore, of immediate reflex contraction upon the receipt of an injury cannot be overestimated, and the intimate association of the cutaneous and muscular fibres in the same nerve produces a much more immediate response on the part of the muscles to any peripheral stimulation of the cutaneous filaments than would be the case if the two sets of fibres were derived from independent sources.

Again, the nerves supplying the abdominal muscles and skin derived from the lower intercostal nerves are intimately connected with the sympathetic supplying the abdominal viscera through the lower thoracic ganglia from which the splanchnic nerves are derived. In consequence of this, in laceration of the abdominal viscera and in acute peritonitis the muscles of the belly-wall become firmly contracted, and thus as far as possible preserve the abdominal contents in a condition of rest.

THE LUMBAR NERVES.

The **lumbar nerves** are five in number on each side. The first appears between the first and second lumbar vertebræ, and the last between the last lumbar and the base of the sacrum.

The **roots** of the **lumbar nerves** are the largest, and their filaments the most numerous, of all the spinal nerves, and they are closely aggregated together upon the lower end of the cord. The anterior roots are the smaller, but there is not the

same disproportion between them and the posterior roots as in the cervical nerves. The roots of these nerves have a vertical direction, and are of considerable length, more especially the lower ones, since the spinal cord does not extend beyond the first lumbar vertebra. The roots become joined in the intervertebral foramina, and the nerves so formed divide at their exit into two divisions, posterior and anterior.

The Posterior Divisions of the Lumbar Nerves.

The **posterior divisions of the lumbar nerves** (Fig. 415) diminish in size from above downward; they pass backward between the transverse processes, and divide into internal and external branches.

The *internal branches*, the smaller, pass inward close to the articular processes of the vertebræ, and supply the Multifidus spinæ and Interspinales muscles.

The *external branches* supply the Erector spinæ and Intertransverse muscles. From the three upper branches cutaneous nerves are derived which pierce the aponeurosis of the Latissimus dorsi muscle and descend over the back part of the crest of the ilium, to be distributed to the integument of the gluteal region, some of the filaments passing as far as the trochanter major.

The Anterior Divisions of the Lumbar Nerves.

The **anterior divisions of the lumbar nerves** increase in size from above downward. At their origin they communicate with the lumbar ganglia of the sympathetic by long, slender filaments, which accompany the lumbar arteries round the sides of the bodies of the vertebræ, beneath the Psoas muscle. The nerves pass obliquely outward behind the Psoas magnus or between its fasciculi, distributing filaments to it and the Quadratus lumborum. The anterior divisions of the four upper nerves are connected together in this situation by anastomotic loops, and form the *lumbar plexus*. The anterior division of the fifth lumbar, joined with a branch from the fourth, descends across the base of the sacrum to join the anterior division of the first sacral nerve and assist in the formation of the sacral plexus. The cord resulting from the union of the fifth lumbar and the branch from the fourth is called the *lumbo-sacral cord*.

The Lumbar Plexus (Fig. 416).

The **lumbar plexus** is formed by the loops of communication between the anterior divisions of the four upper lumbar nerves. The plexus is narrow above, and often connected with the last dorsal by a slender branch, the *dorsi-lumbar nerve;* it is broad below, where it is joined to the sacral plexus by the lumbo-sacral cord. It is situated in the substance of the Psoas muscle near its posterior part, in front of the transverse process of the lumbar vertebræ.

The mode in which the plexus is arranged varies in different subjects. It differs from the brachial plexus in not forming an intricate interlacement, but the several nerves of distribution arise from one or more of the spinal nerves, somewhat in the following manner: The first lumbar nerve receives a branch from the last dorsal, and gives off a larger branch, which subdivides into the ilio-hypogastric and ilio-inguinal; a communicating branch which passes down to the second lumbar nerve; and a third branch which unites with a branch of the second lumbar to form the genito-crural nerve. The second, third, and fourth lumbar nerves divide into an anterior and a posterior division. The anterior division of the second divides into two branches, one of which joins with the above-mentioned branch of the first nerve to form the genito-crural; the other unites with the anterior division of the third nerve, and a part of the anterior division of the fourth nerve to form the obturator nerve. The remainder of the anterior division of the fourth nerve passes down to communicate with the fifth lumbar nerve. The posterior divisions of the second and third nerves divide into two branches, a smaller branch from each uniting to form the external cutaneous nerve, and a larger branch from each, which join with

the whole of the posterior division of the fourth lumbar nerve to form the anterior crural. The accessory obturator, when it exists, is formed by the union of two small branches given off from the third and fourth nerves.

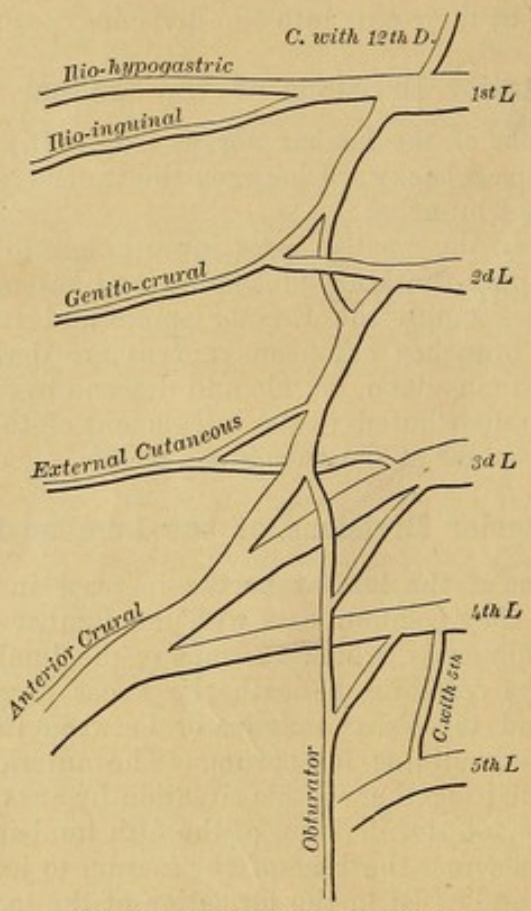

FIG. 416.—Plan of the lumbar plexus.

From this arrangement it follows that the ilio-hypogastric and ilio-inguinal are derived entirely from the first lumbar nerve; the genito-crural from the first and second nerves; the external cutaneous from the second and third; the anterior crural and obturator by fibres derived from the second, third, and fourth; and the accessory obturator, when it exists, from the third and fourth.

The branches of the lumbar plexus are—the

Ilio-hypogastric.	Anterior crural.
Ilio-inguinal.	Obturator.
Genito-crural.	Accessory obturator.
External cutaneous.	

The **Ilio-hypogastric Nerve** arises from the first lumbar nerve. It emerges from the outer border of the Psoas muscle at its upper part, and crosses obliquely in front of the Quadratus lumborum to the crest of the ilium. It then perforates the Transversalis muscle at its posterior part near the crest of the ilium, and divides between it and the Internal oblique into two branches, iliac and hypogastric.

The *iliac branch* pierces the Internal and External oblique muscles immediately above the crest of the ilium, and is distributed to the integument of the gluteal region, behind the lateral cutaneous branch of the last dorsal nerve (Fig. 422). The size of this nerve bears an inverse proportion to that of the cutaneous branch of the last dorsal nerve.

The *hypogastric branch* (Fig. 418) continues onward between the Internal oblique and Transversalis muscles. It then pierces the Internal oblique, and becomes cutaneous by perforating the aponeurosis of the External oblique, about

an inch above and a little to the outer side of the external abdominal ring, and is distributed to the integument of the hypogastric region.

The ilio-hypogastric nerve communicates with the last dorsal and ilio-inguinal nerves.

The **Ilio-inguinal Nerve**, smaller than the preceding, arises with it from the first lumbar nerve. It emerges from the outer border of the Psoas just below the ilio-hypogastric, and, passing obliquely across the Quadratus lumborum and Iliacus muscles, perforates the Transversalis near the fore part of the crest of the ilium, and communicates with the ilio-hypogastric nerve between that muscle and the Internal oblique. The nerve then pierces the Internal oblique, distributing filaments to it; and, accompanying the spermatic cord through the external abdominal ring, is distributed to the integument of the upper and inner part of the thigh, and to the scrotum in the male and to the labium majus in the female. The size of this nerve is in inverse proportion to that of the ilio-hypogastric. Occasionally it is very small, and ends by joining the ilio-hypogastric; in such cases a branch from the ilio-hypogastric takes the place of the ilio-inguinal, or the latter nerve may be altogether absent.

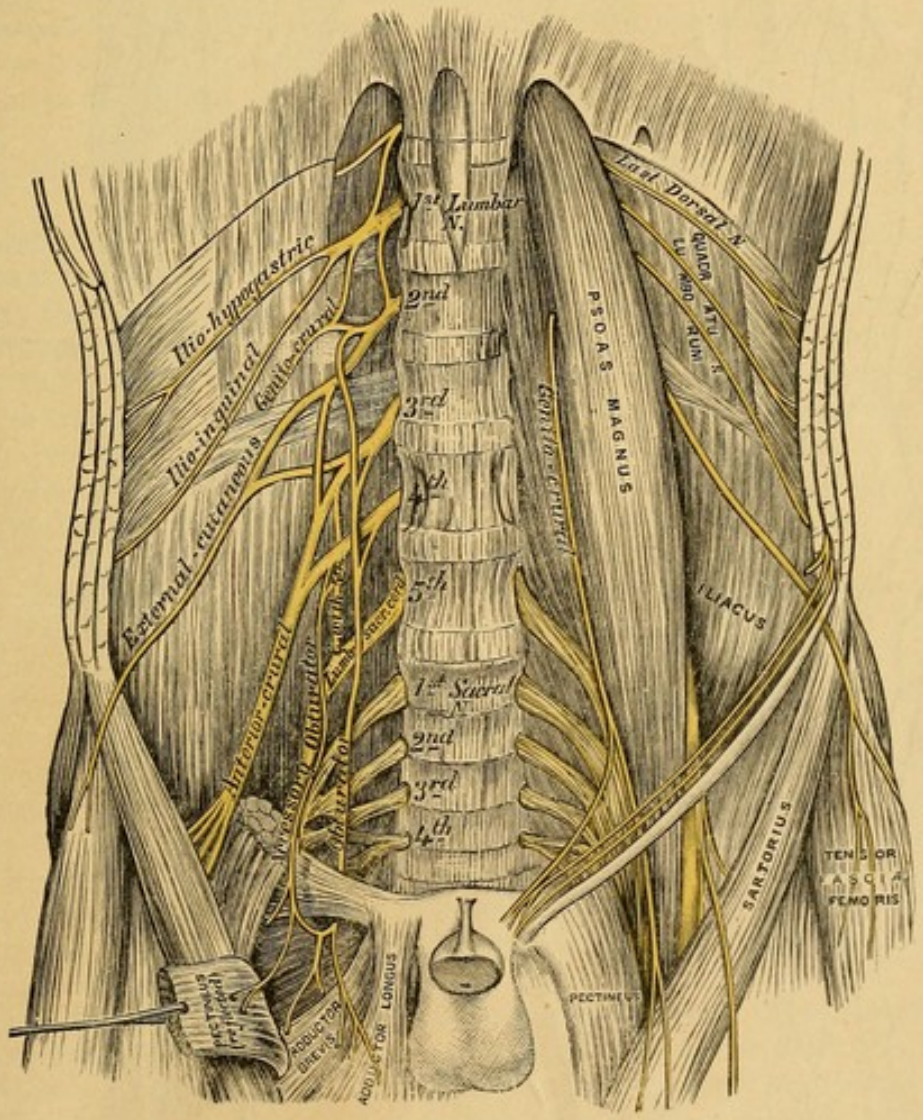

FIG. 417.—The lumbar plexus and its branches.

The **Genito-crural Nerve** arises from the first and second lumbar nerves. It passes obliquely through the substance of the Psoas, and emerges from its inner border at a level corresponding to the intervertebral substance between the third and fourth lumbar vertebræ; it then descends on the surface of the Psoas muscle, under cover of the peritoneum, and divides into a genital and a crural branch.

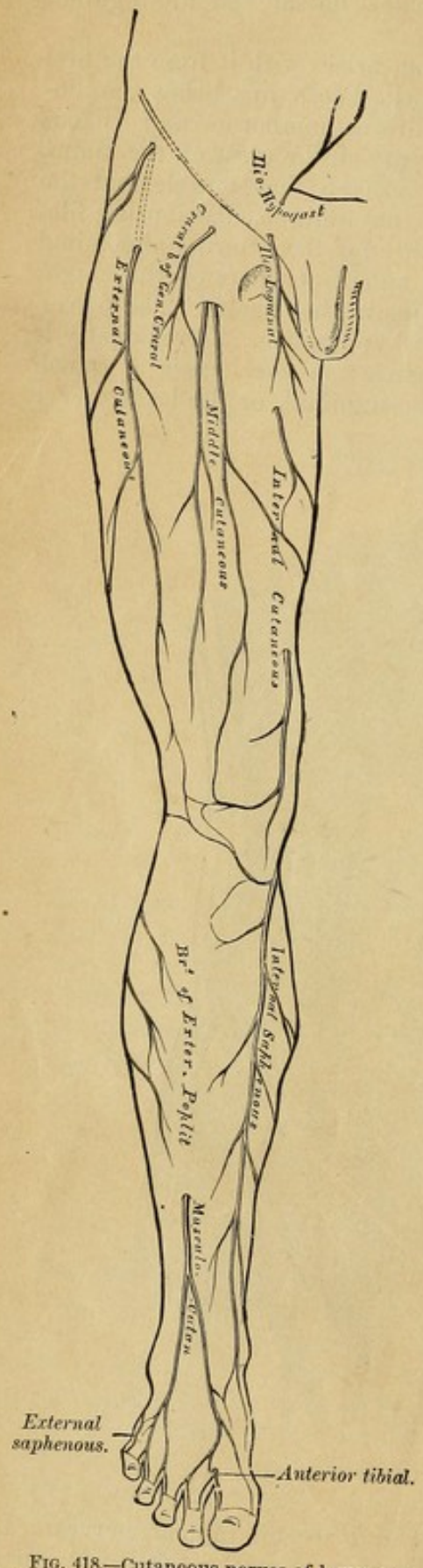

FIG. 418.—Cutaneous nerves of lower extremity. Front view.

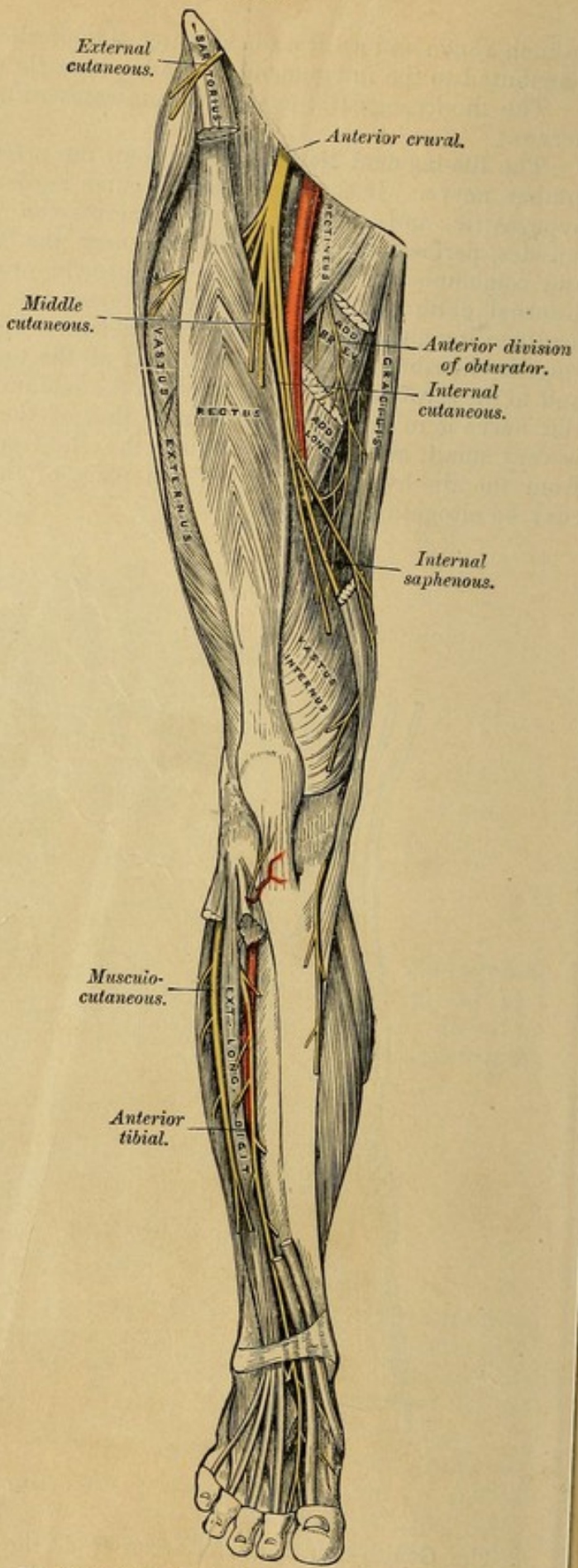

FIG. 419.—Nerves of the lower extremity. Front view.

The *genital branch* passes outward on the Psoas magnus, and pierces the fascia transversalis, or passes through the internal abdominal ring; it then descends along

the back part of the spermatic cord to the scrotum, and supplies, in the male, the Cremaster muscle. In the female, it accompanies the round ligament, and is lost upon it.

The *crural branch* descends on the external iliac artery, sending a few filaments round it, and, passing beneath Poupart's ligament to the thigh, enters the sheath of the femoral vessels, lying superficial and a little external to the femoral artery. It pierces the anterior layer of the sheath of the vessels, and, becoming superficial by passing through the fascia lata, it supplies the skin of the anterior aspect of the thigh as far as midway between the pelvis and knee. On the front of the thigh it communicates with the outer branch of the middle cutaneous nerve, derived from the anterior crural.

A few filaments from this nerve may be traced on to the femoral artery; they are derived from the nerve as it passes beneath Poupart's ligament.

The **External Cutaneous Nerve** arises from the second and third lumbar nerves. It emerges from the outer border of the Psoas muscle about its middle, and crosses the Iliacus muscle obliquely, toward the anterior superior spine of the ilium. It then passes under Poupart's ligament and over the Sartorius muscle into the thigh, where it divides into two branches, anterior and posterior.

The *anterior branch* descends in an aponeurotic canal formed in the fascia lata, becomes superficial about four inches below Poupart's ligament, and divides into branches which are distributed to the integument along the anterior and outer part of the thigh, as far down as the knee. This nerve occasionally communicates with a branch of the long saphenous nerve in front of the knee-joint.

The *posterior branch* pierces the fascia lata, and subdivides into branches which pass backward across the outer and posterior surface of the thigh, supplying the integument from the crest of the ilium as far as the middle of the thigh.

The **Obturator Nerve** supplies the obturator externus and Adductor muscles of the thigh, the articulations of the hip and knee, and occasionally the integument of the thigh and leg. It arises by three branches—from the second, the third, and the fourth lumbar nerves. Of these, the branch from the third is the largest, while that from the second is often very small. It descends through the inner fibres of the Psoas muscle, and emerges from its inner border near the brim of the pelvis; it then runs along the lateral wall of the pelvis, above the obturator vessels, to the upper part of the obturator foramen, where it enters the thigh, and divides into an anterior and a posterior branch, separated by some of the fibres of the Obturator externus (Fig. 257), and lower down by the Adductor brevis muscle.

The *anterior branch* (Fig. 419) passes down in front of the Adductor brevis, being covered by the Pectineus and Adductor longus, and at the lower border of the latter muscle communicates with the internal cutaneous and internal saphenous nerves, forming a kind of plexus. It then descends upon the femoral artery, upon which it is finally distributed. The nerve, near the obturator foramen, gives off an articular branch to the hip-joint. Behind the Pectineus it distributes muscular branches to the Adductor longus and Gracilis, and usually to the Adductor brevis, and in rare cases to the Pectineus, and receives a communicating branch from the accessory obturator nerve.

Occasionally the communicating branch to the internal cutaneous and internal saphenous nerves is continued down, as a cutaneous branch, to the thigh and leg. When this is so, this *occasional cutaneous* branch emerges from beneath the lower border of the Adductor longus, descends along the posterior margin of the Sartorius to the inner side of the knee, where it pierces the deep fascia, communicates with the long saphenous nerve, and is distributed to the integument of the inner side of the leg as low down as its middle. When this communicating branch is small, its place is supplied by the internal cutaneous nerve.

The *posterior branch of the obturator nerve* pierces the Obturator externus, sending branches to supply it, and passes behind the Adductor brevis on the front of the Adductor magnus, where it divides into numerous muscular branches, which

supply the Adductor magnus, and the Adductor brevis when the latter does not receive a branch from the anterior division of the nerve. One of the branches gives off a filament to the knee-joint.

The *articular branch for the knee-joint* is sometimes absent; it perforates the lower part of the Adductor magnus, and enters the popliteal space; it then descends upon the popliteal artery, as far as the back part of the knee-joint, where it perforates the posterior ligament, and is distributed to the synovial membrane. It gives filaments to the artery in its course.

The **Accessory Obturator Nerve** (Fig. 417) is not constantly present. It is of small size, and arises by separate filaments from the third and fourth lumbar nerves. It descends along the inner border of the Psoas muscle, crosses the ascending ramus of the os pubis, and passes under the outer border of the Pectineus muscle, where it divides into numerous branches. One of these supplies the Pectineus, penetrating its under surface; another is distributed to the hip-joint; while a third communicates with the anterior branch of the obturator nerve. When this nerve is absent the hip-joint receives two branches from the obturator nerve. Occasionally it is very small, and becomes lost in the capsule of the hip-joint.

The **Anterior Crural Nerve** (Figs. 417, 419) is the largest branch of the lumbar plexus. It supplies muscular branches to the Iliacus, Pectineus, and all the muscles on the front of the thigh, excepting the Tensor fasciæ femoris; cutaneous filaments to the front and inner side of the thigh, and to the leg and foot; and articular branches to the hip and knee. It arises from the second, third, and fourth lumbar nerves. It descends through the fibres of the Psoas muscle, emerging from it at the lower part of its outer border, and passes down between it and the Iliacus, and beneath Poupart's ligament, into the thigh, where it becomes somewhat flattened, and divides into an anterior and a posterior part. Under Poupart's ligament it is separated from the femoral artery by a portion of the Psoas muscle, and lies beneath the iliac fascia.

Within the abdomen the anterior crural nerve gives off from its outer side some small branches to the Iliacus, and a branch to the femoral artery which is distributed upon the upper part of that vessel. The origin of this branch varies: it occasionally arises higher than usual, or it may arise lower down in the thigh.

External to the pelvis the following branches are given off:

From the Anterior Division.	*From the Posterior Division.*
Middle cutaneous.	Long saphenous.
Internal cutaneous.	Muscular.
Muscular.	Articular.

The *middle cutaneous nerve* (Fig. 418) pierces the fascia lata (generally the Sartorius also) about three inches below Poupart's ligament, and divides into two branches, which descend in immediate proximity along the fore part of the thigh, to supply the integument as low as the front of the knee, where it communicates with the internal cutaneous and the patellar branch of the internal saphenous nerve, to form the patellar plexus. In the upper part of the thigh the outer division of the middle cutaneous communicates with the crural branch of the genito-crural nerve.

The *internal cutaneous nerve* passes obliquely across the upper part of the sheath of the femoral artery, and divides in front or at the inner side of that vessel into two branches, anterior and posterior or internal.

The *anterior branch* runs downward on the Sartorius, perforates the fascia lata at the lower third of the thigh, and divides into two branches, one of which supplies the integument as low down as the inner side of the knee; the other crosses to the outer side of the patella, communicating in its course with the nervus cutaneus patellæ, a branch of the internal saphenous nerve.

The *posterior* or *internal branch* descends along the inner border of the Sartorius muscle to the knee, where it pierces the fascia lata, communicates with

the long saphenous nerve, and gives off several cutaneous branches. The nerve then passes down the inner side of the leg, to the integument of which it is distributed. This nerve, beneath the fascia lata, at the lower border of the Adductor longus, joins in a plexiform network by uniting with branches of the long saphenous and obturator nerves (Fig. 419). When the communicating branch from the obturator nerve is large and continued to the integument of the leg, the inner branch of the internal cutaneous is small and terminates at the plexus, occasionally giving off a few cutaneous filaments.

The internal cutaneous nerve, before dividing, gives off a few filaments, which pierce the fascia lata, to supply the integument of the inner side of the thigh, accompanying the long saphenous vein. One of these filaments passes through the saphenous opening; a second becomes subcutaneous about the middle of the thigh; and a third pierces the fascia at its lower third.

Muscular Branches of the Anterior Division.—The *nerve to the Pectineus* is often duplicated; it arises from the anterior crural immediately below Poupart's ligament, and passes inward behind the femoral sheath to enter the anterior surface of the muscle. The *nerve to the Sartorius* arises in common with the middle cutaneous.

The *long* or *internal saphenous nerve* is the largest of the cutaneous branches of the anterior crural. It approaches the femoral artery where this vessel passes beneath the Sartorius, and lies in front of it, beneath the aponeurotic covering of Hunter's canal, as far as the opening in the lower part of the Adductor magnus. It then quits the artery, and descends vertically along the inner side of the knee, beneath the Sartorius, pierces the fascia lata opposite the interval between the tendons of the Sartorius and Gracilis, and becomes subcutaneous. The nerve then passes along the inner side of the leg, accompanied by the internal saphenous vein, descends behind the internal border of the tibia, and, at the lower third of the leg divides into two branches: one continues its course along the margin of the tibia, terminating at the inner ankle; the other passes in front of the ankle, and is distributed to the integument along the inner side of the foot, as far as the great toe, communicating with the internal branch of the musculo-cutaneous nerve.

Branches.—The long saphenous nerve *about the middle of the thigh* gives off a communicating branch which joins the plexus formed by the obturator and internal cutaneous nerves.

At the inner side of the knee it gives off a large patellar branch (*nervus cutaneus patellæ*) which pierces the Sartorius and fascia lata, and is distributed to the integument in front of the patella. This nerve communicates above the knee with the anterior branch of the internal cutaneous and with the middle cutaneous; below the knee, with other branches of the long saphenous; and on the outer side of the joint, with branches of the external cutaneous nerve, forming a plexiform network, the *plexus patellæ*. The cutaneous nerve of the patella is occasionally small, and terminates by joining the internal cutaneous, which supplies its place in front of the knee.

Below the knee the branches of the long saphenous nerve are distributed to the integument of the front and inner side of the leg, communicating with the cutaneous branches from the internal cutaneous or from the obturator nerve.

The *muscular branches of the posterior division* supply the four parts of the Quadriceps extensor muscle.

The *branch to the Rectus muscle* enters its under surface high up, sending off a small filament to the hip-joint.

The *branch to the Vastus externus*, of large size, follows the course of the descending branch of the external circumflex artery to the lower part of the muscle. It gives off an articular filament to the knee-joint.

The *branch to the Vastus internus* is a long branch which runs down on the outer side of the femoral vessels in company with the internal saphenous nerve for its upper part. It enters the muscle about its middle, and gives off a filament which can usually be traced downward on the surface of the muscle to the knee-joint.

The *branch to the Crureus* enters the muscle on its anterior surface about the middle of the thigh, and sends a filament through the muscle to the Subcrureus and the knee-joint.

The *articular branch to the hip-joint* is derived from the nerve to the Rectus.

The *articular branches to the knee-joint* are three in number. One, a long, slender filament, is derived from the nerve to the Vastus externus, and penetrates the capsular ligament of the joint on its anterior aspect. Another is derived from the nerve to the Vastus internus. It can usually be traced downward on the surface of this muscle to near the joint; it then penetrates the muscular fibres, and accompanies the deep branch of the anastomotica magna artery, pierces the capsular ligament of the joint on its inner side, and supplies the synovial membrane. The third branch is derived from the nerve to the Crureus.

THE SACRAL AND COCCYGEAL NERVES.

The *sacral nerves* are five in number on each side. The four upper ones pass from the sacral canal through the sacral foramina; the fifth through the foramen between the sacrum and coccyx.

The *roots of the upper sacral nerves* are the largest of all the spinal nerves; while those of the lowest sacral and coccygeal nerve are the smallest. They are longer than those of any of the other spinal nerves, on account of the spinal cord not extending beyond the first lumbar vertebra. From their great length, and the appearance they present in connection with their attachment to the spinal cord, the roots of origin of these nerves are called collectively the *cauda equina*.

Each sacral and coccygeal nerve separates into two divisions, posterior and anterior.

The **posterior divisions of the sacral nerves** (Fig. 420) are small, diminish in

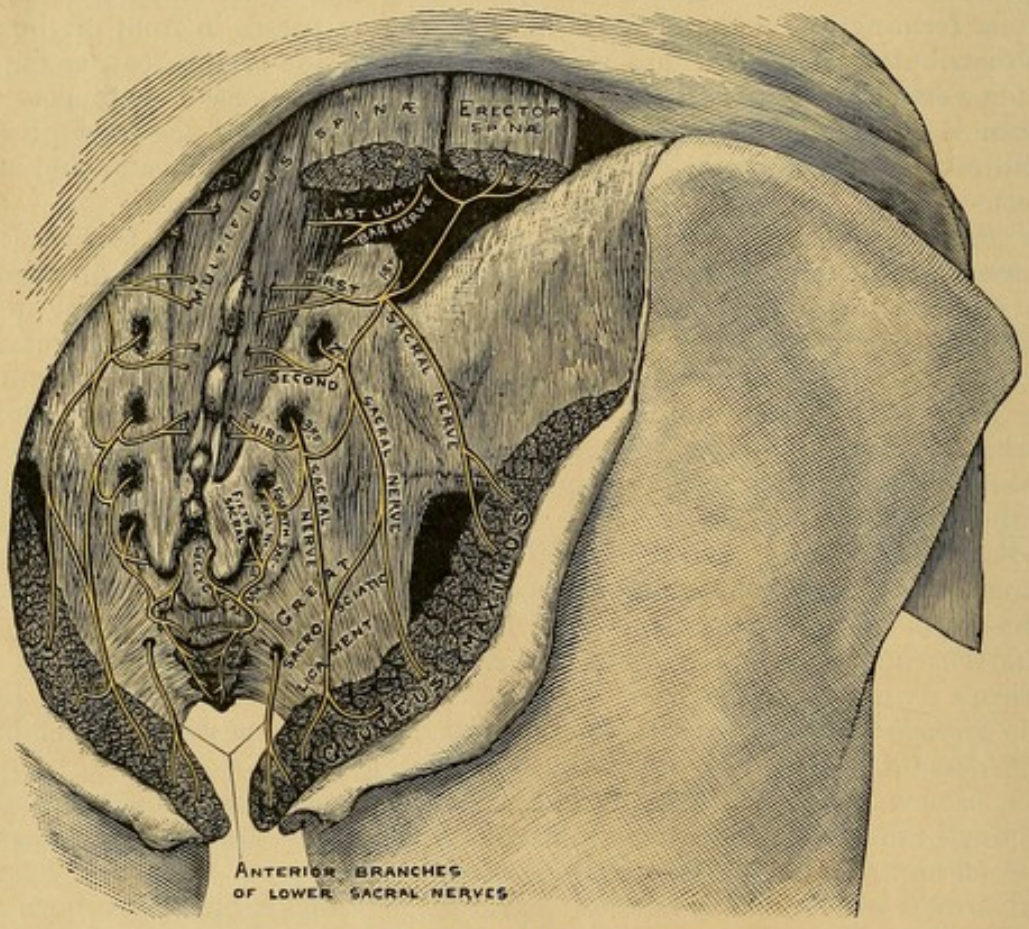

FIG. 420.—The posterior sacral nerves.

size from above downward, and emerge, except the last, from the sacral canal by the posterior sacral foramina.

The *three upper ones* are covered, at their exit from the sacral canal, by the Multifidus spinæ, and divide into internal and external branches.

The *internal branches* are small, and supply the Multifidus spinæ.

The *external branches* join with one another, and with the last lumbar and fourth sacral nerves, in the form of loops on the posterior surface of the sacrum. From these loops branches pass to the outer surface of the great sacro-sciatic ligament, where they form a second series of loops beneath the Gluteus maximus. Cutaneous branches from this second series of loops, usually two or three in number, pierce the Gluteus maximus along a line drawn from the posterior superior spine of the ilium to the tip of the coccyx. They supply the integument over the posterior part of the gluteal region.

The *posterior divisions of the two lower sacral nerves* are situated below the Multifidus spinæ. They are of small size, and do not divide into internal and external branches, but join with each other, and with the coccygeal nerve, so as to form loops on the back of the sacrum, filaments from which supply the Extensor coccygis and the integument over the coccyx.

The **coccygeal nerve** divides into its anterior and posterior divisions in the spinal canal. The *posterior division* is the smaller. It does not divide, but receives, as already mentioned, a communicating branch from the last sacral, and is lost in the integument over the back of the coccyx.

The **anterior divisions of the sacral nerves** diminish in size from above down-

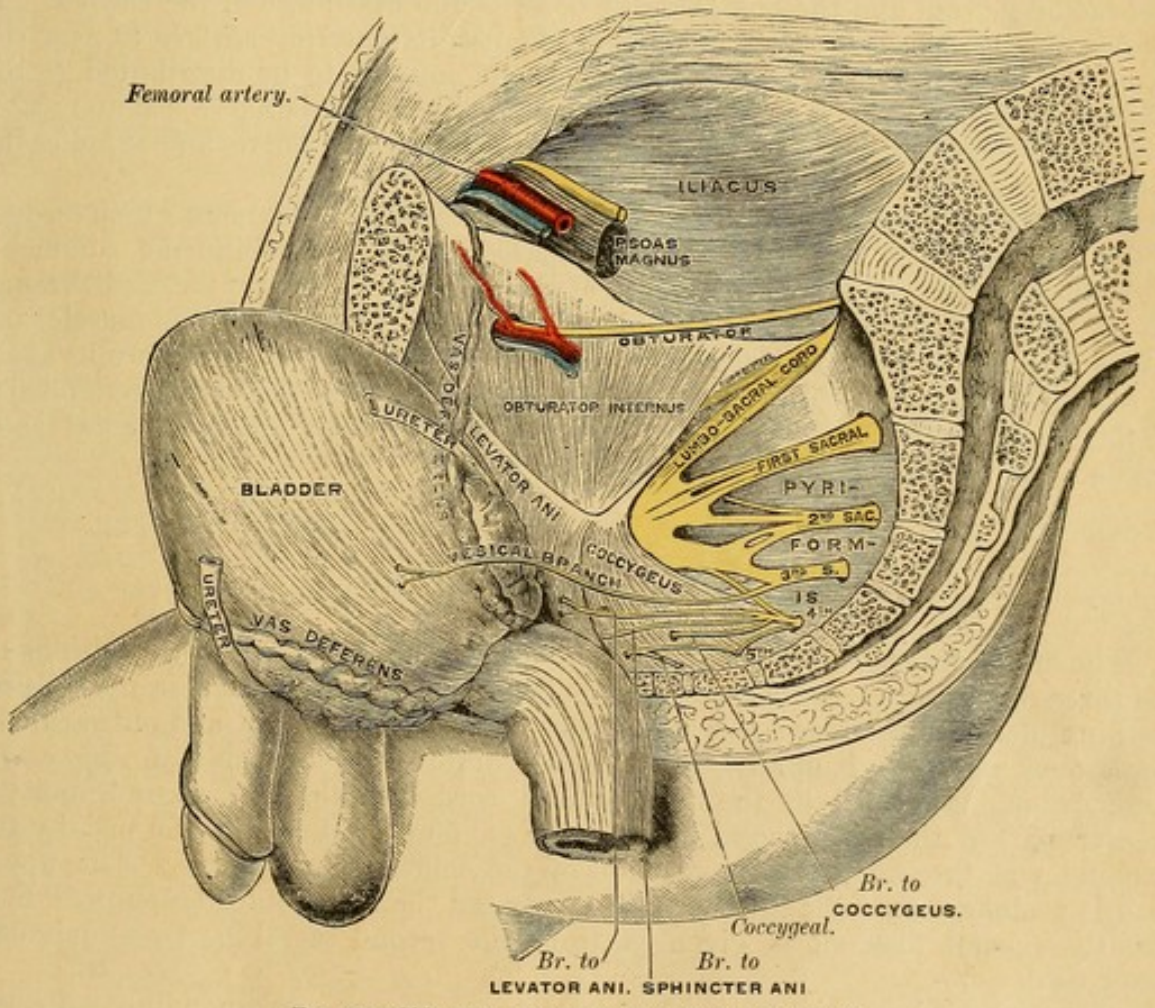

FIG. 421.—Side view of pelvis, showing sacral nerves.

ward. The four upper ones emerge from the anterior sacral foramina: the anterior division of the fifth, after emerging from the spinal canal through its terminal opening, curves forward between the sacrum and the coccyx. All the anterior sacral nerves communicate with the sacral ganglia of the sympathetic at their exit from the sacral foramina. The *first nerve*, of large size, unites with the *lumbo-sacral cord*, formed by the fifth lumbar, and a branch from the fourth lum-

bar. The *second*, equal in size to the preceding, and the *third*, about one-fourth the size of the second, unite with this trunk, and form, with a small fasciculus from the fourth, the *sacral plexus*, a visceral branch being given off from the third nerve to the bladder.

The **fourth anterior sacral nerve** sends a branch to join the sacral plexus. The remaining portion of the nerve divides into visceral and muscular branches, and a communicating filament descends to join the fifth sacral nerve. The *visceral branches* are distributed to the viscera of the pelvis, communicating with the sympathetic nerve. These branches ascend upon the rectum and bladder, and in the female upon the vagina, communicating with branches of the sympathetic from the pelvic plexus. The *muscular branches* are distributed to the Levator ani, Coccygeus, and Sphincter ani. The branch to the Sphincter ani pierces the Levator ani, so as to reach the ischio-rectal fossa, where it is found lying in front of the coccyx. Cutaneous filaments arise from the latter branch, which supply the integument between the anus and coccyx. Another cutaneous branch is frequently given off from this nerve, though sometimes from the pudic (Schwalbe). It perforates the great sacro-sciatic ligament, and, winding round the lower border of the Gluteus maximus, supplies the skin over the lower and inner part of this muscle.

The **fifth anterior sacral nerve**, after passing from the lower end of the sacral canal, curves forward through the fifth sacral foramen, formed between the lower part of the sacrum and the transverse process of the first piece of the coccyx. It pierces the Coccygeus muscle, and descends upon its anterior surface to near the tip of the coccyx, where it again perforates the muscle, to be distributed to the integument over the back part and side of the coccyx. This nerve communicates above with the fourth sacral and below with the coccygeal nerve, and supplies the Coccygeus muscle.

The **anterior division of the coccygeal nerve** is a delicate filament which escapes at the termination of the sacral canal; it passes downward behind the rudimentary transverse process of the first piece of the coccyx, and curves forward through the notch between the first and second pieces, piercing the Coccygeus muscle, and descending on its anterior surface to near the tip of the coccyx, where it again pierces the muscle, to be distributed to the integument over the back part and side of the coccyx. It is joined by a branch from the fifth anterior sacral as it descends on the surface of the Coccygeus muscle.

The Sacral Plexus (Fig. 421).

The **sacral plexus** is formed by the lumbo-sacral cord, the anterior divisions of the three upper sacral nerves, and part of that of the fourth. These nerves proceed in different directions: the upper ones obliquely downward and outward, the lower ones nearly horizontally, and they all unite into two cords: an *upper* and larger, which is formed by the lumbo-sacral cord with the first, second, and the greater part of the third sacral nerves; and a *lower* and smaller, formed by the remainder of the third, with a portion of the fourth sacral nerve. The upper cord is prolonged into the great sciatic nerve and the lower into the pudic. Frequently a small filament is given off from the second sacral nerve to join the lower cord.

The sacral plexus is triangular in form, its base corresponding with the exit of the nerves from the sacrum, its apex with the lower part of the great sacro-sciatic foramen. It rests upon the anterior surface of the Pyriformis, and is covered in front by the pelvic fascia, which separates it from the sciatic and pudic branches of the internal iliac artery and from the viscera of the pelvis.

The branches of the sacral plexus are:

branches (*descending*) are numerous filaments, derived
Collat ves, which are distributed to the back, inner, and outer
skin covering the popliteal space, and to the upper part

taneous Nerve usually arises from the second and third sacral
all size. It is continued backward through the great sacro-
id, winding round the lower border of the Gluteus maximus,
The Muscular ament covering the inner and lower part of that muscle.
Gemelli, and th erve. is the direct continuation of the lower cord of the sacral
the upper two ves its fibres from the third and fourth sacral nerves, and frequently
Obturator int d also. It leaves the pelvis through the great sacro-sciatic foramen,
nerves: it p riformis. It then crosses the spine of the ischium, and re-enters the
the Pyrifor gh the lesser sacro-sciatic foramen. It accompanies the pudic vessels
the lesser d forward along the outer wall of the ischio-rectal fossa, being contained
the bran th of the obturator fascia, termed *Alcock's canal*, and divides into two
rator int branches, the perineal nerve and the dorsal nerve of the penis or clitoris.
small br division it gives off the inferior hemorrhoidal nerve.
upper p *inferior hemorrhoidal nerve* is occasionally derived separately from the
the Pyri exus. It passes across the ischio-rectal fossa, with its accompanying
tendon c oward the lower end of the rectum, and is distributed to the Sphincter
rior suri nus and to the integument round the anus. Branches of this nerve com-
branch i with the inferior pudendal and superficial perineal nerves at the fore part
The rineum.
sacral c *erineal nerve*, the inferior and larger of the two terminal branches of the
pelvis th situated below the pudic artery. It accompanies the superficial perineal
panied a the perineum, dividing into cutaneous and muscular branches.

The cutaneous branches (superficial perineal) are two in number, posterior and
supp ior. The *posterior* or *external branch* pierces the base of the triangular
ment of the urethra, and passes forward along the outer side of the urethral
d ngle in company with the superficial perineal artery; it is distributed to the
fe n of the scrotum. It communicates with the inferior hemorrhoidal, the inferior
lendal, and the other superficial perineal nerve. The *anterior* or *internal branch*
sa pierces the base of the triangular ligament, and passes forward nearer to the
It dle line, to be distributed to the inner and back part of the scrotum. Both
mu e nerves supply the labia majora in the female.
mu The muscular branches are distributed to the Transversus perinæi, Accelerator
æ, Erector penis, and Compressor urethræ. A distinct branch is given off
an the nerve to the Accelerator urinæ, which pierces this muscle, and supplies
bra corpus spongiosum, ending in the mucous membrane of the urethra. This
issu nerve to the bulb.
mus he *dorsal nerve of the penis* is the deepest division of the pudic nerve; it
lowe panies the pudic artery along the ramus of the ischium; it then runs forward
fasci the inner margin of the ramus of the os pubis, between the superficial and
regi layers of the triangular ligament. Piercing the superficial layer it gives a
the e to the corpus cavernosum, and passes forward, in company with the dorsal
commu the penis, between the layers of the suspensory ligament, on to the dorsum
The nis, along which it is carried as far as the glans, to which it is distributed.
follows e female the dorsal nerve is very small, and supplies the clitoris.

The **Great sciatic nerve** (Fig. 423) supplies nearly the whole of the integument
which t , the muscles of the back of the thigh, and those of the leg and foot. It
integum gest nervous cord in the body, measuring three-quarters of an inch in
The nd is the continuation of the upper division of the sacral plexus. It
inner si t of the pelvis through the great sacro-sciatic foramen, below the Pyri-
the *infe* iscle. It descends between the trochanter major and tuberosity of the
lata, an long the back part of the thigh, to about its lower third, where it divides
tributed large branches, the *internal* and *external popliteal nerves*.
commu division may take place at any point between the sacral plexus and the

bar. The *second*, equal in size to the preceding, and
the size of the second, unite with this trunk, and for
from the fourth, the *sacral plexus*, a visceral branch
third nerve to the bladder.

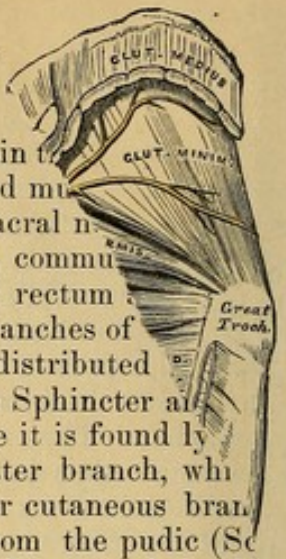

The **fourth anterior sacral nerve** sends a branch to join t
remaining portion of the nerve divides into visceral and mu
a communicating filament descends to join the fifth sacral n
branches are distributed to the viscera of the pelvis, commu
sympathetic nerve. These branches ascend upon the rectum
in the female upon the vagina, communicating with branches of
from the pelvic plexus. The *muscular branches* are distributed
ani, Coccygeus, and Sphincter ani. The branch to the Sphincter a
Levator ani, so as to reach the ischio-rectal fossa, where it is found ly
of the coccyx. Cutaneous filaments arise from the latter branch, whi
the integument between the anus and coccyx. Another cutaneous bra
quently given off from this nerve, though sometimes from the pudic (Sc
It perforates the great sacro-sciatic ligament, and, winding round the lc
der of the Gluteus maximus, supplies the skin over the lower and inner
this muscle.

The **fifth anterior sacral nerve**, after passing from the lower end of t
canal, curves forward through the fifth sacral foramen, formed between t
part of the sacrum and the transverse process of the first piece of the coc
pierces the Coccygeus muscle, and descends upon its anterior surface to
tip of the coccyx, where it again perforates the muscle, to be distribute
integument over the back part and side of the coccyx. This nerve comn
above with the fourth sacral and below with the coccygeal nerve, and sup
Coccygeus muscle.

The **anterior division of the coccygeal nerve** is a delicate filament which es
at the termination of the sacral canal; it passes downward behind the rudin
ary transverse process of the first piece of the coccyx, and curves forward throu
the notch between the first and second pieces, piercing the Coccygeus muscle, a
descending on its anterior surface to near the tip of the coccyx, where it ag
pierces the muscle, to be distributed to the integument over the back part and s
of the coccyx. It is joined by a branch from the fifth anterior sacral as
descends on the surface of the Coccygeus muscle.

The Sacral Plexus (Fig. 421).

The **sacral plexus** is formed by the lumbo-sacral cord, the anterior division
the three upper sacral nerves, and part of that of the fourth. These nerves
ceed in different directions: the upper ones obliquely downward and outward
lower ones nearly horizontally, and they all unite into two cords: an *upper*
larger, which is formed by the lumbo-sacral cord with the first, second, an
greater part of the third sacral nerves; and a *lower* and smaller, formed
remainder of the third, with a portion of the fourth sacral nerve. The
cord is prolonged into the great sciatic nerve and the lower into the pudic
quently a small filament is given off from the second sacral nerve to
lower cord.

The sacral plexus is triangular in form, its base corresponding
exit of the nerves from the sacrum, its apex with the lower part of
sacro-sciatic foramen. It rests upon the anterior surface of the P
and is covered in front by the pelvic fascia, which separates it from t
and pudic branches of the internal iliac artery and from the viscer
pelvis.

The branches of the sacral plexus are:

The *femoral cutaneous branches* (*descending*) are numerous filaments, derived from both sides of the nerves, which are distributed to the back, inner, and outer sides of the thigh, to the skin covering the popliteal space, and to the upper part of the leg.

The **Perforating Cutaneous Nerve** usually arises from the second and third sacral nerves, and is of small size. It is continued backward through the great sacro-sciatic ligament, and, winding round the lower border of the Gluteus maximus, supplies the integument covering the inner and lower part of that muscle.

The **Pudic Nerve.** is the direct continuation of the lower cord of the sacral plexus, and derives its fibres from the third and fourth sacral nerves, and frequently from the second also. It leaves the pelvis through the great sacro-sciatic foramen, below the Pyriformis. It then crosses the spine of the ischium, and re-enters the pelvis through the lesser sacro-sciatic foramen. It accompanies the pudic vessels upward and forward along the outer wall of the ischio-rectal fossa, being contained in a sheath of the obturator fascia, termed *Alcock's canal*, and divides into two terminal branches, the perineal nerve and the dorsal nerve of the penis or clitoris. Before its division it gives off the inferior hemorrhoidal nerve.

The *inferior hemorrhoidal nerve* is occasionally derived separately from the sacral plexus. It passes across the ischio-rectal fossa, with its accompanying vessels, toward the lower end of the rectum, and is distributed to the Sphincter ani externus and to the integument round the anus. Branches of this nerve communicate with the inferior pudendal and superficial perineal nerves at the fore part of the perineum.

The *perineal nerve*, the inferior and larger of the two terminal branches of the pudic, is situated below the pudic artery. It accompanies the superficial perineal artery in the perineum, dividing into cutaneous and muscular branches.

The cutaneous branches (superficial perineal) are two in number, posterior and anterior. The *posterior* or *external branch* pierces the base of the triangular ligament of the urethra, and passes forward along the outer side of the urethral triangle in company with the superficial perineal artery; it is distributed to the skin of the scrotum. It communicates with the inferior hemorrhoidal, the inferior pudendal, and the other superficial perineal nerve. The *anterior* or *internal branch* also pierces the base of the triangular ligament, and passes forward nearer to the middle line, to be distributed to the inner and back part of the scrotum. Both these nerves supply the labia majora in the female.

The muscular branches are distributed to the Transversus perinæi, Accelerator urinæ, Erector penis, and Compressor urethræ. A distinct branch is given off from the nerve to the Accelerator urinæ, which pierces this muscle, and supplies the corpus spongiosum, ending in the mucous membrane of the urethra. This is the nerve to the bulb.

The *dorsal nerve of the penis* is the deepest division of the pudic nerve; it accompanies the pudic artery along the ramus of the ischium; it then runs forward along the inner margin of the ramus of the os pubis, between the superficial and deep layers of the triangular ligament. Piercing the superficial layer it gives a branch to the corpus cavernosum, and passes forward, in company with the dorsal artery of the penis, between the layers of the suspensory ligament, on to the dorsum of the penis, along which it is carried as far as the glans, to which it is distributed.

In the female the dorsal nerve is very small, and supplies the clitoris.

The **Great sciatic nerve** (Fig. 423) supplies nearly the whole of the integument of the leg, the muscles of the back of the thigh, and those of the leg and foot. It is the largest nervous cord in the body, measuring three-quarters of an inch in breadth, and is the continuation of the upper division of the sacral plexus. It passes out of the pelvis through the great sacro-sciatic foramen, below the Pyriformis muscle. It descends between the trochanter major and tuberosity of the ischium, along the back part of the thigh, to about its lower third, where it divides into two large branches, the *internal* and *external popliteal nerves*.

This division may take place at any point between the sacral plexus and the

lower third of the thigh. When the division occurs at the plexus, the two nerves descend together side by side; or they may be separated, at their commencement, by the interposition of part or the whole of the Pyriformis muscle. As the nerve descends along the back of the thigh, it rests upon the posterior surface of the ischium, the nerve to the Quadratus femoris, and the External rotator muscles, in company with the small sciatic nerve and artery, being covered by the Gluteus maximus; lower down, it lies upon the Adductor magnus, and is covered by the long head of the Biceps.

The *branches* of the nerve, before its division, are articular and muscular.

The *articular branches* arise from the upper part of the nerve; they supply the hip-joint, perforating the posterior part of its fibrous capsule posteriorly. These branches are sometimes derived from the sacral plexus.

The *muscular branches* are distributed to the flexors of the leg: viz., the Biceps, Semitendinosus, and Semimembranosus, and a branch to the Adductor magnus. These branches are given off beneath the Biceps muscle.

The **Internal Popliteal Nerve,** the larger of the two terminal branches of the great sciatic, descends along the back part of the thigh, through the middle of the popliteal space, to the lower part of the Popliteus muscle, where it passes with the artery beneath the arch of the Soleus and becomes the posterior tibial. It is overlapped by the hamstring muscles above, and then becomes more superficial, and lies to the outer side of, and some distance from, the popliteal vessels; opposite the knee-joint it is in close relation with the vessels, and crosses to the inner side of the artery. Below, it is overlapped by the Gastrocnemius.

The *branches* of this nerve are—articular, muscular, and a cutaneous branch, the *communicans tibialis nerve.*

The *articular branches*, usually three in number, supply the knee-joint: two of these branches accompany the superior and inferior internal articular arteries, and a third, the azygos articular artery.

The *muscular branches*, four or five in number, arise from the nerve as it lies between the two heads of the Gastrocnemius muscle; they supply that muscle, the Plantaris, Soleus, and Popliteus. The filaments which supply the Popliteus turn round its lower border and are distributed to its deep surface.

The *communicans tibialis* descends between the two heads of the Gastrocnemius muscle, and about the middle of the back of the leg pierces the deep fascia, and joins a communicating branch (*communicans peronei*) from the external popliteal nerve to form the external or short saphenous (Fig. 422). The external saphenous nerve, formed by the communicating branches of the internal and external popliteal nerves, passes downward and outward near the outer margin of the tendo Achillis, lying close to the external saphenous vein, to the interval between the external malleolus and the os calcis. It winds round the outer malleolus, and is distributed to the integument along the outer side of the foot and little toe, communicating on the dorsum of the foot with the musculo-cutaneous nerve. In the leg its branches communicate with those of the small sciatic.

The **Posterior Tibial Nerve** (Fig. 423) commences at the lower border of the Popliteus muscle, and passes along the back part of the leg with the posterior tibial vessels to the interval between the inner malleolus and the heel, where it divides into the *external* and *internal plantar nerves.* It lies upon the deep muscles of the leg, and is covered in the upper part by the muscles of the calf, lower down by the skin and fascia. In the upper part of its course it lies to the inner side of the posterior tibial artery, but it soon crosses that vessel, and lies to its outer side as far as the ankle. In the lower third of the leg it is placed parallel with the inner margin of the tendo Achillis.

The *branches of the posterior tibial nerve* are muscular, calcaneo-plantar, and articular.

The *muscular branches* arise either separately or by a common tru[illegible]om the upper part of the nerve. They supply the Soleus, Tibialis posticus, Fle[illegible]longus digitorum, and Flexor longus hallucis muscles; the branch to the l[illegible] muscle

accompanying the peroneal artery. The branch to the Soleus enters its deep surface, while the branch which this muscle receives from the internal popliteal enters its superficial aspect.

The *calcaneo-plantar* (*internal calcanean*) *branch* perforates the internal annular ligament, and supplies the integument of the heel and inner side of the sole of the foot.

The *articular branch* is given off just above the bifurcation of the nerve and supplies the ankle-joint.

The **Internal Plantar Nerve** (Fig. 424), the larger of the two terminal branches of the posterior tibial, accompanies the internal plantar artery along the inner side of the foot. From its origin at the inner ankle it passes beneath the Abductor hallucis, and then forward between this muscle and the Flexor brevis digitorum, divides opposite the bases of the metatarsal bones into four digital branches, and communicates with the external plantar nerve.

Branches.—In its course the internal plantar nerve gives off *cutaneous branches*, which pierce the plantar fascia and supply the integument of the sole of the foot; *muscular branches*, which supply the Abductor hallucis and Flexor brevis digitorum; *articular branches*, to the articulations of the tarsus and metatarsus; and *four digital branches*. The three outer branches pass between the divisions of the plantar fascia in the clefts between the toes: the first (innermost) branch becomes cutaneous farther back between the Adductor hallucis and Flexor brevis digitorum. They are distributed in the following manner: The *first* supplies the inner border of the great toe, and sends a filament to the Flexor brevis hallucis muscle; the *second* bifurcates, to supply the adjacent sides of the great and second toes, sending a filament to the First lumbrical muscle;[1] the *third digital branch* supplies the adjacent sides of the second and third toes; the *fourth* supplies the corresponding sides of the third and fourth toes, and receives a communicating branch from the external plantar nerve. Each digital nerve gives off cutaneous and articular filaments; and opposite the last phalanx sends a dorsal branch, which supplies the structures around the nail, the continuation of the nerve being distributed to the ball of the toe. It will be observed that the distribution of these branches is precisely similar to that of the median nerve in the hand.

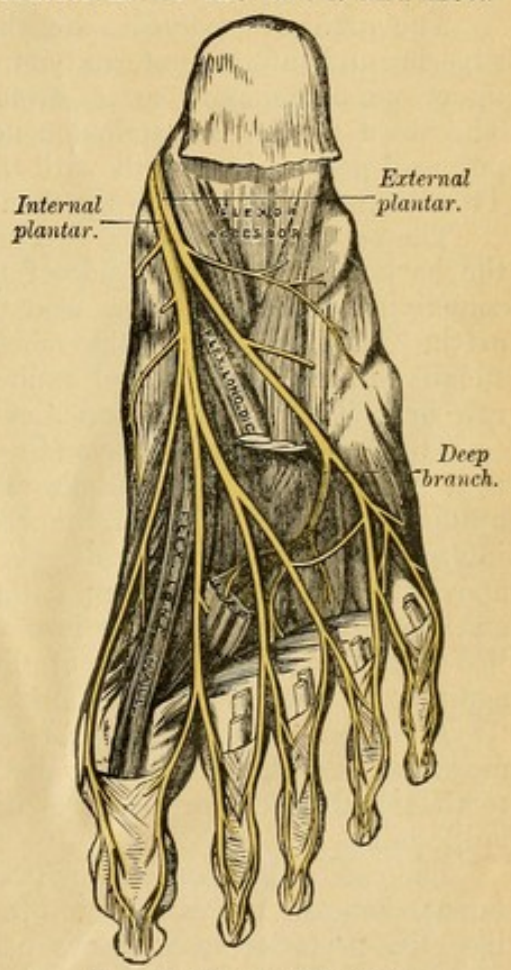

FIG. 424.—The plantar nerves.

The **External Plantar Nerve**, the smaller of the two, completes the nervous supply to the structures of the sole of the foot, being distributed to the little toe and one-half of the fourth, as well as to most of the deep muscles, its distribution being similar to that of the ulnar in the hand. It passes obliquely forward with the external plantar artery to the outer side of the foot, lying between the Flexor brevis digitorum and Flexor accessorius, and in the interval between the former muscle and Abductor minimi digiti divides into a superficial and a deep branch. Before its division it supplies the Flexor accessorius and Abductor minimi digiti.

The *superficial branch* separates into two digital nerves: one, the smaller of the two, supplies the outer side of the little toe, the Flexor brevis minimi digiti,

[1] See foot-note, page 448.

and the two Interosseous muscles of the fourth metatarsal space; the other and larger digital branch supplies the adjoining sides of the fourth and fifth toes, and communicates with the internal plantar nerve.

The *deep or muscular branch* accompanies the external plantar artery into the deep part of the sole of the foot, beneath the tendons of the Flexor muscles and Adductor obliquus hallucis, and supplies all the Interossei (except those in the fourth metatarsal space), the three outer Lumbricales, the Adductor obliquus hallucis, and the Adductor transversus hallucis.

The **External Popliteal** or **Peroneal Nerve** (Fig. 423), about one-half the size of the internal popliteal, descends obliquely along the outer sides of the popliteal space to the head of the fibula, close to the inner margin of the Biceps muscle. It is easily felt beneath the skin behind the head of the fibula at the inner side of the tendon of the Biceps. It passes between the tendon of the Biceps and outer head of the Gastrocnemius muscle, winds round the neck of the fibula, between the Peroneus longus and the bone, and divides beneath the muscle into the anterior tibial and musculo-cutaneous nerves.

The *branches of the peroneal nerve*, previous to its division, are articular and cutaneous.

The *articular branches* are three in number; two of these accompany the superior and inferior external articular arteries to the outer side of the knee. The upper one occasionally arises from the great sciatic nerve before its bifurcation. The third (*recurrent*) articular nerve is given off at the point of division of the peroneal nerve; it ascends with the anterior recurrent tibial artery through the Tibialis anticus muscle to the front of the knee, which it supplies.

The *cutaneous branches*, two or three in number, supply the integument along the back part and outer side of the leg; one of these, larger than the rest, the *communicans peronei*, arises near the head of the fibula, crosses the external head of the Gastrocnemius to the middle of the leg, and joins with the communicans tibialis to form the external saphenous. This nerve occasionally exists as a separate branch, which is continued as far down as the heel.

The **Anterior Tibial Nerve** (Fig. 419) commences at the bifurcation of the peroneal nerve, between the fibula and upper part of the Peroneus longus, passes obliquely forward beneath the Extensor longus digitorum to the fore part of the interosseous membrane, and gets into relation with the anterior tibial artery above the middle of the leg; it then descends with the artery to the front of the ankle-joint, where it divides into an external and an internal branch. This nerve lies at first on the outer side of the anterior tibial artery, then in front of it, and again at its outer side at the ankle-joint.

The *branches of the anterior tibial nerve* in its course through the leg are the muscular branches to the Tibialis anticus, Extensor longus digitorum, Peroneus tertius, and Extensor proprius hallucis muscles, and an *articular branch* to the ankle-joint.

The *external* or *tarsal branch of the anterior tibial* passes outward across the tarsus, beneath the Extensor brevis digitorum, and, having become enlarged, like the posterior interosseous nerve at the wrist, supplies the Extensor brevis digitorum. From the enlargement three minute *interosseous branches* are given off which supply the tarsal joints and the metatarso-phalangeal joints of the second, third, and fourth toes. The first of these sends a filament to the second dorsal interosseous muscle.

The *internal branch*, the continuation of the nerve, accompanies the dorsalis pedis artery along the inner side of the dorsum of the foot, and at the first interosseous space divides into two branches, which supply the adjacent sides of the great and second toes, communicating with the internal branch of the musculo-cutaneous nerve. Before it divides it gives off an *interosseous branch* to the first space, which supplies the metatarso-phalangeal joint of the great toe, and sends a filament to the First dorsal interosseous muscle.

The **Musculo-cutaneous Nerve** (Fig. 419) supplies the muscles on the outer dorsal

side of the leg and the integument of the dorsum of the foot. It passes forward between the Peronei muscles and the Extensor longus digitorum, pierces the deep fascia at the lower third of the leg on its front and outer side, and divides into two branches. This nerve in its course between the muscles gives off muscular branches to the Peroneus longus and brevis, and cutaneous filaments to the integument of the lower part of the leg.

The *internal branch of the musculo-cutaneous nerve* passes in front of the ankle-joint, and divides into two branches, one of which supplies the inner side of the great toe, the other, the adjacent sides of the second and third toes. It also supplies the integument of the inner ankle and inner side of the foot, communicating with the internal saphenous nerve, and joining with the anterior tibial nerve, between the great and second toes.

The *external branch*, the smaller, passes along the outer side of the dorsum of the foot, and divides into two branches, the inner being distributed to the contiguous sides of the third and fourth toes, the outer to the opposed sides of the fourth and fifth toes. It also supplies the integument of the outer ankle and outer side of the foot, communicating with the short saphenous nerve.

The branches of the musculo-cutaneous nerve supply all the toes excepting the outer side of the little toe, and the adjoining sides of the great and second toes, the former being supplied by the external saphenous, and the latter by the internal branch of the anterior tibial. It frequently happens, however, that some of the outer branches of the musculo-cutaneous are absent, their place being then taken by branches of the external saphenous nerve.

Surgical Anatomy.—The lumbar plexus passes through the Psoas muscle, and, therefore in psoas abscess any or all of its branches may be irritated, causing severe pain in the part to which the irritated nerves are distributed. The genito-crural nerve is the one which is most frequently implicated. This nerve is also of importance, as it is concerned in one of the principal reflexes employed in the investigation of diseases of the spine. If the skin over the inner side of the thigh just below Poupart's ligament, the part supplied by the crural branch of the genito-crural nerve, be gently tickled in a male child, the testicle will be noticed to be drawn upward through the action of the Cremaster muscle, supplied by the genital branch of the same nerve. The same result may sometimes be noticed in adults, and can almost always be produced by severe stimulation. This reflex, when present, shows that the portion of the cord from which the first and second lumbar nerves are derived is in a normal condition.

The anterior crural nerve is in danger of being injured in fractures of the true pelvis, since the fracture most commonly takes place through the ascending ramus of the os pubis, at or near the point where this nerve crosses the bone. It is also liable to be injured in fractures and dislocations of the femur, and is likely to be pressed upon, and its functions impaired, in some tumors growing in the pelvis. Moreover, on account of its superficial position, it is exposed to injury in wounds and stabs in the groin. When this nerve is paralyzed, the patient is unable to flex his hip completely, on account of the loss of motion in the Iliacus; or to extend the knee on the thigh, on account of paralysis of the Quadriceps extensor cruris; there are complete paralysis of the Sartorius and partial paralysis of the Pectineus. There is loss of sensation down the front and inner side of the thigh, except in that part supplied by the crural branch of the genito-crural, and by the ilio-inguinal. There is also loss of sensation down the inner side of the leg and foot as far as the ball of the great toe.

The obturator nerve is of special surgical interest. It is rarely paralyzed alone, but occasionally in association with the anterior crural. The principal interest attached to it is in connection with its supply to the knee; pain in the knee being symptomatic of many diseases in which the trunk of this nerve, or one of its branches, is irritated. Thus it is well known that in the earlier stages of hip-joint disease the patient does not complain of pain in that articulation, but on the inner side of the knee, or in the knee-joint itself, both these articulations being supplied by the obturator nerve, the final distribution of the nerve being to the knee-joint. Again, the same thing occurs in sacro-iliac disease: pain is complained of in the knee-joint or on its inner side. The obturator nerve is in close relationship with the sacro-iliac articulation, passing over it, and, according to some anatomists, distributing filaments to it. Again, in cancer of the sigmoid flexure, and even in cases where masses of hardened fæces are impacted in this portion of the gut, pain is complained of in the knee. The left obturator nerve lies beneath the sigmoid flexure, and is readily pressed upon and irritated when disease exists in this part of the intestine. Finally, pain in the knee forms an important diagnostic sign in obturator hernia. The hernial protrusion as it passes out through the opening in the obturator membrane presses upon the nerve and causes pain in the parts supplied by its peripheral filaments. When the obturator nerve is paralyzed, the patient is unable to press his knees together or to cross one leg over the other, on account of paralysis of the Adductor muscles.

Rotation outward of the thigh is impaired from paralysis of the Obturator externus. Sometimes there is loss of sensation in the upper half of the inner side of the thigh.

The great sciatic nerve is liable to be pressed upon by various forms of pelvic tumors, giving rise to pain along its trunk, to which the term sciatica is applied. Tumors growing from the pelvic viscera, or bones, aneurisms of some of the branches of the internal iliac artery, calculus in the bladder when of large size, accumulation of fæces in the rectum, may all cause pressure on the nerve inside the pelvis, and give rise to sciatica. Outside the pelvis exposure to cold, violent movements of the hip-joint, exostoses or other tumors growing from the margin of the sacro-sciatic foramen, may also give rise to the same condition. When paralyzed there is loss of motion in all the muscles below the knee, and loss of sensation in the same situation, except the upper half of the back of the leg, supplied by the small sciatic and the upper half of the inner side of the leg, when the communicating branch of the obturator is large (see page 785).

The sciatic nerve has been frequently cut down upon and stretched, or has been acupunctured for the relief of sciatica. The nerve has also been stretched in cases of locomotor ataxy, the anæsthesia of leprosy, etc. In order to define it on the surface, a point is taken at the junction of the middle and lower third of a line stretching from the posterior superior spine of the ilium to the outer part of the tuber ischii, and a line drawn from this to the middle of the upper part of the popliteal space. The line must be slightly curved with its convexity outward, and as it passes downward to the lower border of the Gluteus maximus is slightly nearer the tuber ischii than the great trochanter, as it crosses a line drawn between these two points. The operation of stretching the sciatic nerve is performed by making an incision over the course of the nerve about the centre of the thigh. The skin, superficial structures, and deep fascia having been divided, the interval between the inner and outer hamstrings is to be defined, and these muscles pulled inward and outward with retractors. The nerve will be found a little to the inner side of the Biceps. It is to be separated from the surrounding structures, hooked up with the finger, and stretched by steady and continuous traction for two or three minutes. The sciatic nerve may also be stretched by what is known as the "dry" plan. The patient is laid on his back, the foot is extended, the leg flexed on the thigh, and the thigh strongly flexed on the abdomen. While the thigh is maintained in this position the leg is forcibly extended to its full extent, and the foot as fully flexed on the leg.

The position of the external popliteal, close behind the tendon of the Biceps on the outer side of the ham, should be remembered in subcutaneous division of the tendon. After it is divided, a cord often rises up close beside it, which might be mistaken for a small undivided portion of the tendon, and the surgeon might be tempted to reintroduce his knife and divide it. This must never be done, as the cord is the external popliteal nerve, which becomes prominent as soon as the tendon is divided.

THE SYMPATHETIC NERVE.

The **Sympathetic Nervous System** consists of (1) a series of ganglia, connected together by intervening cords, extending from the base of the skull to the coccyx, one on each side of the middle line of the body, partly in front and partly on each side of the vertebral column; (2) of three great gangliated plexuses or aggregations of nerves and ganglia, situated in front of the spine in the thoracic, abdominal, and pelvic cavities respectively; (3) of smaller ganglia, situated in relation with the abdominal viscera; and (4) of numerous nerve-fibres. These latter are of two kinds: *communicating*, by which the ganglia communicate with each other and with the cerebro-spinal nerves; and *distributory*, supplying the internal viscera and the coats of the blood-vessels.

Each **gangliated cord** may be traced upward from the base of the skull into its cavity by an ascending branch, which passes through the carotid canal, forms a plexus on the internal carotid artery, and communicates with the ganglia on the first and second divisions of the fifth nerve. According to some anatomists, the two cords are joined, at their cephalic extremities, by these ascending branches communicating in a small ganglion (the *ganglion of Ribes*), situated upon the anterior communicating artery. The ganglia of these cords are distinguished as cervical, dorsal, lumbar, and sacral, and except in the neck they correspond pretty nearly in number to the vertebræ against which they lie. They may be thus arranged:

Cervical portion	. .	3 pairs of ganglia.
Dorsal "	. .	12 " "
Lumbar "	. .	4 " "
Sacral "	. .	4 or 5 " "

In the neck they are situated in front of the transverse processes of the vertebræ; in the dorsal region, in front of the heads of the ribs; in the lumbar region, on the sides of the bodies of the vertebræ; and in the sacral region, in front of the sacrum. As the two cords pass into the pelvis they converge and unite together in a single ganglion (*ganglion impar*) placed in front of the coccyx. Each ganglion may be regarded as a distinct centre, and, in addition to its branches of distribution, possesses also branches of communication which communicate with other ganglia and with the cerebro-spinal nerves.

The branches of communication between the ganglia are composed of gray and white nerve-fibres, the latter being continuous with those fibres of the spinal nerves which pass to the ganglia.

The branches of communication between the ganglia and the cerebro-spinal nerves also consist of white and gray nerve-fibres, which may be contained in separate filaments or united in a single branch; the former proceeding from the spinal nerve *to* the ganglion, the latter passing *from* the ganglion to the spinal nerve, so that a double interchange takes place between the two systems. While gray communicating fibres pass from all the sympathetic ganglia to all the spinal nerves, it would appear that the white communicating fibres from the spinal nerves to the sympathetic only exist in the dorsal and upper lumbar regions.

The **three great gangliated plexuses** are situated in front of the spine in the thoracic, abdominal, and pelvic regions, and are named, respectively, the *cardiac*, the *solar* or *epigastric*, and the *hypogastric plexus*. They consist of collections of nerves and ganglia, the nerves being derived from the gangliated cords and from the cerebro-spinal nerves. They distribute branches to the viscera.

Smaller ganglia are also found lying amidst the nerves, some of them of microscopic size, in certain viscera—as, for instance, in the heart, the stomach, and the uterus. They serve as additional centres for the origin of nerve-fibres.

The *branches of distribution* derived from the gangliated cords, from the prevertebral plexuses, and also from the smaller ganglia, are principally destined for the blood-vessels and thoracic and abdominal viscera, supplying the involuntary muscular fibre of the coats of the vessels and the hollow viscera, and the secreting cells, as well as the muscular coats of the vessels in the glandular viscera.

THE GANGLIATED CORD.

Cervical Portion of the Gangliated Cord.

The cervical portion of the gangliated cord consists of three ganglia on each side, which are distinguished, according to their position, as the superior, middle, and inferior cervical.

The **Superior Cervical Ganglion**, the largest of the three, is placed opposite the second and third cervical vertebræ. It is of a reddish-gray color, and usually fusiform in shape, sometimes broad and flattened, and occasionally constricted at intervals, so as to give rise to the opinion that it consists of the coalescence of several smaller ganglia; and it is usually believed that it is formed by the coalescence of the four ganglia corresponding to the four upper cervical nerves. It is in relation, in front, with the sheath of the internal carotid artery and internal jugular vein; behind, it lies on the Rectus capitis anticus major muscle.

Its branches may be divided into superior, inferior, external, internal, and anterior.

The *superior branch* appears to be a direct prolongation of the ganglion. It is soft in texture and of a reddish color. It ascends by the side of the internal carotid artery, and, entering the carotid canal in the temporal bone, divides into two branches, which lie, one on the outer, and the other on the inner, side of that vessel.

The *outer branch*, the larger of the two, distributes filaments to the internal carotid artery and forms the *carotid plexus*.

The *inner branch* also distributes filaments to the internal carotid, and, continuing onward, forms the *cavernous plexus*.

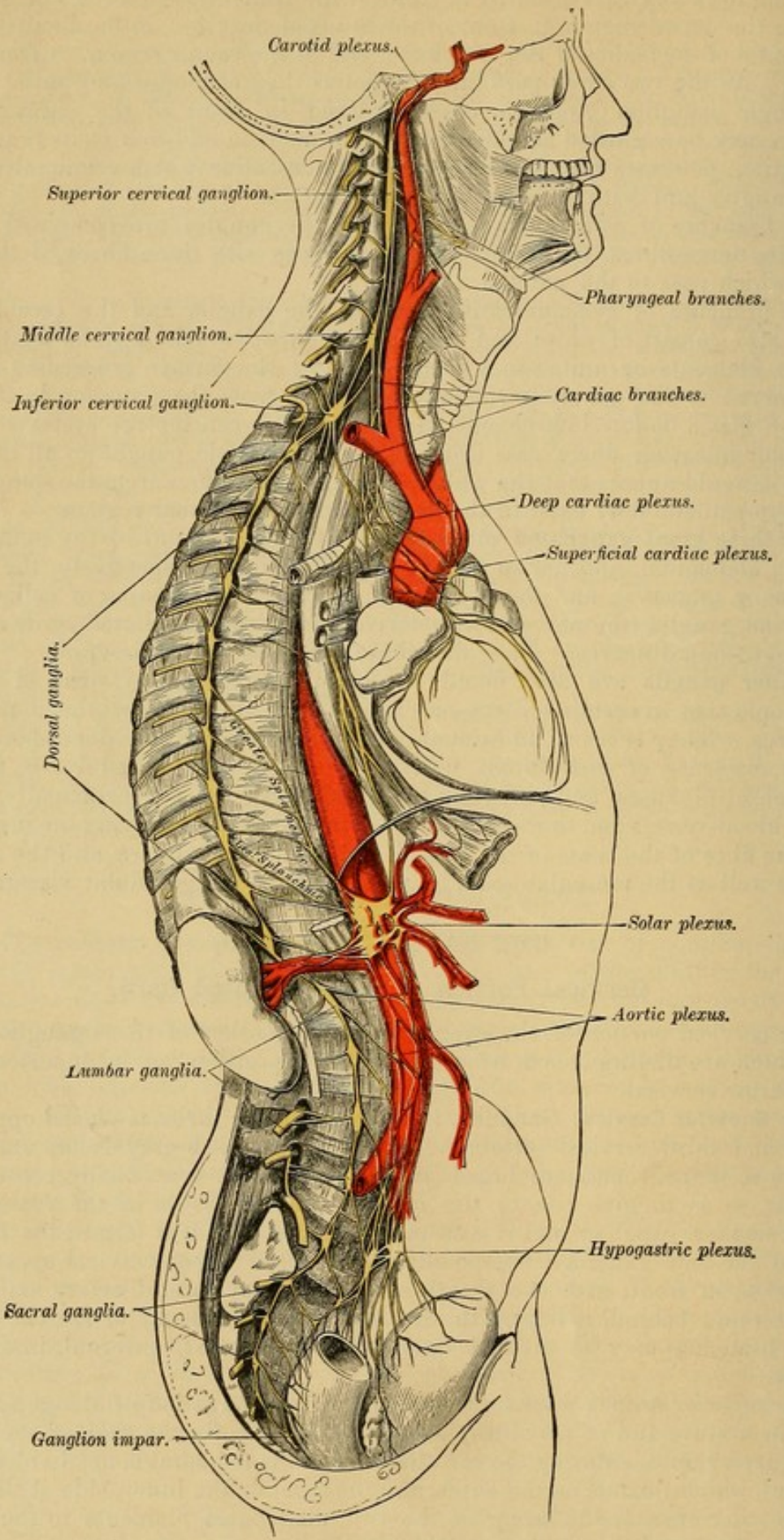

FIG. 425.—The sympathetic nerve.

The Carotid Plexus.

The carotid plexus is situated on the outer side of the internal carotid. Filaments from this plexus occasionally form a small gangliform swelling on the under surface of the artery, which is called the carotid ganglion. The carotid plexus communicates with the Gasserian ganglion, with the sixth nerve, and the spheno-palatine ganglion, and distributes filaments to the wall of the carotid artery and to the dura mater (Valentin), while in the carotid canal it communicates with Jacobson's nerve, the tympanic branch of the glosso-pharyngeal.

The *communicating branches with the sixth nerve* consist of one or two filaments which join that nerve as it lies upon the outer side of the internal carotid. Other filaments are also connected with the Gasserian ganglion. The communication with the spheno-palatine ganglion is effected by a branch, the *large deep petrosal*, which is given off from the plexus on the outer side of the artery, and which passes through the cartilage filling up the foramen lacerum medium, and joins the great superficial petrosal to form the Vidian nerve. The Vidian nerve then proceeds along the pterygoid or Vidian canal to the spheno-palatine ganglion. The communication with Jacobson's nerve is effected by two branches, one of which is called the *small deep petrosal nerve*, and the other the *carotico-tympanic ;* the latter may consist of two or three delicate filaments.

The Cavernous Plexus.

The cavernous plexus is situated below and internal to that part of the internal carotid which is placed by the side of the sella Turcica in the cavernous sinus, and is formed chiefly by the internal division of the ascending branch from the superior cervical ganglion. It communicates with the third, the fourth, the ophthalmic division of the fifth, and the sixth nerves, and with the ophthalmic ganglion, and distributes filaments to the wall of the internal carotid. The branch of communication with the third nerve joins it at its point of division; the branch to the fourth nerve joins it as it lies on the outer wall of the cavernous sinus; other filaments are connected with the under surface of the trunk of the ophthalmic nerve; and a second filament of communication joins the sixth nerve.

The filament of connection with the ophthalmic ganglion arises from the anterior part of the cavernous plexus; it accompanies the nasal nerve or continues forward as a separate branch.

The terminal filaments from the carotid and cavernous plexuses are prolonged along the internal carotid, forming plexuses which entwine round the cerebral and ophthalmic arteries; along the former vessels they may be traced on to the pia mater; along the latter, into the orbit, where they accompany each of the subdivisions of the vessel, a separate plexus passing, with the arteria centralis retinæ, into the interior of the eyeball. The filaments prolonged on to the anterior communicating artery form a small ganglion, the *ganglion of Ribes*,[1] which serves, as mentioned above, to connect the sympathetic nerves of the right and left sides.

The **inferior** or **descending branch of the superior cervical ganglion** communicates with the middle cervical ganglion.

The **external branches** are numerous, and communicate with the cranial nerves and with the four upper spinal nerves. Sometimes the branch to the fourth spinal nerve may come from the cord connecting the upper and middle cervical ganglia. The branches of communication with the cranial nerves consist of delicate filaments, which pass from the superior cervical ganglion to the ganglion of the trunk of the pneumogastric and to the hypoglossal nerve. A separate filament from the cervical ganglion subdivides and joins the petrosal ganglion of the glosso-pharyngeal and the ganglion of the root of the pneumogastric in the jugular foramen.

The **internal branches** are three in number—the *pharyngeal*, *laryngeal*, and *superior cardiac nerve*. The *pharyngeal branches* pass inward to the side of the

[1] The existence of this ganglion is doubted by some observers.

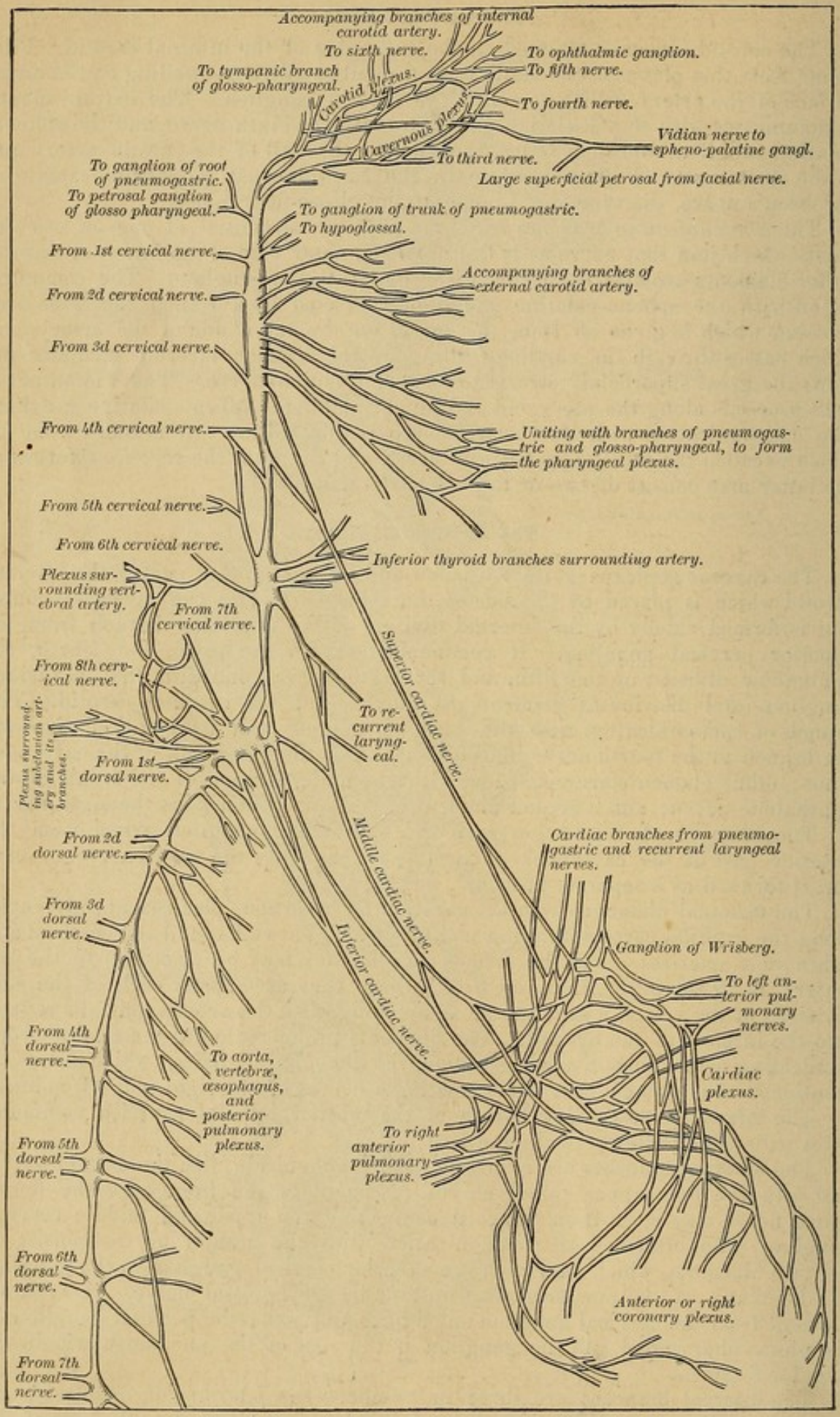

FIG. 426.—Plan of the cervical portion of the sympathetic. (After Flower.)

pharynx, where they join with branches from the glosso-pharyngeal, pneumogastric, and external laryngeal nerves to form the *pharyngeal plexus*. The *laryngeal branches* unite with the superior laryngeal nerve and its branches.

The *superior cardiac nerve* (*nervus superficialis cordis*) arises by two or more branches from the superior cervical ganglion, and occasionally receives a filament from the cord of communication between the first and second cervical ganglia. It runs down the neck behind the common carotid artery, lying upon the Longus colli muscle, and crosses in front of the inferior thyroid artery and recurrent laryngeal nerve.

The *right superior cardiac nerve*, at the root of the neck, passes either in front of or behind the subclavian artery, and along the arteria innominata, to the back part of the arch of the aorta, where it joins the deep cardiac plexus. This nerve, in its course, is connected with other branches of the sympathetic: about the middle of the neck it receives filaments from the external laryngeal nerve; lower down, one or two twigs from the pneumogastric; and as it enters the thorax it is joined by a filament from the recurrent laryngeal. Filaments from this nerve communicate with the thyroid branches from the middle cervical ganglion.

The *left superior cardiac nerve*, in the chest, runs by the side of the left common carotid artery and in front of the arch of the aorta to the superficial cardiac plexus, but occasionally it passes behind the aorta and terminates in the deep cardiac plexus.

The **anterior branches** ramify upon the external carotid artery and its branches, forming round each a delicate plexus, on the nerves composing which small ganglia are occasionally found. The plexuses accompanying some of these arteries have important communications with other nerves. That surrounding the external carotid is connected with the branch of the facial nerve to the Stylo-hyoid muscle; that surrounding the facial communicates with the submaxillary ganglion by one or two filaments; and that accompanying the middle meningeal artery sends offsets which pass to the otic ganglion and to the geniculate ganglion of the facial nerve (external petrosal).

The **Middle Cervical Ganglion** (*thyroid ganglion*) is the smallest of the three cervical ganglia, and is occasionally altogether wanting. It is placed opposite the sixth cervical vertebra, usually upon, or close to, the inferior thyroid artery; hence the name, "thyroid ganglion," assigned to it by Haller. It is probably formed by the coalescence of two ganglia corresponding to the fifth and sixth cervical nerves.

Its *superior branches* ascend to communicate with the superior cervical ganglion.

Its *inferior branches* descend to communicate with the inferior cervical ganglion.

Its *external branches* pass outward to join the fifth and sixth spinal nerves. These branches are not constantly found.

Its *internal branches* are the thyroid and the middle cardiac nerve.

The *thyroid branches* are small filaments which accompany the inferior thyroid artery to the thyroid gland; they communicate, on the artery, with the superior cardiac nerve, and, in the gland, with branches from the recurrent and external laryngeal nerves.

The *middle cardiac nerve* (*nervus cardiacus magnus*), the largest of the three cardiac nerves, arises from the middle cervical ganglion or from the cord between the middle and inferior ganglia. On the right side it descends behind the common carotid artery, and at the root of the neck passes either in front of or behind the subclavian artery; it then descends on the trachea, receives a few filaments from the recurrent laryngeal nerve, and joins the right side of the deep cardiac plexus. In the neck it communicates with the superior cardiac and recurrent laryngeal nerves. On the left side the middle cardiac nerve enters the chest between the left carotid and subclavian arteries, and joins the left side of the deep cardiac plexus.

The **Inferior Cervical Ganglion** is situated between the base of the transverse

process of the last cervical vertebra and the neck of the first rib on the inner side of the superior intercostal artery. Its form is irregular; it is larger in size than the preceding, and frequently joined with the first thoracic ganglion. It is probably formed by the coalescence of two ganglia which correspond to the two last cervical nerves.

Its *superior branches* communicate with the middle cervical ganglion.

Its *inferior branches* descend, some in front of, others behind, the subclavian artery, to join the first thoracic ganglion.

Its *internal branch* is the inferior cardiac nerve.

The *inferior cardiac nerve* (*nervus cardiacus minor*) arises from the inferior cervical or first thoracic ganglion. It passes down behind the subclavian artery and along the front of the trachea to join the deep cardiac plexus. It communicates freely behind the subclavian artery with the recurrent laryngeal and middle cardiac nerves.

The *external branches* consist of several filaments, some of which communicate with the seventh and eighth spinal nerves; others accompany the vertebral artery along the vertebral canal, forming a plexus round the vessel, supplying it with filaments, which are continued up the vertebral and basilar to the cerebral arteries. The branches communicate with the cervical spinal nerves.

The Thoracic Portion of the Gangliated Cord.

The thoracic portion of the gangliated cord consists of a series of ganglia which usually correspond in number to that of the vertebræ, but, from the occasional coalescence of two, their number is uncertain. These ganglia are placed on each side of the spine, resting against the heads of the ribs and covered by the pleura costalis; the last two are, however, anterior to the rest, being placed on the side of the bodies of the eleventh and twelfth dorsal vertebræ. The ganglia are small in size and of a grayish color. The first, larger than the rest, is of an elongated form and frequently blended with the last cervical. They are connected together by cord-like prolongations from their substance.

The *external branches* from each ganglion, usually two in number, communicate with each of the dorsal spinal nerves.

The *internal branches from the five or six upper ganglia* are very small; they supply filaments to the thoracic aorta and its branches, besides small branches to the bodies of the vertebræ and their ligaments. Branches from the third and fourth, and sometimes also from the first and second ganglia, form part of the posterior pulmonary plexus.

The *internal branches from the six or seven lower ganglia* are large and white in color; they distribute filaments to the aorta, and unite to form the three splanchnic nerves. These are named the *great*, the *lesser*, and the *smallest* or *renal splanchnic*.

The *great splanchnic nerve* is of a white color, firm in texture, and bears a marked contrast to the ganglionic nerves. It is formed by branches from the thoracic ganglia between the fifth or sixth and the ninth or tenth, but the fibres in the higher roots may be traced upward in the sympathetic cord as far as the first or second thoracic ganglia. These roots unite to form a large round cord of considerable size. It descends obliquely inward in front of the bodies of the vertebræ along the posterior mediastinum, perforates the crus of the Diaphragm, and terminates in the semilunar ganglion of the solar plexus, distributing filaments to the renal and suprarenal plexus.

The *lesser splanchnic nerve* is formed by filaments from the tenth and eleventh ganglia, and from the cord between them. It pierces the Diaphragm with the preceding nerve, and joins the solar plexus. It communicates in the chest with the great splanchnic nerve, and occasionally sends filaments to the renal plexus.

The *smallest* or *renal splanchnic nerve* arises from the last ganglion, and,

piercing the Diaphragm, terminates in the renal plexus and lower part of the solar plexus. It occasionally communicates with the preceding nerve.

A striking analogy appears to exist between the splanchnic and the cardiac nerves. The cardiac nerves are three in number; they arise from the three cervical ganglia, and are distributed to a large and important organ in the thoracic cavity. The splanchnic nerves, also three in number, are connected probably with all the dorsal ganglia, and are distributed to important organs in the abdominal cavity.

The Lumbar Portion of the Gangliated Cord.

The lumbar portion of the gangliated cord is situated in front of the vertebral column along the inner margin of the Psoas muscle. It consists usually of four ganglia, connected together by interganglionic cords. The ganglia are of small size, of a grayish color, shaped like a barleycorn, and placed much nearer the median line than the thoracic ganglia.

The *superior* and *inferior branches of the lumbar ganglia* serve as communicating branches between the chain of ganglia in this region. They are usually single and of a white color.

The *external branches* communicate with the lumbar spinal nerves. From the situation of the lumbar ganglia these branches are longer than in the other regions. They are usually two in number from each ganglion, but their connection with the spinal nerves is not so uniform as in other regions. They accompany the lumbar arteries around the sides of the bodies of the vertebræ, passing beneath the fibrous arches from which some of the fibres of the Psoas muscle arise.

Of the *internal branches*, some pass inward, in front of the aorta, and help to form the aortic plexus. Other branches descend in front of the common iliac arteries, and join over the promontory of the sacrum, helping to form the hypogastric plexus. Numerous delicate filaments are also distributed to the bodies of the vertebræ and the ligaments connecting them.

Pelvic Portion of the Gangliated Cord.

The pelvic portion of the gangliated cord is situated in front of the sacrum along the inner side of the anterior sacral foramina. It consists of four or five small ganglia on each side, connected together by interganglionic cords. Below, these cords converge and unite on the front of the coccyx by means of a small ganglion (the *coccygeal ganglion* or *ganglion impar*).

The *superior* and *inferior branches* are the cords of communication between the ganglia above and below.

The *external branches*, exceedingly short, communicate with the sacral nerves. They are two in number from each ganglion. The coccygeal nerve communicates either with the last sacral or coccygeal ganglion.

The *internal branches* communicate, on the front of the sacrum, with the corresponding branches from the opposite side; some, from the first two ganglia, pass to join the pelvic plexus, and others form a plexus which accompanies the middle sacral artery and sends filaments to the coccygeal gland.

THE GREAT PLEXUSES OF THE SYMPATHETIC.

The great plexuses of the sympathetic are the large aggregations of nerves and ganglia, above alluded to, situated in the thoracic, abdominal, and pelvic cavities respectively. From them are derived the branches which supply the viscera.

The Cardiac Plexus.

The cardiac plexus is situated at the base of the heart, and is divided into a *superficial part*, which lies in the concavity of the arch of the aorta, and a *deep*

part, which lies between the trachea and aorta. The two plexuses are, however, closely connected.

The **great** or **deep cardiac plexus** (*plexus magnus profundus*, Scarpa) is situated in front of the trachea at its bifurcation, above the point of division of the pulmonary artery and behind the arch of the aorta. It is formed by the cardiac nerves derived from the cervical ganglia of the sympathetic and the cardiac branches of the recurrent laryngeal and pneumogastric. The only cardiac nerves which do not enter into the formation of this plexus are the left superior cardiac nerve and the inferior cervical cardiac branch from the left pneumogastric.

The branches from the *right side* of this plexus pass, some in front of, and others behind, the right pulmonary artery; the former, the more numerous, transmit a few filaments to the anterior pulmonary plexus, and are then continued onward to form part of the anterior coronary plexus; those behind the pulmonary artery distribute a few filaments to the right auricle, and are then continued onward to form part of the posterior coronary plexus.

The branches from the *left side* of the deep cardiac plexus distribute a few filaments to the superficial cardiac plexus, to the left auricle of the heart, and to the anterior pulmonary plexus, and then pass on to form the greater part of the posterior coronary plexus.

The **superficial (anterior) cardiac plexus** lies beneath the arch of the aorta, in front of the right pulmonary artery. It is formed by the left superior cardiac nerve, the left (and occasionally the right) inferior cervical cardiac branches of the pneumogastric, and filaments from the deep cardiac plexus. A small ganglion (*cardiac ganglion of Wrisberg*) is occasionally found connected with these nerves at their point of junction. This ganglion, when present, is situated immediately beneath the arch of the aorta, on the right side of the ductus arteriosus. The superficial cardiac plexus forms the chief part of the anterior coronary plexus, and several filaments pass along the pulmonary artery to the left anterior pulmonary plexus.

The **posterior** or **right coronary plexus** is chiefly formed by filaments prolonged from the left side of the deep cardiac plexus, and by a few from the right side. It surrounds the branches of the coronary artery at the back of the heart, and its filaments are distributed with those vessels to the muscular substance of the ventricles.

The **anterior** or **left coronary plexus** is formed chiefly from the superficial cardiac plexus, but receives filaments from the deep cardiac plexus. Passing forward between the aorta and pulmonary artery, it accompanies the left coronary artery on the anterior surface of the heart.

Valentin has described nervous filaments ramifying under the endocardium; and Remak has found, in several mammalia, numerous small ganglia on the cardiac nerves, both on the surface of the heart and in its muscular substance.

The Epigastric or Solar Plexus (Figs. 425, 427).

The **Epigastric** or **Solar plexus** supplies all the viscera in the abdominal cavity. It consists of a great network of nerves and ganglia, situated behind the stomach and in front of the aorta and crura of the Diaphragm. It surrounds the cœliac axis and root of the superior mesenteric artery, extending downward as low as the pancreas and outward to the suprarenal capsules. This plexus, and the ganglia connected with it, receive the great and small splanchnic nerves of both sides, and some filaments from the right pneumogastric. It distributes filaments which accompany, under the name of plexuses, all the branches from the front of the abdominal aorta.

Of the ganglia of which the solar plexus is partly composed the principal are the two **semilunar ganglia**, which are situated one on each side of the plexus, and are the largest ganglia in the body. They are large irregular gangliform masses formed by the aggregation of smaller ganglia, having interspaces between them.

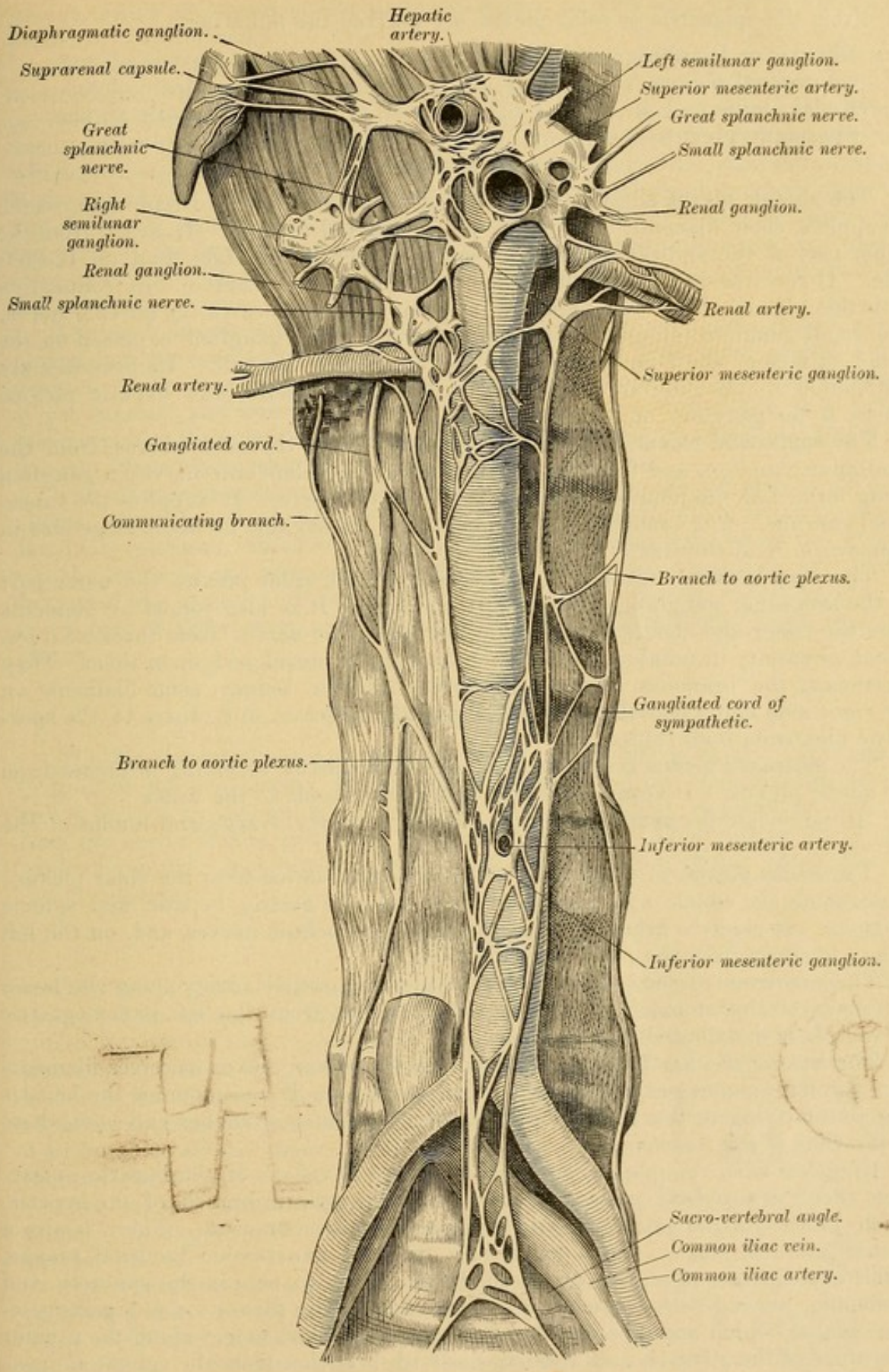

FIG. 427.—Lumbar portion of the gangliated cord, with the solar and hypogastric plexuses. (After Henle.)

They are situated in front of the crura of the Diaphragm, close to the suprarenal capsules: the one on the right side lies beneath the inferior vena cava; the upper part of each ganglion is joined by the greater splanchnic nerve, and to the inner side of each the branches of the solar plexus are connected.

From the epigastric or solar plexus are derived the following:

Phrenic or Diaphragmatic plexus.	Gastric plexus.
Suprarenal plexus.	Cœliac plexus { Splenic plexus.
Renal plexus.	Hepatic plexus.
Spermatic plexus.	Superior mesenteric plexus.
Aortic plexus.	

The **phrenic plexus** accompanies the phrenic artery to the Diaphragm, which it supplies, some filaments passing to the suprarenal capsule. It arises from the upper part of the semilunar ganglion, and is larger on the right than on the left side. It receives one or two branches from the phrenic nerve. In connection with this plexus, on the right side, at its point of junction with the phrenic nerve, is a small ganglion (*ganglion diaphragmaticum*). This ganglion is placed on the under surface of the Diaphragm, near the suprarenal capsule. Its branches are distributed to the inferior vena cava, suprarenal capsule, and hepatic plexus. There is no ganglion on the left side.

The **suprarenal plexus** is formed by branches from the solar plexus, from the semilunar ganglion, and from the phrenic and great splanchnic nerves, a ganglion being formed at the point of junction of the latter nerve. It supplies the suprarenal capsule. The branches of this plexus are remarkable for their large size in comparison with the size of the organ they supply.

The **renal plexus** is formed by filaments from the solar plexus, the outer part of the semilunar ganglion, and the aortic plexus. It is also joined by filaments from the lesser and smallest splanchnic nerves. The nerves from these sources, fifteen or twenty in number, have numerous ganglia developed upon them. They accompany the branches of the renal artery into the kidney, some filaments on the right side being distributed to the inferior vena cava, and others to the spermatic plexus on both sides.

The **spermatic plexus** is derived from the renal plexus, receiving branches from the aortic plexus. It accompanies the spermatic vessels to the testes.

In the female the **ovarian plexus** is distributed to the ovaries and fundus of the uterus.

The **cœliac plexus,** of large size, is a direct continuation from the solar plexus: it surrounds the cœliac axis and subdivides into the gastric, hepatic, and splenic plexuses. It receives branches from the lesser splanchnic nerves, and, on the left side, a filament from the right pneumogastric.

The *gastric* or *coronary plexus* accompanies the gastric artery along the lesser curvature of the stomach, and joins with branches from the left pneumogastric nerve. It is distributed to the stomach

The *hepatic plexus*, the largest offset from the cœliac plexus, receives filaments from the left pneumogastric and right phrenic nerves. It accompanies the hepatic artery, ramifying in the substance of the liver upon its branches and upon those of the vena portæ.

Branches from this plexus accompany all the divisions of the hepatic artery. Thus there is a *pyloric plexus* accompanying the pyloric branch of the hepatic, which joins with the gastric plexus and pneumogastric nerves. There is also a *gastro-duodenal plexus*, which subdivides into the pancreatico-duodenal plexus, which accompanies the pancreatico-duodenal artery, to supply the pancreas and duodenum, joining with branches from the mesenteric plexus; and a *gastro-epiploic plexus,* which accompanies the right gastro-epiploic artery along the greater curvature of the stomach and anastomoses with branches from the splenic plexus. A *cystic plexus*, which supplies the gall-bladder, also arises from the hepatic plexus near the liver.

The *splenic plexus* is formed by branches from the cœliac plexus, the left semilunar ganglia, and from the right pneumogastric nerve. It accompanies the splenic artery and its branches to the substance of the spleen, giving off, in its course, filaments to the pancreas (*pancreatic plexus*) and the *left gastro-epiploic*

plexus, which accompanies the gastro-epiploica sinistra artery along the convex border of the stomach.

The **superior mesenteric plexus** is a continuation of the lower part of the great solar plexus, receiving a branch from the junction of the right pneumogastric nerve with the cœliac plexus. It surrounds the superior mesenteric artery, which it accompanies into the mesentery, and divides into a number of secondary plexuses, which are distributed to all the parts supplied by the artery—viz. pancreatic branches to the pancreas; intestinal branches, which supply the whole of the small intestine; and ileo-colic, right colic, and middle colic branches, which supply the corresponding parts of the great intestine. The nerves composing this plexus are white in color and firm in texture, and have numerous ganglia developed upon them near their origin.

The **aortic plexus** is formed by branches derived, on each side, from the solar plexus and the semilunar ganglia, receiving filaments from some of the lumbar ganglia. It is situated upon the sides and front of the aorta, between the origins of the superior and inferior mesenteric arteries. From this plexus arise part of the spermatic, the inferior mesenteric, and the hypogastric plexuses; and it distributes filaments to the inferior vena cava.

The *inferior mesenteric plexus* is derived chiefly from the left side of the aortic plexus. It surrounds the inferior mesenteric artery, and divides into a number of secondary plexuses, which are distributed to all the parts supplied by the artery—viz. the left colic and sigmoid plexuses, which supply the descending and sigmoid flexure of the colon; and the superior hæmorrhoidal plexus, which supplies the upper part of the rectum and joins in the pelvis with branches from the pelvic plexus.

The Hypogastric Plexus.

The **Hypogastric Plexus** supplies the viscera of the pelvic cavity. It is situated in front of the promontory of the sacrum, between the two common iliac arteries, and is formed by the union of numerous filaments, which descend on each side from the aortic plexus and from the lumbar ganglia. This plexus contains no evident ganglia; it bifurcates, below, into two lateral portions, which form the *pelvic plexuses*.

The Pelvic Plexus.

The **pelvic plexus** (sometimes called *inferior hypogastric*) supplies the viscera of the pelvic cavity, is situated at the side of the rectum in the male, and at the side of the rectum and vagina in the female. It is formed by a continuation of the hypogastric plexus, by branches from the second, third, and fourth sacral nerves, and by a few filaments from the first two sacral ganglia. At the point of junction of these nerves small ganglia are found. From this plexus numerous branches are distributed to all the viscera of the pelvis. They accompany the branches of the internal iliac artery.

The **inferior hæmorrhoidal plexus** arises from the back part of the pelvic plexus. It supplies the rectum, joining with branches of the superior hæmorrhoidal plexus.

The **vesical plexus** arises from the fore part of the pelvic plexus. The nerves composing it are numerous, and contain a large proportion of spinal nerve-fibres. They accompany the vesical arteries, and are distributed at the side and base of the bladder. Numerous filaments also pass to the vesiculæ seminales and vas deferens; those accompanying the vas deferens join, on the spermatic cord, with branches from the spermatic plexus.

The **prostatic plexus** is continued from the lower part of the pelvic plexus. The nerves composing it are of large size. They are distributed to the prostate gland, vesiculæ seminales, and erectile structure of the penis. The nerves

supplying the erectile structure of the penis consist of two sets, the small and large cavernous nerves. They are slender filaments, which arise from the fore part of the prostatic plexus, and, after joining with branches from the internal pudic nerve, pass forward beneath the pubic arch.

The *small cavernous nerves* perforate the fibrous covering of the penis near its roots.

The *large cavernous nerve* passes forward along the dorsum of the penis, joins with the dorsal branch of the pudic nerve, and is distributed to the corpus cavernosum and spongiosum.

The **vaginal plexus** arises from the lower part of the pelvic plexus. It is lost on the walls of the vagina, being distributed to the erectile tissue at its anterior part and to the mucous membrane. The nerves composing this plexus contain, like the vesical, a large proportion of spinal nerve-fibres.

The **uterine plexus** arises from the upper part of the pelvic plexus above the point where the branches from the sacral nerves join the plexus. Its branches accompany the uterine arteries to the side of the organ between the layers of the broad ligament, and are distributed to the cervix and lower part of the body of the uterus, penetrating its substance.

Other filaments pass separately to the body of the uterus and Fallopian tube.

Branches from the plexus accompany the uterine arteries into the substance of the uterus. Upon these filaments ganglionic enlargements are found.

THE ORGANS OF SPECIAL SENSE.

THE Organs of the Senses are five in number, viz., those of Touch, of Taste, of Smell, of Hearing, and of Sight. The skin, which is the principal seat of the sense of touch, will be described in the section on General Anatomy. The remaining four are the Organs of Special Sense.

THE TONGUE.

The Tongue is the organ of the special sense of taste. It is situated in the floor of the mouth, in the interval between the two lateral portions of the body of the lower jaw.

Its base or root is directed backward, and connected with the os hyoides by the Hyo-glossi and Genio-hyo-glossi muscles and the hyo-glossal membrane; with the epiglottis by three folds (*glosso-epiglottic*) of mucous membrane; with the soft palate by means of the anterior pillars of the fauces; and with the pharynx by the Superior constrictors and the mucous membrane. Its apex or tip, thin and narrow, is directed forward against the inner surface of the lower incisor teeth. The under surface of the tongue is connected with the lower jaw by the Genio-hyo-glossi muscles; from its sides the mucous membrane is reflected to the inner surface of the gums; and from its under surface on to the floor of the mouth, where, in the middle line, it is elevated into a distinct vertical fold, the *frænum linguæ*. To the outer side of the frænum is a slight fold of the mucous membrane, the *plica fimbriata*, the free edge of which exhibits a series of fringe-like processes.

The tip of the tongue, part of the under surface, its sides, and dorsum are free.

The dorsum of the tongue is convex, marked along the middle line by a raphé, which divides it into symmetrical halves; this raphé terminates behind, about an inch from the base of the organ, in a depression, the *foramen cæcum*, from which a shallow groove, the *sulcus terminalis* of His, runs outward and forward on each side to the lateral margin of the tongue. The part of the dorsum of the tongue in front of this groove, forming about two-thirds of its upper surface, is rough and covered with papillæ; the posterior third is smoother, and contains numerous muciparous glands and lymphoid follicles.

Structure of the Tongue.—The tongue is partly invested by mucous membrane and a submucous fibrous layer. It consists of symmetrical halves, separated from each other, in the middle line, by a fibrous septum. Each half is composed of muscular fibres arranged in various directions (page 325), containing much interposed fat, and supplied by vessels and nerves.

The **mucous membrane** invests the entire extent of the free surface of the tongue. On the dorsum it is thicker behind than in front, and is continuous with the sheath of the muscles attached to it, through the submucous fibrous layer. On the under surface of the organ, where it is thin and smooth, it can be traced on each side of the frænum through the ducts of the submaxillary and the sublingual glands. As it passes over the borders of the organ it gradually assumes its papillary character.

The **structure of the mucous membrane of the tongue** differs in different parts. That covering the under surface of the organ is thin, smooth, and identical in

structure with that lining the rest of the oral cavity. The mucous membrane covering the tongue behind the foramen cæcum and sulcus terminalis is thick and freely movable over the subjacent parts. It contains a large number of lymphoid follicles, which together constitute what is sometimes termed the *lingual tonsil.* Each follicle forms a rounded eminence, the centre of which is perforated by a minute orifice leading into a funnel-shaped cavity or recess; around this recess are grouped numerous oval or rounded nodules of lymphoid tissue, each enveloped by a capsule derived from the submucosa, while opening into the bottom of the recesses are also seen the ducts of mucous glands. The mucous membrane on the anterior part of the dorsum of the tongue is thin and intimately adherent to the

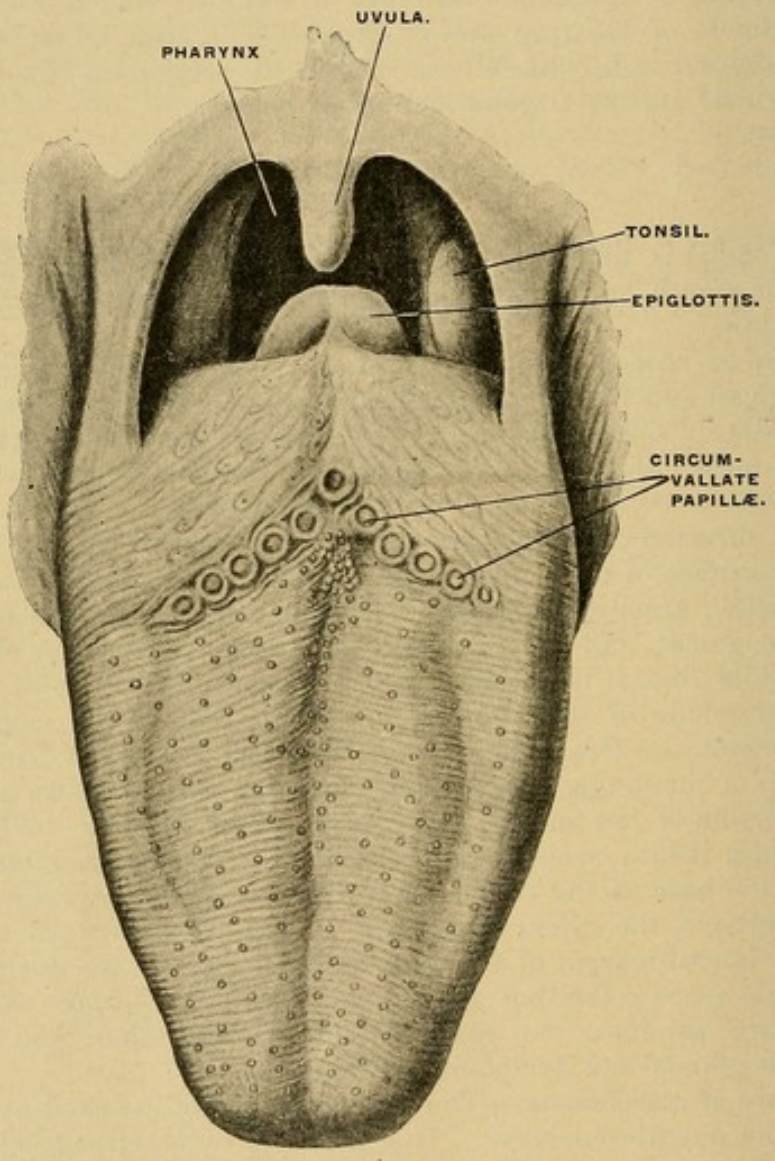

FIG. 428.—Upper surface of the tongue.

muscular tissue, and covered with minute eminences, the *papillæ* of the tongue. It consists of a layer of connective tissue, the *corium* or *mucosa*, supporting numerous papillæ, and covered, as well as the papillæ, with epithelium.

The epithelium is of the scaly variety, like that of the epidermis. It covers the free surface of the tongue, as may be easily demonstrated by maceration or boiling, when it can be easily detached entire: it is much thinner than on the skin: the intervals between the large papillæ are not filled up by it, but each papilla has a separate investment from root to summit. The deepest cells may sometimes be detached as a separate layer, corresponding to the rete mucosum, but they never contain coloring matter.

The *corium* consists of a dense feltwork of fibrous connective tissue, with numerous elastic fibres, firmly connected with the fibrous tissue forming the septa between the muscular bundles of the tongue. It contains the ramifications of the numerous vessels and nerves from which the papillæ are supplied, large plexuses of lymphatic vessels, and the glands of the tongue.

The Papillæ of the Tongue.—These are papillary projections of the corium. They are thickly distributed over the anterior two-thirds of its upper surface, giving to it its characteristic roughness. The varieties of papillæ met with are—the papillæ maximæ (*circumvallatæ*), papillæ mediæ (*fungiformes*), papillæ minimæ (*conicæ* or *filiformes*), and papillæ simplices.

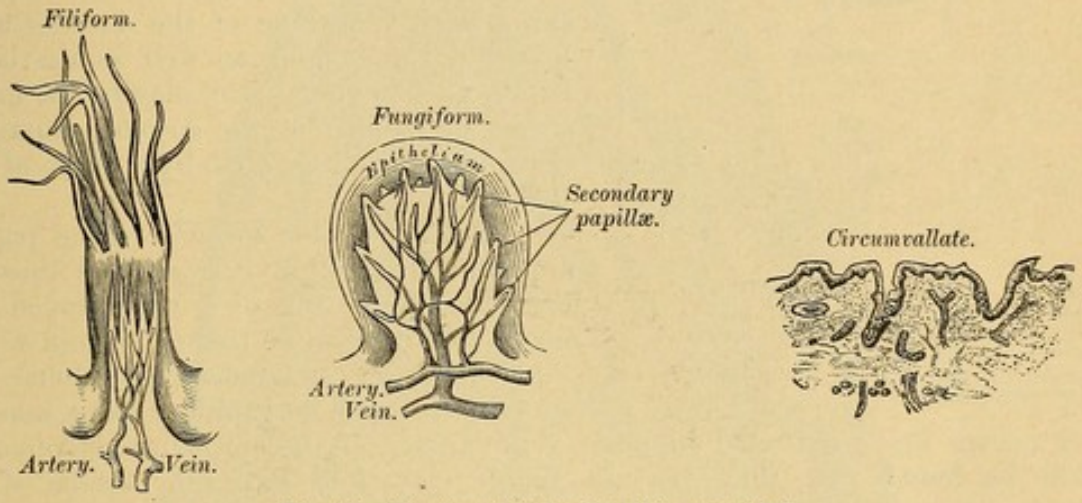

FIG. 429.—The three kinds of papillæ, magnified.

The *papillæ maximæ* (circumvallatæ) are of large size, and vary from eight to twelve in number. They are situated at the back part of the dorsum of the tongue, near its base, forming a row on each side, which, running backward and inward, meet in the middle line, like the two lines of the letter V inverted. Each papilla consists of a projection of mucous membrane from $\frac{1}{20}$ to $\frac{1}{12}$ of an inch wide, attached to the bottom of a cup-shaped depression of the mucous membrane; the papilla is in shape like a truncated cone, the smaller end being directed downward and attached to the tongue, the broader part or base projecting on the surface and being studded with numerous small secondary papillæ, which, however, are covered by a smooth layer of the epithelium. The cup-shaped depression forms a kind of fossa round the papilla, having a circular margin of about the same elevation covered with smaller papillæ.

Immediately behind the apex of the V is the foramen cæcum, mentioned above. This, according to His, represents the remains of the invagination which forms the median rudiment of the thyroid body, and for a time opens by a duct, the *thyroglossal duct*, on to the dorsum of the tongue. It may extend downward toward the hyoid bone. Kanthack, however, disputes this view.[1]

The *papillæ mediæ* (fungiformes), more numerous than the preceding, are scattered irregularly and sparingly over the dorsum of the tongue, but are found chiefly at its sides and apex. They are easily recognized among the other papillæ, by their large size, rounded eminences, and deep-red color. They are narrow at their attachment to the tongue, but broad and rounded at their free extremities, and covered with secondary papillæ. Their epithelial investment is very thin.

The *papillæ minimæ* (conicæ or filiformes) cover the anterior two-thirds of the dorsum of the tongue. They are very minute, more or less conical or filiform in shape, and arranged in lines corresponding in direction with the two rows of the papillæ circumvallatæ, excepting at the apex of the organ, where their direction

[1] *Journal of Anat. and Physiol.*, 1891.

is transverse. Projecting from their apices are numerous filiform processes or secondary papillæ; these are of a whitish tint, owing to the thickness and density of the epithelium of which they are composed, and which has here undergone a peculiar modification, the cells having become cornified and elongated into dense, imbricated, brush-like processes. They contain also a number of elastic fibres, which render them firmer and more elastic than the papillæ of mucous membrane generally.

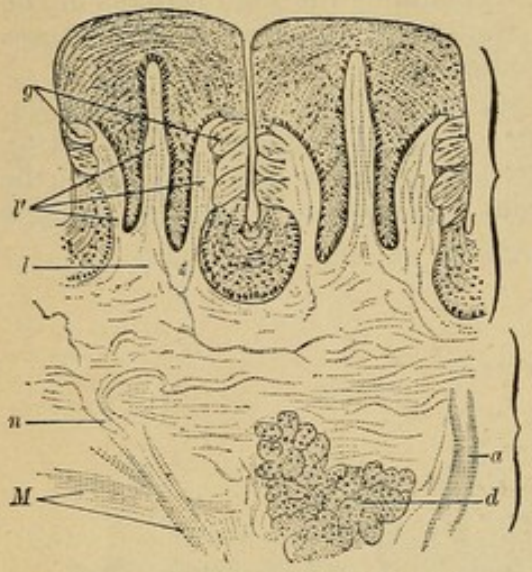

FIG. 430.—Circumvallate papillæ of tongue of rabbit, showing position of taste-goblets. (Stöhr.) *a*. Duct of gland. *d*. Serous gland. *g*. Taste-buds. *l*. Primary septa, and *l'*, secondary septa, of papillæ. *n*. Medullated nerve. *M*. Muscular fibres.

Simple papillæ, similar to those of the skin, cover the whole of the mucous membrane of the tongue, as well as the larger papillæ. They consist of closely set, microscopic elevations of the corium, containing a papillary loop, covered by a layer of epithelium.

Structure of the Papillæ.—The papillæ apparently resemble in structure those of the cutis, consisting of a cone-shaped projection of connective tissue, covered with a thick layer of squamous epithelium, and contain one or more capillary loops, amongst which nerves are distributed in great abundance. If the epithelium is removed, it will be found that they are not simple elevations like the papillæ of the skin, for the surface of each is studded with minute conical processes of the mucous membrane, which form secondary papillæ (Todd and Bowman). In the papillæ circumvallatæ the nerves are numerous and of large size; in the papillæ fungiformes they are also numerous, and terminate in a plexiform network, from which brush-like branches proceed; in the papillæ filiformes their mode of termination is uncertain. Buried in the epidermis of the papillæ circumvallatæ, and in some of the fungiformes, are certain peculiar bodies, called *taste-buds*.[1] They are flask-like in shape, their broad base resting on the corium, and their neck opening by an orifice, the *gustatory pore*, between the cells of the epithelium. They are formed by two kinds of cells; supporting cells and gustatory cells. The *supporting cells* are mostly arranged like the staves of a cask, and form an outer envelope for the bud. Some, however, are found in the interior of the bud between the gustatory cells. The *gustatory cells* occupy the central portion of the bud; they are spindle-shaped, and each possesses a large spherical nucleus near the middle of the cell. The peripheral end of the cell terminates at the gustatory pore in a fine, hair-like filament, the *gustatory hair*. The central process passes toward the deep extremity of the bud, and there ends in a single or bifurcated varicose filament, which was formerly supposed to be continuous with the terminal fibril of a nerve; the investigations of Lenhossék and others would seem to prove, however, that this is not so, but that the nerve-fibrils after losing their medullary sheaths enter the taste-bud, and terminate in a fine extremity between the gustatory cells. Other nerve-fibrils may be seen ramifying between the cortical cells and terminating in fine extremities; these, however, are believed to be nerves of ordinary sensation, and not gustatory.

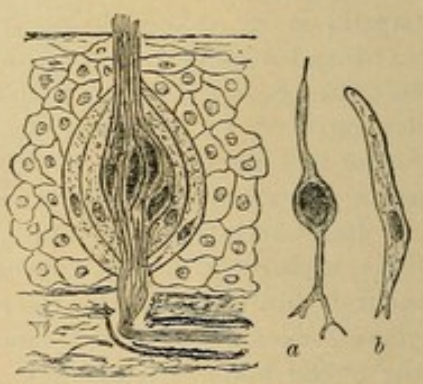

FIG. 431.—Taste-buds. *a*, Supporting cells. *b*. Gustatory cell.

[1] These bodies are also found in considerable numbers at the side of the base of the tongue, just in front of the anterior pillars of the fauces, and also on the posterior surface of the epiglottis and anterior surface of the soft palate.

Glands of the Tongue.—The tongue is provided with mucous and serous glands.

The *mucous glands* are similar in structure to the labial and buccal glands. They are found especially at the back part, behind the circumvallate papillæ, but are also present at the apex and marginal parts. In connection with these glands a special one has been described by Blandin or Nuhn. It is situated near the apex of the tongue on either side of the frænum, and is covered over by a

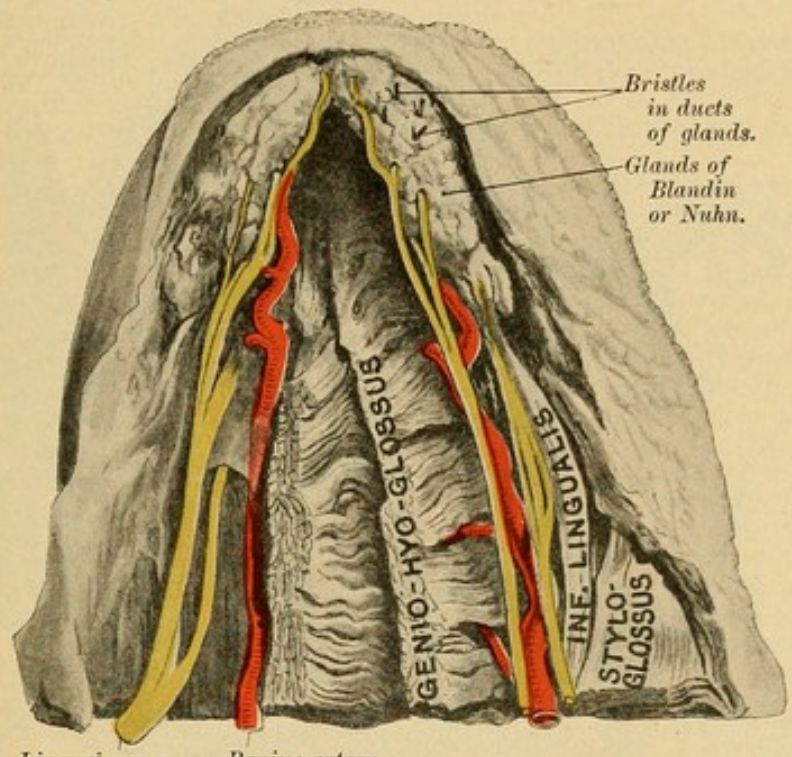

FIG. 432.—Under surface of tongue, showing position and relations of gland of Blandin or Nuhn. (From a preparation in the Museum of the Royal College of Surgeons of England.)

fasciculus of muscular fibre derived from the Stylo-glossus and Inferior lingualis. It is from half an inch to nearly an inch long and about the third of an inch broad. It has from four to six ducts, which open on the under surface of the apex.

The *serous glands* occur only at the back of the tongue in the neighborhood of the taste-buds, their ducts opening for the most part into the fossæ of the circumvallate papillæ. These glands are racemose, the duct branching into several minute ducts, which terminate in alveoli lined by a single layer of more or less columnar epithelium. Their secretion is of a watery nature, and probably assists in the distribution of the substance to be tasted over the taste-area (Ebner).

The *fibrous septum* consists of a vertical layer of fibrous tissue, extending throughout the entire length of the middle line of the tongue, from the base to the apex, though not quite reaching the dorsum. It is thicker behind than in front, and occasionally contains a small fibro-cartilage about a quarter of an inch in length. It is well displayed by making a vertical section across the organ.

The **Hyo-glossal membrane** is a strong fibrous lamina which connects the under surface of the base of the tongue to the body of the hyoid bone. This membrane receives, in front, some of the fibres of the Genio-hyo-glossi.

Vessels of the Tongue.—The *arteries of the tongue* are derived from the lingual, the facial, and ascending pharyngeal. The *veins* open into the internal jugular.

Muscles of the Tongue.—The muscular fibres of the tongue run in various directions. These fibres are divided into two sets, Extrinsic and Intrinsic, which have already been described (page 325).

The *lymphatic vessels from the tongue* pass to one or two small glands situated

on the Hyo-glossus muscle in the submaxillary region, and thence to the deep glands of the neck.

The *nerves of the tongue* are five in number in each half: the lingual branch of the fifth, which is distributed to the papillæ at the fore part and sides of the tongue, and forms the nerve of ordinary sensibility for its anterior two-thirds; the chorda tympani, which runs in the sheath of the lingual, is generally regarded as

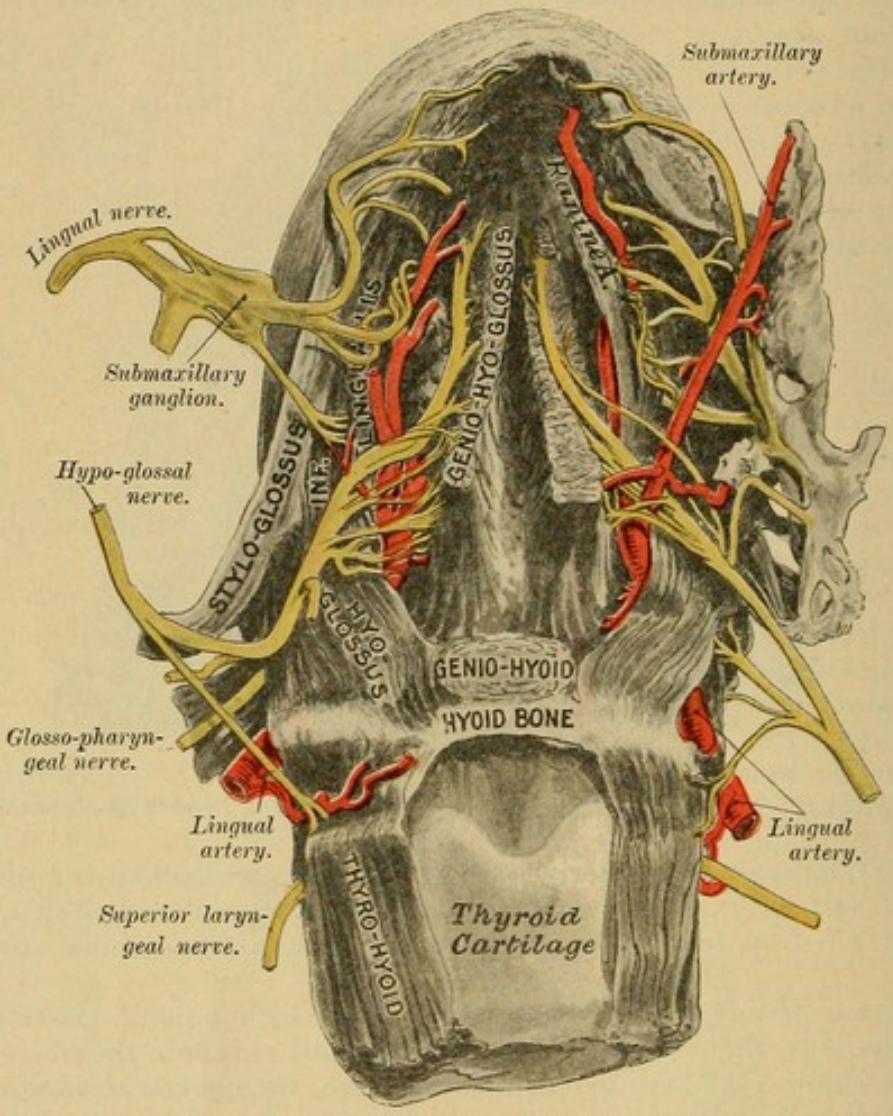

FIG. 433.—Under surface of tongue, showing the distribution of nerves to this organ. (From a preparation in the Museum of the Royal College of Surgeons of England.)

the nerve of taste for the same area; the lingual branch of the glosso-pharyngeal, which is distributed to the mucous membrane at the base and sides of the tongue, and to the papillæ circumvallatæ, and which supplies both sensory and gustatory filaments to this region; the hypo-glossal nerve, which is the motor nerve to the muscular substance of the tongue; and the superior laryngeal, which sends some fine branches to the root near to the epiglottis. Sympathetic filaments also pass to the tongue from the nervi molles on the lingual and other arteries supplying it.

Surgical Anatomy.—The diseases to which the tongue is liable are numerous, and its surgical anatomy of importance, since any or all the structures of which it is composed—muscles, connective tissue, mucous membrane, glands, vessels, nerves, and lymphatics—may be the seat of morbid changes. It is not often the seat of congenital defects, though a few cases of vertical cleft have been recorded, and it is occasionally, though much more rarely than is commonly supposed, the seat of "tongue-tie," from shortness of the frænum. (See page 489.)

There is, however, one condition which must be regarded as congenital, though it does not sometimes evidence itself until a year or two after birth, which is not uncommon. This is an enlargement of the tongue which is due primarily to a dilatation of the lymph-channels and a greatly increased development of the lymphatic tissue throughout the tongue. This is often

aggravated by inflammatory changes induced by injury or exposure, and the tongue may assume enormous dimensions and hang out of the mouth, giving the child an imbecile expression. The treatment consists in excising a V-shaped portion and bringing the cut surfaces together with deeply-placed silver sutures. Compression has been resorted to in some cases and with success, but it is difficult to apply. Acute inflammation of the tongue, which may be caused by injury and the introduction of some septic or irritating matter, is attended by great swelling from infiltration of its connective tissue, which is in considerable quantity. This renders the patient incapable of swallowing or speaking, and may seriously impede respiration. It may run on to suppuration and the formation of an acute abscess. Chronic abscess, which has been mistaken for cancer, may also occur in the substance of the tongue.

The mucous membrane of the tongue may become chronically inflamed, and presents different appearances in different stages of the disease, to which the terms leucoplakia, psoriasis, and ichthyosis have been given.

The tongue, being very vascular, is often the seat of nævoid growths, and these have a tendency to grow rapidly.

The tongue is frequently the seat of ulceration, which may arise from many causes, as from the irritation of jagged teeth, dyspepsia, tubercle, syphilis, and cancer. Of these the cancerous ulcer is the most important, and probably also the most common. The variety is the squamous epithelioma, which soon develops into an ulcer with an indurated base. It produces great pain, which speedily extends to all parts supplied with sensation by the fifth nerve, especially to the region of the ear. The pain in these cases is conducted to the ear and temporal region by the lingual nerve, and from it to the other branches of the inferior maxillary nerve, especially the auriculo-temporal. Possibly pain in the ear itself may be due to implication of the fibres of the glosso-pharyngeal nerve, which by its tympanic branch is conducted to the tympanic plexus.

Cancer of the tongue may necessitate removal of a part or the whole of the organ, and many different methods have been adopted for its excision. It may be removed from the mouth by the écraseur or the scissors. Probably the better method is by the scissors, usually known as Whitehead's method. The mouth is widely opened with a gag, the tongue transfixed with a stout silk ligature, by which to hold and make traction on it and the reflection of mucous membrane from the tongue to the jaw, and the insertion of the Genio-hyo-glossus first divided with a pair of curved blunt scissors. The Palato-glossus is also divided. The tongue can now be pulled well out of the mouth. The base of the tongue is cut through by a series of short snips, each bleeding vessel being dealt with as soon as divided, until the situation of the ranine artery is reached. The remaining undivided portion of tissue is to be seized with a pair of Wells's forceps, the tongue removed, and the vessel secured. In the event of the ranine artery being accidentally injured hæmorrhage can be at once controlled by passing two fingers over the dorsum of the tongue as far as the epiglottis and dragging the root of the tongue forcibly forward.

In cases where the disease is confined to one side of the tongue this operation may be modified by splitting the tongue down the centre and removing only the affected half. In cases where the submaxillary glands are involved Kocher's operation should be performed. He removes the tongue from the neck, having performed a preliminary tracheotomy, by an incision from near the lobule of the ear, down the anterior border of the Sterno-mastoid to the level of the great cornu of the hyoid bone, then forward to the body of the hyoid bone, and upward to near the symphysis of the jaw. The lingual artery is now secured, and by a careful dissection the submaxillary lymphatic glands and the tongue removed. Regnoli advocated the removal of the tongue by a semilunar incision in the submaxillary triangle along the line of the lower jaw, and a vertical incision from the centre of the semilunar one backward to the hyoid bone. Care must be taken not to carry the first incision too far backward, so as to wound the facial arteries. The tongue is thus reached through the floor of the mouth, pulled out through the external incision, and removed with the écraseur or knife. The great objection to this operation is that all the muscles which raise the hyoid bone and larynx are divided, and that therefore the movements of deglutition and respiration are interfered with.

Finally, where both sides of the floor of the mouth are involved in the disease, or where very free access is required on account of the extension backward of the disease to the pillars of the fauces and the tonsil, or where the lower jaw is involved, the operation recommended by Syme must be performed. This is done by an incision through the central line of the lip, across the chin, and down as far as the hyoid bone. The lower jaw is sawn through at the symphysis, and the two halves of the bone forcibly separated from each other. The mucous membrane is separated from the bone, and the Genio-hyo-glossi detached from the bone, and the Hyo-glossi divided. The tongue is then drawn forward and removed close to its attachment to the hyoid bone. Any glands which are enlarged can be removed, and if the bone is implicated in the disease, it can also be removed by freeing it from the soft parts externally and internally, and making a second section with the saw beyond the diseased part.

Formerly many surgeons before removing the tongue performed a preliminary tracheotomy: (1) to prevent blood entering the air-passages; and (2) to allow the patient to breathe through the tube and not inspire air which had passed over a sloughy wound, and which was loaded with septic organisms and likely to induce septic pneumonia. By the judicious use of iodoform this secondary evil may be obviated, and the preliminary tracheotomy is now usually dispensed with.

THE NOSE.

The nose is the peripheral organ of the sense of smell: by means of the peculiar properties of its nerves it protects the lungs from the inhalation of deleterious gases and assists the organ of taste in discriminating the properties of food.

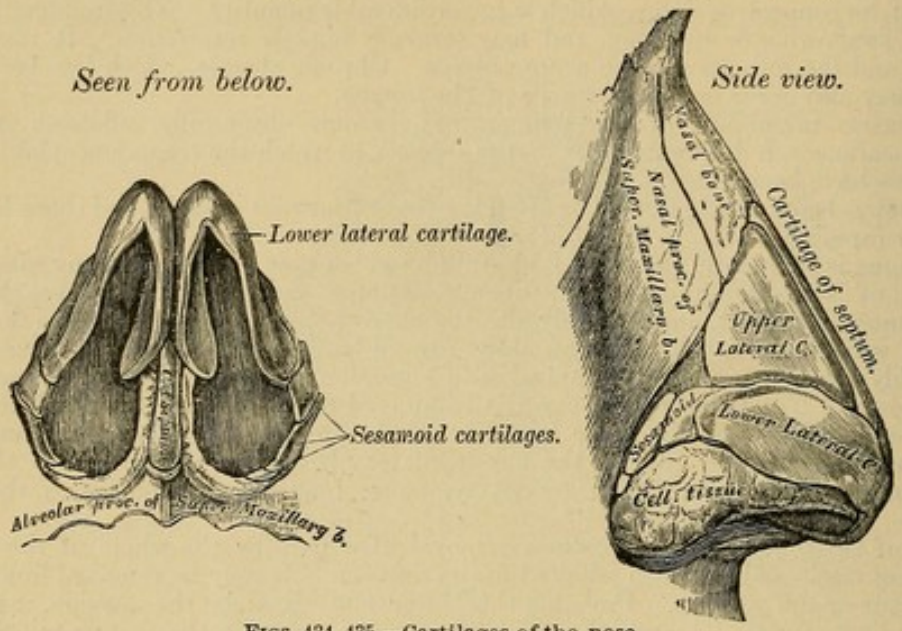

FIGS. 434, 435.—Cartilages of the nose.

The organ of smell consists of two parts: one external, the *outer nose;* the other internal, the *nasal fossæ.*

The *outer nose* (nasus externus) is the more anterior and prominent part of the organ of smell. Of a triangular form, it is directed downward, and projects from the centre of the face, immediately above the upper lip. Its summit, or *root*, is connected directly with the forehead. Its inferior part, or *base*, presents two elliptical orifices, the nostrils or anterior nares, separated from each other by an anteroposterior septum, the *columna.* The margins of these orifices are provided with a number of stiff hairs, or *vibrissæ*, which arrest the passage of foreign substances carried with the current of air intended for respiration. The lateral surfaces of the nose form, by their union in the middle line, the *dorsum*, the direction of which varies considerably in different individuals. The lateral surface terminates below in a rounded eminence, the *ala nasi.*

The nose is composed of a framework of bones and cartilages, the latter being slightly acted upon by certain muscles. It is covered externally by the integument, internally by mucous membrane, and supplied with vessels and nerves.

The *bony framework* occupies the upper part of the organ: it consists of the nasal bones and the nasal processes of the superior maxillary.

The *cartilaginous framework* consists of five pieces, the two upper and the two lower lateral cartilages and the cartilage of the septum.

The *upper lateral cartilages* are situated below the free margin of the nasal bones; each cartilage is flattened and triangular in shape. Its anterior margin is thicker than the posterior, and continuous with the cartilage of the septum. Its posterior margin is attached to the nasal process of the superior maxillary and nasal bones. Its inferior margin is connected by fibrous tissue with the lower lateral cartilage; one surface is turned outward, the other inward toward the nasal cavity.

The *lower lateral cartilages* are two thin, flexible plates situated immediately below the preceding, and bent upon themselves in such a manner as to form the inner and outer walls of each orifice of the nostril. The portion which forms the inner wall, thicker than the rest, is loosely connected with the same part of the opposite cartilage, and forms a small part of the columna. Its inferior border, free, rounded, and projecting, forms, with the thickened integument and subjacent tissue and the corresponding parts of the opposite side, the septum mobile

nasi. The part which forms the outer wall is curved to correspond with the ala of the nose; it is oval and flattened, narrow behind, where it is connected with the nasal process of the superior maxilla by a tough fibrous membrane, in which are found three or four small cartilaginous plates (sesamoid cartilages—*cartilagines minores*). Above, it is connected by fibrous tissue to the upper lateral cartilage and front part of the cartilage of the septum; below, it falls short of the margin of the nostril; the ala being formed by dense cellular tissue covered by skin. In front the lower lateral cartilages are separated by a notch which corresponds with the point of the nose.

The *cartilage of the septum* is somewhat quadrilateral in form, thicker at its margins than at its centre, and completes the separation between the nasal fossæ in front. Its anterior margin, thickest above, is connected with the nasal bones, and is continuous with the anterior margins of the two upper lateral cartilages. Below, it is connected to the inner portions of the lower lateral cartilages by fibrous tissue. Its posterior margin is connected with the perpendicular lamella of the ethmoid; its inferior margin with the vomer and the palate processes of the superior maxillary bones.

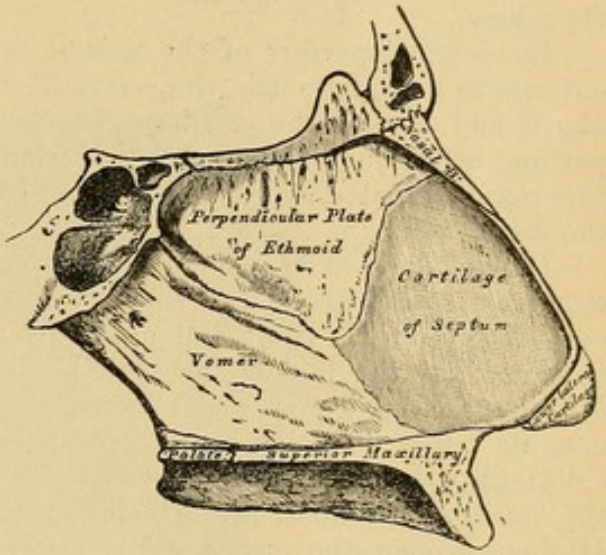

FIG. 436.—Bones and cartilages of septum of nose. Right side.

It may be prolonged backward (especially in children) for some distance between the vomer and perpendicular plate of the ethmoid, forming what is termed the *processus sphenoidalis*. The septal cartilage does not reach as far as the lowest part of the nasal septum. This is formed by the inner portions of the lower lateral cartilages and by the skin; it is freely movable, and hence is termed the *septum mobile nasi*.

These various cartilages are connected to each other and to the bones by a tough fibrous membrane, which allows the utmost facility of movement between them.

The *muscles of the nose* are situated beneath the integument: they are (on each side) the Pyramidalis nasi, the Levator labii superioris alæque nasi, the Dilatator naris, anterior and posterior, the Compressor nasi, the Compressor narium minor, and the depressor alæ nasi. They have been described above (page 306).

The *integument* covering the dorsum and sides of the nose is thin, and loosely connected with the subjacent parts: but where it forms the tip and the alæ of the nose it is thicker and more firmly adherent, and is furnished with a large number of sebaceous follicles, the orifices of which are usually very distinct.

The *mucous membrane* lining the interior of the nose is continuous with the skin externally and with that which lines the nasal fossæ within.

The *arteries of the nose* are the lateralis nasi from the facial, and the inferior artery of the septum from the superior coronary, which supply the alæ and septum, the sides and dorsum being supplied from the nasal branch of the ophthalmic and the infra-orbital.

The *veins of the nose* terminate in the facial and ophthalmic.

The *nerves* for the muscles of the nose are derived from the facial, while the skin receives its branches from the infra-orbital, infratrochlear, and nasal branches of the ophthalmic.

Nasal Fossæ.

The nasal fossæ are two irregular cavities situated in the middle of the face, and extending from before backward. They open in front by the two anterior nares, and terminate, behind, by the posterior nares in the naso-pharynx. The *anterior nares* are somewhat pear-shaped apertures, each measuring about one inch antero-posteriorly and half an inch transversely at their widest part. The *posterior nares* are two oval openings, which are smaller in the living or recent subject than in the skeleton, because they are narrowed by the mucous membrane. Each measures an inch in the vertical, and half an inch in the transverse direction in a well-developed adult skull.

For the description of the bony boundaries of the nasal fossæ see section on Osteology.

Inside the aperture of the nostril is a slight dilatation, the *vestibule*, which extends as a small pouch, the *ventricle*, toward the point of the nose. The fossa, above and behind the vestibule, has been divided into two parts: an *olfactory* portion, consisting of the upper and central part of the septum and probably the superior turbinated bone, and a *respiratory* portion, which comprises the rest of the fossa.

Outer Wall.—The sphenoidal air sinus opens into the *spheno-ethmoidal recess*, a narrow recess above the superior turbinated bone. The posterior ethmoidal cells open into the front and upper part of the superior meatus. On raising or cutting away the middle turbinated bone the outer wall of the middle meatus is fully exposed, and presents (1) a rounded elevation, termed the *bulla ethmoidalis*, opening on or immediately above which are the orifices of the middle ethmoidal cells; (2) a deep, narrow, curved groove, in front of the bulla ethmoidalis, termed the *hiatus semilunaris*, into which the anterior ethmoidal cells and the antrum of Highmore open, the orifice of the latter being placed near the level of its roof. The middle meatus is prolonged, above and in front, into the *infundibulum*, which leads into the frontal sinus. The anterior extremity of the meatus is continued into a depressed area, which lies above the vestibule and is named the *atrium*. The *nasal duct* opens into the anterior part of the inferior meatus, the opening being frequently overlapped by a fold of mucous membrane.

The inner wall or septum is frequently more or less deflected from the mesial plane, thus limiting the size of one fossa and increasing that of the other. Ridges or spurs of bone growing outward from the septum are also sometimes present. Immediately over the incisive foramen at the lower edge of the cartilage of the septum a depression, the *naso-palatine recess*, may be seen. In the septum close to this recess a minute orifice may be discerned: it leads into a blind pouch, the rudimentary *organ of Jacobson*, which is well developed in some of the lower animals, and is supported by a plate of cartilage, the *cartilage of Jacobson*.

The *mucous membrane* lining the nasal fossæ is called the *pituitary*, from the nature of its secretion; or *Schneiderian*, from Schneider, the first anatomist who showed that the secretion proceeded from the mucous membrane, and not, as was formerly imagined, from the brain. It is intimately adherent to the periosteum or perichondrium, over which it lies. It is continuous externally with the skin through the anterior nares, and with the mucous membrane of the naso-pharynx through the posterior nares. From the nasal fossæ its continuity may be traced with the conjunctiva through the nasal duct and lachrymal canals; with the lining membrane of the tympanum and mastoid cells through the Eustachian tube; and with the frontal, ethmoidal, and sphenoidal sinuses, and the antrum of Highmore through the several openings in the meatuses. The mucous membrane is thickest and most vascular over the turbinated bones. It is also thick over the septum, but in the intervals between the spongy bones and on the floor of the nasal fossæ it is very thin. Where it lines the various sinuses and the antrum of Highmore it is thin and pale.

Owing to the great thickness of this membrane, the nasal fossæ are much

narrower, and the turbinated bones, especially the lower ones, appear larger and more prominent than in the skeleton. From the same circumstance also the various apertures communicating with the meatuses are considerably narrowed or completely closed.

The vestibule is lined by modified skin, and contains hairs or vibrissæ which guard the entrance of the nostril.

Structure of the Mucous Membrane.—The epithelium covering the mucous membrane differs in its character according to the functions of the part of the nose in which it is found. In the respiratory portion of the nasal cavity the epithelium is columnar and ciliated. Interspersed among the columnar ciliated cells are goblet or mucin cells, while between their bases are found smaller pyramidal cells. In this region, beneath the epithelium and its basement membrane, is a fibrous

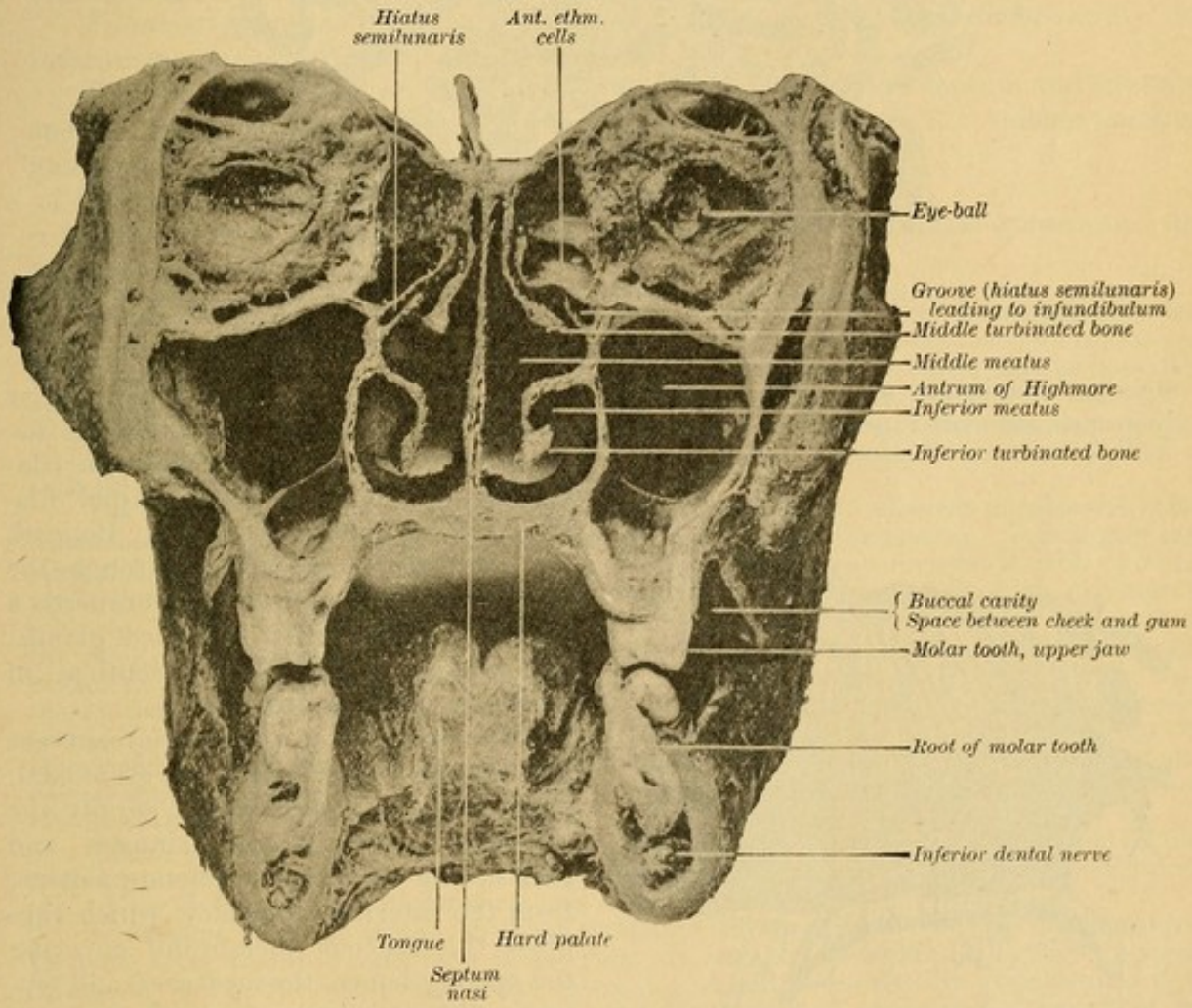

FIG. 437.—Transverse vertical section of the nasal fossæ. The section is made anterior to the superior turbinated bones. (Cryer.)

layer infiltrated with lymph-corpuscles, so as to form in many parts a diffuse adenoid tissue, and beneath this a nearly continuous layer of smaller and larger glands, some mucous and some serous, the ducts of which open upon the surface. In the olfactory region the mucous membrane is yellowish in color and the epithelial cells are columnar and non-ciliated; they are of two kinds, supporting cells and olfactory cells. The *supporting cells* contain oval nuclei, situated in the deeper parts of the cells: the free surface of each cell presents a sharp outline, and its deep extremity is prolonged into a process which runs inward, branching to communicate with similar processes from neighboring cells, so as to form a network in the deep part of the mucous membrane. Lying between these central processes of the supporting cells are a large number of spindle-shaped cells, the *olfactory cells*, which consist of a large spherical nucleus surrounded by a small

amount of granular protoplasm, and possessing two processes, of which one runs outward between the columnar epithelial cells, and projects on the surface of the



FIG. 438.—Section of the olfactory mucous membrane. (Cadiat.) *a*. Epithelium. *b*. Glands of Bowman. *c*. Nerve bundles.

mucous membrane as a fine, hair-like process, the *olfactory hair;* the other or deep process runs inward, is frequently beaded like a nerve-fibre, and is believed by most observers to be in connection with one of the terminal filaments of the olfactory nerve. Beneath the epithelium, extending through the thickness of the mucous membrane, is a layer of tubular, often branched, glands, the *glands of Bowman*, identical in structure with serous glands.

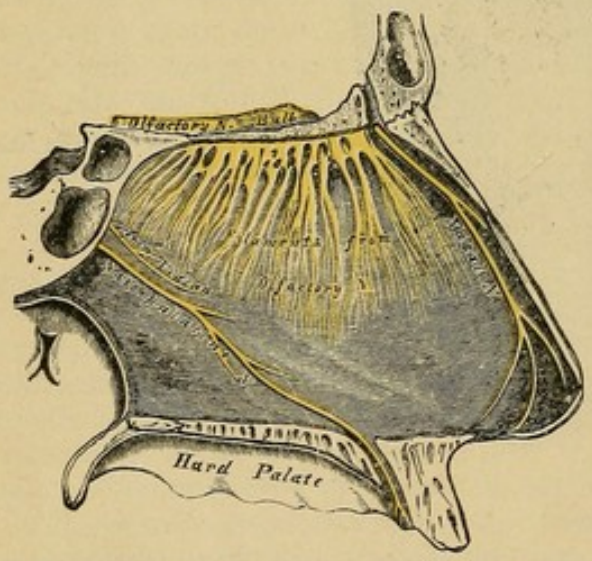

FIG. 439.—Nerves of septum of nose. Right side.

The *arteries of the nasal fossæ* are the anterior and posterior ethmoidal, from the ophthalmic, which supply the ethmoidal cells, frontal sinuses, and roof of the nose; the spheno-palatine, from the internal maxillary, which supplies the mucous membrane covering the spongy bones, the meatuses, and septum; the inferior artery of the septum, from the superior coronary of the facial; and the infraorbital and alveolar branches of the internal maxillary, which supply the lining membrane of the antrum. The ramifications of these vessels form a close, plexiform network, beneath and in the substance of the mucous membrane.

The *veins of the nasal fossæ* form a close, cavernous-like network beneath the mucous membrane. This cavernous appearance is especially well marked over the lower part of the septum and over the middle and inferior turbinated bones. Some of the veins pass, with those accompanying the spheno-palatine artery, through the spheno-palatine foramen; and others, through the alveolar branch, to join the facial vein; some accompany the ethmoidal arteries, and terminate in the ophthalmic vein; and, lastly, a few communicate with the veins in the interior of the

skull, through the foramina in the cribriform plate of the ethmoid bone, and the foramen cæcum.

The *lymphatics* can be injected from the subdural and subarachnoid spaces, and form a plexus in the superficial portion of the mucous membrane. The lymph is drained partly into one or two glands which lie near the great cornu of the hyoid bone and partly into a gland situated in front of the axis.

The *nerves* are: the olfactory, the nasal branch of the ophthalmic, filaments from the anterior dental branch of the superior maxillary, the Vidian, the naso-palatine, descending anterior palatine, and nasal branches of Meckel's ganglion.

The *olfactory*, the special nerve of the sense of smell, is distributed to the olfactory region, already referred to (page 820).

The *nasal branch of the ophthalmic* distributes filaments to the fore part of the septum and outer wall of the nasal fossæ.

Filaments from the anterior dental branch of the superior maxillary supply the inferior meatus and inferior turbinated bone.

The *Vidian nerve* supplies the upper and back part of the septum and superior spongy bone, and the *upper anterior nasal branches* from the spheno-palatine ganglion have a similar distribution.

The *naso-palatine nerve* supplies the middle of the septum.

The *larger* or *anterior palatine nerve* supplies the *lower nasal branches* to the middle and lower spongy bones.

Surgical Anatomy.—Instances of congenital deformity of the nose are occasionally met with, such as complete absence of the nose, an aperture only being present; or perfect development on one side, and suppression or malformation on the other; or there may be imperfect apposition of the nasal bones, so that the nose presents a median cleft or furrow. Deformities which have been acquired are much more common, such as flattening of the nose, the result of syphilitic necrosis, or imperfect development of the nasal bones in cases of congenital syphilis, or a lateral deviation of the nose may result from fracture.

The skin over the alæ and tip of the nose is thick and closely adherent to subjacent parts. Inflammation of this part is therefore very painful, on account of the tension. It is largely supplied with blood, and, the circulation here being terminal, vascular engorgement is liable to occur, especially in women at the menopause and in both sexes from disorders of digestion, exposure to cold, etc. The skin of the nose also contains a large number of sebaceous follicles, and these, as the result of intemperance, are apt to become affected and the nose reddened, congested, and irregularly swollen. To this the term "grog-blossom" is popularly applied. In some of these cases there is enormous hypertrophy of the skin and subcutaneous tissues, producing pendulous masses, termed lipomata nasi. Epithelioma and rodent ulcer may attack the nose, the latter being the more common of the two. Lupus and syphilitic ulceration frequently attack the nose, and may destroy the whole of the cartilaginous portion. In fact, lupus vulgaris begins more frequently on the ala of the nose than in any other situation.

Cases of congenital occlusion of one or both nostrils, or adhesion between the ala and septum may occur, and may require immediate operation, since the obstruction much interferes with sucking. Bony closure of the posterior nares may also occur.

To examine the nasal cavities, the head should be thrown back and the nose drawn upward, the parts being dilated by some form of speculum. It can also be examined with the little finger or a probe, and in this way foreign bodies detected. A still more extensive examination can be made by Rouge's operation, which was introduced for the cure of ozæna by the removal of any dead bone which may be present in this disease. The whole framework of the nose is lifted up by an incision made inside the mouth, through the junction of the upper lip with the bone; the septum nasi and the lateral cartilages are divided with strong scissors till the anterior nares are completely exposed. The posterior nares can be explored by reflected light from the mouth, by which the posterior nares can be illuminated. The examination is very difficult to carry out, and, as a rule, sufficient information regarding the presence of foreign bodies or tumors in the naso-pharynx can be obtained by the introduction of the finger behind the soft palate through the mouth. The septum of the nose may be displaced or deviate from the middle line: this may be the result of an injury or from some congenital defect in its development; in the latter case the deviation usually occurs along the line of union of the vomer and mesethmoid, and rarely occurs before the seventh year. Sometimes the deviation may be so great that the septum may come in contact with the outer wall of the nasal fossæ, and may even become adherent to it, thus producing complete obstruction. Perforation of the septum is not an uncommon affection and may arise from several causes: syphilitic or tubercular ulceration, blood-tumor or abscess of the septum, and especially in workmen exposed to the vapor of bichromate of potash, from the irritating and corrosive action of fumes. When small, the perforation may cause a peculiar whistling sound during respiration. When large, it may lead to the falling in of the bridge of the nose.

Epistaxis is a very common affection in children. It is rarely of much consequence, and will almost always subside, but in the more violent hæmorrhages of later life it may be necessary to plug the posterior nares. In performing this operation it is desirable to remember the size of the posterior nares. A ready method of regulating the size of the plug to fit the opening is to make it of the same size as the terminal phalanx of the thumb of the patient to be operated on.

Nasal polypus is a very common disease, and presents itself in three forms: the gelatinous, the fibrous, and the malignant. The first is by far the most common. It grows from the mucous membrane of the outer wall of the nasal fossa, where there is an abundant layer of highly vascular submucous tissue; rarely from the septum, where the mucous membrane is closely adherent to the cartilage and bone, without the intervention of much, if any, submucous tissue. Their most common seat is probably the middle turbinated bone. The fibrous polypus generally grows from the base of the skull behind the posterior nares or from the roof of the nasal fossæ. The malignant polypi, both sarcomatous or carcinomatous, may arise in the nasal cavities and the naso-pharynx; or they may originate in the antrum, and protrude through its inner wall into the nasal fossa.

Rhinoliths, or nose-stones, may sometimes be found in the nasal cavities, from the formation of phosphate of lime upon either a foreign body or a piece of inspissated secretion.

THE EYE.

The eyeball is contained in the cavity of the orbit. In this situation it is securely protected from injury, whilst its position is such as to ensure the most extensive range of sight. It is acted upon by numerous muscles, by which it is capable of being directed to different parts; it is supplied by vessels and nerves, and is additionally protected in front by several appendages, such as the eyebrow, eyelids, etc.

The eyeball is imbedded in the fat of the orbit, but is surrounded by a thin membranous sac, the *capsule of Tenon*, which isolates it, so as to allow of free movement.

The **capsule of Tenon** consists of a thin membrane which envelops the eyeball from the optic nerve to the ciliary region, separating it from the orbital fat and forming a socket in which it plays. Its inner surface is smooth, and is in contact with the outer surface of the sclerotic, the *perisclerotic lymph-space* only intervening. This lymph-space is continuous with the subdural and subarachnoid spaces, and is traversed by delicate bands of connective tissue which extend between the capsule and the sclerotic. The capsule is perforated behind by the ciliary vessels and nerves and by the optic nerve, being continuous with the sheath of the latter. In front it blends with the ocular conjunctiva, and with it is attached to the ciliary region of the eyeball. It is perforated by the muscles which move the eyeball and on each it sends a tubular sheath. The sheath of the Superior oblique is carried as far as the fibrous pulley of that muscle; that on the Inferior oblique reaches as far as the floor of the orbit, to which it gives off a slip. The sheaths on the recti are gradually lost in the perimysium, but they give off important expansions. The expansion from the Superior rectus blends with the tendon of the Levator palpebræ; that of the Inferior rectus is attached to the inferior tarsal plate. These two recti, therefore, will exercise some influence on the movements of the eyelids. The expansions from the sheaths of the Internal and External recti are strong, especially the one from the latter muscle, and are attached to the lachrymal and malar bones respectively. As they probably check the action of these two recti, they have been named the *internal* and *external check ligaments*.

Lockwood has also described a thickening of the lower part of the capsule of Tenon, which he has named the *suspensory ligament of the eye*. It is slung like a hammock below the eyeball, being expanded in the centre and narrow at its extremities, which are attached to the malar and lachrymal bones respectively.[1]

The eyeball is composed of segments of two spheres of different sizes. The anterior segment is one of a small sphere, and forms about one-sixth of the eyeball. It is more prominent than the posterior segment, which is one of a much larger sphere, and forms about five-sixths of the globe. The segment of the larger sphere

[1] See a paper by C. B. Lockwood, *Journal of Anatomy and Physiology*, vol. xx., part i., p. 1.

is opaque, and formed by the sclerotic, the tunic of protection to the eyeball; the smaller sphere is transparent, and formed by the cornea. The term *anterior pole* is applied to the central point of the anterior curvature of the eyeball, and that of *posterior pole* to the central point of its posterior curvature; a line joining the two poles forms its *sagittal axis*. The axes of the eyeballs are nearly parallel, and therefore do not correspond to the axes of the orbits, which are directed outward. The optic nerves follow the direction of the axes of the orbits, and are therefore not parallel; each enters its eyeball about 1 mm. below and 3 mm. to the inner or nasal side of the posterior pole. The eyeball measures rather more in its transverse and antero-posterior diameters than in its vertical diameter, the former amounting to nearly an inch, the latter to about nine-tenths of an inch.

The eyeball is composed of three investing tunics and of three refracting media.

TUNICS OF THE EYE.

From without inward the three tunics are:

1. Sclerotic and Cornea.
2. Choroid, Ciliary Body, and Iris.
3. Retina.

I. The Sclerotic and Cornea.

The sclerotic and cornea (Fig. 440) form the external tunic of the eyeball; they are essentially fibrous in structure, the sclerotic being opaque, and forming the posterior five-sixths of the globe; the cornea, which forms the remaining sixth, being transparent.

The **Sclerotic** (*σκληρός, hard*) has received its name from its extreme density and hardness; it is a firm, unyielding, fibrous membrane, serving to maintain the form of the globe. It is much thicker behind than in front. Its *external surface* is of a white color, and is in contact with the inner surface of the capsule of Tenon; it is quite smooth, except at the points where the Recti and Obliqui muscles are inserted into it, and its anterior part is covered by the conjunctival membrane: hence the whiteness and brilliancy of the front of the eyeball. Its *inner surface* is stained of a brown color, marked by grooves, in which are lodged the ciliary nerves and vessels; this is loosely connected by an exceedingly fine cellular tissue (*lamina fusca*) with the outer surface of the choroid, an extensive lymph-space (*perichoroidal*) intervening between the sclerotic and choroid. Behind it is pierced by the optic nerve, and is continuous with its fibrous sheath, which is derived from the dura mater. At the point where the optic nerve passes through the sclerotic, this tunic forms a thin cribriform lamina (the *lamina cribrosa*); the minute orifices in this region serve for the transmission of the nervous filaments, and the fibrous septa dividing them from one another are continuous with the membranous processes which separate the bundles of nerve-fibres. One of these openings, larger than the rest, occupies the centre of the lamella; it transmits the arteria centralis retinæ to the interior of the eyeball. Around the cribriform lamella are numerous small apertures for the transmission of the ciliary vessels and nerves, and about midway between the margin of the cornea and the entrance of the optic nerve are four or five large apertures, for the transmission of veins (*venæ vorticosæ*). In front, the fibrous tissue of the sclerotic is directly continuous with that of the cornea by direct continuity of tissue, but the opaque sclerotic slightly overlaps the outer surface of the transparent cornea.

Structure.—The sclerotic is formed of white fibrous tissue intermixed with fine elastic fibres, and of flattened connective-tissue corpuscles, some of which are pigmented, contained in cell-spaces between the fibres. These fibres are aggregated into bundles, which are arranged chiefly in a longitudinal direction. It yields gelatin on boiling. Its vessels are not numerous, the capillaries being of small size, uniting at long and wide intervals. Its nerves are derived from the ciliary nerves, but their exact mode of ending is not known.

The **Cornea** is the projecting transparent part of the external tunic of the eyeball, and forms the anterior sixth of the globe. It is almost circular in shape, occasionally a little broader in the transverse than in the vertical direction. It is convex anteriorly, and projects forward from the sclerotic in the same manner that a watch-glass does from its case. Its degree of curvature varies in different individuals, and in the same individual at different periods of life, it being more prominent in youth than in advanced life, when it becomes flattened. The cornea is dense and of uniform thickness throughout; its posterior surface is perfectly circular in outline, and exceeds the anterior surface slightly in extent, from the latter being overlapped by the sclerotic.

Structure.—The cornea consists of four layers—namely, (1) several strata of epithelial cells, continuous with those of the conjunctiva; (2) a thick central

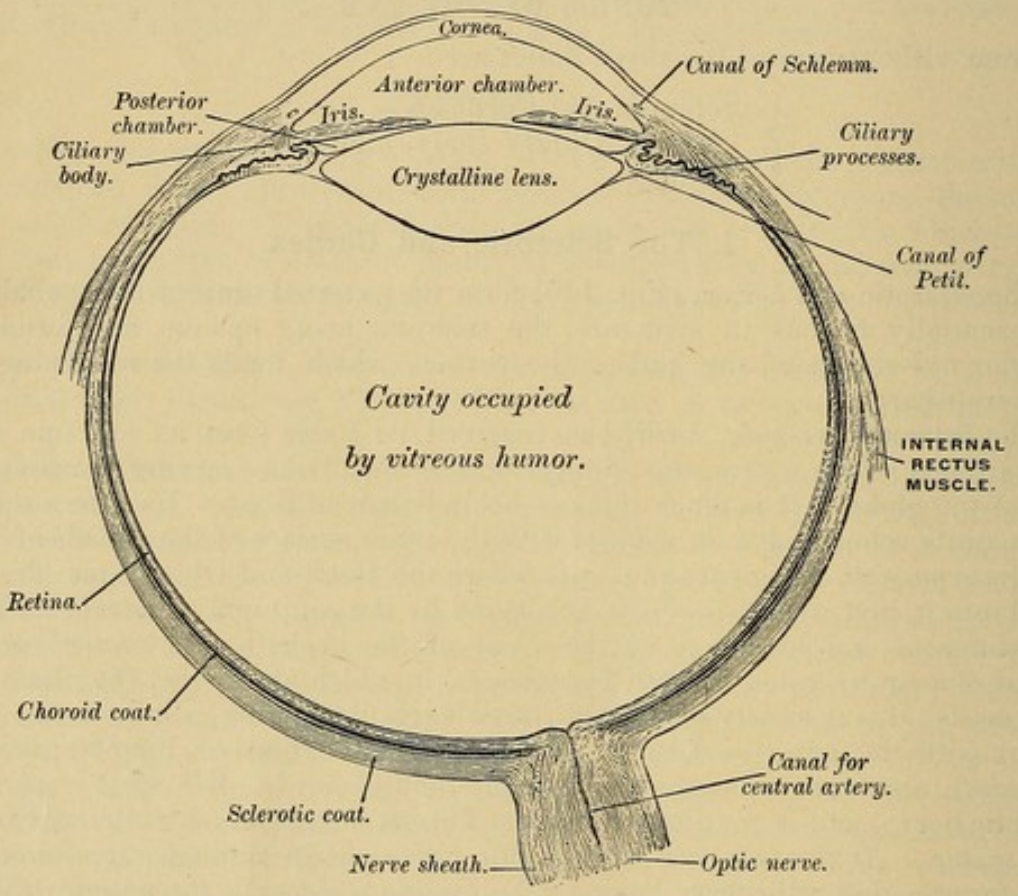

FIG. 440.—A horizontal section of the eyeball. (Allen.)

fibrous structure, the *substantia propria;* (3) a homogeneous elastic lamina; and (4) a single layer of endothelial cells forming part of the lining membrane of the anterior chamber of the eyeball.

The *conjunctival epithelium*, which covers the front of the cornea proper, consists of several strata of epithelial cells. The deepest layers are columnar: then follow two or three layers of polyhedral cells, the majority of which present finger-like processes (*i. e.*, prickle-cells), similar to those found in the cuticle. Lastly, there are three or four layers of scaly epithelium with flattened nuclei.

The *proper substance of the cornea* is fibrous, tough, unyielding, perfectly transparent, and continuous with the sclerotic. It is composed of about sixty flattened lamellæ, superimposed one on another. These lamellæ are made up of bundles of modified connective tissue, the fibres of which are directly continuous with the fibres of the sclerotic. The fibres of each lamella are for the most part parallel with each other; those of alternating lamellæ at right angles to each other. Fibres, however, frequently pass from one lamella to the next.

The lamellæ are connected with each other by an interstitial cement-substance,

in which are spaces, the *corneal spaces*. The spaces are stellate in shape, and have numerous offsets by which they communicate with each other. Each contains a cell, the *corneal corpuscle*, which resembles in form the space in which it is lodged, but it does not entirely fill it.

Immediately beneath the conjunctival epithelium the cornea proper presents certain characteristics which have led some anatomists to regard it as a distinct membrane, and it has been named by Bowman the *anterior elastic lamina*. It differs, however, from the true elastic lamina or membrane of Descemet in many essential particulars, presenting evidence of fibrillar structure, and not having the same tendency to curl inward or to undergo fracture when detached from the other layers of the cornea. It consists of extremely closely interwoven fibrils, similar to those found in the rest of the cornea proper, but contains no corneal corpuscles. It ought, therefore, to be regarded as a part of the proper tissue of the cornea.[1]

The *posterior elastic lamina* (*membrane of Descemet or Demours*), which covers the proper structure of the cornea behind, presents no structure recognizable under the microscope. It consists of an elastic, and perfectly transparent homogeneous membrane, of extreme thinness, which is not rendered opaque by either water, alcohol, or acids. It is very brittle, but its most remarkable property is its extreme elasticity, and the tendency which it presents to curl up, or roll upon itself, with the attached surface innermost, when separated from the proper substance of the cornea. Its use appears to be (as suggested by Dr. Jacob) "to preserve the requisite permanent correct curvature of the flaccid cornea proper."

At the margin of the cornea this posterior elastic membrane breaks up into fibres to form a reticular structure at the outer angle of the anterior chamber, the intervals between the fibres forming small cavernous spaces, the *spaces of Fontana*. These little recesses communicate with a circular canal in the substance of the sclerotic close to its junction with the cornea. This is the *canal of Schlemm*, or *sinus venosus sclerœ;* it communicates internally with the anterior chamber through the spaces of Fontana, and externally with the scleral veins. Some of the fibres of this reticulated structure are continued into the front of the iris, forming the *ligamentum pectinatum iridis;* while others are connected with the fore part of the sclerotic and choroid.

The *endothelial lining of the aqueous chamber* covers the posterior surface of the elastic lamina, is reflected on to the front of the iris, and also lines the spaces of Fontana. It consists of a single layer of polygonal flattened transparent nucleated cells, similar to those lining other serous cavities.

Arteries and Nerves.—The cornea is a non-vascular structure, the capillary vessels terminating in loops at its circumference. Lymphatic vessels have not as yet been demonstrated in it, but are represented by the channels in which the bundles of nerves run; these are lined by an endothelium and are continuous with the cell-spaces. The nerves are numerous, twenty-four to thirty-six in number (Kölliker), forty to forty-five (Waldeyer and Sümisch); they are derived from the ciliary nerves and enter the laminated tissue of the cornea. They ramify throughout its substance in a delicate network, and their terminal filaments form a firm and closer plexus on the surface of the cornea proper beneath the epithelium. This is termed the *subepithelial plexus*, and from it fibrils are given off which ramify between the epithelial cells, forming a network which is termed the *intra-epithelial plexus*.

Dissection.—In order to separate the sclerotic and cornea, so as to expose the second tunic, the eyeball should be immersed in a small vessel of water and held between the finger and thumb. The sclerotic is then carefully incised, in the equator of the globe, till the choroid is exposed. One blade of a pair of probe-pointed scissors is now introduced through the opening thus made, and the sclerotic divided around its entire circumference, and removed in separate portions. The front segment being then drawn forward, the handle of the scalpel should be pressed gently against it at its connection with the iris, and, these being separated, a quantity

[1] This layer has been called by Reichert the "anterior limiting layer"—a name which appears more applicable to it than that of "anterior elastic lamina."

of perfectly transparent fluid will escape; this is the aqueous humor. In the course of the dissection the ciliary nerves may be seen lying in the loose cellular tissue between the choroid and sclerotic or continued in delicate grooves on the inner surface of the latter membrane.

II. The Choroid, Ciliary Body, and Iris.

The Second Tunic of the Eye (*tunica vasculosa oculi*) is formed from behind forward by the choroid, the ciliary body, and the iris.

The choroid is the vascular and pigmentary tunic of the eyeball, investing the posterior five-sixths of the globe, and extending as far forward as the ora serrata of the retina; the ciliary body connects the choroid to the circumference of the iris. The iris is the circular muscular septum, which hangs vertically behind the cornea, presenting in its centre a large rounded aperture, the *pupil*.

The **Choroid** is a thin, highly vascular membrane, of a dark-brown or chocolate color, which invests the posterior five-sixths of the globe, and is pierced behind by the optic nerve, and in this situation is firmly adherent to the sclerotic. It is thicker behind than in front. Externally, it is loosely connected by the lamina fusca with the inner surface of the sclerotic. Its inner surface is attached to the retina.

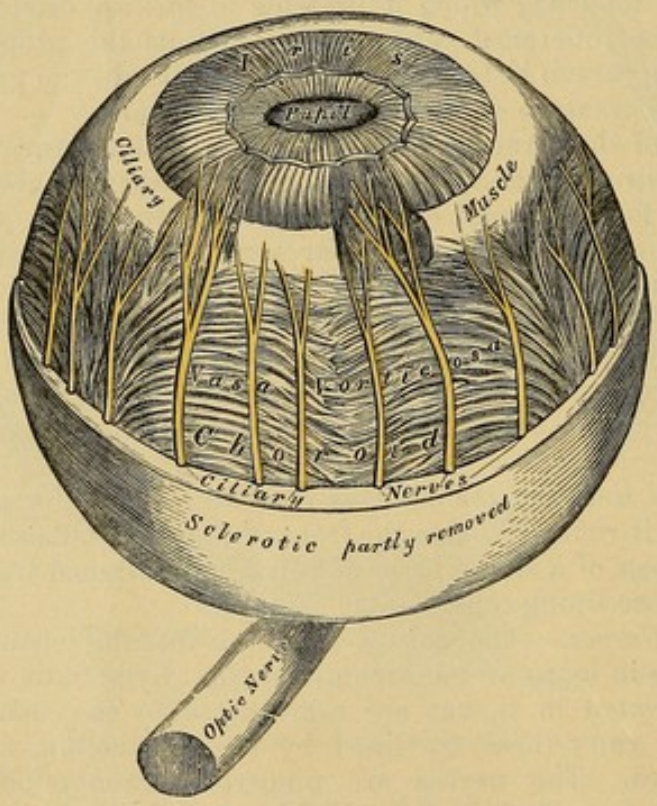

FIG. 441.—The choroid and iris. (Enlarged.)

Structure.—The choroid consists mainly of a dense capillary plexus and of small arteries and veins, carrying the blood to and returning it from this plexus. On its external surface—*i. e.*, the surface next the sclerotic—is a thin membrane, the *lamina superchoroidea*, composed of delicate non-vascular lamellæ, each lamella consisting of a network of fine elastic fibres, among which are branched pigment-cells. The spaces between the lamellæ are lined by endothelium, and open freely into the perichoroidal lymph-space, which, in its turn, communicates with the perisclerotic space by the perforations in the sclerotic through which the vessels and nerves are transmitted.

Internal to this is the *choroid proper*, and, in consequence of the small arteries and veins being arranged on the outer surface of the capillary network, it is customary to describe this as consisting of two layers: the outermost, composed of small arteries and veins, with pigment-cells interspersed between them, and the inner, consisting of a capillary plexus. The *external layer* or *lamina vasculosa*

consists, in part, of the larger branches of the short ciliary arteries which run forward between the veins, before they bend inward to terminate in the capillaries; but is formed principally of veins, which are named, from their arrangement, *venæ vorticosa*. They converge to four or five equidistant trunks, which pierce the sclerotic midway between the margin of the cornea and the entrance of the optic nerve. Interspersed between the vessels are dark star-shaped pigment-cells, the offsets from which, communicating with similar branchings from neighboring cells, form a delicate network or stroma, which toward the inner surface of the choroid loses its pigmentary character. The *internal layer* consists of an exceedingly fine capillary plexus, formed by the short ciliary vessels, and is known as the *lamina chorio-capillaris* or *tunica Ruyschiana*. The network is close, and finer at the hinder part of the choroid than in front. About half an inch behind the cornea its meshes become larger, and are continuous with those of the ciliary processes.

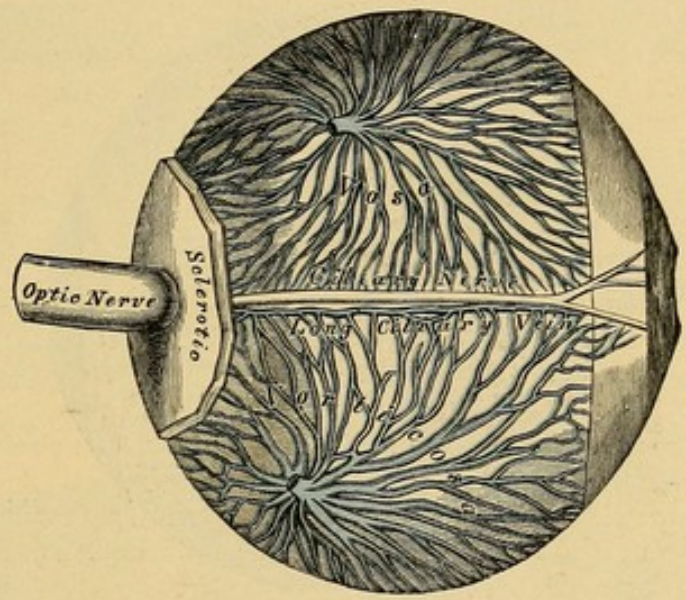

FIG. 442.—The veins of the choroid. (Enlarged.)

These two laminæ are connected by an *intermediate stratum*, which is destitute of pigment-cells and consists of fine elastic fibres. On the inner surface of the lamina chorio-capillaris is a very thin, structureless, or, according to Kölliker, faintly fibrous membrane, called the *lamina basalis* or membrane of Bruch; it is closely connected with the stroma of the choroid, and separates it from the pigmentary layer of the retina.

Tapetum.—This name is applied to the iridescent appearance which is seen in the outer and posterior part of the choroid of many animals.

The ciliary body should now be examined. It may be exposed, either by detaching the iris from its connection with the Ciliary muscle, or by making a transverse section of the globe, and examining it from behind.

The **ciliary body** comprises the orbiculus ciliaris, the ciliary processes, and the Ciliary muscle.

The *orbiculus ciliaris* is a zone of about one-sixth of an inch in width, directly continuous with the anterior part of the choroid; it presents numerous ridges arranged in a radial manner.

The *ciliary processes* are formed by the plaiting and folding inward of the various layers of the choroid—*i. e.*, the choroid proper and the lamina basalis—at its anterior margin, and are received between corresponding foldings of the suspensory ligament of the lens, thus establishing a connection between the choroid and inner tunic of the eye. They are arranged in a circle, and form a sort of plaited frill behind the iris, round the margin of the lens. They vary between sixty and eighty in number, lie side by side, and may be divided into large and small; the latter, consisting of about one-third of the entire number, are situated in the spaces

between the former, but without regular alternation. The larger processes are each about one-tenth of an inch in length, and are attached by their periphery to three or four of the ridges of the orbiculus ciliaris, and are continuous with the layers of the choroid: the opposite margin is free, and rests upon the circumference of the lens. Their anterior surface is turned toward the back of the iris, with the circumference of which they are continuous. The posterior surface is connected with the suspensory ligament of the lens.

Structure.—The ciliary processes are similar in structure to the choroid, but the vessels are larger, and have chiefly a longitudinal direction. They are covered on their inner surface by two strata of black pigment-cells, which are continued forward from the retina, and are named the *pars ciliaris retinæ*. In the stroma of the ciliary processes there are also stellate pigment-cells, which, however, are not so numerous as in the choroid itself.

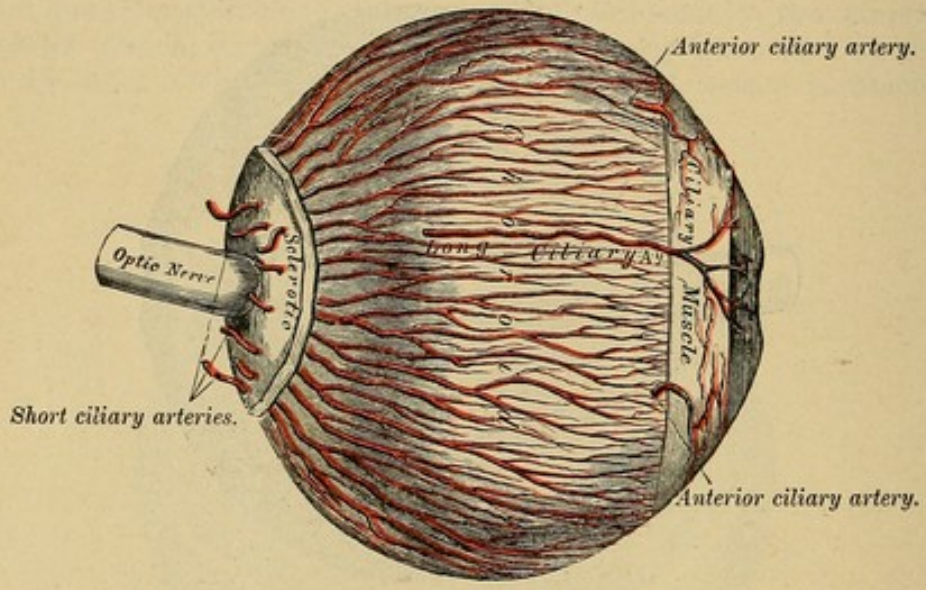

FIG. 443.—The arteries of the choroid and iris. The sclerotic has been mostly removed. (Enlarged.)

The *Ciliary muscle* (Bowman) consists of unstriped fibres: it forms a grayish, semitransparent, circular band, about one-eighth of an inch broad, on the outer surface of the fore part of the choroid. It is thickest in front, and gradually becomes thinner behind. It consists of two sets of fibres, radiating and circular. The former, much the more numerous, arise at the point of junction of the cornea and sclerotic, and partly also from the ligamentum pectinatum iridis, and, passing backward, are attached to the choroid opposite to the ciliary processes. One bundle, according to Waldeyer, is continued backward to be inserted into the sclerotic. The circular fibres are internal to the radiating ones and to some extent unconnected with them, and have a circular course around the attachment of the iris. They are sometimes called the "ring muscle" of Müller, and were formerly described as the ciliary ligament. They are well developed in hypermetropic, but are rudimentary or absent in myopic eyes. The Ciliary muscle is admitted to be the chief agent in accommodation,—*i. e.*, in adjusting the eye to the vision of near objects. Bowman believed that this was effected by its compressing the vitreous body, and so causing the lens to advance; but the view which now prevails is that the contraction of the muscle, by drawing on the ciliary processes, relaxes the suspensory ligament of the lens, thus allowing the anterior surface of the lens to become more convex. The pupil is at the same time slightly contracted.[1]

The **Iris** (*iris*, a rainbow) has received its name from its various colors in different individuals. It is a thin, circular-shaped, contractile curtain, suspended in

[1] See explanation and diagram in Power's *Illustrations of some of the Principal Diseases of the Eye*, p. 590.

the aqueous humor behind the cornea, and in front of the lens, being perforated a little to the nasal side of its centre by a circular aperture, the *pupil*, for the transmission of light. By its circumference it is continuous with the ciliary body, and is also connected with the posterior elastic lamina of the cornea by means of the pectinate ligament; its inner or free edge forms the margin of the pupil; its surfaces are flattened, and look forward and backward, the anterior toward the cornea, the posterior toward the ciliary processes and lens. The anterior surface of the iris is variously colored in different individuals, and marked by lines which converge toward the pupil. The posterior surface is of a deep purple tint, from being covered by two layers of pigmented, columnar epithelium, which are continuous posteriorly with the pars ciliaris retinæ. This pigmented epithelium is termed the *pars iridica retinæ*, though it is sometimes named *uvea*, from its resemblance in color to a ripe grape.

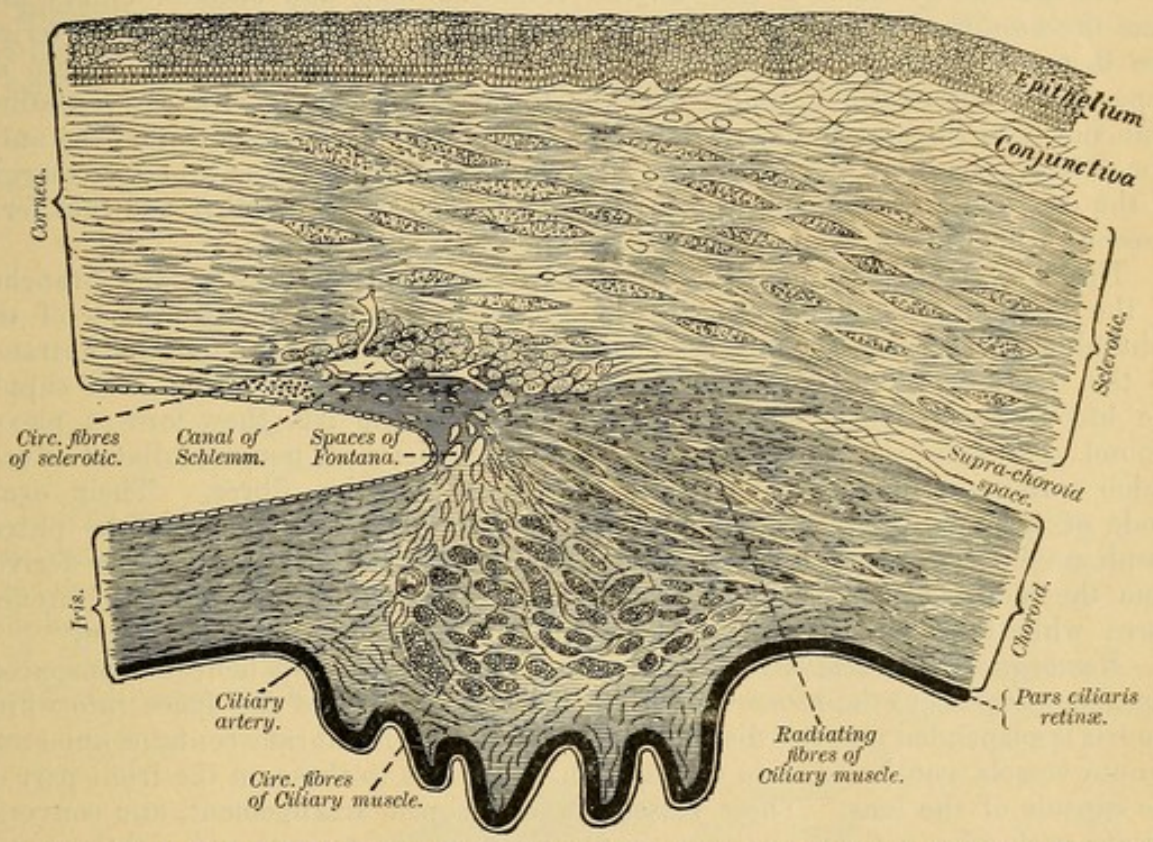

FIG. 444.—Section of the eye, showing the relations of the cornea, sclerotic, and iris, together with the Ciliary muscle and the cavernous spaces near the angle of the anterior chamber. (Waldeyer.)

Structure.—The iris is composed of the following structures:

1. In front is a layer of flattened endothelial cells placed on a delicate hyaline basement-membrane. This layer is continuous with the epithelial layer covering the membrane of Descemet, and in men with dark-colored irides the cells contain pigment-granules.

2. *Stroma.*—The stroma consists of fibres and cells. The former are made of fine, delicate bundles of fibrous tissue, of which some few fibres have a circular direction at the circumference of the iris, but the chief mass consists of fibres radiating toward the pupil. They form, by their interlacement, a delicate mesh, in which the vessels and nerves are contained. Interspersed between the bundles of connective tissue are numerous branched cells with fine processes. Many of them in dark eyes contain pigment-granules, but in blue eyes and the pink eyes of albinos they are unpigmented.

3. The *muscular fibre* is involuntary, and consists of circular and radiating fibres. The *circular fibres* (sphincter pupillæ) surround the margin of the pupil on the posterior surface of the iris, like a sphincter, forming a narrow band about one-thirtieth of an inch in width, those near the free margin being closely aggre-

gated; those more external somewhat separated, and forming less complete circles. The *radiating fibres* (dilator pupillæ) converge from the circumference toward the centre, and blend with the circular fibres near the margin of the pupil. These fibres are regarded by some as elastic, not muscular.

4. *Pigment.*—The situation of the pigment-cells differs in different irides. In the various shades of blue eyes the only pigment-cells are several layers of small round or polyhedral cells filled with dark pigment, situated on the posterior surface of the iris and continuous with the pigmentary lining of the ciliary processes. The color of the eye in these individuals is due to this coloring-matter showing more or less through the texture of the iris. In the albino even this pigment is absent. In the gray, brown, and black eye there are, as mentioned above, pigment-granules to be found in the cells of the stroma and in the epithelial layer on the front of the iris; to these the dark color of the eye is due.

The *arteries of the iris* are derived from the long and anterior ciliary and from the vessels of the ciliary processes (see page 509). The long ciliary arteries, two in number, having reached the attached margin of the iris, divide into an upper and a lower branch, and, encircling the iris, anastomose with corresponding branches from the opposite side; into this vascular zone (circulus major) the anterior ciliary pour their blood. From this zone vessels converge to the free margin of the iris, and these communicate by branches from one to another and thus form a second zone (circulus minor) in this situation.

The *nerves of the choroid and iris* are derived from the ciliary branches of the lenticular ganglion, and the long ciliary from the nasal branch of the ophthalmic division of the fifth. They pierce the sclerotic around the entrance of the optic nerve, and run forward in the perichoroidal space, and supply the blood-vessels of the choroid. After reaching the iris they form a plexus around its attached margin; from this are derived non-medullated fibres which terminate in the circular and radiating muscular fibres. Their exact mode of termination has not been ascertained. Other fibres from the plexus terminate in a network on the anterior surface of the iris. The fibres derived from the motor root of the lenticular ganglion (third nerve) supply the circular fibres, while those derived from the sympathetic supply the radiating fibres.

Membrana Pupillaris.—In the fœtus the pupil is closed by a delicate transparent vascular membrane, the *membrana pupillaris*, which divides the space into which the iris is suspended into two distinct chambers. This membrane contains numerous minute vessels, continued from the margin of the iris to those on the front part of the capsule of the lens. These vessels have a looped arrangement, and converge toward each other without anastomosing. Between the seventh and eighth months the membrane begins to disappear, by its gradual absorption from the centre toward the circumference, and at birth only a few fragments remain. It is said sometimes to remain permanent and produce blindness.

III. The Retina.

The **Retina** is a delicate nervous membrane, upon the surface of which the images of external objects are received. Its outer surface is in contact with the choroid; its inner with the vitreous body. Behind, it is continuous with the optic nerve; it gradually diminishes in thickness from behind forward; and, in front, extends nearly as far as the ciliary body, where it appears to terminate in a jagged margin, the *ora serrata*. Here the nervous tissues of the retina end, but a thin prolongation of the membrane extends forward over the back of the ciliary processes and iris, forming the *pars ciliaris retinæ* and *pars iridica retinæ*, already referred to. This forward prolongation consists of the pigmentary layer of the retina together with a stratum of columnar epithelium. The retina is soft, semi-transparent, and of a purple tint in the fresh state, owing to the presence of a coloring-material named *rhodopsin* or *visual purple;* but it soon becomes clouded, opaque, and bleached when exposed to sunlight. Exactly in the centre of the

posterior part of the retina, corresponding to the axis of the eye, and at a point in which the sense of vision is most perfect, is an oval yellowish spot, called, after its discoverer, the *yellow spot* or *macula lutea* of Sömmerring, having a central depression, the *fovea centralis*. The retina in the situation of the fovea centralis is exceedingly thin, and the dark color of the choroid is distinctly seen through it; so that it presents more the appearance of a foramen, and hence the name "foramen of Sömmerring" at first given to it. It exists only in man, the quadrumana, and some saurian reptiles. About one-eighth of an inch (3 mm.) to the inner side of the yellow spot is the point of entrance of the optic nerve (*porus opticus*); here the nervous substance is slightly raised so as to form an eminence (*colliculus nervi optici*); the arteria centralis retinæ pierces its centre. This is the only part of the surface of the retina from which the power of vision is absent, and is termed the "blind spot."

Structure.—The retina is an exceedingly complex structure, and, when examined microscopically by means of sections made perpendicularly to its surface, is found to consist of ten layers, which are named from within outward, as follows:

1. Membrana limitans interna.
2. Layer of nerve-fibres (stratum opticum).
3. Ganglionic layer, consisting of nerve-cells.
4. Inner molecular, or plexiform, layer.
5. Inner nuclear layer, or layer of inner granules.
6. Outer molecular, or plexiform, layer.
7. Outer nuclear layer, or layer of outer granules.
8. Membrana limitans externa.
9. Jacob's membrane (layer of rods and cones).
10. Pigmentary layer (tapetum nigrum).

1. The *membrana limitans interna* is the most internal layer of the retina, and is in contact with the hyaloid membrane of the vitreous humor. It is derived from the supporting framework of the retina, with which tissue it will be described.

2. The *layer of nerve-fibres* is formed by the expansion of the optic nerve. This nerve passes through all the other layers of the retina, except the membrana

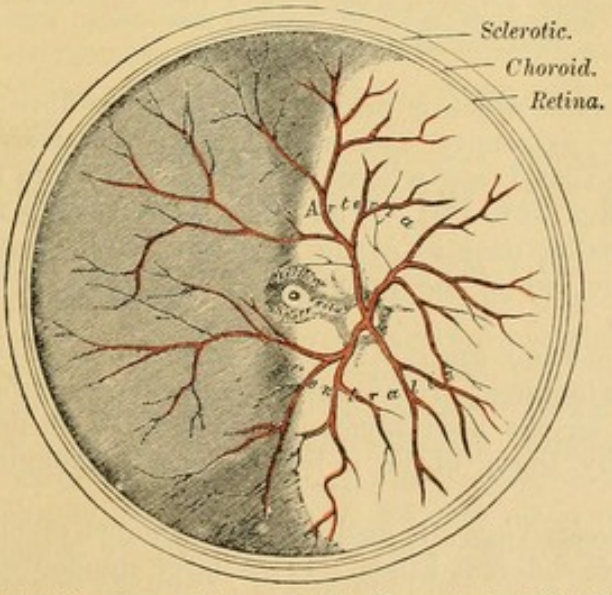

FIG. 445.—The arteria centralis retinæ, yellow spot, etc., the anterior half of the eyeball being removed. (Enlarged.)

limitans interna, to reach its destination. As the nerve passes through the lamina cribrosa of the sclerotic coat, the fibres of which it is composed lose their medullary sheaths and are continued onward, through the choroid and retina, as simple axis-cylinders. When these non-medullated fibres reach the internal surface of the

retina, they radiate from their point of entrance over the surface of the retina, grouped in bundles, and in many places, according to Michel, arranged in plexuses. Most of the fibres in this layer are centripetal, and are the direct continuations of the axis-cylinder processes of the cells of the next layer, but a few of them (centrifugal fibres) pass through it and the next succeeding layer to ramify in the inner molecular and inner nuclear layers, where they terminate in enlarged extremities (Fig. 448, 1, *m*). The layer is thickest at the optic nerve entrance, and gradually diminishes in thickness toward the ora serrata.

3. The *ganglionic layer* consists of a single layer of large ganglion-cells; except in the macula lutea, where there are several strata. The cells are somewhat flask-shaped, their rounded internal margin resting on the preceding layer

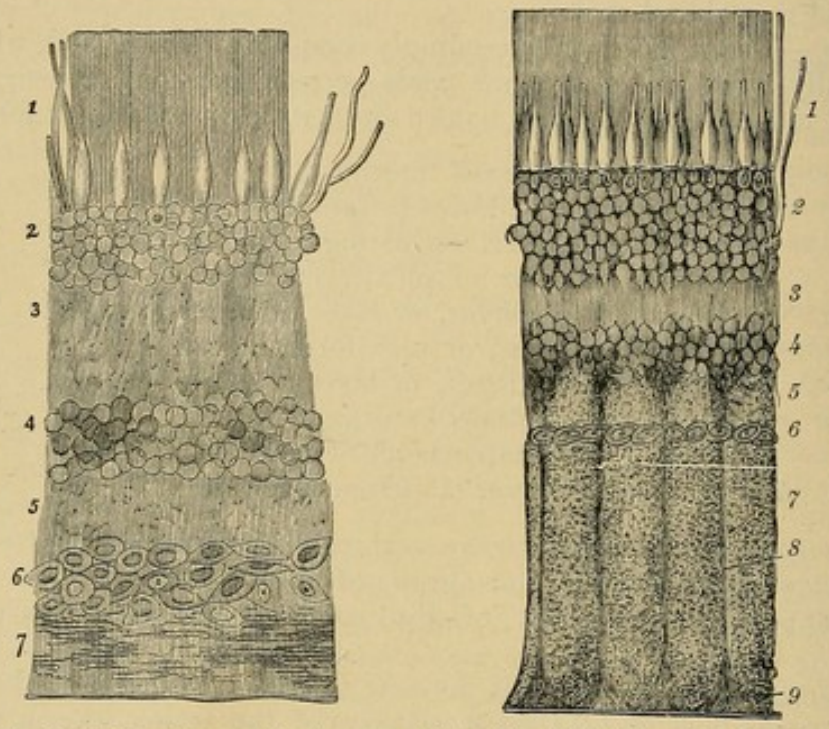

FIG. 446 and 447.—Vertical sections of the human retina. Fig. 446, half an inch from the entrance of the optic nerve. Fig. 447, close to the latter. 1. Layer of rods and cones, Jacob's membrane, bounded underneath by the *membrana limitans externa*. 2. Outer nuclear layer. 3. Outer molecular layer. 4. Inner nuclear layer. 5. Inner molecular layer. 6. Ganglionic layer. 7. Layer of nerve-fibres. 8. Sustentacular fibres of Müller. 9. Their attachment to the *membrana limitans interna*.

and sending off an axon which is prolonged as a nerve-fibre into the fibrous layer. From the opposite extremity numerous thicker processes (dendrites) extend into the inner molecular layer, where they branch out into flattened arborizations at different levels (Fig. 448, VII). The ganglion-cells vary much in size, and the dendrites of the smaller ones as a rule arborize in the inner molecular layer as soon as they enter it; while the processes of the larger cells ramify close to the inner nuclear layer.

4. The *inner molecular layer* is made up of a dense reticulum of minute fibrils, formed by the interlacement of the dendrites of the ganglion-cells with those of the cells contained in the next layer, immediately to be described. Within the reticulum formed by these fibrils a few branched spongioblasts are sometimes imbedded.

5. The *inner nuclear layer* is made up of a number of closely packed cells, of which there are three different kinds. (1) A large number of oval cells, which are commonly regarded as bipolar nerve-cells, and are much more numerous than either of the other kind. They each consist of a large oval body placed vertically to the surface, and containing a distinct nucleus: they are surrounded by a small amount of protoplasm, which is prolonged into two processes: one of these passes inward into the inner molecular layer, is varicose in appearance, and ends in a terminal ramification, which is often in close proximity to the ganglion-cells (Fig. 448 1, *c*).

The outer process passes outward into the outer molecular layer, and there breaks up into a number of branches. According to Cajal, there are two varieties of these bipolar cells: one in which the outer process arborizes around the knobbed ends of the rod-fibres, and the inner around the cells of the ganglionic layer; these he calls *rod-bipolars* (Fig. 448, 1, *c*, *d*); the others are those in which the outer process breaks up in a horizontal ramification, in contact with the end of a cone-fibre; these are the *cone-bipolars*, and their inner process breaks up into its terminal ramifications in the inner molecular layer (Fig. 448, 1, *e*). (2) At the innermost part of this inner nuclear layer is a stratum of cells, which are named by Cajal *amacrine* cells, from the fact that they have no axis-cylinder process, but they give a number of short protoplasmic processes which extend into the inner molecular layer and there ramify (Fig. 448, 1, *h*). There are also at the outermost part of this layer some cells, the processes of which extend into and ramify in the outer molecular layer. These are the *horizontal* cells of Cajal. (3) Some few cells are also found in this layer, connected with the fibres of Müller, and will be described with those structures.

6. The *outer molecular layer* is much thinner than the inner molecular layer; but, like it, consists of a dense network of minute fibrils, derived from the processes of the horizontal cells of the preceding layer and the outer processes of the bipolar cells, which ramify in it, forming arborizations around the ends of the rod-fibres and with the branched foot-plates of the cone-fibres.

7. *The Outer Nuclear Layer.*—Like the inner nuclear layer, this layer contains several strata of clear oval nuclear bodies; they are of two kinds, and on account of their being respectively connected with the rods and cones of Jacob's membrane are named rod-granules and cone-granules. The *rod-granules* are much the more numerous, and are placed at different levels throughout the layer. Their nuclei present a peculiar cross-striped appearance, and prolonged from either extremity of the granule is a fine process: the outer process is continuous with a single rod of Jacob's membrane; the inner passes inward toward the outer molecular layer and terminates in an enlarged extremity, and is embedded in the tuft into which the outer process of the rod-bipolars break up. In its course it presents numerous varicosities. The *cone-granules*, fewer in number than the rod-granules, are placed close to the membrana limitans externa, through which they are continuous with the cones of Jacob's membrane. They do not present any cross-striping, but contain a pyriform nucleus which almost completely fills the cell. From their inner extremity a thick process passes inward to the outer molecular layer, upon which it rests by a somewhat pyramidal enlargement, from which are given off numerous fine fibrils, which enter the outer molecular layer, where they come in contact with the outer processes of the cone-bipolars.

8. *The Membrana Limitans Externa.*—This layer, like the membrana limitans interna, is derived from the fibres of Müller, with which structures it will be described.

9. *Jacob's Membrane* (*Layer of Rods and Cones*).—The elements which compose this layer are of two kinds, *rods* and *cones*, the former being much more numerous than the latter. The *rods* are of nearly uniform size, and arranged perpendicularly to the surface. Each rod consists of two portions, an outer and inner, which are of about equal length. The segments differ from each other as regards refraction and in their behavior with coloring reagents, the inner portion becoming stained by carmine, iodine, etc., the outer portion remaining unstained with these reagents, but staining yellowish brown with osmic acid. The outer portion of each rod is marked by transverse striæ, and is made up of a number of thin disks superimposed on one another. It also exhibits faint longitudinal markings. The inner portion of each rod, at its deeper part where it is joined to the outer process of the rod-granule, is indistinctly granular; its more superficial part presents a longitudinal striation, being composed of fine, bright, highly refracting fibrils. The visual purple or rhodopsin is found only in the outer segments of the rods.

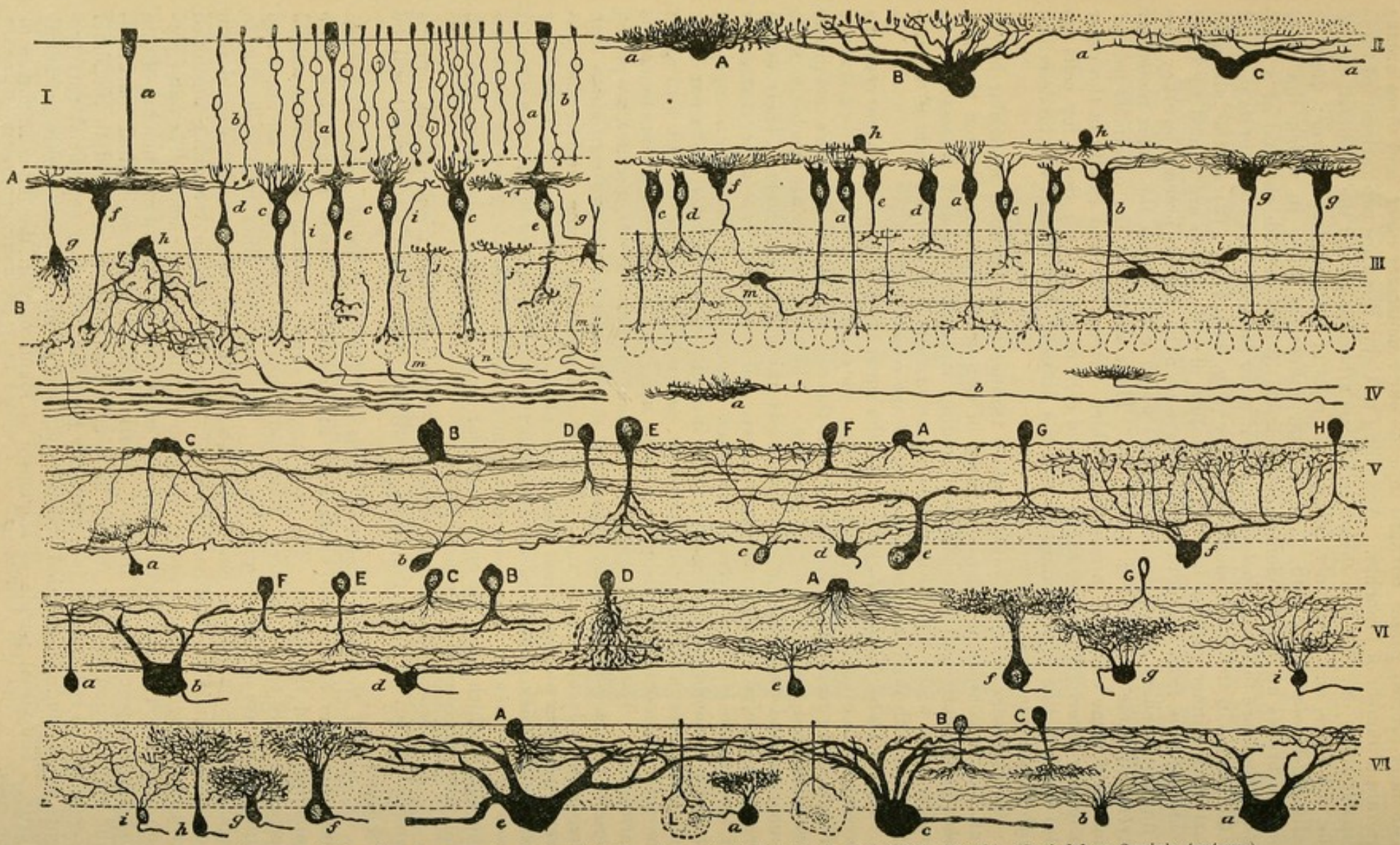

FIG. 448.—Elements of the retina of mammals, displayed by the chromate of silver method of Golgi. (Cajal.) (Copied from Quain's *Anatomy.*)

The *cones* are conical or flask-shaped, their broad ends resting upon the membrana limitans externa, the narrow pointed extremity being turned to the choroid. Like the rods, they are made up of two portions, outer and inner; the outer portion is a short conical process, which, like the outer segment of the rods, presents transverse striæ. The inner portion resembles the inner portion of the rods in structure, presenting a superficial striated and deeper granular part; but differs from it in size, being bulged out laterally and presenting a flask shape. The chemical and optical characters of the two portions are identical with those of the rods.

10. *The Pigmentary Layer, or Tapetum Nigrum.*—The most external layer of the retina, formerly regarded as a part of the choroid, consists of a single layer of hexagonal epithelial cells, loaded with pigment-granules. They are smooth externally, where they are in contact with the choroid, but internally they are prolonged into fine, straight processes, which extend between the rods, this being especially the case when the eye is exposed to light. In the eyes of albinos, the cells of the pigmentary layer are present, but they contain no coloring-matter. In many of the mammals also, as in the horse, and many of the carnivora, there is no pigment in the cells of this layer, and the choroid possesses a beautiful iridescent lustre, which is termed the *tapetum lucidum.*

Supporting Framework of the Retina.—Almost all these layers of the retina are connected together by a supporting framework, formed by the *fibres of Müller*, or *radiating fibres*, from which the membrana limitans interna et externa are derived. These fibres are found stretched between the two limiting layers, "as columns between a floor and a ceiling," and passing through all the nervous layers except Jacob's membrane. Each commences on the inner surface of the retina by a conical hollow base, which sometimes contains a spheroidal body, stained deeply with hæmatoxylin, the edges of the bases of adjoining fibres being united and thus forming a boundary line, which is the membrana limitans interna. As they pass through the nerve-fibre and ganglionic layers they give off few lateral branches; in the inner nuclear layer they give off numerous lateral processes for the support of the inner granules, while in the outer nuclear layer they form a network around the rod and cone-fibrils, and unite to form the external limiting membrane at the bases of the rods and cones. In the inner nuclear layer each fibre of Müller presents a clear oval nucleus, which is sometimes situated at the side of, sometimes altogether within, the fibre.

DESCRIPTION OF FIG. 448.

I. Section of the dog's retina. *a*, Cone-fibre. *b*, Rod-fibre and nucleus. *c*, *d*, Bipolar cells (inner granules) with vertical ramification of outer processes destined to receive the enlarged ends of rod-fibres. *e*, Bipolars with flattened ramification for ends of cone-fibres. *f*, Giant bipolar with flattened ramification. *g*, Cell sending a neuron or nerve-fibre process to the outer molecular layer. *h*, Amacrine cell with diffuse arborization in inner molecular layer. *i*, Nerve-fibrils passing to outer molecular layer. *j*, Centrifugal fibres passing from nerve-fibre layer to inner molecular layer. *m*, Nerve-fibril passing into inner molecular layer. *n*, Ganglionic cells.

II. Horizontal or basal cells of the outer molecular layer of the dog's retina. A, Small cell with dense arborization. B, Large cell, lying in inner nuclear layer, but with its processes branching in the outer molecular. *a*, Its horizontal neuron. C, Medium-sized cell of the same character.

III. Cells from the retina of the ox. *a*, Rod-bipolars with vertical arborizations. *b*, *c*, *d* *e*, Cone-bipolars with horizontal ramification of outer process. *h*, Cells lying on the outer surface of the outer molecular layer, and ramifying within it. *i*, *j*, *m*, Amacrine cells within the substance of the inner molecular layer.

IV. Neurons or axis-cylinder processes belonging to horizontal cells of the outer molecular layer, one of them, *b*, ending in a close ramification at *a*.

V. Nervous elements connected with the inner molecular layer of the ox's retina. A, Amacrine cell, with long processes ramifying in the outermost stratum. B, Large amacrine with thick processes ramifying in second stratum. C, Flattened amacrine with long and fine processes ramifying mainly in the first and fifth strata. D, Amacrine with radiating tuft of fibrils destined for third stratum. E, Large amacrine, with processes ramifying in fifth stratum. F, Small amacrine, branching into second stratum. G, H, Other amacrines destined for fourth stratum. *a*, Small ganglion-cell sending its processes to fourth stratum. *b*, A small ganglion-cell with ramifications in three strata. *c*, A small cell ramifying ultimately in first stratum. *d*, A medium-sized ganglion-cell ramifying in fourth stratum. *e*, Giant-cell, branching in third stratum. *f*, A bistratified cell ramifying in second and fourth strata.

VI. Amacrines and ganglion-cells from the dog. A, Amacrine with radiating tuft. B, Large amacrine passing to third stratum. C and G, Small amacrines with radiations in second stratum. F, Small amacrine passing to third stratum. D, Amacrine with diffuse arborization. E, Amacrine belonging to fourth stratum. *a*, *d*, *e*, *g*, Small ganglion-cells, ramifying in various strata. *b*, *f*, Large ganglion-cells showing two different characters of arborization. *i*, Bistratified cell.

VII. Amacrines and ganglion-cells from the dog. A, B, C, Small amacrines ramifying in middle of molecular layer. *b*, *d*, *g*, *h*, *i*, Small ganglion-cells showing various kinds of arborization. *f*, A larger cell, similar in character to *g*, but with longer branch. *a*, *c*, *e*, Giant-cells with thick branches ramifying in the first, second, and third layers. L, L, Ends of bipolars branching over ganglion-cells.

Macula Lutea and Fovea Centralis.—The structure of the retina at the yellow spot presents some modifications. In the macula lutea (1) the nerve-fibres are

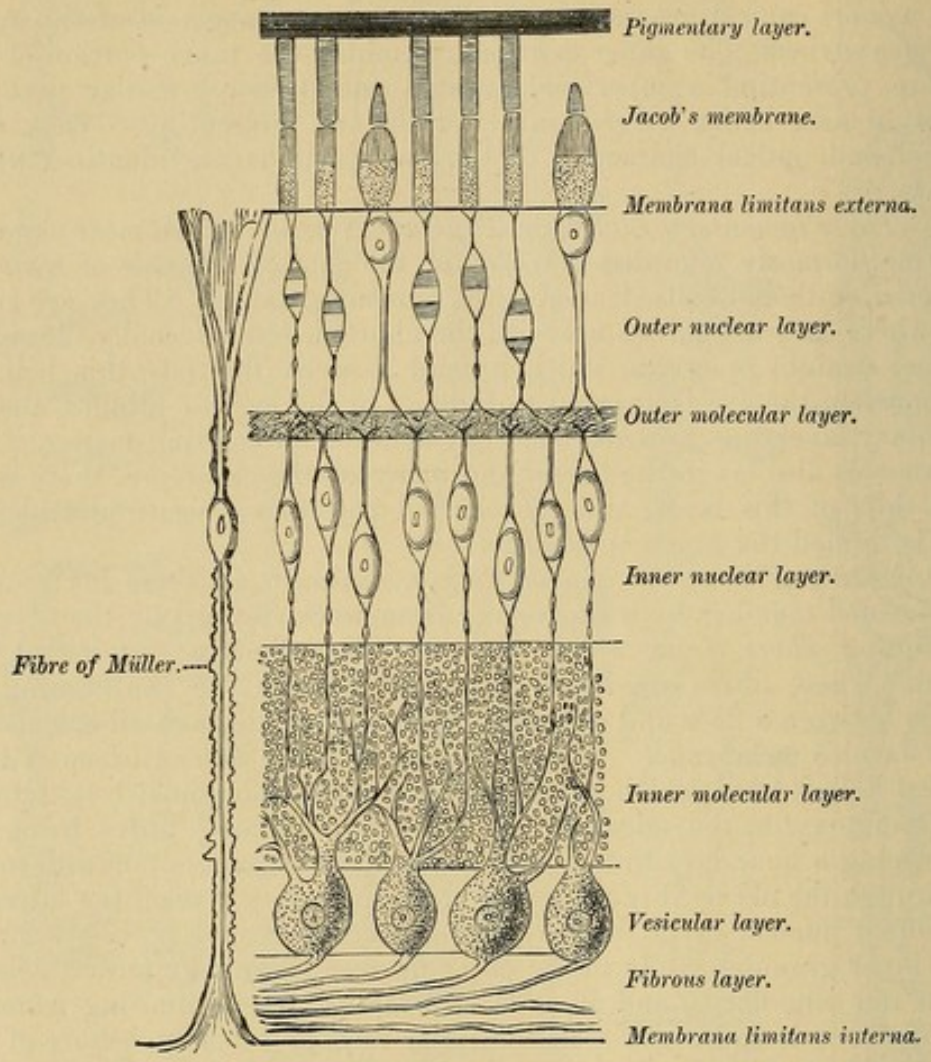

FIG. 449.—The layers of the retina (diagrammatic). (After Schultze.)

wanting as a continuous layer; (2) the ganglionic layer consists of several strata of cells, instead of a single layer; (3) in Jacob's membrane there are no rods, but only cones, and these are longer and narrower than in other parts; and (4) in the outer nuclear layer there are only cone fibres, which are very long and arranged in curved lines. At the fovea centralis the only parts which exist are the cones of Jacob's membrane, the outer nuclear layer, the cone-fibres of which are almost horizontal in direction, and an exceedingly thin inner granular layer, the pigmentary layer, which is thicker and its pigment more pronouncod than elsewhere. The color of the macula seems to imbue all the layers except Jacob's membrane; it is of a rich yellow, deepest toward the centre, and does not appear to consist of pigment-cells, but simply a staining of the constituent parts.

At the ora serrata the nervous layers of the retina terminate abruptly, and the retina is continued onward as a single layer of elongated columnar cells covered by the pigmentary layer. This prolongation is known as the *pars ciliaris retinæ*, and can be traced forward from the ciliary processes on to the back of the iris, where it is termed the *pars iridica retinæ* or *uvea*.

From the description given of the nervous elements of the retina it will be seen that there is no direct continuity between the structures which form its different layers except between the ganglionic and nerve-fibre layers, the majority of the nerve-fibres being formed of the axons of the ganglionic cells. In the inner molecular layer the dendrites of the ganglionic layer interlace with those of the cells of the inner nuclear layer, while in the outer molecular layer a like

synapsis occurs between the processes of the inner granules and the rod and cone elements.

The *arteria centralis retinæ* and its accompanying vein pierce the optic nerve, and enter the globe of the eye through the porus opticus. It immediately bifurcates into an upper and a lower branch, and each of these again divides into an inner, or nasal, and an outer, or temporal, branch, which at first run between the hyaloid membrane and the nervous layer; but they soon enter the latter, and pass forward, dividing dichotomously. From these branches a minute capillary plexus is given off, which does not extend beyond the inner nuclear layer. The macula receives small twigs from the temporal branches and others directly from the central artery; these do not, however, reach as far as the fovea centralis, which has no blood-vessels. The branches of the arteria centralis retinæ do not anastomose with each other—in other words, they are "terminal arteries." In the fœtus, a small vessel passes forward, through the vitreous humor, to the posterior surface of the capsule of the lens.

REFRACTING MEDIA.

The Refracting media are three, viz.:

Aqueous humor. Vitreous body. Crystalline lens.

I. Aqueous Humor.

The **aqueous humor** completely fills the anterior and posterior chambers of the eyeball. It is small in quantity (scarcely exceeding, according to Petit, four or five grains in weight), has an alkaline reaction, in composition is little more than water, less than one-fiftieth of its weight being solid matter, chiefly chloride of sodium.

The *anterior chamber* is the space bounded in front by the cornea; behind, by the front of the iris. The *posterior chamber* is a narrow chink between the peripheral part of the iris, the suspensory ligament of the lens, and the ciliary processes.

In the adult, these two chambers communicate through the pupil; but in the fœtus of the seventh month, when the pupil is closed by the membrana pupillaris, the two chambers are quite separate.

II. Vitreous Body.

The **vitreous body** forms about four-fifths of the entire globe. It fills the concavity of the retina, and is hollowed in front, forming a deep concavity, the *fossa patellaris*, for the reception of the lens. It is perfectly transparent, of the consistence of thin jelly, and is composed of an albuminous fluid enclosed in a delicate transparent membrane, the *membrana hyaloidea*. It has been supposed by Hannover, that from its inner surface numerous thin lamellæ are prolonged inward in a radiating manner, forming spaces in which the fluid is contained. In the adult, these lamellæ cannot be detected even after careful microscopic examination in the fresh state, but in preparations hardened in weak chromic acid it is possible to make out a distinct lamellation at the periphery of the body; and in the fœtus a peculiar fibrous texture pervades the mass, the fibres joining at numerous points, and presenting minute nuclear granules at their point of junction. In the centre of the vitreous humor, running from the entrance of the optic nerve to the posterior surface of the lens, is a canal, filled with fluid and lined by a prolongation of the hyaloid membrane. This is the *canal of Stilling*, which in the embryonic vitreous humor conveyed the minute vessel from the central artery of the retina to the back of the lens. The fluid from the vitreous body resembles nearly pure water; it contains, however, some salts and a little albumin.

The hyaloid membrane encloses the whole of the vitreous humor. In front of the ora serrata it is thickened by the accession of radial fibres and is termed

the *zonule of Zinn* or *zonula ciliaris*. It presents a series of radially arranged furrows, in which the ciliary processes are accommodated and to which they are adherent, as evidenced by the fact that when removed some of their pigment remains attached to the zonule. The zonule of Zinn splits into two layers, one of which is thin and lines the fossa patellaris; the other is named the *suspensory ligament of the lens;* it is thicker, and passes over the ciliary body to be attached to the capsule of the lens a short distance in front of its equator. Scattered and delicate fibres are also attached to the region of the equator itself. This ligament retains the lens in position, and is relaxed by the contraction of the radial fibres of the Ciliary muscle, so that the lens is allowed to become more convex. Behind the suspensory ligament there is a sacculated canal, the *canal of Petit*, which encircles the equator of the lens and which can be easily inflated through a fine blow-pipe inserted through the suspensory ligament.

In the fœtus, the centre of the vitreous humor presents the canal of Stilling, already referred to, which transmits a minute artery to the capsule of the lens. *In the adult*, no vessels penetrate its substance; so that its nutrition must be carried on by the vessels of the retina and ciliary processes, situated upon its exterior.

III. Crystalline Lens.

The **crystalline lens**, enclosed in its capsule, is situated immediately behind the pupil, in front of the vitreous body, and encircled by the ciliary processes, which slightly overlap its margin.

The *capsule of the lens* is a transparent, highly elastic, and brittle membrane, which closely surrounds the lens. It rests, behind, in the fossa patellaris in the fore part of the vitreous body; in front, it is in contact with the free border of the iris, this latter receding from it at the circumference, thus forming the posterior chamber of the eye; and it is retained in its position chiefly by the suspensory ligament of the lens, already described. The capsule is much thicker in front than behind, and structureless in texture; when ruptured, the edges roll up with the outer surface innermost, like the elastic lamina of the cornea.

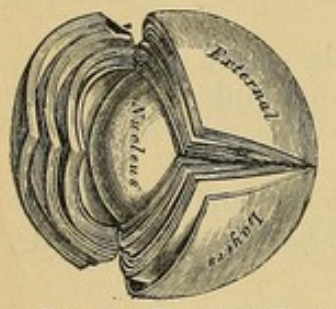

FIG. 450.—The crystalline lens, hardened and divided. (Enlarged.)

The anterior surface of the lens is covered by a single layer of transparent, polygonal, nucleated cells. At the circumference of the lens, these cells undergo a change in form: they become elongated, and Babucin states that he can trace the gradual transition of the cells into proper lens-fibres, with which they are directly continuous. There is no epithelium on the posterior surface.

In the fœtus, a small branch from the arteria centralis retinæ runs forward, as already mentioned, through the vitreous humor to the posterior part of the capsule of the lens, where its branches radiate and form a plexiform network, which covers its surface, and they are continuous round the margin of the capsule with the vessels of the pupillary membrane and with those of the iris. In the adult no vessels enter its substance.

The *lens* is a transparent, biconvex body, the convexity being greater on the posterior than on the anterior surface. The central points of its anterior and posterior surfaces are known as its *anterior* and *posterior poles*. It measures from 9 to 10 mm. in the transverse diameter, and about 4 mm. in the antero-posterior. It consists of concentric layers, of which the external in the fresh state are soft and easily detached (*substantia corticalis*); those beneath are firmer, the central ones forming a hardened nucleus (*nucleus lentis*). These laminæ are best demonstrated by boiling or immersion in alcohol, and consist of minute parallel fibres, which are hexagonal prisms, the edges being dentated, and the dentations fitting accurately into each other; their breadth is about $\frac{1}{5000}$ of an inch. Faint lines radiate from the anterior and posterior poles to the circumference of

the lens. In the adult there may be six or more of these, but in the fœtus they are only three in number and diverge from each other at angles of 120° (Fig. 451). On the anterior surface one line ascends vertically and the other two diverge downward and outward. On the posterior surface one ray descends vertically

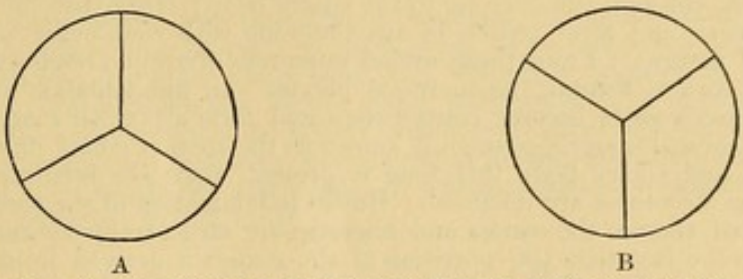

FIG. 451.—Diagram to show the direction and arrangement of the radiating lines on the front and back of the fœtal lens. (A) from the front. (B) from the back.

and the other two diverge upward. They correspond with the free edges of an equal number of septa in the lens, along which the ends of the lens fibres come into apposition and are joined by transparent amorphous substance. The fibres run in a curved manner from the septa on the anterior surface to those on the posterior surface. No fibres pass from pole to pole, but they are arranged in such a way that fibres which commence near the pole on the one aspect of the lens terminate near the peripheral extremity of the plane on the other, and *vice versâ*. The fibres of the outer layers of the lens each contain a nucleus, which together form a layer (nuclear layer) on the surface of the lens, most distinct toward its circumference.

The *changes produced in the lens by age* are the following:

In *the fœtus* its form is nearly spherical, its color of a slightly reddish tint, it is not perfectly transparent, and is so soft as to break down readily on the slightest pressure.

In the adult the posterior surface is more convex than the anterior; it is colorless, transparent, and firm in texture.

In old age it becomes flattened on both surfaces, slightly opaque, of an amber tint, and increases in density.

The *arteries of the globe of the eye* are the short, long, and anterior ciliary arteries and the arteria centralis retinæ. They have been already described (see page 509).

The *ciliary veins* are seen on the outer surface of the choroid, and are named, from their arrangement, the *venæ vorticosæ*. They converge to four or five equidistant trunks, which pierce the sclerotic midway between the margin of the cornea and the entrance of the optic nerve. Another set of veins accompany the anterior ciliary arteries and open into the ophthalmic vein.

The *ciliary nerves* are derived from the nasal branch of the ophthalmic and from the ciliary or ophthalmic ganglion.

Surgical Anatomy.—From a surgical point of view the cornea may be regarded as consisting of three layers: (1) of an external epithelial layer, developed from the epiblast, and continuous with the external epithelial covering of the rest of the body, and therefore in its lesions resembling those of the epidermis; (2) of the cornea proper, derived from the mesoblast, and associated in its diseases with the fibro-vascular structures of the body; and (3) the posterior elastic layer with its endothelium, also derived from the mesoblast and having the characters of a serous membrane, so that inflammation of it resembles inflammation of the other serous and synovial membranes of the body.

The cornea contains no blood-vessels, except at its periphery, where numerous delicate loops, derived from the anterior ciliary arteries, may be demonstrated on the anterior surface of the cornea. The rest of the cornea is nourished by lymph, which gains access to the proper substance of the cornea and the posterior layer through the spaces of Fontana. This lack of a direct blood-supply renders the cornea very apt to inflame in the cachectic and ill-nourished. In cases of granular lids there is a peculiar affection of the cornea, called *pannus*, in which the anterior layers of the cornea become vascularized, and a rich network of blood-vessels may be seen on the cornea; and in interstitial keratitis new vessels extend into the cornea, giving it a pinkish hue, to which the term "salmon patch" is applied. The cornea is richly supplied with

nerves, derived from the ciliary, which enter the cornea through the fore part of the sclerotic and form plexuses in the stroma, terminating between the epithelial cells by free ends or in corpuscles. In cases of glaucoma the ciliary nerves may be pressed upon as they course between the choroid and sclerotic, and the cornea becomes anæsthetic. The sclerotic has very few blood-vessels and nerves. The blood-vessels are derived from the anterior ciliary, and form an open plexus in its substance. As they approach the corneal margin this arrangement is peculiar. Some branches pass through the sclerotic to the ciliary body; others become superficial and lie in the episcleral tissue, and form arches, by anastomosing with each other, some little distance behind the corneal margin. From these arches numerous straight vessels are given off, which run forward to the cornea, forming its marginal plexus. In inflammation of the sclerotic and episcleral tissue these vessels become conspicuous, and form a pinkish zone of straight vessels radiating from the corneal margin, commonly known as the zone of ciliary injection. In inflammation of the iris and ciliary body this zone is present, since the sclerotic speedily becomes involved when these structures are inflamed. But in inflammation of the cornea the sclerotic is seldom much affected, though the cornea and sclerotic are structurally continuous. This would appear to be due to the fact that the nutrition of the cornea is derived from a different source from that of the sclerotic. The sclerotic may be ruptured subcutaneously without any laceration of the conjunctiva, and the rupture usually occurs near the corneal margin, where the tunic is thinnest. It may be complicated with lesions of adjacent parts—laceration of the choroid, retina, iris, or suspensory ligament of the lens—and is then often attended with hæmorrhage into the anterior chamber, which masks the nature of the injury. In some cases the lens has escaped through the rent in the sclerotic, and has been found under the conjunctiva. Wounds of the sclerotic are always dangerous, and are often followed by inflammation, suppuration, and by sympathetic ophthalmia.

One of the functions of the choroid is to provide nutrition for the retina and to convey vessels and nerves to the ciliary body and iris. Inflammation of the choroid is therefore followed by grave disturbance in the nutrition of the retina, and is attended with early interference with vision. In its diseases it bears a considerable analogy to those which affect the skin, and, like it, is one of the places from which melanotic sarcomata may grow. These tumors contain a large amount of pigment in their cells, and grow only from those parts where pigment is naturally present. The choroid may be ruptured without injury to the other tunics, as well as participating in general injuries of the eyeball. In cases of uncomplicated rupture the injury is usually at its posterior part, and is the result of a blow on the front of the eye. It is attended by considerable hæmorrhage, which for a time may obscure vision, but in most cases this is restored as soon as the blood is absorbed.

The iris is the seat of a malformation, termed *coloboma*, which consists in a deficiency or cleft, which in a great number of cases is clearly due to an arrest in development. In these cases it is found at the lower aspect, extending directly downward from the pupil, and the gap frequently extends through the choroid to the entrance of the optic nerve. In some rarer cases the gap is found in other parts of the iris, and is then not associated with any deficiency of the choroid. The iris is abundantly supplied with blood-vessels and nerves, and is therefore very prone to become inflamed. And when inflamed, in consequence of the intimate relationship which exists between the vessels of the iris and choroid this latter tunic is very apt to participate in the inflammation. And, in addition, inflammation of adjacent structures, the cornea and sclerotic, is apt to spread into the iris. The iris is covered with epithelium, and partakes of the character of a serous membrane, and, like these structures, is liable to pour out a plastic exudation when inflamed, and contract adhesions, either to the cornea in front (*synechia anterior*), or to the capsule of the lens behind (*synechia posterior*). In iritis the lens may become involved, and the condition known as secondary cataract may be set up. Tumors occasionally commence in the iris; of these, cysts, which are usually congenital and sarcomatous tumors, are the most common and require removal. Gummata are not unfrequently found in this situation. In some forms of injury of the eyeball, as the impact of a spent shot, the rebound of a twig, or a blow with a whip, the iris may be detached from the Ciliary muscle, the amount of detachment varying from the slightest degree to the separation of the whole iris from its ciliary connection.

The retina, with the exception of its pigment-layer and its vessels, is perfectly transparent, so as to be invisible when examined by the ophthalmoscope, so that its diseased conditions are recognized by its loss of transparency. In retinitis, for instance, there is more or less dense and extensive opacity of its structure, and not unfrequently extravasations of blood into its substance. Hæmorrhages may also take place into the retina from rupture of a blood-vessel without inflammation.

The retina may become displaced from effusion of serum between it and the choroid or by blows on the eyeball, or may occur without apparent cause in progressive myopia, and in this case the ophthalmoscope shows an opaque, tremulous cloud. Glioma, a form of sarcoma, and essentially a disease of early life, is occasionally met with in connection with the retina.

The lens has no blood-vessels, nerves, or connective tissue in its structure, and therefore is not subject to those morbid changes to which tissues containing these structures are liable. It does, however, present certain morbid or abnormal conditions of various kinds. Thus, variations in shape, absence of the whole or a part of the lens, and displacements are amongst its congenital defects. Opacities may occur from injury, senile changes, malnutrition, or errors in growth or development. Senile changes may take place in the lens, impairing its elasticity and render-

ing it harder than in youth, so that its curvature can only be altered to a limited extent by the Ciliary muscle. And, finally, the lens may be dislocated or displaced by blows upon the eyeball, and its relations to surrounding structures altered by adhesions or the pressure of new growths.

There are two particular regions of the eye which require special notice: one of these is known as the "filtration area," and the other as the "dangerous area." The *filtration area* is the circumcorneal zone immediately in front of the iris. Here are situated the cavernous spaces of Fontana, which communicate with the canal of Schlemm, through which the chief transudation of fluid from the eye is now believed to take place. The *dangerous area of the eye* is the region in the neighborhood of the ciliary body, and wounds or injuries in this situation are peculiarly dangerous; for inflammation of the ciliary body is liable to spread to many of the other structures of the eye, especially to the iris and choroid, which are intimately connected by nervous and vascular supplies. Moreover, wounds which involve the ciliary region are especially liable to be followed by sympathetic ophthalmia, in which destructive inflammation of one eye is excited by some irritation in the other.

The Appendages of the Eye.

The appendages of the eye (*tutamina oculi*) include the eyebrows, the eyelids, the conjunctiva, and the lachrymal apparatus—viz. the lachrymal gland, the lachrymal sac, and the nasal duct.

The **eyebrows** (*supercilia*) are two arched eminences of integument which surmount the upper circumference of the orbit on each side, and support numerous short, thick hairs, directed obliquely on the surface. In structure the eyebrows consist of thickened integument, connected beneath with the Orbicularis palpebrarum, Corrugator supercilii, and Occipito-frontalis muscles. These muscles serve, by their action on this part, to control to a certain extent the amount of light admitted into the eye.

The **eyelids** (*palpebræ*) are two thin, movable folds placed in front of the eye, protecting it from injury by their closure. The upper lid is the larger and the more movable of the two, and is furnished with a separate elevator muscle, the *Levator palpebræ superioris*. When the eyelids are opened an elliptical space (*fissura palpebrarum*) is left between their margins, the angles of which correspond to the junction of the upper and lower lids, and are called *canthi*.

The *outer canthus* is more acute than the inner, and the lids here lie in close contact with the globe; but the *inner canthus* is prolonged for a short distance inward toward the nose, and the two lids are separated by a triangular space, the *lacus lachrymalis*. At the commencement of the lacus lachrymalis, on the margin of each eyelid, is a small conical elevation, the *lachrymal papilla*, the apex of which is pierced by a small orifice, the *punctum lachrymale*, the commencement of the lachrymal canal.

The *eyelashes* (*cilia*) are attached to the free edges of the eyelids; they are short, thick, curved hairs, arranged in a double or triple row at the margin of the lids: those of the upper lid, more numerous and longer than the lower, curve upward; those of the lower lid curve downward, so that they do not interlace in closing the lids. Near the attachment of the eyelashes are the openings of a number of glands, *glands of Moll*, arranged in several rows close to the free margin of the lid. They are regarded as enlarged and modified sweat-glands.

Structure of the Eyelids.—The eyelids are composed of the following structures, taken in their order from without inward:

Integument, areolar tissue, fibres of the Orbicularis muscle, tarsal plate, and its ligament, Meibomian glands and conjunctiva. The upper lid has, in addition, the aponeurosis of the Levator palpebræ.

The *integument* is extremely thin, and continuous at the margin of the lids with the conjunctiva.

The *subcutaneous areolar tissue* is very lax and delicate, seldom contains any fat, and is extremely liable to serous infiltration.

The *fibres of the Orbicularis muscle*, where they cover the palpebræ, are thin, pale in color, and possess an involuntary action.

The *tarsal plates* are two thin elongated plates of dense connective tissue

about an inch in length. They are placed one in each lid, contributing to their form and support.

The *superior*, the larger, is of a semilunar form, about one-third of an inch in breadth at the centre, and becoming gradually narrowed at each extremity. To the anterior surface of this plate the aponeurosis of the Levator palpebræ is attached.

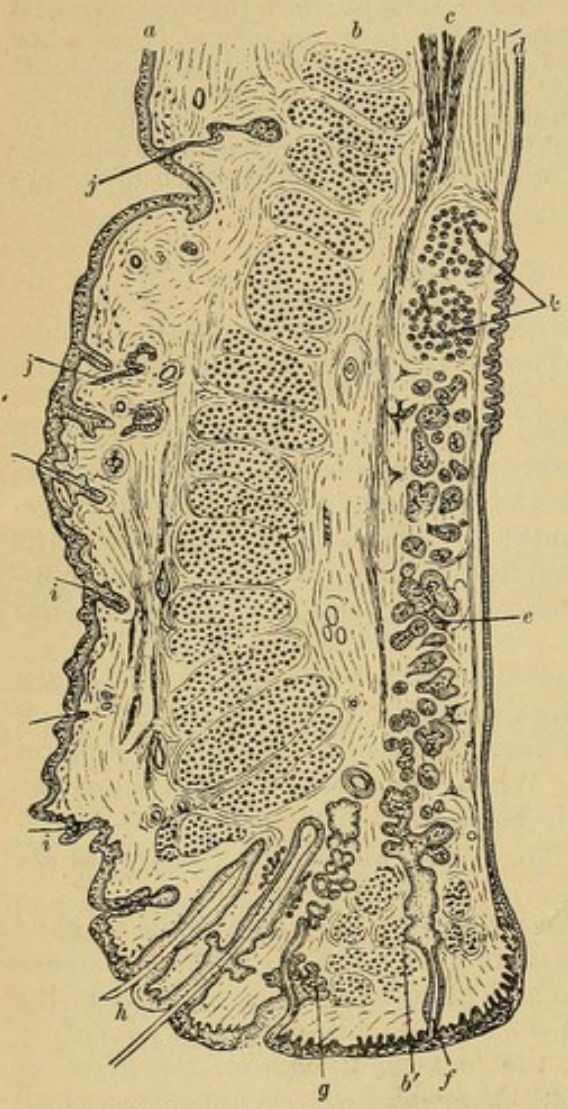

FIG. 452.—Vertical section through the upper eyelid. (After Waldeyer.) *a*. Skin. *b*. Orbicularis palpebrarum. *b'*. Marginal fasciculus of orbicularis (ciliary bundle). *c*. Levator palpebræ. *d*. Conjunctiva. *e*. Tarsal plate. *f*. Meibomian gland. *g*. Sebaceous gland. *h*. Eyelashes. *i*. Small hairs of skin. *j*. Sweat-glands. *k*. Posterior tarsal glands.

The *inferior tarsal plate*, the smaller, is thinner and of an elliptical form.

The *free* or *ciliary margin* of these plates is thick, and presents a perfectly straight edge. The *attached* or *orbital margin* is connected to the circumference of the orbit by the fibrous membrane of the lids, with which it is continuous. The outer angle of each plate is attached to the malar bone by the external tarsal ligament. The inner angles of the two plates terminate at the commencement of the lacus lacrimalis; they are attached to the nasal process of the superior maxilla by the internal tarsal ligament or tendo oculi.

The *palpebral* ligaments are membranous expansions situated one in each lid, and are attached marginally to the edge of the orbit, where they are continuous with the periosteum. The superior ligament blends with the tendon of the Levator palpebræ, the inferior with the inferior tarsal plate. Externally the two ligaments fuse to form the external tarsal ligament, just referred to; internally they are much thinner and, becoming separated from the internal tarsal ligament, are fixed to the lachrymal bone immediately behind the lachrymal sac. Together, the ligaments form an incomplete septum, the *septum orbitale*, which is perforated by the vessels and nerves which pass from the orbital cavity to the face and scalp.

The *Meibomian glands* (Fig. 453) are situated upon the inner surface of the eyelids between the tarsal plates and conjunctiva, and may be distinctly seen through the mucous membrane on everting the eyelids, presenting the appearance of parallel strings of pearls. They are about thirty in number in the upper eyelid, and somewhat fewer in the lower. They are imbedded in grooves in the inner surface of the tarsal plates, and correspond in length with the breadth of each plate; they are, consequently, longer in the upper than in the lower eyelid. Their ducts open on the free margin of the lids by minute foramina, which correspond in number to the follicles. The use of their secretion is to prevent adhesions of the lids.

Structure of the Meibomian Glands.—These glands are a variety of the cutaneous sebaceous glands, each consisting of a single straight tube or follicle, having a cæcal termination, and with numerous small secondary follicles opening into it. The tubes consist of basement-membrane, lined at the mouths of the tubes by stratified epithelium; the deeper parts of the tubes and the secondary follicles are

lined by a layer of polyhedral cells. They are thus identical in structure with the sebaceous glands.

The **conjunctiva** is the mucous membrane of the eye. It lines the inner surface of the eyelids, and is reflected over the fore part of the sclerotic and cornea. In each of these situations its structure presents some peculiarities.

The *palpebral portion of the conjunctiva* is thick, opaque, highly vascular, and covered with numerous papillæ, its deeper parts presenting a considerable amount of lymphoid tissue. At the margin of the lids it becomes continuous with the lining membrane of the ducts of the Meibomian glands, and, through the lachrymal canals, with the lining membrane of the lachrymal sac and nasal duct. At the outer angle of the upper lid the lachrymal ducts open on its free surface; and at the inner angle of the eye it forms a semilunar fold, the *plica semilunaris*. The folds formed by the reflection of the conjunctiva from the lids on to the eye are called the *superior* and *inferior palpebral folds*, the former being the deeper of the two. Upon the *sclerotic* the conjunctiva is loosely connected to the globe: it becomes thinner, loses its papillary structure, is transparent, and only slightly vascular in health. Upon the *cornea* the conjunctiva consists only of epithelium, constituting the anterior layer of the cornea (conjunctival epithelium) already described (see page 826). Lymphatics arise in the conjunctiva in a delicate zone around the cornea, from which the vessels run to the ocular conjunctiva.

At the point of reflection of the conjunctiva from the lid on to the globe of the eye, termed the *fornix conjunctivæ*, are a number of mucous glands which are much convoluted. They are chiefly found in the upper lid. Other glands, analogous to

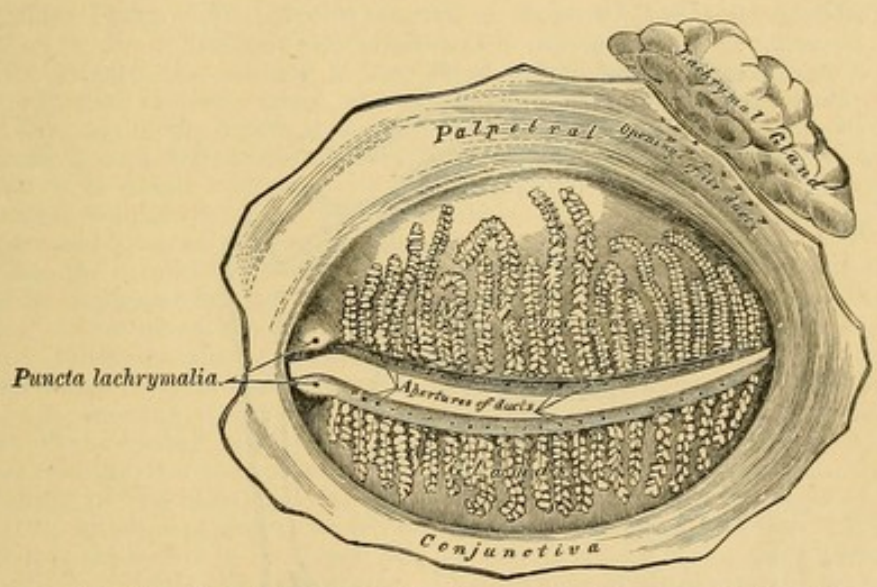

FIG. 453.—The Meibomian glands, etc., seen from the inner surface of the eyelids.

lymphoid follicles, and called by Henle *trachoma glands*, are found in the conjunctiva, and, according to Strohmeyer, are chiefly situated near the inner canthus of the eye. They were first described by Brush, in his description of Peyer's patches of the small intestines, as "identical structures existing in the under eyelid of the ox."

The nerves in the conjunctiva are numerous and form rich plexuses. According to Krause, they terminate in a peculiar form of tactile corpuscle, which he terms the "terminal bulb."

The *caruncula lachrymalis* is a small, reddish, conical-shaped body, situated at the inner canthus of the eye, and filling up the small triangular space in this situation, the *lacus lachrymalis*. It consists of a small island of skin containing sebaceous and sweat glands, and is the source of the whitish secretion which constantly collects at the inner angle of the eye. A few slender hairs are attached to its surface. On the outer side of the caruncula is a slight semilunar fold of mucous membrane, the concavity of which is directed toward the

cornea; it is called the *plica semilunaris*. Müller found smooth muscular fibres in this fold, and in some of the domesticated animals a thin plate of cartilage has been discovered. This structure is considered to be the rudiment of the third eyelid in birds, the *membrana nictitans*.

The Lachrymal Apparatus (Fig. 454).

The lachrymal apparatus consists of the lachrymal gland, which secretes the tears, and its excretory ducts, which convey the fluid to the surface of the eye. This fluid is carried away by the lachrymal canals into the lachrymal sac, and along the nasal duct into the cavity of the nose.

The **lachrymal gland** is lodged in a depression at the outer angle of the orbit, on the inner side of the external angular process of the frontal bone. It is of an oval form, about the size and shape of an almond. Its upper convex surface is in contact with the periosteum of the orbit, to which it is connected by a few fibrous bands. Its under concave surface rests upon the convexity of the eyeball and upon the Superior and External recti muscles. Its vessels and nerves enter its posterior border, whilst its anterior margin is closely adherent to the back part of the upper eyelid, where it is covered to a slight extent by the reflection of the conjunctiva. The fore part of the gland is separated from the rest by a fibrous septum; hence it is sometimes described as a separate lobe, called the *palpebral portion of the gland* (*accessory gland of Rosenmüller*). Its ducts, from six to twelve in number run obliquely beneath the mucous membrane for a short distance, and, separating from each other, open by a series of minute orifices on the upper and outer half

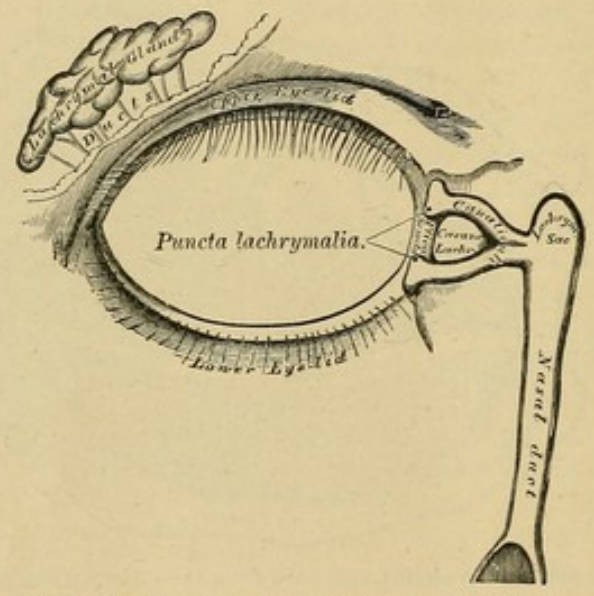

FIG. 454.—The lachrymal apparatus. Right side.

of the conjunctiva near its reflection on to the globe. These orifices are arranged in a row, so as to disperse the secretion over the surface of the membrane.

Structure of the Lachrymal Gland.—In structure and general appearance the lachrymal resembles the serous salivary glands (page 885). In the recent state the cells are so crowded with granules that their limits can hardly be defined. They contain an oval nucleus, and the cell-protoplasm is finely fibrillated.

The **lachrymal canals** commence at the minute orifices, *puncta lachrymalia*, on the summit of a small conical elevation, the *lachrymal papilla*, seen on the margin of the lids at the outer extremity of the lacus lachrymalis. The *superior canal*, the smaller and shorter of the two, at first ascends, and then bends at an acute angle, and passes inward and downward to the lachrymal sac. The *inferior canal* at first descends, and then, abruptly changing its course, passes almost horizontally inward to the lachrymal sac. These canals are dense and

elastic in structure and somewhat dilated at their angle. The mucous membrane is covered with scaly epithelium.

The **lachrymal sac** is the upper dilated extremity of the nasal duct, and is lodged in a deep groove formed by the lachrymal bone and nasal process of the superior maxillary. It is oval in form, its upper extremity being closed in and rounded, whilst below it is continued into the nasal duct. It is covered by a fibrous expansion derived from the tendo oculi, and on its deep surface it is crossed by the Tensor tarsi muscle (Horner's muscle, page 302), which is attached to the ridge on the lachrymal bone.

Structure.—It consists of a fibrous elastic coat, lined internally by mucous membrane, the latter being continuous, through the lachrymal canals, with the mucous lining of the conjunctiva, and, through the nasal duct, with the pituitary membrane of the nose.

The **nasal duct** is a membranous canal, about three-quarters of an inch in length, which extends from the lower part of the lachrymal sac to the inferior meatus of the nose, where it terminates by a somewhat expanded orifice, provided with an imperfect valve, the *valve of Hasner*, formed by the mucous membrane. It is contained in an osseous canal formed by the superior maxillary, the lachrymal, and the inferior turbinated bones, is narrower in the middle than at each extremity, and takes a direction downward, backward, and a little outward. It is lined by mucous membrane, which is continuous below with the pituitary lining of the nose. This membrane in the lachrymal sac and nasal duct is covered with columnar epithelium, as in the nose. This epithelium is in places ciliated.

Surface Form.—The palpebral fissure, or opening between the eyelids, is elliptical in shape, and differs in size in different individuals and in different races of mankind. In the Mongolian races, for instance, the opening is very small, merely a narrow fissure, and this makes the eyeball appear small in these races, whereas the size of the eye is relatively very constant. The normal direction of the fissure is slightly oblique, in a direction upward and outward, so that the outer angle is on a slightly higher level than the inner. This is especially noticeable in the Mongolian races, in whom, owing to the upward projection of the malar bone and the shortness of the external angular process of the frontal bone, the tarsal plate of the upper lid is raised at its outer part and gives an oblique direction to the palpebral fissure.

When the eyes are directed forward, as in ordinary vision, the upper part of the cornea is covered by the upper lid, and the lower margin of the cornea corresponds to the level of the lower lid, so that about the lower three-fourths of the cornea is exposed under ordinary circumstances. On the margins of the lids, about a quarter of an inch from the inner canthus, are two small openings, the *puncta lachrymalia*, the commencement of the lachrymal canals. They are best seen by everting the eyelids. In the natural condition they are in contact with the conjunctiva of the eyeball, and are maintained in this position by the Tensor tarsi muscle, so that the tears running over the surface of the globe easily find their way into the lachrymal canals. The position of the lachrymal sac into which the canals open is indicated by a little tubercle (page 119), which is plainly to be felt on the lower margin of the orbit. The lachrymal sac lies immediately above and to the inner side of this tubercle, and a knife passed through the skin in this situation would open the cavity. The position of the lachrymal sac may also be indicated by the tendo oculi or internal tarsal ligament. If both lids be drawn outward, so as to tense the skin at the inner angle, a prominent cord will be seen beneath the tightened skin. This is the *tendo oculi*, which lies immediately over the lachrymal sac, bisecting it, and thus forming a useful guide to its situation. A knife entered immediately beneath the tense cord would open the lower part of the sac. A probe introduced through this opening can be readily passed downward through the duct into the inferior meatus of the nose. The direction of the duct is downward, outward, and backward, and this course should be borne in mind in passing the probe, otherwise the point may be driven through the thin bony walls of the canal. A convenient plan is to direct the probe in such a manner that if it were pushed onward it would strike the first molar tooth of the lower jaw on the same side of the body. In other words, the surgeon standing in front of his patient should carry in his mind the position of the first molar tooth, and should push his probe onward in such a way as if he desired to reach this structure.

Beneath the internal angular process of the frontal bone the pulley of the Superior oblique muscle of the eye can be plainly felt by pushing the finger backward between the upper and inner angle of the eye and the roof of the orbit; passing backward and outward from this pulley, the tendon can be felt for a short distance.

Surgical Anatomy.—The eyelids are composed of various tissues, and consequently are liable to a variety of diseases. The skin which covers them is exceedingly thin and delicate, and is supported on a quantity of loose and lax subcutaneous tissue which contains no fat. In consequence of this it is very freely movable, and is liable to be drawn down by the contraction of neighboring cicatrices, and thus produce an eversion of the lid known as *ectropion*. Inversion

of the lids (*entropion*) from spasm of the Orbicularis palpebrarum or from chronic inflammation of the palpebral conjunctiva may also occur. The eyelids are richly supplied with blood, and are often the seat of vascular growths, such as nævi. Rodent ulcer also frequently commences in this situation. The loose cellular tissue beneath the skin is liable to become extensively infiltrated either with blood or inflammatory products, producing very great swelling. Even from very slight injuries to this tissue the extravasation of blood may be so great as to produce considerable swelling of the lids and complete closure of the eye, and the same is the case when inflammatory products are poured out. The follicles of the eyelashes or the sebaceous glands associated with these follicles may be the seat of inflammation, constituting the ordinary "sty." The Meibomian glands are affected in the so-called "tarsal tumor;" the tumor, according to some, being caused by the retained secretion of these glands; by others it is believed to be a neoplasm connected with the gland. The ciliary follicles are liable to become inflamed, constituting the disease known as *blepharitis ciliaris*, or "blear-eye." Irregular or disorderly growth of the eyelashes not unfrequently occurs, some of them being turned toward the eyeball and producing inflammation and ulceration of the cornea, and possibly eventually complete destruction of the eye. The Orbicularis palpebrarum may be the seat of spasm, either in the form of slight quivering of the lids or repeated twitchings, most commonly due to errors of refraction in children, or more continuous spasm, due to some irritation of the fifth or seventh cranial nerve. The Orbicularis may be paralyzed, generally associated with paralysis of the other facial muscles. Under these circumstances the patient is unable to close the lids, and, if he attempts to do so, rolls the eyeball upward under the upper lid. The tears overflow from displacement of the lower lid, and the conjunctiva and cornea, being constantly exposed and the patient being unable to wink, become irritated from dust and foreign bodies. In paralysis of the Levator palpebræ superioris there is drooping of the upper eyelid and other symptoms of implication of the third nerve. The eyelids may be the seat of bruises, wounds, or burns. In these latter injuries adhesions of the margins of the lids to each other or adhesion of the lids to the globe may take place. The eyelids are sometimes the seat of emphysema after fracture of some of the thin bones forming the inner wall of the orbit. If shortly after such an injury the patient blows his nose, air is forced from the nostril through the lacerated structures into the connective tissue of the eyelids, which suddenly swell up and present the peculiar crackling characteristic of this affection.

Foreign bodies frequently get into the conjunctival sac and cause great pain, especially if they come in contact with the corneal surface, during the movements of the lid and the eye on each other. The conjunctiva is frequently involved in severe injuries of the eyeball, but is seldom ruptured alone; the most common form of injury to the conjunctiva alone is from a burn, either from fire, strong acids, or lime. In these cases union is liable to take place between the eyelid and the eyeball. The conjunctiva is often the seat of inflammation arising from many different causes, and the arrangement of the conjunctival vessels should be remembered as affording a means of diagnosis between this condition and injection of the sclerotic, which is present in inflammation of the deeper structures of the globe. The inflamed conjunctiva is bright red; the vessels are large and tortuous, and greatest at the circumference, shading off toward the corneal margin; they anastomose freely and form a dense network, and they can be emptied or displaced by gentle pressure.

The lachrymal gland is occasionally, though rarely, the seat of inflammation, either acute or chronic; it is also sometimes the seat of tumors, benign or malignant, and for these may require removal. This may be done by an incision through the skin just below the eyebrow; and the gland, being invested with a special capsule of its own, may be isolated and removed without opening the general cavity of the orbit. The canaliculi may be obstructed, either as a congenital defect or by some foreign body, as an eyelash or a dacryolith, causing the tears to run over the cheek. The canaliculi may also become occluded as the result of burns or injury; overflow of the tears may in addition result from deviation of the puncta or from chronic inflammation of the lachrymal sac. This latter condition is set up by some obstruction to the nasal duct frequently occurring in tubercular subjects. In consequence of this the tears and mucus accumulate in the lachrymal sac, distending it. Suppuration in the lachrymal sac is sometimes met with; this may be the sequel of a chronic inflammation; or may occur after some of the eruptive fevers in cases where the lachrymal passages were previously quite healthy. It may lead to lachrymal fistula.

THE EAR.

The organ of hearing is divisible into three parts—the external ear, the middle ear or tympanum, and the internal ear or labyrinth.

The External Ear.

The **external ear** consists of an expanded portion named *pinna* or *auricle*, and the auditory canal or *meatus*. The former serves to collect the vibrations of the air by which sound is produced; the latter conducts those vibrations to the tympanum.

The **pinna**, or **auricle** (Fig. 455), is of an ovoid form, with its larger end directed

upward. Its outer surface is irregularly concave, directed slightly forward, and presents numerous eminences and depressions which result from the foldings of its fibro-cartilaginous element. To each of these, names have been assigned. Thus the external prominent rim of the auricle is called the *helix*. Another curved prominence, parallel with and in front of the helix, is called the *antihelix;* this bifurcates above, so as to enclose a triangular depression, the *fossa of the antihelix* (*fossa triangularis*). The narrow curved depression between the helix and antihelix is called the *fossa of the helix* (*Scapha*); the antihelix describes a curve round a deep, capacious cavity, the *concha*, which is partially divided into two parts by the *crus helicis* or the commencement of the helix; the upper part is termed the *cymba conchæ*, the lower part the *cavum conchæ*. In front of the concha, and projecting backward over the meatus, is a small pointed eminence, the *tragus*, so called from its being generally covered on its under surface with a tuft of hair resembling a goat's beard. Opposite the tragus, and separated from it by a deep notch (*incisura intertragica*) is a small tubercle, the *antitragus*. Below this is the *lobule*, composed of tough areolar and adipose tissue, wanting the firmness and elasticity of the rest of the pinna. Where the helix turns downward a small tubercle, the *tubercle of Darwin*, is frequently seen. This tubercle is very evident about the sixth month of fœtal life; at this stage the human pinna has a close resemblance to that of some of the adult monkeys.

The cranial surface of the pinna presents elevations which correspond to the depressions on its outer surface and after which they are named, *e. g.*, eminentia conchæ, eminentia triangularis, etc.

Structure of the Pinna.—The pinna is composed of a thin plate of yellow fibro-cartilage, covered with integument, and connected to the surrounding parts by the extrinsic ligaments and muscles; and to the commencement of the external auditory canal by fibrous tissue.

The *integument* is thin, closely adherent to the cartilage, and covered with hairs furnished with sebaceous glands, which are most numerous in the concha and scaphoid fossa. The hairs are most numerous and largest on the tragus and antitragus.

The *cartilage of the pinna* consists of one single piece: it gives form to this part of the ear, and upon its surface are found all the eminences and depressions above described. It does not enter into the construction of all parts of the auricle: thus it does not form a constituent part of the lobule; it is deficient also between the tragus and beginning of the helix, the notch between them being filled up by dense fibrous tissue. At the front part of the pinna, where the helix bends upward, is a small projection of cartilage, called the *spina helicis*, while the lower part of the helix is prolonged downward as a tail-like process, the *cauda helicis;* this is separated from the antihelix by a fissure, the *fissura antitragohelicina*. The cartilage of the pinna presents several intervals or fissures in its substance which partially separate the different parts. The fissure of the helix is a short vertical slit, situated at the fore part of the pinna. Another fissure, the fissure of the tragus, is seen upon the anterior surface of the tragus. The cartilage of the pinna is very pliable, elastic, of a yellowish color, and belongs to that form of cartilage which is known under the name of yellow fibro-cartilage.

The *ligaments of the pinna* consist of two sets: 1. The extrinsic set, or those connecting it to the side of the head. 2. The intrinsic set, or those connecting the various parts of its cartilage together.

The *extrinsic ligaments*, the most important, are two in number, anterior and posterior. The *anterior ligament* extends from the spina helicis and tragus to the root of the zygoma. The *posterior ligament* passes from the posterior surface of the concha to the outer surface of the mastoid process of the temporal bone.

The chief *intrinsic ligaments* are: (1) a strong fibrous band, stretching across from the tragus to the commencement of the helix, completing the meatus in front, and partly encircling the boundary of the concha; and (2) a band which extends

between the anti-helix and the cauda helicis. Other less important bands are found on the cranial surface of the pinna.

The *muscles of the pinna* (Fig. 456) consist of two sets: 1. The *extrinsic*, which connect it with the side of the head, moving the pinna as a whole—viz., the Attollens, Attrahens, and Retrahens auriculum (page 301); and 2. The *intrinsic*, which extend from one part of the auricle to another, viz.:

Helicis major.	Antitragicus.
Helicis minor.	Transversus auriculæ.
Tragicus.	Obliquus auriculæ.

The *Musculus helicis major* is a narrow vertical band of muscular fibres, situated upon the anterior margin of the helix. It arises, below, from the cauda helicis, and is inserted into the anterior border of the helix, just where it is about to curve backward. It is pretty constant in its existence.

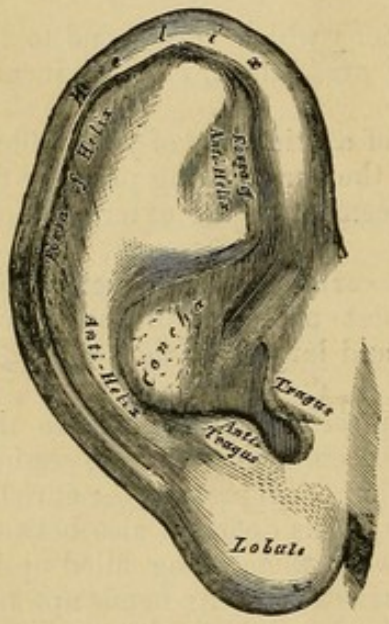

FIG. 455.—The pinna, or auricle. Outer surfaces.

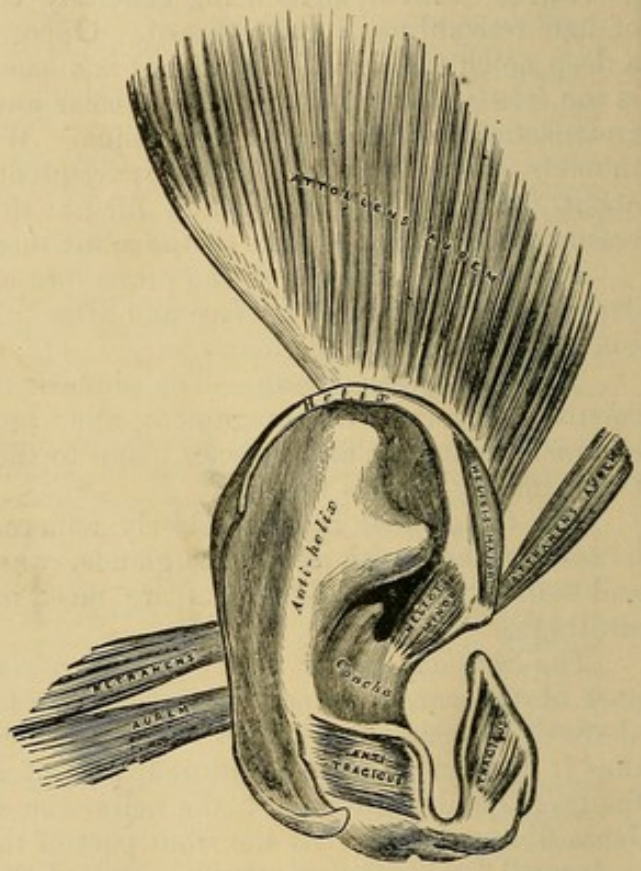

FIG. 456.—The muscles of the pinna.

The *Musculus helicis minor* is an oblique fasciculus which covers the crus helicis.

The *Tragicus* is a short, flattened band of muscular fibres situated upon the outer surface of the tragus, the direction of its fibres being vertical.

The *Antitragicus* arises from the outer part of the antitragus: its fibres are inserted into the cauda helicis and antihelix. This muscle is usually very distinct.

The *Transversus auriculæ* is placed on the cranial surface of the pinna. It consists of scattered fibres, partly tendinous and partly muscular, extending from the convexity of the concha to the prominence corresponding with the groove of the helix.

The *Obliquus auriculæ* (Tod) consists of a few fibres extending from the upper and back part of the concha to the convexity immediately above it.

The *arteries of the pinna* are the posterior auricular from the external carotid, the anterior auricular from the temporal, and an auricular branch from the occipital artery.

The *veins* accompany the corresponding arteries.

The *nerves* are: the auricularis magnus, from the cervical plexus; the auricu-

lar branch of the pneumogastric; the auriculo-temporal branch of the inferior maxillary nerve; the occipitalis minor from the cervical plexus, and the occipitalis major or internal branch of the posterior division of the second cervical nerve. The muscles of the pinna are supplied by the facial nerve.

The **Auditory Canal** (*meatus auditorius externus*) extends from the bottom of the concha to the membrana tympani (Fig. 457). It is about an inch and a half in length if measured from the tragus; from the bottom of the concha its length is about an inch. It forms a sort of S-shaped curve, and is directed at first inward, forward, and slightly upward (*pars externa*); it then passes inward and backward (*pars media*), and lastly is carried inward, forward, and slightly downward (*pars interna*). It forms an oval cylindrical canal, the greatest diameter being in the vertical direction at the external orifice, but in the transverse direction at the tympanic end. It presents two constrictions, one near the inner end of the cartilaginous portion, and another, the *isthmus*, in the osseous portion, about three-quarters of an inch from the bottom of the concha. The membrana tympani, which occupies the termination of the meatus, is obliquely directed, in consequence of which the floor of the canal is longer than the roof, and the anterior wall longer than the posterior. The auditory canal is formed partly by cartilage and membrane, and partly by bone, and is lined by skin.

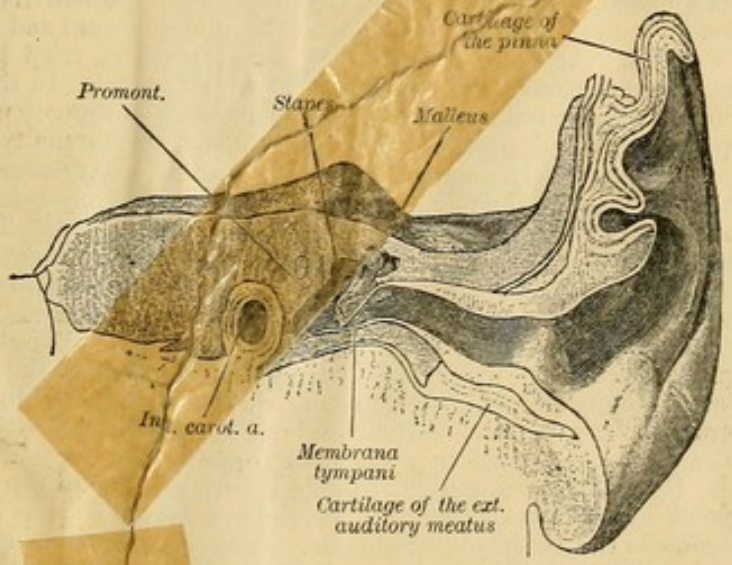

FIG. 457.—Transverse section of external anditory meatus and tympanum. Left side. (Gegenbaur.)

The *cartilaginous portion* is about one-third of an inch (8 mm.) in length, it is formed by the cartilage of the pinna, prolonged inward, and firmly attached to the circumference of the auditory process of the temporal bone. The cartilage is deficient at its upper and back part, its place being supplied by fibrous membrane. This part of the canal is rendered extremely movable by two or three deep fissures (*incisuræ Santorini*), which extend through the cartilage in a vertical direction.

The *osseous portion* is about two-thirds of an inch (16 mm.) in length, and narrower than the cartilaginous portion. It is directed inward and a little forward, forming a slight curve in its course, the convexity of which is upward and backward. Its inner end, which communicates, in the dry bone, with the cavity of the tympanum, is smaller than the outer and sloped, the anterior wall projecting beyond the posterior about two lines; it is marked, except at its upper part, by a narrow groove, the *sulcus tympanicus*, for the insertion of the membrana tympani. Its outer end is dilated and rough in the greater part of its circumference, for the attachment of the cartilage of the pinna. Its vertical transverse section is oval, the greatest diameter being from above downward. The front and lower parts of this canal are formed by a curved plate of bone, which, in the fœtus, exists as a separate ring (*annulus tympanicus*), incomplete at its upper part. See section on Osteology.

The *skin* lining the meatus is very thin, adheres closely to the cartilaginous and osseous portion of the tube, and covers the surface of the membrana tympani, forming its outer layer. After maceration the thin pouch of epidermis, when withdrawn, preserves the form of the meatus. In the thick subcutaneous tissue of the cartilaginous part of the meatus are numerous ceruminous glands, which secrete the ear-wax. They resemble in structure sweat-glands, and their ducts open on the surface of the skin.

Relations of the Meatus.—In front of the osseous part is the condyle of the mandible, which, however, is separated from the cartilaginous part by the retro-mandibular part of the parotid gland. The movements of the jaw influence to some extent the lumen of this latter portion. Behind the osseous part are the mastoid air-cells, separated from it by a thin layer of bone.

The *arteries* supplying the meatus are branches from the posterior auricular, internal maxillary, and temporal.

The *nerves* are chiefly derived from the auriculo-temporal branch of the inferior maxillary nerve and the auricular branch of the pneumogastric.

Surface Form.—At the point of junction of the osseous and cartilaginous portions the tube forms an obtuse angle, which projects into the tube at its antero-inferior wall. This produces a sort of constriction in this situation, and renders it the narrowest portion of the canal—an important point to be borne in mind in connection with the presence of foreign bodies in the ears. The cartilaginous is connected to the bony part by fibrous tissue, which renders the outer part of the tube very movable, and therefore by drawing the pinna upward and backward the canal is rendered almost straight. At the external orifice are a few short, crisp hairs which serve to prevent the entrance of small particles of dust, or flies or other insects. In the external auditory meatus the secretion of the ceruminous glands serves to catch any small particles which may find their way into the canal, and prevent their reaching the membrana tympani, where their presence might excite irritation. In young children the meatus is very short, the osseous part being very deficient, and consisting merely of a bony ring (*annulus tympanicus*), which supports the membrana tympani. In the fœtus the osseous part is entirely absent. The shortness of the canal in children should be borne in mind in introducing the aural speculum, so that it be not pushed in too far, at the risk of injuring the membrana tympani; indeed, even in the adult the speculum should never be introduced beyond the constriction which marks the junction of the osseous and cartilaginous portions. In using this instrument it is advisable that the pinna should be drawn upward, backward, and a little outward, so as to render the canal as straight as possible, and thus assist the operator in obtaining, by the aid of reflected light, a good view of the membrana tympani. Just in front of the membrane is a well-marked depression, situated on the floor of the canal and bounded by a somewhat prominent ridge; in this foreign bodies may become lodged. By aid of the speculum, combined with traction of the auricle upward and backward, the whole of the membrana tympani is rendered visible. It is a pearly-gray membrane, slightly glistening in the adult, placed obliquely, so as to form with the floor of the meatus a very acute angle, (about 55°) while with the roof it forms an obtuse angle. At birth it is more horizontal, situated in almost the same plane as the base of the skull. About midway between the anterior and posterior margins of the membrane, and extending from the centre obliquely upward, is a reddish-yellow streak; this is the handle of the malleus, which is inserted into the membrane. At the upper part of this streak, close to the roof of the meatus, a little white rounded prominence is plainly to be seen; this is the processus brevis of the malleus, projecting against the membrane. The membrana tympani does not present a plane surface; on the contrary, its centre is drawn inward, on account of its connection with the handle of the malleus, and thus the external surface is rendered concave.

The Middle Ear, or Tympanum.

The **middle ear**, or **tympanum**, is an irregular cavity, compressed from without inward, and situated within the petrous bone. It is placed above the jugular fossa; the carotid canal lying in front, the mastoid cells behind, the meatus auditorius externally, and the labyrinth internally. It is filled with air, and communicates with the naso-pharynx by the Eustachian tube. The tympanum is traversed by a chain of movable bones, which connect the membrana tympani with the labyrinth, and serve to convey the vibrations communicated to the membrana tympani across the cavity of the tympanum to the internal ear.

The tympanic cavity consists of two parts: the *atrium*, or *tympanic cavity* proper, opposite the tympanic membrane, and the *attic* or *epitympanic* recess, above the level of the upper part of the membrane; the latter contains the upper half of the

malleus and the greater part of the incus. Its diameter, including the attic, measures about 15 mm. vertically and transversely. From without inward it measures about 6 mm. above and 4 mm. below; opposite the centre of the tympanic membrane it is only about 2 mm. It is bounded externally by the membrana tympani and meatus; internally, by the outer surface of the internal ear; and communicates, behind, with the mastoid antrum and through it with the mastoid cells; and in front with the Eustachian tube and canal for the Tensor tympani. Its roof and floor are formed by thin osseous laminæ, the one forming the roof being a thin plate situated on the anterior surface of the petrous portion of the temporal bone, close to its angle of junction with the squamous portion of the same bone.

The **roof** (*paries tegmentalis*) is broad, flattened, and formed of a thin plate of bone (*tegmen tympani*), which separates the cranial and tympanic cavities. It is prolonged backward so as to roof in the mastoid antrum; it is also carried forward to cover in the canal for the Tensor tympani muscle,

The **floor** (*paries jugularis*) is narrow, and is separated by a thin plate of bone (*fundus tympani*) from the jugular fossa. It presents, near the inner wall, a small aperture for the passage of Jacobson's nerve.

The **outer wall** is formed mainly by the membrana tympani, partly by the ring of bone into which this membrane is inserted. This ring of bone is incomplete at its upper part, forming a notch (*incisura Rivini*). Close to it are three small apertures; the iter chordæ posterius, the Glaserian fissure, and the iter chordæ anterius.

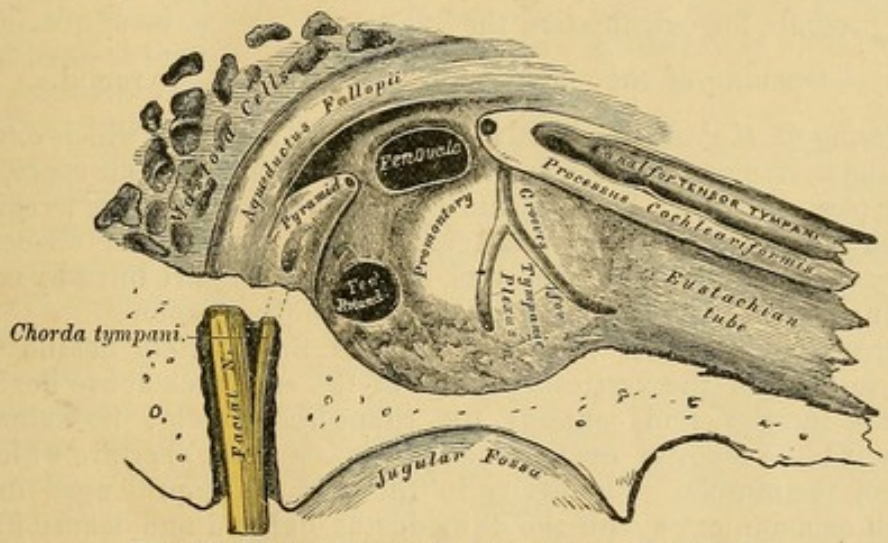

FIG. 458.—View of inner wall of tympanum. (Enlarged.)

The *iter chordæ posterius* is in the angle of junction between the posterior and external walls of the tympanum, immediately behind the membrana tympani and on a level with the upper end of the handle of the malleus; it leads into a minute canal, which descends in front of the aquæductus Fallopii, and terminates in that canal near the stylo-mastoid foramen. Through it the chorda tympani nerve enters the tympanum.

The *Glaserian fissure* opens just above and in front of the ring of bone into which the membrana tympani is inserted; in this situation it is a mere slit about a line in length. It lodges the long process and anterior ligament of the malleus, and gives passage to the tympanic branch of the internal maxillary artery.

The *iter chordæ anterius* is seen at the inner end of the preceding fissure; it leads into a canal (*canal of Huguier*), which runs parallel with the Glaserian fissure. Through it the chorda tympani nerve leaves the tympanum.

The **internal wall of the tympanum** (*paries labyrinthica*) (Fig. 458) is vertical in direction, and looks directly outward. It presents for examination the following parts:

Fenestra ovalis.	Promontory.
Fenestra rotun[illegible]	Ridge of the aquæductus Fallopii.

The *fenestra ovalis* is a reniform opening leading from the tympanum into the vestibule; its long diameter is directed horizontally, and its convex border is upward. The opening in the recent state is occupied by the base of the stapes, which is connected to the margin of the foramen by an annular ligament.

The *fenestra rotunda* is an aperture placed at the bottom of a funnel-shaped depression leading into the cochlea. It is situated below and rather behind the fenestra ovalis, from which it is separated by a rounded elevation, the *promontory;* it is closed in the recent state by a membrane (*membrana tympani secundaria*, Scarpa). This membrane is concave toward the tympanum, convex toward the cochlea. It consists of three layers: the external, or mucous, derived from the mucous lining of the tympanum; the internal, from the lining membrane of the cochlea; and an intermediate, or fibrous layer.

The *promontory* is a rounded hollow prominence, formed by the projection outward of the first turn of the cochlea; it is placed between the fenestræ, and is furrowed on its surface by three small grooves, which lodge branches of the tympanic plexus. A minute spicule of bone frequently connects the promontory to the pyramid.

The *rounded eminence of the aquæductus Fallopii*, the prominence of the bony canal in which the facial nerve is contained, traverses the inner wall of the tympanum above the fenestra ovalis, and behind that opening curves nearly vertically downward along the posterior wall.

The **posterior wall of the tympanum** (*paries mastoidea*) is wider above than below, and presents for examination the

Opening of the antrum. Pyramid.

The *opening of the antrum* is a large irregular aperture, which extends backward from the epitympanic recess and leads into a considerable air space, the *antrum mastoideum* (see page 68). The antrum communicates with large irregular cavities contained in the interior of the mastoid process, the *mastoid air-cells*. These cavities vary considerably in number, size, and form; they are lined by mucous membrane continuous with that lining the cavity of the tympanum.

The *pyramid* is a conical eminence situated immediately behind the fenestra ovalis, and in front of the vertical portion of the eminence above described; it is hollow in the interior, and contains the Stapedius muscle; its summit projects forward toward the fenestra ovalis, and presents a small aperture which transmits the tendon of the muscle. The cavity in the pyramid is prolonged into a minute canal, which communicates with the aquæductus Fallopii and transmits the nerve which supplies the Stapedius.

The **anterior wall of the tympanum** (*paries carotica*) is wider above than below; it corresponds with the carotid canal, from which it is separated by a thin plate of bone, perforated by the tympanic branch of the internal carotid artery. It presents for examination the

Canal for the Tensor tympani. Orifice of the Eustachian tube.
The processus cochleariformis.

The orifice of the canal for the Tensor tympani and the orifice of the Eustachian tube are situated at the upper part of the anterior wall, being separated from each other by a thin, delicate, horizontal plate of bone, the *processus cochleariformis*. These canals run from the tympanum forward, inward, and a little downward, to the retiring angle between the squamous and petrous portions of the temporal bone.

The *canal for the Tensor tympani* is the superior and the smaller of the two; it is rounded and lies beneath the forward prolongation of the tegmen tympani. It extends on to the inner wall of the tympanum and ends immediately above the fenestra ovalis. The processus cochleariformis passes backward below this part of the canal, forming its outer wall and floor; it expands above the anterior extremity of the fenestra ovalis and terminates by curving outward so as to form a pulley over which the tendon passes.

The *Eustachian tube* is the channel through which the tympanum communicates with the pharynx. Its length is an inch and a half (36 mm.), and its direction downward, forward, and inward, forming an angle of about 45° with the sagittal plane and one of from 30° to 40° with the horizontal plane. It is formed partly of bone, partly of cartilage and fibrous tissue.

The *osseous portion* is about half an inch in length. It commences in the anterior wall of the tympanum, below the processus cochleariformis, and, gradually narrowing, terminates at the angle of junction of the petrous and squamous portions, its extremity presenting a jagged margin which serves for the attachment of the cartilaginous portion.

The *cartilaginous portion*, about an inch in length, is formed of a triangular plate of elastic fibro-cartilage, the apex of which is attached to the margin of the inner extremity of the osseous canal, while its base lies directly under the mucous membrane of the naso-pharynx, where it forms an elevation or cushion behind the pharyngeal orifice of the tube. The upper edge of the cartilage is curled upon itself, being bent outward so as to present on transverse section the appearance of a hook; a groove or furrow is thus produced, which opens below and externally, and this part of the canal is completed by fibrous membrane. The cartilage is fixed to the base of the skull, and lies in a groove between the petrous-temporal and the greater wing of the sphenoid; this groove ends opposite the middle of the internal pterygoid plate. The cartilaginous and bony portions of the tube are not in the same plane, the former inclining downward a little more than the latter. The diameter of the canal is not uniform throughout, being greatest at the pharyngeal orifice and least at the junction of the bony and cartilaginous portions, where it is named the *isthmus;* it again expands somewhat as it approaches the tympanic cavity. The position and relations of the pharyngeal orifice are described with the anatomy of the naso-pharynx. Through this canal the mucous membrane of the pharynx is continuous with that which lines the tympanum. The mucous membrane is covered with ciliated epithelium and is thin in the osseous portion, while in the cartilaginous portion it contains many mucous glands and near the pharyngeal orifice a considerable amount of adenoid tissue, which has been named by Gerlach the *tube-tonsil*. The tube is opened during deglutition by the Salpingo-pharyngeus and Dilator tubæ muscles.

The **membrana tympani** separates the cavity of the tympanum from the bottom of the external meatus. It is a thin, semi-transparent membrane, nearly oval in form, somewhat broader above than below, and directed very obliquely downward and inward so as to form an angle of about 55° with the floor of the meatus. The greater part of its circumference is thickened to form an annular ring which is fixed in a groove, the *sulcus tympanicus*, at the inner extremity of the meatus. This sulcus is deficient superiorly at the incisure or notch of Rivinus. From the extremities of this notch two bands, the *anterior* and *posterior malleolar folds*, are prolonged to the short process of the malleus. The small, somewhat triangular part of the membrane situated above these folds is lax and thin, and is named the *membrana flaccida* of Shrapnell; in it a small orifice is sometimes seen. The handle of the malleus is firmly attached to the inner aspect of the membrane as far as its centre, which it draws inward toward the cavity of the tympanum. The outer surface of the membrane is thus concave, and the most depressed part of this concavity is named the *umbo* or *navel*.

Structure.—This membrane is composed of three layers, an external (cuticular), a middle (fibrous), and an internal (mucous). The *cuticular lining* is derived from the integument lining the meatus. The fibrous layer consists of two strata, an external, of *radial fibres*, which diverge from the handle of the malleus, and an internal, of *circular fibres*, which are plentiful around the circumference but sparse and scattered near the centre of the membrane. Branched or *dendritic* fibres, as pointed out by Grüber, are also present, especially in the posterior half of the membrane.

The arteries are derived from the deep auricular branch of the internal maxil-

lary, which ramifies beneath the cuticular layer and from the stylo-mastoid branch of the posterior auricular and tympanic branch of the internal maxillary, which are distributed on the mucous surface. The superficial veins open into the external jugular; those on the mucous surface drain themselves partly into the lateral sinus and veins of the dura mater and partly into a plexus on the Eustachian tube. The membrane receives its nervous supply from the auriculo-temporal branch of the inferior maxillary, the auricular branch of the vagus, and the tympanic branch of the glosso-pharyngeal.

Ossicles of the Tympanum (Fig. 459).

The tympanum is traversed by a chain of movable bones, three in number, the *malleus*, *incus*, and *stapes*. The first is attached to the membrana tympani, the last to the fenestra ovalis, the incus being placed between the two, and is connected to both by delicate articulations.

The **Malleus**, so named from its fancied resemblance to a hammer, consists of a head, neck, and three processes—the handle or manubrium, the processus gracilis, and the processus brevis.

The *head* is the large upper extremity of the bone; it is oval in shape, and articulates posteriorly with the incus, being free in the rest of its extent. The facet for articulation with the incus is constricted near the middle, and is divided by a ridge into an upper, larger, and lower, lesser part, which form nearly a right angle with each other. Opposite the constriction the lower margin of the facet projects in the form of a process, the *cog-tooth* or *spur* of the malleus.

The *neck* is the narrow contracted part just beneath the head; and below this is a prominence, to which the various processes are attached.

The *manubrium* is a vertical process of bone, which is connected by its outer margin with the membrana tympani. It is directed downward, inward, and backward; it decreases in size toward its extremity, where it is curved slightly forward, and flattened from within outward. On the inner side, near its upper end, is a slight projection, into which the tendon of the Tensor tympani is inserted.

The *processus gracilis* is a long and very delicate process, which passes from the eminence below the neck forward and outward to the Glaserian fissure, to which it is connected by ligamentous fibres. In the fœtus this is the longest process of the malleus, and is in direct continuity with the cartilage of Meckel.

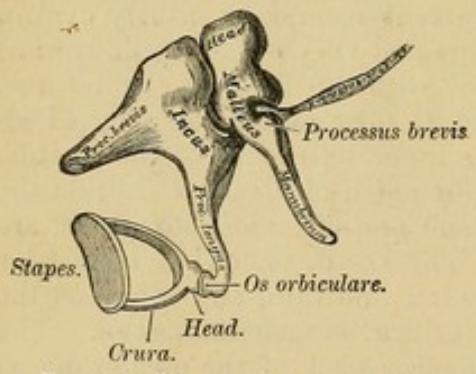

FIG. 459.—The small bones of the ear, seen from the outside. (Enlarged.)

The *processus brevis* is a slight conical projection, which springs from the root of the manubrium; it is directed outward, and is attached to the upper part of the tympanic membrane.

The **Incus** has received its name from its supposed resemblance to an anvil, but it is more like a bicuspid tooth, with two roots, which differ in length, and are widely separated from each other. It consists of a body and two processes.

The *body* is somewhat quadrilateral but compressed laterally. On its anterior surface is a deeply concavo-convex facet, which articulates with the head of the malleus; in the fresh state it is covered with cartilage and the joint lined with synovial membrane.

The two processes diverge from one another nearly at right angles.

The *short process*, somewhat conical in shape, projects nearly horizontally backward, and articulates with a depression, the *fossa incudis*, in the lower and back part of the epitympanic recess.

The *long process*, longer and more slender than the preceding, descends nearly

vertically behind and parallel to the handle of the malleus, and, bending inward, terminates in a rounded globular projection, the *os orbiculare* or *lenticular process*, which is tipped with cartilage, and articulates with the head of the stapes. In the fœtus the os orbiculare exists as a separate bone.

The **Stapes,** so called from its close resemblance to a stirrup, consists of a head, neck, two crura, and a base.

The *head* presents a depression, tipped with cartilage, which articulates with the os orbiculare.

The *neck*, the constricted part of the bone succeeding the head, receives the insertion of the Stapedius muscle.

The *two crura* diverge from the neck and are connected at their extremities by a flattened, oval-shaped plate (the *base*), which forms the foot-plate of the stirrup and is fixed to the margin of the fenestra ovalis by ligamentous fibres. Of the two crura, the anterior is shorter and less curved than the posterior.

Ligaments of the Ossicula.—These small bones are connected with each other and with the walls of the tympanum by ligaments, and moved by small muscles. The articular surfaces of the malleus and incus and the orbicular process of the incus and head of the stapes are covered with cartilage, connected together by delicate capsular ligaments and lined by synovial membrane. The ligaments connecting the ossicula with the walls of the tympanum are five in number—three for the malleus, one for the incus, and one for the stapes.

The *anterior ligament of the malleus* was formerly described by Sömmerring as a muscle (*Laxator tympani*). It is now, however, believed by most observers to consist of ligamentous fibres only. It is attached by one extremity to the neck of the malleus, just above the processus gracilis, and by the other to the anterior wall of the tympanum, close to the Glaserian fissure, some of its fibres being prolonged through the fissure to reach the spine of the sphenoid.

The *superior ligament of the malleus* is a delicate, round bundle of fibres which descends perpendicularly from the roof of the epitympanic recess to the head of the malleus.

The *external ligament of the malleus* is a triangular plane of fibres passing from the posterior part of the notch in the tympanic ring (incisura Rivini) to the short process of the malleus.

The *posterior ligament of the incus* is a short, thick, ligamentous band which connects the extremity of the short process of the incus to the posterior and lower part of the epitympanic recess, near the margin of the opening of the mastoid cells.

The inner surface and the circumference of the base of the stapes are covered with hyaline cartilage, and the *annular ligament of the stapes* connects the circumference of the base to the margin of the fenestra ovalis.

A *superior ligament of the incus* has been described by Arnold, but it is little more than a fold of mucous membrane.

The **muscles of the tympanum** are two:

Tensor tympani. Stapedius.

The *Tensor tympani*, the larger, is contained in the bony canal above the osseous portion of the Eustachian tube, from which it is separated by the processus cochleariformis. It arises from the under surface of the petrous bone, from the cartilaginous portion of the Eustachian tube, and from the osseous canal in which it is contained. Passing backward through the canal, it terminates in a slender tendon which enters the tympanum and makes a sharp bend outward round the extremity of the processus cochleariformis, and is inserted into the handle of the malleus near its root. It is supplied by a branch from the otic ganglion.

The *Stapedius* arises from the side of a conical cavity hollowed out of the interior of the pyramid; its tendon emerges from the orifice at the apex of the pyramid, and, passing forward, is inserted into the neck of the stapes. Its surface is aponeurotic, its interior fleshy, and its tendon occasionally contains a slender bony

spine, which is constant in some mammalia. It is supplied by the tympanic branch of the facial nerve.

Actions.—The Tensor tympani draws the membrana tympani inward and thus heightens its tension. The Stapedius draws the head of the stapes backward, and thus causes the base of the bone to rotate on a vertical axis drawn through its own centre: in doing this the back part of the base would be pressed inward toward the vestibule, while the fore part would be drawn from it. It probably compresses the contents of the vestibule.

The **mucous membrane of the tympanum** is continuous with the mucous membrane of the pharynx through the Eustachian tube. It invests the ossicula, and the muscles and nerves contained in the tympanic cavity; forms the internal layer of the membrana tympani, and the outer layer of the membrana tympani secundaria, and is reflected into the mastoid antrum and cells, which it lines throughout. It forms several vascular folds, which extend from the walls of the tympanum to the ossicles; of these, one descends from the roof of the tympanum to the head of the malleus and upper margin of the body of the incus, a second invests the Stapedius muscle: other folds invest the chorda tympani nerve and the Tensor tympani muscle. These folds separate off pouch-like cavities, and give the interior of the tympanum a somewhat honey-comb appearance. One of these pouches is well marked—viz., the *pouch of Prussak*, which lies between the neck of the malleus and the membrana flaccida. In the tympanum this membrane is pale, thin, slightly vascular, and covered for the most part with columnar ciliated epithelium, but that covering the pyramid, ossicula, and membrana tympani possesses a flattened non-ciliated epithelium. In the antrum and mastoid cells its epithelium is also non-ciliated. In the osseous portion of the Eustachian tube the membrane is thin; but in the cartilaginous portion it is very thick, highly vascular, covered with ciliated epithelium, and provided with numerous mucous glands.

The **arteries supplying the tympanum** are six in number. Two of them are larger than the rest—viz., the tympanic branch of the internal maxillary, which supplies the membrana tympani; and the stylo-mastoid branch of the posterior auricular, which supplies the back part of the tympanum and mastoid cells. The smaller branches are—the petrosal branch of the middle meningeal, which enters through the hiatus Fallopii; a branch from the ascending pharyngeal and another from the Vidian, which accompany the Eustachian tube; and the tympanic branch from the internal carotid, given off in the carotid canal and perforating the thin anterior wall of the tympanum.

The **veins of the tympanum** terminate in the pterygoid plexus and in the superior petrosal sinus.

The **nerves of the tympanum** constitute the tympanic plexus, which ramifies upon the surface of the promontory. The plexus is formed by (1) the tympanic branch of the glosso-pharyngeal; (2) the small deep petrosal nerve; (3) the small superficial petrosal nerve; and (4) a branch which joins the great superficial petrosal.

The *tympanic branch of the glosso-pharyngeal* (Jacobson's nerve) enters the tympanum by an aperture in its floor close to the inner wall and divides into branches, which ramify on the promontory and enter into the formation of the plexus. The *small deep petrosal nerve* from the carotid plexus of the sympathetic passes through the wall of the carotid canal, and joins the branches of Jacobson's nerve. The branch to the great superficial petrosal passes through an opening on the inner wall of the tympanum in front of the fenestra ovalis. The *small superficial petrosal nerve*, derived from the otic ganglion, passes through a foramen in the middle fossa of the base of the skull (sometimes the foramen ovale), passes backward and enters the petrous bone through a small aperture, situated external to the hiatus Fallopii on the anterior surface of this bone; it then courses downward through the bone, and, passing by the gangliform enlargement of the facial nerve, receives a connecting filament from it and enters the tympanic cavity, where

it communicates with Jacobson's nerve, and assists in forming the tympanic plexus.

The *branches of distribution* of the tympanic plexus are distributed to the mucous membrane of the tympanum; one special branch passing to the fenestra ovalis, another to the fenestra rotunda, and a third to the Eustachian tube. The small superficial petrosal may be looked upon as a branch from the plexus to the otic ganglion.

In addition to the tympanic plexus there are the nerves supplying the muscles. The Tensor tympani is supplied by a branch from the third division of the fifth through the otic ganglion, and the Stapedius by the tympanic branch of the facial.

The *chorda tympani* nerve crosses the tympanic cavity. It is given off from the facial as it passes vertically downward at the back of the tympanum, about a quarter of an inch before its exit from the stylo-mastoid foramen. It passes from below upward and forward in a distinct canal, and enters the cavity of the tympanum through an aperture, *iter chordæ posterius*, already described (page 853), and becomes invested with mucous membrane. It passes forward, through the cavity of the tympanum, crossing internal to the membrana tympani and over the handle of the malleus to the anterior inferior angle of the tympanum, and emerges from that cavity through the *iter chordæ anterius*, or *canal of Huguier*. It is invested by the fold of mucous membrane already mentioned, and therefore lies between the mucous and fibrous layers of the membrana tympani.

The Internal Ear or Labyrinth.

The **internal ear** is the essential part of the organ of hearing, receiving the ultimate distribution of the auditory nerve. It is called the **labyrinth**, from the complexity of its shape, and consists of two parts: the *osseous labyrinth*, a series of cavities channelled out of the substance of the petrous bone, and the *membranous labyrinth*, the latter being contained within the former.

The Osseous Labyrinth.

The **osseous labyrinth** consists of three parts: the *vestibule*, *semicircular canals*, and *cochlea*. These are cavities hollowed out of the substance of the bone, and

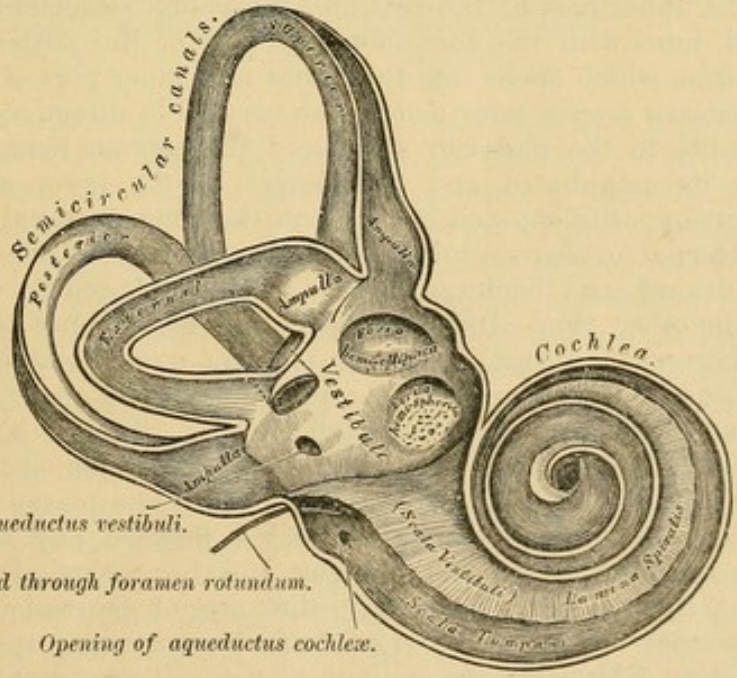

FIG. 460.—The osseous labyrinth laid open. (Enlarged.)

lined by periosteum; they contain a clear fluid, perilymph, or liquor Cotunnii, in which the membranous labyrinth is situated.

The **Vestibule** (Fig. 460) is the common central cavity of communication

between the parts of the internal ear. It is situated on the inner side of the tympanum, behind the cochlea, and in front of the semicircular canals. It is somewhat ovoidal in shape from before backward, flattened from within outward, and measures about one-fifth of an inch from before backward, as well as from above downward, and about one-eighth of an inch from without inward. On its *outer* or *tympanic wall* is the fenestra ovalis, closed, in the recent state, by the base of the stapes, and its annular ligament. On its *inner wall*, at the fore part, is a small circular depression, *fovea hemisphærica* or *recessus sphæricus*, which is perforated, at its anterior and inferior part, by several minute holes (*macula cribrosa media*) for the passage of filaments of the auditory nerve to the saccule; and behind this depression is a vertical ridge, the *crista vestibuli*. This ridge bifurcates below to enclose a small depression, the *fossa cochlearis*, which is perforated by a number of holes for the passage of filaments of the auditory nerve which supply the posterior end of the ductus cochlearis. At the hinder part of the inner wall is the orifice of the *aquæductus vestibuli*, which extends to the posterior surface of the petrous portion of the temporal bone. It transmits a small vein, and contains a tubular prolongation of the lining membrane of the vestibule, the *ductus endolymphaticus*, which ends in a *cul-de-sac* between the layers of the dura mater within the cranial cavity. On the *upper wall* or *roof* is a transversely oval depression, *fovea semi-elliptica*, separated from the fovea hemisphærica by the crista vestibuli already mentioned. *Behind*, the semicircular canals open into the vestibule by five orifices. In *front* is an elliptical opening, which communicates with the scala vestibuli of the cochlea by an orifice, *apertura scalæ vestibuli cochleæ*.

The **Semicircular canals** are three bony canals situated above and behind the vestibule. They are of unequal length, compressed from side to side, and describe the greater part of a circle. They measure about one-twentieth of an inch in diameter, and each presents a dilatation at one end, called the *ampulla*, which measures more than twice the diameter of the tube. These canals open into the vestibule by five orifices, one of the apertures being common to two of the canals.

The *superior semicircular canal* is vertical in direction, and is placed transversely to the long axis of the petrous portion of the temporal bone, on the anterior surface of which its arch forms a round projection. It describes about two-thirds of a circle. Its outer extremity, which is ampullated, communicates by a distinct orifice in the upper part of the vestibule; the opposite end of the canal, which is not dilated, joins with the corresponding part of the posterior canal to form the *crus commune*, which opens into the upper and inner part of the vestibule.

The *posterior semicircular canal*, also vertical in direction, is directed backward, nearly parallel to the posterior surface of the petrous bone; it is the longest of the three; its ampullated end commences at the lower and back part of the vestibule, its opposite end joining to form the common canal already mentioned.

The *external* or *horizontal canal* is the shortest of the three, its arch being directed outward and backward; thus each semicircular canal stands at right angles to the other two. Its ampullated end corresponds to the upper and outer angle of the vestibule, just above the fenestra ovalis, where it opens close to the ampullary end of the superior canal; its opposite end opens by a distinct orifice at the upper and back part of the vestibule.

The **Cochlea** bears some resemblance to a common snail-shell: it forms the anterior part of the labyrinth, is conical in form, and placed almost horizontally in front of the vestibule; its apex is directed forward and outward, with a slight inclination downward, toward the upper and front part of the inner wall of the tympanum; its base corresponds with the anterior depression at the bottom of the internal auditory meatus, and is perforated by numerous apertures for the passage of the cochlear division of the auditory nerve. It measures nearly a quarter of an inch (5 mm.) from base to apex, and its breadth across the base is somewhat greater (about 9 mm.). It consists of a conical-shaped central axis, the *modiolus* or *columella*; of a canal, the inner wall of which is formed by the central axis, wound spirally around it for two turns and three-quarters, from the base to the

apex, and of a delicate lamina (the *lamina spiralis ossea*) which projects from the modiolus, and, following the windings of the canal, partially subdivides into two. In the recent state certain membranous layers are attached to the free border of this lamina, which project into the canal and completely separate it into two passages, which, however, communicate with each other at the apex of the modiolus by a small opening, named the *helicotrema*.

The *modiolus* or *columella* is the central axis or pillar of the cochlea. It is conical in form, and extends from the base to the apex of the cochlea. Its base is broad, and appears at the bottom of the internal auditory meatus, where it corresponds with the area cochleæ; it is perforated by numerous orifices, which transmit filaments of the cochlear division of the auditory nerve, the nerves for the first turn and a half being transmitted through the foramina of the tractus spiralis foraminosus; the fibres for the apical turn passing up through the foramen centrale. The foramina of the tractus spiralis foraminosus pass up through the modiolus and successively bend outward to reach the attached margin of the lamina spiralis ossea. Here they become enlarged, and by their apposition form a spiral canal (*canalis spiralis modioli*), which follows the course of the attached margin of the lamina spiralis ossea and lodges the ganglion spirale. The foramen centrale is continued as a canal up the middle of the modiolus to its apex. The axis diminishes rapidly in size in the second and succeeding coil.

The bony canal of the cochlea (Fig. 461) takes two turns and three-quarters round the modiolus. It is a little over an inch in length (about 30 mm.), and

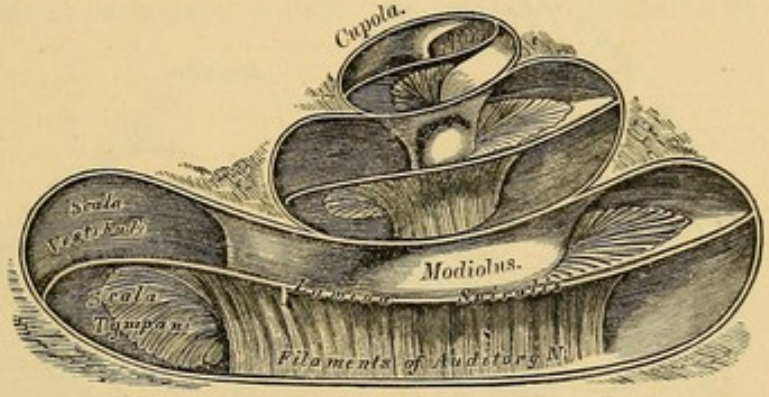

FIG. 461.—The cochlea laid open. (Enlarged.)

diminishes gradually in size from the base to the summit, where it terminates in a *cul-de-sac*, the *cupola*, which forms the apex of the cochlea. The commencement of this canal is about the tenth of an inch in diameter; it diverges from the modiolus toward the tympanum and vestibule, and presents three openings. One, the *fenestra rotunda*, communicates with the tympanum; in the recent state this aperture is closed by a membrane, the *membrana tympani secundaria*. Another aperture, of an elliptical form, enters the vestibule. The third is the aperture of the aquæductus cochleæ, leading to a minute funnel-shaped canal, which opens on the basilar surface of the petrous bone and transmits a small vein, and also forms a communication between the subarachnoidean space of the skull and the perilymph contained in the scala tympani.

The *lamina spiralis ossea* is a bony shelf or ledge which projects outward from the modiolus into the interior of the spiral canal, and, like the canal, takes two and three-quarter turns round the modiolus. It reaches about half-way toward the outer wall of the spiral tube, and partially divides its cavity into two passages or scalæ, of which the upper is named the *scala vestibuli*, while the lower is termed the *scala tympani*. Near the summit of the cochlea the lamina terminates in a hook-shaped process, the *hamulus*, which assists to form the boundary of a small opening, the *helicotrema*, by which the two scalæ communicate with each other. From the canalis spiralis modioli numerous foramina pass outward through the osseous spiral lamina as far as its outer or free edge. In the lower part of the first

turn a second bony lamina (*lamina spiralis secundaria*) projects inward from the outer wall of the bony tube; it does not, however, reach the primary osseous spiral lamina, so that if viewed from the vestibule a narrow fissure, the *fissura vestibuli*, is seen between them.

The Membranous Labyrinth (Fig. 462).

The **membranous labyrinth** is contained within the bony cavities just described, having the same general form as the cavities in which it is contained, though considerably smaller, being separated from the bony walls by a quantity of fluid, the *perilymph*. It does not, however, float loosely in this fluid, but in places is fixed to the walls of the cavity. The membranous sac contains fluid, the *endolymph*, and on it the ramifications of the auditory nerve are distributed.

Within the osseous vestibule the membranous labyrinth does not quite preserve the form of the bony cavity, but presents two membranous sacs, the *utricle* and the *saccule*. The *utricle* is the larger of the two, of an oblong form, compressed laterally, and occupies the upper and back part of the vestibule, lying in contact with the fovea semi-elliptica and the part below it. That portion which is lodged in the fovea forms a sort of pouch or *cul-de-sac*, the floor and anterior wall of which are much thicker than elsewhere, and form the *macula acustica utricularis*, which receives the utricular filaments of the auditory nerve and has attached to its

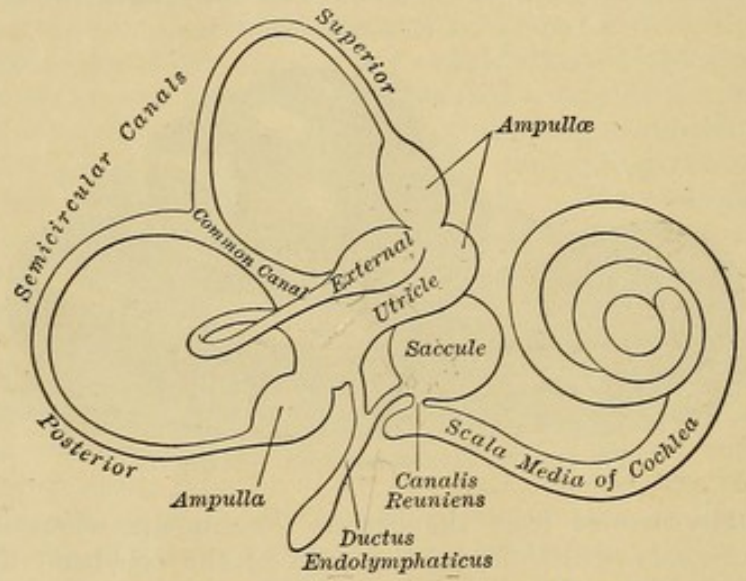

FIG. 462.—The membranous labyrinth. (Enlarged.)

internal surface a layer of calcareous particles (otoliths). The cavity of the utricle communicates behind with the membranous semicircular canals by five orifices. From its anterior wall is given off a small canal, which joins with a canal from the saccule to form the *ductus endolymphaticus*.

The *saccule* is the smaller of the two vestibular sacs; it is globular in form, lies in the fovea hemisphærica near the opening of the scala vestibuli of the cochlea. Its anterior part exhibits an oval thickening, the *macula sacculari*s, to which are distributed the saccular filaments of the auditory nerve. Its cavity does not directly communicate with that of the utricle. From the posterior wall is given off a canal, which joins with a similar canal given off from the utricle to form the *ductus endo-lymphaticus*. This duct passes along the aquæductus vestibuli and ends in a blind pouch on the posterior surface of the petrous portion of the temporal bone, where it is in contact with the dura mater. From the lower part of the saccule a short tube, the *canalis reuniens* of Hensen, passes downward and outward to open into the ductus cochlearis (Fig. 462).

The *membranous semicircular canals* are about one-third the diameter of the osseous canals, but in number, shape, and general form they are precisely similar,

and present at one end an ampullary enlargement. They open by five orifices into the utricle, one opening being common to two canals. In the ampullæ the wall is thickened, and projects into the cavity as a fiddle-shaped, transversely placed elevation, the *septum transversum*, in which the nerves end.

The utricle, saccule, and membranous canals are held in position by numerous fibrous bands which stretch across the space between them and the bony walls.

Structure.—The walls of the utricle, saccule, and semicircular canals consist of three layers. The *outer layer* is a loose and flocculent structure, apparently composed of ordinary fibrous tissue, containing blood-vessels and pigment-cells analogous to those in the pigment coat of the retina. The *middle layer*, thicker and more transparent, bears some resemblance to the hyaloid membrane, but it presents on its internal surface, especially in the semicircular canals, numerous papilliform projections, and, on the addition of acetic acid, presents an appearance of longitudinal fibrillation and elongated nuclei. The *inner layer* is formed of polygonal nucleated epithelial cells. In the maculæ of the utricle and saccule, and in the transverse septa of the ampullæ of the canals, the middle coat is thickened and the epithelium is columnar, and consists of *supporting cells* and *hair-cells*, the free ends of the latter being surmounted by a long, tapering filament (auditory hair) which projects into the cavity. The filaments of the auditory nerve enter these parts, and, having pierced the outer and thickened middle layer, they lose their medullary sheath, and their axis-cylinders ramify between the hair-cells.

Two small rounded bodies termed *otoliths*, and consisting of a mass of minute crystalline grains of carbonate of lime, held together in a mesh of delicate fibrous

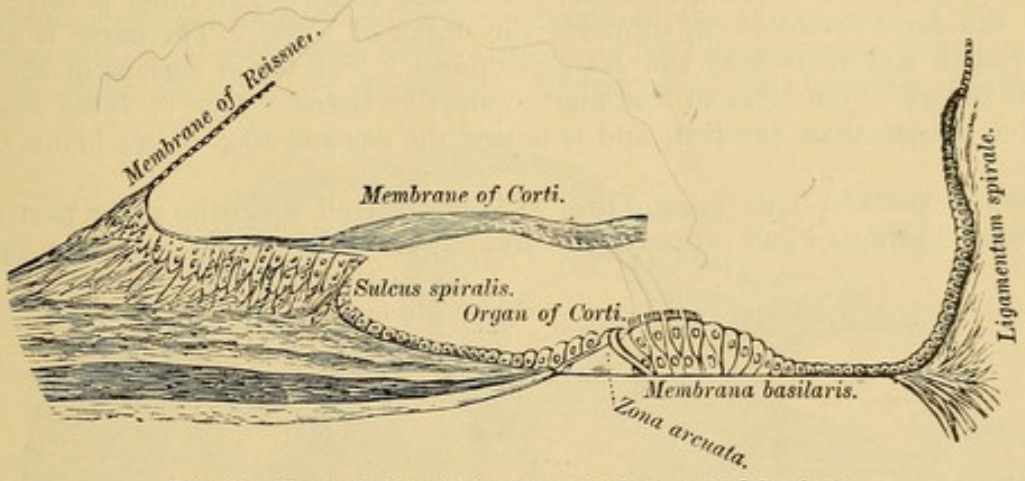

FIG. 463.—Floor of scala media, showing the organ of Corti, etc.

tissue, are contained in the walls of the utricle and saccule opposite the distribution of the nerves. A calcareous material is also, according to Bowman, sparingly scattered in the cells lining the ampullæ of the semicircular canals.

The **membranous cochlea, ductus cochlearis,** or **scala media** consists of a spirally arranged tube enclosed in the bony canal of the cochlea and lying along its outer wall. The manner in which it is formed will now be described.

The osseous spiral lamina, as above stated, extends only part of the distance between the modiolus and the outer bony wall of the cochlea. A membrane, the *membrana basilaris*, stretches from its free edge to the outer wall of the cochlea, and completes the roof of the scala tympani. A second and more delicate membrane, the *membrane* of *Reissner*, extends from the thickened periosteum covering the lamina spiralis ossea to the outer wall of the cochlea, to which it is attached at some little distance above the membrana basilaris. A canal is thus shut off between the scala tympani below and the scala vestibuli above; this is the *membranous canal of the cochlea*, *ductus cochlearis*, or *scala media*. It is triangular on transverse section, its roof being formed by the membrane of Reissner, its outer wall by the periosteum which lines the bony canal, and its floor by the

membrana basilaris, and the outer part of the lamina spiralis ossea, on the former of which is placed the organ of Corti. Reissner's membrane is thin and homogeneous, and is covered on its upper and under surfaces by a layer of epithelium. The periosteum, which forms the outer wall of the ductus cochlearis, is greatly thickened and altered in character, forming what is called the *ligamentum spirale*. It projects inward below as a triangular prominence, the *crista basilaris*, which gives attachment to the outer edge of the membrana basilaris, and immediately above which is a concavity, the *sulcus spiralis externus*. The upper portion of the ligamentum spirale contains numerous capillary loops and small blood-vessels, and forms what is termed the *stria vascularis*.

The lamina spiralis ossea consists of two plates of bone extending outward; between these are the canals for the transmission of the filaments of the auditory nerve. On the upper plate of that part of the osseous spiral lamina which is outside Reissner's membrane the periosteum is thickened to form the *limbus laminæ spiralis*, and this terminates externally in a concavity, the *sulcus spiralis internus*, which presents, on section, the form of the letter C; the upper part of the letter, formed by the overhanging extremity of the limbus, is named the *labium vestibulare;* the lower part, prolonged and tapering, is called the *labium tympanicum*, and is perforated by numerous foramina (*foramina nervosa*) for the passage of the cochlear nerves. Externally, the labium tympanicum is continuous with the membrana basilaris. The upper surface of the labium vestibulare is intersected at right angles by a number of furrows, between which are numerous elevations; these present the appearance of teeth along the free margin of the labium, and have been named by Huschke the *auditory teeth*. The basilar membrane may be divided into two areas, inner and outer. The inner is thin, and is named the *zona arcuata:* it supports the organ of Corti. The outer is thicker and striated, and is termed the *zona pectinata*. The under surface of the membrane is covered by a layer of vascular connective tissue. One of these vessels is somewhat larger than the rest, and is named the *vas spirale;* it lies below Corti's tunnel.

Organ of Corti.[1]—This organ (Fig. 464) is situated upon the inner part of the membrana basilaris, and appears at first sight as a papilla, winding spirally

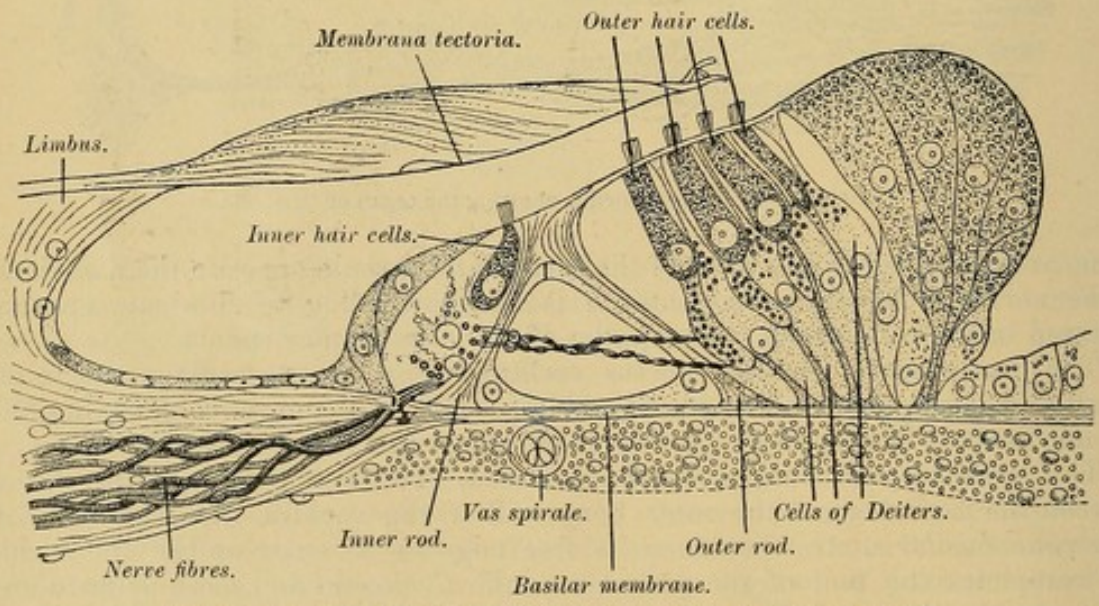

FIG. 464.—Section through the organ of Corti. Magnified. (G. Retzius.)

throughout the whole length of the ductus cochlearis, from which circumstance it has been designated the *papilla spiralis*. More accurately viewed, it is seen to be composed of a remarkable arrangement of cells, which may be likened to the keyboard of a pianoforte. Of these cells, the two central ones are rodlike bodies

[1] Corti's original paper is in the *Zeitschrift f. Wissen. Zool.*, iii., 109.

and are called the inner and outer *rods of Corti*. They are placed on the basilar membrane, at some little distance from each other, but are inclined toward each other, so as to meet at their opposite extremities, and form a series of arches roofing over a minute tunnel, the *tunnel of Corti*, between them and the basilar membrane, which ascends spirally through the whole length of the cochlea.

The *inner rods*, some 6000 in number, are more numerous than the outer ones, and rest on the basilar membrane, close to the labium tympanicum; they project obliquely upward and outward, and terminate above in expanded extremities which resemble in shape the upper end of the ulna, with its sigmoid cavity, coronoid and olecranon processes. On the outer side of the rod, in the angle formed between it and the basilar membrane, is a nucleated mass of protoplasm; while on the inner side is a row of epithelial cells (*inner hair-cells*), surmounted by a brush of fine, stiff, hairlike processes. On the inner side of these cells are two or three rows of columnar supporting cells, which are continuous with the cubical cells lining the sulcus spiralis internus.

The *outer rods*, numbering about 4000, also rest by a broad foot on the basilar membrane; they incline upward and inward, and their upper extremity resembles the head and bill of a swan: the back of the head fitting into the concavity—the analogue of the sigmoid cavity—of one or more of the internal rods, and the bill projecting outward as a phalangeal process of the membrana reticularis, presently to be described.

In the head of these outer rods is an oval portion, where the fibres of which the rod appears to be composed are deficient, and which stains more deeply with carmine than the rest of the rod. At the base of the rod, on its internal side—that is to say, in the angle formed by the rod with the basilar membrane—is a similar protoplasmic mass to that found on the outer side of the base of the inner rod; these masses of protoplasm are probably the undifferentiated portions of the cells from which the rods are developed. External to the outer rod are three or

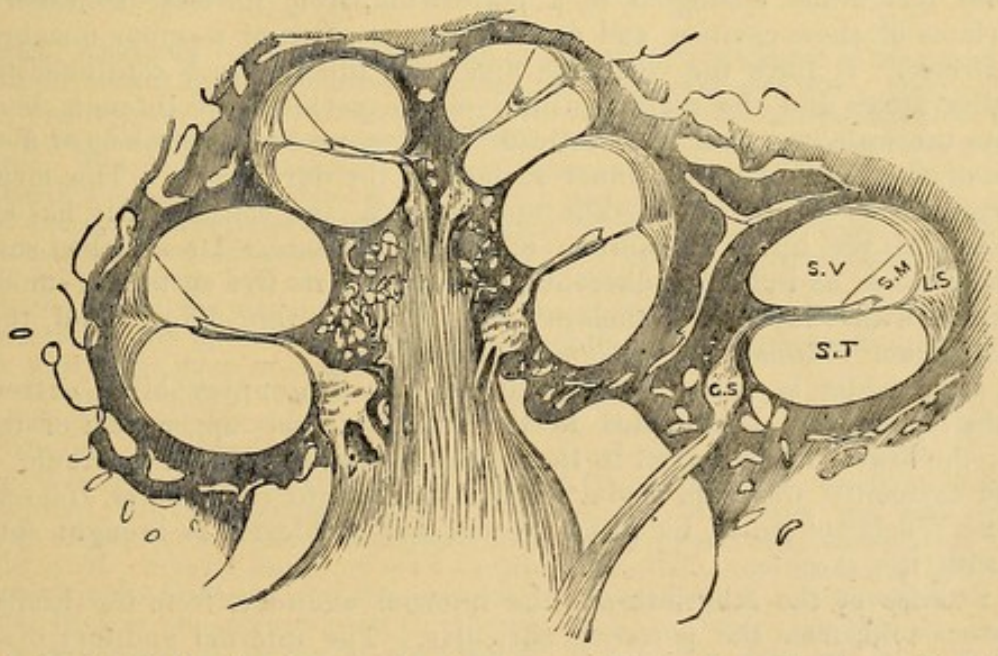

FIG. 465.—Longitudinal section of the cochlea, showing the relations of the scalæ, the ganglion spirale, etc. S. V. Scala vestibuli. S. T. Scala tympani. S. M. Scala media. L. S. Ligamentum spirale. G. S. Ganglion spirale.

four successive rows of epithelial cells, more elongated than those found on the internal side of the inner rod. but, like them, furnished with minute hairs or cilia. These are termed the *outer hair-cells*. in contradistinction to the *inner hair-cells* above referred to. There are about 12,000 outer hair-cells, and about 3500 inner hair-cells.

The hair-cells are somewhat oval in shape; their free extremities are on a level with the heads of Corti's rods, and from each some twenty fine hairlets

project and are arranged in the form of a crescent, the concavity of which opens inward. The deep ends of the cells are rounded and contain large nuclei: they reach only as far as the middle of Corti's rods, and are in contact with the ramifications of the nervous filaments. Between the rows of the outer hair-cells are rows of supporting cells, called the *cells of Deiters;* their expanded bases are planted on the basilar membrane, while their opposite ends present a clubbed extremity or *phalangeal* process. Immediately to the outer side of Deiters's cells are some five or six rows of columnar cells, the *supporting cells of Hensen.* Their bases are narrow, while their upper parts are expanded and form a rounded elevation on the floor of the ductus cochlearis. The columnar cells lying outside Hensen's cells are termed the *cells of Claudius.* A space is seen between the outer rods of Corti and the adjacent hair-cells; this is called the *space of Nuel.*

The *lamina reticularis* or *membrane of Kölliker* is a delicate framework perforated by rounded holes. It extends from the inner rods of Corti to the external row of the outer hair-cells, and is formed by several rows of "minute fiddle-shaped cuticular structures," called *phalanges*, between which are circular apertures containing the free ends of the hair-cells. The innermost row of phalanges consists of the phalangeal processes of the outer rods of Corti; the outer rows are formed by the modified free ends of Deiters's cells.

Covering over these structures, but not touching them, is the *membrana tectoria*, or membrane of Corti, which is attached to the vestibular surface of the lamina spiralis close to the attachment of the membrane of Reissner. It is thin near its inner margin, and overlies the auditory teeth of Huschke. Its outer half is thick, and along its lower edge, opposite the inner hair-cells, is a clear band, named *Hensen's stripe.* Externally, the membrane becomes much thinner, and is attached to the outer row of Deiters's cells (Retzius).

The *inner surface of the osseous labyrinth* is lined by an exceedingly thin fibro-serous membrane, analogous to a periosteum, from its close adhesion to the inner surfaces of these cavities, and performing the office of a serous membrane by its free surface. It lines the vestibule, and from this cavity is continued into the semicircular canals and the scala vestibuli of the cochlea, and through the helicotrema into the scala tympani. A delicate tubular process is prolonged along the aqueduct of the vestibule to the inner surface of the dura mater. This membrane is continued across the fenestra ovalis and rotunda, and consequently has no communication with the lining membrane of the tympanum. Its attached surface is rough and fibrous, and closely adherent to the bone; its free surface is smooth and pale, covered with a layer of epithelium, and secretes a thin, limpid fluid, the *aqua labyrinthi, liquor Cotunnii*, or *perilymph* (Blainville).

The scala media is closed above and below. The upper blind extremity is termed the *lagena*, and is attached to the cupola at the upper part of the helicotrema; the lower end is lodged in the recessus cochlearis of the vestibule. Near this blind extremity, the scala media receives the *canalis reuniens of Hensen* (Fig. 462), a very delicate canal, by which the ductus cochlearis is brought into continuity with the saccule.

The **arteries of the labyrinth** are the internal auditory, from the basilar, and the stylo-mastoid, from the posterior auricular. The internal auditory divides at the bottom of the internal meatus into two branches: cochlear and vestibular.

The cochlear branch subdivides into from twelve to fourteen twigs, which traverse the canals in the modiolus, and are distributed, in the form of a capillary network, in the substance of the lamina spiralis.

The vestibular branches accompany the nerves, and are distributed, in the form of a minute capillary network, in the substance of the membranous labyrinth.

The **veins** (auditory) of the vestibule and semicircular canals accompany the arteries, and, receiving those of the cochlea at the base of the modiolus, terminate in the posterior part of the superior petrosal sinus or in the lateral sinus.

The **auditory nerve**, the special nerve of the sense of hearing, divides, at the

bottom of the internal auditory meatus, into two branches, the cochlear and vestibular.

The *vestibular nerve*, the posterior of the two, presents, as it lies in the internal auditory meatus, a ganglion, the *ganglion of Scarpa;* it divides into three branches which pass through minute openings at the upper and back part of the bottom of the meatus (*area vestibular superior*), and, entering the vestibule, are distributed to the utricle and to the ampulla of the external and superior semicircular canals.

The nervous filaments enter the ampullary enlargements opposite the septum transversum, and arborize around the hair-cells. In the utricle and saccule the nerve-fibres pierce the membrana propria of the maculæ, and end in arborizations round the hair-cells.

The *cochlear nerve* gives off the branch to the saccule, the filaments of which are transmitted from the internal auditory meatus through the foramina of the *area vestibularis inferior*, which lies at the lower and back part of the floor of the meatus. It also gives off the branch for the ampulla of the posterior semicircular canal, which leaves the meatus through the *foramen singulare*.

The rest of the cochlear nerve divides into numerous filaments at the base of the modiolus; those for the basal and middle coils pass through the foramina in the tractus foraminosus, those for the apical coil through the canalis centralis, and the nerves bend outward to pass between the lamellæ of the osseous spiral lamina. Occupying the spiral canal of the modiolus is the *ganglion spirale*, consisting of bipolar nerve-cells, which really constitute the true cells of origin of this nerve, one pole being prolonged centrally to the brain and the other peripherally to the hair-cells of Corti's organ. Reaching the outer edge of the osseous spiral lamina, they pass through the foramina in the labium tympanicum, and end, some by arborizing around the bases of the inner hair-cells, while others pass between Corti's rods and through the tunnel, to terminate in a similar manner in relation to the outer hair-cells.

Surgical Anatomy.—Malformations, such as imperfect development of the external parts, absence of the meatus, or supernumerary auricles, are occasionally met with. Or the pinna may present a congenital fistula which is due to defective closure of the first visceral cleft, or rather of that portion of it which is not concerned in the formation of the Eustachian tube, tympanum, and meatus. The skin of the auricle is thin and richly supplied with blood, but in spite of this it is frequently the seat of frost-bite, due to the fact that it is much exposed to cold, and lacks the usual underlying subcutaneous fat found in most other parts of the body. A collection of blood is sometimes found between the cartilage and perichondrium (*hæmatoma auris*), usually the result of traumatism, but not necessarily due to this cause. It is said to occur most frequently in the ears of the insane. Keloid sometimes grows in the auricle around the puncture made for earrings, and epithelioma occasionally affects this part. Deposits of urate of soda are often met with in the pinna in gouty subjects.

The external auditory meatus can be most satisfactorily examined by light reflected down a funnel-shaped speculum; by gently moving the latter in different directions the whole of the canal and membrana tympani can be brought into view. The points to be noted are, the presence of wax or foreign bodies, the size of the canal, and the condition of the membrana tympani. The accumulation of wax is often the cause of deafness, and may give rise to very serious consequences, causing ulceration of the membrane and even absorption of the bony wall of the canal. Foreign bodies are not infrequently introduced into the ear by children, and, when situated in the first portion of the canal, may be removed with tolerable facility by means of a minute hook or loop of fine wire, with reflected light; but when they have slipped beyond the narrow middle part of the meatus, their removal is in no wise easy, and attempts to effect it, in inexperienced hands, may be followed by destruction of the membrana tympani and possibly the contents of the tympanum. The calibre of the external auditory canal may be narrowed by inflammation of its lining membrane, running on to suppuration; by periostitis; by polypi, sebaceous tumors, and exostoses. The membrana tympani, when seen in a healthy ear, "reflects light strongly, and, owing to its peculiar curvature, presents a bright spot of triangular shape at its lower and anterior portion." From the apex of this, proceeding upward and slightly forward, is a white streak formed by the handle of the malleus, while near the upper part of the membrane may be seen a slight projection, caused by the short process of the malleus. In disease alterations in color, lustre, curvature or inclination, and perforation must be noted. Such perforations may be caused by a blow, a loud report, a wound, or as the result of suppuration in the middle ear.

The upper wall of the meatus is separated from the cranial cavity by a thin plate of bone;

the anterior wall is separated from the temporo-mandibular joint and parotid gland by the bone forming the glenoid fossa; and the posterior wall is in relation with the mastoid cells; hence inflammation of the external auditory meatus may readily extend to the membranes of the brain, to the temporo-mandibular joint, or to the mastoid cells; and, in addition to this, blows on the chin may cause fracture of the wall of the meatus.

The nerves supplying the meatus are the auricular branch of the pneumogastric, the auriculo-temporal, and the auricularis magnus. The connections of these nerves explain the fact of the occurrence, in cases of any irritation of the meatus, of constant coughing and sneezing from implication of the pneumogastric, or of yawning from implication of the auriculo-temporal. No doubt also the association of earache with toothache in cancer of the tongue is due to implication of the same nerve, a branch of the fifth, which supplies also the teeth and the tongue. The vessels of the meatus and membrana tympani are derived from the posterior auricular, temporal, and internal maxillary arteries. The upper half of the membrana tympani is much more richly supplied with blood than the lower half. For this reason, and also to avoid the chorda tympani nerve and ossicles, incisions through the membrane should be made at the lower and posterior part.

The principal point in connection with the surgical anatomy of the tympanum is its relations to other parts. Its roof is formed by a thin plate of bone, which, with the dura mater, is all that separates it from the temporal lobe of the brain. Its floor is immediately above the jugular fossa behind and the carotid canal in front. Its posterior wall presents the openings of the mastoid cells. On its anterior wall is the opening of the Eustachian tube. Thus it follows that in disease of the middle ear we may get subdural abscess, septic meningitis, or abscess of the cerebrum or cerebellum from extension of the inflammation through the bony roof: thrombosis of the lateral sinus, with or without pyæmia, by extension through the floor; or mastoid abscess by extension backward. In addition to this, we may get fatal hemorrhage from the internal carotid in destructive changes of the middle ear; and in throat disease we may get the inflammation extending up the Eustachian tube to the middle ear. The Eustachian tube is accessible from the nose. If the nose and mouth be closed and an attempt made to expire air, a sense of pressure with dulness of hearing is produced in both ears, from the air finding its way up the Eustachian tube and bulging out the membrana tympani. During the act of swallowing, the pharyngeal orifice of the tube, which is normally closed, is opened, probably by the action of the Dilator tubea muscle. This fact was employed by Politzer in devising an easy method of inflating the tube. The nozzle of an india-rubber syringe is inserted into the nostril; the patient takes a mouthful of water and holds it in his mouth; both nostrils are closed with the finger and thumb to prevent the escape of air, and the patient is then requested to swallow; as he does so the air is forced out of the syringe into his nose, and is driven into the Eustachian tube, which is now open. The impact of the air against the membrana tympani can be heard, if the membrane is sound, by means of a piece of india-rubber tubing, one end of which is inserted into the meatus of the patient's ear, the other into that of the surgeon. The direct examination of the Eustachian tube is made by the Eustachian catheter. This is passed along the floor of the nostril, close to the septum, with the point touching the floor, to the posterior wall of the pharynx. When this is felt, the catheter is to be withdrawn about half an inch, and the point rotated outward through a quarter of a circle, and pushed again slightly backward, when it will enter the orifice of the tube, and will be found to be caught, and air forced into the catheter will be heard impinging on the tympanic membrane if the ears of the patient and surgeon are connected by an india-rubber tube.

THE ORGANS OF DIGESTION.

THE Apparatus for the Digestion of the Food consists of the alimentary canal and of certain accessory organs.

The **alimentary canal** is a musculo-membranous tube, about thirty feet in length, extending from the mouth to the anus, and lined throughout its entire extent by mucous membrane. It has received different names in the various parts of its course: at its commencement, the mouth, we find provision made for the mechanical division of the food (*mastication*), and for its admixture with a fluid secreted by the salivary glands (*insalivation*); beyond this are the organs of deglutition, the pharynx and the œsophagus, which convey the food into that part of the alimentary canal (the stomach) in which the principal chemical changes occur, and in which the reduction and solution of the food take place; in the small intestines the nutritive principles of the food (the *chyle*) are separated, by its admixture with the bile, pancreatic and intestinal fluids, from that portion which passes into the large intestine, most of which is expelled from the system.

Alimentary Canal.

Mouth.
Pharynx.
Œsophagus.
Stomach.
Small intestine { Duodenum. Jejunum. Ileum.
Large intestine { Cæcum. Colon. Rectum.

Accessory Organs.

Teeth.
Salivary glands { Parotid. Submaxillary. Sublingual.
Liver.
Pancreas.
Spleen.

THE MOUTH.

The **mouth** (*oral* or *buccal cavity*) is placed at the commencement of the alimentary canal; it is a nearly oval-shaped cavity, in which the mastication of the food takes place (Fig. 466). It consists of two parts; an outer, smaller portion, the vestibule (vestibulum oris), and an inner, larger part, the cavity proper of the mouth (cavum oris proprium).

The *vestibulum oris* is a slit-like aperture, bounded in front and laterally by the lips and cheeks; behind and internally by the gums and teeth. Above and below it is limited by the reflection of the mucous membrane from the lips and cheeks to the gum covering the upper and lower alveolar arch respectively. It receives the secretion from the parotid glands, and communicates, when the jaws are closed, with the cavum oris by an aperture on each side behind the wisdom teeth.

The *cavum oris proprium* is bounded laterally and in front by the alveolar arches with their contained teeth; behind it communicates with the pharynx by a constricted aperture termed the *isthmus faucium*. It is roofed in by the hard and soft palate, while the greater part of the floor is formed by the tongue, the remainder being completed by the reflection of the mucous membrane from the sides and under surface of the tongue to the gum lining the inner aspect of the mandible. It receives the secretion from the submaxillary and sublingual glands.

The *mucous membrane* lining the mouth is continuous with the integument at the free margin of the lips and with the mucous lining of the pharynx behind; it is of a rose-pink tinge during life, and very thick where it covers the hard parts bounding the cavity. It is covered by stratified epithelium.

The **lips** are two fleshy folds which surround the orifice of the mouth, formed

externally by integument and internally by mucous membrane, between which are found the Orbicularis oris muscle, the coronary vessels, some nerves, areolar tissue, and fat, and numerous small labial glands. The inner surface of each lip is connected in the middle line to the gum of the corresponding jaw by a fold of mucous membrane, the *frænum labii superioris* and *inferioris*—the former being the larger of the two.

The *labial glands* are situated between the mucous membrane and the Orbicularis oris round the orifice of the mouth. They are rounded in form, about the size of small peas, their ducts opening by small orifices upon the mucous membrane. In structure they resemble the salivary glands.

The **cheeks** form the sides of the face and are continuous in front with the lips. They are composed externally of integument, internally of mucous membrane, and between the two of a muscular stratum, besides a large quantity of fat, areolar tissue, vessels, nerves, and buccal glands.

The *mucous membrane* lining the cheek is reflected above and below upon the gums, where its color becomes lighter; it is continuous behind with the lining mem-

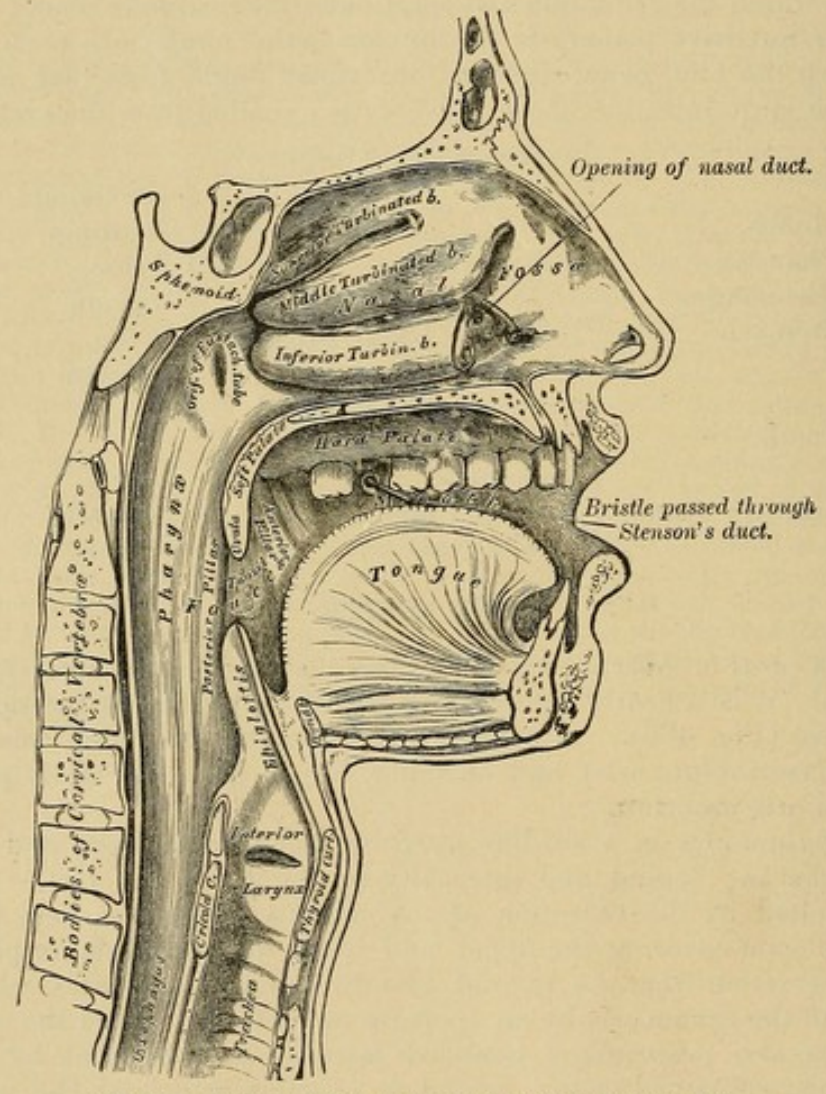

FIG. 466.—Sectional view of the nose, mouth, pharynx, etc.

gums, and it is continuous behind with the lining membrane of the soft palate. Opposite the second molar tooth of the upper jaw is a papilla, the summit of which presents the aperture of the duct of the parotid gland. The principal muscle of the cheek is the Buccinator, but numerous other muscles enter into its formation —viz., the Zygomatici, Risorius Santorini, and Platysma myoides.

The *buccal glands* are placed between the mucous membrane and Buccinator muscle: they are similar in structure to the labial glands, but smaller. Two or three of larger size than the rest are placed between the Masseter and Buccinator muscles; their ducts open into the mouth opposite the last molar tooth. They are called *molar glands*.

The **gums** are composed of a dense fibrous tissue closely connected to the

periosteum of the alveolar processes and surrounding the necks of the teeth. They are covered by smooth and vascular mucous membrane, which is remarkable for its limited sensibility. Around the necks of the teeth this membrane presents numerous fine papillæ; and from this point it is reflected into the alveolus, where it is continuous with the periosteal membrane lining that cavity.

THE TEETH.

The human subject is provided with two sets of teeth, which make their appearance at different periods of life. The first set appear in childhood, and are called the *temporary*, *deciduous*, or *milk teeth*. The second set are named *permanent*.

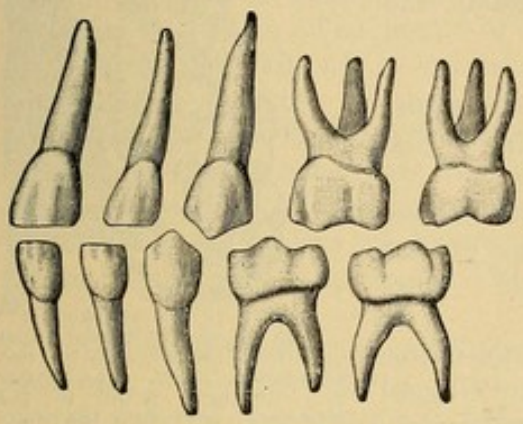

FIG. 467.—Deciduous teeth. Left side.

The *temporary teeth* are twenty in number—four incisors, two canine, and four molars, in each jaw (Fig. 467).

The *permanent teeth* are thirty-two in number—four incisors (two central and two lateral), two canines, four bicuspids, and six molars in each jaw (Fig. 468).

General Characters.—Each tooth consists of three portions: the *crown*, or *body*, projecting above the gum; the *root*, or *fang*, entirely concealed within the alveolus; and the *neck*, the constricted portion, between the root and crown.

The *surfaces* of a tooth are named thus: that which looks toward the lips is the *labial;* that toward the tongue is the *lingual;* that toward the mesial line, *proximal;* that away from the same, *distal;* that toward the cheek, the *buccal* surface. This applies to the roots as well as to the crowns of teeth.

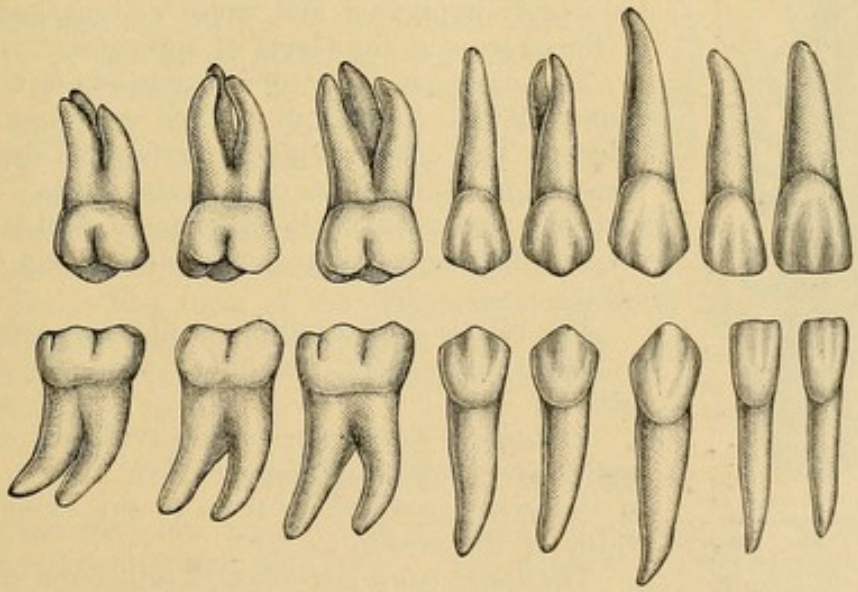

FIG. 468.—Permanent teeth. Right side (Burchard).

The *roots of the teeth* are firmly implanted within the alveoli (Fig. 472); these depressions are lined with periosteum (the pericementum) which is reflected on to the tooth at the point of the root and covers it as far as the neck. At the margin of the alveolus the periosteum becomes continuous with the fibrous structure of the gums.

Permanent Teeth (Figs. 469 and 470).

The **incisors**, or cutting teeth, are so named from their presenting a sharp cutting edge, adapted for incising the food. They are eight in number, and comprise the four front teeth in each jaw.

The *crown* is directed almost vertically and is spade-like in form; it has the form of a truncated cone whose top has been compressed into a sharp horizontal cutting edge. Before being subjected to attrition this edge presents three small elevations. *The labial* surface is convex, and marked by three longitudinal ridges extending from the edge tubercles toward the neck of the tooth. The *lingual* surface is concave, and is marked by two marginal ridges extending from an encircling ridge at the neck to the angles of the cutting edge of the tooth. The ridge at the neck is termed the cingulum or basal ridge.

The *mesial* and *distal surfaces* are triangular, the apex of the triangle at the cutting edge.

The *neck* of the tooth is constricted.

The *root* is long, single, and has the form of a transversely flattened cone, thicker before than behind. The root may be curved.

The *incisors of the upper jaw* are altogether larger and stronger than those of the lower jaw, the central incisors being larger and flatter than the laterals. They are directed obliquely downward and forward.

The *incisors of the lower jaw* are smaller and flatter than the upper, and the elevations upon their lingual faces are not marked. The two central are smaller than the two lateral incisors, being the smallest of all the teeth. The roots of these teeth are flattened laterally.

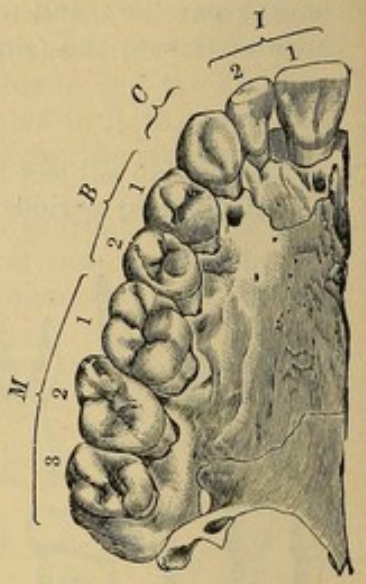

FIG. 469.—Right half of upper jaw (from below), with the corresponding teeth. The letters and numbers point to the classes of teeth and the numbers in classes.

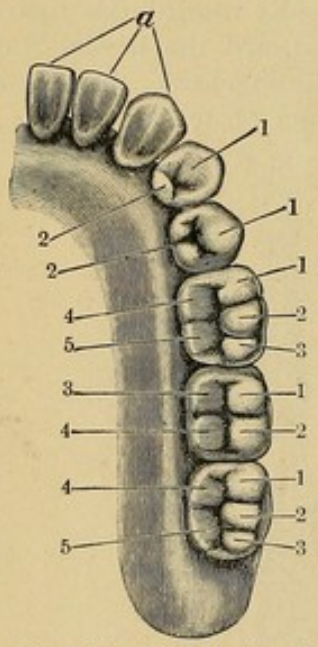

FIG. 470.—Right half of lower jaw, with the corresponding teeth. The letter and numbers point to the various cusps or their modifications on the different teeth (Burchard).

The *canine teeth* (cuspidati) are four in number, two in the upper, two in the lower jaw—one being placed distal to each lateral incisor. They are larger and stronger than the incisors, especially in the roots, which are deeply implanted and cause well-marked prominence of the process at the places of insertion.

The *crown* is large, of spear-head, form and its very convex labial surface is marked by three longitudinal ridges. The concave labial surface is also marked by three ridges which unite at a basal ridge. The point or cusp is longer than in the other teeth, and is the point of division between a short mesial and a long distal cutting edge.

The *root* is oval or elliptical in transverse section, and is longer and more prominent than the roots of the incisors.

The *upper canines* or cuspids (vulgarly called the eye teeth) are larger and longer than the two lower, and in occlusion are distal to them to the extent of half the width of the crown.

The *lower canines* (vulgarly called the stomach teeth) have the general form of the upper cuspids, but their lingual surfaces are much more flattened, owing to the absence of the elevations marking the upper. Their roots are more flattened and may be bifid at their apices.

The **bicuspid teeth** (premolars) are eight in number, four in each jaw; they are placed distal to the cuspid teeth, two upon each side. They are double cuspids in form.

The *crown* is surmounted by two cusps, one buccal and one lingual, separated by a groove, the buccal being more prominent and larger than the lingual. The lower bicuspids are not truly bicuspid, the first having but a primitive lingual cusp, the second having the lingual cusp divided into two sections—*i. e.* it is usually tricuspid.

The *necks* of the teeth are oval; the roots are laterally compressed, that of the

first upper bicuspid being frequently bifid. The first upper bicuspid is usually the largest of the series.

The **molar teeth** (*multicuspidati;* or grinders) are the largest teeth of the denture. They are adapted by their forms for the crushing and grinding of the food. They are twelve in number, six in each jaw, three being placed posterior to each second bicuspid.

The *crowns* are cuboidal in form, are convex buccally and lingually; they are flattened mesially and distally. They are formed by the fusion of three primitive cuspids in the upper and four in the lower. To these are added in the first and second upper molars a disto-lingual tubercle, and in the first and third molars of the lower jaw a disto-buccal tubercle. The unions of the primitive forms are marked by sulci. The necks of these teeth are large and rhomboidal in form.

The *roots* of the upper molars are three in number—one large lingual and two smaller buccal roots. In the lower, two roots are found, a mesial and a distal, each of which is much flattened from before backward.

The *first molar teeth* are the largest of the dental series: they have four cusps on the upper and five in the lower—three buccal and two lingual.

The *second molars* are smaller; the crown of the upper is compressed until the disto-lingual cusp is reduced. The crowns of the lower are almost rectangular, with a cusp at each angle.

The *third molars* are called the wisdom teeth (*dentes sapientiæ*) from their late eruption: they have three cusps upon the upper and five upon the lower. The three roots of the upper are frequently fused together, forming a grooved cone, which is usually curved backward. The roots of the lower, two in number, are compressed together and curve backward.

Temporary Teeth (Figs. 467 and 471).

The **temporary** or **milk teeth** are smaller, but resemble in form those of the permanent set. The neck is more marked, owing to the greater degree of convexity of the labial and lingual surfaces of the crown. The hinder of the two temporary molars is the largest of all the deciduous teeth, and is succeeded by the second bicuspid. The first upper molar has only three cusps—two labial, one lingual; the second upper molar has four cusps. The first lower molar has four cusps; the second lower molar has five. The roots of the temporary molar teeth are smaller and more diverging than those of the permanent set, but in other respects bear a strong resemblance to them.

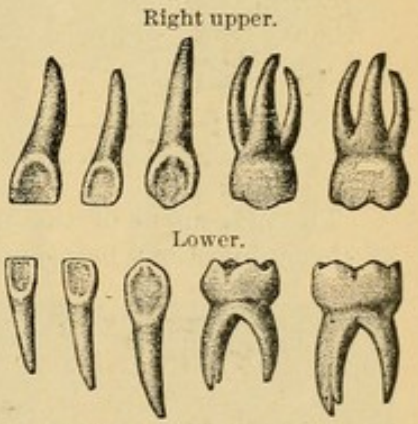

FIG. 471.—Deciduous teeth. Lingual view.

Arrangement of the Teeth.[1]

The human teeth are arranged in two parabolic arches, the upper arch being larger, its teeth overlapping the lower. The average distance between the centres of the condyles of the inferior maxillary bones is about four inches, which is also the distance from either of these points to the line of junction between the lower incisor teeth. Whether the jaw be large or small, the equilateral triangle indicated is included in it; the range of size is between $3\frac{1}{2}''$–$4\frac{1}{2}''$.

Owing to the smaller sizes of the lower incisors, the teeth of the lower jaw are each one half a tooth in advance of its upper fellow, so that each tooth of the dental series has two antagonists, with the exception of the lower central incisors and upper third molars (Figs. 472, 473).

The grinding faces of the upper bicuspids and molars curve progressively upward and point outward, the first molar being at the lowest point of the curve,

[1] After Dr. W. G. A. Bonwill.

the third molar at the highest. The curve of the lower dental arch is the reverse, the first molar at its deepest part, the third molar at its extremity. The greater the depth to which the upper incisors overlap the lower, the more marked this curve and the more pointed are the cusps of the grinding teeth.

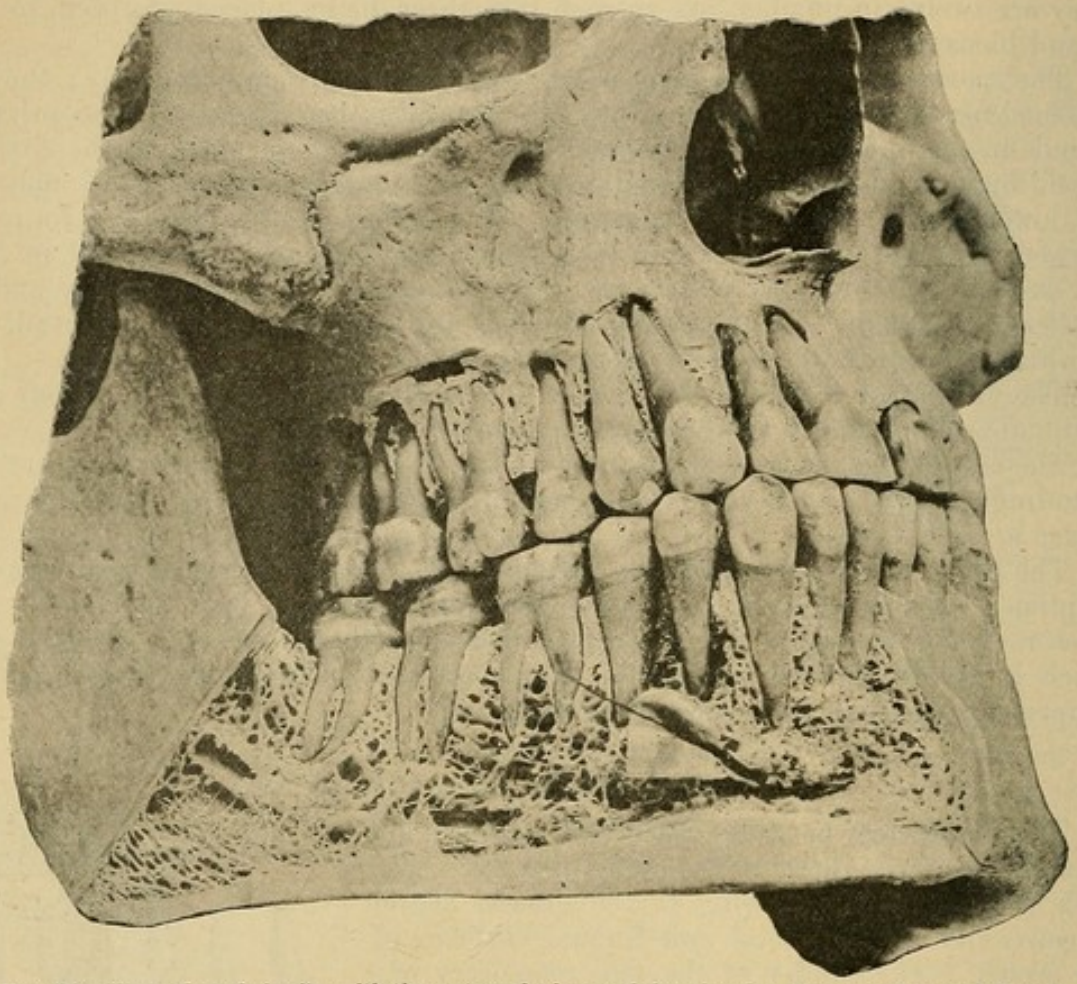

FIG. 472.—View of teeth *in situ*, with the external plates of the alveolar processes removed (Cryer).

The movement of the human mandible is forward and downward, the resultant of these directions being an oblique line, upon an average 35° from the horizontal plane.[1] When the lower jaw is advanced until the cutting edges of the incisors are in contact, the jaws are separated, but as the highest point of the lower arch, its third molar advances, it meets and rests upon a high point, second molar of the upper arch, and thus undue strain of the incisors is obviated.

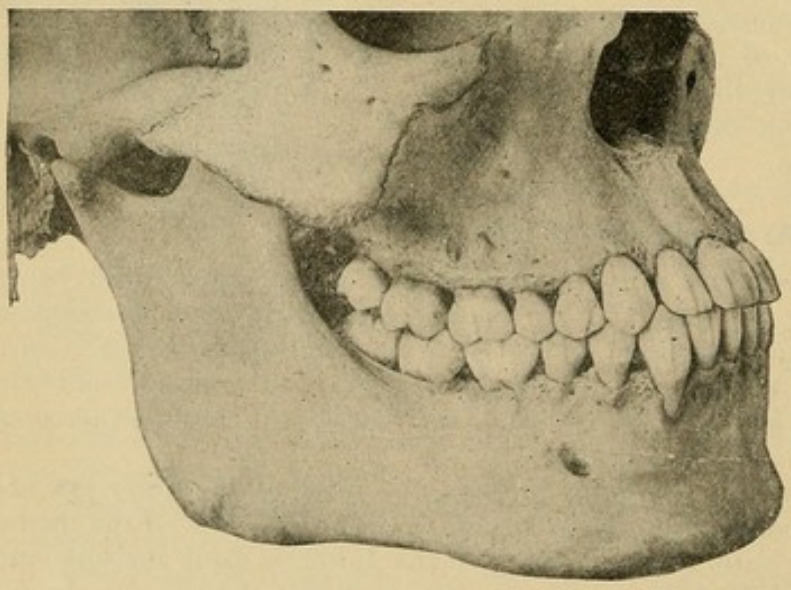

FIG. 473.—Front and side views of the teeth and jaws.

In the lateral movements of the mandible but one side is in effective action at one time; the oblique positions of the cusps of the opposite teeth are such that when either side is in action the other is balanced at two or more points.

[1] W. E. Walker, *Dental Cosmos*, 1896.

There is an anatomical correspondence between the forms and arrangement of the teeth, the form of the condyle of the inferior maxilla, and the muscular arrangement. Individuals who have teeth with long cusps have the head of the bone much rounded from before behind, and have a preponderance of the direct over the oblique muscles of mastication, and *vice versâ;* teeth with short or no cusps are associated with a flattened condyle and strong oblique muscles.

Very great aberrations in the dental arrangement are frequently followed by accomodative changes in the heads of the inferior maxilla.

Structure of the Teeth.

The Dental Pulp.—A longitudinal section of a tooth will show the presence of a central chamber having the general form of the crown of the tooth. Processes of the chamber pass from its body, one for each root and down each root, and open at

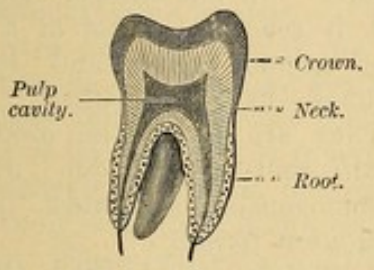

FIG. 474.—Vertical section of a molar tooth.

the apex by a minute orifice, the apical foramen. This cavity is known as the pulp-chamber, the minute canals the pulp-canals. The cavity contains a soft, vascular, and sensitive organ called the dental pulp. It is made up of myxomatous tissues, and contains numerous blood-vessels and nerves, which enter by way of the apical foramina. It does not possess lymphatics. The periphery of the pulp is bounded by a layer of cells arranged like columnar epithelium, each cell sending one or more branched processes through the basic substance of the dentine. These are the dentine-forming cells, the odontoblasts of Waldeyer. The blood-vessels break up into innumerable capillary loops which lie beneath the layer of odontoblasts. The nerve-fibrils break up into numberless non-medullary filaments, which spread out beneath the odontoblasts, and probably send terminal filaments to the extreme periphery of the pulp outside the odontoblasts.

The matrix cells and their processes are irregularly arranged in the body of the pulp, but in the canal portion the fibrillæ are in the direction of the axis of the root.

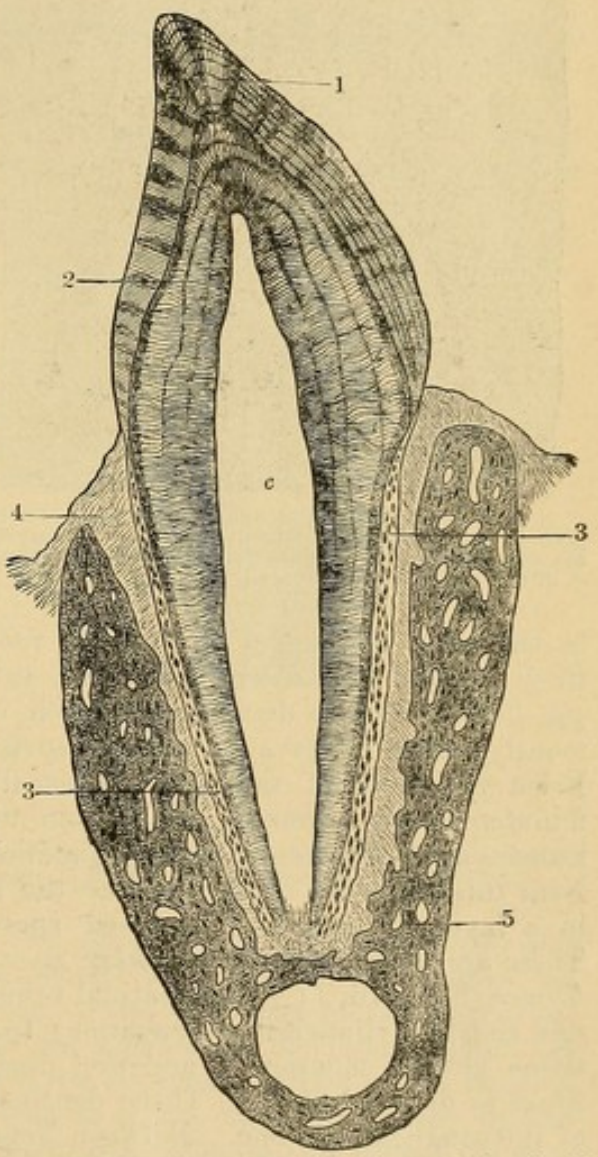

FIG. 475.—Vertical section of a tooth *in situ* (15 diameters). c is placed in the pulp-cavity, opposite the cervix or neck of the tooth; the part above is the crown, that below is the root (fang). 1. Enamel with radial and concentric markings. 2. Dentine with tubules and incremental lines. 3. Cement or crusta petrosa, with bot. corpuscles. 4. Dental periosteum. 5. Bone of lower jaw.

The section will exhibit three hard tissues in a tooth, one forming the greater mass of the tooth; hence its name *dentine* (the ivory). The dentine upon the crown is sheathed by a layer called the enamel; the dentine of the root is enclosed

in a distinct tissue, the cementum or crusta petrosa; both cementum and enamel are thinnest at the neck and thickest upon their distal portions.

The **solid portion** of the tooth consists of three distinct structures—viz. the proper dental substance, which forms the larger portion of the tooth, the *ivory* or *dentine;* a layer which covers the exposed part of the crown, the *enamel;* and a thin layer, which is disposed on the surface of the fang, the *cement* or *crusta petrosa.*

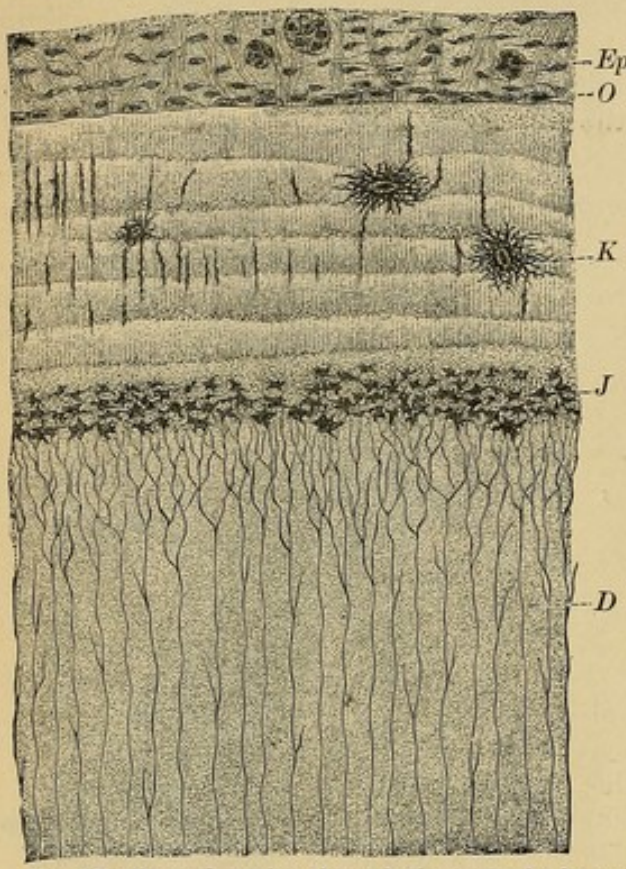

FIG. 476.—Ground section through the root of a human premolar: *D*, dentine; *K*, cement corpuscles; *O*, osteoblasts; *Ep.*, remains of Hertwig's epithelial sheath, 200 diameters; *J*, interglobular spaces (Röse).

The **ivory**, or **dentine** (Fig. 475), forms the principal mass of a tooth; in its central part is the cavity enclosing the pulp. It is a modification of osseous tissue, from which it differs, however, in structure. On microscopic examination it is seen to consist of a number of minute wavy and branching tubes having *distinct parietes.* They are called the *dentinal tubuli*, and are imbedded in a dense homogeneous substance, the *intertubular tissue.*

The *dentinal tubuli* (Fig. 476) are placed parallel with one another, and open at their inner ends into the pulp-cavity. In their course to the periphery they present two or three curves, and are twisted on themselves in a spiral direction. The direction of these tubes varies: they are vertical in the upper portion of the crown, oblique in the neck and upper part of the root, and toward the lower part of the root they are inclined downward. The tubuli, at their commencement, are about $\frac{1}{4500}$ of an inch in diameter; in their course they divide and subdivide dichotomously, so as to give to the cut surface of the dentine a striated appearance. From the sides of the tubes, especially in the root, ramifications of extreme minuteness are given off, which join together in loops in the intertubular substance, or terminate in small dilatations, from which branches are given off. Near the periphery of the dentine the finer ramifications of the tubuli terminate in a layer of irregular branched spaces which communicate with each other. These are called the *interglobular spaces of Czermak*, or the *granular layer of Tomes* (Fig. 476, *J*). The dentinal tubuli have comparatively thick walls, and contain slender cylindrical prolongations from the processes of the cells of the pulp-tissue already mentioned, and first described by Mr. Tomes and named Tomes's fibres or dentinal fibres. These dentinal fibres are analogous to the soft contents of the canaliculi of bone. Between Tomes's fibres and the ivory around the canals there is a tissue which is markedly resistant to the action of acids—the *dentinal sheath of Neumann.*

The *intertubular substance* or *tissue* is translucent, and contains the chief part of the earthy matter of the dentine. After the earthy matter has been removed by steeping a tooth in weak acid the animal basis remaining may be torn into laminæ which run parallel with the pulp-cavity across the direction of the tubules. These laminæ show the method of growth to be by deposition of successive strata of dentine. Fibrils have been found in the matrix of the intertubular substance, and are probably continuous with the dentinal fibres of Tomes. In a *dry* tooth a

section of dentine often displays a series of lines—the *incremental lines of Salter*—which are parallel with the laminæ above mentioned. These lines are caused by two facts: (1) The imperfect calcification of the dentinal laminæ immediately adjacent to the line; (2) The drying process, which reveals these defects in the calcification. These lines are wide or narrow according to the number of laminæ involved, and along their course, in consequence of the imperfection in the calcifying process, little irregular cavities are left, which are the *interglobular spaces* already referred to. They have received their name from the fact that they are surrounded by minute nodules or globules of dentine. Other curved lines may be seen parallel to the surface. These are the *lines of Schreger*, and are due to the optical effect of simultaneous curvature of the dentinal tubules.

Chemical Composition.—According to Berzelius and Bibra, dentine consists of 28 parts of animal and 72 of earthy matter. The animal matter is resolvable by boiling into gelatin. The earthy matter consists of phosphate and carbonate with calcium, with a trace of fluoride of calcium, phosphate of magnesia, and other salts.

The **enamel** is the hardest and most compact part of a tooth, and forms a thin crust over the exposed part of the crown as far as the commencement of the root. It is thickest on the grinding surface of the crown until worn away by attrition, and becomes thinner toward the neck. It consists of a congeries of minute hexagonal rods, columns, or prisms. They lie parallel with one another, resting by one extremity upon the dentine, which presents a number of minute depressions for their reception, and forming the free surface of the crown by the other extremity. These fibres are directed vertically on the summit of the crown,

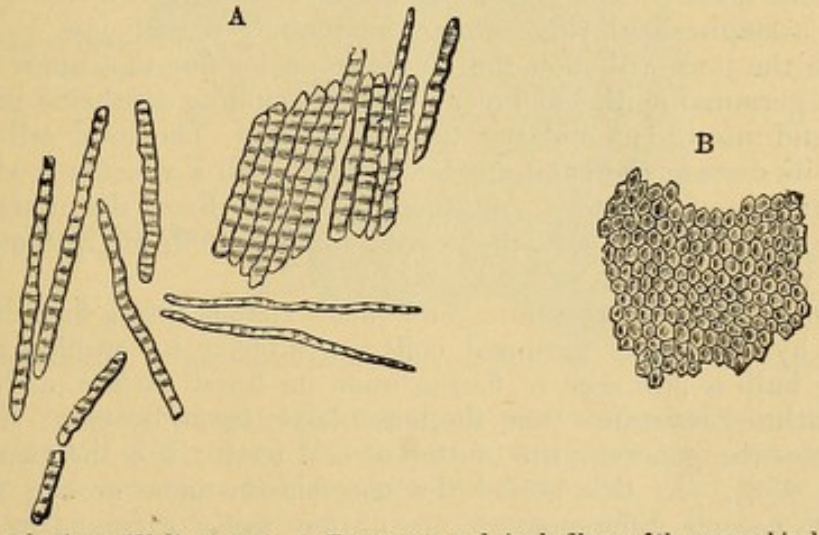

FIG. 477.—Enamel prisms (350 diameters). A. Fragments and single fibres of the enamel isolated by the action of hydrochloric acid. B. Surface of a small fragment of enamel, showing the hexagonal ends of the fibres.

horizontally at the sides; they are about the $\frac{1}{5500}$ of an inch in diameter, and pursue a more or less wavy course. Each enamel rod is crossed by a series of dark transverse lines, which mark the mode of the formation of the rods (Fig. 477). Another series of lines, having a brown appearance, and denominated the *parallel striæ of Retzius*, or the *colored lines*, are seen on a section of the enamel. These lines are concentric and *cross* the enamel rods. They are caused by the mode of enamel deposition. Inasmuch as the enamel columns, when near the dentine, cross each other and only become parallel farther away, a series of radial markings, light and dark alternately, is obtained (Fig. 475).

Numerous minute interstices intervene between the enamel-fibres near their dentinal surface. It is noted in rare cases that the dentinal fibres penetrate a certain distance between the rods of the enamel. No nutritive canals exist in the enamel.

Chemical Composition.—According to Bibra, enamel consists of 96.5 per cent. of earthy matter and 3.5 per cent. of animal matter. The earthy matter consists

of the phosphate with the carbonate of calcium, with traces of fluoride of calcium, phosphate of magnesia, and other salts.

The **cortical substance**, or **cementum** (*crusta petrosa*), is disposed as a thin layer on the roots of the teeth, from the termination of the enamel as far as the apex of the root, where it is usually very thick. In structure and chemical composition it resembles bone. It contains, sparingly, the lacunæ and canaliculi which characterize true bone; the lacunæ placed near the surface have the canaliculi radiating from the side of the lacunæ toward the periodontal membrane, *dental periosteum*, and those more deeply placed join with adjacent dentinal tubuli. In the thicker portions of the crusta petrosa the lamellæ and Haversian canals peculiar to bone are also occasionally found.

As age advances the cement increases in thickness, and gives rise to those bony growths, or exostoses, so common in the teeth of the aged; the pulp-cavity becomes also partially filled up by a hard substance intermediate in structure between dentine and bone (*osteo-dentine*, Owen; *secondary dentine*, Tomes). It is formed by the odontoblasts, the dental pulp lessening in volume.

Development of the Teeth.

The teeth are an evolution from the dermoid system, and not of the bony skeleton: they are developed from two of the blastodermic layers, the epiblast and mesoblast. From the former the enamel is developed, from the latter the dental pulp, dentine, cementum, and pericementum. It is customary to view the development of the permanent and temporary teeth as separate studies.

The earliest evidence of tooth-formation in the human embryo is observed in about the seventh week. The mucous membrane covering the embryonic jaws is seen to rise as a longitudinal ridge along the summit of each jaw.[1] A transverse section through the jaws will show the elevation to be due to a linear and outlined activity of the germinal epithelial layer: a corresponding epithelial growth is seen to sink as a band into the mesoblastic tissue beneath. The local cell-activity continues, and in its descent the band appears to meet with a resistance which causes a flattening of its extremity into a continuous lamina. From the inner (toward the tongue) edge of the lamina epithelial cords are given off, ten in number, one for each temporary tooth.

The growth of each cord continues, and each expands into a flask-like form, the walls covered by a layer of germinal cells, its interior by swollen mature cells. The ingrowing bulb is now seen to flatten upon its lower surface, as though it had met with an outlined resistance from the mesoblastic tissue beneath. The epithelial ingrowth assumes the general form of the several teeth; it is the enamel-organ of the tooth (Fig. 478). At this period the mesoblastic tissue around each enamel-organ is seen to become differentiated into fibrous tissue surrounding the enamel-organs, but at some distance from them. Islets of bone are also seen to be forming the beginning of the bony maxillæ.

The indentation of the base of the enamel-organ continues until it assumes the form of the future teeth. The cells bounding the organ assume a cylindrical form; the cells of the interior become much expanded, irregular in size and form.

The mesoblastic tissue underlying the enamel-organ is much condensed; evidences of cellular differentiation and a vascular system appear. Bone continues to develop until all of the tooth-follicles are embraced in a gutter of bone. From the lingual side of the cords of the temporary teeth epithelial buds are given off, which sink into the mesoblastic tissue and form the enamel-organs of the permanent teeth. The condensation of fibrous tissue continues until each embryonic tooth is enveloped in a sac, the dental sac; this, together with all of its contents, is called the dental follicle.

The cells of the enamel-organ now undergo a series of differentiations: the inner layer is arranged as columnar epithelium, and is called the ameloblastic or

[1] The maxillary rampart of Kolliker Waldeyer.

enamel-forming layer (Figs. 479 and 480). The cells of the outer wall remain cuboidal; the cells which lie between become much distended, and on account of

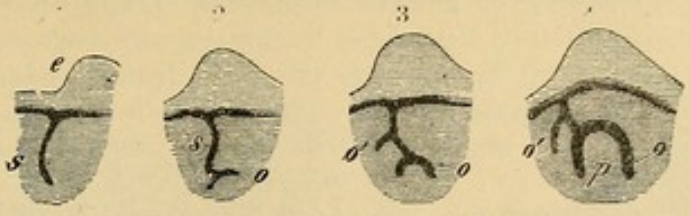

FIG. 478.—Diagram of method of development of the teeth. 1. Early stage. 4. Later stage. 2, 3. Intermediate stages. *s*. Common dental germ. *o*. Special dental germ (milk). *o'*. Special dental germ (permanent). *p*. Papilla. *e*. Dental furrow. (Gegenbaur.)

their appearance when seen in section this portion of the organ is called the stellate reticulum (the enamel-jelly). The layer of cells immediately contiguous to the ameloblasts form a layer called the stratum intermedium (Fig. 480A—*D*).

The enclosed mesoblastic papilla (the future dental pulp) has its peripheral cells differentiated into columnar bodies disposed as a layer, each cell having a large

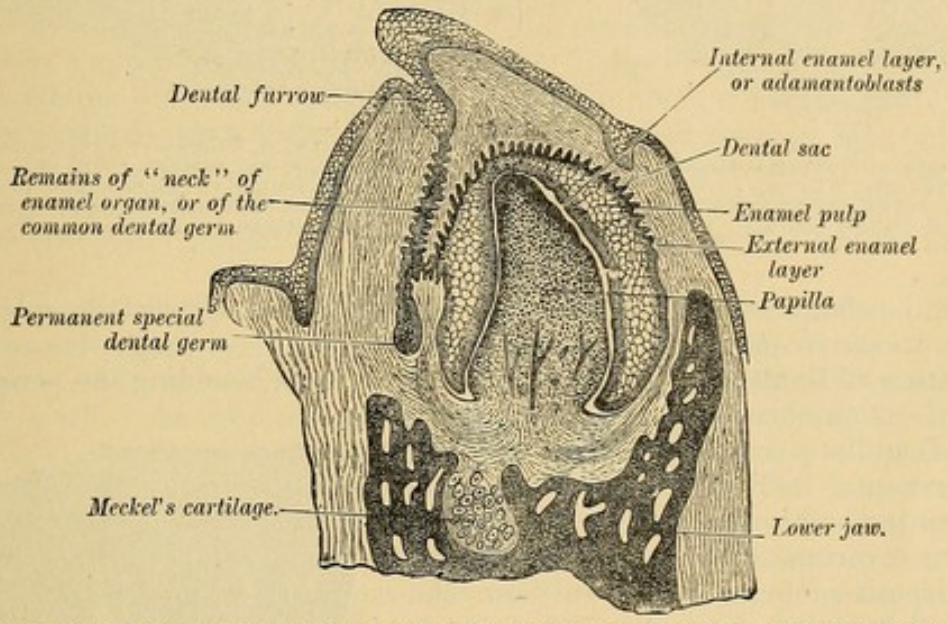

FIG. 479.—Vertical section of the inferior maxilla of an early human fœtus. (Magnified 25 diameters.)

nucleus. The vascular supply of the pulp is now well marked. A section of a follicle at this period will exhibit the follicular wall springing from the base of the dental papilla and having a well-marked blood-supply. The bony alveolar walls are well outlined, and evidences of a periosteum appear (Figs. 479 and 480).

Development of Enamel.—In point of time, the deposition of dentine actually begins before that of enamel, so that the first-formed layer of enamel is deposited against a layer of immature dentine. The enamel is built up of two distinct substances—globules of uniform size which are formed by the ameloblasts, and a cementing substance, probably an albuminate of calcium (calco-globulin), the basis of all the calcified tissues. At the ends of the ameloblasts, next to the dentine, the secretion calco-globulin is deposited, and into the plastic mass the enamel-globules are extruded, each globule remaining connected with the ameloblasts by plasmic strings, which also join the globules laterally.[1]

The first deposit of enamel begins in the tips of the cusps, and is quickly followed by a disappearance of the stellate reticulum at that point; the stellate reticulum now appears to atrophy, so that the vascular follicular wall is brought into direct apposition with the stratum intermedium, which becomes differentiated into a glandular (secreting) tissue which elaborates the calcic albuminous basis of the enamel. The secretion passes from the cells of the stratum intermedium through a membrane into the ameloblasts, where it is in part combined with the cellular

[1] J. L. Williams, *Dental Cosmos*, 1896.

globules, and irregular masses of it extruded as cementing substance. The deposition continues until the enamel-cap has its typical form. The deposition of the layers of globules is indicated by parallel lines transverse to the axes of the enamel-

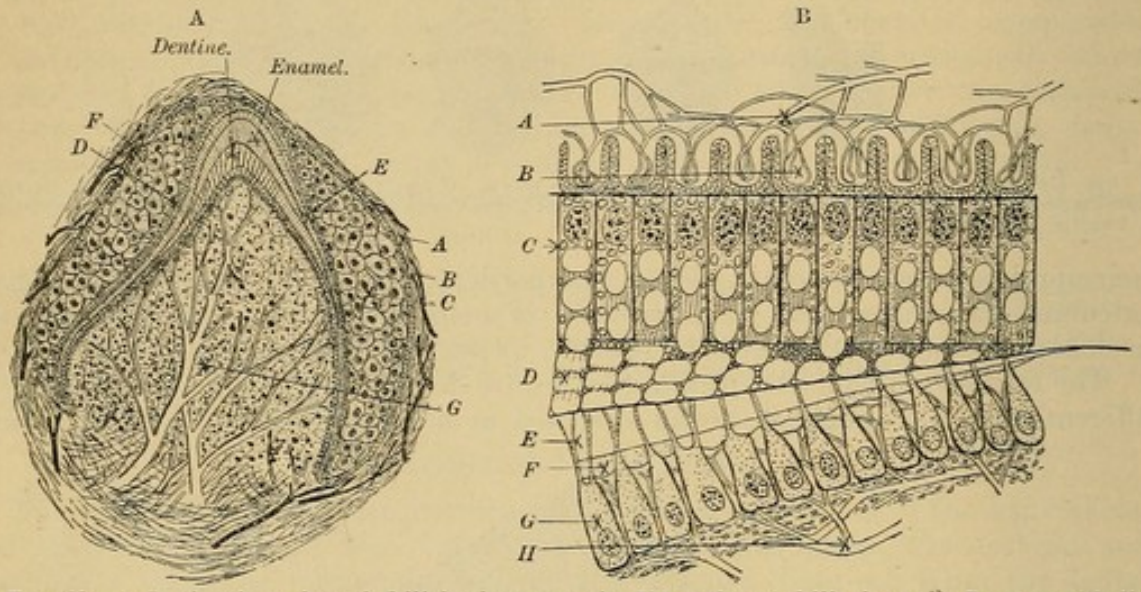

FIG. 480.—A. Section through tooth-follicle—human canine 7½ months: *A*, follicular wall; *B*, outer epithelial coat; *C*, stellate reticulum; *D*, stratum intermedium; *E*, ameloblasts; *F*, odontoblasts; *G*, pulp.

B. Diagram after Williams (*Dental Cosmos*, 1896), mode of enamel deposition: *A*, blood supply to *B*, secreting papillæ; *C*, layer of ameloblasts containing enamel globules and droplets of calcoglobulin; *D*, enamel-globules deposited; *E*, formed dentine; *F*, forming dentine; *G*, layer of odontoblasts; *H*, blood supply to odontoblastic layer.

rods. At the completion of amelification the ameloblasts are partially calcified and form the *cuticula dentis* or Nasmyth's membrane.

Formation of Dentine.—The layer of columnar cells bounding the periphery of the pulp (the odontoblasts) are in apposition with a plexus of capillary vessels (Fig. 480, *A*). Each cell is a secreting body which selects the material for dentine-building. Against the layer of ameloblasts covering the dental papilla the odontoblasts deposit globules of the calcium albuminate, and, receding as the deposits are made, leave one or more protoplasmic processes in the calcic deposit (Tomes's fibres). The process continues until the normal dentine thickness is formed. The deposit is laid down in a scaffolding of finely fibrillated tissue. The layer of formative cells remains constant.

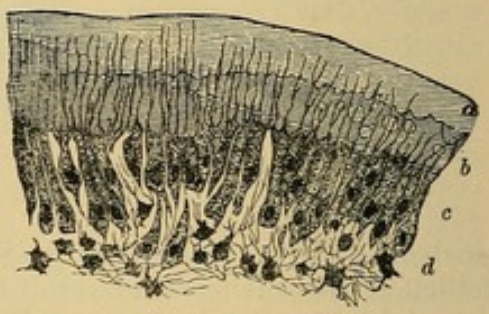

FIG. 481.—Part of section of developing tooth of young rat, showing the mode of deposition of the dentine (highly magnified). *a*. Outer layer of fully-calcified dentine. *b*. Uncalcified matrix with a few nodules of calcareous matter. *c*. Odontoblasts with processes extending into the dentine. *d*. Pulp. The section is stained with carmine, which colors the uncalcified matrix, but not the calcified part.

Formation of Cementum.—Hertwig asserts that the epithelial edge of the enamel-organ formed by the inner and outer epithelial layers of the organ grows downward, or rather the developing tooth grows upward until the future root-form of the tooth is outlined by a double layer of epithelial cells (the root-sheath of Hertwig). The growth of alveolar process is synchronous.

Upon the pulp side of the sheath a layer of odontoblasts is developed; upon the outer side the fibrous encasement becomes closely attached to the sheath and a layer of osteogenetic cells (cementoblasts) is differentiated. The growth of the dentine of the root is the same as in the crown. The epithelial sheath undergoes atrophic changes, leaving epithelial whorls which remain in the pericementum. The cementum is developed as subperiosteal bone. The cementum over the apex of the root is not formed until after the eruption of the tooth.

Formation of Alveoli.—By the time the crowns of the teeth have formed, each

is enclosed in a loculus of bone which has developed around it and at some distance from it; the loculus is open at the top toward the gums, where it is closed by fibrous tissue; the developing permanent tooth is contained in the same loculus, but is later separated from the temporary tooth by a growth of bone. The alveolar process is not completed until after the eruption of the teeth. During eruption that portion of the process overlying the crown undergoes absorption, and as soon as the immature tooth has erupted the alveolar process is developed about the root, whose formation is also completed after eruption.

Development of the Permanent Teeth.—The permanent teeth as regards their development may be divided into two sets: (1) those which replace the temporary teeth, and which, like them, are ten in number: these are the *successional permanent teeth;* and (2) those which have no temporary predecessors, but are superadded at the back of the dental series. These are three in number on either side in each jaw, and are termed the *superadded permanent teeth.* They are the three molars of the permanent set, the molars of the temporary set being replaced by the premolars or bicuspids of the permanent set.

The development of the *successional permanent teeth*—the ten anterior ones in either jaw—will be first considered. As already stated, the germ of each milk tooth is a special thickening of the "free" edge of the common dental germ or dental lamina. In like manner is formed the special dental germ of each of the successional permanent teeth. But these thickenings are not at the "free" edge of the dental lamina, but occur behind and lateral to each of the milk-tooth germs (Fig. 478). There are ten of these, and they appear in order, about the sixteenth week, on each side, the central incisor germs being the first.

These special dental germs now go through the same transformations (and become enamel-organs) as were described in connection with those of the milk teeth; that is, they recede into the substance of the gum behind the germs of the temporary teeth. As they recede they become flask-shaped, form an expansion of their distal extremity, and finally meet a papilla, which has been formed in the mesoblast, just in the same manner as was the case in the temporary teeth. The apex of the papilla indentates the dental germ, which encloses it, and forming a cap for it, undergoes analogous changes to those described in the development of the milk teeth, and becomes converted into the enamel, whilst the papilla forms the dentine, of the permanent tooth. In its development it becomes enclosed in a dentinal sac which adheres to the *back* of the sac of the temporary tooth. The sac of each permanent tooth is also connected with the fibrous tissue of the gum by a slender band or *gubernaculum*, which passes to the margin of the jaw behind the corresponding milk tooth (see above).

The *superadded permanent teeth*—three on each side in each jaw—arise from successive extensions backward—*i. e.* along the line of the jaw—of the common dental germ from the back part of the special dental germ of the immediately preceding tooth. During the fourth month or seventeenth week, in that portion of the common dental germ which lies behind—*i. e.* lateral to the special dental germ of the last temporary molar tooth, and which has hitherto remained unaltered, there is developed the special dental germ of the first permanent molar into which a papilla projects. In a similar manner, about the fourth month after birth the second molar is formed, and about the third year the third molar.

Eruption.—When the calcification of the different tissues of the *milk* tooth is sufficiently advanced to enable it to bear the pressure to which it will be afterward subjected, its eruption takes place, the tooth making its way through the gum. The gum is absorbed by the pressure of the crown of the tooth against it, which is itself pressed up by the increasing size of the fang. At the same time the septa between the dentinal sacs, at first fibrous in structure, ossify and thus form the loculi or alveoli; these firmly embrace the necks of the teeth and afford them a solid basis.

Previous to the *permanent teeth* penetrating the gum, the bony partitions which separate their sacs from the deciduous teeth are absorbed, the roots of the temporary teeth disappear by absorption through the agency of particular multinucleated cells, called *odontoclasts*, which are developed at the time in the neighborhood of the root, and the permanent teeth become placed under the loose crown of the deciduous teeth; the latter finally become detached, and the permanent teeth take their place in the mouth (Fig. 482).

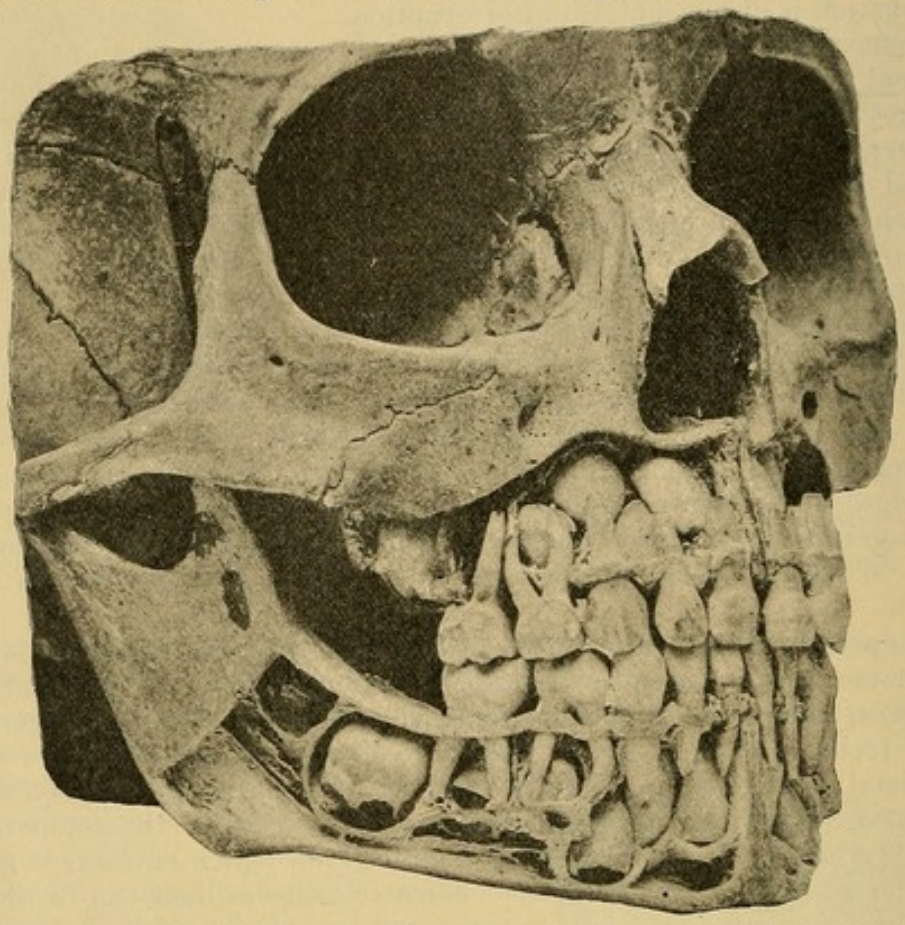

FIG. 482.—The milk-teeth in a child of about four years. The permanent teeth are seen in their alveoli. (Cryer.)

Calcification of the permanent teeth proceeds in the following order: First molar, soon after birth; the central incisor, lateral incisor, and cuspid, about six months after birth; the bicuspids, at the second year or later; second molar, end of second year; third molar, about the twelfth year.

The *eruption of the temporary teeth* commences at the seventh month, and is complete about the end of the second year.

The periods for the eruption of the temporary set are (C. S. Tomes)—

Lower central incisors	6 to 9 months.
Upper incisors	8 to 10 "
Lower lateral incisors and first molars	15 to 21 "
Canines	16 to 20 "
Second molars	20 to 24 "

The *eruption of the permanent teeth* takes place at the following periods, the teeth of the lower jaw preceding those of the upper by a short interval:

6½ years, first molars.
7th year, two middle incisors.
8th year, two lateral incisors.
9th year, first bicuspid.
10th year, second bicuspid.
11th to 12th year, canine.
12th to 13th year, second molars.
17th to 21st year, third molars.

THE PALATE.

The **palate** forms the roof of the mouth: it consists of two portions, the hard palate in front, the soft palate behind.

The **hard palate** is bounded in front and at the sides by the alveolar arches and gums; behind, it is continuous with the soft palate. It is covered by a dense structure formed by the periosteum and mucous membrane of the mouth, which are intimately adherent. Along the middle line is a linear ridge or raphé, which terminates anteriorly in a small papilla corresponding with the inferior opening of the anterior palatine fossa. This papilla receives filaments from the naso-palatine and anterior palatine nerves. On either side and in front of the raphé the mucous membrane is thick, pale in color, and corrugated; behind, it is thin, smooth, and of a deeper color: it is covered with squamous epithelium, and furnished with numerous glands (palatal glands), which lie between the mucous membrane and the surface of the bone.

The **soft palate** (*velum pendulum palati*) is a movable fold suspended from the posterior border of the hard palate, and forming an incomplete septum between the mouth and pharynx. It consists of a fold of mucous membrane enclosing muscular fibres, an aponeurosis, vessels, nerves, adenoid tissue, and mucous glands. When occupying its usual position (*i. e.* relaxed and pendent) its anterior surface is concave, continuous with the roof of the mouth, and marked by a median ridge or raphe, which indicates its original separation into two lateral halves. Its posterior surface is convex, and continuous with the mucous membrane covering the floor of the posterior nares. Its upper border is attached to the posterior margin of the hard palate, and its sides are blended with the pharynx. Its lower border is free.

Hanging from the middle of its lower border is a small, conical-shaped pendulous process, the *uvula*, and arching outward and downward from the base of the uvula on each side are two curved folds of mucous membrane, containing muscular fibres, called the *arches*, or *pillars of the soft palate*, or *pillars of the fauces*.

The *anterior pillars* run downward, outward, and forward to the sides of the base of the tongue, and are formed by the projection of the Palato-glossi muscles, covered by mucous membrane.

The *posterior pillars* are nearer to each other and larger than the anterior; they run downward, outward, and backward to the sides of the pharynx, and are formed by the projection of the Palato-pharyngei muscles, covered by mucous membrane. The anterior and posterior pillars are separated below by a triangular interval in which the tonsil is lodged.

The space left between the arches of the palate on the two sides is called the *isthmus of the fauces*. It is bounded, above, by the free margin of the soft palate; below, by the back of the tongue; and on each side, by the pillars of the fauces and the tonsil.

The *mucous membrane of the soft palate* is thin, and covered with squamous epithelium on both surfaces, excepting near the orifice of the Eustachian tube, where it is columnar and ciliated.[1] Beneath the mucous membrane on the oral surface of the soft palate is a considerable amount of adenoid tissue. The palatine glands form a continuous layer on its posterior surface and round the uvula.

The *aponeurosis of the soft palate* is a thin but firm fibrous layer attached above to the posterior border of the hard palate, and becoming thinner toward the free margin of the velum. Laterally, it is continuous with the pharyngeal aponeurosis. It forms the framework of the soft palate, and is joined by the tendon of the Tensor palati muscle.

[1] According to Klein, the mucous membrane on the nasal surface of the soft palate in the fœtus is covered throughout by columnar ciliated epithelium, which subsequently becomes squamous; and some anatomists state that it is covered with columnar ciliated epithelium, except at its free margin, throughout life.

The *muscles of the soft palate* are five on each side: the Levator palati, Tensor palati, Azygos uvulæ, Palato-glossus, and Palato-pharyngeus (see page 329). The following is the relative position of these structures in a dissection of the soft palate from the posterior or nasal to the anterior or oral surface: Immediately beneath the nasal mucous membrane is a thin stratum of muscular fibres, the posterior fasciculus of the Palato-pharyngeus muscle, joining with its fellow of the opposite side in the middle line. Beneath this is the Azygos uvulæ, consisting of two rounded fleshy fasciculi, placed side by side in the median line of the soft palate. Next comes the aponeurosis of the Levator palati, joining with the muscle of the opposite side in the middle line. Fourthly, the anterior fasciculus of the Palato-pharyngeus, thicker than the posterior, and separating the Levator palati from the next muscle, the Tensor palati. This muscle terminates in a tendon which, after winding round the hamular process, expands into a broad aponeurosis in the soft palate, anterior to the other muscles which have been enumerated. Finally, we have a thin muscular stratum, the Palato-glossus muscle, placed in front of the aponeurosis of the Tensor palati, and separated from the oral mucous membrane by adenoid tissue.

The **Tonsils** (*amygdalæ*) are two prominent bodies situated one on each side of the fauces, between the anterior and posterior pillars of the soft palate. They are of a rounded form, and vary considerably in size in different individuals. A recess, the *fossa supra-tonsillaris*, may be seen, directed upward and backward above the tonsil. His regards this as the remains of the lower part of the second visceral cleft. It is covered by a fold of mucous membrane termed the *plica triangularis*. Externally the tonsil is in relation with the inner surface of the Superior constrictor, to the outer side of which is the Internal pterygoid muscle. The internal carotid artery lies behind and to the outer side of the tonsil, and nearly an inch (20 to 25 mm.) distant from it. It corresponds to the angle of the lower jaw. Its *inner surface* presents from twelve to fifteen orifices, leading into small recesses, from which numerous follicles branch out into the substance of the gland. These follicles are lined by a continuation of the mucous membrane of the pharynx, covered with epithelium; around each follicle is a layer of closed capsules imbedded in the submucous tissue. These capsules are analogous to those of Peyer's glands, consisting of adenoid tissue. No openings from the capsules into the follicles can be recognized. They contain a thick grayish secretion. Surrounding each follicle is a close plexus of lymphatic vessels. From these plexuses the lymphatic vessels pass to the deep cervical glands in the upper part of the neck, which frequently become enlarged in affections of these organs.

The *arteries* supplying the tonsil are the dorsalis linguæ from the lingual, the ascending palatine and tonsillar from the facial, the ascending pharyngeal from the external carotid, the descending palatine branch of the internal maxillary, and a twig from the small meningeal.

The *veins* terminate in the tonsillar plexus, on the outer side of the tonsil.

The *nerves* are derived from Meckel's ganglion and from the glosso-pharyngeal.

THE SALIVARY GLANDS (Fig. 483).

The principal salivary glands communicating with the mouth and pouring their secretion into its cavity are the parotid, submaxillary, and sublingual.

The **parotid gland**, so called from being placed near the ear (*παρά*, near; *οὖς*, *ὠτός*, the ear), is the largest of the three salivary glands, varying in weight from half an ounce to an ounce. It lies upon the side of the face immediately below and in front of the external ear. It is limited above by the zygoma; below, by the angle of the jaw and by a line drawn between it and the mastoid process: anteriorly, it extends to a variable extent over the Masseter muscle; posteriorly, it is bounded by the external meatus, the mastoid process, and the Sterno-mastoid and Digastric muscles, slightly overlapping the two muscles.

Its *anterior surface* is grooved to embrace the posterior margin of the ramus of the lower jaw, and advances forward beneath the ramus, between the two Pterygoid muscles and superficial to the ramus over the Masseter muscle. Its *outer surface*, slightly lobulated, is covered by the integument and parotid fascia, and has one or two lymphatic glands resting on it. Its *inner surface* extends deeply into the neck by means of two large processes, one of which dips behind the styloid process and projects beneath the mastoid process and the Sterno-mastoid muscle: the other is situated in front of the styloid process, and passes into the back part of the glenoid fossa, behind the articulation of the lower jaw. The structures passing through the parotid gland are—the external carotid artery, giving off its three terminal branches: the posterior auricular artery emerges from the gland behind; the temporal artery above; the transverse facial, a branch of the temporal, in front;

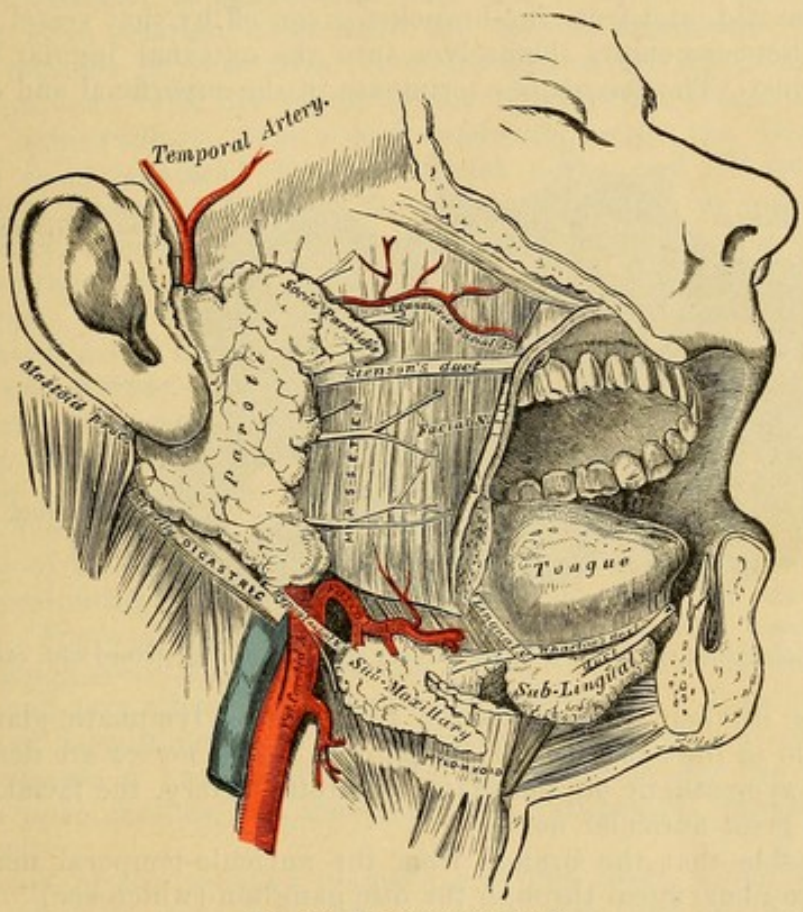

FIG. 483.—The salivary glands.

and the internal maxillary winds through it as it passes inward, behind the neck of the jaw. Superficial to the external carotid is the trunk formed by the union of the temporal and internal maxillary veins; a branch, connecting this trunk with the internal jugular, also passes through the gland. It is also traversed by the facial nerve and its branches, which emerge at its anterior border; branches of the great auricular nerve pierce the gland to join the facial, and the auriculo-temporal branch of the inferior maxillary nerve emerges from the upper part of the gland. The internal carotid artery and internal jugular vein lie close to its deep surface.

The **duct of the parotid gland** (*Stenson's*) is about two inches and a half in length. It commences by numerous branches from the anterior part of the gland, crosses the Masseter muscle, and at its anterior border dips down into the substance of the Buccinator muscle, which it pierces; it then runs for a short distance obliquely forward between the Buccinator and mucous membrane of the mouth, and opens upon the inner surface of the cheek by a small orifice opposite the second molar tooth of the upper jaw. While crossing the Masseter it receives the duct of a small

detached portion of the gland, *socia parotidis*, which occasionally exists as a separate lobe, just beneath the zygomatic arch. In this position it has the transverse facial artery above it and some branches of the facial nerve below it.

Structure.—The parotid duct is dense, of considerable thickness, and its canal about the size of a crowquill, but at its orifice on the inner aspect of the cheek its lumen is greatly reduced in size; it consists of an external or fibrous coat, of considerable density, containing contractile fibres, and of an internal or mucous coat lined with short columnar epithelium.

Surface Form.—The direction of the duct corresponds to a line drawn across the face about a finger's breadth below the zygoma; that is, from the lower margin of the concha to midway between the free margin of the upper lip and the ala of the nose.

Vessels and Nerves.—The *arteries* supplying the parotid gland are derived from the external carotid, and from the branches given off by that vessel in or near its substance. The *veins* empty themselves into the external jugular through some of its tributaries. The *lymphatics* terminate in the superficial and deep cervical

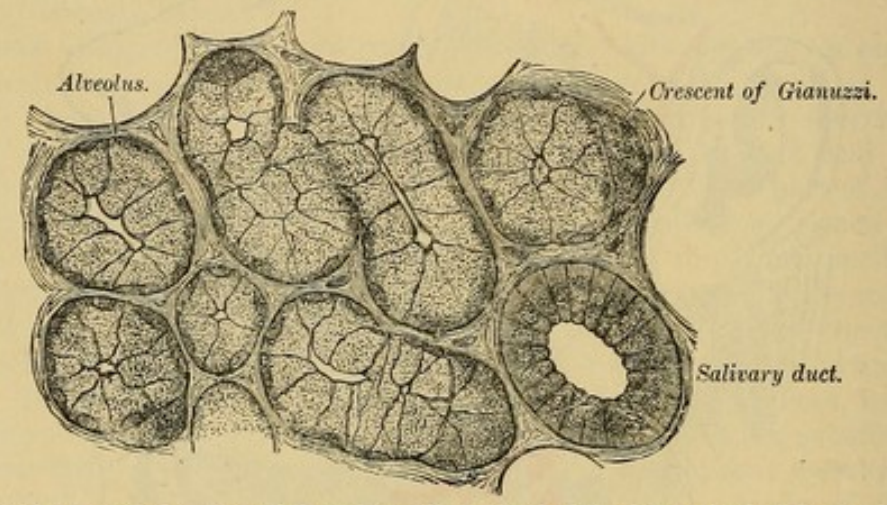

FIG. 484.—A highly magnified section of the submaxillary gland of the dog, stained with carmine. (Kölliker.)

glands, passing in their course through two or three lymphatic glands placed on the surface and in the substance of the parotid. The *nerves* are derived from the plexus of the sympathetic on the external carotid artery, the facial, the auriculo-temporal, and great auricular nerves.

It is probable that the branch from the auriculo-temporal nerve is derived from the glosso-pharyngeal through the otic ganglion (which see). At all events, in some of the lower animals this has been proved experimentally to be the case.

The **submaxillary gland** is situated below the jaw, in the anterior part of the submaxillary triangle of the neck. It is irregular in form and weighs about two drachms (8–10 grammes). It is covered by the integument, Platysma, deep cervical fascia, and the body of the lower jaw, corresponding to a depression on the inner surface of the bone, and lies upon the Mylo-hyoid, Hyo-glossus, and Stylo-glossus muscles, a portion of the gland passing beneath the posterior border of the Mylo-hyoid. In front of it is the anterior belly of the Digastric; behind, it is separated from the parotid gland by the stylo-maxillary ligament, and from the sublingual gland in front by the Mylo-hyoid muscle. The facial artery lies imbedded in a groove in its posterior and upper border.

The **duct of the submaxillary gland** (*Wharton's*) is about two inches in length, and its walls are much thinner than those of the parotid duct. It commences by numerous branches from the deep portion of the gland which lies on the upper surface of the Mylo-hyoid muscle, and passes forward and inward between the Mylo-hyoid and the Hyo-glossus and Genio-hyo-glossus muscles, then between the sublingual gland and the Genio-hyo-glossus, and opens by a narrow orifice on the

summit of a small papilla at the side of the frænum linguæ. On the Hyo-glossus muscle it lies between the lingual and hypoglossal nerves, but at the anterior border of the muscle it crosses under the lingual nerve, and is then placed above it.

Vessels and Nerves.—The *arteries* supplying the submaxillary gland are branches of the facial and lingual. Its *veins* follow the course of the arteries. The *nerves* are derived from the submaxillary ganglion, through which it receives filaments from the chorda tympani of the facial and lingual branch of the inferior maxillary, sometimes from the mylo-hyoid branch of the inferior dental, and from the sympathetic.

The **sublingual gland** is the smallest of the salivary glands. It is situated beneath the mucous membrane of the floor of the mouth, at the side of the frænum linguæ, in contact with the inner surface of the lower jaw, close to the symphysis. It is narrow, flattened, in shape somewhat like an almond, and weighs about a drachm. It is in relation, *above*, with the mucous membrane; *below*, with the Mylo-hyoid muscle; *in front*, with the depression on the side of the symphysis of the lower jaw, and with its fellow of the opposite side; *behind*, with the deep part of the submaxillary gland; and *internally*, with the Genio-hyo-glossus, from which it is separated by the lingual nerve and Wharton's duct. Its excretory ducts (*ducts of Rivinus*), from eight to twenty in number; some join Wharton's duct; others open separately into the mouth, on the elevated crest of mucous membrane caused by the projection of the gland, on either side of the frænum linguæ. One or more join to form a tube which opens into the Wharton-ian duct; this is called the *duct of Bartholin*.

Vessels and Nerves.—The sublingual gland is supplied with blood from the sublingual and submental arteries. Its nerves are derived from the lingual.

Structure of Salivary Glands.—The salivary are compound racemose glands, consisting of numerous lobes, which are made up of smaller lobules connected together by dense areolar tissue, vessels, and ducts. Each lobule consists of the ramifications of a single duct, "branching frequently in a tree-like manner," the branches terminating in dilated ends or alveoli, on which the capillaries are distributed. These alveoli, however, as Pflüger points out, are not necessarily spherical, though sometimes they assume that form; sometimes they are perfectly cylindrical, and very often they are mutually compressed. The alveoli are enclosed by a basement membrane which is continuous with the membrana propria of the duct. It presents a peculiar reticulated structure, having the appearance of a basket with open meshes, and consisting of a network of branched and flattened nucleated cells.

The alveoli of the salivary glands are of two kinds, which differ both in the appearance of their secreting cells, in their size, and in the nature of their secretion. The one variety secretes a ropy fluid which contains mucin, and has therefore been named the *mucous*, whilst the other secretes a thinner and more watery fluid, which contains serum-albumin, and has been named *serous* or *albuminous*. The sublingual gland may be regarded as an example of the former variety, the parotid of the latter. The submaxillary is of the mixed variety, containing both mucous and serous alveoli, the latter, however, preponderating.

Both alveoli are lined by cells, and it is by the character of these cells that the nature of the gland is chiefly to be determined. In addition, however, the alveoli of the serous glands are smaller than those of the mucous ones.

The **cells in the mucous alveoli** are spheroidal in shape, glassy, transparent, and dimly striated in appearance. The nucleus is usually situated in the part of the cell which is next the basement membrane, against which it is sometimes flattened. The most remarkable peculiarity presented by these cells is, that they give off an extremely fine process, which is curved in a direction parallel to the surface of the alveolus, lies in contact with the membrana propria, and overlaps the process of neighboring cells. The cells contain a quantity of mucin, to which their clear, transparent appearance is due.

Here and there in the alveoli are seen peculiar half-moon-shaped bodies lying between the cells and the membrana propria of the alveolus. They are termed the *crescents of Gianuzzi* or the *demilunes of Heidenhain* (Fig. 484), and are composed of polyhedral granular cells, which Heidenhain regards as young epithelial cells destined to supply the place of those salivary cells which have undergone disintegration. This view, however, is not accepted by Klein.

Serous Alveoli.—In the serous alveoli the cells almost completely fill the cavity, so that there is hardly any lumen perceptible. Instead of presenting the clear, transparent appearance of the cells of the mucous alveoli, they present a granular appearance, due to distinct granules of an albuminous nature imbedded in a closely reticulated protoplasm. The ducts which originate out of the alveoli are lined at their commencement by epithelium which differs little from the pavement type. As the ducts enlarge, the epithelial cells change to the columnar type, and the part of the cell next the basement-membrane is finely striated. The lobules of the salivary glands are richly supplied with blood-vessels which form a dense network in the interalveolar spaces. Fine plexuses of nerves are also found in the interlobular tissue. The nerve-fibrils pierce the basement-membrane of the alveoli, and end in branched varicose filaments between the secreting cells. There is no doubt that ganglia are to be found in some salivary glands in connection with the nerve-plexuses in the interlobular tissue; they are to be found in the submaxillary, but not in the parotid.

In the submaxillary and sublingual glands the lobes are larger and more loosely united than in the parotid.

Mucous Glands.—Besides the salivary glands proper, numerous other glands are found in the mouth. They appear to secrete mucus only, which serves to keep the mouth moist during the intervals of the salivary secretion, and which is mixed with that secretion in swallowing. Many of these glands are found at the posterior part of the dorsum of the tongue, behind the circumvallate papillæ, and also along its margins as far forward as the apex.[1] Others lie around and in the tonsil between its crypts, and a large number are present in the soft palate. These glands are of the ordinary compound racemose type.

Surface Form.—The orifice of the mouth is bounded by the lips, two thick, fleshy folds covered externally by integument and internally by mucous membrane, and consisting of muscles, vessels, nerves, areolar tissue, and numerous small glands. The size of the orifice of the mouth varies considerably in different individuals, but seems to bear a close relation to the size and prominence of the teeth. Its corners correspond pretty accurately to the outer border of the canine teeth. In the Mongolian tribes, where the front teeth are large and inclined forward, the mouth is large; and this, combined with the thick and everted lips which appear to be associated with prominent teeth, gives to the negro's face much of the peculiarity by which it is characterized. The smaller teeth and the slighter prominence of the alveolar arch of the more highly civilized races render the orifice of the mouth much smaller, and thus a small mouth is an indication of intelligence, and is regarded as an evidence of the higher civilization of the individual.

Upon looking into the mouth, the first thing we may note is the tongue, the upper surface of which will be seen occupying the floor of the cavity. This surface is convex, and is marked along the middle line by a raphe which divides it into two symmetrical portions. The anterior two-thirds is rough and studded with papillæ; the posterior third smooth and tuberculated, covered by numerous glands which project from the surface. Upon raising the tongue the mucous membrane which invests the upper surface may be traced covering the sides of the under surface, and then reflected over the floor of the mouth on to the inner surface of the lower jaw, a part of which it covers. As it passes over the borders of the tongue it changes its character, becoming thin and smooth and losing the papillæ which are to be seen on the upper surface. In the middle line the mucous membrane on the under surface of the tip of the tongue forms a distinct fold, the *frænum linguæ*, by which this organ is connected to the symphysis of the jaw. Occasionally it is found that this frænum is rather shorter than natural, and, acting as a bridle, prevents the complete protrusion of the tongue. When this condition exists and an attempt is made to protrude the organ, the tip will be seen to remain buried in the floor of the mouth, and the dorsum of the tongue is rendered very convex, and more or

[1] It has been shown by Ebner that many of these glands open into the trenches around the circumvallate papillæ, and that their secretion is more watery than that of ordinary mucous glands. He supposes that they assist in the more rapid distribution of the substance to be tasted over the region where the special apparatus of the sense of taste is situated.

less extruded from the mouth; at the same time a deep furrow will be noticed to appear in the middle line of the anterior part of the dorsum. Sometimes, a little external to the frænum, the ranine vein may be seen immediately beneath the mucous membrane. The corresponding artery, being more deeply placed, does not come into view, nor can its pulsation be felt with the finger. On either side of the frænum, in the floor of the mouth, is a longitudinal elevation or ridge, produced by the projection of the sublingual gland, which lies immediately beneath the mucous membrane. And close to the attachment of the frænum to the tip of the tongue may be seen on either side the slit-like orifices of Wharton's ducts, into which a fine probe may be passed without much difficulty. By everting the lips the smooth mucous membrane lining them may be examined, and may be traced from them on to the outer surface of the alveolar arch. In the middle line, both of the upper and lower lip, a small fold of mucous membrane passes from the lip to the bone, constituting the *fræna;* these are not so large as the frænum linguæ. By pulling outward the angle of the mouth, the mucous membrane lining the cheeks can be seen, and on it may be perceived a little papilla which marks the position of the orifice of Stenson's duct—the duct of the parotid gland. The exact position of the orifice of the duct will be found to be opposite the second molar tooth of the upper jaw. The introduction of a probe into this duct is attended with considerable difficulty. The teeth are the next objects which claim our attention upon looking into the mouth. There are, as stated above, ten in either jaw in the temporary set, and sixteen in the permanent set. The gums, in which they are implanted, are dense, firm, and vascular.

At the back of the mouth is seen the *isthmus of the fauces*, or, as it is popularly called, "the throat:" this is the space between the pillars of the fauces on either side, and is the means by which the mouth communicates with the pharynx. Above, it is bounded by the soft palate, the anterior surface of which is concave and covered with mucous membrane, which is continuous with that lining the roof of the mouth. Projecting downward from the middle of its lower border is a conical-shaped projection, the *uvula*. On either side of the isthmus of the fauces are the anterior and posterior pillars, formed by the Palato-glossus and Palato-pharyngeus muscles respectively, covered over by mucous membrane. Between the two pillars on either side is situated the tonsil. The extirpation of this body is not unattended with danger of hemorrhage. Dr. Weir has stated that he believes that when hemorrhage occurs after their removal it arises from one of the palatine arteries having been wounded. These vessels are large: they lie in the muscular tissue of the palate, and when wounded are constantly exposed to disturbance from the contraction of the palatine muscles. The vessels of the tonsil, Dr. Weir states, are small and lie in the soft tissue, and readily contract when wounded.

When the mouth is wide open a prominent tense fold of mucous membrane may be seen and felt, extending upward and backward from the position of the fang of the last molar tooth to the posterior part of the hard palate. This is caused by the Pterygo-maxillary ligament, which is attached by one extremity to the apex of the internal pterygoid plate, and by the other to the posterior extremity of the mylo-hyoid ridge of the lower jaw. It connects the Buccinator with the Superior constrictor of the pharynx. The fang of the last molar tooth indicates the position of the lingual (gustatory) nerve, where it is easily accessible, and can with readiness be divided in cases of cancer of the tongue (see page 735). On the inner side of the last molar tooth we can feel the hamular process of the internal pterygoid plate of the sphenoid bone, around which the tendon of the Tensor palati plays. The exact position of this process is of importance in performing the operation of staphylorraphy. About one-third of an inch in front of the hamular process, and the same distance directly inward from the last molar tooth, is the situation of the opening of the posterior palatine canal, through which emerges the posterior or descending palatine branch of the internal maxillary artery and one of the descending palatine nerves from Meckel's ganglion. The exact position of the opening on the subject may be ascertained by driving a needle through the tissues of the palate in this situation, when it will be at once felt to enter the canal. The artery emerging from the opening runs forward in a groove in the bone just internal to the alveolar border of the hard palate, and may be wounded in the operation for the cure of cleft palate. Under these circumstances the palatine canal may require plugging. By introducing the finger into the mouth the anterior border of the coronoid process of the jaw can be felt, and is especially prominent when the jaw is dislocated. By throwing the head well back a considerable portion of the posterior wall of the pharynx may be seen through the isthmus faucium, and on introducing the finger the anterior surface of the bodies of the upper cervical vertebræ may be felt immediately beneath the thin muscular stratum forming the wall of the pharynx. The finger can be hooked around the posterior border of the soft palate, and by turning it forward the posterior nares, separated by the septum, can be felt, or the presence of any adenoid or other growths in the naso-pharynx ascertained.

THE PHARYNX.

The **pharynx** is that part of the alimentary canal which is placed behind the nose, mouth, and larynx. It is a musculo-membranous tube, somewhat conical in form, with the base upward and the apex downward, extending from the under surface of the skull to the level of the cricoid cartilage in front and that of the intervertebral disk between the fifth and sixth cervical vertebræ behind.

The pharynx is about four inches and a half in length, and broader in the transverse than in the antero-posterior diameter. Its greatest breadth is opposite the cornua of the hyoid bone; its narrowest point, at its termination in the œsophagus. It is limited, *above*, by the body of the sphenoid and basilar process of the occipital bone; *below*, it is continuous with the œsophagus; *posteriorly*, it is connected by loose areolar tissue with the cervical portion of the vertebral column and the Longi colli and Recti capitis antici muscles; *anteriorly*, it is incomplete, and is attached in succession to the internal pterygoid plate, the pterygo-maxillary ligament, the lower jaw, the tongue, hyoid bone, and thyroid and cricoid cartilages; *laterally*, it is connected to the styloid processes and their muscles, and is in contact with the common and internal carotid arteries, the internal jugular veins, and the glosso-pharyngeal, pneumogastric, hypoglossal, and sympathetic nerves, and above with a small part of the Internal pterygoid muscles.

It has seven openings communicating with it—the two posterior nares, the two Eustachian tubes, the mouth, larynx, and œsophagus.

The pharynx may be subdivided from above downward into three parts, nasal, oral, and laryngeal. The nasal part of the pharynx (*pars nasalis*) or naso-pharynx lies behind the nose and above the level of the soft palate: it differs from the two lower parts of the tube in that its cavity always remains patent. In front it communicates through the choanæ with the nasal fossæ. On its lateral wall is the pharyngeal orifice of the Eustachian tube, which presents the appearance of a vertical cleft bounded behind by a firm prominence, the *cushion*, caused by the inner extremity of the cartilage of the tube impinging on the deep surface of the mucous membrane. A vertical fold of mucous membrane, the *plica salpingo-pharyngea*, stretches from the lower part of the cushion to the pharynx; it contains the Salpingo-pharyngeus muscle. A second and smaller mucous fold may be seen stretching from the upper part of the cushion to the palate, the *plica salpingo-palatina*. Behind the orifice of the Eustachian tube is a deep recess, the *fossa of Rosenmüller*, which represents the remains of the upper part of the second branchial cleft.

The oral part of the pharynx (*pars oralis*) reaches from the soft palate to the level of the hyoid bone. It opens anteriorly, through the isthmus faucium, into the mouth, while in its lateral wall, between the two pillars of the fauces, is the tonsil.

The laryngeal part of the pharynx (*pars laryngea*) reaches from the hyoid bone to the lower border of the cricoid cartilage, where it is continuous with the œsophagus. In front it presents the triangular aperture of the larynx, the base of which is directed forward and is formed by the epiglottis, while its lateral boundaries are constituted by the aryteno-epiglottidean folds. On either side of the laryngeal orifice is a recess, termed the *sinus pyriformis*; it is bounded internally by the aryteno-epiglottidean fold, externally by the thyroid cartilage and thyro-hyoid membrane.

Structure.—The pharynx is composed of three coats—mucous, fibrous, and muscular.

The *pharyngeal aponeurosis*, or *fibrous coat*, is situated between the mucous and muscular layers. It is thick above, where the muscular fibres are wanting, and is firmly connected to the basilar process of the occipital and petrous portion of the temporal bones. As it descends it diminishes in thickness, and is gradually lost. It is strengthened posteriorly by a strong fibrous band which is attached above to the pharyngeal spine on the under surface of the basilar portion of the occipital bone, and passes downward, forming a median raphe, which gives attachment to the Constrictor muscles of the pharynx.

The *mucous coat* is continuous with that lining the Eustachian tubes, the nares, the mouth and the larynx. In the naso-pharynx it is covered by columnar ciliated epithelium; in the buccal and laryngeal portions the epithelium is of the squamous variety. Beneath the mucous membrane are found racemose mucous glands; they are especially numerous at the upper part of the pharynx around the orifices of the Eustachian tubes. Throughout the pharynx are also numerous crypts or

recesses, the walls of which are surrounded by lymphoid tissue similar to what is found in the tonsils. Across the back part of the pharyngeal cavity, between the two Eustachian tubes, a considerable mass of this tissue exists, and has been named the *pharyngeal tonsil*. Above this in the middle line is an irregular, flask-shaped depression of the mucous membrane, extending up as far as the basilar process of the occipital bone. It is known as the *bursa pharyngea*, and was regarded by Luschka as the remains of the diverticulum, which is concerned in the development of the anterior lobe of the pituitary body. Other anatomists believe that it is connected with the formation of the pharyngeal tonsils.

The *muscular coat* has been already described (page 328).

Surgical Anatomy.—The internal carotid artery is in close relation with the pharynx, so that its pulsations can be felt through the mouth. It has been occasionally wounded by sharp-pointed instruments introduced into the mouth and thrust through the wall of the pharynx. In aneurism of this vessel in the neck the tumor necessarily bulges into the pharynx, as this is the direction in which it meets with the least resistance, nothing lying between the vessel and the mucous membrane except the thin Constrictor muscle, whereas on the outer side there is the dense cervical fascia, the muscles descending from the styloid process, and the margin of the Sterno-mastoid.

The mucous membrane of the pharynx is very vascular, and is often the seat of inflammation, frequently of a septic character, and dangerous on account of its tendency to spread to the larynx. On account of the tissue which surrounds the pharyngeal wall being loose and lax, the inflammation is liable to spread through it far and wide, extending downward into the posterior mediastinum along the œsophagus. Abscess may form in the connective tissue behind the pharynx, between it and the vertebral column, constituting what is known as retro-pharyngeal abscess. This is most commonly due to caries of the cervical vertebræ, but may also be caused by suppuration of a lymphatic gland which is situated in this position opposite the axis, and which receives lymphatics from the nares, or by a gumma or by acute pharyngitis. In these cases the pus may be easily evacuated by an incision, with a guarded bistoury, through the mouth, but, for aseptic reasons, it is desirable that the abscess should be opened from the neck. In some instances this is perfectly easy; the abscess can be felt bulging at the side of the neck and merely requires an incision for its relief, but this is not always so, and then an incision should be made along the posterior border of the Sterno-mastoid and the deep fascia divided. A director is now to be inserted into the wound, the forefinger of the left hand being introduced into the mouth and pressure made upon the swelling. This acts as a guide, and the director is to be pushed onward until pus appears in the groove. A pair of sinus forceps are now inserted along the director and the opening into the cavity dilated.

Foreign bodies not infrequently become lodged in the pharynx, and most usually at its termination at about the level of the cricoid cartilage, just beyond the reach of the finger, as the distance from the arch of the teeth to the commencement of the œsophagus is about six inches.

THE ŒSOPHAGUS.

The **œsophagus**, or **gullet**, is a muscular canal, about nine inches in length, extending from the pharynx to the stomach. It commences at the upper border of the cricoid cartilage, opposite the intervertebral disk between the fifth and sixth cervical vertebræ, descends along the front of the spine through the posterior mediastinum, passes through the Diaphragm, and, entering the abdomen, terminates at the cardiac orifice of the stomach opposite the tenth dorsal vertebra or the intervertebral disk between the tenth and eleventh dorsal vertebræ. The general direction of the œsophagus is vertical, but it presents two or three slight curves in its course. At its commencement it is placed in the median line, but it inclines to the left side as far as the root of the neck, gradually passes to the middle line again, and finally again deviates to the left as it passes forward to the œsophageal opening of the Diaphragm. The œsophagus also presents an antero-posterior flexure, corresponding to the curvature of the cervical and thoracic portions of the spine. It is the narrowest part of the alimentary canal, being most contracted at its commencement and at the point where it passes through the Diaphragm.

Relations.—*In the neck* the œsophagus is in relation, *in front*, with the trachea, and at the lower part of the neck, where it projects to the left side, with the thyroid gland and thoracic duct; *behind*, it rests upon the vertebral column and Longi colli muscles; *on each side*, it is in relation with the common carotid artery (especially the left, as it inclines to that side) and part of the lateral lobes of the thyroid gland; the recurrent laryngeal nerves ascend between it and the trachea.

In the thorax, it is at first situated a little to the left of the median line; it then passes behind the aortic arch, separated from it by the trachea, and descends in the posterior mediastinum, along the right side of the aorta, nearly to the Diaphragm, where it passes in front and a little to the left of the artery, previous to entering the abdomen. It is in relation, *in front*, with the trachea, the arch of the aorta, the left carotid and left subclavian arteries, which incline toward its left side, the left bronchus, the pericardium, and the Diaphragm; *behind*, it rests upon the vertebral column, the Longi colli muscles, the right intercostal arteries, and the vena azygos minor; and below, near the Diaphragm, upon the front of the aorta; *laterally*, it comes in contact with both pleuræ, especially with the left pleura above and the right pleura below: it overlaps the vena azygos major, which lies on its right side, while the descending aorta is placed on its left side. The pneumogastric nerves descend in close contact with it, the right nerve passing down behind, and the left nerve in front of it; the two nerves uniting to form a plexus (the *plexus gulæ*) around the tube.

In the lower part of the posterior mediastinum the thoracic duct lies to the right side of the œsophagus; higher up, it is placed behind it, and, crossing about the level of the fourth dorsal vertebra, is continued upward on its left side.

Structure.—The œsophagus has three coats—an external or muscular; a middle or areolar; and an internal or mucous coat.

The *muscular coat* is composed of two planes of fibres of considerable thickness, an external longitudinal and an internal circular.

The *longitudinal fibres* are arranged, at the commencement of the tube, in three fasciculi: one in front, which is attached to the vertical ridge on the posterior surface of the cricoid cartilage; and one at each side, which is continuous with the fibres of the Inferior constrictor: as they descend they blend together and form a uniform layer, which covers the outer surface of the tube.

Accessory slips of muscular fibres are described by Cunningham as passing between the œsophagus and the left pleura, where it covers the thoracic aorta (almost always), or the root of the left bronchus (usually), or the back of the pericardium, as well as other still more rare accessory fibres. In Fig. 485, taken from a dissection in the Museum of the Royal College of Surgeons of England, several of these accessory slips may be seen passing from the œsophagus to the pleura, and two slips to the back of the trachea just above its bifurcation.

The *circular fibres* are continuous above with the Inferior constrictor; their direction is transverse at the upper and lower parts of the tube, but oblique in the central part.

The muscular fibres in the upper part of the œsophagus are of a red color, and consist chiefly of the striped variety, but below they consist for the most part of involuntary muscular fibre.

The *areolar coat* connects loosely the mucous and muscular coats.

The *mucous coat* is thick, of a reddish color above and pale below. It is disposed in longitudinal folds, which disappear on distension of the tube. Its surface is studded with minute papillæ, and it is covered throughout with a thick layer of stratified pavement epithelium. Beneath the mucous membrane, between it and the areolar coat, is a layer of longitudinally arranged non-striped muscular fibres. This is the *muscularis mucosæ*. At the commencement it is absent, or only represented by a few scattered bundles; lower down it forms a considerable stratum.

The *œsophageal glands* are numerous small compound racemose glands scattered throughout the tube; they are lodged in the submucous tissue, and open upon the surface by a long excretory duct. They are most numerous at the lower part of the tube, where they form a ring round the cardiac orifice.

Vessels of the Œsophagus.—The arteries supplying the œsophagus are derived from the inferior thyroid branch of the thyroid axis of the subclavian, from the descending thoracic aorta, and from the gastric branch of the cœliac

axis, and from the left inferior phrenic of the abdominal aorta. They have for the most part a longitudinal direction.

Nerves of the Œsophagus.—The nerves are derived from the pneumogastric and from the sympathetic; they form a plexus in which are groups of ganglion-cells between the two layers of the muscular coats, and also a second plexus in the submucous tissue.

Surgical Anatomy.—The relations of the œsophagus are of considerable practical interest to the surgeon, as he is frequently required, in cases of stricture of this tube, to dilate the canal by a bougie, when it is of importance that the direction of the œsophagus and its relations to surrounding parts should be remembered. In cases of malignant disease of the œsophagus, where its tissues have become softened from infiltration of the morbid deposit, the greatest care is requisite in directing the bougie through the strictured part, as a false passage may easily be made, and the instrument may pass into the mediastinum, or into one or the other pleural cavity, or even into the pericardium.

The student should also remember that obstruction of the œsophagus, and consequent symptoms of stricture, are occasionally produced by an aneurism of some part of the aorta pressing upon this tube. In such a case the passage of a bougie could only hasten the fatal issue.

In passing a bougie the left fore finger should be introduced into the mouth and the epiglottis felt for, care being taken not to throw the head too far backward. The bougie is then to be passed beyond the finger until it touches the posterior wall of the pharynx. The patient is now asked to swallow, and at the moment of swallowing the bougie is passed gently onward, all violence being carefully avoided.

It occasionally happens that a foreign body becomes impacted in the œsophagus which can neither be brought upward nor moved downward. When all ordinary means for its removal have failed, excision is the only resource. This, of course, can only be performed when it is not very low down. If the foreign body is allowed to remain, extensive inflammation and ulceration of the œsophagus may ensue. In one case the foreign body ultimately penetrated the intervertebral substance, and destroyed life by inflammation of the membranes and substance of the cord.

The operation of œsophagotomy is thus performed: The patient being placed upon his back, with the head and shoulders slightly elevated, an incision, about four inches in length, should be made on the left side of the trachea, from the thyroid cartilage downward, dividing the skin, Platysma, and deep fascia. The edges of the wound being separated, the Omo-hyoid muscle should, if necessary, be divided, and the fibres of the Sterno-hyoid and Sterno-thyroid muscles drawn inward; the sheath of the carotid vessels, being exposed, must be drawn outward, and retained in that position by retractors: the œsophagus will now be exposed, and should be divided over the foreign body, which can then be removed. Great care is necessary to avoid wounding the thyroid vessels, the thyroid gland, and the laryngeal nerves.

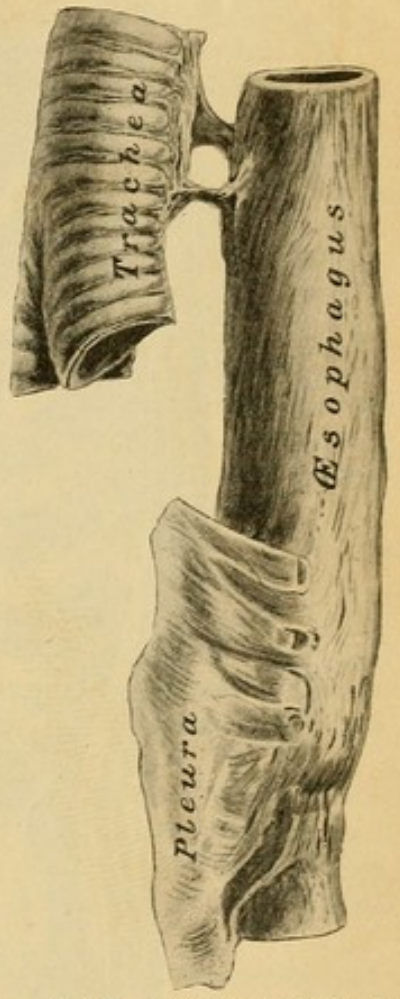

FIG. 485.—Accessory muscular fibres between the œsophagus and pleura, and œsophagus and trachea. (From a preparation in the Museum of the Royal College of Surgeons of England.)

The œsophagus may be obstructed not only by foreign bodies, but also by changes in its coats, producing stricture, or by pressure on it from without of new growths or aneurism, etc.

The different forms of stricture are: (1) the spasmodic, usually occurring in nervous women, and intermittent in character, so that the dysphagia is not constant; (2) fibrous, due to cicatrization after injuries, such as swallowing corrosive fluids or boiling water; and (3) malignant, usually epitheliomatous in its nature. This is situated generally either at the upper end of the tube, opposite to the cricoid cartilage, or at its lower end at the cardiac orifice, but is also occasionally found at that part of the tube where it is crossed by the left bronchus.

The operation of œsophagostomy has occasionally been performed in cases where the stricture in the œsophagus is at the upper part, with a view to making a permanent opening below the stricture through which to feed the patient, but the operation has been far from a successful one, and the risk of setting up diffuse inflammation in the loose planes of connective tissue deep in the neck is so great that it would appear to be better, if any operative interference is undertaken, to perform gastrostomy. The operation is performed in the same manner as œsophagotomy, but the edges of the opening in the œsophagus are stitched to the skin incision.

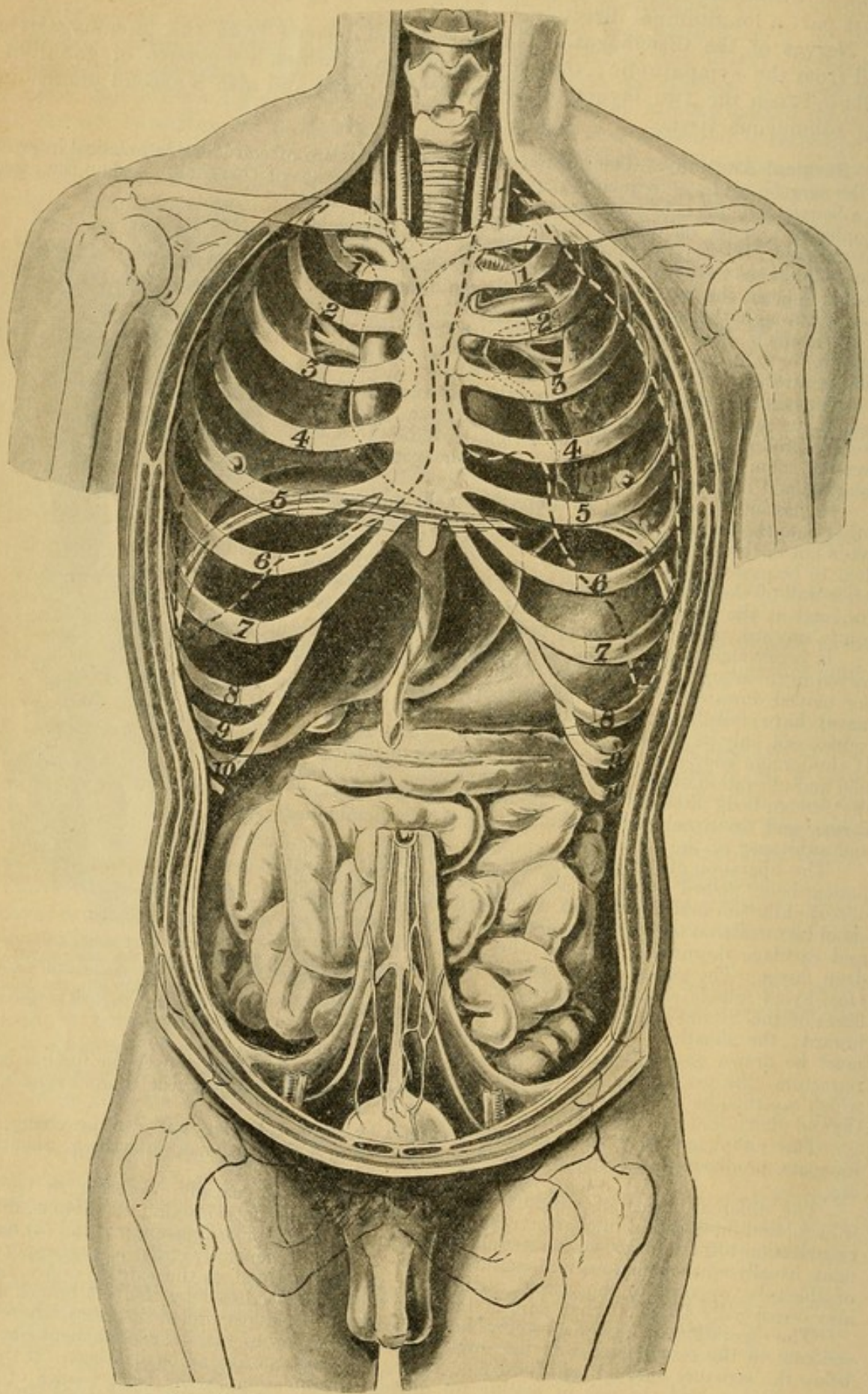

FIG. 486.—Topography of thoracic and abdominal viscera.

THE ABDOMEN.

The **Abdomen** is the largest cavity in the body. It is of an oval form, the extremities of the oval being directed upward and downward: the upper one being formed by the under surface of the Diaphragm, the lower by the upper concave surface of the Levatores ani. In order to facilitate description, it is artificially divided into two parts: an upper and larger part, the *abdomen proper;* and a lower and smaller part, the *pelvis.* These two cavities are not separated from each other, but the limit between them is marked by the brim of the true pelvis. The space is wider above than below, and measures more in the vertical than in the transverse diameter.

The abdomen proper differs from the other great cavities of the body in being bounded for the most part by muscles and fasciæ, so that it can vary in capacity and shape according to the condition of the viscera which it contains; but, in addition to this, the abdomen varies in form and extent with age and sex. In the adult male, with moderate distention of the viscera, it is oval or barrel-shaped, but at the same time flattened from before backward. In the adult female, with a fully developed pelvis, it is conical with the apex above, and in young children it is conical with the apex below.

Boundaries.—The boundary between the thorax and abdomen is the Diaphragm. This muscle forms a dome over the abdomen, and the cavity extends high into the bony thorax, reaching to the level of the junction of the fourth costal cartilage with the sternum. The lower end of the abdomen is limited by the structures which clothe the inner surface of the bony pelvis, principally the Levatores ani and Coccygei muscles on either side. These muscles are sometimes termed the *Diaphragm of the pelvis.* The **abdomen proper** is bounded *in front* and *at the sides* by the lower ribs, the abdominal muscles, and the venter ilii; *behind*, by the vertebral column and the Psoas and Quadratus lumborum muscles; *above*, by the Diaphragm; *below*, by the brim of the pelvis. The muscles forming the boundaries of the cavity are lined upon their inner surface by a layer of fascia, differently named, according to the part which it covers.

The abdomen contains the greater part of the alimentary canal; some of the accessory organs to digestion, viz., the liver and pancreas; the spleen, the kidneys, and suprarenal capsules. Most of these structures, as well as the wall of the cavity in which they are contained, are covered by an extensive and complicated serous membrane, the *peritoneum.*

The *apertures* found in the walls of the abdomen, for the transmission of structures to or from it, are, the *umbilicus*, for the transmission (in the fœtus) of the umbilical vessels; the *caval opening* in the Diaphragm, for the transmission of the inferior vena cava; the *aortic opening*, for the passage of the aorta, vena azygos major, and thoracic duct; and the *œsophageal opening*, for the œsophagus and pneumogastric nerves. *Below*, there are two apertures on each side: one for the passage of the femoral vessels, and the other for the transmission of the spermatic cord in the male, and the round ligament in the female.

Regions.—For convenience of description of the viscera, as well as of re to the morbid conditions of the contained parts, the abdomen is artificially into nine regions. Thus, if two circular lines are drawn round the bod outline.) through the extremities of the ninth ribs where they join their costal cart on, and may the other through the highest point of the crests of the ilia right side. is divided into three zones—an upper, a middle, and a l the abdominal wall and of are drawn perpendicularly upward from the cer former is lined and the latter more these zones is subdivided into three parts—s rane, the *peritoneum.*

[1] Anatomists are far from agreed as to the be **oneum.**
Cunningham suggests that the lower line should en
of the iliac crest, as seen from the front—a point membrane in the body, and consists, in
outer lip of the iliac crest about two inches behi
careful analysis of the abdominal viscera in forty s applied against the abdominal parietes,

[1] *Journal of Anatomy and Physi* e contained viscera. In the female the

The middle region of the upper zone is called the *epigastric* (*ἐπί, over; γαστήρ, the stomach*); and the two lateral regions, the *right* and *left hypochondriac* (*ὑπο, under; χονδροι, the cartilages*). The central region of the middle zone is the *umbilical;* and the two lateral regions, the *right* and *left lumbar*. The middle region of the lower zone is the *hypogastric* or *pubic region;* and the lateral regions are the *right* and *left inguinal* or *iliac*. The viscera contained in these different regions are the following (Fig. 487).

Right Hypochondriac.	*Epigastric Region.*	*Left Hypochondriac.*
The greater part of right lobe of the liver, the hepatic flexure of the colon, and part of the right kidney.	The greater part of the stomach, including both cardiac and pyloric orifices, the left lobe and part of the right lobe of the liver and the gall-bladder, the pancreas, the duodenum, the suprarenal capsules, and parts of the kidneys.	The fundus of the stomach, the spleen and extremity of the pancreas, the splenic flexure of the colon, and part of the left kidney.
Right Lumbar.	*Umbilical Region.*	*Left Lumbar.*
Ascending colon, part of the right kidney, and some convolutions of the small intestines.	The transverse colon, part of the great omentum and mesentery, transverse part of the duodenum, and some convolutions of the jejunum and ileum, and part of both kidneys.	Descending colon, part of the omentum, part of the left kidney, and some convolutions of the small intestines.
Right Inguinal (Iliac).	*Hypogastric Region.*	*Left Inguinal (Iliac).*
The cæcum and vermiform appendix.	Convolutions of the small intestines, the bladder in children, and in adults if distended, and the uterus during pregnancy.	Sigmoid flexure of the colon.

If the anterior abdominal wall is reflected in the form of four triangular flaps by means of vertical and transverse incisions—the former from the ensiform cartilage to the symphysis pubis, the latter from flank to flank at the level of the umbilicus—the abdominal or peritoneal cavity is freely opened into and the contained viscera are in part exposed.[1]

Above and to the right side is the liver, situated chiefly under the shelter of ght ribs and their cartilages, but extending across the middle line, and reaching some distance below the level of the ensiform cartilage. Below and to the e liver is the stomach, from the lower border of which an apron-like fold eum, the *great omentum*, descends for a varying distance, and obscures, lesser extent, the other viscera. Below it, however, some of the coils generally be seen, while in the right and left iliac regions *igmoid flexure* of the colon are exposed. The f the pelvis, and, if distended, will project



) two lateral lines drawn vertically through a point and the symphysis pubis; (3) an upper transverse he supra-sternal notch; and (4) a lower transverse

FIG. 486.—Topography of thorax and of the symphysis pubis.

he term abdominal cavity is used, there is, under ymph-space, since the viscera are everywhere in

above the symphysis pubis; the rectum lies in the concavity of the sacrum, but is usually obscured by the coils of the small intestine.

If the stomach is followed from left to right it will be found to be continuous with the first part of the small intestine, or *duodenum*, the point of continuity being marked by a thickened ring which indicates the position of the pyloric valve. The duodenum passes toward the under surface of the liver, and then curving downward, is lost to sight. If, however, the great omentum be thrown upward over the chest, the terminal part of the duodenum will be observed passing across the spine toward the left side, where it becomes continuous with the *coils of the small intestine*. These measure some twenty feet in length, and if followed downward will be seen to end in the right iliac fossa by opening into the *cæcum* or commencement of the *large intestine*. From the cæcum the large intestine takes an arched course, passing at first upward on the right side, then across the middle line and downward on the left side, and forming respectively the *ascending, transverse, and descending parts of the colon*. In the left iliac region it makes still another bend, the *sigmoid flexure*, and then follows the curve of the sacrum as the *rectum*.

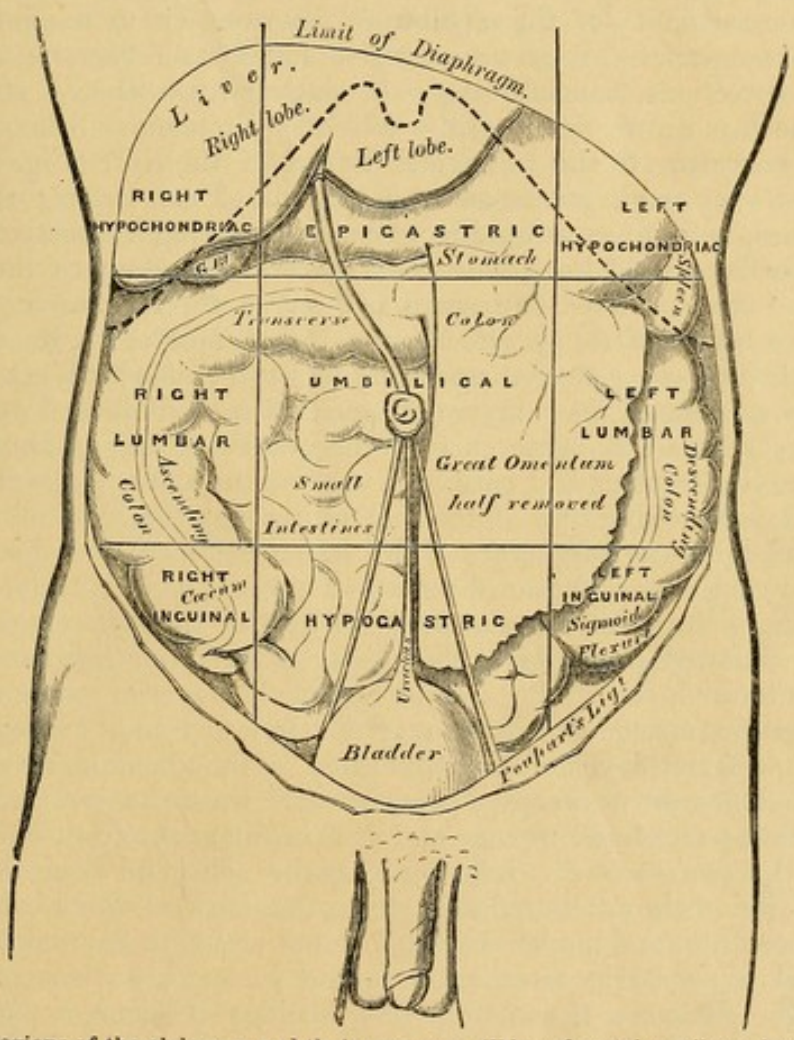

FIG. 487.—The regions of the abdomen and their contents. (Edge of costal cartilages in dotted outline.)

The *spleen* lies behind the stomach in the left hypochondriac region, and may be in part exposed by pulling the stomach over toward the right side.

The glistening appearance of the deep surface of the abdominal wall and of the exposed viscera is due to the fact that the former is lined and the latter more or less completely covered by a serous membrane, the *peritoneum*.

The Peritoneum.

The peritoneum is the largest serous membrane in the body, and consists, in the male, of a closed sac, a part of which is applied against the abdominal parietes, while the remainder is reflected over the contained viscera. In the female the

peritoneum is not a closed sac, since the free extremities of the Fallopian tubes open directly into the peritoneal cavity. The former constitutes the *parietal*, the latter the *visceral* part of the peritoneum. The *free surface* of the membrane is smooth, covered by a layer of flattened endothelium, and lubricated by a small quantity of serous fluid. Hence the viscera can glide freely against the wall of the cavity or upon one another with the least possible amount of friction. Its *attached surface* is rough, being connected to the viscera and inner surface of the parietes by means of *areolar tissue* termed the *subserous areolar tissue*. The parietal portion is loosely connected with the fascia lining the abdomen and pelvis, but more closely to the under surface of the Diaphragm and also in the middle line of the abdomen.

The peritoneum differs from the other serous membranes of the body in presenting a much more complex arrangement—an arrangement which can only be clearly understood by following the changes which take place in the alimentary canal during its development; and therefore the student is advised to preface his study of the peritoneum by reviewing the chapter dealing with this subject in the section on Embryology.

To trace the continuity of the membrane from one viscus to another, and from the viscera to the parietes, it is necessary to follow its reflections in the vertical and horizontal directions, and in doing so it matters little where a start is made.

If the stomach is drawn downward, a fold of peritoneum will be seen stretching from its lesser curvature to the transverse fissure of the liver (Fig. 488). This is the *gastro-hepatic* or *small omentum*, and consists of two layers; these, on being traced downward, split to envelop the stomach, covering respectively its anterior and posterior surfaces. At the greater curvature of the stomach they again come into contact and are continued downward in front of the transverse colon, forming the anterior two layers of the *great* or *gastro-colic* omentum. Reaching the free edge of this fold they are reflected upward as its two posterior layers, and thus the great omentum consists of four layers of peritoneum. Followed upward the two posterior layers separate so as to enclose the transverse colon, above which they once more come into contact and pass backward to the abdominal wall as the *transverse mesocolon*. Reaching the abdominal wall about the level of the transverse part of the duodenum, the two layers of the transverse mesocolon become separated from each other and take different directions; the upper or anterior layer ascends (ascending layer of transverse mesocolon) in front of the pancreas, and its further course will be followed presently. The lower or posterior layer is carried downward, as the anterior layer of the *mesentery*, by the superior mesenteric vessels to the small intestine, around which it may be followed and subsequently traced upward as the posterior layer of the mesentery to the abdominal wall. From the posterior abdominal wall it sweeps downward over the aorta into the pelvis, where it invests the first part of the rectum and attaches it to the front of the sacrum by a fold termed the *mesorectum*. Leaving first the sides and then the front of the second part of the rectum it is reflected on to the back of the bladder, and, after covering the posterior and upper aspects of this viscus, is carried by the urachus and obliterated hypogastric arteries on to the posterior surface of the anterior abdominal wall. Between the rectum and bladder it forms a pouch, the *recto-vesical pouch*, bounded on each side by a crescentic or *semilunar fold*; the bottom of this pouch is about on a level with the middle of the vesiculæ seminales—*i. e.*, three inches or so from the orifice of the anus. When the bladder is distended the peritoneum is carried up with the expanded viscus, so that a considerable part of the anterior surface of the latter lies directly against the abdominal wall without the intervention of the peritoneal membrane.

In the female the peritoneum is reflected from the rectum on to the upper part of the posterior vaginal wall, forming the *recto-vaginal pouch* or *pouch of Douglas*. It is then carried over the posterior aspect and fundus of the uterus on to its anterior surface, which it covers as far as the junction of the body and cervix uteri, forming here a second but shallower depression, the *utero-vesical pouch*. It

is also reflected from the sides of the uterus to the lateral walls of the pelvis as two expanded folds, the *broad ligaments of the uterus*, in the free margin of each of which can be felt a thickened cord-like structure, the *Fallopian tube*.

On following the parietal peritoneum upward on the back of the anterior abdominal wall it is seen to be reflected around a fibrous band, the *ligamentum teres* or *obliterated umbilical vein*, which reaches from the umbilicus to the under surface of the liver. Here the membrane forms a somewhat triangular fold, the *falciform* or *suspensory ligament* of the liver, which attaches the upper and anterior surfaces of that organ to the Diaphragm and abdominal wall. With the exception of the line of attachment of this ligament the peritoneum covers the under surface of the anterior part of the Diaphragm and is reflected from it on to the upper surface of the liver as the *anterior* or *superior layer of the coronary ligament*. Covering the upper and anterior surfaces of the liver it is reflected round its sharp margin on to its under surface as far as the transverse fissure, where it is continuous with the anterior layer of the small omentum from which a start was made. The posterior layer of this omentum is carried backward from the transverse fissure over the under surface and Spigelian lobe of the liver, and is then reflected, as the *posterior* or *inferior layer of the coronary ligament*, on to the Diaphragm and is prolonged downward over the pancreas to become continuous with the ascending layer of the transverse mesocolon. Between the two layers of the coronary ligament there is a triangular surface of the liver which is devoid of peritoneum; it is named the *bare area* of the liver, and is attached to the Diaphragm by connective tissue. If, however, the two layers of the coronary ligaments are traced toward the right and left margins of the liver, they approach each other, and, ultimately fusing, they form the right and left lateral ligaments of the liver and attach its right and left lobes respectively to the Diaphragm.

If the small omentum is followed toward the right side it is seen to form a distinct free edge around which its anterior and posterior layers are continuous with each other and between which are situated the portal vein, hepatic artery, and bile-duct. If the finger is introduced behind this free edge, it passes through a somewhat constricted ring, the *foramen of Winslow*. This is the communication between what are termed the greater and lesser sacs of the peritoneum and has the following boundaries: in front, the free edge of the gastro-hepatic omentum with the portal vein, hepatic artery, and bile-duct between its two layers; behind, the vena cava inferior; above, the Spigelian and caudate lobes of the liver; below, the duodenum and the hepatic artery, as the latter passes forward and upward from the cœliac axis.

The *lesser sac of the peritoneum* therefore lies behind the small omentum and has the following dimensions: above, it is limited by the portion of the liver which lies behind the transverse fissure; below, it extends downward into the great omentum, reaching, in the fœtus, as far as its free edge; in the adult, however, its vertical extent is limited by adhesions between the layers of the omentum. In front, it is bounded by the small omentum, stomach, and anterior two layers of the great omentum; behind, by the two posterior layers of the great omentum, the transverse colon, and ascending layer of the transverse mesocolon which passes upward in front of the pancreas as far as the posterior surface of the liver. Laterally the lesser sac reaches from the foramen of Winslow on the right side as far as the spleen on the left, where it is limited by the lieno-renal ligament. The extent of the lesser sac and its relations to surrounding parts can be definitely made out by tearing through the small omentum and inserting the hand through the opening thus made.

It should be stated that during a considerable part of fœtal life the transverse colon is suspended from the posterior abdominal wall by a mesentery of its own—the two posterior layers of the great omentum passing, at this stage, in front of the colon. This condition sometimes persists throughout adult life, but as a rule adhesion occurs between the mesentery and the transverse colon and the posterior layer of the great omentum, with the result that the colon appears to receive

its peritoneal covering by the splitting of the two posterior layers of the latter fold.

In addition to tracing the peritoneum vertically, it is necessary to trace it horizontally. If this is done below the transverse colon, the circle is extremely simple, as it includes only the greater sac of the peritoneum (Fig. 488). Above the level of the transverse colon the arrangement is more complicated, on account of the existence of the two sacs.

Starting from the linea alba, below the level of the transverse colon, and tracing the continuity in a horizontal direction to the right, the peritoneum covers the internal surface of the abdominal wall almost as far as the anterior border of the Quadratus lumborum muscle; it encloses the cæcum, and is reflected over the sides and anterior surface of the ascending colon, fixing it to the abdominal wall, from which it can be traced over the kidney to the front of the bodies of the vertebræ. It then passes along the mesenteric vessels to invest the small intes-

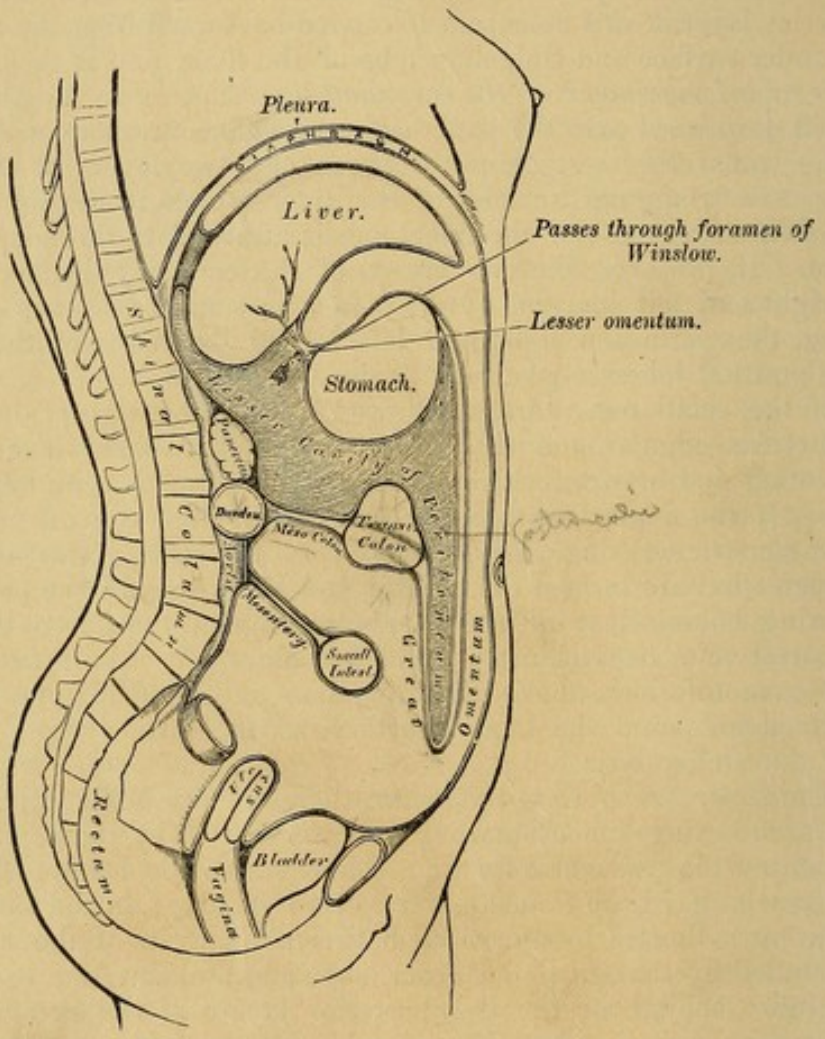

FIG. 488.—The reflections of the peritoneum, as seen in a vertical section of the abdomen.

tine, and back again to the spine, forming the mesentery, between the layers of which are contained the mesenteric blood-vessels, nerves, lacteals, and glands. Lastly, it passes over the left kidney to the sides and anterior surface of the descending colon, and, reaching the abdominal wall, is continued along it to the middle line of the abdomen.

Above the transverse colon (Fig. 489) the peritoneum can be traced, forming the greater and lesser cavities, and their communication through the foramen of Winslow can be demonstrated. Commencing in the middle line of the abdomen, the membrane may be traced lining its anterior wall, and sending a process backward to encircle the obliterated umbilical vein (the round ligament of the liver), forming the falciform or longitudinal ligament of the liver. Continuing its course

to the right, it is reflected over the front of the upper part of the right kidney, across the vena cava inferior and aorta, and over the left kidney to the hilum of the spleen, forming the anterior layer of the *lieno-renal ligament*, the posterior layer being formed by the termination of the *cul-de-sac* of the greater cavity between the kidney and spleen. From the hilum of the spleen it is reflected to the stomach, forming the posterior layer of the *gastro-splenic omentum*. It covers the posterior surface of the stomach, and from its lesser curvature it passes around the portal vein, hepatic artery, and bile-duct, and back again to the stomach, as the lesser omentum, and thus it forms the anterior boundary of the foramen of Winslow. It now covers the front of the stomach, and upon reaching the cardiac extremity it passes to the hilum of the spleen, forming the anterior layer of the gastro-splenic omentum. From the hilum of the spleen it can be traced over the surface of this organ, to which it gives a serous covering; it is then reflected from the posterior border of the hilum on to the left kidney, forming the posterior layer of the lieno-renal ligament.

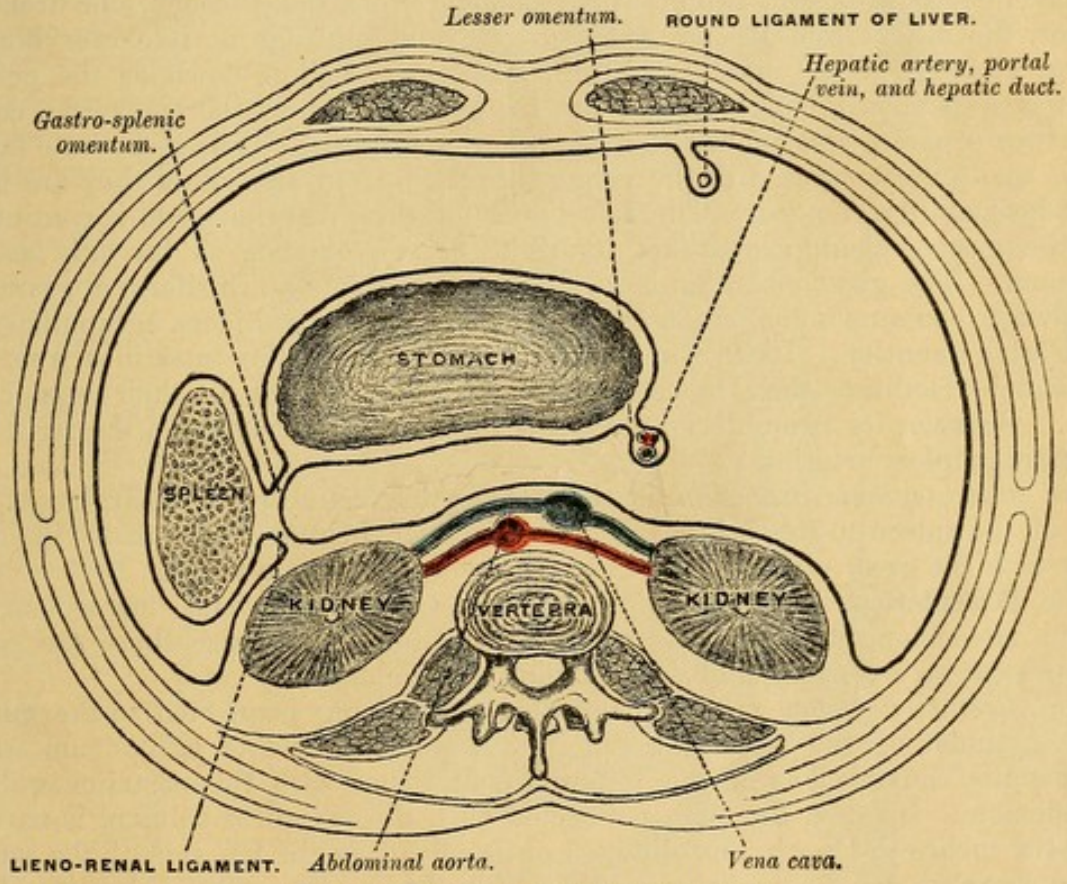

FIG. 489.—Transverse section of peritoneum.

Numerous folds, formed by the peritoneum, extend between the various organs or connect them to the parietes. These serve to hold them in position, and at the same time enclose the vessels and nerves proceeding to each part. Some of these folds are called *ligaments*, such as the ligaments of the liver and the false ligaments of the bladder. Others, which connect certain parts of the intestine with the abdominal wall, constitute the *mesenteries;* and lastly, those which proceed from the stomach to certain viscera in its neighborhood are called *omenta*.

The **Ligaments,** formed by folds of the peritoneum, include those of the liver, spleen, bladder, and uterus. They will be found described with their respective organs.

The **Omenta** are: the lesser omentum, the great omentum, and the gastro-splenic omentum.

The *lesser omentum* (*gastro-hepatic*) is the duplicature which extends between the transverse fissure of the liver and the lesser curvature of the stomach. It is extremely thin, and consists of two layers of peritoneum: that is, the two layers

covering respectively the anterior and posterior surfaces of the stomach. When these two layers reach the lesser curvature of the stomach, they join together and ascend as the double fold to the transverse fissure of the liver; to the left of this fissure the double fold is attached to the fissure of the ductus venosus as far as the Diaphragm, where the two layers separate to embrace the end of the œsophagus. At the right border the lesser omentum is free, and the two layers of which it is composed are continuous. The anterior layer, which belongs to the greater sac, turns round the hepatic vessels to become continuous with the posterior layer belonging to the lesser one. They here form a free, rounded margin, which contains between its layers the hepatic artery, the common bile-duct, the portal vein, lymphatics, and the hepatic plexus of nerves—all these structures being enclosed in loose areolar tissue, called *Glisson's capsule*. Between the layers where they are attached to the stomach lie the gastric artery and the pyloric branch of the hepatic, anastomosing with it.

The *great omentum* (*gastro-colic*) is the largest peritoneal fold. It consists of four layers of peritoneum, two of which descend from the stomach, one from its anterior, the other from its posterior surface, and, uniting at its lower border, descend in front of the small intestines, sometimes as low down as the pelvis; they then turn upon themselves, and ascend again as far as the transverse colon, where they separate and enclose that part of the intestine. These separate layers may be easily demonstrated in the young subject, but in the adult they are more or less inseparably blended. The left border of the great omentum is continuous with the gastro-splenic omentum: its right border extends as far only as the duodenum. The great omentum is usually thin, presents a cribriform appearance, and always contains some adipose tissue, which in fat subjects accumulates in considerable quantity. Its use appears to be to protect the intestines from the cold, and to facilitate their movement upon each other during their vermicular action. Between its two anterior layers is the anastomosis between the right and left gastro-epiploic arteries.

The *gastro-splenic omentum* is the fold which connects the margins of the hilum of the spleen to the *cul-de-sac* of the stomach, being continuous by its lower border with the great omentum. It contains the vasa brevia vessels.

The **Mesenteries** are: the mesentery proper, the transverse mesocolon, the sigmoid mesocolon, and the mesorectum. In addition to these there are sometimes present an ascending and a descending mesocolon.

The *mesentery* (*μέσον ἔντερον*), so called from being connected to the middle of the cylinder of the small intestine, is the broad fold of peritoneum which connects the convolutions of the jejunum and ileum with the posterior wall of the abdomen. Its *root*, the part connected with the vertebral column, is narrow, about six inches in length, and directed obliquely from the left side of the second lumbar vertebra to the right sacro-iliac symphysis (Fig. 490). Its intestinal border is much longer; and here its two layers separate so as to enclose the intestine, and form its peritoneal coat. Its breadth, between its vertebral and intestinal border, is about eight inches. Its *upper border* is continuous with the under surface of the transverse mesocolon: its *lower border*, with the peritoneum covering the cæcum and ascending colon. It serves to retain the small intestines in their position, and contains between its layers the mesenteric vessels and nerves, the lacteal vessels, and mesenteric glands.

In most cases the peritoneum covers only the front and sides of the ascending and descending parts of the colon. Sometimes, however, these are surrounded by the serous membrane and attached to the posterior abdominal wall by an ascending and a descending mesocolon respectively. At the place where the transverse colon turns downwards to form the descending colon, a fold of peritoneum is continued to the under surface of the Diaphragm opposite the tenth and eleventh ribs. This is the *phreno-colic ligament*; it passes below the spleen, and serves to support this organ, and therefore it has received the second name of *sustentaculum lienis*.

The *transverse mesocolon* is a broad fold, which connects the transverse colon to the posterior wall of the abdomen. It is formed by the two ascending or posterior layers of the great omentum, which, after separating to surround the transverse colon, join behind it, and are continued backward to the spine, where they diverge in front of the duodenum. This fold contains between its layers the vessels which supply the transverse colon.

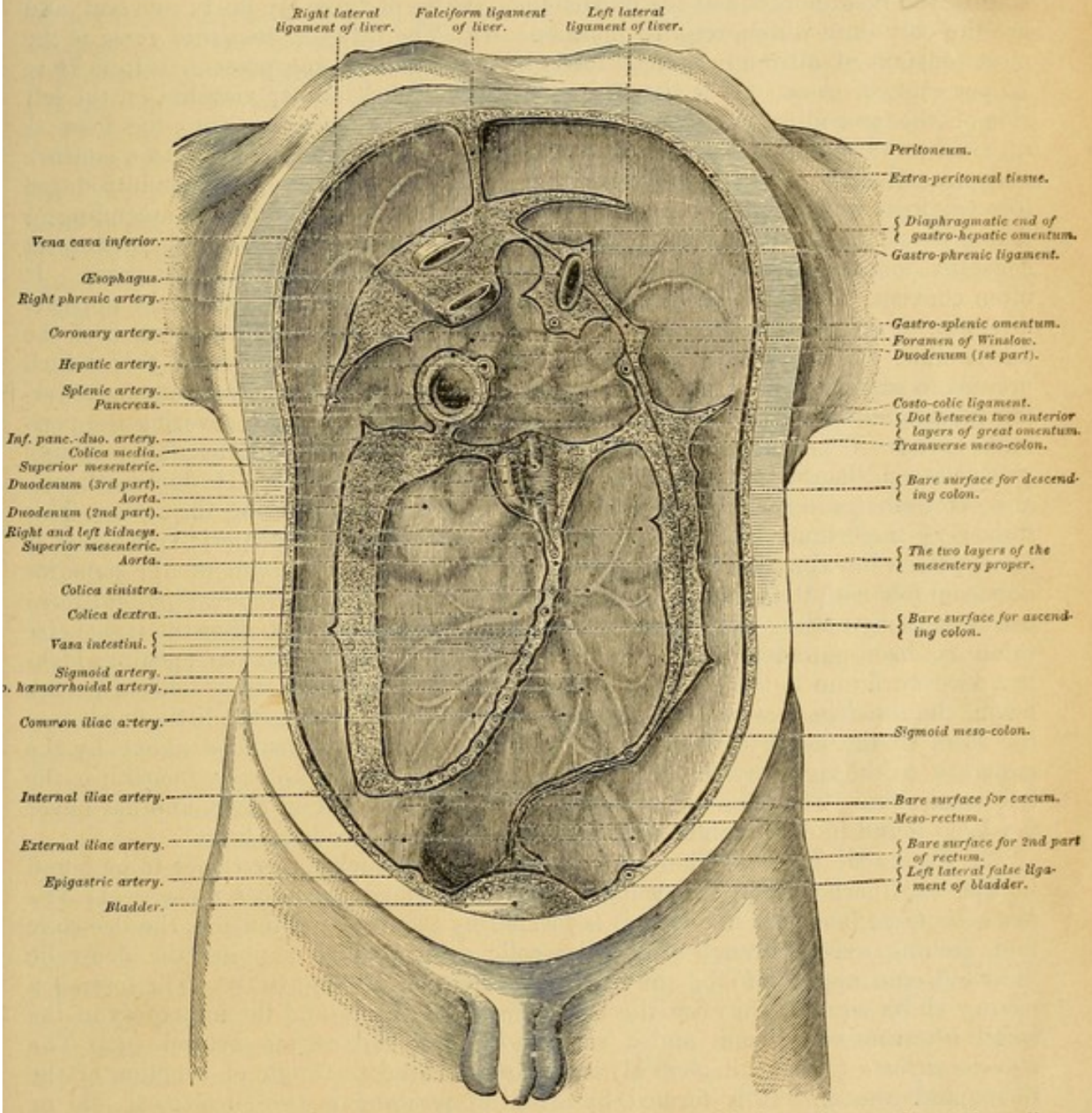

FIG. 490.—Diagram devised by Dr. Delépine to show the lines along which the peritoneum leaves the wall of the abdomen to invest the viscera.

The *sigmoid mesocolon* is the fold of peritoneum which retains the sigmoid flexure in connection with the left iliac fossa.

The *mesorectum* is the narrow fold which connects the upper part of the rectum with the front of the sacrum. It contains the superior hemorrhoidal vessels.

The *appendices epiploicæ* are small pouches of the peritoneum filled with fat and situated along the colon and upper part of the rectum. They are chiefly appended to the transverse colon.

Retro-peritoneal fossæ.—In certain parts of the abdominal cavity there are recesses of peritoneum forming *culs-de-sac* or pouches, which are of surgical inter-

est in connection with the possibility of the occurrence of retro-peritoneal hernia. One of these is the lesser sac of the peritoneum, which may be regarded as a recess of peritoneum through the foramen of Winslow, in which a hernia may take place, but there are several others, of smaller size, which require mention.

These recesses of fossæ may be divided into three groups, viz.: (1) the duodenal fossæ; (2) pericæcal fossæ; and (3) the intersigmoid fossa.

1. *Duodenal Fossæ.*—Moynihan has described no less than nine fossæ as occurring in the neighborhood of the duodenum. Three of these are fairly constant, and are the only ones which require mention. (*a*) The *inferior duodenal fossa* is the most constant of all the peritoneal fossæ in this region, being present in from 70 to 75 per cent. of cases. It is situated opposite the third lumbar vertebra on the left side of the ascending portion of the duodenum. The opening into the fossa is directed upward, and is bounded by a thin sharp fold of peritoneum with a concave margin, called the *inferior duodenal fold.* The tip of the index finger introduced into the fossa under the fold passes some little distance up behind the ascending or fourth portion of the duodenum. (*b*) The *superior duodenal fossa* is the next most constant pouch or recess, being present in from 40 to 50 per cent. of cases. It often coexists with the inferior one, and its orifice looks downward, in the opposite direction to the preceding fossa. It lies to the left of the ascending portion of the duodenum. It is bounded by the free edge of the *superior duodenal fold*, which presents a semilunar margin; to the right it is blended with the peritoneum covering the ascending duodenum, and to the left with the peritoneum covering the perirenal tissues. The fossa is bounded in front by the superior duodenal fold; behind by the second lumbar vertebra; to the right by the duodenum. Its depth is 2 cm., and it terminates in the angle formed by the left renal vein crossing the aorta. This fossa is of importance, as it is in relation with the inferior mesenteric vein: that is to say, the vein almost always corresponds to the line of union of the superior duodenal fold with the posterior parietal peritoneum. (*c*) The *duodeno-jejunal fossa* can be seen by pulling the jejunum downward and to the right, after the transverse colon has been pulled upward. It will appear as an almost circular opening, looking downward and to the right, and bounded by two free borders or folds of peritoneum, the *duodeno-mesocolic ligaments.* The opening admits the little finger into the fossa to the depth of from 2 to 3 cm. The fossa is bounded above by the pancreas, to the right by the aorta, and to the left by the kidney; beneath is the left renal vein. The fossa exists in from 15 to 20 per cent. of cases, and has never yet been found in conjunction with any other form of duodenal fossa.

2. *Pericæcal Fossæ.*—There are at least three pouches or recesses to be found in the neighborhood of the cæcum, which are termed *pericæcal fossæ.* (1) The *ileo-colic fossa* (superior ileo-cæcal) is formed by a fold of peritoneum, the ileo-colic fold, arching over a branch of the ileo-colic artery, which supplies the ileo-colic junction, and appears to be the direct continuation of the artery. The fossa is a narrow chink situated between the ileo-colic fold in front, and the mesentery of the small intestine, the ileum, and a small portion of the cæcum behind. (2) The *ileo-cæcal fossa* (inferior ileo-cæcal) is situated behind the angle of junction of the ileum and cæcum. It is formed by a fold of peritoneum (the ileo-cæcal fold or bloodless fold of Treves), the upper border of which is attached to the ileum, opposite its mesenteric attachment, and the lower border, passing over the ileo-cæcal junction, joins the mesentery of the appendix, and sometimes the appendix itself; hence this fold is sometimes called the ileo-appendicular. Between this fold and the mesentery of the vermiform appendix is the ileo-cæcal fossa. It is bounded above by the posterior surface of the ileum and the mesentery; in front and below by the ileo-cæcal fold, and behind by the upper part of the mesentery of the appendix. (3) The *subcæcal fossa* (retro-cæcal) is situated immediately behind the cæcum, which has to be raised to bring it into view. It varies much in size and extent. In some cases it is sufficiently large to admit the index finger, and extends upward behind the ascending colon in the direction of the kidney: in others it is merely a shallow depression. It is bounded and formed by two folds: one, the *parieto-colic*,

which is attached by one edge to the abdominal wall from the lower border of the kidney to the iliac fossa and by the other to the postero-external aspect of the colon; and the other, *mesenterico-parietal*, which is in reality the insertion of the mesentery into the iliac fossa. In some instances the subcæcal fossa is double.

3. The *Intersigmoid fossa* is constant in the fœtus and during infancy, but disappears in a certain percentage of cases as age advances. Upon drawing the sigmoid flexure upward, the left surface of the sigmoid mesocolon is exposed, and on it will be seen a funnel-shaped recess of the peritoneum, lying on the external iliac vessels, in the interspace between the Psoas and Iliacus muscles. This is the orifice leading to the fossa intersigmoidea, which lies behind the sigmoid mesocolon, and in front of the parietal peritoneum. The fossa varies in size; in some instances it is a mere dimple, whereas in others it will admit the whole of the index finger.

Any of these fossæ may be the site of a retro-peritoneal hernia. The pericæcal fossæ are of especial interest, because hernia of the vermiform appendix frequently takes place into one of them, and may there become strangulated. The presence of these pouches also explains the course which pus has been known to take in cases of perforation of the appendix, where it travels upward behind the ascending colon as far as the Diaphragm.[1]

THE STOMACH.

The **Stomach** is the principal organ of digestion. It is the most dilated part of the alimentary canal, and is situated between the termination of the œsophagus and the commencement of the small intestine. Its form is somewhat pyriform with the large end (*fundus*) directed upward and the small end bent to the right. It is situated in the left hypochondriac and epigastric regions, and is placed, in part, immediately behind the anterior wall of the abdomen and beneath the Diaphragm. Viewing the stomach from in front it appears that the right margin of the œsophagus is continued downward as the upper two-thirds of the lesser curvature of the stomach, the remaining third of this border bending sharply backward and to the right, to complete the smaller curvature (Fig. 491). The greater curvature begins at the left border of the termination of the œsophagus in a somewhat acute angle; it then passes upward and to the left to the under surface of the Diaphragm, with which it lies in contact for some distance, and then sweeps downward with a convexity to the left, and, continued across the middle line of the body, finally turns upward and backward, to terminate at the commencement of the small intestine. It will thus be seen that the stomach may be divided into a main or *cardiac* portion, the long axis of which is directed downward, with a little inclination forward and to the right, and a smaller or *pyloric* portion, the long axis of which is horizontal with an inclination backward. Of the two openings, the *cardiac orifice*, by which it communicates with the œsophagus, is situated slightly to the left of the middle line of the body to the right of the *fundus*, or dilated upper extremity of the stomach, and is directed downward; the other, the *pyloric orifice*, by which it communicates with the small intestine, is on a lower plane, close to the right of the mid-line, and looks directly backward.

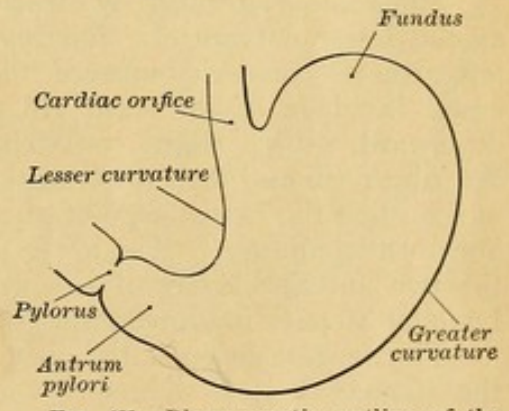

FIG. 491.—Diagrammatic outline of the stomach.

The stomach has two surfaces, called anterior and posterior, and two borders, termed the greater and lesser curvatures.

Surfaces.—With regard to the so-called anterior and posterior surfaces of the stomach, it must be borne in mind that these names are not strictly correct, as the anterior surface has a certain amount of inclination upward and the posterior downward.

[1] On the anatomy of these fossæ, see the *Arris and Gale Lectures* by Moynihan, 1899.

The *anterior* surface has a somewhat flattened appearance when the stomach is empty, but when it is full the surface becomes convex. It is in relation with the Diaphragm; the thoracic wall formed by the anterior parts of the seventh, eighth, and ninth ribs of the left side; the left lobe of the liver; and the anterior abdominal wall. Between the part covered by the liver and that covered by the left ribs there is a triangular segment of the anterior wall of the stomach, which is in contact with the abdominal wall and is the only part of the stomach which is visible when the abdominal wall is removed and the viscera allowed to remain *in situ*. It is of about 40 sq. cm. and is of great importance to the surgeon, as the stomach can readily be reached in this situation. Occasionally the transverse colon may be found lying in front of the lower part of the anterior surface of the stomach. The whole of this surface of the stomach is covered by peritoneum.

The *posterior* surface of the stomach is in relation with the Diaphragm, the gastric surface of the spleen, the left supra-renal capsule, the upper part of the left kidney, the anterior surface of the pancreas, the splenic flexure of the colon, and the ascending layer of the transverse mesocolon. These structures form a shallow concavity or *bed* on which this surface of the stomach rests. The transverse mesocolon intervenes between the stomach and the duodeno-jejunal junction and commencement of the ileum. Its greater curvature is in relation with the transverse colon and has attached to it the anterior two layers of the great omentum. Almost the whole of this surface is covered with peritoneum, but behind the cardiac orifice there is a small portion of the stomach which is uncovered by peritoneum and is in contact with the Diaphragm and frequently with the upper portion of the left supra-renal capsule.

The *lesser curvature* of the stomach extends between the cardiac and pyloric orifices along the right border of the organ. It descends in front of the left crus of the Diaphragm, along the left side of the eleventh and twelfth dorsal vertebræ, and then turning to the right it crosses the first lumbar vertebra and ascends to the pylorus. It gives attachment to the two layers of the gastro-hepatic omentum, between which blood-vessels and lymphatics pass to reach the organ.

The *greater curvature* is directed to the left, and is four or five times as long as the lesser curvature. Starting from the cardiac orifice, it forms an arch to the left with its convexity upward, the highest point of which is on a level with the costal cartilage of the sixth rib of the left side. It then passes nearly straight downward, with a slight convexity to the left, as low as the costal cartilage of the ninth rib and then turns to the right to end at the pylorus. As it crosses the median line the lowest edge of the greater curvature is about two fingers' breadth above the umbilicus. The lower part of the greater curvature gives attachment to the two anterior layers of the great omentum, between which layers, vessels and lymphatics pass to the organ.

The *cardiac orifice* is the opening by which the œsophagus communicates with the stomach. It is therefore sometimes termed the *œsophageal opening*. It is the most fixed part of the stomach, and is situated about two inches below the highest part of the fundus on a level with the body of the tenth or eleventh dorsal vertebra to the left and a little in front of the aorta. This would correspond on the anterior surface of the body to the articulation of the seventh left costal cartilage to the sternum.

The *pyloric orifice* communicates with the duodenum, the aperture being guarded by a valve. Its position varies with the movements of the stomach. When the stomach is empty the pylorus is situated just to the right of the median line of the body, on a level with the upper border of the first lumbar vertebra. On the anterior surface of the body its position would be indicated by a point one inch below the tip of the ensiform cartilage and a little to the right. As the stomach becomes distended the pylorus moves to the right, and in a fully distended stomach may be situated two or three inches to the right of the median line. Near the pylorus the stomach frequently exhibits a slight dilatation, which is named the *antrum pylorus*.

The size of the stomach varies considerably in different subjects. When moderately distended its greatest length, from the top of the fundus to the lowest part of the greater curvature, is from ten to twelve inches; and its diameter at the widest part from four to five inches. The distance between the two orifices is three to six inches, and the measurement from the anterior to the posterior wall three and a half inches. Its weight, according to Clendinning, is about four ounces and a half, and its capacity in the adult male is five to eight pints.

Alterations in Position.—There is no organ in the body the position and connections of which present such frequent alterations as the stomach. *When empty*, it lies at the back part of the abdomen, some distance from the surface. Its pyloric end is situated close to or very slightly to the right of the middle line, covered in front by the left lobe of the liver, and being on a level with the first lumbar vertebra. When empty, the stomach assumes a more or less cylindrical form, especially noticeable at its pyloric end. *When the stomach is distended*, its surfaces, which are flattened when the organ is empty, become convex. The greater curvature is elevated and carried forward, so that the anterior surface is turned more or less upward and the posterior surface downward, and the stomach brought well against the anterior wall of the abdomen. Its fundus expands and rises considerably above the level of the cardiac orifice: in doing this the

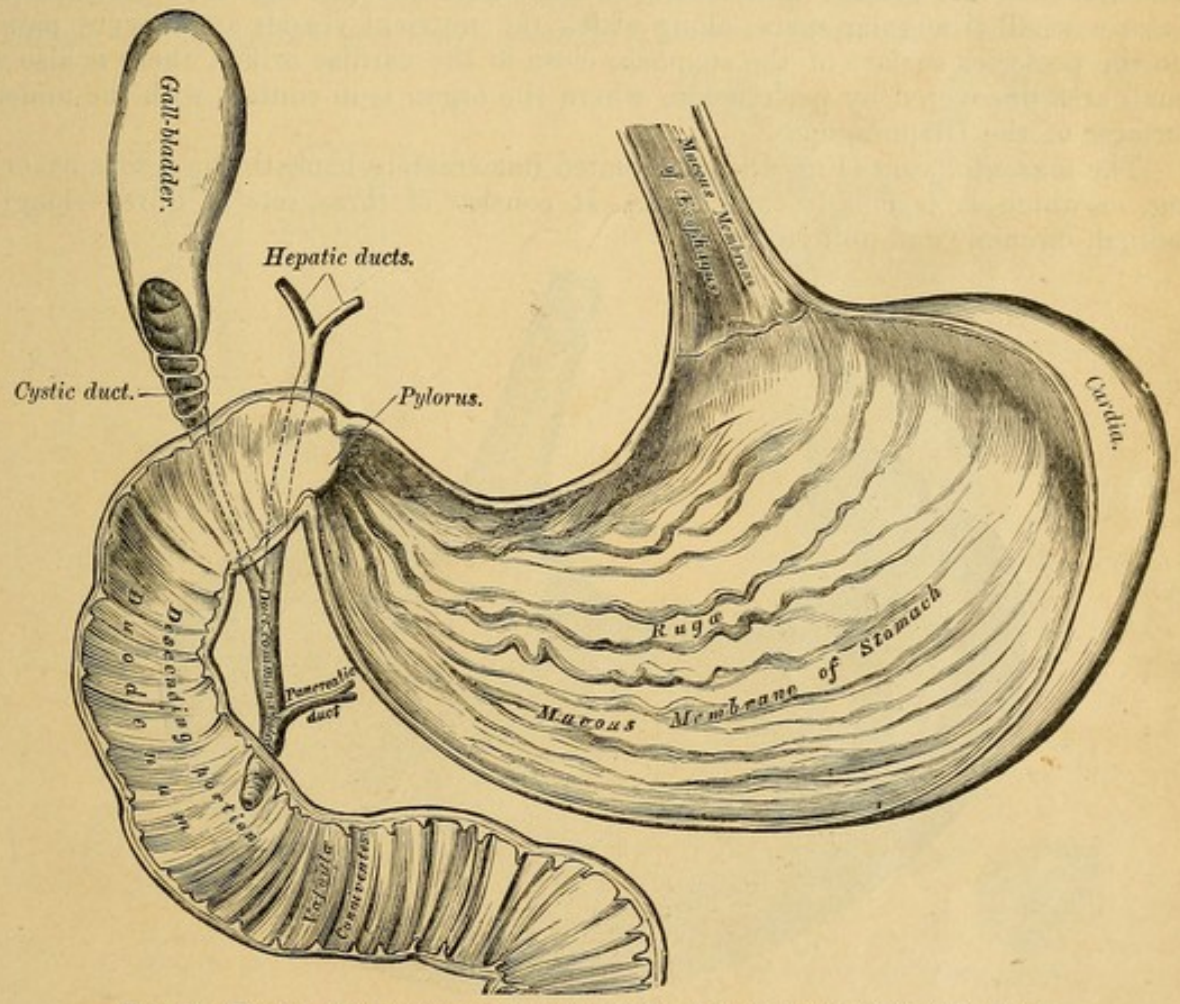

FIG. 492.—The mucous membrane of the stomach and duodenum with the bile-ducts.

Diaphragm is forced upward, contracting the cavity of the chest; hence the dyspnœa complained of, from inspiration being impeded. The apex of the heart is also tilted upward; hence the oppression in this region and the palpitation experienced in extreme distention of the stomach. The left lobe of the liver is pushed to the right side. When the stomach becomes distended the change in the position of the pylorus is very considerable; it is shifted to the right, some two or three inches from the median line, and lies under cover of the liver, near the neck of the gall-bladder. In consequence of the distention of the stomach the lesser *cul-de-sac* bulges over the pylorus, concealing it from view, and causing it to undergo a rotation, so that its orifice is directed backward. *During inspiration* the stomach is displaced downward by the descent of the Diaphragm, and elevated by the pressure of the abdominal muscles during expiration. *Pressure from without*, as from tight lacing, pushes the stomach down toward the pelvis. In disease, also, the position and connection of the organ may be greatly changed, from the accumulation of fluid in the chest or abdomen, or from alteration in size of any of the surrounding

viscera. *Variations according to Age.*—In an early period of development the stomach is vertical, and in the newborn child it is more vertical than later on in life, as owing to the large size of the liver it is more pushed over to the left side of the abdomen, and the whole of the anterior surface is covered by the left lobe of this organ.

On looking into the pyloric end of the stomach, the mucous membrane is found projecting inward in the form of a circular fold, the *pyloric valve*, leaving a narrow circular aperture, about half an inch in diameter, by which the stomach communicates with the duodenum.

The *pyloric valve* is formed by a reduplication of the mucous membrane of the stomach, containing numerous circular fibres, which are aggregated into a thick circular ring; the longitudinal fibres and serous membrane being continued over the fold without assisting in its formation.

Structure.—The wall of the stomach consists of four coats: serous, muscular, areolar, and mucous, together with vessels and nerves.

The *serous coat* is derived from the peritoneum, and covers the entire surface of the organ, excepting along the greater or lesser curvatures, at the points of attachment of the greater and lesser omenta; here the two layers of peritoneum leave a small triangular space, along which the nutrient vessels and nerves pass. On the posterior surface of the stomach, close to the cardiac orifice, there is also a small area uncovered by peritoneum, where the organ is in contact with the under surfaces of the Diaphragm.

The *muscular coat* (Fig. 493) is situated immediately beneath the serous covering, to which it is closely connected. It consists of three sets of fibres—longitudinal, circular, and oblique.

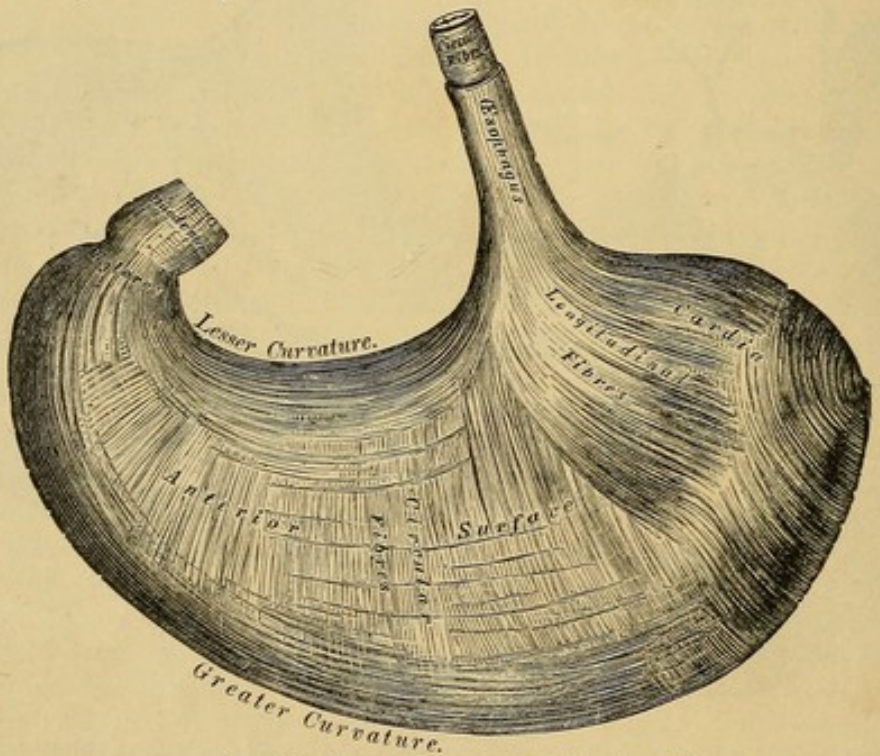

FIG. 493.—The muscular coat of the stomach.

The *longitudinal fibres* are most superficial; they are continuous with the longitudinal fibres of the œsophagus, radiating in a stellate manner from the cardiac orifice. They are most distinct along the curvatures, especially the lesser, but are very thinly distributed over the surfaces. At the pyloric end they are more thickly distributed, and continuous with the longitudinal fibres of the small intestine.

The *circular fibres* form a uniform layer over the whole extent of the stomach beneath the longitudinal fibres. At the pylorus they are most abundant, and are aggregated into a circular ring, which projects into the cavity, and forms, with the fold of mucous membrane covering its surface, the *pyloric valve*. They are continuous with the circular fibres of the œsophagus.

The *oblique fibres* are limited chiefly to the cardiac end of the stomach, where they are disposed as a thick uniform layer, covering both surfaces, some passing obliquely from left to right, others from right to left, round the cardiac end.

The *areolar* or *submucous coat* consists of a loose, filamentous, areolar tissue, connecting the mucous and muscular layers. It supports the blood-vessels previous to their distribution to the mucous membrane: hence it is sometimes called the *vascular coat.*

The *mucous membrane* is thick; its surface smooth, soft, and velvety. In the fresh state it is of a pinkish tinge at the pyloric end, and of a red or reddish-brown color over the rest of its surface. In infancy it is of a brighter hue, the vascular redness being more marked. It is thin at the cardiac extremity, but thicker toward the pylorus. During the contracted state of the organ it is thrown into numerous plaits or rugæ, which for the most part have a longitudinal direction, and are most marked toward the lesser end of the stomach and along the greater curvature (Fig. 492). These folds are entirely obliterated when the organ becomes distended.

Structure of the Mucous Membrane.—When examined with a lens the inner surface of the mucous membrane presents a peculiar honeycomb appearance, from

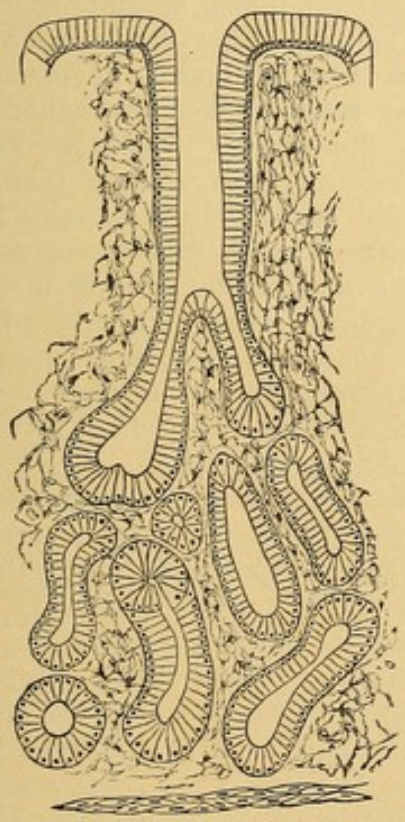

FIG. 494.—Pyloric gland.

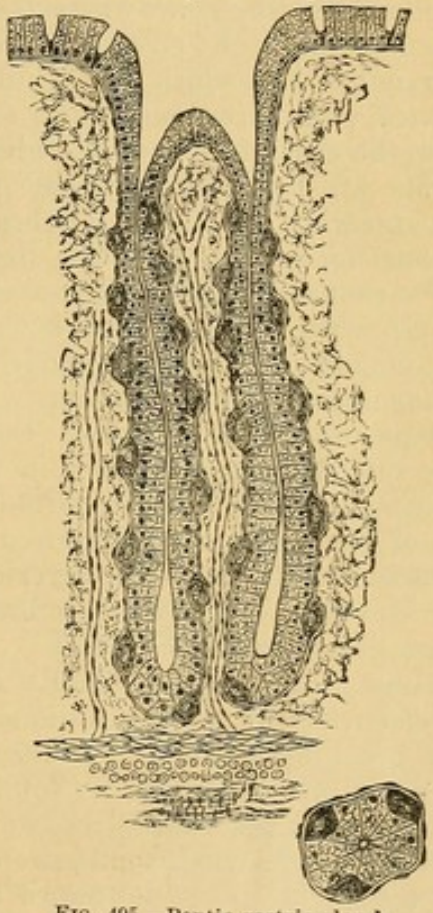

FIG. 495.—Peptic gastric gland.

being covered with small shallow depressions or alveoli of a polygonal or hexagonal form, which vary from $\frac{1}{100}$ to $\frac{1}{200}$ of an inch in diameter, and are separated by slightly elevated ridges. In the bottom of the alveola are seen the orifices of minute tubes, the *gastric glands*, which are situated perpendicularly side by side throughout the entire substance of the mucous membrane. The surface of the mucous membrane of the stomach is covered by a single layer of columnar epithelium; it lines the alveoli, and also for a certain distance the mouths of the gastric glands. This epithelium commences very abruptly at the cardiac orifice, where the cells suddenly change in character from the stratified epithelium of the œsophagus. The cells are elongated, and consist of two parts, the inner or attached portions being granular, and the outer or free parts being clear and occupied by a muco-albuminous substance.

The gastric glands are of two kinds, which differ from each other in structure, and it is believed also in the nature of their secretion. They are named respectively *pyloric* and *cardiac* or *oxyntic glands*. They are both tubular in character, and are formed of a delicate basement-membrane, lined by epithelium. The basement-membrane consists of flattened transparent endothelial cells, with processes which extend between and support the epithelium. The *pyloric glands* (Fig. 494) are most numerous at the pyloric end of the stomach, and from this fact have received their name. They consist of two or three short, closed tubes opening into a common duct, the external orifice of which is situated at the bottom of an alveolus. The cæcal tubes are wavy, and are of about equal length with the duct. The tubes and duct are lined throughout with epithelium, the duct being lined by columnar cells continuous with the epithelium lining the surface of the mucous membrane of the stomach, the tubes with shorter and more cubical cells which are finely granular. The *cardiac glands* (Fig. 495) are found all over the surface of the stomach, but occur most numerously at the cardiac end. Like the pyloric glands, they consist of a duct, into which open two or more cæcal tubes. The duct, however, in these glands is shorter than in the other variety, sometimes not amounting to more than one-sixth of the whole length of the gland; it is lined throughout by columnar epithelium. At the point where the terminal tubes open into the duct, and which is termed the neck, the epithelium alters, and consists of short columnar or polyhedral, granular cells, which almost fill the tube, so that the lumen becomes suddenly constricted, and is continued down as a very fine channel. They are known as the *chief* or the *central* cells of the glands. Between these cells and the basement-membrane are found other darker granular-looking cells, studded throughout the tube at intervals, and giving it a beaded or varicose appearance. These are known as the *parietal* or *oxyntic cells*. Between the glands the mucous membrane consists of a connective-tissue framework with lymphoid tissue. In places this latter tissue, especially in early life, is collected into little masses, which to a certain extent resemble the solitary glands of the intestine, and are by some termed the *lenticular* glands of the stomach. They are not, however, so distinctly circumscribed as the solitary glands. Beneath the mucous membrane, and between it and the submucous coat, is a thin stratum of involuntary muscular fibre (*muscularis mucosæ*), which in some parts consists only of a single longitudinal layer; in others, of two layers, an inner circular, and an outer longitudinal.

Vessels and Nerves.—The arteries supplying the stomach are—the gastric, the pyloric and right gastro-epiploic branches of the hepatic, the left gastro-epiploic and vasa brevia from the splenic. They supply the muscular coat, ramify in the submucous coat, and are finally distributed to the mucous membrane. The arrangement of the vessels in the mucous membrane is somewhat peculiar. The arteries break up at the base of the gastric tubules into a plexus of fine capillaries which run upward between the tubules, anastomosing with each other, and ending in a plexus of larger capillaries, which surround the mouths of the tubes and also form hexagonal meshes around the alveoli. From these latter the *veins* arise, and pursue a straight course downward between the tubules, to the submucous tissue, and terminate either in the splenic and superior mesenteric veins or directly in the portal vein. The *lymphatics* are numerous; they consist of a superficial and deep set, which pass through the lymphatic glands found along the two curvatures of the organ. The *nerves* are the terminal branches of the right and left pneumogastric, the former being distributed upon the back, and the latter upon the front part of the organ. A great number of branches from the sympathetic also supply the organ.

Surface Form.—The stomach lies for the most part in the left hypochondriac region, but also slightly in the epigastric region, and is partly in contact with the abdominal wall, partly under cover of the lower ribs on the left side, and partly under the left lobe of the liver. Its cardiac orifice corresponds to the articulation of the seventh left costal cartilage with the sternum. The pyloric orifice is in a vertical line drawn from the right border of the sternum, two and a half or three inches below the level of the sterno-xiphoid articulation. According to Braune, when the stomach is distended, the pylorus moves considerably to the right, as much

sometimes as three inches. The fundus of the stomach reaches, on the left side, as high as the level of the sixth costal cartilage of the left side, being a little below and behind the apex of the heart. The portion of the stomach which is in contact with the abdominal walls, and is therefore accessible for opening in the operations of gastrotomy and gastrostomy, is represented by a triangular space, the base of which is formed by a line drawn from the tip of the tenth costal cartilage on the left side to the tip of the ninth costal cartilage on the right, and the sides by two lines drawn from the extremity of the eighth costal cartilage on the left side to the ends of the base line.

Surgical Anatomy.—Operations on the stomach are frequently performed. By "gastrotomy" is meant an incision into the stomach for the removal of a foreign body, the opening being immediately afterward closed—in contradistinction to "gastrostomy," the making of a more or less permanent fistulous opening. *Gastrotomy* is probably best performed by an incision in the linea alba, especially if the foreign body is large, by a cut from the ensiform cartilage to the umbilicus, but may be performed by an incision over the body itself, where this can be felt, or by one of the incisions for gastrostomy, to be mentioned immediately. The peritoneal cavity is opened, and the point at which the stomach is to be incised decided upon. This portion is then brought out of the abdominal wound and sponges carefully packed around. The stomach is now opened by a transverse incision and the foreign body extracted. The wound in the stomach is then closed by Lembert's sutures—*i. e.* by sutures passed through the peritoneal and muscular coats in such a way that the peritoneal surfaces on each side of the wound are brought into apposition, and in this way the wound is closed. *Gastrostomy* was formerly done in two stages by the *direct* method. The first stage consisted in opening the abdomen, drawing up the stomach into the external wound, and fixing it there; and the second stage, performed from two to four days afterward, consisted in opening the stomach. The operation is now done by a *valvular* method. An incision is commenced opposite the eighth intercostal space, two inches from the median line, and carried downward for three inches. By this incision the fibres of the Rectus muscle are exposed and these are separated from each other in the same line with a steel director. The posterior layer of the sheath, the transversalis fascia and the peritoneum, are then divided, and the peritoneal cavity opened. The anterior wall of the stomach is now seized and drawn out of the wound and a silk suture passed through its muscular and serous coats at the point selected for opening the viscus. This is held by an assistant so that a long conical diverticulum of the stomach protrudes from the external wound, and the parietal peritoneum and the posterior layer of the sheath of the rectus are sutured to it. A second incision is made through the skin, over the margin of the costal cartilage, above and a little to the outer side of the first incision. With a pair of dressing forceps a track is made under the skin through the subcutaneous tissue from the one opening to the other and the diverticulum of the stomach is drawn along this track by means of the suture inserted into it; so that its apex appears at the second opening. A small perforation is now made into the stomach through this protruding apex and its margins carefully and accurately sutured to the margin of the external wound. The remainder of this incision and the whole of the first incision are then closed in the ordinary way and the wound dressed.

In cases of gastric ulcer perforation sometimes takes place, and this was formerly regarded as an almost fatal complication. In the present day, by opening the abdomen and closing the perforation, which is generally situated on the anterior surface of the stomach, a considerable percentage of cases are cured, provided the operation is undertaken within twelve or fifteen hours after the perforation has taken place. The opening is best closed by bringing the peritoneal surfaces on either side into apposition by means of Lembert's sutures.

Excision of the pylorus has occasionally been performed, but the results of this operation are by no means favorable, and, in cases of cancer of the pylorus, before operative proceedings are undertaken, the tumor has become so fixed and has so far implicated surrounding parts that removal of the pylorus is impossible and gastro-enterostomy has to be substituted. The object of this operation is to make a fistulous communication between the stomach, on the cardiac side of the disease, and the small intestine, as high up as is possible.

Digital dilatation of the pylorus for simple stricture was first performed by Loreta. He exposed the stomach and opened it by a transverse incision near the pylorus. He then inserted the forefingers of both hands and passed these through the pylorus and stretched it with some degree of force. The operation has now, however, dropped out of use and been replaced by pyloro-plasty. This consists in making a longitudinal incision from the stomach through the pylorus into the duodenum, and converting this longitudinal incision into a transverse one by traction at the centre of the incision, and retaining it permanently in this position by sutures.

THE SMALL INTESTINE.

The small intestine is a convoluted tube, extending from the pylorus to the ileo-cæcal valve, where it terminates in the large intestine. It is about twenty feet in length,[1] and gradually diminishes in size from its commencement to its

[1] Treves states that, in one hundred cases, the average length of the small intestine in the adult male was 22 feet 6 inches, and in the adult female 23 feet 4 inches: but that it varies very much, the extremes in the male being 31 feet 10 inches in one case, and 15 feet 6 inches in another, a difference of over 15 feet. He states that he has convinced himself that the length of the bowel is independent, in the adult, of age, height, and weight.

termination. It is contained in the central and lower part of the abdominal cavity, and is surrounded above and at the sides by the large intestine; a portion of it extends below the brim of the pelvis and lies in front of the rectum; it is in relation, in front, with the great omentum and abdominal parietes; and connected to the spine by a fold of peritoneum, the mesentery. The small intestine is divisible into three portions—the duodenum, the jejunum, and ilium.

The **duodenum** has received its name from being about equal in length to the breadth of twelve fingers (ten inches). It is the shortest, the widest, and the most fixed part of the small intestine. Its course presents a remarkable curve, which in the adult, as regards the greater part of its extent, is U-shaped; though sometimes, in consequence of the transverse portion being very short or altogether wanting, it partakes more of the character of the letter V. In children, up to the age of about seven, the duodenum is annular; its two extremities are on about the same level; and between them it describes a regular curve embracing the head of the pancreas, the neck of which lies between the two extremities of the ring.

In the adult the course of the duodenum is as follows: commencing at the pylorus the direction of the first portion depends upon the amount of distention of the stomach and therefore upon the position of the pylorus. When the stomach is empty and the pylorus situated at the right of the upper border of the first lumbar vertebra, it is nearly horizontal and transverse; but where the stomach is distended, in consequence of the alteration of the position of the pylorus to the right the proximal end of the duodenum also becomes altered in position, while the distal end remains fixed and the direction of this portion of the bowel is now antero-posterior. Whether directed transversely or antero-posteriorly, it reaches the under surface of the liver, where it takes a sharp curve and descends along the right side of the vertebral column, for a variable distance, generally to the body of the fourth lumbar vertebra. It now takes a second bend, and passes across the front of the vertebral column from right to left and finally ascends on the left side of the vertebral column and aorta to the level of the upper border of the second lumbar vertebra and there terminates in the jejunum. As it unites with the jejunum it often turns abruptly forward, forming the *duodeno-jejunal angle*. From the above description it will be seen that the duodenum may be divided for purposes of description into four portions—superior, descending, transverse, and ascending.

The first or *superior portion* (Fig. 496) is very variable in length, but is usually estimated as being about two inches. Beginning at the pylorus, it ends at the neck of the gall-bladder. It is the most movable of the four portions. It is almost completely covered by peritoneum derived from the two layers of the lesser omentum, but a small part of its posterior surface near the neck of the gall-bladder and the inferior vena cava is uncovered. It is in such close relation with the gall-bladder that it is usually found to be stained by bile after death, especially on its anterior surface. It is in relation above and in front with the quadrate lobe of the liver and the gall-bladder; behind with the gastro-duodenal artery, the common bile-duct, and the vena porta; and below with the head of the pancreas.

The second or *descending portion* is between three and four inches in length, and extends from the neck of the gall-bladder on a level with the first lumbar vertebra along the right side of the vertebral column as low as the body of the fourth lumbar vertebra. It is crossed in its middle third by the transverse colon, the posterior surface of which is uncovered by peritoneum and is connected to the duodenum by a small quantity of connective tissue (Fig. 490). The portions of the descending part of the duodenum above and below this interspace are named the supra- and infra-colic portions, and are covered in front by peritoneum. The right side of the supra-colic portion is covered by peritoneum derived from the anterior surface of the right kidney, the left side of the same portion being covered by the peritoneum forming the lesser sac. The infra-colic part is covered by the right leaf of the mesentery. Posteriorly the descending portion of the duodenum is uncovered by peritoneum. It is in relation, in front, with the transverse colon, and above this with the liver; behind with the front of the right kidney, to which

it is connected by loose areolar tissue, the renal vessels and the vena cava inferior; at its inner side is the head of the pancreas, and the ductus communis choledochus; to its outer side is the hepatic flexure of the colon. The common bile-duct and the

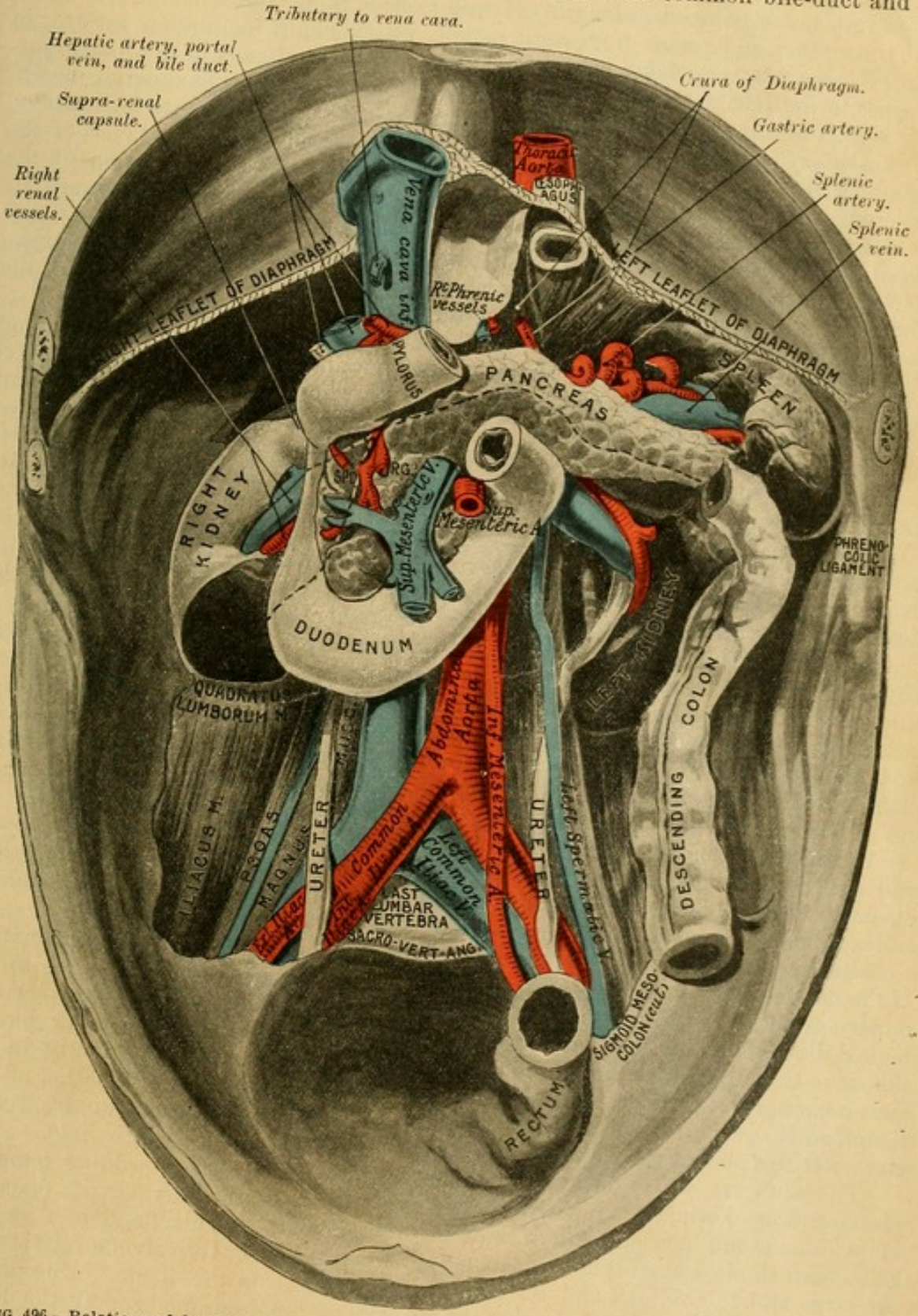

FIG. 496.—Relations of duodenum, pancreas and spleen. (From a cast by Professor Birmingham.[1]) The dotted line represents the line of attachment of the transverse mesocolon.

pancreatic duct perforate the inner side of this portion of the intestine obliquely, ome three or four inches below the pylorus. The relations of the second part of he duodenum to the right kidney present considerable variations.

[1] In the subject from which the cast was taken the left kidney was lower than normal.

The third or *transverse portion* (pre-aortic portion) varies much in length; when the duodenum assumes the ordinary U-shaped form, it measures from two to three inches; but when it presents the rarer V-shaped form, it is practically wanting or very much reduced in length. It commences at the right side of the fourth lumbar vertebra and passes from right to left, with a slight inclination upward, in front of the great vessels and crura of the Diaphragm, and ends in the fourth portion just to the left of the abdominal aorta. It is crossed by the superior mesenteric vessels and mesentery. Its front surface is covered by the anterior layer of the mesentery, but near the middle line it is separated from this layer of the mesentery by the superior mesenteric vessels as they cross this portion of the duodenum. Its posterior surface is uncovered by peritoneum, except toward its left extremity, where the posterior layer of the mesentery may sometimes be found covering it to a variable extent. This surface rests upon the aorta, the vena cava inferior, and the crura of the Diaphragm. By its upper surface this portion of the duodenum is in relation with the head of the pancreas.

The fourth or *ascending portion* of the duodenum is about two inches long. It ascends on the left side of the vertebral column and aorta, as far as the level of the upper border of the second lumbar vertebra, where it turns abruptly forward to become the jejunum, forming the *duodeno-jejunal flexure*. It is covered entirely in front and partly at the sides by peritoneum, derived from the left portion of the mesentery. It touches the left kidney, slightly overlapping its inner margin, and rests upon the left crus of the Diaphragm.

The first part of the duodenum, as stated above, is somewhat movable, but the rest is practically fixed and is bound down to neighboring viscera and the posterior abdominal wall by the peritoneum. In addition to this, the fourth part of the duodenum and the duodeno-jejunal flexure is further bound down and fixed by a structure to which the name of *musculus suspensorius duodeni* has been given. This structure commences in the connective tissue around the cœliac axis and left crus of the Diaphragm, and passes downward to be inserted into the superior border of the duodeno-jejunal curve and a part of the ascending duodenum, and from this it is continued into the mesentery. It possesses, according to Treitz, plain muscular fibres mixed with the fibrous tissue, of which it is principally made up. It is of little importance as a muscle, but acts as a suspensory ligament.

Vessels and Nerves.—The *arteries* supplying the duodenum are the pyloric and pancreatico-duodenal branches of the hepatic, and the inferior pancreatico-duodenal branch of the superior mesenteric. The *veins* terminate in the splenic and superior mesenteric. The *nerves* are derived from the solar plexus.

Jejunum and Ileum.—The remainder of the small intestine from the termination of the duodenum is named *jejunum* and *ileum;* the former term being given to the upper two-fifths and the latter to the remaining three-fifths. There is no morphological line of distinction between the two, and the division is arbitrary; but at the same time it must be noted that the character of the intestine gradually undergoes a change from the commencement of the jejunum to the termination of the ileum, so that a portion of the bowel taken from these two situations would present characteristic and marked differences. These are briefly as follows:

The *jejunum*, which derives its name from the Latin word *jejunus* (empty), because it was formerly supposed to be empty after death, is wider, its diameter being about one inch and a half, and is thicker, more vascular, and of a deeper color than the ileum, so that a given length weighs more. Its valvulæ conniventes are large and thickly set and its villi are larger than in the ileum. The glands of Peyer are almost absent in the upper part of the jejunum, and in the lower part are less frequently found than in the ileum, and are smaller and tend to assume a circular form. Brunner's glands are only found in the upper part of the jejunum. By grasping the jejunum between the finger and thumb the valvulæ conniventes can be felt through the walls of the gut: these being absent in the lower part of the ileum, it is possible in this way to distinguish the upper from the lower part of the small intestine.

The *ileum*, so called from the Greek word εἱλεῖν (to twist), on account of its numerous coils and convolutions, is narrow, its diameter being one inch and a quarter, and its coats thinner and less vascular than those of the jejunum. It possesses but few valvulæ conniventes, and they are small and disappear entirely toward its lower end, but Peyer's patches are larger and more numerous. The jejunum for the most part occupies the umbilical and left iliac regions, while the ileum occupies chiefly the umbilical, hypogastric, right iliac, and pelvic regions, and terminates in the right iliac fossa by opening into the inner side of the commencement of the large intestine. The jejunum and ileum are attached to the posterior abdominal wall by an extensive fold of peritoneum, the *mesentery*, which allows the freest motion, so that each coil can accommodate itself to changes in form and position. The mesentery is fan-shaped; its posterior border, about six inches in length, is attached to the abdominal wall from the left side of the second lumbar vertebra to the right iliac fossa (Fig. 490). Its length is about eight inches from its commencement to its termination at the intestine, and it is rather longer about its centre than at either end of the bowel. According to Lockwood, it tends to increase in length as age advances. Between the two layers of which it is composed are contained blood-vessels, nerves, lacteals, and lymphatic glands, together with a variable amount of fat.

Meckel's Diverticulum.—Occasionally there may be found connected with the lower part of the ileum, on an average of about three and a half feet from its termination, a blind diverticulum or tube, varying in length. It is attached to and communicates with the lumen of the bowel by one extremity, and by the other is unattached or may be connected with the abdominal wall or some other portion of the intestine by a fibrous band. This is Meckel's diverticulum, and represents the remains of the vitelline or omphalo-mesenteric duct, the duct of communication between the umbilical vesicle and the alimentary canal in early fœtal life.

Structure.—The wall of the small intestine is composed of four coats—serous, muscular, areolar, and mucous.

The *serous coat* is derived from the peritoneum. The first or ascending portion of the duodenum is almost completely surrounded by this membrane near its pyloric end, but only in front at the other extremity; the second or descending portion is covered by it in front, except where it is carried off by the transverse colon; and the third or transverse portion lies behind the peritoneum, which passes over it, without being closely incorporated with the other coats of this part of the intestine, and is separated from it in the middle line by the superior mesenteric artery. The remaining portion of the small intestine is surrounded by the peritoneum, excepting along its attached or mesenteric border; here a space is left for the vessels and nerves to pass to the gut.

The *muscular coat* consists of two layers of fibres, an external or longitudinal, and an internal or circular layer. The *longitudinal fibres* are thinly scattered over the surface of the intestine, and are more distinct along its free border. The *circular fibres* form a thick, uniform layer; they surround the cylinder of the intestine in the greater part of its circumference, and are composed of plain muscle-cells of considerable length. The muscular coat is thicker at the upper than at the lower part of the small intestine.

The *areolar* or *submucous coat* connects together the mucous and muscular layers. It consists of loose, filamentous areolar tissue, which forms a nidus for the subdivision of the nutrient vessels, previous to their distribution to the mucous surface.

The *mucous membrane* is thick and highly vascular at the upper part of the small intestine, but somewhat paler and thinner below. It consists of the following structures: next the areolar or submucous coat is a layer of unstriped muscular fibres, the *muscularis mucosæ;* internal to this is a quantity of retiform tissue, enclosing in its meshes lymph-corpuscles, and in which the blood-vessels and nerves ramify. Lastly, a basement-membrane, supporting a single layer of epithelial cells, which throughout the intestines are columnar in character. They

are granular in appearance, and possess a clear, oval nucleus. At their superficial or unattached end they present a distinct layer of highly refracting material, marked by vertical striæ, which were formerly believed to be minute channels by which the chyle was taken up into the interior of the cell, and by them transferred to the lacteal vessels of the mucous membrane.

The mucous membrane presents for examination the following structures contained within it or belonging to it:

Valvulæ conniventes.
Villi.
Simple follicles.
Glands { Duodenal glands. Solitary glands. Peyer's or agminate glands.

The **valvulæ conniventes** (valves of Kerkring) are large folds or valvular flaps projecting into the lumen of the bowel. They are composed of reduplications or folds of the mucous membrane, the two layers of the fold being bound together by submucous tissue; they contain no muscular fibres, and, unlike the folds in the stomach, they are permanent, and are not obliterated when the intestine is distended. The majority extend transversely across the cylinder of the intestine

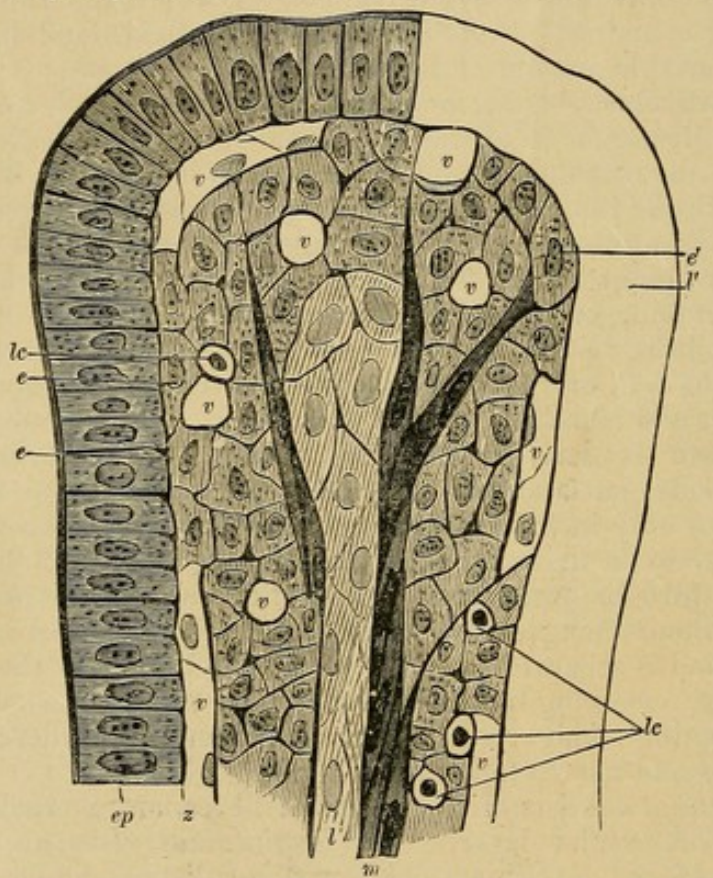

FIG. 497.—Diagrammatic section of a villus. (Watney.) *ep*. Epithelium only partially shaded in. *l*. Central chyle-vessel; the cells forming the vessel have been less shaded to distinguish them from the cells of the parenchyma of the villus. *m*, Muscle-fibres running up by the side of the chyle-vessel. It will be noticed that each muscle-fibre is surrounded by the reticulum, and by this reticulum the muscles are attached to the cells forming the membrana propria, as at *e'*, or to the reticulum of the villus. *lc*. Lymph-corpuscles, marked by a spherical nucleus and a clear zone of protoplasm. *l'*. Upper limit of the chyle-vessel. *e*, *e*, *e'*. Cells forming the membrana propria. It will be seen that there is hardly any difference between the cells of the parenchyma, the endothelium of the *upper* part of the chyle-vessel, and the cells of the membrana propria. V. Blood-vessels. *z*. Dark line at base of the epithelium formed by the reticulum. It will be seen that the reticulum penetrates between all the other elements of the villus. The reticulum contains thickenings or "nodal points." The diagram shows that the cells of the upper part of the villus are larger and contain a larger zone of protoplasm than those of the lower part. The cells of the upper part of the chyle-vessel differ somewhat from those of the lower part in that they more nearly resemble the cells of the parenchyma.

for about one-half or two-thirds of its circumference, but some form complete circles, and others have a spiral direction; the latter usually extend a little more than once round the bowel, but occasionally two or three times. The spiral arrangement is the characteristic one of the shark family of fishes. The larger folds are about one-third of an inch in depth at their broadest part; but the greater number are of smaller size. The larger and smaller folds alternate with each other. They are not found at the commencement of the duodenum, but

begin to appear about one or two inches beyond the pylorus. In the lower part of the descending portion, below the point where the bile and pancreatic ducts enter the intestine, they are very large and closely approximated. In the transverse portion of the duodenum and upper half of the jejunum they are large and numerous; and from this point, down to the middle of the ileum, they diminish considerably in size. In the lower part of the ileum they almost entirely disappear; hence the comparative thinness of this portion of the intestine as compared with the duodenum and jejunum. The valvulæ conniventes retard the passage of the food along the intestines, and afford a more extensive surface for absorption.

The villi are minute, highly vascular processes, projecting from the mucous membrane of the small intestine throughout its whole extent, and giving to its surface a velvety appearance. In shape, according to Rauber, they are short and leaf-shaped in the duodenum, tongue-shaped in the jejunum, and filiform in the ileum. They are largest and most numerous in the duodenum and jejunum, and become fewer and smaller in the ileum. Krause estimates their number in the upper part of the small intestine at from fifty to ninety in a square line; and in the lower part from forty to seventy, the total number for the whole length of the intestine being about four millions.

Structure of the Villi (Fig. 497).—The structure of the villi has been studied by many eminent anatomists. We shall here follow the description of Watney,[1] whose researches have a most important bearing on the physiology of that which is the peculiar function of this part of the intestine, the absorption of fat.

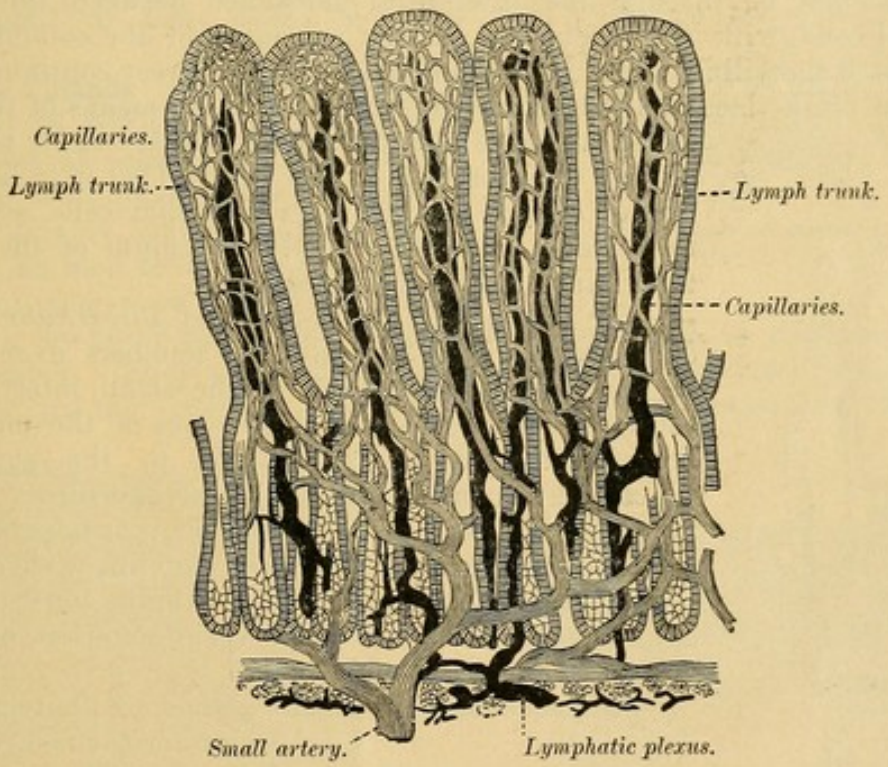

FIG. 498.—Villi of small intestine. (Cadiat.)

The essential parts of a villus are—the lacteal vessel, the blood-vessels, the epithelium, the basement membrane and muscular tissue of the mucosa, these structures being supported and held together by retiform lymphoid tissue.

These structures are arranged in the following manner: situated in the centre of the villus is the lacteal, terminating near the summit in a blind extremity; running along this vessel are unstriped muscular fibres: surrounding it is a plexus of capillary vessels, the whole being enclosed by a basement-membrane, and covered by columnar epithelium. Those structures which are contained within the basement-membrane—namely, the lacteal, the muscular tissue, and the blood-vessels—

[1] *Phil. Trans.*, vol. clxv., pt. ii.

are surrounded and enclosed by a delicate reticulum which forms the matrix of the villus, and in the meshes of which are found large flattened cells with an oval nucleus, and, in smaller numbers, lymph-corpuscles. These latter are to be distinguished from the larger cells of the villus by their behavior with reagents, by their size, and by the shape of their nucleus, which is spherical. Transitional forms, however, of all kinds are met with between the lymph-corpuscles and the proper cells of the villus. Nerve-fibres are contained within the villi; they form ramifications throughout the reticulum.

The *lacteals* are in some cases double, and in some animals multiple. Situated in the axis of the villi, they commence by dilated cæcal extremities near to, but not quite at, the summit of the villus. The walls are composed of a single layer of endothelial cells, the interstitial substance between the cells being continuous with the reticulum of the matrix.

The *muscular fibres* are derived from the muscularis mucosæ, and are arranged in bundles around the lacteal vessel, extending from the base to the summit of the villus, and giving off laterally, individual muscle-cells, which are enclosed by the reticulum, and by it are attached to the basement membrane.

The *blood-vessels* form a plexus between the lacteal and the basement membrane, and are enclosed in the reticular tissue; in the interstices of the capillary plexus, which they form, are contained the cells of the villus.

These structures are surrounded by the basement membrane, which is made up of a stratum of endothelial cells, and upon which is placed a layer of columnar epithelium. The reticulum of the matrix is continuous through the basement membrane (that is, through the interstitial substance between the individual endothelial cells) with the interstitial cement substance of the columnar cells on the surface of the villus. Thus we are enabled to trace a direct continuity between the interior of the lacteal and the surface of the villus by means of the reticular tissue, and it is along this path that the chyle passes in the process of absorption by the villi. That is to say, it passes first of all into the columnar epithelial cells, and, escaping from them, is carried into the reticulum of the villus, and thence into the central lacteal.

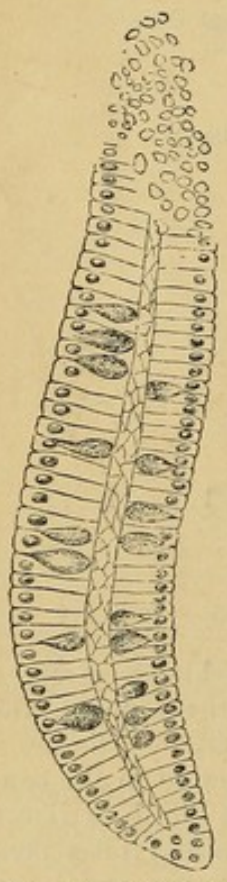

FIG. 499.—Longitudinal section of crypts of Lieberkühn. Goblet-cells seen among the columnar epithelial cells. (Klein and Noble Smith.)

The **simple follicles**, or *crypts of Lieberkühn* (Figs. 499, 500), are found in considerable numbers over every part of the mucous membrane of the small intestine. They consist of minute tubular depressions of the mucous membrane, arranged perpendicularly to the surface, upon which they open by small circular apertures. They may be seen with the aid of a lens, their orifices appearing as minute dots scattered between the villi. Their walls are thin, consisting of a basement-membrane lined by columnar epithelium, and covered on their exterior by capillary vessels.

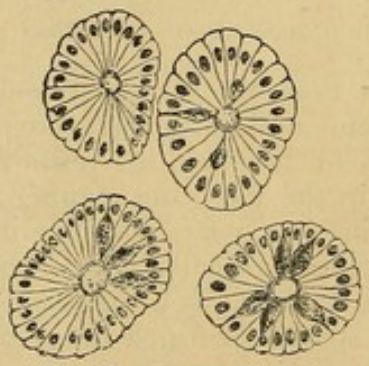

FIG. 500.—Transverse section of crypts of Lieberkühn. (Klein and Noble Smith.)

The **duodenal** or **Brunner's glands** are limited to the duodenum and commencement of the jejunum. They are small, flattened, granular bodies embedded in the submucous areolar tissue, and open upon the surface of the mucous membrane by minute excretory ducts. They are most numerous and largest near the pylorus. They are small compound acino-tubular glands, and much resemble the small glands which are found in the mucous membrane of the

mouth. They are believed by Watney to be direct continuations of the pyloric glands of the stomach. They consist of a number of tubular alveoli, lined by epithelium, and opening by a single duct on the inner surface of the intestine.

The **solitary glands** (*glandulæ solitariæ*) are found scattered throughout the mucous membrane of the small intestine, but are most numerous in the lower part of the ileum. They are small, round, whitish bodies, from half a line to a line in diameter. Their free surface is covered with villi, and each gland is surrounded by the openings of the follicles of Lieberkühn. They are now recognized as lymph-follicles, and consist of a dense interlacing retiform tissue closely packed with lymph-corpuscles, and permeated with an abundant capillary network (Fig. 501). The interspaces of the retiform tissue are continuous with larger lymph-spaces at the base of the gland, through which they communicate with the lacteal system. They are situated partly in the submucous tissue, partly in the mucous membrane, whence they form slight projections of its epithelial layer, after having penetrated the muscularis mucosæ. The villi which are situated on them are generally absent from the very summit (or "cupola," as Frey calls it) of the gland.

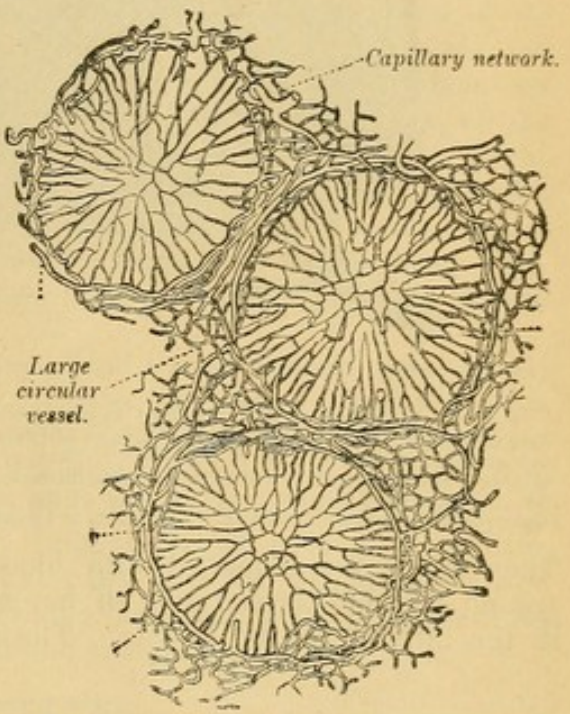

FIG. 501.—Transverse section through the equatorial plane of three of Peyer's follicles from the rabbit.

Peyer's glands (agminated glands) (Figs. 501 to 504) may be regarded as aggregations of solitary glands, forming circular or oval patches from twenty to thirty in number, and varying in length from half an inch to four inches. They are largest and most numerous in the ileum. In the lower part of the jejunum they are small, of a circular form, and few in number. They are occasionally seen in the duodenum. They are placed lengthwise in the intestine, and are situated in the portion of the tube most

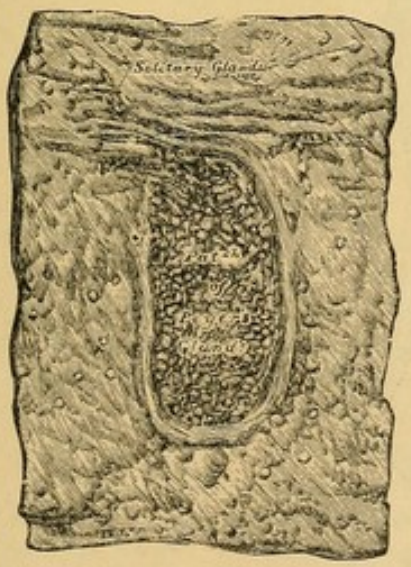

FIG. 502.—Patch of Peyer's glands. From the lower part of the ileum.

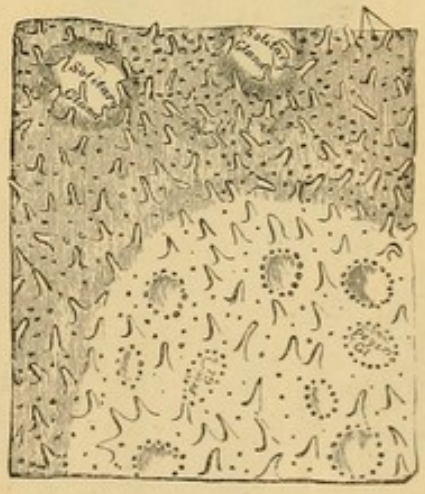

FIG. 503.—A portion of the above magnified.

distant from the attachment of the mesentery. Each patch is formed of a group of the above-described solitary glands covered with mucous membrane, and in almost every respect are similar in structure to them. They do not, however, as

a rule, possess villi on their free surface. Each patch is surrounded by a circle of the crypts of Lieberkühn. They are best marked in the young subject, becoming indistinct in middle age, and sometimes altogether disappearing in advanced life.

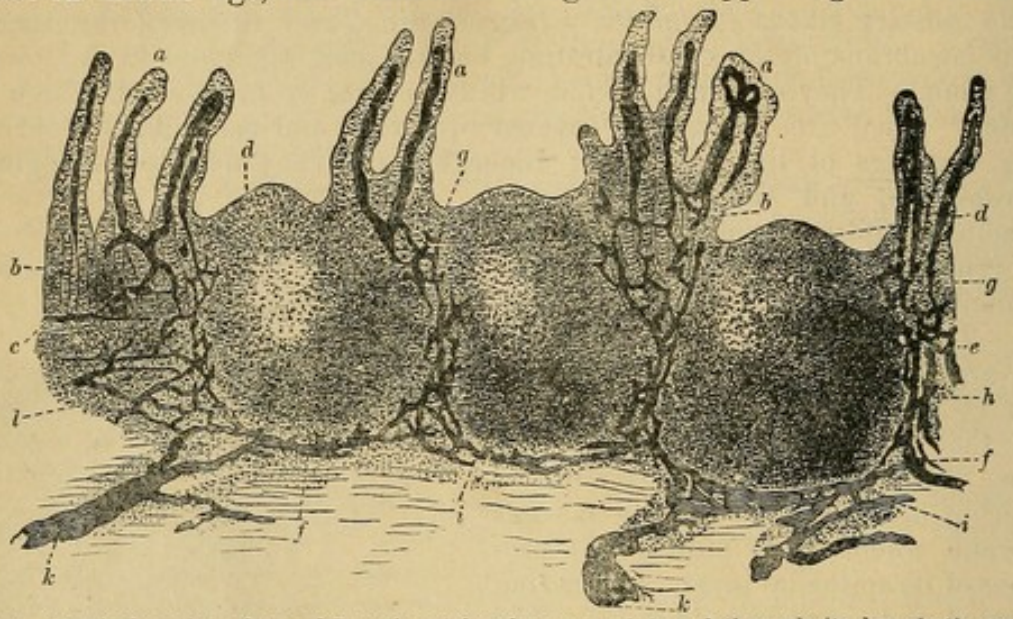

FIG. 504.—Vertical section of one of Peyer's patches from man, injected through its lymphatic canals. *a*. Villi with their chyle-passages. *b*. Follicles of Lieberkühn. *c*. Muscularis mucosæ. *d*. Cupola or apex of solitary glands. *e*. Mesial zone of glands. *f*. Base of glands. *g*. Points of exit of the chyle-passages from the villi, and entrance into the true mucous membrane. *h*. Retiform arrangement of the lymphatics in the mesial zone. *i*. Course of the latter at the base of the glands. *k*. Confluence of the lymphatics opening into the vessels of the submucous tissue. *l*. Follicular tissue of the latter.

They are largely supplied with blood-vessels, which form an abundant plexus around each follicle and give off fine branches which permeate the lymphoid tissue in the interior of the follicle. The lacteal plexuses which are found throughout

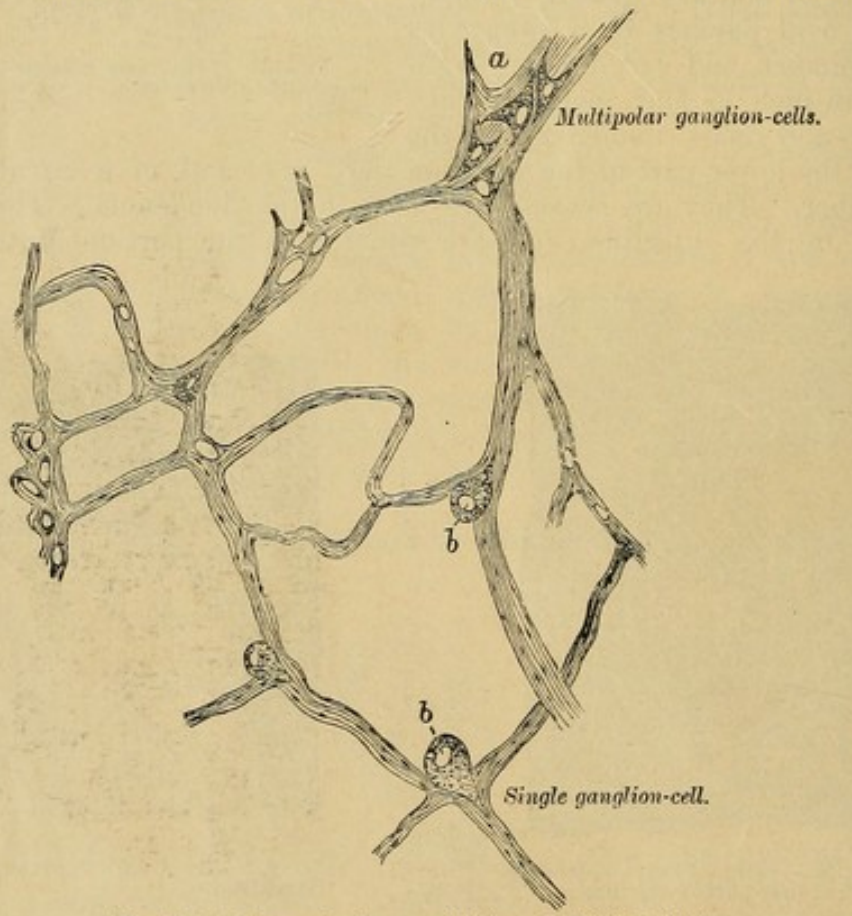

FIG. 505.—Meissner's plexus. (Klein and Noble Smith.)

the small intestine are especially abundant around these patches; here they form rich plexuses with sinuses around the glands (Fig. 504).

Vessels and Nerves.—The jejunum and ileum are supplied by the superior mesenteric artery, the branches of which, having reached the attached border of the bowel, run between the serous and muscular coats, with frequent inosculations to the free border, where they also anastomose with other branches running round the opposite surface of the gut. From these vessels numerous branches are given off, which pierce the muscular coat, supplying it and forming an intricate plexus in the submucous tissue. From this plexus minute vessels pass to the glands and villi of the mucous membrane. The veins have a similar course and arrangement to the arteries. The *lymphatics of the small intestines* (lacteals) are arranged in two sets, those of the mucous membrane, and those of the muscular coat. The lymphatics of the villi commence in these structures in the manner described above, and form an intricate plexus in the mucous and submucous tissue, being joined by the lymphatics from the lymph-spaces at the bases of the solitary glands, and from this pass to larger vessels at the mesenteric border of the gut. The lymphatics of the muscular coat are situated to a great extent between the two layers of muscular fibres, where they form a close plexus, and throughout their course communicate freely with the lymphatics from the mucous membrane, and empty themselves in the same manner into the commencement of the lacteal vessels at the attached border of the gut.

The *nerves of the small intestines* are derived from the plexuses of sympathetic nerves around the superior mesenteric artery. From this source they run to a plexus of nerves and ganglia situated between the circular and longitudinal muscular fibres (*Auerbach's plexus*), from which the nervous branches are distributed to the muscular coats of the intestine. From this plexus a secondary plexus is derived (*Meissner's plexus*), and is formed by branches which have perforated the circular muscular fibres (Fig. 505). This plexus lies between the muscular and mucous coats of the intestine. It is also gangliated, and from it the ultimate fibres pass to the muscularis mucosæ and to the villi and mucous membrane.

THE LARGE INTESTINE.

The large intestine extends from the termination of the ileum to the anus. It is about five feet in length, being one-fifth of the whole extent of the intestinal canal. It is largest at its commencement at the cæcum, and gradually diminishes as far as the rectum, where there is a dilatation of considerable size just above the anus. It differs from the small intestine in its greater size, its more fixed position, its sacculated form, and in possessing certain appendages to its external coat, the *appendices epiploicæ*. Further, its longitudinal muscular fibres do not form a continuous layer around the gut, but are arranged in three longitudinal bands or *tæniæ*. The large intestine, in its course, describes an arch, which surrounds the convolutions of the small intestine. It commences in the right inguinal region, in a dilated part, the *cæcum*. It ascends through the right lumbar and hypochondriac regions to the under surface of the liver; it here takes a bend (the *hepatic flexure*) to the left, and passes transversely across the abdomen on the confines of the epigastric and umbilical regions, to the left hypochondriac region; it then bends again (the *splenic flexure*), and descends through the left lumbar region to the left iliac fossa, where it becomes con-

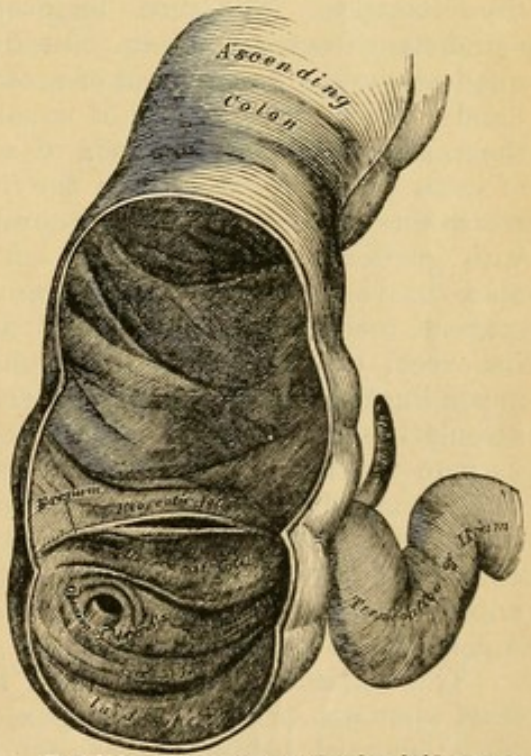

FIG. 506.—The cæcum and colon laid open to show the ileo-cæcal valve.

voluted, and forms the sigmoid flexure; finally it enters the pelvis, and descends along its posterior wall to the anus. The large intestine is divided into the cæcum, colon, and rectum.

The **Cæcum** (cæcus, *blind*) is the large blind pouch, or *cul-de-sac*, situated below the ileo-cæcal valve, in which the large intestine commences (Fig. 506). Its blind end is directed downward, and its open end upward, communicating directly with the colon, of which this blind pouch appears to be the beginning or head, and hence the old name *caput cæcum coli* was applied to it. Its size is variously estimated by different authors, but on an average it may be said to be two and a half inches in length and three in breadth. It is situated in the right iliac fossa, above the outer half of Poupart's ligament: it rests on the Ilio-psoas muscle and lies immediately behind the abdominal wall. As a rule, it is entirely enveloped on all sides by peritoneum, but in a certain number of cases (6 per cent., Berry) the peritoneal covering is not complete, so that a small portion of the upper end of the posterior surface is uncovered and connected to the iliac fascia by connective tissue. The cæcum lies quite free in the abdominal cavity and enjoys a considerable amount of movement, so that it often becomes herniated down the right inguinal canal, and has occasionally been found in an inguinal hernia on the left side. The cæcum varies in shape, but, according to Treves, in man it may be classified under one of four types. In early fœtal life it is short, conical, and broad at the base, with its apex turned upward and inward toward the ileo-cæcal junction. It then resembles the cæcum of some of the monkey tribe, *e. g.*, Mangabey monkey. As the fœtus grows the cæcum increases in length more than in breadth, so that it forms a longer tube than in the primitive form and without the broad base, but with the same inclination inward of the apex toward the ileo-cæcal junction. This form is seen in others of the monkey tribe, *e. g.*, the spider monkey. As development goes on, the lower part of tube ceases to grow and the upper part becomes greatly increased, so that at birth there is a narrow tube, the vermiform appendix, hanging from a conical projection, the cæcum. This is the infantile form, and as it may persist throughout life, in about 2 per cent. of cases, it is regarded by Treves as the *first* of his four types of human cæca. The cæcum is conical and the appendix rises from its apex. The three longitudinal bands start from the appendix and are equidistant from each other. In the *second* type, the conical cæcum has become quadrate by the growing out of a saccule on either side of the anterior longitudinal band. These saccules are of equal size, and the appendix arises from between them, instead of from the apex of a cone. This type is found in about 3 per cent. of cases. The *third* type is the normal type of man. Here the two saccules, which in the second type were uniform, have grown at unequal rates: the right with greater rapidity than the left. In consequence of this an apparently new apex has been formed by the growing downward of the right saccule, and the original apex, with the appendix attached, is pushed over to the left toward the ileo-cæcal junction. The three longitudinal bands still start from the base of the appendix, but they are now no longer equidistant from each other, because the right saccule has grown between the anterior and postero-external bands, pushing them over to the left. This type occurs in about 90 per cent. of cases. The *fourth* type is merely an exaggerated condition of the third; the right saccule is still larger, and at the same time the left saccule has been atrophied, so that the original apex of the cæcum, with the appendix, is close to the ileo-cæcal junction, and the anterior band courses inward to the same situation. This type is present in about 4 per cent. of cases.

The **vermiform appendix** is a long, narrow, worm-shaped tube, which starts from what was originally the apex of the cæcum, and may pass in several directions: upward behind the cæcum; to the left behind the ileum and mesentery; or downward and inward into the true pelvis. It varies from one to nine inches in length, its average being about three inches. It is retained in position by a fold of peritoneum derived from the left leaf of the mesentery, which forms a mesentery for it. This is triangular in shape, but does not extend the whole length of the

tube, but leaves the distal third free and completely covered by peritoneum. Between its two layers lies a considerable branch of the ileo-colic artery, the artery of the appendix. Its canal is small, extends throughout the whole length of the tube, and communicates with the cæcum by an orifice which is placed below and behind the ileo-cæcal opening. It is sometimes guarded, according to Gerlach, by a semilunar valve formed by a fold of mucous membrane, but this is by no means constant. Its coats are the same as those of the intestine: serous, muscular, submucous, and mucous, the latter containing an abundant supply of retiform tissue, especially in young subjects.

It is stated that the vermiform appendix tends to undergo obliteration as an involution change of a functionless organ.

The Ileo-cæcal Valve (*Valvula Bauhini*).—The lower end of the ileum terminates by opening into the inner and back part of the large intestine, at the point of junction of the cæcum with the colon. The opening is guarded by a valve, consisting of two semilunar segments, an upper or colic and lower or cæcal, which project into the lumen of the large intestine. The upper one, nearly horizontal in direction, is attached by its convex border to the point of junction of the ileum with the colon; the lower segment, which is more concave and longer, is attached to the point of junction of the ileum with the cæcum. At each end of the aperture the two segments of the valve coalesce, and are continued as a narrow membranous ridge around the canal for a short distance, forming the *frænа* or *retinacula* of the valve. The left or anterior end of the aperture is rounded; the right or posterior is narrow and pointed.

Each segment of the valve is formed by a reduplication of the mucous membrane and of the circular muscular fibres of the intestine, the longitudinal fibres and peritoneum being continued uninterruptedly across from one portion of the intestine to the other. When these are divided or removed, the ileum may be drawn outward, and all traces of the valve will be lost, the ileum appearing to open into the large intestine by a funnel-shaped orifice of large size.

The surface of each segment of the valve directed toward the ileum is covered with villi, and presents the characteristic structure of the mucous membrane of the small intestine; while that turned toward the large intestine is destitute of villi, and marked with the orifices of the numerous tubular glands peculiar to the mucous membrane of the large intestine. These differences in structure continue as far as the free margin of the valve.

When the cæcum is distended, the margins of the opening are approximated so as to prevent any reflux into the ileum.

The **colon** is divided into four parts—the ascending, transverse, descending, and the sigmoid flexure.

The **ascending colon** is smaller than the cæcum, with which it is continuous. It passes upward, from its commencement at the cæcum, opposite the ileo-cæcal valve, to the under surface of the right lobe of the liver, on the right of the gall-bladder, where it is lodged in a shallow depression, the impressio colica; here it bends abruptly inward to the left, forming the *hepatic flexure*. It is retained in contact with the posterior wall of the abdomen by the peritoneum, which covers its anterior surface and sides, its posterior surface being connected by loose areolar tissue with the Quadratus lumborum and Transversalis muscles, and with the front of the lower and outer part of the right kidney (Figs. 507 and 508). Sometimes the peritoneum almost completely invests it, and forms a distinct but narrow mesocolon.[1] It is in relation, in front, with the convolutions of the ileum and the abdominal parietes.

[1] Treves states that, after a careful examination of one hundred subjects, he found that in fifty-two there was neither an ascending nor a descending mesocolon. In twenty-two there was a descending mesocolon, but no trace of a corresponding fold on the other side. In fourteen subjects there was a mesocolon to both the ascending and the descending segments of the bowel; while in the remaining twelve there was an ascending mesocolon, but no corresponding fold on the left side. It follows, therefore, that in performing lumbar colotomy a mesocolon may be expected on the left side in 36 per cent. of all cases, and on the right in 26 per cent. (*The Anatomy of the Intestinal Canal and Peritoneum in Man*, 1885, p. 55.)

The **transverse colon**, the longest part of the large intestine, passes transversely from right to left across the abdomen, opposite the confines of the epigastric and umbilical zones, into the left hypochondriac region, where it curves downward

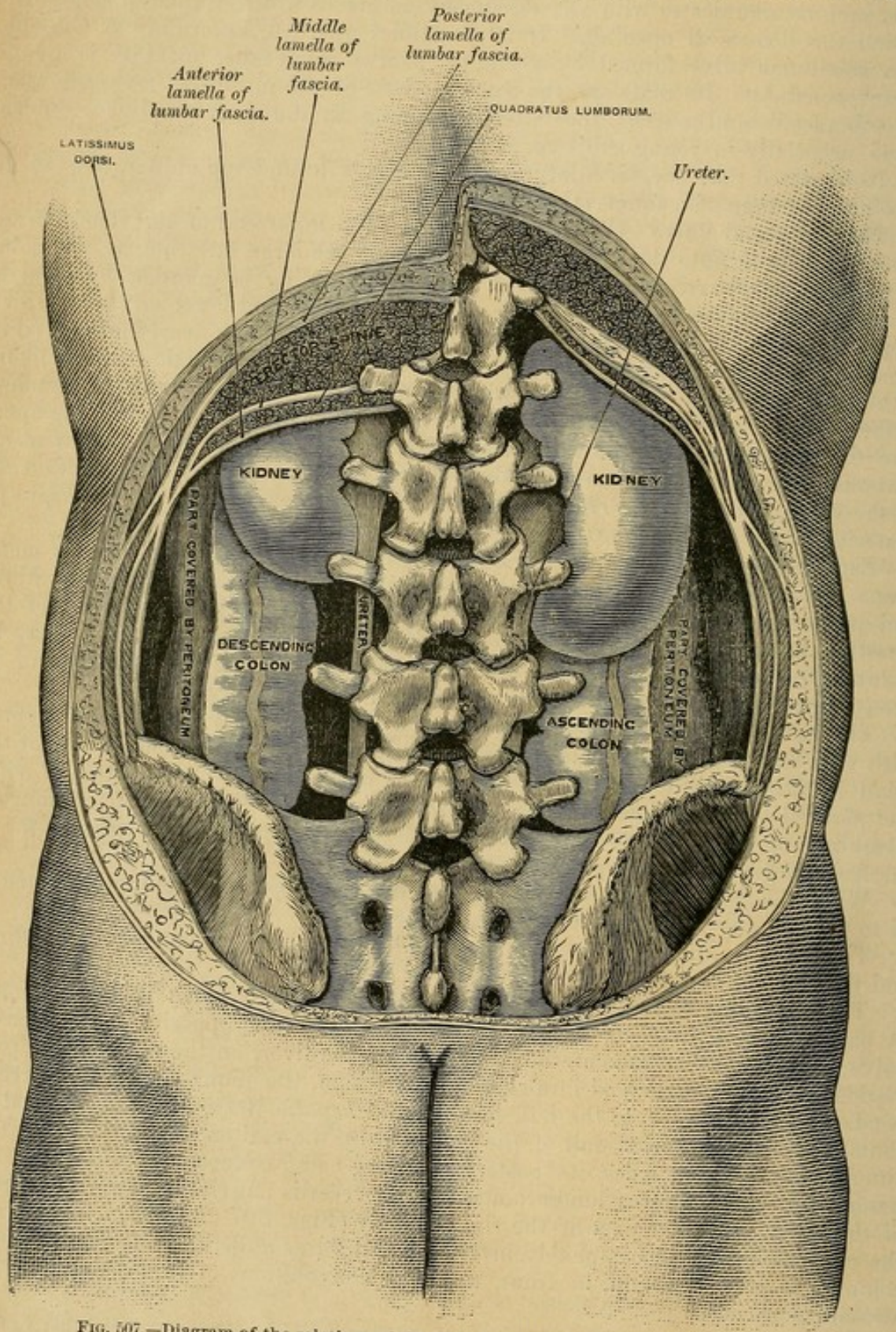

FIG. 507.—Diagram of the relations of the large intestine and kidney, from behind.

beneath the lower end of the spleen, forming the *splenic flexure*. In its course it describes an arch, the concavity of which is directed backward toward the vertebral column and a little upward; hence the name *transverse arch of the colon*. This is the most movable part of the colon, being almost completely invested by

peritoneum, and connected to the spine behind by a large and wide duplicature of that membrane, the *transverse mesocolon*. It is in relation, by its upper surface, with the liver and gall-bladder, the great curvature of the stomach, and the lower end of the spleen; by its under surface, with the small intestines; by its anterior surface, with the anterior layers of the great omentum and the abdominal parietes; its posterior surface on the right side is in relation with the second portion of the duodenum, and on the left is in contact with some of the convolutions of the jejunum and ileum.

The **descending colon** passes downward through the left hypochondriac and lumbar regions along the outer border of the left kidney. At the lower end of the kidney it turns inward toward the outer border of the Psoas muscle, along which it descends to the crest of the ilium, where it terminates in the sigmoid flexure. At its commencement it is connected with the Diaphragm by a fold of peritoneum, the *phreno-colic* ligament (see page 902). It is retained in position by the peritoneum, which covers its anterior surface and sides, its posterior surface being connected by areolar tissue with the outer border of the left kidney, and the Quadratus lumborum and Transversalis muscles (Figs. 507, 508). It is smaller in calibre and more deeply placed than the ascending colon, and is more frequently covered with peritoneum on its posterior surface than the ascending colon (Treves).

The **sigmoid flexure** is the narrowest part of the colon: it is situated in the left iliac fossa, commencing from the termination of the descending colon, at the margin of the crest of the ilium, and ending in the rectum at the brim of the true pelvis opposite the left sacro-iliac symphysis. It curves in the first place forward, downward, and inward for about two inches, and then forms a loop, which varies in length and position, and which terminates in the rectum.[1] The first portion is in close relation with the iliac fascia, and is covered by peritoneum on its sides and anterior surface only. The loop is entirely surrounded by peritoneum, and is retained in its place by a loose fold of peritoneum, the *sigmoid mesocolon*, which connects it to the Psoas muscle. This loop, which normally hangs downward, sometimes into the true pelvis, is very movable, and may be displaced upward in cases of distention of the pelvic viscera. The sigmoid flexure is in relation in front with the small intestines and abdominal parietes. The sigmoid mesocolon is attached to a line running downward and inward from the crest of the ilium, across the Psoas muscle, to become continuous with the *mesorectum* near the bifurcation of the common iliac artery (Fig. 490). In its left layer is the inter-sigmoid fossa (see page 905).

The **rectum** is the terminal part of the large intestine, and extends from the sigmoid flexure to the anal orifice. The superior limit cannot be determined precisely, since there is no point of demarcation between the sigmoid flexure and the first part of the rectum; but the brim of the true pelvis, opposite the left sacro-iliac joint, is arbitrarily given as its point of commencement. From this point it passes downward, backward, and to the right to the level of the third sacral vertebra, where it lies in the middle line. This is the *first part* of the rectum. The *second part* curves forward and is continued downward as far as the apex of the prostate gland, about an inch in front of the tip of the coccyx. From this point the bowel is directed backward, and, passing downward, terminates at the anal orifice. This is the third portion of the rectum, or, as described by Symington, the *anal canal*. It will be seen, therefore, that the rectum presents two antero-posterior curves: the first, with its convexity backward, is due to the conformation of the sacro-coccygeal column, and represents the arc of a circle, the centre of which is opposite the third sacral vertebra. The lower one has its convexity forward, and is angular. Its centre corresponds to a line drawn between the anterior parts of the ischial tuberosities. Two lateral curves are also described:

[1] Treves describes the sigmoid flexure somewhat differently. He includes in his description of this portion of the bowel the upper part of the rectum, and makes it terminate opposite the third portion of the sacrum. Instead of forming a sigmoid curve, he describes it as a large loop or bend, more like the Greek letter Ω (omega).

the one to the right, opposite the junction of the third and fourth sacral vertebræ; the other to the left, opposite the sacro-coccygeal articulation. They are of little importance.

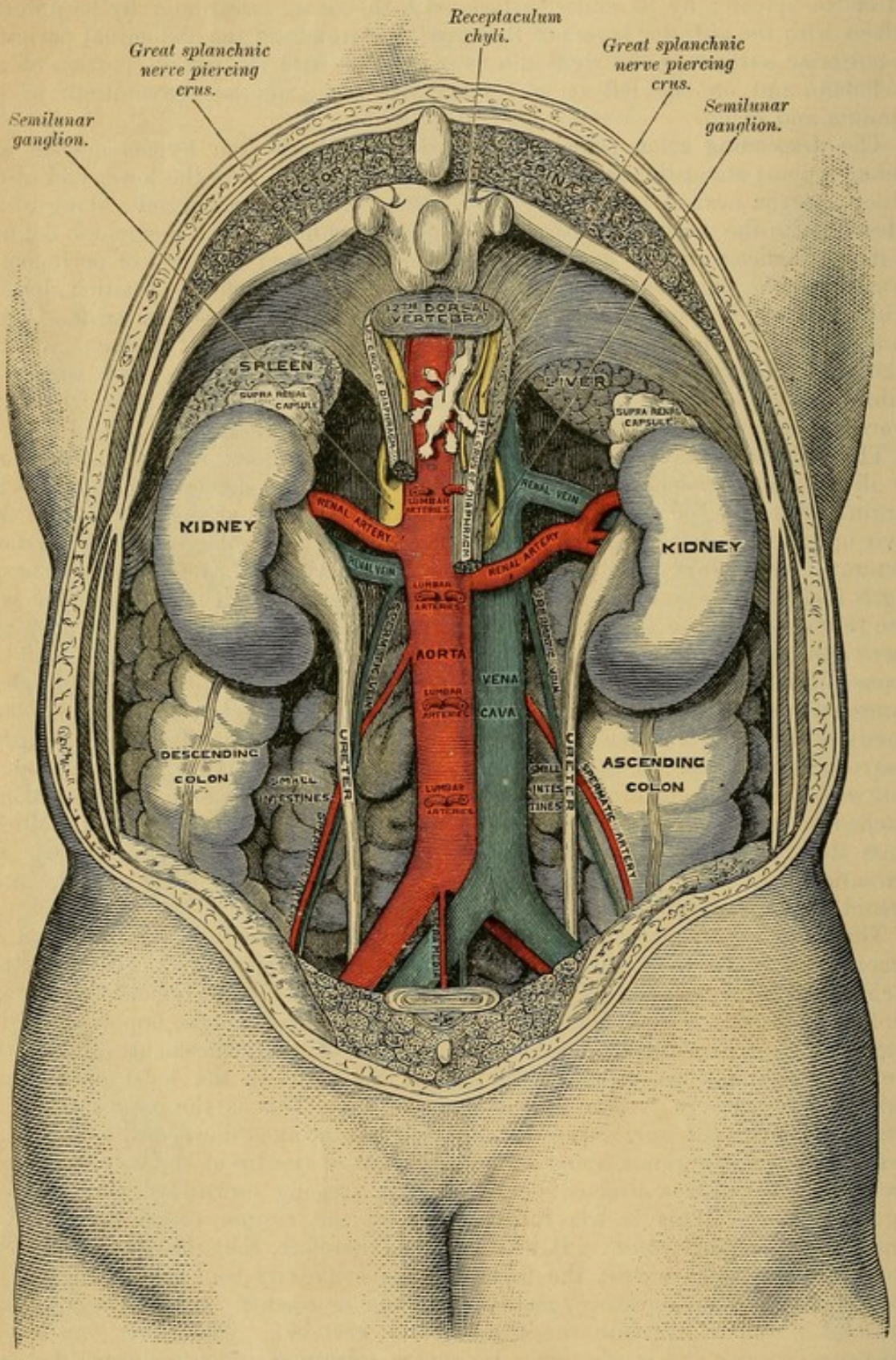

FIG. 508.—The relations of the viscera and large vessels of the abdomen. (Seen from behind, the last dorsal vertebra being well raised.)

The length of the rectum is about eight inches. The first part is four inches, the second three, and the third one to one and a half, being rather longer in the male than in the female. The rectum is narrower in its upper part than the sig-

moid flexure, but is capable of considerable distention. In the lower second portion it becomes a transverse slit, its anterior and posterior close together when the tube is empty, on account of the organs in the f. of the pelvis pushing the rectum backward on the sacrum and coccyx. Th. part of the rectum, the anal canal, is also a slit, with, however, an antero-p. rior direction, so that its lateral walls are in apposition (Fig. 509).

The first portion of the rectum is almost completely surrounded by peritoneum, and is connected to the anterior surface of the sacrum by a double fold, called the *mesorectum*, which is continuous above with the sigmoid mesocolon. The meso-rectum is triangular in shape, the apex of which ends below at the third sacral vertebra; between its two layers is the superior hemorrhoidal artery. The second portion has no mesorectum, but is covered in front and laterally by peritoneum at its upper part; gradually the peritoneum leaves its sides, and about an inch above the prostate is reflected from the anterior surface of the bowel on to the posterior wall of the bladder in the male, and the upper fifth of the posterior wall of the vagina in the female, forming the recto-vesical and recto-vaginal pouches, respectively. The third portion of the rectum has no peritoneal covering. The level at which the peritoneum leaves the anterior wall of the rectum to be reflected on to the viscus in front of it is of considerable importance from a surgical point of view, in connection with removal of the lower part of the rectum. It is higher in the male than in the female. In the former the height of the recto-vesical pouch is about three inches; that is to say, the height to which an ordinary index finger can reach from the anus. In the female the height of the recto-vaginal pouch is about $2\frac{1}{4}$ inches from the anal orifice.

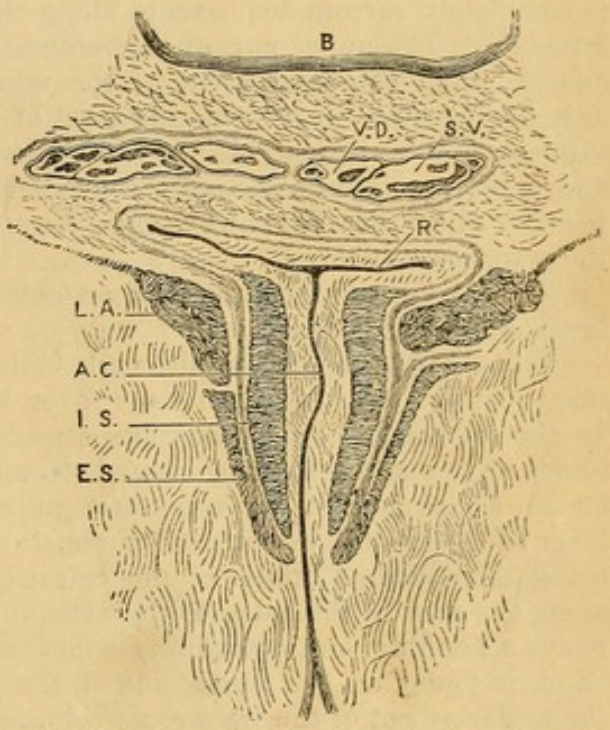

FIG. 509.—Coronal section through the anal canal. (Symington.) B. Cavity of bladder. VD. Vas deferens. SV. Seminal vesicle. R. Second part of rectum. AC. Anal canal. LA. Levator ani. IS. Internal sphincter. ES. External sphincter.

The *first portion* of the rectum is in relation, behind, with the mesorectum and the superior hemorrhoidal artery, the left Pyriformis muscle, and left sacral plexus of nerves, which separate it from the anterior surface of the upper sacral vertebræ; to its left side are the branches of the left internal iliac artery and the left ureter; in front it is separated, in the male, from the posterior surface of the bladder; in the female, from the posterior surface of the uterus and its appendages, by some convolutions of the small intestine, and frequently by the sigmoid flexure of the colon. The *second portion* of the rectum is in relation, in front, in the male, with the recto-vesical pouch, the triangular portion of the base of the bladder, the vesiculæ seminales, and vasa deferentia, and more anteriorly with the under surface of the prostate. In the female, with the posterior wall of the vagina below, and the recto-vaginal pouch above, in which are some convolutions of the small intestine. The *third portion* or *anal canal* is invested by the Internal sphincter, supported by the Levatores ani muscles, and surrounded at its termination by the External sphincter; in the empty condition it presents the appearance of a longitudinal slit. In the male it is separated from the membranous portion and bulb of the urethra by a triangular space; and in the female it is separated from the lower end of the vagina by the perineal body. Laterally is the fat in the ischio-rectal fossæ.

.cture.—The large intestine has four coats—serous, muscular, areolar, and s.

The *serous coat* is derived from the peritoneum, and invests the different portions of the large intestine to a variable extent. The cæcum is completely covered by the serous membrane, except in a small percentage of cases (5 or 6 per cent.), where a small portion of the upper end of the posterior surface is uncovered. The ascending and descending colon are usually covered only in front and at the sides: a variable amount of the posterior surface is uncovered.[1] The transverse colon is almost completely invested, the parts corresponding to the attachment of the great omentum and transverse mesocolon being alone excepted. The sigmoid flexure is completely surrounded, except along the line to which the sigmoid mesocolon is attached. The upper part of the rectum is completely invested by the peritoneum, except along the attachment of the mesorectum; the middle portion is covered only on its anterior surface, and part of its sides in the upper portion; and the lower portion is entirely devoid of any serous covering. In the course of the colon and upper part of the rectum the peritoneal coat is thrown into a number of small pouches filled with fat, called *appendices epiploicæ*. They are chiefly appended to the transverse colon.

The *muscular coat* consists of an external longitudinal and an internal circular layer of muscular fibres.

The *longitudinal fibres*, although found to a certain extent all round the intestine, do not form a uniform layer over the whole surface of the large intestine. In the cæcum and colon they are especially collected into three flat longitudinal bands or tæniæ, each being about half an inch in width. These bands commence at the attachment of the vermiform appendix, which is surrounded by a uniform layer of longitudinal muscular fibres, to the cæcum: one, the posterior, is placed along the attached border of the intestine; the anterior, the largest, corresponds along the arch of the colon to the attachment of the great omentum, but is in front in the ascending and descending colon and sigmoid flexure; the third, or lateral band, is found on the inner side of the ascending and descending colon, and on the under aspect of the transverse colon. These bands are nearly one-half shorter than the other coats of the intestine, and serve to produce the sacculi which are characteristic of the cæcum and colon; accordingly, when they are dissected off, the tube can be lengthened, and its sacculated character becomes lost. In the sigmoid flexure the longitudinal fibres become more scattered; but upon its lower part, and round the rectum, they spread out and form a layer which completely encircles this portion of the gut, but is thicker on the anterior and posterior surfaces, where it forms two bands, than on the lateral surfaces. In addition to the muscular fibres of the bowels, two bands of plain muscular tissue arise from the second and third coccygeal vertebræ, and pass downward and forward to blend with the longitudinal muscular fibres on the posterior wall of the anal canal. These are known as the *recto-coccygeal* muscles.

The *circular fibres* form a thin layer over the cæcum and colon, being especially accumulated in the intervals between the sacculi; in the rectum they form a thick layer, especially at its lower end, where they become numerous, and constitute the Internal sphincter.

The *areolar coat* connects the muscular and mucous layers closely together.

The *mucous membrane*, in the cæcum and colon, is pale, smooth, destitute of villi, and raised into numerous crescentic folds which correspond to the intervals between the sacculi. In the rectum it is thicker, of a darker color, more vascular, and connected loosely to the muscular coat, as in the œsophagus. When the lower part of the rectum is contracted, its mucous membrane is thrown into a number of folds, some of which, near the anus, are longitudinal in direction, and are effaced by the distention of the gut. Besides these there are certain permanent folds, of a semilunar shape, known as Houston's valves.[2] They are usually three in number; sometimes a fourth is found, and occasionally only two are present. One is situated

[1] See foot-note, p. 924.

[2] *Dublin Hosp. Reports*, vol. v. p. 163.

near the commencement of the rectum, on the right side; another extends inward from the left side of the tube, opposite the middle of the sacrum; the largest and most constant one projects backward from the fore part of the rectum, opposite the base of the bladder. When a fourth is present, it is situated about an inch above the anus on the back of the rectum. These folds are about half an inch in width, and contain some of the circular fibres of the gut. In the empty state of the intestine they overlap each other, as Houston remarks, so effectually as to require considerable manœuvering to conduct a bougie or the finger along the canal of the intestine. Their use seems to be "to support the weight of fecal matter, and prevent its urging toward the anus, where its presence always excites a sensation demanding its discharge."

As in the small intestine, the mucous membrane consists of a muscular layer, the muscularis mucosæ; of a quantity of retiform tissue in which the vessels ramify; of a basement-membrane and epithelium, which is of the columnar variety, and exactly resembles the epithelium found in the small intestine. The mucous membrane of this portion of the bowel presents for examination simple follicles and solitary glands.

The *simple follicles* are minute tubular prolongations of the mucous membrane arranged perpendicularly, side by side, over its entire surface; they are longer, more numerous, and placed in much closer apposition than those of the small intestine; and they open by minute rounded orifices upon the surface, giving it a cribriform appearance.

The *solitary glands* (Fig. 510) in the large intestine are most abundant in the *cæcum* and *vermiform appendix*, but are irregularly scattered also over the rest of the intestine. They are similar to those of the small intestine.

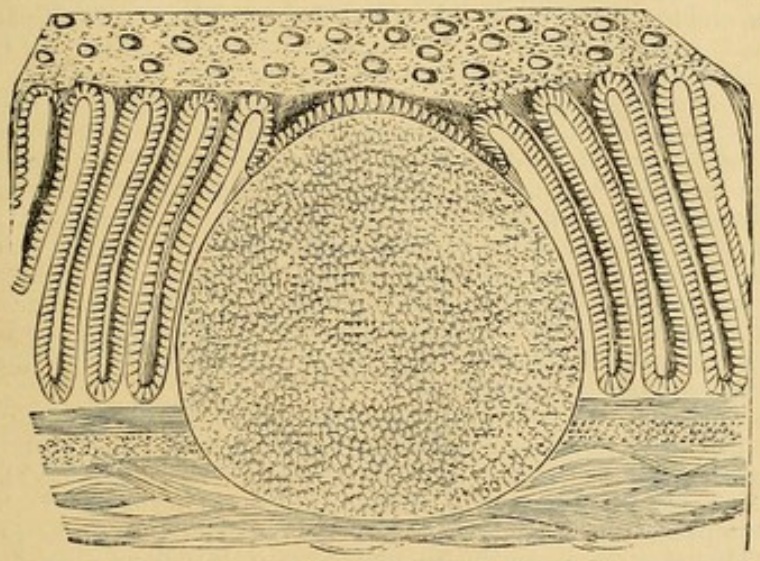

FIG. 510.—Minute structure of large intestine.

Vessels and Nerves.—The arteries supplying the large intestine give off large branches, which ramify between the muscular coats supplying them, and, after dividing into small vessels in the submucous tissue, pass to the mucous membrane The rectum is supplied mainly by the superior hemorrhoidal branch of the inferior mesenteric, but also at its lower end by the middle hemorrhoidal from the internal iliac, and the inferior hemorrhoidal from the pudic artery. The superior hemorrhoidal, the continuation of the superior mesenteric, divides into two branches, which run down either side of the rectum to within about five inches of the anus; they here split up into about six branches, which pierce the muscular coat and descend between it and the mucous membrane in a longitudinal direction, parallel with each other as far as the Internal sphincter, where they anastomose with the other hemorrhoidal arteries and form a series of loops around the anus. The veins of

the rectum commence in a plexus of vessels which surrounds the lower extremity of the intestinal canal. In the vessels forming this plexus are small saccular dilatations just within the margin of the anus; from it about six vessels of considerable size are given off. These ascend between the muscular and mucous coats for about five inches, running parallel to each other; they then pierce the muscular coat, and, by their union, form a single trunk, the superior hemorrhoidal vein. This arrangement is termed the *hemorrhoidal plexus;* it communicates with the tributaries of the middle and inferior hemorrhoidal veins at its commencement, and thus a communication is established between the systemic and portal circulations. The nerves are derived from the plexuses of the sympathetic nerve around the branches of the superior and inferior mesenteric arteries that are distributed to the large intestine. They are distributed in a similar way to those in the small intestine. The lymphatic vessels of the large intestine are found in the submucosa, where they form a wide-meshed network, and also, more deeply seated, beneath the simple follicles. Those from the colon open into the mesenteric glands; those from the sigmoid flexure into the lumbar glands; those from the rectum enter the glands which are situated in the hollow of the sacrum; and those around the anus open into the glands in the groin.

Surface Form.—The coils of the small intestine occupy the front of the abdomen below the transverse colon, and are covered more or less completely by the great omentum. For the most part the coils of the jejunum occupy the left side of the abdominal cavity—*i. e.* the left lumbar and inguinal regions and the left half of the umbilical region—whilst the coils of the ileum are situated to the right, in the right lumbar and inguinal regions, in the right half of the umbilical region, and also the hypogastric. The cæcum is situated in the right inguinal region. Its position varies slightly, but the mid-point of a line drawn from the anterior superior spinous process of the ilium to the symphysis pubis will about mark the middle of its lower border. It is comparatively superficial. From it the ascending colon passes upward through the right lumbar and hypochondriac regions, and becomes more deeply situated as it ascends to the hepatic flexure, which is deeply placed under cover of the liver. The transverse colon crosses the belly transversely on the confines of the umbilical and epigastric regions, its lower border being on a level slightly above the umbilicus, its upper border just below the greater curvature of the stomach. The splenic flexure of the colon is situated behind the stomach in the left hypochondrium, and is on a higher level than the hepatic flexure. The descending colon is deeply seated, passing down through the left hypochondriac and lumbar regions to the sigmoid flexure, which is situated in the left inguinal region, and which can be felt in thin persons, with relaxed abdominal walls, rolling under the fingers when empty, and when distended forming a distinct tumor. The position of the base of the vermiform appendix is indicated by a point two inches from the anterior superior spinous process of the ilium, in a line drawn from this process to the umbilicus. This is known as *McBurney's spot.* Another mode of defining the position of the base of the appendix is to draw a line between the anterior superior spines of the ilia and marking the point where this line intersects the right semilunar line.

Upon introducing the finger into the rectum, the membranous portion of the urethra can be felt, if an instrument has been introduced into the bladder, exactly in the middle line; behind this the prostate gland can be recognized by its shape and hardness and any enlargement detected; behind the prostate the fluctuating wall of the bladder when full can be felt, and if thought desirable it can be tapped in this situation; on either side and behind the prostate the vesiculæ seminales can be readily felt, especially if enlarged by tuberculous disease. Behind, the coccyx is to be felt, and on the mucous membrane one or two of Houston's folds. The ischio-rectal fossæ can be explored on either side, with a view to ascertaining the presence of deep-seated collections of pus. Finally, it will be noted that the finger is firmly gripped by the sphincter for about an inch up the bowel. By gradual dilatation of the sphincter, the whole hand can be introduced into the rectum so as to reach the descending colon. This method of exploration is rarely, however, required for diagnostic purposes.

Surgical Anatomy.—The small intestines are much exposed to injury, but, in consequence of their elasticity and the ease with which one fold glides over another, they are not so frequently ruptured as would otherwise be the case. Any part of the small intestine may be ruptured, but probably the most common situation is the transverse duodenum, on account of its being more fixed than other portions of the bowel, and because it is situated in front of the bodies of the vertebræ, so that if this portion of the intestine is struck by a sharp blow, as from the kick of a horse, it is unable to glide out of the way, but is compressed against the bone and so lacerated. Wounds of the intestine sometimes occur. If the wound is a small puncture, under, it is said, three lines in length, no extravasation of the contents of the bowel takes place. The mucous membrane becomes everted and plugs the little opening. The bowels, therefore, may be safely punctured with a fine capillary trocar, in cases of excessive distension of the intestine with gas, without fear of extravasation. A longitudinal wound gapes more than a transverse, owing to

the greater amount of circular muscular fibres. The small intestine, and most frequently the ileum, may become strangulated by internal bands, or through apertures, normal or abnormal. The bands may be formed in several different ways: they may be old peritoneal adhesions from previous attacks of peritonitis; or an adherent omentum from the same cause; or the band may be formed by Meckel's diverticulum, which has contracted adhesions at its distal extremity; or the band may be the result of the abnormal attachment of some normal structure, as the adhesion of two appendices epiploicæ, or an adherent vermiform appendix or Fallopian tube. Intussusception or invagination of the small intestine may take place in any part of the jejunum and ileum, but the most frequent situation is at the ileo-cæcal valve, the valve forming the apex of the entering tube. This form may attain great size, and it is not uncommon in these cases to find the valve projecting from the anus. Stricture, the impaction of foreign bodies, and twisting of the gut (*volvulus*) may lead to intestinal obstruction.

Resection of a portion of the intestine may be required in cases of gangrenous gut; in cases of intussusception; for the removal of new growth in the bowel; in dealing with artificial anus; and in cases of rupture. The operation is termed *enterectomy*, and is performed as follows: the abdomen having been opened and the amount of bowel requiring removal having been determined upon, the gut must be clamped on either side of this portion in order to prevent the escape of any of the contents of the bowel during the operation. The portion of bowel is then separated above and below by means of scissors. If the portion removed is small, it may be simply removed from the mesentery at its attachment and the bleeding vessels tied; but if it is large, it will be necessary to remove also a triangular piece of the mesentery, and, having secured the vessels, suture the cut edges of this structure together. The surgeon then proceeds to unite the cut ends of the bowel together by the operation of what is termed end-to-end anastomosis. There are many ways of doing this, which may be divided into two classes: one where the anastomosis is made by means of some mechanical appliance, such as Murphy's button, or one of the forms of decalcified bone bobbins; and the other, where the operation is performed by suturing the ends of the bowel in such a manner that the peritoneum covering the free divided ends of the bowel is brought into contact, so that speedy union may ensue.

The vermiform appendix is very liable to become inflamed. This condition may be set up by the appendix becoming twisted, owing to the shortness of its mesentery, in consequence of distention of the cæcum. As the result of this its blood-supply, which is mainly through one large artery running in the mesentery, becomes interfered with. Again, in rarer cases, the inflammation is set up by the impaction of a solid mass of feces or a foreign body in it. The inflammation may result in ulceration and perforation, or, if the torsion is very acute, in gangrene of the appendix. These conditions may require operative interference, and in cases of recurrent attacks of appendicitis it is generally advisable to remove this diverticulum of the bowel. In external hernia the ileum is the portion of bowel most frequently herniated. When a part of the large intestine is involved, it is usually the cæcum, and this may occur even on the left side. In some few cases the vermiform appendix has been the part implicated in cases of strangulated hernia, and has given rise to serious symptoms of obstruction. Occasionally ulceration of the duodenal glands may occur in cases of burns, but is not a very common complication. The ulcer may perforate one of the large duodenal vessels, and may cause death from hemorrhage, or it may perforate the coats of the intestine and produce fatal septic peritonitis. The diameter of the large intestine gradually diminishes from the cæcum, which has the greatest diameter of any part of the bowel, to the point of junction of the sigmoid flexure with the rectum, at or a little below which point stricture most commonly occurs and diminishes in frequency as one proceeds upward to the cæcum. When distended by some obstruction low down, the outline of the large intestine can be defined throughout nearly the whole of its course—all, in fact, except the hepatic and splenic flexures, which are more deeply placed; the distention is most obvious in the two flanks and on the front of the abdomen just above the umbilicus. The cæcum, however, is that portion of the bowel which is, of all, most distended. It sometimes assumes enormous dimensions, and has been known to give way from the distention, causing fatal peritonitis. The hepatic flexure and the right extremity of the transverse colon are in close relationship with the liver, and abscess of this viscus sometimes bursts into the gut in this situation. The gall-bladder may become adherent to the colon, and gall-stones may find their way through into the gut, where they may become impacted or may be discharged per anum. The mobility of the sigmoid flexure renders it more liable to become the seat of a volvulus or twist than any other part of the intestine. It generally occurs in patients who have been the subjects of habitual constipation, and in whom, therefore, the meso-sigmoid flexure is elongated. The gut at this part being loaded with feces, from its weight falls over the gut below, and so gives rise to the twist.

The surgical anatomy of the rectum is of considerable importance. There may be congenital malformation due to arrest or imperfect development. Thus, there may be no inflection of the epiblast, and consequently a complete absence of the anus; or the hind-gut may be imperfectly developed, and there may be an absence of the rectum, though the anus is developed; or the inflection of the epiblast may not communicate with the termination of the hind-gut from want of solution of continuity in the septum which in early fœtal life exists between the two. The mucous membrane is thick and but loosely connected to the muscular coat beneath, and thus favors prolapse, especially in children. The vessels of the rectum are arranged, as mentioned above, longitudinally, and are contained in the loose cellular tissue between the

mucous and muscular coats, and receive no support from surrounding tissues, and this favors varicosity. Moreover, the veins, after running upward in a longitudinal direction for about five inches in the submucous tissue, pierce the muscular coats, and are liable to become constricted at this by the contraction of the muscular wall of the gut. In addition to this there are no valves in the superior hemorrhoidal veins, and the vessels of the rectum are placed in a dependent position, and are liable to be pressed upon and obstructed by hardened feces. The anatomical arrangement, therefore, of the hemorrhoidal vessels explains the great tendency to the occurrence of piles. The presence of the Sphincter ani is of surgical importance, since it is the constant contraction of this muscle which prevents an ischio-rectal abscess from healing and causes it to become a fistula. Also, the reflex contraction of this muscle is the cause of the severe pain complained of in fissure of the anus. The relations of the peritoneum to the rectum are of importance in connection with the operation of removal of the lower end of the rectum for malignant disease. This membrane gradually leaves the rectum as it descends into the pelvis; first leaving its posterior surface, then the sides, and then the anterior surface to become reflected in the male on to the posterior wall of the bladder, forming the recto-vesical pouch, and in the female on to the posterior wall of the vagina, forming Douglas's pouch. The recto-vesical pouch of peritoneum extends to within three inches from the anus, so that it is not desirable to remove more than two and a half inches of the entire circumference of the bowel, for fear of the risk of opening the peritoneum. When, however, the disease is confined to the posterior surface of the rectum, or extends farther in this direction, a greater amount of the posterior wall of the gut may be removed, as the peritoneum does not extend on this surface to a lower level than five inches from the margin of the anus. The recto-vaginal or Douglas's pouch in the female extends somewhat lower than the recto-vesical pouch of the male, and therefore it is necessary to remove a less length of the tube in this sex. Of recent years, however, much more extensive operations have been done for the removal of cancer of the rectum, and in these the peritoneal cavity has necessarily been opened. If, in these cases, the opening is plugged with antiseptic wool until the operation is completed and then the edges of the wound in the peritoneum accurately brought together with sutures, no evil result appears to follow. For cases of cancer of the rectum which are too low to be reached by abdominal section, and too high to be removed by the ordinary operation from below, Kraske has devised an operation which goes by his name. The patient is placed on his right side and an incision is made from the second sacral spine to the anus. The soft parts are now separated from the back of the left side of the sacrum as far as its left margin, and the greater and lesser sacro-sciatic ligaments are divided. A portion of the lateral mass of the sacrum, commencing on the left border at the level of the third posterior sacral foramen, and running downward and inward through the fourth foramen to the cornu, is now cut away with a chisel. The left side of the wound being now forcibly drawn outward, the whole of the rectum is brought into view, and the diseased portion can be removed, leaving the anal portion of the gut, if healthy. The two divided ends of the gut can then be approximated and sutured together in front, the posterior part being left open for drainage.

The colon frequently requires opening in cases of intestinal obstruction, and by some surgeons this operation is performed in cases of cancer of the rectum, as soon as the disease is recognized, in the hope that the rate of growth may be retarded by removing the irritation produced by the passage of fecal matter over the diseased surface. The operation of colotomy may be performed either in the inguinal or lumbar region; but inguinal colotomy has in the present day almost superseded the lumbar operation. The main reason for preferring this operation is that a spur-shaped process of the meso-colon can be formed which prevents any fecal matter finding its way past the artificial anus and becoming lodged on the diseased structures below. The sigmoid flexure being almost entirely surrounded by peritoneum, a coil can be drawn out of the wound and the greater part of its calibre removed, leaving the remainder attached to the meso-colon, which forms a spur, much the same as in an artificial anus caused by sloughing of the gut after a strangulated hernia, and this prevents any fecal matter finding its way from the gut above the opening into that below. The operation is performed by making an incision two or three inches in length from a point one inch internal to the anterior superior spinous process of the ilium, parallel to Poupart's ligament. The various layers of abdominal muscles are cut through, and the peritoneum opened and sewn to the external skin. The sigmoid flexure is now sought for, and pulled out of the wound and fixed by passing a needle threaded with carbolized silk through the meso-colon close to the gut and then through the abdominal wall. The intestine is now sewn to the skin all round, the suture passing only through the serous and muscular coats. The wound is dressed, and on the second to the fourth day, according to the requirements of the case, the protruded coil of intestine is opened and removed with scissors.

Lumbar colotomy is performed by placing the patient on the side opposite to the one to be operated on, with a firm pillow under the loin. A line is then drawn from the anterior superior to the posterior superior spine of the ilium, and the mid-point of this line (Heath) or half an inch behind the mid-point (Allingham) is taken, and a line drawn vertically upward from it to the last rib. This line represents, with sufficient correctness, the position of the normal colon. An oblique incision four inches in length is now made midway between the last rib and the crest of the ilium, so that its centre bisects the vertical line, and the following parts successively divided: (1) The skin, superficial fascia, with cutaneous vessels and nerves and deep fascia. (2) The posterior fibres of the External oblique and anterior fibres of the Latissimus dorsi.

(3) The Internal oblique. (4) The lumbar fascia and the external border of the Quadratus lumborum. The edges of the wound are now to be held apart with retractors, and the transversalis fascia will be exposed. This is to be opened with care, commencing at the posterior angle of the incision. If the bowel is distended, it will bulge into the wound, and no difficulty will be found in dealing with it. If, however, the gut is empty, this bulging will not take place, and the colon will have to be sought for. The guides to it are the lower end of the kidney, which will be plainly felt, and the outer edge of the Quadratus lumborum. The bowel having been found, is to be drawn well up into the wound, and it may be opened at once and the margins of the openings stitched to the skin at the edge of the wound; or, if the case is not an urgent one, it may be retained in this position by two harelip pins passed through the muscular coat, the rest of the wound closed, and the bowel opened in three or four days, when adhesion of the bowel to the edges of the wound has taken place.

THE LIVER.

The **Liver** is the largest gland in the body, and is situated in the upper and right part of the abdominal cavity, occupying almost the whole of the right hypochondrium, the greater part of the epigastrium, and extending into the left hypochondrium as far as the mammary line. In the male it weighs from fifty to sixty ounces; in the female, from forty to fifty. It is relatively much larger in the fœtus than in the adult, constituting, in the former, about one-eighteenth, and in the latter, about one thirty-sixth of the entire body-weight. Its greatest transverse measurement is from eight to nine inches. Vertically, near its lateral or right surface, it measures about six or seven inches, while its greatest antero-posterior diameter is on a level with the upper end of the right kidney and is from four to five inches. Opposite the vertebral column its measurement from before backward is reduced to about three inches. Its consistence is that of a soft solid; it is, however, friable and easily lacerated; its color is a dark reddish-brown, and its specific gravity is 1.05.

To obtain a correct idea of its shape, it must be hardened *in situ*, and it will then be seen to present the appearance of a wedge, the base of which is directed

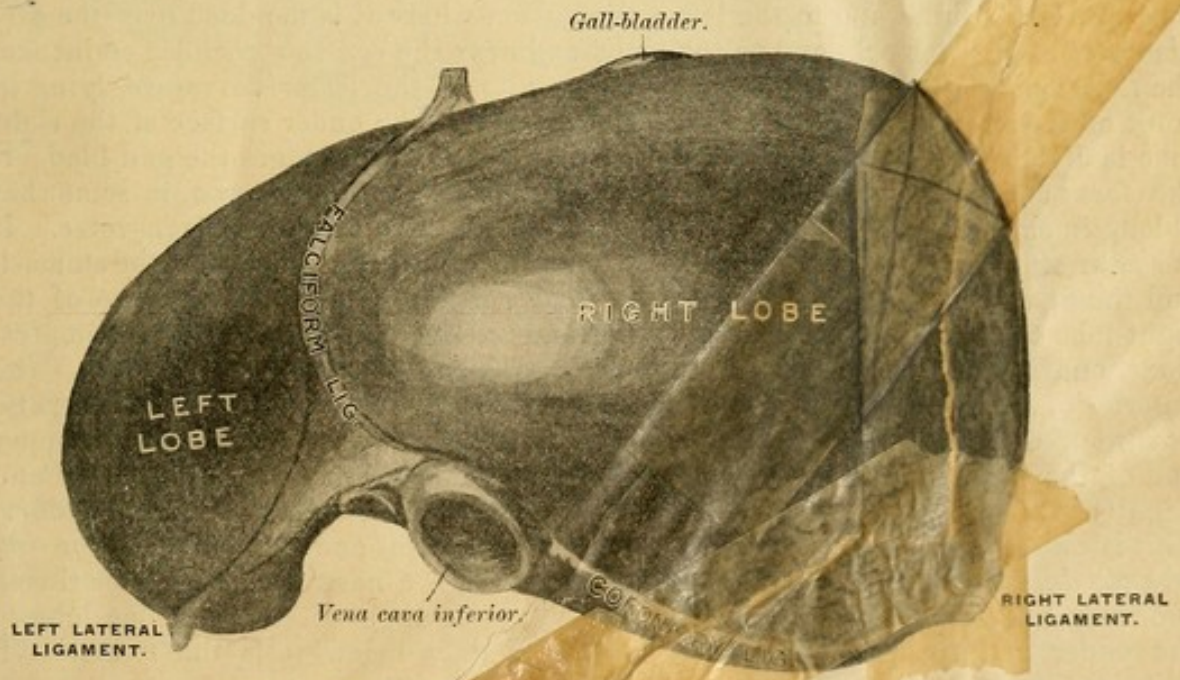

FIG. 511.—The liver [illegible] (Drawn from His's models.)

to the right and the thin edge toward[illegible]e left. Symington describes its shape as that "of a right-angled triangular [illegible]n with the right angles rounded off." It possesses five surfaces, viz., su[illegible]erior, inferior, anterior, posterior, and lateral.

The superior and anterior [illegible]ces are separated from each other by a thick rounded border, and are attached to the Diaphragm and anterior abdominal wall by a triangular or falciform fold of peritoneum, the *suspensory* or *falciform ligament*, which divides the liver into two unequal parts, termed the right and left

lobes. Except along the line of attachment of this ligament to the liver, the superior and anterior surfaces are covered by peritoneum.

The *superior surface* (Fig. 511) comprises a part of both lobes, and, as a whole, is convex, and fits under the vault of the Diaphragm; its central part, however, presents a shallow depression, which corresponds with the position of the heart on the upper surface of the Diaphragm. It is separated from the anterior, posterior, and lateral surfaces by thick, rounded borders. Its left extremity is separated from the under surface by a prominent sharp margin.

The *anterior surface* is large and triangular in shape, comprising also a part of both lobes. It is directed forward, and the greater part of it is in contact with the Diaphragm, which separates it from the right lower ribs and their cartilages. In the middle line it lies behind the ensiform cartilage, to the left of which it is protected by the seventh and eighth left costal cartilages. In the angle between the diverging rib cartilages of opposite sides the anterior surface is in contact with the abdominal wall. It is separated from the inferior surface by a sharp margin, and from the superior and lateral surfaces by thick rounded borders.

The *lateral* or *right surface* is convex from before backward and slightly so from above downward. It is directed toward the right side, forming the base of the wedge, and lies against the lateral portion of the Diaphragm, which separates it from the lower part of the left pleura and lung, outside which are the right costal arches from the seventh to the eleventh inclusive.

Its *under* or *visceral surface* (Figs. 512, 513) is uneven, concave, directed downward and backward and to the left, and is in relation with the stomach and duodenum, the hepatic flexure of the colon, and the right kidney and suprarenal capsule. The surface is divided by a longitudinal fissure into a right and a left lobe, and is almost completely invested by peritoneum; the only parts where this covering is absent are where the gall-bladder is attached to the liver and at the transverse fissure, where the two layers of the lesser omentum are separated from each other by the blood-vessels and duct of the viscus. The under surface of the left lobe presents behind and to the left a depression where it is moulded over the cardiac part of the stomach, and to the right and near the centre a rounded eminence, the *tuber omentale*, which fits into the concavity of the lesser curvature, lying in front of the anterior layer of the lesser omentum. The under surface of the right lobe is divided into two unequal portions by a fossa, which lodges the gall-bladder, the *fossa vesicalis*; the portion to the left, the smaller of the two, is somewhat oblong in shape, its antero-posterior diameter being greater than its transverse. It is known as the *quadrate lobe*, and is in relation with the pyloric end of the stomach and the first portion of the duodenum. The portion of the under surface of the right lobe to the right of the fossa vesicalis presents two shallow concave impressions, one situated behind the other, the two being separated by a ridge. The anterior of these two impressions, the *impressio colica*, is produced by the hepatic flexure of the colon; the posterior, the *impressio renalis*, is occupied by the upper end of the right kidney. To the inner side of the latter impression is a third and slightly marked impression, lying between it and the neck of the gall-bladder. This is caused by the second portion of the duodenum, and is known as the *impressio duodenalis*. Just in front of the vena cava is a narrow strip of liver tissue, the caudate lobe, which connects the right inferior angle of the Spigelian lobe to the under surface of the right lobe. Immediately below it is the foramen of Winslow.

The *posterior surface* is rounded and broad behind the right lobe, but narrow on the left. Over a large part of its extent it is not covered by peritoneum; this uncovered portion is about three inches broad, and is in direct contact with the Diaphragm. It is marked off from the upper surface by the line of reflection of the upper or anterior layer of the coronary ligament. It is in the same way marked off from the under surface of the liver by the line of reflection of the lower layer of the coronary ligament. In its centre this posterior surface is deeply notched for the vertebral column and crura of the Diaphragm, and to the right

of this it is indented for the inferior vena cava, which is often partly imbedded in its substance. Close to the right of this indentation and immediately above the renal impression is a small triangular depressed area (*impressio suprarenalis*), the greater part of which is devoid of peritoneum; it lodges the right suprarenal capsule. To the left of the inferior vena cava is the *Spigelian lobe*, which lies between the fissure for the vena cava and the fissure for the ductus venosus. Below and in front it projects and forms part of the posterior boundary of the transverse fissure. Here, to the right, it is connected with the under surface of the right lobe of the liver by the caudate lobe, and to the left it presents a tubercle, the *tuber papillaire*. It is opposite the tenth and eleventh dorsal vertebræ, and rests upon the aorta and crura of the Diaphragm, being covered by the peritoneum of the lesser sac. The lobe is nearly vertical in position, and is directed backward: it is longer from above downward than from side to side, and is somewhat concave in the transverse direction. On the posterior surface to the left of the Spigelian lobe is a groove indicating the position of the œsophageal orifice of the stomach.

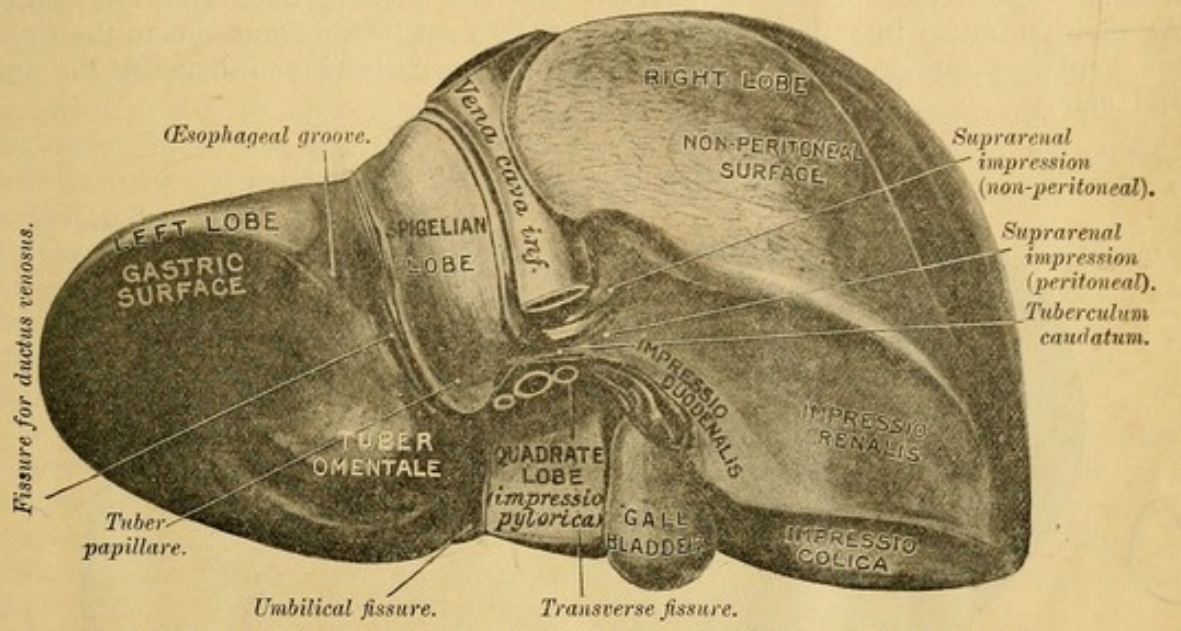

FIG. 512.—The liver. Posterior and inferior surfaces. (Drawn from His's models.)

The *inferior border* is thin and sharp, and marked opposite the attachment of the falciform ligament by a deep notch, the *umbilical notch*, and opposite the cartilage of the ninth rib by a second notch for the fundus of the gall-bladder. In adult males this border usually corresponds with the margin of the ribs in the right nipple line; but in women and children it usually projects below the ribs.

The *left extremity of the liver* is thin and flattened from above downward.

Fissures (Fig. 512).—Five fissures are seen upon the under and posterior surfaces of the liver, which serve to divide it into five lobes. They are, the umbilical fissure, the fissure of the ductus venosus, the transverse fissure, the fissure for the gall-bladder, and the fissure for the inferior vena cava. They are arranged in the form of the letter H. The left limb of the H is known as the *longitudinal fissure*. The right limb is formed in front by the *fissure for the gall-bladder*, and behind by the *fissure for the inferior vena cava;* these two fissures are separated from each other by the caudate lobe. The connecting bar of the H is the *transverse* or *portal fissure*. It separates the quadrate lobe in front from the caudate and Spigelian lobes behind.

The *longitudinal fissure* is a deep groove, which extends from the notch on the anterior margin of the liver to the upper border of the posterior surface of the organ. It separates the right and left lobes; the transverse fissure joins it, at right angles, and divides it into two parts. The anterior part is called the *umbilical fissure:* it is deeper than the posterior, and lodges the umbilical vein in

the fœtus, and its remains (the round ligament) in the adult; the posterior part contains the ductus venosus, and is known as the *fissure of the ductus venosus*. This fissure lies between the quadrate lobe and the left lobe of the liver, and is often partially bridged over by a prolongation of the hepatic substance, the *pons hepatis*.

The *fissure of the ductus venosus* is the back part of the longitudinal fissure, and is situated mainly on the posterior surface of the liver. It lies between the left lobe and the lobe of Spigelius. It lodges in the fœtus the ductus venosus, and in the adult a slender fibrous cord, the obliterated remains of that vessel.

The *transverse* or *portal fissure* is a short but deep fissure, about two inches in length, extending transversely across the under surface of the left portion of the right lobe, nearer to its posterior surface than its anterior border. It joins, nearly at right angles, with the longitudinal fissure, and separates the quadrate lobe in front from the caudate and Spigelian lobes behind. By the older anatomists this fissure was considered the gateway (*porta*) of the liver; hence the large vein which enters at this fissure was called the *portal vein*. Besides this vein, the fissure transmits the hepatic artery and nerves, and the hepatic duct and lymphatics. At their entrance into the fissure, the hepatic duct lies in front and to the right, the hepatic artery to the left, and the portal vein behind and between the duct and artery.

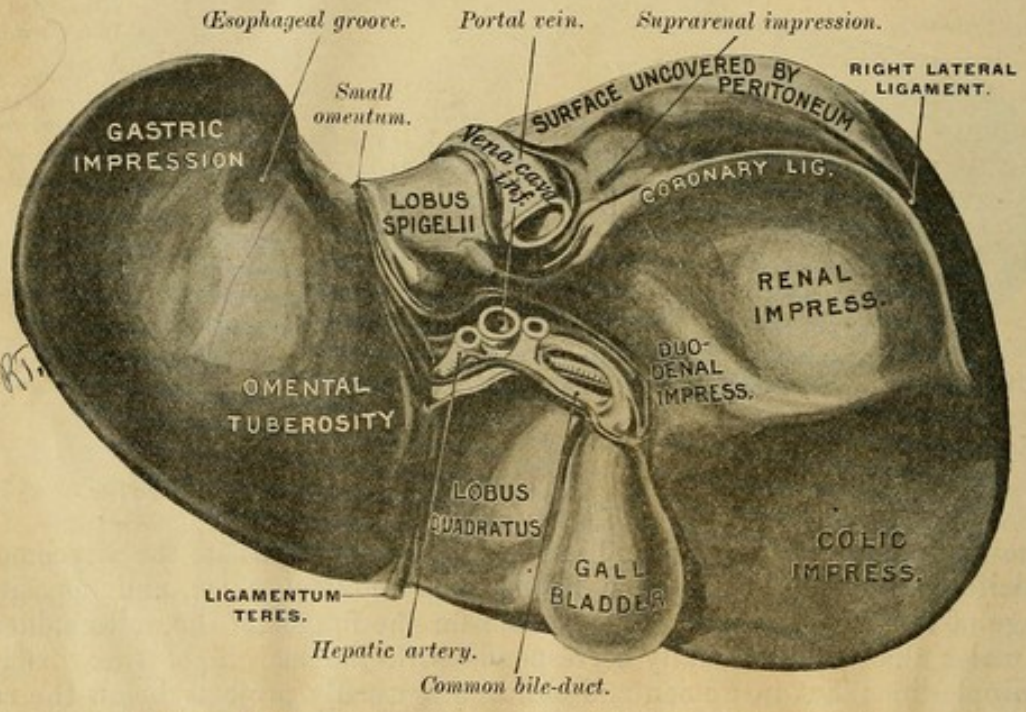

FIG. 513.—Posterior and under surfaces of the liver. (From Ellis.)

The *fissure for the gall-bladder* (*fossa vesicalis*) is a shallow, oblong fossa, placed on the under surface of the right lobe, parallel with the longitudinal fissure. It extends from the anterior free margin of the liver, which is notched for its reception, to the right extremity of the transverse fissure.

The *fissure for the inferior vena cava* is a short deep fissure, occasionally a complete canal, in consequence of the substance of the liver surrounding the vena cava. It extends obliquely upward from the lobus caudatus, which separates it from the transverse fissure, on the posterior surface of the liver, and separates the Spigelian from the right lobe. On slitting open the inferior vena cava the orifices of the hepatic veins will be seen opening into this vessel at its upper part, after perforating the floor of this fissure.

Lobes.—The lobes of the liver, like the ligaments and fissures, are five in number—the right lobe, the left lobe, the lobus quadratus, the lobus Spigelii, and the lobus caudatus, the last three being merely parts of the right lobe.

The *right lobe* is much larger than the left; the proportion between them being as six to one. It occupies the right hypochondrium, and is separated from the left lobe, on its upper and anterior surfaces by the falciform ligament; on its under and posterior surfaces by the longitudinal fissure; and in front by the umbilical notch. It is of a somewhat quadrilateral form, its under and posterior surfaces being marked by three fissures—the transverse fissure, the fissure for the gall-bladder, and the fissure for the inferior vena cava, which separate its left part into three smaller lobes—lobus Spigelii, lobus quadratus, and lobus caudatus. On it are seen four shallow impressions, one in front (*impressio colica*), for the hepatic flexure of the colon; a second behind (*impressio renalis*), for the right kidney; a third internal, between the last-named and the gall-bladder (*impressio duodenalis*), for the second part of the duodenum; and a fourth on its posterior surface, for the suprarenal capsule (*impressio suprarenalis*).

The *lobus quadratus*, or square lobe, is situated on the under surface of the right lobe, bounded in front by the inferior margin of the liver; behind by the transverse fissure; on the right, by the fissure of the gall-bladder; and on the left by the umbilical fissure.

The *lobus Spigelii* is situated upon the posterior surface of the right lobe of the liver. It looks directly backward, and is nearly vertical in direction. It is bounded, above, by the upper layer of the coronary ligament; below, by the transverse fissure; on the right, by the fissure for the vena cava; and, on the left, by the fissure for the ductus venosus. Its left upper angle forms part of the groove for the œsophagus.

The *lobus caudatus*, or tailed lobe, is a small elevation of the hepatic substance extending obliquely outward, from the lower extremity of the lobus Spigelii to the under surface of the right lobe. It is situated behind the transverse fissure, and separates the fissure for the gall-bladder from the commencement of the fissure for the inferior vena cava.

The *left lobe* is smaller and more flattened than the right. It is situated in the epigastric and left hypochondriac regions. Its upper surface is slightly convex; its under surface is concave, and presents a shallow depression for the stomach (*gastric impression*). This is situated in front of the groove for the œsophagus, and is separated from the longitudinal fissure by the *omental tuberosity*, which lies against the small omentum and lesser curvature of the stomach.

Ligaments.—The liver is connected to the under surface of the Diaphragm and the anterior wall of the abdomen by five ligaments, four of which are peritoneal folds; the fifth is a round, fibrous cord, resulting from the obliteration of the umbilical vein. These ligaments are the falciform, two lateral, coronary, and round. It is also attached to the lesser curvature of the stomach by the gastro-hepatic or small omentum (see page 902).

The *falciform ligament* (broad or suspensory ligament) is a broad and thin antero-posterior peritoneal fold, falciform in shape, its base being directed downward and backward, its apex upward and backward. It is attached by one margin to the under surface of the Diaphragm, and the posterior surface of the sheath of the right Rectus muscle as low down as the umbilicus; by its hepatic margin it extends from the notch on the anterior margin of the liver, as far back as its posterior surface. It consists of two layers of peritoneum closely united together. Its base or free edge contains the round ligament between its layers.

The *lateral ligaments* (Fig. 511), two in number, right and left, are triangular in shape. They are formed by the apposition of the upper and lower layers of the coronary ligament, and extend from the Diaphragm to the liver—the right being attached to the border between its lateral and inferior surfaces, the left, the longer of the two, to the upper surface of the left lobe, where it lies in front of the œsophageal opening in the Diaphragm.

The *coronary ligament* connects the posterior surface of the liver to the Diaphragm. It is formed by the reflection of the peritoneum from the Diaphragm on to the upper and lower margins of the posterior surface of the organ. The coro-

nary ligament consists of two layers, which are continuous on each side with the lateral ligaments; and, in front, with the falciform ligament. Between the layers a large triangular area is left uncovered by peritoneum, and is connected to the Diaphragm by firm areolar tissue.

The *round ligament* (ligamentum teres) is a fibrous cord resulting from the obliteration of the umbilical vein. It ascends from the umbilicus, in the free margin of the falciform ligament, to the notch in the anterior border of the liver, from which it may be traced along the longitudinal fissure on the under surface of the liver; on the posterior surface it is continued as the obliterated ductus venosus as far back as the inferior vena cava.

Vessels.—The vessels connected with the liver are also five in number: they are, the hepatic artery, the portal veins, the hepatic vein, the hepatic duct, and the lymphatics.

The *hepatic artery* and *portal vein*, accompanied by numerous lymphatics and nerves, ascend to the transverse fissure between the layers of the gastro-hepatic omentum. The *hepatic duct*, lying in company with them, descends from the transverse fissure between the layers of the same omentum. The relative position of the three structures is as follows: the hepatic duct lies to the right, the hepatic artery to the left, and the portal vein behind and between the other two. They are enveloped in a loose areolar tissue, the *capsule of Glisson*, which accompanies the vessels in their course through the *portal canals* in the interior of the organ.

The *hepatic veins* convey the blood from the liver. They commence in the substance of the liver, in the capillary terminations of the portal vein and hepatic artery; these tributaries, gradually uniting, usually form three veins, which converge toward the posterior surface of the liver and open into the inferior vena cava, while that vessel is situated in the groove at the back part of this organ. Of these three veins, one from the right and another from the left lobe open obliquely into the vena cava; that from the middle of the organ and lobus Spigelii having a straight course.

The hepatic veins have very little cellular investment; what there is binds their parietes closely to the walls of the canals through which they run; so that, on section of the organ, these veins remain widely open and solitary, and may be easily distinguished from the branches of the portal vein, which are more or less collapsed, and always accompanied by an artery and duct. The hepatic veins are destitute of valves.

Structure.—The substance of the liver is composed of lobules held together by an extremely fine areolar tissue, and of the ramifications of the portal vein, hepatic duct, hepatic artery, hepatic veins, lymphatics, and nerves, the whole being invested by a serous and a fibrous coat.

The *serous coat* is derived from the peritoneum, and invests the greater part of the surface of the organ. It is intimately adherent to the fibrous coat.

The *fibrous coat* lies beneath the serous investment and covers the entire surface of the organ. It is difficult of demonstration, excepting where the serous coat is deficient. At the transverse fissure it is continuous with the capsule of Glisson, and on the surface of the organ with the areolar tissue separating the lobules.

The *lobules* form the chief mass of the hepatic substance; they may be seen either on the surface of the organ or by making a section through the gland. They are small granular bodies about the size of a millet-seed, measuring from one-twentieth to one-tenth of an inch in diameter. In the human subject their outline is very irregular, but in some of the lower animals (for example, the pig) they are well-defined, and when divided transversely have a polygonal outline. If divided longitudinally they are more or less foliated or oblong. The bases of the lobules are clustered round the smallest radicles (*sublobular*) of the hepatic veins, to which each is connected by means of a small branch which issues from the centre of the lobule (*intralobular*). The remaining part of the surface of each lobule is imperfectly isolated from the surrounding lobules by a thin stratum of

areolar tissue in which is contained a plexus of vessels (the *interlobular plexus*) and ducts. In some animals, as the pig, the lobules are completely isolated one from another by this interlobular areolar tissue.

If one of the sublobular veins be laid open, the bases of the lobules may be seen through the thin wall of the vein on which they rest, arranged in the form of a tesselated pavement, the centre of each polygonal space presenting a minute aperture, the mouth of an intralobular vein (Fig. 514).

Microscopic Appearance.—Each lobule is composed of a mass of cells (*hepatic cells*) surrounded by a dense capillary plexus, composed of vessels which penetrate from the circumference to the centre of the lobule, and terminate in a single

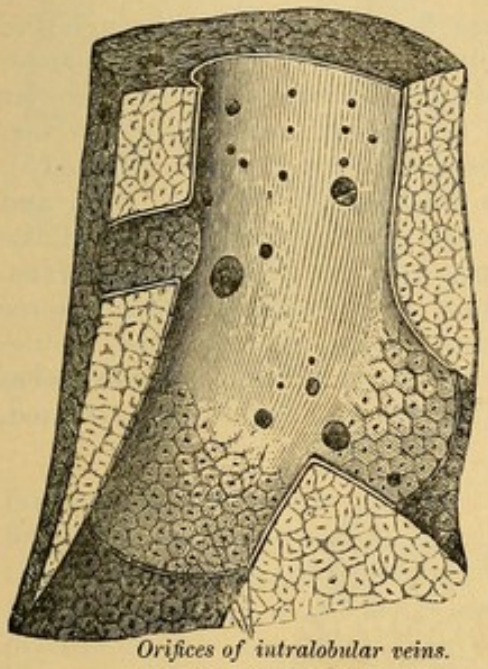

FIG. 514.—Longitudinal section of an hepatic vein. (After Kiernan.)

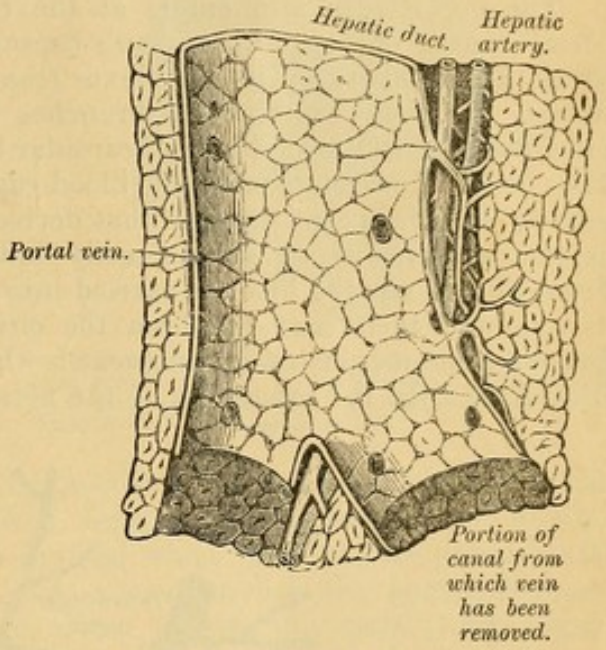

FIG. 515.—Longitudinal section of a small portal vein and canal. (After Kiernan.)

straight vein, which runs through its centre, to open at its base into one of the radicles of the hepatic vein. Between the cells are also the minute commencements of the bile-ducts. Therefore in the lobule we have all the essentials of a secreting gland; that is to say: (1) *cells*, by which the secretion is formed; (2) *blood-vessels*, in close relation with the cells, containing the blood from which the secretion is derived; and (3) *ducts*, by which the secretion, when formed, is carried away. Each of these structures will have to be further considered.

(1) The *hepatic cells* are of more or less spheroidal form, but may be rounded, flattened, or many-sided from mutual compression. They vary in size from the $\frac{1}{1000}$ to the $\frac{1}{2000}$ of an inch in diameter. They consist of a honeycomb network (Klein) without any cell-wall, and contain one or sometimes two distinct nuclei. In the nucleus is a highly refracting nucleolus with granules. Embedded in the honeycomb network are numerous yellow particles, the coloring matter of the bile, and oil-globules. The cells adhere together by their surfaces so as to form rows, which radiate from the centre to the circumference of the lobules.[1] As stated above, they are the chief agents in the secretion of the bile.

(2) *The Blood-vessels.*—The blood in the capillary plexus around the liver-cells is brought to the liver principally by the portal vein, but also to a certain extent by the hepatic artery. For the sake of clearness the distribution of the blood derived from the hepatic artery may be considered first.

[1] Delépine states that there are evidences of the arrangement of these cells in the form of columns, which form tubes with narrow lumina branching from terminal bile-ducts. This branching is evidenced by a divergence of the columns from lines extending between adjacent portal vessels. The columns of cells group round terminal bile-ducts, and not round the so-called intralobular veins. (*Lancet*, 1895, vol. i., p. 1254.)

The *hepatic artery*, entering the liver at the transverse fissure with the portal vein and hepatic duct, ramifies with these vessels through the portal canals. It gives off *vaginal branches* which ramify in the capsule of Glisson, and appear to be destined chiefly for the nutrition of the coats of the large vessels, the ducts, and the investing membranes of the liver. It also gives off *capsular branches* which reach the surface of the organ, terminating in its fibrous coat in stellate plexuses. Finally it gives off *interlobular branches* which form a plexus on the outer side of each lobule, to supply its wall and the accompanying bile-ducts. From this, lobular branches enter the lobule and end in the capillary network between the cells. Some anatomists, however, doubt whether it transmits any blood directly to the capillary network.

The *portal vein* also enters at the transverse fissure and runs through the portal canals, enclosed in Glisson's capsule, dividing into branches in its course, which finally break up into a plexus (the *interlobular plexus*) in the interlobular spaces. In their course these branches receive the vaginal and capsular veins, corresponding to the vaginal and capsular branches of the hepatic artery (Fig. 515). Thus it will be seen that all the blood carried to the liver by the portal vein and hepatic artery, except perhaps that derived from the interlobular branches of the hepatic artery, directly or indirectly finds its way into the interlobular plexus. From this plexus the blood is carried into the lobule by fine branches which pierce its wall and then converge from the circumference to the centre of the lobule, forming a number of converging vessels which are connected by transverse branches (Fig. 516). In the interstices of the network of vessels thus formed are situated,

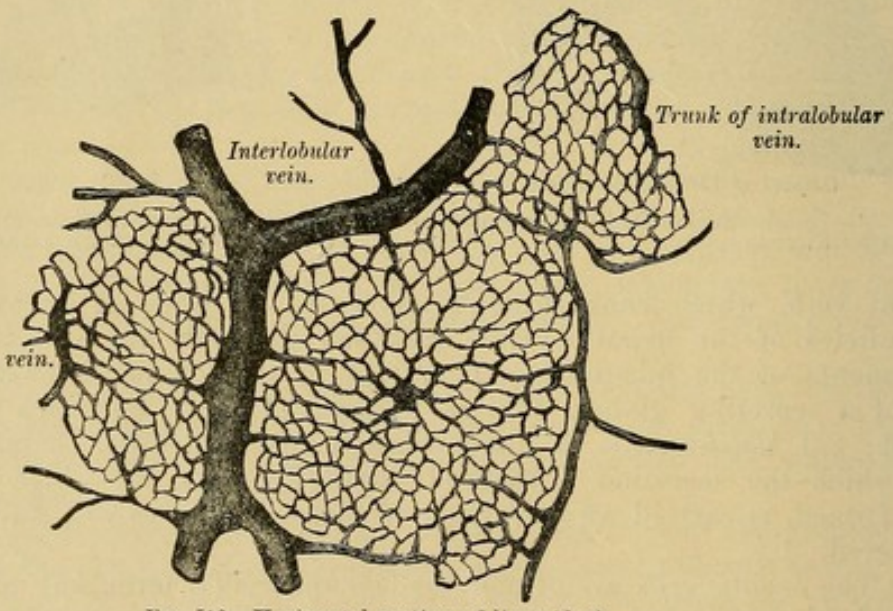

FIG. 516.—Horizontal section of liver (dog).

as before said, the liver-cells: and here it is that, the blood being brought into intimate connection with the liver-cells, the bile is secreted. Arrived at the centre of the lobule, all these minute vessels empty themselves into one vein, of considerable size, which runs down the centre of the lobules from apex to base and is called the *intralobular vein*. At the base of the lobule this vein opens directly into the *sublobular vein*, with which the lobule is connected, and which, as before mentioned, is a radicle of the hepatic vein. The sublobular veins, uniting into larger and larger trunks, end at last in the hepatic veins, which do not receive any intralobular veins. Finally, the hepatic veins, as mentioned at page 619, converge to form three large trunks which open into the inferior vena cava, while that vessel is situated in the fissure appropriated to it at the back of the liver.

(3) *The Ducts.*—Having shown how the blood is brought into intimate relation with the hepatic cells in order that the bile may be secreted, it remains now only to consider the way in which the secretion, having been formed, is carried away.

Several views have prevailed as to the mode of origin of the hepatic ducts; it seems, however, to be clear that they commence by little passages which are formed between the cells, and which have been termed *intercellular biliary passages* or *bile-capillaries*. These passages are merely little channels or spaces left between the contiguous surfaces of two cells or in the angle where three or more liver-cells meet (Fig. 517), and it seems doubtful whether there is any delicate membrane

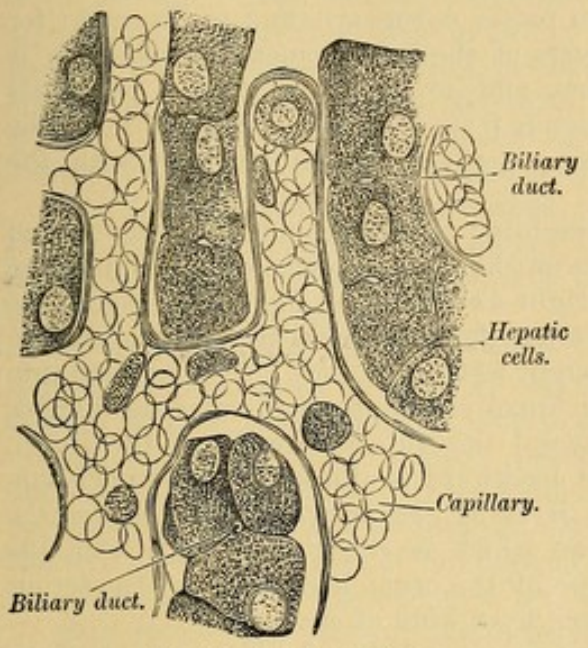

FIG. 517.—Section of liver.

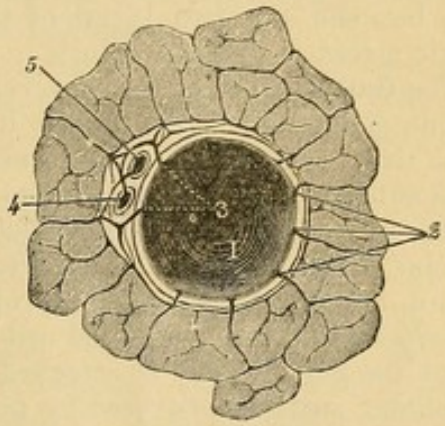

FIG. 518.—A transverse section of a small portal canal and its vessels. (After Kiernan.) 1. Portal vein. 2. Interlobular branches. 3. Vaginal branches. 4. Hepatic duct. 5. Hepatic artery.

forming the wall of the channel. The channels thus formed radiate to the circumference of the lobule, and, piercing its wall, form a plexus (*interlobular*) between the lobules. From this plexus ducts are derived which pass into the portal canals, become enclosed in Glisson's capsule, and, accompanying the portal vein and hepatic artery (Fig. 518), join with other ducts to form two main trunks, which leave the liver at the transverse fissure, and by their union form the hepatic duct.

Structure.—The coats of the smallest biliary ducts, which lie in the interlobular spaces, are a connective-tissue coat, in which are muscle-cells, arranged both circularly and longitudinally, and an epithelial layer, consisting of short columnar cells. In the larger ducts, which lie in the portal canals, there are a number of orifices disposed in two longitudinal rows, which were formerly regarded as the openings of mucous glands, but which are merely the orifices of tubular recesses. They occasionally anastomose, and from the sides of them saccular dilatations are given off.

Lymphatics of the Liver.—The lymphatics in the substance of the liver commence in lymphatic spaces around the capillaries of the lobules; they accompany the vessels of the interlobular plexus, often enclosing and surrounding them. These unite and form larger vessels, which run in the portal canals, enclosed in Glisson's capsule, and emerge at the portal fissure to be distributed in the manner described. Other superficial lymphatics form a close plexus, under the peritoneum, where this membrane covers the liver, and pass in various directions through the ligaments of the liver (page 634).

Nerves of the Liver.—The nerves of the liver derived from the pneumogastric and sympathetic enter the liver at the transverse fissure and accompany the vessels and ducts to the interlobular spaces. Here, according to Korolkow, the medullated fibres are distributed almost exclusively to the coats of the blood-vessels; while the non-medullated enter the lobules and ramify between the cells.

The Excretory Apparatus of the Liver.

The excretory apparatus of the liver consists of (1) the *hepatic duct*, which, as we have seen, is formed by the junction of the two main ducts, which pass out of the liver at the transverse fissure, and are formed by the union of the bile-capil-

laries; (2) the *gall-bladder*, which serves as a reservoir for the bile; (3) the *cystic duct*, which is the duct of the gall-bladder; and (4) the *common bile-duct*, formed by the junction of the hepatic and cystic ducts.

The Hepatic Duct.—Two main trunks of nearly equal size issue from the liver at the transverse fissure, one from the right, the other from the left lobe; these unite to form the hepatic duct, which then passes downward and to the right for about an inch and a half, between the layers of the lesser omentum, where it is joined at an acute angle by the cystic duct, and so forms the ductus communis choledochus. The hepatic duct, as it descends from the transverse fissure of the liver, between the two layers of the lesser omentum, lies in company with the hepatic artery and portal vein.

The **Gall-bladder** is the reservoir for the bile; it is a conical or pear-shaped musculo-membranous sac, lodged in a fossa on the under surface of the right lobe of the liver, and extending from near the right extremity of the transverse fissure to the anterior border of the organ. It is about four inches in length, one inch in breadth at its widest part, and holds from eight to ten drachms. It is divided into a fundus, body, and neck. The *fundus*, or broad extremity, is directed downward, forward, and to the right, and projects beyond the anterior border of the liver; the *body* and *neck* are directed upward and backward to the left. The upper surface of the gall-bladder is attached to the liver by connective tissue and vessels. The under surface is covered by peritoneum, which is reflected on to it from the surface of the liver. Occasionally the whole of the organ is invested by the serous membrane, and is then connected to the liver by a kind of mesentery.

Relations.—The *body of the gall-bladder* is in relation, by its upper surface, with the liver, to which it is connected by areolar tissue and vessels; by its under surface, with the commencement of the transverse colon; and further back, with the upper end of the descending portion of the duodenum or sometimes with the pyloric end of the stomach or first portion of the duodenum. The *fundus* is completely invested by peritoneum; it is in relation, in front, with the abdominal parietes, immediately below the ninth costal cartilage; behind with the transverse arch of the colon. The *neck* is narrow, and curves upon itself like the letter S; at its point of connection with the cystic duct it presents a well-marked constriction.

When the gall-bladder is distended with bile or calculi, the fundus may be felt through the abdominal parietes, especially in an emaciated subject: the relations of this sac will also serve to explain the occasional occurrence of abdominal biliary fistulæ, through which biliary calculi may pass out, and of the passage of calculi from the gall-bladder into the stomach, duodenum, or colon, which occasionally happens.

Structure.—The gall-bladder consists of three coats—serous, fibrous and muscular, and mucous.

The *external* or *serous coat* is derived from the peritoneum; it completely invests the fundus, but covers the body and neck only on their under surface.

The *fibro-muscular coat* is a thin but strong layer which forms the framework of the sac, consisting of dense fibrous tissue which interlaces in all directions and is mixed with plain muscular fibres which are disposed chiefly in a longitudinal direction, a few running transversely.

The *internal* or *mucous coat* is loosely connected with the fibrous layer. It is generally tinged with a yellowish-brown color, and is everywhere elevated into minute rugæ, by the union of which numerous meshes are formed; the depressed intervening spaces having a polygonal outline. The meshes are smaller at the fundus and neck, being most developed about the centre of the sac. Opposite the neck of the gall-bladder the mucous membrane projects inward in the form of oblique ridges or folds, forming a sort of screw-like valve.

The mucous membrane is covered with columnar epithelium, and secretes an abundance of thick viscid mucus; it is continuous through the hepatic duct with the mucous membrane lining the ducts of the liver, and through the ductus communis choledochus with the mucous membrane of the alimentary canal.



The **Cystic Duct,** the smallest of the three biliary ducts, is about an inch and a half in length. It passes obliquely downward and to the left from the neck of the gall-bladder, and joins the hepatic duct to form the common bile-duct. It lies in the gastro-hepatic omentum in front of the vena portæ, the hepatic artery lying to its left side. The mucous membrane lining its interior is thrown into a series of crescentic folds, from five to twelve in number, similar to those found in the neck of the gall-bladder. They project into the duct in regular succession, and are directed obliquely round the tube, presenting much the appearance of a continuous spiral valve. When the duct is distended, the spaces between the folds are dilated, so as to give to its exterior a sacculated appearance.

The **Ductus Communis Choledochus,** or *common bile-duct*, the largest of the three, is the common excretory duct of the liver and gall-bladder. It is about three inches in length, of the diameter of a goose-quill, and formed by the junction of the cystic and hepatic ducts.

It descends along the right border of the lesser omentum behind the first portion of the duodenum, in front of the vena portæ, and to the right of the hepatic artery; it then passes between the pancreas and descending portion of the duodenum, and running for a short distance along the right side of the pancreatic duct, near its termination, passes with it obliquely between the mucous and muscular coats. The two ducts open by a common orifice upon the summit of a papilla, situated at the inner side of the descending portion of the duodenum, a little below its middle and about three or four inches below the pylorus.

Structure.—The coats of the large biliary ducts are an external or fibrous, and an internal or mucous. The fibrous coat is composed of strong fibro-areolar tissue, with a certain amount of muscular tissue arranged, for the most part, in a circular manner around the duct. The mucous coat is continuous with the lining membrane of the hepatic ducts and gall-bladder, and also with that of the duodenum; and, like the mucous membrane of these structures, its epithelium is of the columnar variety. It is provided with numerous mucous glands, which are lobulated and open by minute orifices scattered irregularly in the larger ducts. The coats of the smallest biliary ducts, which lie in the interlobular spaces, are a connective-tissue coat, in which, according to Heidenhain, are muscle-cells arranged both circularly and longitudinally, and an epithelial layer, consisting of short columnar cells.

Surface Relations.—The liver is situated in the right hypochondriac and the epigastric regions, and is moulded to the arch of the Diaphragm. In the greater part of its extent it lies under cover of the lower ribs and their cartilages, but in the epigastric region it comes in contact with the abdominal wall, in the subcostal angle. The *upper limit of the right lobe of the liver* may be defined in the middle line by the junction of the mesosternum with the ensiform cartilage; on the right side the line must be carried upward as far as the fifth rib cartilage in the line of the nipple and then downward to reach the seventh rib at the side of the chest. The *upper limit of the left lobe* may be defined by continuing this line to the left with an inclination downward to a point about two inches to the left of the sternum on a level with the sixth left costal cartilage. The *lower limit of the liver* may be indicated by a line drawn half an inch below the lower border of the thorax on the right side as far as the ninth right costal cartilage, and thence obliquely upward across the subcostal angle to the eighth left costal cartilage. A slight curved line with its convexity to the left from this point—*i. e.*, the eighth left costal cartilage—to the termination of the line indicating the upper limit will denote the left margin of the liver. The fundus of the gall-bladder approaches the surface behind the anterior extremity of the ninth costal cartilage, close to the outer margin of the Right rectus muscle.

It must be remembered that the liver is subject to considerable alterations in position, and the student should make himself acquainted with the different circumstances under which this occurs, as they are of importance in determining the existence of enlargement or other diseases of the organ.

Its position varies according to the posture of the body. In the erect position in the adult male the edge of the liver projects about half an inch below the lower edge of the right costal cartilages, and its anterior border can be often felt in this situation if the abdominal wall is thin. In the supine position the liver gravitates backward and recedes above the lower margin of the ribs, and cannot then be detected by the finger. In the prone position it falls forward, and can then generally be felt in a patient with loose and lax abdominal walls. Its position varies also with the ascent or descent of the Diaphragm. In a deep inspiration the liver descends below the ribs; in expiration it is raised behind them. Again, in emphysema, where the lungs are

distended and the Diaphragm descends very low, the liver is pushed down; in some other diseases, as phthisis, where the Diaphragm is much arched, the liver rises very high up. Pressure from without, as in tight-lacing, by compressing the lower part of the chest, displaces the liver considerably, its anterior edge often extending as low as the crest of the ileum; and its convex surface is often at the same time deeply indented from the pressure of the ribs. Again, its position varies greatly according to the greater or less distension of the stomach and intestines. When the intestines are empty the liver descends in the abdomen, but when they are distended it is pushed upward. Its relations to surrounding organs may also be changed by the growth of tumors or by collections of fluid in the thoracic or abdominal cavities.

Surgical Anatomy.—On account of its large size, its fixed position, and its friability, the liver is more frequently ruptured than any of the abdominal viscera. The rupture may vary considerably in extent, from a slight scratch to an extensive laceration completely through its substance, dividing it into two parts. Sometimes an internal rupture without laceration of the peritoneal covering takes place, and such injuries are most susceptible of repair; but small tears of the surface may also heal; when, however, the laceration is extensive, death usually takes place from hæmorrhage, on account of the fact that the hepatic veins are contained in rigid canals in the liver-substance and are unable to contract, and are moreover unprovided with valves. The liver may also be torn by the end of a broken rib perforating the Diaphragm. The liver may be injured by stabs or other punctured wounds, and when these are inflicted through the chest-wall both pleural and peritoneal cavities may be opened up and both lung and liver be wounded. In cases of wound of the liver from the front, hernia of a part of this viscus may take place, but can generally easily be replaced. In cases of laceration of the liver, when there is evidence that bleeding is going on, the abdomen must be opened, the laceration sought for, and the bleeding arrested. This may be done temporarily by introducing the forefinger into the foramen of Winslow and placing the thumb on the gastro-hepatic omentum and compressing the hepatic artery and portal vein between the two. Any bleeding points can then be seen and tied and the margins of the laceration, if small, brought together and sutured by means of a blunt curved needle passed from one side of the wound to the other. All sutures must be passed before any are tied, and this must be done with the greatest gentleness, as the liver substance is very friable. When the laceration is extensive it must be packed with iodoform gauze, the end of which is allowed to hang out of the external wound. Abscess of the liver is of not infrequent occurrence, and may open in many different ways on account of the relations of this viscus to other organs. Thus it has been known to burst into the lungs and the pus coughed up, or into the stomach and the pus vomited; it may burst into the colon, or into the duodenum; or, by perforating the diaphragm, it may empty itself into the pleural cavity. Frequently it makes its way forward, and points on the anterior abdominal wall, and finally it may burst into the peritoneal or pericardiac cavities. Abscesses of the liver frequently require opening, and this must be done by an incision in the abdominal wall, in the thoracic wall, or in the lumbar region, according to the direction in which the abscess is tracking. The incision through the abdominal wall is to be preferred when possible. The abdominal wall is incised over the swelling, and unless the peritoneum is adherent, sponges are packed all around the exposed liver surface and the abscess opened, if deeply seated preferably by the thermo-cautery. Hydatid cysts are more often found in the liver than in any other of the viscera. The reason of this is not far to seek. The embryo of the egg of the tænia echinococcus being liberated in the stomach by the disintegration of its shell, bores its way through the gastric walls and usually enters a blood-vessel, and is carried by the blood-stream to the hepatic capillaries, where its onward course is arrested, and where it undergoes development into the fully formed hydatid. Tumors of the liver have recently been subjected to surgical treatment by removal of a portion of the organ. The abdomen is opened and the diseased portion of liver exposed; the circulation is controlled by compressing the portal vein and the hepatic artery in the gastro-hepatic omentum and a wedge-shaped portion of liver containing the tumor removed; the divided vessels are ligated and the cut surfaces brought together and sutured in the manner directed above.

When the *gall-bladder* or one of its main ducts is ruptured, which may occur independently of laceration of the liver, death usually occurs from peritonitis. If the symptoms have led to the performance of a laparotomy and a rent is found, it should be sutured if small, or the gall-bladder removed if it is extensive. If the cystic duct is torn, its intestinal end must be closed and the gall-bladder removed. In rupture of either of the other ducts, the only thing which can be done is to provide for free drainage, in the hope that a biliary fistula may form.

The gall-bladder may become distended with bile in cases of obstruction of its duct or the common bile-duct, or from a collection of gall-stones within its interior, thus forming a large tumor. The swelling is pear-shaped, and projects downward and forward to the umbilicus. It moves with respiration, since it is attached to the liver. To relieve this condition the gall-bladder must be opened and the gall-stones removed. The operation is performed by an incision two or three inches long in the right semilunar line, commencing at the costal margin. The peritoneal cavity is opened, and, the tumor having been found, sponges are packed round it to protect the peritoneal cavity, and it is aspirated. When the contained fluid has been evacuated the flaccid bladder is drawn out of the abdominal wound and its wall incised to the extent of an inch; any gall-stones in the bladder are now removed and the interior of the sac sponged dry. If the case is one of obstruction of the duct, an attempt must be made to dislodge the stone by manipulation through the wall of the duct; or it may be crushed from without by the fingers or carefully

padded forceps. If this does not succeed, the safest plan is to incise the duct, extract the stone, and close the incision by fine sutures in two layers. After all obstruction has been removed, four courses are open to the surgeon: 1. The wound in the gall-bladder may be at once sewn up, the organ returned into the abdominal cavity, and the external incision closed. 2. The edges of the incision in the gall-bladder may be sutured to the external wound, and a fistulous communication established between the gall-bladder and the exterior; this fistulous opening usually closes in the course of a few weeks. 3. The gall-bladder may be connected with the intestinal canal, preferably the duodenum, by means of a lateral anastomosis; this is known as cholecystenterostomy. 4. The gall-bladder may be completely removed.

THE PANCREAS.

Dissection.—The pancreas may be exposed for dissection in three different ways: 1. By raising the liver, drawing down the stomach, and tearing through the gastro-hepatic omentum and the ascending layer of the transverse mesocolon. 2. By raising the stomach, the arch of the colon, and great omentum, and then dividing the inferior layer of the transverse mesocolon and raising its ascending layer. 3. By dividing the two layers of peritoneum, which descend from the great curvature of the stomach to form the great omentum; turning the stomach upward, and then cutting through the ascending layer of the transverse mesocolon (see Fig. 488, page 900).

The **Pancreas** (*παν-κρέας, all flesh*) is a compound racemose gland, analogous in its structure to the salivary glands, though softer and less compactly arranged than those organs. It is long and irregularly prismatic in shape, and has been compared to a human or a dog's tongue: its right extremity being broad, is called the *head*—this is connected to the main portion of the organ, the *body*, by a slight constriction, the *neck;* while its left extremity gradually tapers to form the *tail.* It is situated

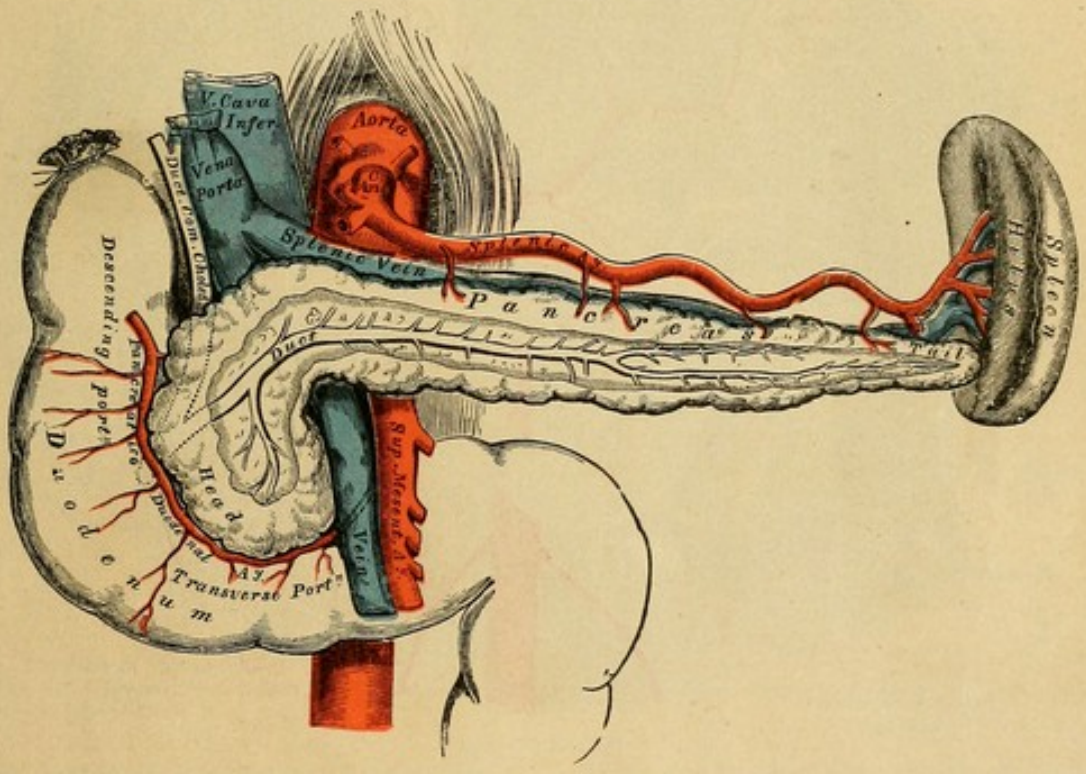

FIG. 519.—The pancreas and its relations.

transversely across the posterior wall of the abdomen at the back of the epigastric and left hypochondriac regions. Its length ... the s... om five ... breadth is an inch and a half, and its thickr ... creas, called the **pancreatic duct** or **canal** greater at its right extremity and along i ... ransversely from left to right through the two to three and a half ounces, but it m ... o expose it, the superficial portion of the

The *right extremity* or *head of the* ... es by the junction of the small ducts of the of a hammer, being elongated both a ... creas, and, running from right to left through backward, and conforms to the whole ... ducts of the various lobules composing the overlapped by it. The anterior sun ... *d Physiolgy*, vol. xxxi. pt. 1, p. 102.

superior mesenteric vessels, and at its lower end it is crossed by the transverse colon and its mesocolon. Behind, the head of the pancreas is in relation with the inferior vena cava, the left renal vein, the right crus of the Diaphragm, and the aorta. The common bile-duct descends behind, between the duodenum and pancreas; and the pancreatico-duodenal artery descends in front between the same parts.

The *neck of the pancreas* is about an inch long, and passes upward and forward to the left, having the first part of the duodenum above it, and the termination of the fourth portion below. It lies in front of the commencement of the vena portæ, and is grooved on the right by the gastro-duodenal and superior pancreatico-duodenal arteries. The pylorus lies just above it.

The *body and tail of the pancreas* are somewhat prismatic in shape, and have three surfaces: anterior, posterior, and inferior.

The *anterior surface* is somewhat concave, and is covered by the posterior surface of the stomach which rests upon it, the two organs being separated by the lesser sac of the peritoneum. At its right extremity there is a well-marked prominence, called by His the *omental tuberosity*.

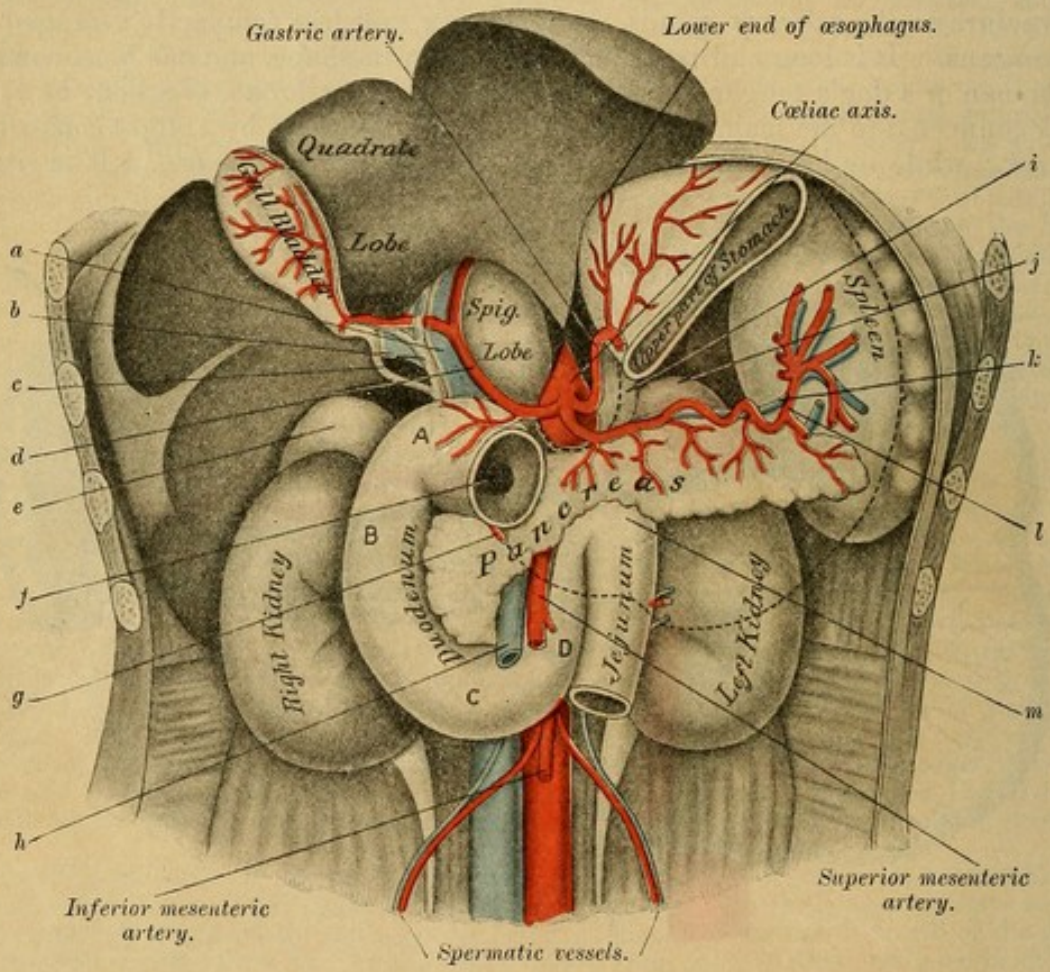

FIG. 520.—The duodenum and pancreas. The liver has been lifted up and the greater part of the stomach removed. (Testut.) *a*, Portal vein; *b*, Hepatic duct; *c*, Cystic duct; *d*, Hepatic artery; *e*, Right suprarenal capsule; *f*, Pyloric orifice; *g*, Right gastro-epiploic artery; *h*, Superior mesenteric vein; *i*, Left crus of diaphragm; *j*, Left suprarenal capsule; *k*, Splenic vein; *l*, Splenic artery; *m*, Duodeno-jejunal junction; A, B, C, D, The four portions of the duodenum.

tumor. The swelling is p ped, and pi
moves with respiration, since it is attached to th from the vertebral column by the aorta, the
must be opened and the gall-stones removed. T sels, the left suprarenal capsule, the pillars
three inches long in the right semilunar line, comi superior mesenteric artery.
cavity is opened, and, the tumor having been found
peritoneal cavity, and it is aspirated. When the cos upon the duodeno-jejunal flexure and
bladder is drawn out of the abdominal wound and its mity rests on the splenic flexure of the
gall-stones in the bladder are now removed and the in
is one of obstruction of the duct, an attempt must be
through the wall of the duct; or it may be crushed and flat to the right; narrow and sharp

to the left, near the tail. It commences to the right in the omental tuberosity, and is in relation with the cœliac axis, from which the hepatic artery courses to the right just above the gland, while the splenic branch runs in a groove along this border to the left.

The *anterior border* is the position where the two layers of the transverse mesocolon separate: the one passing upward in front of the anterior surface, the other backward below the inferior surface.

The *lesser end* or *tail of the pancreas* is narrow; it extends to the left as far as the lower part of the inner aspect of the spleen.

Birmingham describes the body of the pancreas as projecting forward as a prominent ridge into the abdominal cavity and forming a sort of shelf on which the stomach lies. He says: "The portion of the pancreas to the left of the middle line has a very considerable antero-posterior thickness; as a result the anterior surface is of considerable extent, it looks strongly upward, and forms a large and important part of the shelf. As the pancreas extends to the left toward the spleen it crosses the upper part of the kidney, and is so moulded on to it that the top of the kidney forms an extension inward and backward of the upper surface of the pancreas and extends the bed in this direction. On the other hand, the extremity of the pan-

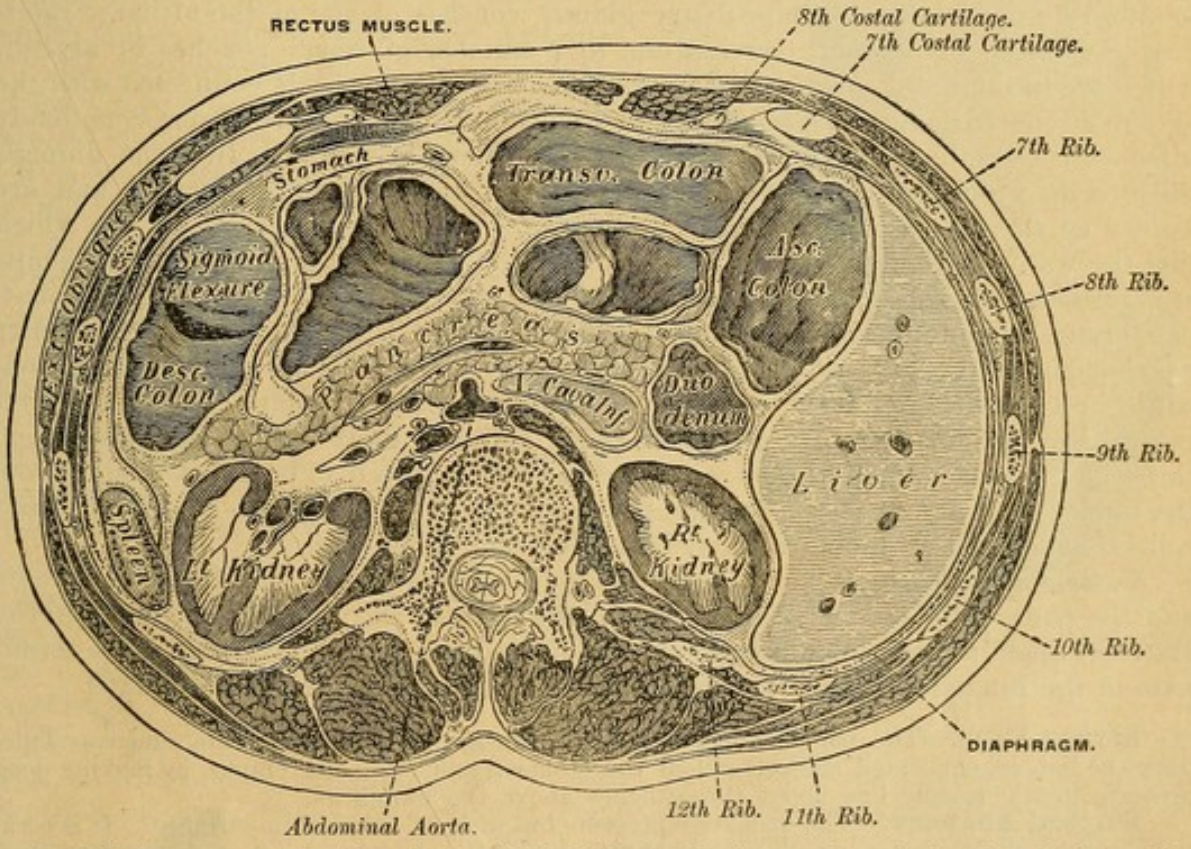

FIG. 521.—Transverse section through the middle of the first lumbar vertebra, showing the relations of the pancreas. (Braune.)

creas comes in contact with the spleen in such a way that the plane of its upper surface runs with little interruption upward and backward into the concave gastric surface of the spleen, which completes the bed behind and to the left, and running upward, forms a partial cap for the wide end of the stomach"[1] (see Fig. 496).

The principal excretory duct of the pancreas, called the **pancreatic duct** or **canal of Wirsung,** from its discoverer, extends transversely from left to right through the substance of the pancreas. In order to expose it, the superficial portion of the gland must be removed. It commences by the junction of the small ducts of the lobules situated in the tail of the pancreas, and, running from right to left through the body, it constantly receives the ducts of the various lobules composing the

[1] *Journal of Anatomy and Physiolgy,* vol. xxxi. pt. 1, p. 102.

gland. Considerably augmented in size, it reaches the neck, and turning obliquely downward, backward, and to the right, it comes into relation with the common bile-duct, lying to its left side; leaving the head of the gland, it passes very obliquely through the mucous and muscular coats of the duodenum, and terminates by an orifice common to it and the ductus communis choledochus upon the summit of an elevated papilla, situated at the inner side of the descending portion of the duodenum, three or four inches below the pylorus.

Sometimes the pancreatic duct and ductus communis choledochus open separately into the duodenum. Occasionally there is an accessory duct, which is given off from the canal of Wirsung in the neck of the pancreas and passes horizontally to the right to open into the duodenum about an inch above the orifice of the main duct. This is known as the *ductus pancreaticus accessorius* or *ductus Santorini.*

The pancreatic duct, near the duodenum, is about the size of an ordinary quill: its walls are thin, consisting of two coats, an external fibrous and an internal mucous; the latter is smooth, and furnished near its termination with a few scattered follicles.

In **structure**, the pancreas resembles the salivary glands. It differs from them, however, in certain particulars, and is looser and softer in its texture. It is not enclosed in a distinct capsule, but is surrounded by areolar tissue, which dips into its interior, and connects together the various lobules of which it is composed. Each lobule, like the lobules of the salivary glands, consists of one of the ultimate ramifications of the main duct, terminating in a number of cæcal pouches or alveoli, which are tubular and somewhat convoluted. The minute ducts connected with the alveoli are narrow and lined with flattened cells. The alveoli are almost completely filled with secreting cells, so that scarcely any lumen is visible. In some animals those cells which occupy the centre of the alveolus are spindle-shaped, and are known as the *centro-acinar cells of Langerhans.* The true secreting cells which line the wall of the alveolus are very characteristic. They are columnar in shape and present two zones: an outer one clear and finely striated next the basement-membrane, and an inner granular one next the lumen. During activity the granular zone occupies the greater part of the cell: before the cells are called into action, while in a condition of rest, the outer or clear zone is the larger. In some secreting cells of the pancreas is a spherical mass, staining more easily than the rest of the cells; this is termed the *paranucleus*, and is believed to be an extension from the nucleus. The connective tissue between the alveoli presents in certain parts collections of cells, which are termed *inter-alveolar cell-islets.*

Vessels and Nerves.—The *arteries of the pancreas* are derived from the splenic and the pancreatico-duodenal branches of the hepatic and the superior mesenteric. Its *veins* open into the splenic and superior mesenteric veins. Its *lymphatics* terminate in the lumbar glands. Its *nerves* are filaments from the splenic plexus.

Surface Form.—The pancreas lies in front of the second lumbar vertebra, and can sometimes be felt, in emaciated subjects, when the stomach and colon are empty, by making deep pressure in the middle line about three inches above the umbilicus.

Surgical Anatomy.—The pancreas presents but little of surgical importance. It is occasionally the seat of cancer, which usually affects the head or duodenal end, and therefore often speedily involves the common bile-duct, leading to persistent jaundice. Cysts are also occasionally found in it, which may present in the epigastric region, above and to the right of the umbilicus, and may require opening and drainage. The fluid in them contains some of the elements of the pancreatic secretion and is very irritating, so that, if allowed to come in contact with the skin of the abdominal wall, it is likely to produce intractable eczema. It has been said that the pancreas is the only abdominal viscus which has never been found in a hernial protrusion; but even this organ has been found, in company with other viscera, in rare cases of diaphragmatic hernia. The pancreas has been known to become invaginated into the intestine, and portions of the organ have sloughed off. In cases of excision of the pylorus great care must be exercised to avoid wounding the pancreas, as the escape of the pancreatic fluid may be attended with serious results. According to Billroth, it is likely, in consequence of its peptonizing qualities, to dissolve the cicatrix of the stomach.

THE SPLEEN.

The **Spleen** belongs to that class of bodies which are known as *ductless glands.* It is probably related to the blood-vascular system, but in consequence of its anatomical relationship to the stomach and its physiological relationship to the liver it is convenient to describe it in this place. It is situated principally in the left hypochondriac region, its upper and inner extremity extending into the epigastric region; lying between the fundus of the stomach and the Diaphragm. It is the largest of the ductless glands, and measures some five or six inches in length. It is of an oblong, flattened form, soft, of very brittle consistence, highly vascular, and of a dark purplish color.

Surfaces.—The *external* or *phrenic surface* is convex, smooth, and is directed upward, backward, and to the left, except at its upper end, where it is directed slightly inward. It is in relation with the under surface of the Diaphragm, which separates it from the eighth, ninth, tenth, and eleventh ribs of the left side, and in part from the lower border of the left lung and pleura.

The *internal surface* is concave, and divided by a ridge into an anterior or larger, and a posterior or smaller portion.

The *anterior portion* of the internal surface or *gastric surface*, which is directed forward and inward, is broad and concave, and is in contact with the posterior wall of the great end of the stomach; and below this with the tail of the pancreas. It presents near its inner border a long fissure, termed the *hilum*. This is pierced by several irregular apertures, for the entrance and exit of vessels and nerves.

The *posterior portion* of the internal surface or *renal surface* is directed inward and downward. It is somewhat flattened, does not reach as high as the gastric surface, is considerably narrower than the latter, and is in relation with the upper part of the outer surface of the left kidney and occasionally with the left suprarenal capsule.

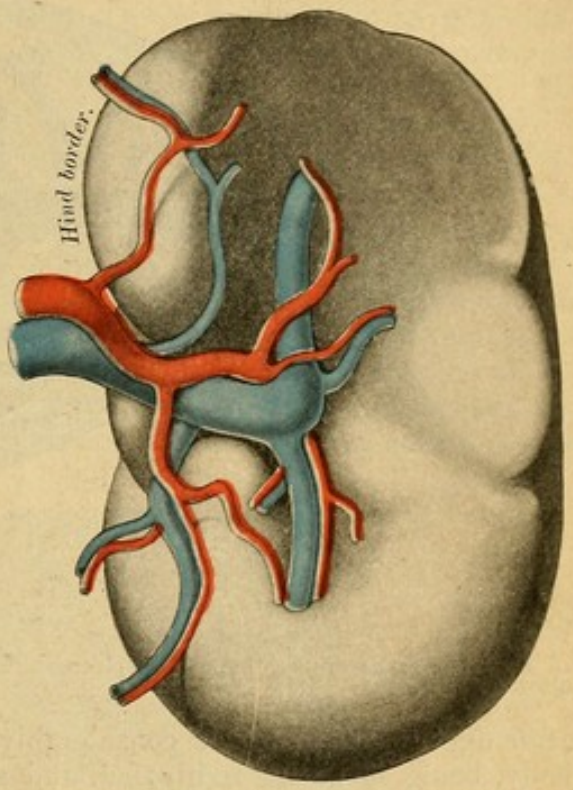

FIG. 522.—The spleen, showing its gastric and renal surfaces. (Testut.)

The *upper end* is directed inward, toward the vertebral column, where it lies on a level with the eleventh dorsal vertebra. The *lower end*, sometimes termed the *basal surface*, is flat, triangular in shape, and rests upon the splenic flexure of the colon and the phreno-colic ligament, and is generally in contact with the tail of the pancreas. The *anterior* border is free, sharp, and thin, and is often notched, especially below. It separates the phrenic from the gastric surface. The *posterior* border is more rounded and blunter than the anterior. It separates the renal portion of the internal surface from the phrenic surface. It corresponds to the lower border of the eleventh rib and lies between the Diaphragm and left kidney. The *internal* border is the name sometimes given to the ridge which separates the renal and gastric portions of the internal surface.

The spleen is almost entirely surrounded by peritoneum, which is firmly adherent to its capsule, and is held in position by two folds of this membrane: one, the *lieno-renal ligament*, is derived from the layers of peritoneum forming the greater and lesser sacs, where they come into contact between the left kidney and the spleen. Between its two layers the splenic vessels pass (Fig. 489); the second, the *gastro-splenic omentum*, also formed of two layers, derived from the greater

and lesser sacs, respectively, where they meet between the spleen and stomach (Fig. 489). Between these two layers run the vasa brevia of the splenic artery and vein. It is also supported by the phreno-colic ligament, upon which its lower end rests (see page 902).

The size and weight of the spleen are liable to very extreme variations at different periods of life, in different individuals, and in the same individual under different conditions. *In the adult*, in whom it attains its greatest size, it is usually about five inches in length, three inches in breadth, and an inch or an inch and a half in thickness, and weighs about seven ounces. *At birth*, its weight, in proportion to the entire body, is almost equal to what is observed in the adult, being as 1 to 350: while in the adult it varies from 1 to 320 and 400. *In old age*, the organ not only decreases in weight, but decreases considerably in proportion to the entire body, being as 1 to 700. The size of the spleen is increased during and

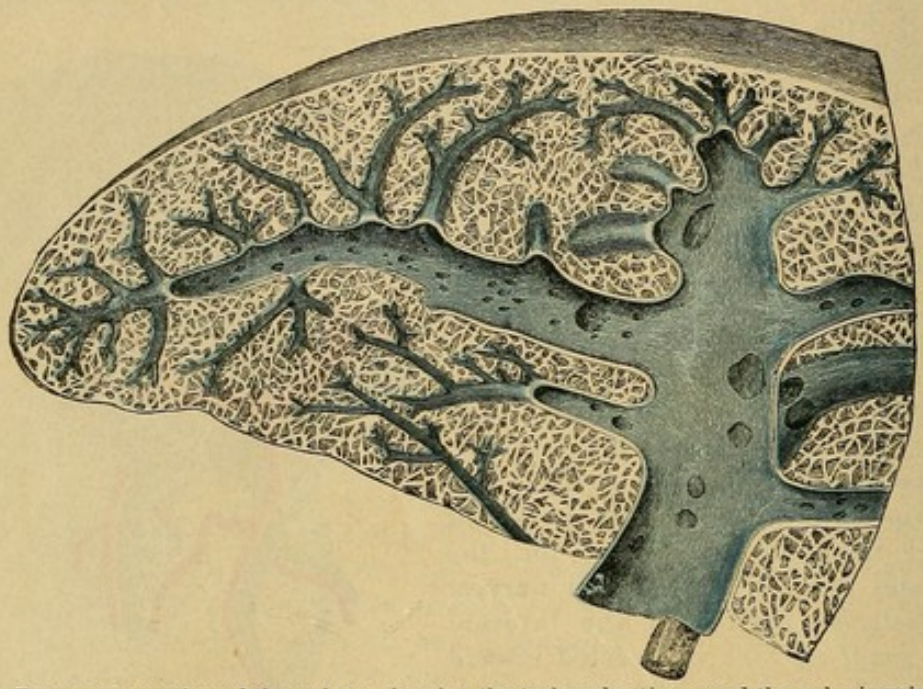

FIG. 523.—Transverse section of the spleen, showing the trabecular tissue and the splenic vein and its trfbutaries.

after digestion, and varies considerably according to the state of nutrition of the body, being large in highly fed, and small in starved animals. In intermittent and other fevers it becomes much enlarged, weighing occasionally from 18 to 20 pounds.

Frequently in the neighborhood of the spleen, and especially in the gastro-splenic and great omenta, small nodules of splenic tissue may be found, either isolated or connected to the spleen by thin bands of splenic tissue. They are known as *supernumerary* or *accessory spleens*. They vary in size from that of a pea to that of a plum.

Structure.—The spleen is invested by two coats—an external serous, and an internal fibro-elastic coat.

The *external* or *serous coat* is derived from the peritoneum; it is thin, smooth, and in the human subject intimately adherent to the fibro-elastic coat. It invests the entire organ, except at the places of its reflection on to the stomach and Diaphragm and at the hilum.

The *fibro-elastic coat* forms the framework of the spleen. It invests the organ, and at the hilum is reflected inward upon the vessels in the form of sheaths. From these sheaths, as well as from the inner surface of the fibro-elastic coat, numerous small fibrous bands, *trabeculæ* (Fig. 524), are given off in all directions; these uniting, constitute the framework of the spleen. This resembles a sponge-like material, consisting of a number of small spaces or *areolæ* formed by the trabeculæ, which are given off from the inner surface of the capsule, or from the

sheaths prolonged inward on the blood-vessels. In these spaces or areolæ is contained the *splenic pulp*.

The proper coat, the sheaths of the vessels and the trabeculæ, consist of a dense mesh of white and yellow elastic fibrous tissues, the latter considerably predominating. It is owing to the presence of this tissue that the spleen possesses a considerable amount of elasticity, which allows of the very great variations in size that it presents under certain circumstances. In addition to these constituents of this tunic, there is found in man a small amount of non-striped muscular fibre, and in some mammalia (*e. g.* dog, pig, and cat) a very considerable amount, so that the trabeculæ appear to consist chiefly of muscular tissue. It is probably owing to this structure that the spleen exhibits, when acted upon by the galvanic current, faint traces of contractility.

The *proper substance of the spleen* or *spleen-pulp* is a soft mass of a dark reddish-brown color, resembling grumous blood. When examined, by means of a thin section, under a microscope, it is found to consist of a number of branching cells and an intercellular substance. The cells are connective-tissue corpuscles, and have been named the *sustentacular* or *supporting cells of the pulp*. The processes of these branching cells communicate with each other, thus forming a delicate reticulated tissue in the interior of the areolæ formed by the trabeculæ of the capsule; so that each primary space may be considered to be divided into a number of smaller spaces by the junction of these processes of the branching corpuscles. These secondary spaces contain blood, in which, however, the white corpuscles are found to be in larger proportions than they are in ordinary blood. The sustentacular cells are either small uni-nucleated or larger multi-nucleated cells; they do not become deeply stained with carmine, like the cells of the Malpighian bodies, presently to be described (W. Müller), but like them they possess amœboid movements (Cohnheim). In many of them may be seen deep red

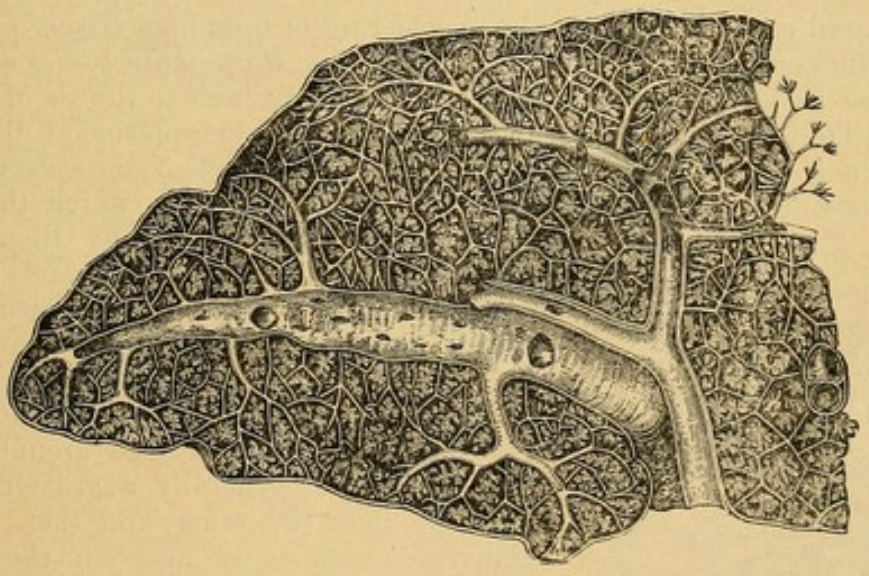

FIG. 524.—Transverse section of the human spleen, showing the distribution of the splenic artery and its branches.

or reddish-yellow granules of various sizes which present the characters of the hæmatin of the blood. Sometimes, also, unchanged blood-disks are seen included in these cells, but more frequently blood-disks are found which are altered both in form and color. In fact, blood-corpuscles in all stages of disintegration may be noticed to occur within them. Klein has recently pointed out that sometimes these cells in the young spleen contain a proliferating nucleus; that is to say, the nucleus is of large size, and presents a number of knob-like projections, as if small nuclei were budding from it by a process of gemmation. This observation is of importance, as it may explain one possible source of the colorless blood-corpuscles.

The interspaces or areolæ formed by the framework of the spleen are thus filled

by a delicate reticulum of branched connective-tissue corpuscles the interstices of which are occupied by blood, and in which the blood-vessels terminate in the manner now to be described.

Blood-vessels of the Spleen.—The splenic artery is remarkable for its large size in proportion to the size of the organ, and also for its tortuous course. It divides into six or more branches, which enter the hilum of the spleen and ramify throughout its substance (Fig. 524), receiving sheaths from the involution of the external fibrous tissue. Similar sheaths also invest the nerves and veins.

Each branch runs in the transverse axis of the organ from within outward, diminishing in size during its transit, and giving off in its passage smaller branches, some of which pass to the anterior, others to the posterior part. These ultimately leave the trabecular sheaths, and terminate in the proper substance of the spleen in small tufts or pencils of minute arterioles, which open into the interstices of the reticulum formed by the branched sustentacular cells. Each of the larger branches of the artery supplies chiefly that region of the organ in which the branch ramifies, having no anastomosis with the majority of the other branches.

The *arterioles*, supported by the minute trabeculæ, traverse the pulp in all directions in bundles or penicilli of straight vessels. Their external coat, on leaving the trabecular sheaths, consists of ordinary connective tissue, but it gradually undergoes a transformation, becomes much thickened, and is converted into a lymphoid material.[1] This change is effected by the conversion of the connective tissue into a lymphoid tissue, the bundles of connective tissue becoming looser and laxer, their fibrils more delicate, and containing in their interstices an abundance of lymph-corpuscles (W. Müller). This lymphoid material is supplied with blood by minute vessels derived from the artery with which they are in contact, and which terminates by breaking up into a network of capillary vessels.

The altered coat of the arterioles, consisting of lymphoid tissue, presents here and there thickenings of a spheroidal shape, the *Malpighian bodies of the spleen*. These bodies vary in size from about the $\frac{1}{100}$ of an inch to the $\frac{1}{25}$ of an inch in diameter. They are merely local expansions or hyperplasiæ of the lymphoid tissue of which the external coat of the smaller arteries of the spleen is formed. They are most frequently found surrounding the arteriole, which thus seems to tunnel them, but occasionally they grow from one side of the vessel only, and present the appearance of a sessile bud growing from the arterial wall. Klein, however, denies this, and says it is incorrect to describe the Malpighian bodies as isolated masses of adenoid tissue, but that they are always formed around an artery, though there is generally a greater amount on one side than the other, and that, therefore, in transverse sections the artery in the majority of cases is found in an eccentric position. These bodies are visible to the naked eye on the surface of a fresh section of the organ, appearing as minute dots of semi-opaque whitish color in the dark substance of the pulp. In minute structure they resemble the adenoid tissue of lymphatic glands, consisting of a delicate reticulum in the meshes of which lie ordinary lymphoid cells.

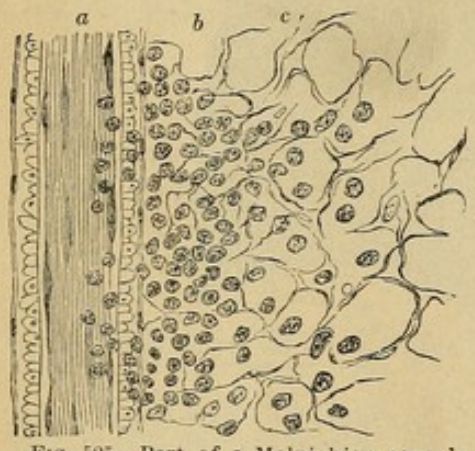

FIG. 525.—Part of a Malpighian capsule of the spleen of man. (Klein and Noble Smith.) *a*, Arterial branch in longitudinal section. *b*, Adenoid tissue, still containing the lymph-corpuscles; only their nuclei are shown. *c*, Adenoid reticulum, the lymph-corpuscles accidentally removed.

The reticulum of the tissue is made up of extremely delicate fibrils, and is comparatively open in the centre of the corpuscle, becoming closer at the periphery

[1] According to Klein, it is the sheath of the small vessel which undergoes this transformation, and forms a "solid mass of adenoid tissue which surrounds the vessel like a cylindrical sheath" (*Atlas of Histology*, p. 424).

of the body. The cells which it encloses, like the supporting cells of the pulp, are possessed of amœboid movements, but when treated with carmine become deeply stained, and can thus easily be recognized from those of the pulp.

The arterioles terminate in capillaries, which traverse the pulp in all directions;

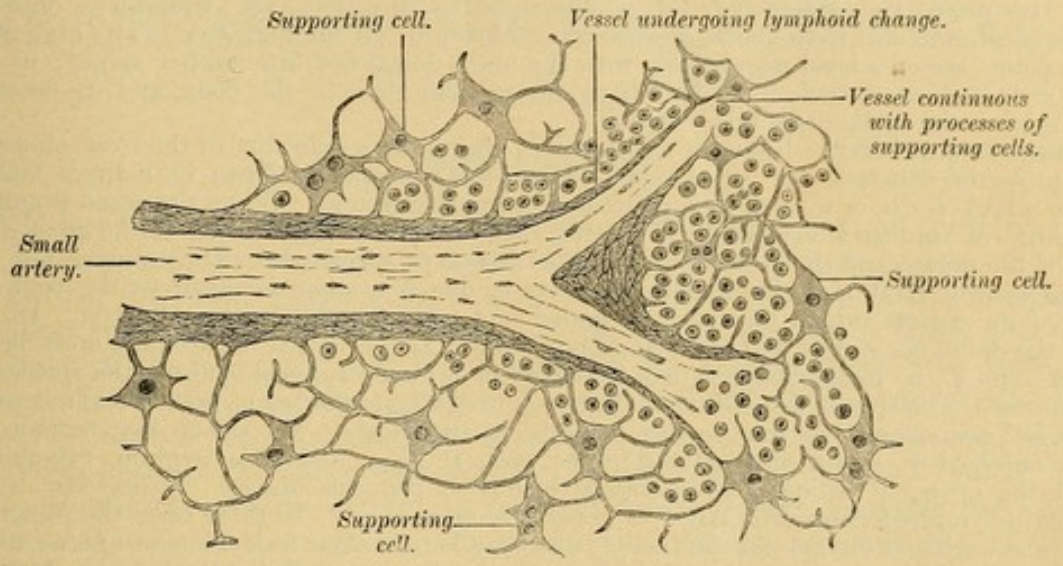

FIG. 526.—Section of spleen, showing the termination of the small blood-vessels.

their walls become much attenuated, lose their tubular character, and the cells of the lymphoid tissue of which they are composed become altered, presenting a branched appearance and acquiring processes which are directly connected with the processes of the sustentacular cells of the pulp (Fig. 526). In this manner the capillary vessels terminate, and the blood flowing through them finds its way into the interstices of the reticulated tissue formed by the branched connective-tissue corpuscles of the splenic pulp. Thus the blood passing through the spleen is brought into intimate relation with the elements of the pulp, and no doubt undergoes important changes.

After these changes have taken place the blood is collected from the interstices of the tissue by the rootlets of the veins, which commence much in the same way as the arteries terminate. Where a vein is about to commence the connective-tissue corpuscles of the pulp arrange themselves in rows in such a way as to form an elongated space or sinus. They become changed in shape, being elongated and spindle-shaped, and overlap each other at their extremities. They thus form a sort of endothelial lining of the path or sinus, which is the radicle of a vein. On the outer surface of these cells are seen delicate transverse lines or markings which are due to minute elastic fibrillæ arranged in a circular manner around the sinus. Thus the channel obtains a continuous external investment, and gradually becomes converted into a small vein, which after a time presents a coat of ordinary connective tissue, lined by a layer of fusiform epithelial cells which are continuous with the supporting cells of the pulp. The smaller veins unite to form larger ones which do not accompany the arteries, but soon enter the trabecular sheaths of the capsule, and by their junction form from six or more branches which emerge from the hilum and, uniting, form the splenic vein, the largest radicle of the vena porta.

The veins are remarkable for their numerous anastomoses, while the arteries hardly anastomose at all.

The lymphatics originate in two ways,—*i. e.*, from the sheaths of the arteries and in the trabeculæ. The former accompany the blood-vessels, the latter pass to the superficial lymphatic plexus, which may be seen on the surface of the organ. The two sets communicate in the interior of the organ. They pass through the lymphatic glands at the hilum, and terminate in the thoracic duct.

The *nerves* are derived from branches of the right and left semilunar ganglia, and from the right pneumogastric nerve.

Surface Form.—The spleen is situated under cover of the ribs of the left side, being separated from them by the Diaphragm, and above by a small portion of the lower margin of the left lung and pleura. Its position corresponds to the eighth, ninth, tenth, and eleventh ribs. It is placed very obliquely. "It is oblique in two directions, viz., from above downward and outward, and also from above downward and forward" (Cunningham). "Its highest and lowest points are on a level respectively with the ninth dorsal and first lumbar spines; its inner end is distant about an inch and a half from the median plane of the body, and its outer end about reaches the midaxillary line" (Quain).

Surgical Anatomy.—Injury of the spleen is less common than that of the liver, on account of its protected situation and connections. It may be ruptured by direct or indirect violence, torn by a broken rib, or injured by a punctured or gunshot wound. When the organ is enlarged the chance of rupture is increased. The great risk is hæmorrhage, owing to the great vascularity of the organ, and the absence of a proper system of capillaries. The injury is not, however, necessarily fatal, and this would appear to be due in a great measure to the contractile power of its capsule, which narrows the wound and prevents the escape of blood. In cases where the diagnosis is clear and the symptoms indicate danger to life laparotomy must be performed; and if the hæmorrhage cannot be stayed by ordinary surgical methods the spleen must be removed. The spleen may become displaced, producing great pain from stretching of the vessels and nerves, and this may require removal of the organ. The spleen may become enormously enlarged in certain diseased conditions, such as ague, leukæmia, syphilis, valvular disease of the heart, or without any obtainable history of previous disease. It may also become enlarged in lymphadenoma as a part of a general blood-disease. In these cases the tumor may fill the abdomen and extend into the pelvis, and may be mistaken for ovarian or uterine disease.

The spleen is sometimes the seat of cystic tumors, especially hydatids, and of abscess. These cases require treatment by incision and drainage; and in abscess great care must be taken if there are no adhesions between the spleen and abdominal cavity, to prevent the escape of any of the pus into the peritoneal cavity. If possible, the operation should be performed in two stages. Sarcoma and carcinoma are occasionally found in the spleen, but very rarely as a primary disease.

Extirpation of the spleen has been performed for wounds or injuries, in floating spleen, in simple hypertrophy, and in leukæmic enlargement: but in these latter cases the operation is now regarded as unjustifiable, as every case in which it has been performed has terminated fatally. The incision is best made in the left semilunar line: the spleen is isolated from its surroundings, and the pedicle transfixed and ligatured in two portions, before the tumor is turned out of the abdominal cavity, if this is possible, so as to avoid any traction on the pedicle, which may cause tearing of the splenic vein. In applying the ligature care must be taken not to include the tail of the pancreas, and in lifting out the organ to avoid rupturing the capsule.

THE ORGANS OF VOICE AND RESPIRATION.

THE LARYNX.

THE Larynx is the organ of voice, placed at the upper part of the air-passage. It is situated between the trachea and base of the tongue, at the upper and fore part of the neck, where it forms a considerable projection in the middle line. On either side of it lie the great vessels of the neck; behind, it forms part of the boundary of the pharynx, and is covered by the mucous membrane lining that cavity. Its vertical extent corresponds to the fourth, fifth, and sixth cervical vertebræ, but it is placed somewhat higher in the female and also during childhood. In infants between six and twelve months of age Symington found that the tip of the epiglottis was a little above the level of the cartilage, between the odontoid process and body of the axis, and that between infancy and adult life the larynx descends for a distance equal to two vertebral bodies and two intervertebral disks. According to Sappey, the average measurements of the adult larynx are as follows:

	In males.	In females.
Vertical diameter	44 mm.	36 mm.
Transverse diameter	43 "	41 "
Antero-posterior diameter . . .	36 "	26 "
Circumference	136 "	112 "

Until puberty there is no marked difference between the larynx of the male and that of the female. In the latter its further increase in size is only slight, whereas in the former it is great; all the cartilages are enlarged, and the thyroid becomes prominent as the *pomum Adami* in the middle line of the neck, while the length of the glottis is nearly doubled.

The larynx is broad above, where it presents the form of a triangular box, flattened behind and at the sides, and bounded in front by a prominent vertical ridge. Below, it is narrow and cylindrical. It is composed of cartilages, which are connected together by ligaments and moved by numerous muscles. It is lined by mucous membrane, which is continuous above with that lining the pharynx and below with that of the trachea.

The **Cartilages of the Larynx** are nine in number, three single, and three pairs:

Thyroid.	Two Arytenoid.
Cricoid.	Two Cornicula Laryngis.
Epiglottis.	Two Cuneiform.

The **thyroid** (*θυρεός, a shield*) is the largest cartilage of the larynx. It consists of two lateral lamellæ or alæ, united at an acute angle in front, forming a vertical projection in the middle line which is prominent above, and called the *pomum Adami*. This projection is subcutaneous, more distinct in the male than in the female, and occasionally separated from the integument by a bursa mucosa.

Each lamella is quadrilateral in form. Its *outer surface* presents an oblique ridge, which passes downward and forward from a tubercle, situated near the root of the superior cornu, to a small tubercle near the anterior part of the lower border. This ridge gives attachment to the Sterno-thyroid and Thyro-hyoid

muscles, and the portion of cartilage included between it and the posterior border to part of the Inferior constrictor muscle.

The *inner surface* of each ala is smooth, slightly concave, and covered by mucous membrane above and behind; but in front, in the receding angle formed by their junction, are attached the epiglottis, the true and false vocal cords, the Thyro-arytenoid and Thyro-epiglottidean muscles, and the thyro-epiglottidean ligament.

The *upper border of the thyroid cartilage* is sinuously curved, being concave at its posterior part, just in front of the superior cornu, then rising into a convex outline, which dips in front to form the sides of a notch, the *thyroid notch*, in the middle line, immediately above the pomum Adami. This border gives attachment throughout its whole extent to the thyro-hyoid membrane.

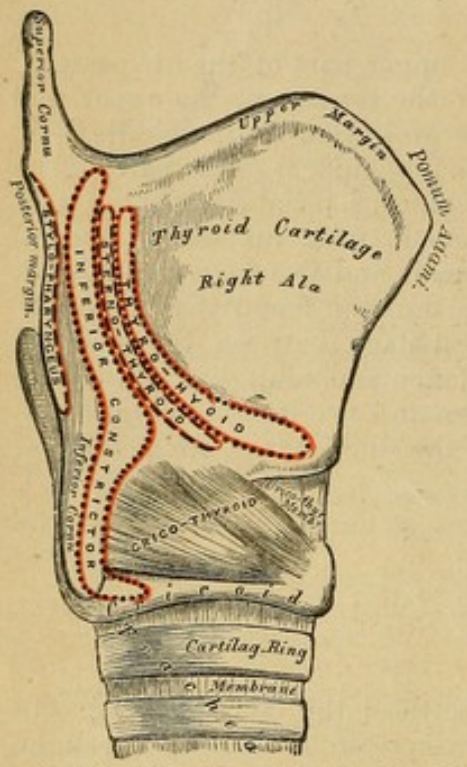

FIG. 527.—Side view of the thyroid and cricoid cartilages.

The *lower border* is nearly straight in front, but behind, close to the cornu, is concave. It is connected to the cricoid cartilage, in and near the median line, by the middle portion of the crico-thyroid membrane; and, on each side, by the Crico-thyroid muscle.

The *posterior borders*, thick and rounded, terminate, above, in the *superior cornua*, and below, in the *inferior cornua*. The two superior cornua are long and narrow, directed upward, backward, and inward, and terminate in conical extremities, which give attachment to the lateral thyro-hyoid ligament. The two inferior cornua are short and thick; they pass downward, with a slight inclination forward and inward, and present, on their inner surfaces, a small oval articular facet for articulation with the side of the cricoid cartilage. The posterior border receives the insertion of the Stylo-pharyngeus and Palato-pharyngeus muscles on each side.

During infancy the alæ of the thyroid cartilage are joined to each other by a narrow, lozenge-shaped strip, named the *intra-thyroid cartilage*. This strip extends from the upper to the lower border of the cartilage in the middle line, and is distinguished from the alæ by being more transparent and more flexible.

The **cricoid cartilage** is so called from its resemblance to a signet ring (*κρίκος, a ring*). It is smaller, but thicker and stronger than the thyroid cartilage, and forms the lower and back part of the cavity of the larynx. It consists of two parts: a quadrate portion, situated behind, and a narrow ring or arch, one-fourth or one-fifth the depth of the posterior part, situated in front. The posterior square portion rapidly narrows at the sides of the cartilage, at the expense of the upper border, into the anterior portion.

Its *posterior portion* is very deep and broad, and measures from above downward about an inch (2–3 cm.); it presents, on its posterior surface, in the middle line, a vertical ridge for the attachment of the longitudinal fibres of the œsophagus; and on either side a broad depression for the Crico-arytenoideus posticus muscle.

Its *anterior portion* is narrow and convex, and measures vertically about one-fourth or one-fifth of an inch (5–7 cm.); it affords attachment externally in front and at the sides to the Crico-thyroid muscles, and behind, to part of the Inferior constrictor.

At the point of junction of the posterior quadrate portion with the rest of the cartilage is a small round elevation, for articulation with the inferior cornu of the thyroid cartilage.

The *lower border* of the cricoid cartilage is horizontal, and connected to the upper ring of the trachea by fibrous membrane.

Its *upper border* is directed obliquely upward and backward, owing to the great depth of the posterior surface. It gives attachment, in front, to the middle portion of the crico-thyroid membrane; at the sides, to the lateral portion of the same membrane and to the lateral Crico-arytenoid muscle; behind, it presents, in the middle, a shallow notch, and on each side of this is a smooth, oval surface, directed upward and outward, for articulation with the arytenoid cartilage.

The *inner surface* of the cricoid cartilage is smooth, and lined by mucous membrane.

The **arytenoid cartilages** are so called from the resemblance they bear, when approximated, to the mouth of a pitcher (*ἀρύταινα, a pitcher*). They are two in number, and situated at the upper border of the cricoid cartilage, at the back of the larynx. Each cartilage is pyramidal in form, and presents for examination three surfaces, a base, and an apex.

The *posterior surface* is triangular, smooth, concave, and gives attachment to the Arytenoid muscle.

The *anterior* or *external surface* is somewhat convex and rough. It presents rather below its centre a transverse ridge, to the inner extremity of which is attached the false vocal cord, and to the outer part, as well as the surfaces above and below, is attached the Thyro-arytenoid muscle.

The *internal surface* is narrow, smooth, and flattened, covered by mucous membrane, and forms the lateral boundary of the respiratory part of the glottis.

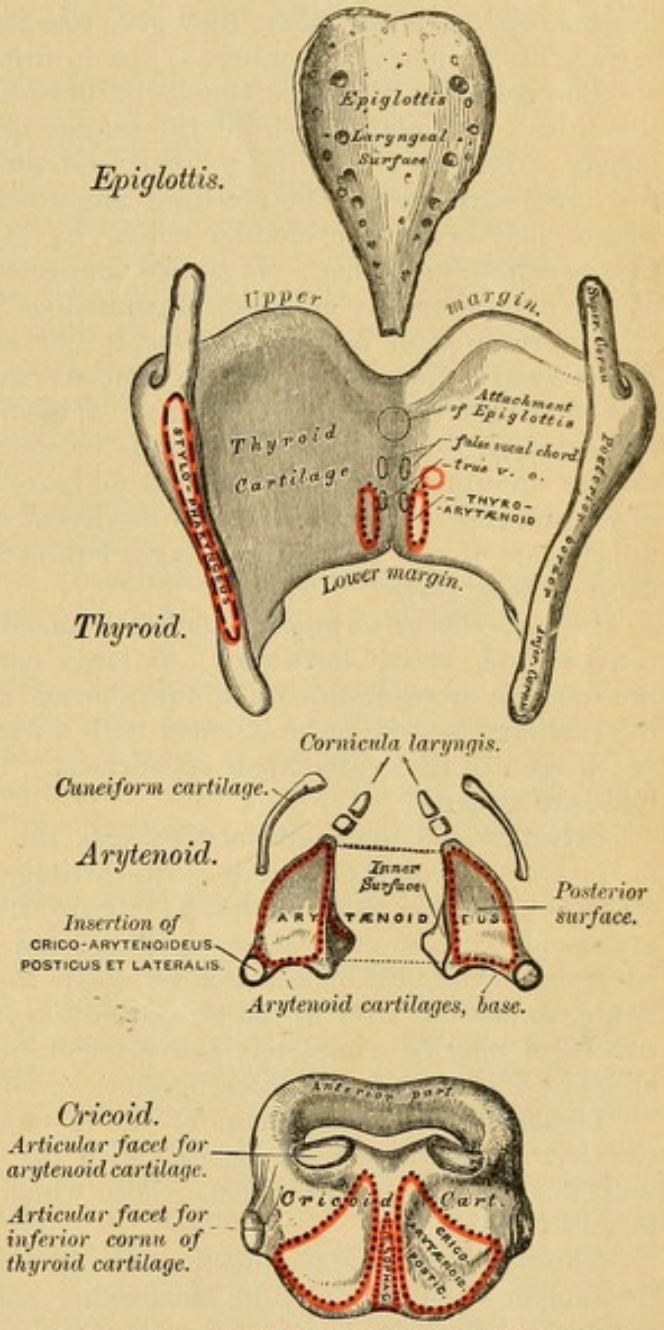

FIG. 528.—The cartilages of the larynx. Posterior view.

The *base* of each cartilage is broad, and presents a concave smooth surface, for articulation with the cricoid cartilage. Two of its angles require special mention: the *external*, which is short, rounded, and prominent, projects backward and outward, and is termed the *muscular process*, from receiving the insertion of the Posterior and Lateral crico-arytenoid muscles. The *anterior angle*, also prominent, but more pointed, projects horizontally forward, and gives attachment to the true vocal cord. This angle is called the *vocal process*.

The *apex* of each cartilage is pointed, curved backward and inward, and surmounted by a small conical, cartilaginous nodule, the *corniculum laryngis*.

The **cornicula laryngis** (*cartilages of Santorini*) are two small conical nodules, consisting of white fibro-cartilage, which articulate with the summit of the arytenoid cartilages and serve to prolong them backward and inward. To them are

attached the aryteno-epiglottidean folds. They are sometimes united to the arytenoid cartilages.

The **cuneiform cartilages** (*cartilages of Wrisberg*) are two small, elongated, cartilaginous bodies, placed one on each side, in the fold of mucous membrane which extends from the apex of the arytenoid cartilage to the side of the epiglottis (*aryteno-epiglottidean fold*); they give rise to small whitish elevations on the inner surface of the mucous membrane, just in front of the arytenoid cartilages.

The **epiglottis** is a thin lamella of fibro-cartilage, of a yellowish color, shaped like a leaf, and placed behind the tongue in front of the superior opening of the larynx. Its free extremity is broad and rounded; its attached part is long, narrow, and connected to the receding angle between the two alæ of the thyroid cartilage, just below the median notch, by a long, narrow ligamentous band, the *thyro-epiglottic ligament*. It is also connected to the posterior surface of the body of the hyoid bone by an elastic ligamentous band, the *hyo-epiglottic ligament*.

Its *anterior* or *lingual surface* is curved forward, toward the tongue, and covered at its upper, free part by mucous membrane, which is reflected on to the sides and base of the organ, forming a median and two lateral folds, the *glosso-epiglottidean folds*. The depressions between the epiglottis and the base of the tongue, on either side of the median fold, are named the *valleculæ*. The lower part of its anterior surface lies behind the hyoid bone, the thyro-hyoid membrane, and upper part of the thyroid cartilage, but is separated from these structures by a mass of fatty tissue.

Its *posterior* or *laryngeal surface* is smooth, concave from side to side, concavo-convex from above downward; its lower part projects backward as an elevation, the *tubercle* or *cushion*; when the mucous membrane is removed, the surface of the cartilage is seen to be studded with a number of small mucous glands, which are lodged in little pits upon its surface. To its sides the aryteno-epiglottidean folds are attached.

Structure.—The cuneiform cartilages, the epiglottis, and the apices of the arytenoids are composed of yellow fibro-cartilage, which shows little tendency to calcification; on the other hand, the thyroid, cricoid, and the greater part of the arytenoids consist of hyaline cartilage, and become more or less ossified as age advances. Ossification commences about the twenty-fifth year in the thyroid cartilage, somewhat later in the cricoid and arytenoids; by the sixty-fifth year these cartilages may be completely converted into bone. The cornicula laryngis consist of white fibro-cartilage, which becomes osseous about the seventieth year.

Ligaments.—The ligaments of the larynx are *extrinsic*—*i. e.*, those connecting the thyroid cartilage and epiglottis with the hyoid bone, and the cricoid cartilage with the trachea; and *intrinsic*, those which connect the several cartilages of the larynx to each other.

The ligaments connecting the thyroid cartilage with the hyoid bone are three in number—the thyro-hyoid membrane, and the two lateral thyro-hyoid ligaments.

The *thyro-hyoid membrane*, or *middle thyro-hyoid ligament*, is a broad, fibro-elastic, membranous layer, attached below to the upper border of the thyroid cartilage, and above to the posterior border of the body and greater cornua of the hyoid bone, thus passing behind the postero-inferior surface of the hyoid, and being separated from it by a synovial bursa, which facilitates the upward movement of the larynx during deglutition. It is thicker in the middle line than at either side, and is pierced, in the latter situation, by the superior laryngeal vessels and the internal branch of the superior laryngeal nerve. Its anterior surface is in relation with the Thyro-hyoid, Sterno-hyoid, and Omo-hyoid muscles, and with the body of the hyoid bone.

The *two lateral thyro-hyoid ligaments* are rounded, elastic cords, which pass between the superior cornua of the thyroid cartilage and the extremities of the greater cornua of the hyoid bone. A small cartilaginous nodule (*cartilago triticea*), sometimes bony, is frequently found in each.

The ligament connecting the epiglottis with the hyoid bone is the *hyo-epiglottic*. In addition to this extrinsic ligament, the epiglottis is connected to the tongue by the three glosso-epiglottidean folds of mucous membrane, which may also be considered as extrinsic ligaments of the epiglottis.

The *hyo-epiglottic ligament* is an elastic band, which extends from the anterior surface of the epiglottis, near its apex, to the upper border of the body of the hyoid bone.

The ligaments connecting the thyroid cartilage to the cricoid are also three in number—the crico-thyroid membrane, and the capsular ligaments.

The *crico-thyroid membrane* is composed mainly of yellow elastic tissue. It consists of three parts, a central, triangular portion and two lateral portions. The central part is thick and strong, narrow above and broadening out below. It connects together the contiguous margins of the thyroid and cricoid cartilages. It is convex, concealed on each side by the Crico-thyroid muscle, but subcutaneous in the middle line; it is crossed horizontally by a small anastomotic arterial arch, formed by the junction of the two crico-thyroid arteries. The lateral portions are thinner and lie close under the mucous membrane of the larynx. They extend from the superior border of the cricoid cartilage to the inferior margin of the true vocal cords, with which they are continuous.

The lateral portions are lined internally by mucous membrane, and covered by the lateral Crico-arytenoid and Thyro-arytenoid muscles.

A *capsular ligament* encloses the articulation of the inferior cornu of the thyroid with the cricoid cartilage on each side. The articulation is lined by synovial membrane.

The ligaments connecting the arytenoid cartilages to the cricoid are two *capsular ligaments* and two *posterior crico-arytenoid ligaments*. The *capsular ligaments* are thin and loose capsules attached to the margin of the articular surfaces; they are lined internally by synovial membrane. The *posterior crico-arytenoid ligaments* extend from the cricoid to the inner and back part of the base of the arytenoid cartilage.

The ligament connecting the epiglottis with the thyroid cartilage is the thyro-epiglottic.

The *thyro-epiglottic ligament* is a long, slender, elastic cord which connects the apex of the epiglottis with the receding angle of the thyroid cartilage, immediately beneath the median notch, above the attachment of the vocal cords.

The *crico-tracheal ligament* connects the cricoid cartilage with the first ring of the trachea. It resembles the fibrous membrane which connects the cartilaginous rings of the trachea to each other.

Interior of the Larynx.—The *cavity of the larynx* extends from its superior aperture to the lower border of the cricoid cartilage. It is divided into two parts by the projection inward of the true vocal cords, between which is a narrow triangular fissure or chink, the *rima glottidis*. The portion of the cavity of the larynx above the true vocal cords, sometimes called the *vestibule*, is broad and triangular in shape, and corresponds to the interval between the alæ of the thyroid cartilage; it contains the false vocal cords, and between these and the true vocal cords are the ventricles of the larynx. The portion below the true vocal cords widens out, and is at first of an elliptical and lower down of a circular form, and is continuous with the tube of the trachea.

The *superior aperture of the larynx* (Fig. 529) is a triangular or cordiform opening, wide in front, narrow behind, and sloping obliquely downward and backward. It is bounded, in front, by the epiglottis; behind, by the apices of the arytenoid cartilages and the cornicula laryngis; and laterally, by a fold of mucous membrane, enclosing ligamentous and muscular fibres, stretched between the sides of the epiglottis and the apices of the arytenoid cartilages: these are the *arytenoepiglottidean folds*, on the margins of which the cuneiform cartilages form more or less distinct whitish prominences.

The *rima glottidis* is the elongated fissure or chink between the inferior or true

vocal cords in front, and between the bases and vocal processes of the arytenoid cartilages behind. It is therefore frequently subdivided into an anterior interligamentous or *vocal* portion (*glottis vocalis*) and a posterior intercartilaginous or *respiratory* part (*glottis respiratoria*). Posteriorly it is limited by the mucous membrane passing between the arytenoid cartilages. The vocal portion averages about three-fifths of the length of the entire aperture. It is the narrowest part of

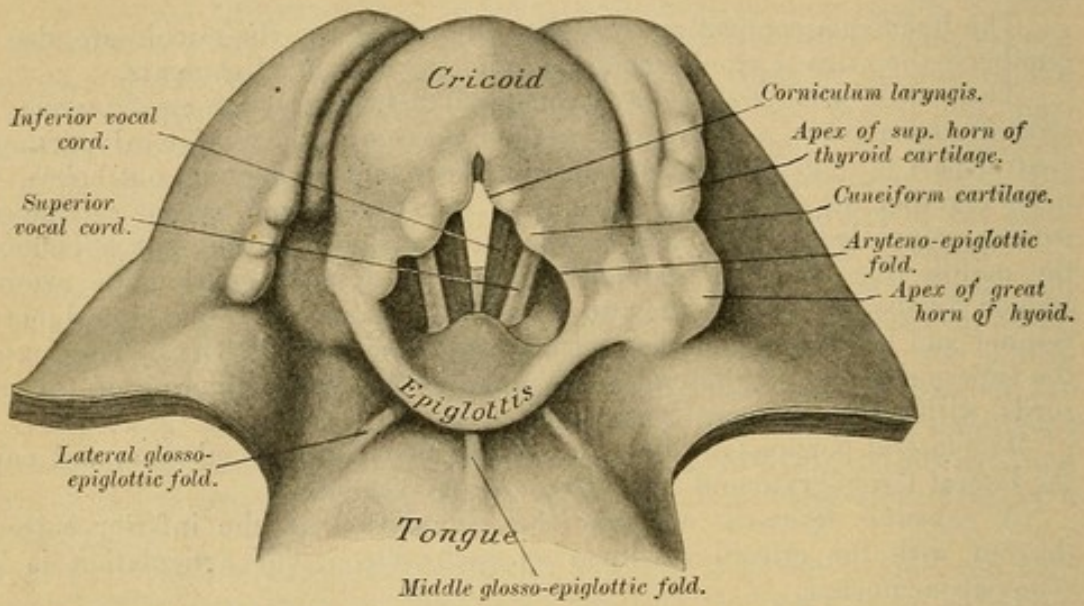

FIG. 529.—Larynx, viewed from above. (Testut.)

the cavity of the larynx, and its level corresponds to the bases of the arytenoid cartilages. Its length, in the male, measures rather less than an inch (20–25 mm.); in the female it is shorter by 5 or 6 mm., or three lines. The width and shape of the rima glottidis vary with the movements of the vocal cords and arytenoid cartilages during respiration and phonation. In the condition of rest—*i. e.*, when these structures are uninfluenced by muscular action, as in quiet respiration—the glottis vocalis is triangular, with its apex in front and its base behind, the latter being represented by a line about 8 mm. long, connecting the anterior extremities of the vocal processes, while the inner surfaces of the arytenoids are parallel to each other, and hence the glottis respiratoria is rectangular. During extreme adduction of the cords, as in the emission of a high note, the glottis vocalis is reduced to a linear slit by the apposition of the cords, while the glottis respiratoria is triangular, its apex corresponding to the anterior extremities of the vocal processes of the arytenoids, which are approximated by the inward rotation of the cartilages. Conversely in extreme abduction of the cords, as in forced inspiration, the arytenoids and their vocal processes are rotated outward, and the glottis respiratoria is triangular in shape, but with its apex directed backward. In this condition the entire glottis is somewhat lozenge-shaped, the sides of the glottis vocalis diverging from before backward, those of the glottis respiratoria diverging from behind forward, the widest part of the aperture corresponding with the attachment of the cords to the vocal processes.[1]

The *superior* or *false vocal cords*, so called because they are not directly concerned in the production of the voice, are two thick folds of mucous membrane, enclosing a narrow band of fibrous tissue, the *superior thyro-arytenoid ligament*, which is attached in front to the angle of the thyroid cartilage immediately below the attachment of the epiglottis, and behind to the anterior surface of the arytenoid cartilage. The lower border of this ligament, enclosed in mucous membrane, forms a free crescentic margin, which constitutes the upper boundary of the ventricle of the larynx.

[1] On the shape of the rima glottidis, in the various conditions of breathing and speaking, see Czermak, *On the Laryngoscope*, translated for the New Sydenham Society.

The *inferior* or *true vocal cords*, so called from their being concerned in the production of sound, are two strong bands (*inferior thyro-arytenoid ligaments*), covered on their surface by a thin layer of mucous membrane. Each ligament consists of a band of yellow elastic tissue, attached in front to the depression between the two alæ of the thyroid cartilage, and behind to the anterior angle (vocal process) of the base of the arytenoid. Its lower border is continuous with the thin lateral part of the crico-thyroid membrane. Its upper border forms the lower boundary of the ventricle of the larynx. Externally, the Thyro-arytenoideus muscle lies parallel with it. It is covered internally by mucous membrane, which is extremely thin, and closely adherent to its surface.

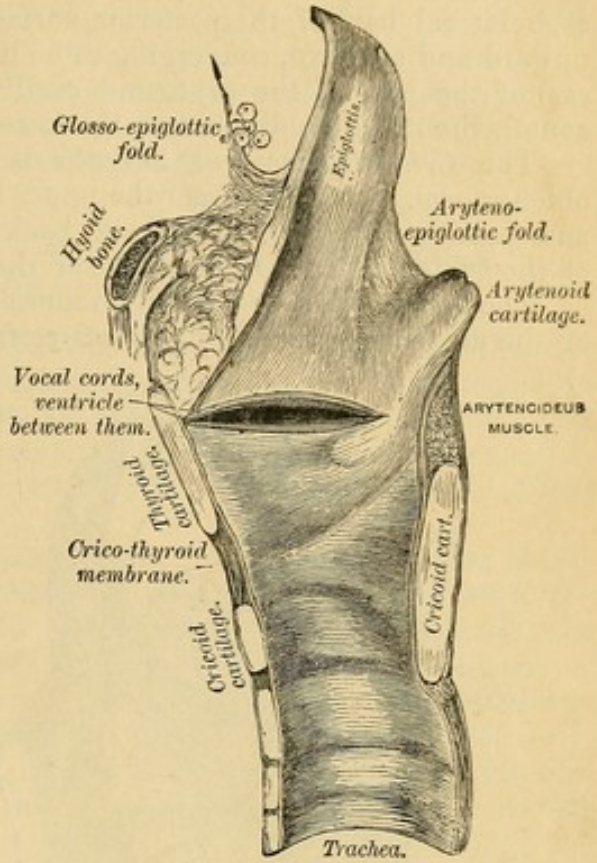

FIG. 530.—Vertical section of the larynx and upper part of the trachea.

The *ventricle of the larynx* is an oblong fossa, situated between the superior and inferior vocal cords on each side, and extending nearly their entire length. This fossa is bounded, above, by the free crescentic edge of the superior vocal cord; below, by the straight margin of the true vocal cord; externally, by the mucous membrane covering the corresponding Thyro-arytenoideus muscle. The anterior part of the ventricle leads up by a narrow opening into a cæcal pouch of mucous membrane of variable size, called the *laryngeal pouch*.

The *sacculus laryngis*, or laryngeal pouch, is a membranous sac, placed between the superior vocal cord and the inner surface of the thyroid cartilage, occasionally extending as far as its upper border or even higher: it is conical in form, and curved slightly backward. On the surface of its mucous membrane are the openings of sixty or seventy mucous glands, which are lodged in the submucous areolar tissue. This sac is enclosed in a fibrous capsule, continuous below with the superior thyro-arytenoid ligament: its laryngeal surface is covered by the Aryteno-epiglottideus inferior muscle (*Compressor sacculi laryngis*, Hilton); while its exterior is covered by the Thyro-arytenoideus and Thyro-epiglottideus muscles. These muscles compress the sacculus laryngis, and discharge the secretion it contains upon the chordæ vocales, the surfaces of which it is intended to lubricate.

Muscles.—The intrinsic muscles of the larynx are eight in number, five of which are the muscles of the vocal cords and rima glottidis, and three are connected with the epiglottis.

The five muscles of the vocal cords and rima glottidis are the—

Crico-thyroid.
Crico-arytenoideus posticus.
Crico-arytenoideus lateralis.
Arytenoideus.
Thyro-arytenoideus.

The *Crico-thyroid* is triangular in form, and situated at the fore part and side of the cricoid cartilage. It arises from the front and lateral part of the cricoid cartilage; its fibres diverge, passing obliquely upward and outward to be inserted into the lower border of the thyroid cartilage and into the anterior border of the lower cornua.

The inner borders of these two muscles are separated in the middle line by a triangular interval occupied by the central part of the crico-thyroid membrane.

The *Crico-arytenoideus posticus* arises from the broad depression occupying each lateral half of the posterior surface of the cricoid cartilage; its fibres pass upward and outward, converging to be inserted into the outer angle (muscular process) of the base of the arytenoid cartilage. The upper fibres are nearly horizontal, the middle oblique, and the lower almost vertical.[1]

The *Crico-arytenoideus lateralis* is smaller than the preceding, and of an oblong form. It arises from the upper border of the side of the cricoid cartilage, and, passing obliquely upward and backward, is inserted into the muscular process of the arytenoid cartilage in front of the preceding muscle.

The *Arytenoideus* is a single muscle filling up the posterior concave surface of the arytenoid cartilages. It arises from the posterior surface and outer border of one arytenoid cartilage, and is inserted into the corresponding parts of the opposite cartilage. It consists of three planes of fibres, two oblique and one transverse. The *oblique fibres*, the most superficial, form two fasciculi,

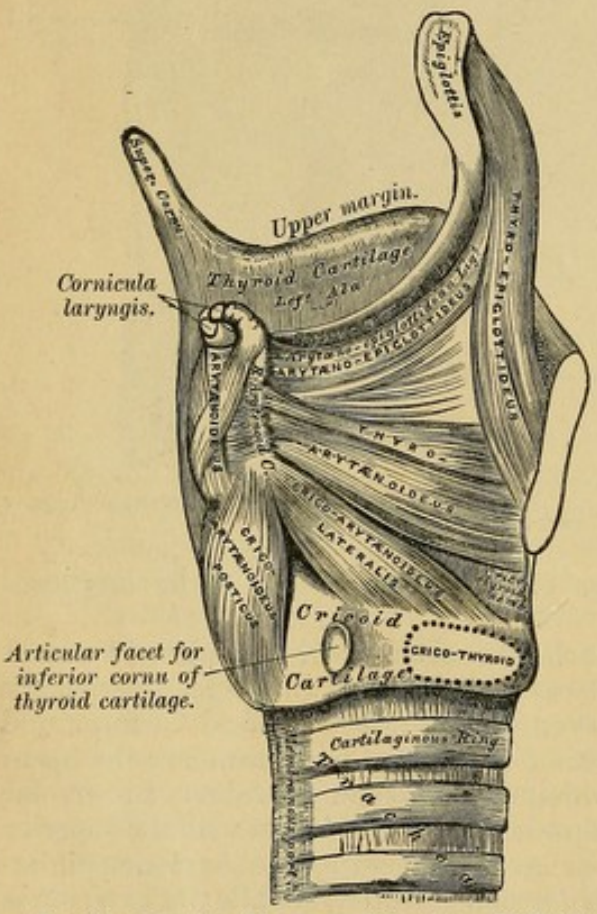

FIG. 531.—Muscles of larynx. Side view. Right ala of thyroid cartilage removed.

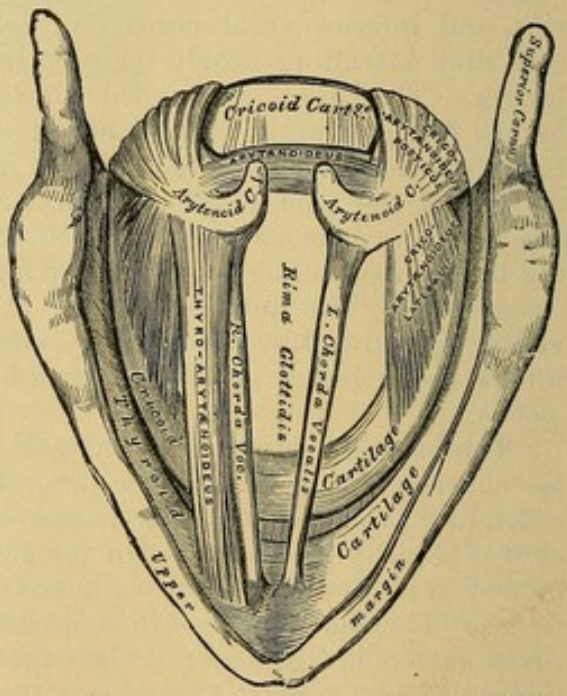

FIG. 532.—Interior of the larynx, seen from above. (Enlarged.)

which pass from the base of one cartilage to the apex of the opposite one. The *transverse fibres*, the deepest and most numerous, pass transversely across between the two cartilages; hence the Arytenoideus was formerly considered as three muscles, the transverse and the two oblique. A few of the oblique fibres are occasionally continued round the outer margin of the cartilage, and blend with the Thyro-arytenoid or the Aryteno-epiglottideus muscle.

The *Thyro-arytenoideus* is a broad, flat muscle, which lies parallel with the outer side of the true vocal cord. It arises in front from the lower half of the receding angle of the thyroid cartilage, and from the crico-thyroid membrane. Its

[1] Merkel, of Leipsic, has described a muscular slip which occasionally extends between the outer border of the posterior surface of the cricoid cartilage and the posterior margin of the inferior cornu of the thyroid; this he calls the "Musculus kerato-cricoideus." It is not found in every larynx, and when present exists usually only on one side, but is occasionally found on both sides. Sir William Turner (*Edinburgh Medical Journal*, Feb., 1860) states that it is found in about one case in five. Its action is to fix the lower horn of the thyroid cartilage backward and downward, opposing in some measure the part of the Crico-thyroid muscle, which is connected to the anterior margin of the horn.

fibres pass backward and outward, to be inserted into the base and anterior surface of the arytenoid cartilage. This muscle consists of two fasciculi.[1] The *inner or inferior portion*, the thicker, is inserted into the vocal process of the arytenoid cartilage, and into the adjacent portion of its anterior surface; it lies parallel with the true vocal cord, to which it is adherent. The *outer* or *superior fasciculus*, the thinner, is inserted into the anterior surface and outer border of the arytenoid cartilage above the preceding fibres; it lies on the outer side of the sacculus laryngis, immediately beneath the mucous membrane.[2]

The muscles of the epiglottis are the—

Thyro-epiglottideus. Aryteno-epiglottideus superior.
Aryteno-epiglottideus inferior.

The *Thyro-epiglottideus* is a delicate fasciculus, which arises from the inner surface of the thyroid cartilage, just external to the origin of the Thyro-arytenoid muscle, of which it is sometimes described as a part, and spreads over the outer surface of the sacculus laryngis; some of its fibres are lost in the aryteno-epiglottidean fold, while the others are continued forward to the margin of the epiglottis (*Depressor epiglottidis*).

The *Aryteno-epiglottideus superior* consists of a few delicate muscular fasciculi, which arise from the apex of the arytenoid cartilages, and become lost in the fold of mucous membrane extending between the arytenoid cartilage and the side of the epiglottis (*aryteno-epiglottidean fold*).

The *Aryteno-epiglottideus inferior* (*Compressor sacculi laryngis*, Hilton) arises from the arytenoid cartilage, just above the attachment of the superior vocal cord; passing forward and upward, it spreads out upon the anterior surface of the epiglottis. This muscle is separated from the preceding by an indistinct areolar interval.[3]

Actions.—In considering the action of the muscles of the larynx, they may be conveniently divided into two groups, viz.: 1. Those which open and close the glottis. 2. Those which regulate the degree of tension of the vocal cords.

1. The muscles which open the glottis are the Crico-arytenoidei postici; and those which close it are the Arytenoideus and the Crico-arytenoidei laterales. 2. The muscles which regulate the tension of the vocal cords are the Crico-thyroidei, which tense and elongate them; and the Thyro-arytenoidei, which relax and shorten them. The Thyro-epiglottideus is a depressor of the epiglottis, and the Aryteno-epiglottidei constrict the superior aperture of the larynx, compress the sacculi laryngis, and empty them of their contents.

The *Crico-arytenoidei postici* separate the chordæ vocales, and consequently open the glottis, by rotating the arytenoid cartilages outward around a vertical axis passing through the crico-arytenoid joints, so that their vocal processes and the vocal cords attached to them become widely separated.

The *Crico-arytenoidei laterales* close the glottis by rotating the arytenoid cartilages inward so as to approximate their vocal processes.

The *Arytenoideus muscles* approximate the arytenoid cartilages, and thus close the opening of the glottis, especially at its back part.

The *Crico-thyroid muscles* produce tension and elongation of the vocal cords. This is effected as follows: the thyroid cartilage is fixed by its extrinsic muscles; then the Crico-thyroid muscles, when they act, draw upward the front of the cricoid cartilage, and so depress

[1] Henle describes these two portions as separate muscles, under the names of External and Internal thyro-arytenoid.

[2] Luschka has described a small but fairly constant muscle as the *Arytenoideus rectus*. It is attached below to the posterior concave surface of the arytenoid cartilage, beneath the Arytenoideus muscle, and, passing upward, emerges at the upper border of this muscle, and is inserted into the posterior surface of the cartilage of Santorini (*Anatomy*, by Hyrtl, page 718).

[3] Musculus triticeo-glossus. Bochdalek, jun. (*Prager Vierteljahrsschrift*, 2d part, 1866), describes a muscle hitherto entirely overlooked, except a brief statement in Henle's *Anatomy*, which arises from the nodule of cartilage (*corpus triticeum*) in the posterior thyro-hyoid ligament, and passes forward and upward to enter the tongue along with the Hyo-glossus muscle. He met with this muscle eight times in twenty-two subjects. It occurred in both sexes, sometimes on both sides, at others on one only.

the posterior portion, which carries with it the arytenoid cartilages, and thus elongate the vocal cords.

The *Thyro-arytenoidei muscles*, consisting of two parts having different attachments and different directions, are rather complicated as regards their action. Their main use is to draw the arytenoid cartilages forward toward the thyroid, and thus shorten and relax the vocal cords. But, owing to the connection of the inner portion with the vocal cord, this part, if acting separately, is supposed to modify its elasticity and tension, and the outer portion, being inserted into the outer part of the anterior surface of the arytenoid cartilage, may rotate it inward, and thus narrow the rima glottidis by bringing the two cords together.

The *Thyro-epiglottidei* may depress the epiglottis; they assist in compressing the sacculi laryngis. The Aryteno-epiglottideus superior constricts the superior aperture of the larynx, when it is drawn upward, during deglutition. The *Aryteno-epiglottideus inferior*, together with some fibres of the Thyro-arytenoidei, compress the sacculus laryngis.

The **Mucous Membrane of the Larynx** is continuous above with that lining the mouth and pharynx, and it is prolonged through the trachea and bronchi into the lungs. It lines the posterior surface and the anterior part of the upper surface of the epiglottis, to which it is closely adherent, and forms the aryteno-epiglottidean folds which form the laterial boundaries of the superior aperture of the larynx. It lines the whole of the cavity of the larynx; forms, by its reduplication, the chief part of the superior or false vocal cord; and, from the ventricle, is continued into the sacculus laryngis. It is then reflected over the true vocal cords, where it is thin and very intimately adherent; covers the inner surface of the crico-thyroid membrane and cricoid cartilage; and is ultimately continuous with the lining membrane of the trachea. The fore part of the anterior surface and the upper half of the posterior surface of the epiglottis, the upper part of the aryteno-epiglottidean folds, and the true vocal cords are covered by stratified squamous epithelium; all the rest of the laryngeal mucous membrane is covered by columnar ciliated cells.

Glands.—The mucous membrane of the larynx is furnished with numerous muciparous glands, the orifices of which are found in nearly every part; they are very numerous upon the epiglottis, being lodged in little pits in its substance; they are also found in large numbers along the posterior margin of the aryteno-epiglottidean fold, in front of the arytenoid cartilages, where they are termed the *arytenoid glands*. They exist also in large numbers upon the inner surface of the sacculus laryngis. None are found on the free edges of the vocal cords.

Vessels and Nerves.—The *arteries of the larynx* are the laryngeal branches derived from the superior and inferior thyroid. The *veins* accompany the arteries: those accompanying the superior laryngeal artery join the superior thyroid vein which opens into the internal jugular vein; while those accompanying the inferior laryngeal artery join the inferior thyroid vein which opens into the innominate vein. The *lymphatics* consist of two sets, superior and inferior. The former accompany the superior laryngeal artery and pierce the thyro-hyoid membrane, to terminate in the glands situated near the bifurcation of the common carotid artery. The latter pass through the crico-thyroid membrane, and open into one or two glands lying either in front of that membrane or to the side of the cricoid cartilage. The nerves are derived from the internal and external laryngeal branches of the superior laryngeal nerve, from the inferior or recurrent laryngeal, and from the sympathetic. The internal laryngeal nerve is almost entirely sensory, but some motor filaments are said to be carried by it to the Arytenoideus muscle. It divides into a branch which is distributed to both surfaces of the epiglottis, a second to the aryteno-epiglottidean folds, and a third, the largest, which supplies the mucous membrane over the back of the larynx and communicates with the recurrent laryngeal. The external laryngeal nerve supplies the Crico-thyroid muscle. The recurrent laryngeal passes upward under the lower border of the Inferior constrictor, and enters the larynx between the cricoid and thyroid cartilages. It supplies all the muscles of the larynx except the Crico-thyroid and part of the Arytenoideus. The sensory branches of the laryngeal nerves form subepithelial plexuses, from which fibres ascend to end between the cells covering the mucous membrane.

Over the posterior surface of the epiglottis, in the aryteno-epiglottidean folds, and less regularly in some other parts, taste-buds, similar to those in the tongue, are found.

THE TRACHEA (Fig. 533).

The **trachea, or windpipe,** is a cartilaginous and membranous cylindrical tube, flattened posteriorly, which extends from the lower part of the larynx, on a level with the sixth cervical vertebra, to opposite the fourth, or sometimes the fifth,

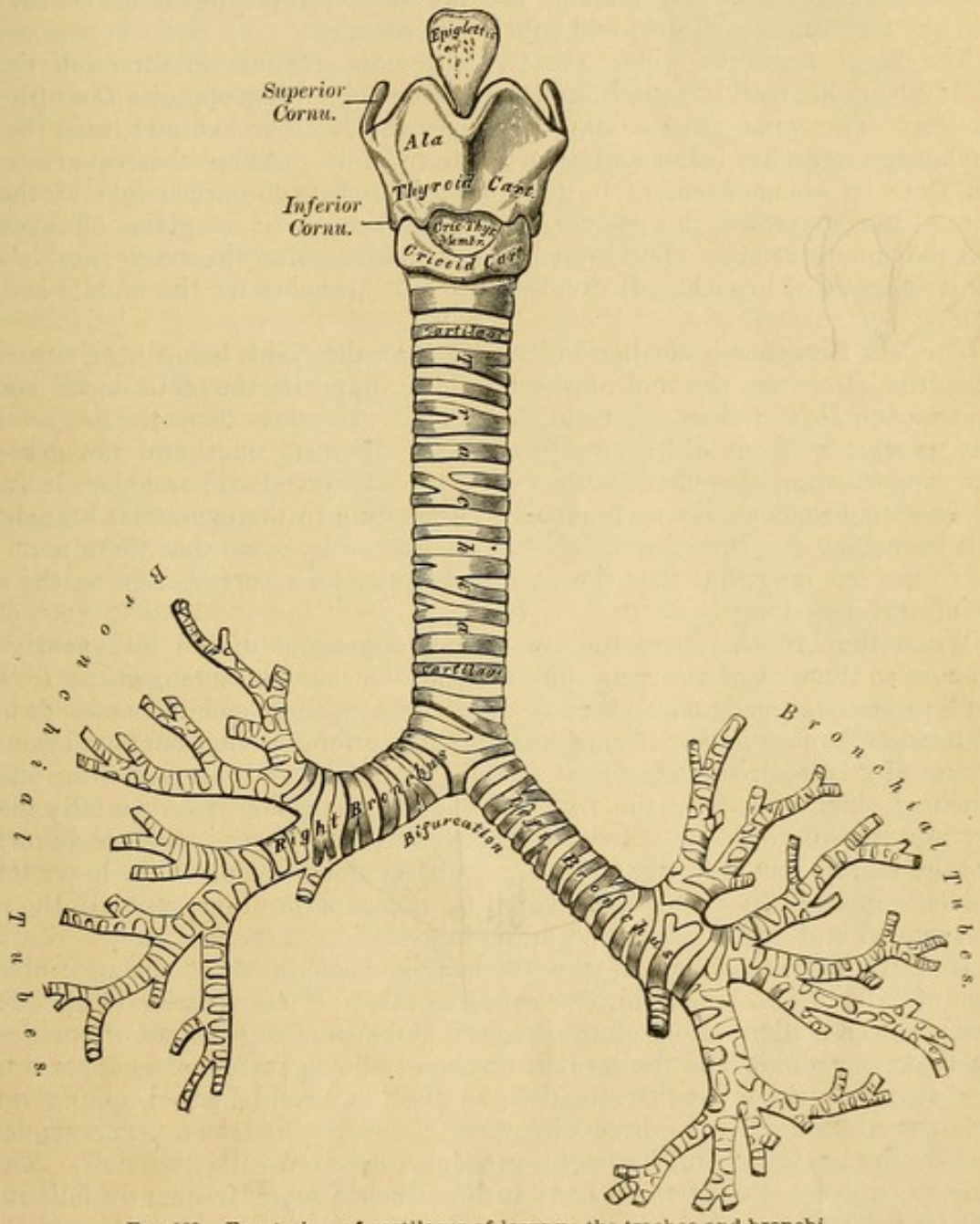

FIG. 533.—Front view of cartilages of larynx; the trachea and bronchi.

dorsal vertebra, where it divides into two bronchi, one for each lung. The trachea measures about four inches and a half in length; its diameter, from side to side, is from three-quarters of an inch to an inch, being always greater in the male than in the female.

Relations.—The anterior surface of the trachea is convex, and covered *in the neck*, from above downward, by the isthmus of the thyroid gland, the inferior thyroid veins, the arteria thyroidea ima (when that vessel exists), the Sterno-hyoid and Sterno-thyroid muscles, the cervical fascia, and more superficially, by the anastomosing branches between the anterior jugular veins: *in the thorax* it is

covered from before backward by the first piece of the sternum, the remains of the thymus gland, the left innominate vein, the arch of the aorta, the innominate and left common carotid arteries, and the deep cardiac plexus. Posteriorly, it is in relation with the œsophagus; laterally, *in the neck*, it is in relation with the common carotid arteries, the lateral lobes of the thyroid gland, the inferior thyroid arteries, and recurrent laryngeal nerves; and, *in the thorax*, it lies in the upper part of the interpleural space (superior mediastinum), and is in relation on the right to the pleura and right vagus, and near the root of the neck to the innominate artery; on its left side are the recurrent laryngeal nerve, the aortic arch, the left common carotid and subclavian arteries.

The **Right Bronchus**, wider, shorter, and more vertical in direction than the left, is about an inch in length, and enters the right lung opposite the fifth dorsal vertebra. The vena azygos major arches over it from behind; and the right pulmonary artery lies below and then in front of it. About three-quarters of an inch from its commencement it gives off a branch to the upper lobe of the right lung. This is termed the *eparterial* branch, because it is given off above the right pulmonary artery. The bronchus now passes below the artery, and is known as the *hyparterial* branch. It divides into two branches for the middle and lower lobes.

The **Left Bronchus** is smaller and longer than the right, being nearly two inches in length. It enters the root of the left lung, opposite the sixth dorsal vertebra, about an inch lower than the right bronchus. It passes beneath the arch of the aorta, crosses in front of the œsophagus, the thoracic duct, and the descending aorta, and has the left pulmonary artery lying at first above, and then in front of it. The left bronchus has no branch corresponding to the eparterial branch of the right bronchus, and therefore it has been supposed by some that there is no upper lobe to the left lung, but that the so-called upper lobe corresponds to the middle lobe of the right lung.

When the bronchi enter the lung they appear to divide into nearly equal branches at the root of the lung, but a somewhat similar arrangement to what is found in many animals may be made out where each bronchus passes downward and backward toward the extremity of the lower lobe, giving off four branches at intervals in two directions, dorsally and ventrally, and, in addition, accessory branches, which arise from the front of the bronchus and pass mesially and dorsally into the inferior lobe. In the right bronchus the *first ventral* branch supplies the middle lobe, the other three and all the dorsal going to the lower lobe; in the left bronchus, the *first ventral* supplies the superior lobe, and all the others, both ventral and dorsal, go to the lower lobe.

If a transverse section of the trachea is made a short distance above its point of bifurcation, and a bird's-eye view taken of its interior (Fig. 534), the septum placed at the bottom of the trachea and separating the two bronchi will be seen to occupy the left of the median line, and the right bronchus appears to be a more direct continuation than the left, so that any solid body dropping into the trachea would naturally be directed toward the right bronchus. This tendency is aided by the larger size of the right tube as compared with its fellow. This fact serves to explain why a foreign body in the trachea more frequently falls into the right bronchus.[1]

Structure.—The trachea is composed of imperfect cartilaginous rings, fibrous membrane, muscular fibres, mucous membrane, and glands.

The **cartilages** vary from sixteen to twenty in number: each forms an imperfect ring, which surrounds about two-thirds of the cylinder of the trachea, being imperfect behind, where the tube is completed by fibrous membrane. The cartilages are placed horizontally above each other, separated by narrow membranous intervals. They measure about two lines in depth, and half a line in thickness. Their outer surfaces are flattened, but internally they are convex,

[1] Reigel asserts that the entry of a foreign body into the *left* bronchus is by no means so infrequent as is generally supposed. See also *Med.-Chir. Trans.*, vol. lxxi., p. 121.

from being thicker in the middle than at the margins. Two or more of the cartilages often unite, partially or completely, and are sometimes bifurcated at their extremities. They are highly elastic, but sometimes become calcified in advanced life. In the right bronchus the cartilages vary in number from six to eight; in the left, from nine to twelve. They are shorter and narrower than those of the trachea. The peculiar cartilages are the first and the last.

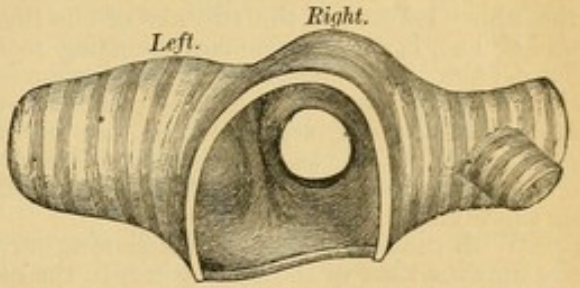

FIG. 534.—Transverse section of the trachea, just above its bifurcation, with a bird's-eye view of the interior.

The *first cartilage* is broader than the rest, and sometimes divided at one end; it is connected by fibrous membrane with the lower border of the cricoid cartilage, with which or with the succeeding cartilage it is sometimes blended.

The *last cartilage* is thick and broad in the middle, in consequence of its lower border being prolonged into a triangular hook-shaped process which curves downward and backward between the two bronchi. It terminates on each side in an imperfect ring which encloses the commencement of the bronchi. The cartilage above the last is somewhat broader than the rest at its centre.

The Fibrous Membrane.—The cartilages are enclosed in an elastic fibrous membrane which forms a double layer, one layer, the thicker of the two, passing over the outer surface of the ring, the other over the inner surface; at the upper and lower margins of the cartilages these two layers blend together to form a single membrane, which connects the rings one with another. They are thus, as it were, imbedded in the membrane. In the space behind, between the extremities of the rings, the membrane forms a single distinct layer.

The **muscular fibres** are disposed in two layers, longitudinal and transverse. The *longitudinal fibres* are the most external, and consist merely of a few scattered longitudinal bundles of fibres.

The *transverse fibres* (Trachealis muscle, Todd and Bowman), the most internal, form a thin layer, which extends transversely between the ends of the cartilages and the intervals between them at the posterior part of the trachea. The muscular fibres are of the unstriped variety.

The **Mucous membrane** is continuous above with that of the larynx, and below with that of the bronchi. Microscopically, it consists of areolar and lymphoid tissue, and presents a well-marked basement-membrane, supporting a layer of columnar, ciliated epithelium, between the deeper ends of which are smaller triangular cells, the bases of which, often branched, are attached to the basement-membrane. These triangular cells are mucus-secreting, and may be seen as goblet- or chalice-cells when their contents have been discharged. In the deepest part of the mucous membrane, and especially between the mucous and submucous layers, longitudinally arranged fibres are very abundant and form a distinct layer.

The **Tracheal glands** are found in great abundance at the posterior part of the trachea. They are racemose glands, and consist of a basement-membrane lined by columnar mucus-secreting cells. They are situated at the back of the trachea, outside the layer of muscular tissue, between it and the outer fibrous layer. Their excretory ducts pierce the muscular and inner fibrous layers, and pass through the submucous and mucous layers to open on the surface of the mucous membrane. Some glands of smaller size are also found at the sides of the trachea, between the layers of fibrous tissue connecting the rings, and others immediately beneath the mucous coat. The secretion from these glands serves to lubricate the inner surface of the trachea.

Vessels and Nerves.—The trachea is supplied with blood by the inferior thyroid arteries. The *veins* terminate in the thyroid venous plexus. The *nerves* are derived from the pneumogastric and its recurrent branches and from the sympathetic.

Surface Form.—In the middle line of the neck some of the cartilages of the larynx can be readily distinguished. In the receding angle below the chin the hyoid bone can easily be made out (see page 126), and a finger's breadth below it is the pomum Adami, the prominence between the upper borders of the two alæ of the thyroid cartilage. About an inch below this, in the middle line, is a depression corresponding to the crico-thyroid space, in which the operation of laryngotomy is performed. This depression is bounded below by a prominent arch, the anterior ring of the cricoid cartilage, below which the trachea can be felt, though it is only in the emaciated adult that the separate rings can be distinguished. The lower part of the trachea is not easily made out, for as it descends in the neck it takes a deeper position, and is farther removed from the surface. The level of the vocal cords corresponds to the middle of the anterior margin of the thyroid cartilage.

With the laryngoscope, the following structures can be seen: The base of the tongue and the upper surface of the epiglottis, with the glosso-epiglottic ligaments; the superior aperture of the larynx, bounded on either side by the aryteno-epiglottidean folds, in which may be seen two rounded eminences corresponding to the cornicula and cuneiform cartilages. Beneath these, the true and false vocal cords, with the ventricle between them. Still deeper, the cricoid cartilage and some of the anterior parts of the rings of the trachea, and sometimes, in deep inspiration, the bifurcation of the trachea.

Surgical Anatomy.—*Foreign bodies* often find their way into the air-passages. These may be either large soft substances, as a piece of meat, which may become lodged in the upper aperture of the larynx or in the rima glottidis, and cause speedy suffocation unless rapidly got rid of, or unless an opening is made into the air-passages below, so as to enable the patient to breathe. Smaller bodies, frequently of a hard nature, such as cherry or plum stones, small pieces of bone, buttons, etc., may find their way through the rima glottidis into the trachea or bronchus, or may become lodged in the ventricle of the larynx. The dangers then depend not so much upon the mechanical obstruction as upon the spasm of the glottis which they excite from reflex irritation. When lodged in the ventricle of the larynx, they may produce very few symptoms beyond sudden loss of voice or alteration in the voice sounds, immediately following the inhalation of the foreign body. When, however, they are situated in the trachea, they are constantly striking against the vocal cords during expiratory efforts, and produce attacks of dyspnœa from spasm of the glottis. When lodged in the bronchus, they usually become fixed there, and, occluding the lumen of the tube, cause a loss of the respiratory murmur on the affected side, which is, as stated above, more often the right.

Beneath the mucous membrane of the upper part of the air-passages there is a considerable amount of submucous tissue which is liable to become much swollen from effusion in inflammatory affections, constituting the disease known as "œdema of the glottis." This effusion does not extend below the level of the vocal cords, on account of the fact that the mucous membrane is closely adherent to these structures, without the intervention of any submucous tissue. So that, in cases of this disease in which it is necessary to open the air-passages to prevent suffocation, the operation of laryngotomy is sufficient.

Chronic laryngitis is an inflammation of the mucous glands of the larynx, which occurs in those who speak much in public, and is known as "clergyman's sore throat." It is due to the dryness induced by the large amount of cold air drawn into the air-passages during prolonged speaking, which incites increased activity in the mucous glands to keep the parts moist, and this eventually terminates in inflammation of these structures.

Ulceration of the larynx may occur from syphilis, either as a superficial ulceration, or from the softening of a gumma; from tuberculous disease (laryngeal phthisis), or from malignant disease (epithelioma).

The air-passages may be opened in two different situations: through the crico-thyroid membrane (*laryngotomy*), or in some part of the trachea (*tracheotomy*); and to these some surgeons have added a third method, by opening the crico-thyroid membrane and dividing the cricoid cartilage with the upper ring of the trachea (*laryngo-tracheotomy*).

Laryngotomy is anatomically the more simple operation: it can readily be performed, and should be employed in those cases where the air-passages require opening in an emergency for the relief of some sudden obstruction to respiration. The crico-thyroid membrane is very superficial, being covered only in the middle line by the skin, superficial fascia, and the deep fascia. On each side of the middle line it is also covered by the Sterno-hyoid and Sterno-thyroid muscles, which diverge from each other at their upper parts, leaving a slight interval between them. On these muscles rest the anterior jugular veins. The only vessel of any importance in connection with this operation is the crico-thyroid artery, which crosses the crico-thyroid membrane, and which may be wounded, but rarely gives rise to any trouble. The operation is performed thus: the head being thrown back and steadied by an assistant, the finger is passed over the front of the neck, and the crico-thyroid depression felt for. A vertical incision is then made through the skin, in the middle line over this spot, and carried down through the fascia until the crico-thyroid membrane is exposed. A cross cut is then made through the membrane, close to the upper border of the cricoid cartilage, so as to avoid, if possible, the crico-thyroid artery, and a tracheotomy tube introduced. It has been recommended, as a more rapid way of performing the operation, to make a transverse instead of a longitudinal cut, through the superficial structures, and thus to open at once the air-passages. It will be seen, however, that in operating in this way the anterior jugular veins would be in danger of being wounded.

Tracheotomy may be performed either above or below the isthmus of the thyroid body, or this structure may be divided and the trachea opened behind it.

The isthmus of the thyroid gland usually crosses the second and third rings of the trachea; along its upper border is frequently to be found a large transverse communicating branch between the superior thyroid veins; and the isthmus itself is covered by a venous plexus formed between the thyroid veins of the opposite sides. Theoretically, therefore, it is advisable to avoid dividing this structure in opening the trachea.

Above the isthmus the trachea is comparatively superficial, being covered by the skin, superficial fascia, deep fascia, Sterno-hyoid and Sterno-thyroid muscles, and a second layer of the deep fascia, which, attached above to the lower border of the hyoid bone, descends beneath the muscles to the thyroid body, where it divides into two layers and encloses the isthmus.

Below the isthmus the trachea lies much more deeply, and is covered by the Sterno-hyoid and the Sterno-thyroid muscles and a quantity of loose areolar tissue in which is a plexus of veins, some of them of large size; they converge to two trunks, the inferior thyroid veins, which descend on either side of the median line on the front of the trachea and open into the innominate veins. In the infant the thymus gland ascends a variable distance along the front of the trachea, and opposite the episternal notch the windpipe is crossed by the left innominate vein. Occasionally also, in young subjects, the innominate artery crosses the tube obliquely above the level of the sternum. The thyroidea ima artery, when that vessel exists, passes from below upward along the front of the trachea.

From these observations it must be evident that the trachea can be more readily opened above than below the isthmus of the thyroid body.

Tracheotomy above the isthmus is performed thus: the patient should, if possible, be laid on his back on a table in a good light. A pillow is to be placed under the shoulders and the head thrown back and steadied by an assistant. The surgeon standing on the right side of his patient makes an incision from an inch and a half to two inches in length in the median line of the neck from the top of the cricoid cartilage. The incision must be made exactly in the middle line, so as to avoid the anterior jugular veins, and after the superficial structures have been divided the interval between the Sterno-hyoid muscles must be found, the raphe divided, and the muscles drawn apart. The lower border of the cricoid cartilage must now be felt for, and the upper part of the trachea exposed from this point downward in the middle line. Bose has recommended that the layer of fascia in front of the trachea should be divided transversely at the level of the lower border of the cricoid cartilage, and, having been seized with a pair of forceps pressed downward with the handle of the scalpel. By this means the isthmus of the thyroid gland is depressed, and is saved from all danger of being wounded, and the trachea cleanly exposed. The trachea is now transfixed with a sharp hook and drawn forward in order to steady it, and is then opened by inserting the knife into it and dividing the two or three upper rings from below upward. If the trachea is to be opened below the isthmus, the incision must be made from a little below the cricoid cartilage to the top of the sternum.

In the child the trachea is smaller, more deeply placed, and more movable than in the adult. In fat or short-necked people, or in those in whom the muscles of the neck are prominently developed, the trachea is more deeply placed than in the opposite conditions.

A portion of the larynx or the whole of it has been removed for malignant disease, *laryngectomy*. The results which have been obtained from the removal of the whole of it have not been very satisfactory, and the cases in which the operation is justifiable are very few. It may be removed by a median incision through the soft parts, freeing the cartilage from the muscles and other structures in front, separating the larynx from the trachea below, and dissecting off the deeper structure from below upward.

THE PLEURÆ.

Each lung is invested, upon its external surface, by an exceedingly delicate serous membrane, the **pleura,** which encloses the organ as far as its root, and is then reflected upon the inner surface of the thorax. The portion of the serous membrane investing the surface of the lung and dipping into the fissures between its lobes, is called the *pleura pulmonalis* (visceral layer of pleura), while that which lines the inner surface of the chest is called the *pleura costalis* (parietal layer of pleura). The space between these two layers is called the *cavity of the pleura*, but it must be borne in mind that in the healthy condition the two layers are in contact, and there is no real cavity until the lung becomes collapsed and a separation of it from the wall of the chest takes place. Each pleura is therefore a shut sac, one occupying the right, the other the left half of the thorax, and they are perfectly separate from each other. The two pleuræ do not meet in the middle line of the chest, excepting anteriorly opposite the second and third pieces of the sternum—a space being left between them, which contains all the viscera of the thorax excepting the lungs: this is the *mediastinum*.

Reflections of the Pleura (Fig. 535).—Commencing at the sternum, the pleura passes outward, lines the costal cartilages, the inner surface of the ribs and

Intercostal muscles, and at the back part of the thorax passes over the thoracic ganglia and their branches, and is reflected upon the sides of the bodies of the

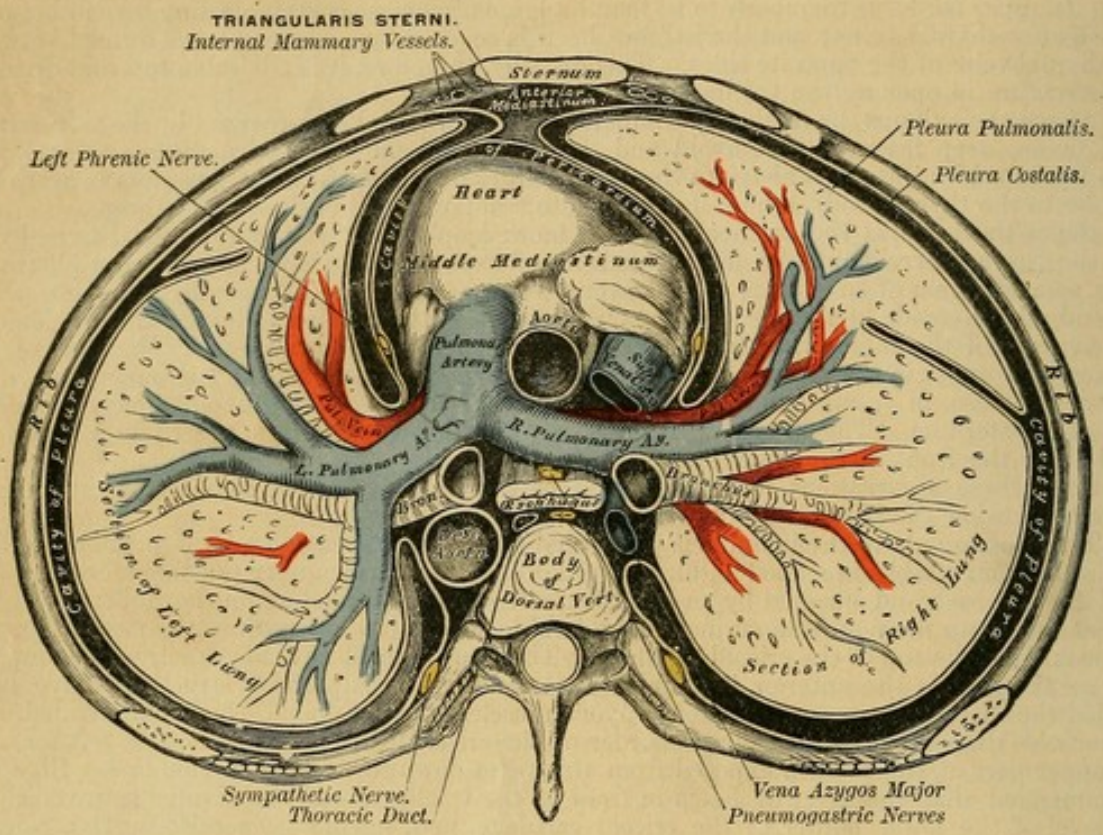

FIG. 535.—A transverse section of the thorax, showing the relative position of the viscera and the reflections of the pleuræ.

vertebræ, where it is separated by a narrow interval, the *posterior mediastinum*, from the opposite pleura. From the vertebral column the pleura passes to the side of the pericardium, which it covers to a slight extent; it then covers the back part of the root of the lung, from the lower border of which a triangular fold descends vertically by the side of the posterior mediastinum to the Diaphragm. This fold is the broad ligament of the lung, the *ligamentum latum pulmonis*, and serves to retain the lower part of that organ in position. *From the root* the pleura may be traced over the convex surface of the lung, the summit and base, and also over the sides of the fissures between the lobes on to its inner surface and the front part of its root; from this it is reflected on to the pericardium, and from it to the back of the sternum. *Below*, it covers the upper surface of the Diaphragm, and extends in front as low as the costal cartilage of the seventh rib; at the side of the chest, to the lower border of the tenth rib on the left side, and to the upper border of the same rib on the right side; and behind, it reaches as low as the twelfth rib, and sometimes even as low as the transverse process of the first lumbar vertebra. *Above*, its apex projects, in the form of a *cul-de-sac*, through the superior opening of the thorax into the neck, extending from one to two inches above the margin of the first rib, and receives the summit of the corresponding lung; this sac is strengthened, according to Sibson, by a dome-like expansion of fascia, attached in front to the posterior border of the first rib, and behind to the anterior border of the transverse process of the seventh cervical vertebra. This is covered and strengthened by a few spreading muscular fibres derived from the Scaleni muscles.

In the front of the chest, where the parietal layer of the pleura is reflected backward to the pericardium, the two pleural sacs are in contact for a considerable extent. At the upper part of the chest, behind the manubrium, they are not in contact; the point of reflection being represented by a line drawn from the sterno-clavicular articulation to the mid-point of the junction of the manubrium to the body of the sternum. From this point the two pleuræ descend in close contact to the level of

the fourth costal cartilage. Here the line of reflection on the right side is continued onward in nearly a straight line to the lower end of the gladiolus and then turns outward, while on the left side the line of reflection diverges outward, so that opposite the seventh cartilage it is about three-quarters of an inch from the left border of the sternum. It, however, always extends considerably farther over the pericardium than the corresponding lung. The lower limit of the pleura is on a considerably lower level than the lower limit of the lung, but does not extend to the attachment of the Diaphragm, so that below the line of reflection of the pleura from the chest wall on to the Diaphragm the latter is in direct contact with the rib cartilages and the Internal intercostal muscles. Moreover, in ordinary inspiration the thin margin of the base of the lung does not extend as low as the line of pleural reflection, with the result that the costal and diaphragmatic pleura are here in contact, the narrow slit between the two being termed the *phrenico-costal sinus.* A similar condition exists behind the sternum and rib cartilages, where the anterior thin margin of the lung falls short of the line of pleural reflection, and where the slit-like cavity between the two layers of pleura forms what is sometimes called the *costo-mediastinal sinus.*

The inner surface of the pleura is smooth, polished, and moistened by a serous fluid; its outer surface is intimately adherent to the surface of the lung, and to the pulmonary vessels as they emerge from the pericardium; it is also adherent to the upper surface of the Diaphragm: throughout the rest of its extent it is somewhat thicker, and may be separated from the adjacent parts with extreme facility.

The right pleural sac is shorter, wider, and reaches higher in the neck than the left.

Vessels and Nerves.—The *arteries of the pleura* are derived from the intercostal, the internal mammary, the musculo-phrenic, thymic, pericardiac, and bronchial. The *veins* correspond to the arteries. The *lymphatics* are very numerous. The *nerves* are derived from the phrenic and sympathetic (Luschka). Kölliker states that nerves accompany the ramification of the bronchial arteries in the pleura pulmonalis.

Surgical Anatomy.—In operations upon the kidney it must be borne in mind that the pleura may sometimes extend below the level of the last rib, and may therefore be opened in these operations, especially when the last rib is removed in order to give more room.

THE MEDIASTINUM.

The **Mediastinum** is the space left in the median portion of the chest by the non-approximation of the two pleuræ. It extends from the sternum in front to the spine behind, and contains all the viscera in the thorax excepting the lungs. The mediastinum may be divided for purposes of description into two parts—an upper portion, above the upper level of the pericardium, which is named the *Superior mediastinum* (Struthers); and a lower portion, below the upper level of the pericardium. This lower portion is again subdivided into three—that part which contains the pericardium and its contents, the *middle mediastinum;* that part which is in front of the pericardium, the *anterior mediastinum;* and that part which is behind the pericardium, the *posterior mediastinum.*

The **superior mediastinum** is that portion of the interpleural space which lies above the upper level of the pericardium, between the manubrium sterni in front and the upper dorsal vertebræ behind. It is bounded below by a plane passing backward from the junction of the manubrium and gladiolus sterni to the lower part of the body of the fourth dorsal vertebra, and laterally by the lungs and pleuræ. It contains the origins of the Sterno-hyoid and Sterno-thyroid muscles and the lower ends of the Longi colli muscles; the arch of the aorta; the innominate, the thoracic portion of the left carotid and subclavian arteries; the upper half of the superior vena cava and the innominate veins, and the left superior intercostal vein; the pneumogastric, cardiac, phrenic, and left recurrent laryngeal nerves; the trachea, œsophagus, and thoracic duct; the remains of the thymus gland and some lymphatic glands.

The **anterior mediastinum** is bounded in front by the sternum, on each side by the pleura, and behind by the pericardium. It is narrow above, but widens out a little below, and, owing to the oblique course taken by the left pleura, it is directed from above obliquely downward and to the left. Its anterior wall is formed by the left Triangularis sterni muscle and the fifth, sixth, and seventh left

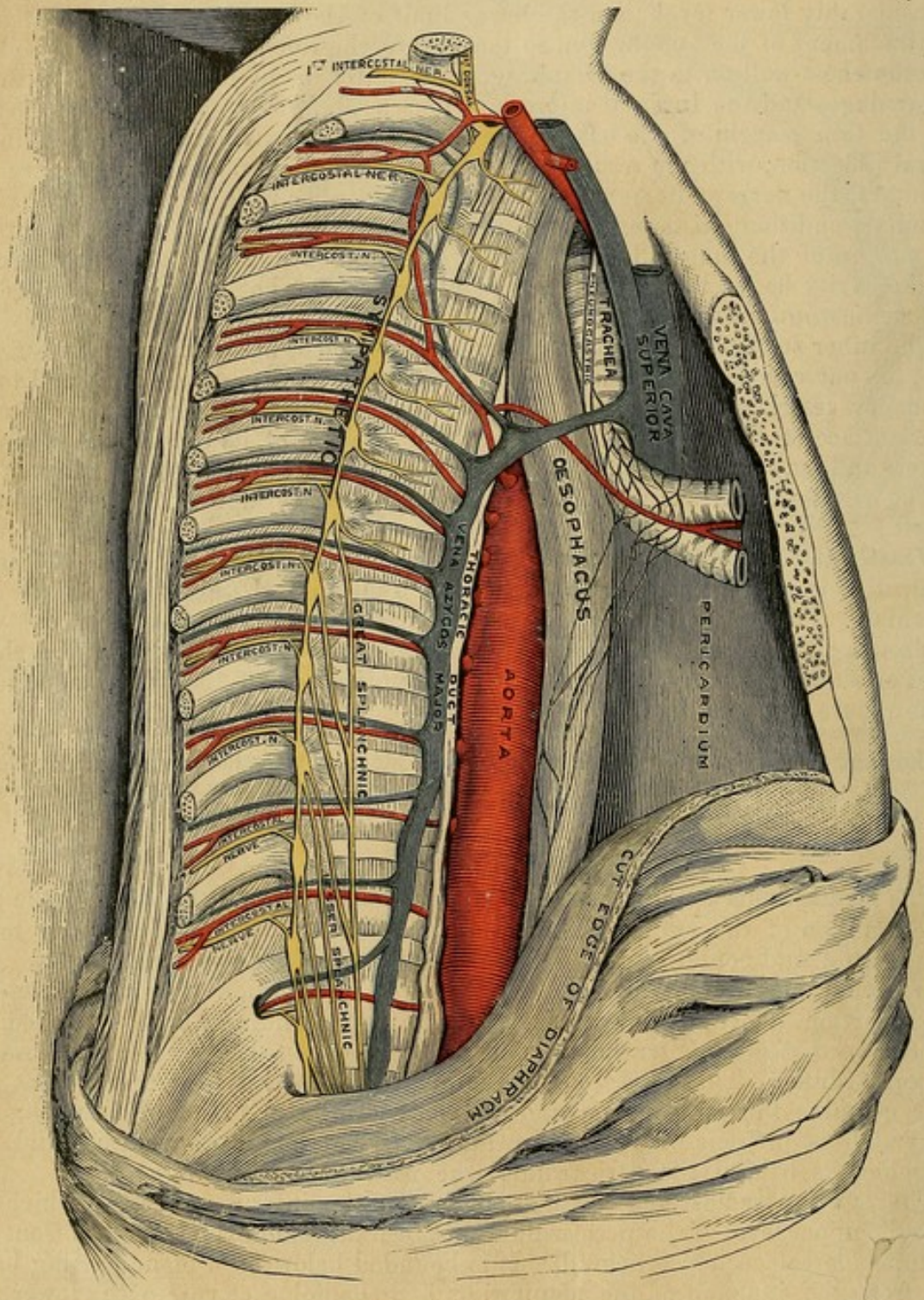

FIG. 536.—The posterior mediastinum.

costal cartilages. It contains a quantity of loose areolar tissue, some lymphatic vessels which ascend from the convex surface of the liver, two or three lymphatic glands (anterior mediastinal glands), and the small mediastinal branches of the internal mammary artery.

The **middle mediastinum** is the broadest part of the interpleural space. It contains the heart enclosed in the pericardium, the ascending aorta, the lower half of

the superior vena cava, with the vena azygos major opening into it, the bifurcation of the trachea and the two bronchi, the pulmonary artery dividing into its two branches and the right and left pulmonary veins, the phrenic nerves, and some bronchial lymphatic glands.

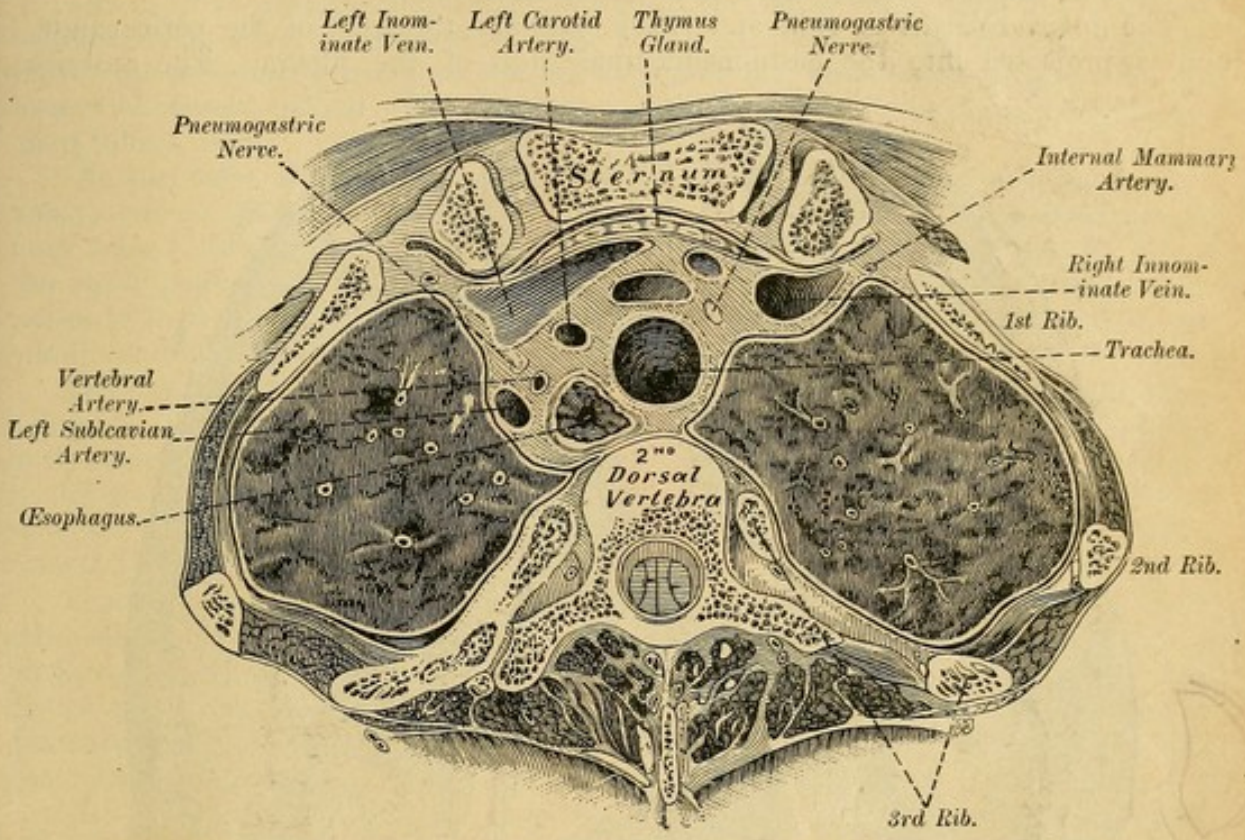

FIG. 537.—Transverse section through the upper margin of the third dorsal vertebra. (Braune.)

The **posterior mediastinum** (Fig. 536) is an irregular triangular space running parallel with the vertebral column; it is bounded in front by the pericardium and roots of the lungs, behind by the vertebral column from the lower border of the fourth dorsal vertebra, and on either side by the pleura. It contains the descending thoracic aorta, the greater and lesser azygos veins, the pneumogastric and splanchnic nerves, the œsophagus, thoracic duct, and some lymphatic glands.

THE LUNGS.

The **Lungs** are the essential organs of respiration; they are two in number, placed one on each side of the chest, separated from each other by the heart and other contents of the mediastinum. Each lung is conical in shape, and presents for examination an apex, a base, two borders, and two surfaces (Fig. 538).

The *apex* forms a tapering cone which extends into the root of the neck about an inch to an inch and a half above the level of the first rib.

The *base* is broad, concave, and rests upon the convex surface of the Diaphragm, which separates the right lung from the upper surface of the right lobe of the liver and the left lung from the upper surface of the left lobe of the liver, the stomach, and spleen; its circumference is thin, and projects for some distance into the phrenico-costal sinus of the pleura, between the lower ribs and the costal attachment of the Diaphragm, extending lower down externally and behind than in front.

The *external* or *thoracic surface* is smooth, convex, of considerable extent, and corresponds to the form of the cavity of the chest, being deeper behind than in front. dilatations become m

The *inner surface* is concave. It not it loses its cylindrical character corresponding

to the convex surface of the pericardium, and behind a deep fissure (the hilum pulmonis) which gives attachment to the root of the lung.

The *posterior border* is rounded and broad, and is received into the deep concavity on either side of the spinal column. It is much longer than the anterior border, and projects, below, into the phrenico-costal sinus.

The *anterior border* is thin and sharp, overlaps the front of the pericardium, and is projected into the costo-mediastinal sinus of the pleura. The anterior

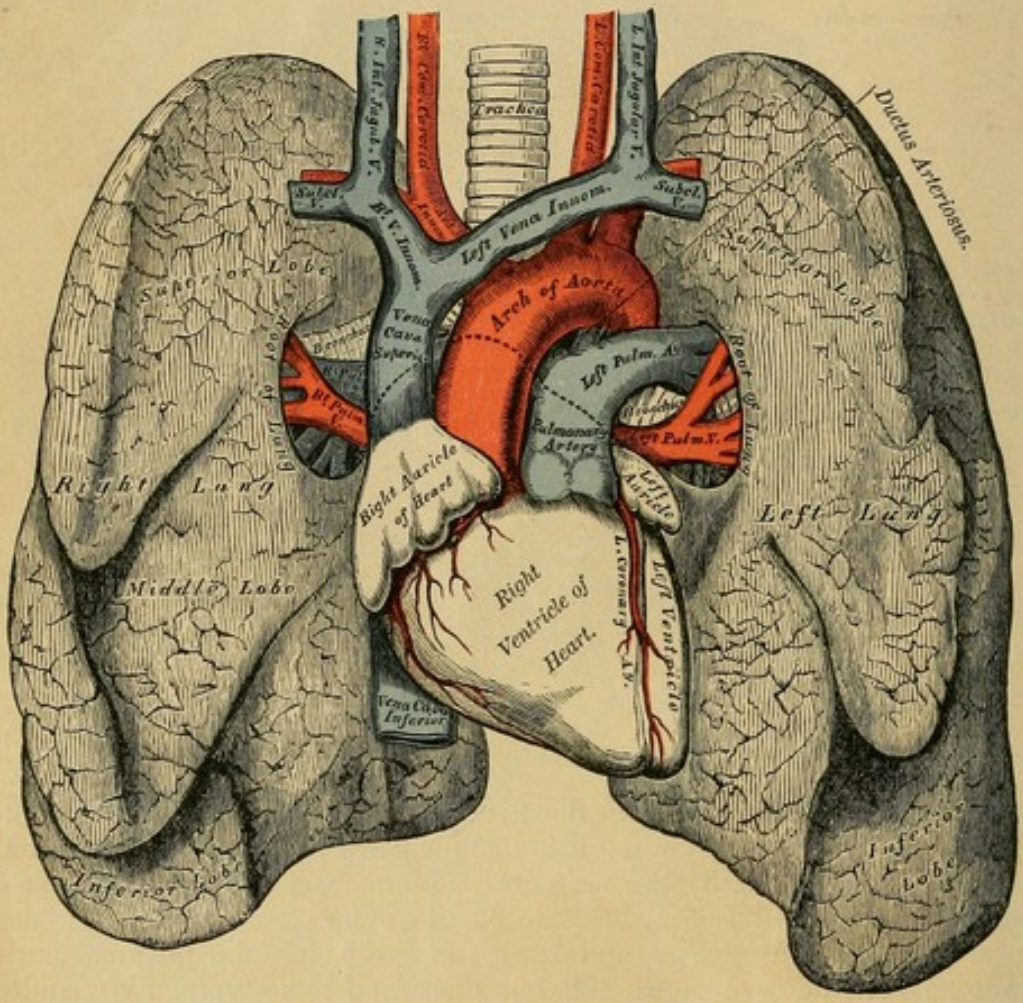

FIG. 538.—Front view of the heart and lungs.

border of the right lung is almost vertical; that of the left presents, below, an angular notch, the *incisura cardiaca*, into which the heart and pericardium are received.

Each lung is divided into two lobes, an upper and a lower, by a long and deep fissure, which extends from the upper part of the posterior border of the organ about three inches from its apex, downward and forward to the lower part of its anterior border. This fissure penetrates nearly to the root. In the right lung the upper lobe is partially subdivided by a second and shorter fissure, which extends almost horizontally forward from the middle of the preceding to the anterior margin of the organ, marking off a small triangular portion, the middle lobe.

The *right lung* is the larger and heavier; it is broader than the left, owing to the inclination of the heart to the left side; it is also shorter by an inch, in consequence of the Diaphragm rising higher on the right side to accommodate the liver.

The Root of the Lungs.—A little above the middle of the inner surface of each lung, and nearer its posterior than its anterior border, is its root, by which the lung is connected to the heart and the trachea. The root is formed by the bronchial tube, the pulmonary artery and veins, the bronchial arteries and veins, the pulmonary nerves, bronchial glands, and areolar tissue, all enclosed in the pericardium and pleura. The root of the right lung lies

Mediastinum is the broad
the heart
which

behind the superior vena cava and ascending portion of the aorta and below the vena azygos major. That of the left lung passes beneath the arch of the aorta and in front of the descending aorta; the phrenic nerve and the anterior pulmonary plexus lie in front of each, and the pneumogastric and posterior pulmonary plexus behind each.

The chief structures composing the root of each lung are arranged in a similar manner from before backward on both sides—viz., the two pulmonary veins in front; the pulmonary artery in the middle; and the bronchus, together with the bronchial vessels, behind. From above downward, on the two sides, their arrangement differs, thus:

On the right side their position is—bronchus, pulmonary artery, pulmonary veins; but on the left side their position is—pulmonary artery, bronchus, pulmonary veins. It should be noted that the entire right bronchus does not lie above the right pulmonary artery, but only its eparterial branch (see page 966), which passes to the upper lobe of the right lung; the divisions of the bronchus for the middle and lower lobes lie below the artery.

The *weight* of both lungs together is about forty-two ounces, the right lung being two ounces heavier than the left; but much variation is met with according to the amount of blood or serous fluid they may contain. The lungs are heavier in the male than in the female, their proportion to the body being in the former as 1 to 37, in the latter as 1 to 43. The specific gravity of the lung-tissue varies from 0.345 to 0.746, water being 1000.

The *color* of the lungs at birth is a pinkish-white; in adult life a dark slate-color, mottled in patches; and as age advances this mottling assumes a black color. The coloring matter consists of granules of a carbonaceous substance deposited in the areolar tissue near the surface of the organ. It increases in quantity as age advances, and is more abundant in males than in females. The posterior border of the lung is usually darker than the anterior.

The *surface* of the lung is smooth, shining, and marked out into numerous polyhedral spaces, indicating the lobules of the organ; the area of each of these spaces is crossed by numerous lighter lines.

The *substance* of the lung is of a light, porous, spongy texture; it floats in water and crepitates when handled, owing to the presence of air in the tissue; it is also highly elastic; hence the collapsed state of these organs when they are removed from the closed cavity of the thorax.

Structure.—The lungs are composed of an external serous coat, a subserous areolar tissue, and the pulmonary substance or parenchyma.

The *serous coat* is derived from the pleura; it is thin, transparent, and invests the entire organ as far as the root.

The *subserous areolar tissue* contains a large proportion of elastic fibres; it invests the entire surface of the lung, and extends inward between the lobules.

The *parenchyma* is composed of lobules which, although closely connected together by an interlobular areolar tissue, are quite distinct from one another, and may be teased asunder without much difficulty in the fœtus. The lobules vary in size; those on the surface are large, of pyramidal form, the base turned toward the surface; those in the interior, smaller and of various forms. Each lobule is composed of one of the ramifications of a bronchial tube and its terminal air-cells, and of the ramifications of the pulmonary and bronchial vessels, lymphatics, and nerves, all of these structures being connected together by areolar tissue.

The *bronchus*, upon entering the substance of the lung, divides and subdivides bipinnately, throughout the entire organ. Sometimes three branches arise together, and occasionally small lateral branches are given off from the sides of a main trunk. Each of the smaller subdivisions of the bronchi enters a pulmonary lobule, and is termed a *lobular bronchial tube* or *bronchiole*. Its wall now begins to present irregular dilatations, *air-cells* or *alveoli*, at first sparingly and on one side of the tube only, but as it proceeds onward these dilatations become more numerous and surround the tube on all sides, so that it loses its cylindrical character. The

bronchiole now becomes enlarged, and is termed the *atrium* or *alveolar passage;* from it are given off, on all sides, ramifications, called *infundibula*, which are closely beset in all directions by *alveoli* or *air-cells*. Within the lungs the bronchial tubes are circular, not flattened, and present certain peculiarities of structure.

Changes in the Structure of the Bronchi in the Lungs.—1. *In the Lobes of the Lungs.*—In the lobes of the lungs the following changes take place. The *cartilages* are not imperfect rings, but consist of thin laminæ, of varied form and size, scattered irregularly along the sides of the tube, being most distinct at the points of division of the bronchi. They may be traced into tubes, the diameter of which is only one-fourth of a line. Beyond this point the tubes are wholly membranous. The fibrous coat is continued into the smallest ramifications of the bronchi. The muscular coat is disposed in the form of a continuous layer of annular fibres, which may be traced upon the smallest bronchial tubes, and consists of the unstriped variety of muscular tissue. The mucous membrane lines the bronchi and its ramifications throughout, and is covered with columnar ciliated epithelium.

In the Lobules of the Lung.—In the lobular bronchial tubes and in the infundibula the following changes take place: The muscular tissue begins to disappear, so that in the infundibula there is scarcely a trace of it. The fibrous coat becomes thinner, and degenerates into areolar tissue. The epithelium becomes non-ciliated and flattened. This occurs gradually; thus, in the lobular bronchioles patches of non-ciliated flattened epithelium may be found scattered among the columnar ciliated epithelium; then these patches of non-ciliated flattened epithelium become more and more numerous, until in the infundibula and air-cells all the epithelium is of the non-ciliated pavement variety. In addition to these flattened cells, there are small polygonal granular cells in the air-sacs, in clusters of two or three, between the others.

The air-cells are small, polyhedral recesses composed of a fibrillated connective tissue and surrounded by a few involuntary muscular and elastic fibres. Free in their cavity are to be seen under the microscope granular, rounded, amœboid cells (eosinophile leucocytes), often containing carbonaceous particles. The air-cells are well seen on the surface of the lung, and vary from $\frac{1}{200}$th to $\frac{1}{70}$th of an inch in diameter, being largest on the surface at the thin borders and at the apex, and smallest in the interior.

The *pulmonary artery* conveys the venous blood to the lungs; it divides into branches which accompany the bronchial tubes, and terminates in a dense capillary network upon the walls of the intercellular passages and air-cells. In the lung the branches of the pulmonary artery are usually above and in front of a bronchial tube, the vein below.

The *pulmonary capillaries* form plexuses which lie immediately beneath the mucous membrane in the walls and septa of the air-cells and of the infundibula. In the septa between the air-cells the capillary network forms a single layer. The capillaries form a very minute network, the meshes of which are smaller than the vessels themselves;[1] their walls are also exceedingly thin. The arteries of neighboring lobules are independent of each other, but the veins freely anastomose together.

The *pulmonary veins* commence in the pulmonary capillaries, the radicles coalescing into larger branches, which run along through the substance of the lung, independently from the minute arteries and bronchi. After freely communicating with other branches they form large vessels, which ultimately come into relation with the arteries and bronchial tubes, and accompany them to the hilum of the organ. Finally they open into the left auricle of the heart, conveying oxygenated blood to be eventually distributed to all parts of the body by the aorta.

The *bronchial arteries* supply blood for the nutrition of the lung; they are derived from the thoracic aorta or from the upper aortic intercostal arteries, and,

[1] The meshes are only 0.002‴ to 0.008‴ in width, while the vessels are 0.003‴ to 0.005‴ (Kölliker, *Human Microscopic Anatomy*).

accompanying the bronchial tubes, are distributed to the bronchial glands, and upon the walls of the larger bronchial tubes and pulmonary vessels. Those supplying the bronchial tubes form a capillary plexus in the muscular coat, from which branches are given off to form a second plexus in the mucous coat. This plexus communicates with branches of the pulmonary artery, and empties itself into the pulmonary vein. Others are distributed in the interlobular areolar tissue, and terminate partly in the deep, partly in the superficial, bronchial veins. Lastly, some ramify upon the surface of the lung beneath the pleura, where they form a capillary network.

The *bronchial vein* is formed at the root of the lung, receiving superficial and deep veins corresponding to branches of the bronchial artery. It does not, however, receive all the blood supplied by the artery, as some of it passes into the pulmonary vein. It terminates on the right side in the vena azygos major, and on the left side in the superior intercostal or left upper azygos vein.

The **lymphatics** consist of a superficial and deep set: they terminate at the root of the lung, in the bronchial glands.

Nerves.—The lungs are supplied from the anterior and posterior pulmonary plexuses, formed chiefly by branches from the sympathetic and pneumogastric. The filaments from these plexuses accompany the bronchial tubes, upon which they are lost. Small ganglia are found upon these nerves.

Surface Form.—The apex of the lung is situated in the neck, behind the interval between the two heads of origin of the Sterno-mastoid. The height to which it rises above the clavicle varies very considerably, but is generally about one inch. It may, however, extend as much as an inch and a half or an inch and three-quarters, or, on the other hand, it may scarcely project above the level of this bone. In order to mark out the anterior margin of the lung, a line is to be drawn from the apex-point, one inch above the level of the clavicle, and rather nearer the posterior than the anterior border of the Sterno-mastoid muscle, downward and inward across the sterno-clavicular articulation and first piece of the sternum until it meets, or almost meets, its fellow of the other side opposite the articulation of the manubrium and gladiolus. From this point the two lines are to be drawn downward, one on either side of the mesial line and close to it, as far as the level of the articulation of the fourth costal cartilages to the sternum. From here the two lines diverge; the left is to be drawn at first passing outward with a slight inclination downward, and then taking a bend downward with a slight inclination outward to the apex of the heart, and thence to the sixth costo-chondral articulation. The direction of the anterior border of this part of the left lung is denoted with sufficient accuracy by a curved line with its convexity directed upward and outward from the articulation of the fourth right costal cartilage of the sternum to the fifth intercostal space, an inch and a half below and three-quarters of an inch internal to the left nipple. The continuation of the anterior border of the right lung is marked by a prolongation of its line from the level of the fourth costal cartilages vertically downward as far as the sixth, when it slopes off along the line of the sixth costal cartilage to its articulation with the rib.

The lower border of the lung is marked out by a slightly curved line with its convexity downward from the articulation of the sixth costal cartilage to its rib to the spinous process of the tenth dorsal vertebra. If vertical lines are drawn downward from the nipple, the mid-axillary line, and the apex of the scapula, while the arms are raised from the sides, they should intersect this convex line, the first at the sixth, the second at the eighth, and the third at the tenth rib. It will thus be seen that the pleura (see page 971) extends farther down than the lung, so that it may be wounded, and a wound pass through its cavity into the Diaphragm, and even injure the abdominal viscera, without the lung being involved.

The posterior border of the lung is indicated by a line drawn from the level of the spinous process of the seventh cervical vertebra, down either side of the spine, corresponding to the costo-vertebral joints as low as the spinous process of the tenth dorsal vertebra. The trachea bifurcates opposite the spinous process of the fourth dorsal vertebra, and from this point the two bronchi are directed outward.

The position of the great fissure in the right lung may be indicated by a line drawn from the fourth dorsal vertebra round the side of the chest to the anterior margin of the lung opposite the seventh rib, and the smaller or secondary fissure by a line drawn from the preceding where it bisects the mid-axillary line to the junction of the fourth costal cartilage to the sternum. The great fissure in the left lung is a little higher, extending from the third dorsal vertebra round the side of the chest to reach the anterior margin of the lung opposite the sixth costal cartilage.

Surgical Anatomy.—The lungs may be wounded or torn in three ways: (1) By compression of the chest, without any injury to the ribs. (2) By a fractured rib penetrating the lung. (3) By stabs, gunshot wounds, etc.

The first form, where the lung is ruptured by external compression without any fracture of the ribs, is very rare, and usually occurs in young children, and affects the root of the lung—

i.e., the most fixed part—and thus, implicating the great vessels, is frequently fatal. It would seem *a priori* a most unusual injury, and its exact mode of causation is difficult to interpret. The probable explanation is that immediately before the compression is applied a deep inspiration is taken and the lungs are fully inflated; owing then to spasm of the glottis at the moment

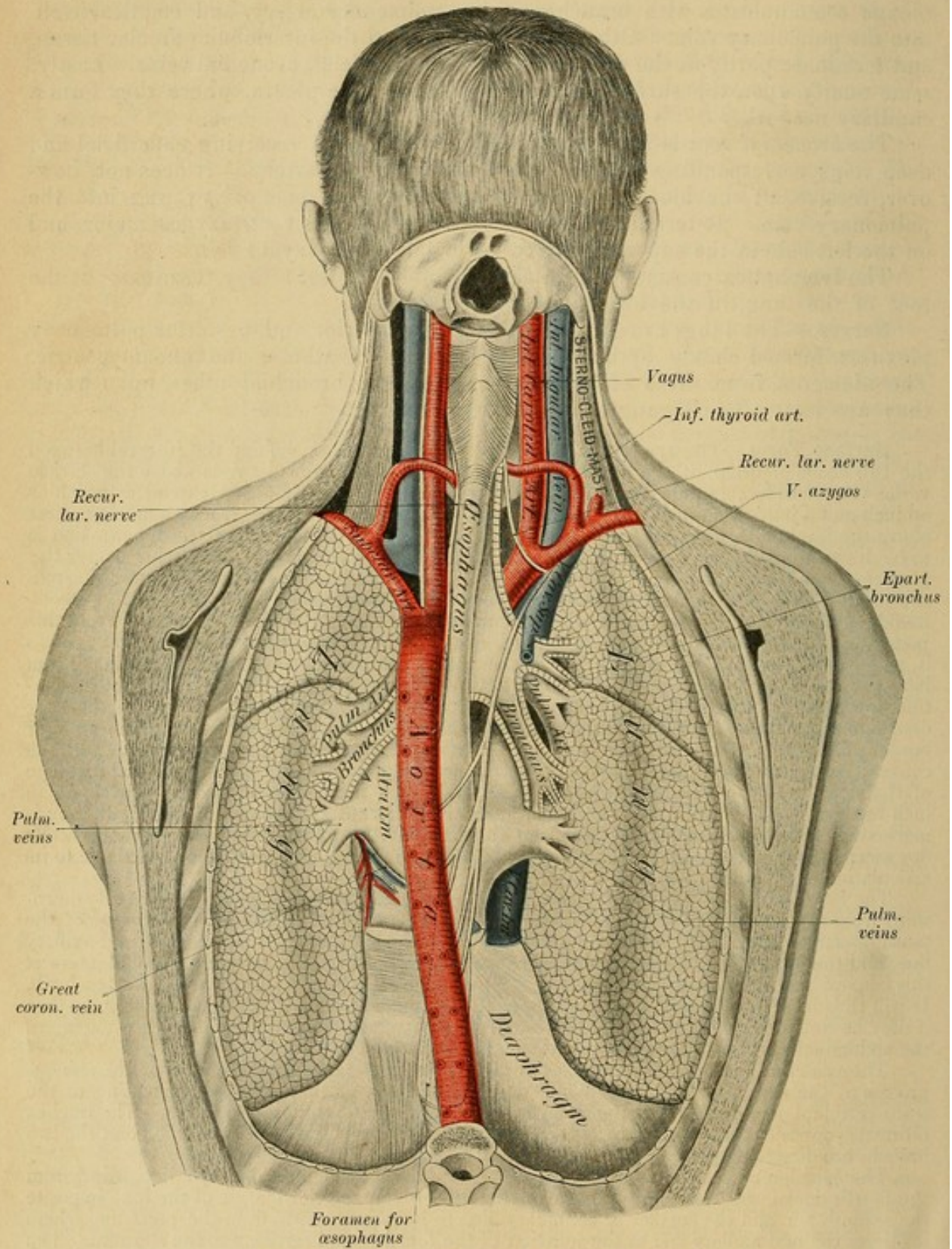

FIG. 539.—Thoracic contents seen from behind. (Joessel.)

of compression, the air is unable to escape from the lung, which is not able to recede, and consequently gives way.

In the second variety, when the wound in the lung is produced by the penetration of a broken rib, both the pleura costalis and pulmonalis must necessarily be injured, and consequently the air taken into the wounded air-cells may find its way through these wounds into the cellular

tissue of the parietes of the chest. This it may do without collecting in the pleural cavity; the two layers of the pleura are so intimately in contact that the air passes straight through from the wounded lung into the subcutaneous tissue. Emphysema constitutes, therefore, the most important sign of injury to the lung in cases of fracture of the ribs. Pneumothorax, or air in the pleural cavity, is much more likely to occur in injuries to the lung of the third variety; that is to say, from external wounds, from stabs, gunshot injuries, and such like, in which cases air passes either from the wound of the lung or from an external wound into the cavity of the pleura during the respiratory movements. In these cases there is generally no emphysema of the subcutaneous tissue unless the external wound is small and valvular, so that the air drawn into the wound during inspiration is then forced into the cellular tissue around during expiration because it cannot escape from the external wound. Occasionally in wounds of the parietes of the chest no air finds its way into the cavity of the pleura, because the lung at the time of the accident protrudes through the wound and blocks the opening. This occurs where the wound is large, and constitutes one form of *hernia* of the lung. Another form of hernia of the lung occurs, though very rarely, after wounds of the chest wall, when the wound has healed and the cicatrix subsequently yields from the pressure of the viscus behind. It forms a globular, elastic, crepitating swelling, which enlarges during expiratory efforts, falls in during inspiration, and disappears on holding the breath.

THE THYROID GLAND.

The **thyroid gland** is classified with the thymus, suprarenal capsules, and spleen, under the head of *ductless glands—i. e.*, glands which do not possess an excretory duct. From its situation in connection with the trachea and larynx, the thyroid body is usually described with those organs, although it takes no part in the function of respiration. It is situated at the front and sides of the neck, and consists of two lateral lobes connected across the middle line by a narrow transverse portion, the *isthmus*.

The weight of the gland is somewhat variable, but is usually about one ounce. It is somewhat heavier in the female, in whom it becomes enlarged during menstruation and pregnancy.

The lobes are conical in shape, the apex of each being directed upward and outward as far as the junction of the middle with the lower third of the thyroid cartilage; the base looks downward, and is on a level with the fifth or sixth tracheal ring.

The *external* or *superficial surface* is convex, and covered by the skin, the superficial and deep fascia, the Sterno-mastoid, the anterior belly of the Omo-hyoid, the Sterno-hyoid and Sterno-thyroid muscles, and beneath the last muscle by the pre-tracheal layer of the deep fascia, which forms a capsule for the gland.

The *deep* or *internal surface* is moulded over the underlying structures, viz., the thyroid and cricoid cartilages, the trachea, the inferior constrictor and posterior part of the Crico-thyroid muscles, the œsophagus (particularly on the left side of the neck), the superior and inferior thyroid arteries, and the recurrent laryngeal nerves.

Its *anterior border* is thin, and inclines obliquely from above downward and inward toward the middle line of the neck, while the *posterior border* is thick and overlaps the common carotid artery. Each lobe is about two inches in length, its greatest width is about one inch and a quarter, and its thickness about three quarters of an inch.

The *isthmus* connects the lower third of the two lateral lobes; it measures about half an inch in breadth and the same in depth, and usually covers the second and third rings of the trachea. Its situation presents, however, many variations, a point of importance in the operation of tracheotomy. In the middle line of the neck it is covered by the skin and fascia, and close to the middle line, on either side, by the Sterno-hyoid. Across its upper border runs a branch of the superior thyroid artery; at its lower border are the inferior thyroid veins. Sometimes the isthmus is altogether wanting.

A third lobe, of conical shape, called the *pyramid*, occasionally arises from the upper part of the isthmus, or from the adjacent portion of either lobe, but most commonly the left, and ascends as high as the hyoid bone. It is occasionally quite detached, or divided into two or more parts, or altogether wanting.

A few muscular bands are occasionally found attached, above, to the body of the hyoid bone, and below to the isthmus of the gland or its pyramidal process. These form a muscle, which was named by Sommerring the *Levator glandulæ thyroidæ.*

Small detached portions of thyroid tissue (*accessory thyroid*) are sometimes found above the isthmus, and their presence is readily explained by a reference to the manner in which the gland is developed. They represent isolated portions of the median thyroid rudiment. (See section on Embryology.)

Structure.—The thyroid body is invested by a thin capsule of connective tissue which projects into its substance and imperfectly divides it into masses of irregular form and size. When the organ is cut into, it is of a brownish-red color, and is seen to be made up of a number of closed vesicles containing a yellow glairy fluid and separated from each other by intermediate connective tissue.

According to Baber, who has published some important observations on the minute structure of the thyroid,[1] the vesicles of the thyroid of the adult animal are generally closed cavities; but in some young animals (*e. g.*, young

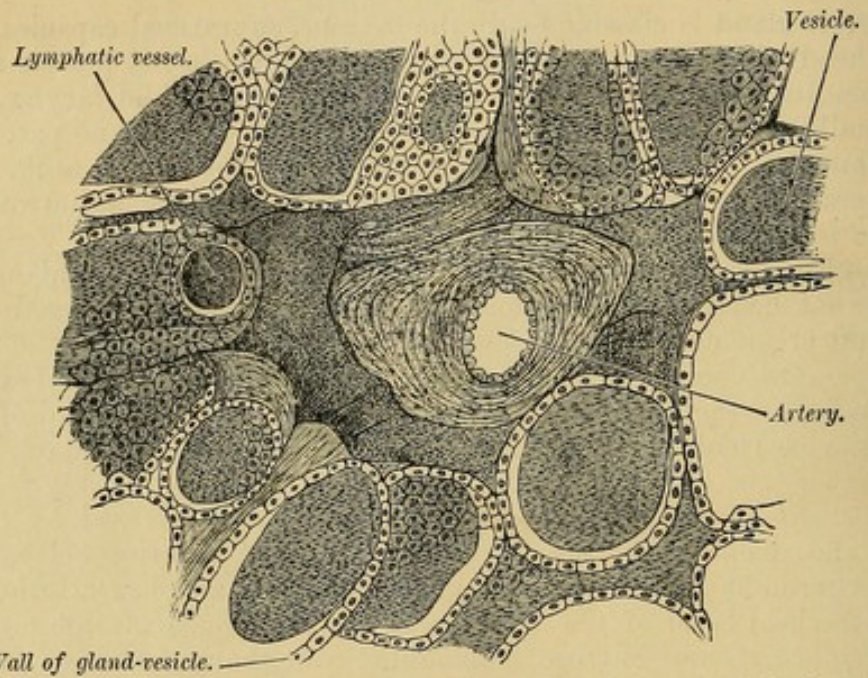

FIG. 540.—Minute structure of thyroid. From a transverse section of the thyroid of a dog. (Semi-diagrammatic.) (Baber.)

dogs) the vesicles are more or less tubular and branched. This appearance he supposes to be due to the mode of growth of the gland, and merely indicating that an increase in the number of vesicles is taking place. Each vesicle is lined by a single layer of epithelium, the cells of which, though differing somewhat in shape in different animals, have always a tendency to assume a columnar form. Between the epithelial cells exists a delicate reticulum. The vesicles are of various sizes and shapes, and contain as a normal product a viscid, homogeneous, semi-fluid, slightly yellowish material which frequently contains blood, the red corpuscles of which are found in it in various stages of disintegration and decolorization, the yellow tinge being probably due to the hæmoglobin, which is thus set free from the colored corpuscles. Baber has also described in the thyroid gland of the dog large round cells ("parenchymatous cells"), each provided with a single oval-shaped nucleus, which migrate into the interior of the gland-vesicles.

The capillary blood-vessels form a dense plexus in the connective tissue around the vesicles, between the epithelium of the vesicles and the endothelium of the lymph-spaces, which latter surround a greater or smaller part of the circumference of the vesicle. These lymph-spaces empty themselves into lymphatic vessels which run in the interlobular connective tissue, not uncommonly surrounding the

[1] "Researches on the Minute Structure of the Thyroid Glands," *Phil. Trans.*, part iii., 1881.

arteries which they accompany, and communicates with a network in the capsule of the gland. Baber has found in the lymphatics of the thyroid a viscid material which is morphologically identical with the normal constituent of the vesicle.

Vessels and Nerves.—The *arteries* supplying the thyroid are the superior and inferior thyroid, and sometimes an additional branch (thyroidea media or ima) from the innominate artery or the arch of the aorta, which ascends upon the front of the trachea. The arteries are remarkable for their large size and frequent anastomoses. The *veins* form a plexus on the surface of the gland and on the front of the trachea, from which arise the superior, middle, and inferior thyroid veins, the two former terminating in the internal jugular, the latter in the innominate vein. The *lymphatics* are numerous, of large size, and terminate in the thoracic and right lymphatic ducts. The *nerves* are derived from the middle and inferior cervical ganglia of the sympathetic.

Surgical Anatomy.—The thyroid gland is subject to enlargement, which is called goitre. This may be due to hypertrophy of any of the constituents of the gland. The simplest (parenchymatous goitre) is due to an enlargement of the follicles. The *fibroid* is due to increase of the interstitial connective tissue. The *cystic* is that form in which one or more large cysts are formed from dilatation and possibly coalescence of adjacent follicles. The *pulsating goitre* is where the vascular changes predominate over the parenchymatous, and the vessels of the gland are especially enlarged. Finally, there is *exophthalmic goitre* (Graves's disease), where there is great vascularity and often pulsation, accompanied by exophthalmos, palpitation, and rapid pulse.

For the relief of these growths various operations have been resorted to, such as injection of tincture of iodine or perchloride of iron, especially applicable to the cystic form of the disease, ligature of the thyroid arteries, excision of the isthmus, and extirpation of the whole or a part of the gland. This latter operation is one of difficulty, and when the entire gland has been removed the operation has been followed by a condition resembling myxœdema. In removing the organ great care must be taken to avoid tearing the capsule, as if this happens the gland-tissue bleeds profusely. The thyroid arteries should be ligatured before an attempt is made to remove the mass, and in ligaturing the inferior thyroids the position of the recurrent laryngeal nerve must be borne in mind, so as not to include it in the ligature. A large number of cases of what were formerly supposed to be goitre are now known to be cases of adenomatous enlargement, where an adenoma, starting in one part of the gland, gradually spreads and involves the whole organ.

Parathyroids.—These are small rounded, brownish-red bodies, with an average diameter of about a quarter of an inch, situated in or near the thyroid gland, from which, however, they differ in structure, being composed of masses of cells arranged in a more or less columnar fashion with numerous intervening capillaries. They are divided from their situation into *external* and *internal*. The former, usually two in number, are situated, one on each side, in relation to the postero-internal surface of the lateral lobe; sometimes they are duplicated. The latter, also usually two in number, are placed one in each lateral lobe, generally near its mesial surface.

THE THYMUS GLANDS.

The **thymus gland** is a temporary organ, attaining its full size at the end of the second year, when it ceases to grow, and gradually dwindles, until at puberty it has almost disappeared. If examined when its growth is most active, it will be found to consist of two lateral lobes placed in close contact along the middle line, situated partly in the superior mediastinum, partly in the neck, and extending from the fourth costal cartilage upward as high as the lower border of the thyroid gland. It is covered by the sternum and by the origins of the Sterno-hyoid and Sterno-thyroid muscles. Below, it rests upon the pericardium, being separated from the arch of the aorta and great vessels by a layer of fascia. In the neck it lies on the front and sides of the trachea, behind the Sterno-hyoid and Sterno-thyroid muscles. The two lobes generally differ in size; they are occasionally united so as to form a single mass, and sometimes separated by an intermediate lobe. The thymus is of a pinkish-gray color, soft, and lobulated on its surfaces. It is about two inches in length, one and a half in breadth below, and about three or four lines in thickness. At birth it weighs about half an ounce.

Structure.—Each lateral lobe is composed of numerous lobules held together by delicate areolar tissue, the entire gland being enclosed in an investing capsule of a similar but denser structure. The primary lobules vary in size from a pin's head to a small pea, and are made up of a number of small nodules or follicles which are irregular in shape and are more or less fused together, especially toward the interior of the gland. Each follicle consists of a medullary and cortical portion, which differ in many essential particulars from each other. The *cortical portion* is mainly composed of lymphoid cells supported by a delicate reticulum. In addition to this reticulum, of which traces only are found in the medullary portion, there is also a network of finely branched cells which is continuous with a similar network in the medullary portion. This network forms an adventitia to the blood-vessels. In the *medullary portion* there are but few lymphoid cells, but there are, especially toward the centre, granular cells and concentric corpuscles. The granular cells are rounded or flask-shaped masses attached (often by fibrillated extremities) to blood-vessels and to newly formed connective tissue. The concentric corpuscles are composed of a central mass consisting of one or more granular cells, and of a capsule which is formed of epithelioid cells which are continuous with the branched cells forming the network mentioned above.

Each follicle is surrounded by a capillary plexus from which vessels pass into the interior and radiate from the periphery toward the centre, and form a second zone just within the margin of the medullary portion. In the centre of the medulla there are very few vessels, and they are of minute size.

Watney has recently made the important observation that hæmoglobin is found in the thymus either in cysts or in cells situated near to or forming part

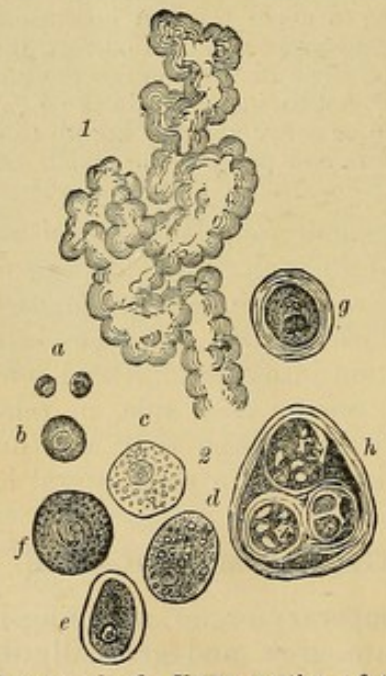

FIG. 541.—Minute structure of thymus gland. Upper portion of the thymus of a fœtal pig of 2″ in length, showing the bud-like lobuli and glandular elements. 2. Cells of the thymus, mostly from a man. *a*. Free nuclei. *b*. Small cells. *c*. Larger. *d*. Larger, with oil-globules, from the ox. *e*, *f*. Cells completely filled with fat, at *f* without a nucleus. *g*, *h*. Concentric bodies. *g*. An encapsulated nucleated cell. *h*. A composite structure of a similar nature.

of the concentric corpuscles. This hæmoglobin varies from granules to masses exactly resembling colored blood-corpuscles, oval in the bird, reptile, and fish; circular in all mammals except in the camel. Dr. Watney has also discovered in the lymph issuing from the thymus similar cells to those found in the gland, and, like them, containing hæmoglobin either in the form of granules or masses. From these facts he arrives at the physiological conclusion that the thymus is one source of the colored blood-corpuscles.

Vessels and Nerves.—The *arteries* supplying the thymus are derived from the internal mammary and from the superior and inferior thyroid. The *veins* terminate in the left innominate vein and in the thyroid veins. The *lymphatics*

are of large size, arise in the substance of the gland, and are said to terminate in the internal jugular vein. The *nerves* are exceedingly minute; they are derived

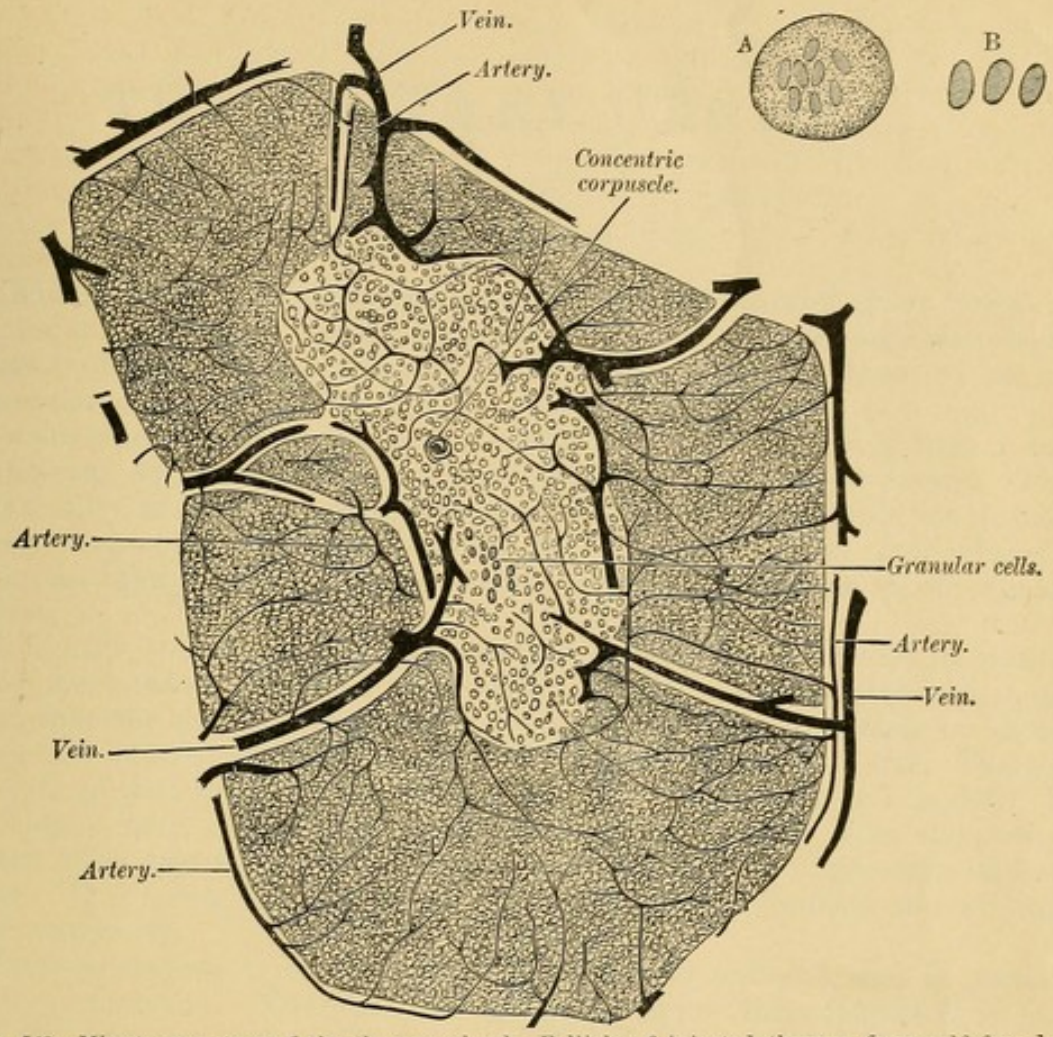

FIG. 542.—Minute structure of the thymus gland. Follicle of injected thymus from calf, four days old, slightly diagrammatic, magnified about 50 diameters. The large vessels are disposed in two rings, one of which surrounds the follicle, the other lies just within the margin of the medulla. (Watney.) A and B. From thymus of camel, examined without addition of any reagent. Magnified about 400 diameters. A. Large colorless cell containing small oval masses of hæmoglobin. Similar cells are found in the lymph-glands, spleen, and medulla of bone. B. Colored blood-corpuscles.

from the pneumogastric and sympathetic. Branches from the descendens hypoglossi and phrenic reach the investing capsule, but do not penetrate into the substance of the gland.

THE URINARY ORGANS.

THE KIDNEYS.

THE Kidneys, two in number, are situated in the back part of the abdomen, and are for the purpose of separating from the blood certain materials which, when dissolved in a quantity of water, also separated from the blood by the kidneys, constitute the urine.

They are placed in the loins, one on each side of the vertebral column, behind the peritoneum, and surrounded by a mass of fat and loose areolar tissue. Their upper extremity is on a level with the upper border of the twelfth dorsal vertebra, their lower extremity on a level with the third lumbar. The right kidney is usually on a slightly lower level than the left, probably on account of the vicinity of the liver.

Each kidney is about four inches in length, two to two and a half in breadth, and rather more than one inch in thickness. The left is somewhat longer, though narrower, than the right. The weight of the kidney in the adult male varies from 4½ ounces to 6 ounces; in the adult female, from 4 ounces to 5½ ounces. The combined weight of the two kidneys in proportion to the body is about 1 in 240.

The kidney has a characteristic form. It is flattened on its sides and presents at one part of its circumference a hollow. It is larger at its upper than its lower extremity. It presents for examination two surfaces, two borders, and an upper and lower extremity.

Its *anterior surface* is convex, looks forward and outward, and is partially covered by peritoneum. The right kidney in its upper three-fourths is in contact with the posterior part of the under surface of the right lobe of the liver, on which it produces a concave impression, the *impressio renalis* (page 918). Toward its inner border it is covered by the second part of the duodenum, while its lower and outer part is in relation with the hepatic flexure of the colon. The relation of the second part of the duodenum to the front of the right kidney is a varying one. The left kidney is covered above by the posterior surface of the stomach, below the stomach by the pancreas, behind which are the splenic vessels. Its lower half is in contact with some of the coils of the small intestine and sometimes with the third part of the duodenum. Near its outer border the anterior surface lies behind the spleen and the splenic flexure of the colon.

The kidneys are partly covered in front by peritoneum and partly uncovered. On the right kidney, the *hepatic area*, that is to say that portion of the kidney which produces the renal impression on the liver, is covered by peritoneum, which therefore separates the kidney from the liver: the *duodenal* and *colic areas* are not peritoneal, and these structures are connected to the kidney by loose connective tissue; at the lower and inner extremity is a small area, the *mesocolic area*, which is covered by a layer of peritoneum of the greater sac and by the colic vessels. On the left kidney, the *gastric area* is covered by the peritoneum of the lesser sac; the *pancreatic* and *colic areas* are non-peritoneal: while, as on the right side, at the lower and inner extremity, is an area, *mesocolic*, which is covered by the peritoneum of the greater sac and by the colic vessels.

The posterior surface of the kidney is flatter than the anterior and is directed backward and inward. It is entirely devoid of peritoneal covering, being imbedded in areolar and fatty tissue. It lies upon the Diaphragm, the anterior layer of the lumbar aponeurosis, the external and internal arcuate ligaments, the Psoas

and Transversalis muscles, one or two of the upper lumbar arteries, the last dorsal, ilio-hypogastric, and ilio-inguinal nerves. The right kidney rests upon the twelfth rib, the left usually on the eleventh and twelfth. The Diaphragm separates the kidney from the pleura as it dips down to form the phrenico-costal sinus, but frequently the muscular fibres of the Diaphragm are defective or absent over a triangular area immediately above the external arcuate ligament, and when this is the case the perirenal areolar tissue is in immediate apposition with the diaphragmatic pleura.

The *external border* is convex, and is directed outward and backward, toward the postero-lateral wall of the abdomen. On the left side it is in contact, at its upper part, with the spleen.

The *internal border* is concave, and is directed forward and a little downward. It presents a deep longitudinal fissure, bounded by a prominent overhanging anterior and posterior lip. This fissure is named the *hilum*, and allows of the passage of the vessels, nerves, and ureter into and out of the kidney.

The *superior extremity*, directly slightly inward as well as upward, is thick and rounded, and is surmounted by the suprarenal capsule, which covers also a small portion of the anterior surface.

The *inferior extremity*, directed a little outward as well as downward, is smaller and thinner than the superior. It extends to within two inches of the crest of the ilium.

At the hilum of the kidney the relative position of the main structures passing into and out of the kidney is as follows: the vein is in front, the artery in the middle, and the duct or ureter behind and toward the lower part. By a knowledge of these relations the student may distinguish between the right and left kidney. The kidney is to be laid on the table before the student on its posterior surface, with its lower extremity toward the observer—that is to say, with the ureter *behind* and *below* the other vessels; the hilum will then be directed to the side to which the kidney belongs.

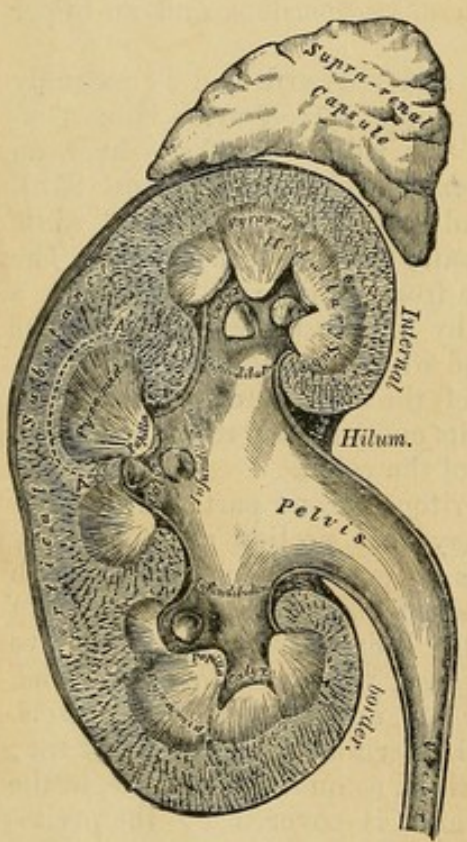

FIG. 543.—Vertical section of kidney.

General Structure of the Kidney.—The kidney is surrounded by a distinct investment of fibrous tissue which forms a firm, smooth covering to the organ. It closely invests it, but can be easily stripped off, in doing which, however, numerous fine processes of connective tissue and small blood-vessels are torn through. Beneath this coat a thin wide-meshed network of unstriped muscular fibre forms an incomplete covering to the organ. When the fibrous coat is stripped off, the surface of the kidney is found to be smooth and even and of a deep-red color.

In infants fissures extending for some depth may be seen on the surface of the organ, a remnant of the lobular construction of the gland. The kidney is dense in texture, but is easily lacerable by mechanical force. In order to obtain a knowledge of the structure of the gland, a vertical section must be made from its convex to its concave border, and the loose tissue and fat removed around the vessels and the excretory duct (Fig. 543). It will be then seen that the kidney consists of a central cavity surrounded at all parts but one by the proper kidney-substance. This central cavity is called the *sinus*, and is lined by a prolongation of the fibrous coat of the kidney, which enters through a longitudinal fissure, the *hilum* (before mentioned), which is situated at that part of the cavity which is not surrounded

by kidney-structure. Through this fissure the blood-vessels of the kidney and its excretory duct pass, and therefore these structures, upon entering the kidney, are contained within the sinus. The excretory duct, or *ureter*, after entering, dilates into a wide, funnel-shaped sac named the *pelvis*. This divides into two or three tubular divisions, which subdivide into several short, truncated branches named *calices* or *infundibula*, all of which are contained in the central cavity of the kidney. The blood-vessels of the kidney, after passing through the hilum, are contained in the sinus or central cavity, lying between its lining membrane and the excretory apparatus, before entering the kidney-substance.

This central cavity, as before mentioned, is surrounded on all sides except at the hilum by the substance of the kidney, which is at once seen to consist of two parts—viz. of an external granular investing part, which is called the *cortical portion;* and of an internal part, the *medullary portion*, made up of a number of dark-colored pyramidal masses, with their bases resting on the cortical part and their apices converging toward the centre, where they form prominent papillæ which project into the interior of the calices.

The cortical substance is of a bright reddish-brown color, soft, granular, and easily lacerable. It is found everywhere immediately beneath the capsule, and is seen to extend in an arched form over the base of each medullary pyramid. The part separating the sides of any two pyramids through which the arteries and nerves enter, and the veins and lymphatics emerge, from the kidney, is called a *cortical column* or *column of Bertin* (A, A′, Fig. 543); while that portion which stretches from one cortical column to the next, and intervenes between the base of the pyramid and the capsule (marked by the dotted line extending from A to A′ in Fig. 543), is called a *cortical arch*, the depth of which varies from a third to half an inch.

The *medullary substance*, as before stated, is seen to consist of red-colored, striated, conical masses, the *pyramids of Malpighi*, the number of which, varying from eight to eighteen, corresponds to the number of lobes of which the organ in the fœtal state is composed. The base of each pyramid is surrounded by a cortical arch, and directed toward the circumference of the kidney; the sides are contiguous with the cortical columns; while the apex, known as the *papilla* or *mammilla* of the kidney, projects into one of the calices of the ureter, each calyx receiving two or three papillæ.

These two parts, *cortical* and *medullary*, so dissimilar in appearance, are very similar in structure, being made up of urinary tubes and blood-vessels united and bound together by a connecting matrix or stroma.

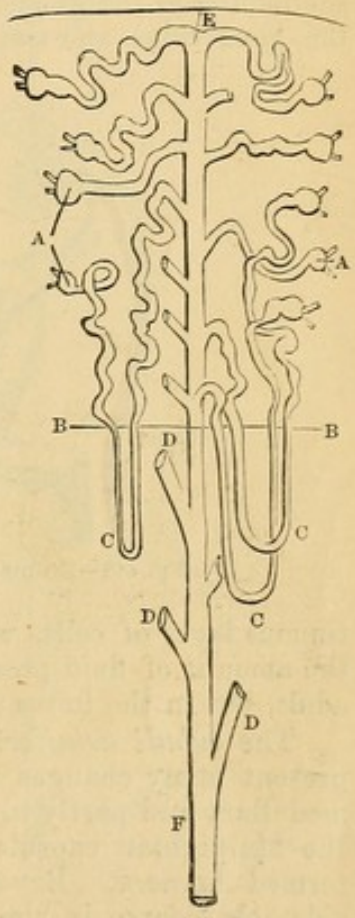

FIG. 544.—Plan of uriniferous tubes. A, A. Malpighian bodies. B, B. Margin of medullary structure. C, C, C. Loops of Henle. D, D, D. Straight tubes cut off. E. Commencing straight tubes. F. Termination of straight tube.

Minute Anatomy.—The *tubuli uriniferi*, of which the kidney is for the most part made up, commence in the cortical portion of the kidney, and, after pursuing a very circuitous course through the cortical and medullary parts of the kidney, finally terminate at the apices of the Malpighian pyramids by open mouths (Fig. 544), so that the fluid which they contain is emptied into the dilated extremity of the ureter contained in the sinus of the kidney. If the surface of one of the papillæ is examined with a lens, it will be seen to be studded over with a number of small depressions, from sixteen to twenty in number, and in a fresh kidney, upon pressure being made, fluid will be seen to exude from these depressions. They are the orifices of the tubuli uriniferi, which terminate in this situation. They commence in the cortical portion of the kidney as the *Malpighian*

bodies, which are small rounded masses, varying in size, but average about $\frac{1}{120}$ of an inch in diameter. They are of a deep-red color, and are found only in the cortical portion of the kidney. Each of these little bodies is composed of two parts—a central glomerulus of vessels, called a *Malpighian tuft*, and a membranous envelope, the *Malpighian capsule*, or *capsule of Bowman*, which latter is a small pouch-like commencement of a uriniferous tubule.

The *Malpighian tuft*, or vascular glomerulus, is a network of convoluted capillary blood-vessels held together by scanty connective tissue and grouped into from two to five lobules. This capillary network is derived from a small arterial twig, the *afferent vessel*, which pierces the wall of the capsule, generally at a point opposite that at which the latter is connected with the tube; and the resulting vein, the *efferent vessel*, emerges from the capsule at the same point. The afferent vessel is usually the larger of the two (Fig. 545). The *Malpighian* or *Bowman's capsule*, which surrounds the glomerulus, is formed of a hyaline membrane supported by a small amount of connective tissue which is continuous with the connective tissue of the tube. It is lined on its inner surface by a layer of squamous epithelial cells which are reflected from the lining membrane on to the glomerulus at the point of entrance or exit of the afferent and efferent vessels. The whole surface of the glomerulus is covered with a continuous layer of the same cells on a delicate supporting membrane, which with the cells dips in between the lobules of the glomerulus, closely surrounding them (Fig. 546). Thus, between the glomerulus and the capsule a space is left, forming a cavity lined by a con-

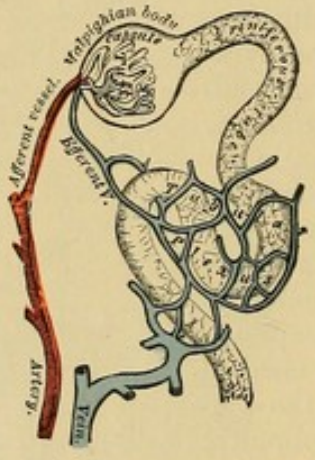

FIG. 545.—Minute structure of kidney.

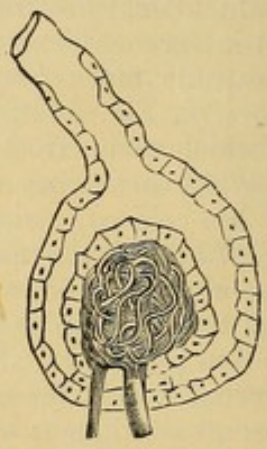

FIG. 546.—Malpighian body.

tinuous layer of cells, which varies in size according to the state of secretion and the amount of fluid present in it. The cells, as above stated, are squamous in the adult, but in the fœtus and young subject they are polyhedral or even columnar.

The *tubuli uriniferi*, commencing in the Malpighian bodies, in their course present many changes in shape and direction, and are contained partly in the medullary and partly in the cortical portions of the organ. At their junction with the Malpighian capsule they present a somewhat constricted portion which is termed the *neck*. Beyond this the tube becomes convoluted, and pursues a considerable course in the cortical structure, constituting the *proximal convoluted tube*. After a time the convolutions disappear, and the tube approaches the medullary portion of the kidney in a more or less spiral manner. This section of the tube has been called the *spiral tube of Schachowa*. Throughout this portion of their course the tubuli uriniferi have been contained entirely in the cortical structure, and have presented a pretty uniform calibre. They now enter the medullary portion, and suddenly become much smaller, quite straight in direction, and dip down for a variable depth into the pyramids, constituting the *descending limb of Henle's loop*. Bending on themselves, they form a kind of loop, the *loop of Henle*, and, reascending, become suddenly enlarged and again spiral in direction, forming the *ascending limb of Henle's loop*, and re-enter the cortical

structure. This portion of the tube does not present a uniform calibre, but becomes narrower as it ascends and irregular in outline. As a narrow tube it enters the cortex and ascends for a short distance, when it again becomes dilated, irregular, and angular. This section is termed the *irregular tubule;* it terminates in a convoluted tube which exactly resembles the proximal convoluted tubule; and is called the *distal convoluted tubule.* This again terminates in a narrow *curved tube,* which enters the straight or collecting tube.

Each *straight,* otherwise called a *collecting* or *receiving, tube* commences by a small orifice on the summit of one of the papillæ, thus opening and discharging its contents into the interior of one of the calices. Traced into the substance of the pyramid, these tubes are found to run from apex to base, dividing dichotomously in their course and slightly diverging from each other. Thus dividing and subdividing, they reach the base of the pyramid, and enter the cortical structure greatly increased in number. Upon entering the cortical portion they continue a straight course for a variable distance, and are arranged in groups called *medullary rays,* several of these groups corresponding to a single pyramid. The tubes in the centre of the group are the longest, and reach almost to the surface of the kidney, while the external ones are shorter, and advance only a short distance into the

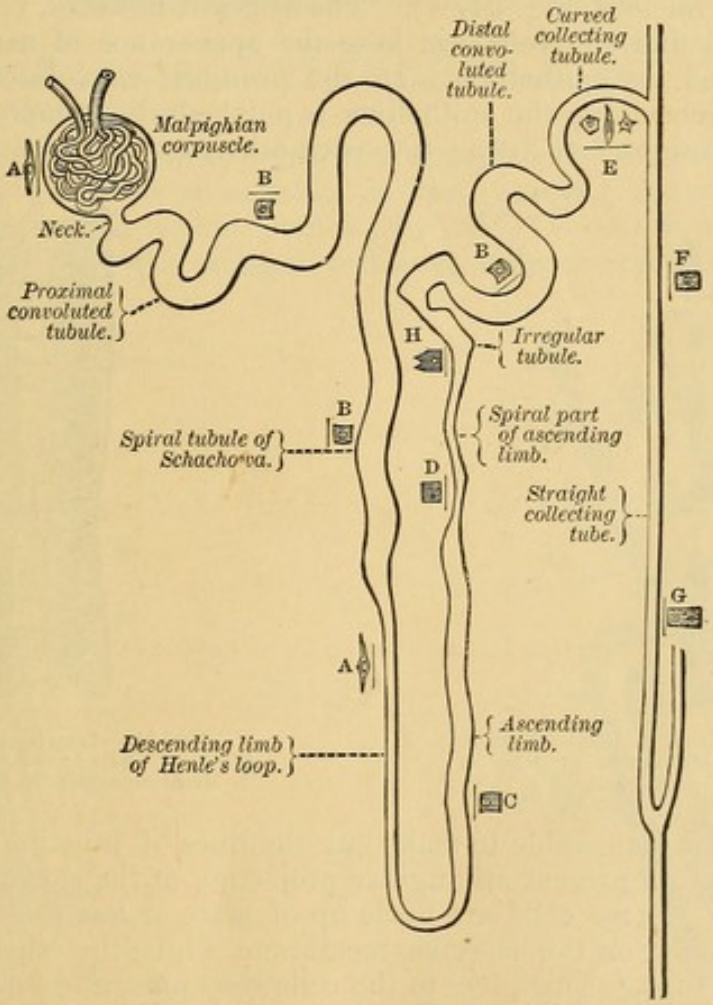

FIG. 547.—Uriniferous tube. For the sake of clearness the epithelial cells have been represented more highly magnified than the tubes in which they are contained.

cortex. In consequence of this arrangement the cortical portion presents a number of conical masses, the apices of which reach the periphery of the organ, and the bases are applied to the medullary portion. These are termed the *pyramids of Ferrein.* As they run through the cortical portion the straight tubes receive on either side the curved extremity of the convoluted tubes, which, as stated above, commence at the Malpighian bodies.

It will be seen from the above description that there is a continuous series of tubes from their commencement in the Malpighian bodies to their termina-

tion at the orifices on the apices of the pyramids of Malpighi, and that the urine, the secretion of which commences in the capsule, finds its way through these tubes into the calices of the kidney, and so into the ureter. To recapitulate: the tube first presents a constricted portion, (1) the *neck*. 2. It forms a wide convoluted tube, the *proximal convoluted tube*. 3. It becomes spiral, the *spiral tubule of Schachowa*. 4. It enters the medullary structure as a narrow, straight tube, the *descending limb of Henle's loop*. 5. Forming a loop and becoming dilated, it ascends somewhat spirally, and, gradually diminishing in calibre, again enters the cortical structure, the *ascending limb of Henle's loop*. 6. It now becomes irregular and angular in outline, the *irregular tubule*. 7. It then becomes convoluted, the *distal convoluted tubule*. 8. Diminishing in size, it forms a curve, the *curved tubule*. 9. Finally, it joins a straight tube, the *straight collecting tube*, which is continued downward through the medullary substance to open at the apex of a pyramid.

The Tubuli Uriniferi: their Structure.—The tubuli uriniferi consist of basement membrane lined with epithelium. The epithelium varies considerably in different sections of the uriniferous tubes. In the neck the epithelium is continuous with that lining the Malpighian capsule, and, like it, consists of flattened cells with an oval nucleus (Fig. 547 A). The cells are, however, very indistinct and difficult to trace, and the tube has here the appearance of a simple basement membrane unlined by epithelium. In the proximal convoluted tubule and the spiral tubule of Schachowa the epithelium is polyhedral in shape, the sides of the cells not being straight, but fitting into each other, and in some animals so fused



FIG. 548.[1]—Longitudinal section of Henle's descending limb. *a*. Membrana propria. *b*. Epithelium.

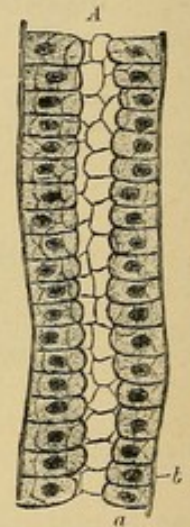

FIG. 549.—Longitudinal section of straight tube. *a*. Cylindrical or cubical epithelium. *b*. Membrana propria.

together that it is impossible to make out the lines of junction. In the human kidney the cells often present an angular projection of the surface next the basement membrane. These cells are made up of more or less rod-like fibres, which rest by one extremity on the basement membrane, whilst the other projects toward the lumen of the tube. This gives to the cells the appearance of distinct striation (Heidenhain) (Fig. 547, B). In the descending limb of Henle's loop the epithelium resembles that found in the Malpighian capsule and the commencement of the tube, consisting of flat transparent epithelial plates with an oval nucleus (Figs. 547, A, 548). In the ascending limb, on the other hand, the cells partake more of the character of those described as existing in the proximal convoluted tubule, being polyhedral in shape and presenting the same appearance of striation. The nucleus, however, is not situated in the centre of the cell, but near the lumen (Fig. 547, C). After the ascending limb of Henle's loop becomes narrower upon entering the cortical structure, the striation appears to be confined to the outer part of the cell:

[1] From *Handbook for the Physiological Laboratory*.

at all events, it is much more distinct in this situation, the nucleus, which appears flattened and angular, being still situated near the lumen (Fig. 547, D). In the irregular tubule the cells undergo a still farther change, becoming very angular, and presenting thick bright rods or markings, which render the striation much more distinct than in any other section of the urinary tubules (Fig. 547, H). In

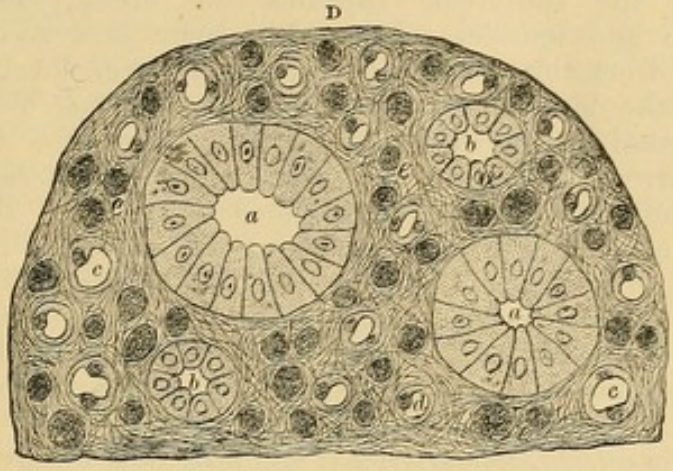

FIG. 723.—Transverse section of pyramidal substance of kidney of pig, the blood-vessels of which are injected. *a*. Large collecting tube cut across, lined with cylindrical epithelium. *b*. Branch of collecting tube cut across, lined with epithelium with shorter cylinders. *c* and *d*. Henle's loops cut across. *e*. Blood-vessels cut across. D. Connective-tissue ground-substance.

the distal convoluted tubule the epithelium appears to be somewhat similar to that which has been described as existing in the proximal convoluted tubule, but presents a peculiar refractive appearance (Fig. 547, B). In the curved tubule, just before its entrance into the straight collecting tube, the epithelium varies greatly

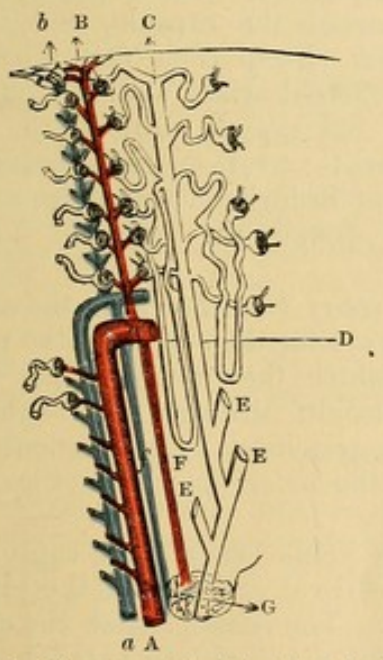

FIG. 551.—Diagrammatical sketch of the blood-vessels of kidney.

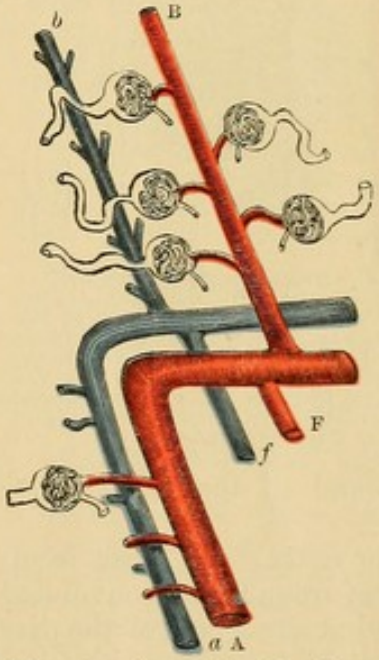

FIG. 552.—A portion of Fig. 551 enlarged. (The references are the same.)

A, *a*. Proper renal artery and vein, the former giving off the renal afferents, the latter receiving the renal efferents. B, *b*. Interlobular artery and vein, the latter commencing from the stellate veins, and receiving branches from the plexus around the tubuli contorti, the former giving off renal afferents. C. Straight tube, surrounded by tubuli contorti, with which it communicates, as more fully shown in Fig. 544. D. Margin of medullary substance. E, E, E. Receiving tubes cut off. F, *f*. Arteriolæ et venæ rectæ, the latter arising from (G) the plexus at the medullary apex.

as regards the shape of the cells, some being angular with short processes, others spindle-shaped, others polyhedral (Fig. 547, E).

In the straight tubes the epithelium is more or less columnar; in its papillary portion the cells are distinctly columnar and transparent (Figs. 549, 550), but as the tube approaches the cortex the cells are less uniform in shape; some are polyhedral, and others angular with short processes (Fig. 547, F and G).

The Renal Blood-vessels.—The kidney is plentifully supplied with blood by the renal artery, a large offset of the abdominal aorta. Previously to entering the kidney, each artery divides into four or five branches, which are distributed to its substance. At the hilum these branches lie between the renal vein and ureter, the vein being in front, the ureter behind. Each vessel gives off some small branches to the suprarenal capsules, the ureter, and the surrounding cellular tissue and muscles. Frequently there is a second renal artery, which is given off from the abdominal aorta at a lower level, and supplies the lower portion of the kidney. It is termed the *inferior renal artery*. The branches of the renal artery whilst in the sinus give off a few twigs for the nutrition of the surrounding tissues, and terminate in the *arteriæ propriæ renales*, which enter the kidney proper in the columns of Bertin. Two of these pass to each pyramid of Malpighi and run along its sides for its entire length, giving off as they advance the afferent vessels of the Malpighian bodies in the columns. Having arrived at the bases of the pyramids, they make a bend in their course, so as to lie between the bases of the pyramids and the cortical arches, where they break up into two distinct sets of branches devoted to the supply of the remaining portions of the kidney.

The *first set*, the *interlobular arteries* (Figs. 551, 552, B), are given off at right angles from the side of the arteriæ propriæ renales looking toward the cortical substance, and, passing directly outward between the pyramids of Ferrein, they reach the capsule, where they terminate in the capillary network of this part. In their outward course they give off lateral branches; these are the *afferent vessels* for the Malpighian bodies (see page 988), and, having pierced the capsule, end in the Malpighian tufts. From each tuft the corresponding renal efferent arises, and, having made its egress from the capsule near to the point where the afferent vessel entered, breaks up into a number of branches which form a dense *venous plexus* around the adjacent urinary tubes (Fig. 553).

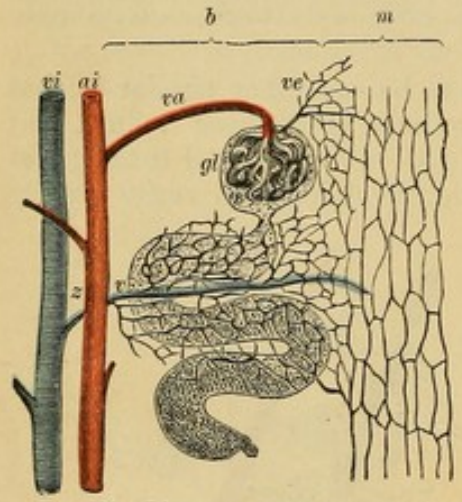

FIG. 553.—Diagrammatic representation of the blood-vessels in the substance of the cortex of the kidney. *m*. Region of the medullary ray. *b*. Region of the tortuous portion of the tubules. *ai*. Arteria interlobularis. *vi*. Vena interlobularis. *va*. Vas afferens. *gl*. Glomerulus. *ve*. Vas efferens. *vr*. Venous twig of the interlobularis. (From Ludwig, in Stricker's *Handbook*.)

The *second set of branches* from the arteriæ propriæ renales are for the supply of the medullary pyramids, which they enter at their bases; and, passing straight through their substance to their apices, terminate in the venous plexuses found in that situation. They are called the *arteriolæ rectæ* (Figs. 551, 552, F).

The *renal veins* arise from *three sources*—the veins beneath the capsule, the plexuses around the convoluted tubules in the cortical arches, and the plexuses situated at the apices of the pyramids of Malpighi. The veins beneath the capsule are stellate in arrangement, and are derived from the capillary network of the capsule, into which the terminal branches of the interlobular arteries break up. These join to form the *venæ interlobulares*, which pass inward *between* the pyramids of Ferrein, receive branches from the plexuses around the convoluted tubules, and, having arrived at the bases of the Malpighian pyramids, join with the venæ rectæ, next to be described (Figs. 551, 552, *b*).

The *Venæ Rectæ* are branches from the plexuses at the apices of the medullary pyramids, formed by the terminations of the arteriolæ rectæ. They pass outward in a straight course between the tubes of the medullary structure, and joining, as above stated, the venæ interlobulares, form the proper renal veins (Figs. 551, 552, *f*).

These vessels, *Venæ Propriæ Renales*, accompany the arteries of the same name, running along the entire length of the sides of the pyramids; and, having received

in their course the efferent vessels from the Malpighian bodies in the cortical structure adjacent, quit the kidney substance to enter the sinus. In this cavity they inosculate with the corresponding veins from the other pyramids to form the *renal vein*, which emerges from the kidney at the hilum and opens into the inferior vena cava, the left being longer than the right, from having to cross in front of the abdominal aorta.

Nerves of the Kidney.—The nerves of the kidney, although small, are about fifteen in number. They have small ganglia developed upon them, and are derived from the renal plexus, which is formed by branches from the solar plexus, the lower and outer part of the semilunar ganglion and aortic plexus, and from the lesser and smallest splanchnic nerves. They communicate with the spermatic plexus, a circumstance which may explain the occurrence of pain in the testicle in affections of the kidney. So far as they have been traced, they seem to accompany the renal artery and its branches, but their exact mode of termination is not known.

The *lymphatics* consist of a superficial and deep set which terminate in the lumbar glands.

Connective Tissue, or Intertubular Stroma.—Although the tubules and vessels are closely packed, a certain small amount of connective tissue, continuous with the capsule, binds them firmly together. This tissue was first described by Goodsir, and subsequently by Bowman. Ludwig and Zawarykin have observed distinct fibres passing around the Malpighian bodies, and Henle has seen them between the straight tubes composing the medullary structure.

Surface Form.—The kidneys, being situated at the back part of the abdominal cavity and deeply placed, cannot be felt unless enlarged or misplaced. They are situated on the confines of the epigastric and umbilical regions internally, with the hypochondriac and lumbar regions externally. The left is somewhat higher than the right. According to Morris, the position of the kidney may be thus defined: *Anteriorly:* "1. A horizontal line through the umbilicus is below the lower edge of each kidney. 2. A vertical line carried upward to the costal arch from the middle of Poupart's ligament has one-third of the kidney to its outer side and two-thirds to its inner side—*i. e.* between this line and the median line of the body." In adopting these lines it must be borne in mind that the axes of the kidneys are not vertical, but oblique, and if continued upward would meet about the ninth dorsal vertebra. *Posteriorly:* The upper end of the left kidney would be defined by a line drawn horizontally outward from the spinous process of the eleventh dorsal vertebra, and its lower end by a point two inches above the iliac crest. The right kidney would be half to three-quarters of an inch lower. Morris lays down the following rules for indicating the position of the kidney on the posterior surface of the body: "1. A line parallel with, and one inch from, the spine, between the lower edge of the tip of the spinous process of the eleventh dorsal vertebra and the lower edge of the spinous process of the third lumbar vertebra. 2. A line from the top of this first line outward at right angles to it for $2\frac{3}{4}$ inches. 3. A line from the lower end of the first transversely outward for $2\frac{3}{4}$ inches. 4. A line parallel to the first and connecting the outer extremities of the second and third lines just described."

The hilum of the kidney lies about two inches from the middle line of the back, at the level of the spinous process of the first lumbar vertebra.

Surgical Anatomy.—Malformations of the kidney are not uncommon. There may be an entire absence of one kidney, though, according to Morris, the number of these cases is "excessively small": or there may be congenital atrophy of one kidney, when the kidney is very small, but usually healthy in structure. These cases are of great importance, and must be duly taken into account, when nephrectomy is contemplated. A more common malformation is where the two kidneys are fused together. They may be only joined together at their lower ends by means of a thick mass of renal tissue, so as to form a horseshoe-shaped body or they may be completely united, forming a disc-like kidney, from which two ureters descend into the bladder. These fused kidneys are generally situated in the middle line of the abdomen, but may be misplaced as well.

One or both kidneys may be misplaced as a congenital condition, and remain fixed in this abnormal position. They are then very often misshapen. They may be situated higher or lower than normal or removed farther from the spine than usual or they may be displaced into the iliac fossa, over the sacro-iliac joint, on to the promontory of the sacrum, or into the pelvis between the rectum and bladder or by the side of the uterus. In these latter cases they may give rise to very serious trouble. The kidney may also be misplaced as a congenital condition, but may not be fixed. It is then known as a *floating kidney.* It is believed to be due to the fact that the kidney is completely enveloped by peritoneum which then passes backward to the spine as a double layer, forming a mesonephron, which permits of movement taking place. The kidney may also be misplaced as an acquired condition; in these cases the kidney is mobile in

the tissues by which it is surrounded, either moving in its capsule or else moving with the capsule in the perinephric tissues. This condition is known as *movable kidney*, and is more common in the female than the male. Other malformations are the persistence of the fœtal lobulation; the presence of two pelves or two ureters to the one kidney. In some rare instances a third kidney may be present.

The kidney is imbedded in a large quantity of loose fatty tissue, and is but partially covered by peritoneum; hence rupture of this organ is not nearly so serious an accident as rupture of the liver or spleen, since the extravasation of blood and urine which follows is, in the majority of cases, outside the peritoneal cavity. Occasionally the kidney may be bruised by blows in the loin or by being compressed between the lower ribs and the ilium when the body is violently bent forward. This is followed by a little transient hæmaturia, which, however, speedily passes off. Occasionally, when rupture involves the pelvis of the kidney or the commencement of the ureter, this duct may become blocked, and hydronephrosis follow.

The loose cellular tissue around the kidney may be the seat of suppuration, constituting *perinephritic abscess*. This may be due to injury, to disease of the kidney itself, or to extension of inflammation from neighboring parts. The abscess may burst into the pleura, constituting empyema; into the colon or bladder; or may point externally in the groin or loin. Tumors of the kidney, of which, perhaps, sarcoma in children is the most common, may be recognized by their position and fixity; by the resonant colon lying in front of it; by their not moving with respiration; and by their rounded outline, not presenting a notched anterior margin like the spleen, with which they are most likely to be confounded. The examination of the kidney should be bimanual; that is to say, one hand should be placed in the flank and firm pressure made forward, while the other hand is buried in the abdominal wall, over the situation of the organ. Manipulation of the kidney frequently produces a peculiar sickening sensation, with sometimes faintness.

The kidney is mainly held in position by the mass of fatty matter in which it is embedded. If this fatty matter is loose or lax or is absorbed, the kidney may become movable and may give rise to great pain. This condition occurs, therefore, in badly nourished people or in those who have become emaciated from any cause, and is more common in women than in men. It must not be confounded with the *floating kidney:* this is a congenital condition due to the development of a mesonephron, which permits the organ to move more or less freely. The two conditions cannot, however, be distinguished until the abdomen is opened or the kidney explored from the loin.

The kidney has, of late years, been frequently the seat of surgical interference. It may be exposed for exploration or the evacuation of pus (nephrotomy); it may be incised for the removal of stone (nephro-lithotomy); it may be sutured when movable or floating (nephrorraphy); or it may be removed (nephrectomy).

The kidney may be exposed either by a lumbar or abdominal incision. The operation is best performed by a lumbar incision, except in cases of very large tumors or of wandering kidneys with a loose mesonephron, on account of the advantages which it possesses of not opening the peritoneum and of affording admirable drainage. It may be performed either by an oblique, a vertical, or a transverse incision. Perhaps the preferable, as affording the best means for exploring the whole surface of the kidney, is an incision from the tip of the last rib backward to the edge of the Erector spinæ. This incision must not be quite parallel to the rib, but its posterior end must be at least three-quarters of an inch below it, lest the pleura be wounded. This cut is quite sufficient for an exploration of the organ. Should it require removal, a vertical incision can be made downward to the crest of the ilium, along the outer border of the Quadratus lumborum. The structures divided are the skin, the superficial fascia with the cutaneous nerves, the deep fascia, the posterior border of the External oblique muscle of the abdomen, and the outer border of the Latissimus dorsi; the Internal oblique and the posterior aponeurosis of the Transversalis muscle; the outer border of the Quadratus lumborum, and the deep layer of the lumbar fascia, and the transversalis fascia. The fatty tissue around the kidney is now exposed to view, and must be separated by the fingers or a director in order to reach the kidney.

The abdominal operation is best performed by an incision in the linea semilunaris on the side of the kidney to be removed, as recommended by Langenbuch; the kidney is then reached from the outer side of the colon, ascending or descending, as the case may be, and the vessels of the colon are not interfered with. If the incision is made in the linea alba, the kidney is reached from the inner side of the colon, and the vessels running to supply it must necessarily be interfered with. The incision is made of varying length according to the size of the kidney, commencing just below the costal arch. The abdominal cavity is opened. The intestines are held aside, and the outer layer of the mesocolon incised, so that the fingers can be introduced behind the peritoneum and the renal vessels sought for. These are then to be ligatured: if tied separately, care must be taken to ligature the artery first. The kidney must now be enucleated, and the vessels and the ureter divided, and the latter tied, or if thought necessary, stitched to the edge of the wound.

THE URETERS.

The **Ureters** are the two tubes which conduct the urine from the kidneys into the bladder. They commence within the sinus of the kidney by a number of short truncated branches, the *calices* or *infundibula*, which unite either directly

or indirectly to form a dilated pouch, the *pelvis*, from which the ureter, after passing through the hilum of the kidney, descends to the bladder. The *calices* are cup-like tubes encircling the apices of the Malpighian pyramids; but inasmuch as one calyx may include two or even more papillæ, their number is generally less than the pyramids themselves, the former being from seven to thirteen, whilst the latter vary from eight to eighteen. These calices converge into two or three tubular divisions which by their junction form the *pelvis* or dilated portion of the ureter. The portion last mentioned, where the pelvis merges into the ureter proper, is found opposite the spinous process of the first lumbar vertebra, in which situation it is accessible behind the peritoneum (see Fig. 507, page 924).

The *ureter proper* is a cylindrical membranous tube, about sixteen inches in length and of the diameter of a goosequill, extending from the pelvis of the kidney to the bladder. Its course is obliquely downward and inward through the lumbar region into the cavity of the pelvis where it passes downward, forward, and inward across that cavity to the base of the bladder, into which it then opens by a constricted orifice, after having passed obliquely for nearly an inch between its muscular and mucous coats.

Relations.—In its course it rests upon the Psoas muscle, being covered by the peritoneum, and crossed obliquely, from within outward, by the spermatic vessels; the right is crossed by the branches of the mesenteric arteries, which are distributed to the ascending, and the left by those for the descending colon; the right ureter lying close to the outer side of the inferior vena cava. Opposite the first piece of the sacrum it crosses either the common or external iliac artery, lying behind the ileum on the *right* side and the sigmoid flexure of the colon on the *left*. In the pelvis it enters the posterior false ligament of the bladder, below the obliterated hypogastric artery, the vas deferens in the male passing between it and the bladder. In the female the ureter passes along the side of the neck of the uterus and upper part of the vagina. At the base of the bladder it is situated about two inches from its fellow: lying, in the male, about an inch and a half from the vesical orifice of the urethra, at one of the posterior angles of the trigone.

Structure.—The *ureter* is composed of three coats—a fibrous, muscular, and mucous.

The *fibrous coat* is the same throughout the entire length of the duct, being continuous at one end with the capsule of the kidney at the floor of the sinus, while at the other it is lost in the fibrous structure of the bladder.

In the pelvis of the kidney the muscular coat consists of two layers, longitudinal and circular: the longitudinal fibres become lost upon the sides of the papillæ at the extremities of the calices; the circular fibres may be traced surrounding the medullary structure in the same situation. In the ureter proper the muscular fibres are very distinct, and are arranged in three layers—an external longitudinal, a middle circular, and an internal layer, less distinct than the other two, but having a general longitudinal direction. According to Kölliker, this internal layer is only found in the neighborhood of the bladder.

The *mucous coat* is smooth, and presents a few longitudinal folds which become effaced by distension. It is continuous with the mucous membrane of the bladder below, whilst it is prolonged over the papillæ of the kidney above. Its epithelium is of a peculiar character, and resembles that found in the bladder. It is known by the name of "transitional" epithelium. It consists of several layers of cells, of which the innermost—that is to say, the cells in contact with the urine—are quadrilateral in shape, with a concave margin on their outer surface, into which fits the rounded end of the cells of the second layer. These, the intermediate cells, more or less resemble columnar epithelium, and are pear-shaped, with a rounded internal extremity which fits into the concavity of the cells of the first layer, and a narrow external extremity which is wedged in between the cells of the third layer. The external or third layer consists of conical or oval cells varying in number in different parts, and presenting processes which extend down into the basement membrane.

The *arteries* supplying the ureter are branches from the renal, spermatic, internal iliac, and inferior vesical.

The *nerves* are derived from the inferior mesenteric, spermatic, and pelvic plexuses.

Surgical Anatomy.—Subcutaneous rupture of the ureter is not a common accident, but occasionally occurs from a sharp, direct blow on the abdomen, as from the kick of a horse. It may be either torn completely across or only partially divided, and, as a rule, the peritoneum escapes injury. If torn completely across, the urine collects in the retroperitoneal tissues; if it is not completely divided, the lumen of the tube may become obstructed and hydro-nephrosis or pyo-nephrosis result. The ureter may be accidentally wounded in some abdominal operations; if this should happen, the divided ends must be sutured together, or, failing to accomplish this, the upper end must be implanted into the bladder or the intestine.

THE SUPRARENAL CAPSULES.

The **Suprarenal Capsules** belong to the class of ductless glands. They are two small flattened bodies, of a yellowish color, situated at the back part of the abdomen, behind the peritoneum, and immediately above and in front of the upper end of each kidney; hence their name. The right one is somewhat triangular in shape, bearing a resemblance to a cocked hat; the left is more semilunar, usually larger and placed at a higher level than the right. They vary in size in different individuals, being sometimes so small as to be scarcely detected: their usual size is from an inch and a quarter to nearly two inches in length, rather less in width, and from two to three lines in thickness. Their average weight is from one to one and a half drachms each.



FIG. 554.—Vertical section of the suprarenal capsule. From Elberth, in Stricker's *Manual*.

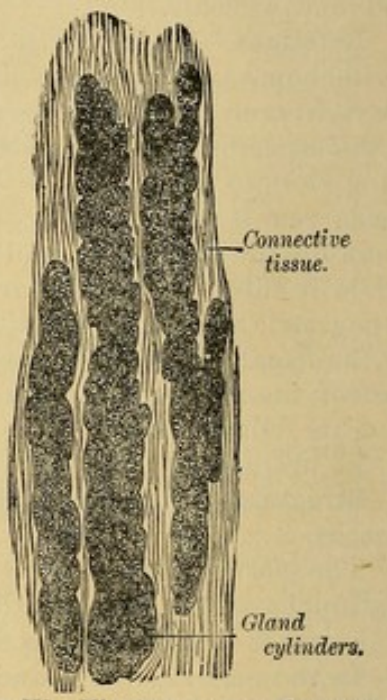

FIG. 555.—Minute structure of suprarenal capsule.

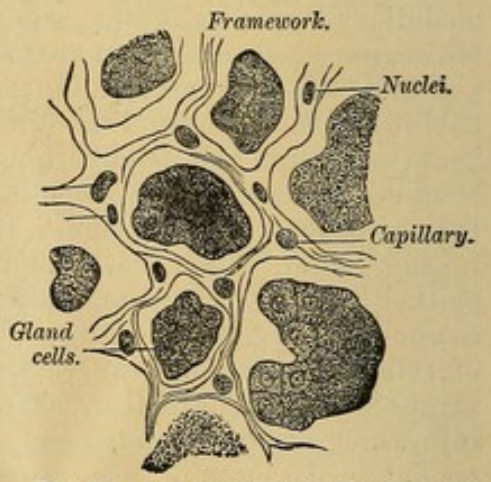

FIG. 556.—Minute structure of suprarenal capsule.

Relations.—The relations of the suprarenal capsules differ on the two sides of the body. The *right suprarenal* is roughly triangular in shape, its angles pointing upward, downward, and outward. It presents two surfaces for examination, an anterior and a posterior. The *anterior surface* presents two areas, separated by a furrow, the *hilum:* one area occupying about one-third of the whole surface, is situated above and internally; it is depressed, uncovered by peritoneum, and is in contact in front with the posterior surface of the right lobe of the liver, and along its inner border with the inferior vena cava; the remaining area is elevated, and is divided into a non-peritoneal portion, in contact with the hepatic flexure of the duodenum, and a portion covered by peritoneum forming the hepatorenal fold. The *posterior surface* is slightly convex, and rests upon the Diaphragm. The *base* is concave, and is in contact with the upper end and the adjacent part of the anterior surface of the kidney. The *left suprarenal* is crescentic in shape, its concavity being adapted to the upper end of the left kidney. It presents an inner border which is convex, and an outer which is concave; its upper border is narrow, and its lower rounded. Its *anterior surface* presents two areas: an upper one, covered by the peritoneum forming the lesser sac, which separates it from the cardiac end of the stomach and to a small extent from the superior extremity of the spleen; and a lower one, which is in contact with the pancreas and splenic artery, and is therefore not covered by the peritoneum. Its *posterior surface* presents a vertical ridge, which divides it into two areas. The ridge lies in the sulcus between the kidney and crus of the Diaphragm, while the area on either side of it lies on these parts respectively; the outer area, which is thin, resting on the kidney, and the inner and smaller area resting on the left crus of the Diaphragm. The surface of the suprarenal gland is surrounded by areolar tissue containing much fat, and closely invested by a thin fibrous coat, which is difficult to remove, on account of numerous fibrous processes and vessels which enter the organ through the furrows on its anterior surface and base.

Small accessory suprarenals are often to be found in the connective tissue around the suprarenals. The smaller of these, on section, show a uniform surface, but in some of the larger a distinct medulla can be made out.

Structure.—On making a perpendicular section, the gland is seen to consist of two substances—external or cortical, and internal or medullary. The former, which constitutes the chief part of the organ, is of a deep yellow color. The medullary substance is soft, pulpy, and of a dark brown or black color, whence the name *atrabiliary capsules* formerly given to these organs. In the centre is often seen a space, not natural, but formed by breaking down after death of the medullary substance.

The **cortical portion** consists chiefly of narrow columnar masses placed perpendicularly to the surface. This arrangement is due to the disposition of the capsule, which sends into the interior of the gland processes passing in vertically and communicating with each other by transverse bands so as to form spaces which open into each other. These spaces are of slight depth near the surface of the organ, so that there the section somewhat resembles a net; this is termed the *zona glomerulosa;* but they become much deeper or longer farther in, so as to resemble pipes or tubes placed endwise, the *zona fasciculata.* Still deeper down, near the medullary part, the spaces become again of small extent; this is named the *zona reticularis.* These processes or trabeculæ, derived from the capsule and forming the framework of the spaces, are composed of fibrous connective tissue with longitudinal bundles of unstriped muscular fibres. Within the interior of the spaces are contained groups of polyhedral cells, which are finely granular in appearance, and contain a spherical nucleus, and not infrequently fat-globules. These groups of cells do not entirely fill the spaces in which they are contained, but between them and the trabeculæ of the framework is a channel which is believed to be a lymph-path or sinus, and which communicates with certain passages between the cells composing the group. The lymph-path is supposed

to open into a plexus of efferent lymphatic vessels which are contained in the capsule.

In the **medullary portion** the fibrous stroma seems to be collected together into a much closer arrangement, and forms bundles of connective tissue which are loosely applied to the large plexus of veins of which this part of the organ mainly consists. In the interstices lie a number of cells compared by Frey to those of columnar epithelium. They are coarsely granular, do not contain any fat-molecules, and some of them are branched. Luschka has affirmed that these branches are connected with the nerve-fibres of a very intricate plexus which is found in the medulla: this statement has not been verified by other observers, for the tissue of the medullary substance is less easy to make out than that of the cortical, owing to its rapid decomposition.

The numerous arteries which enter the suprarenal bodies from the sources mentioned below penetrate the cortical part of the gland, where they break up into capillaries in the fibrous septa, and these converge to the very numerous veins of the medullary portion, which are collected together into the suprarenal vein, which usually emerges as a single vessel from the centre of the gland.

The *arteries* supplying the suprarenal capsules are numerous and of large size; they are derived from the aorta, the phrenic, and the renal; they subdivide into numerous minute branches previous to entering the substance of the gland.

The *suprarenal vein* returns the blood from the medullary venous plexus, and receives several branches from the cortical substance; it opens on the right side into the inferior vena cava, on the left side into the renal vein.

The *lymphatics* terminate in the lumbar glands.

The *nerves* are exceedingly numerous, and are derived from the solar and renal plexuses, and, according to Bergmann, form the phrenic and pneumogastric nerves. They enter the lower and inner part of the capsule, traverse the cortex, and terminate round the cells of the medulla. They have numerous small ganglia developed upon them, from which circumstance the organ has been conjectured to have some function in connection with the sympathetic nervous system.

THE CAVITY OF THE PELVIS.

The **cavity of the pelvis** is that part of the general abdominal cavity which is below the level of the linea ilio-pectinea and the promontory of the sacrum.

Boundaries.—It is bounded behind by the sacrum, the coccyx, the Pyriformis muscle, and the great sacro-sciatic ligaments; in front and at the sides by the ossa pubis and ischia, covered by the Obturator muscles; above, it communicates with the cavity of the abdomen; and below, the outlet is closed by the triangular ligament, the Levatores ani and Coccygei muscles, and the visceral layer of the pelvic fascia, which is reflected from the wall of the pelvis on to the viscera.

Contents.—The viscera contained in this cavity are—the urinary bladder, the rectum, and some of the generative organs peculiar to each sex, and some convolutions of the small intestines; they are partially covered by the peritoneum, and supplied with blood-vessels, lymphatics, and nerves.

THE BLADDER.

The **bladder** is the reservoir for the urine. It is a musculo-membranous sac situated in the pelvis, behind the pubes, and in front of the rectum in the male, the cervix uteri and vagina intervening between it and that intestine in the female. The shape, position, and relations of the bladder are greatly influenced by age, sex, and the degree of distention of the organ. *During infancy* it is conical in shape, and projects above the upper border of the ossa pubis into the hypogastric region. *In the adult*, when quite empty and contracted, it is cup-shaped, and on vertical median section its cavity, with the adjacent portion of the urethra, presents a Y-shaped cleft, the stem of the Y corresponding to the urethra. It is

placed deeply in the pelvis, flattened from before backward, and reaches as high as the upper border of the symphysis pubis. When slightly distended, it has a rounded form, and is still contained within the pelvic cavity; and when greatly distended it is ovoid in shape, rising into the abdominal cavity, and often extending nearly as high as the umbilicus. It is larger in its vertical diameter than from side to side, and its long axis is directed from above obliquely downward and backward, in a line directed from some point between the symphysis pubis and umbilicus (according to its distention) to the end of the coccyx. The bladder, when distended, is slightly curved forward toward the anterior wall of the abdomen, so as to be more convex behind than in front. In the female it is larger in the transverse than in the vertical diameter, and its capacity is said to be greater

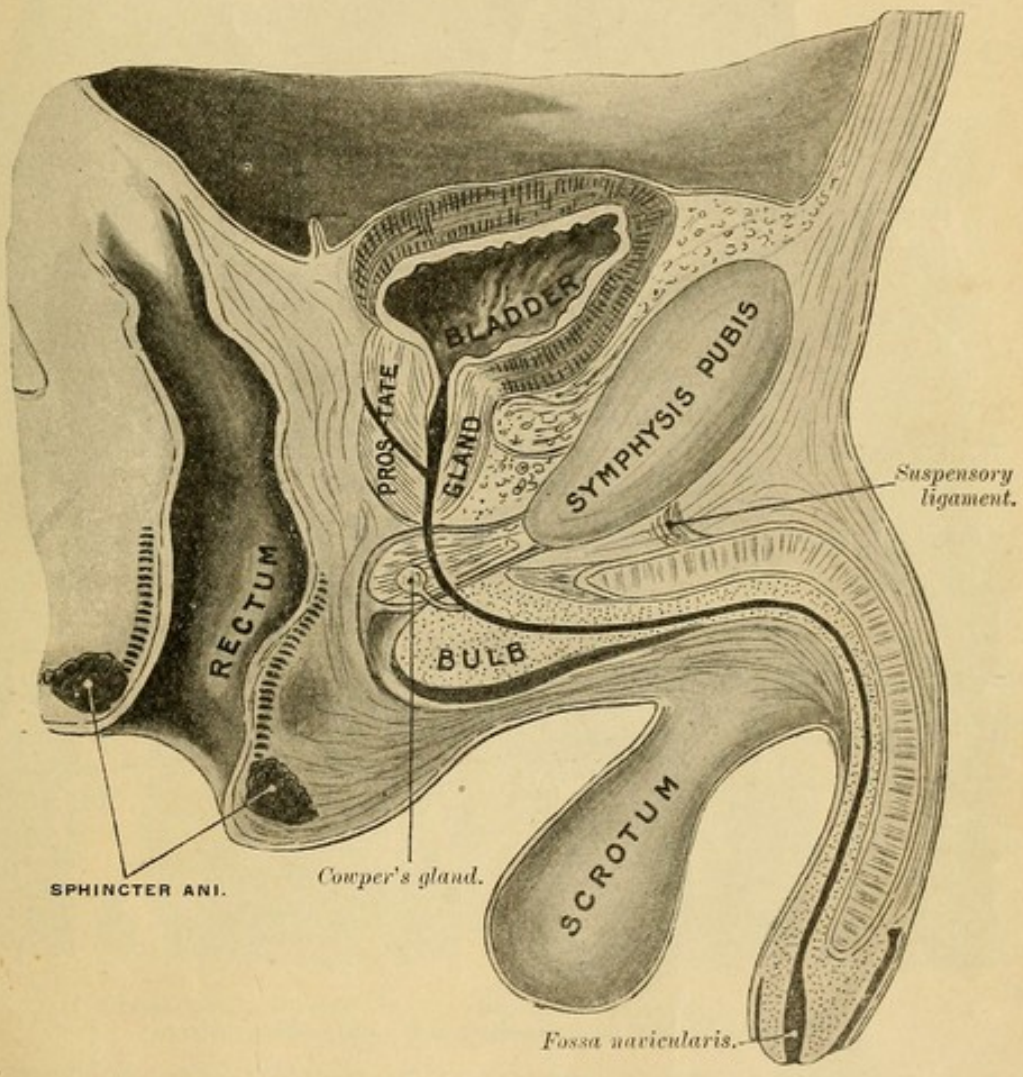

FIG. 557.—Vertical section of bladder, penis, and urethra.

than in the male.[1] When moderately distended, it measures about five inches in length, and three inches across, and the ordinary amount which it contains is about a pint.

The bladder is divided for purposes of description into a superior, an antero-inferior, and two lateral surfaces, a base or fundus and a summit or apex.

The **superior** or **abdominal** surface is entirely free, and is covered throughout by peritoneum. It looks almost directly upward into the abdominal cavity, and extends in an antero-posterior direction from the apex to the base of the bladder. It is in relation with the small intestine and sometimes with the sigmoid flexure, and in the female, with the uterus. On each side, in the male, a portion of the

[1] According to Henle, the bladder is considerably smaller in the female than in the male.

vas deferens is in contact with the hinder part of this surface, lying beneath the peritoneum.

The **antero-inferior** or **pubic surface** looks downward and forward. In the undistended condition it is uncovered by peritoneum, and is in relation with the Obturator internus muscle on each side, with the recto-vesical fascia, and anterior true ligaments of the bladder. It is separated from the body of the pubis by a triangular interval, the *space of Retzius*, occupied by fatty tissue. As the bladder

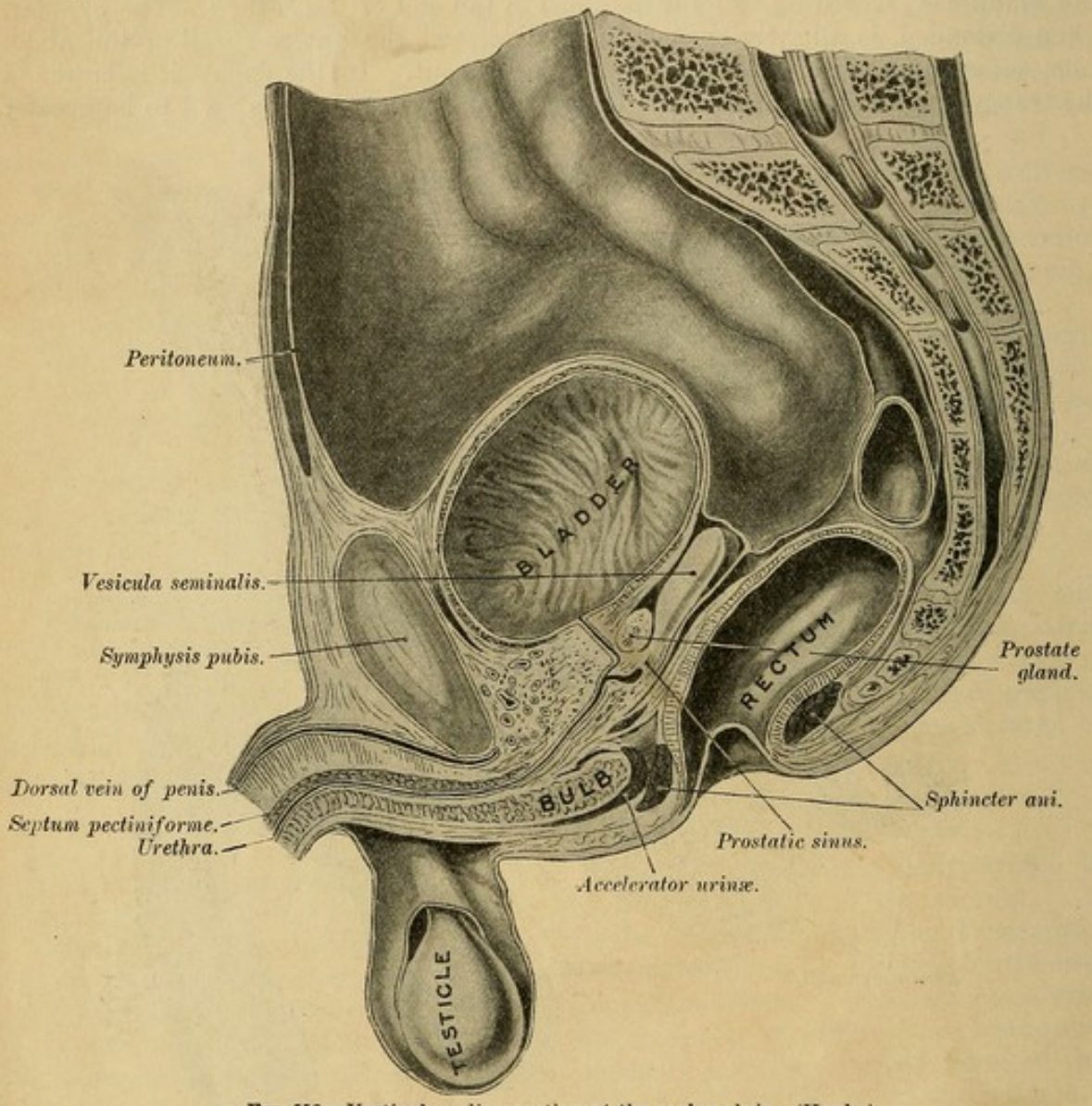

FIG. 558.—Vertical median section of the male pelvis. (Henle.)

ascends into the abdominal cavity during distention the distance between its apex and the umbilicus is necessarily diminished, and the urachus is thus relaxed; so that, instead of passing directly upward to the umbilicus, it descends first on the upper part of the anterior surface of the bladder, and then, curving upward, ascends on the back of the abdominal wall. The peritoneum, which follows the urachus, thus comes to form a pouch of varying depth between the anterior surface of the viscus and the abdominal wall. Thus, when the bladder is distended, the upper part of its anterior surface is in relation to the urachus and is covered by peritoneum. The lower part of its anterior surface, a distance of about two inches above the symphysis pubis, is devoid of peritoneum, and is in contact with the abdominal wall.

The **lateral surfaces** are covered behind and above by peritoneum, which extends as low as the level of the obliterated hypogastric artery; below and in front of this, these surfaces are uncovered by peritoneum, and are separated from

the Levatores ani muscles and walls of the pelvis by a quantity of loose areolar tissue containing fat. In front this surface is connected to the recto-vesical fascia by a broad expansion on either side, the *lateral true ligaments*. The vas deferens crosses the hinder part of the lateral surface obliquely, and passes between the ureter and the bladder.

The **fundus** or **base** is directed downward and backward, and is partly covered by peritoneum and partly uncovered. In the male the upper portion, to within about an inch and a half of the prostate, is covered by the recto-vesical pouch of peritoneum. The lower part is in direct contact with the anterior wall of the second part of the rectum and the vesiculæ seminales and vasa deferentia. The ureters enter the bladder at the upper part of its base, about two inches above the prostate gland.

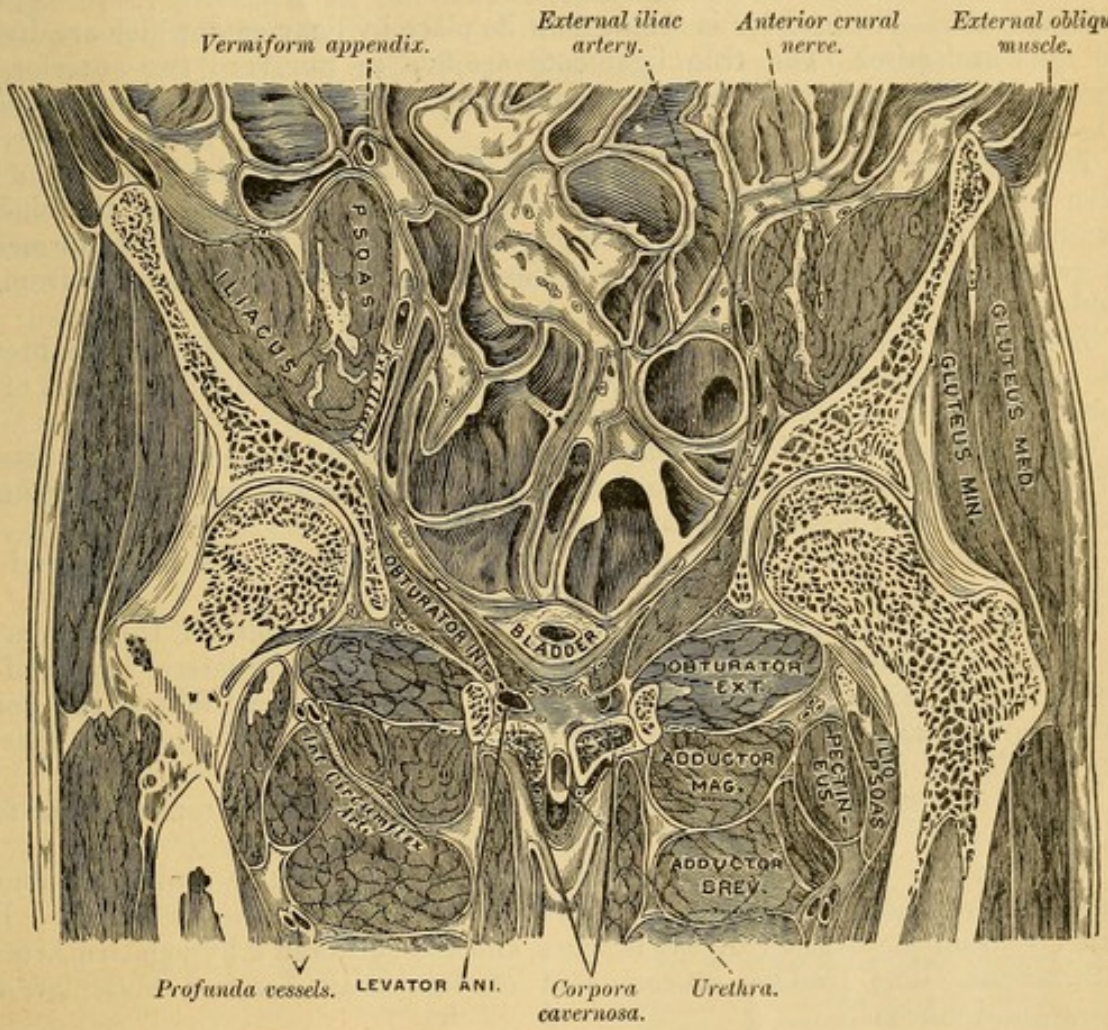

FIG. 559.—Frontal section of the lower part of the abdomen. Viewed from the front. (Braune.)

The portion of the bladder in relation with the rectum corresponds to a triangular space, bounded, below, by the prostate gland; above, by the recto-vesical fold of the peritoneum; and on each side, by the vesicula seminalis and vas deferens. It is separated from direct contact with the rectum by the recto-vesical fascia. When the bladder is very full, the peritoneal fold is raised with it, and the distance between its reflection and the anus is about four inches; but this distance is much diminished when the bladder is empty and contracted. *In the female*, the base of the bladder is connected to the anterior aspect of the cervix uteri by areolar tissue, and is adherent to the anterior wall of the vagina. Its upper surface is separated from the anterior surface of the body of the uterus by the utero-vesical pouch of peritoneum.

The so-called *neck* (*cervix*) *of the bladder* is the point of commencement of the urethra; there is, however, no tapering part, which would constitute a true neck,

but the bladder suddenly contracts to the opening of the urethra. In the male its direction is oblique in the erect posture, and it is surrounded by the prostate gland. In the female its direction is obliquely downward and forward.

The **urachus** is the obliterated remains of the tubular canal of the *allantois*, which exists in the embryo, and a portion of which becomes expanded to form the bladder (see section on Embryology). It passes upward, from the apex of the bladder, between the transversalis fascia and peritoneum, to the umbilicus, becoming thinner as it ascends. It is composed of fibrous tissue, mixed with plain muscular fibres. On each side of it is placed a fibrous cord, the obliterated portion of the hypogastric artery, which, passing upward from the side of the bladder, approaches the urachus above its summit. In the infant, at birth, it is occasionally found pervious, so that the urine escapes at the umbilicus, and calculi have been found in its canal.

Ligaments.—The bladder is retained in its place by ligaments, which are divided into true and false. The true ligaments are five in number: two anterior, two lateral, and the urachus. The false ligaments, also five in number, are formed by folds of the peritoneum.

The *anterior true ligaments* (*pubo-prostatic*) extend from the back of the ossa pubis, one on each side of the symphysis, to the front of the neck of the bladder, over the anterior surface of the prostate gland. These ligaments are formed by the recto-vesical fascia, and contain a few muscular fibres prolonged from the bladder.

The *lateral true ligaments*, also formed by the recto-vesical fascia, are broader and thinner than the preceding. They are attached to the lateral parts of the prostate and to the sides of the base of the bladder.

The *urachus* is the fibro-muscular cord already mentioned, extending between the summit of the bladder and the umbilicus. It is broad below, at its attachment to the bladder, and becomes narrower as it ascends.

The *false ligaments of the bladder* are two posterior, two lateral, and one superior.

The *two posterior* pass forward, in the male, from the sides of the rectum; in the female, from the sides of the uterus, to the posterior and lateral aspect of the bladder: they form the lateral boundaries of the recto-vesical fold of the peritoneum, and contain the obliterated hypogastric arteries, and the ureters, together with vessels and nerves.

The *two lateral ligaments* are reflections of the peritoneum, from the iliac fossæ and lateral walls of the pelvis to the sides of the bladder.

The *superior ligament* (*ligamentum suspensorium*) is the prominent fold of peritoneum extending from the summit of the bladder to the umbilicus. It is carried off from the bladder by the urachus and the obliterated hypogastric arteries.

Structure.—The bladder is composed of four coats—serous, muscular, submucous, and mucous.

The *serous coat* is partial, and derived from the peritoneum. It invests the superior surface and the upper part of the lateral surfaces and base, and is reflected from these parts on to the abdominal and pelvic walls.

The *muscular coat* consists of three layers of unstriped muscular fibre: an external layer, composed of fibres having for the most part a longitudinal arrangement; a middle layer, in which the fibres are arranged, more or less, in a circular manner; and an internal layer, in which the fibres have a general longitudinal arrangement.

The *fibres of the external longitudinal layer* arise from the posterior surface of the body of the os pubis in both sexes (*musculi pubo-vesicalis*), and in the male from the adjacent part of the prostate gland and its capsule. They pass, in a more or less longitudinal manner, up the anterior surface of the bladder, over its apex, and then descend along its posterior surface to its base, where they become attached to the prostate in the male and to the front of the vagina in the female.

At the sides of the bladder the fibres are arranged obliquely and intersect one another. This layer has been named the *detrusor urinæ muscle.*

The *middle circular layers* are very thinly and irregularly scattered on the body of the organ, and, though to some extent placed transversely to the long axis of the bladder, are for the most part arranged obliquely. Toward the lower part of the bladder, round the cervix and commencement of the urethra, they are disposed in a thick circular layer, forming the *sphincter vesicæ*, which is continuous with the muscular fibres of the prostate gland.

The *internal longitudinal layer* is thin, and its fasciculi have a reticular arrangement, but with a tendency to assume for the most part a longitudinal direction.

Two bands of oblique fibres, originating behind the orifices of the ureters, converge to the back part of the prostate gland, and are inserted, by means of a fibrous process, into the middle lobe of that organ. They are the *muscles of the ureters*, described by Sir C. Bell, who supposed that during the contraction of the bladder they served to retain the oblique direction of the ureters, and so prevent the reflux of the urine into them.

The *submucous coat* consists of a layer of areolar tissue connecting together the muscular and mucous coats, and intimately united to the latter.

The *mucous coat* is thin, smooth, and of a pale rose color. It is continuous above through the ureters with the lining membrane of the uriniferous tubes, and below with that of the urethra. It is connected loosely to the muscular coat by a layer of areolar tissue, and is therefore thrown into folds or *rugæ* when the bladder is empty. The epithelium covering it is of the transitional variety, consisting of a superficial layer of polyhedral flattened cells, each with one, two, or three nuclei; beneath these, a stratum of large club-shaped cells with the narrow extremity directed downward and wedged in between smaller spindle-shaped cells, containing an oval nucleus (Figs. 560, 561). There are no true glands in the mucous mem-

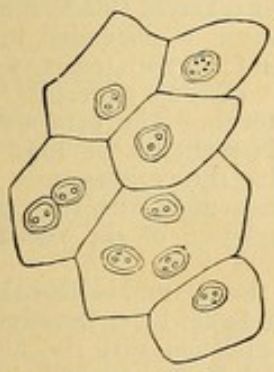

FIG. 560.—Superficial layer of the epithelium of the bladder. Composed of polyhedral cells of various sizes, each with one, two, or three nuclei. (Klein and Noble Smith.)



FIG. 561.—Deep layers of epithelium of bladder, showing large club-shaped cells above, and smaller, more spindle-shaped cells below, each with an oval nucleus. (Klein and Noble Smith.)

brane of the bladder, though certain mucous follicles which exist, especially near the neck of the bladder, have been regarded as such.

Objects seen on the Inner Surface.—Upon the inner surface of the bladder are seen the orifices of the ureters, the trigone, and the commencement of the urethra.

The Orifices of the Ureters.—These are situated at the base of the trigone, being distant from each other about two inches; they are about an inch and a half from the base of the prostate and the commencement of the urethra.

The *trigonum vesicæ*, or *trigone vesical*, is a triangular smooth surface, with the apex directed forward, situated at the base of the bladder, immediately behind the urethral orifice. It is paler in color than the rest of the interior, and never presents any rugæ, even in the collapsed condition of the organ, owing to the intimate adhesion of its mucous membrane to the subjacent tissue. It is bounded at each posterior angle by the orifice of the ureter, and in front by the orifice of the urethra.

Projecting from the lower and anterior part of the bladder, and reaching to the orifice of the urethra, is a slight elevation of mucous membrane, called the *uvula vesicæ*. It is formed by a thickening of the submucous tissue.

The *arteries* supplying the bladder are the superior, middle, and inferior vesical in the male, with additional branches from the uterine and vaginal in the female. They are all derived from the anterior trunk of the internal iliac. The obturator and sciatic arteries also supply small visceral branches to the bladder.

The *veins* form a complicated plexus round the neck, sides, and base of the bladder, and terminate in the internal iliac vein.

The *lymphatics* form two plexuses, one in the muscular and another in the submucous coat; they are most numerous in the neighborhood of the trigone. They accompany the blood-vessels, and ultimately terminate in the internal iliac glands.

The *nerves* are derived from the pelvic plexus of the sympathetic and from the third and the fourth sacral nerves; the former supplying the upper part of the organ, the latter its base and neck. According to F. Darwin, the sympathetic fibres have ganglia connected with them, which send branches to the vessels and muscular coat.

Surface Form.—The surface form of the bladder varies with its degree of distention and under other circumstances. In the young child it is represented by a conical figure, the apex of which, even when the viscus is empty, is situated in the hypogastric region, about an inch above the level of the symphysis pubis. In the adult, when the bladder is empty, its apex does not reach above the level of the upper border of the symphysis pubis, and the whole organ is situated in the pelvis; the neck, in the male, corresponding to a line drawn horizontally backward through the symphysis a little below its middle. As the bladder becomes distended, it gradually rises out of the pelvis into the abdomen, and forms a swelling in the hypogastric region which is perceptible to the hand as well as to percussion. In extreme distention it reaches into the umbilical region. Under these circumstances the lower part of its anterior surface, for a distance of about two inches above the symphysis pubis, is closely applied to the abdominal wall, without the intervention of peritoneum, so that it can be tapped by an opening in the middle line just above the symphysis pubis, without any fear of wounding the serous membrane. When the rectum is distended, the prostatic portion of the urethra is elongated and the bladder lifted out of the pelvis and the peritoneum pushed upward. Advantage is taken of this by some surgeons in performing the operation of suprapubic cystotomy. The rectum is distended by an India-rubber bag, which is introduced into this cavity empty, and then filled with ten or twelve ounces of water. If now the bladder is injected with about half a pint of some antiseptic fluid, it will appear above the pubes plainly perceptible to the sight and touch. The peritoneum will be pushed out of the way, and an incision three inches long may be made in the linea alba, from the symphysis pubis upward, without any great risk of wounding the peritoneum. Other surgeons object to the employment of this bag, as its use is not unattended with risk, and because it causes pressure on the prostatic sinuses and produces congestion of the vessels over the bladder and a good deal of venous hemorrhage.

When distended, the bladder can be felt in the male, from the rectum, behind the prostate, and fluctuation can be perceived by a bimanual examination, one finger being introduced into the rectum and the distended bladder tapped on the front of the abdomen with the finger of the other hand. This portion of the bladder—that is, the portion felt in the rectum by the finger—is also uncovered by peritoneum, and the bladder may here be punctured from the rectum, in the middle line, without risk of wounding the serous membrane.

Surgical Anatomy.—A defect of development in which the bladder is implicated is known under the name of *extroversion of the bladder*. In this condition the lower part of the abdominal wall and the anterior wall of the bladder are wanting, so that the posterior surface of the bladder presents on the abdominal surface, and is pushed forward by the pressure of the viscera within the abdomen, forming a red, vascular tumor, on which the openings of the ureters are visible. The penis, except the glans, is rudimentary and is cleft on its dorsal surface, exposing the floor of the urethra—a condition known as *epispadias*. The pelvic bones are also arrested in development (see page 183).

The bladder may be ruptured by violence applied to the abdominal wall when the viscus is distended without any injury to the bony pelvis, or it may be torn in cases of fracture of the pelvis. The rupture may be either intraperitoneal or extraperitoneal—that is, may implicate the superior surface of the bladder in the former case, or one of the other surfaces in the latter. Rupture of the antero-inferior surface alone is, however, very rare. Until recently intraperitoneal rupture was uniformly fatal, but now abdominal section and suturing the rent with Lembert's suture are resorted to, with a very considerable amount of success. The sutures are inserted only through the peritoneal and muscular coats in such a way as to bring the serous surfaces at the margins of the wound into apposition, and one is inserted just beyond each end of the wound. The bladder should be tested as to whether it is water-tight before closing the external incision.

The muscular coat of the bladder undergoes hypertrophy in cases in which there is any

obstruction to the flow of urine. Under these circumstances the bundles of which the muscular coat consists become much increased in size, and, interlacing in all directions, give rise to what is known as the *fasciculated bladder*. Between these bundles of muscular fibres the mucous membrane may bulge out, forming sacculi, constituting the *sacculated bladder*, and in these little pouches phosphatic concretions may collect, forming *encysted calculi*. The mucous membrane is very loose and lax, except over the trigone, to allow of the distention of the viscus.

Various forms of tumors have been found springing from the wall of the bladder. The innocent tumors are the papilloma and the mucous polypus, arising from the mucous membrane; the fibrous, from the submucous tissue; and the myoma, originating in the muscular tissue; and, very rarely, dermoid tumors, the exact origin of which it is difficult to explain. Of the malignant tumors, epithelioma is the most common, but sarcomata are occasionally found in the bladder of children.

Puncture of the bladder may be performed either above the pubes or through the rectum, in both cases without wounding the peritoneum. The former plan is generally to be preferred, since in puncture by the rectum a permanent fistula may be left from abscess forming between the rectum and the bladder; or pelvic cellulitis may be set up; moreover, it is exceedingly inconvenient to keep a cannula in the rectum. In some cases in performing this operation the recto-vesical pouch of peritoneum has been wounded, inducing fatal peritonitis. The operation, therefore, has been almost completely abandoned.

THE MALE URETHRA.

The **urethra in the male** extends from the neck of the bladder to the meatus urinarius at the end of the penis. It presents a double curve in the flaccid state of the penis (Fig. 557), but in the erect state of this organ it forms only a single curve, the concavity of which is directed upward. Its length varies from eight to nine inches; and it is divided into three portions, the *prostatic*, *membranous*, and *spongy*, the structure and relations of which are essentially different. Except during the passage of the urine or semen, the urethra is a more transverse cleft or slit, with its upper and under surfaces in contact. At the meatus urinarius the slit is vertical, and in the prostatic portion somewhat arched.

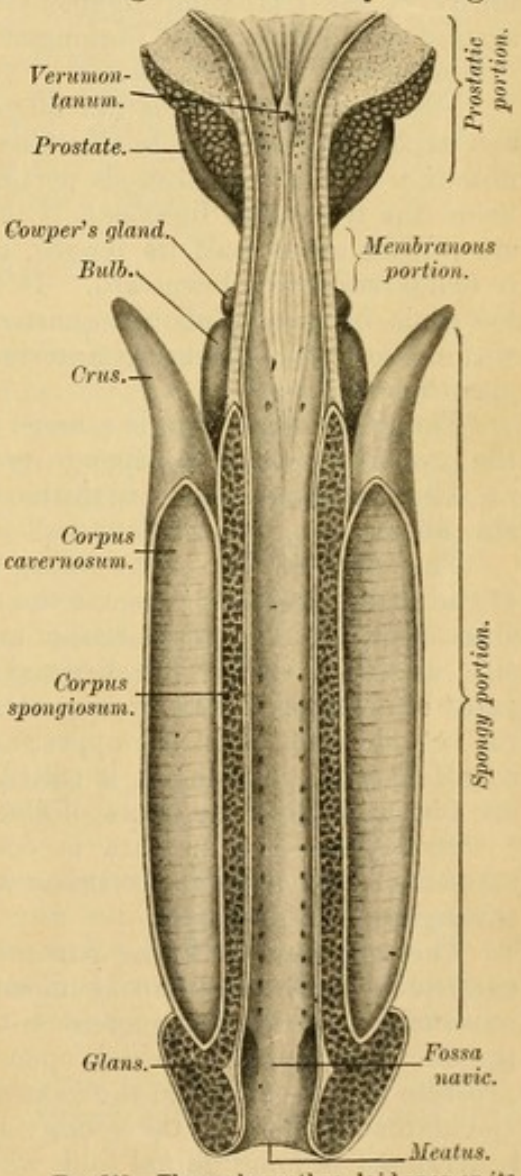

FIG. 562.—The male urethra, laid open on its anterior (upper) surface. (Testut.)

The **Prostatic Portion** is the widest and most dilatable part of the canal. It passes through the prostate gland, from its base to the apex, lying nearer its anterior than its posterior surface. It is about an inch and a quarter in length; the form of the canal is spindle-shaped, being wider in the middle than at either extremity, and narrowest below, where it joins the membranous portion. A transverse section of the canal as it lies in the prostate is horse-shoe in shape, the convexity being directed forward (Fig. 563), since the direction of the canal is nearly vertical.

Upon the floor of the canal is a narrow longitudinal ridge, the *verumontanum*, or *caput gallinaginis*, formed by an elevation of the mucous membrane and its subjacent tissue. It is eight or nine lines in length, and a line and a half in height; and contains, according to Kobelt, muscular and erectile tissues. When distended, it may serve to prevent the passage of the semen backward into the bladder. On each side of the verumontanum is a slightly depressed fossa, the *prostatic sinus*, the floor of which is perforated by numerous apertures, the *orifices of the prostatic ducts* from the lateral lobes of the gland; the ducts of the middle lobe open behind the

verumontanum. At the fore part of the verumontanum, in the middle line, is a depression, the *sinus pocularis* (*vesicula prostatica*); and upon or within its margins are the slit-like openings of the ejaculatory ducts. The sinus pocularis forms a *cul-de-sac* about a quarter of an inch in length, which runs upward and backward in the substance of the prostate behind the middle lobe; its prominent anterior wall partly forms the verumontanum. Its walls are composed of fibrous tissue, muscular fibres, and mucous membrane, and numerous small glands open on its inner surface. It has been called by Weber, who discovered it, the *uterus masculinus*, from its being developed from the united lower ends of the atrophied Müllerian ducts, and therefore homologous with the uterus and vagina in the female.

The **Membranous Portion of the Urethra** extends between the apex of the prostate and the bulb of the corpus spongiosum. It is the narrowest part of the canal (excepting the meatus), and measures three-quarters of an inch along its upper, and half an inch along its lower, surface, in consequence of the bulb projecting backward beneath it. Its anterior concave surface is placed about an inch below and behind the pubic arch, from which it is separated by the dorsal vessels and nerves of the penis, and some muscular fibres. Its posterior convex surface is separated from the rectum by a triangular space, which constitutes the perineum. The membranous portion of the urethra lies between the inferior and superior layers of the triangular ligament. As it pierces the inferior layer, the fibres around the opening are prolonged over the tube. It is also surrounded by the Compressor urethræ muscle.

The **Spongy Portion** is the longest part of the urethra, and is contained in the corpus spongiosum. It is about six inches in length, and extends from the termination of the membranous portion of the meatus urinarius. Commencing just below the triangular ligament, it inclines downward for a short distance; it next ascends for about half its length, and then, in the flaccid condition of the penis, it bends suddenly downward. It is narrow, and of uniform size in the body of the penis, measuring about a quarter of an inch in diameter; being dilated behind, within the bulb; and again anteriorly within the glans penis, where it forms the *fossa navicularis*.

The *Bulbous portion* is a name given, in some descriptions of the urethra, to the posterior part of the spongy portion contained within the bulb.

The *meatus urinarius* is the most contracted part of the urethra; it is a vertical slit, about three lines in length, bounded on each side by two small labia.

The inner surface of the lining membrane of the urethra, especially on the floor of the spongy portion, presents the orifices of numerous mucous glands and follicles situated in the submucous tissue, and named the *glands of Littre*. They vary in size, and their orifices are directed forward, so that they may easily intercept the point of a catheter in its passage along the canal. One of these lacunæ, larger than the rest, is situated in the upper surface of the fossa navicularis, about an inch and a half from the orifice; it is called the *lacuna magna*. Into the bulbous portion are found opening the ducts of Cowper's glands.

Structure.—The urethra is composed of a continuous mucous membrane, supported by a submucous tissue which connects it with the various structures through which it passes.

The *mucous coat* forms part of the genito-urinary mucous membrane. It is continuous with the mucous membrane of the bladder, ureters, and kidneys; externally with the integument covering the glans penis; and is prolonged into the ducts of the glands which open into the urethra—viz. Cowper's glands and the prostate gland—and into the vasa deferentia and vesiculæ seminales through the ejaculatory ducts. In the spongy and membranous portions the mucous membrane is arranged in longitudinal folds when the tube is empty. Small papillæ are found upon it near the orifice, and its epithelial lining is of the columnar variety, excepting near the meatus, where it is squamous.

The *submucous tissue* consists of a vascular erectile layer, outside which is a

layer of unstriped muscular fibres, arranged in a circular direction, which separates the mucous membrane and submucous tissue from the tissue of the corpus spongiosum.

Surgical Anatomy.—The urethra may be ruptured by the patient falling astride of any hard substance and striking his perinæum, so that the urethra is crushed against the pubic arch. Bleeding will at once take place from the urethra, and this, together with the bruising in the perinæum and the history of the accident, will at once point to the nature of the injury.

The surgical anatomy of the urethra is of considerable importance in connection with the passage of instruments into the bladder. Otis was the first to point out that the urethra is capable of great dilatability, so that, excepting through the external meatus, an instrument corresponding to 18 English gauge (29 French) can usually be passed without damage. The orifice of the urethra is not so dilatable, and therefore frequently requires slitting. A recognition of this dilatability caused Bigelow to very considerably modify the operation of lithotrity and introduce that of litholapaxy. In passing catheters, especially fine ones, the point of the instrument should be kept as far as possible along the upper wall of the canal, as the point is otherwise very liable to enter one of the lacunæ. Stricture of the urethra is a disease of very common occurrence, and is generally situated in the spongy portion of the urethra, most commonly in the bulbous portion, just in front of the membranous urethra, but in a very considerable number of cases in the penile or ante-scrotal part of the canal.

THE FEMALE BLADDER AND URETHRA.

The **Bladder** is situated at the anterior part of the pelvis. It is in relation, *in front*, with the symphysis pubis; *behind*, with the utero-vesical pouch of peritoneum, which separates it from the body of the uterus; its *base* lies in contact with the connective tissue in front of the cervix and upper part of the vagina. *Laterally*, is the recto-vesical fascia. The bladder is said by some anatomists to be larger in the female than in the male. At any rate, it does not rise above the symphysis pubis till more distended than in the male, but this is perhaps owing to the more capacious pelvis rather than to its being of actually larger size.

THE URETHRA.

The **Urethra** is a narrow membranous canal, about an inch and a half in length, extending from the neck of the bladder to the meatus urinarius. It is placed beneath the symphysis pubis, imbedded in the anterior wall of the vagina; and its direction is obliquely downward and forward, its course being slightly curved, the concavity directed forward and upward. Its diameter when undilated is about a quarter of an inch. The urethra perforates the triangular ligament, and its external orifice is situated directly in front of the vaginal opening and about an inch behind the glans clitoridis.

Structure.—The urethra consists of three coats: muscular, erectile, and mucous.

The *muscular coat* is continuous with that of the bladder; it extends the whole length of the tube, and consists of a circular stratum of muscular fibres. In addition to this, between the two layers of the triangular ligament, the female urethra is surrounded by the Compressor urethræ, as in the male.

A *thin layer of spongy erectile tissue*, containing a plexus of large veins intermixed with bundles of unstriped muscular fibre, lies immediately beneath the mucous coat.

The *mucous coat* is pale, continuous externally with that of the vulva, and internally with that of the bladder. It is thrown into longitudinal folds, one of which, placed along the floor of the canal, resembles the verumontanum in the male urethra. It is lined by laminated epithelium, which becomes transitional near the bladder. Its external orifice is surrounded by a few mucous follicles.

The urethra, from not being surrounded by dense resisting structures, as in the male, admits of considerable dilatation, which enables the surgeon to remove with considerable facility calculi or other foreign bodies from the cavity of the bladder.

THE MALE ORGANS OF GENERATION.

THE PROSTATE GLAND.

THE **Prostate Gland** (*προϊστημι, to stand before*) is a pale, firm, partly glandular and partly muscular body, which is placed immediately below the neck of the bladder and around the commencement of the urethra. It is placed in the pelvic cavity, behind the lower part of the symphysis pubis, and above the deep layer of the triangular ligament, and rests upon the rectum, through which it may be distinctly felt, especially when enlarged. In shape and size it resembles a chestnut.

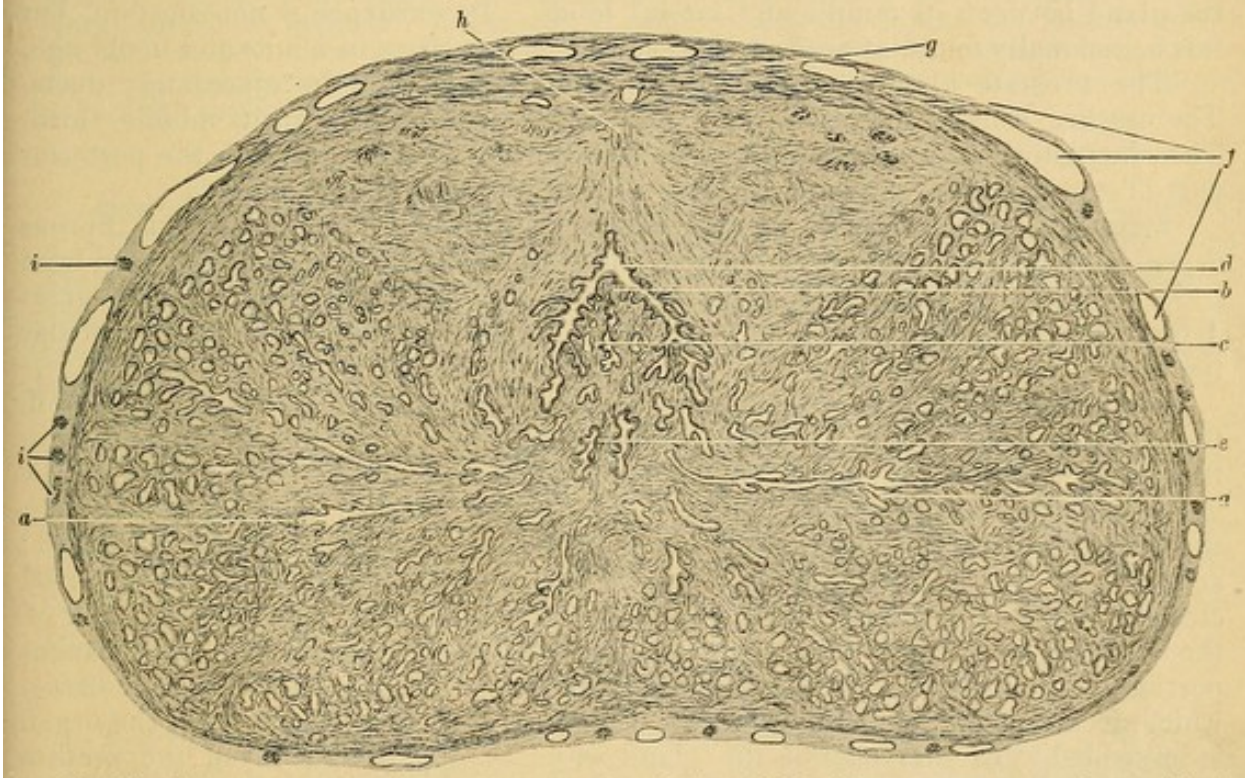

FIG. 563.—Transverse section of normal prostate through the middle of the verumontanum, from a subject aged nineteen years. (Taylor.) *a*, Longitudinal sections of ducts leading from the lobules of the prostatic glands; *b*, verumontanum; *c*, sinus pocularis; *d*, urethra; *e*, ejaculatory ducts; *f*, arteries, veins, and venous sinuses in capsule of prostate; *g*, nerve trunks in capsule; *h*, point of origin of fibro-muscular bands encircling urethra; *i*, zone of striated voluntary muscle on superior surface. (Drawn from Erdinger projection apparatus.)

Its *base* is directed upward, and is situated immediately below the neck of the bladder.

Its *apex* is directed downward to the deep layer of the triangular ligament, which it touches.

Its *posterior surface* is flattened, marked by a slight longitudinal furrow, and rests on the second part of the rectum, and is distant about one inch and a half from the anus.

Its *anterior surface* is convex, and placed about three-quarters of an inch behind the pubic symphysis, from which it is separated by a plexus of veins and a quantity of loose fat. It is connected to the pubic bone on either side by the pubo-prostatic ligaments.

The *lateral surfaces* are prominent, and are covered by the anterior portions

of the Levatores ani muscles, which are, however, separated from the gland by a plexus of veins.

The prostate measures about an inch and a half transversely at the base, an inch in its antero-posterior diameter, and an inch and a quarter in its vertical diameter. Its weight is about four and a half drachms. It is held in position by the anterior ligaments of the bladder (*pubo-prostatic*); by the deep layer of the triangular ligament, which invests the commencement of the membranous portion of the urethra and prostate gland; and by the anterior portions of the Levatores ani muscles, which pass backward from the os pubis and embrace the sides of the prostate. These portions of the Levatores ani, from the support they afford to the prostate, are named the *Levator prostatæ*.

The prostate consists of two lateral lobes and a middle lobe.

The *two lateral lobes* are of equal size, separated by a deep notch behind, and by a slight furrow upon the anterior and posterior surfaces of the gland, which indicates the bilobed condition of the organ in some animals.

The third, or *middle lobe*, is a small transverse band, occasionally a rounded or triangular prominence, placed between the two lateral lobes at the posterior part of the organ. It lies immediately beneath the neck of the bladder, behind the commencement of the urethra, and above the ejaculatory ducts, which pass through the gland between its middle and lateral lobes. Its existence is not constant, but it is occasionally found at an early period of life, as well as in adults and in old age.

The prostate gland is perforated by the urethra and the ejaculatory ducts. The urethra usually lies along the junction of its anterior with its middle third. The ejaculatory ducts pass obliquely downward and forward through the posterior part of the prostate, and open into the prostatic portion of the urethra.

Structure.—The prostate is immediately enveloped by a thin but firm fibrous capsule, distinct from that derived from the recto-vesical fascia, and separated from it by a plexus of veins. Its substance is of a pale reddish-gray color, of great density and not easily torn. It consists of glandular substance and muscular tissue.

The muscular tissue, according to Kölliker, constitutes the proper stroma of the prostate, the connective tissue being very scanty, and simply forming thin trabeculæ between the muscular fibres, in which the vessels and nerves of the gland ramify. The muscular tissue is arranged as follows: immediately beneath the fibrous capsule is a dense layer which forms an investing sheath for the gland; secondly, around the urethra as it lies in the prostate, is another dense layer of circular fibres, continuous above with the internal layer of the muscular coat of the bladder, and below blending with the fibres surrounding the membranous portion of the urethra. Between these two layers strong bands of muscular tissue, which decussate freely, form meshes in which the glandular structure of the organ is imbedded. In that part of the gland which is situated in front of the urethra the muscular tissue is especially dense, and there is here little or no gland tissue; while in that part which is behind the urethra the muscular tissue presents a wide-meshed structure, which is densest at the base of the gland—that is, near the bladder—becoming looser and more sponge-like toward the apex of the organ.

The *glandular substance* is composed of numerous follicular pouches, opening into elongated canals, which join to form from twelve to twenty small excretory ducts. The follicles are connected together by areolar tissue, supported by prolongations from the fibrous capsule and muscular stroma, and enclosed in a delicate capillary plexus. The epithelium lining of both the canals and the terminal vesicles is of the columnar variety. The prostatic ducts open into the floor of the prostatic portion of the urethra.

Vessels and Nerves.—The *arteries* supplying the prostate are derived from the internal pudic, vesical, and hæmorrhoidal. Its *veins* form a plexus around the sides and base of the gland; they receive in front the dorsal vein of the penis, and terminate in the internal iliac vein. The *nerves* are derived from the pelvic plexus.

Surgical Anatomy.—The relation of the prostate to the rectum should be noted: by means of the finger introduced into the gut the surgeon detects enlargement or other disease of this organ; he can feel the apex of the gland, which is the guide to Cock's operation for stricture; he is enabled also by the same means to direct the point of a catheter when its introduction is attended with difficulty either from injury or disease of the membranous or prostatic portions of the urethra. When the finger is introduced into the bowel the surgeon may, in some cases, especially in boys, learn the position, as well as the size and weight, of a calculus in the bladder; and in the operation for its removal, if, as is not unfrequently the case, it should be lodged behind an enlarged prostate, it may be displaced from its position by pressing upward the base of the bladder from the rectum. The prostate gland is occasionally the seat of suppuration, either due to injury, gonorrhœa, or tuberculous disease. The gland, being enveloped in a dense unyielding capsule, determines the course of the abscess, and also explains the great pain which is present in the acute form of the disease. The abscess most frequently bursts into the urethra, the direction in which there is least resistance, but may occasionally burst into the rectum, or more rarely in the perinæum. In advanced life the prostate becomes considerably enlarged, and projects into the bladder so as to impede the passage of the urine. According to Dr. Messer's researches, conducted at Greenwich Hospital, it would seem that such obstruction exists in 20 per cent. of all men over sixty years of age. In some cases the enlargement affects principally the lateral lobes, which may undergo considerable enlargement without causing much inconvenience. In other cases it would seem that the middle lobe enlarges most, and even a small enlargement of this lobe may act injuriously, by forming a sort of valve over the urethral orifice, preventing the passage of the urine, and the more the patient strains, the more completely will it block the opening into the urethra. In consequence of the enlargement of the prostate a pouch is formed at the base of the bladder behind the projection, in which water collects and cannot entirely be expelled. It becomes decomposed and ammoniacal, and leads to cystitis. For this condition "prostatectomy" is sometimes done. The bladder is opened by an incision above the symphysis pubis, the mucous membrane incised, and the enlarged and projecting middle lobe enucleated.

COWPER'S GLANDS.

Cowper's Glands are two small, rounded, and somewhat lobulated bodies of a yellow color, about the size of peas, placed behind the fore part of the membranous portion of the urethra, between the two layers of the triangular ligament. They lie close above the bulb, and are enclosed by the transverse fibres of the Compressor urethræ muscle. Their existence is said to be constant: they gradually diminish in size as age advances.

Structure.—Each gland consists of several lobules held together by a fibrous investment. Each lobule consists of a number of acini lined by columnar epithelial cells, opening into one duct, which, joining with the ducts of other lobules outside the gland, form a single excretory duct. The excretory duct of each gland, nearly an inch in length, passes obliquely forward beneath the mucous membrane, and opens by a minute orifice on the floor of the bulbous portion of the urethra.

THE PENIS.

The **Penis** consists of a root, body, and extremity or *glans penis*.

The *root* is firmly connected to the rami of the os pubis and ischium by two strong tapering, fibrous processes, the *crura*, and to the front of the symphysis pubis by the *suspensory ligament*, a strong band of fibrous tissue which passes downward from the front of the symphysis pubis to the upper surface of the root of the penis, where it splits into two portions and blends with the fascial sheath of the organ.

The *extremity* or *glans penis*, presents the form of an obtuse cone, flattened from above downward. At its summit is a vertical fissure, the orifice of the urethra (*meatus urinarius*). The base of the glans forms a rounded projecting border, the *corona glandis*, and behind the corona is a deep constriction, the *cervix*. Upon both of these parts numerous small sebaceous glands are found, the *glandulæ Tysonii odoriferæ*. They secrete a sebaceous matter of very peculiar odor, which probably contains caseine and becomes easily decomposed.

[1] Stieda (*Comptes rendus du XII Congrès International de Médecine*, Moscow, 1897) asserts that Tyson's glands are never found on the corona glandis, and that what have hitherto been mistaken for glands are really large papillæ.

The *body of the penis* is the part between the root and extremity. In the flaccid condition of the organ it is cylindrical, but when erect has a triangular prismatic form with rounded angles, the broadest side being turned upward, and called the *dorsum*. The body is covered by integument, and contains in its interior a large portion of the urethra. The integument covering the penis is remarkable for its thinness, its dark color, its looseness of connection with the deeper parts of the organ, and its containing no adipose tissue. At the root of the penis the integument is continuous with that upon the pubes and scrotum, and at the neck of the glans it leaves the surface and becomes folded upon itself to form the *prepuce*.

The internal layer of the prepuce is attached behind to the cervix, and approaches in character to a mucous membrane; from the cervix it is reflected over the glans penis, and at the meatus urinarius is continuous with the mucous lining of the urethra.

The integument covering the glans penis contains no sebaceous glands, but projecting from its free surface are a number of small, highly sensitive papillæ. At the back part of the meatus urinarius a fold of mucous membrane passes backward to the bottom of a depressed raphé, where it is continuous with the prepuce; this fold is termed the *frænum præputii*.

Structure of the Penis.—The penis is composed of a mass of erectile tissue enclosed in three cylindrical fibrous compartments. Of these, two, the *corpora cavernosa*, are placed side by side along the upper part of the organ; the third, or *corpus spongiosum*, encloses the urethra and is placed below.

The **Corpora Cavernosa** form the chief part of the body of the penis. They consist of two fibrous cylindrical tubes, placed side by side, and intimately connected along the median line for their anterior three-fourths, whilst at their back part they separate from each other to form the *crura*, which are two strong tapering fibrous processes firmly connected to the rami of the os pubis and ischium. Each crus commences by a blunt-pointed process in front of the tuberosity of the ischium, and before its junction with its fellow to form the body of the penis it presents a slight enlargement, named by Kobelt the *bulb of the corpus cavernosum*. Just beyond this point they become constricted, and retain an equal diameter to their anterior extremity, where they form a single rounded end which is received into a fossa in the base of the glans penis. A median groove on the upper surface lodges the dorsal vein of the penis, and the groove on the under surface receives the corpus spongiosum. The root of the penis is connected to the symphysis pubis by the suspensory ligament.

Structure.—The corpora cavernosa are surrounded by a strong fibrous envelope, consisting of two sets of fibres—the one, longitudinal in direction, being common to the two corpora cavernosa, and investing them in a common covering; the other, internal, circular in direction, and being proper to each corpus cavernosum. The internal circular fibres of the two corpora cavernosa form, by their junction in the mesial plane, an incomplete partition or septum between the two bodies.

The *septum* between the two corpora cavernosa is thick and complete behind, but in front it is incomplete, and consists of a number of vertical bands, which are arranged like the teeth of a comb, whence the name which it has received, *septum pectiniforme*. These bands extend between the dorsal and the urethral surface of the corpora cavernosa. This fibrous investment is extremely dense, of considerable thickness, and consists of bundles of shining white fibres, with an admixture of well-developed elastic fibre, so that it is possessed of great elasticity.

From the internal surface of the fibrous envelope, as well as from the sides of the septum, are given off a number of bands or cords which cross the interior of the corpora cavernosa in all directions, subdividing them into a number of separate compartments, and giving the entire structure a spongy appearance. These bands and cords are called *trabeculæ*, and consist of white fibrous tissue,

elastic fibres, and plain muscular fibres. In them are contained numerous arteries and nerves.

The component fibres of which the trabeculæ are composed are larger and stronger round the circumference than at the centre of the corpora cavernosa; they are also thicker behind than in front. The interspaces, on the contrary, are larger at the centre than at the circumference, their long diameter being directed transversely; they are largest anteriorly. They are occupied by venous blood, and are lined by a layer of flattened cells similar to the endothelial lining of veins.

The whole of the structure of the corpora cavernosa contained within the fibrous sheath consists, therefore, of a sponge-like tissue of areolar spaces freely communicating with each other and filled with venous blood. The spaces may therefore be regarded as large cavernous veins.

The arteries bringing the blood to these spaces are the arteries of the corpora cavernosa and branches from the dorsal artery of the penis, which perforate the fibrous capsule, along the upper surface, especially near the fore part of the organ.

These arteries on entering the cavernous structure divide into branches which are supported and enclosed by the trabeculæ. Some of these terminate in a capillary network, the branches of which open directly into the cavernous spaces; others assume a tendril-like appearance, and form convoluted and somewhat dilated vessels, which were named by Müller *helicine arteries*. They project into the spaces, and from them are given off small capillary branches to supply the trabecular structure. They are bound down in the spaces by fine fibrous processes, and are more abundant in the back part of the corpora cavernosa (Fig. 564).

The blood from the cavernous spaces is returned by a series of vessels, some of which emerge in considerable numbers from the base of the glans penis and

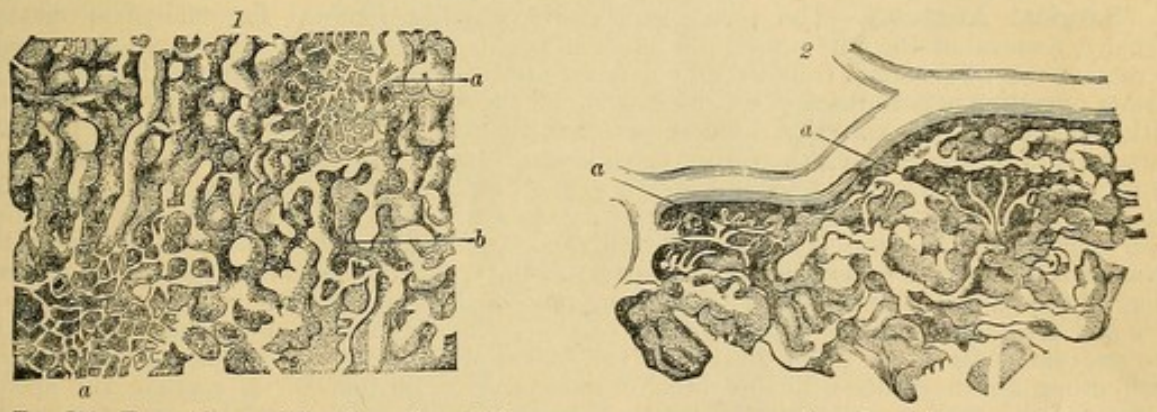

FIG. 564.—From the peripheral portion of the corpus cavernosum penis under a low magnifying power. (Copied from Langer.) 1. *a*. Capillary network. *b*. Cavernous spaces. 2. Connection of the arterial twigs (*a*) with the cavernous spaces.

converge on the dorsum of the organ to form the dorsal vein; others pass out on the upper surface of the corpora cavernosa and join the dorsal vein; some emerge from the under surface of the corpora cavernosa, and, receiving branches from the corpus spongiosum, wind round the sides of the penis to terminate in the dorsal vein; but the greater number pass out at the root of the penis and join the prostatic plexus.

The **Corpus Spongiosum** encloses the urethra, and is situated in the groove on the under surface of the corpora cavernosa. It commences posteriorly below the superficial layer of the triangular ligament of the urethra, between the diverging crura of the corpora cavernosa, where it forms a rounded enlargement, the *bulb*, and terminates anteriorly in another expansion, the *glans penis*, which overlaps the anterior rounded extremity of the corpora cavernosa. The central portion, or body of the corpus spongiosum, is cylindrical, and tapers slightly from behind forward.

The *bulb* varies in size in different subjects; it receives a fibrous investment

from the superficial layer of the triangular ligament, and is surrounded by the Accelerator urinæ muscle. The urethra enters the bulb nearer its upper than its lower surface, being surrounded by a layer of erectile tissue, a thin prolongation of which is continued backward round the membranous and prostatic portions of the canal to the neck of the bladder, lying between the two layers of muscular tissue. The portion of the bulb below the urethra presents a partial division into two lobes, being marked externally by a linear raphé, whilst internally there projects, for a short distance, a thin fibrous septum, which is more distinct in early life.

Structure.—The corpus spongiosum consists of a strong fibrous envelope, enclosing a trabecular structure, which contains in its meshes erectile tissue. The fibrous envelope is thinner, whiter in color, and more elastic than that of the corpora cavernosa. The trabeculæ are more delicate, nearly uniform in size, and the meshes between them smaller than in the corpora cavernosa, their long diameter, for the most part, corresponding with that of the penis. The external envelope or outer coat of the corpus spongiosum is formed partly of unstriped muscular fibre, and a layer of the same tissue immediately surrounds the canal of the urethra.

The *lymphatics of the penis* consist of a superficial and deep set; the former are derived from a dense network on the skin of the glans and prepuce and from the mucous membrane of the urethra, and terminate in the superficial inguinal glands; the latter emerge from the corpora cavernosa and corpus spongiosum, and, passing beneath the pubic arch, join the deep lymphatics of the pelvis.

The *nerves* are derived from the internal pudic nerve and the pelvic plexus. On the glans and bulb some filaments of the cutaneous nerves have Pacinian bodies connected with them, and, according to Krause, many of them terminate in a peculiar form of end-bulb.

Surgical Anatomy.—The penis occasionally requires removal for malignant disease. Usually, removal of the ante-scrotal portion is all that is necessary, but sometimes it is requisite to remove the whole organ from its attachment to the rami of the ossa pubis and ischia. The former operation is performed either by cutting off the whole of the anterior part of the penis with one sweep of the knife, or, what is better, cutting through the corpora cavernosa from the dorsum, and then separating the corpus spongiosum from them, dividing it at a level nearer the glans penis. The mucous membrane of the urethra is then slit up, and the edges of the flap attached to the external skin, in order to prevent contraction of the orifice, which would otherwise take place. The vessels which require ligature are the two dorsal arteries of the penis, the arteries of the corpora cavernosa, and the artery of the septum. When the entire organ requires removal the patient is placed in the lithotomy position, and an incision is made through the skin and subcutaneous tissue round the root of the penis, and carried down the median line of the scrotum as far as the perineum. The two halves of the scrotum are then separated from each other, and a catheter having been introduced into the bladder as a guide, the spongy portion of the urethra below the triangular ligament is separated from the corpora cavernosa and divided, the catheter having been withdrawn just behind the bulb. The suspensory ligament is now severed, and the crura separated from the bone with a periosteum scraper, and the whole penis removed. The membranous portion of the urethra, which has not been removed, is now to be attached to the skin at the posterior extremity of the incision in the perinæum. The remainder of the wound is to be brought together, free drainage being provided for.

THE TESTES AND THEIR COVERINGS (Fig. 565).

The **Testes** are two glandular organs, which secrete the semen; they are situated in the scrotum, being suspended by the spermatic cords. At an early period of fœtal life the testes are contained in the abdominal cavity, behind the peritoneum. Before birth they descend to the inguinal canal, along which they pass with the spermatic cord, and, emerging at the external abdominal ring, they descend into the scrotum, becoming invested in their course by numerous coverings derived from the serous, muscular, and fibrous layers of the abdominal parietes, as well as by the scrotum. The coverings of the testes are—the

Skin
Dartos } Scrotum.
Intercolumnar, or External spermatic fascia.
Cremasteric fascia.
Infundibuliform, or Fascia propria (Internal spermatic fascia).
Tunica vaginalis.

The **Scrotum** is a cutaneous pouch which contains the testes and part of the spermatic cords. It is divided on its surface into two lateral portions by a median line, or *raphé*, which is continued forward to the under surface of the penis and backward along the middle line of the perineum to the anus. Of these two lateral portions, the left is longer than the right, and corresponds with the greater length of the spermatic cord on the left side. Its external aspect varies under different circumstances: thus under the influence of warmth and in old and debilitated persons it becomes elongated and flaccid, but under the influence of cold and in the young and robust it is short, corrugated, and closely applied to the testes.

The scrotum consists of two layers, the integument and the dartos.

The **integument** is very thin, of a brownish color, and generally thrown into folds or rugæ. It is provided with sebaceous follicles, the secretion of which has a peculiar odor, and is beset with thinly-scattered, crisp hairs, the roots of which are seen through the skin.

The **dartos** is a thin layer of loose reddish tissue, endowed with contractility: it forms the proper tunic of the scrotum, is continuous, around the base of the scrotum, with the two layers of the superficial fascia of the groin and perinæum,

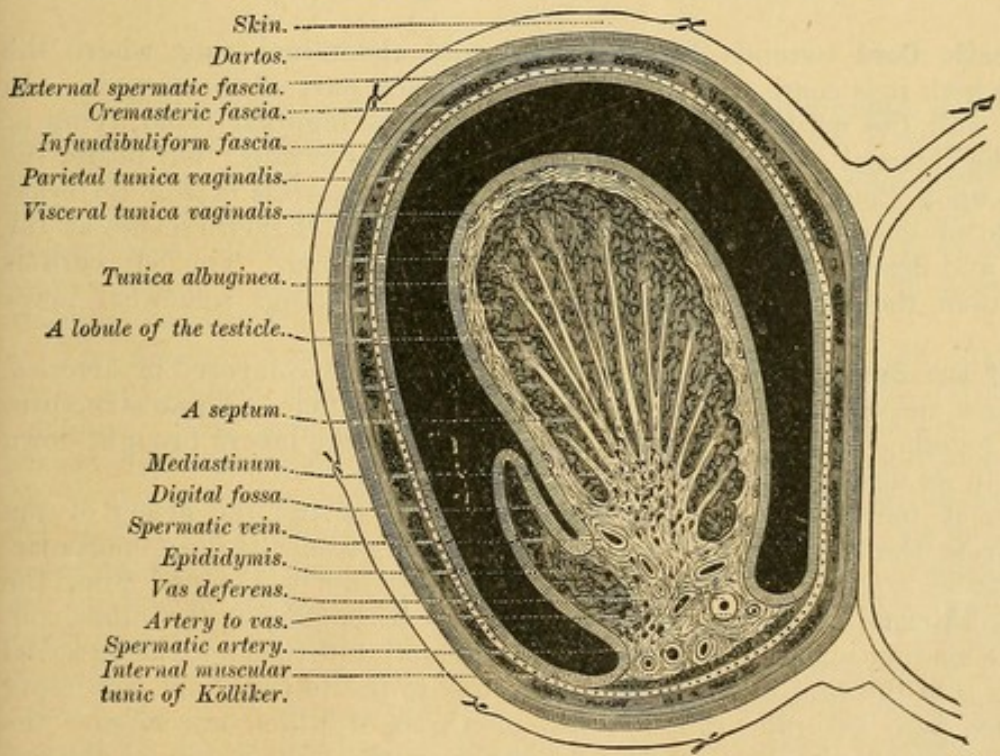

FIG. 565.—Transverse section through the left side of the scrotum and the left testicle. The sac of the tunica vaginalis represented in a distended condition. (Delépine.)

and sends inward a distinct septum, *septum scroti*, which divides it into two cavities for the two testes, the septum extending between the raphe and the under surface of the penis as far as its root.

The dartos is closely united to the skin externally, but connected with the subjacent parts by delicate areolar tissue, upon which it glides with the greatest facility. The dartos is very vascular, and consists of a loose areolar tissue containing unstriped muscular fibre, but no fat. Its contractility is slow, and excited by cold and mechanical stimuli, but not by electricity.

The **intercolumnar fascia** is a thin membrane derived from the margin of the

pillars of the external abdominal ring, during the descent of the testes in the fœtus, which is prolonged downward around the surface of the cord and testis. It is separated from the dartos by loose areolar tissue, which allows of considerable movement of the latter upon it, but is intimately connected with the succeeding layers.

The **cremasteric fascia** consists of scattered bundles of muscular fibres (*Cremaster muscle*) connected together into a continuous covering by intermediate areolar tissue. The muscular fibres are continuous with the lower border of the Internal oblique muscle (see page 360).

The **infundibuliform fascia** is a thin membranous layer, which loosely invests the surface of the cord. It is a continuation downward of the fascia transversalis. Beneath it is a quantity of loose connective tissue which connects this layer of fascia with the spermatic cord and posterior part of the testicle. This connective tissue is continuous above with the subserous areolar tissue of the abdomen. These two layers, the infundibuliform fascia and the tissue beneath it, are known collectively as the *fascia propria*.

The **tunica vaginalis** is described with the testis.

Vessels and Nerves.—The *arteries* supplying the coverings of the testis are: the superficial and deep external pudic, from the femoral; the superficial perineal branch of the internal pudic; and the cremasteric branch from the epigastric. The *veins* follow the course of the corresponding arteries. The *lymphatics* terminate in the inguinal glands. The *nerves* are: the ilio-inguinal branch of the lumbar plexus, the two superficial perineal branches of the internal pudic nerve, the inferior pudendal branch of the small sciatic nerve, and the genital branch of the genito-crural nerve.

The **Spermatic Cord** extends from the internal abdominal ring, where the structures of which it is composed converge, to the back part of the testicle. In the abdominal wall the cord passes obliquely along the inguinal canal, lying at first between the Internal oblique and upon the fascia transversalis; but nearer the pubes it rests upon Poupart's ligament, having the aponeurosis of the External oblique in front of it and the conjoined tendon behind it. It then escapes at the external ring, and descends nearly vertically into the scrotum. The left cord is rather longer than the right, consequently the left testis hangs somewhat lower than its fellow.

Structure of the Spermatic Cord.—The spermatic cord is composed of arteries, veins, lymphatics, nerves, and the excretory duct of the testicle. These structures are connected together by areolar tissue, and invested by the layers brought down by the testicle in its descent.

The *arteries of the cord* are: the spermatic, from the aorta; the artery of the vas deferens, from the superior vesical; the cremasteric, from the deep epigastric.

The *spermatic artery*, a branch of the abdominal aorta, escapes from the abdomen at the internal or deep abdominal ring, and accompanies the other constituents of the spermatic cord along the inguinal canal and through the external abdominal ring into the scrotum. It then descends to the testicle, and, becoming tortuous, divides into several branches, two or three of which accompany the vas deferens and supply the epididymis, anastomosing with the artery of the vas deferens; others pierce the back of the tunica albuginea and supply the substance of the testis.

The *cremasteric artery* is a branch of the deep epigastric artery. It accompanies the spermatic cord and supplies the Cremaster muscle and other coverings of the cord, anastomosing with the spermatic artery.

The *artery of the vas deferens*, a branch of the superior vesical, is a long slender vessel which accompanies the vas deferens, ramifying upon the coats of that duct, and anastomosing with the spermatic artery near the testis.

The spermatic veins emerge from the back of the testis and receive tributaries from the epididymis; they unite and form a convoluted plexus (*plexus pampiniformis*), which forms the chief mass of the cord: the vessels composing this plexus

are very numerous, and ascend along the cord in front of the vas deferens; below the external or superficial abdominal ring they unite to form three or four veins, which pass along the inguinal canal, and, entering the abdomen through the internal or deep abdominal ring, coalesce to form two veins. These again unite to form a single vein, which opens on the right side into the inferior vena cava at an acute angle, and on the left side into the renal vein at a right angle.

The *lymphatic vessels* terminate in the lumbar glands.

The *nerves* are the spermatic plexus from the sympathetic, joined by filaments from the pelvic plexus which accompany the artery of the vas deferens.

Surgical Anatomy.—The scrotum forms an admirable covering for the protection of the testicle. This body, lying suspended and loose in the cavity of the scrotum and surrounded by a serous membrane, is capable of great mobility, and can therefore easily slip about within the scrotum, and thus avoid injuries from blows or squeezes. The skin of the scrotum is very elastic and capable of great distension, and on account of the looseness and amount of subcutaneous tissue the scrotum becomes greatly enlarged in cases of œdema, to which this part is especially liable on account of its dependent position. The scrotum is frequently the seat of epithelioma; this is no doubt due to the rugæ on its surface, which favor the lodgment of dirt, and this, causing irritation, is the exciting cause of the disease, which is especially common in chimney-sweeps from the lodgment of soot. The scrotum is also the part most frequently affected by elephantiasis.

On account of the looseness of the subcutaneous tissue considerable extravasations of blood may take place from very slight injuries. It is therefore generally recommended never to apply leeches to the scrotum, since they may lead to considerable ecchymosis, but rather to puncture one or more of the superficial veins of the scrotum in cases where local bloodletting from this part is judged to be desirable. The muscular fibre in the dartos causes contraction and considerable diminution in the size of a wound of the scrotum, as after the operation of castration, and is of assistance in keeping the edges together and covering the exposed parts.

THE TESTES.

The **Testes** are suspended in the scrotum by the spermatic cords. As the left spermatic cord is rather longer than the right one, the left testicle hangs somewhat lower than its fellow. Each gland is of an oval form, compressed laterally, and having an oblique position in the scrotum, the upper extremity being directed forward and a little outward, the lower, backward and a little inward; the anterior convex border looks forward and downward; the posterior or straight border, to which the cord is attached, backward and upward.

The anterior border and lateral surfaces, as well as both extremities of the organ, are convex, free, smooth, and invested by the visceral layer of the tunica vaginalis. The posterior border, to which the cord is attached, receives only a partial investment from that membrane. Lying upon the outer edge of this posterior border is a long, narrow, flattened body, named from its relation to the testis, the epididymis (*δίδυμος*, testis). It consists of a central portion, or *body;* an upper enlarged extremity, the head, or *globus major;* and a lower pointed extremity, the tail, or *globus minor*. The globus major is intimately connected with the upper end of the testicle by means of its efferent ducts, and the globus minor is connected with its lower end by cellular tissue and a reflection of the tunica vaginalis. The outer surface and upper and lower ends of the epididymis are free and covered by serous membrane; the body is also completely invested by it, excepting along its posterior border, and between the body and the testicle is a pouch or *cul-de-sac*, named the *digital fossa*. The epididymis is connected to the back of the testis by a fold of the serous membrane. Attached to the upper end of the testis, close to the globus major, are two small pedunculated bodies. One of them is pear-shaped, and attached by its narrow stalk; the other is small and sessile; they are believed to be the remains of the upper extremity of the Müllerian duct, and are termed the *hydatids of Morgagni;* some observers, however, regard the stalked hydatid as being a rudiment of the pronephros. When the testiele is removed from the body, the position of the vas deferens, on the posterior surface of the testicle and inner side of the epididymis, marks the side to which the gland has belonged.

Size and Weight.—The average dimensions of this gland are from one and a half to two inches in length, one inch in breadth, and an inch and a quarter in the antero-posterior diameter, and the weight varies from six to eight drachms, the left testicle being a little the larger.

The testis is invested by three tunics—the tunica vaginalis, tunica albuginea, and tunica vasculosa.

The **Tunica Vaginalis** is the serous covering of the testis. It is a pouch of serous membrane, derived from the peritoneum during the descent of the testis in the fœtus from the abdomen into the scrotum. After its descent that portion of the pouch which extends from the internal ring to near the upper part of the gland becomes obliterated, the lower portion remaining as a shut sac, which invests the outer surface of the testis, and is reflected on to the internal surface of the scrotum; hence it may be described as consisting of a visceral and parietal portion.

The *visceral portion of the tunica vaginalis* covers the outer surface of the testis, as well as the epididymis, connecting the latter to the testis by means of a distinct fold. From the posterior border of the gland it is reflected on to the internal surface of the scrotum.

The *parietal portion of the tunica vaginalis* is far more extensive than the visceral portion, extending upward for some distance in front and on the inner side of the cord, and reaching below the testis. The inner surface of the tunica vaginalis is free, smooth, and covered by a layer of endothelial cells. The interval between the visceral and parietal layers of this membrane constitutes the cavity of the tunica vaginalis.

The obliterated portion of the pouch may generally be seen as a fibro-cellular thread lying in the loose areolar tissue around the spermatic cord; sometimes this may be traced as a distinct band from the upper end of the inguinal canal, where it is connected with the peritoneum, down to the tunica vaginalis; sometimes it gradually becomes lost on the spermatic cord. Occasionally no trace of it can be detected. In some cases it happens that the pouch of peritoneum does not become obliterated, but the sac of the peritoneum communicates with the tunica vaginalis. This may give rise to one of the varieties of oblique inguinal hernia (page 1049). Or in other cases the pouch may contract, but not become entirely obliterated; it then forms a minute canal leading from the peritoneum to the tunica vaginalis.[1]

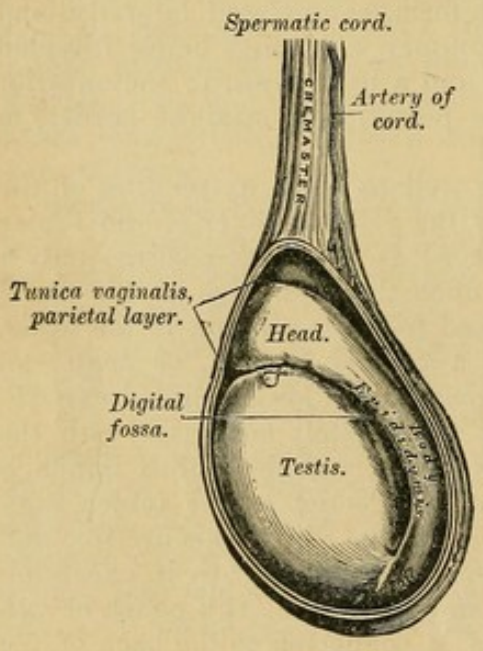

FIG. 566.—The testis *in situ*, the tunica vaginalis having been laid open.

The **Tunica Albuginea** is the fibrous covering of the testis. It is a dense fibrous membrane, of a bluish-white color, composed of bundles of white fibrous tissue, which interlace in every direction. Its outer surface is covered by the tunica vaginalis, except at the points of attachment of the epididymis to the testicle, and along its posterior border, where the spermatic vessels enter the gland. This membrane surrounds the glandular structure of the testicle, and at its posterior border is reflected into the interior of the gland, forming an incomplete vertical septum, called the *mediastinum testis* (*corpus Highmorianum*).

The *mediastinum testis* extends from the upper, nearly to the lower, extremity

[1] It is recorded that in the post-mortem examination of Sir Astley Cooper this minute canal was found on both sides of the body. Sir Astley Cooper states that when a student he suffered from inguinal hernia; probably this was of the congenital variety, and the canal found after death was the remains of the one down which the hernia travelled (*Lancet*, 1824, vol. ii., p. 116).

of the gland, and is wider above than below. From the front and sides of this septum numerous slender fibrous cords and imperfect septa (*trabeculæ*) are given off, which radiate toward the surface of the organ, and are attached to the inner surface of the tunica albuginea. They therefore divide the anterior of the organ into a number of incomplete spaces, which are somewhat cone-shaped, being broad at their bases at the surface of the gland, and becoming narrower as they converge to the mediastinum. The mediastinum supports the vessels and ducts of the testis in their passage to and from the substance of the gland.

The **Tunica Vasculosa** is the vascular layer of the testis, consisting of a plexus of blood-vessels held together by a delicate areolar tissue. It covers the inner surface of the tunica albuginea and the different septa in the interior of the gland, and therefore forms an internal investment to all the spaces of which the gland is composed.

Structure.—The glandular structure of the testis consists of numerous lobules (*lobuli testis*). Their number, in a single testis, is estimated by Berres at 250, and by Krause at 400. They differ in size according to their position, those in the middle of the gland being larger and longer. The lobules are conical in shape, the base being directed toward the circumference of the organ, the apex toward the mediastinum. Each lobule is contained in one of the intervals between the fibrous cords and vascular processes which extend between the mediastinum testis and the tunica albuginea, and consists of from one to three or more minute convoluted tubes, the *tubuli seminiferi*. The tubes may be separately unravelled by careful dissection under water, and may be seen to commence either by free cæcal ends or by anastomotic loops. The total number of tubes is considered by Munro to be about 300, and the length of each about sixteen feet; by Lauth their number is estimated at 840, and their average length two feet and a quarter. The diameter varies from $\frac{1}{200}$ to $\frac{1}{150}$ of an inch. The tubuli are pale in color in early life, but in old age they acquire a deep yellow tinge from containing much fatty matter. Each tube consists of a basement layer, formed of epithelioid cells united edge to edge, outside which are other layers of flattened cells arranged in interrupted laminæ, which give to the tube an appearance of striation in cross section. The cells of the outer layers gradually pass into the interstitial tissue. Within the basement-membrane are epithelial cells arranged in several irregular layers, which are not always clearly separated, but which may be arranged in three different groups. Among these cells may be seen the *spermatozoa* in different stages of development. 1. Lining the basement-membrane and forming the outer zone is a layer of cubical cells, with small nuclei; these are known as the *lining cells* or *spermatogonia*. The nucleus of some of them may be seen to be in the process of indirect division (*karyokinesis*), and in consequence of this daughter cells are formed, which constitute the second zone. 2. Within this first layer is to be seen a number of larger cells with clear nuclei, arranged in two or three layers; these are the *intermediate cells* or *spermatocytes*. Most of these cells are in a condition of karyokinetic division, and the cells which result from this division form those of the next layer, the *spermatoblasts* or *spermatids*. 3. The third layer of cells therefore consists of the spermatoblasts or spermatids, and each of these, without further subdivision, becomes a *spermatozoon*. They are ill-defined granular masses of protoplasm, of an elongated form, with a nucleus which becomes the head of the future spermatozoon. In addition to these three layers of cells others are seen, which are termed the *supporting cells*, or *cells of Sertoli*. They are elongated and columnar, and project inward from the basement-membrane toward the lumen of the tube. They give off numerous lateral branches, which form a reticulum for the support of the three groups of cells just described. As development of the spermatozoa proceeds the latter group themselves around the inner extremities of the supporting cells. The nuclear part of the spermatozoon, which is partly imbedded in the supporting cell, is differentiated to form the head of the spermatozoon, while the cell protoplasm becomes lengthened out to form the middle piece

and tail, the latter projecting into the lumen of the tube. Ultimately the heads are separated and the spermatozoa are set free.

Spermatogenesis.—The stages in the development of the spermatozoa are as follows: The spermatogonia become enlarged to form the spermatocytes, and each spermatocyte subdivides into two cells, and each of these again divides into two spermatids or young spermatozoa, so that the spermatocyte gives origin to four spermatozoa.

The process of spermatogenesis bears a close relation to that of maturation of the ovum. The spermatocyte is equivalent to the immature ovum. It undergoes subdivision, and ultimately gives origin to four spermatozoa, each of which contains, therefore, only one-fourth of the chromatin elements of the nucleus of the spermatocyte. In the process of maturation of the ovum its nucleus divides, one half being extended as the first polar body. The remaining half of the nucleus again subdivides, one half being extended as the second polar body. The portion of the nucleus which is retained to form the female pronucleus of the now matured ovum contains, therefore, only one-fourth of the chromatin elements of the original nucleus, and thus the spermatozoon and the matured ovum, so far as their nuclear elements are concerned, may be regarded as of the same morphological value.

The tubules are enclosed in a delicate plexus of capillary vessels, and are held together by an intertubular connective tissue, which presents large interstitial spaces lined by endothelium, which are believed to be the rootlets of lymphatic vessels of the testis.

In the apices of the lobules the tubuli become less convoluted, assume a nearly straight course, and unite together to form from twenty to thirty larger ducts, of about $\frac{1}{50}$ of an inch in diameter, and these, from their straight course, are called *vasa recta*.

The *vasa recta* enter the fibrous tissue of the mediastinum, and pass upward and backward, forming, in their ascent, a close network of anastomosing tubes, which are merely channels in the fibrous stroma, lined by flattened epithelium, and having no proper walls; this constitutes the *rete testis*. At the upper end of the mediastinum the vessels of the rete testis terminate in from twelve to fifteen or twenty ducts, the *vasa efferentia:* they perforate the tunica albuginea, and carry the seminal fluid from the testis to the epididymis. Their course is at first straight; they then become enlarged and exceedingly convoluted, and form a series of conical masses, the *coni vasculosi*, which, together, constitute the globus major of the epididymis. Each cone consists of a single convoluted duct from six to eight inches in length, the diameter of which gradually decreases from the testis to the epididymis. Opposite the bases of the cones the efferent vessels open at narrow intervals into a single duct, which constitutes, by its complex convolutions, the body and globus minor of the epididymis. When the convolutions of this tube are unravelled, it measures upward of twenty feet in length, and it increases in diameter and thickness as it approaches the vas deferens. The convolutions are held together by fine areolar tissue and by bands of fibrous tissue.

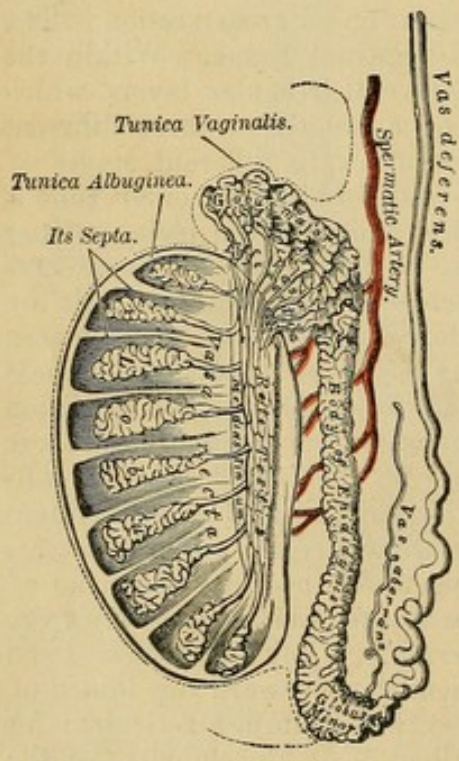

FIG. 567.—Vertical section of the testicle, to show the arrangement of the ducts.

The vasa recta are of smaller diameter than the seminal tubes, and have very thin parietes. They, like the channels of the rete testis, are lined by a single layer of flattened epithelium. The vasa efferentia and the tube of the epididymis

have walls of considerable thickness, on account of the presence in them of muscular tissue, which is principally arranged in a circular manner. These tubes are lined by columnar ciliated epithelium.

The **Vas Deferens**, the excretory duct of the testis, is the continuation of the epididymis. Commencing at the lower part of the globus minor, it ascends along the posterior border of the testis and inner side of the epididymis, and along the back part of the spermatic cord, through the inguinal canal to the internal or deep abdominal ring. From the ring it curves round the outer side of the epigastric artery, crosses the external iliac vessels, and descends into the pelvis at the side of the bladder; it arches backward and downward to its base, crossing over the obliterated hypogastric artery and to the inner side of the ureter. At the base of the bladder it lies between that viscus and the rectum, running along the inner border of the vesicula seminalis. In this situation it becomes enlarged and sacculated, forming the *ampulla*, and then, becoming narrowed at the base of the prostate, unites with the duct of the vesicula seminalis to form the ejaculatory duct. The vas deferens presents a hard and cord-like sensation to the fingers; it is about two feet in length, of cylindrical form, and about a line and a quarter in diameter. Its walls are dense, measuring one-third of a line, and its canal is extremely small, measuring about half a line.

Structure.—The vas deferens consists of three coats: 1. An external or areolar coat. 2. A muscular coat, which in the greater part of the tube consists of two layers of unstriped muscular fibre: an outer, longitudinal in direction, and an inner, circular; but in addition to these, at the commencement of the vas deferens, there is a third layer, consisting of longitudinal fibres, placed internal to the circular stratum, between it and the mucous membrane. 3. An internal or mucous coat, which is pale, and arranged in longitudinal folds; its epithelial covering is of the columnar variety.

A long narrow tube, the *vas aberrans of Haller*, is occasionally found connected with the lower part of the canal of the epididymis or with the commencement of the vas deferens. It extends up into the cord for about two or three inches, where it terminates by a blind extremity, which is occasionally bifurcated. Its length varies from an inch and a half to fourteen inches, and sometimes it becomes dilated toward its extremity; more commonly it retains the same diameter throughout. Its structure is similar to that of the vas deferens. Occasionally it is found unconnected with the epididymis.

Organ of Giraldes.—This term is applied to a small collection of convoluted tubules, situated in front of the lower part of the cord or above the globus major of the epididymis. These tubes are lined with columnar ciliated epithelium, and probably represent the remains of a part of the Wolffian body.

Surgical Anatomy.—The testicle frequently requires removal for malignant disease; in tuberculous disease; in cystic disease; in cases of large hernia testis, and in some instances of incompletely descended or misplaced testicles. The operation of castration has also been, during the last few years, performed for enlargement of the prostate; for it has been found that removal of the testicle is followed by very rapid and often considerable diminution in the size of the prostate. The operation is, however, one of severity, and is frequently followed by death in these cases, performed, as it necessarily is, in old men. Reginald Harrison has proposed to substitute for it excision of a portion of the vasa deferentia. The operation of castration is a comparatively simple one. An incision is made into the tunica vaginalis from the external ring to the bottom of the scrotum. The coverings are shelled off the organ, and the mesorchium, stretching between the back of the testicle and the scrotum, divided. The cord is then isolated, and an aneurism needle, armed with a double ligature, passed under it, as high as is thought necessary, and the cord tied in two places, and divided between the ligatures. Sometimes, in cases of malignant disease, it is desirable to open the inguinal canal and tie the cord as near the internal abdominal ring as possible.

Spermatozoa.—The spermatozoa are minute, thread-like bodies, which constitute the essential elements of the semen. Each consists of a *head*, a middle piece or *body*, and an elongated filament or *tail*. The head, on surface view, appears oval in shape, but if seen in profile it is narrow and pointed at its free end. It represents

the modified nucleus of the spermatid, and consists chiefly of chromatin, and so stains readily with nuclear reagents; it is covered by a thin cap of protoplasm. The body is a short cylindrical or conical piece, intervening between the head and tail, and is therefore sometimes spoken of as the intermediate segment. The tail is about four times the combined lengths of the head and body; its terminal part is extremely fine, and is named the *end-piece*. Contained within the body and tail is an axial filament, surrounded, except in the end-piece, by a thin layer of protoplasm; this axial filament terminates just below the head in a rounded knob or button. In virtue of their tails, which act as propellers, the spermatozoa, in the fresh condition, are capable of free movement, and if placed in favorable surroundings (*e. g.*, in the female passages) may retain their vitality for some days or even weeks.

VESICULÆ SEMINALES.

The **Seminal Vesicles** are two lobulated membranous pouches placed between the base of the bladder and the rectum, serving as reservoirs for the semen, and secreting a fluid to be added to the secretion of the testicles. Each sac is somewhat pyramidal

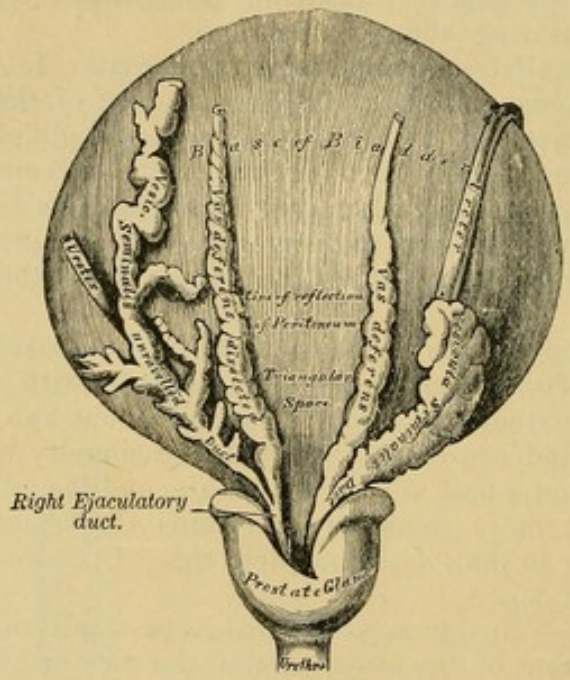

FIG. 568.—Base of the bladder, with the vasa deferentia and vesiculæ seminales.

in form, the broad end being directed backward and the narrow end forward toward the prostate. They measure about two and a half inches in length, about five lines in breadth, and two or three lines in thickness. They vary, however, in size, not only in different individuals, but also in the same individual on the two sides. Their *upper surface* is in contact with the base of the bladder, extending from near the termination of the ureters to the base of the prostate gland. Their *under surface* rests upon the rectum, from which they are separated by the recto-vesical fascia. Their *posterior extremities* diverge from each other. Their *anterior extremities* are pointed, and converge toward the base of the prostate gland, where each joins with the corresponding vas deferens to form the ejaculatory duct. Along the inner margin of each vesicula runs the enlarged and convoluted vas deferens. The inner border of the vesiculæ and the corresponding vas deferens form the lateral boundaries of a triangular space, limited behind by the recto-vesical peritoneal fold; the portion of the bladder included in this space rests on the rectum.

Each vesicula consists of a single tube, coiled upon itself and giving off several irregular cæcal diverticula, the separate coils, as well as the diverticula, being connected together by fibrous tissue. When uncoiled this tube is about the diameter of a quill, and varies in length from four to six inches; it terminates posteriorly in

a *cul-de-sac ;* its anterior extremity becomes constricted into a narrow straight duct, which joins with the corresponding vas deferens, and forms the ejaculatory duct.

The **ejaculatory ducts**, two in number, one on each side, are formed by the junction of the ducts of the vesiculæ seminales with the vasa deferentia. Each duct is about three-quarters of an inch in length ; it commences at the base of the prostate, and runs forward and downward between its middle and lateral lobes, and along the side of the sinus pocularis, to terminate by a separate slit-like orifice close to or just within the margins of the sinus. The ducts diminish in size and also converge toward their termination.

Structure.—The vesiculæ seminales are composed of three coats : an *external* or *areolar ;* a *middle* or *muscular coat*, which is thinner than in the vas deferens, arranged in two layers, an outer, longitudinal, and inner, circular ; an *internal* or *mucous coat*, which is pale, of a whitish-brown color, and presents a delicate reticular structure, like that seen in the gall-bladder, but the meshes are finer. The epithelium is columnar.

The coats of the ejaculatory ducts are extremely thin. They are : an *outer fibrous layer*, which is almost entirely lost after their entrance into the prostate ; a *layer of muscular fibres*, consisting of an outer thin circular and an inner longitudinal layer ; and the *mucous membrane.*

Vessels and Nerves.—The *arteries* supplying the vesiculæ seminales are derived from the middle and inferior vesical and middle hæmorrhoidal. The *veins* and *lymphatics* accompany the arteries. The *nerves* are derived from the pelvic plexus.

Surgical Anatomy.—The vesiculæ seminales are often the seat of an extension of the disease in cases of tuberculous disease of the testicle, and should always be examined from the rectum before coming to a decision with regard to castration in this affection.

the modified nucleus of the spermatid, and consists chiefly of chromatin, and so stains readily with nuclear reagents; it is covered by a thin cap of protoplasm. The body is a short cylindrical or conical piece, intervening between the head and tail, and is therefore sometimes spoken of as the intermediate segment. The tail is about four times the combined lengths of the head and body; its terminal part is extremely fine, and is named the *end-piece*. Contained within the body and tail is an axial filament, surrounded, except in the end-piece, by a thin layer of protoplasm; this axial filament terminates just below the head in a rounded knob or button. In virtue of their tails, which act as propellers, the spermatozoa, in the fresh condition, are capable of free movement, and if placed in favorable surroundings (*e. g.*, in the female passages) may retain their vitality for some days or even weeks.

VESICULÆ SEMINALES.

The **Seminal Vesicles** are two lobulated membranous pouches placed between the base of the bladder and the rectum, serving as reservoirs for the semen, and secreting a fluid to be added to the secretion of the testicles. Each sac is somewhat pyramidal

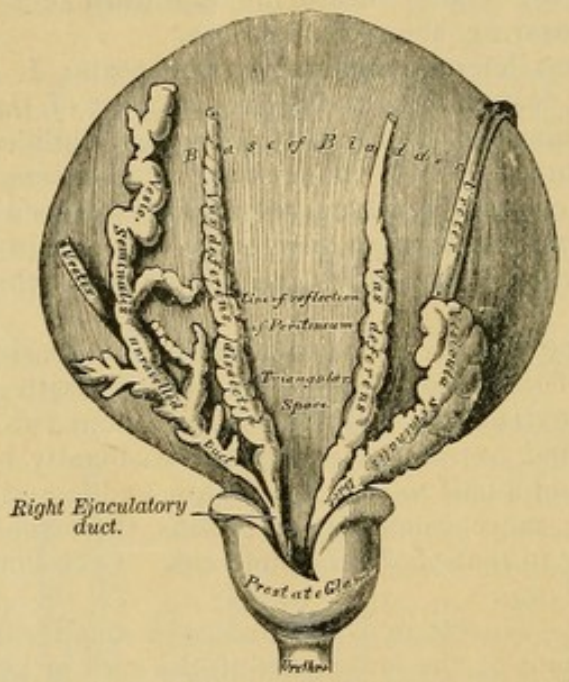

FIG. 568.—Base of the bladder, with the vasa deferentia and vesiculæ seminales.

in form, the broad end being directed backward and the narrow end forward toward the prostate. They measure about two and a half inches in length, about five lines in breadth, and two or three lines in thickness. They vary, however, in size, not only in different individuals, but also in the same individual on the two sides. Their *upper surface* is in contact with the base of the bladder, extending from near the termination of the ureters to the base of the prostate gland. Their *under surface* rests upon the rectum, from which they are separated by the recto-vesical fascia. Their *posterior extremities* diverge from each other. Their *anterior extremities* are pointed, and converge toward the base of the prostate gland, where each joins with the corresponding vas deferens to form the ejaculatory duct. Along the inner margin of each vesicula runs the enlarged and convoluted vas deferens. The inner border of the vesiculæ and the corresponding vas deferens form the lateral boundaries of a triangular space, limited behind by the recto-vesical peritoneal fold; the portion of the bladder included in this space rests on the rectum.

Each vesicula consists of a single tube, coiled upon itself and giving off several irregular cæcal diverticula, the separate coils, as well as the diverticula, being connected together by fibrous tissue. When uncoiled this tube is about the diameter of a quill, and varies in length from four to six inches; it terminates posteriorly in

a *cul-de-sac ;* its anterior extremity becomes constricted into a narrow straight duct, which joins with the corresponding vas deferens, and forms the ejaculatory duct.

The **ejaculatory ducts,** two in number, one on each side, are formed by the junction of the ducts of the vesiculæ seminales with the vasa deferentia. Each duct is about three-quarters of an inch in length ; it commences at the base of the prostate, and runs forward and downward between its middle and lateral lobes, and along the side of the sinus pocularis, to terminate by a separate slit-like orifice close to or just within the margins of the sinus. The ducts diminish in size and also converge toward their termination.

Structure.—The vesiculæ seminales are composed of three coats : an *external* or *areolar ;* a *middle* or *muscular coat,* which is thinner than in the vas deferens, arranged in two layers, an outer, longitudinal, and inner, circular ; an *internal* or *mucous coat,* which is pale, of a whitish-brown color, and presents a delicate reticular structure, like that seen in the gall-bladder, but the meshes are finer. The epithelium is columnar.

The coats of the ejaculatory ducts are extremely thin. They are : an *outer fibrous layer,* which is almost entirely lost after their entrance into the prostate ; a *layer of muscular fibres,* consisting of an outer thin circular and an inner longitudinal layer ; and the *mucous membrane.*

Vessels and Nerves.—The *arteries* supplying the vesiculæ seminales are derived from the middle and inferior vesical and middle hæmorrhoidal. The *veins* and *lymphatics* accompany the arteries. The *nerves* are derived from the pelvic plexus.

Surgical Anatomy.—The vesiculæ seminales are often the seat of an extension of the disease in cases of tuberculous disease of the testicle, and should always be examined from the rectum before coming to a decision with regard to castration in this affection.

enclosing the common urino-sexual opening. Each labium has two surfaces, an outer, which is pigmented and covered with strong, crisp hairs; and an inner, which is smooth and is beset with large sebaceous follicles and is continuous with the genito-urinary mucous tract; between the two there is a considerable quantity of areolar tissue, fat, and a tissue resembling the dartos of the scrotum, besides vessels, nerves, and glands. The labia are thicker in front, where they form by their meeting the *anterior commissure*. Posteriorly they are not really joined, but appear to become lost in the neighboring integument, terminating close to, and nearly parallel with, each other. Together with the connecting skin between them, they form the posterior commissure or posterior boundary of the vulval orifice. The

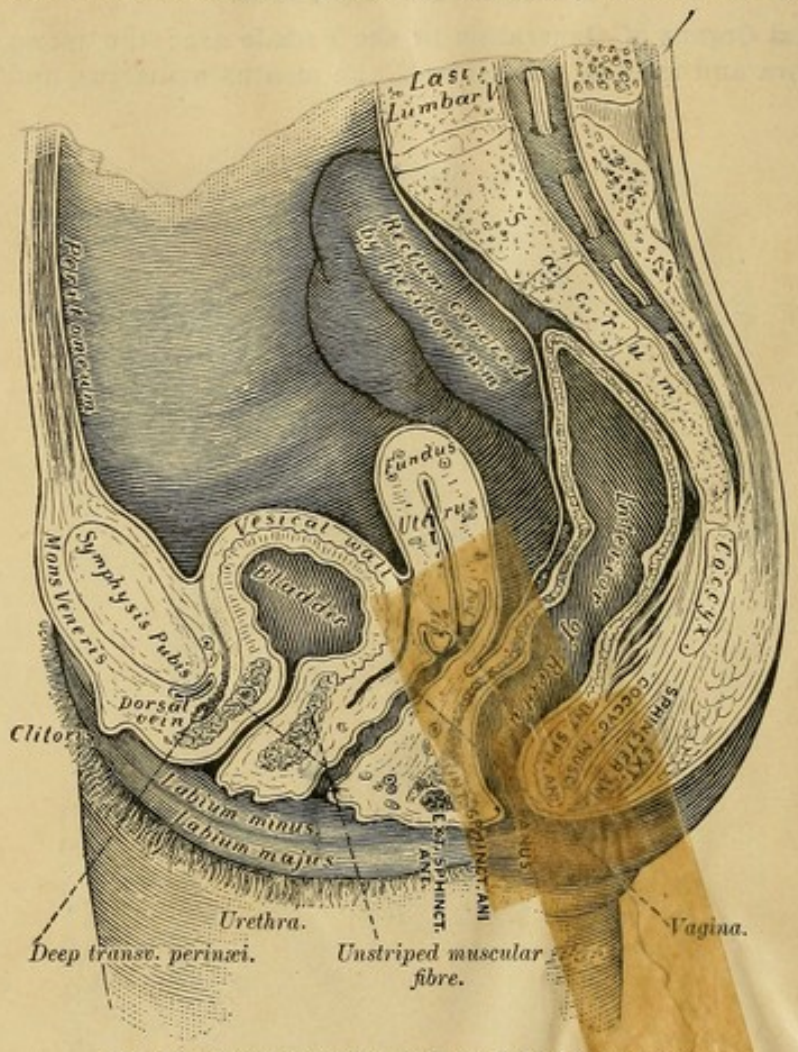

FIG. 570.—Vertical median section of the female pelvis.

interval between the posterior commissure and the anus, about an inch to an inch and a quarter in length, constitutes the perinæum. The *fourchette* is the anterior edge of the perineum, and between it and the hymen is a depression, the *fossa navicularis*. The labia correspond to the scrotum in the male.

The **Labia Minora,** or **Nymphæ,** are two small cutaneous folds, situated within the labia majora, and extending from the clitoris obliquely downward, outward, and backward for about an inch and a half on each side of the orifice of the vagina, between which and the labia majora they are lost. Anteriorly, the two labia minora meet and form the *frænum of the clitoris*. The *prepuce* of the clitoris, passing backward on each side, is inserted, as it were, into the labium minora, but is not actually a part of them. The nymphæ are really modified skin. Their internal surfaces have numerous sebaceous follicles.

The **Clitoris** is an erectile structure analogous to the corpora cavernosa of the penis. It is situated beneath the anterior commissure, partialy hidden between the anterior extremities of the labia minora. It is connected to the rami of the

and ischium on each side by a crus; the body is short and concealed beneath the labia; the free extremity, or *glans clitoridis*, is a small rounded tubercle, consisting of spongy erectile tissue, and highly sensitive. It is provided, like the penis, with a suspensory ligament, and with two small muscles, the Erectores clitoridis, which are inserted into the crura of the clitoris. The clitoris consists of two corpora cavernosa, composed of erectile tissue enclosed in a dense layer of fibrous membrane, united together along their inner surfaces by an incomplete fibrous pectiniform septum.

Between the clitoris and the entrance of the vagina is a triangular smooth surface, bounded on each side by the nymphæ; this is the *vestibule*.

The orifice of the urethra (**meatus urinarius**) is situated at the back part of the vestibule, about an inch below the clitoris and near the margin of the vagina, surrounded by a prominent elevation of the mucous membrane. Below the meatus urinarius is the orifice of the vagina, more or less closed in the virgin by a membranous fold, the *hymen*.

The **Hymen** varies much in shape. Its commonest form is that of a ring, generally broadest posteriorly: sometimes it is represented by a semilunar fold, with its concave margin turned toward the pubes. A complete septum stretched across the lower part of the vaginal orifice is called "imperforate hymen." Occasionally it is cribriform, or its free margin forms a membranous fringe, or it may be entirely absent. It may persist after copulation, so that it cannot be considered as a test of virginity. After parturition the small rounded elevations known as the *carunculæ myrtiformes* are found as the remains of the hymen.

Glands of Bartholin.—On each side of the commencement of the vagina, and behind the hymen, is a round or oblong body, of a reddish-yellow color, and of the size of a horse-bean, analogous to Cowper's gland in the male. It is called the *gland of Bartholin*. Each gland opens by means of a long single duct immediately external to the hymen, in the angle or groove between it and the nympha.

Bulbi Vestibuli.—Extending from the clitoris, along either side of the vestibule, and lying a little behind the nymphæ, are two large oblong masses, about an inch in length, consisting of a plexus of veins enclosed in a thin layer of fibrous membrane. These bodies are narrow in front, rounded below, and are connected with the crura of the clitoris and rami of the pubes: they are termed by Kobelt the *bulbi vestibuli*, and he considers them analogous to the bulb of the corpus spongiosum in the male. Immediately in front of these bodies is a smaller venous plexus, continuous with the bulbi vestibuli behind and the glans clitoridis in front: it is called by Kobelt the *pars intermedia*, and is considered by him as analogous to that part of the body of the corpus spongiosum which immediately succeeds the bulb.

INTERNAL ORGANS.

The **Internal Organs of Generation** are—the vagina, the uterus and its appendages, the Fallopian tubes, the ovaries and their ligaments.

The **Vagina** extends from the vulva to the uterus. It is situated in the cavity of the pelvis, behind the bladder and in front of the rectum. Its direction is curved upward and backward, at first in the line of the outlet, and afterward in that of the axis of the cavity of the pelvis. Its walls are ordinarily in contact, and its usual shape on transverse section is that of an **H**, the transverse limb being slightly curved forward or backward, whilst the lateral limbs are somewhat convex toward the median line. Its length is about two and a half inches along its anterior wall, and three and a half inches along its posterior wall. It is constricted at its commencement, and becomes dilated medially, and narrowed near its uterine extremity; it surrounds the vaginal portion of the cervix uteri, a short distance from the os, its attachment extending higher up on the posterior than on the anterior wall of the uterus.

Relations.—Its *anterior surface* is in relation with the base of the bladder and with the urethra. Its *posterior surface* is connected for the lower three-fourths of its extent to the anterior wall of the rectum, the upper fourth being separated from that tube by the recto-vaginal pouch of peritoneum, or pouch of Douglas, between the vagina and rectum. Its sides are enclosed between the Levatores ani muscles.

Structure.—The vagina consists of an internal mucous lining, of a muscular coat, and between the two of a layer of erectile tissue.

The *mucous membrane* is continuous above with that lining the uterus. Its inner surface presents, along the anterior and posterior walls, a longitudinal ridge or raphé, called the *columns of the vagina*, and numerous transverse ridges or rugæ, extending outward from the raphé on either side. These rugæ are divided by furrows of variable depth, giving to the mucous membrane the appearance of being studded over with conical projections or papillæ; they are most numerous near the orifice of the vagina, especially in females before parturition. The epithelium covering the mucous membrane is of the squamous variety. The submucous tissue is very loose and contains numerous large veins, which by their anastomoses form a plexus, together with smooth muscular fibres from the muscular coat; it is regarded by Gussenbauer as an erectile tissue. It contains a number of mucous crypts, but no true glands.

The *muscular coat* consists of two layers: an external longitudinal, which is far the stronger, and an internal circular layer. The longitudinal fibres are continuous with the superficial muscular fibres of the uterus. The strongest fasciculi are those attached to the recto-vesical fascia on each side. The two layers are not distinctly separable from each other, but are connected by oblique decussating fasciculi which pass from the one layer to the other. In addition to this the vagina at its lower end is surrounded by a band of striped muscular fibres, the *sphincter vaginæ* (see page 375).

External to the muscular coat is a layer of connective tissue containing a large plexus of blood-vessels.

The *erectile tissue* consists of a layer of loose connective tissue situated between the mucous membrane and the muscular coat; imbedded in it is a plexus of large veins, and numerous bundles of unstriped muscular fibres derived from the circular muscular layer. The arrangement of the veins is similar to that found in other erectile tissues.

THE UTERUS.

The **Uterus** is the organ of gestation, receiving the fecundated ovum in its cavity, retaining and supporting it during the development of the fœtus, and becoming the principal agent in its expulsion at the time of parturition.

In the virgin state it is pear-shaped, flattened from before backward, and situated in the cavity of the pelvis between the bladder and the rectum; it is retained in its position by the round and broad ligaments on each side, and projects into the upper end of the vagina below. Its upper end, or base, is directed upward and forward; its lower end, or apex, downward and backward, in the line of the axis of the inlet of the pelvis. It therefore forms an angle with the vagina, since the direction of the vagina corresponds to the axis of the cavity and outlet of the pelvis. The uterus measures about three inches in length, two in breadth at its upper part, and nearly an inch in thickness, and it weighs from an ounce to an ounce and a half.

It consists of two parts: (1) the *body*, with its upper broad extremity, the *fundus;* and (2) the *cervix*, or *neck*, which is partly above the vagina and partly in the vagina. The fundus is placed on a line below the level of the brim of the pelvis, and its direction varies with the condition of the bladder.

The division between the body and cervix is indicated externally by a slight constriction, and by the reflection of the peritoneum from the anterior surface of the uterus on to the bladder, and internally by a narrowing of the canal, called the *internal os*.

The *body* gradually narrows from the fundus to the neck. Its anterior surface is flattened, covered by peritoneum, which becomes separated from it at its union with the cervix, in order to form the utero-vesical pouch, which lies between the uterus and bladder. Its *posterior surface* is convex transversely, covered by peritoneum throughout, and separated from the rectum by some convolutions of the intestine. Its *lateral margins* are concave, and give attachment to the Fallopian tube above, the round ligament below and in front of this, and the ligament of the ovary behind both of these structures.

The *cervix* is the lower constricted segment of the uterus; around its circumference is attached the upper end of the vagina, which extends upward a greater distance behind than in front.

The supravaginal portion is not covered by peritoneum in front; a pad of cellular tissue is interposed between it and the bladder. Behind, the peritoneum is extended over it. The vaginal portion is the rounded lower end projecting into

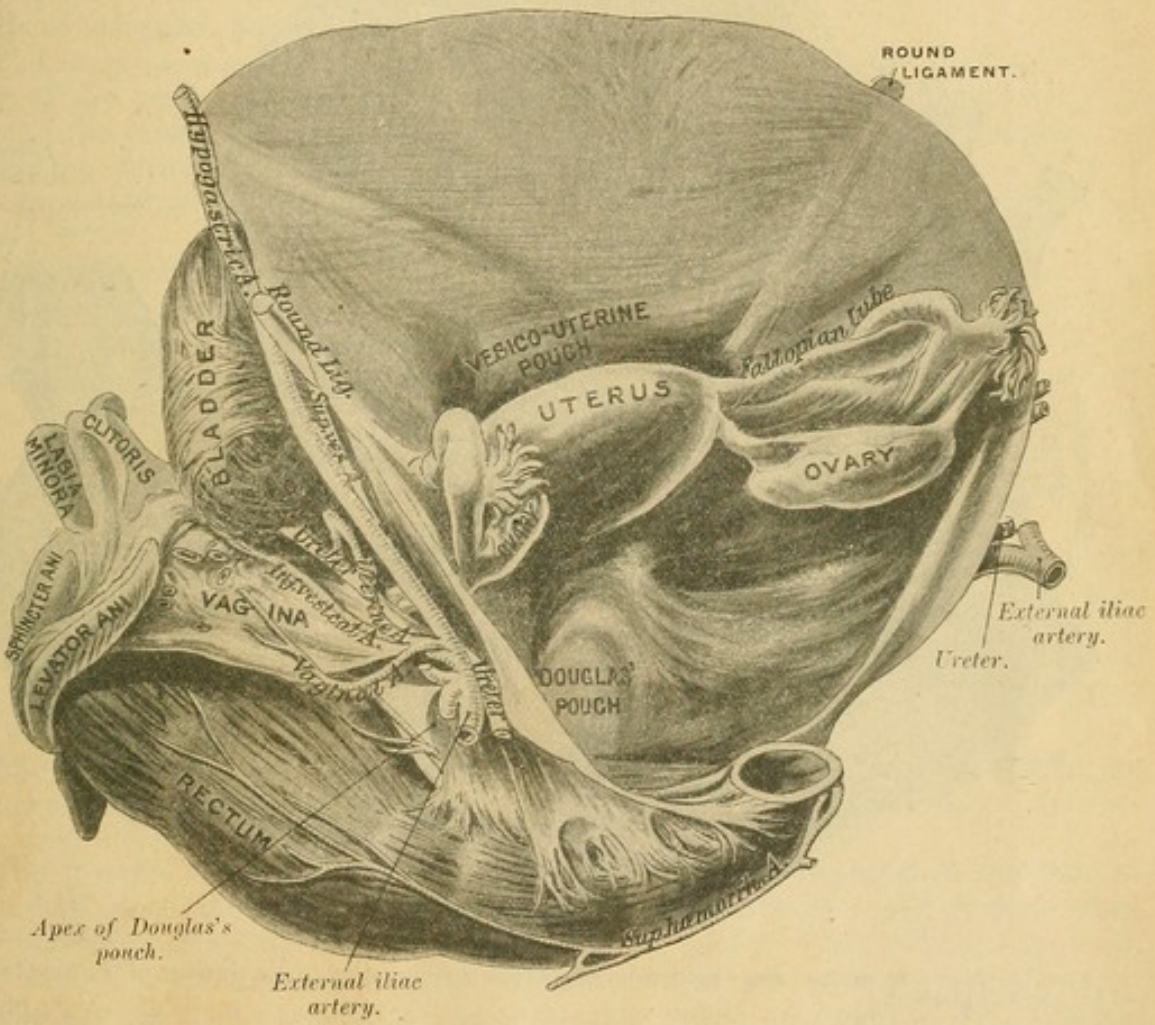

FIG. 571.—Douglas's pouch. (From a preparation in the Museum of the Royal College of Surgeons of England.)

the vagina. On its surface is a small aperture, the *os uteri*, generally circular in shape, but sometimes oval or almost linear. The margin of the opening is, in the absence of past parturition or disease, quite smooth.

Ligaments.—The ligaments of the uterus are eight in number: one anterior; one posterior; two lateral or broad; two sacro-uterine.—all these being formed of peritoneum—and, lastly, two round ligaments.

The *anterior ligament* (vesico-uterine) is reflected on to the bladder from the front of the uterus, at the junction of the cervix and body.

The *posterior ligament* (recto-uterine) passes from the posterior wall of the uterus over the upper fourth of the vagina, and thence on to the rectum and sacrum. It thus forms a pouch called *Douglas's pouch* (Fig. 571), the boundaries of which are,

in front, the posterior wall of the uterus, the supravaginal cervix, and the upper fourth of the vagina; behind, the rectum and sacrum; above, the small intestine; and, laterally, the sacro-uterine ligaments.

The *two lateral* or *broad ligaments* pass from the sides of the uterus to the lateral walls of the pelvis, forming a septum across the pelvis, which divides that cavity into two portions. In the anterior part are contained the bladder, urethra, and vagina; in the posterior part, the rectum. Between the two layers of each broad ligament are contained—(1) the Fallopian tubes superiorly; (2) the round ligament; (3) the ovary and its ligament; (4) the parovarium, or organ of

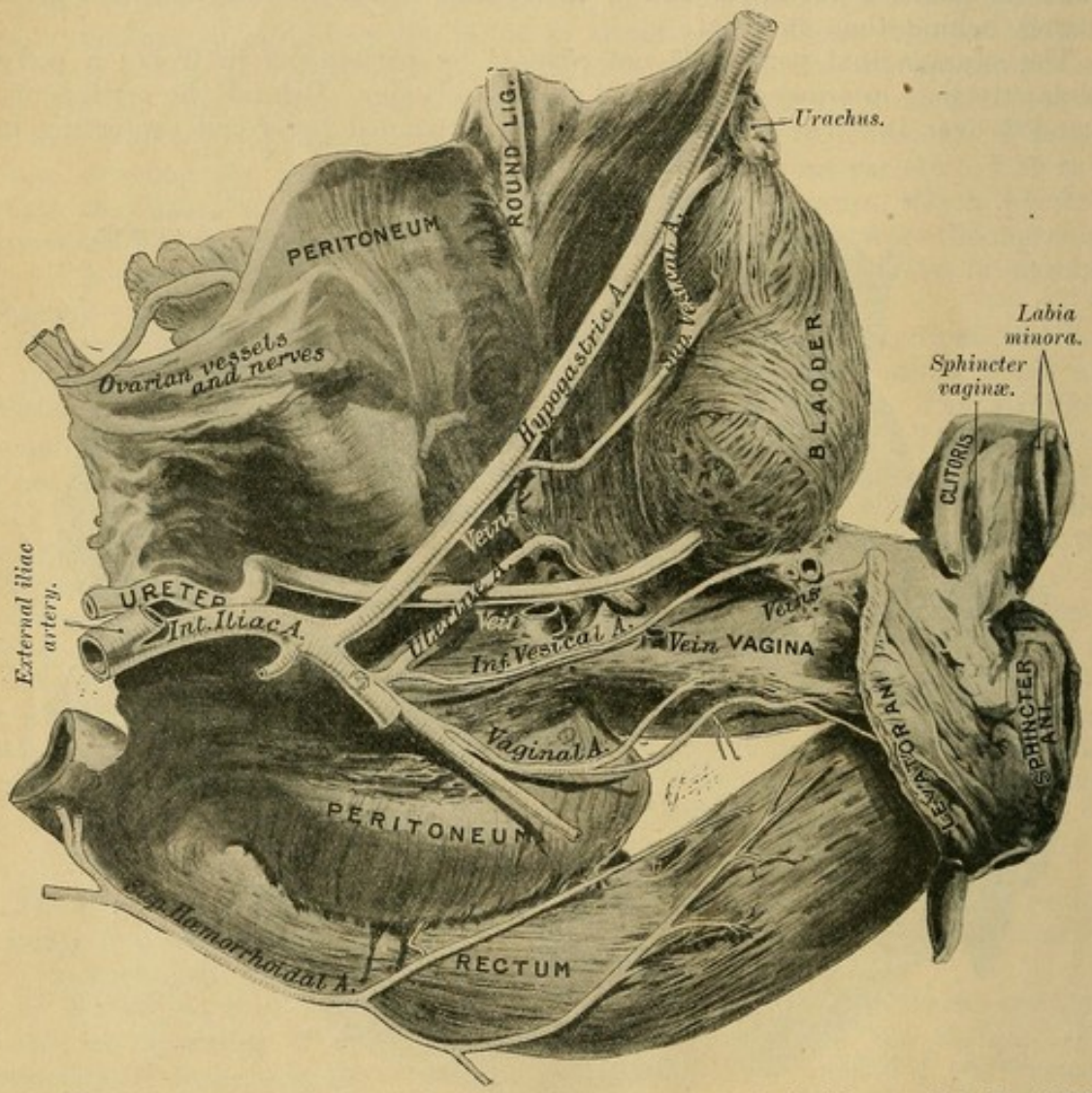

FIG. 572.—Side view of the female pelvic organs. (From a preparation in the Museum of the Royal College of Surgeons of England.)

Rosenmüller; (5) connective tissue; (6) unstriped muscular fibre; and (7) blood-vessels and nerves. The Fallopian tube is contained in a special fold of the broad ligament, which is attached to the part of the ligament near the ovary, and is known by the name of the *mesosalpinx*. Between the fimbriated extremity of the tube and the lower attachment of the broad ligament is a concave rounded margin, called the *infundibulo-pelvic ligament* (Fig. 574).

The *sacro-uterine ligaments* pass from the second and third bones of the sacrum, downward and forward on the lateral aspects of the rectum to be attached one on each side of the uterus at the junction of the supravaginal cervix and the body, this point corresponding internally to the position of the os internum.

The *round ligament* will be described in the sequel.

The **cavity of the uterus** is small in comparison with the size of the organ;

that portion of the cavity which corresponds to the body is triangular, flattened from before backward, so that its walls are closely approximated, and having its base directed upward toward the fundus. At each superior angle is a funnel-shaped cavity, which constitutes the remains of the division of the body of the uterus into two cornua, and at the bottom of each cavity is the minute orifice of the Fallopian tube. At the inferior angle of the uterine cavity is a small constricted opening, the internal orifice (*ostium internum*), which leads into the cavity of the cervix.

The **cavity of the cervix** is somewhat fusiform, flattened from before backward, broader at the middle than at either extremity, and communicates below with the vagina. The wall of the canal presents, anteriorly and posteriorly, a longitudinal column, from which proceed a number of small oblique columns, giving the appearance of branches from the stem of a tree; and hence the name *arbor vitæ uterina* applied to it. These folds usually become very indistinct after the first labor.

Structure.—The uterus is composed of three coats: an external serous coat, a middle or muscular, and an internal mucous coat.

The *serous coat* is derived from the peritoneum; it invests the fundus and the whole of the posterior surface of the uterus; but covers the anterior surface only as far as the junction of the body and cervix. In the lower fourth of the posterior surface the peritoneum, though covering the uterus, is not closely connected with it, being separated from it by a layer of loose cellular tissue and some large veins.

The *muscular coat* forms the chief bulk of the substance of the uterus. In the unimpregnated state it is dense, firm, of a grayish color, and cuts almost like cartilage. It is thick opposite the middle of the body and fundus, and thin at the orifices of the Fallopian tubes. It consists of bundles of unstriped muscular fibres, disposed in layers, intermixed with areolar tissue, blood-vessels, lymphatic vessels, and nerves. In the impregnated state the muscular tissue becomes more prominently developed, and is disposed in three layers—external, middle, and internal.

The external layer is placed beneath the peritoneum, disposed as a thin plane on the anterior and posterior surfaces. It consists of fibres which pass transversely across the fundus, and, converging at each superior angle of the uterus, are continued on the Fallopian tube, the round ligament, the ligament of the ovary: some passing at each side into the broad ligament, and others running backward from the cervix into the sacro-uterine ligaments.

The middle layer of fibres, which is thickest, presents no regularity in its arrangement, being disposed longitudinally, obliquely, and transversely. It contains most blood-vessels.

The internal or deep layer consists of circular fibres arranged in the form of two hollow cones, the apices of which surround the orifices of the Fallopian tubes, their bases intermingling with one another on the middle of the body of the uterus. At the internal os these circular fibres form a distinct sphincter.

The *mucous membrane* is thin, smooth, and closely adherent to the subjacent tissue. It is continuous, through the fimbriated extremity of the Fallopian tubes, with the peritoneum, and through the os uteri with the lining of the vagina.

In the *body* of the uterus it is smooth, soft, of a pale red color lined by columnar ciliated epithelium, and presents, when viewed with a lens, the orifices of numerous tubular follicles arranged perpendicularly to the surface. It is unprovided with any submucosa, but is intimately connected with the innermost layer of the muscular coat, which is regarded as the muscularis mucosæ. In structure its *corium* differs from ordinary mucous membrane, consisting of an embryonic nucleated and highly cellular form of connective tissue in which run numerous large lymphatics. In it are the tube-like *uterine glands*, which are of small size in the unimpregnated uterus, but shortly after impregnation become enlarged, elongated, presenting a contorted or waved appearance toward their closed extrem-

ities, which reaches into the muscularis, and may be single or bifid. They consist of a delicate membrane, lined by an epithelium, which becomes ciliated toward the orifices. The changes which take place in the mucous membrane of the impregnated uterus are more fully dealt with in the section on Embryology.

In the *cervix* the mucous membrane is sharply differentiated from that of the uterine cavity. It is thrown into numerous oblique ridges, which diverge from an anterior and posterior longitudinal raphé, presenting an appearance which has received the name of *arbor vitæ*. In the upper two-thirds of the canal the mucous membrane is provided with numerous deep glandular follicles, which secrete a clear viscid alkaline mucus; and in addition, extending through the whole length of the canal, are a variable number of little cysts, presumably follicles, which have become occluded and distended with retained secretion. They are called the *ovula Nabothi*. The mucous membrane covering the lower half of the cervical canal

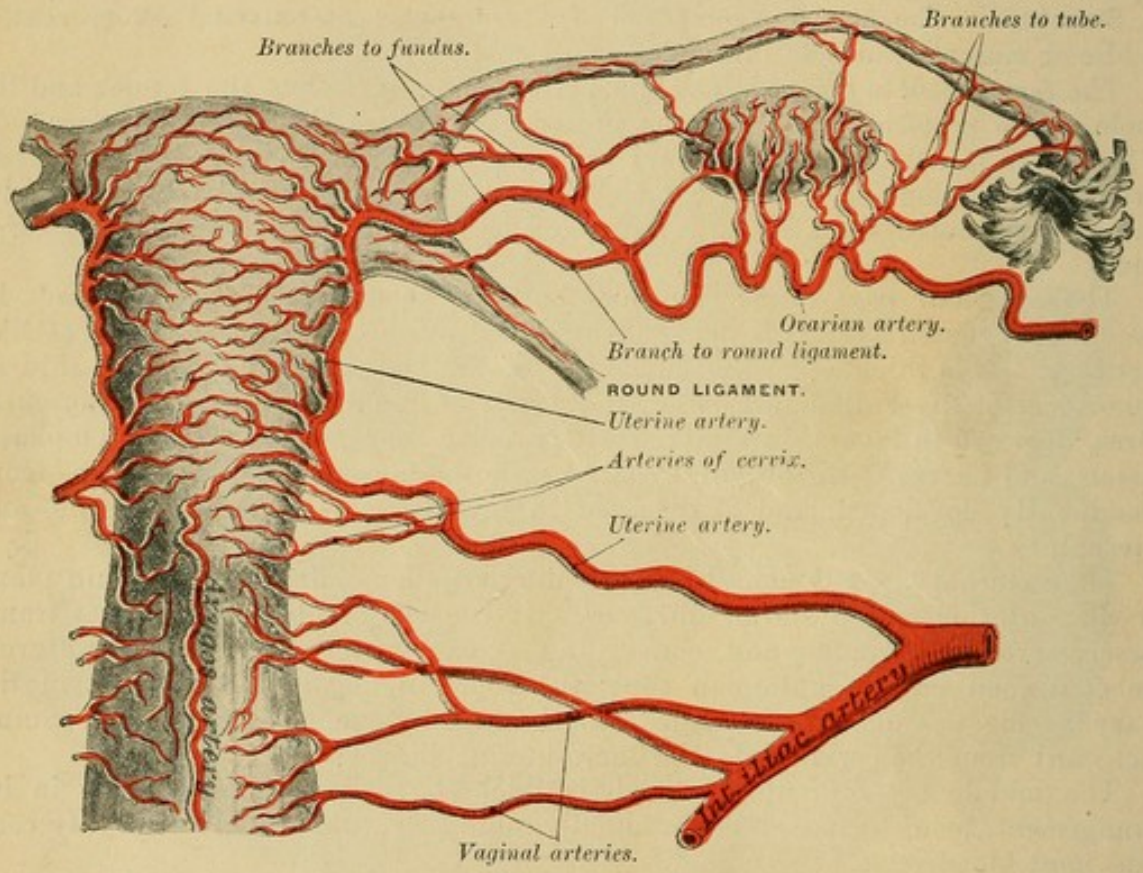

FIG. 573.—The arteries of the internal organs of generation of the female, seen from behind. (After Hyrtl.)

presents numerous papillæ. The epithelium of the upper two-thirds is cylindrical and ciliated, but below this it loses its cilia, and gradually changes to squamous epithelium close to the external os.

Vessels and Nerves.—The *arteries of the uterus* are the uterine, from the internal iliac, and the ovarian, from the aorta. They are remarkable for their tortuous course in the substance of the organ and for their frequent anastomoses. The termination of the ovarian artery meets the termination of the uterine artery, and forms an anastomotic trunk from which branches are given off to supply the uterus, their disposition being, as shown by Sir John Williams, circular. The *veins* are of large size, and correspond with the arteries. In the impregnated uterus these vessels form the *uterine sinuses*, consisting of the lining membrane of the veins adhering to the walls of the canal channelled through the substance of the uterus. They terminate in the uterine plexuses. The *lymphatics* of the body terminate in the lumbar glands, those of the cervix in the pelvic glands. The *nerves* are derived from the inferior hypogastric and ovarian plexuses, and from the third and fourth sacral nerves.

The form, size, and situation of the uterus vary at different periods of life and under different circumstances.

In the fœtus the uterus is contained in the abdominal cavity, projecting beyond the brim of the pelvis. The cervix is considerably larger than the body.

At puberty the uterus is pyriform in shape, and weighs from eight to ten drachms. It has descended into the pelvis, the fundus being just below the level of the brim of this cavity. The arbor vitæ is distinct, and extends to the upper part of the cavity of the organ.

The position of the uterus in the adult is liable to considerable variation, depending chiefly on the condition of the bladder and rectum. When the bladder is empty the entire uterus is directed forward, and is at the same time bent on itself at the junction of the body and cervix, so that the body lies upon the bladder. As the latter fills the uterus gradually becomes more and more erect, until with a fully distended bladder the fundus may be directed backward toward the sacrum.

During menstruation the organ is enlarged and more vascular, its surfaces rounder; the os externum is rounded, its labia swollen, and the lining membrane of the body thickened, softer, and of a darker color. According to Sir J. Williams, at each recurrence of menstruation a molecular disintegration of the mucous membrane takes place, which leads to its complete removal, only the bases of the glands imbedded in the muscle being left. At the cessation of menstruation by a proliferation of the remaining structures a fresh mucous membrane is formed.

During pregnancy the uterus becomes enormously enlarged, and in the ninth month reaches the epigastric region. The increase in size is partly due to growth of pre-existing muscle and partly to development of new fibres.

After parturition the uterus nearly regains its usual size, weighing about an ounce and a half; but its cavity is larger than in the virgin state, the external orifice is more marked, its edges present a fissured surface, its vessels are tortuous, and its muscular layers are more defined.

In old age the uterus becomes atrophied, and paler and denser in texture; a more distinct constriction separates the body and cervix. The ostium internum and, occasionally, the vaginal orifice often become obliterated, and its labia almost entirely disappear.

Surgical Anatomy.—The uterus may require removal in cases of malignant disease or for fibroid tumors. Carcinoma is the most common form of malignant disease of the uterus, though cases of sarcoma do occur. It may show itself either as a columnar carcinoma or as a squamous carcinoma; the former commencing either in the cervix or body of the uterus, the latter always commencing in the epithelial cells of the mucous covering of the vaginal surface of the cervix. The columnar form may be treated in the early stage, before fixation has taken place, by removal of the uterus, either through the vagina or by means of abdominal section. The former operation is the better of the two, and is attended by a much smaller death-rate. Vaginal hysterectomy is performed by placing the patient in the lithotomy position and introducing a large duckbill speculum. The cervix is then seized with a volsellum and pulled down as far as possible and the mucous membrane of the vagina incised around the cervix and as near to it as the disease will allow, especially in front, where the ureters are in danger of being wounded. A pair of dressing forceps are then pushed through into Douglas's pouch and opened sufficiently to allow of the introduction of the two forefingers, by means of which the opening is dilated laterally as far as the sacro-uterine ligaments. A somewhat similar proceeding is adopted in front, but here the bladder has to be separated from the anterior wall of the uterus for about an inch before the vesico-uterine fold of peritoneum can be reached. This is done by carefully burrowing upward with a director and stripping the tissues off the anterior uterine wall. When the vesico-uterine pouch has been opened and the opening dilated laterally, the uterus remains attached only by the broad ligaments, in which are contained the vessels that supply the uterus. Before division of the ligaments, these vessels have to be dealt with. The forefinger of the left hand is introduced into Douglas's pouch and an aneurism needle, armed with a long silk ligature, is inserted into the vesico-uterine pouch, and is pushed through the broad ligament about an inch above its lower level and at some distance from the uterus. One end of the ligature is now pulled through the anterior opening, and in this way we have the lowest inch of the broad ligament, in which is contained the uterine artery (Fig. 573), enclosed in a ligature. This is tied tightly, and the operation is repeated on the other side. The broad ligament is then divided on either side, between the ligature and the uterus, to the extent to which it has been constricted. By traction on the volsellum which grasps the cervix, the uterus can be pulled considerably further down in the vagina, and a second inch of the broad ligament is treated in a similar way. This second ligature will embrace the pampiniform plexus of veins, and, when the broad ligament has been divided on either side, it will be found that a third ligature can be made to pass over the Fallopian tube and top of the broad ligament, after the uterus has been dragged down as far as possible. After the third ligature has been tied and the structures between it and the uterus divided, this organ will be freed from all its connections and can be removed from the vagina. This canal is then sponged out and lightly dressed with gauze; no sutures being used. The gauze may be removed at the end of the second day. In squamous epithelioma, amputation of the cervix is all that is necessary in those cases where the disease is recognized before it has invaded the walls of the vagina or the neighboring broad ligaments. The operation consists in removing a wedge-shaped piece of the uterus, including

the cervix, through the vagina and attaching the cut surfaces of the stump to the anterior and posterior vaginal walls, so as to prevent retraction. In the treatment of uterine fibroids which require operative interference, removal of the whole of the uterus together with the tumors through an abdominal incision gives the most satisfactory results; for, if the tumor is large, its size acts as a barrier to its safe delivery through the pelvis and genital passages. After the abdomen has been opened the uterine vessels are secured and the broad ligaments divided in a similar manner to that employed in vaginal hysterectomy, except that the proceeding is commenced from above. When the two first ligatures have been tied, and the broad ligament divided, it will be found that the uterus can be raised out of the pelvis. A transverse incision is now made through the peritoneum, where it is reflected from the anterior surface of the uterus on to the back of the bladder and the serous membrane peeled from the surface of the uterus until the vagina is reached. The anterior wall of this canal is cut across. The uterus is now turned forward and the peritoneum at the bottom of Douglas's pouch incised transversely, and the posterior wall of the vagina cut across until it meets the incision on the anterior wall. The uterus is now almost free, and is held only by the lower part of the broad ligament on either side, containing the uterine artery. A third ligature is made to encircle this, and, after having been tied, the structures are divided between the ligature and the uterus. The organ can now be removed. The vagina is plugged with gauze, and the external wound closed in the usual way. The vagina acts as a drain, and therefore the opening into it is not sutured.

APPENDAGES OF THE UTERUS.

The **appendages of the uterus** are the Fallopian tubes, the ovaries and their ligaments, and the round ligaments. They are placed in the following order: in front is the round ligament; the Fallopian tube occupies the upper margin of the broad ligament; the ovary and its ligament are behind and below both.

THE FALLOPIAN TUBES.

The **Fallopian Tubes,** or **Oviducts,** convey the ova from the ovaries to the cavity of the uterus. They are two in number, one on each side, situated in the upper margin of the broad ligament, extending from each superior angle of the uterus to the sides of the pelvis. Each tube is about four inches in length; and is described as consisting of three portions: (1) the *isthmus*, or inner constricted third; (2) the *ampulla*, or outer dilated portion, which curves over the ovary; and (3) the

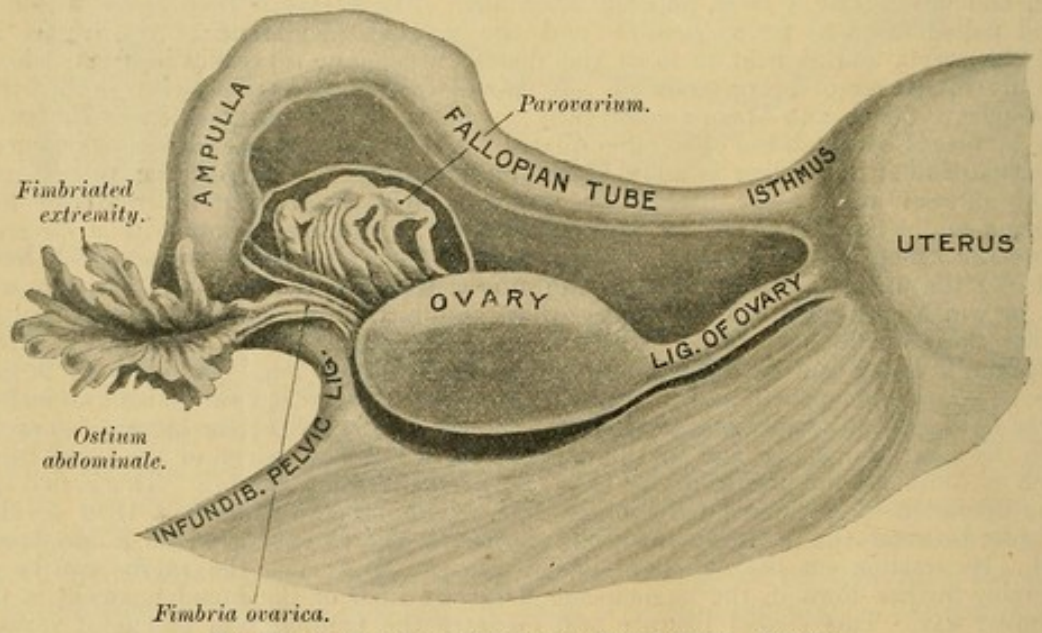

FIG. 574.—Uterine appendages, seen from behind. (Henle.)

infundibulum with its *ostium abdominale,* surrounded by fimbriæ, one of which is attached to the ovary, the *fimbria ovarica.* The general direction of the Fallopian tube is outward, backward and downward. The uterine opening is minute, and will admit only a fine bristle; the abdominal opening is somewhat larger. In connection with the fimbriæ of the Fallopian tube or with the broad ligament close

to them there is frequently one or more small vesicles floating on a long stalk of peritoneum. These are termed the *hydatids of Morgagni.*

Structure.—The Fallopian tube consists of three coats—serous, muscular, and mucous.

The *external* or *serous coat* is peritoneal.

The *middle* or *muscular coat* consists of an external longitudinal and an internal circular layer of muscular fibres continuous with those of the uterus.

The *internal* or *mucous coat* is continuous with the mucous lining of the uterus and, at the free extremity of the tube, with the peritoneum. It is thrown into longitudinal folds, which in the outer, larger part of the tube, or ampulla, are much more extensive than in the narrow canal of the isthmus. The lining epithelium is columnar ciliated. This form of epithelium is also found on the inner surface of the fimbriæ, while on the outer or serous surfaces of these processes the epithelium gradually merges into the endothelium of the peritoneum.

THE OVARIES.

The **ovaries** (*testes muliebres*, Galen) are analogous to the testes in the male. They are oval-shaped bodies of an elongated form, flattened from above downward, situated one on each side of the uterus, in the posterior layer of the broad ligament behind and below the Fallopian tubes. Each ovary is connected by its anterior straight margin to the broad ligament; by its lower extremity to the uterus by a proper ligament, the *ligament of the ovary;* and by its upper end to the fimbriated extremity of the Fallopian tube by the ovarian fimbria; its mesial and lateral surfaces and posterior convex border are free. The ovaries are of a grayish-pink color, and present either a smooth or puckered, uneven surface. They are each about an inch and a half in length, three-quarters of an inch in width, and about a third of an inch thick, and weigh from one to two drachms.

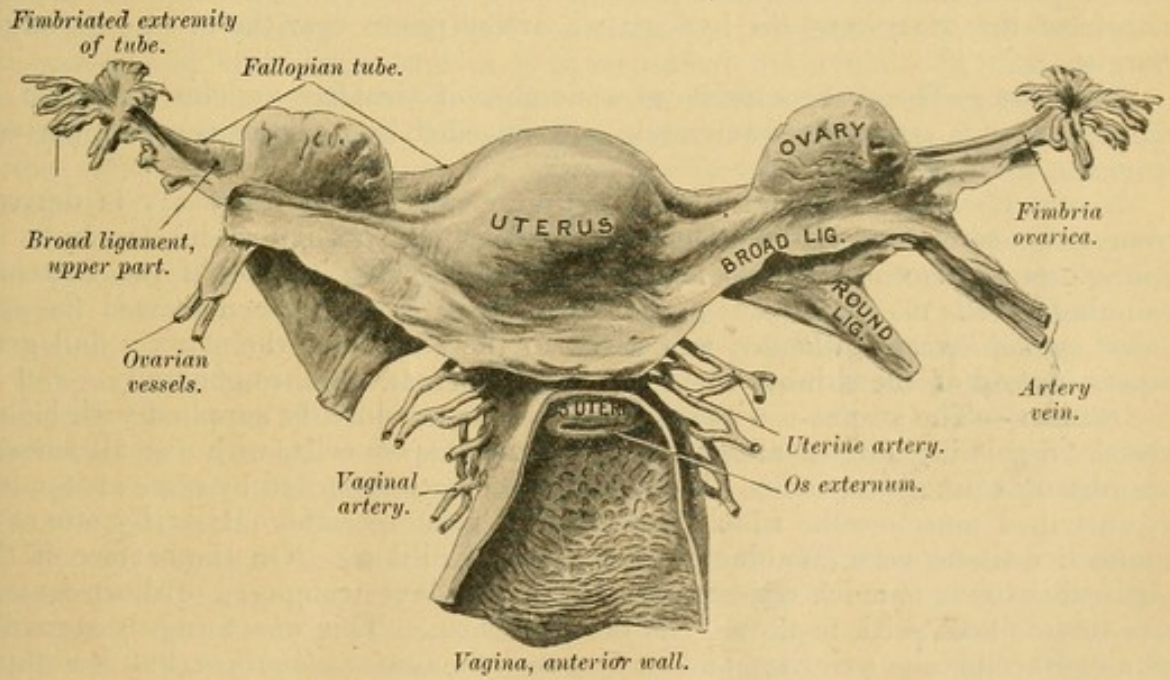

FIG. 575.—The uterus and its appendages. Posterior view. The parts have been somewhat displaced from their proper position in the preparation of the specimen; thus the right ovary has been raised above the Fallopian tube, and the fimbriated extremities of the tubes have been turned upward and outward. (From a preparation in the Museum of the Royal College of Surgeons of England.)

The exact position of the ovary has been the subject of considerable difference of opinion, and writers differ much as to what is to be regarded as the normal position. The fact appears to be that it is differently placed in different individuals. Hasse has described it as being situated with its long axis transverse, or almost transverse, to the pelvic cavity. Schultze, on the other hand, believes that its

long axis is antero-posterior. Kölliker asserts that the truth lies between these two views, and that the ovary is placed obliquely in the pelvis, its long axis lying parallel to the external iliac vessels, with its surface directed inward and outward, and its convex free border upward. His has made some important observations on this subject, and his views are largely accepted. He teaches that the uterus rarely lies symmetrically in the middle of the pelvic cavity, but is generally inclined to one or other side, most frequently to the left, in the proportion of three to two. The position of the two ovaries varies according to the inclination of the uterus. When the uterus is inclined to the left, the ovary of this side lies with its long axis vertical and with one side closely applied to the outer wall of the pelvis, while the ovary of the opposite side, being dragged upon by the inclination of the uterus, lies obliquely, its outer extremity being retained in close apposition to the side of the pelvis by the infundibulo-pelvic ligament (page 1030). When, on the other hand, the uterus is inclined to the right, the position of the two ovaries is exactly reversed, the right being vertical and the left oblique. In whichever position the ovary is placed, the Fallopian tube forms a loop around it, the uterine half ascending obliquely over it, and the outer half, including the dilated extremity, descending and bulging freely behind it. From this extremity the fimbriæ pass upward on to the ovary and closely embrace it.

Waldeyer[1] states, as the result of the examination of fifty female subjects, ranging from early childhood to advanced age, that the ovary "lies on the lateral pelvic wall and vertically when the woman takes the erect posture." Its *tubal* extremity is near the external iliac vein; its uterine end is directed downward, while the Fallopian tube overlies it so as to cover it on its medial face entirely or nearly so. Its convex margin looks downward and backward toward the pelvic cavity and rectum, while its straight margin or hilum lies laterally on the pelvic wall attached to the mesosalpinx. He also finds that it lies in a distinct but shallow groove (*fossa ovarii*) limited above by the hypogastric artery and below by the ureter, in such a manner that the ureter lies along the convex margin of the ovary, and the hypogastric artery passes near the hilum or straight margin.

Structure.—The ovary consists of a number of Graafian vesicles imbedded in the meshes of a stroma or framework, and invested by a serous covering derived from the peritoneum.

Serous Covering.—Though the investing membrane of the ovary is derived from the peritoneum, it differs essentially from that structure, inasmuch as its epithelium consists of a single layer of columnar cells, instead of the flattened endothelial cells of other parts of the membrane; this has been termed the *germinal epithelium of Waldeyer*, and gives to the surface of the ovary a dull gray aspect instead of the shining smoothness of serous membranes generally.

Stroma.—The stroma is a peculiar soft tissue, abundantly supplied with blood-vessels, consisting for the most part of spindle-shaped cells, with a small amount of ordinary connective tissue. These cells have been regarded by some anatomists as unstriped muscle-cells, which, indeed, they most resemble (His); by others as connective-tissue cells (Waldeyer, Henle, and Kölliker). On the surface of the organ this tissue is much condensed, and forms a layer composed of short connective-tissue fibres, with fusiform cells between them. This was formerly regarded as a distinct fibrous covering, and was termed the *tunica albuginea*, but is nothing more than a condensed layer of the stroma of the ovary.

Graafian Vesicles.—Upon making a section of an ovary numerous round transparent vesicles of various sizes are to be seen; they are the *Graafian vesicles* or ovisacs containing the ova. Immediately beneath the superficial covering is a layer of stroma, in which are a large number of minute vesicles of uniform size, about $\frac{1}{100}$ of an inch in diameter. These are the Graafian vesicles in their earliest condition, and the layer where they are found has been termed the *cortical layer*. They are especially numerous in the ovary of the young child. After puberty

[1] *Journal of Anatomy and Physiology*, vol. xxxii.

and during the whole of the child-bearing period large and mature, or almost mature, Graafian vesicles are also found in the cortical layer in small numbers, and also "corpora lutea," the remains of vesicles which have burst and are undergoing atrophy and absorption. Beneath this superficial stratum other large and more mature Graafian vesicles are found imbedded in the ovarian stroma.

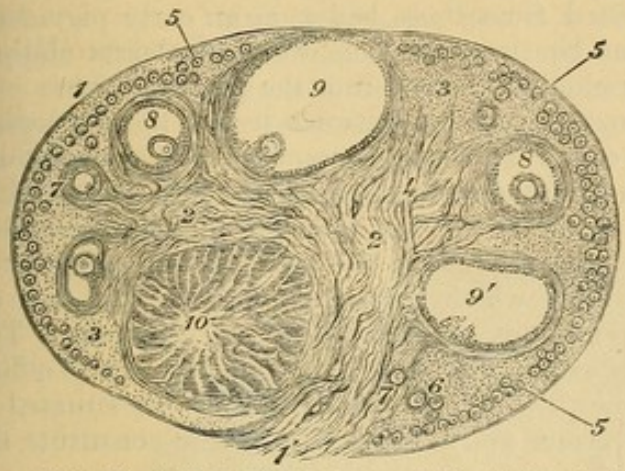

FIG. 576.—Section of the ovary. (After Schron.) 1. Outer covering. 1'. Attached border. 2. Central stroma. 3. Peripheral stroma. 4. Blood-vessels. 5. Graafian follicles in their earliest stage. 6, 7, 8. More advanced follicles. 9. An almost mature follicle. 9'. Follicle from which the ovum has escaped. 10. Corpus luteum.

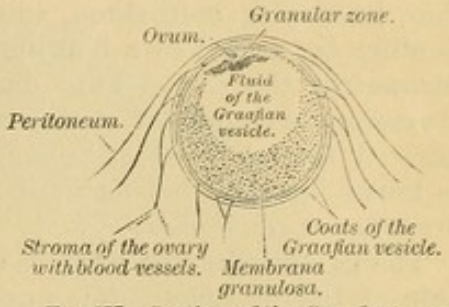

FIG. 577.—Section of the Graafian vesicle. (After Von Baer.)

These increase in size as they recede from the surface toward a highly vascular stroma in the centre of the organ, termed the *medullary substance* (*zona vasculosa*, Waldeyer). This stroma forms the tissue of the hilum by which the ovary is attached, and through which the blood-vessels enter; it does not contain any Graafian vesicles.

The larger *Graafian follicles* consist of an external fibro-vascular coat connected with the surrounding stroma of the ovary by a network of blood-vessels; and an internal coat, named *ovicapsule*, which is lined by a layer of nucleated cells, called the *membrana granulosa*. The fluid contained in the interior of the vesicles is transparent and albuminous, and in it is suspended the ovum. In that part of the mature Graafian vesicle which is nearest the surface of the ovary the cells of the membrana granulosa are collected into a mass which projects into the cavity of the vesicle. This is termed the *discus proligerus*, and in this the ovum is imbedded.[1]

The ova are formed from the germinal epithelium on the surface of the ovary. This becomes thickened, and in it are seen some cells which are larger and more rounded than the rest; these are termed the *primordial ova*. The germinal epithelium grows downward in the form of tubes or columns, termed the *egg tubes* of Pflüger, into the ovarian stroma, which grows outward between the tubes, and ultimately cuts them off from the germinal epithelium. These tubes are further subdivided into rounded *nests* or groups, each containing a primordial ovum which undergoes further development and growth while the surrounding cells of the nest form the epithelium of the Graafian follicle.

The development and maturation of the Graafian vesicles and ova continue uninterruptedly from puberty to the end of the fruitful period of woman's life, while their formation commences before birth. Before puberty the ovaries are small, the Graafian vessels contained in them are disposed in a comparatively thick layer in the cortical substance; here they present the appearance of a large number of minute closed vesicles, constituting the early condition of the Graafian vesicle; many, however, never attain full development, but shrink and disappear. At puberty the ovaries enlarge, and become more vascular, the Graafian vesicles are developed in greater abundance, and their ova are capable of fecundation.

Discharge of the Ovum.—The Graafian vesicles, after gradually approaching the surface of the ovary, burst: the ovum and fluid contents of the vesicles are

[1] For a description of the ovum, see section on Embryology.

liberated, and escape on the exterior of the ovary, passing thence into the Fallopian tube.[1]

In the fœtus the ovaries are situated, like the testes, in the lumbar region, near the kidneys. They may be distinguished from those bodies at an early period by their elongated and flattened form, and by their position, which is at first oblique and then nearly transverse. They gradually descend into the pelvis.

Lying above the ovary in the broad ligament between it and the Fallopian tube is the *organ of Rosenmüller*, called also the *parovarium* or *epoöphoron*. This is the remnant of a fœtal structure, the development of which is described in the section on Embryology. In the adult it consists of a few closed convoluted tubes, lined with epithelium, which converge toward the ovary at one end and at the other are united by a longitudinal tube, which is the homologue of the *duct of Gärtner* in the cow. This duct terminates in a bulbous enlargement. The parovarium is connected at the uterine extremity with the remains of the Wolffian duct. A few scattered rudimentary tubules, best seen in the child, are situated in the broad ligament between the parovarium and the uterus. These constitute the *paroöphoron of Waldeyer*.

The **ligament of the ovary** is a rounded cord, which extends from each superior angle of the uterus to the inner extremity of the ovary; it consists of fibrous tissue and a few muscular fibres derived from the uterus.

The **Round Ligaments** are two rounded cords, between four and five inches in length, situated between the layers of the broad ligament in front of and below the Fallopian tube. Commencing on each side at the superior angle of the uterus, this ligament passes forward, upward, and outward through the internal abdominal ring, along the inguinal canal, to the labia majora, in which it becomes lost. The round ligament consists principally of muscular tissue prolonged from the uterus; also of some fibrous and areolar tissue, besides blood-vessels and nerves, enclosed in a duplicature of peritoneum, which in the fœtus is prolonged in the form of a tubular process for a short distance into the inguinal canal. This process is called the *canal of Nuck*. It is generally obliterated in the adult, but sometimes remains pervious even in advanced life. It is analogous to the peritoneal pouch which precedes the descent of the testis.

Vessels and Nerves.—The *arteries of the ovaries and Fallopian tubes* are the ovarian from the aorta. They enter the attached border, or hilum, of the ovary. The *veins* follow the course of the arteries; they form a plexus near the ovary, the *pampiniform plexus*. The *nerves* are derived from the inferior hypogastric or pelvic plexus, and from the ovarian plexus, the Fallopian tube receiving a branch from one of the uterine nerves.

THE MAMMARY GLANDS.

The **mammæ**, or breasts, secrete the milk, and are accessory glands of the generative system. They exist in the male as well as in the female; but in the former only in the rudimentary state, unless their growth is excited by peculiar circumstances. In the female they are two large hemispherical eminences situated toward the lateral aspect of the pectoral region, corresponding to the intervals between the third and sixth or seventh ribs, and extending from the side of the sternum to the axilla. Their weight and dimensions differ at different periods of life and in different individuals. Before puberty they are of small size, but enlarge as the generative organs become more completely developed. They increase during pregnancy, and especially after delivery, and become atrophied in old age. The left mamma is generally a little larger than the right. Their base is nearly circular, flattened or slightly concave, and has its long diameter directed upward and outward toward the axilla; they are separated from the Pectoral

[1] This is effected either by application of the tube to the ovary, or by a curling upward of the fimbriated extremity, so that the ovum is caught as it falls.

muscles by a layer of fascia. The outer surface of the mamma is convex, and presents, just below the centre, a small conical prominence, the nipple (*mammilla*). The surface of the nipple is dark-colored and surrounded by an areola having a colored tint. In the virgin the areola is of a delicate rosy hue; about the second month after impregnation it enlarges and acquires a darker tinge, which increases as pregnancy advances, becoming in some cases of a dark-brown or even black color. This color diminishes as soon as lactation is over, but is never entirely lost throughout life. These changes in the color of the areola are of importance in forming a conclusion in a case of suspected first pregnancy.

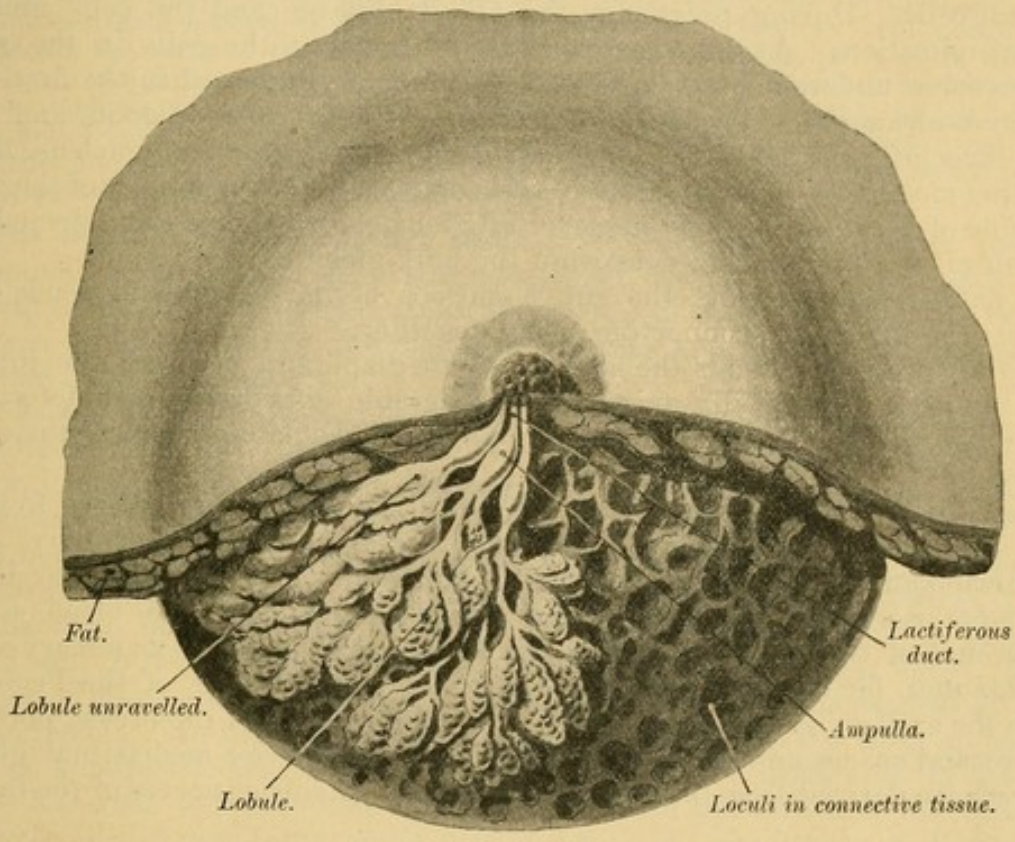

FIG. 578.—Dissection of the lower half of the female breast during the period of lactation. (From Luschka.)

The **nipple** is a cylindrical or conical eminence capable of undergoing a sort of erection from mechanical excitement, a change mainly due to the contraction of its muscular fibres. It is of a pink or brownish hue, its surface wrinkled and provided with papillæ, and it is perforated by numerous orifices, the apertures of the lactiferous ducts. Near the base of the nipple and upon the surface of the areoli are numerous sebaceous glands, which become much enlarged during lactation, and present the appearance of small tubercles beneath the skin. These glands secrete a peculiar fatty substance, which serves as a protection to the integument of the nipple during the act of sucking. The nipple consists of numerous vessels, intermixed with plain muscular fibres, which are principally arranged in a circular manner around the base, some few fibres radiating from base to apex.

Structure.—The mamma consists of gland-tissue; of fibrous tissue, connecting its lobes; and of fatty tissue in the intervals between the lobes. The gland-tissue, when freed from fibrous tissue and fat, is of a pale reddish color, firm in texture, circular in form, flattened from before backward, thicker in the centre than at the circumference, and presenting several inequalities on its surface, especially in front. It consists of numerous lobes, and these are composed of lobules connected together by areolar tissue, blood-vessels, and ducts. The smallest lobules consist of a cluster of rounded alveoli, which open into the smallest branches of the lactiferous ducts; these ducts, uniting, form larger ducts, which terminate in a single canal, corresponding with one of the chief subdivisions of the gland. The number of excretory ducts

varies from fifteen to twenty : they are termed the *tubuli lactiferi*, or *galactophori*. They converge toward the areola, beneath which they form dilatations, or *ampullæ*, which serve as reservoirs for the milk, and at the base of the nipple become contracted and pursue a straight course to its summit, perforating it by separate orifices considerably narrower than the ducts themselves. The ducts are composed of areolar tissue, with longitudinal and transverse elastic fibres ; muscular fibres are entirely absent ; their mucous lining is continuous, at the point of the nipple, with the integument. The epithelium of the mammary gland differs according to the state of activity of the organ. In the gland of a woman who is not pregnant or suckling the alveoli are very small and solid, being filled with a mass of granular polyhedral cells. During pregnancy the alveoli enlarge and the cells undergo rapid multiplication. At the commencement of lactation the cells in the centre of the alveolus undergo fatty degeneration, and are eliminated in the first milk as *colostrum-corpuscles*. The peripheral cells of the alveolus remain, and form a single layer of granular, short columnar cells, with a spherical nucleus, lining the limiting membrana propria. These cells during the state of activity of the gland are capable of forming, in their interior, oil-globules, which are then ejected into the lumen of the alveolus and constitute the milk-globules.

The *fibrous tissue* invests the entire surface of the breast, and sends down septa between its lobes, connecting them together.

The *fatty tissue* surrounds the surface of the gland and occupies the interval between its lobes. It usually exists in considerable abundance, and determines the form and size of the gland. There is no fat immediately beneath the areola and nipple.

Vessels and Nerves,—The *arteries* supplying the mammæ are derived from the thoracic branches of the axillary, the intercostals, and internal mammary. The *veins* describe an anastomotic circle round the base of the nipple, called by Haller the *circulus venosus*. From this large branches transmit the blood to the circumference of the gland and end in the axillary and internal mammary veins. The *lymphatics*, for the most part, run along the lower border of the Pectoralis major to the axillary glands ; some few, from the inner side of the breast, perforate the intercostal spaces and empty themselves into the anterior mediastinal glands. The *nerves* are derived from the anterior and lateral cutaneous nerves of the thorax.

THE SURGICAL ANATOMY OF HERNIA.

Dissection (Fig. 217).—For dissection of the parts concerned in inguinal hernia a male subject, free from fat, should always be selected. The body should be placed in the supine position, the abdomen and pelvis raised by means of blocks placed beneath them, and the lower extremities rotated outward, so as to make the parts as tense as possible. If the abdominal walls are flaccid, the cavity of the abdomen should be inflated through an aperture made at the umbilicus. An incision should be made along the middle line from a little below the umbilicus to the symphysis pubis, and continued along the front of the scrotum, and a second incision from the anterior superior spine of the ilium to just below the umbilicus. These incisions should divide the integument, and the triangular-shaped flap included between them should be reflected downward and outward, when the superficial fascia will be exposed.

The Superficial Fascia of the Abdomen.—This, over the greater part of the abdominal wall, consists of a single layer of fascia, which contains a variable amount of fat; but as it approaches the groin it is easily divisible into two layers, between which are found the superficial vessels and nerves and the superficial inguinal lymphatic glands.

The *superficial layer* (*fascia of Camper*), is thick, areolar in texture, containing adipose tissue in its meshes, the quantity of which varies in different subjects. Below, it passes over Poupart's ligament, and is continuous with the outer layer of the superficial fascia of the thigh. In the male this fascia is continued over the penis and over the outer surface of the cord to the scrotum, where it helps to form the dartos. As it passes to the penis and over the cord to the scrotum it changes its character, becoming thin, destitute of adipose tissue, and of a pale reddish color; and in the scrotum it acquires some involuntary muscular fibres. From the scrotum it may be traced backward, to be continuous with the superficial fascia of the perinæum. In the female this fascia is continued into the labia majora.

The *hypogastric branch of the ilio-hypogastric nerve* perforates the aponeurosis of the External oblique muscle about an inch above and a little to the outer side of the external abdominal ring, and is distributed to the integument of the hypogastric region.

The *ilio-inguinal nerve* escapes at the external abdominal ring, and is distributed to the integument of the upper and inner part of the thigh, to the scrotum in the male and to the labium in the female.

The *superficial epigastric artery* arises from the femoral about half an inch below Poupart's ligament, and, passing through the saphenous opening in the fascia lata, ascends on to the abdomen, in the superficial fascia covering the External oblique muscle, nearly as high as the umbilicus. It distributes branches to the superficial inguinal lymphatic glands, the superficial fascia, and the integument, anastomosing with branches of the deep epigastric and internal mammary arteries.

The *superficial circumflex iliac artery*, the smallest of the cutaneous branches, arises close to the preceding, and, piercing the fascia lata, runs outward, parallel with Poupart's ligament, as far as the crest of the ilium, dividing into branches which supply the superficial inguinal lymphatic glands, the superficial fascia, and the integument, anastomosing with the deep circumflex iliac and with the gluteal and external circumflex arteries.

The *superficial external pudic* (*superior*) *artery* arises from the inner side of the femoral artery close to the preceding vessels, and, after passing through the saphenous opening, courses inward across the spermatic cord, to be distributed to the integument on the lower part of the abdomen, the penis and scrotum in the male, and the labium in the female, anastomosing with branches of the internal pudic.

The Superficial Veins.—The veins accompanying these superficial vessels are

usually much larger than the arteries; they terminate in the internal saphenous vein.

The *superficial inguinal lymphatic glands* are placed immediately beneath the integument, are of large size, and vary from eight to ten in number. They are divisible into two groups: an upper, disposed irregularly along Poupart's ligament, which receive the lymphatic vessels from the integument of the scrotum, penis, parietes of the abdomen, perineal and gluteal regions, and the mucous membrane of the urethra; and an inferior group, which surround the saphenous opening in the fascia lata, a few being sometimes continued along the saphenous

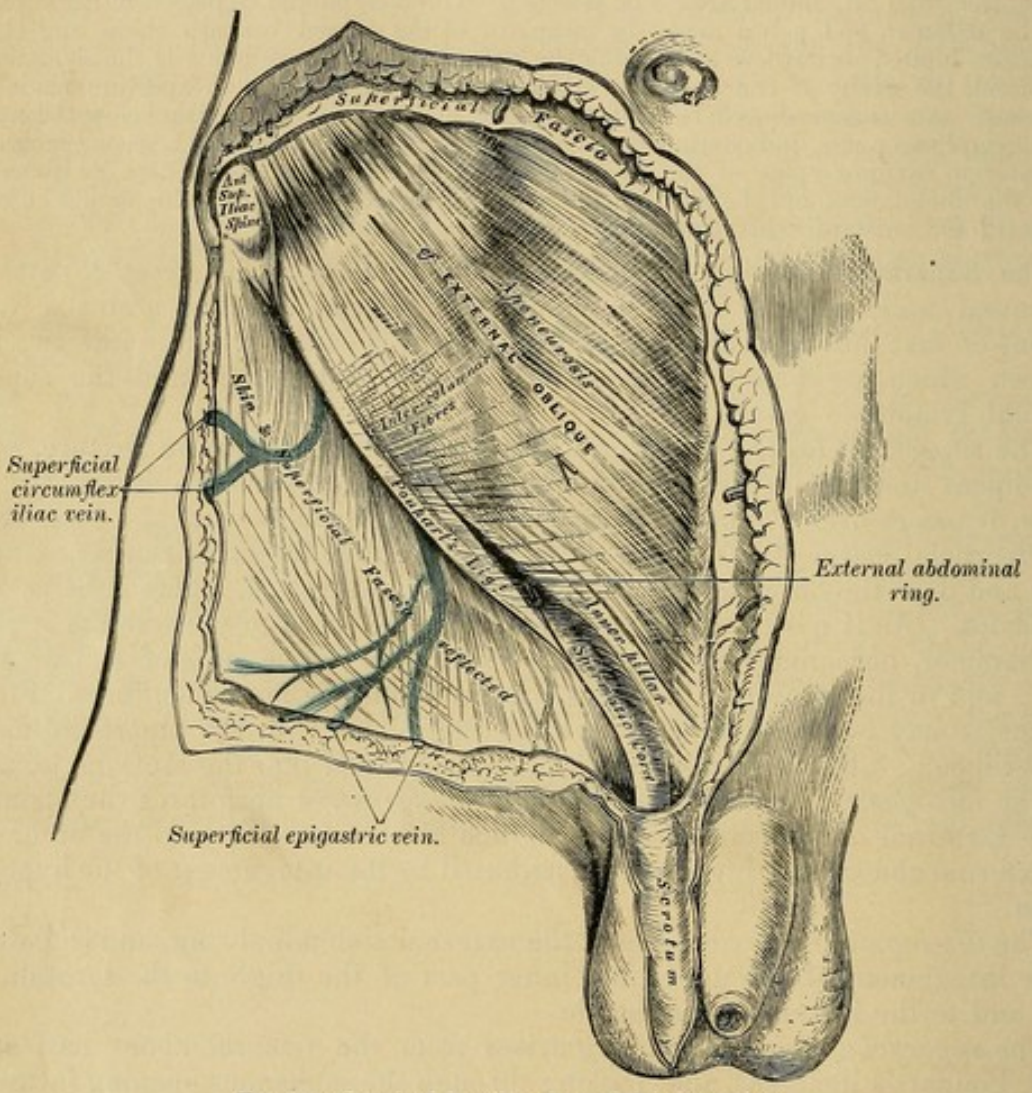

FIG. 579.—Inguinal hernia. Superficial dissection.

vein to a variable extent. This latter group receive the superficial lymphatic vessels from the lower extremity.

The *deep layer of the superficial fascia* (*fascia of Scarpa*) is thinner and more membranous in character than the superficial layer. In the middle line it is intimately adherent to the linea alba; above, it is continuous with the superficial fascia over the rest of the trunk; below, it blends with the fascia lata of the thigh a little below Poupart's ligament; below and internally, in the male, it is continued over the penis and over the outer surface of the cord to the scrotum, where it helps to form the dartos. From the scrotum it may be traced backward to be continuous with the base of the triangular ligament of the urethra. In the female it is continuous with the labia majora.

The scrotum is a cutaneous pouch which contains the testes and part of the spermatic cords, and into which an inguinal hernia frequently descends (see page 1014).

The Aponeurosis of the External Oblique Muscle.—This is a thin but strong

membranous aponeurosis, the fibres of which are directed obliquely downward and inward. That portion of the aponeurosis which extends between the anterior superior spine of the ilium and the spine of the os pubis is a broad band, folded inward and continuous below with the fascia lata; it is called *Poupart's ligament.* The portion which is reflected from Poupart's ligament at the spine of the os pubis, along the pectineal line, is called *Gimbernat's ligament.* From the point of attachment of the latter to the pectineal line a few fibres pass upward and inward, behind the inner pillar of the ring, to the linea alba. They diverge as they ascend, and form a thin, triangular, fibrous band, which is called the *triangular fascia of the abdomen.*

The External or Superficial Abdominal Ring.—Just above and to the outer side of the crest of the os pubis an interval is seen in the aponeurosis of the External oblique, called the *external abdominal ring.* This aperture is oblique in direction, somewhat triangular in form, and corresponds with the course of the fibres of the aponeurosis. It usually measures from base to apex about an inch, and transversely about half an inch. It is bounded below by the crest of the os pubis; above, by a series of curved fibres, the *intercolumnar*, which pass across the upper angle of the ring, so as to increase its strength; and on either side, by the margins of the opening in the aponeurosis, which are called the *columns* or *pillars of the ring.*

The *external pillar*, which at the same time is *inferior* from the obliquity of its direction, is the stronger; it is formed by that portion of Poupart's ligament which is inserted into the spine of the os pubis; it is curved, so as to form a kind of groove, upon which the spermatic cord rests.

The *internal* or *superior pillar* is a broad, thin, flat band, which is attached to the front of the body of the os pubis, interlacing with its fellow of the opposite side in front of the symphysis pubis, that of the right side being superficial.

The external abdominal ring gives passage to the spermatic cord in the male and round ligament in the female; it is much larger in men than in women, on account of the large size of the spermatic cord, and hence the great frequency of inguinal hernia in men.

The *intercolumnar fibres* are a series of curved tendinous fibres which arch across the lower part of the aponeurosis of the External oblique. They have received their name from stretching across between the two pillars of the external ring; they increase the strength of the lower part of the aponeurosis and prevent the divergence of the pillars from one another. They are thickest below, where they are connected to the outer third of Poupart's ligament, and are inserted into the linea alba, describing a curve, with the convexity downward. They are much thicker and stronger at the outer angle of the external ring than internally, and are more strongly developed in the male than in the female. These intercolumnar fibres, as they pass across the external abdominal ring, are themselves connected together by delicate fibrous tissue, thus forming a fascia which, as it is attached to the pillars of the ring, covers it in, and is called the *intercolumnar fascia.* This intercolumnar fascia is continued downward as a tubular prolongation around the outer surface of the cord and testis, and encloses them in a distinct sheath; hence it is also called the *external spermatic fascia.* The sac of an inguinal hernia in passing through the external abdominal ring receives an investment from the intercolumnar fascia.

If the finger is introduced a short distance into the external ring, and then, if the limb is extended and rotated outward, the aponeurosis of the External oblique, together with the iliac portion of the fascia lata, will be felt to become tense and the external ring much contracted; if the limb is, on the contrary, flexed upon the pelvis and rotated inward, this aponeurosis will become lax, and the external ring sufficiently enlarged to admit the finger with comparative ease; hence the patient should always be put in the latter position when the taxis is applied for the reduction of an inguinal hernia, in order that the abdominal walls may be relaxed as much as possible.

The aponeurosis of the External oblique should be removed by dividing it across in the same direction as the external incisions, and reflecting it downward and outward: great care is requisite in separating it from the aponeurosis of the muscle beneath. The lower part of the Internal oblique and the Cremaster are then exposed, together with the inguinal canal, which contains the spermatic cord (Fig. 580). The mode of insertion of Poupart's and Gimbernat's ligaments into the os pubis should also be examined.

Poupart's ligament, or the crural arch, is the lower border of the aponeurosis of the External oblique muscle, which extends from the anterior superior spine of the ilium to the spine of the os pubis. From this latter point it is reflected outward to be attached to the pectineal line for about half an inch, forming

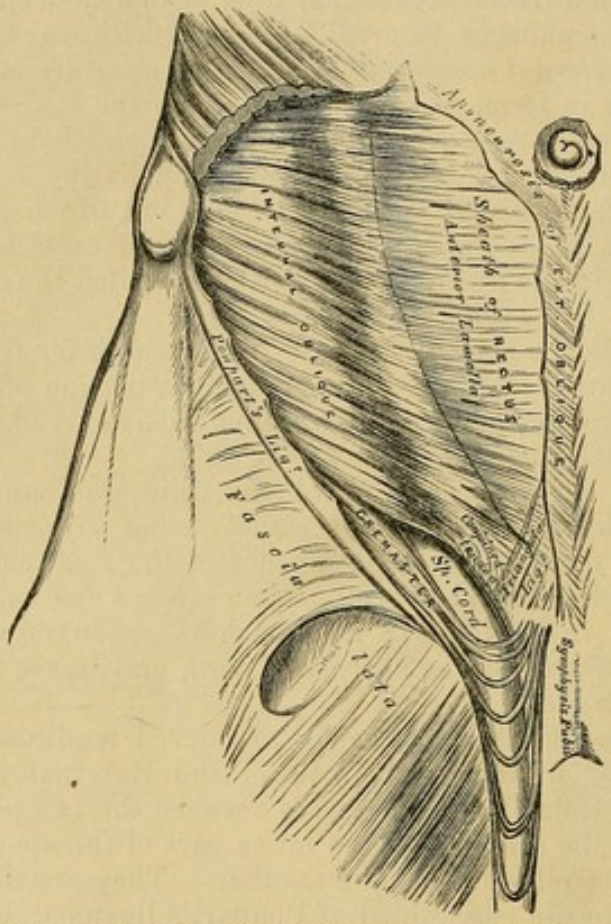

FIG. 580.—Inguinal hernia. Dissection showing the Internal oblique and Cremaster.

Gimbernat's ligament. Its general direction is curved downward toward the thigh, where it is continuous with the fascia lata. Its outer half is rounded and oblique in direction; its inner half gradually widens at its attachment to the os pubis, is more horizontal in direction, and lies beneath the spermatic cord.

Gimbernat's Ligament (Fig. 588) is that portion of the aponeurosis of the External oblique muscle which is reflected upward and outward from the spine of the os pubis to be inserted into the pectineal line. It is about half an inch in length, larger in the male than in the female, almost horizontal in direction in the erect posture, and of a triangular form, with the base directed outward. Its base or outer margin is concave, thin, and sharp, and lies in contact with the femoral sheath, forming the inner boundary of the crural ring (see Fig. 588). Its apex corresponds to the spine of the os pubis. Its posterior margin is attached to the pectineal line, and is continuous with the pubic portion of the fascia lata. Its anterior margin is continuous with Poupart's ligament.

The **triangular fascia of the abdomen** is a band of tendinous fibres, of a triangular shape, which is attached by its apex to the pectineal line, where it is continuous with Gimbernat's ligament. It passes inward beneath the spermatic cord, and expands into a somewhat fan-shaped fascia lying behind the inner pillar

of the external abdominal ring and in front of the conjoined tendon, and interlaces with the ligament of the other side at the linea alba.

The **Internal oblique muscle** has been previously described (page 360). The part which is now exposed is partly muscular and partly tendinous in structure. Those fibres which arise from Poupart's ligament, few in number and paler in color than the rest, arch downward and inward across the spermatic cord, and, becoming tendinous, are inserted, conjointly with those of the Transversalis, into the crest of the os pubis and pectineal line, forming what is known as the conjoined tendon of the Internal oblique and Transversalis. This tendon is inserted immediately behind the inguinal canal and external abdominal ring, serving to protect what would otherwise be a weak point in the abdominal wall. Sometimes this tendon is insufficient to resist the pressure from within, and is carried forward in front of the protrusion through the external ring, forming one of the coverings of direct inguinal hernia, or the hernia forces its way through the fibres of the conjoined tendon.

The **Cremaster** is a thin muscular layer composed of a number of fasciculi which arise from the middle of Poupart's ligament at the inner side of the Internal oblique, being connected with that muscle and also occasionally with the Transversalis. It passes along the outer side of the spermatic cord, descends with it through the external ring upon the front and sides of the cord, and forms a series of loops which differ in thickness and length in different subjects. Those at the upper part of the cord are exceedingly short, but they become in succession longer and longer, the longest reaching down as low as the testicle, where a few are inserted into the tunica vaginalis. These loops are united together by areolar tissue, and form a thin covering over the cord and testis, the *fascia cremasterica*. The fibres ascend along the inner side of the cord, and are inserted by a small pointed tendon into the crest of the os pubis and front of the sheath of the Rectus muscle.

It will be observed that the origin and insertion of the Cremaster is precisely similar to that of the lower fibres of the Internal oblique. This fact affords an easy explanation of the manner in which the testicle and cord are invested by this muscle. At an early period of fœtal life the testis is placed at the lower and back part of the abdominal cavity, but during its descent toward the scrotum, which takes place before birth, it passes beneath the arched border of the Internal oblique. In its passage beneath this muscle some fibres are derived from its lower part which accompany the testicle and cord into the scrotum.

It occasionally happens that the loops of the Cremaster surround the cord, some lying behind as well as in front. It is probable that under these circumstances the testis in its descent passes through, instead of beneath, the fibres of the Internal oblique.

In the descent of an oblique inguinal hernia, which takes the same course as the spermatic cord, the Cremaster muscle forms one of its coverings. This muscle becomes largely developed in cases of hydrocele and large old scrotal herniæ. No such muscle exist in the female, but an analogous structure is developed in those cases where an oblique inguinal hernia descends beneath the margin of the Internal oblique.

The Internal oblique should be detached from Poupart's ligament, separated from the Transversalis to the same extent as in the previous incisions, and reflected inward on to the sheath of the Rectus (Fig. 581). The deep circumflex iliac vessels, which lie between these two muscles, form a valuable guide to their separation.

The **Transversalis muscle** has been previously described (page 362). The part which is now exposed is partly muscular and partly tendinous in structure; it arises from the outer third of Poupart's ligament, its fibres curve downward and inward, and are inserted, together with those of the Internal oblique, into the lower part of the linea alba, into the crest of the os pubis and the pectineal line, forming what is known as the conjoined tendon of the Internal oblique and Trans-

versalis. Between the lower border of this muscle and Poupart's ligament a space is left in which is seen the transversalis fascia.

The **inguinal** or **spermatic canal** contains the spermatic cord in the male and the round ligament in the female. It is an oblique canal, about an inch and a half in length, directed downward and inward and placed parallel with, and a little above, Poupart's ligament. It commences above at the internal or deep abdominal ring, which is the point where the cord enters the inguinal canal, and terminates below at the external or superficial ring. It is bounded, *in front*, by the integument and superficial fascia, by the aponeurosis of the External oblique throughout its whole length, and by the Internal oblique for its outer third; *behind*, by the triangular fascia, the conjoined tendon of the Internal oblique and Transversalis, transversalis fascia, and the subperitoneal fat and peritoneum; *above*, by the arched fibres of the Internal oblique and Transversalis; *below*, by the union of the transversalis fascia with Poupart's ligament. That form of hernia in which the intestine follows the course of the spermatic cord along the inguinal canal is called *oblique inguinal hernia*.

The **transversalis fascia** is a thin aponeurotic membrane which lies between

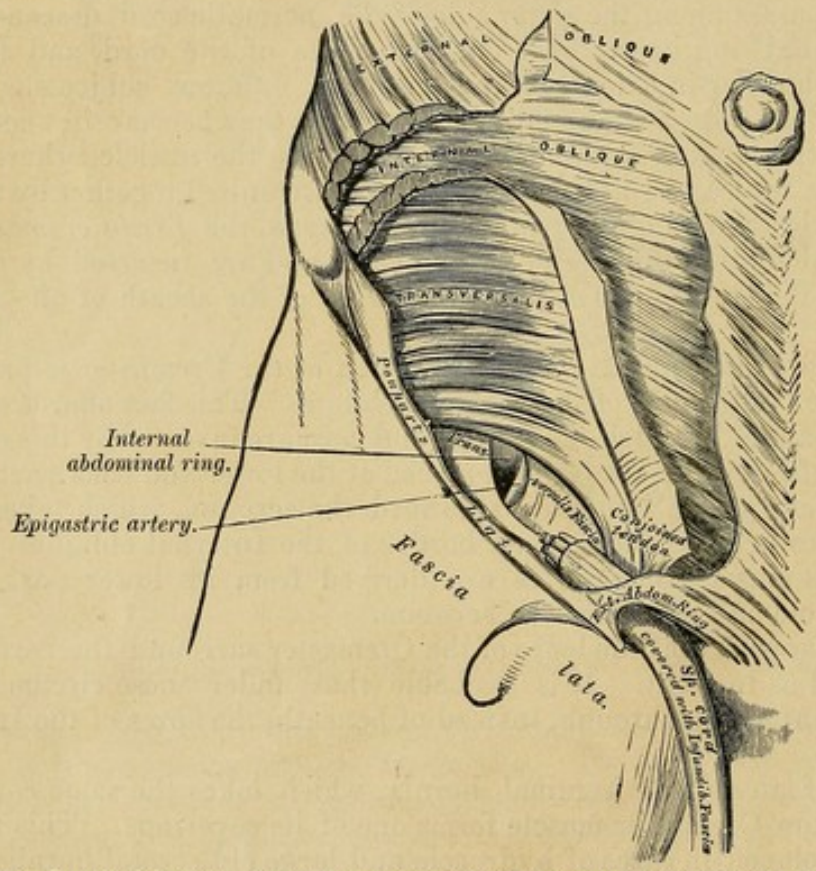

FIG. 581.—Inguinal hernia. Dissection showing the Transversalis muscle, the transversalis fascia, and the internal abdominal ring.

the inner surface of the Transversalis muscle and the peritoneum. It forms part of the general layer of fascia which lines the interior of the abdominal and pelvic cavities, and is directly continuous with the iliac and pelvic fasciæ.

In the inguinal region the transversalis fascia is thick and dense in structure, and joined by fibres from the aponeurosis of the Transversalis muscle; but it becomes thin and cellular as it ascends to the Diaphragm. Below, it has the following attachments: external to the femoral vessels it is connected to the posterior margin of Poupart's ligament, and is there continuous with the iliac fascia. Internal to the vessels it is thin, and attached to the os pubis and pectineal line behind the conjoined tendon, with which it is united; and, corresponding to the points where the femoral vessels pass into the thigh, this fascia descends in front of them, forming the anterior wall of the femoral sheath. The spermatic cord

in the male and the round ligament in the female pass through this fascia; the point where they pass through is called the internal or deep abdominal ring. This opening is not visible externally, owing to a prolongation of the transversalis fascia on the structures forming the infundibuliform fascia.

The **internal** or **deep abdominal ring** is situated in the transversalis fascia, midway between the anterior superior spine of the ilium and symphysis pubis, and about half an inch above Poupart's ligament. It is of an oval form, its long diameter being directed upward and downward; it varies in size in different subjects, and is much larger in the male than in the female. It is bounded above and externally by the arched fibres of the Transversalis muscle, below and internally by the deep epigastric vessels. It transmits the spermatic cord in the male and the round ligament in the female. From its circumference, a thin, funnel-shaped membrane, the *infundibuliform fascia*, is continued round the cord and testis, enclosing them in a distinct pouch. When the sac of an oblique inguinal hernia passes through the internal or deep abdominal ring, the infundibuliform fascia constitutes one of its coverings.

The Subperitoneal Areolar Tissue.—Between the transversalis fascia and the peritoneum is a quantity of loose areolar tissue. In some subjects it is of considerable thickness and loaded with adipose tissue. Opposite the internal ring it is continued round the surface of the cord, forming a loose sheath for it.

The *deep epigastric artery* arises from the external iliac artery a few lines above Poupart's ligament. It at first descends to reach this ligament, and then ascends obliquely along the inner margin of the internal or deep abdominal ring, lying between the transversalis fascia and the peritoneum, and passing upward pierces the transversalis fascia and enters the sheath of the Rectus muscle by passing over the semilunar fold of Douglas. Consequently the deep epigastric artery bears a very important relation to the internal abdominal ring as it passes obliquely upward and inward from its origin from the external iliac. In this part of its course it lies along the lower and inner margin of the internal ring and beneath the commencement of the spermatic cord. At its commencement it is crossed by the vas deferens in the male and by the round ligament in the female.

The **peritoneum**, corresponding to the inner surface of the internal ring, presents a well-marked depression, the depth of which varies in different subjects. A thin fibrous band is continued from it along the front of the cord for a variable distance, and becomes ultimately lost. This is the remains of the pouch of peritoneum which, in the fœtus, precedes the cord and testis into the scrotum, the obliteration of which commences soon after birth. In some cases the fibrous band can only be traced a short distance, but occasionally it may be followed, as a fine cord, as far as the upper end of the tunica vaginalis. Sometimes the tube of peritoneum is closed only at intervals and presents a sacculated appearance, or a single pouch may extend along the whole length of the cord, which may be closed above, or the pouch may be directly continuous with the peritoneum by an opening at its upper part.

In the female fœtus the peritoneum is also prolonged in the form of a tubular process for a short distance into the inguinal canal. This process is called the canal of Nuck. It is generally obliterated in the adult, but sometimes it remains pervious even in advanced life.

In order to understand the relation of the peritoneum to inguinal hernia, it is necessary to view the anterior abdominal wall from its internal aspect, when it will be seen as shown in Fig. 582. Between the upper margin of the front of the pelvis and the umbilicus, the peritoneum, when viewed from behind, will be seen to be raised into five vertical folds, with intervening depressions, by more or less prominent bands which converge to the umbilicus. One of these is situated in the median line, and is caused by the urachus, the remnant of the allantois: it extends from the summit of the bladder to the umbilicus. The fold of peritoneum covering it is known as the *plica urachi*. On either side of this is a prominent band, caused by the obliterated hypogastric artery, which extends from the side of the bladder

obliquely upward and inward to the umbilicus. This is covered by a fold of peritoneum, which is known as the *plica hypogastrica*. To either side of these three cords is the deep epigastric artery, which ascends obliquely upward and inward from a point midway between the symphysis pubis and the anterior superior spine of the ilium to the semilunar fold of Douglas, in front of which it disappears. It is covered by a fold of peritoneum, which is known as the *plica epigastrica*. Between these raised folds are depressions of the peritoneum, constituting so-called fossæ. The most internal, between the plica urachi and the plica hypogastrica, is known as the *internal inguinal fossa* (fovea supravesicalis). The middle one is situated between the plica hypogastrica and the plica epigastrica, and is termed the *middle inguinal fossa* (fovea inguinalis mesialis). The external one is external to

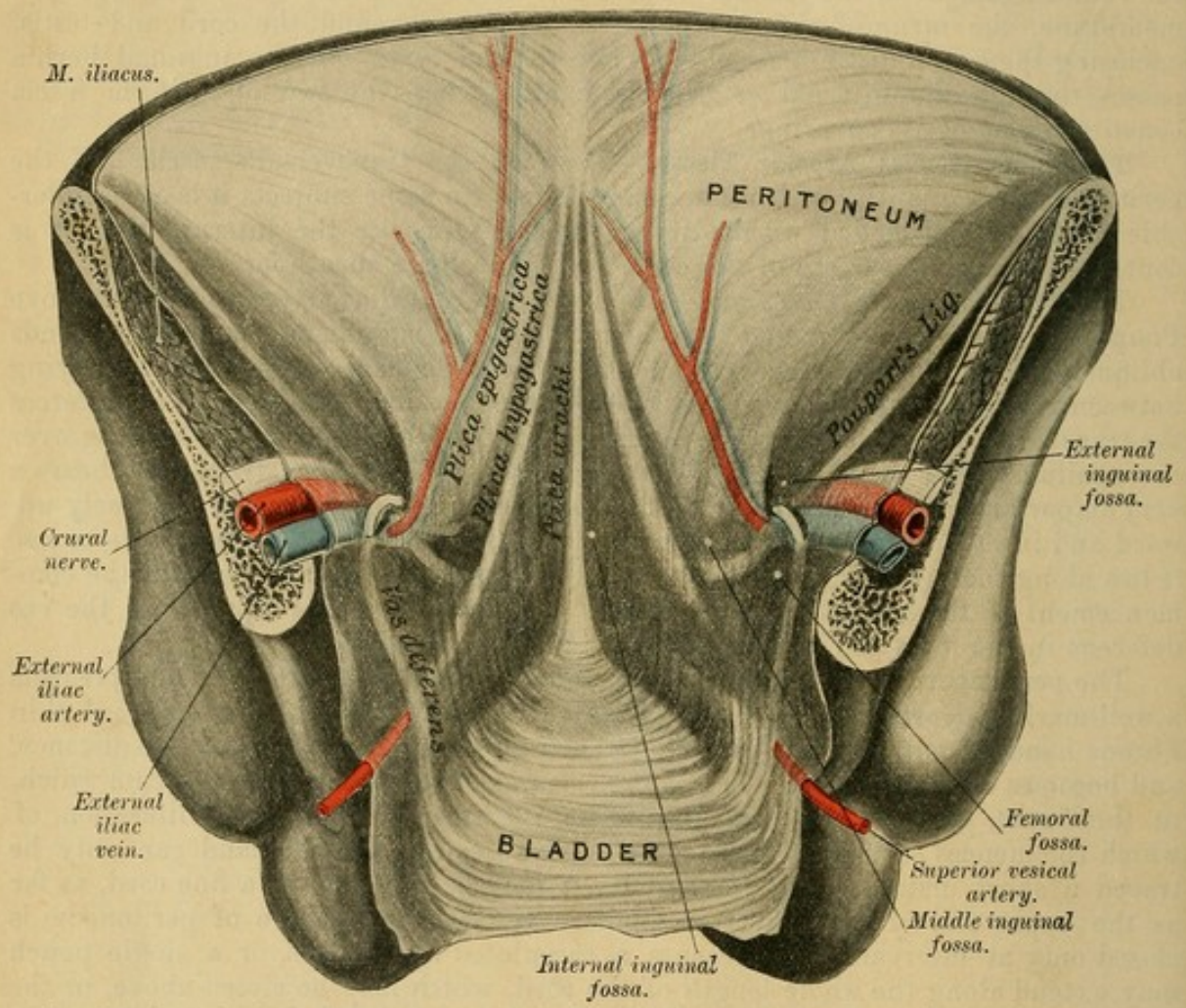

FIG. 582.—Posterior view of the anterior abdominal wall in its lower half. The peritoneum is in place, and the various cords are shining through. (After Joessel.)

the plica epigastrica, and is known as the *external inguinal fossa* (fovea inguinalis lateralis). Occasionally the deep epigastric artery corresponds in position to the obliterated hypogastric artery, and then there is but one fold on each side of the middle line, and the two external fossæ are merged into one. In the usual condition of the parts the floor of the external inguinal fossa corresponds to the internal abdominal ring, and into this fossa an oblique inguinal hernia descends. To the inner side of the plica epigastrica are the two internal fossæ, and through either of these a direct hernia may descend, as will be explained in the sequel (page 1052). The whole of this space, that is to say, the space between the deep epigastric artery, the margin of the Rectus and Poupart's ligament, is commonly known as *Hesselbach's triangle*. These three depressions or fossæ are situated above the level of Poupart's ligament, and in addition to them is another below the ligament, corresponding to the position of the femoral ring, and into which a femoral hernia descends.

INGUINAL HERNIA.

Inguinal hernia is that form of protrusion which makes its way through the abdomen in the inguinal region.

There are two principal varieties of inguinal hernia—external or oblique, and internal or direct.

External or *oblique inguinal hernia*, the more frequent of the two, takes the same course as the spermatic cord. It is called *external* from the neck of the sac being on the outer or iliac side of the deep epigastric artery.

Internal or *direct inguinal hernia* does not follow the same course as the cord, but protrudes through the abdominal wall on the inner or pubic side of the deep epigastric artery.

Oblique Inguinal Hernia.

In **oblique inguinal hernia** the intestine escapes from the abdominal cavity at the internal ring, pushing before it a pouch of peritoneum, which forms the hernial

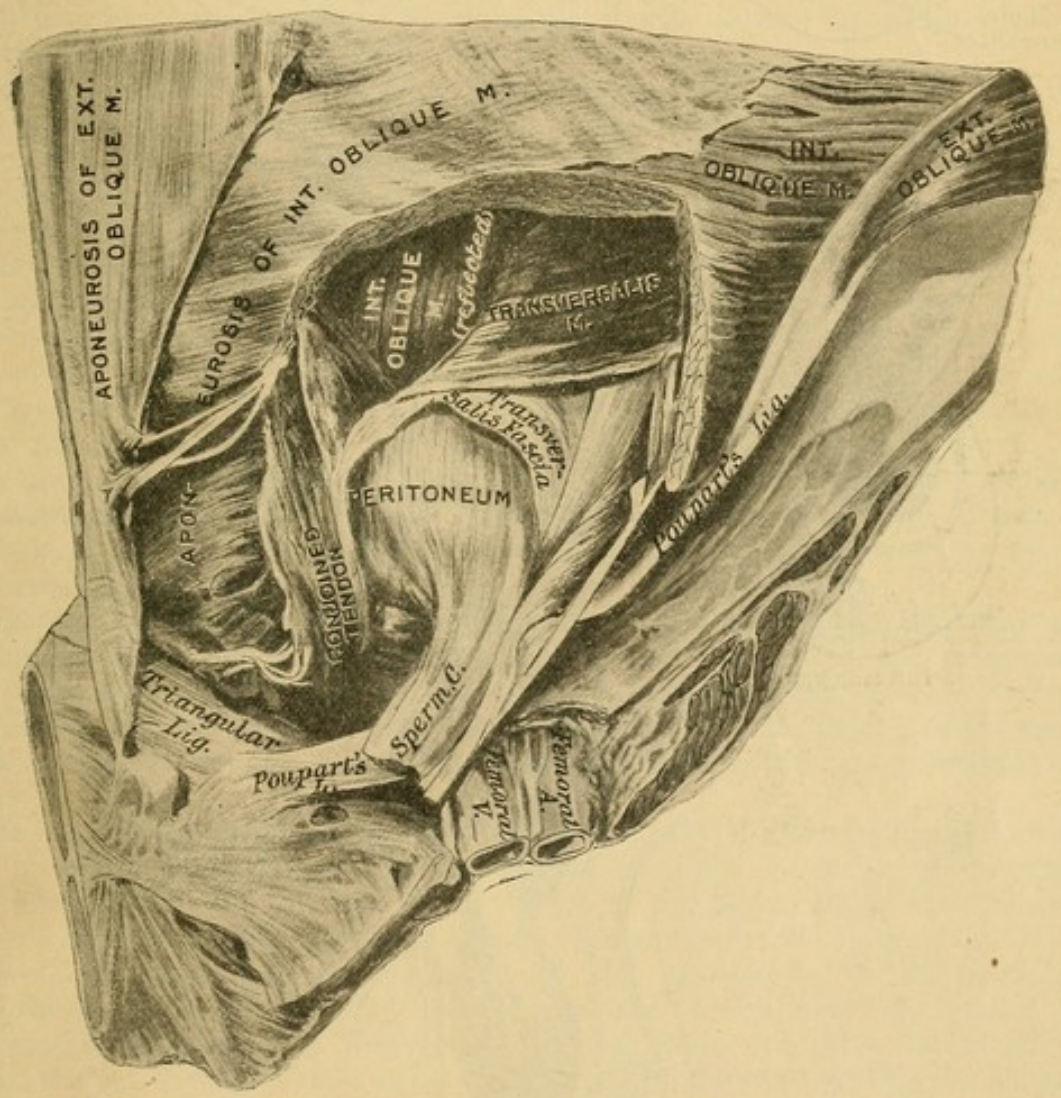

FIG. 583.—Oblique inguinal hernia, showing its various coverings. (From a preparation in the Museum of the Royal College of Surgeons.)

sac (Fig. 584, A). As it enters the inguinal canal it receives an investment from the subserous areolar tissue, and is enclosed in the infundibuliform process of the transversalis fascia. In passing along the inguinal canal it displaces upward the arched fibres of the Transversalis and Internal oblique muscles, and is surrounded by the fibres of the Cremaster. It then passes along the front of the cord, and escapes from the inguinal canal at the external ring, receiving an investment from

the intercolumnar fascia. Lastly, it descends into the scrotum, receiving coverings from the superficial fascia and the integument.

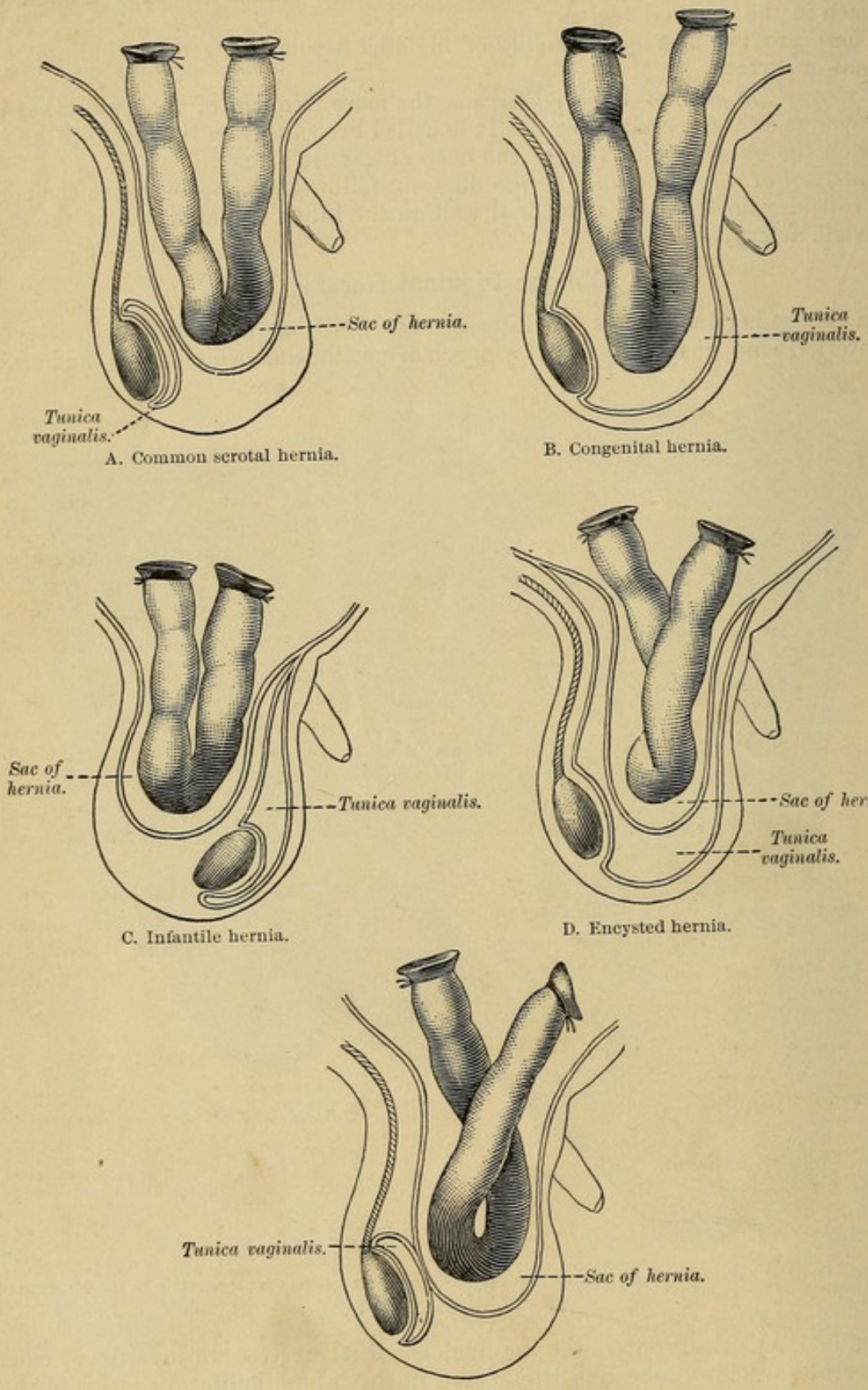

A. Common scrotal hernia.

B. Congenital hernia.

C. Infantile hernia.

D. Encysted hernia.

E. Hernia into the funicular process.

FIG. 584.—Varieties of oblique inguinal hernia.

The coverings of this form of hernia, after it has passed through the external ring, are, from without inward, the integument, superficial fascia, intercolumnar

fascia, Cremaster muscle, infundibuliform fascia, subserous areolar tissue, and peritoneum.

This form of hernia lies in front of the vessels of the spermatic cord and seldom extends below the testis, on account of the intimate adhesion of the coverings of the cord to the tunica vaginalis.

The *seat of stricture* in oblique inguinal hernia is either at the external ring, in the inguinal canal, caused by the fibres of the Internal oblique or Transversalis; or at the internal ring, most frequently in the latter situation. If it is situated at the external ring, the division of a few fibres at one point of its circumference is all that is necessary for the replacement of the hernia. If in the inguinal canal or at the internal ring, it may be necessary to divide the aponeurosis of the External oblique so as to lay open the inguinal canal. In dividing the stricture the direction of the incision should be upward.

When the intestine passes along the inguinal canal and escapes from the external ring into the scrotum, it is called *complete oblique inguinal* or *scrotal hernia*. If the intestine does not escape from the external ring, but is retained in the inguinal canal, it is called *incomplete inguinal hernia*, or *bubonocele*. In each of these cases the coverings which invest it will depend upon the extent to which it descends in the inguinal canal.

There are some other varieties of oblique inguinal hernia depending upon congenital defects in the processus vaginalis. The testicle in its descent from the abdomen into the scrotum is preceded by a pouch of peritoneum, which about the period of birth becomes shut off from the general peritoneal cavity by a closure of that portion of the pouch which extends from the internal abdominal ring to near the upper part of the testicle, the lower portion of the pouch remaining persistent as the tunica vaginalis. It would appear that this closure commences at two points—viz. at the internal abdominal ring and at the top of the epididymis—and gradually extends until, in the normal condition, the whole of the intervening portion is converted into a fibrous cord. From failure in the completion of this process variations in the relation of the hernial protrusion to the testicle and tunica vaginalis are produced, which constitute distinct varieties of inguinal hernia, and which have received separate names and are of surgical importance. These are congenital, infantile, encysted, and hernia of the funicular process.

Congenital Hernia (Fig. 584, B).—Where the pouch of peritoneum which precedes the cord and testis in its descent remains patent throughout and is unclosed at any point, the cavity of the tunica vaginalis communicates directly with the peritoneum. The intestine descends along this pouch into the cavity of the tunica vaginalis, which constitutes the sac of the hernia, and the gut lies in contact with the testicle.

Infantile and Encysted Hernia.—Where the pouch of peritoneum is occluded at the internal ring only, and remains patent throughout the rest of its extent, two varieties of oblique inguinal hernia may be produced, which have received the names of infantile and encysted hernia. In the *infantile* form (Fig. 584, C) the bowel, pressing upon the septum and the peritoneum in its immediate neighborhood, causes it to yield and form a sac, which descends behind the tunica vaginalis, so that in front of the bowel there are three layers of peritoneum, the two layers of the tunica vaginalis and its own sac. In the *encysted* form (Fig. 584, D) pressure in the same position—namely, at the occluded spot in the pouch—causes the septum to yield and form a sac which projects *into* and not *behind* the tunica vaginalis, as in the infantile form, and thus it constitutes a sac within a sac, so that in front of the bowel there are two layers of peritoneum—one layer of the tunica vaginalis and its own sac.

Hernia into the Funicular Process (Fig. 584, E).—Where the pouch of peritoneum is occluded at the lower point only—that is, just above the testicle—the intestine descends into the pouch of peritoneum as far as the testicle, but is prevented from entering the sac of the tunica vaginalis by the septum which has

formed between it and the pouch, so that it resembles the congenital form in all respects, except that, instead of enveloping the testicle, that body can be felt below the rupture.

Direct Inguinal Hernia.

In **direct inguinal hernia** the protrusion makes its way through some part of the abdominal wall internal to the epigastric artery.

At the lower part of the abdominal wall is a triangular space (*Hesselbach's triangle*), bounded externally by the deep epigastric artery, internally by the margin of the Rectus muscle, below by Poupart's ligament (Fig. 582). The conjoined tendon is stretched across the inner two-thirds of this space, the remaining portion of the space having only the subperitoneal areolar tissue and the transversalis fascia between the peritoneum and the aponeurosis of the External oblique muscle.

In some cases the hernial protrusion escapes from the abdomen on the outer side of the conjoined tendon, pushing before it the peritoneum, the subserous areolar tissue, and the transversalis fascia. It then enters the inguinal canal, passing along nearly its whole length, and finally emerges from the external ring, receiving an investment from the intercolumnar fascia. The coverings of this form of hernia are precisely similar to those investing the oblique form, with the insignificant difference that the infundibuliform fascia is replaced by a portion derived from the general layer of the transversalis fascia.

In other cases—and this is the more frequent variety—the hernia is either forced through the fibres of the conjoined tendon or the tendon is gradually distended in front of it so as to form a complete investment for it. The intestine then enters the lower end of the inguinal canal, escapes at the external ring lying on the inner side of the cord, and receives additional coverings from the superficial fascia and the integument. This form of hernia has the same coverings as the oblique variety, excepting that the conjoined tendon is substituted for the Cremaster, and the infundibuliform fascia is replaced by a portion derived from the general layer of the transversalis fascia.

The difference between the position of the neck of the sac in these two forms of direct inguinal hernia has been referred, with some probability, to a difference in the relative positions of the obliterated hypogastric artery and the deep epigastric artery. When the course of the obliterated hypogastric artery corresponds pretty nearly with that of the deep epigastric the projection of these arteries toward the cavity of the abdomen produces two fossæ in the peritoneum. The bottom of the external fossa of the peritoneum corresponds to the position of the internal abdominal ring, and a hernia which distends and pushes out the peritoneum lining this fossa is an oblique hernia. When, on the other hand, the obliterated hypogastric artery lies considerably to the inner side of the deep epigastric artery, corresponding to the outer margin of the conjoined tendon, it divides the triangle of Hesselbach into two parts, so that three depressions will be seen on the inner surface of the lower part of the abdominal wall, viz., an external one, on the outer side of the deep epigastric artery; a middle one, between the deep epigastric and the obliterated hypogastric arteries; and an internal one, on the inner side of the obliterated hypogastric artery (see page 1051). In such a case a hernia may distend and push out the peritoneum forming the bottom of either fossa. When the hernia distends and pushes out the peritoneum forming the bottom of the external fossa, it is an oblique or external inguinal hernia. These fossæ are the *inguinal fossæ*.

When the hernia distends and pushes out the peritoneum forming the bottom of either the middle or the internal fossa, it is a direct or internal hernia.

The anatomical difference between these two forms of direct or internal inguinal hernia is that, when the hernia protrudes through the middle fossa—that is, the fossa between the deep epigastric and the obliterated hypogastric arteries—it will enter the upper part of the inguinal canal; consequently its coverings will be

the same as those of an oblique hernia, with the insignificant difference that the infundibuliform fascia is replaced by a portion derived from the general layer of the transversalis fascia, whereas when the hernia protrudes through the internal fossa it is either forced through the fibres of the conjoined tendon or the tendon is gradually distended in front of it so as to form a complete investment for it. The intestine then enters the lower part of the inguinal canal, and escapes from the external abdominal ring lying on the inner side of the cord.

This form of hernia has the same coverings as the oblique variety, excepting that the conjoined tendon is substituted for the Cremaster, and the infundibuliform fascia is replaced by a portion derived from the general layer of the fascia transversalis.

The *seat of stricture* in both varieties of direct hernia is most frequently at the neck of the sac or at the external ring. In that form of hernia which perforates the conjoined tendon it not unfrequently occurs at the edges of the fissure through which the gut passes. In dividing the stricture the incision should in all cases be directed upward.[1]

If the hernial protrusion passes into the inguinal canal, but does not escape from the external abdominal ring, it forms what is called *incomplete direct hernia.* This form of hernia is usually of small size, and in corpulent persons very difficult of detection.

Direct inguinal hernia is of much less frequent occurrence than the oblique, their comparative frequency being, according to Cloquet, as one to five. It occurs far more frequently in men than in women, on account of the larger size of the external ring in the former sex. It differs from the oblique in its smaller size and globular form, dependent most probably on the resistance offered to its progress by the transversalis fascia and conjoined tendon. It differs also in its position, being placed over the os pubis and not in the course of the inguinal canal. The deep epigastric artery runs on the outer or iliac side of the neck of the sac, and the spermatic cord along its external and posterior side, not directly behind it, as in oblique inguinal hernia.

FEMORAL HERNIA.

The dissection of the parts comprised in the anatomy of femoral hernia should be performed, if possible, upon a female subject free from fat. The subject should lie upon its back: a block is first placed under the pelvis, the thigh everted, and the knee slightly bent and retained in this position. An incision should then be made from the anterior superior spinous process of the ilium along Poupart's ligament to the symphysis pubis; a second incision should be carried transversely across the thigh about six inches beneath the preceding; and these are to be connected together by a vertical one carried along the inner side of the thigh. These several incisions should divide merely the integument; this is to be reflected outward, when the superficial fascia will be exposed.

The **superficial fascia** forms a continuous layer over the whole of the thigh, consisting of areolar tissue, containing in its meshes much fat, and capable of being separated into two or more layers, between which are found the superficial vessels and nerves. It varies in thickness in different parts of the limb. In the groin it is thick, and the two layers are separated from one another by the superficial inguinal lymphatic glands, the internal saphenous vein, and several smaller vessels. One of these layers, the superficial, is continuous with the superficial fascia of the abdomen.

The superficial layer should be detached by dividing it across in the same direction as the external incisions; its removal will be facilitated by commencing at the lower and inner angle of the space, detaching it at first from the front of the internal saphenous vein, and dissecting it off from the anterior surface of that vessel and its tributaries; it should then be reflected out-

[1] In all cases of inguinal hernia, whether oblique or direct, it is proper to divide the stricture directly upward: the reason of this is obvious, for by cutting in this direction the incision is made parallel to the deep epigastric artery—either external to it in the oblique variety, or internal to it in the direct form of hernia—and thus all chance of wounding the vessel is avoided. If the incision was made outward, the artery might be divided if the hernia was direct; and if made inward, it would stand an equal chance of injury if the case was one of oblique inguinal hernia.

ward in the same manner as the integument. The cutaneous vessels and nerves and superficial inguinal glands are then exposed, lying upon the deep layer of the superficial fascia. These are the internal saphenous vein and the superficial epigastric, superficial circumflex iliac, and superficial external pudic vessels, as well as numerous lymphatics, ascending with the saphenous vein to the inguinal glands.

The *internal* or *long saphenous vein* ascends along the inner side of the thigh, and, passing through the saphenous opening in the fascia lata, terminates in the femoral vein about an inch and a half below Poupart's ligament. This vein receives at the saphenous opening the superficial epigastric, the superficial circumflex iliac, and the superficial external pudic veins.

The *superficial external pudic artery* (superior) arises from the inner side of the femoral artery, and, after passing through the saphenous opening, courses inward across the spermatic cord, to be distributed to the integument on the lower part of the abdomen, the penis and scrotum in the male and the labium in the female, anastomosing with branches of the internal pudic.

The *superficial epigastric artery* arises from the femoral about half an inch below Poupart's ligament, and, passing through the saphenous opening in the fascia lata, ascends on to the abdomen, in the superficial fascia covering the

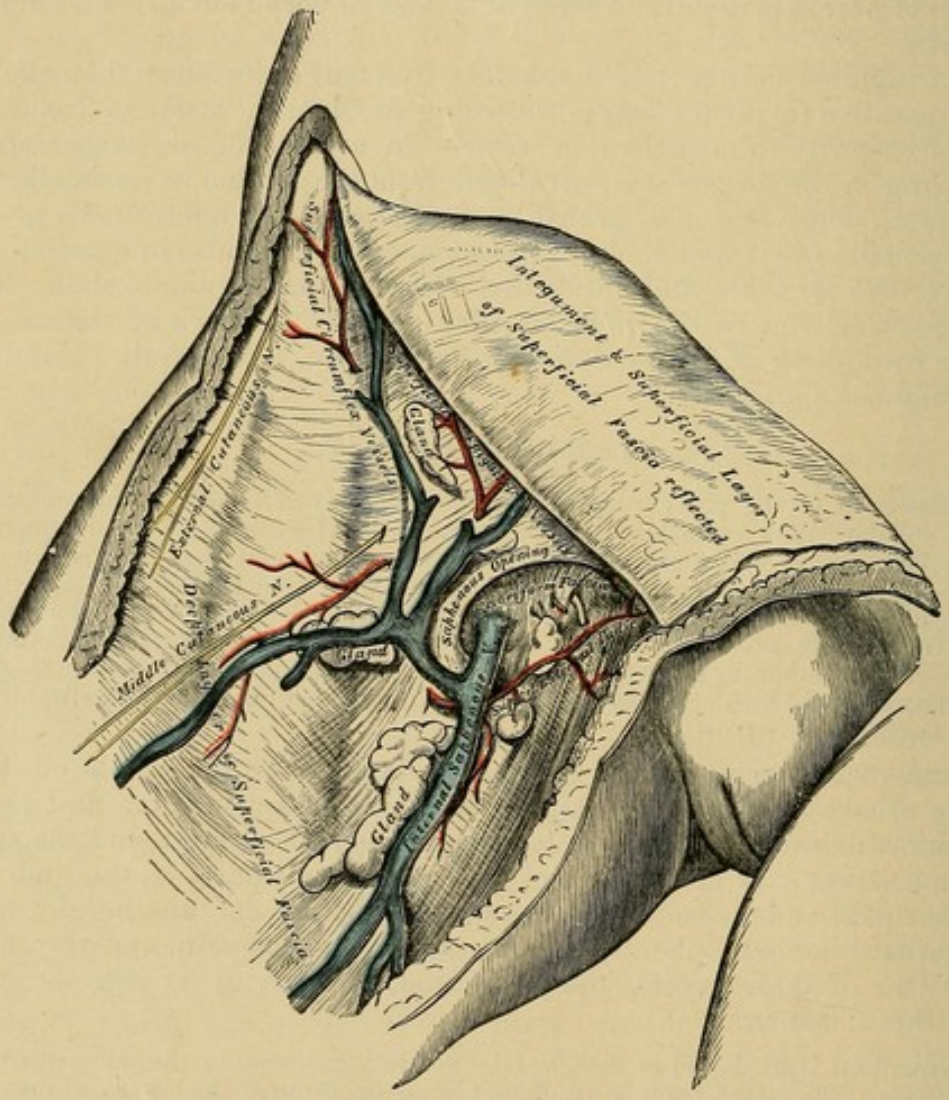

FIG. 585.—Femoral hernia. Superficial dissection.

External oblique muscle, nearly as high as the umbilicus. It distributes branches to the superficial inguinal lymphatic glands, the superficial fascia, and the integument, anastomosing with branches of the deep epigastric and internal mammary arteries.

The *superficial circumflex iliac artery*, the smallest of the cutaneous branches, arises close to the preceding, and, piercing the fascia lata, runs outward, parallel

with Poupart's ligament, as far as the crest of the ilium, dividing into branches which supply the superficial inguinal lymphatic glands, the superficial fascia, and the integument of the groin, anastomosing with the deep circumflex iliac, and with the gluteal and external circumflex arteries.

The Superficial Veins.—The veins accompanying these superficial arteries are usually much larger than the arteries: they terminate in the internal or long saphenous vein at the saphenous opening.

The *superficial inguinal lymphatic glands*, placed immediately beneath the integument, are of large size and vary from eight to ten in number. They are divisible into two groups: an upper, disposed irregularly along Poupart's ligament, which receive the lymphatic vessels from the integument of the scrotum, penis, parietes of the abdomen, perineal and gluteal regions, and the mucous membrane of the urethra; and an inferior group, which surround the saphenous opening in the fascia lata, a few being sometimes continued along the saphenous vein to a variable extent. This latter group receive the superficial lymphatic vessels from the lower extremity.

The *ilio-inguinal nerve* arises from the first lumbar nerve. It escapes at the external abdominal ring, and is distributed to the integument of the upper and inner part of the thigh—to the scrotum in the male and to the labium in the female. The size of this nerve is in inverse proportion to that of the ilio-hypogastric. Occasionally it is very small, and ends by joining the ilio-hypogastric: in such cases a branch of the ilio-hypogastric takes the place of the ilio-inguinal, or the latter nerve may be altogether absent. The *crural branch of the genito-crural nerve* passes along the inner margin of the Psoas muscle, beneath Poupart's ligament, into the thigh, entering the sheath of the femoral vessels, and lying superficial and a little external to the femoral artery. It pierces the anterior layer of the sheath of the vessels, and, becoming superficial by passing through the fascia lata, it supplies the skin of the anterior aspect of the thigh as far as midway between the pelvis and knee. On the front of the thigh it communicates with the outer branch of the middle cutaneous nerve, derived from the anterior crural.

The *deep layer of the superficial fascia* is a very thin fibrous layer, best marked on the inner side of the long saphenous vein and below Poupart's ligament. It is placed beneath the subcutaneous vessels and nerves, and upon the surface of the fascia lata, to which it is intimately adherent at the lower margin of Poupart's ligament. It covers the saphenous opening in the fascia lata, is closely united to its circumference, and is connected to the sheath of the femoral vessels corresponding to its under surface. The portion of fascia covering this aperture is perforated by the internal saphenous vein and by numerous blood- and lymphatic vessels; hence it has been termed the *cribriform fascia*, the openings for these vessels having been likened to the holes in a sieve. The cribriform fascia adheres closely both to the superficial fascia and to the fascia lata, so that it is described by some anatomists as a part of the fascia lata, but it is usually considered (as in this work) as belonging to the superficial fascia. It is not till the cribriform fascia has been cleared away that the saphenous opening is seen, so that this opening does not in ordinary cases exist naturally, but is the result of dissection. A femoral hernia in passing through the saphenous opening receives the cribriform fascia as one of its coverings.

The deep layer of superficial fascia, together with the cribriform fascia, having been removed, the fascia lata is exposed.

The **Fascia Lata** has been already described with the muscles of the front of the thigh (page 419). At the upper and inner part of the thigh, a little below Poupart's ligament, a large oval-shaped aperture is observed after the superficial fascia has been cleared away; it transmits the internal saphenous vein and other smaller vessels, and is called the *saphenous opening*. In order the more correctly to consider the mode of formation of this aperture, the fascia lata in this part of the thigh is described as consisting of two portions, an iliac portion and a pubic portion.

The *iliac portion* is all that part of the fascia lata on the outer side of the

saphenous opening. It is attached externally to the crest of the ilium and its anterior superior spine; to the whole length of Poupart's ligament; and to the pectineal line in conjunction with Gimbernat's ligament. From the spine of the os pubis it is reflected downward and outward, forming an arched margin, the outer boundary or falciform process or superior cornu of the saphenous opening. This margin overlies and is adherent to the anterior layer of the sheath of the femoral vessels; to its edge is attached the cribriform fascia, and below it is continuous with the pubic portion of the fascia lata.

The *pubic portion of the fascia lata* is situated at the inner side of the saphenous opening: at the lower margin of this aperture it is continuous with the iliac portion: traced upward, it covers the surface of the Pectineus, Adductor longus, and Gracilis muscles; and, passing behind the sheath of the femoral vessels, to which it is closely united, is continuous with the sheath of the Psoas and Iliacus muscles, and is attached above to the ilio-pectineal line, where it becomes continuous with the fascia covering the Iliacus muscle. From this description it may be observed that the iliac portion of the fascia lata passes in front of the femoral vessels and the pubic portion behind them, so that an apparent aperture

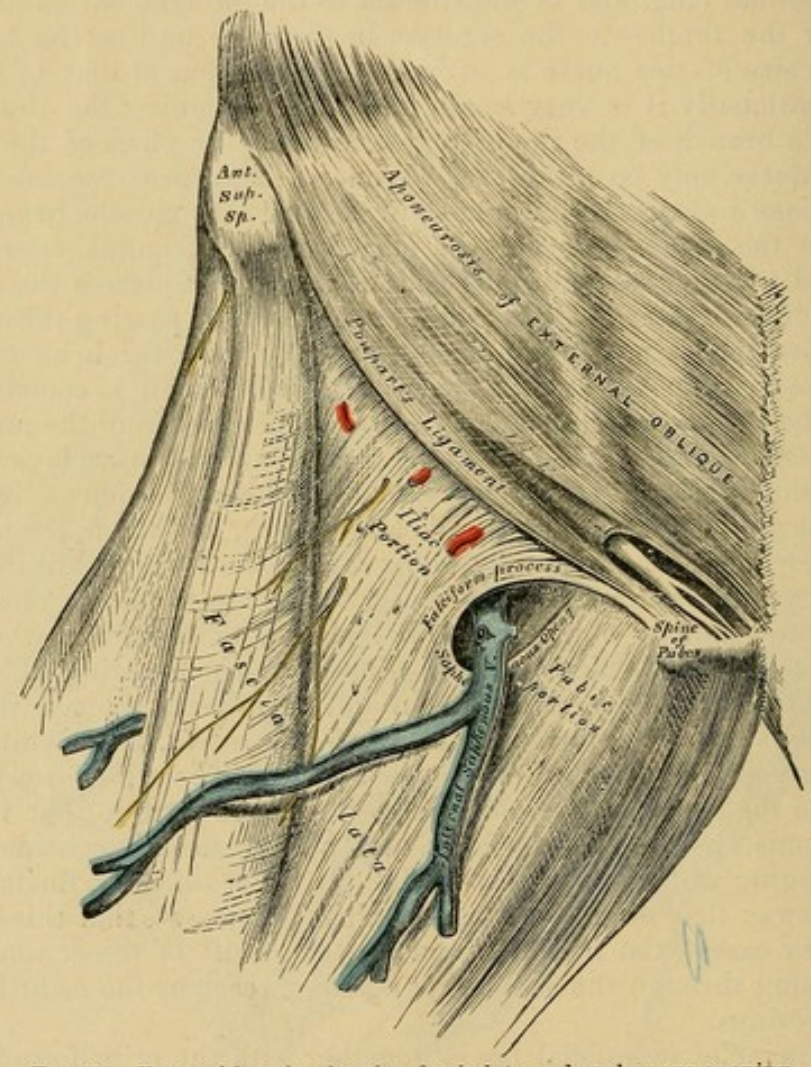

FIG. 586.—Femoral hernia, showing fascia lata and saphenous opening.

consequently exists between the two, through which the internal saphenous joins the femoral vein.

The **Saphenous Opening** is an oval-shaped aperture measuring about an inch and a half in length and half an inch in width. It is situated at the upper and inner part of the front of the thigh, below Poupart's ligament, and is directed obliquely downward and outward.

Its *outer margin* is of a semilunar form, thin, strong, sharply defined, and lies on a plane considerably anterior to the inner margin. If this edge is traced

upward, it will be seen to form a curved elongated process, the *falciform process* or *superior cornu*, which ascends in front of the femoral vessels, and, curving inward, is attached to Poupart's ligament and to the spine of the os pubis and pectineal line, where it is continuous with the pubic portion. If traced downward, it is found continuous with another curved margin, the concavity of which is directed upward and inward: this is the inferior cornu of the saphenous opening, and is blended with the pubic portion of the fascia lata covering the Pectineus muscle.

The *inner boundary of the opening* is on a plane posterior to the outer margin and behind the level of the femoral vessels; it is much less prominent and defined than the outer, from being stretched over the subjacent Pectineus muscle. It is through the saphenous opening that a femoral hernia passes after descending along the crural canal.

If the finger is introduced into the saphenous opening while the limb is moved in different directions, the aperture will be found to be greatly constricted on extending the limb or rotating it outward, and to be relaxed on flexing the limb

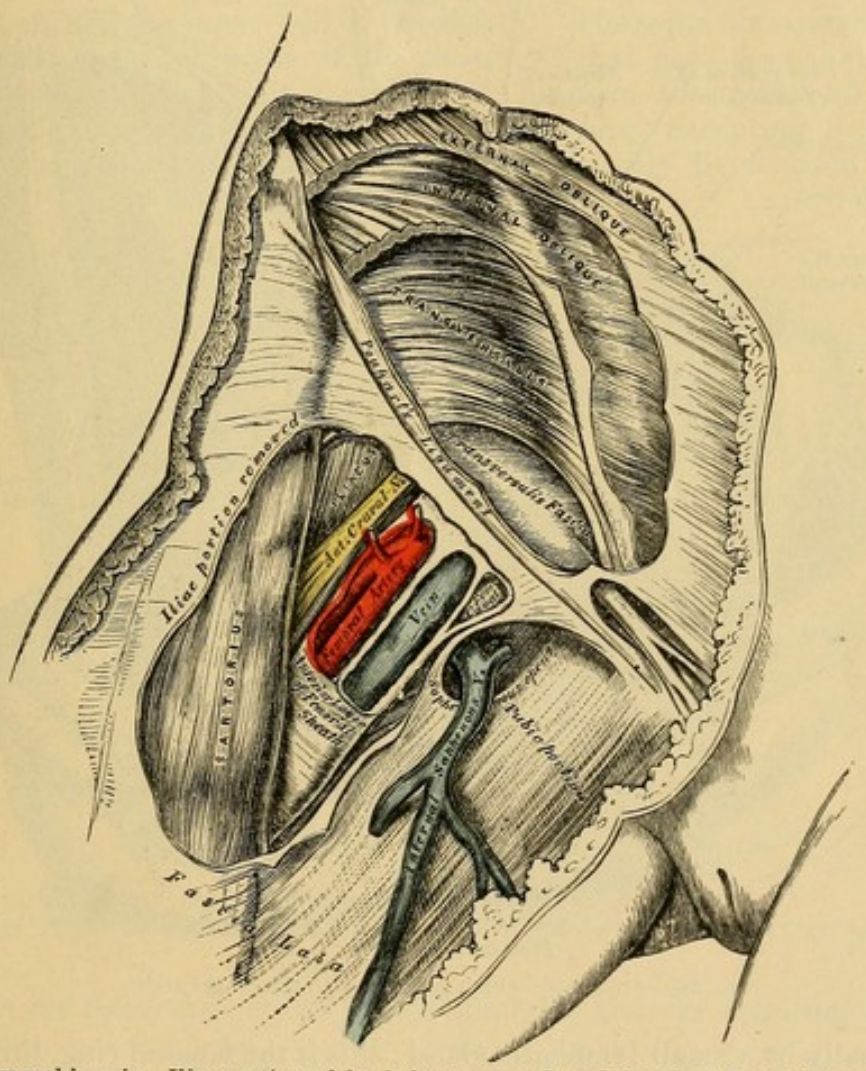

FIG. 587.—Femoral hernia. Iliac portion of fascia lata removed, and sheath of femoral vessels and femoral canal exposed.

and inverting it: hence the necessity for placing the limb in the latter position in employing the taxis for the reduction of a femoral hernia.

The iliac portion of the fascia lata, but not its falciform process, should now be removed by detaching it from the lower margin of Poupart's ligament, carefully dissecting it from the subjacent structures, and turning it inward, when the sheath of the femoral vessels is exposed, descending beneath Poupart's ligament (Fig. 587).

Poupart's Ligament, or the **Crural Arch,** is the lower border of the aponeurosis of the External oblique muscle, which extends from the anterior superior spine of

the ilium to the spine of the os pubis. From this latter point it is reflected outward, to be attached to the pectineal line for about half an inch, forming Gimbernat's ligament. Its general direction is curved downward toward the thigh, where it is continuous with the fascia lata. Its outer half is rounded and oblique in direction. Its inner half gradually widens at its attachment to the os pubis, is more horizontal in direction, and lies beneath the spermatic cord. Nearly the whole of the space included between the crural arch and innominate bone is filled in by the parts which descend from the abdomen into the thigh (Fig. 588). The outer half of the space is occupied by the Iliacus and Psoas muscles, together with the external cutaneous and anterior crural nerves. The pubic half of the space is occupied by the femoral vessels included in their sheath, a small oval-shaped interval existing between the femoral vein and the inner wall of the sheath, which is occupied merely by a little loose areolar tissue, a few lymphatic vessels,

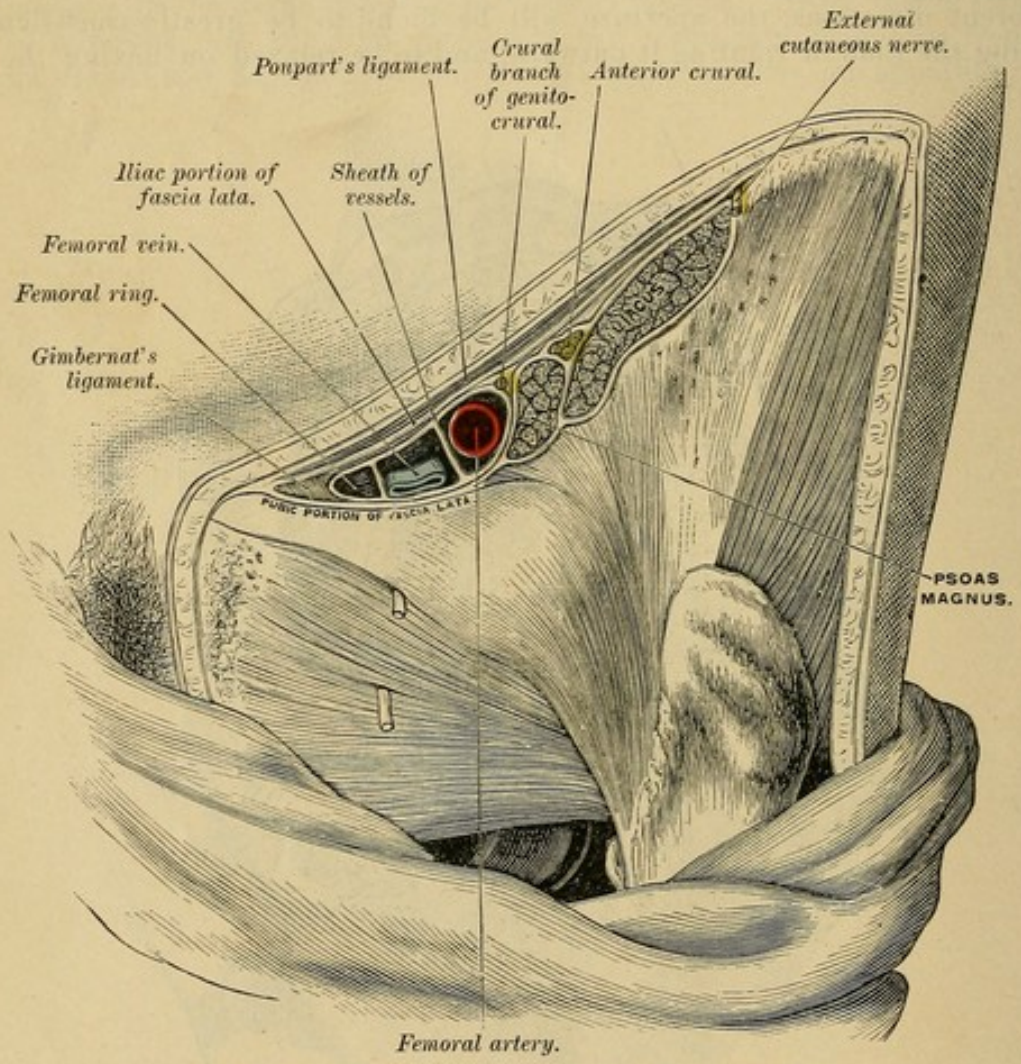

FIG. 588.—Structures which pass beneath the crural arch.

and occasionally by a small lymphatic gland; this is the femoral ring, through which the gut descends in femoral hernia.

Gimbernat's Ligament (Figs. 588, 589) is that part of the aponeurosis of the External oblique muscle which is reflected backward and outward from the spine of the os pubis, to be inserted into the pectineal line. It is about half an inch in length, larger in the male than in the female, almost horizontal in direction in the erect posture, and of a triangular form, with the base directed outward. Its *base*, or outer margin, is concave, thin, and sharp, and lies in contact with the femoral sheath. Its *apex* corresponds to the spine of the os pubis. Its *posterior margin* is attached to the pectineal line, and is continuous with the pubic portion of the fascia lata. Its *anterior margin* is continuous with Poupart's ligament.

Femoral Sheath.—The femoral or crural sheath is a continuation downward of the fasciæ that line the abdomen, the transversalis fascia passing down in front of the femoral vessels, and the iliac fascia descending behind them; these fasciæ are directly continuous on the iliac side of the femoral artery, but a small space exists between the femoral vein and the point where they are continuous on the pubic side of that vessel, which constitutes the femoral or crural canal. The femoral sheath is closely adherent to the contained vessels about an inch below the saphenous opening, being blended with the areolar sheath of the vessels, but opposite Poupart's ligament it is much larger than is required to contain them; hence the funnel-shaped form which it presents. The outer border of the sheath is perforated by the genito-crural nerve. Its inner border is pierced by the internal saphenous vein and numerous lymphatic vessels. In front it is covered by the iliac portion of the fascia lata; and behind it is the pubic portion of the same fascia.

If the anterior wall of the sheath is removed, the femoral artery and vein are seen lying side by side, a thin septum separating the two vessels, while another septum may be seen lying just internal to the vein, and cutting off a small space between the vein and the inner wall of the sheath. The septa are stretched between the anterior and posterior walls of the sheath, so that each vessel is enclosed in a separate compartment. The interval left between the vein and the inner wall of the sheath is not filled up by any structure, excepting a little loose areolar tissue, a few lymphatic vessels, and occasionally by a small lymphatic

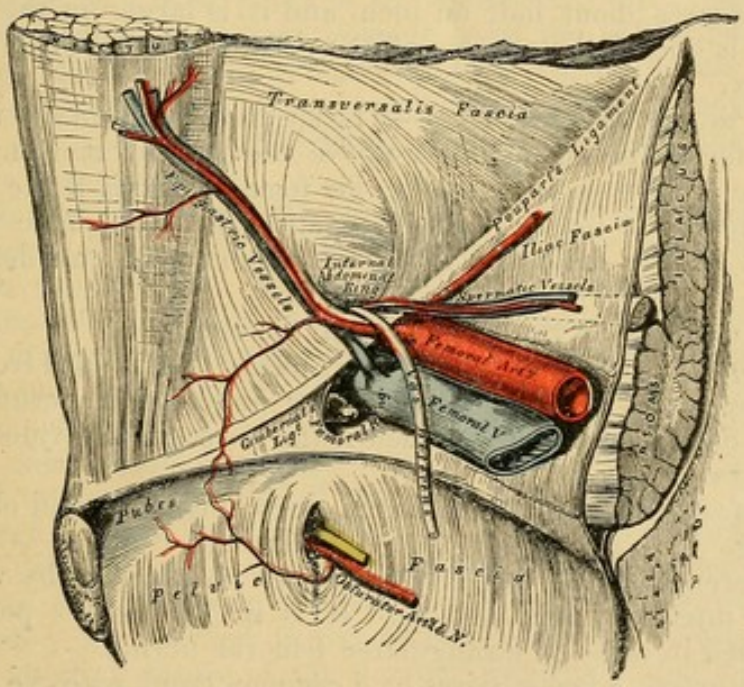

FIG. 589.—Hernia. The relations of the femoral and internal abdominal rings, seen from within the abdomen. Right side.

gland: this is the femoral or crural canal, through which the intestine descends in femoral hernia.

Deep Crural Arch.—Passing across the front of the femoral sheath on the abdominal side of Poupart's ligament, and closely connected with it, is a thickened band of fibres called the *deep crural arch*. It is apparently a thickening of the transversalis fascia, joining externally to the centre of Poupart's ligament, and arching across the front of the crural sheath, to be inserted by a broad attachment into the pectineal line behind the conjoined tendon. In some subjects this structure is not very prominently marked, and not infrequently it is altogether wanting.

The **crural canal** is the narrow interval between the femoral vein and the inner wall of the femoral sheath. It exists as a distinct canal only when the sheath has

been separated from the vein by dissection or by the pressure of a hernia or tumor. Its length is from a quarter to half an inch, and it extends from Gimbernat's ligament to the upper part of the saphenous opening.

Its *anterior wall* is very narrow, and formed by a continuation downward of the transversalis fascia, under Poupart's ligament, covered by the falciform process of the fascia lata.

Its *posterior wall* is formed by a continuation downward of the iliac fascia covering the pubic portion of the fascia lata.

Its *outer wall* is formed by the fibrous septum separating it from the inner side of the femoral vein.

Its *inner wall* is formed by the junction of the processes of the transversalis and iliac fasciæ, which form the inner side of the femoral sheath, and lies in contact at its commencement with the outer edge of Gimbernat's ligament.

This canal has two orifices—an upper one, the *femoral* or *crural ring*, closed by the septum crurale; and a lower one, the *saphenous opening*, closed by the cribriform fascia.

The **femoral** or **crural ring** (Fig. 589) is the upper opening of the femoral canal, and leads into the cavity of the abdomen. It is bounded in front by Poupart's ligament and the deep crural arch; behind, by the os pubis, covered by the Pectineus muscle and the pubic portion of the fascia lata; internally, by the base of Gimbernat's ligament, the conjoined tendon, the transversalis fascia, and the deep crural arch; externally, by the fibrous septum lying on the inner side of the femoral vein. The femoral ring is of an oval form; its long diameter, directed transversely, measures about half an inch, and it is larger in the female than in the male, which is one of the reasons of the greater frequency of femoral hernia in the former sex.

Position of Parts around the Ring.—The spermatic cord in the male and round ligament in the female lie immediately above the anterior margin of the femoral ring, and may be divided in an operation for femoral hernia if the incision for the relief of the stricture is not of limited extent. In the female this is of little importance, but in the male the spermatic artery and vas deferens may be divided.

The *femoral vein* lies on the outer side of the ring.

The *deep epigastric artery* in its passage upward and inward from the external iliac artery passes across the upper and outer angle of the crural ring, and is consequently in danger of being wounded if the stricture is divided in a direction upward and outward.

The *communicating branch* between the deep epigastric and obturator lies in front of the ring.

The circumference of the ring is thus seen to be bounded by vessels in every part, excepting internally and behind. It is in the former position that the stricture is divided in cases of strangulated femoral hernia.

The *obturator artery*, when it arises by a common trunk with the deep epigastric, which occurs once in every three subjects and a half, bears a very important relation to the crural ring. In most cases it descends on the inner side of the external iliac vein to the obturator foramen, and will consequently lie on the outer side of the crural ring, where there is no danger of its being wounded in the operation for dividing the stricture in femoral hernia (see Fig. 314, page 565, fig. A). Occasionally, however, the obturator artery curves along the free margin of Gimbernat's ligament in its passage to the obturator foramen: it would consequently skirt along the greater part of the circumference of the crural ring, and could hardly avoid being wounded in the operation (see Fig. 314, page 565, fig. B).

Septum Crurale.—The femoral ring is closed by a layer of condensed areolar tissue called, by J. Cloquet, the *septum crurale*. This serves as a barrier to the protrusion of a hernia through this part. Its upper surface is slightly concave, and supports a small lymphatic gland by which it is separated from the subserous areolar tissue and peritoneum. Its under surface is turned toward the femoral

canal. The septum crurale is perforated by numerous apertures for the passage of lymphatic vessels connecting the deep inguinal lymphatic glands with those surrounding the external iliac artery.

The size of the femoral canal, the degree of tension of its orifices, and consequently the degree of constriction of a hernia, vary according to the position of the limb. If the leg and thigh are extended, abducted, or everted, the femoral canal and its orifices are rendered tense from the traction on these parts by Poupart's ligament and the fascia lata, as may be ascertained by passing the finger along the canal. If, on the contrary, the thigh is flexed upon the pelvis, and at the same time adducted and rotated inward, the femoral canal and its orifices become considerably relaxed; for this reason the limb should always be placed in the latter position when the application of the taxis is made in attempting the reduction of a femoral hernia.

The *subperitoneal areolar tissue* is continuous with the subserous areolar tissue of surrounding parts. It is usually thickest and most fibrous where the iliac vessels leave the abdominal cavity. It covers over the small interval (crural ring) on the inner side of the femoral vein. In some subjects it contains a considerable amount of adipose tissue. In such cases, where it is protruded forward in front of the sac of a femoral hernia, it may be mistaken for a portion of omentum. The peritoneum lining the portion of the abdominal wall between Poupart's ligament and the brim of the pelvis is similar to that lining any other portion of the abdominal wall, being very thin. It has here no natural aperture for the escape of intestine.

Descent of the Hernia.—From the preceding description it follows that the femoral ring must be a weak point in the abdominal wall: hence it is that when violent or long-continued pressure is made upon the abdominal viscera a portion of intestine may be forced into it, constituting a femoral hernia; and the changes in the tissues of the abdomen which are produced by pregnancy, together with the larger size of this aperture in the female, serve to explain the frequency of this form of hernia in women.

When a portion of the intestine is forced through the femoral ring, it carries before it a pouch of peritoneum, which forms what is called the *hernial sac;* it receives an investment from the subserous areolar tissue and from the septum crurale, and descends vertically along the crural canal in the inner compartment of the sheath of the femoral vessels as far as the saphenous opening; at this point it changes its course, being prevented from extending farther down the sheath on account of the narrowing of the sheath and its close contact with the vessels, and also from the close attachment of the superficial fascia and crural sheath to the lower part of the circumference of the saphenous opening; the tumor is consequently directed forward, pushing before it the cribriform fascia, and then curves upward on to the falciform process of the fascia lata and lower part of the tendon of the External oblique, being covered by the superficial fascia and integument. While the hernia is contained in the femoral canal it is usually of small size, owing to the resisting nature of the surrounding parts; but when it has escaped from the saphenous opening into the loose areolar tissue of the groin, it becomes considerably enlarged. The direction taken by a femoral hernia in its descent is at first downward, then forward and upward; this should be borne in mind, as in the application of the taxis for the reduction of a femoral hernia pressure should be directed in the reverse order.

Coverings of the Hernia.—The coverings of a femoral hernia, from within outward, are—peritoneum, subserous areolar tissue, the septum crurale, crural sheath, cribriform fascia, superficial fascia, and integument.[1]

[1] Sir Astley Cooper has described an investment for femoral hernia, under the name of "fascia propria," lying immediately external to the peritoneal sac, but frequently separated from it by more or less adipose tissue. Surgically, it is important to remember the existence (at any rate, the occasional existence) of this layer, on account of the ease with which an inexperienced operator may mistake the fascia for the peritoneal sac and the contained fat for omentum. Anatomically, this fascia appears identical with what is called in the text "subserous areolar tissue," the areolar tissue being thickened and caused to assume a membranous appearance by the pressure of the hernia.

Varieties of Femoral Hernia.—If the intestine descends along the femoral canal only as far as the saphenous opening, and does not escape from this aperture, it is called *incomplete femoral hernia*. The small size of the protrusion in this form of hernia, on account of the firm and resisting nature of the canal in which it is contained, renders it an exceedingly dangerous variety of the disease, from the extreme difficulty of detecting the existence of the swelling, especially in corpulent subjects. The coverings of an incomplete femoral hernia would be, from without inward, integument, superficial fascia, falciform process of fascia lata, crural sheath, septum crurale, subserous areolar tissue, and peritoneum. When, however, the hernial tumor protrudes through the saphenous opening and directs itself forward and upward, it forms a *complete femoral hernia*. Occasionally the hernial sac descends on the iliac side of the femoral vessels or in front of these vessels, or even sometimes behind them.

The *seat of stricture of a femoral hernia* varies: it may be in the peritoneum at the neck of the hernial sac; in the greater number of cases it would appear to be at the point of junction of the falciform process of the fascia lata with the lunated edge of Gimbernat's ligament, or at the margin of the saphenous opening in the thigh. The stricture should in every case be divided in a direction upward and inward, and the extent necessary in the majority of cases is about two or three lines. By these means all vessels or other structures of importance in relation with the neck of the hernial sac will be avoided.

SURGICAL ANATOMY OF THE PERINÆUM.

Dissection.—The student should select a well-developed muscular subject, free from fat, and the dissection should be commenced early, in order that the parts may be examined in as recent a state as possible. A staff having been introduced into the bladder and the subject placed in the position shown in Fig. 590, the scrotum should be raised upward, and retained in that position, and the rectum moderately distended with tow.

The **Perinæum** corresponds to the inferior aperture or outlet of the pelvis. Its deep boundaries are, in front, the pubic arch and subpubic ligament; behind, the tip of the coccyx; and on each side, the rami of the os pubis and ischium, the tuberosities of the ischium, and great sacro-sciatic ligaments. The space included by these boundaries is somewhat lozenge-shaped, and is limited on the surface of the body by the scrotum in front, by the buttocks behind, and on each side by the inner side of the thighs. A line drawn transversely between the anterior part of the tuberosity of the ischium, on each side, in front of the anus, divides this space into two portions. The anterior portion contains the penis and urethra, and is called the *perinæum proper* or *genito-urinary region*. The posterior portion contains the termination of the rectum, and is called the *ischio-rectal* or *anal region*.

ISCHIO-RECTAL REGION.

The **ischio-rectal region** contains the termination of the rectum and a deep fossa, filled with fat, on each side of the intestine, between it and the tuberosity of the ischium: this is called the *ischio-rectal fossa*.

The **ischio-rectal region** presents in the middle line the *aperture of the anus*: around this orifice the integument is thrown into numerous folds, which are obliterated on distension of the intestine. The integument is of a dark color, continuous with the mucous membrane of the rectum, and provided with numerous follicles, which occasionally inflame and suppurate, and may be mistaken for fistulæ. The veins around the margin of the anus are occasionally much dilated, forming a number of hard pendent masses, of a dark bluish color, covered partly by mucous membrane and partly by the integument. These tumors constitute the disease called *external piles*.

Dissection (Fig. 590).—Make an incision through the integument, along the median line, from the base of the scrotum to the anterior extremity of the anus: carry it round the margins of this aperture to its posterior extremity, and continue it backward to about an inch behind the tip of the coccyx. A transverse incision should now be carried across the base of the scrotum, joining the anterior extremity of the preceding; a second, carried in the same direction, should be made in front of the anus; and a third at the posterior extremity of the first incision. These incisions should be sufficiently extensive to enable the dissector to raise the integument from the inner side of the thighs. The flaps of skin corresponding to the ischio-rectal region should now be removed. In dissecting the integument from this region great care is required, otherwise the Corrugator cutis ani and External sphincter will be removed, as they are intimately adherent to the skin.

The **superficial fascia** is exposed on the removal of the skin: it is very thick, areolar in texture, and contains much fat in its meshes. In it are found ramifying two or three branches of the perforating cutaneous nerve; these turn round the inferior border of the Gluteus maximus and are distributed to the integument around the anus.

In this region, and connected with the lower end of the rectum, are four

muscles: the Corrugator cutis ani; the two Sphincters, External and Internal; and the Levator ani.

These muscles have been already described (see page 368).

The **ischio-rectal fossa** is situated between the end of the rectum and the tuberosity of the ischium. It is triangular in shape; its base, directed to the surface of the body, is formed by the integument of the ischio-rectal region; its *apex*, directed upward, corresponds to the point of division of the obturator fascia and the thin membrane given off from it, which covers the outer surface of the Levator ani (ischio-rectal or anal fascia). Its dimensions are about an inch in breadth at the base and about two inches in depth, being deeper behind than in front. It is bounded, *internally*, by the Sphincter ani, Levator ani, and Coccygeus muscles; *externally*, by the tuberosity of the ischium and the obturator fascia, which covers the inner surface of the Obturator internus muscle; *in front*, it is limited by the line of junction of the superficial fascia with the base of the triangular ligament; and *behind*, by the margin of the Gluteus maximus and the great sacro-sciatic ligament. This space is filled with a large mass of adipose tissue, which explains the frequency with which abscesses in the neighborhood of the rectum burrow to a considerable depth.

If the subject has been injected, on placing the finger on the outer wall of this fossa the internal pudic artery, with its accompanying veins and the two divisions of the nerve, will be felt about an inch and a half above the margin of the ischiatic tuberosity, but approaching nearer the surface as they pass forward along the inner margin of the pubic arch. These structures are enclosed in a sheath (canal of Alcock) formed by the obturator fascia, the pudic nerve lying below the artery and the dorsal nerve of the penis above it (Fig. 315). Crossing the space transversely, about its centre are the inferior hemorrhoidal vessels and nerves, which are distributed to the integument of the anus and to the muscles of the lower end of the rectum. These vessels are occasionally of large size, and may give rise to troublesome hemorrhage when divided in the operation of lithotomy or in that for fistula in ano. At the back part of this space, near the coccyx, may be seen a branch of the fourth sacral nerve, and at the fore part of the space the superficial perineal vessels and nerves can be seen for a short distance.

THE PERINÆUM PROPER IN THE MALE.

The perineal space is of a triangular form; its deep boundaries are limited, laterally, by the rami of the pubic bones and ischia, meeting in front at the pubic arch; behind, by an imaginary transverse line extending between the anterior parts of the tuberosities of the ischia. The lateral boundaries are, in the adult, from three inches to three inches and a half in length, and the base from two to three inches and a half in breadth, the average extent of the space being two inches and three-quarters.

The variations in the diameter of this space are of extreme interest in connection with the operation of lithotomy and the extraction of a stone from the cavity of the bladder. In those cases where the tuberosities of the ischia are near together it would be necessary to make the incisions in the lateral operation of lithotomy less oblique than if the tuberosities were widely separated, and the perineal space consequently wider. The perinæum is subdivided by the median raphe into two equal parts. Of these, the left is the one in which the operation of lithotomy is performed.

In the middle line the perinæum is convex, and corresponds to the bulb of the urethra. The skin covering it is of a dark color, thin, freely movable upon the subjacent parts, and covered with sharp crisp hairs, which should be removed before the dissection of the part is commenced. In front of the anus a prominent line commences, the *raphe*, continuous in front with the raphe of the scrotum.

Upon removing the skin and superficial structures from this region, in the manner shown in Fig. 590, a plane of fascia will be exposed, covering in the triangular space and stretching across from one ischio-pubic ramus to the other. This is the *deep layer of the superficial fascia* or *fascia of Colles*. It has already

been described (page 370). It is a layer of considerable strength, and encloses and covers a space in which are contained muscles, vessels, and nerves. It is continuous in front with the dartos of the scrotum; on each side it is firmly attached to the margin of the ischio-pubic ramus and to the tuberosity of the ischium; and posteriorly it curves down behind the Transversus perinæi muscles to join the base of the triangular ligament.

It is between this layer of fascia and the triangular ligament of the urethra that extravasation of urine most frequently takes place in cases of rupture of the urethra. The triangular ligament of the urethra (see page 373) is attached to the ischio-pubic rami, and in front to the subpubic ligament. It is clear, therefore, that when extravasation of fluid takes place between these two layers, it cannot pass backward, because the two layers are continuous with each other around the Transversi perinæi muscles: it cannot extend laterally, on account of the connection of both these layers to the rami of the os pubis and ischium; it cannot find its way into the pelvis, because the opening into this cavity is closed by the triangular ligament, and, therefore, so long as these two layers remain intact, the only direction in which the fluid can make its way is forward into the areolar tissue of the scrotum and penis, and then on to the anterior wall of the abdomen.

When the deep layer of the superficial fascia is removed, a space is exposed, between this fascia and the triangular ligament, in which are contained the superficial perineal vessels and nerves and some of the muscles connected with the penis and urethra, viz., in the middle line, the Accelerator urinæ; on each side, the Erector penis; and behind, the transversus perinæi; together with the crura of the corpora cavernosa and the bulb of the corpus spongiosum. Here also is seen the *central tendinous point of the perineum*. This is a fibrous point in the middle line of the perineum between the urethra and the rectum, being about half an inch in front of the anus. At this point four muscles converge and are attached, viz.,

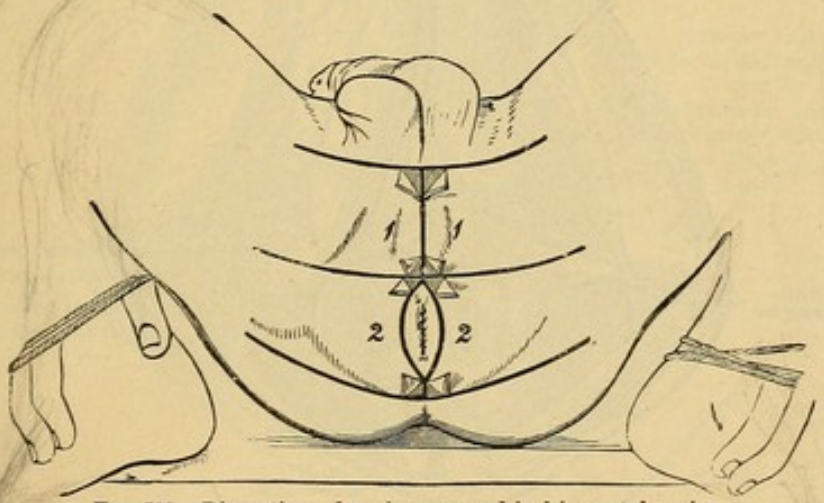

FIG. 590.—Dissection of perinæum and ischio-rectal region.

the External sphincter ani, the Accelerator urinæ, and the two Transversi perinæi muscles; so that by the contraction of these muscles, which extend in opposite directions, it serves as a fixed point of support.

The Accelerator urinæ, the Erector penis, and the Transversus perinæi muscles have been already described (page 371). They form a triangular space, bounded, internally, by the Accelerator urinæ; externally, by the Erector penis; and behind, by the Transversus perinæi. The floor of this space is formed by the triangular ligament of the urethra; and running from behind forward in it are the superficial perineal vessels and nerves, and the transverse perineal artery coursing along the posterior boundary of the space, on the Transversus perinæi muscle.

The Accelerator urinæ and Erector penis should now be removed, when the triangular ligament of the urethra will be exposed, stretching across the front of the outlet of the pelvis. The urethra is seen perforating its centre, just behind the bulb; and on each side is the crus penis, connecting the corpus cavernosum with the rami of the ischium and os pubis.

The **Triangular Ligament**, which has already been described (see page 373), consists of two layers, the inferior superficial layer of which is now exposed.

It is united to the superior or deep layer behind, but is separated in front by a subfascial space in which are contained certain structures.

The *inferior layer of the triangular ligament* consists of a strong fibrous membrane, the fibres of which are disposed transversely, which stretches across from one ischio-pubic ramus to the other and completely fills in the pubic arch; it is attached in front to the subpubic ligament, except just in the centre, where a small interspace is left for the dorsal vein of the penis. In the erect position of the body it is almost horizontal. It is perforated by the urethra in the middle line, and on each side of the urethral opening by the ducts of Cowper's glands and by the arteries of the bulb; in front, and external to this, by the artery of the corpus cavernosum, immediately before this vessel enters the crus penis. Near its apex the ligament is perforated by the termination of the pudic artery and by the dorsal nerve of the penis. The *crura penis* are exposed, lying superficial to this ligament. They will be seen to be attached by blunt-pointed processes to the rami of the os pubis and ischium, in front of the tuberosities, and passing forward and inward, joining to form the body of the penis. In the middle line the bulb and corpus spongiosum are exposed by the removal of the Accelerator urinæ muscle.

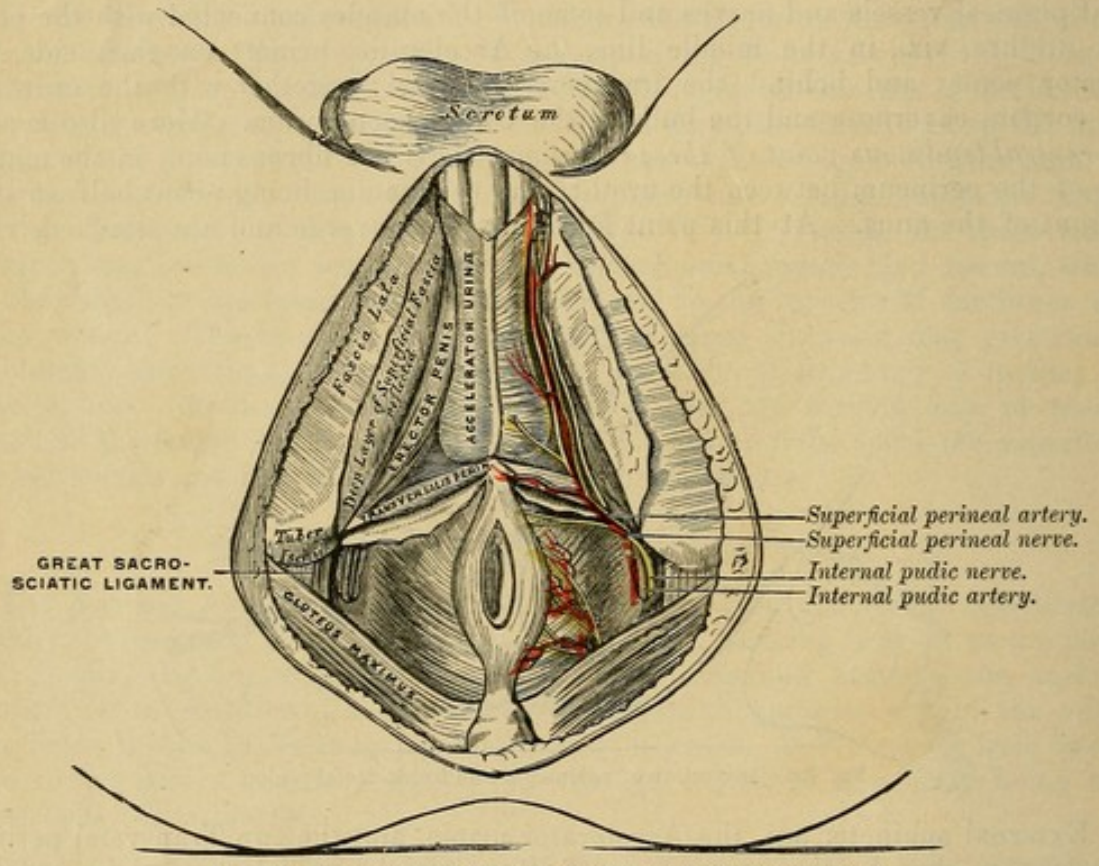

FIG. 591.—The superficial muscles and vessels of the perinæum.

If the superficial layer of the deep perineal fascia is detached on either side, the deep perineal interspace will be exposed and the following parts will be seen between it and the deep layer of the ligament: the subpubic ligament in front, close to the symphysis pubis; the dorsal vein of the penis; the membranous portion of the urethra and the Compressor urethræ muscle; Cowper's glands and their ducts; the pudic vessels and the dorsal nerve of the penis; the artery and nerve of the bulb and a plexus of veins.

The *superior layer of the triangular ligament*, or *deep perineal fascia*, is derived from the obturator fascia, and is continuous with it along the pubic arch. Behind, it joins with the superficial layer of the triangular ligament, and is continuous with the anal fascia. Above it is the prostate gland, supported by the anterior fibres of the Levator ani, which act as a sling for the gland and form the Levator prostatæ muscle. The superior layer of the triangular ligament is continuous

round the anterior free edge of this muscle with the recto-vesical layer covering the prostate gland. The superior layer of the triangular ligament is perforated by the urethra. Between the two layers of the triangular ligament are situated the membranous part of the urethra, enveloped by the Compressor urethræ muscle; the ducts of Cowper's glands; the arteries to the bulb; the pudic vessels and the dorsal nerve of the penis. The membranous part of the urethra is about three-quarters of an inch in length, and passes downward and forward behind the symphysis pubis, from which it is distant about an inch. It is the narrowest part of the tube, and is enveloped, as has already been stated, by the Compressor urethræ muscle.

The **Compressor urethræ** has already been described (page 374). In addition to this muscle and immediately beneath it *circular muscular fibres* surround the membranous portion of the urethra from the bulb in front to the prostate behind, and are continuous with the muscular fibres of the bladder. These fibres are involuntary.

Cowper's glands are situated immediately below the membranous portion of the urethra, close behind the bulb, and below the artery of the bulb.

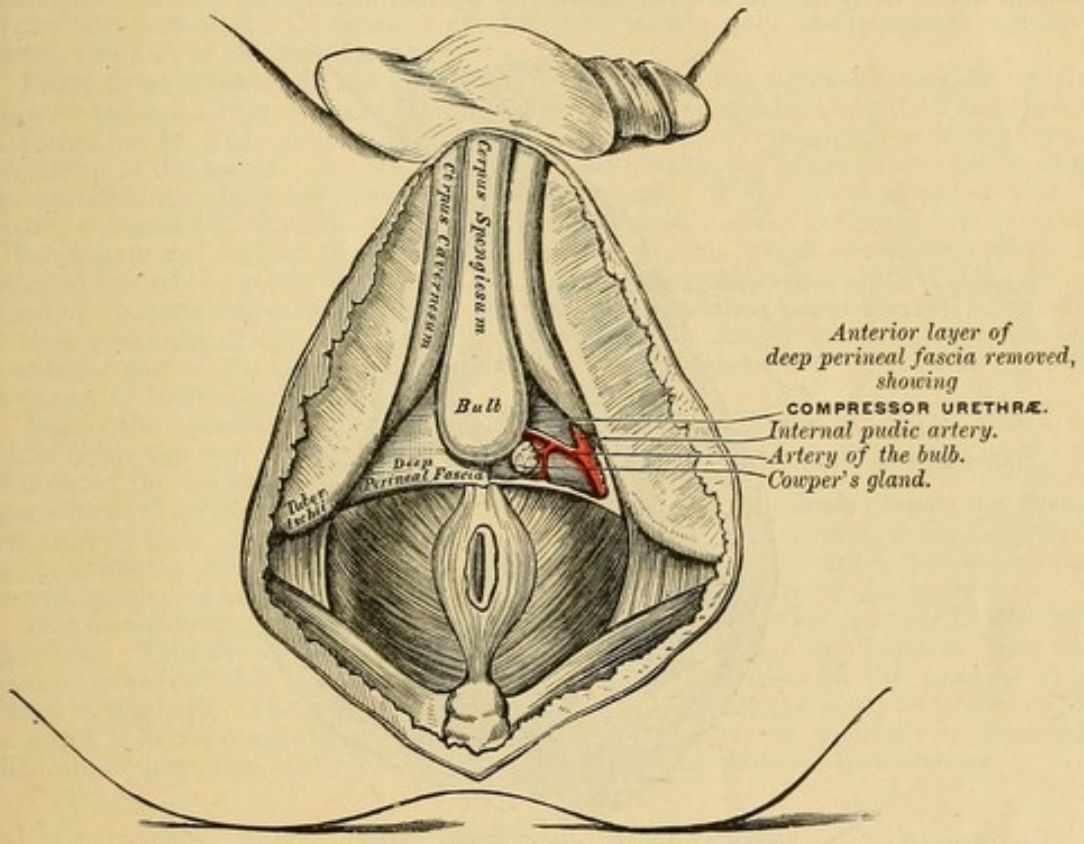

FIG. 592.—Deep perineal fascia. On the left side the anterior layer has been removed.

The **pudic vessels** and **dorsal nerve of the penis** are placed along the inner margin of the pubic arch (pages 565 and 793).

The **artery of the bulb** passes transversely inward, from the internal pudic along the base of the triangular ligament, between its two layers, accompanied by a branch of the pudic nerve (page 567). If the deep layer of the triangular ligament is removed and the crus penis of one side detached from the bone, the under or perineal surface of the Levator ani is brought fully into view. This muscle, with the triangular ligament in front and the Coccygeus and Pyriformis behind, closes the outlet of the pelvis.

The Levator ani and Coccygeus muscles have already been described (page 369).

Position of the Viscera at the Outlet of the Pelvis.—Divide the central tendinous point of the perinæum, separate the rectum from its connections by dividing the fibres of the Levator ani, which descend upon the sides of the prostate gland, and draw the gut backward toward the coccyx, when the under surface of the prostate gland, the neck and base of the bladder, the vesiculæ seminales, and the vasa deferentia will be exposed.

The **Prostate Gland** is a pale, firm, glandular body which is placed immediately below the neck of the bladder, around the commencement of the urethra. It is placed in the pelvic cavity, behind the lower part of the symphysis pubis, above the deep layer of the triangular ligament, and rests upon the rectum, through which it may be distinctly felt, especially when enlarged. In shape and size it resembles a chestnut. Its base is directed upward toward the neck of the bladder. Its apex is directed downward to the deeper layer of the triangular ligament, which it touches.

Its posterior surface is smooth, marked by a slight longitudinal furrow, and rests on the second part of the rectum, to which it is connected by areolar tissue. Its anterior surface is flattened, marked by a slight longitudinal furrow, and placed about three-quarters of an inch below the pubic symphysis. It measures about an inch and a half in its transverse diameter at the base, an inch in its antero-posterior diameter, and three-quarters of an inch in depth. Hence the greatest extent of incision that can be made in it without dividing its substance completely across is obliquely backward and outward. This is the direction in which the incision is made in it in the lateral operation of lithotomy.

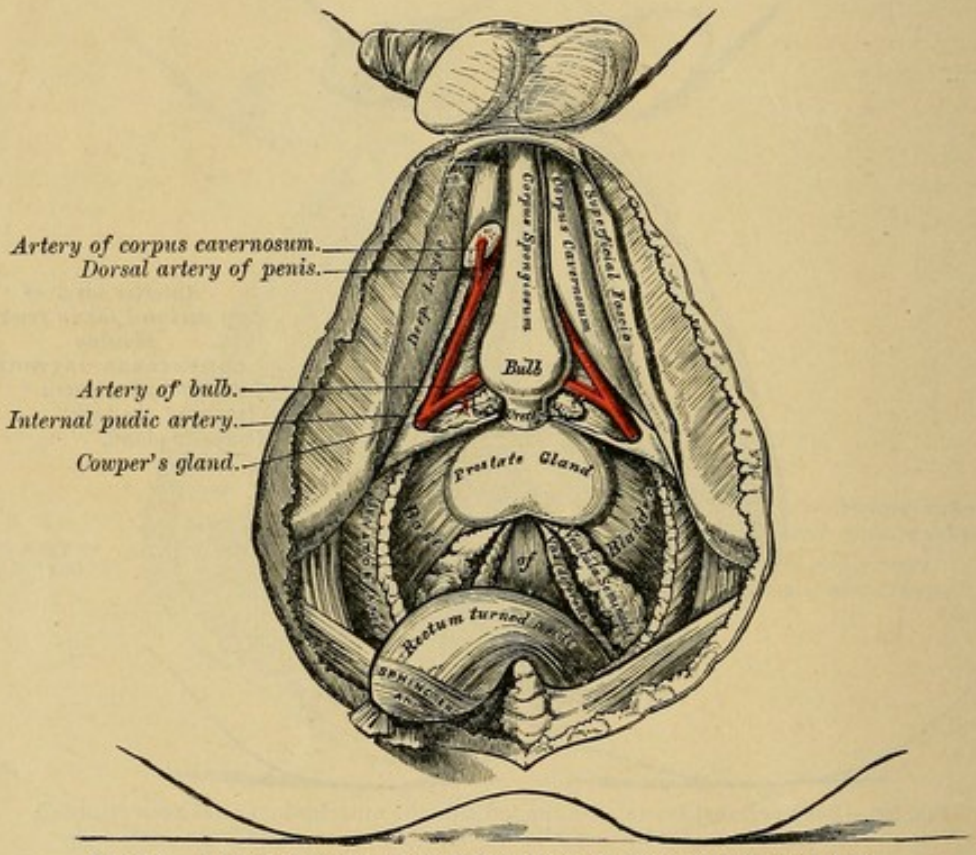

FIG. 593.—A view of the position of the viscera at the outlet of the pelvis.

Above the prostate a small triangular portion of the bladder is seen, bounded, in front and below, by the prostate gland; above, by the recto-vesical fold of the peritoneum; on each side, by the vesicula seminalis and the vas deferens. It is separated from direct contact with the rectum by the recto-vesical fascia. The relation of this portion of the bladder to the rectum is of extreme interest to the surgeon. In cases of retention of urine this portion of the organ is found projecting into the rectum, between three and four inches from the margin of the anus, and may be easily perforated without injury to any important parts: this portion of the bladder is, consequently, occasionally selected for the performance of the operation of tapping the bladder.

Surgical Anatomy.—The student should consider the position of the various parts in reference to the lateral operation of lithotomy. This operation is performed on the left side of the perinæum, as it is most convenient for the right hand of the operator. A grooved staff having been

introduced into the bladder, the first incision is commenced midway between the anus and the back of the scrotum (*i. e.* in an ordinary adult perinæum about an inch and a half in front of the anus) a little on the left side of the raphe, and carried obliquely backward and outward to midway between the anus and tuberosity of the ischium. The incision divides the integument and superficial fascia, the inferior hæmorrhoidal vessels and nerves, and the superficial and transverse perineal vessels. If the forefinger of the left hand is thrust upward and forward into the wound, pressing at the same time the rectum inward and backward, the staff may be felt in the membranous portion of the urethra. The finger is fixed upon the staff, and the structures covering it are divided with the point of the knife, which must be directed along the groove toward the bladder, the edge of the knife being turned outward and backward, dividing in its course the membranous portion of the urethra and part of the left lobe of the prostate gland to the extent of about an inch. The knife is then withdrawn, and the forefinger of the left hand passed along the staff into the bladder. The position of the stone having been ascertained, the staff is to be withdrawn, and the forceps is introduced over the finger into the bladder. If the stone is very large, the opposite side of the prostate may be notched before the forceps is introduced: the finger is now withdrawn, and the blades of the forceps opened and made to grasp the stone, which must be extracted by slow and cautious undulating movements.

Parts Divided in the Operation.—The various structures divided in this operation are as follows: the integument, superficial fascia, inferior hæmorrhoidal vessels and nerves, and probably the superficial perineal vessels and nerves, the posterior fibres of the Accelerator urinæ, the Transversus perinæi muscle and artery, the triangular ligament, the anterior fibres of the Levator ani, part of the Compressor urethræ, the membranous and prostatic portions of the urethra, and part of the prostate gland.

Parts to be Avoided in the Operation.—In making the necessary incisions in the perinæum for the extraction of a calculus the following parts should be avoided: The primary incision should not be made too near the middle line, for fear of wounding the bulb of the corpus spongiosum or the rectum; nor too far externally, otherwise the pudic artery may be implicated as it ascends along the inner border of the pubic arch. If the incisions are carried too far forward, the artery of the bulb may be divided; if carried too far backward, the entire breadth of the prostate and neck of the bladder may be cut through, which allows the urine to become infiltrated behind the pelvic fascia into the loose areolar tissue between the bladder and rectum, instead of escaping externally; diffuse inflammation is consequently set up, and peritonitis, from the close proximity of the recto-vesical peritoneal fold, is the result. If, on the contrary, only the anterior part of the prostate is divided, the urine makes its way externally, and there is less danger of infiltration taking place.

During the operation it is of great importance that the finger should be passed into the bladder *before* the staff is removed; if this is neglected, and if the incision made in the prostate and neck of the bladder is too small, great difficulty may be experienced in introducing the finger afterward; and in the child, where the connections of the bladder to the surrounding parts are very loose, the force made in the attempt is sufficient to displace the bladder upward into the abdomen, out of the reach of the operator. Such a proceeding has not unfrequently occurred, producing the most embarrassing results and total failure of the operation.

It is necessary to bear in mind that the arteries in the perinæum occasionally take an abnormal course. Thus the artery of the bulb, when it arises, as sometimes happens, from the pudic opposite the tuber ischii, is liable to be wounded in the operation for lithotomy in its passage forward to the bulb. The accessory pudic may be divided near the posterior border of the prostate gland, if this is completely cut across; and the prostatic veins, especially in people advanced in life, are of large size, and give rise, when divided, to troublesome hæmorrhage.

THE FEMALE PERINÆUM.

The **female perinæum** presents certain differences from that of the male, in consequence of the whole of the structures which constitute it being perforated in the middle line by the vulvo-vaginal passage.

The **superficial fascia,** as in the male, consists of two layers, of which the superficial one is continuous with the superficial fascia over the rest of the body, and the deep layer, corresponding to the fascia of Colles in the male, is like it attached to the ischio-pubic ramus, and in front is continued forward through the labia majora to the inguinal region. It is of less extent than the male, in consequence of being perforated by the aperture of the vulva.

On removing this fascia the muscles of the female perinæum, which have already been described (page 374), are exposed. The Sphincter vaginæ, corresponding to the Accelerator urinæ in the male, consists of an attenuated plane of fibres, forming an orbicular muscle around the orifice of the vagina, instead of being united in a median raphe, as in the male. The Erector clitoridis is proportionately reduced in size, but differs in no other respect, and the Transversus perinæi is similar to the muscle of the same name in the male.

The triangular ligament of the urethra is not strongly marked as in the male. It transmits the urethra and the tube of the vagina.

The **Compressor Urethræ** (*Transversus perinæi profundus*) corresponds with the Compressor urethræ in the male. It arises from the ischio-pubic ramus, and, passing inward, its anterior fibres blend with the muscle of the opposite side, in front of the urethra; its middle fibres, the most numerous, are inserted into the side of the vagina, and the posterior fibres join the central point of the perinæum.

The distribution of the internal pudic artery is the same as in the male (see page 567), and the pudic nerve has also a similar arrangement, the dorsal nerve being, however, very small and supplying the clitoris.

The corpus spongiosum is divided into two lateral halves, which are represented by the *bulbi vestibuli* and *partes intermediales* (see page 1027).

The **perineal body** fills up the interval between the lower part of the vagina and the rectum. Its base is covered by the skin lying between the anus and

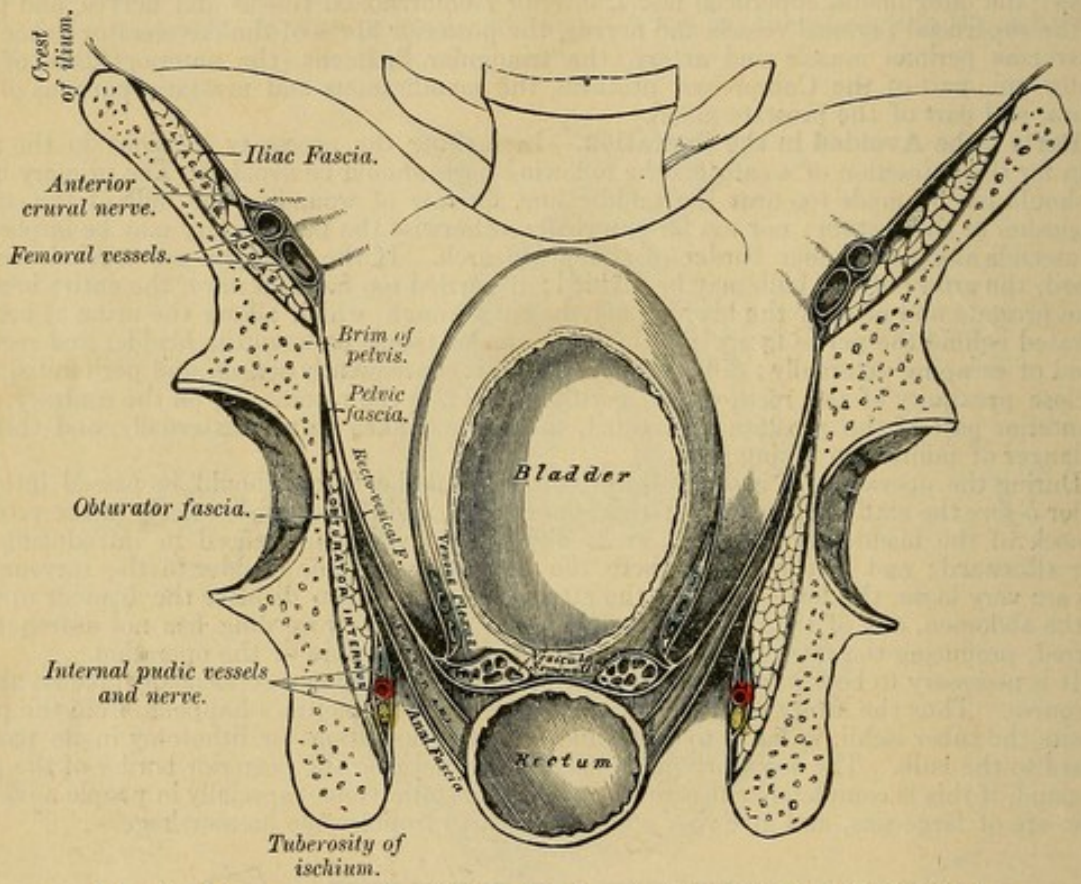

FIG. 594.—A transverse section of the pelvis, showing the pelvic fascia from behind.

vagina on what is called the "perinæum." Its anterior surface lies behind the posterior vaginal wall, and its posterior surface lies in front of the anterior rectal wall and the anus. It measures about an inch and a quarter from before backward, and laterally extends from one tuberosity of the ischium to the other. In it are situated the muscles belonging to the external organs of generation. Through its centre runs the transverse perineal septum, which is of great strength in women, and forms on either side, behind the posterior commissure, a hard, ill-defined body, consisting of connective tissue, with much yellow elastic tissue and interlacing bundles of involuntary muscular fibres, in which the voluntary muscles of the perinæum are inserted.

THE PELVIC FASCIA.

The **Pelvic fascia** (Fig. 595) is a thin membrane which lines the whole of the cavity of the pelvis and is continuous over the back part of the ilio-pectineal line with the iliac fossa. It is attached to the brim of the pelvis, for a short dis-

tance, at the side of the cavity, and to the inner surface of the bone round the attachment of the Obturator internus. At the posterior border of this muscle it is continued backward as a very thin membrane in front of the Pyriformis muscle and sacral nerves to the front of the sacrum. In front it follows the attachment of the Obturator internus to the bone, arches beneath the obturator vessels, completing the orifice of the obturator canal, and at the front of the pelvis is attached to the lower part of the symphysis pubis. At the level of a line extending from the lower part of the symphysis pubis to the spine of the ischium is a thickened whitish band, termed the *white line;* this marks the attachment of the Levator ani muscle to the pelvic fascia, and corresponds to its point of division into two layers, the *obturator* and *recto-vesical.*

The **obturator fascia** descends and covers the Obturator internus muscle. It is a direct continuation of the parietal pelvic fascia below the white line above mentioned, and is attached to the pelvic arch, the ischial tuberosities, and to the margin of the great sacro-sciatic ligaments. This fascia forms a canal for the pudic

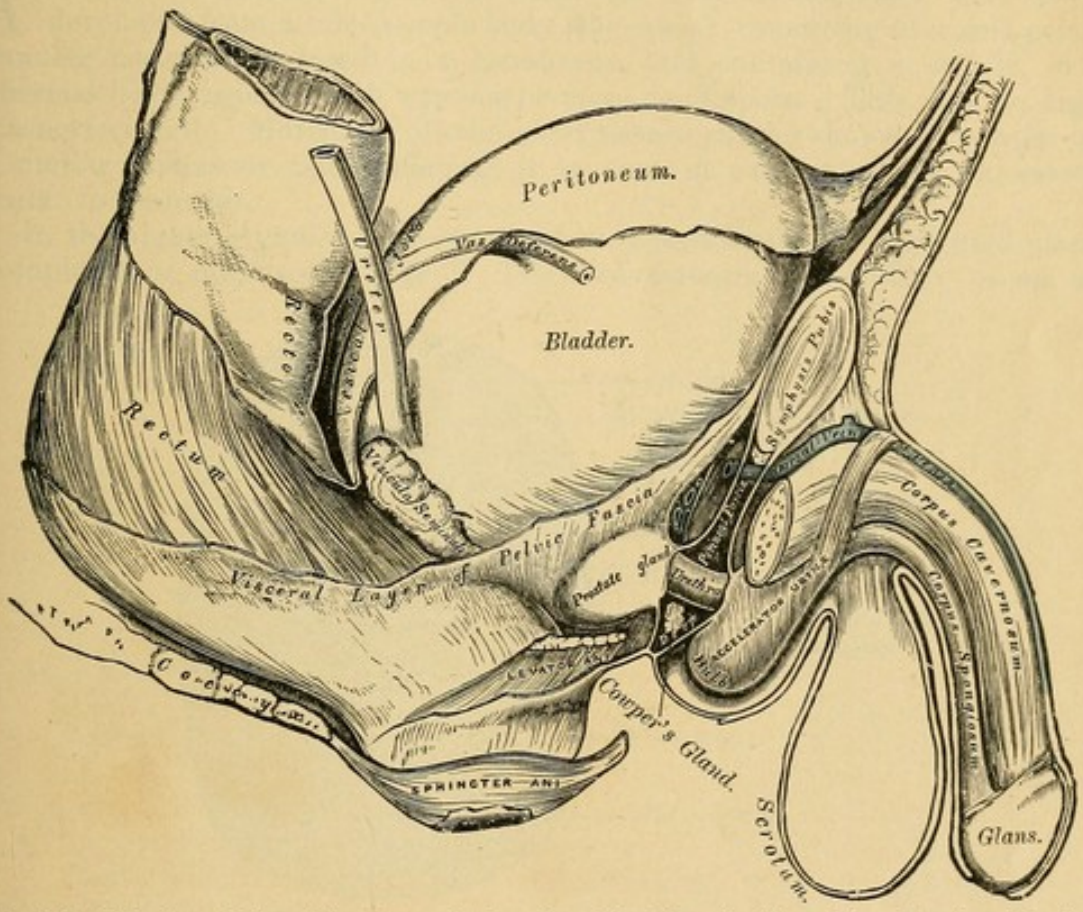

FIG. 595.—Side view of the pelvic viscera of the male subject, showing the pelvic and perineal fasciæ.

vessels and nerve in their passage forward to the perinæum, and gives off a thin membrane which covers the perineal aspect of the Levator ani muscle, called the *ischio-rectal* (*anal*) *fossa.* From its attachment to the rami of the os pubis and ischium a process is given off which is continuous with a similar process from the opposite side, so as to close the front part of the outlet of the pelvis, forming the deep layer of the triangular ligament.

The **recto-vesical fascia** (*visceral layer of the pelvic fascia*) descends into the pelvis upon the upper surface of the Levator ani muscle, and invests the prostate, bladder, and rectum. From the inner surface of the symphysis pubis a short rounded band is continued, on each side of the middle line, to the upper surface of the prostate and neck of the bladder, forming the pubo-prostatic or anterior true ligaments of the bladder. At the side this fascia is connected to the side of the prostate, enclosing this gland and the vesico-prostatic plexus of veins, and is continued

on to the side of the bladder, forming the lateral true ligaments of the organ. Another prolongation invests the vesiculæ seminales, and passes across between the bladder and rectum, being continuous with the same fascia of the opposite side. Another thin prolongation is reflected round the surface of the lower end of the rectum. The Levator ani muscle arises from the point of division of the pelvic fascia, the visceral layer of the fascia descending upon and being intimately adherent to the upper surface of the muscle, while the under surface of the muscle is covered by a thin layer derived from the obturator fascia, called the *ischio-rectal* or *anal fascia*. In the female the vagina perforates the recto-vesical fascia, and receives a prolongation from it.

GENERAL ANATOMY OR HISTOLOGY.

THE ANIMAL CELL (Fig. 596).

ALL the tissues and organs of which the body is composed were originally developed from a microscopic body (the *ovum*), consisting of a soft gelatinous granular material enclosed in a membrane, and containing a vesicle, or small spherical body, inside which are one or more solid spots. This may be regarded as a perfect cell. Moreover, all the solid tissues can be shown to consist largely of similar bodies or cells, differing, it is true, in external form, but essentially similar to an ovum.

In the higher organisms all such cells may be defined as "nucleated masses of protoplasm of microscopic size." The two essentials, therefore, of an animal

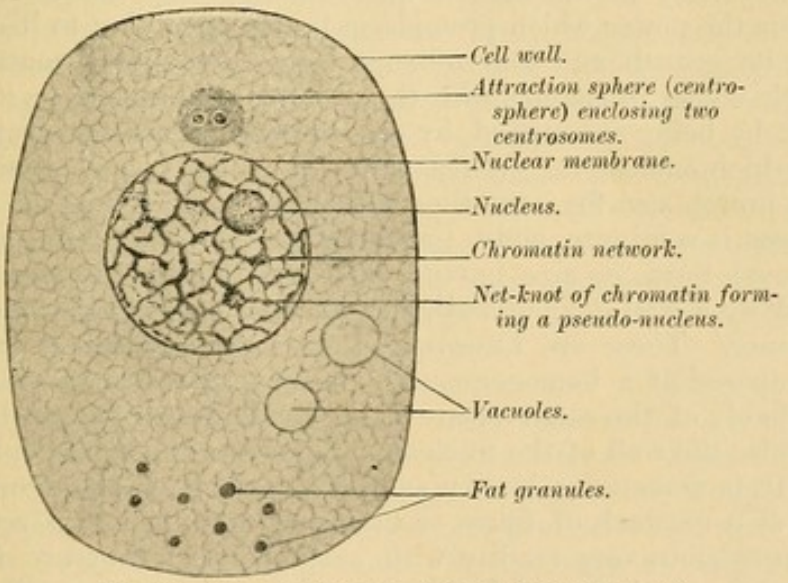

FIG. 596.—Diagram of a cell. (Modified from Wilson.)

cell in the higher organisms are, the presence of a soft gelatinous granular material, similar to that found in the ovum, and which is usually styled *protoplasm;* and a small spherical body imbedded in it, and termed a *nucleus;*[1] the remaining constituents of the ovum—viz., its limiting membrane and the solid spot contained in the nucleus, called the *nucleolus*—are not considered essential to the cell, and in fact many cells exist without them.

Protoplasm (*cytoplasm*) is a material probably of variable constitution, but yielding to the chemist on its disintegration bodies chiefly of proteid nature. Lecithin and cholesterin are constantly found in it, as well as inorganic salts, chief among which are the phosphates and chlorides of the alkali metals and calcium. It is of a semifluid, viscid consistence, and appears either as a hyaline substance, homogeneous and clear, or else it exhibits a granular appearance. This gran-

[1] In certain lower forms of life masses of protoplasm without a nucleus have been described by Huxley and others as cells.

ular appearance, under a high power of the microscope, is seen to be due to the fact that protoplasm consists of a network or honeycombed reticulum, containing in its meshes a homogeneous substance. The former is known as *spongioplasm*, the latter as *hyaloplasm*. The granular appearance is often caused by the knots of the network being mistaken for granules; but, in addition to this, protoplasm often contains true granules, some of which are proteid in nature and probably essential constituents; others are fat- or pigment-granules, and are regarded as adventitious material taken in from without. The size and shape of the meshes of the spongioplasm vary in different cells and in different parts of the same cell. In many fixed cells, *e. g.*, epithelial cells, the external layer becomes denser than the rest, and often altered by the deposition in it of some chemical substance, so as to constitute a membrane which encloses the rest of the protoplasm and forms the *cell-wall*. The relative amount of spongioplasm and hyaloplasm varies in different cells; the latter preponderating in the young cell and the former increasing in amount, at the expense of the hyaloplasm, as the cell grows.

The most striking characteristics of protoplasm are its vital properties of *motion* and *nutrition*. By motion is meant the property which protoplasm has of changing its shape and position by some intrinsic power, which enables it to thrust out from its main body an irregular process, into which the whole of the protoplasmic substance is gradually drawn, so that the mass comes to occupy a new position. This, on account of its resemblance to the movements observed in the Amœba or Proteus animalcule, has been termed "amœboid movement." Ciliary movement, or the vibration of hair-like processes from the surface of any structure, may also be regarded as a variety of the motion with which protoplasm is endowed.

Nutrition is the power which protoplasm has of attracting to itself the materials necessary for its growth and maintenance from surrounding matter. When any foreign particle comes in contact with the protoplasmic substance, it becomes incorporated in it by being enwrapped by one or more processes projected from the parent mass which enclose it. When thus taken up, it may remain in the substance of the protoplasm for some time without change, or may be again extruded.

The **nucleus** is a minute body, imbedded in the protoplasm, and usually of a spherical or oval form, its size having little relation to the size of the cell. It is surrounded by a well-defined wall, the *nuclear membrane*, which encloses the nuclear contents. These are known as the *nuclear substance* (nuclear matrix), which is composed of a homogeneous material and a stroma or network. The former is probably of the same nature as the hyaloplasm of the cell, but the latter, which forms also the wall of the nucleus, differs from the spongioplasm of the cell-substance. It is sometimes known as the *chromoplasm* or *intranuclear network*, and consists of a network of fibres or filaments arranged in a reticular manner. These filaments stain very readily with certain dyes; they are therefore named *chromatin;* while the interstitial substance does not stain readily, and is hence called *achromatin*. In some resting nuclei, *i. e.*, nuclei which are not undergoing subdivision, the nuclear filaments do not form a network, but present the appearance of a convoluted skein, similar to that found in a nucleus about to undergo division, and which will be immediately described.

Within the nuclear matrix are one or more highly refracting bodies, termed *nucleoli*, connected with the nuclear membrane by the nuclear filaments. They are regarded as being of two kinds. Some are mere local condensations of the chromoplasm; these are irregular in shape and are termed *pseudo-nucleoli*; others are distinct bodies differing from the pseudo-nucleoli both in nature and chemical composition; they may be termed *true nucleoli*, and are usually found in resting cells.

The nuclear substance differs chemically from ordinary protoplasm in containing *nuclein*, in its power of resisting the action of acids and alkalies, in its imbibing more intensely the stain of carmine, hæmatoxylin, etc., and in its remaining unstained by some reagents which color ordinary protoplasm.

Recent investigations tend to show that most living cells contain, in addition to their protoplasm and nucleus, a minute particle which, on account of the power it appears to possess of attracting the surrounding protoplasmic granules, is termed the *attraction-particle* or *centrosome;* it usually lies near the nucleus. The spherical arrangement of fibrillar rows of granules surrounding the central particle is termed the *attraction-sphere* or *centrosphere.* These spheres are usually double, and are connected by a spindle-shaped system of delicate fibrils (*achromatic spindle*). They are best seen in young cells which are about to undergo the process of division, a process believed to commence in these bodies.

The process of reproduction of cells is usually described as being brought about by *indirect* or by *direct division. Indirect division* or *karyokinesis* (*karyomitosis*) has been observed in all the tissues—generative cells, epithelial tissue, connective tissue, muscular tissue, and nerve-tissue—and probably it will ultimately be shown that the division of cells always takes place in this way, and that the process of reproduction of cells by direct division is, as is believed by some observers, merely a sort of imperfect or abnormal karyokinesis.

The process of indirect cell-division is characterized by a series of complex changes in the nucleus, leading to its subdivision; this being followed by cleavage of the cell-protoplasm. Starting with the nucleus in the quiescent or *resting* stage, these changes may be briefly grouped under the four following phases:

1. *Prophase.*—The nuclear network of chromatin-filaments assumes the form of a twisted *skein* or *spirem*, while the nuclear membrane and nucleolus disappear. The convoluted skein of chromatin divides into a definite number of V-shaped loops or *chromosomes.* Coincident with or preceding these changes the centrosome, or attraction-particle, which usually lies by the side of the nucleus, undergoes subdivision, and the two resulting centrosomes, each surrounded by a centrosphere, are seen to be connected by a spindle of delicate achromatic fibres, the *achromatic spindle.* These centrosomes move away from each other—one toward each extremity of the nucleus—and the fibrils of the achromatic spindle are correspondingly lengthened. The centrosomes are now situated one at either extremity or pole of the elongated spindle, and each is surrounded by a centrosphere, from which fibrils radiate into the investing protoplasm. A line encircling the spindle midway between its poles is named the *equator*, and around this the V-shaped chromosomes arrange themselves in the form of a star, thus constituting the *mother star* or *monaster.*

2. *Metaphase.*—Each V-shaped chromosome now undergoes longitudinal cleavage into two equal halves or *daughter chromosomes*, the cleavage commencing at the apex of the V and extending along its divergent limbs. The daughter chromosomes, thus separated, travel in opposite directions along the fibrils of the achromatic spindle toward the centrosomes, around which they group themselves, and thus two star-like figures are formed, one at either pole of the achromatic spindle. This is termed the *diaster.*

3. *Anaphase.*—The V-shaped daughter chromosomes now assume the form of a *skein* or *spirem*, and eventually form the network of chromatin which is characteristic of the resting nucleus. The nuclear membrane and nucleolus are also differentiated during this phase. The cell-protoplasm begins to appear constricted around the equator of the achromatic spindle, where double rows of granules are also sometimes seen. The constriction deepens and the original cell gradually becomes divided.

4. *Telophase.*—In this stage the cell is completely divided into two new cells, each with its own nucleus, centrosome, and centrosphere, which assume the ordinary positions occupied by such structures in the resting stage.

In the case of prickle-cells the subdivision of the cell is incomplete; here the achromatic spindle-threads appear to persist and bridge across the intercellular spaces, constituting the prickles.

The series of diagrams (Fig. 597), by Professor S. Delépine, is intended to explain the formation of some of the most important changes observed in nuclei

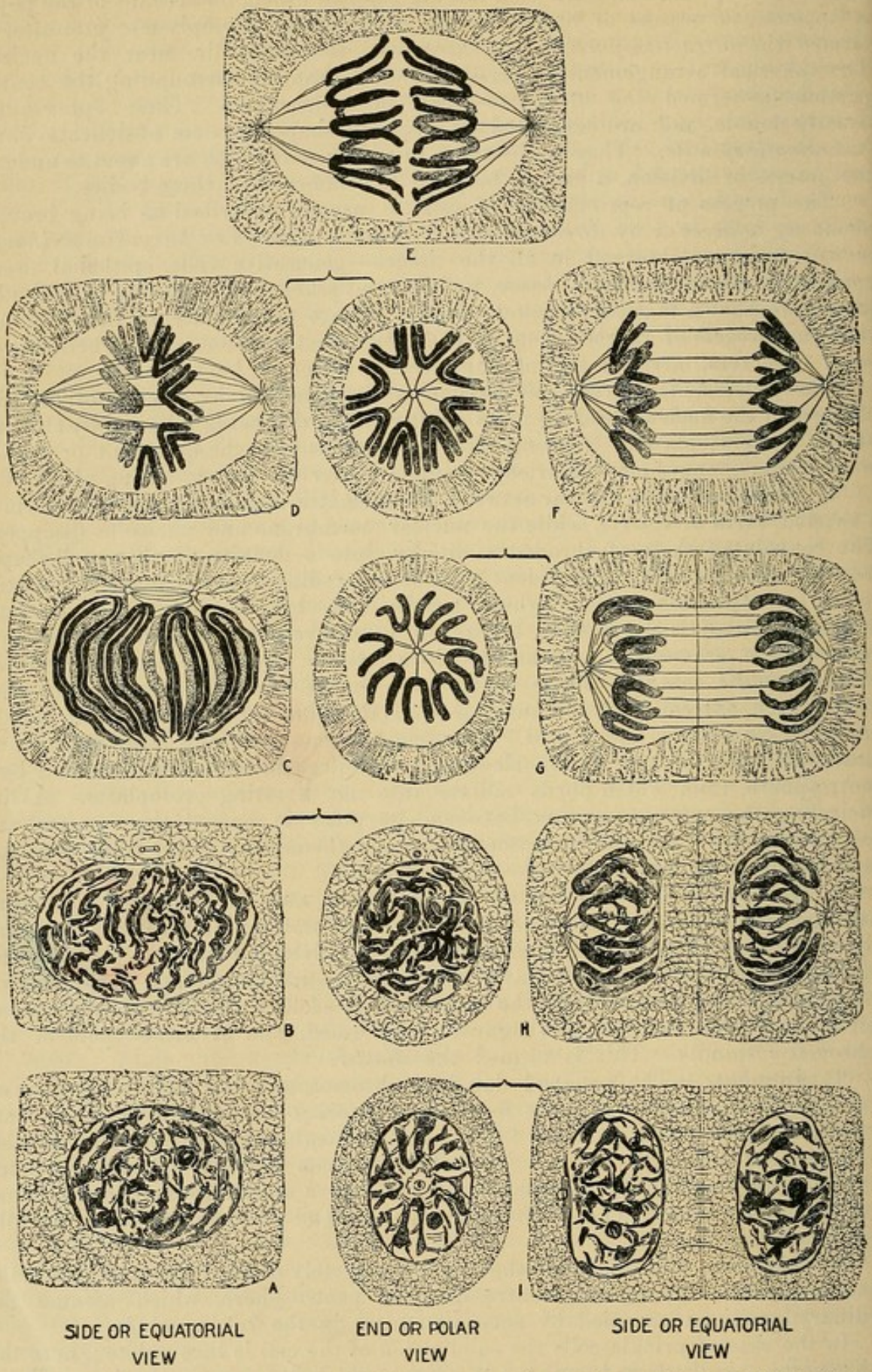

FIG. 597.—Karyokinesis; or indirect cell-division. A. Resting nucleus. B. Skein or spirem, close. C Skein or spirem, open. D. Mother star, monaster. E. Metaphase. F. Daughter stars or diaster. G. Daughte skeins or dispirem, beginning to form. H. Daughter skeins or dispirem, formed. I. Resting daughter nuclei.

of cells during karyokinesis (mitosis); it is based chiefly on the work of Flemming, Strasburger, E. van Beneden, Rabl, O'Hertwig, Henneguy, etc. A. *Resting nucleus.* Nucleolus and nuclear membrane visible. A centrosome is represented near the nucleus. B and C. *Skein* or *spirem.* Chromatic filaments much convoluted. Evidence of longitudinal splitting begins to be distinct in several parts. The centrosome has divided; the nuclear membrane is becoming indistinct. The two centrosomes are widely separated, and the space between them is occupied by the achromatic spindle. (Two arrows indicate the position which the centrosomes will ultimately occupy; during their passage to these points the achromatic spindle seems to be within the nucleus.) The nuclear membrane has disappeared. D. *Mother star, monaster.* The nuclear segments (chromosomes) resulting from the breaking-up of the chromatic filament into fragments of nearly equal length have moved toward the equator of the spindle, where they now form an equatorial plate. These segments are all split longitudinally. E. *Metaphase.* One half of each chromosome moves toward one pole and the other half toward the other pole, being guided toward the centrosomes by the achromatic filaments. F. *Daughter stars* or *diaster.* G. *Daughter skeins* or *dispirem*, beginning to form. Segments in the form of thick loops not closely packed. H. *Daughter skeins* or *dispirem*, formed. Segments more closely packed and less distinct, owing to the formation of anastomoses. 1. *Resting daughter nuclei.* Cell completely divided into two, but bridges remain between them in the region previously occupied by the achromatic filaments, these being specially distinct in certain cells, *e. g.*, prickle-cells. The nucleus has a distinct nuclear membrane and a nucleolus.

In the reproduction of cells by *direct* division the process is brought about either by segmentation or by gemmation. In reproduction by *segmentation* or *fission* the nucleus becomes constricted in its centre, assuming an hour-glass shape, and then divides into two. This leads to a cleavage or division of the whole protoplasmic mass of the cell; and thus two daughter cells are formed, each containing a nucleus. These daughter cells are at first smaller than the original mother cell; but they grow, and the process may be repeated in them. so that multiplication may take place rapidly. In reproduction by *gemmation* a budding-off or separation of a portion of the nucleus and parent-cell takes place, and, becoming separated, forms a new organism.

The **cell-wall**, which is not an essential constituent, and in fact is often absent, is merely the external layer of the protoplasm, firmer than the rest of the cell, and often thickened by the deposit in it of certain chemical substances. It forms a flexible, transparent, finely striated membrane, sometimes furnished with minute pores, so as to be permeable to fluids.

THE NUTRITIVE FLUIDS.

The **circulating fluids of the body**, which subserve its nutrition, are the blood, the lymph, and the chyle.

THE BLOOD.

The blood is an opaque, rather viscid fluid, of a bright-red or scarlet color when it flows from the arteries, of a dark-red or purple color when it flows from the veins. It is salt to the taste, and has a peculiar faint odor and an alkaline reaction. Its specific gravity is about 1.060, and its temperature is generally about 100° F., though varying slightly in different parts of the body.

General Composition of the Blood.—Blood consists of a faintly yellow fluid, the *plasma* or *liquor sanguinis*, in which are suspended numerous minute particles, the *blood-corpuscles*, the majority of which are colored and give to the blood its red tint. If a drop of blood is placed in a thin layer on a glass slide and examined under the microscope, a number of these corpuscles will be seen immersed in the clear fluid plasma.

The **Blood-corpuscles** are chiefly of two kinds: (1) colored corpuscles or

erythrocytes, (2) colorless corpuscles or leucocytes. A third variety, the blood-platelets, are of subsidiary importance.

1. **Colored or red corpuscles** (*erythrocytes*), when examined under the microscope, are seen to be circular disks, biconcave in profile. They have no nuclei, but in consequence of their biconcave shape present, according to the alteration of focus under an ordinary high power, a central part, sometimes bright, sometimes dark, which has the appearance of a nucleus (Fig. 598, *a*). It is to their aggregation that the blood owes its red hue, although when examined by transmitted light their color appears to be only a faint reddish yellow. Their size varies slightly even in the same drop of blood; but it may be stated that their ordinary diameter is about $\frac{1}{3200}$ of an inch, while their thickness is about $\frac{1}{12000}$ of an inch or nearly one-quarter of their diameter. Besides these there are found, especially in disease (*e. g.*, anæmic conditions), certain smaller corpuscles of about one-half or one-third of the size just indicated; these are termed *microcytes*, and are very scarce in human blood. The number of red corpuscles in the blood is enormous; between 4,000,000 and 5,000,000 are contained in a cubic millimetre. Power states that the red corpuscles of an adult would present an aggregate surface of about 3000 square yards. Each corpuscle consists of a colorless elastic spongework or stroma, condensed at the periphery to form an investing membrane, and uniformly diffused throughout this are the colored fluid contents. The stroma is composed mainly of *nucleo-proteid* and of the fatty substances, *lecithin* and *cholesterin*, while the colored material consists chiefly of the respiratory proteid, *hæmoglobin*, which contains a proportion of iron in addition to the ordinary proteid elements. This proteid has a great affinity for oxygen, and when removed from the body crystallizes readily under certain circumstances. It is very soluble in water, the addition of which to a drop of blood speedily dissolves out the hæmoglobin from the corpuscles.

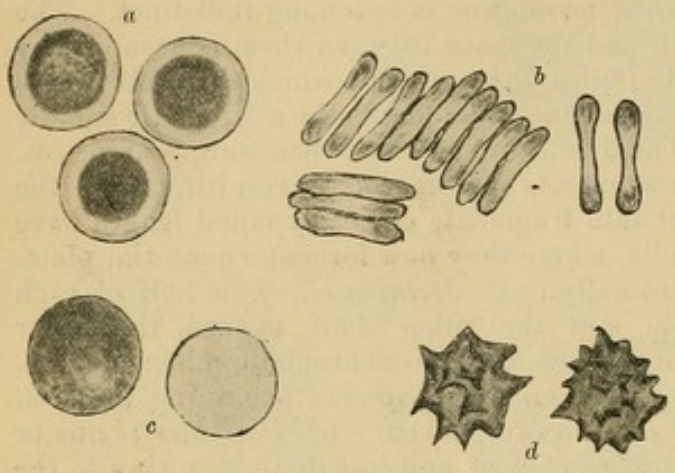

FIG. 598.—Human red blood-corpuscles. Highly magnified. *a*. Seen from the surface. *b*. Seen in profile and forming rouleaux. *c*. Rendered spherical by water. *d*. Rendered crenate by salt solution.

If the web of a frog's foot is spread out and examined under the microscope, the blood is seen to flow in a continuous stream through the vessels, and the corpuscles show no tendency to adhere to each other or to the wall of the vessel. Doubtless the same is the case in the human body; but when the blood is drawn and examined on a slide without reagents, the corpuscles often collect into heaps like rouleaux of coins (Fig. 598, *b*). It has been suggested that this phenomenon may be explained by alteration in surface tension.

During life the red corpuscles may be seen to change their shape under pressure so as to adapt themselves to some extent to the size of the vessel. They are, however, highly elastic, and speedily recover their shape when the pressure is removed. They are soon influenced by the medium in which they are placed, and by the specific gravity of the medium. In water they swell up, lose their shape, and become globular (Fig. 598, *c*). Subsequently the hæmoglobin becomes dissolved out, and the envelope can be barely distinguished as a faint, circular outline. Solutions of salt or sugar, denser than the plasma, give them a stellate or crenated appearance (Fig. 598, *d*); but the usual shape may be restored by diluting the solution to the same specific gravity as the plasma. The crenated outline may be produced as the first effect of the passage of an electric shock; subsequently, if sufficiently strong, the shock ruptures the envelope. A solution

of salt or sugar of the same specific gravity as the plasma, merely separates the blood-corpuscles mechanically without changing their shape.

The **colorless corpuscles** (*leucocytes*) are of various sizes, some no larger, others even smaller, than the red corpuscles. In human blood, however, the majority are rather larger than the red corpuscles, and measure about $\frac{1}{2000}$ to $\frac{1}{2500}$ of an inch in diameter. On the average from 10,000 to 12,000 leucocytes are found in each cubic millimetre of blood.

They consist of minute masses of nucleated protoplasm, and exhibit several varieties, which are differentiated from each other chiefly by the occurrence or non-occurrence of granules in their protoplasm and by the staining reactions of these granules when present (Fig. 599). (1) The most numerous and important are spherical in shape, and are characterized by a nucleus, which often consists of two or three parts (multipartite) connected together by fine threads of chromatin. The protoplasm is clear, and contains a number of very fine granules, which stain with acid dyes, as eosin (Fig. 599, 3). (2) A second variety comprises about 2.4 per cent. of the leucocytes; they are larger than the previous kind, and are made up of a coarsely granular protoplasm, the granules being highly refractile and grouped round a single nucleus of horseshoe shape (Fig. 599, 1). These granules stain deeply with eosin, and the cells are therefore often termed *eosinophile corpuscles*. (3) A leucocyte characterized by the presence of a trilobed nucleus, and having in its protoplasm fine granules which stain with basic dyes, such as methylene-blue, is found in small numbers (Fig. 599, 5). (4) The fourth variety is called the *hyaline* cell (Fig. 599, 4). This is usually about the same size as that of the eosinophile cell, and, when at rest, is spherical in shape and contains a single round or oval nucleus. The protoplasm is free from granules, but is not quite transparent, having the appearance of ground glass. (5) The fifth kind of colorless corpuscle is designated the *lymphocyte* (Fig. 599, 2), because it is identical with the lymphoid cell derived from the lymphatic glands, the spleen, tonsil, and thymus. It is the smallest of the leucocytes, and consists chiefly of a spheroidal nucleus with very little surrounding protoplasm of a homogeneous nature; it is regarded as the immature form of the hyaline cell. The fourth and fifth varieties together constitute from 20 to 30 per cent. of the colorless cells, but of these two varieties the lymphocytes are by far the more numerous.

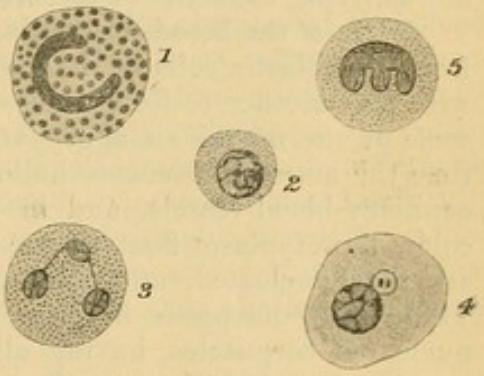

FIG. 599.—Varieties of leucocytes found in human blood. 1. Eosinophile cell with coarse granules and horseshoe-shaped nucleus. 2. Lymphocyte. 3. Polynuclear or finely granular cell. 4. Hyaline cell, showing nucleus with chromatin threads and two centrosomes in clear protoplasm. 5. Finely granular leucocyte; the nucleus is lobed, the granules stain with basic dyes, such as methylene-blue.

The white corpuscles are very various in shape in living blood (Fig. 600), because many of them have the power of constantly changing their form by protruding finger-shaped or filamentous processes of their own substance, by which



FIG. 600.—Human colorless blood-corpuscle, showing its successive changes of outline within ten minutes when kept moist on a warm stage. (Schofield.)

they move, and may take up granules from the surrounding medium. In locomotion the corpuscle pushes out a process of its substance—a *pseudopodium*, as it is called—and then shifts the rest of the body into it. In the same way when any granule or particle comes in its way it wraps a pseudopodium round it, and then withdrawing it, lodges the particle in its own substance. By means of these amœboid properties the cells have the power of wandering or emigrating from the blood-

vessels by penetrating their walls and thus finding their way into the extra-vascular spaces. A chemical investigation of the protoplasm of the leucocytes shows the presence of nucleo-proteid and of a globulin. The occurrence of small amounts of fat and glycogen may also be demonstrated.

The **Blood-platelets** are discoid or irregularly shaped, colorless, refractile bodies, much smaller than the red cells. Considerable discussion has arisen as to their significance. In spite of the fact that they have been observed in the blood-vessels during life, there is, at present, a tendency to regard them as products of disintegration of the white cells, or as precipitates, possibly of nucleo-proteid, and not as living elements of the blood.

Origin of the Blood-corpuscles.—In the embryo the red corpuscles are developed from mesoblastic cells in the vascular area of the blastoderm. These cells unite with one another to form a network, their nuclei multiply in number, and around some of the nuclei an aggregation of colored protoplasm takes place. After a time the network becomes hollowed out by an accumulation of fluid, and forms capillary blood-vessels, and in the fluid those nuclei which are surrounded by colored protoplasm float as the first red blood-cells.[1] The embryonic corpuscles are thus nucleated, and, further, they have the power of amœboid movement. These cells disappear in later embryonic life, to be replaced by smaller non-nucleated corpuscles, having all the characters of the adult erythrocyte, which, according to Schäfer, are formed within certain cells of the connective tissue. Small globules of reddish coloring-matter appear in the protoplasm of these cells, and these eventually becoming larger, more uniform in size and disk-shaped, float in a cavity which results from the coalescence of numerous vacuoles. The cells becoming more hollowed join with neighboring cells to form new blood-vessels, and these become connected with previously existing vessels. In post-embryonic life the important source of the red corpuscles is the red marrow in the ends of the long bones and especially in the ribs and sternum. Here are found special, nucleated, colored cells, termed *erythroblasts*, which are probably direct descendants of the nucleated, embryonic red cells. These erythroblasts by atrophy and disappearance of their nuclei (or, as some observers maintain, by their extrusion) and by assumption of the biconcave form are transformed into the adult red corpuscle. Of the white corpuscles of the blood, the lymphocytes are derived from lymphatic tissue generally, and from the lymphatic glands especially, and enter the blood by way of the lymph-stream; the hyaline cells probably develop from the lymphocytes, while the eosinophile cells are believed to originate mainly in the bone-marrow and possibly also in the connective tissues.

The **Plasma** or **Liquor Sanguinis**, the fluid portion of the blood, has a yellowish tint, is alkaline in reaction, and of a specific gravity of 1.028. It contains in solution about 10 per cent. of solids, of which four-fifths are proteid in nature; the remainder being salts, chiefly chlorides, phosphates, and sulphates of the alkali metals; carbohydrates, chiefly sugar; fats and soaps, cholesterin, urea, and other nitrogenous extractives. The proteids are three in number, *serum albumen*, *serum globulin*, and *fibrinogen*. Fibrinogen is a body of the globulin class, but differs from serum globulin in several respects. It is the substance from which the *fibrin*, which plays so important a part in the clotting of the blood, is derived.

Coagulation of the Blood.—When blood is drawn from the body and allowed to stand, it solidifies in the course of a very few minutes into a jelly-like mass or "clot," which has the same appearance and volume as the fluid blood and, like it, looks quite uniform. Soon, however, drops of a transparent yellowish fluid, the "serum," begin to ooze from the surface of the mass and to collect around it. Coincidently the clot begins to contract, so that in the course of about twenty-four hours, having become considerably smaller and firmer than the first formed jelly-like mass, it floats in a quantity of yellowish serum. The clotting of the blood is due to the formation of a fine meshwork of the insoluble material, *fibrin*, which

[1] Recent observations tend to show that the endothelial lining of the vessels and the blood-corpuscles are of hypoblastic origin.

entangles and encloses the blood-corpuscles. It is supposed that when blood is drawn a nucleo-proteid, termed *prothrombin*, appears in the plasma, probably as the result of disintegration of some of the white cells and perhaps also the blood-platelets. This substance interacts with soluble lime salts in the blood, and a fresh body, *thrombin* or *fibrin-ferment*, is the result. The thrombin then acts on the fibrinogen in solution in the plasma, converting it into insoluble fibrin, while at the same time a very small amount of a new proteid of the globulin type passes into solution.

Fibrin may be obtained, practically free from corpuscles, by whipping the blood, after it has been withdrawn from the body, with a bundle of twigs, to which the fibrin adheres as it is formed. By various means the clotting of the blood may be retarded, so that the plasma may be obtained free from corpuscles; from this plasma there may be derived fibrin and serum, without the cellular elements. Fibrin thus obtained is a white or buff-colored stringy substance, and when observed in the course of formation, under the microscope, shows a meshwork of fine fibrils. After exposure to the air for some time it becomes hard, dry, brown, and brittle. It is one of the class of coagulated proteids, insoluble in hot or cold water, saline solution, alcohol, or ether. Under the action of dilute hydrochloric acid it swells up but does not dissolve, but when thus swollen is readily dissolved by a solution of pepsin.

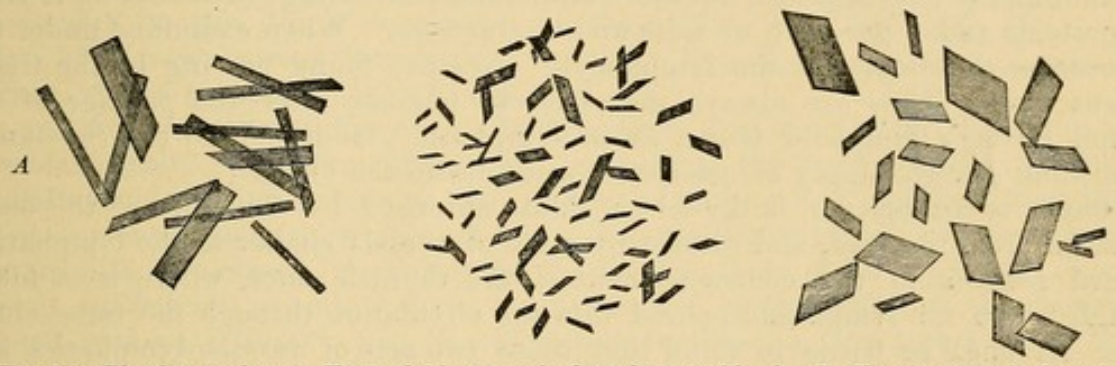

FIG. 601.—Blood-crystals: *A*. Hæmoglobin crystals from human blood. *B*. Hæmin crystals from blood treated with acetic acid. *C*. Hæmatoidin crystals from an old apoplectic clot.

Serum, with the exception of its proteids, has a composition identical with that of plasma. The fibrinogen characteristic of plasma has disappeared, and the fibrin-ferment or thrombin is found instead, together with the serum albumen and serum globulin which are not involved in the process of coagulation.

The relation of the various constituents of the blood to each other may be easily understood by a reference to the subjoined plan:

Blood { Corpuscles } Clot
Blood { Plasma { Fibrin } Clot
Blood { Plasma { Serum

Gases of the Blood.—When blood is exposed to the vacuum of an air-pump, 100 volumes are found to yield about 60 volumes of gas. The gases present are carbon dioxide, oxygen, and nitrogen, and they occur in the following proportions in arterial and venous blood:

	Carbon dioxide.	Oxygen.	Nitrogen.
Arterial blood . .	40 vols.	20 vols.	1 to 2 vols.
Venous blood . .	46 to 50 vols.	10 to 12 vols.	1 to 2 vols.

The greater quantity of the oxygen is in loose chemical combination with the hæmoglobin of the red corpuscles. The carbon dioxide exists in combination for the most part as sodium bicarbonate and carbonate. The nitrogen is in simple solution in the plasma.

Blood-crystals.—Hæmoglobin, as already stated, readily crystallizes when

separated from the blood-corpuscles. In human blood the crystals are elongated prisms (Fig. 601, *A*), and in the majority of animals belong to the rhombic system, though in the squirrel hexagonal plates are met with. Small brown prismatic crystals of *hæmin* (Fig. 601, *B*) may be obtained by mixing dried blood with common salt and boiling with a few drops of glacial acetic acid. A drop of the mixture on a slide will show the characteristic crystals on cooling. *Hæmatoidin* crystals (Fig. 601, *C*) occur sometimes in old blood-clots.

LYMPH AND CHYLE.

Lymph is a transparent, colorless or slightly yellow fluid, which is conveyed by a set of vessels named *lymphatics* into the blood. These vessels arise in nearly all parts of the body as *lymph-capillaries*. They take up the blood-plasma which has exuded from the blood-capillaries into the tissue-spaces where it has nourished the tissue-elements, and return it into the veins close to the heart, there to be mixed with the mass of blood. The greater number of these lymphatics empty themselves into one main duct, the *thoracic duct*, which passes upward along the front of the spine and opens into the large veins on the left side of the root of the neck. The remainder empty themselves into a smaller duct which terminates in the corresponding veins on the right side of the neck.

Lymph, as its name implies, is a watery fluid of sp. gr. about 1.015, closely resembling the blood-plasma, but more dilute and containing only about 5 per cent. of proteids and 1 per cent. of salts and extractives. When examined under the microscope, leucocytes of the lymphocyte class are found floating in the transparent fluid. They are always increased in number after the passage of the lymph through lymphoid tissue, as in lymphatic glands. They are constantly furnishing a fresh supply of colorless corpuscles to the blood.

Chyle is an opaque, milky-white fluid, absorbed by the villi of the small intestine from the food, and carried by a set of vessels similar to the lymphatics, named *lacteals*, to the commencement of the thoracic duct, where it is intermingled with the lymph and poured into the circulation through the same channels. It must be borne in mind that these two sets of vessels, lymphatics and lacteals, though differing in name, are identical in structure, and that the character of the fluid they convey is different only while digestion is going on. At other times the lacteals convey a transparent, nearly colorless lymph.

Chyle exactly resembles lymph in its physical and chemical properties, except that it has, in addition to the other constituents of lymph, a quantity of finely divided fatty particles, the so-called "molecular basis of chyle," to which the milky appearance is due. It contains a little more proteid than lymph, but the chief difference lies in the large quantity of fats, soaps, lecithin, and cholesterin present in the former. Lymph and chyle, containing, as they do, fibrinogen in solution and leucocytes, clot on removal from the body, the coagulum being free from red cells, and presenting a clear or whitish jelly-like appearance.

EPITHELIUM.

All the surfaces of the body—the external surface of the skin, the internal surface of the digestive, respiratory, and genito-urinary tracts, the closed serous cavities, the inner coat of the vessels, and the acini and ducts of all secreting and excreting glands, the ventricles of the brain, and the central canal of the spinal cord—are covered by one or more layers of simple cells, called *epithelium* or *epithelial cells*. These cells are also present in the terminal parts of the organs of special sense, and in some other structures, as the pituitary and thyroid bodies. They serve various purposes, forming in some cases a protective layer, in others acting as agents in secretion and excretion, and again in others being concerned in the elaboration of the organs of special sense. Thus, in the skin, the main purpose served by the epithelium (here called the *epidermis*) is that of protection. As the surface is worn away by the agency of friction or change of

temperature new cells are supplied, and thus the surface of the true skin and the vessels and nerves which it contains are defended from damage. In the gastro-intestinal mucous membrane and in the glands the epithelial cells appear to be the principal agents in separating the secretion from the blood or from the alimentary fluids. In other situations (as the nose, fauces, and respiratory passages) the chief office of the epithelial cells appears to be to maintain an equable temperature by the moisture with which they keep the surface always slightly lubricated. In the serous cavities they also keep the opposed layers moist, and thus facilitate their movements on each other. Finally, in all internal parts they insure a perfectly smooth surface.

Of late years there has been a tendency on the part of many histologists to divide these several epithelial structures into two classes: (1) *epithelium*, consisting of nucleated protoplasmic cells, which form continuous masses on the skin and mucous surfaces and the linings of the ducts and alveoli of secreting and excreting glands; and (2) *endothelium*, which is composed of a single layer of flattened transparent squamous cells, joined edge to edge in such a manner as to form a membrane of cells. This is found on the free surfaces of the serous membranes, as the lining membrane of the heart, blood-vessels, and lymphatics; on the surface of the brain and spinal cord, and in the anterior chamber of the eye. Endothelium originates from the embryonic mesoblast, while epithelium arises, as a rule, from the epiblast or hypoblast.

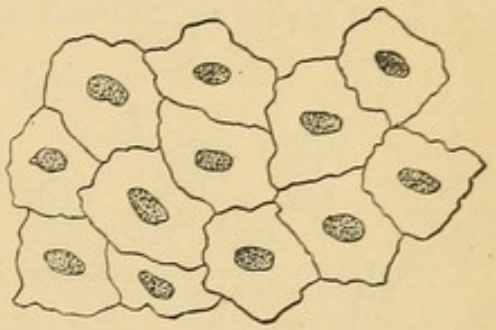

FIG. 602.—Simple pavement epithelium.

Epithelium consists of one or more layers of cells united together by an interstitial cement-substance, supported on a basement-membrane, and is naturally grouped into two classes, according as to whether there is a single layer of cells (*simple epithelium*) or more than one (*stratified epithelium*). A third variety (*transitional epithelium*) is that in which cells in three or four layers are so fitted together that the appearance is not one of distinct stratification. The different varieties of simple epithelium are usually spoken of as squamous or pavement, columnar, glandular or spheroidal, and ciliated.

The *pavement* epithelium (Fig. 602) is composed of flat nucleated scales of various shapes, usually polygonal, and varying in size. These cells fit together by their edges, like the tiles of a mosaic pavement. The nucleus is generally flattened, but may be spheroidal. The flattening depends upon the thinness of the cell. The protoplasm of the cell presents a fine reticulum or honeycombed

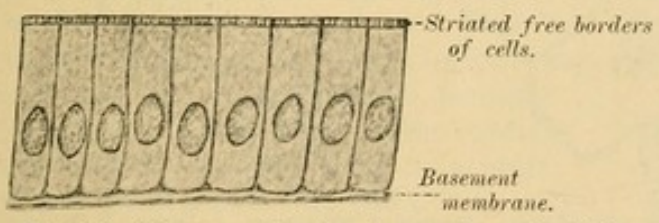

FIG. 603.—Columnar epithelium from an intestinal villus.

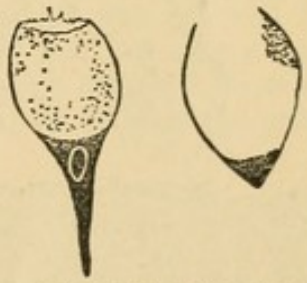

FIG. 604.—Goblet cells. (From Kirk's *Physiology*.)

network, which gives to the cell the appearance of granulation. This kind of epithelium forms the lining of the air-cells of the lungs. The endothelium, which covers the serous membranes, and which lines the heart, bloodvessels, lymphatics, and the anterior chamber of the eye, is also of the pavement type.

The *columnar* or *cylindrical* epithelium (Fig. 603) is formed of cylindrical or rod-shaped cells set together so as to form a complete layer, resembling, when viewed in profile, a palisade. The cells have a prismatic figure, more or less

flattened from mutual pressure, and are set upright on the surface on which they are supported. Their protoplasm is always more or less reticulated, and fine longitudinal striæ may be seen in it. They possess a nucleus which is oval in shape and contains an intranuclear network.

This form of epithelium covers the mucous membrane of nearly the whole gastro-intestinal tract and the glands of that part, the greater part of the

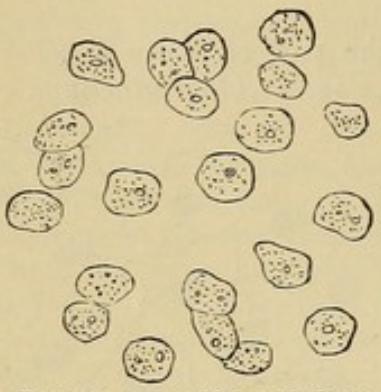

FIG. 605.—Spheroidal epithelium. Magnified 250 times.

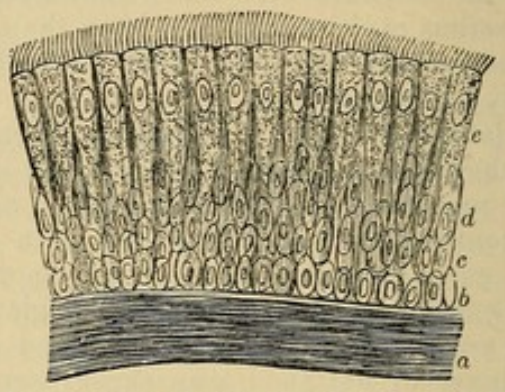

FIG. 606.—Ciliated epithelium from the human trachea. Magnified 350 times. *a*. Innermost layers of the elastic longitudinal fibres. *b*. Homogeneous innermost layer of the mucous membrane. *c*. Deepest round cells. *d*. Middle elongated cells. *e*. Superficial cells, bearing cilia.

urethra, the vas deferens, the prostate, Cowper's glands, Bartholini's glands, and a portion of the uterine mucous membrane. In a modified form it also covers the ovary.

Goblet- or *chalice*-cells are a modification of the columnar cell. They appear to be formed by an alteration in shape of the columnar epithelium (ciliated or otherwise) consequent on the formation of granules which consist of a substance called *mucigen* in the interior of the cell. This distends the upper part of the cell, while the nucleus is pressed down toward its deep part, until the cell bursts and the mucus is discharged on to the surface of the mucous membrane as shown in Fig. 604, the cell then assuming the shape of an open cup or chalice.

The *glandular* or *spheroidal* epithelium (Fig. 605) is composed of spheroidal or polyhedral cells, but the cells may be columnar or cubical in shape in some situ-

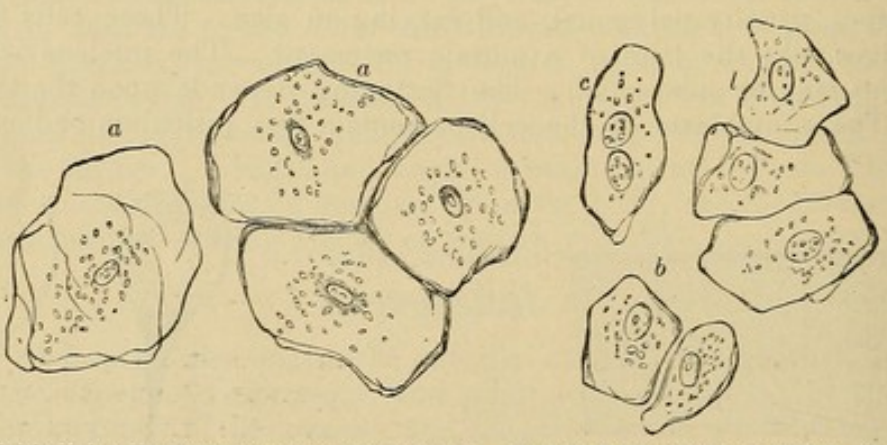

FIG. 607.—Epithelial cells from the oral cavity of man. Magnified 350 times. *a*. Large. *b*. Middle sized. *c*. The same with two nuclei.

ations. Like other forms of epithelial cells, the protoplasm is a fine reticulum, which gives to the cell the appearance of granulation. They are found in the terminal recesses of secreting glands, and the protoplasm of the cells usually contains the materials which the cells secrete.

Ciliated epithelium (Fig. 606) may be of any of the preceding forms, but usually inclines to the columnar shape. It is distinguished by the presence of minute processes, which are direct prolongations of the cell-protoplasm, like hairs or eye-

lashes (cilia), standing up from the free surface. If the cells are examined during life or immediately on removal from the living body (for which in the human subject the removal of a nasal polypus offers a convenient opportunity) in a weak solution of salt, the cilia will be seen in lashing motion; and if the cells are separate, they will often be seen to be moved about in the field by this motion.

The situations in which ciliated epithelium is found in the human body are: the respiratory tract from the nose downward to the smallest ramifications of the bronchial tube (except a part of the pharynx and the surface of the vocal cords), the tympanum and Eustachian tube, the Fallopian tube and upper portion of the uterus, the vasa efferentia, coni vasculosi, and the first part of the excretory duct of the testicle, and the ventricles of the brain and central canal of the spinal cord.

Stratified epithelium (Fig. 608) consists of several layers of cells superimposed one on the top of the other and varying greatly in shape. The cells of the deepest layer are for the most part columnar in form, and as a rule form a single layer, placed vertically on the supporting membrane; above these are several layers of spheroidal cells, which as they approach the surface become more and more compressed, until the superficial layers are found to consist of flattened scales (Fig. 607), the margins of which overlap one another, so as to present an imbricated appearance. They here undergo a chemical change from the conversion of their protoplasm into a horny substance (*keratin*).

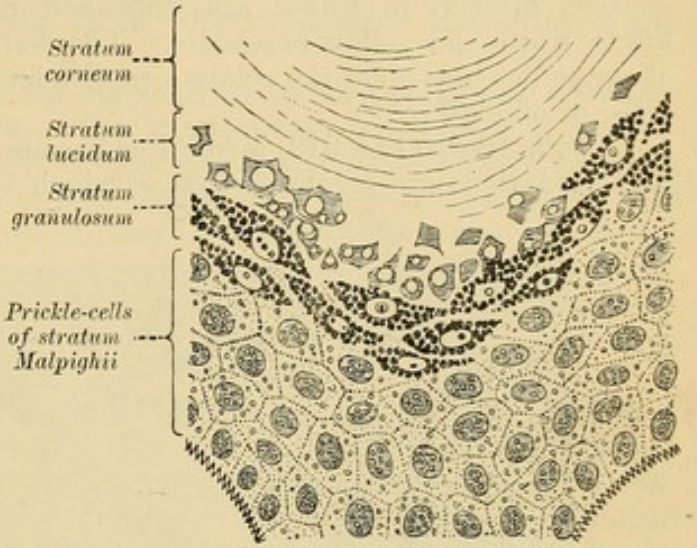

FIG. 608.—Portion of epidermis from a section of the skin of the finger. (Ranvier.) (From Schafer's "Essentials of Histology.")

Certain cells found in the deeper layers of stratified epithelium, and termed *prickle-cells* (Fig. 608), constitute a variety of squamous epithelium. These cells possess short fine fibrils which pass from their margins to those of neighboring cells, serving to connect them together. They are not closely connected together by cement-substance, but are separated from each other by intercellular channels, across which these fine fibrils may be seen bridging; this gives to the cell, when isolated, the appearance of being covered over with a number of short spines, in consequence of the fibrils being broken through. They were first described by Max Schultze and Virchow, and it was believed by them that the cells were dovetailed together. Subsequently this was shown not to be so by Martyn, who pointed out that the prickles were attached to each other by their apices; and recently Delépine has stated that he believes the prickles of prickle-cells are parts of fibrils forming internuclear bundles between the nuclei of the cells of an epithelium in a state of active growth (see Fig. 597).

Transitional epithelium occurs in the ureters and urinary bladder. Here the cells of the most superficial layer are cubical, with depressions on their under surfaces, which fit on to the rounded ends of the cells of the second layer, which are pear-shaped, the apices touching the basement-membrane. Between their tapering points is a third variety of cells, filling in the intervals between them, and of smaller size than those of the other two layers (Fig. 609).

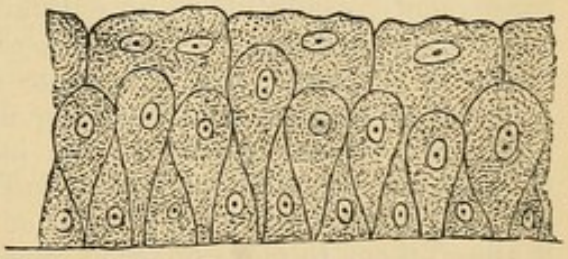

FIG. 609.—Transitional epithelium.

CONNECTIVE TISSUES.

The term **connective tissue** includes a number of tissues which possess this feature in common, viz., that they serve the general purpose in the animal economy of supporting and connecting the tissues of the body. These tissues may differ considerably from each other in appearance, but they present, nevertheless, many points of relationship, and are, moreover, developed from the same layer of the embryo, the mesoblast. They are divided into three great groups: (1) the connective tissues proper, (2) cartilage, and (3) bone. Blood, which has already been described, is, strictly speaking, a form of connective tissue, and is so dealt with by many histologists.

The Connective Tissues Proper.—Several forms or varieties of connective tissue are recognized: (1) Areolar tissue. (2) White fibrous tissue. (3) Yellow elastic tissue. (4) Mucous tissue. (5) Retiform tissue. They are all composed of a homogeneous matrix, in which are imbedded cells and fibres—the latter of two kinds, white and yellow or elastic. The distinction between the different forms of tissue depends upon the relative preponderance of one or other kind of fibre, of cells, or of matrix.

Areolar tissue (Fig. 610) is so called because its meshes are easily distended, and thus separated into areolæ or spaces, which open freely into each other, and are

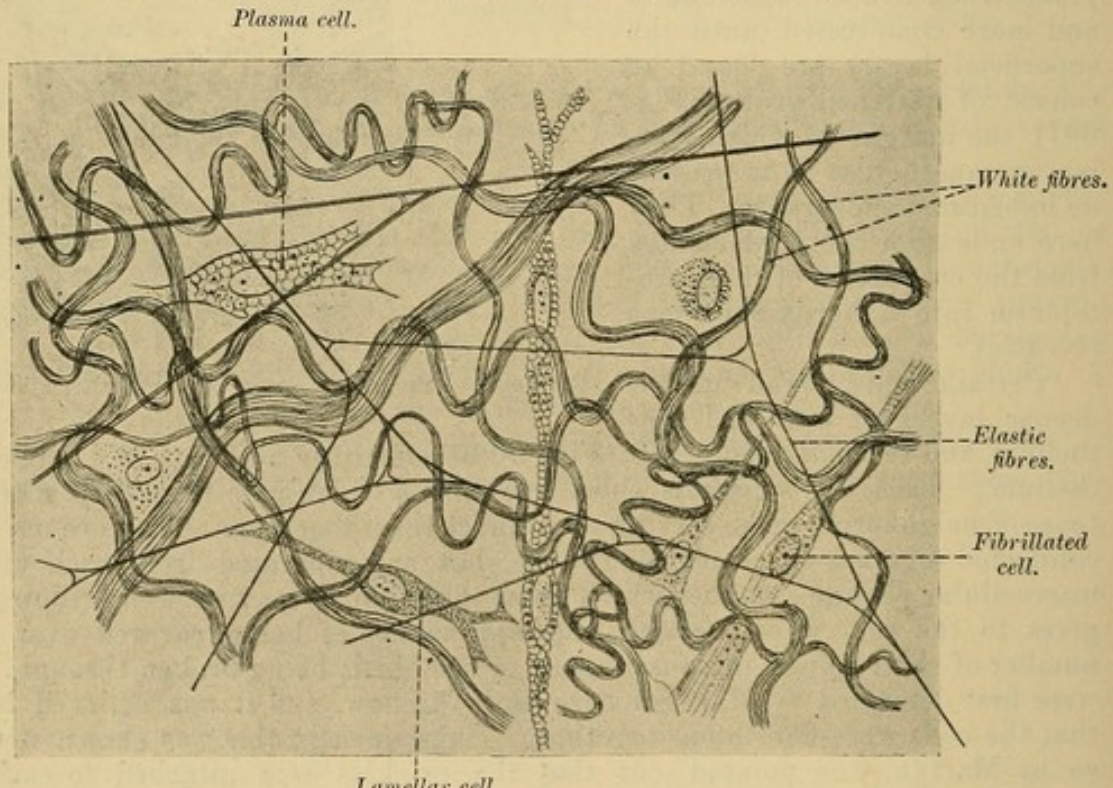

FIG. 610.—Subcutaneous tissue from a young rabbit. Highly magnified. (Schäfer.)

consequently easily blown up with air, or permeated by fluid when injected into any part of the tissue. Such spaces, however, do not exist in the natural condition of the body, but the whole tissue forms one unbroken membrane composed of a number of interlacing fibres, variously superimposed. Hence the term "the cellular membrane" is in many parts of the body more appropriate than its more modern equivalent. The chief use of the areolar tissue is to bind parts together, while by the laxity of its fibres and the permeability of its areolæ it allows them to move on each other, and affords a ready exit for inflammatory and other effused fluids. It is one of the most extensively distributed of all the tissues. It is found beneath the skin in a continuous layer all over the body, connecting it to the subjacent parts. In the same way it is situated beneath the mucous and serous membranes. It is also found between muscles, vessels, and

nerves, forming investing sheaths for them, and connecting them with surrounding structures. In addition to this, it is found in the interior of organs, binding together the various lobes and lobules of the compound glands, the various coats of the hollow viscera, and the fibres of muscles, etc., and thus forms one of the most important connecting media of the various structures or organs of which the body is made up. In many parts the areolæ or interspaces of areolar tissue are occupied by fat-cells, constituting *adipose tissue*, which will presently be described.

Areolar tissue presents to the naked eye a flocculent appearance, somewhat like spun silk. When stretched out, it is seen to consist of delicate soft elastic threads interlacing with each other in every direction and forming a network of extreme delicacy. When examined under the microscope (Fig. 610) it is found to be composed of white fibres and elastic fibres intercrossing in all directions, and united together by a homogeneous cement or ground-substance, the *matrix*, showing cell-spaces wherein lie many cellular elements, the *connective-tissue corpuscles;* these contain the protoplasm out of which the whole is developed and regenerated.

The white fibres are arranged in waving bands or bundles of minute transparent homogeneous filaments or fibrillæ. The bundles have a tendency to split up longitudinally or send off slips to join neighboring bundles and receive others in return, but the individual fibres are unbranched and never join other fibres; the *yellow elastic fibres* have a well-defined outline and are considerably larger in size than the white fibrillæ. They vary much, being from the $\frac{1}{24000}$ to the $\frac{1}{4000}$ of an inch in diameter. The fibres form bold and wide curves, branch, and freely anastomose with each other. They are homogeneous in appearance, and tend to curl up, especially at their broken ends.

Connective-tissue Corpuscles.—The cells of areolar tissue are of three principal kinds: (1) Flattened lamellar cells, which may be either branched or unbranched. The branched lamellar cells are composed of clear cell-substance, in which is contained an oval nucleus. The processes of these cells unite so as to form an open network, as in the cornea. The unbranched cells are joined edge to edge like the cells of an epithelium. The "tendon-cells," presently to be described, are an example of this variety. (2) Granule-cells, which are ovoid or spheroidal in shape and formed of a soft protoplasm, containing granules which are albuminous in character and stain deeply with eosin. (3) Plasma-cells of Waldeyer, varying greatly in size and form, but always to be distinguished from the other two varieties by containing a largely vacuolated protoplasm. The vacuoles are filled with fluid, and the protoplasm between the spaces is clear, with occasionally a few scattered granules.

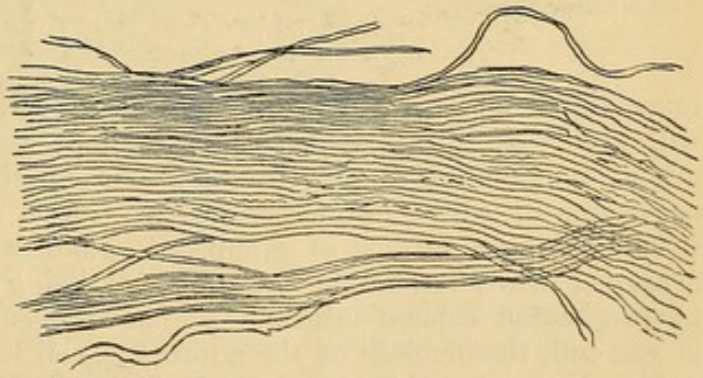

Fig. 611.—White fibrous tissue. High power.

In addition to these three typical forms of connective-tissue corpuscles, areolar tissue may be seen to possess *wandering cells*, *i. e.*, leucocytes which have emigrated from the neighboring vessels, and in some instances, as in the choroid coat of the eye, cells filled with granules of pigment (*pigment-cells*).

The connective-tissue corpuscles lie in spaces in the ground-substance between the bundles of fibres, and these spaces may be brought into view by treating the tissue with nitrate of silver and exposing it to the light. This will color the ground-substance and leave the cell-spaces unstained.

The **white fibrous tissue** (Fig. 611) is a true connecting structure, and serves

three purposes in the animal economy. In the form of ligaments it serves to bind bones together; in the form of tendons, it serves to connect muscles to bones or other structures, and it forms an investing or protecting structure to various organs in the form of membranes. Examples of where it serves this latter office are to be found in the muscular fasciæ or sheaths, the periosteum, and perichondrium; the investments of the various glands (such as the tunica albuginea testis, the capsule of the kidney, etc.), the investing sheath of the nerves (epineurium), and of various organs, as the penis and the eye (sheath of the corpora cavernosa and corpus spongiosum, and of the sclerotic). In white fibrous tissue, as its name implies, the white fibres predominate, the matrix being apparent only as a cement-substance, the yellow elastic fibres comparatively few, while the tissue-cells are arranged in a special manner. It presents to the naked eye the appearance of silvery-white glistening fibres, covered over with a quantity of loose, flocculent tissue which binds the fibres together and carries the blood-vessels (Fig. 612). It is not possessed of any elasticity, and only the very slightest extensibility; it is exceedingly strong, so that upon the application of any external vio-

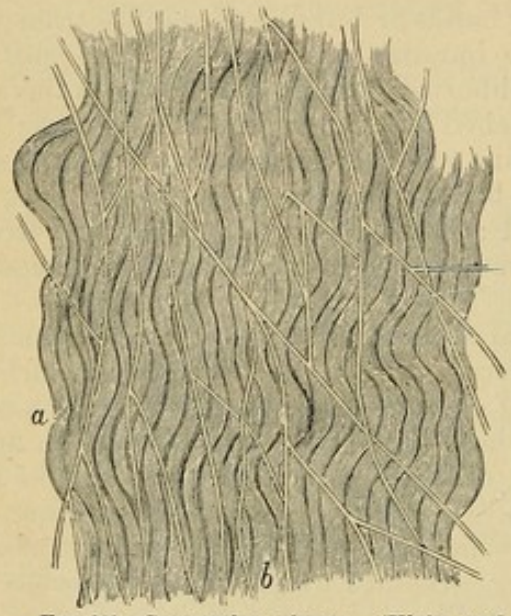

FIG. 612.—Connective tissue. (Klein and Noble Smith.) *a*. The white fibrous element—a layer of more or less sharply-outlined, parallel, wavy bundles of connective-tissue fibrils. On the surface of this layer is *b*, a network of fine elastic fibres.



FIG. 613.—Tendon of mouse's tail, stained with hæmatoxylin, showing chains of cells between the tendon-bundles. (From Quain's *Anatomy*. E. A. Schafer.)

lence the bone with which it is connected will fracture before the fibrous tissue will give way. In ligaments and tendons the bundles run parallel with each other; in membranes they intersect one another in different places. The cells occurring in white fibrous tissue are often called "tendon cells." They are situated on the surface of groups of bundles and are quadrangular in shape, arranged in rows in single file, each cell being separated from its neighbors by a narrow line of cement-substance. The nucleus is generally situated at one end of the cell, the nucleus of the adjoining cell being in close proximity to it (Fig. 613). Upon the addition of acetic acid to white fibrous tissue it swells up into a glassy-looking, indistinguishable mass. When boiled in water it is converted almost completely into gelatin. The white fibres being composed of the albuminoid *collagen*, which is often regarded as the anhydride of gelatin.

Yellow Elastic Tissue.—In certain parts of the body a tissue is found which when viewed in mass is of a yellowish color, and is possessed of great elasticity, so that it is capable of considerable extension, and when the extending force is withdrawn returns at once to its original condition. This is *yellow elastic tissue*, which may be regarded as a connective tissue in which the yellow elastic fibres

have developed to the practical exclusion of the other elements. It is found in the ligamenta subflava, in the vocal cords, in the longitudinal coat of the trachea and bronchi, in the inner coats of the blood-vessels, especially the larger arteries, and to a very considerable extent in the thyro-hyoid, crico-thyroid, and stylo-hyoid ligaments. It is also found in the ligamentum nuchæ of the lower animals (Fig. 614). In some parts, where the fibres are broad and large and the network close, the tissue presents the appearance of a membrane, with gaps or perforations corresponding to the intervening space. This is to be found in the inner coat of the arteries, and to it the name of *fenestrated membrane* has been given by Henle. The yellow elastic fibres remain unaltered by acetic acid. Chemically they are composed of the albuminoid body, *elastin*.

Vessels and Nerves of Connective Tissue.—The *blood-vessels* of connective tissue are very few—that is to say, there are few actually destined for the tissue itself,

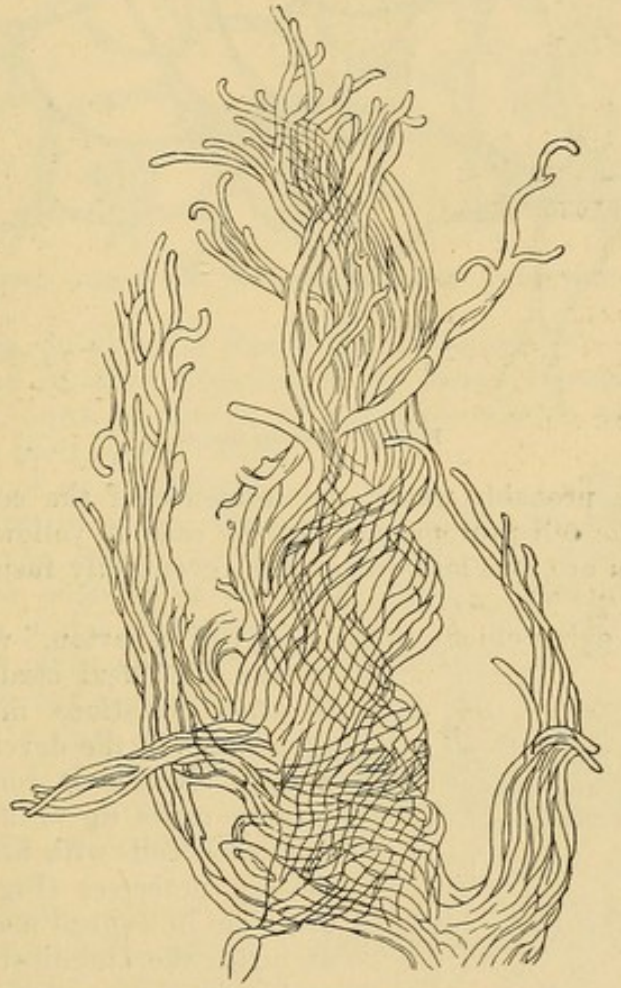

FIG. 614.—Yellow elastic tissue. High power.

although many vessels may permeate one of its forms, the areolar tissue, carrying blood to other structures. In white fibrous tissue the blood-vessels usually run parallel to the longitudinal bundles and between them, sending transverse communicating branches across, and in some forms, as the periosteum and dura mater, they are fairly numerous. In the yellow elastic tissue the blood-vessels also run between the fibres, and do not penetrate them. *Lymphatic* vessels are very numerous in most forms of connective tissue, especially in the areolar tissue beneath the skin and the mucous and the serous surfaces. They are also found in abundance in the sheaths of tendons, as well as in the tendons themselves. *Nerves* are to be found in the white fibrous tissue, where they terminate in a special manner; but it is doubtful whether any nerves terminate in areolar tissue; at all events, they have not yet been demonstrated, and the tissue is possessed of very little sensibility.

Development of Connective Tissue.—Connective tissue is developed from embryonic connective-tissue cells derived from the mesoblast. These cells, at first rounded, become fusiform and branched, and ultimately become the connective-tissue corpuscles. A mucinous intercellular substance or matrix, partly formed from the cells themselves and partly from the lymph exuded by the neighboring blood-vessels, gradually separates the cells. In the matrix the

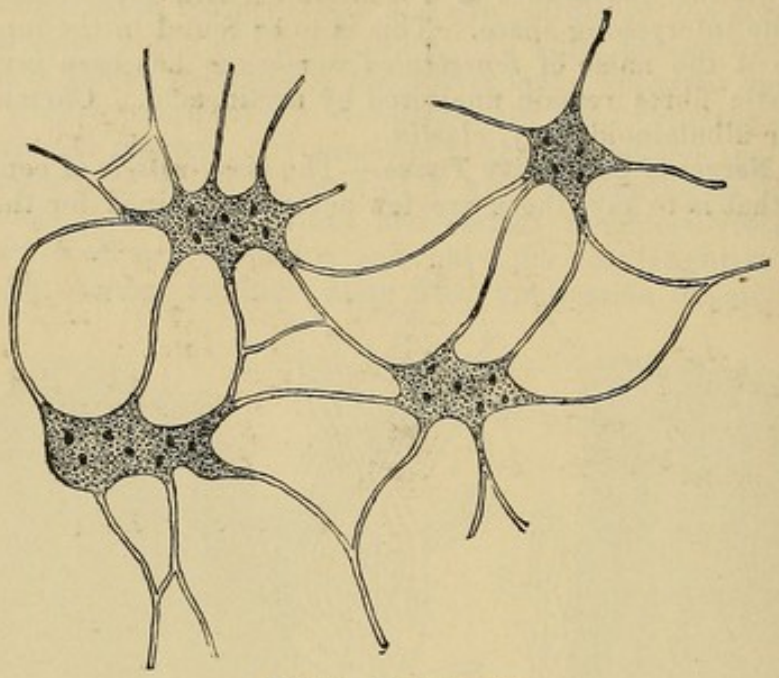

FIG. 615.—Mucous tissue.

fibres are deposited, probably under the influence of the cells, but not by any transformation of the cell protoplasm. In the case of yellow elastic fibres, rows of granules of elastin are first laid down, these eventually fusing to form the fully developed fibre.

1. **Mucous** tissue exists chiefly in the "jelly of Wharton," which forms the bulk of the umbilical cord, but is also found in other situations in the fœtus, chiefly as a stage in the development of the connective tissue. It consists of a matrix, largely made up of mucin, in which are nucleated cells with branching and anastomosing processes (Fig. 615). Few fibres are seen in typical mucous tissue, though, at birth, the umbilical cord shows considerable development of fibres. In the adult the vitreous humor of the eye is a persistent form of mucous tissue, in which there are no fibres, and from which the cells have disappeared, leaving only the mucinous ground-substance.

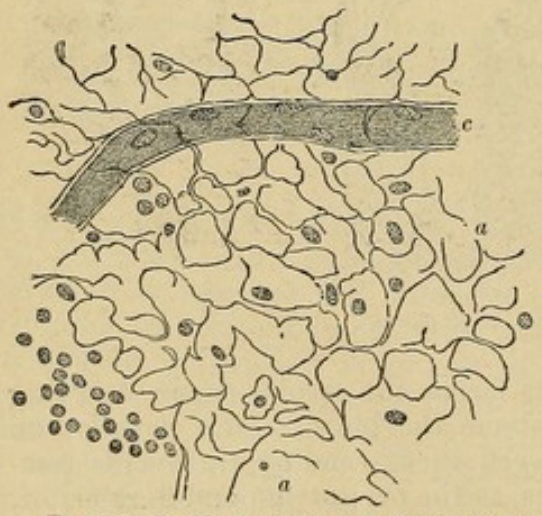

FIG. 616.—Retiform connective tissue, from a lymphatic gland; most of the lymph-corpuscles are removed. (From Klein's "Elements of Histology.") *a*, The reticulum. *c*, A capillary blood-vessel.

2. **Retiform** connective tissue is found extensively in many parts of the body, forming the framework of some organs and entering into the construction of many mucous membranes. It is a form of connective tissue, in which the intercellular or ground-substance has, in a great measure, disappeared, and has been replaced by fluid. It is apparently composed almost entirely of extremely fine bundles of white fibrous tissue, forming an intricate network, yet chemically it yields, besides gelatin, a fresh substance, *reticulin*. The fibres are covered and concealed by flattened branched connective-tissue cells, and these must be

removed or brushed away before the fibres become visible. In many situations the interstices of the network are filled with rounded lymph-corpuscles, and the tissue is then termed **lymphoid** or **adenoid tissue** (Fig. 616).

3. **Basement-membranes**, formerly described as homogeneous membranes, are really a form of connective tissue. They constitute the supporting membrane,

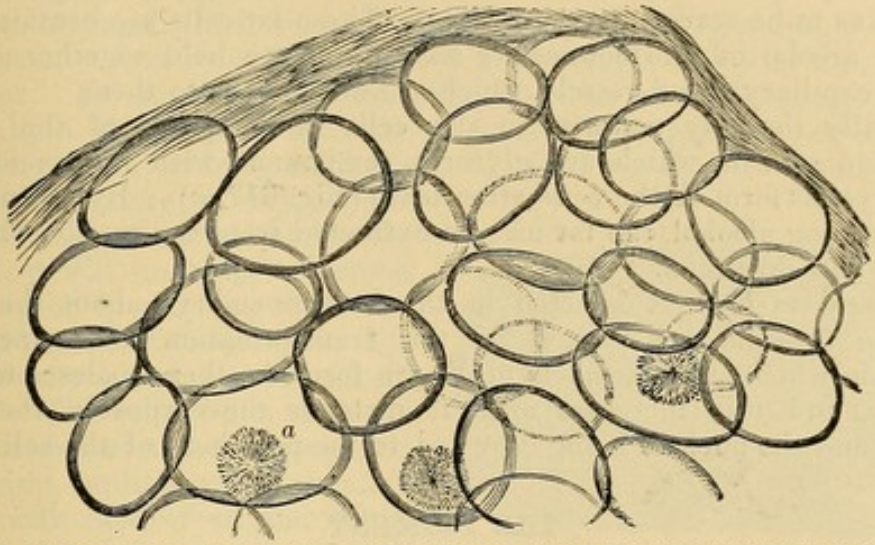

FIG. 617.—Adipose tissue. High power. *a*, Star-like appearance from crystallization of fatty acids.

or membrana propria, on which is placed the epithelium of mucous membranes or secreting glands, and in other situations. By means of staining with nitrate of silver they may be shown to consist of flattened cells in close opposition, and joined together by their edges, thus forming an example of an epithelioid arrangement of connective-tissue cells. In some situations the cells, instead of adhering by their edges, give off branching processes, which join with similar processes of other cells, and so form a network rather than a continuous membrane. In other instances basement-membranes are composed of elastic tissue, as in the cornea, or, again, in other cases of condensed ground-substance.

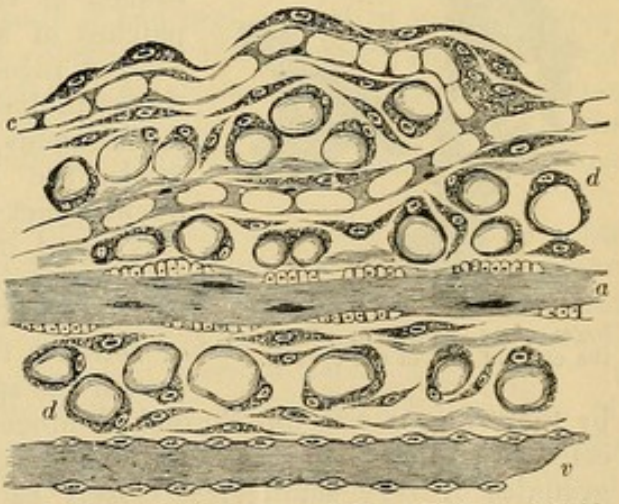

FIG. 618.—Development of fat. (Klein and Noble Smith.) *a*, Minute artery. *v*, Minute vein. *c*, Capillary blood-vessels in the course of formation; they are not yet completely hollowed out, there being still left in them protoplasmic septa. *d*, The ground-substance, containing numerous nucleated cells, some of which are more distinctly branched and flattened than others, and appear therefore more spindle-shaped.

Adipose Tissue.—In almost all parts of the body the ordinary areolar tissue contains a variable quantity of fat. The principal situations where it is not found are the subcutaneous tissue of the eyelids, the penis and scrotum, the nymphæ, within the cavity of the cranium, and in the lungs, except near their roots. Nevertheless, its distribution is not uniform: in some parts it is collected in great abundance, as in the subcutaneous tissue, especially of the abdomen; around the kidneys; on the surface of the heart between the furrows; and in some other situations. Lastly, fat enters largely into the formation of the marrow of bones. A distinction must be made between fat and adipose tissue; the latter being a distinct issue, the former an oily matter, which in addition to forming adipose tissue is also widely present in the body, as in the fat of the brain and liver, and in the blood and chyle, etc.

Adipose tissue consists of small vesicles, *fat-cells*, lodged in the meshes of areolar tissue. The fat-cells (Fig. 617) vary in size, but of about the average

diameter of $\frac{1}{500}$ of an inch. They are formed of an exceedingly delicate protoplasmic membrane, filled with fatty matter, which is liquid during life, but becomes solidified after death. They are round or spherical where they have not been subjected to pressure; otherwise they assume a more or less angular outline. A nucleus is always present, and can be easily demonstrated by staining with hæmatoxylin; in the natural condition it is so compressed by the contained oily matter as to be scarcely recognizable. These fat-cells are contained in clusters in the areolæ of fine connective tissue, and are held together mainly by a network of capillary blood-vessels, which are distributed to them.

Chemically the oily material in the cells is composed of the fats, olein, palmitin, and stearin, which are glycerin compounds with fatty acids. Sometimes fat-crystals form in the cells after death (Fig. 617, *a*). By boiling the tissue in ether or strong alcohol, the fat may be extracted from the vesicle, which is then seen empty and shrunken.

Fat is said to be first detected in the human embryo about the fourteenth week. The fat-cells are formed by the transformation of connective-tissue corpuscles, in which small droplets of oil are formed; these coalesce to produce a larger drop, and this increases until it distends the corpuscle, the remaining protoplasm and the nucleus being crowded to the periphery of the cell (Fig. 618).

THE PIGMENT.

In various parts of the body *pigment* is found; most frequently in epithelial cells and in the cells of connective tissue. Pigmented epithelial cells are found in the external layer of the retina and on the posterior surface of the iris. Pigment is also found in the epithelial cells of the deeper layers of the cuticle in some parts of the body —such as the areola of the nipple and in colored patches of skin, and especially in the skin of the colored races, and also in hair. It is also found in the epithelial cells of the olfactory region and of the membranous labyrinth of the ear.

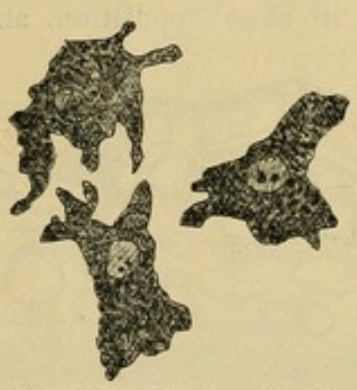

FIG. 619. — Pigment-cells from the choroid coat of the eyeball.

In the *connective-tissue cells* pigment is frequently met with in the lower vertebrates. In man it is found in the choroid coat of the eye (Fig. 619) and in the iris of all but the light-blue eyes and the albino. It is also occasionally met with in the cells of retiform tissue and in the pia mater of the upper part of the spinal cord. These cells are characterized by their larger size and branched processes, which, as well as the body of the cells, are filled with granules. The pigment consists of dark-brown or black granules of very small size, closely packed together within the cells, but not invading the nucleus. Occasionally the pigment is yellow, and when occurring in the cells of the cuticle constitutes "freckles."

THE CARTILAGE.

Cartilage is a non-vascular structure which is found in various parts of the body—in adult life chiefly in the joints, in the parietes of the thorax, and in various tubes, such as the air-passages, nostrils, and ears, which are to be kept permanently open. In the fœtus at an early period the greater part of the skeleton is cartilaginous. As this cartilage is afterward replaced by bone, it is called *temporary*, in contradistinction to that which remains unossified during the whole of life, and which is called *permanent*.

Cartilage is divided, according to its minute structure, into hyaline cartilage, fibro-cartilage, and yellow or elastic white fibro-cartilage. Besides these varieties met with in the adult human subject, there is a variety called *cellular cartilage*, which consists entirely, or almost entirely, of cells, united in some cases by a

network of very fine fibres, in other cases apparently destitute of any intercellular substance. This is found in the external ear of rats, mice, and some other animals, and is present in the chorda dorsalis of the human embryo, but is not found in any other human structure. The various cartilages in the body are also classified, according to their function and position, into articular, interarticular, costal, and membraniform.

Hyaline cartilage, which may be taken as the type of this tissue, consists of a gristly mass of a firm consistence, but of considerable elasticity and of a pearly-bluish color. Except where it coats the articular ends of bones, it is covered externally by a fibrous membrane, the *perichondrium*, from the vessels of which it imbibes its nutritive fluids, being destitute of blood-vessels. It contains no nerves. Its intimate structure is very simple. If a thin slice is examined under the microscope, it will be found to consist of a rounded or bluntly angular form, lying in groups of two or more in a granular or almost homogeneous matrix (Fig. 620). The cells, when arranged in groups of two or more, have generally a straight outline where they are in contact with each other, and in the rest of their circumference are rounded. The cell-contents consist of clear translucent protoplasm, in which fine interlacing filaments and minute granules may sometimes be seen; imbedded in this are one or two round nuclei, having the usual intranuclear network. The cells are imbedded in cavities in the matrix, called *cartilage lacunæ;* around these the matrix is arranged in concentric lines, as if it had been formed in successive portions around the cartilage-cells. This constitutes the so-called *capsule* of the space. Each lacuna is generally occupied by a single cell, but during the division of the cells it may contain two, four, or eight cartilage-cells. By exposure to the action of an electric shock the cell assumes a jagged outline and shrinks away from the interior of the capsule.

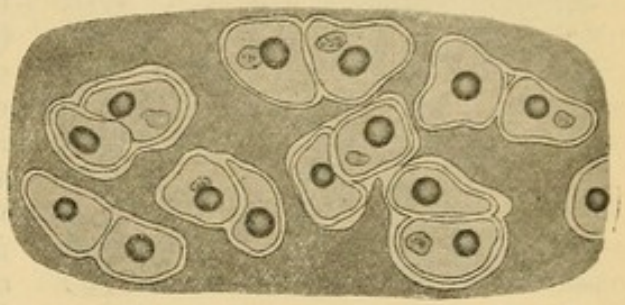

FIG. 620.—Human cartilage-cells from the cricoid cartilage. × 350.

The matrix is transparent and apparently without structure, or else presents a dimly granular appearance, like ground glass. Some observers have shown that the matrix of hyaline cartilage, and especially the articular variety, after prolonged maceration, can be broken up into fine fibrils. These fibrils are probably of the same nature, chemically, as the white fibres of connective tissue. It is believed by some histologists that the matrix is permeated by a number of fine channels, which connect the lacunæ with each other, and that these canals communicate with the lymphatics of the perichondrium, and thus the structure is permeated with a current of nutrient fluid. This, however, is somewhat doubtful.

Articular cartilage, costal cartilage, and temporary cartilage are all of the hyaline variety. They present minute differences in the size and shape of their cells and in the arrangement of their matrix. In **articular cartilage,** which shows no tendency to ossification, the matrix is finely granular under a high power; the cells and nuclei are small, and are disposed parallel to the surface in the superficial part, while nearer to the bone they become vertical. Articular cartilages have a tendency to split in a vertical direction; in disease this tendency becomes very manifest. Articular cartilage is not covered by perichondrium, on its free surface, where it is exposed to friction, though a layer of connective tissue can be traced in the adult over a small part of its circumference continuous with that of the synovial membrane, and here the cartilage-cells are more or less branched and pass insensibly into the branched connective-tissue corpuscles of the synovial membrane.

Articular cartilage forms a thin incrustation upon the joint-surfaces of the bones, and its elasticity enables it to break the force of any concussion, while its smoothness affords ease and freedom of movement. It varies in thickness accord-

ing to the shape of the articular surface on which it lies; where this is convex the cartilage is thickest at the centre, where the greatest pressure is received; and the reverse is the case on the concave articular surfaces. Articular cartilage appears to derive its nutriment partly from the vessels of the neighboring synovial membrane, partly from those of the bone upon which it is implanted. Toynbee has shown that the minute vessels of the cancellous tissue as they approach the articular lamella dilate and form arches, and then return into the substance of the bone.

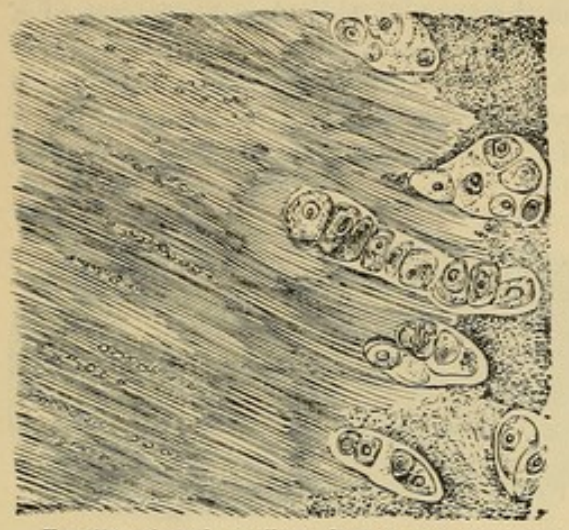

FIG. 621.—Costal cartilage from a man seventy-six years of age, showing the development of fibrous structure in the matrix. In several portions of the specimen two or three generations of cells are seen enclosed in a parent cell-wall. High power.

In **costal cartilage** the cells and nuclei are large, and the matrix has a tendency to fibrous striation, especially in old age (Fig. 621). In the thickest parts of the costal cartilages a few large vascular channels may be detected. This appears, at first sight, to be an exception to the statement that cartilage is a non-vascular tissue, but is not so really, for the vessels give no branches to the cartilage substance itself, and the channels may rather be looked upon as involutions of the perichondrium. The ensiform cartilage may be regarded as one of the costal cartilages, and the cartilages of the nose and of the larynx and trachea (except the epiglottis and cornicula laryngis, which are composed of elastic fibro-cartilage) resemble them in microscopical characters.

Temporary cartilage and the process of its ossification will be described with bone. The hyaline cartilages, especially in adult and advanced life, are prone to calcify—that is to say, to have their matrix permeated by the salts of lime without any appearance of true bone. The process of calcification occurs also and still more frequently, according to Rollett, in such cartilages as those of the trachea and in the costal cartilages, which are prone afterward to conversion into true bone.

White fibro-cartilage consists of a mixture of white fibrous tissue and cartilaginous tissue in various proportions; it is to the first of these two constituents that its flexibility and toughness are chiefly owing, and to the latter its elasticity. When examined under the microscope it is found to be made up of fibrous connective tissue arranged in bundles, with cartilage-cells between the bundles; these to a certain extent resemble tendon-cells, but may be distinguished from them by being surrounded by a concentrically striated area of cartilage matrix and by their being less flattened (Fig. 622). The fibro-cartilages admit of arrangement into four groups —interarticular, connecting, circumferential, and stratiform.

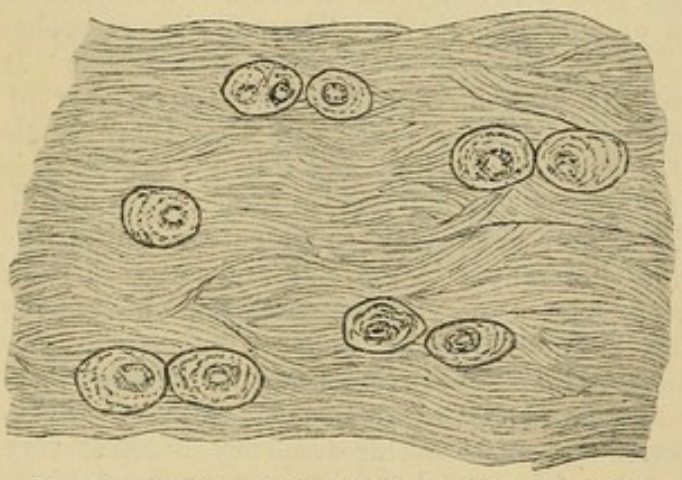

FIG. 622.—White fibro-cartilage from an intervertebral disc.

1. The **interarticular fibro-cartilages** (*menisci*) are flattened fibro-cartilaginous plates, of a round, oval, triangular, or sickle-like form, interposed between the articular cartilages of certain joints. They are free on both surfaces, thinner toward their centre than at their circumference, and held in position by the attachment of their

margins and extremities to the surrounding ligaments. The synovial membrane of the joint is prolonged over them a short distance from their attached margins. They are found in the temporo-mandibular, sterno-clavicular, acromio-clavicular, wrist- and knee-joints. These cartilages are usually found in those joints which are most exposed to violent concussion and subject to frequent movement. Their use is to maintain the apposition of the opposed surfaces in their various motions; to increase the depth of the articular surfaces and give ease to the gliding movement; to moderate the effects of great pressure and deaden the intensity of the shocks to which the parts may be subjected. Humphry has pointed out that these inter-articular fibro-cartilages serve an important purpose in increasing the variety of movements in a joint. Thus, in the knee-joint there are two kinds of motion, viz., angular movement and rotation, although it is a hinge joint, in which, as a rule, only one variety of motion is permitted; the former movement takes place between the condyles of the femur and the interarticular cartilage, the latter between the cartilage and the head of the tibia. So, also, in the temporo-mandibular joint, the upward and downward movement of opening and shutting the mouth takes place between the fibro-cartilage and the jaw-bone, the grinding movement between the glenoid cavity and the fibro-cartilage, the latter moving with the jaw-bone.

2. The **connecting fibro-cartilages** are interposed between the bony surfaces of those joints which admit of only slight mobility, as between the bodies of the vertebræ and between the pubic bones. They form disks, which adhere closely to both of the opposed surfaces, and are composed of concentric rings of fibrous tissue, with cartilaginous laminæ interposed, the former tissue predominating toward the circumference, the latter toward the centre.

3. The **circumferential fibro-cartilages** consist of a rim of fibro-cartilage, which surrounds the margin of some of the articular cavities, as the cotyloid cavity of the hip and the glenoid cavity of the shoulder; they serve to deepen the articular surface, and to protect its edges.

4. The **stratiform fibro-cartilages** are those which form a thin coating to osseous grooves through which the tendons of certain muscles glide. Small masses of fibro-cartilages are developed also in the tendons of some muscles, where they glide over bones, as in the tendons of the Peroneus longus and the Tibialis posticus.

Yellow or elastic fibro-cartilage is found in the human body in the auricle of the external ear, the Eustachian tubes, the cornicula laryngis, and the epiglottis. It consists of cartilage-cells and a matrix, the latter being pervaded in every direction, except immediately around each cell, where there is a variable amount of non-fibrillated hyaline, intercellular substance, by a network of yellow elastic fibres, branching and anastomosing in all directions (Fig. 623). The fibres resemble those of yellow elastic tissue, both in appearance and in being unaffected by acetic acid; and according to Rollett their continuity with the elastic fibres of the neighboring tissue admits of being demonstrated.



FIG. 623.—Yellow cartilage, ear of horse. High power.

The distinguishing feature of cartilage as to its chemical composition is that it yields on boiling a substance called *chondrin*, very similar to gelatin, but differing from it in several of its reactions. • It is now believed that chondrin is not a simple body, but a mixture of gelatin with mucinoid substances, chief among which, perhaps, is a compound termed *chondro-mucoid*.

THE BONE.

Structure and Physical Properties of Bone.—Bone is one of the hardest structures of the animal body; it possesses also a certain degree of toughness and elasticity. Its color, in a fresh state, is of a pinkish white externally, and a deep red within. On examining a section of any bone, it is seen to be composed of two kinds of tissue, one of which is dense in texture, like ivory, and is termed *compact* tissue; the other consists of slender fibres and lamellæ, which join to form a reticular structure; this, from its resemblance to lattice-work, is called *cancellous tissue*. The compact tissue is always placed on the exterior of the bone; the cancellous is always internal. The relative quantity of these two kinds of tissue varies in different bones, and in different parts of the same bone, as strength or lightness is requisite. Close examination of the compact tissue shows it to be extremely porous, so that the difference in structure between it and the cancellous tissue depends merely upon the different amount of solid matter, and the size and number of spaces in each; the cavities being small in the compact tissue and the solid matter between them abundant, while in the cancellous tissue the spaces are large and the solid matter in smaller quantity.

Bone during life is permeated by vessels and is enclosed, except where it is coated with articular cartilage, in a fibrous membrane, the *periosteum*, by means of which many of these vessels reach the hard tissue. If the periosteum is stripped from the surface of the living bone, small bleeding points are seen, which mark the entrance of the periosteal vessels; and on section during life every part of the bone will be seen to exude blood from the minute vessels which ramify in it. The interior of the bones of the limbs presents a cylindrical cavity filled with marrow and lined by a highly vascular areolar structure, called the *medullary membrane* or *internal periosteum*, which, however, is rather the areolar envelope of the cells of the marrow than a definite membrane.

The **periosteum** adheres to the surface of the bones in nearly every part, excepting at their cartilaginous extremities. When strong tendons or ligaments are attached to the bone, the periosteum is incorporated with them. It consists of two layers closely united, the outer one formed chiefly of connective tissue, containing occasionally a few fat-cells; the inner one, of elastic fibres of the finer kind, forming dense membranous networks, which can again be separated into several layers. In young bones the periosteum is thick and very vascular, and is intimately connected at either end of the bone with the epiphyseal cartilage, but less closely with the shaft, from which it is separated by a layer of soft tissue, containing a number of granular corpuscles or "osteoblasts," in which ossification proceeds on the exterior of the young bone. Later in life the periosteum is thinner, less vascular, and the osteoblasts have become converted into an epithelioid layer, which is separated from the rest of the periosteum in many places by cleft-like spaces, which are supposed to serve for the transmission of lymph. The periosteum serves as a nidus for the ramification of the vessels previous to their distribution in the bone; hence the liability of bone to exfoliation or necrosis, when denuded of this membrane by injury or disease. Fine nerves and lymphatics, which generally accompany the arteries, may also be demonstrated in the periosteum.

The **marrow** not only fills up the cylindrical cavity in the shafts of the long bones, but also occupies the spaces of the cancellous tissue and extends into the larger bony canals (Haversian canals) which contain the blood-vessels. It differs in composition in different bones. In the shafts of adult long bones the marrow is of a *yellow* color, and contains, in 100 parts, 96 of fat, 1 of areolar tissue and vessels, and 3 of fluid, with extractive matter, and consists of a matrix of fibrous tissue, supporting numerous blood-vessels and cells, most of which are fat-cells, but some are "marrow-cells," such as occur in the red marrow, to be immediately described. In the flat and short bones, in the articular ends of the long bones, in the bodies of the vertebræ, in the cranial diploë, and in the sternum and ribs,

it is of a *red* color, and contains, in 100 parts, 75 of water and 25 of solid matter, consisting of cell-globulin, nucleo-proteid, extractives, salts, and only a small proportion of fat. The red marrow consists of a small quantity of connective tissue, blood-vessels, and numerous cells (Fig. 624), some few of which are fat-cells, but the great majority roundish nucleated cells, the true "marrow-cells" of Kölliker. These marrow-cells proper resemble in appearance lymphoid corpuscles, and like them are amœboid. Among them may be seen smaller cells, which possess a slightly pinkish hue; these are the *erythroblasts*, from which, as we have seen, the red corpuscles of the adult are derived, and which may be regarded as descendants of the nucleated colored corpuscles of the embryo.

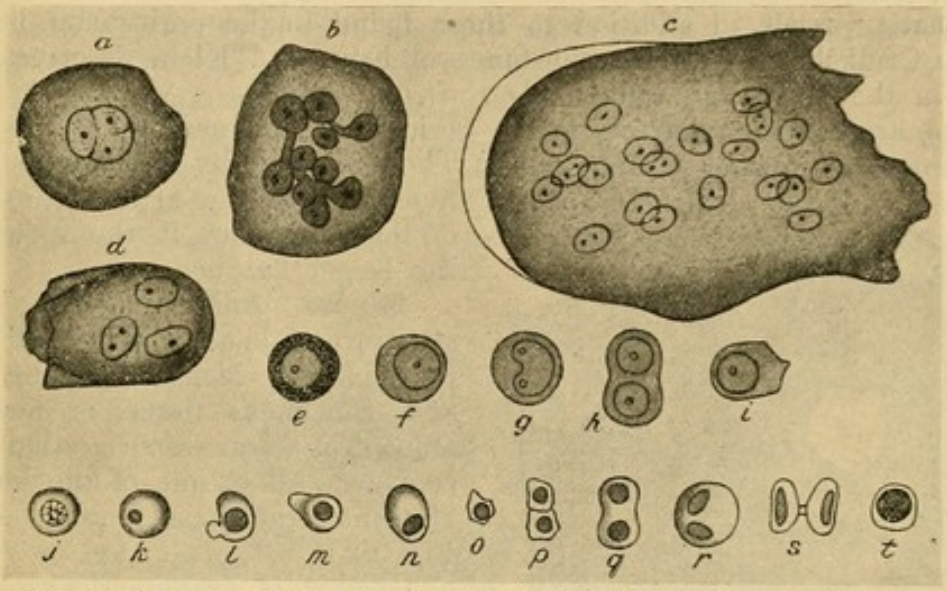

FIG. 624.—Cells of red marrow of the guinea-pig. (Schäfer.) *a-d*. Myeloplaques. *e-i*. Marrow-cells proper. *j-t*. Erythroblasts—some in process of division.

Giant-cells (*myelo-plaques*, *osteoclasts*), large, multinucleated, protoplasmic masses, are also to be found in both sorts of adult marrow, but more particularly in red marrow. They were believed by Kölliker to be concerned in the absorption of bone matrix, and hence the name which he gave to them—*osteoclasts*. They excavate small shallow pits or cavities, which are named *Howship's lacunæ*, in which they are found lying.

Vessels of Bone.—The blood-vessels of bone are very numerous. Those of the compact tissue are derived from a close and dense network of vessels ramifying in the periosteum. From this membrane vessels pass into the minute orifices in the compact tissue, running through the canals which traverse its substance. The cancellous tissue is supplied in a similar way, but by a less numerous set of larger vessels, which, perforating the outer compact tissue, are distributed to the cavities of the spongy portion of the bone. In the long bones numerous apertures may be seen at the ends near the articular surfaces, some of which give passage to the arteries of the larger set of vessels referred to; but the most numerous and largest apertures are for the veins of the cancellous tissue, which run separately from the arteries. The medullary canal in the shafts of the long bones is supplied by one large artery (or sometimes more), which enters the bone at the nutrient foramen (situated in most cases near the centre of the shaft), and perforates obliquely the compact structure. The *medullary* or *nutrient* artery, usually accompanied by one or two veins, sends branches upward and downward to supply the medullary membrane, which lines the central cavity and the adjoining canals. The ramifications of this vessel anastomose with the arteries both of the cancellous and compact tissues. In most of the flat, and in many of the short spongy bones, one or more large apertures are observed, which transmit, to the central parts of the bone, vessels corresponding to the medullary arteries and veins. The veins emerge from the long bones in three places (Kölliker): (1) by one or two large veins,

which accompany the artery; (2) by numerous large and small veins at the articular extremities; (3) by many small veins which arise in the compact substance. In the flat cranial bones the veins are large, very numerous, and run in tortuous canals in the diploic tissue, the sides of the canals being formed by a thin lamella of bone, perforated here and there for the passage of branches from the adjacent cancelli. The same condition is also found in all cancellous tissue, the veins being enclosed and supported by osseous structure and having exceedingly thin coats. When the bony structure is divided, the vessels remain patulous, and do not contract in the canals in which they are contained. Hence the occurrence of purulent absorption after amputation in those cases where the stump becomes inflamed and the cancellous tissue is infiltrated and bathed in pus.

Lymphatic vessels, in addition to those found in the periosteum, have been traced by Cruikshank, into the substance of bone, and Klein describes them as running in the Haversian canals.

Nerves are distributed freely to the periosteum, and accompany the nutrient arteries into the interior of the bone. They are said by Kölliker to be most numerous in the articular extremities of the long bones, in the vertebræ and the larger flat bones.

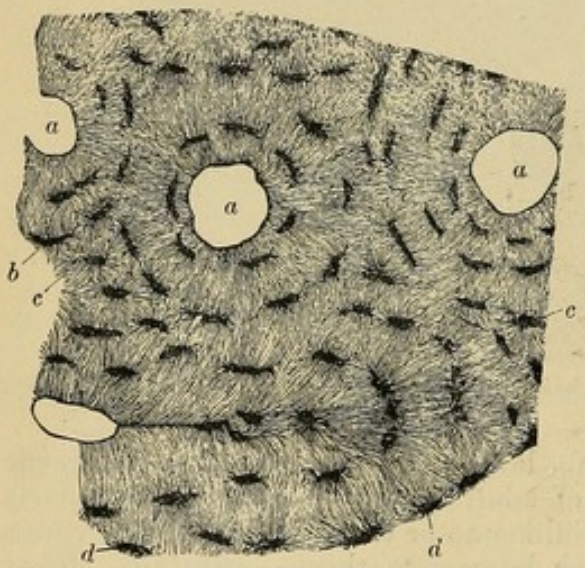

FIG. 625.—From a transverse section of the shaft of the humerus. Magnified 350 times. *a*. Haversian canals. *b*. Lacunæ, with their canaliculi in the lamellæ of these canals. *c*. Lacunæ of the interstitial lamellæ. *d*. Others at the surface of the Haversian systems, with canaliculi given off from one side.

Minute Anatomy.—The intimate structure of bone, which in all essential particulars is identical in the compact and cancellous tissue, is most easily studied in a transverse section from the compact wall of one of the long bones after maceration, such as is shown in Fig. 625.

If this is examined with a rather low power the bone will be seen to be mapped out into a number of circular districts, each one of which consists of a central hole, surrounded by a number of concentric rings. These districts are termed *Haversian systems;* the central hole is an *Haversian canal*, and the rings around are layers of bone-tissue arranged concentrically around the central canal, and termed *lamellæ*. Moreover, on closer examination, it will be found that between these lamellæ, and therefore also arranged concentrically around the central canal, are a number of little dark specks, the *lacunæ*, and that these lacunæ are connected with each other and with the central Haversian canal by a number of fine dark lines, which radiate like the spokes of a wheel and are called *canaliculi*. All these structures —the concentric lamellæ, the lacunæ, and the canaliculi—may be seen in any single Haversian system, forming a circular district round a central, Haversian, canal. Between these circular systems, filling in the irregular intervals which are left between them, are other lamellæ, with their lacunæ and canaliculi, running in various directions, but more or less curved (Fig. 626). These are termed *interstitial* lamellæ. Again, other lamellæ, for the most part found on the surface of the bone, are arranged concentrically to the circumference of bone, constituting, as it were, a single Haversian system of the whole bone, of which the medullary cavity would represent the Haversian canal. These latter lamellæ are termed *circumferential*, or by some authors *primary* or *fundamental* lamellæ, to distinguish them from those laid down around the axis of the Haversian canals, which are then termed *secondary* or *special* lamellæ.

The *Haversian canals*, seen as round holes in a transverse section of bone at or about the centre of each Haversian system, may be demonstrated to be true

canals if a longitudinal section is made, as in Fig. 628. It will then be seen that these round holes are tubes cut across, which run parallel with the longitudinal axis of the bone for a short distance, and then branch and communicate. They vary considerably in size, some being as large as $\frac{1}{200}$ of an inch in diameter; the average size being, however, about $\frac{1}{500}$ of an inch. Near the medullary cavity the canals are larger than those near the surface of the bone. Each canal contains two blood-vessels, with a small quantity of delicate connective tissue and some nerve-filaments. In the larger ones there are also lymphatic spaces and branched cells, the processes of which communicate, through the canaliculi, with the branched processes of certain bone-cells in the substance of the bone. Those canals near the surface of the bone open upon it by minute orifices, and those near the medullary cavity open in the same way into this space, so that the whole of the bone is permeated by a system of blood-vessels running through the bony canals in the centre of the Haversian systems.

The *lamellæ* are thin plates of bone-tissue encircling the central canal, and may be compared, for the sake of illustration, to a number of sheets of paper pasted one over another around a central hollow cylinder. After macerating a piece of bone in dilute mineral acid these lamellæ may be stripped off in a lon-

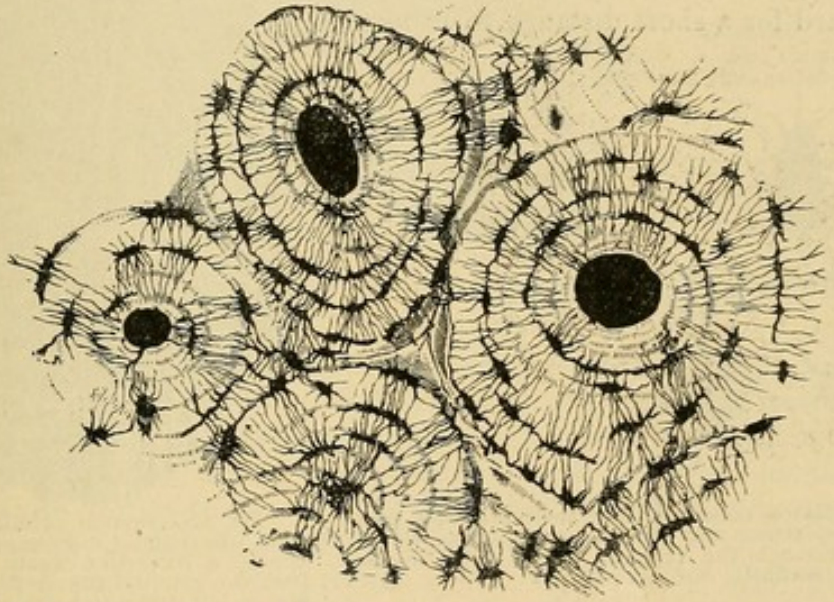

FIG. 626.—Transverse section of compact tissue of bone. Magnified about 150 diameters. (Sharpey.)

gitudinal direction as thin films. If one of these is examined with a high power under the microscope, it will be found to be composed of a finely reticular structure, presenting the appearance of lattice-work made up of very slender, transparent fibres, decussating obliquely, and coalescing at the points of intersection so as to form an exceedingly delicate network. These fibres are composed of fine fibrils, identical with those of white connective tissue. The intercellular matrix between the fibres has been replaced by calcareous deposit, which the acid dissolves. In many places the various lamellæ may be seen to be held together by tapering fibres, which run obliquely through them, pinning or bolting them together. These fibres were first described by Sharpey, and were named by him *perforating fibres* (Fig. 630).

The *lacunæ* are situated between the lamellæ, and consist of a number of oblong spaces. In an ordinary microscopic section, viewed by transmitted light, they appear as dark, oblong, opaque spots, and were formerly believed to be solid cells. Subsequently, when it was seen that the Haversian canals were channels which lodge the vessels of the part, and the canaliculi, minute tubes by which the plasma of the blood circulates through the tissue, the theory was formulated that the lacunæ were hollow spaces filled during life with the same fluid, and only lined (if

lined at all) by a delicate membrane. But this view was subsequently proved to be erroneous, for examination of the structure of bone, when recent, led Virchow to believe that the lacunæ are occupied during life by a branched cell, termed a bone-cell or bone-corpuscle, the processes from which pass down the canaliculi—a view which is now universally received (Fig. 627). It is by means of these cells that the fluids necessary for nutrition are brought into contact with the ultimate tissue of bone.

The *canaliculi* are exceedingly minute channels, which pass *across* the lamellæ and connect the lacunæ with the neighboring lacunæ and also with the Haversian canal. From this central canal a number of the canaliculi are given off, which radiate from it, and open into the first set of lacunæ, arranged around the Haversian canal, between the first and second lamellæ. From these lacunæ a second set of canaliculi are given off, which pass outward to the next series of lacunæ, and so on until they reach the periphery of the Haversian system: here the canaliculi given off from the last series of lacunæ do not communicate with the lacunæ of neighboring Haversian systems, but after passing outward for a short distance form loops and return to their own lacuna. Thus every part of the Haversian system is supplied with nutrient fluids derived from the vessels in the Haversian canals and traversing the canaliculi and lacunæ.

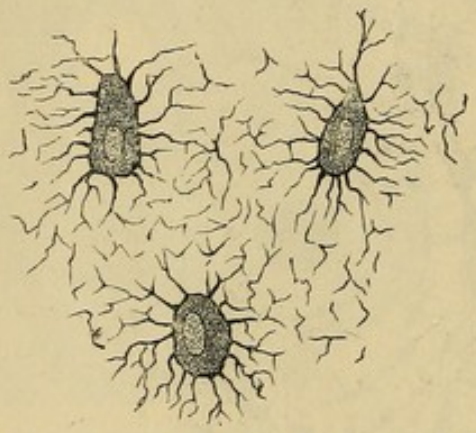

FIG. 627.—Nucleated bone-cells and their processes, contained in the bone-lacunæ and their canaliculi respectively. From a section through the vertebra of an adult mouse. (Klein and Noble Smith.)

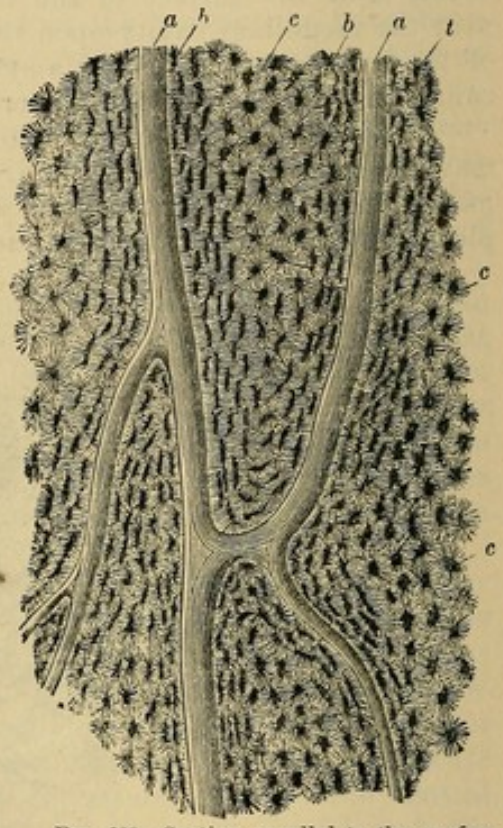

FIG. 628.—Section parallel to the surface from the shaft of the femur. Magnified 100 times. *a*, Haversian canals. *b*, Lacunæ seen from the side. *c*, Others seen from the surface in lamellæ which are cut horizontally.

The *bone-cells* are contained in the lacunæ, which, however, they do not completely fill. They are flattened nucleated cells, which Virchow has shown are homologous with those of connective tissue. The cells are branched, and the branches, especially in young bones, pass into the canaliculi from the lacunæ.

If a longitudinal section is examined, as in Fig. 628, the structure is seen to be the same. The appearance of concentric rings is replaced by that of lamellæ or rows of lacunæ, parallel to the course of the Haversian canals, and these canals appear like half-tubes instead of circular spaces. The tubes are seen to branch and communicate, so that each separate Haversian canal runs only a short distance. In other respects the structure has much the same appearance as in transverse sections.

In sections of thin plates of bone (as in the walls of the cells which form the cancellous tissue) the Haversian canals are absent, and the canaliculi open into the spaces of the cancellous tissue (medullary spaces), which thus have the same function as the Haversian canals in the more compact bone.

Chemical Composition.—Bone consists of an animal and an earthy part intimately combined together.

The animal part may be obtained by immersing the bone for a considerable time in dilute mineral acid, after which process the bone comes out exactly the same shape as before, but perfectly flexible, so that a long bone (one of the ribs, for example) can easily be tied in a knot. If now a transverse section is made (Fig. 630), the same general arrangement of the Haversian canals, lamellæ, lacunæ, and canaliculi is seen, though not so plainly, as in the ordinary section.

The earthy part may be obtained separate by calcination, by which the animal matter is completely burned out. The bone will still retain its original form, but

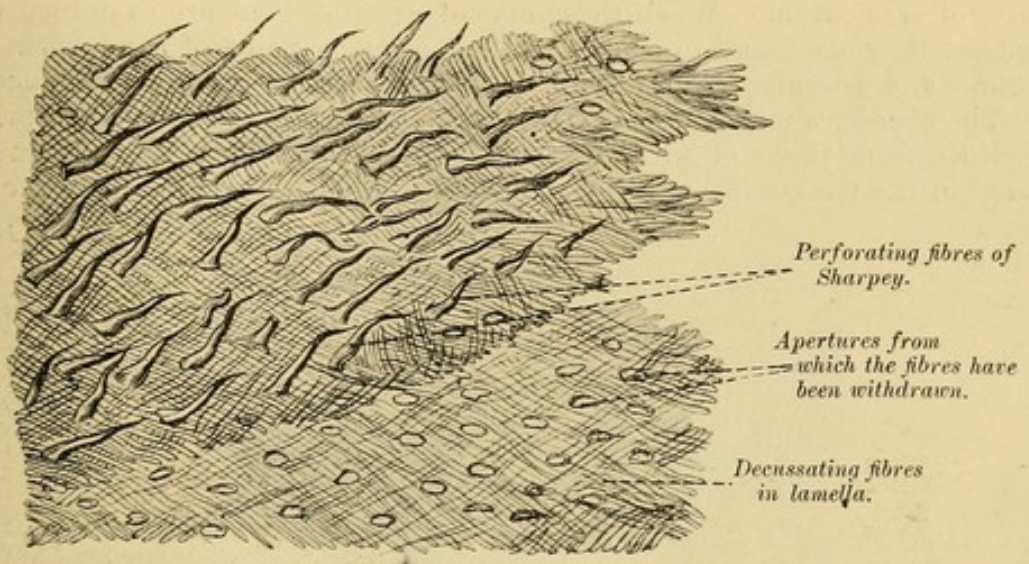

FIG. 629.—Lamellæ torn from a decalcified human parietal bone to show the perforating fibres of Sharpey. (Copied from a drawing by Allen Thomson.)

it will be white and brittle, will have lost about one-third of its original weight, and will crumble down with the slightest force. The earthy matter confers on bone its hardness and rigidity, and the animal matter its tenacity.

The animal basis is largely composed of *ossein*, which is identical with the collagen of white fibrous tissue, so that when boiled with water, especially under pressure, it is almost entirely resolved into gelatin.

The organic matter of bone forms about *one-third*, or 33.3 per cent.; the inorganic matter, *two-thirds*, or 66.7 per cent. Of the earthy matter, five-sixths is calcium phosphate, the remainder consisting of calcium carbonate, calcium fluoride, calcium chloride, and magnesium phosphate, with small amounts of sodium chloride and sulphate. Even after the removal of all the marrow a small percentage of fat is still found in bone.

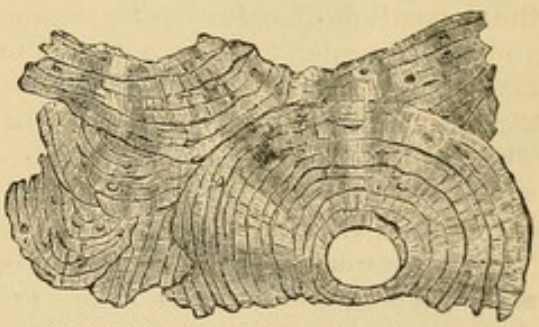

FIG. 630.—Section of bone after the removal of the earthy matter by the action of acids.

Some of the diseases to which bones are liable mainly depend on the disproportion between the two constituents of bone. Thus in the disease called rickets, so common in the children of the poor, the bones become bent and curved, either from the superincumbent weight of the body or under the action of certain muscles. This depends upon some defect of nutrition by which bone becomes deprived of its normal proportion of earthy matter, while the animal matter is of unhealthy quality. In the vertebræ of a rickety subject Bostock found in 100 parts 79.75 animal and 20.25 earthy matter.

Development of Bone.—In the fœtal skeleton some bones are preceded by

membrane, such as those forming the roof and sides of the skull; others, such as the bones of the limbs, are preceded by rods of cartilage. Hence two kinds of ossification are described: the *intramembranous* and the *intracartilaginous*.

Intramembranous Ossification.—In the case of bones which are developed in membrane no cartilaginous mould precedes the appearance of the bone-tissue. The membrane, which occupies the place of the future bone, is of the nature of connective tissue, and ultimately forms the periosteum. At this stage it is seen to be composed of fibres and granular cells in a matrix. The outer portion is more fibrous, while internally, the cells or *osteoblasts* predominate; the whole tissue is richly supplied with blood-vessels. At the outset of the process of bone formation a little network of bony spiculæ is first noticed radiating from the point or centre of ossification. When these rays of growing bone are examined with a microscope, they are found to consist at their growing point of a network of fine clear fibres and granular corpuscles with an intervening ground substance (Fig. 631). The fibres are termed *osteogenetic* fibres, and are made up of fine fibrils differing little from those of white fibrous tissue. Like them, they are probably deposited in the matrix through the influence of the cells—in this case the osteo-

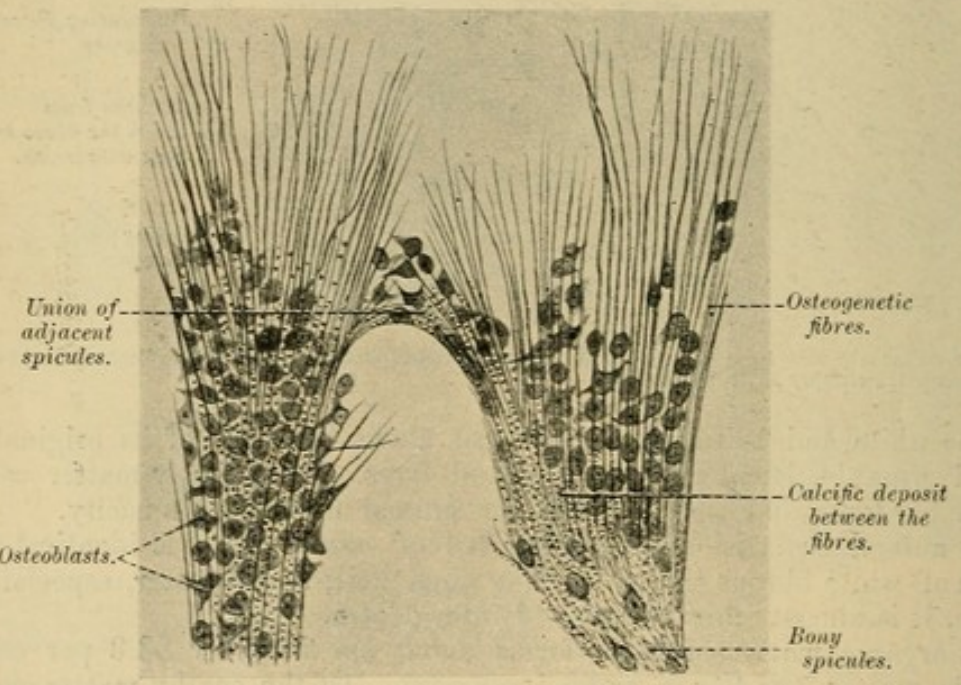

FIG. 631.—Part of the growing edge of the developing parietal bone of a fœtal cat. (After J. Lawrence.)

blasts. The osteogenetic fibres soon assume a dark and granular appearance from the deposition of calcareous granules in the fibres and in the intervening matrix, and as they calcify they are found to enclose some of the granular corpuscles or osteoblasts. By the fusion of the calcareous granules the bony tissue again assumes a more transparent appearance, but the fibres are no longer so distinctly seen. The involved osteoblasts form the corpuscles of the future bone, the spaces in which they are enclosed constituting the lacunæ. As the osteogenetic fibres grow out to the periphery they continue to calcify, and give rise to fresh bone spicules. Thus a network of bone is formed, the meshes of which contain the blood-vessels and a delicate connective tissue crowded with osteoblasts. The bony trabeculæ thicken by the addition of fresh layers of bone formed by the osteoblasts on their surface, and the meshes are correspondingly encroached upon. Subsequently successive layers of bony tissue are deposited under the periosteum and round the larger vascular channels, which become the Haversian canals, so that the bone increases much in thickness.

Intracartilaginous Ossification.—Just before ossification begins the bone is entirely cartilaginous, and in a long bone, which may be taken as an example, the process commences in the centre and proceeds toward the extremities, which for

some time remain cartilaginous. Subsequently a similar process commences in one or more places in those extremities and gradually extends through them. The extremities do not, however, become joined to the shaft by bony tissue until growth has ceased, but are attached to it by a layer of cartilaginous tissue termed the *epiphyseal cartilage*.

The first step in the ossification of the cartilage is that the cartilage-cells, at the point where ossification is commencing and which is termed a *centre of ossification*, enlarge and arrange themselves in rows (Fig. 632). The matrix in which they are imbedded increases in quantity, so that the cells become further separated from each other. A deposit of calcareous material now takes place in this matrix,

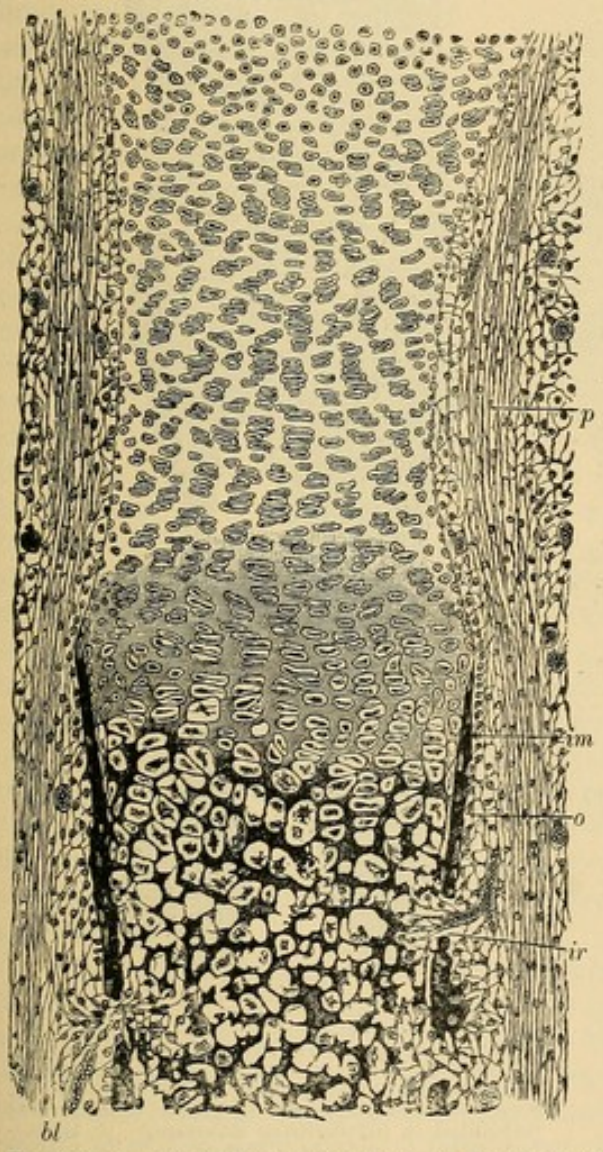

FIG. 632.—Section of fœtal bone of cat. *ir.* Irruption of the subperiosteal tissue. *p.* Fibrous layer of the periosteum. *o.* Layer of osteoblasts. *im.* Subperiosteal bony deposit. (From Quain's *Anatomy*, E. A. Schäfer.)

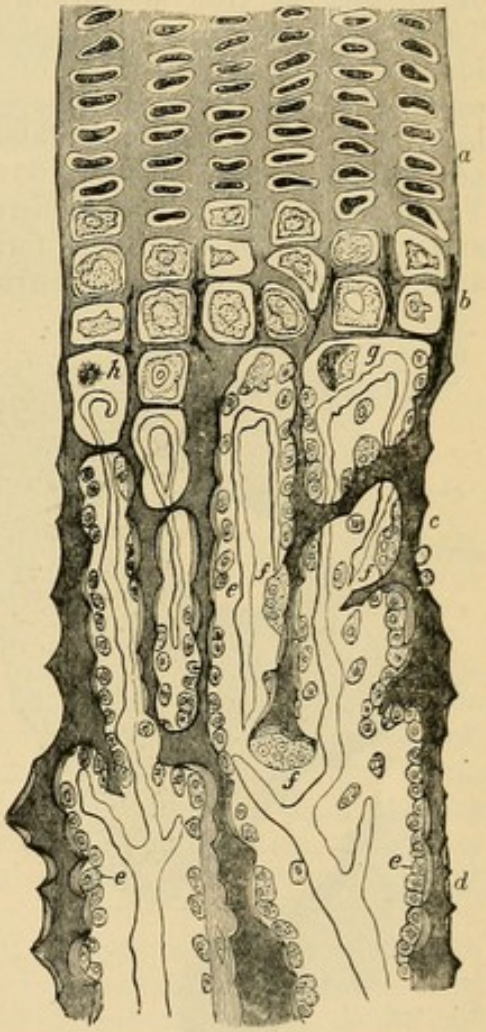

FIG. 633.—Part of a longitudinal section of the developing femur of a rabbit. *a.* Flattened cartilage-cells. *b.* Enlarged cartilage-cells. *c. d.* Newly-formed bone. *e.* Osteoblasts. *f.* Giant-cells or osteoclasts. *g. h.* Shrunken cartilage-cells. (From *Atlas of Histology*, Klein and Noble Smith.)

between the rows of cells, so that they become separated from each other by longitudinal columns of calcified matrix, presenting a granular and opaque appearance. Here and there the matrix between two cells of the same row also becomes calcified, and transverse bars of calcified substance stretch across from one calcareous column to another. Thus there are longitudinal groups of the cartilage-cells enclosed in oblong cavities, the walls of which are formed of calcified matrix, which cuts off all nutrition from the cells, and they, in consequence, waste, leaving spaces called the *primary areolæ* (Sharpey).

At the same time that this process is going on in the centre of the solid bar of cartilage of which the fœtal bone consists, certain changes are taking place on

its surface. This is covered by a very vascular membrane, the *perichondrium*, entirely similar to the embryonic connective tissue already described as constituting the basis of membrane-bone, on the inner surface of which, that is to say, on the surface in contact with the cartilage, are gathered the formative cells, the *osteoblasts*. By the agency of these cells a thin layer of bony tissue is being formed between the perichondrium and the cartilage, by the *intramembranous* mode of ossification just described. There are then, in this first stage of ossification, two processes going on simultaneously: in the centre of the cartilage the formation of a number of oblong spaces, formed of calcified matrix and containing the withered cartilage-cells, and on the surface of the cartilage the formation of a layer of true membrane-bone. The second stage consists in the prolongation into the cartilage of processes of the deeper or osteogenetic layer of the perichondrium, which has now become periosteum (Fig. 632, *ir*). The processes consist of blood-vessels and cells—*osteoblasts* or bone-formers, and *osteoclasts*, or bone-destroyers.

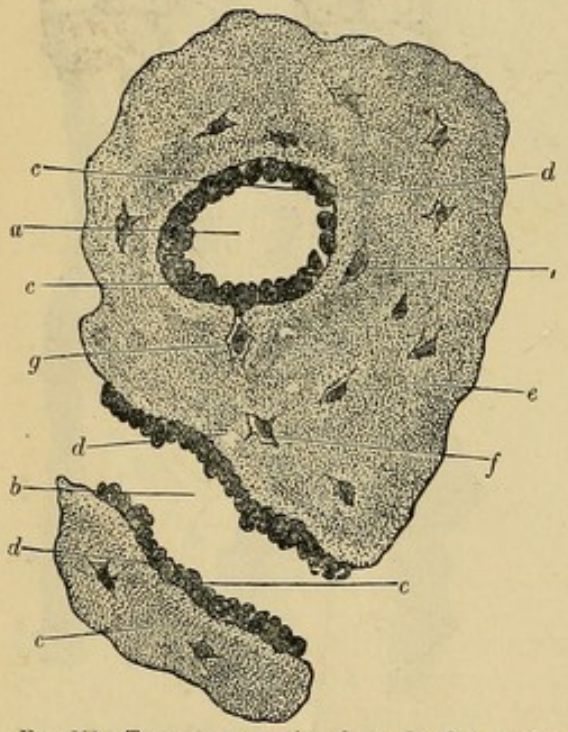

FIG. 634.—Transverse section from the femur of a human embryo about eleven weeks old. *a*. A medullary sinus cut transversely; and *b*, another, longitudinally. *c*. Osteoblasts. *d*. Newly-formed osseous substance of a lighter color. *e*. That of greater age. *f*. Lacunæ with their cells. *g*. A cell still united to an osteoblast.

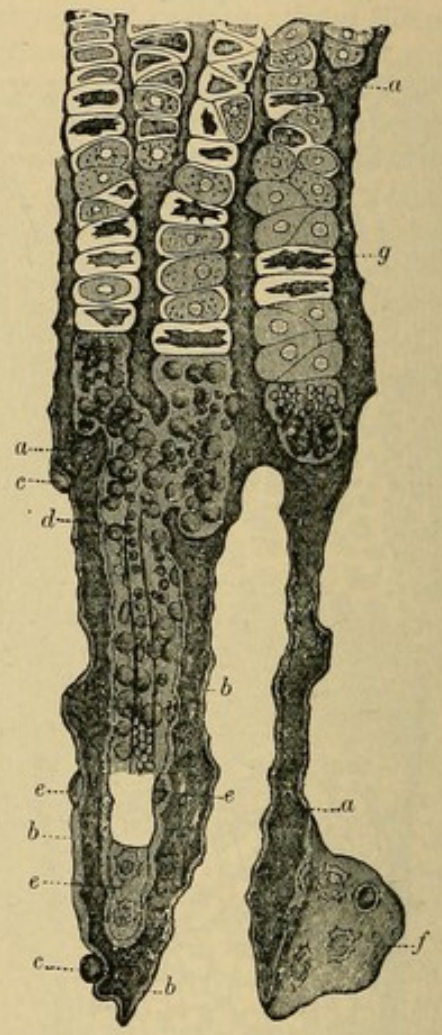

FIG. 635.—Vertical section from the edge of the ossifying portion of the diaphysis of a metatarsal bone from a fœtal calf. (After Müller.) *a*. Ground-mass of the cartilage. *b*. Of the bone. *c*. Newly-formed bone-cells in profile, more or less imbedded in intercellular substance. *d*. Medullary canal in process of formation, with vessels and medullary cells. *e*. *f*. Bone-cells on their broad aspect. *g*. Cartilage-capsules arranged in rows, and partly with shrunken cell-bodies.

The latter are similar to the giant-cells (myelo-plaques) found in marrow, and they excavate passages through the new-formed bony layer by absorption, and pass through it into the calcified matrix (Fig. 632). Wherever these processes come in contact with the calcified walls of the primary areolæ they absorb it, and thus cause a fusion of the original cavities and the formation of larger spaces, which are termed the *secondary areolæ* (Sharpey) or *medullary spaces* (Müller). In these secondary spaces the original cartilage-cells having disappeared, become filled with embryonic marrow, consisting of osteoblasts and vessels, and derived in the manner described above, from the osteogenetic layer of the periosteum (Fig. 633).

Thus far there has been traced the formation of enlarged spaces (secondary areolæ), the perforated walls of which are still formed by calcified cartilage-matrix, containing an embryonic marrow, derived from the processes sent in from the osteogenetic layer of the periosteum, and consisting of blood-vessels and round cells, osteoblasts (Fig. 633). The walls of these secondary areolæ are at this time of only inconsiderable thickness, but they become thickened by the deposition of layers of new bone on their interior. This process takes place in the following manner: Some of the osteoblasts of the embryonic marrow, after undergoing rapid division, arrange themselves as an epithelioid layer on the surface of the wall of the space (Fig. 634). This layer of osteoblasts form a bony stratum, and thus the wall of the space becomes gradually covered with a layer of true osseous substance. On this a second layer of osteoblasts arrange themselves, and in their turn form an osseous layer. By the repetition of this process the original cavity becomes very much reduced in size, and at last only remains as a small circular hole in the centre, containing the remains of the embryonic marrow — that is, a blood-vessel and a few osteoblasts. This small cavity constitutes the Haversian canal of the perfectly ossified bone. The successive layers of osseous matter which have been laid down and which encircle this central canal constitute the lamellæ of which, as we have seen, each Haversian system is made up. As the successive layers of osteoblasts form osseous tissue, certain of the osteoblastic cells remain included between the various bony layers. These persist as the corpuscles of the future bone, the spaces enclosing them forming the lacunæ (Figs. 634 and 636). The **canaliculi**, at first extremely short, are supposed to be extended by absorption, so as to meet those of neighboring lacunæ.

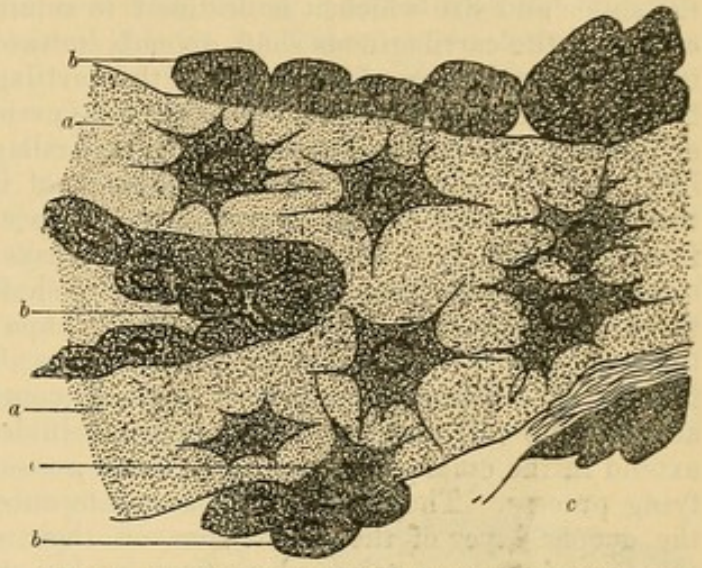

FIG. 636.—Osteoblasts from the parietal bone of a human embryo thirteen weeks old. (After Gegenbauer.) *a*, Bony septa with the cells of the lacunæ. *b*, Layers of osteoblasts. *c*, The latter in transition to bone-corpuscles.

Such are the changes which may be observed at one particular point, the centre of ossification. While they have been going on here a similar process has been set up in the surrounding parts and has been gradually proceeding toward the end of the shaft, so that in the ossifying bone all the changes described above may be seen in different parts, from the true bone in the centre of the shaft to the hyaline cartilage at the extremities. The bone thus formed differs from the bone of the adult in being more spongy and less regularly lamellated.

Thus far, then, we have followed the steps of a process by which a solid bony mass is produced, having vessels running into it from the periosteum, Haversian canals in which those vessels run, medullary spaces filled with fœtal marrow, lacunæ with their contained bone-cells, and canaliculi growing out of these lacunæ.

This process of ossification, however, is not the origin of the whole of the skeleton, for even in those bones in which the ossification proceeds in a great measure from a single centre, situated in the cartilaginous shaft of a long bone, a considerable part of the original bone is formed by intramembranous ossification beneath the perichondrium or periosteum; so that the girth of the bone is increased by bony deposit from the deeper layer of this membrane. The shaft of the bone

is at first solid, but a tube is hollowed out in it by absorption around the vessels passing into it, which becomes the medullary canal. This absorption is supposed to be brought about by large "giant-cells," the so-called osteoclasts of Kölliker (Fig. 633). They vary in shape and size, and are known by containing a large number of clear nuclei, sometimes as many as twenty. The occurrence of similar cells in some tumors of bones has led to such tumors being denominated "myeloid."

As more and more bone is removed by this process of absorption from the interior of the bone to form the medullary canal, so more and more bone is deposited on the exterior from the periosteum, until at length the bone has attained the shape and size which it is destined to retain during adult life. As the ossification of the cartilaginous shaft extends toward the articular ends it carries with it, as it were, a layer of cartilage, or the cartilage grows as it ossifies, and thus the bone is increased in length. During this period of growth the articular end, or epiphysis, remains for some time entirely cartilaginous; then a bony centre appears in it, and it commences the same process of intracartilaginous ossification; but this process never extends to any great distance. The epiphyses remain separated from the shaft by a narrow cartilaginous layer for a definite time. This layer ultimately ossifies, the distinction between shaft and epiphysis is obliterated, and the bone assumes its completed form and shape. The same remarks also apply to the processes of bone which are separately ossified, such as the trochanters of the femur. The bones, having been formed, continue to grow until the body has acquired its full stature. They increase in length by ossification continuing to extend in the epiphysial cartilage, which goes on growing in advance of the ossifying process. They increase in circumference by deposition of new bone, from the deeper layer of the periosteum, on their external surface, and at the same time an absorption takes place from within, by which the medullary cavity is increased.

The medullary spaces which characterize the cancellous tissue are produced by the absorption of the original fœtal bone in the same way as the original medullary canal is formed. The distinction between the cancellous and compact tissue appears to depend essentially upon the extent to which this process of absorption has been carried; and we may perhaps remind the reader that in morbid states of the bone inflammatory absorption produces exactly the same change, and converts portions of bone naturally compact into cancellous tissue.

The number of ossific centres is different in different bones. In most of the short bones ossification commences by a single point in the centre, and proceeds toward the circumference. In the long bones there is a central point of ossification for the shaft or diaphysis; and one or more for each extremity, the epiphysis. That for the shaft is the first to appear. The union of the epiphyses with the shaft takes place in the reverse order to that in which their ossification began, with the exception of the fibula, and appears to be regulated by direction of the nutrient artery of the bone. Thus the nutrient arteries of the bones of the arm and forearm are directed toward the elbow, and the epiphyses of the bones forming this joint become united to the shaft before those at the opposite extremity. In the lower limb, on the other hand, the nutrient arteries pass in a direction from the knee: that is, upward in the femur, downward in the tibia and fibula; and in them it is observed that the upper epiphysis of the femur, and the lower epiphysis of the tibia and fibula, become first united to the shaft.

Where there is only one epiphysis, the medullary artery is directed toward that end of the bone where there is no additional centre, as toward the acromial end of the clavicle, toward the distal end of the metacarpal bone of the thumb and great toe, and toward the proximal end of the other metacarpal and metatarsal bones.

Besides these epiphyses for the articular ends, there are others for projecting parts or processes, which are formed separately from the bulk of the bone. For

an account of these the reader must be referred to the description of the individual bones in the sequel.

A knowledge of the exact periods when the epiphyses become joined to the shaft is often of great importance in medico-legal inquiries. It also aids the surgeon in the diagnosis of many of the injuries to which the joints are liable; for it not infrequently happens that, on the application of severe force to a joint, the epiphysis becomes separated from the shaft, and such injuries may be mistaken for fracture or dislocation.

THE MUSCULAR TISSUE.

The **muscles** are formed of bundles of reddish fibres, endowed with the property of contractility. The two principal kinds of muscular tissue found in the body are voluntary and involuntary. The former of these, from the characteristic appearances which their fibres exhibit under the microscope, are known as the "striped" muscles, and from the fact that it is capable of being put into action and controlled by the will, as "voluntary" muscle. The fibres of the latter do not present any cross-striped appearance, and for the most part are not under the control of the will; hence they are known as the "unstriped" or "involuntary" muscles. The muscular fibres of the heart differ in certain particulars from both these groups, and they are therefore separately described as "cardiac" muscular fibres.

Thus it will be seen that there are three varieties of muscular fibres: (1) Transversely striated muscular fibres, which are for the most part voluntary and under the control of the will, but some of which are not so, such as the muscles of the pharynx and upper part of the œsophagus. This variety of muscle is sometimes called *skeletal*. (2) Transversely striated muscular fibres, which are not under the control of the will—*i. e.*, the cardiac muscle. (3) Plain or unstriped muscular fibres, which are involuntary and controlled by a different part of the nervous system from that which controls the activity of the voluntary muscles. Such are the muscular walls of the stomach and intestine, of the uterus and bladder, of the blood-vessels, etc.

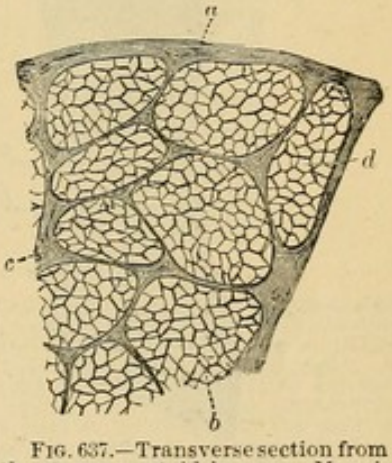

FIG. 637.—Transverse section from the sterno-mastoid in man. Magnified 50 times. *a*. External perimysium. *b*. Fasciculus. *c*. Internal perimysium. *d*. Fibre.

The **striped** or **voluntary muscles** are composed of bundles of fibres enclosed in a delicate web called the "perimysium," in contradistinction to the sheath of areolar tissue which invests the entire muscle, the "epimysium" (Fig. 637). The bundles are termed "fasciculi"; they are prismatic in shape, of different sizes in different muscles, and for the most part placed parallel to one another, though they have a tendency to converge toward their tendinous attachments. Each fasciculus is made up of a bundle of *fibres*, which also run parallel with each other, and which are separated from one another by a delicate connective tissue derived from the perimysium, and termed *endomysium*. This does not form the sheath of the fibres, but serves to support the blood-vessels and nerves ramifying between them. The fibres are enclosed in a separate and distinct sheath of their own, but it is not areolar tissue, and is therefore not derived from the perimysium.

A *muscular fibre* may be said to consist of a soft contractile substance enclosed in a tubular sheath, named by Bowman the *sarcolemma*. The fibres are cylindrical or prismatic in shape, and are of no great length, not exceeding, it is said, an inch and a half. They end either by blending with the tendon or aponeurosis, or else by rounded or tapering extremities which are connected to the neighboring fibres by means of the sarcolemma. Their breadth varies in man from $\frac{1}{200}$ to $\frac{1}{600}$ of an inch. As a rule, the fibres do not divide or anastomose; but occasionally, especially in the tongue and facial muscles, the fibres may be

seen to divide into several branches. The precise mode in which the muscular fibre joins the tendon has been variously described by different observers. It may, perhaps, be sufficient to say that the sarcolemma, or membranous investment of the muscular fibre, appears to become blended with a small bundle of fibres, into which the tendon becomes subdivided, while the muscular substance terminates abruptly and can readily be made to retract from the point of junction. The areolar tissue between the fibres appears to be prolonged more or less into the tendon, so as to form a kind of sheath around the tendon bundles for a longer or shorter distance. When muscular fibres are attached to the skin or mucous membranes, their fibres are described by Hyde Salter as becoming continuous with those of the areolar tissue.

The *sarcolemma*, or tubular sheath of the fibre, is a transparent, elastic, and apparently homogeneous membrane of considerable toughness, so that it will sometimes remain entire when the included substance is ruptured (see Fig. 638). On

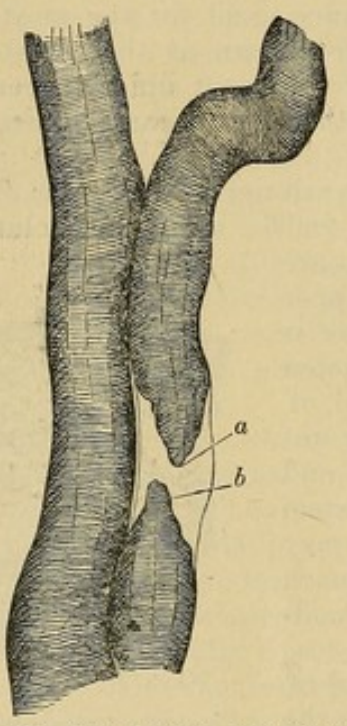

FIG. 638.—Two human muscular fibres. Magnified 350 times. In the one, the bundle of fibrillæ (*b*) is torn, and the sarcolemma (*a*) is seen as an empty tube.

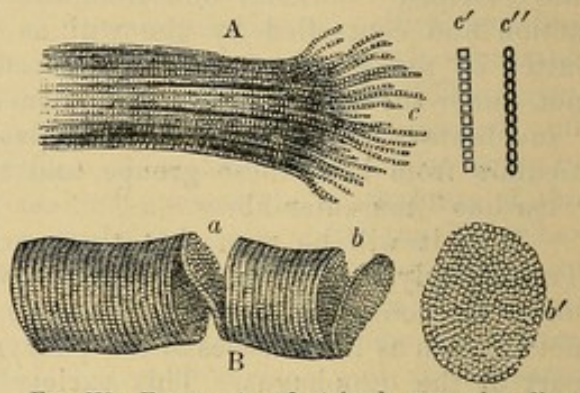

FIG. 639.—Fragments of striped muscular fibres, showing a cleavage in opposite directions. Magnified 300 diameters. A. Longitudinal cleavage. The longitudinal and transverse lines are both seen. Some longitudinal lines are darker and wider than the rest, and are not continuous from end to end. This results from partial separation of the fibrillæ. *c*. Fibrillæ separated from one another by violence at the broken end of the fibre, and marked by transverse lines equal in width to those on the fibre. *c'*, *c''* represent two appearances commonly presented by the separated single fibrillæ (more highly magnified). At *c'* the borders and transverse lines are all perfectly rectilinear, and the included spaces perfectly rectangular. At *c''* the borders are scalloped and the spaces bead-like. When most distinct and definite the fibrilla presents the former of these appearances. B. Transverse cleavage. The longitudinal lines are scarcely visible. *a*. Incomplete fracture following the opposite surfaces of a disk, which stretches across the interval, and retains the two fragments in connection. The edge and surfaces of this disk are seen to be minutely granular, the granules corresponding in size to the thickness of the disk and to the distance between the faint longitudinal lines. *b*. Another disk nearly detached. *b'*. Detached disk, more highly magnified, showing the sarcous elements.

the internal surface of the sarcolemma in mammalia, and also in the substance of the fibre in the lower animals, elongated nuclei are seen, and in connection with these a row of granules, apparently fatty, is sometimes observed.

Upon examination of a voluntary muscular fibre by transmitted light, it is found to be apparently marked by alternate light and dark bands or striæ, which pass transversely, or somewhat obliquely, round the fibre (Fig. 638). The dark and light bands are of nearly equal breadth, and alternate with great regularity. They vary in breadth from about $\frac{1}{1200}$ to $\frac{1}{1700}$ of an inch. If the surface is carefully focussed, rows of granules will be detected at the point of junction of the dark and light bands, and very fine longitudinal lines may be seen running through the dark bands and joining these granules together. By treating the specimen with certain reagents (*e. g.*, chloride of gold) fine lines may be seen running transversely between the granules, uniting them together. This appearance is believed to be due to a reticulum or network of interstitial substance lying between the contractile portions of the muscle. The longitudinal striation gives

the fibre the appearance of being made up of a bundle of fibrillæ, which have been termed *sarcostyles* or *muscle-columns;* and if the fibre is hardened in alcohol, it can be broken up longitudinally and the sarcostyles separated from each other (Fig. 639, A). The reticulum, with its longitudinal and transverse meshes, is *sarcoplasm.*

If now a transverse section of a muscular fibre is made, it is seen to be divided into a number of areas, called the *areas of Cohnheim*, more or less polyhedral in shape, and consisting of the transversely divided sarcostyles, surrounded by transparent series of sarcoplasm (Fig. 639, B, *b*).

Upon closer examination, and by somewhat altering the focus, the appearances become more complicated, and are susceptible of various interpretations. The transverse striation, which in Figs. 638 and 639 appears as a mere alternation of dark and light bands,is resolved into the appearance seen in Fig. 640, which shows a series of broad dark bands, separated by light bands, which are divided into two by a dark dotted line. This line is termed *Krause's membrane* (Fig. 642, K), because it was believed by Krause to be an actual membrane continuous with

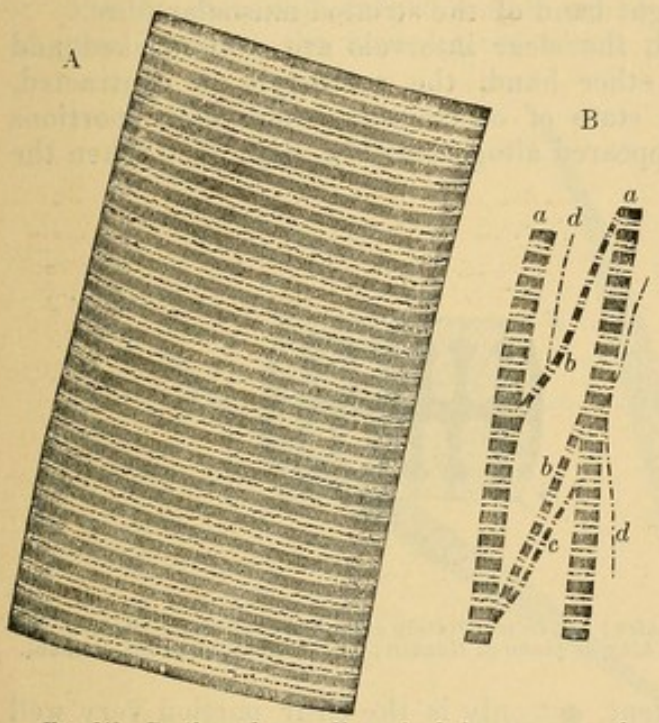

FIG. 640.—Portion of a medium-sized human muscular fibre. Magnified nearly 800 diameters. B. Separated bundles of fibrils, equally magnified. *a. a.* Larger, and *b. b.* smaller collections. *c.* Still smaller. *d. d.* The smallest which could be detached.



FIG. 641.—Part of a striped muscular fibre of the water-beetle, prepared with absolute alcohol. Magnified 300 diameters. (Klein and Noble Smith.) *a.* Sarcolemma. *b.* Membrane of Krause; owing to contraction during hardening, the sarcolemma shows regular bulgings. At the side of Krause's membrane is the transparent lateral disk. Several nuclei of muscle-corpuscles are shown, and in them a minute network.

the sarcolemma, and dividing the light band into two compartments. It is now more usually regarded as being due to an optical phenomenon, from the light being reflected between disks of different refrangibility. In addition to the membrane of Krause, fine clear lines may be made out, with a sufficiently high power, crossing the centre of the dark band; these are known as the *lines of Hensen* (Fig. 642, H).

Formerly it was supposed by Bowman that a muscular fibre was made up of a number of quadrangular particles, which he named sarcous elements, joined together like so many bricks forming a column, and he came to this conclusion because he found that under the influence of certain reagents the fibre could be broken up transversely into disks, as well as longitudinally into fibrillæ (Fig. 639, B). But it is now believed that this cross-cleavage is purely artificial, and that a muscular fibre is built up of fibrillæ and not of small quadrangular particles.

Assuming that this is so, we have now to consider a little more in detail the minute structure of these longitudinal fibrillæ, or sarcostyles, as they are termed. Perhaps there are few subjects in histology which have received more attention,

and in which the appearances seen under the microscrope have been more differently interpreted, than the minute anatomy of muscular fibre. Schäfer has recently worked out this subject, particularly in the wing-muscles of insects, which are peculiarly adapted for this purpose on account of the large amount of interstitial sarcoplasm which separates the sarcostyles. In the following description we shall closely follow that given by Professor Schäfer (Fig. 642).

Each sarcostyle may be said to be made up of successive portions, each of which Schäfer terms a *sarcomere*. This is the portion, situated between two membranes of Krause, which transversely divides the light band. Each sarcomere consists of a central dark part, which forms a portion of the dark band of the whole fibre, and is named by Schäfer a *sarcous element*.[1] This sarcous element really consists of two parts, superimposed one on the top of the other, and when the fibre is stretched, these two parts become separated from each other at the line of Hensen (Fig. 642, A). On either side of this central dark portion is a clear layer, most visible when the fibre is extended; this is situated between the dark centre and the membrane of Krause, and when the sarcomeres are joined together to form the sarcostyle, constitutes the light band of the striated muscular fibre.

When the sarcostyle is extended, the clear intervals are well marked and plainly to be seen; when, on the other hand, the sarcostyle is contracted, that is to say, the muscle is in a state of contraction, these clear portions are very small or they may have disappeared altogether (Fig. 642, B). When the

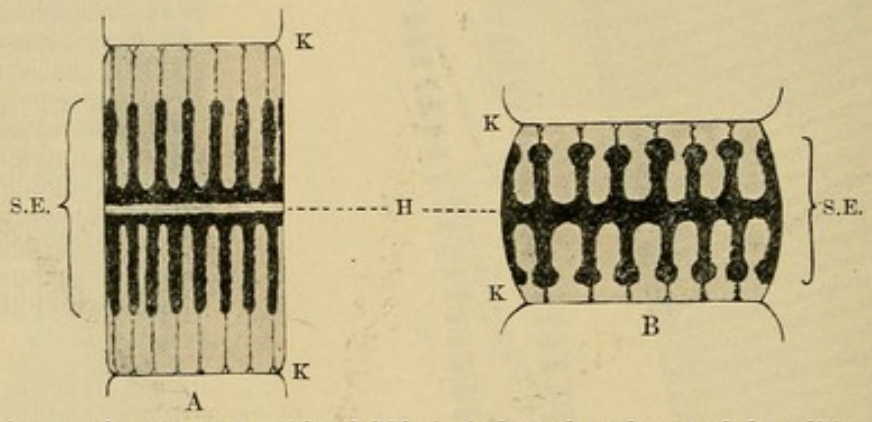

FIG. 642.—Diagram of a sarcomere. (After Schäfer.) A. In moderately extended condition. B. In a contracted condition. K.K. Membranes of Krause; H. Line or plane of Hensen; S.E. Poriferous sarcous element.

sarcostyle is stretched to its full extent, not only is the clear portion very well marked, but the dark portion—the sarcous element—will be seen to be separated into its two constituents along the line of Hensen.

The sarcous element does not lie free in the sarcomere, for when the sarcostyle is stretched, so as to render the clear portion visible, very fine lines, which are probably septa, may be seen running through it from the sarcous element to the membrane of Krause.

Schäfer explains these phenomena in the following way. He considers that each sarcous element is made up of a number of longitudinal channels, which open into the clear part toward the membrane of Krause, but are closed at the line of Hensen. When the muscular fibre is contracted the *clear* part of the muscular substance finds its way into these channels or tubes, and is therefore hidden from sight, but at the same time it swells up the sarcous element and widens and shortens the sarcomere. When, on the other hand, the fibre is extended, this clear substance finds its way out of the tubes and collects between the sarcous element and the membrane of Krause, and gives the appearance of the light part between these two structures; by this means it elongates and narrows the sarcomere.

If this view is true, it is a matter of great interest, and, as Schäfer has shown, harmonizes the contraction of muscle with the amœboid action of proto-

[1] This must not be confused with the "sarcous element of Bowman." (See above.)

plasm. In an amœboid cell there is a framework of spongioplasm, which stains with hæmatoxylin and similar reagents, enclosing in its meshes a clear substance, hyaloplasm, which will not stain with these reagents. Under stimulation the hyaloplasm passes into the pores of the spongioplasm; without stimulation it tends to pass out as in the formation of pseudopodia. In muscle there is the same thing: viz., a framework of spongioplasm staining with hæmatoxylin—the substance of the sarcous element—and this encloses a clear hyaloplasm, the clear substance of the sarcomere, which resists staining with this reagent. During contraction of the muscle—*i. e.*, stimulation—this clear substance passes into the pores of the spongioplasm; while during extension of the muscle—*i. e.*, when there is no stimulation—it tends to pass out of the spongioplasm.

In this way the contraction is brought about: under stimulation the protoplasmic material (the clear substance of the sarcomere) recedes into the sarcous element, causing the sarcomere to widen out and shorten. The contraction of the muscle is merely the sum total of this widening out and shortening of these bodies.

The *capillaries* of striped muscle are very abundant, and form a sort of rectangular network, the branches of which run longitudinally in the endomysium

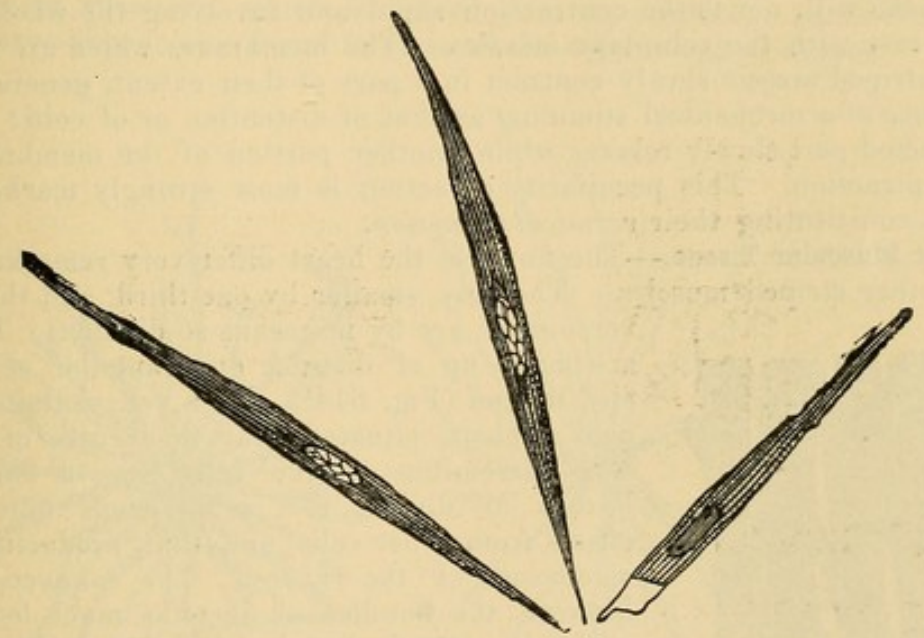

FIG. 643.—Non-striated muscular fibre. (From Kirke's *Physiology*.)

between the muscular fibres, and are joined at short intervals by transverse anastomosing branches. The larger vascular channels, arteries and veins, are found only in the perimysium, between the muscular fasciculi.

Nerves are profusely distributed to striped muscle. The mode of their termination will be described on a subsequent page.

The existence of *lymphatic* vessels in striped muscle has not been ascertained, though they have been found in tendons and in the sheath of the muscle.

The **unstriped plain, or involuntary muscle,** is found in the walls of the hollow viscera—viz., the lower half of the œsophagus and the whole of the remainder of the gastro-intestinal tube; in the trachea and bronchi, and the alveoli and infundibula of the lungs; in the gall-bladder and ductus communis choledochus; in the large ducts of the salivary and pancreatic glands; in the pelvis and calices of the kidney, the ureter, bladder, and urethra; in the female sexual organs—viz., the ovary, the Fallopian tubes, the uterus (enormously developed in pregnancy), the vagina, the broad ligaments, and the erectile tissue of the clitoris; in the male sexual organs—viz., the dartos of the scrotum, the vas deferens and epididymis, the vesiculæ seminales, the prostate gland, and the corpora cavernosa and corpus spongiosum; in the ducts of certain glands, as in Wharton's duct; in the capsule

and trabeculæ of the spleen; in the mucous membranes, forming the muscularis mucosæ; in the skin, forming the arrectores pilorum, and also in the sweat-glands; in the arteries, veins, and lymphatics: in the iris and the ciliary muscle.

Plain or unstriped muscle is made up of spindle-shaped cells, called *contractile fibre-cells*, collected into bundles and held together by a cement-substance (Fig. 643). These bundles are further aggregated into larger bundles or flattened bands, and bound together by ordinary connective tissue.

The *contractile fibre-cells* are elongated, spindle-shaped, nucleated cells of various lengths, averaging from $\frac{1}{600}$ to $\frac{1}{300}$ of an inch in length, and $\frac{1}{4500}$ to $\frac{1}{3500}$ of an inch in breadth. On transverse section they are more or less polyhedral in shape, from mutual pressure. They present a faintly longitudinal striated appearance, and consist of an elastic cell-wall containing a central bundle of fibrillæ, representing the contractile substance, and an oval or rod-like nucleus, which includes, within a membrane, a fine network communicating at the poles of the nucleus with the contractile fibres (Klein). The adhesive interstitial cement-substance, which connects the fibre-cells together, represents the endomysium, or delicate connective tissue which binds the fibres of striped muscular tissue into fasciculi; while the tissue connecting the individual bundles together represents the perimysium. The unstriped muscle, as a rule, is not under the control of the will, nor is the contraction rapid and involving the whole muscle, as is the case with the voluntary muscles. The membranes which are composed of the unstriped muscle slowly contract in a part of their extent, generally under the influence of a mechanical stimulus, as that of distention or of cold; and then the contracted part slowly relaxes while another portion of the membrane takes up the contraction. This peculiarity of action is most strongly marked in the intestines, constituting their *vermicular motion*.

Cardiac Muscular Tissue.—The fibres of the heart differ very remarkably from those of other striped muscles. They are smaller by one-third, and their transverse striæ are by no means so distinct. The fibres are made up of distinct quadrangular cells joined end to end (Fig. 644). Each cell contains a clear oval nucleus, situated near the centre of the cell. The extremities of the cells have a tendency to branch or divide, the subdivisions uniting with offsets from other cells, and thus producing an anastomosis of the fibres. The connective tissue between the bundles of fibres is much less than in ordinary striped muscle, and no sarcolemma has been proved to exist.

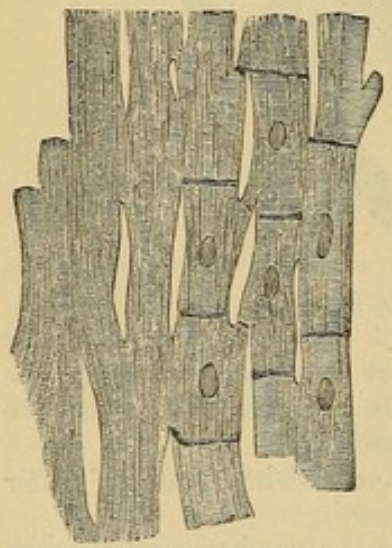

FIG. 644.—Anastomosing muscular fibres of the heart, seen in a longitudinal section. On the right the limits of the separate cells with their nuclei are exhibited somewhat diagrammatically.

Development of Muscle-Fibres.—Voluntary muscular fibres are developed from the mesoblast, the embryonic cells of which elongate, show multiplication of nuclei, and eventually become striated; the striation is first obvious at the side of the fibre, spreads around the circumference, and ultimately extends to the centre. The nuclei, at first situated centrally, gradually pass out to assume their final position immediately beneath the sarcolemma. In the case of plain muscle the mesoblastic cells assume a pointed shape at the extremities and become flattened, the nucleus also lengthening out to its permanent rod-like form.

Chemical Composition of Muscle.—In chemical composition the muscular fibres may be said, in round numbers, to consist of 75 per cent. of water, about 20 per cent. of proteids, 2 per cent. of fat, 1 per cent. of nitrogenous extractives and carbohydrates, and 2 per cent. of salts, which are mainly potassium phosphate and carbonate.

THE NERVOUS TISSUE.

The **nervous tissues** of the body are comprised in two great systems—the *cerebro-spinal* and the *sympathetic;* and each of these systems consist of a *central organ*, or series of central organs, and of *nerves.*

The *cerebro-spinal* system comprises the brain (including the medulla oblongata), the spinal cord, the cranial nerves, the spinal nerves, and the ganglia connected with both these classes of nerves. The *sympathetic* system consists of a double chain of ganglia, with the nerves which go to and come from them. It is not directly connected with the brain or spinal cord, though it is so indirectly by means of its numerous communications with the cranial and spinal nerves.

All these nervous tissues are composed chiefly of two different structures—the *gray* or *cineritious* and the *white* or *fibrous.* It is in the former, as is generally supposed, that nervous impressions and impulses originate, and by the latter that they are conducted. Hence the gray matter forms the essential constituent of all the ganglionic centres, both those in the isolated ganglia and those aggregated in the cerebro-spinal axis; while the white matter is found in all the commissural portions of the nerve-centres and in all the cerebro-spinal nerves. The nerves of the sympathetic system are chiefly composed of a material of a somewhat different structure, which is named *gray* or *gelatinous* nerve-fibre. This form of nerve-fibre is also found in some of the cerebro-spinal nerves.

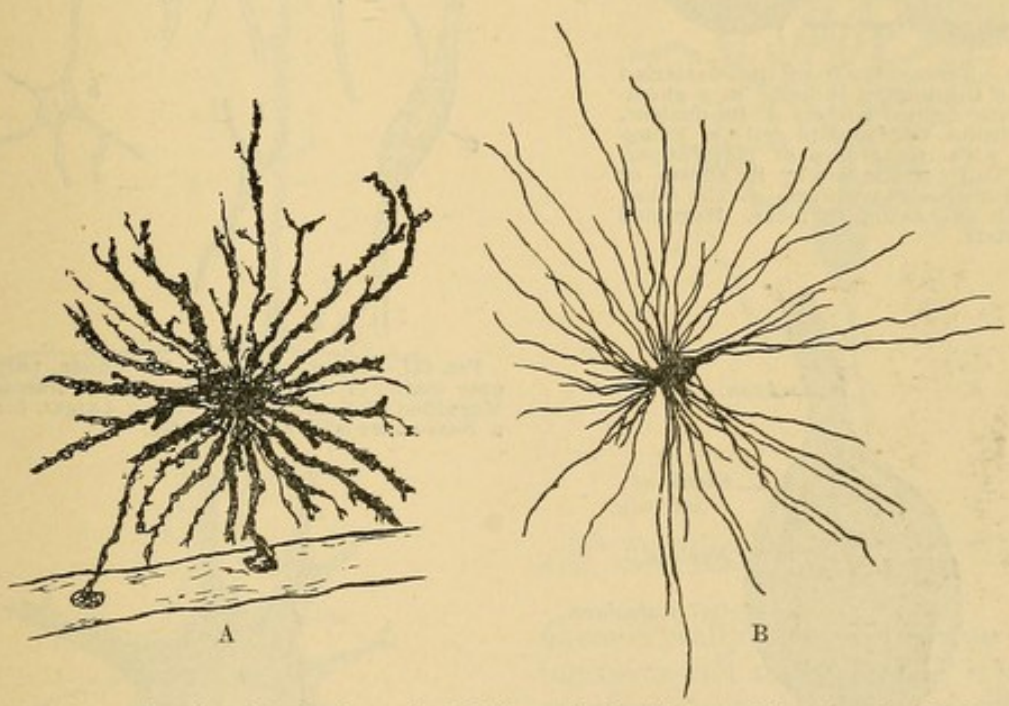

FIG. 645.—Neuroglia-cells of brain shown by Golgi's method. (After Andriezen.) (Copied from Schäfer's *Essentials of Histology.*) A. Cell with branched processes. B. Spider-cell with unbranched processes.

The **gray nervous substance** is distinguished by its dark reddish-gray color and soft consistence. It is found in the brain, spinal cord, and various ganglia intermingled with the fibrous nervous substance, and also in some of the nerves of special sense, and in gangliform enlargements which are found here and there in the course of certain cerebro-spinal nerves. It is composed of cells, commonly called *nerve-cells* or *ganglion-corpuscles*, containing nuclei and nucleoli. The cells together with the blood-vessels in the gray nerve-substance, and the nerve-fibres and vessels in the white nerve-substance, are imbedded in a peculiar ground substance, named by Virchow *neuroglia.* It consists of fibres and cells. Some of the cells are stellate in shape, and their fine processes become neuroglia-fibres, which extend radially and unbranched (Fig. 645, B) among the nerve-cells and fibres which they aid in supporting. Other cells give off fibres which branch repeatedly (Fig. 645, A). In addition to these fibres there are others which do

not appear to be connected with the neuroglia-cells. They start from the epithelial cells lining the ventricles of the brain and central canal of the spinal cord, and pass through the nervous tissue, branching repeatedly to terminate in slight enlargements on the pia mater. Thus, neuroglia is evidently a connective tissue in function, but is not so in development; it is epiblastic in origin, whereas all connective tissues are mesoblastic.

Each nerve-cell consists of a finely fibrillated protoplasmic material, of a reddish or yellowish-brown color, which occasionally presents patches of a deeper

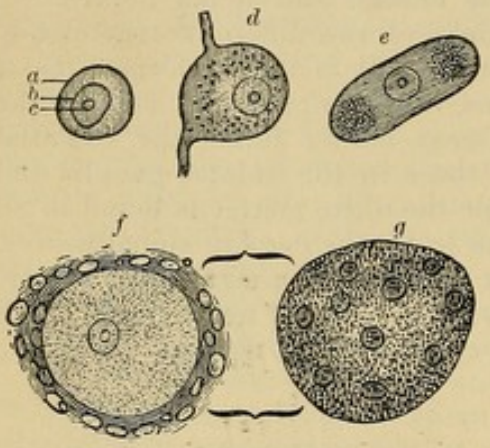

FIG. 646.—Nerve-cells from the Gasserian ganglion of the human subject. *a*. A globular one with defined border. *b*. Its nucleus. *c*. Its nucleolus. *d*. Caudate cell. *e*. Elongated cell with two groups of pigment-particles. *f*. Cell surrounded by its sheath or capsule of nucleated particles. *g*. The same, the sheath only being in focus. Magnified 300 diameters.

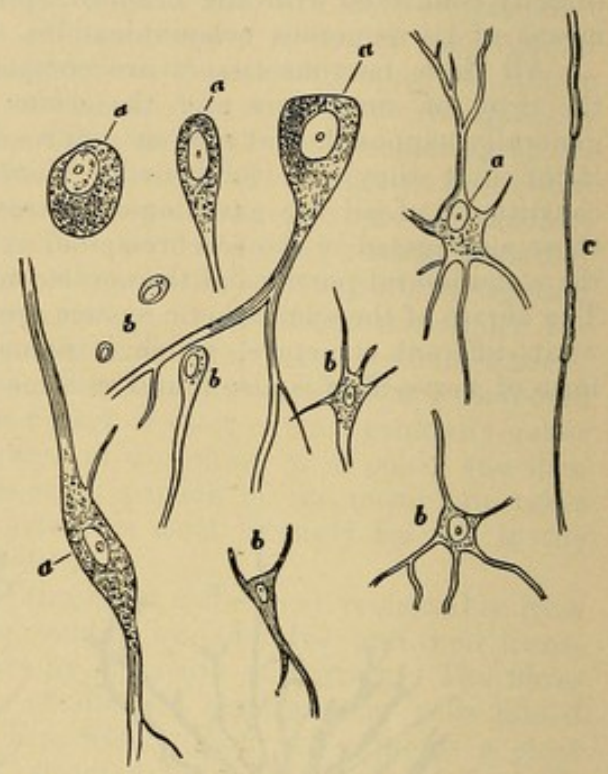

FIG. 647.—Nerve-cells from the inner part of the gray matter of the convolutions of the human brain. Magnified 350 times. Nerve-cells: *a*. Larger. *b*. Smaller. *c*. Nerve-fibre with axis-cylinder.

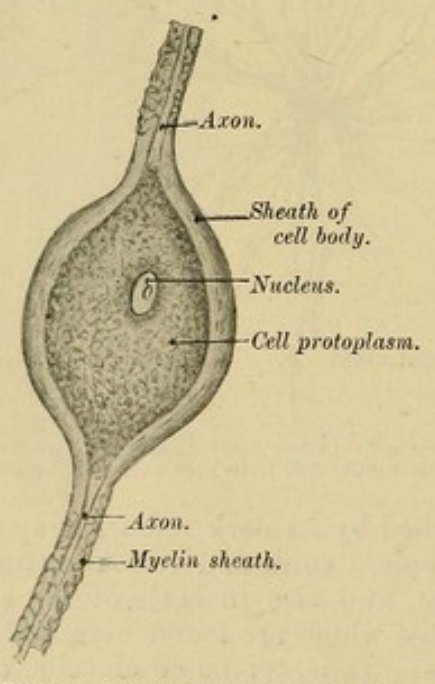

FIG. 648.—Bipolar nerve-cell from the spinal ganglion of the pike. (After Kölliker.)

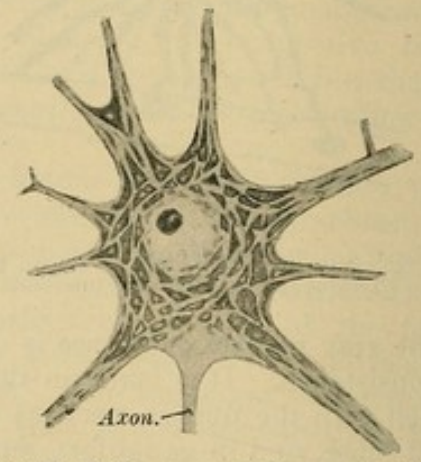

FIG. 649.—Motor nerve-cell from ventral horn of spinal cord of rabbit. (After Nissl.) The angular and spindle-shaped Nissl bodies are well shown.

tint, caused by the aggregation of pigment-granules at one side of the nucleus, as in the substantia nigra and locus cœruleus. The protoplasm also sometimes contains peculiar angular granules, which stain deeply with basic dyes, such as methylene-blue; these are known as *Nissl's granules* (Fig. 649). The nucleus is, as a rule, a large, well-defined, round, vesicular body, often presenting an intranuclear network, and containing a nucleolus which is peculiarly clear and

brilliant. The nerve-cells vary in shape and size, and have one or more processes. They may be divided for purposes of description into three groups, according to the number of processes which they possess: (1) Unipolar cells, which are found in the spinal ganglia; their single process, after a short course, divides in a T-shaped manner. (2) Bipolar cells, also found in the spinal ganglia (Fig. 648), when the cells are in an embryonic condition. They are best demonstrated in the sympathetic ganglion-cells of a frog. Sometimes the processes come off from opposite poles of the cell, and the cell then assumes a spindle-shape; at others they both emerge at the same point. In some cases where two fibres are apparently connected with a cell, one of the fibres is really derived from an adjoining nerve-cell and is passing to end in a ramification around the ganglion-cell, or, again, it may be coiled spirally round the nerve process which is issuing from the cell. (3) Multipolar cells, which are caudate or stellate in shape, and characterized by their large size and by the tail-like processes which issue from them. The processes are of two kinds: one of them is termed the *axis-cylinder process* or *axon*, because it becomes the axis-cylinder of a nerve-fibre (Figs. 649, 650, 651). The others are termed the *protoplasmic processes* or *dendrons;* they begin to divide and subdivide as soon as they emerge from the cell, and finally end in minute twigs and become lost among the other elements of the nervous tissue.

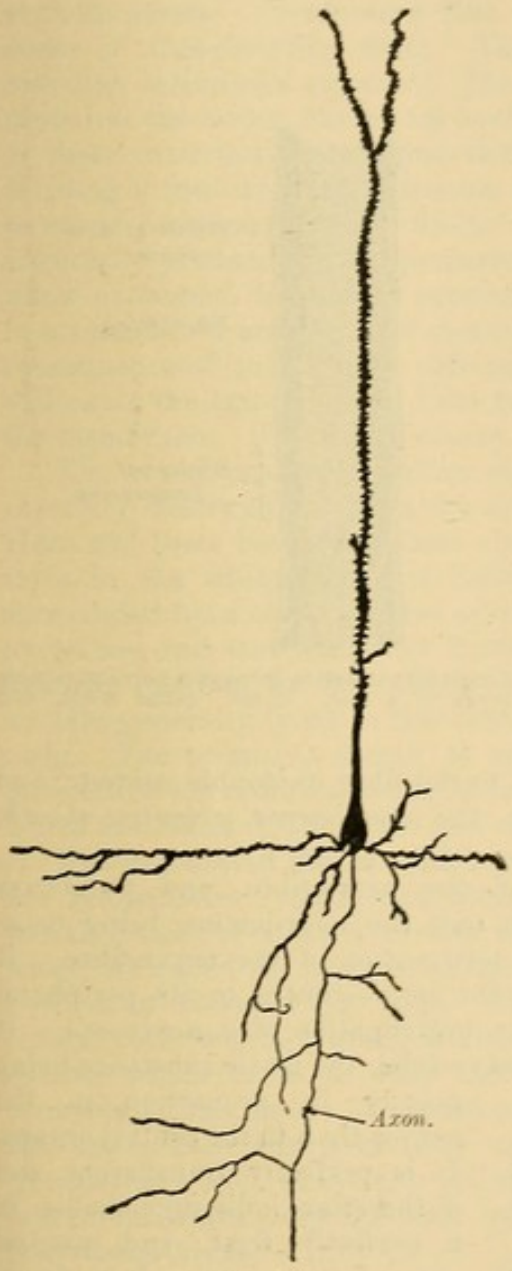

FIG. 650.—Pyramidal cell from the cerebral cortex of a mouse. (After Ramón y Cajal.)

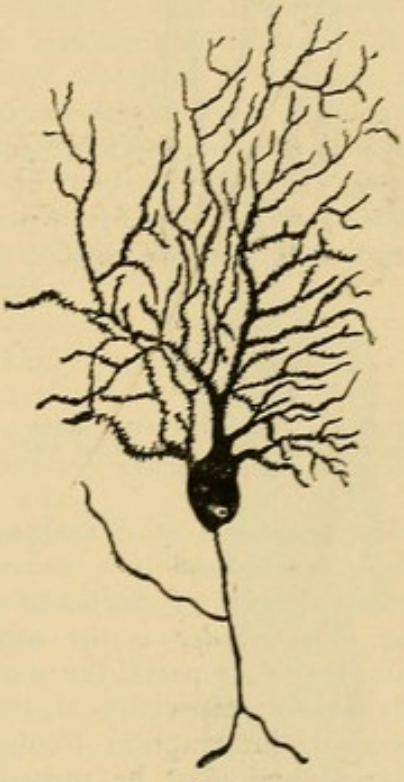

FIG. 651.—Cell of Purkinje from the cerebellum of a cat. (After Ramón y Cajal.)

The **white** or **fibrous** nerve-substance or *nerve-fibre* is found universally in the nervous cords, and also constitutes a great part of the brain and spinal cord. The fibres of which it consists are of two kinds, the *medullated* or *white* fibres, and the *non-medullated* or *gray* fibres.

The **medullated** fibres form the white part of the brain and spinal cord, and also the greater part of the cerebro-spinal nerves, and gives to these structures their opaque, white aspect. When perfectly fresh they appear to be homogeneous; but soon after removal from the body they present, when examined by transmitted light, a double outline or contour, as if consisting of two parts (Fig. 652). The central portion is named the *axis-cylinder of Purkinje;* around this is a sort of sheath of fatty material, staining black with osmic acid, named



FIG. 652.—White or medullated nerve-fibres showing the sinuous outline and double contours. (After Schäfer.)

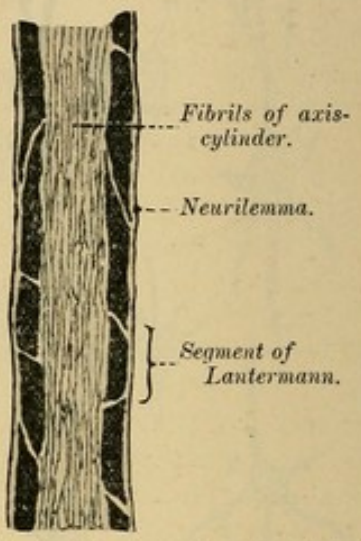

FIG. 653.—Longitudinal section through a nerve-fibre from the sciatic nerve of a frog. × 830. (After Böhm and Davidoff.)

the *white substance of Schwann,* which gives to the fibre its double contour, and the whole is enclosed in a delicate membrane, the *neurilemma, primitive sheath,* or *nucleated sheath of Schwann* (Fig. 652).

The *axis-cylinder* is the essential part of the nerve-fibre, and is always present; the other parts, the medullary sheath and the neurilemma, being occasionally absent, especially at the origin and termination of the nerve-fibre. It undergoes no interruption from its origin in the nerve-centre to its peripheral termination, and must be regarded as a direct prolongation of a nerve-cell. It constitutes about one-half or one-third of the nerve-tube, the whole substance being greater in proportion in the nerves than in the central organs. It is perfectly transparent, and is therefore indistinguishable in a perfectly fresh and natural state of the nerve. It is made up of exceedingly fine fibrils, which stain darkly with gold chloride (Fig. 653). At its termination the axis-cylinder of a nerve-fibre may be seen to break up into fibrillæ, confirming the view of its structure. These fibrillæ have been termed the *primitive fibrillæ* of Schultze. The axis-cylinder is said by some to be enveloped in a special, reticular sheath, which separates it from the white matter of Schwann, and is composed of a substance called *neurokeratin.* The more common opinion is that this network or reticulum is contained in the white matter of Schwann, and by some it is believed to be produced by the action of the reagents employed to show it. The *medullary sheath* or *white matter of Schwann* (Fig. 653) is regarded as being a fatty matter in a fluid state, which insulates and protects the essential part of the nerve—the axis-cylinder. The white matter varies in thickness to a very

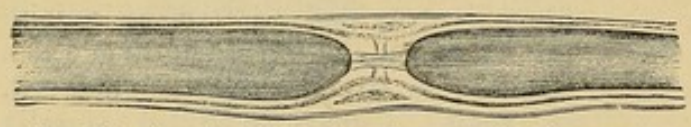

FIG. 654.—A node of Ranvier of a medullated nerve-fibre, viewed from above, magnified about 750 diameters. The medullary sheath is discontinuous at the node, whereas the axis-cylinder passes from one segment into the other. At the node the sheath of Schwann appears thickened. (Klein and Noble Smith.)

considerable extent, in some forming a layer of extreme thinness, so as to be scarcely distinguishable; in others forming about one-half the nerve-tube. The size of the nerve-fibres, which varies from $\frac{1}{2000}$ to $\frac{1}{1200}$ of an inch, depends mainly upon the amount of the white substance, though the axis-cylinder also varies in size within certain limits. The white matter of Schwann does not always form a continuous sheath to the axis-cylinder, but undergoes interruptions in its continuity at regular intervals, giving to the fibre the appearance of constriction at these points. These were first described by Ranvier, and are known as the *nodes of Ranvier* (Fig. 654). The portion of nerve-fibre between two nodes is called an *internodal segment*. The neurilemma or primitive sheath is not interrupted at the nodes, but passes over them as a continuous membrane. In addition to these interruptions oblique clefts may be seen in the medullary sheath, subdividing it into irregular portions, which are termed *medullary segments*, or *segments of Lantermann* (Fig. 653). There is reason to believe that these clefts are artificially produced in the preparation of the specimens. Medullated nerve-fibres, when examined, frequently present a beaded or varicose appearance: this is due to manipulation and pressure causing the oily matter to collect into drops, and in consequence of the extreme delicacy of the primitive sheath, even slight pressure will cause the transudation of the fatty matter, which collects as drops of oil outside the membrane. This is, of course, promoted by the action of certain reagents.

The *neurilemma* or *primitive sheath* (sometimes called the *tubular membrane* or *sheath of Schwann*) presents the appearance of a delicate, structureless membrane. Here and there beneath it, and situated in depressions in the white matter of Schwann, are nuclei surrounded by a small amount of protoplasm. The nuclei are oval and somewhat flattened, and bear a definite relation to the nodes of Ranvier; one nucleus generally lying in the centre of each internode. The primitive sheath is not present in all medullated nerve-fibres, being absent in those fibres which are found in the brain and spinal cord.

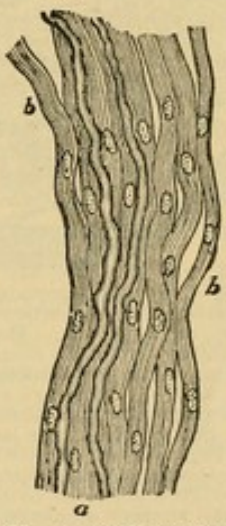

FIG. 655.—A small nervous branch from the sympathetic of a mammal. *a*. Two medullated nerve-fibres among a number of gray nerve-fibres, *b*.

Non-medullated Fibres.—Most of the nerves of the sympathetic system, and some of the cerebro-spinal, consist of another variety of nervous fibres, which are called the *gray* or *gelatinous* nerve-fibres —*fibres of Remak* (Fig. 655). These consist of a central core or axis-cylinder enclosed in a nucleated sheath, which tends to split into fibrillæ, and is probably of the nature of neurokeratin. In external appearance the gelatinous nerves are semi-transparent and gray or yellowish-gray. The individual fibres vary in size, generally averaging about half the size of the medullated fibres.

Development of Nerve-cells and Fibres.—The nerve-cells are developed from certain of the cells which line the neural canal or form the neural crest of the embryo (see section on Development). Some of these cells assume a rounded form and are termed *neuroblasts*, and from each neuroblast there grows out a process, the axis-cylinder process or axon, and subsequently the branching processes or dendrons. The axis-cylinders, at first naked, acquire their medullary sheath, possibly by some metamorphosis of their outer layer. The neurilemma is thought to be derived from mesoblastic cells which become flattened and wrapped round the fibre, the cement-substance at their apposed ends forming the material which stains with silver nitrate at the nodes of Ranvier. Nerve-cells in the sympathetic and peripheral ganglia take their origin from small collections of neuroblasts, which are split off from the rudimentary spinal ganglia. Cells which are, originally, similar to neuroblasts seem to give rise to neuroglia-cells, numerous processes sprouting from the cell to form the neuroglial fibres.

Chemical Composition.—The amount of water in nervous tissue varies with the situation. Thus in the gray matter of the cerebrum it constitutes about 83 per cent., in the white matter from the same region about 70 per cent., while in the peripheral nerves, such as the sciatic, it may fall to 60 per cent. The solids consist of proteids (in the gray matter they form half the total solids), neurokeratin, nuclein, protagon, lecithin, cerebrosides, cholesterin, nitrogenous extractives, and salts, with some gelatin and fat from the adherent connective tissue.

The nervous structures are divided, as before mentioned, into two great systems, viz., the *cerebro-spinal*, comprising the brain and spinal cord, the nerves connected with these structures, and the ganglia situated on them; and the *sympathetic*, consisting of a double chain of ganglia and the nerves connected with them. All these structures require separate consideration; they are composed of the two kinds of nervous tissue above described, intermingled in various proportions, and having, in some parts, a very intricate arrangement.

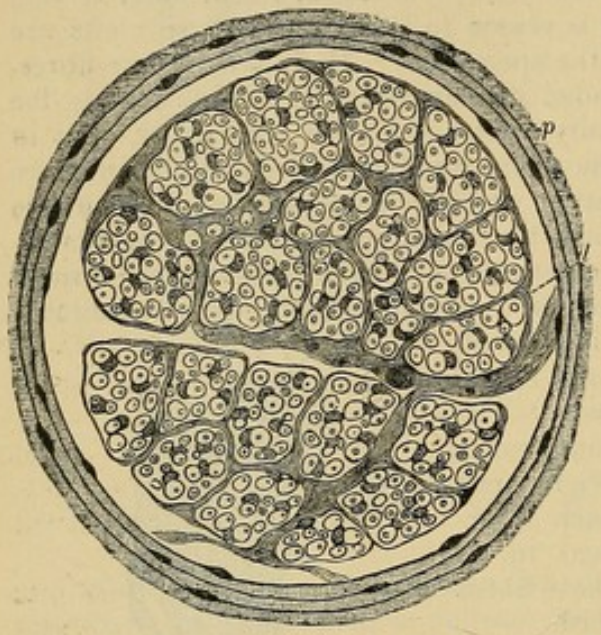

FIG. 656.—Transverse section through a microscopic nerve, representing a compound nerve-bundle, surrounded by perineurium. Magnified 120 diameters. The medullated fibres are seen as circles with a central dot—viz., medullary sheath and axis-cylinder—in transverse section. They are embedded in endoneurium, containing numerous nuclei, which belong to the connective-tissue cells of the latter. (Klein and Noble Smith.) *p*. Perineurium, consisting of laminæ of fibrous connective-tissues, alternating with flattened nucleated connective-tissue cells. *l*. Lymph-space between epineurium and surface of nerve-bundle.

The **brain** or **encephalon** is that part of the cerebro-spinal system which is contained in the cavity of the skull. It is divided into several parts, which will be described in the sequel. In these parts the gray or vesicular nervous matter is found partly on the surface of the brain, forming the convolutions of the cerebrum and the laminæ of the cerebellum. Again, gray matter is found in the interior of the brain, collected into large and distinct masses or ganglionic bodies, such as the corpus striatum, optic thalamus, and corpora quadrigemina. Finally, gray matter is found intermingled intimately with the white, but without definite arrangement, as in the gray matter in the pons Varolii and the floor of the fourth ventricle.

The white matter of the brain is divisible into three distinct classes of fibres: (1) Diverging or peduncular fibres, which connect the hemispheres with the medulla oblongata and the spinal cord. (2) Commissural fibres, which connect together the two hemispheres. (3) Association fibres, which connect different parts of the same hemisphere.

The manner in which these fibres are intermingled with each other and with the gray matter in the brain and spinal cord is very intricate, and can be fully understood only by a careful study of the details of its descriptive anatomy in the sequel. The further consideration of this subject will therefore be deferred until after the description of the various divisions of which the cerebro-spinal system is made up.

The **nerves** are round or flattened cords, formed of the nerve-fibres already described. They are connected at one end with the cerebro-spinal centre or with the ganglia, and are distributed at the other end to the various textures of the body; they are subdivided into two great classes—the *cerebro-spinal*, which proceed from the cerebro-spinal axis, and the *sympathetic* or *ganglionic* nerves, which proceed from the ganglia of the sympathetic. The **cerebro-spinal nerves** consist of numerous nerve-fibres collected together and enclosed in a membranous sheath (Fig. 656). A small bundle of primitive fibres, enclosed in a tubular sheath, is called a *funiculus*; if the nerve is of small size, it may consist only of a single funiculus; but if large, the funiculi are collected together into larger bundles or

fasciculi, which are bound together in a common membranous investment, and constitute the nerve.

In structure the common membranous investment, or sheath of the whole nerve, which is called the *epineurium*, as well as the septa given off from it, and which separate the fasciculi, consists of connective tissue, composed of white and yellow elastic fibres, the latter existing in great abundance. The tubular sheath of the funiculi, called the *perineurium*, consists of a fine, smooth, transparent membrane, which may be easily separated, in the form of a tube, from the fibres it encloses; in structure it consists of connective tissue, which has a distinctly lamellar arrangement, consisting of several lamellæ, separated from each other by spaces containing lymph. The nerve-fibres are held together and supported within the funiculus by delicate connective tissue called the *endoneurium*. It is continuous with septa which pass inward from the innermost layer of the perineurium, and consists of a ground-substance in which are embedded fine bundles of fibrous connective tissue which run for the most part longitudinally. It serves to support the capillary vessels, which are arranged so as to form a network with elongated meshes. The cerebro-spinal nerves consist almost exclusively of the medullated nerve-fibres, the non-medullated existing in very small proportions.

The blood-vessels supplying a nerve terminate in a minute capillary plexus, the vessels composing which pierce the perineurium and run, for the most part, parallel with the fibres; they are connected together by short, transverse vessels, forming narrow, oblong meshes, similar to the capillary system of muscle. Fine non-medullated nerve-fibres accompany these capillary vessels, *vaso-motor fibres*, and break up into elementary fibrils, which form a network around the vessel. Horsley has also demonstrated certain medullated fibres as running in the epineurium and terminating in small spheroidal tactile corpuscles or end-bulbs of Krause. These nerve-fibres, which Marshall believes to be sensory, and which he has termed *nervi nervorum*, are considered by him to have an important bearing upon certain neuralgic pains.

The nerve-fibres, as far as is at present known, do not coalesce, but pursue an uninterrupted course from the centre to the periphery. In separating a nerve, however, into its component funiculi, it may be seen that they do not pursue a perfectly insulated course, but occasionally join at a very acute angle with other funiculi proceeding in the same direction; from this, branches are given off, to join again in like manner with other funiculi. It must be distinctly understood, however, that in these communications the nerve-fibres do not coalesce, but merely pass into the sheath of the adjacent nerve, become intermixed with its nerve-fibres, and again pass on, to become blended with the nerve-fibres in some adjoining funiculus.

Nerves, in their course, subdivide into branches, and these frequently communicate with branches of a neighboring nerve.

The communications which take place between two or more nerves form what is called a *plexus*. Sometimes a plexus is formed by the primary branches of the trunks of the nerves—as the cervical, brachial, lumbar, and sacral plexuses—and occasionally by the terminal funiculi, as in the plexuses formed at the periphery of the body. In the formation of a plexus the component nerves divide, then join, and again subdivide in such a complex manner that the individual funiculi become interlaced most intricately; so that each branch leaving a plexus may contain filaments from each of the primary nervous trunks which form it. In the formation also of smaller plexuses at the periphery of the body there is a free interchange of the funiculi and primitive fibres. In each case, however, the individual filaments remain separate and distinct, and do not inosculate with one another.

It is probable that through this interchange of fibres the different branches passing off from a plexus have a more extensive connection with the spinal cord than if they each had proceeded to be distributed without such connection with other nerves. Consequently the parts supplied by these nerves have more extended

relations with the nervous centres; by this means, also, groups of muscles may be associated for combined action.

The **sympathetic** nerves are constructed in the same manner as the cerebro-spinal nerves, but consist mainly of non-medullated fibres, collected into funiculi, and enclosed in a sheath of connective tissue. There is, however, in these nerves a certain admixture of medullated fibres, and the amount varies in different nerves, and may be known by their color. Those branches of the sympathetic which present a well-marked gray color are composed more especially of gelatinous nerve-fibres, intermixed with a few medullated fibres; while those of a white color contain more of the latter fibres and a few of the former. Occasionally, the gray and white cords run together in a single nerve, without any intermixture, as in the branches of communication between the sympathetic ganglia and the spinal nerves, or in the communicating cords between the ganglia.

The nerve-fibres, both of the cerebro-spinal and sympathetic system, convey impressions of a twofold kind. The sensory nerves, called also *centripetal* or *afferent* nerves, transmit to the nervous centres impressions made upon the peripheral extremities of the nerves, and in this way the mind, through the medium of the brain, becomes conscious of external objects. The *motor* nerves, called also *centrifugal* or *efferent* nerves, transmit impressions from the nervous centres to the parts to which the nerves are distributed, these impressions either exciting muscular contraction, or influencing the processes of nutrition, growth, and secretion.

Origin and Termination of Nerves.—By the expression "the termination of nerve-fibres" is signified their connection with the nerve-centres, and with the parts they supply. The former are sometimes called their *origin*, or *central* termination; the latter their *peripheral* termination. The origin in some cases is single—that is to say, the whole nerve emerges from the nervous centre by a single root; in other instances the nerve arises by two or more roots, which come off from different parts of the nerve-centre, sometimes widely apart from each other, and it often happens, when a nerve arises in this way by two roots, that the functions of these two roots are different; as, for example, in the spinal nerves, each of which arises by two roots, the anterior of which is motor and the posterior sensory. The point where the nerve root or roots emerge from the nervous centre is named the *superficial* or *apparent* origin, but the fibres of which the nerve consists can be traced for a certain distance into the nervous centre to some portion of the gray substance, which constitutes the *deep* or *real* origin of the nerve.

The manner in which these fibres arise at their deep origin varies with their functions. The centrifugal or efferent nerve-fibres originate in the nerve-cells of the gray substance, the axis-cylinder processes of these cells being prolonged to form the fibres. In the case of the centripetal or afferent nerves the fibres grow inward either from nerve-cells in the organs of special sense (*e. g.*, the retina) or from nerve-cells in the ganglia. Having entered the nerve-centre, they branch and send their ultimate twigs among the cells, without, however, uniting with them.

Peripheral Terminations of Nerves.—Nerve-fibres terminate peripherally in various ways, and these may be conveniently studied in the sensory and motor nerves, respectively. **Sensory** nerves would appear to terminate either in *minute primitive fibrillæ* or networks of these; or else in special terminal organs, which have been termed *peripheral end-organs*, and of which there are several principal varieties, viz., the end-bulbs of Krause, the tactile corpuscles of Wagner, the Pacinian corpuscles, and the neuro-tendinous and neuro-muscular spindles.

Termination in Fibrillæ.—When a medullated nerve-fibre approaches its termination, the white matter of Schwann suddenly disappears, leaving only the axis-cylinder, surrounded by the neurilemma, and forming a non-medullated fibre. This, after a time, loses its neurilemma, and consists only of an axis-cylinder, which can be seen, in preparations stained with chloride of gold, to be made up of fine varicose fibrils. Finally, the axis-cylinder breaks up into its constituent primitive nerve-fibrillæ, which often present regular varicosities and anastomose

with one another, thus forming a network. This network passes between the elements of the tissue to which the nerves are distributed, which is always epithelial, the nerve-fibrils lying in the interstitial substance between the epithelial cells, and there terminating, though some observers maintain that the actual terminations are within the cells. In this way nerve-fibres have been found to terminate in the epithelium of the skin and mucous membranes, and in the anterior epithelium of the cornea.

The **end-bulbs of Krause** (Fig. 657) are minute cylindrical or oval bodies, consisting of a capsule formed by the expansion of the connective-tissue sheath of a medullated fibre, and containing a soft semifluid core in which the termination of the axis-cylinder is situated, ending either as a bulbous extremity, or in a coiled-up plexiform mass. End-bulbs are found in the conjunctiva of the eye, where they are spheroidal in shape in man, but cylindrical in most other animals, in the mucous membrane of the lips and tongue, and in the epineurium of nerve-trunks. They are also found in the genital organs of both sexes, the penis in the male, and the clitoris in the female. In this situation they have a mulberry-like appearance, from being constricted by connective-tissue septa into from two to six knob-like masses, and have received the name of *genital corpuscles.* Very similar corpuscles are found in the epineurium of nerve-trunks. In the synovial membrane of certain joints (*e. g.*, those of the fingers), rounded or oval end-bulbs have been found; these are designated *articular end-bulbs.*

Tactile corpuscles have been described by Grandry as occurring in the papillæ of the beak and tongue of birds, and by Merkel as occurring in the papillæ and epithelium of the skin of man and animals, especially in those parts of the skin devoid of hair. They consist of a capsule composed of a very delicate, nucleated membrane, and contain two or more granular, somewhat flattened cells, between which the medullated nerve-fibre, which enters the capsule by piercing its investing membrane, is supposed to terminate.

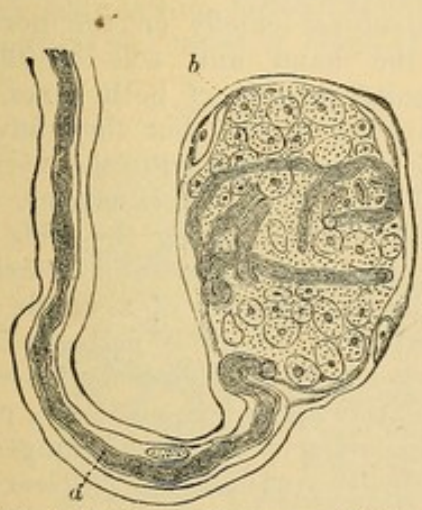

FIG. 657.—End-bulb of Krause. *a.* Medullated nerve-fibre. *b.* Capsule of corpuscle. (From Klein's *Elements of Histology.*)

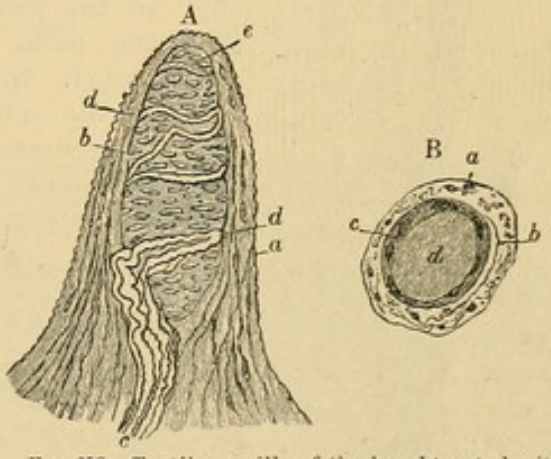

FIG. 658.—Tactile papilla of the hand treated with acetic acid. Magnified 370 times. A. Side view of a papilla of the hand. *a.* Cortical layer. *b.* Tactile corpuscle, with transverse nuclei. *c.* Small nerve of the papilla, with neurilemma. *d.* Its two nervous fibres running with spiral coils around the tactile corpuscle. *e.* Apparent termination of one of these fibres. B. A tactile papilla seen from above, so as to show its transverse section. *a.* Cortical layer. *b.* Nerve-fibre. *c.* Outer layer of the tactile body, with nuclei. *d.* Clear interior substance.

The **tactile corpuscles** (Fig. 658), described by Wagner and Meissner, are oval-shaped bodies, made up of connective tissue, and consisting of a capsule, and imperfect membranous septa, derived from it, which penetrate its interior. The axis-cylinder of the medullated fibres passes through the capsule, and having entered the corpuscle terminates in a small globular or pyriform enlargement, near the inner surface of the capsule. These tactile corpuscles have been described as occurring in the papillæ of the corium of the hand and foot, the front of the

forearm, skin of the lips, and the mucous membrane of the tip of the tongue, the palpebral conjunctiva, and the skin of the nipple. They are not found in all the papillæ; but from their existence in those parts in which the skin is highly sensi-

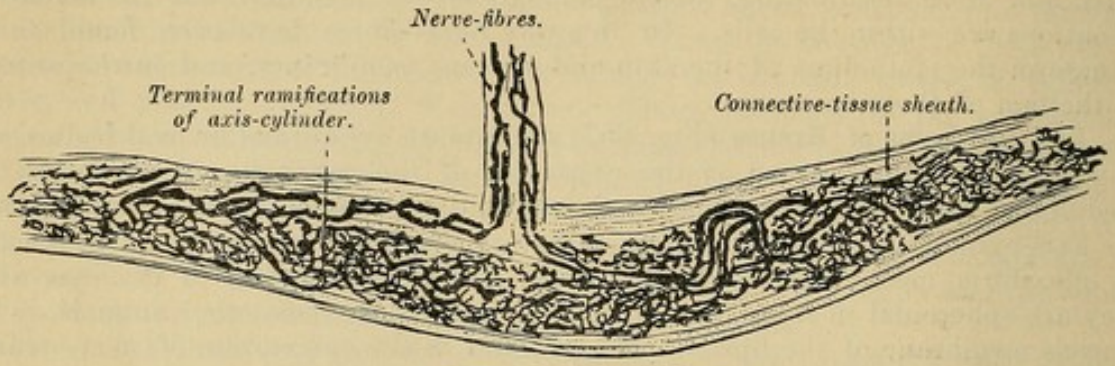

FIG. 659.—Nerve-ending of Ruffini. (After A. Ruffini, *Arch. ital. de Biol.*, Turin, t. xxi. 1894.)

tive, it is probable that they are specially concerned in the sense of touch, though their absence from the papillæ of other tactile parts shows that they are not essential to this sense.

Ruffini has described a special variety of nerve-ending in the subcutaneous tissue of the human finger (Fig. 659). These are usually known as *Ruffini's endings*. They are principally situated at the junction of the corium with the subcutaneous tissue; they are oval in shape, and consist of a strong connective-tissue sheath, inside which the nerve-fibre divides into numerous branches, which show varicosities and end in small free knobs. They resemble the corpuscles of Golgi.

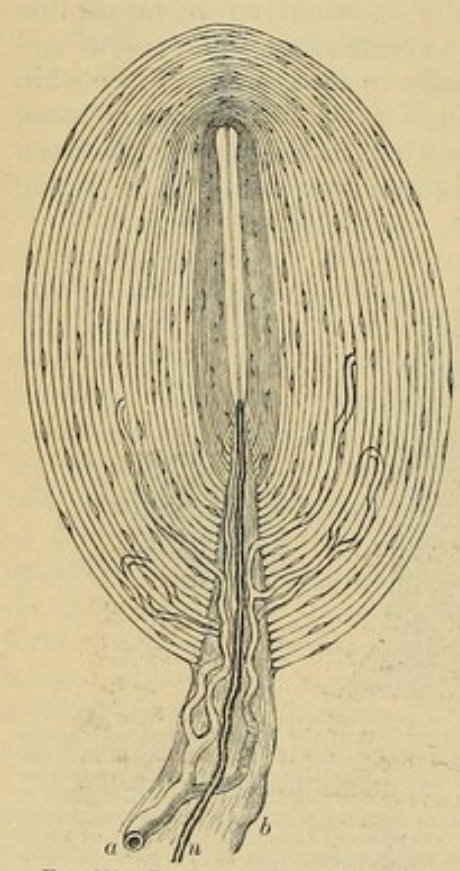

FIG. 660.—Pacinian corpuscle, with its system of capsules and central cavity. *a*. Arterial twig, ending in capillaries, which form loops in some of the intercapsular spaces, and one penetrates to the central capsule. *b*. The fibrous tissue of the stalk prolonged from the perineurium. *n*. Nerve-tube advancing to the central capsule, there losing its white matter, and stretching along the axis to the opposite end, where it is fixed by a tubercular enlargement.

The **Pacinian corpuscles**[1] (Fig. 660) are found in the human subject chiefly on the nerves of the palm of the hand and sole of the foot and in the genital organs of both sexes, lying in the subcutaneous tissue; but they have also been described as connected with the nerves of the joints, and in some other situations, as the mesentery of the cat and along the tibia of the rabbit. Each of these corpuscles is attached to and encloses the termination of a single nerve-fibre. The corpuscle, which is perfectly visible to the naked eye (and which can be most easily demonstrated in the mesentery of a cat), consists of a number of lamellæ or capsules, arranged more or less concentrically around a central clear space, in which the nerve-fibre is contained. Each lamella is composed of bundles of fine connective-tissue fibres, and is lined on its inner surface by a single layer of cells. The central clear space, which is elongated or cylindrical in shape, is filled with a transparent material, in the middle of which is the single medullated fibre, which traverses the space to near its distal extremity. Here it terminates in a rounded knob or end, sometimes bifurcating previously, in which case each branch has a similar arrangement. Todd and Bowman have described minute arteries as entering by the sides of the nerves and forming capillary loops in the intercapsular spaces, and even penetrating into the central space.

[1] Often called in German anatomical works "corpuscles of Vater."

Other authors describe the artery as entering the corpuscle at the pole opposite to the nerve-fibre.

Herbst has described a somewhat similar "nerve-ending" to the Pacinian corpuscle, as being found in the mucous membrane of the tongue of the duck and in some other situations. It differs, however, from the Pacinian corpuscles, in being smaller, its capsules thinner and more closely approximated, and especially in the fact that the axis-cylinder in the central clear space is coated with a continuous row of nuclei. These bodies are known as the *corpuscles of Herbst.*

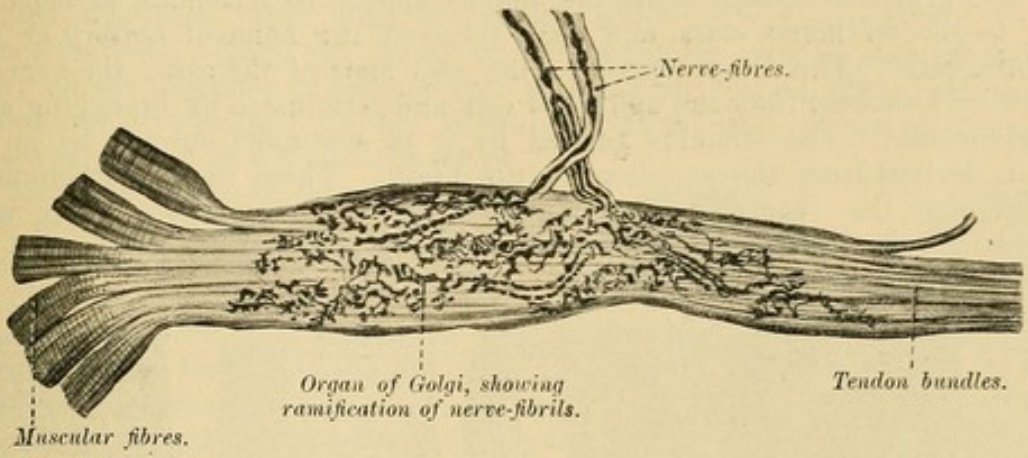

FIG. 661.—Organ of Golgi (neuro-tendinous spindle) from the human tendon Achillis. (After Ciaccio.)

Neuro-tendinous spindles.—The nerves supplying tendons have a special modification of the terminal fibres, especially numerous at the point where the tendon is becoming muscular. The tendon bundles become enlarged, and the nerve-fibres—one, two, or more in number—penetrate between the fasciculi of the tendon and spread out between the fibres to end in irregular discs or varicosities. A spindle-shaped body is thus formed, composed of tendon bundles and nerve-fibres, which is known as the *organ of Golgi* (Fig. 661).

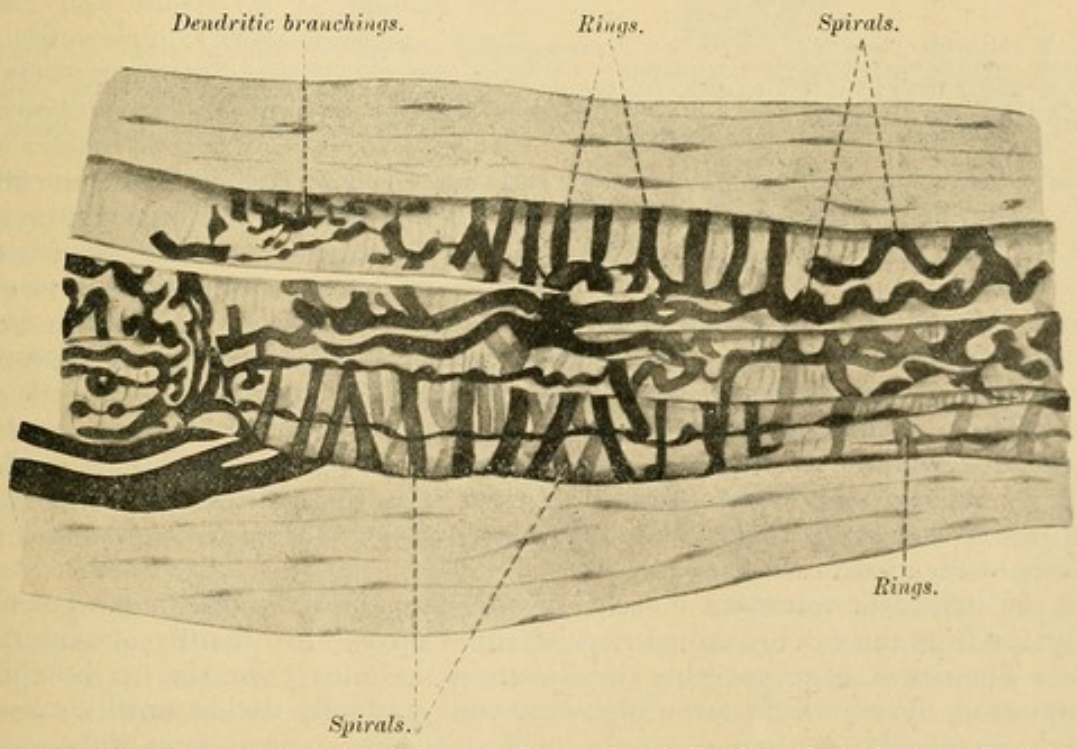

FIG. 662.—Middle third of a terminal plaque in the muscle spindle of an adult cat. (After Ruffini.)

Neuro-muscular spindles.—In the majority of voluntary muscles there have been found special end-organs consisting of a small bundle of peculiar muscular fibres (intrafusal fibres), embryonic in type, invented by a capsule within which

nerve-fibres, experimentally shown to be sensory in origin, terminate. These neuro-muscular spindles vary in length from $\frac{1}{30}$ to $\frac{1}{5}$ of an inch and have a distinctly fusiform appearance. The large medullated nerve-fibres passing to the end-organ are from one to three or four in number; entering the fibrous capsule they divide several times, and, losing their medulla, ultimately end in naked axis-cylinders encircling the intrafusal fibres by flattened expansions, or irregular ovoid or rounded discs (Fig. 662). Neuro-muscular spindles have not yet been demonstrated in the tongue or eye muscles.

In the organs of **special sense** the nerves appear to terminate in cells which belong to the epithelial class, and have received the name of *sensory* or *nerve-epithelium* cells. This is not, however, the real state of the case; the nerve-fibre is in reality a process from the epithelial cell, and terminates by branching around a ganglion-cell. The stimulus carried by it is continued onward by an axis-cylinder, derived from the ganglion, to the brain. These nerve-epithelium cells must therefore be regarded as modified forms of nerve-cells. They will be more particularly described in the sequel, in connection with the description of the organs of special sense.

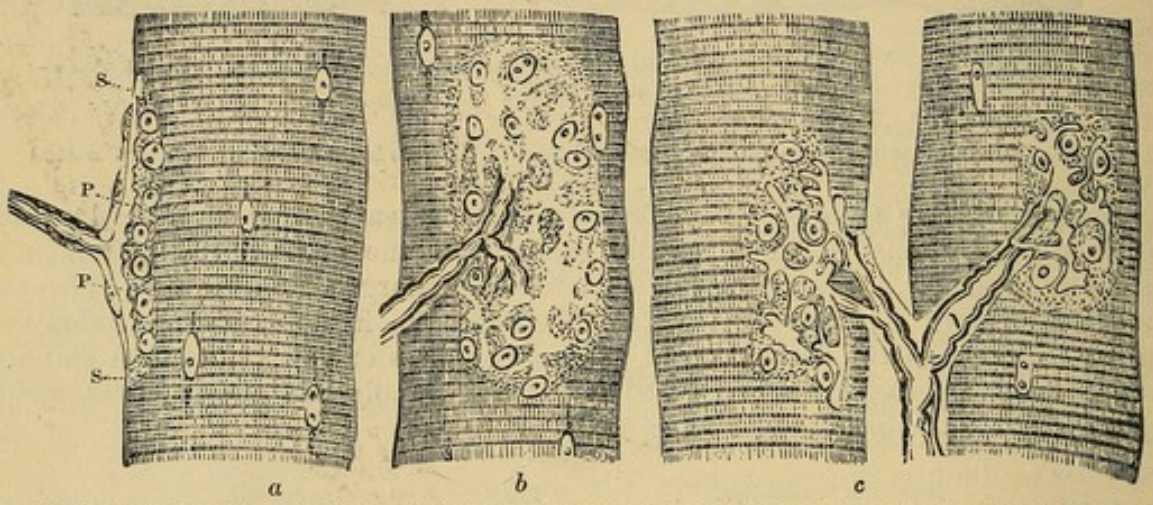

FIG. 663.—Muscular fibres of *Lacerta viridis* with the terminations of nerves. *a*. Seen in profile. P.P. The nerve end-plates. S.S. The base of the plate, consisting of a granular mass with nuclei. *b*. The same as seen in looking at a perfectly fresh fibre, the nervous ends being probably still excitable. (The forms of the variously-divided plate can hardly be represented in a woodcut by sufficiently delicate and pale contours to reproduce correctly what is seen in nature.) *c*. The same as seen two hours after death from poisoning by curare.

Motor nerves are to be traced either into unstriped or striped muscular fibres. In the **unstriped** or **involuntary** muscles the nerves are derived from the sympathetic, and are composed mainly of the non-medullated fibres. Near their termination they divide into a number of branches, which communicate and form an intimate plexus. At the junction of the branches small triangular nuclear bodies (ganglion-cells) are situated. From these plexuses minute branches are given off, which divide and break up into the ultimate fibrillæ of which the nerve is composed. These fibrillæ course between the involuntary muscle-cells, and, according to Elischer, terminate on the surface of the cell, opposite the nucleus, in a minute swelling. Arnold and Frankenhäuser believed that these ultimate fibrillæ penetrated the muscular cell and ended in the nucleus. More recent observation, however, has tended to disprove this.

In the **striped** or **voluntary** muscle, the nerves supplying the muscular fibres are derived from the cerebro-spinal nerves, and are composed mainly of medullated fibres. The nerve, after entering the sheath of the muscle, breaks up into fibres, or bundles of fibres, which form plexuses, and gradually divide until, as a rule, a single nerve-fibre enters a single muscular fibre. Sometimes, however, if the muscular fibre is long, more than one nerve-fibre enters it. Within the muscular fibre the nerve terminates in a special expansion, called by Kühne, who first accurately described them, *motorial end-plates* (Fig. 663).[1] The nerve-fibre,

[1] They had, however, previously been noticed, though not accurately described, by Doyère, who named them "nerve-hillocks."

on approaching the muscular fibre, suddenly loses its white matter of Schwann, which abruptly terminates; the neurilemma becomes continuous with the sarcolemma of the muscle; and only the axis-cylinder enters the muscular fibre, where it immediately spreads out, ramifying like the roots of a tree, immediately beneath the sarcolemma, and is imbedded in a layer of granular matter, containing a number of clear, oblong nuclei, the whole constituting an end-plate from which the contractile wave of the muscular fibre is said to start.

The **Ganglia** may be regarded as separate small aggregations of nerve-cells, connected with each other, with the cerebro-spinal axis, and with the nerves in various situations. They are found on the posterior root of each of the spinal nerves; on the posterior or sensory root of the fifth cranial nerve; on the facial and auditory nerves; and on the glosso-pharyngeal and pneumogastric nerves. They are also found in a connected series along each side of the vertebral column, forming the trunk of the sympathetic; and on the branches of that nerve, generally in the plexuses or at the point of junction of two or more nerves with each other or with branches of the cerebro-spinal system. On section they are seen to consist of a reddish-gray substance, traversed by numerous white nerve-fibres; they vary considerably in form and size; the largest are found in the cavity of the abdomen; the smallest, not visible to the naked eye, exist in considerable numbers upon the nerves distributed to the different viscera. The ganglia are invested by a smooth and firm, closely adhering membranous envelope, consisting of dense areolar tissue; this sheath is continuous with the perineurium of the nerves, and sends numerous processes into the interior of the ganglion, which support the blood-vessels supplying its substance.

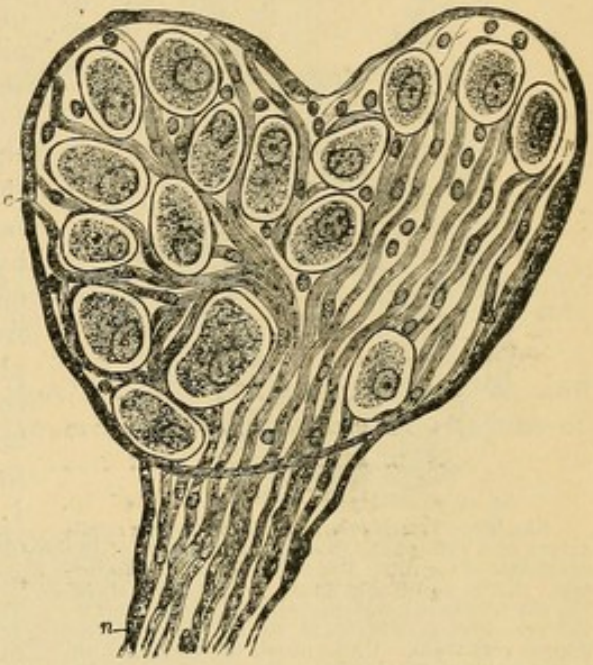

FIG. 664.—Section through a microscopic ganglion. Magnified 300 diameters. (Klein and Noble Smith.) *c*. Capsule of the ganglion. *n*. Nerve-fibres passing out of the ganglion. The nerve-fibres which entered the ganglion are not represented. The nerve-fibres are ordinary medullated fibres, but the details of their structure are not shown, owing to the low magnifying power. The ganglion-cells are invested by special capsules, lined by a few nuclei, which are here represented as if contained in the capsule.

In structure all ganglia are essentially similar (Fig. 664), consisting of the same structural elements as the other nervous centres, viz., a collection of nerve-cells and nerve-fibres. Each nerve-cell has a nucleated sheath, which is continuous with the sheath of the nerve-fibre with which the cell is connected. The nerve-cells in the ganglia of the spinal nerves are pyriform in shape, and have only one process, the axis-cylinder or axon. A short distance from the cell, and while still within the ganglion, this process divides in a T-shaped manner, one limb of the cross-bar passing centrally and forming the central portion of a sensory nerve-fibre; the other limb passing peripherally to form the axis-cylinder process of the peripheral nerve-fibre. In the sympathetic ganglia the nerve-cells are multipolar and have one axis-cylinder process or axon and several protoplasmic processes or dendrons. The former of these emerges from the ganglion as a non-medullated nerve-fibre. Similar cells are found in the ganglia connected with the fifth cranial nerve, and these ganglia are therefore regarded by some as the cranial portions of the sympathetic system. The nerve-cells are disposed in the ganglia in groups of varying size, and these groups are separated from each other by bundles of nerve-fibres, some of which traverse the ganglia without being connected with the cells.

THE VASCULAR SYSTEM.

The **Vascular System**, exclusive of its central organ, the heart, is divided into four classes of vessels: the arteries, capillaries, veins, and lymphatics; the minute structure of these vessels will be briefly described here, the reader being referred to the body of the work for the details of their ordinary anatomy.

Structure of Arteries (Fig. 665).—The arteries are composed of three coats: internal or endothelial coat (*tunica intima* of Kölliker); middle muscular coat (*tunica media*); and external connective-tissue coat (*tunica adventitia*).

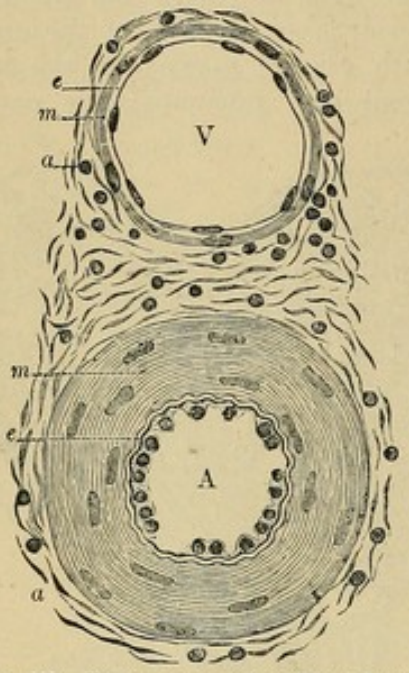

FIG. 665.—Transverse section through a small artery and vein of the mucous membrane of the epiglottis of a child. Magnified about 350 diameters. (Klein and Noble Smith.) A. Artery, showing the nucleated endothelium, *e*, which lines it: the vessel being contracted, the endothelial cells appear very thick. Underneath the endothelium is the wavy elastic intima. The chief part of the wall of the vessel is occupied by the circular muscle-coat *m*; the staff-shaped nuclei of the muscle-cells are well seen. Outside this is *a*, part of the adventitia. This is composed of bundles of connective-tissue fibres, shown in section, with the nuclei of the connective-tissue corpuscles. The adventitia gradually merges into the surrounding connective tissue. V. Vein showing a thin endothelial membrane, *e*, raised accidentally from the intima, which on account of its delicacy is seen as a mere line on the media *m*. This latter is composed of a few circular unstriped muscle-cells. *a*. The adventitia, similar in structure to that of an artery.

The two inner coats together are very easily separated from the external, as by the ordinary operation of tying a ligature on an artery. If a fine string be tied forcibly upon an artery and then taken off, the external coat will be found undivided, but the internal coats are divided in the track of the ligature and can easily be further dissected from the outer coat. The *inner coat* can be separated from the middle by a little maceration, or it may be stripped off in small pieces; but, on account of its friability, it cannot be separated as a complete membrane. It is a fine, transparent, colorless structure which is highly elastic, and is commonly corrugated into longitudinal wrinkles. The inner coat consists of—1. A layer of pavement-endothelium, the cells of which are polygonal, oval, or fusiform, and have very distinct round or oval nuclei. This endothelium is brought into view most distinctly by staining with nitrate of silver. 2. A subendothelial layer, consisting of delicate connective tissue with branched cells lying in the interspaces of the tissue. In arteries of less than a line in diameter the subendothelial layer consists of a single stratum of stellate cells, and the connective tissue is only largely developed in vessels of a considerable size. 3. An elastic or fenestrated layer, which consists of a membrane containing a network of elastic fibres, having principally a longitudinal direction and in which, under the microscope, small, elongated apertures or perforations may be seen, giving it a fenestrated appearance. It was therefore called by Henle the *fenestrated membrane*. This membrane forms the chief thickness of the inner coat, and can be separated into several layers, some of which present the appearance of a network of longitudinal elastic fibres, and others present a more membranous character, marked by pale lines having a longitudinal direction. The fenestrated membrane in microscopic arteries is a very thin layer, but in the larger arteries, and especially in the aorta, it has a very considerable thickness.

The *middle coat* (*tunica media*) is distinguished from the inner by its color and by the transverse arrangement of its fibres, in contradistinction to the longitudinal direction of those of the inner coat. In the smaller arteries it consists principally of muscular tissue, being made up of plain muscle-fibres in fine bundles, arranged in lamellæ and disposed circularly around the vessel. These lamellæ vary in number according to the size of the vessel; the very small arteries having only a

single layer, and those not larger than one-tenth of a line in diameter three or four layers. It is to this coat that the great thickness of the walls of the artery is

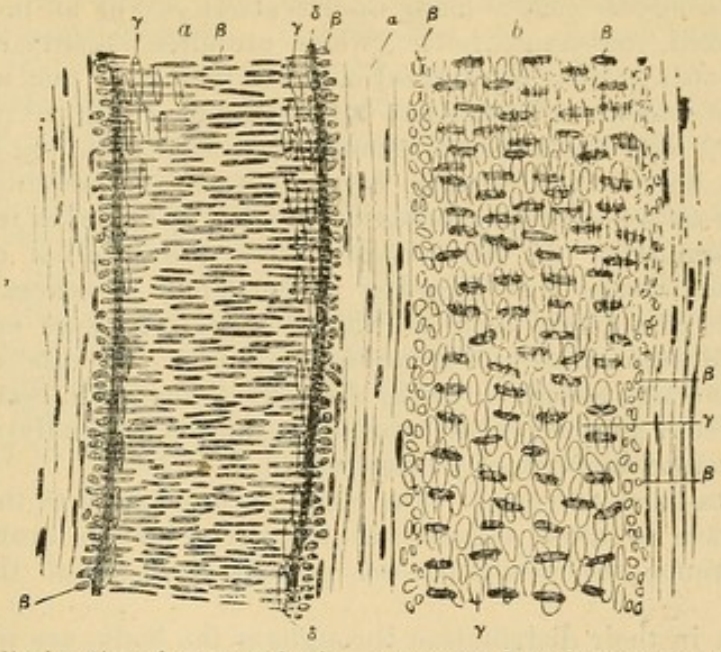

FIG. 666.—Longitudinal section of artery and vein. *a*, an artery from the mesentery of a child, .062‴, and *b*, vein .067‴ in diameter, treated with acetic acid and magnified 350 times. α. Tunica adventitia, with elongated nuclei. β. Nuclei of the contractile fibre-cells of the tunica media, seen partly from the surface, partly apparent in transverse section. γ. Nuclei of the endothelial cells. δ. Elastic longitudinal fibrous coat.

mainly due (Fig. 665, A, *m*). In the larger vessels, as the iliac, femoral, and carotid, elastic fibres unite to form lamellæ, which alternate with the layers of

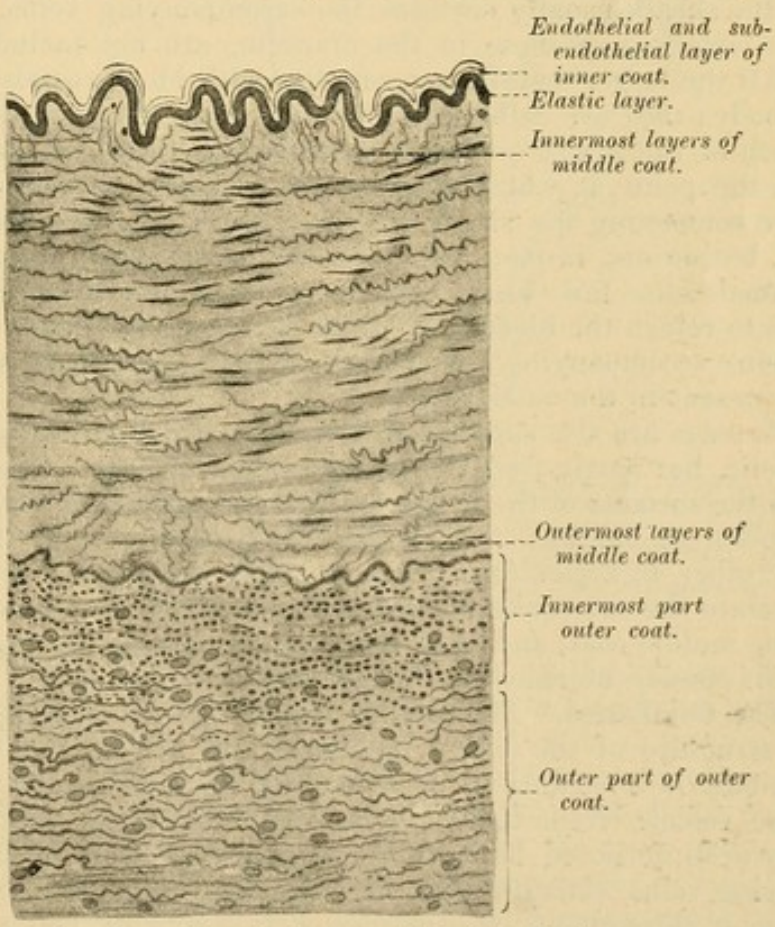

FIG. 667.—Section of a medium-sized artery. (After Grünstein.)

muscular fibre and are united by elastic fibres which pass between the muscular bundles, and are connected with the fenestrated membrane of the inner coat (Fig. 667). In the largest arteries, as the aorta and innominate, the amount of elastic

tissue is very considerable. In these vessels also bundles of white connective tissue have been found in small quantities in the middle coat. The muscle-fibre cells of which the middle coat is made up are about $\frac{1}{500}$ of an inch in length, and contain well-marked, rod-shaped nuclei, which are often slightly curved.

The *external* coat (*tunica adventitia*) consists mainly of fine and closely felted bundles of white connective tissue, but also contains elastic fibres in all but the smallest arteries. The elastic tissue is much more abundant next the tunica media, and is sometimes described as forming here, between the adventitia and media, a special layer, the *tunica elastica externa* of Henle. This layer is most marked in arteries of medium size. In the largest vessels the external coat is relatively thin; but in small arteries it is of greater proportionate thickness. In the smaller arteries it consists of a single layer of white connective tissue and elastic fibres; while in the smallest arteries, just above the capillaries, the elastic fibres are wanting, and the connective tissue, of which the coat is composed, becomes more homogeneous the nearer it approaches the capillaries, and is gradually reduced to a thin membranous envelope which finally disappears.

Some arteries have extremely thin coats in proportion to their size; this is especially the case in those situated in the cavity of the cranium and spinal canal, the difference depending on the greater thinness of the external and middle coats.

The arteries, in their distribution throughout the body, are included in a thin fibro-areolar investment, which forms what is called their *sheath*. In the limbs this is usually formed by a prolongation of the deep fascia; in the upper part of the thigh it consists of a continuation downward of the transversalis and iliac fasciæ of the abdomen; in the neck, of a prolongation of the deep cervical fascia. The included vessel is loosely connected with its sheath by a delicate areolar tissue; and the sheath usually encloses the accompanying veins, and sometimes a nerve. Some arteries, as those in the cranium, are not included in sheaths.

All the larger arteries are supplied with blood-vessels like the other organs of the body; they are called the *vasa vasorum*. These nutrient vessels arise from a branch of the artery or from a neighboring vessel, at some considerable distance from the point at which they are distributed; they ramify in the loose areolar tissue connecting the artery with its sheath, and are distributed to the external coat, but do not, in man, penetrate the other coats; though in some of the larger mammals some few vessels have been traced into the middle coat. Minute veins serve to return the blood from these vessels; they empty themselves into the vein or veins accompanying the artery. Lymphatic vessels and lymphatic spaces are also present in the outer coat.

Arteries are also supplied with nerves, which are derived chiefly from the sympathetic, but partly from the cerebro-spinal system. They form intricate plexuses upon the surfaces of the larger trunks, and run along the smaller arteries as single filaments or bundles of filaments, which twist around the vessel and unite with each other in a plexiform manner. The branches derived from these plexuses penetrate the external coat, and are principally distributed to the muscular tissue of the middle coat, and thus regulate, by causing the contraction and relaxation of this tissue, the amount of blood sent to any part.

The Capillaries.—The smaller arterial branches (excepting those of the cavernous structure of the sexual organs, of the spleen, and in the uterine placenta) terminate in a network of vessels which pervade nearly every tissue of the body. These vessels, from their minute size, are termed capillaries (*capillus*, a hair). They are interposed between the smallest branches of the arteries and the commencing veins, constituting a network, the branches of which maintain the same diameter throughout; the meshes of the network being more uniform in shape and size than those formed by the anastomoses of the small arteries and veins.

The *diameter* of the capillaries varies in the different tissues of the body, their usual size being about $\frac{1}{3000}$ of an inch. The smallest are those of the brain and

the mucous membranes of the intestines; and the largest those of the skin and the marrow of bone, where they are stated to be as large as $\frac{1}{1200}$ of an inch.

The *form* of the capillary net varies in the different tissues, the meshes being generally rounded or elongated. The *rounded form of mesh* is most common, and prevails where there is a dense network, as in the lungs, in most glands and mucous membranes, and in the cutis; here the meshes are more or less angular, sometimes nearly quadrangular or polygonal; or more often irregular and not of an absolutely circular outline.

Elongated meshes are observed in the muscles and nerves, the meshes being usually of a parallelogram form, the long axis of the mesh running parallel with the long axis of the nerve and fibre. Sometimes the capillaries have a *looped* arrangement; a single vessel projecting from the common network and returning after forming one or more loops, as in the papillæ of the tongue and skin. The number of the capillaries, and the size of the meshes, determine the degree of vascularity of a part. The closest network and the smallest interspaces are found in the lungs and in the choroid coat of the eye. In these situations the inter-

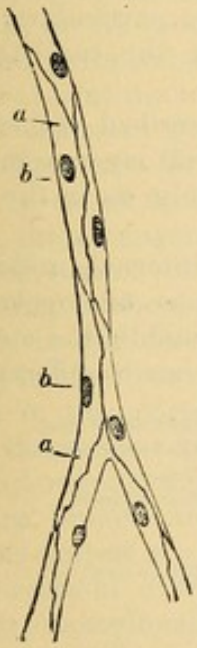

FIG. 668.—Capillaries from the mesentery of a guinea-pig after treatment with solution of nitrate of silver. *a*. Cells. *b*. Their nuclei.

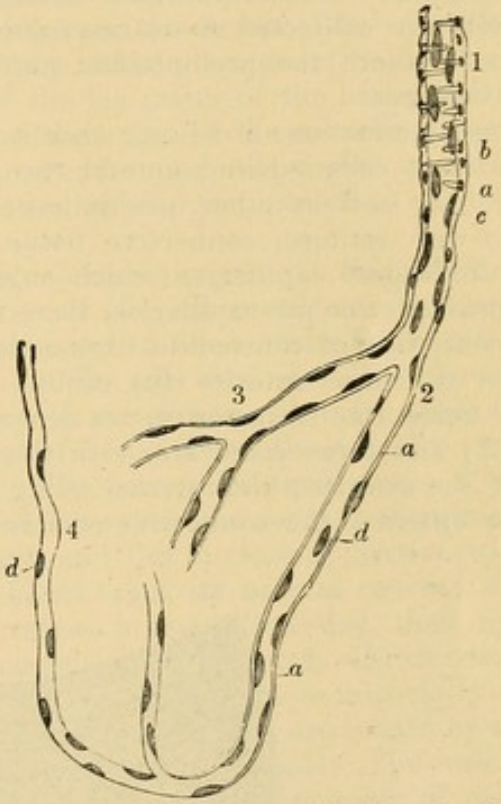

FIG. 669.—Finest vessels on the arterial side. From the human brain. Magnified 300 times. 1. Smallest artery. 2. Transition vessel. 3. Coarser capillaries. 4. Finer capillaries. *a*. Structureless membrane still with some nuclei, representative of the tunica adventitia. *b*. Nuclei of the muscular fibre-cells. *c*. nuclei within the small artery, perhaps appertaining to an endothelium. *d*. Nuclei in the transition vessels.

spaces are smaller than the capillary vessels themselves. In the kidney, in the conjunctiva, and in the cutis the interspaces are from three to four times as large as the capillaries which form them; and in the brain from eight to ten times as large as the capillaries in their long diameter, and from four to six times as large in their transverse diameter. In the adventitia of arteries the width of the meshes is ten times that of the capillary vessels. As a general rule, the more active the function of the organ, the closer is its capillary net and the larger its supply of blood; the meshes of the network being very narrow in all growing parts, in the glands, and in the mucous membranes; wider in bones and ligaments, which are comparatively inactive; and nearly altogether absent in tendons, in which very little organic change occurs after their formation.

Structure.—The walls of the capillaries consist of a fine, transparent, endothelial

layer, composed of cells joined edge to edge by an interstitial cement-substance, and continuous with the endothelial cells which line the arteries and veins. When stained with nitrate of silver the edges which bound the epithelial cells are brought into view (Fig. 668). These cells are of large size and of an irregular polygonal or lanceolate shape, each containing an oval nucleus which may be brought into view by carmine or hæmatoxylin. Between their edges, at various points of their meeting, roundish dark spots are sometimes seen, which have been described as stomata, though they are closed by intercellular substance. They have been believed to be the situation through which the white corpuscles of the blood, when migrating from the blood-vessels, emerge; but this view, though probable, is not universally accepted.

Kolossow, a Russian observer, describes these cells as having a rather more complex structure. He states that they consist of two parts: of hyaline ground-plates, and of a protoplasmic granular part, in which is imbedded the nucleus, on the outside of the ground-plates. The hyaline internal coat of the capillaries does not form a complete membrane, but consists of "plates" which are inelastic, and, though in contact with each other, are not continuous; when, therefore, the capillaries are subjected to intra-vascular pressure, the plates become separated from each other; the protoplasmic portions of the cells, on the other hand, are united together.

In many situations a delicate sheath or envelope of branched nucleated connective-tissue cells is found around the simple capillary tube, particularly in the larger ones; and in other places, especially in the glands, the capillaries are invested with retiform connective tissue.

In the largest capillaries (which ought, perhaps, to be described rather as the smallest arteries or pre-capillaries) there is, outside the epithelial layer, a muscular layer, consisting of contractile fibre-cells, arranged transversely, as in the tunica media of the larger arteries (Fig. 669).

The **veins**, like the arteries, are composed of three coats—internal, middle, and external; and these coats are, with the necessary modifications, analogous to the coats of the arteries; the internal being the endothelial, the middle the muscular, and the external the connective or areolar (Fig. 670). The main difference be-

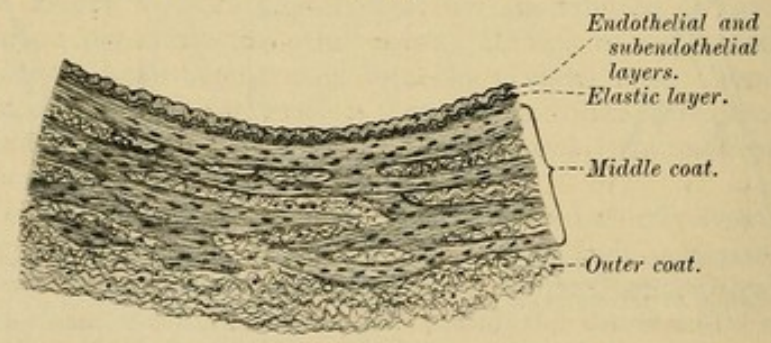

FIG. 670.—Transverse section of part of the wall of one of the posterior tibial veins. (After Schäfer).

tween the veins and the arteries is the comparative weakness of the middle coat of the former, and to this is due the fact that the veins do not stand open when divided, as the arteries do, and that they are passive rather than active organs of the circulation.

In the veins immediately above the capillaries the three coats are hardly to be distinguished. The endothelium is supported on an outer membrane separable into two layers, the outer of which is the thicker, and consists of a delicate, nucleated membrane (adventitia), while the inner is composed of a network of longitudinal elastic fibres (media). In the veins next above these in size (one-fifth of a line, according to Kölliker) a muscular layer and a layer of circular fibres can be traced, forming the middle coat, while the elastic and connective elements of the outer coat become more distinctly perceptible. In the middle-sized veins the typical structure of these vessels becomes clear. The endothelium is of the same character

as in the arteries, but its cells are more oval, less fusiform. It is supported by a connective-tissue layer, consisting of a delicate network of branched cells, and external to this is a layer of longitudinal elastic fibres, but seldom any appearance of a fenestrated membrane. This constitutes the *internal* coat. The *middle* coat is composed of a thick layer of connective tissue with elastic fibres, intermixed, in some veins, with a transverse layer of muscular fibres. The white fibrous element is in considerable excess, and the elastic fibres are in much smaller proportion in the veins than in the arteries. The *outer* coat consists of areolar tissue, as in the arteries, with longitudinal elastic fibres. In the largest veins the outer coat is from two to five times thicker than the middle coat, and contains a large number of longitudinal muscular fibres. This is most distinct in the inferior vena cava, and at the termination of this vein in the heart, in the trunks of the hepatic veins, in all the large trunks of the vena portæ, in the splenic, superior mesenteric, external iliac, renal, and azygos veins. In the renal and portal veins it extends through the whole thickness of the outer coat, but in the other veins mentioned a layer of connective and elastic tissue is found external to the muscular fibres. All the large veins which open into the heart are covered for a short distance with a layer of striped muscular tissue continued on to them from the heart. Muscular tissue is wanting in the veins—(1) of the maternal part of the placenta; (2) in the venous sinuses of the dura mater and the veins of the pia mater of the brain and spinal cord; (3) in the veins of the retina; (4) in the veins of the cancellous tissue of bones; (5) in the venous spaces of the corpora cavernosa. The veins of the above-mentioned parts consist of an internal endothelial lining supported on one or more layers of areolar tissue.

Most veins are provided with valves, which serve to prevent the reflux of the blood. They are formed by a reduplication of the inner coat, strengthened by connective tissue and elastic fibres, and are covered on both surfaces with endothelium, the arrangement of which differs on the two surfaces. On the surface of the valve next the wall of the vein the cells are arranged transversely; whilst on the other surface, over which the current of blood flows, the cells are arranged vertically in the direction of the current. The valves are semilunar. They are attached by their convex edge to the wall of the vein; the concave margin is free, directed in the course of the venous current, and lies in close apposition with the wall of the vein as long as the current of blood takes its natural course; if, however, any regurgitation takes place, the valves become distended, their opposed edges are brought into contact, and the current is interrupted. Most commonly two such valves are found placed opposite one another, more especially in the smaller veins or in the larger trunks at the point where they are joined by smaller branches; occasionally there are three and sometimes only one. The wall of the vein on the cardiac side of the point of attachment of each segment of the valve is expanded into a pouch or sinus, which gives to the vessel, when injected or distended with blood, a knotted appearance. The valves are very numerous in the veins of the extremities, especially of the lower extremities, these vessels having to conduct the blood against the force of gravity. They are absent in the very small veins—*i. e.* those less than $\frac{1}{12}$ of an inch in diameter; also in the venæ cavæ, the hepatic veins, portal vein and most of its branches, the renal, uterine, and ovarian veins. A few valves are found in the spermatic veins, and one also at their point of junction with the renal vein and inferior vena cava, respectively. The cerebral and spinal veins, the veins of the cancellated tissue of bone, the pulmonary veins, and the umbilical vein, and its branches, are also destitute of valves. They are occasionally found, few in number, in the venæ azygos and intercostal veins.

The veins are supplied with nutrient vessels, *vasa vasorum*, like the arteries. Nerves also are distributed to them in the same manner as to the arteries, but in much less abundance.

The **lymphatic** vessels, including in this term the lacteal vessels, which are identical in structure with them, are composed of three coats. The *internal* is an

endothelial and elastic coat. It is thin, transparent, slightly elastic, and ruptures sooner than the other coats. It is composed of a layer of elongated endothelial cells with serrated margins, by which the adjacent cells are dovetailed into one another. These are supported on a single layer of longitudinal elastic fibres. The *middle* coat is composed of smooth muscular and fine elastic fibres, disposed in a transverse direction. The *external*, or fibro-areolar, coat consists of filaments of connective tissue, intermixed with smooth muscular fibres, longitudinally or obliquely disposed. It forms a protective covering to the other coats, and serves to connect the vessel with the neighboring structures. The above description applies only to the larger lymphatics; in the smaller vessels there is no muscular or elastic coat, and their structure consists only of a connective-tissue coat, lined by endothelium. The thoracic duct (Fig. 671) is a somewhat more complex structure than the other lymphatics; it presents a distinct subendothelial layer of branched corpuscles, similar to that found in the arteries,



FIG. 671.—Transverse section through the coats of the thoracic duct of man. Magnified 30 times. *a*. Endothelium, striated lamellæ, and inner elastic coat. *b*. Longitudinal connective tissue of the middle coat. *c*. Transverse muscles of the same. *d*. Tunica adventitia, with *e*, the longitudinal muscular fibres.

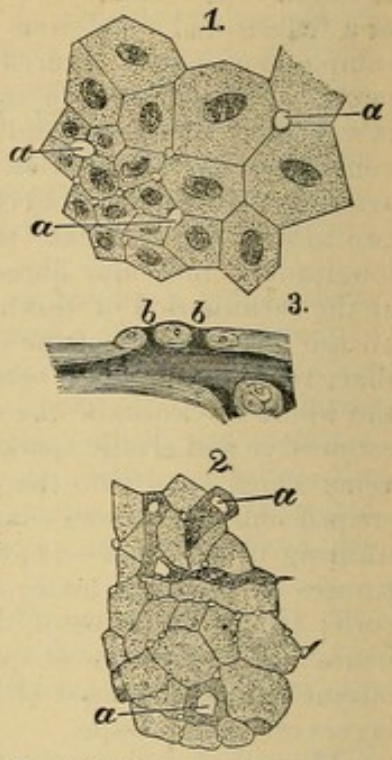

FIG. 672.—Stroma of serous membranes. 1. Endothelium from the under surface of the *centrum tendineum* of the rabbit. *a*. Stomata. 2. Endothelium of the mediastinum of the dog. *a*. Stomata. 3. Section through the pleura of the same animal. *b*. Free orifices of short lateral passages of the lymph-canals. (Copied from Ludwig, Schweigger-Seydel, and Dybkowsky.)

and in the middle coat is a layer of connective tissue with its fibres arranged longitudinally. The lymphatics are supplied by nutrient vessels, which are distributed to their outer and middle coats; and here also have been traced many non-medullated nerve-fibres in the form of a fine plexus of fibrils.

The lymphatics are very generally provided with valves, which assist materially in effecting the circulation of the fluid they contain. These valves are formed of a thin layer of fibrous tissue, lined on both surfaces by endothelium, which presents the same arrangement upon the two surfaces as was described in connection with the valves of veins. Their form is semilunar; they are attached by their convex edge to the sides of the vessel, the concave edge being free and directed along the course of the contained current. Usually two such valves, of equal size, are found opposite one another; but occasionally exceptions occur, especially at or near the anastomoses of lymphatic vessels. Thus, one valve may be of very rudimentary size and the other increased in proportion.

The valves in the lymphatic vessels are placed at much shorter intervals than in the veins. They are most numerous near the lymphatic glands, and they are found more frequently in the lymphatics of the neck and upper extremity than in the lower. The wall of the lymphatics immediately above the point of attachment of each segment of a valve is expanded into a pouch or sinus, which gives to these vessels, when distended, the knotted or beaded appearance which they present. Valves are wanting in the vessels composing the plexiform network in which the lymphatics usually originate on the surface of the body.

Origin of Lymphatics.—The finest visible lymphatic vessels (lymphatic capillaries) form a plexiform network in the tissues and organs, and they consist of a single layer of endothelial plates, with more or less sinuous margins. These ves-

sels commence in an intercommunicating system of clefts or spaces which have no complete endothelial lining in the connective tissue of the different organs. They have been named the *rootlets* of the lymphatics, and are identical with the spaces in which the connective-tissue corpuscles are contained. This then is properly regarded as one method of their commencement, when the lymphatic vessels are apparently continuous with spaces in the connective tissue, and Klein has described and figured a direct communication between these spaces and the lymphatic vessel.[1] But the lymphatics have also other modes of origin, for the intestinal lacteals commence by closed extremities, though some observers believe that the closed extremity is continuous with a minute network contained in the substance of the villus, through which the lacteal is connected with the endothelial cells covering it. Again, it seems now to be conclusively proved that the serous membranes present stomata or openings between the endothelial cells (Fig. 672) by which there is an open communication with the lymphatic system, and through which the lymph is thought to be pumped by the alternate dilatation and contraction of the serous surface, due to the movements of respiration and circulation,[2] so that the serous and synovial sacs may be regarded, in a certain sense, as large lymph-cavities or sinuses. Von Recklinghausen was the first to observe the passage of milk and other colored fluids through these stomata on the peritoneal surface of the central tendon of the diaphragm. Again, in most glandular structures the lymphatic capillaries have a lacunar origin. Here they begin in irregular clefts or spaces in the tissue of the part; occupying the penetrating connective tissue and surrounding the lacunæ or tubules of the gland, and in many places separating the capillary network from the alveolus or tubule, so that the interchange between the blood and the secreting cells of the part must be carried on through this lymph-space or lacuna. Closely allied to this is the mode of origin of lymphatics in perivascular and perineural spaces. Sometimes a minute artery may be seen to be ensheathed for a certain distance by a lymphatic capillary vessel, which is often many times wider than a blood-capillary. These are known as perivascular lymphatics.

Terminations of Lymphatics.—The lymphatics, including the lacteals, discharge their contents into the veins at two points; namely, at the angles of junction of the subclavian and internal jugular veins: on the left side by means of the thoracic duct, and on the right side by the right lymphatic duct. (See description of lymphatics on page 623.)

Lymphatic glands (*conglobate glands*) are small oval or bean-shaped bodies, situated in the course of lymphatic and lacteal vessels, so that the lymph and chyle pass through them on their way to the blood. They generally present on one side a slight depression—the *hilum*—through which the blood-vessels enter and leave the interior. The efferent lymphatic vessel also emerges from the gland at this spot, while the afferent vessels enter the organ at different parts of the periphery. On section (Fig. 673), a lymphatic gland displays two different structures: an external, of lighter color—the *cortical;* and an internal, darker—the *medullary*. The cortical structure does not form a complete investment, but is deficient at the hilum, where the medullary portion reaches the surface of the gland; so that the efferent vessel is derived directly from the medullary structure, while the afferent vessels empty themselves into the cortical substance.

Lymphatic glands consist of (1) a fibrous envelope, or *capsule*, from which a framework of processes (*trabeculæ*) proceed inward, dividing the gland into open spaces (*alveoli*) freely communicating with each other; (2) a quantity of lymphoid tissue occupying these spaces without completely filling them; (3) a free supply of blood-vessels, which are supported on the trabeculæ; and (4) the *afferent* and *efferent* vessels. Little is known of the nerves, though Kölliker describes some fine nervous filaments passing into the hilum.

[1] *Atlas of Histology*, pl. viii. fig. xiv.

[2] The resemblance between lymph and serum led Hewson long ago to regard the serous cavities as sacs into which the lymphatics open. Recent microscopic discoveries confirm this opinion in a very interesting manner.

The *capsule* is composed of a layer of connective tissue, and from its internal surface are given off a number of membranous septa or lamellæ, consisting, in man, of connective tissue, with a small admixture of plain muscle-fibres; but in many of the lower animals composed almost entirely of involuntary muscle. They pass inward, radiating toward the centre of the gland, for a certain distance; that is to say, for about one-third or one-fourth of the space between the circumference and the centre of the gland. They thus divide the outer part of its interior into a number of oval compartments or *alveoli* (Fig. 673). This is the cortical portion of the gland. After having penetrated into the gland for some distance, these septa break up into a number of smaller trabeculæ, which form flattened bands or cords, interlacing with each other in all directions, forming in the central part of the organ a number of intercommunicating spaces, also called *alveoli*. This is the medullary portion of the gland, and the spaces or alveoli in it not only freely communicate with each other, but also with the alveoli of the cortical portion. In these alveoli or spaces (Fig. 674) is contained the proper gland-substance or lymphoid tissue.

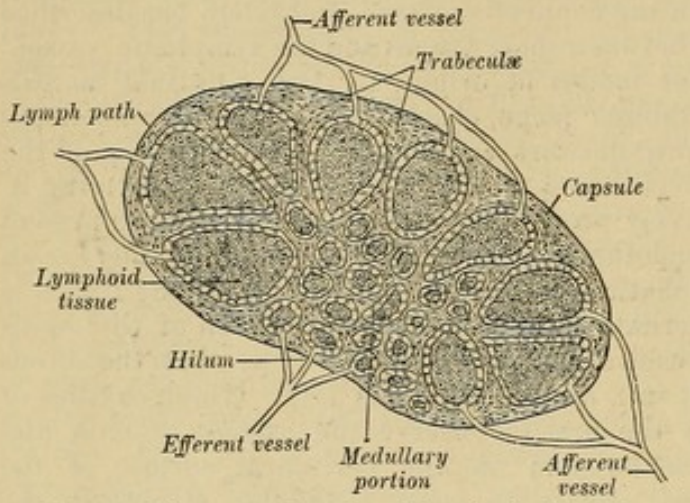

FIG. 673.—Diagrammatic section of lymphatic gland, showing the course of the lymph.

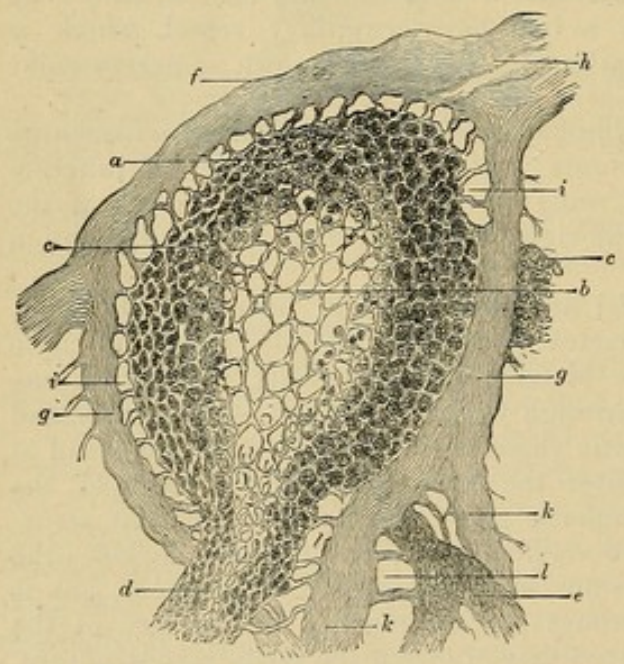

FIG. 674.—Follicle from a lymphatic gland of the dog, in vertical section. *a*. Reticular sustentacular substance of the more external portion, *b*, of the more internal, and *c*, of the most external and most finely webbed part on the surface of the follicle. *d*. Origin of a large lymph-tube. *e*. Of a smaller one. *f*. Capsule. *g*. Septa. *h*. Vas afferens. *i*. Investing space of the follicle, with its retinacula. *k*. One of the divisions of the septa. *l,l*. Attachment of the lymph-tubes to the septa.

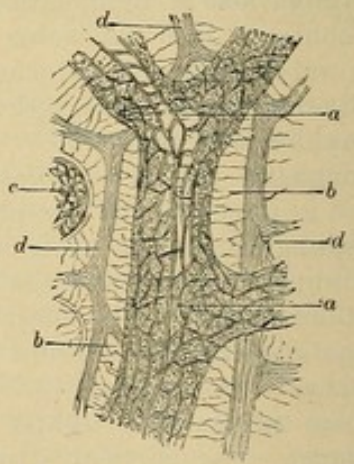

FIG. 675.—From the medullary substance of an inguinal gland of the ox. (After His.) *a*. Lymph-tube, with its complicated system of vessels. *b*. Retinacula stretched between the tube and the septa. *c*. Portion of another lymph-tube. *d*. Septa.

The gland-pulp does not, however, completely fill the alveolar spaces, but leaves, between its outer margin and the trabeculæ forming the alveoli a channel or space of uniform width throughout. This is termed the *lymph-path* or *lymph-sinus* (Fig. 676). Running across it are a number of trabeculæ of retiform connective tissue, the fibres of which are, for the most part, covered by ramified cells. This tissue

appears to serve the purpose of maintaining the gland-pulp in the centre of the space in its proper position.

On account of the peculiar arrangement of the framework of the organ, the gland-pulp in the cortical portion is disposed in the form of nodules, and in the medullary part in the form of rounded cords. It consists of ordinary lymphoid tissue, being made up of a delicate reticulum of retiform tissue, which is continuous with that in the lymph-paths, but marked off from it by a closer reticulation; in its meshes are closely packed lymph-corpuscles, traversed by a dense plexus of capillary blood-vessels.

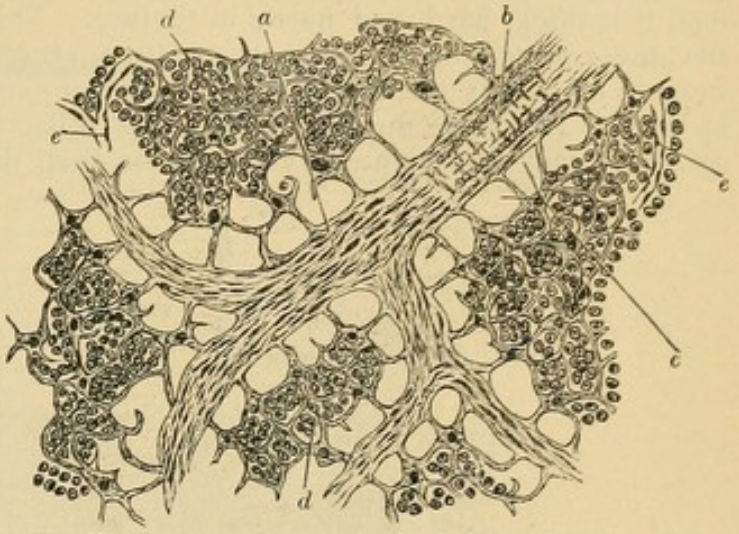

FIG. 676.—Section of lymphatic gland tissue. *a*. Trabeculæ. *b*. Small artery in substance of same. *c*. Lymph-paths. *d*. Lymph-corpuscles. *e*. Capillary plexus.

The *afferent vessels*, as above stated, enter at all parts of the periphery of the gland, and after branching and forming a dense plexus in the substance of the capsule, open into the lymph-sinuses of the cortical part. In doing this they lose all their coats except their endothelial lining, which is continuous with a layer of similar cells lining the lymph-paths. In like manner the *efferent* vessel commences from the lymph-sinuses of the medullary portion. The stream of lymph carried to the gland by the afferent vessel thus passes through the plexus in the capsule to the lymph-paths of the cortical portion, where it is exposed to the action of the gland-pulp; flowing through these, it enters the paths or sinuses of the medullary portion, and finally emerges from the hilum by means of the efferent vessel. The stream of lymph in its passage through the lymph-sinuses is much retarded by the presence of the reticulum. Hence morphological elements, either normal or morbid, are easily arrested and deposited in the sinuses. This is a matter of considerable importance in connection with the subject of poisoned wounds and the absorption of the poison by the lymphatic system, since by this means septic organisms carried along the lymphatic vessels may be arrested in the lymph-sinuses of the gland tissue, and thus be prevented from entering the general circulation. Many lymph-corpuscles pass with the efferent lymph-stream to join the general blood-stream. The arteries of the gland enter at the hilum, and either pass at once to the gland-pulp, to break up into a capillary plexus, or else run along the trabeculæ, partly to supply them and partly running across the lymph-paths to assist in forming the capillary plexus of the gland-pulp. This plexus traverses the lymphoid tissue, but does not pass into the lymph-sinuses. From it the veins commence, and emerge from the organ at the same place as that at which the artery enters.

THE SKIN AND ITS APPENDAGES.

The **skin** (Fig. 677) is the principal seat of the sense of touch, and may be regarded as a covering for the protection of the deeper tissues; it plays an important part in the regulation of the body temperature, and is also an excretory and absorbing organ. It consists principally of a layer of vascular tissue, named the *derma*, *corium*, or *cutis vera*, and an external covering of epithelium, termed the *epidermis* or *cuticle*. On the surface of the former layer are the sensitive *papillæ;* and within, or imbedded beneath it, are certain organs with special functions, namely, the *sweat-glands*, *hair-follicles*, and *sebaceous glands*.

The **epidermis** or **cuticle** (*scarf-skin*) is non-vascular, and consists of stratified epithelium (Fig. 678). It is accurately moulded on the papillary layer of the derma. It forms a defensive covering to the surface of the true skin, and limits the evaporation of watery vapor from its free surface. It varies in thickness in different parts. In some situations, as in the palms of the hands and soles of the feet, it is thick, hard, and horny in texture. This may be partly due to the fact that these parts are exposed to intermittent pressure, but that this is not the only cause is proved by the fact that the condition exists to a very considerable extent at birth. The more superficial layer of cells, called the *horny* layer (*stratum corneum*), may be separated by maceration from the deeper layers, which are called

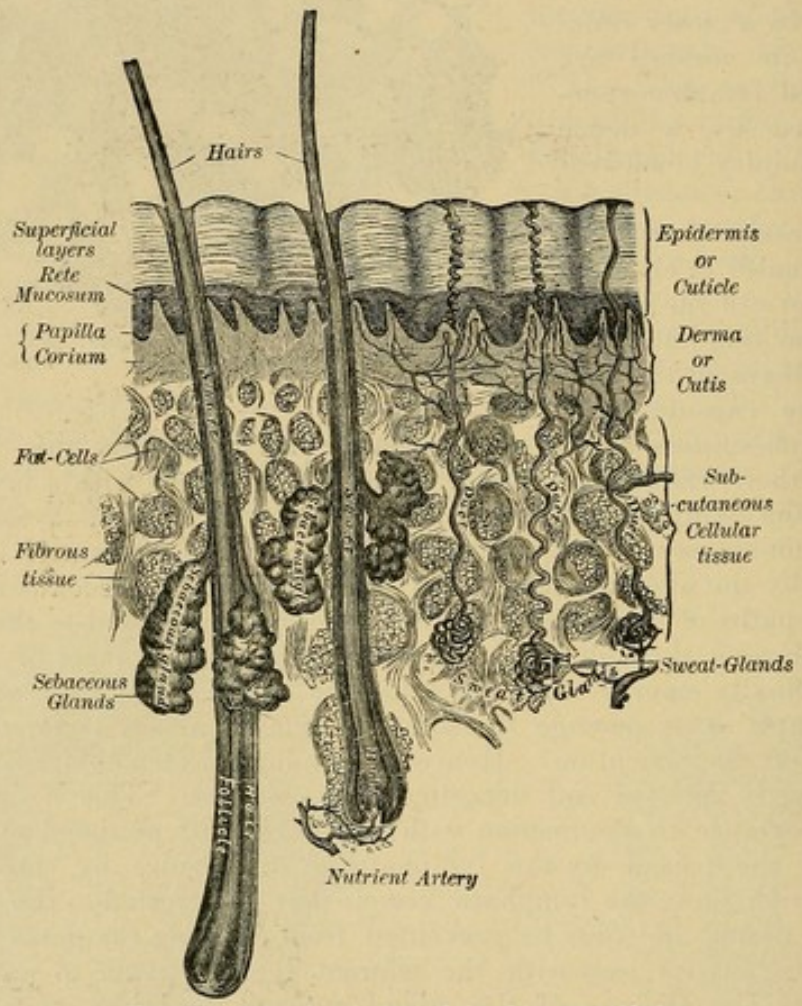

FIG. 677.—A sectional view of the skin (magnified).

the *rete mucosum* or *stratum Malpighii*, and which consist of several layers of differently shaped cells. The free surface of the epidermis is marked by a network of linear furrows of variable size, marking out the surface into a number of spaces of polygonal or lozenge-shaped form. Some of these furrows are large, as opposite the flexures of the joints, and correspond to the folds in the dermis produced by their movements. In other situations, as upon the back of the hand, they are exceedingly fine, and intersect one another at various angles; upon the palmar surface of the hand and fingers and upon the sole of the foot these lines are very distinct and are disposed in curves. They depend upon the large size and peculiar arrangement of the papillæ upon which the epidermis is placed. The deep surface of the epidermis is accurately moulded upon the papillary layer of the dermis, each papilla being invested by its epidermic sheath; so that when this layer is removed by maceration, it presents on its under surface a number of pits or depressions corresponding to the elevations in the papillæ, as well as the ridges left in the intervals between them. Fine tubular prolongations are continued from this layer into the ducts of the sudoriferous and sebaceous glands.

In structure the epidermis consists of several layers of epithelial cells agglutinated together and having a laminated arrangement. These several layers may be described as composed of four different strata from within outward: (1) The *stratum Malpighii*, composed of several layers of epithelial cells, of which the deepest layer is columnar in shape and placed perpendicularly on the surface of the corium,

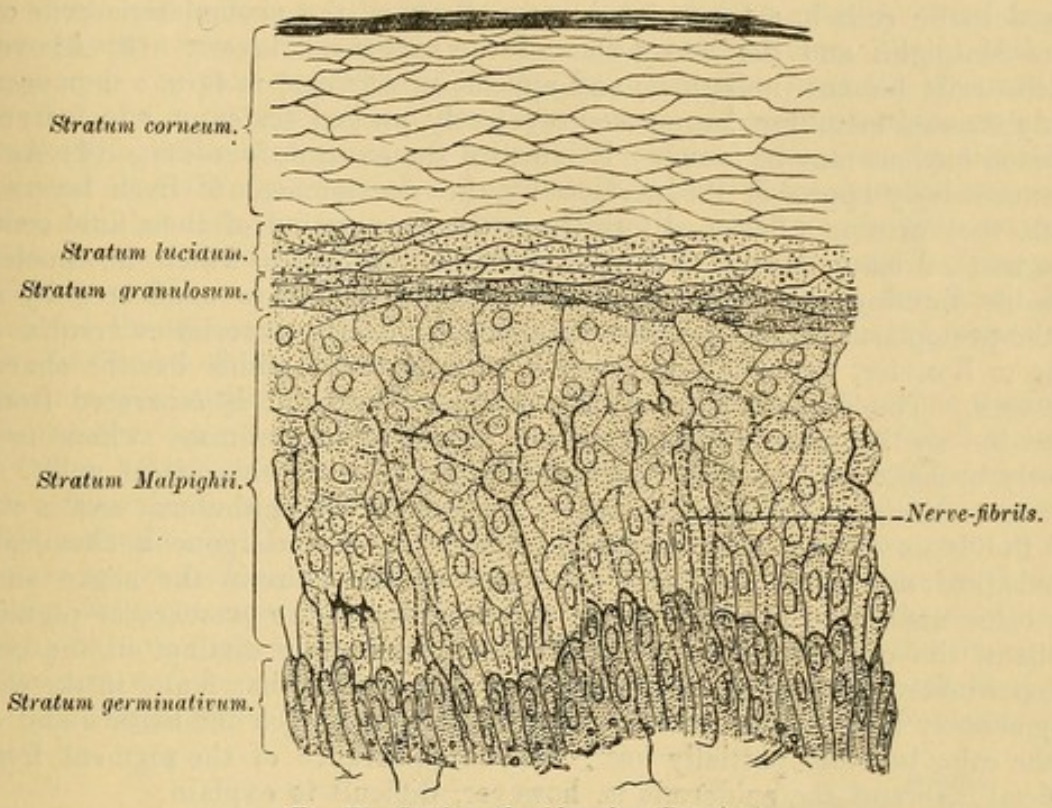

FIG. 678.—Section of epidermis. (Ranvier.)

their lower ends being denticulate, to fit into corresponding denticulations of the true skin; this deepest layer is sometimes termed the basilar layer or *stratum germinativum*; the succeeding laminæ consist of cells of a more rounded or polyhedral form, the contents of which are soft, opaque, granular, and soluble in acetic acid.

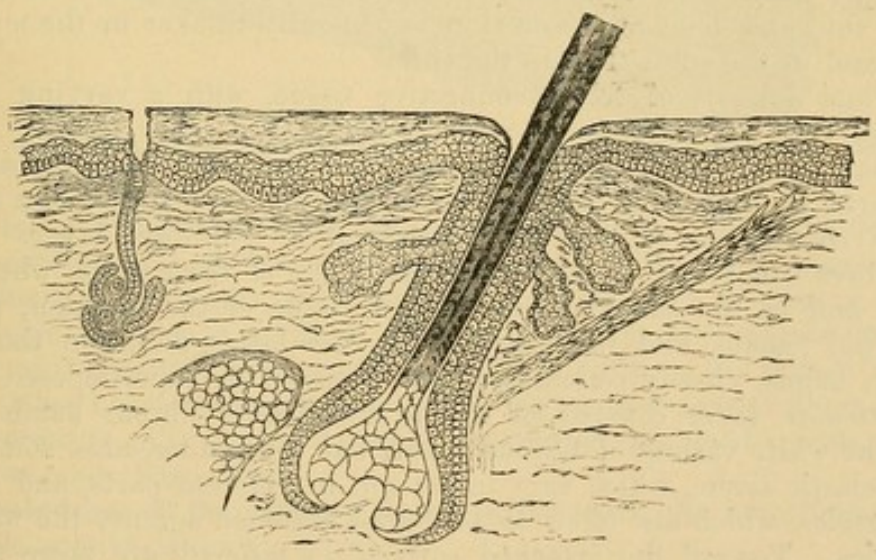

FIG. 679.—Microscopic section of skin, showing the epidermis and derma; a hair in its follicle; the erector pili muscle; sebaceous and sudoriferous glands.

They are often marked on their surfaces with ridges and furrows, and are covered with numerous fibrils, which connect the surfaces of the cells: these are known as *prickle* cells. (See page 1075.) They contain numerous epidermic fibrils, which are stained violet with hæmatoxylin and red by carmine, and form threads of union

connecting adjacent cells. Between the cells are fine intercellular clefts, which serve for the passage of lymph and in which lymph-corpuscles or pigment granules may be found. (2) Immediately superficial to these are two or three layers of flattened, spindle-shaped cells, the *stratum granulosum*, which contain granules that become deeply stained in hæmatoxylin; the granules consist of a material named *eleidin*, an intermediate substance in the formation of horn. They are supposed to be cells in a transitional stage between the protoplasmic cells of the stratum Malpighii and the horny cells of the superficial layers. (3) Above this layer the cells become indistinct, and appear, in sections, to form a homogeneous or dimly striated membrane, composed of closely packed scales, in which traces of a flattened nucleus may be found. It is called the *stratum lucidum*. (4) As these cells successively approach the surface by the development of fresh layers from beneath, they assume a flattened form from the evaporation of their fluid contents, and consist of many layers of horny epithelial scales in which no nucleus is discernible, forming the *stratum corneum*. These cells are unaffected by acetic acid, the protoplasm having become changed into horny material or *keratin*. According to Ranvier, they contain granules of a material which has the characters of beeswax. The deepest layer of the stratum Malpighii is separated from the papillæ by an apparently homogeneous basement membrane, which is most distinctly brought into view, in specimens prepared with chloride of gold. This, according to Klein, is merely the deepest portion of the epithelium, and is "made up of the basis of the individual cells, which have undergone a chemical and morphological alteration." The black color of the skin in the negro and the tawny color among some of the white races is due to the presence of pigment in the cells of the cuticle. This pigment is more especially distinct in the cells of the deeper layer, or stratum Malpighii, and is similar to that found in the cells of the pigmentary layer of the retina. As the cells approach the surface and desiccate, the color becomes partially lost; the disappearance of the pigment from the superficial layers of the epidermis is, however, difficult to explain.

The **derma, corium,** or **cutis vera,** is tough, flexible, and highly elastic, in order to defend the parts beneath from violence.

It varies in thickness, from a quarter of a line to a line and a half, in different parts of the body. Thus it is very thick in the palms of the hands and soles of the feet; thicker on the posterior aspect of the body than the front, and on the outer than the inner side of the limbs. In the eyelids, scrotum, and penis it is exceedingly thin and delicate. The skin is generally thicker in the male than in the female, and in the adult than in the child.

The corium consists of felted connective tissue, with a varying amount of elastic fibres and numerous blood-vessels, lymphatics, and nerves. The fibro-areolar tissue forms the framework of the cutis, and is differently arranged in different parts, so that it is usual to describe it as consisting of two layers: the deeper or *reticular* layer, and the superficial or *papillary* layer. Unstriped muscular fibres are found in the superficial layers of the corium, wherever hairs are found; and in the subcutaneous areolar tissue of the scrotum, penis, labia majora of the female, and the nipples. In the latter situation the fibres are arranged in bands, closely reticulated and disposed in superimposed laminæ.

The *reticular* layer consists of strong interlacing fibrous bands, composed chiefly of the white variety of fibrous tissue, but containing, also, some fibres of the yellow elastic tissue, which vary in amount in different parts, and connective-tissue corpuscles, which are often to be found flattened against the white fibrous tissue-bundles. Toward the attached surface the fasciculi are large and coarse, and the areolæ which are left by their interlacement are large, and occupied by adipose tissue and sweat-glands. Below this the elements of the skin become gradually blended with the subcutaneous areolar tissue, which, except in a few situations, contains fat. Toward the free surface the fasciculi are much finer, and their mode of interlacing close and intricate.

The *papillary layer* is situated upon the free surface of the *reticular layer;* it con-

sists of numerous small, highly sensitive, or vascular eminences, the *papillæ*, which rise perpendicularly from its surface. The papillæ are conical-shaped eminences, having a round or blunted extremity, occasionally divided into two or more parts and are received into corresponding pits on the under surface of the cuticle. Their average length is about $\frac{1}{100}$ of an inch, and they measure at their base $\frac{1}{250}$ of an inch in diameter. On the general surface of the body, more especially in those parts which are endowed with slight sensibility, they are few in number, short, exceedingly minute, and irregularly scattered over the surface; but in some situations, as upon the palmar surface of the hands and fingers, upon the plantar surface of the feet and toes, and around the nipple, they are long, of large size, closely aggregated together, and arranged in parallel curved lines, forming the elevated ridges seen on the free surface of the epidermis. Each ridge contains two rows of papillæ, and between the two rows the ducts of the sweat-glands pass outward to open on the summit of the ridges. In structure the papillæ consist of very small and closely interlacing bundles of finely fibrillated tissue, with a few elastic fibres; within this tissue is a capillary loop, and in some, especially in the palms of the hands and fingers, there are tactile corpuscles.

The *arteries* supplying the skin form a network in the subcutaneous tissue, from which branches are given off to supply the sweat-glands, the hair-follicles, and the fat. Other branches are given off which form a plexus immediately beneath the corium; from this fine capillary vessels pass into the papillæ, forming, in the smaller papillæ, a single capillary loop, but in the larger a more or less convoluted vessel. There are numerous *lymphatics* supplied to the skin which form two networks, superficial and deep, communicating with each other and with those of the subcutaneous tissue by oblique branches. They originate in the cell-spaces of the tissue.

The *nerves* of the skin terminate partly in the epidermis and partly in the cutis vera. The former are prolonged into the epidermis from a dense plexus in the

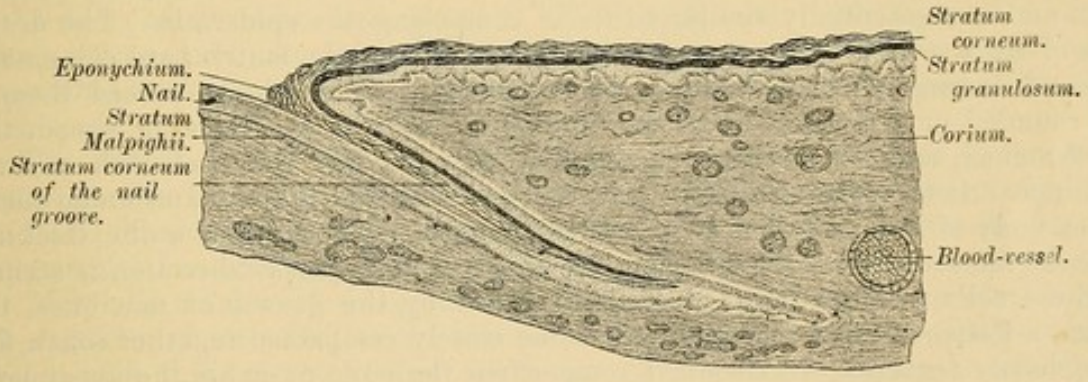

FIG. 680.—Longitudinal section through human nail and its nail groove (sulcus). (From Böhm and Davidoff's *Histology*).

superficial layer of the corium and terminate between the cells in bulbous extremities; or, according to some observers, in the deep epithelial cells themselves. The latter terminate in end-bulbs, touch-corpuscles, or Pacinian bodies, in the manner already described; and, in addition to these, a considerable number of fibrils are distributed to the hair-follicles, which are said to entwine the follicle in a circular manner. Other nerve-fibres are supplied to the plain muscular fibres of the hair-follicles (arrectores pili) and to the muscular coat of the blood-vessels. These are probably non-medullated fibres.

The **appendages of the skin** are the nails, the hairs, the sudoriferous and sebaceous glands, and their ducts.

The nails and hairs are peculiar modifications of the epidermis, consisting essentially of the same cellular structure as that tissue.

The **nails** (Figs. 680, 681) are flattened, elastic structures of a horny texture, placed upon the dorsal surface of the terminal phalanges of the fingers and toes. Each nail is convex on its outer surface, concave within, and is implanted by a portion, called the *root*, into a groove in the skin; the exposed portion is called the

body, and the anterior extremity the *free edge*. The nail has a very firm adhesion to the cutis, being accurately moulded upon its surface, as the epidermis is in other parts. The part of the cutis beneath the body and root of the nail is called the *matrix*, because it is the part from which the nail is produced. Corresponding to the body of the nail, the matrix is thick, and raised into a series of longitudinal

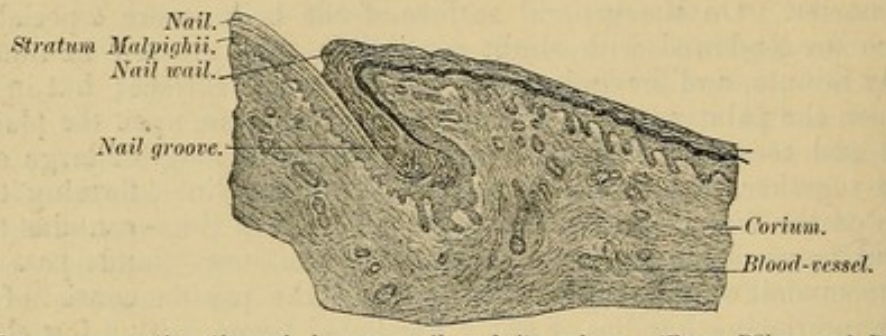

FIG. 681.—Transverse section through human nail and its sulcus. (From Böhm and Davidoff's *Histology*.)

ridges, which are very vascular, and the color is seen through the transparent tissue. Behind this, near the root of the nail, the papillæ are small, less vascular, and have no regular arrangement, and here the tissue of the nail is somewhat more opaque; hence this portion is of a whiter color, and is called the *lunula* on account of its shape.

The cuticle, as it passes forward on the dorsal surface of the finger or toe, is attached to the surface of the nail, a little in advance of its root; at the extremity of the finger it is connected with the under surface of the nail a little behind its free edge. The cuticle and horny substance of the nail (both epidermic structures) are thus directly continuous with each other. The nails consist of a greatly thickened stratum lucidum, the stratum corneum forming merely the thin cuticular fold (*eponychium*) which overlaps the lunula. The cells have a laminated arrangement, and are essentially similar to those composing the epidermis. The deepest layer of cells, which lie in contact with the papillæ of the matrix, are columnar in form and arranged perpendicularly to the surface; those which succeed them are of a rounded or polygonal form, the more superficial ones becoming broad, thin, and flattened, and so closely compacted as to make the limits of each cell very indistinct. It is by the successive growth of new cells at the root and under surface of the body of the nail that it advances forward and maintains a due thickness, while, at the same time, the growth of the nail in the proper direction is secured. As these cells in their turn become displaced by the growth of new ones, they assume a flattened form, and finally become closely compacted together into a firm, dense, horny texture. In *chemical composition* the nails resemble the upper layers of the epidermis. According to Mulder, they contain a somewhat larger proportion of carbon and sulphur.

The **hairs** are peculiar modifications of the epidermis, and consist essentially of the same structure as that membrane. They are found on nearly every part of the surface of the body, excepting the palms of the hands, soles of the feet, and the glans penis. They vary much in length, thickness, and color in different parts of the body and in different races of mankind. In some parts, as in the skin of the eyelids, they are so short as not to project beyond the follicles containing them; in others, as upon the scalp, they are of considerable length: again, in other parts, as the eyelashes, the hairs of the pubic region, and the whiskers and beard, they are remarkable for their thickness. Straight hairs are stronger than curly hairs, and present on transverse section a cylindrical or oval outline; curly hairs, on the other hand, are flattened.

A hair consists of a *root*, the part implanted in the skin; the *shaft* or *stem*, the portion projecting from its surface; and the *point*.

The *root of the hair* presents at its extremity a bulbous enlargement, which is whiter in color and softer in texture than the shaft, and is lodged in a follicular involution of the epidermis called the *hair-follicle* (Fig. 679). When the hair is

of considerable length the follicle extends into the subcutaneous cellular tissue. The hair-follicle commences on the surface of the skin with a funnel-shaped opening, and passes inward in an oblique or curved direction—the latter in curly hair—to become dilated at its deep extremity, where it corresponds with the bulbous condition of the hair which it contains. It has opening into it, near its free extremity, the orifices of the ducts of one or more sebaceous glands. At the bottom of each hair-follicle is a small conical, vascular eminence or papilla, similar in every respect to those found upon the surface of the skin; it is continuous with the dermic layer of the follicle, is highly vascular, and probably supplied with nervous fibrils. In structure the hair-follicle consists of two coats—an outer or *dermic*, and an inner or *epidermic*.

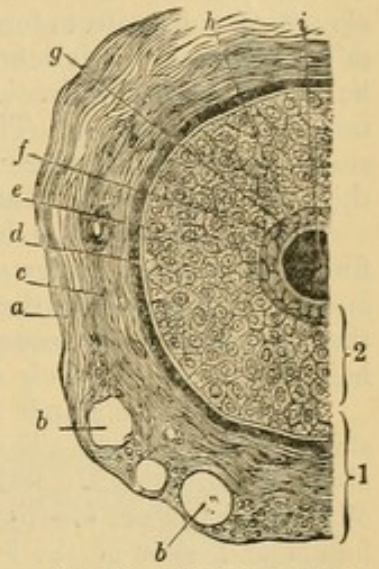

FIG. 682.—Transverse section of hair-follicle. 1. Dermic coat of follicle. 2. Epidermic coat or root-sheath. *a*, Outer layer of dermic coat, with blood-vessels. *b, b*. Vessels cut across. *c*. Middle layer. *d*. Inner or hyaline layer. *e*. Outer root-sheath. *f. g*. Inner root-sheath. *h*. Cuticle of root-sheath. *i*. Hair. (From Quain's *Anatomy*, Biesiadecki.)

The *outer* or *dermic* coat is formed mainly of fibrous tissue; it is continuous with the corium, is highly vascular, and supplied by numerous minute nervous filaments. It consists of three layers (Fig. 682). The most internal, next the cuticular lining of the follicle, consists of a hyaline basement-membrane, having a glassy, transparent appearance, which is well marked in the larger hair-follicles, but is not very distinct in the follicles of minute hairs. It is continuous with the basement-membrane of the surface of the corium. External to this is a compact layer of fibres and spindle-shaped cells arranged circularly around the follicle. This layer extends from the bottom of the follicle as high as the entrance of the ducts of the sebaceous glands. Externally is a thick layer of connective tissue, arranged in longitudinal bundles, forming a more open texture and corresponding to the reticular part of the corium. In this are contained the blood-vessels and nerves.

The *inner* or *epidermic* layer is closely adherent to the root of the hair, so that when the hair is plucked from its follicle this layer most commonly adheres to it and forms what is called the *root-sheath*. It consists of two strata, named respectively the *outer* and *inner root-sheath;* the former of these corresponds with the Malpighian layer of the epidermis, and resembles it in the rounded form and soft character of its cells; at the bottom of the hair-follicle these cells become continuous with those of the root of the hair. The *inner* root-sheath consists of a delicate cuticle next the hair, composed of a thin layer of imbricated scales having a downward direction, so that they fit accurately over the upwardly directed imbricated scales of the hair itself; then of one or two layers of horny, flattened, nucleated cells, known as *Huxley's layer;* and finally of a single layer of horny oblong cells without visible nuclei, called *Henle's layer*.

The hair-follicle contains the root of the hair, which terminates in a bulbous extremity, and is excavated so as to exactly fit the papilla from which it grows. The bulb is composed of polyhedral epithelial cells, which as they pass upward into the root of the hair become elongated and spindle-shaped, except some in the centre which remain polyhedral. Some of these latter cells contain pigment-granules, which give rise to the color of the hair. It occasionally happens that these pigment-granules completely fill the cells in the centre of the bulb, which gives rise to the dark tract of pigment often found, of greater or less length, in the axis of the hair.

The *shaft of the hair* consists of a central pith or medulla, the fibrous part of the hair, and the cortex externally. The medulla occupies the centre of the shaft and ceases toward the point of the hair. It is usually wanting in the fine hairs covering the surface of the body, and commonly in those of the head. It is more

opaque and deeper colored when viewed by transmitted light than the fibrous part; but when viewed by reflected light it is white. It is composed of rows of polyhedral cells, which contain granules of eleidin and frequently air-bubbles. The fibrous portion of the hair constitutes the chief part of the shaft; its cells are elongated and unite to form flattened fusiform fibres. Between the fibres are found minute spaces which contain either pigment-granules in dark hair or minute air-bubbles in white hair. In addition to this there is also a diffused pigment contained in the fibres. The cells which form the cortex of the hair consist of a single layer which surrounds those of the fibrous part; they are converted into thin, flat scales, having an imbricated arrangement.

Connected with the hair-follicles are minute bundles of involuntary muscular fibres, termed *arrectores pili*. They arise from the superficial layer of the corium, and are inserted into the outer surface of the hair-follicle, below the entrance of the duct of the sebaceous gland. They are placed on the side toward which the hair slopes, and by their action elevate the hair (Fig. 679).[1]

The **sebaceous glands** are small, sacculated, glandular organs, lodged in the substance of the corium. They are found in most parts of the skin, but are especially abundant in the scalp and face: they are also very numerous around the apertures of the anus, nose, mouth, and external ear; but are wanting in the palms of the hands and soles of the feet. Each gland consists of a single duct, more or less capacious, which terminates in a cluster of small secreting pouches or saccules. The sacculi connected with each duct vary, as a rule, in number from two to five, but in some instances may be as many as twenty. They are composed of a transparent, colorless membrane, enclosing a number of epithelial cells. Those of the outer or marginal layer are small and polyhedral, and are continuous with the lining cells of the duct. The remainder of the sac is filled with larger cells, containing fat, except in the centre, where the cells have become broken up, leaving a cavity containing their débris and a mass of fatty matter, which constitutes the sebaceous secretion. The orifices of the ducts open most frequently into the hair-follicles, but occasionally upon the general surface, as in the labia minora and the free margin of the lips. On the nose and face the glands are of large size, distinctly lobulated, and often become much enlarged from the accumulation of pent-up secretion. The largest sebaceous glands are those found in the eyelids—the Meibomian glands.

The **sudoriferous** or **sweat-glands** are the organs by which a large portion of the aqueous and gaseous materials is excreted by the skin. They are found in almost every part of this structure, and are situated in small pits on the under surface of the corium, or, more frequently, in the subcutaneous areolar tissue, surrounded by a quantity of adipose tissue. They are small, lobular, reddish bodies, consisting of a single convoluted tube, from which the efferent duct proceeds upward through the corium and cuticle, becomes somewhat dilated at its extremity, and opens on the surface of the cuticle by an oblique valve-like aperture. The efferent duct, as it passes through the epidermis, presents a spiral arrangement, being twisted like a corkscrew, in those parts where the epidermis is thick; where, however, it is thin, the spiral arrangement does not exist. In the superficial layers of the corium the duct is straight, but in the deeper layers it is convoluted or even twisted. The spiral course of these ducts is especially distinct in the thick cuticle of the palm of the hand and sole of the foot. The size of the glands varies. They are especially large in those regions where the amount of perspiration is great, as in the axillæ, where they form a thin, mammillated layer of a reddish color, which corresponds exactly to the situation of the hair in this region; they are large also in the groin. Their number varies. They are most numerous on the palm of the hand, presenting, according to Krause, 2800 orifices on a square

[1] Arthur Thomson suggests that the contraction of these muscles on follicles which contain weak flat hairs will tend to produce a permanent curve in the follicle, and this curve will be impressed on the hair which is moulded within it, so that the hair, on emerging through the skin, will be curled. Curved hair-follicles are characteristic of the scalp of the Bushman.

inch of the integument, and are rather less numerous on the sole of the foot. In both of these situations the orifices of the ducts are exceedingly regular, and open on the curved ridges. In other situations they are more irregularly scattered, but the number in a given extent of surface presents a fairly uniform average. In the neck and back they are least numerous, their number amounting to 417 on the square inch (Krause). Their total number is estimated by the same writer at 2,381,248, and, supposing the aperture of each gland to represent a surface of $\frac{1}{576}$ of a line in diameter, he calculates that the whole of these glands would present an evaporating surface of about eight square inches. Each gland consists of a single tube intricately convoluted, terminating at one end by a blind extremity, and opening at the other end upon the surface of the skin. In the larger glands this single duct usually divides and subdivides dichotomously; the smaller ducts ultimately terminating in short cæcal pouches, rarely anastomosing. The wall of the duct is thick, the width of the canal rarely exceeding one-third of its diameter. The tube, both in the gland and where it forms the excretory duct, consists of two layers—an outer, formed by fine areolar tissue, and an inner layer of epithelium (Fig. 683). The external or fibro-cellular coat is thin, continuous with the superficial layer of the corium, and extends only as high as the surface of the true skin. The epithelial lining in the distal part of the coiled tube of the gland proper consists of a single layer of cubical epithelium, supported on a basement-membrane, and beneath it, between the epithelium and the fibro-cellular coat, is a layer of longitudinally or obliquely arranged fibres, which are usually regarded as muscular, though the evidence that this is so is not conclusive. In the duct and the proximal part of the coiled tube of the gland proper there are two or more layers of polyhedral cells, lined on their internal surface—*i. e.*, next the lumen of the tube—by a delicate membrane or cuticle, and on their outer surface by a limiting membrana propria, but there are no muscular fibres. The epithelium is continuous with the epidermis and with the delicate internal cuticle of the epidermic portion of the tube. When the cuticle is carefully removed from the surface of the cutis, these convoluted tubes of epithelium may be drawn out and form short, thread-like processes on its under surface.

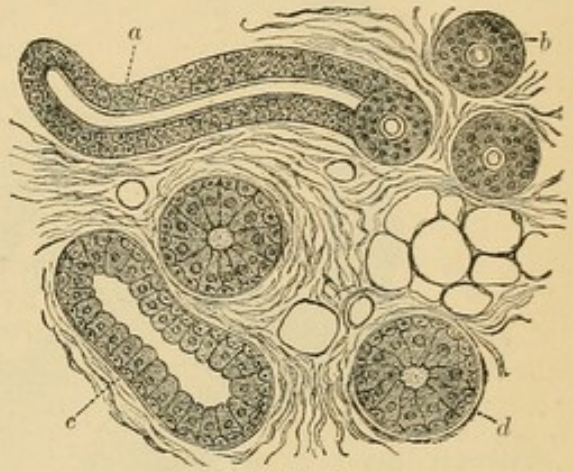

FIG. 683.—Coiled tube of a sweat-gland cut in various directions. *a*. Longitudinal section of the proximal part of the coiled tube. *b*. Transverse section of the same. *c*. Longitudinal section of the distal part of the coiled tube. *d*. Transverse section of the same. (From Klein and Noble Smith's *Atlas of Histology*.)

The contents of the smaller sweat-glands are quite fluid; but in the larger glands the contents are semifluid and opaque, and contain a number of colored granules and cells which appear analogous to endothelial cells.

SEROUS MEMBRANES.

The **serous membranes** form shut sacs, and may be regarded as lymph-sacs, from which lymphatic vessels arise by stomata or openings between the endothelial cells. (See page 1133.) The sac consists of one portion which is applied to the walls of the cavity which it lines—the *parietal* portion; and another reflected over the surface of the organ or organs contained in the cavity—the *visceral* portion. Sometimes the sac is arranged quite simply, as the tunica vaginalis testis; at others with numerous involutions or recesses, as the peritoneum, in which, nevertheless, the membrane can always be traced continuously around the whole circumference. The sac is completely closed, so that no communication exists between the serous cavity and the parts in its neighborhood. An apparent exception exists in the peritoneum of the female; for the Fallopian tube opens freely into the peritoneal cavity in the dead subject, so that a bristle can be passed from the one into the other.

But this communication is closed during life, except at the moment of the passage of the ovum out of the ovary into the tube, as is proved by the fact that no interchange of fluids ever takes place between the two cavities in dropsy of the peritoneum or in accumulation of fluid in the Fallopian tubes.[1] The serous membrane is often supported by a firm, fibrous layer, as is the case with the pericardium, and such membranes are sometimes spoken of as "fibro-serous."

The various serous membranes are the peritoneum, lining the cavity of the abdomen; the two pleuræ and the pericardium, covering the lungs and heart respectively; and the tunicæ vaginales, surrounding each testicle in the scrotum.[2] Serous membranes are thin, transparent, glistening structures, lined on their inner surface by a single layer of polygonal or pavement endothelial cells, supported on a matrix of fibrous connective tissue, with networks of fine elastic fibres, in which are contained numerous capillaries and lymphatics. On the surface of the endothelium between the cells numerous apertures or interruptions are to be seen. Some of these are stomata, surrounded by a ring of cubical endothelium (see Fig. 684),

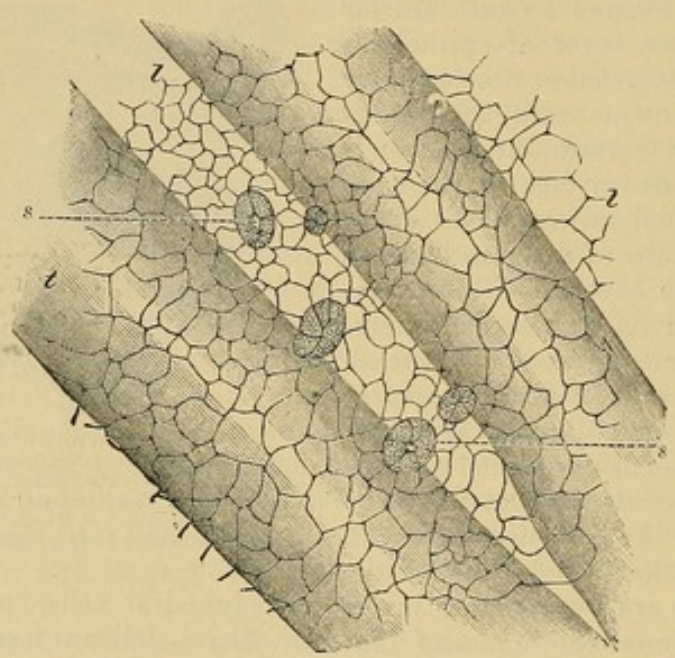

FIG. 684.—Part of peritoneal surface of the central tendon of diaphragm of rabbit, prepared with nitrate of silver. *s*. Stomata. *l*. Lymph-channels. *t*. Tendon-bundles. The stomata are surrounded by germinating epithelial cells. (From *Handbook for the Physiological Laboratory*, Klein.)

and communicating with a lymphatic capillary; others (*pseudostomata*) are mere interruptions in the endothelial layer, and are occupied by processes of the branched connective-tissue corpuscle of the subjacent tissue or by accumulations of the intercellular cement-substance.

The amount of fluid contained in these closed sacs is, in most cases, only sufficient to moisten the surface, but not to furnish any appreciable quantity of fluid. When a small quantity can be collected, it is found to resemble lymph, and like that fluid coagulates spontaneously; but when secreted in large quantities, as in dropsy, it is a more watery fluid, but still contains a considerable amount of proteid which is coagulated on boiling.

[1] The communication between the uterine cavity and the peritoneal sac is not only apparent in the dead subject, but is an anatomical fact, which is established by the continuity of its epithelium with that covering the uterus, Fallopian tubes, and fimbriæ.

[2] The arachnoid membrane, lining the brain and spinal cord, was formerly regarded as a serous membrane, but is now no longer classed with them, as it differs from them in structure, and does not form a shut sac as do the other serous membranes.

SYNOVIAL MEMBRANES.

Synovial membranes, like serous membranes, are connective-tissue membranes placed between two movable tissues, so as to diminish friction, as in movable joints; or between a tendon and a bone, where the former glides over the latter; and between the skin and various subcutaneous bony prominences.

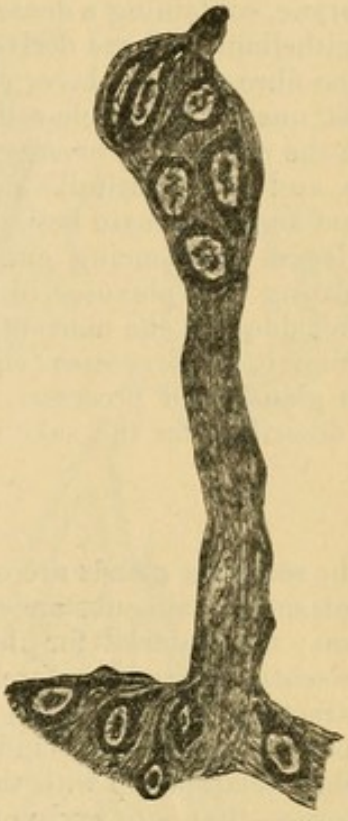

FIG. 685.—Villus of synovial membrane. (After Hammar).

The synovial membranes are composed essentially of connective tissue, with the cells and fibres of that structure, containing numerous vessels and nerves. It was formerly supposed that these membranes were analogous in structure to the serous membranes, and consisted of a layer of flattened cells on a basement-membrane. No such continuous layer, however, exists, although here and there are patches of cells probably epithelial in nature. They are surrounded and held together by an albuminous ground-substance. Long villus-like processes (Fig. 685) are often found projecting from the surface of synovial membranes; they are covered by small rounded cells, and are supposed to extend the surface for the secretion of the fluid which moistens the membranes, and which is named *synovia*. It is a rich lymph, plus a mucin-like substance, and to the latter constituent it owes its viscidity. A further description of the synovial membranes will be found in the descriptive anatomy of the joints.

MUCOUS MEMBRANE.

Mucous membranes line all those passages by which the internal parts communicate with the exterior, and are continuous with the skin at the various orifices of the surface of the body. They are soft and velvety, and very vascular, and their surface is coated over by their secretion, *mucus*, which is of a tenacious consistence, and serves to protect them from the foreign substances introduced into the body with which they are brought in contact.

They are described as lining the two tracts—the gastro-pulmonary and the genito-urinary; and all, or almost all, mucous membranes may be classed as belonging to and continuous with the one or the other of these tracts.

The deep surfaces of these membranes are attached to the parts which they line by means of connective tissue, which is sometimes very abundant, forming a loose and lax bed, so as to allow considerable movement of the opposed surfaces on each other. It is then termed the *submucous tissue*. At other times it is exceedingly scanty, and the membrane is closely connected to the tissue beneath; sometimes, for example, to muscle, as in the tongue; sometimes to cartilage, as in the larynx; and sometimes to bone, as in the nasal fossæ and sinuses of the skull.

In structure a mucous membrane is composed of *corium* and *epithelium*. The epithelium is of various forms, including the squamous, columnar, and ciliated, and is often arranged in several layers. This epithelial layer is supported by the corium, which is analogous to the dermis of the skin, and consists of connective tissue, either simply areolar or containing a greater or less quantity of lymphoid

tissue. This tissue is usually covered on its external surface by a transparent basement-membrane generally composed of clear flattened cells, placed edge to edge; on this the epithelium rests. It is only in some situations that the basement-membrane can be demonstrated. The corium is an exceedingly vascular membrane, containing a dense network of capillaries, which lie immediately beneath the epithelium, and are derived from small arteries in the submucous tissue.

The fibro-vascular layer of the corium contains, besides the areolar tissue and vessels, unstriped muscle-cells, which form in many situations a definite layer, called the *muscularis mucosæ*. These are situated in the deepest part of the membrane, and are plentifully supplied with nerves. Other nerves pass to the epithelium and terminate between the cells. Lymphatic vessels are found in great abundance, commencing either by cæcal extremities or in networks, and communicating with plexuses in the submucous tissue.

Imbedded in the mucous membrane are found numerous glands, and projecting from it are processes (villi and papillæ) analogous to the papillæ of the skin. These glands and processes, however, exist only at certain parts, and they have been described for the sake of convenience, and with the parts as they occurred.

SECRETING GLANDS.

The **secreting glands** are organs whose cells produce, by the metabolism of their protoplasm, certain substances, called "secretions," of a more or less definite composition; the material for the secretion being primarily selected from the blood. The essential parts, therefore, of a secreting gland are *cells*, which have the power of extracting from the blood certain matters, and in some cases converting them into new chemical compounds; and *blood-vessels*, by which the blood is brought into close relationship with these cells. The general arrangement in all secreting structures—that is to say, not only in secreting glands, but also in secreting membranes—is that the cells are arranged on one surface of an extravascular basement-membrane, which supports them, and a minute plexus of capillary vessels ramifies on the other surface of the membrane. The cells then extract from the blood certain constituents which pass through the membrane into the cells, where they are prepared and elaborated. The basement-membrane does not, however, always exist, and any free surface would appear to answer the same purpose in some cases.

By the various modifications of this secreting surface the different glands are formed. This is generally effected by an invagination of the membrane in different ways, the object being to increase the extent of secreting surface within a given bulk.

In the simplest form a single invagination takes place, constituting a *simple* gland; this may be either in the form of an open tube (Fig. 686, A), or the walls of the tube may be dilated so as to form a saccule (Fig. 686, B). These are named the *simple tubular* or *saccular* glands. Or, instead of a short tube, the invagination may be lengthened to a considerable extent, and then coiled up to occupy less space. This constitutes the *simple convoluted tubular* gland, an example of which may be seen in the sweat-glands of the skin (Fig. 686, C).

If, instead of a single invagination, secondary invaginations take place from the primary one, as in Fig. 686, D and E, the gland is then termed a compound one. These secondary invaginations may assume either a saccular or tubular form, and so constitute the two subdivisions—the *compound saccular* or *racemose* gland, and the *compound tubular*. The racemose gland in its simplest form consists of a primary invagination which forms a sort of duct, upon the extremity of which are found a number of secondary invaginations called saccules or alveoli, as in Brunner's glands (Fig. 686, D). But, again, in other instances, the duct, instead of being simple, may divide into branches, and these again into other branches, and so on; each ultimate ramification terminating in a dilated cluster of saccules, and thus we may have the secreting surface almost indefinitely extended, as in the salivary

glands (Fig. 686, E). In the *compound tubular* glands the division of the primary duct takes place in the same way as in the racemose glands, but the branches retain their tubular form, and do not terminate in saccular recesses, but become greatly lengthened out (Fig. 686, F). The best example of this form of gland is to

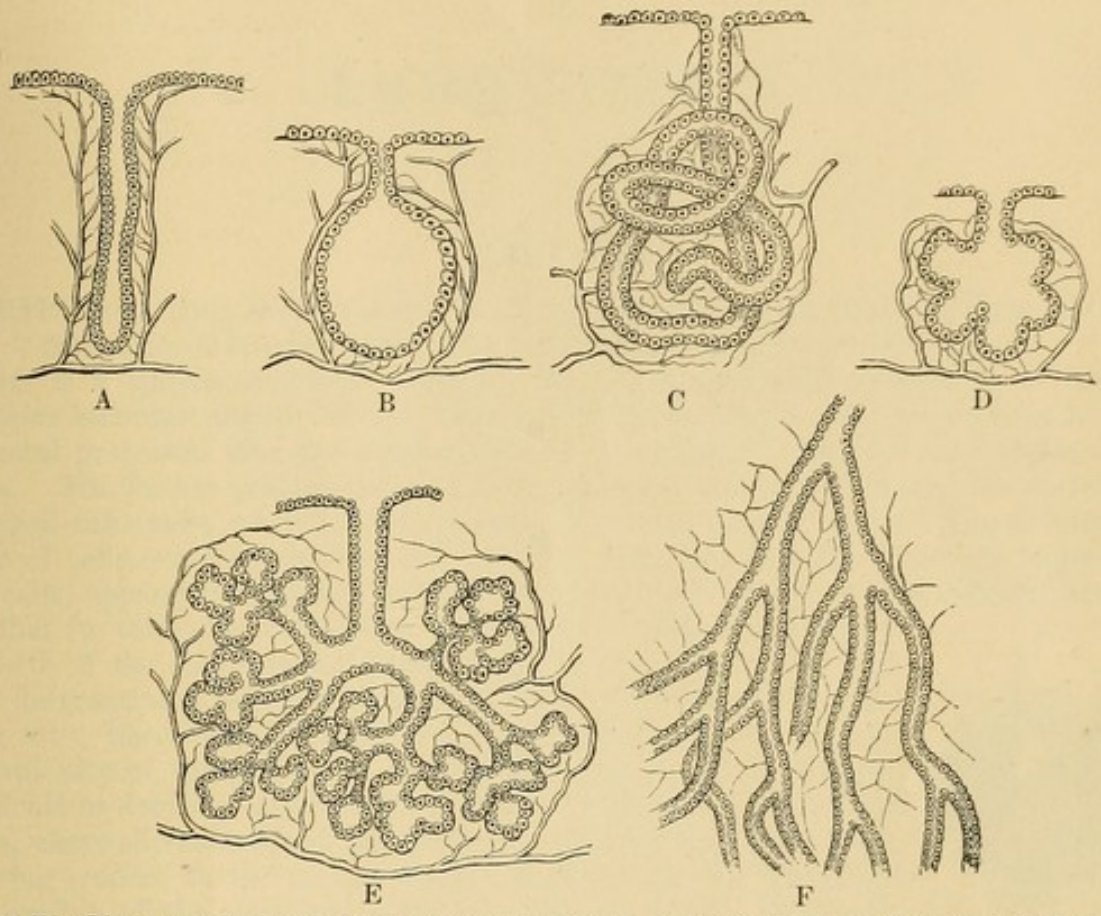

FIG. 686.—Diagrammatic plan of varieties of secreting glands. A. Simple gland. B. Sacculated simple gland. C. Simple convoluted tubular gland. D, E. Racemose gland. F. Compound tubular gland.

be found in the kidney. All these varieties of glands are produced by a more or less complicated invagination of a secreting membrane, and they are all identical in structure; that is to say, the saccules or tubes, as the case may be, are lined with cells, generally spheroidal or columnar in figure, and on their outer surface is an intimate plexus of capillary vessels. The secretion, whatever it may be, is eliminated by the cells from the blood, and is poured into the saccule or tube, and so finds it way out through the primary invagination on to the free surface of the secreting membrane. In addition, however, to these glands, which are formed by an *invagination* of the secreting membrane, there are some few others which are formed by a *protrusion* of the same structure, as in the vascular fringes of synovial membranes. This form of secreting structure is not nearly so frequently met with.

EMBRYOLOGY.

THE OVUM.

THE whole body is developed out of the **ovum** or female element (Figs. 687 and 688) after it has been fertilized by the spermatozoön or male element. The ovum is a simple nucleated cell, and all the complicated changes by which the various intricate organs of the body are formed from it may be reduced to two general processes, viz., the *segmentation* or *cleavage* of cells, and their *differentiation*. The former process consists in the division of the nucleus and the surrounding cell-substance, whereby the original cell is represented by two. The differentiation of cells is a term used to describe that unknown power or tendency impressed on cells, apparently identical in structure, whereby they grow into different forms; so that (to take one of the first phenomena which occurs in the growth of the embryo) the indifferent cells of the vascular area are differentiated, some of them into blood-globules, others into the solid tissue which forms the blood-vessels. The extreme complexity of the process of development renders it at all times difficult to describe intelligibly, and still more so in a work like this, where adequate space and illustration can hardly be afforded, having respect to the main purpose of the work, and therefore an outline of the principal facts only will be given. Many of the statements which are accepted in human embryology are made on the strength of what has been observed to occur in the lower animals, and their existence in the human subject is merely a matter of inference. Within recent years, however, much has been added to our knowledge of the development of the human embryo, and this more especially by the important researches of Professor His and others.

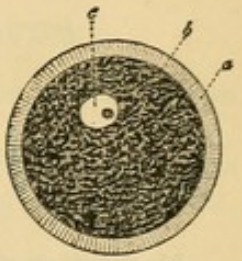

FIG. 687.—Human ovum from a middle-sized follicle. Magnified 350 times. *a*. Zona pellucida or zona radiata. *b*. External border of the yolk and internal border of the vitelline membrane. *c*. Germinal vesicle and germinal spot.

The **ovum** is a small spheroidal body situated in the immature Graafian follicle near its centre, but in the mature one in contact with the membrana granulosa,[1] at that part of the follicle which projects from the surface of the ovary. The cells of the membrana granulosa are accumulated round the ovum in greater number than at any other part of the follicle, forming a kind of granular zone, the *discus proligerus*.

The **human ovum** (Fig. 687) is extremely minute, measuring from $\frac{1}{150}$ to $\frac{1}{125}$ of an inch in diameter. It is a cell consisting externally of a transparent striated envelope, the *zona pellucida*, *zona radiata*, or *vitelline membrane*. The extra-nuclear protoplasm contained within the zona pellucida is known as *the cytoplasm;* it is a sponge-like material, containing in its meshes numerous large fatty and albuminous granules, which constitute the *yolk* or *vitellus;* in the neighborhood of the nucleus, however, these granules are comparatively few in number. The nucleus is a large spherical body, which is known by the name of the *germinal vesicle*, and resembles in structure the nucleus of an ordinary cell. Within it there is generally one nucleolus, which is large and well marked, and is known as the *germinal spot*. The zona pellucida is believed to be pierced by numerous pores which are probably channels of nutrition and which give it

[1] See the description of the ovary at a future page.

the appearance of being radially striated, while in some animals (*e.g.*, insects) it presents a small perforation or hole, which is known by the name of the *micropyle*, and is believed to be the means by which the spermatozoa enter the ovum.

The phenomena attending the discharge of the ova from the Graafian follicles, since they belong as much or more to the ordinary function of the ovary than to the general subject of the development of the body, are described with the anatomy of the ovaries on a subsequent page.

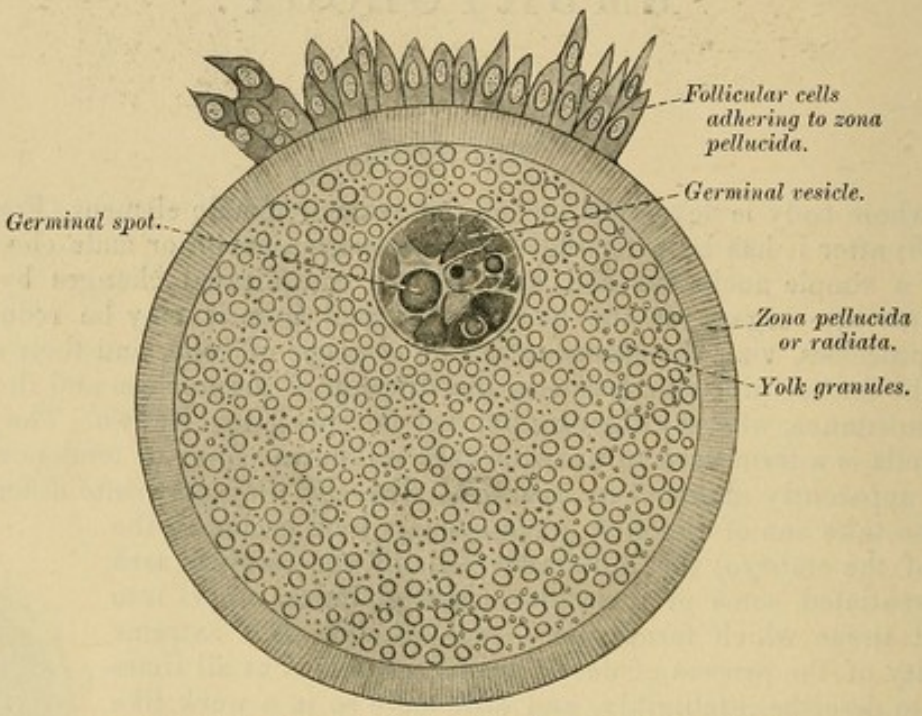

FIG. 688.—Ovum of rabbit. Highly magnified. (After Waldeyer.)

Maturation of the Ovum previous to Fertilization.—Either before or immediately after its escape from the Graafian follicle, important changes take place in the nucleus of the ovum, which result in its partial disappearance and in the formation and extrusion from the yolk of two peculiar bodies, the *polar bodies* or *polar globules* of Robin. These changes constitute what is termed the *maturation of the ovum*, and are preparatory to its being fertilized by the male element or spermatozoon. The nucleus approaches the periphery of the ovum and undergoes the changes associated with karyokinesis; it then divides into two, and the upper daughter nucleus, with a thin investment of protoplasm, becomes extruded as the first polar body into a space between the yolk and the vitelline membrane, which has been formed in consequence of a contraction or shrinking of the yolk. The lower daughter nucleus undergoes the same process of division, and forms a second polar body, which is in like manner extruded (Fig. 689). The greater part (three-fourths) of the original nucleus is therefore expelled from the yolk in the form of the two polar bodies, and the remaining fourth, which is now called the *female pronucleus*, recedes toward the centre of the ovum. The shrinking of the vitellus still continues, and a fluid—the *perivitelline* fluid—collects in the space between it and the zona pellucida; in it, spermatozoa, which have passed through the zona pellucida, may sometimes be seen.

Although the process of maturation has been closely followed in many of the lower animals, it has not yet been successfully demonstrated in mammals.

It is interesting to note that a similar nuclear reduction occurs in connection with the development of spermatozoa. In the germinal ridge, which is to become the future testicle, certain cells, identical with primitive ova, are found. These are termed *spermatoblasts*, and they become enlarged to form what are called *spermatocytes*, while each spermatocyte ultimately divides into four *spermatids*. The spermatids become changed, without further subdivision, into spermatozoa, and

hence the fully developed spermatozoon contains only one-fourth of the nucleus of the original spermatocyte. The matured ovum and the spermatozoon may therefore be looked upon as of the same morphological value.

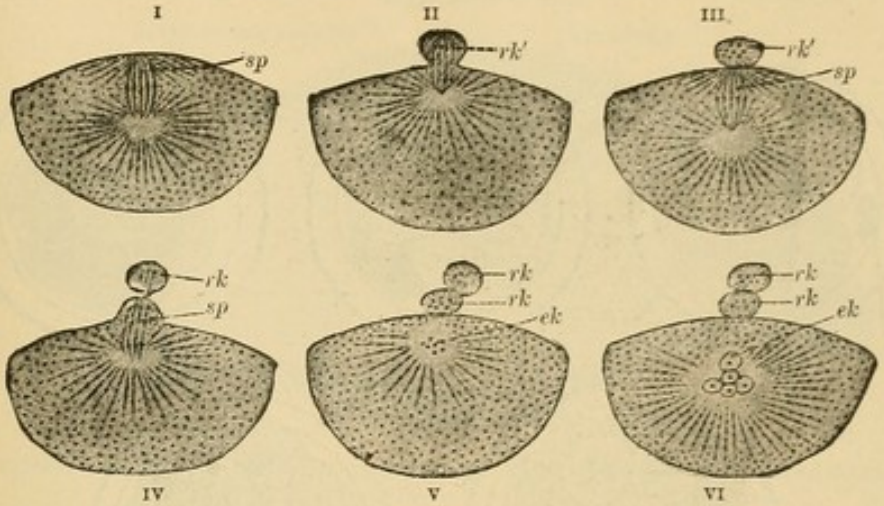

FIG. 689.—Formation of polar bodies in Asterias glacialis. (Hertwig.) In I. the polar spindle (*sp*) has advanced to the surface of the egg. In II. a small elevation (*rk*) is formed which receives a half of the spindle. In III. the elevation is constricted off, forming a polar body (*rk'*). Out of the remaining half of the previous spindle a second complete spindle (*sp*) has arisen. In IV. is seen a second elevation, which in V. has become constricted off as the second polar body. Out of the remainder of the spindle (IV.) is developed the female pronucleus.

FERTILIZATION AND SEGMENTATION OF THE OVUM.

The first changes in the ovum which take place at the time of conception are as follows:

1. **Impregnation.**—One, or perhaps more, spermatozoa penetrate the zona pellucida and are contained in the perivitelline fluid. A single spermatozoon,

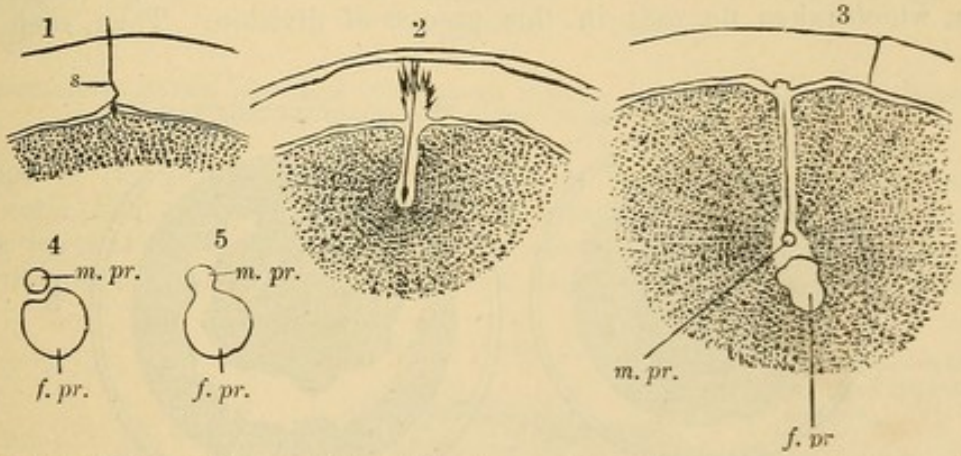

FIG. 690.—Fertilization of the ovum of an echinoderm. *s.* Spermatozoon. *m. pr.* Male pronucleus. *f. pr.* Female pronucleus. 1. Accession of a spermatozoon to the periphery of the vitellus. 2. Its penetration. 3. Transformation of the head of the spermatozoon into the male pronucleus. 4, 5. Blending of the male and female pronuclei. (From Quain's *Anatomy*, Selenka.)

more advanced than the rest, becomes buried in the yolk, the tail disappears, and the head constitutes the *male pronucleus*. This gradually approaches the female pronucleus, and ultimately the two pronuclei come into contact and fuse to form a new nucleus, containing both male and female elements, and named the *segmentation* or *cleavage* nucleus, and the whole cell thus modified is called the blastosphere (Fig. 690). It seems as if this normally occurs in the Fallopian tube,[1] but it is possible that it sometimes takes place before the ovum has entered

[1] Many physiologists, as Bischoff and Dr. M. Barry, taught that the ovum is fecundated in the ovary, but the reasoning of Dr. Allen Thomson appears very cogent in proving that the usual spot at which the spermatozoa meet the ovum is in the tube, down which it slowly travels to the uterus, in its course becoming surrounded by an albuminous envelope derived from the walls of the tube.

the tube, or even after it has passed through the tube and reached the cavity of the uterus; abnormally it may take place in the peritoneal cavity.

2. **Segmentation.**—The first result of fertilization is a cleavage or subdivision of the ovum, which is first cleft into two masses, the segmentation nucleus having

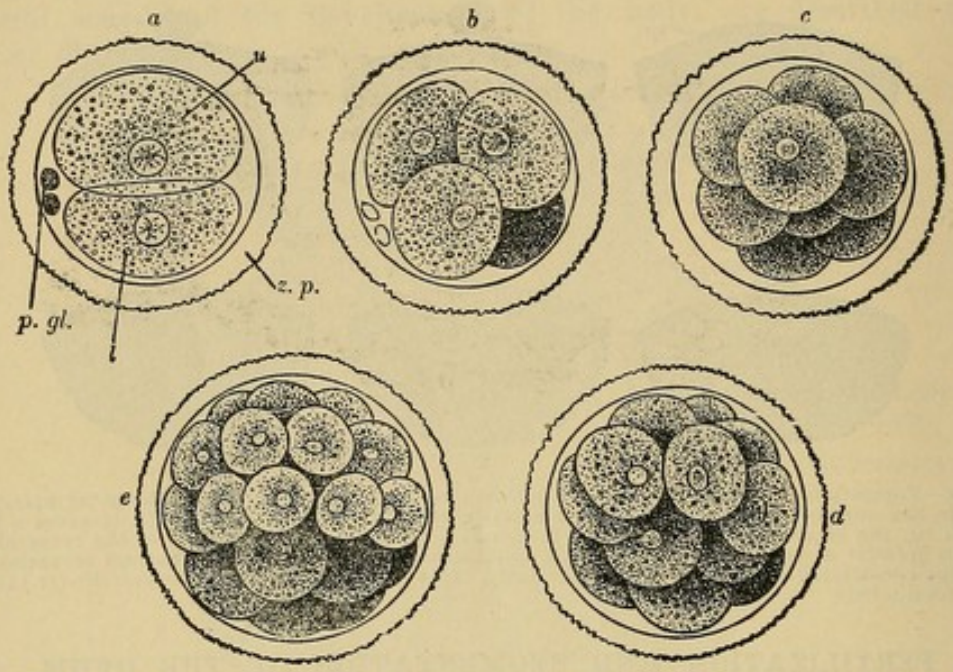

FIG. 691.—First stages of segmentation of a mammalian ovum: semi-diagrammatic. (From a drawing by Allen Thomson.) *z.p.* Zona pellucida. *p. gl.* Polar globules. *u.* Epiblastic cell. *l.* Hypoplastic cell. *a.* Division into two spheres. *b.* Stage of four spheres. *c.* Eight spheres, the epiblastic cells partially enclosing the hypoblastic cells. *d, e.* Succeeding stages of segmentation, showing the more rapid division of the epiblastic cells and the enclosure of the hypoblastic cells by them.

previously split up into two; so that it now consists of two separate masses of protoplasm, each containing a nucleus, and situated within the original zona pellucida, which takes no part in this process of division. Then, each of these

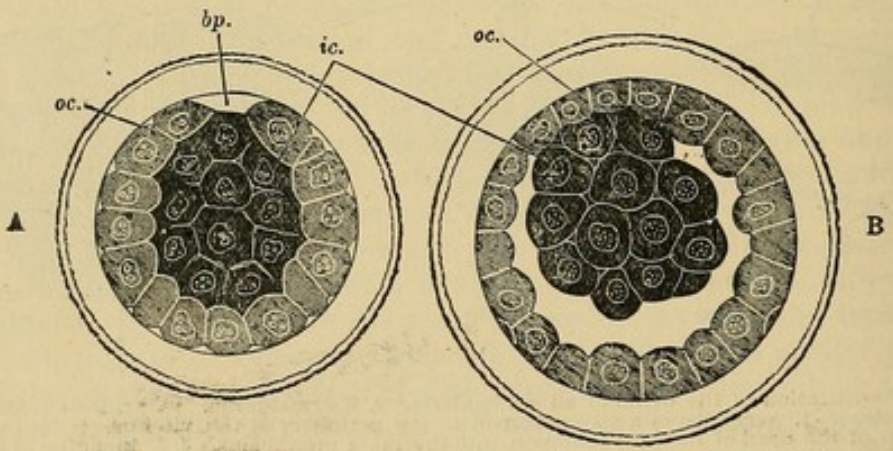

FIG. 692.—Ovum of the rabbit at the end of the process of segmentation. *oc.* Primitive epiblast. *ic.* Primitive hypoblast. *bp.* Place where the epiblast has not yet grown over the hypoblast. (From Balfour, after Ed-van Beneden.)

two divides in like manner, and thus four are formed, and so on, until at length a mulberry-like agglomeration of nucleated masses of protoplasm results (Fig. 691). These masses are sometimes termed *vitelline spheres*.

The manner in which segmentation occurs is somewhat peculiar. The two cells resulting from the first cleavage are of unequal size. One, which for the sake of distinction may be called the *upper*, is slightly larger and paler than the other, or *lower*. After they have subdivided three or four times the rate of cleavage in the cells derived from the upper becomes more rapid than that in the cells derived from the lower. In addition, the upper cells have a tendency to spread over and

enclose the lower cells, so that by the ninth or tenth division there is an external layer of pale cells enclosing a mass of slightly smaller, more opaque cells, which, in consequence of their diminished rate of cleavage, are fewer in number (Fig.

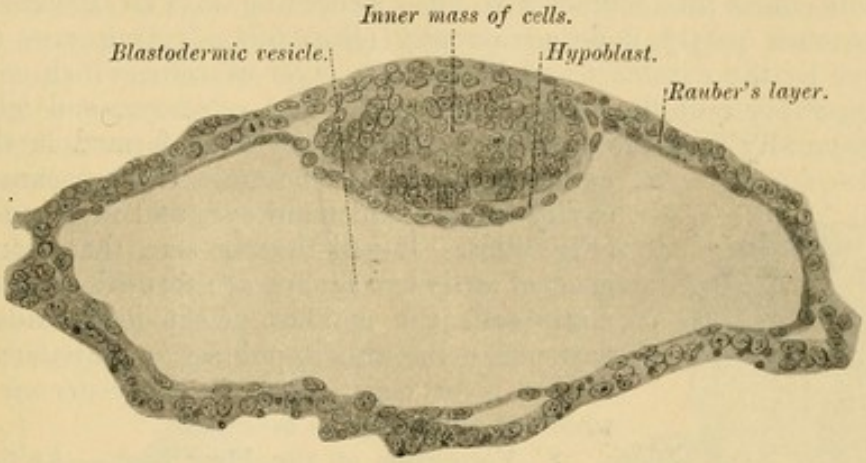

FIG. 693.—Blastodermic vesicle of Vespertilio murinus. (After Van Beneden.) (Reduced from a drawing in the *Anatomischer Anzeiger*, xvi. Band, Sept. 8, 1899.)

692). Fluid collects between the two sets of cells, except at one part, termed the *embryonal pole*, so that a vesicle, the *blastodermic vesicle*, is formed. This vesicle consists of an outer layer of cells, termed Rauber's layer, derived from the

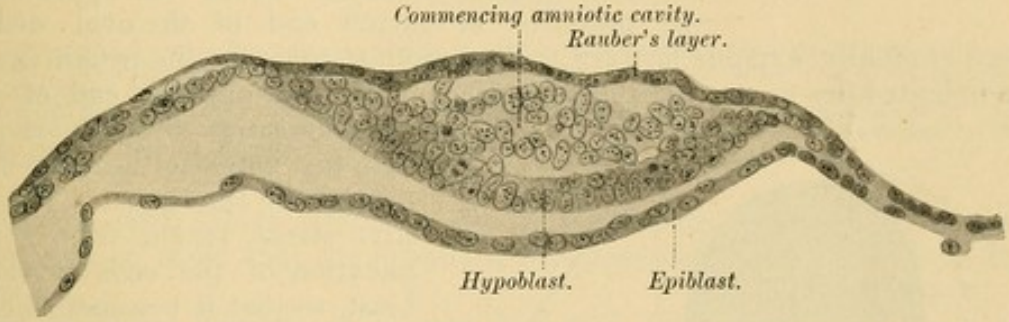

FIG. 694.—Section through embryonic area of Vespertilio murinus. (After Van Beneden.) (Reduced from a drawing in the *Anatomischer Anzeiger*, xvi. Band, Sept. 8, 1899.)

subdivision of the primary upper cell, enclosing at the embryonal area an inner mass of cells (Fig. 693) resulting from the cleavage of the primary lower cell. Rauber's layer takes no share in the formation of the embryo proper, which is entirely developed from the inner mass of cells. The deepest cells of this mass

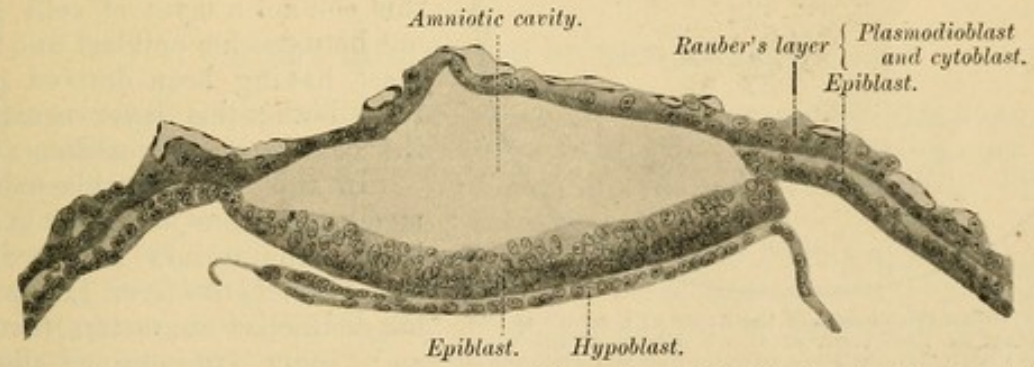

FIG. 695.—Section through embryonic area of Vespertilio murinus (after Van Beneden), to show the formation of the amniotic cavity. (Reduced from a drawing in the *Anastomischer Anzeiger*, xvi. Band, Sept. 8, 1899.)

become differentiated as a layer of flattened cells, termed the *hypoblast*, which spreads outward beneath Rauber's layer. The latter, by subdivision of the cells of its upper hemisphere, is differentiated into two strata, the outer of which becomes rapidly thickened and forms a *plasmodioblast* (*i. e.*, a mass of protoplasm containing numerous nuclei, but not subdivided into individual cells by means of

cell-walls); the inner layer assumes the form of a prismatic epithelium, and is named the *cytoblast* (Fig. 695). These two layers form the *ectoplacenta* or *chorion*, and entirely replace the lining epithelium of the uterus where the blastodermic vesicle comes into contact with it. According to Van Beneden, the cells of the inner mass partly undergo atrophy (Fig. 694), giving rise to a cavity, limited above by the cytoblast and below by a layer of cells, which constitutes the primitive upper layer of the embryo, the *epiblast* or *ectoderm*, and which is continuous peripherally with the cytoblast. The cavity thus formed is the *primitive amniotic cavity*, and becomes the permanent amniotic cavity in man and monkeys, and in some of the bats (Fig. 695). It will thus be seen that from the inner mass of cells two layers are formed—an outer of prismatic cells, the epiblast or ectoderm, and an inner of flattened cells, the hypoblast or entoderm—and this double layer constitutes the *blastodermic membrane*, which at this stage is *bilaminar*.[1]

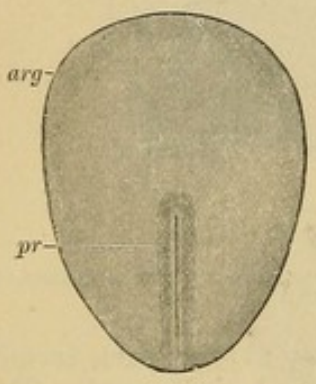

FIG. 696.—Embryo of a rabbit of eight days. (After Kölliker.) *arg.* Embryonic area. *pr.* Primitive streak.

3. **Formation of the Mesoblast.**—At first the area of the blastodermic membrane assumes the form of a small disk, the *germinal disk* or *germinal area*. This disk becomes oval in shape, with its more pointed end situated posteriorly. In it the first traces of the embryo are seen as a faint streak, the *primitive streak* (Fig. 696), which makes its appearance at the posterior or narrow end of the oval disk and from there gradually extends forward. The epiblast covering the primitive streak becomes indented by a groove, the *primitive groove*, the anterior end of which communicates through a canal with the yolk-sac, forming what is termed the *blastopore*. The primitive streak results from a multiplication of the cells of the epiblast, so that it becomes thickened and grows downward toward the hypoblast, which also undergoes proliferation. Together they form a thick cellular column, in which it is no longer possible to distinguish the epiblastic from the hypoblastic cells. From the sides of this column a layer of cells grows out between the epiblast and hypoblast, having been derived partly from both; this layer constitutes the *mesoblast* or *mesoderm*.

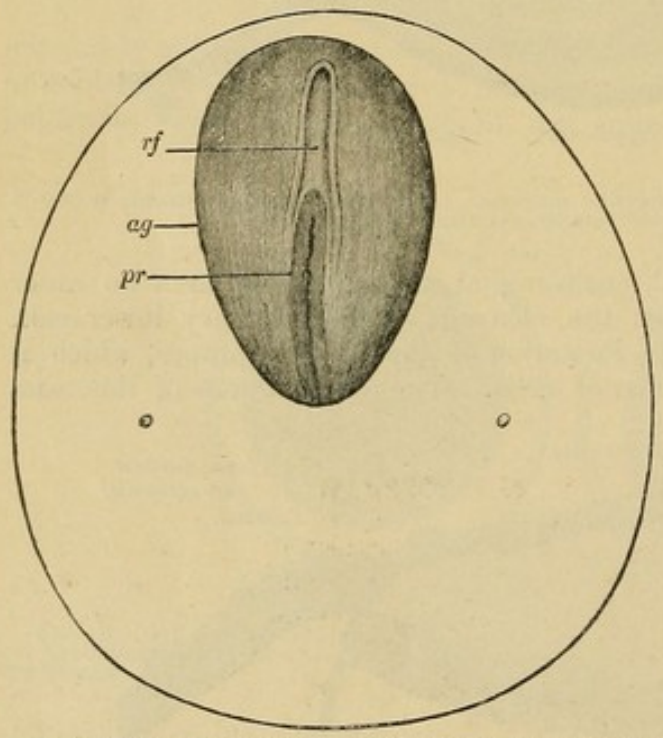

FIG. 697.—Embryonic area of the ovum of a rabbit at the seventh day. *ag.* Embryonic area. *o o.* Region of the blastodermic vesicle immediately surrounding the embryonic area. *pr.* Primitive streak. *rf.* Medullary groove. (From Kölliker.)

In this way the blastodermic membrane comes to consist of three layers, and is now known as the *trilaminar blastoderm*. Each layer has distinctive characters, the outer and inner presenting the appearance of epithelial cells, while the middle consists of a mass of branched cells without any definite arrangement. The external is termed the *epiblast*, or *ectoderm*; the internal the *hypoblast*, or *entoderm*; and the middle, the *mesoblast*, or *mesoderm* (Fig. 698).

[1] Consult, in this connection, articles by Van Beneden and Kollmann, *Anatomischer Anzeiger*, 1899 and 1900.

The *epiblast* consists of a layer of columnar epithelial cells, which, however, are somewhat flattened toward the circumference of the germinal disk. It forms the whole of the nervous system (central and peripheral), the epidermis of the skin, the hairs and nails, the lining cells of the sebaceous, sweat, and mammary glands, the enamel of the teeth, and the epithelial lining of the nasal passage and of portions of the mouth and pharynx.

The *hypoblast* consists, at first, of flattened epithelial cells, which subsequently become columnar and even larger than those of the epiblast. It forms the epithelial lining of the whole of the alimentary canal except the anus and part of the mouth (which are developed from involutions of the epiblast), the epithelial lining of all the glands opening into the alimentary canal, the epithelium of the Eustachian tube and tympanic cavity, and of the trachea, bronchial tubes, and air-sacs of the lungs, the epithelium of the bladder and urethra, and also that which lines the follicles of the thyroid and thymus glands. The endothelial lining of the heart,

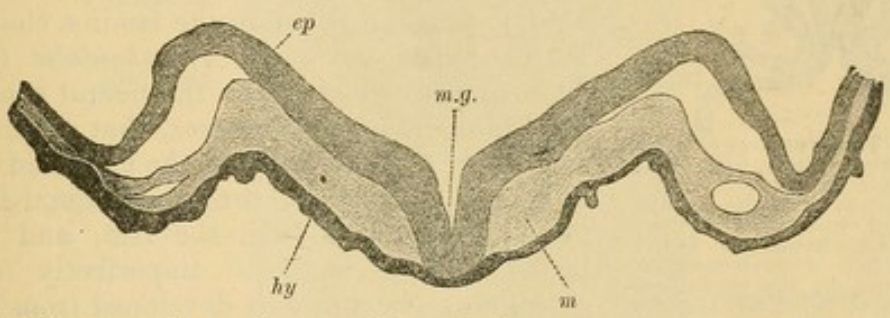

FIG. 698.—Section across the anterior part of the medullary groove of an early embryo of the guinea-pig. (By Schäfer. From Quain's *Anatomy*, 1890.) Folds of epiblast rising up on either side of the middle line, and thus bounding the medullary groove. *mg.* Middle of medullary groove. *hy.* Hypoblast, which is in contact with the medullary epiblast at the middle of the groove, but is elsewhere separated from it by mesoblast, *m*, which has burrowed forward between the two primary layers. A cleft is seen in the mesoblast on either side; this is the commencement of the anterior part of the body-cavity.

blood-vessels, and serous cavities is also of hypoblastic origin, while recent observations tend to show that the primitive red blood-cells are derived from the same source.

The *mesoblast* consists of loosely arranged branched cells, which are surrounded by a considerable amount of intercellular fluid, and which therefore may be considered as resembling embryonic connective tissue. All the other tissues of the embryo are developed from it, including the extra-endothelial portion of the walls of the blood-vessels, the skeleton and voluntary muscles, the connective tissues, the spleen, the generative and urinary organs (except the epithelium of the bladder and urethra), and the involuntary muscles.

FIRST RUDIMENTS OF THE EMBRYO.

The *primitive streak* alluded to above is a very transitory structure, which merely marks the direction of the embryonic axis, the embryo proper being developed immediately in front of it in the following manner (Figs. 697 and 701):

First, two longitudinal ridges, caused by a looping or folding up of the epiblast, appear, one on either side of the middle line. These commence in the anterior part of the area germinativa, where they are united, and extend backward, one on either side of the primitive streak, gradually enclosing it, and thus converting the blastopore into the *neurenteric canal*. This folding up of the epiblast gives rise to a longitudinal groove, the *medullary* or *neural groove* (Figs. 697 and 698), in consequence of the manner in which the cells of the epiblast are heaped up into two longitudinal ridges, with a furrow between them so that the sides and floor of the groove are formed of epiblastic cells (Fig. 698). The mesoblast fills up the space between the epiblast and hypoblast, so that the sides of the groove are occupied by a longitudinal thickening of mesoblast; the two longitudinal thicken-

ings of mesoblast being at first separated at the bottom of the groove by the junction of the epiblast and hypoblast (Fig. 698). The groove becomes deeper in consequence of the further growing up of the cells to form the ridge on either side. In this way the ridges eventually become two plates, the *laminæ dorsales* or *medullary plates*, which finally coalesce and form a closed tube, the *neural canal*, which is lined and covered by epiblast (Figs. 699 and 700). These lining and covering layers of epiblast are at first in contact with one another, but eventually become separated by mesoblast which grows up between them. The coalescence of the medullary plates first takes place in the region of the future hind-brain of the embryo, and then extends toward the cephalic and caudal ends. The posterior extremity presents a rhomboidal appearance before the laminæ close; this has been termed the *sinus rhomboidalis* (Fig. 701). The epiblast which lines the neural canal is developed into the nervous centres, that which covers the canal into the epidermis of the back and head. The cephalic extremity of the neural canal is soon seen to be more dilated than the rest, and to present restrictions dividing it imperfectly into three chambers: the brain is developed from this dilated portion; the spinal cord takes its origin from the remainder of the tube. Below the neural canal, in front of the internal opening of the blastopore, a longitudinal groove forms in the hypoblast; this groove becomes closed off from the roof of the future enteron and forms a rod of cells which lies between the hypoblast and the neural canal. This rod of cells is known as the *notochord* or *chorda dorsalis*, and when fully developed is composed of clear epithelium-like cells enclosed in a homogeneous sheath (Fig. 700). It is essentially an embryonic structure, though traces of it remain in the centre of the intervertebral disks throughout life. The collection of mesoblastic cells, which forms a thick longitudinal column on either side of the neural canal, is termed the *paraxial* mesoblast, as distinguished from the outer or *lateral* part of the meso-

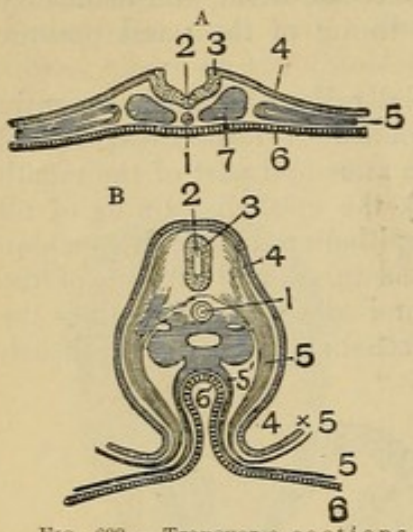

FIG. 699.—Transverse sections through the embryo chick, before and some time after the closure of the medullary canal, to show the upward and downward inflections of the blastoderm. (After Remak.) A. At the end of the first day. 1. Notochord. 2. Primitive groove in the medullary canal. 3. Edge of the dorsal lamina. 4. Corneous layer or epiblast. 5. Mesoblast divided in its inner part. 6. Hypoblast or epithelial layer. 7. Section of protovertebral plate. B. On the third day in the lumbar region. 1. Notochord in its sheath. 2. Medullary canal now closed in. 3. Section of the medullary substance of the spinal cord. 4. Corneous layer. 5. Somatopleure of the mesoblast. 5'. Splanchnopleure (one figure is placed in the pleuro-peritoneal cavity). 6. Layers of hypoblast in the intestines spreading also over the yolk. 4 × 5. Part of the fold of the amnion formed by epiblast and somatopleure.

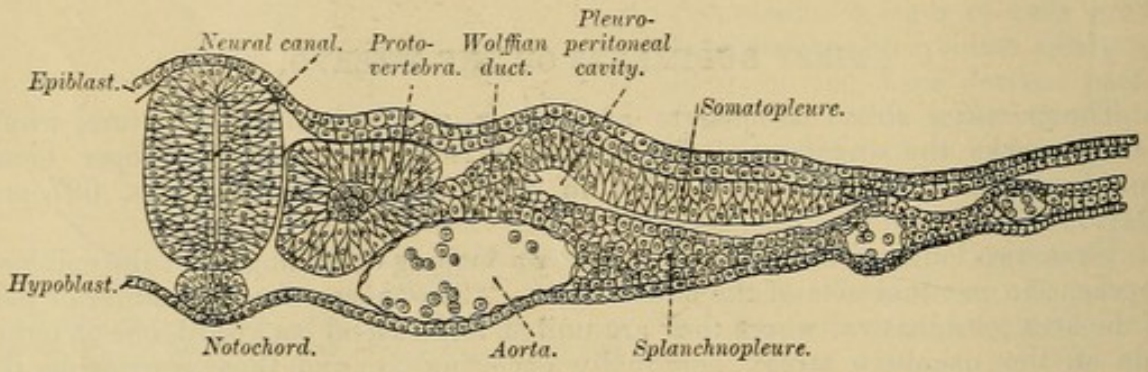

FIG. 700.—Section across the dorsal part of a chick embryo of forty-five hours' incubation. (Balfour.)

blastic layer. The paraxial mesoblast undergoes a series of transverse segmentations and becomes converted into a row of well-defined, dark, square segments or masses, the *protovertebræ* or *mesoblastic somites*, separated by clear, transverse intervals (Figs. 700 and 701). They first make their appearance in the region which afterward becomes the neck, and from there extend backward along the

entire length of the trunk. These bodies, as will be explained hereafter, are not the representatives of the permanent vertebræ, but are differentiated, partly into the vertebræ and partly into the muscles and true skin. On either side of the protovertebræ the lateral mesoblast splits into two layers; the upper becomes applied to the epiblast, forming with it the *somatopleure* or body wall, while the lower becomes attached to the hypoblast and with it forms the *splanchnopleure* or wall of the alimentary tube (Fig. 699). The space between them is the *cælum* or

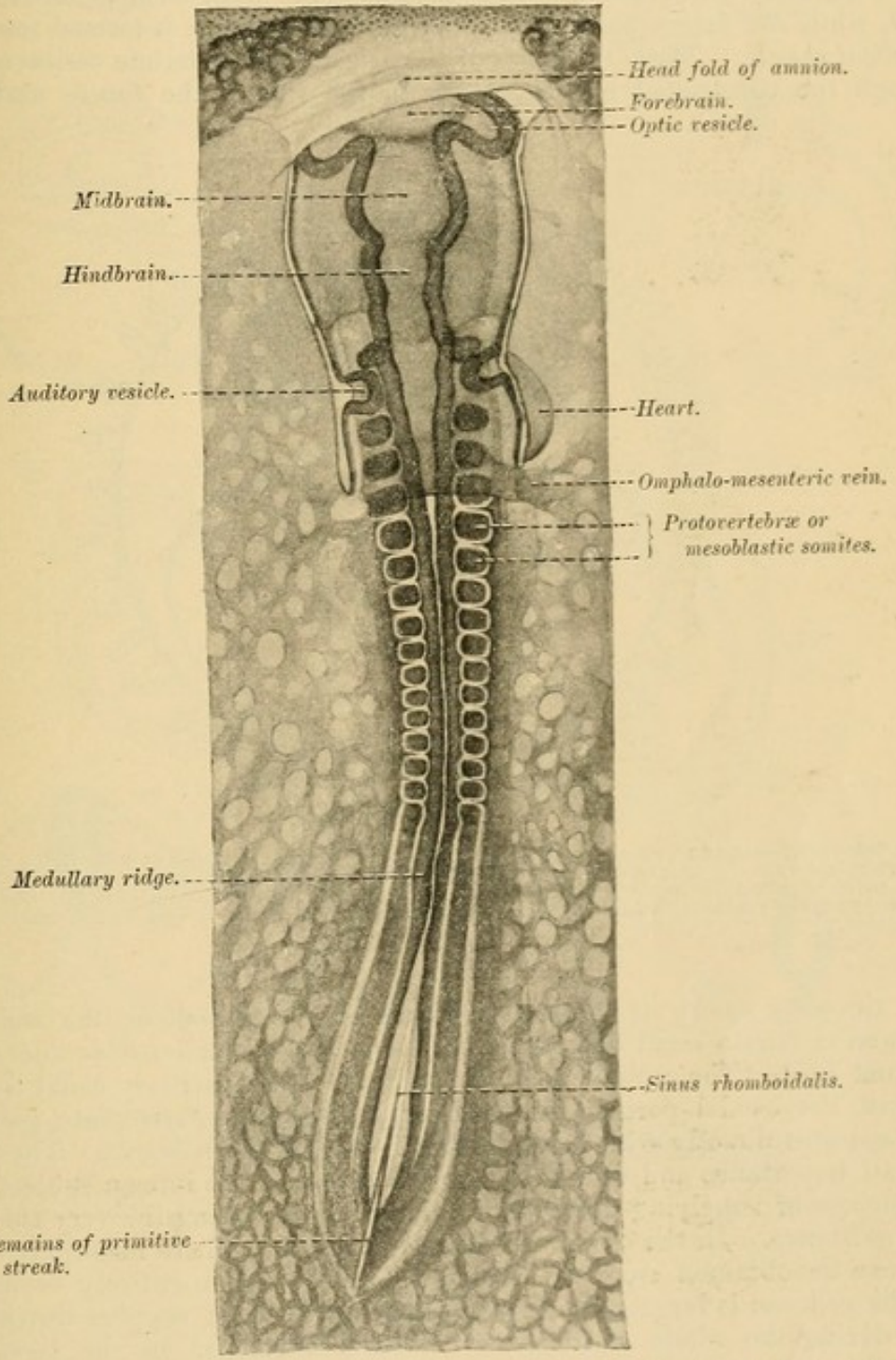

FIG. 701.—Chick embryo of thirty-three hours' incubation, viewed from the dorsal aspect; × 30. (From Duval's *Atlas d'Embryologie.*)

pleuro-peritoneal cavity (Fig. 700). While the parietes of the body are still unclosed, this cavity is continuous with the space between the amnion and chorion, as seen in Fig. 705. The embryo, which at first seems to be a mere streak, extends longitudinally and laterally. As its grows forward the cephalic end becomes

remarkably curved on itself (cephalic flexure), and a smaller but similar folding-over takes place at its hinder end (caudal flexure). At the same time the sides of the embryo, formed by the somatopleure, grow and curve ventrally toward each other, so that the embryo at this stage is aptly compared to a canoe turned over, and becomes marked off from the general blastoderm by a *limiting sulcus*. In consequence of this incurving of the embryo, both in an antero-posterior and a lateral direction, the blastodermic vesicle becomes nipped by the somatopleure and resembles an hour-glass with two unequal parts. The smaller portion is enclosed within the body of the embryo, and constitutes the *enteron* or primitive alimentary canal, while the larger portion, left outside the embryo, is termed the *yolk-sac* or *umbilical vesicle*. These two parts of the original blastodermic vesicle communicate through the constricted portion, which is the site of the future umbilicus, and,

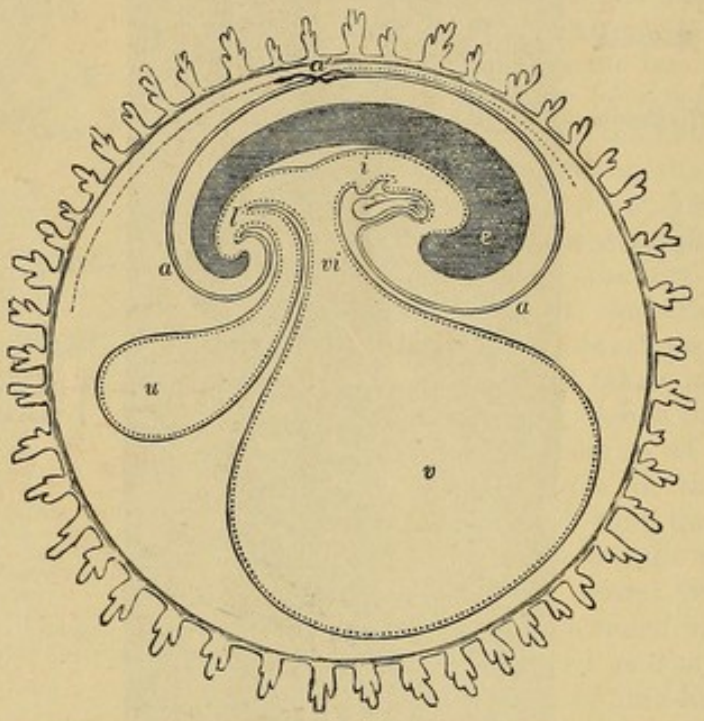

FIG. 703.—Diagrammatic action through the ovum of a mammal in the long axis of the embryo. *e*. The cranio-vertebral axis. *i, i*. The cephalic and caudal portions of the primitive alimentary canal. *a*. The amnion. *a'*. The point of reflection into the false amnion. *v*. Yolk-sac, communicating with the middle part of the intestine by *v i*, the vitello-intestinal duct. *u*. The allantois. The ovum is surrounded externally by the villous chorion.

when the body cavity is ultimately closed at the umbilicus, the constriction is narrowed to form a small duct, the *omphalo-mesenteric* or *vitelline duct* (Figs. 702, 703, and 705). The cephalic part of the primitive alimentary canal is named the *fore-gut*, the caudal portion the *hind-gut*, while the intermediate portion which communicates directly with the yolk-sac, is termed the *mid-gut*. The yolk-sac is of small importance and very temporary duration in the human subject. It is for the purpose of supplying nutrition to the embryo during the very earliest period of its existence. In the oviparous animals, however, where no supply of nourishment can be obtained from the mother, since the egg is entirely separated from her, the yolk-sac is large and of great importance, as it supplies nutrition to the chick during the whole of fœtation. Vessels developed in the mesoblast soon cover the yolk-sac, forming the *vascular* area; these are named the *omphalo-mesenteric* vessels, and are two in number (Fig. 704). They appear to absorb the fluid of the yolk-sac which, when the fluid has disappeared, dries up and has no further function. The activity of the yolk-sac ceases about the fifth or sixth week, at the same time that the allantois, which is the great bond of vascular connection between the embryo and the uterine tissues, is formed. The yolk-sac remains visible, however, up to the fourth or fifth month, with its pedicle and the omphalo-

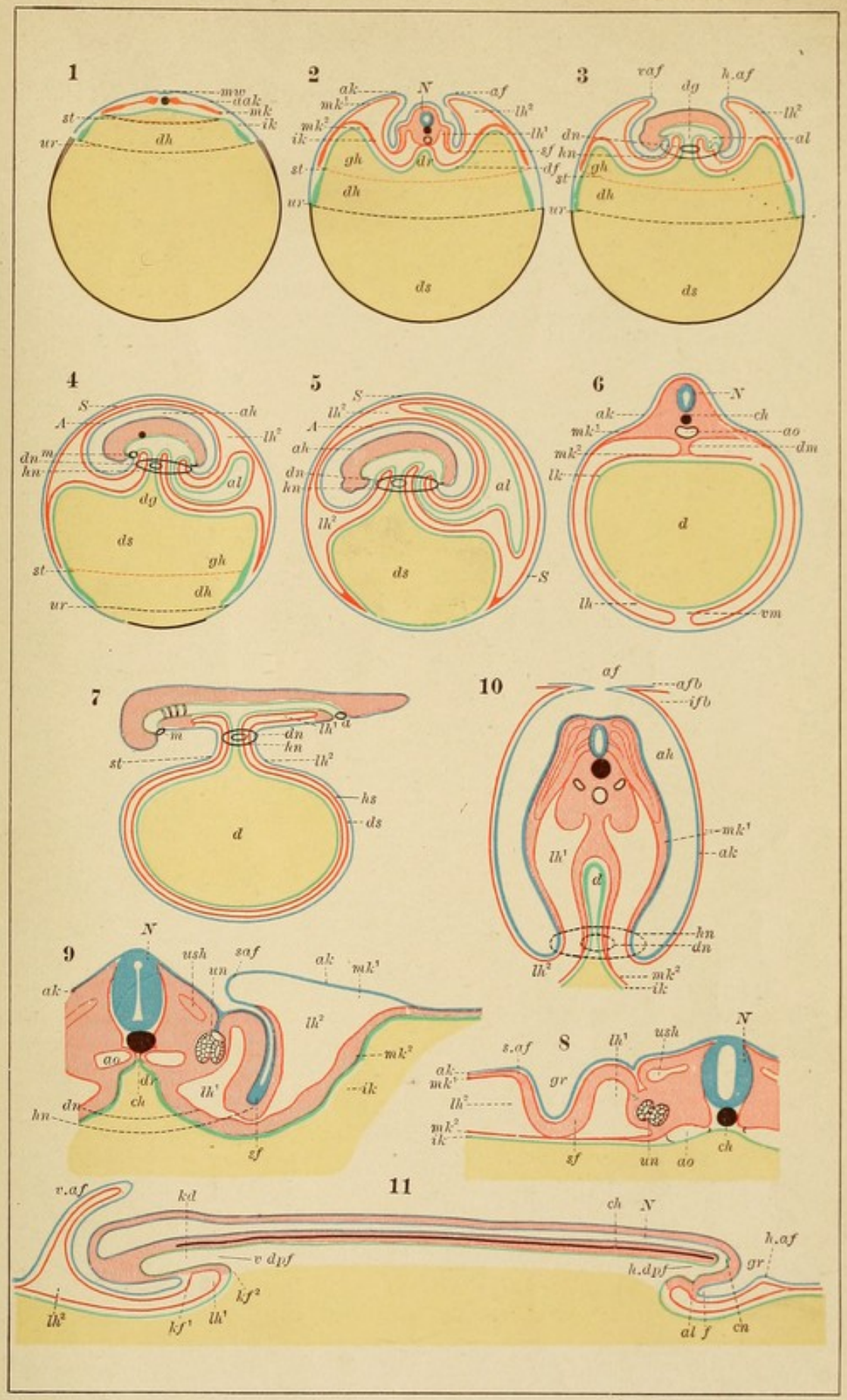

Fig. 702.—Diagrams to illustrate the development of the embryo with its yolk-sac, amnion, and allantois.
(From Hertwig's 'Embryology.')

a. External germinal layer. *mw*. Medullary groove. *N*. Neutral canal. *af*. Amnion fold. *vaf*. Anterior. *haf*. Posterior. *saf*. Lateral amniotic folds. *A*. Amnion. *ah*. Amniotic cavity. *S*. Serous covering. *hn*. Umbilicus. *sf*. Lateral folds. *kf*¹, *kf*². Head fold. *afb*. External. *ifb*. Internal layers of amnion. *ur*. Border of embryonic area. *dr*. Intestinal groove. *dg*. Vitelline duct. *al*. Allantois. *ds*. Vitellus. *dn*. Intestinal portion of umbilicus. *mk*. Middle germinal layer. *mk*¹. Parietal leaf of mesoderm. *mk*². Visceral leaf of mesoderm. *st*. Sinus terminalis. *dm*. Dorsal. *vm*. Ventral mesenterium. *lh*. Somatic cavity. *lh*¹. Embryonal portion. *lh*². Extra-embryonal portion of somatic cavity. Figs. 1, 2, 6, 8, 9, and 10 transections. Figs. 3, 4, 5, 7, and 11 long-sections of embryo. Figs. 1, 2, 3, 4, and 5 chick embryo. Fig. 6 fish embryo. Figs. 7 and 11 selachian embryo.

mesenteric vessels. The latter vessels become atrophied as the functional activity of the body with which they are connected ceases.

So far we have traced: (1) the segmentation or cleavage of the ovum and the formation of a blastodermic vesicle, consisting of (*a*) an external envelope, and (*b*) an internal mass of cells applied to it at the embryonal pole, but separated elsewhere by an albuminous fluid. (2) The separation of the hypoblast from the inner surface of this internal mass and its extension as a lining to the external envelope. (3) The development of the epiblast, also from the internal mass of cells, absorption taking place between it and the external layer to form a cavity, the primitive amniotic cavity. (4) The formation of an oval-shaped disk, the germinal disk, and the appearance of the primitive streak at its posterior end.

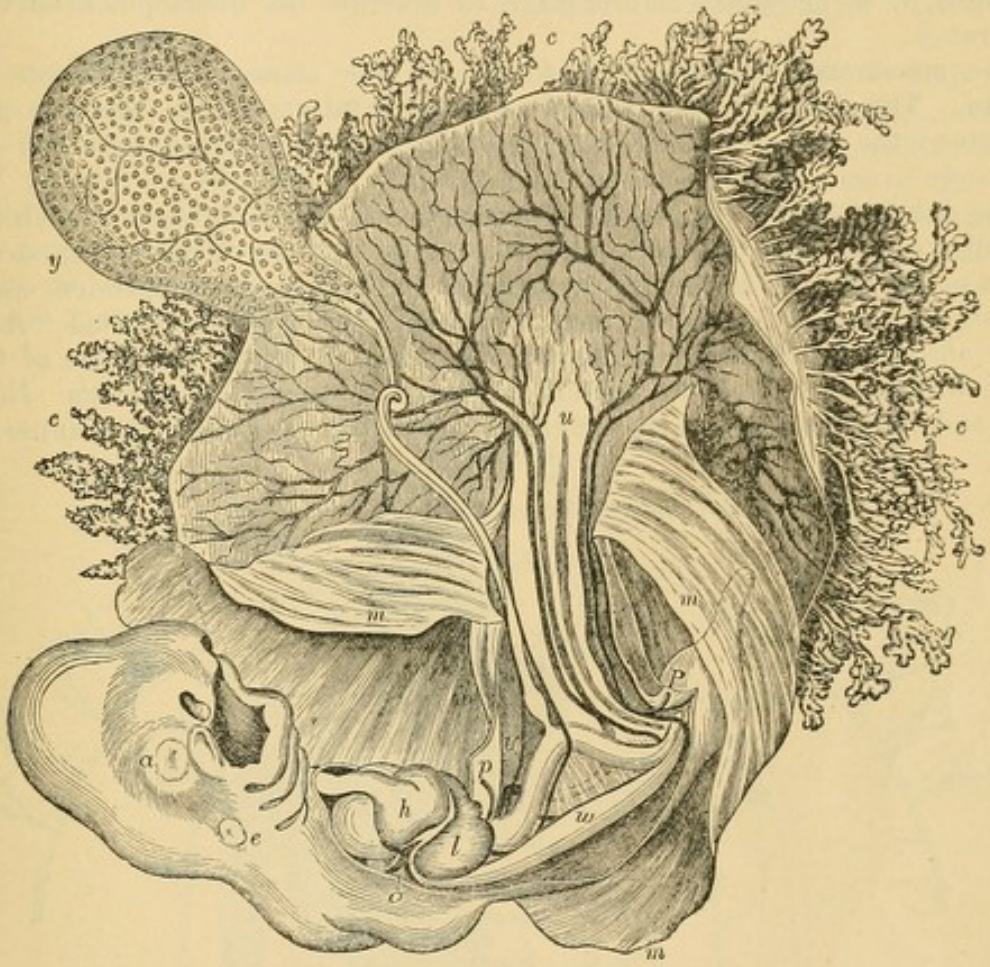

FIG. 704.—Magnified view of the human embryo of four weeks, with the membranes opened. (From Leishman, after Coste.) *y*. The umbilical vesicle with the omphalo-mesenteric vessels, *v*, and its long tubular attachment to the intestine. *c*. The villi of the chorion. *m*. The amnion opened. *u*. Cul-de-sac of the allantois, and on each side of this the umbilical vessels passing out to the chorion. In the embryo: *a*. The eye. *e*. The ear-vesicle. *h*. The heart. *l*. The liver. *o*. The upper; *p*. the lower limb. *w*. Wolffian body, in front of which are the mesentery and fold of intestine. The Wolffian duct and tubes are not represented.

(5) The development of the mesoblast from the primitive streak and its extension between the epiblast and mesoblast. (6) The formation of the "neural groove" in front of this primitive streak, caused by the growing-up of the epiblast on either side of it, so as to form two longitudinal ridges, called the "laminæ dorsales." (7) The increase and incurvation of these laminæ dorsales, until they meet dorsally and enclose the "neural canal," from the epiblastic lining of which the nervous centres are developed. (8) The formation, from the hypoblast immediately under the canal, of a continuous rod of cells, the "cauda dorsalis" or "notochord." (9) The formation, from the paraxial mesoblast, on either side of the notochord, of a number of square segments, the "protovertebræ" or "mesoblastic somites." (10) The splitting of the lateral mesoblast into two layers

to form the "somatopleure" and "splanchnopleure," the space between the two constituting the "cœlum" or "pleuro-peritoneal cavity." (11) The curving of the embryo on itself, both longitudinally and laterally, so as to be comparable to a canoe, part of the blastodermic vesicle being enclosed within the embryo to form the "primitive alimentary tube," part being left outside as the "yolk-sac," the two communicating by a duct, the "omphalo-mesenteric" duct. The yolk-sac provides nutrition to the embryo through the omphalo-mesenteric vessels until such time as the placenta is formed.

FORMATION OF MEMBRANES.

In order to have a clear understanding of the manner in which the embryo is developed, it is necessary at this stage to describe the development of the fœtal membranes.

The **membranes** investing the fœtus are the amnion, the chorion, and the decidua. The first two are developed from fœtal structures, and are proper to the fœtus; the last is formed in the uterus, and is derived from the maternal structures.

The Amnion.—The amnion is the innermost of the membranes which surround the embryo. It is at first of small size, but increases considerably toward the middle of pregnancy, as the fœtus acquires the power of independent movement. It exists only in reptiles, birds, and mammals, which are hence called "Amniota," but is absent in amphibia and fishes. In man, monkeys, and some of the bats, the primitive amniotic cavity, already described on page 1154, persists. In reptiles, birds, and certain mammals the amnion is formed in the following manner. At or

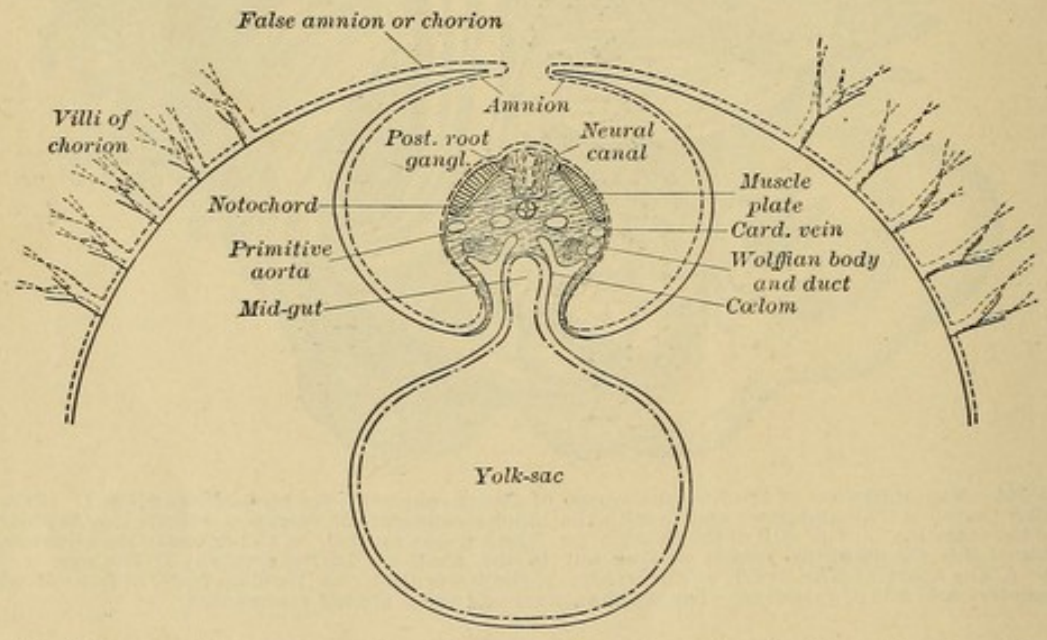

FIG. 705.—Diagram of a transverse section of a mammalian embryo, showing the mode of formation of the amnion. The amniotic folds have nearly united in the middle line. (From Quain's *Anatomy*, vol. i. pt. i. 1890.) Epiblast, ····; mesoblast, —·—·—; hypoblast and notochord, continuous line.

near the extremities of the incurved fœtus—that is to say, at the point of constriction of the blastodermic vesicle where the primitive alimentary canal of the embryo joins the yolk-sac—a reflection or folding backward of the somatopleure, which has become separated from the splanchnopleure by the formation of the pleuro-peritoneal cavity, takes place (Fig. 702, 2, 3). This fold commences first at the cephalic extremity, and subsequently at the caudal end and sides, and deepens more and more, in consequence of the sinking of the embryo into the blastodermic vesicle, until, gradually approaching, the different parts meet on the dorsal aspect of the embryo (Figs. 702, 10, and 705). After they come in contact

they fuse together, and the septum between them disappears; so that the inner layer of the cephalic fold becomes continuous with the inner layer of the caudal and lateral folds, and the outer with the outer. Thus we have two membranes, one formed by the inner layer of the fold—*the true amnion*—which encloses a space over the back of the embryo—the *amniotic cavity* (Fig. 702, 4, 5)—containing a clear fluid, the *liquor amnii*. The other, the outer layer of the fold—the *false amnion*—lines the internal surface of the original zona pellucida. Between the two is an interval, which of course communicates with the pleuro-peritoneal cavity until the body-walls of the embryo have coalesced at the umbilicus. Then the amniotic fold is carried downward, and encloses the umbilical cord, by which the fœtus is attached to the placenta. The true amnion—or, as it is usually called, the amnion—is formed of two layers, inner and outer, derived respectively from the epiblast and from the parietal layer of the mesoblast.

The amnion is at first in close contact with the surface of the body of the embryo, but about the fourth or fifth week fluid begins to accumulate, and thus separates the two. The quantity of fluid steadily increases up to about the sixth month of pregnancy, after which it diminishes somewhat. The use of the liquor amnii is believed to be chiefly to allow of the movements of the fœtus in the later stages of pregnancy, though it no doubt serves other purposes. It contains about 1 per cent. of solid matter, chiefly albumen, with traces of urea, the latter probably derived from the urinary secretion of the fœtus.

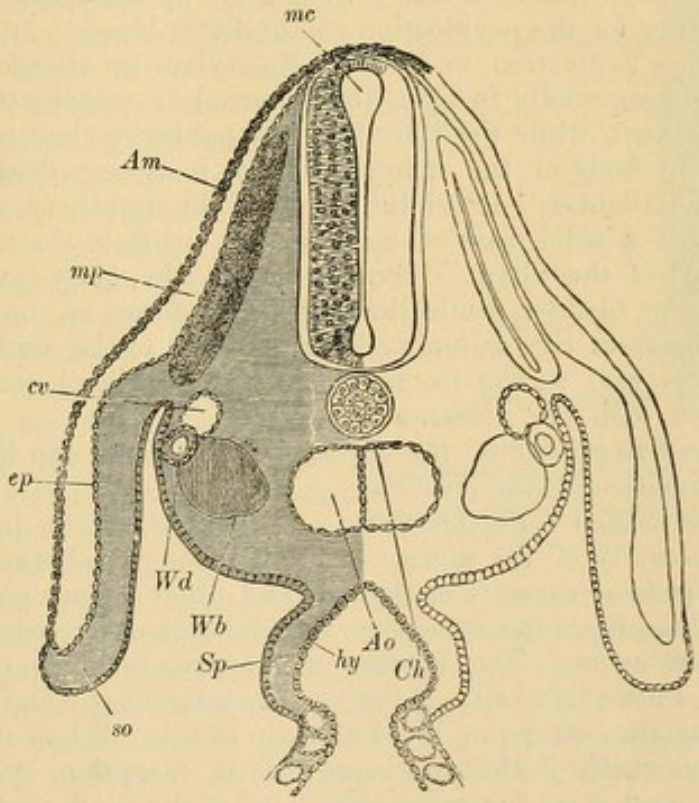

FIG. 706.—Transverse section through the dorsal region of an embryo chick, end of third day. (From Foster and Balfour.) *Am.* Amnion. *mp.* Muscle-plate. *cv.* Cardinal vein. *Ao.* Dorsal aorta, at the point where its two roots begin to join. *Ch.* Notochord. *Wd.* Wolffian duct. *Wb.* Commencement of formation of Wolffian body. *ep.* Epiblast. *So.* Somatopleure. *Hy.* Hypoblast. The section passes through the place where the alimentary canal (*hy*) communicates with the yolk-sac. *Sp.* Splanchnopleure.

The Chorion.—The chorion takes its origin, as has already been seen (page 1154), from the external covering of the blastodermic vesicle the cells of the decidua or uterine mucous membrane contributing no elements to it. From its outer surface numerous finger-like processes, termed the *villi of the chorion*, project. These increase rapidly in size and at the same time undergo great ramification; hence they were likened by Dalton to tufts of seaweed (Figs. 705 and 708). They invade

the decidua of the uterus and probably absorb from it nutritive materials for the growth of the embryo: they can be forcibly withdrawn from the decidua until the third month of pregnancy. Until about the end of the second month the villi cover the whole surface of the chorion and are of an almost uniform size, but after this they develop unequally. On that part which invades the decidua serotina they increase greatly in size and complexity, and constitute the *chorion frondosum*, which becomes the fœtal part of the placenta (Fig. 708). Over the remainder of the chorion they undergo atrophy, so that by the fourth month hardly any trace of them is left, and hence this part becomes smooth, and is therefore named the *chorion lævе*. The chorionic villi are at first non-vascular, but subsequently they become vascularized by the growth into them of the allantoic mesoblast, which carries to them the branches of the allantoic arteries.

The Allantois.—The allantois grows outward as a hollow bud from the hind gut, and is therefore lined by hypoblast and covered by mesoblast (Figs. 702, 4, 5, and 703). It is projected into the space between the amnion and the chorion, and in its mesoblast are carried a pair of arteries, the *allantoic* or *umbilical arteries*, which are continued from the two primary aortæ. The allantoic mesoblast gradually spreads out on the inner surface of the chorion, and, invading the chorionic villi, supplies them with blood-vessels. In this way the allantois becomes the chief agent of the fœtal circulation, since it carries the vessels which convey the blood of the embryo to the chorion, where it is exposed to the influence of the maternal blood circulating in the decidua; from the maternal blood it imbibes the materials of nutrition and to it it gives up effete materials, the removal of which is necessary for the purification of the fœtal blood. In some animals the allantois is a hollow projection, and is usually styled the *allantoic vesicle;* but in most mammals, and especially in man, the external or mesoblastic element undergoes great development, while the internal or hypoblastic element undergoes little increase beyond the body of the embryo, so that it is very doubtful whether any cavity exists in the allantois beyond the limits of the umbilicus, or whether it does not rather consist of a solid mass of material derived from the mesoblastic tissue.[1] The proximal part of the allantoic vesicle within the body-cavity is eventually destined to form the bladder, while the remainder forms an impervious cord, the *urachus*, stretching from the summit of the bladder to the umbilicus. The part of the allantois external to the fœtus forms the umbilical cord, by which the fœtus is connected with the placenta.

The Decidua.—The growth of the chorion and placenta can be understood only by tracing the formation of the decidua.

The decidua is formed from the uterine mucous membrane before the fertilized ovum reaches the cavity of the uterus. The mucous membrane becomes vascular and tumid, its glands are greatly elongated, and their deeper portions are dilated and tortuous, while the interglandular tissue becomes crowded with epithelial-like cells (*decidual cells*). The mucous membrane, thus altered, is named the *decidua vera;* it lines the cavity of the uterus as far as the os internum, without, however, occluding the orifices of the Fallopian tubes. When the fertilized ovum reaches the uterus, which is thus prepared for its reception, it becomes attached to the decidua, in most cases in the neighborhood of the fundus uteri. The decidua then grows up around the ovum and ultimately covers it in. The part of the decidua which grows up to envelop the ovum is named the *decidua reflexa;* that portion to which the ovum originally became attached is termed the *decidua serotina*, and from it the maternal part of the placenta is derived. After conception the cervix uteri is closed by a plug of mucus (Fig. 708).

By the fourth month the decidua vera has acquired a thickness of about half

[1] Indeed, it would appear, from the researches of His, that in the human embryo the allantois is formed unusually early, being present from a very early period as a stalk of mesoblast connecting the posterior extremity of the embryo with the chorion. This stalk is termed the *abdominal stalk* (Bauchstiel).

an inch, and consists of the following strata: (1) *Stratum compactum*, next the free surface, in which the uterine glands are little altered and where they preserve a comparatively narrow lumen lined by columnar epithelium; between the glands are large numbers of decidual cells. (2) *Stratum spongiosum*, in which the gland tubes are very tortuous and greatly dilated, while their lining cells are flattened or cubical. (3) *Basal layer*, next the uterine muscular wall, in which the glands are not dilated and where they retain their columnar epithelium. It is through this basal layer that the placenta is separated after the birth of the child (Fig. 707).

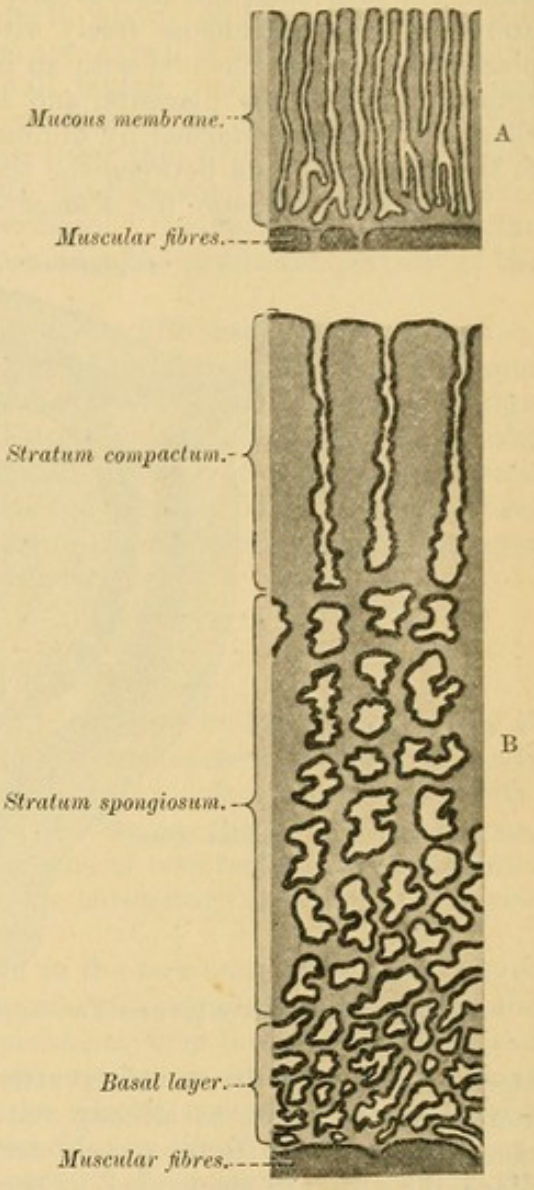

FIG. 707.—Diagrammatic sections of the uterine mucous membrane: (A) of the non-pregnant uterus; (B) of the pregnant uterus, showing the thickened mucous membrane and the altered condition of the uterine glands.

The decidua reflexa is gradually expanded by the growing ovum, and ultimately comes into contact and blends with the decidua vera so as completely to obliterate the uterine cavity. This obliteration is followed by the degeneration of the deciduæ; the glands of the decidua reflexa become atrophied, and the entire decidua practically disappears, while the decidua vera is much thinned and its glands also disappear, except their deepest portions, which persist in the basal layer.

In this manner the embryo becomes surrounded by three membranes: (1) the *amnion*, derived, in the case of reptiles, birds, and some mammals, from the outer layer of the mesoblast and the epiblast; (2) the *chorion*, formed by the allantois (which is derived from the hypoblast and inner layer of the mesoblast) and the false amnion; and (3) the *decidua*, derived from the mucous membrane of the uterus.

Much additional interest has been given to the physiology of the decidua by the fact, which seems to be now established by the researches of Sir John Williams, that every discharge of an ovum, whether impregnated or not, is, as a rule, accompanied by the formation of a decidua, and that the essence of menstruation consists in the separation of a decidual layer of the mucous membrane from the uterus; while in the case of pregnancy there is no exfoliation of the membrane, but, on the contrary, it undergoes further development in the manner described above.

Formation of the Placenta.—The placenta is developed partly from maternal and partly from fœtal tissues—the maternal portion being derived from the decidua serotina, the fœtal from the villi of the chorion frondosum. These villi penetrate the decidua serotina, which then undergoes a series of complicated and, as yet, imperfectly understood changes. Decidual cells accumulate between the uterine glands, while the glands with their epithelial lining undergo degeneration—a degeneration which does not, however, extend as deep as the basal layer, where the glands persist, and retain their epithelial lining throughout the entire period of gestation. Ultimately the superficial portion of the decidual tissue disappears, and the uterine vessels become expanded to form a labyrinth of freely communi-

cating blood-channels or sinuses, which are filled with maternal blood, and in which are suspended the now greatly ramified tufts of the chorionic villi. These uterine sinuses anastomose freely with one another, and form, at the edge of the placenta, a venous channel with an irregular calibre, which runs round the whole circumference of the placenta, and is termed the *marginal sinus*. Some of the chorionic villi are attached by fibrous bands to the basal layer of the decidua and to the imperfect septa between the sinuses, but the majority of them hang free.

Circulation through the Placenta.—The maternal blood is brought to the

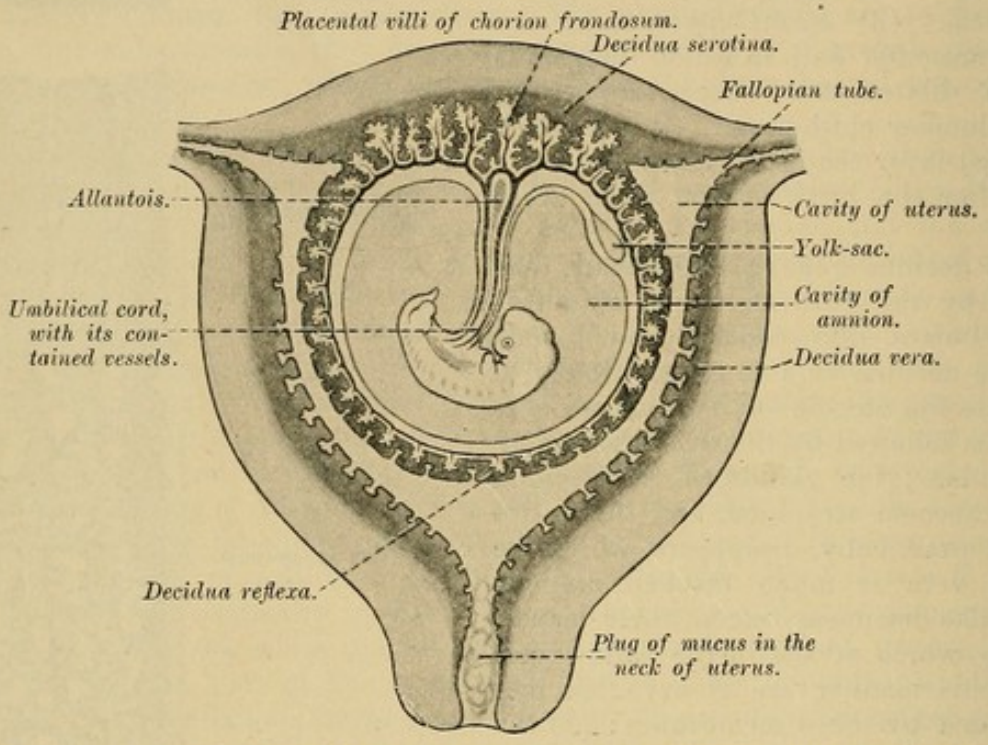

FIG. 708.—Sectional plan of the gravid uterus in the third and fourth months. (Modified from Wagner.)

uterine sinuses by the "curling arteries" of the uterus and drained away by the uterine veins, while, as already stated, within the chorionic villi are found the ramifications of the fœtal vessels derived from the allantoic or umbilical arteries. Since the villi are suspended in the sinuses, they are necessarily bathed in the maternal blood, and hence it follows that the maternal and fœtal blood-currents are brought into close relationship. There is, however, no intermingling of the two currents, or, in other words, no direct communication between the vascular system of the mother and that of the fœtus, the interchange of materials necessary for the growth of the fœtus and for the purification of the fœtal blood taking place through the walls of the villi. The purified blood is carried back to the fœtus by the umbilical vein. From what has been said, it will be understood that the placenta is the organ by which the connection between the fœtus and the mother is established, and which subserves the purposes of nutrition, respiration, and excretion.

Placenta.—At the end of the gestation period the placenta presents the form of a disk which weighs about a pound and has a diameter of from six to eight inches. Its average thickness is about an inch and a quarter, but diminishes rapidly near the circumference of the disk. Its outer or *decidual* surface blends with the uterine wall, but if examined after the separation of the placenta, it presents a comparatively smooth surface, which on inspection is seen to be incompletely divided into a number of masses named *cotyledons*. Its inner or *chorionic* surface is smooth, being closely invested by the amnion. The umbilical cord is attached near the centre of this surface, and from this attachment the larger branches of the umbilical vessels are seen radiating under the amnion. On section the placenta presents a soft, spongy appearance, caused by its freely communicating blood-

sinuses with their contained villi. Owing to the rapid thinning of the placenta at the periphery of the disk, the decidual and chorionic surfaces come into contact.

Separation of the Placenta.—After the birth of the child the placenta and the membranes (*i. e.*, the amnion and chorion) are expelled as the *after-birth*, the separation of the placenta from the uterine wall taking place through the basal layer of the decidua and necessarily causing rupture of the uterine vessels. The orifices of the torn vessels are, however, closed by the firm contraction of the uterine muscular fibres, and this, together with the formation of a blood-clot over the placental site, prevents *post-partum hemorrhage*. The epithelial lining of the uterus is regenerated from the epithelium which lines the persistent portions of the uterine glands in the basal layer of the decidua.

The **umbilical cord** appears about the end of the fifth week after conception. It consists of the coils of two arteries and a single vein, the *umbilical arteries and vein*, united together by a gelatinous tissue (*jelly of Wharton*). There are originally two umbilical veins, but one of these vessels becomes obliterated, as do also the two omphalo-mesenteric arteries and veins and the duct of the umbilical vesicle, all of which are originally contained in the rudimentary cord. The umbilical cord also contains the remains of the allantois, and is covered externally by a layer of the amnion, reflected over it from the umbilicus.

DEVELOPMENT OF THE EMBRYO.

The further development of the embryo will, perhaps, be better understood if we follow briefly the principal facts relating to the development of the chief parts of which the body consists, viz., the spine, the cranium, the pharyngeal cavity, mouth, etc., the nervous centres, the organs of the senses, the circulatory system, the alimentary canal and its appendages, the organs of respiration, and the genito-urinary organs. The reader is also referred to the chronological table of the development of the fœtus at the end of this section.

Development of the Spine.—The first steps in the formation of the spine have already been traced, viz.: (1) The looping up of two longitudinal folds from the cells of the epiblast in front of the primitive streak, to form the *neural groove*, and the gradual growing together of the *laminæ dorsales* so as to convert the groove into the *neural canal*. (2) The formation on the ventral aspect of this groove of a continuous cellular cord, the *notochord* or *chorda dorsalis* (Fig. 700), which extends from the cephalic to the caudal extremity of the embryo, and lies in the situation which is afterward occupied by the bodies of the vertebræ. (3) The segmentation of the paraxial mesoblast on either side of the neural canal into a number of quadrilateral masses, the *protovertebræ* or *mesoblastic somites* (Fig. 701). The process of segmentation commences in the cervical region and proceeds successively through the other regions of the spine until a number of segments are formed, which correspond very closely to the number of the permanent vertebræ. Subsequently the protovertebral somites divide into two parts—a ventral and a dorsal. From the ventral division the vertebræ are formed; the dorsal is termed the *muscle-plate*, and from it the muscles of the back are developed. From the ventral division of the protovertebral somites masses of cells are budded off, which grow inward toward the middle line, those from opposite sides meeting and enclosing the notochord and extending dorsally around the neural canal, which they also envelop. Fusion of the ventral divisions also occurs in the antero-posterior direction, so that all trace of their originally segmented condition is lost and the notochord and spinal cord are surrounded by a continuous investment of mesoblast, the *membranous vertebral column*. This investment also extends forward and envelops the primitive brain, forming the *membranous* or *primordial cranium*. From this investment the base of the skull, the vertebræ and their ligaments, and the membranes of the cerebro-spinal nervous system are developed. The future vertebræ make their first appearance about the beginning of the second month in the form of two small masses of cartilage which

are seen in the membranous vertebral column, one on each side of the notochord. These small masses lie opposite to the intervals between the muscle-plates and so alternate with these structures. They are soon joined across the middle line on the ventral aspect of the notochord by a hypochordal cartilaginous bar, which ultimately disappears, except in the case of the atlas vertebra, where it forms the anterior arch of that bone. The vertebral bodies are formed immediately to the dorsal aspect of these hypochordal bars, alternating with the muscle-plates which represent the original mesoblastic somites. The notochord contained in the centre of this chondrifying mass does not continue to grow, but becomes in the human subject relatively smaller, so as, at last, to form a mere slender thread, except opposite the intervals between the bodies of the permanent vertebræ. Here it presents thickenings and

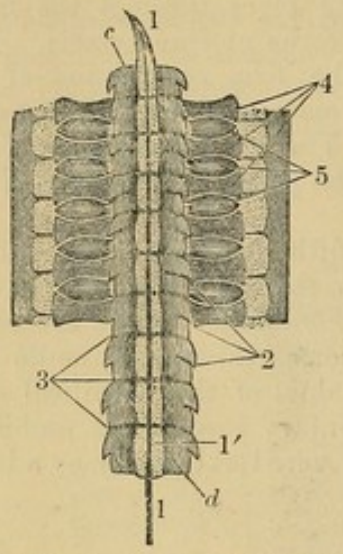

FIG. 709.—Cervical part of the primitive vertebral column and adjacent parts of an embryo of the sixth day, showing the division of the primitive vertebral segments. (From Kölliker, after Remak.) 1, 1 Chorda dorsalis in its sheath, pointed at its upper end. 2 points by three lines to the original intervals of the primitive vertebræ. 3, in a similar manner, indicates the places of new division into permanent bodies of vertebræ. *c* indicates the body of the first cervical vertebra; in this and the next the primitive division has disappeared, as also in the two lowest represented, viz., *d* and the one above; in those intermediate the line of division is shown. 4 points in three places to the vertebral arches; and 5, similarly, to three commencing ganglia of the spinal nerves; the dotted segments outside these parts are the muscular plates.

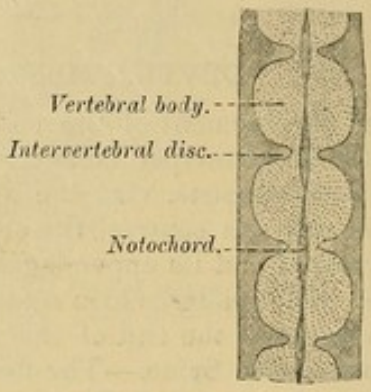

FIG. 710.—Longitudinal section of vertebral column of an eight weeks' human fœtus. (Kölliker.)

forms an irregular network, the remains of which are to be found at all periods of life in the central pulp of the intervertebral disks (Figs. 709, 710, and 711).

Development of the Ribs and Sternum.—The ribs are formed from the muscle-plates of the protovertebral somites, from which also the muscles of the back and the true skin of the body-wall are formed. The ribs consist of extensions of this mesoblastic material, which speedily undergo chondrification, and appear as cartilaginous bars, which become separated from the vertebræ at their posterior extremities. At their anterior ends the nine upper costal bars turn upward and fuse together so as to form a cartilaginous strip bounding a central median fissure. The strips on either side then join in the middle line from before backward, and so give rise to a longitudinal piece of cartilage, which represents the manubrium and gladiolus of the sternum. In the process of development the sternal attachment of the eighth rib disappears, while that of the ninth subdivides, one portion remaining attached to the inferior extremity of the cartilaginous sternum and becoming developed into the ensiform cartilage, the other portion receding from the sternum and becoming attached to the cartilage of the eighth rib.

The further development of the vertebræ, ribs, and sternum, and the ossification of their cartilaginous framework, are described in the body of the work.

Development of the Cranium and Face.—It has been seen that the first trace of the embryo consists in the formation of a longitudinal fold of the epiblast on either side of the neural groove, and that these folds or ridges grow backward and meet in the median line, thus forming the neural canal. This canal, at the cephalic extremity of the embryo, is dilated and forms a bulbous enlargement. The bulbous enlargement soon expands into three vesicular dilatations, the three *primary*

cerebral vesicles, from which all the different parts of the encephalon are developed. The primary cerebral vesicles at this time freely communicate with each other at the points of constriction.

The three cavities are lined by epiblast and covered by the same structure. Between these two layers of epiblast a layer of mesoblast spreads over the whole surface of the cerebral vesicles and forms the membranous cranium. From these structures the cranium and its contents are developed. The external layer of the epiblast forms the epidermis and hairs of the scalp. The mesoblastic layer forms the true skin, the blood-vessels (all but their endothelial lining), muscles, connective tissue, bones of the skull, and membranes of the brain. The layer of epiblast lining the vesicles forms the nervous substance of the encephalon, while the vesicles themselves constitute the ventricles.

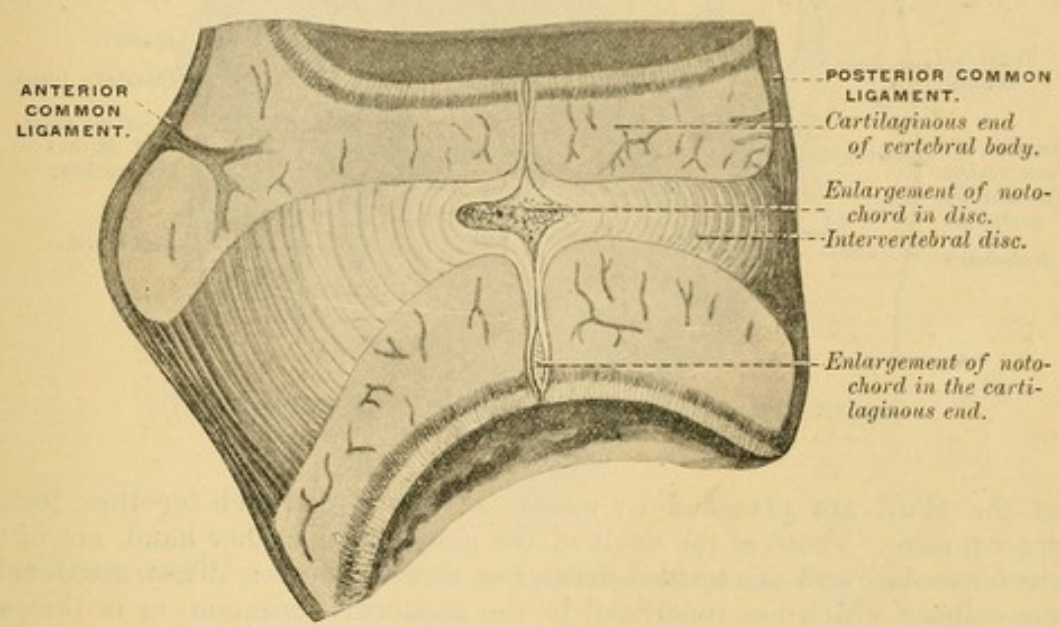

FIG. 711.—Sagittal section through the intervertebral disk and adjacent parts of two vertebræ of an advanced sheep's embryo. (Kölliker.)

The cephalic end of the notochord terminates in a pointed extremity which extends as far forward as the situation of the future basi-sphenoid, and is imbedded in a mass of mesoblast, the "investing mass of Rathke." The posterior part of this mass, which corresponds to the future basi-occipital, shows a subdivision into four segments, the three roots of the hypoglossal nerve indicating their lines of separation. Two cartilaginous bars, the *parachordal cartilages*, then become developed in this investing mass, and these surround the notochord, meeting first on its ventral and next on its dorsal aspect to form the *basilar plate*, the anterior margin of which forms the future dorsum sellæ. From this plate are developed the basi-occipital and basi-sphenoid, and by lateral expansions from it the ex-occipitals and the greater wings of the sphenoid. On either side of the parachordal cartilage a cartilaginous capsule, the *labyrinthine* or *periotic cartilage*, surrounds the otic vesicle, and from it the petrous and mastoid portions of the temporal bone are developed. In front of the investing mass of Rathke two lateral bars are directed forward, enclosing between them a space, which forms the pituitary fossa, in which the pituitary body is eventually developed. These bars are named the *prechordal cartilages* or *trabeculæ cranii*, and extend as far forward as the anterior extremity of the head, where they coalesce with each other to form the *ethmoid plate* (Fig. 712). This encloses the olfactory pits forming the cartilaginous nasal capsule, from which the ethmoid and turbinated bones are developed. A portion of the ethmoid plate remains unossified and constitutes the cartilaginous part of the nasal septum and the cartilages of the outer nose. From the trabeculæ cranii the presphenoid is developed, and from this two lateral expansions extend to form its

lesser wings; each of these arises by two roots, one above and one below the optic nerve, and, uniting outside the nerve, enclose the optic foramen. The base of the primitive cranium therefore consists of two parts, *prechordal* and *parachordal:* the former receives the organ of smell and is indented by the eyeball; the latter surrounds the auditory vesicle. Thus it will be seen that the bones which form the

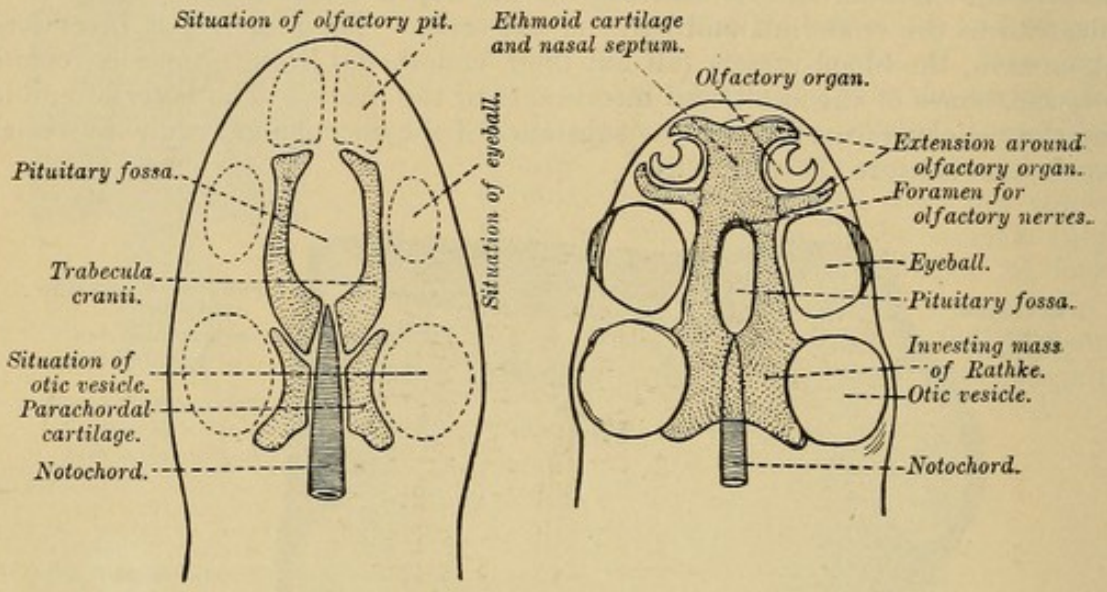

FIG. 712.—Diagrams of the cartilaginous cranium. (Wiedersheim.)

base of the skull are preceded by masses of cartilage, which together form the *chondrocranium*. Those of the vault of the skull, on the other hand, are of membranous formation, and are termed *dermal* or *covering bones*. They are developed in the mesoblast which lies superficial to the primordial cranium, or in that which lies subjacent to the epithelial lining of the foregut. They comprise the upper portion of the tabular part of the occipital (interparietal), the squamous-temporals and tympanic rings, the two parietals, the frontal, the vomer, the internal pterygoid plates, and the bones of the face. Some of them remain distinct throughout life (*e. g.*, parietal and frontal), while others join with the bones of the chondrocranium (*e. g.*, interparietal, squamous-temporal, and internal pterygoid plates).

The head at first consists simply of a cranial cavity, the face and neck being subsequently developed in the manner now to be described.

In all vertebrate animals there is at one period of their development a series of grooves in the upper neck region of the embryo. These are named the *branchial* or *visceral clefts*, and in man are four in number from before backward. They take origin as paired grooves or pouches from the side of the pharynx, and over each groove a corresponding indentation of the epiblast occurs, so that the latter comes into contact with the hypoblast lining the pharynx, and these two layers unite to form thin septa, along the bottom of the grooves, between the pharyngeal cavity and the exterior. In gill-bearing animals these septa disappear and the grooves become complete clefts, the gill clefts, opening from the pharynx on to the exterior; perforation does not, however, occur in birds and mammals. In front and behind each cleft the mesoblast becomes thickened in the form of arches, the *branchial arches* (Figs. 713, 750). In the human embryo there are five pairs of these arches, one in front of the first cleft, one behind the last, and the three remaining ones between the first and second, the second and third, and the third and fourth clefts, respectively. The first arch is named the *mandibular;* the second the *hyoid;* the third the *thyro-hyoid*, while the fourth and fifth have no distinctive names. In each arch there is developed a cartilaginous bar which gives

it firmness and stability, and in each there is also found one of the primitive aortic arches. Continuous with the dorsal end of the first arch and growing forward from it is a triangular process, the *maxillary process* (Figs. 714, 716, 738). Ventrally it is separated from the mandibular arch by a V-shaped notch; the first branchial arch may therefore be said to divide into two, viz., the mandibular arch

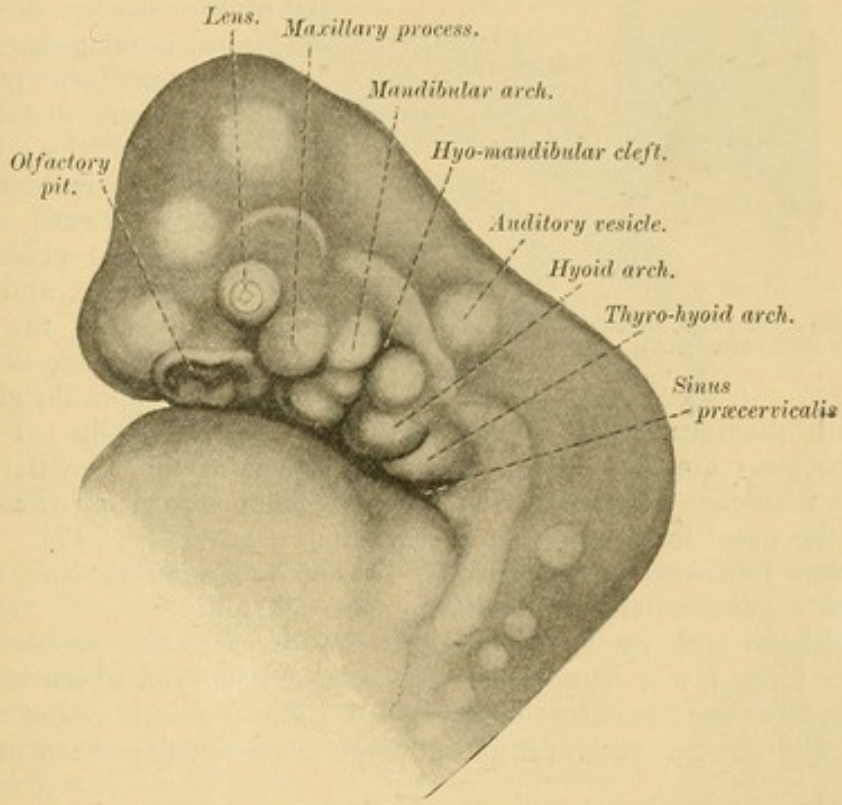

FIG. 713.—Profile view of the head of a human embryo, estimated as twenty-seven days old. (After His.)

and the maxillary process. In front of the mandibular arch is a pentagonal depression, termed the *oral sinus* or *stomodæum*, since it forms the future mouth. It is bounded anteriorly by a median process, the *fronto-nasal* process, and laterally by the maxillary processes (Fig. 714), and will be referred to again.

These parts must now be considered with a little more detail.

The *fronto-nasal process* covers the forebrain and contains the coalesced portion of the trabeculæ cranii; it consists of a central or *mid-frontal* process and two lateral parts. By the invagination of the *olfactory pits*, which communicate below with the cavity of the mouth, each lateral portion is subdivided into an *outer* and an *inner nasal process*—the latter having been termed by His the *processus globularis*. The lateral nasal process is separated from the maxillary process by a groove which extends from the eye to the olfactory pit; this is the rudiment of the lachrymal duct (Figs. 714, 715, and 716). The globular processes are prolonged backward as plates, termed the *nasal laminæ*: these laminæ are at first some distance apart, but, gradually approaching, they ultimately fuse and form the nasal septum, while the globular processes themselves meet in the middle line and form the præmaxillæ and central part of the upper lip (Fig. 717). The depressed part of

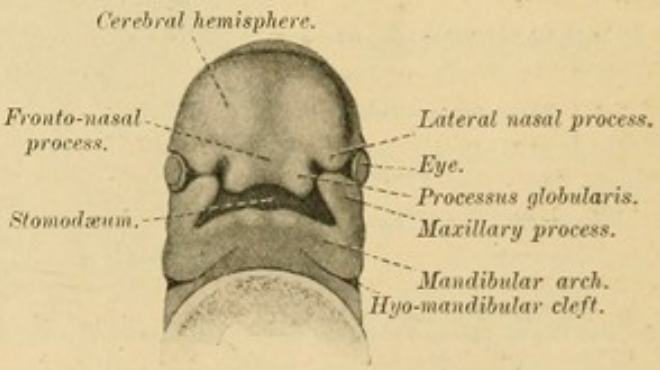

FIG. 714.—Under surface of the head of a human embryo, about twenty-nine days old. (After His.)

the midfrontal process between the globular processes forms the lower part of the nasal septum, while above this is seen a prominent angle which becomes the future point, and still higher, a flat area, the future bridge of the nose (Figs. 717, 718). The alæ of the nose are developed from the lateral nasal processes.

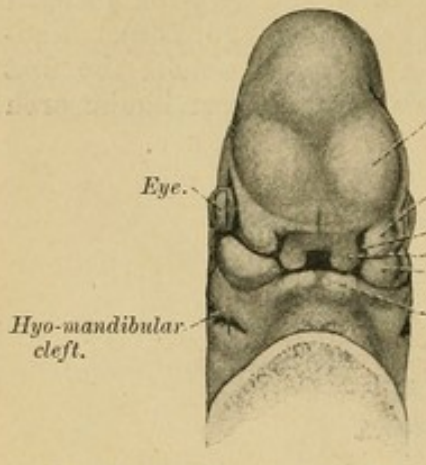

FIG. 715.—Under surface of the head of a human embryo, about thirty days old. (After His.)

The *maxillary* processes descend for a short distance, forming the outer wall of the orbit, in which the malar bone is developed; they then incline inward, and, meeting the lateral nasal process, form the floor of the orbit, and shut it off from the rest of the face; continuing their course downward and inward, they join the globular processes, and with them complete the alveolar arch and upper lip. Finally a pair of palatal processes are formed by inward extensions of the maxillary processes; these coalesce with each other in the median line, thus separating the cavity of the mouth from the nasal fossæ, and completing the palate (Fig. 717). In front the palatal processes join with the premaxillæ, except in the middle line, where a cleft remains which constitutes the naso-palatine canal.

The *mandibular* arch, by its junction with the corresponding process on the other side, forms the lower jaw or mandible. The cartilaginous rod which it contains has long been known as the "cartilage of Meckel." The proximal end of this cartilage is in contact with the periotic capsule, and from it are developed two of the ossicles

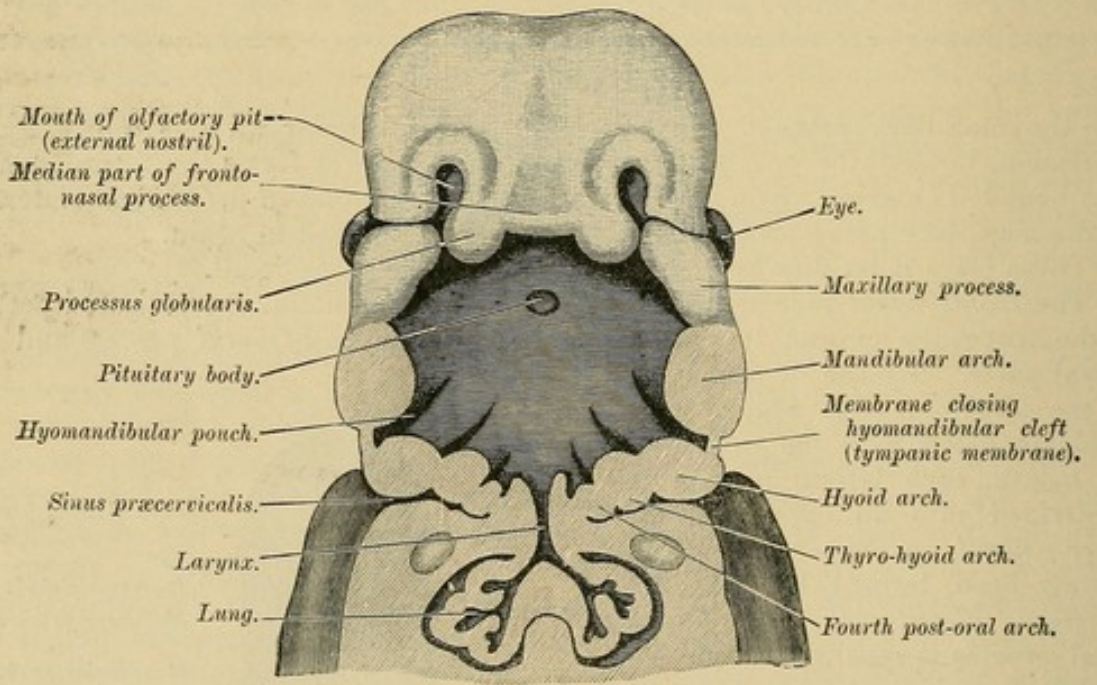

FIG. 716.—The head and neck of a human embryo thirty-two days old, seen from the ventral surface. The floor of the mouth and pharynx have been removed. (His.) (From Marshall's *Vertebrate Embryology.*)

of the middle ear, the malleus and incus[1] (Fig. 719). The remainder of the rod is associated with the formation of the lower jaw, though the greater part of that bone is developed from membrane. The *second visceral arch* is named the *hyoid* arch: from it are formed the styloid process, the stylo-hyoid ligament, and the lesser cornu of the hyoid bone. The third, or *thyro-hyoid* arch, gives origin to the

[1] The incus is by some regarded as arising from the proximal end of the hyoid bar.

great cornu of the hyoid bone, while the body of this bone is formed between the second and third arches. The *fourth* and *fifth* arches are rudimentary.

Between the maxillary processes and the mandibular arch the buccal cavity or mouth is formed. As has already been stated (page 1157) the cephalic end of the

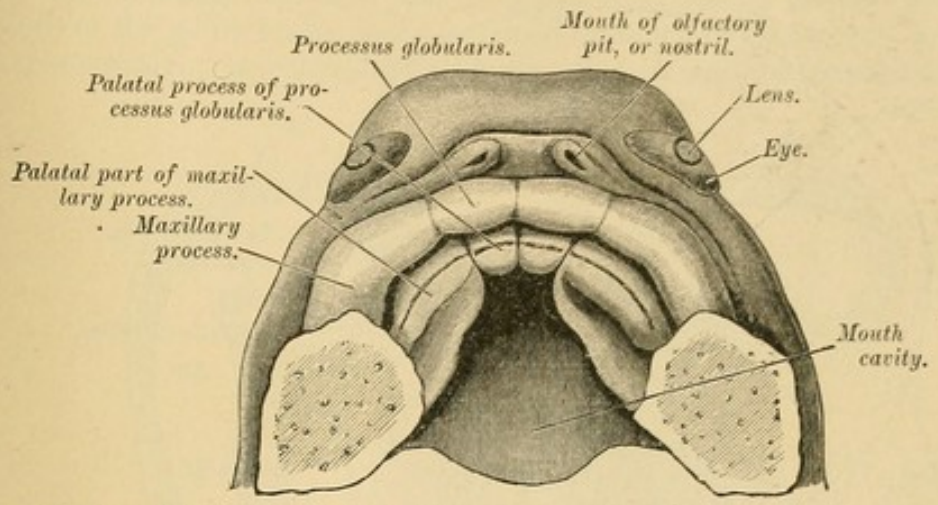

FIG. 717.—The roof of the mouth of a human embryo of about two and a half months old, showing the mode of formation of the palate. (His.) (From Marshall's *Vertebrate Embryology.*)

embryo becomes remarkably curved on itself, the fore-brain and mid-brain bending downward over the anterior portion of the original blastodermic vesicle, which is thus enclosed within the body of the embryo and constitutes the fore-gut; the fore-gut terminates in a blind extremity beneath the head (Figs. 720 and 759). Another prominence, the rudimentary heart, appears on the ventral surface of the fore-gut. Between these two prominences, caused by the projection of the fore-brain and the heart, an involution of the epiblast takes place, gradually deepening until it comes in contact with the blind end of the fore-gut. This is the *oral pit* or *stomodæum*, already referred to; it presents the form of a pentangular opening, bounded in front by the fronto-nasal process, behind by the mandibular arch, and laterally by the maxillary processes. From the beginning the mesoblast is absent in the region of the oral pit, and hence its epiblastic lining meets the hypoblastic covering of the blind anterior end of the fore-gut and forms a thin septum, the *pharyngeal septum* (Fig. 759); this soon breaks down, and a communication is established between the mouth and the future pharynx. The oral pit or stomodæum is not equivalent in extent to the adult mouth, since the latter includes the tongue, which is developed from the floor of the pharynx; in fact, as His has pointed out, the anterior pillars of the fauces are developed from the second branchial or hyoid arch.



FIG. 718.—Head of a human embryo of about eight weeks, in which the nose and mouth are formed. (His.)

From the upper part of the stomodæum a pocket-like involution of the epiblast, the *pouch of Rathke*, extends upward between the trabeculæ cranii toward the thalamencephalon. This involution ultimately loses its connection with the stomodæum, and, becoming applied to the infundibulum, forms the anterior lobe of the pituitary body (Fig. 720).

The anterior visceral arches grow more rapidly than the posterior, with the result that the latter become telescoped within the former, and a deep depression, the *sinus præcervicalis*, is produced. This sinus is bounded in front by the hyoid arch, and ultimately becomes obliterated by the fusion of its anterior and posterior walls.

Before leaving the subject of the visceral arches and clefts it is necessary to mention that the clefts disappear early in embryonic life, with the exception of portions of the first, which remain permanent—the inner portion, or the Eustachian tube and tympanum; the outer, as the external auditory meatus, while the septum

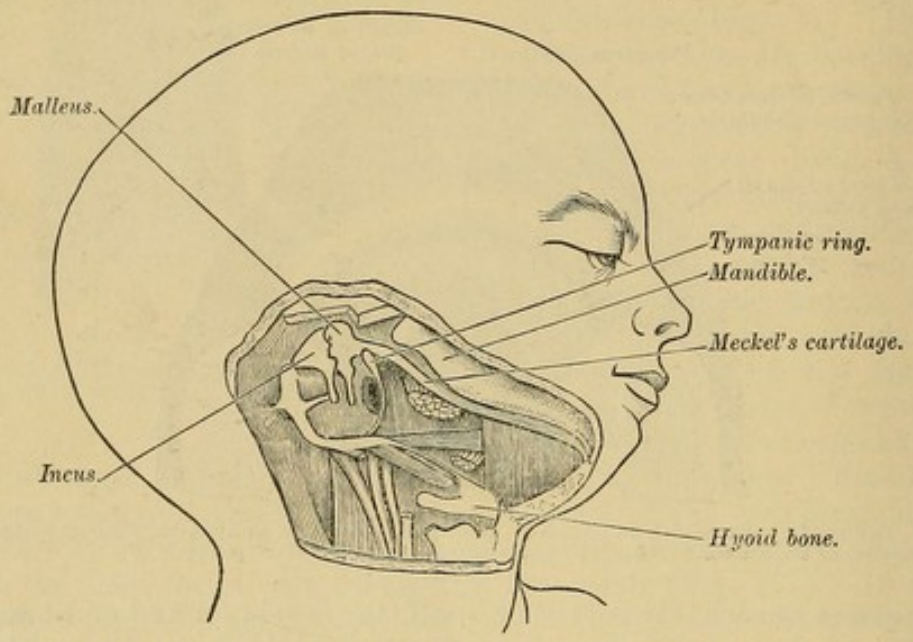

FIG. 719.—Head and neck of a human embryo eighteen weeks old, with Meckel's cartilage and hyoid bar exposed. (After Kölliker.)

between the two portions becomes invaded by mesoblast and forms the membrana tympani.

Development of the Nervous Centres and the Nerves.—The medullary or neural groove already described (page 1155) is the rudiment of the cerebro-spinal axis. As has been seen, this groove is converted into a canal (the neural canal): its cephalic end becomes dilated into a sac, from which the brain is developed; the remainder forms the spinal cord. The cavity of the canal becomes the central canal of the spinal cord, and that of the upper dilated portion the ventricles of the brain. The wall of the canal, formed of epiblastic cells, undergoes great changes, and from it the nervous matter and neuroglia are developed. It consists at first of a layer of columnar epithelium, covered on its exterior by a basement-membrane. The wall becomes thickened, partly by the elongation of the columnar cells and partly by the formation of new cells. The elongation of the columnar cells, now called *spongioblasts*, is followed by the breaking up of their outer ends into a reticulum, which is termed the *myelo-spongium*, and eventually forms the neuroglia. The new cells which are formed appear between the inner ends of the columnar cells as rounded masses, which speedily divide, and are termed *neuroblasts;* they become pear-shaped, and projecting from each of them is a tapering process which perforates the basement-membrane. These neuroblasts are the primitive nerve-cells, and their tapering processes the rudimentary axis-cylinders of the cells (Figs. 721 and 722).

It will be convenient, in the first place, to trace the changes which take place in the cavity of the cerebro-spinal axis, ignoring for a time those which go on in the enclosing wall. But before doing so, it is necessary to mention that, in consequence of the curve which the cephalic portion of the embryo undergoes, a marked bend forward of the canal takes place, so that the plane of the ventricles is almost at right angles with the long axis of the central canal of the cord.

The early stage thus consists of a hollow sac, which is the rudimentary brain, and a hollow canal, which is the rudimentary cord; the sac and the canal freely communicate with each other. The sac first of all becomes elongated; then two constrictions appear in it, which partially divide it into three; these are named *anterior*, *middle*, and *posterior cerebral vesicles*, or the *fore-brain*, *mid-brain*, and

hind-brain (Fig. 701). Subsequently the anterior and posterior vesicles each become constricted into two, while the middle one remains undivided. It will thus be seen that at the anterior extremity of the medullary canal there are five dilatations, separated from each other by constrictions, through which, however, they freely communicate with each other. These five vesicles are the five fundamental divisions of the adult brain, and are named from before backward: prosencephalon, thalamencephalon, mesencephalon, epencephalon, and metencephalon (Figs. 723

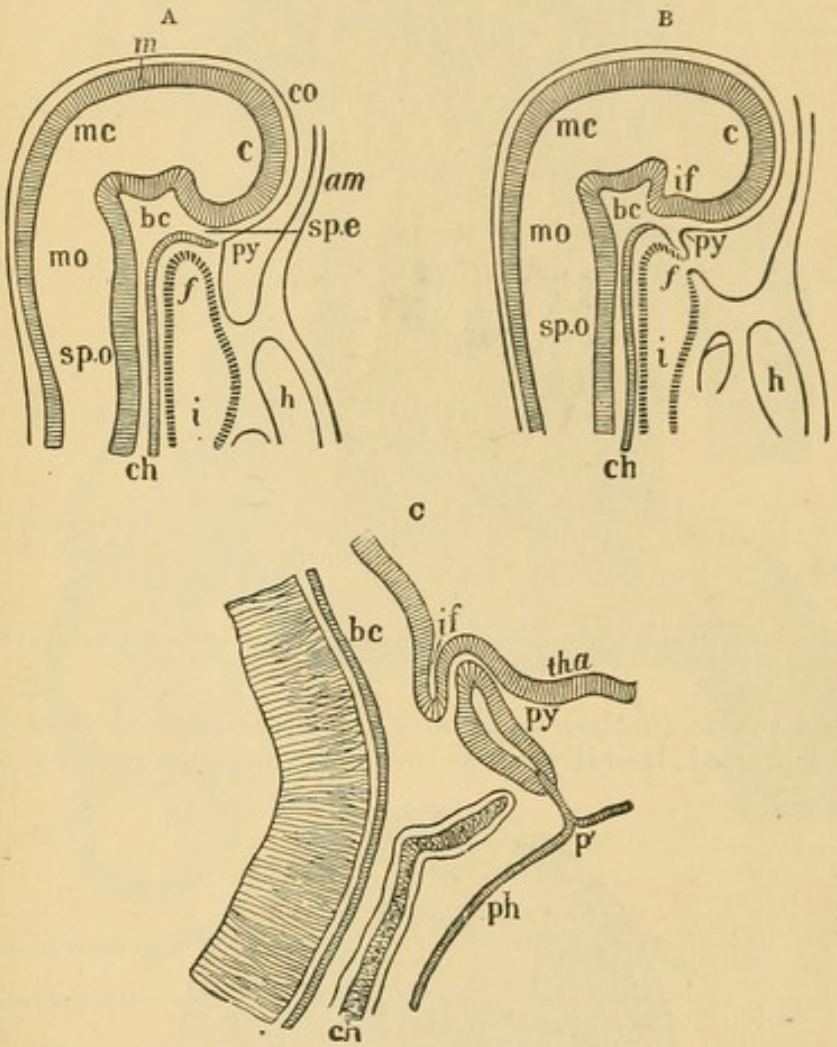

FIG. 720.—Vertical section of the head in early embryos of the rabbit. Magnified. (From Mihalkovics.) A. From an embryo five millimetres long. B. From an embryo six millimetres long. C. Vertical section of the anterior end of the notochord and pituitary body, etc., from an embryo sixteen millimetres long. In A, the faucial opening is still closed. In B, it is formed. *c.* Anterior cerebral vesicle. *mc.* Mesocerebrum. *mo.* Medulla oblongata. *co.* Corneous layer. *m.* Medullary layer. *if.* Infundibulum. *am.* Amnion. *spe.* Spheno-ethmoidal. *bc.* Central (dorsum sellæ), and *spo.* spheno-occipital parts of the basis-cranii. *h.* Heart. *f.* Anterior extremity of primitive alimentary canal and opening (later) of the fauces. *i.* Cephalic portion of primitive intestine. *tha.* Thalamus. *p'.* Closed opening or the involuted part of the pituitary body (*py*). *ch.* Notochord. *ph.* Pharynx.

and 725). They are at first fairly uniform in size and shape, but soon begin to grow at different rates and assume different forms. The changes are most marked in the first vesicle.

The first secondary vessel (*prosencephalon*) sends out two hollow protrusions, one on either side, from the forepart of its lateral surface; these grow rapidly and spread out and extend forward, laterally, and backward over the sides of the first and second vesicles, forming large cavities, which become the lateral ventricles (Fig. 725, G). From each, three prolongations take place: one, forward and outward; a second, backward and inward; and a third, at first backward, outward, and downward, and then forward and inward; these form the horns of the lateral ventricles. These prolongations far exceed in size the original vesicle from which they sprung, which does not increase to any great extent. It remains as the anterior part of the third ventricle (Fig. 725, A), and

the communication between it and the future lateral ventricle persists as the *foramen of Monro* (Fig. 725, H).

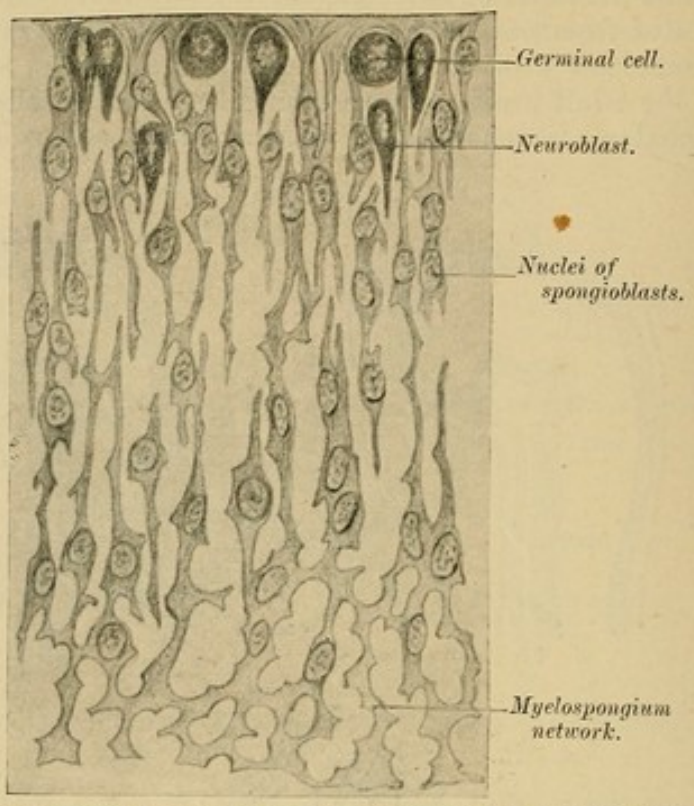

FIG. 721.—Transverse section of the spinal cord of a human embryo at the beginning of the fourth week. (After His.) The top of the figure corresponds to the lining of the central canal.

The second vesicle (*thalamencephalon*) becomes elongated from before backward and compressed laterally so as to form the greater part of the third

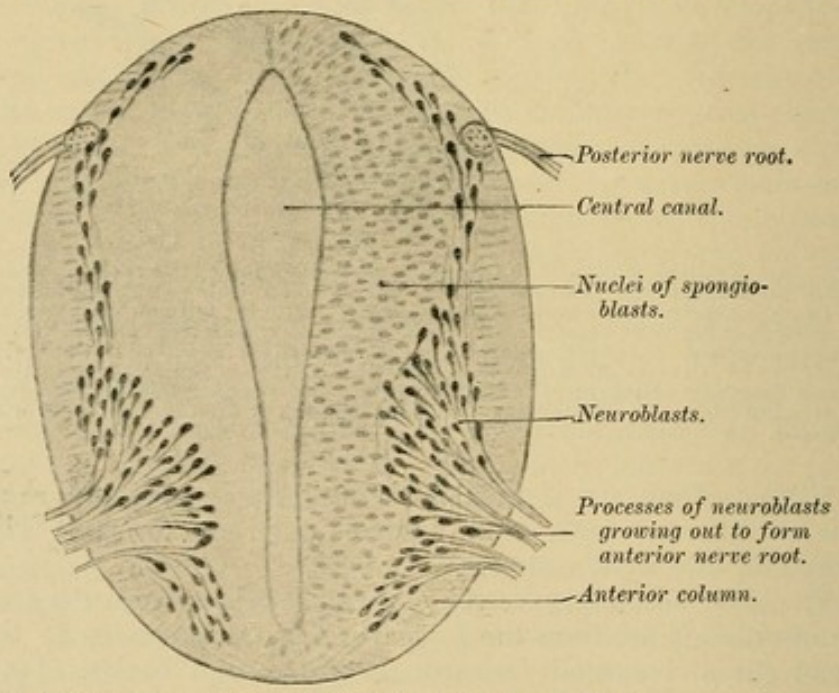

FIG. 722.—Section of spinal cord of a four weeks' embryo. (His.)

ventricle (Fig. 725, B). From each side of that part of the forebrain which ultimately becomes the second vesicle is budded off a hollow projection, the primary optic vesicle, which is developed eventually into optic nerve and retina: it will be considered later on. The constriction between the first and second vesicle disappears, so as to throw the whole of the cavity (the future third

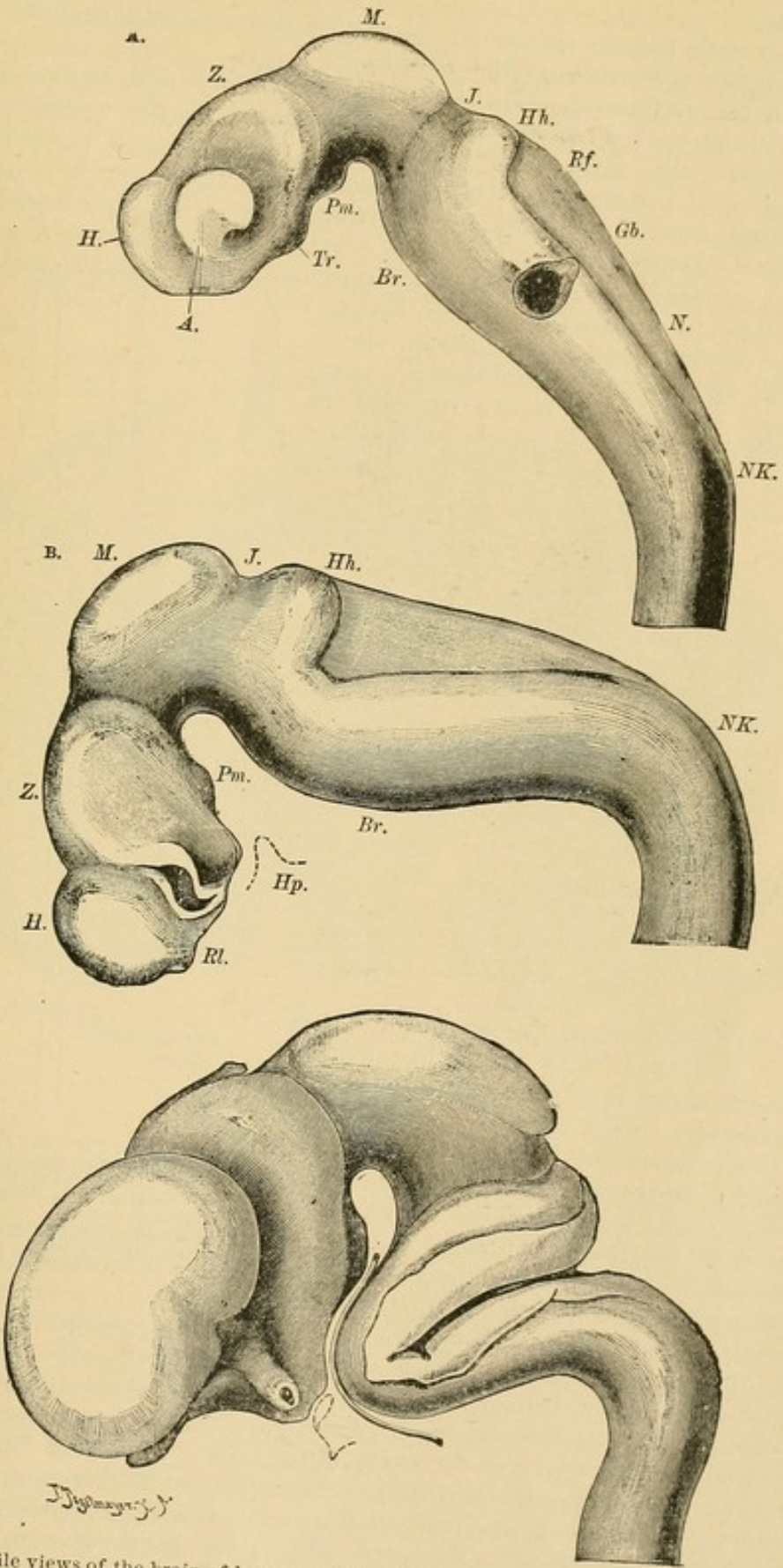

FIG. 723.—Profile views of the brain of human embryos at three several stages, reconstructed from sections. (His.) (Copied from Quain's *Anatomy*.) A. Brain of an embryo of about fifteen days, magnified 35 diameters. B. Brain of an embryo about three and a half weeks old. The optic vesicle has been cut away. C. Brain of an embryo about seven and a half weeks old. The optic stalk is cut through. *A*. Optic vesicle. *H*. Vesicle of cerebral hemisphere, first secondary vesicle. *Z*. Thalamencephalon, second secondary vesicle. *M*. Mid-brain. *J*. Isthmus between mid- and hind-brain. *Hh*. Fourth secondary vesicle. *N*. Fifth secondary vesicle. *Gb*. Otic vesicle. *Rf*. Fourth ventricle. *NK*. Neck curvature. *Br*. Pons curvature. *Pm*. Mammillary process. *Tr*. Infundibulum. *Hp*. (in B). Outline of hypophysis-fold of buccal epiblast. *Rl*. Olfactory fold. In C the basilar artery is represented along its whole course.

ventricle), formed by the remains of the first vesicle and the whole of the second vesicle, into one.

The third vesicle (*mesencephalon*) is converted into a narrow channel, the *iter a tertio ad quartum ventriculum* (Fig. 725, C).

The fourth vesicle (*epencephalon*) becomes widened out, and assumes a triangular form, with its apex directed forward, and situated at the original point of constriction where the third vesicle joins the fourth. It is at the same time flattened from above downward, and constitutes the anterior half of the fourth ventricle (Fig. 725, D).

The fifth vesicle (*metencephalon*) undergoes the same change in form as the fourth, becoming triangular in shape and flattened from above downward, but with this difference, that the apex of the triangle is directed backward, and is continuous with the portion of the medullary canal which goes to form the central canal of the spinal cord (Fig. 725, E). The base is directed forward and is continuous with the base of the triangular space formed by the fourth vesicle; the constriction between the two vesicles having disappeared, the two spaces freely communicate, and together form a rhomboidal cavity which is the fourth ventricle.

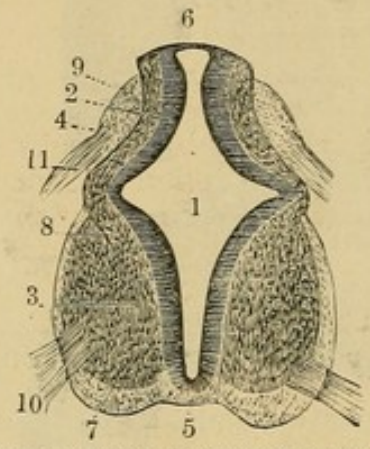

FIG. 724.—Section of the medulla in the cervical region, at six weeks. Magnified 50 diameters. 1. Central canal. 2. Its epithelium. 3. Anterior gray matter. 4. Posterior gray matter. 5. Anterior commissure. 6. Posterior portion of the canal, closed by the epithelium only. 7. Anterior column. 8. Lateral column. 9. Posterior column. 10. Anterior roots. 11. Posterior roots.

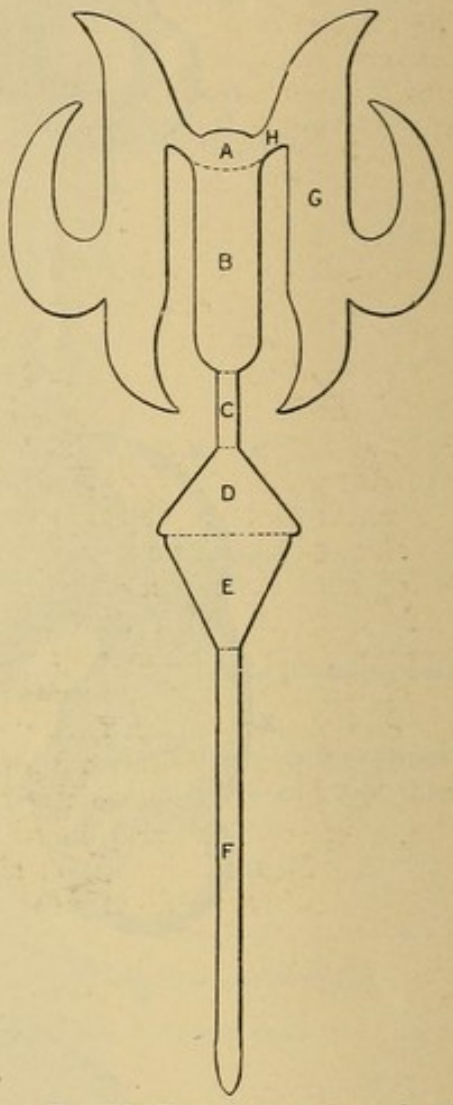

FIG. 725.—Plan showing the mode of formation of the ventricles of the brain and the central canal of the spinal cord. (After Gerrish.) A. Prosencephalon. B. Thalamencephalon. C. Mesencephalon. D. Epencephalon. E. Metencephalon. F. Central canal of cord. G. Lateral ventricle. H. Foramen of Monro.

These vesicles do not remain in the same plane, but certain definite flexures take place, which result in an alteration of the position of the vesicles to one another. The first of these flexures (*cephalic*) is opposite the base of the middle vesicle, which becomes sharply bent on itself over the end of the notochord. This has the effect of causing the mid-brain to become the most prominent part of the encephalon on the convexity of the curve (Fig. 723). A second flexure (*pontal*), with its curve in the opposite direction, takes place in the epencephalon, and is very abrupt. A third but less marked flexure (*nuchal*) takes place in the metencephalon at its junction with the cord. The first of these curves or flexures remains permanent, but the second and third almost entirely disappear in the further development of the brain.

The manner in which the different parts of the encephalon and cord are formed from the walls of this greatly altered medullary canal must now be considered, and it will be convenient first of all to study the development of the spinal cord.

The lateral walls of the medullary canal become thickened and marked off into two laminæ: a dorsal, or *alar lamina*, and a ventral, or *basal lamina*, the portion of the canal in the mid-line both on its dorsal and ventral surfaces remaining thin, and form the *roof* and *floor plates* respectively (Fig. 724). In the thickened lateral portion the neuroblasts begin to collect into groups; one especially being noticeable in the basal lamina at the situation of the future anterior horn. The processes of this group of cells pass out of the cord and form the anterior nerve-roots: outside this group of cells is the reticulated tissue of the myelospongium, which represents the white matter at this stage, and through which these processes pass obliquely before they leave the cord (Fig. 722). The anterior and posterior columns make their appearance soon after, and as the cornua

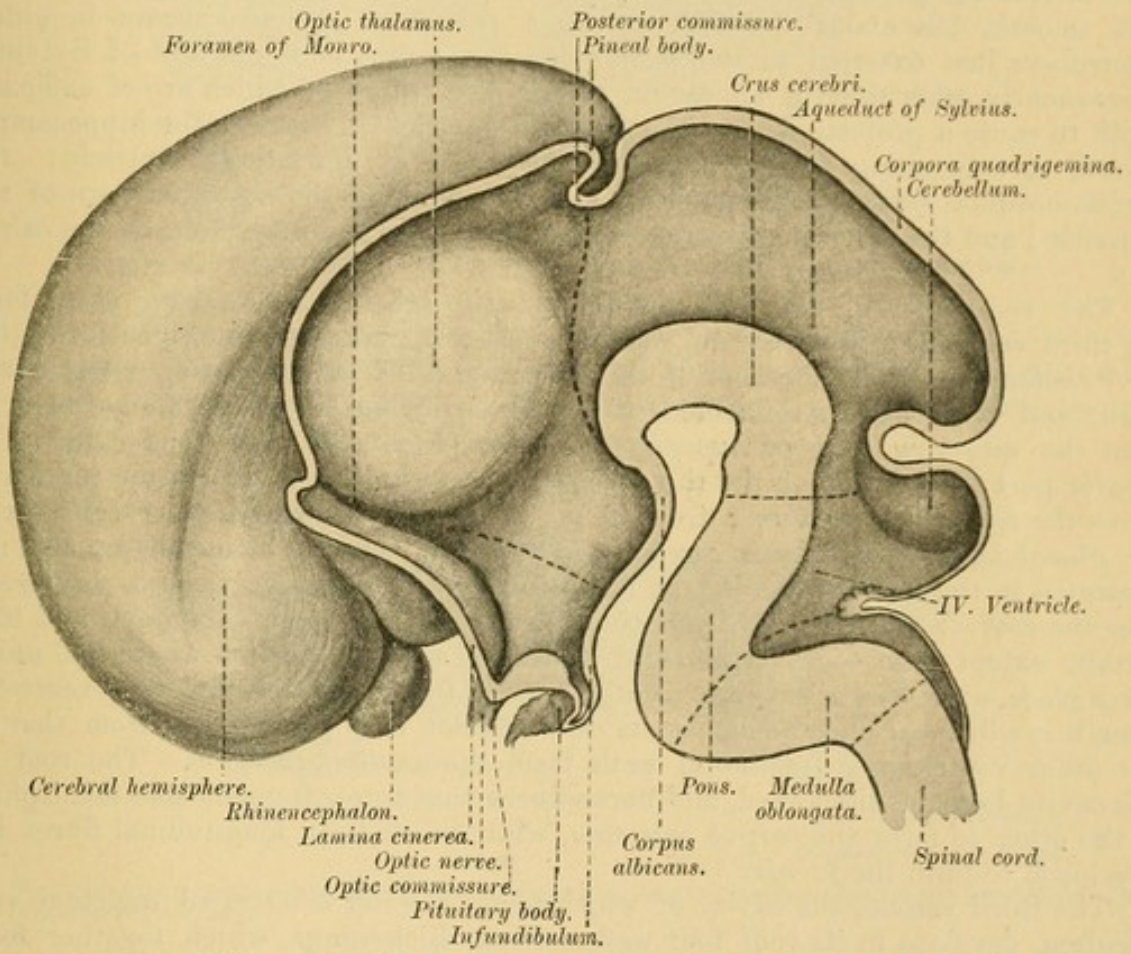

FIG. 726.—Median section of brain of human fœtus during the third month. (After His.)

of gray matter grow out from the central mass the fissures begin to appear. The anterior fissure is a cleft left between the lateral halves of the cord. The mode of formation of the posterior fissure is uncertain; many believe that it is a portion of the neural canal, which, dividing into two, forms an anterior part, the *permanent* canal, and a posterior portion, which becomes filled with a septum of connective tissue from the pia mater, and forms the posterior fissure of the cord. Others are of opinion that it is developed independently of the central canal, as a cleft formed by the enlargement of the lateral halves of the cord, into which an ingrowth of connective tissue from the pia mater takes place.

At first the fœtal spinal cord occupies the whole length of the spinal canal, but after the fourth month the spinal column begins to grow in length more rapidly than the cord, so that the latter no longer occupies the lower part of the canal.

The ventricles of the encephalon are developed in the manner above described from the five secondary vesicles into which the primary expansion of the anterior extremity of the medullary tube is differentiated.

The first vesicle or prosencephalon sends out two hollow protrusions, which spread rapidly, and in the walls of these nervous matter is developed, which constitutes the cerebral hemispheres (Fig. 723, H), the cavities remaining as the lateral ventricles. As these hemispheres extend they grow forward in front of the anterior extremity of the primitive brain, and lie side by side, separated by the longitudinal fissure; they also grow upward, and again lying side by side are separated by another portion of the same fissure, containing a thin layer of mesoblast, which forms the falx cerebri; behind and laterally they overlap the roof and sides of the other cerebral vesicles, so that by the seventh month they project behind them. In the floor of each of these hemispheres there occurs a local thickening, which forms the *corpus striatum*, which is continuous behind with the optic thalamus, presently to be described. The surface of the hemisphere is at first smooth, but about the fifth month a sulcus or groove appears in either hemisphere just external to the corpus striatum; this is the fissure of Sylvius: subsequently other fissures appear on the surface, three of which are of sufficient depth to cause a projection into the lateral ventricle. These are the hippocampal fissure, corresponding to the hippocampus major of the lateral ventricle; the parieto-occipital fissure, corresponding with the bend of the posterior horn of the ventricle; and the calcarine fissure, corresponding with the projection of the calcar avis.

The remainder of the first vesicle and the second, as we have seen, form the third ventricle; in its normal walls a thickening takes place, which forms the *optic thalamus*. From the floor of this ventricle a hollow protrusion passes downward, and is intimately connected with a diverticulum from the stomodæum, to form the *pituitary body* or *hypophysis cerebri* (Figs. 720, 723, and 726). The greater part of the roof of the third ventricle is very thin, and with the pia mater forms the *velum interpositum;* from its posterior part an outgrowth of cells forms the *pineal body* or *epiphysis cerebri*. Where the cerebral hemispheres are not separated in the middle line by the falx, in front and for some distance backward over the roof of the third ventricle their mesial surfaces come in contact, and to a certain extent fuse together, leaving however a small portion where no union takes place, and thus a slit-like cavity is left; this is termed the *fifth ventricle*, though it will be at once seen that its development is quite different from that of the other ventricles. Its lateral walls form the *septum lucidum*. The roof of this cavity becomes thickened, and nerve-fibres pass across from the one hemisphere to the other to form the *corpus callosum*, while in its floor longitudinal fibres are developed to form the *fornix*.

The third vesicle, the cavity of which forms the iter a tertio ad quartum ventriculum, develops in its roof four well-marked thickenings, which together form the *corpora quadrigemina*, while its lateral regions become thickened to form the *crura cerebri* (Fig. 726).

The dorsal surface of the fourth vesicle, or epencephalon, forms the covering of the fourth ventricle, and in it a thickening occurs, which is developed into the *cerebellum;* its ventral and lateral regions form the *pons* (Fig. 726).

In the fifth vesicle or metencephalon the lateral parts increase and grow downward on each side toward the middle line, forming the *medulla*, while the dorsal surface assists in forming the roof of the fourth ventricle.

On making a transverse section of the lower part of the fourth ventricle, the alar and basal laminæ, already referred to as being present in the cord, are readily recognized, while the thin roof-plate is seen to be greatly expanded laterally. The dorsal part of the alar lamina becomes folded outward and downward, forming what is termed the *rhomboid lip* (Fig. 727). This is at first separated by a groove from the lateral aspect of the alar lamina, but ultimately fuses with it. As the central canal of the cord opens out to form the fourth ventricle, the alar and basal laminæ come to occupy the floor of the ventricle—the basal lamina lying nearest the mesial plane.

The Nerves.—The nerves are developed, like the rest of the nervous system,

from epiblast. The spinal nerves are developed as follows: close to the point of involution of the epiblast in the median line, that is to say, in the angle of junction of the neural and general epiblast, a cellular swelling, the *neural crest*,

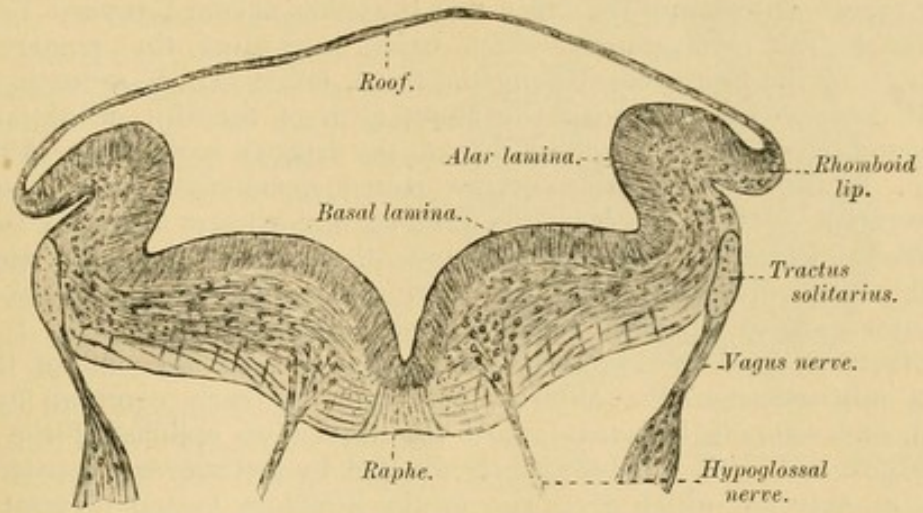

FIG. 727.—Transverse section of medulla oblongata of human embryo. (After His.)

appears and forms a continuous ridge of epiblast on the dorsal aspect of the neural canal (Fig. 728). On this crest enlargements occur corresponding with the middle of each protovertebral segment. These enlargements grow downward between

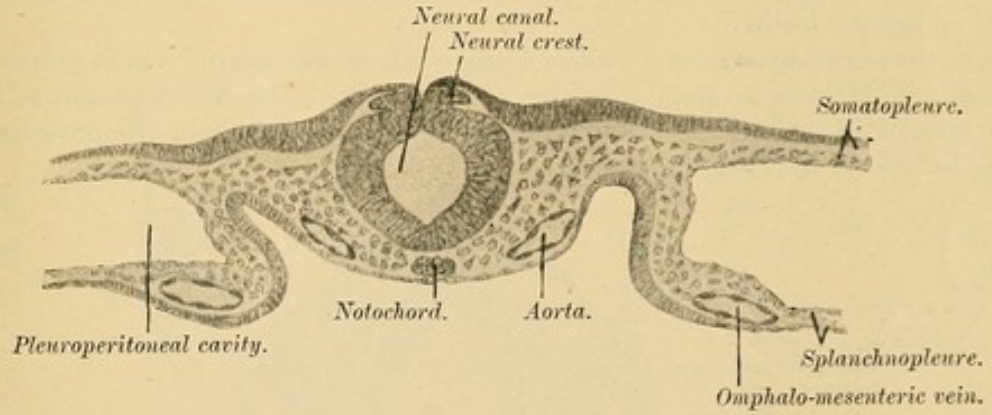

FIG. 728.—Transverse section of a portion of a chick embryo of twenty-nine hours' incubation. (From Duval's *Atlas d'Embryologie.*)

the neural canal and the protovertebræ, and occupy a position on the lateral wall of the canal. They are the rudiments of the ganglia of the posterior roots, and at first are attached to the neural crest from which they spring, but subsequently this attachment becomes lost, and they then form isolated masses on either side of the neural canal. They consist of oval cells, from either end of which a process eventually springs; one, growing centrally, passes into the embryonic cord and constitutes the posterior root of the nerve; the other, growing peripherally, joins the fibres of the anterior root to form the spinal nerve.

The anterior root is, according to the researches of His, a direct outgrowth of the neuroblasts which are found in the rudimentary cord (Fig. 722). These cells, at first rounded or oval, become pear-shaped, with their tapering prolongations directed outward toward the surface of the cord. These prolongations are the future axis-cylinders of the anterior nerve-roots; they pass out of the cord in bundles and penetrate the mesoblast to join with the fibres of the posterior root, and from the point of union the nerve grows toward its peripheral termination.

Cranial Nerves.—With the exception of the olfactory and optic nerves, which will be specially referred to, the cranial nerves may be developmentally considered

as consisting of two sets: (1) those which arise as outgrowths from neuroblasts situated in the brain, similar to the mode of origin of the anterior spinal nerve-roots; (2) those which arise from ganglionic rudiments situated outside the brain and derived from the neural crest; from the neuroblasts of these ganglionic rudiments one process grows into the brain and the other outward toward the periphery, similar to the arrangement which exists regarding the posterior spinal nerve-roots. To the first group belong the third, fourth, sixth, seventh, eleventh, and twelfth nerves, together with the motor roots of the fifth, ninth, and tenth. To the second group belong the eighth and the sensory roots of the fifth, ninth, and tenth. While, however, the anterior spinal nerve-roots arise in one series from the ventral part of the cord, the cranial motor fibres arise by two sets of roots, *ventral* and *lateral;* the former include the roots of the sixth and twelfth and probably those of the third and fourth, the latter embrace the spinal accessory and the motor roots of the fifth, seventh, ninth, and tenth.

The olfactory lobe, or rhinencephalon, arises toward the end of the fourth week as a protrusion of the antero-ventral part of each cerebral hemisphere (Fig. 726), and extends forward toward the thickened epiblast of the olfactory area (see page 1169). It is subsequently divided by a transverse constriction into two parts: an anterior, which gives rise to the olfactory bulb and tract together with the trigonum olfactorium, and a posterior, which becomes the peduncle of the corpus callosum and the greater part of the anterior perforated space. Neuroblastic cells, formed within the olfactory area, pass out and form a ganglion between the area and the olfactory bulb. From this ganglion cell-processes grow centripetally to form the nerve-roots, and centrifugally to form the olfactory nerves which ramify in the olfactory mucous membrane, while the ganglion itself fuses with the olfactory bulb.

The optic nerve arises as a hollow outgrowth of the brain, which subsequently becomes solid. It will be considered in connection with the development of the eye.

The sympathetic nerves are developed as outgrowths from the ganglia on the roots of the spinal and cranial nerves.

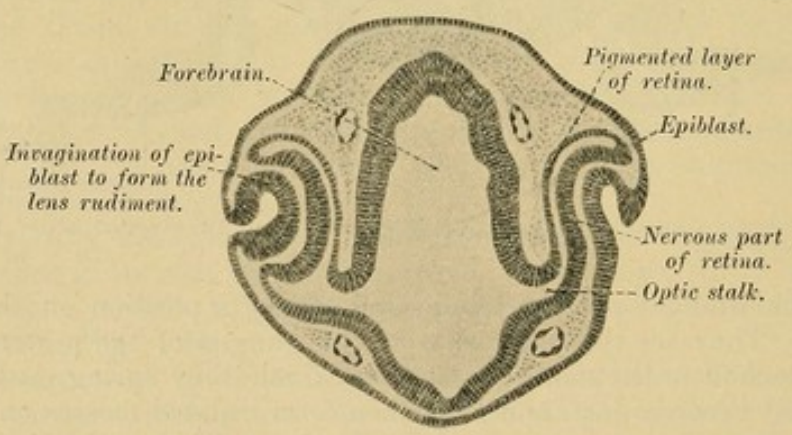

FIG. 729.—Transverse section of head of chick embryo of forty-eight hours' incubation; ×55. (From Duval's *Atlas d'Embryologie.*)

Development of the Eye.—The optic nerve and retina are developed as an outgrowth from the rudimentary brain, which extends toward the side of the head, and is there met by an ingrowth from the epiblast, out of which the lens and the epithelium of the conjunctiva and cornea are developed.

The first appearance of the eye consists in a hollow protrusion of the forebrain; this is called the *primitive optic vesicle.* It is at first an open cavity communicating by a hollow stalk with that of the cerebral vesicle. As it is prolonged forward, the epiblast lying immediately over it becomes thickened, and then forms a depression which gradually encroaches on the most prominent part of the primitive ocular vesicle; this in its turn appears to recede before it, so as to become at first depressed and then inverted in the manner indicated

in Figs. 729 and 730, so that the cavity of the vesicle is almost obliterated by the folding back of its anterior half, and the original vesicle converted into a cup, the *optic cup*, in which the involuted epiblastic layer, the rudiment of the lens, is received (Fig. 730); at the same time the proximal part of the vesicle becomes elongated and narrowed into a hollow stalk, the *optic stalk*. This cup-shaped cavity consists therefore of two layers: one, the outer, originally the posterior half of the primitive ocular vesicle, is thin, and eventually forms the pigmented layer of the retina;[1] the other layer, the inner, originally the anterior or more prominent half, which has become folded back, is much thicker, and is converted into the nervous layers of the retina (Figs. 730 and 732). Between the two is the remnant of the cavity of the original primary optic vesicle, which finally becomes obliterated by the union of its two layers. When the retina is established, the optic nerve-fibres originate from its cells and grow backward toward the brain, along the optic stalk, and thus convert it into a solid optic nerve. The nerve-fibres become ultimately connected with the mesencephalon, a relationship

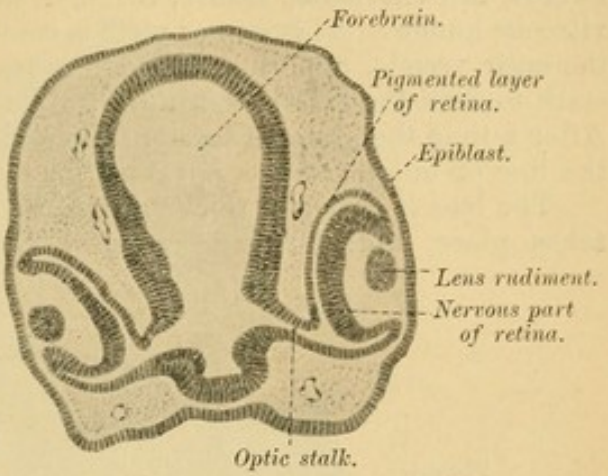

FIG. 730.—Transverse section of head of chick embryo of fifty-two hours' incubation. (From Duval's *Atlas d'Embryologie.*)

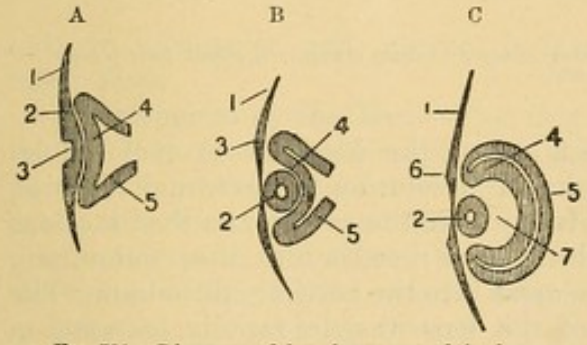

FIG. 731.—Diagram of development of the lens. A, B, C. Different stages of development. 1. Epidermic layer. 2. Thickening of this layer. 3. Crystalline depression. 4. Primitive ocular vesicle, its anterior part pushed back by the crystalline depression. 5. Posterior part of the primitive ocular vesicle, forming the external layer of the secondary ocular vesicle. 6. Point of separation between the lens and the epidermic layer. 7. Cavity of the secondary ocular vesicle, occupied by the vitreous.

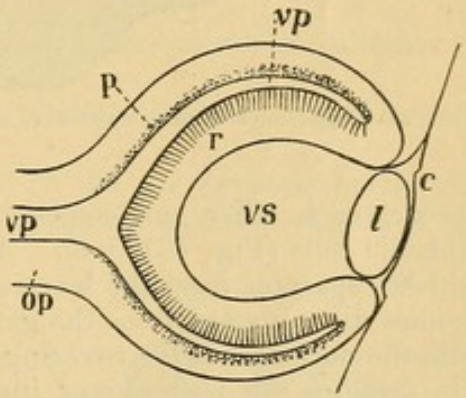

FIG. 732.—Diagrammatic sketch of a vertical longitudinal section through the eyeball of a human fœtus of four weeks. (After Kölliker.) Magnified 100 diameters. The section is a little to the side, so as to avoid passing through the ocular cleft. *c.* The cuticle, where it becomes later the epithelium of the cornea. *l.* The lens. *op.* Optic nerve formed by the pedicle of the primary optic vesicle. *vp.* Primary medullary cavity of the optic vesicle. *p.* The pigment layer of the retina. *r.* The inner wall forming the nervous layers of the retina. *vs.* Secondary optic vesicle containing rudiment of the vitreous humor.

which is permanently maintained. The mouth of the optic cup overlaps the equator of the lens as far as the future aperture of the pupil. In this region the inner or retinal layer of the cup does not become differentiated into nervous elements, but remains as a single layer of columnar cells, which becomes applied to the cells of the pigmented layer, and the conjoined strata form the *pars ciliaris pars iridica retinæ* of the adult (Fig. 734). As development proceeds the optic cup increases in size, and thus a space is formed between it and the rudimentary lens; this is the *secondary optic vesicle*, and in it the vitreous humor is developed (Figs, 731, c, and 732). The folding in of the primary optic vesicle to produce

[1] This layer was formerly described as belonging to the choroid, but developmentally it is seen to be a part of the retina.

the optic cup not only takes place in front, at its most prominent part, opposite the lens, but also along its postero-inferior aspect, where a cleft or fissure is formed, the *choroidal fissure*, through which the mesoblast extends to form the vitreous humor. This gap or cleft is continued for some distance into the stalk of the optic vesicle, and thus allows a process of the mesoblast to extend down the stalk to form the arteria centralis retinæ and its accompanying vein (Fig. 733). After a time the gap or fissure becomes closed, by a coalescence of its margins, but the line of union remains apparent for a considerable period.

The lens is at first a thickening of the epiblast, then a depression or involution takes place, thus forming an open follicle, the margins of which gradually

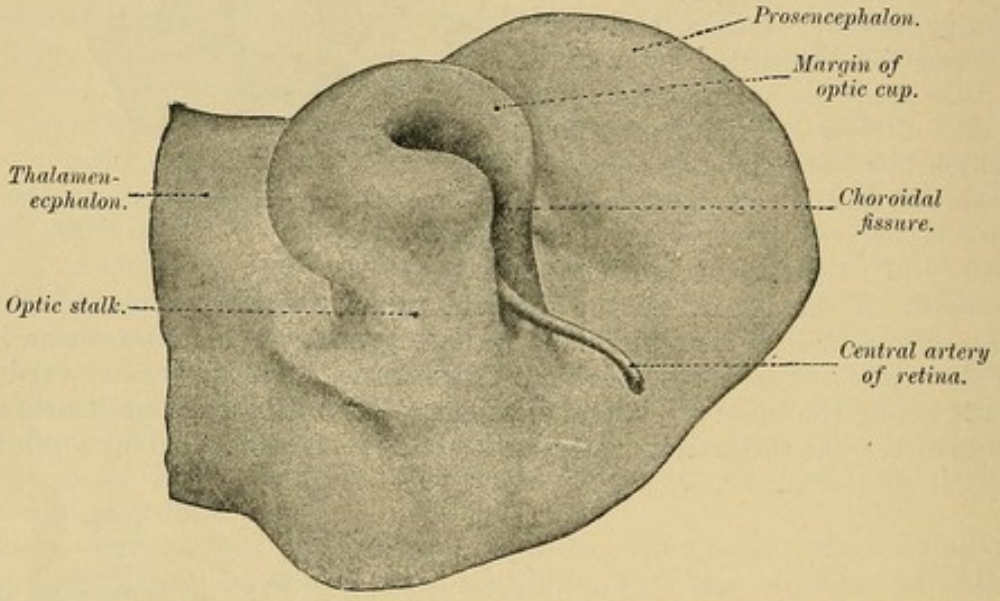

FIG. 733.—Optic cup and choroidal fissure seen from below, from a human embryo of about four weeks. (Kollmann.)

approach each other and coalesce, forming a cavity, the *lens vesicle*, enclosed by epiblastic cells (Fig. 731, B C). At the point of involution the external layer of epiblast separates from the lens and passes freely over the surface, so that the lens becomes disconnected from the general epiblast, and recedes into the ocular cup, while the cuticular layer covering it is developed into the corneal epithelium. The cells forming the posterior or inner wall of the lens vesicle rapidly increase in size, becoming elongated and developed into the lens-fibres, and, filling up the cavity, convert it into a solid body. The cells on the anterior wall retain their cellular character, and form the anterior lens epithelium of the adult. The secondary optic vesicle, or space between the lens and the hollow of the optic cup (Figs. 731, 7, and 734), contains a quantity of mesoblastic tissue continuous with the general mesoblast through the choroidal fissure. This tissue becomes converted into the vitreous humor, and surrounds the lens with a vascular membrane, the *vascular capsule of the lens*. From the central artery of the retina several branches are prolonged forward through the vitreous body to the capsule of the lens, but by the sixth month these have all undergone atrophy except one, which persists till the ninth month as the *arteria hyaloidea*. It disappears, however, before birth, and its position is indicated in the adult by the *canalis hyaloideus of Stilling*. The front part of the vascular capsule of the crystalline lens forms the *membrana pupillaris*, and also attaches the iris to the capsule of the lens. It disappears about the seventh month. The sclera, cornea, and choroid are developed from the mesoblast surrounding the optic vesicle.

The eyelids are formed at the end of the third month, as small cutaneous folds (Fig. 734), which come together and unite in front of the globe and cornea. This union is broken up and the eyelids separate before the end of fœtal life.

The lachrymal sac and nasal duct appear to result from a thickening of the

epiblast in the groove between the lateral nasal and maxillary processes. This thickening becomes hollowed out into a channel, and the lips of the groove meet

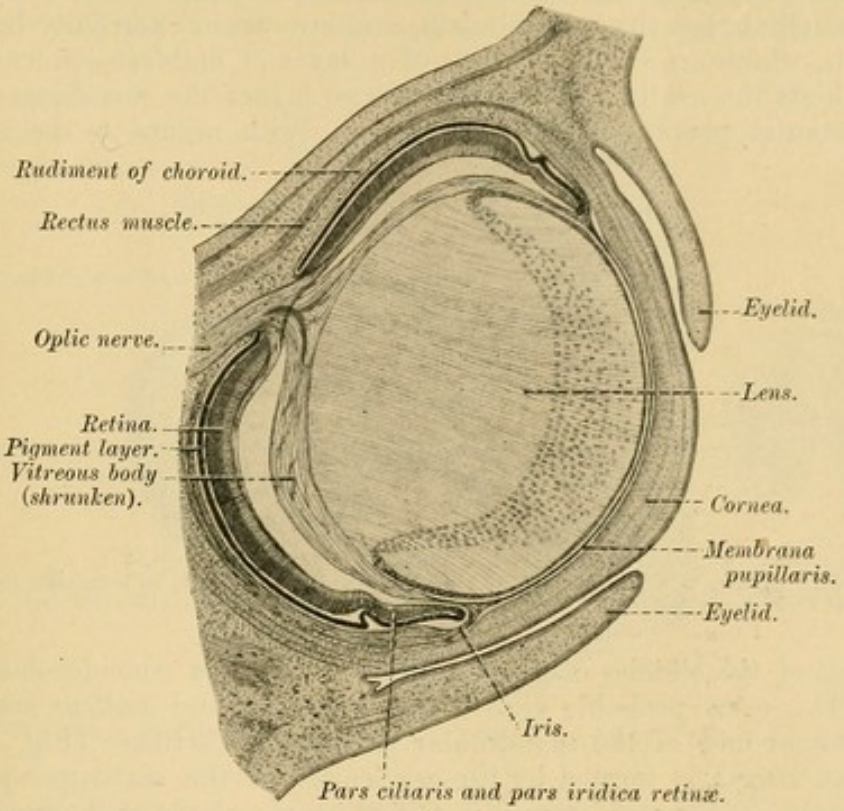

FIG. 734.—Horizontal section through the eye of an eighteen days' embryo rabbit; × 30. (Kölliker.)

over it, enclose it, and convert it into a duct, which eventually opens into the nasal fossa.

Development of the Ear.—The first rudiment of the ear appears shortly after that of the eye, in the form of a thickening of the epiblast, on the outside of that part of the third primary cerebral vesicle which eventually forms the medulla oblongata. The thickening is then followed by an involution of the epiblast (Fig. 735), which becomes deeper and deeper, and sinking toward the base of the skull, forms a flask-shaped cavity; by the narrowing of the external aperture the neck of the flask constitutes the *recessus labyrinthi*. The mouth of the flask then becomes closed, and thus a shut sac is formed, the *primitive auditory* or *otic vesicle* (Fig. 736), which by its sinking inward comes to be placed between the ali-sphenoid and basi-occipital matrices. From it the epithelial lining of the labyrinth is formed.

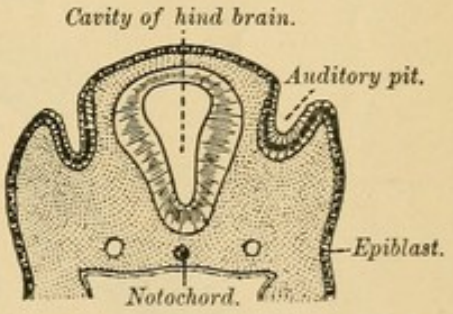

FIG. 735.—Section through the head of a human embryo, about twelve days old, in the region of the hind-brain. (Kollmann.)

The primary otic vesicle becomes imbedded in a mass of mesoblastic tissue, which rapidly undergoes chondrification and ossification. The vesicle is at first flask- or pear-shaped; the neck of the flask, or *recessus labyrinthi*, prolonged backward, forms the aquæductus vestibuli. From it are given off certain prolongations or diverticula, from which the various parts of the labyrinth are formed. One from the anterior end gradually elongates, and, forming a tube, bends on itself and becomes the cochlea. Three others, which appear on the surface of the vesicle, form the semicircular canals, of which the external canal is the last to be developed (Figs. 738 and 739). Subsequently a constriction takes place in the original vesicle, which nearly divides it into two, and from these are formed the utricle and saccule (Fig. 739). Finally, the auditory nerve, which has been devel-

oped from the "neural crest" in the manner above described (page 1180), pierces the auditory capsule in two main divisions—one for the vestibule, the other for the cochlea. The middle ear and Eustachian tube are the remains of the inner part of the first branchial cleft (hyomandibular), and are closed externally by the membrana tympani, which originally consists of a layer of epiblast externally, and a layer of hypoblast internally; between these two layers the mesoblast extends to form the substantia propria of the membrane. With regard to the exact mode

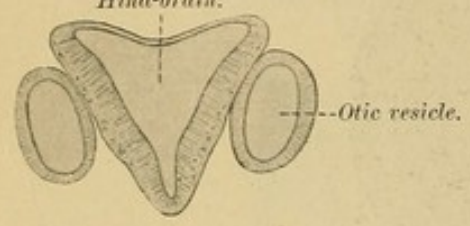

FIG. 736.—Section through hind-brain and otic vesicle of an embryo more advanced than that of Fig. 735. (After His.)

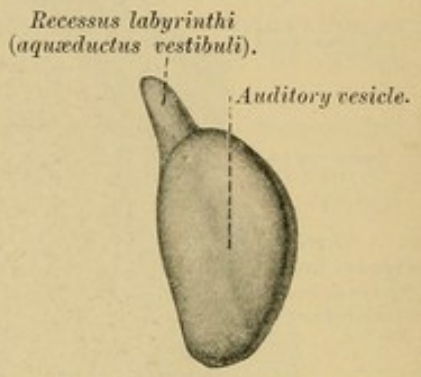

FIG. 737.—Left auditory vesicle of a human embryo of four weeks, seen from the outer surface. (W. His, Jr.)

of development of the ossicles of the middle ear there is considerable difference of opinion. The most probable view is that the *incus* and *malleus* are developed from the proximal end of the mandibular (Meckel's) cartilage (Fig. 719): that the base of the *stapes* is formed by the ossification of the cartilage which fills in the foramen ovale and its arch from the ossified proximal end of the hyoidean arch.

The external auditory meatus is formed from the outer part of the hyo-

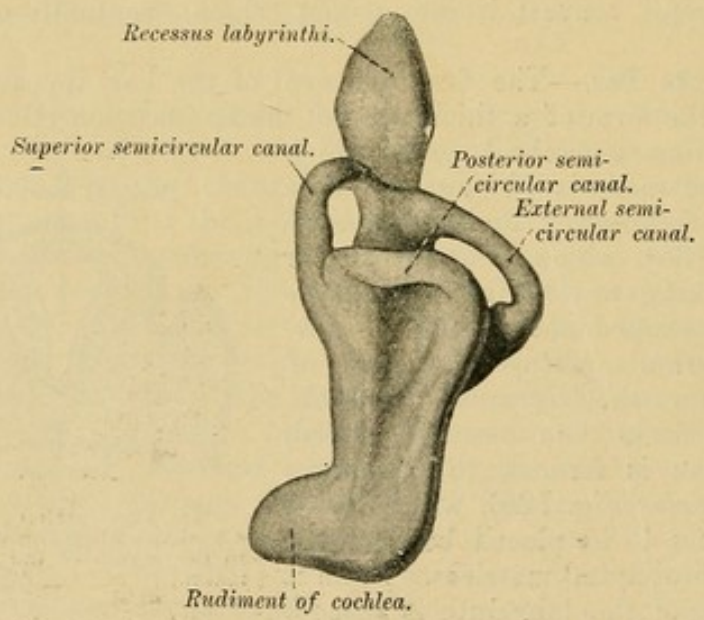

FIG. 738.—Left auditory vesicle of a human embryo of five weeks, seen from the outer surface. (W. His, Jr.)

mandibular cleft, while the pinna is developed by the gradual differentiation of a series of processes which appear around the outer margin of the cleft (Fig. 741).

Development of the Nose.—The olfactory fossæ, like the primary auditory vesicles, are formed in the first instance by a thickening and involution of the epiblast, which takes place about the fourth week, at a point below and in front of the ocular vesicle (Fig. 723). The borders of the involuted portion very soon become prominent, in consequence of the development of the mesial and lateral nasal processes already referred to (page 1169), and which are formed on either side of the rudimentary fossa (Figs. 714, 715). As these processes increase, the fossa deepens

and becomes converted into a channel, which eventually forms the olfactory region of the nose; this comprises the portion to which the olfactory nerves are distributed. At this time the nasal cavity is continuous with the buccal cavity; but as the palatal septum is formed, the buccal cavity is divided into two parts, the upper of which

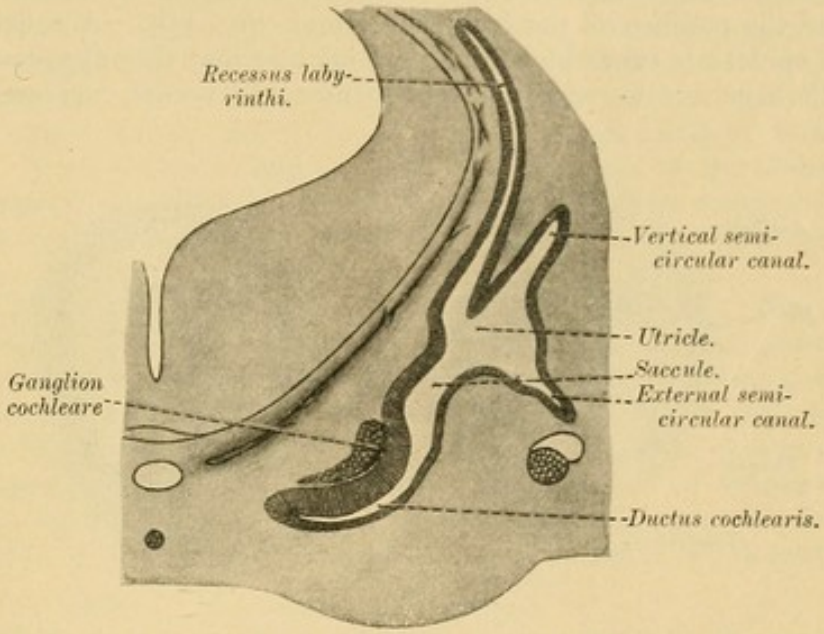

FIG. 739.—Transverse section through head of fœtal sheep, in the region of the labyrinth. × 30. (After Boettcher.)

forms the lower part of the nasal fossæ, while the remainder forms the permanent mouth. On the mesial wall of the nasal fossa a small blind pit of epiblast becomes invaginated and extends backward into the nasal septum. This forms the rudiment of *Jacobson's organ*, which ultimately becomes partly enclosed in a curved cartilaginous plate derived from a cartilage of the nasal septum.

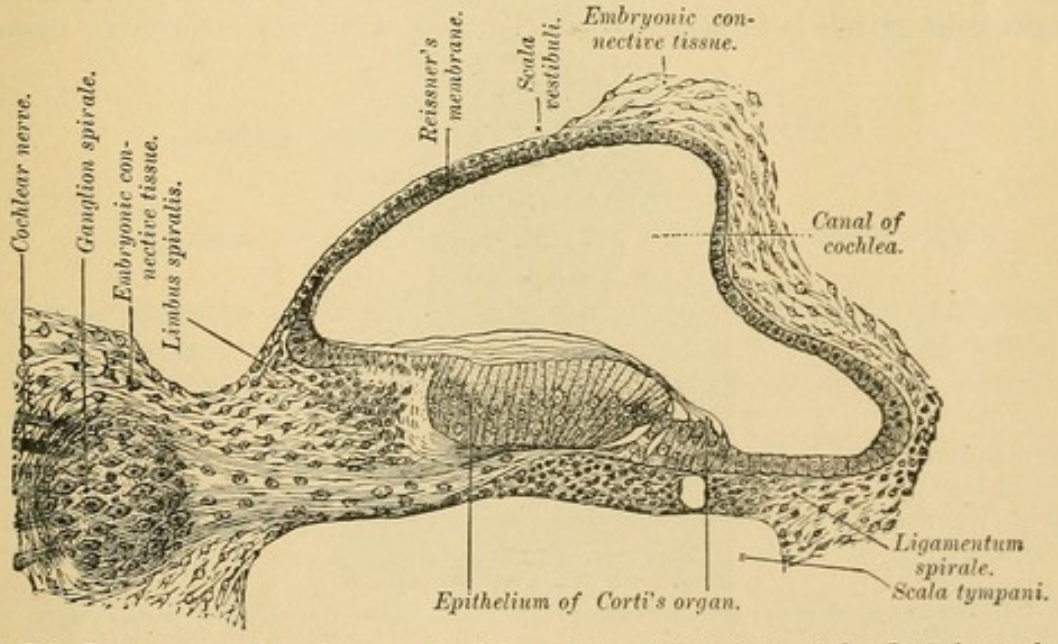

FIG. 740.—Transverse section of the canal of the cochlea of a fœtal cat. (After Boettcher and Ayres.) (From Kollmann's *Entwickelungsgeschichte*.)

The development of the external nose has already been described. It is perceptible about the end of the second month. The nostrils are at first closed by epithelium, but this disappears about the fifth month.

The olfactory lobe (rhinencephalon) is formed, as already explained, by an evagination of the anterior cerebral vesicle.

Development of the Skin, Glands, and Soft Parts.—The epidermis and its appendages, consisting of the hairs, nails, sebaceous and sweat glands, are developed from the epiblast, while the corium or true skin is of mesoblastic origin. About the fifth week the epidermis consists of two layers of cells, the deeper one corresponding to the rete mucosum. The subcutaneous fat forms about the fourth month, and the papillæ of the true skin about the sixth. A considerable desquamation of epidermis takes place during fetal life, and this desquamated epidermis, mixed with a sebaceous secretion, constitutes the *vernix caseosa*, with which the

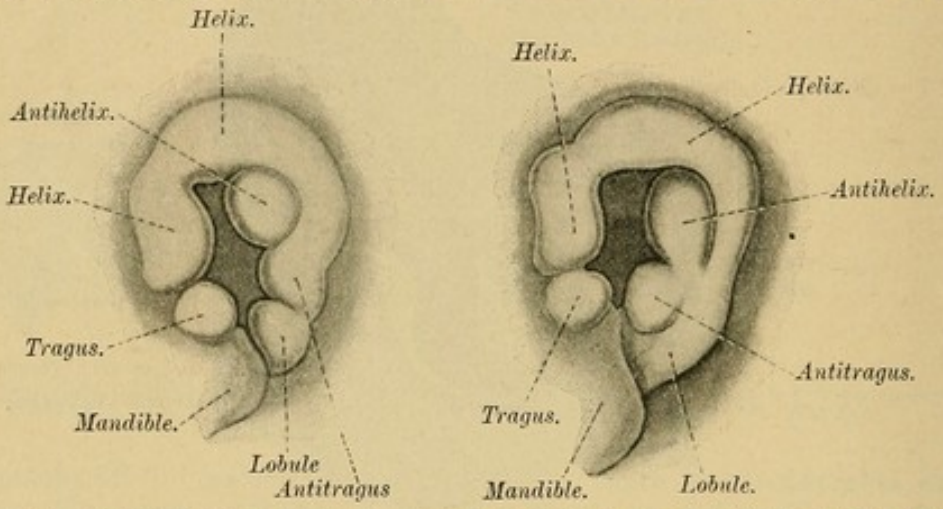

FIG. 741.—Left ears of human embryos, estimated at thirty-five and thirty-eight days respectively. (After His.)

skin is smeared during the last three months of fetal life. The nails are formed at the third month, and begin to project from the epidermis about the sixth. The hairs appear between the third and fourth months in the form of solid downgrowths of the deeper layer of the epidermis, which then become inverted by papillary projections from the corium. About the fifth month, the fetal hairs (*lanugo*) appear, first on the head and then on the other parts; they drop off after birth, and give place to the permanent hairs. The cellular structure of the sudoriferous and sebaceous glands is formed from the epiblast, while the connective tissue and

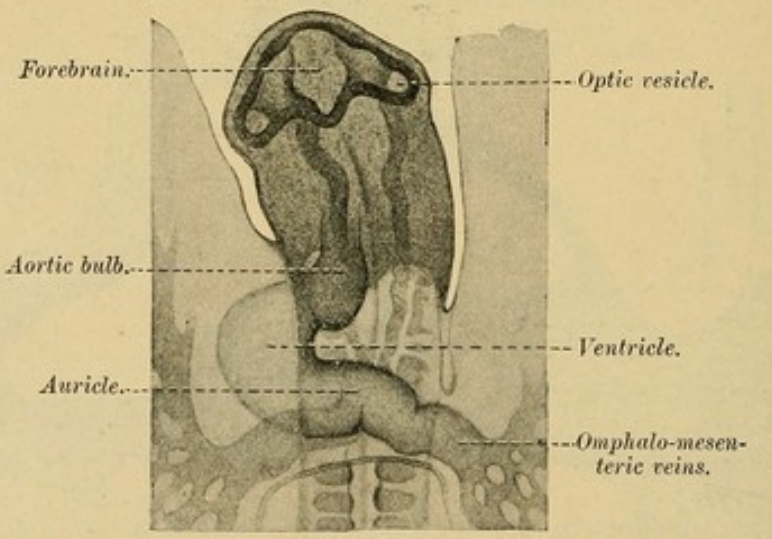

FIG. 742.—Head of chick embryo of about thirty-eight hours' incubation, viewed from the ventral surface. (From Duval's *Atlas d'Embryologie.*)

blood-vessels are derived from the mesoblast. The mammary gland is also formed partly from mesoblast and partly from epiblast—its blood-vessels and connective tissue being derived from the former, its cellular elements from the latter. Its first rudiment is seen about the third month, in the form of a small projection inward of epithelial elements, which invade the mesoblast; from this, similar tracts of cellular elements radiate; these subsequently give rise to the glandular

follicles and ducts. The development of the former, however, remains imperfect, except in the adult female.

Development of the Limbs.—The upper and lower limbs begin to project, as buds, from the anterior and posterior part of the embryo about the fourth week. These buds are formed by a projection of the somatopleure from the point where the mesoblast splits into its parietal and visceral layers, just external to the vertebral somites, of which they may be regarded as lateral extensions. The division of the terminal portion of the bud into fingers and toes is early indicated, and soon a notch or constriction marks the future separation of the hand or foot from the forearm or leg. Next, a similar groove appears at the site of the elbow or knee. The indifferent tissue, of which the whole projection is at first composed, is differentiated into muscle and cartilage, before the appearance of any internal clefts for the joints between the chief bones.

The **muscles** become visible about the seventh or eighth week. The voluntary muscles are developed from the muscle-plates of the protovertebral somites, which are at first segmentally arranged on either side of the rudimentary spine. Each muscle-plate becomes differentiated into two parts, superficial and deep. The former is termed the *cutis plate*, and from it the corium or true skin is developed, while the latter becomes developed into longitudinal groups of muscle-fibres, extending forward into the neck and head region of the embryo and laterally to enclose the cavities of the thorax and abdomen. The muscles of the limbs are also

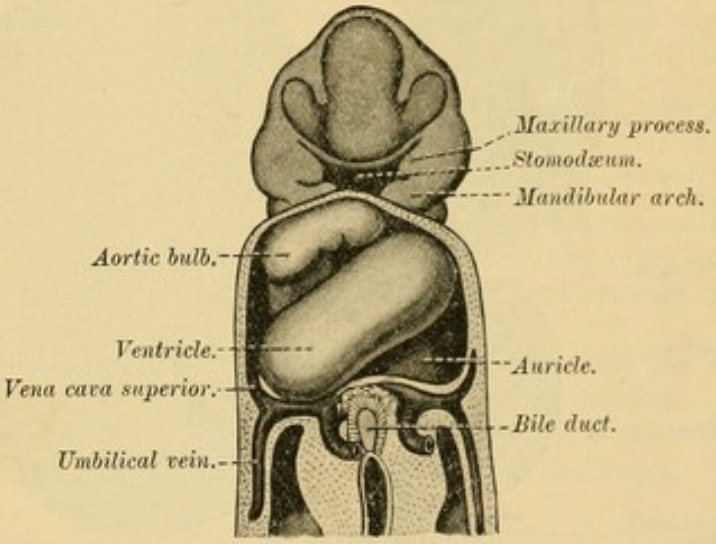

FIG. 743.—Heart of human embryo of about fifteen days. (Reconstruction by His.)

formed from the same source, being produced by outgrowths from the protovertebral somites in those situations where the limb buds appear. The involuntary muscles are derived from the splanchnopleure mesoblast, and are therefore not connected in any way with the protovertebral somites.

Development of the Blood-vascular System.—There are three distinct stages in the development of the circulatory system, each in accordance with the manner in which nourishment is provided for at different periods of the existence of the individual. In the first stage there is the *vitelline circulation*, during which nutriment is extracted from the *vitellus* or contents of the yolk-sac. In the second stage there is the *placental circulation*, during which nutrition is obtained by means of the placenta from the blood of the mother. In the third stage there is the *complete circulation of the adult*, commencing at birth, during which nutrition is provided for by the organs of the individual itself.

1. The **vitelline circulation** is carried on partly within the body of the embryo, and partly external to it in the vascular area of the yolk-sac. It consists of a median tubular heart, from which two vessels (arteries) project anteriorly. These carry the blood to a plexus of capillaries spread over the vascular area, from which

the blood is returned by two vessels (veins) which enter the heart posteriorly, and thus a complete circulation is formed (Fig. 744).

In these vessels and the heart a fluid (*blood*) is contained, in which rudimentary corpuscles are found. The mode of formation of these elementary parts must first be considered.

In mammalia the heart is formed by a longitudinal fold of the splanchnopleure with its underlying hypoblast on either side of the median line in front of the anterior extremity of the rudimentary pharynx, at about the level of the posterior primary cerebral vesicle. The folds become tubes, their walls thicken and present two distinct strata of cells: the inner and thinner layer, derived from the hypoblast, forms the endocardium; the outer and thicker, derived from the visceral mesoblast, forms the muscular wall of the heart. In its primitive condition, the heart consists therefore of a pair of tubes, one on either side of the body. These, however, soon coalesce in the median line, and, fusing together, form a single central tube.[1] Each of the two primary tubes receives posteriorly a large vein (the omphalo-mesenteric vein), and is prolonged anteriorly into an artery (the primitive aorta). So that after fusion of the heart-tubes has taken place there is, in the primitive vitelline circulation, as above mentioned, a single tubular heart,

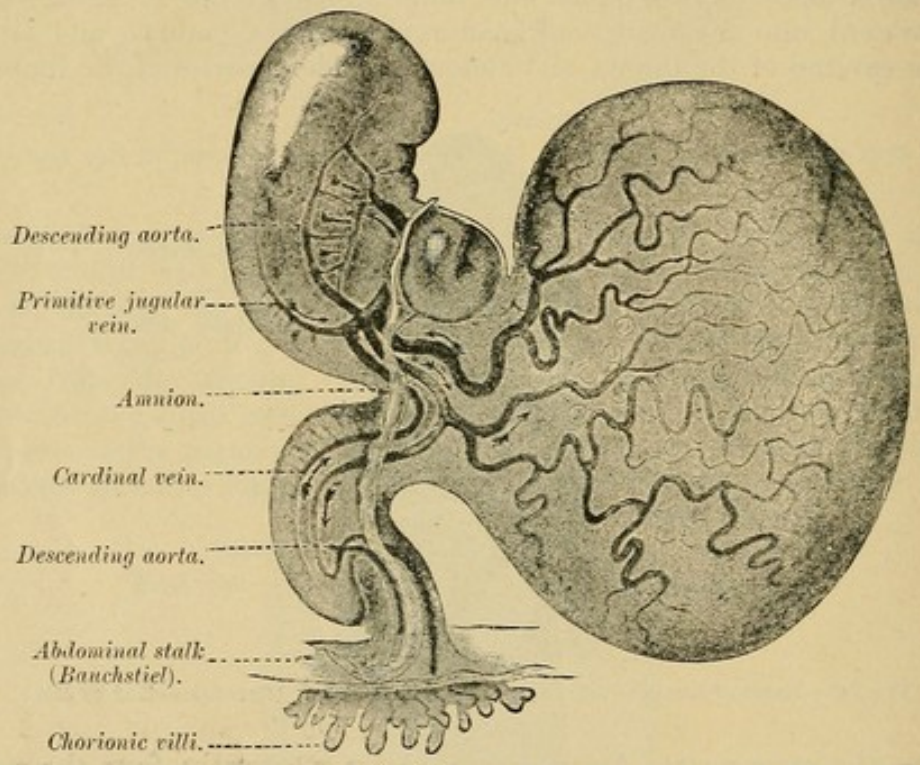

FIG. 744.—Human embryo of about fourteen days, with yolk-sac. (After His.) (From Kollmann's *Entwickelungsgeschichte.*)

with two arteries proceeding from it and two veins emptying themselves into it. The first blood-vessels are developed as follows: The nucleated embryonic cells of the mesoblast send out processes in various directions. These processes fuse together, and an irregular network is formed. The nuclei of the cells multiply, and, accumulating around themselves a small quantity of the protoplasm of the cell, they acquire a tinge of color and form the first red blood-corpuscles. The protoplasm of the cells and their branched network become hollowed out into a system of canals containing fluid, in which the newly formed corpuscles float (Fig. 745).[2]

The earliest blood-corpuscles are all nucleated, and in this and other respects—that is, in their possession of amœboid movements and in their capability of under-

[1] In most fishes and in amphibia the heart originates as a single median tube.

[2] Recent observers incline to the view that the blood-corpuscles are of hypoblastic origin, being developed from the endothelium of the vessels, the sequence of the development of the different structures being: first the heart, then the blood-vessels, and lastly the blood-corpuscles. (Consult Dr. Ernest Mehnert's *Biomeckanik*, Jena, 1898.)

going multiplication by division—resemble the white corpuscles. Soon, however, true white corpuscles make their appearance, and it seems that they are derived from the rudiments of the thymus gland.[1] The nucleated condition of the red globules ceases before birth. The vitelline circulation commences about the fifteenth day and lasts till the fifth week. When fully established, it is carried on as follows: Proceeding from the anterior end of the tubular heart are two arteries, the primitive aortæ; these run down in front of the primitive vertebræ and behind the walls of the intestinal cavity into the two *omphalo-mesenteric* arteries, which ramify in the *vascular area* of the yolk-sac. Here they terminate peripherally in a circular vessel—the *terminal sinus*, which surrounds the vascular area. The blood is collected from the capillaries of the vascular area into the two *omphalo-mesenteric* veins, which open into the posterior extremity of the heart.

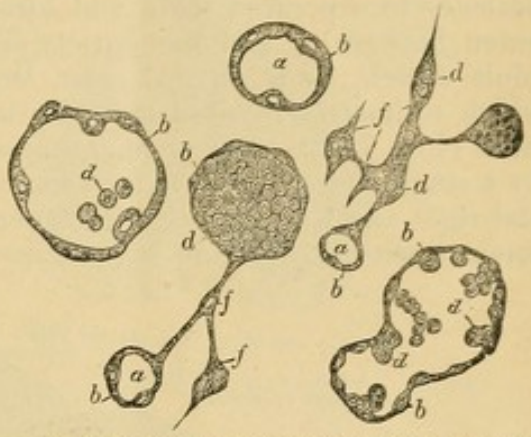

FIG. 745.—Various forms of mother-cells undergoing development into blood-vessels, from the middle layer of the chick's blastoderm. (Klein.) *a*. Large mother-cell vacuolated, forming the rudimentary vessel. *b*. The wall of this cell formed of protoplasm, with nuclei embedded, and in some cases more or less detached and projecting. *c*. Processes connected with neighboring cells, formed of the common cellular substance of the germinal area. *d*. Blood-corpuscles. *f*. Small mother-cells—vacuolation commencing. *B*. Mother-cell in which only obscure granular matter is found.

2. **The Placental Circulation.**—As the umbilical vesicle diminishes, the allantois and the placenta are developed in the manner above described (page 1162). When the umbilical vesicle atrophies the placenta becomes the only source of nutrition for the embryo. The allantois carries with it two arteries (*umbilical* or *allantoic*), derived from the primitive aortæ, and two veins; these vessels become much enlarged as the placental circulation is established, but subsequently one of the veins disappears, and in the later stages of uterine life the circulation is carried on between the fœtus and the placenta by two umbilical arteries and one umbilical vein.

During the occurrence of these changes great alterations take place in the primitive heart and blood-vessels, and now require description.

Further Development of the Heart.—The following is an outline of the changes which take place during the further development of the heart.

The simple tubular heart, already described, becomes elongated and bent on itself, so as to form an S-shaped loop, the anterior part bending to the right and the posterior part to the left. The intermediate portion arches transversely from right to left, and then turns sharply forward into the anterior part of the loop. Slight constrictions make their appearance in the tube and divide it into four parts, viz.: (1) the *sinus venosus* (*sinus reuniens* of His); (2) the common auricle; (3) the common ventricle: (4) the aortic bulb. The common auricle and ventricle communicate by a short canal, the *auricular* canal (Figs. 742, 743, and 746).

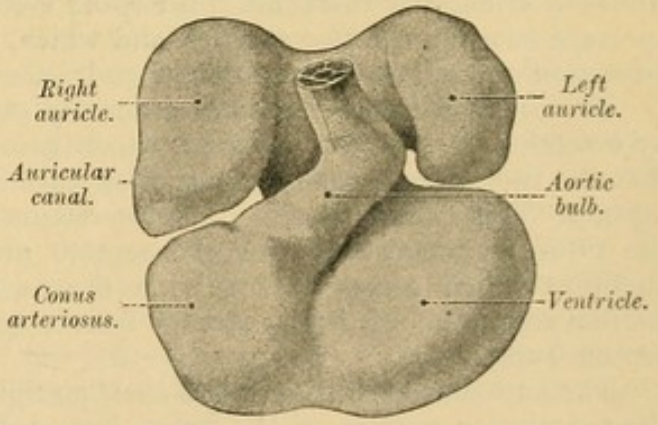

FIG. 746.—Heart of a human embryo of 5 mm. in length, seen from the front; × 30. (His.)

The sinus venosus is situated in the septum transversum (a layer of mesoblast from which the ventral part of the Diaphragm is developed) behind the common

[1] Consult an article by J. Beard, *Anatomischer Anzeiger*, December, 1900.

auricle, and is formed by the union of three pairs of veins, viz., (1) the veins or ducts of Cuvier from the body of the embryo; (2) the omphalo-mesenteric veins from the yolk-sac; (3) the umbilical veins from the placenta (Fig. 747). The sinus is at first placed transversely, and opens by a median aperture into the common auricle. Soon, however, it assumes an oblique position, and its right half or horn becomes larger than the left, while the opening into the auricle is found to be in the right portion of the auricular cavity. The right horn ultimately becomes incorporated with and forms a part of the right auricle, the line of union between it and the auricle proper being indicated in the interior of the adult auricle by a vertical crest, the *crista terminalis* of His. The left horn, which ultimately receives only the left duct of Cuvier, persists as the coronary sinus (Fig. 753). The omphalo-mesenteric and umbilical veins are soon replaced by a single vessel, the inferior vena cava, and the three veins (inferior vena cava and right and left Cuvierian ducts) open into the dorsal aspect of the auricle by a common slit-like aperture. The upper part of this aperture represents the opening

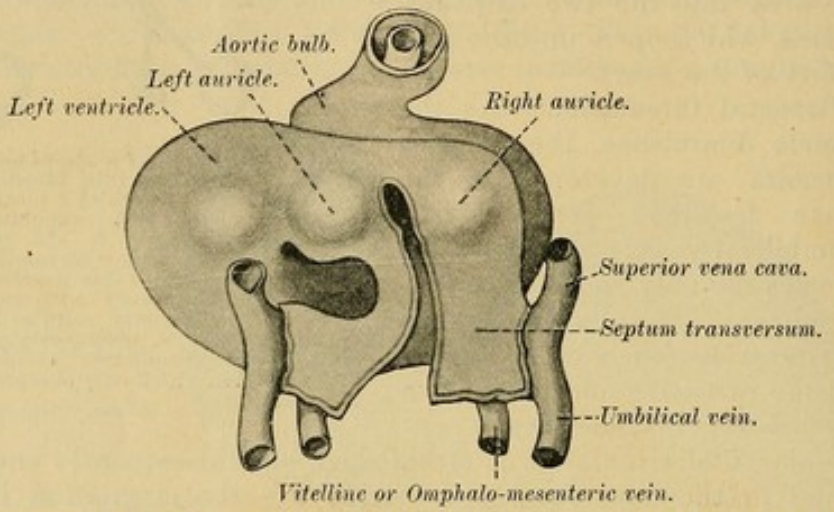

FIG. 747.—Heart of a human embryo 4.2 mm. in length, seen from behind. (His.)

of the permanent superior vena cava, the lower part that of the inferior vena cava, and the intermediate part the orifice of the coronary sinus. The slit-like aperture lies obliquely, and is bordered on its mesial and lateral aspects by a fold of endocardium. The mesial part of the fold disappears, while from the lateral part the Eustachian and Thebesian valves are developed. At the lower extremity of the slit is a triangular thickening, the *spina vestibuli* of His, which partly closes the aperture between the two auricles, and which, according to His, takes a part in the formation of both the interauricular and interventricular septum.

The common auricle becomes gradually subdivided into right and left auricles by a septum, the *septum superius*, which grows from its dorsal and upper wall so that the two auricles communicate with each other only below the margin of this septum. This communication (*ostium primum* of Born) does not, however, represent the future foramen ovale, for the septum grows downward and blends with the partition which comes to subdivide the auricular canal. The foramen ovale (*ostium secundum* of Born) results from a perforation of the upper part of the septum superius.

The auricular canal is at first a short straight tube connecting the auricular with the ventricular portion of the heart, but it becomes overlapped by the growing auricles and ventricles so that its position on the surface of the heart is indicated only by an annular constriction (Fig. 746). Its lumen is reduced to a transverse slit, and a thickening appears on its dorsal and ventral walls. These thickenings, or *endocardial cushions* as they are termed, project into the canal, and, meeting in the middle line, divide the canal into two channels, the future right and left auriculo-ventricular orifices.

The common ventricle becomes divided by a septum, the *septum inferius*, which

grows upward from the lower part of the ventricle, its position being indicated on the surface of the heart by a furrow. It extends upward almost as far as the auricular canal, but for some time an interventricular foramen exists between it and the septum of the auricular canal (Fig. 748).

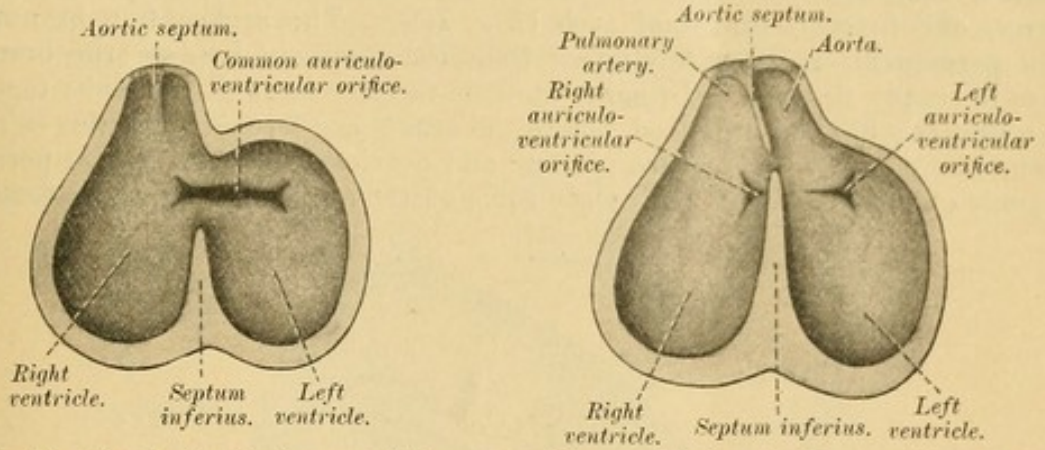

FIG. 748.—Showing the development of the septum of the aortic bulb and of the ventricles. (Born.)

The aortic bulb is divided by the *aortic septum*. This makes its appearance at the distal end of the bulb as two ridge-like thickenings of its endothelial lining; these increase in size, and, projecting into the lumen, ultimately fuse to form the septum, and thus the aortic bulb is divided into the pulmonary artery and the aorta. The aortic septum takes a spiral course toward the proximal end of the bulb, so that the two vessels lie side by side above; but near the heart the pulmonary artery is in front of the aorta (Fig. 749). The septum grows down into the ventricle as an oblique partition, which ultimately blends with the septum

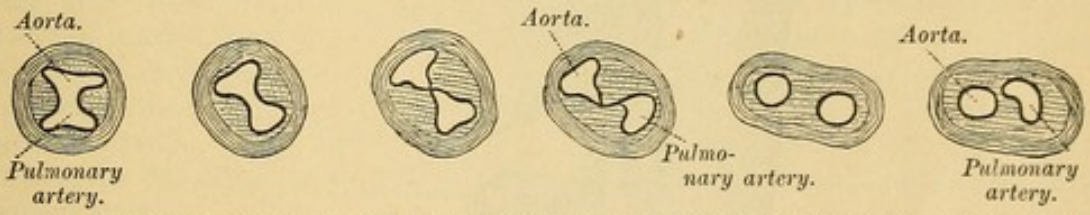

FIG. 749.—Transverse sections through the aortic bulb to show the growth of the aortic septum. The lowest section is on the left, the highest on the right, of the figure. (After His.)

inferius of the ventricles in such a way as to bring the left ventricle into communication with the aorta and the right with the pulmonary artery.

Peculiarities of the Fœtal Heart.—In early fœtal life the heart is placed directly under the head and is relatively of large size. Later it assumes its position in the thorax but lies at first in the middle line; toward the end of pregnancy it gradually becomes oblique. Its auricular portion is at first larger than the ventricular part, and the two auricles communicate freely through the foramen ovale. In consequence of the communication, through the ductus arteriosus, between the pulmonary artery and the aorta, the contents of the right ventricle are mainly carried into the latter vessel instead of to the lungs, and hence the wall of the right ventricle is as thick as that of the left. At the end of fœtal life, however, the left ventricle is thicker than the right, a difference which becomes more and more emphasized after birth.

Further Development of the Arteries.—In the vitelline circulation, two arteries were described as coming off from the primitive heart, and running down in front of the developing vertebræ. The first change consists in the fusion of these arteries into one vessel at some distance from the heart; this vessel is the descending thoracic and abdominal aorta. In consequence of the lengthening of the neck the heart falls backward to its lower part and then into the thorax, and the two original arteries, proceeding from the heart to their point of fusion in the common

descending aorta, become elongated and assume an arched form, curving backward on each side, from the front of the body toward the vertebral column (Fig. 751, A). These are the *first* or *primitive aortic arches*. As the heart recedes into the thorax, and these arches, which correspond in position to the mandibular arch, become elongated, four additional pairs of arches are formed behind them around the pharynx, one in each branchial arch (Fig. 750). The arches, five in number, remain permanent in fishes, giving off from their convex borders the branchial arteries to supply the gills. In many animals the five pairs do not exist together, for the first two have disappeared before the others are formed; but this is not so in man, where all five arches are present and pervious during a certain period of embryonic existence (Fig. 750). Only some of the arches in mammalia remain as

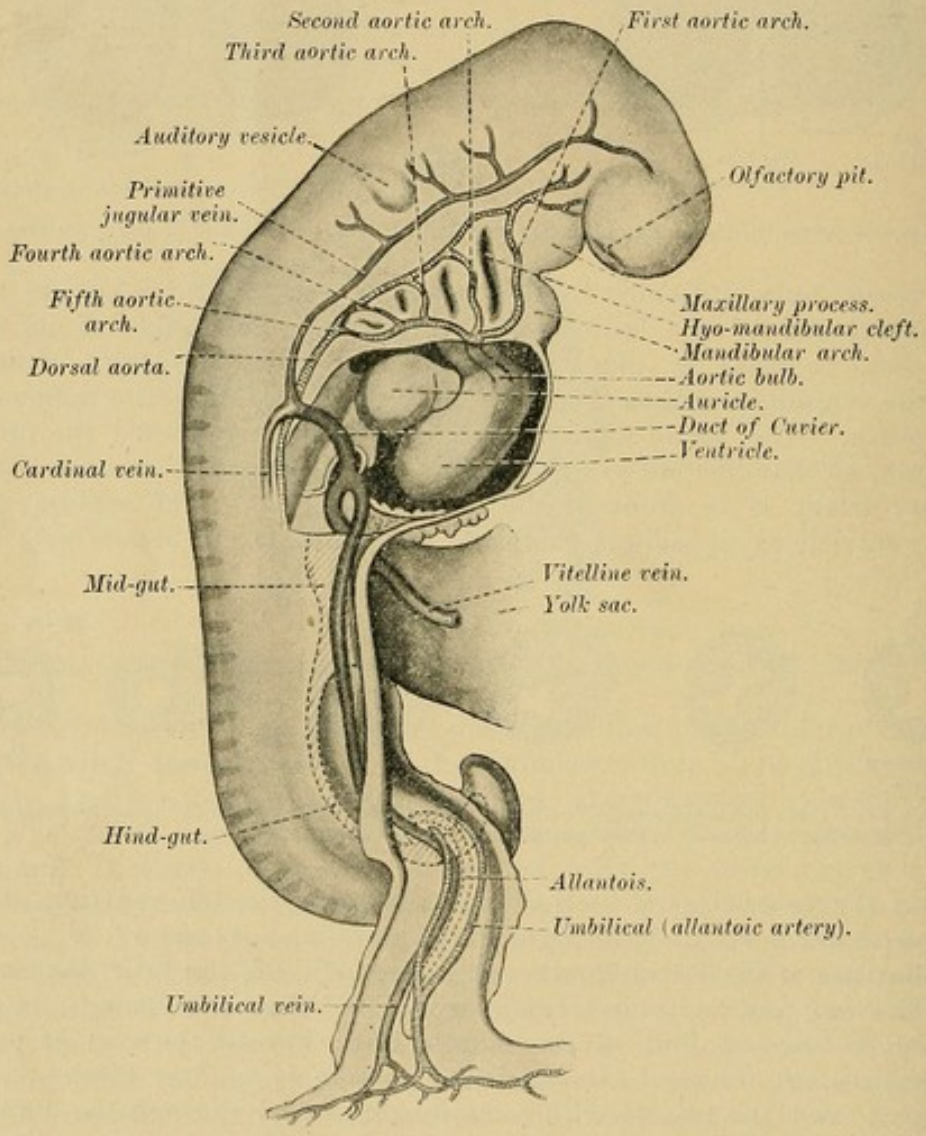

FIG. 750.—Profile view of a human embryo, estimated at twenty or twenty-one days old. (After His.)

permanent structures; the others, or portions of them, become obliterated or disappear. The first two arches entirely disappear. The third remains as a part of the internal carotid artery, the remainder being formed by the upper part of the posterior aortic root—*i. e.*, the descending part of the original vessel which proceeded from the rudimentary tubular heart. The common and external carotid arteries are formed from the anterior aortic root—that is, the ascending portion of the same primitive vessel. The fourth arch on the left side becomes developed into the permanent arch of the aorta in mammals; but in birds it is the fourth arch on the right side which forms the aortic arch; in reptiles the fourth arch on both sides persists, so that these animals possess a permanent double aortic arch. The fourth arch on the right side forms the subclavian artery, and by the junction of its com-

mencement with the anterior aortic root, from which the common carotid is developed, it forms the innominate artery.[1] The fifth arch on the left side forms the pulmonary artery and the ductus arteriosus; that on the right side becomes atrophied and disappears. The first part of the fifth left arch remains connected with that part of the aortic bulb which is separated as the pulmonary stem, and with it forms the common pulmonary artery. From about the middle of this arch two branches are given off, which form the right and left pulmonary arteries,

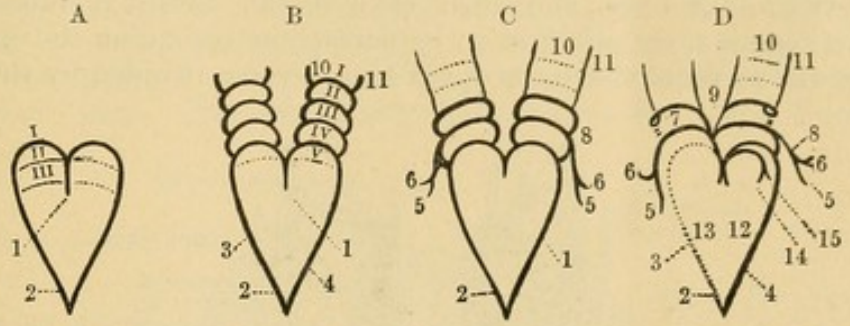

FIG. 751.—Showing the formation of the aortic arches and the large arteries. I. II. III. IV. V. First, second, third, fourth, and fifth aortic arches. A. Common trunk from which the first pair spring; the place where the succeeding pairs are formed is indicated by dotted lines. B. Common trunk, with four arches and a trace of the fifth. C. Common trunk, with the three last pairs, the first two having been obliterated. D. The persistent arteries, those which have disappeared being indicated by dotted lines. 1. Common arterial trunk. 2. Thoracic aorta. 3. Right branch of the common trunk which is only temporary. 4. Left branch, permanent. 5. Axillary artery. 6. Vertebral. 7, 8. Subclavian. 9. Common carotid. 10. External, and 11. Internal carotid. 12. Aorta. 13. Pulmonary artery. 14, 15. Right and left pulmonary arteries.

respectively, and the remaining portion—that is, the part beyond the origin of the branches—communicates with the left fourth arch, and constitutes the ductus arteriosus. This duct remains pervious during the whole of fœtal life, but after birth becomes obliterated (Fig. 752). A series of intersegmental or intervertebral arteries arise from the primitive dorsal aortæ, those in the neck alternating with the cervical segments of the spine. The intersegmental artery which lies between the sixth and seventh segments forms the lower part of the vertebral artery; its upper part is formed by an antero-posterior anastomosis between the higher intersegmental vessels. The subclavian artery is originally a branch of the vertebral, but, owing to the subsequent growth of the upper limb, it comes to exceed in size the parent trunk.

The development of the arteries in the lower part of the body is going on during the same time. It has been seen that originally there were two primitive aortæ coming off from the simple tubular heart. These two vessels course downward, one on either side of the notochord, and supply the omphalo-mesenteric arteries to the yolk-sac. At the hinder end of the embryo the primitive aortæ give off the two umbilical or allantoic arteries which run in the walls of the allantois to the umbilicus, beyond which they are carried in the umbilical cord to the placenta. The two primitive aortæ soon fuse to form a single vessel, the future descending aorta; the fusion begins in the thoracic region, and from there proceeds backward and forward, and the umbilical arteries now appear as if resulting from the bifurcation of the single vessel; the part of the fused vessels, beyond their origin, is indicated, however, by the middle sacral artery. The common and internal iliac arteries represent the proximal end of the umbilical artery; the remainder of the vessel, with the exception of the part which gives off the superior vesical artery, becomes obliterated after birth; and the obliterated portions of the two umbilical arteries, together with the urachus, carry off the peritoneum from the bladder as its superior false ligament. The external iliac and femoral arteries are developed from a minute branch given off from the umbilical artery near its origin, and are at first of comparatively small size.

[1] This is interesting in connection with the position of the recurrent laryngeal nerve, which is thus seen to hook round the *same* primitive fœtal structure, which becomes on the right side the subclavian artery, on the left the arch of the aorta.

Development of the Veins.—The formation of the great veins of the embryo may be best considered under two groups, visceral and parietal.

The *visceral veins* are the two vitelline or omphalo-mesenteric veins bringing the blood from the yolk-sac, and the two umbilical or allantoic veins returning the blood from the placenta; these four veins open close together into the sinus venosus (Fig. 747).

The vitelline veins run upward at first in front, and subsequently on either side of the intestinal canal. They unite on the ventral aspect of the canal before they reach the liver, and then encircle the intestinal tube by forming around it two venous rings, the first on its dorsal, the second on its ventral aspect. The portions of the veins above the upper ring become invaded by the developing

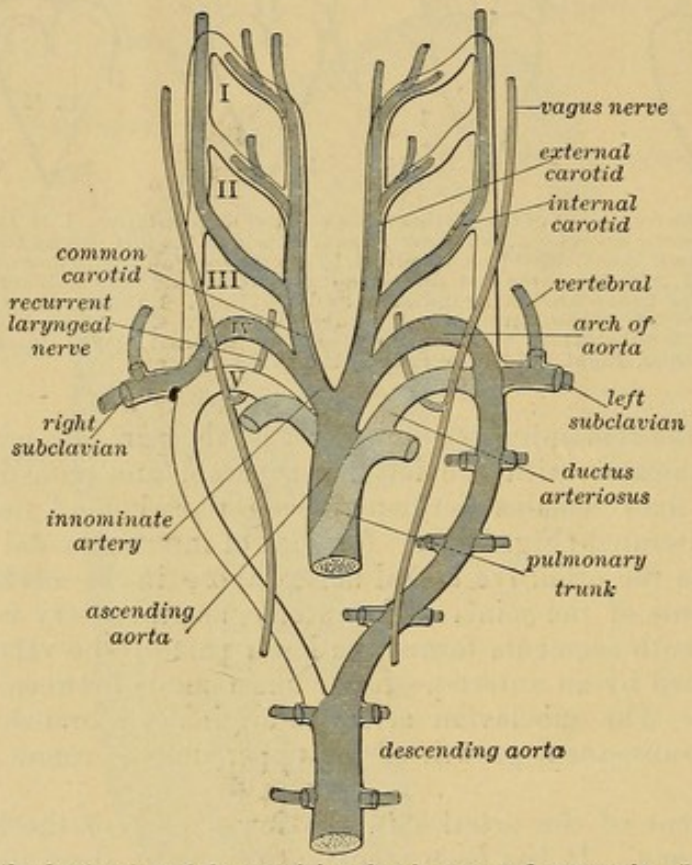

FIG. 752.—Showing the destination of the arterial arches in man and mammals. (Modified from Rathker.) (From Quain's *Anatomy*, 1890, vol. i., pt. 1.) The truncus arteriosus and the five arterial arches springing from it are represented in outline only; the permanent vessels in shade—those belonging to the aortic system in heavy shaded line, to the pulmonary system in light shaded line.

liver and broken up by it into a network of smaller vessels, the central part of the network consisting of a capillary plexus. The branches which convey the blood to this plexus are named the *venæ advehentes*, and become the branches of the portal vein; while the vessels which drain the plexus into the sinus venosus are termed the *venæ revehentes*, and form the future hepatic veins (Figs. 753 and 754).

The lower part of the *portal vein* is formed from the fused vitelline veins which receive the veins from the alimentary canal; its upper part is derived from the venous rings by the persistence of the left half of the lower and the right half of the upper ring, so that the vessel forms a spiral turn round the duodenum (Fig. 754).

The two umbilical veins fuse early to form a single trunk in the allantois, but remain double for some time in the embryo and pass forward to the sinus venosus in the side walls of the body. Like the vitelline veins, their direct connection with the sinus venosus becomes interrupted by the invasion of the liver, and thus at this stage the whole of the blood from the yolk-sac and placenta passes through the substance of the liver before it reaches the heart. The right umbilical vein

shrivels up and almost entirely disappears; the left, on the other hand, becomes much enlarged after the establishment of the placental circulation, and opens into the upper venous ring. Finally a direct branch is established between this ring and the right hepatic vein; this branch is the *ductus venosus* or *vena ascendens*, and, enlarging rapidly, it forms a wide channel through which most of the blood, returned from the placenta, is carried direct to the heart (Fig. 754).

The Parietal Veins.—The first indication of a parietal system consists in the appearance of two short transverse veins (the *ducts of Cuvier*), which open, one on either side, into the auricular portion of the heart. Each of these ducts is formed by an ascending and a descending vein. The ascending veins return the blood from the parietes of the trunk and from the Wolffian bodies, and are called *cardinal* veins. The descending veins return the blood from the head,

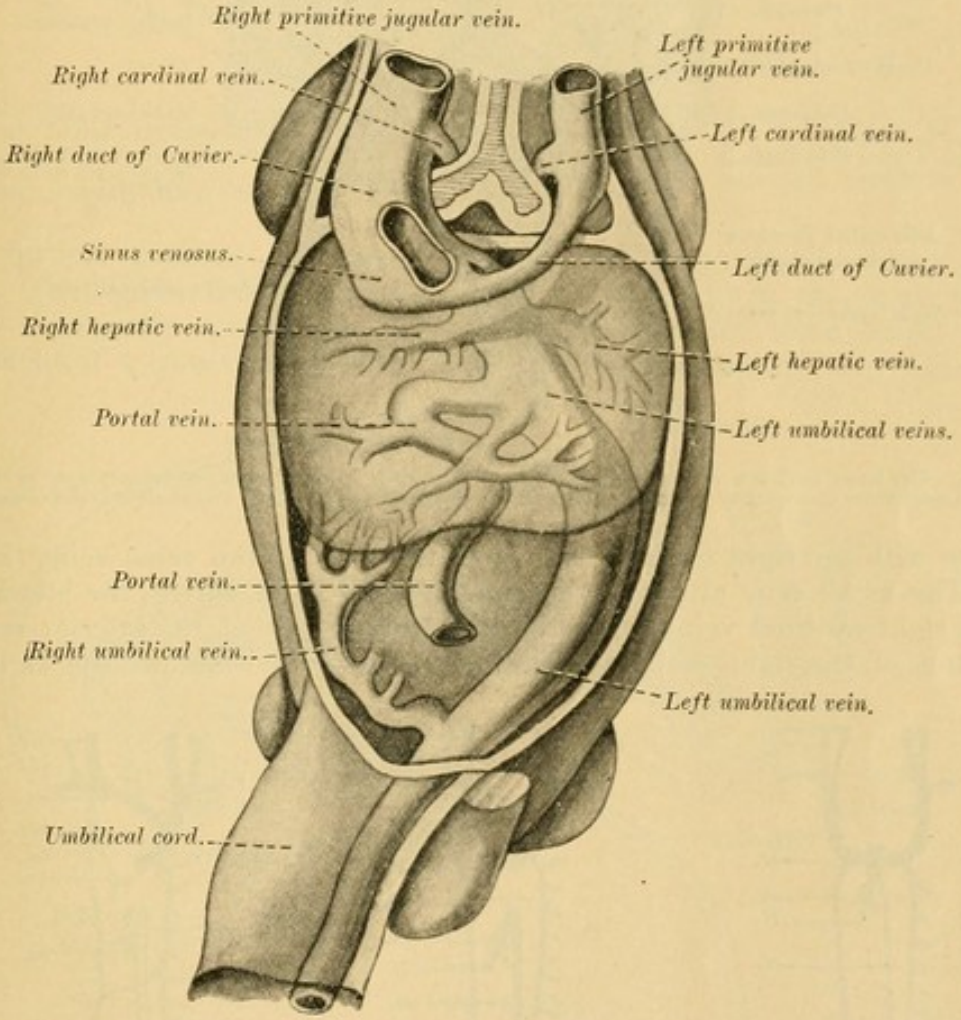

FIG. 753.—Human embryo with heart and anterior body wall removed to show the sinus venosus and its tributaries. (From Kollmann's *Entwickelungsgeschichte.*) (After His.)

and are called *primitive jugular* veins (Fig. 750). The blood from the lower limbs is collected by the iliac veins, which empty themselves into the cardinal veins. In the earlier stages of development the right and left iliac veins open into the corresponding right and left cardinal veins (Fig. 756), but later on a transverse branch connects the lower ends of the two cardinal veins, and through this the blood from the left iliac vein is carried into the right cardinal vein. By the development of a similar transverse branch higher up the blood from the left kidney is also carried into the right cardinal vein (Fig. 755, 2). The portion of the left cardinal vein above the origin of the lower transverse branch becomes atrophied as high as the level of the renal vein, above which it persists as the vena azygos minor. The right cardinal vein, which now receives the blood from both lower extremities, forms a large venous trunk along the posterior

abdominal wall; it receives the renal veins from the kidneys, and forms, up to this level, the inferior vena cava. Above the level of the renal veins the inferior vena cava first makes its appearance as a small vein lying in the tissue between the two kidneys. Superiorly it opens into the sinus venosus, while below it com-

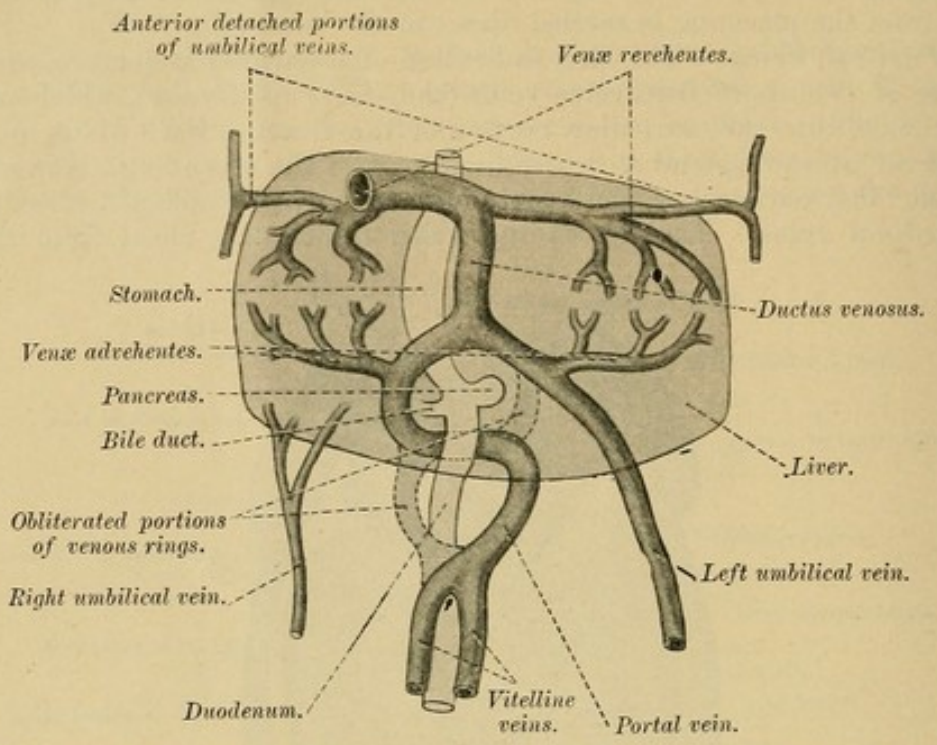

FIG. 754.—The liver, and the veins in connection with it, of a human embryo, twenty-four or twenty-five days old, as seen from the ventral surface. (After His.) (Copied from Milnes Marshall's *Embryology*.)

municates with the right cardinal vein near the level of the renal veins (Fig. 755, 1, 2). This small vein ultimately becomes enlarged, and carries the blood upward from the right cardinal vein, and so forms the upper part of the inferior vena cava. The portion of the right cardinal vein above the renal veins persists as the vena

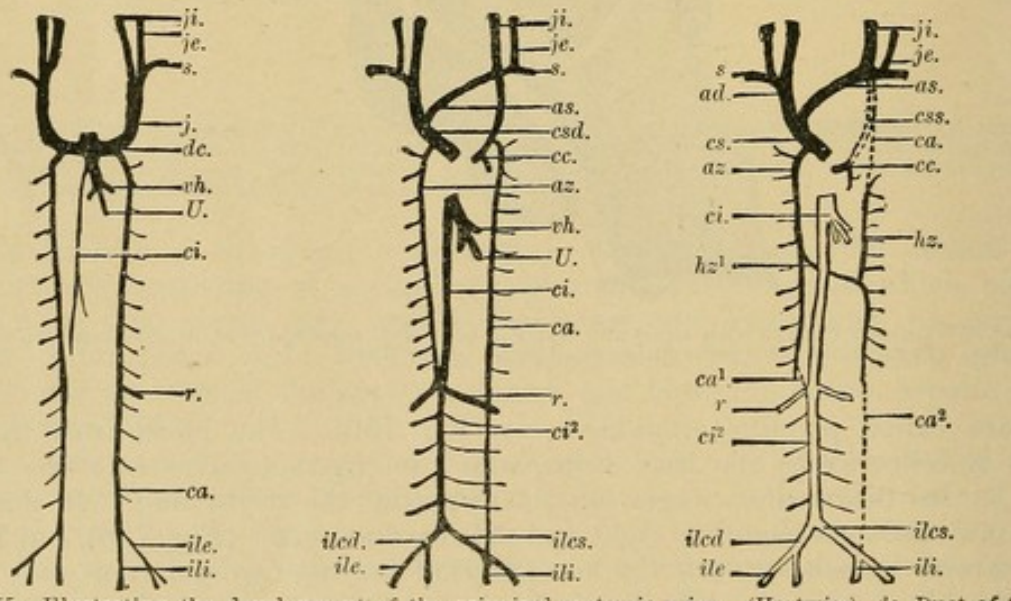

FIG. 755.—Illustrating the development of the principal systemic veins. (Hertwig.) *dc.* Duct of Cuvier. *je, ji.* External and internal jugular veins. *s.* Subclavian. *vh.* Hepatic veins. *U.* Umbilical. *ci, ci².* Vena cava inferior. *ca* (*ca¹, ca², ca³*). Cardinal veins. *ilcd, ilcs.* Right and left common iliac veins. *ad, as.* Right and left innominate veins. *cs.* Vena cava superior. *css.* Rudimentary portion of left superior vena cava. *cc.* Coronary sinus. *az.* Azygos major. *hz, hz¹.* Azygos minor. *ile.* External iliac. *ili.* Internal iliac. *r.* Renal vein.

azygos major, and receives the right intercostal veins, while the vena azygos minor is brought into communication with it by the development of transverse branches in front of the spinal column (Fig. 755, 2, 3).

In consequence of the atrophy of the Wolffian bodies the cardinal veins diminish in size; the primitive jugular veins, on the other hand, become enlarged, owing to the rapid development of the head and brain. They are further augmented by receiving the vein (*subclavian*) from the upper extremity, and so come to form the chief veins of the Cuvierian ducts; these ducts gradually assume an

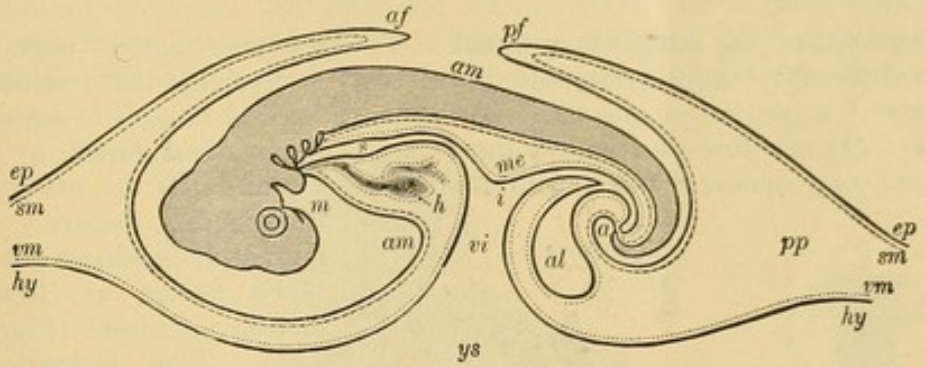

FIG 756.—Diagrammatic outline of a longitudinal vertical section of the chick on the fourth day. *ep.* Epiblast. *sm.* Somatic mesoblast *hy.* Hypoblast. *vm.* Visceral mesoblast. *af.* Cephalic fold. *pf.* Caudal fold. *am.* Cavity of true amnion. *ys.* Yolk-sac *i.* Intestine *s.* Foregut. *a.* Future anus, still closed. *m.* The mouth. *me.* The mesentery. *al.* The allantoic vesicle. *pp.* Space between inner and outer folds of amnion. (From Quain's *Anatomy*, Allen Thomson.)

almost vertical position in consequence of the descent of the heart into the thorax. The right and left Cuvierian ducts are originally of the same diameter, and are frequently termed the *right and left superior venæ cavæ*. By the development of a transverse branch (the future *left innominate vein*) between the

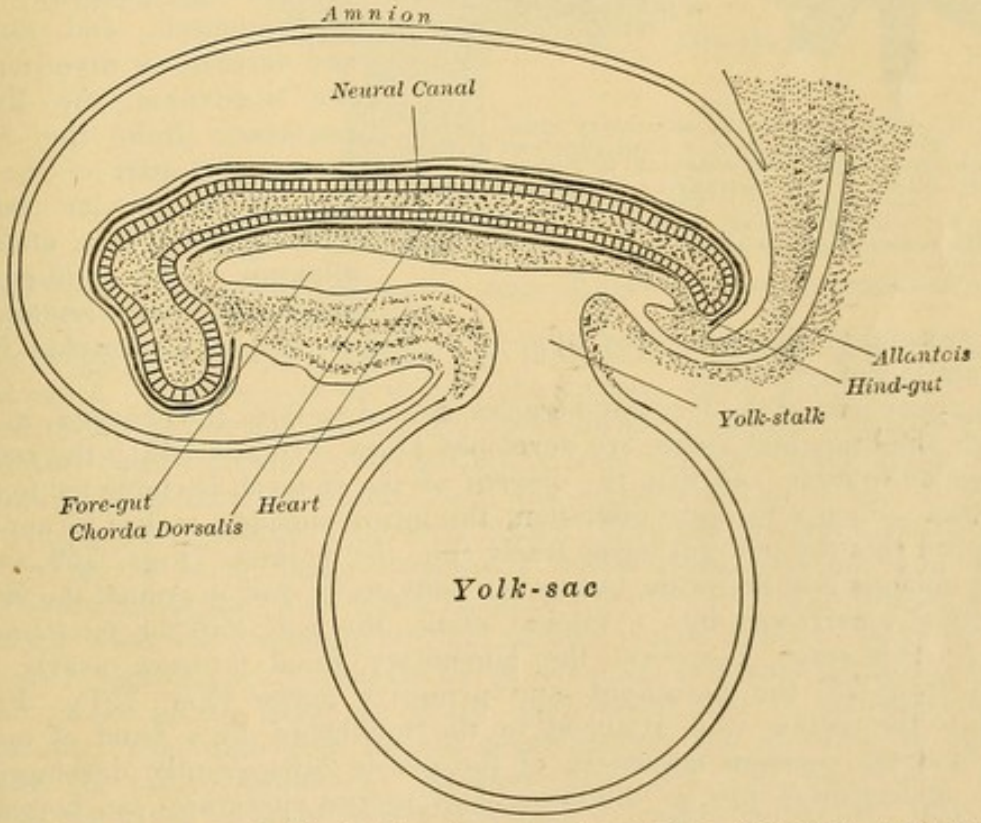

FIG. 757.—Diagram of a longitudinal section of a mammalian embryo. Very early. (After Quain.)

two ducts the blood is carried from the left duct into the right, which thus becomes much enlarged and forms the permanent *superior vena cava*, and into which the vena azygos major opens. The left duct atrophies; its upper part remains pervious as a small vein, which receives the *left superior intercostal vein*; its intermediate portion is represented by the *vestigial fold* of Marshall; its lower part persists as a small vein, the oblique vein of Marshall, which runs downward across the back of the left auricle to join the coronary sinus; this

sinus, as has been indicated, represents the persistent left horn of the sinus venosus. The primitive jugular veins become the internal jugular veins of the adult; the lower part of the right primitive jugular vein forms also the right innominate veins (Figs. 755, 1, 2, 3).

The fœtal circulation has been described in the section on the Blood-Vascular System.

Development of the Alimentary Canal.—As already indicated (page 1157), the primitive alimentary canal is formed, at an early stage, by the enclosure within the embryo of a portion of the blastodermic vesicle, and is seen to consist of three parts, viz.: (1) the *fore-gut*, within the cephalic flexure and dorsal to the heart; (2) the *mid-gut*, opening freely into the yolk-sac; and (3) the *hind-gut*, within the caudal flexure. The fore-gut and hind-gut end blindly, there being at first neither mouth nor anus (Figs. 756 and 757). The formation of the mouth or stomodæum, and the subsequent communication between it and the cephalic end of the fore-gut, have already been considered; the manner in which the anus is formed will presently be discussed.

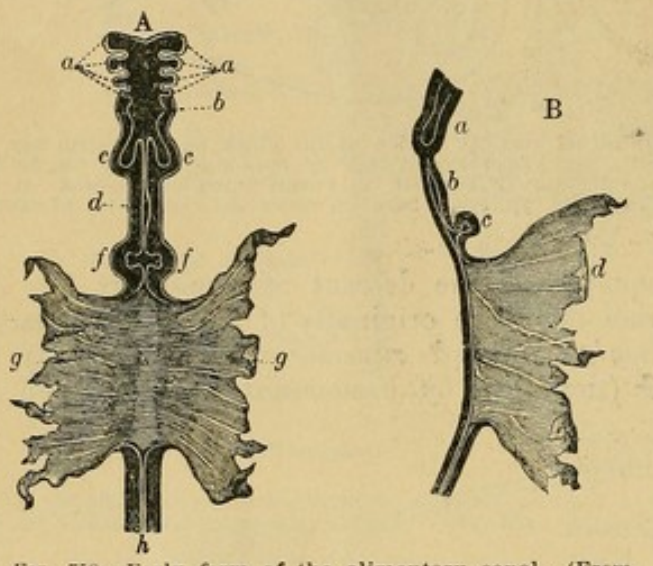

FIG. 758.—Early form of the alimentary canal. (From Kölliker, after Bischoff.) In A a front view and in B an antero-posterior section are represented. *a*. Four pharyngeal or visceral plates. *b*. The pharynx. *c, c*. The commencing lungs. *d*. The stomach. *f, f*. The diverticula connected with the formation of the liver. *g*. The yolk-sac into which the middle intestinal groove opens. *h*. The posterior part of the intestine.

From the fore-gut are developed the pharynx, œsophagus, stomach, and duodenum, and further, as diverticula from the duodenum, the liver and pancreas; from the hind-gut, the greater part of the rectum, and as a tubular outgrowth from it the hollow stalk of the allantois; the mid-gut gives origin to the remainder, or longest section, of the alimentary tube—*i. e.*, the portion which reaches from the duodenum to the rectum.

The upper part of the fore-gut becomes dilated to form the pharynx, in relation to which the branchial arches are developed (Figs. 716 and 759); the succeeding part remains tubular, and with the descent of the stomach is elongated to form the œsophagus. Soon a fusiform dilatation, the future stomach, makes its appearance, and beyond this the mid-gut opens freely into the yolk-sac (Figs. 759 and 760).

This opening is at first wide, but, as the body-walls close in around the umbilicus, it is gradually narrowed into a tubular stalk, the *yolk-stalk* or *vitello-intestinal duct*. At this stage, therefore, the alimentary canal forms a nearly straight tube in front of the notochord and primitive aortæ (Fig. 757). From the stomach to the rectum it is attached to the notochord by a band of mesoblast, from which the common mesentery of the gut is subsequently developed. The stomach undergoes a further dilatation, and its two curvatures can be recognized (Figs. 760 and 764), the greater directed toward the vertebral column and the lesser toward the anterior wall of the abdomen, while of its two surfaces one looks to the right and the other to the left. The mid-gut also undergoes great elongation, and forms a V-shaped loop which projects downward and forward; from the bend or angle of the loop the vitello-intestinal duct passes to the umbilicus (Fig. 764). For a time a part of the loop extends beyond the abdominal cavity into the umbilical cord, but by the end of the third month this is withdrawn. With the lengthening of the tube, the mesoblast, which attaches it to the future vertebral column and which carries the blood-vessels for the supply of the gut, is

thinned and drawn out to form the *primitive* or *common mesentery*. The portion of this mesentery which is attached to the greater curvature of the stomach is named the *mesogastrium*, and the parts which suspend the colon and rectum are respectively termed the *mesocolon* and *mesorectum* (Fig. 764). About the sixth week a lateral diverticulum makes its appearance a short distance beyond the vitello-intestinal duct, and indicates the future cæcum or boundary between the small and the large intestine. This cæcal diverticulum has at first a uniform calibre, but its blind extremity remains rudimentary and forms the vermiform

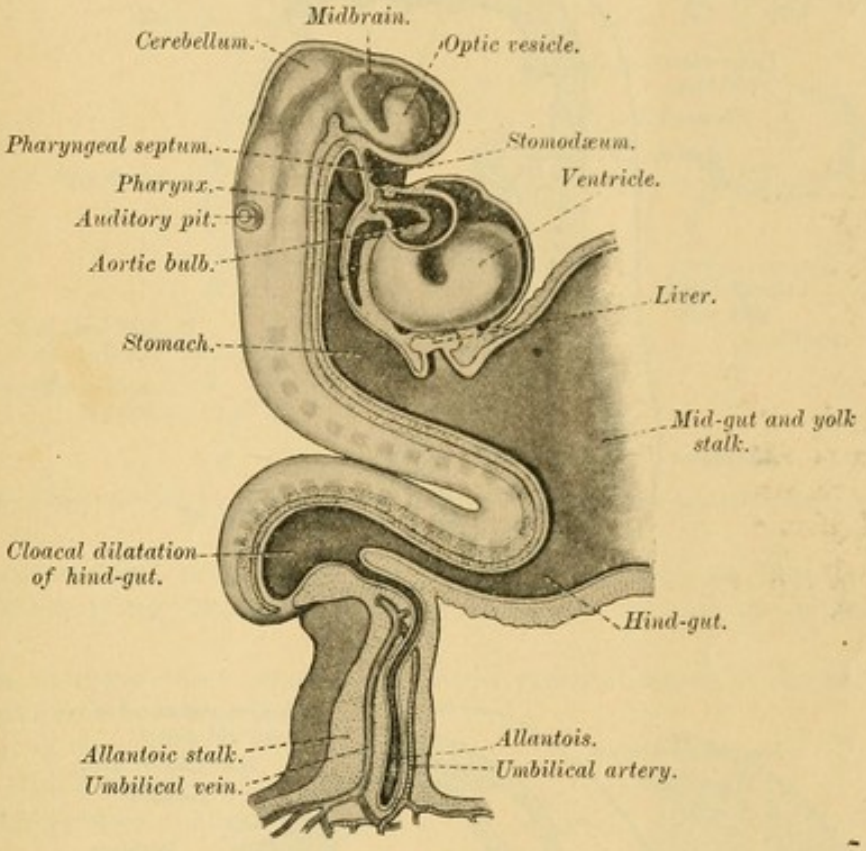

FIG. 759.—Human embryo, about fifteen days old. Brain and heart represented from right side; alimentary canal and yolk-sac in mesial section. (After His.)

appendix (Figs. 764, 765). Changes also take place in the position and direction of the stomach. It falls over on to its right surface, which henceforth is directed backward, while its original left surface looks forward; further, its greater curvature is drawn downward and to the left, away from the vertebral column, while its lesser curvature is directed upward, and the commencement of the duodenum is pushed over to the right side of the middle line. The mesogastrium, being attached to the greater curvature, must necessarily follow its movements, and hence it becomes greatly elongated and drawn outward from the vertebral column, and, like the stomach, what was originally its right surface is now directed backward and its left forward. In this way a pouch, the *bursa omentalis*, is formed behind the stomach; this pouch is the future lesser sac of the peritoneum, and it increases in size as the alimentary tube undergoes further development; the entrance to the pouch constitutes the future *foramen of Winslow* (Figs. 761, 765, and 768). The remainder of the canal becomes greatly increased in length, so that the tube is coiled on itself, and this increase in length demands a corresponding increase in the width of the intestinal attachment of the mesentery, so that it becomes plaited or folded.

At this stage the small and the large intestine are attached to the vertebral column by a common mesentery, the coils of the small intestine falling to the right of the middle line, while the large intestine lies on the left side.[1]

[1] Sometimes this condition persists throughout life, and it is then found that the duodenum does not cross from the right to the left side of the vertebral column, but lies entirely on the right side of the mesial plane, where it is continued into the jejunum; the arteries to the small intestine (rami intestini tenuis) also arise from the right instead of the left side of the superior mesenteric artery.

The gut now becomes rotated upon itself, so that the large intestine is carried over in front of the small intestine, and the cæcum is placed immediately below

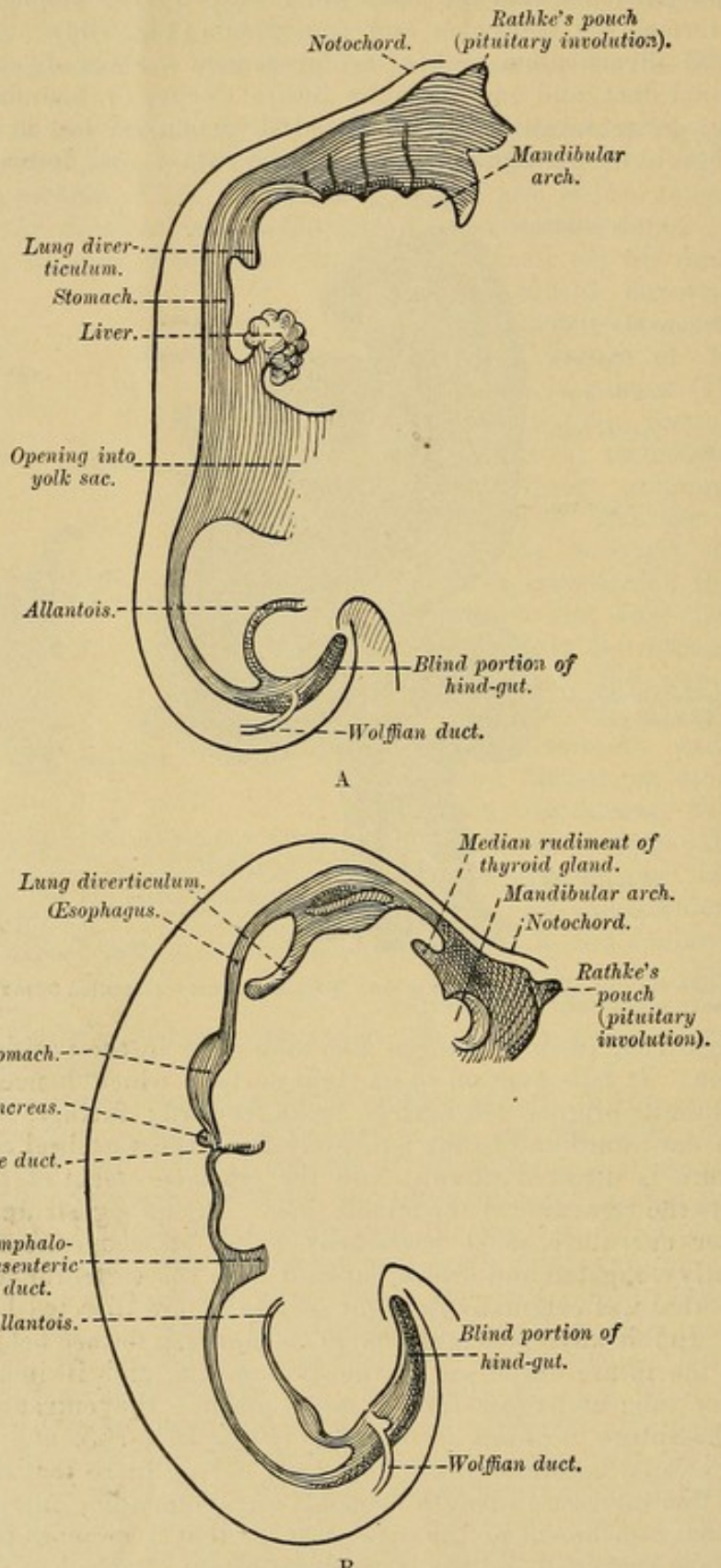

FIG. 760.—Sketches in profile of two stages in the development of the human alimentary canal. (His.) Fig. A × 30. Fig. B × 20.

the liver; about the sixth month the cæcum descends into the right iliac fossa, and the large intestine now forms an arch consisting of the ascending, transverse, and descending portions of the colon—the transverse portion crossing in front

of the duodenum and lying just below the greater curvature of the stomach; within this arch the coils of the small intestine are disposed (Fig. 765). Some-

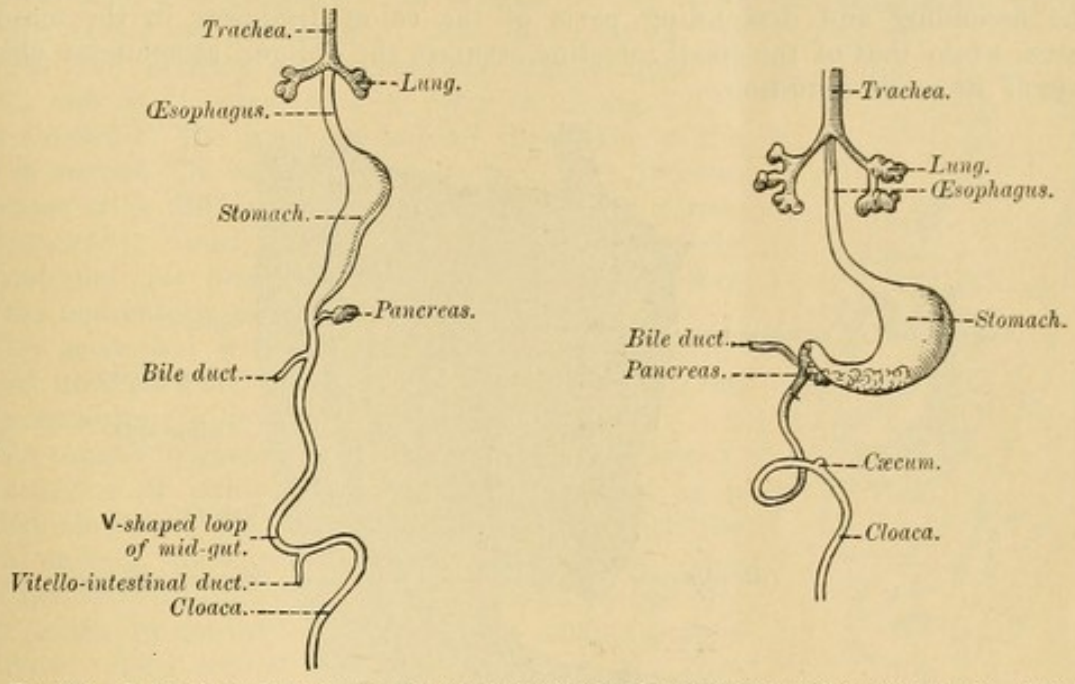

FIG. 761.—Front view of two successive stages in the development of the alimentary canal. (His.)

times the downward progress of the cæcum is arrested, so that in the adult it may be found lying immediately below the liver instead of in the right iliac region.

Further changes take place in the bursa omentalis and in the common mesentery, and give rise to the peritoneal relations seen in the adult. The bursa omentalis, which at first reaches only as far as the greater curvature of the

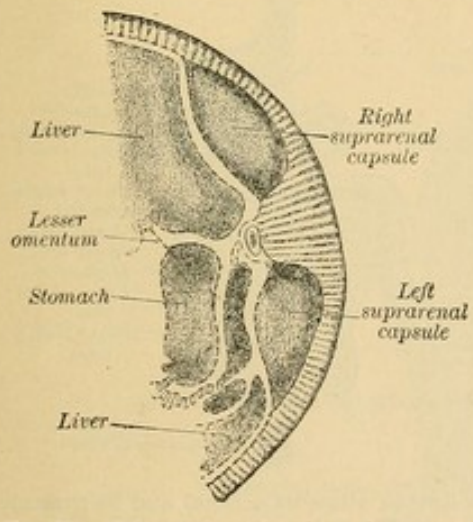

FIG. 762.—Schematic and enlarged cross-section through the body of a human embryo in the region of the mesogastrium. Beginning of third month. (Toldt.)

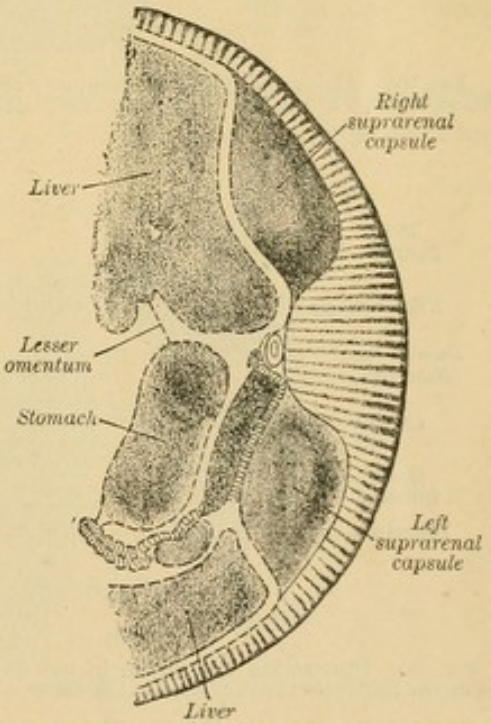

FIG. 763.—Same section as in Fig. 762, at end of third month. (Toldt.)

stomach, grows downward to form the great omentum, and this downward extension lies in front of the transverse colon and the coils of the small intestine. The anterior layer of the transverse mesocolon is at first quite distinct from the posterior wall of the bursa omentalis, but ultimately the two blend, and hence the great omentum appears as if attached to the transverse colon (Figs. 768, 769, and 770). The

mesentery of the duodenum, in which the rudiment of the pancreas is enclosed, disappears, and so this part of the gut becomes fixed to the posterior abdominal wall, and the pancreas lies entirely behind the peritoneal membrane. The mesenteries of the ascending and descending parts of the colon disappear in the majority of cases, while that of the small intestine assumes the oblique attachment characteristic of its adult condition.

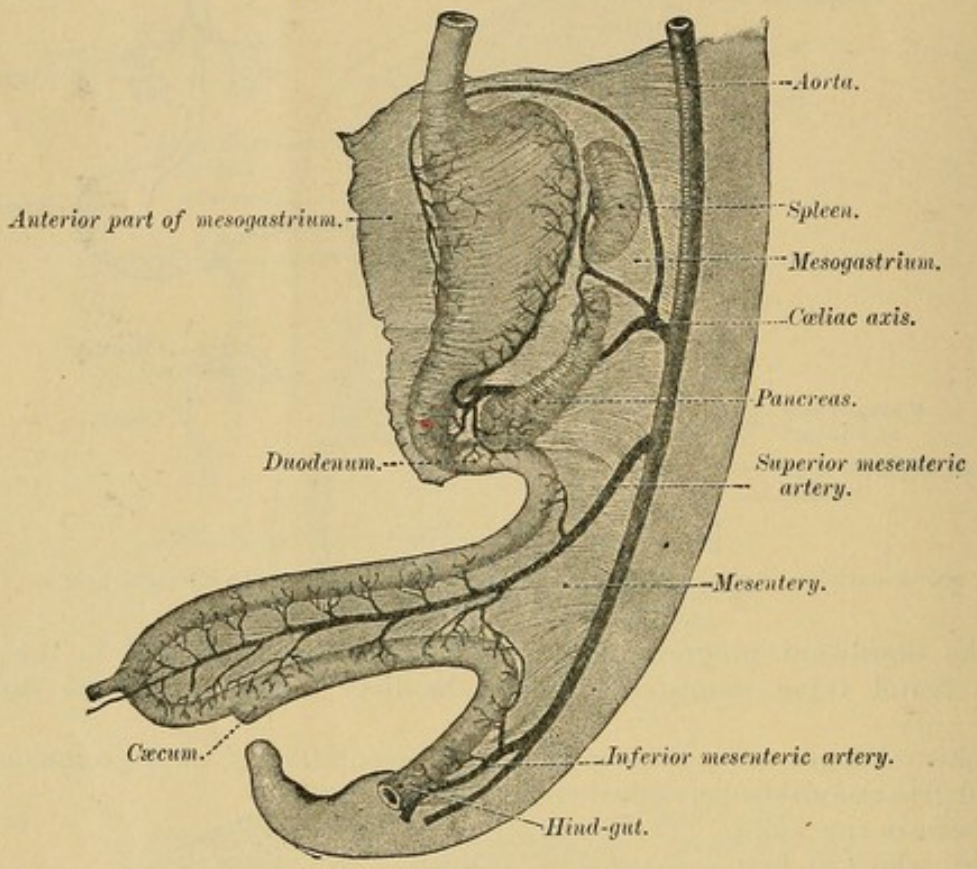

FIG. 764.—Abdominal part of alimentary canal and its attachment to the primitive or common mesentery. Human embryo of six weeks. (After Toldt.) (From Kollmann's *Entwickelungsgeschichte.*)

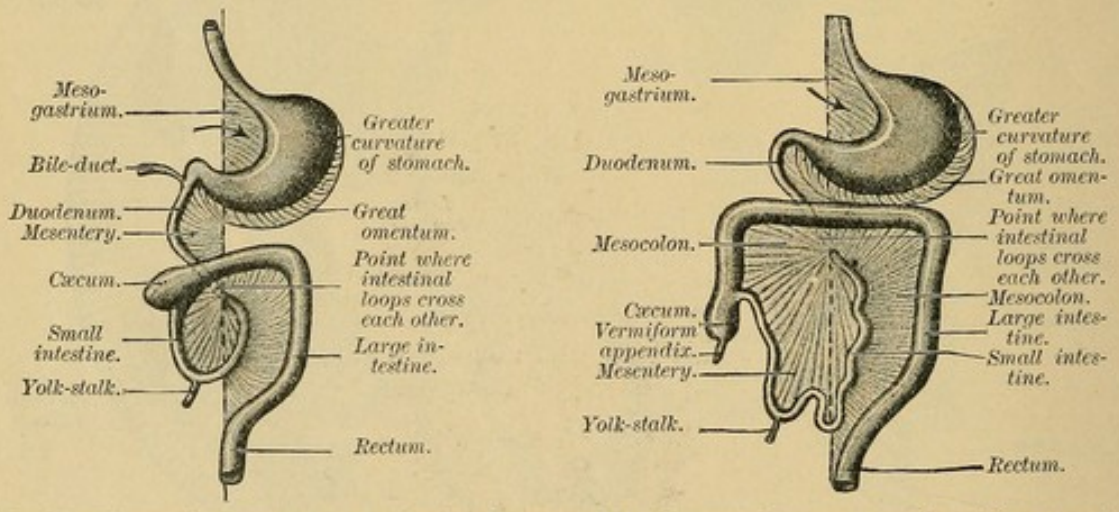

FIG. 765.—Illustrating two stages in the development of the human alimentary canal and its mesentery. The arrow indicates the entrance to the bursa omentalis.

The small omentum is formed by a thinning of the mesoblast or *anterior primitive mesentery*, which attaches the lesser curvature of the stomach to the anterior abdominal wall. By the subsequent growth of the liver this leaf of mesoblast is divided into two parts, viz., the small omentum between the stomach and liver, and the falciform ligament between the liver and the abdominal wall and Diaphragm (Fig. 767).

The anus is developed as a slight invagination of the epiblast a short distance

in front of the posterior end of the hind-gut. This invagination is termed the *proctodæum*; the mesoblast between it and the hypoblastic lining of the hind-gut is thinned, and ultimately the septum breaks down and disappears, and the hind-gut opens on the surface; into this part of the hind-gut the urinary and generative organs open for a time, and so it constitutes a *common cloaca*. The small portion of the hind-gut behind the orifice of the anus is named the *caudal* or *post-anal* gut; it communicates with the neural tube by means of a canal, the *neurenteric canal*, already referred to. Ultimately the post-anal gut becomes obliterated, and it, together with the neurenteric canal, finally disappears.

The peritoneal cavity is the space left between the visceral and parietal layers of the mesoblast, and the serous membrane is developed from these layers.

The tongue originates from the floor of the pharynx. The anterior or papillary portion first appears as a rounded elevation, the *tuberculum impar*, between the ventral ends of the mandibular and hyoid arches. Between the third and fourth arches a second larger elevation arises, in the centre of which is a median groove or furrow. This second elevation is termed the *furcula*, and from it the epiglottis is developed, while the median furrow becomes the entrance to the larynx (Fig. 771). The tuberculum impar and the furcula are at first in apposition, but are soon separated by a ridge produced by the forward growth of the second and third arches. This ridge gives rise to the posterior part of the tongue and extends forward in the form of a V, so as to embrace between its two limbs the tuberculum impar. At the apex of the V there is a pit-like invagination to form the middle thyroid rudiment, and this depression persists as the foramen cæcum of the adult. The union of the two parts of the tongue is indicated even

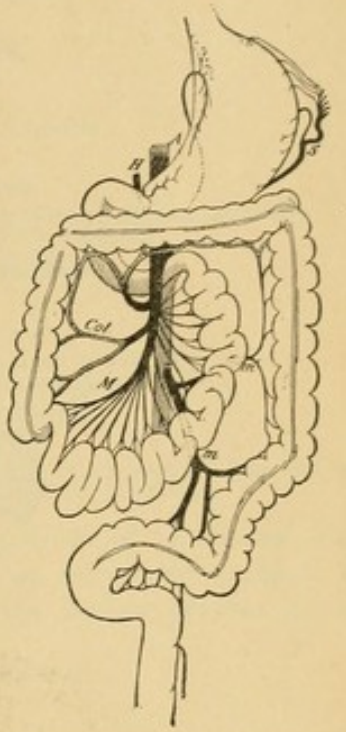

FIG. 766.—Final disposition of the intestines and their vascular relations. (Jonnesco.) *A.* Aorta. *H.* Hepatic artery. *S.* Splenic artery. *M. Col.* Branches of superior mesenteric artery. *m, m'.* Branches of inferior mesenteric artery.

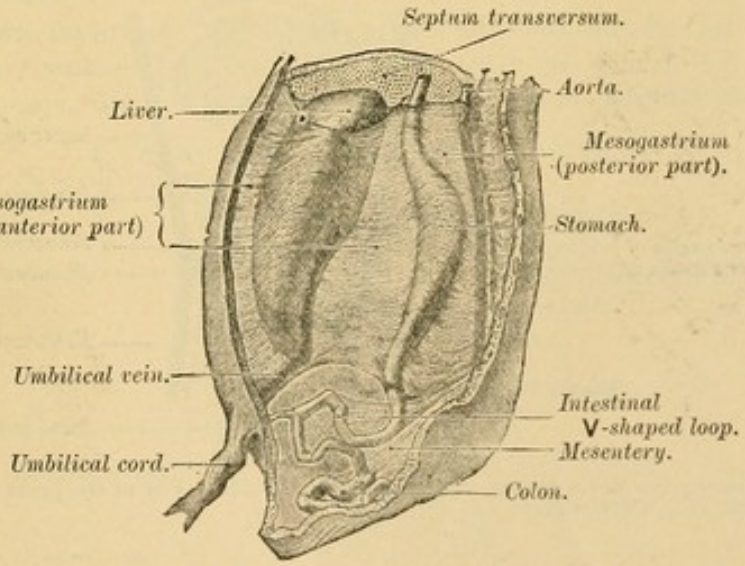

FIG. 767.—The primitive mesentery of a six weeks' human embryo, half schematic. (Kollmann.)

in the adult by a V-shaped depression, the apex of which is at the foramen cæcum, while the two limbs run outward and forward parallel to but a little behind the circumvallate papillæ, which are therefore developed from the tuberculum impar (Figs. 772, 773). The tonsils are developed from the second branchial cleft, and make their appearance between the fourth and fifth months.

The *liver* arises in the form of two diverticula or hollow outgrowths from the ventral surface of that portion of the fore-gut which afterward becomes the

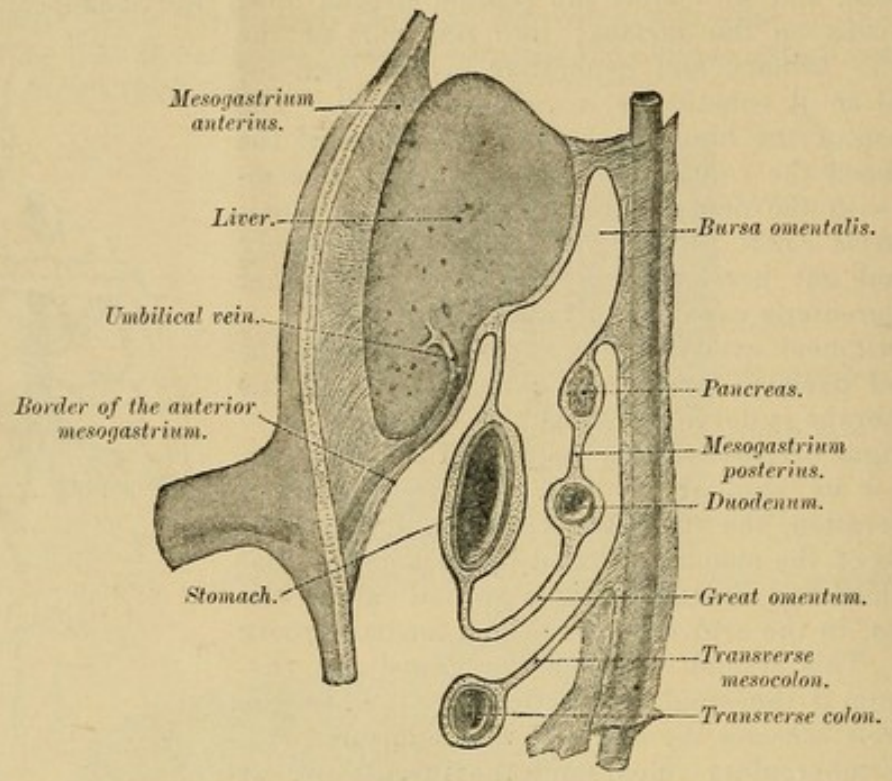

FIG. 768.—Schematic figure of the bursa omentalis, etc. Human embryo of eight weeks. (Kollmann.)

duodenum (Figs. 759, 760). The outgrowths, which represent the right and the left lobes, respectively, of the adult liver, give off solid buds of cells, which grow into columns or cylinders: these unite with one another in every direction to form a close network, in the meshes of which are contained the capillary blood-vessels. Some of these columns become hollowed out and form the bile-ducts, while the

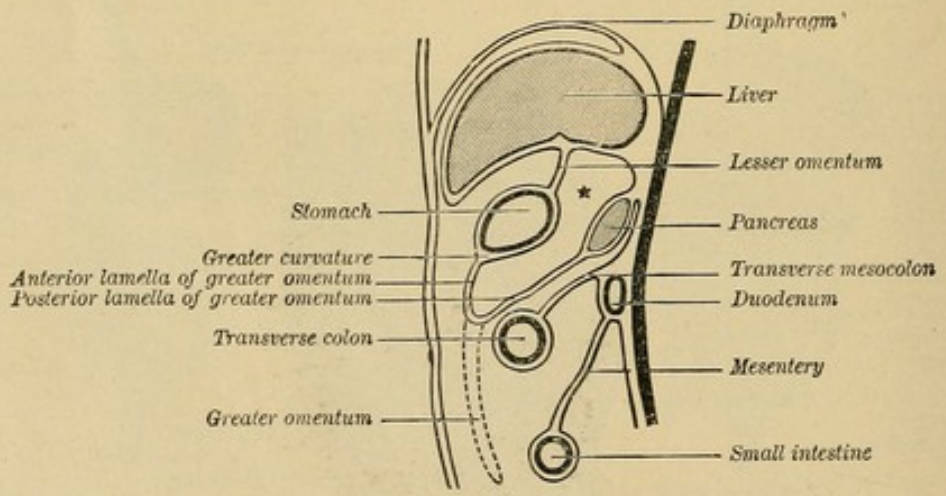

FIG. 769.—Illustrating the development of the bursa omentalis, cavity of the great omentum or lesser sac. Fœtal stage. * Lesser sac. (Hertwig.)

remainder constitute the secreting structure. The minute ducts thus produced unite to form the right and left hepatic ducts; while the common bile-duct is developed as a protrusion from the duodenal wall, and as it grows the liver becomes shifted away from the duodenum. The gall-bladder and cystic duct are formed by a hollow evagination from the wall of the common bile-duct. About the third month the liver almost fills the abdominal cavity. From this period the relative development of the liver is less active, more especially that of the left lobe, which

now becomes smaller than the right; but up to the end of fœtal life the liver remains relatively larger than in the adult.

The *pancreas* is also an early formation, being far advanced in the second

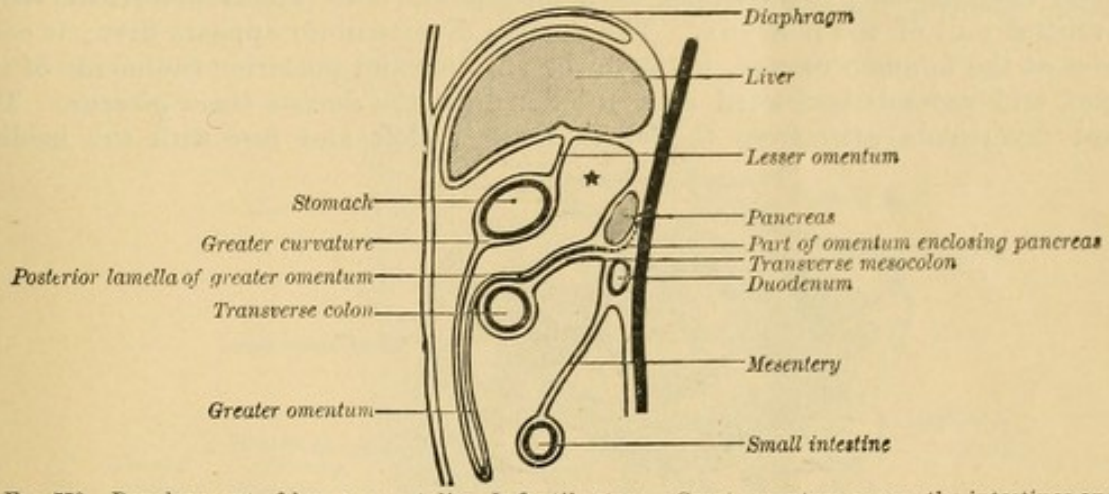

FIG. 770.—Development of bursa omentalis. Infantile stage. Great omentum covers the intestines and has fused with the transverse mesocolon. Pancreas is free from peritoneum posteriorly. (Hertwig.)

month. It originates as a hollow projection from the hypoblast of the dorsal wall of the duodenum (Figs. 760 and 761), opposite the hepatic diverticula, which, as we have already seen, spring from its ventral wall. This hollow process grows

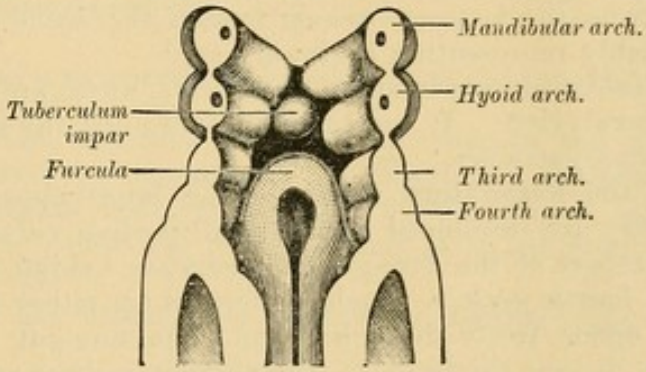

FIG. 771.—The floor of the pharynx of a human embryo about fifteen days old; × 50. (From His.)

between the two layers of the dorsal mesentery and sends out offshoots, which branch abundantly and form a complicated tubular gland. As torsion of the stomach takes place, the pancreas assumes a transverse position and becomes fixed

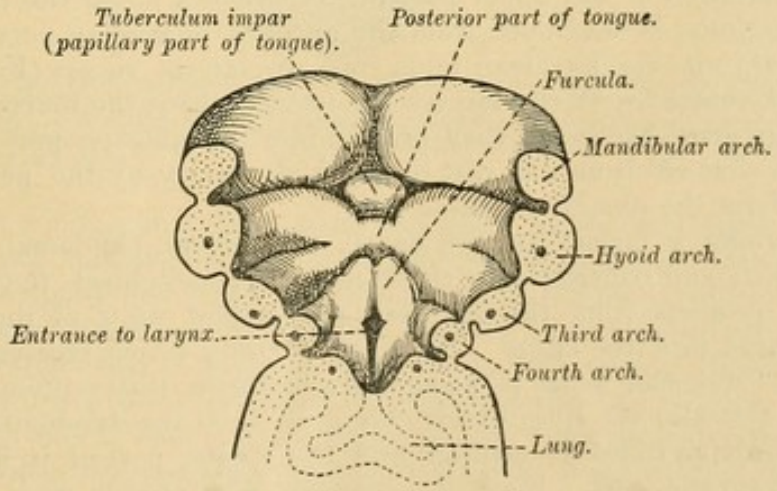

FIG. 772.—The floor of the pharynx of a human embryo about twenty-three days old; × 30. (From His.)

across the dorsal wall of the abdomen, the posterior layer of its mesentery undergoing absorption. Its duct ultimately opens into the duodenum together with the common bile-duct.

The *spleen*, on the other hand, is of mesoblastic origin, for there is never any

connection between the intestinal cavity and the substance of this organ. It originates in the mesenteric fold which connects the stomach to the vertebral column (mesogastrium) (Fig. 764).

The thyroid body is developed as a median and two lateral diverticula from the ventral wall of the pharynx. The median diverticulum appears first; it commences at the foramen cæcum, between the anterior and posterior rudiments of the tongue, and extends backward as a tubular duct, the *ductus thyro-glossus*. The lateral diverticula arise from the fourth visceral cleft and fuse with the median

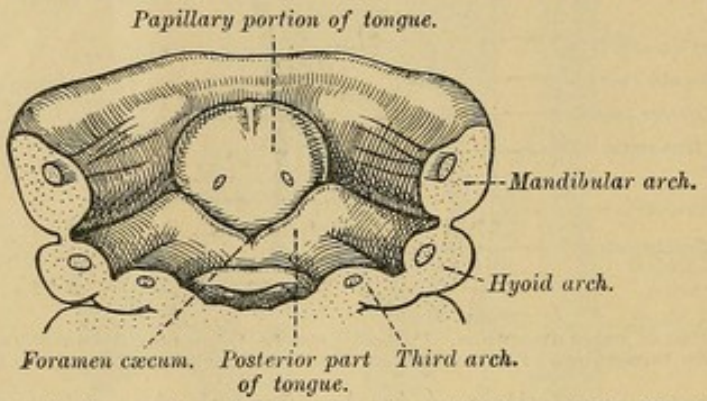

FIG. 773.—Floor of mouth of an embryo slightly older than that shown in Fig. 772. × 16. (From His.)

part to form the thyroid body. The connection of the lateral diverticula with the pharynx disappears early, but the remains of the ductus thyro-glossus may persist as a tube leading from the foramen cæcum toward the hyoid bone, the *pyramid* of the thyroid probably representing its lower part.[1]

The thymus is developed from bilateral diverticula, which are principally derived from the third visceral cleft. It increases in size until the second year of life, after which it undergoes atrophy.

Development of the Respiratory Organs.—The lungs appear somewhat later than the liver. They are developed from a small median *cul-de-sac* or diverticulum from the upper part of the fore-gut, immediately behind the fourth visceral cleft. During the fourth week a pouch is formed on either side of the central diverticulum, and opens freely through it into the fore-gut (pharynx). These lateral pouches soon become subdivided—the right into three and the left into two parts, these subdivisions being the early indications of the lobes of the lungs (Figs. 716 and 761). The two primary pouches have thus a common tube of communication with the pharynx. This common tube becomes the larynx and trachea, the latter rapidly elongating as development proceeds. The larynx first becomes evident as a dilatation of the upper part of the trachea about the end of the fifth week. The epiglottis is developed from the anterior or median portion of the furcula, and the aryteno-epiglottidean folds from its lateral ridges (Fig. 772). The vocal cords and ventricles of the larynx are formed about the fourth month.

As the lungs grow backward they project into the anterior part of the cœlum, which becomes shut off from the rest of the body-cavity by the pericardium and Diaphragm to form the pleural cavities.

The Diaphragm is formed in two parts: (*a*) ventral, (*b*) dorsal. The ventral part appears first, and consists of a thick septum of mesoblast, the *septum transversum*, which projects from the anterior and lateral walls of the embryo, and which ends behind in a free edge. The sinus venosus, which receives the vitelline, umbilical, and Cuvierian veins is placed originally in this septum, and into the posterior part of it also the liver diverticula grow from the duodenum. The sinus separates itself above from the septum, and the greater part of it is incorporated with the right auricle. The liver also becomes separated from it below, except where the veins pass through into the heart. The septum transversum shuts

[1] Kanthack (*Journal of Anat. and Physiol.*, vol. xxv., p. 155) disputed this view. He examined 100 subjects, 60 of which were fœtuses or infants, and found that in many cases there was no trace of foramen cæcum and that, when it was present, it formed a short canal near the surface and was lined with stratified squamous, not columnar, epithelium. Further, after careful microscopical examination he found no trace of a tubular lumen in the pyramid of the thyroid body.

off the greater part of the thoracic from the abdominal cavity, but posteriorly there remain two channels of communication, one on each side of the alimentary tube; these channels subsequently become the pleural cavities, and are shut off from the abdomen by folds which grow from the lateral and posterior parts of

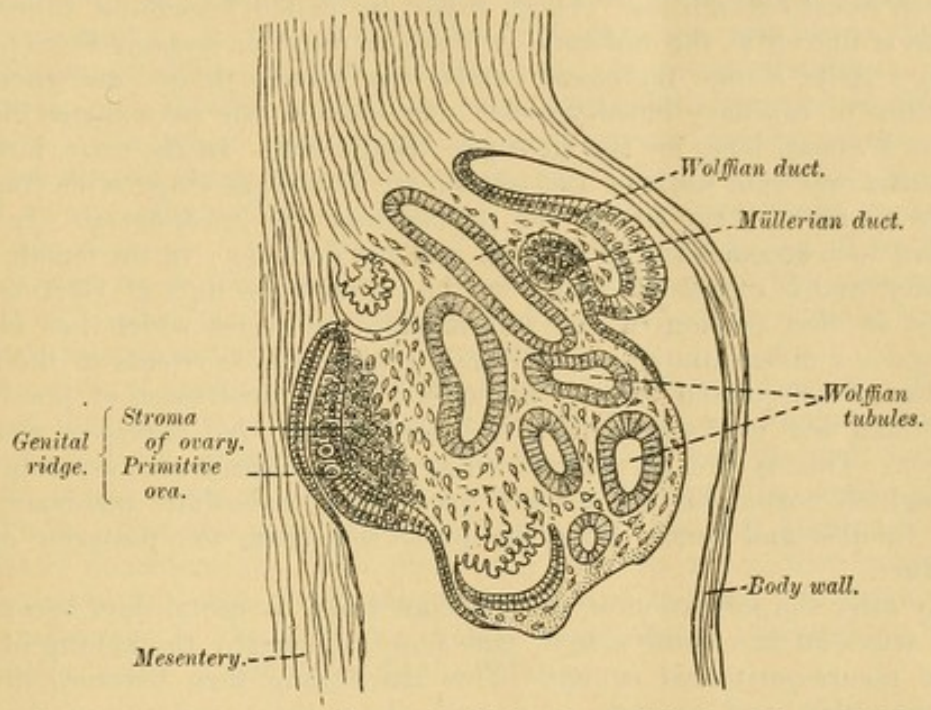

FIG. 774.—Section of the urogenital area of a chick embryo of the fourth day. (Waldeyer.)

the trunk and which fuse with the posterior edge of the septum transversum. Sometimes the fusion is incomplete, thus leaving a permanent communication between the abdominal and one or other of the pleural cavities, and through which some of the abdominal contents may pass, forming what is termed a *diaphragmatic hernia*.

Development of the Urinary and Generative Organs.—The urinary organs are

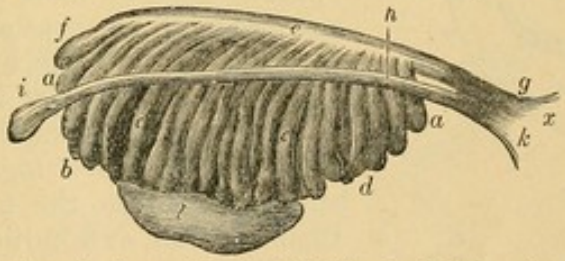

FIG. 775.—Enlarged view from the front of the left Wolffian body before the establishment of the distinction of sex. (From Farre, after Kobelt.) *a, a, b, d*, Tubular structure of the Wolffian body; *e*, Wolffian duct; *f*, Its upper extremity; *g*, Its termination in *x*, the urogenital sinus; *h*, The duct of Müller; *i*, Its upper, funnel-shaped extremity; *k*, Its lower end, terminating in the urogenital sinus; *l*, The mass of blastema for the reproductive organ, ovary or testicle.

developed from a ridge of mesoblast at the point where this layer separates into somatopleure and splanchnopleure. As this ridge is situated close to the epiblast, between the paraxial mesoblast and the common pleuro-peritoneal cavity, it has been named the "intermediate cell-mass." It is at first solid, and in it is formed a cord-like arrangement of some of the cells, which extends longitudinally from just below the heart to the posterior extremity of the body-cavity. In this cord-like structure a tube is hollowed out; it gradually becomes separated from the rest of the intermediate cell-mass, and is then named the *Wolffian duct* (Fig. 700).[1] Its posterior end becomes connected with and eventually opens into the hind-gut. Its anterior end becomes connected with pit-like involutions of the peritoneal epithelium, and in the mesoblastic tissue between these invaginations a vascular glomerulus is formed which projects into the peritoneal cavity. It is known as the *head-kidney*

[1] By some embryologists the Wolffian duct is regarded as being of epiblastic origin and formed by a longitudinal invagination of the epiblast.

or *pronephros* (Lankester), and is a very rudimentary organ which speedily disappears. Behind this body and to the inner side of the Wolffian duct, between it and the body-cavity, a number of tubes are formed, which communicate by one extremity with the Wolffian duct, and, passing transversely toward the body-cavity, terminate in cæcal extremities. These tubes are called segmental tubes, and the whole mass is known as the *mid-kidney*, *Wolffian body*, or *mesonephros* (Lankester) (Fig. 775). After a time the cæcal extremities become dilated and enclose a tuft or glomerulus of capillary blood-vessels. As soon as the permanent kidneys are formed, the Wolffian body for the most part disappears. In the male, however, the vasa efferentia and rete testis of the testicle are formed as outgrowths from it. In the female traces of it are left as the *parovarium* and *epoöphoron*. In the male the Wolffian duct becomes the epididymis and vas deferens; in the female it undergoes atrophy, and is represented only by the functionless duct of Gärtner.

Finally, in that portion of the intermediate cell-mass which lies behind the Wolffian body, a differentiation of cells takes place which results in the formation of a number of convoluted tubes; into this a hollow protrusion of the lower end of the Wolffian duct grows up, and thus is formed the *hind-kidney* or *metanephros* (Lankester). This is the permanent kidney. The uriniferous convoluted tubes and Malpighian corpuscles are formed from the intermediate cell-mass, and the collecting tubules and ureter from the protrusion from the posterior end of the Wolffian duct.

Shortly after the formation of the Wolffian body, a second duct becomes developed. It arises on the outer side of this body as a slight thickening of the cells lining the pleuro-peritoneal cavity. This thickening then becomes invaginated into the mesoblast and extends as a cord along the outer side of the Wolffian body, to the posterior extremity of the embryo. It speedily acquires a lumen, and is then known as the *Müllerian duct* (Fig. 774). In its passage to the posterior extremity of the embryo it comes into close relation with the Wolffian duct, and the two ducts on either side become connected with their fellows on the opposite side by their cellular substance into a single cord, the *genital cord* (Fig. 776, G, C), in which the Wolffian ducts lie side by side in front, and the ducts of Müller behind. These latter tubes in the substance of the genital cord become fused together, and open by a single orifice into the hind-gut (cloaca). At their anterior extremities the ducts of Müller open by a somewhat funnel-shaped orifice into the pleuro-peritoneal cavity. In the female the greater part of the Müllerian duct is developed into the Fallopian tube, but the posterior fused portion of the two ducts is converted into the uterus and vagina (Fig. 777). In the male the greater part of the ducts disappears; the posterior fused portion is believed to be represented by the *sinus pocularis* (*uterus masculinus*) of the urethra.

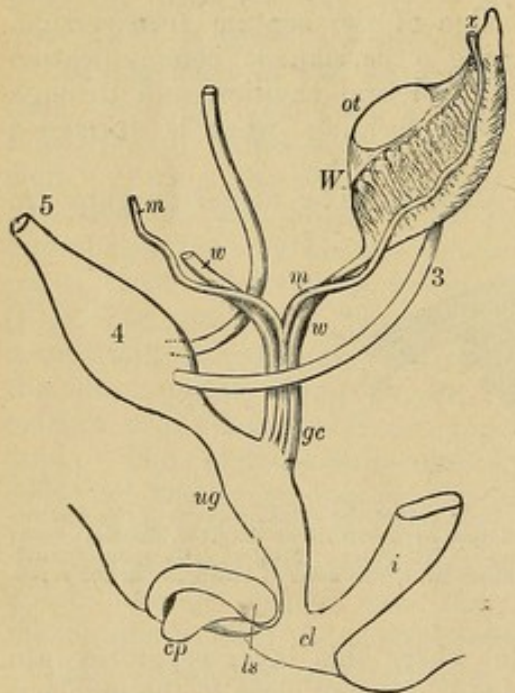

FIG. 776.—Diagram of the primitive urogenital organs in the embryo previous to sexual distinction. The parts are shown chiefly in profile, but the Müllerian and Wolffian ducts are seen from the front. 3. Ureter. 4. Urinary bladder. 5. Urachus. *ot*, The mass of blastema from which ovary or testicle is afterward formed; *W*, Left Wolffian body; *w*, *w*, Right and left Wolffian ducts; *m*, *m*, Right and left Müllerian ducts uniting together and with the Wolffian ducts in *gc*, the genital cord; *ug*, Sinus urogenitalis; *i*, Lower part of the intestine; *cl*, Common opening of the intestine and urogenital sinus; *cp*, Elevation which becomes clitoris or penis; *ls*, Ridge from which the labia majora or scrotum are formed.

It has been seen that the Wolffian and Müllerian ducts open into the common cloaca, which is the termination of the intestinal cavity, and into which the allantois also opens in front (Fig. 776). As the allantois expands into the urinary bladder this common cavity is divided into two by a septum, to form the urogenital sinus in front and the

rectum behind, and the Wolffian and Müllerian ducts now open into the urogenital sinus.

The *urinary bladder*, as before stated, is formed by a dilatation of a part of the intra-embryonic portion of the allantois. At the end of the second month the middle part of this portion of the allantois becomes dilated into a spindle-shaped cavity, which persists as the *urinary bladder*. Between the lower extremity of the spindle-shaped dilatation and the intestine is the *urogenital sinus*, into which the Müllerian and Wolffian ducts now open, and which becomes the first part of the urethra. The upper part of the intra-embryonic portion of the allantois, which is not dilated, forms the *urachus* (Fig. 776); this extends into the umbilical cord, and at an early period of embryonic existence forms a tube of communication with the allantois. It is obliterated before the termination of fœtal life, but the cord formed by its obliteration is perceptible throughout life, passing from the upper part of the bladder to the umbilicus. It occasionally remains patent after birth, constituting a well-known malformation.

The *suprarenal* bodies are developed from two different sources. The medullary part of the organ is of epiblastic origin, and is derived from the tissues forming the sympathetic ganglia of the abdomen, while the cortical portion is of mesoblastic origin, and originates as an outgrowth from the upper part of the Wolffian body. The two parts are at first quite distinct, but become combined in the process of development. The suprarenal capsules are at first larger than the kidneys; about the tenth week they equal them in size, and from that time decrease relatively to the kidney, though they remain, throughout fœtal life, proportionally much larger than in the adult.

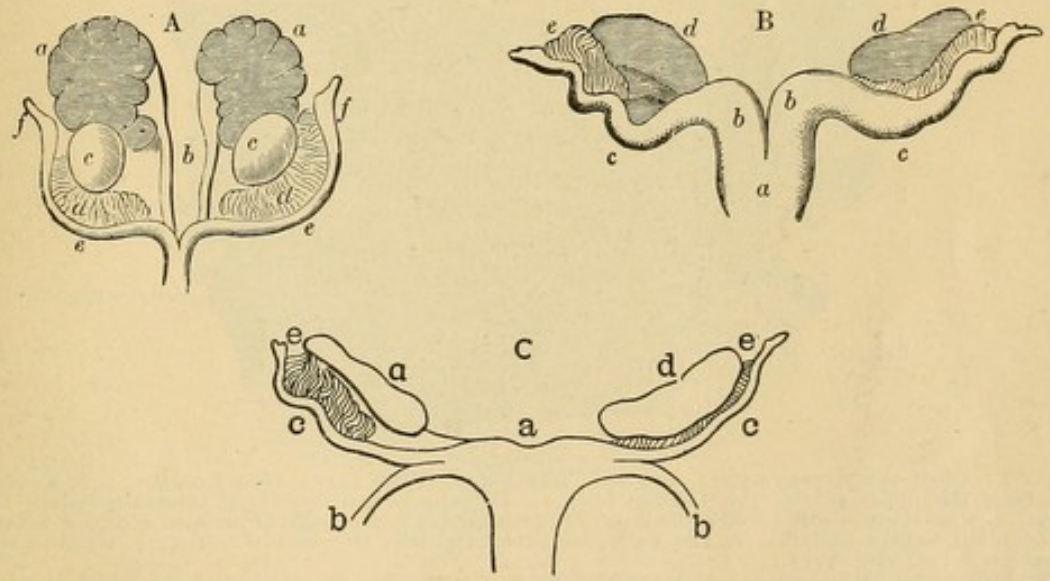

FIG. 777.—Female genital organs of the embryo, with the remains of the Wolffian bodies. (After J. Müller.) A. From a fœtal sheep: *a*. The kidneys. *b*. The ureters. *c*. The ovaries. *d*. Remains of the Wolffian bodies. *e*. Fallopian tubes. *f*. Their abdominal openings. B. More advanced, from a fœtal deer: *a*. Body of the uterus. *b*. Cornea. *c*. Tubes. *d*. Ovaries. *e*. Remains of the Wolffian bodies. C. Still more advanced, from the human fœtus of three months: *a*. The body of the uterus. *b*. The round ligament. *c*. The Fallopian tubes. *d*. The ovaries. *e*. Remains of the Wolffian bodies.

Ovaries and Testicles.—The first appearance of the reproductive organs is essentially the same in the two sexes, and consists in a thickening of the epithelial layer which lines the peritoneal or body-cavity close to the inner side of the Wolffian body. Beneath this thickened epithelium an increase in the mesoblast takes place, forming a distinct projection or ridge. This is termed the *genital ridge* (Fig. 774), and from it the testicle in the one sex, and the ovary in the other, are developed. As the embryo grows the genital ridge gradually becomes pinched off from the Wolffian body, with which it is at first continuous, though it still remains connected to the remnant of this body by a fold of peritoneum, the *mesorchium* or *mesovarium*. About the seventh week the distinction of sex begins to be perceptible.

The ovary, thus formed from the genital ridge, consists of a central part of connective tissue covered by a layer or layers of epithelium, the *germinal epithelium*. Columns of this epithelium, termed *egg-tubes*, grow down into the stroma, and simultaneously with this an upward growth of the connective tissue takes place between the columns of epithelial cells. It results from this that the columns of cells become enclosed in meshes of connective tissue (Fig. 784). Each egg-tube or nest represents a primitive Graafian follicle, one cell of which becomes enlarged to form the ovum; the remainder form the epithelium of the follicle. The remains of the germinal epithelium on the surface of the ovary form the permanent epithelial covering of this organ. According to Beard, the primitive ova are early set apart during the segmentation of the ovum and migrate into the germinal ridge.

The testicle is developed in a very similar way to the ovary, but the processes are not so well marked. Like the ovary, in its earliest stages it consists of a central mass of connective tissue covered by germinal epithelium. A downward growth of columns of this epithelium into the central connective tissue takes place. From these the seminiferous tubules are developed and become connected with outgrowths from the Wolffian body, which, as before mentioned, form the rete testis and vasa efferentia.

With regard to the other parts of the internal female organs, the Fallopian tube, as has been mentioned, is developed from the upper part of the duct of Müller, while the lower parts of the two ducts approach each other, and, lying

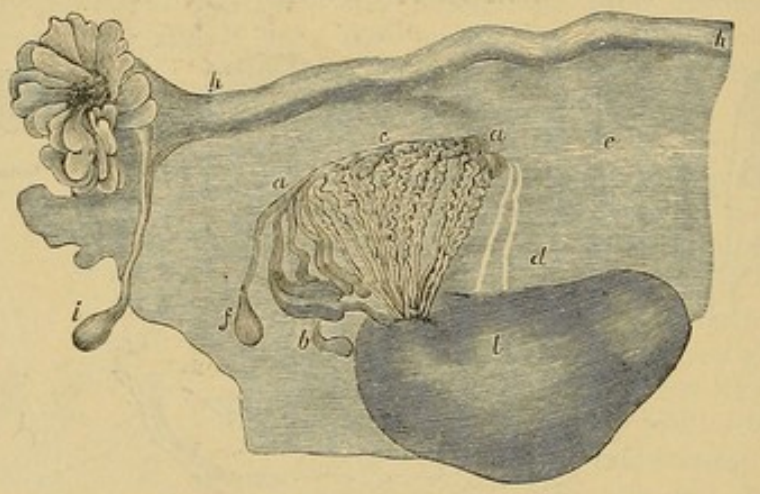

FIG. 778.—Adult ovary, parovarium, and Fallopian tube. (From Farre, after Kobelt.) *a*, *a*. Epoöphoron formed from the upper part of the Wolffian body. *b*. Remains of the uppermost tubes sometimes forming hydatids. *c*. Middle set of tubes. *d*. Some lower atrophied tubes. *e*. Atrophied remains of the Wolffian duct. *f*. The terminal bulb or hydatid. *h*. The Fallopian tube, originally the duct of Müller. *i*. Hydatid attached to the extremity. *l*. The ovary.

side by side, finally coalesce to form the cavity of the uterus and vagina.—This coalescence commences in the middle of the genital cord, and corresponds to the body of the uterus. With regard to the further changes in the female organs, the only remains of the Wolffian body in the complete condition are two rudimentary or vestigial structures, which can be found, on careful search, in the broad ligament near the ovary: the *parovarium* or *organ of Rosenmüller* and the *epoöphoron* (Fig. 778). The organ of Rosenmüller consists of a number of tubes which converge to a transverse portion, the epoöphoron, and this is sometimes prolonged into a distinct duct, running transversely, the *duct of Gärtner*, which is much more conspicuous and extends further in some of the lower animals. This, as has been pointed out, is the remains of the Wolffian duct. About the fifth month an annular constriction marks the position of the neck of the uterus, and after the sixth month the walls of the uterus begin to thicken. The round ligament is derived from a band containing involuntary muscular fibres, which runs downward from the lower part of the Wolffian body to the groin, and which in

the male forms the gubernaculum testis; the peritoneum constitutes the broad ligament; the superior ligament of the Wolffian body, which serves to connect it with the Diaphragm, disappears with that body.

With regard to the other parts of the male organs, the Müllerian ducts disappear, with the exception of their lower ends. These unite in the middle line, and open by a common orifice into the urogenital sinus. This constitutes the *utriculus hominis* or *sinus prostaticus*. Frequently, however, the upper end of the duct of Müller remains visible in the male as a little pedunculated body, called the hydatid of Morgagni, in the neighborhood of the epididymis,[1] between the testis and globus major.

The epididymis, the vas deferens, and ejaculatory duct are formed from the Wolffian duct. One or more of the tubes of the Wolffian body form the vas aberrans and a structure described by Giraldès, and called, after him, "the organ of Giraldès," which bears some resemblance to the organ of Rosenmüller in the other sex. It consists of a number of convoluted tubules, lying in the cellular tissue in front of the cord, and close to the head of the epididymis.

Descent of the Testes.—The testes, at an early period of fœtal life, are placed at the back part of the abdominal cavity, behind the peritoneum and a little below the kidneys. The anterior surface and sides are invested by peritoneum. At about the third month of intra-uterine life a peculiar structure, the *gubernaculum testis*, makes its appearance. This structure is at first a slender band, extending

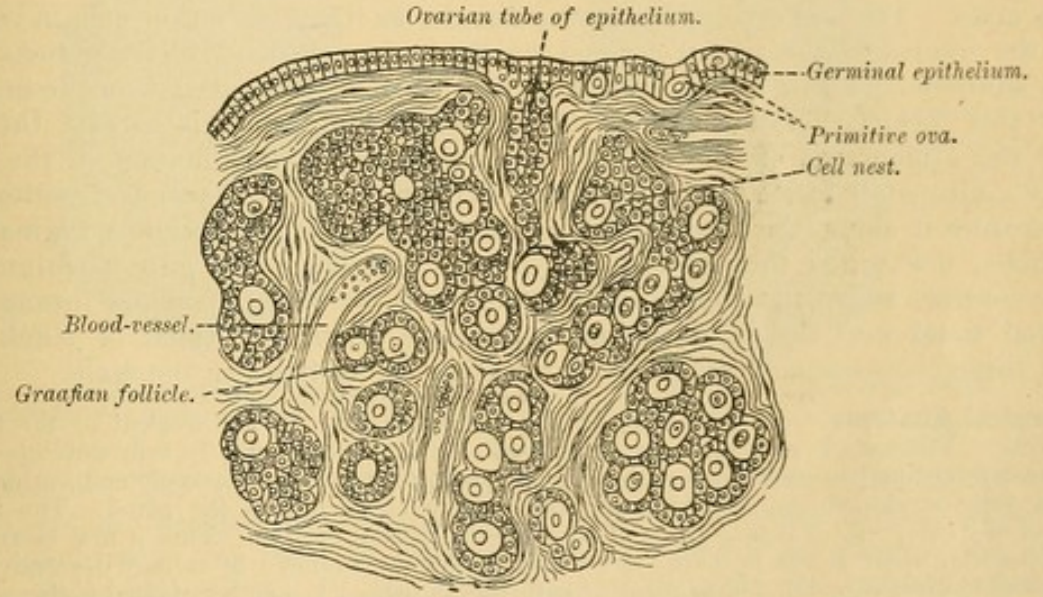

FIG. 779.—Section of the ovary of a newly born child. (Waldeyer.)

from that part of the skin of the groin which afterward forms the scrotum through the inguinal canal to the body and epididymis of the testicle, and is then continued upward in front of the kidney toward the Diaphragm. As development advances the peritoneum covering the testicle encloses it and forms a mesentery, the *mesorchium*, which also encloses the gubernaculum and forms two folds, one above the testicle and the other below it. The one above the testicle is the *plica vascularis*, and contains ultimately the spermatic vessels; the one below, the *plica gubernatrix*, contains the lower part of the gubernaculum, which has now grown into a thick cord; it terminates below at the internal ring in a tube of peritoneum, the processus vaginalis, which protrudes itself down the inguinal canal. The lower part of the gubernaculum by the fifth month has become a thick cord, while the upper part has disappeared. The lower part can now be seen to consist of a central core of unstriped muscle-fibre, and outside this of a firm layer of striped elements, connected, behind the peritoneum, with the abdominal wall. As the scrotum

[1] Mr. Osborn, in the *St. Thomas's Hospital Reports*, 1875, has written an interesting paper pointing out the probable connection between this fœtal structure and one form of hydrocele.

develops, the lower end of the gubernaculum is carried with the skin to which it is attached to the bottom of this pouch. The fold of peritoneum, constituting the processus vaginalis, projects itself downward into the inguinal canal, and emerges at the external abdominal ring, pushing before it a part of the internal oblique muscle and the aponeurosis of the external oblique, which form, respectively, the cremaster muscle and the external spermatic fascia. It forms a gradually elongating depression or *cul-de-sac*, which eventually reaches the bottom of the scrotum, and into this the testicle is drawn by the growth of the body of the fœtus, for the gubernaculum does not grow commensurately with the growth of other parts, and therefore the testicle, being attached by the gubernaculum to the bottom of the scrotum, is prevented from rising as the bottom grows, and is drawn first into the inguinal canal and eventually into the scrotum. It seems certain also that the gubernacular cord becomes shortened as development proceeds, and this assists in causing the testicle to reach the bottom of the scrotum. By the eighth month the testicle has reached the scrotum, preceded by the lengthened pouch of peritoneum, the processus vaginalis, which communicates by its upper extremity with the peritoneal cavity. Just before birth the upper part of the pouch usually becomes closed, and this obliteration extends gradually downward to within a short distance of the testis. The process of peritoneum surrounding the testis, which is now entirely cut off from the general peritoneal cavity, constitutes the *tunica vaginalis*.[1]

In the female there is also a gubernaculum, which effects a considerable change in the position of the ovary, though not so extensive a change as that of the testicle in the male. The gubernaculum in the female, as it lies on either side in contact with the fundus of the uterus formed by the union of the Müllerian ducts, contracts adhesions to this organ, and thus the ovary is prevented from descending below this level. The remains of the gubernaculum—that is to say, the part below the attachment of the cord to the uterus to its termination in the labia majora—ultimately forms the round ligament of the uterus. A pouch of peritoneum accompanies it along the inguinal canal, analogous to the processus vaginalis in the male; it is called the *canal of Nuck*. In rare cases the gubernaculum may fail to contract adhesions to the uterus, and then the ovary descends through the inguinal canal into the labia majora, extending down the canal of Nuck, and under these circumstances resembles in position the testicles in the male.

Surgical Anatomy.—Abnormalities in the formation and in the descent of the testicle may occur. The testicle may fail to be developed; or the testicle may be fully developed, and the vas deferens may be undeveloped in whole or part; or, again, both testicle and vas deferens may be fully developed, but the duct may not become connected to the gland. The testicle may fail in its descent, or it may descend into some abnormal position. Thus it may be retained in the position where it was primarily developed, below the kidney; or it may descend to the internal abdominal ring, but fail to pass through this opening; it may be retained in the inguinal canal, which is perhaps the most common position; or it may pass through the external abdominal ring and remain just outside it, failing to pass to the bottom of the scrotum. On the other hand, it may get into some abnormal position: it may pass the scrotum and reach the perineum, or it may fail to enter the inguinal canal, and may find its way through the femoral ring into the crural canal, and present itself on the thigh at the saphenous opening. There is still a third class of cases of abnormality of the testicle: where the organ has descended in due course into the scrotum, but is malplaced. The most common form of this is where the testicle is *inverted;* that is to say, the organ is rotated so that the epididymis is connected to the front of the scrotum, and the body, surrounded by the tunica vaginalis, is directed backward. In these cases the vas deferens is to be felt in the front of the cord. The condition is of importance in connection with hydrocele and hæmatocele, and the position of the testicle should always be carefully ascertained before performing any operation for these affections. Again, more rarely, the testicle may be *reversed*. This is a condition in which the top of the testicle, indicated by the globus major of the epididymis, is at the bottom of the scrotum, and the vas deferens comes off from the summit of the organ. Cases sometimes occur, generally in the young adult, in which the spermatic cord becomes twisted. In consequence of this the circulation through it is partially or completely arrested; if the latter, the testicle becomes gangrenous; if the former, it may undergo atrophy.

The **external organs of generation** (Fig. 780), like the internal, pass through

[1] The obliteration of the process of peritoneum which accompanies the cord, and is hence called the *funicular process*, is often incomplete. See section on Inguinal Hernia.

a stage in which there is no distinction of sex. It is therefore necessary to describe this stage, and then follow the development of the female and male organs respectively.

As stated above, the anal depression, or proctodæum, at an early period is formed by an involution of the epiblast, and the intestine is still closed at its lower end. When the septum between the two opens, which is about the fourth week, the urachus in front and the intestine behind both communicate with the anal

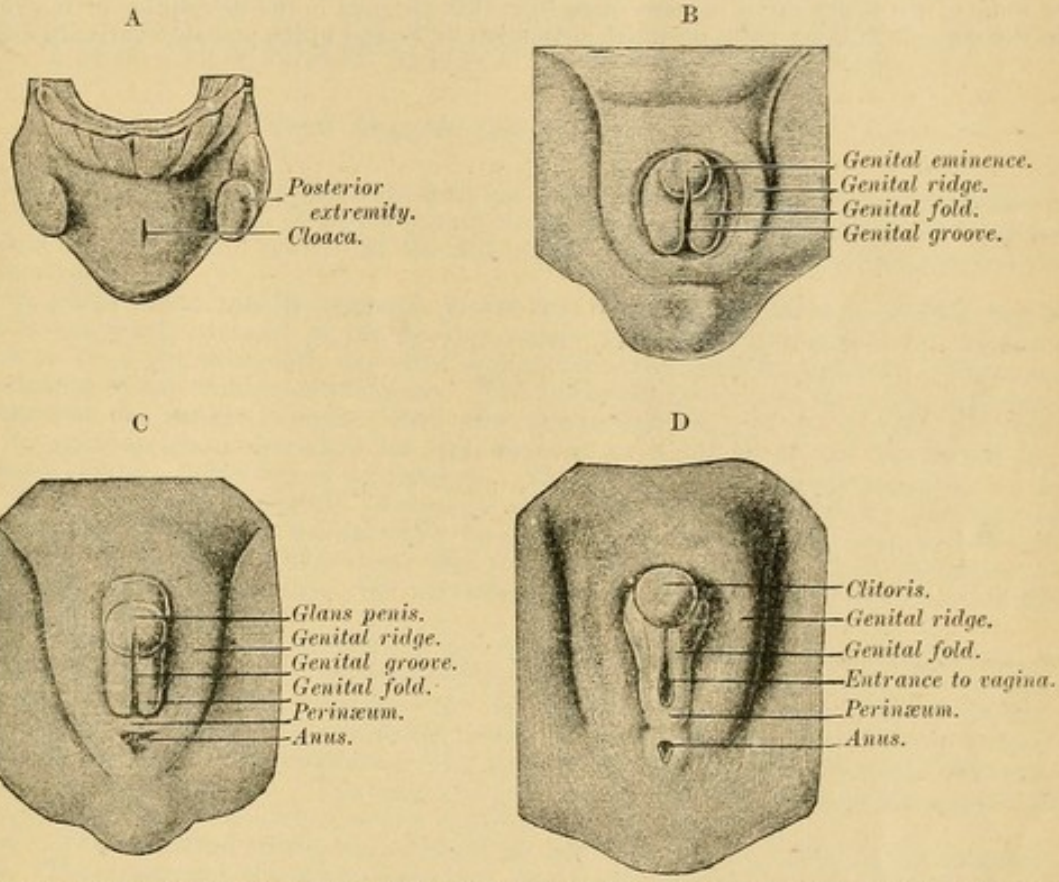

FIG. 780.—Stages in the development of the external sexual organs in the male and female. (After the Ecker-Ziegler wax models.) (From Hertwig's *Entwickelungsgeschichte.*)

depression. This, which is now called the *cloaca*, is afterward divided by a transverse septum, the *perinæum*, which appears about the second month. Two tubes are thus formed: the posterior becomes the lower part of the rectum, the anterior is the urogenital sinus. In the sixth week a tubercle, the *genital eminence*, is formed in front of the cloaca, and this is soon surrounded by two folds of skin, the *genital ridges*. Toward the end of the second month the genital tubercle presents, on its lower aspect, a groove, the *genital groove*, which extends downward toward the cloaca. This groove becomes deeper, and is bounded laterally by projecting folds of skin, the *genital folds*. All these parts are well developed by the second month, yet no distinction of sex is possible.

Female Organs.—The female organs are developed by an easy transition from the above. The urogenital sinus persists as the vestibule of the vagina and the urethra. The genital eminence forms the clitoris, the genital ridges the labia majora, and the lips of the genital groove the labia minora, which remain open. An innovation of the epithelium takes place on either side close to the root of the genital tubercle, which becomes the glands of Bartholin.

Male Organs.—In the male the changes are greater. The genital eminence is developed into the penis, the glans appearing in the third month, the prepuce and corpora cavernosa in the fourth. The genital groove closes and thus forms a canal, the spongy portion of the urethra. The urogenital sinus becomes elongated and forms the membranous urethra. The genital ridges unite in the middle line to form the scrotum, at about the same time as the genital groove closes, viz.,

between the third and fourth month. A similar involution of epithelium to that which in the female forms the glands of Bartholin takes place in the male and becomes the glands of Cowper.

The following table is translated from the work of Beaunis and Bouchard, with some alterations, especially in the earlier weeks. It will serve to present a *résumé* of the above facts in an easily accessible form.[1]

[1] It will be noticed that the time assigned in this table for the appearance of the first rudiment of some of the bones varies in some cases from that assigned in the description of the various bones in the sequel. This is a point on which anatomists differ, and which probably varies in different cases.

CHRONOLOGICAL TABLE

OF

THE DEVELOPMENT OF THE FŒTUS.

(From Beaunis and Bouchard.)

First Week.—During this period the ovum is in the Fallopian tube. Having been fertilized in the upper part of the tube, it slowly passes down, undergoing segmentation, and reaches the uterus probably about the end of the first week. During this time it does not undergo much increase in size.

Second Week.—The ovum rapidly increases in size and becomes imbedded in the decidua, so that it is completely enclosed in the decidua reflexa by the end of this period. An ovum believed to be of the thirteenth day after conception is described by Reichert. There was no appearance of any embryonic structure. The equatorial margins of the ovum were beset with villi, but the surface in contact with the uterine wall and the one opposite to it were bare. In another ovum, described by His, believed to be of about the fourteenth day, there was a distinct indication of an embryo. There was a medullary groove bounded by folds. In front of this a slightly prominent ridge, the rudimentary heart. The amnion was formed and the embryo was attached by a stalk, the allantois, to the inner surface of the chorion. It may be said, therefore, that these parts, the amnion and the allantois, and the first rudiments of the embryo, the medullary groove, and the heart, are formed at the end of the second week.

Third Week.—By the end of the third week the flexures of the embryo have taken place, so that it is strongly curved. The protovertebral disks, which begin to be formed early in the third week, present their full complement. In the nervous system the primary divisions of the brain are visible, and the primitive ocular and auditory vesicles are already formed. The primary circulation is established. The alimentary canal presents a straight tube communicating with the yolk-sac. The branchial arches are formed. The limbs have appeared as short buds. The Wolffian bodies are visible.

Fourth Week.—The umbilical vesicle has attained its full development. The caudal extremity projects. The upper and the lower limbs and the cloacal aperture appear. The heart separates into a right and left heart. The special ganglia and anterior roots of the spinal nerves, the olfactory fossæ, the lungs and the pancreas can be made out.

Fifth Week.—The allantois is vascular in its whole extent. The first traces of the hands and feet can be seen. The primitive aorta divides into aorta and pulmonary artery. The duct of Müller and genital gland are visible. The ossification of the clavicle and the lower jaw commences. The cartilage of Meckel occupies the first post-oral arch.

Sixth Week.—The activity of the umbilical vesicle ceases. The pharyngeal clefts disappear. The vertebral column, primitive cranium, and ribs assume the cartilaginous condition. The posterior roots of the nerves, the membranes of the nervous centres, the bladder, kidney, tongue, larynx, thyroid body, the germs of teeth, and the genital tubercle and folds are apparent.

Seventh Week.—The muscles begin to be perceptible. The points of ossification of the ribs, scapula, shaft of humerus, femur, tibia, palate, and upper jaw appear.

Eighth Week.—The distinction of arm and forearm, and of thigh and leg, is apparent, as well as the interdigital clefts. The capsule of the lens and pupillary membrane, the interventricular and commencement of the interauricular septum, the salivary glands, the spleen, and suprarenal capsules are distinguishable. The larynx begins to become cartilaginous. All the vertebral bodies are cartilaginous. The points of ossification for the ulna, radius, fibula, and ilium make their appearance. The two halves of the hard palate unite. The sympathetic nerves are now for the first time to be discerned.

[1] [Eternod (*Anat. Anzeiger*, Band xv., 1898) described an ovum which he reconstructed. It had a precise history, from which he concluded that it must have belonged to the end of the second or the beginning of the third week. Including the villi it measured $10 \times 8.2 \times 6$ mm. It was flattened on its embryonal side, and the embryo measured 1.3 mm. The amnion was completely formed and the allantois existed as a long canal. The vitelline circulation was established and the villi of the chorion were beginning to be vascularized. The blastopore still opened into the amniotic cavity, with the primitive groove behind it and the rudimentary groove in front. The notochord was closing in and all three layers of the blastoderm were distinct, except around the blastopore, where they formed an undivided mass.—Eds.]

Ninth Week.—The corpus striatum and the pericardium are first apparent. The ovary and testicle can be distinguished from each other. The genital furrow appears. The osseous nuclei of the bodies and arches of the vertebræ, of the frontal, vomer, and malar bones of the shafts of the metacarpal and metatarsal bones, and of the phalanges appear. The union of the hard palate is completed. The gall-bladder is seen.

Third Month.—The formation of the fœtal placenta advances rapidly. The projection of the caudal extremity disappears. It is possible to distinguish the male and female organs from each other. The cloacal aperture in divided into two parts. The cartilaginous arches on the dorsal region of the spine close. The points of ossification for the occipital, sphenoid, lachrymal, nasal, squamous portion of temporal and ischium appear, as well as the orbital centre of the superior maxillary. The pons Varolii and fissure of Sylvius can be made out. The eyelids, the hair, and the nails begin to form. The mammary gland, the epiglottis, and prostate are beginning to develop. The union of the testicle with the canals of the Wolffian body takes place.

Fourth Month.—The closure of the cartilaginous arches of the spine is complete. Osseous points for the first sacral vertebra and os pubis appear. The ossification of the malleus and incus takes place. The corpus callosum, the membrana lamina spiralis, the cartilage of the Eustachian tube, and the tympanic ring are seen. Fat is first developed in the subcutaneous cellular tissue. The tonsils are seen, and the closure of the genital furrow and the formation of the scrotum and prepuce take place.

Fifth Month.—The two layers of the decidua begin to coalesce. Osseous nuclei of the axis and odontoid process, of the lateral points of the first sacral vertebra, of the median points of the second, and of the lateral masses of the ethmoid make their appearance. Ossification of the stapes and the petrous bone and ossification of the germs of the teeth take place. The germs of the permanent teeth and the organ of Corti appear. The eruption of hair on the head commences. The sudoriferous glands, Brunner's glands, the follicles of the tonsil and base of the tongue, and the lymphatic glands appear at this period. The differentiation between the uterus and vagina becomes apparent.

Sixth Month.—The points of ossification for the anterior root of the transverse process of the seventh cervical vertebra, the lateral points of the second sacral vertebra, the median points of the third, the manubrium sterni and the os calcis appear. The sacro-vertebral angle forms. The cerebral hemispheres cover the cerebellum. The papillæ of the skin, the sebaceous glands, and Peyer's patches make their appearance. The free border of the nail projects from the corium of the dermis. The walls of the uterus thicken.

Seventh Month.—The additional points of the first sacral vertebra, the lateral points of the third, the median point of the fourth, the first osseous point of the body of the sternum, and the osseous point for the astragalus appear. Meckel's cartilage disappears. The cerebral convolutions, the island of Reil, and the tubercula quadrigemina are apparent. The pupillary membrane atrophies. The testicle passes into the vaginal process of the peritoneum.

Eighth Month.—Additional points for the second sacral vertebra, lateral points for the fourth and median points for the fifth sacral vertebræ, can be seen.

Ninth Month.—Additional points for the third sacral vertebra, lateral points for the fifth, osseous points for the middle turbinated bone, for the body and great cornu of the hyoid, for the second and third pieces of the body of the sternum, and for the lower end of the femur appear. Ossification of the bony lamina spiralis and axis of the cochlea takes place. The eyelids open, and the testicles are in the scrotum.

INDEX.

A.

Abdomen, 895
  apertures found in, 895
  boundaries of, 895
  lymphatics of, 632
  muscles of, 356
  regions of, 895
  viscera of, 896
Abdominal aorta, 549
    branches of, 550
    surface-marking of, 550
    surgical anatomy of, 550
  muscles, 356
  ring, external, 357, 1043
    internal, 366, 1047
  stalk, *note*, 1162
  viscera, position of, 896
Abdomino-thoracic arch, 133
Abducent nerve, 738
    surgical anatomy of, 740
Abductor hallucis muscle, 444
  indicis muscle, 408
  minimi digiti muscle, foot, 445
      hand, 406
  pollicis muscle, 404
Aberrant duct of testis, 1021
Absorbent glands, 623
Absorbents, 623
Accelerator urinæ muscle, 371
Accessorius ad ilio-costalem muscle, 343
  pedis, 446
Accessory descending palatine canals, 91
  gland of Rosenmüller, 845
  obturator nerve, 786
  olivary nuclei, 703
  processes, 42
  pudic artery, 565
  thyroid glands, 980
Acervulus cerebri, 673
Acetabulum, 177
Achromatic spindle, 1075
Achromatin, 1074
Acromial end of clavicle, fracture of, 412
  region, muscles of, 382
  thoracic artery, 532
Acromio-clavicular joint, 248
    surface form of, 249
    surgical anatomy of, 249
Acromion process, 140
    fracture of, 412
Actions of muscles. See each group of muscles.
Adamantoblasts, 879
Adductor brevis muscle, 425
  longus muscle, 424
  magnus muscle, 425
  obliquus hallucis, 447
    pollicis, 404
Adductor transversus hallucis, 447
  pollicis, 405
  tubercle, 187
Adenoid connective tissue, 1091
Adipose tissue, 1091
Adminiculum lineæ albæ, 360
Afferent nerves, 1120
  vessels of kidney, 992
Air-cells, 976
Ala cinerea, 698, 702
  lobuli centralis, 686
  nasi, 818
    artery of, 491
Alæ of sacrum, 48
  of vomer, 95
Alar lamina, 1177
  ligaments, 230
    of knee, 278
  thoracic artery, 533
Alcock, canal of, 565, 1064
Alimentary canal, 869
    development of, 1198
    subdivisions of, 869
Allantoic vesicle, 1162
  vessels, 1162
Allantois, 1162
Alveolar artery, 499
  process, 86, 98
Alveoli, formation of, 880
  of lower jaw, 98
  of stomach, 910
  of upper jaw, 86
Alveus, 666
Amacrine cells of retina, 835
Amnion, 1160
  false, 1161
  true, 1161
Amniotic cavity, 1161
    primitive, 1154
Amphiarthrosis, 219
Ampullæ of semicircular canals, 860
  of tubuli lactiferi, 1040
Amygdalæ, 884
  of cerebellum, 688
Amygdaloid nucleus, 662
Anal canal, 925
  fascia, 369, 1071
Anaphase of karyokinesis, 1075
Anastomosis of arteries, 474
Anastomotica magna of brachial, 536
    of femoral, 580
Anatomical neck of humerus, 144
      fracture of, 149
Anconeus muscle, 397
Andersch, ganglion of, 748
Aneurisms of abdominal aorta, 550
  of arch of aorta, 479
Aneurisms of thoracic aorta, 547
Angle of jaw, 101
  of Ludwig, 132
  of os pubis, 176
  of rib, 129
  sacro-vertebral, 46
Angular artery, 492
  convolution, 651
  movement, 222
  process, external, 62
    internal, 62
  vein, 595
Animal cell, 1073
  constituent of bone, 1102
Ankle-joint, 283
  relations of tendons and vessels to, 285
  surface form of, 285
  surgical anatomy of, 285
Annular ligament of ankle, anterior, 442
      external, 443
      internal, 442
    of radius and ulna, 259
    of stapes, 857
    of wrist, anterior, 401
      posterior, 402
Annulus ovalis, 462
  tympanicus, 851
Ansa hypoglossi, 756
  peduncularis, 672
Anterior annular ligament, ankle, 442
      wrist, 401
  chamber of eye, 839
  crescentic lobe, 686
  crural nerve, 786
      surgical anatomy of, 797
  dental canal, 83
  ethmoidal cells, 79
  fontanelle, 81
  fossa of skull, 103
  and internal frontal artery 510
  nasal spine, 88
  nerve-roots, 717
  palatine canal, 87
    fossa, 87, 108
  perforated space, 655
  region of skull, 112
  triangle of neck, 500
Antero-lateral ascending tract of cord, 714
  ganglionic artery, 511
  ground bundle, 714
Antero-median ganglionic artery, 510
Antihelix, 849
  fossa of, 849
Antitragicus muscle, 850
Antitragus, 849

Antrum of Highmore, 83
mastoid, 68, 854
pylori, 906
Anus, 1063
development of, 1202
muscles of, 368
Aorta, 475
abdominal, 549
branches of, 550
surgical anatomy of arch of, 479
arch of, 478
branches of, 480
peculiarities of, 479
branches of, 480
sinuses of, 477
surgical anatomy of, 479
descending, 546
development of, 1191
thoracic, 546
branches of, 547
sinuses of, 477
surgical anatomy of, 547
transverse, 478
Aortic isthmus, 478
opening of diaphragm, 353
of heart, 466
plexus, 809
semilunar valves, 467
septum, 1191
sinuses, 467
spindle, 478
vestibule, 468
Apertura scalæ vestibuli cochleæ, 861
Apex cornu of cord, 712
Aponeurosis, 296
of deltoid, 382
of external oblique in inguinal region, 357
of occipito-frontalis, 300
of soft palate, 883
suprahyoid, 321
Apophysis, 34
Apparatus ligamentosus coli, 230
Appendages of eye, 843
surgical anatomy of, 847
of skin, 1139
of uterus, 1034
Appendices epiploicæ, 928
Appendix of left auricle, 465
of right auricle, 461
vermiformis, 922
Aqua labyrinthi, 866
Aquæductus cochleæ, 69, 861
Fallopii, 69, 854
Sylvius, 676
vestibuli, 69, 860
Aqueous humor, 839
Arachnoid of brain, 641
of cord, 707
Arantii corpora, 464
Arbor vitæ of cerebellum, 689
uterina, 1031, 1032
Arch of aorta, 478
branches of, 480
peculiarities of, 479
surgical anatomy of, 479
crural, 1057
deep, 539
of os pubis, 182
palmar superficial, 544
plantar, 592
supraorbital, 61
Arch of a vertebra, 34
zygomatic, 111
Arches, aortic, fœtal, 1292
branchial, 1168
Arciform or arcuate fibres of medulla oblongata, 696, 701
Arcuate fibres of cerebellum, 691
Area of Broca, 655
of Cohnheim, 1109
cribrosa, media, 69
superior, 69
germinal, 1154
vestibularis, inferior, 867
superior, 867
Areas of Cohnheim, 1109
Areola of breast, 1039
Areolæ of bone, primary, 1103
secondary, 1105
Areolar tissue, 1086
Arm, arteries of, 514
back of, muscles of, 388
bones of, 144
fascia of, 386
front of, muscles of, 386
lymphatic glands of, 628
lymphatics of, 628
nerves of, 764
superficial fascia of, 382
veins of, 607
Arnold's ganglion, 736
nerve, 751
canal, 70
Arrectores pili, 1142
Arteria centralis retinæ, 509
hyaloidea, 1182
magna, 475
Arteriæ hallucis, 588
propriæ renales, 992
receptaculi, 505
Arteries, anastomoses of, 474
capillary, 1128
development of, 1191
distribution of, 474
general anatomy of, 1126
mode of division, 474
of origin of branches, 474
nerves of, 1128
sheath of, 1128
structure of, 1126
subdivision of, 474
systemic, 474
vessels of, 1128
Arteries or artery, accessory pudic, 566
acromial, thoracic, 532
alar thoracic, 533
alveolar, 499
anastomotica magna of brachial, 537
of femoral, 580
angular, 492
anterior cerebral, 510
choroid, 512
ciliary, 509
communicating, 511
inferior cerebellar, 522
intercostal, 526
internal frontal, 510
spinal, 521
antero-lateral ganglionic, 511
antero-median ganglionic, 510
aorta, 475
abdominal, 549
arch of, 478
ascending part, 476
Arteries or artery, aorta, descending part, 546
thoracic, 546
articular knee, 583
ascending cervical, 523
pharyngeal, 494
auditory, 522
auricular, anterior, 495
posterior, 494
axillary, 529
azygos of knee, 584
basilar, 522
brachial, 533
bronchial, 547, 976
buccal, 498
of bulb, 567
bulbar, 522
calcanean, external, 591
internal, 591
carotid, common, 482
external, 486
internal, 502
carpal, radial, 540
ulnar, 544
of cavernous body, 567
centralis retinæ, 509
cerebellar, 522
cerebral, 509, 511, 522
ascending cervical, 523
princeps, 493
profunda, 527
superficial cervical, 524
choroid, anterior, 512
posterior, 523
ciliary, 509
circle of Willis, 512, 523
circumflex, of arm, 533
of iliac, deep, 572
superficial, 578
of thigh, 579
coccygeal, 568
cochlear, 866
cœliac axis, 551
colica dextra, 555
media, 555
sinistra, 555
comes nervi ischiadici, 568
phrenici, 526
common carotid, 482
iliac, 559
communicating, anterior cerebri, 510
branch of ulnar, 544
posterior cerebri, 511
coronary of heart, 477
of lip, 491
cremasteric, 571
crico-thyroid, 488
cystic, 553
deep branch of ulnar, 545
cervical, 527
palmar arch, 538
temporal, 498
deferent, 563
dental, anterior, 499
inferior, 498
descending aorta, 546
coronary, 478
palatine, 499
digital plantar, 592
of ulnar, 545
dorsal, of penis, 565
of scapula, 533
dorsalis hallucis, 587, 588
indicis, 541

Arteries or artery, dorsalis linguæ, 489
pedis, 587
pollicis, 541
epigastric, deep, 571
superficial, 578
superior, 527
ethmoidal, 506
external carotid, 486
iliac, 570
plantar, 591
facial, 489
femoral, 572
deep, 578
frontal, 508
gastric, 551, 553
gastro-duodenalis, 552
gastro-epiploica dextra, 553
sinistra, 553
gluteal, 569
inferior, 568
helicine, 1013
hemorrhoidal inferior, 567
middle, 563
superior, 555
hepatic, 551
hyoid branch of lingual, 489
of superior thyroid, 488
hypogastric, in fœtus, 473, 562
ileo-colic, 555
iliac, common, 559
external, 570
internal, 561
ilio-lumbar, 569
inferior cerebellar, anterior, 522
posterior, 521
dental, 498
labial, 491
laryngeal, 523
mesenteric, 555
profunda, 537
thyroid, 523
infraorbital, 499
infundibular, 478
innominate, 480
intercostal, 547
anterior, 526
superior, 527
internal auditory, 866
carotid, 502
iliac, 561
mammary, 526
maxillary, 496
plantar, 591
interosseous, of foot, 588
of hand, 543
ulnar, 543
intestini tenuis, 554
labial inferior, 491
lachrymal, 506
laryngeal, inferior, 523
superior, 488
lateral nasal, 491
sacral, 569
spinal, 521
lingual, 488
long ciliary, 509
thoracic, 532
lumbar, 558
malleolar, 587
mammary, internal, 528
marginal, 477
masseteric, 498
maxillary, internal, 496
Arteries or artery, median, of forearm, 543
of spinal cord, 522
mediastinal, 526
posterior, 547
meningeal, anterior, 505
middle, 496
small, 498
from occipital, 493
from pharyngeal, 495
from vertebral, 520
mesenteric, inferior, 555
superior, 553
metacarpal, 540
metatarsal, 588
middle cerebral, 511
sacral, 558
musculo-phrenic, 527
mylo-hyoid, 498
nasal, of ophthalmic, 508
of septum, 491
inferior, 491
superior, 499
nutrient, of femur, 579
of fibula, 590
of humerus, 526
of tibia, 590
obturator, 564
occipital, 493
œsophageal, 547
ophthalmic, 505
ovarian, 557
palatine, ascending, 491
descending, 499
palmar arch, deep, 544
superficial, 544
of pharyngeal, 494
palmar interossei, 541
palpebral, 508
pancreatic, 553
pancreatico-duodenalis, 553
inferior, 554
perforating, of foot, 592
of hand, 541
of internal mammary, 526
of thigh, 579
pericardiac, 526, 547
perineal, superficial, 567
transverse, 567
peroneal, 590
anterior, 590
pharyngeal, ascending, 494
phrenic, 557
plantar, 591
popliteal, 582
posterior auricular, 494
cerebral, 522
communicating, 511
meningeal, from vertebral, 521
tibial, 588
princeps cervicis, 493
pollicis, 541
profunda of arm, inferior, 537
superior, 537
cervicis, 527
femoris, 578
pterygoid, 498
pterygo-palatine, 499
pudic, deep external, 578
internal, in female, 567
in male, 565
superficial external, 578
pulmonary, 475, 976
Arteries or artery, pyloric, 552
radial, 538
radialis indicis, 541
ranine, 489
recurrent interosseous, 544
radial, 539
tibial, anterior, 586
posterior, 586
ulnar, anterior, 543
posterior, 543
renal, 556
sacral, lateral, 569
middle, 558
scapular, posterior, 526
sciatic, 567
short ciliary, 509
sigmoid, 555
spermatic, 557, 1016
spheno-palatine, 499
spinal, anterior, 521
lateral, 521
median, 521
posterior, 521
splenic, 553
sterno-mastoid, 493
stylo-mastoid, 494
subclavian, 502
subcostal, 547
sublingual, 489
submaxillary, 491
submental, 491
subscapular, 533
superficial cervical, 524
circumflex iliac, 578
palmar arch, 544
perineal, 567
temporal, 495
superficialis volæ, 540
superior cerebellar, 522
epigastric, 527
hemorrhoidal, 555
intercostal, 527
laryngeal, 488
mesenteric, 553
profunda, 537
thoracic, 532
thyroid, 489
supra-acromial, 524
supraorbital, 506
suprarenal, 556
suprascapular, 524
suprasternal, 524
sural, 583
tarsal, 588
temporal, 495
anterior, 495
deep, 498
middle, 495
posterior, 495
thoracic, acromial, 532
alar, 533
aorta, 546
long, 532
superior, 532
thyroid axis, 523
inferior, 523
superior, 487
thyroidea ima, 481
tibial, anterior, 585
posterior, 588
recurrent, 586
tonsillar, 491
transverse, coronary, 477
facial, 495
transversalis colli, 524

Arteries or artery, tympanic, from internal carotid, 505
from internal maxillary, 524
ulnar, 542
recurrent anterior, 543
posterior, 543
umbilical, in fœtus, 562, 473
uterine, 563
vaginal, 564
vasa aberrantia of arm, 535
brevia, 553
intestini tenuis, 554
of vas deferens, 563
vertebral, 520
vesical, inferior, 563
middle, 563
superior, 563
Vidian, 499
Arteriolæ rectæ, 992
Arthrodia, 220
Articular arteries (knee), from popliteal, 584
cartilage, 1093
end-bulbs, 1121
lamella of bone, 217
processes of vertebræ, 36
synovial membranes, 217
Articulations, acromio-clavicular, 248
ankle, 283
astragalo-calcanean, 287
navicular, 288
atlanto-axial, 227
calcaneo-astragaloid, 287
-cuboid, 287
-navicular, 288
carpal, 263
carpo-metacarpal, 265
chondro-sternal, 238
classification of, 218
coccygeal, 244
costo-central, 234
-transverse, 234
-vertebral, 234
of cuboid with external cuneiform, 290
of cuneiform with each other, 290
different kinds of, 218
elbow of, 255
femoro-tibial, 274
in general, 217
hip, 268
immovable, 218
knee, 274
metacarpal, 263
metacarpo-phalangeal, 267
metatarsal, 291
metatarso-phalangeal, 292
mixed, 219
movable, 219
movements of, 220
naviculo-cuboid, 289
-cuneiform, 289
occipito-atlantal, 229
-axial, 230
pelvis, 241
with spine, 242
phalanges, 268
pubic, 244
radio-carpal, 262
-ulnar, inferior, 260
middle, 259
superior, 259
Articulations, sacro-coccygeal, 244
-iliac, 242
-sciatic, 242
-vertebral, 240
scapulo-clavicular, 248
-humeral, 250
shoulder, 251
sterno-clavicular, 246
of sternum, 239
tarsal, 287
tarso-metatarsal, 290
temporo-mandibular, 231
tibio-fibular, inferior, 283
middle, 283
superior, 283
of tympanic bones, 857
vertebral column, 223
wrist, 262
Arytæno-epiglottidean folds, 959
Arytæno-epiglottideus, inferior, 963
superior, 963
Arytenoid cartilages, 957
glands, 964
muscle, 962
Arytenoideus rectus, *note*, 963
Ascending colon, 923
cutaneous nerve, 791
frontal artery, 511
nerve tracts, 719
oblique muscle of abdomen, 360
palatine artery, 491
parietal artery, 511
pharyngeal artery, 494
surgical anatomy of, 495
Association fibres of hemispheres of brain, 678
Asterion, 1151
Astragalus, 203
development of, 211
Atlanto-axial articulation, 227
Atlas, 36
development of, 43
Atlo-odontoid joint, 227
Atrabiliary capsules, 997
Atrium, 819
of right auricle, 461
of tympanic cavity, 853
Attic of epitympanic process, 853
of tympanum, 1109
Attollens auriculam muscle, 301
Attraction particle, or centrosome, 1075
sphere, or centrosphere, 1075
Attrahens auriculam muscle, 300
Auditory artery, 866
internal, 523
canal, 851
meatus, external, 69
surface form of, 852
internal, 69
nerve, 745, 866
surgical anatomy of, 746
teeth, 864
veins, 866
Auerbach's plexus, 921
Auricle of ear, 848
cartilage of, 849
ligaments of, 849
of heart, left, 465
appendix of, 465
Auricle of heart, left, sinus of, 465
right, 461
openings in, 462
septum of, 402
sinus of, 461
valves in, 462
Auricular artery, anterior, 495
posterior, 494
fissure, 70, 107
lymphatic glands, 625
nerve of vagus, 751
posterior, from facial, 743
surface of sacrum, 47
veins, anterior, 596
posterior, 597
Auricularis anterior muscle, 300
magnus nerve, 762
posterior muscle, 301
superior muscle, 301
Auriculo-temporal nerve, 735
Auriculo-ventricular groove of heart, 460
opening, left, 466
right, 462
Axes of the pelvis, 181
Axilla, 527
dissection of, 376
surgical anatomy of, 527
Axillary artery, 529
branches of, 532
lymphatic glands, 628
peculiarities of, 531
space, 528
surface-marking of, 531
surgical anatomy of, 531
vein, 609
surgical anatomy of, 609
Axis, cerebro-spinal, 639
cœliac, 551
development of, 45
or second vertebra, 37
thyroid, 523
Axis-cylinder of nerve-fibres, 1116
Axon of nerve-cells, 1115
Azygos artery, articular, 584
of vagina, 563, 564
uvulæ muscle, 330
veins, 611

B.

Back, muscles of, fifth layer, 346
first layer, 336
fourth layer, 343
second layer, 340
third layer, 341
Ball-and-socket joint. See *Enarthrodia*.
Band of Baillarger, 664
of Giacomini, 653
of Gennari, 678
inner, 678
outer, 678
Bartholin, duct of, 887
glands of, 1027
Basal lamina, 1177
layer of decidua, 1163
ridge, 872
Base of brain, 655
of sacrum, 48
of skull, 103
external surface, 106
internal surface, 103

Basement membranes, 1091
Basi-hyal of hyoid bone, 122
Basilar artery, 522
groove, 58
membrane of cochlea, 863
plate, 1167
process, 56
suture, 102
Basilic vein, 608
median, 608
Basis vertebrarum venæ, 612
Basket cells of cerebellum, 692
Bauhin, valve of, 923
Beak of corpus callosum, 659
Beaunis et Bouchard, Table of Development of Fœtus from, 1215
Bechterew, nucleus of, 745
Bend of elbow, 534
Biceps flexor cruris, 432
cubiti, 387
Bicipital fascia, 387
groove, 144
ridges, 146
tuberosity, 155
Bicuspid teeth, 872
Biliary ducts, 942, 943
structure, 943
Bird's nest of cerebellum, 688
Biventer cervicis muscle, 346
Biventral lobe, 689
Bladder, 998
development of, 1208
female, 1007
ligaments of, 1002
surface form of, 1004
surgical anatomy of, 1004
trigone of, 1003
vessels and nerves of, 1004
Blastodermic membrane, 1154
vesicle, 1153
Blastopore, 1154
Blood, circulation of, in adult, 460
in fœtus, 471
coagulation of, 1080
gases of, 1081
general composition of, 1077
plasma of, 1080
Blood-corpuscles, 1077
Blood-crystals, 1081
Blood-disks, development of, 1188
Blood-globules, 1078
Blood-plaques, 1080
Blood-vascular system, development of, 1187
Blood-vessels of brain, 512
Bochdalek, ganglion of, 731
on musculus triticeo-glossus, 963, *note*.
Body of a tooth, 871
of a vertebra, 35
Bone, animal constituent of, 1101
apophysis of, 34
articular lamella of, 217
canaliculi of, 1100
cancellous tissue of, 1096
cells, 1100
chemical composition of, 1101
compact tissue of, 1096
development of, 1101
diploë of, 34
earthy constituent of, 1101
eminences and depressions of, 34
Bone, epiphysis of, 34
general anatomy of, 1096
growth of, 1106
Haversian canals of, 1098
systems of, 1098
inorganic constituent of, 1101
lacunæ of, 1099
lamellæ of, 1099
lymphatics of, 1098
marrow of, 1096
medullary canal of, 33, 1096
membrane of, 1096
minute anatomy, 1098
nerves of, 1098
organic constituent of, 1101
ossific centres, number of, 1106
ossification of, 1102
periosteum of, 1096
spongy tissue of, 33
vessels of, 1007
Bones, forms of, viz., long, flat, short, mixed, irregular, 33
number of, in the body, 33
Bones or bone, astragalus, 203
atlas, 36
axis, 37
calcaneum, 199
carpal, 158
clavicle, 135
coccyx, 50
cranial, 55
cuboid, 204
cuneiform, of carpus, 163
of tarsus, 205
descriptive anatomy of, 33
ear, 856
ethmoid, 77
facial, 81
femur, 183
fibula, 196
frontal, 61
hand, 158
humerus, 144
hyoid, 122
ilium, 171
incus, 856
inferior maxillary, 96
turbinated, 94
innominate, 171
ischium, 171, 174
lachrymal, 88
lesser lachrymal, 88
lingual, 122
magnum, 164
malar, 89
malleus, 856
maxillary, inferior, 96
superior, 83
metacarpal, 165
metatarsal, 208
nasal, 81
navicular, 205
occipital, 55
orbicular, 857
palate, 91
parietal, 59
patella, 191
pelvic, 179
phalanges of foot, 210
of hand, 169
pisiform, 162
pubic, 176
radius, 155
ribs, 128
Bones or bone, sacrum, 45
scaphoid, 161
scapula, 138
semilunar, 162
sesamoid, 214
sphenoid, 73
sphenoidal, spongy, 76
stapes, 857
sternum, 126
superior maxillary, 81
tarsal, 199
temporal, 65
tibia, 192
trapezium, 163
trapezoid, 163
triquetral, 80
turbinate, inferior, 94
middle, 79
superior, 79
tympanic, 71
ulna, 150
unciform, 165
vertebra prominens, 39
vertebræ, cervical, 35
dorsal, 39
lumbar, 41
vomer, 95
Wormian, 81
Bowman, glands of, 822
sarcous elements of, 1109
Bowman's capsule, 988
Brachia of corpora quadrigemina, 675
Brachial artery, 533
branches of, 536
peculiarities of, 534
surface marking of, 535
surgical anatomy of, 535
lymphatic glands, 628
plexus, 764
surgical anatomy of, 776
region, anterior, muscles of, 390, 392
posterior, muscles of, 396
veins, 609
Brachialis anticus muscle, 388
Brachio-cephalic artery. See *Innominate*.
Brachio-radialis muscle. See *Supinator longus*.
Brain, 643
base of, 655
convolutions of, 644
development of, 1172
dura mater of, 639
general anatomy of, 1118
hemispheres of, 643
interior of, 659
lobes of, 648
membranes and dissection, 639
subdivision into parts, 643
weight of, 703
Branchial arches, 1168
clefts, 1168
Breasts, 1038
Bregma, 103
Brim of pelvis, 180
Broad ligament of uterus, 1030
formation of, 899
Broca, convolution of, 649
Bronchi, right and left, 966
septum of, 967
in lung, 975
Bronchial arteries, 547, 976
branch of innominate, 481

Bronchial lymphatic glands, 636
septum, 967
tubes. See *Bronchi.*
veins, 612, 977
Brunner's glands, 918
Bubonocele, 1051
Buccal arteries, 498
cavity, 869
development of, 1171
glands, 625
lymphatic glands, 625
nerve of facial, 744
of inferior maxillary, 734
veins, 596
Buccinator muscle, 309
Bucco-pharyngeal fascia, 316
Bulb, artery of, 567
of corpus cavernosum, 1012
spongiosum, 1013
of internal jugular vein, 598
olfactory, 654, 720
posterior horn, 662
Bulbar arteries, 522
portion of spinal accessory nerve, 753
Bulbi vestibuli, 1027
Bulbo-cavernous muscle, 371
Bulbous portion of the urethra, 1006
Bulla ethmoidalis, 820
Bundle of Vicq d'Azyr, 657, 665
Burdach's tract, 715
Bursa omentalis, 1199
pharyngea, 891
Bursæ of knee, 278
mucosæ, 218
of shoulder, 251
synoviæ, 218
Bursal synovial membranes, 218

C.

Cæcum, 922
Calamus scriptorius, 697
Calcanean arteries, external, 591
internal, 591
Calcaneo-astragaloid ligaments, 287
Calcaneo-cuboid ligaments, 287
Calcaneo-navicular ligaments, 288
Calcaneo-plantar nerve, 795
Calcaneum, 199
Calcar avis, 662
femorale, 189
Calcarine fissure, 647
Calices of kidney, 987
Callosal fissure, 653
Camper, fascia of, 356
Camper's ligament. See *Triangular Ligament of Urethra.*
Canaliculi of bone, 1100
Canalis centralis cochleæ, 69
hyaloideus of Stilling, 1182
membranous cochlea, 863
reuniens, 862
spiralis modioli, 861
Canals or canal, accessory palatine, 91
alimentary, 869
anterior, for Arnold's nerve, 70
dental, 84
palatine, 87
auditory, 851
Canals or canal, carotid, 70
for chorda tympani, 66, 853
of cochlea, 863
crural, 1059
dental, posterior, 84
ethmoidal, 64
Haversian, of bone, 1098
of Huguier, 66
inferior dental, 98
infraorbital, 84
inguinal, 1046
for Jacobson's (tympanic) nerve, 70
lachrymal, 845
naso-palatine, 87
of Nuck, 1038, 1047, 1212
of Petit, 840
palatine, anterior, 87
posterior, 85
pterygo-palatine, 74
sacral, 47
of Schlemm, 827
semicircular, 860
spermatic, 1046
of spinal cord, 712
spiral, of cochlea, 860
of modiolus, 861
of Stilling, 839
temporo-malar, 90
for tensor tympani, 71, 854
vertebral, 53
Vidian, 75
of Wirsung, 947
Cancellous tissue of bone, 1096
Canine eminence, 83
fossa, 83
teeth, 872
Canthi of eyelids, 843
Capillaries, 1128
structure of, 1129
Capitellum of humerus, 147
Capsula extrema, 664
Capsular ligament of hip, 268
of knee, 274
of shoulder, 251
of thumb, 265
of vertebræ, 225
Capsule, external, of brain, 664
in fœtus, 1182
of Glisson, 938
internal, of brain, 663
of kidney, 986
of lens, 840
of Tenon, 824
Capsules, suprarenal, 996
Caput cornu of cord, 712, 715
gallinaginis, 1005
Cardiac lymphatics, 637
muscular tissue, 1112
nerves, 803
from pneumogastric, 752
plexus of nerves, deep, 806
superficial, 806
veins, 621
Cardinal veins, fœtal, 1196
Carotid artery, common, 482
branches of (occasional), 485
peculiarities of, 484, 485
surface-marking of, 485
surgical anatomy of, 485
external, 486
branches of, 487
surface-marking of, 487
surgical anatomy of, 487
Carotid artery, internal, 502
branches of, 505
peculiarities of, 504
surgical anatomy of, 505
tubercle, 36
branch of Vidian, 732
canal, 68
ganglion, 801
groove, 73
plexus, 799
triangle, anterior, 500
inferior, 500
superior, 500
Carpal arch, anterior, 540
posterior, 540
arteries, from radial, 540
from ulnar, 544
ligaments, 263
Carpo-metacarpal articulations, 265
Carpus, 158
articulations of, 263
development of, 170
surface form of, 169
surgical anatomy of, 170
Cartilage, articular, 1093
arytenoid, 957
of bronchi, 976
cellular, 1092
costal, 132, 1094
cricoid, 956
cuneiform, 958
of ear, 849
ensiform, 124
of epiglottis, 958
fibro-, 1095
general anatomy, 1092
hyaline, 1093
of Jacobson, 820
of larynx, 955
matrix of, 1093
of the nose, 818
permanent, 1092
of the pinna, 849
of Santorini, 957
semilunar, of knee, 276
of septum of nose, 819
temporary, 1094
thyroid, 955
of trachea, 966
white fibro-, 1094
of Wrisberg, 958
yellow elastic, 1095
xiphoid, 124
Cartilage-cells, 1092
Cartilage-lacunæ, 1093
Cartilagines minores, 819
Cartilago triticea, 958
Caruncula lachrymalis, 846
Carunculæ myrtiformes, 1027
Cauda equina, 788
helicis, 849
Caudal or post-anal gut, 1203
Cava, inferior, 617
peculiarities of, 618
superior, 611
Cavernous body, artery of, 567
groove, 73
nerves of penis, 810
plexus, 799
sinus, 603
nerves in, 739
surgical anatomy of, 604
Cavity, cotyloid, 177
glenoid, 141

Cavity of pelvis, 180
sigmoid, greater, 152
lesser, 152
Cavum conchæ, 849
Meckelii, 726
oris proprium, 869
Cells, animal, 1073
of bone, 1100
chalice-, 1084
of Claudius, 866
column lateral, 717
definition of, 1073
division of, direct, 1077
indirect, 1075
ethmoidal, 78
fat, 1092
goblet-, 1084
of Golgi, 680
of Martinotti, 680
mastoid, 67
nucleus of, 1074
prickle, 1085
reproduction of, 1075
of Sertoli, 1019
structure of, 1073
wall, 1077
Cement of teeth, 880
formation of, 880
Central canal of cord, 713
ganglionic vessels of brain, 513
ligament of cord, 709
lobe of cerebrum, 652
tendon of diaphragm, 353
Centres of ossification, 1106
Centrifugal nerve-fibres, 1120
Centripetal nerve-fibres, 1120
Centro-acinar cells of Langerhans, 948
Centrosomes, 1075
Centrosphere, 1075
Centrum ovale majus, 659
minus, 659
vertebra, 35
Cephalic vein, 608
flexure of embryonic brain, 1176
median, 607
Cerato-hyal of hyoid bone, 123
Cerebellar arteries, anterior-inferior, 522
posterior-inferior, 522
superior, 522
column, 714
notch, anterior, 684
posterior, 684
veins, 601
Cerebellum, 684
corpus dentatum of, 689, 693
hemispheres of, 684
lamina of, 685
lobes of, 684
median, 684
peduncles, 689
under surface, 688
upper surface, 685
weight of, 693
Cerebral arteries, 510
anterior, 510
middle, 511
posterior, 522
convolutions, 644
lymphatics, 626
topography, 705
veins, 600
ventricles, 660, 666, 669, 697
Cerebral vesicles, 1172
Cerebro-spinal axis, 639
fluid, 642
nerves, 1118
system, 1113
Cerebrum, 643
base of, 655
commissural fibres of, 677
commissures of, 665, 671
convolutions of, 644
crura of, 674
fibres of, 677
fissures of, 646
general arrangement of its parts, 643
gray matter of, 678, 1118
hemispheres of, 643
interior of, 659
labia of, 659
lobes of, 646
peduncles of, 673
structure of, 677
sulci, 644
under surface, 655
ventricles of, 660, 666, 669, 697
Ceruminous glands, 852
Cervical artery, ascending, 523
superficial, 524
fascia, 314
ganglion, inferior, 803
middle, 803
superior, 799
lymphatic glands, deep, 628
superficial, 628
surgical anatomy of, 628
nerves, 758
anterior divisions of, 760
posterior divisions of, 759
roots of, 758
plexus, 761
deep branches of, 763
posterior branches of, 759
superficial branches of, 761
rib, 39
veins, deep, 599
vertebræ, 35
surgical anatomy of, 231
Cervicalis ascendens muscle, 345
Cervico-facial nerve, 744
Cervix cornu of cord, 715
uteri, 1028
Chalice-cells, 1085
Chambers of the eye, 839
Chassaignac's tubercle, 36
Check ligaments, 231
of eye, 824
Cheek, muscles of, 308
Cheeks, structure of, 870
Chest, muscles of front, 377
of side, 381
surface form of, 132
surgical anatomy of, 132
Chiasma, or optic commissure, 721
Choanæ, 117
Cholesterin, 1078
Chondrin, 1095
Chondro-glossus muscle, 324
Chondro-mucoid, 1095
Chondro-sternal ligaments, 238
Chondro-xiphoid ligament, 238
Chorda dorsalis, 1156
tympani nerve, 741, 859
Chordæ tendineæ, of left ventricle, 466
Chordæ tendineæ of right ventricle, 464
vocales, 961
Willisii, 602
Chorion, 1161
frondosum, 1162
læve, 1162
Choroid arteries, anterior, 512
posterior, 523
coat of eye, 828
plexus of fourth ventricle, 698
of lateral ventricle, 666
of third ventricle, 669
veins of brain, 601
Choroidal fissure, 1182
Chromatin, 1074
Chromoplasm, 1074
Chromosomes, 1075
Chyle, 1082
Chyli receptaculum, 624
Cilia, or eyelashes, 643
Ciliary arteries, 509, 905
ganglion, 728
muscle, 832
nerves, long, 729
short, 729
processes of eye, 829
Ciliated epithelium, 1084
Cineritious nervous tissue, 1113
Cingulum, 653, 678
Circle of Willis, 523
Circular sinus, 603
Circulation of blood in adult, 460
in fœtus, 471
Circulus of iris, major, 509
minor, 509
tonsillaris, 733
Circumduction, 226
Circumferential fibro-cartilage, 1095
Circumflex artery of arm, anterior, 533
posterior, 533
of thigh, external, 579
internal, 579
iliac artery, deep, 572
superficial, 578
nerve, 769
surgical anatomy of, 776
vein, deep, 618
superficial, 614
Circumflexus palati muscle, 329
Circumvallate papillæ of tongue, 813
Cistern of Pecquet, 624
Cisterna magna, 641
pontis, 641
Clarke's vesicular column, 717
Claustrum, 662
Clava of funiculus gracilis, 696
Clavicle, 135
development of, 137
fracture of, 411
peculiarities in sexes, 137
surface form of, 137
surgical anatomy of, 137
Cleft palate, 332
Clinging fibres of cerebellum, 693
Clinoid processes, anterior, 75
middle, 73
posterior, 73
Clitoris, 1026
frænum of, 1026
lymphatics of, 634
muscles of, 375, 1027

Clitoris, prepuce of, 1027
Clivus, 73
monticuli of cerebellum, 686
Cloaca, 1213
Coccygeal artery, 568
gland, 558
nerves, 789
Coccygeus muscle, 369
Coccyx, 50
development of, 51
Cochlea, 860
aqueduct of, 69
arteries of, 866
central axis of, 861
cupola of, 861
lamina spiralis of, 861
nerves of, 866
scalæ of, 861
spiral canal of, 860
veins of, 866
Cochlear artery, 866
nerve, 867
Cochleariform process, 71, 855
Cœliac axis, 551
plexus, 808
Cœlum, 1157
Cohnheim, areas of, 1109
Colica dextra artery, 555
media, 555
sinistra, 555
Collagen, 1088
Collateral circulation. See *Surgical Anatomy of each Artery.*
fibres of cerebrum, 677
fissure, 647
intercostal artery, 549
Collecting tubes of kidney, 989
Colles, fascia of, 370
Colliculus nervi optici, 833
Colon, 923
Colored line of Retzius, 877
or red corpuscles, 1078
Colorless corpuscles, 1079
Colostrum corpuscles, 1040
Columella cochleæ, 861
Columna nasi, 818
Columnæ carneæ of left ventricle, 467
of right ventricle, 464
fornicis, 664
papillares, 464, 467
Columnar epithelium, 1083
Columns of abdominal ring, 1043
of spinal cord, 711
of vagina, 1028
Comes nervi ischiadici artery, 568
phrenici artery, 526
Comma tract, descending, 715
Commissural fibres of brain, 677
Commissure of brain, anterior, 665
middle or soft, 670
posterior, 671
of Gudden, 721
optic, 721
of spinal cord, gray, 712
white, 712
Common cloaca, 1203
ligaments of vertebræ, 223
Communicans peronei, 794
tibialis, 794
Communicantes hypoglossi nerve, 793
Communicating artery of brain, anterior, 511
posterior, 511
from dorsalis pedis, 588
ulnar, 544
Compact tissue of bone, 33, 1096
Complexus muscle, 345
Compressor narium minor, 306
nasi, 306
sacculi laryngis, 963
urethræ, 374
in female, 375
Conarium, 672
Concentric corpuscles of thymus, 982
Conception, where effected, 1151
Concha, 849
Conducting tracts of cord, 713
Conductor, sonorous, 699
Condyles of bones. See *Bones.*
Condyloid articulations, 220
foramina, 56
process, 99
veins, posterior, 599
Cone-bipolar cells, 835
-gradules of retina, 835
Cones of retina, 835
Congenital fissures in cranium 81
hernia, 1051
Conglobate glands, 623, 1133
Conjoined tendon of internal oblique and transversalis, 360, 1045
Conjunctiva, 844
Connecting fibro-cartilages, 1095
Connective tissue, 1086
adenoid, 1091
corpuscles, 1087
development of, 1090
elastic, 1088
fibrous, 1087
lymphatics of, 1089
lymphoid, 1091
mucous, 1090
nerves of, 1089
retiform, 1090
vessels of, 1089
yellow, 1088
Conoid ligament, 249
tubercle, 135
Constrictor inferior muscle, 327
isthmi faucium, 328
medius muscle, 328
superior muscle, 328
urethræ in female, 375
in male, 374
Contractile fibre-cells, 1112
Conus arteriosus, 463
medullaris, 711
Convoluted tubular gland, 1146
Convolutions, angular, 651
of Broca, 649
of cerebrum, structure of, 642
topography of, 705
of corpus callosum, 653
cuneate, 651
dentate, 653
frontal, 648
hippocampal, 653
marginal, 650
occipital, 651
occipito-temporal, 652
orbital, 649
parietal, 650
Convolutions, precuneus, 651
quadrate, 651
supramarginal, 651
temporal, 652
Cooper, ligament of, 359
Coraco-acromial ligament, 249
Coraco-brachialis muscle, 387
Coraco-clavicular ligament, 249
Coraco-humeral ligament, 251
Coracoid ligament, 250
process, 141
fracture of, 412
Cord, spermatic, 1016
spinal, 710
umbilical, 1165
Cordiform tendon of diaphragm, 353
Corium of mucous membrane, 1145
of skin, 1135
of tongue, 813
Cornea, 826
Corneal corpuscles, 827
spaces, 827
Cornu Ammonis, 666
Cornua of the coccyx, 50
of hyoid bone, 123
of sacrum, 47
of thyroid cartilage, 955
Corona glandis, 1011
radiata, 677
Coronal suture, 101
Coronary arteries of lip, 491
of heart, 477
descending, 477
marginal, 477
peculiarities of, 478
transverse, 477
artery of stomach, 551
ligament of liver, 937
ligaments of knee, 277
plexus, anterior, 806
posterior, 806
sinus, 621
opening of, 462
Coronoid depression, 147
process of jaw, 99
of ulna, 152
Corpora albicantia, 656
Arantii, 464
bigemina, 675
cavernosa clitoridis, 1027
penis, 1012
crura of, 1012
geniculata, 676
mamillaria, 656
quadrigemina, 675
striatum, 662
veins of, 601
Corpus callosum, 659
convolutions of, 653
genu of, 659
peduncles of, 659
cavernosum, artery of, 567
dentatum of cerebellum, 693
fimbriatum, 665
Highmorianum, 1019
of olivary body, 702
spongiosum, 1013
striatum, 662
subthalamicum, 676
trapezoides of pons, 683
Corpuscles, blood-, 1077
colored, 1078
colorless, 1079

Corpuscles, colorless, origin of, 1080
development of, 1188
of Herbst, 1123
Malpighian, of kidney, 988
Pacinian, 1122
of Purkinje, 692
of spleen, 952
tactile, 1121
of Vater, 1122, *note.*
Corrugator cutis ani, 368
supercilii muscle, 302
Cortex of cerebellum, 691
of cerebrum, 678
Corti, membrane of, 866
organ of, 864
rods of, 865
tunnel of, 865
Cortical arches, 987
arteries of brain, 513
columns, 987
substance of brain, 644
of kidney, 987
of suprarenal capsules, 997
visual centre, 722
Costal cartilages, 132, 1094
connection with ribs, 239
process, 36
Costo-central articulation, 234
Costo-chrondral articulation, 239
Costo-chrondro-xiphoid ligaments, 238
Costo-clavicular ligament, 246
Costo-coracoid ligament, 379
membrane, 379
Costo-mediastinal sinus, 971
Costo-transverse articulations, 336
Costo-vertebral articulations, 234
ligaments, 234
Cotunnius, nerve of, 733
Cotyloid cavity, 177
ligament, 270
notch, 177
Coverings of direct inguinal hernia, 1052
of femoral hernia, 1061
of oblique hernia, 1049
of testis, 1014
Cowper's glands, 1011, 1067
Cranial bones, 55
articulations of, 103
fossæ, 103
nerves, 720
development of, 1179
eighth, 745
eleventh, 753
fifth, 725
first pair, 720
fourth, 724
ninth, 746
second, 721
seventh, 740
sixth, 738
tenth, 749
third, 722
twelfth, 754
sutures, 101
Cranium, 55
congenital fissures in, 81
development of, 80, 1166
lymphatics of, 626
Cremaster muscle, 361
formation of, 361, 1045
Cremasteric artery, 571
Cremasteric fascia, 361
Crescentic lobe, anterior, 686
posterior, 686
Crescents of Giannuzzi, 888
Crest, frontal, 61
of ilium, 171
lachrymal, 88
nasal, 82
occipital, 55
internal, 57
of spine of scapula, 140
turbinated, of palate, 92
of os pubis, 176
of the superior maxillary, 85
of tibia, 193
Cribriform fascia, 418, 1055
plate of ethmoid, 78
Crico-arytenoideus lateralis muscle, 962
posticus muscle, 962
Crico-thyroid artery, 488
membrane, 959
muscle, 961
Cricoid cartilage, 956
Crista basilaris, 864
falciformis, 69
galli, 78
pubis, 176
terminalis, 461, 1190
vestibuli, 860
Crossed pyramidal tract, 714
Crown of a tooth, 872
Crucial anastomosis, 568, 579
ligaments of knee, 276
Cruciform ligament, 228
Crura cerebri, 673
of corpora cavernosa, 1012
of clitoris, 1027
of diaphragm, 352
of fornicis, 664
Crural arch, 359, 1057
deep, 366, 1059
canal, 1059
nerve, anterior, 786
surgical anatomy of, 797
ring, 1060
sheath, 1059
septum, 1060
Crureus muscle, 422
Crus commune, 860
helicis, 849
penis, 1012
Crusta of crus cerebri, 673, 677
petrosa of teeth, 878
Crypts of Lieberkühn, 918
Crystalline lens, 840
Crystals, blood, 1081
Cuboid bone, 204
Culmen, monticuli of cerebellum, 686
Cuneate funiculus, 695
lobe, 651
tubercle, 696
Cuneiform bone, foot, external, 207
internal, 206
middle, 206
hand, 162
cartilages, 958
Cuneus, 651
Cupola of cochlea, 861
Curvatures of the spine, 52
Cushion of epiglottis, 958
Cuspidate teeth, 872
Cusps of tricuspid valve, 464
Cutaneous branches of accessory obturator, 786
of anterior tibial nerve, 796
of arm, musculo-cutaneous, 770
of buttock and thigh, 793
of cervical plexus, 763
of circumflex, 770
of dorsal nerve of penis, 793
of dorsal nerves, 780
of external popliteal, 796
of ilio-hypogastric, 782
of ilio-inguinal, 783
of inferior hemorrhoidal nerve, 793
of inguinal region, 1055
of intercostal nerves, 779
internal, 770
lesser, 771
of internal popliteal, 794
of ischio-rectal region, 1064
from obturator, 785
of lesser sciatic nerve, 791
of lumbar nerves, 781
of median, 772
of musculo-spiral, 775
of patella, 787
of perineal nerve, 791
of plantar nerve, 795
of posterior tibial, 795
of radial, 775
of sacral nerves, 789
of thigh, external, 785
internal, 787
middle, 788
of ulnar nerve, 773
Cuticle of skin, 1136
Cuticula dentis, 880
Cutis plate, 1187
vera, 1138
Cuvier, ducts of, 1195
Cylindrical epithelium, 1083
Cymba conchæ, 849
Cystic artery, 553
duct, 943
valve of, 943
plexus of nerves, 808
veins, 621
Cytoblast, 1154
Cytoplasm, 1073, 1149

D.

Dacryon, 114
Dartos, 1015
Darwin's tubercle, 849
Decidua, 1162
reflexa, 1162
serotina, 1162
vera, 1162
Decidual cells, 1162
Deciduous teeth, 871
Decussation of fillet, 719
of optic nerves, 721
of pyramids, 693
Deep crural arch, 366, 1059
palmar arch, 539
perineal fascia, 373, 1066
transverse fascia of leg, 434, 438
Deferent artery, 563
Deglutition, actions of, 332
Deiter's nucleus, 684, 745
Deltoid aponeurosis, 382

Deltoid muscle, 382
tubercle, 135
Demilunes of Heidenhain, 888
Démours, membrane of, 827
Dendron of nerve-cell, 1115
Dens sapientiæ, 873
Dental artery, anterior, 499
inferior, 498
posterior, 499
canal, anterior, 84
inferior, 98
posterior, 84
furrow, 876
germ, common, 887
special, 888
groove, 887
lamina, 887
nerves, anterior, 731
inferior, 736
middle, 730
posterior, 730
pulp, 875
ridges, 887
sacs, 881
tubuli, 876
vein, inferior, 597
Dentate convolutions, 653
fissure, 653
Dentinal tubuli, 876
Dentine, 875
formation of, 880
Depressions of Pacchionian bodies, 60
Depressor alæ nasi, 306
anguli oris, 308
epiglottidis, 1107
labii inferioris, 308
Derma, or true skin, 1138
Dermic coat of hair-follicle, 1141
Descemet, membrane of, 827
Descendens, hypoglossi nerve, 756
Descending aorta, 546
colon, 925
comma tract, 715
nerve tracts, 718
oblique muscle of abdomen, 356
Descent of testicle, 1211
Detrusor urinæ, 1003
Development of alimentary canal and its appendages, 1198
arteries, 1191
atlas, 44
axis, 44
bone, 1101
carpus, 170
clavicle, 138
coccyx, 51
cranium, 80, 1166
ear, 1183
ethmoid, 80
eye, 1180
face, 1166
femur, 189
fibula, 198
foot, 211
frontal bone, 64
genital organs, 1213
hand, 170
heart, 1189
humerus, 148
hyoid bone, 123
inferior turbinated bone, 95
Development of lachrymal bone, 89
lens, 1182
lower jaw, 99
lumbar vertebræ, 43
malar bone, 90
mammæ, 1186
metacarpus, 171
metatarsus, 211
muscle, 1187
muscle fibre, 1112
nasal bone, 82
nervous centres, 1172
nose, 1184
occipital bone, 58
os innominatum, 177
Organs, Chronological Table of, 1215
palate, 1170
bone, 93
parietal bone, 61
patella, 192
permanent teeth, 881
phalanges of foot, 211
of hand, 171
radius, 151
ribs, 131
sacrum, 49
scapula, 142
seventh cervical, 45
skin, 1186
sphenoid, 76
spine, 1165
sternum, 128
superior maxillary bone, 87
tarsus, 210
temporal bone, 71
temporary teeth, 878
tibia, 196
ulna, 154
veins, 1194
vertebræ, 43
vomer, 96
Wormian, 81
Diameters of pelvis, 179
Diaphragm, 352
development of, 1206
lymphatics of, 636
of pelvis, 895
Diaphragma sellæ, 641
Diaphysis, 1106
Diarthrosis, 219
Digastric fossa, 67
lobe of cerebellum, 687
muscle, 321
nerve, from facial, 743
Digestion, organs of, 869
Digital arteries from palmar arch, 545
from plantar, 592
fossa, 185
nerves, of foot, 795
from median, 772
from radial, 775
from ulnar, 773
Dilatator naris, anterior, 306
posterior, 306
Diploë, 34
veins of, 599
Direct cerebellar tract of cord, 714
inguinal hernia, 1052
course of, 1052
coverings of, 1053
pyramidal tract, 713
Discus proligerus, 1037, 1149
Dissection of abdominal muscles, 360
arm, 386
auricular region, 300
axilla, 376
back, 336
epicranial region, 298
eye, 827
face, 301
femoral hernia, 1053
foot, 442
forearm, 389
gluteal region, 426
hand, 401
heart, left auricle, 465
left ventricle, 465
right auricle, 461
right ventricle, 463
hernia, femoral, 1053
inguinal, 1041
iliac region, 415
inferior maxillary region, 308
infrahyoid region, 319
inguinal hernia, 1041
inter-maxillary region, 308
ischio-rectal region, 1063
leg, 434
lingual region, 323
neck, 314
orbit, 303
palatal region, 329
palm of hand, 401
palpebral region, 301
pancreas, 945
pectoral region, 376
perineum, 1063
pharynx, 327
pterygoid muscles, 312
radial region, 395
scalp, 298
sole of foot, 443
spinal cord and membranes, 707
suprahyoid region, 321
temporal muscle, 311
thigh, back of, 432
front of, 418
inner side of, 423
Diverticulum, Meckel's, 915
Division of cells, 1075
direct, 1077
indirect, 1075
Dorsal artery of penis, 565
auditory nucleus, 702
nerve of penis, 793
nerves, 776
anterior divisions of, 777
peculiar, 777
of penis, 793
posterior divisions of, 777
roots of, 776
vein of penis, 617
vertebræ, 39
peculiar, 41
Dorsales pollicis arteries, 541
Dorsalis hallucis artery, 588
indicis, 541
linguæ, 489
nasi artery, 509
pedis, 587
branches of, 588
peculiarities of, 587
surface marking of, 587
surgical anatomy of, 587

Dorsalis scapulæ, 533
Dorsi-lumbar nerve, 781
Dorsi-spinal veins, 612
Dorsum of scapula, 140
ephippii or sellæ, 73
Douglas, pouch of, 898, 1029
semilunar fold of, 364
Ducts or duct of Bartholin, 887
biliary, 940
of Cowper's glands, 1006
Cuvier, 1195
cystic, 943
ejaculatory, 1023
galactophorous, 1040
of Gärtner, 1038, 1210
hepatic, 941
of kidney, 989
lactiferous, 1040
of liver, 940
lymphatic, right, 625
nasal, 847
of pancreas, 947
parotid, 884
Rivini, 887
seminal, 1021
Stenson's, 885
thoracic, 624
Wharton's, 886
Ductless glands: spleen, 949
suprarenal capsule, 996
thyroid, 979
thymus, 981
Ductus arteriosus, 471, 475
how obliterated in fœtus, 473
communis choledochus, 943
endolymphaticus, 69, 862
pancreaticus accessorius, 948
Rivini, 887
Santorini, 948
thyro-glossus, 1206
venosus, 471, 1195
how obliterated, 473
Duodenal fold, 904
fossæ, 904
superior, 904
glands, 918
Duodeno-jejunal flexure, 914
fossa, 904
-mesocolic ligament, 904
Duodenum, 912
vessels and nerves of, 914
Dura mater of brain, 639
arteries of, 640
endosteal layer of, 639
meningeal layer of, 639
nerves of, 640
processes of, 640
structure of, 639
veins of, 640
of cord, 707
peculiarities of, 708
Dyaster, or daughter star, 1075

E.

Ear, 848
arteries of, 850, 858, 1066
auditory canal, 851
cochlea, 860
development of, 1183
internal, or labyrinth, 859
membranous labyrinth, 862
muscles of auricle, 850
of tympanum, 857
ossicula of, 856
Ear, pinna, or auricle of, 848
semicircular canals, 860
surface form of, 852
surgical anatomy of, 867
tympanum, 852
vestibule, 859
Earthy constituents of bone, 1101
Ectoderm, 1154
Ectoplacenta, or chorion, 1154
Efferent nerves, 1119
Egg-tubes, 1037, 1210
Eighth nerve, 745
surgical anatomy of, 745
Ejaculator seminis muscle, 371
Ejaculatory ducts, 1023
Elastic cartilage, 1095
connective tissue, 1088
lamina of cornea, 827
Elbow, anastomoses around, 537
bend of, 534
joint, 255
surface form of, 258
surgical anatomy of, 258
vessels and nerves of, 256, 257
Eleidin, 1138
Eleventh nerve, 753
surgical anatomy of, 753
Embryo, development of, 1165
first rudiments of, 1155
Eminence of aquæductus Fallopii, 854
canine, 83
frontal, 61
genital, 1213
ilio-pectineal, 177
nasal, 61
parietal, 60
Eminences and depressions of bones, 34
Eminentia articularis, 65
cinerea, 698
collateralis, 666
teres, 699
Emissary veins, 605
Enamel cells, 878
epithelium, 878
germ, 878
neck of, 878
organ, 878
pulp, 880
rods, 877
of teeth, 877
formation of, 878
Enarthrosis, 221
Encephalon, 643
End-bulbs of Krause, 1121
Endings of Ruffini, 1122
Endocardial cushions, 1190
Endocardium, 468
Endolymph, 862
Endomysium, 1107
Endoneurium, 1119
Endosteal layer of dura mater, 639
Endothelium, 1083
End-plates, motorial, of Kühne, 1124
Ensiform appendix, 124
Enteron, 1158
Entoderm, 1154
Eosinophile corpuscles, 1079
Eparterial division of bronchus, 966
Epencephalon, 643, 1176
Ependyma, 661
Epiblast, 1154
Epicardium, 468
Epicondyle, 148
Epidermic coat of hair follicle, 1141
Epidermis, development of, 1186
structure of, 1082, 1135
Epididymis, 1017
development of, 1211
Epigastric artery, deep, 571
peculiarities, 572
relation to femoral ring, 1060
with internal ring, 1047
superficial, 578
superior, 527
plexus, 806
region, 895
vein, deep, 616
superficial, 614
Epiglottic glands, 964
Epiglottis, 958
Epimysium, 1107
Epineurium, 1119
Epiphysial cartilage, 1103, 1106
Epiphysis, 34, 1107
cerebri, 672
Epithelium, 1082. See *Various Organs.*
ciliated, 1084
columnar, 1083
cylindrical, 1083
enamel, 879
external, 879
internal, 879
pavement, 1083
spheroidal or glandular, 1084
stratified, 1085
transitional, 1085
Epitrochlea, 148
Epitympanic recess, 68
Eponyclium, 1140, 1210
Epoöphoron, 1038
Erectile tissue of clitoris, 1026
of penis, 1012
its structure, 1012
Erector clitoridis, 375, 1026
penis, 372
spinæ, 343
Eruption of the teeth, 881
Erythroblasts, 1080, 1097
Erythrocytes, 1078
Ethmo-frontal suture, 103
Ethmo-sphenoidal suture, 103
Ethmoid bone, 77
articulations of, 80
cribriform plate of, 78
development of, 80
lateral masses of, 78
os planum of, 79
perpendicular plate of, 78
plate, 1167
unciform process of, 79
Ethmoidal artery, 506
canal, anterior, 64
posterior, 64
cells, 78
notch, 63
process of inferior turbinated, 95
spine, 73
Eustachian tube, 855
surgical anatomy of, 867
valve, 462

Eustachian valve, in fœtal heart, 470
Expiration, muscles of, 355
Extensor brevis digitorum muscle, 444
carpi radialis brevior, 396
longior, 396
pollicis, 399
ulnaris, 397
coccygis, 347
communis digitorum (hand), 396
indicis, 399
longus digitorum (foot), 435
pollicis, 399
minimi digiti, 397
ossis metacarpi pollicis, 399
primi internodii pollicis. See *Extensor longus pollicis.*
proprius hallucis, 435
secundi internodii pollicis. See *Extensor brevis pollicis.*
External abdominal ring, 366, 1043
annular ligament, 443
capsule, 662
inguinal hernia, 1049
medullary lamina, 672
orbital foramina, 75
pterygoid plate, 75
spermatic fascia, 1043
sphincter ani, 368
Extrinsic muscles of tongue, 325
Eye, 824
appendages of, 843
aqueous humors of, 839
chambers of, 839
choroid, 828
ciliary muscle, 830
processes of, 829
conjunctiva, 845
cornea, 826
crystalline lens, 840
development of, 1180
elastica lamina of cornea, 827
hyaloid membrane, 820
humors of, 839
iris, 830
Jacob's membrane, 835
membrana pupillaris, 832
pupil of, 831
retina, 832
sclerotic, 825
surgical anatomy of, 841
tunics of, 825
uvea of, 831
vessels of globe of, 841
vitreous humors of, 839
Eyeball, muscles of, 303
nerves, 841
vessels of, 841
Eyebrows, 843
Eyelashes, 843
Eyelids, 843
cartilages or plates of, 843
development of, 1182
Meibomian glands of, 844
muscles of, 297
tarsal ligament of, 844
Eye-teeth, 871

F.

Face, arteries of, 489
bones of, 54, 80
development of, 1166
Face, lymphatics of, 626
muscles of, 297
nerves of, 740
veins of, 594
Facial artery, 489
peculiarities of, 493
surgical anatomy of, 493
transverse, 495
bones, 81
nerve, 740
surgical anatomy of, 744
vein, 596
surgical anatomy of, 596
Falciform ligament of liver, 937
of sacro-sciatic articulation, 243
process of fascia lata, 420
Fallopian tubes, 1034
development of, 1210
fimbriated extremity of, 1034
lymphatics of, 634
nerves of, 1038
structure of, 1035
vessels of, 1038
False ligaments of bladder, 1002
pelvis, 179
ribs, 128
Falx cerebelli, 641
cerebri, 641
Fangs of teeth, 871
Fascia or fasciæ, anal, 1071
of arm, 386
bucco-pharyngeal, 316
of Camper, 356
cervical, deep, 315
superficial, 314
clavi-pectoral, 529
of Colles, 370
costo-coracoid, 378
of cranial region, 298
cremasteric, 361
cribriform, 418, 1055
deep, 297
dentata, 653
dorsal, of foot, 443
fibro-areolar, its structure, 296
general description of, 295
iliac, 415
infundibuliform, 1016, 1047
intercolumnar, 359
intercostal, 350
intermuscular, of arm, 386
of foot, 443
ischio-rectal, 1071
lata, 419, 1055
falciform process of, 1056
iliac portion of, 420, 1055
pubic portion, 420, 1056
of leg, 434
deep transverse, 438
lumborum, 342
of mamma, 375
masseteric, 310
of neck, 313
obturator, 1071
palmar, 402
parotid, 310
pelvic, 1070
perineal, deep, 1066
superficial, 1064
plantar, 443
of foot, 443
of forearm, 390
of hand, 402
Fascia or fasciæ, prevertebral, 315
propria, of spermatic cord, 1015
recto-vesical, 1071
of Scarpa, 356
spermatic, 358, 1043
superficial, 296
of inguinal region, 1041
of ischio-rectal region, 1064
of thigh, 418
temporal, 310
of thigh, deep, 418
superficial, 418
of thorax, 350, 377
transversalis, 1046
triangular, 359
visceral layer of pelvic, 1071
Fasciculus teres, 684, 699
of Türck, 713
Fasciola cinerea, 653
Fat, 1091
Fat-cells, 1091
development of, 1092
Fauces, isthmus of, 883
Fecundation of ovum, 1151
Female organs of generation:
bulbi vestibuli, 1027
carunculæ myrtiformes, 1027
clitoris, 1026
development of, 1209, 1213
fossa navicularis, 1026
glands of Bartholin, 1027
hymen, 1027
labia majora, 1025
minora, 1026
nymphæ, 1026
uterus, 1028
vagina, 1027
vestibule, 1027
Femoral artery, 572
branches of, 578
common, 573
deep, 578
peculiarities of, 575
superficial, 574
surface marking of, 575
surgical anatomy of, 575
or crural canal, 1060
variation in size of, according to position of limb, 1061
cutaneous nerve, 793
hernia, complete, 1061
coverings of, 1061
descent of, 1061
dissection of, 1053
incomplete, 1062
seat of stricture, 1062
surgical anatomy of, 1053
region, muscles of, anterior, 418
internal, 423
posterior, 432
ring, 1060
position of surrounding parts, 1060
sheath, 1059
spur, 189
vein, 616
relation of femoral ring, 1060
Femur, 183
articulations of, 189
attachment of muscles to, 189
condyles of, 187, 188

Femur, development of, 189
fracture of, above condyles, 451
below trochanters, 451
head of, 184
neck of, 184
structure of, 188
surface form of, 190
surgical anatomy of, 190
trochanters of, 185
Fenestra ovalis, 854
rotunda, 854, 861
Fenestrated membrane of Henle, 1089, 1126
Ferrein, pyramids of, 989
Fertilization of ovum, 1151
Fibræ propriæ of cerebellum, 691
Fibre-cells, contractile, 1112
Fibres of Müller, 837
of muscle, 1107
of nerves, 1115
of Remak, 1117
Fibrin, 1080, 1081
ferment, 1081
Fibrinogen, 1080
Fibro-cartilage, 1094
circumferential, 1095
connecting, 1095
interarticular, 1094
stratiform, 1095
yellow, 1095
Fibro-cartilages, acromio-clavicular, 248
intercoccygean, 245
intervertebral, 224
of knee, 277
of lower jaw, 233
pubic, 245
radio-ulnar, 260
sacro-coccygean, 244
sterno-clavicular, 246
Fibro-serous membranes, 1143
Fibrous cartilage, 1094
connective tissue, 1087
nervous matter, 1115
rings of heart, 468
tissue, white, 1087
yellow, 1088
Fibula, 196
articulations of, 198
attachment of muscles to, 198
development of, 198
fracture of, with dislocation of the foot, 453
surface form of, 198
Fibular region, muscles of, 440
Fifth nerve, 725
surface marking of, 737
surgical anatomy of, 738
ventricle of brain, 665
Filiform papillæ of tongue, 813
Fillet, lower, 674
mesial, 674
upper, 674
Filum terminale of cord, 709
Fimbriæ of Fallopian tube, 1034
Fimbrio-dentate fissure, 667
First nerve, 720
surgical anatomy of, 721
Fissura palpebrarum, 843
prima, 655
Fissure or fissures, antitragohelicina, 849
auricular, 70
brain, 644
calcarine, 646
Fissure or fissures, callosal, 653
cerebellum, 686
post-central, 686
post-clival, 686
post-nodular, 688
post-pyramidal, 688
pre-central, 686
pre-clival, 686
pre-pyramidal, 688
collateral, 646
congenital, in cranium, 81
dentate, 647
of ductus venosus, 936
of gall-bladder, 935
Glaserian, 66, 853
horizontal, of cerebellum, 685
longitudinal, of cerebrum, 643, 655
of liver, 935
of lung, 974
median, of medulla oblongata, 694
parieto-occipital, 646
post-limbic, 647
pterygo-maxillary, 112
of Rolando, 646
sphenoidal, 75
spheno-maxillary, 112
spinal cord, 711
of Sylvius, 645, 658
transverse, of cerebrum, 668
of liver, 935
umbilical, 935
Flat bones, 33
Flexor accessorium muscle, 446
brevis digitorum, 444
hallucis, 446
minimi digiti (foot), 447
(hand), 406
pollicis, 404
carpi radialis, 391
ulnaris, 391
digitorum sublimis, 392
profundus, 393
longus digitorum, 439
hallucis, 438
pollicis (hand), 394
ossi metacarpi pollicis, 406
Flexures of embryonic brain, cephalic, 1176
nuchal, 1176
pontal, 1176
Floating ribs, 128
Floccular fossa, 69
Flocculus, 688
Flood's ligament, 251
Fluids, nutritive, 1077
Fœtus, circulation in, 471
Eustachian valve in, 470
foramen ovale in, 470, 1190
liver of, distribution of its vessels, 471
vascular system in, peculiarities, 470
Fold of Douglas, 364
Folds, aryteno-epiglottidean, 959
genital, 1213
recto-uterine, 1029
-vesical, 1002
vesico-uterine, 1029
Folia of cerebellum, 659
Folium cacuminis, 686
Follicle of hair, 1141
of intestine, 918
Follicles, sebaceous, 1142
Fontana, spaces of, 827
Fontanelles, 58, 81
Foot, arteries of, 587, 591
bones of, 199
development of, 211
dorsum, muscles of, 444
fascia of, 443
ligaments of, 442
nerves of, 795
sole of, fascia of, 443
muscles of, 443
surface form of, 213
surgical anatomy of, 213
veins of, 614
Foramen cæcum, of frontal bone, 63, 103
of medulla oblongata, 693
of Vicq d'Azyr, 694
of tongue, 813
carotid, 70
condyloid, 56
dental inferior, 98
ethmoidal, 104
of Huschke, 71
infraorbital, 83
intervertebral, 35
jugular, 106
lacerum anterius, 105
medium, 106
posterius, 106
magnum, 56
of Majendie, 641, 698, 708
mastoid, 67
mental, 97
of Monro, 664, 671
obturator, 177
optic, 75, 105
ovale of heart, 470, 1190
of sphenoid, 74
palatine, anterior, 87, 106
posterior, 92, 108
parietal, 60
pterygo-palatine, 74
quadratum of diaphragm, 354
rotundum, 74, 105
sacro-sciatic, 174, 242
of Scarpa, 87, 108
singulare, 69, 867
of Sömmerring, 833
spheno-palatine, 93, 116
spinosum, 74, 105
of Stenson, 87, 108
sternal, 125
stylo-mastoid, 70
supraorbital, 62
thyroid, 177
Vesalii, 74, 105
of Winslow, 899
Foramina of diaphragm, 354
external orbital, 74
of Key and Retzius, 642, 698
malar, 89
nervosa, 864
olfactory, 77
sacral, 47
Thebesii, 462, 622
Forceps, major, 660
minor, 660
Forearm, arteries of, 538
bones of, 150
fascia of, 389
lymphatics of, 628
muscles of, 389
nerves of, 769
veins of, 607

Fore-brain, 643
Fore-gut, 1158
development of, 1198
Form of bones, 33
Formatio reticularis of medulla alba, 701
grisea, 701
of cord, 716
of mid-brain, 674
Fornix, 664
conjunctivæ, 845
pillar, 664
Fossa acetabuli, 177
of antihelix, 849
canine, 83
cochlearis, 860
condyloid, 56
digastric, 67
digital, 185
glenoid, 65
of helix, 849
iliac, 174
incisive, 83, 97
incudis, 856
infra- and supraspinous, 140
inguinalis lateralis, 1048
mesialis, 1048
supra-vesiculus, 1048
ischio-rectal, 1064
jugular, 71
lachrymal, 63
myrtiform, 83
navicularis of urethra, 1006
of vulva, 1026
occipital, 56
olfactory, of fœtus, 1185
ovalis, 462
ovarii, 1036
palatine, anterior, 87
patellaris, 839
pituitary, 73
pterygoid of lower jaw, 99
of sphenoid, 75
of Rosenmüller, 890
scapha, 849
scaphoid, 76
sigmoidea, 67
skull, anterior, 103
middle, 105
posterior, 106
spheno-maxillary, 112
sublingual, 97
submaxillary, 97
subscapular, 139
supra-tonsillaris, 884
temporal, 110
triangularis, 849
trochanteric, 185
vesicalis, 936
zygomatic, 111
Fossæ, nasal, 115, 820
of skull, 103
Fourchette, 1026
Fourth nerve, 724
surgical anatomy of, 725
ventricle, 697
Fovea centralis retinæ, 833
hemispherica, 860
inferior, of fourth ventricle, 698
inguinalis lateralis, 1048
mesialis, 1048
semi-elliptica, 860
superior, of fourth ventricle, 698
Fovea supra-vesicalis, 1048
Fracture of acromial end of clavicle, 412
acromion process, 412
centre of clavicle, 411
coracoid process, 412
coronoid process of ulna, 413
femur above condyles, 451
below trochanters, 451
fibula, with dislocation of tibia, 453
humerus, anatomical neck, 413
shaft of, 412
non-union, 149
surgical neck, 412
neck of femur, 451
olecranon process, 413
patella, 452
Pott's, 453
radius, 413
lower end of, 414
neck of, 413
shaft of, 414
and ulna, 414
tibia, shaft of, 453
ulna, shaft of, 414
Frœna of ilio-cæcal valve, 923
Frœnulum cerebellum, 686
Frœnum clitoridis, 1026
labii superioris et inferioris, 870
linguæ, 811
præputii, 1012
Frontal artery, 508
bone, 61
articulations of, 64
attachment of muscles to, 64
development of, 64
structure of, 64
crest, 63
eminence, 61
lobe, 646
nerve, 726
process of malar, 90
sinuses, 64
suture, 61, 64
vein, 595
Frontalis muscle, 300
Fronto-nasal process, 1169
Fronto-sphenoidal suture, 101, 102
Fundus tympani, 853
of uterus, 1028
Fungiform papillæ of tongue, 813
Funiculus cuneatus, 695
gracilis, 695
of nerve, 1118
of Rolando, 695
solitarius, 701
teres, 699
Furcula, 1203
Furrow, sternal, 132
Furrowed band of cerebellum, 688

G.

Galactophorous ducts, 1040
Galen, veins of, 601, 669
Gall-bladder, 942
development of, 1205
fissure for, 935
structure of, 942
surface form of, 943
Gall-bladder, valve of, 942
Ganglion or ganglia of Andersch, 748
Arnold's 736
of Bochdalek, 731
cardiac, 805
carotid, 801
cephalic, 729
of cerebellum, 693
cervical inferior, 803
middle, 803
superior, 799
ciliary, 729
on circumflex nerve, 769
corpuscles, 1125
diaphragmatic, 808
on facial nerve, 740
of fifth nerve, 729
Gasserian, 725
general anatomy of, 1125
of glosso-pharyngeal, 748
geniculate, 741
of habenula, 672
impar, 799, 805
inferus, 749
intercarotid, 803
interpedunculare, 672
jugular, 748
lateral root of eighth nerve, 745
lenticular, 729
lumbar, 805
Meckel's, 731
mesenteric, 809
ophthalmic, 729
otic, 736
petrous, 748
pharyngeal, 801
of pneumogastric, 750
of portio dura, 741
on posterior interosseous nerve, 775
radicis cochlearis, 702
of Ribes, 801
of root of vagus, 749
sacral, 805
of Scarpa, 867
semilunar, of abdomen, 806
of fifth nerve, 726
spheno-palatine, 732
of spinal nerves, 757
spirale, 867
submaxillary, 737
suprarenal, 808
of sympathetic nerve, 798
thoracic, 804
of trunk of vagus, 749
of Valentin, 731
of Wrisberg, 806
Ganglionic branch of nasal nerve, 729
nerves, 1118
Gärtner, duct of, 1210
Gases of the blood, 1081
Gasserian ganglion, 725
depression for, 69
Gastric arteries (vasa brevia), 553
artery, 551
glands, 909
impression of liver, 937
nerves from vagus, 752
plexus, 808
vein, 620
Gastrocnemius muscle, 436

Gastro-colic omentum, 902
Gastro-duodenal artery, 552
plexus, 808
Gastro-epiploic plexus, 808
veins, 620
Gastro-epiploica dextra artery, 553
sinistra, 553
Gastro-hepatic omentum, 901
Gastro-splenic omentum, 902, 949
Gemellus inferior muscle, 430
superior muscle, 430
Generative organs, development of, 1207
female, 1025
male, 1009
Genial tubercles, 97
Geniculate bodies, 675
ganglion, 741
Genio-hyo-glossus muscle, 323
Genio-hyoid muscle, 322
Genital cord, 1209
corpuscles, 1121
eminence, 1213
folds, 1213
groove, 1213
ridge, 1213
Genito-crural nerve, 783
Genu of the corpus callosum, 659
Germ, common dental, 877
special dental, 877
Germinal area, 1154
disk, 1154
epithelium, 1210
spot, 1149
vesicle, 1149
Giacomini, band of, 653
Giant cells, 1097
Gianuzzi, crescents of, 888
Gimbernat's ligament, 357, 1044
Gingival branches of dental nerves, 730
Ginglymus, 220
Giraldès, organ of, 1021, 1211
Girdle, pelvic, 134
shoulder, 134
Glabella of frontal bone, 61, 112
Gladiolus, 125
Gland or glands, arytenoid, 964
of Bartholin, 1027
of biliary ducts, 943
of Bowman, 822
Brunner's, 918
buccal, 870
ceruminous, 852
coccygeal, 558
Cowper's, 1011, 1067
development of, 1133
ductless, 949
spleen, 949
suprarenal, 996
thymus, 981
thyroid, 979
duodenal, 918
epiglottic, 963
gastric, 909
of Havers, 218
labial, 870
lachrymal, 846
of larynx, 964
lingual, 816
of Littré, 1006
of Luschka, 558
lymphatic, 1133
mammary, 1038
Gland or glands, Meibomian, 844
molar, 870
of Moll, 843
mucilaginous, of Havers, 218
odoriferæ, 1011
œsophageal, 892
of Pacchioni, 602, 642
palatal, 883, 888
parotid, 884
Peyer's, 919
pharyngeal, 890
pineal, 672
pituitary, 656
prostate, 1009
racemose or saccular, 1146
of Rosenmüller, accessory, 846
salivary, 884
sebaceous, 1142
secreting, 1146
simple, 1146
solitary, 919
sublingual, 887
submaxillary, 886
sudoriferous, 1142
suprarenal, 996
thymus, 981
thyroid, 979
tracheal, 967
tubular, 1146
compound, 1146
convoluted, 1146
of Tyson, 1011
uterine, 1031
of vulva, 1027
Glandulæ odoriferæ, 1011
Pacchioni, 602, 642
Glandular epithelium, 1084
Glans penis, 1011
clitoridis, 1027
Glaserian fissure, 65, 66, 853
Gleno-humeral ligament, 251
Glenoid cavity, 141
fossa, 65
ligament of Cruveilhier, 267
of phalanges, 267
of shoulder, 251
Gliding movement, 222
Glisson's capsule, 902, 938, 940
Globus major of epididymis, 1017
minor, 1017
pallidus, 663
Glosso-epiglottic ligaments, 811, 959
-pharyngeal nerve, 746
Glottis respiratoria, 960
rima of, 959
vocalis, 960
Gluteal aponeurosis, 427
artery, 569
inferior, 568
lymphatic glands, 681
nerve, inferior, 791
superior, 791
region, lymphatics of, 633
muscles of, 426
ridge, 186
veins, 616
Gluteus maximus muscle, 426
medius, 427
minimus, 428
Goblet-cells, 1084
Golgi-cells of cerebellum, 693
organs of, 1123
Goll's column, 715
Gomphosis, 219
Gower's tract, 714
Graafian membrana granulosa of, 1037
ovicapsule of, 1037
structure of, 1037
vesicles, 1036
Gracilis muscle, 423
Grande lobe limbique, 652
Grandy, tactile corpuscles of, 1121
Granule cells, 1087
Gray matter of cerebellum, 691
of cerebrum, 678
of medulla oblongata, 699
of spinal cord, 715
nervous substance, 1113
Great occipital nerve, 760
omentum, 902
sciatic nerve, 793
surgical anatomy of, 797
sinus of aorta, 477
Greater wings of sphenoid, 74
Groin, 1053
cutaneous vessels and nerves of, 1054
superficial fascia of, 1053
surgical anatomy of, 1053
Groove, auriculo-ventricular, 460
bicipital, 144
cavernous, 73
infraorbital, 84
lachrymal, 85
mylo-hyoid, 97
nasal, 82
occipital, 67
optic, 73
subclavian, 130
Grooves in the radius, 156
interventricular, 460
Growth of bones, 1106
Gubernaculum dentis, 881
testis, 1211
Gums, 870
Gustatory hair, 814
nerve, 735
pore, 814
Gyri brevis, 652
or convolutions of brain, 644
Gyrus cinguli, 653
first annectant, 651
fornicatus, 653
hippocampi, 653
longus, 652
marginal, 650
paracentral, 650
rectus, 650
second annectant, 651
third annectant, 651

H.

Hæmatoidin crystals, 1082
Hæmin crystals, 1082
Hæmoglobin, 1078
crystals, 1081
Hæmorrhoidal artery, inferior, 567
middle, 563
superior, 555
nerve, inferior, 793
plexus of nerves, 809

Hæmorrhoidal venous plexus, 616
surgical anatomy of, 616
Hair-cells of internal ear, 865
outer, 865
Hair-follicles, 1140
Hairs, 1140
root-sheath of, 1140
shaft of, 1141
structure of, 1140
Ham, region of, 581
Hamstring tendons, surgical anatomy of, 433
Hamular process of humerus, 146, *note*.
of lachrymal, 88
of sphenoid, 76
Hamulus, 861
Hand, arteries of, 542
bones of, 158
fascia of, 400
ligaments of, 262
muscles of, 400
nerves of, from median, 772
from radial, 775
from ulnar, 773
surface form of, 169, 409
veins of, 607
Hard palate, 883
Harmonia, 219
Hasner, valve of, 847
Havers, glands of, 218
Haversian canals of bone, 1098
system of bone, 1098
Head, kidney, 1208
lymphatics of, 625
muscles of, 297
of scapula, 141
of ulna, 154
veins of, 594
Heart, 640
annular fibres of auricles, 468
arteries of, 469, 480
circular fibres of, 468
component parts of, 460
development of, 1189
endocardium, 468
fibres of the auricles, 468
of the ventricles, 468
fibrous rings of, 468
fœtal relics in, 462
infundibulum of, 463
left auricle, 465
ventricle, 465
looped fibres of auricles, 468
lymphatics of, 469, 636
muscular fibres of, 468
structure of, 1112
nerves of, 469, 752, 803
position of, 460
right auricle, 461
ventricle, 463
septum ventriculorum, 463
size and weight, 460
spiral fibres of, 468
structure of, 468
subdivision into cavities, 460
superficial fibres of auricles, 468
surface-marking of, 470
veins of, 621
vortex of, 469
Heidenhain, demilunes of, 888
Helicine arteries, 1013
Helicis major muscle, 850
Helicis minor, 850
Helicotrema of cochlea, 861
Helix, 849
fossa of, 849
muscles of, 850
spine of, 849
Hemispheres of brain, 643
Henle, ligaments of, 361
looped tubes of, 988
Henle's layer of hair-follicle, 1141
Hensen, canalis reuniens of, 866
lines of, 1109
supporting cells of, 866
Hensen's stripe, 866
Hepatic artery, 551, 940
cells, 939
duct, 941
plexus, 808
veins, 619, 941
Herbst, corpuscles of, 1123
Hernia, congenital, 1051
direct inguinal, 1052
dissection of, 1053
encysted, 1051
femoral, coverings of, 1061
descent of, 1061
of funicular process, 1051
infantile, 1051
inguinal, 1049
dissection of, 1041
oblique inguinal, 1049
scrotal, 1051
Hesselbach's ligament, 361
triangle, 1048, 1052
Hiatus Fallopii, 69
semilunaris, 820
Highmore, antrum of, 85
Hilton's muscle, 963
Hilum of kidney, 986
of spleen, 949
Hind-gut, 1158
development of, 1203
Hind-kidney, 1208
Hinge-joint, 220
Hip-joint, 268
muscles of, 426
in relation with, 291
surface form of, 272
surgical anatomy of, 272
Hippocampal convolution, 653, 666
Hippocampus major, 666
minor, 647, 662
Horizontal cells of retina, 835
plate of ethmoid, 78
of palate, 91
Horner's muscle, 302
Houston's folds of rectum, 928
Howship's lacunæ, 1097
Huguier, canal of, 66, 853
Humerus, 144
anatomical neck, fracture of, 413
articulations of, 148
attachment of muscles to, 149
development of, 148
head of, 144
neck of, 144
nutrient artery of, 537
shaft of, fracture of, 412
surface form of, 149
surgical anatomy of, 149
neck, fracture of, 412
Humerus, tuberosities of, greater and lesser, 144
Humors of the eye, 839
Hunter's canal, 572
Huschke, foramen of, 71
Huxley's layer of hair-follicles, 1141
Hyaline cartilage, 1093
cell, 1079
Hyaloid membrane of eye, 839
Hyaloplasm, 1074
Hydatid of Morgagni, 1017, 1035, 1211
Hymen, 1027
Hyo-epiglottic ligament, 959
Hyo-glossal membrane, 815
Hyo-glossus muscle, 324
Hyoid arch (fœtal), 1170
artery of superior thyroid, 487
bone, 122
attachment of muscles to, 123
cornua of, 123
development of, 123
branch of lingual artery, 489
region, muscles of, infra-, 319
supra-, 321
Hyparterial branch of bronchus, 966
Hypoblast, 1153, 1154
Hypochondriac regions, 896
Hypogastric arteries in fœtus, 471, 562
how obliterated, 473
plexus, 809
inferior, 809
region, 896
Hypoglossal nerve, 754
surgical anatomy of, 756
Hypophysis cerebri, 756

I.

Ileo-cæcal fossa, 904
valve, 923
Ileo-colic artery, 555
fossa, 904
Ileum, 914
Iliac arteries, common, 559
peculiarities of, 559
surface-marking of, 560
surgical anatomy of, 560
external, 570
surface-marking of, 570
surgical anatomy of, 570
internal, 561
at birth, 562
peculiarities in the fœtus, 562
surgical anatomy of, 562
fascia, 415
fossa, 174
furrow, 182
lymphatic glands, 633
portion of fascia lata, 416
region, muscles of, 415
veins, common, 617
peculiarities of, 617
external, 616
internal, 616
Iliacus muscle, 417
Ilio-costalis muscle, 343
Ilio-femoral ligament, 269
Ilio-hypogastric nerve, 782
Ilio-inguinal nerve, 783
Ilio-lumbar artery, 569

Ilio-lumbar ligament, 241
vein, 618
Ilio-pectineal eminence, 177
ligament, 416
Ilio-tibial band, 419
Ilio-trochanteric ligament, 270
Ilium, 172
crest of, 174
dorsum of, 172
spines of, 174
venter of, 174
Impregnation, 1151
Impressio colica, 937
duodenalis, 937
renalis, 937
suprarenalis, 937
Incisive fossa, 83
Incisor teeth, 871
Incisura cardiaca, 974
cerebelli anterior, or semilunaris, 684
posterior, or marsupialis, 684
intertragica, 849
Rivini, 853
Santorini, 851
Incremental lines of dentine, 876
Incus, 856
development of, 1184
ligament of, 857
superior, 857
Infantile hernia, 1051
Inferior dental artery, 498
canal, 88
external frontal artery, 511
internal frontal artery, 510
maxillary bone, 96
changes produced by age in, 99
meatus of nose, 116
occipital protuberance, 57
posterior lobe of cerebellum, 689
profunda artery, 537
turbinated bones, 94
articulations of, 95
development of, 95
ethmoidal process of, 95
lachrymal process of, 95
maxillary process of, 95
vena cava, 617
Infracostal muscles, 351
Infraglenoid tubercles, 141
Inframaxillary nerves from facial, 744
Infraorbital artery, 499
branches of facial nerve, 744
canal, 84
foramen, 83
groove, 84
plexus of nerves, 730
Infraspinatus muscle, 384
Infraspinous fascia, 384
fossa, 140
Infra-sternal depression, 133
Infratrochlear nerve, 729
Infundibula of kidney, 987
Infundibular artery, 477
Infundibuliform fascia, 366, 1047
Infundibulum of brain, 656
of ethmoid, 79
of heart, 463
Ingrassias, processes of, 75
Inguinal canal, 1046
glands, deep, 630
superficial, 630, 1042
hernia, 1041
dissection of, 1042
region, 895
Inlet of pelvis, 180
Innominate artery, 480
peculiarities of, 481
surgical anatomy of, 481
bone, 171
articulations of, 178
attachment of muscles to, 178
development of, 177
veins, 609
peculiarities of, 610
Inorganic constituents of bone, 1101
Insertion of muscles, 296
Inspiration, muscles of, 355
Interalveolar cell islets, 948
Interarticular fibro-cartilage, 1094
of acromio-clavicular joint, 248
of jaw, 233
of knee, 276
of radio-ulnar joint, 260
of sterno-clavicular joint, 247
ligament of ribs, 238
Intercavernous sinus, 604
Intercellular biliary passages, 941
Interchondral ligaments, 239
Interclavicular ligaments, 246
Intercolumnar fascia, 357, 1043
fibres, 358
Intercondyloid notch, 187
Intercostal arteries, 547
anterior, 526
superior, 527
fasciæ, 350
lymphatic glands, 636
lymphatics, 637
muscles, 350
nerves, 777
spaces, 128
veins, superior, 611
Intercosto-humeral nerves, 771, 779
Interlobular arteries of kidney, 999
biliary plexus, 940
spaces, 876
Intermaxillary suture, 113
Intermediate cell mass, 1208
Intermembranous ossification, 1102
Internal abdominal ring, 1047
annular ligament, 442
capsule, 662
carotid artery, 502
cutaneous nerve, 771
inguinal hernia, 1049
mammary artery, 526
vein, 610
maxillary artery, 496
branches of, 496
peculiarities of, 496
surgical anatomy of, 498
medullary lamina, 672
oblique muscle, 360
occipital crest, 57
Internal pterygoid plate, 75
sphincter, 368
Internasal suture, 113
Internodal segment of nerves, 1117
Internodia or phalanges, 169
Interossei muscles, dorsal, of foot, 448
of hand, 408
palmar, 408
plantar, 448
Interosseous artery of foot, 588
of forearm, 541
recurrent, 544
fibro-cartilage, 219
membrane of forearm, 260
of leg, 283
nerve, anterior, 772
posterior, 775
veins of forearm, 608
Interpeduncular space of brain, 656
Intersigmoid fossa, 905
Interspinales muscles, 347
Interspinous ligaments, 226
Intertransversales laterales, 347
mediales, 347
muscles, 347
Intertransverse ligaments, 226
Intertrochanteric line, anterior, 185
posterior, 185
Intertubular stroma of kidney, 993
Intervertebral foramina, 53
notches, 35
substance, 224
Intestinal lymphatic trunk, 635
Intestine, coats of, 915
development of, 1198
large, coats of, 928
lymphatics of, 635
small, 911
surface form of, 930
surgical anatomy of, 930
Intracartilaginous ossification, 1102
Intralobular veins, 940
Intramembranous ossification, 1102
Intranuclear network, 1074
Intraparietal sulcus, 650
thyroid cartilage, 956
Intrinsic muscle of tongue, 325
Intumescentia gangliformis, 741
Investing mass of Rathke, 1167
Involuntary muscle, 1111
Iris, 830
Irregular bones, 34
Ischiatic lymphatic glands, 631
Ischio-capsular ligament, 269
Ischio-rectal fascia, 1071
fossa, 1064
position of vessels and nerves in, 1064
region, surgical anatomy of, 1063
Ischium, 174
body of, 174
ramus of, 176
spine of, 175
tuberosity of, 175
Island of Reil, 652
Isthmus, aortic, 478
of auditory canal, 851

Isthmus cerebri, 673
of the fauces, 883
faucium, 869
of thyroid gland, 979
Iter a tertio ad quartum ventriculum, 676
chordæ anterius, 742
posterius, 742
Ivory of tooth, 874

J.

Jacob's membrane, 835
Jacobson's cartilage, 820
nerve, 748, 858
canal for, 70
organ, 820
Jaw, lower, 95
articulations of, 99
attachment of muscles to, 99
changes produced in, by age, 99
condyle of, 99
development of, 99
ligaments of, 231, 232
oblique line of, 97
pterygoid fossa of, 99
rami of, 98
sigmoid notch of, 99
symphysis of, 96
upper. See *Maxillary Bone.*
Jejunum, 914
Jelly of Wharton, 1090, 1165
Joint. See *Articulations.*
Jugular foramen, 106
fossa, 71
ganglion, 748
process, 56
surface, 70
vein, anterior, 598
external, 597
surgical anatomy of, 597
internal, 598
sinus or gulf of, 598
surgical anatomy of, 599
posterior, external, 598

K.

Karyokinesis, 1075
Karyomitosis, 1075
Keratin, 1138
Kerkering, valves of, 916
Kidney, 985
calices, 987
cortical substance of, 987
development of, 1207
ducts of, 994
hilum of, 986
infundibula of, 987
lymphatics of, 634, 993
Malpighian bodies of, 988
mamillæ of, 987
medullary substance, 987
nerves of, 993
papillæ of, 987
pelvis of, 987
pyramids of Ferrein, 989
renal artery, 556, 992
sinus of, 986
surface-marking of, 993
surgical anatomy of, 993
tubuli uriniferi, 988
veins of, 619, 992
Kidney, weight and dimensions, 985
Knee-joint, 274
surface form of, 280
surgical anatomy of, 280
Krause, end-bulbs of, 1121
membrane of, 1109
Küschner on structure of the heart's valves, 463

L.

Labia cerebri, 659
pudendi majora, 1025
minora, 1026
lymphatics of, 634
Labial artery, 491
glands, 870
veins, inferior, 596
superior, 596
Labio-dental furrow, 877
strand, 877
Labium tympanicum, 864
vestibulare, 864
Labyrinth, 859
arteries of, 866
fibro-serous membrane of, 866
Labyrinthine cartilage, 1167
Lachrymal apparatus, 846
artery, 506
bone, 88
articulations of, 89
attachment of muscles to, 89
development of, 89
canals, 846
caruncula, 845
crest, 88
fossa, 63
gland, 846
groove, 85
nerve, 726
notch, 84
papilla, 846
process of inferior turbinated bone, 95
puncta, 846
sac, 847
tubercle, 86
Lacteals, 623, 918, 1082
Lactiferous ducts, 1039
Lacuna magna, 1006
Lacunæ of bone, 1099
Howship's, 1087
Lacus lachrymalis, 843, 846
Lagema, 866
Lambda, 103
Lambdoid suture, 101
Lamella of bone, articular, 217
horizontal, of ethmoid, 78
perpendicular, of ethmoid, 78
Lamellæ of bone, 1099
Lamina, bursalis, 829
of cerebellum, 685
chorio-capillaris, 829
cinerea, 656
of cornea, 664
elastic, 827
cribrosa, 69
of sclerotic, 825
dental, 877
fusca, 825
spiralis ossea of cochlea, 861
suprachoroidea, 828
vasculosa, 828
Lamina of the vertebræ, 34
Laminæ dorsales, 1156, 1165
Lancisi, nerves of, 659
Lanugo (fœtal hairs), 1186
Large intestine, 921
areolar coat, 928
cæcum, 922
colon, 923
ileo-cæcal valve, 923
mucous coat, 928
muscular coat, 928
rectum, 925
serous coat, 928
Laryngeal artery, inferior, 523
superior, 488
nerve, external, 751
internal, 751
recurrent, 751
superior, 751
surgical anatomy of, 752
from sympathetic, 803
pouch, 961
veins, 610
Laryngo-tracheotomy, 969
Laryngotomy, 968
Larynx, 955
actions of muscles of, 963
arteries of, 948
cartilages of, 955
cavity of, 959
glands of, 964
interior of, 959
ligaments of, 958
lymphatics of, 964
mucous membrane of, 964
muscles of, 961
nerves of, 964
rima glottidis, 959
superior aperture of, 959
surface form of, 968
surgical anatomy of, 968
veins of, 964
ventricle of, 961
vocal cords of, false, 960
true, 961
Lateral acoustic tubercle, 702
cell column, 717
horn of spinal cord, 716
masses of ethmoid, 78
patellar ligaments, 274
recess of fourth ventricle, 697
region of skull, 110
sinus of brain, 602
tract of medulla oblongata, 695, 699
Lateralis nasi artery, 491
Latissimus dorsi muscle, 399
Lecithin, 1078
Leg, arteries of, 585
bones of, 191
fascia of, 434
deep transverse, 438
ligaments of, 268
lymphatics of, 640
muscles of, 434
back of, 436
front of, 435
nerves of, 790
veins of, 614
Lemniscus, 674, 701
Lens, 840
changes produced in, by age, 841
development of, 1182

Lens, suspensory ligament of, 840
vesicle, 1182
Lenticular ganglion, 729
glands of stomach, 910
Lesser lachrymal bone, 88
omentum, 901
sciatic nerve, 791
wings of sphenoid, 75
Leucocytes, 1079
development of, 1079, 1188
Levator anguli oris, 307
scapulæ, 340
ani, 369
labii inferioris, 308
superior alæque nasi, 307
superioris, 307
menti, 308
palati, 329
palpebræ, 302
prostatæ, 369
Levatores costarum, 352
Lieberkühn, crypts of, 918
Lieno-renal ligament, 901, 949
Ligament, structure of, 217
acromio-clavicular, inferior, 248
superior, 248
alar, of knee, 278
of ankle, anterior, 284
lateral, 284
annular, of ankle, 284
external, 284
internal, 284
of radius, 259
of stapes, 857
of wrist, anterior, 262
posterior, 262
anterior, of knee, 274
arcuate, 352
aryteno-epiglottic, 958
astragalo-navicular, 289
atlanto-axial, anterior, 227
posterior, 227
of bladder, false, 1002
true, 1002
broad, of liver, 937
calcaneo-astragaloid, external, 287
interosseous, 287
posterior, 287
calcaneo-cuboid, internal, 287
long, 287
short, 288
superior, 287
calcaneo-navicular, inferior, 288
calcaneo-navicular, superior, 288
capsular. See *Individual Joints.*
carpo-metacarpal, dorsal, 263
interosseous, 263
palmar, 263
of carpus, 263
central, of spinal cord, 709
check, 230
chondro-sternal, anterior, 238
posterior, 238
common vertebral, anterior, 223
posterior, 223
conoid, 249
of Cooper, 359
coraco-acromial, 249
coraco-clavicular, 249
Ligament, coraco-humeral, 251
coracoid, 250
coronary, of liver, 937
costo-clavicular, 246
costo-vertebral, or stellate, 234
cotyloid, 270
crico-arytenoid, 959
crico-thyroid, 959
crucial, of knee, 276
cruciform, 228
deltoid, 284
dorsal. See *Individual Joints.*
of elbow, 255
anterior, 255
external lateral, 256
internal lateral, 256
posterior, 256
falciform, of liver, 937
of pelvis, 240
Flood's, 251
Gimbernat's, 357, 1044, 1058
glenoid, 252
glosso-epiglottidean, 811, 959
of Henle, 361
of Hesselbach, 361, 364
of hip, 268
hyo-epiglottic, 958
ilio-femoral, 269
ilio-lumbar, 241
ilio-pectineal, 416
ilio-trochanteric, 270
of incus, 857
interarticular, of ribs, 235
interchondral, 238
interclavicular, 246
interosseous. See *Individual Joints.*
interspinous, 226
intertransverse, 226
intervertebral, 224
ischio-capsular, 269
of jaw, 231
of knee, 274
of larynx, 958
lateral. See *Individual Joints.*
patellar, 274
longitudinal, of liver, 938
long plantar, 287
lumbo-sacral, 240
of malleus, 857
metacarpal, 267
metacarpo-phalangeal, 267
metatarsal, 291
metatarso-phalangeal, 292
mucosum, of knee, 274
nuchæ, 339
oblique, 259
sacro-iliac, 242
obturator, 429
occipito-atlantal, anterior, 229
lateral, 229
posterior, 229
occipito-axial, 230
odontoid, 230
orbicular, 259
of ossicula, 857
of ovary, 1038
palpebral or tarsal, 844
of patella, 274
of pelvis, 240
of the phalanges, (foot), 293
(hand), 268
phreno-colic, 902
of the pinna, 279
plantar, 291
Ligament, posterior, of knee, or posticum Winslowii, 274
Poupart's, 357, 1044, 1057
pterygo-maxillary, 309
pubic, anterior, 245
posterior, 245
superior, 245
pubo-femoral, 269
pubo-prostatic, 1002
radio-carpal, 262
radio-ulnar joint, inferior, 260
middle, 259
superior, 259
recto-uterine, 1029
rhomboid, 246
round, of hip, 269
of liver, 936
of radius and ulna, 259
of uterus, 1038
sacro-coccygeal, anterior, 244
posterior, 244
sacro-iliac, anterior, 242
oblique, 242
posterior, 242
sacro-sciatic, greater, 242
lesser, 243
sacro-uterine, 1029
sacro-vertebral, 240
of scapula, 249
scapulo-clavicular, 248
of shoulder, 251
spring, 289
stellate, 234
sterno-clavicular, anterior, 246
posterior, 246
sterno-pericardiac, 458
of sternum, 239
stylo-mandibular, 232
subpubic, 245
supraspinous, 225
suspensory, of incus, 857
of lens, 840
of liver, 937
of malleus, 857
of mamma, 377
of penis, 1011
spheno-mandibular, 232
spino-glenoid, 250
sutural, 217
tarsal, of eyelids, 843
tarso-metatarsal, 290
of tarsus, 287
teres, of hip, 270
of thumb, 265
thyro-arytenoid, inferior, 961
superior, 960
thyro-epiglottic, 959
thyro-hyoid, 958
tibio-tarsal, 283
transverse, of atlas, 227
of hip, 267
humeral, 252
of knee, 277
of scapula, 250
trapezoid, 249
triangular, of tympanic bones, 856
of urethra, 1065
of uterus, 1029
of vertebræ, 224
vesico-uterine, 1029
of Winslow, 274
of Wrisberg, 277
of wrist, anterior, 262
lateral external, 262

Ligament of wrist, lateral internal, 262
posterior, 262
of Zinn, 304
Ligamenta alaria, 278
subflava, 225
suspensoria, of mamma, 377
Ligamentous action of muscles, 222
Ligamentum arcuatum externum, 352
internum, 352
arteriosum, 475
denticulatum, 709
latum pulmonalis, 970
mucosum, 277
nuchæ, 339
patellæ, 274
pectinatum iridis, 830
posticum Winslowii, 274
spirale, 864
teres, 270
Ligature of arteries. See each *Artery*.
Ligula, 698
Limbic lobe, 652
Limbs, development of, 1187
Limbus laminæ spiralis, 864
Limiting sulcus, 1158
Linea alba, 365
aspera, 186
ilio-pectinea, 174
quadrati, 186
splendens, 709
supracondylar, 187
suprema, 56
Lineæ semilunares, 365
transverse, of abdomen, 365
Lines of Henson, 1109
Lingual artery, 488
surgical anatomy of, 489
bone, 122
lobule, 652
nerve, 735
tonsils, 812
veins, 598
Lingualis muscle, inferior, 326
superior, 326
transverse, 326
vertical, 326
Lingula, 686
of inferior maxilla, 98
of sphenoid, 73
Lips, 869
arteries of, 491
Liquor amnii, 1161
Cotunnii, 866
sanguinis, 1080
Lissauer, tract of, 714
Lithotomy, parts avoided in operation, 1069
concerned in operation of, 1068
divided in operation, 1069
Littré, glands of, 1006
Liver, 933
change of position in, 943
development of, 1204
distribution of vessels to, in fœtus, 471
ducts of, 941
fibrous coat of, 938
fissures of, 935
hepatic artery 940
cells, 939
Liver, hepatic duct, 941
veins, 938
ligaments of, 937
coronary, 937
lateral, 937
round, 938
lobes of, 936
lobules of, 938
lymphatics of, 634
nerves of, 808
portal vein, 621
situation, size, and weight, 933
structure of, 938
surface form of, 943
surfaces of, 934
surgical anatomy of, 944
vessels of, 938
Lobe or lobes, central, 652
of cerebellum, 685
of cerebrum, 646
cuneate, 651
frontal, 648
of kidney, 986
limbic, 652
of liver, 936
of lung, 974
marginal, 650
occipital, 651
orbital, 649
parietal, 650
of prostate, 1010
quadrate, 651
temporal, 652
of testis, 1019
of thymus, 981
of thyroid, 979
Lobule of the ear, 849
Lobules of kidney, 986
of liver, 938
of lung, 975
Lobuli testes, 1019
Lobulus centralis, 686
Lobus caudatus, 934
clivus monticuli, 686
culmen monticuli, 686
quadratus, 934
Spigelii, 936
Locus cœruleus, 699
Long bones, 33
saphenous nerve, 787
Longissimus dorsi muscle, 345
Longitudinal fasciculus, inferior, 678
perpendicular, 678
superior, 678
fissure of brain, 643, 655
of liver, 935
sinus of brain, inferior, 602
superior, 602
Longus colli muscle, 333
Looped tubes of Henle, 988
Lower extremity, arteries of, 572
bones of, 171
fascia of, 415
ligaments of, 268
lymphatics of, 631
muscles of, 415
nerves of, 780
surface form of muscles of, 449
veins of, 614
visual centre, 722
Lower, tubercle of, 463
Lumbar arteries, 558
fascia or aponeurosis, 342
ganglia, 805
glands, 632
nerves, 780
anterior divisions of, 781
posterior divisions of, 781
roots of, 780
surgical anatomy of, 797
plexus of nerves, 781
region, 896
vein, ascending, 618
veins, 618
vertebræ, 41
development of, 43
Lumbo-iliac ligament, 241
Lumbo-sacral ligament, 240
nerve, 781
Lumbricales muscles (of the foot), 446
(of the hand), 408
Lungs, 973
air-cells of, 976
bronchial arteries, 976
veins, 976
capillaries of, 976
development of, 1206
lobes and fissures of, 974
lobules of, 975
lymphatics of, 637, 977
nerves of, 977
pulmonary artery, 976
veins, 976
roots of, 974
structure of, 975
surface-marking, 977
surgical anatomy of, 977
weight, color, etc., 975
Lunulæ of nails, 1140
Luschka's gland, 558
Lymph, 1082
capillaries, 1082
path or sinus, 1134
Lymphatic or lymphatics of abdomen, 632
of arm, 630
of bladder, 634
bone, 1098
broad ligaments, 634
cardiac, 637
cerebral, 626
cervical, superficial and deep, 627, 628
chest, 636
of clitoris, 633
of cranium, 626
diaphragm, 636
duct, right, 625
face, deep, 626
superficial, 626
Fallopian tubes, 633
general anatomy of, 1131
glands, anterior mediastinal, 636
auricular posterior, 625
axillary, 628
brachial, 628
bronchial, 636
buccal, 625
cervical, deep, 628
superficial, 628
in front of elbow, 625
general anatomy of, 1133
gluteal, 631
of head, 625

Lymphatic or lymphatics, glands, iliac, external, 632
internal, 631
inguinal, deep, 630
superficial, 630
intercostal, 636
internal mammary, 636
ischiatic, 631
of large intestine, 635
of lower extremity, 631
lumbar, 632
of neck, 628
occipital, 625
parotid, 625
of pelvis, 632
popliteal, 631
radial, 628
sacral, 632
of small intestines, 635
of spleen, 635
of stomach, 635
submaxillary, 625
of thorax, 636
tibial anterior, 631
ulnar, 638
of upper extremity, 628
gluteal region, 633
head, superficial, 625
heart, 636
intercostal, 636
internal mammary, 636
intestines, 635
kidneys, 634
labia, 634
lacteals, 635
large intestine, 635
leg, 631
liver, 634
lower extremity, 631
lung, 637
lymphatic duct, 625
right, 625
meningeal, 626
mouth, 627
neck, 625
nose, 627
nymphæ, 634
œsophagus, 637
origin of, 1132
ovaries, 634
pancreas, 635
pelvis, 632
penis, 633
perinæum, 633
pharynx, 628
pia mater, 626
prostate, 634
rectum, 634
scrotum, 633
small intestine, 635
spleen, 635
stomach, 635
subdivisions into deep and superficial, 623
terminations of, 1133
testicle, 634
thoracic duct, 624
thorax, 636
thymic, 637
upper extremity, 630
deep, 630
superficial, 630
uterus, 634
valves of, 1132
vagina, 634
Lymphocyte, 1079
Lymphoid connective tissue, 1091
Lyra of fornix, 665

M.

Macula acustica utricularis, 862
cribrosa, 860
lutea, 833
sacculiaris, 862
Magnum of carpus, 164
Majendie, foramen of, 641, 708
Malar bone, 89
articulations of, 91
attachment of muscles to, 91
development of, 90
foramina, 89
frontal process of, 90
maxillary process of, 90
orbital process of, 90
zygomatic process of, 90
canals, 90
nerves, from fascial, 743
process of superior maxillary, 85
Male urethra, 1005
Malleolar arteries, external and internal, 587
folds, anterior and posterior, 855
Malleolus, external, 197
internal, 195
Malleus, 855
development of, 1184
superior ligament of, 857
Malpighi, pyramids of, 987
Malpighian bodies of kidney, 988
of spleen, 952
capsules, 988
tufts, 988
Mamma, areola of, 1039
lobules of, 1039
nerves of, 1040
nipple or mammilla of, 1039
vessels of, 1039
Mammæ, development of, 1186
Mammary artery, internal, 526
glands, 1038
lymphatic glands, 625
veins, internal, 610
Mammilla of breast, 1039
of kidney, 987
Mammillary processes, 42
Mandibular arch, 1170
nerve, 744
Manubrium of malleus, 856
of sternum, 124
Marginal artery, 477
gyrus, 650
lobe, 650
sinus, 1164
Marrow of bone, 1096
Marshall, vestigial fold of, 460, 1197
Masseter muscle, 310
Masseteric arteries, 498
fascia, 310
nerve, 734
veins, 596
Mastoid antrum, 68
Mastoid antrum, opening of, 854
cells, 67
foramen, 67
portion of temporal bone, 67
process, 67
vein, 597
Masto-occipital suture, 102
Masto-parietal suture, 102
Matrix of nail, 1140
Maturation of ovum, 1150
Maxillary artery, internal, 496
bone, inferior, 96
superior, 83
development of, 87
nerve, inferior, 734
superior, 729
process of inferior turbinated, 94
of malar bone, 90
processes, fœtal, 1169
sinus, 85
tuberosity, 84
vein, anterior internal, 596
internal, 596
Meatus auditorius externus, 68, 851
internus, 69
of nose, inferior, 117
middle, 117
superior, 116
urinarius, female, 1027
male, 1006
Meatuses of the nose, 117, 820
Meckel's cartilage, 1170
diverticulum, 915
ganglion, 732
Median artery of forearm, 543
of spinal cord, 522
nerve, 771
surgical anatomy of, 776
vein, 607
Mediastinal arteries, from internal mammary, 526
posterior, from aorta, 548
lymphatic glands, 636
subpleural plexus, 526
Mediastinum, anterior, 972
middle, 972
posterior, 973
superior, 971
testis, 1018
Medio-tarsal joint, 285
Medulla oblongata, 693
arcuate fibres of, 696
back of, 696
fissures of, 694
formatio reticularis of, 700
funiculus cuneatus of, 695
gracilis of, 695
of Rolando of, 695
gray matter of, 699
lateral column of, 695
tract of, 699
olivary body of, 695
pyramids of, 694
restiform bodies of, 696
raphé of, 703
structure of, 699
spinalis, 710
Medullary artery of bone, 1097
canal of bone, 33, 1096
formation of, 1105
groove, 1155
laminæ, external, 672
internal, 672

Medullary membrane of bone, 1096
plates, 1156
segments of nerves, 1117
sheath of nerve-fibres, 1116
spaces of bone, 1104
of kidney, 987
of suprarenal capsules, 997
velum, inferior, of cerebellum, 688, 697
superior, 697
Medullated nerve-fibres, 1116
Medulli-spinal veins, 612
Meibomian glands, 844
Meissner's plexus, 921
tactile corpuscles, 1121
Membrana basilaris, 863
fusca, 825
flaccida, 855
granulosa, of Graafian vesicle, 1036
hyaloidea, 839
limitans of retina, 833, 837
nictitans, 846
propria, 1091
pupillaris, 832
sacciformis, 266
tectoria, 866
tympani, 855
secundaria, 854
Membrane of aqueous chamber, 827
arachnoid, spinal, 707
cerebral, 641
choroid, 828
of Corti, 866
costo-coracoid, 378
crico-thyroid, 959
of Descemet, 827
fenestrated, 1126
hyaloid, 839
Jacob's, 835
of Kölliker, 866
of Krause, 1109
limiting, 833, 835
pituitary, 820
pupillary, 832
of Reissner, 863
Schneiderian, 820
thyro-hyoid, 958
Membranes of brain, 639
of fœtus, 1160
of spinal cord, 707
Membranous cranium, 1165
labyrinth, 862
portion of urethra, 1005
semicircular canals, 862
vertebral column, 1165
Meningeal artery, from ascending pharyngeal, 494
anterior, from internal carotid, 505
middle, from internal maxillary, 496
from occipital, 493
posterior, from vertebral, 521
small, from internal maxillary, 498
layer of dura mater, 639
lymphatics, 626
veins, 596, 640
Meninges. See *Membranes*.
Menisci, 1094
Menisco-femoral joint, 280
Menisco-tibial joint, 280
Mental foramen, 97, 113
process, 97
tubercles, 97
Mesencephalon, 643, 1176
Mesenteric artery, inferior, 555
superior, 553
glands, 635
plexus of nerves, inferior, 809
superior, 809
vein, inferior, 619
superior, 619
Mesenterico-parietal folds, 905
Mesenteries, 902
development of, 1198
Mesial fillet of midbrain, 674
Mesoblast, 1154, 1155
Mesoblastic somites, 1156
Mesocolon, 1199
ascending, 902
descending, 902
transverse, 903
Mesoderm, 1154
Mesogastrium, 1199
Mesonephros, 1208
Mesorchium, 1209, 1211
Mesorectum, 1199
Mesosalpinx, 1030
Mesosternum, 125
Mesovarium, 1209
Metacarpal artery, 540
articulations, 267
Metacarpo-phalangeal articulations, 267
Metacarpus, 165
common characters of, 165
development of, 171
peculiar bones of, 166
Metanephros, 1208
Metaphase of karyokinesis, 1075
Metasternum, 125
Metatarsal artery, 588
articulations, 291
bones, 208
Metatarso-phalangeal articulations, 292
Metatarsus, 208
development of, 208
Metencephalon, 643, 1176
Metopic suture, 64
Microcytes, 1078
Micropyle, 1150
Mid-carpal joint, 265
Mid-frontal process, fœtal, 1169
Mid-gut, 1158
development of, 1198
Mid-kidney, 1208
Middle clinoid processes, 73, 105
ear, or tympanum, 582
ethmoidal cells, 79
fossa of skull, 105
internal frontal artery, 510
meatus, 117
of nasal fossæ, 117
odontoid ligament, 231
Milk teeth, 874
Mitral cells, 681
valve, 466
Mixed bones, 34
Moderator band, 464
Modiolus of cochlea, 861
Molar glands, 870
teeth, 872
Moll, glands of, 843
Monaster or mother star, 1075
Monro, foramen of, 671
Mons Veneris, 1025
Morgagni, hydatid of, 1211
sinus of, 328
Motor nerves, 1124
efferent or descending nerve tract, 718
oculi nerve, 722
surgical anatomy of, 724
Motorial end-plates, 1124
Mouth, 869
mucous membrane of, 870
muscles of, 307
surface form of, 888
Movement admitted in joints, 220
Mucilaginous glands, 218
Mucous glands of tongue, 815
membrane, 1145
tissue, 1090
Müller, duct of, 1208
fibres of, 837
Multicuspidate teeth, 872
Multifidus spinæ muscle, 346
Muscle, general anatomy of, 1107
arrangement of fibres of, 1107
bipenniform, 295
blood-vessels of, 1111
chemical composition of, 1112
derivation of names, 295
development of, 1112
fasciculi of, 1107
fibres of, 1107
form of, 295
fusiform, 295
insertion of, 296
involuntary, 1111
lymphatics of, 1111
meaning of the terms "origin" and "insertion," 296
mode of connection of, with bone, cartilage, skin, etc., 296
nerves of, 1111, 1123
origin of, 925
penniform, 925
plate, 1165
quadrilateral, 295
rhomboidal, 295
sarcous elements of, 1110
sheath of, 1107
size of, 295
skeletal, 1107
striped, 1107
structure of, 1107
tendons of, 296
triangular, 295
unstriped, 1111
voluntary, 1107
Muscles or muscle, descriptive anatomy:
of abdomen, 356
abductor hallucis, 444
indicis, 408
minimi digiti (foot), 445
(hand), 406
pollicis (hand), 404
accelerator urinæ, 371
accessorii orbicularis oris, 308
accessorius pedis, 446
ad ilio-costalem, 343
adductor brevis, 425
longus, 424

Muscles or muscle, descriptive anatomy:
adductor magnus, 425
obliquus hallucis, 447
pollicis (hand), 405
transversus hallucis, 447
pollicis, 405
anconeus, 397
antitragicus, 850
aryteno-epiglottideus, inferior, 963
superior, 963
arytenoideus, 962
rectus, *note*, 963
attollens auriculam, 301
attrahens auriculam, 300
azygos uvulæ, 330
biceps (arm), 387
(thigh), 431
biventer cervicis, 346
brachialis anticus, 388
buccinator, 309
cervicalis ascendens, 345
chondro-glossus, 324
ciliary, of eye, 830
circumflexus palati, 329
coccygeus, 369
columns, 1109
complexus, 345
compressor naris, 306
narium minor, 306
sacculi laryngis, 963
urethræ, 375
in female, 375
constrictor isthmi faucium, 325, 331
pharyngeus inferior, 327
medius, 328
superior, 328
coraco-brachialis, 387
corrugator of cranial region, 298
cutis ani, 368
supercilii, 302
cremaster, 361
crico-arytenoideus lateralis, 962
posticus, 962
crico-thyroid, 961
crureus, 422
deltoid, 382
depressor alæ nasi, 306
anguli oris, 308
epiglottidis, 963
labii inferioris, 308
diaphragm, 352
digastric, 321
dilatator naris, anterior, 306
posterior, 306
erector clitoridis, 375
penis, 372
spinæ, 343
extensor brevis digitorum, 444
pollicis, 399
carpi longior, 396
radialis brevior, 396
ulnaris, 397
coccygis, 347
digitorum communis, 396
indicis, 399
longus digitorum, 435
pollicis, 399
minimi digiti, 397
ossi metacarpi pollicis, 399

Muscles or muscle, descriptive anatomy:
primi internodii pollicis, 399
proprius hallucis, 435
of external ear, 301
sphincter, 368
of face, 301
femoral region, anterior, 418
internal, 423
posterior, 432
fibular region, 440
flexor accessorius, 446
brevis digitorum, 444
hallucis, 446
minimi digiti (foot), 447
(hand), 406
pollicis (hand), 404
carpi radialis, 391
ulnaris, 391
digitorum sublimis, 392
longus digitorum, 439
hallucis, 438
pollicis (hand), 394
ossis metacarpi pollicis, 404
profundus digitorum, 393
frontalis, 299
gastrocnemius, 436
gemellus, inferior, 430
superior, 430
genio-hyo-glossus, 323
genio-hyoid, 322
gluteus maximus, 426
medius, 427
minimus, 428
gracilis, 423
of hand, 404
of head and face, 297
helicis, major, 850
minor, 850
Hilton's, 963
of hip, 426
Horner's, 302
hyo-glossus, 324
iliac region, 415
iliacus, 417
ilio-costalis, 343
infracostal, 351
infraspinatus, 384
intercostal, 350
internal sphincter, 368
interossei of foot, 448
of hand, 408
interspinales, 347
intertransversales, 347
labial, 308
of larynx, 961
latissimus dorsi, 339
of leg, 434
levator anguli oris, 307
scapulæ, 340
ani, 369
glandulæ thyroideæ, 980
labii inferioris, 308
menti, 308
superioris, 307
alæque nasi, 306
palati, 329
palpebræ, 302
prostatæ, 370
levatores costarum, 352
lingualis, 323
longissimus dorsi, 345
longus colli, 333
lumbricales (foot), 446
(hand), 408

Muscles or muscle, descriptive anatomy:
masseter, 310
multifidus spinæ, 346
musculus accessorius ad ilio-costalem, 343
mylo-hyoid, 322
naso-labialis, 306
of neck, 313
obliquus abdominis externus, 356
internus, 360
auriculæ, 850
capitis inferior, 348
superior, 348
obturator externus, 430
internus, 429
occipitalis, 299
occipito-frontalis, 298
oculi, inferior, 304
superior, 304
omo-hyoid, 320
opponens minimi digiti, 406
pollicis, 404
orbicularis oris, 308
palpebrarum, 301
palate, 329
palato-glossus, 325, 331
palato-pharyngeus, 331
palmaris brevis, 406
longus, 391
pectineus, 424
pectoralis, major, 378
minor, 379
of perineum, female, 375
male, 370
peroneus brevis, 441
longus, 440
tertius, 435
pharyngo-glossus, 325
of pharynx, 327
plantaris, 437
plates, 1165
platysma myoides, 314
popliteus, 438
pronator quadratus, 394
radii teres, 390
psoas magnus, 416
parvus, 417
pterygoid, external, 312
internal, 312
pyramidalis abdominis, 364
nasi, 306
pyriformis, 428
quadratus femoris, 430
lumborum, 367
menti, 308
quadriceps extensor cruris, 421
rectus abdominis, 362
capitis anticis major, 332
minor, 332
posticus major, 347
minor, 348
lateralis, 333
oculi, externus, superior, inferior, and internus, 304
retrahens auriculam, 301
rhomboides major, 340
minor, 340
risorius, 310
rotatores spinæ, 347
sacro-lumbalis, 343
salpingo-pharyngeus, 331
sartorius, 421

Muscles or muscle, descriptive anatomy:
scalenus anticus, 334
medius, 335
posticus, 335
semimembranosus, 432
semispinalis colli, 346
dorsi, 346
semitendinosus, 432
serratus magnus, 381
posticus, inferior, 341
superior, 341
sole of foot, 442
first layer, 444
fourth layer, 448
second layer, 446
third layer, 446
soleus, 436
sphincter, external, 368
internal, 368
vaginæ, 375
spinalis colli, 345
dorsi, 345
splenius, 342
capitis, 342
colli, 342
stapedius, 837
sterno-cleido-mastoid, 317
sterno-hyoid, 319
sterno-thyroid, 319
stylo-glossus, 324
stylo-hyoid, 322
stylo-pharyngeus, 329
subanconeus, 389
subclavius, 380
subcrureus, 423
subscapularis, 383
supinator brevis, 398
longus, 395
supraspinales, 347
supraspinatus, 384
temporal, 311
tensor fasciæ femoris, 420
palati, 329
tarsi, 302
tympani, 857
teres major, 386
minor, 385
thyro-arytenoideus, 962
thyro-epiglottideus, 963
thyro-hyoid, 320
tibialis anticus, 434
posticus, 439
of tongue, 325
trachelo-mastoid, 345
tragicus, 850
transversalis abdominis, 362
colli, 345
transversus auriculæ, 850
perinæi (female), 375
profundus, 1070
trapezius, 337
triangularis sterni, 351
triceps, extensor cubiti, 388
of tympanum, 857
of ureters, 1003
vastus externus, 422
internus and crureus, 422
zygomaticus major, 307
minor, 307
Muscles of expression, 314
of inspiration and expiration, 355
of pelvic outlet, 367
Muscular fibres of heart, 1112
Muscular process of arytenoid, 957
Muscularis mucosæ, 1146
Musculi papillares, left ventricle, 467
right ventricle, 464
pectinati in left auricle, 465
in right auricle, 461
pulvo-vesicalis, 1002
Musculo-cutaneous nerve of arm, 770
from peroneal, 796
Musculo-phrenic artery, 527
Musculo-spiral groove, 146
nerve, 774
surgical anatomy of, 776
Musculus accessorius ad ilio-costalem, 343
incisivus, inferior, 309
superior, 309
suspensorius duodeni, 914
Myelo-plaques, 1097
Myelo-spongium, 1172
Mylo-hyoid artery, 498
groove, 98
muscle, 322
nerve, 736
ridge, 98
Myocardium, 468
Myrtiform fossa, 83

N.

Nails, 1139
lunula of, 1140
matrix of, 1140
Nares, anterior, 117, 820
posterior, 117, 820, 890
septum of, 116, 820
Nasal angle, 82
artery, of internal maxillary, 499
transverse, 508
of ophthalmic, 508
of septum, 491
bones, 81
articulations of, 82
development of, 82
cartilages, 818
crest, 87
duct, 847
eminence, 61
fossæ, 115, 820
arteries of, 822
mucous membrane of, 820
nerves of, 823
surgical anatomy of, 823
veins of, 822
groove, 82
laminæ, 1169
nerve, 727
nerves from Meckel's ganglion, 732
notch, 62
process, 86
spine, 62
anterior, 87, 113
posterior, 89
venous arch, 595
Nasi dorsalis artery, 509
Nasion, 112
Nasmyth's membrane, 879
Naso-labialis muscle, 309
Naso-maxillary suture, 113
Naso-palatine nerve, 733
Naso-palatine, recess, 820
Nates of brain, 675
Navicular bone, 205
articulations of, 205
attachment of muscles to, 205
tuberosity of, 205
Neck, glands of, 627
lymphatics of, 625
muscles of, 313
triangle of, anterior, 500
posterior, 501
veins of, 597
Nélaton's line, 190
Nerve-cells, or ganglion corpuscles, 1113
Nerve-epithelium cells, 1124
Nerve-roots, anterior, 717
posterior, 717
Nerve-tracts of cord, 717
Nerves, general anatomy of, 1118
cerebro-spinal, 1118
development of, 1172, 1178
endoneurium, 1119
epineurium, 1119
funiculi of, 1118
origin of, 1120
perineurium of, 1119
plexus of, 1119
sheath of, 1119
spinal roots of, 756
sympathetic, 1120
termination of, 1120
vessels of, 1119
Nerves or nerve, descriptive anatomy:
of abducens, 738
accessory obturator, 786
anterior crural, 786
auditory, 745
auricular, posterior, 743
of vagus, 751
auricularis magnus, 762
of auriculo-temporal, 735
of second cervical, 762
of small occipital, 761
of brachial plexus, 764
buccal, 734
of facial, 744
calcaneo-plantar, 795
cardiac, 803
inferior, 804
middle, 803
plexus, deep, 806
superficial, 806
of pneumogastric, 752
superior, 803
cavernous, of penis, 810
cervical, anterior, 760
posterior, 759
superficial, 762
cervico-facial, 744
chorda tympani, 741
ciliary, long, 729, 859
short, 729
circumflex, 769
coccygeal, 789
cochlear, 746
communicans hypoglossi, 763
peronei, 796
of Cotunnius, 733
cranial, 720
crural anterior, 786
cutaneous. See *that heading.*
deep palmar, 773

Nerves or nerve, descriptive anatomy:
deep temporal, 734
dental, anterior superior, 731
inferior, 736
middle superior, 731
posterior superior, 730
descendens hypoglossi, 756
digastric, from facial, 743
digital, 795
foot, 795
dorsal (hand), 776
peculiar, 777
of penis, 793
spinal, 777
dorsi-lumbar, 781
of dura mater, 640
eighth pair, 745
eleventh pair, 753
of eyeball, 721
facial, 740
femoral cutaneous, 793
fifth, 725
fourth, 724
frontal, 726
ganglionic branch of nasal, 729
gastric branches of vagus, 808
genito-crural, 783
glosso-pharyngeal, 746
gluteal, inferior, 791
superior, 791
great petrosal, 732
splanchnic, 804
gustatory, 735
hemorrhoidal inferior, 793
of heart. See *Cardiac.*
hepatic, 808
hypoglossal, 754
ilio-hypogastric, 782
ilio-inguinal, 783
incisive, 736
inferior maxillary, 734
inframaxillary, of facial, 744
infraorbital, of facial, 744
infratrochlear, 729
intercostal, 777
intercosto-humeral, 779
interosseous, anterior, 772
posterior, 775
ischiadic, great, 793
small, 791
Jacobson's, 748
labial, 731
of labyrinth, 866
lachrymal, 726
of Lancisi, 659
large cavernous, 810
laryngeal, external, 751
internal, 751
recurrent, 751
superior, 751
lesser splanchnic, 804
lingual, of fifth, 735
of glosso-pharyngeal, 748
long ciliary, 729
saphenous, 787
thoracic, 768
lumbar, 780
lumbo-sacral, 781
malar branch of facial, 743
of orbital, 730
masseteric, 734
maxillary, inferior, 734
superior, 729
Nerves or nerve, descriptive anatomy:
median, 771
mental, 736
middle cardiac, 803
motor of the eye, common, 722
external, 739
musculo-cutaneous, of arm, 770
of leg, 796
musculo-spiral, 774
mylo-hyoid, 736
nasal, from Meckel's ganglion, 731
from ophthalmic, 726
from Vidian, 733
naso-palatine, 733
ninth, 746
obturator, 785
occipital, of facial, 742
great, 760
small, 762
of third cervical, 760
œsophageal, 752
olfactory, 720
ophthalmic, 726
optic, 721
orbital nerves in cavernous sinus, 739
in orbit, 739
their relation, 739
in sphenoidal fissure, 739
of superior maxillary, 729
palatine, anterior or large, 733
external, 733
posterior or small, 733
palmar, cutaneous, of median, 772
ulnar, 773
palpebral, 731
par vagum, 749
pars intermedia, 740
perforans Casserii, 770
perforating cutaneous, 793
perineal, 793
superficial, 793
peroneal, 796
petrosal, deep large, 732
small, 858
superficial, 858
long, 748
superficial, external, or large, 732
small, 748
pharyngeal, of external laryngeal, 751
of glosso-pharyngeal, 748
of Meckel's ganglion, 733
of pneumogastric, 751
of sympathetic, 801
phrenic, 763
plantar, cutaneous, 795
external, 795
internal, 795
pneumogastric, 749
popliteal, external, 796
internal, 794
portia dura, 740
mollis, 740
posterior auricular, 742
pterygoid, 734
pterygo-palatine, 733
pudendal, inferior, 791
pudic, 793
pulmonary, from vagus, 752
Nerves or nerve, descriptive anatomy:
radial, 775
recurrent laryngeal, 751
to tentorium, 725
renal splanchnic, 804
respiratory, external, 768
internal, 763
sacral, 788
plexus, 790
saphenous, long or internal, 787
short or external, 794
sciatic, great, 793
of second cervical, 760
small, 791
short ciliary, 729
sixth, 738
small cavernous, 810
spinal, 756
accessory, 753
splanchnic, great, 804
small, 804
smallest, 804
stylo-hyoid of facial, 743
suboccipital, 758
posterior branch of, 759
subscapular, 769
superficialis colli, 762
superior cardiac, 803
maxillary, 729
supra-acromial, 763
supraclavicular, 763
supramaxillary of facial, 744
supra-orbital, 727
suprascapular, 768
suprasternal, 762
supratrochlear, 727
temporal, of auriculo-temporal, 735
deep, 734
of facial, 743
temporo-facial, 743
temporo-malar, 730
tenth, 749
third, or motor oculi, 722
thoracic, anterior, 769
posterior, 768
thyro-hyoid, 756
tibial, anterior, 796
posterior, 794
of tongue, 816
tonsillar, 748
trifacial or trigeminus, 725
trochlear, 724
twelfth, 754
tympanic, of facial, 742
of glosso-pharyngeal, 748, 858
ulnar, 772
uterine, 810
vaginal, 810
vagus, 749
vestibular, 745
Vidian, 732
of Wrisberg, 771
Nervi-nervorum, 1119
Nervous centres, development of, 1172
tissue, general anatomy of, 1113
fibrous, nervous matter, 1115
ganglia, 1125
gelatinous fibres, 1117
gray or cineritious substance, 1113

Nervous tissue, sympathetic, 1120
chemical composition of, 1118
white or fibrous substance, 1115
Nervus cardiacus magnus, 803
minor, 804
petrosus profundus, 732
superficialis cordis, 803
Nest of egg-tubes, 1037
Neumann, dentinal sheath of, 876
Neural arch, 34
canal, 1156
crest, 1179
groove, 1155
Neurenteric canal, 1155, 1203
Neurilemma, 1116, 1117
of cord, 734
Neuroblasts, 1117, 1172
Neuroglia, 1113
of cord, 713
Neurokeratin, 1116
Neuro-muscular spindles, 1123
Neuro-tendinous spindles, 1123
Nidus avis of cerebellum, 688
Ninth nerve, 746
Nipple, 1039
Nissl's granules, 1114
Nodes of Ranvier, 1117
Nodules of cerebellum, 688
Non-medullated nerve-fibres, 1117
Nose, 818
arteries of, 822
bones of, 81
cartilage of septum of, 819
cartilages of, 818
development of, 1184
fossæ of, 115, 820
mucous membrane of, 820
muscles of, 305
nerves of, 823
surgical anatomy of, 823
veins of, 822
Notch, cotyloid, 177
ethmoidal, 64, 78
intercondyloid, 187
nasal, 62
sacro-sciatic, greater, 175
lesser, 175
sigmoid, 99
spheno-palatine, 93
supra-orbital, 62
suprascapular, 141
supra-sternal, 336
Notochord, 1156, 1166
Nuchal flexure of embryonic brain, 1176
Nuck, canal of, 1047, 1212
Nuclear membrane, 1074
substance, 1074
Nucleated sheath of Schwann, 1116
Nuclei, accessory olivary, 703
auditory, 702
of auditory nerve, 684
of fifth nerve, 683
of glosso-pharyngeal and vagus nerves, 702
independent, 702
pontis, 684
Nucleoli, 1074
pseudo-, 1074
true, 1074
Nucleo-proteid, 1078
Nucleus, ambiguus, 702
amygdale, 664
of Bechterew, 745
of Deiters, 745
caudatus, 662
of a cell, 1074
emboliformis, 693
of facial nerve, 683
fastigii, 693
globosus, 693
hypoglossal nerve, 702
lentis, 840
lenticularis, 662
of olivary body, 702
of optic thalamus, inner, 671
outer, 671
sixth nerve, 683
spinal accessory nerve, 702
superior olivary, 683
of the tegmentum, 674
vagi, 749
Nutrient artery of bone, 1097
Nutritive fluids, 1077
Nymphæ, 1026
lymphatics of, 634

O.

Obelion, 103
Obex, 698
Oblique inguinal hernia, 1049
coverings of, 1050
ligament, 259
line of the clavicle, 135
of the fibula, 197
of lower jaw, 97
of radius, 156
ridge of ulna, 154
Obliquus auriculæ muscle, 850
externus abdominis, 357
inferior capitis, 348
oculi, 304
internus abdominis, 359
superior capitis, 348
oculi, 304
Obturator artery, 564
peculiarities of, 565
relation of, to femoral ring, 1060
externus muscle, 430
fascia, 1071
foramen, 177
internus muscle, 429
ligament or membrane, 429
membrane, 429
nerve, 785
accessory, 786
surgical anatomy of, 797
veins, 617
Occipital artery, 493
bone, 55
articulations of, 59
attachment of muscles to, 59
development of, 58
crests, 56, 57
protuberances, 56, 57
fossæ, 56
lobe, 646
lymphatic glands, 625
groove, 67
sinus, 603
triangle, 501
vein, 597
Occipitalis muscle, 299
Occipitalis nerve, major, 760
minor, 762
Occipito-atlantal articulation, 229
Occipito-axial articulation, 230
Occipito-frontalis muscle, 298
Occiput, arteries of, 493
Odontoblasts, 874
Odontoclasts, 882
Odontoid ligaments, 230
tubercle for, 57
process of axis, 38
Œsophageal arteries, 547
branches of vagus nerve, 752
glands, 892
opening of diaphragm, 354
plexus, 752
Œsophagus, 891
lymphatics of, 637
structure of, 892
surgical anatomy of, 893
Olecranon fossa, 147
process, 150
fracture of, 413
Olfactory bulb, 654, 720
cells, 821
fasciculus, 665
foramina, 79
fossæ, fœtal, 1184
hair, 822
lobe, 654
lobule, anterior, 654
posterior, 654
nerve, 720
surgical anatomy of, 721
sulcus, 649
Olivary bodies of medulla oblongata, 695, 699
nuclei, accessory, 703
nucleus, 702
peduncle, 703
process, 73
Omenta, 901
Omental tuberosity of liver, 934
of pancreas, 946
Omentum, gastro-colic, 902
gastro-hepatic, 901
gastro-splenic, 902
great, 902
lesser, 901
Omo-hyoid muscle, 320
Omphalo-mesenteric arteries, fœtal, 1189
duct, 1158
veins, 1189
vessels, 1158
Opening of aorta in left ventricle, 466
aortic, in diaphragm, 353
canal, in diaphragm, 353
of coronary sinus, 462
of inferior cava, 462
left auriculo-ventricular, 466
œsophageal, in diaphragm, 354
of pulmonary artery, 463
veins, 465
right auriculo-ventricular, 466
saphenous, 419, 1056
superior cava, 464
Operations: amputations of foot, 213
of penis, 1014
arteries, ligature of, abdominal aorta, 550

Operations: arteries, axillary, 531
brachial, 536
carotid, common, 485
external, 487
internal, 505
femoral, 575
iliac, common, 560
external, 570
internal, 562
innominate, 481
lingual, 489
popliteal, 582
radial, 539
subclavian, 518
thyroid, inferior, 524
tibial, anterior, 586
posterior, 589
ulnar, 542
catheterism of Eustachian tube, 868
cholecystotomy, 945
for cleft palate, 332
colotomy, 932
division of nerves, facial, 744
infraorbital, 738
lingual, 738
sciatic, great, 798
spinal accessory, 753
supra-orbital, 738
excision of ankle, 286
elbow, 258
hip, 273
knee, 281
of shoulder, 254
extirpation of spleen, 954
of thyroid, 981
gastrostomy, 911
gastrotomy, 911
hamstring tendons, division of, 434
laryngotomy, 968
lithotomy, 1068
nephrotomy and nephrectomy, 994
œsophagotomy, 893
paracentesis of pericardium, 460
prostatectomy, 1011
puncture of the bladder, 1005
removal of the clavicle, 138
lower jaw, 122
scapula, 143
testis, 1021
tongue, 327, 817
upper jaw, 122
for strabismus, 306
tapping chest, 134
for torticollis, 319
tracheotomy, 968
venesection, 608
Opercula of the insula, 652
Ophthalmic artery, 505
ganglion, 729
nerve, 726
vein, 604
inferior, 604
Opponens minimi digiti muscle, foot, 447
hand, 406
pollicis muscle, 404
Optic commissure, 721
cup, 1181
foramen, 73, 105
groove, 73, 105
Optic lobes, 675
nerve, 721
surgical anatomy of, 722
radiations or posterior stalk of optic thalamus, 672
recess, 670
thalamus, 671
anterior tubercle of, 671
inner nucleus of, 671
outer nucleus of, 671
posterior tubercle of, 671
stalk of, 672
tract, 271
vesicle, primitive, 1180
secondary, 1181
Ora serrata, 832
Oral cavity, 869
pit, 1171
sinus, 1169
Orbicular bone, 857
ligament, 259
Orbicularis ciliaris, 301
latus, 301
oris muscle, 308
palpebrarum, 301
Orbiculus ciliaris, 829
Orbit, 113
arteries of, 506
muscles of, 303
relation of nerves in, 739
Orbital fascia, 305
foramina, 75
lobe, 649
nerve, 730
process of malar, 90
of palate, 93
sulcus, 649
Organic constituent of bone, 1101
Organs of Giraldès, 102, 1211
of Golgi, 1123
of Jacobson, 820
of Rosenmüller, 1038, 1210
Orifice, cardiac, of stomach, 906
pyloric, of stomach, 906
Origin of muscles, 296
Os acetabuli, 178
calcis, 199
development of, 211
cordis, 468
hyoids, 123
innominatum, 171
development of, 177
magnum of carpus, 164
orbiculare, 857
planum, 79
pubis, 176
trigonum, 204
uteri, 1029
Ossa triquetra, 81
unguis, 88
Ossicula auditus, 856
ligaments of, 857
Ossification of bone, 1102
defects in, 54
intracartilaginous, 1102
intramembranous, 1102
of spine, progress in, 45
subperiosteal, 1106
Osteoblasts, 1096, 1104
Osteoclasts, 1097, 1104
Osteogenetic fibres, 1102
Osteology, 33
Ostium abdominale of Fallopian tube, 1034
internum or uterinum, 1031
Ostium primum, 1190
secundum, 1190
Otic ganglion, 736
vesicle, 1183
Otoliths, 863
Outlet of pelvis, 180
Ovarian arteries, 557
plexus of nerves, 808
veins, 618
Ovary, 1035
development of, 1209
Graafian vesicles of, 1036
ligament of, 1038
lymphatics of, 634
nerves of, 1038
ovicapsule of, 1037
shape, position, and dimensions, 1035
stroma of, 1036
tunica albuginea, 1036
vessels of, 1038
Ovicapsule of Graafian follicles, 1037
Oviducts, 1034
Ovisacs of ovary, 1036
Ovula of Naboth, 1032
Ovum, 1073, 1149
discharge of, 1028
discus proligerus of, 1149
early changes in, 1150
fertilization of, 1151
germinal spot of, 1149
vesicle of, 1149
vitelline membrane of, 1149
yolk of, 1149
zona pellucida of, 1149
Oxyntic cells of peptic glands, 910
glands, cardiac, 910
pyloric, 910

P.

Pacchionian depressions, 60
glands, 602, 639, 642
Pacinian corpuscles, 1122
Pad of corpus callosum, 759
Palatal glands, 883
Palate, arches of, 883
bone, 91
articulations of, 94
attachment of muscles to, 94
development of, 93
horizontal plate of, 91
orbital process of, 93
process of superior maxillary, 87
sphenoidal process of, 93
turbinated crest of, 92
vertical plate of, 92
development of, 1170
hard, 883
muscles of, 329
soft, 883
Palatine aponeurosis, 330
artery, ascending, 491
descending or posterior, 499
canal, accessory, 91
anterior, 87
posterior, 91
fossa, anterior, 87
nerves, 773
process of superior maxillary, 87
veins, inferior, 596

Palato-glossus muscle, 325, 331
Palato-pharyngeus, 331
Palmar arch, deep, 538
superficial, 544
surface-marking of, 545
cutaneous nerve, 772, 773
fascia, 402
interossei arteries, 541
nerve, deep, of ulnar, 773
superficial, of ulnar, 773
veins, 607
Palmaris brevis muscle, 406
longus muscle, 391
Palpebræ, 843
Palpebral arteries, 508
external, 506
cartilages or plates, 844
fissures, 843
surface form of, 847
folds of conjunctiva, 845
ligaments, 844
muscles, 301
veins, inferior, 596
superior, 596
Pampiniform plexus of veins, 618, 1016, 1038
Pancreas, 945
development of, 1205
lymphatics of, 635
structure of, 948
surface form of, 948
surfaces of, 948
surgical anatomy of, 948
vessels and nerves of, 948
Pancreatic arteries, 554
duct, 947
plexus of nerves, 808
veins, 619
Pancreatica magna artery, 553
Pancreatico-duodenal artery, inferior, 554
superior, 553
plexus of nerves, 808
vein, 619
Papilla lachrymalis, 846
spiralis, 864
Papillæ conicæ vel filiformes, 813
fungiformes (mediæ), 813
of kidney, 987
maximæ (circumvallatæ), 813
of skin, 1139
of teeth, 878, 880
of tongue, 813
Papillary layer of skin, 1138
Paracentral gyrus, 650
Parachordal cartilage, 1167
Parallel sulcus, 652
Paramastoid process, 56
Paranucleus, 948
Parathyroids, 981
Paraxial mesoblast, 1156
Paries carotica, 854
jugularis, 853
labyrinthica, 853
mastoidea, 854
tegmentalis, 853
Parietal bones, 59
articulations of, 61
attachment of muscles to, 61
development of, 61
cells of gastric glands, 910
eminence, 60
foramen, 60
lobe, 646
veins, 1195
Parieto-colic fold, 904
Parieto-occipital fissure, 646
Parieto-temporal artery, 512
Paroöphoron of Waldeyer, 1038
Parotid duct, 885
fascia, 310, 315
gland, 884
accessory portion of, 886
nerves of, 886
vessels of, 886
lymphatic glands, 625
veins, 596
Parovarium, 1038, 1208
Par vagum, 749
Pars basalis, 649
ciliaris retinæ, 832
externa, interna et media of auditory canal 851
intermedia of Wrisberg, 740
iridica retinæ, 831
laryngea, 890
nasalis, 890
oralis, 890
orbitalis, 649
triangularis, 649
Patella, 191
articulations of, 192
attachment of muscles to, 192
development of, 192
fracture of, 452
surface form of, 192
surgical anatomy of, 192
Patellar ligament, 274
Pecquet, reservoir of, 624
Pectineus muscle, 424
Pectiniform septum, 1012
Pectoral region, dissection of, 376
Pectoralis major, 378
minor, 379
Peculiar dorsal vertebræ, 41
Pedicles of a vertebra, 34
Peduncles of cerebellum, 689
of cerebrum, 658, 673
of corpus callosum, 656
of pineal gland, 673
Peduncular fibres of cerebellum, 689
of cerebrum, 677
Pedunculus conarii, 672
Pelvic fascia, 1070
parietal or obturator layer, 1071
visceral layer, 1071
girdle, 134
plexus, 809
Pelvis, 179, 998
arteries of, 561
articulations of, 241
axes of, 181
boundaries of, 179
brim of, 179
cavity of, 180
diameters of, 181
false, 179
in fœtus, 182
inlet of, 180
of kidney, 986
ligaments of, 241
lymphatics of, 632
male and female, differences of, 181
outlet of, 180
position of, 181
of viscera, at outlet of, 1067
true, 179
Pelvis, surface form of, 182
surgical anatomy of, 183
Penis, 1011
arteries of, 1013
body of, 1012
corpora cavernosa, 1012
corpus spongiosum, 1013
development of, 1215
dorsal artery of, 567
nerve of, 793
vein of, 617
lymphatics of, 633, 1014
muscles of, 372
nerves of, 1014
prepuce of, 1012
root of, 1011
surgical anatomy of, 1014
suspensory ligament, 1011
Penniform muscle, 295
Perforans Casserii nerve, 770
Perforated space, anterior, 655
posterior, 657
Perforating arteries of hand, 541
from mammary artery, 526
from plantar, 591
from profunda, 579
cutaneous nerve, 793
Pericæcal fossæ, 904
Pericardiac arteries, 526, 547
Pericardium, diverticula of, 458
fibrous layer of, 459
nerves of, 459
relations of, 457
serous layer of, 459
structure of, 458
transverse sinus of, 459
vessels of, 459
vestigial fold of, 459
Perichondrium, 1093, 1104
Perichoroidal lymph-space, 825
Perilymph, 866
Perimysium, 1107
Perineal artery, superficial, 567
transverse, 567
fascia, deep, 373, 1066
superficial, 370
nerve, 793
cutaneous, 791
superficial, 793
Perineum, abnormal course of arteries in, 1070
deep boundaries of, 1064
development of, 1213
in the female, 1069
lymphatics of, 633
in the male, 1064
muscles of, 367
surgical anatomy of, 1063
Perineurium, 1119
Periosteum, 1096
internal, 1096
of teeth, 871
Periotic cartilage, 1167
Peripheral termination of nerves, 1120
Perisclerotic lymph-spaces, 824
Peritoneum, lesser sac of, 899
ligaments of, 901
mesenteries of, 902
omenta of, 901
reflections traced, 900
Perivascular lymphatics, 661, 1133
Perivitelline fluid, 1150
Permanent cartilage, 1092

Permanent teeth, 871
Peroneal artery, 590
anterior, 590
peculiarities of, 590
nerve, 796
tubercle, 202
veins, 615
Peroneus brevis muscle, 441
longus muscle, 440
tertius muscle, 435
Perpendicular line of ulna, 154
plate of ethmoid, 78
Pes accessorius, 662
anserinus, 741
of crus cerebri, 673
hippocampi, 665
Petit, canal of, 840
triangle of, 357
Petro-mastoid portion of temporal bone, 71
Petro-occipital suture, 102
Petro-sphenoidal suture, 102
Petro-squamous sinus, 603
Petrosal nerve, deep large, from Vidian, 732
small, 858
small superficial, 858
superficial large, 732
process, 73
sinus, inferior, 605
superior, 604
Petrous ganglion, 748
portion of temporal bone, 68
Peyer's glands, 919
Phalanges of cochlea, 866
of hand, 169
articulations of, 169, 268
development of, 169
of foot, 210
articulations of, 211, 293
development of, 211
Pharyngeal aponeurosis, 890
artery, ascending, 494
glands, 890
nerve, from external laryngeal, 751
from glosso-pharyngeal, 748
from Meckel's ganglion, 733
from sympathetic, 801
from vagus, 751
plexus of nerves, 751, 801
septum, 1171
spine, 57
tonsil, 890
vein, 598
Pharyngo-glossus muscle, 325
Pharynx, 889
aponeurosis of, 890
arteries of, 494
development of, 1198
mucous membrane of, 890
muscles of, 327
surgical anatomy of, 891
Phleboliths, 617
Phrenic arteries, 551
nerve, 763
plexus of nerves, 808
veins, 619
Phrenico-costal sinus, 971
Phreno-colic ligament, 902
Pia mater of brain, 642
of cord, 709
Pigment, 1092
cells, 1087
Pigment of iris, 832
of skin, 1138
Pigmentary layer of retina, 837
Pillars of diaphragm, 352
of external abdominal ring, 358, 1043
of fauces, 883
Pineal eye of lizards, 673
glands, 672
peduncles of, 673
recess, 671
Pinna of ear, 848
ligaments of, 849
muscles of, 850
nerves of, 850
vessels of, 850
Pisiform bone, 162
Piso-metacarpal ligament, 264
Piso-uncinate ligament, 264
Pit of stomach, 133
Pituitary body, 656
development of, 1178
fossa, 73
membrane, 820
Pivot-joint, 220
Placenta, 1164
circulation through, 1164
formation of, 1163
separation of, 1165
Placental circulation, 1189
Plain muscle, 1112
Plantar arch, 591
artery, external, 591
internal, 591
fascia, 443
ligaments, 288
nerve, external, 795
internal, 795
veins, external, 615
internal, 615
Plantaris muscle, 437
Plasma, 1077, 1080
cells, 1087
Plasmodioblast, 1153
Platelets of blood, 1080
Plates, tarsal, 843
Platysma myoides, 314
Pleura, 969
cavity of, 969
costalis, 969
pulmonalis, 969
reflections of, traced, 969
surgical anatomy of, 971
vessels and nerves of, 971
Pleuro-peritoneal cavity, 1157
Plexus of nerves, 1119
aortic, 809
brachial, 764
cardiac, deep, 806
superficial, 806
carotid, 801
external, 801
cavernous, 801
cervical, 761
posterior, 762
cœliac, 808
of cornea, intra-epithelial, 827
sub-epithelial, 827
coronary, anterior, 806
posterior, 806
cystic, 808
diaphragmatic, 808
epigastric or solar, 806
facial, 801
Plexus, gastric, 808
gastro-duodenal, 808
gastro-epiploic, 808
left, 808
great cardiac, 806
hæmorrhoidal, inferior, 809
superior, 809
hepatic, 808
hypogastric, 809
inferior, 809
ileo-colic, 809
infraorbital, 731
lumbar, 781
magnus profundus, 806
mesenteric, inferior, 809
superior, 809
œsophageal, 752
ovarian, 808
pancreatic, 808
pancreatico-duodenal, 808
patellæ, 787
pharyngeal, 751, 801
phrenic, 808
prostatic, 809
pulmonary, anterior, 752
posterior, 752
pyloric, 808
renal, 808
sacral, 788
sigmoid, 809
solar, 806
spermatic, 808
splenic, 808
superficial cardiac, 806
suprarenal, 808
tonsillar, 748
tympanic, 858
uterine, 810
vaginal, 810
of veins. See *Veins.*
vertebral, 804
vesical, 809
Plica epigastrica. 1048
fimbriata, 811
gubernatrix, 1211
hypogastrica, 1048
salpingo-palatina, 890
salpingo-pharyngea, 890
semilunaris, 845
triangularis, 884
urachi, 1047
vascularis, 1211
Pneumogastric nerve, 749
Polar bodies or globules o Robin, 1150
Pomum Adami, 955
Pons, hepatis, 936
Tarina, 657
Varolii, 681
Pontal flexure of embryoni brain, 1176
Ponticulus of Arnold, 694
Popliteal artery, 581
branches of, 583
peculiarities of, 582
surface-marking of, 582
surgical anatomy of, 581
unusual branches, 582
lymphatic glands, 631
nerve, external, 796
surgical anatomy of, 797
internal, 794
notch, 193
space, 581
surface of femur, 186

Popliteal vein, 615
Popliteus muscle, 438
Pores of the skin, 1142
Portal canals, 938
fissure, 936
vein, 621, 938, 940
Portio dura of seventh nerve, 740
mollis or auditory nerve, 740
Porus opticus of sclerotic, 833
Post-central fissure, 686
Post-central sulcus, 650
Post-clival fissure, 686
Posterior. See *under each separate head.*
choroid artery, 523
crescentic lobe, 685
glenoid process, 73
inferior lobe, 689
internal frontal artery, 511
nerve roots, 717
superior lobe, 685
vesicular column, 717
Postero-lateral ganglionic arteries, 523
Postero-median ganglionic arteries, 523
Post-glenoid process, 65
Post-gracile fissure, 687
Post-limbic fissure, 647
Post-nodular fissure, 688
Post-patellar bursa, 423
Post-pyramidal fissure, 688
Pott's fracture, 453
Pouch of Douglas, 1029
of Prussak, 858
of Rathke, 1171
Pouches, laryngeal, 961
Poupart's ligament, 359, 1044, 1057
Pre-central fissure, 686
sulcus, 648
Prechordal cartilages, 1167
Pre-clival fissure, 686
Precuneus of lobe of brain, 651
Prepatellar bursa, 423
Prepuce, 1012
of clitoris, 1026
Pre-occipital notch, 646
Pre-pyramidal fissure, 688
Presternal notch, 124
Presternum, 124
Prevertebral fascia, 317
Prickle cells, 1085, 1137
Primary areolæ of bone, 1103
cerebral vesicles, 1166
Primitive amniotic cavity, 1154
aorta, 1191
aortic arches, 1192
fibrillæ of Schultze, 1116
groove, 1154
jugular veins, 1195
optic vesicle, 1180
otic vesicle, 1183
sheath of nerve-fibre, 1116
streak, 1154, 1155
Primordial cranium, 1165
ova, 1037
Princeps cervicis artery, 493
pollicis artery, 541
Processes or process: acromion, 140
alveolar, 86
angular, external, 62
internal, 62
basilar, 56
Process or process: ciliary, 829
clinoid, anterior, 75
middle, 73
posterior, 73
cochleariform, 71, 854
condyloid, of lower jaw, 99
coracoid, 141
coronoid, of lower jaw, 99
of ulna, 150
costal, 36
ethmoidal, of inferior turbinated, 95
frontal, of malar, 90
hamular, of lachrymal, 88
of sphenoid, 76
of Ingrassias, 75
jugular, 56
lachrymal, of inferior turbinated bone, 95
malar, 85
of malar bone, 89
mammillary, 42
mastoid, 67
maxillary, of inferior turbinated, 95
mental, 97
nasal, 86
odontoid, of axis, 38
olecranon, 150
olivary, 73
orbital, of malar, 90
of palate, 93
palate, of superior maxillary, 86
post-glenoid, 65
pterygoid, of palate bone, 92
of sphenoid, 75
sphenoidal, of palate, 93
spinous, of ilium, 174
of sphenoid, 74
of tibia, 192
styloid, of radius, 156
of temporal, 70
of ulna, 154
unciform, 165
of ethmoid, 79
vaginal, of sphenoid, 74
of temporal, 70
vermiform, of cerebellum, inferior, 686
superior, 685
zygomatic, 90
Processus brevis of malleus, 856
cochleariformis, 71, 854
globularis, 1169
gracilis of malleus, 856
sphenoidalis, 819
Proctodeum, 1203
Profunda cervicis artery, 527
femoris artery, 578
inferior artery of arm, 537
superior artery of arm, 537
vein, 616
Promontory of sacrum, 46
of tympanum, 854
Pronator quadratus muscle, 394
radii teres muscle, 390
ridge, 154
Pronephros, 1208
Pronucleus, female, 1150
male, 1151
Prophase of karyokinesis, 1075
Prosencephalon, 643, 1173
Prostate gland, 1009
levator muscle of, 369, 1010
Prostate gland, lobes of, 1010
lymphatics of, 634
surgical anatomy of, 1011
vessels and nerves of, 1010
Prostatic plexus of nerves, 809
of veins, 617
portion of urethra, 1005
sinus, 1005
Prothrombin, 1081
Protoplasm, 1073
Protovertebræ, 1156, 1165
Protuberance, occipital, external, 56
internal, 57
Pseudo-nucleoli, 1074
Pseudopodium, 1079
Pseudostomata of serous membranes, 1144
Psoas magnus muscle, 416
surgical anatomy of, 417
parvus, 417
Pterion ossicle, 81
Pterygoid arteries, 498
fossa of jaw, 99
of sphenoid, 75
muscles, 312
nerve, 735
notch, 75
plexus of veins, 596
process of palate bone, 92
processes of sphenoid, 75
ridge, 74
tubercle, 76
Pterygo-maxillary fissure, 112
ligament, 309
Pterygo-palatine artery, 499
canal, 74
nerve, 733
Pubic arch, 180
articulations of, 244
portion of fascia lata, 420
Pubis, angle of, 176
crest of, 176
os, 176
spine of, 176
symphysis of, 176, 244
Pubo-femoral ligament, 269
Pubo-prostatic ligaments, 1002, 1010
Pudendum, 1025
Pudic artery, accessory, 566
deep, external, 578
internal, 565
in female, 567
in male, 565
peculiarities of, 566
superficial external, 578
nerve, 793
vein, 614
internal, 616
Pulmonary artery, 475, 976
opening of, in right ventricle, 463
capillaries, 976
nerve from vagus, 752
sinuses, 465
veins, 593, 594, 976
openings of, left auricle, 465
Pulp-cavity of tooth, 874
enamel, 879
formative, 880
permanent, 880
of spleen, 951
of teeth, development of, 882

Pulvinar of optic thalamus, 671
Puncta lachrymalia, 846
vasculosa, 659
Pupil of eye, 831
membrane of, 832
Purkinje, axis-cylinder of, 1116
corpuscles of, 692
Putamen, 663
Pyloric artery, 552
inferior, 552
glands, 910
plexus, 808
Pylorus, 906
Pyramid of cerebellum, 689
of thyroid gland, 979
of tympanum, 854
Pyramidal cell of cerebral cortex, 679
decussation, superior, 719
Pyramidalis muscle, 364
nasi, 307
Pyramids of Ferrein, 989
of Malpighi, 987
of medulla, 694
decussation of, 695
of the spine, 52
Pyriformis muscle, 428

Q.

Quadrate lobe, 651
Quadratus femoris muscle, 430
lumborum, 367
fascia covering, 367
menti, 308
Quadriceps extensor cruris muscle, 421
Quadrigeminal bodies, 675

R.

Racemose glands, 1146
Radial artery, 538
branches of, 539
peculiarities of, 539
surface marking of, 539
surgical anatomy of, 539
fossa, 147
lymphatic glands, 628
nerve, 775
recurrent artery, 539
region, muscles of, 395
vein, 607
Radialis indicis artery, 541
Radio-carpal articulation, 262
surface form of, 263
surgical anatomy of, 263
Radio-ulnar articulations, inferior, 260
middle, 259
superior, 259
region, muscles of, anterior, 390
posterior, 396
Radius, 155
articulations of, 157
development of, 157
fracture of, 413
grooves in lower end of, 157
muscles attached to, 157
oblique line of, 156
sigmoid cavity of, 156
surface form of, 157
surgical anatomy of, 157
tuberosity of, 155
Radius and ulna, fracture of, 414
Rami of the lower jaw, 98
Ramus of ischium, 176
of os pubis, 176
ascending, 176
descending, 177
Ranine artery, 489
vein, 598
Ranvier, nodes of, 1117
Raphé of corpus callosum, 659
of medulla, 702
of palate, 883
of perineum, 1064
of scrotum, 1015
of tongue, 811
Rathke, investing mass of, 1167
pouch of, 1171
Receiving tubes of kidney, 989
Receptaculi arteriæ, 505
Receptaculum chyli, 624
Recess, optic, 670
pineal, 671
Recessus labyrinthi, 1183
sphericus, 860
Reciprocal reception, articulation by, 220
Recto-coccygeus muscle, 928
Recto-uterine ligaments, 1029
Recto-vesical fascia, 1071
fold, peritoneal, 1002
Rectum, 925
development of, 1200
folds of, 929
lymphatics of, 636
relations of, female, 927
male, 927
surgical anatomy of, 930
Rectus abdominis, 362
capitis anticus major, 332
minor, 332
lateralis, 333
femoris muscle, 421
surgical anatomy of, 423
oculi, internus, superior, inferior, and externus, 304
posticus major, 347
minor, 348
Recurrent artery, interosseous, 544
radial, 539
tibial, anterior, 586
posterior, 586
ulnar, anterior, 543
posterior, 543
laryngeal nerve, 751
nerves to tentorium, 726
Red corpuscles, 1078
nucleus, 675
Region of abdomen, 895
muscles of, 356
acromial, muscles of, 382
auricular, 300
of back, muscles of, 336
cervical superficial, muscles of, 314
cranial, 298
epigastric, 896
femoral, muscles of, anterior, 418
internal, 423
posterior, 432
fibular, 440
of foot, dorsum of, 444
sole of, 444
gluteal, muscles of, 426
Region of groin, 1053
of hand, muscles of, 400
humeral, anterior, 386
posterior, 388
hypochondriac, 896
hypogastric, 896
iliac, muscles of, 415
infrahyoid, 319
inguinal, 896, 1041
intermaxillary, muscles of, 308
ischio-rectal, 1063
laryngo-tracheal, surgical anatomy of, 896
lingual, muscles of, 323
lumbar, 896
maxillary, muscles of, inferior, 308
superior, 307
nasal, muscles of, 306
orbital, muscles of, 303
palatal, muscles of, 329
palmar, 400
palpebral, 301
perineum, 1056
pharyngeal, muscles of, 327
popliteal, 581
pterygo-mandibular, muscles of, 312
radial, muscles of, 395
radio-ulnar, anterior, muscles of, 390
posterior, muscles of, 396
scapular, muscles of, anterior, 383
posterior, 384
Scarpa's triangle, 572
suprahyoid, muscles of, 321
temporo-mandibular, muscles of, 310
thoracic, 350
anterior, 377
lateral, 381
tibio-fibular, anterior, 434
posterior, 436
ulnar, of hand, 406
umbilical, 896
vertebral, muscles of, anterior, 332
lateral, 334
Reil, island of, 652
Remak, fibres of, 1117
Renal afferent vessels, 988, 992
artery, 556, 992
efferent vessels, 988, 992
plexus, 808
veins, 619, 992
Reservoir of Pecquet, 624
Respiration, muscles of, 355
organs of, 955
Respiratory nerves of Bell, external, 768
internal, 763
organs, development of, 1206
Restiform bodies of medulla oblongata, 696
Rete mucosum of skin, 1136
testis, 1020
Reticular layer of skin, 1138
lamina of Kölliker, 866
Reticulin, 1090
Retiform connective tissue, 1090
Retina, 832
arteria centralis of, 509, 839
fovea centralis of, 833

Retina, membrana, layers of, 833, 834, 835
limitans externa, 835
interna, 833
structure of, 833
Retinacula of capsular ligament of hip, 268
of ileo-cæcal valve, 923
Retrahens auriculam muscle, 301
Retro-peritoneal fossæ, 903
Retro-pharyngeal space, 316
Rhinencephalon, 1180
Rhodopsin, or visual purple, 832
Rhomboid impression, 136
ligament, 246
lip, 1178
Rhomboideus major, 340
minor, 340
Ribes, ganglion of, 798
Ribs, 128
angle of, 129
articulations of, 234
attachment of muscles to, 131
development of, 131, 1166
false, 128
floating, 128
head of, 129
ligaments of, 234, 235
neck of, 129
peculiar, 131
true, 128
tuberosity of, 129
Ridge, mylo-hyoidean, 97
superciliary, 61
temporal, 65, 111
terminal occipital, 57
Rima glottidis, 959
Ring, abdominal, external, 357, 1043
internal, 1047
femoral or crural, 1060
fibrous, of heart, 468
muscle, 830
Risorius muscle, 310
Rivini, ducts of, 887
incisura of, 853, 855
Robin, polar globules of, 1150
Rod-bipolar cells, 835
Rod-granules of retina, 835
Rods of Corti, 865
of retina, 835
Rolando, fissure of, 646
funiculus of, 695
topography of, 706
tubercle of, 695
Roof nuclei of Stilling, 693
Root of lung, 974
sheath of hair, 1141
of spinal nerves, 717
of teeth, 873
of zygomatic process, 65
Rosenmüller, accessory gland of, 846
organ of, 1038, 1210
Rostrum of corpus callosum, 659
of sphenoid bone, 74
Rotation, 222
Rotatores spinæ muscles, 347
Round ligaments of liver, 938
of uterus, 1038
relations of, to femoral ring, 1060
Ruffini's endings, 1122
Rugæ of stomach, 909
of vagina, 1028
Rupture of urethra, course taken by urine in, 1065
Rust-colored layer of cerebellar cortex, 692

S.

Sac, lachrymal, 847
Saccular secretory glands, 1146
Saccule of vestibule, 862
Sacculus laryngis, 961
Sacra-media artery, 558
Sacral arteries, lateral, 569
canal, 48
cornua, 47
foramina, 46
ganglia, 805
groove, 47
lymphatic gland, 632
nerves, 788
anterior divisions of, 789
posterior divisions of, 788
roots of, 788
plexus, 790
vein, lateral, 617
middle, 617
peculiarities of, 617
Sacro-coccygeal ligaments, 244
Sacro-iliac articulations, 242
Sacro-lumbalis muscle, 343
Sacro-sciatic foramen, greater, 175, 243
lesser, 175, 243
ligaments, 242
notch, greater, 175
lesser, 175
Sacro-uterine ligament, 1030
Sacro-vertebral angle, 46
ligament, 242
Sacrum, 45
ala of, 48
articulations of, 50
attachment of muscles to, 50
development of, 49
peculiarities of, 49
structure of, 49
Sacs, dental, 879
Saddle-joint, 220
Sagittal suture, 101
Salivary glands, 884
structure of, 887
Salpingo-pharyngeus, 331
Salter, incremental lines of, 876
Santorini, cartilages of, 957
Saphena veins, surgical anatomy of, 615
Saphenous nerve, long or internal, 787
short, 791
opening, 419, 1055
vein, external or short, 614
internal or long, 614, 1054
surgical anatomy of, 615
Sarcolemma, 1108
Sarcoplasm, 1109
Sarcostyles, 1109
Sarcous elements of muscle, 1110
Sartorius muscle, 421
Scala media, 863
tympani of cochlea, 861
vestibuli of cochlea, 861
Scalæ of cochlea, 861
Scalenus anticus, 334
medius, 335
posticus, 335
Scalp, skin of, 298
Scaphoid bone (foot), 205
(hand), 161
fossa of sphenoid, 76
Scapula, 138
articulations of, 143
attachment of muscles to, 143
development of, 142
dorsum of, 140
glenoid cavity of, 141
head of, 380
ligaments of, 249, 250
muscles of, 383, 384
spine of, 140
surface form of, 143
surgical anatomy of, 143
venter of, 138
Scapular artery, posterior, 526
notch, great, 140
region, muscles of, anterior, 383
posterior, 384
Scapulo-clavicular articulation, 248
Scarfskin, 1136
Scarpa, fascia of, 356
foramina of, 87, 108
Scarpa's triangle, 572
Schachowa, spiral tubes of, 988
Schindylesis, 219
Schlemm, canal of, 827
ligaments of, 251
Schneiderian membrane, 820
Schreger, lines of, 876
Schultze, primitive fibrillæ of, 1116
Schwann, white substance of, 1116
Sciatic artery, 568
nerve, greater, 793
surgical anatomy of, 797
lesser, 791
veins, 617
Sclerotic, 825
Scrobiculus cordis, 133
Scrotal hernia, 1051
Scrotum, 1015
dartos of, 1015
development of, 1215
lymphatics of, 633
nerves of, 1016
septum of, 1015
surgical anatomy of, 1017
vessels of, 1016
Sebaceous glands, 1142
Second nerve, 721
surgical anatomy of, 722
Secondary areolæ of bone, 1104
optic vesicle, 1181
Secreting glands, 1146
Segment, internodal, 1117
Segmentation of ovum, 1152
medullary, 1117
of Lantermann, 1117
Sella Turcica, 73
Semicircular canals, 860
Semilunar bone, 161
fascia, 387
fibro-cartilages of knee, 276
fold of Douglas, 364
ganglion of abdomen, 806
of fifth nerve, 725
lobe, inferior of cerebellum, 688
valves, aortic, 467

Semilunar valves, pulmonic, 465
Semimembranosus muscle, 432
Seminal cells, 1019
tubes, 1019
vesicles, 1022
Semispinalis muscle, 346
Semitendinosus muscle, 432
Senses, organs of the special, 811
Sensory, afferent, or ascending nerve tracts, 719
decussation, 719
epithelium cells, 1124
Septum auricularum, 466
between bronchi, 966
crurale, 1060
inferius, 1190
lucidum, 660
mobile nasi, 819
of nose, 117
artery of, 491
cartilage of, 820
orbital, 844
pectiniforme, 1012
scroti, 1015
superius, 1190
of tongue, 815
transversum, 1206
of semicircular canals, 863
ventriculorum, 467
Serous glands of tongue, 815
membranes, 1143
Serratus magnus, 381
posticus, inferior, 341
superior, 341
Serum, 1081
-albumen, 1080
-globulin, 1080
Sesamoid bones, 214
cartilages, 819
Seventh nerve, 740
surgical anatomy of, 744
Shaft of a bone, its structure, 33
of a hair, 1141
Sheath of arteries, 1128
of femoral or crural, 1059
of muscles, 1107
of nerves, 1118
of rectus muscle, 363
Shin, 193
Short bones, 33
Shoulder-girdle, 134
-joint, 251
actions of, 252
surface form of, 254
surgical anatomy of, 254
muscles of, 377
vessels and nerves of, 252
Sigmoid artery, 555
cavity, greater and lesser, of radius, 155
of ulna, 152
flexure of colon, 925
of meso-colon, 903
notch of lower jaw, 99
Sinus of external jugular vein, 597
great, of aorta, 476
intercavernous, 604
of internal jugular vein, 598
of kidney, 986
of Morgagni, 328
petro-squamous, 603
pocularis, 1006, 1208
præcervicalis, 1171
prostaticus, 1005
Sinus pyriformis, 890
reuniens of His, 1189
rhomboidales, 1156
spheno-parietal, 603
transverse pericardial, 459
venæ portæ, 827
venosus, 461, 1189
Sinuses, cavernous, 603
circular, 604
of coronary vein, 462, 622
cranial, 61, 594, 602
ethmoidal, 78
frontal, 61
of heart, of left auricle, 465
of right auricle, 462
lateral, 602
longitudinal inferior, 602
superior, 602
maxillary, 85
of nose, 61
occipital, 603
petrosal, inferior, 605
superior, 604
sphenoidal, 74
straight, 602
transverse, 605
of Valsalva, aortic, 467, 477
pulmonary, 465
Sixth nerve, 738
surgical anatomy of, 740
Skeletal muscles, 1107
Skeleton, 33
number of its pieces, 33
Skin, appendages of, 1139
arteries of, 1139
corium of, 1138
cuticle of, 1136
derma, or true skin, 1138
development of, 1186
epidermis of, 1136
furrows of, 1136
general anatomy of, 1135
hairs, 1140
muscular fibres of, 1142
nails, 1139
nerves of, 1139
papillary layer of, 1138
rete mucosum of, 1136
sebaceous glands of, 1142
sudoriferous or sweat-glands of, 1142
tactile corpuscles of, 1121
vessels of, 1139
Skull, 54, 103
anterior region, 112
base of, external surface, 103
internal surface, 103
fossa of, anterior, 103
middle, 105
posterior, 106
lateral region of, 109
surface-marking of, 118
surgical anatomy of, 119
tables of, 33
vertex of, 103
vitreous table of, 34
Slender lobe of cerebellum, 688
Small intestine, 911
areolar coat of, 915
duodenum, 912
ileum, 914
jejunum, 914
mucous coat, 915
muscular coat, 915
serous coat, 915
Small intestine, simple follicles, 918
valvulæ conniventes, 916
villi of, 917
Socia parotidis, 886
Soft palate, 883
aponeurosis of, 883
arches or pillars of, 883
muscles of, 884
structure of, 883
Solar plexus, 806
Sole of foot, muscles of, first layer, 444
fourth layer, 448
second layer, 446
third layer, 446
Soleus muscle, 436
Solitary glands, 919
Somatopleure, 1157
Sömmerring, yellow spot of, 833
Space, anterior perforated, 656
axillary, 527
intercostal, 128
of Mull, 866
popliteal, 581
posterior perforated, 657
of Retzius, 1000
Spaces of Fontana, 827
Spermatic artery, 557, 1016
canal, 1046
cord, 1016
arteries of, 1016
course of, 1016
lymphatics of, 1017
nerves of, 1017
relation to femoral ring, 1060
of, in inguinal canal, 1016
fascia, external, 359, 1043
plexus of nerves, 808
of veins, 618
veins, 618, 1016
surgical anatomy of, 618
Spermatids, 1019, 1150
Spermatoblasts, 1019, 1150
Spermatocytes, 1019, 1150
Spermatogenesis, 1020
Spermatogonia, 1019
Spermatozoa, 1021
Spheno-ethmoidal recess, 117, 820
Sphenoid bone, 72
articulations of, 77
attachment of muscles to, 77
body of, 72
development of, 76
greater wings of, 74
lesser wings of, 75
pterygoid processes of, 75
rostrum of, 74
spinous processes of, 74
vaginal processes of, 74
Sphenoidal fissure, 75
nerves in, 739
process of palate, 93
sinuses, 74
spongy or turbinated bones, 76
Spheno-mandibular ligament, 232
Spheno-maxillary fissure, 112
fossa, 112
Spheno-palatine artery, 499
foramen, 93
ganglion, 732
nerves, 732
notch, 93
Spheno-parietal suture, 102
Spheroidal epithelium, 1084

Sphincter muscle of bladder, 1003
of rectum, external, 368
internal, 368
of vagina, 375
vesicæ, 1003
Spina bifida, 53
helicis, 849
vestibuli, 1190
Spinal accessory nerve, 753
surgical anatomy of, 753
arteries, anterior, 521
lateral, 521
median, 521
posterior, 521
canal, 53
cord, 710
arachnoid of, 708
arrangement of gray and white matter in, 712
central canal of, 712
ligament of, 709
columns of, 711
development of, 1165
dura mater of, 707
fissures of, 711
fœtal, peculiarity of, 710
gray commissure of, 712
ligamentum denticulatum of, 709
minute structure of, 713
neuroglia of, 713
pia mater of, 709
sections of, 712
surgical anatomy of membranes of, 709
white commissure of, 712
white matter of, 713
foramen, 35
nerves, 756
arrangement into groups, 756
development of, 1178
distribution of, 757
divisions of, anterior, 758
posterior, 758
ganglia of, 757
origin of, in cord, 756
of roots, anterior, 757
posterior, 757
points of emergence, 758
veins, 612
longitudinal, anterior, 613
posterior, 613
Spinalis colli muscle, 345
dorsi muscle, 345
Spindle, achromatic, 1075
poles of, 1075
aortic, 478
Spine, 34
articulations of, 223
development of, 1165
general description of, 51
ossification of, 45
surface form of, 53
surgical anatomy of, 53
Spines of bones, ethmoidal, 73
of ischium, 175
nasal, 62
anterior, 87
posterior, 90
of os pubis, 176
pharyngeal, 57
of scapula, 140
Spino-glenoid ligament, 250
Spinous process of ilium, 174
of sphenoid, 74
of tibia, 192
of vertebræ, 35
Spiral canal of cochlea, 861
line of femur, 185
Spirem or skein, 1075
Splanchnic nerve, greater, 804
lesser, 804
smallest or renal, 804
Splanchnopleure, 1157
Spleen, 949
artery of, 952
capillaries of, 953
development of, 1205
fibro-elastic coat of, 950
lymphatics of, 635, 953
Malpighian bodies of, 952
nerves of, 954
proper substance of, 951
relations of, 949
serous coat of, 950
size and weight of, 950
structure of, 950
surface-marking of, 954
surgical anatomy of, 954
trabeculæ of, 950
veins of, 953
Splenic artery, 553
distribution of, 952
corpuscles, 952
plexus, 808
pulp, 951
vein, 619
Splenium of corpus callosum, 659
Splenius muscle, 342
Spongioblasts, 1172
Spongioplasm, 1074
Spongy portion of urethra, 1006
tissue of bone, 33
Spring ligament, 289
Spur of malleus, 856
Squamo-parietal suture, 102
Squamo-sphenoidal suture, 102
Squamo-zygomatic portion of temporal bone, 71
Squamous portion of temporal bone, 65
Stalk of optic thalamus, anterior, 672
inferior, 672
posterior, 672
Stapedius muscle, 857
Stapes, 857
annular ligament, 857
development of, 1184
Stellate ligament, 234
plexus of kidney, 992
Stenson, foramina of, 87, 108
Stenson's duct, 885
Stephanion, 109
Sternal end of clavicle, fracture of, 411
foramen, 127
furrow, 132
ligaments, 239
Sterno-clavicular articulation, 246
surface form of, 247
surgical anatomy of, 247
Sterno-hyoid muscle, 319
Sterno-mastoid artery, 493
muscle, 317
Sterno-pericardiac ligament, 458
Sterno-thyroid muscle, 319
Sternum, 124
articulations of, 128
attachment of muscles to, 128
development of, 125, 1166
ligaments of, 239
Stilling, canal of, 839
Stomach, 905
alteration in position of, 907
alveoli of, 909
areolar coat of, 909
cardiac glands of, 910
curvatures of, 906
development of, 1198
fundus of, 905
gastric follicles of, 909
lymphatics of, 635
mucous membrane of, 909
muscular coat of, 908
orifices of, 905
pyloric end of, 905
glands of, 905
pylorus, 906
serous coat of, 908
structure of, 908
surface marking of, 910
surfaces of, 905
surgical anatomy of, 911
vessels and nerves of, 910
Stomodœum, 1169, 1171
Straight sinus, 602
tubes of kidney, 990
Strand, labio-dental, 877
Stratified epithelium, 1085
Stratiform fibro-cartilage, 1095
Stratum cinereum, 675
compactum of decidua, 1163
corneum, 1136
dorsale, 676
germinativum, 1137
granulosum, 1138
lemnisci, 675
lucidum, 1138
Malpighii, 1136
opticum, 675, 1138
spongiosum, 1163
zonale, 675
Striæ laterales, 659
longitudinales, 659
medullaris vel acusticæ, 698
pinealis, 670, 673
Striped muscle, 1107
Stroma of ovary, 1036
Stylo-glossus muscle, 324
Stylo-hyoid ligament, 322
muscle, 322
nerve from facial, 743
Stylo-mandibular ligament, 232
Stylo-mastoid artery, 494
foramen, 70
vein, 597
Stylo-pharyngeus muscle, 329
Styloid process of fibula, 196
of radius, 156
of temporal bone, 70
of ulna, 154
Subanconeous muscle, 389
Subarachnoid fluid, 642
space of brain, 641
anterior, 641
posterior, 641
of cord, 708
of septum, 708
tissue, 641

Subcæcal fossa, 904
Subcalcarine convolution, 652
Subclavian arteries, 514
branches of, 520
first part of, left, 516
right, 514
peculiarities of, 517
second portion of, 516
surface form of, 518
surgical anatomy of, 518
third portion of, 516
groove, 130
nerve, 768
triangle, 502
vein, 609
Subclavius muscle, 380
Subcollateral convolution, 652
Subcostal angle, 124
artery, 547
muscle, 351
Subcrureus muscle, 423
Subcutaneous malar nerve, 731
Subdural space, 641, 708
Sublingual artery, 489
fossa, 97
gland, 887
vessels and nerves of, 887
Sublobular veins, 940
Submaxillary artery, 491
fossa, 97
ganglion, 737
gland, 886
nerves of, 887
vessels of, 887
lymphatic gland, 627
triangle, 501
vein, 596
Submental artery, 491
vein, 596
Suboccipital nerve, 758
posterior branch of, 759
triangle, 348, 520
Subpleural mediastinal plexus, 526
Subpubic ligament, 245
Subscapular angle, 139
artery, 533
fascia, 383
fossa, 138, 139
nerves, 768
Subscapularis muscle, 383
Substantia cinerea gelatinosa, 716
corticalis, 840
ferruginea, 699
gelatinosa centralis, 712
nigra, 673
Subthalamic region, 676
Sudoriferous glands, 1142
Sulci of cerebrum, 644
Sulcus centralis, 652
frontal inferior, 648
frontalis medius, 649
mesialis, 649
superior, 648
intraparietal, 650
longitudinalis medianus, 698
occipital, inferior, 651
middle, 651
superior, 651
oculi motorii, 673
olfactory, 649
orbital, 649
parallel, 652
post-central, 650
Sulcus precentral, 648
spiralis, internus et externus, 845
temporal, first, 652
second, 652
third, 652
terminalis of His, 811
of right auricle, 461
tri-radiate, 649
tympanicus, 851, 855
vallecutæ, 688
Supercilia, 843
Superciliary ridge, 61
Superficial cervical artery, 524
circumflex iliac artery, 518
epigastric artery, 578
external pudic artery, 578
palmar arch, 544
perineal artery, 567
temporal artery, 495
surgical anatomy of, 496
transverse ligament of fingers, 404
Superficialis colli nerve, 762
volæ artery, 540
Superior maxillary bone, 81
articulations of, 88
attachment of muscles to, 88
changes in, produced by age, 88
development of, 87
nerve, 729
ligament of incus, 857
of malleus, 857
meatus, 116
mediastinum, 971
medullary velum, 697
olivary nucleus, 683
profunda artery, 537
pyramidal decussation, 719
thyroid artery, 487
surgical anatomy of, 488
turbinated crest, 85
of palate, 92
vena cava, 611
Supernumerary spleens, 950
Supinator brevis muscle, 398
longus muscle, 395
Supporting cells of Hensen, 866
Supra-acromial artery, 524
nerves, 763
Supra-clavicular nerves, 763
Supracondylar ridge, external, 146
internal, 146
Supraglenoid tubercle, 141
Suprahyoid aponeurosis, 321
Supramarginal convolution, 651
Supramastoid crest, 66
Supramaxillary nerves from facial, 744
Supraorbital arch, 61
artery, 506
foramen, 62, 113
nerve, 727
notch, 62
Suprarenal arteries, 556
capsules, 996
development of, 1209
nerves of, 998
vessels of, 998
plexus, 808
veins, 619
Suprascapular artery, 524
Suprascapular ligament, 250
nerve, 769
notch, 141
Supraspinales muscles, 347
Supraspinatus muscle, 384
Supraspinous fascia, 384
fossa, 140
ligaments, 225
Suprasternal artery, 524
nerves, 762
notch, 336
Supratrochlear foramen, 148
nerve, 727
Sural arteries, 583
veins, 616
Surface form or marking of abdominal aorta, 550
of acromio-clavicular joint, 249
of ankle-joint, 285
of anterior tibial artery, 586
of axillary artery, 531
of bladder, 1004
of brachial artery, 535
of branches of internal iliac artery, 569
of carpus, 169
of cerebral convolutions, 705
of clavicle, 137
of common carotid artery, 485
iliac artery, 560
of cranium, 118
of dorsalis pedis artery, 587
of elbow, 258
of external auditory meatus, 852
carotid artery, 487
iliac artery, 560
of femoral artery, 575
of femur, 190
of fibula, 198
of fifth cranial nerve, 737
of foot, 213
of heart, 470
of hip-joint, 293
of humerus, 149
of hyoid bone, 123
of intestines, 930
of kidney, 993
of knee-joint, 280
of knuckles, 268
of larynx, 968
of liver, 943
of lungs, 977
of mouth, 888
of muscles of abdomen, 366
of back, 349
of head and face, 313
of lower extremity, 449
of neck, 335
of upper extremity, 409
of palmar arches, 545
of palpebral fissure, 847
of pancreas, 948
of patella, 192
of pelvis, 183
of plantar arch, 592
of popliteal artery, 582
of posterior tibial artery, 589
of radial artery, 539
of radio-ulnar joint, inferior, 261
superior, 259

Surface form of radius, 157
of scapula, 143
of shoulder-joint, 254
of skull, 118
of spleen, 954
of spine, 53
of sterno-clavicular joint, 247
of sterno-mastoid, 319
of stomach, 910
of subclavian artery, 518
of tarsus and foot, 213
of temporo-mandibular joint, 234
of thorax, 132
of tibia, 196
of ulna, 155
of ulnar artery, 542
of vertebral column, 53
of wrist and hand, 169
of wrist-joint, 263
Surgical anatomy of abdominal aorta, 550
of abducent nerve, 740
of acromio-clavicular joint, 249
of adductor longus muscle, 426
of ankle-joint, 285
of anterior tibial artery, 586
of arch of aorta, 479
of artery of the bulb, 567
of ascending pharyngeal artery, 495
of auditory nerve, 746
of axilla, 529
of axillary artery, 531
glands, 628
vein, 609
of azygos veins, 612
of base of bladder, 1068
of bend of elbow, 534
of bones of face, 119
of brachial artery, 535
plexus, 776
of branches of internal iliac, 570
of cavernous sinus, 604
of cervical glands, 628
vertebræ, 231
of clavicle, 137
of club-foot, 441
of common carotid, 485
iliac, 560
of deep epigastric, 572
of deltoid muscle, 383
of descending aorta, 547
of dorsalis pedis artery, 587
of elbow-joint, 258
of Eustachian tube, 868
of extensor muscles of thumb, 400
of external carotid artery, 487
ear, 847
iliac artery, 560
gular vein, 597
eye, 841
facial artery, 493
nerve, 744
vein, 596
femoral artery, 575
hernia, 1053
femur, 190
foot, bones of, 213
forearm, bones of, 157
Surgical anatomy of gluteal artery, 570
of hæmorrhoidal veins, 616
of hamstrings, 433
of hand, bones of, 170
of heart, 470
of hip-joint, 272
of humerus, 149
of hyoid bone, 123
of hypoglossal nerve, 756
of iliac fascia, 417
of inferior thyroid artery, 524
vena cava, 612
of inguinal glands, 630
hernia, 1041
of innominate artery, 481
of intercostal nerves, 780
of internal carotid artery, 505
iliac artery, 570
jugular vein, 599
mammary artery, 527
pudic artery, 566
of intestines, 930
of ischio-rectal region, 1063
of joints of cervical vertebræ, 231
of kidneys, 993
of knee-joint, 280
of lachrymal apparatus, 847
of laryngeal nerves, 752
of laryngo-tracheal region, 968
of larynx, 968
of leg, bones of, 198
of lingual artery, 489
of liver, 944
of lumbar plexus, 797
of lungs, 977
of middle meningeal artery, 498
of motor oculi nerve, 724
of muscles of eye, 306
of lower extremity, 451
of soft palate, 332
of upper extremity, 411
of musculo-spiral nerve, 776
of nasal fossæ, 823
of nose, 823
of œsophagus, 893
of olfactory nerve, 721
of optic nerve, 721
of palmar arch, 545
fascia, 404
of pancreas, 948
of patella, 192
of pelvis, bones of, 182
of penis, 1014
of perinæum, 1063
of peroneal or external popliteal nerve, 797
of pharynx, 891
of plantar arch, 592
ligaments, 288
of pleura, 971
of popliteal artery, 582
of posterior tibial, 589
of pronator radii teres muscle, 391
of prostate gland, 1011
of psoas magnus, 417
of radial artery, 539
of radio-ulnar joint, superior, 259
Surgical anatomy of rectus femoris muscle, 423
of ribs, 133
of saphena veins, 615
of scapula, 143
of Scarpa's triangle, 572
of sciatic artery, 570
nerve (great), 797
of scrotum, 1017
of serratus magnus muscle, 382
of shoulder-joint, 254
of skull, 119
of spermatic veins, 618
of spinal accessory nerve, 753
of spleen, 954
of sterno-clavicular joint, 247
of sterno-mastoid muscle, 319
of sternum, 133
of stomach, 911
of subclavian artery, 518
of superior thyroid artery, 488
of synovial sheaths of tendons of wrist, 402
of talipes, 441
of tarsal joints, 288, 290
of temporal artery, 496
of temporo-mandibular joint, 234
of testis, 1021
of thoracic aorta, 547
of thorax, 133
of thyroid gland, 981
of tongue, 327, 816
of triangles of neck, 500
of triceps, 389
of trifacial nerve, 738
of trochlear nerve, 725
of ulnar artery, 542
of upper extremity, 411
of urethra, 1007
of vertebral artery, 522
of vesico-prostatic plexus, 617
of vesiculæ seminales, 1023
of wrist-joint, 263
Suspensory ligament of eye, 824
of lens, 840
of liver, 937
of penis, 1011
Sustentacular cells of spleen, 951
Sustentaculum lienis, 902
tali, 203
Sutura, 219
dentata, 219
harmonia, 219
limbosa, 219
notha, 219
serrata, 219
squamosa, 219
vera, 219
Sutural ligament, 101
Suture, basilar, 102
coronal, 101
cranial, 101
fronto-parietal, 101
fronto-sphenoidal, 101, 102
intermaxillary, 113
internasal, 113
interparietal, 101
lambdoid, 101

Suture, masto-occipital, 102
masto-parietal, 102
metopic, 64
occipito-parietal, 101
petro-occipital, 102
petro-sphenoidal, 102
petro-squamous, 68
sagittal, 101
spheno-parietal, 102
squamo-parietal, 102
squamo-sphenoidal, 102
transverse facial, 102
Sweat-glands, 1142
Sylvius, aqueduct of, 676
fissure of, 645
surface-marking of, 706
Sympathetic nerve, 798, 1120
cervical portion, 799
cranial portion, 799
lumbar portion, 805
pelvic portion, 805
thoracic portion, 804
plexuses, 805
cardiac, 805
epigastric, 806
hypogastric, 809
pelvic, 809
solar, 806
Symphysis, 219, 221
of jaw, 96
pubis, 176, 244
Synarthrosis, 218
Synchondrosis, 219, 221
Syndesmo-odontoid joint, 227
Syndesmosis, 219, 221
Synovia, 218, 1145
Synovial ligaments, 218
membrane, 217, 1145
articular, 217
bursal, 218
vaginal, 218. See also *Individual joints.*
sheaths, 218
System, Haversian, 1098
Systemic arteries, 474
veins, 593

T.

Tables of the skull, 33
Tactile corpuscles of Grandy, 1121
of Wagner and Meissner, 1121
Tænia of fourth ventricle, 698
hippocampi, 667
semicircularis, 664
Tæniæ of muscular coat of intestine, 921
tectæ, 659
Tapetum, or mat, 660
of choroid, 829
lucidum, 837
nigrum, 837
Tarsal artery, 588
bones, 199
ligament of eyelid, 843
ligaments, 287
plates of eyelid, 844
Tarso-metatarsal articulations, 290
Tarsus, 199
articulations of, 287
surface form of, 213
surgical anatomy of, 213
Tarsus, synovial membranes of, 287
development of, 211
Taste-buds, 814
Teeth, 871
bicuspid, 872
body of, 871
canine, 872
cement of, 876
cortical substance of, 877
crown of, 871
crusta petrosa of, 877
cuspidate, 872
deciduous, 871
dental tubuli of, 875
dentine of, 874
development of, 877
enamel of, 877
eruption of, 852
eye, 871
false molars, 872
fang of, 872
general characters of, 871
growth of, 881
incisors, 871
intertubular substance of, 876
ivory of, 874
milk, 871, 874
molar, 872
multicuspidate, 872
permanent, 871
pulp-cavity of, 874
root of, 871
structure of, 874
temporary, 871, 874
true or large molars, 872
wisdom, 874
Tegmen tympani, 68, 853
Tegmentum of crus cerebri, 673, 677
Tela choroidea, inferior, 643, 697
Telophase of karyokinesis, 1075
Temporal artery, 495
anterior, 495
deep, 498
middle, 495
posterior, 495
surgical anatomy of, 496
bone, 65
articulations of, 72
attachment of muscles to, 72
development of, 71
mastoid portion, 67
petrous portion, 68
squamous portion, 65
structure of, 71
fascia, 311
fossæ, 110
lobe, 646, 652
muscle, 311
nerves of auriculo-temporal, 735
deep, 734
of facial, 743
ridge, 62, 65, 111
veins, 596
Temporary cartilage, 1094
teeth, 871, 874
Temporo-facial nerve, 743
Temporo-malar nerve, 730
Temporo-mandibular articulation, 231
surface form of, 234
surgical anatomy of, 234
Temporo-maxillary vein, 597
Tendo Achillis, 437
palpebrarum or oculi, 302
Tendon, central or cordiform, of diaphragm, 353
conjoined, of internal, oblique and transversalis, 361, 1045
structure of, 296
of wrist, relation of, 401
Tendril fibres of cerebellum, 693
Tenon, capsule of, 824
Tensor fasciæ femoris muscle, 420
palati muscle, 329
tarsi muscle, 302
tympani muscle, 857
canal for, 71, 854
Tenth nerve, 749
surgical anatomy of, 752
Teres major muscle, 386
minor muscle, 385
Terminal sinus, 1189
Testes, 1017
coni vasculosi of, 1020
coverings of, 1017
development of, 1210
gubernaculum testis, 1211
lobules of, 1019
lymphatics of, 634
mode of descent, 1211
muliebres, 1035
rete testis, 1020
size and weight of, 1018
structure of, 1019
surgical anatomy of, 1021
tubuli seminiferi of, 1019
tunica albuginea, 1018
vaginalis, 1018
vasculosa, 1019
vas aberrans of, 1021
vas deferens of, 1021
vas recta of, 1020
vasa efferentia of, 1020
Thalamencephalon, 643, 1173
Thalami optici, 671
Thebesii foramina, 622
venæ, 622
Thigh, deep fascia, fascia lata, 418, 419
muscles of back of, 430
of front of, 419
superficial fascia of, 418, 1053
Third nerve, 722
surgical anatomy of, 724
ventricle of the brain, 669
Thoracic aorta, 546
surgical anatomy of, 547
artery, acromial, 532
alar, 533
long, 532
superior, 532
duct, 624, 1082
ganglia of sympathetic, 804
nerves, anterior, 769
posterior, or long, 768
region, muscles of anterior, 377
lateral, 381
Thorax, base of, 456
bones of, 124
boundaries of, 456
cavity of, 456
cutaneous nerves of, anterior, 779
lateral, 779
fasciæ of, 350

Thorax, general description of, 456
lower opening of, 124
lymphatics of, 636
muscles of, 350
parts passing through upper opening of, 456
surface form of, 132
upper opening of, 124
Thrombin of fibrin ferment, 1081
Thumb, articulation of, with carpus, 265
muscles of, 404
Thymic artery, 481
lymphatic vessels, 637
Thymus gland, 981
lobes of, 981
lymphatics of, 982
structure of, 982
Thyro-arytenoid ligament, inferior, 961
superior, 960
Thyro-arytenoideus muscle, 962
Thyro-epiglottic ligament, 959
Thyro-epiglottideus muscle, 963
Thyro-glossal duct, 813, 1206
Thyro-hyal of hyoid bone, 123
Thyro-hyoid arch (fœtal), 1170
ligaments, 958
membrane, 958
muscle, 320
nerve, 756
Thyroid artery, inferior, 523
superior, 487
surgical anatomy of, 488
axis, 523
branches of sympathetic, 803
cartilage, 955
foramen, 177
ganglion, 803
gland, 979
isthmus of, 979
veins, inferior, 610
middle, 599
superior, 598
Thyroidea ima artery, 481
Tibia, 192
articulations of, 196
attachment of muscles to, 196
crest of, 193
development of, 196
fracture of shaft of, 453
nutrient artery of, 590
spinous process of, 192
surface form of, 196
surgical anatomy of, 198
tubercle of, 193
tuberosities of, 192
Tibial artery, anterior, 585
branches of, 586
peculiarities of, 586
surface-marking of, 586
surgical anatomy of, 585
posterior, 588
branches of, 590
peculiarities of, 589
surface marking of, 589
surgical anatomy of, 589
lymphatic glands, 631
nerve, anterior, 796
posterior, 794
recurrent artery, 586
veins, anterior, 615
posterior, 615
Tibialis anticus muscle, 434
Tibialis posticus muscle, 439
Tibio-fibular articulations, 282
region, anterior, muscles of, 434
posterior, muscles of, 436
Tongue, 811
arteries of, 815
development of, 1171
fibrous septum of, 815
frænum of, 811
mucous glands of, 815
membrane of, 811
muscles of, 324
nerves of, 816
papillæ of, 813
serous glands of, 815
surgical anatomy of, 816
Tonsillar artery, 491
nerves, 748
Tonsils, 884
of cerebellum, 688
nerves of, 884
vessels of, 884
Torcular Herophili, 58, 602
Trabeculæ of corpus cavernosum, 1012
cranii, 1167
of fœtal skull, 1167
of spleen, 950
of testis, 1019
Trachea, 965
cartilages of, 966
glands of, 967
relations of, 965
structure of, 966
surgical anatomy of, 968
vessels and nerves of, 967
Trachealis muscle, 967
Trachelo-mastoid muscle, 345
Tracheotomy, 968
Trachoma glands, 845
Tract, afferent or ascending, 719
of cord, antero-lateral, 714
ground-bundle, 714
of Burdach, 715
crossed pyramidal, 714
efferent or descending, 718
descending comma, 715
direct cerebellar, 714
pyramidal, 713
of Goll, 715
of Gowers, 714
of Lissauer, 714
Tractus spiralis foramenulentus, 69, 861
Tragicus muscle, 850
Tragus, 849
Transitional epithelium, 1085
Transversalis cervicis muscle, 345
colli artery, 524
muscle, 345
fascia, 1046
humeri artery, 524
muscle, 362
Transverse arteries of basilar, 522
colon, 924
coronary artery, 477
facial artery, 495
vein, 596
fissure of brain, 669
of liver, 935
humeral ligament, 252
joint of foot, 285
Transverse ligament of atlas, 227
of hip, 270
of knee, 277
metatarsal, 292
of scapula, 250
of shoulder, 252
superficial, of fingers, 404
tibio-fibular, 283
mesocolon, 903
nasal artery, 508
process of a vertebra, 35
sinus, 605
of pericardium, 459
suture, 102
Transversus auriculæ, 850
perinei, 371
(in female), 325
profundus, 1070
Trapezium, bone, 163
of pons, 683
Trapezius muscle, 337
Trapezoid bone, 163
ligament, 249
nucleus, 745
Treitz, muscle of, 914
Triangle of elbow, 534
of Hesselbach, 1048, 1052
inferior carotid, 500
of neck, anterior, 500
posterior, 501
occipital, 501
Scarpa's, 572
subclavian, 502
submaxillary, 501
suboccipital, 520
superior carotid, 500
Triangular interarticular fibro-cartilage, 261
fascia of abdomen, 357, 1044
of urethra, 373
Triangularis sterni muscle, 351
menti muscle, 308
Triceps extensor cubiti, 388
suræ, *note*, 437
Tricuspid valves, 463
Trifacial or trigeminus nerves, 725
surface-marking of, 737
surgical anatomy of, 738
Trigone of bladder, 1003
Trigonum acustici, 699
habenulæ, 672
hypoglossi, 699
olfactorium, 655
vagi, 698
ventriculi, 662
Trilaminar blastoderm, 1154
Tri-radiate sulcus, 649
Trochanter, greater, 185
lesser, 185
Trochanteric fossa, 185
Trochlea of femur, 187
of humerus, 147
Trochlear fossa, 63
nerve, 724
surgical anatomy of, 725
Trochoides, 220
Trolard, anastomotic vein of, 601
True ligaments of bladder, 1002
pelvis, 179
nucleoli, 1074
ribs, 128
Trunk, articulations of, 223
muscles of, 336
Tube, Eustachian, 855

Tube, Fallopian, 1034
tonsil, 855
Tuber annulare, 681
cinereum, 656
ischii, 175
omentale, 934
papillare, 935
valvulæ or posticum of cerebellum, 689
Tubercle, adductor, 187
carotid or Chassaignac's, 36
conoid, 135
cuneate, 696
of Darwin, 849
deltoid, 135
of epiglottis, 958
of the femur, 185
genial, 97
of hyoid bone, 122
lachrymal, 86
of Lower, 463
mental, 97
of navicular bone, 205
for odontoid ligaments, 56
of the quadratus, 186
of ribs, 129
of Rolando, 695
of scaphoid, 161
of tibia, 193
of ulna, 152
of zygoma, 66
Tubercula quadrigemina, 675
Tuberculum acusticum, 699
caudatum, 696
impar, 1203
Tuberosities of humerus, greater and lesser, 144
of tibia, 192
Tuberosity, cuboid, 204
of ischium, 174
maxillary, 84
of navicular bone, 205
of palate bone, 93
of radius, 155
of ribs, 129
Tubes, bronchial, 966
structure of, in lung, 975
Tubular membrane of nerves, 1117
secreting glands, 1146
substance of kidney, 988
Tubuli, dental, 875
lactiferi, 1040
seminiferi, 1019
uriniferi, 988
Tuft, vascular, in Malpighian bodies of kidney, 988
Tunica adventitia, 1126
albuginea, 1018
of eye, 304
elastica externa, 1128
intima, of arteries, 1126
media, 1126
of ovary, 1036
Ruyschiana, 829
vaginalis, 1018
vasculosa oculi, 828
testis, 1019
Tunnel of Corti, 865
Turbinated bone, inferior, 94
middle, 79
superior, 79
crest, inferior, 85
superior, 85
Türck, fasciculus of, 713
Tutamina oculi, 713
Twelfth nerve, 754
surgical anatomy of, 756
Tympanic artery, from internal carotid, 505
maxillary, 496
nerve, 748, 859
of facial, 742
plate, 66
Tympanum, 852
arteries of, 858
cavity of, 852
membrane of, 855
mucous membrane of, 858
muscles of, 857
nerves of, 858
ossicula of, 856
veins of, 858
Types of human cæca, 1011
Tyson's glands, 1011

U.

Ulna, 150
articulations of, 155
coronoid process of, 152
development of, 154
fracture of coronoid process of, 413
muscles attached to, 155
of olecranon, 413
process of, 150
of shaft, 413
sigmoid cavities of, 152
styloid process of, 154
surface form of, 155
surgical anatomy of, 157
tubercle of, 152
Ulnar artery, 542
branches of, 543
peculiarities of, 542
recurrent, anterior, 543
posterior, 543
surface-marking of, 542
surgical anatomy of, 542
collateral branch of musculospiral, 775
lymphatic glands, 628
nerve, 772
surgical anatomy of, 776
vein, anterior, 607
posterior, 607
Umbilical arteries in fœtus, 471, 1162
how obliterated, 473
cord, 1165
fissure of liver, 935
region, contents of, 896
vein, 1194
vesicle, 1158
Umbilicus, 365
Umbo, 855
Unciform bone, 165
process of, 165
process of ethmoid, 79
Uncinate fasciculus, 678
Uncus, 653
Ungual phalanges, 169
Unstriped muscle, 1111
Upper extremities, arteries of, 514
bones of, 134
fascia of, 376
ligaments of, 245
lymphatics of, 628
Upper extremities, muscles of, 376
nerves of, 768
surface form of, 409
surgical anatomy of, 411
veins of, 607
Urachus, 1002, 1162, 1209
Ureters, 994
muscles of, 1003
nerves of, 996
structure of, 995
vessels of, 996
Urethra, bulbous portion of, 1006
caput gallinaginis, 1005
development of, 1215
female, 1007
male, 1005
membranous portion, 1006
prostatic portion, 1005
rupture of, course taken by urine in, 1065
sinus pocularis of, 1006
spongy portion of, 1006
structure of, 1006
surgical anatomy of, 1007
verumontanum, 1006
Urinary organs, 985
development of, 1207
Urogenital sinus, 1209
Uterine arteries, 563
plexus, 810
of veins, 617
Uterus, 1028
after parturition, 1033
appendages of, 1034
arbor vitæ of, 1032
broad ligaments of, 1030
cavity of, 1030
development of, 1210
in fœtus, 1033
fundus, body, and cervix of, 1028
ganglia of, 810
nerves of, 810
ligaments of, 1029
lymphatics of, 634
masculinus or utriculus hominis, 1006, 1208, 1211
during menstruation, 1033
nerves of, 1032
in old age, 1033
during pregnancy, 1033
at puberty, 1033
round ligaments of, 1038
shape, position, dimensions, 1028
structure of, 1031
vessels of, 1032
Utricle of vestibule, 862
Uvea, 831
Uvula of cerebellum, 687
of throat, 883
vesicæ, 1004

V.

Vagina, 1027
columns of, 1028
lymphatics of, 634
orifice of, 1025
Vaginal arteries, 564
plexus of nerves, 810
of veins, 617
portal plexus, 940

Vaginal process of temporal, 66, 70
processes of sphenoid, 74
synovial membranes, 217
Vagus, ganglion of root of, 750
nerve, 749
trunk of, 750
Valentin, ganglion of, 731
Vallecula of cerebellum, 684
Sylvii, 645
Valleculæ of larynx, 958
Valsalva, sinuses of, 465, 468, 476
Valve, of Bauhin, 923
coronary, 462
of cystic duct, 943
Eustachian, 462
of gall-bladder, 942
of Hasner, 847
ileo-cæcal, 923
of Kerkring, 916
mitral, 466
of Vieussens, 697
Valves of lymphatics, 1132
pulmonic, 462
in right auricle, 462
semilunar aortic, 467
pulmonic, 464
tricuspid, 464
of veins, 1131
Valvulæ conniventes, 916
Vasa aberrantia, from brachial artery, 535
afferentia of lymphatic glands, 624
brevia arteries, 553
veins, 619
efferentia of lymphatic glands, 624
of testis, 1020
intestini tenuis, 554
recta, 1020
vasorum of arteries, 1128
of veins, 1131
Vascular area of yolk sac, 1189
capsule of yolk sac, 1182
system, changes in, at birth, 473
general anatomy of, 1126
peculiarities in the fœtus, 471
Vas aberrans, 1021
deferens, 1021
structure of, 1021
Vas spirale, 864
Vaso-motor nerves, 1119
Vastus externus muscle, 422
internus and crureus, 422
Vater, corpuscles of, *note*, 1122
Veins, general anatomy of, 1130
anastomoses of, 593
coats of, 1130
development of, 1194
muscular tissue of, 1131
plexuses of, 593
size, form, etc, 593
structure of, 1131
valves of, 1131
vessels and nerves of, 1131
Veins or vein, descriptive anatomy of, 593
of alæ nasi, 596
angular, 595
articular, of knee, 615
auditory, 866
auricular, anterior, 596
posterior, 597
axillary, 609
Veins or vein, azygos, left lower, 611
upper, 612
right, 611
basilic, 608
basi-vertebral, 613
of bone, 1097
brachial, 609
brachio-cephalic or innominate, 609
bronchial, 612
buccal, 597
cardiac, 621
anterior, 621
left, 621
posterior, 621
right, 621
cardinal, 1196
cava inferior, 617
superior, 611
cephalic, 608
cerebellar, 601
cerebral, 600
cervical, ascending, 599
deep, 599
choroid, of brain, 601
circumflex, iliac, 616
superficial, 614
condyloid posterior, 599, 603
of corpora cavernosa, 1013
of corpus spongiosum, 617
striatum, 601
cystic, 621
deep, or venæ comites, 594
dental inferior, 597
digital, of hand, 608
of diploë, 599
dorsal, of penis, 617
dorsalis nasi, 596
pedis, 614
dorsi-spinal, 612
emissary, 605
surgical anatomy of, 606
epigastric, deep, 616
superficial, 614
of eyeball, 841
facial, 596
femoral, 616
frontal, 595
of Galen, 601
gastric, 620
gastro-epiploic, 619
gluteal, 616
hæmorrhoidal, 616
of head, 594
hepatic, 619
iliac, common, 617
external, 616
internal, 616
ilio-lumbar, 618
inferior cava, 617
innominate, 609
intercostal, superior, 611
interlobular, of kidney, 992
of liver, 940
interosseous, of forearm, 608
intralobular, of liver, 940
jugular, anterior, 598
external, 597
posterior, 598
internal, 598
of kidney, 992
labial, inferior, 596
superior, 596
laryngeal, 611
Veins or vein, lateral sacral, 617
lingual, 598
of liver, 940
longitudinal inferior, 602
lumbar, 618
ascending, 618
mammary, internal, 610
masseteric, 596
mastoid, 597
maxillary, internal, 596
median basilic, 608
cephalic, 608
medulli-spinal, 612
meningeal, 597
meningo-rachidian, 613
mesenteric, inferior, 619
superior, 619
nasal, 594
oblique cardiac, 622
obturator, 616
occipital, 597
œsophageal, 611
ophthalmic, 604
ovarian, 618
inferior, 604
palatine, inferior, 596
palmar, deep, 608
palpebral, inferior, 596
superior, 596
pancreatic, 619
pancreatico-duodenal, 619
parotid, 596
peroneal, 615
pharyngeal, 598
phrenic, 619
plantar, external, 615
internal, 615
plexuses, of ovarian, 1038
pampiniform, 618, 1016, 1038
pharyngeal, 598
pterygoid, 596
spermatic, 618, 1016
uterine, 617
vaginal, 617
vesico-prostatic, 599
popliteal, 615
portal, 593, 621, 940
profunda femoris, 616
pterygoid plexus, 596
pubic, external, 614
internal, 616
pulmonary, 594
radial, 607
ranine, 596, 598
renal, 619, 992
sacral, lateral, 617
middle, 617
salvatella, 607
saphenous, external, or short, 614
internal, or long, 614, 1054
sciatic, 616
spermatic, 618
spheno-palatine, 599
spinal, 612
splenic, 619
stylo-mastoid, 597
subclavian, 609
sublobular, 940
submaxillary, 596
submental, 598
superficial, 593
supraorbital, 595
suprarenal, 619

Veins or vein, suprascapular, 598
sural, 616
systemic, 593
temporal, 596
middle, 596
temporo-maxillary, 597
thyroid, inferior, 610
middle, 599
superior, 598
tibial, anterior, 615
posterior, 615
transverse cervical, 597
facial, 596
ulnar, anterior, 607
common, 607
deep, 608
posterior, 607
umbilical, 471
vaginal, of liver, 940
vasa brevia, 619
vertebral, 599
Vidian, 598
Velum interpositum, 669
pendulum palati, 883
Vena ascendens, 1195
cava, fœtal, 1198
inferior, 617
peculiarities of, 617
superior, 611
magna Galeni, 669
Venæ basis vertebræ, 35
comites, 594
hepaticæ advehentes, 1194
revehentes, 1194
interlobulares of kidney, 992
rectæ of kidney, 992
salvatella, 607
Thebesii, or minimæ cordis, 462, 622
vorticosæ, 829
Venesection, 608
Venous lacunæ of dura mater, 640
Venter of ilium, 174
of scapula, 138
Ventral auditory nucleus, 702
Ventricle of brain, fifth, 666
fourth, 697
lining membrane of, 699
third, 670
of heart, left, 465
right, 463
of larynx, 961
lateral, 660
of nasal fossæ, 820
Vermicular motion, 1112
Vermiform process of cerebellum, inferior, 686
superior, 685
Vernix caseosa, 1186
Vertebra prominens, 39
development of, 43
Vertebræ, 34
cervical, 35
development of, 43
dorsal, 39
general characters, 34
ligaments of, 223
lumbar, 41
sacral, 45
structure of, 43
Vertebral aponeurosis, 341
artery, 520
column, 51
articulation of, 223
Vertebral column, ossification of, 43
surface form of, 53
surgical anatomy of, 53
ligaments, 223
region, muscles of, anterior, 332
lateral, 334
vein, 599
Vertex of skull, 103
Vertical plate of palate bone, 92
Verumontanum, 1005
Vesical artery, inferior, 563
middle, 563
superior, 563
plexus of nerves, 809
Vesicle, auditory, 1183
cerebral, 1167
germinal, 1149
optic, 1180
umbilical, 1158
Vesicles, Graafian, 1036
Vesico-prostatic plexus of veins, 617
Vesico-uterine ligaments, 1029
Vesicula prostatica, 1006
Vesiculæ seminales, 1022
surgical anatomy of, 1023
vessels and nerves of, 1023
Vesicular column, posterior, of Clarke, 717
Vestibular artery, 866
nerve, 867
Vestibule, aortic, 466
of ear, 859
aqueduct of, 69
of nose, 820
Vestibulumoris, 869
Vestigial fold of pericardium, 459
Vibrissæ, 818
Vicq d'Azyr, bundle of, 657
Vidian artery, 499
canal, 76
nerve, 732
Vieussens, valve of, 697
Villi, 917
of the chorion, 1161
Viscera, pelvic, position of, in abdominal region, 896
at outlet of pelvis, 1067
Visual centres, cortical, 722
lower, 722
Vitelline circulation, 1187
duct, 1158
membrane, 1149
spheres, 1152
Vitello-intestinal duct, 1198
Vitellus, 1149
Vitreous humor of the eye, 839
table of the skull, 34
Vocal cords, inferior or true, 961
superior or false, 960
process, 957
Voice, organs of, 955
Voluntary muscles, 1107
Vomer, 95
alæ of, 96
articulations of, 96
development of, 96
Vomerine cartilage, 96
Vortex of heart, 469
Vulva, 1025
development of, 1213

W.

Wagner, tactile corpuscles of, 1121
Wandering cells, 1087
Watney on the structure of thymus, 982
Weight of organs. See *Individual Organs.*
Wharton's duct, 886
White fibro-cartilage, 1094
fibrous tissue, 1087
substance of cord, 713
nervous, 1115
of Schwann, 1116
Willis, circle of, 512, 523
Winslow, foramen of, 899
ligament of, 274
Wisdom tooth, 874
Wolffian body, 1208
duct, 1207
Womb. See *Uterus.*
Worm. See *Vermiform process.*
Wormian bones, 81
Wrisberg, cartilages of, 958
ganglion of, 806
ligament of, 277
nerve of, 771
Wrist-joint, 262
surface form of, 169, 263
surgical anatomy of, 263
Wry-neck, 319

X.

Xiphoid appendix, 125

Y.

Y-ligament, 270
Y-shaped centre of acetabulum, 178
Yellow cartilage, 1095
elastic fibrous tissue, 1088
spot of retina, 833
Yolk, 1149
cleavage of, 1151
sac, 1158
stalk, 1198

Z.

Zinn, ligament of, 304
Zona arcuata, 864
fasciculata, 997
glomerulosa, 997
incerta, 676
orbicularis, 269
pectinata, 864
pellucida, 1147
radiata, 1147
reticularis, 997
vasculosa, 1037
Zonula ciliaris, 840
Zonule of Zinn, 840
Zygoma, 65
roots of, 65
tubercle of, 66
Zygomatic arch, 111
fossæ, 111
process of malar, 90
Zygomaticus major muscle
minor, 307



Vas sp
Vaso-r
Vastus
inter
Vater,
Veins,
anas
coats
deve
musc
plexu
size,
struct
valve
vessel
Veins o
o
of alæ
angula
articul
andito
auricu
post
1 axillar

COLUMBIA UNIVERSITY LIBRARIES (hsl,stx)
QM 23 G79 1901 C.1
Anatomy, descriptive and surgical
2002153289