

**Atlas and abstract of the diseases of the larynx / by L. Grünwald ;
authorized translation from the German edited by Charles P. Grayson.**

Contributors

Grünwald, L. 1863-1927.

Grayson, Charles P. 1859-1939.

Augustus Long Health Sciences Library

Publication/Creation

Philadelphia : W.B Saunders, 1902, ©1898.

Persistent URL

<https://wellcomecollection.org/works/dy2tmqs4>

License and attribution

This material has been provided by This material has been provided by the Augustus C. Long Health Sciences Library at Columbia University and Columbia University Libraries/Information Services, through the Medical Heritage Library. The original may be consulted at the the Augustus C. Long Health Sciences Library at Columbia University and Columbia University. where the originals may be consulted.

This work has been identified as being free of known restrictions under copyright law, including all related and neighbouring rights and is being made available under the Creative Commons, Public Domain Mark.

You can copy, modify, distribute and perform the work, even for commercial purposes, without asking permission.

**wellcome
collection**

Wellcome Collection
183 Euston Road
London NW1 2BE UK
T +44 (0)20 7611 8722
E library@wellcomecollection.org
<https://wellcomecollection.org>

COLUMBIA LIBRARIES OFFSITE
HEALTH SCIENCES STANDARD



HX64132544


RC794 .G92

Atlas and abstract o

RECAP

SAUNDERS'

MEDICAL HAND-ATLASES.



THE series of books included under this title are authorized translations into English of the world-famous

Lehmann Medicinische Handatlanten,

which f
cheapn

Each
ous illus
most sk
pression
panied b
densed l

One
ready a
servatio
and eve
hospital
will be
venient
by the n

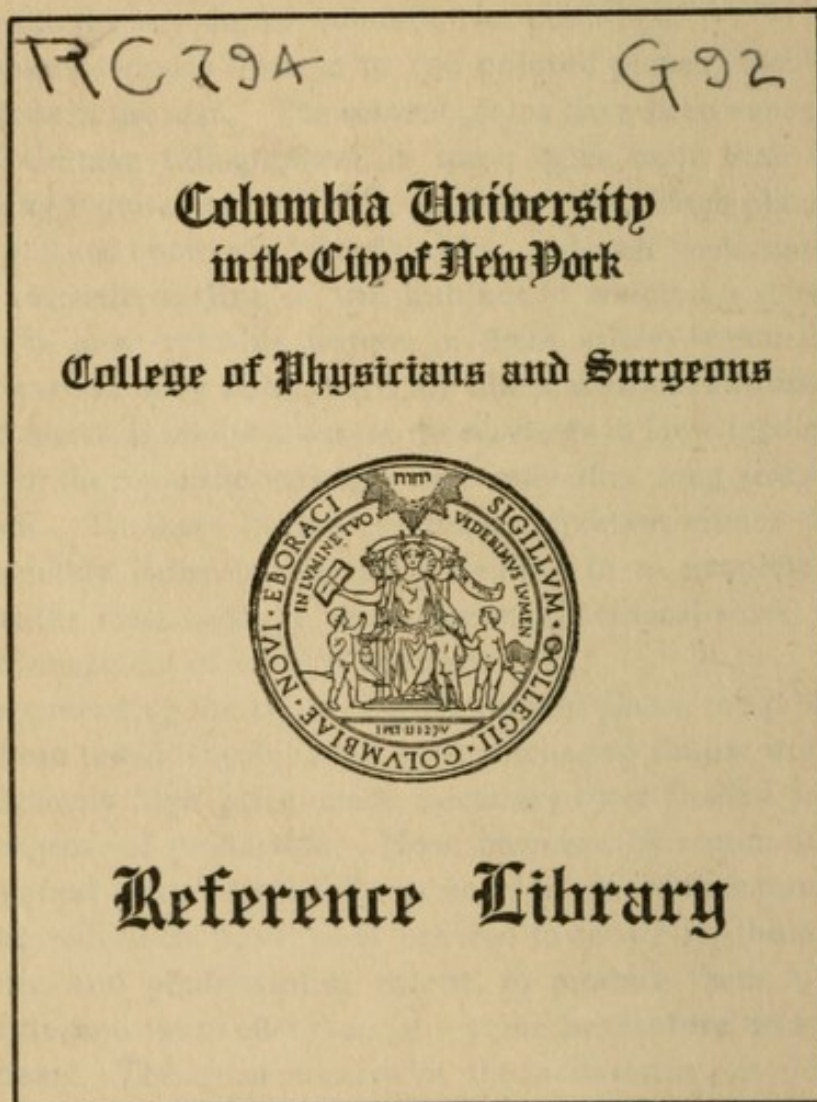
Whi
heretof
of their
enormo
jected u
tributio
best ar
elegant
in chea
by the f
langua

Japanese, Danish, Swedish, Roumanian, Bohemian, and Hungarian.

The same careful and competent editorial supervision has been secured in the English edition as in the originals. The translations have been edited by the leading American specialists in the different subjects. The volumes are of a uniform and convenient size (5 × 7½ inches), and are substantially bound in cloth.

(For List of Books, Prices, etc. see back cover.)

Pamphlet containing specimens of the Colored Plates
sent free on application.





, and

umer-
by the
y im-
ecom-
a con-

offer a
ch ob-
nters;
outine
books
con-
creted

n has
cause
nd an
pro-
al dis-
es the
most
ched
trated
erent
utch,





ATLAS AND ABSTRACT
OF THE
DISEASES OF THE LARYNX

BY
DR. L. GRÜNWARD
of Munich

AUTHORIZED TRANSLATION FROM THE GERMAN

EDITED BY
CHARLES P. GRAYSON, M. D.

Lecturer on Laryngology and Rhinology in the University of Pennsylvania
Physician-in-Charge of the Throat and Nose Department,
Hospital of the University of Pennsylvania

With 107 Colored Figures on 44 Plates

PHILADELPHIA AND LONDON
W. B. SAUNDERS & COMPANY

1902

Copyright, 1898, by W. B. Saunders.

Reprinted September, 1900, and November, 1902.

PREFACE.

IN the preparation of this little Atlas of the Diseases of the Larynx the author has adopted the same plan as that pursued in his earlier Atlas of the Diseases of the Nose and Throat. Its object is to help the beginner in the art of observing and interpreting. As, however, a knowledge of the previous history of the disease and the examination of contiguous, as well as of more distant organs are indispensable for diagnosis, especially in this region, each picture is accompanied by the necessary data in the form of a short history.

By adopting this method the author believes he has also presented a valuable aid to the physician who has few opportunities of seeing diseases of the larynx and yet wishes to be able to recognize them. At the same time a clearer mental image is obtained which may compensate for possible imperfections in the actual picture.

The illustrations are arranged solely according to external appearances, without regard to the nature of the disease; partly in order to train the eye by comparing conditions similar in appearance, though differing widely in their true nature, and partly to make it easier to find the illustrations which most resemble the particular case

to be diagnosed. Many well-known pictures, as, for instance, that of diphtheria, are therefore omitted.

To prepare the student for this course in the theory and practice of diagnosis a short, systematic abstract has been added.

In the author's opinion, a knowledge of the histology of morbid processes is most essential to a proper understanding of them. Twelve plates showing the most important elementary alterations have accordingly been devoted to this purpose. This department of pathology, which has been somewhat neglected in the text-books, affords the best means of arriving at clear, definite ideas.


Figure 1 is taken from Luschka's work on anatomy, two illustrations of cadavers from the well-known atlas by Bollinger. All the other illustrations were prepared by the (academic) painter Mr. Keilitz, from sketches or preparations by the author, who takes this opportunity of expressing his thanks for the care and skill with which they were executed.

THE AUTHOR.

EDITOR'S PREFACE.

IF it be true that "good wine needs no bush," 'tis certainly true that so good a book as this needs no preface. The American editor only ventures to add a few words relative to the method of instruction adopted in this book. It exemplifies a happy blending of the didactic and clinical such as is scarcely to be found in any other volume upon this subject with which we are acquainted. It is upon the value of the clinical portion of the work that the editor would dwell with particular emphasis. The beginner will find here a series of pathological conditions, illustrated with a remarkable fidelity to Nature, that it would undoubtedly require him a number of years to duplicate in actual practice; while the veteran, however rich his experience, will note a precision, a *finesse* in diagnosis that cannot fail to be instructive and, perhaps, even inspiring. The admirable translation, which is the work of Mr. R. Max Goepp, has been carefully compared with the original, and the editor's comments are intended as expository of, rather than as actual additions to, the text.

C. P. G.



CONTENTS.

	PAGE
INTRODUCTORY REMARKS ON THE ANATOMY AND PHYSIOLOGY OF THE LARYNX	9
METHODS OF EXAMINATION	19
1. Indirect Laryngoscopy	19
2. Direct Laryngoscopy	24
3. Inspection	25
4. Palpation	25
5. Auscultation	26
PRACTICAL HINTS FOR THE EXAMINATION	28
GENERAL REMARKS ON THE CAUSES AND TREATMENT OF DISEASES OF THE LARYNX	31

Pathology and Treatment.

I. Acute Inflammations	36
1. Superficial	36
2. Exudative	39
3. Interstitial	44
4. Inflammations of the Muscles	48
5. Inflammations of the Joints	49
6. Inflammations of the Perichondrium	51
7. Symptomatic (complicated) forms of Acute Inflamma- tions	54
II. Chronic Inflammations	59
1. Superficial	59
2. Submucous	62
3. Inflammations of the Muscles	63
4. Inflammations of the Joints	63
5. Inflammations of the Perichondrium and Cartilages . .	64
6. Complicated Forms	64
(a) Tertiary Syphilis	64
(b) Tuberculosis	68
(c) Leprosy	74
(d) Sclerosis	74
(e) Gout and Arthritis Deformans	75

	PAGE
III. Neoplasms	75
1. Homologous	75
(a) Neoplasms of Individual Tissues	75
(b) Hyperplasiæ	77
2. Heterologous	81
IV. Disturbances of Motility	86
1. Mechanical	86
2. Neuroses	88
(a) Hyperkinetic	88
(b) Hypokinetic	90
(c) Parakinetic	94
V. Disturbances of Sensibility	96
V ^a . Complicated (functional) Motor and Sensory Disturbances	97
VI. Disturbances of the Circulation	100
VII. Solutions of Continuity	100
VIII. Foreign Bodies	102
IX. Malformations	102

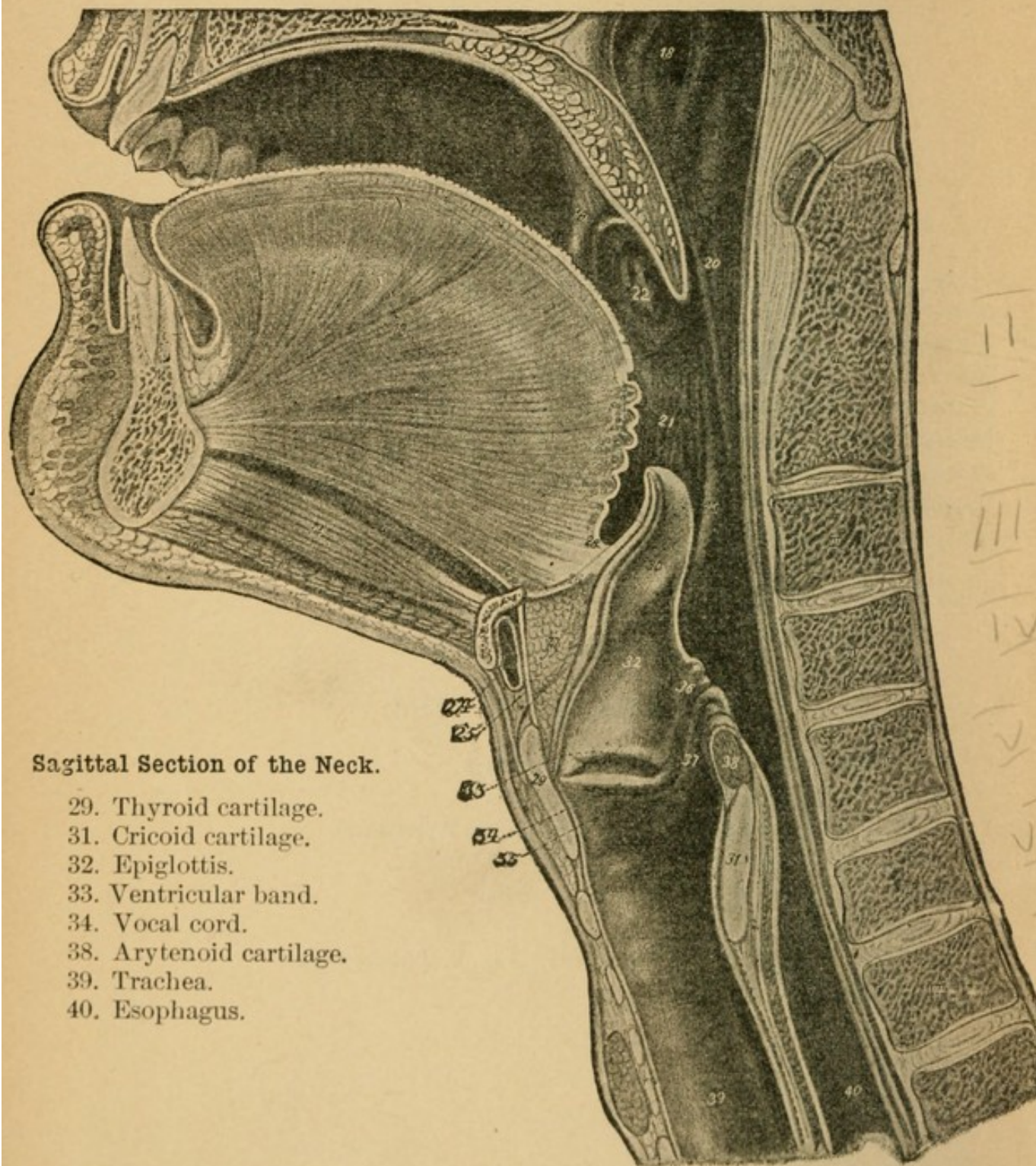
LIST OF ILLUSTRATIONS.

MACROSCOPIC PLATES.

- Plates 1-3.** Various Laryngoscopic Images.
Plates 4-7. Alterations of the Epiglottis.
Plates 8-16. Diseases of the Vocal Cords.
Plate 17. Subcordal Alterations.
Plate 18. Disease of the Ventricular Bands.
Plates 19-26. Disease of the Posterior Wall.
Plate 27. Alterations at the Superior Aperture of the Larynx.
Plates 28-30. Diffuse Alterations.
Plate 31, 32, and Fig. 15. Alterations at the Superior Aperture of the Larynx.
Figs. 16-23. Paralyses.
-

MICROSCOPIC PLATES.

- Plates 33-36.** Alterations in the Epithelium.
Plate 37. Sarcoma and Carcinoma.
Plate 38. Alterations of the Lymphatic Apparatus.
Plate 39. Cysts and Angioma.
Plate 40. Disease of the Blood-vessels.
Plate 41. Syphilitic Tumors.
Plate 42. Fig. 1, Syphilitic Ulcer ; Fig. 2, Tuberculosis.
Plates 43-45. Tuberculosis.



INTRODUCTORY REMARKS

ON THE

ANATOMY AND PHYSIOLOGY OF THE
LARYNX.

BOTH form and functions of the larynx are based on its skeleton. This is built up mainly on two large cartilages, the thyroid and the cricoid. Assuming that their shape and smaller solid portions are sufficiently well known from general anatomy, we proceed at once to a description of their topographical relations. The two broad alæ of the thyroid embrace the lateral plates of the cricoid which are narrower in front than behind, while the anterior border or curvature of the cricoid is thrust forward under the thyroid. Between this anterior border of the cricoid and the lower part of the thyroid an interval filled with soft structures can easily be felt in the living subject. Above and at the sides, parts of the thyroid only can be felt: the lateral plates (alæ) and the cornua. In front, the upper border of the thyroid cartilage projects sharply forward, and, with its notch which can be plainly felt, especially in men, forms the prominence in the throat known as Adam's apple; the latter is also occasionally visible in the more vigorous of the daughters of Eve. The true base of the entire structure is therefore the cricoid cartilage, which also supports the smaller ones: the arytenoid, Santorini's, and the cuneiform cartilages. The latter are called cartilages of motion, to distinguish them from the supporting cartilages.

The arytenoid cartilages articulate with the upper bor-

der of the cricoid by two symmetrical articular facets in such a manner that, seen from above in a resting position, they present a triangular cross-section, one leg looking forward and inward (toward the median line), one backward and inward, and the wide sweep of the hypotenuse forward and outward. The joint itself is in the form of a saddle, having one side directed forward and inward, the other backward and outward.

Above, the concave surface of each arytenoid cartilage presents a process on which rests the small, horn-shaped cartilage of Santorini (*corniculum laryngis*), while at the sides the cuneiform, or Wrisberg's, cartilages form another link in the cartilaginous chain surrounding the upper border of the cricoid.

In front, this chain finds a point of attachment in the epiglottis which resists pressure in both directions, its principal movement being backward and forward.

All of these solid parts are bound together by a continuous sheet of elastic connective tissue, which becomes thickened to form cords and ligaments wherever there is increased active or passive strain. Of these ligaments (the names and form of which we again assume to be known), the cricothyroid membrane can be felt from the outside. We may consider the structures known as the true vocal cords and the ventricular bands, or false vocal cords, to be folds of the connective tissue which respond to the pull of the movable cartilages.

The larynx is connected with the surrounding structures partly by ligaments and partly by muscles. It forms the beginning of the air-passage, and is attached to the hyoid bone by means of the thyrohyoid ligaments, the middle one of which, with its overlying muscle, can be felt in the living subject; posteriorly it is held in position by the laryngeal and pharyngeal muscles. The latter, assisted by the thyrohyoid muscles, elevate the larynx or one side of it, while the sternothyroid muscle depresses it and, by virtue of its insertion in the lower back part of the thyroid cartilage, tends to rotate it about the crico-

thyroid articulation as a pivot, depressing it behind and elevating it in front.

Below, the larynx is connected with the trachea by the cricotrachean membrane.

The posterior surface of the larynx (formed by the posterior half of the cricoid cartilage and the upper border of the epiglottis) corresponds to the anterior surface of the esophagus, and may therefore be regarded as belonging either to the lowest division of the pharynx or to the upper division of the esophagus. In a sense the posterior and also the lateral walls of the larynx are free and project into the lumen of the pharynx. Thus the larynx, by pushing out a semicircular fold of the mucous membrane of the esophagus, narrows the lumen of that tube so that it almost disappears in the median line at this point and is forced to find room on the sides, where the soft parts offer less resistance than the rigid spinal column. This results in the formation of lateral extensions known as *sinus pyriformes* (*pirus*, a pear), which can be seen in the living subject with the laryngoscope, although in the resting position they are flattened out by the pressure of the adjacent soft parts.

In front, the larynx is covered by the muscles already described, and more superficially by the sternohyoid muscle and the cervical fascia.

The anterior border of the cricoid cartilage also gives attachment to the thyroid fascia. Occasionally a third lobe of the thyroid gland, known as the pyramidal lobe, extends upward in front of the cricoid cartilage, while the lateral plates are partially covered by the two principal lobes of the gland.

It should be remembered that of the many lymph-glands in the neck one, a small one, lies in front of the larynx, immediately in front of the cricothyroid membrane. The lymph-channels of the organ empty into the submaxillary and cervical lymphatic glands.

Besides the muscles already mentioned there is a series of smaller ones to afford movement of the several cartil-

ages on each other—the intrinsic muscles. It will be best to consider them in connection with their individual actions.

The lateral and posterior crico-arytenoid muscles are inserted into the outer angle of the base of the arytenoid cartilages; therefore known as the muscular process. The lateral portions arise by a fan-shaped origin from the sides of the arytenoid cartilages externally; the posterior, on the other hand, have their broad origin on the posterior surface of the same cartilage. The posterior muscles embrace the posterior and lateral portions of the muscular processes; the lateral muscles only the lateral. As the center of the arytenoid cartilage must form the pivot, the action of these muscles is clear. The lateral crico-arytenoid muscles draw the muscular process forward and outward, so that the vocal process (anterior angle of the base of the arytenoid cartilage) moves inward and backward; the posterior crico-arytenoid muscles have a directly antagonistic action. As the true vocal cords are attached to the vocal process, they necessarily follow these movements, and the muscles are therefore known respectively as the adductors and abductors of the true vocal cords.

The transverse arytenoid muscle passes transversely across between the two arytenoid cartilages in the middle line, and by its contraction effects mesial approximation of the two cartilages. When these muscles, assisted by the lateral crico-arytenoid muscles, are put on the stretch they effectually fix the arytenoid cartilages, so that the latter afford a fixed origin to another muscle, the thyro-arytenoid, which again consists of two fasciculi, the inferior or internal and superior or external. The inferior thyro-arytenoid muscle lies within the membranous fold known as the true vocal cord (and parallel with it), the superior within the fold known as the ventricular band; both are inserted into the lower half of the thyroid cartilage at the line of junction of the two alæ. The action of the muscles is, therefore, to put these folds on the stretch whenever both their anterior and posterior points of attach-

ment become fixed so that they cannot approach each other. In order to fix the posterior origin, it is further necessary that the arytenoid cartilage be fixed to the cricoid by means of the mechanism already described.

The thyroid and cricoid cartilages move against each other by means of the cricothyroid articulation. As this is placed rather far back, the upper anterior border of the thyroid traverses the greater distance at each excursion. (It is immaterial whether the lower border of the thyroid is drawn toward the upper border of the cricoid or the contrary takes place.) Approximation is effected by contraction of the cricothyroid muscle, while the action of the sternothyroid, as stated above, is directly antagonistic. In order to stretch the folds of membrane attached to the cartilages these two muscles must act together, for, if the cricothyroid muscle alone were contracted, the cricoid cartilage would simply follow the pull of that muscle; while if the sternothyroid alone were contracted, the same would be true of the thyroid cartilage.

It follows, therefore, that passive stretching or tension of the true vocal cords can take place only

- (1) When the arytenoid cartilages are fixed to the cricoid cartilage ;
- (2) When the cricoid cartilage is drawn backward and the thyroid forward.

To effect this the following muscles are required :

- (1) The lateral crico-arytenoid, or the transverse arytenoid muscles, or these two groups together ;
- (2) The cricothyroid and the sternothyroid muscles.

We should observe, at the outset, that the action of the true vocal cords consists not only in passive tension, which must necessarily accompany *reduction in width*, but also in active contraction, which results in *increased width*, both actions being required to give them the elasticity necessary for voice-production. The latter is accomplished by contraction of the inferior thyro-arytenoid muscles, which are able to act as soon as their origin and insertion are fixed in the manner just described.

In like manner the superior thyro-arytenoid muscles contract the ventricular bands within which they are enclosed ; this happens regularly in swallowing, but only exceptionally in speaking.

The actions of the several muscles will be better understood by the aid of the following diagram :

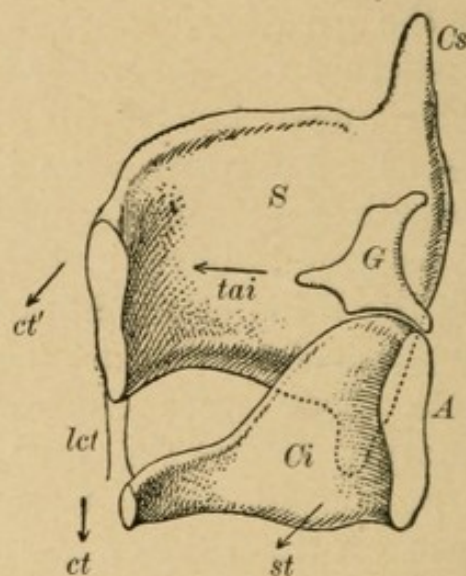


FIG. 2.

S, thyroid cartilage, *A*, cricoid cartilage, both cut in a mesial sagittal plane. *G*, arytenoid cartilage. *ct*, direction of pull of the cricothyroid muscle. Action : approximation of anterior inferior margin of thyroid, and upper border of cricoid cartilages. *ct'*, direction in which the upper border of the thyroid is at the same time tilted forward.

st, direction of pull of the sternothyroid muscle. Action : to depress the cricoid cartilage. *st'*, direction in which the upper border of the cricoid is at the same time tilted backward.

tai, direction of pull of the inferior thyro-arytenoid.

Schema (Fig. 3) of the action of muscles on the arytenoid cartilage and on the true vocal cords. Both parts in horizontal section and in respiratory position. The cords are seen to consist of a ligamentous, and a cartilaginous portion (*pl* and *pc*). According to their respective functions,

the middle part of the cartilage is called the vocal process, the lateral portion the muscular process (*pv* and *pm*).

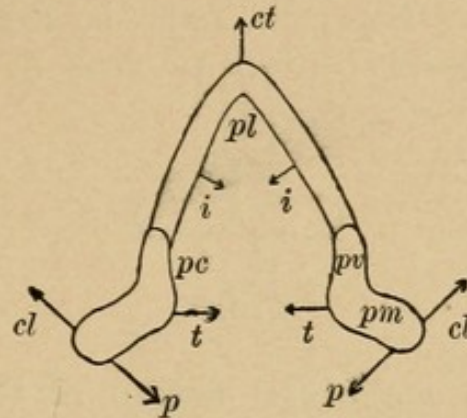


FIG. 3.

i, direction of the contraction of the inferior thyro-arytenoid muscles. Action: tension of the edges of the true vocal cords.

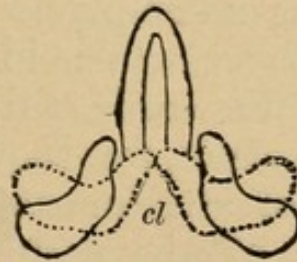


FIG. 4.

cl, direction of pull of the lateral crico-arytenoid muscles. Action: rotation of arytenoid cartilage about the articulation which is in the centre; adduction of the true vocal cords.

p (Fig. 3), direction of pull of the posterior crico-aryte-

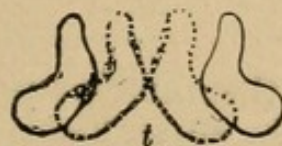

FIG. 5.

noid muscles. Action: rotation in opposite directions; abduction of the true vocal cords.

t (Fig. 3), direction of pull of the transverse arytenoid muscle. Action: horizontal approximation of arytenoid cartilages without rotation.

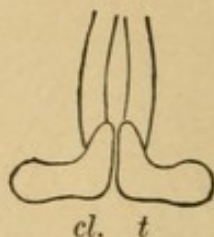


FIG. 6.

Schema of the combined action of the adductor and transverse arytenoid muscles: rotation inward of arytenoid cartilages until the vocal processes come in contact with each other and even the posterior portions of the cartilages are approximated, resulting in closure of the glottis cartilaginea. The glottis ligamentosa is still open. Closure of the latter is accomplished only by the coöperation of the internal thyro-arytenoid muscles (see Fig. 7).

The inner edges of the cords still present a wavy outline; that is, they are slack, for they cannot be stretched taut until *both* points of attachment are fixed in opposite directions. Fixation of the posterior point (arytenoid cartilage) has already been effected by the action of the

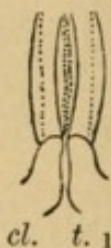


FIG. 7.

above muscles; to fix the anterior point (thyroid cartilage) the cricothyroid muscle must be contracted. Both parts of the glottis are now seen to be closed and the true vocal cords are taut (Fig. 8).

The movements of the arytenoid cartilages in the perpendicular plane are not important for a study of their

function. These movements result from the irregular curve of the crico-arytenoid articulation, which is highest at the center and slopes away outward and backward, and inward and forward, so that the apices of the cartilages are brought into higher or lower planes during motion.

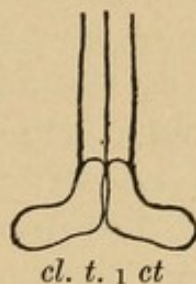


FIG. 8.

The *covering* of the larynx consists of mucous membrane of varying thickness, containing acinous glands, found chiefly where the submucosa is thick and loosely attached to the underlying tissue. They are especially numerous about the upper margin of the posterior surface of the larynx, in the ventricular bands, and in the ventricles—in fact, in all those parts which are most concerned in deglutition and phonation. The mucous membrane is closely adherent to the free edges of the true vocal cords, whereby it is enabled to take part in their vibrations. Here and on the under surface the mucous membrane forms thin strips, running for the most part in the sagittal plane, in some places forming a network which, in vertical transverse sections, appears as papillæ (see Plate 36, Fig. 3). It is important to know this so as to avoid mistaking these structures for pathological formations, and also because they explain why papillary neoplasms are so apt to form in this situation. Their similarity to the papillæ of the skin is very marked, and the propensity of both varieties to form horny epithelial warts is therefore readily understood.

In the epiglottis we also find true lymph-follicles, which we must be careful not to confound with miliary tubercles, if they are at all well developed.

The upper layer of the mucous membrane is composed of epithelium, as elsewhere. On the parts nearest the fauces it consists of stratified squamous cells in layers of varying thickness. Squamous epithelium, then, is found on both surfaces of the epiglottis, on the upper surfaces of the aryepiglottidean folds—in short, on what is known as the superior aperture of the larynx, and also extends from the central portion of the arytenoid cartilages to the true vocal cords. On the edges of the cords the mucous membrane consists of a smooth layer which fills up the interstices; sometimes it follows the elevations and depressions, so as still more to simulate the appearance of papillary neoplasms. The remaining parts of the mucous membrane are covered with the characteristic ciliated columnar epithelium of the air-passages.

The *innervation* is supplied exclusively by the pneumogastric. One branch, the superior laryngeal nerve, is given off opposite the angle of the jaw, and divides above the hyoid bone into two branches: the external laryngeal branch, containing motor fibers, which descends along the side of the thyroid cartilage to supply the thyro-epiglottideus and cricothyroid muscles; and the internal laryngeal branch, which pierces the thyrohyoid membrane about the middle of the upper border of the thyroid cartilage and supplies the entire mucous membrane of the larynx with sensory fibers.

The second branch, the inferior or recurrent laryngeal nerve, follows a different course on the two sides of the body. The right recurrent nerve arises at the level, and in front, of the right subclavian artery, around which it winds from before backward, ascends between the trachea and the esophagus, enters the larynx at the lower border of the cricoid cartilage and distributes its fibers to the muscles.

The left recurrent arises at the level, and in front, of the arch of the aorta, winds around this structure, also from before backward, and ascends a little in front of its fellow—that is, rather beside than behind the trachea—to enter the larynx in the same way as the right recurrent.

This condition explains why aneurysm of the aorta preferably affects the left, and cancer of the esophagus the right recurrent nerve.

The recurrent laryngeal nerves supply all the other muscles of the larynx (in addition to those already mentioned); they may supply the thyro-epiglottideus muscle instead of the superior laryngeal nerves, just as the latter in some cases supply the transverse arytenoid muscle instead of the recurrent laryngeal nerves.

The fibers of the recurrent laryngeal nerves present some differences in their physiological action, some supplying the muscles which effect closure of the glottis and stretching of the true vocal cords, while others supply the dilators of the glottis, the posterior crico-arytenoid muscles. In lesions of the nerve-trunk the latter fibers suffer first, so that we have at first paralysis of the abductors and secondarily paralysis of the adductors.

The sensibility of the larynx varies in different situations; it is greatest in the interarytenoid space; hence diseases of this part are so troublesome on account of the intense pain and constant irritation and desire to cough; even superficial irritation in this region may give rise to attacks of convulsive cough (see Plate 18, Fig. 2).

The center which presides over the movements of the larynx is found, at least in animals, at the base of the ascending frontal convolution. From this point the fibers run through the inner capsule to the medulla oblongata. Systemic diseases involving these areas must therefore have an injurious effect on the action of the larynx.

METHODS OF EXAMINATION.

(1) INDIRECT LARYNGOSCOPY WITH THE MIRROR.

The laryngoscopic image, as is well known, is inverted or, in reality, only half inverted, since in the mirror which is held at an angle of about 45 degrees to the plane

of the arytenoid cartilages, ignoring the cuneiform, which merely follow the movements of the former passively.

The external surface of the posterior wall forms the anterior boundary of the entrance to the esophagus; at the sides the latter opens into the sinus pyriformes, *s.p.*

Within the larynx the glottis, *g*, extends between the true vocal cords, *c.v.*, the ligamentous portion, *p.l.*, forming the anterior two thirds, the cartilaginous portion, *p.c.*, the posterior third; the lumen of the glottis, of course, varies with the position of the vocal cords.

Above the true vocal cords (whose normal color is a dull yellowish-white) lie the ventricular bands, ligamenta thyroidea superiora, *l.t.s.*, their under surface projecting into the ventricle of the larynx, *v.M.* (ventricle of Morgagni).

Marked prominence of the ventricular bands produces apparent narrowing of the true vocal cords (Plate 3, Fig. 1).

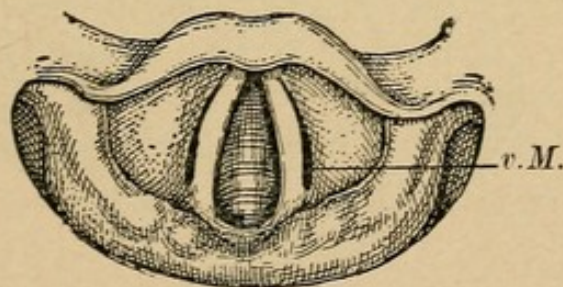


FIG. 10.

If, on the contrary, they recede unduly, the interior of the ventricle, *v.M.*, is exposed. The anterior surface of the cricoid cartilage can also be seen in this image, and, through the glottis, the front of the trachea and its rings. If the glottis is opened exceptionally wide, the deepest parts of the trachea and the bifurcation come into view (Plate 1, Fig. 2); sometimes it is even possible to look into the bronchi. On the other hand, part of the larynx is sometimes hidden, especially in children, in whom the epiglottis is frequently curved in the shape of an Ω , so that one has difficulty in seeing the true vocal cords even

(Plate 2, Fig. 1). In some cases the larynx may be so obliquely placed—either from pathological causes or as an individual peculiarity—that it partly disappears under the epiglottis (Plate 2, Fig. 2); in others, abnormal growths may cut off part of the image above (Plate 2, Fig. 3; Plate 16, Fig. 1) and behind (Fig. 15).

Ordinarily the light strikes the larynx from behind; but in Killian's posture, where the operator applies the mirror from below, making the patient bend well forward, the image is taken more from the front. Consequently more is seen of the lingual surface of the epiglottis and less of the anterior portions of the true vocal cords; on the other hand, their posterior attachment can be plainly seen, as well as the entire front of the cricoid cartilage, but no part of its posterior surface (Plate 1, Fig. 1).

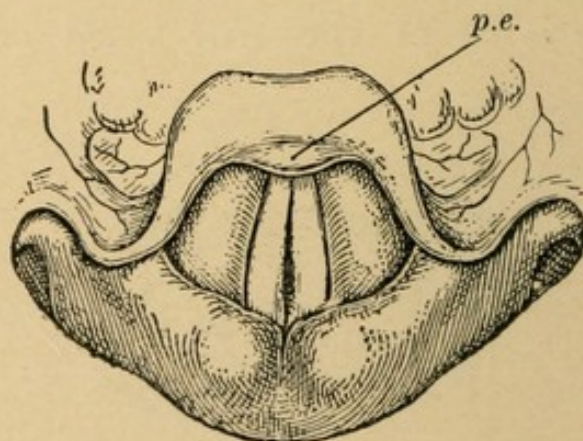


FIG. 11.

In *phonation* (Fig. 11) the epiglottis is raised in front, so as to bring the petiolus, *p.e.*, into view. The arytenoid cartilages approach each other, so that the interarytenoid space almost disappears; the true and the false vocal cords also approach the median line and lie in so-called juxtaposition. The glottis is reduced to a narrow, spindle-shaped chink which is barely visible, the posterior extremity coming in relation with the vocal processes. This is the image of the so-called chest-voice.

In the production of head or falsetto notes the glottis is even more tightly closed behind, but gapes wide apart in

front (Figs. 12 and 13). This posterior closure reaches its highest degree in the production of so-called abdominal notes—ventriloquist's voice (Fig. 14), in which the convulsive contraction of the adductors may even result

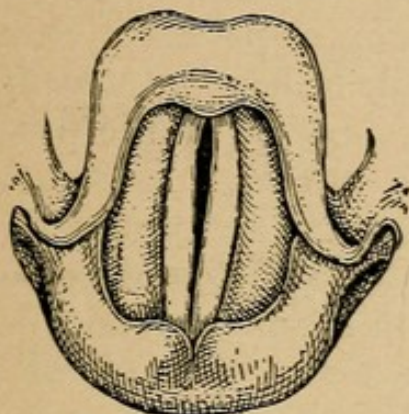


FIG. 12.

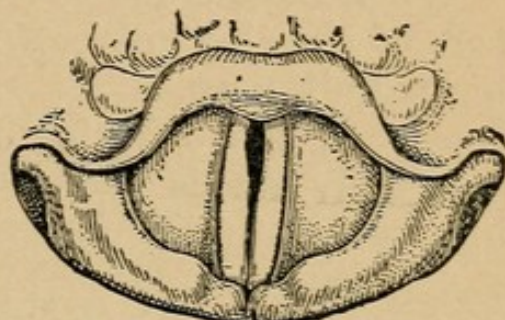


FIG. 13.

in overlapping of the true vocal cords in their posterior half. At the same time the arytenoid cartilages are pressed tightly together, and the true vocal cords appear somewhat narrower on account of the projection of the inner edges of the ventricular bands.

If for any mechanical reason the true vocal cords cannot be stretched, it occasionally happens that the superior thyro-arytenoid muscles contract violently and stretch the

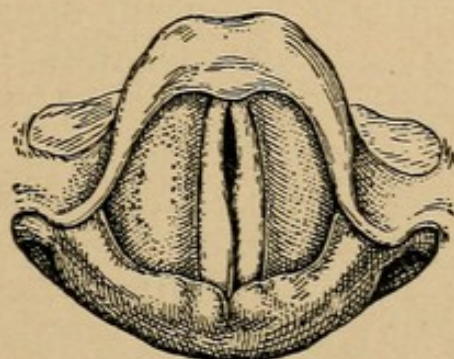


FIG. 14.

ventricular bands to such a degree that their inner edges are thrown into vibration by the air-current—resulting in so-called false vocal-cord phonation; the true vocal cords are, of course, entirely concealed.

(2) DIRECT LARYNGOSCOPY.

This method was introduced by Kirstein, and has the advantage that the larynx is viewed directly. A specially constructed, grooved compressor is used to press the tongue forward and exclude it from the field of vision, the patient holding his head as high and as far back as possible.

When the method can be used at all, it has the advantage of showing more of the anterior surface of the posterior wall than is the case with the mirror. It is also free from the objection of having the image partly obscured by mucus and foreign material, a factor of some importance in the examination of children and unconscious patients; indeed, for the latter the method will probably always be indispensable. For the rest, its indication and its application are still in the experimental stage.

Whatever method of examination be used, reflected light is preferable to direct light, which is always more or less cut off by the head of the operator; we therefore use a reflector which is fastened either to the operator's forehead or to a stand constructed for the purpose.

Any strong light will do for the source; the choice will therefore depend on the conveniences at hand. One disadvantage which is common to all is the color; it is least in the electric arc light or in Auer's gas-burner.¹ The latter was used for all the laryngeal images illustrated in this work. If it is especially desirable to obtain the natural color in any particular case, or if, in general, sunlight is easily obtainable, it will be found to be decidedly the best light. In order, however, to minimize the changes incident to the different times of the day, and at the same time to diminish the glare, it will be best to let the sunlight fall first on a large reflector, after it has passed through the window, and from that by the ordinary reflector into the larynx.

¹ [The Welsbach light, the mantle being pure white, used in conjunction with a condensing lens, is certainly unexcelled, if not unequalled, in its color and illuminating power, by any other artificial source of light.—Ed.]

Laryngoscopy is, of course, the principal method of examining the larynx, as it gives results which can be studied directly; still we must not entirely neglect other methods which formerly constituted the only means of arriving at a diagnosis and even now have not entirely lost their value. We refer to *external inspection*, *palpation*, and *auscultation* of the voice and possible adventitious sounds.

(3) INSPECTION.

By inspection we note unusual shape, and especially displacement of the larynx, usually due to lateral pressure by tumors in the neck. The cartilages are sometimes displaced far to one side, or even close to the angle of the jaw, the line connecting the upper notch of the thyroid with the center of the lower border being oblique instead of perpendicular.

(4) PALPATION.

Palpation informs us whether the two halves of the thyroid cartilage are *symmetrical*. It sometimes happens—as an abnormality, however—that one half is pushed back under the other, with the result that, instead of a well-defined line of junction in front, we feel two surfaces meeting the median line of the neck at different angles, one overlapping the other, so that the finger sinks into an obtuse angle facing sideways.

Irregularities on the surfaces of the cartilages are more significant, the surfaces being normally smooth. Such irregularities may indicate a perichondritic or a chondritic process, or the effects of one; sometimes tumors, especially malignant growths, betray their presence in this way: here, as elsewhere, cancer often manifests itself in prominent, nodular, dense infiltrations. If, however, a marked condition of this kind be felt by the examiner, he should not immediately pronounce the tumor a malignant growth, for syphilitic perichondritis presents a very similar picture; and if no signs, or, at least, no positive signs, are found within the larynx, it will be advisable, as a

matter of routine, to take that possibility into consideration. Miraculous cures are sometimes effected by such "perfunctory" reasoning and corresponding line of treatment.

Under certain conditions palpation may play a prominent part by enabling one to determine paralyses which could not otherwise be recognized. In total paralysis of the recurrent nerve, or at least in complete phonatory paralysis, the normal vibration of the thyroid cartilage may be absent on the affected side; the value of palpation is obvious in such cases, especially if laryngoscopy is impossible.

In paralysis of the cricothyroid muscle the normal vibration of the cricothyroid membrane and the approximation of the lower border of the thyroid and upper border of the cricoid cartilages, normally felt in phonation, are absent.

If the posterior portion of the upper border of the thyroid is compressed and the entire organ moved about with the fingers, *crepitation*, produced by the rubbing of the posterior wall against the spinal column, is felt. This crepitation is distinguished from pathological crepitation by its disappearing if, during the movement, the entire larynx is drawn forward. The phenomenon occurs pathologically, so that it can be both felt and heard, in arthritic processes affecting the crico-arytenoidean articulation. (For details see below.)

It seems superfluous to say that sensitive spots must always be felt for; it is important, however, to warn against pronouncing as pathological the extreme sensitiveness of the superior laryngeal nerves, which enter the larynx at the center of the upper lateral border of the cricoid cartilage.

(5) AUSCULTATION

nowadays is practically confined to the sounds heard by the unaided ear in respiration and in phonation. Respi-

ration is normally noiseless, but respiratory sounds are heard whenever the lumen of the upper air-passages becomes constricted. The term stridor is applied to these sounds. They are usually long drawn out, and, if there is marked obstruction, quite loud; they are heard best in inspiration, especially in laryngeal stenoses, but may also be audible in expiration. The reason of this phenomenon probably is that air-hunger in stenosis induces more intense inspiration, while the excessive CO₂ production is not so distressing, and therefore does not excite expiration to the same degree. (This difference, of course, disappears in severe stenoses, which tend to accelerate even the slower expiratory blast.)

We must not forget that it is also possible for the movable parts about the aperture of the larynx to be drawn down into the constricted lumen during inspiration (by a sort of suction); while, of course, expiration can only blow them out into the open space beyond.

It happens not infrequently that the respiratory efforts lead to perverse innervation of the larynx and consequent approximation of the true vocal cords, which only aggravates the stenosis. Pure expiratory stridor is probably always due to such false innervation.

Although it may be possible to distinguish between laryngeal and tracheal stenosis by direct auscultation with the stethoscope, it is both easier and surer to make the diagnosis by direct inspection.

In rare cases a rattling noise is heard in respiration, or even in phonation, produced by some obstruction to the air-current—a foreign body free to move up and down, a very movable tumor, or movable secretion.

It is important to note the *voice*; a practised ear can make a diagnosis by the voice alone. Complete aphonia, in which the patient cannot speak above a whisper, occurs in paralysis of the muscles which close the glottis and stretch the cords, in nervous or in muscular affections, in paralysis of both recurrent nerves, in violent acute catarrh, and in destruction or rigid infiltration of the muscles of

the cords from any cause. Rough (raucous), croaking, or grunting sounds are heard mostly in tertiary syphilis; a hoarse, discordant voice, especially in the second stage of the disease. In subacute and chronic catarrh the dysphonia often alternates with better, more sonorous tones. There are, besides, many minor shades of difference.

The examination is by no means complete even after laryngoscopy and all the other diagnostic methods of ascertaining the condition of the larynx have been exhausted. Only a few unimportant affections of the larynx are independent of systemic disease or of disease of neighboring organs.

Since, then, the interpretation of doubtful cases will always depend largely on examination of the contiguous parts of the air-passages, especially the fauces, of the alimentary canal, and of the entire body, it is always best, in the absence of a very large experience, to make a careful general examination in order to check even such local findings as seem to be perfectly clear and easy to explain; not infrequently a preconceived opinion concerning the primary cause of the disease is in this way shown to be erroneous. The examination cannot be too thorough: in no other organ of the body is disease so dependent on the general condition as in the larynx, and, conversely, the finding of certain conditions in the larynx often throws light on latent or obscure processes in the entire organism. The importance of these remarks will be better appreciated after a careful study of the histories accompanying the plates.

PRACTICAL HINTS FOR THE EXAMINATION.

A perfect technique in the examination of the larynx in the living subject is only achieved by constant practice, and it is not to be supposed that any one would expect to learn it by theoretical instruction; we therefore assume that the reader has often made the examination on dead and living subjects. As the latter usually com-

prise the individuals used in clinics, who have been drilled for passive laryngoscopy, and the few patients who, from having been through the ordeal so often, are readily examined even by beginners, we need hardly say that the difficulties encountered in private practice are incomparably greater; in most cases the physician is confronted with organs which have never been examined and are extremely sensitive. In order to enable the beginner to overcome these difficulties a few *practical hints* may not be unwelcome.

In the first place, it is always better to make the examination *before* meals; there is less danger of vomiting and, if it does occur, it will do less damage to either party.

Have the patient *protrude* the tongue *actively*, not draw it out with his fingers; and then hold it yourself rather than risk the annoyance of having the patient release it at the most interesting moment.

If the tongue is so thick, or the lower incisors are so sharp, that there is danger of excessive friction of, or even injury to, the frenum, the soft parts should be protected by placing a thick strip of cotton over the teeth. If this is put in place with a forceps after the tongue is drawn forward and before it is drawn down, it will not slip off.

If the root of the tongue bulges upward, it will often have to be pressed down with a spatula (a Türck's, if possible) before a view of the uvula can be obtained. Compress *gradually*, not with a sudden violent movement, using, however, *considerable force*: firm pressure is easily borne, whereas timid little dabs only tickle the organ. This precaution, by the way, should also be observed in laryngoscopy with the spatula after Kirstein.

The mirror is to be held gently but *firmly* against the uvula; not above it or to one side. If it slips past the mirror, use a larger one; in general, the largest possible mirror is always advisable because the light is stronger and the image larger.

If the patient chokes before the mirror is in place, or even at the first touch, make him say "a" as in "fate" (not "ah") very loud and long, and introduce the mirror during phonation.

It is absolutely impossible to see the image if the patient holds his breath convulsively: the larynx is drawn high up under the root of the tongue, the pillars of the fauces are stretched to the utmost, and the glottis is closed. Many patients do this as soon as they open their mouths and put out their tongues. In such cases, before attempting to introduce the mirror, have the patient take long, deep breaths with the mouth in the proper position to receive the mirror, until the respiration is no longer disturbed by the introduction of the instrument. Psychological irritability is sometimes diminished by *closing the eyes*, but they must not be shut convulsively, lest it cause the oral cavity to become narrower.

Remember that the tendency to choke is constantly aggravated by accumulation of saliva from excessive reflex secretion; the patient should therefore be allowed to expectorate, *without hawking*, as that only aggravates reflex sensibility. By this means and by suitable encouragement one can also prevent constant swallowing, which is so troublesome and dims the mirror every time.

Never, not even for practice, have the patient say "ah," but always "a," as the epiglottis is only raised in high-pitched notes, and often a mere trial-examination affords a satisfactory view of the larynx.

If, as happens in rare instances, the epiglottis even then fails to rise and expose the larynx, a slight pressure and forward pull with a long spatula (Fränkel's, for instance) on the median fold of the glosso-epiglottidean ligament will bring about the desired result.

Choking and vomiting are sometimes so excessive that they can only be overcome by painting the parts to be touched with cocain. A pledget of cotton the size of a pea does not hold enough of the 10 per cent. solution to make an application to the mucous membrane at all dan-

gerous.¹ At least three minutes should be allowed for the anesthetic to take effect: if it fails to act, it is usually because there has not been time enough.

The choking depends more on subjective resistance than on objective impossibility to overcome the irritation: many patients will only become quiet after a touch with a probe has convinced them that anesthesia is complete.

The reflector should always be held *in front of the eyes*, not merely on the forehead, else a part of the light is sure to be intercepted by the upper lip. Use both eyes, not only the one behind the hole. It is not enough to examine the phonatory image only; the condition in respiration should also be studied, although it is harder to see than the former.

If the case is at all doubtful, do not neglect to ascertain the sensibility by testing with a probe. Remember that the larynx forms only a part of the air-tube, and that the lungs and trachea, as well as the upper passages, the nose and throat, may furnish as important data for the diagnosis as the heart, the abdomen, the nervous system, and the urine. Above all, bear in mind that disease of one organ is not always isolated, and that you are first a physician and then a laryngologist.

As regards treatment, I would add a warning against annoying the patient more than the whole trouble is worth. Often the patient cares less about getting rid of a slight annoyance than the physician, who feels himself in duty bound either by ambition or the love of science. Let us be kind and noble as well as helpful!

GENERAL REMARKS ON THE CAUSES AND TREATMENT OF DISEASES OF THE LARYNX.

Painting the throat and gargling will not cure a diseased larynx, but suitable general treatment, even without

¹ [Putting aside the question of danger, we do not think it necessary to use a solution of such percentage. One of 4 per cent. strength will produce all the anesthesia necessary to make the examination successfully.—ED.]

local applications, may accomplish a good deal, and it is the latter that is too often neglected. A patient suffering from laryngeal trouble should not be allowed to talk, any more than a man with a sore foot is allowed to walk : the first requisite for the cure of an inflamed or injured organ is *absolute rest*, which incidentally removes one of the commonest causes, overexertion. Loud talking should, therefore, be forbidden altogether ; the patient should converse as little as possible and always in a whisper.¹ The only exceptions are certain psychical or essential paralyses, when it is desired to restore the functional activity of the organ.

Smoking and drinking, and the eating of highly seasoned food, must be restricted or prohibited entirely, at least in the acute and subacute stages.

The *digestion* must be *regulated* ; this is of no small importance, as constipation tends to aggravate peripheral hyperemias.

Cough due to disease of higher or deeper adjoining organs (nose and throat, lungs and bronchi) must be checked as much as possible, for it is one of the worst mechanical irritants of the larynx.

Still more injurious is the hawking so often excited by disturbances of secretion in the upper air-passages (nose and nasopharynx). Combined with the dripping of pus and mucus on the larynx from above, it is one of the commonest causes of the various forms of "chronic laryngeal catarrh." The first step in the treatment of this disease, therefore, should be a careful examination of the upper organs ; often the entire treatment may consist exclusively in removing anomalies in those organs.

Local treatment is indicated : *first*, in the comparatively rare primary diseases of the larynx ; *secondly*, whenever mechanical alterations require mechanical interference.

Liquids, especially astringents, should be applied di-

¹ [If even the privilege of whispering is permitted, it is too often apt to be abused. Besides, whispering is but little, if at all, less objectionable than actual phonation.—ED.]

rectly by means of a brush or syringe; inhalations are generally useless. Nitrate of silver in 2-5 per cent. solution, 2-4 per cent. carbolic-acid solution, and concentrated lactic acid are used.¹ Ichthyol is an excellent remedy in secondary catarrh and in scab-formations: R_y. Ammon. sulpho-ichthyol., 10.0; glycerin., 40.0; 1. menth. pip., gtt. v. It is best applied with a pledget of cotton at the end of an applicator; the pledget is thrown away and the applicator boiled after using. Spraying is not necessary, as a rule; its use is more a matter of taste.

The pledget of cotton is pressed lightly against the epiglottis from behind, so that the fluid drips down; or it is introduced into the open glottis during respiration, when its contents are squeezed out by the approximation of the cords. Painting—that is, mechanical rubbing in—is injurious, and should be avoided except in the treatment of ulcers with carbolic acid or lactic acid, when it should be done energetically and thoroughly.

For an astringent dusting-powder use alum 1 : 10, with sach. lact. or amyl trit. For disinfectants the iodine preparations, iodoform and iodol, are principally used.

Dusting with these and other similar powders is confined to open ulcers; in general, it is to be remembered that deep-seated and grave diseases, especially tuberculosis, will not yield to such superficial and wholly inadequate treatment, but demand more energetic destructive measures. The mildest form is *cauterization*. Lunar caustic fused upon the end of a probe, or trichloroacetic acid, will serve for cauterizing superficial ulcers of every kind, and even for more energetic procedures against hypertrophy of the epithelium, so common in chronic inflammations.

Electrolysis is a more drastic measure. The duration as well as the intensity of the dose can be regulated. A current of 15-20 ma. for five minutes is the usual dose.

¹ [For the less experienced reader it may be well to state that the use of lactic acid had better be begun with a 50 per cent. solution and the strength gradually increased. For the earlier applications previous cocaineization of the larynx will be a wise precaution.—Ed.]

The requisites are an ampèremeter and rheostat to measure the strength of the current and to introduce and remove it without causing pain. Ten to fifteen cells suffice for its generation. It is applied with the double needle, stabbing deeply after the parts have been well cocainized. It is best to screw the needle directly to the conducting wires. The treatment is used to remove secondary epithelial hyperplasiæ (warts, "pachydermiæ"), and especially in small tuberculous infiltrations; sometimes also to melt out the base of a previously extirpated ulcer.

Galvanocautery is still more heroic. The sharp-pointed stabbing cautery is a powerful tissue-destroyer. It is therefore properly used in nodular tuberculosis and in deep ulcers. As the reaction is more severe than in electrolysis, great care must be exercised in its application; only the diseased parts must be touched, and one must be especially careful to avoid burning the surface. The loop may be successfully used to remove pedunculated, hard tumors or such as threaten hemorrhage.

Sharp instruments are used to separate or excise diseased parts.

Operating-knives, either sharp-pointed or blunt, with a cutting-edge, are employed to make incisions in edematous or purulent swellings and to remove flat ulcers.

Curets, single and double, Heryng's or Krause's, are used to remove diseased parts from healthy tissue, especially in tuberculosis, and to expose deeper infiltrations so that they may be cast off more easily.

If curettage is resorted to at all, it must be done thoroughly, down to the healthy tissue; it is, therefore, indicated only when there is reasonable hope of success. Furthermore, the operation should be exhaustive, and completed at one sitting, not split up into innumerable little pickings. Many failures are attributable to such senseless and ineffectual methods.

The use of the numerous instruments devised for extirpating tumors (loops, tonsillotomes, forceps, annular knives, etc.) can only be learnt by practice.

In all kinds of instruments the shaft should be bent to the right near the handle, so that the operator's hand does not encroach on the field of vision. The handles themselves should be flexible. Frequently it is impossible to reach the deeper and more remote parts of the larynx with certainty, unless the handle of the instrument has been previously bent in the proper direction according to measurements obtained by means of a sound, because the oral cavity limits the play of the instrument.

Muscular and nervous paralyses occasionally require electrical treatment to prevent the occurrence of atrophy; peripheral nerve-lesions, if amenable to treatment at all, also appear to be favorably influenced by electricity. Whether the electricity is applied to the larynx internally or externally is a matter of taste. A faradic current, strong enough to produce powerful, but not painful, contractions in the tongue, is applied for from one-half to one minute once daily; or a galvanic current of 5 ma. internally and 10-15 ma. externally, from one to three minutes, with change of poles and interruption. Great care is necessary to avoid burning the delicate mucous membrane; therefore use broad electrodes.

To remove transient or chronic stenoses we employ intubation after O'Dwyer, dilatation with bougies or tin bolts after Schrötter (the latter only after tracheotomy), and finally the insertion of chimney-shaped cannulæ after Mikulicz in thyreotomized larynges. But good results are often obtained without these complicated appliances in less marked stenoses and membranes, by forcing successive tampons of increasing thickness through them, especially if the treatment can be assisted by bloody dilatation.

PATHOLOGY AND TREATMENT.

I. ACUTE INFLAMMATIONS.

1. SUPERFICIAL INFLAMMATIONS.

(a) Idiopathic.

This division includes all inflammations which directly attack the larynx in consequence of unfavorable external influences, though they may be synchronous with disease in other parts of the body.

First in order is simple catarrh, a frequent accompaniment of coryza.

Etiology.—Catching cold, especially if the patient forces his voice in defiance of noticeable impairment, or persists in the use of tobacco and alcohol. Inhaling irritant gases or dust (street-dust in windy weather, brick-dust, dust of chromic acid, spices, and similar materials in factories and warehouses).

Symptoms.—Dryness of the throat, slight difficulty in swallowing and in speaking, hoarseness (rough, deep voice) or complete aphonia. At first there is slight cough, which soon becomes more severe; it is dry and irritating, and secretion is still scanty; later, when the secretion has become looser and more copious, it is brought up more easily and with less irritation, at the same time slight râles may be heard. The breathing is shallow, as deep inspiration excites cough. The subjective symptoms vary a good deal according to the principal seat of the disease.

Laryngeal Image.—Inflammation and slight swelling of the entire mucous membrane or of single areas. Later a glairy secretion is seen, and, rarely, toward the close, a

yellowish secretion. Depending upon the seat of the inflammation, the epiglottis and, perhaps, the aryteno-epiglottidean folds as well, are seen to be inflamed (especially after thermal irritation, when dysphagia is the principal symptom), or the ventricular bands (see Plate 8, Fig. 2), or the true vocal cords, either in their whole extent (Plate 9, Fig. 1) or only in part (Plate 8, Fig. 1), in which case dysphonia is the principal symptom. In very rare cases the appearances are confined to the interarytenoid space (Plate 19, Fig. 2), when the voice may be perfectly clear; while, on the other hand, cough is incessant and uncontrollable, causing great discomfort to the patient. Occasionally the mucous membrane of the under surface of the true vocal cords becomes swollen, especially in children, a condition which is aptly designated as laryngitis hypoglottica (pseudocroup).

In some cases the hoarseness is caused by impaired vibration of the thickened true vocal cords, in others by insufficiency of the muscles concerned in phonation, either from inflammatory infiltration or from neuritis. We therefore meet with the picture of paralysis of the internal thyro-arytenoid muscle (Plate 9, Fig. 1), or of the transverse arytenoid (Plate 8, Fig. 1), or of both together (Plate 8, Fig. 2); quite frequently also that of the lateral crico-arytenoid muscle (Fig. 6).

The inflammation, whatever may be its seat, sometimes goes on to exudation within the mucous membrane, resulting in slight edema; the true vocal cords then appear round like sausages. The integrity of the blood-vessels may be impaired by the inflammatory process, so as to give rise to small hemorrhages, especially during a paroxysm of coughing; these hemorrhages appear as blood-red, and later as black spots in or upon the mucous membrane. The delicate organs of singers are particularly liable to suffer in this way after functional abuse. In other cases, especially in cases of long duration, the epithelium may be softened by the inflammatory infiltration and cast off. If this process is confined to the surface, dull whitish

specks appear; but if the desquamation reaches the mucosa, shallow yellowish depressions, so-called *erosions* (see Plate 11, Fig. 1), result, which may become at times quite extensive.

Prognosis.—Spontaneous cure if the voice is allowed to rest; if it is overexerted, and no care is taken to avoid fresh exposure, chronic inflammation develops.

Treatment.—At first only general, *no local treatment*: sweating, regulation of the bowels, Priessnitz bandage about the throat; talking and smoking to be forbidden; lukewarm, non-irritating food and drink. Later—after ten to fourteen days—perhaps painting with a 2–4 per cent. solution of nitrate of silver; in the hemorrhagic form or in erosions *dusting* with aluminis crudi 20.0, sach. lact. 30.0, dose 1–2 gr. In the last two conditions the use of the voice must be strictly prohibited.

If the erosions persist a long time, they may be cauterized *once* with solid nitrate of silver, but on no account are they to be painted. Violent cough may demand morphin (0.1 : 15.0 aq. dest., 10–15 drops three times a day).

Acute catarrh in children presents some peculiarities. The secretion is scanty and there is constant, dry, barking cough. Swellings in the ventricles, causing actual stenosis, combined with the extreme reflex sensibility characteristic of childhood, bring on disturbances of respiration in the form of choking fits; they are also caused by perverse innervation of the adductors of the glottis. The similarity of these symptoms to those of diphtheria suggested the term *pseudocroup*, but the term *catarrh* is anatomically more correct. The attacks of stenosis are best controlled by a cold douche in a warm bath. The bowels must be carefully regulated, better a little diarrhea than constipation. Give 2–3 knife-points daily of pulv. glycyrrh. comp.

(b) *Symptomatic catarrh* is met with in all the acute infectious diseases. As it is associated both in time and in situation with other anatomical alterations, partly specific in character, it will be treated with these separately.

2. EXUDATIVE INFLAMMATIONS.

(a) **Diphtheria.**

Etiology.—The Löffler bacillus is now universally acknowledged to be the cause of this inflammation. Its action, however, undoubtedly depends on individual disposition and usually on predisposing external causes. Though the latter may not be absolutely essential, they furnish the only explanation for the cases being most numerous in winter, in regions characterized by sudden changes in temperature and under unfavorable hygienic conditions. The latter must not be understood to mean only poverty; poor children in the country are often better off hygienically than rich children in the city, and the want of cleanliness among the latter may be as great as in poorer families.

Morbid Anatomy.—The first manifestation of the morbid process is an exudation of lymphatic elements from the blood-vessels. These migrating cells soon undergo coagulative necrosis and lose their structure, so that nothing remains but a reticulated infiltration, consisting chiefly of fibrin from the broken-down cells. According to the gravity of the case and the point of entrance of the poison, this network of fibrin penetrates only the epithelium and superficial, or even deeper, layers of the mucosa. At first there is a line of demarcation between the necrosed and the living parts, and then the former are cast off. As the infiltration spreads out over the surface it comes away in the form of a membrane. If the demarcation has been insufficient, the membranes can only be removed with difficulty and by sacrificing some of the living tissue; in the contrary case they are easily removed. That demarcation occurs more easily in superficial infiltrations is self-evident and explains why the latter separate more easily; hence there is no fundamental difference between removable and non-removable membranes.

If the blood-vessels are affected by the violence of the morbid process to such an extent that the nutrition of the

parts suffers, either from injury to the walls and consequent impaired metabolism, or from thrombosis, extensive areas of the mucous membrane die off, and we have the so-called gangrenous form. In the milder forms the membranes often present a shining white, or occasionally a cloudy, yellowish appearance; the dreaded green and black discolorations, on the other hand, are due to admixture of necrotic blood-corpuscles by the above-mentioned process. The *appearance* of the diseased parts, therefore, varies. In the beginning the mucous membrane is only slightly inflamed, soon it becomes covered with single, opaque, whitish streaks or circular spots, or even with a broader ring of a delicate bluish-white. Later the spots run together to form larger opaque areas, white or yellowish-white in color. They may appear in any part of the larynx; sometimes the entire organ is covered, especially in complications with disease of the trachea and bronchi. After the adhesions become loosened they separate in the form of shreds or membranes, or even regular tracheal casts.

General Symptoms.—During the onset the symptoms are general: a feeling of discomfort, lassitude, loss of appetite, constipation, slight difficulty in swallowing, and hoarseness. If the true nature of the disease is not already apparent from the appearance of the throat, it is often revealed by a dry, barking cough accompanying the first indications of laryngeal disease. Laryngoscopy, if it be possible, will even at this stage show the beginning of membrane-formation.

The temperature is like that in continued fever, with slight morning remissions; sometimes with greater fluctuations, according to the progress or abeyance of the morbid process. In the most severe cases, the septic ones, the temperature may be normal or subnormal.

The voice is affected in the mildest cases; usually it becomes quite toneless—after the membranes come away, sometimes rough and deep, or shrill, in rapid alternation. The respiration is always disturbed even to the point of

extreme dyspnea, if there is active membrane-formation. The dyspnea shows itself in long drawn-out, sighing inspirations; the head is retracted, and all the accessory respiratory muscles are contracted to the utmost; the skin is both cyanosed and pale, and cold to the touch from cardiac weakness.

The pulse is not characteristic; it merely serves as a manometer to register the general reaction of the body. Partial loosening of the membranes sometimes betrays itself by a rattling noise during inspiration; complete separation is followed by discharge. The latter may occur as the final stage of the process; that is, during convalescence, or in the course of the disease, so that we may have new membranes forming after the discharge of the first.

In addition to the laryngeal symptoms, the throat, and especially the trachea, bronchi, and the parenchyma of the lungs, demand attention. It goes without saying that the general condition, as shown by consciousness or unconsciousness, pulse, reaction to irritants, state of the bowels, must be carefully watched.

The *duration* is usually a week, although sudden death or more speedy recovery is not rare.

Death results either from heart-failure or from CO₂ poisoning, or from both together, since, in the cases with stenosis, the heart-failure is to be attributed as much to interference with the circulation through insufficient ventilation of the lungs and inadequate supply of oxygen, as to the absorption of toxins.

Recovery may be complete or may be followed by sequelæ, particularly in the nervous system: paralysis of the ciliary muscle and loss of accommodation; paralysis of the muscles of the pharynx and esophagus, so that particles of food and liquids regurgitate through the nose and cannot be swallowed; of the sensory laryngeal nerves, causing the patient to swallow into the respiratory tract; and finally of the motor laryngeal nerves which may result in prolonged paralysis of the true vocal cords (see

Plate 13, Fig. 2). The life of the patient may even be threatened by paralysis of the phrenic or of the pneumogastric nerve, resulting in respiratory insufficiency and impaired heart-action; even pareses and paralysees of the extremities are among the possible sequelæ.

Fortunately, however, these nervous disturbances are rare compared with sequelæ in the lymphatic system and in the ear. The latter frequently follow complications of the nose and throat, and are sufficiently important to merit a passing mention; they are—permanent enlargements of the palatine and pharyngeal tonsils and purulent disease of the middle ear.

The **treatment** must be more general than local. The remedy of prime importance is antitoxin. Although it may be years before we can judge of its true value, its evident harmlessness and very successful clinical career justify and even compel its use. Other therapeutic measures must, however, not be neglected, especially such as are indicated by local alterations.

We cannot here go into the treatment required in complications or in primary formations of foci in the throat.

Very little can be done in the larynx itself. In a few cases the membranes may be loosened and wiped away with tampons dipped in lime-water, but this is not often successful, and half-way measures only produce dangerous irritation. *Caustics are absolutely contra-indicated.* The loosening process may be assisted by constant inhalations of moist air, vapor of lime-water being the best; the value of all other remedies, even of the vaunted emetics, is very questionable. Deep breathing and vigorous expectoration may be successfully induced by cold douches. If the temperature is high, the douches may be given in an empty tub; if moderate, in a tepid bath (50° C.) with water at 12°–15° C.

The bowels are to be regulated. Nutrition must be encouraged by giving small doses of stimulating foods and condiments at frequent intervals: beef-tea, chaudéau, egg-nogg, warm beer with the yolk of an egg, biscuits,

boiled chopped meat, plenty of milk, and occasionally, but only when the strength begins to fail, alcohol in the form of somewhat diluted Cognac or good Bordeaux.

If disturbances of the respiration manifest themselves in the form of frequent choking fits or even lasting dyspnea, it is better to interfere too soon than too late. If the bronchi are still open, simple intubation may be sufficient; but if they, as well as the trachea, are already involved and the tubes are in imminent danger of becoming clogged, or if the external conditions (lack of necessary attendants) preclude such measures, tracheotomy is to be preferred. The operation should not be delayed till the stage of asphyxia has set in (cold, cyanosis, deep traction of the diaphragm on the thorax), but even then it should not be omitted.

The author prefers high tracheotomy, because it avoids the thyroid gland, which can be safely separated from the upper margin of the cricoid cartilage by means of Rose's transverse incision. Care must be taken not to injure or divide the cricoid cartilage, as cricotomy is frequently followed by the dreaded granulation which interferes so much with removal of the tubes.

During convalescence disturbances of accommodation must be looked out for as precursors of other paralyses. If paralysis of the esophageal muscles or of the sensory nerves of the larynx supervenes (cough in swallowing), the patient should immediately be fed through a sound or per rectum exclusively; the former method is to be preferred. Paralysis of the vagus is combated with complete rest and digitalis. Strychnin-injections are futile, the paralysis progressing serenely in spite of them.

Symptomatic diphtheria may be due to other deleterious causes, whenever a necrotic process in the epithelium is accompanied by inflammatory phenomena in the mucosa; membrane-formation is therefore not a specific anatomical evidence of such processes. It occurs after scaldings of the larynx through inhalations of steam or irritant gases (ammonia) and in the course of scarlet fever

and small-pox. These affections are therefore identical with diphtheria only in an anatomical sense, and etiologically quite distinct.

It follows that the treatment is purely symptomatic, directed against a possible stenosis: intubation or tracheotomy.

3. INFLAMMATIONS OF THE INTERSTITIAL TISSUE.

These may be divided, according to the kind and degree of the inflammatory infiltration, into simple *edema*, in which a serous exudation into the submucosa is associated with very slight round-celled infiltration, and *phlegmons*, in which cellular infiltration is the prominent feature. Although the two forms may be present at the same time and in the same situation, and be due to the same causes, we are nevertheless justified in making the anatomical distinction, since the treatment will be influenced by the form of the inflammation in special cases. Nor is it superfluous to describe separately simple *laryngeal erysipelas* with its typical general and local phenomena, in order to preserve the analogy with dermatological nomenclature. If we remember that all these varieties are essentially identical when dependent on an *infectious* process, it will help us to form a clear and logical idea of them. Their true nature will be better understood if we divide them into infectious and non-infectious forms.

(a) Infectious Interstitial Inflammations.

(a) Primary Forms.

Etiology.—Invasion by specific micro-organisms: the streptococcus pyogenes, the various forms of staphylococci, the pneumococcus, and possibly the bacterium coli.

The way is opened by inflammations in neighboring organs, especially the throat, the nasal cavities, and the tongue. Entrance is effected either through the lymph-spaces, or through traumatic lesions which may be so

small as to be invisible—such as are produced by a foreign body, for instance.

Metastases through the lymphatic glands and vessels are possible, though very rare.

It is quite unnecessary to construct a specific disease (“infectious angina”) out of any of these inflammations. They are entirely analogous to panaris (felons), erysipelas, and phlegmon on the surface of the body.

Local Phenomena.—In *edema* the swelling is sharply defined, as a rule, yellowish-gray or yellow in color, occasionally reddish and glistening; in the *erysipelatous* form the swelling is similar, but very red; in the *phlegmonous* variety the infiltration is tougher and the outline is more irregular. Collateral edema may occur from pressure on the veins by the infiltration. In rapidly fatal cases it may be impossible to recognize any stages in the local inflammation.

In the final stage there is either gradual reduction of the swelling, or abscess-formation, preceded by a yellowish gathering at one point.

The infiltrations are greatest in the looser tissues, the epiglottis or the investment of the arytenoid cartilages. They usually end where these tissues have their attachment to denser ones; if the latter also become softened, an atypical, but not abnormal, extension of the process occurs.

In the *laryngeal image* the parts involved are seen to be altered by convolutions of various shapes and hues, according to the locality and the variety of infiltration present: the epiglottis swells on one side (Plate 8, Fig. 1), or on both (Plate 7, Fig. 2)—then usually in the form of a turban; the true vocal cords are thickened and resemble sausages; the posterior wall is converted into a thick bolster (Plate 25, Fig. 1). The lumen of the larynx is constricted in various planes, depending on the site and severity of the process; sometimes it becomes completely obstructed, especially in swellings of the ventricles.

General Symptoms.—Fever, ranging from 38.5° to

the highest temperatures, in mild, simple forms lasting several days, with slight morning remissions, in others presenting the jerky type of erysipelas. In cases of longer duration, ending in pus-formation, the temperature presents the irregular character of septic fever; occasionally, in the severe septic forms, the temperature may be very low or even subnormal. The pulse corresponds to the fever: strong and full, or very frequent, small, and compressible. The patient feels very sick; in severe cases we may have the typhoid state. Frequently there are headache and constipation.

Great pain in the throat on swallowing and speaking, a feeling of tension and dryness, constant desire to swallow and, consequently, increased secretion of saliva and mucus.

The inflammatory swelling may spread to the glands and to the connective tissue of the neck; the swelling in the latter is sometimes edematous, sometimes of a board-like hardness. A corresponding affection of the fauces and tongue is usually to be interpreted as a primary trouble.

Dyspnea sets in as soon as the inflammation attacks the aperture of the larynx or deeper parts; it is rarely caused by the epiglottis alone. In the former case there are hoarseness and aphonia.

The **course** is characterized by sudden onset and rapid increase in the symptoms. Dyspnea and suffocation in many cases set in early; in grave, septic cases death sometimes occurs from the toxemia alone, before the occurrence of stenosis. In favorable cases recovery occurs in from a few days to two weeks, with, at times, abscess-formation as the final stage.

The **diagnosis** is based on the sudden onset without previous disease, or immediately after a corresponding inflammation in higher situations, as acute syphilitic disease may present the same clinical picture. The differential diagnosis from typhoid and meningitis is made by the aid of laryngoscopy.

Treatment.—Apply moist bandages to the throat and

have the patient swallow cracked ice ; talking is to be forbidden and the bowels must be kept open. Possible cardiac weakness must be properly treated. If stenosis occurs, resort to deep puncturing of the swollen parts and, if possible, inject a few drops of a 2 per cent. solution of carbolic acid ; early tracheotomy as a prophylactic measure rather than too late.

Always search for the purulent focus and open it as early as possible (phlegmons in the fauces and throat, caries or periostitis of the teeth, abscess on the tongue, etc.).

In all cases where the swelling extends beyond the epiglottis the patient should be kept under constant and careful supervision, as life-threatening symptoms often appear quite unexpectedly.

(β) Any of the foregoing conditions may occur as secondary processes in the acute infectious diseases. They must then be interpreted as mixed infections ; that is, as the products of the above-mentioned inflammatory and pyogenic bacteria, whose entrance was made possible by the specific lesion in the mucous membrane.

Metastatic abscesses occasionally occur. The symptoms are sometimes very pronounced (Plate 6, Fig. 1 ; Plate 26, Fig. 1). Course, diagnosis, and treatment are the same as in the idiopathic form.

(b) Non-infectious Interstitial Inflammations.

The number of these is extremely small, being limited to chemical and thermal lesions. Accidental corrosions (from swallowing caustic lyes or acids) or the therapeutic application of concentrated solutions of nitrate of silver or of chromic acid may produce edema in the affected parts ; it may also occur after scalding of the larynx by the swallowing of hot liquids or the inhaling of hot vapors, or after therapeutic heat-applications. These lesions present in addition other anatomical features, and will therefore be treated elsewhere.

The tissue-destruction brought about by such accidents may in turn give rise to infectious inflammations, so that a division on etiological grounds is impossible in the later stages.

4. INFLAMMATIONS OF THE MUSCLES.

These hardly ever occur as *primary* affections, but they accompany catarrhal or interstitial processes and manifest themselves in pareses or even paralyses of certain muscle-groups. One of the commonest phenomena in acute or subacute catarrh is paresis of the thyro-arytenoid muscles (Plate 9, Fig. 1), next of the transverse arytenoid muscle (Plate 8, Fig. 1); not infrequently the adductor muscles are involved; in fact, any simple or mixed form of paresis may be met with (Plate 8, Fig. 2). The sudden appearance of dyspnea in the course of an apparently mild or interstitial inflammation is sometimes explained by an inflammatory palsy of the abductor muscles. The picture of median, or at least cadaveric, position is not rare in affections of the posterior wall (Plate 22, Fig. 2, and Plate 25, Fig. 1), and simple swellings may produce the same effect by accidental inflammation or collateral edema.

Finally, disturbances of deglutition (mis-swallowing or mere reflex cough) are sometimes attributable to inflammatory palsy of the sphincter muscles of the larynx (all except the cricothyroid and posterior crico-arytenoid muscles) and of the depressor of the epiglottis (thyro-epiglottideus muscle).

Apparent primary "rheumatic" paresis of one or more muscles probably depends less on inflammation than on intramuscular hemorrhages, such as sometimes follow sudden exertion. *Sudden* paralysis occurring in the course of a catarrh may be explained in this way.

The *image* is always that of peripheral palsy.

The disease usually disappears with the primary cause and requires *no treatment*, at least in the acute stage.

5. INFLAMMATIONS OF THE JOINTS.

(a) These may occur as *primary* affections, presenting a clinical picture which is calculated to mask the real condition of affairs. This is true particularly of the very common localization in the *crico-arytenoid articulation*. (The author has never seen a primary lesion in other joints, which, of course, does not preclude their occurrence.) Of the morbid anatomy nothing is known. As in other joints, there is at first probably a serous synovitis which may, of course, run on to a plastic and purulent form.

The **etiology** embraces colds and acute infections. The latter will be assumed in cases which are feverish from the start, especially if they are preceded or accompanied by a lacunar angina. Occasionally the cause may be found in a *traumatism*.

Symptoms.—The patient complains of an odd, uncomfortable feeling on either side of the throat, especially during the act of swallowing; it may also be referred to the angle of the jaw or the hyoid bone, or the glands. It is most pronounced when the patient assumes the *recumbent posture* (passive dorsal), especially if he swallows at the same time. Palpation reveals pain on pressure of the affected side, in the “region of the crico-arytenoid articulation,” the posterior extremity of the upper margin of the cricoid. At the same time that pressure is exerted at this spot the laryngoscope ought to show an inward movement of the corresponding arytenoid cartilage to make the diagnosis certain. Pain is also felt if the region of the joint is touched with a probe from the esophageal side.

If the entire cricoid cartilage is carefully fixed with one hand and the right spot is pressed with the other, crepitation may sometimes be both felt and heard, caused by friction of the inflamed, rough articular surfaces.

Quite frequently *laryngoscopy* shows no alterations. It is only after neighboring parts have been invaded by the inflammation that *periarthritis* manifests itself in swelling

and redness of the soft parts covering the articulation—perhaps even of the posterior portions of the true and false vocal cords. The mobility of the true vocal cords is usually not affected except in very severe inflammations, in which case the motion is *uneven* and *jerky* instead of smooth and gliding; or the parts may even become fixed in any position. It will be impossible to distinguish such cases from paralysis, except in the rare instances where the abnormal position differs from that found typically in paralysis; to distinguish them from perichondritis during life is practically impossible. It follows that only the milder stages are susceptible of diagnosis. For similar reasons purulent synovitis cannot be diagnosed *in vivo*, as the symptoms must coincide with those of phlegmon and attritions.

Treatment.—Priessnitz bandage; rubbing the painful spot with ung. bellad. 15.0, ung. ciner. 5.0, the size of a pea; laxatives.

(b) *Secondary* acute articular inflammation is unquestionably much more frequent than is generally known; it occurs principally as a localization of acute *articular rheumatism*. *Syphilitic* and *tuberculous* processes also attack this region. The former can only be recognized by obtaining a clear history of infection or inheritance; the latter, no doubt on account of the virulence of the specific cause, does not appear to have been met with except in complication with other conditions: swelling and ultimate destruction of the adjoining parts. In all cases where there is *atypical disturbance of movement*, out of all proportion to visible alterations, the cause must be sought in the joint, as well as in a possible dyscrasia, so that (in syphilis) something may yet be accomplished by timely treatment. In all such cases and in cases due to *typhoid* and *influenza* we have to deal more with extensive chondritis and perichondritis and their phenomena than with simple joint-lesions; still it may help to clear up many doubtful cases if the joint itself is carefully considered in the diagnosis.

Prognosis.—Recovery is the usual termination ; occasionally, however, more or less permanent disturbances of movement, without further inflammation, remain in the form of partial or complete *ankyloses*. The former are characterized by imperfect excursion of one or both true vocal cords in *both* directions, or by a variation in mobility—that is to say, fixation is seen in different positions at different examinations—or the ankylosis may betray itself by the uneven, jerky movements, as in acute inflammation. Complete ankylosis can be distinguished from paralysis only when the true vocal cord is fixed in a position which is atypical of muscular or nervous palsy ; ankylosis may be inferred, even when the position is typical of paralysis, if after prolonged observation no local or general cause can be found for peripheral or central paralysis. Periarthritic inflammations, or the remains of such, are characterized by permanent thickening, in addition to the abnormal fixation. Treatment of these ankyloses is usually of no avail. If, however, the true vocal cords are fixed in adduction, an attempt becomes imperative on account of the grave dyspnea. External massage and gradual widening from within are indicated.

The treatment of active processes is therefore the same as that described under the respective heads of those diseases.

6. INFLAMMATIONS OF THE PERICHONDRIUM.

Primary perichondritis is very rare, and is probably the expression of an infectious process which escapes detection. “Rheumatic” forms exist only in the imagination of the perplexed diagnostician.

With more probability the cause has been sought in traumatism which exposed the perichondrium to direct infection or favored its gradual advance.

Secondary perichondritis is more common, either as the direct result of a specific infection or in consequence of a mixed infection after a specific destructive process. Pyemic

metastases, small-pox, and typhoid fever follow the first method; diphtheria, tuberculosis, and malignant tumors prefer the second; syphilis acts in both ways.

The morbid anatomy presents the usual variations; beginning with simple swelling and running on to serous, later to fibroplastic and purulent, cellular exudation, and finally to necrosis. The exudate usually collects between the cartilage and its investing membrane (perichondrium), so that the swelling is at first subperichondral. From there the exudate frequently breaks through to the outer surface, and gives rise to secondary swelling and infiltration in the interstitial tissue (secondary edema and phlegmon and superficial abscess-formation). The forcible separation of the perichondrium from the cartilage is followed by the changes which necessarily ensue when a tissue is separated from its matrix—retrogressive nutritive disturbances in the form of partial atrophy or total necrosis. If the process is arrested in the first stage and the nutrition of the cartilage is restored, the changes will be confined to the thickenings caused by the infiltration, or, possibly, to adhesions in the region of the joints, which may then give rise to motile disturbances. Sometimes, especially in tuberculosis, ossification of the cartilage forms the final stage of the nutritive disturbance.

In the more advanced stages and in more intense inflammations the cartilage becomes necrosed as a result of the impaired nutrition. If the necrosis is only partial, the necrosed parts may be absorbed and leave only a deformity; but if the necrosis is at all extensive and the inflammatory process continues after necrosis has set in, sequestra result and persist for a long time, setting up a constantly recurring irritation in the soft parts, or they may be cast off in a short time. Which of these processes will occur in a particular case depends, of course, on the primary cause; little can be hoped for in tuberculosis or in syphilis, or in any condition where there is a malign influence constantly at work.

The *clinical* picture presents some special features, in

addition to those already mentioned, according to the *localization* of the process. Perichondritis of the *thyroid cartilage* manifests itself on the outside by swelling of the *alæ*, which can readily be felt; the painful region is sharply defined. There may also be an inward bulging, which is then seen below the true vocal cords in the anterior angle. However, this is the least frequent localization.

The perichondrium of the *arytenoid cartilages* is more frequently attacked, perhaps because they play such an active part in the function of the organ. The consequences are swelling over the cuneiform cartilages, abnormal movements—that is, delayed action of the true vocal cords. Whether this is due to disuse of the joint or to destruction of the muscle-attachments cannot be determined during life, and is quite immaterial from a clinical point of view. The disease can be recognized with certainty only when the symptoms are very pronounced, especially if the resulting necrosis can be reached with the probe or leads to the separation of a sequestrum. The swelling may extend beyond the vocal process—that is, over the true vocal cord, and thus facilitate differentiation from other affections.

Secondary perichondritis in the *cricoid cartilage* is very common. Typhoid, syphilis, and tuberculosis preferably attack this cartilage. The posterior surface, from its exposure to the effects of friction and decubitus, is a favorite site, although the inflammation in this cartilage commonly proceeds from the upper articular surface toward the arytenoid cartilages. The latter are almost always found to be involved in an advanced necrosis. Hence the swelling is often found in the same spot, as in perichondritis of the arytenoid cartilages; it is typical only when seen beneath the true vocal cords in the form of sub-cordal convolutions (Plate 28, Fig. 2). Perichondritis in this situation often produces grave stenoses, as the posterior crico-arytenoid muscles and the crico-arytenoid articulation become involved.

Perichondritis of the smaller cartilages cannot be recognized clinically.

The **treatment** depends upon the primary cause. Traumatic infectious perichondritis calls for opening of the foci and removal of the secretions, also incision, usually from without, tamponage, and drainage. A syphilitic process may sometimes be arrested by general treatment. Tuberculous forms are usually associated with a grave general condition, so that any attempt at treatment is hopeless; still, even tuberculous necroses should be treated according to general surgical principles whenever they appear principally as local manifestations.

Perichondritic stenosis is the commonest indication for tracheotomy in cases of chronic dyspnea.

7. SYMPTOMATIC (COMPLICATION) FORMS OF ACUTE INFLAMMATIONS.

The inflammations which accompany the *acute exanthemata*, although they have not often been described, occur very frequently.

Measles rarely runs its course without laryngitis. It appears usually in the mildest form of diffuse catarrh, characterized by hoarseness and aphonia, and appearing in the mirror as a diffuse redness and slight swelling. The interstitial tissue may be invaded by the inflammation, and the slight edematous swelling which results may produce in young children subjective or objective stenoses. This incipient form of the inflammation often resembles a specific exanthema; the redness appears in spots, as on the skin, and the infiltration being stronger at certain points (inside the follicles) gives rise to minute papules analogous to the small eminences felt in the skin and due to infiltration of the hair-follicles.

Later the epithelium may become macerated and cast off, so that the mucous membrane assumes a dull, velvety sheen. In the parts which are functionally active and subject to friction erosions may appear, extending as far as, or even within, the mucosa (the true vocal cords, vocal processes, and especially the arytenoid region). Fibrinous

exudation into the epithelium and mucosa is another common symptom of the local inflammation.

The *symptoms* are barking, and sometimes noiseless cough, and eventually dyspnea.

The *treatment* is principally directed against the dyspnea: massage of the throat with mercurial ointment; warm, moist bandages; laxatives; timely tracheotomy, if indicated. Generally the parts heal spontaneously. To avoid ulceration, or to procure rest if it is present, the cough should be controlled with small doses of morphin, unless contraindicated by the condition of the lungs and bronchi. Running ulcers are almost invariably tuberculous, and do not belong here.

In **scarlet fever** laryngitis occurs less frequently. The catarrhal inflammation presents no special features. The diphtheritic form is more common (see p. 43).

In **small-pox** the larynx is often, if not always, involved. The clinical picture, which is that of simple catarrh, frequently presents a specific discoloration from the presence of small, whitish prominences which indicate circumscribed epithelial necroses. If they increase in size and prominence, a certain similarity to skin-pustules is suggested, although not histologically, since they never extend beyond the epithelium. Pus-collections also occur under the epithelium, but only in the submucous layer, and must therefore be regarded as pustules rather than as true abscesses. After the loss of the epithelial covering, the latter, like superficial necroses, result in erosions or in true ulcers, which do not, however, possess any typical features. The appearance of all these exanthemata becomes modified in "black" small-pox by the characteristic hemorrhages. Either as the last stage of the process, or in the early stages, we may get the typical diphtheroid appearance of the larynx, in which the exudate forms a membrane of mingled fibrin and blood; the external appearances and clinical consequences are the same as in diphtheria.

The marked inflammatory appearances in the submucosa and perichondrium have no specific character.

Typhoid fever affects the larynx by direct deposition of the specific bacilli. Catarrh develops in the infiltration stage; the epithelium is attacked and readily separates, exposing the surface to superficial ulceration and slight hemorrhages. The specific character shows itself in the *circumscribed* nature of the invasions, particularly at the aperture and at the vocal processes. The erosions preferably select the sharp edge of the epiglottis. In analogy with the intestinal process we further get diffuse or circumscribed "marrow" infiltrations and secondary infiltration resembling the intestinal form. Ulceration is occasionally preceded by a definite scaly stage, in the form of diphtheritic membranes. If the ulceration extends to the perichondrium, perichondritis with all its evil consequences ensues. According to the degree of intensity, the parts either heal completely, or grave defects, tightly drawn scars, membranous and other stenoses, remain (Plate 17, Fig. 2). In *exanthematous typhoid* the phenomena are similar, but milder.

In the *treatment* we must always take the laryngeal complications into account. By keeping the upper parts of the alimentary and respiratory passages clean we may hope to influence the process favorably. Local treatment accomplishes nothing. Stenoses demand early tracheotomy, as the unexpected appearance of secondary edema is particularly common in this complication.

Influenza attacks every part of the respiratory tract. In the larynx the interarytenoidal mucous membrane is often found to be inflamed, and therefore (see p. 19) we have barking, dry, convulsive cough, resembling and sometimes mistaken for whooping-cough. There is a marked tendency to hemorrhage, and superficial epithelial necrosis appears in the form of white spots on the true vocal cords; these result in small erosions. In rare cases interstitial inflammations running on to abscess-formation have been observed. The predilection of influenza for

the nervous system sometimes shows itself in affections of the recurrent nerves. All these lesions, however, tend to heal of themselves.

The *treatment* is purely symptomatic, and consists principally in rest. Graver complications demand the usual interference.

The general infection known as **herpes** in very rare instances becomes localized in the larynx, and may or may not be preceded by previous disease in the mouth and fauces. The patient feels very sick and has shaking-chills; soon very minute, clear vesicles appear arranged in groups on one or both sides of the larynx, usually at the aperture only. The epithelium rapidly separates and the vesicles are converted into small, flat ulcers with sharp outlines, covered with a layer of white or yellow secretion, so that usually ulcers only are seen (Plate 6, Fig. 1). The pain is violent and burning, both spontaneous and on swallowing; the voice is seldom affected. The *duration* is from two to eight days.

Treatment consists in ordering complete rest and very simple diet. The pain from the ulcers is often so great as to make swallowing impossible, in which case it can be allayed by carefully touching the parts with nitrate of silver (see p. 33).

In **whooping-cough** the laryngeal complications are chiefly mechanical. In the stage characterized by repeated paroxysms the constant irritation betrays itself by a redness of the anterior surface of the posterior wall; the expiratory blast is unable to remove the scanty secretion. Ecchymoses, and even extensive hematmata, occur in the laryngeal, as in other mucous membranes. Local treatment is of no avail.

The most important acute infectious inflammation is that which occurs in the secondary stage of **sypilis**. The first and mildest manifestation, a diffuse erythema, can be distinguished from benign catarrh only by the anamnesis and the absence of any known cause. Nothing but the subsequent appearance of specific signs will serve

to distinguish it from the catarrhal condition to which syphilitic subjects are particularly liable after an eruption, and which justifies the warning against catching cold during treatment with unguents. Perhaps the only external characters of syphilitic erythema are found in a certain velvety quality and looseness of the mucous membrane and in a graver interference with phonation than would be inferred from the appearance of the surface. If a specific form is really present in a given case, the characteristic signs soon make their appearance: the mucous membrane *papilla* develops. The red background is overshadowed by a delicate, bluish-white veil covering the redness, now in definite circumscribed areas, again in isolated whitish spots (Plate 11, Fig. 2). The discolorations rest on a swollen base and sometimes occupy the greater part of the larynx. At other times the papilla appears without these forerunners; it is then usually isolated, also in the form of a whitish eminence, but surrounded by a zone of intense inflammation (Plate 12, Fig. 1).

The appearance is often so characteristic as to afford a *diagnosis* in itself. The cervical glands are invariably swollen, and traces of other secondary eruptions in the infected region are rarely wanting. Until the papulæ are plainly made out, however, there is danger of confounding the condition with catarrhal erosions.

The *general treatment* must be supplemented by local measures (the author has found internal doses of hydrarg. chlor. mit. 0.1, opii pur. 0.01, t. i. d. in milk, very effective whenever the use of unguents was impossible). Energetic cauterization of the papulæ with nitrate of silver or chromic acid (caution!) fused upon the end of a probe, to be repeated once or twice after the scab has come away, is very effective not only to hasten recovery, but even more to allay the violent pain which accompanies and inhibits the act of deglutition.

The *prognosis* is good. Neglected cases, it is true, tend to interstitial proliferation and to the production of per-

manent *post-syphilitic* hyperplasiæ (Plate 14, Fig. 1). Their treatment must be purely surgical.

The rarest complications occur in connection with **acute articular rheumatism**. Violent pain in the visible and palpable cartilages, with swelling of the connective tissue, sometimes even a thickening of the cartilage, appears to indicate that the joints of the larynx occasionally share the fate of other joints in the body. Of course, if attacks of acute articular rheumatism are followed by motile disturbances (fixations or irregular interference with the excursions of the true vocal cords), we may unhesitatingly regard them as sequelæ of such severe articular inflammations.

In the acute stage the general treatment may be supplemented by local cathartic measures (ung. hydr. applied to the throat in small quantities and a warm, moist bandage); later, electrical excitation and massage of the muscles may be appropriate.

II. CHRONIC INFLAMMATIONS.

1. THE SUPERFICIAL FORM.

The *primary* forms arise either from acute beginnings or as the result of repeated, though slight, irritation, such as violent crying, prolonged exertion of the voice in speaking, excessive smoking, singing in unsuitable postures, inhalation of *dust*, especially of a chemical nature, etc. The symptoms consist in moderate hoarseness or a rough, rasping voice, slight cough, and scanty expectoration of grayish mucus streaked with dust or other impurities. A dusky-red hue is observed over the entire larynx, or only in the parts about the true vocal cords; the latter are often slightly thickened, and slow and incomplete in their closure upon phonation. Occasionally circumscribed areas of hyperplastic tissue make their appearance, and rapidly disappear again as soon as the above-mentioned

causes are removed, thus explaining their origin. The *treatment* must, therefore, be especially directed against these adverse influences; rest should be insisted on and voice-use greatly restricted. The inflammation meanwhile may be combated with applications of nitrate of silver (2-5 per cent. sol.), and, if there are hypertrophies, with ichthyol solution (see p. 33). If there is great sensibility of the mucous membrane with a tendency to hemorrhage, the local treatment must be limited to dusting with alum 1 : 10 sacch. alb. These measures are to be repeated daily at first; later, every two or three days. The functions of the digestive tract must be carefully attended to at the same time.

Secondary forms are met with much more frequently. Nine-tenths of all the cases may be regarded as sequelæ of nose and throat disease. The constant hawking and scraping so common in most of these troubles are very injurious to the true vocal cords. Another source of injury to the cords is the constant dripping of pus and mucus, which gradually find their way from the arch of the palate to the larynx (where a layer of them is occasionally seen in the interarytenoid space) and moisten the inner surface. This secretion acts in several ways: first, by direct infection; secondly, by maceration; and, finally, the secretion dries and sticks fast, tearing off epithelial shreds when it is expelled by violent coughing, and even giving rise to hemorrhages, which in turn expose the submucosa to infection.

Another cause of secondary catarrh is found in syphilitic infection. Even if the larynx is only slightly affected in the beginning, it becomes extremely sensitive to ordinary adverse influences; hyperemias of long duration develop and finally lead to hyperplasia (Plate 14, Fig. 1), or, in milder cases, to permanent irritability of the mucous membrane.

Alcoholism has no special effect, although it undoubtedly exercises an indirect influence on the development of the disease, inasmuch as catarrh of the throat is very

common among heavy drinkers, and the hawking it occasions acts very injuriously on the larynx ; some cases are aggravated by excessive smoking, the usual concomitant of alcoholic abuse. The *picture* of the secondary affection may be very similar to, or identical with, that of primary catarrh, the only feature which is at all characteristic being the accompanying nasal affection. This is usually so much in evidence that attempts have been made to class it as a special disease, forgetting that both forms are due to a common cause.

In one case we may see a pale, slightly granular mucous membrane after closely adherent crusts of pus have been removed by coughing, or, when necessary on account of dyspnea, by direct interference ; the true and false vocal cords narrowed and evidently atrophic, the surface of the former a dirty yellow or dotted over with greenish spots (Plate 10, Fig. 3)—the picture of so-called laryngitis sicca. In another case the prominent feature may be hypertrophy of the mucous membrane, especially of the epithelium, giving rise to wart-like eminences (Plate 22, Fig. 3) ; again, wheals appear on one or both true vocal cords, presenting by certain indentations, which correspond in position to the points where they are firmly attached to the cartilage below, and by the formation of ridges from the reciprocal pressure, a clinical picture which has been described as “*pachydermia verrucosa*,” and, with small show of reason, classed as a special disease (Plate 10, Fig. 1). In addition to hyperplasia and the maceration already referred to, the reaction of the epithelium to the constant irritation may show itself in hemorrhages, brought about by laceration of the mucous membrane as the secretion is coughed up ; these hemorrhages are characteristically found associated with hypertrophies (Plate 10, Fig. 1).

The *prognosis* may be epitomized in the maxim : *Immanente causa non cessabit effectus*. The fundamental principle in the *treatment* is, therefore, removal of the nose and throat disease. This in itself often suffices to

bring about recovery. If the primary trouble cannot be got rid of at once, it should at least be kept within bounds as much as possible by frequent and thorough cleansing of the nasal and postnasal cavities. The larynx must also be treated; the use of the voice must be absolutely prohibited for weeks; all irritating food and drink must be eschewed. Ichthyol applications (p. 33) are very good; large hyperplasiæ may be treated with electrolysis, or removed with the curet, snare, etc. It is hardly necessary to add that intemperance must be combated in the alcoholic, that abdominal plethora must be removed, and that antisymphilitic measures must be resorted to if necessary. The last direction, of course, does not apply to affections of a clearly postsymphilitic nature.

2. INFLAMMATIONS OF THE SUBMUCOSA

are rarely *primary*. As soon as the causes which we have just discussed in connection with chronic superficial affections exert a deeper effect, they may give rise to interstitial infiltration, and later to sclerosis and hyperplasia.

Secondary forms following a specific infection are far more common.

Syphilis, on account of its predilection for connective tissue, plays a prominent part; by means of the secondary disease of the vessels which it entails, extensive alterations are often brought about in the deeper layers. New growths of a tough, fibrous nature develop, together with active superficial proliferations (Plate 5, Figs. 1 and 3), either at once or after more or less tissue-destruction has taken place. True fibromata may be simulated in this way. The subcordal mucous membrane is another favorite seat of such processes, with the result that grave stenoses develop.

The same locality is frequently chosen by **typhoid** (Plate 17, Fig. 2), and **tuberculosis** also occasionally produces here similar convolutions to those to which

it gives rise in the interarytenoid mucous membrane (Plate 14, Fig. 2).

But it is in **scleroma** that we find this disease, syphilis, in its most typical form. The thick, firm, uneven, pale swellings and the extensive cicatricial contractions are most characteristic of this disease, which practically attacks the submucosa exclusively and inevitably results in grave and extensive stenoses.

Leprosy also shows a preference for the connective tissues, where it first forms hyperplastic tubercles and eventually leaves an exceedingly tough, fibrous growth productive of the gravest stenoses.

The *treatment* in most cases is necessarily mechanical. The new growths must be destroyed with "fire and sword," either from within or after thyrotomy; if that is impossible, the stenosis must be combated with bougies or by means of intubation, and, if necessary, tracheotomy.

3. CHRONIC INFLAMMATIONS OF THE MUSCLES

are always *secondary*, so far as our present knowledge goes. We really have very little positive knowledge; even those tuberculous infiltrations of the muscles which are sometimes the first visible signs of the infection are but imperfectly understood. So-called atony of the true vocal cords, especially if unilateral or otherwise isolated, is probably to be explained in this way (Plate 9, Fig. 2). In tuberculosis there is probably a toxic degeneration of the muscle-substance; trichinosis attacks the muscle directly.

We can, of course, readily understand that the muscular tissues should be involved in any extensive process of infiltration or ulceration of whatsoever description, but the fact has no special importance except in affections of the abductors of the vocal cords (see below).

4. CHRONIC INFLAMMATIONS OF THE JOINTS

are more easily recognized. They are practically always

the result of acute inflammations (see p. 49); the symptoms are similar, only not quite so severe.

Many a so-called "rheumatic" paralysis of the recurrent nerves is, in fact, nothing but an ankylosis of the arytenoid cartilage. The differential diagnosis will be found under the head of Hypokinesis.

The **treatment** promises very little. Electrical stimulation of the muscular activity and massage of the articular region constitute the only available measures.

5. CHRONIC INFLAMMATIONS OF THE PERICHONDRIUM AND CARTILAGES

present exactly the same phenomena as the acute forms which we have described, and to which we therefore refer the reader (p. 49). The symptoms may be less pronounced, or, if the formation of sequestra has led to separation of the cartilages, more intense.

In regard to the **etiology**, it must be added that both *gout* and *arthritis deformans* occasionally form deposits in the larynx whose true nature can only be recognized by their intimate relation to other unmistakable localizations. The **treatment** in such cases can only be general; occasionally, however, the gouty foci may soften and eventually demand surgical interference. We have very little knowledge of this latter process.

6. COMPLICATED FORMS OF CHRONIC INFLAMMATION.

(a) Tertiary Syphilis of the Larynx

manifests itself in diffuse or circumscribed *infiltrations*, in *swellings*, and in *ulcerations*. The latter appear either at once or after the two first-named conditions.

The diffuse *infiltration* is seldom limited to the mucous membrane; it usually penetrates the submucosa and often extends to the muscles and to the perichondrium, as is proved by the marked interference with movement which occurs very early. The mucous membrane is red and

velvety; the normal shape is masked by thick convolutions more or less clearly outlined against the surrounding parts (Plate 13, Fig. 1). Purely inflammatory swelling and edema often complicate the picture (Plate 23, Fig. 2). If the infiltrations are round and distinctly separated from the healthy tissue, they may be termed *gummata*, as in other parts of the body (Plate 4, Fig. 1). This character becomes accentuated if they are elevated above the surface and form *true swellings* (Plate 18, Fig. 3, and Plate 22, Fig. 2). Histologically such swellings are found to be true *syphilomata* (Plate 41, Fig. 2). These appearances, however, do not persist for any length of time; disintegration early supervenes, and we get the typical ulcers with red, steep, clear-cut ("punched-out") edges and a greenish-gray depression (Plate 5, Fig. 2). Usually the two conditions are seen at the same time.

The favorite *seat* is the superior aperture of the larynx, especially the epiglottis, though any other part may also be involved. The principle of least resistance asserts itself in the greatest frequency of the ulcers on the true vocal cords, as they are most concerned in the function of the organ, and, after that, on the lingual surface of the epiglottis, which is most exposed to injury from ingested food (chilling and over-heating) and to infection from the mouth.

In the first, the infiltration-stage, the *course* is *treacherously slow*. The deposit may accumulate for weeks without betraying its nature by any perceptible characteristic signs. The patients during this period feel so little discomfort that they rarely present themselves for examination. In most cases they consult a physician only when they begin to feel serious inconvenience, which does not occur until nearly the end of the infiltration-stage or in the beginning of degeneration. Before this time—depending upon the seat of the affection—the voice may have become impaired, or the patient may have felt a dryness and "scratchy" feeling in the throat; but now he complains of pain, usually slight but sometimes violent,

stabbing and burning in character during the act of swallowing, after sleeping, and also in speaking, and there are marked vocal disturbances. The epiglottis may fail to act as a result of mechanical interference, and there may be consequent dysphagia.

The ulcerative stage is succeeded by *cicatrization*. The original marked increase of connective tissue is replaced by a corresponding contraction; where the infiltration occupied the place of normal parts we get greatly diminished volume; and, on the other hand, masses of tissue may be deposited in places where there was none before. In one case we shall have defects (Plate 4, Fig. 3); in the other, marked cicatricial contractions and membrane-formation (Plate 30, Fig. 3).

The disease does not always end with the effects of syphilitic infection; mixed infections may continue their work in spite of antisyphilitic treatment, especially in situations unfavorable to the elimination of the morbid products—the submucous layer, the perichondrium, and the articulations; the only hope then lies in the recuperative powers of the organism or in operative interference. The latter is to be considered only when larger necrosed particles—*sequestra*—are to be eliminated; their presence is often an indication of a constant or recurring reaction in any one situation.

Such *postsyphilitic* complications following the specific cure betray themselves by persistent swellings, etc., sometimes, too, by the subsequent recurrence of proliferation. The former condition is illustrated in Plate 13, Fig. 3; the latter, in Plate 5, Figs. 1 and 3.

The difference between such postsyphilitic inflammations and specific granulomata is best seen histologically: Plate 40, Fig. 2, and Plate 41, Fig. 1, represent the first variety, secondary wart-formations; while Fig. 2 on Plate 41 shows a true syphiloma.

The **diagnosis** of tertiary disease will rarely be based on the findings in one situation only, as, for instance, in the larynx; anamnesis, other accompanying symptoms,

and, above all, remains of former specific disease in other parts of the body, must be taken into account. The marked inflammation of surrounding structures in the active stage, the painful swelling of the glands, the smooth, steep edges of the ulcers, the rapid degeneration in infiltration, the wide extent of both ulceration and infiltration—all these factors afford valuable signs for differentiation from other processes.

The duration of the disease and the condition of lungs and character of sputum serve to distinguish it from tuberculosis, while malignant growths are excluded by observing the advance of the process and whether the infiltration degenerates rapidly—above all, by noting the effect of antisymphilitic treatment. Hence diagnosis is often arrived at *ex juvantibus*.

It is even more difficult to recognize *postsymphilitic* processes as such. The anamnesis must be absolutely positive. It is to be remembered that they are very common; many a stubborn "hypertrophic catarrh," many motile disturbances described as "nervous" or paralytic, are really nothing but the remains of earlier infectious processes.

The **treatment** cannot be begun too early, if it is to be effective. Infiltrations may show no changes for weeks, and thus deceive the practitioner as to their true nature, whereas they can be reduced by therapeutic measures. When the characteristic, ulcerative degeneration has once set in, its progress can no longer be arrested; it is (simply) a sign that necrosis is already *completed*. Hence the importance of the maxim, *obstare principiis*.

As in all the graver forms of syphilis, among which laryngeal syphilis must be included in spite of its comparative infrequency, iodid of potassium alone, especially in small doses, sometimes fails to act. The following mixture is recommended:

Ry. Sol. pot. iod.,	10.0 : 150.0 ;
Sod. carb.,	5.0 ;
Syr. cort. aurant.,	25.0.—M.

Sig. One tablespoonful three times daily before meals.

This should be supplemented, if possible, by unguents or the hypodermic injection of a mercurial salt; the author prefers

Hydrarg. salicyl.,	1.0 ;
Paraffin. liquid.,	9.0.

Sig. One Pravaz syringe-ful every three days.

Local treatment is required only in complications: in the mixed infection following ulcerative degeneration, of course; and in sequelæ of other diseases or other threatening symptoms.

The first of these—ulceration—may be effectively combated by cauterization with solid nitrate of silver, not to be repeated until after the scab has come away; the scab acts as a bar to the constant infection by contact, as a means of removing necrosed tissue more quickly, and also as a protection against pain.

Dyspnea should be relieved, if possible, by mechanical means: scarification of infiltrated parts, removal of swellings, and, if necessary, tracheotomy.

The sequelæ are sequestra, the discharge of which is hastened by curettage, but may sometimes demand thyrotomy; deep abscesses, which must be opened from within or from without; swellings, which must be removed; finally, cicatricial contractions or hyperplasiæ, which call for mechanical stretching or operative removal.

(b) Tuberculosis of the Larynx.

Etiology.—The infection may invade the organ primarily, as it does practically every other organ in the body, but is more often secondary to disease elsewhere.

The path of the infection is, if anything, more difficult to explain than it is in other localities. Either it traverses apparently intact or injured epithelium, or it follows the course of the lymph-channels: the former is most likely in the diseases secondary to pulmonary phthisis; the latter, in the forms which at first sight appear to be primary, but are in reality the result of latent disease in the upper portions of the respiratory and alimentary tubes. There is no doubt that diseased cervical glands are capable of infecting the larynx; many a so-called "primary" case is no doubt due to this cause.

Morbid Anatomy.—The principal feature is the tuberculous infiltration, usually showing the structure of the Schüppel-Langerhaus tubercle very plainly, sometimes taking the form of irregular, diffuse, round-celled infiltration, especially about the vessels and glands. The seat of predilection is the middle of the posterior wall (Plate 19, Fig. 3; Plate 21, Fig. 1), by reason of the loose arrangement of the tissue and the accumulation of (pulmonary) sputum in that locality. Other parts are occasionally attacked first; the epiglottis less frequently than any other. Sometimes the infiltration is circumscribed; at others very extensive both in width and in length. The reaction of neighboring structures is, in general, very slight, and their resistance proportionately feeble. If, however, the advance of the infection is checked before it has reached the deeper layers, we get the *lupoid* form of the disease, characterized by numerous protuberances in the infiltration, a very slow progress, and showing histologically marked reactionary proliferation of epithelium.

If, on the other hand, the process continues, the infiltration soon undergoes necrosis, forming ulcers on the surface and hard or soft sequestra in the deeper layers (Plate 12, Fig. 2; Plate 20; Plate 21, Fig. 2; Plate 29).

The first condition opens the way for a mixed infection, although (infective) reaction may in rare instances be strong enough to drive out the focus of the disease. De-

generation is more likely to occur where function has become impaired, the infiltration extending far beyond the limits of the visible ulcer (Plate 20).

In some cases the tubercle-formation proceeds for a long time within the deep layers, and occasionally gives rise to non-specific proliferations in the epithelial and mucous layers. These appear as swellings and are usually found to consist also of diseased tissue. The proliferations may lead to the formation of actual tumors, their true nature being masked by the intact appearance of the surface and the presence of a pedicle (Plate 21, Fig. 2; Plate 21, Fig. 1; Plate 26, Fig. 2; Plate 28, Fig. 2).

If the perichondrium is more extensively invaded, there result edematous swellings, and later necroses, preferably in the cricoid and arytenoid cartilages, corresponding to the most frequent localization in the mucous membrane of the posterior wall.

All these various anatomical features are very often blended in a strange picture of deformity and devastation.

Laryngoscopic Image.—In the initial stages we often see round or pointed eminences projecting from the interarytenoidean region, beneath which ulceration may have already begun. These projections are usually pale; in fact, the entire larynx and even the fauces are usually anemic: there are, however, many exceptions to this rule. Sometimes the process first betrays itself by paresis or redness of one or both true vocal cords. These also may be the seat of slight hypertrophies and excrescences. If the infiltration in the vocal cords breaks down, we see discolored yellow, and sometimes, from protrusion of the granulated background, reddish erosions with more or less swollen or uneven edges (Plate 12, Fig. 2; Plate 21, Fig. 2). The decubital action of the other vocal cord leads to complete longitudinal fission of the affected one, so that it appears to be divided into an upper and a lower half (Plate 16, Fig. 2).

The false vocal cords are usually somewhat thickened,

and, if infiltration is present, they will appear to be narrowed (Plate 25, Fig. 2).

In the epiglottis the follicles are frequently attacked, especially at the edges, and soon degenerate; the extreme thinness of the investing membrane there often gives rise to perichondritis with enormous swellings (Plate 6, Fig. 2).

Tuberculomata are common; they are recognized by unmistakable accompanying symptoms and also by their general appearance, irregular, uneven surface, and broad base.

The **diagnosis** is often quite difficult. The first thing to bear in mind is that tuberculosis of the larynx usually forms only a part of a general process; but, on the other hand, it must not be forgotten that a patient may have pulmonary phthisis and laryngeal syphilis at the same time; in fact, the two diseases have even been observed in the larynx at the same time (Plate 21, Fig. 1).

In general, tuberculous deposits in the larynx are characterized by slow development, moderate redness, and uniform extension to the adjoining tissue. Tuberculous ulcers are distinguished by raised and slightly papillary or convoluted edges; often the edges alone are visible in the form of pointed eminences on the posterior wall. This phenomenon is so frequent in the early stages of the disease that its appearance in this locality has been considered pathognomonic.

Tuberculomata, we repeat, are recognized by their broad base and uneven surface; infiltrations, by their rigidity and pale color. Plain as all these phenomena may be to the eye of the experienced, a combination of all, or of some of them, which is usually present, will materially facilitate the diagnosis, especially if the individual forms are atypical, for the picture is often greatly altered by mixed infections and by functional irritation.

It is absolutely indispensable to collect all the corroborative evidence possible by thorough examination of the entire body, and especially of the lungs, as well as of the

secretions of ulcers and of extirpated portions of swellings. In obtaining the secretions the parts must be previously cleansed with the greatest possible care to guard against contamination with lung-sputum. The course of the disease is compared with that of syphilis, carcinoma, etc.; sometimes it is advisable to try the effect of antisyphilitic treatment. In general, it may be said that it is impossible to teach anyone theoretically how to make a diagnosis from the picture in any given case, because, in order to arrive at a decision, one must first learn the development of many successive pictures by long personal observation. Not the picture of to-day, but that of yesterday and that of to-morrow must decide for or against laryngeal tuberculosis.

The **symptoms** are vocal disturbances, often very early, due to degeneration or infiltration of the muscles, later to alterations in the mucous membrane of the vocal cords or of the interarytenoidean space; in inflammations, particularly of the posterior wall, great desire to cough; dysphagia, due to ulceration of the parts concerned in function; and, finally, dyspnea in cases of perichondritis, extensive infiltration, and large tumors.

The **treatment** is strictly divided into *curative* and *symptomatic* treatment.

The former is to be employed in all cases which, from the condition of the lungs, the general health, and the previous course of the disease, promise permanent, complete recovery after the laryngeal trouble shall have been removed. Spontaneous cure of the local affection is so rare that it practically need not be taken into consideration. The curative measures are, in circumscribed incipient infiltrations, thorough curettage, and, if necessary, destruction of the base with the cautery-needle or by electrolysis; in more diffused forms, excision with double curet, especially on the upper surface of the posterior wall; in ulcerations, vigorous scraping and painting with 30–80 per cent. solution of lactic acid; tumors must be removed with curet or galvanocautery. If the extent or the seat

of the morbid process is such as to make complete extermination of the diseased tissue *per vias naturales* impracticable, thyreotomy should be practised, and be followed up with a thorough cleansing. It is advisable to examine the wound again after two or three days, as important points are often overlooked during the operation on account of the hemorrhage. In our opinion, extirpation of the larynx is not practicable even in very extensive disease; partial excision of diseased cartilages, on the other hand, may be practised with good results in chondroperichondritis.

The *symptomatic* treatment must be employed when the condition of the larynx requires interference and the general condition is such that permanent cure or even lasting improvement is not to be expected.

Painful ulcers which impede deglutition are treated with lactic acid, and, if the underlying infiltration is very extensive, with energetic curettage; tumors interfering with respiration must be removed; perichondritic abscesses must be drained; if the dyspnea continues and cannot be relieved in any of these ways, especially if it is due to perichondritis or to subcordal abscess, tracheotomy must be resorted to. This operation is also indicated in extensive ulcer-formations, for complete rest of the larynx will do much to lessen the pain and discomfort, and may be followed by actual improvement. In addition, morphin should be freely used in hopeless cases, remembering that the patient cannot in any case live long enough to contract the morphin-habit. (We say nothing here of general treatment, such as is required in tuberculosis.) Inhalations of balsamic substances may be employed with advantage, if only to cover up the offensive odor; their therapeutic value is doubtful, to say the least. Let the patient inhale turpentine, menthol, Peruvian balsam, or ol. pini pumilionis from a cotton pledget saturated with any of these substances and placed in the bowl of a clean earthenware pipe, or the drug may be poured on hot water and the vapor inspired through a paper funnel.

For general treatment we will emphasize the importance of staying in a quiet place where the air is free from dust. Whether the treatment is symptomatic or curative, talking should be strictly prohibited, so as to insure absolute rest for the organ. In conclusion, let it be remembered that occasionally the symptomatic treatment has the effect of a curative one, agreeably surprising the practitioner by unexpected recovery.

(c) **Leprosy of the Larynx,**

although only a rather unusual complication of a general infection, is important on account of the fatal stenosis which it occasions. The rigid, nodular infiltration, which is quite analogous to the phenomena in the skin, encroaches upon the lumen considerably, and the condition is further aggravated by the resulting ulcers and cicatricial contractions.

Mutilations of the organ from extensive tissue-destruction, especially in the epiglottis, are not rare.

The **diagnosis** is very simple, as the disease never attacks the larynx alone. Tracheotomy is the only possible **treatment**.

(d) **Scleroma**

is more commonly seen in Germany. Until a short time ago it was known only in the form of rhinoscleroma, which is suggestive of the important fact in the diagnosis that the larynx and trachea are always attacked secondarily. The same characteristic pale, gristle-like, widespread infiltrations and flat, lumpy ulcers, covered with dry pus-scabs, are seen as in the nose. The subcordal space is particularly liable to be attacked, so that we see thick, soft wheals projecting into the lumen.

In doubtful cases the diagnosis is made certain by the presence of the characteristic bacteria in the excised tissue.

So far as our present knowledge goes, any attempt to

combat the disease is hopeless; tracheotomy often becomes necessary.

(e) **Gout and Arthritis Deformans,**

according to some observers, furnish a few cases of chronic inflammation in the larynx. Gouty deposits are found on the epiglottis and also on the large cartilages. The mucous membrane bulges out in broad and circumscribed areas and possesses a conspicuous light yellowish-red color; the infiltration is hard and gritty. Softening with ulceration is, of course, possible as in other localities.

The second disease attacks the joints of the larynx and gives rise to motile disturbances (see p. 51), the true cause of which, as in gout, can only be determined by their close relation to the general symptoms.

III. NEOPLASMS OF THE LARYNX

may be divided into *homologous*, the tissue and structure of which correspond to those of the fundamental tissue or parts of it; and *heterologous*, in which either tissue or structure is different, giving rise, in the latter contingency, to an *atypical* growth. The first category may be further divided into neoplasms of individual tissues, and hyperplasiae containing several or all the histological constituents.

1. HOMOLOGOUS TUMORS.

(a) **Neoplasms of Individual Tissues.**

Fibroma, defined as a pure connective-tissue tumor, associated with some extension of the epithelium which is only secondary and does not attain the same degree of proliferation, is, in reality, very rare, although the diagnosis

of fibroma is often made, as it is readily confounded with inflammatory hyperplasiae.

The *histological* constituents of the tumor are chiefly fibrous tissue, a few (yellow) elastic fibers, and no round cells, or only a few on the surface, probably due to mechanical irritation.

Edematous and mucous degeneration often exists in the interior without materially altering the character of the tumor. If the process goes on to a softening of the tissues, they may be completely absorbed and a *cyst* may be formed (Plate 39, Fig. 1).

The *seat* of the tumor varies; usually it is in the looser parts of the tissue; the *appearance* is pale to light red, sometimes white or spotted from maceration and fatty or horny degeneration of the epithelium (Plate 31, Fig. 2). The *surface* is smooth or slightly convoluted, or it may present papillary elevations and a mulberry outline, as is so frequently seen in the nose. It is then termed *papillary fibroma*.

Fibroma usually occurs in middle-aged men (between thirty and fifty), sometimes much later in life; it is perfectly innocent.

Chondromata are very rare; they are really ecchondroses of the laryngeal cartilages, causing the mucous membrane to bulge out. Their origin is unknown.

Adenomata.—We know them only in the form of *cysts*, due to dilated, obsolete glands. Their favorite seat is the epiglottis, where they may be so large as to interfere with respiration.

Epithelioma.—This term may be applied to proliferations of the epithelium which grow toward the surface, and in which, therefore, the ground-tissue is not crowded aside nor involved in the proliferation. Such isolated growths are, however, very rare; an example is seen in Plate 34, Fig. 3. It is a benign growth and does not recur even after many years.

True **angiomata** arise from dilated veins or capillaries. Plate 39, Fig. 2, shows an example of the former variety.

The enormous alveoli are included in a slender stroma of fibrous, partly edematous connective tissue. The surface of the tumor may be rough or smooth; the color varies from red to purple (Plate 21, Fig. 2); the volume is subject to variations. They are much given to internal or external bleeding. These tumors are by no means common; quite often the ground-tissue becomes involved.

The lymphatics occasionally undergo dilatation to the extent of forming tumors. **Lymphangiomata** then develop either from simple dilatation or from proliferation of the vessel-walls; sometimes they, too, lead to the formation of *cysts*. They usually exhibit hydropic degeneration of tissue in certain places. In their external appearance they do not differ materially from fibromata or from hyperplasiæ.

Another part of the lymphatic apparatus, the follicles, occasionally degenerates in the course of general leukemia. The favorite seat of these **lymphomata** is the epiglottis, which is normally very rich in follicles; they are also found at the aperture of the larynx. They appear as whitish, spherical segments. Their identification (except by microscopical examination) will depend on other localizations and on the blood-count. The *treatment* can only be general.

Far more common than these simple structures are mixed tumors.

(b) Hyperplasiæ of Entire Layers.

Etiology.—They generally originate in an inflammation, sometimes obtained from the anamnesis, and are characterized anatomically by more or less disease in the vessels. The latter is particularly marked in syphilitic forms, while in the non-specific hypertrophies secondary to tuberculosis the epithelial proliferation is the prominent feature. In view of this constant extraneous origin, the term *Secondary Neoplasms* might be fitly applied to this

group. These tumors do not usually attain the size of those described above; still they are capable of producing grave disturbances in both phonation and respiration.

We may further subdivide this intrinsically homogeneous class, if not by clinical, at least by histological characters, bearing in mind, however, that the various subdivisions are essentially alike.

Fibro-epithelioma is the most frequent form; at times proliferation predominates in the epithelium (Plate 33, Fig. 3; Plate 34, Fig. 1), at others in the connective tissue (Plate 33, Fig. 1); while in a third class of cases the overgrowth is uniform in both (Plate 33, Fig. 2; Plate 35, Fig. 1; Plate 40, Fig. 2; Plate 41, Fig. 1).

The connective tissue is more or less rich in fibers, according as the inflammatory round-celled infiltration is more or less prominent. It develops preferably about the vessels, forming at times dense conglomerations, at others long streaks under the epithelium, or the fibers may be distributed more widely. The vessel-walls (arteries) themselves are often affected; the media in particular reaches enormous proportions, although intima and adventitia also occasionally constitute the most conspicuous features of the picture. These hypertrophies of the vessel-walls are always most pronounced in postsyphilitic proliferations.

The veins are less frequently affected; dilatation is met with occasionally, and may lead to the formation of angiomata (Plate 33, Fig. 1). The epithelium really furnishes the typical appearance in these tumors, notwithstanding its overgrowth is only a secondary phenomenon; nothing could be more conspicuous than its excessive proliferation. If the section examined is too superficial, the inexperienced may even be led to suppose carcinoma, as the far-reaching projections on half horizontal section appear completely isolated in the surrounding tissue. The picture is further complicated by enormous horny excrescences and by fatty and colloid degenerations.

If the blood-vessels are hypertrophied either in the direction of their axis (Plate 40, Fig. 1), or transversely

(Plate 39, Fig. 3), the tumor may be termed an angio-fibroma; overgrowths of the lymphatics (Plate 33, Fig. 2) constitute a lymphangio-fibroma.

If the glands are much involved in the proliferation, their epithelium degenerates, and we get *colloid tumors*, which may lead to the formation of cysts.

The most interesting of these neoplasms are the *papillary* forms. The *papillary fibro-epithelioma* even presents some clinical peculiarities. The histological characters consist in branch-like processes of connective tissue, emanating either from a broad base parallel to the surface, or from a thick stem, covered with an exceedingly thick coating of epithelium. Each branch is supplied by a vascular loop containing an artery and a vein. Of the origin of these neoplasms in adults, we know nothing; the theory that their peculiar form depends upon specific irritation finds much support in the fact that the same tumors in children are unquestionably due to acute infectious processes (like measles and whooping-cough).

These tumors also exhibit at times angiectatic and arteritic phenomena, as well as round-celled infiltration, as signs of inflammatory irritation.

According to their seat, appearance, and clinical behavior, the tumors of this group have received various names, without regard to etiology or histological classification. In general, their seat depends on the kind of irritation to which they are due.

Small, hard neoplasms are often seen on the free edge of the vocal cords between the middle and anterior thirds; they are called singer's nodules (Plate 14, Fig. 2; Plate 33, Fig. 1). In this situation they are usually caused by excessive functional irritation.¹

¹ [The theory that the origin of these nodules, otherwise known as *chorditis tuberosa*, is due solely to the method of tone-production termed "coup de glotte" or "stroke of the glottis," cannot be sustained. They are a clinical variety of pachydermia, and are to be attributed rather to overuse of the voice than to merely its faulty or inartistic use. If the singing voice is accurately "placed," or, in other words, if the direction and reinforcement of the tone are proper, the mere mode of attack

If fibro-epitheliomata develop on the vocal processes, they often take the form of cup-shaped deposits on one side and wart-like excrescences on the other, so that the latter are pressed into the former during phonation. The posterior wall presents similar dense, flat formations, either in connection with the former or independently (Plate 10, Fig. 1; Plate 16, Fig. 1; Plate 22, Fig. 3). On account of the altered appearances which are the mechanical result of this localization, observers have been led to describe them as a specific disease under the name of pachydermia laryngis. For the etiology of this variety of irritative hypertrophy see p. 60.

Larger neoplasms of this kind are most apt to be found where the connective tissue is loose, and may look exactly like ordinary fibromata (Plate 31, Fig. 1).

If portions of the mucous membrane of the ventricles become hypertrophied, they may loosen the ground-tissue by their weight to such a degree that the tumor may be moved in and out of the ventricle either with a probe or by the movement of the larynx alone; we thus get the picture of *prolapse of the ventricle of Morgagni* (Plate 18, Fig. 1).

The proliferations which accompany syphilis and tuberculosis also elect the seats of greatest irritation, either in the neighborhood of ulcers or over infiltrations; if they follow in the wake of syphilis, it is safe to assume a hidden inflammatory focus, though it may remain latent for a long time.

The **symptoms** of homologous tumors are, according to the situation, dysphonia (muffled or peculiar "gruff" quality, subdued voice, temporary or permanent aphonia), occasionally irritative cough with reflex spasms of the cords (attacks of dyspnea), and, if size and situation are such as to produce it, constant dyspnea. If the tumor is movable, the symptoms may vary a good deal from time to time and a new symptom may arise: a rattling noise, is of but little, if any, consequence considered in its relation to diseases or injuries of the vocal cords.—ED.]

heard either in respiration or in phonation, and caused by the striking of the mass against the walls of the organ as it is moved by the current of air (Plate 31, Fig. 2).

The **treatment** of the larger tumors consists in mechanical removal; in hypertrophies special attention must be paid to the etiology, if they are to be successfully exterminated. If the irritation is functional, smoking, talking, singing, or, at least, incorrect singing, must be forbidden; if the cause lies in disease of nose and fauces, it must be effectively treated; any foci of syphilitic or tuberculous infection must be carefully searched for.

It is to be remembered that the papillary forms unquestionably originate in the basal connective tissue, although the method of growth is unknown. To avoid recurrence of the tumor, the tissue in question must therefore be extirpated. In papillary tumors with broad bases, especially in children, the operative field may have to be laid open by means of laryngotomy in order to accomplish this end.

We need not here go into the technic of tumor-excision.

2. HETEROLOGOUS NEOPLASMS.

Two kinds of tumors, *lipoma* and *struma*, are types of this class.

Lipoma occurs in the form of broad, deeply lobulated tumors with finger-shaped projections in places where the mucous membrane is loosely attached, especially at the aperture of the larynx. They rarely develop from metastasis, and must be attributed to fatty degenerations of fibromata.

Tumors consisting of *thyroid-gland tissue* sometimes spring from dislocated portions of the gland; that is to say, a malformation (*struma accessoria*). They are covered with normal mucous membrane, and usually are of slow growth. They must not be confounded with true *struma* bulging into the pharynx or larynx (Fig. 17).

In contrast with these foreign tumors the malignant

growths spring from normal tissues, and only become heterologous through their atypical growth.

Carcinoma.

Carcinoma is practically always primary.

Of the *origin* of cancer we know nothing positive; heredity, no doubt, has something to do with it.¹ It is also known that syphilitic and other ulcerations may set up an atypical proliferation of the epithelium. The *structure* is usually that of the so-called epithelial cancer; more rarely the tumors spring from the glands. Usually the cancerous growth infiltrates the surrounding tissues, which remain passive; in rare cases (Plate 27, Fig. 1; Plate 28, Fig. 3) the connective tissue grows so as to form a dense pedicle on which the carcinoma rests; sometimes the connective tissue surrounds the invading tumor with a network of dense fibers and arrests its growth (scirrhus).

The *laryngoscopic image* varies greatly; quite often the tumor itself cannot be seen, and all that appears is a secondary superficial proliferation of benign character, caused by the irritation in the deeper layers. Such innocent tumors may exist for years before the malignant growth becomes manifest, and this has given rise to the theory that innocent tumors may become converted into carcinoma.

The tumors assume the most variegated forms: in one case, multiple papillary proliferations are seen on the edges of the vocal cords; in another, a general metamorphosis of a part of the larynx into rigid knots or nodules (Plate 14, Fig. 2), or a flat papillary layer (Plate 28, Fig. 1); again, a rigid, slightly roughened, widespread infiltration; finally, very large, lumpy tumors (Plate 17, Fig. 1). As the process goes on, the tumor always breaks down, and the combination of evident neoplasm with the

¹ [So far from increasing his belief in the hereditary transmission of cancer, Herbert Snow says that his experience makes him the more doubtful of the malignant nature of a new growth, if there happens to be a history of such disease in the patient's ancestry.—ED.]

signs of tissue-destruction becomes most characteristic (Plate 28, Fig. 1). Sometimes, however, especially in the absence of secondary proliferations, the centrally located tumor may hide itself under the appearance of a uniform swelling of some part of the larynx, especially the ventricular band. Later on the picture is complicated by alterations due to infection of the ulcerated portions, by edema and abscesses, and finally by necrosis of the cartilage after the perichondrium has become absorbed. A most conspicuous feature is the early interference with function; if the tumor is situated on the true vocal cord or near the crico-arytenoid articulation, as is usually the case, motile disturbances (sluggish action) manifest themselves out of all proportion to the small tumor which may be visible; the appearance of this symptom should lead us strongly to suspect cancer.

Metastases into the glands usually occur very late; sometimes they far surpass the original tumor in extent.¹

The *diagnosis* can be made without much trouble in the advanced stages by the characteristics just enumerated; in the early stage it may sometimes be suggested by the last-named symptom. Any marked subjective symptom where little objective alteration is visible must be looked upon with suspicion. Pronounced sensibility, periodic hemorrhages, or obstinate hoarseness, the smallest *unilateral* proliferation or infiltration that cannot be easily accounted for, in patients over forty years of age, are most suspicious signs of cancer. The diagnosis is confirmed by clinical observation or microscopic examination. In elderly people the rigidity which has been mentioned almost suffices for the diagnosis. In obscure cases, if the

¹ [The time at which secondary infiltration of the neighboring lymphatic glands occurs varies with the situation of the primary growth. Krishaber, Butlin, and others classify malignant growths of the larynx into *extrinsic* and *intrinsic*. The former include those involving the epiglottis, arytenoids, aryepiglottic folds, and pyriform sinuses, and the latter those affecting the vocal cords and ventricular bands, and the infraglottic growths. It is the extrinsic which earliest lead to secondary adenopathies.—ED.]

presence of some kind of tumor is evident, the diagnosis of cancer is confirmed by the results of continued observation, such as: rapid growth, increased pain and discomfort, and rapid recurrence of superficial portions of the tumor after excision, even when the microscopic examination gives a negative result.

In the early stages microscopic examination is not always decisive, as the real tumor may be seated far below the surface. If the changes in the latter are not advanced enough for a vertical section to exhibit distinct carcinomatous characters (epithelial outgrowths and cancer-nests pervading normal or newly formed tissue), it becomes our duty, as well as our right, to secure deeper-lying portions for examination, even if it should necessitate performing thyreotomy.

Such an exploratory operation in the early stages (providing, of course, there are strong grounds for suspecting cancer) is the more justifiable, as it is frequently followed by complete recovery.

In doubtful cases, even if there are no indications of syphilis, it is always well to try potassium iodid; it is astonishing what good results sometimes follow the exhibition of this drug. Tuberculosis of the larynx *in the advanced stages* is also a frequent source of error (Plate 28, Fig. 2); this mistake is not so fatal, however, as failure to recognize curable syphilis or the early, operative stage of cancer.

The only *treatment* is total excision of the tumor with a surrounding zone of healthy tissue. If the diagnosis is made early, this can usually be done by means of laryngotomy; the prognosis is, of course, much better if the process is circumscribed than in extensive disease necessitating partial or total extirpation. The fate of cases not operated on is sad indeed—death from asphyxia, dysphagia, or sepsis.

One of the forms of papillary fibroma deserves mention on account of its tendency to atypical growth; it is the very rare

Destructive Papillary Fibro-epithelioma.

It is a papillary ("Brussels sprouts") tumor which is exceedingly prone to recur *in loco* after removal, and even carries its infection by leaping, as it were, to other parts of the mucous membrane. The first characteristics can be explained on histological grounds; the epithelial masses spread not only about and into the newly formed connective tissue, but, also, to the basal tissue and even into the glandular layer (Plate 36, Figs. 1 and 2). Even here, however, the connective tissue seems to play the principal part, on the one hand, by throwing out processes, on the other, by drawing the epithelium down with it into the deeper layers. More advanced cases are needed to throw further light on the subject.

Sarcoma

in the larynx probably always springs from the endothelium or from the adventitia of blood-vessels or lymphatics. It may retain the alveolar type (Plate 37, Figs. 1 and 2), or it may diffuse itself into the adjacent tissues; if its origin is endothelial, it may take on a *papillary* character by proliferation into the open spaces and be mistaken for an epithelial tumor. The usual varieties occur here as elsewhere: medullary, round-celled, fibroid, giant-celled, and melanotic sarcoma. It is worth noting that occasionally the tumor is separated from the healthy tissue by a fibrous stalk.

Before the growth breaks through to the surface, it is often accompanied by excessive proliferation of the epithelium; the adjacent connective tissue also reacts to the irritation by small-celled *non-heterologous* proliferations (Plate 37, Fig. 1).

As regards symptoms, physical characters, metastasis, and the diagnosis, sarcoma is essentially the same as carcinoma. Possibly the sarcomata are distinguished by a more uniform surface.

One final warning for the diagnosis seems apposite: if,

in examining an extirpated portion for malignancy, we think only of cancer, the finding of epithelial proliferations—not an uncommon occurrence in sarcoma—may cause us to exclude cancer without at the same time awakening a suspicion of sarcoma. We must not forget, therefore, that sarcoma may be present even when the examination gives a negative result for cancer.

IV. DISTURBANCES OF MOTILITY.

1. MECHANICAL.

Mechanical disturbances are directly due to *muscular insufficiency*. These develop in acute and chronic inflammations and infiltrations, as the result of muscle-degeneration in general tuberculosis, in trichinosis, in grave anemias, and after grave acute infections (typhoid, diphtheria, etc.); also from overexertion in singing and speaking. The diagnosis is based on typical positions of the vocal cords during phonation or respiration.

Palsy of the lateral crico-arytenoid muscle causes a gaping of the glottis cartilaginea with the angle formed by the two cartilages opening forward (p. 15, Fig. 5), while in paralysis of the transverse arytenoid muscle the angle of divergence looks backward (p. 15, Fig. 4). In paralysis of the thyro-arytenoid muscles the glottis ligamentosa forms a semi-elliptical or elliptical cleft in phonation, according as the paralysis is unilateral or bilateral (p. 16, Fig. 6; Plate 9, Figs. 1 and 2). If the lateral crico-arytenoid muscle is affected at the same time, this cleft extends to the cartilaginous portion; if the transverse arytenoid is involved in conjunction with the thyro-arytenoids, a double ellipse is seen, the point of contact corresponding to the apices of the vocal processes. If all three muscles are paralyzed, the corresponding vocal cord is arrested in respiratory posture.

Paralysis of the posterior crico-arytenoid muscle produces arrest of the vocal cord in respiration at or very near the middle line (Figs. 21 and 22).

The *symptoms* of these paralyses are (in the adductor group) vocal disturbances running on to complete aphonia. In rare instances the ventricular bands, by a vicarious action, are drawn over the true vocal cords (which are not sufficiently adducted or stretched), so as to effect phonation; the result is a rough, rumbling voice (Plate 3, Fig. 2). Paralysis of the posterior crico-arytenoid, if unilateral, may present no symptoms; bilateral paralysis necessarily produces intense dyspnea, which is often aggravated (in unilateral paralysis produced) by perverse contraction of the adductors brought on by the efforts to overcome the dyspnea.

The *treatment* must be chiefly directed against the primary trouble; in addition to this, direct excitation of the muscles by electricity from within or without may be employed with advantage (p. 35).

That inflammation in and about the *crico-arytenoid articulation* may be attended by motile disturbances has been mentioned (p. 49 *et seq.*), and the diagnosis in the active stage described in the same connection. We shall now bring out those points which, after the disappearance of all symptoms referring to the joint, establish with more or less certainty the presence of an articular obstacle. It is quite clear that all such phenomena must be due to diminished *passive* mobility.

First, we would mention any fixation of the vocal cords which does not correspond in position with any of the muscular paralyses just described, or with the nervous paralyses to be described in the next section; if, for instance, a vocal cord assumes a position midway between that of the cadaver and that of respiration or phonation, or if, during phonation, it is adducted only to the cadaveric position—if, in short, its excursions are incomplete. Secondly, the jerky movements of the cords, which have been mentioned, as if they were being dragged over ob-

stacles. In addition, we have those cases where the vocal cords at first functionate properly enough and gradually become more and more sluggish and insufficient in their movements, or where the opposite takes place. If the motile disturbances alternate in position between adduction and abduction, we can exclude muscular or nervous paralysis with certainty. Often we have to content ourselves with a theory, especially when the condition does not present fixation, but only impeded motion.

2. NEUROTIC DISTURBANCES.

(a) Hyperkinetic Neuroses.

Both tonic and clonic spasms occur in practically all the laryngeal muscles.

Tonic spasms of the abductors have a *central* origin; they are frequently seen in *tabes dorsalis*, and give rise to the well-known laryngeal crises: sudden attack of dyspnea with loud inspiration, the cords often remaining fixed in adduction for a considerable length of time; they also occur in *tetanus* and in *tetany* and occasionally in *hydrophobia*.

Spasms sometimes proceed from the *trunks* of the *recurrent nerves* as forerunners of a paralysis, when the causal injury is slight and temporary in its action.

Reflex adduction forms follow direct irritation of the larynx or even of the mucous membrane of the fauces, by therapeutic applications, by the entrance of foreign bodies, or by the aspiration and unintentional swallowing of intensely irritating materials ("irrespirable" gases), and by tumors in or near the larynx. The spasm may also be excited by irritation in other parts of the body, especially if reflex irritability is great. This is always the case in the early years of childhood—in fact, these spasms are so frequent and so dangerous that they have been described as a special disease under the name of *laryngospasmus infantum*. Nevertheless, it is only a

symptom, not a disease, and may be due to the most varied causes. If it cannot be referred to a veiled and obscure tetany, its cause is usually found in intestinal disturbances, brought on by artificial foods in sucklings, by intestinal catarrh, tape-worm or constipation in older children.

Tonus of the *abductors* has been observed in hydrophobia. The vocal cords are fixed in extreme abduction.

Clonic spasms are also usually seen in the adductor muscles, and always have a *central* origin. They are characterized by a rhythmical twitching inward of the vocal cords, sometimes persisting for months. Such spasms have been observed in conjunction with similar ones in the pillars of the fauces, on one or both sides, in brain syphilis, after meningitis, direct or indirect disease of the medulla oblongata in the neighborhood of the accessory nucleus, pressure on the medulla from tumor of the cerebellum. They have also been seen in paralysis agitans, accompanying the tremulous movements of the extremities—the effect probably of increased irritability by psychical impressions.

A mixture of clonic and tonic spasms has been observed in the depressors of the epiglottis; the organ would sink down upon the aperture for variable periods of time, or merely exhibit slight twitchings.

The *treatment* of spasms of central origin is purely symptomatic, as the primary disease is usually incurable. In tabetic crises and in all longer attacks it is best to reduce the excitability of the respective centers by means of morphin injections, especially as the violent, forced inspirations only tend to increase the dyspnea by sucking in the vocal cords and the epiglottis. If the dyspnea is prolonged, tracheotomy is indicated.

Spasm of the glottis in children endangers life and must be allayed; cold douches in a warm bath are employed with good success; the etiological factors must, of course, be looked for and removed. A change from artificial food to the breast often puts an effectual stop to

the attacks. Attention must be given to the functions of the gastro-intestinal tract.

(b) Hypokinetic Neuroses.

Paralyses or pareses affect the muscles supplied by the superior and inferior laryngeal nerves. Those innervated by the *recurrent* nerves are the most frequently involved.

The *picture* in paralysis of the recurrent nerve varies according as the paralysis is unilateral or bilateral, partial or total.

In total paralysis the affected vocal cord is fixed midway between respiration and phonation—the so-called *cadaveric position*. We regard this as the position of passive equilibrium, as neither adductors nor abductors are acting. In addition, the free edge of the vocal cord appears more concave than usual, showing a loss of physiological tonus in the stretching muscle (Fig. 17); if the attack is prolonged, the muscle atrophies and the vocal cord loses in width (Plate 13, Fig. 2). The arytenoid cartilage on the affected side projects forward (Figs. 17, 18, and 19).

In *phonation* one vocal cord remains immovable, while the other, as usual, moves to the middle line (Fig. 17), and sometimes beyond it as a compensation (Fig. 18). At the same time the arytenoid cartilage of the sound side is advanced in front of that of the affected side, which is pushed aside; not infrequently, however, the latter is seen to twitch slightly inward and forward, as the transverse arytenoid muscle is often supplied by the superior laryngeal nerve, instead of the recurrent, and therefore retains its efficiency even in paralysis of the recurrent. As this movement, when present, is proof of the *passive* mobility of the articulation, it constitutes a reliable means of excluding joint-disease. The epiglottis is also occasionally seen to twitch on the *sound* side whenever the depressor of the epiglottis is supplied by the recurrent instead of by the superior laryngeal. It is also a

certain sign that the lesion is nervous and not articular. In bilateral paralysis both vocal cords remain immovable in the cadaveric position.

The *symptoms* of unilateral paralysis are : at first rough, feeble voice, later somewhat improved through compensation ; so called air-waste, which can be felt by the hand held over the mouth as superfluous air rushes through the excessive cleft of the glottis. Bilateral paralysis produces complete aphonia. A want of vibration in the thyroid cartilage of the affected side is not without significance. In the beginning we sometimes have mis-swallowing, due probably to paresis of the epiglottis.

Total paralysis is always preceded by *partial* paralysis, although the latter may sometimes escape observation. It is confined to the abductors, so that the *picture* shows one or both vocal cords in the median position (Figs. 23 and 24). (The arytenoid cartilage of the affected side is in front of that of the sound side.) The reason must be sought in the greater vulnerability of the abductor fibers.

In unilateral median posture there are practically no *symptoms* ; the voice is good and respiration is not impaired except upon great exertion. Bilateral median posture, on the other hand, interferes seriously with respiration, as the respiratory cleft is excessively narrowed (even more than is shown in Fig. 22).

Paralyses originate by injury to the centers, to the vagus at any point in its course, or to the recurrent laryngeal itself.

Central paralyses we know only in connection with diseases in the medulla oblongata, more particularly of the accessorio-vagal nucleus. Nothing positive is known of any cortical origin. We know only that disease about Broca's speaking-center (left inferior frontal convolution) inhibits *functional* movement of the larynx.

Positive signs of a central paralysis can be obtained only by a general examination and the recognition of a general disease, or by other symptoms pointing to a focus.

Among the known causes are: thrombotic or apoplectic softening of the medulla oblongata, neoplasms, abscesses, and aneurysm compressing and destroying the bulb, disease of the nuclei in the medulla (bulbar paralysis), lateral sclerosis, progressive muscular atrophy, syringomyelitis, and tabes cervicalis; finally, general nutritive disturbances such as are produced by syphilitic disease of the blood-vessels. It goes without saying that the diagnosis of all these diseases (which we will not go into here) must be established before it can be made use of as an etiological factor.

Peripheral palsies follow disease of the vagus, direct traumatic or operative injury, aneurysm of the internal carotid, malignant tumors on the base of the brain, in the glands or in the mediastinum, struma, and cervical phlegmon (purulent neuritis).

Any one of these causes can be recognized by the pulse-acceleration which always accompanies injury in this region; if the paralysis begins above the origin of the superior laryngeal nerve, the latter will, of course, be involved also, and eventually the paralysis will extend to the pharynx (through the pharyngeal branch). Sometimes the pharynx is involved in paralysis of the recurrent alone, probably as a result of an ascending neuritis. In most cases other cerebral nerves are paralyzed, so that we often get the picture of pseudobulbar paralysis.

Disease of the recurrent nerves is in the majority of cases caused by some morbid process in the adjacent tissues, and is, therefore, an important factor in the diagnosis of such lesions. The latter include: aneurysm of the arch (especially for the left nerve), aneurysm of the innominate artery (for the right), pericarditis (left), pleuritis of the apices (more right), and large pleural exudates; all the diseases of the mediastinal tissues and of the mediastinal glands (carcinoma, sarcoma, tuberculosis, syphilis, malignant lymphoma, echinococcus, etc.), very frequently goiter (more on the left side), and cancer of the esophagus (more on the right side); rarely, direct injuries (in stru-

meotomy, injections into the parenchyma of a goiter, ligation of vessels).

Infectious neuritis of the trunk occurs in syphilis, diphtheria, the acute exanthemata, influenza, pneumonia, and typhoid; toxic neuritis in lead-poisoning and, perhaps, in alcoholism. A "rheumatic" origin is very problematical.

The *diagnosis* of paralysis of the vocal cord is based on the laryngoscopic image, on the course of the disease, and on the exclusion of etiological factors. The signs of total paralysis of the recurrent in the laryngoscopic picture are: cadaveric position and twitching either of the diseased arytenoid cartilage, or of the sound side of the epiglottis.

A median position is shown to be due to a nerve-lesion by the subsequent course of the disease—that is to say, if it is followed by perfect mobility or by the cadaveric position; conversely, a cadaveric position is of a nervous nature if it was preceded by a median position.

If the above factors are not, or have not been, present, we cannot at once decide whether a fixation of one or both cords is due to paralysis or to ankylosis. We must, before making a diagnosis, establish the existence of a central or peripheral lesion which can produce paralysis, and cannot produce mechanical alterations in or about the joint. For instance, struma or cancer of the esophagus can affect the nerve only, while tuberculosis and syphilis can affect the nerve through the pleuræ or the glands, and also the joint either directly or through the perichondrium. If such an ambiguous process is at work, paralysis of the recurrent can be recognized only by the subsequent course, or if the laryngoscopic image is unmistakable. Otherwise the diagnosis had best be left open. There is no doubt that the cadaveric position in so-called rheumatic palsies (which means that no cause can be found) is often due to mechanical disturbances, and not to paralysis. In the absence then of a nervous origin and of unmistakable signs in the course of the disease, or of a characteristic

laryngeal condition, cadaveric position alone cannot be regarded as sufficient proof of total, nor median position of partial paralysis of the recurrent.

The *prognosis* of paralysis of the recurrent is, in general, unfavorable, as most of the causal conditions are incurable. If the cause can be removed, as in goiter, syphilis, etc., it must be done as early as possible; partial paralysis in such cases disappears without further trouble; but if the paralysis was complete, irreparable atrophy of nerves and muscles (Plate 13, Fig. 2), or at least abnormal movements, may be the result (Fig. 25).

The *treatment* must, therefore, be directed against the primary cause. Local applications (internal and external electricity) may be advisable to combat the muscular inactivity; their value in so-called rheumatic paralysis is, of course, proportionate to the problematical nature of that condition.

Paralyses of the superior laryngeal nerves are of very rare occurrence. They manifest themselves by inaction of the cricothyroid muscle, and later of the depressor of the epiglottis, and by anesthesia of the laryngeal mucous membrane.

The first lesion relaxes the true vocal cords, as the tensor muscles can no longer put them on the stretch in the absence of a resisting force; the free edges, therefore, show a wavy outline (Fig. 23).

If the cricoid and thyroid cartilages are approximated mechanically, the voice is immediately improved.

The paralysis occurs as a result of direct injury (operative); more frequently, in part at least, as a sensory paralysis after diphtheria.

Concerning the etiology we are still very much in the dark.

(c) **Parakinetic Neuroses.**

This term is applied to disturbances of innervation in which deviations from the normal movements take place.

They are few in number, and may be divided into *organic* and *functional*.

To the first class belong the disturbances of motility met with in multiple sclerosis and in tabes. In the former it has been observed that the vocal cords in phonation alternately relax and contract (intention-tremor); they exhibit fibrillar twitchings and sluggish closure of the glottis; then, in inspiration, the glottis is closed so that the inspirations are shrill, especially in laughing. Sometimes the glottis is closed by a spasmodic movement in phonation.

In tabes the vocal cords have been observed to move by jerks and to stop half-way, both when phonation and inspiration were attempted, constituting therefore a true ataxia. Similar phenomena have been observed in hemiplegias, as a kind of fatigue-symptom.

Functionally aberrant movements in the opposite direction to the one intended are quite common; they must all be regarded as the effects of perverse innervation. The latter occurs as the result of an existing paralysis, or through physical or psychical association-fatigue. Thus we have a convulsive respiratory closure of the glottis in tabetic or other neurotic median position, or in median position on one side and cadaveric position on the other; also in the so-called respiratory spasm of the glottis, in which the vocal cords after phonation scarcely separate at all, or only as far as the cadaveric position. The false movements are most pronounced in moments of psychical excitement, or when an attempt is made to breathe properly. In paralysis of the abductors the false movements may be regarded as deviations of the innervation from the proper paths, which are closed, into improper channels, while spontaneous respiratory spasm may be explained on the ground that the correct anatomical innervation is disturbed by the intervention of consciousness (attention). This is a matter of every-day occurrence in other parts of the body whenever coördinated movements, which are usually performed semi-consciously, are forcibly brought under the sway of conscious will-power. Thus a well-drilled recruit may suddenly turn to the right, instead of to the

left, when a new inspection takes place, and the stutterer stutters most when he is trying hardest to avoid stuttering.

Another form is *phonic* spasm of the vocal cords, in which the cords, instead of being simply approximated in phonation so as still to allow the passage of some air, are convulsively pressed together, so that not a sound can pass. This *overaction* is probably susceptible of the same explanation as perverse innervation. When this condition has persisted for some time, it is no doubt aggravated subjectively by the patient's conviction that he could not do otherwise if he tried.

As these two forms of parakinesis are of a purely psychical character and probably occur only in "nervous" patients, the *treatment* must be purely psychical: revive the patient's fallen self-confidence, raise his powers of resistance, and divert his attention from his ailment, especially from its symptoms.

Sometimes we meet with such intention-disturbances and irregular phonatory movements, manifesting themselves in tremulousness of the voice in professional men, as the result of over-exertion of the voice—*i. e.*, fatigue-symptoms. The term *mogiphony* has been used. It is characteristic that they manifest themselves only during the acts which produced them in the first place—preaching, reading aloud, singing, etc. They are, therefore, true occupation-neuroses, and their cause must be sought in the difficulty experienced in bringing the tired muscles and nerves into action.

V. DISTURBANCES OF SENSIBILITY.

They take the form of increased, diminished, or absent sensibility of the larynx.

Hyperesthesia is very hard to define, as the reflex

sensibility of the larynx is normally very great. Reflex sensibility is much more marked than normal sensation. Hyperesthesia of the superior laryngeal nerve, which can sometimes be determined by palpating the upper lateral border of the thyroid at its centre, belongs under this head. It is important to become familiar with it, so as to be able to distinguish it from sensitiveness of the crico-arytenoid articulation, which lies more posteriorly.

Organic *anesthesia* and *hyperesthesia* are met with in total paralysis of the superior laryngeal nerve (see p. 94), or in partial paralysis affecting only the sensory fibers (after diphtheria, etc.). Functional anesthesia, so far as our observations have gone, occurs only as a psychological disturbance (hysteria). Even the healthy larynx is sometimes very callous to irritation (with the sound), without the conditions, indicating hypesthesia.

Paresthesiæ of the larynx cannot very well be dissociated from paresthesiæ of other organs in the throat; they consist simply of abnormal sensations without any organic foundation or definite localization. They are identical with general paresthesiæ in the region of the throat and esophagus, and are produced by the same cause—the attention being unduly directed to the organ by unusual conditions (general excitement, pregnancy, climacteric, menstruation, dread of impending disease).

Suggestion-therapy offers the greatest promise of success, unless the subjective resistance is too great or the psychological cause cannot be determined.

V^a. COMPLICATED (FUNCTIONAL) MOTOR AND SENSORY DISTURBANCES.

These forms must be discussed separately, if only on account of their peculiar etiology, since they are nothing but local manifestations of hysteria. Every variety of muscular or nervous paralysis or hyperkinesis may be functionally simulated by reason of the psychological excitement. The hysterical symptoms do not in any sense

depend upon paralysis, but are due to defective function from want of volitional impulse; they are not true spasms, but simply the expression of perverted or excessive, semi-conscious volitional impulses. As in other parts of the body, so in the larynx the hysterical phenomena are the external manifestations of imperfect psychical processes, the bodily recollections of unconscious experiences.

The phenomena are of the most varied description; they range from loss of function of single muscles or areas of sensibility to total loss of movement and sensation; from the insignificant "globus" paresthesia to grave laryngeal crises ending in vertigo and unconsciousness, the so-called laryngeal vertigo.

The surest sign of movements and paralyses being independent of the will or of reflexes is the disappearance of the symptoms when the (morbid) will is eliminated. Patients with complete aphonia (from inability to adduct the vocal cords) have a loud cough (Fig. 16), and spasms of the adductors, or paralyses of the abductors with intense dyspnea, disappear in narcosis. The phenomena are so very variable that we must not pronounce certain conditions, as, for instance, that of isolated anesthesia of the larynx, hysterical, even if no organic foundation can be demonstrated.

The latter may at first be entirely latent, and only manifest itself later in the disease; or it may be actually absent, as in functional neuroses, without proving that the psychical phenomena are produced by that peculiar perversion of the will-power found only in hysteria.

The fundamental difference between purely functional and hysterical disturbances is that the former are always intentional, while the latter apparently appear and disappear spontaneously. This variability or constancy of the phenomena, which must appear inexplicable and "capricious" to the observer, depends on certain latent psychical processes in the mind of the patient which interrupt or sustain them.

The hysterical akineses may be momentarily or permanently interrupted by the sudden assertion of the will-power; sometimes the motile disturbance has ceased to be caused by psychical conditions, and simply persists from force of habit by *vis inertiae*; such cases are the most grateful and promise a speedy cure. But where the psychical chain is still unbroken every effort fails; we may, for instance, restore the voice to-day by some means or other, only to find it absent again to-morrow. The treatment must, therefore, concern itself primarily with the discovery and removal of the latent psychical process. As long as that continues all remedies will fail. A great many have been recommended: pressure on the ovaries, shaking the larynx during attempted phonation, electricity.

The patients themselves are usually *not* cognizant of the psychical cause, and the best way to find it out is to inquire into the events, both physical and psychical, which accompanied the first appearance of the symptom.

If the psychical chain has been broken, either through the efforts of the physician or by accidental, unknown events, our professional assistance may still be required to restore the will-power or power of coördination lost through disuse.

This is best accomplished by gradually converting involuntary into voluntary movements: have the patient cough and sustain the sound he makes in the act; once the larynx has become accustomed to the unwonted action, improvement is rapid. Occasionally the patient has to be taught to speak all over again. If the psychical cause is deeply hidden and cannot be exterminated, we can readily understand that the case will be hopeless. Symptomatic treatment is required only when the symptoms threaten health and life: crises and convulsions. The former must be treated by anesthesia during the attack and by general tonics; the latter may call for tracheotomy.

VI. DISTURBANCES OF THE CIRCULATION.

They occur in the larynx as accompaniments or sequelæ of disease in other situations, or as idiopathic affections.

Among the former we have *edema from stasis*, which occurs with chronic or acute nephritis, cirrhosis of the liver, or cardiac insufficiency; sometimes, too, in consequence of pressure on a vein by an exudate or a tumor, in which case the edema is local. The nephritic edema may precede all the other symptoms, and thus determine the diagnosis comparatively early in the disease.

Edema due to vasomotor disturbances, *angioneurotic edema*, has been observed to occur spontaneously in connection with similar cutaneous edema and to disappear again as rapidly.

Sometimes a similar form of *toxic edema* appears after the exhibition of potassium iodid. We do not know why this, as well as the apparently purely nervous form, occurs only in certain individuals, nor to what the edema is due.

The *treatment* in all these forms is primarily concerned with the removal of life-threatening symptoms, if necessary, by tracheotomy. In some cases cathartic remedies and cold applications or scarification may suffice.

VII. SOLUTIONS OF CONTINUITY

may be produced by insignificant causes if the vulnerability is *abnormal*, or by ordinary *traumatism*.

The former occur in hemophilia, general arteriosclerosis, syphilis, tumors, tedious catarrhs of long duration, and in secondary macerations (see p. 60). Comparatively slight injuries, such as forcing the voice, violent cough, painting the larynx, may suffice in such cases to bring on hemorrhages in or on the surface of the tissues, or even

fissures and transverse severing of the vocal cords. In the two first-named diatheses small operations, which ordinarily are attended with only very little bleeding, may endanger life by the hemorrhages they occasion. If a severe hemorrhage in the larynx cannot be controlled by making the patient swallow ice, by the application of cocain, a strong alum solution, or the galvanocautery, tracheotomy must be performed immediately *without anesthesia*—as blood is aspirated during anesthesia even when the head hangs down—and the larynx packed with tampons from above or from below.

Traumatic lesions of the larynx result from shot-wounds, cuts, and stab-wounds, or from contusions. According to situation and intensity, there is more or less division or fracture of the cartilages, or hematomata appear in the mucous membrane, or even free hemorrhages. The immediate consequence (where asphyxia does not occur at once) is fatal dislocation of the respiratory path, and this usually demands tracheotomy and eventually intubation. Cut-wounds may heal entirely after removal of the sutures, but usually they leave a membranous or cicatricial stenosis which must be removed by excision or by stretching, either from within or after opening the larynx.

It is always well, in doubtful cases, to perform this last operation at once, in order to clear up the diagnosis and to remove any possible obstructions (luxated fragments of cartilage, etc.). It is just such injuries as these that give rise to the curious deformities which we meet with in the larynx.

Thermal or chemical injuries of the larynx result from the aspiration of hot or caustic gases, or from accidental entrance of caustic liquids into the larynx in deglutition. The consequence in light cases is violent catarrh with erosions; in more severe cases, diphtheritic membrane-formation, edema, ulcers, and, finally, intense cicatrization. The treatment is purely symptomatic: ice internally and externally; if necessary, tracheotomy, *not* intubation.

VIII. FOREIGN BODIES

frequently find their way into the interior of the larynx, especially in children. Convulsive cough, spasm of the vocal cords, injuries, or direct mechanical suffocation, later irritative inflammations and decubital ulcers, are the consequences.

Every means must be tried to remove the obstruction on account of the danger of asphyxiation or, at least, aspiration into the bronchi and consequent inspiration-pneumonia. Small, movable bodies are easily coughed up after tracheotomy, especially if no cannula is introduced and the edges of the tracheal wound are sewed to the edges of the skin. In other cases the foreign body must be removed from within or after performing the operation of laryngofissure.

IX. MALFORMATIONS.

The development of male larynges may be retarded so that they come to resemble the female larynx in size and shape; it occurs especially as a part of a general *feminism*. Imperfect union of the two halves, as in cleft palate, with which it is usually associated, has been observed in the form of longitudinal *fission of the epiglottis*. Congenital absence of the epiglottis has also been described.

A kind of atavistic malformation is seen in the lateral expansion of the ventricles of Morgagni, analogous to the resonating-pouches of anthropoid apes, known as *laryngocele*. In well-developed examples the pouch pushes the hyothyroid membrane before it and becomes visible on the outside of the neck, especially during attacks of coughing. Smaller extensions are more common.

Congenital *membranes* have been observed occasionally within the ventricle, dividing it into two compartments.


They are more frequent between the vocal cords; the least developed forms appear as a mere broadening of the commissure.

Extensive membrane-formations, sometimes of the hardness of cartilage and always beginning at the commissure, produce severe dyspnea in addition to complete aphonia, and often demand radical excision, to be followed by a course of stretching.

Membranes have even been observed above the vocal cords, completely covering the glottis.

The treatment is the same.

We have already referred to the occurrence of dislocated tissue from the thyroid gland on p. 81.





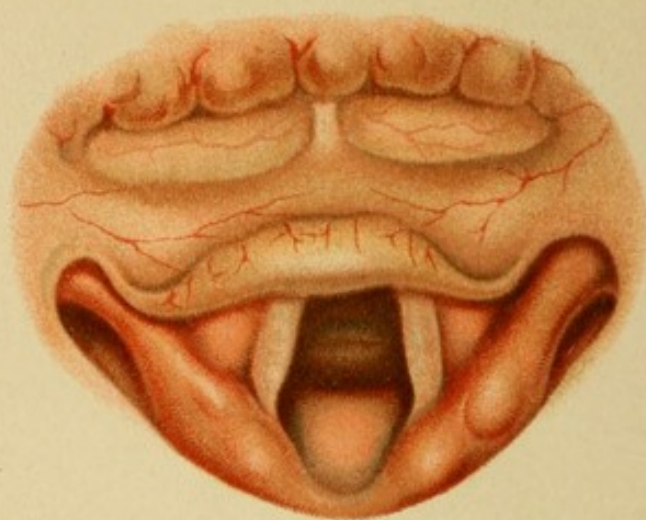


Fig. 2.

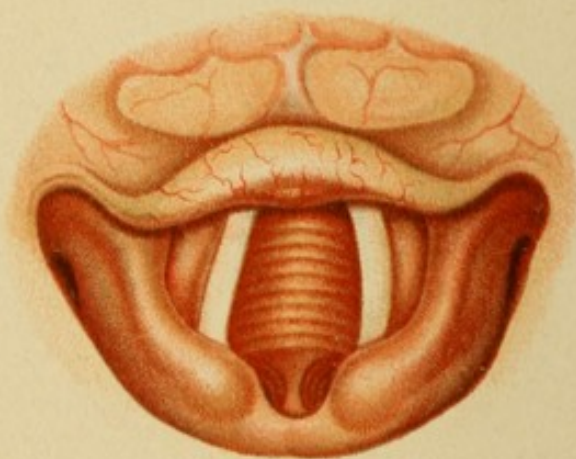


Fig. 1.


PLATE 1.

Fig. 1

shows an image of the anterior surface of the epiglottis taken in the Killian posture (head bent well forward); the lower border of the cricoid is seen projecting from the trachea, which is exposed to some depth.

Fig. 2

is the picture of a very large and wide female larynx, showing the anterior wall of the trachea, the bifurcation, and parts of the main bronchi.






PLATE 2.

Fig. 1.

represents the shape of a child's larynx (the "omega" shape). The posterior parts are sometimes even more approximated, so that the aperture of the larynx is entirely covered.

Fig. 2.

A gentleman, 65 years old, has an enormously enlarged neck from a struma (circumference, $51\frac{1}{2}$ cm.).

The larynx is displaced to the left about 3 cm. from the middle line; the upper border of the cricoid is higher on the right, than on the left side. Marked stridor and cyanosis point to a stenosis. Voice normal.

The epiglottis and the posterior wall are bent slightly backward on the right side. The right true and false vocal cords cannot be seen at all, as the commissure is under the middle of the petiolus, instead of, as usual, at the right angle of the epiglottis.

In phonation the left vocal cord is drawn far over to the right and the arytenoid cartilage is drawn sharply inward. The peculiar image is therefore due to

Oblique Position of the Larynx from Struma.

Fig. 3.

A woman, 46 years old, complains of difficulty in swallowing for the past year; there is no pain, but inability to swallow any large morsel.

There is nothing abnormal in the pharynx.

Larynx.—There is not much alteration, except a broad red swelling which projects from the posterior wall.

The tumor does not move in phonation; on the contrary, the posterior wall is seen to glide past it, and it becomes evident that the tumor does not arise from the larynx.

Digital palpation reveals that it is seated immediately above, but not in relation with the aperture of the larynx, and extends sideways as well as upward and downward on the posterior wall of the pharynx. The tumor is very hard and the mucous membrane is stretched very tight. This tumor must, therefore, originate in the vertebræ, and probably has nothing to do with the dysphagia, as the finger easily glides past it into the sinus pyriformis. It is, in fact, an old

Lordosis of the Cervical Vertebræ.

A sound was introduced, and the dysphagia explained by the finding of a solid obstacle in the esophagus, in the neighborhood of the bifurcation.

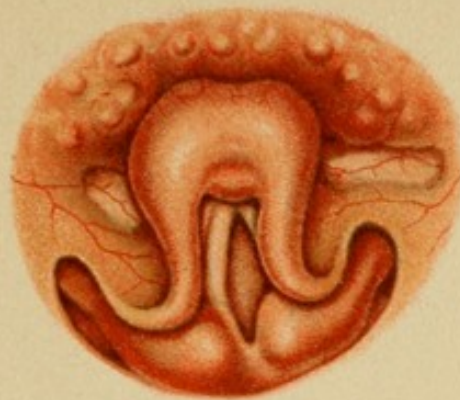


Fig. 1.

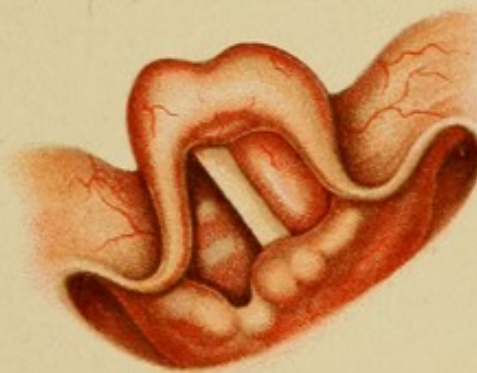

Fig. 2.

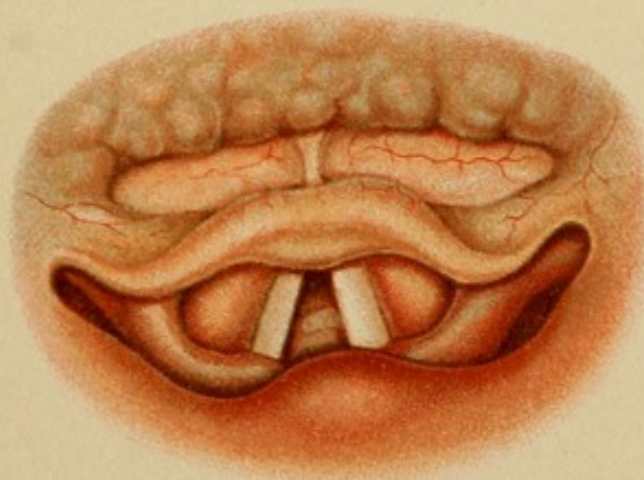



Fig. 3.





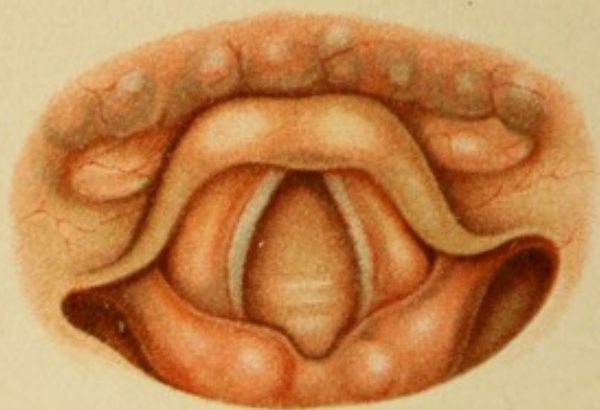


Fig. 1.

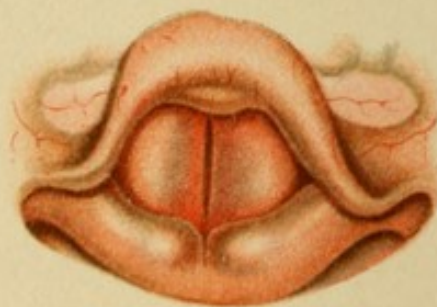

Fig. 2.




PLATE 3.

Fig. 1

represents a normal larynx of somewhat unusual appearance, because in respiration the true vocal cords recede more than is normal under the ventricular bands, the latter making a wide curve inward and backward.

Fig. 2.

A man, 27 years old, has a deep, rough voice and betrays great exertion during phonation. We may mention briefly that anamnesis and examination reveal recently developed tuberculosis of the lungs and larynx (slight infiltration of the posterior wall and pale, relaxed vocal cords).

In phonation the true vocal cords suddenly disappear under the ventricular bands, which are drawn unusually far toward the middle line; the edges of the latter are slightly red and form another superior glottis, responding to the current of air by perceptible, coarse vibrations. It is the picture of so-called

Vicarious Phonation of False Vocal Cords.

Fig. 3.

A girl, 17 years old, is examined for nose-bleed and headache, which are found to be caused by deep tertiary syphilitic ulcers in the interior of the nose. Deficiencies in the soft palate and uvula show that similar processes have taken place before. The voice has a good sound, but its quality, owing to these deficiencies, is nasal.

Laryngoscopy at once shows an extensive destruction involving more than half the epiglottis. Of the latter only the anterior, basal half remains. There are several notches on the left side and a deep incision in the middle. What remains is pale red; the edge is slightly wavy, and the surface covered with fairly uniform, flat nodules.

The other parts are pale but otherwise intact. From the findings in other parts of the body it is evident that these alterations are the

Remains of Syphilitic Ulcers.

PLATE 4.

Fig. 1.

A gentleman, 54 years old, with all the signs of a *viveur*, has been hoarse for the past six weeks. Home remedies had no effect.

Nothing abnormal in mouth, nose, or fauces.

Laryngoscopy shows the right edge of the epiglottis to be hypertrophied and slightly red. The hypertrophy consists of several smooth, round nodules, about the size of a barley-corn. The right true and false vocal cords are slightly red and hypertrophied.

No swelling of glands nor abnormalities in the skin or skeleton could be made out; lungs and heart normal. Patient denies any infection but gonorrhea. The nodules on the epiglottis can hardly be regarded as swollen lymph-follicles, though they exist in this region; the fact that they are limited to one side, and the unilateral inflammation of deeper-lying parts, point either to an infectious or to a malignant process. The latter is excluded by the occurrence of two essentially different eruptions in different localities. There remain tuberculosis and syphilis. The former is improbable in view of the man's general health, which is robust, and also on account of the short duration and the marked inflammatory symptoms. Everything is in favor of syphilis; his denial goes for nothing. We have to deal with the initial stage of a tertiary process with

Fresh Gummata on the Epiglottis and Syphilitic Infiltration of the Right True Vocal Cord.

Fig. 2.

A heavy drinker, 32 years old, has been suffering from hoarseness and occasional irritating cough for six months. No expectoration. No family history could be obtained. The voice is entirely without sound. The fauces present nothing unusual; the mucous membrane is thickened and of a dull red, as is frequently the case with drinkers.

Larynx.—The under surface of the epiglottis is somewhat broad and covered with numerous flat, pale red nodules closely packed together. Similar nodules are seen along both true and false vocal cords and on the anterior surface of the arytenoid cartilages; in the latter situation they take the form of actual tumors.

Movement of both cords is only slightly impaired. Although examination of the lungs gives no very abnormal result, the appearance of the chronic, nodular, and diffuse infiltration in various situations permits the diagnosis of

Tuberculosis resembling Lupus.

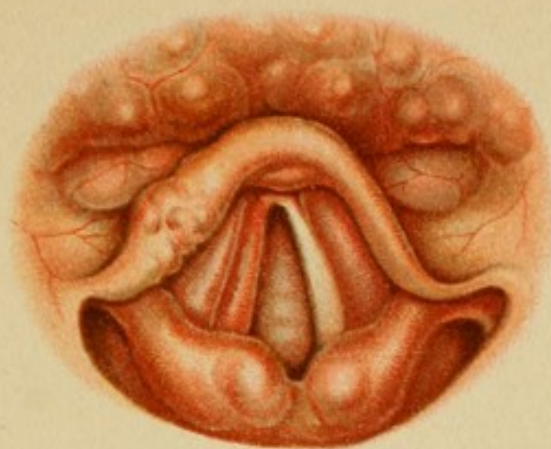


Fig. 1.

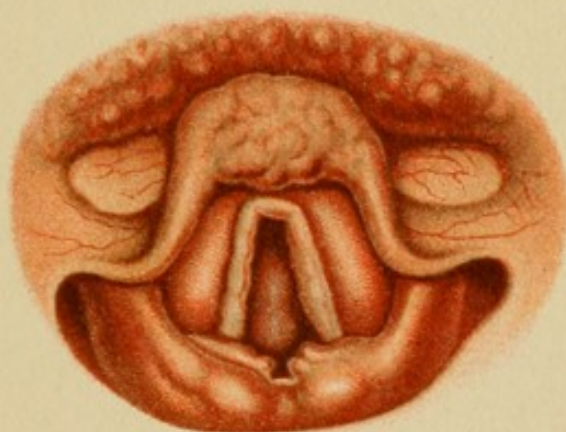


Fig. 2.

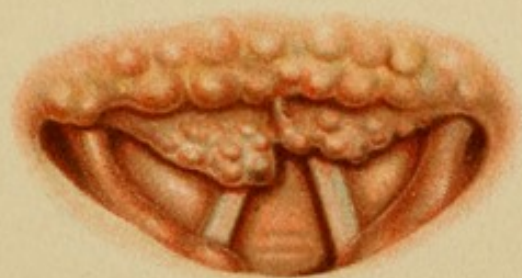



Fig. 3.





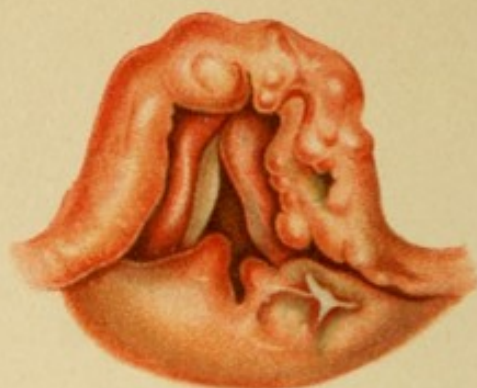


Fig. 1.

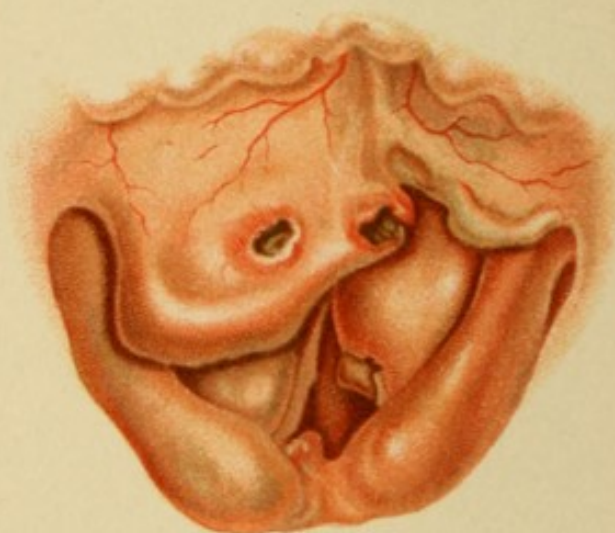

Fig. 2.

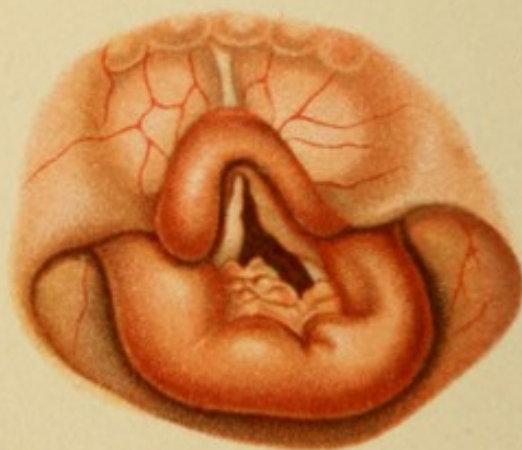

Fig. 3.

PLATE 5.

Fig. 1.

A man, 45 years old, has been suffering for six months with increasing hoarseness and, lately, dyspnea on going up-stairs, etc. He himself attributes his trouble to a chancre-infection received four years ago.

The voice is raucous and almost without sound; the general appearance is robust and well nourished; lungs are sound, only the inguinal glands are slightly swollen. In the nose there is nothing abnormal, but on the posterior wall of the pharynx are seen welt-like scars, and the **larynx** presents extensive changes.

The epiglottis as a whole is hypertrophied; the edges, especially the anterior, uneven and in parts covered with large nodules.

The left half presents a deep fissure, so that a superficial fragment can be isolated from the deeper-lying remainder of the substance. The posterior portion is further defaced by a discolored, dirty-yellow ulcer.

The left true and false vocal cords are replaced by a thick, wavy strip of dense, dark-red tissue; the right ventricular band is of a brighter red, and swollen in front and behind to such a degree that it completely covers the true cord, which is also hypertrophied and yellowish-red in color. A thick red projection rises abruptly from the posterior wall on the right side, and a lower ragged excrescence on the left side, as well as the investment of the arytenoid cartilage, is covered by a radiating white scar.

Without a histological examination of extirpated tissue, or the observation of the subsequent course of the disease, it is impossible to decide between

Syphilis and Tuberculosis.

(Later the disease turns out to be purely syphilitic in character. The hyperplasia on the posterior wall is due to a latent perichondritis.)

Fig. 2.

A man, 32 years old, was treated a year ago for tertiary syphilis of the nose. Now he complains that his throat has been troubling him for several months and he has gradually almost lost his voice.

Nothing unusual in the fauces.

In the place of the epiglottis we see a shapeless mass of tissue: a broad, irregular plate, the free edge very much thickened, overhangs the left side of the epiglottis. The upper surface presents two circumscribed inflammatory areas and, in the center of each, an ulcer as large as a pea with well-marked

edges and dirty-yellow floor; the one lying near the middle line has taken part in the destruction of the free edge of the overhanging plate. A deep ragged cleft separates this entire mass from a smaller fragment on the left, which evidently represents the remains of the left half of the epiglottis.

Owing to the swollen ventricular band the vocal cord on the right side appears to be narrowed, injected, and rough (at the free edge); on the left side it is entirely hidden by the ventricular band, which is very red and swollen. All that apparently remains of the true cord is a spur projecting from under a similar ulcer to the one just described, and perhaps the remains of the processus vocalis. Both aryepiglottidean ligaments are likewise red and swollen; the right one has a yellowish hue. From under the latter a blunt red pyramid about half as large as a pea is seen to project into the lumen.

The appearance of these sharply circumscribed ulcers, even without the anamnesia, gives the diagnosis of

Tertiary Infiltrative and Destructive Syphilis.

Fig. 3.

A man, 40 years old, was infected with syphilis seventeen years ago; since then he has had manifestations of the disease in the skin of the back, on the shins, in the nose, and finally, six years ago, in the larynx. Although the laryngeal affection was relieved by general treatment, as far as the pain was concerned, he now begins to suffer more and more from dyspnea.

The entire larynx is deformed. The epiglottis consists of a swollen band, thicker on the right side than on the left and approaching the turban-shape. The surface is smooth and red. The ventricular bands are replaced by thick pale-red shreds of tissue; only one little corner of the vocal cord is seen on the left side, the right does not appear at all (not even in phonation). The entire posterior wall is converted into a massive horseshoe, on the anterior surface of which are two broad elevations, the left one marked with a notch. A number of smaller convolutions, resembling a chain of hills, spring from the anterior surface of the cricoid cartilage. The mucous membrane appears to be intact everywhere.

The voice is feeble and of a deep, grunting quality (false vocal cord phonation).

The whole picture may be explained as the remains of destructive gummata, although the hypertrophy of the posterior wall is very remarkable.


The proliferation of the tumors must be restricted in order to relieve the dyspnea: microscopic examination of the extirpated portions reveals only harmless connective tissue and epithelial proliferation. (See Pl. 41, Fig. 1.)

The tumors recur, however, and pain is frequently felt in speaking and in swallowing.

This state of affairs continues several years. The long duration without material changes in the type, more, even, than the histological picture, excludes malignant growths. Nor have we to deal with syphilitic manifestations, as there is no reaction to mercury or potassium iodid, and no signs are found elsewhere on the body. We are therefore inclined to regard the recurring proliferations as the expression of the reaction to a still-existing inflammatory irritation, to which we may also refer the hypertrophy of the posterior wall.

We assume then, with some show of probability, a

Chronic Secondary (Post-syphilitic) Perichondritis,
caused by necroses which have not yet been eliminated.





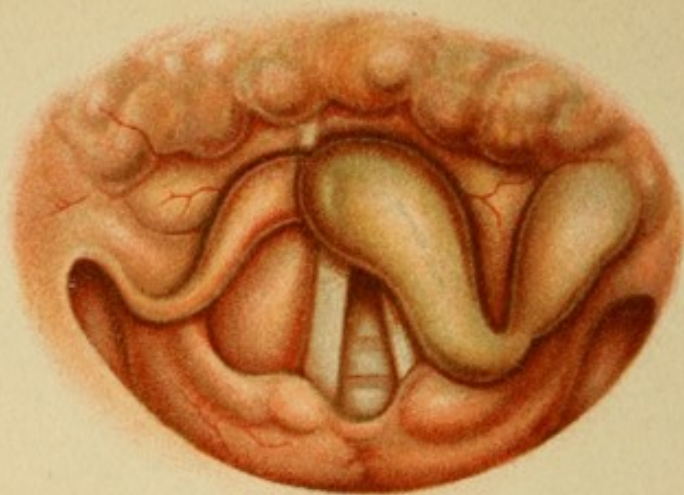


Fig. 1.

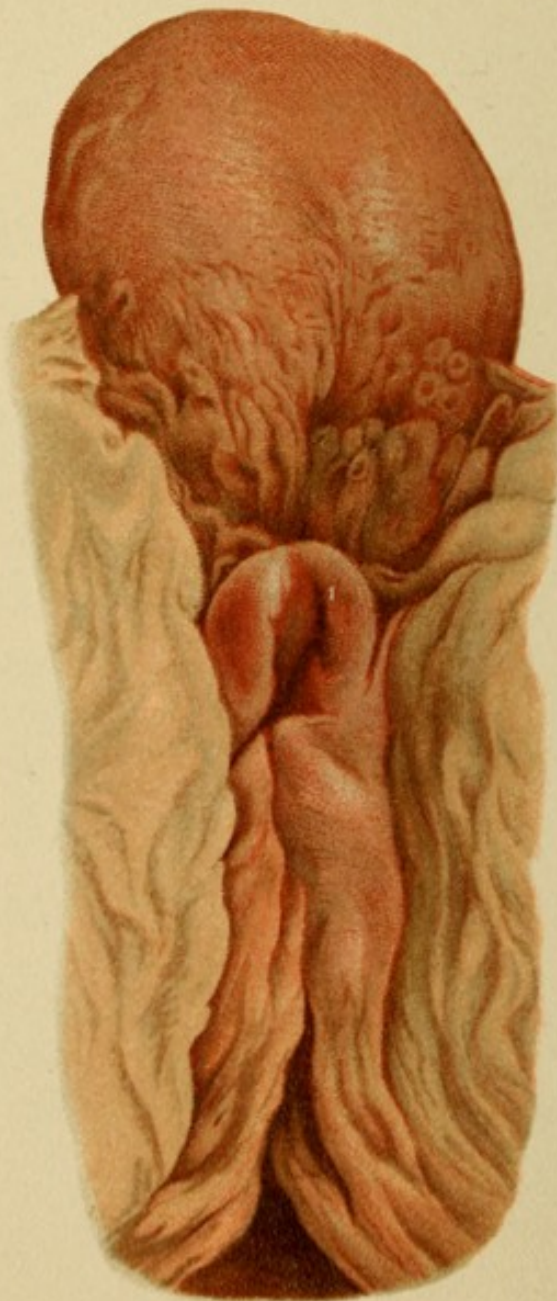


Fig. 2.

PLATE 7.

Fig. 1.

A single woman, 31 years old, has been ill two days with fever, sore-throat, and hoarseness. No dyspnea. The soft palate and both tonsils are slightly red; the left tonsil slightly enlarged and flecked with pus. The posterior pillar on the right side is also slightly enlarged.

Submaxillary glands on the left side palpable and painful.

Laryngoscopy.—The entire left half of the epiglottis, as well as the left glosso-epiglottidean ligament, is converted into tense, shiny tumors of a yellowish-gray color. The left ary-epiglottidean ligament is slightly thickened. The vocal cords, on the other hand, are white.

Their mobility is, however, much impaired: both approximation and tension are incomplete in phonation.

The picture is interpreted as that of

Acute Infectious Edema

originating in tonsillar infection.

Fig. 2

is the postmortem picture of the larynx of a very fat man who died suddenly of asphyxia. The entire epiglottis and the mucous membrane covering the right half of the cricoid cartilage are puffed out and very red and swollen. In this case a more intense process was at work than in the last illustration—an

Acute Infectious Phlegmon,

probably erysipelatous in character.

PLATE 8.

Fig. 1.

A man with a weak, sighing, high-pitched voice comes with a history of acute catarrh which began ten days ago.

In this case also the arytenoidean region is especially inflamed, although the rest of the laryngeal mucous membrane is likewise somewhat injected. During phonation the posterior part of the glottis remains open in the form of a triangle, while the anterior part is spasmodically closed.

It is therefore an

Inflammatory Paralysis of the Transverse Arytenoid Muscle.

Fig. 2.

A man, 38 years old, caught cold at a ball two days ago and has been hoarse since. His throat is dry and he has a "scratchy" feeling when he swallows.

The uvula is slightly red; otherwise the fauces are normal.

The redness is limited to the internal edges of the true vocal cords, and is especially marked between the two arytenoid cartilages. There is almost no sound in phonation, the arytenoid cartilages not approximating perfectly; the glottis forms a double ellipse, the point of tangency being at the apices of the two vocal processes.

Diagnosis:


Inflammatory Paralysis of the Internal Thyro-arytenoid and of the Transverse Arytenoid Muscles.

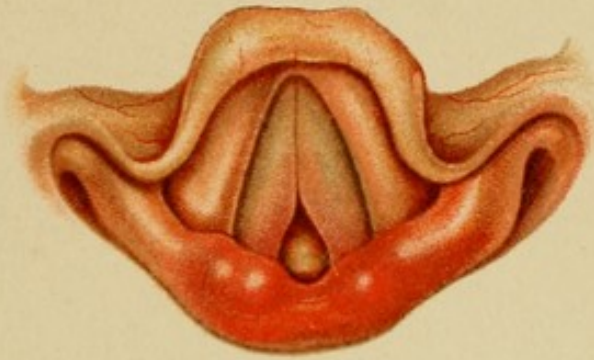

Fig. 1.

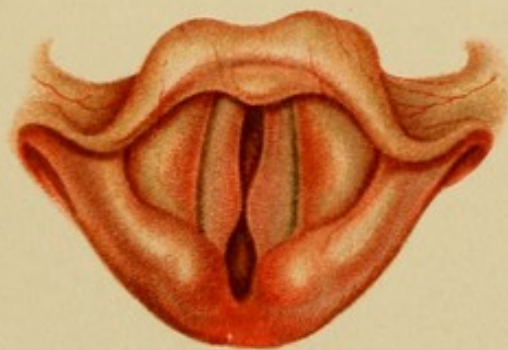

Fig. 2.





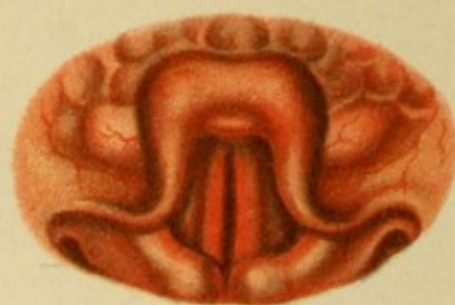


Fig. 1.

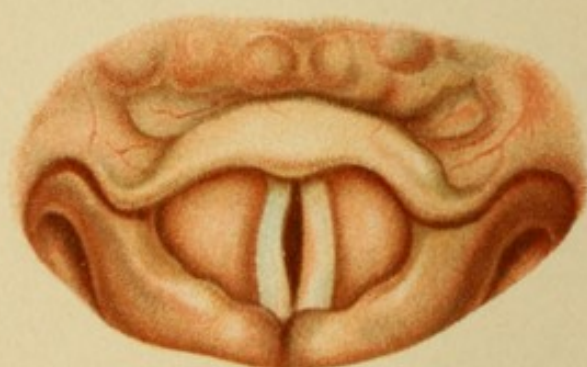


Fig. 2.

PLATE 9.

Fig. 1.

A girl, 25 years old, with a history similar to that of Fig. 2 in Pl. 8, presents a somewhat different picture.

The epiglottis is strongly injected and the mucous membrane over the arytenoid cartilages also appears red, especially the vocal cords. In phonation they exhibit a rather wide elliptical cleft; the voice is rough and very feeble.

We have to deal with a case of

Acute Laryngeal Catarrh with Inflammatory Paresis of the Internal Thyro-arytenoid Muscles.

Fig. 2.

Marked vocal disturbance is the most conspicuous symptom in a man suffering from incipient tuberculous infiltration of both apices.

The epiglottis is unusually pale; the outline of the free margin is interrupted by two small, nodular eminences on the left side.

The rima glottidis gapes during phonation, because the pars phonatoria of the right vocal cord presents an elliptical concavity of the free edge. The left cord is properly stretched, but its middle third shows an area of redness limited externally by a convex boundary.

This "unilateral catarrh" without any other symptoms is suspicious. The want of tone in the right vocal cord is probably not due to muscular weakness alone, such as occurs in the early stages of tuberculosis, but, from the fact that it is unilateral, also to tuberculous infiltration of the thyro-arytenoid muscle. Besides, the nature of the nodules on the epiglottis is unmistakable. We must, therefore, diagnose

Multiple Tuberculous Infiltrations in the Early Stage.

PLATE 10.

Fig. 1.

A gentleman, 65 years old, is hampered in the discharge of his professional duties by an intense hoarseness which has been recurring at varying intervals for years. The present attack began six weeks ago. He also complains of violent "stomach-trouble," which manifests itself in morning retching and vomiting, although the appetite is entirely undisturbed. He has been very temperate in the use of alcohol and tobacco for years.

Examination of the chest reveals only slight emphysema with traces of bronchial catarrh.

The fauces are of a dusky red; the mucous membrane everywhere presents an uneven surface traversed by dilated veins; even the base of the tongue is hypertrophied and deep red in color.

In the pharynx some tough mucus. Traces of a similar secretion are seen on the floor of the nose and on the septum in front.

The anterior extremities of the middle turbinated bones are enlarged.

The larynx, as a whole, is of a dark-red color. A smooth fold of mucous membrane projects from the posterior wall, and similar ones from the lower borders of the vocal processes. On the posterior portions of the vocal cords are seen some irregular dark-red spots, flat and adherent, not movable in coughing.

This is a general picture of **secondary chronic laryngitis**, somewhat specialized in this case by

Inflammatory Hyperplasiæ and Hemorrhages.

Fig. 2.

A girl, 17 years old, has been suffering for six months with hoarseness and loss of appetite. Every morning she hawks up and discharges from the nose a great quantity of tough, yellow mucus. The act is attended with much difficulty and often followed by complete aphonia. The father has tuberculosis of the larynx. The voice is very rough and croaking, and often changes suddenly to a different register. The general condition is reduced ("flaccid"); complexion a dirty yellow, although the mucous membrane of the mouth is not much discolored. Lungs and heart normal. Urine free from albumin.

The posterior wall of the pharynx and the arch of the palate are covered with tough masses of mucus; also the anterior extremities of both middle and turbinated bones. (Upon closer examination a purulent focus is found on both sides of the septum in front.)

Larynx.—General anemia. Both vocal cords are of a yellowish-gray, covered with spots; the surface uneven and giving the effect of maceration; the free edges are rough, so that closure is incomplete during phonation (Fig. 2a).

The diagnosis of **secondary maceration of the true vocal cords by pus from the nose**, which was made from the objective signs, is confirmed by the subsequent course, inasmuch as all the phenomena were made to disappear by treating the purulent focus in the nose.

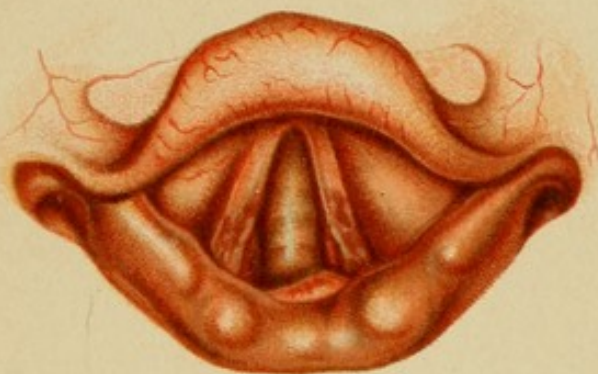

Fig. 1.

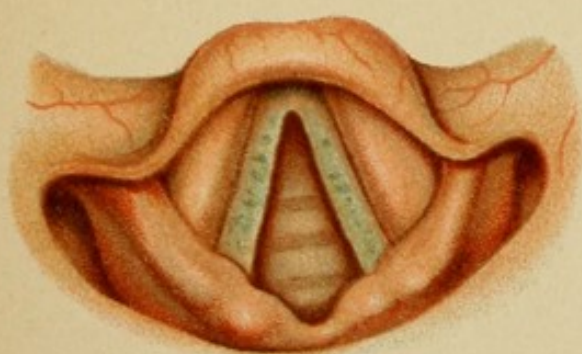


Fig. 2.

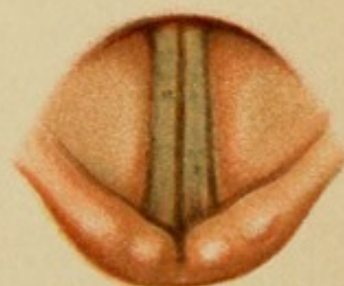



Fig. 3.





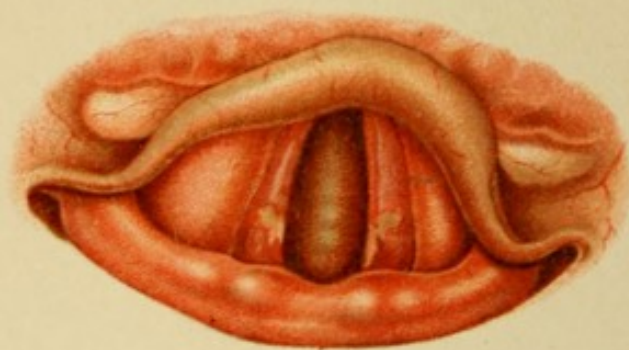


Fig. 1.

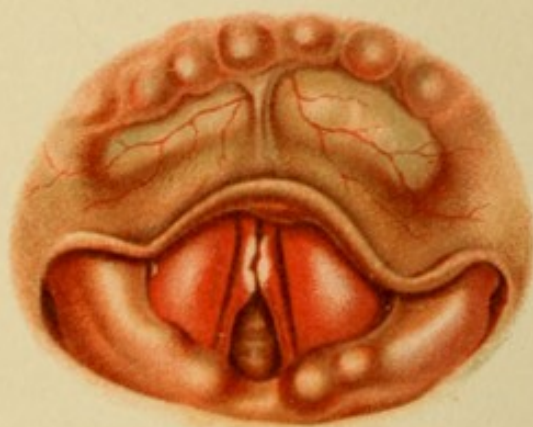

Fig. 2.

PLATE 11.

Fig. 1.

A gentleman, in his 56th year, seeks advice for hoarseness which began about six months ago. The voice is deep, toneless, and rough; sometimes it is lost entirely. The man has a well-nourished appearance; is not too fat for his years; his face is somewhat red. There is a little cough, weak and noiseless and sometimes painful. He complains chiefly of dryness and occasional stabbing-pains in the throat; the patient has been a heavy smoker, but a moderate drinker. Physical examination reveals some enlargement of the lung-area, otherwise nothing abnormal.

The entire larynx, and especially the vocal cords, are very red. The latter also exhibit a yellow discoloration in the neighborhood of the apices of the vocal processes, circumscribed in character and not affected by cough, extending over the upper surface and along the inner margin.

They are, therefore, not depositions of secretions, but alterations of the epithelium itself—erosions. As there are no grounds for suspecting any other cause than the evident catarrhal condition, they may be regarded as

Catarrhal Erosive Ulcers

of decubital origin (from compression of the processus vocales).

Fig. 2.

An apparently healthy man, 62 years of age, lost his voice three weeks ago; it had been growing weaker and weaker for some time. He says he has never been sick. Nothing abnormal in nose and throat. Aphonia.

The posterior half of each vocal cord is apparently narrowed, while the anterior portion is thrust forward in the form of a flabby irregular lobule. These lobules are of a dull-white color, while the remaining visible portions of the vocal cords and the median borders of the ventricular bands are intensely red. The apparent narrowing of the vocal cords is due to the inflammatory swelling of the ventricular bands.

These alterations, from their *acute* onset, permit of but one interpretation; they are

Syphilitic Papillomata.

Neither the patient's age nor his denial should affect the diagnosis.

PLATE 12.

Fig. 1.

A young man who was affected with syphilis ten weeks ago complains of pain in the mouth and throat; he took cold two weeks ago and has since become hoarse.

In the mouth conspicuous condylomata are seen on the mucous membranes of the cheek. The entire larynx is somewhat injected. Both vocal cords are red, the right more than the left. Over the right vocal process there is a whitish-yellow prominence with sharply defined red base reposing on the somewhat swollen background—a true

Syphilitic Papilloma.

Fig. 2.

A man, 30 years old, who has been under treatment for pulmonary tuberculosis for years and has been much benefited by climatic cures, seeks relief for chronic hoarseness.

The voice is raucous but loud.

There is some dulness at the apices of both lungs, with circumscribed bronchial breathing and a few râles.

The larynx as a whole is rather pale. The posterior wall, which is hypertrophied, presents on its anterior surface several rows of flat, wavy elevations merging into one another. The left vocal cord is reduced to a narrow strip; the right, which is broader and has an uneven edge, presents about the middle a whitish eminence surrounded by a narrow, pale-red zone of inflammatory tissue; behind the latter two other nodules are seen, pale red in color and about the size of a millet-seed. The right ventricular band appears to blend with these nodules, and for the rest is also swollen and convoluted.

On the left side we probably have the remains of a destructive process; *cicatrizization* is now complete, as is shown by the absence of proliferation or inflammation. On the right side the process is evidently still going on, while the hypertrophy of the posterior wall appears to depend on deeper-lying alterations, since the superficial proliferations still persist. The entire picture, viewed in connection with the anamnesis, represents therefore a

Mixture of Destructive and Retrogressive Tuberculous Infiltrations.

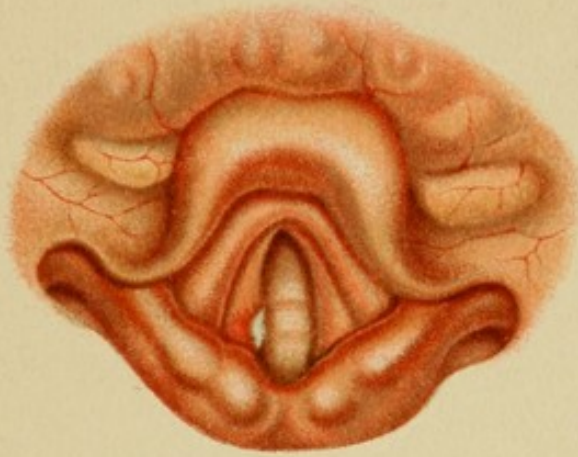



Fig. 1.

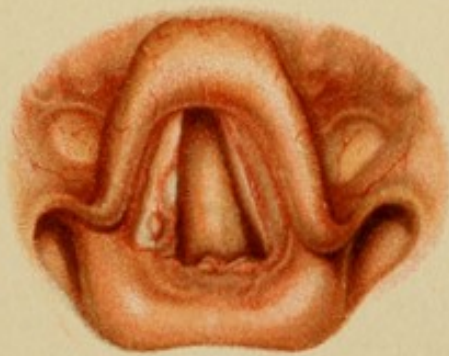

Fig. 2.





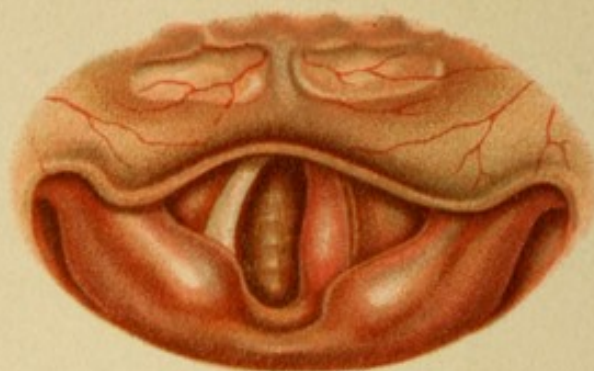


Fig. 1.

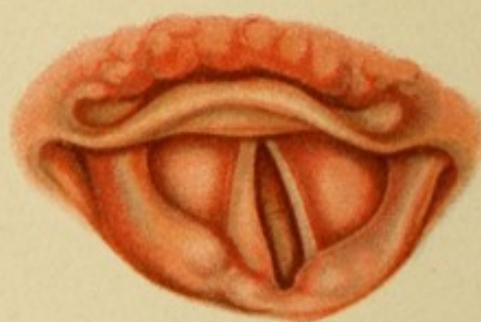

Fig. 2.

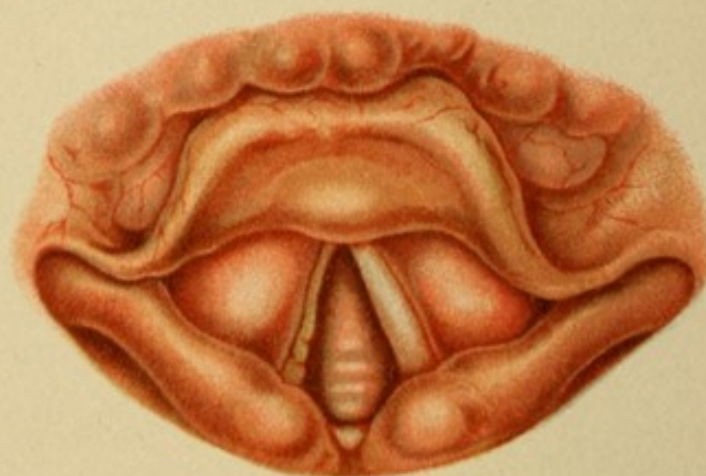

Fig. 3.

PLATE 13.

Fig. 1.

A woman, 28 years old, has been suffering for the past week with pain in the left side of the throat radiating toward the ear. The voice was entirely without sound; sometimes the patient could not speak above a whisper. Now the voice is croaking, and small in volume almost to aphonia. The woman is well nourished and shows no signs of illness. She says she has always been well.

In the larynx everything is normal but the left vocal cord. It is almost twice as broad as its fellow, of a rounded form and strongly injected.

Mobility is only slightly impaired.

These phenomena are apparently purely catarrhal in character, but there is no such thing as unilateral catarrh; such affections always depend upon a deeper lesion, usually of an infectious nature. That it is infectious in this case is proved by the short duration, which, together with the intense inflammation, leads us to decide in favor of syphilis. Although the anamnesis furnishes no positive data, we nevertheless abide by this diagnosis and conclude that we have to deal with the tertiary period. It is, therefore, a

Gummatous Infiltration of the Vocal Cord.

Fig. 2.

A girl, 16 years old, has been hoarse ever since she had diphtheria, nine years ago. Although she is slender and delicate, and rather pale, heart- and lung-examination reveals nothing abnormal; the slight degree of anemia may perhaps be explained by her previous residence in an educational institution. The voice is almost without sound; air-waste during phonation is plainly perceptible.

On examining the larynx (which is oblique) we are at once struck by the cadaver position of the left vocal cord. It is also much narrower and somewhat paler than its fellow. The free edge is slightly concave and curves outward.

During phonation it remains immovable, while the right is approximated. At the same time the right vocal process is seen to spring forward. On the left side the upper part of the posterior wall appears somewhat narrowed.

The picture is unmistakable:

Paralysis of the Left Recurrent Nerve, with Secondary Atrophy of the Paralyzed Muscles.

Fig. 3.

A gentleman, 47 years old, was infected with syphilis twenty-one years ago, and has since had depositions in the testicles, in the muscles of the upper arm, and in the palm, which always yielded to potassium iodid.

Five months ago he caught a bad cold and became suddenly hoarse. He also had pains radiating toward the right ear; the pains disappeared under potassium iodid and local application of mercurial ointment to the throat; the hoarseness, however, remained.

At the present time there are at both angles of the mouth white, wrinkled condylomata, raised above the surface, not detachable, which do not bleed on being touched. On the inner aspect of the right thigh, over a vein, which can be seen and felt to be slightly thickened, there is a stripe-like, slightly abraded sore.

In the larynx the right vocal cord appears not a little narrowed from the overhanging, hypertrophied ventricular band. The latter is rough and yellowish-gray at the edge and on the surface, especially in its posterior half.

The movements of the vocal cords are uniform and sufficient.

The nature of the disease is not easy to determine. The patient's age and the persistence of infiltration-phenomena in spite of antiluetic treatment arouse a suspicion of malignant growth. But the fact that other syphilitic or postsyphilitic symptoms on the body (leukoplakia and psoriasis) have resisted the treatment argues against this theory. As it sometimes happens that just such chronic forms only heal a long time after the treatment has been discontinued, the diagnosis will depend on the subsequent course of the disease.

Two months later the larynx had practically regained its normal appearance. We therefore had to deal with

Remains of Syphilitic Ulcers.

PLATE 14.

Fig. 1.

A man, 34 years of age, had a chancre four years ago, the nature of which was abundantly explained by a subsequent exanthema. Ten months ago the skin affection broke out afresh, and since then he has had pain in the throat and hoarseness, with occasional aphonia.

The voice is raucous.

The fauces present a diffuse redness.

The larynx as a whole is also injected. The ventricular bands are so swollen that the vocal cords appear to be narrowed. The latter are also red throughout their whole extent, and on the anterior third of their inner margins are smooth, flap-like prominences.

The latter become still more prominent in phonation. The disease is unquestionably of a syphilitic nature, and the only question that remains is: To what pathological category does this picture belong? We evidently have here not mere swellings, but true hyperplasie. They are distinguished from ordinary condylomata by their absolutely smooth surface without epithelial alterations. Remembering that such inflammatory neoplasms may develop in the soil of a chronic catarrhal irritation, although usually found in other situations, we describe these formations as

Connective-tissue Hyperplasie from Protracted Syphilitic Catarrh;
that is to say, as postsyphilitic.

Fig. 2.

A lady, 32 years old, presents herself with a feeble, very hoarse, toneless voice.

This hoarseness has lasted for six months, according to the patient's statement, since a local application to the larynx; before that event there had been occasional improvement in the voice. For several years she has had frequent coughing-spells without apparent cause and without being able to expectorate.

Patient is apparently in a flourishing state of health. The posterior wall of the pharynx is granulated and the pillars are hypertrophied. Irritation of these parts with a sound is immediately followed by spasmodic cough.

Larynx.—The left vocal cord is smooth and somewhat reddened, the anterior two-thirds of the inner edge slightly curved outward. The right cord is pale yellow, the entire surface slightly granulated, and at the boundary between the anterior and middle thirds of the free border there is a flat, rounded, double eminence about the size of a millet-seed.

During phonation this eminence interferes with the approximation of the cords, so that a gap remains at the rear. If the hand is held before the mouth during phonation, the outgoing current of air can be felt (phonatory air-waste). The diagnosis is

Benign Neoplasm of the Vocal Cord.

The microscopic picture after extirpation confirms the diagnosis.

Fig. 3.

A man, 59 years old, has been hoarse for the past two years, but has never had any pain or dyspnea. The voice, besides being hoarse, easily breaks into a falsetto.

The larynx is pale. On the left side, above and below the vocal cords, of which only a narrow strip is visible, are two nodular tumors of fairly uniform thickness and pale, grayish-red color.

During phonation the left true vocal cord remains immovable in cadaveric position.

The middle of the left plate of the thyroid cartilage is slightly rough to the touch. No glands can be felt.

Heart and lungs show no changes but those due to age.

Infection is denied.

The age of the patient, the appearance of the tumor, the sound portion surrounded by proliferations, the infiltrations of the deeper parts about the joint as proved by the fixation of the true vocal cord, and the evident participation of the thyroid cartilage itself on the one hand and, on the other, the absence of any symptoms or data pointing to a syphilitic or a tuberculous infection, induce us to describe the tumor as a malignant one, most probably

Carcinoma.

Experimental excision with a view to operation was not permitted.

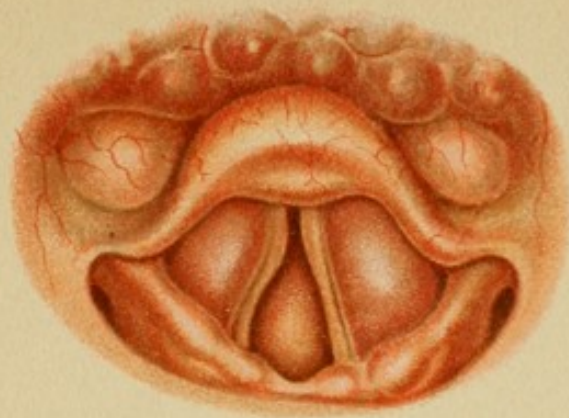


Fig. 1.

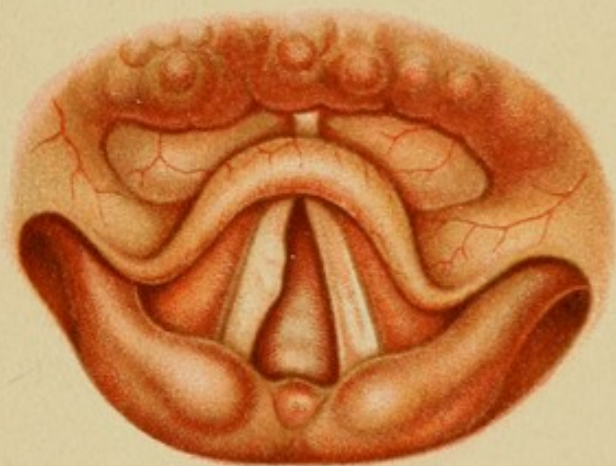


Fig. 2.

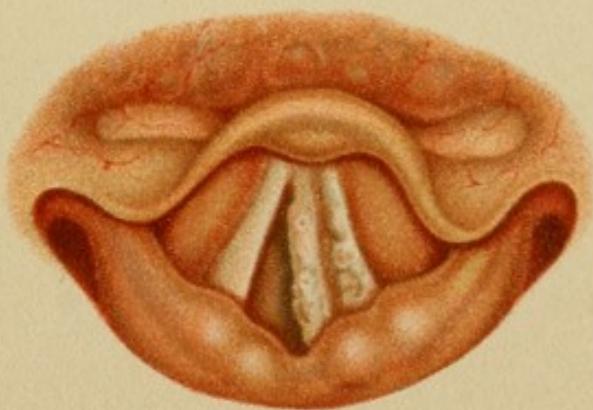

Fig. 3.





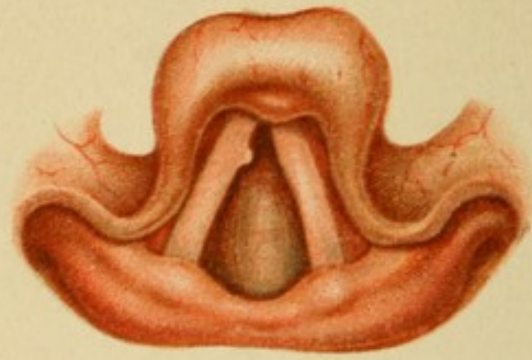


Fig. 1.

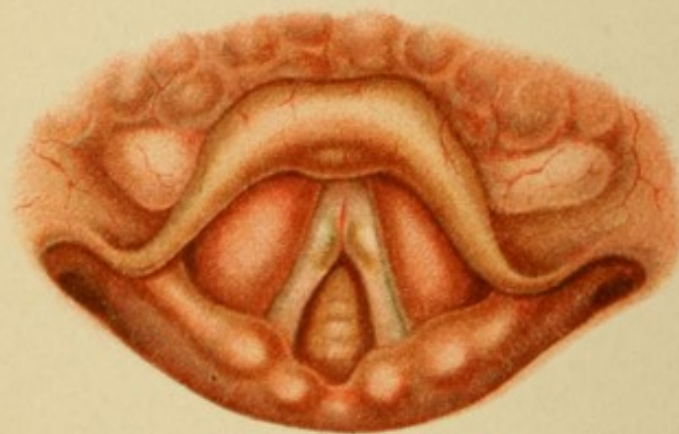

Fig. 2.

PLATE 15.

Fig. 1.

A man, 56 years of age, presents himself for examination on account of dyspnea and asthmatic attacks. Although a well-developed emphysema with chronic bronchial catarrh is recognized as a sufficient cause for these symptoms, the patient's voice is so rough and discordant that the disturbance cannot be wholly attributed to the accompanying chronic hyperemia of the upper air-passages.

Laryngoscopy reveals the cause in a round, shining, white tumor, as large as the head of a pin, situated on the free border of the right vocal cord, at the boundary between the anterior and middle thirds. The cord is rather inflamed and, on the whole, somewhat broader than its fellow.

The movements are not affected, the disturbance being due to encroachment by the tumor on the rima glottidis. Its peculiar appearance, the patient's age, and the comparatively short duration—six months—of the hoarseness, lead us to suspect a malignant growth. A trial extirpation, penetrating to apparently healthy tissue, proves quite reassuring, as shown in Pl. 33, Fig. 3. It is, therefore, a

Hard Wart.

The future course of the disease must, however, be carefully watched.

Fig. 2.

A robust man, 32 years of age, has noticed an alteration in his voice for the past year. At the present time it is deep, rough, and vibrating, sometimes almost toneless.

The larynx is normal except for a grayish-white, shining eminence on each vocal cord. The tumors are exactly equal in size, about half as large as a lentil, and placed exactly opposite each other, partly on the free border and partly on the upper surface of the respective vocal cord, at the boundary between the middle and anterior thirds. The remaining portions of the cords are slightly inflamed.

During phonation the posterior part of the glottis, of course, stands wide open, as complete approximation is prevented by the intervening tumors.

In the entire absence of other symptoms of disease, and in view of the bilateral distribution of the tumors, we are justified in pronouncing them innocent connective-tissue neoplasms; that is to say,

Edematous Fibromata.

Microscopic examination later showed that the edema had progressed to complete cyst-formation (Pl. 39, Fig. 1).

PLATE 16.

Fig. 1.

A man, 24 years old, complains of hoarseness and aphonia. After much laborious coughing he sometimes succeeds in expectorating small, dried masses of secretion.

The mucous membranes of the fauces are hypertrophied and of a dusky-red color.

Behind the pillars and in the posterior nares some grayish-yellow, mucous secretion is seen. The isthmus is filled up by the hypertrophied tonsils. A similar thick secretion covers the floor of the nose; the posterior extremities of both inferior turbinate bones are enlarged.

A dusky-red discoloration pervades the entire interior of the larynx, especially the vocal cords. The latter are thickened and of a rounded form, the left more so than the right. A receding fold of mucous membrane rises high above the left vocal process in such a way as to make it appear double. It is the typical picture of

Pachydermatous Swelling.

The inflammation which produced the condition was evidently caused by pus from the nose and fauces.

Fig. 2.

A woman, 36 years old, lost her voice six weeks ago. On being closely questioned she admits that she had been hoarse for some time previous. No expectoration, but a good deal of irritative cough and pain in the right ear on swallowing. The mother died of some throat-trouble and a sister was "scrofulous" when she was young. The patient herself had an attack of pleurisy two years ago. She is of rather slight build, but not especially thin. Examination of the chest gives markedly impaired resonance over the right base, and the right apex is somewhat depressed. At this point there is a slight friction-sound in both inspiration and expiration, which does not appear after coughing; the respiratory murmur over the lower area of impaired resonance is weak, but vesicular.

Larynx.—The color of the epiglottis and of the aperture appears somewhat darker than normal. The left ventricular band is irregularly swollen and inflamed. The vocal cord of the same side presents similar alterations, except that the process has gone on to distinct nodule-formation. The right vocal cord appears divided into two parts by a discolored ulcer running lengthwise of the cord and especially marked on the surface. The edges are also hypertrophied and covered with nodules.

This ulcer, the origin of which can easily be traced to decubital softening of a former infiltration, associated with the nodular form of the latter, is very characteristic of

Infiltrative and Ulcerative Tuberculosis.

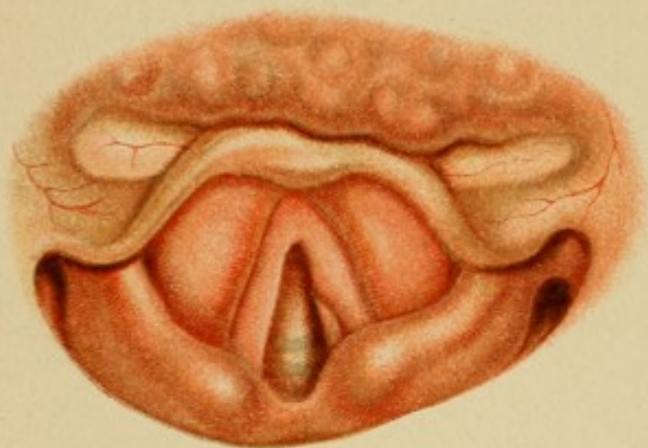

Fig. 1.

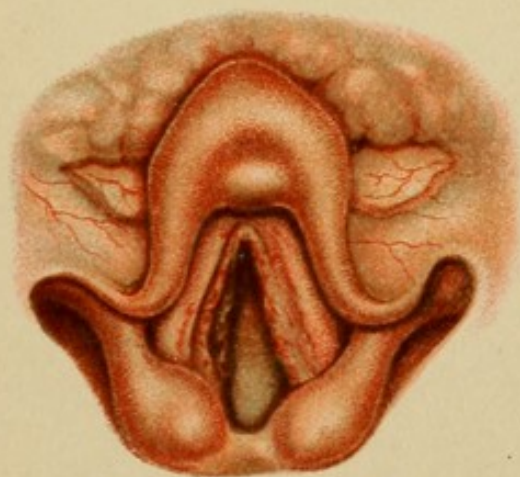




Fig. 2.





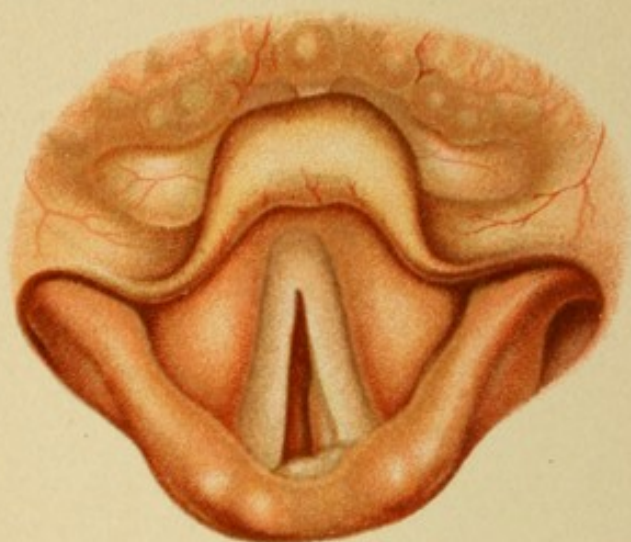


Fig. 1.

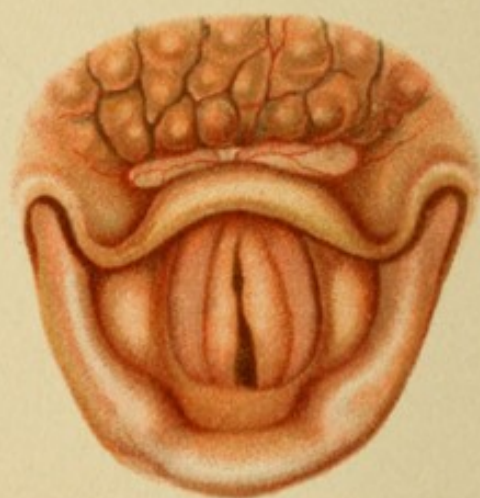

Fig. 2.

PLATE 17.

Fig. 1.

A man, 45 years old, has had dyspnea for the past few months; his voice became rough before the dyspnea, which has been growing steadily worse, developed. The patient appears strong, although thin, with slight cyanosis of nose, ears, chin, and fingers. There is audible inspiratory stridor after violent exercise. The voice is rough and rumbling. No areas of dulness in the lungs; some emphysema and dry catarrh. Arterial sclerosis; heart somewhat enlarged. The mucous membranes are pale and slightly livid.

The same pallor in the larynx. The rima glottidis is extremely narrow, the vocal cords almost meeting in the middle line. A pale strip of tissue projects from under the left cord, along the processus vocalis. Behind this a broad, pale, rather shiny eminence is seen projecting from the posterior wall. (In phonation the right cord is drawn over to the left, which is completely immovable; the same thing happens with the arytenoid cartilages. Palpation of the larynx gives nothing abnormal.)

That this is not a palsy appears from the mobility of the right cord and the position of the left; we have to deal, therefore, with an abnormal fixation of both vocal cords, which must be due to inflammatory or swelling-infiltration; in other words, to destruction of the articular surfaces. The arytenoid cartilages are probably not involved, as there is no swelling over them; we therefore assume disease of the cricoid cartilage, preferably of the left side. The superficial wheals do not resemble neoplastic formations, but point rather to a chronic inflammatory process.

The choice lies between tuberculosis and syphilis, and we decide in favor of the former; it is evident from the steady development of the symptoms that the process is still going on, while, if it were syphilitic, it would have produced more marked signs of inflammation and destruction. While awaiting further developments we are, therefore, justified in assuming

Tuberculous Perichondritis of the Cricoid Cartilage.

Fig. 2.

An unmarried woman, 38 years old, has been troubled with shortness of breath on going up stairs for the past two years, and lately the dyspnea has become very severe.

Five years ago she had typhoid fever, and her voice was bad for a long time afterward.

Loud stridor is heard during inspiration, a somewhat softer breathing-sound during expiration. The face is somewhat bloated, not cyanotic, but pale. The voice is loud and pure, and only occasionally a little hoarse. The larynx moves up and down during respiration; the posture of the head is normal.

The base of the tongue is crossed by bluish-red, dilated vessels; the mucous membrane of the larynx as a whole is pale. The vocal cords are slightly injected and in the cadaver-position. Two pale-red bands, of the same width as the vocal cords, project from under them, curving a little outward in the back part of the glottis. These bands have thin, uneven edges and a smooth surface, and extend almost continuously to the anterior portion of the cricoid cartilage.

During phonation the cords are perfectly approximated, while the subcordal bands remain immovable.

The lungs present only a little enlargement; heart, etc., normal. No swollen glands, nothing suspicious in the anamnesis. The neoplasm may be either malignant in character or it may be due to chronic plastic inflammation. Although the bilateral distribution does not exclude the former, yet the movability of the vocal cords, at least toward the middle line, argues against it. Further observation showed no increase in size. It was a

Stenosis from Chronic Perichondritis of the Cricoid following Typhoid Fever.

PLATE 18.

Fig. 1.

A robust man, 28 years old, has been hoarse for six months. No other symptoms. Syphilis denied. Lungs and heart normal.

The entire larynx presents the picture of chronic inflammation. The vocal cords in particular are thickened and of a dark-red color. The center of the left cord is covered by a smooth, dark-red, spindle-shaped tumor which extends to the ventricular band. The tumor appears to be seated immediately upon the vocal cord, like an extinguisher.

It is small and can easily be pushed aside with a sound, so that it almost disappears under the ventricular band in the ventricle of Morgagni. Everything points to an inflammatory origin. It is the relaxed and hypertrophied mucous membrane of the under surface of the ventricular band which has prolapsed, presenting the picture of

Prolapse of the Ventricle of Morgagni.

Fig. 2.

A woman, 58 years old, has been hoarse for eight years; often she loses her voice entirely. No other symptoms.

The voice is rough and low, easily breaks into falsetto, and is produced with great difficulty.

The larynx is very large. A very red, smooth, semi-elliptical tumor, with blood-vessels ramifying over its surface, projects from the right ventricle of Morgagni and covers the greater part of the vocal cord.

In phonation the tumor is held against the left ventricular band. Examination with a sound reveals a broad base, seated upon the upper surface of the vocal cord.

Both the appearance and the seat of the neoplasm, as well as the external conditions, attest its innocent nature. It is a

Soft Fibroma.

Subsequent microscopical examination confirms the diagnosis.

Fig. 3.

A gentleman, 38 years old, who has been treated for syphilitic ulcers in the throat, complains of hoarseness and a feeling of dryness in the throat for some weeks.

The epiglottis is slightly, the right vocal cord intensely inflamed; the surface of the latter also exhibits areas of yellowish discoloration. The most anterior portion of the vocal cords,

and especially the anterior half of the ventricular bands, are overshadowed by a smooth, dark-red, semi-elliptical tumor, which apparently springs from the posterior surface of the epiglottis.

Although the tumor looks very much like an innocent neoplasm, yet the unilateral character of the inflammation and the destruction of epithelium show that a more complicated process is going on—first infiltrative, then destructive—and the diagnosis of

Tertiary Syphilitic Depositions

finds further support in the anamnesis.

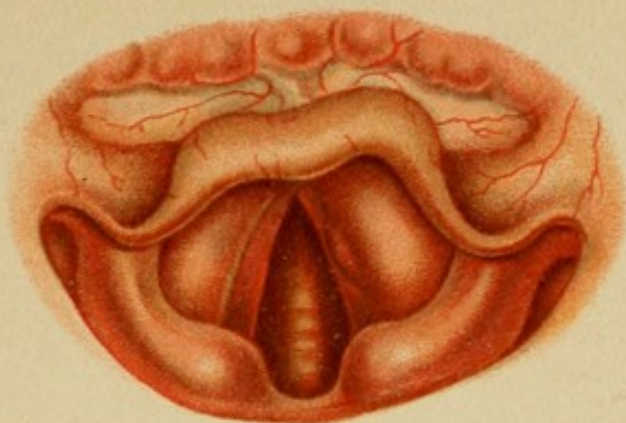


Fig. 1.

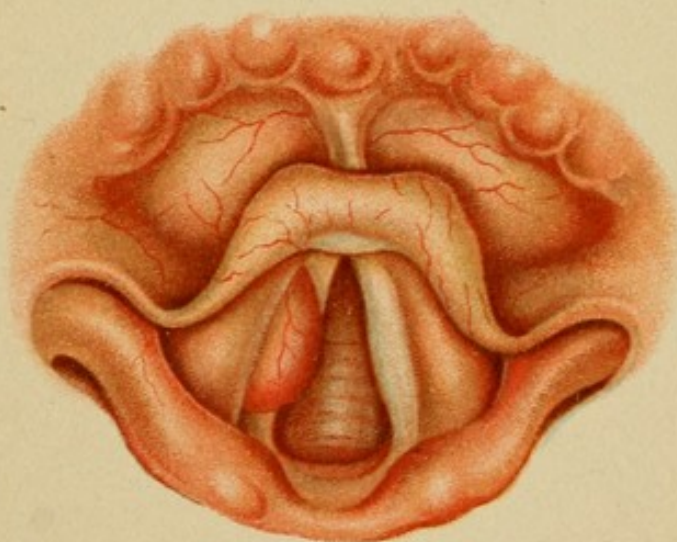


Fig. 2.

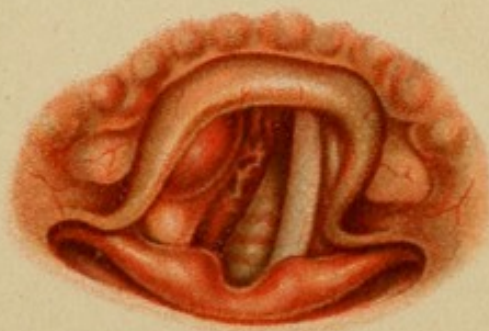

Fig. 3.

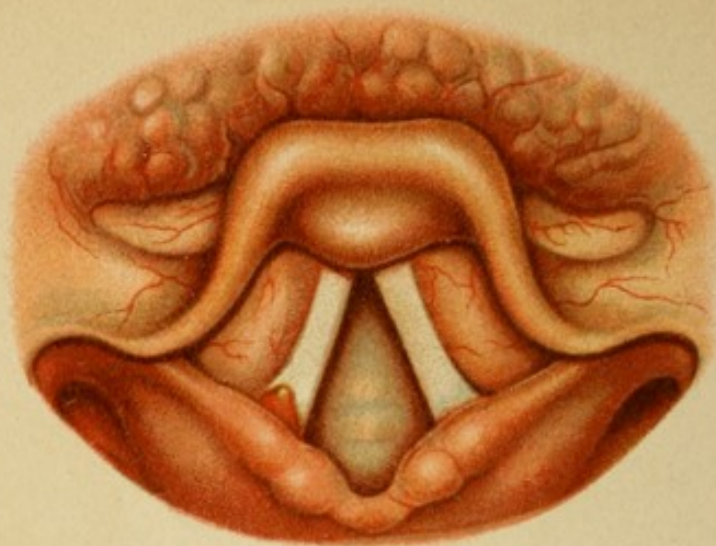


Fig. 1.

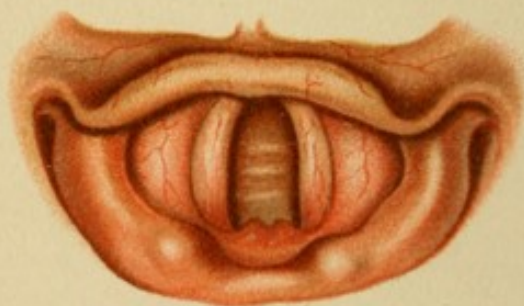


Fig. 2.

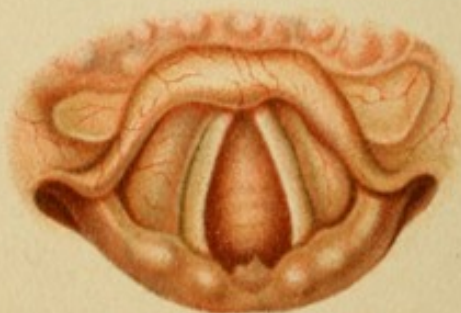

Fig. 3.

PLATE 19.

Fig. 1.

A gentleman, 30 years old, complains of stabbing-pains in the right side of the throat, felt on swallowing and when he wakes up. No cough or fever. The symptoms began a week ago, when the patient took cold after dancing. He also remembers that he swallowed a large piece of candy whole.

The region of the right crico-arytenoidean articulation is painful to pressure from the outside. The throat shows no swelling or inflammation.

Larynx.—A broad, red eminence, capped with a yellowish discoloration, protrudes over the posterior extremity of the right vocal cord in the region of the upper surface of the right cartilage of Wrisberg.

The probe meets with no abnormal resistance, nor does anything else point to the presence of a foreign body. The mobility of the right vocal cord and the voice itself are unimpaired. All the symptoms disappeared within a week with no other treatment than rest. The only possible diagnosis, therefore, is

Circumscribed Inflammation with Abscess-formation

of unknown origin, probably of a traumatic nature.

Fig. 2.

A strongly built man, 27 years old, has had attacks of convulsive cough for a week; no expectoration, or at most a trace of gray mucus.

Nothing abnormal in nose, throat, or lungs.

The entire larynx is slightly inflamed. The redness of the posterior wall is particularly noticeable; on it are seen two flat prominences more intensely colored than the surrounding surface.

The patient was examined a short time ago and nothing of the kind was visible, so that these formations must be of acute origin. The convulsive cough is also very characteristic of

Acute Interarytenoid Laryngitis.

Fig. 3.

A pale, thin girl of 23 says she has noticed a loss of tone in her voice for the past three months; she has also lost strength and perspires very easily. Little cough and no expectoration. The mother died of some lung-disease.

Conjunctivæ, mouth, and throat are very pale. Chest narrow, with slight respiratory movement; auscultation reveals no areas of impaired

resonance or other abnormal signs, only the breath-sounds are very faint. Heart-dulness a little smaller than normal ; pulse 85, and weak.

Nothing abnormal in nose or fauces.

The larynx in general is rather pale ; the posterior wall exhibits a slight jagged dentation ; to the left of the petiolus of the epiglottis the tissues are slightly inflamed and hypertrophied.

It is only by great effort that an approximate closure of the glottis is brought about.

This *want of tone* in the muscles shows that the inflammation of the epiglottis and the formation of the posterior wall are not due to mere irritation of the mucous membrane from external causes, but correspond to the

First Stage of Tuberculous Infiltration.

The positive value of these findings is not diminished by the failure to determine the presence of lung-disease, and is furthermore supported by the general decline of the entire body.




PLATE 20.

Figs. 1 and 2.

The patient mentioned in the preceding history died soon afterward of hemorrhage from the lungs.

FIG. 1.—The larynx is opened from the front; in the middle of the posterior wall is a small ulcer, hardly as large as a lentil, with raised, slightly nodular edges; the floor is of a grayish-green. (The edges appear flatter in the cadaver than in the living subject.) After making two lateral incisions it is found that the destruction is much more extensive than was supposed.

FIG. 2.—The mucous membrane is extensively undermined beyond the domain of the arytenoid cartilages. The floor of the ulcer presents a grayish-green discoloration and is covered with a scanty, thin, purulent secretion.

Palpation with the finger and with the sound shows that the floor of the ulcer is hard and rough; the cartilage is therefore exposed and eroded and at the same time converted into bone. It is the usual process in tuberculosis—

Ossifying and Rarefying Perichondritis and Chondritis.

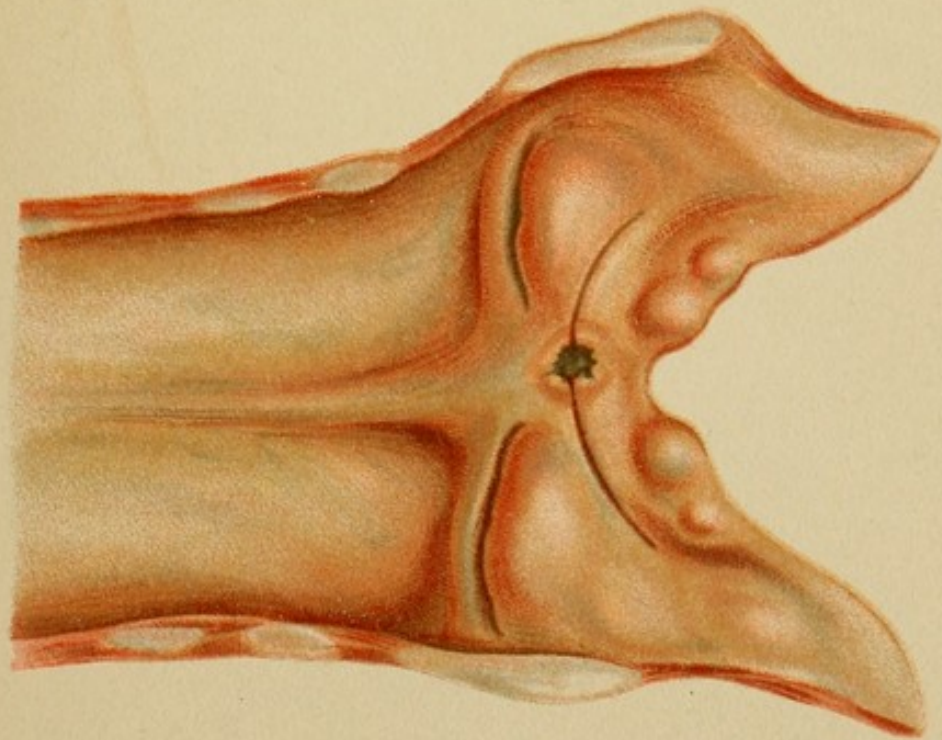


Fig. 1.

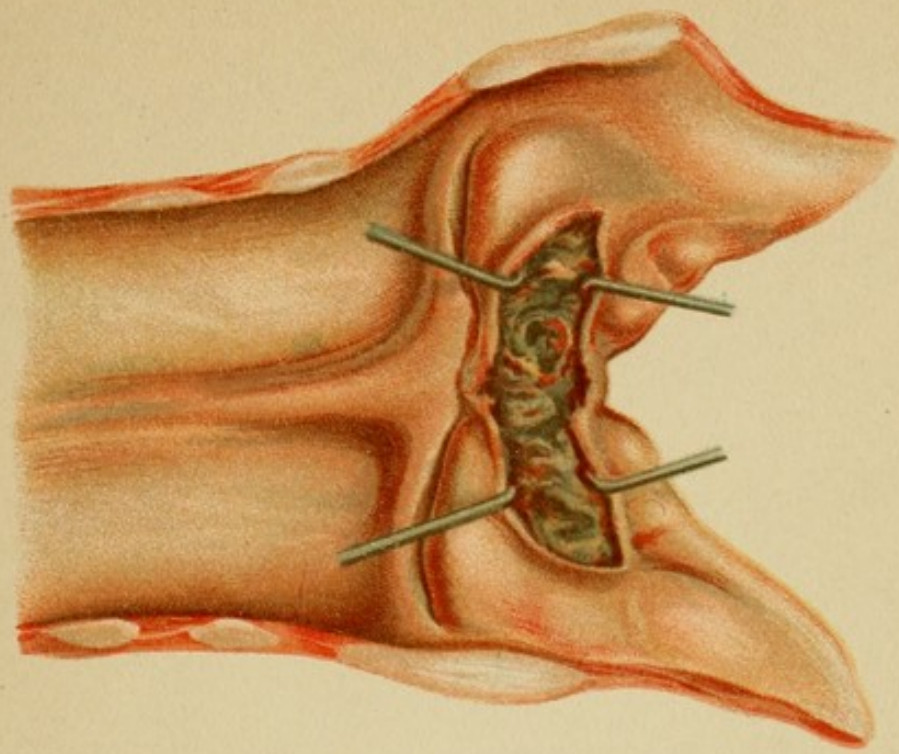




Fig. 2.

Lith. Anst. F. Reichhold, München.





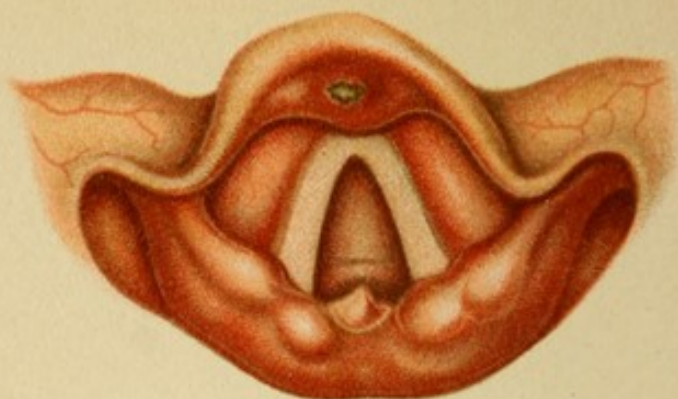


Fig. 1.

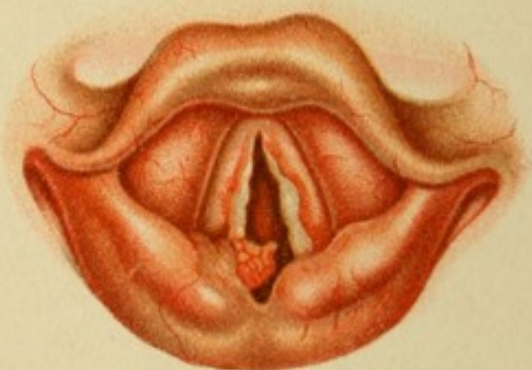

Fig. 2.

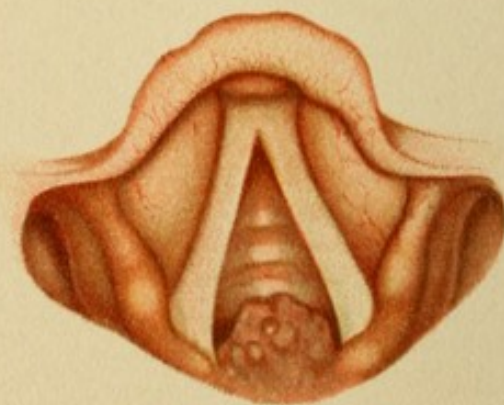

Fig. 3.

PLATE 21.

Fig. 1.

A man, 35 years old, has had cough for the past three months; in the last two weeks he has also had pain, both spontaneous and on swallowing. No expectoration.

There is marked pallor and impaired nutrition. The chest is flat; the right apex is depressed, resonance is impaired, and there is accentuated, prolonged expiration.

The heart is small and its action weak. On the breast are several radiating scars.

A rough, sharp-pointed eminence with a broad base springs from the center of the posterior wall. The mucous membrane at the back of the epiglottis over the petiolus is intensely inflamed; in the center of this zone is a yellowish-gray discolored ulcer with smooth, straight edges.

Although the general condition of the entire body and of the lungs is in perfect accord with the lesion in the posterior wall, which exhibits the typical appearance of tuberculous hyperplasia, the very acute course of the ulcer, without infiltration of the surrounding tissue, argues against tuberculosis.

Upon being more closely questioned the patient admits that he was infected a year ago, and had a rash and pustules on the breast, so that our suspicion of syphilis is confirmed. At the same time this does not influence our judgment as to the nature of the infiltration in the posterior wall. We have two processes going on side by side,

Tuberculosis and Active Tertiary Syphilis.

The diagnosis is confirmed by the subsequent course of the disease.

Fig. 2.

A woman, 25 years old, seeks relief for entire aphonia. She says she is not sick otherwise except for "a slight cough," which, she thinks, amounts to nothing. It appears, however, that this "slight cough" brings up yellow mucus in considerable quantities. The father died of "inflammation of the lungs." "How long was he ill?" "Only a year and a half." The husband is well; two children always sickly.

The patient is strongly built but decidedly emaciated. Breathing is superficial. Respiratory movement impaired on the right side. A somewhat shortened note over both apices, more on the right side than on the left. Over the right base behind, a little inside of the scapular line, is a zone of high-pitched tympanitic note. In the same situation loud sonorous râles and bronchial breathing. Over the apices accentuated inspiration and interrupted expiration. The fauces are very pale; the gums retracted.

Larynx.—The anterior surface of the right arytenoid cartilage is converted into two small, pale prominences. A thickish,

PLATE 22.

Fig. 1.

A woman, 47 years old, afflicted with advanced tuberculosis of the lungs, comes to be treated for dyspnea and total loss of voice. The dyspnea can hardly be explained by the lung-disease alone. She does not complain of pain on swallowing, but the epiglottis frequently fails to protect the larynx from the entrance of foreign matters.

The larynx in general is rather pale—a yellowish-gray. A rough, brownish-yellow tumor springs from the free edge of the right vocal cord; it is rather flat and apparently very dense, and the line of demarcation from the surrounding healthy tissue is indistinct. A similar, though much larger tumor, in shape like a blunt pyramid, arises between the two arytenoid cartilages. The posterior wall is uniformly hypertrophied, its left outline being somewhat irregular.

The movements are very slow in phonation, as if all the parts were rigid, showing that the infiltration is tough. The appearance of the alterations alone, without regard to the condition of the lungs, tells the experienced observer that he has to deal with

Tuberculous Tumors and Tuberculous Infiltration.

Fig. 2.

A man, 28 years old, seeks relief for constant hoarseness. Three months ago he went through an antisiphilitic cure for indurated ulcer. Mouth and throat are free from symptoms.

In the larynx there is a smooth, dark-red tumor, shaped like the segment of a sphere, bulging out from the posterior wall far down under the glottis.

The tumor may immediately be pronounced a

Gumma on the Anterior Plate of the Cricoid Cartilage,

for it is evident from the hoarseness that the infiltration must extend deeply.

The diagnosis is confirmed by the rapid disappearance of the tumor with the use of potassium iodid.

Fig. 3.

A man, 32 years old, was treated a year ago for syphilis of the palate and nose. The ulceration was followed by a tedious secondary sup-puration of the nose, the secretion pouring itself into the throat exclusively. The voice, which had been fairly good, has become very rough in the last three months.

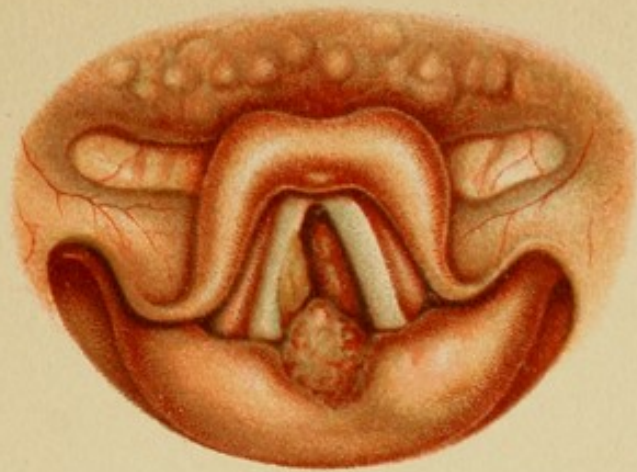

Fig. 1.

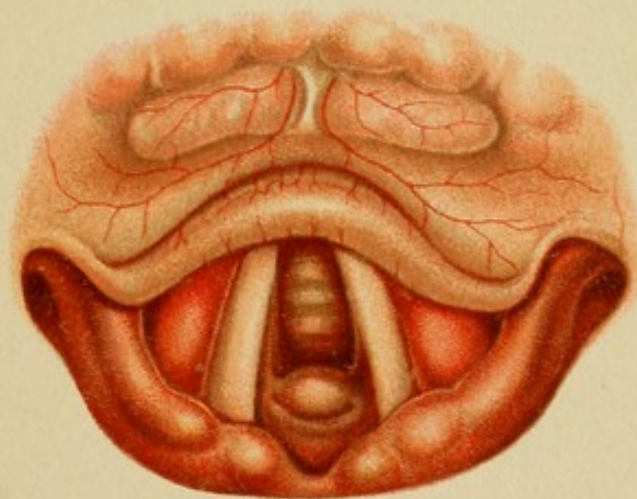




Fig. 2.

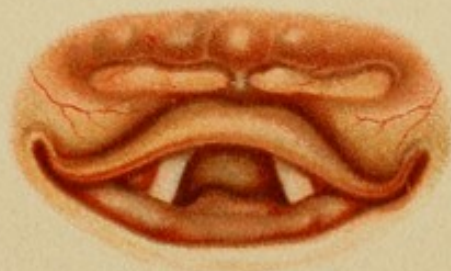

Fig. 3.





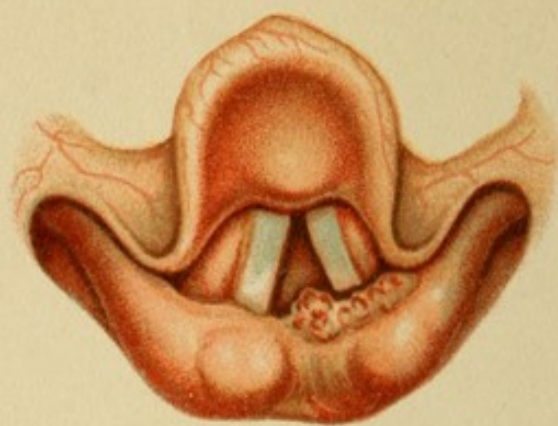


Fig. 1.

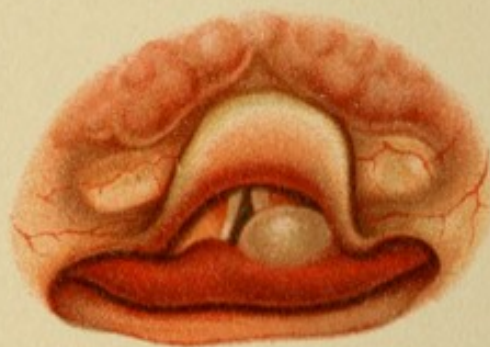


Fig. 2.

PLATE 23.

Fig. 1.

A man, 40 years old, comes to us in the Spring with a history of dryness in the throat and roughened voice, which, he says, began with the cold weather and persist obstinately. Occasionally he is troubled with convulsive cough. The throat is slightly inflamed.

The larynx is rather pale. The region below the apex of the left arytenoid cartilage is somewhat hypertrophied; in front the hypertrophy merges into a red, granular tumor with a broad base and apparently of a dense consistence, ending in a fairly sharp point.

The movement of the left cord is imperfect and the closure of the glottis is not complete. Exploration with a sound shows that the tumor is very hard. The lungs are apparently normal. Nothing suspicious in the family history, but the patient says he has lost strength considerably.

The last-mentioned circumstances confirm the suspicion, based on the granular appearance and dense consistence of the tumor and on the probability that the infiltration extends more deeply, that the disease is

Hyperplastic Tuberculosis.

Further confirmation is furnished by trial curettage and microscopic examination.

Fig. 2.

A woman, 26 years old, has been hoarse for the past six weeks, and in the course of the last few days severe dyspnea has been superadded. She also has pains radiating to the left ear.

The body appears badly nourished; the color of the skin is a dirty white. Inspiratory stridor. Great tenderness on pressure at the upper and back part of the left thyroid cartilage. The glands under the angle of the jaw and in the neck are swollen on both sides, but only the left cervical glands are painful. The speech is entirely aphonic. The hair has been dropping out fast lately. No birth, no abortion. The patient cannot recall any personal or family disease.

Only the (posterior) margin of the epiglottis retains its normal yellow color; from that point to the line of version the injection of the tissues becomes more and more marked and culminates in a deep, dark-red discoloration. The mucous membrane of the posterior wall is red and swollen on the right side; on the left the swelling has resulted in the formation of a grayish-red, shiny sac (edema). The left vocal cord is in the cadaver-position and immovable during phonation, as is the entire region of the arytenoid cartilage.

We have all the signs of an acute, far-reaching inflammatory process, showing that the immobility of the left side, which is considerably more

Lungs are intact; glands not swollen; syphilis denied. The process is evidently a chronic one, dependent anatomically on some grave disturbance of the motile apparatus, as the posture of the vocal cords shows. Whether this disturbance is in the muscles or in the cartilages, is hard to decide, as the posture corresponds to paralysis of the posterior crico-arytenoid muscles. Nor is it quite clear if inflammation or a new growth is at the bottom of the trouble. The appearances are more in favor of the former (inflammatory edema); on the other hand, the irregular surface and angular form of the tumor are rather suspicious of the latter. The ulcer also has no typical character. In any case, the disease is not tuberculosis. As we are in doubt, we resort to antiluetic treatment.

At first this treatment is apparently effective, for after six weeks the breathing is so much improved that the advisability of removing the cannulæ is considered. Meanwhile, however, the appearance of the picture is so much changed that there is no further doubt as to its true nature.

(Fig. 3.) During respiration the right vocal cord still occupies a median position, while the left is abducted. The latter is of a pale red. The tumor on the posterior wall has diminished, but is still quite marked.

Close to the ulcer, which is now reduced in size one-half (?), on the median side is a pale-red, wavy tumor as large as a lentil, irregular in outline, and merging into the larger tumor.

This formation occurs only in

Malignant Growth.

Microscopic examination of an extirpated portion shows it to be an alveolar sarcoma. (See Pl. 37, Figs. 1 and 2.)

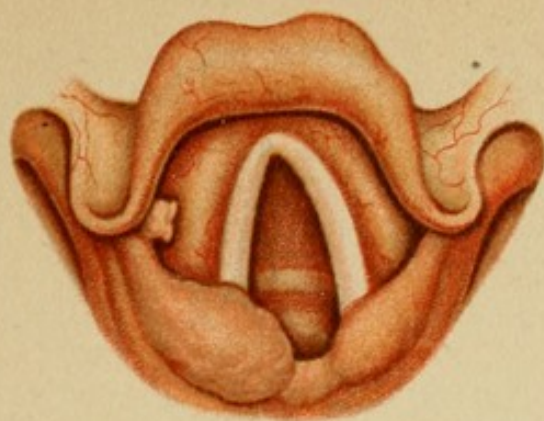


Fig. 1.

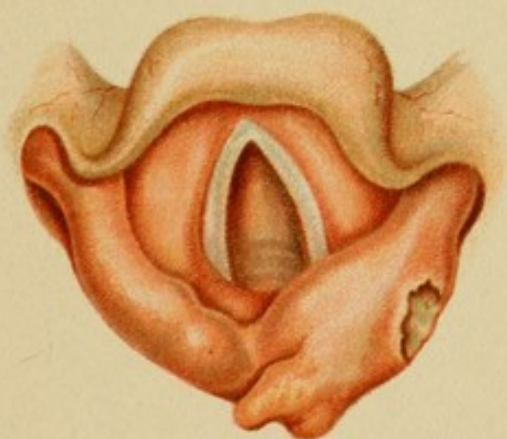




Fig. 2.

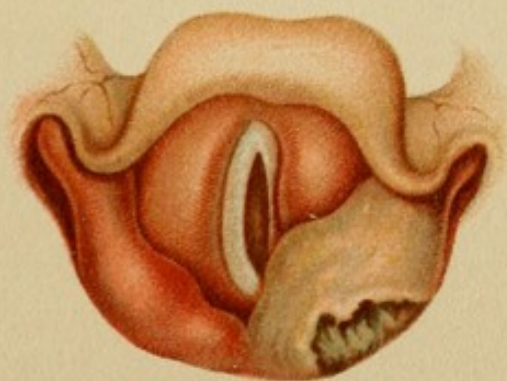

Fig. 3.

Lith. Anst F. Reichhold, München.





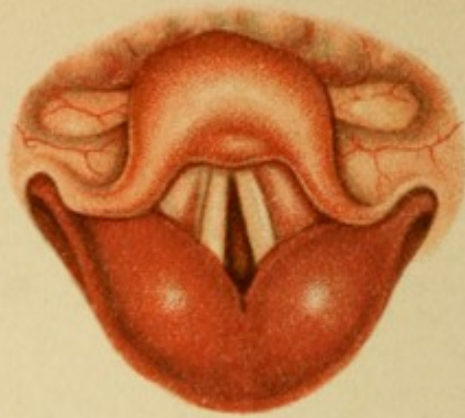


Fig. 1.

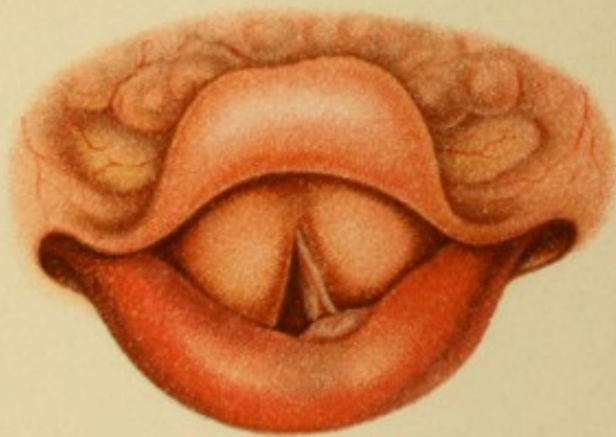


Fig. 2.

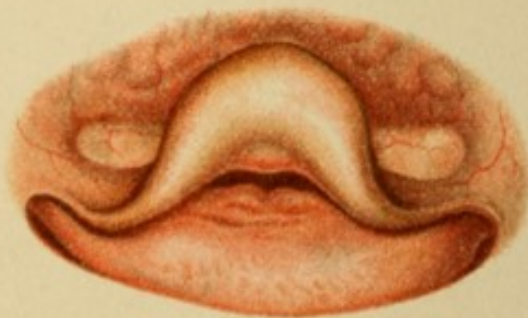

Fig. 3.

PLATE 25.

Fig. 1.

A girl, 16 years old, has been ill for two days with headache, fever, and violent pain on swallowing. This morning hoarseness and some dyspnea set in. Bowels constipated.

The patient is weak, cheeks very red, respiration short, and the sensorium is reduced. Pulse 110, temperature 39.5° C. In the pharynx there is nothing abnormal except a slight redness of the posterior wall. The voice is toneless; even the whispered sounds are very weak.

Larynx.—The epiglottis is inflamed. The vocal cords are a very little hyperemic and in the cadaver-position. But the posterior wall consists of two enormously swollen, glistening, blood-red masses which prevent all motion.

Such phenomena are produced only by

Laryngeal Erysipelas.

Fig. 2.

A gentleman, 67 years old, who had formerly always enjoyed good health, became very ill nine months ago after an attack of influenza: fever in the evening, sweats, loss of flesh, copious yellowish-gray expectoration, and, in the last few months, hoarseness and shortness of breath.

The body is still fairly robust, but the flabby skin testifies to the loss of substance. On percussion: above and behind on both sides almost complete dulness; on the right side under the clavicle, from the second to the fourth rib, dull tympanitic note, increased at the point where it is best heard when the mouth is opened. Numerous râles over the entire lung; over the right apex loud bronchial breathing with tinkling râles. Posteriorly above, bronchial breathing on both sides with crackling râles.

Respiration short, accelerated, and faintly audible.

The entire larynx is bright red. The posterior wall is hypertrophied and resembles a sausage. On the left side a smooth, thick swelling rises from its anterior surface. The right vocal cord is entirely hidden by the swollen ventricular band; in the region of the vocal process the left appears to be split in two; in reality, however, it is a doubling of the fold of mucous membrane; for the reason mentioned above (the thickening of the ventricular band) it also appears narrower. Abduction is evidently incomplete, as neither cord moves beyond the cadaver-position in its outward excursion.

The larynx is not sensitive to pressure from the outside. The voice is discordant, deep, rough, almost aphonic, and often changes to a whisper.

PLATE 26.

Fig. 1.

A patient, 36 years old (male), afflicted with pulmonary and laryngeal phthisis, is treated with a Koch injection. On the following day this picture is seen.

Both aryteno-epiglottidean folds, as well as the entire upper border of the posterior wall of the larynx, especially on the left side, are converted into a smooth, glistening, balloon-like swelling. The ventricular bands also appear hypertrophied. In respiration both vocal cords are very near the middle line, between cadaveric and phonation-posture; they are discolored and harder than normal, with rough, uneven edges. A small spur projects in front of the left vocal process.

The tumors must all be attributed to

Acute Inflammatory Edema

over the tuberculous portions.

Fig. 2.

An extremely emaciated woman, 24 years old, with hectic flush, copious purulent expectoration, extreme debility—in short, all the signs of advanced pulmonary phthisis, which is further confirmed by the physical examination—is suffering, in addition, from intense dyspnea. Orthopnea and stridor are also present in a marked degree.

With the exception of the epiglottis, the entire larynx is diseased. The right vocal cord is not visible at all; of the left, only a small strip near the vocal process is to be seen. Everything else is hidden by the ventricular bands, which are converted into pale, rigid, somewhat uneven tumors. The aryteno-epiglottidean folds are also very much hypertrophied, grayish-yellow in color, and glistening (edematous). On the right side is a broad, club-shaped tumor as large as a bean and slightly nodular, blocking up the back part of the already narrowed lumen.

No signs of degeneration, at least on the surfaces exposed to view.

The presence of edema in the posterior portion proves that, in addition to the more superficial lesions which are at once recognized, a deeper morbid process is at work, probably in the cartilaginous framework; it is, therefore,

Diffuse Tuberculous Infiltration of the Entire Larynx and Tuberculous Tumor-formation.

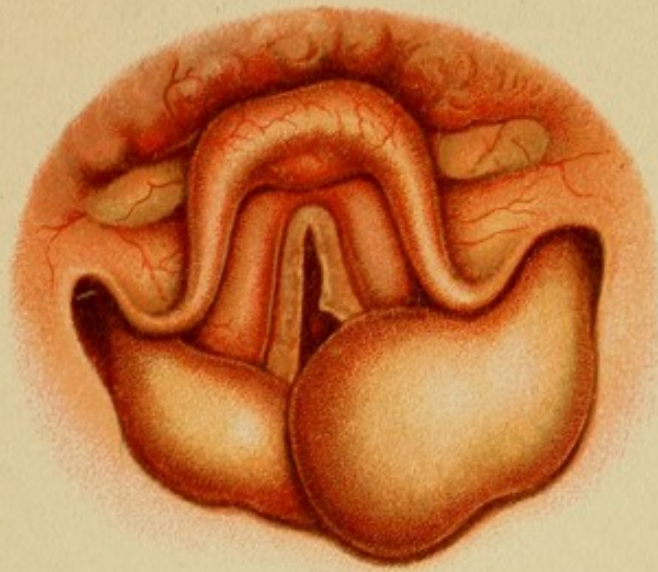


Fig. 1.

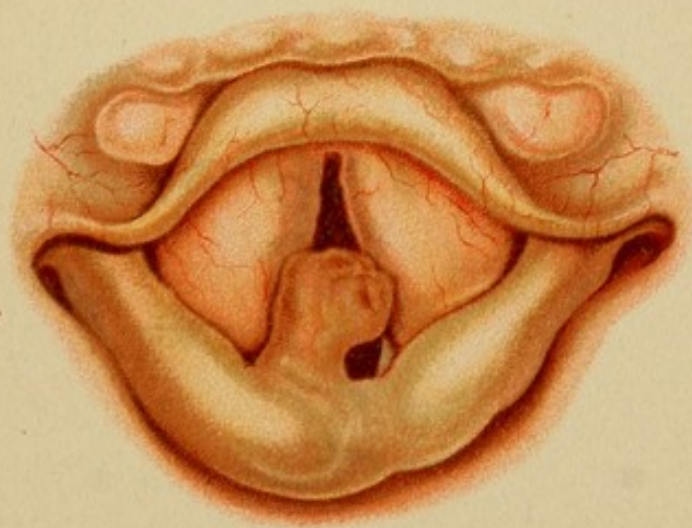




Fig. 2.





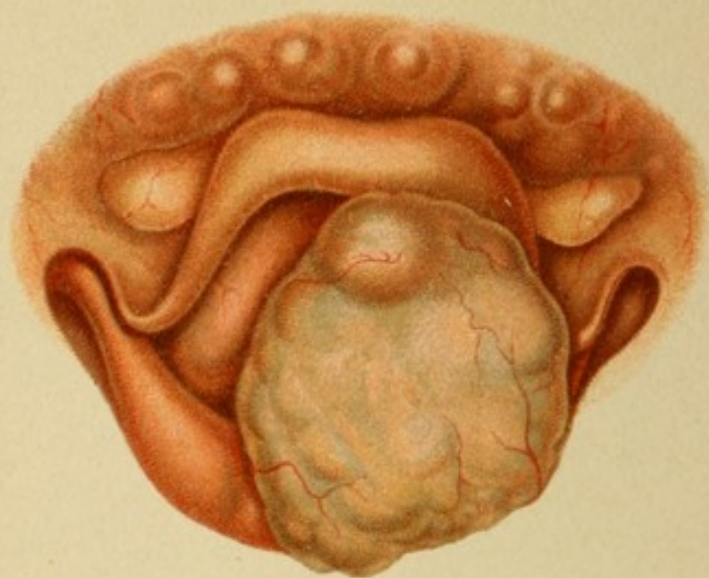


Fig. 1.

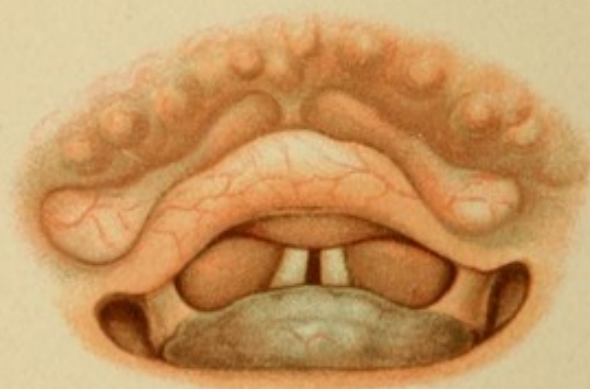


Fig. 2.

PLATE 27.

Fig. 1.

A gentleman, 47 years old, of robust appearance, has been suffering from increasing dyspnea for the past year; occasionally he also experiences difficulty in swallowing solid food.

The voice is raucous and easily breaks into another register; respiration somewhat stenotic.

A tumor as large as a walnut blocks up the entrance to the larynx, so that only a part of the ventricular band and the ary-epiglottidean fold on the right side are visible.

The tumor is yellowish-gray in color; the surface lumpy and irregular, and crossed by numerous blood-vessels.

There is still some mobility, most marked in the anterior portion, so that the origin of the tumor may be in the left arytenoid region. Its nature cannot be determined with any degree of certainty; in the absence of swelling of the cervical glands and of metastases, the rapid development perhaps points to malignancy.

Microscopic examination of the excised tumor shows it to be a

Squamous Epithelioma.

(See Pl. 39, Fig. 3.)

Fig. 2.

A woman, 62 years old, has experienced increasing difficulty in swallowing during the past six months, and latterly has been able to take only liquid nourishment. She never had pain. Has lost strength a good deal.

Pale, emaciated subject; no discoloration of the skin or mucous membranes. No glands can be felt in the neck; nothing abnormal on palpation.

The throat and larynx are very pale; the posterior half of the latter is concealed by a pale, bluish-red, slightly uneven tumor, which gradually disappears in the posterior wall of the pharynx. The base of the tumor is continuous with the upper margin of the larynx.

Phonation is not impeded; the voice is weak, but pure. The tumor can be easily moved and lifted away from the posterior wall of the pharynx with a sound. Respiration is free; heart and lungs present only alterations incident to age.

Owing to the curious seat of the tumor and the age of the patient, no diagnosis could be made until after the extirpation. The tumor was found to have a broad base, resting on the posterior wall of the cricoid cartilage. Microscopic examination revealed an

Innocent Connective-tissue Neoplasm.

(See Pl. 40, Fig. 1.)




PLATE 28.

Fig. 1.

After suffering for a year with "throat-catarrh" and extreme hoarseness, a gentleman, 56 years old, would like to have his throat examined. He can barely produce a feeble, rough sound, and also has difficulty in swallowing.

The general habit is vigorous, but somewhat anemic. The neck hangs in folds; is not swollen. On palpation the left plate of the thyroid is found to be hypertrophied and lumpy, and more or less adherent to the surrounding connective tissue. Two small glands can be felt under the chin.

Larynx.—The epiglottis alone is normal; it leans far backward, obstructing the view into the interior (more so than is represented in the picture). The right vocal cord is slightly inflamed; the left is replaced by a rather red, granular tumor resembling a raspberry, which fades away gradually into the ventricular band. Both aryteno-epiglottidean folds are very much hypertrophied, especially the left, which is swollen to about double its natural size and presents a shapeless, irregular mass. On the upper and anterior surface is an ulcer of irregular, sinuous outline, becoming deeper as it sweeps backward, with raised edges surrounding it like a rampart and grayish-green, discolored floor.

During phonation the left side is immovable, from which we may deduce that the infiltration extends deeply and has involved the joint.

The infiltration is evidently extensive, and the true nature of the tumor is clearly shown by its appearance and by the duration of the process. It is evidently a true neoplasm which, judging by its extent, degeneration, invasion of surrounding tissues, and the glandular metastases, can only be a

Carcinoma.

Fig. 2.

A man, 47 years old, calls in the physician for imminent asphyxia. Dyspnea has existed for some months, also a good deal of cough *without expectoration*. For several weeks the patient has been able to swallow only liquid food.

Extreme emaciation, explained by the last point in the anamnesis. Intense inspiratory stridor; expiration very much prolonged, all the accessory muscles being called into action. Although the patient is very weak, he sits up straight all the time, with head retracted.

Percussion gives marked increase in lung-area; no dulness anywhere. Auscultation impossible on account of the stenotic respiration, which drowns all other sounds.

The temperature has been taken for several days, and there is no fever.

The larynx as a whole is anemic and leaves only a narrow cleft for the passage of air. The right vocal cord is yellowish-white. A smooth, red band, nearly as broad as the cord, lies directly underneath and gradually fades away in the commissure, the anterior part being slightly swollen at the edge. The left vocal cord at its middle third is converted into a rough, red tumor, while the posterior third is hidden by another thick, pale-red growth as large as a bean, its broad base resting on the posterior wall, which is very much hypertrophied.

The cervical glands are not swollen. The left ala of the thyroid is somewhat thick and uneven to the touch, but not sensitive.

During phonation the left side is immovable.

It is clear from the anatomical alterations that the left half of the cricoid cartilage is the principal seat of the disease. The subcordal band, however, shows that the right half has also become secondarily involved. The predominant character of the lesion is that of a tumor; the only inflammatory features appear in the subcordal band, which is probably an inflammatory edema overlying a perichondritis. As the tumor is associated with extensive infiltration of the deeper parts, and has also attacked the cartilaginous structure, to judge from the fixation of the joint, the process must be a destructive one. There are three possibilities: malignant growth, syphilis, and tuberculosis.

There are many points in favor of the first: the unilateral character of the disease, the patient's age, the gradual development, the absence of general and pulmonary symptoms. There is nothing either in the anamnesis or in the results of physical examination to suggest syphilis; slow, gradual development is not characteristic of that disease. Tuberculosis might produce a similar picture,—in fact, the pale, uneven tumor simulates that disease very closely; but, on the other hand, the intact condition of one vocal cord is very unusual in such an advanced stage; besides there is no expectoration and no fever (the patient has been under observation for several weeks).

As even the microscopic examination of part of the tumor on the true vocal cord gives no positive result, we must be content with a provisional diagnosis of

Carcinoma ?

(See following plate.)

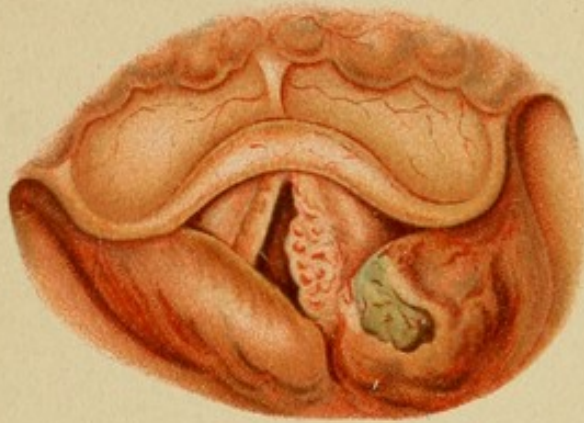

Fig. 1.

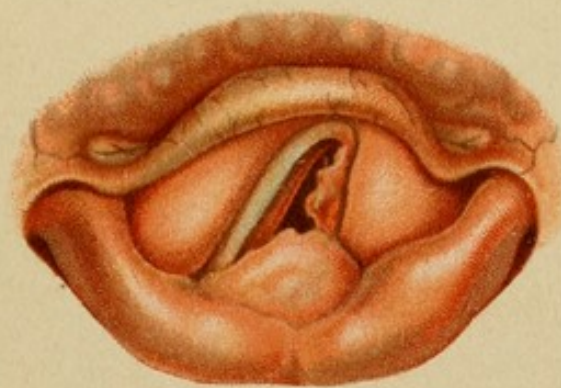




Fig. 2.





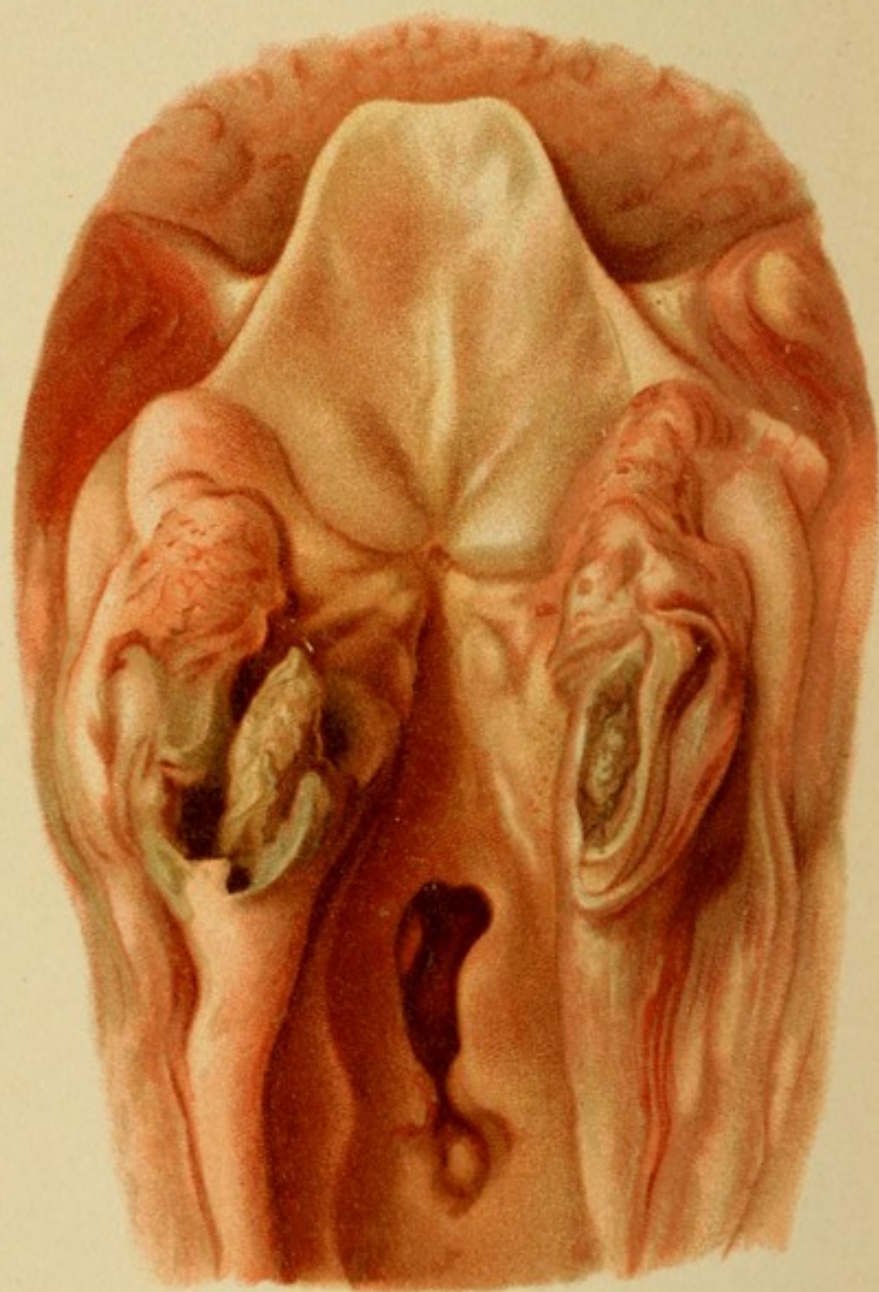


Fig. 1.

PLATE 29.

To the foregoing history must be added that, a few weeks after tracheotomy was performed, high hectic fever set in, the patient expectorated copiously, and the sputum contained tubercle bacilli. Thus the diagnosis of

Tuberculous Perichondritis of the Cricoid

was at last established.

How extensive it was is seen by the result of the autopsy, held six weeks after the patient first came under observation.

The cut surfaces of the cricoid cartilages exhibit a uniform green discoloration; the left side contains a large ulcerated cavity, in which a large (ossified) sequestrum is freely movable.

In the trachea is seen the wound of the tracheotomy-tube, very much enlarged by suppuration of the edges.

These data are too meager for us to form an opinion of the true nature of the disease, and for the present we must be content with an anatomical diagnosis.

The process is evidently an inflammatory one, involving the greater part of the mucous membrane of the larynx. That its action is also deeper than this, is shown by the motile disturbances in the vocal cords, which correspond exactly with paralysis of the crico-arytenoidei postici; that is, of the abduction-fibers in the recurrent laryngeal nerve. But such disturbances may be of a purely mechanical nature, produced by any obstruction in or about the joint, in this case the crico-arytenoidean articulation. The latter theory is supported by the diffuse character of the inflammation. We assume, then, an arthritic process, associated with inflammation of the cartilage or rather of the matrix. This view is further confirmed by the marked swelling and inflammation of the aryepiglottidean folds.

Without further hesitation we may, therefore, make the diagnosis of
Crico-arytenoidean Perichondritis and Inflammatory Ankylosis of the Crico-arytenoidean Articulation.

The subsequent course of the case revealed the cause. After performing tracheotomy and putting the patient on an active potassium-iodid treatment we see the following picture.

Fig. 3.

The swelling has disappeared in the entire larynx, except in the posterior wall. Over the left cuneiform cartilage is a spherical, grayish-yellow, glistening eminence in the mucous membrane (edema), between which and the cartilage of Wrisberg a notch is seen.

The right vocal cord is white and smooth; the left is still inflamed and somewhat rough at the edge. The glottis is perfectly widened during respiration. A smooth, red, horizontal band of tissue projects from under the commissure and covers half the lumen, ending behind in a convex margin. The uncovered part of the trachea exhibits a bright luminous line.

The latter evidently corresponds with the tracheotomy-tube, which is still in position. The band of tissue, on being examined with a sound, is found to be smooth, of the hardness of cartilage, and about 3 mm. in thickness. Taking everything into consideration we may pronounce it a

Syphilitic Cicatricial Diaphragm.

Our earlier supposition, that the impeded abduction was due to an inflammatory, ankylotic condition, also proves correct, for the mechanical alterations disappeared at the same time and in the same measure as the inflammatory symptoms; remains of them are still found in the edema over the apex of the left arytenoid cartilage and in the secondary inflammation of the corresponding vocal cord.

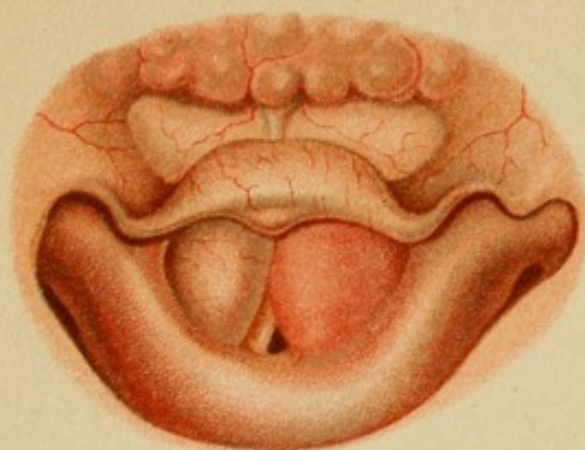

Fig. 1.

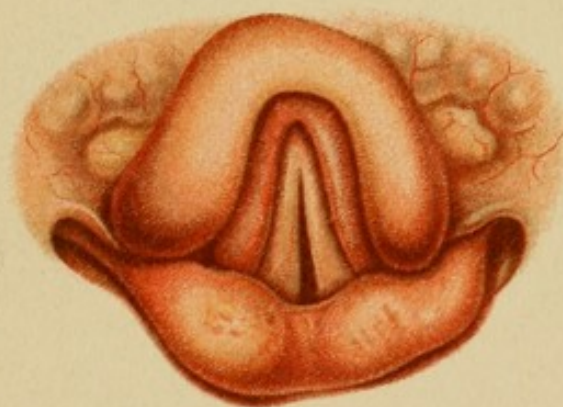



Fig. 2.

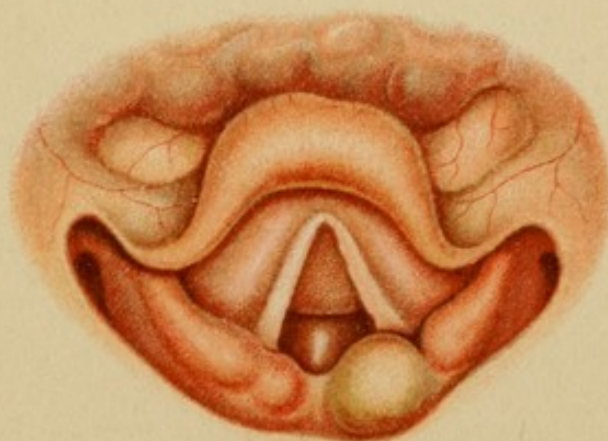

Fig. 3.





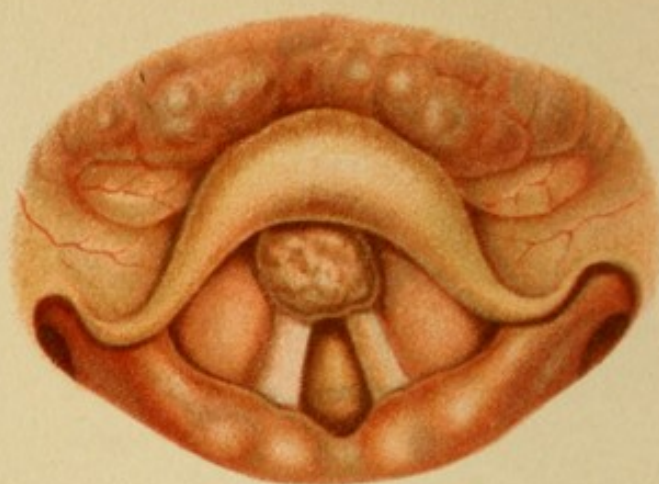


Fig. 1.

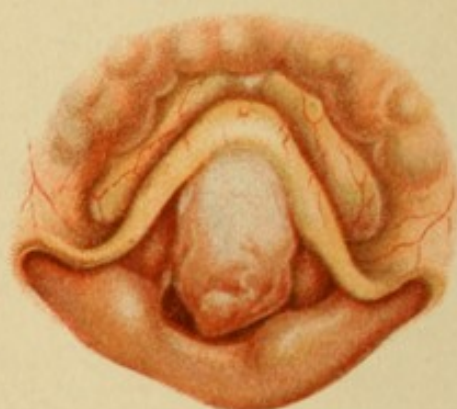

Fig. 2.

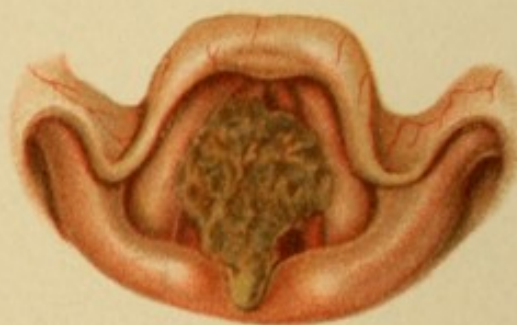

Fig. 3.

PLATE 31.

Fig. 1.

A strongly built man, 63 years old, otherwise quite healthy, has suffered for the last two years with disturbance of the voice and great hoarseness; the symptoms have become more marked in the past two months. No pain, no cough. The voice is rough and toneless.

Larynx.—In front, under the epiglottis, the petiolus of which it hides completely, is a rounded, somewhat uneven tumor, a little larger than a pea. The surface is covered with red and white spots. The rest of the larynx presents no marked alterations, except that the left vocal cord and the posterior margin of the epiglottis are slightly more injected. The movements of the true and false vocal cords are unimpaired.

The patient's age and the irregular appearance of the tumor lead us to suspect a malignant growth, but the disease has lasted a long time (at least two years) without invading the surrounding tissues or giving rise to disturbances of motility, so that we are justified in assuming an

Innocent Neoplasm.

To be conscientious, however, we must make a histological examination of the extirpated tumor (the result is illustrated on Pl. 34, Fig. 1) and watch the patient for some time after. (The tumor did not recur.)

Fig. 2.

A vigorous man, 56 years old, has suffered with dysphonia for ten years. No other symptoms to complain of; no pain, no dyspnea.

The voice is all but aphonic—a mere rough whisper; phonation is always preceded by a long, audible inspiration, and the first expiratory sound is accompanied by a distant rattling sound. The larynx does not move during inspiration and is thrown into strong vibration by phonation. Otherwise there is nothing abnormal on palpation. The face and the mucous membrane of the back of the mouth are highly colored, but not cyanotic.

At the first glance into the **larynx** the entire interval between the epiglottis and the posterior wall is seen to be filled by a mass which is moved by the expiratory blast; the surface is somewhat rough, white in front, more of a reddish hue behind. The parts which are still visible (arytenoid cartilages, small portions of the ventricular bands and of the right vocal cord) do not deviate from the norm. The mass is intimately adherent to the anterior portions of the aperture, but its origin cannot be made out very clearly.

The absence of any signs of destruction at or about the seat of the tumor, its duration, and general appearance permit the diagnosis of

Innocent Tumor.

Histological examination shows it to be a hard fibroma.

Fig. 3.

A woman, 40 years old, is in imminent danger of asphyxiation. The dyspnea, which had existed occasionally in a slight degree, has developed rapidly in the last few hours.

The patient sits upright, breathing slowly and painfully, and using all the muscles of the neck; a loud noise is heard both in inspiration and in expiration. The voice is rough, almost aphonic. As soon as the tongue is drawn forward a greenish-yellow, half-dried bolus of muco-pus is seen on the posterior wall of the pharynx, extending upward.

The entire entrance to the larynx is covered by a thick, grayish-green, dry mass, the back part of which, judging from the more uniformly glistening appearance, is a little more moist. It is everywhere raised above the level of the surrounding, inflamed mucous membrane.

This crust is immovable even during phonation.

Nose and fauces are filled with a mass of liquid and solid pus, the source of which is found in a diseased condition of the cribriform plate of the ethmoid bone.

The foreign body in the larynx is, therefore, also a crust of pus; it is simply an

Obstruction by a Foreign Body.




PLATE 32.

Fig. 1.

A boy, $3\frac{1}{2}$ years old, comes to be examined for complete aphonia and intense dyspnea. Inspiration especially is labored and very prolonged; all the accessory muscles are plainly seen to assist in the act, which is also accompanied by loud stridor. At the same time the larynx is deeply depressed. Expiration is somewhat less difficult. Face and extremities are markedly cyanotic. The condition developed in the last two years after an attack of whooping-cough.

Laryngoscopy.—The mucous membrane of the epiglottis, which is displaced forward, shows a faint bluish-red discoloration. Under the epiglottis and covering the entire aperture of the larynx is a bright, brick-red tumor, the surface of which exactly resembles that of a mulberry. On palpation with the finger the tumor is found to be soft and very slightly movable. It is evidently a

Papilloma,

a form of laryngeal tumor very characteristic of childhood.

Fig. 2.

A woman, 30 years old, complains of hoarseness and dyspnea. The hoarseness has existed three or four years; the dyspnea has increased lately. She has lost strength, has night-sweats and cough, but no expectoration. Her father died of pulmonary phthisis. The woman is slender and delicate; she has lost her voice entirely, and there is audible laryngeal stridor when she breathes; the thyroid cartilage at the same time moves up and down. Under the angle of the jaw on each side is a gland as large as a pigeon's egg. There is resonance all over the lungs, but the right apex is somewhat depressed; under the right clavicle accentuated, prolonged expiration is heard. Accentuated breath-sounds and dry râles are heard all over the lung. Heart-action is weak, dullness small, heart-sounds pure.

The larynx as a whole is rather anemic (as is the mucous membrane of the mouth); the interior is completely filled with slightly papillary, raspberry-colored tumors, which grow out from the ventricular bands and the posterior wall, so that only the posterior third of each vocal cord is visible. These latter are rough and grayish in color. No ulceration is seen anywhere. The tumors, when touched with a sound, are found to be very hard.

The wide, diffuse distribution and the appearance of the tumors, together with the general condition, permit a provisional diagnosis of

Tuberculous Tumors.


Diagnosis confirmed by microscopic examination.

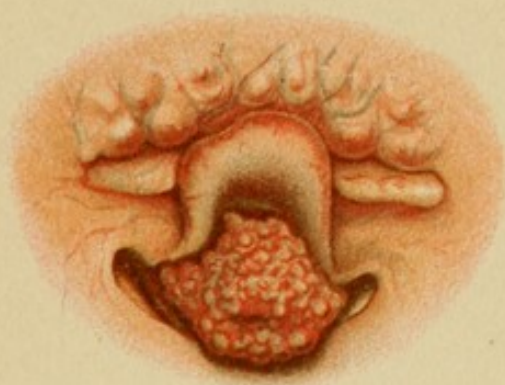

Fig. 1.

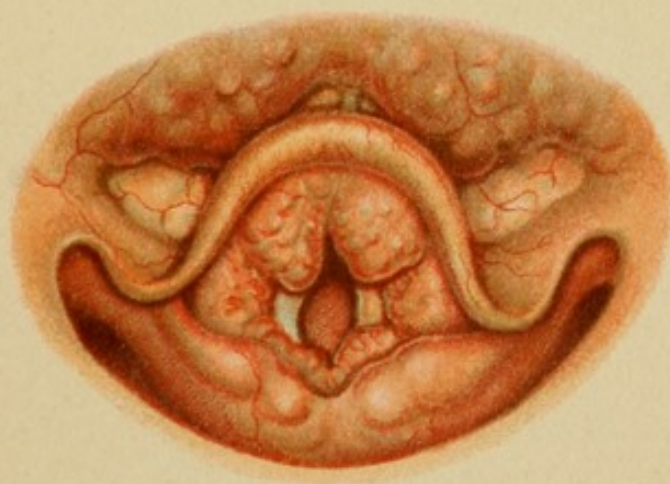

Fig. 2.





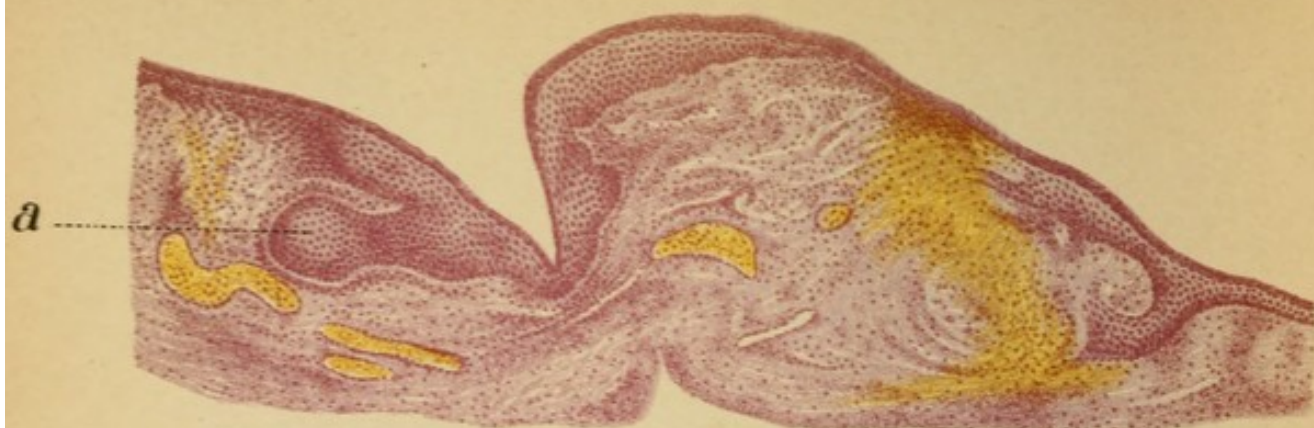


Fig. 1. Vergr. $30\frac{1}{1}$

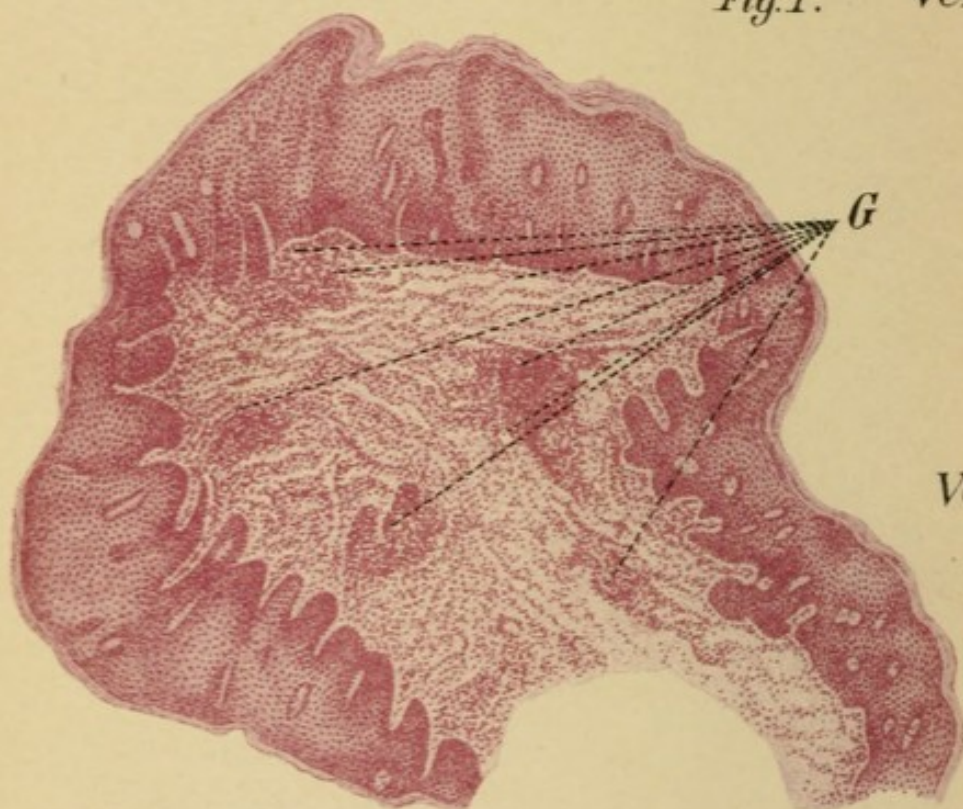


Fig. 2.
Vergr. $25\frac{1}{1}$

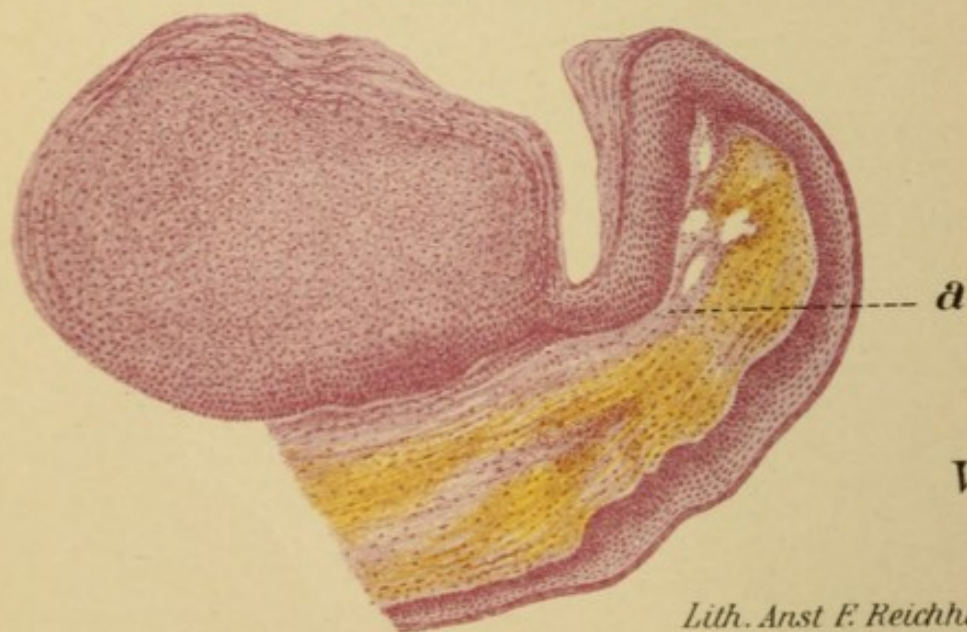

Fig. 3.
Vergr. $20\frac{1}{1}$

PLATE 33.

Fig. 1.

The nodules on the true vocal cord, shown in Plate 14, Fig. 2, were removed and a horizontal section was made.

The base consists of fairly dense connective tissue, the lymph-spaces of which are surrounded by slight accumulations of round cells. Some of the vessels are much dilated and filled with blood. On the right, the tissue is filled with blood from a profuse hemorrhage, evidently traumatic in origin.

The surface is formed by two elevations consisting chiefly of epithelium, divided by a deep vertical incision. The epithelium exhibits great proliferation; toward the left a thick, club-shaped mass extends as far as a greatly dilated vessel, curved like an S. This mass is surrounded by a band of round-celled infiltration as by a cordon. The superficial layers are horny.

The inflammatory origin of the neoplasm is at once evident from the alterations in the vessels; the epithelium probably proliferated secondarily, chiefly in consequence of the pressure from the other vocal cord during phonation.

The tumor is, therefore, an

Inflammatory Hyperplasia.

Fig. 2.

In its essential features this preparation is similar to the preceding.

The epithelial proliferation is more active, and has resulted in the formation of villous processes which tend to coalesce. The same band of round-celled infiltration appears along the upper boundary. The grouping of the round-celled infiltration about the blood-vessels is very conspicuous, and the cornification of the superficial layers has gone on to the formation of lamellæ. Like the preceding, this tumor, which grew like a wart on the posterior wall of the chronically inflamed larynx of a man, 46 years old, is an

Inflammatory Fibro-epithelioma.

Fig. 3.

The preparation is a vertical transverse section of the tumor shown in Plate 15, Fig. 1.

The root of connective tissue almost disappears between the two layers of epithelium which enclose it above and below.

The upper layer, which corresponds to the little whitish tumor seen macroscopically, forms an enormous epithelial mass. It is chiefly made up of very large polygonous squamous cells; at the base some stratified squamous epithelium is seen, while the surface consists of numerous horizontal lamellæ, the original epithelial character of which is shown by the few remaining nuclei. The enormous thickness of this zone of horny epithelium explains the white color of the living tumor.

The connective tissue is filled with blood and presents numerous clefts, due, no doubt, to edematous swelling of the tissue, which was but poorly nourished through its slender pedicle.

(With a higher power numerous elastic fibers are seen at "a," representing proliferations of the media of blood-vessels, showing that all the tissues were involved.)

Innocent Horny Epithelioma.




PLATE 34.

Figs. 1 and 2.

A sagittal section was made of the tumor shown in Plate 31, Fig. 1.

This preparation shows, even better than any of the preceding ones, the round-celled infiltration of chronic inflammation associated with the highest degree of epithelial hyperplasia. The villous processes of the latter extend almost to the boundary of the healthy tissue. The superficial layers present a very curious picture: the large polygonal cells with vesicular nuclei are replaced by a network, the meshes of which correspond approximately with the cell-areas, but contain only a few scattered nuclei. Instead of these, numerous large masses of a homogeneous color are scattered through the network, and in many places the meshes are larger than the adjoining cells.

This difference is emphasized in the peripheral portion (marked R), shown under a higher power (Fig. 2). The alterations manifest themselves as extensive fatty degeneration of the epithelium; the fat has collected to form the lumps at "a," while at "b" some cells are still to be seen, though their contents are disintegrated and granular. This mixture of fatty and of partially intact areas is responsible for the peculiar, mottled (macroscopic) appearance of the surface.

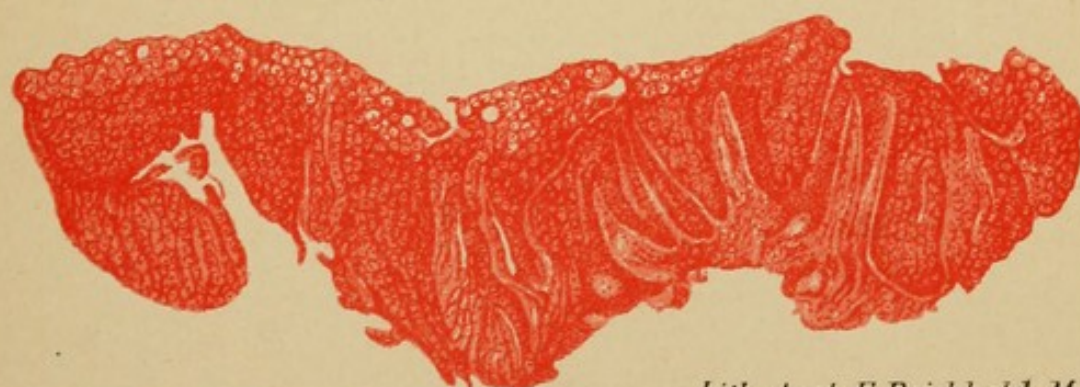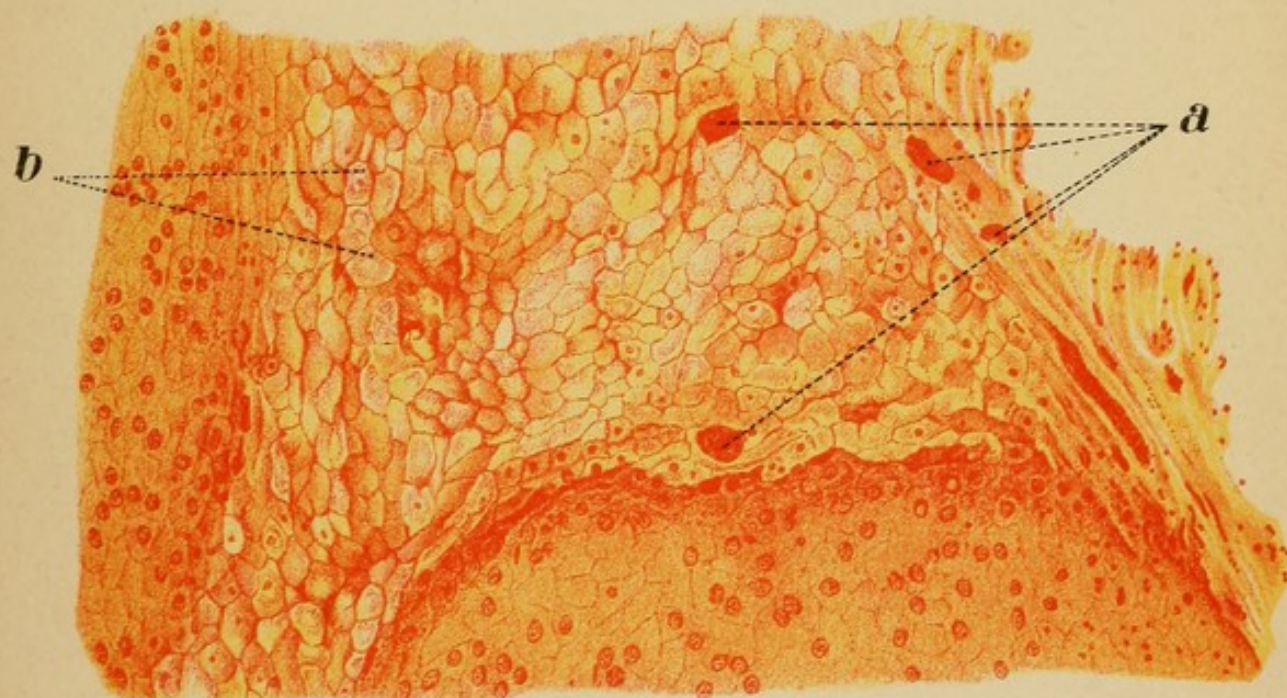
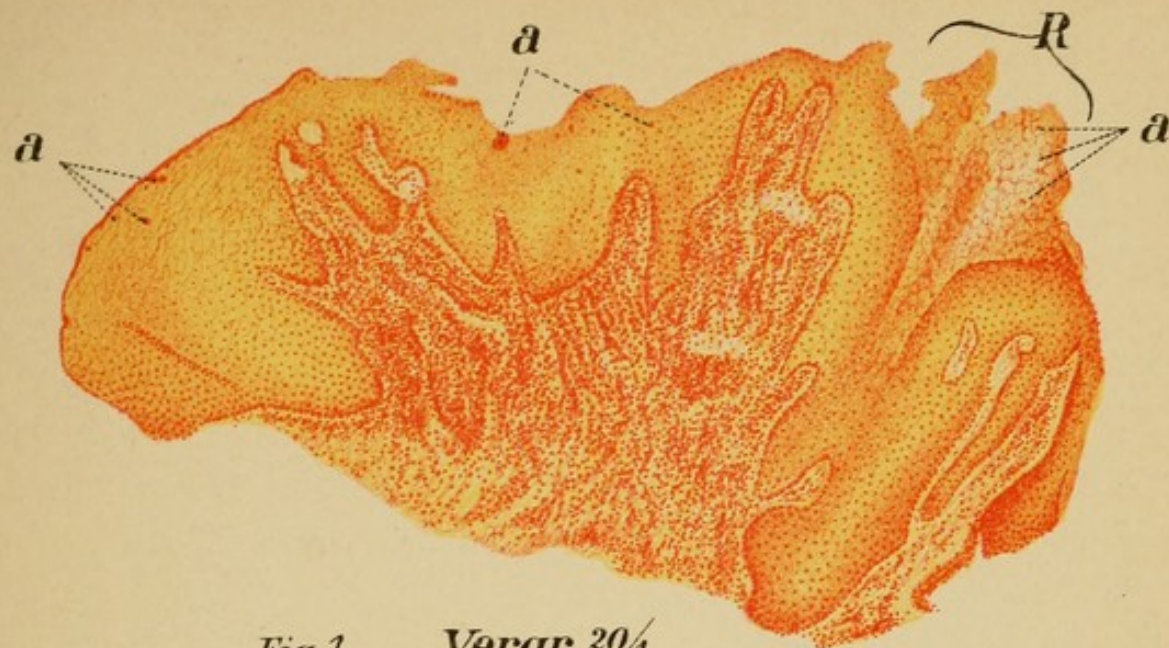
Inflammatory Hyperplasia, with Epithelial Degeneration.


Fig. 3.


This illustration presents a similar form of degeneration.

The flat, superficial growth (taken from the vocal cord of a lady, 42 years old) consists almost exclusively of epithelial proliferations, undergoing degeneration not only at the surface, but clear through to the bottom. The protoplasm is on the verge of absorption, as the numerous bright spaces in it show; in places it is swollen, and the nuclei have disappeared for the most part. As in the preceding case, the outlines of the cells have remained substantially the same, instead of becoming flattened and forming lamellæ, as in cornification.

Epithelial Hyperplasia in Process of Degeneration.







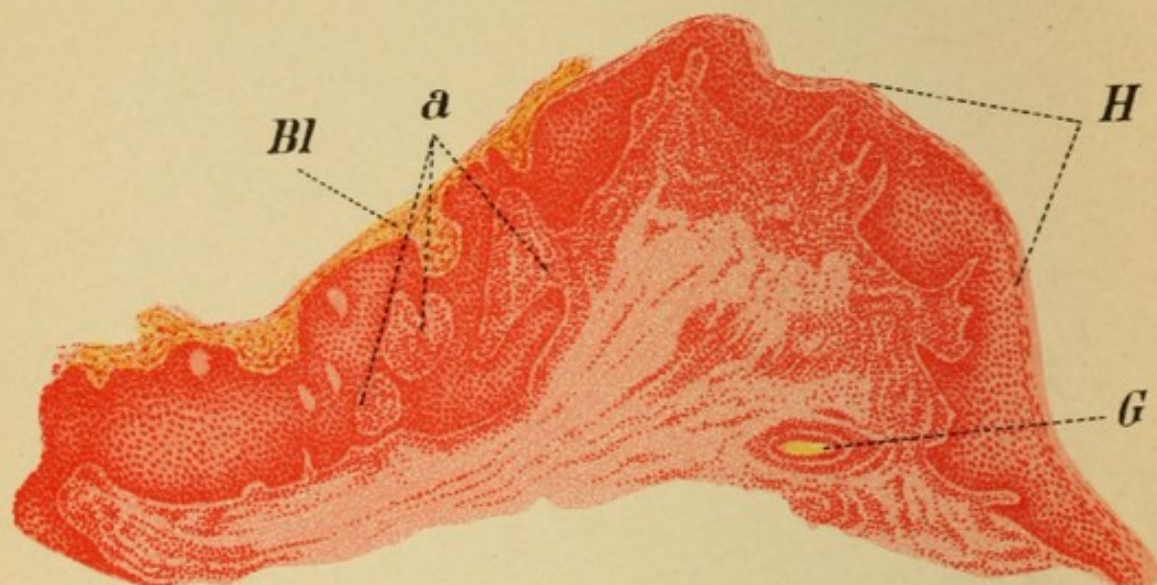


Fig. 1. Vergr. $20\times$

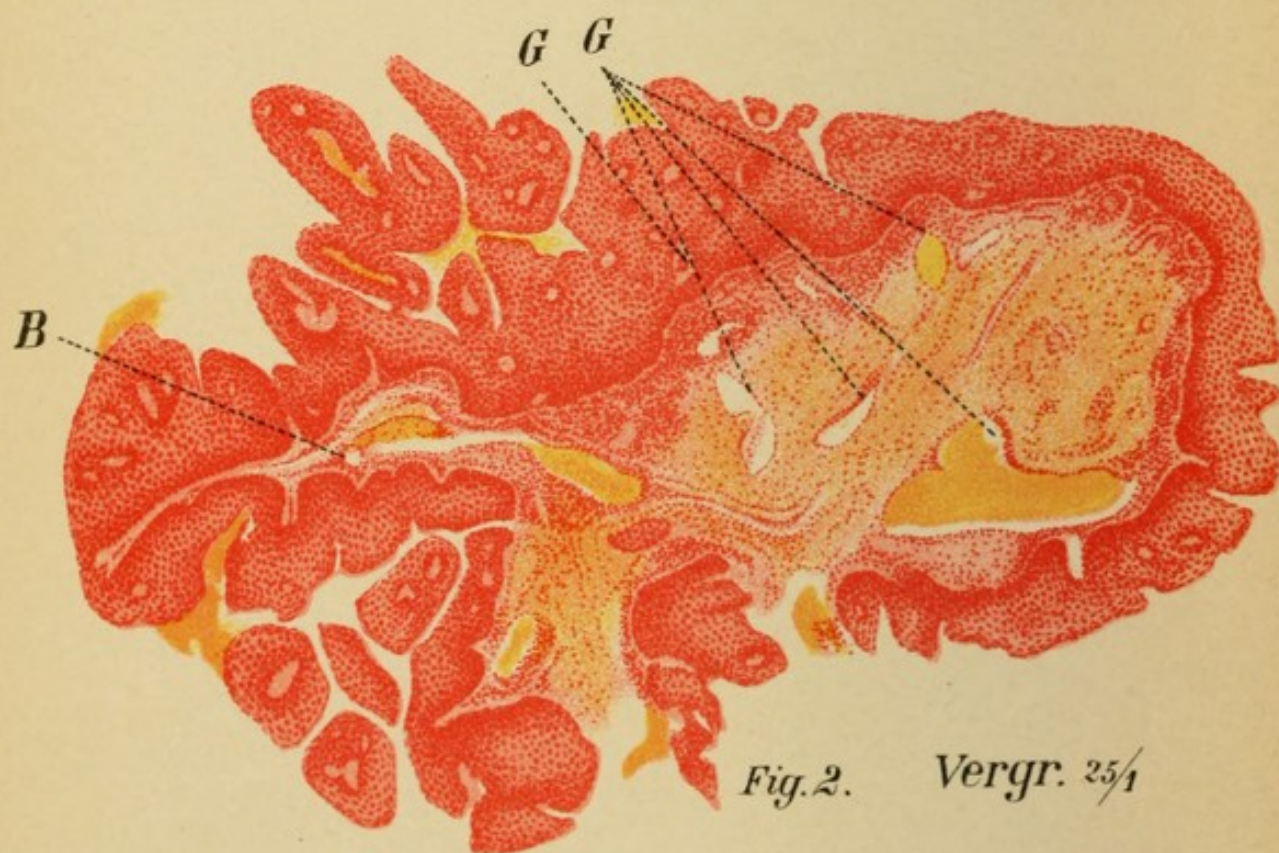


Fig. 2. Vergr. $25\times$

PLATE 35.

Fig. 1.

A dense, pale-red, uneven tumor was removed from the left ventricular band of a man 40 years old.

In a horizontal section the core of dense, fibrous connective tissue appears in the form of an elevation, partly covered over, and partly traversed by numerous layers of squamous epithelium, so that several isolated islands of connective tissue, "a," are seen in its substance. These islands, as well as other areas near the epithelium, especially the portions surrounding the blood-vessels, exhibit profuse round-celled infiltration. The surface is horny and covered at "Bl" by a thick layer of clotted blood, which shows beginning metamorphosis into connective tissue.

Inflammatory Hyperplasia.

Fig. 2.

The mulberry-shaped tumor, light pink in color, was removed from the left vocal cord of a man 50 years old. The cold-wire snare was used. The tumor had a very narrow, smooth pedicle, surrounded on all sides by wavy masses of proliferated epithelium from the surface. A vertical section down to the base does not, therefore, include the center, but only lateral portions of the tumor, and is bounded on all sides by epithelium. The real framework consists of dense, fibrous connective tissue, containing dilated blood-vessels (G), the walls of which are in part hypertrophied. On the free surface the epithelium is arranged in numerous horizontal layers, while further down the layers of epithelium occupy a plane at right angles to that of the base, the transition between the two directions being effected gradually. The similarity of the tissue to epidermis is unmistakable. The boundary-line between epithelium and connective tissue is fairly even in some parts, in others it is more or less deeply indented, wherever the connective tissue sends out projections into the epithelial layer. On the left there is a very extensive projection of this kind (B), enclosed on both sides by a thick shell of epithelium, which in turn shows numerous indentations. Several large islands of epithelial tissue are grouped about the surface of the tumor without any apparent connection with it. Each of these islands contains a central core of connective tissue, and many similar cores are also seen in the substance of the thick epithelial zone itself, showing

that it is not a homogeneous formation, but rather the result of fusion of contiguous processes. The islands are, in fact, only peninsulas; their isthmuses are to be found in deeper, or in more superficial sections. The whole formation might be compared to a tree with a rich network of interlacing branches.

It is to be noted that each of the larger outgrowths of connective tissue has its own vascular supply; this does not appear everywhere in the picture, owing to the low power used, but is quite plainly seen at G.

Papillary Fibro-epithelioma.

PLATE 36.

Fig. 1.

This preparation was taken from the epiglottis of a little girl, 9 years old, who died of multiple recurrent tumors, resembling cauliflower, in the larynx and trachea.

At the base of the sagittal section the cut surfaces of the cartilage are seen. Next is a broad layer of loosely arranged fibers (G), and tissue-islands in process of hyaline degeneration (d); above this is a dense layer of connective tissue, surrounded at its upper boundary by round-celled infiltration. As in the preceding case, the epithelial layer in some places is enormously hypertrophied; the boundary-line between it and the basal tissue is marked by undulations and indentations corresponding to outgrowths from the connective tissue. At certain points we see the evidences of connective-tissue processes growing in from different planes. But, whereas in the preceding case the changes in outline were produced exclusively by hyperplasia of the basal tissue—in other words the growth was chiefly eccentric (centrifugal) in character—we here see, in addition, an active proliferation of the epithelium itself at one spot, resulting in the formation of a process which extends almost to the deeper tissue-layers. The epithelial proliferation has, therefore, begun to absorb the normal tissue, and this gives the growth a malignant character. We are accordingly justified in pronouncing it a

Destructive Papillary Epithelioma.

The diagnosis is confirmed when, under a higher power, the dividing-line between epithelium and round-celled infiltration, at the projections marked b, appears so indistinct that the epithelium may be assumed to be migrating directly into the connective tissue.

Fig. 2.

Four years ago a man, 42 years old, had a number of multiple raspberry-like tumors removed from his larynx. Two years afterward there was no sign of recurrence; now, two years after the last examination, the entire larynx is again filled with pale-red, papillary tumors. The preparation was taken from one of the vocal cords after death. It shows numerous projections of connective tissue covered with a thin layer of epithelium. Some thicker strands of epithelium have even penetrated as far as the glandular layer, displacing normal tissue in their

atypical, eccentric growth. Still, the general direction of these processes is more or less parallel to the surface, so that we can hardly pronounce the growth a carcinoma ; rather, in view of the uniform proliferation of the surface, is it to be regarded as a

Destructive Papillary Epithelioma.

Fig. 3.

Vertical transverse section of the free border of the vocal cord ; the upper portion is shown at O, the lower at U. The fibers are found chiefly in the lower half of the cord, and run parallel with each other from before backward. The preparation also shows the appearances of *chronic catarrh* in the accumulations of round-cell infiltrations about the blood-vessels G.

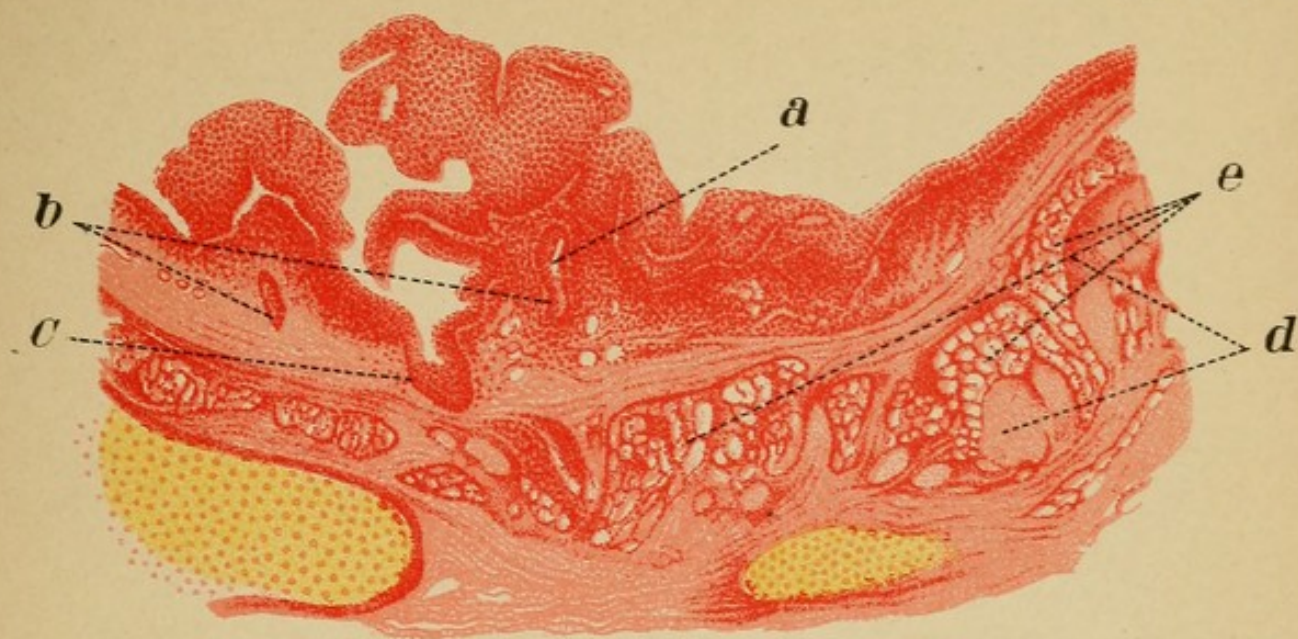


Fig. 1. Vergr. $20\times$

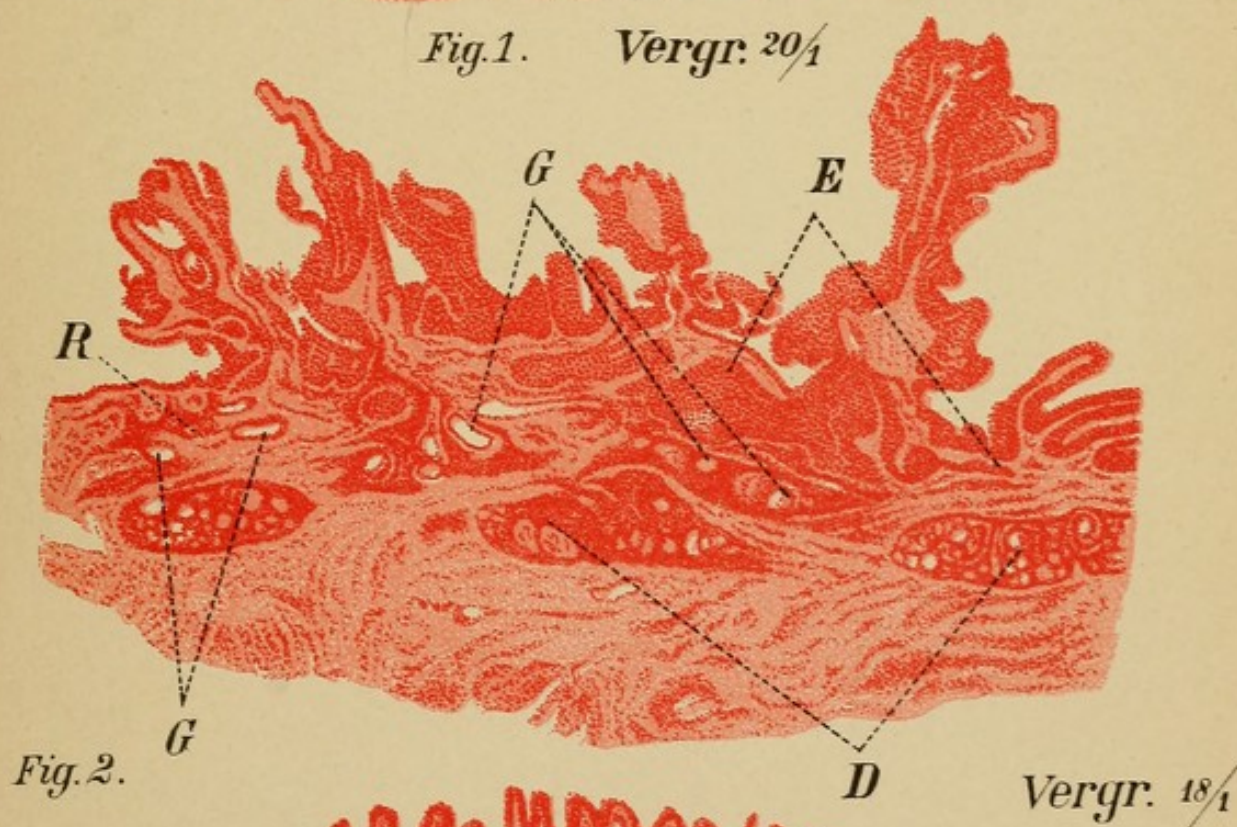


Fig. 2.

Vergr. $18\times$

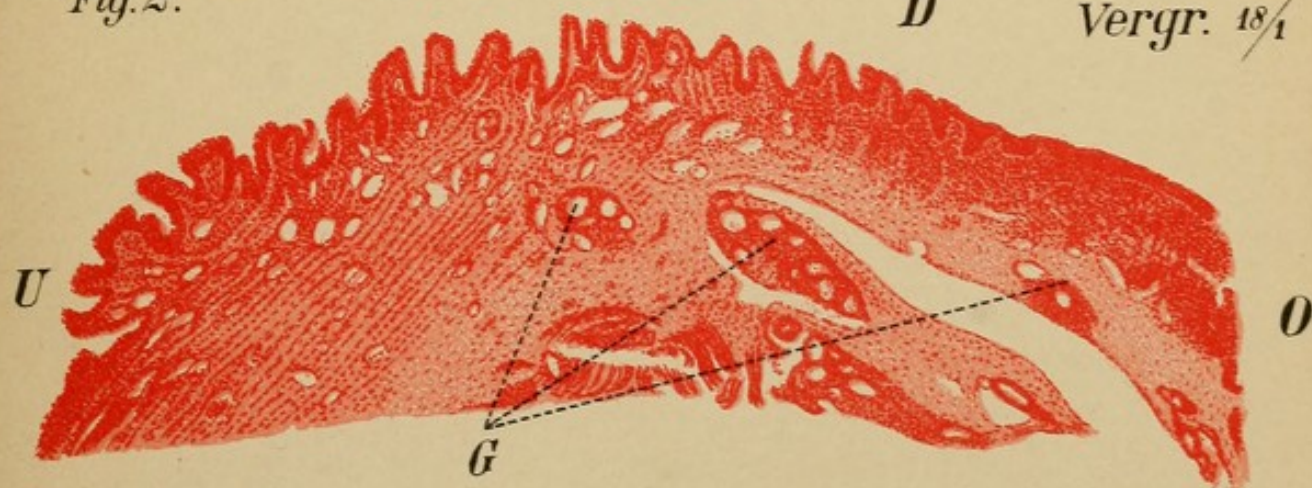




Fig. 3. Vergr. $18\times$





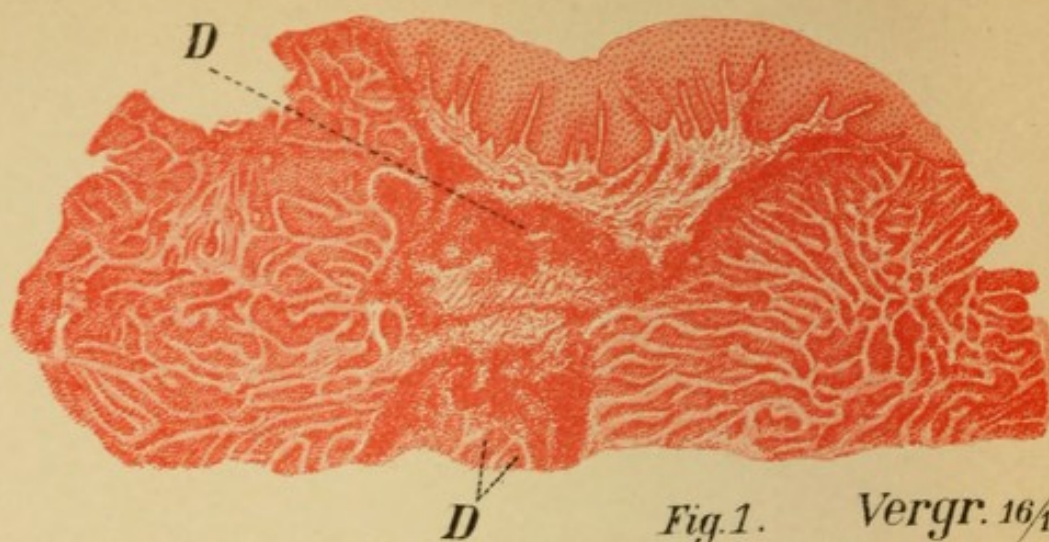


Fig. 1. Vergr. 16 $\frac{1}{4}$

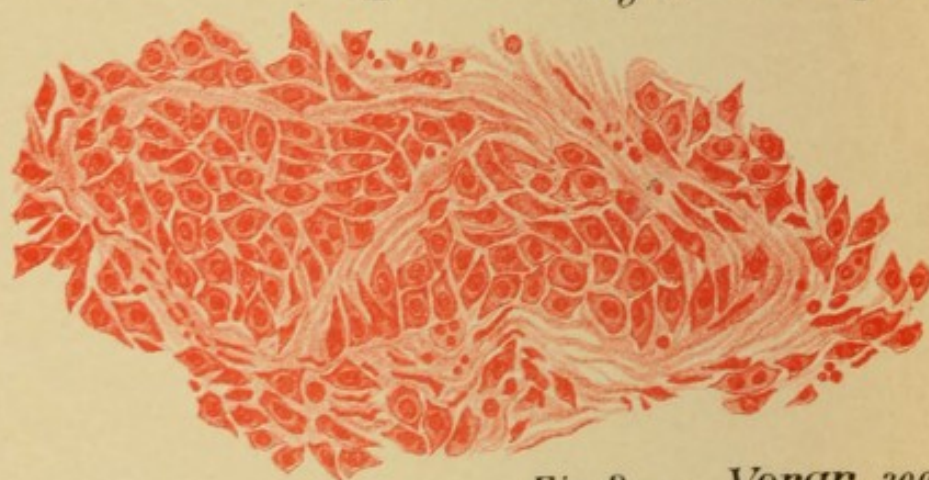


Fig. 2. Vergr. 300 $\frac{1}{4}$

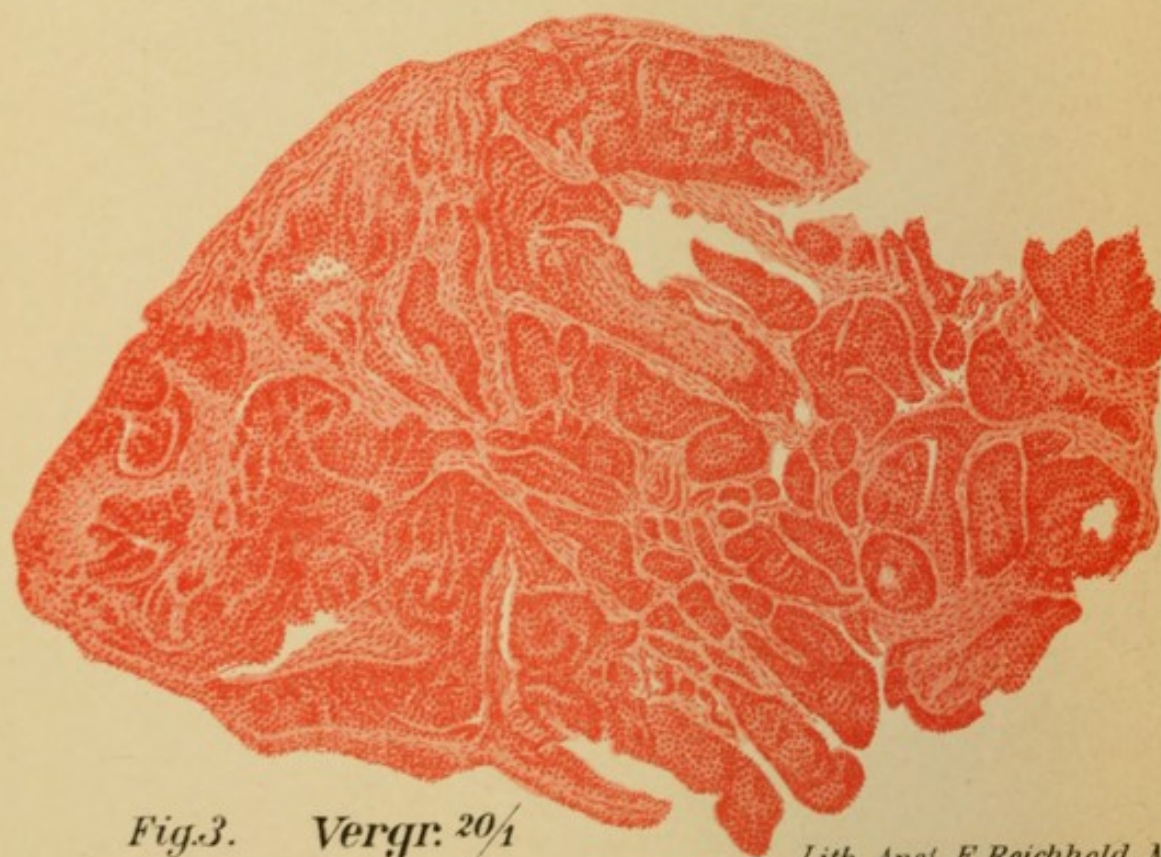

Fig. 3. Vergr. 20 $\frac{1}{4}$

PLATE 37.

Figs. 1 and 2.

This is a section of the tumor shown in Pl. 24, Fig. 3. Only the central portion of the surface is covered with proliferating epithelium sending down numerous thick processes; immediately beneath is a layer of soft connective tissue containing dense areas of round-celled infiltration and groups of glands (D), wedged in between the two lateral portions. The latter consist almost entirely of an irregular network of epithelioid cells in chains, with here and there a narrow strip of connective tissue—a tumor of alveolar character.

The higher amplification in Fig. 2 reveals the nature of the cells forming the parenchyma of the tumor. They resemble the epithelial elements found in the pelvis of the kidney, having irregular round bodies with sharp processes. Some of them are multinuclear and probably engaged in reproduction. The individual cells, however, are not in immediate contact with each other, being separated by slender interstitial fibers of connective tissue, so that even this epithelioid structure is really a connective-tissue formation. Judging from the situation and appearance of the cells, we are inclined to regard them as degenerated endothelium from the lymph-spaces. It is therefore an

Alveolar Sarcoma.

Fig. 3.

At first sight, this picture appears very similar to the preceding: numerous large spherical and club-shaped masses resembling epithelium, separated by small quantities of connective tissue. The part of the surface on the left is not covered by epithelium; it consists largely of naked connective tissue, lined on the free edge by a narrow border of densely packed round cells, so closely simulating true epithelium that their real nature is only recognized with a very high power—a *pseudo-epithelium*.

The cells of the tumor itself prove to be true epithelial cells in close contact with each other (without any intervening spaces).

The tumor, which is seen macroscopically in Pl. 27, Fig. 1, is therefore a

Carcinoma.




PLATE 38.

Fig. 1.

A thick, smooth tumor from the left vocal process of a man, 26 years old. The outer covering, which is fairly uniform in thickness, consists of several layers of squamous epithelium; next comes a layer of dense tissue of about the same thickness, containing spindle-shaped cells. The interior consists of loose connective tissue poorly supplied with cells and broken up into large cavities with thin walls; the latter are lined with a single layer of endothelium (En), and correspond to dilated lymph-spaces or lymphatic ducts. Part of the supporting tissue (a), even when seen under a high power, shows no nuclei and appears to be made up of structureless debris; it is, therefore, engaged in retrogressive metamorphosis. This, as well as the lymph-spaces, must be regarded as a manifestation of an edematous process. The tumor is an

Edematous Lymphangiofibroma.

Fig. 2.

This smooth, pale-red tumor, from the right vocal cord of an elderly man, presents a similar formation on the surface as well as in the deeper parts. The proliferation of epithelium (E) toward the base is more active and shows the characteristic villous formation; the cells are more abundant in the body of the tumor, and there are large clefts not lined with endothelium. The latter are, therefore, not lymph-spaces, but simple mechanical dilatations of the tissues by edema. Signs of edema are also seen at "O," where the tissue is still continuous, and of impaired nutrition in the form of structural loss at "a."

As the lymph-spaces themselves are but little involved, the tumor is practically an

Edematous Fibroma.

Fig. 2.

The accompanying cut represents a part of the epithelial covering of the above preparation. The upper half is engaged in complete metamorphosis. The cells, which are quite small in the deeper layers, gradually increase in size, and their protoplasm becomes more and more granular as they approach

the surface. At last the cell-boundaries are lost entirely, the nuclei disappear, and only a few "shadow" cells are distinguishable. The latter are enlarged to forty-five times their

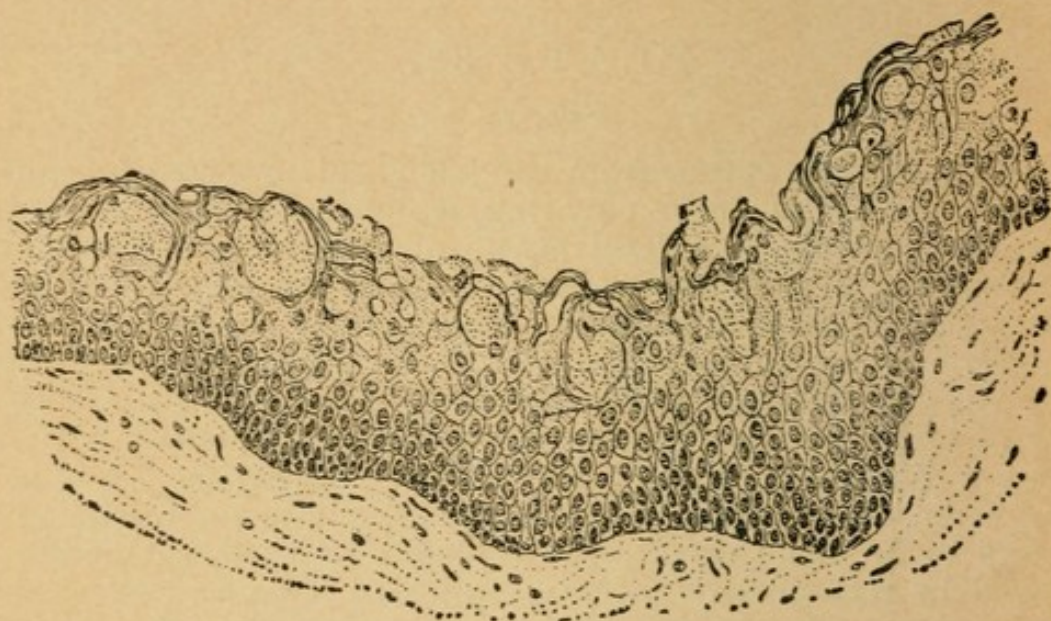


FIG. 24.

normal size and completely filled with granular material. The whole is covered by several layers of dense lamellæ without nuclei—the results of cornification.

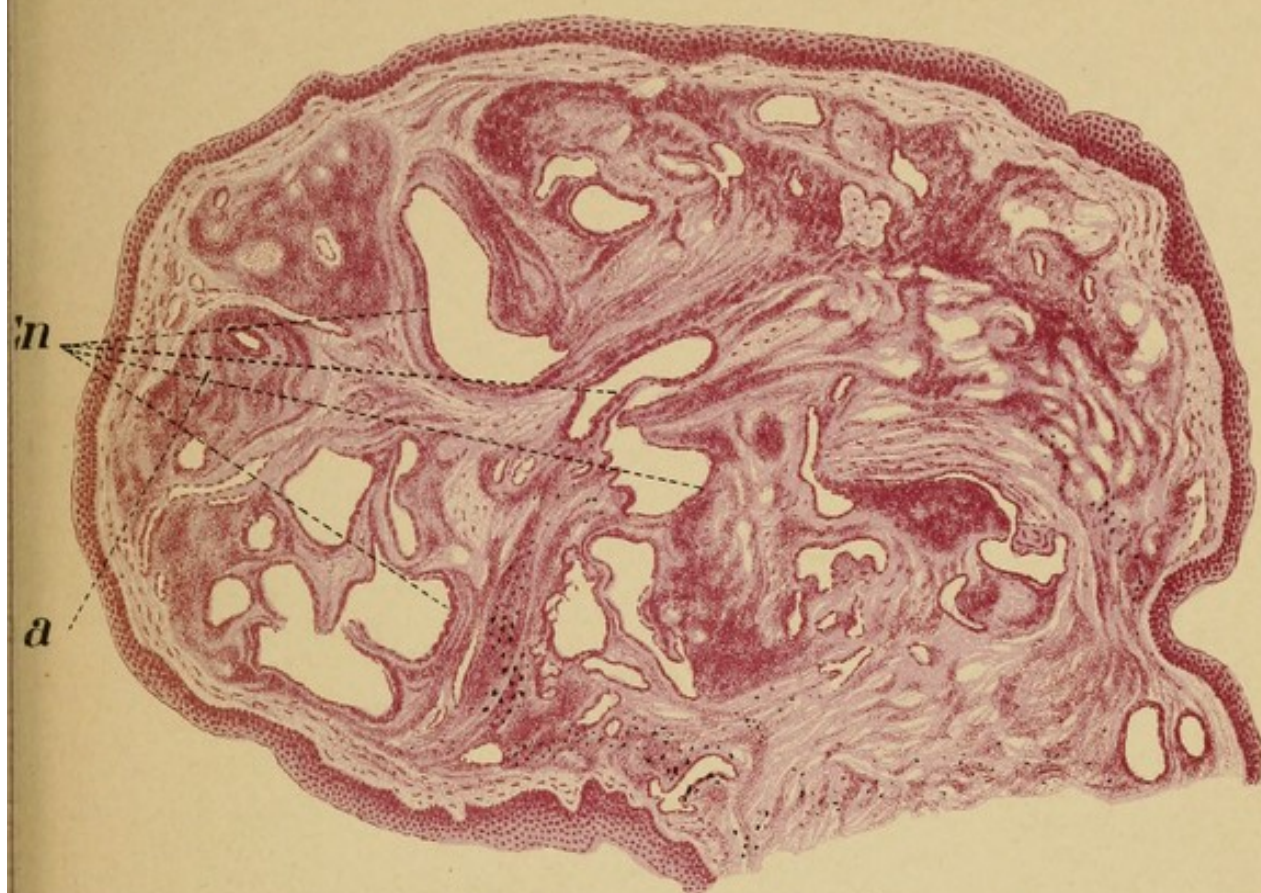



Fig. 1. Vergr. $\frac{25}{1}$

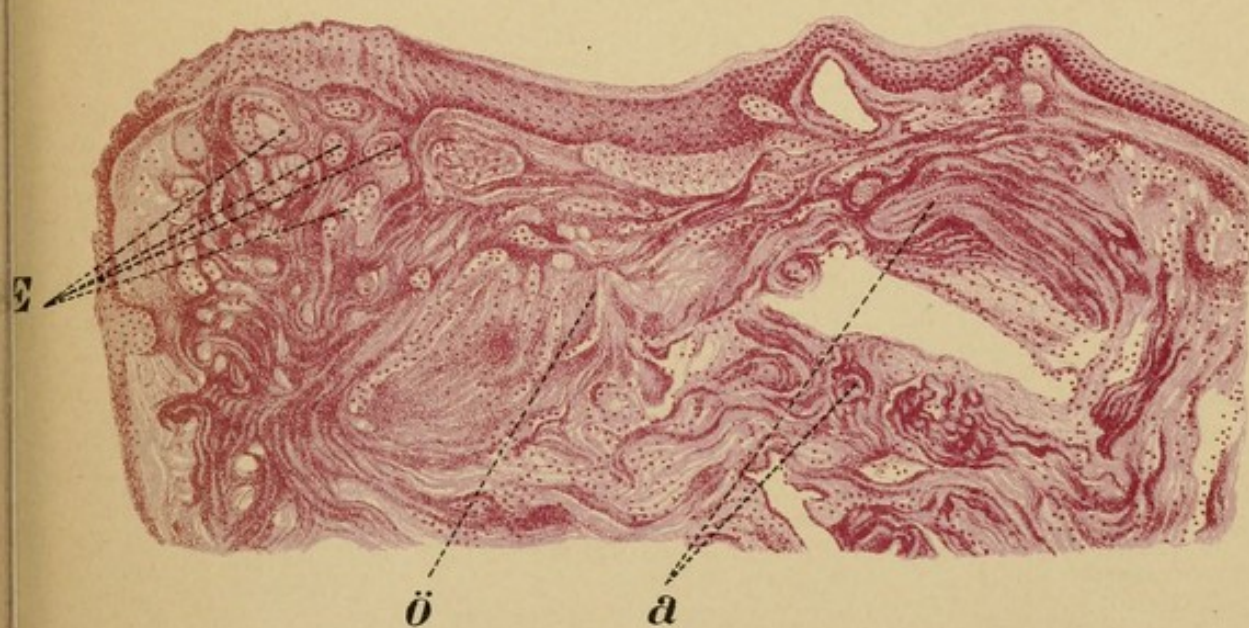

Fig. 2. Vergr. $\frac{25}{1}$

Lith. Anst. F. Reichhold, München.





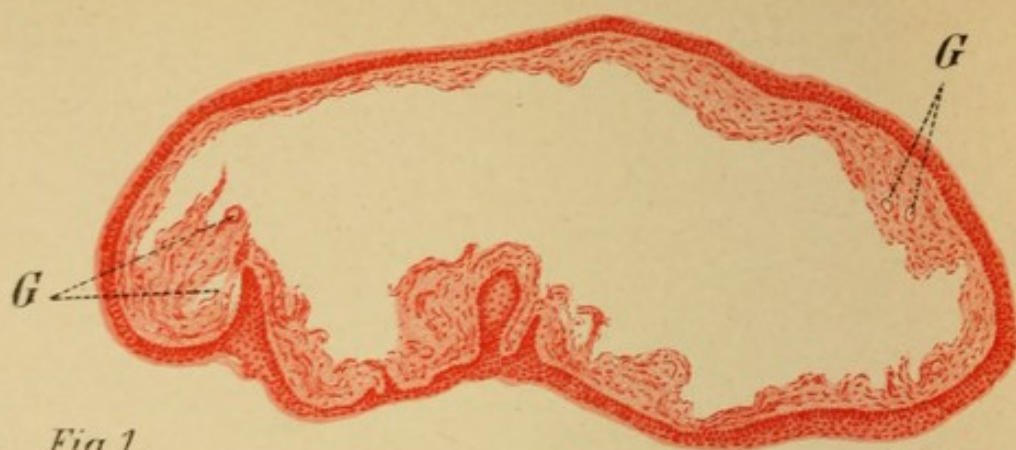


Fig. 1.

Vergr. 20 $\frac{1}{1}$

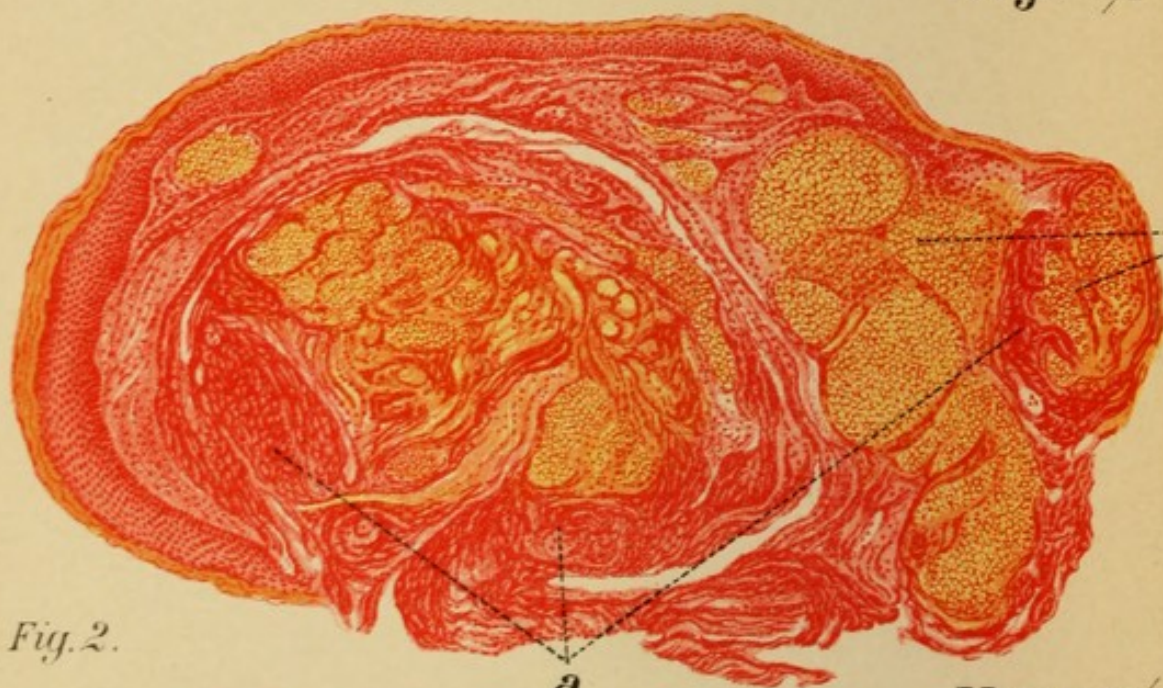


Fig. 2.

Vergr. 30 $\frac{1}{1}$

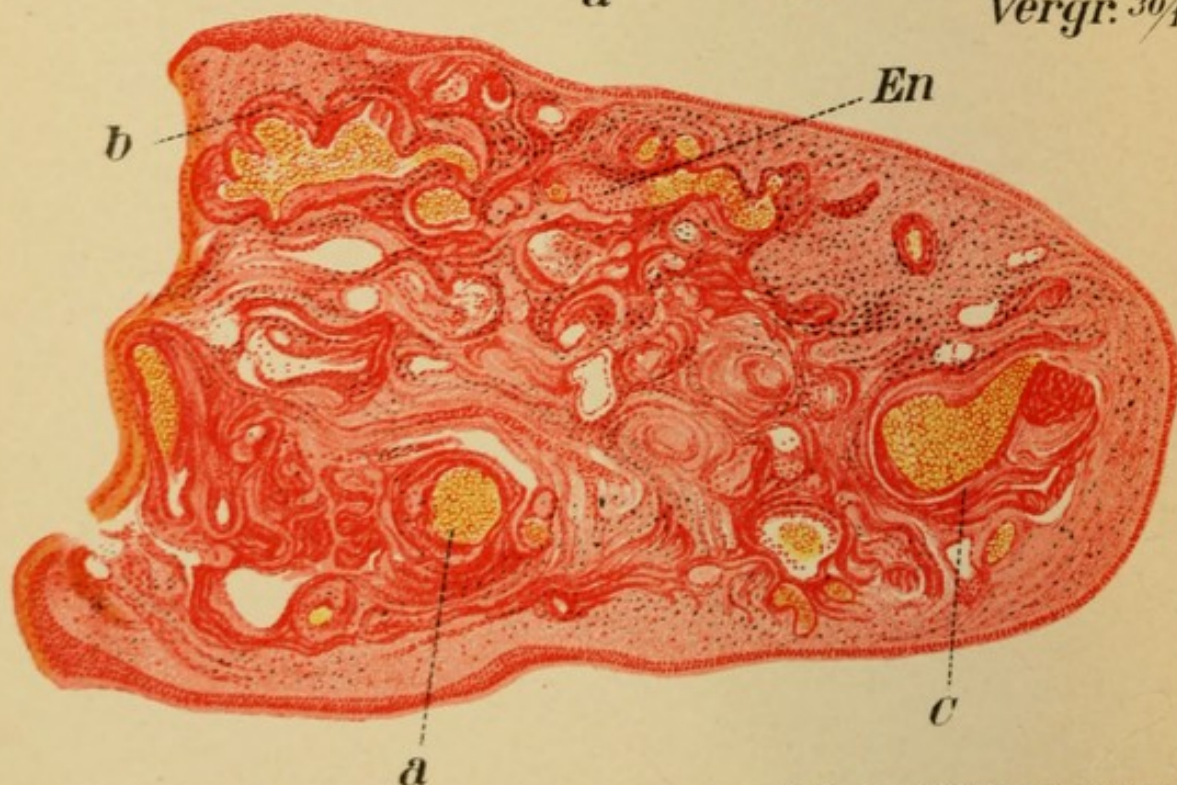


Fig. 3. Vergr. 25 $\frac{1}{1}$

PLATE 39.

Fig. 1.

This preparation is a sagittal section of one of the two small symmetrical tumors shown in Pl. 15, Fig. 2. The growth consists of a hollow sac filled with a clear mucoid substance; the cavity occupies almost the entire body of the tumor and merges, without any clearly defined line of demarcation, into a delicate connective tissue moderately rich in cells and thick blood-vessels. The whole is covered by a layer of squamous epithelium of varying thickness, which sends down villous processes here and there toward the center of the tumor. The cavity is evidently due to loss of substance. In order to get a clearer understanding of the way in which this cavity was formed let us compare it with Fig. 25.

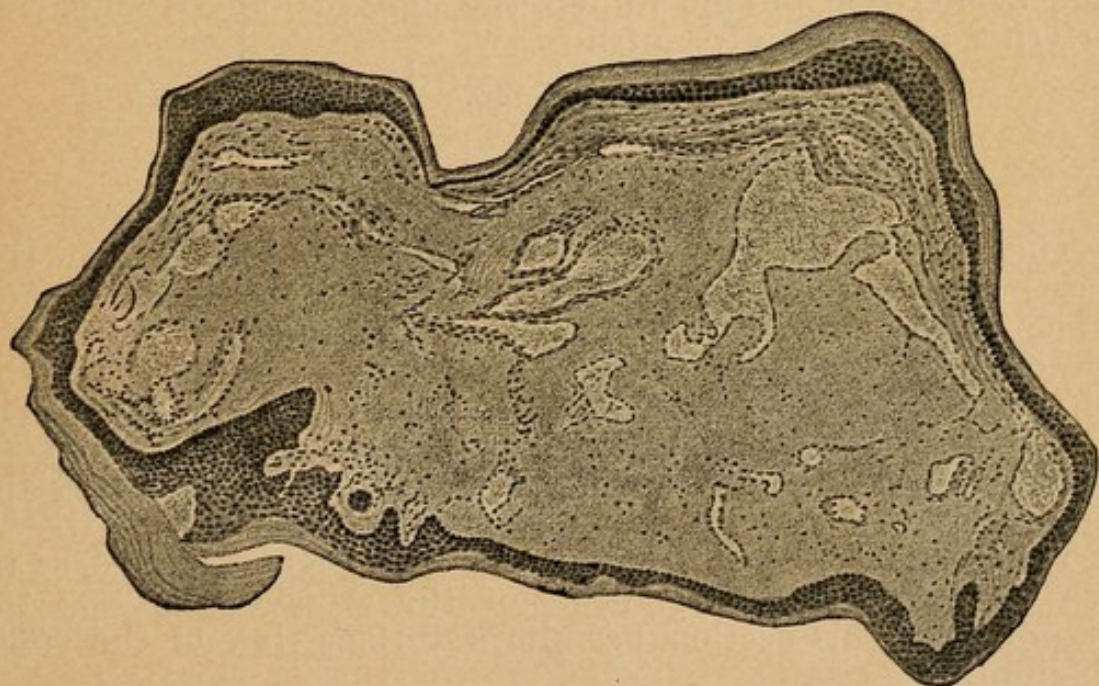


FIG. 25.

The interior of this preparation is almost homogeneous, with only a few groups of round cells scattered here and there; if we imagine this area to have undergone the same degeneration (by colliquation and absorption of the broken-down cells) that is seen in the first preparation, we shall obtain an almost exactly similar picture, the only difference being the narrow peripheral zone of denser connective tissue. It is therefore an

Absorption-cyst within a Soft Fibroma.

PLATE 40.

Fig. 1.

This cut also exhibits marked changes in the blood-vessels, although somewhat different in character from the preceding. It is taken from the tumor shown in Pl. 27, Fig. 2.

The hyperplastic, horny epithelial covering encloses a core of connective tissue filled with numerous dilated lymph-spaces, in accord with the gelatinous nature of the edematous infiltration described macroscopically. There is only a very light sprinkling of cells. On the right is seen a rich network of small arteries with hypertrophied and thickly infiltrated walls, but without dilatation. The condition is, therefore, not an inflammatory, but a purely hyperplastic one. The concentric mode of the hypertrophy has led to obliteration of the lumen in many situations, and hence, by stasis, to edema. We have before us, therefore, an

Edematous Angiofibroma.

Fig. 2.

Again the most striking feature, after the enormous proliferation of squamous epithelium, is the diseased condition of the blood-vessels. The section corresponds to the excrescence on the posterior wall of the larynx shown in Pl. 5, Fig. 1. Numerous small lumina of blood-vessels, some of them dilated, are seen at G. Some present only a slight uniform hypertrophy of the media, while others are surrounded by huge masses of round cells. In places the round cells have even filled up the lumen, and in the upper right-hand portion they are on the point of attacking the epithelium. This is not a simple inflammation of the vessel-walls; the uniform character of the densely packed cells imbedded in loose areolar tissue (as seen with a higher power), and disposed in spherical masses, characterizes the process even macroscopically as

Syphilitic Meso- and Peri-arteritis, changing to Gumma-formation.

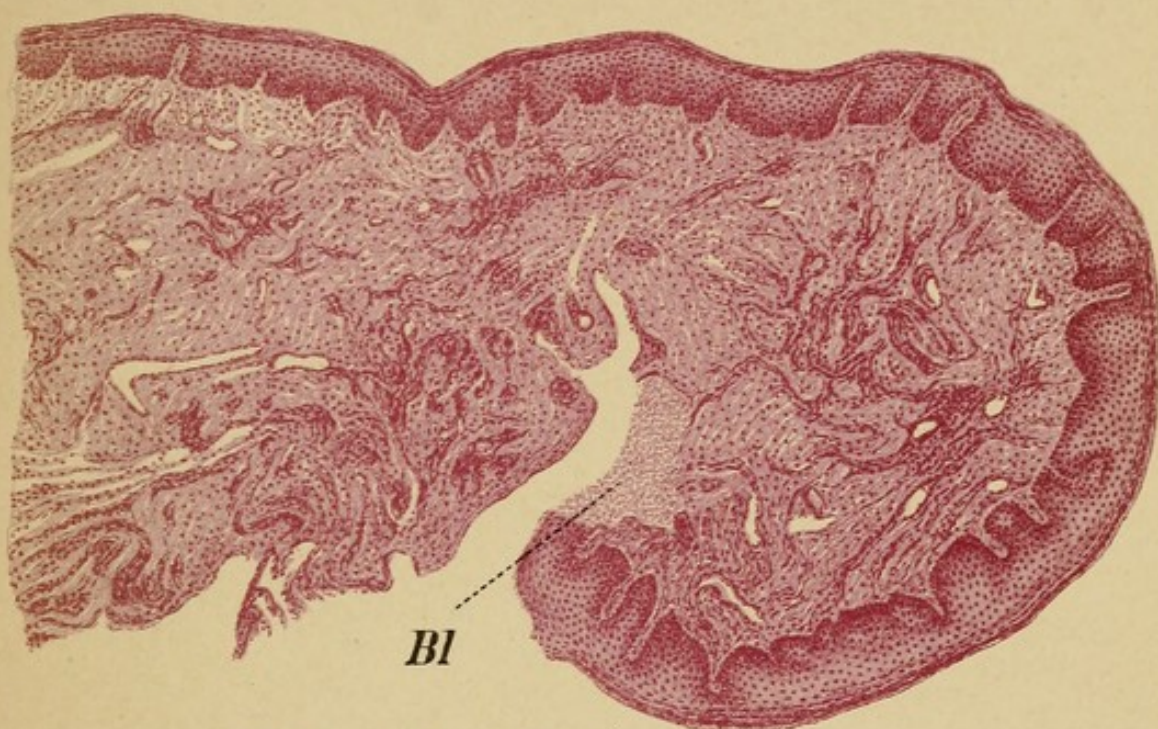


Fig. 1. Vergr. $20\times$

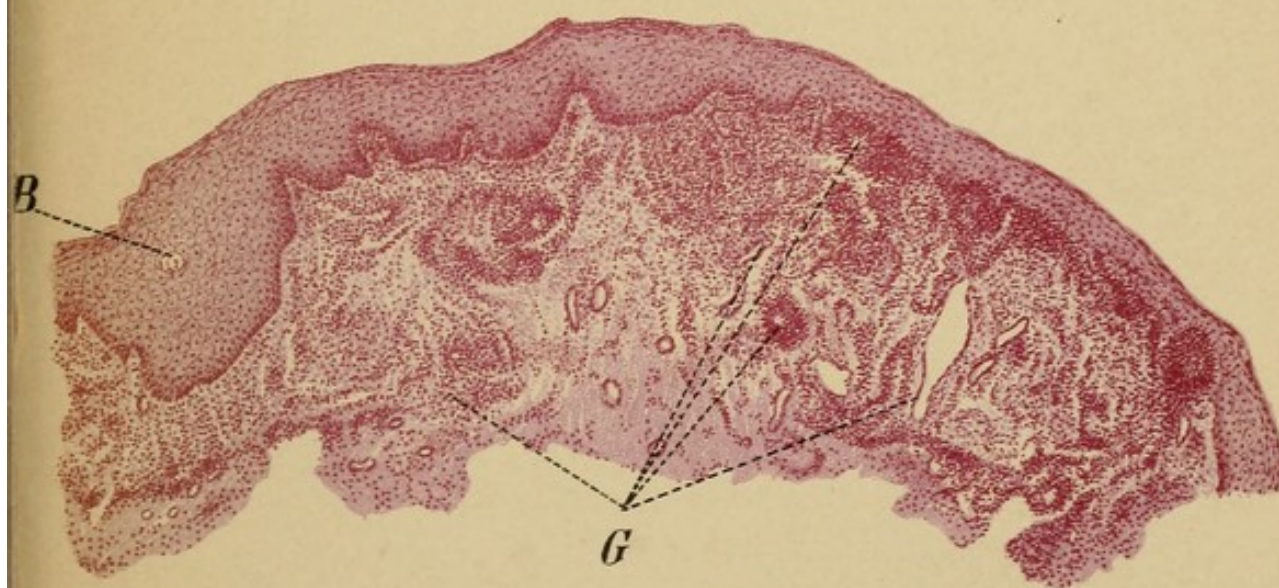




Fig. 2. Vergr. $20\times$





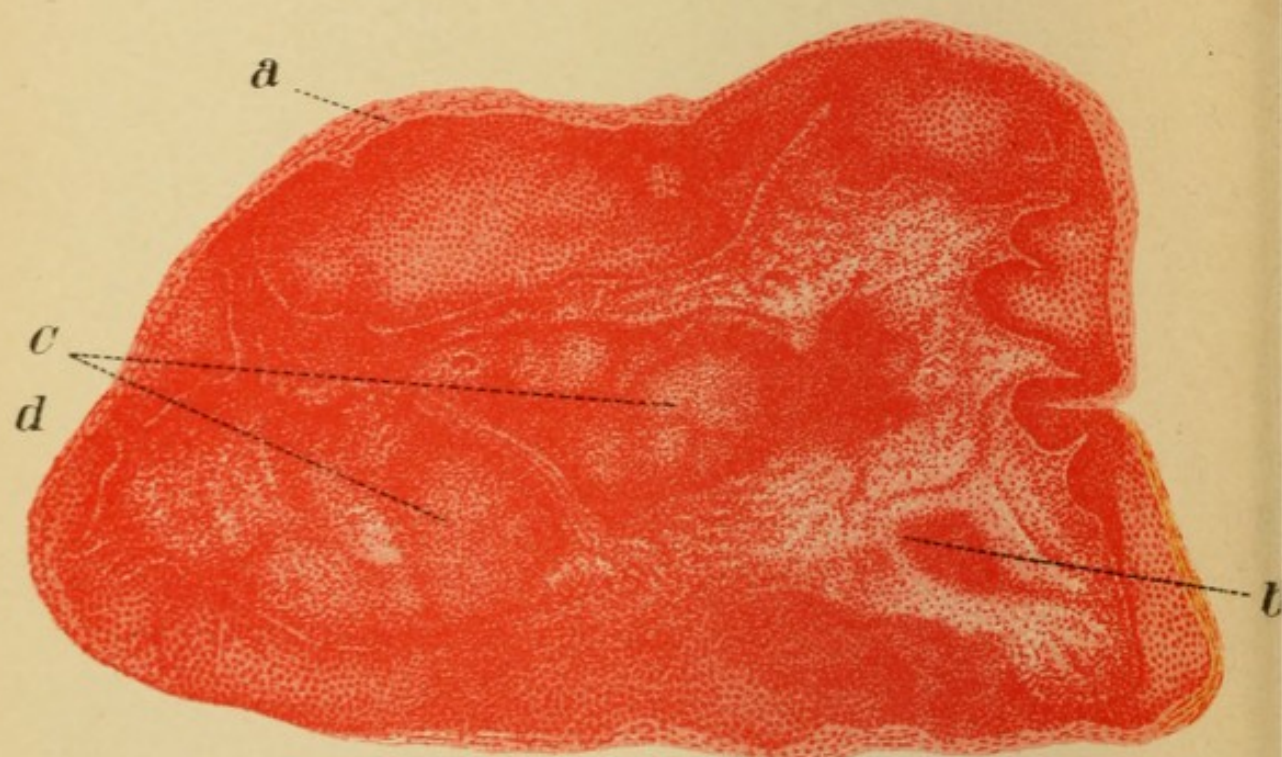
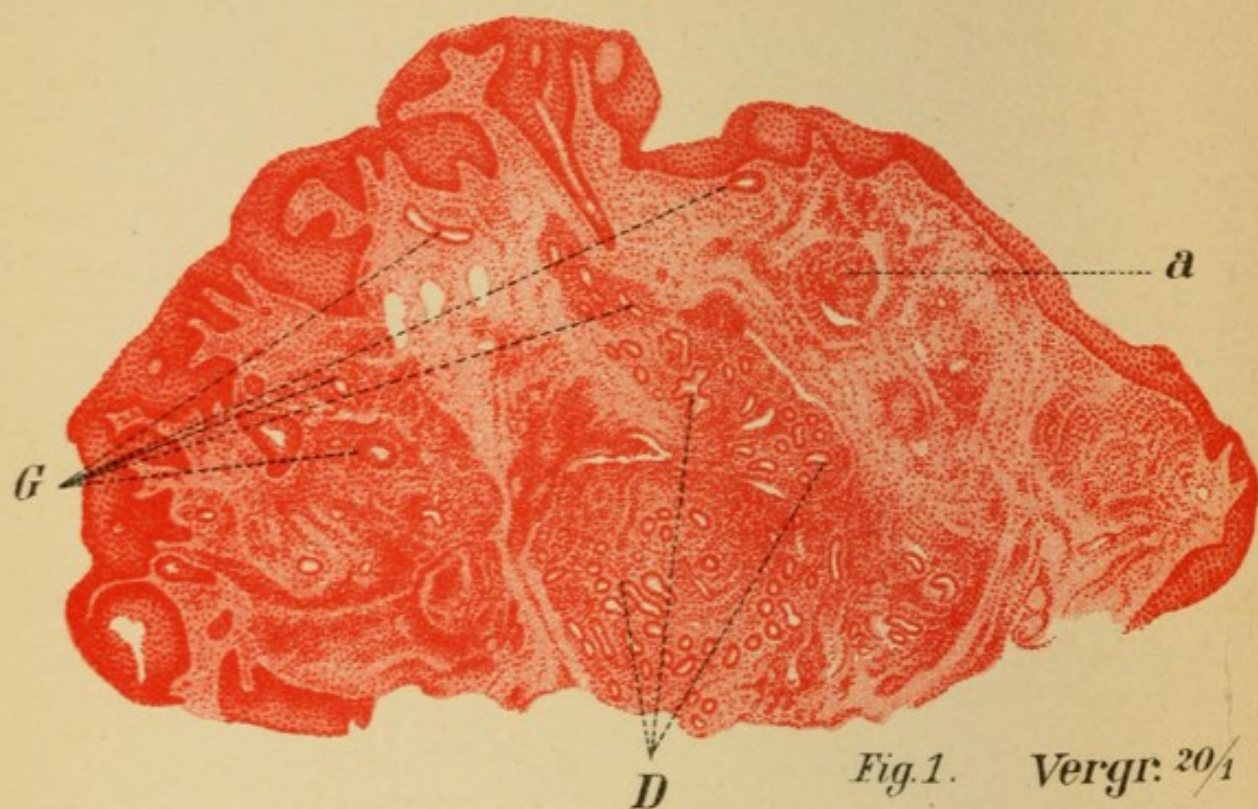


PLATE 41.

Fig. 1.

One of the convolutions on the posterior wall, represented in Pl. 5, Fig. 3, was removed with the galvanocautery; it was found to be exceedingly hard. In horizontal section the growth appears as a roundish elevation of connective tissue covered by an epithelial layer of varying thickness. At certain points the epithelium is very abundant and, especially on the left side, sends down long ramifications into the basal tissue. That the proliferation proceeds downward is also proved by the smooth outline of the free surface. Here and there we see open spaces which probably correspond to the transverse sections of invaginated portions of the epithelial layer. The central portion of the base is occupied by numerous glands, some of which exhibit considerable uniform enlargement, while in others the hypertrophy of the walls betrays itself in the irregular outline of the transverse section. A zone of round-celled infiltration of varying density surrounds this area of gland-tissue and the blood-vessels which are seen at G. In some of the latter the lumen is considerably narrowed from hypertrophy of the inner wall, which at one point (a) forms a mushroom-like elevation; this pronounced form of hyperplastic endarteritis, as well as the peri-arteritis, accords perfectly with the syphilitic nature of the tumor. It does not, however, possess any distinctive syphilitic features; it is a general hyperplasia of *all* the elements composing the mucous membrane, without any typical characters, so that the tumor cannot be regarded as syphilitic. It is simply a

Postsyphilitic Inflammatory Hyperplasia.

The probable cause of the growth has already been discussed in connection with Pl. 5.

Fig. 2.

This preparation is taken from Pl. 18, Fig. 3; it is a vertical, transverse section of the tumor on the ventricular band. At first sight, it seems to be a hard wart, for we observe a very heavy epithelial covering, the upper layers of which, being flat and showing no nuclear stain, have, therefore, become horny. On the right the epithelium is seen to dip down into the basal tissue. The core of the tumor, however, is anything but normal: there are three distinct areas of infiltration, a small one in the lower right-hand portion (b), and two larger adjoining

groups (c, d), which occupy almost the whole of the center and are in turn made up of smaller, round aggregations of cells, lighter at the center than at the periphery, where the cells are massed in heavier layers. In addition, we see a dense infiltration along the course of small blood-vessels—a sign of periarteritis.

With a higher power we note that the round cells are fairly uniform in size and disposed in groups of varying density, but no giant-cells can be made out. The cells are imbedded in a delicate areolar stroma; at the center of the large group on the left they appear more scattered and are not stained so deeply.

We know from the anamnesis that syphilis is present; but the histological appearances alone would suffice for the diagnosis. They are

Confluent Gummata in the Deeper Tissues, with Hyperplasia of the Superficial Elements.




PLATE 42.

Fig. 1.

This is a vertical section of the ulcer on the epiglottis shown in Pl. 5, Fig. 1.

The dense ground-tissue (G) shows numerous sclerotic arteries; overlying this is a layer of tubular glands (D), the most superficial of which are already being absorbed by numerous small masses of round cells. The latter are in direct relation with the free surface, the epithelium being entirely lost; hence the ulceration extends almost to the glandular tissue. The uniform (areolar) infiltration is of a gummatous nature; we have before us a

Syphilitic Ulcer.

Fig. 2.

A horizontal section of the larynx taken from a tuberculous subject; only a slight fold had been visible on the anterior surface of the posterior wall. The section shows even in this slight alteration the signs of beginning infection. KK, the arytenoid cartilages in transverse section; M, muscle-bundles; D, glands. Exactly in the centre (E) the epithelium is much hypertrophied and forms a small wart-like elevation which corresponds to the ominous interarytenoidal spur seen macroscopically. Immediately beneath we see small aggregations of round cells (T), which under a higher power reveal themselves as a true tuberculous infiltration. The (reactive) epithelial proliferation extends some distance laterally over the surface.

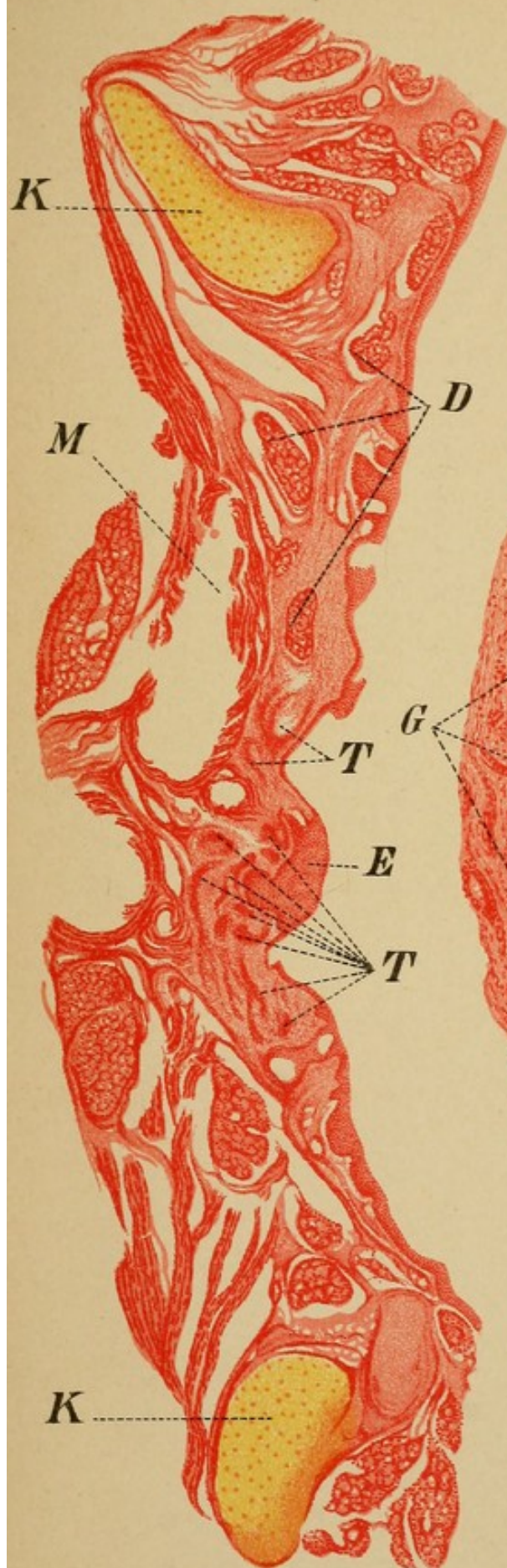



Fig. 2.

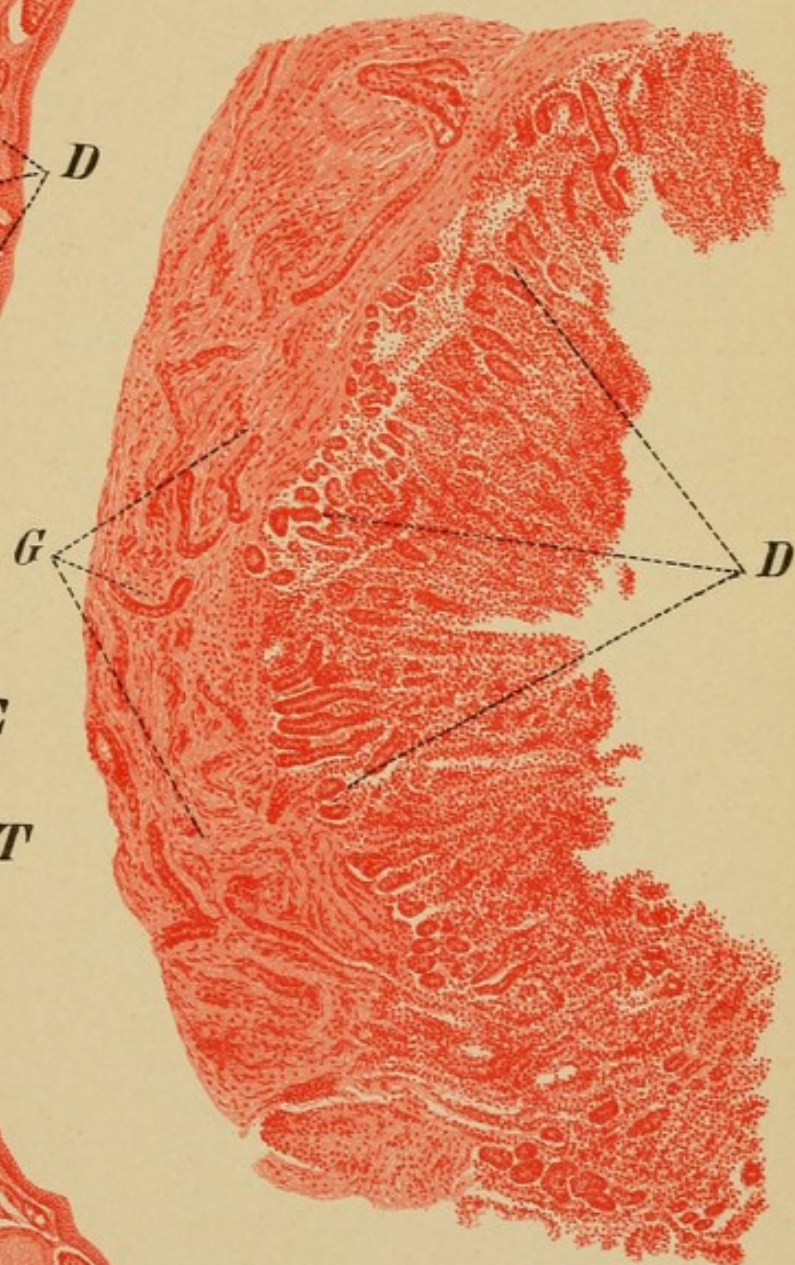

Fig. 1.





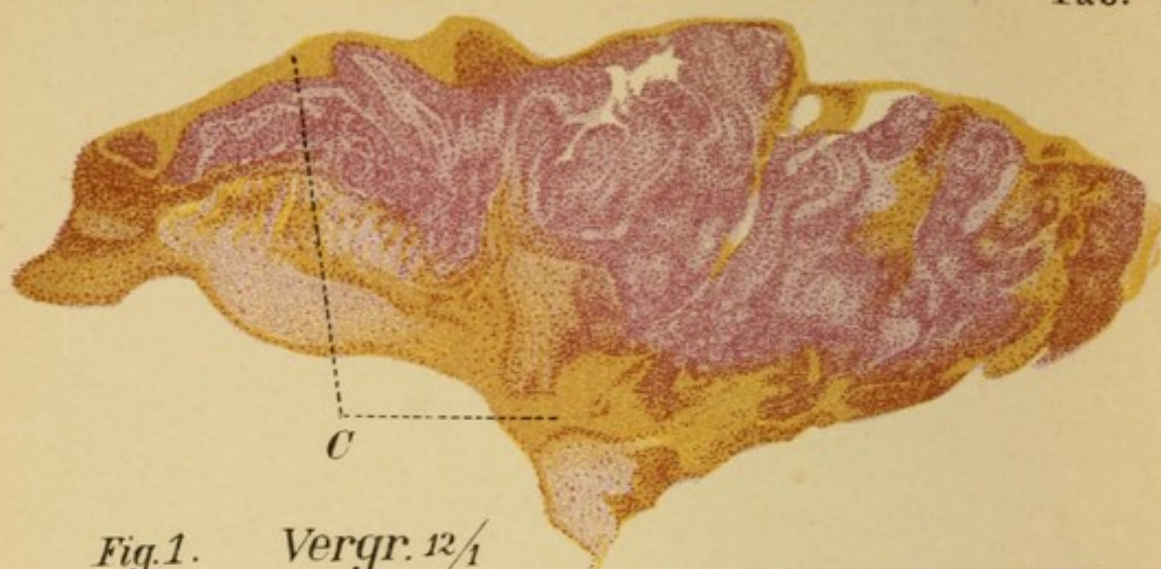


Fig. 1. Vergr. $12\frac{1}{1}$

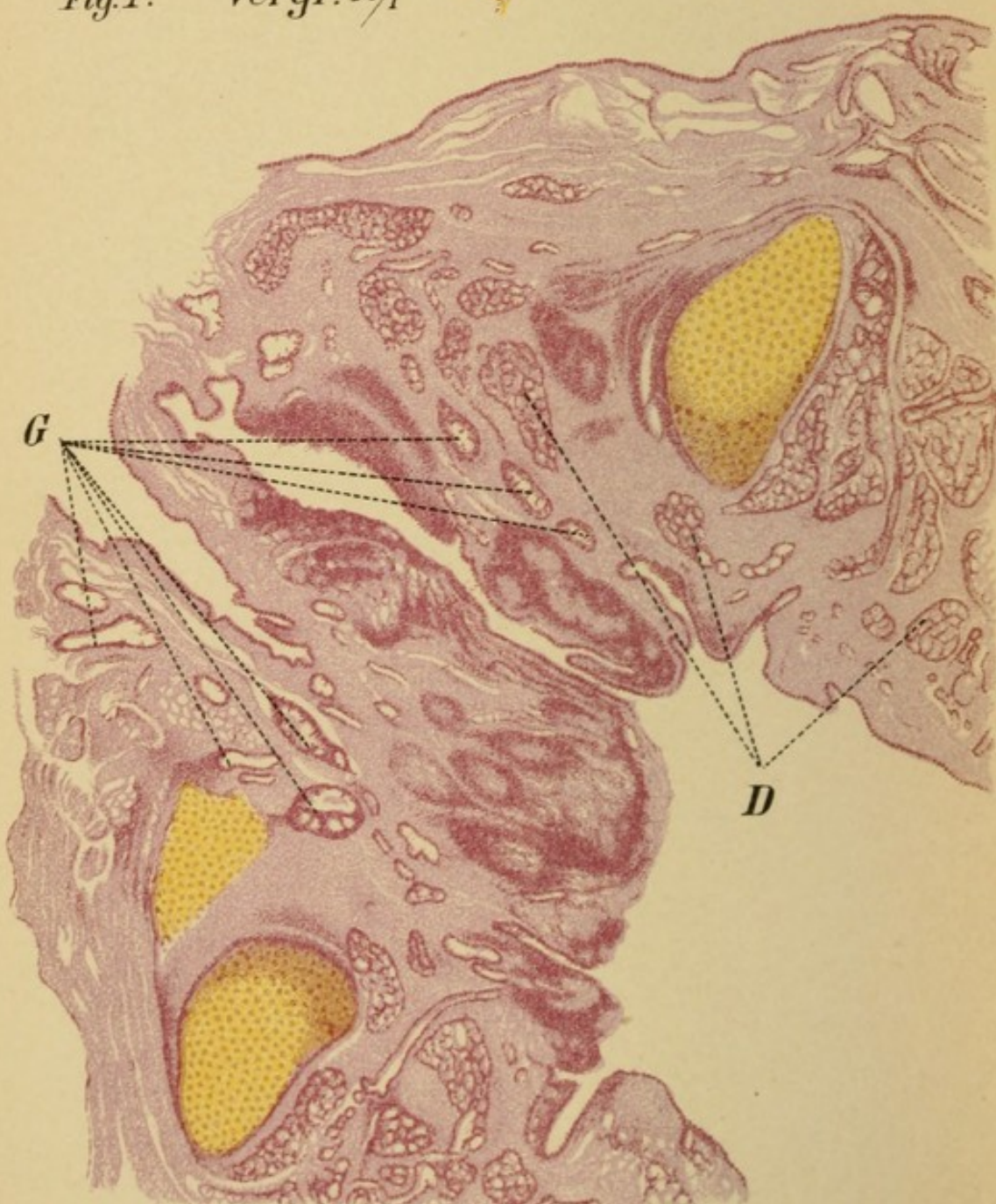


Fig. 2. Vergr. $10\frac{1}{1}$

PLATE 43.

Fig. 1.

This preparation was removed with a curet from a tuberculous infiltration on the posterior wall of the larynx.


The figure shows principally a conglomeration of tuberculous proliferations merging into one another. These overlie a central mass of dense connective tissue (in the lower left-hand portion) which forms the boundary of the cut surface, showing that it was made within the limits of healthy tissue. (The yellow portions are not tissue, but portions of the imbedding-material.)

Fig. 2.

A horizontal section of the larynx of a tuberculous cadaver which showed prominent, pale, rigid infiltration of the posterior wall.

We see two large areas of infiltration separated by a deep fissure, lined with a thin layer of epithelium. At the bottom of the fissure the infiltration has invaded the epithelium and in part crowded it out entirely, so that it appears completely naked. The infiltration possesses a pronounced tuberculous character, even under the low power. The cells exhibit a circular arrangement with a lighter area in the center, poor in nuclei, showing that degeneration has begun. Even the perichondrium of the upper cross-section of the (left) arytenoid cartilage shows infiltration.

The (non-specific) reaction manifests itself in this case not in the epithelium, but in the vessels, whose walls are much hypertrophied: the beginning of sclerosis so common in tuberculosis.






PLATE 44.

Fig. 1.

A section of a club-shaped tumor on the left ventricular band of a man 44 years old. Macroscopically the tumor presented the appearance of a pale, uneven papilloma, about $\frac{3}{4}$ cm. in length, 6 mm. in breadth, and $\frac{1}{2}$ cm. in thickness. Three other similar tumors were seated in the same situation. The remaining parts of the larynx and the lungs were normal. The epithelium (E) presents numerous villous processes which descend quite deeply into the basal tissue. Just as in true papillary tumors, we see a part of the growth diverging from the main body to such an extent that in transverse section it appears as an isolated mass (Fig. 1^b). But whereas such isolated portions usually consist entirely of epithelium, with only a slender pedicle (Pl. 30, Fig. 2), in this case the external epithelial layer is very thin and encloses an ovoid kernel consisting chiefly of round cells with only a narrow ring of connective tissue (T). Many such masses or kernels are seen in the tumor itself, the cells being more densely packed near the periphery than at the center.

With a higher power we find that the center contains also epithelioid and giant-cells, revealing the true nature of the growth. It is a

Papillary Tuberculous Tumor.

Fig. 2.

This preparation corresponds to the tumor shown in Pl. 32, Fig. 2. The general appearance is that of a connective-tissue growth with abundant round-celled infiltration. The surface is enclosed in a cellular band of varying thickness, which under a higher power is also found to consist of round cells—another example of pseudo-epithelium (P) (see Pl. 37, Fig. 3). In the center the infiltration about the vessels varies much in density, without, however, forming typical tubercles. Only at one spot on the surface is there anything approaching in appearance a tubercle. We must call the tumor a

Diffuse Tuberculous Hyperplasia.

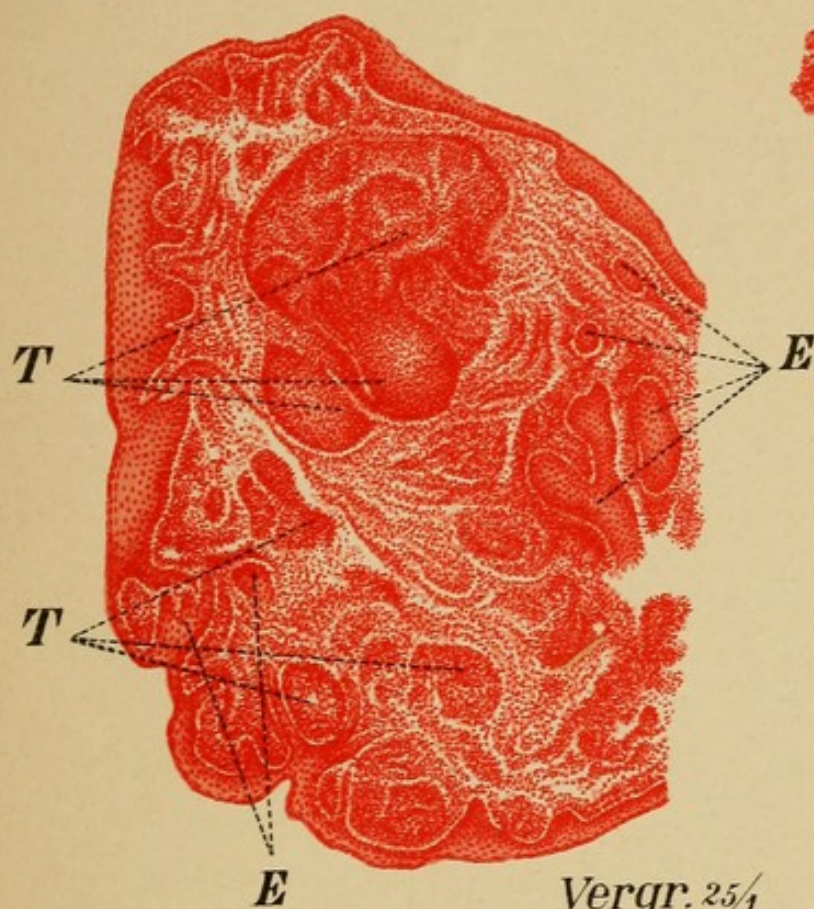


Fig. 1^a

Vergr. $25\frac{1}{4}$

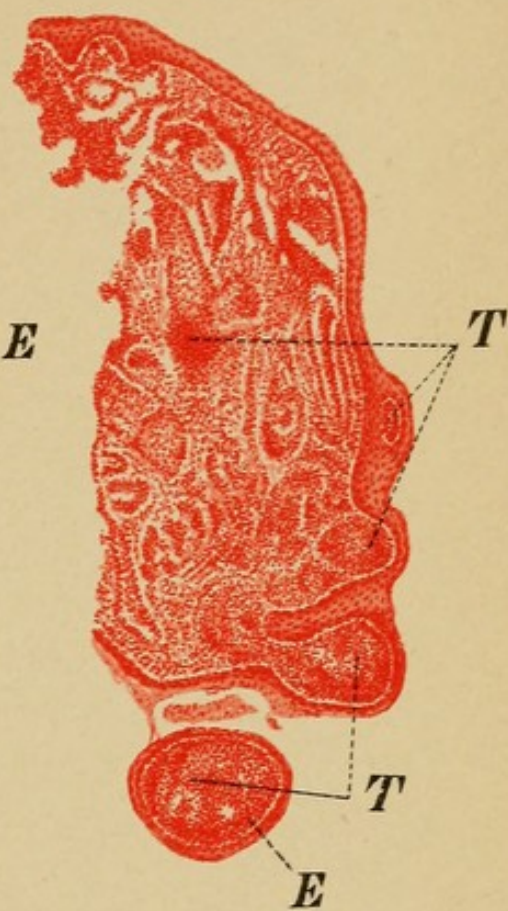


Fig. 1^b

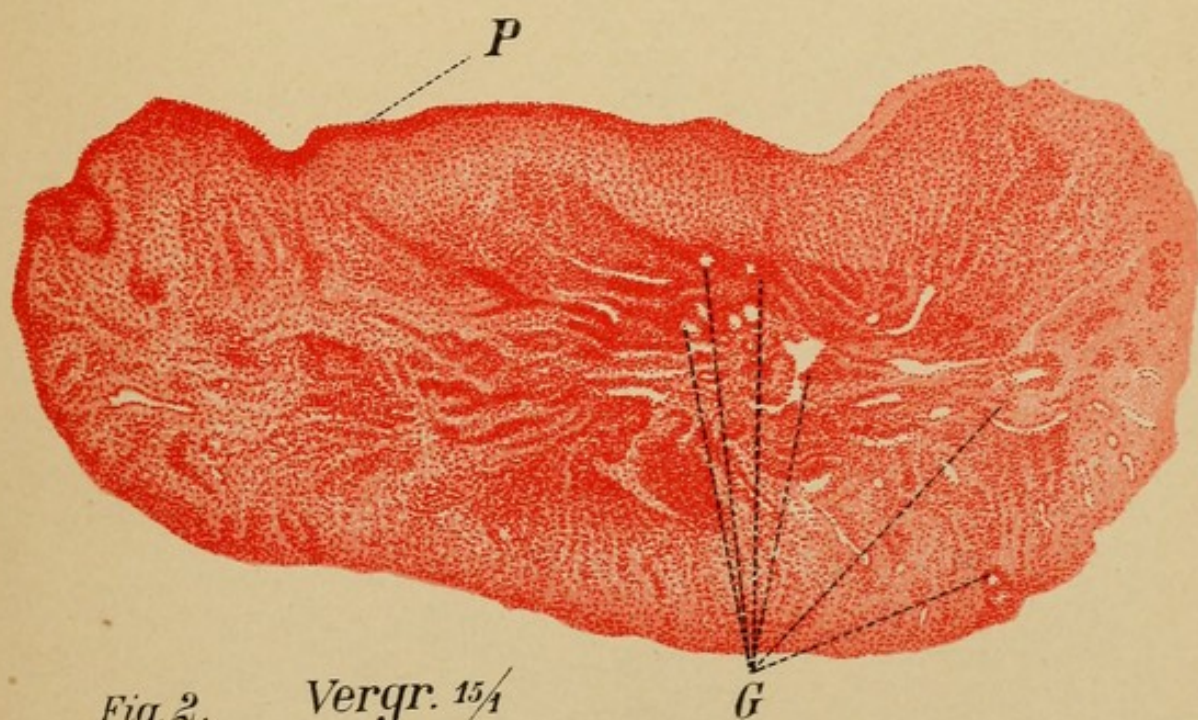





Fig. 2. Vergr. $15\frac{1}{4}$







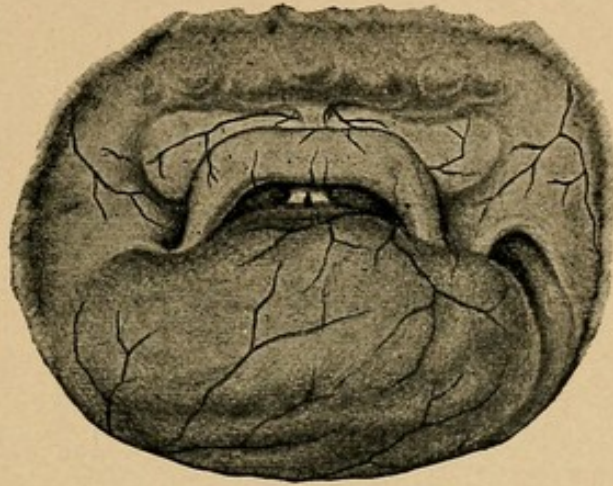


Fig. 15.

A woman, 43 years old, seeks relief for increasing dyspnea and difficulty in swallowing. The cyanosis of the face is very striking, and there is rough, audible stridor in inspiration. The voice is rough and sometimes aphonic.

The larynx is entirely concealed by a dark-red tumor as large as a walnut, with a slightly wavy surface traversed by a few large vessels. The tumor is free behind and on the left side, while on the right it is continuous with the lateral wall of the pharynx. In front nothing is visible but the epiglottis and the commissure.

A slight goiter is noticeable on the outside of the throat. On palpation the right lobe is found to extend more deeply than the left. Pressure on this part causes the internal tumor to move slightly toward the left. On bimanual palpation (right index finger on the tumor inside, left hand on the goiter outside) the effect of pressure on one side is even more plainly felt. The tumor is, therefore, beyond doubt a

Struma Retropharyngea Dextra.

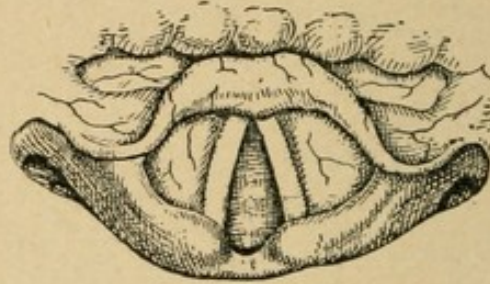


Fig. 16.

A young lady, 23 years old, has lost her voice entirely; she cannot speak above a whisper, but from time to time she coughs loudly. This condition has lasted two weeks; at the same time she complains of violent pain in the region of the right cornu of the hyoid bone. The larynx as a whole is rather pale.

During respiration the vocal cords exhibit a slight twitching movement toward the middle line.

When the patient tries to phonate the vocal cords approach only to the cadaveric position.

Occasionally, however, when she coughs, the arytenoid cartilages are seen to move more distinctly inward.

The fact that the closers of the glottis are insufficient when a voluntary attempt at innervation is made, yet respond to an involuntary act of the same character (loud cough), and the absence of inflammatory signs, at once establish the diagnosis as

Hysterical Aphonia.

Later it appears that the hysteria was caused by a great psychical excitement.

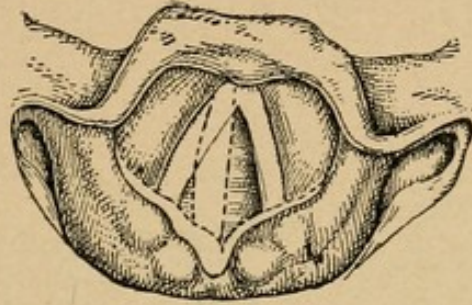


Fig. 17.

A woman, 40 years old, has been hoarse since she was operated on for struma.

The right vocal cord is widely abducted during respiration, the left remains midway between respiration and phonation-posture. The left arytenoid region is thrust somewhat farther forward than the right. During phonation (dotted lines) the right cord moves to the middle line, while the left is immovable. The cartilages on the right side move forward and inward, as usual; those on the left also, but not to the same extent; at the same time the left aryteno-epiglottidean ligament is slightly put on the stretch.

From the anamnesis and from the absence of any mechanical obstacle we must diagnosticate

Traumatic Paralysis of the Left Recurrent Nerve, with Marked Vicarious Function of the Transverse Arytenoid Muscle.

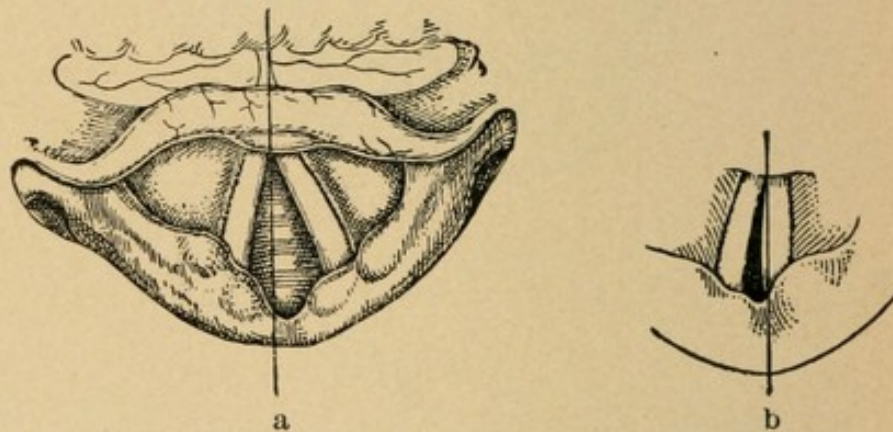


Fig. 18.

In another patient the right vocal cord is also fixed in the cadaveric position both in respiration and in phonation. In respiration (a) the right arytenoid cartilage stands a little farther toward the front than the left, while in phonation (b) the opposite occurs.

It is another case of

Paralysis of the Right Recurrent,
but without function of the arytænoideus transversus.

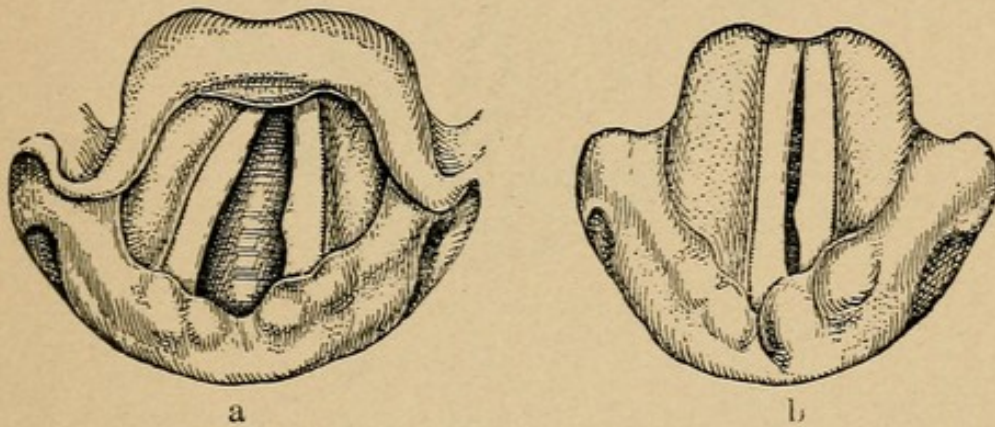


Fig. 19.

In a third case of this kind the paralyzed left vocal cord and its cartilage are immovable during phonation. The right arytenoid cartilage, however, passes underneath the left; the right vocal cord moves farther over, and almost perfect closure of the glottis is effected during phonation. The voice is accordingly good, only a slight hoarseness being noticeable.

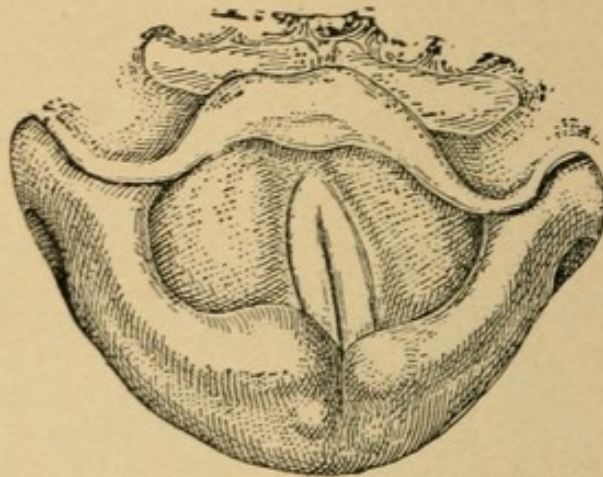


Fig. 20.

A male singer, 23 years old, suddenly lost his voice eight months ago. It gradually returned, but since that time he occasionally becomes almost aphonic for one or two days at a time. During the intervals between the attacks he is able to sing well and loud.

Both vocal cords are grayish-yellow and somewhat succulent.

Both vocal cords move during phonation, but the right moves so far beyond the middle line that the left does not get beyond the cadaveric position. At the same time the right arytenoid cartilage comes in front of the left.

During respiration both vocal cords are perfectly abducted. This irregularity, which formerly was, without good reason, designated by the special name of *asymmetria arytenoidea cruciata*, is very suggestive of the posture seen in paralysis of the recurrent. In view of the anamnesis, it may be regarded as the

Remnant of an Old Paralysis of the Left Recurrent.

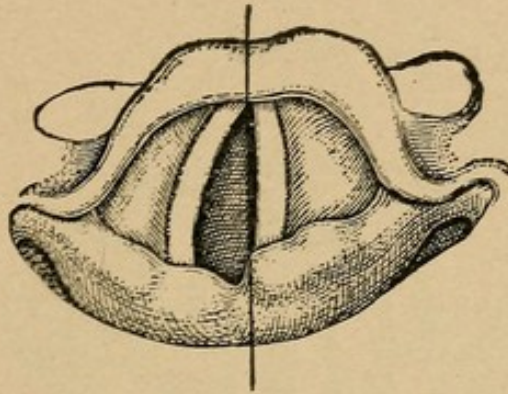


Fig. 21.

A woman, 36 years old, has had dyspnea for years; it has been gradually getting worse, and in the last few days suddenly became intense. The cause is a goiter, not very extensive, but easily felt on deep palpation; it is on the left side of the throat.

With the laryngoscope the trachea is seen to be pushed to one side.

In the larynx the position of the left vocal cord is striking. During phonation it stands exactly in the middle line, and during respiration it maintains the same position, only the free edge, which was stretched taut before, becomes slightly concave.

It is the typical position of

Paralysis of the Left Posterior Arytenoid Muscle.

As usual, it represents the first stage of pressure-paralysis of the left recurrent by the struma.

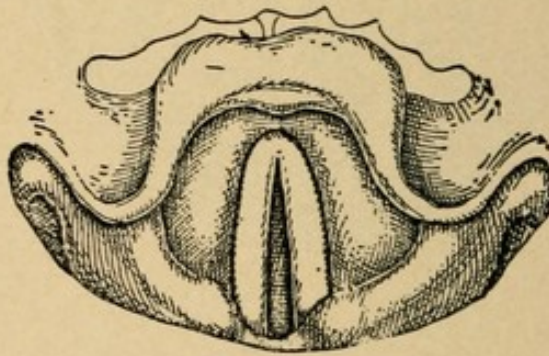


Fig. 22.

A man, 45 years old, who is found to have been suffering with tabes dorsalis for three or four years, began to be troubled with dyspnea about a week ago, so that any active exercise has become impossible. The voice is loud and has a good tone.

Instead of separating, the vocal cords remain immovable during respiration, at a short distance from the middle line.

As there is nothing to indicate a mechanical obstacle to abduction of the cords, it must be that the abductor muscles are paralyzed.

Tabetic Paralysis of the Posterior Crico-arytenoid Muscles.

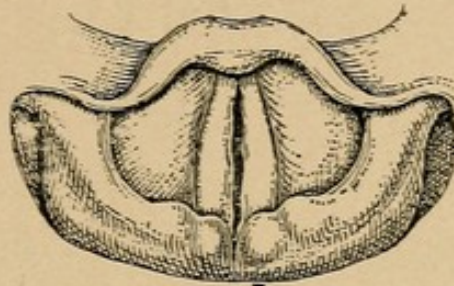


Fig. 23.

A woman, 63 years old, has been hoarse for some time. The voice is feeble, rough, and toneless.

The only abnormality in the larynx is observed during phonation, which presents the following curious picture. The edges of the vocal cords present in the resting position, as usual, a smooth, slightly concave outline; but as soon as the glottis is closed the edges become wavy, so that closure is not complete.


A sound can be introduced without causing the patient to cough; in fact, she does not feel it when she closes her eyes. Even the finger elicits no reflex either from the epiglottis or from the superior aperture of the larynx.

If the finger is held on the cricothyroid ligament during phonation, no tension or movement of the two arytenoid cartilages can be felt. We, therefore, have to deal with paralysis of the cricothyroid muscle and of the sensory nerves of the larynx.

As these constitute the entire domain of the superior laryngeal nerves, we have before us a

Paralysis of the Superior Laryngeal Nerves.

As no other abnormal condition can be found in the body, it is impossible to determine the cause.



INDEX.

(Fig. indicates Figure; Pl. indicates Plate.)


- ANGIOFIBROMA, Pl. 39, Fig. 3; Pl. 40, Fig. 1
 Angioma, Pl. 21, Fig. 3; Pl. 39, Fig. 2
 Aphonia, hysterical, Fig. 16
 CARCINOMA, Pl. 14, Fig. 3; Pl. 27, Fig. 1; Pl. 28, Figs. 1 and 2; Pl. 29; Pl. 37, Fig. 3
 Cartilages of larynx, 9, 10
 Catarrh, Pl. 9, Fig. 1; Pl. 11, Fig. 1; Pl. 14, Fig. 1; Pl. 36, Fig. 3
 Cauterization, 33
 Chondritis, Pl. 20
 Cortical center for movements of larynx, 19
 Crepitation, 26
 Croup, pseudo-, 38
 Cyst, absorption, Pl. 39, Fig. 1
 DIPHTHERIA, 39
 EDEMA, acute inflammatory, Pl. 7, Fig. 1; Pl. 26, Fig. 1
 Electrolysis, 33
 Epiglottis, 10
 Ω shape, 21, Pl. 2, Fig. 1
 Epithelioma, Pl. 36, Figs. 1 and 2
 Epithelium, distribution of, 18
 Erysipelas, Pl. 25, Fig. 1
 FALSETTO voice production, 22
 Fibro-epithelioma, Pl. 33, Fig. 2; Pl. 35, Fig. 2; Pl. 45, Fig. 2
 Fibroma, Pl. 15, Fig. 2; Pl. 18, Fig. 2; Pl. 38, Fig. 2; Pl. 39, Fig. 1
 Foreign-body stenosis, Pl. 31, Fig. 3
 GALVANOCAUTERY, 34
 HERPES, 57, Pl. 6, Fig. 1
 Hyperplasia, connective-tissue, Pl. 14, Fig. 1
 epithelial, Pl. 34, Fig. 3
 inflammatory, Pl. 10, Fig. 1; Pl. 22, Fig. 3; Pl. 33, Fig. 1; Pl. 35, Fig. 1
 pachydermatous, Pl. 16, Fig. 1
 post-syphilitic, Pl. 41, Fig. 1
 tuberculous, Pl. 21, Fig. 2; Pl. 23, Fig. 1; Pl. 44, Fig. 2
 Hysterical aphonia, Fig. 16
 INFLAMMATION, Pl. 19, Fig. 1
 Influenza, laryngitis in, 56
 Innervation of larynx, 18
 false, 27
 Intubation, 35
 KILLIAN'S POSTURE, 22, Pl. 1, Fig. 1


INDEX.

- Kirstein's method of direct laryngoscopy, 24, 29
- LARYNGITIS, acute, Pl. 19, Fig. 2
secondary chronic, Pl. 10, Fig. 1
- Ligaments of larynx, 10, 11
- Light in laryngoscopy, 24
- Lordosis of cervical vertebræ, Pl. 2, Fig. 3
- Lymphangiofibroma, Pl. 38, Fig. 1
- Lymph-follicles, distinguished from miliary tubercles, 17
- MACERATION by pus, Pl. 10, Fig. 2
- Measles, laryngitis in, 54
- Muscles of larynx, extrinsic, 10
intrinsic, 12 *et seq.*
- Muscular process, 12
- PAPILLOMA, Pl. 32, Fig. 1
- Perichondritis, syphilitic, Pl. 5, Fig. 3; Pl. 24, Fig. 1
tuberculous, 29, Pl. 17, Fig. 1; Pl. 20
after typhoid, Pl. 17, Fig. 2
- Phlegmon, Pl. 7, Fig. 2
- Phonation, 22
false vocal cord, 23, Pl. 3, Fig. 2
- Process, muscular, 12, 15
vocal, 12, 15
- RHEUMATISM, 59
- SARCOMA, ALVEOLAR, Pl. 24, Figs. 2 and 3; Pl. 37, Figs. 1 and 2
- Scarlet fever, laryngitis in, 55
- Sinuses, pyriform, 11
- Small-pox, laryngitis in, 55
- Stenosis, by foreign body, Pl. 31, Fig. 3
- Stridor, 27
- Struma, Fig. 15
- Syphilis, catarrh, Pl. 14, Fig. 1
gumma, Pl. 4, Fig. 1; Pl. 5, Fig. 1; Pl. 13, Fig. 1; Pl. 22, Fig. 2; Pl. 40, Fig. 2; Pl. 41, Fig. 2
membrane, Pl. 30, Fig. 3
meso- and peri-arteritis, Pl. 40, Fig. 2
papules, Pl. 11, Fig. 2; Pl. 12, Fig. 1
perichondritis, Pl. 5, Fig. 3; Pl. 24, Fig. 1
tertiary, Pl. 5, Fig. 2; Pl. 21, Fig. 1
depositions, Pl. 18, Fig. 3
infiltrate, Pl. 23, Fig. 2
ulcers, Pl. 13, Fig. 3; Pl. 42
- TUBERCULOSIS in fibro-epithelioma, Pl. 45, Fig. 2
hyperplastic, Pl. 21, Figs. 1 and 2; Pl. 23, Fig. 1; Pl. 44, Fig. 2
infiltrative, Pl. 5, Fig. 1; Pl. 6, Fig. 2; Pl. 9, Fig. 2; Pl. 12, Fig. 2; Pl. 16, Fig. 2; Pl. 19, Fig. 3; Pl. 22, Fig. 1; Pl. 25, Figs. 2 and 3; Pl. 26, Fig. 2; Pl. 43, Figs. 1 and 2
lupous form, Pl. 4, Fig. 2
perichondritis, Pl. 17, Fig. 1; Pl. 29
tumors, Pl. 22, Fig. 1; Pl. 31, Fig. 2; Pl. 44, Fig. 1; Pl. 45, Fig. 1
ulcerative, Pl. 16, Fig. 2
- Tumors, benign, Pl. 14, Fig. 2; Pl. 16, Fig. 1; Pl. 27, Fig. 2; Pl. 31, Figs. 1 and 2; Pl. 33, Fig. 3
tuberculous, see *Tuberculosis*.

INDEX.

- | | |
|---|--|
| <p>Typhoid fever, laryngitis in, 56</p> <p>VENTRICLE of Morgagni, prolapse of, Pl. 18, Fig. 1</p> <p>Ventricular bands, 14</p> <p>Ventriloquy, 23</p> <p>Vocal cords, 13</p> <p> color of, 21</p> <p> position of, in cadaver, Pl. 13, Fig. 2; Pl. 17, Fig. 2; Pl. 23, Fig. 2; Pl. 25, Fig. 1; Figs. 16, 18, 22</p> | <p>Vocal cords, position of, in phonation, 22</p> <p> in respiration, Pl. 3, Fig. 1</p> <p> paralyses, Figs. 16 to 23; Pl. 8; Pl. 13, Fig. 2</p> <p> process, 12</p> <p>Voice, character of, 27</p> <p> production, 13, 22</p> <p>WART, hard, Pl. 15, Fig. 1</p> <p>Whooping-cough, 57</p> |
|---|--|





SAUNDERS' MEDICAL HAND-ATLASES

Atlas and Epitome of Internal Medicine and Clinical Diagnosis. By DR. CHR. JAKOB, of Erlangen. Edited, with additions, by AUGUSTUS A. ESHNER, M. D., Professor of Clinical Medicine in the Philadelphia Polyclinic. With 179 colored figures on 68 plates and 240 pages of text. Cloth, \$3.00 net.

"Dr. J.
present.

Atlas of
tions, b
of Phy:
half-top

"It is, well an *Medica*

Atlas and
 Edited,
 and No
 figures

"Exce
of the l

Atlas an
From :
J. CHA
Surgery
Enlarg

"It ma
scope."

Atlas and
MRACE
of Gen
York.

"A gla
Journ

Atlas ar
Edited,
in the
pages c

"The
physicist
of the

Atlas ar
Edited,
tology,
illustrat

"The i
will ser

Atlas an
Edited,
Medica
Gastro-
tem, Sl
of text.

"The
beautiful
the vari

Atlas an
Berlin.

Physici
ures on

"This volume appeals not only to the medical student and the practitioner, but to the medico-legal specialist and accident insurance companies also."—*New York Med. Jour.*

Atlas and Epitome of Gynecology. By DR. O. SCHAEFFER, of Heidelberg. *From the Second Revised and Enlarged German Edition.* Edited, with additions, by RICHARD C. NORRIS, A. M., M. D., Gynecologist to the Methodist Episcopal and Philadelphia Hospitals. With 207 colored illustrations on 90 plates, 65 text-illustrations, and 308 pages of text. \$3.50 net.

"The book contains much valuable material. . . . Rarely have we seen such a valuable collection of gynecological plates."—*Bulletin of Johns Hopkins Hospital.*

Date Due

18-24-32

JUN 14 1938

APR 20 1956



SAUNDERS' MEDICAL HAND-ATLASES

Atlas and Epitome of Human Histology and Microscopic Anatomy.

Heide
C. E.
Medic

"A c
experi

Atlas an

of Hei
with a
Cornel
tration

"The
midwif

Atlas an

JAKO

Edite
Syste
pages

"Re
the n

Atlas a

O. H.
with
versit

"Nov
eye-fu

Atlas c

PROF.
Revisi

M. D.
Chica
of tex

"The
much

Atlas an

of PRO
M. D.

ored fi
"The

fessor

Atlas an

of Gött
Surger

"For t
The bo

Surgica

Atlas an

HELFE
Associa

64 litho
Such a

represe

Atlas an

GRÜN

WALD, of Munich.

From the Second Revised and Enlarged German Edition.

Edited, with additions, by JAMES E. NEWCOMB, M. D., Clinical Instructor in Laryngology, Cornell University Medical School. With 102 colored figures on 42 lithographic plates, 41 text-cuts, and 219 pages of text. Cloth, \$3.00 net.

This work also contains an admirable exposition of the anatomy and physiology of the organs under discussion.

Atlas and Epitome of Human Histology and Microscopic Anatomy.

By PR. DR.

J. SOBOTTA, of Würzburg.

Edited, with additions, by G. CARL HUBER, M. D., Junior Prof. of Anatomy and Director of the Histological Laboratory, University of Michigan.

214 colored figures on 80 plates, 68 text-cuts, and 248 pages of text. Cloth, \$4.50 net.

This work will serve as an atlas, text-book, and book of reference, combining, as it does, most accurate illustrations with a concise text.

RC 79A

G 92

Grünwald

Diseases of the Larynx

Collection

EFFER, of
ited by J.
University
\$2.00 net.
d clinical

LAEFFER,
Edited,
idwifery.
her illus-
3.00 net.
scientific

R. CHR.

tion.
vous

215
net.

y of
cine.

Dr.
ited,

Uni-
net.

the
s.

By
cond

VER,
ege,

iges
net.

are

tion
TH,

col-
net.

pro-

AN,
r on

ext.
net.

nce.
and

H.
D.,

s on
net.

and

L.

W. B. SAUNDERS & COMPANY

Philadelphia

New York

London

